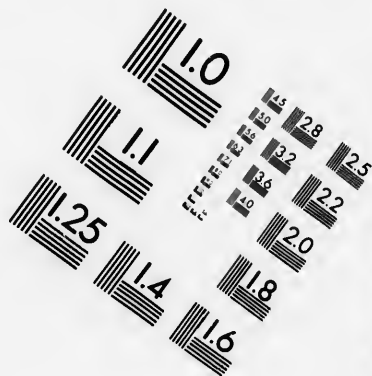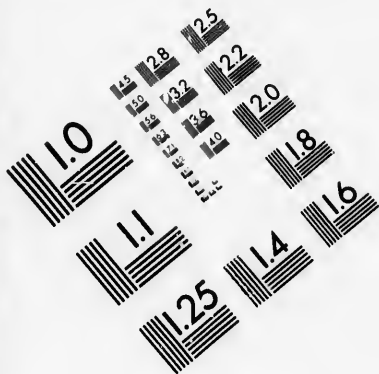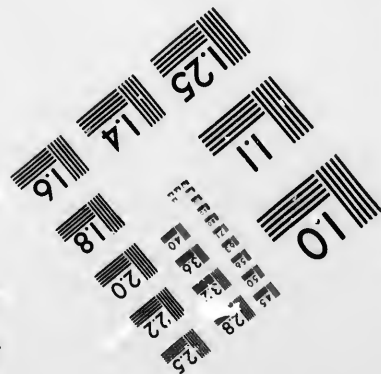
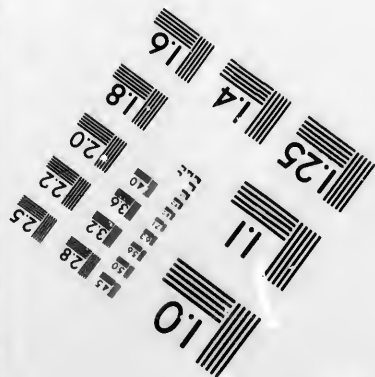




**IMAGE EVALUATION
TEST TARGET (MT-3)**



**Photographic
Sciences
Corporation**

23 WEST MAIN STREET
WEBSTER, N.Y. 14586
(716) 872-4503

**CIHM/ICMH
Microfiche
Series.**

**CIHM/ICMH
Collection de
microfiches.**



Canadian Institute for Historical Microreproductions / Institut canadien de microreproductions historiques

© 1981

Technical and Bibliographic Notes/Notes techniques et bibliographiques

The Institute has attempted to obtain the best original copy available for filming. Features of this copy which may be bibliographically unique, which may alter any of the images in the reproduction, or which may significantly change the usual method of filming, are checked below.

L'Institut a microfilmé le meilleur exemplaire qu'il lui a été possible de se procurer. Les détails de cet exemplaire qui sont peut-être uniques du point de vue bibliographique, qui peuvent modifier une image reproduite, ou qui peuvent exiger une modification dans la méthode normale de filmage sont indiqués ci-dessous.

- Coloured covers/
Couverture de couleur
- Covers damaged/
Couverture endommagée
- Covers restored and/or laminated/
Couverture restaurée et/ou pelliculée
- Cover title missing/
Le titre de couverture manque
- Coloured maps/
Cartes géographiques en couleur
- Coloured ink (i.e. other than blue or black)/
Encre de couleur (i.e. autre que bleue ou noire)
- Coloured plates and/or illustrations/
Planches et/ou illustrations en couleur
- Bound with other material/
Relié avec d'autres documents
- Tight binding may cause shadows or distortion along interior margin/
La reliure serrée peut causer de l'ombre ou de la distortion le long de la marge intérieure
- Blank leaves added during restoration may appear within the text. Whenever possible, these have been omitted from filming/
Il se peut que certaines pages blanches ajoutées lors d'une restauration apparaissent dans le texte, mais, lorsque cela était possible, ces pages n'ont pas été filmées.
- Additional comments:
Commentaires supplémentaires:

- Coloured pages/
Pages de couleur
- Pages damaged/
Pages endommagées
- Pages restored and/or laminated/
Pages restaurées et/ou pelliculées
- Pages discoloured, stained or foxed/
Pages décolorées, tachetées ou piquées
- Pages detached/
Pages détachées
- Showthrough/
Transparence
- Quality of print varies/
Qualité inégale de l'impression
- Includes supplementary material/
Comprend du matériel supplémentaire
- Only edition available/
Seule édition disponible
- Pages wholly or partially obscured by errata slips, tissues, etc., have been refilmed to ensure the best possible image/
Les pages totalement ou partiellement obscurcies par un feuillet d'errata, une pelure, etc., ont été filmées à nouveau de façon à obtenir la meilleure image possible.

This item is filmed at the reduction ratio checked below/
Ce document est filmé au taux de réduction indiqué ci-dessous.

10X	12X	14X	16X	18X	20X	22X	24X	26X	28X	30X	32X
<input type="checkbox"/>	<input type="checkbox"/>	<input type="checkbox"/>	<input type="checkbox"/>	<input type="checkbox"/>	<input type="checkbox"/>	<input type="checkbox"/>	<input type="checkbox"/>	<input checked="" type="checkbox"/>	<input type="checkbox"/>	<input type="checkbox"/>	<input type="checkbox"/>

The copy filmed here has been reproduced thanks to the generosity of:


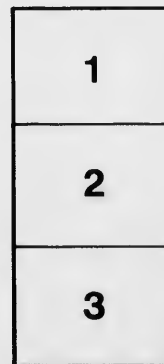
National Library of Canada

The images appearing here are the best quality possible considering the condition and legibility of the original copy and in keeping with the filming contract specifications.

Original copies in printed paper covers are filmed beginning with the front cover and ending on the last page with a printed or illustrated impression, or the back cover when appropriate. All other original copies are filmed beginning on the first page with a printed or illustrated impression, and ending on the last page with a printed or illustrated impression.

The last recorded frame on each microfiche shall contain the symbol \rightarrow (meaning "CONTINUED"), or the symbol ∇ (meaning "END"), whichever applies.

Maps, plates, charts, etc., may be filmed at different reduction ratios. Those too large to be entirely included in one exposure are filmed beginning in the upper left hand corner, left to right and top to bottom, as many frames as required. The following diagrams illustrate the method:



L'exemplaire filmé fut reproduit grâce à la générosité de:

Bibliothèque nationale du Canada

Les images suivantes ont été reproduites avec le plus grand soin, compte tenu de la condition et de la netteté de l'exemplaire filmé, et en conformité avec les conditions du contrat de filmage.

Les exemplaires originaux dont la couverture en papier est imprimée sont filmés en commençant par le premier plat et en terminant soit par la dernière page qui comporte une empreinte d'impression ou d'illustration, soit par le second plat, selon le cas. Tous les autres exemplaires originaux sont filmés en commençant par la première page qui comporte une empreinte d'impression ou d'illustration et en terminant par la dernière page qui comporte une telle empreinte.

Un des symboles suivants apparaîtra sur la dernière image de chaque microfiche, selon le cas: le symbole \rightarrow signifie "A SUIVRE", le symbole ∇ signifie "FIN".

Les cartes, planches, tableaux, etc., peuvent être filmés à des taux de réduction différents. Lorsque le document est trop grand pour être reproduit en un seul cliché, il est filmé à partir de l'angle supérieur gauche, de gauche à droite, et de haut en bas, en prenant le nombre d'images nécessaire. Les diagrammes suivants illustrent la méthode.

ails
du
difier
une
image


rata
p

elure,
à



672

TUBO-PERITONEAL ECTOPIC GESTATION



TUBO-PERITONEAL ECTOPIC
GESTATION

BY

J. CLARENCE WEBSTER, B.A., M.D., M.R.C.P.ED.,

ASSISTANT TO THE PROFESSOR OF MIDWIFERY AND DISEASES OF WOMEN AND
CHILDREN IN THE UNIVERSITY OF EDINBURGH.

EDINBURGH AND LONDON:
YOUNG J. PENTLAND

1892

EDINBURGH: PUBLISHED FOR THE ROYAL COLLEGE OF PHYSICIANS BY YOUNG J. FENTLAND,
11 TEVIOT PLACE; AND 38 WEST SMITHFIELD, LONDON, E.C.

TO
PROFESSOR A. R. SIMPSON,
PRESIDENT,
AND THE
FELLOWS OF THE ROYAL COLLEGE OF PHYSICIANS OF EDINBURGH,
IN RECOGNITION OF THEIR EFFORTS TO PROMOTE SCIENTIFIC RESEARCH IN MEDICINE,
AND
IN ACKNOWLEDGMENT OF THE GENEROUS ENCOURAGEMENT WHICH THE AUTHOR
HAS RECEIVED FROM THEM,
THIS WORK IS DEDICATED.



PREFACE

THIS monograph gives a detailed account of an original research into the nature of a mixed variety of Ectopic Gestation, partly within the left Fallopian tube (Extra-peritoneal) and partly within the peritoneal cavity (Intra-peritoneal). Such a variety has never yet been described, and to it I propose to give the name "Tubo-Peritoneal." The work of investigation has been carried out at the Laboratory of the Royal College of Physicians during the past two years. I desire to express my deepest thanks to the Laboratory officials for the generous manner in which they have supplied my many needs during the prosecution of the research, and to acknowledge especially the kindness of Dr. J. Batty Tuke, Curator, Dr. Noël Paton, Superintendent, and Dr. G. Sims Woodhead, former Superintendent of the Laboratory.

J. CLARENCE WEBSTER.

EDINBURGH, *October* 1892.



TABLE OF CONTENTS

CHAP.	PAGE
I. CLASSIFICATION	1
II. CLINICAL HISTORY	4
III. METHOD OF INVESTIGATION	9
IV. NAKED EYE SECTIONAL EXAMINATION	12
V. NAKED EYE DISSECTIONAL EXAMINATION	29
VI. MICROSCOPIC EXAMINATION	32
VII. RÉSUMÉ	38
BIBLIOGRAPHY	51
INDEX	53





TUBO-PERITONEAL ECTOPIC GESTATION



TUBO-PERITONEAL ECTOPIC GESTATION

CHAPTER I

CLASSIFICATION

THERE is at present a considerable difference of opinion among writers regarding the varieties of Ectopic Gestation.¹

Until the year 1837 four varieties were recognised,² viz.—

- | | |
|-------------|------------------|
| 1. Tubal. | 3. Abdominal. |
| 2. Ovarian. | 4. Interstitial. |

In that year Dezeimeris³ published a new classification embracing several previously undescribed forms. It was as follows :

- | | |
|-------------------------------|---------------------------|
| 1. Tubal. | 6. Utero-tubal. |
| 2. Ovarian. | 7. Utero-tubo-abdominal. |
| 3. Abdominal. | 8. Tubo-ovarian. |
| 4. Interstitial-tubo-uterine. | 9. Tubo-abdominal. |
| 5. Utero-interstitial. | 10. Sub-peritoneo-pelvic. |

A few words in explanation of these terms are necessary.

The first, second, and third, in this list require no explanation.

Interstitial-tubo-uterine was the term given to a gestation in the uterine portion of the tube.

Utero-interstitial was used to designate a gestation taking place in the substance of the uterine wall proper (owing probably to the escape of the ovum through a rupture in the uterine part of the tube).

¹ I do not here include Cornual pregnancies under Ectopic Gestation.

² Parry : *Extra-Uterine Preg.*, 1876.

³ *Journal des Connaissances Med. Chir.*, Jan. 1837.

Utero-tubal was the name given by Dezeimeris to a gestation occurring partly in the uterine portion of the tube and partly in the cavity of the uterus.

Utero-tubo-abdominal was the variety in which the fœtus was in the abdominal cavity, while the umbilical cord passed through the Fallopian tube to the placenta, which was in the interior of the uterus.

Tubo-ovarian gestation was one which developed in the pavilion of the tube, the fimbriated end forming adhesions with the ovary.

The *Tubo-abdominal* gestation developed in the same place, the end of the tube contracting adhesions with the side wall of the pelvis or viscera in the neighbourhood.

Sub-peritoneo-pelvic was the name given by Dezeimeris to a gestation developing within the layers of the broad ligament.

This classification has, with slight variations, been used in the text-books of all countries, until the present time. Recently, however, Lawson Tait and Berry Hart have called into question its accuracy, and have stated that several of the varieties so long described have never at all been demonstrated.

The former describes¹ only the following forms :

1. *Interstitial or tubo-uterine*, in which the gestation is within the uterine portion of the tube. This, so far as is known, is uniformly fatal before the fifth month by rupture into the peritoneal cavity.

2. *Tubal*, in which the gestation occurs in the free part of the tube. At or before the fourteenth week of pregnancy rupture always occurs —

(a) Into the peritoneal cavity. This is always a fatal event unless recourse is had to abdominal section.

(b) Into the broad ligament. In this case there may result either of the following conditions, viz. :

(1) Development of the gestation in the extra-peritoneal tissue up to full time (sub-peritoneo-pelvic and sub-peritoneo-abdominal).

(2) Death of the fœtus and absorption of the mass as a *hematoma*.

(3) Death of the fœtus and discharge by suppuration through the abdominal wall, bladder, vagina, or intestines.

¹ *Dis. of Women and Abd. Surg.*, vol. i. p. 443.

(4) Formation of a lithopedion.

(5) Rupture may afterwards take place into the peritoneal cavity.

As to Ovarian gestation, he says that it is not yet proved, though it is possible. Neither does he believe in the occurrence of the Abdominal variety.

Berry Hart,¹ in his recent article, says that only the following forms have been demonstrated, viz.—“Tubal” (including the interstitial), “Tubo-Ovarian, Sub-peritoneo-pelvic, Sub-peritoneo-abdominal.” He says that an Abdominal variety, purely intra-peritoneal, has yet to be demonstrated, as is also the case with the Ovarian. He also says that an Abdominal variety, partly intra-peritoneal and partly extra-peritoneal, is only probable.

Since these authorities have published their views we have been shown undoubted evidence of the occurrence of Ovarian pregnancy. Two specimens of this condition were demonstrated by Leopold² at the recent International Medical Congress at Berlin.

Bland Sutton,³ however, is still of the opinion that “*ovarian gestation* has no existence.” He thinks that the few cases described as such were in reality gestation occurring in a complete ovarian sac, an abortion having taken place from the tube, in which the pregnancy started, through the fimbriated end which opened into the sac.

I am now able, in this thesis, to describe a variety of Ectopic Gestation never before demonstrated.⁴ It is a mixed variety, partly extra- and partly intra-peritoneal. As the extra-peritoneal portion is entirely tubal, and the remaining part within the peritoneal cavity, I propose to give to this variety the name of *Tubo-Peritoneal*.

The cadaver, the study of which has enabled me to establish this new form, I owe to the kindness of Dr. Halliday Croom, in whose practice the case occurred. To him, also, I am indebted for the following history of the patient. It has been compiled from Dr. Croom's private notes, as well as from the account of the Clinical Clerk of Ward 28 of the Royal Infirmary given in the *Ward Journal*, vol. 7, p. 85.

¹ *Lab. Reports R.C.P.E.*, vol. i. p. 34.

⁴ Since the completion of my investigations

² *Trans. of Inter. Med. Congress*, Berlin, 1890.

a somewhat similar case has been recently re-

³ *Surgical Diseases of the Ovaries and Fallopian tubes*, 1891, p. 372.

ported by Lawson Tait.

CHAPTER II

CLINICAL HISTORY

Mrs. K., 1-para, aged 33, was admitted to Ward 28 on Feb. 11th, 1890, complaining of pain in the left flank and lower part of the abdomen, as well as of great swelling of the abdomen.

The swelling was first noticed in July 1889, in the lower part of the abdomen to the left of the middle line. Ever since, it had continued to increase, extending gradually upwards as well as to the right side. During the two weeks previous to admission, the patient noticed a more rapid enlargement taking place.

Pain was first felt in December 1889 and had continued with intermissions ever since; it occurred chiefly in left flank, in the hypochondriac and lumbar regions. This pain was sharp and very severe at times; after an exacerbation an ill-defined uncomfortable feeling was left in the regions affected. The pain was not in any way connected with respiration.

During the week previous to admission she suffered from spasms of pain throughout a still larger area of the abdomen.

Early in the third month of her pregnancy she felt a sudden though not very severe pain in the left iliac region. It was not accompanied by any fainting or collapse, and passed completely away after four or five days' rest. (The patient's physician believed it to be a peritonitic attack.)

Foetal movements were felt to within a few days before admission. Throughout pregnancy she complained of constipation. In June and July 1889 she had been troubled with frequency of micturition, but during the month before her admission she complained of difficulty in micturition. She had been losing flesh during the month.

The history of the patient previous to the present illness, as well as her family history, was good and contained no facts of special importance.

The type of the patient's menstruation was never regular. It varied from the 21 to 28 day type. The flow usually lasted for five days. She always had considerable pain in connection with it, felt chiefly in the lower part of the abdomen. It came on before the flow began, continued during the first day and then disappeared, often returning again on the third day.

Her last well-marked menstruation took place in M 389, beginning on the 2nd and ending on the 6th. In June she missed her period. In July at the time corresponding to the menstrual period, she had a small discharge of blood from the genital passage, lasting for five minutes. Her physician, believing an abortion to be threatened, put her to bed and kept her there for some time. Again in August she had another similar discharge of blood. In September, October, November, and December there was no discharge. Near the end of January 1890 she again lost a small quantity of blood.

The patient had been married for two years and had not been before pregnant.

The patient was well developed and fairly well nourished. Her face had a weary and anxious expression. There was œdema of the legs and ankles. The abdomen was greatly distended, the girth at the level of the umbilicus measuring 45 inches. The umbilicus was prominent. Old and recent striae were present. There was no *linea nigra* nor any pigmentation. No foetal movements were seen nor felt. Fluctuation was obtained over the whole abdomen. On percussion the front of the abdomen was non-resonant, while there was a resonant note in the flanks. On palpation a hard mass was felt in the right iliac fossa somewhat movable. On auscultation no foetal heart could be heard, but there was a well-marked souffle heard in each iliac region. (No further examination of the patient was made on Feb. 11th.)

Feb. 12th. A bi-manual examination was made. The vagina was patulous and very soft. The cervix appeared to be about its normal level, soft, smooth, enlarged—not shortened. The cervical canal easily admitted

the forefinger. The Uterus was lying anteverted, but also lateriverted towards the *right* side. It was about 4 in. in length. No fetal parts could be palpated.

Feb. 13th. Pains came on in the lower part of the abdomen, intermittent and wave-like, resembling those of normal labour. The patient had all the appearances, outwardly, of a woman in the first stage of labour. The bi-manual examination was performed, and the uterus was found to be contracting during the pains, the cervical canal being somewhat opened. A forefinger was passed into the uterine cavity, which was found empty. Some membrane was scraped from the wall and given to Dr. Woodhead to examine. He found it to be well-formed decidual tissue.

Feb. 15th. It was determined to perform an abdominal section. The operation was done by Dr. Croom in the following manner :

A vertical mesial incision 5 in. in length was made through the abdominal wall above the symphysis pubis. Inside it lay the large sac containing the fetus. Between the two—*i.e.* sac and abdominal walls—several adhesions were felt with the exploring fingers. In front, these were soft and easily broken down; towards the side and bottom of the pelvis, however, very firm adhesions were found to exist.

The anterior wall of the sac was cut through, numerous vessels being tied, and about twenty-five pints of yellowish-green, grumous, non-viscid fluid evacuated.

A coil of the cord then appeared and the fetus was found lying dead, in an attitude of flexion, its head lying in the right iliac fossa, with the occiput to the back, the breech being in the left hypochondrium. It was adherent to the sac wall in several places, especially over the scalp. The separation of these adhesions caused some bleeding. The cord was cut close to the child, after being tied, and the fetus removed through the incision, which had to be enlarged for that purpose.

The sac was then examined. The wall which had been cut seemed to consist of an inner fleshy-looking and an outer yellowish-looking part. It was impossible to determine its nature or relation—whether it was extra-uterine or the distended horn of a bicornuate uterus.

The placenta lay in the left half of the pelvis. It appeared as a thick

discoid mass, which reached around in front almost to the middle line. It was not interfered with, but left undisturbed.

The sac and peritoneal cavity were next washed and sponged out with an antiseptic lotion and the edge of the sac-wall incision stitched to that of the abdominal-wall incision. The latter was then closed at its upper and lower ends, an opening being left in the middle leading into the sac cavity. The cord was drawn into the opening and the cavity was packed with iodoform gauze and drained by two glass tubes. Over the wound was placed a dressing of iodoform gauze and corrosive sublimate wool.

The patient was under chloroform for three hours. She was completely out of its influence at 2 P.M.

At 2.10 P.M. an enema of brandy was given, followed by a one grain morphine suppository. For six hours the patient complained of some pain in the region of the abdominal incision, which afterwards passed off. There was no vomiting.

At midnight patient seemed comfortable, having slept for four hours. Pulse 124 per minute and feeble. Temperature was 101.2 degrees, having risen steadily since the morning. The dressing was changed because it had become soaked with a blood-stained discharge.

Feb. 16th, 7 A.M. The patient had slept only lightly after midnight. No pain. Dressing again changed.

9 A.M. Pulse 120, very feeble. Temperature 101 degrees. Some twitchings noticed in arms and hands.

11.10 A.M. Enema of brandy with mXX of tincture of Strophanthus given. Feed brandy and water given by mouth every hour.

Noon. Enema repeated. Pulse 124, and very feeble. Temperature 101.6 degrees. Respirations 20 per minute.

4 P.M. Patient became drowsy after noon and soon semi-comatose and delirious. Pulse 138. Temperature 100.2 degrees. Twitching less marked in the upper extremities. No odour in breath.

8 P.M. Late in the afternoon the coma had become deeper, the breathing more exaggerated and accompanied by tracheal râles. Pulse 150, very weak and irregular. Twitching of the face, especially on the left side, noticed. Twitching of fingers increased.

8.55 p.m. Patient died. For an hour and a half before death she had continued to call out in a wild incoherent manner. The total amount of urine passed after the operation (a period of about 38 hours) was 18 ounces. It contained urea in the proportion of 2.6 grains per ounce. The bowels were not moved after the operation.

CHAPTER III

METHOD OF INVESTIGATION

IN investigating the nature of this case, I have employed two methods of research—the naked eye and the microscopic. In the former of these I have relied both upon the sectional and dissectional methods, chiefly, however, upon the sectional.

The great value of the study of the body, in normal as well as in many pathological conditions, by means of frozen sections, is now well recognised, at least in this and in many Continental Schools; and in no department of medicine have more important results been obtained from the employment of the *sectional methods* than in Midwifery and Gynecology. By it one obtains the best idea of topographical relationships. For all other purposes, however, the dissectional method is to be employed. To obtain the truest results they should be employed together. The value of this method in the study of Ectopic Gestation has already been great, although thus far it has only been *fully*¹ employed in two cases. These have been described by Berry Hart.

One of these cases he proved to be a variety never before demonstrated, though long thought very probable by Lawson Tait—the sub-peritoneo-abdominal. In this form the gestation commencing in the tube developed in the layers of the broad ligament and then grew extra-peritoneally, extending upwards towards the diaphragm behind the peritoneum, which it stripped upwards from the pelvic floor and viscera, the placenta even

¹ Barbour (*Obstet. Trans.*, Edin., vol. vii. p. 143) made a Vertical Mesial Section of the case of Professor Simpson's, but in attempting to dissect the halves of the pelvis, he found so many

adhesions that he was unable to make out the relation of the parts. He could not decide whether it was a sub-peritoneo-pelvic or a tubo-abdominal gestation.

being moved upwards out of the pelvis. By the ordinary *post-mortem* examination the nature of this case would never in all probability have been made clear. It would doubtless have been called an "*abdominal pregnancy*." It was only after the most careful tracing of the peritoneum, in the various slabs into which the body had been cut, that the gestation was found to be not intra- but extra-peritoneal. Tait and Hart are both of the opinion that many of the cases described in books as abdominal, *i.e.* intra-peritoneal, are really extra-peritoneal.

Hart's other case was also an extra-peritoneal one, but at an earlier stage of pregnancy—the so-called sub-peritoneo-pelvic of Dezeimeris. He showed that this was also a Fallopian-tube gestation which had developed between the layers of the broad ligament. This had not been demonstrated before. Dezeimeris¹ believed that the ovum, after leaving the ovary, did not enter the Fallopian tube, but passed between the folds of the broad ligament and there grew. In my own case, I cannot but believe that a dissectional study might have led to erroneous conclusions regarding its nature, and would not have furnished the large number of valuable facts which I am able to bring forward regarding this very interesting pathological condition.

In view of these results it is evident that a great many of the statistics regarding many of the described forms of ectopic gestation are entirely untrustworthy. Conclusions have been arrived at, in many cases from ordinary *post-mortem* examination, which would undoubtedly have proved wrong had more minute and careful methods of investigation been adopted.

It is not going too far to say that by the ordinary *post-mortem* method of study it is impossible to acquire an accurate knowledge of the anatomy and pathology of many forms of ectopic gestation. Frozen sections supplemented by dissectional and microscopic examination are necessary. *Ante-mortem* examination before or at the time of operation is, in advanced pregnancy, utterly untrustworthy.

In Hart's cases the body was undisturbed, the foetus, a most valuable landmark, being *in situ*. In my case certain complications were introduced as a result of the operative procedure carried out. These were as follows :

¹ *Op. cit.*

- (a) The opening of the abdomen as well as the sac containing the foetus ;
- (b) The separation of some of the adhesions between the sac and the anterior abdominal wall ;
- (c) Post-operation changes in the placenta and the wall to which it was attached.

These complications have not been very important, and have not seriously interfered with the complete investigation of the case save as regards certain points in the structure of the placenta.

As a result of my investigation I am able to describe the exact nature of the gestation, its probable anatomical and pathological history during pregnancy, and also the post-operation changes which have taken place.

TECHNIQUE.

The whole abdomen and pelvis were removed from the *cadaver* and frozen for three days in a mixture of equal parts of salt and ice. At the end of this time a vertical mesial section was made with a thin broad-bladed saw. The specimen was thus divided into two equal parts with very little loss of substance and no disturbance of parts. The sawn surfaces were perfectly flat ; that of the left half was then sketched (Pl. I.) An exact outline of the various structures seen was first traced upon a transparent gelatine sheet and then transferred to paper, the details being filled in and coloured *ad naturam*.

The two parts were then carefully placed together and six transverse sections (Pl. II.-VII.) made at different levels, drawings being made, in each case, of the cut surface of the lower part. The description of each section, and its measurements, were made in the frozen condition. While one part was being sketched and described the rest of the specimen was kept in the freezing mixture.

In this way the body has been rendered practically transparent, the abdominal and pelvic contents being preserved *in situ*, their form and relation undisturbed by *post-mortem* manipulations.

The various slabs were next carefully hardened in methylated spirits and examined in detail, small pieces being removed from various parts for microscopic investigation.

CHAPTER IV

NAKED EYE SECTIONAL EXAMINATION

Vertical Mesial Section (Plate I.)

THIS section is made in the vertical mesial plane of the body, in line with the sagittal suture. The left half of the pelvis and lower part of the abdomen is here shown.

The bones seen in the section are the symphysis pubis in front and the lumbar, sacral, and coccygeal vertebræ behind.

Bony Pelvis.—The sacrum and coccyx form one well-marked curve from above downwards. The sacrum measures $4\frac{5}{8}$ in. in length and the coccyx $1\frac{1}{4}$ in. The symphysis pubis measures $1\frac{1}{2}$ in. vertically and $\frac{3}{4}$ in. in its widest transverse diameter.

Conjugate of brim (anatomical)	measures	$4\frac{5}{8}$ in.
„ „ (obstetrical)	„	$4\frac{9}{16}$ in.
„ cavity	„	5 in.
„ outlet (sacral)	„	$4\frac{5}{16}$ in.
„ „ (coccygeal)	„	$3\frac{5}{8}$ in.

The symphysis pubis is not parallel to the upper part of the sacrum, but diverges slightly from above downwards.


Uterus.—The Uterus lies opposite the 3rd, 4th, and 5th sacral vertebræ. The body only is cut through near to its right side. The section is somewhat oval, has a pale grey pink appearance, and is of a very firm consistence. No blood-vessels can be seen in its substance. Its highest point is $1\frac{1}{8}$ in. below the brim or just below the middle of the second sacral vertebra. Its greatest antero-posterior measurement is $1\frac{1}{8}$ in. The posterior surface is more rounded than the anterior. Three-eighths of an inch below the upper border is seen the right Fallopian tube

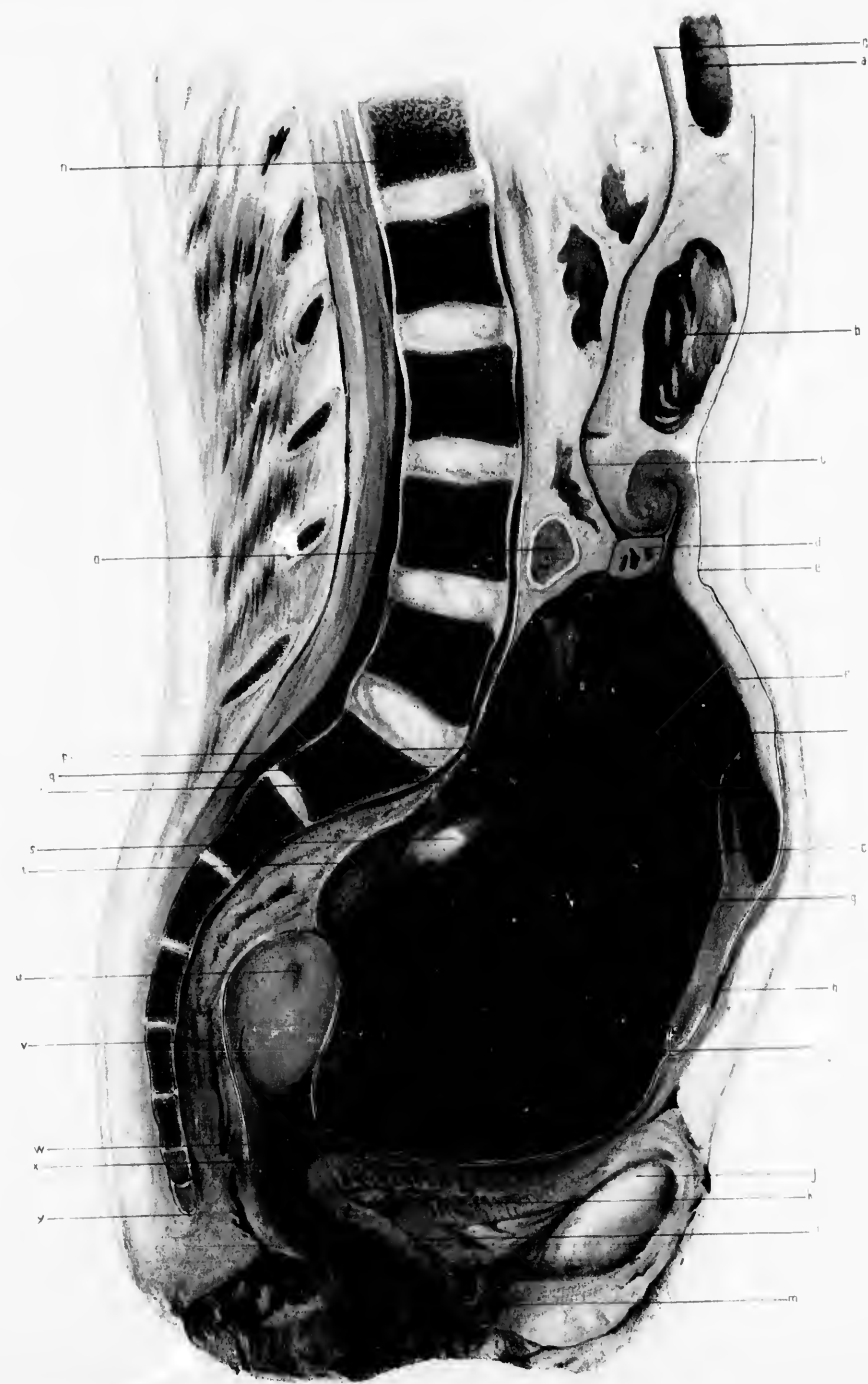
PLATE I.

VERTICAL MESIAL SECTION.

(Reduced by $\frac{1}{3}$.)

- a.* Pyloric end of stomach.
- b.* Transverse colon.
- c.* Secondary or amniotic sac in which foetus lay.
- d.* Umbilical cord.
- e.* Peritoneal cavity behind anterior abdominal wall.
- f.* Great omentum altered in character, being dense and fibrous in its inner part, and entering into the formation of the secondary sac.
- g.* Wall of primary or tubal sac containing the placenta.
- h.* Adhesion between anterior abdominal wall and great omentum.
- i.* Blood and torn up placenta forming the mass in the primary sac.
- j.* Symphysis pubis.
- k.* Bladder.
- l.* Urethra.
- m.* Vagina.
- n.* First lumbar vertebra.
- o.* Small intestines.
- p.* Fold of amniotic cavity dipping down into top of primary sac caused by extension upwards of anterior part of sac by hemorrhage into it.
- q.* Promontory.
- r.* Adhesions between posterior wall of primary sac and parietal peritoneum.
- s.* Pale firm mass, remains of old blood extravasation into placenta.
- t.* Space containing fluid in wall of primary sac.
- u.* Right Fallopian tube in wall of uterus.
- v.* Rectum.
- w.* Adhesions between primary sac wall and bottom of utero-vesical pouch.
- x.* Pouch of Douglas.
- y.* Tip of coccyx.







in the substance of the muscle. It contains dark fluid; the tissue immediately around it is darker than the rest of the uterus.

Below the body, the section passes through the junction of the right broad ligament with the supra-vaginal portion of the cervix.

This broad ligament tissue is of a light purple colour and of softer texture than the uterus. It passes downwards to become continuous with the vaginal walls and the posterior part of the bladder. It measures antero-posteriorly $\frac{3}{4}$ in.

Relations.—Its anterior surface is in contact with the peritoneum covering the posterior surface of the placental sac. Several small adhesions exist near the upper border.

The posterior surface is entirely in relation to the rectum.

Vagina.—The vagina is a sigmoid slit $2\frac{1}{8}$ in. in length. The upper end is nearly the highest part of the right fornix and lies $3\frac{1}{2}$ in. below the brim, in a line joining the lower edge of the symphysis with the lower end of the sacrum. The *rugae* are well marked, and the walls are deeply congested.

The *perineum* is well formed and darkly stained with blood.

Rectum.—The anus looks downwards and backwards. (It was distended with a little wool before freezing.) From the anus the rectum passes upwards and forwards for 1 in. in a direction at right angles to the brim, and then passes backwards and upwards, following the sacro-cocecygeal curve, reaching almost to the promontory. The cavity is cut through almost continuously as far as the middle of the 2nd sacral vertebra. It is quite closed. Above the cavity only the wall and meso-rectum is cut through. Above the uterus the anterior surface of the rectum is in relation to the surface of the placental sac.

Bladder.—The bladder is almost empty and lies compressed below the placental sac. Its upper surface is flattened.

The highest point is behind the pubes, $1\frac{1}{8}$ in. below the brim; from this it slopes backwards and downwards for $2\frac{1}{8}$ in., the posterior end being $3\frac{1}{8}$ in. below the brim; the posterior surface is connected with the cervix and vagina by loose connective tissue in which are seen a few small vessels filled with blood. The average thickness of the walls is

$\frac{1}{4}$ in., their colour being of a pale grey pink tinge. The cavity is $2\frac{1}{4}$ in. in length, of which $1\frac{3}{8}$ in. lies in front of the urethral opening. Behind the latter is a small quantity of urine.

The Urethra is sigmoid shaped, being curved chiefly at its lower end. Its length is $1\frac{3}{8}$ in. Immediately above the bladder is retro-pubic fat $\frac{5}{16}$ in. in thickness. It is continuous below with a triangular portion of considerable size in front of the urethra and bladder.

Peritoneum.—That lining the anterior abdominal wall can be traced down to a point $1\frac{7}{8}$ in. above the brim. Then for half an inch it is adherent to the outer surface of the great omentum, which enters into the formation of the sac in which the child lay. Below this it can be traced uninterruptedly as far as the middle of the upper surface of the bladder. Behind this point there are several slight adhesions between the bladder and the placental sac for $1\frac{3}{4}$ in. Above this the peritoneum is free nearly to the upper end of the uterus, where again there are a few adhesions. It descends over the back of the uterus $3\frac{1}{4}$ in. below the brim to form the pouch of Douglas, and again up in front of the rectum, interrupted here and there by adhesions, behind the placental sac as far as the fourth lumbar vertebra, where it is reflected to form part of the mesentery.

Amniotic Cavity.—This cavity, which contained the child, is really that part of the peritoneal cavity behind the great omentum. The walls are in apposition. The upper end lies opposite the upper part of the first lumbar vertebra, $1\frac{3}{4}$ in., below the liver and 2 in. in front of the vertebral column. It extends downwards and backwards until opposite the lower part of the 3rd lumbar vertebra, where its posterior wall is only $\frac{3}{4}$ in. in front of the vertebrae. Below this it passes downwards and forwards in front of the placental sac. The lowest end is $1\frac{1}{2}$ in. above the brim.

In front the sac has the following relations. Opposite the 1st lumbar vertebra is the stomach. Opposite the 2nd and 3rd lumbar vertebrae is the transverse colon. Below this is the great omentum, which is somewhat crumpled just below the colon. From the upper end as far as the 4th lumbar vertebra, the wall adjacent to the cavity is of a dark reddish colour, varying in thickness from $\frac{1}{16}$ to $\frac{1}{8}$ in.

Outside this is pale tissue, evidently chiefly connective tissue and fat. Below the colon the wall becomes thicker. It consists of great omentum, which towards the cavity has become fibrous in nature. Opposite the promontory is a folding of it.

The posterior wall, as far down as the lower edge of the 4th lumbar vertebra, has behind it chiefly small intestine and mesentery. Next the cavity is a thin dark red layer, and behind this fat, connective tissue, and the muscles of the intestinal wall.

Below the 4th lumbar vertebra is seen a deep fold of the wall extending into the placental mass for $2\frac{1}{4}$ in. (This slit is probably a post-operation formation, and is no doubt due to the elevation of the anterior part of the placental sac by blood extravasation. It contains *vernix caseosa*.) The remaining part of the posterior wall is really the anterior wall of the placental sac and can be traced down as far as $1\frac{1}{8}$ in. above the brim, where it joins the lower end of the great omentum, just above the point of junction of the latter with the anterior abdominal wall.

Opposite the 4th lumbar vertebra the umbilical cord lies in the amniotic sac, immediately above the placental sac.

Placental sac.—This fills a large part of the pelvis and lower part of the abdomen. It lies behind and below the amniotic sac. The highest point is $3\frac{1}{8}$ in. above the brim opposite the lower part of the 4th lumbar vertebra. From this point it extends downwards, gradually widening to a point $\frac{1}{2}$ in. below the brim, where it begins to narrow again. Its lowest end is in the utero-vesical pouch, which it completely fills. The deep fold of the amniotic sac, which appears to extend from above into the substance of the placental mass, divides the upper part of the sac and its contents into two distinct portions,—a posterior portion which is of dense firm fibrous appearance and an anterior larger portion, softer and of a dark red-black blood-stained colour.

Below the fold, for a couple of inches, the same distinction is noticed, the posterior portion just below the promontory being a yellow fibrous mass.

The greatest vertical height of the sac is $6\frac{7}{8}$ in. Its antero-posterior measurement opposite the last lumbar vertebra is $2\frac{1}{2}$ in., and $\frac{1}{2}$ in. below the brim $3\frac{5}{8}$ in.

In the wall of the sac just above the uterus is a cyst-like structure, containing brown-stained fluid through which run thin membranous bands from side to side. Close to it are seen two venous sinuses filled with blood. Opposite the upper part of the last lumbar vertebra sections of vessels are seen in the posterior wall of the sac. There are sections of the umbilical vessels passing down to enter the placenta. The sac wall cannot be distinctly made out in all places. Behind, it is too intimately connected with its contents. Below, it is a thin fibrous membrane. In front, it appears as a fleshy-looking band $1\frac{1}{16}$ to $\frac{1}{8}$ in. thick.

First Transverse Section (Plate II.)

This passes in front through the descending rami of the pubes, immediately below the symphysis; behind, through the middle of the 4th sacral vertebra, and laterally through the ischial tuberosities. The transverse diameter of the pelvic cavity measures $4\frac{3}{8}$ in.

Uterus.—The uterus is cut nearly transversely. It lies nearly altogether to the left of the middle line at this level. Its left border bulges into the left great sacro-sciatic foramen in a marked manner—for about $\frac{5}{8}$ in.

Its transverse measurement is $2\frac{3}{8}$ in., its antero-posterior $1\frac{7}{16}$ in. The cavity is a transverse slit $\frac{1}{16}$ in. wide and from $\frac{1}{16}$ to $\frac{1}{8}$ in. antero-posteriorly. The wall is a pink grey in colour with a reddish mottling due to small vessels cut through. The right lateral is a little thicker than the left lateral wall. The anterior and posterior walls are of almost the same thickness.

The anterior surface is more rounded than the posterior and is related to the paravesical and parametric tissues in its left half, and in its right to the lowest part of the placental mass.

The posterior wall is indented in its left half by the left edge of the sacrum. The right edge is continuous with the right parametric tissue (lower part of the broad ligament). The left edge is not so rounded as the right. It bulges into the left great sacro-sciatic foramen for $\frac{5}{8}$ in. and is continuous with the left parametric tissue, which it compresses to a marked degree.

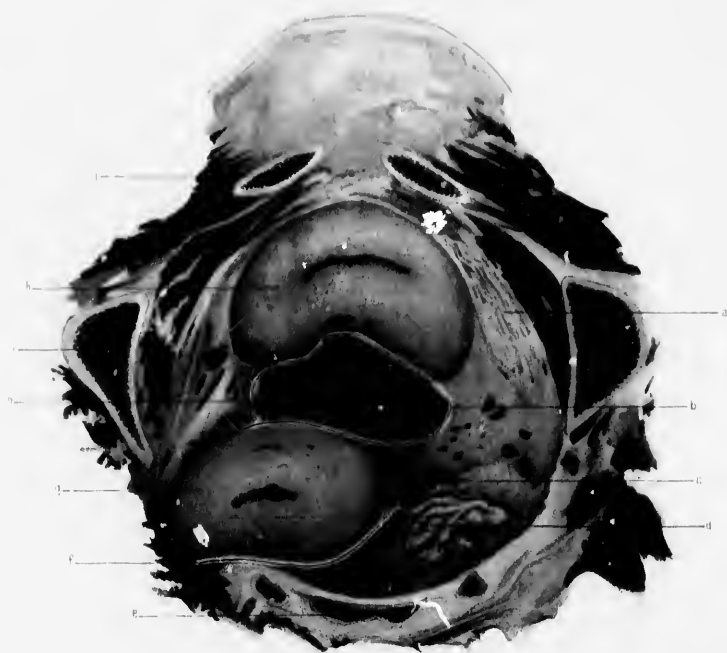
PLATE II.


FIRST TRANSVERSE SECTION.

(Reduced by $\frac{1}{2}$.)

- a.* Paravesical connective tissue containing fluid in its spaces.
- b.* Utero-vesical pouch of peritoneum partly closed by adhesions on the left side.
- c.* Right broad ligament.
- d.* Rectum.
- e.* Fourth sacral vertebra.
- f.* Pouch of Douglas.
- g.* Left side of uterus bulging into great sacro-sciatic notch.
- h.* Placenta and blood mass in primary sac, occupying utero-vesical pouch.
- i.* Ischium.
- j.* Descending ramus of pubes immediately below the symphysis.
- k.* Bladder.
- l.* Left broad ligament pushed against the pelvic wall by the uterus.







Bladder.—The bladder is cut through obliquely and presents a somewhat crescentic appearance with the cavity directed backwards. In the middle line in front it is $\frac{9}{16}$ in. from the symphysis; from the middle of each ramus it is $3\frac{1}{2}$ in. The right posterior extremity is $1\frac{5}{8}$ in. from the sacrum, its left $2\frac{1}{4}$ in. The left edge is nearer the left side of the pelvis than the right is to the right side.

The greatest thickness of the whole organ, from before backwards, is $1\frac{5}{16}$ in. The cavity is a curved transverse slit, $1\frac{1}{4}$ in. in length. The walls are of a pale grey pink colour; extending backwards on each side is the paravesical tissue continuous with that lining the pelvic wall, as well as with the parametric tissue.

The tissue between the bladder and pelvic wall is closely compressed, being due to the pressure of the placental and blood mass in front of the uterus.

The bladder is, as a whole, not exactly mesially situated, but somewhat rotated so that its left edge has moved a little forwards and to the left.

Rectum.—The rectum lies compressed behind the uterus and right broad ligament, against the sacrum. It extends almost across the latter, being moulded by the posterior surface of the uterus. A little more than half lies to the right of the middle line. The cavity is quite empty.

Peritoneum.—The utero-vesical pouch is almost entirely occupied by the lowermost part of the placental sac, to which it is attached by delicate adhesions which scarcely prevent the dark red mass from being lifted up from its bed. The width of the pouch is $1\frac{2}{3}$ in., of which only $\frac{1}{4}$ in. lies to the right of the middle line. (The greatest depth below the surface of the section is $\frac{1}{2}$ in. to the left of the middle line, where it is $\frac{5}{16}$ in.)

The pouch of Douglas lies nearly altogether to the left of the middle of the sacrum. It is a curved slit 2 in. wide. The left extremity lies in the great sacro-sciatic notch, nearly $\frac{1}{2}$ in. being to the left of the sacrum.

Ligaments, Connective Tissues, etc.—The right parametric tissue appears to be of greater transverse width than on the left side, but has a very much smaller antero-posterior measurement; it is looser in texture, its vessels gape to a greater extent, and are not so close together. These

differences are due to the stretching of the right parametrium and the compression of the left by the uterus pushed over to the left side of the pelvis. A considerable difference is also seen between the paravesical tissue of the right and left sides. That on the right side is wider, of looser texture, and contains a good deal of serum in the meshes of its tissue.

The right broad ligament is well marked, but appears thicker than normal, on account of its having been cut somewhat obliquely. On the left side a broad ligament can scarcely be distinguished. The distance between the utero-vesical pouch and the pouch of Douglas is much greater than on the left side. This is due to two causes, viz. the closure of the left side of the utero-vesical pouch by several adhesions, and also the stretching of the right ligament, due to the disturbance of the uterus.

Placental and Blood Mass.—This section passes through the great mass seen in the vertical mesial section, near its lower end. Roughly speaking, its form is triangular, the angles being rounded. It lies in the utero-vesical pouch, more than half being to the right of the middle line. Its greatest antero-posterior thickness is $1\frac{1}{8}$ in., and its transverse $2\frac{1}{2}$ in. It bulges for a considerable extent into the posterior wall of the bladder.

The wall of the sac on the left side is $\frac{1}{16}$ to $\frac{1}{8}$ in. thick; it has a fleshy appearance, and contains two large venous sinuses; as it passes to the right it becomes thin and more fibrous-looking. The mass is of a dark red colour, with paler areas towards the front and several small fibrous-looking patches. The mass can easily be lifted up from the peritoneal pouch in which it lies and to which it is partly attached by fine soft adhesions.

Second Transverse Section (Plate III.)

This passes, in front, through the middle of the symphysis; behind, through the 3rd sacral vertebra about its middle, and on the sides through the acetabula a little below their centres.

Uterus.—The uterus is cut almost at right angles to its long axis, but with a slight obliquity from behind downward and forwards. It lies almost entirely to the left of the middle line. Its transverse measurement is 3 in., of which only $\frac{2}{3}$ in. lies to the right of the middle line. The walls

PLATE III.


SECOND TRANSVERSE SECTION.

(Reduced by $\frac{1}{3}$.)

- a.* Symphysis pubis.
- b.* Upper part of bladder—above its cavity.
- c.* Peritoneal cavity.
- d.* Placenta and blood mass.
- e.* Right broad ligament, the anterior part containing the right round ligament.
- f.* Third sacral vertebra.
- g.* Space containing fluid in or within primary sac wall.
- h.* Fibrous adhesion between primary sac wall and parietal peritoneum.
- j.* Left broad ligament, the anterior part containing the right round ligament.
- k.* Vessels in parametric connective tissue of left side.
- l.* Uterine cavity.
- m.* Uterus.
- n.* Pouch of Douglas.







are pale grey pink, with a purplish mottling; and are darker towards the periphery. A few small closed vessels are seen in the posterior wall, and several in the side walls.

The anterior surface is slightly rounded, and in close contact with the concave posterior surface of the placental sac. The posterior wall is more irregularly curved, and is in close relation with the left side of the sacrum and the rectum.

The left edge is more rounded than the right, because of its being pressed against the tissues filling up the great sacro-sciatic foramen.

The Uterus measures in the middle line from before backwards $1\frac{1}{4}$ in. The anterior wall is slightly thicker than the posterior. The cavity measures $1\frac{1}{4}$ in. transversely and $\frac{1}{2}$ in. from before backwards; projecting into it on its left side is a red fleshy-looking bit of tissue. The wall measures on the left side $\frac{3}{4}$ in., and on the right $1\frac{1}{4}$ in.

Bladder.—Only a small portion of the upper part of the bladder is cut across—a short distance above its cavity. Its transverse width is $1\frac{5}{8}$ in., its antero-posterior in the middle line $\frac{1}{2}$ in. It gets narrower towards the sides. A little more than half lies to the right of the middle line. Its anterior surface lies in relation to the retro-pubic fat and connective tissue; its posterior surface to the placental sac, by which it is moulded.

Rectum.—The rectum lies in front of the sacrum and appears pushed somewhat to the right. Its walls are in apposition. On each side it is continuous directly with the connective tissue lining the pelvic wall. (Though the width of the cavity cut across is only $\frac{3}{4}$ in., it is found to extend for some distance to the right just below the level of the section.)

Peritoneum.—The utero-vesical pouch is occupied by the placental and blood mass. Slight adhesions exist between the sac wall and the peritoneum of the pouch on the right side opposite the right acetabulum for a distance of $2\frac{7}{8}$ in.; and on the left side, from the left border of the uterus to opposite the middle of the left acetabulum. The most anterior of these latter adhesions is a firm band $\frac{1}{4}$ in. in diameter.

The pouch of Douglas is $3\frac{3}{4}$ in. in width. Its right extremity lies behind the right broad ligament, its left is partially obliterated by adhesions; several of the latter also connect the uterus and rectum.

Ligaments, Connective Tissue, etc.—The right broad ligament extends outwards from the uterus for half-an-inch, and then joins the connective tissue of the side wall of the pelvis. Its thickness is on the average about $\frac{3}{8}$ in. A considerable portion of this thickness is round ligament, which passes outwards and forwards and upwards. (Its outer end, as well as that of the left side, can be traced above the level of this section.) The anterior peritoneal layer turns gradually forward to form the parietal layer on the side wall of the pelvis. It is in close relation to the placental and blood mass.

Immediately external to it, as far round as the bladder, the connective tissue is loose and contains a good deal of serum in its spaces. It appears somewhat stretched. External to the broad ligament are seen several partly filled blood-vessels.

The posterior peritoneal layer turns sharply to the left of the posterior wall of the pouch of Douglas.

On the left side the broad ligament, with the round ligament, is about the same size as the right, but is pushed by the uterus against the wall of the pelvis, so that its direction is not directly outwards as on the right side, but forwards and outwards. Several sinuses are seen adjacent to the uterus, but they are nearly closed by the pressure of that organ. No serum-filled spaces are seen in the extra-peritoneal tissue on this side of the pelvis; its structure is more compact than on the other side.

Placental and Blood Mass.—This mass occupied a large portion of the pelvic cavity in front of the uterus. It measures transversely about 4 in. and antero-posteriorly, in the middle line, $2\frac{7}{16}$ in. The right border is $\frac{1}{2}$ in. from the pelvic wall, opposite the centre of the acetabulum. The left border is $\frac{5}{16}$ in. from the bony wall, the extra-peritoneal tissue being compressed between. The longest diameter of the mass is about parallel with the transverse diameter of the pelvic cavity and a little in front of it.

The mass consists of two parts, viz. a liquid and a solid portion. The former is the dark green mass lying to the left and front. It is a cyst either in the wall of the sac or immediately internal to it. Thin fibrous striae run across it. Its length is $1\frac{5}{16}$ in. and its greatest width $\frac{9}{16}$ in. In front it moulds the posterior surface of the bladder.

(On probing its cavity, it is found to end blindly, half-an-inch below the surface, being directed downwards and backwards.)

The solid portion of the mass is somewhat pear-shaped and consists of two parts, which differ both in colour and consistence. One of these is the rounded dark red portion lying mostly to the right of the middle line. It consists largely of placental tissue torn up by recently effused and partly organised blood. In it one or two small fibrous-looking nodules are seen. The anterior portion immediately under the capsule has more the appearance of placental tissue, the blood not having quite torn it up in its whole extent.

The smaller portion forming the extreme left of the mass is a light reddish-brown fleshy mass. It is placental, and is continuous with the tissue lying to the right.

The sac wall on the left is $\frac{1}{8}$ in. thick and of a fleshy fibrous appearance; as it passes to the right it becomes thinner, but is very distinct in its whole extent. Opposite the anterior edge of the left acetabulum is a tongue-like projection of the wall extending backward for an inch.

Third Transverse Section (Plate IV.)

This passes through the junction of the upper fourth and lower three-fourths of the symphysis pubis in front, and through the junction of the 1st and 2nd sacral vertebræ behind. The acetabula are divided on each side.

The uterus and bladder lie below the level of this section.

Rectum.—The rectum lies in front of the body of the vertebræ and measures $1\frac{7}{8}$ in. transversely, a little more than $\frac{1}{2}$ in. to the left of the middle line. The right border is rounded and covered with peritoneum; the left border is directly continuous with the extra-peritoneal connective tissue on the pelvic wall. Its greatest antero-posterior thickness is in the right half, and this part moulds the placental and blood mass.

Right Fallopian Tube and Ovary.—The fimbriated end of the right tube lies free in the peritoneal cavity external to the rectum, in a triangular space bounded by the placental sac in front, the ovary behind, and by the rectum on the left. It is free and can be raised.

Behind it lies the ovary cut across. It extends outwards from behind

the outer part of the rectum for $1\frac{3}{4}$ in., and ends internal to the sacro-iliac joint where it is attached to the broad ligament which passes to the pelvic wall immediately in front of this joint. It lies, therefore, compressed between the broad ligament and the pelvic wall, its free border looking towards the rectum.

Left Tube and Ovary.—The tube is not seen (*vide* p. 30). The left ovary is the pink grey elongated and somewhat bean-shaped mass which lies $\frac{3}{4}$ in. internal to the anterior end of the left sacro-iliac joint and apparently continuous with the great placental and blood mass. The whole of the outer surface lies free in the peritoneal cavity save in front, where a fleshy band $\frac{1}{2}$ in. in width passes across the cavity to the wall of the sac which is here attached by numerous adhesions to the side wall of the pelvis. The ovary can be lifted up somewhat. Below the level of this section it passes downwards and outwards.

Although it is attached to the placental sac, it can scarcely be said to enter into its formation. The latter passes in front of it and the ovary can be moved upon it.

Peritoneum.—The peritoneal cavity lies external to the placental and blood mass. It is free from adhesions in the following places:

- A.—On the front and left side from a point $\frac{3}{4}$ in. to the right of the middle line round to within an inch of the left sacro-iliac joint;
- B.—On the right side from a point nearly opposite the front of the right acetabulum around nearly to the middle line posteriorly;
- C.—Opposite the outer surface of the left ovary.

The adhesions on the front and right side of the sac are very recent and are easily broken down. Those behind and on the left side are older and more fibrous.

Ligaments, Connective Tissue, etc.—The right broad ligament is seen, cut across, lying in front of the ovary. Its outer end joins the pubic wall immediately external to the right sacro-iliac joint. The attachment of the ovary to the posterior surface is seen $\frac{1}{2}$ in. internal to the joint. It passes inwards and backwards for $1\frac{1}{4}$ in., and is continuous with the fimbriated end of the Fallopian tube which lies external to the rectum. In front it is in close relation to the wall of the placental and blood sac.

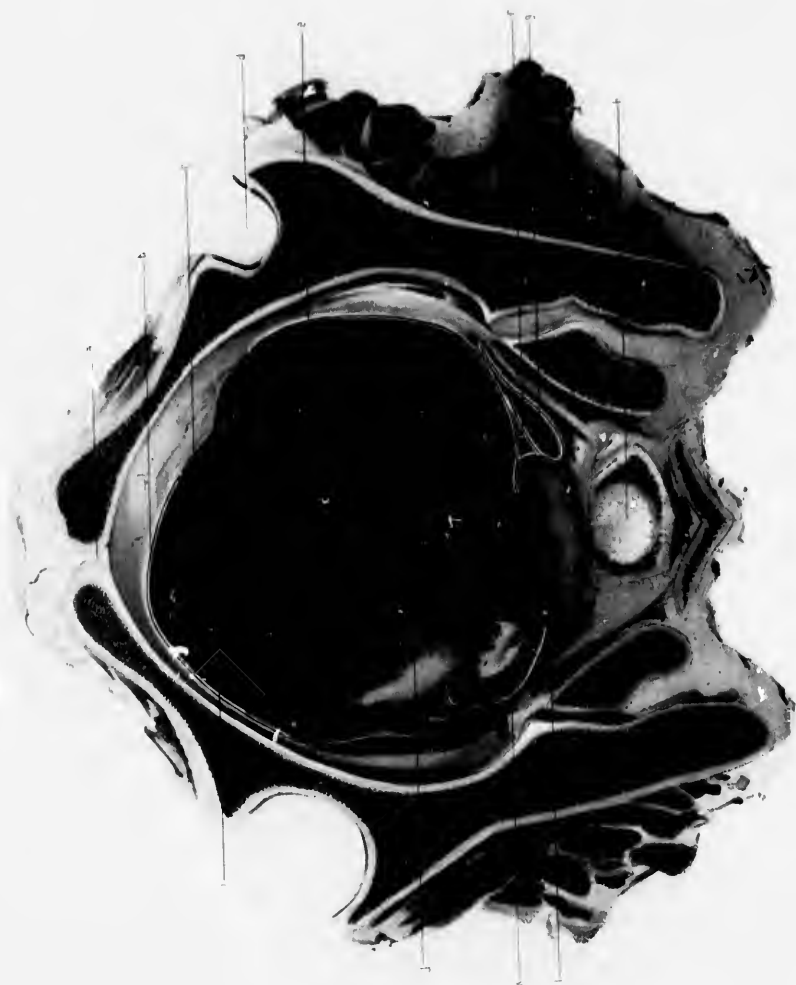PLATE IV.


THIRD TRANSVERSE SECTION.

(Reduced by $\frac{1}{2}$.)

- a.* Symphysis pubis.
- b.* Cavity of peritoneum.
- c.* Adhesions between primary sac wall and parietal peritoneum.
- d.* Right acetabulum.
- e.* Placenta and blood mass.
- f.* Outer end of right Fallopian tube looking upwards.
- g.* Right ovary.
- h.* Cartilage between first and second sacral vertebrae.
- i.* Wall of primary sac.
- j.* Pale firm mass resulting from change in old haemorrhage into placenta.
- k.* Left ovary attached to wall of primary sac.
- l.* Rectum.







The left broad ligament cannot be distinctly made out. It is in front of the ovary and matted to the side wall of the pelvis as well as to the surface of the placental sac by dense adhesion.

The left round ligament is seen cut across obliquely in the extra-peritoneal connective tissue. It is continuous behind with the broad ligament and mass of adhesions in front of the ovary.

The *extra-peritoneal* connective tissue is more compressed on the left than on the right side, and is therefore more compact. In front, to the right of the middle line, a quantity of greenish serum lies in spaces of considerable size, immediately external to the peritoneum.

Placental and Blood Mass.—It occupies the great part of the pelvic cavity. All other pelvic structures are pressed by it against the bony wall, especially on the left side. Its greatest antero-posterior measurement is $\frac{1}{2}$ in. to the left of the middle line, where it is $4\frac{3}{16}$ in.; in the middle line it is 4 in. An inch to the right of this it is $3\frac{5}{16}$ in. The greatest transverse measurement is $4\frac{1}{16}$ in. and is in line with the transverse diameter of the pelvic cavity. In its right half is of a dark red colour with paler areas scattered through it; towards the front the tissue is of a lighter red fleshy colour. In the left half is seen a large solid yellowish-white fibrous mass lying internal to the sac wall. From the inner end of this mass several small fibrous bands pass inwards; one of these, $\frac{1}{4}$ in. thick, passes forwards into the placental tissue. In front of it is seen red-brown placental tissue continuous with that forming the anterior part of the right half of the mass. In front of this is seen a mass of greenish fluid $\frac{1}{2}$ in. in diameter, lying internal to the sac wall.

The wall of the sac varies in appearance in different parts of the section. Immediately in front of the ovary it is, for a distance of half-an-inch, so united with the wall of the pelvis by adhesions that its thickness cannot be accurately defined. In front of this it is a distinct fleshy-looking band $\frac{3}{16}$ in. thick. As it passes forward it gets thinner, and a little to the left of the middle line it is only a strong fibrous membrane. This can be traced around as far as the middle line posteriorly, when it becomes thicker and passes in front of the ovary.

Fourth Transverse Section (Plate V.)

This passes through the promontory behind, and in front goes immediately above the symphysis. On each side the wings of the ilium are cut through.

Rectum.—The rectum extends $1\frac{3}{4}$ in. from the middle line to the right. It is closed and firmly compressed against the sacrum by the placental and blood mass.

Right Ovary and Right Broad Ligament.—Lying external to the rectum is a small bit of tissue $\frac{1}{2}$ in. long and $\frac{1}{8}$ in. thick. Its inner end is free in the peritoneal cavity; at its outer it joins the side wall of the pelvis; it is a small bit of the highest part of the right ovary with a piece of the right infundibulo-pelvic ligament.

Peritoneum.—The peritoneal cavity is occupied by the placental and blood mass. Adhesions exist in the following places between the sac wall and the parietal peritoneum:

- (a) Opposite the left anterior corner of the mass for an inch;
- (b) Opposite the right anterior corner for $2\frac{1}{2}$ in.;
- (c) Opposite the left posterior corner extending from the left border of the rectum around to the left for 4 in.; to the left of the sacrum the adhesions are denser than elsewhere.

Placental and Blood Mass.—Its greatest transverse measure is $5\frac{5}{8}$ in. Its greatest antero-posterior $4\frac{5}{8}$ in. Its wall is well marked. From the posterior angle it extends forwards as a pale grey pink band $\frac{1}{5}$ - $\frac{3}{8}$ in. in width; it gets thinner towards the middle line, and becomes a thin fibrous membrane on the right and posterior surfaces of the mass. In the thick portion are seen several closed sinuses, the most anterior of which are of considerable size. Internal to this capsule two areas of different colour are seen:


- (a) *Pale Area.*—This is irregularly crescentic in shape and lies immediately under the capsule on the left and posterior walls. It extends from an inch behind the posterior wall backwards as far as the posterior end of the right lateral wall. The outer surface is smooth and lines the capsule; the inner is irregular and sends

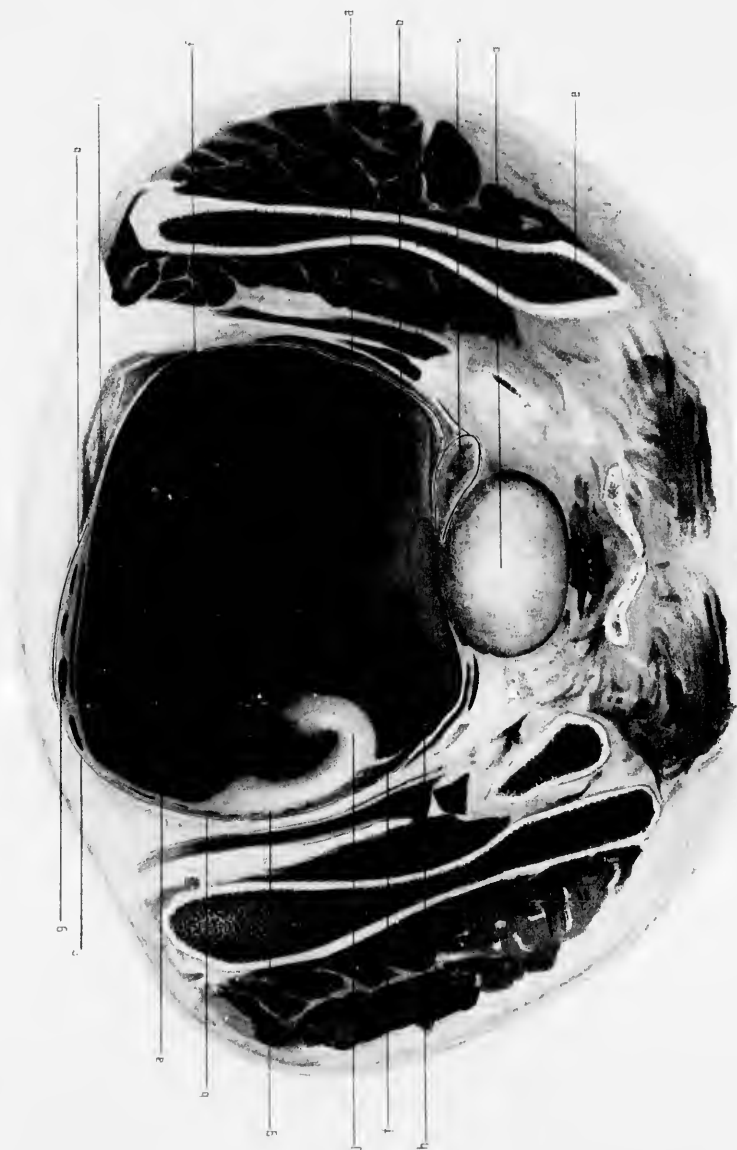PLATE V.

FOURTH TRANSVERSE SECTION.

(Reduced by $\frac{1}{3}$.)

- a.* Placenta and blood mass.
- b.* Peritoneal cavity.
- c.* Rectum.
- d.* Promontory.
- e.* Wing of ilium.
- f.* Adhesions between primary sac and peritoneum.
- g.* Wall of primary sac showing closed sinuses.
- h.* Space containing fluid partly in and partly within primary sac wall.
- i.* Space containing fluid in extra-peritoneal tissues.
- j.* Pale firm mass resulting from old hæmorrhage into placenta.







several prolongations into the dark area. It is a solid yellowish fibrous-looking mass slightly blood-stained in its posterior half. Immediately to the left of the vertebra its structure is interrupted somewhat by a mass of serum across which these membranous bands extend so as to form a large number of loculi.

- (b) *Dark Area*.—Two parts can be distinguished in this. One, continuous in front with the pale area, is brownish red and is mostly placental tissue. At the left extremity it is $1\frac{1}{2}$ in. thick. As it passes to the left it gets thinner. Its inner surface is considerably broken up by blood. The rest of the mass is of a dark red colour with paler areas scattered through it, and consists chiefly of poured out blood with débris of placental and fibrinous masses.

Fifth Transverse Section (Plate VI.)

This passes through the lower part of the intervertebral disc between the last two lumbar vertebrae behind and the anterior abdominal wall in front, $4\frac{3}{8}$ in. above the pubes. The abdominal cavity in its central part is occupied by the placental and blood mass, the intestines being pushed to each side.

Placental and Blood Mass.—The capsule in front is a fleshy band $\frac{1}{6}$ in. thick. It extends from the pale triangular area on the left of the great mass around the front, becoming thinner until it is half-way around the right side of the mass. From this point it passes backwards for a distance of two inches, and is split up into a number of blood-vessels (probably vessels of cord running in the wall and cut obliquely). Beyond this it is much thinner over the left half of the posterior surface, and opposite the left posterior corner of the mass it cannot be traced because of its incorporation with the fibrous tissue internal to it, as well as with the parietal peritoneum by firm adhesions.

The great mass which fills the capsule consists of two parts:

1. An anterior kidney-shaped part separated from the posterior by a fine slit (seen as a black line in the section), which is formed by a dipping downwards of the capsule and amnion from the uppermost end of

*

E

the mass. It forms the greater portion of the mass. At its left extremity is a triangular yellowish-grey area, partly solid and partly spongy in appearance. This is continuous with a fibrous-looking pink-stained band $\frac{1}{4}$ in. thick which passes to the right and joins an oval area with a pink-stained circumference and yellow centre (in which is a mass of dark blood clot, which resembles considerably a laminated blood clot). From the anterior surface of this pale mass prolongations extend into the dark tissue lying immediately in front of it. The dark area is striated transversely in its anterior half (laminated blood clot), while the posterior half looks more solid, having several pale areas scattered through it.

2. A posterior part lying immediately in front of the spine especially on the left side. It is pear-shaped, the large end being to the left side; it lies moulded upon the spine. It is pale grey brown, with several blood-stained patches scattered through it.

Towards the left it is more solid than on the right side, where it has a somewhat spongy appearance. Immediately external to the large end is seen a band of some thickness which consists partly of capsule and partly of adhesions. In it several vessels are divided belonging to the capsule.

Behind each end of the posterior surface of the great mass is seen a mass of dark green fluid with numerous bands running through it. They are probably serous collections in the peritoneal cavity formed in connection with the adhesive processes taking place.

The Amniotic Sac.—This is really peritoneal cavity behind the altered great omentum. Its cavity is a closed slit which can be traced from opposite the middle of the section of the left ilium forwards in front of the great mass and around nearly to the posterior wall; here, however, adhesions occur on the right side and partly close it. In front of the pear-shaped mass is a curved slit running transversely. It is also amniotic cavity dipping into the mass from the upper end. Behind the pear-shaped body, for a space of three inches to the left of the middle line, is free peritoneal cavity. There is no amnion lining this part.

Beyond this, for a considerable distance on each side, adhesions have taken place between the sac wall and peritoneum. In front of these

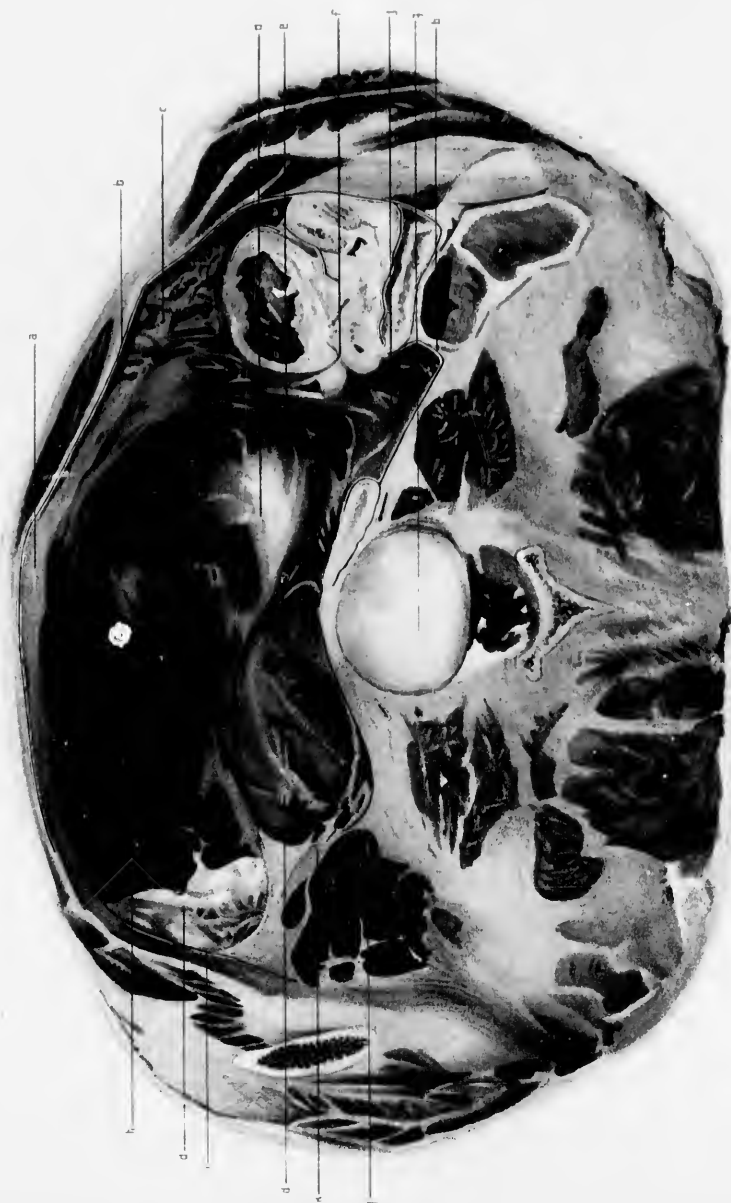PLATE VI.

FIFTH TRANSVERSE SECTION.

(Reduced by $\frac{1}{3}$.)

- a.* Altered great omentum forming anterior wall of secondary sac in which foetus lay.
- b.* Peritoneal cavity.
- c.* Great omentum more normal in appearance.
- d.* Pale fibrous mass resulting from changes in old placental hæmorrhage.
- e.* Large vessels of umbilical cord cut obliquely, as they run from above downwards and to the left to enter the placenta, being at the level in close union with the wall of the primary sac.
- f.* Intestines closely packed in lateral regions of abdomen and matted together by adhesions.
- g.* Junction of fourth and fifth lumbar vertebræ.
- h.* Placenta and blood mass.
- i.* Secondary or amniotic sac cavity which contained the foetus.
- j.* Fluid in spaces among adhesions matting intestines together.
- k.* Wall of primary sac greatly thickened by adhesions.







adhesions the amniotic sac wall is chiefly formed by the altered great omentum. On the right side the intestines are packed in the right lumbar region, somewhat matted together. The anterior large coil is on the right side of the transverse colon. From its anterior surface is seen extending a wide band of tissue, solid in its inner third and of loose texture in its outer part. This is great omentum cut obliquely. Its outer part has more of the normal structure, while the inner part is largely changed into fibrous tissue forming the wall of the sac in which the child lay. Several vessels are seen in the wall. Immediately to the right of the middle line the wall presents a double appearance, one part lying as a tongue-like process within the main part of the wall. This is caused by a fold of the wall having been cut across. To the left of the middle line the wall becomes thinner, $\frac{3}{16}$ in., being cut more transversely. It is nearly all fibrous, the outer fatty appearance being seen only for a short distance to the left of the middle line.

As it passes around the left side it becomes attached to the side wall so that the peritoneal cavity outside it is obliterated at this part. It is almost connected by adhesions with the left posterior corner of the placental and blood mass.

Peritoneal Cavity.—It can be traced among the intestines, lying in the right lumbar region, but is in places obliterated by adhesions. Thence it passes forwards, internal to the abdominal wall and external to the great omentum, as far as a point 4 in. to the left of the middle line. Beyond this it is entirely closed, the great omentum (amniotic sac wall) entering into close union with it. To the right of the vertebra the peritoneum can be traced partly around the coil of intestine lying against it. It can also be traced for a distance on the left side of the spine, but immediately in front of the vertebra it is closed by adhesions.

Sixth Transverse Section (Plate VII.)

This passes through the intervertebral cartilage between the 3rd and 4th lumbar vertebrae behind, and in front through the anterior abdominal wall just below the level of the transverse colon.

The intestines are lying in each lumbar region chiefly in the right.

They are somewhat matted together, so that the peritoneal cavity cannot easily be traced among them. The wide extent of the amniotic sac is seen. It is bounded on each side by intestines; behind, by intestines to the right of the spine, and by the posterior abdominal wall on the left; in front by the great omentum which is, in great part, solid and pinkish grey in colour. Opposite the vertebra several pieces of the wall are seen. The wall was considerably folded at this point, and so has been divided in several places.

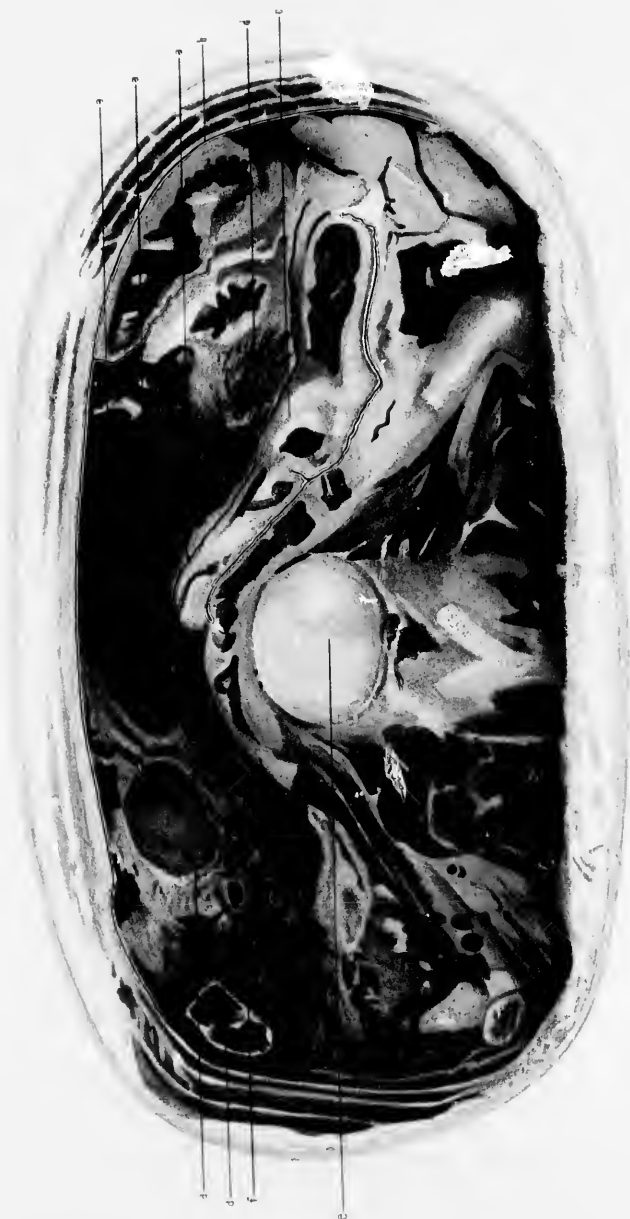PLATE VII.


SIXTH TRANSVERSE SECTION.

(Reduced by $\frac{1}{3}$.)

- a.* Folding of the altered great omentum.
- b.* Peritoneal cavity.
- c.* Intestines.
- d.* Great omentum more normal in appearance.
- e.* Junction of third and fourth lumbar vertebrae.
- f.* Amniotic cavity.







CHAPTER V

NAKED EYE DISSECTIONAL EXAMINATION

Uterus.—The uterus is retro-placed, slightly anteflexed, and almost entirely in the left half of the pelvis. Its long axis has a slight inclination from below upwards and to the right. The highest part of the uterus is the fundus, which lies $1\frac{5}{8}$ in. below the brim, or $\frac{3}{8}$ in. higher than the highest part seen in the vertical mesial section; the lowest part is the anterior lip of the cervix, which is on a level with a line joining the tip of the coccyx and the inferior margin of the symphysis; its entire length is $3\frac{7}{8}$ in. The organ is quite fixed in position, there being numerous adhesions between the anterior surface and the placental sac, and between the posterior surface and the pelvic wall. The adhesions are most numerous around the uterine end of the left Fallopian tube.

The cervix is soft and flattened from before backwards, the anterior lip being lower than the posterior by $\frac{3}{8}$ in. The body is of much firmer consistence. The os externum is patulous, easily admitting the end of the index finger.

The anterior fornix is very shallow, being only $\frac{1}{4}$ in. in depth; the posterior is nearly 1 in. in depth. The highest part of the latter fornix is on a level with a line joining the cartilage between the 4th and 5th sacral vertebræ with the inferior margin of the symphysis.

The left lateral fornix is much narrower than the right, the vaginal portion of the cervix lying almost against the left side of the vagina.

Vagina.—The vagina in its upper part is not symmetrically placed. More than half lies to the left of the middle line. Its walls are in apposition, and show the rugous condition in their whole extent. They are of considerable thickness and deeply blood-stained.

The perineal body is well formed and is deeply congested.

Right Fallopian Tube.—The right tube starts from the left border of the uterus, close behind the round ligament, about $2\frac{1}{5}$ in. below the level of the brim and opposite the junction of the 2nd and 3rd sacral vertebrae.

It runs outward for $1\frac{1}{2}$ in. and then curves upwards and inwards for about $2\frac{1}{4}$ in., ending immediately external to the rectum, the fimbriated end lying upon the uterine end of the tube.

It is, for a considerable extent, adherent to the posterior wall of the placental and blood sac and the right ovary, but the adhesions are not very firm. It is somewhat larger than the tube in the non-pregnant woman.

In the vertical mesial section it is seen cut across in the wall of the uterus.

Right Ovary.—This body lies behind the folded right Fallopian tube and against the posterior pelvic wall external to the rectum. Its length is about $1\frac{5}{8}$ in., its width $\frac{7}{8}$ in., and its average thickness $\frac{1}{4}$ in. Its highest point is immediately below the level of the brim nearly opposite the right sacro-sciatic joint; from this point it slopes downwards and inwards. Its free border looks inwards, its surfaces are anterior and posterior.

Left Fallopian Tube.—The left tube starts from the left side of the uterus opposite the junction of the 2nd and 3rd sacral vertebrae. It is larger than the uterine end of the right tube and thickens greatly as it passes upwards and forwards for half-an-inch immediately above the left round ligament. It can be traced no further as a tube, but opens out to form the wall of the sac which contains the placental and blood mass. The sac wall is thickest where this opening-out takes place, and it is connected to the surrounding structures—viz. uterus, ovary, rectum, and pelvic wall—by numerous adhesions. No trace of the fimbriated end of the tube can be found. It is probably lost among adhesions.

Left Ovary.—This body lies upon the outer part of the fundus behind the placental and blood mass and internal to the origin of the tube. Its

free border and outer surface are partly attached by adhesions to the posterior pelvic wall; its inner surface, which looks downwards, inwards, and forwards, is joined by bands to the outer part of the left half of the fundus.

Its anterior and upper part is in close contact with the wall of the placental sac.

Round Ligaments.—Both can be traced in almost their whole extent. The left is a little higher than the right.

Umbilical Cord.—The outer end lies free in the amniotic sac, above the level of the placental mass. It passes to the right and then disappears in the wall of the sac at the level of the sixth transverse section, where some of its vessels are seen cut obliquely and transversely.

These vessels pass inwards in relation to the posterior part of the placental mass in the region of the most fibrous portion in the mass.

Amniotic Sac.—Its vertical extent has already been noticed. Its capacity has been greatly altered by post-operation changes, the chief of these being the distension of the placental sac upwards into the lower part of the abdomen by blood extravasation into the placental tissue. Its upper end, when the walls are separated, is dome shaped. It lies behind the pyloric end of the stomach, a little more than one half being in the left half of the abdomen.

Below the stomach the anterior wall consists of transverse colon and great omentum. The posterior wall and sides are formed by parietal peritoneum, intestines, and their mesentery considerably matted together in several places, most of all on the right side.

CHAPTER VI

MICROSCOPIC EXAMINATION

(Plates VIII.-XI.)

From each of the slabs into which the body was divided small portions were removed, carefully hardened in alcohol, and then prepared for microscopic study by means of the paraffin method. I have devoted my attention mostly to the wall of the placental sac, the placenta, and the secondary or abdominal sac, twenty different portions of these structures being examined. Besides, I have also examined the condition of the ovaries, the uterus, and the Fallopian tubes.

Placental Sac.—This completely surrounds the placenta and the recently poured out mass of blood. Though to the naked eye it is so intimately connected with the fibrous masses internal to it, and with adhesions outside, that it cannot in certain places (*e.g.* Trans. Sec. VI, left side) be distinguished, microscopically it can be traced all over the outer part of the mass. Vertically it extends from the bottom of the utero-vesical pouch as high as the lower margin of the 4th lumbar vertebra.

It varies in thickness; in general it may be said that the left half of the wall is thicker than the right half. In the former part the thickness is greater, and in the latter part less than that of the normal Fallopian tube wall.

At the level of Trans. Sect. II., on the left side, the sac wall consists of thick bundles of connective tissue with cells, for the most part spindle-shaped, but also oval, lying in spaces between them. In the inner part of the wall, the fibres are considerably larger than those of ordinary connective tissue.

PLATE VIII.

FIG. 1.

Section through right side of primary sac wall and canalised fibrin internal to it. L. P.

- a.* Dense fibrous tissue of wall.
- b.* Fibrin deeply stained.
- c.* Fibrin faintly stained.
- d.* Muscle in wall.

FIG. 2.

Section through left side of primary sac wall where it consists of an outer thin dense layer connected to a middle thick layer and an inner loose layer. The outer and middle portions are connected by loose connective tissue. H. P.

- a.* Muscles cut in various directions.
- b.* Dense fibrous tissue.
- c.* Loose connective tissue.

FIG. 3.

Section through anterior wall of primary sac on the left of the middle line, and through condensed canalised fibrin internal to it. H. P.

- a.* Amniotic layer.
- b.* Condensed fibrin deeply stained.
- c.* Loose connective tissue of wall.
- d.* Vessels of wall obliquely cut.
- e.* Fibrin faintly stained.



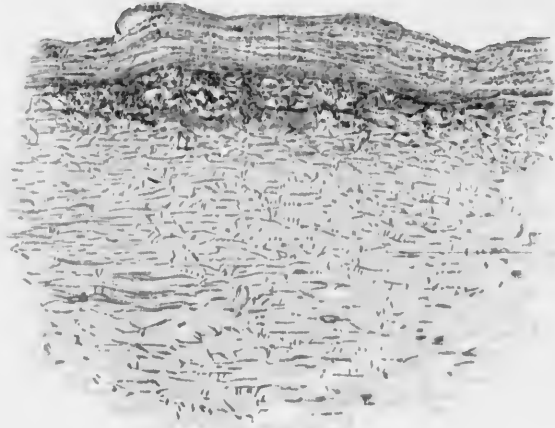


Fig. 2.

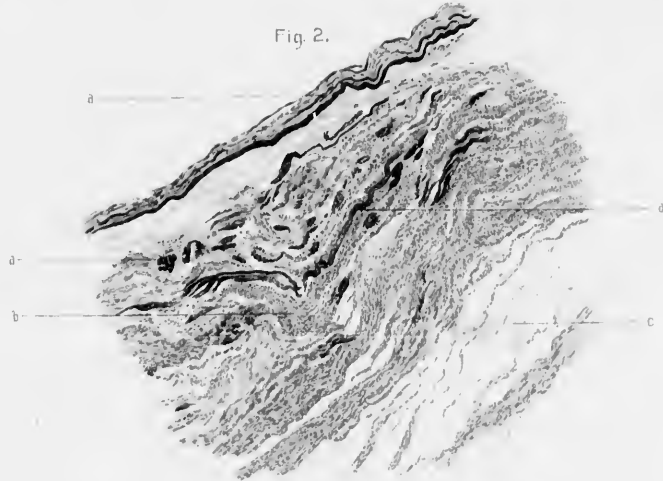
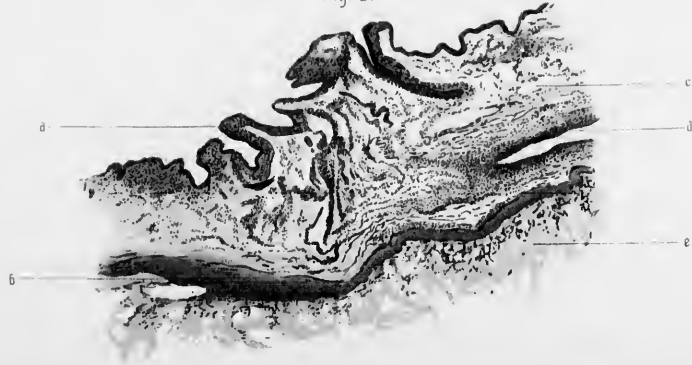

Fig. 3.





Here and there, especially towards the inner part, are seen groups of muscle fibres, some cut transversely, others longitudinally, and others obliquely. Internal to the muscle the fibrous tissue is, in parts, very compact, and contains small elastic fibres. In the deeper layers of the wall are seen several sinus-like spaces containing blood as well as several small arteries. Extending in from the wall are fibrous trabeculae containing vessels. On the right side, at the same level, the wall is thinner, and contains a much smaller proportion of muscular tissue.

On both sides the peritoneal surface is quite smooth save opposite the acetabulum, where it is adherent by a fibrous adhesion to the pelvic wall.

At the level of Trans. Sect. III., on the left side, the wall has much the same appearance as at the above-described lower level, being, however, thicker and containing more muscle. On the right side it is thinner, the fibrous tissue of the larger part of the middle portion being loose in texture; at one part the outer surface is connected to the pelvic wall by a number of rounded cells, the tissue of the sac wall immediately adjacent containing numerous cells of a similar nature.

At the level of Trans. Sect. IV., on the left side, the capsule is still thicker, containing much more muscle than any other part of the wall. The muscle fibres are cut for the most part longitudinally and transversely; some are also cut obliquely. The connective tissue is compact. A large number of arteries and veins are cut through. The former have well-marked muscular walls, the *intima* being very thin.

On the right side the wall contains a much smaller proportion of muscle.

At one part there are many proliferated connective tissue corpuscles, the outer surface opposite being covered with rounded and oval cells, which connect it to the pelvic wall. At the level of Trans. Sect. V., the thickest portion of the wall is the posterior part of the left side, where there are old adhesions between it and the abdominal wall; the rest of the wall is thinner than in any of the parts yet examined. It contains very little muscle. The fibrous tissue is arranged in three layers: an inner one, compact, and forming the chief part of the wall, a middle loose layer, and a thin compact outer layer. The latter is covered with a single layer

of cubical epithelium, and is the amnion adherent to the outer part of the sac. In some places the amnion is smooth, and in others wrinkled. Some of the tissue under the amnion may be chorionic in nature, but it is impossible to settle this doubt.

At the top of the mass, opposite the fourth lumbar vertebra, the capsule is almost entirely fibrous, consisting of an inner layer and a thinner outer one covered with amnion.

Summing now up the chief facts learned regarding the nature of the sac, we find :

- (a) That the increase in the size of the tube accompanying the growth of the placenta is due both to an increase in the connective tissue and muscle.
- (b) That the proportion of these two elements to one another is the reverse of what is found in the normal tube; the connective tissue is greatly in excess.
- (c) That the connective tissue is more compact for the most part, and the fibres in many places larger than in the normal tube.
- (d) That the normal arrangement of the muscle in two layers is here completely altered, the fibres being found in groups, which run in various directions.
- (e) That there is enormous enlargement of the vessels opposite the placental site, and that large sinuses are found chiefly in the deep layers of the wall.
- (f) That trabeculae, containing vessels, extend into the placenta from the wall.
- (g) That the epithelium lining the normal tube no longer exists, so that no structures are found corresponding to the remains of the glands found in the inner part of the wall of the pregnant uterus.
- (h) That only a few decidual cells are found in the primary sac wall.

We cannot speak with certainty as to the hypertrophy of the muscle fibres.

(According to Langhans they become longer and thicker in cases of tubal pregnancy.)

The Placenta.—The exact size and shape of this structure before it

PLATE IX.

FIG. 1.

Section through great omentum where it forms anterior wall of secondary sac. L. P.

- a.* Posterior or amniotic surface.
- b.* Posterior part consisting of greatly condensed fibrous tissue.
- c.* Anterior part consisting of loose connective tissue with abundant masses of fat.
- d.* Outer surface in relation to anterior abdominal wall.

FIG. 2.

Section through posterior wall of stomach as it enters into the formation of anterior wall of secondary sac. L. P.

- a.* Posterior or amniotic surface.
- b.* Dense fibrous tissue closely connected to subjacent muscular wall.
- c.* Loose fibrous tissue and fat.
- d.* Muscularis mucosæ.
- e.* Remains of glandular lining of stomach.

FIG. 3.

Section through wall of primary sac and trabeculæ extending from it into a mass of fibrin. L. P.

- a.* Amniotic surface.
- b.* Outer part of wall.
- c.* Deeper and denser part of wall with a few muscular fibres.
- d.* Trabeculæ from wall broken across by old hæmorrhage.
- e.* Faintly stained fibrin.
- f.* Villi surrounded by partly altered blood.

Fig. 1.

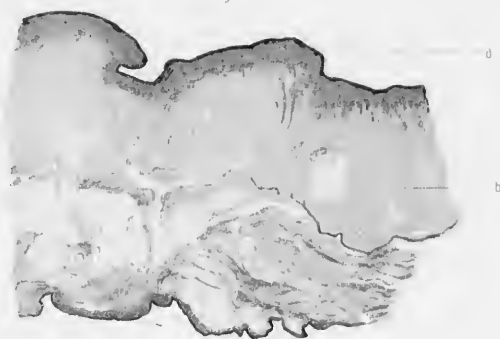


Fig 2.

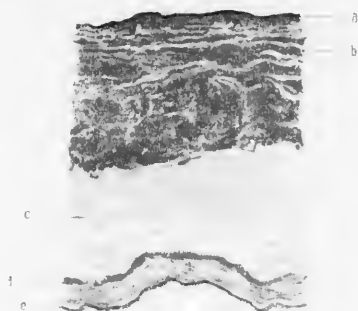
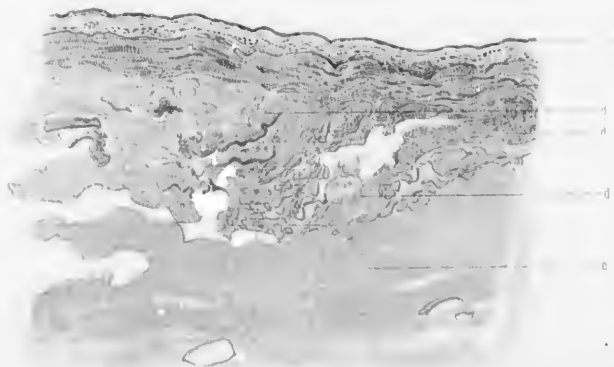

Fig. 3.





became altered by the extravasation of blood throughout its substance we are unable to state. At the operation it was seen in its sac as a discoid mass on the left side of the pelvis reaching above the brim, occupying, also, partly the posterior and partly the anterior wall left of the middle line.

In the cadaver, however, we have to do with placental tissue so torn up by blood extravasation that it is no longer a discoid mass, but an irregularly rounded mass which completely fills up the pelvis. Nowhere can we find a piece of placental tissue which allows us to make a section from the foetal to the maternal surface. We are unable accurately to give the extent of the tube wall to which placenta was attached.

Roughly speaking, the placenta occupied the left two-thirds of the dilated tube.

The detailed examination of the mass is as follows: At the level of Trans. Sect. II., in the left half, is a large amount of fibrin in the form of a network surrounding many villus stems, villi, and trabeculae of various sizes. The latter consist for the most part of masses of dense connective tissue, the cells, oval or spindle-shape, lying singly or in rows between the closely packed bundles. Several vessels are seen, some of which appear as little more than channels lined by a single epithelial layer, others, however, having a distinct muscular wall, outside which are numerous connective tissue cells, while inside scarcely any intima is visible; no elastic fibres are visible. A few trabeculae pass inwards from the tube wall for a distance and are then torn across.

Farther to the right the fibrin is very granular in nature, evidently breaking down. Trabeculae are pushed against the wall.

Farther over are masses of more normal placental tissue, consisting of villi, villus stems, and a few trabeculae. Surrounding them is breaking-down blood, in which very many leucocytes are seen.

The villi have much the appearance of those in a normal placenta. There is an external single layer of cubical epithelium, internal to which is loose connective tissue containing capillary spaces.

At the level of Trans. Sect. III., on the left side, there is a large mass of canalised fibrin, with crystals of blood pigment, and containing villi and villus stems of denser fibrous tissue than is found in the more normal ones.

On the right side is more recently poured out blood surrounding villi and trabeculae as before. Under the capsule and around the large trabeculae and villus stems where large blood masses occur, there is a great exudation of leucocytes (or great proliferation of connective tissue cells) into the latter. Altered blood pigment is also seen in several places.

At the level of Trans. Sect. IV. much the same conditions are found.

At the level of Trans. Sect. V. there is a much greater amount of solid canalised fibrin on the posterior wall—that part lying behind the amniotic layer; in its substance are seen many altered villi and villus stems. The vessels of the latter are almost closed by the increase in dense fibrous tissue which has taken place.

In fact it seems as if in this part the placenta was destroyed in its entire thickness.

From the inner part of the wall covered with amnion, viz. the anterior, trabeculae of various sizes extend inwards.

This is the only place where we can get a section completely through the placenta, but the structure is altogether altered by the old blood extravasations.

Summing up the most important facts regarding the placenta, we find:

- (a) That sections of the unaltered placenta tissues resemble closely those of normal tissue, consisting of villi and villus stems surrounded with blood. The relations and origin of these blood spaces cannot be made out.
- (b) Many villi are seen next to the capsule.
- (c) Trabeculae pass from the deepest layer of the capsule into the substance of the placenta.
- (d) A considerable part of the placenta on the left side as well as in its upper part is greatly altered by old haemorrhages; the compressed villi having become very fibrous, many blood crystals mark the line of the vessels of the villi.
- (e) Recent haemorrhages (post-operation) have completely torn up the remaining portion.

Secondary Sac.—A section made through the anterior wall consisting

PLATE X.

FIG. 1.

Section through a bit of somewhat normal-looking placental tissue.
L. P.

- a.* A villus stem.
- b.* Blood surrounding villi and villus stem.
- c.* Villus.

FIG. 2.

Section through villi and villus stems compressed together and surrounded by fibrin resulting from old hæmorrhage. H. P.

- a.* Part of right wall of primary sac.
- b.* Villus stem.
- c.* Faintly stained fibrin.
- d.* Villus.

FIG. 3.

Section through normal-looking placental tissue. H. P.

- a.* Villus stem covered with a single layer of cubical epithelium.
- b.* Villus covered with a single layer of cubical epithelium.
- c.* Blood surrounding villi.
- d.* Leucocytes.

*



Fig. 1.

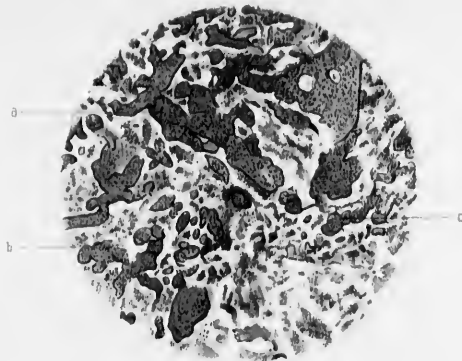


Fig. 2.

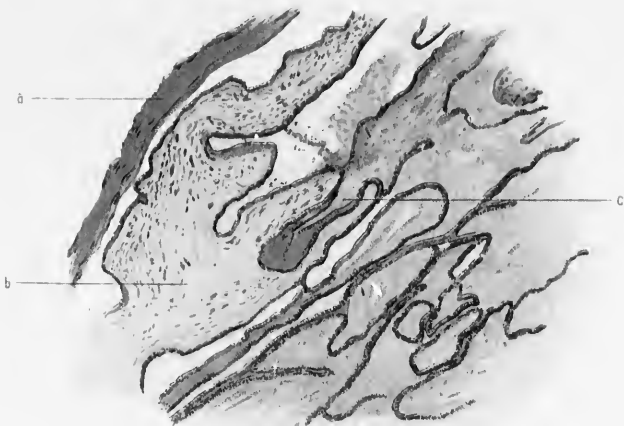

Fig. 3.

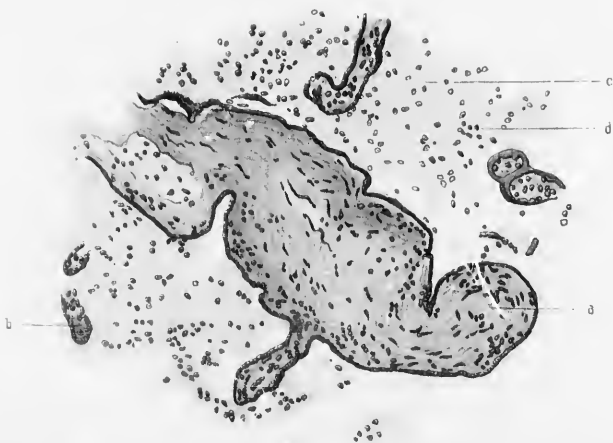



PLATE XI.

FIG. 1.

Section through a pale fibrous-looking area in placenta and blood mass. L. P.

- a.* Fibrin of old extravasated blood.
- b.* Space in the fibrin.
- c.* Villus surrounded by fibrin and greatly altered, being fibrous, without any covering epithelium, and with abundant blood pigment.

FIG. 2.

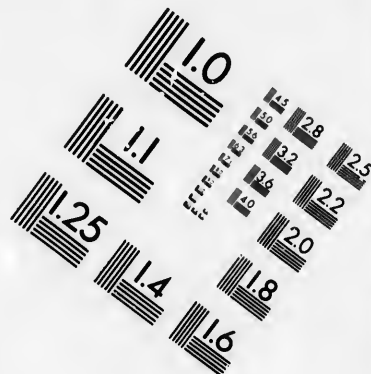
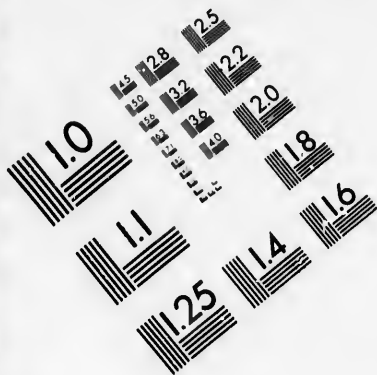
Part of the above, highly magnified, showing altered villus stems with blood-pigment surrounded by fibrin in which are numerous blood crystals.

- a.* Blood crystals causing pigmentation in villus stem.
- b.* Blood-pigment in fibrin.

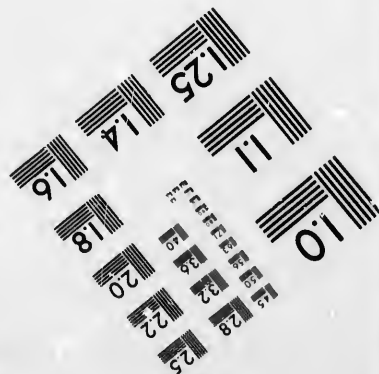



FIG. 3.

Section showing decidual tissue from wall of uterine cavity. H. P.

- a.* Decidual cells.



**IMAGE EVALUATION
TEST TARGET (MT-3)**



**Photographic
Sciences
Corporation**

23 WEST MAIN STREET
WEBSTER, N.Y. 14580
(716) 872-4503

1.5 2.8
2.0 3.2 2.5
3.6 2.2
4.0
8

10

Fig. 1.

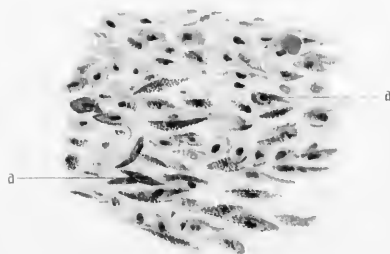


PLATE XI.

Fig. 2.





Fig. 3.





of altered great omentum has the following structure. Next the cavity is the cubical cell layer of the amnion; external to this is a thick dense mass of fibrous tissue; outside this are loose connective tissue and masses of fat cells, external to this is a thinner layer of connective tissue lying under the peritoneum. Many vessels are seen in the wall.

A section through the posterior wall of the stomach which enters into the formation of the upper part of the anterior wall of the sac has the following appearance: Externally is the mucous membrane of the stomach; inside this is the *muscularis mucosa*, then a layer of fat and loose connective tissue, then the muscular coat, outside which is dense connective tissue covered with amnion. The transverse colon is similarly altered in its posterior wall.

Membranes.—Amnion. The presence of this membrane lining the secondary sac has already been noticed. It consists of a layer of cubical epithelial cells, resting on a thin layer of connective tissue. In some places it is wrinkled and in others quite flat. Within the primary sac I have noticed no trace of it in any of the sections after most careful searching. It is most probable that the epithelium was destroyed as a result of the changes which took place after the escape of the fœtus from the tube.

Chorion.—One sees traces of the chorionic surface of the placenta, consisting of rather dense fibrous tissue with villus stems attached. It is impossible, however, to determine with accuracy how much of the chorion has followed the amnion in its escape from the tube. In some places the amnion is connected to underlying structures, through the medium of a layer of connective tissue, which might have been chorionic originally, which now appears in no wise different from the connective tissue of the sac wall.

CHAPTER VII

RÉSUMÉ

WITH the facts obtained from this detailed examination of the specimen, we are now in a position to form our conclusions in regard to the following points :

- a. The nature, growth, and progress of the gestation.
- b. Relation to clinical facts.
- c. Post-operation changes.

The Nature, Growth, and Progress of the Gestation.

The case is one of mixed nature, being partly tubal (extra-peritoneal) and partly abdominal (intra-peritoneal). Clinically, it was impossible to make this diagnosis.

After the most thorough ante-mortem examination it was impossible to say which one of the varieties of extra-uterine gestation might exist. Even the careful inspection of the abdominal cavity at the time of operation failed to give much information.

It is, indeed, only at the end of a complete sectional and microscopic examination that we can be absolutely certain of the nature of the case.

The chief facts which make evident the conclusion arrived at by us are the following :

- a. Two sacs exist, one of which contained the foetus, the other the placenta. The former was formed by the peritoneal cavity behind the stomach, transverse colon, and great omentum ; the latter by the enormously dilated left Fallopian tube lying in front of the uterus and extending vertically from the utero-vesical pouch to the 4th lumbar

vertebra. Though quite distinct from one another, they were connected by means of the umbilical cord and amnion. This membrane lined the secondary (peritoneal) sac and passed into the substance of the primary (tubal) sac.

The umbilical cord also, whose foetal extremity lay free in the secondary sac, passed into the primary sac.

b. The left ovary was found easily, being adherent to the posterior wall of the primary sac.

c. The left broad ligament was of much the same thickness as on the right side. Its anterior layer was for a considerable extent somewhat adherent to the placental sac, which lay in front of it and the left round ligament.

d. The uterus was well formed, so there could be no question of a horn pregnancy. Before the operation it was *pushed to the right*. Afterwards the expansion of the placental sac into the right side of the pelvis, by means of the blood poured out in its substance, caused the uterus to be pushed backwards and to the *left*. (Had the left broad ligament been occupied by the placental mass this latter change could not have taken place.)

It is interesting to note here what Otto Küstner says of the differential diagnosis between tubal gestations which have become intra-ligamentous and those which have not. He says¹ that in the former the uterus is usually carried forwards and upwards in front of the lower part of the tumour (this was so in Hart's sub-peritoneo-pelvic case);² in the latter it is pushed to the opposite side, or retroverted. In the former the ovary of the affected side may often with difficulty be found, whereas, in the latter case, it is usually speedily found.

In the next place, what was the probable history of its growth and development? That the ovum began to grow in the left tube there is no doubt; very early the pregnant tube fell forwards in front of the left broad ligament, where it continued to increase both in an upward and downward direction. Then at some time during the early months,

¹ *Handbuch der Geburtshülfe* herausgegeben von P. Müller, Band II, 2 Hälfte, Stuttgart, 1889, p. 565.

² *Op. cit.* plate 1.

entirely unknown to us, the wall of the sac (possibly at its upper and posterior part) became so greatly thinned that it burst and allowed the foetus to escape, carrying with it the unbroken amnion. It is impossible to say whether any chorionic tissue was carried into the peritoneal cavity along with the amnion. The sub-amniotic layer in the wall of the secondary sac is well formed fibrous tissue, in some parts very dense, in other parts of loose nature, allowing of the folding of the amnion exactly similar to the folding which occurs in that membrane during ordinary uterine labour. Veit¹ and others have noticed the partial hernia-like protrusion of the contents of the tube in tubal pregnancy through a part of the wall whose tissues have become stretched and separated.

It may be, however, that rupture did not occur in this way, but that the fimbriated end became gradually opened up, allowing the foetus to escape.

Küstner² has observed the fimbriated end of the affected tube disposed in three different ways. It may either be attached to the side wall of the pelvis by peritonitis, remain free as a projection on the surface of the gestation sac, or become dilated by the outward pressure of the ovum; he has seen an ovum lying in the dilated fimbriated end, after having gradually worked its way from an inner portion. At any rate, however escape may take place, it is well authenticated that the membranes may escape unbroken with the foetus where the primary gestation sac ruptures into the peritoneal cavity. In a very fully described case published by Professor Sir William Turner,³ where rupture of a three months pregnant horn of a bi-cornuate uterus occurred, resulting in the patient's death, it was found that the foetus, covered with membranes unbroken, lay in the peritoneal cavity, having been protruded together with a part of a placental-like mass through the rupture in the horn.

As the foetus grew the amnion became attached to the peritoneal lining of that part of the abdomen into which it was cast, and as a result the sub-endothelial layer of the peritoneum became thickened and

¹ Schroeder's *Lehrbuch d. Geburtshülfe*,
Zehnte Auflage, 1888, p. 423.

² *Op. cit.*, p. 503.

³ *Edin. Med. Journ.*, May 1860.

fibrous, thus forming a secondary sac wall for the fœtus. The amniotic fluid continued to be secreted, and to such an extent that in the later months hydraunios resulted.

The intestines also became somewhat matted together, especially in each lumbar region, while the great omentum which entered into the formation of the anterior wall of the secondary sac became changed into thick fibrous tissue, especially in its inner layers.

Strong adhesions developed between the primary sac wall and the left side of the pelvis. That part of the wall lying next the cavity of the pelvis became to a considerable extent covered with the escaped amnion, thus forming a portion of the secondary sac wall.

In my review of the literature of Ectopic Gestation I have found no description of such a case.

Küstner,¹ referring to the possibility of the occurrence of such a variety, says, that though there is in the literature of Extra-Uterine Pregnancy no demonstrated case, there is absolutely no reason to be urged against the possibility of its occurrence. (In this connection Küstner makes use of the term "tubo-abdominal." This term, it is to be noted, is employed by most writers² as referring to another variety, viz. that in which the ovum develops in a sac formed by the outer end of the tube and neighbouring peritoneum.) Werth³ also believes that no reliable evidence has ever been produced to warrant us in placing this among the known varieties of extra-uterine gestation.

Very recently, Berry Hart,⁴ in his article on extra-uterine gestation, says that the partly intra- and partly extra-peritoneal form is only probable.

Lawson Tait⁵ and Strahan⁶ practically deny its possibility. Tait says that a tubal pregnancy ruptures at or before the fourteenth week,

¹ *Op. cit.* p. 514.

² Spiegelberg's *Midwifery*, Eng. Trans., vol. i.; Veit, *op. cit.* p. 429; Parry, *Extra-Uterine Pregnancy*, p. 49; Lusk, *Midwifery*, p. 329.

³ *Beiträge zur Anatomie und zur Operativen Behandlung der Extra-uterinschwangerschaft*,

*

Stuttgart, 1887, p. 57.

⁴ *Op. cit.* p. 34.

⁵ *Diseases of Women and Abdominal Surgery*, vol. i. p. 443.

⁶ *Extra-Uterine Pregnancy*, Philadelphia, 1889, p. 3.

and that then the progress of gestation is directed either into a broad ligament (extra-peritoneal) gestation or into an abdominal (intra-peritoneal) gestation, "*uniformly fatal (unless removed by abdominal section), primarily by hæmorrhage, secondarily by suppuration of the sac and peritonitis.*" Again¹ he says that it is only the form which has burst from the tube into the broad ligament which afterwards may give rise to those cases called abdominal pregnancy through secondary rupture of the ovum sac; and, in another place,² he says that the ovum can only survive the process of rupture in those cases where the rupture of the tube takes place into the cavity of the broad ligament.

Strahan merely emphasises Tait's opinion.

On the other hand, Bandl³ records a case in which, after rupture of the primary sac at the fourth month, the fœtus grew to full time in the abdominal cavity and was extracted alive by laparotomy, the mother being *in articulo mortis*. At the *post-mortem* the abdominal cavity in which the child had been lying contained a large quantity of dirty serous fluid, but no membranes could be found. There was matting together of the intestines, the peritoneal lining of the sac being covered with a pseudo-membranous effusion.

Jessop⁴ describes a case in which the fœtus alone escaped into the abdominal cavity after rupture of the primary sac; it lived, and was extracted alive at full time. At the operation the peritoneum was more vascular than normal, and appeared "thick and velvety on section. No trace of cyst or of membranes could be found. A few bands of unorganised lymph of very friable nature were found lying upon, but not adherent to, the intestines." As the mother recovered from the operation, the condition of the appendages, the nature of the gestation sac, and the relations of the placenta and membranes, was not ascertained.

Champneys⁵ also describes a case in which a seventh-month fœtus was removed from the abdomen. It lay among the intestines, covered only by "a dull white membrane." The mother died on the thirty-second

¹ *Op. cit.* p. 442.

² *Op. cit.* p. 488.

³ *Cyc. of Obst. and Gyn.*, vol. xii. p. 690.

⁴ *Trans. Obstet. Soc.*, London, vol. xviii. p. 261.

⁵ *Ibid.* vol. xxix. p. 456.

day after the operation. At the *post-mortem* it was impossible to make out the relation of parts in the pelvis, though the placenta was found *above the pubes* lying loose in a sac.

From the facts given we cannot be at all sure as to the nature of these cases. They may have been ruptured tubal, tubo-ovarian, or sub-peritoneo-pelvic gestations, or possibly, even, in Bandl's case at least, of the sub-peritoneo-abdominal variety in which rupture into the peritoneal cavity had never occurred at all.

Veit¹ says that after rupture of a tubal gestation the ovum may go on developing in the abdominal cavity whether the membranes surrounding the fœtus be broken or not, but *most frequently in the latter case*.

Charpentier,² though believing that in most cases the fœtus dies after rupture, says that it also may live.

The last two authors give no ground for their statements whatever, save an extremely questionable case of one Walther mentioned by Charpentier, in which, after the rupture of an "ovarian" pregnancy, the fœtus developed for four months amidst the abdominal viscera, and "was found at the end of gestation as free and without cyst as at the time of its escape from the ovary."

Relation to Clinical Facts.

How, now, does the history of the development of the gestation in our case, based upon the facts derived from anatomical study, correspond to the clinical phenomena observed during the course of pregnancy?

As regards the *symptoms*, they were, during the greater part of pregnancy, practically the same as those experienced normally by women, *e.g.*—

It was for the first seven months almost a painless gestation—a most remarkable fact.

There neither occurred the symptoms of a rupture into the broad ligament, nor those accompanying rupture into the peritoneal cavity.

The only symptom that might indicate the escape of the fœtus from

¹ Schroeder's *Lehrbuch d. Geburtshülfe*, Zehnte Auflage, p. 430.

² *Traité des Accouchements*, vol. ii. p. 1030.

the tube was a pain in the left side which came rather suddenly during the third month, lasting for four or five days and then disappearing. There was *no* fainting *nor* collapse, and the physician considered it as due to perimetritis or threatening of an abortion. There was no reason in his mind for suspecting anything of a more serious nature. In fact, there were no symptoms whatever to indicate that rupture had occurred. This can only be accounted for by supposing that either the membranes and foetus were forced very slowly through the opened-up fimbriated end of the tube, or that the tube wall itself became so greatly thinned at one point that the bundles of muscle and connective tissue became separated, so that a hernial-like protrusion of the membranes occurred, followed by the foetus, the process being accomplished with little or no hæmorrhage and with no special pain.

Even more remarkable is the fact that the further growth of the amnion in the abdominal cavity was unaccompanied by pain. We have seen that the amnion became attached over a large peritoneal area by changes which resulted in the formation of a considerable amount of fibrous tissue immediately beneath it, that the great omentum was largely changed into fibrous tissue, and that in parts the intestines were matted together. Besides, other inflammatory adhesions occurred between the left side of the primary sac, the parietal peritoneum, the ovary, uterus, and rectum.

It is generally supposed that such changes are accompanied by pain. Veit¹ says that pain always accompanies the inflammatory changes which give rise to the matting of the intestines and the encapsuling of the foetus.

Bandl,² in describing the clinical history of the case already referred to (p. 42), says that at the third month abdominal pain began, and that it continued, with loss of flesh and strength, during the rest of the pregnancy.

We may account for this in one of two ways: either there did exist a certain amount of pain of which the patient, being a primipara, did not complain, considering these as necessary accompaniments of pregnancy; or the adhesions really were formed without pain being caused, just as is the case sometimes with large ovarian tumours. This latter fact is now well established.

¹ *Op. cit.*

² *Op. cit.*, p. 69.

Lawson Tait¹ says that "it is surprising to what extent a tumour may be found to be adherent, and yet throughout its history no indications of inflammatory attacks have been given."

Olshausen² says, "in the *large majority* of cases adhesive inflammations which result in parietal adhesions run an apyrexial and latent course, but that in other cases they are attended with pains which may last for days or weeks."

During the last two months of her pregnancy the patient complained of sharp pains in the left hypochondriac and lumbar regions, intermittent in character and accompanied by dyspnoea. These may possibly have been partly due to the inflammatory changes going on in these regions, but, if so, it is remarkable that similar symptoms were not produced by the same cause acting in the other parts of the abdomen. It is more probable that these attacks of pain and dyspnoea were due to the condition of hydramnios together with the derangement of the alimentary canal which existed. Charpentier,³ in his well-known article on hydramnios, speaks of the characteristic pains in the late months, due to this condition, as occurring sometimes in the hypogastrium, sometimes in the lumbar, inguinal, or sacral region, and being intermittent or continuous in character.

There was considerable gastric and intestinal disturbance throughout pregnancy. On admission to the hospital she was greatly troubled with flatulence, which escaped both by mouth and rectum, and she complained frequently of a pain at her heart, which passed through to the back.

During the last week she also had spasms of pain in the lower part of the abdomen.

As to the signs in the early stage we have very little history. The swelling caused by the growing ovum was noticed in the third month of pregnancy in the left half of the lower part of the abdomen. This is of course quite different from the condition met with in normal pregnancy, where at the same period of gestation the uterus is below the pelvic brim. Had the physician's attention been directed to this swelling it must, apart from its left-sidedness, have aroused his suspicions, and we see no reason to

¹ *Diseases of the Ovaries*, 1883, p. 191.

² *Cyclopediu of Obst. and Gyn.*, vol. viii. p. 88.

³ *Op. cit.* p. 895.

doubt that, had a careful bi-manual been made with the aid of an anaesthetic, the abnormal condition would have been diagnosed. The great majority of tubal gestations are never diagnosed until rupture occurs, because until then no abnormal signs or symptoms make the patient seek for advice.

The menstrual history was similar to that recorded in many cases of extra-uterine pregnancy—a period of amenorrhœa at first, followed by small discharges of blood at intervals afterwards.

In this case there was amenorrhœa for the first two months, while a slight bloody discharge occurred from the uterus in the third, fourth, and eighth months.

The breasts were flabby, not much enlarged, and containing very little colostrum. A well-marked scuffle was heard in the iliac regions.

On examination before operation the vagina was patulous and its walls very soft. The cervix was enlarged, softened, and not at all shortened, the posterior lip being 1 in. in length. (Strahan¹ says that the cervix becomes shortened in extra-uterine pregnancy.)

A finger could be passed for some distance into its canal.

This patulous condition of the cervix in extra-uterine gestation has been noticed by several observers. Tait² says that it is a most important sign, being found in all cases.

Strahan³ says that "the cervix is always open." Küstner⁴ also notes this fact.

The uterus was found at this time pushed to the *right*, upright and somewhat retro-posed. It was enlarged to the length of 4 inches. This growth of the uterus in extra-uterine gestation has long been known, but the variations in size found in different cases of full-time pregnancy have not been satisfactorily explained. In Berry Hart's sub-peritoneo-abdominal case the length of the whole uterus was 4 in., about $\frac{5}{8}$ in. shorter than in this case. In Bandl's mixed case (already referred to) it was 3·2 in.

Bandl⁵ says that the growth of the uterus depends upon the nature of the gestation, and that the nearer the ovum is developed to it "the more

¹ *Op. cit.* p. 13.

² *Op. cit.* p. 502.

³ *Op. cit.* p. 43.

⁴ *Op. cit.* p. 488.

⁵ *Op. cit.* p. 59.

regularly will the uterus participate in development"; thus in interstitial cases the uterus is most of all enlarged, in tubal cases less, and in mixed cases still less.

Küstner¹ also says that the greatest development is found in the interstitial variety.

The uterine mucous membrane was greatly swollen, and on microscopic examination presented the characteristic appearance of decidual tissue. It was well formed, containing many large decidual cells, and closely resembled the uterine decidua in Berry Hart's 4½ months sub-peritoneo-pelvic gestation.²

According to most authorities a uterine decidua is found in most cases of extra-uterine gestation, but Charpentier is the only one, as far as I am able to find out, who says that its character changes with the progress of the pregnancy. He says that it is at first voluminous but that "it soon becomes the seat of true atrophy, of active absorption, so that at term scarcely any traces remain."

Küstner,³ on the contrary, says that at the end of pregnancy, especially after the child's death, a division of the decidua takes place through its middle layer and that this is usually expelled.

In some cases, undoubtedly, no decidua is found, but this is, according to Campbell,⁴ because the examination is made just after it has been thrown off, during the previous discharge of blood from the uterus.

In this case the decidua was well formed and not undergoing perceptible atrophy or absorption. Decidual tissue could be traced from the uterine cavity into the inner end of the left tube. The extent and relations of this were not, however, well made out.

Bandl⁵ says that in tubal pregnancy the uterine end of the pregnant tube is occasionally open, and its decidua extends to the mucous membrane of the uterus.

Shortly before operation, a "spurious labour" took place, lasting for several hours. It consisted of frequent uterine contractions (accompanied

¹ *Op. cit.* p. 499.

² *Op. cit.* vol. ii. plate xxi. fig. ii.

³ *Op. cit.* p. 499.

⁴ *Memoir on Extra-Uterine Gestation*, Edinburgh, 1840.

⁵ *Op. cit.* p. 47.

by straining efforts on the part of the patient) whereby small bits of decidua and clot were expelled.

It is now well established that this usually occurs in cases of full-time ectopic gestation whether the fetus has died or not. According to Tait,¹ Vidal in the year 1652 was the first to notice it.

Küstner² says that also contractions take place *in* the tube wall whereby separation of the placenta and hæmorrhage into its substance may take place, leading to the death of the fetus.

Whether or not this occurred in the present case one cannot say. Judging, however, from the small amount of muscular tissue in the wall of the placental sac, in proportion to the great quantity of connective tissue, we believe that only slight contractions could occur. Certain it is that the hæmorrhage into the placenta was a post-operation occurrence, because the examination of the patient after the "spurious labour" had occurred, just before the operation, showed that the uterus was still in the right side of the pelvis and its relations to surrounding parts the same as in the previous examinations.

There is, indeed, no ground for believing that, in an extra-uterine gestation, where the tube forms part of the sac, contractions will be set up in the wall of the latter in the same way that they are set up in the uterus in a full-time normal pregnancy. Küstner's statement, though possibly true, cannot be at all supported by evidence.

It is more probable that the tearing of the sac wall and placenta is due to the contractions of the abdominal muscles in the violent straining efforts often made by the patient during the "spurious labour." Strahan³ says that this may rupture the gestation sac to such an extent that the blood may be poured outside it into the peritoneal cavity causing death.

The condition of hydramnios is of special interest. I have found only one⁴ mention of its occurrence in extra-uterine pregnancy in the chief literature of the subject. Its cause is unknown to us. We may, however, associate with it the great amount of amniotic membrane lining the sac

¹ *Op. cit.* p. 500.

² *Op. cit.* p. 535.

³ *Op. cit.* p. 48.

⁴ Teuffel, *Archiv f. Gyn.*, bd. xvii.

which contained the fetus—an area much larger than the inner surface of the full-time pregnant uterus.¹ It is to be noted that the signs and symptoms were much the same as those seen in cases of extensive hydramnios in uterine pregnancy.

Post-operation Changes.

These have occurred chiefly in connection with the primary gestation sac—that containing the placenta. The secondary sac, emptied of its contents, is now only a potential cavity, its walls being in apposition.

The pelvic cavity is now occupied by a mass which was not present at the time of the operation. At that time the placental mass occupied the left side of the pelvis extending for about 3 in. above the brim, the uterus being pushed over to the *right* side of the pelvis. Now, the uterus is pushed backwards and against the *left* side while in front of it and to the right is a dark red black mass filling the pelvis, pressing on the bladder below, and reaching above the brim. This mass is not in the secondary sac, nor in the peritoneal cavity, but entirely within the primary sac; it consists of placenta and recently poured out blood in the early stages of alteration. The greater portion of the placenta has been destroyed, more normal portions being on the left side under the wall. In most places these parts are greatly compressed.

The distension of the sac has been upwards, and downwards, and to the right. The wall, as we have seen, is much thinner on the left than on the right side. To understand how the placental sac (tube wall) was capable of such great distension without rupture we must bear in mind the previous escape of the fetus from the tube. When this took place there was left a considerable portion of the sac wall lying flaccid. It must have been pressed against the placenta and probably their opposed amniotic surfaces blended. We are now unable to find any trace of amnion inside the primary

¹ We do not know exactly the average area of the inner surface of the full-time pregnant uterus. Barbour and Webster ("Anatomy of Advanced Pregnancy and of Labour," etc.; *Laboratory Reports R.C.P.E.*, vol. ii.) found the inner wall of the eight-month pregnant uterus to measure 147 square inches, of which the placenta occupied 48 square inches; while that of a full-time uterus in the second stage of labour was 167.09 square inches (including the cervix).

sac, nor can we trace the cord inside the sac, the latter probably entering the placenta close to the wall. It was most probably the existence of the flaccid portion of the wall which allowed such a great distension of the sac to take place.

The hæmorrhage in the sac, occurring chiefly in the right half of the pelvis, pressed the uterus backwards and to the left to such an extent that it bulged into the great sacro-sciatic foramen. To such an extent did the distension take place that the sac fills the pelvis as if in a mould. The uterus and appendages, the rectum, bladder, ligaments and extra-peritoneal tissues are greatly compressed, the vessels being nearly closed. It is easy moreover to see how the action of the ureters may have been greatly interfered with.

The cause of this great hæmorrhage was probably due to the change in pressure which followed the removal of such a large quantity of fluid as was contained in the secondary sac. As to the source of the hæmorrhage we cannot speak with certainty. It may have been a general increase of the blood of the maternal portion of the placenta or it may have been due to the bursting of some of the thin walled sinuses in the inner part of the tube wall.

As to the clinical signs accompanying these changes we know practically nothing; the patient was kept under the influence of morphia for the first 24 hours after the operation, so that all subjective symptoms were masked during that period. Afterwards she felt no pain or sickness; the pulse, however, was feeble and rapid. The symptoms which followed, and only ended with the patient's death, were those of uræmic poisoning.

The catheter was passed from time to time, but only very small quantities of urine were drawn away.

The sections show that the bladder was so compressed by the mass lying above it that scarcely any dilatation of the cavity was possible, and this condition, together with the pressure upon the urethra and the ureters, is the explanation of the passage of such small quantities of urine, and probably also of the consequent symptoms of uræmic poisoning.

BIBLIOGRAPHY

- BANDL, Extra-Uterine Pregnancy, Cyclopaedia of Obst. and Gyn., ed. by Grandin, vol. xii.
- BARBOUR, Diagnosis of Advanced Extra-Uterine Gestation, Obstet. Trans., Edin., vol. vii., 1882.
- BARBOUR and WEBSTER, Anatomy of Advanced Pregnancy and of Labour, Lab. Reports R.C.P.E., vol. ii., 1889.
- CAMPBELL, A Memoir on Extra-Uterine Gestation, Edin., 1840.
- CHAMPNEYS, Trans. Obstet. Soc., Lond., vol. xxix.
- CHARPENTIER, Traité des Accouchements, vol. ii., 1883.
- DEZELMERIS, Jour. des Connaissances Med. Chir., Jan. 1837.
- HART (1), Sectional Anatomy of Advanced Extra-Uterine Gestation, Lab. Rep. R.C.P.E. vol. i. (2) Anatomy of Placenta in Extra-Uterine Gestation, Lab. Rep. R.C.P.E., vol. ii.
- JESSOP, Trans. Obstet. Soc., Lond., vol. xviii.
- KÜSTNER, Handbuch der Geburtshilfe herausgegeben von P. Müller, bd. ii., Stuttgart, 1889.
- LEOPOLD, Trans. of Inter. Medical Congress, Berlin, 1890.
- LUSK, The Science and Art of Midwifery, New York, 1889.
- OLSHAUSEN, Diseases of the Ovaries, Cyc. of Obst. and Gyn., edited by Grandin, vol. viii.
- PARRY, Extra-Uterine Pregnancy, Eng. ed., London, 1876.
- STRAHAN, Extra-Uterine Pregnancy, Philadelphia, 1876.
- SPIEGELBERG, Text-Book of Midwifery, Eng. Trans.
- SUTTON, Surgical Diseases of the Ovaries and Fallopian Tubes, Lond., 1891.
- TAIT, (1) Diseases of Women and Abdominal Surgery, vol. i., Leicester, 1889. (2) Diseases of the Ovaries, 1883.
- TURNER, Edin. Med. Jour., May 1860.
- TEUFFEL, Archiv f. Gyn., bd. xvii.
- VEIT, Schroeder's Lehrbuch d. Geburtshilfe, Zehnte Auflage, Bonn, 1888.
- WERTH, Beiträge zur Anatomie und zur Operativen Behandlung der Extra-Uterin-schwangerschaft, Stuttgart, 1887.



INDEX

- AMNIOTIC SAC, 14, 26, 31, 37, 40.
Barbour's Case, 9.
Bladder, 13, 17, 19, 50.
Cervix, 29, 46.
Clinical History, 4.
Correspondence between Pathology and Clinical History, 43.
First Transverse Section, 16.
Fourth Transverse Section, 21.
Fifth Transverse Section, 25.
Hæmorrhage in Primary Sac, 50.
History of development of Tubo-Peritoneal Gestation, 38.
Hydrannnios, 48.
Jessop's Case, 42.
Ligaments and Connective Tissues, 17, 20, 22, 24, 39.
Menstrual History, 46.
Microscopic Examination, 32
 Amniotic Sac, 36.
 Membranes, 37.
 Placenta, 31
 Placental Sac, 32.
Nature of Case, 38.
Peritoneum, 14, 17, 19, 22, 26, 27, 28, 36.
Placental and Blood Mass, 15, 18, 20, 23, 24, 25, 34, 49.
Post-operation changes, 49.
Primary Sac, 15, 18, 21, 23, 24, 25, 32, 38, 49.
Rectum, 13, 17, 19, 21, 24.
Round Ligaments, 29, 31.
Second Transverse Section, 18.
Sixth Transverse Section, 27.
Spurious Labour, 47.
Technique, 11.
Third Transverse Section, 21.
Tubes and Ovaries, 21, 22, 24, 30, 32, 39.
Turner's Case, 40.
Umbilical Cord, 31.
Uterine Decidua, 6, 47.
Uterus, 12, 16, 18, 29, 46.
Vagina, 13, 29.
Value of Various Methods of Study, 9, 10.
Varieties of Ectopic Gestation, 1, 2, 3.
Vertical Mesial Section, 12.



YOUNG J. PENTLAND'S RECENT PUBLICATIONS.

Third, Enlarged, and thoroughly Revised Edition, 8vo, Cloth, pp. xx. 652. Illustrated with 105 Coloured Plates from Original Drawings. Price 25s.

PRACTICAL PATHOLOGY. A Manual for Students and Practitioners. By GERMAN SIMS WOODHEAD, M.D., F.R.C.P. Ed., Director of the Laboratories of the Royal Colleges of Physicians (London) and Surgeons (England).

Third Edition, Revised and Enlarged, 8vo, Cloth, Gilt Top, pp. xx. 614. With Woodcut and 9 double-page Coloured Illustrations. Price 21s.

DISEASES OF THE SKIN: A Manual for Students and Practitioners. By W. ALLAN JAMESON, M.D., F.R.C.P. Ed., Extra Physician for Diseases of the Skin, Edinburgh Royal Infirmary; Consulting Physician, Edinburgh City Hospital, Lecturer on Diseases of the Skin, School of Medicine, Edinburgh. [*Pentland's Medical Series—Vol. I.*]

In Press, Second Edition, 8vo. To be illustrated with many additional Coloured Plates from Original Drawings.

DISEASES OF THE EYE: A Practical Treatise for Students of Ophthalmology. By GEORGE A. BERRY, M.D., F.R.C.S. Ed., Ophthalmic Surgeon, Edinburgh Royal Infirmary; Senior Surgeon, Edinburgh Eye-Dispensary; Lecturer on Ophthalmology, Royal College of Surgeons, Edinburgh. [*Pentland's Medical Series—Vol. II.*]

8vo, pp. xvi. 640. With Coloured Illustrations from Original Drawings. Price 25s.

DISEASES OF THE THROAT, NOSE, AND EAR. By P. M'BRIDE, M.D., F.R.C.P. Ed., Lecturer on the Diseases of the Ear and Throat, Edinburgh School of Medicine; Aural Surgeon and Laryngologist, Royal Infirmary, Edinburgh; Surgeon, Edinburgh Ear and Throat Dispensary. [*Pentland's Medical Series—Vol. III.*]

2 vols. large 8vo, Cloth, pp. xvi. 1008. Illustrated with Maps and Charts. Price 31s. 6d.

GEOGRAPHICAL PATHOLOGY: An Inquiry into the Geographical Distribution of Infective and Climatic Diseases. By ANDREW DAVIDSON, M.D., F.R.C.P. Ed., late Visiting and Superintending Surgeon, Civil Hospital, and Professor of Chemistry, Royal College, Mauritius.

Large 8vo, pp. xxviii. 772. With 404 Illustrations. Price 31s. 6d.

THE PARASITES OF MAN AND THE DISEASES WHICH PROCEED FROM THEM. A Text-book for Students and Practitioners. By RUDOLF LEUCKART, Professor of Zoology and Comparative Anatomy, Leipzig. Translated from the German, with the co-operation of the Author, by WILLIAM E. HOYLE, M.A. (Oxon.), M.R.C.S., F.R.S.E., "Natural History of Parasites in General." "Systematic Account of the Parasites Inesting Man." "Protozoa—Cestoda."

Large 8vo, Cloth, pp. xvi. 600. With 147 Illustrations, some coloured. Price 30s.

THE REFRACTION AND ACCOMMODATION OF THE EYE AND THEIR ANOMALIES. By E. LANDOLT, M.D., Professor of Ophthalmology, Paris. Translated under the Author's supervision by C. M. CULVER, M.A., M.D., formerly Clinical Assistant to the Author; Member of the Albany Institute, Albany, N.Y.

Large 8vo, Cloth, pp. xvi. 783. Price 25s. Illustrated with 226 Wood Engravings, and 68 pages of Lithograph Plates, exhibiting 91 Figures—317 Illustrations in all.

DISEASES OF THE HEART AND THORACIC AORTA. By BYRON BRAMWELL, M.D., F.R.C.P. Ed., Lecturer on the Principles and Practice of Medicine, and on Practical Medicine and Medical Diagnosis, in the Extra-Academical School of Medicine, Edinburgh; Assistant Physician, Edinburgh Royal Infirmary.

8vo, Cloth, pp. xvi. 270. With 116 Illustrations. Price 14s.

INTRACRANIAL TUMOURS. By BYRON BRAMWELL, M.D., F.R.C.P. Ed., Lecturer on the Principles and Practice of Medicine in the Extra-Academical School of Medicine, Edinburgh; Assistant Physician to the Edinburgh Royal Infirmary.

In one Volume, Royal 4to, Extra Cloth. Price 63s. net.

ATLAS OF VENEREAL DISEASES: A Series of Illustrations from Original Paintings, with Descriptions of the Varied Lesions, their Differential Diagnosis and Treatment. By P. H. MACLAREN, M.D., F.R.C.S. Ed., Surgeon, Edinburgh Royal Infirmary; formerly Surgeon in charge of the Lock wards, Edinburgh Royal Infirmary; Examiner in the Royal College of Surgeons, Edinburgh.

8vo, Cloth, pp. xii. 122. Illustrated with Engravings and numerous Coloured Illustrations. Price 10s. 6d.

LEAD POISONING IN ITS ACUTE AND CHRONIC FORMS. The Goulstonian Lectures delivered in the Royal College of Physicians, March 1891. By THOMAS OLIVER, M.A., M.D., F.R.C.P., Professor of Physiology, University of Durham; Physician to the Royal Infirmary, Newcastle-on-Tyne.

8vo, Cloth, pp. xvi. 104. With 34 full-page Coloured Plates from Original Drawings. Price 16s.

HYDATID DISEASE IN ITS CLINICAL ASPECTS. By JAMES GRAHAM, M.A., M.D., Late Demonstrator of Anatomy, Sydney University; Medical Superintendent, Prince Alfred Hospital, Sydney.

8vo, Cloth, pp. xvi. 1080. Illustrated with Charts. Price 24s.

THE PRINCIPLES AND PRACTICE OF MEDICINE. Designed for the Use of Practitioners and Students of Medicine. By WILLIAM OSLER, M.D., F.R.C.P., Professor of Medicine in the Johns Hopkins University; Physician-in-chief to the Johns Hopkins Hospital, Baltimore.

YOUNG J. PENTLAND,

EDINBURGH: 11 TEVIOT PLACE.

LONDON: 38 WEST SMITHFIELD, E.C.

YOUNG J. PENTLAND'S RECENT PUBLICATIONS.

- Large 8vo, Cloth, pp. xvi. 700. With 178 Fine Engravings, many in Colour. Price 18s.
CLINICAL TEXT-BOOK OF MEDICAL DIAGNOSIS. For Physicians and Students. By OSWALD VIERORDT, M.D., Professor of Medicine at the University of Heidelberg. Translated, with the Author's permission, from the Second Enlarged German Edition, by FRANCIS H. STUART, M.D., Member of the Medical Society of the County of Kings, New York.
- Second Edition, Handsome 8vo, Cloth, pp. 700. With 239 Wood Engravings. Price 18s.
THE SCIENCE AND ART OF OBSTETRICS. By THEOPHILUS PARVIN, M.D., LL.D., Professor of Obstetrics and Diseases of Women and Children in the Jefferson Medical College, Philadelphia.
- In two very Handsome Imperial 8vo Volumes, containing about 1600 Pages. Price 50s. net.
THE NATIONAL MEDICAL DICTIONARY: Including English, French, German, Italian and Latin Technical Terms used in Medicine and the Collateral Sciences, and a Series of Tables of useful data. By JOHN S. BILLINGS, A.M., M.D., LL.D. HARV. and EDIN., D.C.L. OXON., Member of the National Academy of Sciences, Surgeon, U.S.A., etc. With the Collaboration of W. O. ATWATER, M.D.; FRANK BAKER, M.D.; C. S. MINOT, M.D.; JAMES M. FLEET, M.D.; R. LOBINI, M.D.; WASHINGTON MATTHEWS, M.D.; S. M. BURNETT, M.D.; J. H. KIDDER, M.D.; H. C. VARROW, M.D.; WILLIAM LEE, M.D.; W. E. COUNSELMAN, M.D.
- REPORTS FROM THE LABORATORY OF THE ROYAL COLLEGE OF PHYSICIANS, EDINBURGH.** Edited by J. BATTY TUCKER, M.D., G. SIMS WOODHEAD, M.D., and D. NOEL PATON, M.D.
- VOLUME FIRST, 8vo, Cloth, pp. 212, with 23 full page Plates, and 19 Engravings. Price 7s. 6d. net.
VOLUME SECOND, 8vo, Cloth, pp. xiv. 280, with 43 full page Plates, consisting of Lithographs, Chromo-Lithographs, and Micro-Photographs. Price 10s. 6d. net.
VOLUME THIRD, 8vo, Cloth, pp. xii. 304, with 11 Plates and Folding Charts. Price 9s. net.
VOLUME FOURTH, 8vo, Cloth, pp. xii. 254. With 25 Plates and Folding Charts. Price 10s. 6d. net.
- 18mo, pp. xvi. 293, in Flexible Leather Binding, for the Pocket. Price 6s. 6d.
PRESCRIBING AND TREATMENT IN THE DISEASES OF INFANTS AND CHILDREN. By PHILIP E. MUSKETT, late Surgeon to the Sydney Hospital; formerly Senior Resident Medical Officer, Sydney Hospital.
- Crown 8vo, Cloth, pp. xvi. 376. With 101 Illustrations, some coloured. Price 10s. 6d.
PHYSICAL DIAGNOSIS. A Guide to the Methods of Clinical Investigation. By G. A. GIBSON, M.D., D.Sc., F.R.C.P. Ed., Lecturer on the Principles and Practice of Medicine in the Edinburgh Medical School; Examiner on Medicine and Clinical Medicine in the University of Glasgow; and WILLIAM RUSSELL, M.D., F.R.C.P. Ed., Pathologist to the Royal Infirmary of Edinburgh, Lecturer on Pathology and Morbid Anatomy in the Edinburgh Medical School. [*Pentland's Students' Manuals.*]
- Crown 8vo, Cloth, pp. xvi. 226. Price 6s.
SURGICAL ANATOMY: A Manual for Students. By A. MARMADUKE SHEILD, M.B. Cantab., F.R.C.S., Senior Assistant Surgeon; Aural Surgeon and Teacher of Operative Surgery, Charing-Cross Hospital. [*Pentland's Students' Manuals.*]
- Crown 8vo, Cloth, pp. xvi. 612. With 32 pages of Illustrations. Price 12s. 6d.
OUTLINES OF ZOOLOGY. By J. ARTHUR THOMSON, M.A., Lecturer on Zoology, School of Medicine, Edinburgh. [*Pentland's Students' Manuals.*]
- Crown 4to, Extra Cloth, Gilt Top. With 70 Plates, exhibiting over 400 Figures. Price 12s. 6d.
ILLUSTRATIONS OF ZOOLOGY. Invertebrates and Vertebrates. By WILLIAM RAMSAY SMITH, B.Sc., Demonstrator of Anatomy, Edinburgh School of Medicine, Minto House, late Senior Assistant to the Professor of Natural History, University of Edinburgh; and J. STEWART NORWELL, B.Sc.
- 8vo, Cloth, pp. xii. 102. With 4 Illustrations. Price 5s.
SUPPURATION AND SEPTIC DISEASES. Three Lectures delivered at the Royal College of Surgeons of England. By W. WATSON CHEYNE, M.B., F.R.C.S., Hunterian Professor; Surgeon to King's College Hospital; Examiner in Surgery at Edinburgh University.
- 8vo, Cloth, pp. xii. 223. With 7 Illustrations. Price 9s.
ELEMENTS OF PHARMACOLOGY. By DR. OSWALD SCHMEDEBERG, Professor of Pharmacology, and Director of Pharmacological Institute, University of Strassburg. Translated, under the Author's supervision, by THOMAS DRXSON, M.D., Lecturer on Materia Medica in the University of Sydney, N.S.W.
- Crown 8vo, Cloth, pp. xvi. 216. With Coloured Plate and 29 Wood Engravings. Price 5s.
HANDBOOK OF OBSTETRIC NURSING. By F. W. N. HAULTAIN, M.D., F.R.C.P. Ed., Physician to the Royal Dispensary; late Clinical Assistant to Physician for Diseases of Women, Royal Infirmary, Edinburgh; and J. HAIN FERGUSON, M.B., F.R.C.P. Ed., Physician to the New Town Dispensary; late Resident Physician, Royal Maternity Hospital, Edinburgh.

YOUNG J. PENTLAND,

EDINBURGH: 11 TAVIOT PLACE.

LONDON: 38 WEST SMITHFIELD, E.C.

