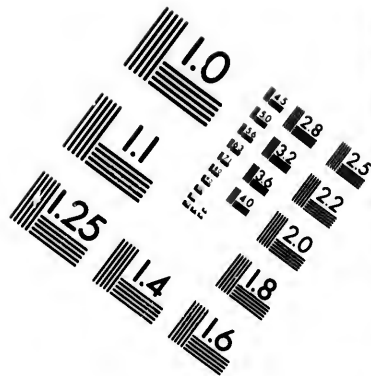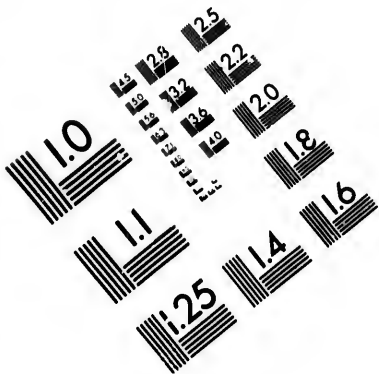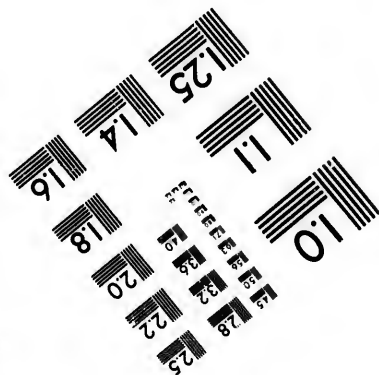
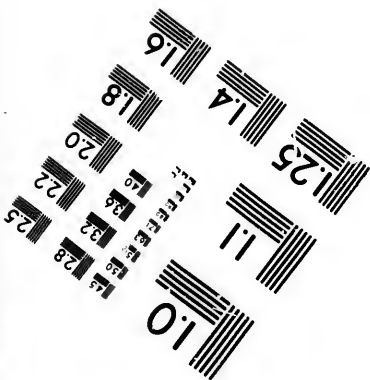
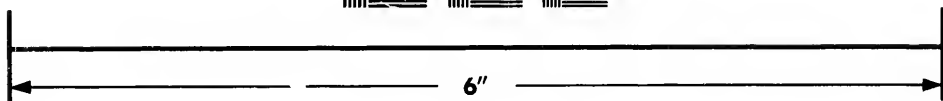
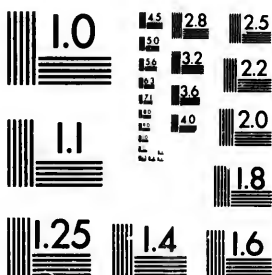


**IMAGE EVALUATION
TEST TARGET (MT-3)**



**Photographic
Sciences
Corporation**

23 WEST MAIN STREET
WEBSTER, N.Y. 14580
(716) 872-4503

**CIHM/ICMH
Microfiche
Series.**

**CIHM/ICMH
Collection de
microfiches.**



Canadian Institute for Historical Microreproductions / Institut canadien de microreproductions historiques

© 1982

Technical and Bibliographic Notes/Notes techniques et bibliographiques

The Institute has attempted to obtain the best original copy available for filming. Features of this copy which may be bibliographically unique, which may alter any of the images in the reproduction, or which may significantly change the usual method of filming, are checked below.

- Coloured covers/
Couverture de couleur
- Covers damaged/
Couverture endommagée
- Covers restored and/or laminated/
Couverture restaurée et/ou pelliculée
- Cover title missing/
Le titre de couverture manque
- Coloured maps/
Cartes géographiques en couleur
- Coloured ink (i.e. other than blue or black)/
Encre de couleur (i.e. autre que bleue ou noire)
- Coloured plates and/or illustrations/
Planches et/ou illustrations en couleur
- Bound with other material/
Relié avec d'autres documents
- Tight binding may cause shadows or distortion
along interior margin/
La reliure serrée peut causer de l'ombre ou de la
distortion le long de la marge intérieure
- Blank leaves added during restoration may
appear within the text. Whenever possible, these
have been omitted from filming/
Il se peut que certaines pages blanches ajoutées
lors d'une restauration apparaissent dans le texte,
mais, lorsque cela était possible, ces pages n'ont
pas été filmées.
- Additional comments:/
Commentaires supplémentaires:

L'Institut a microfilmé le meilleur exemplaire qu'il lui a été possible de se procurer. Les détails de cet exemplaire qui sont peut-être uniques du point de vue bibliographique, qui peuvent modifier une image reproduite, ou qui peuvent exiger une modification dans la méthode normale de filmage sont indiqués ci-dessous.

- Coloured pages/
Pages de couleur
- Pages damaged/
Pages endommagées
- Pages restored and/or laminated/
Pages restaurées et/ou pelliculées
- Pages discoloured, stained or foxed/
Pages décolorées, tachetées ou piquées
- Pages detached/
Pages détachées
- Showthrough/
Transparence
- Quality of print varies/
Qualité inégale de l'impression
- Includes supplementary material/
Comprend du matériel supplémentaire
- Only edition available/
Seule édition disponible
- Pages wholly or partially obscured by errata
slips, tissues, etc., have been refilmed to
ensure the best possible image/
Les pages totalement ou partiellement
obscurcies par un feuillet d'errata, une pelure,
etc., ont été filmées à nouveau de façon à
obtenir la meilleure image possible.

This item is filmed at the reduction ratio checked below/
Ce document est filmé au taux de réduction indiqué ci-dessous.

10X	12X	14X	16X	18X	20X	22X	24X	26X	28X	30X	32X
					✓						

The copy filmed here has been reproduced thanks to the generosity of:

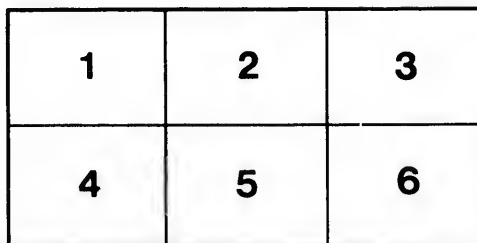
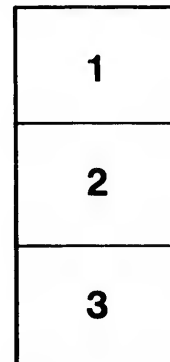
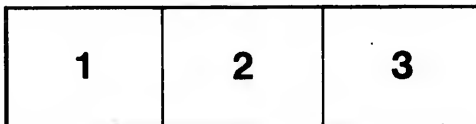
Bibliothèque nationale du Québec

The images appearing here are the best quality possible considering the condition and legibility of the original copy and in keeping with the filming contract specifications.

Original copies in printed paper covers are filmed beginning with the front cover and ending on the last page with a printed or illustrated impression, or the back cover when appropriate. All other original copies are filmed beginning on the first page with a printed or illustrated impression, and ending on the last page with a printed or illustrated impression.

The last recorded frame on each microfiche shall contain the symbol \rightarrow (meaning "CONTINUED"), or the symbol ∇ (meaning "END"), whichever applies.

Maps, plates, charts, etc., may be filmed at different reduction ratios. Those too large to be entirely included in one exposure are filmed beginning in the upper left hand corner, left to right and top to bottom, as many frames as required. The following diagrams illustrate the method:



L'exemplaire filmé fut reproduit grâce à la générosité de:

Bibliothèque nationale du Québec

Les images suivantes ont été reproduites avec le plus grand soin, compte tenu de la condition et de la netteté de l'exemplaire filmé, et en conformité avec les conditions du contrat de filmage.

Les exemplaires originaux dont la couverture en papier est imprimée sont filmés en commençant par le premier plat et en terminant soit par la dernière page qui comporte une empreinte d'impression ou d'illustration, soit par le second plat, selon le cas. Tous les autres exemplaires originaux sont filmés en commençant par la première page qui comporte une empreinte d'impression ou d'illustration et en terminant par la dernière page qui comporte une telle empreinte.

Un des symboles suivants apparaîtra sur la dernière image de chaque microfiche, selon le cas: le symbole \rightarrow signifie "A SUIVRE", le symbole ∇ signifie "FIN".

Les cartes, planches, tableaux, etc., peuvent être filmés à des taux de réduction différents. Lorsque le document est trop grand pour être reproduit en un seul cliché, il est filmé à partir de l'angle supérieur gauche, de gauche à droite, et de haut en bas, en prenant le nombre d'images nécessaire. Les diagrammes suivants illustrent la méthode.



Bibliothèque Nationale du Québec

14.22
446

Mr. Wm. J. Chapman
with the best Compliments

EQ
1133
A7J62

ONE HUNDRED CASES
IN THE
CORONER'S COURT OF MONTREAL,
1893.

BY
WYATT JOHNSTON, M.D., MONTREAL.
Medical Expert to the Coroner's Court, Montreal.

(Reprinted from the Montreal Medical Journal.)

~~8. 614. 13~~

~~8649h~~

ONE HUNDRED CASES
IN THE
CORONER'S COURT OF MONTREAL,
1893.

BY
WYATT JOHNSTON, M.D., MONTREAL.

(Reprinted from the Montreal Medical Journal, September, 1893.)

58362

3100001000
300010-1000


KEQ

1133

A7562.

CONTENTS,

	PAGE.
INTRODUCTION	3
I. DROWNING (22 Cases).....	5
II. POISON.....	25
Arsenic (3 Cases).....	26
Sulphate of Copper	27
Chloral.....	28
Chloroform (2 Cases).....	29
Carbon monoxide (3 Cases).....	30
III. INJURIES.....	32
Fracture of Skull (14 Cases).....	32
Other injuries from crushing	39
Rupture of Liver	39
Dislocation of Neck (3 Cases)	41
Firearms (3 Cases).....	42
Surgical Operation	44
Umbilical Hæmorrhage (?).....	44
Hanging.....	45
Asphyxia by Food	45
Burns (4 Cases)	46
Concussion, Shock, etc. (6 Cases)	47
IV. NATURAL CAUSES.....	49
Pneumonia (6 Cases).....	51
Phthisis (2 Cases).....	54
Pulmonary Embolism	54
Heart Disease (3 Cases).....	55
Granular Kidney	56
Cerebral Hæmorrhage (4 Cases).....	57
Cerebral Abscess.....	59
Still Born (2 Cases)	59
V. DOUBTFUL OR UNKNOWN CAUSES.....	60
Capillary Thrombosis of Brain.....	60
Epilepsy (?) (2 Cases)	61
Inanition—Debility (2 Cases).....	62
Other Causes (6 Cases).....	63




My object has been to show the opportunities for scientific medico-legal study afforded by even a series of one hundred consecutive cases, none of which presented any specially sensational features.

Incidentally these cases have served to illustrate the workings of the Quebec Coroner Law, which places a coroner, who has received a report of a suspicious death, somewhat in the position of the young lady who was permitted to swim but not to go near the water.

The determination of whether a death is due to violence or not chiefly depends upon a knowledge of the cause of death, and this naturally involves a medical examination. But although no coroner is allowed to hold an inquest or summon a jury unless he has first made a declaration under oath that in his opinion death has been due to criminal violence, he is neither allowed to employ medical aid in determining the cause of death, nor, except under exceptional circumstances, to order an autopsy without first summoning and obtaining the consent of a majority of the jury.

It gives me much pleasure to record here my thanks to Coroner McMahon for his many acts of courtesy and consideration, and it may not be out of place to state that, personally, his ideas as to the usefulness of autopsies and the uselessness of juries as a means of investigating violent deaths are quite in accord with my own, and that the proportion of autopsies to inquests has risen from 5 per cent. in 1802 to 15 per cent. in 1803, and to over 25 cent. in 1894. In order to have a satisfactory service, however, autopsies would be necessary in over half the deaths investigated.



ONE HUNDRED CASES
IN THE
CORONER'S COURT OF MONTREAL, 1893.

By WYATT JOHNSTON, M.D., Montreal.

The increased interest taken in the proceedings of the Coroner's Court by the medical profession and the public during the past year, which has led to my being entrusted with the medical examination of bodies upon which inquests are held—as far as was possible under the existing laws and regulations,—makes a faithful report of the work done one of the duties of this position. In a preliminary communication prepared jointly with Dr. G. Villeneuve,* it was found impossible to do much more than deal with the general statistical aspects of the medical evidence, in order to prevent our paper from being too long, so that the scientific details of the cases could not be considered.

It is perhaps necessary to apologize for including so many ordinary and commonplace cases, but, as no such series has yet been published in Canada, it seemed worth while to give a true picture of the ordinary every-day work of a coroner's physician. Although 100 cases form too small a material to offer much that is novel or curious in the way of medico-legal facts, yet it seemed well at the present time to publish a series of observations which would give a general idea of the

* Montreal Medical Journal, Aug., 1893. L'Union Médicale du Canada .Aug., 1893.

usual medical questions coming up for consideration, and the grounds upon which they were decided.

In giving evidence, I have made it a rule to confine my statements of opinion as far as possible to what was clearly demonstrated by the facts observed, and in each case to state fully the facts from which these conclusions were drawn; in other words, to let the facts speak for themselves. In case it became necessary to make statements based upon probabilities, this was frankly admitted, and the possible objections to the view taken fully discussed. The practice of bolstering up weak and inconclusive facts by strong affirmations of opinion is unworthy of the name of medical testimony.

The chief end of the medical evidence was, of course, to establish clearly the cause of death. Many interesting cases of the present series have, unfortunately, not been made clear by the medical testimony, owing to autopsies not being permitted. Out of my 100 cases there were 29 autopsies ordered, testimony being given after external examinations only in the remaining 71 cases.

As a general rule, it was found that where autopsies were performed the cause of death was demonstrated with absolute certainty in almost every case, and testimony of the most positive kind could be given without reserve. On the other hand, in the case of the external examinations, I can only recall half-a-dozen instances where I felt justified in making a positive statement as to the cause of death, and these few were in connection with public accidents, where, in any case, there would have been no reasonable doubt on this point, even if no medical examination at all had been made, as the circumstances of the accidents and their fatal results were clearly established by eye-witnesses.

In two of the more important cases (Nos. 45 and 59) I was fortunate in having the co-operation of Dr. G. Villeneuve in making the examinations, and obtained valuable aid from his thorough knowledge of medico-legal questions and clear reasoning upon the facts observed by us jointly. It is much easier, as a rule, to recognize the facts brought out by a post-mortem

than to decide upon their significance and the extent to which they are to be allowed to influence an opinion. The system at present in vogue, which necessitates hastily formed conclusions being submitted, without time for reflection, to an impatient jury, is one which is bound to lead, sooner or later, to serious error or miscarriage of justice, and which places the medical witness in a most unenviable position.

I have arranged the cases according to the causes of death found, rather than according to the verdicts given, and have considered chiefly the facts brought out by the examination, the conclusions formed from these, and the finding of the jury.

In drawing up reports the French form of protocol has been followed. The German system of numbering each paragraph is convenient for reference afterwards, but was found to be too cumbersome.

I.—DEATH BY DROWNING (22 CASES.)

Of the 22 cases, 18 were identified and 4 were those of unknown persons. Three autopsies were ordered, one of which was upon a body not identified. The remaining examinations were external only. In my opinion, autopsies should always be made where the facts of the death are not proved by eye-witnesses, or where there is any reason to suspect the good faith of such witnesses. Two verdicts of suicide and one of manslaughter were rendered, and in 14 the death was stated to be accidental. In the remaining five cases the verdict was simply found drowned or found in the water. In all but two of the identified persons the circumstances of the death were attested to by eye-witnesses, making the medical testimony merely corroborative. In these cases the bodies were usually found close to the scene of the accident, after the lapse of from a few hours to a few days.

When a body is found in the water, the following questions always arise :

- (a) How long has the body been in the water ?
- (b) Was the death due to drowning ?
- (c) Was the death the result of a crime ?

A.—Indications of Time in Water.

The following signs given by Duvergie and Vibert were prepared from an extensive and accurate knowledge of the appearances of drowned bodies :

TIME.		APPEARANCE.
WINTER.	SUMMER.	
3 to 5 days...	5 to 8 hours.	Rigor mortis; body feels very cold and clammy; epidermis commencing to whiten; finger tips wrinkled.
4 to 8 days...	24 hours....	Limbs flaccid; skin of natural colour; epidermis of palms very bleached; palms wrinkled; rigor in summer.
8 to 12 days..	48 hours....	Flaccidity; bleaching of backs of hands; face waxy-looking.
2 weeks.....	4 days.....	Face puffy, reddened in places; greenish tinge of skin over sternum; epidermis of palms and soles completely bleached and commencing to form folds. Interstitial formation of gases commences. (<i>Green putrefaction period.</i>)
1 month.....	8 to 12 days.	Face reddish-brown; lips and eyelids green; chest greenish; skin of hands and feet wrinkled, swollen and creased as if by poultices, its consistency chalky. Body floats owing to production of gases. (<i>Period of bloating.</i>)
2 months....	1 month....	Face brown and swollen; epidermis largely peeled off from body; nails still attached; hair of scalp readily scraped off; skin begins to get sodden, like wet cardboard or parchment. (<i>Brown putrefaction period.</i>)
2½ months...	Epidermis and nails of hands detached; epidermis of feet detached, nails still adherent; reddening of subcutaneous tissues; partial saponification of cheeks, chin, mammæ and anterior surface of thighs. (<i>Saponification period.</i>)
3½ months...	Partial detachment of scalp, eyelids and nose; saponification of neck and groins; epidermis of hands and feet completely detached and nails fallen off. (<i>Destructive putrefaction period.</i>)
4½ months...	Complete saponification of face, neck and anterior part of thighs; cutis opalescent; cranium denuded and becoming brittle; incrustation of lime in the form of small rounded or conical tubercles, size of peas, in skin of thighs. (<i>Incrustation period.</i>)

Duvergie states that the changes in summer appear about 20 to 22 days earlier than in winter, the rate in spring and autumn being intermediate. In these late periods the signs are uncertain, and the relation between the summer and winter rates of alteration very inconstant. In winter maceration alone occurs; in summer putrefaction and maceration go on simultaneously. Immersion, while it lasts, retards putrefaction, but bodies removed from the water putrify with astonishing rapidity; hence the necessity of their being viewed without delay, in order not to confound the appearances produced while in the water with those which occur subsequently.

I have endeavoured, from my own cases, to check these statements as far as possible, and find out by a study of the appearances of bodies where the period of immersion was known, to see what statements might safely be made with regard to bodies found in the neighbourhood of Montreal.

The collection of facts on this head was made difficult by the fact that nearly all of the examinations had to be made under unfavourable conditions as regards light, the bodies often being laid out in rooms lighted with candles only. The absence of facilities for dictating full notes also made the task more difficult.

The rapid decomposition of bodies after they had been removed from the water was very striking. Bodies which looked perfectly fresh when first removed became almost unrecognizable in the course of a few hours. It was impossible to prevent the occurrence of these changes in the absence of a proper refrigerating chamber. The absence of a suitable morgue made it also impossible for the progress of decomposition to be followed and noted.

As will be seen by reference to the cases, the signs of immersion, or, in other words, the evidences of maceration, came on even more rapidly in summer than might be expected from Duvergie's table. After the end of June this was especially marked. In Cases 96 and 97, an immersion of a few hours in August was found to induce as marked maceration changes than would ensue in as many days in June.

In connection with this, it is of interest to record here my observations of the mean monthly temperature of the water about Montreal, made two years ago. As I have found that the water temperature of 21° C. for August was the same in 1893 as in 1890, it may be assumed that these temperatures are fairly constant. The great size of the bodies of water (St. Lawrence and Ottawa rivers) from which they are taken, renders it unlikely that the daily and weekly variations are considerable in amount. Canal and reservoir water was found to be 2° to 4° C. higher than river water during the summer.

TEMPERATURE IN 1890.*

MONTHS.	Jan.	Feb.	Mar.	April.	May.	June.	July.	Aug.	Sept.	Oct.	Nov.	Dec.
Water, C°	0	0	0	4	10.9	14	18	21	18.3	13	10	4
Air, F°	15	17	26	42	52	65	66	66	62	45	33	7

In the examination of the bodies immersed near Montreal, and recorded in tabular form below, the chief deviation from the results given in text books was the longer duration of rigor mortis, which was still well marked after one to two weeks' immersion during the summer, in spite of the presence of advanced putrefaction in parts of the body. The muscles of the legs appear to resist putrefactive changes for a considerable time. In one case where a body showed marked maceration and decomposition, but where rigor mortis persisted, a bacteriological examination showed the absence of bacteria, microscopically, from the rectus femoris muscle and cultures made from that region remained sterile.

The early appearance of a greenish tinge over the sternum and pectoral region mentioned by Duvergie was often present. It evidently depends upon the early and rapid decomposition of the head and neck, with penetration of the gases along the planes of the fascia. It appears long before a green tinge of the abdomen is seen.

*The temperature of the air is that recorded by Prof. C. H. McLeod at the McGill Observatory.

The wrinkled and bleached condition of the hands was, on the other hand, produced much more rapidly than one would expect from Duvergi's tables. I found in a body (Case 97) recovered from the water on a warm August afternoon, after a submersion of less than an hour, and examined a few hours later, before it had even time to become cold, a quite typical, bleached and wrinkled appearance of the palms and soles, and another body (Case 96) examined earlier on the same day, after being in the water for two hours during the previous night, also presented a typical condition of wrinkling of the epidermis. In neither case was the epidermis specially thick, one being that of a young girl and the other that of a boy of twelve.

Whether the water bacteria, or the bacteria of the body are the active agents in bringing about the decomposition of the bodies is a matter which I hope to deal with in a future communication. The extremely rapid march of putrefaction in immersed bodies appears to depend essentially upon the greater amount of water which the tissues contain, just as a moist gangrene shows much more marked putrefaction phenomena than a dry, senile gangrene. When, however, a body has been for a very long time immersed in water (several months), its putrefaction upon exposure to air is relatively slow, perhaps because the bacteria which have penetrated the tissues have had time to die out, or non-putrescible substances formed in the tissues.

The presence of *cutis anserina* was noted in 2 cases. It did not appear, as would be expected from the statements found in text books, as an early change, and was found in bodies which had been immersed from three to seven days. It appears to be more readily produced by cold air than cold water, and was commonly seen in bodies which were placed on ice.

Shrinking of the penis and scrotum was often seen, but is not a reliable sign, as the external genitals soon become puffy and emphysematous when the bodies are removed from the water. It is said that this appearance may be produced by immersion post mortem.

In several instances the skin over the knee; was white and wrinkled.

B—Did Death result from Drowning?

The distinction between drowning (submersion) and the entrance of a dead body into the water (immersion), I found to be easy to decide in some cases, and difficult or impossible in others.

It may be well here to mention briefly the signs of drowning.

The signs of immersion given above only show that the body has remained for a certain period. In addition to this, certain appearances indicate that the body entered the water alive.

(1) *External Signs of Drowning.*—The only direct and reliable sign is that of a very abundant, fine, white froth which issues from the mouth and nostrils of drowned for a period of a few hours until two or three days after death. This is not well marked until some hours after death and disappears by the time the maceration changes have become advanced, or when putrefaction has fully set in. This foam was found present in 5 of my cases and absent in 17. It is not absolutely characteristic of drowning as I have seen it in two cases of cerebral hæmorrhage, and one of which was spontaneous (case 66), and the other traumatic (case 48), and is of value chiefly in indicating that death has been due to asphyxia. A reddish, frothy fluid, oozing from the mouth and nose of bodies partly decomposed, is no evidence of drowning.

The skin of drowned bodies is blanched.

Ecchymosis of the skin and conjunctivæ, common signs of asphyxia, were not met with in any of my cases of drowning, an observation in accordance with the statements of text-books.

Seminal emissions were twice observed. When not emphysematous, the penis and scrotum were usually shrunken.

The presence of mud, tufts of grass, etc., about the fingers and nails, which is supposed to indicate struggling near a bank, was only met with in one case (No. 61).

(2) *Internal Signs of Drowning.*—These are: (a) *Respiratory tract.*—The epiglottis is stated to be vertical in bodies

which have been drowned, and merely partly raised in those immersed after death. The presence of froth or water in the air passages, with œdema, or sometimes emphysematous inflation, engorgement and sub-pleural or deep-seated ecchymosis of the lungs is highly characteristic. The presence of a pint or so of reddish fluid in the pleural cavity was noted, but has no distinct significance. (*b*) Foreign bodies, such as mud, etc., in the air passages and eustachian tube. These were not seen in the cases where autopsies were made, and their absence has obviously no negative significance where the body is found in a large, clear body of water like the St. Lawrence river. (*c*) Fluid in the stomach. In the three cases examined, the stomach was found practically empty. In one of these the death was sufficiently recent to infer from this that water had not been swallowed in any considerable quantity. In the other two transudation into the peritoneum may or may not have occurred. It has been recommended* to compare by chemical analysis the fluid found in the stomach, middle ear, air passages, etc., with the water in which drowning is supposed to have occurred. (*d*) Water in the middle ear. (*e*) Foreign substances in the middle ear.

The penetration of foreign bodies into the middle ear and bronchi has also been produced artificially by immersing dead bodies in a solution of starch or meal.† This took place in 28 per cent. of the experiments. This is stated by Lacassagne only to occur after death when there is perforation of the tympanum. None were met with in my cases.

The three cases in which autopsies were allowed were all bodies which had been a long time in the water and which had in addition become putrefied after removal, so that the characteristic signs of drowning were absent.

It is stated that œdema of the lungs may occur in post-mortem immersion, also that in an œdematous lung collapse may occur. Paltauf‡ was able to show, by means of the

* Bougier. Thesis, Paris, 1884.

† Iluevkovsky. Arch. l'Anthropol. Criminel, Sept, 1887.

‡ Ueber Tod durch Ertrinkung, 1888.

hæmomometer, that in bodies immersed experimentally the blood in the heart had become diluted.

* Bougier found that in bodies immersed and afterwards frozen that ice crystals were found in the large and middle-sized bronchi, but not as a rule in the bronchioles.

The right heart may either be engorged with blood or completely empty, according to whether death occurs by asphyxia or syncope.

(f) On the whole, the presence of a large amount of watery fluid (over 12 oz.) in the stomach is probably, next to actual froth in the bronchi, the most reliable of signs of drowning, as water does not tend to enter the stomach after death. My own material is too limited to permit me to express an opinion.

C.—Was Death the result of a Crime?

For the distinction between homicidal, suicidal and accidental drowning the medical testimony, apart from other evidence, cannot, as a rule, be very positive. It is impossible, for example, to tell whether the individual simply fell into the water, or was pushed in.

The direct medical evidence bearing upon this point would be the signs of a struggle, bruises, scratches, etc., and for this reason the hands and fingers must be examined with especial care.

In two of my cases (Nos. 93 and 94, drowned at the same time and place) such marks of violence were found. These consisted of numerous spots of ecchymosis on the arms and chest. The opinion given was that bruises had occurred before death, and that certain other lesions of the surface, abrasions and parchmentation had been produced after death, probably in the process of fishing out the bodies, but that the legal significance of the bruises could not be definitely stated without further knowledge of the circumstances of the death. It subsequently transpired that one of the victims, who could not swim, seized hold of the other, who struggled in vain to free himself, and when found the limbs of both were locked in a close embrace.

* H. Bougier. Thesis, Paris, 1884.

Anything pointing to a criminal homicide, after which the body might have been thrown into the water, has to be borne in mind. This was not indicated in any of my cases.

The absence of any marks of violence or evidence of other modes of death affords, to a certain extent, grounds for supposing that death must have been due to drowning, even when the signs of drowning have disappeared, but statements on this head have to be made with extreme caution, as the possibility of poisoning must be borne in mind.

The question of whether wounds have been made before or after death must also be dealt with in a guarded manner, as on the one hand the blood pigments tend to diffuse themselves in a remarkable degree in immersed bodies, and on the other hand an actual blood-clot may be washed away, or decolorized, or even dissolved. Definite ecchymosis of clotted blood about an injury, however, indicates a lesion produced before death.

I venture to offer the present small material for consideration, more from a desire to offer proof of having been "faithful over a few things" than in the hope that the cases quoted are specially interesting to others. The following are the details of the cases:

CASE 47.—*Blow on Head and Drowning.—Autopsy.*—J. B. C., aged 45, labourer, while working upon a dredge, was struck upon the head by the iron scoop and knocked into the water. The body was recovered two weeks later, and an autopsy ordered.

Autopsy performed June 3, 1891, 24 hours after removal from water. Clothing not torn or disarranged. Head and neck greatly swollen, and features nearly obliterated. Genitals emphysematous. *Hair of scalp and moustaches readily scraped off. Skin of palms and soles white and wrinkled.* Over trunk numerous large blebs beneath epidermis filled with greenish fluid. On lower limbs similar vesicles containing clear fluid. Rigor mortis present. Strong odour of putrefaction.

A scalp wound, with ragged, lacerated edges, extends from two inches above the left external angle of the orbit nearly to the vertex. The pericranium is torn, and the bone exposed.

A linear fracture, three inches in length, extends upwards from the left frontal eminence.

On reflecting the scalp, the occipital region is seen to be infiltrated with a bloody, serous fluid extending downwards into the cellular tissue of the upper part of the neck, and *clotted blood is found free in*

the tissue. On removing the skull cap by sawing through the bone and brain together,* it is seen that the fracture is chiefly confined to the outer table of the frontal bone, the inner table presenting only a line of fracture one inch long. There is no ecchymosis about the fracture of the inner table or the dura.

Brain much softened, but the surface and convolutions retain sufficient consistency to be studied at the seat of the injury. There is no evidence of hemorrhage or laceration.

On removal of the dura from the base of the skull, the bone is found free from fracture.

Half a pint of reddish fluid in each pleura. Bronchi free from foreign bodies. Stomach contained about 4 oz. of thick, greyish pulp. No water or foreign bodies found in internal ear.

(Nothing abnormal was found in the other organs).

Conclusions.—1. The body shows signs of maceration corresponding to a stay of about two weeks in rather cold water. The internal organs are sufficiently well preserved to render their examination satisfactory.

2. A lacerated and contused scalp wound and fracture of the outer table of the skull exist. This injury appears to have been produced before death, and been of sufficient severity to stun a man, but not to kill him immediately.

3. The state of the lungs and stomach corresponds with that of a man unable to struggle in the water.

In this case the death was the result of an accident. A verdict of manslaughter was returned, as a foreman was thought to have been guilty of criminal negligence, but the Grand Jury found no bill. The points to be determined at the autopsy were whether death had occurred from drowning or in consequence of the blow. The presence of ecchymosis beneath the scalp showed that bleeding into the tissues had taken place after the blow, and this view was afterwards confirmed by the statement of a witness that after the body had sunk a large amount of blood continued to stain the water, which of course would not have been the case if the blow had been instantly fatal. The state of the stomach, however, showed that no water had been swallowed, and that therefore probably no struggle for air had taken place.

*This method of removing the brain, followed in the Paris morgue, is extremely simple and easy. The study of lesions in the brain and membranes are not interfered with, and one is perfectly sure that lines of fracture are not artificially extended. It is possible in this way to successfully remove a brain which is all but diffluent.

CASE 49.—*Unknown Man—Contusion of Head—
Drowning—Autopsy.*

Body found in Lachine Canal on June 3, 1893. Autopsy on June 5, 1893. Weather very warm. Decomposition advanced. Features unrecognizable. Skin of hands and feet white and wrinkled. Hair not detached. At outer angle of right eyelid a laceration half an inch in length, penetrating half an inch; edges ragged. Cellular tissue in neighbourhood infiltrated with reddish serum. Bones of skull and face intact. Brain a good deal softened; no appearance of hæmorrhage or disease. One pint of reddish fluid in each pleura. No appearance of foreign bodies or froth in bronchi. Stomach almost empty.

Conclusions. 1. The body is that of a man probably over 40 and under 50 years of age.

2. The evidences of maceration point to a week or ten days in the water.

3. The laceration about the eyelid is not shown to have been caused before death. No other signs of violence.

4. There is nothing to indicate that death has not been caused by drowning.

In this case the slight injury in the region of the eye was surrounded by abundant reddish serous infiltration into the tissues, but this is very liable to take place by the action of the water in lesions made after immersion, or gnawed by fishes. The existence of considerable ossification of the cranial bones without calcification of the costal cartilages seemed to place the age between about 40 and 50. The verdict was "Accidentally drowned."

CASE 50.—*Body of Young Woman—Identified Partly by
Teeth—Immersion for Several Months—Autopsy.*

Found in St. Lawrence river June 6, 1893. Autopsy June 7, 1893. Clothing much torn.

External Examination. Height 5 feet 3 inches. Body extensively macerated, but without much putrefactive odour. Scalp and flesh of face all gone, with exception of temporal muscles, leaving bones of skull and face bare. Flesh of trunk and limbs softened and large pieces missing. The subcutaneous adipose tissue is everywhere changed into a white, soapy substance. Skin and muscles mostly gone from hands, leaving tendons and bones exposed. Nails loosened, but still attached to hands and feet. Pubis covered with thick, dark hair. Lower part of abdomen much distended. No signs of injury to the bones nor any marks of violence on the body.

Internal Examination. Muscles of deep, beefy red colour. Mammary glands firm and rounded, areola pale, tissue well preserved. No

signs of any fluid resembling milk. In pleurae about a pint of reddish fluid. Cavities of heart nearly empty. Valves normal. Lungs crepitant throughout. F. uchi reddened, free from foreign bodies. Pharynx disintegrated and reduced to a pulpy condition. Spleen normal. Kidneys normal, in cortex a few whitish, gritty points, apparently tyrosin clusters. Bladder empty; mucosa normal. Pelvic organs appear normal. A corpus luteum of $\frac{1}{4}$ inch diameter, with reddish tint in right ovary. Uterus small, cervix long and narrow, mucosa thick and reddish, looking soft and velvety, length $2\frac{1}{2}$ inches, width between fallopian tubes $1\frac{1}{2}$ inches. Hymen circular, appears intact, orifice large enough to admit the thumb. Liver soft.

Stomach large, U shaped, near the fundus half a teacupful of reddish pulpy lumps, proving on further examination to be the pulp and skin of large grapes, with about a tablespoonful of very large grape seeds. Intestines normal, contain soft faeces and no grape seeds.

Head—On removing skull-cap brain escapes as a thick semi-fluid pulp; no appearance of hæmorrhage. Bones of cranium intact. The sutures of cranium do not appear to be ossified. Inferior maxilla contains three well developed molars on each side. On the right side the posterior premolar is displaced inwards, projecting towards the tongue. First left, and first and second right molars carious, no fillings. Incisors and canines absent from sockets, of which the edges are quite sharp. No signs of gums. Angle of jaw about 130° . Antero-posterior diameter of skull 7 inches; greatest transverse diameter $5\frac{1}{2}$ inches.

Conclusions.—1. The body is that of a fully developed woman, who has never borne children.

2. It has been in the water for over a month, and probably during the entire winter.

3. There is nothing in the result of the autopsy to show that death is due to causes other than drowning. The state of the body is such that the ordinary signs of drowning would have disappeared.

In this case the body was recognized as that of a young girl, aged 18, who had disappeared in October, 1892. The identification was at first thought to be established by a peculiar brooch made from a coin. Afterwards the friends were uncertain, but admitted that the missing girl had a malformation of the teeth similar to that described. The fact that the wisdom teeth were fully formed made it unlikely that the body was only 18 years old. In this case the autopsy was ordered to see if the distension of the abdomen was due to pregnancy or not, as from the external appearances there seemed little chance of learning anything more. I was surprised to find all the vital organs in such good preservation. The jury brought in a verdict of "Wilful suicide."

EXTERNAL EXAMINATIONS.

No.	DATE.	TIME IN WATER.	HISTORY--APPEARANCES.
44	1881. May 25.	12 hours. Montreal Harbour. Examined 12 hrs. after removal.	<p>W. R., sailor, aged 24. Fell off ship. No marks of external injury. Skin of hands firm and smooth. Skin of soles of feet white and wrinkled. A large amount of fine white froth issues from nostrils. Rigor mortis present. Viscid fluid in urethra.</p> <p>In this case the wrinkling of epidermis of soles appeared before that of the hands, owing to the fact that the body had lain with the wet boots and socks on for 12 hours before being examined. <i>Acc. death.</i></p>
46	June 2.	hours in Laachine Canal.	<p>A. R., boy, aged 10. Drowned while bathing. Skin everywhere feels very cold and clammy. Rigor mortis present. Skin of hands and feet not bleached or wrinkled. Fine white foam very plentiful about nostrils. No cutis anserina.—<i>Acc. death.</i></p>
55	June 17.	8 days in Laachine Canal. Examined 20 hrs. after removal.	<p>C. S., aged 11. Fell into canal near sluice gates at Cote St. Paul. Body found at St. Henri.</p> <p>Skin feels cold and moist. Epidermis readily brushed off with hand. Hair not loosened. Skin of palms, soles and anterior surface of knees white and wrinkled. Nails attached. Head and neck swollen and bloated; the skin is reddened. Greenish tinge over chest. Abdomen greatly distended. No froth about nostrils. Reddish fluid containing food particles oozes from mouth. Rigor mortis marked. Moderate lividity. A little feces about buttocks. Deep punctured wound, $\frac{1}{2}$ in. long, over left patally; edges everted and rounded. No ecchymosis.—<i>Accidental death.</i></p>
56	June 12.	24 hrs in St. Lawrence River. Examined 12 hrs. after removal.	<p>P. G., aged 40. Seen to fall off a wharf while placing a gangway, on June 6th, 1893.</p> <p>Marked rigor mortis. Advanced decomposition of head and face. Skin over chest and abdomen discoloured green. Epidermis raised into blebs filled with clear green fluid. Palms and soles white and wrinkled. Nails attached. Hair of scalp not easily detached. A bloody, frothy fluid keeps bubbling from nose.—<i>Accidental death.</i></p>
57	June 11.	5 days in St. Lawrence River. 12 hrs. after removal.	<p>N. D., aged 7. While playing, seen to fall off a wharf.</p> <p>Rigor mortis throughout body. Advanced decomposition. Head and neck reddened and swollen. Nose flattened. Conjunctivae red. Lids swollen. Reddish frothy fluid oozing from nostrils. Skin over chest greenish. Palms, soles and skin over knees white and wrinkled. Epidermis peels off when scraped.—<i>Accidental death.</i></p>

EXTERNAL EXAMINATIONS--Continued.

No.	DATE.	TIME IN WATER.	HISTORY--APPEARANCES.
61	1893. June 20.	3 days in shallow, muddy water near Longueuil. Examined 12 hrs. after removal.	J. M., aged 21. Seen to sink while bathing. Body smeared with thick mud. Numerous larvæ. Rigor mortis present. Skin of hands and feet wrinkled. Epidermis detaches from body. Head and face not much swollen. Genitals puffy.— <i>Accidental death.</i>
62	June 20.	(?) Examined 10 hrs. after removal.	Unknown man. Body found at Maison-neuve. Rigor mortis present. Body much decomposed. Head and neck swollen and nearly black in colour. Features obliterated. Veins appear as bluish-green lines over upper extremity. Skin of hands and feet white and wrinkled. Hair comes off readily in scraping.— <i>Found drowned.</i> (The time of immersion was estimated at one to two weeks.)
65	June 27.	10 days in Montreal Harbour. Examined 12 hrs. after removal.	A. M. Wharf labourer. Last seen on a wharf, and missed by his friends the following day.— <i>Found drowned.</i> Rigor mortis present. Reddish, frothy fluid issues from nose. Head and neck swollen and discoloured. Veins of upper extremity show as dark lines in the skin. Palms and soles wrinkled.
67	June 30.	2 days in Lachine Canal. Examined 10 hrs. after removal.	J. R., aged 15. Seen to drown while bathing. Rigor mortis marked. Lividity posteriorly. Undertaker's incisions for injecting embalming fluid. Skin cold and clammy. No signs of decomposition. Slight wrinkling of skin of palms, none of soles. Cutis anserina absent. Abundant white froth about nostrils. Superficial abrasions about backs of hands.— <i>Accidental death.</i>
69	July 2.	3 days in Lachine Canal. Examined 6 hrs. after removal.	St. P., aged 12. Seen to fall into water while playing. Putrefaction very far advanced; body has an internal putrid smell. Head and neck swollen and reddened. Chest greenish. Rigor mortis present. Skin of soles and scrotum white and wrinkled.— <i>Acc. death.</i>
76	July 13.	(?) in St. Lawrence River. Examined 24 hrs. after removal.	Unknown man, 20 to 30 years old. Mud and grass about fingers. Epidermis detaching over body. Skin of palms and soles white and wrinkled. Hair can be scraped off scalp. Decomposition advanced. Limbs flaccid.— <i>Found drowned.</i> (Immersion estimated at one to two weeks.)

EXTERNAL EXAMINATIONS—Continued.

No.	DATE.	TIME IN WATER.	HISTORY—APPEARANCE.
82	1893. July 25.	(?) in Montreal Aqueduct. Examined 24 hrs. after removal.	Unknown man; no history. Tattoo mark on right forearm. Advanced maceration. Limbs flaccid. Scalp and flesh of head and face almost all detached. Flesh of hands and feet detached, with exception of a few ragged fragments adhering to the bones. Muscles of neck and arms ragged and frayed, apparently from maceration. Subcutaneous fat appears completely saponified. No bones fractured. (Immersion estimated by me at several months.)— <i>Found drowned.</i>
81	July 31.	1 week in St. Lawrence River Examined 20 hrs. after removal.	J. H., age 35. Seen to fall overboard from a hay barge.— <i>Accidental death.</i> Marked rigor mortis. Face bloated and features almost effaced. Great discolouration, reddish black about head and greenish on chest and abdomen. Epidermis detaching. Skin of hands and feet bleached both on palmar and dorsal surfaces. Scalp feels thick and sodden. Hair not loosened.
93	Aug. 13.	2 days in Montreal Harbour. Examined 12 hrs. after removal.	T. W., aged 19. Bathing together with case No. 94. Skin of palms and soles white and wrinkled. Hair not loosened. Marked rigor mortis. Cutis anserina on inner surface of both thighs. Several spots of parchmentation on chest, arms and abdomen, some of which show ecchymosis beneath it; also several bluish spots were found in incising to be ecchymosis. <i>Opinion.</i> —1. The body shows marks of bruises and scratches, some of which have been produced before death and some after. It is impossible to tell what significance these have without other information about the circumstances of the death. 2. The cause of death cannot be stated from external examination.— <i>Acc. death.</i>
94	Aug. 13.	2 days in Montreal Harbour. Examined 10 hrs. after removal.	W. S., aged 25. Drowned on same occasion as case No. 93.— <i>Accidental death.</i> Mold forming on face. Rigor mortis marked. Cutis anserina of thighs. Skin of palms, soles, and knees white and wrinkled. Hair firmly attached. Face swollen and discoloured. Abdomen green. Genitals emphysematous. Greenish froth issuing from mouth. Numerous marks of parchmentation on trunk, which show in some cases ecchymosis beneath them. On left arm small elevated areas due to ecchymosis.

EXTERNAL EXAMINATIONS—Continued.

No.	DATE.	TIME IN WATER.	HISTORY—APPEARANCE.
94	1893. <i>Conf'd.</i>		<p><i>Conclusion.</i>—There is evidence of bruises made before death, and also abrasions apparently made after death. Their significance cannot be determined without more information about the circumstances of the death and recovery of the body.</p> <p><i>NOTE.</i>—It appeared from the evidence that T. W., who was unable to swim, had seized hold of W. S., who could, and a violent struggle took place in consequence of the latter's efforts to save himself. The bodies were found closely locked together. This gave a clear explanation of the ecchymosed spots. The other abrasions may have been caused at the same time, but more probably were due to the grappling irons used in fishing for the bodies.</p>
96	Aug. 16.	2 hours in Lachine Canal. Examined 8 hrs after removal.	<p>C. McA., a girl aged 19, was seen to fall into the canal in attempting to jump from an open drawbridge to the bank. Clothing not removed; body placed on ice.</p> <p>Marked post-mortem rigidity. Face and neck slightly swollen and puffy; not discoloured. No cutis anserina. Skin of palms and soles white and wrinkled. Fine, very abundant white froth about nostrils. Conjunctivæ pale.—<i>Accidental death.</i></p>
97	Aug. 1	Montreal Quarries. 1½ hours. Examined 4 hrs. after removal.	<p>A. D., boy aged 12. Seen to fall out of a boat into a shallow pond. Clothing not removed.</p> <p>Body still warm; limbs flaccid. Conjunctivæ pale. Blood obtained by incising scalp is fluid, not very dark, oozes freely from veins. A little thick, white froth in mouth and nostrils. Skin of palms and soles white and wrinkled. No cutis anserina.—<i>Accidental death.</i></p>
98	Aug. 17.	(?)	<p>W. W. Missing since July 6 (about six weeks). Circumstances of death unknown. Rigor mortis present. Intense putrefaction, odour like that of rancid fat. Epidermis detaching from all parts of body, and has completely separated from the hands and feet. Nails gone from hands and feet. The exposed cutis is smooth, slightly reddened and oily looking. Veins of surface appear as reddish or greenish hues. Hair readily scraped off from scalp. Face and neck swollen and bloated. Tongue protruding between the thickened lips. Eyelids everted and eyeballs protrude. Scalp feels sodden and at the same time puffy and emphysematous. Reddish fluid oozing from nose.</p>

EXTERNAL EXAMINATIONS—*Continued.*

NO.	DATE.	TIME IN WATER.	HISTORY—APPEARANCE.
98	1893. <i>Conf'd.</i>		NOTE:—In this case the length of immersion was estimated as being at least two weeks. Not having data concerning the appearance of bodies immersed for specified times at this season, I was unable to state whether the appearances made it possible that the body had been in the water for the whole six weeks during which he was missing.— <i>Found drowned.</i>
100	Aug. 21.	3 days in Montreal Harbour. Examined 2 hrs. after removal.	Identified as body of J. S., who was one of three men who threw themselves off the long wharf on August 18, 1893, with the intention of committing suicide. The two companions were saved. Rigor mortis present. Lips thick. Face swollen, discoloured and bloated. Reddish fluid in mouth. Testis retracted, scrotum emphysematous. Hair of scalp readily scraped off. Epidermis of hands and feet white and wrinkled, both on dorsal and palmar surface, and partly detached. Skin over knees white and wrinkled. Nails adherent. Greenish tinge over pectoral and sternal regions.— <i>Suicide.</i>

In the above report I have omitted the description of matters concerning identification of bodies, though, of course, these were recorded in the case of the unknown persons.

As a rule the opinions in the cases of external examination were drawn up as follows:

1. The body presents the appearances of having been in the water for
2. The cause of death cannot be stated from external examination.

In five of the cases it was stated that the body presented external appearances found in drowned persons. In several cases it was stated that no external signs of injury were present. This statement I have almost ceased to make, as it is calculated to mislead the jury into supposing that violence by blows, etc., has been proved not to have been committed, whereas it is well known that blows of great force, sufficient, for instance, to fracture the skull, can be inflicted without leaving any traces upon the surface of the body.

In the case of those bodies where the cause of death remained unexplained, it was a matter of keen regret to me that autopsies were only ordered in 2 out of 7 cases. It is true that the autopsy might not have solved this point, owing to the advanced post-mortem changes present, but it might have shown the presence of water or foreign substances in the stomach, air passages, middle ear, etc., on the one hand, or on the other have shown some internal disease or injury. My opinion is that the grounds for ordering an autopsy should be simply that the death is obscure, irrespective of whether the difficulties produced by post-mortem changes lessen the chances of a positive result or not. This is the view held in all European countries, and all physicians charged with medico-legal work are officially notified that *no degree of decomposition or disintegration of the body* ever justifies a medical man either in refusing to perform an autopsy or in neglecting to recommend it.

In my own work this view was always carefully stated in a general way to juries, both by Coroner McMahan and myself. As the matter of autopsies is still in an unsettled state in Montreal and is on its trial, I did not feel justified in directly insisting on their being held, on the off chance of finding out the cause of death under unfavourable circumstances, from the feeling that a large number of negative results at the present time might prejudice the whole question of the routine performance of autopsies. I therefore only insisted strongly on an autopsy in my written report in three instances, where I was able to show beforehand that information would certainly be obtained on special points requiring solution. These were case 47, when a fracture of the skull was found; case 49, where a fracture of the skull was shown to be absent, and case 50, where possibility of pregnancy was negatived. Thus in each case the information looked for was obtained at the autopsy.

That in inquests upon the bodies of unknown persons found dead the inquiry should be habitually closed without having used such an obvious means of investigation as is offered by an

autopsy, is a matter for which the responsibility must be borne by the juries who had it in their power to order autopsies and neglected to do so.

An additional case, not in this series, is added because an autopsy happened to be performed (at the request of a private individual.) The case presents some interesting features.

Case 102, 1893.—J. T., aged 25, coloured, was seen to sink in a public bath. He was able to swim. The statements about the circumstances of the death were somewhat contradictory, but it is certain that the body was removed from the water after an immersion of a few minutes only, and fruitless attempts at resuscitation were practiced by two skillful physicians.

The body when viewed two hours after the accident showed flaccidity of the limbs. A white froth was seen about the nostrils. The surface was still warm and quite dry. No signs of maceration. Two spots of bruising about the forehead. Conjunctivæ pale. A little fluid like sperm in the urethra. Autopsy 24 hours p.m. Rigor mortis marked. Foam still visible in nostrils. A few ounces of reddish fluid in peritoneum and pleuræ. Blood fluid; not thick or dark. Lungs bulky, inflated, crepitant throughout, gorged with blood, and show a few sub-pleural ecchymosis and numerous small areas of hæmorrhage in the substance. Cut surface yields abundant rusty foam, not watery. Trachea, bronchi and larynx reddened and contain reddish foam. Pharynx free. Heart enlarged, weighs 350 grammes; cavities somewhat dilated. Tricuspid orifice dilated, measures 6 inches in circumference; other orifices of usual size. Heart muscles very pale and bloodless, not fatty. A few ecchymosis beneath epicardium; none beneath the endocardium. Coronary arteries normal. Slight atheroma of aorta and mitral valves. Aorta and iliac arteries present slight but widely distributed atheroma. Inter-vertebral arteries slightly atheromatous. Radial arteries normal. Spleen normal. Lymphatics and mesenteric glands full of white chylous fluid. Stomach contains 12 oz. of thick, greyish, sour gruel-like pulp, evidently for the most part digested, but including some lumps of meat nearly the size of walnuts. The mucosa thick and grayish, covered with adherent mucus and with an extremely large number of whitish lymph glands as large as split peas near the pylorus. Intestines full of ordinary looking fæces; their vessels full and injection of mucosa marked. Kidneys large, weigh 200 grammes each; shape somewhat hog-back. Capsules rather thick, surfaces smooth and dark. Stellate veins full. On section cortex thick or coarse looking and *septæ Bertini* wide. Bladder contains 4 oz. of ordinary looking urine. Liver normal. Head—In frontal region, an area of coagulated blood extravasated in subcutaneous tissue beneath pericranium, diameter $1\frac{1}{2}$ inches; bone not injured. Brain normal; vessels moderately full. Middle ear free from water. Vessels of mastoid region extremely full of blood. Skull-cap dense, diploë scanty.

Conclusions.—1. Death has been due to drowning.

2. From the condition of the heart and kidneys it is possible that the submersion may have been due to a syncopal attack, but this cannot be stated with certainty.

3. The significance of the contusion on the forehead cannot be stated; it seems severe enough to have caused stunning.

In this case it was probable from the signs of drowning being marked that some accessory cause was present. Whether this was due to a blow on the head, or to some passing functional failure in a heart not perfectly normal, I am unable to decide, though the jury, by admitting heart failure, seem to have considered themselves in a position to do so.

The stomach at the time of death was still in full digestion, but most of the contents seemed to have been disposed of. Sufficient food remained to have masked the presence of a small quantity of water, say four to five ounces. From the presence of arterio-sclerosis, in the absence of any syphilitic lesions, the possibility of alcohol as a cause of this change had to be considered, but I refrained from making any statement on that point in absence of any conclusive proof, knowing the predilection of juries to bring in what may be termed "alcoholic" verdicts on very slender grounds.

I have endeavoured to show in the discussion of the above cases that the collection of facts, such as they furnish, may enable in the future statements as to the length of the period of immersion to be made with more confidence. I think it is also fairly evident that it would be better as a matter of routine to have autopsies performed in cases of death from drowning than not to have them performed. When the object of the inquiry is to decide the question of wilful homicide, it is indispensable that the physician making the examination should have a large experience in examining drowned bodies. If in ordinary cases the bodies are merely taken out of the water, viewed and buried, without being made available for scientific study, it is evident that no one can possibly be expected to acquire the experience necessary to make him an expert whose opinion, in a really difficult criminal case, would be of much value.

(To be continued.)

II.—DEATH BY POISON (7 CASES.*)

Of the series of 100 cases death was assumed to be due to poison in 7, or 7 per cent. Of these deaths 4 were suicidal and 3 accidental. The nature of the poison was Paris green in two cases, Rough on Rats, chloral, chloroform, copper sulphate and lighting gas each in one case.

In the matter of demanding an official analysis the medical expert is placed in rather an awkward position, as special permission has to be obtained from the department before this can be done. This necessitates an adjournment of the inquest and a considerable increase in the expense, although the modest fee of twenty dollars which is allowed as a minimum for the chemical examination in ordinary cases is too low to permit of any good chemist and analyst profitably undertaking the work.

It is not well understood that, on general principles, the motive for desiring an analysis is simply that the cause of death is not satisfactorily explained either by the autopsy or the other evidence at the inquest. In other words, when an autopsy is performed without decisive results the expert cannot feel certain that poison has not been the cause. In such cases I have made it a practice to state that it "could not be determined by the autopsy whether poison had been taken or not, and *if the other evidence suggested poisoning* an analysis had better be made," thus leaving the matter in the hands of the jury, who should be, of all persons in the world, best qualified to decide the question. It would be better if preliminary qualitative analysis (for a small fee) could be made in all doubtful cases, but under the present jury system this course is impracticable owing to the delay involved †

A further disadvantage lies in the fact that at present we have no means in Montreal of freezing the suspected organs so

* Reference has also been made to a few other cases which came under my notice during the same period.

† I have to thank Dr. R. F. Ruttan for having kindly made qualitative analyses for me in several obscure cases.

as to check the progress of decomposition. Organs left at the ordinary room temperature soon develop putrefactive alkaloids, which closely resemble those of the vegetable poisons, while at the temperature obtained in an ordinary refrigerator, though the development of these ptomaines is less abundant, their composition and reactions resemble still more closely the toxic alkaloids. On the other hand, the more unstable vegetable alkaloids, and especially morphine, rapidly become decomposed and elude chemical analysis. In *frozen* tissues they remain unchanged for an indefinite period, so that nothing is risked by delaying an analysis except the results as regards volatile substances (prussic acid, chloroform, chloral, etc.)

My notes upon the cases of poisoning are as follows :

ARSENIC.

No. 30.—C. S., male, aged 40. Heavy drinker. Stated to have taken a large quantity of Paris green, with suicidal intent. Removed to hospital two hours later, when emetics and demulcents were given, with the result of inducing vomiting of a large quantity of greenish fluid. Moderate diarrhoea. The patient rallied at first, but afterwards died, six days later, in hospital.

It was suspected that the patient had obtained a fresh supply of the poison, and an autopsy was ordered, which revealed a moderately severe reddening and swelling of the mucosa of the stomach and intestines. No ulceration. No traces of the poison were visible to the naked eye. Other organs normal. No analysis ordered.

Verdict.—*Death from suicide by taking Paris green.*

No. 29.—C. G. S., male, aged 55. Had been acting strangely for about a year, but was able to attend to his business. Found about four hours after taking a large quantity of Paris green. A series of doses of sulphate of zinc were given, amounting in all to 160 grains, with mustard and mucilage. This was followed by violent and long-continued vomiting. The patient died from exhaustion.

Autopsy.—Walls of stomach intensely reddened and swollen, being nearly $\frac{3}{4}$ -inch thick through, and œdema and hæmorrhage into the submucosa. Surface of mucosa dark brownish-red, and covered with a brownish, shreddy, sloughy coat. Particles of bright green pigment seen lying on surface. The seproved, on chemical examination by Mr. Wolff, to contain both arsenic and copper. Mucosa and submucosa of small bowel intensely reddened and swollen, especially in the duodenum, which shows numerous bright green grains. Scattered particles of this substance are also seen throughout the whole intestinal tract as far as the rectum.

In the brain, symmetrical cystic spots of softening, involving both internal capsules and reaching from opposite the head of optic thalami back as far as pineal glands.

Conclusions.—1. Death has been due to an irritant poison. Particles of Paris green are found in stomach and intestines. 2. The condition of the brain is such as would probably be attended by mental weakness.

Verdict.—*Suicide while insane.*

(In my limited experience of arsenical poisoning, comprising about a dozen autopsies, I have never met with such intense inflammation and hæmorrhage of the stomach, and am inclined to attribute it partly to the repeated doses of emetic given.)

Case 32.—M. G., female, aged 50. Died two hours after taking a dose of Rough on Rats. Known to have had the poison in her possession for several weeks, and supposed to have taken some during that period. Symptoms.—Vomiting, diarrhoea and collapse. Treated by emetics and stomach-pump, with diluted iron.

Autopsy.—Stomach: Mucosa reddened, punctiform ecchymosis at pylorus, contains 6 oz. of rusty-looking fluid (iron.) This substance seen in small intestine as far down as the valve. Large bowel contains soft, whitish-gray mucus. Intestinal contents free from fæces. Kidneys show nothing special. Throughout the liver, numerous grayish-yellow, blotchy patches, seen on microscopic examination to be dust. Diffuse and irregularly distributed fatty degeneration of the cells, not limited in any way to the periphery of the lobules.

(In this case the condition of the liver was apparently due to a former unsuccessful attempt at suicide. The absence of fatty change in the kidneys may mean that this was not done in the form of small, frequently repeated doses. No analysis was authorized, but a private chemical examination showed the presence of arsenious acid both in the stomach and intestines.)

As Rough on Rats is made by rubbing together white arsenic and charcoal, I thought it possible that some of the wood fibre of the charcoal might be recognized under the microscope in the contents of the intestine, and identified with that of the original powder, some of which was obtained. This did not prove to be the case, as the charcoal was found to be entirely in the form of small amorphous black nodules.)

SULPHATE OF COPPER.

A. G., aged 23, while despondent, made an attempt to cut his throat, which being unsuccessful, he drank nearly a quart of saturated copper sulphate solution out of a battery jar in the electric works where he was employed as night watchman. Death 1½ hours later. Consciousness retained till the last. Intense abdominal cramps, with greenish vomiting and diarrhoea.

Autopsy, 3½ hours p.m.—Intense rigor mortis. Six shallow trans-

verse incisions in anterior region of neck, not penetrating further than the skin, edges lined with scanty dried blood-clot.

Stomach and intestines externally of a leaden-blue colour, contain a large amount of pale, grayish-green, flocculent fluid. The mucosa is dried and shrivelled throughout, and has the appearance of having been tanned. The mucosa of stomach is stained of a deep green, from imbibition of the fluid. Chemically, the contents of the stomach were found to consist of basic sub-sulphate of copper. Heart muscle and liver parenchyma look opaque and grayish. Unfortunately these organs were not examined for copper.

CHLORAL (?)—DILATATION OF STOMACH.—SARCINÆ.

Case 82.—One case of death after a dose of 25 grains of chloral occurred in a hard drinker, A. H., aged 30, male, who was suffering from a mild attack of delirium tremens, and was still under the influence of liquor when the dose was given. He became comatose almost immediately, and died in six hours.

Autopsy.—Lungs voluminous. Numerous small sub pleural ecchymoses. On section, large amount of rusty froth on cut surface, with numerous small areas of hæmorrhage. No œdema. Bronchi filled with reddish froth. Pectoral muscles have a marked odour like alcohol. No special odour noticed in liver or brain. Heart not fatty. Stomach very large, reaching down to pubis; on opening, it contained nearly two quarts of a frothy, brownish paste, having a sweet, alcoholic, yeast-like odour, and containing partly digested food. Under microscope, large numbers of sarcinæ found. Mucosa not thickened. No stenosis of pylorus. Other organs normal.

(In this case I did not feel able to decide whether the alcohol or the chloral, or a combination of the two, had brought about the death. The jury in this case probably came very near the mark in stating that the deceased "died from the effects of alcohol, having succumbed to an ordinary dose of chloral.")

It can hardly be looked upon as a safe procedure to give a full dose of chloral to an alcoholic without first giving him time to eliminate the alcohol from his system.

The coincidence of sarcina ventriculi and dilatation of the stomach was very interesting, this condition never having been, to my knowledge, noted in connection with sudden death. Possibly the dilatation of the stomach may have acted injuriously by impeding respiration, but there was no proof that such had actually been the case, and reflex interference could hardly be seriously considered in the case of a man whose system was narcotized by alcohol and chloral.

I also considered the possibility of the engorgement of the lungs being due to a commencing pneumonia, but this was definitely excluded by the absence of the pneumo-coccus in cover-slip preparations.)

DEATH FROM ALCOHOLISM (?)

I may mention here another case, No. 81, that of D. M., aged 36,

male, a man who was not an habitual tippler, but who had been drinking freely for some days, and was found dead sitting upright in a chair.

Autopsy.—Body that of a hunchback. There was intense congestion of the head and upper part of the body, with numerous small ecchymoses in the skin over the chest and shoulders. The vessels of the brain were found gorged with dark fluid blood, and the lungs were dark, intensely congested, with extensive patches of extravasation of blood in their substance. The bronchi were filled with froth. The other organs were normal. No signs of injury.

(Evidently the immediate cause of death was asphyxia, but what was the primary cause of this asphyxia? A chemical analysis was made for opium and morphia, but with negative results. I am inclined to put down alcohol as the cause, as there appeared to be no mechanical explanation.

In this case I found marked evidences of bronchitis, the bronchial mucosa being coarse and swollen and the tubes filled with mucus. The evidence taken by the coroner showed, however, that, though the deceased had suffered for several years back from bronchitis and asthma, his cough had been much better for some months back, and none of those who had seen him in the last days of his life had noticed him to cough much.)

CHLOROFORM INHALATION.

Case No. 83.—D. L., male, aged 24, laborer. Died suddenly while under chloroform, at the Notre Dame Hospital, for the reduction of a dislocation of the right shoulder. Had inhaled less than ʒij . Took the anæsthetic badly.

Autopsy.—Moderate dilatation of the heart, with slight hypertrophy. Microscopically, no fatty degeneration. Slight diffuse fibrosis of kidneys. Lungs show abundant reddish froth on cut surface. Bronchi contain reddish froth. Other organs normal.

(The opinion given was that, while the heart and kidneys were not perfectly normal, there was not sufficient change in them to indicate that chloroform inhalation would be dangerous.)

I may append another case of death under chloroform, not in the present series.

S. L., aged 25, male. Died after inhaling ʒiv . of chloroform from a Junker inhaler, preparatory to operation for removal of a bronchocele, in the Montreal General Hospital. The operation had not been commenced.

At the autopsy, the only abnormality noted was a decided enlargement of the spleen, which weighed 300 grammes, and a slight enlargement of the kidneys, which weighed 210 grammes each. The heart was found to be absolutely normal.

In both these cases the chloroform used was Duncan and Flockhart's. No analysis of the anæsthetic was ordered.

In answer to a question from the coroner as to whether chloroform was liable to cause death in healthy people, I stated that it was regarded by many as a dangerous anæsthetic, whose use was only advisable where for some reason ether could not be employed. The occurrence of two deaths from chloroform in a city where no death from ether has been recorded for several years, though ether is given probably five times as often as chloroform, seems to me to bear out this statement.

In neither of these cases was the death shown to be in any way due to carelessness or want of skill on the part of those administering it. The usual restoratives—including hypodermics of strychnine—were employed, but, as usual, without result.

ILLUMINATING GAS.

One case of death from this cause, included in my hundred cases, is sufficiently typical.

W., aged 74, who had never been in a city before, was told by the bell-boy in a Montreal hotel that he "could not" blow out the gas. He was found dead in bed next morning, having apparently perished through the attempt to demonstrate the falsity of the bell-boy's statement. The room was small and smelt strongly of gas.

The body, when viewed by me 48 hours after death, showed nothing unusual beyond an extensive rose-red colouration of the skin in the dependant parts. I was unable here to state that this was due to the characteristic change in the blood from the presence of carbon-monoxide, as the body had remained for so long a time in a very cold place, and in bodies kept in the cold a rosy-red change of the superficial parts affected by post-mortem lividity is very common. No autopsy was asked for, and the verdict was death from inhaling illuminating gas.

Some blood obtained after the inquest from the femoral vein was bright cherry-red in colour. On diluting and examining with a hand-spectroscope, *two distinct absorption bands are seen, which appear practically identical with those of oxyhæmoglobin. After adding excess of strong solution of ammonium sulphide, these bands become somewhat fainter, but still remain visible, and the band of reduced hæmoglobin does not appear.* On testing in the same manner blood obtained from a healthy person, the band of reduced hæmoglobin appears promptly on adding a very small quantity of ammonium sulphide.

I have underlined part of the above paragraph because I find that this simple and easily recognized means of establishing beyond doubt the presence of carbon-monoxide poison is not as generally known as it should be. It should be borne in mind that: (1) The spectrum of carbon-monoxide is practically indistinguishable from that oxyhæmoglobin, but (2) on adding a reducing agent the bands of oxyhæmoglobin become altered while those of carbon-monoxide persist.*

* A freshly prepared solution of ferro-ammonium-tartrate works more rapidly than ammonium-sulphide as a reducing agent.

Other tests for the detection of carbon-monoxide are the addition of caustic alkali, tannin solution, and other substances which give a different colour reaction when CO is present, owing to the fact that the monoxide-hæmoglobin resists the action of the reagent more than normal blood. I did not myself find that these reactions were at all as satisfactory as the spectrum test.

It must be remembered that if a victim lives a few hours after removal from the air containing the gas it will have disappeared from the blood. Hence the collection of a sample of blood should not be delayed. Placed in a well corked bottle, however, the blood will remain for a long time (over two years) without becoming altered, especially if diluted with an equal volume of saturated solution of borax.

Properly speaking, spectrum analysis of the blood ought not to be looked upon as part of an external examination of the body, though, as a rule, in other countries it is expected to be done by the physician making the autopsy and not left to the chemist. For practical reasons, however, I now make a spectroscopic examination form part of the view whenever death is supposed to be due to inhalation of gas, as it seems, in the interests of the public, preferable to do so than to have death attributed to this cause without any direct proof being brought forward.

I may cite two other recent cases of gas inhalation where the cause appeared to lay in the defective nature of the stop-cock, in which the catch was so worn away that it could not be known with certainty whether the tap was turned off or not.

Cases 116-117.—Mrs. B., aged 60. Came in to Montreal on a visit from the country and went to bed with her little grandchild in good health and spirits. Both found dead in bed next day. Strong smell of gas in the room six hours later, although windows were open.

External Examination.—Rigor mortis present. Both bodies show rose-red patches in skin of dependent parts. The little girl's body shows white, thick froth about the nose and mouth. No marks of violence. Bodies both lying faces upwards.

Blood obtained in both cases is of a bright cherry-red colour. Examined with spectroscope shows two absorptive bands in the green and yellow spectrum resembling those of oxyhæmoglobin. On adding excess of ammonium sulphide the lines persist and are still distinctly visible several hours later, though somewhat fainter.

III.—DEATH FROM INJURIES (40 CASES).

Death was due to homicide in 1 case, to suicide in 3 cases, and to accidents in 36 cases.

The injuries were caused as follows:—

Homicide by blow, 1; railway accidents, 10; street railway accidents, 2; runaway horse, 2; toboggan, 1; other vehicles, 1; elevator accidents, 3; machinery accident, 1; falling bodies, 5; falls from a height, 2; firearms, 3; explosion, 1; burns, 4; asphyxia by food, 1; hæmorrhage from umbilical cord, 1; surgical operation, 1; hanging, 1. Total, 40.

The causes of death were:—

Fracture of skull (alone, or associated with multiple injuries) 14; penetrating wound of brain, 1; dislocation of neck, 3; gunshot wound of head, 2; gunshot wound of neck, 1; crush of chest, 2; rupture of abdominal organs, 2; peritonitis, 1; umbilical hæmorrhage, 1; asphyxia, 2; burns, 4; concussion, shock and doubtful causes, 5.

FRACTURE OF SKULL (14 CASES).

CASE 7.—C. S., aged 22, brakeman, was missing after train had passed through Victoria Bridge, Feb. 6, 1893. The body was found just at the entrance to the bridge.

Extern. Examination.—Both legs lacerated and crushed, being nearly detached from body. Body and arms uninjured. Thin, reddish, bloody fluid oozing from right ear. Laceration of scalp in right posterior region, beneath which mobility and crepitus of the parietal bone can be felt. Tissues about left orbit ecchymosed.

Verdict—*Accidental death.*

Apparently the blow on the left side of the face caused him to lose his balance and fall between the cars, the skull being fractured in striking the floor of the bridge, and the wheels passing over the legs.

CASE 12.—*Tobogganing Accident—Fracture of the Base.*—J. C., a girl aged 16, thrown violently against a telegraph pole on Côte des Neiges Hill, Feb. 11, 1893.

External Examination.—Bloody fluid oozing from nose and right ear. Marked cutis anserina. No crepitation can be felt in cranial bones. Slight prominence of second cervical vertebra, with increased mobility of neck. No dislocation made out. Diffuse ecchymosis over right mastoid region.

Verdict—*Accidental death.*

In this case death was stated to have been instantaneous, which is rare in fractures of the base of the skull.

CASE 15.—*Elevator Accident*.—J. C. B., male, aged 59. Head caught between elevator and wall of shaft, March 1st, 1893. Fell downwards into lower compartment of elevator, where the body was found.

External Examination.—Blood stains about head and hands; clothing blood-stained. In right temporal region extensive ecchymosis; an extensive depressed fracture felt at junction of right frontal and temporal bones. In the occipital region a large (4" diameter) triangular flap of the scalp is torn nearly off, being attached by its apex only. Left thumb nearly torn from the hand.

Verdict—*Accidental death*.

Being asked in what precise phases of the accident the various injuries were received, I had to decline to make any positive statement from external examination only.

CASE 70.—*Fracture of Skull—Dural Hemorrhage—Electric Shock (?)*.—A. B., aged 40. Motor-man on Montreal Street Railway. While climbing to the roof of a standing trolley car to make some repairs, was seen to let go his hold and fall backwards, striking his head on the ground. Went home and told his wife that he had received an electric shock, which caused him to let go. Soon afterwards became comatose, and died within 24 hours of the accident.

Autopsy 40 hours after death, July 3, 1893. Body a good deal decomposed. Veins of skin form distinct blue-black lines, especially in the upper part of body. Tissues about neck, crepitant. In right occipital region two parchmented areas of skin, each $\frac{1}{2}$ in. diameter, with hæmorrhages on the surface. No other external marks of violence. No appearance resembling a burn.

Head—Extensive ecchymosis beneath the scalp in occipital region, extending down towards the neck. The extravasated blood is completely coagulated.

Extending directly downwards from a point one inch below the left half of the lambdoidal suture to the *foramen magnum* is a fracture involving both tables of the occipital bone. Near the lower end of the fracture, a branch fracture, confined to the inner table, but splintering it in places, extends to the petrous bone on the right side. The broken edges of the bone are covered with blood.

Between the dura and the occipital bone, on the left side, is a solid dark blood clot as large as a hen's egg, the origin of which is seen to be a laceration in the posterior wall of the left lateral sinus. A blood clot the size of a walnut lies external to the pia on the inferior surface of the left lobe of the cerebellum. A little soft clot and fluid blood is seen over the base of the brain, extending anteriorly to the optic chiasm. There is superficial laceration of the under surface of both orbital lobes, with numerous hæmorrhagic points. Brain substance elsewhere normal. Ventricles of brain free from blood. No blood in 4th ventricle. Vessels not atheromatous.

Blood in heart chiefly fluid *but coagulated upon exposure*. Organs appear healthy and free from ecchymosis.

Verdict—Accidental death.

In this case the medico-legal question to be determined was whether the fall was caused by an electric shock. I stated that there was no evidence of a burn such as would result from contact with a "live" wire of high voltage, and that if a slight shock received from some part of the car had caused the fall, there was no post-mortem evidence of it.

CASE 59.—Homicide from Effects of a Blow—Fracture of Bone—Meningitis.—J. H., a boy aged 16, was stated to be struck on the head by another boy with a lacrosse stick; fell over and became unconscious, with oozing of serum from the right ear. Symptoms of meningitis set in on the seventh day, and death occurred ten days after the injury.

Autopsy, made jointly with Dr. George Villeneuve, 32 hours after death, on June 19th, 1893.

Incision made by undertakers for injecting the body; in the right brachial artery and in peritonem.

No external evidences of contusion or other injury about the head. A yellowish dried crust in right auditory meatus. A few small ecchymoses of the skin over right thigh, left knee and right iliac crest.

On removing scalp, a narrow line of ecchymosis extends for 4 inches horizontally along the lower border of the right parietal bone, averaging $\frac{1}{2}$ inch in width, and situated in the subcutaneous tissue, immediately beneath the skin. No evidences of decolorization of the extravasated blood. A line of fracture extends downwards from the upper edge of the right squamo-temporal bone into the glenoid fossa.

Beneath the subcutaneous ecchymosis is a reddish area $\frac{1}{2}$ inch in diameter lying in the bone near the coronal suture. On removing the skull cap and brain this is seen to correspond to a straight linear fracture $\frac{3}{4}$ in. long, near which is a curved fracture 1 inch long, both confined to the inner table of the right parietal bone. At this point there is a circumscribed spot of ecchymosis outside the dura. The thickness of the fractured bone averages from 3 to 5 mm. The fracture of the temporal bone is seen to extend across the petrous bone into the basisphenoid.

The pia is opaque and yellowish, with abundant sticky lymph over the base and convolutions. This exudation is most abundant on the left side, especially near the left Casserian ganglion, where it is distinctly purulent. The subjacent bone and nasal cavities are normal.

No suppuration in either tympanic cavity. Microscopic examination of the arteries of the pia shows an intense cellular arteritis. No appearance of tubercles.

Beyond the styptic effects of the chloride of zinc embalming fluid, the other organs were normal.

Conclusions.—From the condition found at the autopsy, in spite of some peculiarities in the lesions found, there seems to be no reasonable doubt that death has been due to a meningitis which has resulted from a blow upon the right side of the head, fracturing the skull.

The case was presented before the grand jury, who found a No Bill.

An interesting point was the fact that the meningitis was most severe on the side opposite the fracture, and that it arose without any intervening suppuration of the middle ear.

Upon being questioned as to whether the injury was the result directly of the blow or of the fall which followed it, we were inclined to consider the linear ecchymosis beneath the scalp, with a distinct fracture and ecchymosis of the dura lying directly beneath it, sufficient evidence that the fracture showed the effects of a blow from a narrow, smooth instrument. There are probably few more difficult points arising in coroners' cases than are involved in deciding whether fractures are due to the effects of a blow or a fall when both are shown to have taken place, as almost any form of fracture of the skull may result from a fall.

The absence of any signs of decolorization in the ecchymoses, presumably produced ten days previously, was also confusing. Finally, the injection of the body, officiously made by the undertaker, further tended to complicate matters.

The clinical history of the case was kindly furnished by Dr. J. M. Elder.

CASE 48.—*Fracture of the Skull and Body of 11th Dorsal Vertebra, without external signs.*—D. M., sailor, age 23, fell 18 feet into the hold of a ship, striking the head upon some iron rails. Was removed immediately, but was found to be breathing his last.

External Examination.—Whitish foam about nostrils. Skin of nose lacerated and left nasal bone broken; a lacerated and contused wound in R. parietal region.

Internal Examination.—In right parietal region the subcutaneous tissue of the scalp and the pericranium are extensively ecchymosed, the extravasated blood extending behind the right ear down the sheath of the right sterno-mastoid.

A line of fracture extends downwards along the posterior border of the right parietal bone, and through the occipital bone to the *foramen magnum*, and a branch fracture extends through the mastoid and petrous bone into the sphenoidal fissure.

Beneath the pia an extensive diffused hæmorrhage fills the sulci over the right parietal region, the inner surface of the right hemisphere, the lower surface of the left temporal lobe, and the upper surface of the cerebellum. Punctate hæmorrhages are seen in the ganglia at the base.

Heart normal. Lungs crepitant; intensely congested, with small hæmorrhagic foci scattered through their substances. Numerous small

emphysematous bubbles beneath the pleura. Bronchi filled with fine reddish froth. A large area of hæmorrhage behind the aorta just above the diaphragm on the right side, extending behind the pleura. The body of the 11th vertebra is seen to be fractured, and at this point there is hæmorrhage into the spinal canal, but the cord is apparently neither lacerated nor compressed.

Spleen large and soft; weighs 300 grummes. Other organs normal.

An interesting point in this case was that the only injuries detected, on external examination, were the injury to the nose and the laceration of the scalp. No signs of the fracture of the vertebra or skull could be made out externally.

The condition of the spleen possibly explained the fact that the man walked in a remarkably stupid manner into the hatchway, although there was a plank across it, by suggesting that he may have been in the early stage of some acute febrile disorder.

Fracture of Skull with Multiple Crushing Injuries.

J. T. and L. L., workmen employed in tearing down the walls of a building destroyed by fire, were killed by a wall falling upon them.

External Examination Feb. 7, 1893, 4 hours after death, which was nearly instantaneous.

CASE 8.—J. T.—A little clotted blood about nostrils. The skull felt to be extensively shattered, so that the head can be moulded into any desired shape. The superior maxilla felt to be fractured on both sides. Chest flattened on left side and crepitus felt over 7th, 8th and 9th ribs in left axillary region.

Comminuted fracture of left humerus in upper third; dislocation of left shoulder, with separation of coracoid process. Extensive laceration of left thigh on anterior surface from Poupart's ligament nearly to knee. Compound fracture of left femur, tibia and fibula. Luxation of right knee.

Verdict—Accidental death.

CASE 9.—L. L.—Blood oozing from ears. A depressed comminuted fracture of the left parietal bone near the vertex, with laceration of the scalp. Fracture of right superior maxilla and nasal bones. Fracture of right radius in middle third.

Verdict—Accidental death.

An interesting point in connection with cases 9 and 48 was that the nasal bones were fractured, an injury often absent in the ordinary "broken nose."

CASE 20.—M. O., aged 25, killed by falling of a derrick at the Wellington Street bridge, March 25th, 1893.

External Examination.—Extensive comminuted fracture of skull, extending over the vertex from the level of coronal suture to occipital prominence, and laterally to lower border of parietal bones. Blood

oozing from nose and R. ear. Fracture of R. tibia in lower third, and of R. fibula in upper third.

Verdict—Accidental death.

CASE 21.—P. G., aged 37, killed by same accident. Numerous subcutaneous ecchymoses on side of trunk, right arm and right leg. Serous bloody fluid about nose and both ears. Right side of chest flattened, and crepitus is felt in right axillary region from the level of third rib downwards. Fracture of right thigh in lower third, and compound fracture of left tibia and fibula in upper third.

Verdict—Accidental death.

CASE 75.—*Crush of Head and Chest.*—A. B., employé of Royal Electric Co. Body was found extensively lacerated, having apparently been entangled in the machinery. No witness to accident.

External Examination, July 12th, 1893. Scratches about hands, from which hemorrhage has taken place. Comminuted fracture felt in occipital region. Blood oozing from both ears.

A jagged, lacerated wound extends from mid sternum over left shoulder down to the left infra scapular region, severing the four upper left costal cartilages and the clavicle from the sternum. The left subclavian artery and veins are divided, and the left pleura and pericardium torn open, leaving the breast exposed. Cavities of heart moderately full.

Verdict—Accidental death.

As bleeding had occurred from the scratches on the hands, it seemed as if those injuries had possibly been produced before the others. The nature of the force which cut open the thorax from above suggested a rapidly revolving belt, but no positive statement can be made on that point.

CASE 78.—*Fracture of Skull and Multiple Crushing Injuries.*—J. W., pedlar, killed while crossing the railway track, by a passing express train.

External Examination, July 14, 1893. Lacerated scalp wound about 3 inches in length, extending upward and backward from above left ear. Comminuted fracture of skull felt in occipital region. Fracture of ribs in left lower axillary region, and fracture of left side of pelvis. Fracture of left upper arm and right ankle.

Verdict—Accidental death.

CASE 33.—Margaret M., killed by descent of an elevator while she was gazing into the shaft, May 9, 1893.

External Examination.—Head almost decapitated, being attached merely by a strip of skin at occiput. Dislocation and crushing of cervical vertebrae. Cervical vessels severed. Bruising and excoriation of skin about upper part of sternum.

Verdict—Accidental death.

CASE 23.—F. S., aged 63, female. Knocked down and trampled on by a runaway horse.

External Examination.—Bleeding from ears, nose, and mouth.

Bones of face crushed. Upper part of skull freely movable on the base.

Verdict—Accidental death.

CASE 45.—*Railway Injuries giving rise to suspicion of Homicide by Blows—Autopsy.*—P. L., aged 30, a lineman employed by the Bell Telephone Company, left his home to string some wires in the country. Two days later his dead body was sent to his relations with injunctions "not to open the coffin, as the corpse was so horribly mangled by a railway accident as to be scarcely recognizable as that of a human being." The friends learning that the watch had been found on the railway track, ten miles from the spot where the body was found, suspected foul play, and upon opening the coffin found no signs of injury to the body except a severe wound at the back of the head. An inquest was accordingly demanded.

Autopsy made jointly by Dr. George Villeneuve and myself on June 1st, 1893.

External Examination.—The body was considerably decomposed. The clothing was smeared with blood, but not much torn or disarranged. The right external ear filled with clotted blood. A lacerated scalp wound extended from the right frontal eminence to behind the right ear. The bones of the skull were exposed, and showed a small smear of black grease. A vertical scalp wound 1 inch long was found in the left parietal region. The bones of the skull could be felt to be crushed in, and were movable on palpation.

Abrasions were found on the right forehead, chin, right cheek, right upper arm and fore arm, left thigh, left patella, left popliteal region and left shin. These were free from ecchymosis.

Several contused areas of ecchymosis were found about the fingers of the left hand.

Internal Examination.—A very extensive fracture of the skull was found in the right temporo-parietal region, the bones being shattered into fragments not larger than 2" in diameter for an area of over a hand's breadth. The sagittal, coronal and lambdoidal sutures were separated. A line of fracture extended downwards to the left jugular fossa from the left extremity of the lambdoid suture. From the right mastoid region a fracture extended downwards across the right petrous bone and basi-sphenoid to the left sphenoidal fissure. A third line of fracture extended down from the junction of the right coronal and sagittal sutures across the right orbital plate to the sella turcica.

The brain cortex was much lacerated in the right parietal region and about the posterior limb of the sylvian fissure, the right supra marginal and upper temporal convolutions being most injured. Corresponding to this region, the dura was torn. No appearance of severe hemorrhage at this point. The rest of the brain appeared normal.

In pericardium several ounces of dark fluid blood. Near the tip of the auricular appendix was a ragged laceration $\frac{1}{2}$ an inch long. The heart was otherwise normal. Lungs normal. Larynx and organs of neck normal.

Spleen normal. Half a pint of fluid blood in peritoneum. About the right kidney an extensive extravasation of blood behind the peritoneum. Substance of kidney lacerated near the hilus. (This condi-

tion was apparently due to a fracture of the lumbar vertebrae.) Left kidney intact.

Liver presents five lacerations running parallel along the upper surface of the right lobe.

Stomach and intestines showed no signs of injury.

Conclusions.—The appearance of the lesions correspond with a railway injury, but not with homicide by blows.

Subsequently evidence was obtained that the deceased had been seen to be struck by a passing train. The extent of the internal abdominal injuries was very striking, and accounted for the absence of severe hæmorrhage from the wound of the head. The presence of ecchymosis about the contusions of the left hand showed that they must have been produced prior to the other injuries, but no evidence was forthcoming as to how this had happened.

FRACTURE OF SKULL—PENETRATING WOUND OF THE BRAIN.

CASE 10.—J. H., aged 35, stoker in gas works, killed from effects of the explosion of a receiver.

External Examination, Feb. 8th, 1893. Clothing dusty, not torn or burnt. Skull felt to be fractured near the posterior extremity of the sagittal suture. Fragments movable and give crepitus. In right temporal region, 1½ inch above and 1 inch anterior to external auditory meatus, is a deep lacerated wound 1 inch in length, leading directly to a jagged opening in the temporal bone large enough to admit the little finger. No foreign body near the orifice of the wound. The brain substance is seen to be lacerated. A little clotted blood in the nostrils.

Conclusions.—The injuries appear sufficient to explain the death. Their exact nature cannot be made out without an autopsy.

Verdict—*Accidental death.*

OTHER INJURIES FROM CRUSHING (4 CASES).

CASE 22.—*Rupture of Liver.—Peritonitis.*—J. B. V., aged 30, when riding on top of a load of compressed hay, was squeezed between the load and the roof of an archway in the Shedden stables. Died in Notre Dame hospital 4 days later with symptoms of septic peritonitis.

Autopsy on March 27th, 1893, 30 hours after death. Abdomen swollen and dark-coloured. No external signs of injury.

In peritoneal cavity three pints of dark, slightly fetid, bloody fluid. In places slight roughening of the peritoneum from recent lymph. In hypochondria greenish brown staining, apparently from bile pigment. *Liver*—An irregular, wedge-shaped line of rupture extends 3 inches backward from the anterior edge of the right lobe, just to the left of the gall bladder. The edges of the wound are rounded and retracted, and covered with fibrinous exudation. On making sections across the line of rupture a wedge-shaped area of hæmorrhage is seen to penetrate the liver substance almost to the posterior border. In the centre of this, posterior to the rupture is a pale anæmic, wedge-shaped area cor-

responding to which is a grayish thrombus occluding a large branch of the portal vein, and loosely attached to the intima. Liver substance looks normal.

Gall bladder contains a tablespoonful of clear grayish mucus. Common gall and cystic ducts intact and pervious. Intestines contain grayish feces apparently free from bile.

Kidneys show slight parenchymatous swelling, affecting chiefly the columns of Bertini. Other organs normal.

Unfortunately this specimen could not be obtained for further study, but evidently the presence of bile in the peritoneum, and its absence from the intestine without any injury to the common or cystic ducts, pointed to a laceration of one of the larger hepatic ducts. The complete absence of external bruises is not at all uncommon in injuries of abdominal viscera. The verdict was "*accidental death.*"

CASE 90.—*Extensive General Crushing and Laceration.*—A. B., aged 20, brakeman, fell between cars and was run over by two trains.

External Examination made August 17, 1893. The head and right arm have been completely severed from the trunk. The left upper arm is broken in several places. A large area of parchmentation occupies the right side of the chest and abdomen. A transverse lacerated wound penetrating skin and cellular tissue above each knee. The lungs and heart are exposed by the laceration in upper part of thorax.

Verdict—*Accidental death.*

CASE 89.—*Extensive Crush of Chest and Abdomen.*—M. D., aged 25, was run over by a train near St. Henri, while walking on the track. Death was instantaneous.

External Examination made August 3rd, 1893, 20 hours after death. Body in state of marked and advanced decomposition, attracting swarms of flies. Rigor mortis in smaller joints. Chest and abdomen greenish. Chest completely crushed in; all the ribs apparently being fractured. Multiple fractures of both legs and arms. A few cuts and scratches about face and head.

Verdict—*Accidental death.*

In this case the unusually early and rapid decomposition was doubtless due to rupture of the intestines and escape of their contents.

CASE 36.—*Crush of Chest.*—H. T. A., aged 35, struck by an engine near Montreal Junction. Apparently paid no attention to repeated whistles blown.

External Examination, May 22, 1893. Right side of thorax depressed in the axillary and infra-scapular regions. The tissues in this region felt to be emphysematous. The ribs from the 5th to 8th are felt to be fractured just anterior to their angles. An area of ecchymosis, 3" in diameter, in the right flank. Several deep scratches on forehead and nose.

Verdict—*Accidental death.*

Owing to the question being raised of the man being deaf, I examined the tympanum by means of a speculum and mirror, while making the external examination. There was no perforation, but the drum looked dull, livid, and had very much the appearance met with in chronic catarrhal otitis media. On examining, for the purpose of contrast, the drums of two other bodies lying at the same time in the mortuary (both patients had been treated in hospital and were stated not to be deaf) the same dull and sunken appearance of the drum was noted, so that it appeared to be merely a post-mortem change.

DISLOCATION OF NECK AND FRACTURE OF CERVICAL VERTEBRÆ (3 CASES).

CASE 5.—J. V., while driving in a sleigh across a railway track, was struck by the tender of an engine running backwards at the rate of 35 miles an hour. The body was thrown a distance of about 30 feet. Death occurred in a few moments.

External Examination, Feb. 1st, 1893. On moving the head, undue mobility and crepitation felt in upper cervical region, about level of 3rd cervical vertebra. Fracture of left thigh. No other injuries.

Verdict—*Accidental death*.

CASE 6.—A. B., female, killed in same accident, body being thrown a distance of 25 feet. Blood oozing from nostrils. A scalp wound 3' long in left parietal region. On moving and rotating head, great mobility with crepitus made out at the level of the 4th cervical vertebra.

Compound comminuted fracture of right leg.

Verdict—*Accidental death*.

CASE 71.—H. M., male, aged 84. Fell off a load of hay and was picked up dead. No external marks of violence.

Great lateral mobility with distinct crepitus felt in upper part of the neck.

Verdict—*Accidental death*.

In localities where the crowning glory of an inquest lies in the avoidance of an autopsy, the unfortunate medical witness is so often at a loss to account satisfactorily for the death, that it becomes a source of great comfort when he meets with an injury demonstrable by external examination and necessarily fatal. The three cases of this nature occurring in this series of one hundred were, on this account, highly appreciated, though of little general interest.

It would add to the accuracy of coroners' verdicts, and conduce to the economical working of coroners' courts, if this easily recognized and painless mode of death were more generally utilized by the subjects of coroners' inquests.

INJURIES BY FIREARMS (3 CASES).

CASE 92.—*Revolver Wound of Left Side of Head.—Suicide.—Sclerotic Changes in Brain.*—J. A., aged 60, was involved in some business troubles; also complained of pains at the back of the head for some months past. Was noticed by his family to be altered in character, and to have lost his memory. Latterly he kept on repeating the same thing over and over. He was found dead in his office on the morning of August 9th, 1893, with a .38-calibre revolver lying close beside him.

Autopsy, made about 12 hours after death.—Body of a well-nourished, elderly man. Fully dressed. Nothing about body or clothing to indicate a struggle.

On the left side of the head, 1 inch above the external auditory meatus, is a ragged, lacerated wound, 1 inch in diameter. The deeper parts of the wound are blackened, but there is no powder tattooing, blackening, or burning of the hair or skin near the wound.

On the right side of the head, 2 inches above the meatus, is a ragged, lacerated wound, $1\frac{1}{2}$ inches in diameter, free from blackening or powder grains.

Both the wounds communicate directly with the brain. A quantity of clotted blood is seen about the clothing near the neck. The hair is matted with dried blood.

The vault of the cranium can be felt on palpation to be extensively shattered. Extensive ecchymosis about the left orbit. Conjunctiva clear.

On removing scalp, extensive ecchymosis is seen beneath. The skull-cap can be almost entirely removed without the aid of a saw, as a complete line of fracture crosses the frontal bone and runs back across the temporal bone as far as the occiput on the left side and the mastoid on the right, leaving only a narrow bridge of bone to be sawn through.

Besides this circular line of fracture is a line extending up from it in front and passing along parallel to the sagittal suture. A fracture also branches downwards on each side into the temporal fossa. There is much comminution of the bones near the wounds in the front-parietal region. A fracture extends across the base of the skull through the left orbital plate and right petrous bone. Dura mater extensively lacerated in both parietal regions. The falx perforated in lower part.

Brain substance shattered and lacerated throughout the central portion of both hemispheres, and shows extensive hæmorrhage, the origin of which cannot be traced to any one point. The lacerated brain substance contains powder grains. No trace of the bullet found.

Corpus callosum and floor of the lateral ventricles extensively lacerated. Fourth ventricle filled with blood clot. Patches of sclerosis detected in the more intact portions of the white substance of the hemispheres. Anterior part of brain not specially involved in this sclerotic change. Pia not excessively thickened, and strips with ease from convolutions. White matter of upper cervical cord shows translucent gray appearance; under microscope shows areas of sclerosis in posterior and lateral columns.

Spinal dura intact. Heart and lungs normal. Spleen and kidneys

normal. Bladder contains 8 oz. of clear, pale urine. Intestines normal. Stomach contains a cupful of half-digested food. Mucosa normal. Liver normal. Meath contains a little clotted blood. Some bloody froth in larynx.

The capsule of right shoulder joint thickened, and the synovial fluid in excess. Cartilage of head of right humerus softened and slightly eroded and rough near the margin. Right elbow and wrist joints normal. Left shoulder joint normal.

The condition of the right shoulder joint is of interest in accounting for a wound evidently made from the left side, although the deceased was a right-handed man. It was shown by the evidence that he had sprained his right arm some months before, and since then had not been able to use it freely.

The sclerotic changes in the brain and spinal cord were of interest as evidence of actual nervous disorder, though not those commonly found in cases of suicidal mania.

The verdict rendered was "*Suicide while insane.*"

CASE 58.—L. P., aged 30, was stated to have committed suicide by discharging a shotgun into the right side of his head, on June 17th, 1893.

External Examination.—Clotted blood mixed with disintegrated brain matter over the right shoulder and right side of head. A large lacerated wound $1\frac{1}{2}$ inches in diameter involves the anterior half of the right ear and the adjacent skin of the cheek, and from it brain tissue protrudes. The edges of the wound are blackened, and a sooty-looking zone extends for 2 inches about the periphery. Hair about right ear singed. The whole region of the petrous bone appears shattered. The floor of the auditory meatus is intact. No wad or shot found. The bones of the skull can be felt to be fractured in many places, and the head can be moulded in any desired shape. On opening the mouth, superior maxilla and hard palate felt to be fractured on the right side. On the right forearm a sooty mark extends across the radial side, 3 inches above the wrist, the skin being scorched and the hairs singed.

The medical point of chief interest in this case was the line of powder smut across the radial surface of the right wrist, at a point where the skin would have been directly over the vent of the breech-loading shotgun used, had the deceased reached along the barrel to pull the trigger, after placing the muzzle against his head, as he was stated to have done by the chief witness at the inquest, who was present at the time of the suicide.

Verdict, "*Suicide while insane.*"

CASE 90.—J. P., aged 20, accidentally shot in the neck by an intoxicated friend with a shotgun, at 10 feet. Died almost instantly.

External Examination, August 5th, 1893.—Clothing about neck

smeared with blood. In anterior region of neck, at level of larynx, is a large, deep, lacerated wound. The edges of the wound are inverted, and show powder tattooing and blackening for a distance of 1 inch from the wound. The wound is $1\frac{1}{2}$ inches in diameter, and the larynx and trachea are torn open and seen to be filled with bloody froth. No isolated shot holes.

Situated $3\frac{1}{4}$ inches distant from this wound, in a straight line, is a smaller ragged wound in the posterior part of the neck, in the right side, at the same level as the anterior wound. A fragment of muscle tissue protruded posteriorly, and 3 grains of No. 4 shot were extracted.

The cervical vertebrae cannot be ascertained by palpation to be injured.

No other marks of violence.

Conclusions.—The body shows a severe shotgun wound, fired at a distance not exceeding a few feet from a point in front and slightly to the left. The exact nature and extent of the injuries cannot be determined without an autopsy. They are sufficient to cause death.

Verdict.—"Excusable homicide."

PERITONITIS FOLLOWING SURGICAL OPERATION.

D. P., aged 30, consented to have exploratory laparotomy for gall stone performed, after being warned of a possibly fatal result, which followed a few days after the operation. The body showed no signs of jaundice. The abdomen much distended and tympanitic.

The suspicions of the friends had been aroused by certain incidents in the case, which, on inquiry, appeared to be innocent enough. There was no accusation of negligence and therefore, as the performance of the operation in the presence of four legally qualified practitioners showed it not to be of the nature of an unlawful act, the friends withdrew their demand for an inquest.

This case shows the advantage of preliminary medical inquiry in averting a groundless charge of malpractice.

In the event of any case of this kind requiring inquest, it might be well to employ a special jury, half being composed of medical men, to investigate the case. This practice has been followed in New York with excellent results.

UMBILICAL HÆMORRHAGE. (?)

CASE *Autopsy* upon the body of a new-born infant found at St. Louis, Mo., April 9th, 1893. Body of a female.
 Length, 13 inches. No signs of violence. A little vernix present in the axillae and groins. The umbilical cord has been encircled with a piece of knitting wool, tied in a loose knot, but too loosely to compress it. The ligature can be readily slipped off without untying it. The cord appears to have been cut. The umbilical vein and arteries contain a little soft clot. Large intestines filled with meconium. Stomach contains air, but no traces of food. Small intestines empty, and sink in water. The lungs light pink; are fully distended; float as a whole, and also when cut in pieces, except at the base. Portions compressed be-

tween boards still float. They are anæmic. The heart is flabby and collapsed, and its cavities practically empty of blood. Fœtal orifices persist. Spleen, kidneys, liver and brain are all intensely anæmic and almost bloodless. Ossification in sternum and astragalus; none in lower epiphysis of femur.

Conclusions.—The body is that of a fetus at about the seventh month. Death has apparently been due to hemorrhage from the umbilical cord. There are no signs of violence. The child has breathed.

Verdict—*Accidental death.*

The conclusion as to the cause of death seemed justified by the intensely anæmic condition of all the organs.

DEATH BY ASPHYXIA (2 CASES).

Suicide by Hanging.—M. S., aged 40, male. Had made several attempts to commit suicide. Was sent for an ocean voyage in charge of an attendant. Exhibited symptoms of mania and was very despondent. Was constantly picking at and scratching himself. While entering the port of Montreal escaped from his attendant and entered a water-closet, where he succeeded in hanging himself upon a hook by means of a line made by his brace—a necktie and a piece of marline. Upon breaking open the door a few minutes later, he was found to be dead.

External Examination, June 27, 1891. Body of a heavy, muscular man. On the head, left hand, left shin, sacrum and left hip are dried blood crusts, some of which have been detached, leaving a slight scar. Conjunctivæ pale; not ecchymosed. Passing under the chin, just over the thyroid cartilage, and terminating in the hair over the occiput, is a narrow livid groove 3 mm. in diameter bordered by an ecchymotic zone. Viscid greyish fluid exudes from meatus urethrae on pressure.

Verdict—*Suicide by hanging, while insane.*

Asphyxia by Food.—G. M., aged 25. Found dead in bed. Supposed to have committed suicide, being out of work. The body was stated to have been found lying half out of bed, with the arms thrown out.

Autopsy, May 29th, 1892, about 20 hours after death. —Bloody froth about nose and mouth. Numerous ecchymotic spots in skin of back. Intense lividity. Stomach half full of partly digested food. Some food in œsophagus and pharynx. All the organs normal, with the exception of the lungs, which were almost coal-black in colour and had a fetid, sour, disagreeable smell. On section, they seem to be intensely engorged and to present numerous large and small areas of extravasation of blood. The mucosa of bronchi and trachea intensely congested, dark red in colour, and contain bloody froth. Numerous food particles corresponding with the contents of the stomach found in the larynx, trachea, bronchi, and in the most minute bronchioles. The larynx does not appear to be obstructed.

Conclusion.—Death has been caused by the accidental entrance of food into the air passages.

Verdict—*Accidental death.*

Penetration of food particles into the air passages forms a common post mortem change, but the intense hæmorrhagic en-

gorgement of the lungs showed that the condition had arisen during life.

A noticeable feature was the presence of post mortem digestion of the lung parenchyma in places.

It is difficult to imagine how this condition could have arisen except in consequence of an accident, probably of the nature of regurgitation of food while partially asleep.

DEATH FROM EFFECTS OF BURNS (4 CASES).

CASE 26.—P. H., aged 50. While watching beside the dead body of his wife, the drapery of the bier took fire. The body was found near the door after the fire was extinguished.

External Examination, 18 hours p.m.—Clothing much burnt. Face scorched, and hair and eyebrows singed. No blistering. Over back of hands and arms the skin is raised in great flakes, beneath which the cutis is much reddened. Rigor mortis marked. Cutis anserina present.

It was supposed that the deceased had lost his life while trying to extinguish the fire. Some of the curtains with which the room was hung had been pulled down, and the burns of the hands were possibly obtained in doing this.

Verdict—*Accidental death.*

The dead body of the wife was charred and scorched in places, and the cracked condition of the skin, without true vesication, gave an excellent demonstration of the distinctive appearance of burns on a dead body.

In connection with this case it may be noted that a signed certificate of death from "Tumour" was made out by a Montreal physician *two months* (!) before the wife's death, the date being left blank. This is death certification with a vengeance.

CASE 38.—H. B., girl, aged 9.

CASE 39.—A. B., boy, aged 7.

CASE 40.—H. B., boy, aged 2.

These three children were fatally burned by a straw mattress taking fire and partly burning the house.

External Examination, May 25th, 1893.—The bodies were all scorched and the clothing burned. In all cases the heads, hands and backs of the arms and legs showed severe burning of the skin. Signs of inflammatory vesication were present in all the bodies except that of the baby.

Verdict—*Accidental death.*

The youngest child had apparently been suffocated before the burning was severe.

DEATH FROM CONCUSSION, SHOCK, AND DOUBTFUL CAUSES (6 CASES).

CASE 35.—J. O., aged 25, fireman, seen to be killed by a coping stone which fell from a roof and crushed in his helmet. Death instantaneous.

External Examination, May 11, 1893, 20 hours after death. Echy-
mosis of both conjunctiva. No fracture of skull can be felt. Increased
mobility in lower part of neck without positive signs of fracture or dis-
location. Laceration and contusion of scalp over left temple and in oc-
cipital region.

Conclusions.—There are evidences of severe contusions about the
head. The cause of death cannot be stated from external examination.

Verdict—*Accidental death*.

CASE 51.—P. L., aged 50, seen to fall down the shaft of an elevator
for a distance of over 20 feet. Picked up unconscious, and died before
reaching the hospital.

External Examination, June 7th, 1893. A large scalp wound over
the vertex. Cartilage of nose lacerated and nearly detached. Fracture
of left tibia and fibula above the ankle. Abrasions on arms, legs and
trunk.

Conclusions.—The examination shows signs of severe external inju-
ries. The cause of death cannot be stated without making an autopsy.

Verdict—*Accidental death*.

CASE B.—C. W., aged 24, switchman. Supposed to have fallen on
the rails. Was picked up after a car wheel had passed over his legs.
Brought to hospital in profound condition of shock. No evidence of
severe hæmorrhage. Died within a few hours.

External Examination, March 15th, 1893. In upper lumbar region
a feeling of fulness on palpation, of which the cause cannot be made
out.

Both feet and ankles, together with the adjacent parts of tibiae and
fibulae, greatly crushed and lacerated, being almost severed from the
body. Skin not greatly blanched.

Conclusions.—There are severe marks of violence from crushing of
the feet and ankles, with possibly an injury to the vertebrae. The ex-
ternal examination does not show the cause of death.

Verdict—*Accidental death*.

CASE I.—A. B., aged 40., street-car driver. His car collided with a
railway train at a grade crossing and was completely wrecked. Died
half an hour after reaching the Notre Dame hospital on Jan. 8th, 1893.

External Examination, 48 hours after death. Greenish tinge about
neck and abdomen. Large lacerated wound extending from right gluteal
region downwards along outer surface of thigh and upwards over iliac
crest into abdominal wall. A probe can be passed through this wound
into the ischio-rectal fossa, and the right ischium is felt to be fractured.
A distinct faecal odour noticed about the wound.

Verdict—*Accidental death*.

There had apparently been internal hæmorrhage from the
vessels of the pelvis, with rupture of the bowel.

CASE 91.—A. M., aged 55. Was struck by an engine moving very

slowly, and knocked into a cattle guard at the side of a crossing. Was able to walk home. Complained of pain in the right leg and right side. Refused to see a physician, but was treated by a quack. Stayed in bed off and on for 8 days, and afterwards went about. Four days later became unconscious, on Aug. 5th, 1893, and died during the night. Before death a physician was summoned, but was unable to make a diagnosis.

External Examination, Aug. 8, 1893.—Marbling of superficial veins. Emphysema about neck and right side. The lower ribs on right side feel less resistant than normal, and give indistinct crepitation. Beyond a slight abrasion of left hip, which has nearly healed, no external signs of injury.

Conclusions.—The cause of death cannot be determined without an autopsy. (No autopsy ordered.)

Verdict—*Death from the results of his own imprudence.*

CASE 82.—L. H., a boy, aged 13. While out riding, horse took fright. The boy fell from saddle and was dragged along by the stirrup. Death occurred 36 hours later.

Verdict—*Accidental death.*

Private Autopsy, made after the inquest.—At the back of the head is a large lacerated wound, exposing the occipital bone for a distance of 3 inches. The edges look foul and dirty, and there is dirt in the deep tissues exposed. There is ecchymosis about the lower jaw on the right side.

Severe contusions and lacerations of the skin over the shoulders and lower abdomen. Fracture of the right thigh in middle third. Deep lacerated wound of left thigh in region of Hunter's canal. Femora vessels not injured. Laceration of ulnar side of left wrist.

On removal of scalp, extensive subcutaneous oedema on right side in occipital and temporal regions. Cranial bones intact. Dura and pia normal. Brain tissue oedematous throughout, but free from hæmorrhage.

Lungs much congested. In left lower lobe puckering with several gritty, cheesy, encapsulated masses the size of beans, situated near the base. A similar mass near the root of the left lung. Pulmonary vessels free. Microscopically, no evidences of fat emboli.

Heart, spleen, kidneys, liver, stomach and intestines normal.

No thrombi or signs of injury in deep femoral vessels.

The time which had elapsed since the accident, while not excluding death from shock, makes it less probable.

In many of the above cases the manner of death was fairly evident from the testimony of non-medical eye-witnesses. It is just in the most obvious and simple cases, however, that neglect of the precaution of a careful medical examination leads to serious and expensive blunders, as was shown in a case of gunshot fracture of the skull, which I report in a previous paper. An official medical examination, even in apparently simple cases, does not seem to be an unnecessary precaution, or one which can safely be neglected in any case.

IV.—DEATH FROM NATURAL CAUSES (20 CASES).

Under natural causes I have included those cases only where a known natural cause could be fairly considered as proved. Those cases where indefinite verdicts of "natural causes" were rendered have been classed as deaths from unknown causes.

Our great source of inaccuracy in coroner work is the readiness with which probable (and even, improbable) medical explanations of the death are made the basis of verdicts. The phrase "I don't know" is not perhaps as frequently made use of in medical evidence as it might be.

The family physician is placed in a very delicate position when summoned as a witness. He is often examined in the presence of the persons who are his patients, before a jury some of whom may be his patients and he may have already made some informal statement as to the cause of death. He may too, through his attendance on the deceased be in possession of secrets which he hesitates to reveal, 'sine gravi causa,' to a prying and inquisitive jury. Among his patients, the family physician is very properly regarded as an oracle. Personally, when ill most of us infinitely prefer that our medical attendant shall not inflict upon us his doubts and difficulties in our own cases. On the other hand, in legal matters, the oracular functions of the physician remain in abeyance, and it becomes simply a question of what is or is not proved by facts.

An expert is placed in a rather more favorable position than an ordinary medical witness as there are no extraneous reasons why he must appear to know more than the facts clearly establish, and he may without loss of dignity adopt the agnostic as opposed to the oracular stand-point in giving medical evidence. As the information acquired by the expert is not obtained in confidence from a patient, he is more free to divulge it if necessary, and the employment of experts in medico-legal matters is the means in France of securing inviolable secrecy of practicing physicians.

Deaths from natural causes are as a rule harder to interpret than those from violence, and of all natural deaths those which

occur suddenly are usually the most difficult to explain. Often even a post-mortem does not fully clear up the matter, since the detection of structural lesions, except when these from their nature are obviously incompatible with the continuance of life, does not fully explain why the vital function was arrested at a given moment.

Vibert, (*Précis de Médecine Légale*) has made an excellent classification of sudden deaths into the following four groups:—

I. The lesions are such that there can be no doubt that death was due to a natural cause, as, for instance, in cerebral hæmorrhage, rupture of aortic aneurysms, etc. In these the true cause of death is *demonstrated*.

II. The lesion found is such as is capable of producing sudden death but does not exclude the possibility to some other cause having intervened. Thus, although there is organic disease of the heart or kidneys it may be possible that death is really due to some other cause. These lesions may therefore be said to *suggest* rather than to demonstrate the cause of death.

III. The lesions found suffice to indicate a fatal disturbance of vital function but are of a general nature and common to several diverse causes. Thus fatal congestion of the lungs, or of the brain, is compatible with suffocation, alcoholism, narcotic poisoning and many other conditions. Here medical inquiry into the circumstances of the death with reference to the possible causes may make the proof fairly complete.

IV. Neither in the anatomical nor chemical examination of the body, nor in the circumstances of the death is there any explanation of the death. These unexplained cases of death are however rare.

Unexpected deaths occur most commonly among (1) drunkards, (2) old persons and (3) young children.

It must be remembered that because the body is found dead the death has not necessarily been sudden.

The following are the details of the deaths from natural causes met with in this series:—

Death was sudden in 13 cases. In 13 cases there had been

no medical attendance. In 8 cases the bodies were found dead. Autopsies were held in 15 cases.

The causes of death were as follows :

Pneumonia, 6 ; pulmonary embolism, 1 ; phthisis, 2 ; heart disease, 3 ; interstitial nephritis, 1 ; cerebral hæmorrhage, 4 ; cerebral abscess, 1 ; still born, 2.

PNEUMONIA (6 CASES.)

In a number of cases sudden death is due to some serious acute or chronic disease, which has produced few or no symptoms. It has long been known that ambulatory cases of typhoid very often terminate suddenly. One of my recent cases (not included in this series) was of this nature, and the autopsy at once revealed the true cause of what was thought to be a case of poisoning. That a latent pneumonia is often the cause of unexpected deaths is well known in hospital practice, but the medico-legal bearing of this fact does not seem to have been recognized, the large proportion of pneumonia among my cases is of special interest. The disadvantage of the practice of carrying on elaborate circumstantial inquiries instead of making an autopsy at once was well illustrated by the following case of death from pneumonia under alleged suspicious circumstances.

CASE 2.—*Pneumonia—Suspicion of violence and Starvation.*—H. S., aged 70, an old man of intemperate habits was found dead in bed. The body was seen by a doctor who reported to the presence of bruises on the back (which proved to be only post-mortem lividity,) and suspected a violent death. Another theory was that the old man had been starved to death. The jury met and adjourned several times and listened with much attention to a great deal of circumstantial evidence. Finally they decided to authorize an autopsy of which the following is a condensed report :—

Moderate lividity posteriorly. No marks of violence. Right pleura shows trace of recent lymph in axillary region. Heart, right chambers moderately distended contain long stringy pale clots which extend into the branches of the vena cava and pulmonary arteries. Right lung weighs 1920 grammes. The whole of upper lobe except anterior border completely solid and airless. On section, cut surface coarsely granular and gray, bathed with grayish yellow fluid containing small fibrinous particles. The rest of lung intensely engorged but crepitant. Left lung weighs 550 gms., slightly hyperæmic throughout. Kidneys of natural size, show a few cysts on surface, capsules adherent. Stomach contains food. Intestinal contents of ordinary amount and appearance. Brain, subarachnoid fluid abundant, otherwise normal. Other

regions show no evidences of disease. The body throughout shows fatty tissue in normal amount.

Conclusions.—1. Death has been caused by pneumonia. 2. There is no proof of starvation or of violence.

Singularly enough in view of this medical statement the jury returned a verdict that the deceased died of consumption, and that nobody was to blame.

CASE 4.—*Pneumonia—Suspected Poisoning.*—J. M., a woman aged fifty, of intemperate habits, found dead in bed. For some reason suspicions arose that she had been poisoned.

Autopsy,—Jan. 25th, 1893. Body slightly jaundiced. No external signs of violence. Liver extends down to level of umbilicus. Heart muscle brown, valves normal. Right lung emphysematous anteriorly, an area of consolidation found posteriorly, partly in the upper and partly in the adjacent portion of the lower lobe. On section this is found to be grayish in colour, and granular; the surface bathed with a turbid grayish fluid, rest of lung moderately congested throughout but crepitant.

Kidneys small and slightly fibroid. Spleen normal. Intestines normal. Stomach contains a little curdled milk. Liver large, friable, pale and greasy, of orange colour, evidently in advanced stage of fatty degeneration and jaundiced.

Conclusions.—There are evidences of a severe acute pneumonia which has lasted several days and is sufficient to explain the death. There is nothing to indicate poisoning.

CASE 86.—E. P. *et.* 40. A dissolute and drunken woman, arrested for making a disturbance and found dead in the police cell.

Autopsy, on Aug. 1st, 1893. Body of a very stout short woman, no signs of injury. Brain—moderate oedema beneath pia; brain substance feels very firm and dense. Lungs voluminous. Soft yellow lymph over the posterior part of right upper lobe. The greater part of this lobe is consolidated and, on section, granular and greyish red in colour. Portions excised sink in water. The rest of lung engorged with blood. Bronchi contain much muco-pus. Left lung intensely congested but crepitant throughout.

Liver large and slightly fatty.

Kidneys large, antero-posterior diameter greatly increased. Capsules thickened and adherent. Cortex, swollen and coarse looking, of an opaque grayish colour. Nothing of note in the other organs.

Conclusions.—Death has been due to acute pneumonia. The organs show the effects of usual changes found in chronic alcoholism.

CASE 43.—M. R. *et.* 64. Said to be in the habit of getting on occasional sprees, in the intervals worked steadily. Died at the end of a few days illness. His wife was supposed by neighbours to have poisoned or starved him.

Verdict.—“*Death from Alcoholism,*” (he having been known to drink a moderate quantity of whisky during his last illness.)

Private Autopsy.—May 30th, 1893.—Mesenteric glands swollen and succulent. Congestion of serosa of stomach.

In right pleura recent soft adhesions in axillary region, with about 6 oz. of turbid fluid. Right lung weighs 3 lbs. On section almost the whole of the upper and middle lobes and the greater part of the lower lobes solid and airless. Cut surface granular and grayish. On scraping cut surface, a turbid bloody fluid obtained containing minute fibrinous particles. Bronchi reddened and contain a little mucus. Left lung intensely congested and oedematous; near the base a few scattered granular areas of consolidation ranging in size from a cherry to a walnut.

Heart moderately distended, valves normal. Spleen normal. Kidneys slightly granular. Stomach, mucosa thickened and red, covered with grayish mucus; mucosa of colon and lower ileum reddened and swollen. Liver large and pale, cut surface greasy, periphery of lobules whitish. Gall-bladder shows a small patch of croupous exudation in the upper surface 1 inch in diameter.

In this case although the condition of the stomach suggested the effects of alcoholism, the presence of a severe enteritis and croupous cholecystitis could not be explained in that way.

Burial in consecrated ground which had been refused on account of the verdict of the jury, was now sanctioned.

CASE 3.—*Pneumonia, alleged death from neglect.*—E. M., aged 3½ years, stated to have died on account of neglect by her parents.

Autopsy, Jan. 23rd, 1893. Body of a female child 3 ft., in height. Skin is loose and wrinkled. Marked genu valgum. Shape of chest not rachitic. No marks of violence. Subcutaneous fat in moderate amount, but is firm, dry, grayish in color and feels lumpy. Heart normal.

Left lung crepitant throughout, somewhat congested, a good deal of mucopus in the smaller bronchi. Right lung shows an area of consolidation the size of an apple centrally situated in the anterior half of the middle lobe; on section this is grayish and granular and yields a turbid juice on scraping. Several smaller granular looking areas of consolidation seen in adjacent portions of the upper and lower lobes. The adjacent pleura covered with yellow sticky lymph. On squeezing the lung abundant thick yellow mucopus comes from the smaller bronchi.

Stomach rather small but not definitely contracted. Mesenteric fat in moderate amount. Intestines normal but nearly empty. Other organs normal.

Conclusions.—Death has been due to broncho-pneumonia. There are evidences that the child has apparently eaten very little latterly.

Verdict.—*Neglect by parents not criminal in degree.*

CASE 31.—K. E. female aged 1 year. Died unexpectedly in an immigrant train between Montreal and Quebec.

External Examination, May 29th, 1893. No marks of violence. Nothing externally to indicate the cause of death.

Upon questioning the parents, they stated that the child had had a cough during the voyage out and on landing at Quebec had been

exposed to severe cold. Did not appear to be very ill, but was suddenly seized with convulsions.

Conclusions.—The history obtained points to death from bronchopneumonia. There is nothing specially suspicious in the rapidity of the death.

This shows the difficulty of arriving at any result by external examination without being able to make inquiry into medical points; naturally an autopsy would have been more satisfactory but none was allowed.

PHTHISIS.

CASE 30.—A. B., aged 30, known to be in the last stages of consumption, died on the train between Boston and Montreal; an inquest was held.

External Examination, July 19th, 1893. Body much emaciated; œdema about right ankle and the whole of left leg. Finger ends clubbed and nails incurvated. Hollowing under clavicles and dulness in R. infra-clavicular region. No marks of violence.

Conclusions.—The body is that of a person in the advanced stage of a chronic wasting disease,—apparently consumption.

CASE 26.—*Phthisis—Hæmoptysis from aneurysm of pulmonary artery.*—Unknown man (subsequently identified) found dying in the street with severe hæmorrhage from mouth and nose.

Autopsy.—April 29th, 1893. Body of a small, emaciated man about 40 years old. Recent blood stains about coat and shirt. Mouth filled with clotted blood. No marks of violence.

In thorax lungs project and appear inflated to an extreme degree. Numerous small areas of hæmorrhage into the lung tissue near the anterior margins (pulmonary apoplexy). Bronchi and trachea full of fluid blood and soft clot.

An old cicatrix at the right apex; at apex of left lung a cavity the size of an apple, with thick firm grayish walls, which are for the most part smooth but in places covered with a thick layer of shreddy loosely attached decolorized fibrin apparently the residue of former hæmorrhages. Projecting from the wall of the cavity is a small sessile aneurysmal projection as large as a cherry stone springing from a branch of the pulmonary artery the size of a goose quill. The walls of the aneurysm are very thin and flexible and a small laceration 2 mm., long is seen along its most prominent part.

An old cicatrix seen in the region of the cricoid cartilage, extending across the neck.

CASE 23.—*Sudden Death from Pulmonary Embolism following Phlebitis.*—L. M., aged 17. Primipara. Was suddenly seized with convulsions and died almost instantly, 8 days after the birth of an illegitimate child.

Autopsy, Feb. 23, 1893. Body well nourished. Breasts tinned and contained milk. A large laceration in perineum reaching nearly to anus. Surface granulating. Diaphragm at 3rd rib on right side and 3rd space on left. 100 cc. of clear fluid in each pleura. Heart, right chambers contain 200 cc. of fluid blood and clot, the latter not very adherent. Heart muscle flabby and gray-looking. Valves normal. No ecchymoses.

Lungs crepitant, Bronchi contain thick mucus. On splitting up pulmonary arteries, the middle sized branches found to be stuffed with lumpy gray rounded fibrinous masses. A large smooth rounded clot lies just beyond bifurcation. None of the masses adherent. Right lung in same condition, the obstructions being chiefly in the larger branches of the pulmonary artery. Spleen large and soft, 250 g. Kidneys together weigh 450 grammes. Uterus projects above brim of pelvis. Length 12 cm., from fundus to internal os. Placental site anterior, covered by a thick grayish diphtheritic looking membrane. Slight fetor. A few old erosions about cervix. Left ovary contains a corpus luteum 8 mm. in diameter. Pelvic and uterine veins free from thrombosis, as are also the iliac and femoral veins. In right saphena vein a soft grayish red adherent thrombus. Brain normal. Other organs normal.

A point of interest in this case was the source of the embolus in the saphena vein and not in the pelvic veins.

HEART DISEASE (3 CASES).

CASE 79.—J. aet. 50, and dropped dead while sitting at work on an office stool. Said to have fallen with his face against a sharp piece of wood. Had been under treatment for the past 2 years for eczema by a physician of excellent standing who stated that he was ready to certify death as being due to heart disease, as he knew him to be suffering from aortic regurgitation. Recently the deceased had suffered from shortness of breath and precordial oppression. Inquest held July 18th, 1893.

External Examination.—An irregular laceration 1 inch long and 1 inch deep beneath left malar process. No œdema. Precordial dulness not increased.

Conclusions.—The external examination does not show the cause of death.

CASE 38.—S. D., aged 51. Had suffered from acute rheumatism when a young man. Lately very short of breath, obliged to sit up at night owing to a feeling of suffocation. Had a cough. The day previous to death dyspnoea was very severe. Died during the early morning.

External Examination.—Finger ends clubbed, and nails incurvated. Œdema of both feet and ankles, none of face.

Conclusions.—The body shows marked evidences of chronic interference with the circulation, probably from heart disease.

In this case the external evidence of serious organic disease present, combined with the history, left little doubt as to the cause of death.

CASE 77.—MRS. G., aged 40. Found dead in bed. Had been in poor health for some time and was short of breath. Habits intemperate (?)

Autopsy.—July 15th, 1893. No signs of injury. Subcutaneous fat abundant. Heart larger than normal, chambers distended with blood. Left ventricle shows an extreme degree of hypertrophy and dilatation. Aortic and mitral valves show extensive fibroid changes. The middle and right aortic segments are fixed and perfectly rigid, being evidently incompetent. On the ventricular surface of the mitral valve just

beneath the aortic cusp is a projecting calcareous mass. Orifices of normal size. Heart muscle is of good colour, and shows no appearance of degeneration to the naked eye.

Lungs crepitant, moderately filled with blood. Pulmonary vessels free from obstruction. Kidneys considerably reduced in size. Capsules thickened and surfaces granular. Renal arteries very thick, with rigid, stiff walls. Mucosa of stomach thick and grayish red in color, its vessels intensely injected. Intestines, spleen, larynx and pharynx and brain normal.

Conclusions.—There is evidence of severe organic disease of the heart and kidneys, of a kind which frequently leads to sudden death. The naked eye appearance of the organs do not explain why the functions of the heart failed but there is nothing in the present case, except the condition of the heart and kidneys to account for the death and nothing to indicate that death is not due to this cause.

The verdict in this case was "death from paralysis of the heart," owing to my having unguardedly mentioned that this was the explanation usually given the train of symptoms which precedes death in those cases.

Subsequently, I made a microscopic examination of the heart muscle and found the condition of segmentation of the muscle fibres, known under the name of *myocardite segmentaire* which has been supposed to explain on objective grounds the failure of heart function in cases of sudden death, when the muscle appears perfectly normal to the naked eye. Though possibly only an agonal change, it offered some further grounds for attributing death to the diseased heart in this case.

GRANULAR KIDNEYS.

CASE 72.—*Renal Cirrhosis—Uremia (?) Ulceration of Colon—Multiple Sarcoma*—M. K., an elderly woman of intemperate habits. Refused hospital treatment and died in a state of great squalor. Inquest held.

Autopsy, Aug., 8th, 1893.—Considerable emaciation. Skin rough and sallow. Surface anemic. Marked urinous odor of body. No marks of violence.

Heart: right chambers distended with very pale, gelatinous clot which is partly colourless or in places very pale translucent red and evidently formed from extremely anemic blood. Wall of left ventricle over $\frac{3}{4}$ inch thick. Muscle brownish, does not look fatty. Valves normal.

Lungs emphysematous, crepitant throughout. Organs of neck normal. Spleen normal. Liver small and brown.

Kidneys greatly reduced in size, weighing both together only 60 grammes or about one fifth of the normal weight. Capsules adherent and thickened. Surface rough and granular, on section cortex seen to be greatly reduced and the organs cut with greatly increased resistance.

Small intestine intensely congested throughout. Throughout large bowel, from the cecum to the anus are found extensive ulcerated patches, the bases of which are covered with exuberant fungating, granulations, having the appearance of new growth.

In the skull cap, numerous nodules of soft grayish tissue are scattered through the diploe and encroach upon the inner table which is in places completely absorbed. The masses range in size from a pea to a cherry and are evidently secondary deposits of a malignant growth. Brain normal.

Conclusions.—Death has probably been due to uræmia from cirrhosis of the kidney. The deceased was also the subject of cancer. The diseases present would ultimately have been fatal in spite of any medical treatment.

Microscopic examination showed the growths in the skull-cap to be lymphosarcoma. Microscopic sections of the ulcers in the intestine showed no evidence of new growth. The diagnosis of uræmia as the immediate cause of death appeared justified from the fact of coma and convulsions having preceded death. The anæmia was probably due to the cancerous disease of the bone marrow.

CEREBRAL HÆMORRHAGE (5 CASES).

CASE 37.—*Cerebral Hemorrhage—Congenital Cystic Kidney.*—A. L., aged 51. Became suddenly unconscious and died in a few hours on May 23rd, 1893.

Autopsy.—Both kidneys enormously enlarged, weighing 800 and 900 grammes each. They are transformed into a series of cysts set so closely together that no renal tissue can be seen with the naked eye. Ureters and bladder normal. Throughout the liver numerous small cysts ranging from pin head to peas in size and filled with clear fluid. Microscopically these are seen to be dilatations of the minute bile ducts.

On removing brain an extensive recent hæmorrhage is seen originating in the region of the left external capsule. The lateral ventricles are full of blood. The vessels at the base are not atheromatous. The smaller vessels examined microscopically are found to be fatty.

In this case the disease of the kidneys was so striking that this might have been thought to explain the death, had the brain not been examined. There was no history of any renal symptoms. The coincidence of cystic kidney with cysts in the liver is stated to be the rule.

CASE 66.—*Rupture of Cerebellar Artery.*—J. C., aged 50, a saloon-keeper, dropped suddenly dead. Was a heavy eater and drank a good deal.

Autopsy.—June 28th, 1893. Heart greatly hypertrophied. Kidneys large, dark, hog-back in shape and cut with resistance.

Brain, extensive sub-arachnoid hæmorrhage about base, most abundant posteriorly, and evidently compressing the 4th ventricle. Vessels at base thick and rigid. On the right anterior inferiorem cerebellar artery

is an atheromatous patch, at which the vessel presents a lacerated spot of rupture.

CASE 73.—*Cerebral Aneurysm*.—J. C., aged 45. Died suddenly in a brothel where she was an inmate.

Autopsy.—July 11th, 1803. On removing brain the entire base covered with a subarachnoid hæmorrhage extending along the sylvian fissures and over the inferior surface of the cerebellum. The 4th ventricle filled with dark clot moulded to the shape of the ventricle. Lateral ventricles free from clot. A yellow-brown area of softening 1 inch in diameter in the left external capsule near the head of the optic thalamus. The cerebral arteries thick and atheromatous with gritty calcified plates. On the inferior surface of the anterior communicating artery is a sacculated aneurysm the size of a large pea in which a laceration is seen. On the inferior surface of the right temporal lobe is a recent reddish spot of softening in the centre of which is a thrombus occluding a spot of laceration in the wall of a small artery. Heart large. Left ventricle thick. Kidneys below normal size, surfaces granular and cortex greatly reduced. Liver of average size, friable, and pale yellow; in advanced state of fatty degeneration and show calcareous changes. Both ovaries are surrounded by dense adhesions.

In this case it was of interest to note the existence of two hæmorrhages which must have occurred a week or so before the fatal hæmorrhage, without the acquaintances of the deceased having noticed any symptoms.

CASE 74.—*Rupture of Sylvian Artery*.—N. P., aged 50. Died suddenly.

Autopsy.—July 11th, 1803. A fine woolly looking white froth about nostrils. Over sternum is a mustard plaster, beneath which no sign of redness or vesication is seen. Lungs voluminous. Sub-pleural ecchymoses. Heart large, weighs 550 grammes. Left ventricle dilated and its wall hypertrophied. Below the cusps of the aortic valves is a rough calcareous yellow projecting mass, which almost occludes the orifice. On ventricular surface of mitral a few small recent fibrinous vegetations. Lungs oedematous, cut surface rusty looking. Bronchi full of froth. Near lower extremity of spleen a partly decolourized hæmorrhagic infarct the size of an egg.

Brain. On removal, an extensive dark firm clot covers the entire base. A little clot in 4th ventricle. The source of the hæmorrhage is seen to be a rupture of the right sylvian artery at a point where the vessel is extremely atheromatous.

Thus, in three out of the four cases, the source of the hæmorrhage was readily discovered, which is always a source of satisfaction in giving evidence. The verdicts in each case was of course apoplexy.

In some cases when the vessels are atheromatous it often is a point of extreme difficulty to determine whether a fatal hæmorrhage has been due or not to some intervening act of violence involving a slight blow or a fall. This complication did not arise in my cases.

ABSCESS OF BRAIN FROM MIDDLE EAR DISEASE.

CASE 61.—M. C., aged 9 months, an illegitimate female child. Had suffered from double middle disease in the foundling asylum, was afterwards removed by her mother and brought back in a dying condition. No satisfactory explanation obtained.

Autopsy, June 27th, 1893. Body well nourished. No signs of external injury. No discharge from ears.

On sawing through skull cap and brain at the level of corpus colosum, an abscess as large as a hen's egg, filled with greenish yellow pus, is situated in the right hemisphere, lying behind the fissure of Rolando, and has burst into the right lateral ventricle near the descending horn. The cortex external to the abscess is no thicker than a sheet of blotting paper. The abscess wall is formed of thick reddish gray pyogenic membrane. A little pus is found in the left lateral, as well as the 3rd and 4th ventricles. About the optic chiasm and sylvian fissures and over the cerebellum abundant creamy pus lies beneath the arachnoid. Hemorrhagic infiltration of cortex in right temporal lobe. The internal ear, and on both sides, shows abundant reddish gray granulations, in which the ossicles are imbedded. Both drums are perforated. Mastoid antrum contains a little mucoid fluid. The right mastoid cells are soft and appear carious. Sinuses at base of skull normal. All other organs look healthy.

STILL BIRTHS (2 CASES.)

CASE 62.—*Cerebral Hemorrhage in a new-born infant.*

Autopsy.—On an unknown male infant found at Côte St. Paul, on Feb. 24th, 1893. Body frozen, Length 18 inches. Weight 5 lbs. 2 oz. Cord ligatured with white cotton thread. Head obliquely flattened on the right side. A little vernix about armpits and groins. Meconium about anus. Scrotum large and cedematous. Testes descended. No signs of injury to scalp. Large, caput succedaneum in left temporal region. Bones of skull not broken.

At the base of the brain is a blood clot the size of a pigeon's egg, lying near the medulla. A little hemorrhage about sylvian fissures.

Lungs dark red, contain no air, portions excised sink.

Stomach empty. Meconium in large and smaller bowels.

Epiphysis of femur shows a reddish vascular area, but no definite ossification. Hands and nails well formed.

Conclusions.—The child is not quite at term but is viable. There is no proof that it has breathed. Death has been due to cerebral hemorrhage, there is no proof that this has not occurred during labour.

In this case I was obliged to examine the brain while it was still frozen, contrary to the usual directions laid down. I found the examination could be made very well in the frozen state whereas as soon as thawing set in the brain substance melted into a grayish fluid. It has occurred to me that the examination of brain lesions when there is reason to expect

softening from decomposition, might be better made if the head were frozen and frozen sections made.*

CASE 52.—*Still birth. Syphilitic pneumonia and fatty degeneration of heart.—Maceration.*—Supposed case of abortion and infanticide.

Autopsy, June 8th, 1893. Immature male fetus. 12 inches long. No marks of violence. Epidermis somewhat softened. Body appeared free from decomposition. Umbilical cord $2\frac{1}{2}$ inches long, thick and gelatinous looking, well secured by cotton thread. Finger nails extend half way to tips. Toe nails not visible. Head measures $3\frac{1}{2}$ x $2\frac{1}{2}$ inches. Nostrils contain yellow mucus, mouth free. Stomach and small intestine collapsed. Meconium chiefly in sigmoid flexure. Heart muscle pale grayish-yellow, and looks opaque. Microscopically the fibres are filled with coarse granules blackened by osmic acid and soluble in chloroform. Valves normal, fetal orifices open. Lungs, pale grayish white, feel solid and heavy, sinking in water. On section are dry and granular, alveoli are seen under microscope to be distended in places by small cell exudation (white hepatization). A little grayish mucus in stomach.

Brain, sylvian fissure seen as a broad groove. No other fissures visible.

A centre of ossification in calcaneum: none in astragalus or sternum. Placenta not obtained.

Conclusions.—The body has not reached the sixth month. Death has been due to fetal pneumonia with degeneration of the heart muscle, both probably syphilitic.

DEATH FROM UNKNOWN CAUSES (10 CASES).

CASE 101.—*Capillary Thrombosis of Brain.—Punctiform Hemorrhages.*—J. S., aged 30. Out of sorts for some days but able to work. While at work was taken with vomiting and convulsions. Soon became comatose, and died within 36 hours. Urine was albuminous, passed in fair amount.

Autopsy, Aug. 21st, 1893. Body poorly nourished. No external marks of violence. Thoracic and abdominal organs apparently healthy. Microscopic examination of kidneys shows no evidences of disease.

Brain, on dissection shows, in the region of the basal ganglia and the internal capsule numerous (12) areas of punctiform hemorrhage, giving the appearance, on section, of angiomata, the areas ranging from $\frac{1}{2}$ to 1 inch in diameter. The main vessels of the brain look healthy and the organ appears otherwise normal. Microscopical examination of the hemorrhagic areas shows the minute arterioles filled with hyaline thrombi and surrounded by extravasated blood, in which the corpuscles appear normal.

On being asked for my opinion I could only state that there was extensive obstruction of the minute vessels of the brain with no evidence that this condition was due to violence, but that this did not satisfactorily explain the death.

A verdict of death from natural causes was returned. The

* Dr. Cattell, of Philadelphia (*University Med. Magazine*), has also recently called attention to the advisability of freezing the brain under these circumstances.

case was a very puzzling one and a chemical analysis might have been interesting, but it was not demanded as there were no really suspicious circumstances, though the possibility of a toxic origin strongly suggested itself. The capillary hæmorrhages may have been the result and not the cause of the convulsions. The condition of capillary thrombosis seems analagous to that described as occurring in severe burns.

In the following two cases the deaths occurred suddenly in epileptics.

CASE 54.—F. S., aged 28, male. Found dead in bed. Had been treated at Montreal General Hospital for epilepsy. Recently, attacks had not been frequent.

External Examination, June 11th, 1893. Body of a well built muscular young man. Lividity marked in anterior parts of body, a few small vibices over chest and abdomen. Abundant bloody froth about nostrils.

Conclusions.—The cause of death cannot be stated from external examination.

Verdict.—*Death from unknown causes.*

CASE 44.—J. C., aged 75. An old man subject to epileptic fits in which he lost consciousness, while at work mending roads, suddenly called for help and fell down. Immediately afterwards was found to be dead.

External Examination, on May 31st, 1893. Showed no signs of external violence or disease.

Conclusions.—The cause of death cannot be stated from external examination.

Verdict.—*Death from Heart Disease.*

(In the last case there was no history of heart disease and no facts to justify such a verdict being given.)

Upon being asked, in case 44, if epilepsy could be the cause of the death, I could only state that if after an autopsy no organic lesion could be found, this would be a presumption in favour of epilepsy, which is a functional disorder. Being asked if epilepsy was a common cause of sudden death I stated that it was not so regarded, apart from fatal accidental injuries received during the fits. (Of these we had two examples, both from drowning, during 1893.)

Upon looking into the subject more carefully I find that my statement, as to the infrequency of sudden death from epilepsy, is in accordance with the views of all the medico-legal text-books I have been able to consult as it is nowhere mentioned as a cause of sudden death. This view appears to be taken in the special works on nervous diseases

On the other hand in the Registratation Reports for Massa-

chusetts, epilepsy is assigned as the cause of 112 deaths out of a total of 42,087, the total for the year 1888, is 1 to 374, and in 1887, 1 to 379. In 1891, the proportion was about the same, being 1 to 364. In New York, for 1891, the ratio was 1 to 286. In Paris, Berthillon's Statistic for 1888 gives 1 in every 1,222 deaths from all causes as the proportion due to epilepsy. Of course the proportion of deaths from epilepsy among sudden deaths alone, would be much greater.

Lesser (*Vierteljahrscr. Gerichtl. Med.*, Jan. 1888), in an analysis of 171 autopsies in sudden deaths gives 17 as the proportion due to epilepsy. Wynn Westcott, (*British Med. Jour.* Oct. 17th, 1891), in an analysis of 303 cases of sudden death, mentions 8 cases where epilepsy was assumed to be the cause. Vibert reports a case where a marked congestion was found in the brain of a woman, supposed to have died in an epileptic fit. Of course a cerebral hæmorrhage might be brought on by an epileptic seizure.

That it is not safe to jump at conclusions as to causes of death was shown by a subsequent case (No. 106), where an epileptic girl, in whom the seizures were stated to have become alarmingly frequent had died shortly after a violent convulsion. In this case I gave the stereotyped evidence that the cause of death could not be stated without an autopsy and found afterwards upon making a private autopsy, advanced cirrhosis of the kidneys, the convulsions having apparently been uræmic and not epileptic. I do not think a medical witness is justified in ascribing death to epilepsy until he has satisfied himself by an autopsy that it is not due to some organic disease and even then the statement should only be that the symptoms point to epilepsy and nothing is found at the autopsy to indicate otherwise.

DEBILITY (?)

CASE 11.—F. G., aged 5 months. Stated to have died from neglect of her parents.

External Examination.—Great emaciation. Skin rough and loose. No signs of violence.

Conclusion.—The cause of death cannot be stated without an autopsy. The chances of recovery had a physician been summoned shortly before death would have been diminished by the previous ill-health of the child.

Verdict.—No criminal blame attached.

CASE 95.—S. C., aged about 65. A feeble-minded old woman was

lost sight of at a picnic and disappeared. The body was found in a thicket near-by 5 weeks later, and was quite naked, the clothing lying in a heap upon it.

Autopsy.—Aug. 16, 1893. Intense and far advanced putrefaction and denudation of head, and the soft parts of the face and neck have been almost entirely destroyed. These parts are swarming with maggots. No evidence of violence or injury.

The brain is represented by a cup-full of thick greyish fluid.

The muscles are deep red, resembling corned beef and are well preserved. Subcutaneous and omental fat abundant. The abdominal organs are almost free from decomposition and appear healthy. The stomach contains a little coffee colored fluid.

Heart empty. Lungs dried, and shrivelled, the air entering freely about the neck. Organs seem healthy.

Conclusions.—There are no evidences of violence, but their absence cannot be positively affirmed owing to advanced decomposition.

The cause of death cannot be stated.

The jury came to the decision that she died partly from fright and partly from exhaustion through having walked too far. This did not explain in any way the curious fact of the clothing having been removed. Dr. Ruttan kindly examined the viscera for mineral poisons, but with a negative result.

CASE 85.—P. C., aged 87. Previously healthy. Found dead.

External Examination.—July 31, 1893. Shows no marks of violence and nothing to indicate the cause of death.

Verdict.—Died from Heart Disease.

CASE 60.—M. G., female, aged 75. Died suddenly while in apparent good health and spirits.

External Examination.—June 19th, 1893. Body of extremely stout woman. No evidences of violence or disease externally.

Conclusion.—The cause of death cannot be stated without an autopsy.

In this case the jury having been firmly convinced that the deceased had died "*parce que le bon Dieu a voulu la retirer de la terre,*" returned a verdict of death from natural causes through that sense of propriety which keeps jurymen from finding fault with the decrees of Providence when doing so involves a loss of time.

APoplexy (1)

L. C., aged 55, a large powerful man and free liver. Was found dead alone in his house; had been seen apparently in good health two hours before.

External Examination.—Great lividity of face. Moderate edema about ankles. Thin froth in nostrils.

Conclusion.—The dropsy of the ankles indicates that diseased apparently suffered from organic disease of the heart or kidneys. The cause of death cannot be stated.

Verdict.—Death from natural causes.

In this case some medical evidence was given which is worth recording. A physician who was summoned after the man was dead had no hesitation in stating that apoplexy was the cause of death. He had not seen the deceased professionally for 12 years. The reason he assigned for the cause being apoplexy was that the deceased had a very short thick neck.

CASE 21.—A. B., male, aged 48. Rather intemperate. Subject to epileptic fits. Recently had an attack of hemiplegia. Was picked up dying one frosty morning having lain on the road all night.

External Examination.—April 2nd, 1893. Recent scratches on backs of hands, forehead, left ear and chin. No other marks of violence.

Conclusion.—It is impossible to state the cause of death from external examination.

Verdict.—*Death from paralysis aggravated by exposure and intemperance.*

CASE 16.—N. C., aged 45, found lying out of doors in cold weather. Had been drinking the night before and had been seen with a comrade with whom he had quarrelled and fought. The companion disappeared for 20 days and afterwards was arrested and was the chief witness at the inquest.

External Examination.—March 14th, 1893. Contused lacerated wound over the left orbit. Behind the right ear there is contusion and abrasion of the skin.

Conclusion.—The external examination does not justify a statement as to the cause of death.

The bruising behind the ear is sufficiently suspicious to justify an autopsy.

No autopsy was ordered. A verdict of death from exposure being rendered.

In the deaths in this group of cases, it will be seen that when no autopsy was performed next to nothing could be affirmed as to the cause of death.

Probably of all the uses to which a medical expert can be put, the making of profunetory external examinations is perhaps the worst. The only justification of my official function in these cases is that of having said nothing when there was nothing to say. I may finish by mentioning the following verdict, given in a case where I was summoned but could not arrive in time for the inquest, and where the body showed extensive bleeding from the mouth:—“We, the undersigned, find that the deceased came to his death through being suffocated because, having fallen face downward on the floor, he was too weak to raise himself up again.”

