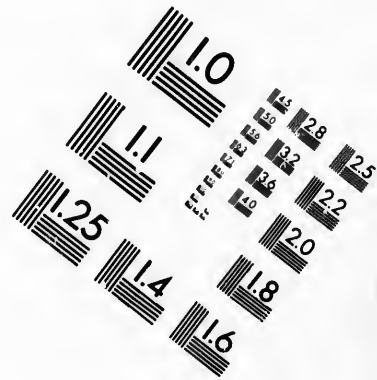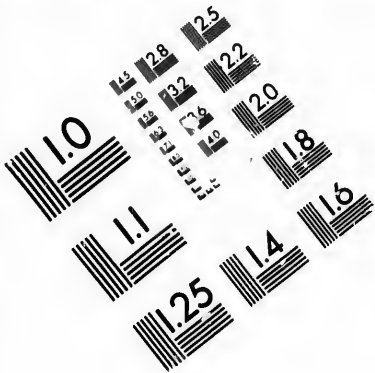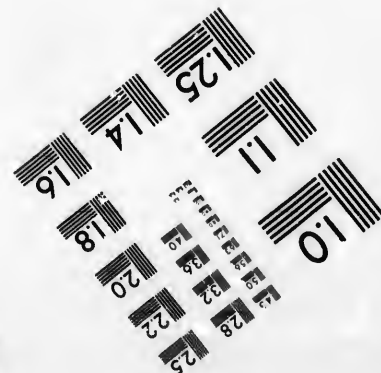
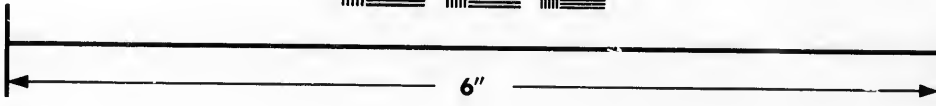



IMAGE EVALUATION TEST TARGET (MT-3)



Photographic
Sciences
Corporation

23 WEST MAIN STREET
WEBSTER, N.Y. 14580
(716) 872-4503

**CIHM/ICMH
Microfiche
Series.**

**CIHM/ICMH
Collection de
microfiches.**



Canadian Institute for Historical Microreproductions / Institut canadien de microreproductions historiques

© 1981

Technical and Bibliographic Notes/Notes techniques et bibliographiques

The Institute has attempted to obtain the best original copy available for filming. Features of this copy which may be bibliographically unique, which may alter any of the images in the reproduction, or which may significantly change the usual method of filming, are checked below.

L'Institut a microfilmé le meilleur exemplaire qu'il lui a été possible de se procurer. Les détails de cet exemplaire qui sont peut-être uniques du point de vue bibliographique, qui peuvent modifier une image reproduite, ou qui peuvent exiger une modification dans la méthode normale de filmage sont indiqués ci-dessous.

- | | |
|--|--|
| <input type="checkbox"/> Coloured covers/
Couverture de couleur | <input type="checkbox"/> Coloured pages/
Pages de couleur |
| <input type="checkbox"/> Covers damaged/
Couverture endommagée | <input type="checkbox"/> Pages damaged/
Pages endommagées |
| <input type="checkbox"/> Covers restored and/or laminated/
Couverture restaurée et/ou pelliculée | <input type="checkbox"/> Pages restored and/or laminated/
Pages restaurées et/ou pelliculées |
| <input type="checkbox"/> Cover title missing/
Le titre de couverture manque | <input checked="" type="checkbox"/> Pages discoloured, stained or foxed/
Pages décolorées, tachetées ou piquées |
| <input type="checkbox"/> Coloured maps/
Cartes géographiques en couleur | <input type="checkbox"/> Pages detached/
Pages détachées |
| <input checked="" type="checkbox"/> Coloured ink (i.e. other than blue or black)/
Encre de couleur (i.e. autre que bleue ou noire) | <input checked="" type="checkbox"/> Showthrough/
Transparence |
| <input checked="" type="checkbox"/> Coloured plates and/or illustrations/
Planches et/ou illustrations en couleur | <input type="checkbox"/> Quality of print varies/
Qualité inégale de l'impression |
| <input type="checkbox"/> Bound with other material/
Relié avec d'autres documents | <input type="checkbox"/> Includes supplementary material/
Comprend du matériel supplémentaire |
| <input type="checkbox"/> Tight binding may cause shadows or distortion
along interior margin/
La reliure serrée peut causer de l'ombre ou de la
distortion le long de la marge intérieure | <input type="checkbox"/> Only edition available/
Seule édition disponible |
| <input type="checkbox"/> Blank leaves added during restoration may
appear within the text. Whenever possible, these
have been omitted from filming/
Il se peut que certaines pages blanches ajoutées
lors d'une restauration apparaissent dans le texte,
mais, lorsque cela était possible, ces pages n'ont
pas été filmées. | <input type="checkbox"/> Pages wholly or partially obscured by errata
slips, tissues, etc., have been refilmed to
ensure the best possible image/
Les pages totalement ou partiellement
obscurcies par un feuillet d'errata, une pelure,
etc., ont été filmées à nouveau de façon à
obtenir la meilleure image possible. |
| <input type="checkbox"/> Additional comments:/
Commentaires supplémentaires: | |

This item is filmed at the reduction ratio checked below/
Ce document est filmé au taux de réduction indiqué ci-dessous.

10X	12X	14X	16X	18X	20X	22X	24X	26X	28X	30X	32X
							/				

The copy filmed here has been reproduced thanks to the generosity of:


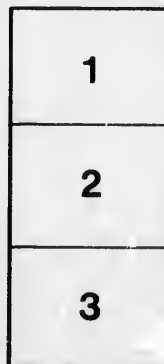

National Library of Canada

The images appearing here are the best quality possible considering the condition and legibility of the original copy and in keeping with the filming contract specifications.

Original copies in printed paper covers are filmed beginning with the front cover and ending on the last page with a printed or illustrated impression, or the back cover when appropriate. All other original copies are filmed beginning on the first page with a printed or illustrated impression, and ending on the last page with a printed or illustrated impression.

The last recorded frame on each microfiche shall contain the symbol → (meaning "CONTINUED"), or the symbol ▼ (meaning "END"), whichever applies.

Maps, plates, charts, etc., may be filmed at different reduction ratios. Those too large to be entirely included in one exposure are filmed beginning in the upper left hand corner, left to right and top to bottom, as many frames as required. The following diagrams illustrate the method:



L'exemplaire filmé fut reproduit grâce à la générosité de:

Bibliothèque nationale du Canada

Les images suivantes ont été reproduites avec le plus grand soin, compte tenu de la condition et de la netteté de l'exemplaire filmé, et en conformité avec les conditions du contrat de filmage.

Les exemplaires originaux dont la couverture en papier est imprimée sont filmés en commençant par le premier plat et en terminant soit par la dernière page qui comporte une empreinte d'impression ou d'illustration, soit par le second plat, selon le cas. Tous les autres exemplaires originaux sont filmés en commençant par la première page qui comporte une empreinte d'impression ou d'illustration et en terminant par la dernière page qui comporte une telle empreinte.

Un des symboles suivants apparaîtra sur la dernière image de chaque microfiche, selon le cas: le symbole → signifie "A SUIVRE", le symbole ▼ signifie "FIN".

Les cartes, planches, tableaux, etc., peuvent être filmés à des taux de réduction différents. Lorsque le document est trop grand pour être reproduit en un seul cliché, il est filmé à partir de l'angle supérieur gauche, de gauche à droite, et de haut en bas, en prenant le nombre d'images nécessaire. Les diagrammes suivants illustrent la méthode.



OPERATIVE GYNECOLOGY

VOLUME II



OPERATIVE GYNECOLOGY

BY

HOWARD A. KELLY, A. B., M. D.

FELLOW OF THE AMERICAN GYNECOLOGICAL SOCIETY;
PROFESSOR OF GYNECOLOGY AND OBSTETRICS IN THE JOHNS HOPKINS UNIVERSITY,
AND GYNECOLOGIST AND OBSTETRICIAN TO THE JOHNS HOPKINS HOSPITAL, BALTIMORE;
FORMERLY ASSOCIATE PROFESSOR OF OBSTETRICS IN THE UNIVERSITY OF PENNSYLVANIA;
CORRESPONDING MEMBER OF THE SOCIÉTÉ OBSTÉTRICALE ET GYNÉCOLOGIQUE DE PARIS,
AND OF THE GESELLSCHAFT FÜR GEBURTSHÜLFE ZU LEIPZIG

*WITH TWENTY-FOUR PLATES AND
FIVE HUNDRED AND NINETY ORIGINAL ILLUSTRATIONS*

VOL. II

TORONTO
GEORGE N. MORANG
63 YONGE STREET
1898

RG104

K26

f.1.

v. 2.

174647

COPYRIGHT, 1898,
BY D. APPLETON AND COMPANY.

PRINTED AT THE APPLETON PRESS
NEW YORK, U. S. A.

CONTENTS.

CHAPTER	PAGE
XX. GENERAL PRINCIPLES AND COMPLICATIONS COMMON TO ABDOMINAL OPERATIONS	1
XXI. CARE OF WOUND AND PATIENT UP TO RECOVERY	44
XXII. COMPLICATIONS ARISING AFTER ABDOMINAL OPERATIONS	56
XXIII. TUBERCULAR PERITONITIS	134
XXIV. SUSPENSION OF THE UTERUS	149
XXV. CONSERVATIVE OPERATIONS ON THE TUBES AND OVARIES	163
XXVI. SIMPLE SALPINGO-OÖPHORECTOMY AND SALPINGO-OÖPHORECTOMY FOR ADHERENT TUBES AND OVARIES	193
XXVII. VAGINAL DRAINAGE AND ENUCLEATION FOR PYOSALPINX, OVARIAN ABSCESS, TUBO- OVARIAN ABSCESS, AND PELVIC ABSCESS	209
XXVIII. HYSTERECTOMY, WITH EXTIRPATION OF OVARIES AND TUBES—ABDOMINAL HYSTERO- SALPINGO OÖPHORECTOMY	236
XXIX. OVARIOTOMY	246
XXX. ABDOMINAL HYSTERECTOMY FOR CARCINOMA AND SARCOMA OF THE UTERUS	305
XXXI. MYOMECTOMY—HYSTERO-MYOMECTOMY	338
XXXII. OPERATIONS DURING PREGNANCY	403
XXXIII. CESAREAN SECTION	415
XXXIV. EXTRA-UTERINE PREGNANCY	428
XXXV. THE RADICAL CURE OF HERNIA	467
XXXVI. INTESTINAL COMPLICATIONS	492
XXXVII. THE MORE REMOTE RESULTS OF ABDOMINAL OPERATIONS	518
XXXVIII. ON THE CONDUCT OF AUTOPSIES, THE MAKING OF PROTOCOLS, AND THE PRESERVA- TION OF TISSUES FOR MICROSCOPIC EXAMINATION IN GYNECOLOGICAL PRACTICE	351



LIST OF ILLUSTRATIONS.

FIG.	PAGE
316. Stricture of rectum due to pelvic inflammatory disease	20
317. Vermiform appendix adherent to a large papillary ovarian cyst	21
318. Extensive pelvic inflammatory disease with general adhesions	22
319. The clear space	24
320. Encysted silk ligature in the right broad ligament	25
321. Closure of the abdominal wound	42
322, 323, 324, 325. Showing the average charts, or composite temperatures and pulse rates in ten cases in each group	54
326. Introducing normal salt solution under the breasts in case of extreme anemia	70
327. Chart showing convalescence complicated by a high pulse rate	72
328. Normal convalescence interrupted by periodical rises of temperature due to the presence of the plasmodium malarie	75
329. Chart of a case of septic peritonitis following myomectomy	86
330. Chart of a case of general sepsis following a perineal operation	102
331. Chart of a case of septicaemia from a purulent peritonitis	103
332. Chart showing an abdominal operation complicated by pneumonia	108
333. Stitch-hole abscess chart	115
334. Tubercular left tube with adherent omentum	135
335. Tubercular right tube, with tubercles over a parovarian cyst	135
336. General tubercular peritonitis	136
337. Tuberculosis of tubes and ovaries	144
338. Tuberculosis of the tube	144
339. Diagram showing the relative advantages of closing or of draining the abdomen in tubercular peritonitis	146
340. Composite chart, showing course of fever after operation in tubercular peritonitis, with- out drainage	146
341. Chart showing recovery after removal of tubes and ovaries in tubercular peritonitis	147
342. Suspension of the uterus, seen from above	150
343. Steps in the reduction of the uterus in the palliative treatment of retroflexion; anterior lip of cervix grasped with tenaculum forceps	151
344. Same, traction straightening out the angle of flexion	151
345. Same, the finger in rectum induces slight antelexion	152
346. Same, forceps carrying the cervix back into the pelvis	152
347. Same, the retroflexion reduced	153
348. Production of an extreme ante-position	154
349. Suspension of the uterus within a year after the operation	155
350. Suspension of the uterus, seen a year after the original operation	156
351. Upper elevator	159
352. Lower elevator	159
353. Suspension of the uterus, showing elevation of the uterus with the lower elevator	160
354. Suspension of the uterus	160
355. Suspension of the uterus, as seen from above	161
356. Suspension of the uterus; outline of operation completed	161

FIG.	PAGE
357. Conservative operation on the ovary	174
358. Párovarian cyst removed from left broad ligament	175
359. Párovarian cyst extirpated without removing either tube or ovary	176
360. Hypertrophy of the ovary, with cystic degeneration	178
361. Hemorrhagic corpus luteum cyst and cystic Graafian follicle in same ovary	179
362. Cyst of the corpus luteum	180
363. Pedunculate corpus luteum cyst of the left ovary	181
364. Cysts of corpora lutea in both ovaries	181
365. Velamentous adhesion of the right uterine tube to itself and to the uterine cornu	183
366. Angular attachment of the left uterine tube to the cornu of the uterus	184
367. Adhesions of the outer free extremities of both uterine tubes to the ovaries	185
368. Conservative operation to preserve the right ovary and left tube	188
369. Diagram of same after removal of the right tube and left ovary	189
370. Double hydrosalpinx	200
371. Large left hydrosalpinx, with numerous adhesions	201
372. Double hydrosalpinx, with adhesions	201
373. Hydrosalpinx	202
374. Hydrosalpinx, with few convolutions	202
375. Same, in longitudinal section	202
376. Hydrosalpinx containing a nodular S-shaped calculus	203
377. Hydrosalpinx, with congenital deficiency in the tube	203
378. Right tubo-ovarian cyst	204
379. Same, laid open	205
380. Tubo-ovarian cyst, from right side	205
381. Same, divided	205
382. Outline of the torsion of the pyosalpinx shown in the colored plate	209
383. Large abscess of the right ovary	214
384. Abscess of the ovary, laid open	215
385. Nodular salpingitis	215
386. Opening a retro-uterine pelvic abscess by puncture	224
387. Stout curved, saw-toothed traction forceps	225
388. Conservative treatment of abscess of both Fallopian tubes	228
389. Same, showing gauze drain behind uterus and extending down into vagina	229
390. Ovarian abscess	234
391. Double pyosalpinx, with carcinoma of the cervix	235
392. Extirpation of myomatous uterus, ovaries, and tubes, with a left ovarian cystoma	237
393. Hystero-salpingo-oöphorectomy for large double hydrosalpinx	240
394. Outline showing extirpation of the uterus, tubes, and ovaries by a continuous incision	241
395. Extirpation of uterus, tubes, and ovaries for pelvic peritonitis	243
396. Diagram showing the relations of an ovarian cyst to the peritoneum of the pelvic floor and broad ligament	248
397. Long pedicle of a papillary ovarian adeno-cystoma	249
398. Diagram showing the relations of an intraligamentary cyst to the anterior and posterior layers of the peritoneum of the broad ligament	250
399. Adherent cyst of the ovary showing the mimicry of the intraligamentary cyst	250
400. Parasitic ovarian cyst of left side, with general peritoneal carcinosis	250
401. Left ovarian cyst with a twisted pedicle	251
402. Same, pedicle untwisted to show its anatomical elements	251
403. The relations of the parasitic multilocular ovarian cyst shown in inset Fig. 400	251
404. Ovarian cyst showi: g natural perforation, with discharge	252
405. Large multilocular ovarian cyst in a negress	253
406. Typical polycystic ovarian tumor, with long twisted pedicle	259
407. Multilocular ovarian cyst, in which smaller cysts project into the cavity of the large one	260
408. Polycystic ovarian tumor and parovarian cyst existing on the same side	261
409. Multiple adeno-cystomata of the ovary	262

FIG.	PAGE
410. Wall of a multilocular ovarian cyst magnified 170 times	263
411. Papillomata of both ovaries, seen <i>in situ</i> from behind	265
412. Inner surface of a papillo-adenocystoma of the left ovary	268
413. Cysto-papilloma of the ovary	270
414. Solid or fibroid papillary adenoma of the ovary	272
415. Adeno-carcinoma (colloid carcinoma) of the ovary	274
416. Cysto-carcinoma of the ovary of unusual form	275
417. Flat carcinomatous metastatic nodules on the intestines	276
418. Large adeno-carcinoma (colloid carcinoma) of the omentum	276
419. Adeno-carcinoma of the omentum, seen in section	276
420. Rudimentary jaw from a dermoid cyst containing molar teeth, and with a wisp of hair growing from its extremity	277
421. Contour of the abdomen in the case of an unusually large dermoid cyst	277
422. Left dermoid cyst of the ovary with a long pedicle	278
423. Complicated dermoid cyst of the right ovary	279
424. Right dermoid cyst with extensive adhesions	280
425. Parovarian cyst situated between the ampulla of the tube and the outer end of the ovary	281
426. Parovarian cyst, showing its translucency and the uterine tube spread out on its surface	281
427. Parovarian cyst, with subsidiary cysts lying beneath the tubo-ovarian fimbria	281
428. Parovarian cyst bulging out on both sides of the tube	282
429. Cyst of the parovarium	283
430. Parovarian cyst	284
431. Parovarian cyst with twisted pedicle	285
432. Subperitoneal cyst developed entirely from the peritoneum	286
433. The pedicle of the hydatid tied about the free tubal fimbria at its base	287
434. Same, enlarged, showing appearance of the degenerated fimbria	287
435. Fibroid tumor of the ovary	288
436. Calculus of the ovary	288
437. Partially calcified fibroma of the right ovary	289
438. Angio-sarcoma of the left ovary, with metastasis in the uterus	290
439. Mono-cystic tumor of the left broad ligament	296
440. Suppurating adherent ovarian cyst	297
441. Suppurating adherent ovarian cyst	298
442. Same, cross-section of the intestinal and mesenteric attachment	298
443. Diagram from a case of intraligamentary cyst, seen from above	299
444. Same, showing closure of wound after enucleation of cyst	299
445. Intraligamentary Graafian follicle cysts, <i>in situ</i>	300
446. Same, removed	301
447. Multiple dermoid cysts of both ovaries	302
448. Left dermoid cyst and right multilocular ovarian cyst with twisted pedicle	302
449. Fibroma of the left ovary with large myomata of the uterus	303
450. Adeno-carcinoma of the cervix, with hydroneurter of both sides	305
451. Carcinoma of the cervix	307
452. Extensive epithelioma of the cervix	308
453. Inoperable epithelioma of the cervix	309
454. Adeno-carcinomatous nodule entirely concealed within the cervix	310
455. Adeno-carcinoma of the body of the uterus, growth stopped at internal os	311
456. Adeno-carcinoma of the body of the uterus	312
457. Same, cut through the anterior wall	313
458. Adeno-carcinoma of the uterine body, with metastatic nodules in the lymph channels of the left broad ligament	313
459. Limited area of carcinoma of the fundus of the uterus on the left side	314
460. Operation for carcinoma of the uterus	316
461. Carcinoma uteri	317
462. Double hydroneurter due to advanced cancer of the cervix uteri	318

FIG.	PAGE
463. Autopsy on a case of carcinoma of the cervix; hydroureter, with double ureter on the left	310
464. The upper half of a hydroureter, with hydronephrosis from compression due to a cancerous cervix	320
465. Relations of the ureter and bladder to the uterus and vagina	323
466. Diagram showing stoppage of bougie in the ureter in the operation for carcinoma of the cervix	324
467. Outline diagram of the steps of the radical operation for cancer of the cervix	325
468. Hysterectomy for carcinoma of the cervix; left broad ligament opened up	326
469. Same, the left uterine artery tied and cut off	327
470. Same, bladder freed and vaginal vault opened anteriorly	329
471. Same, in sagittal section, showing the left side of the pelvis, with the operation completed.	330
472. Epithelioma of the cervix in grapelike mass	331
473. Uterus enucleated per vaginam, in contrast with this method	332
474. Small sarcoma in the right horn of the uterus	332
475. Sarcoma of the body of the uterus	333
476. Sarcomatous nodule in the vagina	334
477. Sarcoma of the uterus and right ovary	335
478. Same, uterus cut open in front	336
479. Greatly enlarged right ovary removed with a myomatous uterus	340
480. Uterus with extensive myomatous involvement	342
481. Myomatous uterus, showing interstitial and subperitoneal masses	343
482. Diagram of Case J. S. S., San. 107	344
483. Globular myomatous uterus presenting form of pregnant uterus at term	345
484. Myomatous uterus, exhibiting a perfect cast of the pelvis	346
485. Large subperitoneal myoma, seen from behind	347
486. Pedunculated myomata, giving a perfect ballottement	350
487. Large globular myoma choking the pelvis	352
488. Same, lifted up into the abdomen	353
489. Uterus after extirpation of a myomatous tumor, showing great muscular hypertrophy	356
490. Myomatous uterus, conservative operation	358
491. Conservative treatment of the myomatous uterus	358
492. Same, after removal of the tumors	359
493. Cullen's myoma enucleator	359
494. Myomatous uterus from which eight myoma were enucleated by seven incisions	361
495. Same, showing incisions closed by interrupted catgut sutures	361
496. Large submucous myoma	362
497. Schematic diagram, showing incision from left to right in extirpating the myomatous uterus	369
498. The operation of hysteromyomectomy	371
499. The last step in the enucleation of the myomatous uterus	372
500. Complicated hysteromyomectomy (hydrosalpinx and ovarian cyst)	375
501. Complicated hysteromyomectomy (intestinal and omental adhesions)	376
502. Globular myomatous uterus complicated by dermoid cysts of the left ovary	379
503. Myoma and carcinoma in a negress	380
504. Myoma with cystic degeneration	381
505. Large fibro-cystic tumor of the uterus attached to a multinodular myomatous uterus	382
506. Torsion of the globular myomatous uterus from left to right	383
507. Same, untwisted	384
508. Pelvis choked by a cup-and-ball myoma	391
509. Large myomatous uterus filling the lower two thirds of the abdomen	391
510. Displacement of the bladder due to a large myomatous uterus	391
511. Large cystic myoma of the left broad ligament filled with pus	394
512. Myomatous uterus weighing thirty-nine pounds	396
513. Complicated hysteromyomectomy, showing extensive subperitoneal development	397

FIG.	PAGE
514. Complicated hysteromyomectomy	399
515. Myomatous uterus presenting an extraordinary mimicry of a child in a transverse position	401
516. Cesarean uterus removed six years after operation	420
517. Porro-Cesarean section for fibroid uterus at term	425
518. Extra-uterine pregnancy gone some six or eight months beyond term	428
519. Tubal diverticula forming the two rounded eminences on the upper border of the ampulla	431
520. Triple tubal ostia	432
521. Fetus and umbilical cord found lying among clots in abdominal cavity	438
522. Extra-uterine pregnancy	439
523. Ruptured left extra-uterine pregnancy with large, free intraperitoneal hemorrhage	439
524. Extra-uterine pregnancy, showing tube cast	440
525. Extra-uterine tubal mole filling and distending the ampulla	441
526. Extra-uterine pregnancy; cross section of the tubal wall in the ampulla	445
527. Extra-uterine pregnancy; tubal abortion	450
528. Same, coagulum turned out	450
529. Extra-uterine pregnancy (right), with tubal abortion	452
530. Operation for ruptured extra-uterine pregnancy	452
531. Lithopedion lying undisturbed in the abdominal cavity	460
532. Lithopedion removed from the abdominal cavity four years after a false labor	461
533. Pregnancy in a rudimentary left uterine horn; rupture, death	465
534. Hernia of the pregnant uterus in the negress	467
535. General principles of the radical operation for hernia; incision made and hernial sac protruding	469
536. Same, with the sac returned and sutures laid	470
537. Same, with the silver-wire mattress sutures drawn up, twisted, and the ends turned down	470
538. Same, the mattress suture tied	471
539. Same, interrupted gutgut sutures passed, but not yet tied, in the intervals between the mattress sutures	471
540. Operation for a ventral hernia	472
541. Tissues grasped by the mattress sutures in closing the hernia	473
542. Mattress sutures uniting the recti muscles and their overlying fasciæ	473
543. Incarcerated umbilical hernia in a fat woman	474
544. Same, the hernial sac removed	475
545. Anatomy of the inguinal canal	476
546. Anatomy of the inguinal canal in its deeper layers	477
547. First step in the operation for inguinal hernia; the sac exposed	478
548. Second step of same; the sac drawn out of wound	479
549. Third step of same; the sac incised	480
550. Fourth step of same; closure of neck of sac with mattress sutures	481
551. Fifth step of same; closure of the inguinal canal with silver-wire mattress sutures	482
552. Sixth step of same; the mattress sutures drawn up and twisted, and the wound being closed by a continuous suture	483
553. Operation for the radical cure of a large inguinal hernia where the conjoined tendon is deficient	484
554. Showing the facility with which the rectus muscle, released from its sheath, can be drawn over and attached to Poupart's ligament, covering in the entire inguinal canal	485
555. Partial hernia of the left ovary	488
556. Left femoral hernia	490
557. Method of dealing with intestinal adhesions where an interval can be developed between the bowel and the adherent surface by slight traction	492
558. First step in the operation for appendicitis	498
559. Second step in the operation for appendicitis	499
560. Third step in the operation for appendicitis	500

FIG.	PAGE
561. Retracted appendical stump within a cuff of peritoneum	501
562. Closure of the peritoneal cuff over the stump by mattress and interrupted sutures	502
563. Inversion and extraperitoneal disposal of the little buttonlike stump beneath the contiguous margins of the mesenteriolum	502
564. Curved intestinal needle	503
565. Halsted's method of preserving the intestinal needles	503
566. Human small intestine magnified one hundred times to show the relative thickness of the various coats	504
567. A section of the colon magnified one hundred times	504
568. Cross-section of the rectum magnified twenty-five times	505
569. Lateral anastomosis. First step; ends of bowel closed and mattress sutures introduced on the lower side	506
570. Same, second step; lower row of sutures tied and the lateral sutures applied	506
571. Same, third step; lateral sutures tied, making a pocket	507
572. Same, fourth step; remaining sutures in place ready to complete the union on all sides	507
573. Same, completed; all sutures tied	508
574. End to end anastomosis without artificial aids; presection sutures in place	508
575. Same; presection sutures tied	509
576. Same; mattress sutures in place	509
577. Same; sutures all tied, accurate approximation of divided ends of bowel	509
578. Circular suture of the intestine	510
579. One of the divided ends of the intestine	511
580. The introduction of the collapsed rubber cylinder between the presection sutures	511
581. After tying the three presection sutures and inserting the rubber bag a fourth stitch, <i>b</i> , is inserted	511
582. The mesenteric mattress suture devised by Mitchell and Hunner	511
583. From ten to twelve mattress sutures are introduced, and the tying begun with the mesenteric suture <i>a</i>	512
584. Two sutures separated to allow the deflated bag to be withdrawn	513
585. Sutures all tied, and the anastomosis completed	514
586. Anastomosis of the sigmoid into the ampulla of the rectum	515
587. Making a sigmoid anus in occlusion of the lower bowel	516
588. Making a sigmoid anus	517
589. Post-operative intra-abdominal hernia	518
590. Strangulated hernia in a patient seventy-five years old, due to ovariectomy twenty-seven years before	521
591. A section through the constricted portion of the bowel shown in Fig. 590	522
592. Showing the ends of the tubes and pieces of the ovary left after an imperfect operation	525

LIST OF PLATES.

PLATE		PAGE
XI.	Fig. 1. Hydrosalpinx simplex	199
	Fig. 2. Hydrosalpinx follicularis.	199
XII.	Hydrosalpinx simplex	199
XIII.	Hydrosalpinx follicularis (Fig. 1, Plate XI magnified)	204
XIV.	A typical pyosalpinx	209
XV.	Section of a small nodule taken from the inner surface of a cysto-papilloma of the ovary (Fig. 413)	270
XVI.	A papillary ovarian cyst exhibiting a few sarcomatous nodules.	275
XVII.	Epithelioma of the cervix	309
XVIII.	Radical operation for cancer of the uterus	321
XIX.	Injected specimen showing the vascular supply of myomata	338
XX.	Angio-myoma of the uterus, with cystic degeneration	382
XXI.	Benign adeno-myoma of the uterus	385
XXII.	Benign adeno-myoma of the uterus; magnified sections of Plate XXI	387
XXIII.	Diagnosis of extra-uterine pregnancy by microscopic examination	448
XXIV.	Pregnancy in a rudimentary left uterine horn; magnified sections of Fig. 533	404



OPERATIVE GYNECOLOGY.

CHAPTER XX.

GENERAL PRINCIPLES AND COMPLICATIONS COMMON TO ABDOMINAL OPERATIONS.

1. Health of the surgeon.
2. Examination of the patient: Lungs, heart and circulation, liver, stomach, family history.
3. Urinalysis.
4. Preliminary preparation of the patient: *a.* To produce the best possible physical condition. *b.* To quicken the emunctories. *c.* To secure aseptic surface of abdomen.
5. Preparation of patient in the operating room.
6. Preparation of surgeon and assistants.
7. Proper dress and conduct of visitors.
8. Length of incision, and how to find the peritoneum: *a.* The exploratory incision. *b.* Cutting through the umbilicus. *c.* Hemorrhage from the incision.
9. Exposure of the field of operation: *a.* Elevated pelvis; advantages and disadvantages. *b.* Illumination.
10. Methods of dealing with adhesions: *a.* Adhesions to pelvic walls, floor, and broad ligaments. *b.* Omental adhesions. *c.* Uterine adhesions. *d.* Rectal adhesions. *e.* Intestinal adhesions. *f.* Appendical adhesions and removal of the vermiform appendix. *g.* Vesical adhesions.
11. Injuries to the bladder and ureters.
12. Ligation of the pedicle.
13. Hemorrhage: *a.* Sources of. *b.* Control.
14. Irrigation of abdomen with normal salt solution.
15. Drainage. 1. Physiology of drainage: (*a.*) Function of the peritoneum under normal and pathological conditions. (*b.*) Mechanism of absorption of fluids and solid particles in the peritoneal cavity. 2. Clinical studies of the subject. 3. Objections to drainage. 4. The prevention and removal of infection without resorting to drainage: (*a.*) Postural drainage. 5. Cases to be drained. 6. How to put in and take out a gauze drain.
16. Closure of the incision.
17. The abdominal dressing.

In order to avoid constant repetition in discussing the various operative procedures as they are taken up, I propose in this chapter to consider certain details common to the technique of all abdominal operations.

The Health of the Surgeon.—The surgeon's physical condition has much to do with the success of his work. I would insist that no man in ill health is justified in doing prolonged surgery, because he is not in condition to stand the great and often prolonged strain upon his attention, with the constant appeals to a clear judgment in rapidly deciding questions of vital importance. Moreover, to meet such serious emergencies as may arise, not only judgment is needed, but a well-balanced nervous and muscular system, which are not at the disposal of an invalid. A surgeon who is affected with an acute tonsillitis, pharyngitis, ozena,

alveolar abscess, furunculosis, or pulmonary tuberculosis should consider himself absolutely debarred from performing abdominal operations of any sort on account of the danger of direct infection of the patient. It is also improper for any one who has an elevation of the temperature to go near the operating table. A suppurating wound of any part of the hand debars the surgeon, assistant, or nurse from operating or assisting until it is healed, so that the part can be thoroughly scrubbed.

Examination of the Patient.—Preceding every abdominal operation a thorough physical examination must be made, including an investigation of every important organ in the body. It is best to do this by taking the organs up in some systematic order, which should not be deviated from. The lungs must be carefully examined for tuberculosis, the pleural cavities for fluid, the heart for valvular lesions and evidences of fatty degeneration, the arterial system for sclerosis, the urine for nephritis, pyelitis, or diabetes, and the liver for cirrhosis. Gastric symptoms, indicating ulcer of the stomach or carcinoma, demand attention. Close inquiry must be made into the patient's former history to discover any tendency toward insanity. Women who have been in an asylum, or those who have at times appeared mentally unsound, although able to remain at home, are peculiarly prone to melancholia or even violent insanity after any operation, whether pelvic or abdominal. In one case, in which I simply repaired the perineum, the patient, who was markedly emotional, developed a profound melancholia which lasted for months. Another woman, a pronounced neurasthenic, three weeks after a suspension operation, attempted suicide by cutting the abdomen with a broken bottle, although up to this time she had shown no signs of actual insanity; about two months later she succeeded in cutting her throat with a razor. Cases might easily be multiplied, but this subject will be discussed more fully in the complications following operations.

A careful preliminary study of his cases after this fashion is of paramount importance to the operator, for unless such a routine examination is followed out in every case, now and then a life will be lost from some unsuspected associated disease. Disease of an extrapelvic organ, sufficiently advanced to cause death independently in the near future, forbids any but an emergency operation. This needs not, however, prohibit operations for pelvic abscess in patients with pulmonary tuberculosis, where there is reason to believe that the patient may live some years in comparative comfort, if the pelvic complication is removed. Old age also forms no barrier, as the results of careful work appear almost as successful in the aged as in the young.

It is my habit, in referring patients from a consultation or from my private office to a hospital for operation, to fill out one or more of the headings on a chart similar to the following one, printed on a sheet of paper large enough to file with the patient's history. Under the "preliminary investigation" I write any notes which may be necessary to call attention to certain features in the general examination to which special attention should be given; as a rule, the history of the patient has brought out some good reason for a particularly careful study of some organ or organs, which is emphasized in this way.

It is also important to note at once just what surgical procedures appear to be needed, as it is quite possible, now that so many operations are done at one sitting, that a busy surgeon may forget one or more where several are indicated.

OUTLINE OF PROPOSED TREATMENT.

<i>Name,</i>	<i>Date,</i>
PRELIMINARY INVESTIGATION OF <i>Chest</i> <i>Digestion</i> <i>Urine</i> <i>Kidneys</i> <i>Blood</i>	OPERATIONS : <i>Upper Abdominal</i> <i>Pelvic</i> <i>Appendix vermiformis.</i> <i>Renal</i> <i>Cervical</i> <i>Rectal</i> <i>Breast</i>

Urinalysis.—No detail in the preparation of a patient for operation is more important than a careful examination of the urine, which must never be omitted. The kidneys are the most important excretories of the body, and their function is especially taxed after an operation; it is therefore essential to note particularly the way they act beforehand, both as a test of present efficiency, as a guide in determining whether or not to do an operation, and to afford a standard of comparison after the operation, should their activity appear impaired. A convalescence is often impeded by unsound kidneys; moreover, every pathologist will attest that renal lesions are commonly brought to light in the autopsies on women dying from gynecological operations. Out of twenty-nine autopsies made upon cases dying in my service at the Johns Hopkins Hospital, nineteen, or 65 per cent, showed some kidney lesion. In eight there was a chronic diffuse nephritis, in eight fatty degeneration and cloudy swelling, in two the ureter was occluded by a ligature, and in one there was atrophy of one kidney. One of the chronic nephritis group had a pyelitis with calcareous incrustation of the papillæ of the pyramids, and one of the two cases with an occluded ureter had a hydronephrosis on the occluded side and a pyonephrosis of the other side. The first of these cases died some months after a hysterectomy and removal of both ovaries and tubes for carcinoma uteri and dermoid cyst, by extension of the cancerous disease.

Only in the two cases with ligatured ureters was the renal condition the cause of death; it must be borne in mind that fatty degeneration and cloudy swelling are almost always due to the peritonitis, and are therefore a part of the infection, and secondary to it, and must not be taken into account in explaining the cause of death.

In none of my cases was the chronic nephritis far advanced, and in no instance could I attribute the death directly to this source, although, as shown by Dr. Simon Flexner in a recent research on terminal infections, lesions of the kidney may impair the powers of resistance, and thus allow certain organisms to gain a foothold and cause a fatal termination.

A knowledge of the condition of the kidneys is of eminent practical value for the following reasons:

First, that we may refuse to operate upon cases presenting advanced renal lesions.

Second, that we may delay the operation in less serious cases until these emunctories are brought into the best possible condition by careful preparatory treatment.

Third, that we may adopt unusual precautions in the course of operations upon cases complicated by a kidney disease.

Fourth, that we may watch such cases carefully throughout their convalescence, avoiding opiates or other drugs which tend to check the secretion, and that we may assist impaired kidneys by throwing the stress of excretion as much as possible upon the skin and bowels.

It is my practice in major operative cases to have several urinalyses made, first, two or three days before operation, then shortly after it to determine whether any disturbance has been produced by the operation, and again when the patient gets out of bed, usually about the twenty-first day, to see if any disturbances previously found have disappeared.

To avoid contamination by leucorrhœal or menstrual discharges, the bladder is catheterized; this is usually done in the early morning, because the night urine approximates the diurnal average in its physical characteristics.

To determine accurately the difference between catheterized and voided specimens of urine, I made a series of thirty analyses of each kind, with the following result: Nine of the voided specimens showed albumin, while the catheterized urine from the same patients showed none. In all the nine cases the patients had a leucorrhœal discharge, showing the source of contamination. It is evident from this that reliance can only be placed upon catheterized specimens, and no examination revealing the presence of lesser grades of albuminuria can be considered final until it is controlled in this way.

The best receptacle for the urine to be examined is a conical glass graduate, which quickly shows the presence of any sediment.

The analysis should include a description of the physical characteristics of the urine, the presence of sediment, its specific gravity and reaction, the presence of albumin or sugar, the average daily amount of urine passed, the percentage of urea, and the microscopical appearances. It is best to record each examination in a book of urinary charts, whose separate leaves can be torn out and filed with the history of the case, leaving a duplicate stub in the book. I give here the chart which I use in my own work.

ANALYSIS OF URINE.

No. _____

Date _____

Name _____

Diagnosis _____

Mixed _____

<i>Date.</i>	<i>Amount.</i>	<i>Time.</i>	<i>Characteristics.</i>	<i>Albumin.</i>	<i>Sugar.</i>	<i>Urea.</i>	<i>Microscope.</i>
			<i>Color</i> <i>Reaction</i> <i>Spec. grav.</i> <i>Sediment</i>				
			<i>Color</i> <i>Reaction</i> <i>Spec. grav.</i> <i>Sediment</i>				
			<i>Color</i> <i>Reaction</i> <i>Spec. grav.</i> <i>Sediment</i>				

The heat test, and Heller's nitric-acid test, are sufficiently delicate and are the best to detect albumin. I used trichloroacetic acid at one time extensively, but found it unnecessarily sensitive, giving evidence of percentages of albumin too minute for practical purposes.

Fehling's solution is the best for the detection of sugar. I have found sugar in the urine in but three out of a thousand urinary examinations in gynecological surgical cases; in two the amount was small and transient and did not prevent an operation; the third case was one of complete tear of the recto-vaginal septum. Upon discovering the sugar all idea of performing an operation was abandoned, and, in spite of appropriate treatment for the diabetes, the patient died in coma a few weeks later.

Out of twelve hundred examinations of the urine I have never seen glycosuria arise after an operation.

From a careful study of five hundred urinary charts of my abdominal cases I deduced the following rules:

First, no case of advanced nephritis should be subjected to an abdominal operation of greater gravity than a simple tapping of a cyst or an ascites.

Second, women with a marked amount of albumin in the urine should be carefully watched for a time, and if the albumin persists no serious operation which is not imperative should be performed. Epithelial and blood casts, associated with the albumin, increase the gravity of the outlook.

Third, hyaline and granular casts do not contraindicate operation unless numerous and persistent. Albumin is found in 23 per cent of all cases, and casts in 5 per cent.

Fourth, vascular changes, high-tension pulse, and heart hypertrophy must always be looked for. These alterations become serious when associated with casts and albumin in the urine.

Fifth, a marked diminution in the excretion of urea in twenty-four hours, associated with a small amount of albumin or a few casts, must be regarded as of serious import.

Sixth, pus in the urine, amounting to more than a trace, is of serious significance, and its source must be determined before operation. This will occasionally be found to come from an unsuspected pyelitis or pyelonephritis.

Seventh, sugar must always be looked for; if scant and transient it may be disregarded, but if persistent no major operation should be performed.

It will be seen by the third rule that a small amount of albumin and a few granular and hyaline casts need not prevent an operation. On the contrary, such minor renal changes are observed in a large percentage of all gynecological cases, and are often directly dependent upon the presence of a pelvic tumor, in which case the renal complication actually constitutes an important indication for the operation. In cases of large cystomata and fibroid tumors I have often seen the albumin disappear entirely within two weeks after the removal of the mass. In sixty-six of my cases with simple albuminuria no untoward renal symptoms were observed after operation.

When an operation is determined upon in the presence of renal changes the operator will diminish the tendency to shock and tax the lessened vitality of the patient as little as possible by avoiding all delays, by proceeding promptly with his work as soon as the patient is anesthetized, by taking all possible precautions to avoid shock during the operation, by the external application of heat and avoidance of exposure of the viscera, and by calling upon the bowels and skin for active supplemental service as soon as possible after it.

There is a definite causal relationship between certain classes of gynecological cases and certain ureteral and renal affections which is in general as follows:

Myomata in many instances press upon the ureters, inducing hydronephrosis and hydronephrosis. This is particularly the case in subperitoneo-pelvic myomata lifting up and displacing the pelvic portions of the ureters into the abdomen. One patient died in the ward without any operation at all, with a pyelonephritis caused by a myomatous uterus choking the pelvis and abdomen.

I have seen pelvic abscess associated with a pyelonephritis of the same side causing death. Although constantly looking for it, I have seen but one case of

extensive amyloid degeneration associated with pelvic suppuration, and that patient was syphilitic. In view of the impression created by the older literature on this subject, the absence of amyloid degeneration in so large a number of chronic pus cases is certainly noteworthy, and dread of its occurrence ought not to be such a bugbear to gynecologists.

Carcinoma of the cervix in its advanced stages compresses the ureters and produces hydronephrosis and death from uremia in a large percentage of cases. Of eight inoperable carcinoma cases in which an autopsy was made, two showed one ureter very greatly enlarged with associated hydronephrosis, while the other cases showed a very great distention of both ureters and kidneys (see Chapter XXX). In five of these cases the patients showed marked symptoms of uremia for days and even weeks before death, and for the last few days before the end came were in profound coma.

Preliminary Preparation of the Patient.—The object in view in preparing the patient is threefold: First, to bring her into the best physical condition possible; second, to quicken her emmetories, and secure a thorough evacuation of the intestinal tract; and third, to secure as nearly as possible an aseptic condition of the skin of the abdomen adjacent to the line of incision.

The exact amount of preparation which it is best to devote to any given case preceding celiotomy will vary with the widely varying conditions of the patients. When the general health is good but one or two days are needed, devoted chiefly to the thorough evacuation of the intestinal tract and the disinfection of the abdominal skin. In urgent cases, such as Caesarean section in an exhausted patient, all preliminary preparations must be dispensed with, and the abdomen cleansed for the first and only time within the few minutes immediately preceding the operation.

Cases of ruptured cysts with hemorrhage, ruptured pelvic abscess, ileus, appendicitis, ruptured ectopic gestation sac, in which the general condition is rapidly growing worse, should be operated upon as speedily as possible, utilizing any little intervening time in stimulating the patient with hypodermics of strychnin, doses of brandy, and rectal enemata.

In private practice the gravity of the patient's symptoms may even demand a sacrifice of some of the important details in the aseptic technique. The operator, for example, may be obliged under these circumstances to make use of hot water from the spigot, and vessels which have only been scalded out. The preparation of the room will often be imperfect, and it may even be found necessary to cleanse a dirty abdomen just before beginning the operation.

Poor women with abdominal tumors, pelvic abscess, or other inflammatory disease, who are in a depressed, run-down condition, and who have only laid aside the burden of exacting household duties and family cares just as they entered the hospital, improve remarkably upon giving them one or two weeks of preparatory treatment with absolute rest in bed, nutritious diet, tonics, and mild stimulation in the shape of kommiss and malt. Daily baths and rubbing with alcohol are valuable adjuvants in bringing back much of the lost tone.

Patients who are greatly depressed physically by prolonged or chronic illness show a greater susceptibility to infection than the strong and robust. As an instance of this statement, in the last twenty cases of cancer of the uterus operated upon by the abdominal method, 50 per cent have had varying degrees of local suppuration of the abdominal wound, varying from a slight discharge of pus to an extensive breaking down of the wound.

The admirable paper of Dr. Simon Flexner, upon terminal infections, bears directly on this point. In an exhaustive analysis of the autopsy records of cases dying in the Johns Hopkins Hospital, he found that patients suffering with chronic heart lesions, nephritis, and other long-standing ailments were in a great proportion of cases carried off by some terminal infection. In other words, the decrease of vital resistance occasioned by the prolonged illness simply paved the way for a terminal infection which then easily carried the patient off.

In the light of this instructive paper all patients with any form of chronic disease should be brought into the best possible physical condition by appropriate tonic treatment before being subjected to any serious operation.

In the pre-antiseptic days no surgeon felt justified in proceeding with an operation without at least two weeks' to a month's preliminary treatment. When healing *per primam* was so exceptional and "laudable pus" so much desired, the practical sense of the early surgeons taught them to first surround their patients with the best possible conditions for increasing their powers of resistance before proceeding with an operation.

Extremely nervous patients require peculiar management, and the operation should, as a rule, be performed within one or two days after the announcement of its necessity has been made, in order to lessen the drawbacks of wakeful nights, disturbed digestion, and nervous apprehensions.

If the patient can be prepared for operation without suspecting it, I sometimes announce it just as I am ready to give the anesthetic. In such a case it is important to have a clear understanding with the relatives or a responsible attending physician.

The best general rule is to take four days to make all the necessary immediate preparations.

The bowels must be regulated, and there must be a thorough evacuation of the whole intestinal tract just before the operation. The presumption in all pelvic tumor cases, even though they complain of diarrhea, is that a fecal stasis exists in the large bowel, and the surgeon should not decide to the contrary before taking the history, making an examination of the rectum through the vagina, and palpating the abdomen to determine the condition of the sigmoid flexure and colon. Tympany is one of the most embarrassing complications, and, in an extreme form, even contraindicates operation. It must therefore first be carried off by active purgation, associated with the use of carminatives and bismuth. The old-fashioned black draught is an efficient saline purge, and the carminative combined with it tends to prevent any griping. The following is the formula:

℞ Magnes. sulph.	ʒj;
Fol. semæ.	ʒiij;
Manne.	ʒij;
Pulv. cardam. sem.	ʒj;
Aq. bullient.	ʒj.

Boil, strain, and give two ounces every two hours.

Vaginal douches of a saturated solution of boric acid or a 2 per cent carbolic-acid solution should be given twice a day before operation if the patient has an offensive or purulent discharge; otherwise they are omitted.

On the preceding evening a general warm bath is given. From twelve to eighteen hours beforehand a purgative dose of citrate of magnesia, castor oil, Epsom salts, licorice powder, or a pill of aloes, strychnin, and belladonna is given, followed early the next morning by a rectal enema. A free purgation quickens the absorptive activities of the peritoneum immediately after the operation, and so promotes the speedy removal of blood and *débris*.

After the patient's bowels are thoroughly evacuated, if necessary using a second enema to effect it, she is prepared for the operation.

In order that the field of operation may be rendered as aseptic as possible before the patient is taken to the operating room, the most active disinfectant measures are employed.

All of the articles necessary to the cleansing of the abdomen are placed in convenient reach. Usually a small stand is placed near the bed, and upon this are placed green soap, flasks of water and of bichloride solution (1-1,000), a package of sterile towels, gauze scrubbing mops, alcohol, and ether.

The abdomen is well exposed, the bed and clothing above and at the sides being protected by a rubber sheet. The skin from the ensiform to just above the pubes is lathered with green soap and water, and shaved well out from the median line. If the abdominal incision is to be made in any other locality than the median line the nurse is so instructed, and varies the shaving to suit the site of operation. After shaving, the skin is thoroughly scrubbed with a gauze mop.

In the case of a nervous, delicate, refined woman, the shaving would better be done on the operating table when she is unconscious.

The nurse now suspends the preparation while she disinfects her own hands, after which the skin is thoroughly rubbed and washed with alcohol, then ether, and finally with a 1-1,000 bichloride of mercury solution.

A large sterile gauze shield is tied by conveniently placed tapes over the abdomen, and the patient's toilet is completed by putting on a clean nightgown. If she is nervous or feels weak, a wine glass of sherry or a small milk punch may be given.

Preparation of the Patient in the Operating Room.—The anæsthetic should be administered in a room adjoining the operating room, arranged as much as possible like an ordinary bedroom, so that the patient may not have the distress of witnessing any of the preparations. The most satisfactory anæsthetizing couch in a hospital is the carriage upon which she has been brought from the ward. When unconscious she may be transferred to the operating table and

placed with her hips resting on the ovariectomy pad, so that its lower border reaches about 15 centimeters (6 inches) below the vulva, and the upper border lies well above the abdomen; a self-draining table in a hospital does away with the necessity of using the pad.

The first step toward disinfection in all abdominal cases after the patient is put upon the table is the thorough cleansing of the vagina by raising and separating the legs and applying soap and warm water vigorously, with a bunch of sterilized cotton held in the grasp of a pair of long dressing forceps. This step need not be carried out in a young woman with an intact hymen. A large funnel or an open speculum may be placed between the thighs close to the body to facilitate drainage of fluids running down from the abdomen onto the pad. The patient's clothes are drawn well above the upper border of the pad, her arms are flexed and folded on the chest, and retained in this position by the undervest being pulled up over them, and by tying the wrists together with a gauze bandage. The chest is protected by a blanket with a rubber sheet over it, and the legs warmly wrapped in a blanket and a sheet in like manner. If the operation is to be long, the feet should rest upon a hot-water bag, and another be placed under the knees, and still others about the chest. For feeble patients I use long, narrow, hot-water bags encased in flannel and reaching from the armpits to the knees.

Cleansing the Abdomen.—The temporary protective gauze bandage, referred to above, is now removed by the nurse, and an assistant, with sterilized hands, proceeds to scrub the abdomen with sterilized cotton balls enveloped in gauze, applying soap and water freely for several minutes. Especial care should be observed, both in the preliminary preparation in the ward as well as upon the operating table, in cleansing the folds of the umbilicus, where it is deep using some absorbent cotton held in forceps. Following the soap and water, the abdomen is scrubbed with alcohol, and after this with ether, and finally with a bichloride solution (1-1,000).

Before disinfecting the abdomen of unusually fat women, the creases formed by the overhanging cutaneous folds should be inspected for a slight dermatitis or an eczema, which often exists, and unless the operation is imperatively demanded, these areas should be entirely healed before an incision is made through the abdomen, as such apparently insignificant surface lesions may conceal virulent organisms.

In one patient, a woman with thick abdominal walls, upon whom I operated, a superficial eczema was noted at the time, but was not considered dangerous because of the thorough disinfection. Notwithstanding these precautions, the patient died of a virulent infection with suppuration of the abdominal wound, which extended into the peritoneum. When we consider the fact that the *staphylococcus epidermidis albus* has its normal habitat in the deeper layers of the corium, it is reasonable to infer that in an eczematous patch in one of the deep folds of the abdomen, which is subjected to constant friction, there may be deeply underlying infected areas uninfluenced by the most radical disinfecting measures.

Arranging the Field of Operation.—Sterilized towels are now laid upon the rubber sheets on the chest and thighs and on the sides of the abdomen, completely covering them; a piece of sterilized gauze, four layers thick and 1 meter (1 yard) square, or a sheet made for the purpose with a hole in the middle, is laid over the patient from breast to knees; finally two sterilized towels are spread above and below over the ends of the cover. A wire bracket resting on the patient's thighs and covered with sterilized towels serves as a convenient receptacle for the instruments which the operator needs to have close at hand if the operation is done with the patient in the horizontal posture. I provide for this when the pelvis is elevated by turning over the end of a towel stretched across the thighs and clamping it to the sheet so as to make a shallow pocket, in which the instruments rest without slipping down.

Preparation of Surgeon and Assistants.—During the preparation of the patient, which is made by a trustworthy assistant, the surgeon cleanse and disinfects his hands according to the method described in Chapter I, page 20.

Having completed the disinfection of his hands, the surgeon begins the operation by cutting an opening in the gauze diaphragm, leaving the abdomen and surrounding parts protected by it.

After the operation is begun it must be the constant effort of the surgeon and his assistants to prevent the importation of any infectious matter from the outside. To this end contact with unsterilized objects must be rigorously avoided, and should it be necessary to use the cautery or other instruments which can not be rendered aseptic, the hands are protected by small squares of sterilized gauze, which are thrown away immediately after use. The aseptic field is confined to the sterilized instruments, sponges, and ligatures, and the protected abdomen of the patient, and should the operator, by accident or unavoidably, step outside of this field and be contaminated, the error in technique must at once be corrected by scrubbing the hands for a minute and immersing them again in the bichloride-of-mercury solution (1-1,000).

Proper Dress and Conduct of Visitors.—Few operations are performed in our large hospitals without the presence of visitors, who often act as a pleasant stimulus to the operator to do his best work and whose presence is in no way detrimental to the patient.

To prevent the possible introduction of infectious matter from outside professional work, visitors should be required to wear fresh long linen dusters. This precaution not only covers in the street dust from their garments, but, by putting the visitor in uniform, as it were, serves as a constant reminder of his relation to the operation and the sterilized objects of the operating room.

Bystanders should keep their dusters buttoned and their hands at their sides or in their pockets, and under no circumstances should they pick up or touch anything, or attempt to assist in any way unless requested to do so. If allowed to step near enough to inspect the wound closely, they must be cautioned not to let their clothes touch the operating table or the patient, and not to bring their heads directly over the wound, or to breathe into it, or to speak over it.

Visitors and students also should not use the same wash basins and towels as the operator and his assistants.

The Length of the Incision, and how to find the Peritoneum.—As to the length of the incision, the best rule is to make it long enough for the operator to work as rapidly as is consistent with proper attention to details. Too long an incision embarrasses the operator by permitting the escape of the bowels at its upper angle, while one that is too short hampers every movement and prevents a proper inspection of the field as the operation progresses. It was a tendency of some of the earliest operators to make enormous incisions. Sir Spencer Wells shows in his book (*On Ovarian and Uterine Tumors*, London, 1882, p. 294) that his percentage of mortality in cases in which the incision did not exceed six inches was 20.65, while the percentage in cases exceeding six inches was 39.43. But with true surgical insight he infers correctly "that the extent of the incision is little less than an indication of the gravity of the case, as it can not be supposed that two or three inches, more or less, of simple division of the parietes of the abdomen would augment the danger to this amount." In general, an incision 4 centimeters ($1\frac{1}{2}$ inch) in length may be called short, and of from 8 to 12 centimeters (3 to 5 inches) medium, and beyond this long. The operator must never allow the shortness of the incision to restrict his manipulations within the abdomen. Difficult operations—such as the removal of large adherent tumors, pelvic abscess, and other inflammatory masses—require a longer incision to facilitate inspection of the field as well as the freer use of the hand in the abdomen.

Exploratory Incision.—The short incision, made for the evacuation of ascitic fluid and for an exploration of the peritoneal cavity, need not be more than 3 to 4 centimeters in length. After the abdomen is collapsed by the escape of the fluid, one or two fingers may then be introduced for the purpose of exploring the pelvis and neighboring viscera. By enlarging the incision upward the whole hand may be inserted and all the important abdominal organs—stomach, spleen, liver, gall bladder, pancreas, omentum, mesentery, aorta, kidneys, vermiform appendix, pelvic viscera, etc.—systematically examined. The length of the incision for suspension of the uterus is also not more than 3 or 4 centimeters.

Incision in Fat Women.—If the abdominal walls are fat the incision must be longer, because the great thickness of the parietes renders more difficult every manipulation within the cavity. In rare cases of enormous accumulation of fat (adiposus, lipomatosis), in which the diagnosis is obscure, great advantage will be gained and danger of suppuration in the convalescence, or of hernia afterward, avoided by making an exploratory incision through the umbilical ring, where the abdominal wall is thinnest from the absence of fat and muscular tissue between the skin and peritoneum. By adopting such a procedure we may avoid making an incision through a fat wall 20 to 30 centimeters (8 to 12 inches) thick. I operated in this way upon a patient of Dr. G. W. Guthrie, of Wilkesbarre, Pa., whose weight was considerably over three hundred pounds. In order to tap her for an ascitic accumu-

lation, Dr. Guthrie had been obliged to have a trocar made 14 inches long, and this barely reached through the fat walls. At the operation I made an incision, 10 centimeters (4 inches) long, through the umbilicus and explored the whole peritoneal cavity, introducing the entire arm. It was fortunate, indeed, that I adopted this plan and did not make the incision lower down, as the patient got out of bed as soon as she regained consciousness and refused to return to it again even at night.

In cases in which there is a tumor within the abdomen the length of the incision is determined in the following manner: When the operator is uncertain as to the exact character of the operation, it is best to begin by making a small incision, beginning about 3 centimeters ($1\frac{1}{8}$ inch) above the symphysis, and then, if necessary, to enlarge it by using the index and middle fingers of the left hand to lift up the abdominal wall from the intestines, while cutting upward in the linea alba with a knife or stout blunt-pointed scissors. A large monoecystic ovarian or parovarian tumor may often be evacuated and easily drawn out of a little incision, provided there are no adhesions or secondary masses which can not be reduced in size. An adherent cyst, on the other hand, may call for an extension of the incision up through the umbilicus. Small non-adherent ovarian and tubal enlargements can easily be turned out through an incision 4 to 6 centimeters ($1\frac{1}{2}$ to $2\frac{1}{2}$ inches) long.

Pelvic abscesses require a longer incision, 8 to 10 centimeters (3 to 4 inches), to give a better exposure and facilitate the tapping and enucleation of the pus sac and the final inspection and cleansing of the pelvis.

In making a long incision I prefer to cut directly through the umbilicus, and then, keeping a little to the left above it, to avoid the suspensory ligament of the liver; in closing this incision the tissue at the umbilicus should be split on each side to gain a broader surface for approximation.

Myomatous uteri and other large solid or semisolid tumors require an incision, in proportion to their size, large enough to permit the mass to be turned out onto the abdominal wall by its small axis without diminution.

In making the incision the operator first fixes the median line with his eye from umbilicus to symphysis; then holding the skin a little tense on either side with thumb and middle finger, he cuts with one sweep, with a sharp, broad-bellied scalpel, through the skin and subcutaneous fat down to the deep fascia covering the muscle. The linea alba is at once seen as a distinct white line, or is felt as a cord between the recti; if not found in this way it may be exposed by making a slightly oblique incision through the fascia from above downward, crossing its course. With the linea as a guide, the incision is continued in between the recti muscles. It does no harm if in the search the sheath is opened and the muscle exposed; when this occurs, the linea is found on that side which yields least upon making gentle traction on the fascia.

The operator and his assistant now catch the underlying fat and connective tissue (subperitoneal fat) with a pair of rat-toothed forceps on either side, a little distance apart, and lift it up; it is then incised and the delicate peritoneum below picked up in like manner. Immediately above the peritoneum

two veins running vertically are usually found close to the median line, 2 or 3 millimeters apart. They are often 1 or 2 millimeters in diameter, and it is advisable not to cut them when it can be avoided. (See Fig. 19.)

At this point, beneath the muscles, the inexperienced operator may become confused and, under the impression that he is gaining access to the abdominal cavity, begin to dissect outward between the muscular and peritoneal layers. I have seen this fruitless and embarrassing quest continued for twenty minutes before the peritoneum was opened. Indeed, it was not uncommon for the older operators to consume from ten minutes to half an hour in making the incision. This error is to be avoided by picking up the tissues on each side of the median line as described and incising them inward, layer by layer, always keeping in the center. The peritoneum must be picked up with great care to avoid catching intestines or omentum in the forceps; when it is nicked slightly, air rushes in and the abdominal wall balloons out a little, while the intestines fall away. This is particularly noticeable when the pelvis is elevated. The opening is then enlarged sufficiently to admit the index finger, which is swept around to make sure that there are no parietal, intestinal, or omental adhesions, and that the bladder is not close to the incision. With this assurance, the incision in the peritoneum is enlarged to the full size of the cut on the skin surface.

Nothing is gained, but much advantage is lost, by making the incision funnel-shaped, long on the skin surface and short on the peritoneum.

Hemorrhage from the incision is not often troublesome, although the preliminary scrubbing of the abdomen may dilate the capillaries and so give rise to a free capillary oozing at first; as a rule, this ceases within a minute or so, and may be disregarded.

In more active bleeding a few artery clamps may be necessary to catch the vessels, which are then tied at once with fine catgut. More care must be taken to prevent the loss of even a small amount of blood in this way if the patient is weak or has had a hemorrhage. By tying all the actively bleeding vessels in the incision at once, the liability to the formation of a hematoma and subsequent suppuration is much lessened.

I have followed this plan of making a median abdominal incision through the linea alba in over two thousand celiotomies, and have no reason to distrust it on the ground advocated by some surgeons that the cicatricial union is less firm and secure than in those cases where the incision is made lateral to the median line.

Exposure of the Field of Operation.—Elevation of the Pelvis—Advantages and Disadvantages.—One of the most important maneuvers in abdominal surgery is the elevation of the pelvis so as to displace the obtruding loops of intestines lying between the incision and the pelvic viscera; by doing this, the field of operation is perfectly exposed to sight and touch. This is especially necessary when numerous adhesions and extensive bleeding areas are to be dealt with, for the work proceeds more rapidly and with greater certainty than without the elevation.

The advantages of this posture were first appreciated by Bardenheuer, of Cologne, as noted by Dr. E. Cushing (see *Die Drainirung der Peritonealhöhle*, Stuttgart, 1881, p. 276).

Before the elevated posture came into general use much dexterity was acquired in manipulating the intestines, to keep them out of the field, with fingers and sponges; this is now unnecessary, because the simple position mechanically throws all the movable viscera up toward the diaphragm and out of the way.

In the elevated posture the patient lies upon her back on an inclined plane, with the pelvis raised more or less above the level of the chest. To secure this elevation in a simple manner, a variety of tables, and attachments for tables already in use, have been devised. These differ in general in two ways, one providing for the tilting of the whole body, the other flexing the back while the shoulders and head lie flat. A number of these tables admirably fulfill the various requirements: such are the Edebohls, Cleveland, and Boldt tables. My own table is provided with a simple rest for the abdomen and hips, which is elevated and held in position by means of a ratchet attachment (see Chapter I).

The advantages of the elevated posture are so great that it is indispensable in all pelvic and lower abdominal work; the parts to be operated upon are perfectly exposed to view as well as touch, giving the operator a clear knowledge of the condition of the structures throughout the operation. One of the most important advantages is the fact that the intestines are kept out of the way without handling them; moreover, by causing the blood to gravitate toward the head the danger of shock is diminished, especially in anemic women. I consider it also an important advantage that the operator looks into the pelvis, and handles the pelvic structures without the necessity of bringing his own and his assistant's head directly over the incision.

The amount of elevation needed will vary with each case. In stout women, where there is a redundancy of fat within the abdomen, it may be necessary to raise the body to an angle of 45° . As a rule, an elevation of from 18° to 30° will be sufficient. When the patient becomes deeply cyanosed and the breathing stertorous, she must be let down lower. The observant operator will discover, after the intestines have once gravitated toward the diaphragm well out of the way, that he may then let the pelvis down much lower, often quite near the table, and continue his operation without embarrassment from protruding bowels. I would say, as a general rule, that it is best to begin with a high elevation, 40° to 30° , and then to continue the operation at a lower elevation. By elevating the patient for one or two minutes just before beginning the operation, on opening the abdomen the bowels will then be found already well out of the way.

In order not to waste time waiting for the intestines to gravitate slowly into the upper abdomen, and to dispose of protruding coils, it is a great help to use non-absorbent cotton pads covered with gauze to push them out of the way and hold them there. I always have at hand for this purpose a number of little bolsters, about 12 centimeters (5 inches) long and 4 to 6 centimeters ($2\frac{1}{2}$ inches) in diameter, made of non-absorbent cotton enclosed in gauze and ster-

ilized. The non-absorbent cotton retains its form and elasticity, and is therefore better than absorbent cotton.

The dangers of the elevated position are four: First, it may be the means of carrying septic matter from the pelvis into the upper abdomen. This will be avoided by packing in gauze and sponges so as to wall off the pelvis from the abdominal cavity in all inflammatory cases where pus is found. If the operator expects to open a pelvic abscess, he must let the patient down almost level and do it in that position. In case of an unexpected rupture of an abscess, or the discovery of free pus in the pelvis on opening the abdomen, the patient must be dropped at once to a level position, and sponges and gauze packed rapidly in to catch the discharge. If the pus has become widely distributed, it is better to irrigate the lower abdomen freely at once and then to pack in sponges and gauze while concluding the operation, after which it is best to irrigate thoroughly once more.

Secondly, the elevated posture tends to check bleeding from vessels, which may become active enough to destroy life when the horizontal posture is resumed. This must always be borne in mind, and will only be avoided by taking unusual care to stop all bleeding, and then by examining the whole field some time after letting the pelvis down, to see if there is any flow.

Thirdly, a perforated omentum may cause death by catching and retaining a loop of intestine in one of its holes, and so causing an ileus. I lost one case in this way. Although the abdomen was opened again and some adhesions broken up and the distended bowel relieved, the incarcerated loop was first discovered at the post-mortem examination.

Fourthly, a stout woman may lose her life in the struggle to keep her diaphragm going against the great weight of fat viscera pressing upon it. The danger signs are rapid stertorous breathing, deep cyanosis, irregular pulse, dilated pupils, and cessation of cardiac pulsation from an overdistended right heart.

Retractors.—Flat and scoop-shaped retractors of three sizes are necessary to hold apart the edges of the abdominal incision, converting the linear opening into an oval which gives a perfect view of the parts beneath. After a thorough exposure and study of the field to determine the exact character of the operation, one of the retractors is removed, and the assistant then follows the surgeon as he proceeds with the enucleation and suturing by retracting, first one side, then the lower angle, and then the opposite side, as the operation progresses. One of the most important uses of the retractors is to avoid the constant contact of the hands with the abdominal incision, increasing the liability to infection.

Where much force has been necessary to hold the incision open, its edges are always bruised and infiltrated with blood. Cases which have come to the post-mortem table have invariably shown widespread ecchymoses on both sides extending out under the peritoneum. This will be in some measure prevented by making a longer incision, not so hard to hold open, and by gentleness in

retracting. The use of the hand as a retractor, protected by gauze, is an advantage in this respect.

Dr. W. E. Ashton has devised an excellent self-retaining bivalve retractor for use in incisions of medium size.

The Illumination of the Field.—The illumination of the field of operation is best obtained through a high window admitting north light. If this can not be obtained, a diffuse light from a number of windows in a room whose walls are painted of a light color is good. But a dull, cloudy day may so obscure the light in the best-appointed operating room that artificial means of illumination should always be at hand. Indeed, I constantly resort to artificial light even under ordinary circumstances. An electric light of sixteen or twenty candle power supplied from a street current is the most satisfactory form of illumination. The burner is attached to a short handle and connected by long insulated wires to the socket on the wall. A good tin reflector, painted black on the outside and with white enamel paint on the inside, encloses one half of the lamp and protects the operator's eyes during the illumination of the abdomen. The assistant holds the light and directs it where it is wanted, taking care to keep it far enough away from the wound not to interfere with the operation. After a little experience the operator will find no difficulty in looking in beside the light, and so gaining a perfect view of all parts of the pelvis, at the same time using instruments and sponges and passing ligatures freely without striking the lamp, which should be held about six inches above the incision. Where the electric current from the street is not available a storage battery can be utilized. The inconveniences of a storage battery are its weight and the uncertainty of the light, which may suddenly give out when most wanted. The latter objection, however, has been largely overcome by improved construction, and I find a storage battery a necessary and valuable adjuvant in my private work. The weight of a battery which is not too large to carry around is about twenty pounds, and it measures 8 by 9 by 10 inches; its working time is about fifteen hours, after which it must be refilled. This may be done from any direct (Edison) street current by interposing a Vetter current adapter, which fits into the ordinary lamp socket and carries a lamp for the necessary resistance between the source of current supply and the battery. The head light which goes with the storage battery is a miniature lamp of four candle power, enclosed in a cylinder with a reflector behind and a plano-convex lens in front of it; it has a ratchet for adjustment, and is attached to a flexible steel head-band with cords to connect it to the battery. A battery a little larger than this is capable of running a hand light of six-candle power for some hours.

In operations conducted in private houses a common candle held in a metal tube with a conical tin reflector will do in case of urgent need. The light from a lamp may even be thrown into the pelvic cavity with a common hand mirror in extreme necessity.

Methods of Dealing with Adhesions.—Operations upon pelvic tumors and inflammatory masses are often complicated by adhesions to the pelvic walls, pelvic floor, omentum, uterus, rectum, small intestines and colon, bladder, and

vermiform appendix. Adhesions to the pelvic walls and floor vary greatly in character, sometimes being light and easily broken, at other times dense, so as only to be severed by sacrificing a portion of the underlying structure. They can usually be freed by carefully distinguishing a plane of cleavage between the peritoneum of the tumor and the visceral peritoneum, and following this cautiously with the fingers as the tumor is stripped off.

Omental Adhesions.—One of the offices of the omentum is to remove foreign materials from the abdominal cavity, or to encapsulate them, and for this reason it is found with extreme frequency adhering to inflammatory masses. If the mass is small the omentum may envelop it completely; where the whole pelvis is choked, it often acts as a diaphragm to separate the pelvis from the abdominal cavity by forming adhesions to the pelvic brim on all sides. In other cases it may adhere to one part of the brim or to the uterus or bladder.

The pelvic inflammatory diseases are most likely to be accompanied by omental adhesions. In a series of one hundred hysterio-sulpingo-oöphorectomies in my clinic I find that there were forty-seven cases (47 per cent) in which the omentum was adherent. The adhesions varied from light velamentous ones, easily separated, to dense indurated masses covering in and encapsulating purulent collections. In five of these cases it was necessary to remove large portions of the omentum attached to purulent foci. In other instances adherent portions of the omentum were simply ligated and cut, the divided portions remaining attached to the enucleated structures. Adhesions to the anterior abdominal wall are frequent, especially after pelvic operations.

An adherent omentum always impedes the operator, and must be released at the outset, either by stripping off light adhesions with the fingers, or by ligating and excising a sufficient portion of a densely adherent omentum to leave a clear field for the pelvic operation. The removal of a portion or all of the omentum does not increase the danger of the operation, and it should be promptly resorted to rather than waste much time in separating adhesions and applying numerous ligatures in trying to save the omentum. Cut or torn omental vessels bleed freely and persistently, and all hemorrhages from this source must be promptly checked. If there are any obscure bleeding points after separation of a number of omental adhesions, they can be located by drawing the omentum out of the incision and spreading it out on clean white gauze; the red stains found on the gauze after a few minutes then correspond to bleeding points. It is always preferable to ligate and excise persistently oozing sections of omentum rather than to search out individual vessels. Areas of omentum which are densely adherent to pelvic structures can be tied off with fine silk or catgut ligatures and cut just below, and left in the pelvis with safety. A rapid way of tying off the omentum is to push a finger or an artery forceps through one of the clear spaces, drawing a ligature back, tying it over the free border, and cutting it just below. By continuing this across the abdomen, the whole omentum can be tied off in small sections, catching several vessels with each ligature.

Uterine Adhesions.—In all pelvic inflammatory diseases the uterus is usually found attached to the adjacent structures by its lateral or posterior sur-

faces. These adhesions are usually peeled off without difficulty in the course of the operation, and only demand attention if oozing is persistent. A small quantity of dry sterilized powdered subsulphate of iron may be applied on the tip of the finger or a bit of gauze with excellent styptic effect to fine bleeding points. Sutures may be passed through the uterine walls with impunity in any number and at any depth, so long as they do not include the mucosa. If the oozing area is limited, a suture threaded directly into a small needle may be passed under the bleeding area a short distance from it. The stitch-hole thus made sometimes bleeds more actively than the points which it is designed to control, but on tying the suture the tissue will become blanched and the oozing cease. Care must be taken not to tie the suture too tightly, or it will cut and the hemorrhage be made worse. This accident will be avoided by observing the surface, as the knot is tied, and ceasing further traction as soon as the oozing is checked.

Hemorrhage from longer and deeper injuries to the uterus may be controlled by a series of interrupted ligatures passed transversely beneath the wound. Oozing areas on the lateral surfaces of the uterus may occasionally be checked by drawing a part of the broad ligament over against it with sutures. When there is a slight persistent oozing over a wide area of the posterior surface of the uterus, which can not be conveniently controlled by the means just described, the uterus may be forced down into retroposition on the pelvic floor without suture. I have found this method effective in a number of cases, and have seen no disadvantage from it.

An adherent retroflexed uterus may be freed by simply stripping up the fundus with the fingers, if the adhesions are light. If they are dense, it is better to expose the uterus and pull the fundus forward, putting the adhesions on the stretch and cutting them with scissors under inspection. If the uterus is extensively adherent, it is better to remove it with the lateral structures (hysterosalpingo-oöphorectomy).

Rectal Adhesions.—Rectal adhesions are the most troublesome as a class, because they are often situated deep down in the pelvis, so as to be almost inaccessible, and because the bowel can not be displaced and brought up into the incision or outside, as with adhesions of the small intestines. In the one hundred cases of pelvic inflammatory disease referred to under the previous heading, thirty-five had more or less extensive adhesions between the inflamed structures and the rectum. These adhesions are best dealt with by lifting the uterus or adherent tube and ovary carefully upward and forward away from the bowel. If the adhesion is stretched a little by this maneuver, so as to present a little space between the adhering organs, the scissors may be used with good effect to separate them. Often in this way a widely adherent area may be released without injury to the bowel. Where the adhesion is flat and the adherent mass can not be raised up from the bowel, the fingers may be tried judiciously, and an effort made to strip off the adhesion by working the fingers in the direction of least resistance, but always keeping the palmar surfaces toward the tumor or the uterus, lifting it off the bowel. A plane of cleavage is almost always found between the old agglutinated peritoneal sur-

faces, and no injury is sustained in the separation. If this plan does not succeed it is better to leave behind a piece of a tumor, or the outer wall of an abscess sac, where the adhesion is so dense that it can not be separated without imminent risk of opening the lumen of the bowel. Such a piece can afterward be trimmed down and its lining membrane peeled, scraped, or burned off.

When any or all of the coats of the bowel are torn, the edges of the tear must be neatly approximated by sutures. This is usually easy on account of the thickness of its coats, which give the suture a good hold. The chief difficulty

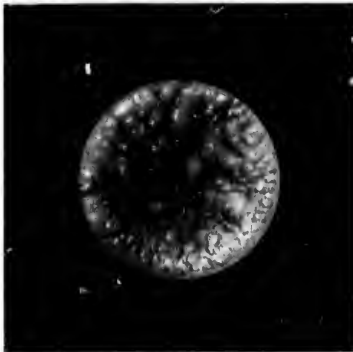


FIG. 316.—STRUCTURE OF THE RECTUM DUE TO PELVIC INFLAMMATORY DISEASE, SEEN THROUGH THE PROCTOSCOPE, 9.5 CENTIMETERS ABOVE THE ANUS. DEC. 8, 1896. NATURAL SIZE.

in suturing often arises from the brittleness of the tissue which is infiltrated with inflammatory products, causing the suture to tear out when the attempt is made to tie it. If a hold can be secured, interrupted mattress sutures or simple interrupted sutures of fine silk are applied and tied at frequent intervals. When the torn area is a large one, I have succeeded in a number of instances in protecting it by lying the uterine down on it in retroposition so that the posterior surface of the uterus made good the defect. In one case, a negress (*J. S.*, 332), operated upon Sept. 2, 1890, there was a long, triangular tear through the muscular coats of the rectum, with its apex just below the promontory of the sacrum. I

closed it by suturing the posterior surface of the uterus to the bowel with two continuous sutures, beginning at the pelvic floor on either side and extending up to the apex. This patient made an excellent recovery without any rectal disturbance (*Johns Hopkins Hospital Report in Gynecology*, vol. ii, p. 413).

When the bowel has been w^h opened, or when the suturing has been unsatisfactory, it is always wiser to put a gauze drain in the pelvis through the vaginal vault to provide for a possible infection through the injured bowel.

It is better to move the bowels on the third day with a pill. The nurse must be cautioned under no circumstances to give a large enema, distending the bowel. At the utmost nothing more than a little glycerin and oil should be injected into the rectum through a syringe with a short nozzle.

Other Intestinal Adhesions.—Intestinal adhesions of all kinds must be handled with extreme care, to avoid wounding the coats of the bowel and so making an avenue for septic invasion of the peritoneal cavity.

In general there are two varieties of these adhesions—the loose membranous or velamentous, and those which are dense and organized—involving one or more of the coats of the intestines. In order to avoid the danger of blindly tearing a hole in the intestines, intestinal adhesions should invariably

be broken up under direct inspection. Velamentous membranous adhesions are readily stripped off without involving the integrity of the bowel, and, on account of their low organization and poor vascularization, they do not give rise to hemorrhage. They prove most difficult to handle if they are bunched together, when they acquire strength, like a string of spider's web. This must be avoided by spreading them out and dealing with them separately.

The case is different with dense flat adhesions, where the plastic lymph has undergone organization, and the peritoneal surfaces are bound intimately together by the newly formed connective tissue, richly supplied with blood vessels. This class of adhesions is most frequently associated with pelvic abscess. On attempting to strip the adjacent loops of intestines loose, the peritoneal coat is torn, and sometimes the external and internal muscular coats are ruptured with it, even into the lumen of the bowel, and if much force is used, the tear will often extend far beyond the point at which it started. To prevent this the whole area must be well exposed and the adherent structures released slowly and gently by dissection, as far as possible with the fingers, using the point of the knife or scissors only when necessary to nick strong bands.

Adhesions to benign tumors and cysts and to the uterus are more easily dealt with, inasmuch as a portion of the wall of the cyst, or a part of a tumor, or a piece of the uterine wall may be cut off with impunity and left attached to the bowel to avoid opening it. If there is oozing from this surface or from the intestine, it may be checked either by cauterizing it lightly or by bringing together its free edges with sutures.

In one hundred cases of pelvic inflammatory disease in which hysterio-salpingo-oöphorectomy was performed the intestines were adherent either to the inflammatory structures or among themselves in fifty-two cases.

In twenty-four cases the intestine was injured in the enucleation, varying in degree from a simple laceration of the external coat to complete rupture of all the coats.

Appendical Adhesions.—A large percentage of pelvic inflammatory diseases and ovarian tumors are associated with adhesions to the vermiform appendix, which is quite often found firmly attached to the mass by its extrem-

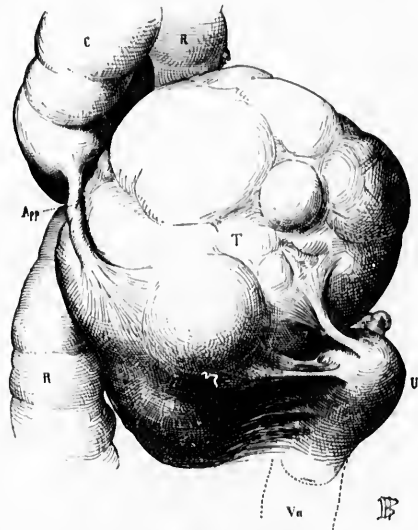


FIG. 317.—VERMIFORM APPENDIX (*App.*) ADHERENT TO A LARGE PAPILLARY OVARIAN CYST. DEC. 22, 1894. $\frac{2}{3}$ NATURAL SIZE.

ity or its lateral wall. The cases in which the vermiform appendix is most likely to be involved are those in which its free end hangs down over the pelvic brim close to, or in contact with, an inflamed right tube. An inflammatory affection of the tube will in this way easily involve the appendix, and an appendicitis will, on the other hand, infect the tube; so that the appendicitis may be either primary or secondary, and the same may be said of the salpingitis. When the appendicitis is secondary it is usually limited to the outer coats.

In one of my cases in which the disease was primarily in the appendix this organ was perforated, the pelvis was filled with pus, and the tube became inflamed and the ovary gangrenous, appearing green and black. The patient sur-

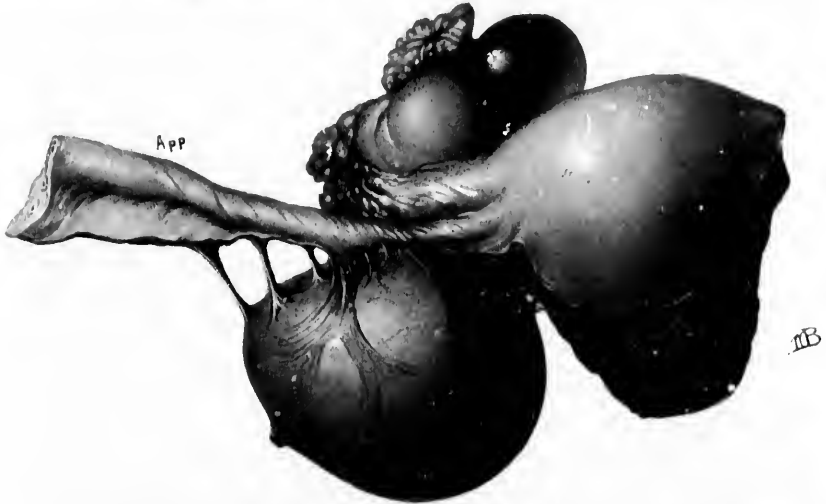

FIG. 318.—EXTENSIVE PELVIC INFLAMMATORY DISEASE WITH GENERAL ADHESIONS, DUE TO TUBERCULAR ENDOMETRITIS, PELVIC PERITONITIS, TUBERCULOSIS OF BOTH TUBES AND OF RIGHT OVARY.

The right ovary is 5 x 4 x 3 centimeters in size, and is filled with pus. The drawing is especially intended to show the densely adherent vermiform appendix. Path. No. 1071. Op. Feb. 15, 1896. Natural size.

vived the operation for the removal of these structures, and was up and going about when she died suddenly on the twenty-eighth day, suffocated by a large peri-hepatic abscess rupturing into a bronchus.

Gentle traction will sometimes suffice to free an adherent appendix, but it must be watched for a time to make sure that it will not continue to bleed if it is dropped without being removed. Sometimes a fine silk suture at the bleeding point will check the flow, but this is often not admissible, because the appendix tends to tear and bleed more freely after the puncture of a needle. If the hemorrhage persists, amputation of the appendix is best.

Where the adhesions are firm it is better not to try to save the appendix, but to remove it with the right tube and ovary (see Chap. XXXVI).

Vesical Adhesions.—The bladder occupies a comparatively isolated position in the anterior part of the pelvis, and for this reason vesical adhesions are rarer than adhesions elsewhere. The omentum is the abdominal organ most liable to contract adhesions with the bladder. In almost all cases the vesical attachments are to the posterior pelvic viscera—that is, to the uterus, rectum, ovaries, and tubes. Sometimes but a few strong bands connect the bladder with one of the organs behind it, at others a large part of the vault of the bladder is drawn over the top of the uterus and its lateral structures by the adhesions to the rectum, completely burying them out of sight. In order not to injure the vascular walls of the bladder, delicate manipulation is required to separate it from the adjacent adherent structures. Adhesions may usually be severed with knife or scissors, leaving behind, if necessary, a part of the uterus or the wall of a tumor. All vesical tears should be repaired at once by suture. If the peritoneal coat alone is injured the rent may be approximated by a continuous suture. A deep tear opening the cavity of the bladder is best remedied by a series of interrupted fine silk sutures placed close together, each one entering on the peritoneal surface and penetrating deeply enough to include the muscular coats, but not the mucous coat. When these sutures are tied there ought to be a perfect approximation, which of itself checks all hemorrhage. If the union is neat no fear need be entertained of a leakage of urine. For this reason abdominal drainage will not be necessary. Urine escaping over the peritoneum during an operation is not harmful, if it does not contain septic matter, as in cystitis. In this case too great care can not be taken to avoid any contamination however slight.

Injuries to the Bladder and Ureters.—Injuries to the bladder in the course of an abdominal operation arise from its displacement either out of the pelvis beneath the abdominal wall in front of the peritoneum, or from its being lifted up into the abdomen by a subperitoneal tumor. Such accidents most commonly occur in the case of large fibroid tumors choking the pelvis and leaving no room for the expansion of the bladder, which is then forced to distend up under the cellular tissue of the abdominal wall. For this reason it is important in all operations for large myomata to make the incision slowly and with great care, and to cut through into the peritoneum preferably high up toward the umbilicus, so as to keep above the bladder, and then to continue the incision downward, guided by a finger within the peritoneum.

I had a case a number of years ago of a suppurating ovarian cyst which had contracted adhesions with the bladder and dragged it halfway up to the umbilicus. In opening the abdomen I unwittingly cut directly through the bladder, whose walls were greatly thickened by inflammation. The result of this accident was a permanent urinary fistula. The bladder is often lifted up into the abdomen by large fibroid tumors, and will inevitably be injured in the process of enucleation if two rules are not observed.

1. The point of reflection of the bladder onto the uterus must be found by making traction on the vesical peritoneum, which is loose and movable, and by noting the line of firm attachment to the uterus.

2. The anterior incision in removing the uterus must always be made from round ligament across to round ligament, following this line.

By neglecting this last rule in extirpating a large subperitoneal fibroid I cut off with the tumor a piece of the bladder as large as the palm of my hand. The hole was at once closed with interrupted sutures, and healed without leaving a fistula.

The ureter is often laid bare from the broad ligament to the pelvic brim by the removal of a subperitoneal fibroid tumor. No ill consequence follows the simple exposure.

There is great danger of tying or piercing a ureter in the effort to check hemorrhage following the removal of an adherent mass from the pelvic floor. On this account I am extremely cautious about using a needle and suture in this situation. I once pierced a ureter in such a case, and the patient had a dribbling of urine from the incision lasting several weeks, when it ceased spontaneously.

The ureter is often tied in removing fibroids or fibrocystic or cancerous uteri, and the only safe rule to avoid such an accident is to trace out the ureter from pelvic brim to vesical ending, making sure of its integrity. It may be accidentally cut when lifted high out of the pelvis on a subperitoneal fibroid. The only way to avoid this is to examine with minute care before tying and cutting any distended vessel found running up over the anterior face of the tumor looking like a vein or lymphatic, 1 or 2 centimeters in diameter (see Chapter XXXI). If divided, a uretero-ureteral anastomosis must be performed (see Chapter XIII, p. 466).

Ligation of the Pedicle.—Silk is the best ligature material for the pedicle of a pelvic tumor, and if not weakened by the sterilization the intermediate size (see Fig. 7) will be strong enough and less liable to lodge septic matter and produce an abdominal fistula.

Where tissue is ligated *en masse*, it is best always, as an additional precaution, to pick up the exposed mouths of the large vessels separately and pull them out a little and throw an additional fine suture about them. By this plan hemorrhage will be avoided, even if the pedicle shrinks. If the pedicle is long and thin, a single ligature may suffice to control it. It is then cut off about 2 centimeters beyond the ligature. A thicker pedicle must be transfixed by two ligatures and tied on opposite sides. It is never safe to tie off sessile tumors or tumors with short pedicles in this way, on account of the extreme danger of the slipping of the ligatures.

In tying off ovarian and tubal tumors I have long since abandoned the plan of pulling the mass up through the incision and transfixing the broad ligament with two ligatures below and tying in opposite directions. There can be no doubt that this time-honored tie is responsible for almost all the hemorrhages occurring after simple salpingo-oophorectomy. I have not found the Staffordshire knot one whit more satisfactory, knowing of many cases of hemorrhage following its use, one of which I saw in the hands of its first advocate.

The best and safest way to tie off the top of the broad ligament is to tie the

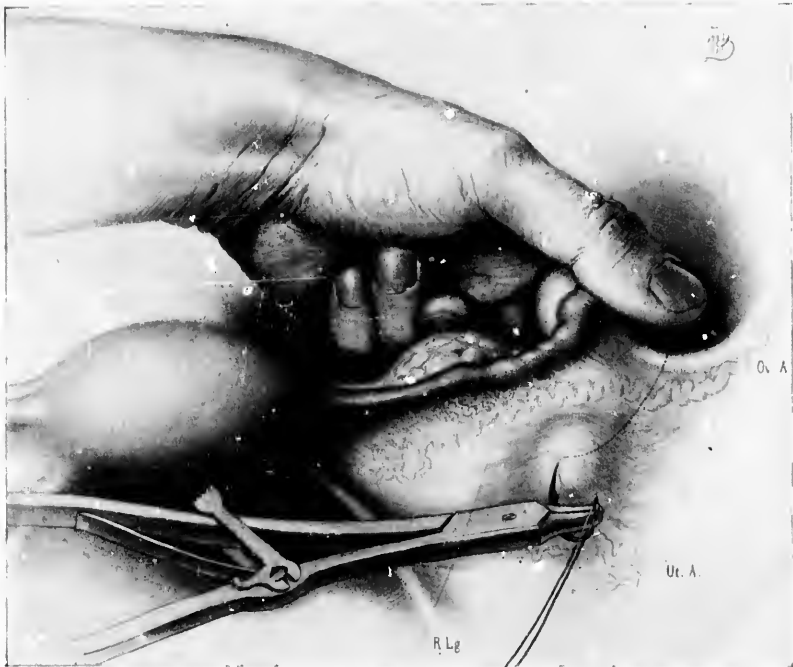


FIG. 319.—THE CLEAR SPACE.

By lifting up the tube and ovary an area is developed in the outer part of the broad ligament where both layers of the ligament come together without any intervening vessels or tissues. In the figure the index finger is seen through the clear space, which it pushes forward. By transfixing with the needle, as shown, and tying over the top of the broad ligament in the direction of the dotted line, all the ovarian vessels are secured.



ovarian and uterine vessels separately, leaving the membranous interval free, and without attempting to draw them together. When the structures are removed this leaves two little bunches of tissue holding the vessels, one at the pelvic brim under the cecum or under the sigmoid flexure, and the other at the uterine cornu; between these the peritoneal layers of the broad ligament fall together in a narrow line.

The ovarian vessels are easily found and tied by transfixing an interval at the outer extremity of the broad ligament which is free from vessels, and then tying over the top of the broad ligament near the brim of the pelvis; in this way all the veins and the artery are included. I have called this interval "the clear space." The clear space is formed by gathering up the broad ligament between

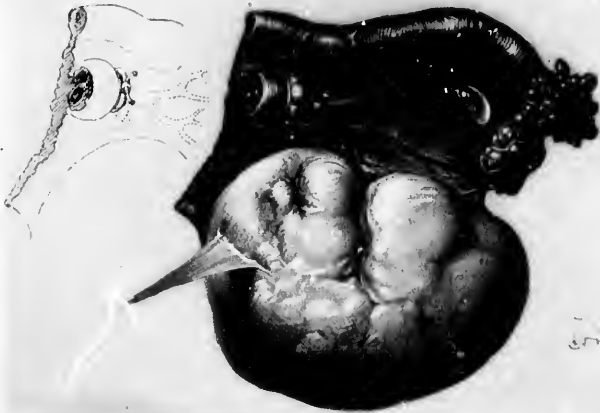


FIG. 320.—ENCYSTED SILK LIGATURE IN THE RIGHT BROAD LIGAMENT.

The ligature had been put in six months previously to ligate the large varicose veins in the ligament. The left-hand figure shows the relations of the ligature. No. 451. Natural size.

the thumb and forefinger, with the thumb in front, just beyond the fimbriated end of the tube and behind the round ligament at the pelvic brim. As the broad ligament is lifted the vessels are raised, and if a light is held behind, the translucent tissues are seen to be made up of two layers of peritoneum and entirely free from any vessels. So thin is this clear space that if it is held a little tense, the needle often punctures it with a click, as if it was going through parchment.

The fine silk ligatures used in ligating the pedicles become encysted in lymph and remain innocuous. Fig. 350 shows one of them as it was found six months after its introduction for the purpose of ligating the enormously dilated ovarian veins. The knotted portion of the ligature remains unchanged, but the loop, if it is a long one, is often dissected apart into its ultimate fibrils by the leucocytes, while the silk is not absorbed, as it can always be found with a microscope.

Hemorrhage.—Active persistent hemorrhage is perhaps the commonest complication in abdominal surgery. The usual source of bleeding is, first, the vessels in the abdominal incision; second, the uterine vein and arteries; third, the ovarian veins and arteries; and fourth, the vessels of adherent structures, such as uterine, pelvic walls and floor, broad ligaments, rectum, small intestines, vermiform appendix, and omentum.

To avoid hemorrhage as far as possible, the surgeon must tie every actively bleeding vessel in the abdomen as soon as it is severed. When the hemorrhage comes from the abdominal walls it is usually enough to clamp the smaller vessels temporarily, and upon removing the forceps later in the operation, when they are in the way, the bleeding will have ceased. Occasionally it will happen that the source of blood accumulating on the floor of the pelvis will actually be found in a small vessel in the lower angle of the incision, from which point it trickles down unobserved over the bladder. Bleeding omental vessels must be tied at once, for if they are allowed to slip up into the abdomen out of sight a large hemorrhage may occur before discovery, especially with an elevated pelvis. If there is obscure bleeding from any part of the pelvic cavity it may be found by putting in a large dry sponge and waiting a while, when, on taking it out, the blood spot will show where the flow is persistent.

I adopt the following precautions for controlling hemorrhage and preventing its recurrence: I make it a rule not to rely solely upon the pedicle ligatures, but in addition to tie the open mouths of all large vessels with a fine ligature, making assurance doubly sure. With a little patience slight bleeding will often cease spontaneously; small pelvic vessels, which are easily accessible, may be caught for a time in artery forceps, and when the forceps are removed the bleeding does not recur. Oozing areas deep down in the pelvis may sometimes be controlled by the application of hot water with pressure upon a sponge or gauze pad.

The cauterizer formerly much used for this purpose ought to be given up, as it checks only the smallest vessels, which can be better controlled in other ways. One of the best means of stopping the flow from a small area, whether on intestines or uterus or pelvic floor low down, is the application of sterilized persulphate of iron. A little of the dry powder is made to adhere to the moistened finger-tip, which is pressed firmly against the bleeding spot for a minute or longer, and then cautiously removed. When there is oozing from a broad surface on the posterior lateral surface of the uterus, the easiest way to control it is by suturing tissue from the adjacent broad ligament over the area and tying the sutures tight.

Persistent hemorrhage from a number of branches of the upper part of the uterine artery may be controlled by a ligature applied to the trunk of the artery low down near the base of the broad ligament, in the cervical region. The arterial trunk can be found by drawing the body of the uterus to the opposite side, so as to expose the broad ligament better, and then deter-

mining the position of the artery by feeling its pulsations. A ligature thrown around it at this point will cut off the blood supply above.

I was obliged in one case to resort to the ligation of the internal iliac artery just below the bifurcation of the common iliac. In removing a cancerous uterus through the abdomen, I had opened up a diseased area at the base of the right broad ligament near the pelvic wall, and was unable by ligature or pressure to control the free oozing in the already profoundly anemic patient. I fixed upon the position of the internal iliac artery by locating the common iliac and finding its point of bifurcation by touch. A small incision was then made through the peritoneum and torn more widely open with the fingers, laying the artery bare. The ureter seen close by was lifted up out of the way toward the pelvic brim. The artery was now loosened from its bed, so that a ligature could be passed beneath it without injuring the vein. This was done and the ligature tied, the circulation controlled, and the patient recovered. In similar operations the ureter must always be recognized and removed to one side, and the artery carefully isolated from the vein. In another case in which I tied both arteries, hoping to check a cancerous development, I had the misfortune to puncture the left common iliac vein. Not knowing that it was the iliac vein, I tied it, and gangrene of the leg followed, necessitating amputation in the middle of the thigh. The patient survived, and died in the natural course of the cancerous affection.

If the patient comes onto the operating table in an anemic state and loses blood freely, or if she is rendered anemic and shocked by the loss of blood during an operation, from half a liter to a liter of normal salt solution must be given subcutaneously.

In all simple operations upon the uterus, ovaries, and tubes, uncomplicated by adhesions, hemorrhage within the abdomen must arise from one of the four principal vessels, uterine or ovarian. Hemorrhage after the removal of tubes and ovaries, or of an ovarian tumor, is always from one of the extremities of the broad ligament at its pelvic or its uterine end; if it comes from the outer extremity, the ovarian vessels are bleeding; if from the inner extremity, at the cornu uteri the uterine vessels furnish the flow. These vessels are all accessible, and can readily be controlled by an additional ligature passed beneath the bleeding point.

Hemorrhage from the ovarian vessels occurring during the operation, after they have been ligated, comes from cutting too close to the ligature, or from a careless handling of the surrounding tissues which serves to drag the pedicle out from under its ligature. This is especially liable to happen in sponging out the pelvis, and in putting tension upon the broad ligaments to remove an ovary and tube from the opposite side. The bleeding area appears as a long, dark, oval slit on top of the broad ligament extending out over the superior strait. This accident may be corrected by catching the outer extremity of the broad ligament with forceps and lifting it well up from the pelvis in order to pass another ligature beneath the ovarian vessels higher up. The great danger at this point is that of including the ureter in the ligature. This must be

avoided by inspecting the ureter and seeing that it remains in its normal position and is not picked up with the vessels. To avoid displacing the ligatures in sponging out the pelvis, two fingers should be introduced into the wound, the index finger to hold the uterus forward, and the middle finger resting on the promontory of the sacrum; between these the sponge may be easily carried into all parts of the posterior pelvis without striking the tops of the broad ligaments and straining the ligatures. In cases of pelvic inflammatory disease, the tearing loose of the ovary from its hilum during enucleation often gives rise to free hemorrhage. The remedy for this accident is to clamp the bleeding vessels with two or more forceps, and then to tie the main trunks at either extremity by passing two or more ligatures through the broad ligament.

Hemorrhage from the uterus, bladder, or intestines can usually be controlled by passing a fine ligature beneath the bleeding point without penetrating the cavity of the viscus, drawing the knot just tight enough to check the flow. An important principle to be observed in the ligation of a bleeding vessel deep down in the pelvis and difficult of access, or oozing so active as to obscure the field, is to introduce and tie a ligature as near the point as possible. If this does not control the hemorrhage, it will at least be in close proximity to the source, and so serve as a tractor to draw the tissue up into better view while another ligature is applied, followed, if necessary, by a third and a fourth. It is occasionally necessary to pass one ligature below the other in this way halfway down the broad ligament before a dry field is secured.

When the hemorrhage is too general to be controlled by the above means, or when the life of a patient is likely to be jeopardized by the length of time necessary to control a number of bleeding points, a gauze drain must be used. If packed tightly, it acts as an efficient hemostatic and removes the blood as well. This method of controlling bleeding will only be necessary in rare instances if the foregoing means are faithfully employed.

Irrigation.—The best means of cleansing the peritoneum after contamination by septic discharges, blood, or the *débris* from tumors, is to wash out the abdomen with a normal salt solution. Pouring the hot solution into the abdomen also serves an excellent purpose as a stimulant. But irrigation, although invaluable in some cases, should not be resorted to frequently. When there has been moderate hemorrhage, limited to the pelvis, the blood should be gently removed with sponges, and any small amount remaining will be absorbed without difficulty. Even the escape of a small quantity of pus does not require irrigation, if it is at once taken up, and if the microscope shows that it is sterile or contains but few germs. When, however, the removal of a large adherent ovarian or myomatous tumor has been accompanied with considerable hemorrhage, or when a large pus sac has ruptured in the pelvis and the pus has been found distributed among the intestines, and when the intestines have been sutured, then thorough irrigation is necessary for the purpose of diluting and removing infectious material which can not be taken up so well by sponges. Pure water is irritating to the peritoneum, and for this reason the normal salt solution (six tenths of one per cent) is employed as the irrigating fluid. Before every abdominal operation

a flask of the solution should be placed on the sand bath and brought to 43.3° to 44.4° C. (110° to 112° F.), as indicated by a long thermometer standing in it. A more convenient method is to bring one flask to the boiling point and have a second cold one ready to mix with it, reducing it at once to the desired temperature. To mix them I use a graduated glass pitcher, devised by Dr. H. Robb, provided with a fixed thermometer. To use irrigation, the solution is poured into the abdominal cavity by a nurse or assistant. By making a funnel of the palmar surface of the hand, the operator can direct the fluid into the pelvis or up into any part of the abdomen among the intestines. When the infection is limited to the pelvis, care must be exercised not to let the water flow up among the intestines, which serves to distribute more widely the infection. This is done in two ways—by keeping the incision widely open, so that it affords the easiest avenue of escape for the water, and by avoiding the use of too much water at one time. A little is poured in and swabbed about in the pelvis with a sponge and removed, then a little more, and so on. The upper abdominal cavity can be better washed out if the pelvis is elevated when the water is poured; in this way it will often receive a liter or more before overflowing. By letting the pelvis down, the fluid either escapes or is easily sponged out. This may be repeated any number of times. I have used as much as 13 liters in this way to wash out the blood from a ruptured extra-uterine pregnancy which had accumulated under the liver. In drying out the abdomen the renal fossæ must not be forgotten, as a considerable quantity of fluid is liable to accumulate there.

In septic cases the sponges must be separated, and those which have been employed in removing pus from a ruptured abscess must be laid aside and not be used later in cleansing out the abdomen. Another efficient method of irrigating is by means of a long glass douche nozzle connected by rubber tubing with a large funnel; in this way the fluid can be directed to any part of the abdomen, and its force increased by raising the funnel. It is a cardinal principle not to irrigate over a wider area than has been contaminated. Thus the pelvis alone will most frequently need it, next the lower abdomen below the omentum, and last of all the entire abdominal cavity from diaphragm to pelvic floor.

Experimental Study of Drainage.—*Physiology of Drainage.*—When to drain, how to drain, and whether or not to drain at all, are questions of the highest import in abdominal surgery. There is perhaps no topic upon which surgeons are more at variance with one another in their practice; for, while some men drain almost all their cases, even the simplest, others have abandoned drainage in all but the rarest instances.

After an extensive experience with all forms of drainage, I have myself been slowly forced to the conclusion that it is rarely of value and often harmful; for example, in the first five hundred abdominal sections performed in my department at the Johns Hopkins Hospital, the glass drainage-tube was extensively employed—seventy-three times in the first one hundred cases.

The whole subject of drainage is one of such fundamental importance that I deem it necessary to present in some detail the arguments drawn from numer-

ous experimental studies and clinical experience in over two thousand of my cases to form a basis from which to draw correct conclusions. For this purpose I have drawn freely upon the work of my late assistant Dr. J. G. Clark (*Johns Hopk. Hosp. Bull.*, Apr., 1897).

Function of the Peritoneum under Normal and Pathological Conditions.—G. Wegner (*Verhand. d. deutsch. Gesell. f. Chir.*, Berlin, 1877), the first investigator who by experiments upon animals endeavored to arrive at some definite conclusion as to the ability of the peritoneum to rid itself of injurious fluids or solid particles, was convinced that a comparatively large quantity of infectious matter could be eliminated or encapsulated by the peritoneal exudate without serious harm to the animal.

Grawitz (*Char. Annal. Jahr.*, xi, 1886) next took up the experimental study of infection of the peritoneum, pursuing his investigations under improved bacteriological technique, and arrived at the following conclusions:

1. The introduction of non-pyogenic organisms into the abdominal cavity, either in small or large quantity, or mixed with formed particles, produces no harm.

2. Great quantities of organisms which ordinarily produce no symptoms may give rise to a general sepsis if the absorptive function of the peritoneum is impaired.

3. Injection of pyogenic organisms into the peritoneal cavity may be quite as harmless as injections of non-pathogenic varieties. (In these experiments he injected a flocculent emulsion of staphylococcus albus and aureus and the streptococcus pyogenes in 10 cubic centimeters of water without any visible reaction.)

4. The introduction of pus-producing cocci into the normal peritoneal cavity produces a purulent peritonitis, first, if the culture fluid is difficult of absorption, and, second, if irritating materials are present which destroy the tissues of the peritoneum, thus preparing a place for the lodgment of the organisms and the production of an exudate upon which they may grow.

Pawlowsky (*Virchow's Archiv*, No. 117, p. 469, 1889), in an excellent experimental study, reviewed Wegner's and Grawitz's work, with whom he agreed in many particulars, but disagreed in others. The main point of difference, however, between Pawlowsky and Grawitz related to the ability of the normal peritoneum to deal with the staphylococcus aureus.

Pawlowsky found that the large quantities of staphylococci injected by Grawitz without harm into dogs produced death very rapidly in the animals upon which he experimented, and that only a minimum quantity was harmless.

Reichel (*Deut. Zeit. f. Chir.*, vol. xxx, 1889) went over the same ground in an experimental research, and in the main agreed with Grawitz. The essential points of value in Reichel's paper are, that peritonitis usually arises, first, because more organisms gain entrance than can be handled by the peritoneum, and, second, because the stagnation of degenerating fluids in dead spaces favors the growth of the organisms.

He also accounts for Grawitz's and Pawlowsky's conflicting results on the

ground that some animals are more susceptible to infection than others, and that there are marked differences in the virulence of cultures of the same organism under varying conditions.

A carefully conducted experimental research by Waterhouse (*Virchow's Archiv*, vol. cxix, p. 342, 1890), carried out under the oversight of Orth, appears to me to settle satisfactorily the question of the ability of the normal peritoneum to take care of infection.

He injected 6 cubic centimeters of a cloudy culture of staphylococcus aureus into the abdominal cavity of dogs, employing both the methods of Grawitz and Pawlowsky, and all of the animals survived. The same results were obtained with the streptococcus, bacillus pyocyaneus, and the intestinal bacteria.

Waterhouse then endeavored to simulate the conditions occasionally met with after operations by introducing 8 cubic centimeters of urine and small quantities of blood with the cultures, and again the results were negative. If, however, 15 to 20 cubic centimeters of fresh blood were introduced into the peritoneal cavity, followed in a few minutes by the staphylococcus aureus, severe peritonitis was produced.

In these experiments Waterhouse agreed with Pawlowsky and Grawitz that the dangers of peritonitis are increased by tardy absorption of fluids, which in effect leaves a culture medium for the growth of the organisms.

After the introduction of blood clots 3 centimeters in size, followed by the staphylococcus aureus, death occurred from peritonitis in twenty-four hours.

Waterhouse also found that the purulent exudate from acute abscesses is extremely virulent, 2 cubic centimeters of the staphylococcus aureus and 1 cubic centimeter of the streptococcus from this source causing death in twenty-four hours. If a very small quantity of the pus, however, was introduced with water, the animals frequently survived.

After the introduction of turpentine with the organisms, as done in Grawitz's experiments, peritonitis did not follow, which is explained by Waterhouse on the ground that the organisms are rendered inactive or are killed by the turpentine. He proved this point by injecting the turpentine first and following it in a short time with the infecting germs; in every instance the animal died of peritonitis.

Dogs with a strangulation of the intestines were easily infected.

In three instances the staphylococcus aureus introduced into the peritoneal cavity of cats suffering from ascites, was quickly followed by death from peritonitis, which resulted, as Waterhouse says, because there was a favorable culture material, a diminished absorption, and an injury to the peritoneal endothelium.

Burginsky (*Baumgarten's Jahresbericht*, vol. vii, 1891), in a series of experiments, also came to the conclusion that the discrepancies in the results of Pawlowsky's and Grawitz's experiments were due to variations in the virulence of the cultures employed.

Halsted (*Johns Hopk. Hosp. Rep.*, vol. ii, 1891) confirmed and extended the views of previous observers concerning the resistance of the normal peritoneum

to infection, and called attention to the dangers of introducing pyogenic organisms about a ligated or strangulated area, or in conjunction with insoluble bodies. Pieces of sterile potato introduced into the peritoneal cavity of controlled animals were soon encapsulated and produced no disturbance, but when infected with pyogenic cocci invariably caused peritonitis.

A recent paper by Cobbett and Melsome (*Journal of Pathology and Bacteriology*, 1895), on *Local and General Immunity*, contains some valuable observations bearing upon the resistance of the peritoneum to infection.

Notwithstanding the injection of large quantities of virulent streptococci, a few of their animals survived. They state that "in those animals which succumbed quickest, free cocci were very numerous in the peritoneal exudation, and in those which survived longest they were either absent or confined within phagocytes."

These observers, in order to discover how quickly the organisms disappeared from the peritoneal cavity, killed two rabbits which appeared about to recover. "In the first, which had received 5 cubic centimeters of broth culture thirty hours before, only one chain of streptococci was found after prolonged search, but many cocci were contained in cells, and broth inoculated with this fluid grew a good culture."

"The second rabbit having shown no signs of illness after an injection of 6 cubic centimeters of anaërobie broth culture, received next day 10 cubic centimeters of a similar material swarming with streptococci. When killed five and a half hours later, not only could no streptococci be seen, either free or in cells, but no growth grew on cultures made from the abdominal fluid."

From this review of the literature bearing upon infection of the peritoneum I make the following summary :

1. Under normal conditions the peritoneum can dispose of large numbers of pyogenic organisms without producing peritonitis.
2. The less the absorption from the peritoneal cavity the greater the danger of infection.
3. Solid sterile particles, such as fecal matter, potato, etc., are partly absorbed and the remainder are encapsulated without the production of peritonitis.
4. Death may be produced by general septicemia and not by peritonitis, where large quantities of organisms are taken up by the lymph streams.
5. Irritant chemical substances destroy the tissues of the peritoneum, and prepare a place for the lodgment of organisms which becomes the starting-point for peritonitis.
6. Stagnation of fluids in dead spaces favors the production of peritonitis by furnishing a suitable culture medium for the growth of bacteria.
7. The association of infectious bacteria with blood clots in the peritoneal cavity is especially liable to produce peritonitis.
8. Traumatic injury or strangulation of large areas of tissue are strong etiological factors in the production of peritonitis when associated with infectious matter.

The accumulated evidence of all these investigators proves beyond question that the peritoneum, under normal conditions or even when greatly handicapped by disease or artificial conditions, is capable of overcoming the invasion of comparatively large quantities of pyogenic bacteria.

Mechanism of Absorption of Fluids and Solid Particles in the Peritoneal Cavity.—Recent investigations by Muscatello (*Virchow's Archiv*, 1895) on the histology of the diaphragmatic peritoneum and the mechanism of absorption of substances from the peritoneal cavity, when considered in conjunction with the above conclusions, give ample ground for my suggestion of the elevated posture as a prophylactic measure against post-operative peritonitis.

Muscatello accepts Bizzozero's and G. Salvioli's classification of the component parts of the diaphragmatic peritoneum which occur in the following order: Endothelium, membrana limitans, and connective-tissue framework. Up to the time of Muscatello's publication, histologists were equally divided on the question of the presence or absence of stomata between the endothelium. He proved beyond doubt that these openings are optical illusions, due to the defective preparation and staining of the microscopical sections. According to Muscatello's opinion, minute foreign particles, leucocytes, and fluids pass through openings between the endothelium of the diaphragm made by the retraction of the protoplasm of the cells.

Beneath the peritoneal endothelium of the diaphragm and between the connective-tissue fibers are open spaces 4 to 16 micromillimeters in diameter, occurring in groups of 50 to 60, which communicate with the lymph vessels. A careful search for these spaces failed to reveal them in any other portion of the peritoneum.

G. Wegner first proved that the peritoneum was capable of absorbing the most remarkable quantities of fluids, equivalent to 3 to 8 per cent of the bodily weight in one hour, or the animal's entire weight in twenty-four hours.

By the injection of foreign particles suspended in a fluid medium into the peritoneal cavities of dogs, Muscatello was able to demonstrate the existence of an intraperitoneal current which carried fluids and small particles toward the diaphragm, regardless of the animal's posture. The rate of transmission of the foreign particles from the peritoneal cavity to their ultimate repository, the lymph glands, could, however, be increased or retarded by the influence of gravity.

In those dogs which were suspended with head down, carmine bodies appeared in the retrosternal and thoracic lymph glands in from five to seven minutes, while in animals in which the posture was reversed it was five and a half hours before they could be recovered from these glands.

Muscatello proved that small particles were carried from the peritoneal cavity into the lymph spaces of the diaphragm through the opening made by the retraction of the endothelium, then into the mediastinal lymphatic vessels and glands, then into the blood current, by which they were transported to the various organs of the body, from which they were picked up by the lymph vessels

and deposited in the collecting glands of each organ. For this reason the large vascular organs, such as the liver, stomach, spleen, and pancreas, show the particles first and in the greatest numbers, while the lymph glands of the mesentery, which gather their vessels from a limited area of the intestine, contain but few of the granules.

The function of the leucocyte is of especial importance in the elimination of foreign particles from the peritoneal cavity.

Muscattello and other observers find, on examining the precipitate in the peritoneal cavity after injecting innocuous foreign particles or bacteria, wandering cells interspersed among the particles, some of which are lightly laden with granules, while others are apparently distended to the point of bursting, and still others which have not yet taken up their burdens.

In some instances where the granules are too large for one leucocyte to encompass it, two or more join forces to surround the invader. The leucocytes are found in greatest abundance beneath the omentum. From the peritoneal cavity Muscattello traces the course of the leucocyte through the channels above described, and finally finds them deposited in the lymph glands in various parts of the body.

In Muscattello's experiments the leucocytes were able to dispose of the innocuous particles rapidly and without apparent ill effect to the animals. In Pawlowsky's, Cobbett's, and Melsome's experiments, on the other hand, the conditions were different, the leucocyte having to meet an antagonistic invader. In those animals which survived the injection the infectious organisms were quickly encompassed by the leucocytes and carried into the general circulation, while in the fatal cases the peritoneal exudate was found swarming with free organisms and only a comparatively few were enclosed in leucocytes.

The important conclusions are:

1. Large quantities of fluids may be absorbed by the peritoneum in a remarkably short time. (Wegner.)
2. Minute foreign particles are carried from the peritoneal cavity through the diaphragm into the mediastinal lymph vessels and glands, and thence into the blood, by which they are transmitted to the organs of the body, especially those of the abdomen, and later appear in the collecting lymph glands of these organs. (Muscattello.)
3. The leucocytes are largely the bearers of foreign particles from the peritoneal cavity. (Muscattello.)
4. There is normally a current in the peritoneal cavity which carries fluids and foreign particles toward the diaphragm, regardless of the posture of the animal, although gravity greatly favors or retards it. (Muscattello.)

Historical Development of the Drainage Question in my Clinic.—The clinical study of a number of my cases, as well as several post-mortem examinations, combined with the bacteriological researches of Drs. H. Robb and A. A. Ghriskey on the infection of the tube tract, convinced me that the glass drainage-tube was often powerless to remove fluids from the pelvis and was a source of grave danger as a channel of infection of clean wounds.

In a series of sixteen cases (*Johns Hopk. Hosp. Bull.*, July, 1891), in which the condition of the drainage-tube tract was studied, in nine no cultures were secured, but in six the staphylococcus albus was found, and in one the staphylococcus aureus, and, notwithstanding the most painstaking technique in the care of the drainage-tube, 44 per cent of the cases showed some form of organism. My fears of the transmission of infection through the tube were further increased by one undoubted case in which an infection occurred at the second dressing of the tube, followed by extensive suppuration of the abdominal wound.

The glass drainage-tube was therefore unconditionally abandoned; I still, however, felt the necessity of providing some means of eliminating fluids collecting in the peritoneal cavity, and so adopted and used the Mikulicz gauze bag in forty cases. This proved no more efficient than the simple gauze drain proposed by Fritsch, which was next used; in January, 1893, following Schauta's observations, but independently, I adopted a new plan, and in order to determine whether drainage should or should not be used, I had cover-glass preparations made of all suspicious fluids found during an operation, and if pathogenic organisms were discovered I used a gauze drain. In forty-four cases of pelvic abscess examined for me by Dr. G. B. Miller, gonococci were found in six cover-glass preparations, but did not grow in cultures; the staphylococcus epidermidis albus was found once in culture; the remaining thirty-seven cases were negative.

These results in general coincide with the investigations of Menge, Schauta, and Reymond and Magill (*Annals of Surgery*, 1896). In an examination of 144 cases by Schauta, streptococci and staphylococci were found four times; Menge has observed the staphylococcus once in twenty-six cases, and Morax once in thirty-six cases.

From this time drainage was limited to infected cases, and no cases were drained simply because of the numerous adhesions separated and the raw surfaces left behind. When pus was found and the microscope showed the entire absence of organisms the drain was not used. When the organisms were sparse the drain was not used. When the gonococcus was found the drain was never used under any circumstances. When staphylococci and the colon bacillus were found in moderate numbers the drain was not used. When staphylococci and the colon bacillus were found more abundantly, and when the streptococcus was found in moderate numbers, a drain was used.

But a further study of the gauze drains in the few cases in which I was now using them, led me to the conclusion that they also usually became infected after operation, through the opening left in the incision, and that this infection might occasionally give rise to a serious and even a fatal result. Of my last hundred cases not one has been drained.

Objections to Drainage.—To summarize, the following are the most important objections to drainage:

1. It is unnecessary to provide for the removal of the sero-sanguineous fluid poured out by the wounded surfaces after an abdominal operation.

2. The very presence of the drain excites a freer flow from the wounded surfaces than would otherwise take place.

3. The drain is an inefficient means of removing this fluid, and in some cases it even acts as a plug to insure its retention.

4. Sooner or later the drain is certain to convey an infection down its track, which may either remain localized, and form a suppurating sinus, or may form the focus of a general peritonitis.

5. The mechanical act of removing the drain may be the means of insuring the infection of the entire tract through the infection already existing in its upper part.

6. The removal of a gauze drain is usually attended by intense pain, and it may be the cause of a prolapse of the intestine or of the omentum from the wound.

7. In one case in the hands of an associate, a fatal hemorrhage followed the dislodgment of a ligature at the time of the removal of the drain.

8. Whenever the drain is used largely the mortality is greater than in a group of similar cases which are not drained.

9. With drainage such post-operative sequelæ as abnormal elevation of the temperature, persistent vomiting, tympany, vesical irritation, and suppuration of the abdominal wound are nearly three times as frequent as without it.

10. Post-operative obstruction of the bowel and fecal fistula is more frequent in drained cases.

11. Hernia is a common sequel in the drained cases (8 per cent), while it is rarely ever seen in the cases which are not drained, if the wound does not suppurate.

12. These remarks refer principally to the gauze drain. Where the glass tube is used, perforation of the intestine and hernia into the openings in the tube occur, the area drained is smaller, and the drainage is inefficient.

In order to arrive at a clearer determination of the source and the avenue of the infection in the drained cases, I have divided them into two groups, the first containing tumors, cysts, etc., in which infection previous to operation is rarely present, the second including the inflammatory cases, such as pelvic abscess, pyosalpinx, acute and chronic salpingitis, and peri-*oöphoritis*.

In the first class drainage was usually employed to control oozing from adherent surfaces and to remove collecting fluids.

Of one hundred of my undrained cases, where there were more or less extensive adhesions, one case was complicated by the formation of a pelvic abscess after the operation; in one hundred similar cases drained, pelvic suppuration occurred in eight, showing that the drain was the avenue of infection in a number of cases which would probably have recovered without suppuration if all communication with the exterior had been cut off and the work of absorption intrusted to the peritoneum alone.

The Prevention and Removal of Infection without Drainage.—It can not be denied but that the greatest advancement along all the lines in abdominal surgery has been made during the same period in which

the drain has been gradually given up. Each improvement in technique tends to lessen the chances of infection and to minimize the demands upon the eliminative powers of the peritoneum. Asepsis has been more perfectly attained before operation and maintained throughout its performance; septic cases are always treated last on operating days, and after treating and examining an acute septic patient, such as a puerperal septicemia, all operative work is abandoned for three days; in this I accord with the conclusions reached by Zweifel.

The technique of the operation is better in the more perfect control of hemorrhage, in the better suturing and covering in of raw surfaces, as well as in the protection of the peritoneum from contamination by infected foci, and in the lessened bruising of the tissues either by unnecessary manipulation or by undue traction upon the edges of the abdominal incision.

The peritoneal cavity is also no longer washed out in a routine manner merely because of adhesions and hemorrhage; when seriously contaminated by an infected focus, the washing out is done with a definite purpose and is made thorough.

How and When to Drain.—**Postural Drainage.**—Following the initiative of my assistant Dr. J. G. Clark, and in a practical way utilizing the experiments of Muscatello, where there is any serious contamination of the peritoneum and therefore danger of infection, from 500 to 1,000 cubic centimeters of a normal saline solution are left in the peritoneal cavity after operation, and the patient is placed in a bed with the foot elevated eighteen inches for twenty-four hours.

This serves to dilute and promote the rapid absorption of all noxious material by calling into active play the diaphragmatic lymph spaces.

Cases to be Drained.—The drain should be used in abscesses which are walled off from the peritoneal cavity and which can not be encircled, as in appendicitis or extensive suppuration in the pelvis, where the abscess can not be reached and drained into the vagina.

A drain is also called for in cases of widespread peritoneal suppuration, where the patient is too feeble to be treated as proposed by Dr. J. M. T. Finney (see Chapter XXII).

A prophylactic drain must also be used when the intestine has been sutured and there is doubt as to the accuracy of the suturing, or of the ability of the tissues to hold the sutures.

How to put in and take out a Drain.—The pieces of gauze used for the drain are folded twice and stitched along the edge; they are 60 centimeters (20 inches) long and 4 to 6 centimeters wide. Gauze is prepared for use according to the formula given in Chapter I; but before insertion it is immersed in water and squeezed out, to remove the excess of iodoform, making a "washed-out iodoform gauze drain" (Singer).

In order to place the drain effectively within the abdomen it is either rolled in a loose coil like a ball of string, so as to pull out from the center, and so laid in the pelvis over the area to be drained, or it is packed in loose layers from side to side so that it can not become tangled in the removal, until the space is

filled. This is best done with the pelvis slightly elevated, to keep the intestines out of the way until the gauze is adjusted. The end coming out of the center of the ball lies in the lower angle of the incision.

In the rare cases in which it is justifiable to drain for persistent hemorrhage a number of gauze strips may be packed firmly against the bleeding surfaces by folding the gauze upon itself from side to side. The end of each piece must be brought out externally and so marked that the last introduced can be recognized and removed first. I had one case in which the end of one piece was not brought out, and in consequence the gauze stayed in the abdomen six weeks, and was only discovered and pulled out as the patient was ready to leave the hospital.

If the area needing drainage is extensive, a large quantity of gauze should be used without hesitation. I have in this way even filled the whole lower abdominal cavity. In the case of an old woman with an ovarian tumor extensively and densely adherent, where the pulse went up over two hundred and it was out of the question to take time to stop a general oozing, I tore up large gauze pads and filled the left side and whole lower abdomen with them. There was a free discharge for a few days, when the pack was removed and recovery followed.

Where there is a widespread infection and general peritonitis, drainage through the median line over the pelvis will not suffice. In this case one or more lateral or posterior openings must be provided as well. I can best demonstrate the value of this way of draining by citing a typical case. I had operated upon a very stout woman with a large extra-uterine sac by opening and draining it *per vaginam*. The sac was irrigated daily with a saturated boric-acid solution, and about the fifth day the nurse pushed the point of the glass nozzle through the thin sac wall into the abdominal cavity and forced a liter of the solution into it. This was continued for two days, when the patient developed a violent general peritonitis and I was obliged to open the abdomen hurriedly by night, when I washed out a large quantity of fluid filled with flakes of lymph, and found a universal adhesive peritonitis. The patient was in a low condition and all the steps of the operation had to be hurried to get her off the table with any chance at all of recovery. The abdomen was well washed out and a large pack placed in the pelvis, another pack extended from the incision out toward the right flank, and a third to the left. Free openings for drainage were also made in each flank in front of the erector spinae muscles by pushing out the abdominal wall with a hand in the abdomen and cutting boldly with a knife from without inward through all its layers at once. These incisions were about 6 centimeters ($2\frac{3}{4}$ inches) long, and the tendency of their thick walls to drop together was prevented by drawing the peritoneum out over the muscles and suturing it to the skin. A large gauze drain, communicating with the drains above, was stuffed into each flank and brought out at these openings. The patient's life was saved by this extensive free drainage. I have adopted this plan on several other occasions with like success.

While the incision must be left well open for the drain to discharge freely out on the surface, too large an opening should not be left, because in vomiting or coughing some coils of intestines may be forced through. On the other hand, it must not be made too small, so as to check the outflow of the discharges. To this end the pieces of gauze coming out on the surface should fit the opening snugly without either being loose or constricted. The point of greatest danger of protrusion is at the upper angle of the opening just above the gauze. If an evident opening remains here after the drain is in place, an additional piece of gauze must be introduced, extending well above the incision and filling the gap.

Where the walls are usually thick there is a tendency to drop together and impede the outflow; in these cases it is well sometimes to fasten the peritoneum with a few sutures just under the skin, converting the long channel into a narrower neck. After two or three days, as the drain is removed, the sutures can be cut and the peritoneum falls back in place.

When there is a reasonable prospect at the time of operation that the drain may be removed in two or three days, several silkworm-gut sutures should be placed in the incision through all the layers, and left untied until the drain is taken out, when they are drawn up and the wound completely closed. The wound above the drain may be closed at the completion of the operation in the usual manner, by bringing the peritoneum together with a continuous suture and uniting the fascia and skin with interrupted silkworm-gut sutures.

The dressing over the drain consists of layers of absorbent gauze and cotton, covering it well on all sides, and being sufficient in quantity to take up all discharges. These should be removed as often as they are saturated by taking them up with sterilized forceps. Much depends upon the time at which the drain is taken out, for with an early removal and closure of the incision the annoyance of a fistulous tract is avoided.

In removing the dressings over the drain, or in taking it out, extreme anti-septic precautions should always be used, and these should never be intrusted to a nurse. The bedclothes are turned down and the nightgown drawn up; the bandage is then thrown open and sterilized towels laid on all sides, covering the abdomen. The dressings are then picked up with forceps and removed down to the drain. If there is no infection it is best to remove the drain in thirty-six hours; in infected cases it may be slowly delivered in the course of four or five days or longer. To remove the drain the end of the gauze is seized and twisted to make it smaller and to loosen it from the edges of the incision; it is then slowly withdrawn, continuing to twist it all the time. If some free flow follows the removal of the first part, it is well to cut it off and remove the rest later. If the patient suffers much from the attempt to take the drain out it will be wiser to administer a little chloroform.

Infection of the drainage tract is to be expected when the pelvis has been the seat of a virulent infection. This is commonest when *staphylococcus aureus* and streptococci are found in abundance in the pus. With the glass drainage-tube the case was quite different; infection of the tract occurred frequently, and often after the simplest operations. In such a case the gauze must be taken out

slowly and fresh pieces put in to keep the wound from following its natural tendency and closing first in the upper part. After ten days the tract may be irrigated down to the bottom and kept clean with peroxide of hydrogen. A streptococcus wound, and the fistula left by draining a tuberculous peritonitis, are both obstinate affections and may take months to close. If numerous and heavy silk ligatures have been used the fistula will not close until they have all been fished out with a crochet needle.

Now that a few fine silk sutures and catgut sutures have replaced the heavy cable suture formerly used for pedicles and in ligating large vessels, a fistulous tract is rarely found kept patulous by a bunch of ligatures.

Closure of the Incision.—A proper closure of the incision is of the utmost importance, as by an incorrect apposition of its layers the walls may be so weakened as to favor the formation of a hernia. It should also be an object in a good closure to leave a fine linear scar, which is neither unsightly nor a source of annoyance to the patient. It must be acknowledged at once that no plan of closure can really restore the parts to their primitive condition, for we have no way of replacing the strong fibrous interlacement of the *linea alba*. The best method of closure is that which brings the tissues into exact approximation layer by layer in the order they occupied before division, and holds them there until firmly united, with the least risk of infection. Experience has shown that the four important layers in the abdominal wall in the median line are the peritoneum, the fascia, the fat, and the skin. A good early union of the peritoneum prevents infection from invading its cavity from without in case of suppuration in the wound. The fascia is the source of strength in holding the two sides together and preventing hernia, and by uniting the fascia the recti muscles in their sheaths are necessarily held also, and therefore need no special suture. The apposition of the fat obliterates the dead space in which blood is likely to accumulate if it is neglected, and thus prevents infection. The union of the skin prevents contamination from without, especially by the white skin staphylococcus.

The first step in the closure common to all methods is to unite the peritoneum from top to bottom by a continuous fine catgut suture; before tying the suture at the lower end, any air in the peritoneal cavity may be expelled by making pressure with the hands on the sides. The skin and strong fascia overlying the recti muscles are next united in one of two ways. First, by a series of interrupted silkworm-gut sutures, each one of which enters on the skin surface half a centimeter from the edge, and then passes through the fat and the fascia of that side; the suture then crosses the wound and catches up the fascia of the opposite side, and emerges on the skin at a point corresponding to that of entrance. If the fascia has retracted it may be drawn out with forceps before transfixing it. It is not necessary to pierce the muscles. All hemorrhage must cease before the sutures are tied. A sponge should be lightly squeezed out in bichloride solution (1-1000) and rubbed well into the interstices of the wound. This should be followed by a light rinsing with sterile water. Where vessels

in the incision continue to bleed, fine ligatures must be applied; otherwise there will be a collection of blood beneath the skin breaking down later. These silk-worm-gut sutures should be applied about 1 centimeter apart. I generally put them all in first, and then tie them afterward. Fine superficial catgut sutures between the silkworm gut give accurate approximation throughout. This form of suture, which was at one time extensively used, is now restricted to cases in which it is necessary to close the incision in a hurry, or where there is malignant disease and there is no prospect that the patient will ever subject her abdominal muscles to much strain.

The second method is always the best in an aseptic case; after closing the peritoneum with the continuous catgut suture, the retracted fascia is pulled out on both sides with artery forceps and held while it is being united from side to side by mattress silver-wire sutures extending 12 millimeters back of the cut side and embracing about 12 millimeters of the tissue, and placed about 4 or 5 centimeters apart. The suture is drawn snugly up but not too tight, and then twisted five times, caught with the artery forceps, cut off, and the end turned down so as to lie on the fascia horizontally, the end neither projecting upward nor downward. The effect of this row of sutures is to quilt the strong fibrous sheath together in a ridge from top to bottom; between these sutures interrupted catgut sutures are used to insure accurate union throughout; silkworm gut may be used in place of silver wire.

Short wounds, less than 6 centimeters long, may be safely closed with catgut throughout, buried sutures to the peritoneum and fascia, and subcuticular to the skin.

The subcutaneous fat is brought into close apposition by a continuous catgut suture. The importance of this can not be insisted upon too strongly. If omitted, a dead space will be left for the collection of blood, which is likely to become infected and cause an abscess.

The skin wound is then closed with a continuous subcuticular fine catgut suture, beginning in one end of the wound and ending in the other. Each time the suture is carried from one side to the other it grasps from 2 to 3 millimeters of the tough corium. This last suture is absorbed in from nine to twelve days, while the silver wire remains buried. The advantages of this plan are a firm closure, freedom from stitch-hole abscess, diminished liability to hernia, and simplicity of after-treatment (see Fig. 521).

When the umbilicus is cut through, it is well to split it on each side before putting in the sutures, to convert the naturally thin surface between the skin and peritoneum into a broader area for better approximation.

Hematoma.—If the bleeding vessels in the subcutaneous fat are not all controlled at the time of the operation a hematoma may form under the skin, where it remains for a few days or a week as an indolent tumor, and then either escapes through the incision, or, in the majority of cases, suppurates. The hematoma may form rather in the form of a slight swelling with a marked discoloration of the adjacent skin area, or it may form a distinct lump, like a marble or a pigeon's egg, under the skin without discoloration.

The temperature is not affected until infection has occurred. The pain is usually not more than a slight discomfort.

The treatment is incision and evacuation; this may be done by freezing the surface with ethyl chloride and then making a small incision with a sharp bistoury, either through the original wound or over the most prominent point.

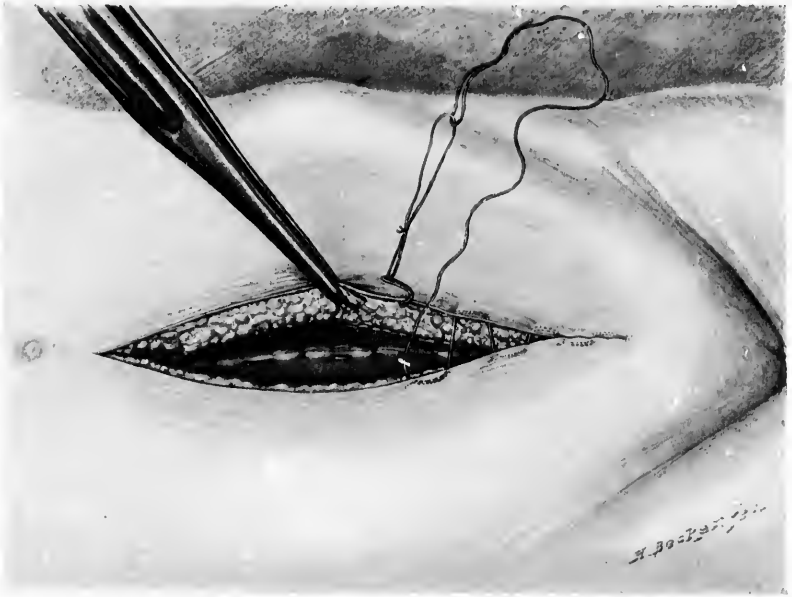

FIG. 321.—CLOSURE OF THE ABDOMINAL WOUND.

The fascia is seen closed in the bottom of the wound by mattress sutures of silver wire with entgut between them. The skin is being closed by the continuous subcuticular entgut suture; the lower angle of the wound is singly closed, while above this the suture has not yet been pulled up. The needle takes up each time a little bit of the corium, but does not appear at any place on the skin surface.

A little pressure at the sides serves to turn out some of the clots and the fluid contents. The wound is then dressed aseptically, and heals without suppuration.

The Abdominal Dressing.—After the incision has been closed, it should first be sponged with water, followed by bichloride of mercury solution (1-1,000), after which the surrounding parts are cleansed and dried. Care should be observed not to cleanse the surrounding parts and then to sponge the wound with the same gauze or sponge. A square of sterilized gauze, six or eight layers in thickness and large enough to project 5 to 10 centimeters (2 to 4 inches) beyond the incision, is spread over the wound. When buried sutures are used the wound is protected, according to Halsted's plan, by films of silver foil, which cling close to the skin, acting both as an occlusive and an antiseptic dressing. A gauze pad is also applied over this and held in place by adhesive strips.

Abundant layers of sterilized cotton are placed over this, and the Scultetus bandage over all. The Scultetus bandage is a sort of T-bandage made of six canton flannel straps, four abdominal straps, laid edge to edge, at right angles, across two perineal straps, and all stitched together. Each piece is 10 centimeters (4 inches) wide and about 55 centimeters (22 inches) long, varying in length according to the size of the patient.

In putting it on, the body of the bandage goes behind, with its lower edge about on a level with the head of the femur. Then beginning at the top, the first strap is drawn firm and flat, obliquely down across the abdominal dressing, first on one side and then on the other. The next strap overlaps this, and so on to the lowest, which is bound straight across. The abdominal straps which are imbricated in this way are held in place by the perineal straps, which are drawn snugly up between the thighs and fastened to all the others with safety pins.

When the convalescence is uninterrupted the bandage is removed when it becomes soiled, but the cotton and gauze dressings remain undisturbed until the tenth day, when the catgut suture will have become absorbed, and the skin union is perfect. Where the skin has been carefully apposed by the subcuticular suture the cicatrix will often be so minute as to be overlooked, except upon the closest inspection.

CHAPTER XXI.

CARE OF WOUND AND PATIENT UP TO RECOVERY.

1. Position in bed.
2. Toilet.
3. Sedatives.
4. Nausea.
5. Thirst.
6. Irritability of bladder and decrease of urinary excretion.
7. Food.
8. Catheter.
9. Bowels.
10. Tympany.
11. Temperature—*a.* Temperature and pulse chart.
12. Pulse.
13. Facial expression.
14. Wound.
15. Bandage.
16. Exercise.

THE after-treatment of most cases following abdominal operations is usually of a definitely routine character. But certain minor disturbances, more or less closely simulating serious complications, may arise and assume importance from the standpoint of a differential diagnosis.

Abdominal operations are always attended by more or less depression, varying in intensity according to the vitality of the patient, the loss of blood, and the length of the operation.

While the patient is still in the operating room the bed has been prepared for her by placing a broad rubber sheet under the linen draw sheet on which she lies and a single blanket between the patient and upper sheet, to be removed after the patient has reacted; the pillow is removed, and several hot-water cans and bottles are laid down the middle. Instead of tucking the bed-coverings in all around, they should be folded back to the edge of the mattress on one side, in order to put the patient to bed with the least possible loss of heat and disturbance of the covers. When put to bed, hot-water bottles or cans are placed down the sides, at the feet, and under the arms, with a single blanket between them and the patient, where they remain until reaction sets in. They must be watched with extreme care on account of the great danger of producing a serious burn. From neglect of this precaution I have seen three ovariectomy patients with extensive sloughs about the hips, and one woman with a bad burn on the heel invaliding her for two years. In my first ovariectomy, a densely adherent tumor weighing 116 pounds, the only serious drawback in the convalescence was an extensive deep water-bag burn on the right thigh.

The room should be darkened and the patient left in exclusive charge of her

nurse, who should under no circumstances leave her alone for a minute. I have often known women to get out of bed, while only semi-conscious, either in eager desire to allay their thirst or to find morphia. After one of my earliest abdominal hysteromyomeotomies, the patient, an old Irish woman, got out of bed and walked through two rooms and over a brick pavement to the closet in the yard. Another patient, a mulatto girl who had an extensive suppurative peritonitis, persisted in getting out of bed and lying upon the floor, never having slept in a bed in her life before. Both of these cases recovered. Perfect quiet must be the rule throughout. The advantage of utilizing the convalescence as an enforced rest cure can not be overestimated. By this means the wear and tear of years of suffering upon the health will sometimes largely be made up within a few weeks. Restraint must be exercised while the effects of the anesthesia are passing off only to the extent of preventing the patient from falling out of bed or tossing continually to and fro.

Position in Bed.—It is not necessary, however, for her to remain persistently on her back for the first week; on the contrary, she may be carefully turned from one side to the other after the effect of the anesthesia has passed off, if the change makes her more comfortable. It is best to avoid frequent turning, especially of nervous patients, who will not be comfortable long in any one position. If the patient becomes very weary after four or five days, she may even be picked up by four assistants catching the corners of the sheet and lifted onto a cot, while her own bed is aired, changed, and shaken up.

Bandage.—After the first dressings are removed a small piece of gauze should be strapped by adhesive plaster over the incision and renewed daily for two months. The value of abdominal bandages to prevent herniæ has been greatly overestimated. I advise their use only in fat women, or where the abdominal wall is exceedingly lax and the muscles atrophic; in all other cases they can be dispensed with, unless the patient feels more comfortable with one on. Where they are necessary they should be worn from six months to a year.

The permanent buried sutures give all the support to the incision that is required.

Toilet.—The personal care of the patient devolving upon the nurse is so important that I add a few directions about cleanliness and toilet.

As soon as consciousness returns the hands and face are bathed in cool water and the mouth cleansed with a gauze sponge dipped in ice water. If there is a tendency to choke up with mucus, the fauces must be wiped out with a clean napkin away back in the throat. After the patient is able, a gargle of hot water relieves the thirst and the unpleasant taste of ether in the mouth.

The head must be kept low, without a pillow at first, to assist breathing and to lessen the nausea. A hair pillow under the flexed knees gives a more comfortable position.

Bathing.—The morning after the operation the patient may be given an alcohol bath—one part alcohol and three parts water—at a temperature of 120° F. Beginning with face and arms, carefully placing towels under the parts so as not to wet the bed, and exposing small portions at a time, the whole body may be

washed with a soft gauze cloth. The alcohol bath should be given during the first forty-eight hours, after which the regular daily bath of warm water and soap may be resumed. The abdominal bandage must not be removed until the surgeon orders it done, after which a fresh bandage should be put on night and morning.

The nightdresses should be made open in the back, to be worn like a pinufore, and a clean one morning and evening adds greatly to the patient's comfort. The hair should be kept neatly braided in two braids, and the mouth cleansed several times a day.

The bed should be changed every morning, except the bottom sheet, which may remain on for four days. The draw sheet should be changed every night and morning with the patient's undershirt.

The room should be always neat and tidy; things should have a place and be kept in it, all unnecessary articles and ornaments having been removed. Every article must be dusted with a damp cloth each morning.

Sedatives.—If the patient is tired and restless, a tepid sponge bath, followed by gentle rubbing and a cup of hot cocoa (not too strong), will often take the place of a narcotic.

If there is much pain after the operation, a hypodermic injection of one eighth or one fourth of a grain of morphin may be given, when consciousness has fully returned, and the dose should be repeated if sleep during the first night can not be secured without it. Milder sedatives are useless, but the morphin must not be continued longer than thirty-six to forty-eight hours. Morphin must be used with greater caution when the woman is hysterical. Indeed, it is often better to allow an hysterical woman to suffer than to use it at all.

I know that the medical profession is divided on the question of using morphin after abdominal operations, some able physicians objecting strongly to its use, while not a few surgeons still venture to assert its necessity. I have no hesitation in declaring myself emphatically in favor of hypodermics of morphin during the first twenty-four hours, in all cases of severe suffering, under the limitations I have just indicated.

Violent movements should be controlled as far as possible by moral suasion with efforts at gentle restraint. Under no circumstances should a woman, semi-conscious and writhing in pain, be pinned down to the bed by force, as I have sometimes seen. She is far more liable to do herself injury in this way than if left uncontrolled.

Nausea.—The nausea from the anesthetic is variable, being most pronounced after long operations; it usually ceases in from twenty-four to forty-eight hours, although it may last three or four days, or even a week. Little or no nourishment should be given at first while the vomiting is active. If the patient is weak and the nausea persists, nutrient rectal enemata of a small cupful of peptonized milk and the yolks of two eggs, with salt, may be given every six or eight hours. Nausea will often be relieved by teaspoonfuls of very hot water, or a drop or two of tincture of capsicum in water, or a quarter of a drop of creosote in a teaspoonful of linewater. A mustard plaster over the pit of

the stomach often helps. The treatment of severe forms of vomiting by washing out the stomach is discussed in Chapter XXII.

Food.—The first food given should be a teaspoonful of milk or hot weak tea, at half-hour intervals, increasing the quantity as the stomach becomes tolerant; limewater may be added to the milk. Strong coffee is also occasionally valuable as a stimulant.

Egg albumen is a tasteless and most nutritious food. It is prepared by beating up the whites of four eggs into a liquid froth, and allowing it to stand in a cool place for an hour or more, when about 50 cubic centimeters (about 2 ounces) of liquid albumen may be drained off, leaving the frothy part behind. Another way of preparing albumen is to pour the white of one egg over half a glass of finely crushed ice; stir gently, and add a little sugar and lemon. Egg albumen should be made fresh every six to twelve hours, according to the time of year. It is best given a teaspoonful or two at a time, mixed in two or three tablespoonfuls of cold water, with a little sugar, with five or ten drops of lemon juice; if preferred, a teaspoonful of sherry wine may be added.

Additional articles of liquid diet are chicken broth, beef tea, and the various gruels. Hot oyster soup, with the oysters taken out, is a valuable and appetizing addition to the diet list when other liquids have become tiresome. Wine whey and clam juice are occasionally useful.

From 120 to 250 cubic centimeters (4 to 8 ounces) of nourishment will be taken in this way in the second twenty-four hours, increased to 300 or 400 cubic centimeters (10 to 13 ounces) in the third.

From the third or fourth to the seventh day, if all is going well, soft diet may be given. This consists of soft-boiled eggs, milk toast, bread, soups, custards and jellies, with milk punch or eggnog. After the first week stronger diet may be gradually resumed.

As the widest divergence of opinion may and does exist as to what a liquid or soft diet is, I add here a diet list prepared by an experienced nurse in my private sanatorium:

DIET LISTS.

LIQUID FOOD:

Milk.—Plain, peptonized, sterilized, malted; with albumen, milk punch, eggnog, koumiss.

Wines.—Grape juice (unfermented), cocoa cordial, wine whey, mulled wine, sherry whip.

Broths.—Beef tea, beef broth, broiled beef essence, chicken broth, oyster broth, clam broth, somatose.

Soups.—Mock bisque, tomato, cream of rice, cream of asparagus, cream of pea, consommé, bouillon.

SOFT FOODS:

Eggs.—Poached, shirred, soft-boiled.

Jellies.—Wine, orange, or coffee jelly.

Creams.—Apple float; whipped, orange, or Spanish cream; cream of tapioca, cream of rice; baked custard in cups, boiled custard with float, tapioca with baked apples, arrowroot blanc mange, orange sherbet, lemon sherbet, junket (plain, or made with wine), panada.

SPECIAL DIETS.

Oysters and Sweetbreads.—Creamed oysters, broiled oysters, oysters on the half shell; creamed sweetbreads, broiled sweetbreads

Eggs.—Poached, shirred, soft-boiled.

Beef.—Scraped beef sandwiches.

Birds.—Partridges (broiled or roasted), broiled squab, chicken stewed with rice.

Porridge.—Wheat flakes, oatmeal (strained).

Thirst.—The thirst for the first twelve hours after abdominal section is sometimes overpowering, and the patient in her desire to allay it scarcely knows what she is doing. One of my patients, a desperate ovariectomy case, reached down to her feet and pulled up the hot water bag, from which she drank at least a quart of warm water. Another, a colored girl, with general suppurative peritonitis, and with a drainage-tube in the abdomen, got out of bed, walked into the hall, and drank a large quantity of water from the spigot of the water cooler; neither of them were apparently hurt by their experiences.

Of the minor complications following abdominal operations, thirst is the commonest, and is often exceedingly distressing.

The best way to treat thirst in all cases is to meet it as far as possible preventively by giving the patient a rectal enema of one liter (quart) of normal saline solution, while she is still on the operating table, at the conclusion of the operation. This is done with the table elevated six to eight inches.

Dr. Clark has recently reviewed the results of the use of the saline enemata in this way in my clinic for the past two years. I quote from his article. (*Amer. Jour. of Obst.*, vol. xxxiv, No. 2.)

In order that the patient may retain the enema she must be under the anesthetic when it is given, otherwise the bowel will not tolerate such a large quantity of liquid. For this reason it is impossible to give liquids in sufficient quantities in the conscious subject to be of any great service in assuaging the thirst.

A stiff rectal tube is inserted well up into the sigmoid flexure, and the fluid slowly poured into a glass funnel, held three feet above the level of the patient's buttocks. In this posture the solution gravitates down into the sigmoid flexure and the descending colon, and is rarely expelled, even in the most violent attacks of retching and vomiting during the recovery from the anesthesia.

By comparing the charts of one hundred abdominal-section cases which have not had the enemata, with another hundred cases which had them, a remarkable alleviation of thirst was noted, as well as a reduction in the amount of the vesical irritability, which is so common in operative cases.

One or two months after the adoption of this plan of using the thirst enemata the head nurses in the gynecological wards, who had not been told of the treatment, began spontaneously to report a remarkable improvement in the intense thirst usually experienced.

In one hundred charts taken at random from our history files since, there

is rarely any note about thirst, and the patients often passed the first twenty-four hours without even asking for water.

Irritability of the Bladder and Decrease in Urinary Excretion.—Since the opening of the gynecological department of the Johns Hopkins Hospital, a careful urinary record has been kept of each case subsequent to abdominal section.

The temporary partial suppression of urine for the first four or five days after an abdominal section is frequently so marked as to give rise to a fear of the possibility of some grave renal disturbance.

In a paper by Dr. W. W. Russell (*Johns Hopk. Hosp. Rep.*, 1894), after a careful review of the urinary charts of many cases, the conclusion was reached that the frequency of vesical irritability in post-operative cases was due to the retention of small quantities of highly concentrated urine in the bladder. This theory is unquestionably correct, for a notable increase in the amount of urine excreted after the saline enemata has been followed by a marked decrease in the frequency of catheterization and in vesical irritability, and consequently post-operative cystitis or vesical irritability now rarely occurs:

A comparison by Dr. Clark of a series of one hundred cases without saline enemata, with a series of one hundred cases with them, show these interesting points:

“The natural result of almost doubling the watery constituent of the urine is to decrease the specific gravity. The specific gravity of cases in which the enemata are not given ranges between 1025 and 1030, while those with it show a reduction to an average of 1021.

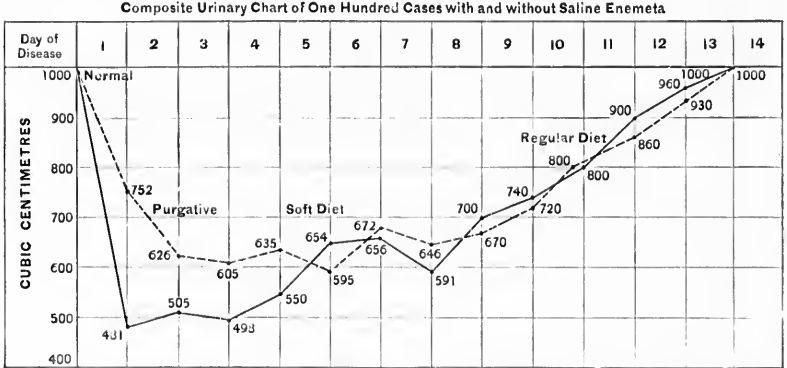
“The physical characteristics of the urine in the two series are also markedly different. As would be expected, the urine with high specific gravity is of a reddish-brown color, at times almost suggesting hemoglobinuria, and after standing deposits a heavy stratum of reddish sediment, consisting largely of the phosphatic salts and urates. The urine of the cases in which the saline solution is given usually presents a normal color, and where more than 900 cubic centimeters are voided in the first twenty-four hours it may even have the clear, limpid appearance of a urine deficient in solid constituents.

“The average daily quantity of urine excreted for the first seven days after operation, in the two series of cases, is as follows:

WITH SALINE ENEMATA.		WITHOUT SALINE ENEMATA.	
First day.....	752 cubic centimeters.	First day.....	481 cubic centimeters.
Second day.....	626 “ “	Second day.....	505 “ “
Third day.....	605 “ “	Third day.....	498 “ “
Fourth day.....	635 “ “	Fourth day.....	550 “ “
Fifth day.....	595 “ “	Fifth day.....	654 “ “
Sixth day.....	672 “ “	Sixth day.....	656 “ “
Seventh day.....	646 “ “	Seventh day.....	591 “ “

“The daily excretion of urine in gynecological cases when they are admitted into the wards is below the normal (1,200 to 1,500 cubic centimeters), rarely being higher than 1,100 cubic centimeters.

"The average quantity in fifty cases which I have had carefully measured is 1,000 cubic centimeters. In constructing the accompanying composite urinary chart I have assumed this quantity to be the normal. This chart brings out a number of interesting points. In following the two lines as they descend from the initial line, the wide difference in the amount excreted by the cases with and without the enemata is seen at a glance.



The broken line is the composite of 100 cases treated by saline enemata. The unbroken line is the composite of 100 cases without the enema. In the table 1,000 cubic centimeters is taken as the normal amount of urinary excretion in twenty-four hours. All the cases were abdominal sections for various diseases. The broken line represents the amount of urine excreted when saline enemata were used. The unbroken line represents the amount of urine excreted when the enemata were not used. One liter of the normal saline solution composed each enema.

"The first series of one hundred cases shows an average of 752 cubic centimeters at the end of the first twenty-four hours, while the second shows but 481 cubic centimeters.

"The solid line (cases without enemata) drops to its lowest point on the first day, and for three days does not rise much above the point, while the broken line (cases with enemata) shows a greater excretion the first day than for seven subsequent days. It is not until the end of the fifth day that the excretion in the two series of cases is of equal amount.

"A further study of this composite chart reveals other interesting points. In both series of cases the least amount of urine is excreted during the third day (605 cubic centimeters in one, 498 cubic centimeters in the other), which is readily accounted for by the fact that it is the routine practice to administer a saline purgative on the evening of the second day, which usually acts on the third day. The diminution is therefore a normal physiological one, due to the hydragogue action of the purgative.

"Soft diet is begun on the fifth and sixth days, and as a result there is another drop in the two lines, as the patient then begins to take more of soft than of liquid diet. At the end of the fifth day the excretion in both series of cases is equal, and from this time the two lines travel together until they again reach the normal base line on the twelfth to thirteenth day.

"There appears to be a further explanation for the greater excretion of urine in the cases which have the saline enemata than that it is merely due to an increase in the amount of water taken into the system. The nausea and vomiting following anesthesia usually disappears by the end of the first twenty-four hours, after which the imbibition of water has not been restricted in either series.

"Notwithstanding the fact that in both series of cases about the same quantity of water is taken by the mouth, the excretion in one remains very low for three days, at no time being above 505 cubic centimeters, while the other shows not less than 600 cubic centimeters, or over 100 cubic centimeters more urine passed daily by the patients who have had the enemata. From this observation it would appear that the persistent renal torpidity is due to the irritant or toxic effects of the greatly concentrated urine, and by supplying the body with a liter of salt solution this partial suppression is to a great extent prevented, and the kidney at once resumes its normal function as soon as the patient begins to take water.

"The accompanying table of two series of fifty cases, with the record of the daily excretion in each individual case, emphasizes the fact which the composite chart brings out.

"In thirty-five of the fifty cases with the enemata the excretion during the first twenty-four hours was greater than it was on the seventh day after operation, while in forty cases without enemata the excretion was less during the first day than during the seventh, the figures in the former being almost exactly reversed in the latter. The following table, taken from these two series of cases, also shows the same result:

URINE EXCRETED.	With enemata.		Without enemata.	
	Cases.		Cases.	
1,000 cubic centimeters or over.	7		1	
900 " " " "	5		1	
800 " " " "	3		..	
700 " " " "	12		2	
600 " " " "	9		7	
500 " " " "	11		8	
400 " " " "	2		14	
300 " " " "	1		15	
200 " " " "		2	
100 " " " "	
Total.	50		50	

Catheter.—The catheter should only be used to draw the urine, if the patient is unable to pass it naturally after six or eight hours, and then the utmost care must be taken to pass a clean catheter, through a clean urethral orifice, under inspection. If the catheter has to be used at all, its use must be discontinued as soon as possible. If vesical irritability is persistent, it will improve upon taking spiri. nitrous ether, twenty to thirty drops, every two hours, or five drops of copala in capsules three times a day.

Bowels.—I have often noticed that surgeons grow too anxious, and work

too hard to get the bowels moved for the first time. If the patient is doing well in other ways, it need cause no worry should the bowels be sluggish and not respond until as late as the fifth or sixth day. Often after two or three days of active efforts, if the patient is left quite alone they move spontaneously in six or eight hours.

As a routine line of treatment, I give on the evening of the second day something which will move the bowels on the following morning. Calomel will be found to be the most efficacious, and is as a rule best borne by the patient. It can be given in one dose of two or three grains, or one quarter to one sixth of a grain may be given every hour until the same amount is reached, followed in the morning by six to eight ounces of a solution of citrate of magnesia. About two hours later an enema of 100 cubic centimeters of olive oil with 30 cubic centimeters of glycerin should be injected as high as possible into the rectum. If this is not effective, four to six hours may be allowed to elapse before another attempt is made with an injection, consisting of a pint of water at a temperature of 110° F. and soapsuds.

A satisfactory saline enema much used by Dr. C. P. Noble is the following concentrated solution of the sulphate of magnesia :

R Magnes. sulph.....	℥ ij ;
Ol. terebinth.....	℥ ss. ;
Glycerinæ.....	℥ j ;
Aquæ.....	q. s. ad ℥ iv.
M. and inject in bowel.	

It is not advisable to use more than three enemata during the third day ; it is better to assist the calomel by castor oil or magnesium sulphate in half-ounce doses, or by a pill of aloin, strychnin, and belladonna.

When the bowels are once opened, they should be kept open by a movement at least every other day.

Tympany, which often occasions much distress, is usually speedily relieved by the free evacuation of the bowels. Drop doses of tincture of capsicum, or a few drops of tincture of nux vomica in a teaspoonful of hot pepper tea, are valuable adjuvants. A rectal enema of 90 cubic centimeters (3 ounces) of milk of asafetida will also often relieve it.

Temperature.—The temperature must always be carefully watched. On the second or third day it is commonly elevated to 100° F., or even 101° F. (37.8° or 38.3° C.), but it usually drops with the first free movement of the bowels. This slight rise in temperature appears to be due to the absorption of a fibrin ferment, and it may in exceptional cases be prolonged for several days beyond the usual period. A persistent temperature, however, above 100° is in most cases due to infection either of the wound or in the peritoneum. A sudden rise in temperature, sometimes attended with chill, toward the end of the first week, is often the first indication of suppuration in the abdominal wall. The wound should be inspected immediately for any hard, red, tender areas on one side or the other, the stitch or stitches at that point removed, and the lips of the

incision slightly separated, to favor the discharge of pus. When the pus has escaped, the temperature falls at once.

A chart showing the composite temperature in ten normal cases for the first week is here given (see Figs. 322-325, p. 54).

Pulse.—The pulse is likely to remain quickened 20 or 30 beats or more for three or four days after any severe operation. If the general condition is good, and the pulse full and compressible, this need cause no anxiety. The normal course is a steadily falling pulse after operation, falling less rapidly if there is much pain. A falling pulse is a good sign; a rising pulse always calls for investigation. In general a pulse from 120 to 130 beats needs watching; a pulse of 140 beats needs closer watching; a pulse of 150 beats needs anxious watching; a pulse of 160 beats does not as a rule recover unless it begins to fall within six to twelve hours after the operation. Neither the temperature nor the pulse, however, should be studied alone, but always in association. If the pulse is high, from 120 to 140 beats, combined with a high temperature after the first day, when the bowels have been freely moved, infection has probably taken place. The most satisfactory sign of progress is a free evacuation of the bowels, with pulse and temperature dropping together.

Facial Expression.—Facial expression is a sign scarcely less significant than the temperature and pulse, and taken together with these forms a good index of the general condition. A bright natural expression is to be looked for during the normal convalescence; a flushed, dusky, anxious, haggard, or a lack-luster look are indicative of complications.

Wound.—Unless some special cause arises, the wound need not be dressed until the tenth day, when fresh gauze and cotton dressings should be put on with the dressing forceps. The bandage may be changed daily, and the back well rubbed with a solution of alcohol and water, half and half. Boric acid and bismuth powder are also good to rub into the back. This rubbing is the best we can do for the severe pain so constantly felt in the back.

Sutures.—The use of the permanent buried silver-wire suture and subcuticular catgut sutures has relieved the patients of considerable anxiety, for often the removal of sutures was looked forward to with great dread. The abdominal dressings need not be disturbed until the tenth day except in case of wound infection. They should be carefully lifted off and replaced by several layers of fresh sterilized gauze. If they have become adherent to the incision a little sterilized water poured on will rapidly loosen them. The skin about the incision should not be cleansed until about the fourteenth day. Pledgets of cotton wet with dilute alcohol are best for this purpose.

The catgut sterilized by the eumol method is usually absorbed by the eighth to the tenth day. Interrupted sutures are removed on the tenth day. First expose the loop by pulling up the suture a little with forceps, then cut it close to the skin, and draw it out toward the side on which it is cut, to avoid pulling the edges of the wound apart. Adhesive straps across the wound after removing the sutures are not necessary. If the bandage is kept well in place, and put

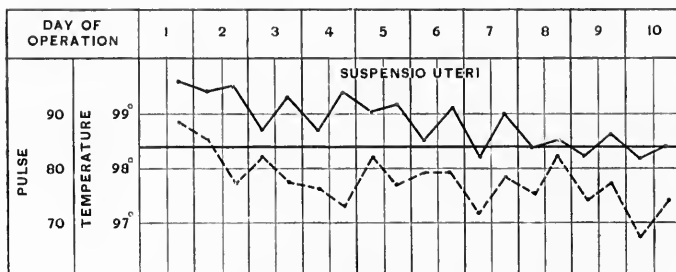


FIG. 322.

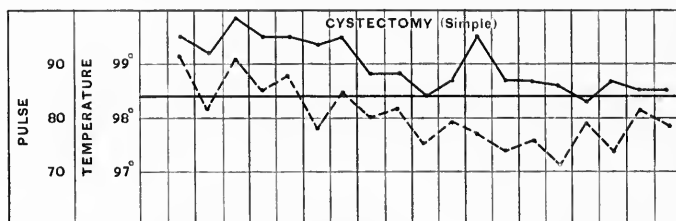


FIG. 323.

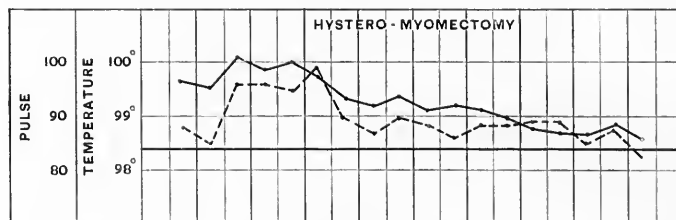
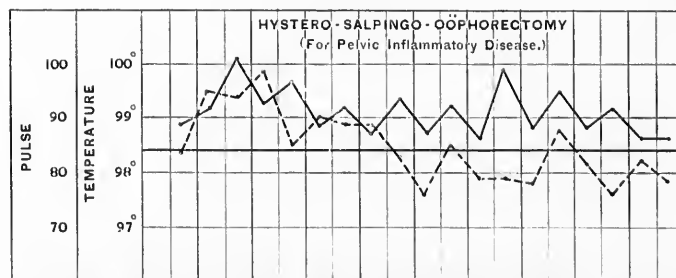


FIG. 324.



— Temperature - - - Pulse FIG. 325.

FIGS. 322, 323, 324, 325, SHOWING THE AVERAGE CHARTS OR COMPOSITE TEMPERATURES AND PULSE RATES IN TEN CASES IN EACH GROUP.

Cases were selected which appeared to run a smooth course to recovery; these were averaged, and the temperature and pulse rates then tabulated, as shown. (See *Johns Hopk. Hosp. Rep.*, 1890, vol. ii, Nos. 3 and 4, p. 177.)

on snugly every time, the wound surfaces will naturally remain in close approximation.

In ten or twelve days usually the patient may be propped up with pillows or on a bed rest, and in from seventeen to twenty-one days, according to the rapidity with which strength is regained, she may spend part of the time in a reclining chair or on a sofa. Throughout the convalescence she must avoid straining the abdominal muscles. While still abed she must not rouse herself to a sitting posture or change her position without aid. Later she must not stoop or lift heavy weights. During active vomiting the least strained position is lying on the side with the body slightly flexed, or on the back with the knees drawn up resting on a pillow. At the end of the fourth or fifth week she should be able to walk around, and perhaps go down stairs. All bodily movements should be gentle at first. The patient must not sit up long enough at first to grow tired of the newness of it, and later on she should avoid tiring herself on her feet. It is best not to hasten the getting out of bed, as a prolonged absolute rest is an important element in securing complete restoration to health. Heavy work and exhaustive exercise of all kinds must be avoided.

The convalescence is by no means at an end when the patient is able to return to her home.

Disappointment will frequently be avoided if she is warned of this beforehand, and kept under observation for a year or more while regaining her physical and nervous balance and passing the period of any unpleasant sequelæ, such as flushes, sweatings, giddiness, and various other nervous manifestations.

Sometimes some of the original discomforts persist for some months, only disappearing gradually, so that complete recovery to health does not take place until after a year or a year and a half.

Fresh air, rest, diet, and tonic treatment, with encouragement, are the most important aids in the convalescence. Change of air and scene are of the greatest value in bringing about complete restoration to health.

The golf field is the best form of moderate exercise I know of, and will prove an invaluable adjuvant as soon as the patient is able to take a little active out-of-door exercise.

CHAPTER XXII.

COMPLICATIONS ARISING AFTER ABDOMINAL OPERATIONS.

1. Shock. 1. Causes: (*a*) Anesthesia; (*b*) loss of blood; (*c*) enfeeblement by disease; (*d*) prolonged exposure of the intestines. 2. Symptoms. 3. Diagnosis: (*a*) Shock and chloroform asphyxia; (*b*) shock and hemorrhage. 4. Prognosis. 5. Preventive treatment: (*a*) Preliminary tonic treatment; (*b*) temperature of operating room; (*c*) care of patient on the table, blankets, hot-water bottles, protection of exposed pelvic viscera, etc.; (*d*) avoidance of hemorrhage. 6. Immediate treatment: (*a*) Hypodermics; (*b*) stimulant enemata; (*c*) external application of heat; (*d*) how to give stimulants and nourishment; (*e*) saline infusion.
2. Secondary hemorrhage. 1. Causes. 2. How to avoid hemorrhage by care during operation. 3. Symptoms. 4. Operation. 5. Saline infusion.
3. Peculiarities of the pulse.
4. Variations in temperature: (1) Subnormal temperature; (2) elevated temperature.
5. Vomiting. 1. Treatment: (*a*) Medicines to settle the stomach; (*b*) lavage; (*c*) hot and cold applications; (*d*) foods and enemata.
6. Tympanites. 1. Treatment: (*a*) Turpentine stupes; (*b*) rectal tube; (*c*) medication; (*d*) purgation; (*e*) Paquein cautery.
7. Excessive pain. 1. Sparing use of sedatives.
8. Peritonitis. 1. Traumatic or plastic peritonitis: (*a*) Symptoms; (*b*) treatment; (1) purgation; (2) diet; (3) hot and cold stupes. 2. Post-operative septic peritonitis: (*a*) Sängers conditions of infection; (1) qualitative; (2) quantitative; (3) constitutional; (*b*) kinds of germs (two typical cases); (*c*) modes of origin; (*d*) symptoms; (*e*) prognosis; (*f*) diagnosis; (*g*) tabulated symptoms of both traumatic and septic peritonitis; (*h*) treatment; (1) prophylaxis; (2) medicines; (3) operative treatment: (*a*) methods of operation; (*b*) indications for operation; (*c*) operation—vaginal; abdominal.
9. Fermentation and septic fevers: 1. Fermentation fever. 2. Septic intoxication. 3. Septicæmia. 4. Pyæmia.
10. Pleurisy: 1. Causes. 2. Symptoms. 3. Treatment.
11. Pneumonia: 1. Causes. (*a*) Anesthetic; (*b*) sepsis. 2. Symptoms. 3. Treatment.
12. Hæm: 1. Causes. 2. Symptoms. 3. Diagnosis. 4. Treatment: (*a*) Prophylaxis; (*b*) enemata and medicines; (*c*) operative.
13. Stitch-hole abscess and suppuration in the line of the incision. 1. Cause of infection. 2. Symptoms. 3. Diagnosis. 4. Treatment.
14. Nephritis. 1. Relation between abdominal operations and nephritis. 2. Treatment.
15. Suppression of urine. 1. Urinary record. 2. Differentiation of nephritis and ligation of one or both ureters. 3. Treatment.
16. Urinary fistula.
17. Fœcal fistula. 1. Causes: (*a*) Trauma; (*b*) necrosis from pressure. 2. Location of fistula. 3. Treatment.
18. Phlebitis: 1. Symptoms. 2. Treatment.
19. Emphysema of the abdominal wall.
20. Sudden death: 1. From embolism. 2. From gas bacillus.

MARKED deviations from the course of normal convalescence, as described in Chapter XXI, comprise complications varying in gravity from the simple functional and local disorders which are soon relieved, all the way to the graver systemic manifestations which are often fatal.

Every normal convalescence is attended with certain minor discomforts—as a rule, neither excessive nor prolonged—and the patient is usually fairly easy by the third or the fourth day. When, however, the discomforts persist or be-

come exaggerated, or a variety of other untoward phenomena arise either to retard recovery or to threaten life, the convalescence becomes complicated.

Greater skill and acumen are oftener shown in the quick detection of these complications, and a prompt adoption of means to overcome them, than in the performance of a difficult operation; for this reason skilled surgical attention is quite as important in the convalescent stage as during the operation itself, and it is unwise for the surgeon to consign the care of the case to other hands when it is in any way possible for him to keep a direct personal supervision until complete recovery.

Shock.—One of the most frequent and alarming effects of an abdominal operation is shock, arising from a profound impression made on the nerve centers, and indicating extreme depression of the patient's vital forces. Shock is usually observed either during or shortly after an operation.

Causes.—One of the most frequent causes of shock is prolonged anesthesia. The administration of an anesthetic for two hours, for instance, is always followed by depression of varying degrees, even though the operation has been a minor one.

Excessive loss of blood during an operation upon a robust or even plethoric individual, or a moderate hemorrhage in an anemic patient, will speedily produce shock, even though the operation be of short duration. I recall one case in which there was the most profound depression following a simple oöphorectomy in a patient who was extremely anemic before the operation from repeated hemorrhages due to internal hemorrhoids. Little blood was lost during the operation, and the duration of the anesthesia was only twenty-two minutes; but when she was removed from the operating table the pulse was barely perceptible, respirations were shallow and jerky, and there were no signs of reacting for ten hours afterward. In this case the slight hemorrhage and the depressing effects of the anesthetic acted conjointly.

A constitution already enfeebled by disease also predisposes to shock; for instance, patients debilitated by advanced carcinoma have scant resisting powers, are often profoundly depressed by the operation, and recuperate slowly.

Prolonged exposure of the intestines and omentum through a long incision, or when lifted out of the abdomen, is one of the most prolific causes of shock through the rapid radiation of heat, especially when there has been already considerable hemorrhage before or during the operation, as in the case of a ruptured ectopic pregnancy.

While any one of these causes acting alone is sufficient to produce shock, two or more or all of them acting in combination induce a condition of profound depression from which it is difficult for the patient to rally. For example, I would cite a case, of not infrequent occurrence—that of a large fibroid uterus with extensive subperitoneal development, with a history of repeated hemorrhages; by pressure on the ureters and interference with the excretion of urine, the tumor has also brought about disease of the kidneys. Such a patient is already greatly weakened by the loss of blood, her resisting powers are lessened

by the renal affection, and, added to these factors, the size and relations of the tumor necessitate a long incision, exposing the intestines, and a prolonged anesthesia is necessary to effect the emelction. We have here all the elements necessary to produce shock, and if we add to these an extensive hemorrhage during the operation, the shock may speedily prove fatal.

Symptoms.—There is often good reason to anticipate shock from the clinical history which reveals some predisposing cause, such as an enfeebled condition of the patient from hemorrhage, or from serious organic disease.

Increasing rapidity of pulse, from 20 to 40 beats, marked pallor and coldness of the surface of the body during an operation, demand the closest attention of the anesthetizer as the forerunners of shock. Additional evidence of prostration is a slow recovery from the anesthetic. As consciousness returns, the patient lies helpless on her back, unable to move, scarcely able to speak above a whisper; the surface of the body is pallid and bathed in a cold sweat, the lips appear bloodless, the features are pinched, the eyelids drooping, and the general appearance that of dissolution. Various associated nervous phenomena, such as hic-cough, twitching, headache, and mild delirium may be present. The special senses are often so blunted that the patient hears and sees and feels with difficulty. Respiration is feeble and gasping, or so weak as barely to be perceptible. The temperature is depressed, falling from one to two degrees below normal. Reaction may not set in for hours, notwithstanding the most vigorous stimulating treatment, and then may be so gradual as to be recognized with difficulty. Occasionally there may be great prostration with a slow, full pulse; in such cases the shock is usually evanescent, disappearing quickly under appropriate stimulants.

Recovery from shock is indicated by the general reaction of all the vital functions; the pulse gradually increases in strength and becomes more regular, the respirations are deeper, the temperature rises, the color improves, the expression of the patient becomes bright, and she loses the listless air so characteristic of shock. But instead of the reaction becoming complete and merging into a normal convalescence, traumatic delirium may supervene. Sometimes the stage of depression may be so short as not to be recognized, and the patient at once becomes delirious after regaining consciousness, or the delirium may be preceded by prolonged shock. The skin becomes flushed, dry, and hot, the temperature rises above normal, the pulse is fuller and more regular, although compressible, the tongue is dry and tremulous, the thirst is urgent, and, instead of lying prone, the patient is restless and tosses from one side of the bed to the other. The delirium may be low and muttering or of the wildest character. I know of instances in which the patients have fallen out of bed, torn the bed-clothing to pieces, and walked from one room to the other, so wildly maniacal as to require the closest watching and restraint.

This traumatic delirium either gradually subsides and the patient recovers, or it is followed by extreme collapse, the pallor again returns, the pulse becomes weak, thready, and is finally imperceptible, and the patient falls into a profound stupor ending in death.

Late Shock.—I have seen several cases of profound shock coming on several hours after an operation for large myomata; although I must admit that these symptoms may have been due to hemorrhage which was afterward absorbed.

The case of M. W., aged forty, No. 3296, operated on Jan. 30, 1895, was a good example of this complication. A hysteromyomectomy was done, lasting forty-three minutes in all, removing a tumor filling the abdomen and adherent to the entire breadth of the omentum; the patient took ether well, and was put to bed at 11.30 a. m. in excellent condition, with a warm skin and a full, regular pulse, beating 84 to the minute. The facial color and expression were also good.

At 2.15 p. m. a decided pallor of the face was noted, the mucous membranes were blue, the nails livid, and the pulse imperceptible at both wrists. The respirations were shallow, she had precordial distress, and the voice was weak. The reassuring features were that the extremities were warm, and there was no moisture on the forehead and no nausea. She was stimulated with strychnin, and coffee and brandy by enemata, but the improvement was slow, and her condition only became normal after five or six days.

Another case exhibiting this alarming complication was that of M. D., 3320, aged twenty-nine, operated on Feb. 8, 1895.

She was a woman of ordinary stature, with an abdomen enlarged to a circumference of 99 centimeters (40 inches) by a myomatous uterus, lifting the bladder up to a point just below the umbilicus and displacing the sigmoid flexure above the umbilicus. After a difficult enucleation of this large unusually vascular subserous mass, lasting twenty-three minutes, she was put to bed with a pulse of 88. On the second day the pulse began to go steadily upward, ranging between 140 and 150 on the third day, when it was scarcely perceptible. As she showed no blanching and seemed bright, I simply stimulated and watched her. From this time the pulse slowly came down, but did not get below 100 again until the twelfth day. In every other respect the convalescence was normal.

Diagnosis.—It is important to differentiate the predisposing or exciting cause of shock, whether from enfeebled vitality, prolonged operation, hemorrhage, anesthesia, or exposure of bowel and omentum, as the treatment depends largely upon the cause.

Chloroform asphyxia must be carefully discriminated from shock. Its onset is sudden, with few or no warning symptoms, the respiration grows shallow, irregular, and finally ceases, the pupils dilate, the face assumes an ashen hue, the pulse becomes weak, entirely disappearing at the radial artery. Upon the prompt withdrawal of the anesthetic, the suspension of the patient with head downward, and the induction of artificial respiration, these symptoms disappear and the patient speedily returns to a normal condition. In shock, the gradual appearance of the symptoms, the absence of precipitate onset, and the slow response to resuscitative measures are marked differential points.

Further, it is of vital importance for the surgeon to differentiate promptly

between the collapse associated with hemorrhage, and shock from nervous depression.

Prognosis.—If, after a few hours, the general condition of the patient begins to improve, as indicated by the return of color to the lips, lessening pulse rhythm, increase in the surface temperature, fuller or deeper respiration, vomiting, and a desire to change from the supine to some other position, the prognosis is favorable. The longer the reaction is delayed, the more serious becomes the prognosis, and if, after twenty-four hours, there is no change for the better, each hour thereafter detracts from the patient's chance of recovery.

A temperature which persists at one or two degrees below normal for a number of hours is also a sign of ill omen, and few cases recover in which the temperature falls to 96° or below. On the other hand, when the reaction goes so far as to merge into traumatic delirium, and the temperature rises to 103° or above, the prognosis becomes grave. A persistently rapid pulse ranging between 140° and 160° is also unfavorable, although one or two days may elapse in some cases before there is marked circulatory reaction, and still recovery may take place.

Preventive Treatment.—It is one of the most important duties of the surgeon so to arrange and conduct his operations that causes predisposing to shock may be avoided.

To this end operations upon weak and debilitated patients, or upon those in whom the pelvic disease is complicated by disease of some other organ, must be delayed until the general condition can be improved by tonics, rest, and regulated diet; provided that the advantage derived from this treatment is not overbalanced by the progress of the disease in the same time.

Operations should never be performed in a cool room; the most suitable temperature is from 24° to 27° C. (75° to 80° F.).

Prolonged exposure of the surface of the body in preparing the patient on the operating table must be avoided, and if during the operation it is necessary to lift the intestines out onto the abdomen, they should be carefully protected with layers of gauze wrung out of a hot salt solution, and a salt solution at a temperature of 43.3° C. (110° F.) should be poured over the gauze at frequent intervals. The lower extremities and chest are wrapped in warm blankets, and these in turn are protected by rubber sheets to prevent them from getting wet; a hot-water can should be placed between the feet, and hot-water bags down the sides from armpits to thighs.

The anesthetic must be administered for as short a time as possible, and all preparations to operate should be completed and the surgeon ready to begin as soon as the patient is fully anesthetized.

Extreme precaution must be taken throughout the operation to avoid loss of blood by the prompt clamping or ligation of actively bleeding vessels, controlling all possible sources of hemorrhage.

Immediate Treatment.—If, in spite of these precautions, shock takes place, a reaction must be set up as quickly as possible. This is best accomplished by the administration of stimulants and the external application of heat.

As soon as the symptoms of shock appear, whether during or after the operation, a hypodermic of brandy, ℥ ss., and sulphate of strychnin, gr. $\frac{3}{16}$, should be given, followed every half hour or every hour with a like quantity of brandy and one half the dose of strychnin (gr. $\frac{1}{16}$). The intervals between the injections must be lengthened if muscular twitching or a stiffening of the jaw is observed. Hypodermic injections, to be quickly effectual, should not be given into the extremities where the circulation is almost completely suspended, but into the deeper tissues of the chest, the sides of the abdomen, the upper parts of the thighs, and the deltoid muscles. As a rapid cardiac stimulant, nitroglycerin in the dose of $\frac{1}{15}$ of a grain, given hypodermically every two hours, is of service.

Stimulating and nutritive enemata should also be resorted to at once. The first enema may be given while the patient is on the table, and it may be repeated at intervals of from three to six hours. The best enema is made as follows: Two ounces of brandy, twenty grains of ammonium carbonate, with sufficient water or beef tea, at a temperature of 37.8° C. (100° F.), to make an eight-ounce mixture. This should be slowly injected into the rectum. Later, when reaction sets in, the brandy and carbonate of ammonium may be diminished, and the yolks of two or more eggs added.

The patient's bed should be thoroughly heated with hot-water bags or cans enveloped in flannel, placed between the blankets half an hour before the completion of the operation. After the patient is transferred to bed great care should be observed to keep the bags or cans at a safe distance from her body. Extensive burns of the second and third degree have resulted from the carelessness of the nurse in not watching the hot-water bags closely enough. The patient is placed between blankets with her head low, to prevent nausea and syncope, and if the shock has been associated with much loss of blood, the foot of the bed should be elevated six, eight, or twelve inches.

In patients suffering from shock the stomach may tolerate a large amount of fluid administered by the anxious attendant, but this should not deceive the surgeon, for there is little or no absorption from the stomach. To derive the full benefit of nourishment and stimulants, they should be given in very small quantities—not more than two or three ounces in an hour. Gentle friction with alcohol may be employed later, when reaction has set in.

When shock has resulted from exhausting hemorrhage, the salt solution infusion must be resorted to when the radial pulse is much quickened.

Secondary Hemorrhage.—One of the most frightful accidents which can occur after an abdominal operation is secondary hemorrhage. The pelvic organs are so richly supplied with blood through large vascular channels that death may occur in a short time if one of the ligatures controlling an important artery or vein slips off after the completion of any major gynecological operation. The occurrence of such a hemorrhage is always due to some error in the technique of the operation, and is therefore especially liable to happen in the hands of an inexperienced surgeon. In my earliest work I met with it as often as once in about every hundred abdominal cases, but by adopting certain stringent precautions

I have been able to eliminate it almost to a certainty as a complication. In 1,800 abdominal sections at the Johns Hopkins Hospital there have been 8 cases of extensive hemorrhage into the peritoneum following operation. One of these died and 7 recovered after opening the abdomen and checking the flow.

Causes.—The chief causes of secondary hemorrhage are :

1. Defective tying.
2. Cutting too close to a ligature.
3. Undue traction on the ligature after tying.
4. The shrinkage of the tissues within the grasp of the ligature.
5. An extensive capillary oozing.

How to avoid Hemorrhage by Care during Operation.

—The most dangerous method of securing a pedicle is the simple transfixion with an aneurysmal needle carrying two ligatures and tying the pedicle both ways. This is peculiarly dangerous when the ligature is applied to structures springing from the top of the broad ligament. A ligature applied at this point is practically placed upon the apex of a pyramid, and the marvel is that it does not more frequently slip over the summit, setting free the blood vessels. The risk of such an accident is increased by yielding to the common inclination to amputate the ovary and the tube as close as possible to the ligatures. It is evident also that a slight pressure upon the uterus will now drag the broad ligament out of the grasp of one or both ligatures. A careless plunging of the sponge held in a holder down into the pelvis, without taking precautions to avoid striking the top of the uterus or the broad ligaments, becomes especially dangerous in this connection.

After the abdomen is closed the straining efforts of vomiting or coughing by forcing the viscera down on the uterus and broad ligaments may produce the same effect.

Catgut tied in an ordinary square knot and cut close will often swell and soften, and so become untied and give rise to hemorrhage.

When tissues are edematous or excessively vascular, the attempt to include a large area in a single ligature is dangerous, because they may shrink soon after the operation and so loosen the ligature.

Extensive adhesions to the anterior abdominal wall and to the pelvic walls are sometimes the source of a prolonged capillary oozing; or bleeding omental vessels, torn in breaking up adhesions, may be overlooked and give rise to profuse hemorrhage in the upper part of the abdomen.

The following precautions should be taken during every operation to avoid the risk of hemorrhage :

None but the long, thin pedicles of ovarian tumors should ever be treated by transfixing and ligating both ways, and then the pedicle should be severed at least a centimeter and a half beyond the ligature.

Wherever large blood vessels are tied it is safest to use silk; catgut alone should not be relied upon. All large vessels, such as the uterine and the ovarian, should be tied twice, first with silk, then the mouths of the vessels should be caught and tied with catgut.

In the removal of ovaries and tubes for pyosalpinx and hydrosalpinx, small tumors and myomata, two or three ligatures should be carried through the broad ligament with needle and carrier, the outermost ones grasping but a small amount of tissue and including the important vessels in the manner described in Chapter XX.

In sponging posterior to the uterus and broad ligament, the uterus should be held forward with index and middle fingers of the left hand resting on sacrum and fundus, furnishing a safe guide for the sponge in its holder. Continued capillary oozing from any quarter must be noted and stopped by suture, puckering the tissues together, or by coating the tip of the finger with a thin layer of powdered persulphate of iron and then making firm pressure on the spot for about half a minute; the finger is then gently and slowly removed, and in most cases the bleeding stops with a single application. The oozing may also sometimes be checked by making pressure upon the part with a sponge wrung out of water so hot that the hands can not be put into it. The sponge is wrung out between layers of gauze and applied for half a minute.

In the extensive raw areas left after stripping off intestinal or omental adhesions, or after the enucleation of dense inflammatory masses or an adherent tumor, there may be a great many oozing points, the bleeding from any one of which would be infinitesimal, but all taken together may cause a dangerous loss of blood. Some of these oozing areas require skill and patience in order to check the flow. Where the oozing areas are situated on the peritoneal and muscular coats of the intestine, or on the posterior surface of the uterus, the best means of controlling it is to pass numerous fine catgut sutures very superficially. A quadrangular or circular suture will usually serve a better purpose in these cases than the simple interrupted stitch; care, however, must be observed in introducing them not to perforate the bowel nor to include enough tissue to cause a narrowing of the bowel when the suture is tied.

When the oozing is free and can not be checked and the patient begins to show decided signs of exhaustion, I desist from further attempts and resort to a gauze drain.

If the pulse is good and the general condition fair, I would prefer to close the abdomen and leave a limited amount of oozing, rather than to employ any form of drainage, on account of the risks of infection.

In cases where the operation has been extensive and where, as the result of the enucleation, there are extensive raw areas and the patient is in a critical condition, it may be necessary to put a firm gauze pack into the pelvis by inserting a long strip packed firmly against the raw surfaces and brought out at the lower angle of the incision.

The difficulty in removing the drain in these cases is even greater than in suppurative cases, because the plastic lymph thrown out between the gauze and the raw surfaces is very tenacious and the early removal is attended with intense pain, and the risk of pulling out omentum and intestines, or even of dislodging an important ligature, and so setting up anew a free oozing. This accident has occurred once in the gynecological wards of the Johns Hopkins Hospital. A

large drain had been put in to check the free oozing following the enucleation of dense inflammatory masses from the pelvis. The operation was done on a Saturday morning, and Sunday morning, twenty-four hours later, the patient was doing so well that it was thought best to remove the drain. Considerable force was required to start it, and then it came away easily. At this time the patient's pulse was good and her general condition excellent. An hour later the pulse had increased in rate and was not so full in volume. From this time on her condition grew steadily worse, until the symptoms of an internal hemorrhage were decided, when the abdomen was reopened and a large amount of free blood found. Notwithstanding the most careful search, however, it was impossible to detect the bleeding points, and a second drain was inserted; under the administration of a saline infusion and cardiac stimulants, the pulse improved and the danger seemed to be passed, when, without warning, respirations ceased, and, in spite of vigorous and prolonged attempts at artificial respiration, the patient died in a short time.

Bleeding omental vessels may be discovered by laying the omentum on a clean piece of gauze, when the spots of blood will indicate the position of any oozing areas.

Hemorrhage from the walls of the abdomen may be detected in the same way by laying a piece of gauze on the intestines under the spot.

One of the most important ways of avoiding hemorrhage is the making of a final thorough inspection of every part of the field of operation just before closing the abdomen, when any bad ties are found out and reinforced, and concealed bleeding areas may be discovered.

Symptoms.—A secondary hemorrhage may occur at any time within forty-eight hours after the operation is over. It may even begin while the patient is still in the operating room, and go on until the symptoms produced are pronounced enough to draw attention to the patient's condition. These symptoms will appear with a rapidity directly in proportion to the previous good or ill condition of the woman and to the activity of the hemorrhage.

Bleeding from capillary vessels in areas bared by peeling off adhesions rarely exceeds 60 or 90 centimeters (2 or 3 ounces), and does not produce serious symptoms attributable to the loss of blood. The greatest danger from this source is the liability to subsequent infection of the unabsorbed mass of blood.

Hemorrhage from uterine or ovarian vessels, or from branches of the uterine artery in the substance of the uterus, or from a large omental vessel, is so rapid that within a short time—fifteen minutes or half an hour—it gives rise to a definite train of symptoms. The actual amount of blood poured out in a given time from a uterine or an ovarian artery will depend upon its size, varying markedly in different individuals; the quantity is largest in the case of uterine fibroids, where a bleeding uterine or ovarian vessel may very quickly terminate a patient's life before any measure can be employed to save her.

An illustration of this statement occurred in my wards at the Johns Hopkins Hospital. A patient had been operated upon for a large symmetrical myoma; the vessels were all securely tied, and she made an uninterrupted con-

valescence until the eighth day. At noon of that day she suddenly cried out, and when the nurse hurried to her she complained of great pain in the left inguinal region. Her pulse was very rapid, and her expression anxious. A resident at once hurried to the ward, arriving there in fifteen minutes; but by this time the pulse had become imperceptible, and the patient was in a dying condition. The collapse was so sudden that the diagnosis of pulmonary embolus was made. The autopsy showed that there was a tremendous hemorrhage from the uterine artery from the absorption and rupture of the catgut ligature, which allowed the organizing thrombus to be pushed out of the short stump of the artery.

If the bleeding takes place in an abdomen with a gauze drain in it, there will be no difficulty in knowing precisely what has occurred. Something about the patient's condition or expression or color excites attention, and when the bedclothes are thrown down the bandage is found wet through with blood. The dressings are saturated, and on pulling the drain out a little the flow continues actively.

The usual train of symptoms in hemorrhage are :

1. Sudden quickening of the pulse and diminution in volume without apparent cause, or even an entire loss of the pulse.
2. Quickened sighing respiration, and the use of the extraordinary muscles of respiration.
3. Increasing pallor and a pearly conjunctiva.
4. Cold, clammy skin.
5. Vertigo.
6. Restlessness, throwing the arms and legs from side to side.
7. Desire to be raised in bed (orthopnea).
8. Pain in the abdomen, often severe.
9. Vomiting sometimes.

The history is often as follows: The patient begins by complaining of pain in the lower abdomen; her color seems a little paler, and the pulse somewhat quickened. The pain comes on in paroxysms and is diffused. She wears an anxious expression, and she may insist on seeing the doctor at once, fearful that she is not doing well. The radial pulse quickly becomes diminished in volume, while its rhythm is increased from twenty to thirty or more beats; the legs and arms become cold as the hemorrhage continues, and the radial pulse finally fails altogether, or becomes so faint that it can be detected with difficulty. The physician, arrived at the bedside, feels no pulse at all, unless it is the pulsation in his own finger tips as they are pressed deep into the wrist in his anxiety to discover some faint beats. The face assumes an ashen hue, the conjunctival mucosa is no longer injected, the lips are blue and the gums blanched. A cold perspiration breaks out on the face, and the respiration is quickened and labored. The temperature is subnormal. She lies flat on her back with chin elevated to make the breathing less difficult, and, although restless and anxious, remains motionless, except for an occasional tossing of the head from side to side as the dyspnea increases. She knows that her condition is changed, but often does not appreciate the gravity of the situation.

If the bleeding continues unchecked, death ensues in a period varying from six to twenty-four hours, or even longer, depending upon the size of the vessel and the anemic or plethoric condition at the outset. After attacks of bilious vomiting the dyspnea often increases.

The accessory respiratory muscles of the neck come into play toward the last, and she complains of a painful or heavy sensation in the cardiac region. This is apt to signalize the beginning of heart failure. With the increasing dyspnea comes a sense of suffocation and desire to have the head raised with pillows placed beneath the shoulders. The distress and the half articulated gasping requests of the patient at this time are peculiarly distressing to the bystanders. The heart impulse may still be distinctly felt, regular, but sudden, short, and violent, on placing the hand gently over the precordium. Gradually, as life ebbs away, the pupils dilate and a condition of apparent obliviousness supervenes, although even this state may be occasionally interrupted by a hurried gasping ejaculation, showing that some consciousness still remains. Complete unconsciousness gradually comes on, the breathing becomes short and gasping, the corners of the mouth are drawn out and expanded in a hideous risus, when at last, after one or two shallow gasping efforts, respiration ceases altogether. The heart continues to beat some time after respiration has ceased, and after the pulsations are no longer felt a slight tickling or faint contraction, more or less rhythmical, may be detected for half a minute or more, and the tragic scene is at an end.

This accident may happen in the best hands, but in the great majority of cases the patient can be saved by prompt action. Eight post-operative hemorrhages have occurred in a series of 1,800 abdominal sections in my service at the Johns Hopkins Hospital with only one death. The two following cases are cited as typical illustrations of the usual course and symptoms of this accident:

M. R., 2752, Sept. 8, 1894; operation simple salpingo-oöphrectomy. Careful ligation of uterine and ovarian vessels separately; suspension of the uterus. The risks of hemorrhage dwelt upon at the operation, and ties carefully made to prevent it. Returned at 12 o'clock to her room in excellent condition. Vomited violently at 3 p. m., when her pulse was 66; at 3.40 p. m., the pulse 128, weak, compressible, pallor marked, the lips dry and marbled, and thirst intense; dyspnea; extremities cold.

Abdomen reopened at 7 p. m. Blood spouted up toward the ceiling on opening the peritoneum, which was full of fluid blood; large clots ladled out of both flanks. At this time the patient was pulseless at the wrist; 160 beats per minute felt at the heart. The ligature at the left cornu uteri was found loose; this was reapplied lower down in the course of the artery; after all the clots were taken out the abdomen was irrigated with a salt solution, and an infusion was given into the radial artery to the amount of 750 centimeters of normal salt solution; following this the pulse reappeared at wrist in two minutes, and the patient recovered and is in good health.

C. L., 1926, April 19, 1893, salpingo-oöphrectomy, removing hematoma of left ovary. Pulse 92-112, fair volume.

Six hours later vomiting; pulse suddenly became irregular and almost imperceptible, rate 160. Dyspnea marked; pain in epigastrium, sides of chest, and flanks. Intense thirst, frequent vomiting of dark-green fluid, extreme pallor and restlessness.

Operation in patient's room in bed; abdomen reopened under cocaine, found filled with blood. Ligature at the cornu uteri found loose. Blood removed and abdomen flushed out with salt solution.

Infused into radial artery 700 centimeters of normal salt solution. Recovery.

Shock is one of the most important conditions liable to be confused with secondary hemorrhage in making a differential diagnosis. Shock, however, does not come on suddenly some hours after operation, and is gradual in its onset. If the patient has been carefully watched, it will often be evident that her shocked condition is but the continuance of a state existing immediately after operation. Such shock, it is true, is often associated with an excessive loss of blood during the operation. It is more profound when in addition to loss of blood is added the depression of a protracted operation in a feeble subject.

The differential diagnosis between hemorrhage and a septic infection may sometimes be impossible if, instead of a gradual onset, the septic symptoms appear suddenly. In either case the treatment by abdominal section is the same. I quote one case as an illustration of the possibility of this confusion:

L. F., 2612, March 1, 1894, operation for right extra-uterine pregnancy, walled off by adhesions and choking the pelvis posterior to the uterus in an excessively fat woman; a vaginal incision was made posterior to the cervix, emptying the sac, followed by irrigation and packing with gauze.

After removal of the pack on the third day the irrigations were continued every second day with a 5 per cent borie solution, followed by the introduction of a fresh gauze pack.

Nine days after the operation the patient was out of bed "doing excellently." Some pain and pallor were evident on the tenth and twelfth days. On the twelfth day the irrigation fluid did not return freely, and there was a discharge of some matter and shreds of tissue; she screamed with pain, and the pulse became suddenly weak and almost imperceptible. She was bathed in a cold sweat, and hands and nails were white and the respirations rapid. There was pain in the hypogastrum, followed by cyanosis, the pulse kept growing more rapid and weaker, with slight abdominal distention, and no tenderness or tenseness. Within five hours all the symptoms of collapse were pronounced.

A diagnosis of secondary hemorrhage was made; the patient, with a pulse of 170, was taken at once to the operating room and put under chloroform anesthesia. As soon as the abdomen was opened, about a liter of thin milky fluid, with shreds of tissue floating in it, escaped. The peritonema was red and injected everywhere, and necrotic areas were found on top of the sac in the pelvis, with a perforation communicating with the sac and so with the vagina. The abdomen was thoroughly washed out with salt solution, and gauze drainage provided at three openings, one at the lower angle of the incision, and one well back in each flank, communicating with the central one. The drains were removed

on the third day covered with a purulent discharge; following this there was a rapid improvement and recovery.

It is of the utmost importance for the operator, his assistants, and the nurses in every case to note the general appearance and the color of the mucous membranes of the patient as she leaves the operating room, in order that they may have a satisfactory standard for comparison in case the question of hemorrhage comes up at a later date.

Operation.—Having once arrived at a diagnosis of secondary hemorrhage, no time must be lost in carrying out the boldest measures to check the flow, and in making up for the deficient volume of blood by infusion.

To check the hemorrhage, all necessary instruments and accessories should always be within easy access wherever there is a patient upon whom an abdominal operation has been performed.

In the hospital it is always best to take the patient back to the conveniences of the operating room if it is safe to move her at all. The preparations are there made for opening and washing out the abdomen and catching and tying the bleeding vessel, and possibly closing the wound with drainage.

If the operation is at a private house or the patient is too weak to be taken out of her room, a table padded with a blanket and covered with a sheet should be placed near a window or under the gas jet, and upon this the inflated ovariotomy cushion is laid. The patient is then lifted upon the table. The nurse in the meantime has given her a hypodermic injection of one sixtieth of a grain of strychnin and a half ounce of brandy. These injections should be repeated every half hour until she has well rallied. Two clean basins are placed on chairs by the table, and the irrigator bag is filled with water, at a temperature of about 43·3° to 46° C. (110° to 115° F.), and suspended near the table. The instruments are laid on a sterilized towel within convenient reach.

While the operation is in progress the servant should prepare hot-water bottles, wrap them in flannel, and lay them in the bed, so that it will be warm when the patient is put back in it.

Preparations are also made to give the patient an enema of brandy (2 ounces = 60 cubic centimeters) in beef tea (8 ounces = 240 cubic centimeters), with ammonium carbonate (20 grains = 1·25 gramme), as soon as the operation is over.

The bladder is catheterized. No time is lost in making elaborate preparations; rather the operator must incur some risk of contamination for the sake of speed. If a good table is not convenient, or the patient is in an alarming condition, the operation may be done on her bed. A nominal amount of anæsthetic is used, and pushed to unconsciousness at the moment the incision is reopened. The operator devotes two or three minutes to scrubbing his hands and arms. The dressing covering the wound is rapidly laid aside and the sutures exposed. Beginning at the lower angle, two or three sutures are cut and removed, the lips of the incision separated, and the peritoneum pulled up and cut open with the scissors. If the diagnosis is correct, dark blood at once wells up and flows out over the surface of the abdomen. No time must be wasted in trying to sponge all the blood out, but the wound must be enlarged and two

fingers carried down into the pelvis, to the uterus, and laterally out to the ovarian stumps. The side where the ligature has slipped will feel lax in contrast to the tight bunching of the ligated pedicle on the other side. If no marked difference is recognized, both pedicles must be brought up and tied over again, taking either indifferently first.

The broad ligament is best exposed by carrying a pair of bullet forceps down into the pelvis, into the pool of blood, guided to the cornu simply by the index finger. The forceps are then opened and the cornu grasped and dragged up into the wound and exposed, and the vessels clamped with a stout pair of artery forceps.

The outer extremity of the broad ligament is next exposed, using the sponge rapidly to clear away the blood. This is clamped, too, unless the ligature is evidently so tight in place that there can be no question as to the possibility of hemorrhage from that point. The opposite side is dealt with in like manner. Any other areas wounded in the operation are now carefully inspected.

If the operation has been a hysterectomy, the uterine stump must be grasped at once with bullet forceps and pulled well up into view. If the inspection of the field reveals the point of hemorrhage the operator passes a fresh ligature, so as to control the trunk below the wound, and another to its free end. If the source does not appear at once he loses no time, but proceeds to ligate both ovarian and both uterine arteries and veins at a point beyond the field of operation. The lower abdomen and pelvis are cleansed by thorough repeated irrigations with a warm salt solution, diluting and washing out the blood, and bringing out clots lodged among the intestines.

Finally all layers of the abdominal wall are united by silk-worm-gut sutures, closing the incision from end to end. The wound is redressed and the fresh bandage applied.

In case of excessive loss of blood, the legs and arms should be wrapped tightly with flannel bandages from the extremities up to the body, to keep the blood in the head and trunk; this is further aided by keeping the foot of the bed elevated on a chair 20 to 30 centimeters (8 or 10 inches) high.

The hot rectal enema of 60 to 90 cubic centimeters (2 to 3 ounces) of brandy and 30 grammes of ammonium carbonate in a liter of normal salt solution is now given on the operating table. Hot bottles are put about the chest and abdomen in the bed. It must be remembered that during shock little or nothing is absorbed from the stomach; and so long as the cold, clammy, shocked condition persists, no amount of fluid ingested will satisfy the thirst. As soon as there is some reaction the best way to satisfy the thirst is to give an enema of a pint of warm beef tea, and to repeat it in two or three hours.

The hypodermics of strychnin should be given in or near the trunk, a sixtieth of a grain every hour, or even every half hour; if muscular twitching is noticed, the dose should be diminished. With this treatment the pulse drops from 160 to 140, and so on, 10 or 20 beats each twenty-four hours, until it is again normal.

The profound anemia may last for weeks or months, and is not to be relieved

by a routine use of iron; but the better course is by hygienic measures combined by tonics, the hypophosphites and gentian, with arsenic and strychnin.

Infusion.—Infusion of salt solution furnishes the quickest and best means of stimulation we possess, and is called for in all cases of hemorrhage.

For a long time I employed infusion of normal salt solution into the radial veins, but gave it up in favor of the arterial infusion, because in the latter the

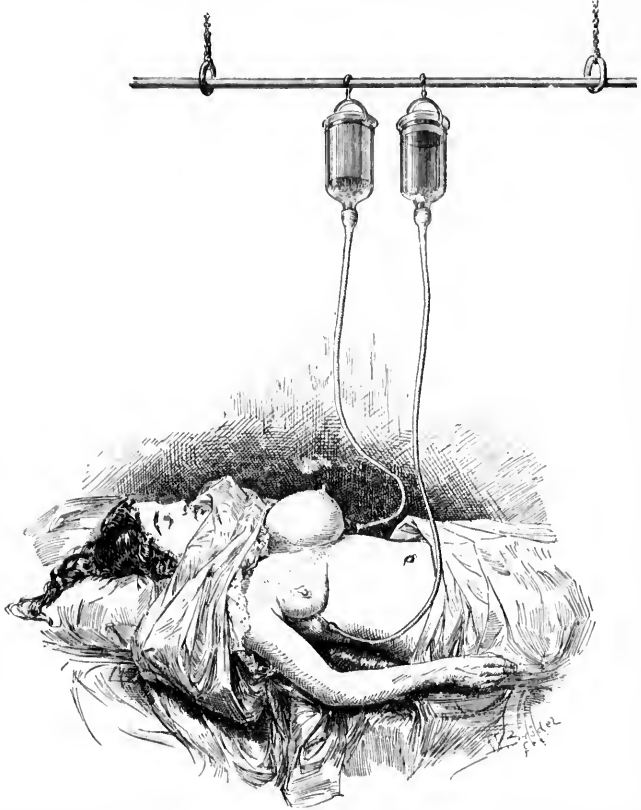

FIG. 326.—INTRODUCING NORMAL SALT SOLUTION UNDER THE BREASTS IN CASE OF EXTREME ANEMIA.

The form of the breast before the injection is seen on the right side, where the trocar has just been introduced beneath the gland; on the left side the breast is fully distended by half a liter of the solution.

fluid enters the artery and is forced up the vessel until the first branches are reached, whence it flows back through the capillaries and is filtered, by which it is diffused with the blood in a more even mixture than when the entire volume of the infusion is injected into the veins. Infusion against the blood current has also a distinct stimulating effect upon the heart.

After repeated ill experiences with the arterial infusion I was finally compelled to give it up. The force necessary to inject the salt solution against the stream of arterial blood causes a much greater distention of the coats of the vessel than is normal, and it is probable that the vessel is permanently injured; in my experience serious sloughing around the area of infusion has occurred in four cases; in one instance the entire hand had to be amputated some months later.

The infusion of saline solution into the cellular tissues under the breasts is so free from any sequelae and is so easily given, and affords such prompt relief, that I now use it in all cases of hemorrhage, and even where the patient is but slightly depressed by the loss of blood.

The method of giving the infusion is simple. I have had graduated bottles made especially for this purpose, which are filled with 1,000 cubic centimeters of the salt solution (0.6 per cent) at a temperature of 100° F. (37.8° C.). A rubber tube six feet long, to which is attached a long, slender, sharp aspirating needle, completes the apparatus.

The solution must be free from all organic particles, such as bits of cotton from the plug of the bottle in which it has been sterilized.

The skin of the breast is carefully disinfected; the breast is then grasped and lifted well up from the chest, while the needle with the salt solution flowing is thrust into the cellular tissue well under the glandular substance. The bottle is elevated six feet above the patient in order to give sufficient hydrostatic pressure to force the fluid into the tissues. As a rule it requires about twenty minutes to infuse from 700 to 1,000 cubic centimeters of the solution under both breasts. If the patient's symptoms are urgent, both breasts are infused simultaneously. As the infusion proceeds the gland becomes greatly distended, and not infrequently the salt solution spurts from the nipple in a fine jet.

At the completion of the operation a piece of adhesive plaster must be placed over the point of puncture to prevent a reflux of some of the injected fluid.

In many cases the relief is so great that the patient is made comparatively comfortable at once and does not even complain of thirst.

In about fifty cases in which I have employed this form of repletion of the circulation there has not been the slightest ill effect in the way of local inflammation about the breasts.

Peculiarities of the Pulse.—As the pulse affords one of the most important indications of the patient's condition, any deviation from the normal should be noted at once and watched by the surgeon with unusual anxiety. The chief value of the pulse is barometrical, as it were, giving an early indication of approaching trouble. In order that the pulse may act as a guide in forming an intelligent opinion of the case, a previous observation as to its natural character is essential. If the pulse is already quickened before the operation, ranging between 100 and 130 or even higher, a simple steady acceleration may be properly regarded as favorable rather than unfavorable, as this is to be expected.

When the operation is prolonged and exhausting the pulse rate may be in-

creased 20 or 30 beats, and may persist so for some hours, or even one or two days, without causing anxiety, providing it maintains its strength, volume, and rhythm. One of the surest signs of reaction, however, is the gradual decrease in the pulse-rate. There is always cause for anxiety when a pulse, previously regular and quiet and but little quickened, begins after twelve hours or more to go up, rising to 120, then 130 or 140 beats per minute, at the same time becoming weaker. If in conjunction with this there is a rise of temperature and the patient assumes a distressed look, complains of pain, is nauseated and vomits occasionally, and the abdomen is tympanitic, septic infection may exist. It is, however, a mistake to consider even the widest variation of the pulse rate as indicating in itself a necessary fatal result.

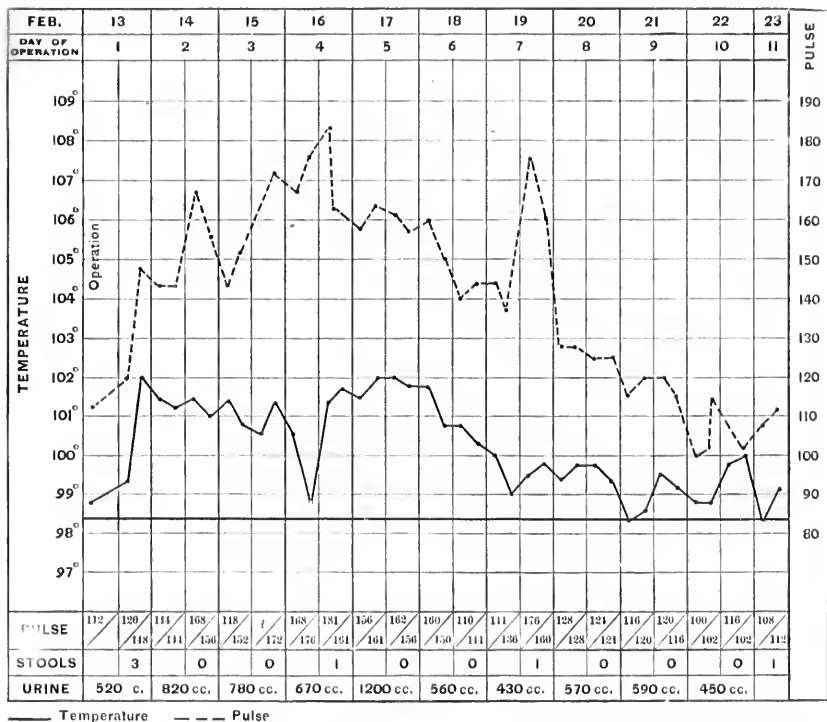


FIG. 327.—CHART SHOWING CONVALESCENCE COMPLICATED BY A HIGH PULSE RATE, FOLLOWED BY RECOVERY.

Operation: cystectomy for multilocular ovarian cyst, begun under cocaine; extensive adhesions, and hemorrhage; pulse counted on table 200 per minute. Temperature caused probably by drain and suture abscesses. No. 5307.

I have repeatedly seen patients recover whose pulse rate was as high as 140 or 150 for some hours; in one instance the pulse ranged between 150 and 162 for three days, after which the patient made an uninterrupted recovery.

I removed an ovarian cyst from a feeble old woman whose pulse went up to 210 during the operation, and one of my residents, by carefully counting the cardiac impulse over the pericardium, made it at one time 240 per minute, and yet she made a good recovery. (See chart, Fig. 327.)

An intermittent pulse is sometimes observed during convalescence when it has been rapid immediately after operation; indeed, an intermittent pulse occasionally occurs after operation without apparent cause. A markedly intermittent pulse is also noted in the latter stages of septic infection, and is always a cause for grave apprehension.

An abnormally slow pulse (bradycardia) is occasionally noticed, but it usually exists also before operation. I had a patient who recovered with a pulse rate of 30 per minute after cholecystotomy, but this had been the normal rate through life.

Variations in Temperature.—Subnormal temperature is indicative of profound depression arising from shock, hemorrhage, or the gradual retrogression of the vital functions preceding death. The temperature may fall slightly below normal during or immediately after an operation from the refrigerant depressing effect of the anesthetic, especially if ether has been employed, but quickly returns or rises even above the normal upon the application of external heat.

A sudden fall of temperature after the patient has recovered from the first effects of an operation, associated with an increase in the pulse rate, is one of the signs of hemorrhage. The gradual depression of temperature preceding natural death is usually coincident with failure in all the other vital functions, and is different from the rapid fall from hemorrhage or severe shock.

Some elevation of temperature, known as simple wound fever, is observed in almost all cases, even where the recovery is otherwise perfectly normal. This need occasion no alarm, although calling for increased watchfulness.

The composite temperature charts in Chapter XXI demonstrate the normal febrile reaction attending the healing of abdominal wounds.

Quite frequently a considerable elevation of temperature occurs, extending over several days, and then subsides without giving any sign of its cause.

So far as the progress of these cases is concerned they may be considered normal, yet since we can not reconcile this abnormal elevation of temperature, extending over several days, with a perfect convalescence in a surgical sense, we are constrained for the present to attribute it to the effects of infection, for undoubtedly mild grades of infection can be combated by the phagocytic action of the leucocytes and the germicidal effects of the blood serum without any other signs than those manifested by these variations of temperature.

Even local suppuration, deep in the abdominal wall or about the stump of an ovarian cyst or the cervix, may occur and never be definitely located, the accumulations of pus being gradually absorbed.

Looking at these abnormal temperatures from this standpoint, the gynecologist must feel anxious about his case until the normal curve is reached.

When malaria is prevalent, or a patient comes from a locality in which it is endemic, a sudden rise of temperature should at once call for a blood examination, and the surgeon may be relieved of grave anxiety by finding the plasmodium malarie present.

During August and December, 1896, my associate, Dr. W. W. Russell, observed several of these cases (see *Johns Hopk. Hosp. Bul.*, Nov., Dec. 1896).

In one instance the patient had been operated upon in the hospital one year previously for a large pelvic abscess, and a quantity of pus was evacuated by vaginal incision and drainage; she remained in perfect health until two weeks before the second admission, when she began again to feel miserable; in a few days severe chills came on, succeeded by headache, backache, and high fever.

Feeling sure that there was a return of her former malady, she hurried at once to the hospital. A vaginal examination revealed some induration at the base of the broad ligament, but there was no sign of any purulent collection.

She was then put to bed and watched for several days, when a blood examination was made and the plasmodium found and the diagnosis of malaria made (see malarial chart).

By keeping in mind the possibility of malaria as the cause of high temperature grave anxiety and even serious mistakes may be avoided. An instance of a mist of this kind is that of a gynecologist who performed salpingo-oöphorectomy in the belief that the adherent appendages that he removed were the cause of the periodical rise in temperature. A subsequent examination of the blood revealed the plasmodium, and a course of quinia speedily relieved the symptoms.

Occasionally the most unaccountable rises of temperature will occur during the convalescence of an abdominal section case. When there is a definite periodicity of these rises, or a slight diurnal variation like that seen in septic cases, some point of infection will usually be discovered to account for the abnormal temperature.

In rare cases the variations in temperature follow no law, rising to an alarmingly high point one day and then abruptly falling to normal, where it may remain for a variable length of time and again show the same excursions. The patient's general condition is usually good, and in no way corresponds with the temperature; she has no accompanying chills or sweating; a careful physical examination and microscopic examination of the blood fails to reveal any cause for the thermal disturbance. On careful review of the history of such a case a marked hysterical temperament may be discovered, which may account for the unusual symptoms; such a diagnosis, however, should only be accepted as a last resort after the most careful exclusion of every other possible source; it is in just such cases that the greatest injustice is sometimes done the patient.

I once operated upon a young woman of neurotic temperament for extensive suppuration of the pelvic organs. The convalescence progressed smoothly, the temperature reaching normal on the seventh day after operation, and continuing so until the twelfth day; then it suddenly rose, between eight and eleven

o'clock in the morning, to 105.5° F. (40.8° C.), and remained at this point until the evening, when it fell abruptly to normal. No further disturbance was noted for six days, when again the same phenomenon occurred. During this time nothing could be detected to account for the rise in temperature, and it was attributed to hysterin. Two days later the temperature again rose to 105° F. (40.5° C.), and for the next nine days showed a typical septic chart, when it again reached the normal and continued so for five days, and again rose to 102° F. (38.9° C.), dropped to normal, and the next day made the highest rise of any time during the convalescence, reaching 106.5° F. (41.5° C.) The patient complained of chills and sweating occasionally, but otherwise showed no ill effects from this hyperpyrexia. For a number of days the chart indicated sep-

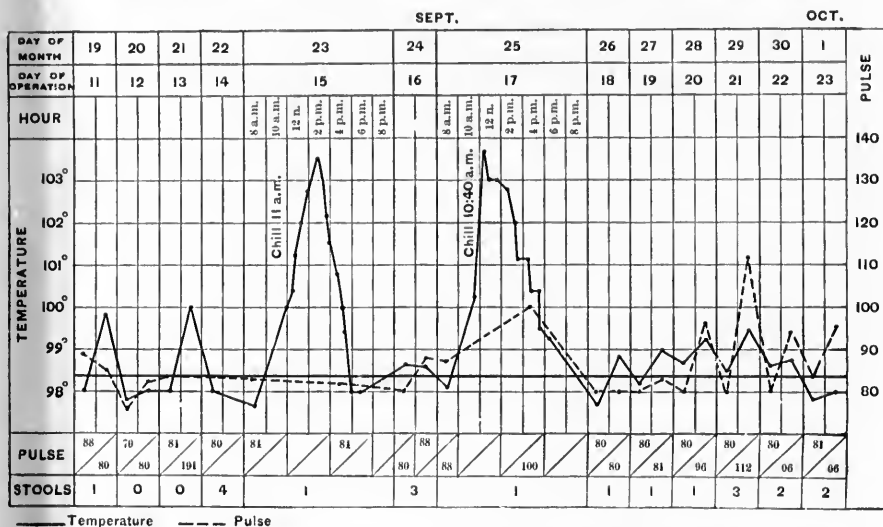
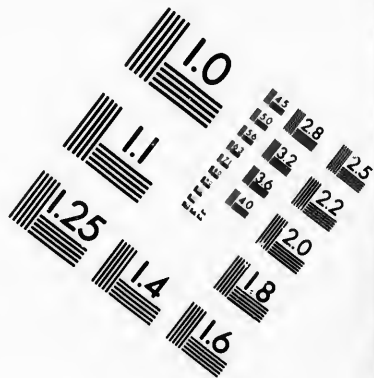
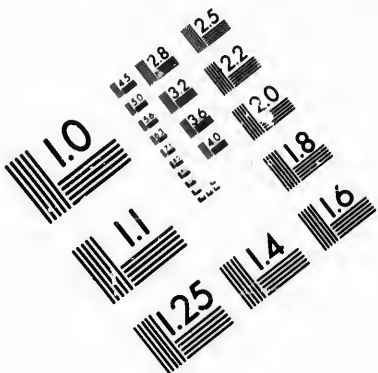


FIG. 328.—NORMAL CONVALESCENCE INTERRUPTED BY PERIODICAL RISES OF TEMPERATURE DUE TO THE PRESENCE OF THE PLASMODIUM MALARIE. No. 4618.

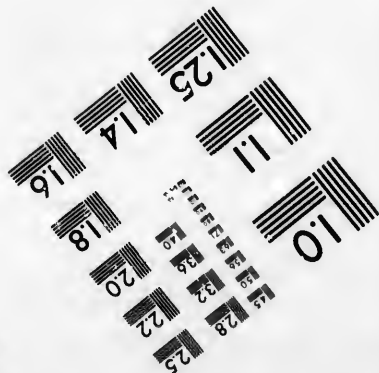


sis, and yet repeated examinations failed to reveal its presence. Since the patient's return home she has had similar attacks, and it has now been more than two years since her operation and she enjoys fairly good health.

Vomiting.—Nausea and vomiting follow the administration of an anesthetic in the great majority of cases where the operation is prolonged, but vomiting can only be considered a complication when it is persistent or excessive.

The personal peculiarities and idiosyncrasies of a patient are an important factor in the case, and should be inquired into before the operation. Patients frequently volunteer the information that they dread the anesthetic on account of an irritable stomach or a tendency to excessive nausea discovered in some former experience.




**IMAGE EVALUATION
TEST TARGET (MT-3)**



**Photographic
Sciences
Corporation**

23 WEST MAIN STREET
WEBSTER, N.Y. 14580
(716) 872-4503



Vomiting may invariably follow the ingestion of liquids or food for three or four days after an operation; indeed, the nausea may be so great as to cause vomiting at the mere sight of food. When this condition is associated with increase of pulse rate, elevation of temperature, tympanites, and severe intermittent abdominal pain, it may be accepted as a sign of peritonitis. In this case the vomiting becomes more frequent and retching in character, the ejeeta consisting of a little yellow or black bile, expelled in small quantities. When excessive emesis is associated with severe intermittent pains and a failing pulse, with but slight elevation of temperature, it points strongly to intestinal obstruction, when the vomited matter may soon become feculent in odor.

Sometimes the appearance of the ejeeta and the severe pain in the epigastrium suggest gastric ulcer, gastritis, or some other affection of the stomach; under these circumstances the history aids in establishing or disproving the supposition.

Treatment.—The stomach must have absolute rest so long as it is in an irritable condition, and nutrition must be maintained largely by rectal alimentation. Internal medication is usually of little service, although occasionally linewater in small quantities seems to allay the excessive irritability. A few drops of the spirits of chloroform may be given at frequent intervals; cocain, 2-per-cent solution, may be given in 10 to 20 minim doses; or bismuth subnitrate or morphin in small doses is also valuable. Ice champagne in 2 or 3 drachm doses frequently has a soothing effect. Two or three drops of tincture of capsicum in a teaspoonful of hot water is often valuable. If the bowels have not been moved, relief is often instantaneous upon a thorough evacuation.

In intractable cases the greatest relief frequently follows the washing out of the stomach with a weak boric-acid solution, and after lavage two or three times the vomiting will often disappear entirely.

For this reason I always resort to lavage when doubtful whether or not the vomiting is a sign of an obscure peritonitis or an ileus, and in several instances it has seemed even to save the patient's life. Its happy effect is well illustrated by case R. B., No. 4828. Operation, Nov. 23, 1896. A hysteromyectomy was performed for an enormous myoma, entirely subperitoneal. All went well until the sixth day, when the patient complained of intense epigastric pains, kept crying out and vomiting violently, and had the appearance of a woman in extreme collapse. It was curious to note that although she was an ignorant woman she persistently declared that her bowels were closed, and if she did not get a passage through she would shortly die. I saw her in this condition on the following day and ordered lavage, which gave immediate and permanent relief.

A hot-water bag, ice bag, or a weak mustard plaster, applied to the epigastrium, usually renders the patient more comfortable, and may bring entire relief from the nausea.

As a rule, it is best to withhold all food by the mouth until there are no more active manifestations of the nausea. Nutrient enemata, if properly prepared, are easily assimilated, and may be relied upon exclusively for a few days.

Among the best formulæ are the following:

1. One egg.
 A little table salt.
 Peptonized milk, 60 to 90 cubic centimeters (2 to 3 ounces).
 Brandy, 30 cubic centimeters; or,
2. The whites of two eggs.
 Peptonized milk, 180 to 200 cubic centimeters.

To allay excessive thirst, a half pint or a pint of water injected high up into the bowel is efficacious.

Dr. E. C. Dudley, of Chicago, recommends enemata of beef tea, which I have used with great satisfaction, as they serve the double purpose, if they are retained, of furnishing food and relieving thirst: and if they are expelled, an early evacuation of the bowels may be secured.

The food in these cases when first given by the mouth must be light and digestible, and given in small quantities at frequent intervals. Albumen, as prepared in Chapter XXI, is the least irritating form of nutriment. Meat jellies, light broths, or koumiss are best retained as soon as the condition of the stomach begins to improve.

Tympanites.—Excessive tympanites is one of the most distressing complications following celiotomy. The abdomen becomes greatly distended and often markedly sensitive, and the upward pressure on the stomach and diaphragm interferes with digestion and impedes respiration to such an extent as to cause great discomfort. I have seen two instances where death seemed to have been due to the paralysis of the diaphragm caused by an excessive tympanites, as the autopsies revealed no other possible cause. Palpitation of the heart and disturbed rhythm are frequently due to this intestinal distention. Tympanites, like the variation in pulse rate and temperature, may be without serious significance, due simply to intestinal atony or constipation, which is promptly relieved by appropriate measures. If it is associated with increasing pulse rate, fever, constipation, and vomiting, it is a symptom of peritonitis.

Treatment.—The application of turpentine stupes to the abdomen is one of the best of the mild remedies often effectual in relieving the condition. The stupe is made by wringing a broad piece of flannel out of hot water containing turpentine in the proportion of 60 cubic centimeters to the liter (1 ounce to the pint). The stupes must not be left on too long, or be too frequently repeated, or they will blister the skin.

The introduction of a rectal tube high up into the lower bowel permits the escape of flatus and often affords relief at once. When there is an excessive accumulation of gas it is advisable to leave the tube in the rectum for some hours. To facilitate the passage of the tube the index finger should be well oiled and introduced as far up as possible to serve as a guide for the end of the tube as it is pushed through the ampulla into the upper bowel where the gas is accumulated. If this is not done the tube will be almost certain to coil up in the ampulla without reaching the upper rectum at all.

Hoffman's anodyne, in the dose of twenty minims to a drachm, given in

cracked ice, is a good internal remedy. Five drops of turpentine in emulsion or on loaf sugar is also of value, stimulating and assisting in the expulsion of the flatus.

The evacuation of the bowel by an active purgative—such as magnesium sulphate, citrate of magnesia, or a pill of aloin, strychnin, and belladonna, followed by repeated enemata of oil or soapsuds—is the best of all means of permanently relieving tympany, and should be resorted to at once if the mild measures fail after a brief trial.

One of the best remedies for a distressing tympany is the light application of the Paquelin cautery. The platinum tip should be heated to dull redness and lightly drawn over the abdomen, only touching the top of the short hairs, and not actually coming in contact with the epidermis. The manipulation of the cautery requires some little skill, or deep burns may be produced. It is best to practice the movement with the cold point on one's own arm before trying it upon the patient. When the entire abdomen has been gone over in this way the patient is usually greatly relieved, and begins at once to expel great volumes of flatus. The relief has been so great in some cases that I have had patients who were almost paralyzed with fear at the sight of the red-hot tip during the first application request a repetition of the treatment on the slightest return of the tympany.

Where there is reason to anticipate a tympanitic condition of the bowel on account of extensive injury to its peritoneal coat or on account of inefficient evacuation of the bowel previous to operation, the cautery can be used with good effect on the slightest indication of distention. In these cases it acts as a prophylactic.

In an extreme case I know of no plan so good as that of Dr. L. M. Sweetnam, of Toronto, which consists in the postural treatment of tympany by putting the patient in the knee-breast posture and introducing a rectal tube. As soon as the tube passes beyond the utero-sacral ligaments volumes of gas begin to escape. One of my patients was desperately ill with tympany—the barrel-like abdomen as tense as a drum, and the pelvis was so choked with distended intestines that the rectal tube could not be passed. I gave her complete relief by putting her under chloroform and introducing, in the knee-breast posture, one of my long rectal specula; the bowel was collapsed until the speculum reached the sigmoid flexure, when the gas began to escape freely, and she recovered.

Excessive Pain.—The surgeon, and especially the family, are often unnecessarily fearful on account of the excessive suffering of the patient after an abdominal operation. The pain is usually referred to the lower abdomen, where it is constant and so severe as to seem almost unendurable. Highly sensitive or nervous women will oftener complain in this way, while others of a phlegmatic temperament, or who are accustomed to exercising self-control, suppress all manifestations of pain and only complain when questioned.

The simplest abdominal operations may be followed by the severest pain, while other cases, where extensive adhesions to adjacent organs have been separated, cause comparatively little or even no suffering.

In the absence of other untoward symptoms there is no occasion for alarm, as the pain usually subsides in from twenty-four to forty-eight hours, and the patient suffers but little afterward. Women addicted to the use of morphin complain most bitterly and are the longest in becoming quiet after operation. If sedatives are persistently withheld these patients become exhausted in one or two days, and are not so importunate in their demands for the drug, and although they may say they have had absolutely no sleep, an observant nurse will have noted many short naps aggregating in all sufficient rest in twenty-four hours. I know of no better method of breaking the common morphin habit than the absolute prohibition of anodynes in any form during their convalescence following operation. The suffering for the first two or three days is undeniably of the severest character, but the moral effect produced by triumphing over real pain, and the realization that it can be accomplished without resort to morphin, are of the greatest value in restoring the moral stamina of the patient. After having gone through such a struggle the patient will rarely return to its use if she has any moral character left to work upon.

In ordinary cases I do not object to the use of one or two hypodermics of morphin in the first twenty-four hours, indeed it is better to use it, but no practice is more pernicious than the repeated administration of sedatives for the relief of pain for several days following abdominal operations. The general tone of the patients who have withstood the pain without anodynes is far better at the end of a week than that of those who have been relieved by morphin.

The severe pain complained of by neurotic or acutely sensitive women must be carefully differentiated from the pain of peritonitis, which is most severe on the second, third, or fourth day after operation, and is intermittent in character, associated with tympanites, elevated temperature, quickened pulse, and a bad facial expression; here, too, morphin should be withheld, as it dulls the patient's mind, locks up the secretions, blunts the sensations, and so tends to mask the symptoms at a critical period.

Peritonitis.—If we accept the views of Grawitz, Klemperer, and others concerning the pathology of peritonitis, we class all forms together as septic or infectious.

A number of observers, however, maintain, from the standpoint of experimental as well as of clinical observation, that there exists a simple, post-operative, traumatic peritonitis without infection. This view would seem to be supported by the common surgical experience that although cultures taken throughout the course and at the end of an operation frequently show no growths and therefore the absence of an infection, yet for the first two or three days after an operation the patient may exhibit many of the symptoms of peritonitis.

The experimental researches of Pawlowsky upon the etiology of peritonitis would seem also to confirm this view; he injected various chemicals into the peritoneal cavity of animals and found that they produced a "simple inflammation."

In several instances where I have been compelled to reopen the abdomen

soon after the original operation to relieve an obstructed bowel I have found an extensive union between adjacent peritoneal surfaces; these cases failed to show any kind of micro-organisms in the peritoneal cavity, and yet the evidence of the pouring out of a plastic lymph with the subsequent formation of adhesions were abundant.

The scientific pathologist seriously questions the propriety of denominating as forms of true peritoneal inflammation those processes which are simply associated with the repair of the injured tissues, and are thus of necessity purely localized at the seat of the injury.

I think, however, that for the more practical purposes of the surgeon it will be well for the present to preserve the customary nomenclature without expressing a definite judgment as to the strictly scientific question involved, for in the first place it behooves the surgeon to be keenly on the alert to detect peritonitis and everything that simulates it, and, in the second place, it is equally certain that if the plastic forms are not themselves true inflammations they unquestionably often form the basis of an inflammation.

Traumatic or Plastic Peritonitis.—The so-called traumatic or plastic peritonitis is a regenerative process, and occurs to some degree in every case in which the abdomen is opened; it is slight and circumscribed after simple operation, and extensive when wide areas of adhesion have been separated, as in the enucleation of adherent tubal and ovarian tumors. The wide area of cellular tissue exposed in some cases gives rise to serous oozing, and the plastic lymph serves to agglutinate adjacent structures to the raw areas, which become vascularized, and finally converted into fibrous tissue. A traumatic "peritonitis" may also be induced by prolonged exposure or rough manipulation of the abdominal viscera without taking away the peritoneal covering. The character of the adhesions formed varies; sometimes they are flat and dense and can only be liberated by tearing the bowel or cutting away the adherent surfaces; and sometimes they are long and weblike or velamentous, and can be freed without difficulty. After some months the most extensive adhesions may disappear spontaneously by absorption. I have opened the abdomen a second time in cases where the adhesions were almost universal at the time of the first operation, and found only a few delicate bands remaining.

Symptoms.—In the milder forms there are no symptoms whatever. The symptoms of the more aggravated forms are vomiting, severe pain in the lower abdomen, tympanites, tenderness on pressure, accelerated pulse, and elevated temperature, rising at first to 99° , then to 100° , or even 101° . The pulse is usually only slightly quickened and remains full in volume, and the patient has a good facial expression, lacking the pale, drawn appearance characteristic of sepsis. Vomiting is less frequent and not so persistent and so retching in character as in septic peritonitis. The ejecta consist of the contents of the stomach, but the vomiting is not, as a rule, of the violent bilious character seen in septic peritonitis. Traumatic peritonitis rarely becomes general, although the extreme tympany and general tenderness over the abdomen often lead to such an inference.

Dangerous symptoms may arise from pressure of the distended intestines on the diaphragm, interfering with respiration, or from ileus, or, later, from strangulation of the bowel by bands of adhesions.

In the usual course of simple plastic peritonitis, in from two to four days after the operation the tympanites disappears, the pain subsides, the temperature gradually falls, the pulse rate decreases, and convalescence becomes established. While the convalescence usually proceeds in this manner, if the fluid is not promptly absorbed another outcome is possible; the few germs which always get into the peritoneum, even in the most aseptically conducted operations, find in the stagnating fluid a rich nutriment under precisely the proper conditions of temperature for a rapid multiplication, and in this way a septic peritonitis may be produced, which would never have arisen in a dry peritoneum.

Treatment.—**Prophylaxis** plays an important rôle in the treatment of traumatic peritonitis. At the operation the intestines must be exposed and handled as little as possible, and kept carefully protected with gauze. No other solution than the normal salt solution should come into contact with the peritoneum. Where denudation is necessary its extent should be as limited as possible, and whenever possible flaps of peritoneum should be left to cover up the denuded areas. The amount of exudation will be lessened by protecting the denuded areas and by checking all hemorrhage before closure.

Free purgation is the sheet anchor in the treatment of traumatic peritonitis, depleting the circulation and actively removing the fluids within the peritoneum. If the stomach is not too unsettled, a hydragogue purgative, such as citrate of magnesia or a concentrated solution of Epsom salts, should be given every hour until the bowels are freely moved. Sometimes, even with considerable nausea, these purgatives may be given by the mouth, and instead of increasing the nausea will often allay it. Calomel in half-grain doses every hour until two grains are administered, followed by a saline cathartic, acts well in many cases.

If the irritability of the stomach is so great as to preclude the administration of drugs by the mouth, the evacuation must be secured by enema, beginning with a pint of warm soapsuds containing three or four ounces of sweet oil or one drachm of spirits of turpentine. This should be repeated every two or three hours until the bowels are freely moved and the flatus expelled.

By the time the lower bowel is thoroughly evacuated the stomach will usually be settled sufficiently to tolerate medicine by the mouth. If the enema is expelled as soon as it is injected, the rectal tube must be introduced again, this time high up into the colon, so that the enema may be thrown at once into the sigmoid flexure, or even higher. One is often surprised, notwithstanding the free evacuation of the bowels before the operation, to see the large amount of fecal matter passed at this time.

The diet should consist of highly nutritious liquid food, which will leave little or no residuum in the intestinal canal; plain milk should therefore be discarded.

To facilitate thorough digestion and to allay nausea the food should be given in small quantities every hour or two. Peptonized milk, beef broth, wine whey,

and mulled wine are all easily assimilated. Iced champagne or soda water in small quantities are often soothing when the stomach is excessively irritable. If the stomach is intolerant to foods, rectal alimentation must be resorted to according to the method described on page 77. A turpentine stupe or a hot-water bag applied to the abdomen is useful in allaying pain.

Patients sometimes experience the greatest relief from the application of iced flannels over the abdomen.

Post-operative Septic Peritonitis.—This form of peritonitis is invariably produced by the invasion of pyogenic micro-organisms into the peritoneal cavity. It is due, therefore, to a localized infection extending from a definite point out over the surrounding peritoneum until it is either checked by a wall of intestinal adhesions or until it has invaded the entire peritoneal cavity. The conditions underlying the infection of the peritoneum are the same as those underlying the infection of all other wounds.

The view of older surgeons that the peritoneum was especially susceptible to infection has been disproved by many clinical and experimental observations; indeed, we have now so far reversed this opinion that we consider the peritoneum one of the most resistant of all the organs to the invasion of micro-organisms. We know also that we are constantly testing its powers of resistance, for in spite of every effort we rarely exclude all infectious germs from the peritoneal cavity during an operation.

The experiments of Pawlowsky, Grawitz, Welch, Halsted, Waterhouse, and others all show that the healthy peritoneum can withstand, without the least visible reaction, great quantities of pyogenic organisms if they are introduced suspended in a fluid culture medium.

Sänger has defined three important conditions concerned in infectious processes: first, qualitative, relating to the pyogenic properties of the infectious germ; second, quantitative, relating to the number of organisms present; and third, the constitutional, referring to the susceptibility of the subject to infection.

Dr. William Welch says: "It is apparent that while there is no reason to doubt that pyogenic cocci are specific agents of infection, the effects which they produce depend upon a variety of conditions, such as the source, the number, and the virulence of the micrococci, the accompanying toxic substances, the part of the body invaded, the readiness of absorption, the presence of foreign bodies and the pathological products, the general state of the patient, and the condition and handling of the wounded tissues."

The more we learn of infectious processes the more are we convinced that the vital resistance of the patient plays an important, if not the greatest part, in the resistance to infection. If a patient is much depressed physically, and is subjected to an abdominal operation in which there is extensive traumatism to the peritoneum attended by considerable oozing, the chances for a serious infection are much increased. To the individual factor of vital resistance is undoubtedly ascribable many of the discrepancies as to the apparent varying degrees

of virulence of the same infection, when under precisely the same conditions one patient will be infected and another escape.

It is a clinical fact, and one which all discriminating physicians have learned to value, that persons suffering from pre-existing chronic cardiac, renal, or hepatic disease are prone to be carried off suddenly by intercurrent acute affections, which it is now recognized are due to pathogenic micro-organisms. If these conditions arise spontaneously, without the aid of traumatism or in consequence of a surgical procedure, it may be regarded as a natural sequence for infection to take place under like circumstances when, as a result of surgical operations, the way is opened for the entrance into the body of pathogenic bacteria; the gravity of the infectious process will, in a given instance, depend upon the degree of absence of resistance to infection in the individual, the nature of the operation, the perfection of the technique employed, and the virulence of the entering micro-organisms.

The pathological and bacteriological study of all the cases of peritonitis which have come to autopsy in the Johns Hopkins Hospital has clearly demonstrated the greater liability to the invasion of bacteria on the part of persons subject to chronic diseases of one or several of the important viscera.

It is well established that the *streptococcus pyogenes* is the most virulent of all the ordinary micro-organisms, and its introduction or escape into the peritoneal cavity is one of the most dangerous accidents that can occur in the course of an operation. I found by a routine examination of all pelvic abscesses that the streptococcus was rarely present, and when it did occur the use of drainage was of little or no avail in resisting a further invasion, as a virulent infection of the peritoneum was almost invariably fatal whether the drain was inserted or not.

The *staphylococcus aureus* under favorable conditions may also give rise to an extensive serous inflammation and septicemia. In the five cases of post-operative peritonitis which occurred in the gynecological department of the Johns Hopkins Hospital in 1893 the infecting organism was the *staphylococcus aureus*.

The *bacillus coli communis* under favorable conditions is capable of producing a peritonitis, although its rôle in this capacity has been questioned. The growth of the bacillus is so vigorous that it would appear to kill the less resistant pyogenic cocci, which are consequently not found by the time the patient is operated upon or at the autopsy table.

Other organisms, besides the simple pyogenic cocci, are capable of causing peritonitis. Cases have been reported in which the *bacillus pyocyaneus*, the *bacillus proteus*, *bacillus typhosus*, and the *micrococcus laevis* have been the infecting agents.

The gonococcus, while occasionally found in purulent collections in the peritoneum, seems only in rare instances to possess the power of exciting an active inflammation of the serous membranes. In many hundreds of bacteriological examinations I have never yet been able to demonstrate this micro-organism as the etiological factor in the production of septic peritonitis. In one case which

came under my observation a pus tube had been ruptured some days previous to operation, giving ample opportunity for the beginning of an inflammation. At the time of operation there was only the slightest local pelvic peritonitis, notwithstanding the fact that a great quantity of pus containing myriads of gonococci was lying free in the pelvis. The patient made an uninterrupted recovery without even the usual symptoms of traumatic peritonitis.

The *staphylococcus albus*, under favorable circumstances, may produce a local peritonitis, but its pyogenic properties are slight.

The group of infectious peritonitic cases may be further subdivided, depending upon the virulence of the infection and the resistance of the patient.

The most fatal of all forms is that where the micro-organism multiplies so rapidly and its toxic products are taken up so quickly by the blood and lymph vessels that the patient is overwhelmed in a very short time and dies as though suffering from severe shock. In these cases the local reaction is slight, and there may be but little evidence of peritonitis, the symptoms being almost entirely constitutional. The peritoneum in these cases is covered with a thin slimy or viscid exudate of fibrin, which, upon microscopical examination, shows myriads of micrococci.

The onset of the symptoms is rapid, the pulse showing an abrupt rise, and the general appearance of the patient becoming much worse. The temperature, as a rule, only rises to 99°, 100°, or 101° F. (37.2°, 37.8°, 38.3° C.), but it may show a wide excursions above the normal.

I cite two cases as examples of this fulminating form of peritonitis, in both of which streptococci were present. V. W. (31. 3). The patient was operated upon Nov. 8, 1894, for multiple myomata of the uterus. The tumor was large and lay in an oblique direction in the abdomen from the right ovarian region to the spleen. The operation was done under the usual precautions, and was not especially difficult. The time of operation from beginning to end was fifty-five minutes. Practically no bleeding occurred, the vessels being securely clamped and tied as the operation progressed. The uterus was amputated just above the cervix, and the uterine cavity appeared normal. The stump was then lightly drawn together with catgut sutures, and over this the peritoneum was sutured. No blood or debris remained in the pelvic cavity at the completion of the operation, and the patient left the operating table in splendid condition and quickly rallied from the effects of the anesthetic.

She was returned to the ward at 10 A. M., and by six o'clock the same day her temperature had reached 101° F. (38.3° C.), and her pulse, which had ranged between 80 and 90, suddenly ran up to 120 and 130 and became irregular. Her appearance was bad, the face was covered with cold perspiration, and the expression was drawn.

Under strong stimulation in the way of rectal enemata and whiskey and strychnin, the patient appeared to improve a little, but by the next morning the

pulse had almost disappeared. The abdomen was tympanitic and tender to pressure.

The symptoms were so rapid in their onset that the possibility of a secondary hemorrhage was seriously discussed.

At eight o'clock the patient was taken to the operating room and the abdomen reopened. There was no trace of hemorrhage. As soon as the stitches were removed from the abdominal wall a few drops of thin, yellowish pus exuded. On opening the abdomen, the intestines and parietal peritoneum were found covered with a very thin viscid layer of fibrin.

The abdomen was irrigated thoroughly and a gauze drain inserted, and salt solution was infused into the radial artery.

Patient regained consciousness, but died within an hour. Her temperature in the early morning hours reached 104.5° F. (40.2° C.).

Autopsy No. 595. Anatomical diagnosis: Laparotomy wound for hysteromyomectomy; wound infection; acute fibrino-purulent peritonitis; cloudy swelling of organs; fatty degeneration of heart, liver, and kidneys; hydronephrosis on the right side with early atrophic changes in the right kidney.

On cutting through the abdominal wall near the line of incision, yellowish-white pus exudes from the muscles and external to them. Over the parietal peritoneum in the neighborhood of the incision a fine deposit of fibrin is visible. The cellular tissues in front of the bladder are markedly edematous. The serous coat of the intestine is markedly congested, especially at points of contact. Fine and coarse flakes of fibrin are present on both small and large intestine, especially in the lower abdomen. The upper part of the abdomen and peritoneum covering the stomach, and the liver, are entirely free from exudate. Slight excess of serous fluid in peritoneal cavity.

Bacteriological examination: Cover-slips from the pus in the wound and from the peritoneal exudate show cocci, chiefly in pairs. Cultures made from the abdominal wound, the peritoneum, the kidney, the lungs, the spleen, and from the heart's blood show myriads of colonies of streptococci.

In such a case as this the vital resistance of the patient was poor and the virulence of the invading micro-organisms marked.

The next grade of infection is less rapid in the onset of its symptoms, and the course of the disease is more prolonged. Pawlowsky has designated this as the purulent hemorrhagic type.

The following case is a good example of this form: E. E. II., No. 6583, myomectomy, Jan. 23, 1893. An abdominal incision about 14 centimeters long was made, exposing a globular uterus choking the pelvis, with a tumor 8.5 centimeters in diameter in its anterior wall, and a similar nodule also 8.5 centimeters in diameter in the posterior wall. Incisions were made into these nodules, and they were enucleated from the uterine tissue, the cavities created were obliterated by buried and superficial catgut sutures; several other small nodules were also enucleated, and the abdomen was then closed by four series of buried catgut sutures. The duration of the operation was thirty-four minutes.

The next day the patient complained of severe stabbing-like pains over the

lower part of the left lung; the pain was increased on deep inspiration, the tongue was moist, slightly coated, and the abdomen was not distended.

Two days after the operation the pulse was rapid, 120 to the minute, but fair in volume; temperature, 104.4° . Her expression, however, was bad, and she was nansated at intervals during the entire day. The abdomen was now

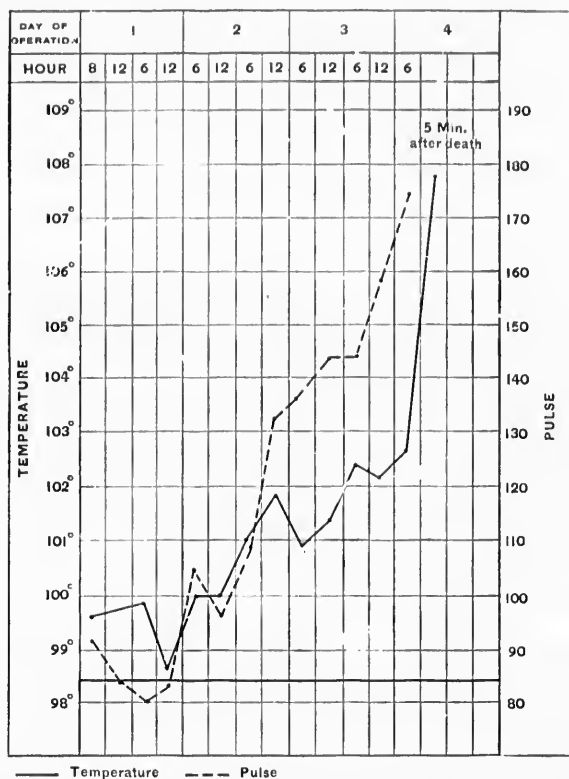


FIG. 329.—CHART OF A CASE OF SEPTIC PERITONITIS FOLLOWING MYOMECTOMY. DEATH ON THE FOURTH DAY. E. H. H., 6583.

tympanic and sensitive. On reopening the lower angle of the wound I was unable to find any evidence of suppuration. Three days after the operation the temperature rose to 107.8° and was quickly followed by death, with the patient conscious to the last.

Autopsy.—Anatomical diagnosis: Stitch-hole abscesses; purulent hemorrhagic peritonitis following laparotomy for myomectomy; myomata of uterus; acute splenic tumor; embolic lung abscesses; congestion of lungs; infection with streptococcus pyogenes and staphylococcus pyogenes aureus.

In the midline is a linear wound 12 centimeters in length, situated between the umbilicus and pubes; the lower angle is gaping, but the upper part of the wound is united. On incising the wound, a purulent, sanguineous exudate is found between the skin and the deep muscles, and the muscle wherever exposed is very red. On cutting through the stitches which hold the abdominal walls together, small accumulations of pus are found about the sutures, forming foci which can be readily distinguished from the general purulent infiltration of the wound. On removing some of the sutures, they are found covered with pus. The deep layer of sutures is likewise covered with pus.

The parietal peritoneum is injected, and on opening it an accumulation of bloody pus is found just beneath the incision. The omentum is adherent to the intestines and to the parietal peritoneum, rolled up, intensely injected, and covered with pus. The peritoneum covering the intestines is vividly injected, and the cavity contains about 500 cubic centimeters of blood. The greatly distended intestines are covered by a layer of fibrin and pus. In the pelvis, covering the superior surface of the uterus and filling up a large part of the cavity, is a mixture of pus, blood, and flakes of fibrin. Along the superior surface of the uterus a row of sutures can be seen, and on cutting into it there is a globular cavity about 2.5 centimeters in diameter filled with blood. On removing the superficial uterine sutures, pus can be squeezed from the cavities left by them. Both the anterior and posterior *culs-de-sac* are covered by a fibrinous exudate, which anteriorly is thick and hemorrhagic and can be stripped off from the peritoneum. The cavity of the uterus is normal. The tubes and ovaries are normal.

Bacteriological Report.—Cover-slips from the cutgut suture in the subcutaneous abdominal wound show numerous cocci arranged singly, in pairs or in bunches, and in chains. Some cocci are enclosed in polymuclear leucocytes. Cover-slips from the uterus, spleen, liver, and kidneys are negative; the small purulent abscesses in the lung contain myriads of cocci arranged in bunches and chains. The cultures show the presence of *staphylococcus pyogenes aureus* in the abdominal wound, in uterine muscle, kidneys, spleen, and liver, and also in the small purulent areas in the right lung. Cultures from the fibrin in the pelvis yield two organisms—a coccus and a bacillus. This coccus on agar rolls forms pin-point white circular colonies. Cover-glass preparations show it to be *streptococcus pyogenes*. On potatoes, bonillon, and agar-slant it gives the typical growth of *streptococcus pyogenes*. The bacillus proves to be *baeillus coli communis*; this organism is also found in the kidney.

If a patient is more resistant to the invasion of the infection, the character of the exudate assumes a distinctly fibrino-purulent character; if the case is a prolonged one, lasting for two to three weeks, the exudate is entirely purulent. The last form is the least virulent of all, but at the best is always a most serious condition. According to Pawlowsky, the first evidence of resistance to micro-organisms on the part of the peritoneum is the throwing out of the exudate. If

the progress of the disease is slow he states that the lymph spaces become occluded with the pyogenic organisms and inflammatory products, thus preventing the invasion of other organs with the infecting germ.

Modes of Origin of Septic Peritonitis.—These pyogenic organisms may find an entrance into the peritoneum in a variety of ways :

First, from the liberation during operation of infected matter, as by the rupture of a pelvic abscess which has been walled off by adhesions.

Second, from injury to the intestinal coat, which permits the direct escape of pus-producing germs from the bowel.

Third, micro-organisms may be imported into the peritoneum from without by the surgeon or his assistants on the hands, sponges, instruments, ligatures, or accessories. Furthermore, several of these factors may co-operate in the same case to produce peritonitis.

In a simple operation unattended with traumatism to the pelvic cellular tissue or viscera there is little to favor the growth of organisms, whereas in more extensive operations, when there is considerable oozing, or when hemorrhagic or other *debris* has been left in the peritoneal cavity, there is much greater danger, and this matter serves as a rich pabulum for the growth of even a few organisms which may have gained access.

Symptoms.—Septic peritonitis following an operation does not manifest itself until the germs have had time to multiply and excite some systemic reaction. The signs of this are both local and general, depending respectively upon the reaction at the point of infection and the absorption of toxic by-products.

The local reaction is a conservative effort on the part of Nature endeavoring to limit the infection, and consists in a gaseous distention of the intestines which produces a marked tympany and so increases the intra-abdominal pressure and opposes a mechanical hindrance to the distribution of the septic fluid. This phenomenon can be readily demonstrated clinically by injecting a colored fluid into a lax peritoneal cavity and also into a tense one; in the former the fluid will be found generally distributed throughout the cavity, while in the latter it will be localized in close proximity to the point of injection.

As a result of the reaction there is an exudate of plastic lymph thrown out at the point of infection, which agglutinates the surrounding viscera and so tends further to impede or to limit the extent of the infection. In all cases where the peritonitis is not general its limitation is due to these adhesions circumscribing and sealing it off from the general peritoneal cavity. A pus pocket may be formed in this way on the floor of the pelvis, or laterally around the stump of a broad ligament, or on the site of an amputated or enucleated myoma, or posterior to the broad ligaments.

In the rapidly fatal type of peritonitis the surgeon may hesitate between the diagnosis of hemorrhage, shock, and infection. In a case of virulent septic peritonitis following a simple exploratory incision for carcinoma of the peritoneum the patient died within twenty-four hours in a state of profound depression without one of the local

symptoms of peritonitis. Within five hours the toxic effects of the micro-organisms began to be manifest. The pulse at first rapid, rising from 10 to 20 beats an hour, grew irregular, and finally disappeared.

The thermometer indicated only a temperature of 101° F. (38·3° C.) in the month, and yet the patient complained of distressing internal heat, which was explained by the rectal temperature of 105° F. (40·5° C.). The heart sound was weak and irregular, the skin cold and clammy, and the fingers and hands assumed the typical appearance of the washerwoman's hands.

These cases present a picture of the most profound depression of all the vital functions. In the less virulent cases the systemic effects of the absorption of the toxic by-products is indicated usually by a chilly sensation or even a rigor, and the pulse becomes rapid, small, and wiry. The rise in temperature is often abrupt immediately after the chill, reaching 104° or 105° F. (40° or 40·5° C.), or it may not rise above 102° or 103° F. (38·9° or 39·5° C.).

After the first rise the temperature remains above normal, but the subsequent elevation is moderate, rising higher in the evening than in the morning, although the diurnal variation is not usually more than one or two degrees.

There is constant abdominal pain with paroxysms, recurring every few minutes and causing the patient to cry out. The appearance of the patient is characteristic; her face is pinched and drawn, the eyes are hollow, and the expression anxious; the skin is often dusky and the forehead is bedewed with sweat. In no surgical disease do we see a more typical Hippocratic facies than in septic peritonitis. Vomiting is one of the earliest symptoms and is frequent and persistent, the violent expulsive efforts causing severe pain throughout the lower abdomen, and especially in the line of incision. The contents of the stomach are first ejected, followed by yellowish or greenish bile, and this by a blackish fluid. Later the vomiting becomes more retching in character and only small quantities of fluid are expelled. The patient can no longer maintain the prone posture on account of the increased pain caused by the tension of the abdominal muscles, and either lies with her shoulders elevated and thighs drawn up or turns on her side with the body curved forward and the thighs flexed on the abdomen. The thirst is often consuming and insatiable, and is not relieved even by the ingestion of large quantities of fluid, which the patient constantly craves, regardless of the fact that drinking makes the vomiting worse.

The respiration is costal in type as the diaphragmatic movements greatly increase the pain. In the majority of cases the tympanites is extreme, although in some of the most virulent cases the abdomen may be quite lax.

Usually the symptoms of septic peritonitis appear on the second or third day after operation, and run a course of from three days to a week, or may even be prolonged to eight or ten days, depending upon the virulence of the infection, the resisting and eliminating powers of the system, and the limitation of the inflammatory process by local barriers.

All cases do not run the typical course just described. There may be marked variations in the most important symptoms; thus the pulse at the outset may continue full and strong and but slightly accelerated, failing only after two or

three days. Vomiting may only occur at intervals of a few hours, and the stomach may even retain all that is administered by the mouth. Just before death, however, a liter or more of the fluid may be ejected, demonstrating the futility of giving medicine and nutriment by this avenue. Such cases simulate at their outset the simple, frank, non-septic peritonitis.

In other instances the first symptom noted will be mild delirium, especially at night, indicated by a slight incoherence in speech, slowness of comprehension, or a peculiar somnolence. The cases in which the abdomen remains flat throughout the course of the disease are the worse forms of peritonitis in which there is no attempt at a local reaction, and the patients quickly succumb.

Prognosis.—Diffuse septic peritonitis usually terminates in death. The most virulent form will kill the patient within twenty-four or forty-eight hours, but death occurs usually within four or five days. If the pulse continues rapid and feeble, ranging between 140 and 160, and there is no abatement in the fever for two or three days, the prognosis is bad. In such cases the pain is usually severe, the vomiting persistent, and the patient finally dies in collapse. In less aggravated cases the patient may live for eight or ten days and then die of exhaustion.

A falling temperature and steady general improvement in the pulse indicate a favorable termination. In such cases there may be complete resolution, or a circumscribed collection of pus may remain as a sequel of the attack.

Diagnosis.—In typical cases the tympanites, the constipation, the fever, the rapid and feeble pulse, the peculiar facial expression, and the vomiting are so characteristic of the affection that a diagnosis can be made without difficulty. A rapid pulse, excessive pain, tympanites, or persisting vomiting, may mislead the surgeon temporarily, but these conditions will be differentiated from a septic peritonitis in the absence of the other symptoms.

Tabulated Symptoms of both Traumatic and Septic Peritonitis.—In view of the necessity of recognizing the essential points in the diagnosis of the two forms of peritonitis, I here tabulate the leading symptoms of both.

SIMPLE TRAUMATIC PERITONITIS.	SEPTIC PERITONITIS.
Symptoms follow directly upon operation.	Symptoms often delayed two or three days.
Pain often severe.	Pain intermittent and excessive. Absent in worse forms.
Tympany variable, generally not excessive.	Tympany excessive, in bad forms often absent.
Tenderness on pressure.	Tenderness on pressure excessive.
Vomiting occasional, but not as a rule excessive.	Vomiting frequent, protracted and retching in character, like that of seasickness.
Temperature only slightly elevated.	Temperature usually high, remaining elevated, with slight or no tendency to fall.
Pulse full and quickened, regular, not often above 120.	Pulse rapid, feeble, rate increasing, running from 130 to 140 and above.
Facial expression good.	Facial expression pinched, anxious.
Mind clear.	Mind becomes cloudy, muttering in sleep, tendency to delirium.
General appearance that of a patient not dangerously ill.	The general appearance that of one extremely ill.

Treatment of Septic Peritonitis—Prophylaxis.—As the most important developments in surgery of recent years have been directed toward securing aseptic conditions in and about the field of operation, an imperative obligation rests upon the surgeon to observe the most scrupulous care in keeping infectious material out of the peritoneum. To this end the field of operation, instruments, ligatures, sponges, dressings, and the hands of the surgeon and assistants must be sterile and must be maintained in this condition. It is only by observing these precautions rigidly that the surgeon is relieved of personal responsibility. Under such conditions all the simpler abdominal operations will run a favorable course.

When the operation is directed against encapsulated septic foci within the abdomen, such as pyosalpinx and ovarian abscess, the purulent mass should always, if possible, be removed without rupture; this can only be done safely when the sac is small and comparatively free. If the sac is large or adherent, it should first be emptied by aspiration and then enucleated.

Sponges and gauze which have become contaminated must be discarded, and fresh ones packed in around the mass before finishing the enucleation. After the free pus has been removed, the hole in the sac must be closed by a suture, and the surgeon and assistants must wash their hands. During the evacuation of the pus only the surgeon and one assistant who handles the sponges should come in contact with it, the first and second assistants avoiding contamination as scrupulously as possible. When the collapsed sac is loosened and lifted up I slip a gauze bag over it several folds thick, pull the draw string tight around the neck of the tumor, and hold it protected in this way until it is completely taken out.

If any septic matter escapes into the pelvis or gets into the abdomen, the lower or the entire abdominal cavity, according to the extent of the distribution, should be washed out with a normal salt solution at a temperature of 43.3 C. (110 F.). At the completion of the enucleation the peritoneal cavity should again be washed out with two or three liters of salt solution.

Many cases are obviated by draining pelvic abscesses into the vault of the vagina instead of attempting a trans-peritoneal enucleation.

Intestinal injuries occurring during the course of an operation must be carefully sutured at once, in order to secure accurate union of the serous and muscular coats of the bowel, and so prevent the escape of septic matter from the bowel into the peritoneal cavity.

The careful checking of all oozing must also be one of the cardinal principles in all these cases.

The danger of fluids in dead spaces in the peritoneal cavity has been recognized for many years. Sims believed that it was the serous discharge which developed some toxic principle while stagnating in the peritoneal cavity that caused the frequent occurrence of post-operative peritonitis, and for this reason he devised a cannula for insertion into Douglas's *cul-de-sac*, to drain the serum and blood as it was discharged from the injured tissues.

By the absolute control of all oozing we obviate the necessity for drainage, which is itself a cause of peritonitis.

Handling the intestines and the parietal peritoneum must be avoided as much as possible, and if the intestines are exposed they should be covered with gauze saturated with warm normal salt solution, which must be renewed as often as it gets cool.

The rough retraction of the walls of the abdominal incision with heavy metal retractors must be avoided. If there is the least question as to the thorough disinfection of the surgeon's or assistants' hands, rubber gloves boiled in soda solution, as first used by Halsted, must be worn.

In all operations where frequent sponging is necessary, especially if reef sponges are used, the assistant in charge of this duty should wear gloves, and it will be safer if all but the operator are similarly protected.

Sterilized white cotton gloves used in my clinic afford a sufficient protection for the assistants who handle instruments and ligatures, as they prevent the transference of any particles of matter from the hands to the patient. They must be sterilized after every use, or after any contamination.

In view of the possibility of limiting the infection and arresting traumatic inflammation in its incipency, the bowels should be thoroughly evacuated, for by this means the pelvic circulation is depleted and the absorption of extravasated blood and serum from the peritoneal cavity is promoted. The remedies suggested under the treatment of traumatic peritonitis may be employed at the onset of the symptoms of septic peritonitis, as the indications to be met at this time are the same in both conditions. The severity of the vomiting usually precludes the administration of purgative by the mouth, and often the enemata are repeatedly expelled only slightly tinged with fecal matter, and the bowels remain unmoved until death.

When the distention of the abdomen is not extreme the constant application of ice bags over the lower abdomen during the early stage is of value in limiting the inflammatory process.

Strychnin hypodermically may be given, in the dose of one sixtieth to one fortieth of a grain every hour, to sustain the heart and the nervous system. Morphine may be used for the relief of extreme suffering or when a fatal issue is unavoidable. Whenever the temperature rises above 38° C. (101° to 103° F.) sponging the body and limbs with cold or iced water will be of material assistance in limiting or reducing the temperature. The administration of food by the mouth is rarely of use, as it is usually vomited, or if retained it is not absorbed. If, however, the intervals between the attacks of vomiting are not too short, a half drachm of liquid food, such as milk and limewater, may be given every fifteen minutes with the hope that some of it will be absorbed. The strength of the patient must be maintained by nutritive and stimulating enemata every six or eight hours, according to the tolerance of the rectum.

Operative Treatment.—I heartily condemn the general rule of opening the abdomen as soon as a septic peritonitis is suspected. Often there is a mistake in the diagnosis, and with a little patience untoward symptoms will subside and the patient will recover without operation, and in other cases the operation is hopeless from the outset, and the patient succumbs all the quicker because of it.

I know of no class of cases in which it is more difficult to decide when to operate and when not to operate, and, in spite of a wide experience and a careful study of all the clinical signs in each case, I still occasionally make mistakes and open the abdomen to find no peritonitis where it was believed to be present, or, thinking the symptoms will subside, I wait until it is too late and the disease is beyond control. This liability to error is due to the fact that in its early stages a septic peritonitis may simulate a variety of simple complications, making a differential diagnosis absolutely impossible.

If any definite rule could be laid down by which we could recognize a septic infection in its incipiency, the rule would be to reopen the abdomen at once and clean out the peritoneum and close up the abdomen, or in most cases clean out and drain, with the exception of a small group in which absolutely all that can be accomplished has been done at the first operation. Such exceptions, for example, are incomplete operations and operations in which the patient is so exhausted that she can not possibly stand any further strain.

A septic peritonitis in its earliest stages must be distinguished from excessive tympany, excessive nausea, excessive pain, unusual torpor of the bowels, unduly elevated temperature, and rapid pulse on the one hand, and from hemorrhage and auto-intoxication on the other.

That surgeon will best differentiate his cases who unremittingly watches every symptom of the early convalescence and proceeds at once to meet any complication that may arise.

Two points must be well weighed in the decision in every doubtful case—in the first place the character of the operation, and in the second place the conditions surrounding the operation—that is to say, the character of the technique of the operation.

If at the time of operation the condition of the patient was bad and septic foci were opened up and the peritoneum widely contaminated, or if the intestines required extensive suturing, then the decision that a post-operative septic peritonitis is under way will be more readily adopted than in a case where these complications were absent, for the percentage of septic cases is vastly greater after complicated than after simpler operations.

Again, if the operation has been conducted under circumstances which prevented the carrying out of a satisfactory technique, as, for example, in an emergency case at the home of the patient, or, when the assistance has been poor, a septic peritonitis will be suspected, when in another case with similar symptoms the absolute assurance that the technique has been perfect in all respects will give the operator courage to persist in a purely palliative line of treatment.

A sudden severe intraperitoneal hemorrhage is marked by symptoms of rapid collapse, anemia, small vanishing pulse, and precordial distress with air-hunger. The sudden anemia and the remarkable rapid change in the pulse serve to distinguish this condition from peritonitis; in either case the treatment, so far as it relates to opening the abdomen promptly and controlling the disease, is the same.

In the event of a slow hemorrhage the signs become most distinct with the onset of a peritonitis, when the indication is also to open the abdomen and clean out the peritoneum.

Auto-intoxication by absorption of toxic elements from the intestinal tract sometimes closely mimics the severe forms of general septic peritonitis. The patient lies listless with a dark skin and sunken eyes, vomiting occasionally, with a quickened pulse, and some elevation of temperature and tympany which may be excessive.

The chief differences lie in the fact that the expression lacks the collapsed pinched look of peritonitis, the vomiting is not usually of the persistent and bilious character, and there is no progressive change from bad to worse. Any gases which pass and alvine evacuations are intensely fetid.

Other complications, such as tympany, nausea, pain, and sluggish bowels, are distinguished by the absence of the train of symptoms of a peritonitis.

The onset of a septic peritonitis is usually noticeable within the first thirty-six hours; the pulse rises 20 or 30 beats, the temperature goes up two or three degrees, tympany increases until the abdomen is distended as tight as a drum, and breathing is embarrassed; the abdominal pains recur at short intervals and vomiting increases in frequency, the stomach pouring out quantities of black bile. The bowels obstinately refuse to respond to every effort to secure a movement. There is soon a notable diminution in the quantity of urine passed, so marked in some cases as to induce the operator to think he may have tied a ureter. The expression of the patient shows that she is desperately ill, and in the later stages the appearance is that of collapse. In the worst cases the septic intoxication is so virulent that none of the reactionary symptoms have time to develop, and she dies without much vomiting, or any tympany at all, or any elevation of temperature. The pulse, quickened at first, breaks down suddenly and runs up to 150, 160, and on up beyond counting.

Whenever the patient is evidently going from bad to worse, and the symptoms point distinctly toward peritonitis, it will be best to operate at once.

In a doubtful case it is important to begin at once in the effort to evacuate the bowels by giving calomel in a dose of 3 or 4 grains followed by an enema of half a liter of warm water and soapsuds containing about three ounces of sweet oil and half a teaspoonful of turpentine.

Castor oil is sometimes a good addition to the enema, or a saturated solution of sulphate of magnesia may be given in a three-ounce mixture.

When the pain is excessive a small dose of morphia or codein in half-grain doses hypodermically must be used.

Preceding an operation for septic peritonitis the abdomen must be examined with the utmost care to discover any evidences of localized inflammation or suppuration. The vagina also must be examined for evidences of fixation of the cervix on one or both sides, or of any fluid accumulation just above the vaginal vault.

The discovery of a point of localization of the infection gives the operation a definite objective point and may limit its scope.

The sthenic type of case, where the infection is still localized, offers the best hope of a recovery after a secondary operation; in such cases there is evidence of a strong resistance to the infection, revealed principally in the pulse, which remains of good volume and advances in its rate but slowly, and the appearance of collapse is wanting. In suitable cases an examination of the abdomen will often reveal areas of hardness and fluctuation in the pelvis surrounded by tympanitic bowels. A vaginal and rectal examination shows the presence of hard masses on one or both sides, and sometimes of fluctuation.

There are, in general, two methods of procedure in the operative treatment of septic peritonitis—first, the evacuation of pockets of pus or fluid by a vaginal incision; second, reopening the incision to clean out septic fluids.

The first method is available in a small percentage of cases only, where an infection is localized on the pelvic floor. In such cases the incision may be made, when distinct fluctuation is felt through the vaginal vault. Preliminary to making the opening the vagina must be thoroughly cleansed; the patient is then brought to the edge of the table and a free incision is made posterior to the cervix, opening up the abscess, which is washed out and drained for a few days with iodoform gauze. A finger in the rectum serves to protect the bowel from any injury during the operation.

Where the infection is not clearly localized the better plan of procedure is to reopen the incision and so expose the wounded area in the pelvis, which is in almost all cases the focus of the infection.

The choice of an anesthetic, indeed the propriety of using any form of anesthesia, is a question of vital import. When the pulse is rapid and feeble—running above 135—and the patient is greatly depressed, no anesthetic should be given, or, at the utmost, but a few whiffs of chloroform when she begins to struggle after the incision is reopened. The production of complete anesthesia under these circumstances is often followed by heart failure, the pulse running higher and higher until it disappears. If the patient's condition permits the use of an anesthetic, chloroform is to be preferred to ether on account of its speedier action. A further objection to the use of ether is that cardiac failure, in a heart already depressed by septic poison, is more likely to follow the struggling and vomiting attending its administration than it is to occur from the depressing effect of chloroform.

At first only the subcutaneous and one buried silver-wire suture are removed from the lower angle of the wound—enough to permit the introduction of the index and middle fingers. The lips of the wound are separated by the finger, or, if too adherent, by introducing scissors, spreading the blades. Especial care must be taken in reopening the incision to keep in the median line, and not to dissect up the tissues on either side.

At the bottom of the wound appears the puckered peritoneum, with its continuous suture, which should be lifted up with the dressing forceps and cut.

Separating the peritoneum, the index finger is inserted, and if it encounters

adherent intestines, it is carried down under the abdominal wall and over the top of the bladder to the uterus and broad ligaments.

Pockets of pus are readily recognized by the finger tips, and the nature of the discharge can be further verified by noting the character of the fluid withdrawn on the fingers. If there is a large quantity of fluid confined under tension, it will gush forth from the incision as soon as it is opened. A small sponge on a holder may be used to remove this, observing the utmost care to avoid separating the coils of intestines adjacent to the purulent focus.

A gentle bimanual examination should be made before closing the incision, with one finger in the peritoneal cavity palpating through the adherent intestines, and the other, protected by sterilized rubber gloves, introduced into the vagina.

Other deposits are easily felt at the sides and broken open so as to discharge into the main cavity first opened.

Irrigation should only be employed when the infection is so widespread that it can not be removed in any other way.

Drainage is the mainstay in the treatment after operation; sufficient gauze should be loosely packed in to fill the cavity, leaving one end projecting from the lower angle of the wound.

If a generalized peritonitis is found the treatment must be even more radical. A sufficiently long incision to admit of easy access to all parts of the peritoneum is made. Quickly withdraw the coils of small intestines from the peritoneal cavity, beginning with the worst coils. Remove all or as much as is necessary of the small intestine, and place to one side, covered with gauze or towels, thus practically disemboweling the patient for the time being. Then thoroughly and systematically wipe out the peritoneal cavity with large pledgets of gauze wrung out of hot salt solution, paying especial attention to the pelvic portion. Next, the small intestine should be systematically gone over loop by loop, while still outside the abdomen, and rendered macroscopically clean by wiping with gauze compresses wrung out of hot salt solution. It is necessary to use a considerable amount of force at times, in order to remove adherent flakes of partly organized lymph. It should be done thoroughly and conscientiously, however, as upon this depends, we believe, in great measure, the success of the operation. It facilitates the cleansing process, as well as lessens the shock of the operation, if the wiping of the intestinal coils is carried on under a continuous irrigation of warm salt solution.

After being cleansed macroscopically of all foreign material, pus, blood, lymph, etc., the intestine should be replaced in the abdomen; if there has been any intestinal suture the worst or sutured coil is returned last, and left most superficial, in order that it may be the better drained by being packed about with gauze if necessary. The abdominal wound should then be sutured in the usual manner, leaving just room enough for the gauze drain.

Six cases of general septic peritonitis have been operated upon up to the present time by Dr. J. M. T. Finney, the originator of this method, and five of them recovered.

Fermentation and Septic Fevers.—"It is desirable to distinguish from septic peritonitis certain post-operative pathological and clinical states which arise independently of the invasion, either of the peritoneum or the body at large, by pathogenic micro-organisms; and it is further necessary to consider some of the more remote consequences of the development in the peritoneal cavity of pyogenic bacteria." The terms septic intoxication, septicæmia, and pyæmia are by some employed more or less interchangeably to designate certain symptoms arising from a bacterial infection of the body at large.

"Although septic intoxication can be separated more or less readily from septicæmia and pyæmia, the distinction between the two latter conditions, while important from a surgical standpoint and convenient from pathological grounds, is much more artificial."

In septicæmia small foci of degenerated cells and necroses of cells are often found within the viscera, and it is therefore not, as it is frequently described, a disease "without demonstrable lesions" in contradistinction to pyæmia, which invariably shows foci of suppuration and necroses.

Septicæmia and pyæmia may be but stages of one process, for in some cases pyogenic bacteria may gain entrance to the blood and circulate throughout the tissues, producing the characteristic symptoms of septicæmia. The process may be held in check at this point, or it may go on to the formation of focal necroses or suppuration in the viscera at some point remote from the original portal of entrance, with the attendant symptoms of pyæmia. Septicæmia and pyæmia are therefore but the generalization through the vascular system of the infection which has first been local; for example, septicæmia often supervenes upon a septic peritonitis in its later stages, and septicæmia or pyæmia may be the result of an infected peritoneal wound.

The organisms which most frequently produce septicæmia and pyæmia are the streptococcus, the staphylococcus aureus, albus, and citreus, the micrococcus lanceolatus, and more rarely the colon bacillus, the gonococcus, the capsulated bacillus of Friedländer, and the typhoid bacillus.

In surgical cases the last two organisms are rarely met with. Any of these organisms may produce either septicæmia or pyæmia, but the streptococcus is more likely to produce septicæmia when it is the infecting organism.

That the staphylococci are often present in local lesions without producing septicæmia or pyæmia is shown by the fact that they are frequently found in localized infections, such as stitch-hole and intramural abscesses, and rarely produce more than a local reaction, while patients infected with streptococci in the same situations rarely escape so easily.

The grave puerperal infections are most frequently produced by the streptococcus, and the slow convalescence in these cases with all the accompanying symptoms of general invasion or infection are well known.

There seems to be a larger variety of organisms which are capable of producing septicæmia than pyæmia, for instance the proteus vulgaris may produce septicæmia, but thus far it has not been found in a true pyæmia.

Some of the specific organisms which usually are the etiological factors in inflammation peculiar to them may under certain conditions give rise to septicæmia. Such examples are furnished by the micrococcus lanceolatus and the gonococcus.

That we can not take a particular pathogenic organism and say that it will invariably produce pyæmia or septicæmia is illustrated by the fact that the pneumococcus which produces in man localized inflammations, such as croupous pneumonia, etc., in animals tends to end in septicæmia.

Sapremia, according to the older conception of the term, implied that at some point in the body there was a focus of putrescent matter containing products of decomposition, and the absorption from this area gave rise to the toxic symptoms. In these cases the symptoms were supposed to be due to the absorption of toxins or ptomaines elaborated by the putrefactive bacteria, and not to the entrance of organisms themselves into the blood.

More recent investigators have shown that this theory is not tenable because all pathogenic organisms are capable of producing toxic substances of one kind or another which are injurious to life. The by-products of the putrefactive bacteria closely resemble in poisonous qualities those of the pathogenic bacteria, but in locally infected wounds the former are rarely met with while the latter are uniformly present. This forces us to ascribe the symptoms, frequently attributed to putrefactive intoxication, to the absorption of toxins elaborated by the more common pyogenic organisms.

For this reason the term "septic intoxication" is a better one under which to classify these symptoms, because it is sufficiently broad to include all conditions arising from the absorption of toxins produced by any forms of bacteria.

In surgical cases the chief agents of septic intoxication are the pyogenic cocci, to which may be added the bacillus pyocyaneus and proteus, perhaps the colon bacillus, and among the anaërobic forms, which more closely resemble the putrefactive germs, the bacillus aerogenes capsulatus, the importance of which has not yet been sufficiently appreciated.

The study of septic intoxication in human pathology is yet in its infancy, and sufficient discrimination has not been made by surgeons between the so-called sapremia and a form of intoxication which may arise from antiseptically treated wounds.

Under the name "fermentation fever," Bergmann, Billroth, and Volkmann have described certain symptoms due to the resorption of fermentation products or of aseptic tissue necrosis. Volkmann ascribes the rise of temperature after operations in which the wound remains aseptic throughout and after operation to the absorption of dead tissue. Bergmann invented the term fermentation fever for the mild febrile disturbances occurring after operations, believing that they were due to the absorption of fibrin-ferment. Edelberg and Angerer confirmed this theory by injecting blood or its products containing fibrin-ferment into animals, and found that it was invariably followed by a rise of temperature.

When viewed from this standpoint the common rise of temperature following all operations of any magnitude can be much more easily accounted for than on the ground of septic infection, for it is not probable that under the painstaking technique of modern surgery all wounds should be infected sufficiently to cause this increase in temperature, while few operations are so slight as not to cause more or less cell death.

The composite temperature and pulse charts which I have constructed of normal convalescence after abdominal operations show this characteristic rise for the first three days.

From a clinical standpoint I will classify the febrile disturbances due to fermentation and septic products under the following headings: 1. Fermentation fever. 2. Septic intoxication. 3. Septicæmia. 4. Pyæmia.

Fermentation Fever.—The rise in temperature produced by the absorption of fibrin-ferment and the products of aseptic tissue necrosis is usually slight and of but short duration. It is oftenest noted by the evening of the day of operation, and may continue from twenty-four to seventy-six hours. Obviously the febrile disturbances following a simple abdominal operation would be much less than in those cases where extensive traumatism occur.

This slight rise of temperature (see composite charts, Chapter XXI) may be considered normal and need give rise to no anxiety.

Septic Intoxication.—This condition, like fermentation fever, may arise shortly after operation or it may occur later when toxic products are produced in the course of a septic infection. In abdominal operations, where pus escapes from abscesses and gains entrance into the blood either through the wounded tissues or through absorption from the peritoneum, the accumulated toxic products which it contains may give rise to a marked febrile reaction. In one case in which I opened a pelvic abscess which contained no living organism, the temperature rose abruptly to 105.5° F. (40.8° C.) in a few hours, remained at this point for about two hours, and then abruptly dropped to the normal.

Associated with this febrile reaction are the usual symptoms of all fevers—dry tongue, thirst, scanty high-colored urine, flushed face, headache, and restlessness. If the symptoms are due to the temporary absorption of toxic products they disappear with the subsidence of the fever.

Until a marked amelioration of symptoms occurs, the surgeon will necessarily feel considerable anxiety, as these same phenomena occur in acute septicæmia. When the symptoms of septic intoxication arise three or four days after operation, the prognosis is more grave, because it usually indicates an active infectious process which has been generated in some part of the wound.

The symptoms in these cases are more gradual in their onset, as the accumulated toxins are not thrown at once into the system, as occurs when an abscess is ruptured, but by a more gradual process associated with the multiplication of the bacteria. When the septic intoxication is severe the systemic disturbances are usually initiated by a chill. The temperature rises more gradually, and may not reach its acme until three or four days. The patient loses her appetite, the tongue becomes furred and dry, the skin is hot and dry, and the tem-

perature may reach as high as 105° F. (40.5° C.), with slight varying remissions. The urine becomes scanty, high-colored, and ranges in specific gravity from 1025 to 1030. Restlessness, insomnia, and occasionally delirium, may accompany the higher rises in temperature. In fatal cases the patient often sinks into a lethargic condition, which shades off into coma, while in others the symptoms of profound shock predominate. The body is covered with a profuse perspiration, the extremities are cold, the pulse is feeble, fluttering, or intermittent.

The prognosis depends entirely upon the local septic process. If the system overcomes the infection, or its source is eliminated by surgical interference, the symptoms quickly disappear, otherwise a rapidly fatal termination may occur within a few hours.

The differential diagnosis between septic intoxication and septicemia can often be made by a bacteriological examination of the blood. Blood cultures and cover-slip preparations from the blood should be made; the presence of bacteria indicates septicemia.

The treatment in these cases is largely expectant; if the patient can retain fluids, pure water should be given in abundance; the use of the saline enemata, which should be given as a routine procedure after all abdominal operations, is of great service in diluting the poison and in assisting the kidneys to eliminate it rapidly. All remedies in these cases should be directed toward aiding the system to eliminate the poison.

Unless there is an active intoxication produced by poisons which are being constantly elaborated at some point and thrown into the system, the symptoms will quickly subside.

In all cases where toxic symptoms arise a few days after the operation, the dressings should be removed and the abdominal wound carefully inspected; if it appears healthy, a vaginal examination should be made to ascertain whether there is a local point of suppuration in the pelvis. In the early stages of the infection the local infectious process may be inferred from an increased tenderness or acute pain produced by the pelvic examination.

Where a gauze drain has been inserted, either through the abdominal incision or through the vagina, the toxic symptoms may arise from the backing up of infected fluids, the drain should therefore invariably be withdrawn sufficiently to ascertain whether there is any retained fluid behind it.

If nothing distinctive of sepsis is discovered the patient should be watched closely for the succeeding days when some point hitherto concealed may become sufficiently evident to localize it. If suppuration has occurred in the abdominal wall, it should be freely opened and repeatedly and thoroughly cleansed with peroxide of hydrogen. When suppuration is detected about the stump of an amputated uterus, or at the site of a pelvic operation, it may be reached and drained either through wide dilatation of the cervix or through a vaginal opening made in the manner described in the treatment of pelvic abscesses.

After the abscess has been opened care should be observed to keep the passage patulous until the cavity has filled with healthy granulation tissue. To

this end a doach should be given daily, the curved glass nozzle inserted well into the abscess cavity. This duty should be attended to by the surgeon, and should not be relegated to a nurse.

If the pulse shows signs of failure, infusions of normal salt solution should be given into the cellular tissue beneath the breasts, employing at least 500 to 1,000 cubic centimeters every twenty-four hours.

Sulphate of strychnin in $\frac{1}{60}$ to $\frac{1}{30}$ grain, depending upon the urgency for stimulation, should be given every two or three hours. Liquid diet should be frequently administered. The bowels must not be permitted to become constipated.

Septicæmia.—The same symptoms noted in septic intoxication are present in true septicæmia, but in the latter condition they are more marked and may tend much more rapidly to a fatal termination.

Septicæmia may arise within a few hours after an operation, from a severe form of mycotic peritonitis or virulent infection of the external wound, or it may come on days after from some localized focus of infection, such as an intramural abscess or a suppuration in the peritoneal cavity.

In an uncomplicated case of hysteromyomectomy, where I had every reason to believe that the operation had been properly conducted, the patient died within twenty-four hours of a virulent streptococcal infection. The symptoms were so severe, and so characteristic of profound shock, that the abdomen was re-opened, with the expectation of finding a post-operative hemorrhage. Another case died almost as quickly from infection of the abdominal wound with virulent streptococci. In both instances the infecting organisms were found in the blood before death.

Usually septicæmia does not run so rapid a course, but shows more or less variation of the symptoms. The temperature may remain uniformly high with slight morning remission, or it may show wide variations. In some cases the temperature may run a typically septic course for a few days, then drop to normal for a day or longer, and again resume its characteristic course.

The following are typical examples of septicæmia, in one instance following immediately after operation, in the other some days later.

S. W., 3304, colored, aged forty years. Diagnosis, myoma uteri. Operation, hysteromyomectomy, Nov. 28, 1894.

The operation was easy and uncomplicated, and the usual technique was carried out in every particular.

Day of Operation.—Returned to ward at twelve o'clock with a good pulse, 80 to the minute. No unusual symptoms following anesthesia noted until twelve midnight, when the temperature was 101.8° F. (38.8° C.), pulse 120 and weak, and she complained of nausea and great pain.

Second Day.—From midnight until morning the pulse steadily failed; at 4 A. M. it was 138, small, and difficult to count. At six o'clock, worse, temperature subnormal, body covered with cold perspiration, extremities cold, abdomen slightly distended, marked tenderness on pressure; the face was pinched and drawn, the tongue dry, and she lay in a profound lethargy. Under vigor-

ous stimulation and application of external heat the temperature rose to normal and the pulse improved slightly.

At ten o'clock the abdominal stitches were loosened, followed by an escape of bloody, purulent fluid; the stitches were then removed. Free pus extended down between the layers of the abdominal muscles and a small amount was found in the peritoneal cavity. Abdomen irrigated. A half liter of salt solution was infused into the radial artery. She rapidly declined and died at eleven o'clock, twenty-four hours from the time of the secondary operation and three days after the original operation.

Abstract of Autopsy Notes.—Autopsy No. 595. Anatomical Diagnosis: Laparotomy wound for hysteromyomectomy; wound infection,

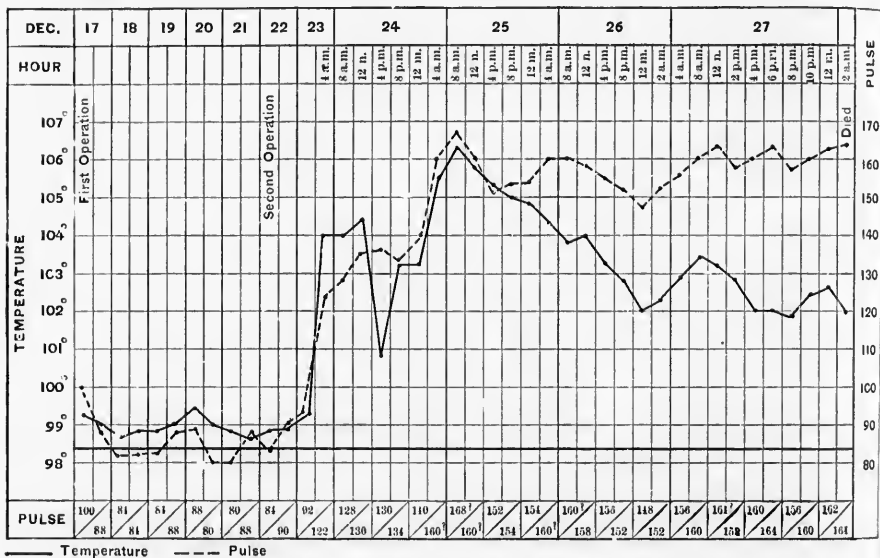


FIG. 330.—GENERAL SEPSIS FROM A FOCUS OF INFECTION IN THE VAGINA FROM A PERINEAL OPERATION.

Sixth day wound opened up and drained; death on the twelfth day. J. McG., 1896.

acute fibrino-purulent peritonitis, cloudy swelling of organs, fatty degeneration of heart, liver, and kidneys; hydronephrosis on right side with early atrophic changes in the right kidney.

On cutting through the abdominal wall in the muscles and external to them near the line of incision, yellowish-white pus exudes. On the parietal peritoneum in the neighborhood of the incision a fine deposit of fibrin is visible, and the cellular tissues in front of the bladder are markedly edematous. The serous coat of intestine is markedly congested, especially at points of contact; fine and coarse flakes of fibrin are present on small and large intestine, especially over the lower abdomen. The upper part of the abdomen and peritoneum covering the

stomach and the liver is entirely free from exudate. The cervical stump and the peritoneum covering it show nothing to suggest this as the portal of entrance of the infectious agent. A small amount of clotted blood exists beneath the peritoneum, which was stitched back over the stump.

Bacteriological Examination.—Cover-slips from pus in wound and peritoneal exudate show cocci chiefly in pairs.

Cultures from the abdominal wound, the peritoneal cavity, heart's blood, kidney, lungs, spleen, and ureter, all show myriads of streptococci.

The following case illustrates the course of septicemia of gradual onset and prolonged duration:

Gynecological No. 3110. A. M., white, single.

Diagnosis.—Pelvic abscess, universal pelvic peritonitis. Operation April 2, 1894. Enucleation of both ovaries and tubes and abscess sac. Complications, dense adhesions; escape of large quantity of fetid pus and free hemorrhage during the operation.

Incision 8 centimeters ($3\frac{1}{2}$ inches) long; the intestine was raised out of pelvis, exposing the uterus right latero-flexed and a large convex cystic mass filling

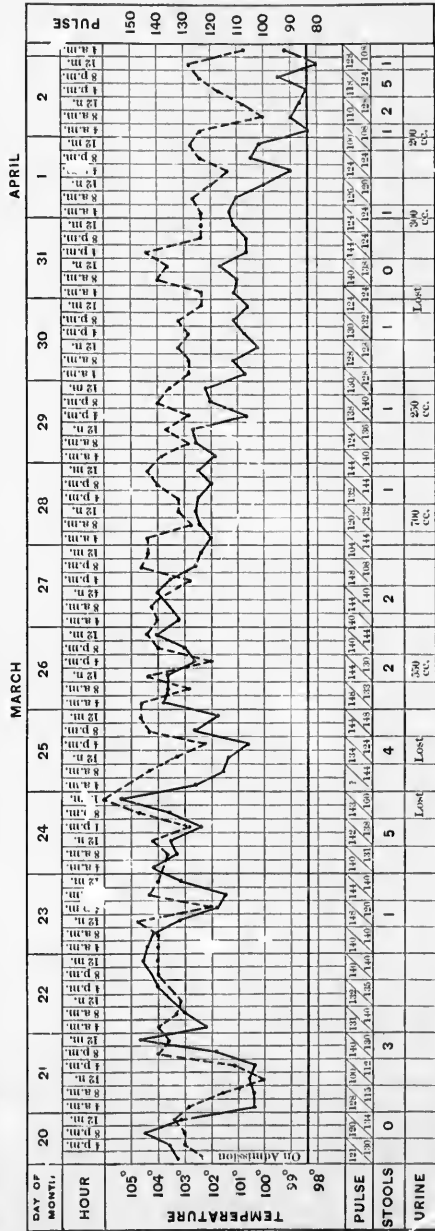


FIG. 331.—SEPTICEMIA FROM A URGENT PERITONITIS, SHOWING A TYPICAL PULSE AND TEMPERATURE RECORD IN A SLOW CASE OF THE DISEASE. U'PERPERAL INFECTION. A. K., MARCH 20, 1894. GEN. NO. 2653.

the whole posterior quadrant and posterior part of pelvis, between the uterus and the sacrum. The rectum covering mass all but small area—3 by 1.5 centimeters—was dissected off without injury. The abscess then broke with the escape of 250 cubic centimeters of fetid yellow pus, caught on sponges and gauze. The hole was sewed up and the enucleation continued; the friable tissue broke down, however, and was removed piecemeal, leaving an extensive bleeding surface on the floor of the pelvis. The ovarian vessels were ligated and the left uterine cornu excised and the vessels controlled by transfixion of the broad ligament low down. After checking the hemorrhage the mass was finally enucleated, with the internal iliac artery laid bare throughout its course. A pyosalpinx on the right side was then removed from a bed of dense adhesions. A gauze drain was inserted after thoroughly washing out the pelvis and abdomen with normal salt solution.

Second Day.—Dressings removed, covered with a large amount of pale hemorrhagic discharge. When the drain was loosened a copious discharge of brownish-red serum escaped; no distention of abdomen; highest pulse 100, and temperature 101.4° F. (38.5° C.) during the day.

Third Day.—About three fourths of the drain removed, followed by a profuse and somewhat offensive purulent discharge. Highest temperature 101.4° F. (38.5° C.), pulse 100.

Fourth Day.—About eight inches more of the gauze removed, followed by bloody purulent discharge. Temperature and pulse same as yesterday.

The general condition remained about the same until the thirteenth day, when the patient had a severe chill lasting half an hour, followed by a temperature of 105.6° F. (40.8° C.). The wound, although discharging freely, appeared healthy. Nothing abnormal detected by vaginal examination, and she complained of no pain. Temperature dropped to normal, where it remained until the nineteenth day, when she again had a severe chill with a temperature following it of 105.4° F. (40.7° C.) and a pulse of 144. Cold sponging used when the temperature rose. Vaginal douches (1-200) of bichloride of mercury solution. By the afternoon the temperature had fallen to 99.3° F. (37.3° C.) and pulse to 100.

Profuse sweating during the pyrexia. Later in the day had some headache. At midnight the temperature had risen to 101.6° F. (38.6° C.) and pulse to 108.

Twentieth Day.—Temperature at 10 A. M. 105.5° F. (40.7° C.), pulse 128.

Twenty-third Day.—Since last note temperature has ranged between 104.5° and 102° F. (40.2° to 38.9° C.) and pulse from 148 to 116.

This varying temperature suddenly dropped to 101° F. (38.3° C.) and pulse to 116.

From the twenty-third to the twenty-eighth day the symptoms gradually subsided, until the pulse and temperature again reached the normal.

The patient, who had up to this time presented the classical symptoms of a slow infection, now began to improve, but five days later had another febrile reaction, the temperature rising to 103° F. (39.5° C.) and the pulse to 120. The following day the temperature rose abruptly from normal to 106° F. (41.1° C.)

and the pulse from 90 to 150, preceded by a severe chill and followed by profuse sweating, nausea, and vomiting.

Three days later the temperature again reached the normal, and continued so until the patient's discharge on the fortieth day after operation. At that time she had regained her appetite and showed all the signs of a rapid return to health.

The prognosis in septicemia depends more or less upon the variety of the organism causing it and largely upon the immediate checking of its development by liberating the localized focus of infection in which it is generated.

In cases in which the blood cultures or cover-glass preparations show streptococci the prognosis is exceedingly grave, for patients rarely survive such an infection.

The staphylococcus aureus, while usually not dangerous so long as it is confined to a localized point, may prove very virulent when it gains entrance to the circulation.

The bacillus aerogenes capsulatus (Welch) is also a virulent organism, and usually produces death quickly.

Under suitable conditions the pneumococcus and colon bacillus may become fatal.

The treatment advised in septic intoxication should be carried out in septicemia. The greatest diligence should be observed in making a thorough examination of these cases in order to discover early the point of suppuration and to open it freely.

Pyemia.—Pyemia is a general infection characterized by the occurrence of metastatic abscesses in parts remote from the original point of infection, and associated with recurrent chills and intermittent fever.

Pyemia occurs in the course of suppurative processes and is due to the entrance of masses of bacteria or of infected emboli into the circulation, which lodge in other parts of the body and produce metastatic abscesses.

The symptoms are similar to those of a slow septicemia. The temperature shows a wide daily excursions, rising in some cases from normal up to 103° or 105° F. (39.5° to 40.5° C.) in the afternoon and then falling during the evening to or near the normal. The rise in the temperature is preceded usually by a chill, which is so regular in its periodicity as to give rise to the belief in some cases that it is of malarial origin. I see perhaps no more common mistake than that of ascribing irregular temperature and recurrent chills produced by purulent collections to malaria.

As the pyemic process increases in severity the chills which may have occurred only every two or three days now occur once or oftener daily. Following the cold stage there is a rise of temperature, which in turn gives way with the appearance of more or less profuse sweating.

The fever is always of an intermittent or remittent type, and in some cases the temperature may fall below normal in the intervals between the chills. The pulse in its fluctuations corresponds to the rise and fall of the temperature, varying between 100 and 150.

The patient is frequently nauseated and the appetite is poor. In severe cases delirium may be present, and occasionally the symptoms of a profoundly typhoid state appear toward the end of a fatal case. As the infection progresses a characteristic yellowish color of the skin appears, due to the destruction of the red blood cells. Albumen and casts usually appear in the urine, and when abundant indicate metastatic abscesses in the kidneys.

The symptoms of metastatic suppuration are varied; when multiple abscesses occur in the lungs they may resemble those of a broncho-pneumonia. Suppurative pleuritis, purulent pericarditis, or endocarditis may arise at any time and cause a rapidly fatal termination.

In acute pyemia the suppurative process is usually so rapidly fatal that only very small necroses and abscesses are found.

As pyemia is not a primary but a secondary infectious process superimposed upon the original localized infection, the prognosis is always exceedingly grave. Cases so affected die with few exceptions. The focal abscesses forming in parts inaccessible to operation sooner or later produce a fatal termination.

Treatment.—Under the aseptic treatment of wounds, pyemia has become one of the rarest post-operative complications. The treatment is unsatisfactory, because remedies have little or no effect in staying its progress. Stimulants and carefully regulated diet should be prescribed.

The wound from which the pyemic process has arisen should be freely opened, if accessible, and kept as clean as possible by frequent irrigations with an antiseptic solution.

Pleurisy.—Pleurisy is comparatively rare after celiotomy, but it does occur either alone or as a part of a septic infection. It is much rarer than pneumonia. One form of pleurisy is the tubercular, associated with a tubercular peritonitis; in this case the onset may be insidious and masked by the peritoneal symptoms so as entirely to escape recognition before operation.

Septic pleurisy, contrary to expectation, is associated usually with the milder grades of infection; it appears four or five days after the onset of the septic symptoms with an abrupt rise in the temperature, preceded by a chill and acceleration of pulse.

I have seen five cases of pleurisy in over twelve hundred sections; four of them were mild and readily passed off. The fifth followed a difficult operation for the removal of large multinodular, subperitoneal cystic myomata weighing thirty-nine pounds. The patient made a rapid uncomplicated recovery, until she sat up in a chair by the window, when she was seized with severe pain in the left side, accompanied with some quickening of the pulse and a temperature of 102° F. and friction râles. A week later there was a relapse with effusion. This quickly subsided, and was followed by complete recovery.

Symptoms.—The symptoms are usually quite characteristic; the patient complains of difficult and painful breathing on one side, accompanied by a short hacking cough. A physical examination shows a diminished respiratory movement and friction râles.

Treatment.—At the outset the pain may be relieved by a mustard

plaster, a turpentine stupe, or a blister. The cautery is a still better counter-irritant, lightly drawn six or eight times over the surface. Great relief follows the application, and often there is no more pain. If the cough continues and respiration is painful, adhesive straps may be used to immobilize the affected side. I have never seen a large effusion needing to be tapped. The best prophylaxis is to keep the patient well covered and out of currents of air during her convalescence.

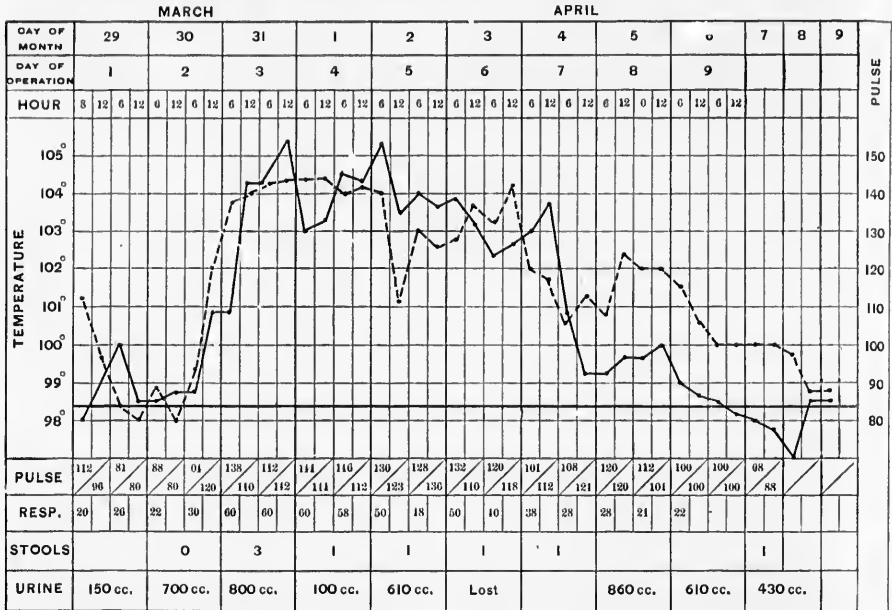
Pneumonia.—**Causes.**—Pneumonia following operations arises from exposure of the body during the operation, or from the irritating effects of an anæsthetic, or from the inhalation of foreign matter (inspiration pneumonia), or from the lodgment in the pulmonary capillaries of septic emboli from a focus of infection at the seat of operation. Pneumonia is often due to a prolonged and unnecessarily free use of the anæsthetic, and is distinguished from the embolic variety by its coming on within the first twenty-four hours. It follows the administration of ether much more frequently than of chloroform. I have only once seen pneumonia after the use of chloroform.

I have seen examples of the so-called non-septic pneumonia seven times in seventeen hundred cases; six times the anæsthetic used was ether, and once it was ether followed by chloroform; in this last case the patient was in good condition for four days, when the respiration and pulse became rapid and the tongue dry and brown. Mucous and gurgling râles were heard over the base of the right lung, which was consolidated. The diagnosis was confirmed at the autopsy.

In another patient (L. Y., No. 2677, March 29, 1894) a right ovary was removed containing pus, and the uterus suspended. On the second day in the evening the rectal temperature was 101.1° F. (38.38° C.), the pulse 110, and respirations 30. Bronchial breathing was found over the right base, contrasting with normal breathing on the left side. Resonance was good on both sides. There was no nausea. The temperature rapidly rose until the following morning, when it was 104.2° F. (40.1° C.), with the pulse at 140; on the evening of the same day the thermometer registered 105.4° F. (40.7° C.). The respirations were now 60, and the patient complained of much pain on inspiration. Three hours later she began to cough and expectorate rusty sputum, and had pain in the chest on deep inspiration. Her temperature continued the next day to 104.5° F. (40.7° C.); pulse 144, diæretic, full and bounding, and respirations 60. The upper part of the right lung now showed typical signs of consolidation. There was no distention of abdomen or abdominal pain. On the fifth day she was looking and feeling better, and had little cough; the lower lobes remained free; temperature 99.2° F. (37.3° C.); pulse 108 and full; constant improvement from this time on. The temperature was normal and the pulse 104 the next day. There was no abdominal complication throughout. The accompanying temperature and pulse chart shows the characteristic course of the disease.

The prognosis of a pneumonia resulting from an anæsthetic is favorable; it usually begins with a bronchitis and runs a typical course, soon reaching a crisis.

I have seen two deaths from pneumonia after operation, one the case of an old woman who had had a severe attack of bronchitis just before the operation, and from the ether was given by an inexperienced man who saturated the patient with the drug; the second followed a hysterectomy for carcinoma, and was severe from its onset, the patient dying on the fifth day from heart failure.



— Temperature - - - Pulse

FIG. 332.—CHART SHOWING AN ABDOMINAL OPERATION COMPLICATED BY PNEUMONIA.

Initial chill on the third day and crisis on the sixth day, with normal temperature on the ninth day. Op., right salpingo-oophorectomy and suspensio-uteri. March 27, 1894. L. Y., 9572.

In septic cases embolic pneumonia may arise many days after the operation, and, if mild, may terminate as an ordinary pneumonia. It often appears also simply as a concomitant of a general septic infection, when it is only one of the determining factors in producing a fatal issue.

Symptoms.—In septic pneumonia the symptoms come on gradually and are so closely associated with those of the general septicemia that they may escape notice. In two cases of pyemia under my observation disseminated patches of septic pneumonia were discovered at the autopsy, although a careful physical examination of the chest had failed to reveal the fact before death. The first symptoms usually appear four or five days or longer after the septic process is under way; there is a slight hacking cough, followed by mucopurulent expectoration, and more or less dyspnea, at times distressing in its severity. The character of the pulse, as a rule, affords no information as to the

thoracic disease, because it is already rapid from the toxemia; the physical examination is also unsatisfactory, for the isolated pneumonic patches often give no demonstrable signs.

The prognosis is grave, as the complication is but an evidence of the general infection.

Treatment.—The treatment of the simple lobar pneumonia is expectant and stimulant. At first it is well to give relief by controlling the excessive coughing with codein in doses of one fourth to one half a grain; this allays irritation without checking expectoration.

A cotton jacket to protect the chest is essential, and should be applied from the first and worn well into the convalescence. If there is much pain in the chest, the application of turpentine stupes and a mustard plaster will give great relief. The condition of the heart must be watched, and at any sign of failure stimulants must be given freely. A whisky eggnog affords both nutrition and stimulation; strychnin in the dose of one fortieth of a grain should also be given every two or three hours. On account of the risk of heart failure, absolute rest in a recumbent position must be enjoined.

In septic pneumonia the treatment should be of a vigorously supporting nature. In addition to strychnin and whisky or brandy, the most nutritious food in concentrated form must be given by mouth or rectum. Quinin in five-grain suppositories may be given night and morning, with apparently good effect in some cases.

Ileus.—Ileus arising after operation is the result of an interference with intestinal peristalsis by one of the following causes:

Either by the strangulation of a knuckle of intestine under a band of adhesion, or by an adhesion of the bowel to a raw surface, or by adhesions of the bowels among themselves about a septic focus, or by the incarceration of a loop of the intestine through a hole in the omentum, or, finally, by a simple twist of a loop of the bowel on its axis.

Symptoms.—The first sign of an ileus is a griping pain more or less localized over one area of the abdomen; it occurs in paroxysms and may recur every two or three minutes, beginning gradually and increasing to a maximum of intensity and then subsiding. At the onset of the paroxysm the patient assumes an expression of intense pain, and as the acme is reached she often cries out.

The peristaltic wave can be readily seen in patients with thin or medium thin abdominal walls, which are most distended above the obstruction. If the obstruction is partial, fluids and flatus are forced through with a gurgling sound, often audible at a distance from the bed. The tense muscular contraction of the peristaltic wave can be felt by the hand, giving at times the sensation of a dense fibrous tumor. After a paroxysm the patient lies prostrated, bedewed with a cold sweat.

One of the most important symptoms is the difficulty of moving the bowels. One or two passages may be secured at first from the lower bowel, but after this there is no further evacuation, and purgatives only increase the vomiting.

The nausea and vomiting are distressing from the beginning. The contents of the stomach are first ejected, and later, when the vomiting becomes more frequent and violent, the ejecta consist of small quantities of bile and mucus, followed by dark fluid with a strong stercoraceous odor, and at last by liquid fecal ejecta. The abdomen soon becomes swollen, tympanitic, and tender.

The patient is rapidly exhausted, and toward the last the vomiting may cease, but the gynecologist should not be misled by this delusive calm, as it is usually but a precursor of collapse. At the last the extremities grow cold, the eyes look sunken and the face pinched, while the pulse becomes rapid and shotty.

If the ileus is not speedily relieved, the patient may die either from exhaustion or from gangrene and peritonitis. Apart from a septic complication, the patient may live many days with an ileus, especially if the strangulation is incomplete. A woman in a weakened condition before the operation succumbs much sooner than one whose vitality is unimpaired.

Diagnosis.—That a correct diagnosis should be made at the earliest possible moment is of the utmost importance, as upon this hinges the immediate active treatment. First of all, ileus must not be confused with an aggravated tympanitis, which often gives rise to symptoms like those of intestinal strangulation. In these cases we find the abdomen swollen and tender, and the bowels at first resist all efforts to empty them, whether by mouth or by enema, and there may be too persistent nausea and vomiting. If to this we add the intestinal tormina common during the first few days after an operation, the picture of an ileus in its early stages seems almost complete. In tympanitis, however, the general pain is not often severely paroxysmal in character, the pulse is but little affected, the general condition is not that of profound depression, and there is an entire absence of the characteristic facial expression of ileus; finally, persistent efforts at evacuation of the bowels are followed by a copious movement. Until this is obtained there is sometimes ground for anxiety as to the correctness of the diagnosis.

The differentiation between ileus and peritonitis may be easy or it may be difficult, especially since both conditions may be present at once. The ileus in the case of infection arises from the adhesions formed about a septic focus, which represent a conservative effort to limit the spread of the infection. The rise in temperature and quickened pulse are here the most marked evidences of the complication. It must be remembered that an ileus may be incomplete, when the intestinal contents will be forced on in small quantities and the bowels may be slightly moved at intervals. Such a case is the following:

Ileus due to incarceration of a loop of small intestine through a hole in the omentum due to the Trendelenburg position.

The patient (M. C., 2193) was operated upon Sept. 11, 1893, for pelvic peritonitis, with cystic ovary and tubes bound down by dense adhesions. In placing her in the Trendelenburg position a loop of bowel slipped through a hole in the omentum and was not discovered in closing the abdomen. The next day she

complained of much pain in the abdomen and slight nausea; pulse, 92. Two days later, pain, distention, and nausea; bowels slightly moved on this and the following day. Two days later, pain not so bad; still vomiting. Slight fecal odor of ejection, intense thirst, less tympany; general condition improved; pulse, 100; temperature, 100° F.

Sixth day, vomiting. Stomach washed out, bringing 1.5 liters blackish fluid; nausea relieved. Abdomen greatly distended in epigastrium; tongue red, dry, swollen; much thirst and griping pains; small dark fluid movement. Ninth day, distention less; lavage daily, offensive ejection with fecal odor. Pain not much, but restless; flatulence marked; enema effectual yesterday and to-day. Eleventh day, almost constant pain, with frequent paroxysmal attacks not definitely located. Large fluid bowel movement. Thirteenth day, semi-formed involuntary movements. Sixteenth day, several movements and frequent vomiting, at one time 600 cubic centimeters dry fetid liquid; anxious expression; much thirst; tongue red and dry. Seventeenth day, abdomen opened above umbilicus, exposing greatly distended small intestines. Tense band found on left side, cutting across bowel and extending down to the left kidney. This was divided and an adherent knuckle of intestine freed from the left lower abdominal wall, with the escape of grumous fluid; counter-puncture with drainage of this area.

The patient died on the twenty-second day after the original operation, and the autopsy revealed a loop of intestine 25 centimeters (10 inches) from the ileo-cecal valve, projecting through an omental hole.

The following is a typical case of a late ileus due to adhesions between the small intestine and the uterus about the stump of a myoma:

The abdomen was closed without drainage. The patient made an uncomplicated recovery, and the sutures were removed on the seventh day, but on the twelfth day she began with a moderate tympanites and vomiting at long intervals. Peristaltic movements were noticed through the abdominal walls, but there was no pain as yet. There was a copious movement on the eleventh day. The pulse was good, the tongue moist, the temperature normal, and the general condition good. On the next day (the thirteenth) she had pain in lower abdomen, but seemed otherwise quite well. Fourteenth day, no movement since the eleventh day, in spite of eight grains of calomel, soap and oil and glycerin enemata.

As the abdomen became more distended and the pain increased with the constant gurgling, and a marked bulging was felt in the pelvis, she was put in the knee-breast position under anesthesia, and by compression and massage the liquid mass was gradually forced out of the pelvis up into the abdomen. This was followed by an evacuation and great relief until early the following morning, when the symptoms returned with stercoraceous vomiting.

I then opened the abdomen and found numerous coils of small intestines densely adherent about the pedicle. The coats appeared gangrenous, and were torn in detaching them, necessitating a resection of 15 centimeters (6 inches) of the bowel; she died five days later.

In uncomplicated ileus the temperature is but slightly or not at all elevated, while in peritonitis there is a definite febrile reaction.

In peritonitis a study of the chart will usually show an elevated temperature of longer duration; the pain is not focal but more diffuse, and lacks the distinctly paroxysmal character. The vomiting is also more continuous, and the pain is the result of the act and not independent of it.

Location of the Ileus.—It is important not only to diagnose the existence of an ileus, but as nearly as possible to locate its position. If the stoppage is in the rectum or in the sigmoid flexure, this will be evident by the more uniform distention of the abdomen and the less frequent retching and lessened pain. In most cases, however, the ileus is due to the pinning down of a knuckle of the small intestines to some point in the pelvis. In such a case the stricture or the adhesion will be found just below the mass of distended intestines. The seat of the obstruction, therefore, is not to be located in the distended gurgling mass of intestines, but in the flat, quiescent part of the abdomen below them.

The prognosis in these cases is always serious, but lessens in gravity the earlier the diagnosis is made. The surgeon is not justified in opening the abdomen before trying to secure an evacuation of the bowels by mechanical agents unless the symptoms are so pronounced that he can be certain of his diagnosis.

In eighteen hundred abdominal-section cases, I have reopened the abdomen four times for ileus; two of the cases recovered and two died. I attribute the successful results to the early diagnosis and operation.

Treatment.—Prophylaxis is the most important point in the treatment, as an ileus can often be prevented by the adoption of certain precautions and rules at the time of the original operation, which I would epitomize as follows:

1. All knuckle adhesions of the small intestine which are found must be released.
2. Adhesions binding the small intestines to the pelvic floor and walls must be freed.
3. All peritoneal bands must be severed.
4. Openings in the omentum must either be closed by suture or excised, or the omentum tucked up close to the colon, taking care at the end of the operation to see that no loop of bowel has slipped through it.
5. As far as possible, all denuded surfaces must be protected by peritoneum.
6. When the intestines have been lifted out they must be replaced carefully, restoring them with their mutual relations undisturbed; this is best done by floating them in water poured into the abdomen.
7. A sound omentum must be drawn down between the intestines and the abdominal incision to protect the former.
8. A loop of intestine twisted on its mesentery must be restored.
9. The pelvis must be filled after an operation as far as possible by rectum and sigmoid, to the exclusion of the small intestines.

General adhesions binding loops of intestines together in their normal mutual relations need not be broken up, as the peristalsis is not interfered with, and the extensive dissection serves no good purpose.

One way of covering in extensive raw areas on the floor of the pelvis, created by the enucleation of adherent tubes and ovaries, is to put the uterus over them in retroposition, presenting its smooth anterior face to the intestines above.

When the elevated pelvic posture is used there is always danger of a loop of intestine dropping into an adventitious opening in the omentum. For this reason the relation of the omentum and the bowels must always be looked into at the close of the operation.

The last steps before closing the abdomen are: First, to lift the small intestines out of the pelvis, and place in the pelvis the rectum and any redundant sigmoid flexure, so that if any adhesions form they will neither produce discomfort nor interfere with function; and second, to see that the small intestines are arranged in the lower abdomen beneath the omentum without any twisting on the mesentery.

Enemata and Medicines.—As soon as the signs of ileus are noted the efforts must at once be directed toward securing a free movement of the bowels by brisk purgation. To this end a large dose of calomel is given by the mouth, and high enemata of soap and water, with a drachm of turpentine to the pint, are given hourly. Rochelle or Epsom salts may be given in half-ounce doses every hour after the calomel.

To relieve the paroxysmal pains, turpentine stipes on the abdomen are valuable. If these measures fail at first it is best to wait a few hours and then try again, in case the patient is in good condition and shows no signs of weakening. If the vomiting is not frequent and the patient can retain and absorb nourishment, it is well to wait longer—even two or three days. If, on the other hand, the signs are urgent and there is a marked increase in pulse rate, with paroxysmal pains and persistent vomiting becoming stercoraceous, the indications are for an immediate operation.

Operative Treatment.—Every precaution must be observed to prevent shock. Chloroform is the best anesthetic on account of its rapid action, and the patient should be anesthetized on the operating table. Hot blankets must be wrapped about her and the external heat kept up by hot-water bottles. If the abdominal dressing has not been removed since the first operation, it will not be necessary to cleanse the abdomen again. Having noted as accurately as possible the position of the suspected ileus, two or more stitches are cut and the wound reopened. If adhesions are detected, a larger opening should be made if necessary to facilitate rapid work. The loops of the intestines are drawn out and laid on hot gauze and inspected. The operator must be slow to conclude that the ileus is due to a slight twist in the intestines, only accepting this as a cause after a careful search has failed to reveal more definite causes, such as strangulation under peritoneal bands, and adhesions in the pelvis. All adhesions must be handled with the utmost caution for fear of tearing off the coats of the bowel.

The site of the obstruction if not at once apparent, must be sought in an orderly way from below upward. The first point to inspect is the ileo-cecal valve. If the small intestine is collapsed here the bowel is then passed rapidly through the fingers until the border between the collapsed and the distended portion is reached, where the cause of the stricture will be found. After removing the obstruction between the collapsed and the distended parts of the bowels the abdomen must be closed at once. In one case the obstruction was in the rectum just above the ampulla.

When the intestine is adherent to the pedicle of a cyst, to the uterine stump, to the broad ligament, or to the abdominal walls, and there is danger of tearing it in the separation, the former structures to which it adheres must be sacrificed as far as possible and left sticking to the intestine, rather than risk a laceration requiring extensive suturing of the distended thin-walled bowel.

Separation of adhesions between loops of intestines should be done with the greatest care, and, in case an unavoidable injury to the muscular coat occurs, it should be repaired with fine silk sutures. The straight round needle threaded with iron-dyed silk is the best for this purpose. If the lumen of the intestine has been opened, it is usually safer to put in a gauze drain on account of possible sepsis.

If at the completion of the operation the patient is much shocked, the abdominal wound is best closed rapidly by silk-worm-gut sutures, including all the layers, and in urgent cases the superficial sutures between may be omitted. The patient should be put back to bed, stimulated, and kept warm.

It is not well to hasten an evacuation of the intestines after such an operation, as this will often occur spontaneously in twelve or twenty-four hours, if the ileus is relieved.

If the upper bowel has been sutured, most of the alimentation should be given by rectal enemata for five days after the operation, and only small quantities of liquid food should be given by the mouth. Where the rectum, sigmoid flexure, colon, or lower end of the ileum are involved I prefer to give all the food by the mouth. In any case foods should be selected which are almost wholly assimilated and leave almost no residue, or which do not tend to cause constipation or produce flatus.

Nature is our great assistant in these cases, for the adhesions between the peritoneal surfaces are rapidly formed and the injured parts protected.

In one case I tried suspending the patient by the heels, hoping that gravitation would drag the adherent bowel out of the pelvis. I also powerfully aided the suspension by an active bimanual manipulation of the intestines through the vagina and rectum, and rectum and lower abdomen. The facility with which the adherent coils could be felt and manipulated was remarkable, but the adhesions were so many and so dense that no impression was made upon them.

Stitch-hole Abscess and Suppuration in the Line of the Incision.—Suppuration in the line of the abdominal incision and stitch-hole abscesses usually appear within ten days after the operation, as the result of an infection which ends in

the formation of an abscess on one side of the incision or causes a separation of the lips of the wound. The defect in the tissue is healed by a slow process of granulation and cicatrization, and the result in some instances is a broad, stellate, unsightly scar.

These abscesses usually form in the superficial layers of fat, to which the infection easily gains an entrance by means of the skin sutures. Abscesses located close to the surface become quickly localized, point into the incision, or to one side of it, and discharge. They may give rise to such symptoms as slight local discomfort and slight elevation of temperature (see chart, Fig. 333), but they are often overlooked until a little pus, sometimes not more than a drop or two, is found on the dressing. When, however, the suppuration occurs in the muscular tissues, forming a true mural abscess, the symptoms are usually pronounced and

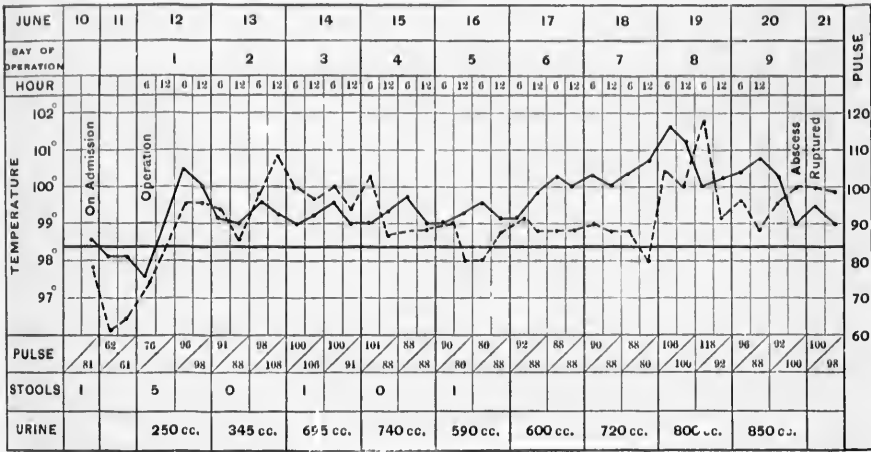


FIG. 333.—STITCH-HOLE ABSCESS CHART.

The chart shows a practically normal course until the sixth day, when a stitch-hole abscess begins to develop. There is a decided rise of temperature for three days, followed by an abrupt decline when the abscess ruptures on the ninth day. Op., hysteromyometomy, complicated by double pyosalpinx. Gyn. No. 4441.

progressive, and, if the infectious matter is not liberated early, may even end in death either through the extent of the abscess or by its discharge into the peritoneal cavity.

Grawitz, from experiments upon animals, concluded that a localized collection of pus in the abdominal wall communicating with the peritoneum could produce the most fatal form of peritonitis. Fortunately, however, the abscesses seldom follow this course.

In a series of seventeen hundred abdominal sections in the Johns Hopkins Hospital, three deaths from peritonitis were attributed to stitch-hole abscesses communicating with the peritoneal cavity.

Causes.—The limitation of this post-operative complication depends more upon the care observed in preserving the vitality of the tissues in the line of the incision and adjacent to it than upon the mere exclusion of infectious germs.

Unnecessary handling of the wound, rough retraction of its edges and prolonged pressure with metal retractors, carelessness in checking bleeding in the incision, strangulation of large bits of tissue by ligatures, and the use of sutures penetrating the skin in closing the incision, all conduce to the formation of stitch abscess.

In a prolonged or difficult operation the vital resistance of the skin and underlying tissues are often greatly impaired by the retractors. Every autopsy upon serious operative cases in which prolonged retraction has been made shows marked discoloration of the tissues not only of the abdominal incision, but also of the parietal peritoneum adjacent to the incision.

To avoid this bruising as much as possible, the incision should be long enough to permit of the freest manipulation and inspection of the field of operation without making undue pressure to expose it.

Every bleeding point in the incision must be checked, as, notwithstanding the greatest care observed in obliterating all dead spaces, small *lacunæ* are likely to be left behind, where blood may accumulate and offer a focus for infection. It is a good rule to tie every actively bleeding vessel as soon as it is cut. Ligatures of fine catgut, which are quickly absorbed, are the best, and only enough force should be used in tying them to stop the bleeding. Large areas of tissue must not be included in the ligature.

In one hundred and twenty-five cases of suspension of the uterus, only one case showed even a drop of pus. This is the most favorable of all operations, as all of the conditions requisite for perfect healing are fulfilled, there being a minimum of traumatism, no prolonged handling of the tissues, slight bleeding, and little danger of infection.

A noteworthy instance of a profound depression of the general system on account of a wasting or chronic disease, and a consequent failure in resistance to infection, is seen in carcinoma of the uterus. In 20 per cent of cases of abdominal hysterectomy for carcinoma in the Johns Hopkins Hospital, the abdominal wounds have showed some degree of suppuration.

Pus cases, contrary to the natural supposition of the clinician, are infrequently followed by a stitch abscess, which may be due to the immunization of the patient by the preceding septic process, but more probably depends upon the fact that most cases contain no living organisms.

The active infecting germs in the great majority of stitch abscesses are the *staphylococcus epidermidis albus* and the *staphylococcus aureus*.

The impossibility of ridding the skin of the *staphylococcus albus* makes it a constant factor to be feared as a possible source of infection in every case. While it is normally a feeble pyogenic coccus, under certain conditions it may become more actively pathogenic.

Symptoms.—The first symptoms are usually observed from four to five days after the operation. The patient complains of abdominal pains, and an elevation of temperature follows, while the pulse does not rise in proportion.

A severe rigor may be the initial symptom; the temperature, instead of falling normally, as shown in the composite chart in Chapter XXI, may rise even four or five degrees. The pain becomes more acute and localized in a day or so. These symptoms may continue several days, when, if the nature of the trouble has not been suspected, a sudden relief is experienced, and on opening the bandage, pus is found oozing in quantity from the wound or a stitch hole. If the infection is widespread, several stitch-hole abscesses are found, from each of which thick creamy pus may be squeezed. If the wound is inspected at the onset of the symptoms, a circumscribed red painful induration will be found at the foci of infection, limited to one side of the incision or about a suture. Later it may involve the entire wound and even occupy an area as large as the open hand.

After the pus has escaped the abscess may heal in a few days. In other cases the large wound cavity continues to discharge profusely for weeks.

It is possible (and this must always be borne in mind) that the discharge, instead of breaking through on the skin surface, may burrow into the peritoneum, where it at once produces a purulent peritonitis, and, on opening the abdomen, pus can be seen oozing out through the stitch-hole onto the peritoneal surface upon pressing on the wall.

All infections are not so severe as those just described, for not infrequently there is a small abscess in the superficial part of the wound, forming a shallow pocket not larger than the end of the little finger and containing a drop or two of muco-purulent discharge. These slight areas of infection are of no moment, and give rise to no symptoms.

Diagnosis.—The diagnosis is simple; inspection and palpation of the abdominal wall reveal a localized point of induration sensitive to pressure, exhibiting the classical signs of acute inflammation, heat, swelling, and pain. Only a deep-seated abscess between the muscles and peritoneum can confuse the diagnosis by simulating a localized infection about the pedicle of a pelvic tumor. The superficial induration and the localized pain are sufficient to remove the doubt.

As the symptoms may not always definitely indicate the real cause of the pain and elevation of temperature, it is important in all cases of post-operative fever to search for an abscess in the abdominal wall.

Treatment.—My experience with various methods of suture has convinced me that where it is avoidable a penetrating suture of the skin should not be used.

In a series of seven hundred abdominal section cases I employed a continuous suture for the peritoneum, and penetrating sutures of silkworm gut for skin, fat, aponeurosis, and muscle. Since the adoption of the method of suture described in Chapter XX, in which the peritoneum, aponeurosis, subcutaneous tissue, and skin are brought together by separate layers of suture, I find by a com-

parison of an equal number of cases of celiotomy closed in this way that the percentage of suppuration is far less than in the previous series. This improvement is no doubt due to the use of the subcutaneous suture and the freedom from strangulation of tissues.

When the induration about the infected area is first detected, one or two sutures in its immediate vicinity may be cut to relieve the tension and to facilitate the discharge of the pus.

Pain is relieved by the application of dry heat and the administration of Dover's powder. The bowels should be thoroughly opened. If there seems to be any obstruction to the escape of pus, a part of the wound should be separated with the forceps, under cocain. Poultices are not advisable unless the area of suppuration is large, because they tend to break the whole wound down. In cases where there is extensive induration of the tissue lateral to the incision, a flaxseed poultice, made up with 1-1,000 bichloride of mercury solution, may be applied there and kept warm by means of a hot-water bag. When the pus is near the surface, the inflamed area must be freely opened, either under the influence of cocain or of a few whiffs of chloroform. Judicious pressure at the side often materially assists the evacuation of pus.

The wound should be washed out with peroxide of hydrogen, followed by a half of one per cent solution of formalin, once or twice daily, and later, if the sides of the incision tend to gap, they should be gently drawn together with adhesive straps, until cicatricial tissue has been formed.

Nephritis.—Although acute congestion of the kidneys or acute nephritis are often assigned as the cause of death after surgical operations, I am unable to find a single record of such a case, either in my clinical histories or autopsy records.

In many instances a temporary increase in the amount of albumen and in the number of hyaline and granular casts, which have been present before operation, is noted, but in no instance has the patient showed signs of uremia.

In many of the fatal cases of peritonitis in which there was coincident kidney disease it is quite certain that the renal lesion has been a contributory cause to the death by decreasing the patient's vital force and thus permitting a bacterial invasion without resistance. This conclusion is brought out clearly by Dr. S. Flexner's recent researches upon terminal infections (*A Statistical and Experimental Study of Terminal Infections. Jour. of Exper. Med.*, vol. i, No. 3, 1896). His statistics are so striking that we must henceforth consider minutely the question of renal or indeed of any chronic visceral disease as a potent factor in opening the way for the easy invasion of the tissues by micro-organisms. In this manner the renal disease may be indirectly the cause of a fatal issue.

Dr. Flexner found in a series of 793 autopsies made in the Johns Hopkins Hospital that 255 were upon cases of chronic heart or kidney disease, or both combined.

In 213 of these cases of chronic disease the bacteriological examination yielded positive results, and the infection thus demonstrated was either local or general; the local infections are much more common than the general, and are

found in a large proportion of all cases of chronic Bright's disease, arterio-sclerosis, cirrhosis of the liver, and other chronic diseases. Affections of the serous membranes (acute peritonitis, pleuritis, and pericarditis), meninges, and endocardium are the most frequent.

Out of 29 cases of end-infections in chronic Bright's disease alone, 26 occurred in which the bacteria were present in some local situation; out of 85 cases of combined kidney and heart disease there were 66 of local infection, and out of 51 cases of chronic kidney disease associated with some other form of chronic disease, there were 35 localized terminal infections.

In 94 of these cases the infection was found in the following situations with the frequency shown:

	Cases.
Acute peritonitis	37
Acute pleuritis (without pneumonia).....	11
Acute pericarditis	23
Acute endocarditis.....	19
Acute meningitis.....	4

In reference to this group, it may be said that the micro-organisms found at the focus of inflammation appeared also in one or more of the organs of the body, but their distribution was not so general as to warrant the classification of the cases among the true septicemias.

The varieties of bacteria found in the peritoneum are shown by the following analysis, which also exhibits the portals of entry of the micro-organisms as far as they could be determined with a fair show of probability:

ACUTE PERITONITIS.

Bacteria.	Frequency.	Infection atrium.	
Streptococcus.....	8	Intestine.....	13 times.
Staphylococcus aureus and albus.....	9	Laparotomy.....	13 "
Micrococcus lanceolatus.....	4	Tapping abdomen.....	2 "
Bacillus aerogenes capsulatus.....	2	Pneumonia.....	3 "
Bacillus coli communis.....	3	Sloughing myoma uteri.....	2 "
Bacillus pyocyaneus.....	1	Pyelonephritis.....	1 time.
Bacillus proteus.....	1	Doubtful.....	3 times.
Bacillus anthracis.....	1		
Staphylococcus cereus flavus.....	1		
Streptococcus and staphylococcus aureus...	2		
Streptococcus and bacillus coli.....	1		
Streptococcus, staphylococcus aureus, and bacillus coli.....	1		
Streptococcus, staphylococcus aureus, and undetermined bacilli.....	1		
Bacillus pyocyaneus and bacillus coli.....	1		
Unidentified bacilli.....	1		

Suppression of Urine.—Following all operations, especially the graver abdominal ones, there is a marked diminution in the amount of urine passed in twenty-four hours, as has been shown in Chapter XX; it is, however, of little import and need occasion no alarm, so long as it does not persist and there are no symptoms of uremia.

After the first twenty-four or forty-eight hours there is a gradual increase in the quantity up to the normal about the tenth day.

In cases of continued suppression the diagnosis lies between nephritis and the ligation of one or both ureters. If nephritis is the cause, the urine shows a large amount of albumen and a greater number of casts than were present before operation, while if it is due to ligation of a ureter, the diminution in the urine will be associated with severe pain on that side radiating up into the kidney, and a microscopic examination of the urine will in some instances show blood cells. It is not practicable, on account of the condition of the patient, to catheterize or to sound the ureters after operation, consequently the symptoms and urinary examination afford the only criteria in making a diagnosis.

Acute nephritis rarely follows an operation except where there has been pre-existing disease.

The use of the high salt solution enemata immediately after every abdominal operation has assisted very materially in eliminating this complication by increasing the volume of urine and so lessening its toxic or irritant effects.

Treatment.—If the suppression of urine is due to an exacerbation of a chronic nephritis no time should be lost in beginning active treatment. The saline purgative must be given earlier than usual, and if there is decided or total suppression saline infusions beneath the breasts should be employed.

The injection of large quantities of salt solution into the subcutaneous tissues works marvelously well in some cases, because the increased capillary tension of the fluid acting upon the kidney starts the dormant renal function, and the suppression is rapidly overcome. Hot water or steam baths are not practicable in surgical cases, so that remedies must be given by the mouth and endermically. Pilocarpine in one-tenth-grain doses every two hours, and elaterium in one-eighth-grain doses, may be employed in the most serious cases.

In suppression due to ligation of the ureter there is but one treatment—re-opening the abdomen and searching out the ligated ureter. Unfortunately, the diagnosis of a ligated ureter is seldom made before autopsy, and consequently the necessary treatment is not applied. In my experience I know that I have ligated the ureters three times, and the accident has occurred in the hands of my assistants twice.

Urinary Fistula.—I have only seen two cases of urinary fistula complicating the convalescence from an abdominal operation. In one of these, after the enucleation of a densely adherent pelvic mass, it was necessary to pass a number of ligatures with a needle about bleeding points on the pelvic floor. In doing this it is quite certain that the left ureter was punctured, for a constant dribbling of urine began through the drainage-tube which lasted for several weeks without influencing the regular evacuation of the bladder, and finally ceased spontaneously. In the other cases, in evacuating a large abscess which filled the lower abdomen, I found the bladder fully 2 centimeters above the symphysis and cut through it accidentally. After evacuation of the abscess the thickened bladder walls were sutured together, but the sutures failed to hold in the diseased tissue and a urinary fistula resulted, which was many months in closing.

The occurrence of a fistula complicating the convalescence will be rare if the abdominal operation is skillfully performed and if the operator examines the entire field before closing the wound, when any injury to the urinary organs will be detected and corrected at once.

One source of fistula has been due to cutting a ureter the end of which was then brought out in the wound. This ought not to occur any longer with our better knowledge of the relations of the ureters to pelvic tumors and inflammatory diseases, coupled with our improved technique in ureteral anastomosis—uretero-ureterostomy and uretero-cystostomy. (See Volume I, Chapter XIII.)

Fecal Fistula.—Fecal fistula is one of the most annoying complications which can arise after an operation, on account of its disagreeable symptoms and its exhausting nature. Its prevention usually lies within the power of the operator, and when it occurs it is an evidence of defective technique.

The two chief causes are injuries to one or two or to all the coats of the bowel during operation, or to necrosis from pressure when a glass drainage-tube is used.

A fistula rarely follows injury to the peritoneal layer of the bowel, but when both the muscular coats and the peritoneal layer are involved it will almost invariably follow.

Fistulae almost always occur in the rectum or sigmoid flexure, owing to the contact of these portions of the intestine with all pelvic inflammatory masses, and the necessary traumatism in the enucleation of adherent appendages, pus sacs, or tumors.

Frequently a pelvic abscess tends to evacuate itself into the rectum, and if an operation is performed for its enucleation at the time when it is on the point of rupturing, there may be only a thin septum between the abscess cavity and the rectum. In such cases a fecal fistula may arise from the breaking down of this septum some days after the operation. In cases in which the fistulous tract has already occurred between an abscess and the bowel it is often almost impossible to close it on account of the dense adhesions and the friability of the surrounding tissues.

All injuries of the bowel must be sought out and repaired, and if there is the slightest danger of the sutured area breaking down, gauze drainage should be employed. If such an accident occurs after the abdomen is closed without drainage, there is imminent danger of a rapidly fatal peritonitis being induced.

If the injury has not involved the mucous coat, adhesions may form before the fistulous tract opens, thus obviating the dangers of general peritonitis.

In all cases where there is danger of a fistula, drainage should be employed. If there is an opening in the intestine which has not been closed, indications of the formation of a fistula will usually be observed within the first twenty-four to forty-eight hours. On changing the dressings the first time, a faint feculent odor may be observed, which becomes marked in character in a few hours, and if the intestinal contents be liquid, feces may escape into the dressings. In this event the dressings should be changed four or five times daily, and the surrounding skin washed with alcohol and anointed

with zinc-oxide ointment. This protection is especially necessary when the fistula communicates with the small intestine, as its discharge is excessively irritating.

During the next four or five days nothing should be done beyond keeping the parts clean, in order that the local adhesions should not be disturbed until they have securely walled off the fistulous tract from the general peritoneal cavity. At the end of five days the first effort should be made to promote the closure of the fistula by washing it out with a warm saline solution (6 per cent). The fluid should be injected into the rectum with great gentleness, and the wound watched until the solution wells up through it. At least one liter of fluid should be injected so as to cleanse the entire fistulous area, removing any large particles, and promoting the formation of healthy granulation tissue. These injections must be repeated daily, and often after a few days the discharge will grow less and the fistula gradually close. If the healing of the tract is prevented by a silk ligature, this should be sought out with a blunt hook and removed at a later date.

The fistula gradually contracts until its outer opening presents a puckered, roseate appearance, the purplish red granulation tissue forming a pointing red marginal ring. When the contraction of the tract reaches this point only fluid feces escapes, and when the bowels are constipated nothing but gas escapes. The escape of gas is most distressing to the patient on account of the odor and the possible noise. Frequently as the discharge diminishes the external opening is closed by a thin skin which breaks open again as soon as the intestinal pressure is increased. The deep ligatures occasionally become dislodged and escape, and so there is a temporary closure of the fistula, but, unfortunately, it usually breaks open again. In this way the patient may be disappointed in her hopes of recovery from month to month.

In cases of a persistent fistula the first effort of the surgeon should be to determine the position of the intestinal opening; in order to do this, inject water into the rectum; if it appears quickly in the external wound, the probability is that the rectum is the site of the inner orifice. This diagnosis may be verified by gently passing a probe down through the fistulous tract and then feeling for the end of it by a finger introduced into the rectum. If, on the other hand, the fluid appears slowly after the injection of a half liter or more of water, it is an evidence that the fistulous opening is higher up in the sigmoid flexure.

Treatment.—Healing is often promoted by the removal of retained ligatures, and for this purpose a crochet hook should be employed. When a loop is caught considerable force may be needed to extract it, and if this maneuver fails, delicate pointed scissors may be used to clip the loop.

After extracting all of the ligatures no further active treatment should be resorted to so long as there are any signs of improvement. Peroxide of hydrogen is a very useful agent in cleansing the tract and should be used daily.

The use of strong antiseptic and astringent injections are frequently advised, but I have failed to derive any benefit from them.

In the process of formation the fistulous tract is at first surrounded by delicate adhesions binding the viscera together and walling it off from the peritoneal cavity. Later these adhesions become organized and form a dense fibrous tube 1 to 2 centimeters ($\frac{3}{8}$ to $\frac{1}{2}$ inch) in diameter, and 6 to 10 centimeters ($3\frac{1}{2}$ to 4 inches) long, with a lumen a few millimeters in diameter and lined with granulation tissue, which often presents the appearance of mucous membrane. The tissue of the fistula is frequently so dense as to give the sensation of cartilage when cut with the knife.

If the fistulous tract persists after all local measures have been exhausted, it should be dissected out and the bowel closed by suture. The treatment of an old fistula by the radical operation requires the complete removal of the fistulous channel, and the severance of the tube from its intestinal attachment.

Before operation the abdomen should be cleansed with the greatest care, and the intestinal tract should be evacuated thoroughly by purgatives and copious enemata, given two hours before operation, and again immediately before the abdomen is cleansed. Sufficient fluid must be injected to cleanse the bowel so thoroughly that it returns from the wound perfectly clean. In this way the danger of feces escaping during the operation is largely avoided. But to make assurance doubly sure, after cleansing the abdomen the fistula is packed with iodoform gauze.

A semilunar incision 8 to 10 centimeters (3 to 4 inches) in length is made 2 to 3 centimeters to one side of the fistulous tract. This exposes the intestines, and the extent of their adhesions to each other, and their relation to the fistula may now be studied.

If the omentum is adherent above the intestines it should be tied off in small sections and released.

The length and direction of the fistulous tube, the density of the adhesions, the point of origin, whether high or low in the intestines, must all be determined carefully, as the prognosis in these cases depends much upon these factors.

When the fistulous tract is long and ends in the rectum, and there are dense adhesions surrounding it, the operation is most difficult and often results in failure.

Having made a careful examination and determined to continue the operation, a second incision is made on the opposite side, corresponding to and joining the first, thus surrounding the fistula by an oval incision. Two stout silk ligatures are now passed through the end of the tube and left long, to serve as retractors, while the intestinal adhesions are being separated.

Bandlike and velamentous adhesions can be severed with the scissors, while those that are dense and flat and bind the fistulous tract closely to the intestine must be dissected off, leaving, if necessary, part of the wall of the fistula adhering to the intestine.

By observing the greatest precaution the fistulous tract may be freed down to its point of origin with little or no injury to the bowels.

Having broken up the adhesions, the intestines should be packed away from the fistulous tract with gauze pads to expose the site of operation and protect the peritoneal cavity from any intestinal discharge which may escape upon severing the fistula.

A transverse oval incision is then made in the gut around the fistulous opening. The transverse incision is preferable to the longitudinal, because it is followed by much less contraction of the bowel, due to the suturing. If the fistulous opening involves a large part of the bowel it may be necessary to resect the bowel and do an end-to-end enterorrhaphy.

The opening in the bowel should be closed by sutures, in a similar manner to that described under intestinal injuries (Chapter XXXVI).

If the opening is large and the first layer of sutures does not close it with perfect accuracy, a sero-serous suture should be applied over this; or a loop of intestines, preferably the sigmoid flexure, can be brought down to cover the site of suture if it is in the rectum.

The latter maneuver is of the greatest utility, as shown by an autopsy on a patient who had died of purulent peritonitis. The case was one of pelvic abscess, which was densely adherent and released with the greatest difficulty. During the enucleation the rectum was lacerated, requiring three sutures to close it, and, as an additional precaution, the sigmoid flexure was drawn down over the sutured area. At the time of the autopsy, four days later, it was found that there had not been the slightest leakage from the rectum, notwithstanding the fact that the sutures had not held properly; for the sigmoid had become adherent, and had effectually protected the rectum with its peritoneal covering, and so excluded the contents of the intestine from the peritoneal cavity.

In no case should the loosely organized tissues of the wall of the fistula be utilized in closing the gut.

At the completion of the operation the peritoneal cavity should be carefully cleansed with salt solution, and a gauze drain laid down to the point of suture in the intestine; if possible, the drain should be brought out through the vagina. The sphincter ani should then be thoroughly dilated to facilitate opening the bowels as well as to prevent any considerable accumulation in the lower bowel.

Drainage may be dispensed with if the fistula is superficially situated and has been easily repaired.

Sometimes when the immediate result of the operation is a failure the new granulation tissue forming in the canal will, after a few days, completely close the opening with as good an ultimate result as though the primary suturing had held. The following case illustrates this means of closure: J. H., 2547, operated upon at her home in the country, April 7, 1891, for densely adherent double pyosalpinx. A glass drainage-tube was inserted, and the patient remained in bed two months and a half. About the third week fecal matter was found escaping through the drainage tract. Since then she has had chills off and on up to the present time (Jan. 30, 1894). Following these attacks there was intense soreness in the lower abdomen, accompanied by a profuse purulent and fecal discharge through the fistula.

Operation for fecal fistula, Feb. 1, 1894. At the lower angle of the abdominal scar is a fistulous tract through which a probe may be passed deep into the pelvis, and above the fistula is a prominent swelling produced by a hernial protrusion.

The operation consisted in an oval excision of the skin around the fistula, including the hernial sac. The sac and the indurated cicatricial ring around it were dissected out. The fistulous tract was then slowly detached and followed down into the pelvis 10 centimeters (4 inches), where it ended at the rectum. The intestines could not be separated from it at this point on account of the dense adhesions. The fistulous mass then broke off close to its entrance into the gut, where, on account of the dense indurated tissue, it was impossible to suture it satisfactorily; consequently a large gauze drain was inserted, in the hope that new forming cicatricial tissue would close the fistula. The abdomen was closed with interrupted silk-worm-gut sutures down to the drainage tract.

For four days subsequent to the operation the patient did well, no gas or fecal fluid escaping from the drainage tract. On the fifth a slight amount of liquid feces appeared; this discharge persisted for nine days, and then ceased entirely, no flatus even escaping through the fistula, and at the time of discharge from the hospital the abdominal wound was perfectly healed, and it has remained so since.

B. W. M., 3108, admitted Oct. 15, 1894, for intestinal fistula following hysteromyomectomy in 1892. Six months after the operation an abscess formed at the lower angle of the incision and ruptured externally, and six months later a silk ligature came away. On June 29, 1893, a number of ligatures were fished out of the fistulous tract with a crochet hook; in July another bunch was discharged. Several times a discharge of fecal matter came through the fistula, and in taking enemata the water escaped through the opening.

Operation, Oct. 16, 1894. Excision of the fistulous tract and suture of the bowel.

The fistulous orifice was cut out by a large oval excision of the skin and the old scar, opening through it to the abdomen.

No adhesions to the abdominal wall. An adherent loop of the ileum to the fistulous tract was separated by excising part of the wall of the fistula, and leaving it on the bowel.

The detached outer end of the fistula was now closed by sutures to prevent the escape of fecal contents, and when enveloped in gauze, it served as a tractor to draw the fistula up, as it was slowly dissected out of its bed of adhesions. Within the abdomen it hugged the anterior abdominal wall, and then entered the pelvis over the left brim and passed over the bladder to the sigmoid flexure, where the bowel was pinned down to the pelvic wall, bladder, and the old stump by dense adhesions. The fistulous tract was now dissected away from its vesical attachments, cutting loose an actively bleeding area on the vault of the bladder 3 by 2 centimeters, but sacrificing the wall of the fistula and not the bladder. After extensive dissection of the sigmoid flexure from its abdominal adhesions posteriorly, and freeing it back to the point where it crossed the brim of the pelvis, a

dense knotted mass was brought up and thought to be dense bladder adhesions. On dissecting this off with a view of sacrificing the bladder rather than the bowel, the uterine stump was found to have been separated and not the bladder.

The stump was excessively vascular, with a cavity in the center, where one silk-worm-gut suture and two or three small silk sutures lay. The fistulous tract was now found to communicate with the rectum by an opening 2 millimeters in diameter, around which for 3 or 4 centimeters a band of dense cicatricial tissue existed. All of the fibrous tissue was trimmed away and the hole in the rectum closed by one mattress and two straight interrupted sutures. The raw area about the fistulous opening was next whipped over with adjacent peritoneum by eight intestinal sutures. The pelvis was then thoroughly irrigated and a gauze drain inserted down to the site of suture, and a complete recovery ensued.

After such an operation the bowels should not be disturbed for four or five days, when a small oil enema, 150 to 200 cubic centimeters (5 to 6 ounces), may be given, with a mild purgative pill or cascara sagrada by the mouth, followed by a repetition of the enema in three hours; this will secure the desired effect without unduly disturbing the bowel and endangering the integrity of the intestinal suture by the increased tension.

Phlebitis.—Phlebitis in the femoral vein occurs as a post-operative complication in a little less than one per cent of all cases. I have had nine cases in twelve hundred operations, once double, beginning first in the left leg and then appearing in the right. It does not occur until two or three weeks after the operation—on the twenty-second day in five of my cases. The latest phlebitis I have seen after operation was on the twenty-sixth day. In all my cases the inflammation was mild in character, and I have never known a death to occur from this cause. The real danger in these cases is the dislodgment of an embolus, which may plug the pulmonary artery.

With this phlebitis of the femoral vein I would also associate a group of cases characterized by the same symptoms—pain coming on about two weeks after operation, elevated temperature and tenderness, passing off slowly—in which, however, the discomforts are felt entirely in the pelvis on one side and there is no evidence of any cellulitis or peritonitis upon making a vaginal examination. I have seen this affection then spread from the pelvic out into the femoral vein of the same side.

Symptoms.—The first symptoms are a rise in the temperature and quickened pulse, together with a deep-seated pain in the line of the inflamed vessel, and soon the leg becomes slightly edematous. The vein becomes hard, swollen, and cordlike, and has a peculiar knobby feel; its course may be marked by a dusky red line, especially if the superficial veins are involved. The edema subsides when the collateral circulation is established, often after some weeks. One of the most annoying symptoms is a lameness which may persist for many weeks.

Treatment.—The local treatment consists in keeping the limb elevated and in the application of cloths saturated with a warm solution of lead water and laudanum, or merely of warm fomentations. A slight flannel pressure bandage

is often of service in relieving pain. The Paquelin cautery lightly touched over the inflamed line often affords great relief. Spontaneous recovery occurs in from three to eight weeks.

Emphysema of the Abdominal Wall.—This complication naturally calls for anxious attention until its cause is definitely settled, as the prognosis of this condition is grave when the bacillus *aërogenes capsulatus* is the infecting organism.

In two cases occurring in my clinic, reported by Dr. W. W. Russell, air had evidently been forced from the abdominal cavity shortly after the operation into the tissues adjacent to the wound.

Winter and Madalener have reported similar cases; the latter, believing that the emphysema is due to the elevation of the pelvis during the operation, recommends lowering the patient to a horizontal position before closing the incision. Heil proved experimentally that when the deeper layers of the abdominal wound were imperfectly brought together emphysema might occur.

Although usually confined to a small area, the emphysema may involve the entire abdominal wall and chest. The air is forced out into the tissues between the skin and muscle, and never, as Leopold suggests, between the peritoneum and muscle.

The following case illustrates this complication :

N. W. W., 377 $\frac{1}{2}$, aged thirty-three; operation, Sept. 12, 1895, suspension of the uterus for retroflexion, with the pelvis elevated during the operation.

The incision was closed by three tiers of sutures—the peritoneum by a continuous catgut suture, the fascia by silver-wire mattress sutures, and the skin by a continuous subcuticular catgut suture. For twelve hours after operation the patient was violently nauseated and vomited several times; the bowels were well moved on the fourth day, and there was but slight pain during the convalescence. The highest temperature was 99.8° F. (37.6° C.), and the pulse ranged between 65 and 90.

The dressings were changed for the first time on the eighth day, when the right side of the abdomen was found sensitive but normal in appearance, while the left side was uniformly distended, sensitive, and yielded a distinct crepitus on pressure; bubbles of gas could be felt escaping from beneath the fingers wherever pressure was made; the union of the wound was perfect, and there was no evidence of infection of any kind.

In a few days the emphysema, which was first noticed to the left of the wound, had completely surrounded it, and then it spread in all directions under the skin, upward to the costal margin, downward to the symphysis pubis and Poupart's ligament, and laterally well into the flanks. The skin did not show any change, nor was any indication apparent beneath it. Cultures and cover-slips made from a small incision through the skin proved negative. When the patient left the hospital about five weeks after operation her general condition was excellent and the emphysema had entirely disappeared.

Since the discovery of the gas bacillus by Dr. Welch numerous cases of infection from this source have been reported.

The notes of a case furnished me by Dr. Bloodgood, resident surgeon in the Johns Hopkins Hospital, are extremely interesting when compared with the case above, as this is the first time the gas bacillus has been found in the abdominal wound.

S. R. Surgical No. 6102. Diagnosis, chronic appendicitis. Operation Feb. 17, 1897; removal of the appendix between the recurring attacks; the incision was made through the right rectus muscle, the adherent appendix was dissected free and excised, and the stump closed by suture; a large gauze drain was packed down to stump.

On the day of operation the patient returned to the ward with a pulse of 100; the evening temperature was 99.3° F. (37.3° C.); pulse 96. At 9.45 p. m. emphysema was discovered in the wound, extending out on the left side of the abdominal wall, and on the right side into a blood clot cavity. The material in the cavity was chocolate-colored and contained bubbles of gas, and the surrounding muscular tissue appeared necrotic. Great numbers of gas bacilli were found in the tissues and in the blood-clot. Cover-slips from the clot showed few leucocytes, a few red blood cells, and *débris*; the field was filled with large capsulated bacilli of three sizes. Numbers one and two were numerous, a few were in chains of five.

Second day: Patient noisy and restless all night. At 4 a. m., sixteen hours after operation, the temperature had risen to 104.4° F. (40.2° C.), pulse 144. At 8 this morning the temperature is 103.5° F. (39.4° C.); pulse 128; respirations 36, now and then intermittent, entirely thoracic. Patient has had no nausea and vomiting since he left the operating room. Small fluid reddish stool; cover-glass preparations from stool show great numbers of gas bacilli.

At 10.30 a. m. the temperature was 104.8° F. (40.5° C.); pulse 136; respirations 50. Wound opened and irrigated; 11 a. m., pulse 160, respirations 60; 12 m., temperature 105.6° F. (40.8° C.), pulse 160, respirations 60; 1 p. m., rapidly failing; died at 1.45 p. m.

Blood cultures taken immediately after death negative. Cultures taken at autopsy eight hours after death from all the organs showed myriads of the bacillus capsulatus *aërogenes*.

Whenever emphysematous areas are discovered about an abdominal wound, a small incision should be made in order to obtain cover-glass preparations and cultures. If *B. coli* or *B. proteus* is found, no time should be lost in opening the wound and irrigating it freely and packing with gauze.

In the case above reported the wound was freely drained, but, notwithstanding this means of exit, the infection proved rapidly fatal.

Sudden Death.—Embolism of the pulmonary arteries stands in close causal relationship to thrombosis of the pelvic and crural veins. Since the work of Mahler in Leopold's clinic has made clear the clinical signs and the underlying pathological conditions of thrombosis and embolism following gynecological operations, numerous cases have been observed and carefully studied post mortem, notably by Olslausen, Wyder, and Gessner (see C. Ruge's *Festschrift*,

Ueber tödtliche Lungenembolie, etc.). A thrombus is formed in one of the pelvic or femoral veins, is dislodged, and swept with the circulation into the pulmonary artery; if the thrombus is a small one the attack is characterized by precordial distress, pain, and dyspnea, associated with a quickened pulse; after one or more of these attacks the patient may recover completely. Lusk saw a case in which the lodgment of such an embolus in the lung was immediately followed by the rapid diminution of a marked edema of the leg (*Brit. Med. Jour.*, 1880, p. 843).

With the lodgment of a larger embolus the patient complains of pain in her side or under the shoulder blades, of suffocation and extreme precordial distress; she sits up in bed with an anxious expression, gasping for breath with all the auxiliary respiratory muscles brought into play, a cold, clammy sweat bedews the face, she becomes cyanosed, and the mind, at first clear, is clouded, and she may die in a few minutes, or indeed in a few seconds, as in the following case under my care:

The patient had been operated upon for a papillomatous ovarian cyst and extensive ascites. The enucleation was a difficult one, and some flat nodules were left scattered over the floor of the pelvis; she made, however, in every way a most satisfactory recovery until the fourteenth day. She had been propped up in bed during that day, and had felt no ill effects from it. When my assistant made the rounds that night she expressed herself as feeling unusually well, and consequently was in the best of spirits. She went to sleep early and rested well until twelve o'clock, when she awakened, complaining of a numb sensation in the left leg. The nurse, supposing that this came from a cramped position in bed, assisted her to turn over, and rubbed the leg vigorously for a few seconds. Suddenly the patient gave a sharp cry, and complained of frightful roaring in the head and a feeling of suffocation. The pulse quickly became weak and intermittent, the breathing spasmodic, and within a few seconds she died.

No autopsy was made, but there can be no doubt but that the cause of death was the lodgment in the pulmonary arteries of a detached embolus from some vessels about the seat of operation.

Whatever causes act to produce and to dislodge a thrombus are also effective in forming an embolus. Thrombi—that is to say, potential emboli—are formed by the prolonged pressure of pelvic tumors upon the pelvic veins, by anemia, by marasmus, notably that associated with carcinoma, by changes in the circulation, diminishing its force, particularly when due to heart disease, and by a local infection spreading through the walls of the veins. The immediate cause of the dislodgment of the clot may be found in an act of coughing, in a sudden change of posture, in straining at stool, etc.

I am inclined to think with Olshausen that an infection in the proximity of the vein, causing a phlebitis with its attendant thrombus, is the real cause in most cases, and I would attribute less importance to such conditions of the heart as "brown atrophy" and "fatty degeneration," although cases have been observed in association with a warty heart or a villous pericardium.

The symptoms in the following case are characteristic of the lodgment of emboli in the lungs, when death is not produced suddenly, but the patient survives one or more attacks.

Thrombi formed in the large veins of the broad ligament from which emboli were detached at varying intervals and lodged in the lungs, producing infarcts. The dyspnea was sudden in its appearance, and continued more or less aggravated until the patient's life was finally terminated suddenly by the lodgment of a large blood clot in the pulmonary arteries. The autopsy notes bear out the clinical symptoms. Infarcts and tumor metastases of varying ages were found, showing that the emboli were lodged at different times.

M. E. H., No. 2225, admitted Sept. 25, 1893.

For over a year she had been feeling tired and languid and not able to do as much work as formerly. Seven months before her admission she ceased to work on account of increasing weakness and a heavy, dull, pressing pain in the left ovarian region; four months later the abdomen began to increase rapidly in size, when pain was felt on the right side as much as on the left. Two weeks ago her feet and ankles began to swell, and about this time great dyspnea developed, and she was unable to lie down.

When first seen she was pale and anemic, her complexion sallow, and her eyes sunken; she had lost flesh rapidly of late. Bowels constipated, defecation painful; great dyspnea, especially on lying down. Pulse small, quick, and wiry. Locomotion difficult and painful.

The abdomen was found greatly distended, most marked to the left of the umbilicus and between the umbilicus and pubes; the skin was glossy and the tumor mass irregular; the largest portion was ovoid, and extended from the left flank down to Poupart's ligament, the second portion was continuous with the first, and extended from the left flank to the median line. Resonance in either flank, dullness and fluctuation over tumor masses. Marked edema of the legs below the knees.

Sept. 28, 1893.—Paracentesis abdominis, one liter of bloody viscid fluid removed, and the dyspnea relieved.

Oct. 8, 1893.—Patient began to suffer intensely with dyspnea this morning. Pulse quick and irregular, 130 to 140. Face pale and livid. Great pain in the lower abdomen. She can only breathe when propped up in bed, and lies with eyes shut and mouth open; the extraordinary muscles of respiration are all brought into action in breathing.

Oct. 15, 1893.—Abdomen again tapped, removing 360 cubic centimeters of dark coffee-colored fluid. Dyspnea still severe, but not so intense as when last noted.

Oct. 25th.—Twenty-three hundred cubic centimeters of bloody viscid fluid evacuated through a small incision.

Nov. 27.—Complains of great shortness of breath; pulse 130, weak and thready. Face livid, expression anxious, dyspnea marked.

Nov. 5th.—Since last note she has gradually failed, is restless, and the air-hunger is intense. She died suddenly at 7 p. m.

Autopsy 467.—Anatomical diagnosis: Sarcoma of the uterus, secondary in the lung; embolism of the pulmonary arteries; thromboses of the veins in the broad ligaments and the mesosalpinx; acute fibrinous peritonitis, acute fibrinous pleurisy, bronchiectatic cavities.

Uterus.—Cavity 13 centimeters in depth; on the right side the wall is 2 centimeters in thickness; the left side is continuous with a large tumor, which occupies the pelvis and extends 4 centimeters above the umbilicus. Continuous with the large tumor mass is another 12 by 18 centimeters, which occupies the right side of abdomen, beginning at the free border of the ribs and extending down into the pelvis.

On section of the tumor, its center is found to be necrotic and sloughing. The upper tumor mass is nodular, and presents on section a grayish-white color. It contains 550 cubic centimeters of brownish fluid in which flakes of necrotic tissue are floating. The inner wall is covered with sloughing masses of tissue. The veins of the broad ligament and mesosalpinx are greatly distended by thromboses which are generally red and not adherent; occasionally partly decolorized thrombi appear.

Lungs.—The pleura is covered with a thin layer of fibrin, and over the base of the lung are areas of intense injection or hemorrhage. On section, the lobe presents a granular appearance; the color is variegated and is predominantly red. Beneath the pleura are a number of areas more solid than the rest and more hemorrhagic in appearance, somewhat wedge-shaped, with the bases toward the pleura. In the upper and middle portion of the lungs is an area more solid than the rest, distinctly projecting; on section its center is hemorrhagic, its borders gray, and on slight pressure a thin puriform fluid escapes. Four centimeters from the base in the middle line is a circumscribed globular area, 2 centimeters in diameter, composed of a grayish-yellow friable tissue beset with hemorrhages. On removing this fissure a tolerably smooth base appears, on which a small amount of connective tissue and vessels are visible. In the base of the upper lobe is a circumscribed area coming to the surface of the pleura, which is covered with fibrin and small hemorrhages.

Pus can be squeezed from the consolidated area. The upper lobe is otherwise pale, slightly edematous, and its anterior edge emphysematous. The pulmonary artery supplying the upper lobe is occupied by a thrombus, the outermost parts of which are moderately firm, yellowish red; the interior is softer and darker. It is only slightly adherent to the vessel wall and can be followed into the branches for some distance. The branches to the lower lobes are also thrombosed. The branch to the middle lobe contains a similar thrombus, and the smaller branches are likewise plugged.

Left lung is collapsed, free from recent adhesions, the apex is retracted, and on section of the retracted portion three cavities separated by septa composed of grayish-red granulation tissue and a firmer tissue apparently containing cartilage. The pleura over the area is injected and the outermost zone of these cavities are formed by the pleura, whereas beneath them in the lung substance is a dense

grayish-white tissue. About the middle of this lobe near the root is another cavity larger than the others. In the lower lobe is a circular consolidated mass the size of a small marble, with sharp, distinct outlines. The pleura over this zone is highly injected, the center opaque. There is a thrombus mass occupying the pulmonary artery distributed to the lower lobe similarly to the right side.

Death from embolism has occurred after myotomy, removal of the tubes and ovaries for myoma, hysteromyomectomy, the extirpation of a carcinomatous uterus, exploratory incision for carcinoma, ovariectomy, ventrofixation of the retroflexed movable uterus, and curettage of the cancerous cervix.

Relatively the greatest number of cases has occurred after myoma operations, which exhibit so large a proportion as eighteen out of a total of forty-three cases (Gessner).

Aside from the clinical signs just detailed, Mahler lays great stress upon a persistent frequency of the pulse rate, which is out of all proportion to the elevation of the temperature. With the attack and the precordial pain and the dyspnea there is usually a rise in the temperature coincident with a rise in the pulse rate, but the temperature drops speedily while the pulse remains high for some days, due, it would appear, to the increased resistance and the elevation of the blood pressure occasioned by the plugging of one or more of the usual larger circulatory channels in the lesser system.

Treatment.—There is no treatment for the severe cases, but for those which are characterized by a succession of attacks and for cases which present any of the signs of thrombi, prophylaxis is of the utmost importance.

Wyder even declares that he will no longer undertake serious gynecological operations when edema is present with a high pulse rate and other signs of a recent thrombosis, provided the general condition of the patient will sanction a postponement.

The occurrence of such a frightful accident, even after so simple an operation as a ventrofixation, teaches anew the important lesson that the surgeon is never warranted in guaranteeing the recovery of the patient even after a seemingly simple operation. Patients whose vitality is depressed, and those who are anemic, should be watched with especial solicitude.

The dangers are increased if an edema before the operation has given evidence of a thrombosis.

The risk increases after the operation when local tenderness and elevation of temperature with a quickened pulse give evidence of the formation of thrombi.

All these cases should be guarded with especial care, kept longer in bed, and any active or straining movements rigorously guarded against.

The avoidance of an artificial anemia produced by excessive loss of blood during an operation, and the use of the subcutaneous saline infusions when it does occur, must also be looked upon as important prophylactic measures.

In case of phlebitis the limb should be kept well bandaged and quiet, and under no circumstances should any vigorous massage movements be made, as was done in the first case cited.

Death from Intestinal Hemorrhage.—In three cases of which I have cognizance death has occurred from the hemorrhage produced by an intestinal ulcer. One of these cases occurred in the practice of Dr. Thad. Reamy, of Cincinnati, another was related to me by Dr. Bela-Wala, of Budapest, and the third occurred in my own clinic, following an operation for a left pyosalpinx, containing from 20 to 30 cubic centimeters of pus, produced by a streptococcus infection. The patient was operated upon by Dr. H. Robb; the abscess ruptured in the enucleation, and she died in four days of an extensive intestinal hemorrhage with a septic peritonitis.

The autopsy showed the presence of a round ulcer of the duodenum 18 millimeter in diameter, with an erosion of a small vein 1 millimeter in diameter, while the large and small intestines contained immense quantities of soft reddish coagula, estimated at about 2 liters.

CHAPTER XXIII.

TUBERCULAR PERITONITIS.

1. Clinical characteristics.
2. Predisposing causes.
3. Symptoms.
4. Diagnosis.
5. Treatment. 1. Abdominal section: *a.* To remove focus of disease; *b.* To remove fluids; *c.* To release adhesions. 2. Drainage after operation for tubercular peritonitis.

TUBERCULOSIS of the peritoneal cavity is one of the most interesting and important affections the gynecologist is called upon to treat; it is interesting on account of the difficulty of forming an accurate diagnosis; it is important on account of its frequency as well as of the surprisingly successful results of surgical treatment. It owes its specific character to an invasion of the peritoneal cavity by the tubercle bacillus, which has usually gained entrance from some other infected point acting as a focus of distribution.

This form of tuberculosis exhibits, more than any other gynecological affection, a remarkable tendency to vary in its morbid manifestations—for example, in one case the disease occurs in the form of a few tubercular nodules scattered over the peritoneal surface of the uterine tube, or even limited to the tubal mucosa, but from this point in more advanced cases it may spread out over the neighboring peritoneum, which then looks as if peppered with little white seeds, most abundant about the mouth of the tube. Spreading farther from such a focus, the whole lower abdomen becomes involved, and both parietal and visceral peritoneum are studded with nodules, single or aggregated, from half a millimeter to several millimeters in diameter.

The appearances on opening the abdomen vary greatly, according as more or less abundant adhesions have been formed, or according to the amount of effusion of free or sacculated, bloody or serous fluid accompanying the peritonitis.

In miliary peritonitis the whole peritoneal cavity is uniformly studded with discrete nodules.

In the acute cases of tubercular peritonitis there is a noticeable congestion of the peritoneum, with fresh vascularized shreds of lymph hanging from the inflamed surfaces. The peritoneum is intensely red and thickened, and the neighboring circulation markedly affected, as shown by the increased hemorrhage from small vessels in incising the abdominal wall. The thickening of the peritoneum may be uniform, and may amount to several millimeters in chronic cases, so that the organ looks like a gray blanket covering all inequalities. The skin around the umbilicus has been noted to be red and edematous in a few instances.





FIG. 335.—TUBERCULAR RIGHT TUBE WITH TUBERCLE NODULES DISTRIBUTED OVER THE SURFACE OF A PAROVARIAN CYST.
 The ovary of this side was not removed. SAN. JAN. 22, 1897. NATURAL SIZE.

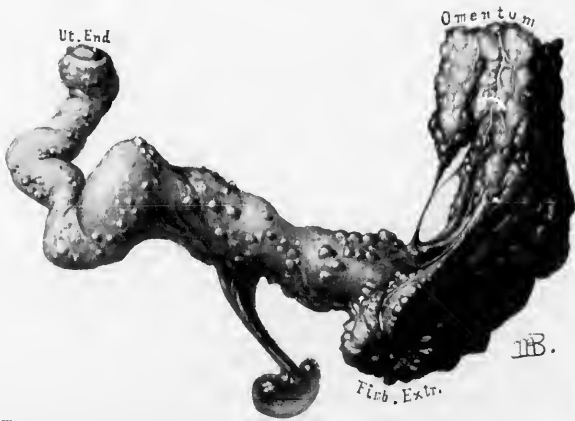


FIG. 334.—TUBERCULAR LEFT TUBE WITH ADHERENT OMENTUM. SAN. JAN. 22, 1897. NATURAL SIZE.

The very fat of the abdominal wall often betrays the nature of the disease, before the peritoneum is opened, by its unhealthy, pale, lusterless, sodden appearance.

Large sacculi of clear or turbid serous fluid are sometimes found in the pelvis or in front of the intestines, and smaller sacculi may be found walled off among them. I have seen abscesses of varying size; one of the largest containing several liters of pus, was situated just beneath the abdominal wall, and extended from the symphysis to the umbilicus.

The omentum in a mild case may be found simply covering in the pelvis, to which it adheres around the borders of the superior strait, or it may adhere by its free border to the anterior abdominal wall. It undergoes extraordinary changes in some advanced cases, contracting and thickening with the deposit of tubercular masses, until it finally forms a thick, solid roll lying across the abdomen from right to left, attached to the transverse colon. The mass is tympanitic and may seem quite movable. In a case of Dr. William Gardner, of Montreal, cited by Osler (*Johns Hopk. Hosp. Rep.*, vol. ii, No. 2), a hard tumor felt down in the right iliac and lumbar regions proved at the operation to be the omentum.

The intestines often adhere lightly to one another and to the pelvic structures; at other times the adhesions are so extensive as to present the peculiar appearance of a large sac, which might easily be mistaken for a cyst, and the attempt made to extirpate it. Close inspection of this sac, however, will reveal fine lines where the coils of intestines are agglutinated, often distinctly marked out by a little deposit of lymph, looking like a white thread on the red surface. I have seen this line everywhere parallel to the line of union of the intestinal coils, but a few millimeters distant from it, showing that the intestines had been pulled away by peristaltic movements, after its formation.

In event of any uncertainty the true nature of this sac may be revealed upon striking a sharp blow with a finger, which sets up a faint vermicular motion.

In a case of extensive tubercular disease which I saw in 1885, I was much embarrassed upon opening the abdomen and removing the fluid to find a large red sac filling the lower abdomen, with its pedicle apparently attached to the posterior abdominal wall. A close inspection revealed the sinuous white lines spoken of, on the surface, and on tapping the sac lightly with the finger a distinct peristaltic wave was started, showing that it consisted of the entire mass of the small intestines. The fluid accumulated in the peritoneal cavity was drained out, and the patient recovered and is living to day.

Tuberculosis of pelvic origin may be associated with a variety of other diseases. In one of my cases, for example, there was a miliary tuberculosis of the left tube, and a dermoid cyst of the right ovary 3 centimeters in diameter. In another case there was an ovarian cyst on the left side about 12 centimeters in diameter (5 inches), and an extensive peritoneal tuberculosis, covering the outer surface of the cyst as well, with effusion. In still another case a tuberculous tubo-ovarian abscess contained gonococci.

Etiology.—The cause in all cases is the invasion of the peritoneum by the tubercle bacillus, which finds in the serous surface a suitable pabulum for germination. The mode of invasion is often difficult to determine. In the cases seen by the gynecologist the proximal avenue is usually by the uterine tube, and in many instances it is quite clear that the disease has reached the tube by the vagina and uterus, because the tubercular lesions are also found in these organs.

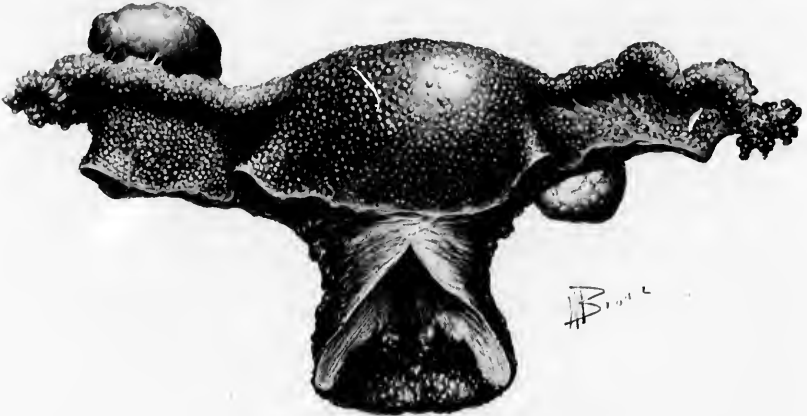

FIG. 336.—GENERAL TUBERCULAR PERITONITIS.

Showing the way in which the uterus, tubes, broad ligaments, and ovaries are studded with tubercles. There is also a commencing tuberculosis of the tubal mucosa. The case is also complicated by a coincident epithelioma of the cervix. July 24, 1895, No. 513. $\frac{2}{3}$ natural size.

Cases of dissemination of the tubercles over the peritoneum may also occur from a broken-down mesenteric gland, or by extension from tuberculous intestinal ulcers.

Miliary tuberculosis involving all the organs of the body may arise from a cheesy thoracic gland opening into a vein and distributing its products throughout the whole system. With this affection we have nothing to do.

Predisposing causes are not easy to determine; in a series of sixteen cases of my own, the family history was good in twelve, tuberculous in two, and cancerous in two.

A previous depressed state of health does not seem to be such an important factor as one would naturally expect, for out of nineteen of my cases, fourteen were well until taken with the present illness, and but five stated that they were previously in ill health.

There is also a wide variance in the histories that are presented as to the time of onset. Six patients out of twenty-one definitely dated their illness from a miscarriage or a labor, two others fixed the beginning of their disease at a period between two and three weeks before applying for relief, six others dated it back some time between three months and a year, and six more from one to seven years; one could not fix any time.

Pregnancy shows a definite causal relationship which has not been adequately noted. Twenty-eight per cent of my cases definitely dated their ailment from a miscarriage or a labor.

Of the married women, 29.41 per cent remained sterile and 11.76 per cent miscarried every time; 41.17 per cent were sometimes delivered at term and sometimes had miscarriages, while but 17.64 per cent always went to term. To the ten child-bearing women thirty-five children were born—an average of 3.5 each—while nine women had twelve miscarriages; one of the mothers bore eight children.

The following history of a patient whom I saw in consultation with Dr. L. M. Sweetnam, of Toronto, is quite characteristic of this group of cases: A woman in the twenties, previously in perfect health, had a mechanically induced abortion between the second and third months; within a month she went to bed with peritonitis, and remained there four weeks. For a year after this she suffered abdominal pain in walking, and had frequent elevation of temperature while going about, sometimes rising over 105° F. (40° C.). When the abdomen was opened the intestines were found extensively and densely adherent, and there were two pus sacs present. Nothing was removed, but 4 grams of iodiform were introduced and distributed through the abdominal cavity, and for twelve months the temperature remained practically normal. Eight or nine months after this the patient had a subacute left pleuritis, and three months later she died of typical acute tubercular meningitis.

The tendency of the disease is either to run an acute course and subside, leaving behind pelvic adhesions involving tubes, ovaries, and uterus, or to assume a chronic phase with exudation or the production of fibroid tissue.

The fact must not be lost sight of that some of the cases which reach the surgeon's hands have passed the period of danger from extension of the tuberculosis, and the relief desired is for the sequelae of the disease.

Contrary to expectation, grave tubercular disease of other organs is not common, not even of the lungs—in fact, the presence of tubercular peritonitis of pelvic origin seems often to afford an immunity to tuberculosis elsewhere. I have seen but four cases of extensive tubercular pelvic disease associated with advanced lesions in the lungs, two of them in a series of twenty-two cases, and it was not possible in either case to determine upon the primary focus of invasion. In one of my cases I drained an encysted tubercular peritonitis and the patient recovered, and died a year later of phthisis.

I do not here refer to cases of tubercular peritonitis arising late in the course of pulmonary or intestinal phthisis, for these do not often come into the hands of the gynecologist for treatment.

Only one patient had pleurisy, although pleurisy with or without effusion has been frequently noted as a common complication. I have never seen either lupus or tubercular joints or tubercular rectal disease associated with peritoneal tuberculosis.

A markedly predisposing factor is found in the age of the patient. The young and the old are comparatively immune from tubercular peritonitis of

pelvic origin, although it is quite common in young children from other sources. The average age of twenty-nine of my cases was 27.59 years, the oldest being forty-seven, and the youngest a black girl of seventeen; the youngest white woman was thirty.

Dr. William Osler (*Johns Hopk. Hosp. Rep.*, vol. ii, No. 2, p. 70) has analyzed 346 cases, male and female, according to age, with the following result: Under ten, 27; between ten and twenty, 75; from twenty to thirty, 87; between thirty and forty, 71; from forty to fifty, 61; from fifty to sixty, 19; from sixty to seventy, 4; above seventy, 2.

It still remains a question whether race exerts an influence on the relative frequency of the disease. In my clinic of thirty beds, in which six were occupied by blacks, twenty-nine cases are recorded in the course of five years, of which eleven were in the blacks.

It would appear from an analysis of my cases that there is some difference in the average age at which the disease attacks the two races: out of my twenty-nine cases, the average age of the white women was 29.55 years, while the average age of the blacks was but 25.63. Sixteen of the twenty-nine cases were between twenty and thirty years of age.

The general appearance of many of these tubercular women on admission to the hospital was a striking contradiction of the opinion that a tubercular patient carries about with her the impress of her disease in a pale, anxious look and an emaciated frame. Quite the contrary may be true. For example, one of the most robust, blooming young women I have ever seen had so extensive a pelvic tuberculosis as to necessitate the removal of uterus, ovaries, and tubes. Dr. Osler has dwelt with especial force upon the latency of the process in some cases when "the eruption takes place so slowly and so painlessly that the patient may not have presented a single symptom of abdominal disease." In one case a man died with a strangulated omental hernia, and an entirely unsuspected extensive fibrous tubercular peritonitis was found on autopsy. A girl died of typhoid fever, and at the autopsy an extensive tubercular peritonitis was found.

One of my own patients (B. M., 14), forty-two years old, had been ill ever since her last child was born, five years before; for a year she had noted an abdominal tumor growing in the left side. Her poor health was associated with a winter cough and pleurisy on the right side. I operated Oct. 18, 1889, and removed a left ovarian tumor as large as a cocoanut and a right ovarian cyst as large as a lemon. The ovarian tumor and the entire peritoneum were covered with miliary tubercles, the intestines were matted together in places, and there were 500 cubic centimeters of free fluid in the peritoneal cavity. The nodules were firm and hard and some of them pigmented, and a microscopic examination showed that they were tubercular. She made a complete recovery, and died later of a malignant disease in the pedicle of the tumor.

Sixteen out of twenty patients, or 80 per cent, are noted to have been in good condition with a good color, while but five, or 20 per cent, were poorly nourished, anemic, and sickly.

The percentage of ill-nourished patients among the negroes was larger than among the whites, holding a relation of 25 per cent to 16.66 per cent.

Symptoms.—Pain is the most constant symptom, and is referred to the back, lower abdomen, and pelvic organs; it is usually persistent and associated with menstrual exacerbations. It varies all the way from a continuous ache or soreness to intense suffering, compelling the patient to stay abed. One patient will complain of a sharp and shooting pain with a sense of bearing down, increased by walking or exertion; another speaks of a sharp, shooting pain during the monthly period, and at other times a dull soreness extending into the thighs, with giddiness.

The abdomen is often distended with wind, and the distention may be permanent or it may recur at intervals; there is often also nausea and vomiting. I have been told by some women that they were suffering from "inflammation of the stomach." The blacks complain of a "misery" in the pit of the stomach. Intense pain in the ovarian regions and severe headaches are frequent.

With the pain there is always a tenderness of the lower abdomen, so that the patient can not endure deep pressure nor stand erect with comfort. They of necessity adopt the posture and gait which are characteristic of the chronic lower abdominal inflammations.

Poor appetite or dyspeptic symptoms were complained of by four fifths of my cases.

Fever is sometimes absent and sometimes present, although the patients not infrequently complain of "chills and fever," with chilly sensations and sometimes night sweats. A persistent slight elevation of temperature between 99° and 100° is often seen, and more rarely a decided elevation from 102° to 104° in the acute cases.

Constipation occurs in one half the cases; 20 per cent complain of pain in defecation, which may be attributed to the disturbance of the inflamed adherent surfaces during the act of straining.

Pain in urination is the most characteristic of all the symptoms. Out of 20 cases, only 3 were free from it; 14 complained of burning pain during micturition; in 8 of these frequency of urination was added; in 3 others there was incontinence with pain.

The menstrual history is noted in 22 cases; 2 of these had amenorrhea, 2 scanty flow, and in 3 the flow was more profuse than formerly. Dysmenorrhea was specially complained of by but 4 cases, while in 9 no change was noted at all. Leucorrhœa was profuse in 8 out of 15 cases; in 3 it was of an irritating character, and in 3 others the patient complained of the bad odor. There was a continuous blood-stained discharge in one instance.

Diagnosis.—In attempting to make a diagnosis of tubercular peritonitis before operation it is at once evident that those symptoms most reliable and characteristic of tuberculosis of other organs fail us here.

In many instances the healthy appearance of the patient and the good family history disarm any suspicion as to latent tuberculosis in the mind of one not specially familiar with its peculiarities.

In three classes of cases, however, the diagnosis is not difficult to make :

First, where extensive pulmonary disease is associated with pelvic inflammatory masses the presumptive diagnosis is that the abdominal trouble is similar in character.

Second, where a persistent uterine discharge or uterine curettings are found to contain tubercular foci, the inflammatory disease lateral to the uterus may confidently be asserted to be similar in its origin.

Third, where there is pelvic inflammatory disease associated with irregular, ill-defined masses with fluctuation in the lower abdomen, and the latter are noted at subsequent examinations to have changed their relations to some extent, the diagnosis will be tuberculosis.

The utility of tuberculin as a means of diagnosis still remains to be determined.

In making a diagnosis the surgeon must in many cases be guided by probabilities only, as the grounds for a positive assertion may not be found.

The chief source of error lies in mistaking a simple pelvic peritonitis, or a pyosalpinx, or carcinoma of the ovary with effusion, or even an ovarian tumor, for tuberculosis. In a case in the hands of Dr. L. M. Sweetnam, with amenorrhea followed by an irregular flow and severe pain, extra-uterine pregnancy was diagnosed, but the patient died later of tuberculosis.

Again, a diagnosis of hysteria or of simple dysmenorrhœa has been made where the affection was tubercular.

I made this mistake at the first examination of a large, healthy, florid young woman with many characteristic hysterical traits, who complained of constant pain in the pelvis, exaggerated at each period. She had general marked sensitiveness on pressure over the vaginal vault and the lower abdomen, but, on account of the depth of the pelvis, the examination was unsatisfactory and nothing was felt. Fortunately, at a later date I made a more thorough examination under anesthesia and found ovaries and tubes still movable, but restricted by long adhesions. An abdominal section showed that ovaries and tubes and uterus were covered with tubercles, and the adhesions were numerous and only separable with difficulty ; the uterus, ovaries, and tubes had to be removed.

A general practitioner will be peculiarly liable to commit this error in similar cases, and he can only avoid it by insisting on an examination under anesthesia, by a competent specialist, in all cases where pelvic pain is persistent.

Tuberculosis must be borne in mind in all cases of pelvic inflammatory disease with masses posterior and lateral to the uterus, with marked tenderness on pressure in the vagina or over the lower abdomen ; the probabilities are still greater if encysted accumulations can be felt in the lower abdomen, more especially if a large amount of fluid has existed and been partially absorbed.

I think the tenderness in tuberculosis greater and more persistent than in simple inflammation.

The history of chills with fever, or the statement by the patient that she has had " malaria " or " dumb chills," must be carefully noted, together with pain

in walking and pain in the back, and especially painful micturition. A phthisical facies will sometimes strongly suggest a diagnosis.

One patient presented such a suggestive history as this: She was first taken suddenly ill with high fever and general pains, and a constant painful, dry cough, with rapid breathing; when these symptoms subsided the abdomen was noticed to be swollen, and by palpation I found distinct masses and loculi of fluid in the lower abdomen. The diagnosis was confirmed by operation.

A negress was confined to bed two years before with a severe illness due to a lung disease; she had had some cough ever since recovery, and caught cold easily. Four months before I saw her she had to go to bed on account of abdominal pains and swelling, with fever. After the removal of adherent tubo-ovarian tubercular masses she recovered her health and gained fifty pounds in weight.

In numerous cases I have noted an enlarged uterus, as large even as a two and a half or three months' pregnancy—indeed, the possibility of pregnancy was seriously considered in three cases. The position of the uterus is variable; it is, as a rule, fixed with the appendages by adhesions to the pelvic walls and floor. The cervix was softened in five of my cases. The lateral masses are often indistinctly outlined.

I mistook one case seen for the first time on the operating table for a multilocular ovarian cyst; there was a marked prominence, with dullness of the anterior part of the abdomen due to four liters of fluid; on the right side was a firm boss as big as a coconut; the flanks were tympanitic. The pelvis was filled with an elastic mass bulging down the floor and pushing the cervix down and to the left, and the fundus could not be felt.

The possibility of an encysted tubercular peritonitis simulating an ovarian cyst in this way has been carefully considered by Dr. W. T. Howard, of Baltimore (*Trans. Amer. Gynecol. Soc.*, 1885, p. 41). Dr. Howard's patient was a negress, twenty-four years old. The abdomen was enlarged to the size of a seven months' pregnancy, and presented the appearance of an ovarian cyst. "The signs of a simple unilocular cyst seemed perfectly developed." She was suffering also from a pleurisy.

The differential signs between tubercular peritonitis and an ovarian cyst or a uterine fibro-cyst must rest first upon the history of the rapid growth of the effusion, upon the fact that the anterior part of the abdomen is tympanitic in peritonitis so long as the amount of effusion is small, and becomes dull and tense only when it has increased enough to lift the anterior wall well up from the mutually adherent intestines. The presence of tympany in the flanks does not help to differentiate a cyst from an effusion in these cases, because the fluid is also encysted by the adhesions. Coincident pleurisy is a most suggestive sign. If the fluid is removed by tapping, the abdominal wall collapses and irregular hard masses are felt within. The most valuable means of arriving at a differential diagnosis is by means of a thorough bimanual examination by the rectum and by the abdomen, at the same time drawing down the cervix so as to bring the pelvic organs within reach. A fibro-cystic tumor will in this way be differ-

entiated from a simple sacculated collection by the connection of the former with the uterus, and an ovarian cyst will be recognized by its pellicle. Carcinomatous disease forming hard masses through the peritoneum, resembling those of tuberculosis, may often be recognized by distinct nodular and papillary masses felt in the pelvis. And in case of tuberculosis the small tubercle knots may sometimes be felt with perfect distinctness through the rectal mucosa.

The tubercle bacilli are rarely found in the ascitic and encapsulated fluids; they are found with difficulty in sections of the tubercles, while they may be abundant in cheesy foci and may also be found by crushing a tubercle and examining it fresh on a cover-glass. It is sometimes necessary to make a painstaking search before the characteristic bacillus is found, but a positive diagnosis may be made from a single typical organism.

As pointed out by Dr. J. W. Williams, a large percentage of the adherent tubes and ovaries removed on account of chronic pelvi-peritonitis is in reality tubercular, but the demonstration can only be made after a most painstaking microscopic investigation; the diagnosis can not be made either before or at the operation.

Tubercle bacilli may be discovered in a vaginal discharge when the uterus is involved, and, as already stated, one of the surest ways of making a diagnosis is by means of uterine scrapings, which exhibit tubercular foci in a large percentage of cases where the disease is advanced in the tubes. Sometimes, too, there is a marked affection of the uterus where disease in the tubes is still in its early stages. The peculiarities of these scrapings have been described in Chapter XIV, p. 489.

I would briefly recapitulate the important clinical diagnostic points, and they are valuable just in proportion as a number of them are associated together, under these eleven heads:

1. Often a sudden onset of the disease, it may be after pregnancy or a miscarriage.
2. A history of chills with fever, or "malaria," but without the plasmodium. Sometimes the stage of invasion is put down as "typhoid fever."
3. Gradual increase of swelling, terminating in a marked enlargement of the abdomen.
4. More or less constant abdominal pain increased especially by walking.
5. Pain in urinating.
6. Pelvic masses which can not be distinctly outlined either by palpation or percussion; there is something puzzling and peculiar about the relations of the masses to the pelvic organs.
7. Apparent change in the position of the masses in the abdomen noted at subsequent examinations.
8. Great tenderness on pressure at the vaginal vault and over the lower abdomen.
9. Sometimes an enlarged uterus.
10. Evidences of an encysted peritonitis.
11. Emaciation—tubercular facies.

12. Slight persistent evening rise of temperature, often with subnormal morning temperature, lasting for weeks or months.

13. The discovery of tubercle bacilli in vaginal or uterine secretions or in the endometrium after enrettage, or more rarely in the fluid obtained by tapping a cyst by the vagina or by the abdomen.

Treatment.—There can be no doubt but that many patients suffering from tubercular peritonitis recover spontaneously, without any assistance whatever. On the other hand, a large number become chronic invalids, showing but little if any change in their condition from year to year; others again grow progressively worse, until the whole peritoneum is studded with tubercles, and the intestines become mutually adherent, or effusion increases rapidly in quantity, greatly distending the abdomen, becoming at times purulent, and the neglected patient dies of exhaustion.

No treatment other than general hygienic measures is called for where the patient has had an attack of peritonitis believed to be tubercular, and is constantly improving; but such a patient ought to be warned of the possibility of a recurrence of the attack and kept under observation. If a tender pelvic mass is found by vaginal examination, and it does not disappear in the course of several months, it should be removed.

When a patient comes under observation with pain, or ascites and pelvic masses, the only proper method of treatment is the removal of as much of the disease as possible by an abdominal section.

With timely treatment all cases originating within the pelvis may be cured. Often even advanced and seemingly hopeless cases, apparently in the last stages, will recover after operation.

Only those cases should be abandoned as hopeless where the patient seems to be actually dying, or where there is such an extreme state of prostration, without marked effusion in the abdomen, that the attempt to remove adherent pelvic structures would be manifestly fatal within a short time.

The curability of the disease by operation is abundantly demonstrated by my own experience. None of the twenty-two cases cited above died from the operation, though one died a month later with numerous adhesions about the site of some tuberculous intestinal ulcers.

One of those not included in this list operated on in 1886 is now living and well.

In a case operated upon by Dr. W. S. Halsted at the Johns Hopkins Hospital, the capsule of the liver was found studded with tuberculous nodules, which were also distributed over the adherent intestines, the diagnosis being confirmed by the microscope. The patient recovered and went out; four months and a half later she returned and died in the hospital ward of pneumonia. At the autopsy no adhesions were found between intestines, but a number of little withered, scarred, pigmented fibrous nodules proved to be tubercles containing in their center numerous bacilli. There were no tubercles in the chest. Thus the abdominal trouble had steadily retrograded and become

innocuous, and the opportunity to examine it was due to the accidental occurrence of a pneumonia.

The object of the operation is threefold:

First, to remove, if possible, the focus of the disease.

Second, to remove all fluid exudate.

Third, to release dangerous adhesions.

The abdominal incision should not be more than 4 or 5 centimeters ($1\frac{1}{2}$ to 2 inches) long at first, and lengthened afterward according to necessity.

In opening the abdomen an unusual vascularity of the walls is often noted, and the fat is frequently of a pale, unhealthy, watery appearance, like the fat which in the market condemns meat to an experienced buyer, and the parietal peritoneum may be 2 to 3 millimeters thick.

The operator must in all cases, where the patient's condition is good enough, remove either one or both tubes and ovaries, if they are the seat of tuberculous disease, and it is better to do this when it is possible, no matter how much the disease has extended beyond its original focus. It is better, too, where the omentum is extensively infiltrated and its utility as an absorbent is lost, to remove it close up to the colon.

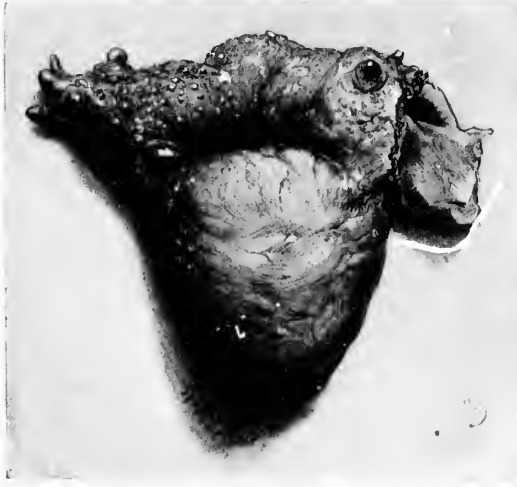

FIG. 358.—TUBERCULOSIS OF THE TUBE, POSTERIOR SURFACE OF THE LEFT OVARY AND TUBE.

Note the thickening of the tube and the disappearance of the mesosalpinx. The fimbriae have all disappeared, except a few little blunt budlike processes. Path. No. 184. Natural size.

Where both sides are extensively involved, as shown in Fig. 337, it will be better to remove the uterus too, on account of the probable involvement of the uterine mucosa.

If the uterus is so buried that its enucleation presents unusual difficulties, the tubes and ovaries may be removed separately, as shown in Fig. 338.

If the ovary is simply involved in adhesions and the disease seems to be almost confined to the tube, this should be removed and the ovary left. This condition is sometimes found in the form of a nodular salpingitis.

Much care must be exercised in the enucleation on account of the rigid friable nature of the structures, which tear widely if injudiciously pulled. In one of my cases the ovary and tube of the left side felt like a mass of bone. The difficulties will be greatly

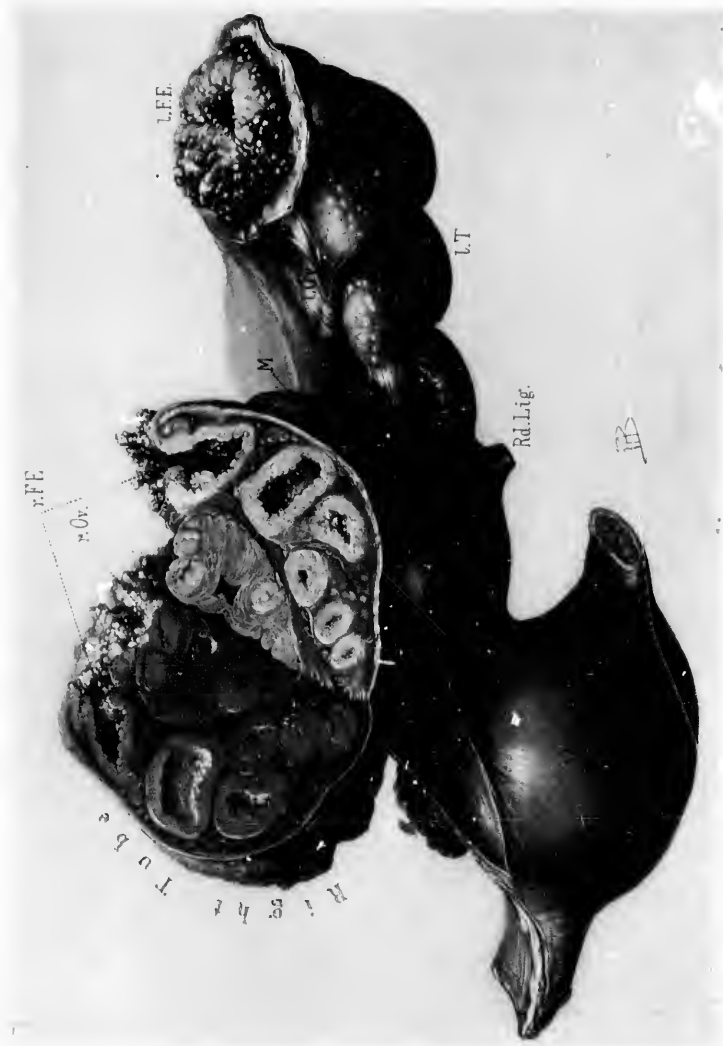

FIG. 337.—TUBERCULOSIS OF TUBES AND OVARIES.

The right tube and ovary divided, showing the extent of the disease in the ovary and in the numerous cross-sections of the tube. *FU* is the fundus of the uterus, and *M* a myoma attached to it. Between the uterus and the myoma is seen a large sac of an encysted peritonitis. The left tube is distended, convoluted, and covered with tubercles; the fimbriated end is swollen and exhibits numerous tubercles. This is pre-eminently a case for extrication of both tubes, ovaries, and uterus. Case of Dr. C. Cone. *Lokus Hosp. Bul.*, May, 1867. $\frac{2}{3}$ natural size.



lessened by a slow, painstaking enucleation, seeking out the points of vantage generally found beneath the ovary on the pelvic floor, and lifting the ovary and tube up and tying off the pedicle at both ends to include uterine and ovarian vessels.

One serious difficulty is that, owing to the rigidity of the broad ligaments, the pedicle can not be brought up into the incision and must be treated down in the pelvis. I tore the rectum in separating dense adhesions in one case, and was obliged to suture it. In another case adherent small intestines were separated by leaving some of the inflammatory mass on the bowel. Sutures were also needed to repair several rents in the bowel.

The details of the operation of salpingo-öophorectomy are given in Chapter XXVI.

Where the pelvic structures can not be removed, the operator must content himself with fulfilling the two remaining indications, which must in any event always be attended to—that is, the removal of all fluid and the relief of the complications.

The fluid of a tubercular peritonitis is sometimes almost syrupy in consistence, and I have repeatedly noticed its coagulation as soon as it is exposed to the air; at other times it is opalescent, brown, and full of flakes of lymph, or purulent. The spontaneous coagulability of the fluid resembles that sometimes seen in fibro-cystic tumors and considered pathognomonic of this affection by Dr. W. L. Atlee and others. Several writers have noted this error, Dr. William T. Howard among others.

All the serous and bloody fluid contained in the abdomen must be thoroughly sponged out after dropping the table to a level, so as to cause the fluid in the upper abdomen to gravitate toward the pelvis. Several liters may be evacuated in this way before the peritoneum is dry.

Purulent collections are usually sacculated, and not infrequently in the middle or upper part of the abdomen behind the anterior wall.

In evacuating such an abscess care must be exercised not to open an avenue into the general abdominal cavity. Multiple abscesses among the intestines are apt to be associated with intestinal tuberculosis, and unless easily reached without injury to the bowel, would best be let alone.

Adhesions must be separated when a single loop of intestine is found attached to the abdominal wall or pinned down in the pelvis, but the general adhesions uniting all the small intestines into one big saclike mass ought not to be touched, for, as is evident from the patient's history, the peristaltic function of the bowels is not interfered with by the general obliteration of the peritoneum where the normal mutual relations are preserved. Paradoxical as it may seem, a single adhesion of a knuckle of the small bowel or colon holding it down in some abnormal position, as to the pelvis or abdominal wall, is far more dangerous.

A piece of the thickened parietal peritoneum, or of an affected omentum, should be removed for microscopic examination, when the ovaries and tubes are not taken out; one of the most satisfactory ways also of demonstrating the na-

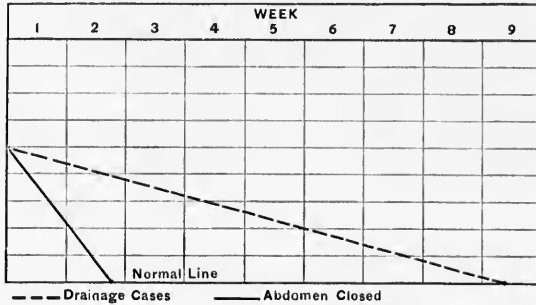


FIG. 329.—DIAGRAM SHOWING THE RELATIVE ADVANTAGES OF CLOSING OR OF DRAINING THE ABDOMEN IN THE TREATMENT OF A TUBERCULAR PERITONITIS.

Beginning with the day of operation the temperature dropped to normal, and recovery ensued in the drained cases by the ninth week; in those which were not drained the temperature became normal and the convalescence well established before the second week.

ture of the disease is by inoculating the peritoneum of a guinea-pig, which will develop tuberculosis and die within the course of two or three months. The nodular tubercular masses may be crushed and examined under the microscope

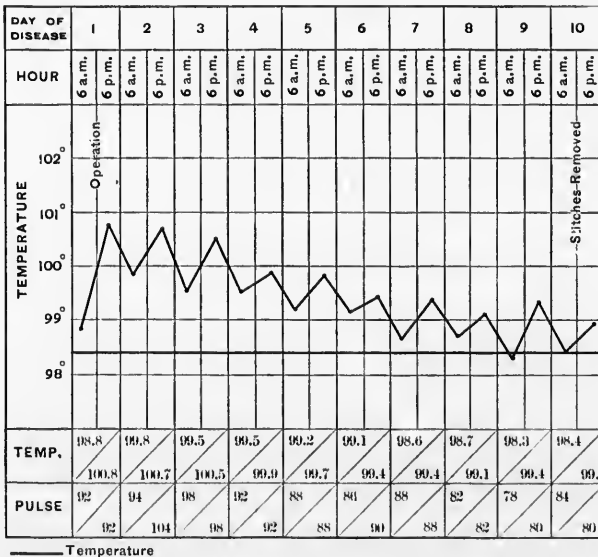


FIG. 340.—COMPOSITE CHART SHOWING THE COURSE AND THE DISAPPEARANCE OF FEVER AFTER OPERATION IN THE CASES OF TUBERCULAR PERITONITIS WHICH WERE NOT DRAINED.

during the operation to relieve any doubt existing as to the diagnosis between tuberculosis and peritoneal carcinoma.

Drainage.—After completing the operation the abdomen should be closed without drainage, unless this is made necessary by some complication, such as the presence of pus, which can not be completely removed, or such an injury to the bowel as can not be satisfactorily repaired and may give rise to a septic peritonitis.

It has long been the fashion to attribute the good results of operation in tubercular peritonitis to drainage. I have abandoned all drainage in these cases for more than five years.

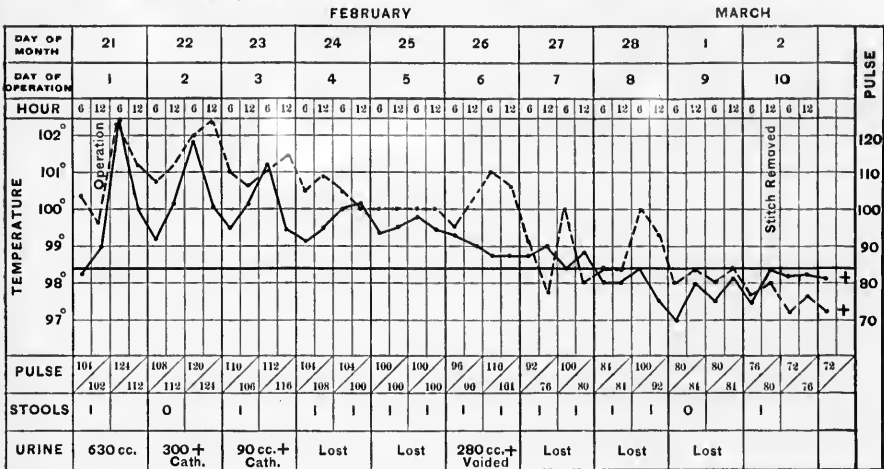


FIG. 341.—CHART SHOWING RECOVERY AFTER REMOVAL OF BOTH UTERINE TUBES AND OVARIES IN A CASE OF TUBERCULAR SALPINGITIS AND PERI-OÖPHORITIS AND TUBERCULAR PERITONITIS.

No drainage was used, and the continuous line shows the speedy defervescence within a week after the operation. K. J., Feb. 17, 1894. Gyn. No. 2597.

Serious objections to drainage are that the track of the drain is liable to remain open indefinitely, much to the annoyance of the patient; a drain also renders the patient liable to hernia.

The following facts, however, are sufficient in themselves to settle this important question in favor of closing the incision completely. The cases referred to as drained are those in which the drain was inserted with a view of curing the disease, and not of providing for the complications above noted.

The average duration of convalescence in six cases up to complete remission of the fever with drainage was 59 days. The average period of convalescence without drainage was 17.3 days.

The longest duration of fever in a drained case was 71 days, and the shortest was 10 days. The longest continuance of the fever in a case which was not drained was 54 days, and the shortest 2 days.

This matter is so important that I present it here in a diagram, which shows the extraordinary difference in the two groups of cases, in the rapidity of the drop from the average temperature at the time of operation down to the base line of normal temperature.

The angle between each of these lines and the perpendicular might also well be taken as the measure of the difference in advantage in the two methods; the smaller the angle the quicker the drop to the normal, and therefore the greater the advantage of the plan.

I present here, also, a composite chart of all the cases which were not drained. It is constructed by adding up, in separate columns, the morning and evening temperatures of the group of cases under consideration, and dividing the sum in each column by the number of cases. For example, the composite temperature of the first evening, on the day of operation, in twelve cases, is the sum of all the temperatures for that evening divided by twelve, and so on for each morning and evening thereafter. We can do this with a degree of precision in surgical cases which will not be quite attainable in medical cases, because the operation gives a definite starting point. The great advantage of this method of investigating the temperature and pulse record is that it obliterates all individual peculiarities and reveals the average or the true type.

In comparison with this I present the chart of a case (K. J., 2597, Feb. 21, 1894), closely approximating the normal in its defervescence, but still showing individual peculiarities.

In the drained cases the temperature curve showed marked daily variations, more like those of a septic fever.

In the cases closed without drainage there was a gradual but regular drop down to the normal.

CHAPTER XXIV.

SUSPENSION OF THE UTERUS.

1. Historical review.
2. Simpler methods of treating retroflexion: 1. Manual reduction. 2. Pessaries. 3. Resection of lax outlet.
3. Indications for suspension.
4. Methods of operation.
5. Answer to objections to this method.
6. Operation: 1. First step, the incision. 2. Second step, introduction of index and middle fingers to elevate the fundus. 3. Third step, attachment of uterus to anterior abdominal wall.
7. Final results.

Historical Review.—Suspension of the uterus, ventrofixation, hysterorrhaphy, and hysteropexy are synonymous terms applied to a number of similar abdominal operations, all of which are employed with a view of permanently overcoming retrodeviations (retroflexions and retroversions) of the uterus by the formation of an artificial ligament or ligaments holding the fundus in an anterior position.

I first called attention to this mode of relieving retroflexion in Germany in the spring and summer of 1886, when I also secured notes of unpublished cases similarly treated by Dr. Brennecke of Magdeburg, Prof. Werth of Kiel, and Prof. Sänger of Leipsic, which were published with an original case of my own. Prof. Olshansen, of Berlin, who had the subject under consideration at the same time, was the first to publish a paper upon it, Oct. 23, 1886, entitled *Ueber ventrale Operationen bei Prolapsus und Retroversio Uteri* (*Centr. f. Gyn.*, No. 43, 1886). My own paper, entitled *Hysterorrhaphy* and describing a case operated upon April 25, 1885, was read before the Philadelphia Obstetrical Society, Nov. 4, 1886, and published in the *Amer. Jour. of Obst.*, Jan., 1887.

Since these publications the correction of retroflexions of the uterus by an abdominal operation has been widely and fully tested, and has undergone in different hands a series of modifications more or less useful.

Simpler Methods of treating Retroflexion.—Suspension of the uterus should be resorted to only in cases of persistent retroflexion which refuse to yield to simpler plans of treatment through the vagina, and then only when the discomforts of the retroflexion are sufficient to interfere seriously with health.

In many cases the physician will be justified in extending his treatment over some months in the endeavor to bring the uterus into anteposition and keep it

there. One or more of the three following plans of treatment are serviceable to this end:

1. Manual reduction.
2. Packs and pessaries.
3. Resection of a lax outlet.

For manual reduction, the vagina should be cleansed and the anterior lip of the cervix caught by a corrugated tenaculum or tenaculum forceps (Fig.

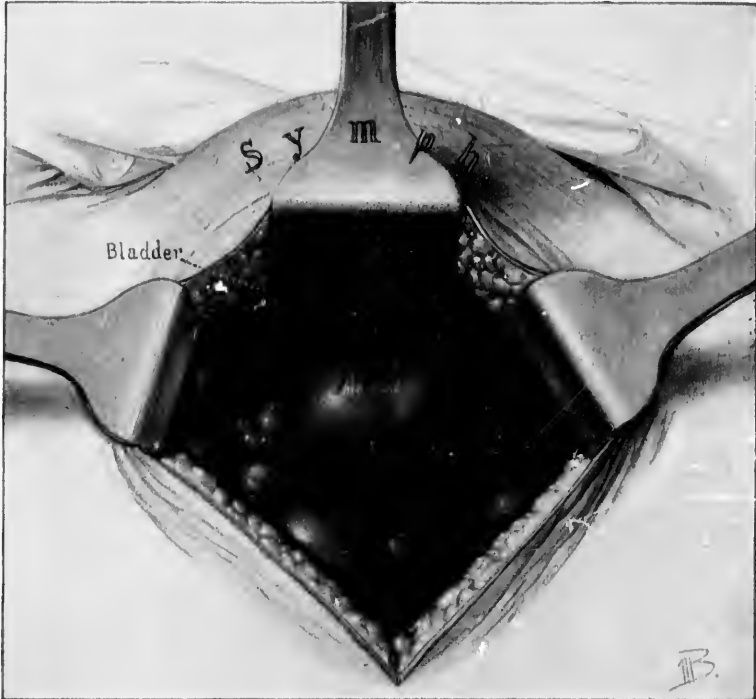


FIG. 342.—SUSPENSION OF THE UTERUS, SEEN FROM ABOVE; FROM A CASE OPENED OVER SIX MONTHS AFTER THE SUSPENSORY OPERATION.

Notice the long fibrous bands uniting the posterior surface of the uterus to the anterior abdominal wall. Jan. 6, 1896.

225) and drawn down toward the vaginal outlet (Fig. 226); while it is held in this position the index finger is introduced into the rectum, and used to raise the fundus up into the pelvis, reducing the angle of flexion (Fig. 229). There is sometimes a sensible jump as the body of the uterus escapes from between the utero-sacral folds where it had lain incarcerated, often giving the false impression that there is a retroflexion with adhesions. As soon as the fundus is elevated in this way the cervix is carried back into the sacral hollow by means

of the forceps, thus rotating the uterine body forward (Fig. 227). The rest of the reduction is now effected bimanually through the vagina and the abdominal walls. The fundus is caught with the abdominal hand pressing deep down into the pelvis, drawn forward and held there, while the vaginal finger indents the

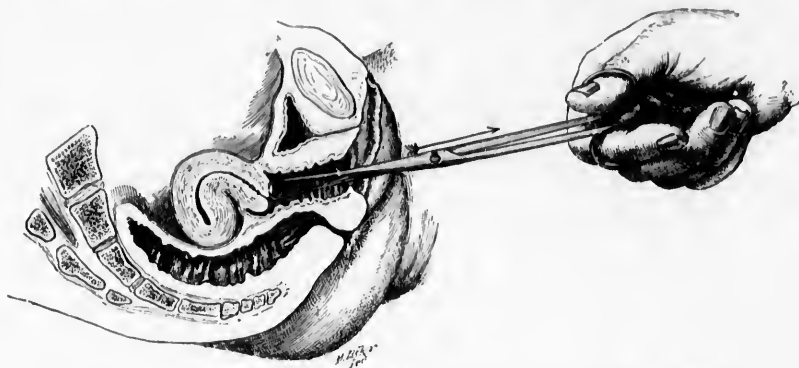

FIG. 343.—STEPS IN THE REDUCTION OF THE UTERUS IN THE PALLIATIVE TREATMENT OF RETROFLEXION.

The anterior lip of the cervix is grasped with a tenaculum forceps and drawn in the direction of the arrow.

uterus on its anterior surface at the junction of the cervix and body, and so brings it into complete anteflexion (Fig. 228). By further pushing the cervix high up toward the promontory of the sacrum and the fundus down behind the symphysis, the anterior position is exaggerated (Fig. 230).

A Hodge, or a Thomas, or a Mundé pessary will in some cases so far alleviate the symptoms of a retroflexion, even though the flexion is not cured, as to obviate the necessity for an operation.

Wool and boroglyceride cotton packs, used for a time, will also often tide the patient over a period of discomfort without operation.

A marked relaxation of the vaginal outlet is often associated with retroflexion where the flexion has followed parturition; in such patients the discomforts often arise from the tugging upon the broad ligaments of a uterus working its way down to the outlet, and the simple flexion is not the cause of the pain. In a considerable number of these cases an oper-

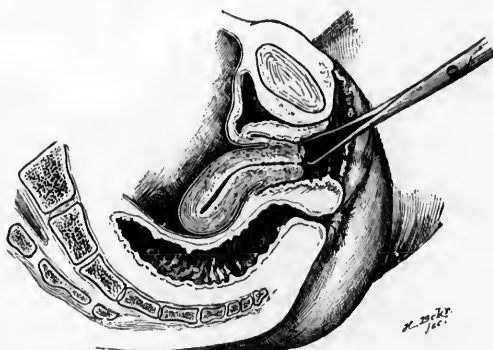

FIG. 344.—The traction straightens out the angle of flexion and brings the body of the uterus within easy reach.

ation restoring the lax outlet relieves both the discomforts and the tendency to prolapse, although the flexion persists. When the patient is not relieved by this, an abdominal operation to correct the flexion may be resorted to later.

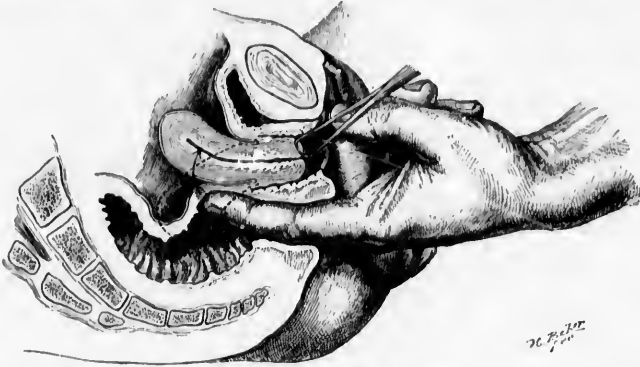


FIG. 345.—The finger is then introduced into the rectum, and by pushing in the direction of the arrow a slight antelexion is produced.

Indications for Operation.—Suspension of the uterus is not indicated in all cases of persistent retroflexion.

The commonest group of symptoms calling for the suspension are a sense of weight, discomfort, or bearing down, aggravated by exertion, inability to walk without pain, backache, and pain in the lower abdomen and thighs. These symptoms are usually worse at the menstrual period, when the pelvic discomforts may be so great as to put the patient to bed for several days. As a rule, women suffering from retroflexion are intensely nervous, liable to dyspepsia, palpitation, neuralgias, and headaches. The case is still clearer if all the symptoms are relieved by rest. Backache is the most fallible symptom, and the surgeon must be cautious about promising its relief. Only rarely is the renal function inter-

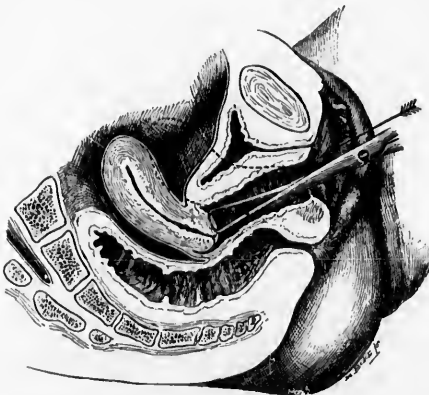

FIG. 346.—The forceps are then used to carry the cervix well back into the pelvis.

fered with by pressure on the ureters, giving rise to attacks of renal colic. Occasionally the pressure of the retroflexed fundus upon the rectum, causing obstinate constipation and great pain in defecation, is the chief indication for operation.

A good way to test the probable effect of an operation for retroflexion is by lifting the uterus and supporting it on a wool pack or a pessary; if this affords decided relief after a fair trial, the flexion may be considered to be the source of the disturbance. Suspension should always be used in those cases which Dr. B. McMonagle has described as "tied to the physician's office by their ailment," now better and now worse, and so continuing indefinitely under treatment.

A retroflexed adherent uterus is, as a rule, the result of a pelvic peritonitis primarily involving the tubes and ovaries, and a suspensory operation after freeing these adhesions is not advisable if they are very extensive. It only exposes a raw surface to the formation of intestinal adhesions, and if the tubes and ovaries are so disensed as to be practically useless, there is no advantage in keeping the dis-

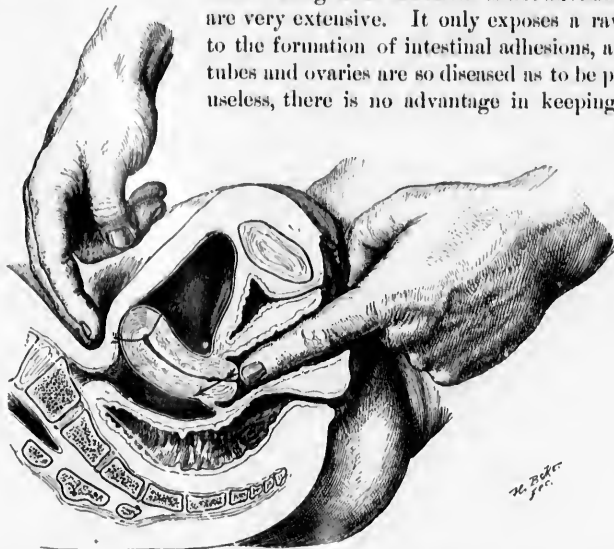


FIG. 347.—The flexion being in this manner reduced, the fundus is within reach of the hand palpating through the abdominal wall, grasping it and forcing it in the direction of the arrow; a finger in the vagina at the same time pushes the cervix back into the sacral hollow.

eased womb. I have, however, in many cases of general light pelvic adhesions, freed uterus and ovaries and then raised the uterus and attached it to the abdominal wall. In one case (E. B., 2701, April 6, 1894) I found the uterine alone adherent and both tubes and ovaries free; the adhesions were easily severed and the uterus suspended.

In prolapse of the uterus, as I have pointed out in Chapter XV, the operations on the cervix and vaginal outlet are generally sufficient to hold the uterus within the pelvis. But when the vaginal floor is so weak and the vault so relaxed that there is doubt as to the sufficiency of the inferior supports to retain the uterus unaided, the abdomen may be opened and the uterus attached to the anterior abdominal wall by its posterior surface, with great mechanical advantage and a greater assurance of success.

Occupation has much to do in deciding upon an operation. Women whose occupations require them to be more or less constantly on their feet and lifting, suffer more from a displacement of the uterus than others whose life is less laborious. On the other hand, high-strung neurotic women will suffer in the same way, while a phlegmatic disposition will experience no discomfort. I recall in this connection an extremely neurasthenic hysterical woman who had spent four years on her back in a hydropathic establishment and recovered perfect health after operation. I once operated, unwittingly, on an epileptic patient in the first month of her pregnancy, and, in spite of the fact that she had from six to eight attacks daily,

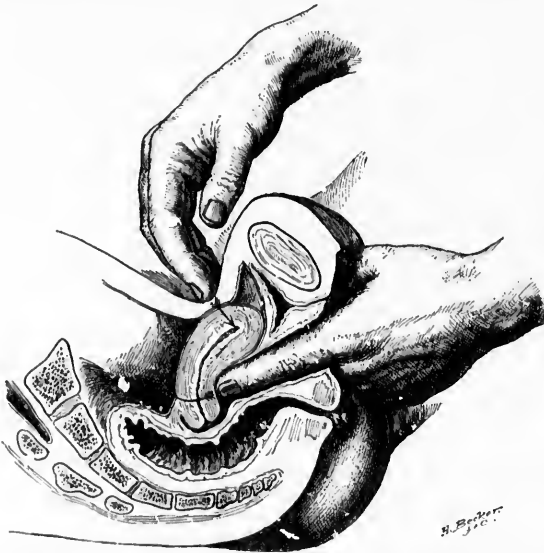

FIG. 348.—The final step is the production of an extreme ante-position of the fundus, and the insertion of a pack into the upper part of the vagina to hold the cervix up.

she went to term. Dr. H. D. Fry, of Washington, operated upon a woman, ten weeks pregnant, with an adherent retroflexed incarcerated uterus; after freeing and suspending it to the anterior abdominal wall, she went to term.

Methods of Operation.—The method at first adopted of suspending the uterus by the fundus or by bringing up its anterior face against the abdominal wall I rejected over six years ago, on account of the mechanical disadvantage in which it left the uterus to resist subsequent retrodisplacement; for a uterus lifted in this way hangs with its whole weight upon its attachments, and the permanent correction of the displacement must depend upon the strength of the adhesions binding it to the anterior abdominal wall.

When, however, the body is brought into a decided *anteflexion* and attached to the abdominal wall by its posterior surface, it then lies in a natural position, and the forces of the intra-abdominal pressure are no longer exercised in adding to its weight and tearing it loose from its moorings; on the contrary, the pressure then simply tends to lengthen out the adhesions and to increase the anteflexion, rendering a recurrence of the retrodisplacement less likely.

My present operation, the *more*, as carried out in over three hundred cases,

consists in the following steps: An abdominal incision just over the symphysis, the introduction of two fingers and elevation of the retroflexed fundus, bringing it into ante flexion, and its retention there by means of sutures through its posterior surface, lifting it up to the abdominal wall.

Answer to Objections to this Method.—Three objections may be raised against the suspension of the uterus in this way to the anterior abdominal wall:

First, that such an operation substitutes a fixed, unnatural ante flexion for a retroflexion, and the suspensory operation is therefore not what it purports to be—a simple correction of the retroflexion with a restoration of the normal condition.

Second, that an attachment of the body of the uterus to the abdominal wall behind the symphysis pubis, and resting upon the bladder, must interfere with the natural distention of this organ and so excite dysuria.

Third, that in the event of pregnancy occurring after suspension the patient's life might be imperiled by the inability of the uterus to develop normally.

An experience of six years has brought a satisfactory answer to each of these queries in favor of the operation.

In the first place, the actual fixation to the abdominal wall lasts but a short time; a few weeks after the operation the uterus will be found, by a bimannual examination, lying with the fundus behind the symphysis and in a position of easy ante flexion at a distance from the anterior abdominal wall, apparently normal in every respect and in no way hindered in its movements until the attempt is made to throw it into retroflexion; it will then be found limited in its movements in this direction by long adhesions between the fundus and the abdominal wall.

In four cases where I have had occasion to open the abdomen at periods varying from one to three years after a suspensory operation the uterus was discovered each time lying in easy ante flexion with its posterior surface 3 to 5

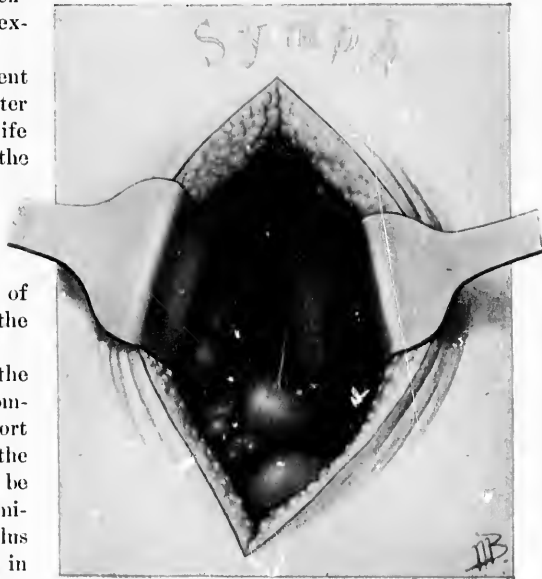


FIG. 349.—SUSPENSION OF THE UTERUS WITHIN A YEAR AFTER THE OPERATION.

Showing the long fibrous band connecting the fundus of the uterus with the anterior abdominal wall. This is continued down in the form of a thin septum over the bladder and anterior face of the uterus. May 27, 1896.

centimeters ($1\frac{1}{4}$ to 2 inches) distant from the anterior abdominal wall, with which it was connected by a dense, smooth, fibrous band from a few millimeters to $1\frac{1}{2}$ centimeter in breadth. In two cases there were two separate slender bands. In one case these suspensory cords were thicker at the ends and thinned out in the middle, and the suspensory sutures remained imbedded in the abdominal end; in another case (Fig. 350) one suture lay at the abdominal wall and the other remained attached to the uterus. There was no tension on these lax bands, and it was evident from the relationship that the fundus of the uterus gradually sinks

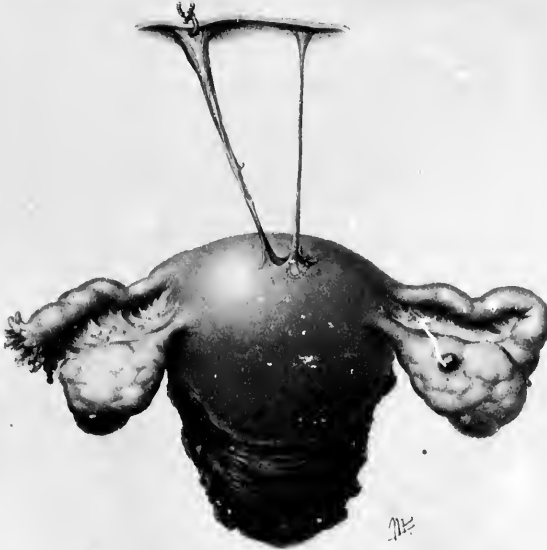

FIG. 350.—SUSPENSION OF THE UTERUS SEEN A YEAR AFTER THE ORIGINAL OPERATION.

Showing the long fibrous bands attaching the fundus to the anterior abdominal wall. One of the suspensory sutures has remained on the fundus, while the other is seen on the abdominal wall. March 2, 1896. $\frac{3}{4}$ natural size.

after the operation, drawing out the fibrous tissue connecting it to the anterior abdominal wall, until the womb comes to lie, without any tugging, in a natural, easy posture.

Secondly, transient irritability of the bladder is occasionally observed, as after all sorts of abdominal operations, but it is not frequent or persistent or in any way peculiar to this operation. The fact is, that the female bladder expands physiologically, like saddle-bags, most from side to side, and least in an antero-posterior direction, and this method of distention becomes more marked in pregnancy. In answer to this objection it is also only necessary to recall the

frequency with which the myomatous uterus was treated a few years ago by pinning the stump in the lower angle of the incision, and yet no untoward bladder symptoms were observed.

Thirdly, a critical study of the effects of ventrofixation and of suspension of the uterus on a subsequent pregnancy has been made by Dr. C. P. Noble, of Philadelphia (*Trans. of the Amer. Gyn. Soc.*, 1896). Dr. Noble has found that all the serious difficulties have been met with in the cases having broad adhesions between the uterus and the abdominal wall; but he did not find it possible in the collation of his statistics to distinguish between the results of the various methods of operating.

I have heard from forty-nine married women upon whom I have performed my suspensory operation at a date sufficiently remote to form a judgment as to the result; they reported fourteen cases of pregnancy, and in only one of these was there any complication attributable to the suspensory operation; that was one of my first Baltimore cases, operated upon Oct. 19, 1889, when the uterus was not suspended by the fundus but by the ovarian ligaments, and the convalescence was delayed by an infection of the wound and discharge of the ligatures which bound the uterus firmly to the abdominal wall by broad dense adhesions. The patient became pregnant and fell into labor Jan. 16, 1894, under the care of Dr. Helena Goodwin, of Philadelphia (see *Amer. Jour. Obs.*, 1894, p. 370). Her labor began with a copious discharge of amnion stained with meconium. The breech presented, and the uterine contractions were regular and frequent. The cervix dilated with mechanical aid. She complained bitterly of pain in the left side and in the abdominal incision. The child, a large, well-formed male, was delivered instrumentally, and died of asphyxia; the placenta came away normally, and a slight perineal tear was repaired. The afterpains were severe and long-continued, associated with extreme tenderness over the uterus and in the left side. Puerperal fever set in on the third day with a chill, and on May 7th the abdomen was opened, when the uterus was found firmly fixed to the anterior abdominal wall. There was a large mass of "exudate" on the left side, which explained the fever. The patient recovered.

The methods of suspending the uterus generally in vogue produce widespread dense attachments of the fundus to the abdominal wall (fixation and not suspension), and are productive of the following serious difficulties in pregnancy and in labor:

Difficulties during Pregnancy.—(a) Marked retraction of the scar due to the tugging adherent uterus.

(b) Constant pain in the hypogastrium.

(c) As pregnancy advances the cervix retracts into the pelvis and may even become displaced posteriorly up into the abdominal cavity.

(d) The anterior portion of the uterine body fails to expand and forms a large, fleshy, tumorous mass, obstructing the superior strait.

(e) On the other hand, the posterior part of the uterus may become as thin as tissue paper.

(f) Abortion or premature labor may come on spontaneously.

(g) Persistent excessive nausea may be due to traction on the sear (case of Dr. Cameron, of Montreal).

Difficulties during Labor.—(a) Labor may be delayed some weeks beyond term.

(b) The labor may be powerless, owing to the inability of the thinned-out posterior uterine segment to expel the fetus.

(c) The labor may be obstructed by the mass of tissue in the anterior uterine wall, as by a tumor.

(d) The proper expansion of the cervix is hindered by its abnormal position high up, even in the abdomen.

(e) Malpositions, particularly the transverse and the breech, are more frequent than the normal position.

(f) The uterine in labor may tear loose from its moorings with the formation of a large hematoma at the point of rupture.

In order to relieve these complications, a variety of obstetric operations have been found necessary, such as turning, the use of the forceps high up, craniotomy, and celiotomy and amputation of the pregnant uterus.

The most important practical suggestion, made by Dr. Noble, is to induce labor at the eighth month if the cervix begins to pull up out of the pelvis.

I am able to answer the important question as to the behavior of the artificial ligaments during pregnancy and labor by the following observation: J. A. H., San. 332, was operated upon for retroflexion June 26, 1892. She became pregnant and at the calculated time, May 30, 1896, labor pains set in, and she gave birth spontaneously to a male child weighing $9\frac{1}{2}$ pounds, after nine hours of normal labor. The only noticeable peculiarity of the labor was a right obliquity of the uterus and an unusual prominence of the abdominal wall.

After the labor was over I could distinctly feel the suspensory band by pushing the finger in through the umbilical ring and at the same time pulling out the sear in the lax abdominal wall; the long, tense suspensory could be traced in this way from the anterior abdominal wall below, over the top of the uterus, to its posterior face, where it was attached a little to the left.

Operation.—The bladder is emptied by catheter, and the customary preparations made for opening the abdomen, after which the pelvis is slightly elevated.

The first step is the making of an incision 4 to 5 centimeters ($1\frac{1}{2}$ to 2 inches) in length through the abdominal wall in the median line, ending at a point within 2 centimeters of the symphysis.

The peritoneum is opened the full length of the skin incision, and caught with artery forceps in the middle on both sides, drawn out, and the forceps laid on the abdomen. This step insures the retention of enough peritoneum to close the peritoneal wound separately at the end of the operation.

The second step is the introduction of the index and middle fingers into the abdominal cavity to elevate the fundus; they are slipped down behind the symphysis, and over the bladder and the anterior face of the retroflexed uterus, until the fundus is reached on the pelvic floor. If there are any adhe-

sions holding it down, they must be separated by gradually introducing one or two fingers behind the uterus and slowly peeling it up, breaking the adhesions a few at a time, until it is finally freed. Dense adhesions must be severed with knife or scissors under inspection, through a larger incision, carefully drawing

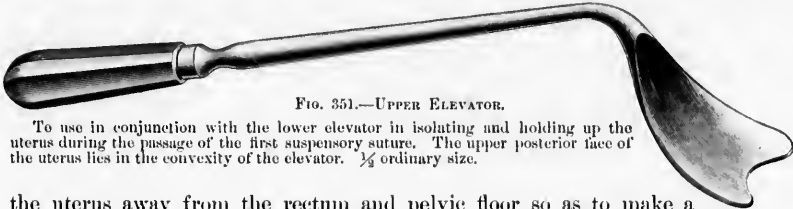


FIG. 351.—UPPER ELEVATOR.

To use in conjunction with the lower elevator in isolating and holding up the uterus during the passage of the first suspensory suture. The upper posterior face of the uterus lies in the convexity of the elevator. $\frac{1}{2}$ ordinary size.

the uterus away from the rectum and pelvic floor so as to make a space large enough to cut between without injuring either organ. When the ovaries and tubes are so diseased as to require removal, the uterus is taken away too instead of suspending it.

Two fingers are hooked under the retroflexed fundus, which is lifted out of its bed and the uterus drawn forward until the fundus lies behind the symphysis, with its posterior surface turned up toward the incision. If the intestines crowd into the incision so as to embarrass the fingers in exposing the uterus, a

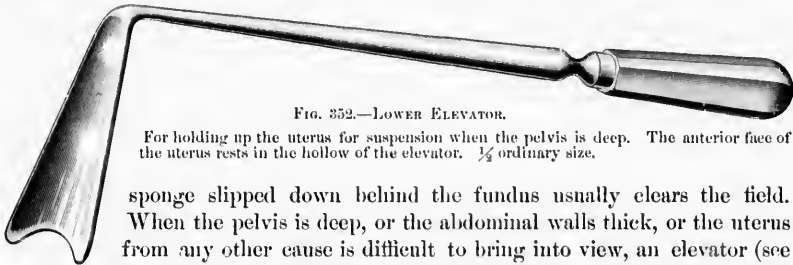


FIG. 352.—LOWER ELEVATOR.

For holding up the uterus for suspension when the pelvis is deep. The anterior face of the uterus rests in the hollow of the elevator. $\frac{1}{2}$ ordinary size.

sponge slipped down behind the fundus usually clears the field. When the pelvis is deep, or the abdominal walls thick, or the uterus from any other cause is difficult to bring into view, an elevator (see Fig. 352) serves as a temporary artificial point of support, against which the uterine body is held while the first suture is passed through the fundus. The elevator used in this way gives a point of support which takes the place of the symphysis under ordinary circumstances. I sometimes use two elevators with advantage, one in front and one behind the uterus. The same end may be attained by catching the fundus with a pair of tenaculum or rat-toothed forceps, drawing it up into the incision, and holding it in view until the first suture is passed.

The third step is the attachment of the uterus to the abdominal wall; this is done by raising one side of the lower angle of the incision with two fingers in order to expose the inner surface; the peritoneum and subperitoneal tissues parallel to the incision are now transfixed at a point 1 to $1\frac{1}{2}$ centimeter away, including an area 8 to 10 millimeters broad (see Figs. 354 to 356). The fundus uteri is next transfixed by the same needle carried transversely through a part of the posterior surface of the uterus 1 or 2 centimeters below a line con-

necting the uterine tubes; the suture takes in uterine tissue about 1 centimeter in breadth and 3 to 4 millimeters in depth. The needle is next carried through the peritoneum and subperitoneal tissue on the opposite side of the incision at a point corresponding to the first side. The intermediate silk suture is now drawn through and pulled tight, and the three points transfixed by it—that is, the uterus and the peritoneum on both sides—are brought snugly together.

A finger is introduced before tying the suture, and a careful examination is made to make sure that no loop of intestine or bit of omentum has been caught between the uterus and the abdominal wall. The first suspensory suture is then tied and the ends cut off close to the knot. A second suture, re-enforcing the first, is now introduced with

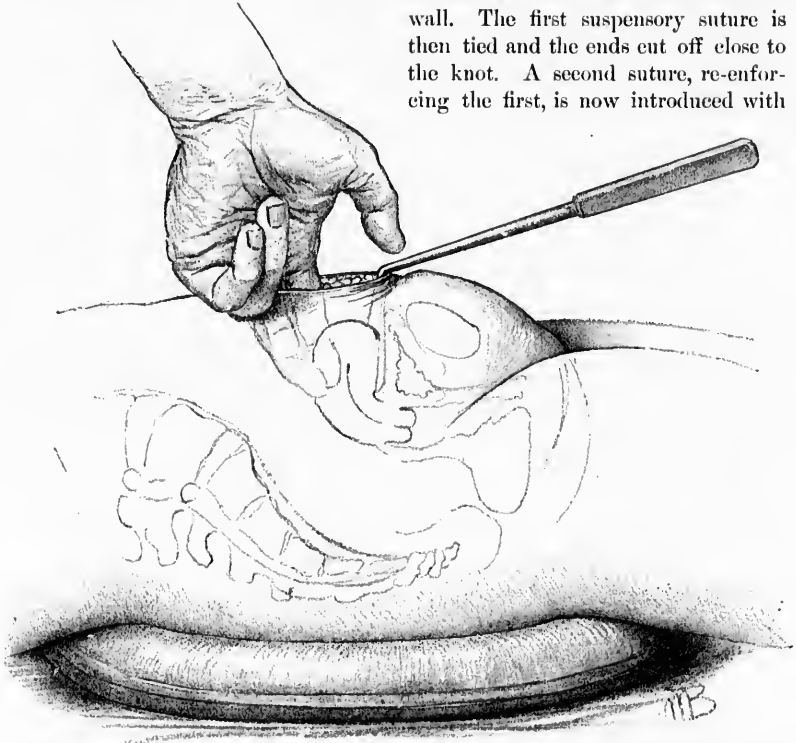


FIG. 353.—SUSPENSION OF THE UTERUS, SHOWING ELEVATION OF THE UTERUS WITH THE LOWER ELEVATOR. The uterus is held up in this way while the first suture is passed.

greater ease; it transfixes a corresponding portion of the abdominal wall on both sides about 1 centimeter above the first suture and the uterine tissue 1 centimeter below it; this is also drawn up snugly, tied, and cut off close to the knot.

The uterus is lifted up and held in ante-flexion by the first suture, while the second brings more of its posterior surface into contact with the abdominal

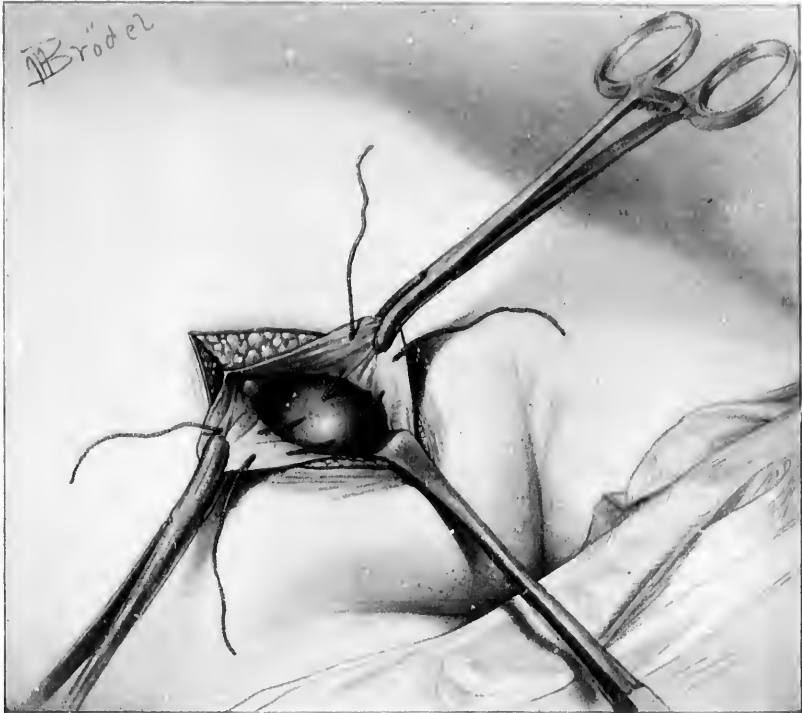


FIG. 354.—SUSPENSION OF THE UTERUS.

Showing the two silk suspensory sutures passing through the peritoneum, the movable subperitoneal fat, and connective tissue on both sides, and through the posterior surface of the uterus in the middle. The suture nearest the symphysis is always tied before introducing the second suture.



wall, still further increasing the antelexion. More than two sutures are not needed unless there is an unusual amount of dragging.

Before closing the abdomen the omentum is drawn down and a final careful examination is made by slipping the finger over the posterior surface of the uterus, around its sides and in front of it, to make sure that no loop of intestine has been caught at any point.

The abdominal incision is closed first by uniting the peritoneum with a continuous suture, then the remainder of the abdominal wall is brought together in the usual manner with a single buried silver-wire suture, with catgut above and below it for the fascia, or by using catgut alone for the fascia, and catgut for the fat and the skin. In some cases, in order not to leave any visible scar, I have opened the abdomen by making a transverse incision in the skin just below the line of growth of the pubic hairs; the edges of the incision were then drawn up and down and the rest of the incision made in a vertical direction. A few months after operation such an incision is entirely concealed from view.

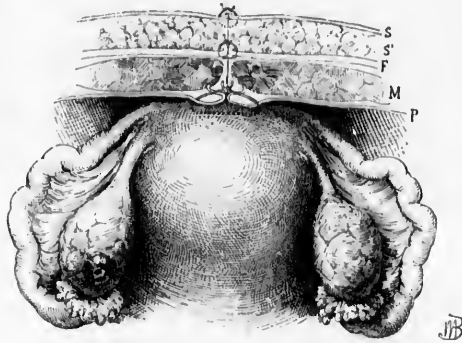


FIG. 355.—SUSPENSION OF THE UTERUS AS SEEN FROM ABOVE.

The uterus is attached by a silk suture to the fundus of a line posterior to the uterine tube, as shown. The cut edges of the peritoneum should be united over this suspensory suture; the fascia is united over this, and the skin over all.

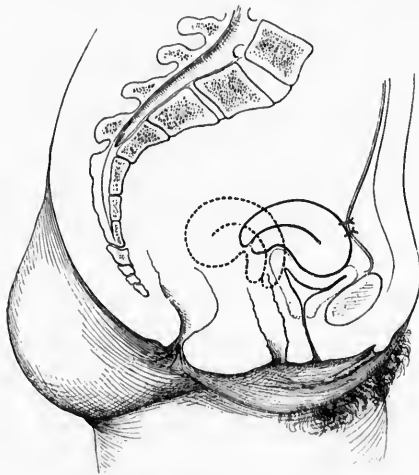


FIG. 356.—SUSPENSION OF THE UTERUS.

Diagram showing the position of the uterus in retroflexion in dotted line, and the position of the uterus held in antelexion by the two suspensory sutures. Note the yielding of the peritoneum.

During the first four days, if necessary, the bladder should be emptied by catheter or spontaneously every three or four hours, and after that the interval should not be longer than four to six hours. Dr. C. P. Noble has seen two cases in which the suspensory sutures have been pulled out during the convalescence by an over-distention of the bladder. His rule is always to use a catheter if there is persistent pain, even if the bladder has just been emptied. The boy should be moved

forty-eight hours after operation. It is not necessary for the patient to remain lying in the dorsal position, and she may without risk be gently turned on either side for rest or sleep. The convalescence is managed as after an ordinary abdominal operation, with the additional precaution of keeping the patient three weeks in bed and urging the necessity of moderate exercise for three or four weeks longer; no heavy work or lifting should be done for at least three months.

Examinations made some months or even years afterward will show that the cervix lies well back in the pelvis, while the body lies in antelexion with the fundus behind the symphysis. The body is separated by an interval of 2 or 3 centimeters from the abdominal wall by the stretching of the adhesions formed about the suspensory sutures, and there is a free mobility in every direction except backward.

I summarize an analysis of 75 cases, made from one to two years after operation, by Dr. J. E. Stokes, of the Johns Hopkins Hospital:

Of these 75 cases, 49 were married and 28 were single. The 49 married women reported 14 pregnancies; 9 were absolutely normal; of the remaining 5, one case suffered from the beginning of gestation with abdominal pain; one patient now pregnant feels wretchedly, with pain over the abdomen; another case miscarried after "violent dancing"; in two more cases the "placenta was retained."

In general, 27 cases were entirely relieved of their discomforts, 37 were greatly benefited, and 11 were unrelieved.

CHAPTER XXV.

CONSERVATIVE OPERATIONS ON THE TUBES AND OVARIES.

1. What conservatism is.
2. Reasons for conservatism.—1. The highest aim of surgery. 2. Importance of the conserved structures: *a.* Mental attitude of the patient. *b.* Menstruation important. *c.* Ovulation and pregnancy important. *d.* Internal secretion. 3. Better knowledge of pelvic diseases. 4. Only the diseased portion of the tube or ovary need be removed. 5. Regeneration of diseased tissues is often possible. 6. Removal of ovary and tube together for purely technical reasons not necessary.
3. Relative importance of ovaries, uterus, tubes.
4. Limits of conservatism.
5. Objections to conservatism.
6. Conservative operations on the ovary: 1. Ovary not removed.—*a.* For tubal disease. *b.* In many cases of parovarian cyst. *c.* In extra-uterine pregnancy. *d.* In hysteromyomectomy. 2. Ovarian adhesions (peri-oöphoritis). 3. Multiple and small Graafian cysts. 4. Enlarged cystic Graafian follicles. 5. Cyst of corpus luteum. 6. Hematoma. 7. Dermoid cysts. 8. Ovarian cystoma. 9. Ovarian abscess.
7. Conservative operations on the uterine tubes: 1. Release of adherent tubes. 2. Opening or resection of closed tubes. 3. Emptying, cleansing, or sterilization of inflamed tubes. 4. Amputation of diseased tubes. 5. Excision of diseased or of strictured tubes. 6. Drainage of tubal abscess. 7. Preservation of the tube or closure of the rent in some cases of extra-uterine pregnancy.
8. Results of conservatism.
9. Cases of pregnancy after conservative operations.

GYNECOLOGICAL conservatism has come to have a new meaning within the past ten years, and it is now the distinctive attitude of the newer and better surgery as contrasted with the widely prevailing radical methods of the last decade.

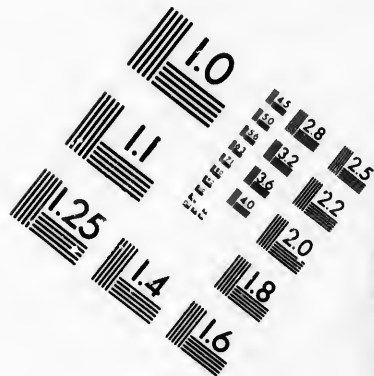
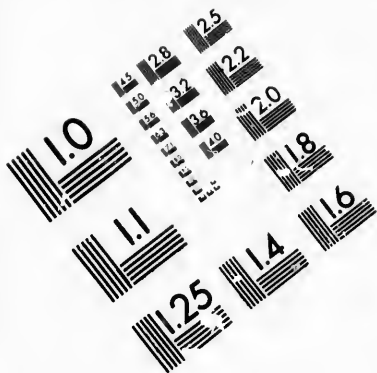
Conservatism is the effort to spare as much as possible of the pelvic organs during an operation, and to conscientiously avoid the removal of any organ or any portion of an organ that is sound, as well as of organs or parts which, though not sound, are deemed capable of regeneration; or, if diseased, to avoid removing organs whose presence is not incompatible with life or fair health.

Fifteen years ago the statement that an operator was conservative meant that in removing a diseased ovary and tube it was not his habit to remove also the opposite sound ovary and tube, under the assumption that "the disease was liable to recur in the opposite side."

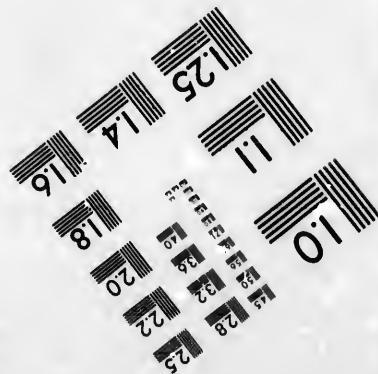



Even yet the pernicious practice prevails in some places of removing ovaries for dysmenorrhœa, and of removing ovaries exhibiting several or more unruptured Graafian follicles under the assumption that they are diseased.

It is only a few years since the rule prevailed widely in regard to pyosalpinx of one side that the opposite side must always be removed too.

The first telling argument in behalf of conservatism was made by Sir Spencer Wells (*Ovarian and Uterine Tumors*, London, 1882, p. 342) in his report of



**IMAGE EVALUATION
TEST TARGET (MT-3)**



**Photographic
Sciences
Corporation**

23 WEST MAIN STREET
WEBSTER, N.Y. 14580
(716) 872-4503



1,000 cases of ovariectomy in tabular form, with a note of the after-history of each case.

An analysis of this table made for me by Dr. J. H. Durkee shows that the ovariectomy was unilateral—that is, that one ovary was left—in 228 women who survived the operation and were under forty years of age; of these 228 women thus left capable of bearing children, 120 actually did bear 230 children; to the women in this group who were over forty years of age four children were born. That is to say, there was an average of one child to every young woman with one ovary left in, and there was a recurrence of the disease in the remaining ovary, necessitating operation, without a death, in but six women. The comparison of the advantage and disadvantage of leaving in an apparently sound ovary is therefore, in each case, the average chance of having one child, as contrasted with the risks of a recurrence of the disease in 2.6 per cent of the cases. If the mortality of ovariectomy is 5 per cent, then the risk of death is thirteen to one against it even if the disease does recur.

C. Schröder (*Die Excision von Ovarientumoren mit Erhaltung des Ovarium. Zeitschrift f. Geb. und Gyn.*, Bd. xi, 1885, p. 353), by the resection of the ovaries, A. Martin (*Ueber partielle Ovarien und Tuben Excirpationen. Samml. klin. Vort.*, 1889, p. 2481), in the resection of ovaries and in opening closed tubes and by extensive myometomies, and Dr. W. M. Polk (*Are the Tubes and Ovaries to be sacrificed in all Cases of Salpingitis? Trans. Amer. Gyn. Soc.*, vol. xii, 1887), by his repeated demonstrations and earnest insistence upon the possibility of restoration of function in diseased adherent tubes and ovaries and of the functional value of opened and amputated tubes—have all helped to lay the foundation stones for the important conservative gynecological work in the immediate future.

The reasons for Conservatism are :

1. That it is the general attitude of all true surgery.
2. The important uses and relation of the conserved structures to the human organism.
3. The recognition that what were once considered diseases of the tubes and ovaries are in many instances no diseases at all.
4. The recognition that a disease of part of a structure, ovary, tube, or uterus may only demand the removal of that portion which is diseased.
5. The discovery that in certain diseases an entire regeneration may take place and badly diseased tubes may again become normal in their functions.
6. On account of the value of the structures involved, ovary and tube are no longer removed *en masse* for purely technical reasons, but a diseased tube or part of a tube, a diseased ovary or part of an ovary, are removed by themselves, each without interfering with the other.

1. Conservatism the highest aim of surgery.

It is almost an aphorism in general surgery that excessive surgery is its opprobrium, and no conscientious surgeon removes a limb or part of the body which could be restored to its usefulness by a careful conservative treatment. I shall never forget the impression made upon me, as a hospital resident in 1882,

when I saw a boy brought in with a clean compound fracture of one forearm and simple fractures of the radius, ulna, and humerus of the other arm, and the surgeon amputated both arms!

If the traditions of surgery and its best principles all point toward conservatism as its highest goal, there is no reason for making any exceptions to these rules in the special field of gynecological surgery.

2. The importance of the conserved structures to the welfare of the patient.

The pelvic organs are indelibly associated in a woman's mind with those fundamental differences between the sexes which impress upon the female organism all that is distinctive and peculiar in her attitude toward the world at large; and with the healthy performance of her functions in the recurring monthly fluxes, ovulation, and the possibility of conception, lie, though the woman may be unconscious of it, some of the deepest wellsprings of her happiness.

The effect of the removal of the sexual organs in woman is, in many instances, entirely analogous to the corresponding operation upon a man, disturbing her psychical and physical balance, and bringing on a state of wretched confusion in the new and anomalous relationship in which she finds herself.

Menstruation has often been denounced as a useless, troublesome function, entailing discomforts and impeding woman's progress in all competitive work, but we are now beginning to realize that so long as its cyclical changes persist, they hold most important fundamental relations to the well-being of the body at large; and while we are as yet unable to state what is definitely accomplished by the act in the way of excretion, or its influence on metabolism, we do know that the sudden artificial induction of the menopause is often a source of extreme and lasting discomforts (see Chapter XXVI). It is still a matter for future demonstration whether or not these sequelæ are in all cases obviated by leaving in one or both ovaries when the uterus and tubes are removed and menstruation so checked.

Ovulation and pregnancy under suitable conditions are, to a degree utterly unappreciable to the male mind, essential elements of woman's happiness. To dwell upon this point would be but to reiterate what any attentive surgeon may gather from his daily experience in the consulting room, and to rehearse well-known facts in the history of womankind.

C. Schröder stated that one of his reasons for the preservation of part of an ovary was to preserve the function of ovulation, even if it were accompanied by but a theoretical possibility of conception. I have dwelt in another chapter on the profound psychic changes and melancholia often brought on by the surgical, forcibly induced menopause.

Internal Secretion.—There is a growing conviction that the ovary belongs to the same group of organs as the thyroid, thymus, and pineal glands, and that, in addition to its function of ovulation, it secretes a substance which is absorbed and consumed in the animal economy, and which is necessary to it in

retaining its physiological balance (see C. H. F. Routh, *Brit. Gyn. Jour.*, May, 1894).

The argument in behalf of the existence of this substance, which we might call "ovarine" were it not for the illegitimate trade uses for which this term has been appropriated, does not yet rest upon the basis of an absolute demonstration, but rather upon the strong analogy which may be drawn between the ovary and the internal secretive glands named, and as evidenced by the disastrous consequences following its removal during the period of its functional activity. C. Martin says (*Brit. Gyn. Jour.*, Nov. 1893, p. 273): "It is probable that the ovaries, like the liver and thyroid gland, modify the blood circulating through them, and add to the blood some peculiar product of their metabolism. It may be that some of the climacteric symptoms are due to the loss of this substance from the system."

An active principle called "spermin," found in sperm by Schreiner in 1878, has been found in the thyroid and thymus glands, and in the spleen, ovaries, testes, and blood, from all of which it has been extracted in the form of an insoluble spermin phosphate.

A. Poehl (*Z. Erkl. d. Wirk. d. Spermins als. physiol. Tonicum auf die Autointoxicationen. Berl. klin. Woch.*, Sept. 4, 1893, p. 873) has elaborately studied this product, and found it in both the male and the female reproductive organs, and as a normal physiological constituent of the prostate, testicles, ovaries, thyroid, thymus, pancreas, and spleen, as well as in the blood.

The crystals of spermin were separated from the semen in a form similar to the Chareot-Leyden crystals of Boettcher, with which they were for a long time confused. Spermin is, as A. Gantier has declared, a lenkomain believed until recently to be a product of the retrogressive metamorphosis of an albumen, either injurious or indifferent to the organism; evidences now in hand, however, go to show that spermin possesses most valuable functions in connection with the activities of living beings, and the spermin secreting and elaborating organs may be called the "apothecaries" of the body, secreting many important medicaments much more active and more accurately representing its true wants under varying conditions than any artificially administered drugs.

Spermin is an active oxidizing agent, assisting by its catalytic action in restoring the oxidizing power of the blood without having recourse to the oxygen derived from the air; this action is remarkably illustrated by the introduction of a small quantity of spermin with metallic magnesium into a watery solution of the chlorides of the noble metals, and some others (AuCl_3 , CuCl_2 , etc.), when the metal is converted into magnesium oxide, the needed oxygen being taken from the water.

Spermin has shown a favorable action when given to patients suffering from diabetes, scurvy, etc., in which auto-intoxications are manifestly the result of an accumulation of retrograde products; injected subcutaneously, it acts as a physiological tonic in all kinds of depressed conditions, such as neurasthenia, anemia, etc. Poehl declares that it increases the nitrogenous excreta of the kidneys. Its action is enhanced by the alkaline condition of the blood.

More positive evidences for an internal secretion of the ovary are furnished by the experiments upon bitches made by G. E. Curatulo and L. Tarulli (*La Secrezione Interna delle Ovaie*, Rome, 1896).

These authors, after regulating the diet of the animals until a certain average quantity of nitrogenous materials and phosphates were excreted daily, removed the ovaries. In each experiment they found the phosphates (P_2O_5) in the urine greatly and permanently reduced in quantity. In one case, where the nitrogenous materials averaged 9.93 grammes and the phosphates 1.5 gramme, a series of daily observations was continued over three months, and demonstrated the fact that, while the nitrogen remained about the same in quantity, the phosphates decreased down to 0.6 gramme.

These data are of such great importance as affording one of the most tangible evidences as yet offered of the existence of this third secretive ovarian function that I present here three of the tables taken from their book, in condensed form. The upper line of figures in each case shows the condition of the bitch before operation; following this are given the dates of the succeeding observations and the condition of the animal at each date; the last line shows what may be considered as the average effect of the castration upon the urine some months after operation.

Table showing the Effect of Castration upon the Composition of Urine.

Date	Weight of animal, gr.	Urine in 24 hours, c. c.	Azote eliminated, gr.	P_2O_5 emitted, gr.
Dog A, both ovaries taken out November 15.				
November 14	9,500	795	9.230	1.710
December 14	7,520	740	9.870	0.740
January 14	8,720	910	10.310	0.700
February 14	9,750	960	10.870	0.665
March 9	10,260	860	10.790	0.650
April 24	9,220	960	9.060	0.576
May 5	10,200	1,065	10.600	0.860
June 23	10,170	680	9.190	0.460
July 12	11,900	790	10.690	0.560
Dog B, both ovaries removed March 10.				
March 9	11,160	840	13.64	1.51
April 9	12,800	870	13.40	1.04
May 8	13,900	900	14.20	0.86
June 9	1,500	700	12.93	0.98
July 6	16,459	620	13.20	0.98
Dog C, uterus and ovaries removed April 24.				
April 15	5,250	470	7.13	0.65
May 15	5,650	530	7.18	0.32
June 15	6,300	500	6.86	0.27

These experiments also explain the utility of castration for the relief of osteomalacia, in permanently diminishing to such a marked degree the excretion of the lime salts which go to form the solid elements of the bones.

Associating Curatulo's results with the evidence given by Poehl of the high oxidizing power of "spermin," we may attribute the effects of castration in de-

creasing the phosphates in the urine, not to the lessened quantity taken in the food, but to a diminished oxidation of the organic phosphates contained in the tissues, which, combined with earthy bases, are finally deposited in the bones in the form of calcium and magnesium phosphates.

Routh (*ut sup.*) gives further important evidence of the existence of an internal ovarian secretion in citing Dr. Airstoff's investigations, which show that when one ovary is removed in a rabbit the other undergoes a compensatory hypertrophy increasing both in size and weight, the follicles mature and wither more quickly, and the medullary portion increases. These changes begin within two months after the operation, and in three or four months the remaining ovary has become nearly double its original size.

Since the ill effects of castration in women, whether the structures are diseased or not, are often so disastrous, it becomes a question of paramount importance to determine whether we can in any way substitute the lost ovarian tissue, and to this end two natural lines of experiments have been tried. E. Knauer (*Cent. f. Gyn.*, No. 20, May 16, 1896, in a communication entitled *Einige Versuche über Ovarientransplantation bei Kaninchen*) has shown that the ovaries may be completely severed from their normal surroundings and successfully transplanted either to a part of the broad ligament or between the muscles of the abdominal wall.

In one of the rabbits experimented upon and examined six months after the transplantation, one ovary excised and implanted in the broad ligament was found as big as a lentil and abundantly nourished, with a normal stroma and numerous follicles of all sizes containing ovules; a number of degenerated follicles was also found, perhaps more than usual. An ovary implanted in the fascia of the abdominal wall was only about a third its original size, but was in other respects normal.

The important conclusion may therefore be drawn that the ovaries may be transplanted even to a distant point differing widely from their normal habitat, where they will not only grow, but will also continue to develop normal Graafian follicles. It still remains to be shown whether these follicles rupture, and of what use transplanted ovaries may be to the animal economy.

The second line of experimental substitution of the lost ovarian tissue is that of feeding to the women deprived of their ovaries one of the various organic juices. This has been tried by R. Chrobak (*Centr. f. Gyn.*, No. 20, May 16, 1896) in a few cases with distinctly encouraging results.

The ovaries of cows, washed in ether and alcohol and dried at a temperature of 45 to 50° C. with an air pump, and then pulverized and made into tablets containing 0.2 gram of ovarian substance each, were used. Two, three, or even four of these tablets were given daily to women suffering from the severe symptoms of an induced climacteric; in one case, after taking two or three tablets daily, the attacks of giddiness, flushes, and sweatings, which the patient had been

having on an average of ten times daily, were reduced to three, and disappeared entirely at night; another patient was entirely relieved of attacks which had been distressing her five or six times a day; in another case, with frequent attacks, as many as twenty a day, they were reduced one half.

If the ovary and thyroid gland both secrete a similar principle, spermin, or if the ovary secretes a principle which is then elaborated for use by the thyroid gland, it is manifest that good results might be expected by the administration of the thyroid gland, or of the thyroid extract, for it shows such remarkable powers of retaining its identity, even in the presence of mineral acids, that it might well be expected to withstand also the chemistry of digestion.

A valuable contribution to this line of observation has been made by Dr. H. B. Stehman, of Chicago (*Amer. Gyn. and Obs. Jour.*, Feb., 1891), who gave thyroid tablets to a series of patients, suffering from various forms of mental and other disturbances, such as excessive flow, amenorrhea, extreme nervousness, and ovarian pains, all of which might, under the present hypothesis of the function of the internal secretions, be attributed to deficient ovarian secretion.

Each tablet given three times daily represented about one sixth of a sheep's thyroid. In each of the six cases such a remarkable improvement was observed within several weeks that the conclusion seems well-founded that "in those cases of neurasthenia, with poor nutrition, and in consequence disordered pelvic function, ovarian tissue is indicated. The extract not only modifies the nutrition of the ovary, but also general nutrition, and this return to the normal makes physiologic processes possible." There exists probably "an intimate nutritive relation between the pelvic generative organs and the thyroid, and the ovary shares, too, in some mysterious manner in the processes of general metabolism."

3. A further reason for the advance made in conservatism is the more intelligent discrimination exercised in regard to pelvic diseases, the result of broader clinical observations, associated with careful microscopic examinations of tissues removed. This has had the effect of compelling gynecologists in general to abandon all enucleations of "cystic ovaries," except in rare cases where the ovary is so greatly hypertrophied as to be converted simply into an aggregation of cysts with the albuginea greatly thickened. A few prominent cysts with clear walls often exhibited in the past as evidences of a "cystic degeneration" are now considered as either entirely normal, or so near normal as never of themselves to justify the removal of the ovary.

"Cirrhosis of the ovary" is still another much-abused term, used even yet to describe the product of a chronic inflammation of the ovary which does not exist as a pathological entity. The so-called cirrhotic ovaries are simply contracted hard bodies, for the most part the result of a protracted malnutrition of the organ, often due to displacement and surrounding adhesions binding it down and cutting off its circulation.

Adhesions of the uterus and adhesions surrounding the tubes and ovaries are often but the evidences of an old attack of pelvic peritonitis due to an infection starting in the mucous surface of the uterus and propagated through the uterine tube; the original disease has, in many instances, long since run its course, and

the lymph bands and adhesions left behind uniting the peritoneal surfaces of the pelvic viscera do not signify any existing disease of the organs themselves. If these adhesions are severed and the accidentally imprisoned organs released, there is no reason, in many instances, why their normal functions should not be re-established and the symptoms relieved without extirpation.

In this connection C. C. Burrows (*Amer. Jour. Obst.*, vol. xxviii, No. 6, 1893) furnishes us with a most instructive case of regeneration. A patient was operated upon and a purulent tube and ovary were removed from the right side; adhesions about the left tube and ovary were broken up, the closed end of the tube was opened, and the cystic ovary was resected, about one third of it being removed. On opening the abdomen a year later to cure a ventral hernia, the tube and the ovary were found free from adhesions and perfectly healthy, the fibriated extremity was open, and no evidences of the ovarian resection could be found; the health of the patient was perfect except for the hernia.

The general rule may then be laid down that adhesions of the ovaries and tubes to the pelvic floor, pelvic walls, or to the broad ligaments, uterus, and intestines, never constitute *per se* a valid reason for the removal of these structures, and if these organs are removed the reason for the extirpation must be grounded in the actual condition of the organ itself.

4. When the disease affects only a portion of a structure, the rule is that the diseased portion should be removed and as much as possible of the sound tissue left.

For example, if the outer extremity of the uterine tube is extensively altered by cicatricial changes the end of the tube may be amputated with a good hope of restoring its function; this procedure will be illustrated in discussing the technique of conservative operations.

If an ovary shows cystic degeneration, the cyst, whether Graafian or corpus luteum follicle, may be excised and the sound tissue left. Even in the case of small ovarian abscesses, 2 to 4 centimeters in diameter, I should advocate opening the abscess, removing its lining membrane or curetting it, and sewing up and saving the ovary.

There is the best clinical evidence to show that even a small bit of ovarian tissue left behind, or the stump of an amputated tube, may not only perform its ordinary functions, but may even contribute and carry an ovum to be lodged in the uterus, and go through the evolutions of a normal pregnancy.

5. The regeneration of inflamed tissues has also been abundantly demonstrated by the best clinical evidences; after draining large pelvic abscesses, the pelvic organs have at a later date been found perfectly restored; uterine tubes presenting a parenchymatous salpingitis have been dropped back and later found healthy, and the best evidence of their perfect function given by the occurrence of pregnancy.

In hydrosalpinx, although distended and thinned by the pressure of the accumulated fluid, the tubal walls preserve their normal epithelial covering, and

after opening the ostium or cutting off the ampullar end the tubes may resume their functions perfectly.

6. The sacrifice of the tube and ovary is often due to purely technical reasons on account of the habit of operators of clinging to a traditional method of removing the tube and the ovary, pulling them up together, and transfixing and tying them off in a bunch.

By the exercise of a more intelligent judgment and with better skill the operator will no longer be embarrassed in removing either tube or ovary alone, or a piece of the tube, or a portion of the ovary.

For the same unintelligent technical reason both tube and ovary have been extirpated in removing parovarian cysts in which it is frequently possible by a simple carefully conducted dissection to extirpate the cyst, leaving behind the otherwise unaffected structures.

Relative Importance of Ovaries, Uterus, Tubes.—In all intelligent conservative efforts the various important objects of the conservatism must be borne in mind, and these are, first, the complete restoration of all the functions without pain; second, to preserve menstruation and ovulation; third, to put the organs in condition to make pregnancy possible; fourth, to preserve ovulation and the internal ovarian secretion, even though the menstruation and possible conception have to be sacrificed.

In each of these four categories the ovaries are essential, for, with the removal of the ovaries, ovulation, internal secretion, and menstruation cease; the ovaries are therefore the organs of paramount importance, and without them both uterine tubes and uteri are useless.

So extremely important are the ovaries that, if the circumstances justify it, even a small piece of sound ovarian tissue should be preserved.

Next in importance to the ovaries comes the uterus, for with the ovaries and the uterus ovulation, internal secretion, and menstruation may continue with due regularity.

There is no reason to believe that the tubes without the uteri and ovaries are of any use; their value is, however, enhanced by the presence of even a small bit of ovarian tissue to such a degree that one or both mutilated tubes may often be preserved with advantage under these circumstances, and pregnancy occur.

Limitations of Conservatism.—Both Nature and disease impose upon our conservative efforts several easily definable limitations.

After a woman has reached the forties, when reparative processes in disease are not as active, and when age makes pregnancy less likely, even under normal conditions, and especially after the menopause, one important reason for conservatism—namely, a chance of conception—loses its force.

This limitation, however, affects only the uterine tubes, whose sole function is to act as transmitters of the ova. The ovaries and the uterus, on the other hand, are of value so long as menstruation persists, for severe nervous disturbances may arise from the removal of both these organs even in the forties.

No age limit can be set upon the utility of the ovaries until it has been demonstrated that the internal secretion also ceases with the menopause, a con-

clusion which is, for the present at least, apparently at variance with the clinical facts. Inasmuch, however, as the ovary has lost at least two of its important uses (ovulation and menstruation), less hesitation should be felt in sacrificing it in the presence of disease.

Malignant disease of an ovary has been generally recognized not only as constituting the strongest possible indication for its removal, but for the removal of its fellow as well, whether apparently diseased or not. I can not concur in this sweeping conclusion, and in the event of discovering such a disease as a superficial papilloma of one ovary at the very beginning, if the other ovary appeared perfectly normal, I should without hesitation save it in a young woman, with the expectation of carefully watching the patient for several years, and of operating at once upon detecting the slightest evidence of disease.

Tumors of the ovaries of the connective-tissue group usually forbid any conservative efforts, as they commonly involve the entire organ.

Objections to Conservatism.—Among the objections urged against conservatism, that of the liability of the disease to recur in the opposite side or in the parts left behind is the most important. When the disease is not of a serious nature, as in the case of Graafian or corpus luteum cysts, there is no evidence to show that the remaining parts are in any way peculiarly liable to disease, and the burden of proof still rests upon those who object to conservatism.

In unilateral inflammatory disease, which is for the most part propagated from the uterine, it is true that the opposite side may subsequently go through the same changes, but there is no more reason for extirpating apparently sound organs than there is for recommending the removal of all infected uteri, unless it is that the open abdomen makes the operation a convenient one.

When both tubes exhibit different stages of the same disease, and one is choked with pus and the other only thickened and inflamed, the question of conservatism is a more difficult one, because the chances of the disease progressing in the healthier side are greater. If, however, the patient has expressed willingness to run the risk of a second operation, the surgeon should be glad, upon removing the worst side, to release all adhesions and to squeeze out and wash out the other tube, and then to dilate, curette, and drain the uterus, in hopes of cutting short the process in this way.

The objection that adherent and inflamed structures are either so far destroyed or crippled by the disease as to be beyond Nature's reparative processes is not borne out by the facts now abundantly laid before the profession. It has also been stated that the risks of an extra-uterine pregnancy were a serious objection to conservative operations upon organs either in themselves diseased or else implicated in neighboring disease, and while this argument demanded careful consideration at first, the fact that no case has ever yet been reported is a sufficient answer to it. There is no risk of infection, sepsis, and death in operations upon non-inflammatory cases, such as resection of the ovary, etc. In inflammatory cases the risk is not increased in the absence of pus, but in some forms of pelvic abscess the risk may be very great.

The history of the case and the severity of the inflammatory process asso-

ciated with a microscopic examination of the pus during the operation will often guide the operator as to the advisability of opening up and washing out and leaving the pus tube or an ovarian abscess.

In the presence of numerous cocci, presumably streptococci, I should not attempt to preserve the structure in which they were found, but I should not hesitate to treat abscesses showing gonococci, or sparse cocci or bacilli of any other sort, by carefully cleansing them and restoring the organs with or without a vaginal drain, according to the extent of the disease.

The published records so far do not show any increase in the mortality from conservatism of this sort.

The risk to life from a second operation is not often increased by the first operation; the abdominal scar may be easily excised, and if a considerable part of the disease has been removed, the second operation is, as a rule, much easier than the first. It is true that the pain, often to the patient the one prominent symptom, may persist and prove the conservatism in any particular case to have been ill-advised; but, to refer again to recorded cases, the patients who have continued to complain constitute a small minority—much smaller than the percentage complaining after the executive operations of a few years ago.

In general the best reply to all these objections is the assertion of the patient's inalienable right in all cases to decide that her pelvic organs shall not be sacrificed under any possible complication of conditions which may exist, and the conscientious surgeon will always abet her in her willingness to take some risks in order to preserve her natural functions.

In case the patient commits her case entirely to the hands of the surgeon to use his best judgment, he should act in all cases as he would do if she were his nearest relative, and try hard to avoid mutilation.

CONSERVATIVE OPERATIONS ON THE OVARY.

The removal of the opposite ovary in disease of one side was the habitual practice of some of the earlier gynecologists, and still continues, as I know by experience, to be the routine custom of men not well trained in their special work. In so far as the question relates to unilateral ovarian cystoma, I have given an unanswerable argument in the early part of this chapter, elaborated from the statistics of Sir Spencer Wells's one thousand cases of ovariectomy.

The question is, however, quite a different one when one ovary is affected with papilloma, sarcoma, or carcinoma; these diseases are so frequently bilateral that there appears at first sight to be a marked liability on the part of both organs to become affected independently of each other, in which case the second ovary, if left behind, will be so liable to require operation at a later date that complete extirpation of both sides is the rule.

I can not, however, assent to this theory, as yet unproved, and so have adopted the following rules:

When the opposite ovary appears perfectly sound and normal in size, consistency, color, and outlines, I in all cases leave it in a young woman.

If it is enlarged and there is reason to suspect disease, I remove it.

In a case in which it is extremely important to retain one ovary and I am not quite sure of its condition, I excise a wedge of the ovarian tissue and harden and examine it immediately, during the operation, under the microscope, and if the piece is found diseased I remove the entire organ; if no disease is found I spare the organ and keep the patient under careful observation for several years.

In a case (L. K. W.) of superficial papilloma of the right ovary in a young woman twenty-seven years old, operated upon Feb. 10, 1892, the left ovary, which appeared sound, was left in; she has since married and continues now, five years after the operation, in good health, without recurrence, as I have assured myself by examination.

In another case (A. W., 5069, March 6, 1897) of papillomatous masses of the right ovary sprouting out between enlarged Graafian cysts, I removed the entire ovary; the left ovary was sound except at its outer pole, where there were three large Graafian cysts, without any evidence of papilloma; these were cut out and the sound portion closed by a continuous catgut suture.

In the case of a large fibroma of the right ovary (A. S. W., 5061, March 10, 1897), attached by a distinct pedicle, 2.5 centimeters long and 1.5 centimeter wide at the inner pole of the ovary, my assistant, Dr. Cullen, excised the pedicle, cutting deeply down into the ovary, and removed the mass; about three fifths of the ovary remained and the wound was closed by a continuous catgut suture.

The following are the various conditions for which conservative operations may be practiced upon the ovary:

1. The ovary is not removed for purely technical reasons and through adherence to a purely traditional style of operating—(a) For tubal disease. (b) In many cases of parovarian cysts. (c) In extra-uterine pregnancy. (d) In hysteromyomectomy.

2. Ovarian adhesions (peri-*o*phoritis).
3. Multiple Graafian cysts.
4. Single large Graafian cyst.
5. Cyst of the corpus luteum.
6. Hematoma.
7. Dermoid cyst.
8. Ovarian cystoma.
9. Ovarian abscess.

The conservative principles applied to the treatment of the ovary under these various conditions involve the puncture of some cysts, the excision of other cysts and sewing together the parts which are left, and the amputation of a greater or lesser part of the ovary with suture of the remainder.

Whenever it is possible, the ovary with the uterine tube should be lifted outside the body and isolated by surrounding it with gauze pads; a large cystic ovary may be emptied first by aspiration and then lifted out, to avoid making a large abdominal incision. The ovarian tissue does not usually bleed freely, but if there is much oozing it may be con-

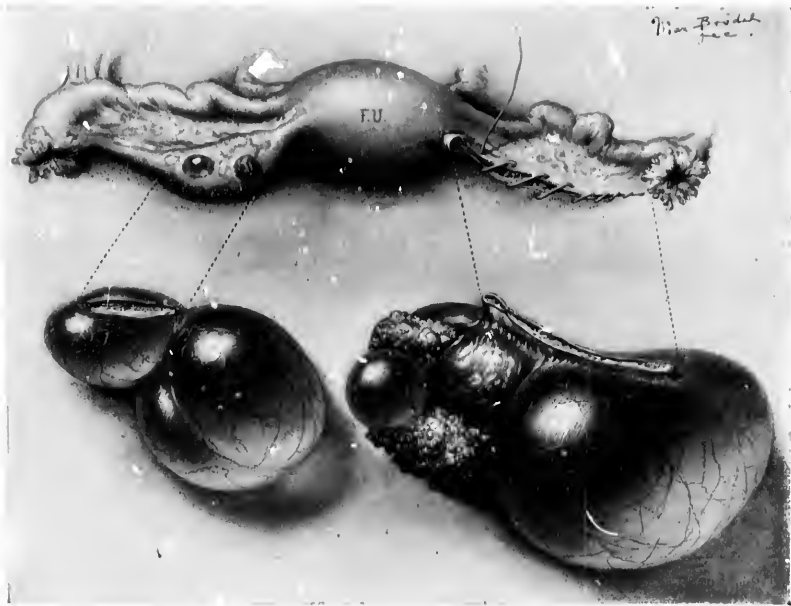


FIG. 357.—CONSERVATIVE OPERATION ON THE OVARY. $\frac{5}{8}$ NATURAL SIZE.

On the right side the entire ovary has been removed for papilloma; on the left, two eystic Graafian follicles have been removed and the ovary sutured and left, as shown. The parts removed are shown in the lower part of the figure. Op., March 6, 1897.

trolled readily by digital compression of the vessels at the poles. The diseased ovarian tissue may be removed either with a knife and forceps or with the fingers when it is friable. As the ovary is but a small organ, and the simple diseases treated conservatively are not liable to recur at the site of extirpation, the dissection should aim simply at shelling out the affected portion with the least possible sacrifice of good tissue.

A wedge-shaped excision, whether in the length or the breadth of the ovary or at one of the poles, is easier to bring together by suture.

A small needle threaded with a fine catgut suture is the best means of approximation. Each suture is passed well down into the tissue, entering and emerging 2 to 3 millimeters from the edges of the cut and tied tight enough to control any hemorrhage; when all are in place the ovary is dropped back into the pelvis. If there is but little tendency to bleed a continuous suture may be used with advantage.

1. **Ovary not Removed for Technical Reasons.**—The ovary should never be removed simply because the tube of the same side is taken out, and as a matter of convenience. The diseased tube can be removed alone after releasing it from its adhesions by cutting it off at the uterine cornu, or by making an incision into the mesosalpinx, just under the fimbriated end, and then cutting or stripping it loose along the mesosalpinx, keeping close beneath the tube, until the detachment is complete. In this way only small vessels are divided and the bleeding is slight and easily controlled by a few fine catgut ligatures; the layers of the mesosalpinx may then be drawn together with a continuous catgut suture.

In all cases of parovarian cysts where the ovary can be traced by means of the utero-ovarian ligament and clearly distinguished from the tumor, there is no need to sacrifice either the ovary or the tube in removing the cyst.

Parovarian cysts with clear walls and of lesser size may be removed by incising the mesosalpinx at a point where there are the fewest vessels, and drawing back the peritoneum on both

sides as the cyst is shelled out from its bed; another plan of removal, useful when the peritoneum stretched out over the cyst is redundant, is to make an oval incision into the peritoneum, removing a sufficiently large piece to permit the remainder to be drawn neatly together after the extirpation.

In large parovarian cysts where the tube is greatly elongated, after tapping

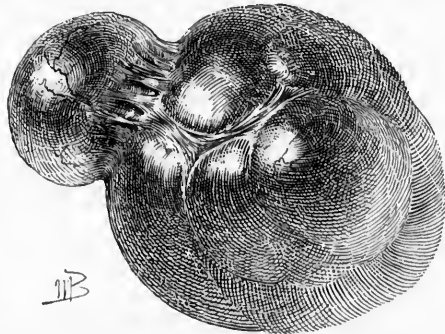


FIG. 358.—PAROVARIAN CYST IN THE LEFT BROAD LIGAMENT REMOVED BY INCISING THE MESOSALPINX AND WITHOUT SACRIFICING EITHER OVARY OR TUBE. SAN, NOV 21, 1895. NATURAL SIZE.

the cyst and bringing it outside and carefully distinguishing the position of the tube and the ovary, the opening into the mesosalpinx is enlarged, the cyst withdrawn, bleeding vessels secured and the peritoneal opening approximated, and the whole dropped back again minus the tumor.

In extra-uterine pregnancy there is no reason whatever for the sacrifice of the ovary in removing a mutilated tube; Dr. J. G. Clark has allowed the ovary to remain without any apparent disadvantage in a case operated upon at my clinic.

In hysteromyomectomy, by tying off the uterine tube at the uterine cornu instead of near the pelvic brim, the tube and ovary are both pushed down into the pelvis and out of the way as soon as the top of the broad ligament is opened, when the rest of the enucleation is conducted as before.

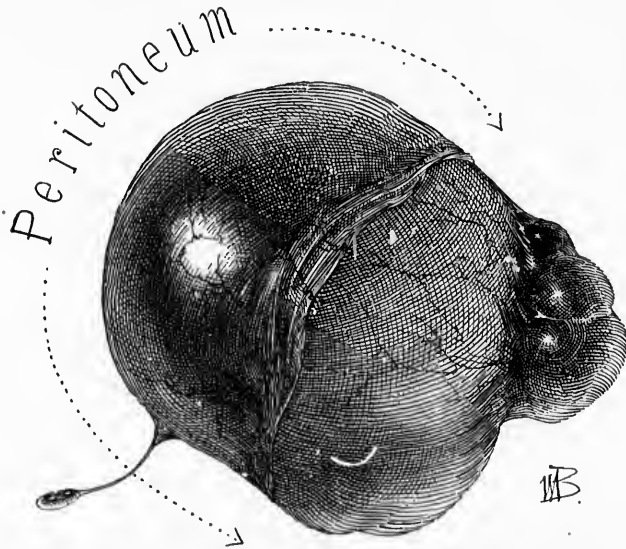


FIG. 359.—PAROVARIAN CYST ENTIRPATED WITHOUT REMOVING EITHER TUBE OR OVARY.

The cap of peritoneum was left on by cutting through it on all sides and then shelling the tumor out of its cellular investment. Note the additional cysts attached to the tumor on the right. *San. Nov. 21, 1895.* Natural size.

2. Adherent Ovaries.—Ovarian adhesions (peri-oöphoritis) may vary all the way from a delicate web between the ovary and the pelvic wall, scarcely appreciable to the touch, to a dense mass of lymph imbedding the ovary so completely out of sight that it appears to be actually within the broad ligament (pseudo-intraligamentary).

The lighter weblike and velamentous adhesions are easily broken up with the fingers, or by exposing the adhesions and using the points of the scissors in conducting a careful dissection until the ovary is freed.

In detaching a more firmly adherent ovary the best plan of procedure is to try to work the fingers in beneath it and so secure a purchase under its free

border for rolling it on its hilum, as an axis, from below up toward the brim of the pelvis. Any attempt to free it by working in a direction from above downward will only result in tearing the tissues. If the ovary hangs low down in the pelvis, after freeing it, the ovarian ligament should be shortened by taking a plait in it, so as to lift the ovary closer up beside the uterus. I have even stitched the ovary directly to the uterine cornu. After controlling any hemorrhage from the pelvic floor and walls the abdomen is closed without a drain.

I would not be understood to recommend opening the abdomen to release any but dense ovarian adhesions, for all others which can be broken up with a moderate amount of force may just as well be handled bimanually and set free through the rectum and abdominal wall.

This is done by securing a thorough evacuation of the bowels and placing the patient under anesthesia; the index finger of one hand is then carried well above the ampulla behind the uterus by pushing the uterus a little back into retroflexion with the other hand; then the index finger, passing along toward the cornu, readily distinguishes the prominent utero-ovarian ligament, and by tracing this out toward the pelvic wall the ovary is found.

After determining its size and outlining any irregularities of its surface, the next effort made is to test its mobility, and this is done, not by pushing it up as a whole, but by introducing the finger, or if need be two fingers, under its lower border and lifting it; if it is free, it will go up easily, rotating on its hilum as an axis; if it is adherent, the adhesions will be felt giving way and snapping one after another as the pressure is increased until the whole surface is freed. The greatest difficulty will be found in completely freeing the pole next to the pelvic wall; after the ovary is entirely free, the finger can be carried around it on every side, above and below and around both poles, and it responds readily to every touch.

3. Multiple and Small Graafian Cysts.—It is not yet decided whether any clinical symptoms arise from the cystic follicles often seen, from the size of a pea to that of a cherry. It has been my habit, as well as that of many other operators, to bring out the ovary and puncture these cysts with a knife point or a needle, and to empty them by pressure. P. Müller and Pozzi use the thermocautery in opening them, to prevent reclosure. Until we know just how far an aggregation of cystic follicles may be a departure from the normal, we shall not be in a position to decide this important question. One thing, however, is quite certain for the present, and that is that they never of themselves justify removal of an ovary or even of a piece of an ovary.

4. Enlarged Cystic Graafian Follicles.—Graafian follicle cysts form a definite group of tumors of the ovary, and are, as indicated in the name, simply enlargements of structures which normally remain small and rupture or disappear.

Such cysts are single or multiple and vary in diameter from 6 to 8 millimeters to 6 or 8 centimeters or even more.

The smaller cysts can only be reckoned as pathological when they occur in large numbers in an enlarged ovary, as shown in Fig. 360, and must be care-

fully distinguished from the few small cysts normally found in ovaries which are not enlarged; they appear as numerous pealike projections over the surface of a large ovoid ovary with a dense coat.

The single cysts increase to the size of a walnut or an orange, occupying a part of the ovary with translucent walls, easily ruptured.

Pathologically these are nothing more than dilated cystic follicles; if they are adherent in the pelvis their surface, instead of being smooth, is roughened by the attachments.

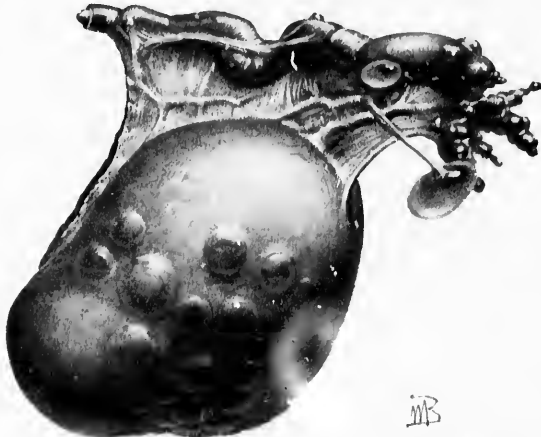

FIG. 360.—HYPERTROPHY OF THE OVARY, WITH CYSTIC DEGENERATION.

Over twenty follicles are visible on the surface, projecting from beneath the thick capsule. Path. No. 282.

The walls, varying in thickness from 1.5 to 2 or 3 millimeters, are thinnest at the most prominent part. The fluid within resembles serum or clear water, or it may be made turbid by hemorrhage. It contains desquamated and fatty epithelial cells. Ova are often found within demonstrating their origin.

The cyst wall exhibits the layers of the Graafian follicle with a single layer of cuboidal or flat epithelium within. Round hyaline masses correspond to degenerate epithelial cells.

I have had one case in which a dilated Graafian follicle and a cystic corpus luteum existed side by side in the same ovary. The partition wall broke down and the two coalesced, forming a single cyst with the characteristics of each in different places.

The symptoms produced are generally more or less constant discomfort or pain on the side on which the tumor is situated, increasing at the menstrual period. The physical signs presented by such cysts are usually definite enough to enable the examiner to make a correct diagnosis.

Such follicles may rupture spontaneously through the increasing tension of the thin walls and the patient experiences a sudden relief, or they are often ruptured accidentally, as I have seen, in making a bimanual examination. In several cases, upon opening the abdomen at once, I have found from 20 to 50 cubic centimeters of blood-tinged serum in the pelvis with the torn edges of the cyst floating in it.

If a positive diagnosis could be made in every case it would never be necessary to open the abdomen for the sole purpose of treating these cysts, for

the plan of rupturing them by pressure made by a finger in the vagina or rectum would be perfectly safe, and probably in most instances just as efficient in curing the affection as an extirpation by celiotomy.

While they can be recognized with certainty in most cases by a well-trained touch, they may be confused with a corpus luteum cyst, an ovarian or tubal abscess, or encysted pelvic peritonitis, or a hydrosalpinx.

The differential points are these: the Graafian cyst has usually such thin, delicate walls that they seem almost ready to rupture on making the gentlest pressure; it is more or less spherical in outline, and at its base connected with the ovary, and as a rule it is not adherent. Abscess cases and encysted peritonitis show evidences of surrounding inflammation in the hardening of the incasing tissues; the hydrosalpinx is elongated and not so circumscribed. Wherever there is any doubt in the diagnosis, the safe rule is not to rupture the cyst, but to take it out by the abdomen or by a vaginal incision.

The cyst may be deliberately ruptured by grasping it between the fingers through the abdomen and rectum and gradually increasing the pressure until it breaks suddenly, and in a moment all trace of the tumor is gone. I have twice opened the abdomen for other causes within two or three days after the unintentional rupture of one of these cysts in the course of a preliminary examination, and found but a few cubic centimeters of blood, serum, and a flaccid collapsed cyst with a wide rent in its wall.

If the sac does not yield to a moderately firm pressure, the effort should be abandoned and the cyst tapped through the vagina. Before tapping, the vagina must be cleansed thoroughly with soap and water; then a long trocar and cannula attached to an aspirator is introduced guided by the finger, which rests on the tumor at the vault of the vagina; an assistant, by making pressure above, brings the cyst firmly down onto the vaginal finger, while the operator pushes the trocar and cannula into the now prominent convex surface close to and a little behind the cervix, in a direction upward and slightly backward. The trocar is withdrawn and the fluid evacuated through the cannula. After evacuation the cannula is withdrawn and the vagina loosely packed with iodoform gauze. There is no reaction following so slight an operation.

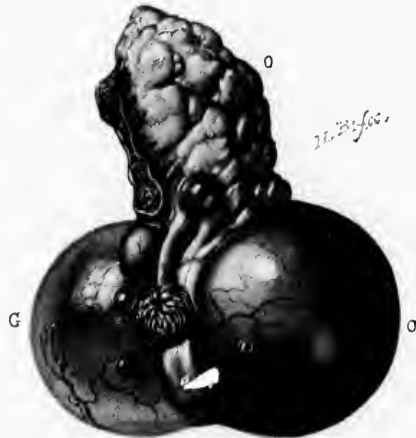

FIG. 361.—HEMORRHAGIC CORPUS LUTEUM CYST (C) AND CYSTIC GRAAFIAN FOLLICLE (G) IN THE SAME OVARY.

The cysts are buckled together and were developed from the outer extremity of the ovary (O) on both sides of the tubo-ovarian fimbria. The tube is held rigid, stretched out in the sulcus between the cysts. May 10, 1896. Natural size.

When such a cyst is ruptured or evacuated in this way it does not, as a rule, refill.

After rupture the patient should be kept in bed two or three days and have the bowels freely opened.

The operation for the removal of the cyst by celiotomy is a simple one. If it is small and can be easily brought out of the incision without rupture, this may be done, but if it is large it is better to tap the cyst and empty it and draw it out in a collapsed condition, rather than to enlarge a small incision. Laying the ovary with the cyst on a small pad, the cyst is then excised, and as it usually lies attached to the superficial free portion of the ovary, this again need not be cut into deeply.

Sometimes it is attached to one of the poles or to the free border, and is almost pedunculate; in this case, an oval incision is made around its base and a careful dissection suffices to peel it out of its bed, and the wound in the ovarian tissue is then closed with a few interrupted catgut sutures, or with a continuous suture, if the wound is a long one.

Multiple large cysts, either connected or isolated, should be treated in the same way.

5. **Cysts of the Corpus Luteum.**—These are corpora lutea which have not ruptured and which have reached abnormal dimensions. The average size is

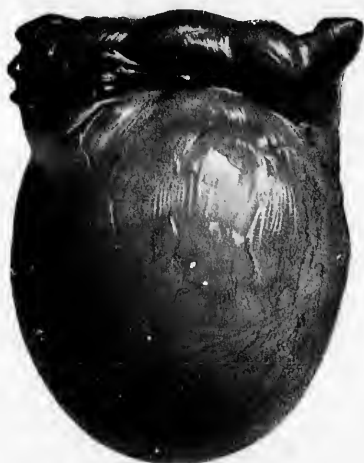

FIG. 362.—CYST OF THE CORPUS LUTEUM.

The uterine tube lies on the cyst above. No. 173. Natural size.

that of a walnut, but they may reach 6 centimeters or more in diameter. If small they are seen as cysts springing from the ovary, but if large they may occupy the greater part of the ovarian tissue. Their walls may be gray, bright red, bluish red, or almost black, but shining through the peritoneal covering, usually there is a yellowish red or golden yellow tissue similar to that seen in a typical corpus luteum. Beneath the peritoneal covering numerous fine branching blood-vessels can be seen. The cyst walls vary from 1 to 2 millimeters in thickness. The inner surface is covered by a reddish yellow membrane to which a few clots may be attached. The cavity is partially or completely filled with blood, which may have undergone retrogressive changes, and accordingly be of a dark chocolate

or inky black color. These cysts are but loosely connected with the tissue of the ovary, and are sometimes even shelled out accidentally while handling the ovary.

Histologically the cyst walls are composed of ovarian stroma, which may contain ova, Graafian follicles, or corpora fibrosa. The inner surface is lined

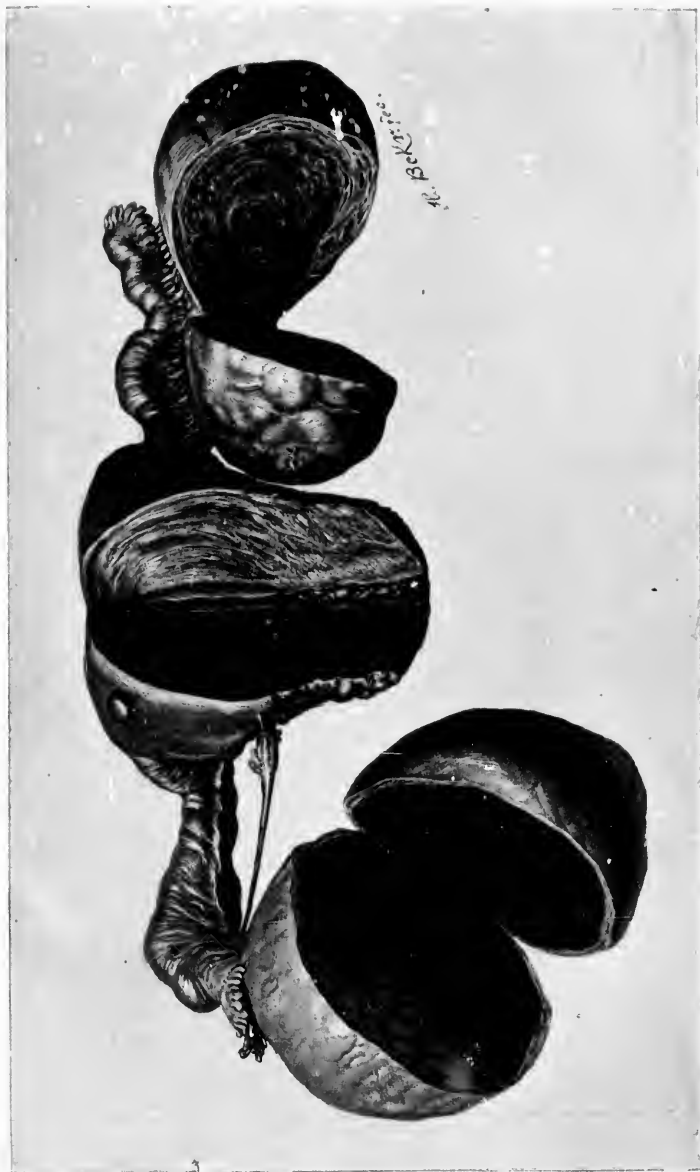

FIG. 364.—CYSTS OF CORPORA LUTEA IN BOTH OVARIES.

by several layers of corpora lutea cells, some of which may be swollen and filled with brown granular pigment, or present a vacuolated appearance. Passing inward from the ovarian stroma are spindle-shaped cells, which divide the corpora lutea cells into rows. Numerous new-formed blood capillaries may accompany these spindle-shaped cells. The cyst cavity contains red blood-corpuscles; degenerate cells, polynuclear leucocytes, and granular material may also be present.

These cysts do not differ in any way clinically from the Graafian cysts just described, unless it be that the wall of the cyst is sometimes thicker and the contents jelly-like and discolored with blood.

The operation is in all respects similar to that described above.

The figures in the text show well how easily such a cyst may be removed, often leaving the ovary almost intact.

6. Hematoma of the Ovary.—The surgical treatment of hematoma will vary with the extent of the disease.

From our present standpoint the hematoma must be reckoned among the benign tumors, and the conservative course of treatment is a proper one whenever it can be of any use. When the entire ovary appears to be taken up by a large hematoma, and no sound ovarian tissue can be found about its hilum, the better plan will be to extirpate the ovary. When, on the other hand, but a portion of the ovary is involved, the affected part should be cut away and the sound portion left. This will often demand a more extensive dissection of the tissue than in cystic disease, on account of the more intimate relation of the hematoma to the ovary; but the suturing and the rest of the treatment is the same.

7. Dermoid Cysts of the Ovary.—Quite another field for conservatism is opened up in the treatment of dermoid tumors and ovarian cystomata.

The first case operated upon in this way was by C. Schröder (*Zeitschr. f. Geb. u. Gyn.*, Bd. xi, p. 360). The patient, twenty-five years old, had had one child, which had died, and she was intensely anxious for another.

Celiotomy was performed Nov. 30, 1882. The tumor on the right side was of a mixed nature—both cystoma and dermoid—and was so developed as to leave intact and sound a considerable part of the ovary, from which the tumor was excised and the wound closed by suture. The left ovary was about three times enlarged by a small dermoid cyst, which was removed by a wedge-shaped excision, and the surfaces united by fourteen sutures. Examination over a year later showed an exudate behind the uterus.



FIG. 363.—PEDUNCULATE CORPUS LUTEUM CYST OF THE LEFT OVARY, IN WHICH THE TUMOR IS ATTACHED TO THE OVARY BY A BROAD PEDICLE OF OVARIAN TISSUE.

Upon removal of the cyst, sound ovarian tissue is left. Jan. 4, 1895. Natural size.

This initial experiment has been most successfully repeated by F. Matthæi (*Zeitschr. f. Geb. u. Gyn.*, Bd. xxxi, 1895, p. 351).

In four cases of dermoid cysts involving both ovaries, the tumor on one side being large and on the other side small—"about the size of a walnut"—the large tumor was extirpated with the ovary, while the small one was excised from the sound ovarian tissue, and the wound sewed up with a continuous cat-gut suture. In each one of these instances the patient either became pregnant or bore a living child within two years after the operation.

8. Ovarian Cystoma.—While an ovarian cystoma commonly involves the entire ovary in such a manner as to prevent the isolation of any definite portion of normal ovarian tissue, in exceptional cases a part, and it may be even the greater part, of the ovary may be found unaffected by cystic degeneration at the base of the tumor; the best guide to discover such a portion of sound tissue is the utero-ovarian ligament, which can always be found. When it has been necessary to remove the other ovary, or when the opposite tube or ovary is extensively diseased, it will be justifiable to remove the cystic portion alone and to leave behind that portion of the ovary which macroscopically appears to be sound. The figure in the text shows a case (G. II. K., 4224) operated upon, March 21, 1896, for multilocular ovarian cystoma with twisted pedicle. Had it been important to preserve this ovary, an examination of the drawing will show how readily the greater part of it could have been left after removing the tumor.

In cases of ovarian sarcoma resembling an ordinary cystoma, the second ovary, if it has presented any suspicious appearances, ought to be removed as soon as the diagnosis is made by the microscopic examination.

In an unfortunate case of Hegar's (*Verhand. d. Deutsch. Gesellsch. f. Gyn.*, 1892, p. 255) a right-sided cystoma was removed, and a left ovary which looked suspicious was left; the microscopic examination showed that the tumor was sarcomatous. The woman went home, became pregnant, and bore a miserable deformed child, and returned to the clinic with a tumor of the opposite ovary, which was inoperable, and from which she died.

9. Ovarian Abscess.—In some cases of ovarian abscess the ovary may be saved by a carefully applied conservatism. In the rare instances in which the abscess is located down in the center of the ovary and surrounded by a thick capsule the ovary may be brought up, laid freely open, the pus evacuated, and the lining membrane of the cavity scraped or dissected out, after which the ovary may be closed by suture and dropped again into the pelvis.

While it is not my intention to speak here in detail of the conservative treatment of pelvic abscesses (see Chapter XXVII), it is important to refer to those cases of pelvic abscess involving both ovary and tube which have recovered by drainage through the vault of the vagina without the extirpation of either ovary or tube. In three instances of this kind in my practice pregnancy has occurred after the healing of the abscess.

CONSERVATIVE OPERATIONS ON THE UTERINE TUBES.

Although the tube is a more delicate structure than the ovary, and its function as a carrier of the ovary is more easily disturbed than is that of the maturation and discharge of the ova from the ovary, it is, however, marvelously amenable to conservative treatment in a variety of affections. The following are the commonest operations which may be practiced upon the uterine tubes:

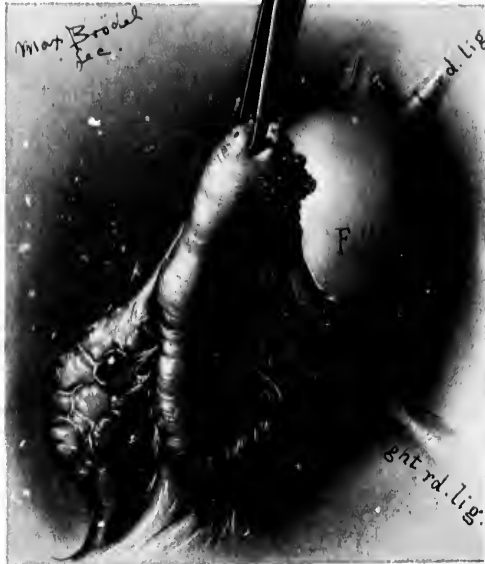

FIG. 365.—VELAMENTOUS ADHESION OF THE RIGHT UTERINE TUBE TO ITSELF AND TO THE UTERINE CORNU. APRIL 1, 1897. NATURAL SIZE.

1. The release of adherent tubes.
2. The opening or resection of closed tubes.
3. The emptying, cleansing, and sterilization of inflamed tubes.
4. The amputation of diseased tubes.
5. The excision of diseased or of strictured tubes.
6. The drainage of tubal abscesses.
7. Preservation of the tube in extra-uterine pregnancy.

1. **Adherent Tubes.**—Adhesions binding the tubes down in the pelvis may often be released by running the fingers down under the tube and breaking them up one after another, or by exposing the uterine end of the tube and making traction upon it, and so tracing the tube down toward the pelvic floor. Adhesions which can not be broken easily with the fingers should be exposed

and divided with the scissors; too great traction, or too rough manipulation must not be made as it is liable to rupture the tube.

It is not only important to set free an imprisoned tube in this way, but to divide every adhesion found in any way connected with its peritoneal surface.

To set a tube free from its pelvic wall adhesions and leave it kinked is to risk an extra-uterine pregnancy afterward. The figure in the text shows an example of a tube flexed at an acute angle by an adhesion upon itself, stretching from the ampulla to its uterine end; the simple division of such band of adhesions sets the tube free and restores its normal mobility.

The tubo-ovarian fimbria is one of the most important parts of the tube, because it is the hinge or arm by which the tube is enabled to apply itself to all parts of the ovary and so to take up the discharged ova, which are then transmitted to the uterus.

I find three kinds of adhesions affecting this important tubal structure, two of which are figured. One is a simple shortening due to adhesions, which restricts the area to which the tube may apply itself to a short radius about the

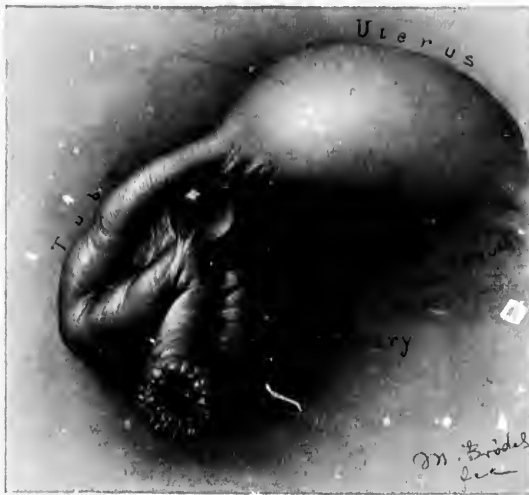

FIG. 366.—ANGULAR ATTACHMENT OF THE LEFT UTERINE TUBE TO THE CORNU OF THE UTERUS.
DEC. 16, 1896.

outer pole; in another the tube is contracted down to the ovary by an obliteration of the outer portion of the mesosalpinx, so that it lies with its orifice directed away from the ovary; in the third the tube is flexed about the ovary with its lumen still open and turned toward one small area, to which it may be closely applied

The treatment of these adhesions simply requires a careful dissection with a

scalpel, detaching the tube from the ovary until the mesosalpinx and the tubo-ovarian fimbria are restored to their normal length.

2. **Closed Tubes.**—When adhesions form about the fimbriated extremity of the uterine tube on its peritoneal surface the tendency of the contracting lymph is to roll in the mucous surfaces, and so to gradually obliterate the

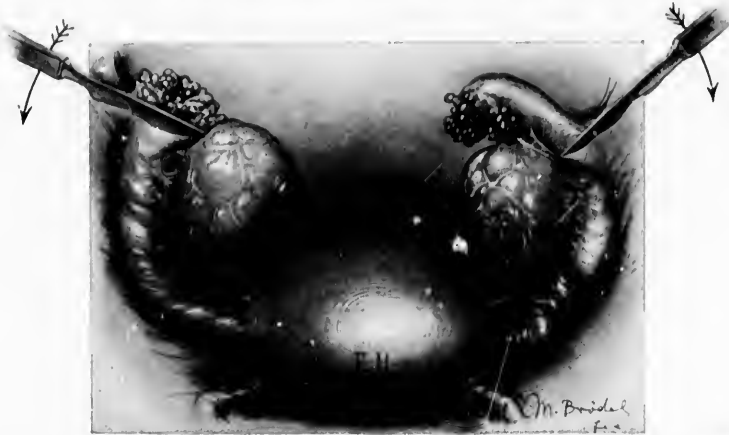

FIG. 367.—ADHESIONS OF THE OUTER FREE EXTREMITIES OF BOTH UTERINE TUBES TO THE OVARIES.

Showing the method of dividing the adhesions with the scalpel and so freeing the tubes. On the right side the tube is attached in such a manner that its open extremity looks away from the ovary; on the left side the tube is fastened down with its orifice facing the ovary. Feb. 1, 1896. $\frac{3}{8}$ natural size.

lumen of the tube. In an earlier form these adhesions may be seen just back of the fimbriae surrounding the tube like a collar, forming a white fibrous band encircling it from 2 to 4 millimeters in diameter; in a more advanced form the lumen may be closed down to a little orifice, out of which pouts one or more congested fimbriae; in its most advanced form the orifice is completely obliterated and replaced by a depressed scar radiating out over the knobbed end. This collar may be divided in several places, releasing the fimbriae.

The closed tube may be opened best by cutting through the scar and up along its dorsum for from 1 to $1\frac{1}{2}$ centimeters, and so laying bare the lumen of the tube and forming a new orifice. The mucous lining should then be drawn out and attached to the peritoneum by fine catgut sutures.

Any contents of the tube must be carefully taken up on gauze, and if they are other than a clear limpid fluid, the tube must be washed out as described in the following section.

3. **Emptying, Cleansing, and Sterilization of Inflamed Tubes.**—Sometimes a catarrhal or a parenchymatous salpingitis is found with a greatly congested and thickened tube, whose orifice is open, and a little milking easily forces out a drop or so of bloody serum or of mixed blood and pus.

Under such circumstances the decision will often be difficult whether it will be safe or not to attempt to save the tube. The surgeon will be guided principally by the intensity of the local reaction already produced on the pelvic peritoneum by the infection, as well as by the character and abundance of the cocci found by an immediate microscopic examination, coupled with such facts as have been elicited from the history. Associated with these data, due weight must be given to the urgency of saving the tube in the particular case in hand. This urgency will naturally be greater if the other tube must be sacrificed, as is often the case when the grade of the inflammatory infection varies on the two sides; the age of the woman and the number of children she has, as well as her condition in life, must also be considered. The most favorable cases are those where no organisms are found at all, or where the gonococci appear alone.

To cleanse a tube, it is lifted out of the abdomen, if possible, and laid on a gauze pad and gently squeezed empty a few times by stroking it from the uterine toward the fimbriated end; the fluid discharged should be used for cover-slip and culture experiments. The tube is then washed out with normal salt solution by a syringe attached to a fine silver cannula with a rounded end perforated with holes; the end of the syringe is introduced as far as it will go easily, and the fluid forced in and collected as it flows out from the fimbriated end.

After washing it clean in this way the tubal mucosa is sterilized with a 1-5,000 bichloride of mercury solution, emptied, wiped dry, and dropped back into the pelvis.

4. Amputation of Diseased Tubes.—If the outer extremity only of a tube is diseased, an amputation may be done so as to remove the disease and leave whatever part is sound.

In this way the end only may be cut off, or half, or even the whole ampulla removed. It is of manifest advantage to leave, if possible, a little of the distal end of the tube in order to secure an open orifice to take up any ova which might by chance fall into it or be drawn into it by the pelvic current which sets toward the orifices of patent tubes.

C. C. Burrows has practiced amputation in cases of pyosalpinx in five instances, as recommended by Polk (*Trans. Amer. Gyn. Soc.*, vol. xviii, p. 182). He says that in some cases there is a healthy patulous portion of the tube next to the uterus, which is shut off from the outer diseased end, and "in such cases where the ovary is healthy and the fimbriated end of the pus tube is not adherent to it," he has amputated the tube at the outer end of the healthy portion, washed it out, slit it up a short distance, and united its serous and mucous coats by fine catgut sutures, forming an artificial abdominal ostium. Five cases treated in this way made perfectly good recoveries.

When the whole ampulla is removed, then even the stump of the isthmus may be serviceable with its small orifice.

In amputating a tube, a ligature is never thrown about its lumen, but it is simply cut off with a scalpel, the bleeding checked, and the permanency of the opening secured by uniting the mucous and peritoneal surfaces by suture.

5. **Excision of Diseased or Strictured Tubes.**—In nodular disease of the tubes, or in the case of a stricture of the tube, or in event of the entire division of the tube into two parts, the diseased portion may be excised and the ends brought together by an end-to-end anastomosis (salpingo-salpingostomy).

If there are several nodes feeling like little hard, ovoid lumps in the tube, often of a yellowish color, it will be better not to try to save the tube, except for stringent reasons, as this is one of the forms in which tuberculosis of the tube is often localized.

After cutting out the disease, the ends of the tube may be united by fine catgut sutures penetrating the peritoneal and muscular coats and introduced at intervals of about 2 millimeters.

In order to graft the isthmus on to the ampulla, it must be slit open on its dorsum to make a lumen corresponding in size to that of the ampulla to which it is to be attached.

6. **Drainage of Tubal Abscesses.**—The treatment of tubal abscesses (pyosalpinx) as ordinarily found walled off by a blanket of adhesions from the rest of the peritoneal cavity, is fully discussed in the chapter on pelvic abscess. I desire here to speak more particularly of the treatment of those tubes full of pus which are found free, or comparatively free, in the pelvis and without any attachments to the vaginal vault.

When one tube is diseased in this way and the other is in better condition, I would sacrifice the tube containing pus and direct my efforts toward saving the one least affected. When both tubes are distended by pus, or when the tube containing pus is the only one remaining, and conservatism is desirable, the following plan may be tried: After bringing the tubes up onto a piece of gauze and opening them on the dorsum at the outer end and washing them out, they are then dropped back into the pelvis and a free opening made in the vaginal vault by puncturing it with scissors introduced into the vagina by an assistant and pushed through into the pelvic cavity under the guidance of the operator's hand within the abdomen; the opening thus made behind the cervix is then enlarged with a dilator, and an iodoform gauze pack introduced so as to fill the lower part of the pelvis loosely and drain into the vagina. The ends of the tubes are loosely imbedded between the folds of this pack; it is removed in five to seven days and the opening allowed to close.

The figures in the text are taken directly from a case treated successfully in this way.

7. **Extra-uterine Pregnancy.**—The radical exciseive method of treating extra-uterine pregnancy can only be justified when the identity of the tube is so distorted or when the tube is so far destroyed that its regeneration is impossible. In many cases where the hemorrhage has long since stopped, and where there is a tubal abortion with an intact tube or a small rent, there is no reason why the tube should not be freed from its adhesions, cleansed as far as possible of all clots, the rent sutured, and the tube, together with its ovary, preserved.

Particular care must be taken to make sure that the lumen of such a tube will admit a probe all the way through to the uterus.

PREGNANCY FOLLOWING CONSERVATISM.

Out of a series of eighty cases treated conservatively by Dr. W. M. Polk, and most of them seen at intervals varying from six months to two years after the operation, all but seven gave excellent results, and four out of the eighty bore children (*N. Y. Jour. Gyn. and Obs.*, Aug., 1893).

A. Martin, in a series of forty-five cases—twenty-one of resection of the ovaries and twenty-four of operations upon the tubes—lost two, one in each group; and of the twenty women surviving the ovarian conservative operations, five became pregnant.

One of his patients, operated upon in Oct., 1888, had the right adnexa removed and the left tube resected for hydrosalpinx, became pregnant, and aborted in April, 1889.

Pregnancy after an Operation leaving One Tube and the Opposite Ovary.—Pregnancy can only take place in the presence of a delicate adjustment of the pelvic organs in their mutual relations, and therefore furnishes perhaps the best test of the success of any conservative

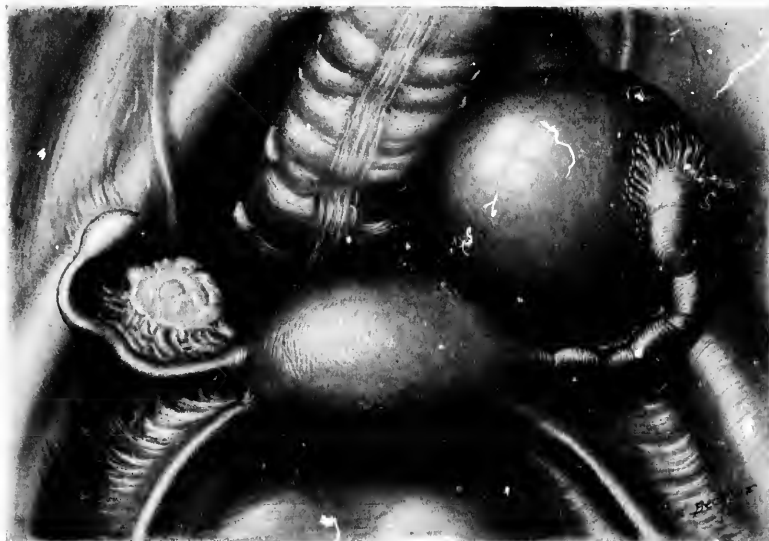


FIG. 368.—CONSERVATIVE OPERATION TO PRESERVE THE RIGHT OVARY AND THE LEFT TUBE.

The right tube, rigid and closed with a bulbous end, was removed. The left ovary, converted into a large hematoma, was also removed. Mrs. B. Op. March 2, 1895.

operation. It must be borne in mind, however, that there are other causes than the disease of the adnexa which conspire to keep down the percentage of pregnancies, as, for example, the fact that many of these patients are single, or, if married, the husband has gonorrhœa (Martin).

In order to secure pregnancy it is not necessary to preserve the ovaries and the uterine tubes in pairs, as the following instance will show:

M. B., 3346, came to me in Feb., 1895, invalided by a constant dull pain in the lower abdomen, with severe exacerbations. On opening the abdomen (March 27, 1895), I removed a left ovary converted into a large hematoma, and

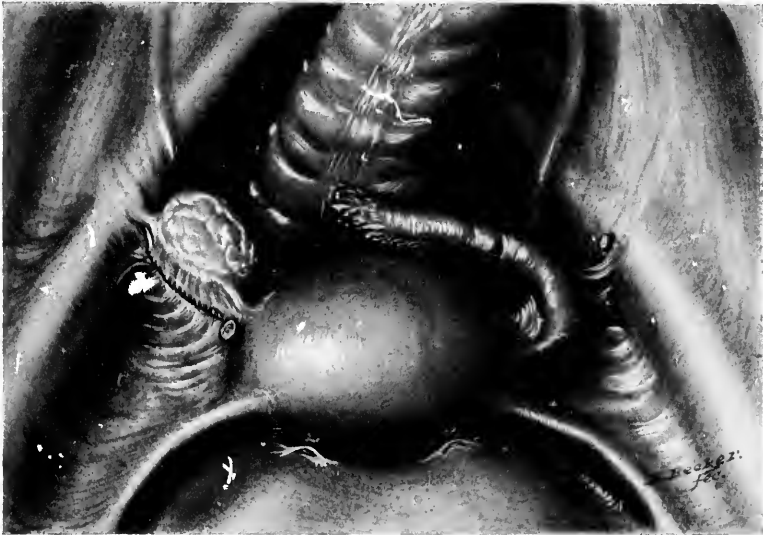


FIG. 369.—DIAGRAM OF THE CONDITION AFTER REMOVAL OF THE RIGHT TUBE AND LEFT OVARY. Showing the distance separating the remaining tube and ovary.

a little, withered right tube with a knobbed, closed end covered with lymph. The left tube was normal, and the right ovary was also normal, except for numerous shreds of lymph attached to it and covering also the posterior surface of the retroflexed uterus. The uterus was held forward by picking up a plica of the vesical peritoneum near the symphysis and attaching it to the fundus on both sides. The left tube and the right ovary were left hanging down into the pelvis, with the fimbriated end of the tube 4 centimeters distant from the ovary (see Figs. 368 and 369). Pregnancy occurred in September of the same year, and the patient had her first child in June, 1896. In Nov., 1897, I had to remove the left tube for a ruptured extra-uterine pregnancy.

Uterus Retroflexed; Appendages firmly Adherent; Ovarian Cysts Opened; Pregnancy within Four Months.—Dr. A. P. Dudley (*Amer. Gyn. and Obs. Jour.*, Feb., 1897) relates a case of a woman, twenty-five years old, operated upon by him in Dec., 1889. The uterus was retroverted, and with the appendages firmly fixed in the pelvic floor; the adhesions were broken up and numerous cysts in the ovaries punctured and evacuated, and the lining capsule scratched to cause it to fill with a blood clot;

the tubes were probed and found patent. The uterus was held forward by an intraperitoneal shortening of the round ligaments. The patient left the hospital in three weeks feeling well, and in four months reported herself pregnant; later she induced abortion by injecting hot water into the uterus.

Extensive Inflammatory Disease involving Right and Left Ovary; Left Tube Normal, Ovary Atrophied; Pregnancy.—In another patient of Dr. Dudley's, forty years old, the uterus and appendages were firmly fixed in the pelvis by an inflammatory mass.

The right appendages, hopelessly diseased and involved in adhesions, were removed, but the left tube was sound with an atrophic ovary; sixteen months later, in her forty-second year, she gave birth to a healthy boy weighing seven pounds.

Left Pyosalpinx and Imbedded Ovary removed; Right Adherent Tube freed and Cystic Ovary punctured; Adherent Uterus elevated and suspended; Pregnancy.—This patient of Dr. B. MacMonagle is an interesting example of successful conservatism and an extraordinary success after suspension of the uterus; she was thirty-four years old and had had one child; the abdomen was opened for extensive pelvic peritonitis and retroflexion with adhesions. A left pyosalpinx with a densely adherent ovary was removed, and on the right side the tube was freed from adhesions binding it down to the pelvic floor, and several large cystic follicles were punctured; the uterus, adherent by its posterior surface, was elevated and suspended by two sutures. Within a year she became pregnant and was confined at term, attended by a neighbor who acted as midwife; three children were born, all lived, and they are now two years old. Normal involution went on, and the uterus remains in anteposition.

Retroflexed Uterus and Appendages Imbedded in Adhesions; Left Ovary and Tube removed Piecemeal; Right Ovary and Tube badly torn, Tube broken off 5 Centimeters from Uterus; Pregnancy in Six Months.—Dr. B. F. Baer (*Annals of Gyn. and Ped.*, Jan., 1894, p. 232) reports a case of pregnancy under the most unusual circumstances. The patient, thirty-two years of age, who had a large retroflexed adherent uterus with hard masses on both sides, submitted to an operation, with the express proviso that one ovary or a part of one should at least be left, that she might not be deprived of the possibility of offspring. The abdomen was opened in Feb., 1891, and the retroflexed uterus and appendages were found so covered by organized false membranes as to be completely out of sight. After breaking through the false membranes with great effort, the uterus was dissected loose and brought forward, covered with shreds of broken adhesions; the left ovary and tube were so firmly bound down to the posterior surface of the broad ligament that they were taken away piecemeal, and a calcareous mass was also removed from the bed of adhesions. The right side was similarly diseased and dissected loose in shreds, the tube being torn off 5 centimeters from the uterus. As Dr. Baer was about to remove the appendages of this side too, he received a positive injunction from the brother of the patient,

who was a physician and was present, not to proceed, as he preferred to assume any risk rather than deprive his sister absolutely of all hope of offspring. The abdomen was therefore closed, an excellent recovery followed, and in fifteen months a child was born.

Extensive Pelvic Inflammatory Disease; Right Tube and Ovary removed; Pus Sac in Left Tube opening into Bowel; Left Tube amputated; Pregnancy.—One of the worst cases for the complications it presents is that of Dr. B. MacMonagle (see Polk, *Trans. Congr. Amer. Phys. and Surg.*, 1894, p. 193).

The patient, twenty-four years old, had been married three years without pregnancy. She had a pelvic abscess discharging at intervals through the rectum, and following a dilatation of the cervix at the hands of another specialist. When seen by Dr. MacMonagle in Oct., 1888, she was emaciated, sallow, had constipation, frequent urination, and night sweats; the abdomen was scarred and discolored by blisters and poultices; the temperature varied from 99° to 101°; a bad-smelling yellowish discharge issued from the uterus and vagina, and pus and blood appeared in the stool every few days; the uterus was fixed, and there was thickening and tenderness over both ovaries and uterine tubes.

The abdomen was opened and the omentum found adherent to the uterus and the neighboring parts; there was a small cyst over the right tube and ovary, and extensive adhesions of the tube and ovary to the bowel and broad ligament, with the fimbriated end of the tube bound down to the ovary. The cyst, ovary, and tube were removed close to the uterus.

On the left side, in attempting to enucleate the tube and ovary, a pus sac in the pelvis opening into the bowel was broken into and there was a sharp hemorrhage; the attempt was made to check this by putting a ligature (Staffordshire knot) deep down in the broad ligament, passing the loops on one side close to the horn of the uterus and on the other outside the ovary; when this was drawn tight it was found to include the ovary and adherent fimbriated extremity of the tube to such an extent that it was impossible to remove these structures and still leave enough tissue distally to prevent the ligature from slipping; only the free portion of the tube was then cut out, and the incision closed with a glass tube drain inserted. Two years after she became pregnant and gave birth to a child.

Ovarian Cysts of Both Ovaries; Right Ovary and Tube extirpated; Left Cyst removed, leaving a Piece of the Ovary and the Tube; Pregnancy.—A woman thirty years old was operated upon in May, 1890, by Dr. A. Sipple (*Central. j. Gyn.*, 1893, No. 3, p. 43) for double ovarian tumors; on the right side no sound tissue was found, and the ovary, about the size of a child's head, was removed with the tube; on the left side the ovary was about as large as a goose's egg, and at its base a strip of macroscopically normal ovarian tissue was found; the tumor was therefore cut away, leaving a piece of ovarian tissue at the hilum 4 centimeters long and 3 or 4 millimeters in thickness, which was sutured and dropped. This patient became pregnant in Aug., 1891, and was normally delivered in due time.

Left Ovarian Cyst and Adherent Uterus; Half of the Right Ovary removed; Tube not removed; Pregnancy.—Another patient of Dr. Dudley's, twenty-nine years old, an ovarian cyst, fully attached to the posterior uterine surface, was removed, leaving the uterus undisturbed; one half of the left ovary was taken away, but the tube, though much enlarged, was allowed to remain, and the uterus fastened forward.

Drainage was used through the vaginal *cul-de-sac*. Pregnancy occurred, and she miscarried at four months.

Hematoma of Both Ovaries; Removal of Left Ovary and Tube; Resection of the Right Ovary; Pregnancy. Operation by W. M. Polk, Dec., 1892.—The left ovary, converted into a hematoma 5 centimeters in diameter, was removed with its tube; two thirds of the right ovary, containing a hematoma, was resected and the remainder brought together by suture; the right tube was not diseased. The patient recovered her health, and when seen on June 5, 1893, was four and a half months' pregnant.

A. Martin reported a case of pregnancy (*German Gyn. Soc.*, 4th meeting, at Bonn, May, 1891) in a woman forty-two years old, operated upon in Oct., 1888, from whom the right adnexa had been removed and the left tube resected for hydrosalpinx. She miscarried in the third month.

Dr. Polk presents further a remarkable example of the possibility of rejuvenation in a case of double hematosalpinx.

The patient, twenty-two years old, was operated upon in Oct., 1890. The right ovary, the seat of an extensive hematoma, was removed with the right tube; on the left side the ovary was normal, but the tube, the seat of a hematosalpinx, was cut off just inside the dilated portion, about an inch from the uterus, and the stump attached close to the ovary. There were extensive adhesions on both sides. Two years after the operation the patient was delivered of a healthy male child.

CHAPTER XXVI.

SIMPLE SALPINGO-OÖPHORECTOMY AND SALPINGO-OÖPHORECTOMY FOR ADHERENT TUBES AND OVARIES.

- A. Simple salpingo-oöphorectomy.
1. Indications and contra-indications for operation: 1. For myoma of the uterus. 2. For osteomalacia. 3. For incomplete development of the genitals. 4. For extreme dysmenorrhœa.
 2. Four typical cases of castration for extreme dysmenorrhœa (out of five hundred abdominal sections).
 3. Operation: 1. The incision and delivery of the tube and ovary. 2. Ligation of the pedicle and removal of the ovary and tube. 3. Inspection of the field and closure of the incision.
- B. Salpingo-oöphorectomy for hydrosalpinx and adherent ovaries and tubes.
1. Hydrosalpinx: (1) Hydrosalpinx simplex. (2) Hydrops tubæ profluens. (3) Hydrosalpinx follicularis. (4) Tubo-ovarian cysts.
 2. Cause.
 3. Symptoms.
 4. Treatment: (1) Conservative. *a.* Breaking up adhesions. *b.* Making a new ostium in a closed tube. *c.* Resecting a diseased tube. (2) Radical.

SIMPLE SALPINGO-OÖPHORECTOMY.

THE simplest form of abdominal operation, next to the purely exploratory incision and to the suspension operation for retroflexion of the uterus, is the removal of tubes and ovaries not adherent, and not in any way or but slightly altered by disease—that is, salpingo-oöphorectomy.

The removal of the normal ovaries and tubes forms, as it were, the type of all extirpative operations upon the uterine tubes and the ovaries, even the most complicated, for after the various complications are met and put aside the final steps in the enucleation remain the same.

The object of a simple salpingo-oöphorectomy is an artificial and premature induction of the menopause for one of several indications—either to secure the effect upon the uterine circulation, as in checking the growth of myomata, to check the progress of an osteomalacia, or to relieve the menstrual molimina in cases of incomplete development of the genitals with functionally perfect ovaries, and, in the rarest instances, for excessive dysmenorrhœa.

The operation has also been performed as the concluding step of a Cesarean section to prevent future conception, but the same end may be obtained here by simply ligating the uterine tubes.

The various neuroses, such as menstrual epilepsy, hysteria and hysterio-epilepsy, and insanity, do not of themselves justify the removal of the uterine tubes and the ovaries. It has long been fondly held by gynecologists that in major epilepsy of a distinctly menstrual type—that is to say, occurring always

during, just before, or immediately after the menstrual period—the expectation of a radical cure from the suppression of the periodical function was fully justified, but the facts of the case do not so far bear out this assumption.

I have myself operated for epilepsy in but one case, that of a feeble-minded girl whose attacks were greatly aggravated at the monthly periods; she improved, but was by no means cured by the operation.

Dr. S. Weir Mitchell, our greatest authority, says (*Univ. Med. Mag.*, March, 1897, p. 389): “In no case seen by me had ablation of ovaries and termination of menstruation cured an epilepsy. I have never sanctioned such operations where the appendages were sound. I have agreed thrice to these operations in epilepsy with such pelvic disease as of itself would justify oöphorectomy. In all three, after some delay, the fits returned and were in no way permanently aided. . . . I recall as an illustration a case in which there were epileptic attacks of great severity only at the menstrual epoch. The ovaries were apparently sound, but, as two physicians and a surgeon were against me, my opinion was not regarded and ovariectomy was performed. The attacks, which had been daily, stopped for seven weeks after the operation, and the case was hastily spoken of as a great triumph. The patient, however, then became worse, and permanent loss of mind resulted. . . . The ease of operation, the freedom from mortality, makes that seem of little moment which should in every case receive the gravest consideration. . . . In all my life I have met with but four reflex epilepsies; none were from uterine or ovarian or tubal disease.”

I can not do better than cite the opinion of the same eminent neurologist regarding the value of oöphorectomy in insanity.

“Because an insane woman is usually worse at her period, it is no reason why the flow should be stopped by operation. That the climacteric puts an end to these disorders is an old delusion; in fact, the change of life so-called, is quite as likely to make them worse as to better them.”

Out of but four cases of neuroses recalled by Dr. Mitchell, one became worse and three were improved by operation. One woman of forty years, after long years of aggravated hysteria, suffered so much from melancholia at her menstrual period that she besought relief, and finally reluctant consent to operation was given. This resulted in a remarkably improved physical condition, but the insanity became abruptly worse, and has now lasted twelve years.

In a case of aggravated hysteria of the type so common in France but rare in this country, the patient finally became violently homicidal at the menstrual epoch. Normal pelvic structures were removed and a gradual improvement followed, until perfect health was regained.

A third case of nymphomania with furious sexual dreams at the menstrual period was similarly treated and relieved, but it must be borne in mind that there were also enlarged ovaries and serious tubal disease.

The fourth case of menstrual melancholia and maddening headaches was also slowly relieved of the melancholia, but the periodical headaches persisted; in this case, too, there was grave disease of the tubes and ovaries, so that we rightly exclude this and the preceding from our category.

It is a question for investigation whether the operation is justifiable under any circumstances in feeble-minded girls with uncontrollable sexual proclivities, or for incurable masturbation.

Salpingo-oöphorectomy has been frequently performed in the past for the sake of its effect in permanently diminishing the blood supply to the uterus where the latter contains myomata which could not be removed without undue risk, but this treatment is now no longer resorted to by the best operators on account of its uncertainty, as well as on account of the improved technique of myomectomy and hysteromyomectomy.

Extreme dysmenorrhea is an indication which I accept with great hesitation, even when the suffering is sufficient to impair the patient's health seriously, and all other simpler plans of treatment have been faithfully tried and have failed.

Of all operations connected with gynecology, salpingo-oöphorectomy performed upon this indication and for hysteria has been most abused, either through a want of good judgment on the part of the surgeon in recommending unsuitable cases for operation, or through his being misled by a hysterical woman into imagining her pelvic condition worse than it actually was the fact.

In all these cases the advice of the neurologist and the general practitioner, as well as that of a conscientious skilled gynecologist, must be sought before deciding upon a radical operation the benefits of which are at best doubtful.

Dysmenorrhea is but a symptom which may arise from so many other causes than disease of the ovaries, that while the removal of these organs may possibly relieve the periodical monthly pain, it may at the same time leave in its place a great number of nervous symptoms infinitely more distressing than the menstrual discomforts. In younger women the removal of the ovaries is followed by more pronounced nervous disturbance than in those who are older.

The patient herself can never be the right judge as to the necessity of removing the ovaries. I have seen young women who suffered so severely at the menstrual periods that they were importunate in their demands for radical relief, and were willing to submit to any operation; removal of the ovaries suppressed the function, but in place of the pain, a train of nervous symptoms appeared, along with the realization that they were unsexed and could not morally assume the relationship of marriage with the hope of maternity, and profound mental depression supervened.

My attitude with regard to the removal of the ovaries for dysmenorrhea will be seen by the fact that in a recent series of five hundred abdominal sections at the Johns Hopkins Hospital only four cases were operated upon for this reason, and in three of these the relief was not what was looked for.

One case, a woman of thirty-eight years (M. H., 4183), who had borne four children, suffered intense agony during the menstrual period. She was not neurotic, and after seeing her through a period there could be no question as to the reality of her sufferings. For four or five days before the flow appeared she had dull headache and bearing-down pain in the lower abdomen, and when

the flow was once established, instead of relieving her symptoms, it only aggravated them. The pain then became sharp and paroxysmal, and the headache was so intense that she could stand no light in her room. These symptoms always persisted for a week, during which time she was bedridden.

The uterus was dilated and curetted. At first the retroflexed uterus was suspended. Both ovaries and tubes were found normal. For one or two periods subsequent to this operation she was somewhat better, but soon the old pains returned with renewed severity, and for the next year she was a constant sufferer.

She then returned to the hospital and I explained the effects of the radical operation and my reluctance to perform it. Both husband and wife, however, insisted upon it, and I extirpated ovaries, tubes, and uterms (March 2, 1896). The patient was well for a year after the operation, and then began again to complain of a variety of nervous symptoms, so that the success of the operation was only partial.

A second case was that of a nurse (E. D., 3391, March 23, 1895), thirty-six years old, totally incapacitated for one week in every month by severe menstrual cramps. Total extirpation of ovaries and tubes was followed by complete relief, and she has since been able to work without interruption.

In the two other cases the patients had enlarged ovaries in which the numerous dilated Graafian cysts were distributed underneath the thick tunica albuginea of the ovary.

One woman was twenty-two years old, and her relief from her pelvic symptoms has been complete, while her subsequent history (J. S., 3333, Feb. 25, 1895) serves well to show that the dysmenorrhea is often only the local expression of a constitutional tendency, and that when the pelvic pain is relieved nervous outbreaks in various other parts of the body are prone to occur. Soon after the operation she suffered from a severe facial neuralgia for which she had all her teeth extracted. She next had an attack of sneezing which lasted almost continually for three days, weakening her so that she nearly died. She is now so weak that she can work but little, and suffers from constant shortness of breath. Defecation is extremely painful, and there is an obstinate constipation, necessitating the constant use of medicines.

The second patient, also a young woman of twenty-two, had suffered since menstruation began with almost a continuous bloody discharge. The menstrual periods were irregular and very painful, and she had long been a confirmed invalid. All forms of treatment, including the tonics, exercise, and diet, had been instituted without relief; instead of improving, she gradually lost ground. I studied the case carefully, and somewhat reluctantly consented to operate.

The patient ceased to menstruate after the operation, and has had no flow for eighteen months; she has gained flesh and strength, and her color is better, but the nervous symptoms are distressing, the flushes and sweatings and a variety of bizarre sensations keeping her constantly miserable. Her depression at times verges onto melancholia.

Since the term "cystic ovary" has been used so frequently, as though it were a pathological condition, to justify many operations for dysmenorrhea, it

should be distinctly understood that the presence of several large Graafian follicles is not pathological, except in rare instances in which the ovary is often twice as large as normal, the tunica albuginea is thick and dense, and multiple cysts may be seen shining through it. On section, the capsule is seen as a thick, white, non-vascular area, and there is only occasional evidence of ruptured follicles.

In the light of our present knowledge of the pathology of the ovary, the attempt to justify the removal of small 'cystic ovaries' must be denounced as both unscientific and immoral.

Operation.—The operation is an epitome of all the operations for the removal of diseased appendages, for the effort of the operator in the most difficult cases is usually to reduce them to the type of the simple enucleation of the tubes and ovaries by first eliminating the complications and then completing the operation as a simple salpingo-oöphorectomy.

The Incision and Delivery of the Ovary and Tube.—The patient should be placed upon the table with the pelvis elevated, and an incision from 4 to 6 centimeters ($1\frac{1}{2}$ to $2\frac{1}{2}$ inches) long—longer if the abdominal walls are unusually thick—should be made through the *linea alba*, beginning 2 or 3 centimeters above the symphysis pubis.

As soon as the abdomen is opened, the index and middle fingers are introduced and conducted along the under surface of the abdominal wall to the symphysis pubis, and from the symphysis down over the bladder onto the uterus, and out over the *cornu uteri* to the broad ligament, behind which the tube and ovary are ordinarily found and picked up.

Futile efforts to pick up the ovary and tube and draw them through the small incision often embarrass the beginner. The best way is to carry the fingers to the outer extremity of the broad ligament, and then, turning the palmar surfaces astride the broad ligament toward the uterus, to carry them down into the pelvis, and bring them up toward the *cornu uteri*, so as to hook up both ovary and tube together, which may now be drawn easily out through the incision and tied off.

The Ligation of the Pedicle and Removal of the Tube and Ovary.—The structures to be removed are the entire length of the tube, the ovary with its hilum and a portion of the utero-ovarian ligament, together with their blood vessels, lymphatics, and nerves. The chief risk of the operation lies in the liability to hemorrhage from improper control of the blood vessels.

The uterine and ovarian vessels must now be tied separately, while the non-vascular portion of the broad ligament between them is left free. This avoids the tension of the broad ligament produced by binding its pelvic and uterine extremities together by interlocking ligatures, and so obviates the imminent risk of hemorrhage as soon as any tension is put upon the ligament by retching, straining, etc. (see *Some Sources of Hemorrhage in Abdominal Pelvic Operations*. *Johns Hopk. Hosp. Rep.*, iii, 1894, p. 419).

It is best to use fine silk ligatures in all cases when large vessels are to be controlled.

The first ligature includes the ovarian veins and artery, and is passed through the clear space in the broad ligament and tied near the pelvic brim over the top of the infundibulo-pelvic ligament well beyond the fimbriated extremity of the tube. A second ligature of catgut is applied to the utero-ovarian ligament posteriorly. A third ligature is passed over the top of the broad ligament at the *cornu uteri*, embracing the uterine vessels which are visible and the isthmus of the tube.

In order to fix the ligatures so that there will be no danger from slipping over the top of the pedicle when the ovary and tube are removed, the free ligature may be carried over the top of the ligament, or over the *cornu*, and made to transfix a small portion of the tissue in a reverse direction from that in which it passed through the broad ligament the first time.

The clear space is a triangular surface near the upper outer extremity of the broad ligament free from vessels, bounded by the ovarian vessels above, the pelvic wall on the outer side, and the round ligament below and on the inside. It is developed, or made larger, by pulling up the top of the broad ligament. If the finger is pushed into this space from behind forward, the anterior and posterior layers of the broad ligament are brought together, and the furrows in the skin of the finger are often clearly visible through them. I utilize the clear space in the following manner in passing the ligatures: The structures to be removed are drawn well up, and the finger is passed down behind the broad ligament under the ovarian vessels and pushed forward into the clear space. A careful observation is then made to be sure that all the large ovarian veins lie above and none of them lie below the end of the finger. A silk suture of intermediate size is then drawn through the clear space from before backward by means of a needle and carrier, and tied tightly over the top of the vessels.

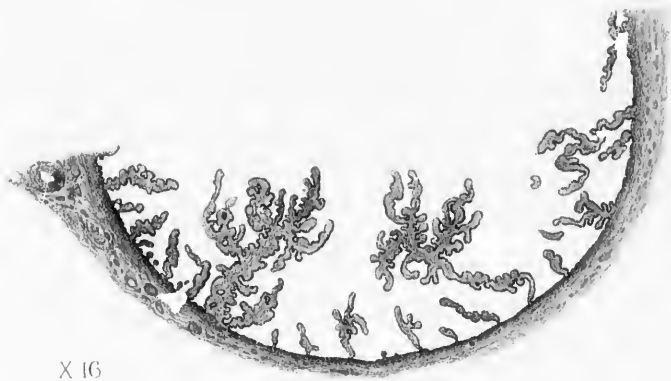
After the ligation the ovary and tube are removed by cutting the pedicle at least 1 centimeter from the ligatures.

Particular attention must be given to the removal of the entire ovary, cutting through a point in the ovarian ligament well away from the ovary, and then cutting under the hilum well away from the ovarian tissue.

As the outer extremity of the broad ligament is severed, its stump, with the ovarian vessels, retracts up to or over the brim of the pelvis, and between this and the *cornu uteri* there is only the thin falciform edge of the anterior and posterior peritoneal layers of the broad ligament. If any small bleeding points are noted in this area they must be caught with forceps and controlled with fine catgut ligatures.

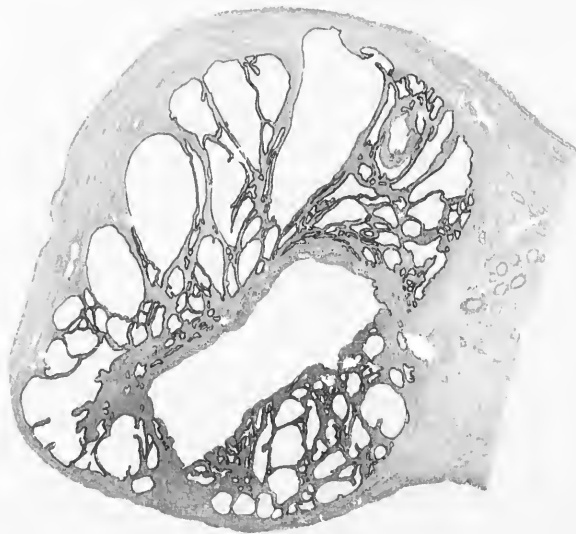
Inspection of the Field and Closure of the Incision.—Finally, after both appendages have been removed, a careful inspection should be made before closure, in order to determine whether there is any bleeding and whether the stumps are well tied, so as to lessen the likelihood of hemorrhage after closure of the incision. If any one of the uterine ligatures or of the





X 16

Fig 1



X 8

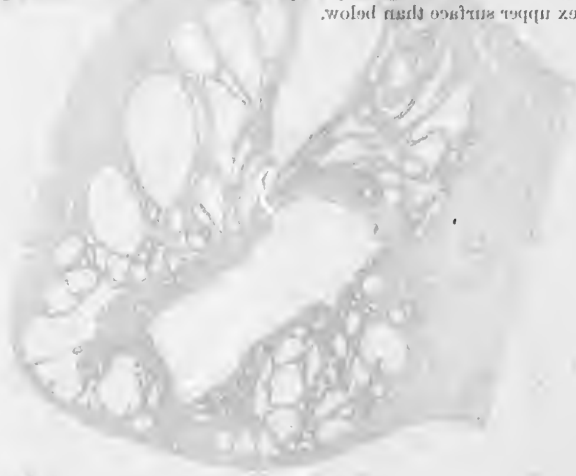Fig 2.



DESCRIPTION OF PLATE XI

FIG. 1.—Hydractinia simplex ($\times 10$). Cross-section through the middle of the tube showing the tentacle and branching folds projecting into the lumen. The smaller folds present marked constrictions at their bases.

FIG. 2.—Hydractinia foliolaria ($\times 8$). Cross-section from a point at the junction of the middle and outer third of the tube. Surrounding the central lumen are many large and small round or irregularly shaped cavities. The dilatation is greater on the free convex upper surface than below.



ovarian arteries appear insecure or doubtful, a second ligature should be thrown around the pedicle to make it secure.

It is not necessary to wash out the abdomen or the pelvis, and drainage ought never to be used.

The patient is now let down from the elevated position, and the omentum is then drawn down over the small intestines as they drop into the pelvis and inspected to see that no loop of intestines has slipped through one of its accidental openings.

The operation is completed by closing the incision with the three or four layers of sutures, catgut to the peritoneal layer, silver wire or silkworm gut to the fascia and muscle, and catgut to the fat if the walls are thick, and finally a subcuticular suture of catgut or silver wire—all as described in Chapter XXI, on the technique of abdominal operations.

SALPINGO-OÖPHORECTOMY FOR HYDROSALPINX AND FOR ADHERENT TUBES AND OVARIES.

The name "hydrosalpinx" is applied to a uterine tube which contains a watery accumulation; the term is therefore not scientifically accurate. It does not in any way define the morbid process that brings about such an accumulation; it simply describes a prominent clinical feature. This accumulation of fluid is due to an occlusion of the tube, forming a retention cyst.

For clinical convenience the various forms of hydrosalpinx may be grouped as—

1. Hydrosalpinx simplex.
2. Hydrocystis tubæ profusa.
3. Hydrosalpinx follicularis.
4. Tubo-ovarian cysts.

1. **Hydrosalpinx Simplex.**—In simple hydrosalpinx there is a conical distention of the tube, which is greatest at the fimbriated and least at the uterine end. On opening the abdomen (see Fig. 370), the tube looks like a transparent thin-walled sac beside or behind the uterus; if both sides are involved, the tubes hang back over the uterus like saddle-bags. The uterine end of the tube is usually on a level with the superior strait, while the dilated extremity dips down toward the pelvic floor. If the tube is only moderately distended, the fluid may all be lodged in that portion which offers the least resistance to expansion—that is, in the ampulla; when it is excessively enlarged so as to hold half a liter, a liter, or more of fluid, it rises up, filling the lower abdomen and partaking of many of the clinical characteristics of a parovarian cyst (see Figs. 371, 372).

Pessier cites an extraordinary case, if his interpretation is to be credited, which contained 18 pounds of fluid (*Ovarian Tumors and Ovariectomy*, 1872, p. 105).

One or more kinks are commonly found in the tube before its removal, due to the flexures necessary to accommodate its posture to the more resisting surrounding structures. Adhesions are uniformly found at the fimbriated end, and

these commonly hold the tube down to the pelvic floor; adhesions to the ovary and to the contiguous pelvic wall are also common. The dorsum of the tube is, however, usually free. In rare instances the ampulla is simply closed and there are no pelvic adhesions.

When the tubal walls are thin and unruptured, *striae* may often be seen on the inside, parallel to its long axis; these are folds in the mucosa. The inner surface is glistening and pinkish in color. Microscopically, the muscular layers

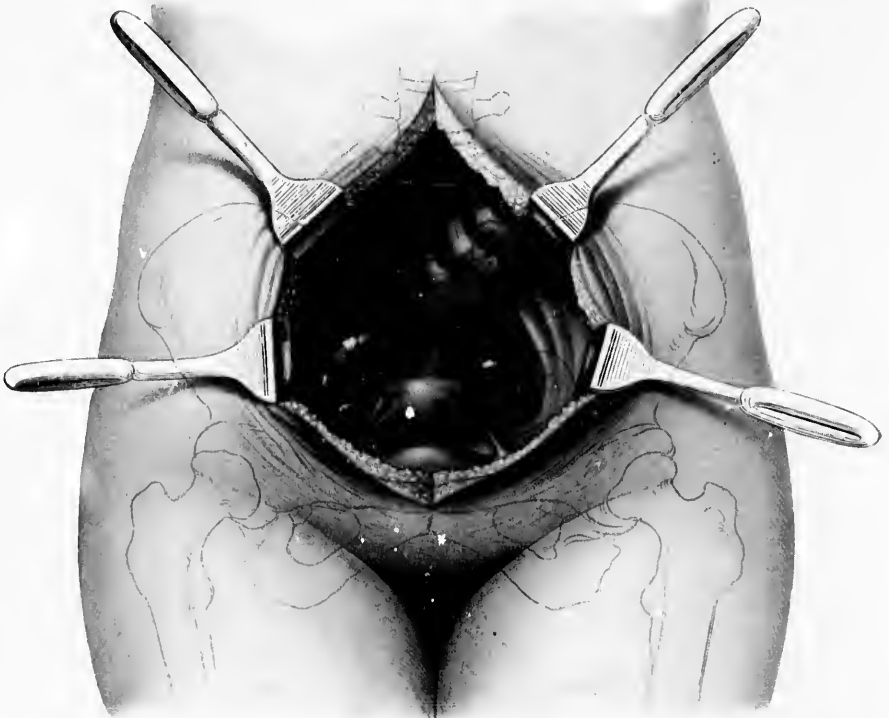


FIG. 370.—DOUBLE HYDROSALPINX, DRAWN FROM NATURE, SHOWING THE RELATIONS BETWEEN THE LARGE TUBES DILATED WITH CLEAR FLUID AND THE UTERUS AND THE POSTERIOR PELVIS.

Note the flexions of the right tube and the adhesions from the uterine cornu to the ampulla.

in the wall of the tube, in the cases with the least distention, may appear normal; in other cases they are thinned out until they may be nearly all gone. Between the muscular bundles a connective-tissue-cell proliferation is often found, and the intermuscular connective tissue may be loose and edematous. Hypertrophy of the muscular coat does not occur.

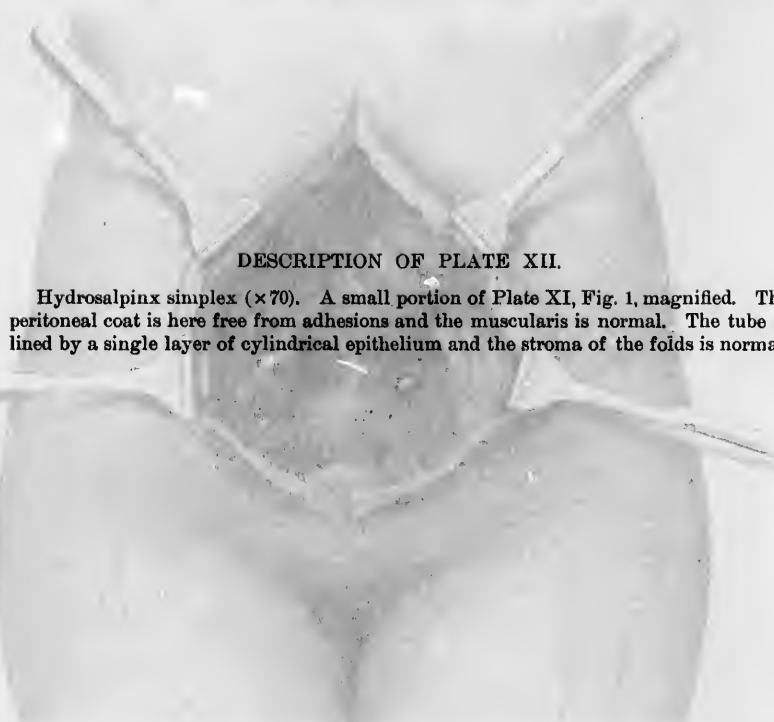
The mucous lining of the tube presents the most remarkable and characteristic changes. The folds, normally so luxuriant and complicated in their branch-

DESCRIPTION OF PLATE XII.
Hydrocephalus simplex ($\times 70$). A small portion of Plate XI, Fig. 1, magnified. The
peritoneal coat is here free from adhesions and the muscularis is normal. The tube is
lined by a single layer of cylindrical epithelium and the strona of the folds is normal.



these commonly hold the tube down to the pelvic floor; adhesions to the ovaries and to the contiguous pelvic wall are also common. The dorsum of the tube is, however, usually free. In rare instances the ampulla is simply closed and there are no pelvic adhesions.

When the tubal walls are thin and unruptured, a cavity may often be seen on the inside, parallel to its long axis; these are folds of the mucosa. The inner surface is glistening and pinkish in color. Microscopically, the muscular layers




DESCRIPTION OF PLATE XII.

Hydrosalpinx simplex (x70). A small portion of Plate XI, Fig. 1, magnified. The peritoneal coat is here free from adhesions and the muscularis is normal. The tube is lined by a single layer of cylindrical epithelium and the stroma of the folds is normal.

FIG. 12.—HYDROSALPINX SIMPLEX. DRAWN FROM NEGATIVE WHICH WAS MADE FROM A PLE LARGELY COVERED WITH CLEAR FLUID. IN THE UPPER PART OF THE ILLUSTRATION THE LUMEN OF THE TUBE IS OPEN TO THE RIGHT AND THE ADHESIONS FROM THE OVARIES AND PELVIC WALLS ARE VISIBLE.

in the wall of the tube, in the cases with the least rupture, may appear normal; in other cases they are thinned out until they are scarcely all gone. Between the muscular bundles connective tissue of regular distribution is often found, and the intermuscular connective tissue may be loose and edematous. Hypertrophy of the muscular coat does not occur.

The mucosa lining of the tube presents the most remarkable and characteristic changes. The folds, normally so luxuriant and complicated in their branch-



X 70



ings, are separated from one another as a result of the distention; they are recognized as branched folds and fingerlike projections.


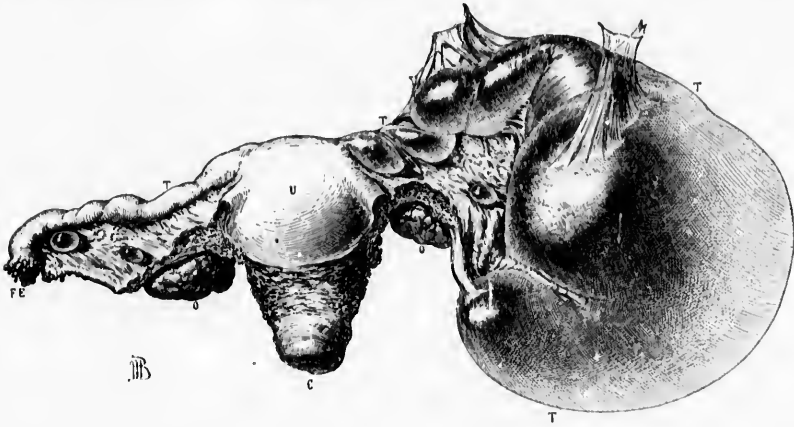


FIG. 371.—LARGE LEFT HYDROSALPINX WITH NUMEROUS ADHESIONS; NORMAL OVARIES, RIGHT TUBE, AND UTERUS.
 Drawn to scale below. March 30, 1895.

The epithelium may retain its cilia even in a tube which is markedly distended; it always occurs in a single layer, cylindrical and cuboidal.

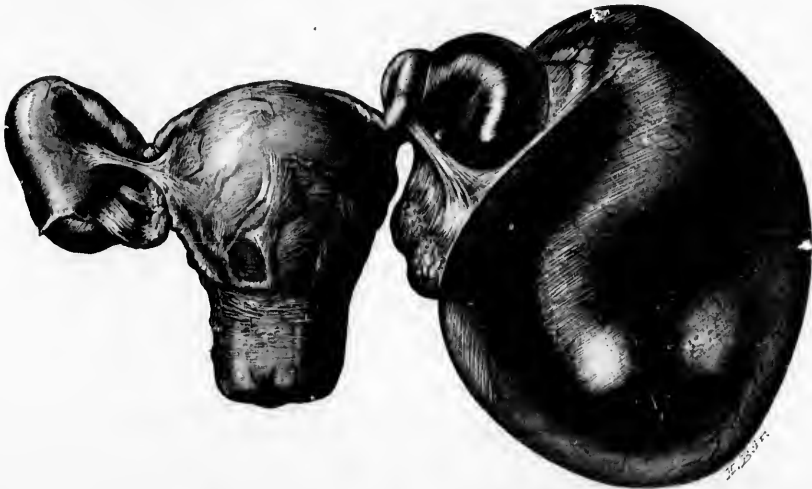


FIG. 372.—DOUBLE HYDROSALPINX, WITH ADHESIONS BRIDGING THE ANGLES IN THE TUBES AND BINDING DOWN THE UTERUS BY ITS POSTERIOR SURFACE. MAY 21, 1895. NATURAL SIZE.

In some cases encalcified plates are found, and in one of my patients I found a long irregular calculus fastened by one end to the isthmus and projecting into the lumen of the dilated tube.

In another instance I found a large hydrosalpinx associated with a congenital deficiency in the tube, dividing its ampulla into two parts, of which the outer end was entirely disconnected with the uterine end and the isthmus (see Fig. 377).



FIG. 373.—HYDROSALPINX.

The large bulbous dilated tube is filled with serumlike fluid and is entirely free from any adhesions to the ovary. The opposite tube and ovary were densely matted together. No. 447. Natural size.

2. **Hydrops Tubæ Profuens.**—This form of hydrosalpinx is characterized by the remarkable clinical sign of a periodical outflow from the tube into the uterus, the vagina, and so out over the person. Martin found four cases out



FIG. 374.—HYDROSALPINX WITH FEW CONVOLUTIONS.

The left tube is intimately adherent to the ovary below on the right. Three glistening subperitoneal cysts are seen where the tube joins the ovary. C. M., No. 228. Natural size.

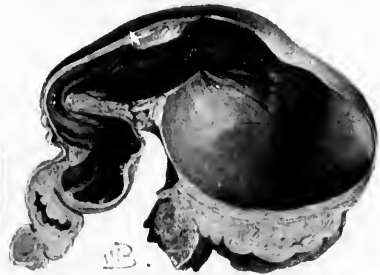


FIG. 375.—HYDROSALPINX SHOWN IN FIGURE 374, SEEN IN LONGITUDINAL SECTION.

The ampulla of the tube is markedly dilated throughout and ends in a large bulbous extremity. The ovary is seen flattened out below the cyst. Note the parallel folds of the tubal mucosa, ending abruptly in little bulbous extremities.

of five hundred cases of tubal disease. Landau states that the muscular walls of the tube are hypertrophied. The manner of discharge of the fluid varies, occurring either constantly with periods of exacerbation, or at intervals of hours or of several days. After the formation of a definite painful tumor the tube is evacuated spontaneously with pain, and the tumor disappears; one of my cases, a large,

stout woman, was made miserable by the recurring paroxysms of pain. The amount of discharge may be as much as half a liter in twenty-four hours; when

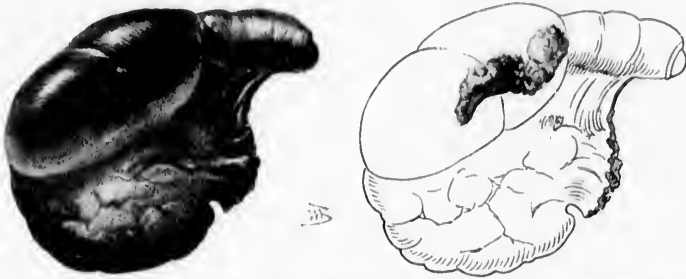

FIG. 376.—HYDROSALPINX CONTAINING A NODULAR S-SHAPED CALCULUS LYING IN THE LUMEN OF THE TUBE, WHICH IS ADHERENT TO THE OVARY.

The calculus is shown in detail in the outline figure to the right. Cambridge, July, 1894.

it accumulates in the vagina, as during the night, on rising it may escape like a gush of warm water, much as if the bladder had suddenly emptied itself.

Cocain sometimes has a marked effect in controlling the flow, but it does not give permanent relief. Removal of one or both tubes alone will cure the disease.

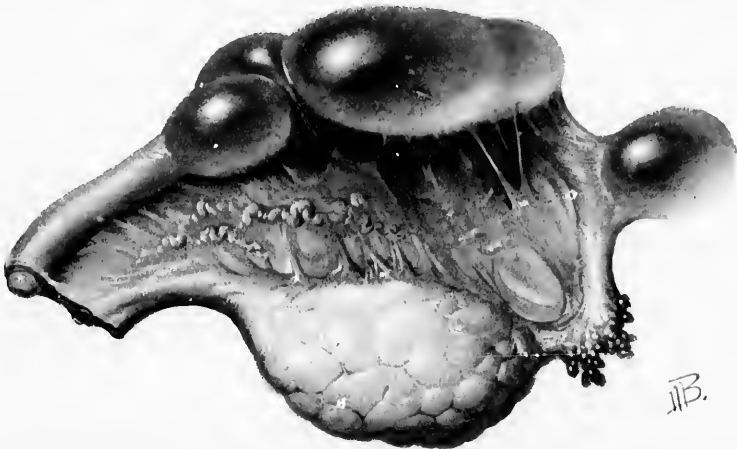


FIG. 377.—HYDROSALPINX, WITH CONGENITAL DEFICIENCY IN THE TUBE.

The tube ends in a group of three cysts, and these are connected with the isolated subperitoneal cyst on the right by a thin band of peritoneum in which there is no portion of a tube. The fimbriated end of the tube lies beyond the single cyst.

3. Hydrosalpinx Follicularis.—In follicular dropsy the tube is usually of small size—not more than 3 centimeters in diameter—and appears externally like the simple dropsical tube just described. On cross-section, however, the lumen of the tube is often diminished or altogether displaced by an open network of

tissues developed in its inner wall and forming oval spaces varying in size from a pin-point to 8 millimeters (see Pl. XI, Fig. 2, and Pl. XIII). These cavities are filled with fluid, and apparently communicate with one another.

The muscular coat shows little alteration, with the exception of some connective tissue cell proliferation between the bundles.

The folds of the mucosa are sparse or absent, and the mucosa itself is occupied by alveoli which are variously subdivided by partitions; the large alveoli are lined by cuboidal epithelium and the smaller ones by cylindrical cells. This may be the outcome of an endosalpingitis follicularis described by A. Martin; Orth states that the alveoli or glandlike spaces may become cystic.

Out of eleven cases of hydrosalpinx, four were follicular and two of them were bilateral. One case presented a follicular hydrosalpinx on the left and a simple hydrosalpinx on the right, tending to show the close genetic relationship between the two varieties.

4. Tubo-ovarian Cysts.—A tubo-ovarian cyst is formed by a communication between a tube and a cyst of the ovary, so that fluid may pass freely from one to the other. The dropsical tube in these cases ends in a bulbous enlargement as big as a thumb or a child's head. What is most remarkable in these cases is the fact that the fimbriated end of the tube is often found spread out over the inner surface of the cyst. J. Bland Sutton (*Surg. Dis. of Ov. and Fal. Tubes*, London, 1896, p. 102), who has made an admirable study of this condition,

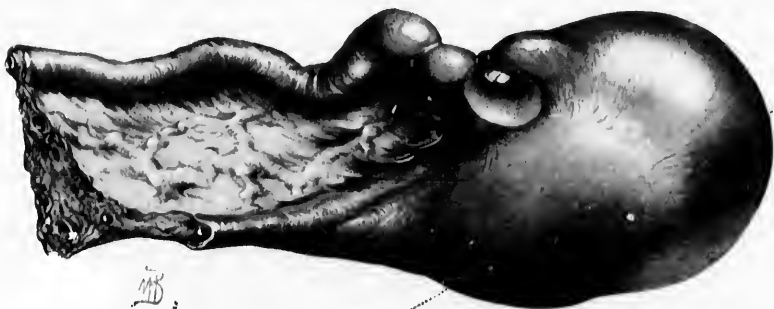
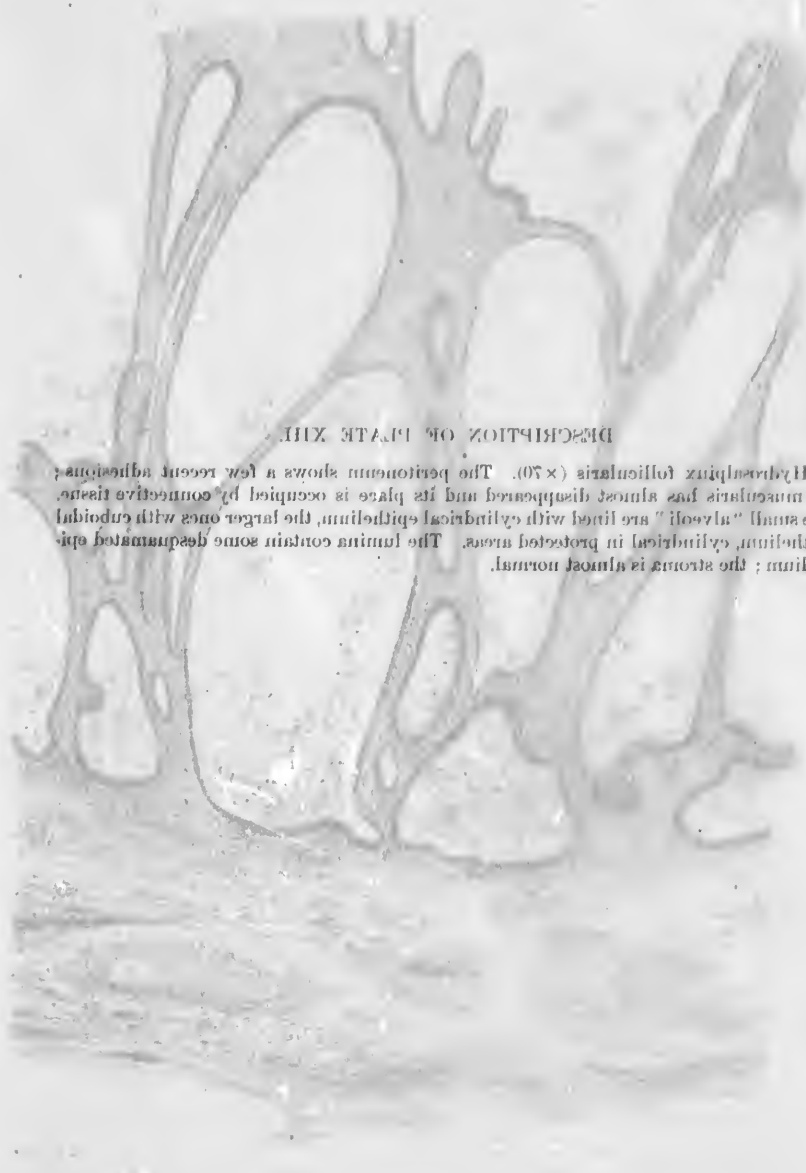
FIG. 378.—RIGHT TUBO-OVARIAN CYST.

The tube above ends in a bulbous extremity, fused with the ovary, with only a slight sulcus between them. The ovarian ligament is shown below, leading out to the cystic ovary. By cutting the cyst open in the direction of the dotted line, the interior of the cyst is seen as in Fig. 379. Path. No. 685. Natural size.

bringing his wide acquaintance with comparative pathology to his aid, considers that these tumors are due to the presence of a tunic of the peritoneum, which occasionally invests the human ovary in the same way that the funicular pouch clothes the testicle, and similar to the peritoneal pouches in some animals, and for this reason he calls the condition an "ovarian hydrocele."

One of my cases of tubo-ovarian cyst, of small size, is seen in Figs. 378 and 379; I have also had one case in which the tumor in the left side was as big as a man's head and filled with a limpid fluid; the valvelike opening out



DESCRIPTION OF PLATE XIII.

Hydranthrix follicularis ($\times 70$). The peritoneum shows a few recent adhesions; the muscularis has almost disappeared and its place is occupied by connective tissue. The small "alveoli" are lined with cylindrical epithelium, the larger ones with cuboidal epithelium, cylindrical in protected areas. The lamina contain some desquamated epithelium; the stroma is almost normal.

tissue developed in its inner wall and forming oval spaces varying in size from a pin-point to 8 millimeters (see Pl. XI, Fig. 2, and Pl. XIII). These cavities are filled with fluid, and apparently communicate with one another.

The muscular coat shows little alteration, with the exception of some connective tissue cell proliferation between the bundles.

The folds of the tunica are sparse or absent, and the stroma itself is occupied by alveoli which are usually subdivided into groups; the large alveoli are lined by cuboidal epithelium and the smaller ones by cylindrical cells. This may be the outgrowth of an endometrial diverticulum like the cysts described by A. Martin. One of them is that the alveoli in question pass into a large cystic.

Of the cases seen of hydrosalpinx four were follicular and two of them were bilateral. One case possessed a follicular hydrosalpinx on the left and was by mesosalpinx on the right, tending to show the close genetic relationship between the two varieties.

4. **Tubo-ovarian Cysts.**—A tubo-ovarian cyst is formed by a communication between a tube and a cyst of the ovary, so that fluid may pass freely from one to the other. This is a bulbous enlargement

DESCRIPTION OF PLATE XIII.
 as big as the bulbous enlargement of the tube. The peritoneum shows a few recent adhesions; the muscularis has almost disappeared and its place is occupied by connective tissue. The small "alveoli" are lined with cylindrical epithelium, the larger ones with cuboidal epithelium, cylindrical in protected areas. The lumina contain some desquamated epithelium; the stroma is almost normal.

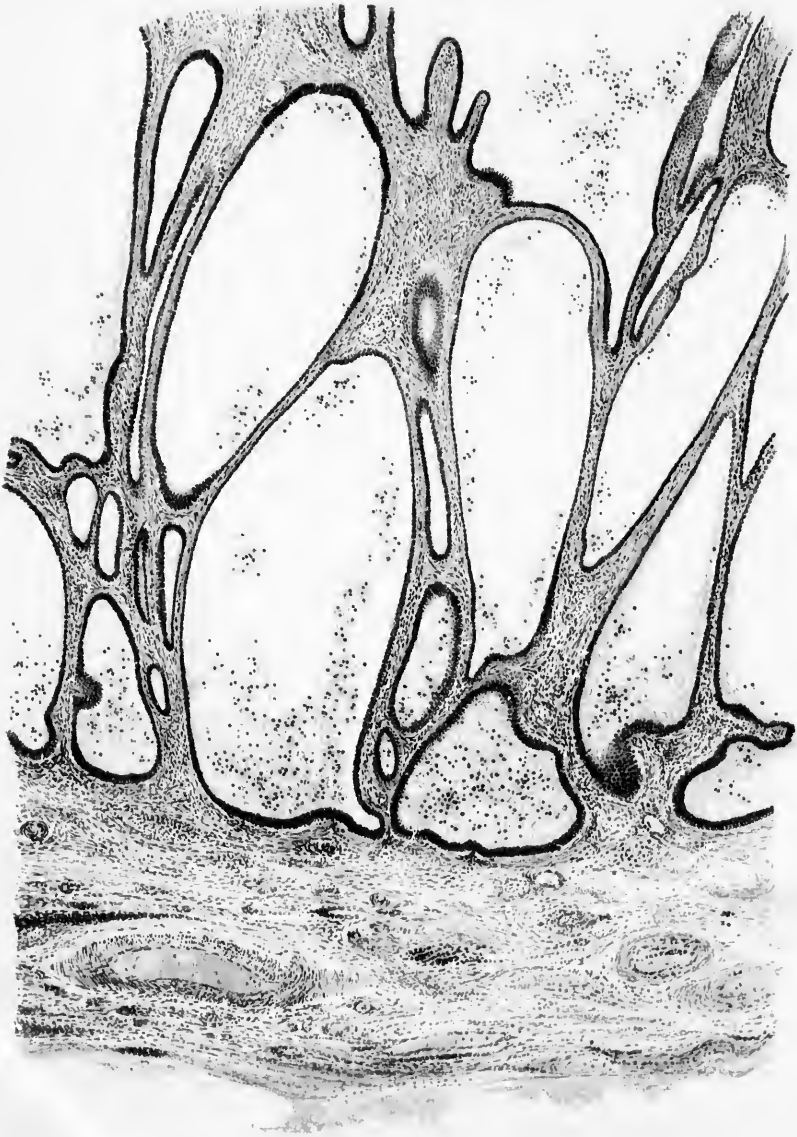


FIG. 13.—Short Tubo-ovarian Cyst.

The tube above ends in a bulbous extremity filled with a clear fluid, communicating between them. The ovarian lumen is shown below, leading into the tube. The dotted line shows the wall of the tube. The dotted line, the interior of the ovary, is shown below. (See also Fig. 13, Natural Size.)

bringing his wide acquaintance with comparative pathology to his aid, considers that these tumors are due to the presence of a lining of the peritoneum, which occasionally invests the human ovary in the same way that the funicular pouch clothes the testicle, and similar to the peritoneal pouches in some animals, and for this reason he calls the condition an "ovarian hydrocele."

One of my cases of tubo-ovarian cyst, of small size, is seen in Figs. 378 and 379; I have also had one case in which the tumor in the left side was as big as a man's head and filled with a limpid fluid; the valve-like opening out



X 70





FIG. 380.—TUBO-OVARIAN CYST FROM THE RIGHT SIDE.

The uterine tube crosses the cyst in the form of an ∞ ; at its right extremity it is kinked and adherent to a piece of the uterine cornu which has been excised with the tumor. The tube ends in the domelike prominence above and to the left. A small, clear subperitoneal cyst marks the border line between the ovarian cyst and the tube. March 8, 1894. $\frac{4}{5}$ natural size.

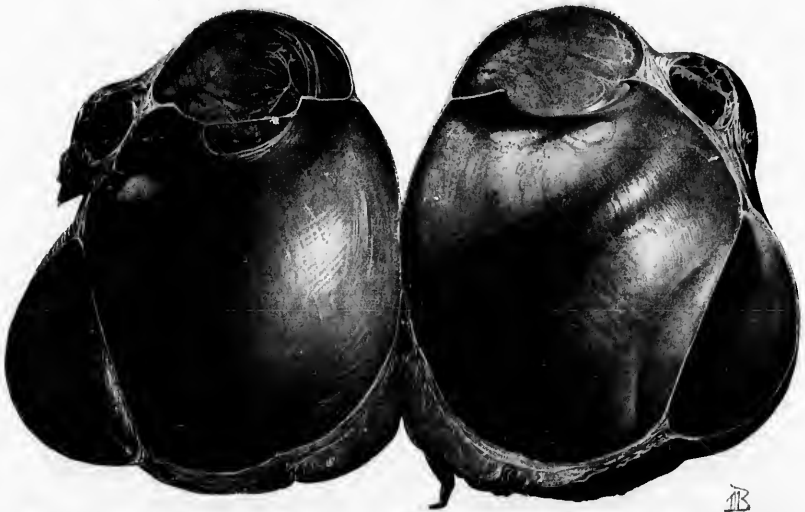

FIG. 381.—TUBO-OVARIAN CYST DIVIDED SO AS TO SHOW THE LARGE OVARIAN CYST WITH THE OVARY FLATTENED OUT ON ITS SURFACE BELOW.

Above, the tube is seen divided twice; the smaller dark opening shows the reticulated appearance of the tube, while the larger opening shows the dilated ampulla with its sickle-shaped opening, through which the tube communicates freely with the ovarian cyst below.

of the tube was partly surrounded by a fringe of fimbriae spread out on the inner wall. Bland Sutton says these cysts occasionally suppurate, but this I have never seen.

The inner surface in one of my cases was lined by flat epithelium and in another by cuboidal. The fluid is clear and watery and does not contain any pseudo-mucin.

Etiology.—The etiology of hydrosalpinx is not yet clear. One thing, however, is quite certain, and that is that it may be produced by any cause



FIG. 379.—TUO-OVARIAN CYST LAID OPEN.

Showing the orifice and fimbriated extremity of the tube and the distribution of the fimbriae over the interior of the cyst, forming a so-called "ovarian hydrocele."

which closes the fimbriated extremity of the tube without destroying its lumen. In this way an infection traveling out through the uterus and the tube into the peritoneal cavity from a general infection; then with the cessation of the suppurative process a hydrosalpinx may develop. Landau states that a pyosalpinx may terminate in a hydrosalpinx by the pus cells undergoing fatty degeneration and leaving the watery elements behind.

If the infection is a violent one and produces a catarrhal or a suppurative salpingitis, the sealing up of the tube is Nature's best way of protecting the peritoneal cavity from a general infection; then with the cessation of the suppurative process a hydrosalpinx may develop. Landau states that a pyosalpinx may terminate in a hydrosalpinx by the pus cells undergoing fatty degeneration and leaving the watery elements behind.

Bland Sutton (*ibid.*, p. 220) holds that hydrosalpinx is often a late stage of pyosalpinx for these reasons: (1) Hydrosalpinx is not found in acute cases; (2) in many chronic cases hydrosalpinx is found on one side of the uterus and a progressive pyosalpinx on the other; (3) the ampulla of a tube may be dilated into a hydrosalpinx, and the isthmus contain pus; (4) the fluid contained in a hydrosalpinx will sometimes be colorless, but the recesses of the tube contain caseous material and cholesterol; (5) the dilated portion of the tube in hydrosalpinx may, as in pyosalpinx, communicate with an enlarged ovarian follicle to form a tubo-ovarian cyst.

It is a remarkable fact that both the tubal mucosa and the muscular walls usually show little or no evidences of any previous inflammatory process. I do not, therefore, believe that the disease is often a sequel of a pyosalpinx.

That the process may be a slow one is evident from the numerous cases in which the fimbriated end of the tube is found in all stages of closure; in one the ends are being turned slightly in and the movements restricted by a band or

a collar of lymph just back of the fimbriæ; in another the end of the tube is rounded off and bulbous, but from the center a rosette of fimbriæ still projects; a little later a little red bud hangs out of a minute orifice; finally this disappears within and the closure is complete.

At the point of completed closure there is a mass of scar tissue, and the tube often presents a marked depression from which bands of connective tissue radiate out to the periphery.

The turning in of the fimbriæ is to be accounted for in the following way: The inflamed peritonæum is the only surface to which the lymph can become attached, and every time a contraction is made a gain is effected and more mucosa is turned in. There is nothing, on the other hand, to evert the mucosa again, except the swelling from an inflammation which tends to subside after the initial stages of the disease have passed.

Symptoms.—The symptoms of hydrosalpinx are variable. When there is much pain and soreness in the pelvis, this is usually due to the coincident pelvic peritonitis and the adhesions formed. The pain is lateral, on one or both sides, and there is marked tenderness developed on pressure, especially if the tube is squeezed bimannally. Upon handling the tube in this way, the patient is often able to locate precisely the focus of her discomforts.

Backache, bearing-down, radiating pains, and painful defecation are symptoms common to pelvic inflammatory disease in general.

Menstruation is painful in over 50 per cent of the cases, but in the remainder it is in no way affected.

When both tubes are occluded the woman, of course, remains sterile; about 25 per cent of my cases in married women were never pregnant at all.

When one tube remains patulous, pregnancy may occur, but there is apt to be an early miscarriage as soon as the enlarging uterus begins to make traction on the unyielding diseased structure.

Two of my patients who had no children became pregnant nine and five times respectively and miscarried every time.

It must be borne in mind in studying the relationship of hydrosalpinx to pregnancy that the disease often makes its first appearance after the woman has had one or more children.

Diagnosis.—The diagnosis will usually be made best by emptying the bowel thoroughly and putting the patient under an anesthetic. Then if the bowel is inflated with air by placing the patient for a short time in the knee-breast posture and letting air in through the anus, a minute examination of the tubes and ovaries can be made and any abnormality detected.

Two things must then be determined: first, that there exists a cystic enlargement lateral to the uterus, but not directly connected with it; and second, that the ovary is not the seat of the enlargement.

A hydrosalpinx is always found lateral to, or lateral and posterior to, the uterus, and is usually elongate, differing in this respect from small ovarian cysts. If its curved course can be traced and one or more kinks made out, a diagnosis may be made. The diagnosis is still more certain when the ovary is carefully

outlined at the same time and the fact made sure that it is not enlarged. When the tube and the ovary are involved in much surrounding inflammation, a diagnosis will be difficult and often quite impossible.

The distinction between hydrosalpinx and pyosalpinx rests upon the thickness of the tubal walls and the dense, often boardlike, feeling of the surrounding peritoneal and cellular tissue engendered by the suppuration.

Treatment.—The treatment of hydrosalpinx and its associated pelvic inflammation consists in the adoption of measures either conservative or radical.

The conservative plan of treatment must always be given the precedence in young women; this has been dwelt upon in detail in Chapter XXV, and in brief consists in breaking up adhesions, either by the rectum or through an abdominal or vaginal incision; in opening and making a new ostium in a closed tube; or in resecting a diseased tube.

It must be remembered that no matter how extensive the surrounding inflammation and how intimately the ovary is involved in it, or how completely the ovary is buried in adhesions, this organ is itself rarely diseased and rarely requires removal. A chronic ovaritis does not exist, and the eirrhotic condition found is due to malnutrition from interference with the circulation.

The only possible reason for removing the ovary is the necessity of cutting short the menstrual function.

Radical Treatment.—When a radical plan is adopted this must not be done as a routine procedure, but only after deliberation and duly weighing the chances of conservatism and formulating sufficient reasons for the extirpation.

The radical course is justified in a young woman only where conservatism has already been tried and has failed, and in older women who are condemned by the pelvic disease to a life of suffering and of more or less invalidism. If the woman is married it must not be forgotten that even after forty, women have borne children under the most discouraging conditions. (See Chapter XXV.)

The operation consists in—

1. The removal of a diseased tube alone, or
2. The removal of both tubes and the uterus, leaving the ovaries, or
3. The removal of the tube and the ovary together, or
4. The removal of uterus, ovaries, and tubes.

The adhesions, the result of a surrounding pelvic peritonitis, vary from light bands easily severed all the way to dense inflammatory masses burying the uterus and its adnexa; these must be carefully and deliberately severed under direct inspection until the pelvic organs are set perfectly free.

When one side is affected the best plan is to sever all adhesions and to remove the tube, leaving the ovary. This may be done by lifting up the tube with its mesosalpinx and viewing it by transmitted light, by which the vessels are plainly seen grouped principally at both ends. The cutgut ligatures may then be passed through the mesosalpinx and tied at both ends so as to include the main vessels; the tube is then stripped off by cutting close under its peritoneal attachment. The edges of the mesosalpinx may then be whipped together by a

fine cat gut suture. A large hydrosalpinx should be tapped and evacuated before attempting to remove the tube.

The removal of a tube and an ovary, or of both tubes and ovaries, is only done in order to check menstruation where its continuance is deemed incompatible with complete recovery; this operation is the same as that of simple salpingo-oöphorectomy, which is fully described in the first section of this chapter.

When the uterus is adherent and buried in the inflammatory disease surrounding the tubes and ovaries, it will be better to remove this organ too, in the manner described in Chapter XXVIII, always remembering to preserve the ovaries in young women, if possible.





CHAPTER

VAGINAL DRAINAGE AND ENUCLEATION OF LOCALITY OVARIAN ABSCESS. TUBO-OVARIAN ABSCESS.

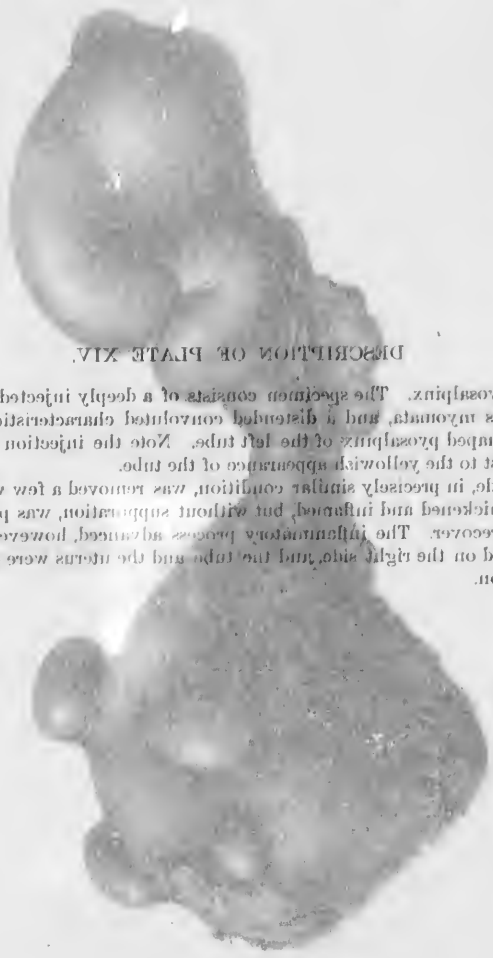
DESCRIPTION OF PLATE XIV.

A typical pyosalpinx. The specimen consists of a deeply injected uterus with four small subserous myomata, and a distended convoluted characteristically yellow and injected club-shaped pyosalpinx of the left tube. Note the injection of the vessels in marked contrast to the yellowish appearance of the tube.

The right side, in precisely similar condition, was removed a few weeks before, and the left tube, thickened and inflamed, but without suppuration, was preserved in hope that it would recover. The inflammatory process advanced, however, steadily to the condition found on the right side, and the tube and the uterus were extirpated at the second operation.

... common usage has restricted it to intra-pelvic suppurations in the neighborhood of the uterus. Considerable confusion existed for many years as to the actual site of these abscesses; it was long supposed that they were all alike located in the cellular tissue, and were the outcome of a cellulitis. As a matter of fact, demonstrations from hundreds of cases minutely observed during the last decade prove that the seat of the abscess, as a rule, is located in the cavity of the ovary, and that it is rarely found in the cellular tissue.

- 1. In the form of accumulations of pus.
- 2. Encompassed in one or both tubes.
- 3. Within the ovary—ovarian abscess.
- 4. In tube and ovary separately.
- 5. In tube and ovary combined—ovarian cavity—a tubo-ovarian abscess.
- 6. In the cornu uteri—cornual abscess.



DESCRIPTION OF PLATE XIV.

A typical proserpinx. The specimen consists of a deeply injected uterus with four small subserous myometria and a distended convoluted characteristically yellow and injected club-shaped proserpinx of the left tube. Note the injection of the vessels in marked contrast to the yellowish appearance of the tube.

The right side in precisely similar condition, was removed a few weeks before, and the left tube thickened and infarcted, but without suppuration, was preserved in hope that it would recover. The inflammatory process advanced, however, steadily to the condition found on the right side, and the tube and the uterus were extirpated at the second operation.

CHAPTER XXVII.

VAGINAL DRAINAGE AND ENUCLEATION FOR PYOSALPINX, OVARIAN ABSCESS, TUBO-OVARIAN ABSCESS, AND PELVIC ABSCESS.

1. Forms of abscess.
2. Causes of suppuration: 1. Gonococcus. 2. Streptococcus. 3. Staphylococcus aureus and albus. 4. Micrococcus lauceolatus. 5. Bacillus lactis aërogenes. 6. Proteus Zenkeri. 7. Tubercle bacillus.
3. Table showing bacteriological examination of pus from ovaries and tubes.
4. Course of an inflammatory process.
5. Symptoms: 1. Natural terminations of an abscess by: (a) Discharge through uterus; (b) discharge through rectum, vagina, bladder, abdominal wall, or into peritoneum; (c) becoming encysted; (d) absorption and disappearance of pus.
6. Prognosis.
7. Diagnosis.
8. Treatment: 1. Expectant. 2. Emptying the sac by massage. 3. Vaginal incision and drainage. 4. Evacuation through the rectum. 5. Evacuation by the vagina aided by an abdominal incision. 6. Enucleation of pyosalpinx and ovarian abscess (salpingo-oophorectomy).

Forms of Abscess.—The term “pelvic abscess” as used in gynecology is somewhat vague, for while it literally includes all forms of pus accumulations found in any part of the pelvis, from the tip of the vermiform appendix to the ischio-rectal fossa, common usage has restricted it to intrapelvic suppurations in the neighborhood of the uterus. Considerable confusion existed for many years as to the actual site of these abscesses; it was long supposed that they were all alike located in the cellular tissue, and were the outcome of a cellulitis. As a matter of fact, demonstrations made from hundreds of cases minutely observed during the last decade prove that the seat of the abscess, as a rule, is located in the uterine tube or the ovary, and that it is rarely found in the cellular tissue.

I have found accumulations of pus—

1. Encapsulated in one or both uterine tubes—pyosalpinx, single and double.
2. Within the ovary—ovarian abscess.
3. In tube and ovary separately—tubal and ovarian abscess.
4. In tube and ovary combined into a common abscess cavity—a tubo-ovarian abscess.
5. In the cornu uteri—cornual abscess.

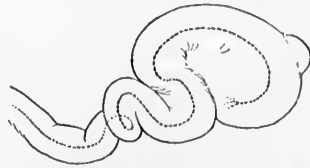


FIG. 382.—OUTLINE OF THE TORSION OF THE PYOSALPINX SHOWN IN THE COLORED PLATE.

The axis is shown by a dotted line which is heavier or lighter according as its plane lies nearer or farther from the observer. Nov. 9, 1894.

6. On the floor of the pelvis below the utero-sacral folds—abscess of Douglas's *cul-de-sac*.

7. Anterior to the uterus in the cellular tissue, as well as in the uterine tube.

8. In and about a vermiform appendix hanging down into the pelvis—suppurative appendicitis.

9. About the vermiform appendix and in the uterine tube at the same time.

10. Between adherent coils of intestine in the pelvis.

11. About the pedicle left after an abdominal operation.

12. In suppurating ovarian and dermoid cysts.

Abscesses are also found (13) in the uterine walls and (14) in the cellular tissue at the bases of the broad ligaments.

Causes of Suppuration.—Suppurative affections of the pelvic organs are due to any of the pus-producing micro-organisms which usually find their entrance through the vagina into the uterus, and then into the pelvis, either by way of the uterine tube or by the lymphatics through the uterine wall and parametrium. The route of extension from the uterus depends largely upon the variety of the organism; the gonococcus almost always travels along the mucous membrane into the tube, where its further extension may be arrested and the reactionary inflammation confined to the tube, or it may escape onto the pelvic peritoneum, setting up a localized peritonitis.

In gonococcal infection the inflammatory process is almost invariably confined to the pelvic organs and their immediate environment, rarely causing more than a local reaction, and never giving rise to a general infection. In a number of cases I have been able to trace the course of the progressive steps of the invasion of the gonococcus all the way from the external genitals to the pelvic organs.

In one instance where a patulous fimbriated extremity of a tube was seen with the pus containing gonococci escaping into the pelvic cavity, at the time of operation for the removal of the tubal abscess, gonococci were also demonstrated in the free pus in the abdomen, in the uterine tube, in the uterus, the vagina, in Bartholin's glands, in Skene's tubules, and in the urethra, making the chain of the infection complete.

Besides the extension of gonococcus infection along the mucosa, it has been shown (Wertheim) that it may also pass into the submucous connective tissue and even enter the circulation. Many writers, and especially E. Noeggerath, Sänger, and A. v. Rosthorn, lay great stress upon the frequency of pyosalpinx due to the gonococcus. The two latter found tubal disease in 33 per cent of all women affected with gonorrhoea. While the cultures taken from the pus in these cases frequently do not show its presence, I am constrained to attribute this failure to defective culture methods rather than to the absence of this germ, because cover-glass preparations frequently show diplococci which resemble gonococci, and the clinical history of the cases points strongly in this direction.

Gonococci have been found in ovarian abscesses by Wertheim, Sänger, and Zweifel.

The history of a streptococcus infection is different from that of the gonococcus, both in its clinical course and in the route of its extension.

Infection from this organism usually occurs during a badly conducted puerperium, or after an abortion, or is introduced into the uterus by dirty instruments in the hands of the physician. Intra-uterine applications, and the introduction of sounds and dilators without proper antiseptic precautions, are among the commonest means of conveying the infection from patient to patient.

When streptococci gain entrance to the uterus they may invade the pelvis by the same route as the gonococci, or they may penetrate the uterine wall, setting up an endometritis or metritis, and then a parametritis, forming a more or less dense swelling, occurs which usually terminates in an indurated phlegmon or a pelvic cellular abscess.

The tube and ovary may then be involved by continuity or by blood infection, or they may escape infection and lie upon the top of the abscess intact.

The staphylococcus, while comparatively rare, is occasionally obtained from pelvic abscesses.

E. Raymond and W. S. Magill, in a careful bacteriological study of salpingo-oöphoritis, while not denying the possibility of staphylococcus infection, say that they have never seen it. K. Menge reports one case in a series of twenty-six bacteriological examinations, V. Morax one in thirty-three cases, while F. Schauta has only seen the streptococcus and the staphylococcus four times in one hundred and forty-four cases.

Wertheim found in 116 cases of pyosalpinx that 72 times there were no bacteria at all, 32 times there were gonococci, 6 times streptococci, and once staphylococci.

In twenty-five cases of pelvic abscess opened through the vagina in my clinic, Dr. G. B. Miller found the staphylococcus aureus twice and the albus twice. In a series of forty-three cases of purulent conditions of the ovaries and tubes one case showed a mixed infection, consisting of the staphylococcus albus and aureus and the streptococcus. Pelvic abscesses may also be due to a colon bacillus infection.

Among the rarer organisms found are the micrococcus lanceolatus, the bacillus lactis aërogenes, and the proteus Zenkeri. Tubercle bacilli are occasionally found in the walls of pelvic abscesses.

In the twenty-five cases of pelvic abscess evacuated *per vaginam* in my clinic the cultures were negative in twelve cases, streptococci were found in three cases, the colon bacillus four times, staphylococcus pyogenes aureus in two cases, staphylococcus pyogenes albus in two cases, and the gonococcus in four cases.

In two cases only were the gonococci grown on culture, the other two being determined from cover-glass preparations.

In a careful bacteriological examination of forty-three cases of pyosalpinx, ovarian abscess, and pelvic abscess, removed through the abdominal incision, organisms were found much less frequently than in the above-mentioned cases, which gives ground for the suspicion that the cultures taken by the vaginal

puncture may have been contaminated. The results of the examination of these forty-three cases are summarized in the following table:

Table showing Bacteriological Examination of Pus from Ovaries and Tubes.

	Diagnosis.	Cover-glass.	Agar.	Glycerin agar.	Acid gelatin.	Blood serum.	Bacteria.
1	Pyosalpinx.	Negative.	Negative.	Negative.	Negative.
2	"	Diplococci in cells.	"	"	Gonococci.
3	"	Diplococci free and in pus cells.	"	"	"
4	"	Negative.	"	"	Negative.
5	"	"	"	"	"
6	Pelvic abscess.	"	"	"	"
7	Pyosalpinx.	"	"	"	"
8	"	"	"	"	"
9	"	"	"	"	Negative.	"
10	"	"	"	"	Do.	Negative.	"
11	"	"	"	"	Do.	Do.	"
12	Salpingitis.	"	"	"	Do.	Do.	"
13	Pyosalpinx.	"	"	"	Do.	Do.	"
14	"	"	Pink yeast.	Pink yeast.	Pink yeast.	Pink yeast, contamination of culture tubes.
15	Ovarian abscess.	"	Negative.	Negative.	Negative.
16	Pyosalpinx.	"	"	"	Negative.	Negative.	"
17	Pelvic abscess.	"	"	"	Do.	Do.	"
18	Pyosalpinx.	"	"	"	"
19	"	"	"	"	"
20	"	Diplococci in cells.	"	"	Gonococci.
21	"	Negative.	"	"	Negative.
22	"	Diplococci in cells.	"	"	Gonococci.
23	"	Negative.	"	"	Negative.	Negative.	Negative.
24	"	"	"	"	Do.	Do.	"
25	"	"	"	"	Do.	Do.	"
26	"	"	"	"	Do.	Do.	"
27	"	"	"	"	Do.	Do.	"
28	"	"	"	"	Do.	Do.	"
29	"	"	"	"	Do.	Do.	"
30	Ovarian abscess.*	Resembling colon bacillus.	"	A white colony.	Undiagnosed.
31	Pyosalpinx.	Negative.	"	Negative.	Negative.
32	"	"	"	"	"
33	"	"	"	Negative.	"
34	"	"	"	"	"
35	"	"	"	"	"
36	"	Gonococci.	"	"	Negative.	Gonococci.
37	"	Negative.	"	"	Do.	Negative.
38	"	"	"	"	"
39	"	"	"	"	"
40	"	Gonococci.	"	"	Gonococci.
41	"	Negative.	"	"	"

* On lactose agar, a white growth resembling that in glycerin agar. No gas fermentation; also a delicate granular growth which liquefies gelatin.

	Diagnosis.	Cover-glass.	Agar.	Glycerin agar.	Acid gelatin.	Blood serum.	Bacteria.
42	Pyosalpinx.	Many cocci in pairs and chains.	Staphylo. pyog. aureus and albus, strepto.	Staphylococcus albus and aureus, streptococcus.
43	"	Diplococci in pairs; extra- and intra-cellular.	Gonococci.	Gonococci.

TOTAL.

1. Negative	33 cases.
2. Gonococcus.....	7 "
3. Colon bacillus.....	0
4. Mixed infection, staphylococcus albus and aureus and streptococcus.....	1 case.
5. Undiagnosed.....	1 "
6. Contaminated.....	1 "

On account of the close proximity of the pelvic organs to the rectum, vermiform appendix, and sigmoid flexure, pyogenic bacteria may escape from one to the other and set up a purulent inflammation. Dr. Hunter Robb has reported a case in which the pus of a pyosalpinx of one side gave negative results on bacteriological examination, while an inflamed tube on the other side, adherent to an acutely inflamed vermiform appendix, contained streptococci.

Mixed infections of two or more different micro-organisms are rarely found. An organism may develop a pelvic abscess and die and pave the way for the secondary invasion by bacteria of another form.

Course of an Inflammatory Process.—The first effect of the entrance of the infecting organism into the uterine tube is to set up a reactionary inflammation which, as a rule, tends to close the fimbriated end. In mild cases the inflammatory condition may pass off without the production of a pyosalpinx; when the infection is more severe, pus forms in the tube and may discharge into the uterus, or the fimbriated end may rupture and permit the escape of pus into the pelvis over the ovary, producing peri-öphoritis and pelvic peritonitis, if it is a gonococcal infection; or a general peritonitis, if more virulent pus-producing organisms are present. The inflammatory condition may be arrested in the uterine tube, but if the infection is persistent it may involve the intraligamentary cellular tissue.

The ovary is usually involved in the surrounding inflammatory condition (peri-öphoritis), and only rarely is the seat of an ovarian abscess. Infection of the ovary, when it does occur, probably takes place through a ruptured Graafian follicle.

In one of my cases (see Fig. 384), like one described by Sanger, the abscess was situated deep in the substance of the ovary, and there was no coincident tubal infection.

The initial stages of salpingitis are associated with a more or less violent local reaction, in which the tubes become thickened and edematous and fall back in the pelvis down toward the pelvic floor. The mucosa becomes congested and swells, and is bathed in a mucoid, semi-purulent, or purulent secretion.

The reactionary inflammation from contiguity of tissues causes the tubes to become adherent by light adhesions to the adjacent organs. As the inflammatory process progresses the adhesions become more dense, and finally the tube becomes closely attached to the posterior surface of the broad ligament, to the

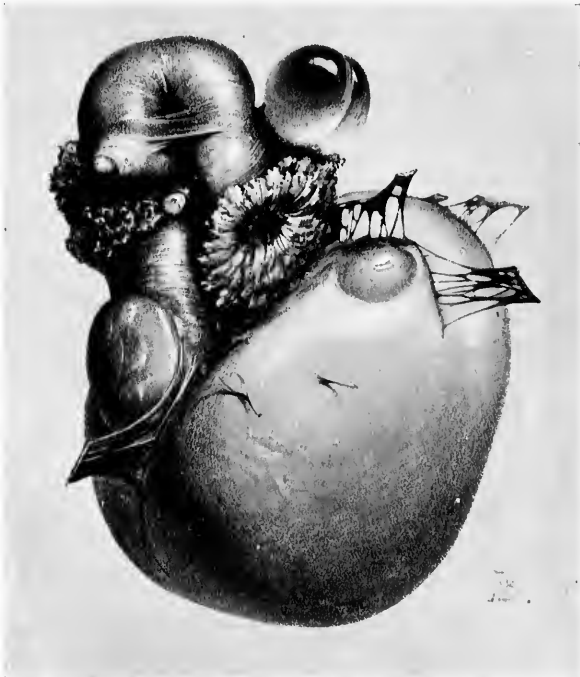


FIG. 383.—LARGE ABSCESS OF THE RIGHT OVARY, WITHOUT PARTICIPATION OF THE TUBE, DUE TO STAPHYLOCOCCUS AUREUS INFECTION.

The areas of denser adhesions are indicated by the bits of tissue attached to the abscess. The tube is buckled on itself and fixed by an isthmio-ampullar adhesion. View from behind. June 1, 1894. No. 317. Natural size.

uterus, the pelvic wall and floor, and covers in the ovary with its mesosalpinx. The rectum is more especially liable to be involved in the adhesions when the inflammation is in the left tube.

The pus varies in appearance from a thin puriform fluid to thick yellow matter; it may be greenish and streaked with blood; sometimes it is intensely fetid, with a strong odor of garlic. This is apt to be the case when the abscess lies in close proximity to the rectum. Both tubes and ovaries may contain pus and only one of them smell badly.

As a rule, both sides are affected, but the abscess on one side is usually larger than on the other. Occasional, however, one side presents an advanced pyosalpinx and its fellow is sound. This liability of both sides to share in the

disease shows that there is a definite tendency in the progression of the disease from without inward.

The term *suctosalpinx* is applied to closed tubes, and according as the contents are watery, bloody, or purulent, the disease is denominated as a *suctosalpinx serosa*, *hemorrhagica*, or *purulenta*. When the tube presents a nodular appearance from separate accumulations in the isthmus, the affection is termed a *salpingitis isthmica nodosa*. This form of salpingitis is most frequently seen in gonorrhoeal affections (see Fig. 385).

Symptoms.—The symptoms produced by the presence of pus in the ovaries, tubes, and surrounding pelvic tissues vary widely according to the stage of the disease and to the variety of infecting organisms. During the acute stage, lasting a week or longer, the patient often suffers intense pain; she lies in bed with knees drawn up and an anxious expression of face. The elevated temperature, quickened pulse, and local tenderness all point to an inflammation localized in the pelvis. From the general tenderness and tympany often present, the physician, however, is apt to draw the erroneous conclusion that there is a general peritonitis.

In gonorrhoeal cases the pelvic inflammation may be preceded by an acute inflammation of the urethra, vulva, and vagina, which may then be

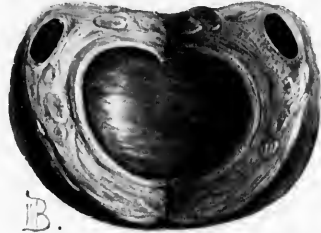


FIG. 384.—ABSCESS OF THE OVARY DEEP DOWN IN THE CENTER, CORPUS NIGRUM AND CORPUS LUTEUM AND CORPORA FIBROSA IN THE SURROUNDING CAPSULE OF OVARIAN SUBSTANCE. MARCH 29, 1894. NATURAL SIZE.

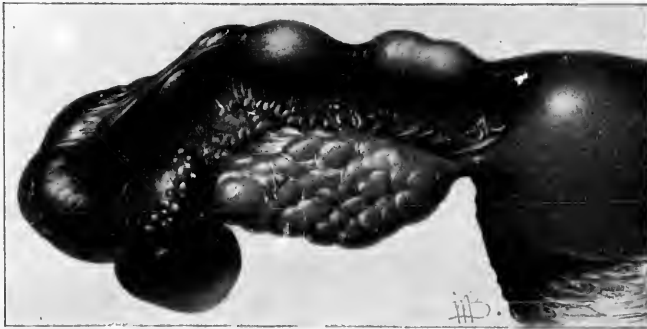

FIG. 385.—NODULAR SALPINGITIS, SALPINGITIS ISTHMICA NODOSA.

Found often in gonorrhoeal salpingitis, and in some tubercular forms. Feb. 24, 1894. Natural size.

quickly followed by pelvic pains and high fever; the pelvic symptoms, on the other hand, may be deferred for several days or months after the primary infection, when the causal relation is not so evident. The onset may then be gradual, beginning with the acute pain in the ovarian regions, a slight rise of

temperature, and painful micturition and defecation. After pus has formed the patient may have rigors, but this is not so frequent as in the graver types of infection. The pulse is good, there is little or no vomiting, the expression is that of a person suffering with pain, but the general condition is excellent.

In a streptococcus infection the attack often dates from a confinement, an abortion, or local treatment of the uterus. The onset is rapid and attended by a chill, high fever, and a rapid pulse. The effect of the septic absorption is soon shown in the general depression; the expression is bad, the pulse becomes more rapid, and the abdominal distention and tenderness is marked. In the streptococcus cases the patient is bedridden from the beginning of the attack, while the patient with a gonorrheal infection may only be bedridden a week or ten days or not at all.

After the acute attack has passed in both the gonorrheal and streptococcus infections the patient may get out of bed, continuing to suffer, but in the streptococcus cases she usually has a septic temperature and the peculiar anemic look of a grave infection.

The attacks of pain and of localized peritonitis tend to recur at variable intervals, and are attended each time with the same symptoms, which may continue until a large abscess has formed behind the uterus on one or both sides, completely filling the posterior pelvis.

Obstinate constipation is sometimes found as a result of the pain on straining at stool, or due to a stricture of the rectum produced by the inflammatory mass bridging its lumen. In cases of long standing the stricture may even become so narrow as to form a serious obstacle in securing the evacuations. This condition was found five times in sixty-five cases of pelvic inflammatory disease treated by vaginal incision in my clinic.

Frequent urination is often distressing and may arise from implication of the bladder and of one or both ureters in the inflammatory mass. Sometimes there is an actual cystitis from an infection of the bladder similar to that existing in the tubes and ovaries.

After the acuter symptoms have subsided the patient is left weak, wan, and sallow, looking as if she had survived a severe illness; she is relaxed, perspires profusely upon slight exertion, and can not walk without distress. The temperature drops a little, but often does not fall to normal for some days or weeks, rising to 99° or 100° F. in the evening. There is often also a persistent fixed pain in the lower abdomen.

Sometimes the symptoms gradually abate, and the patient finally regains complete health. In such cases there is often little or no evidence of the previous inflammatory disease found on a careful examination, or again the appendages may be found adherent but without any evidence of suppuration.

If the pelvic suppuration persists, the symptoms, although less severe than in the acute process, are always present; the patient complains of bearing-down pain, backache, painful defecation and micturition, and often of a purulent vaginal discharge. The gonococcal infection is most likely to subside in this way.

A sudden elevation of the temperature during an attack is always a serious symptom, denoting an extension of the inflammatory trouble, a grave septicæmia, or a general peritonitis. In chronic cases the patients may suffer for twenty years or more from such recurring attacks.

If the abscess is not interfered with, one of four modes of termination may be observed:

1. It may discharge intermittently through the uterus.
2. It may rupture and evacuate itself by the rectum, by the vagina, by the bladder or by the abdominal wall, or it may discharge into the peritoneal cavity.
3. The pus may remain encysted for an indefinite period and small accumulations may become inspissated.
4. It may entirely disappear, leaving behind a hydrosalpinx, or contracted tubes and ovaries bound down and enveloped in adhesions.

In a pelvic abscess which goes on to rupture the process is usually an acute one throughout, running its course with high fever, much pain, and tympany, and ending in the formation of a large pus sac which points into the vaginal vault posterior to the cervix, or into the rectum, or works its way up under the lateral wall of the pelvis, appearing on the anterior abdominal wall above Ponpart's ligament.

Occasionally the bladder is perforated and a large amount of pus suddenly escapes by the urethra.

In rare cases the abscess ruptures through the vaulted free surface of the sac and the pus is poured into the abdominal cavity, escaping among the free intestines and bathing the whole abdomen. It may, however, be limited in its distribution by the coils of distended intestines which adhere to the sac so as to shut it off from the general peritoneal cavity.

The symptoms following this accident will depend upon the character of the pus. In the more virulent cases the patient will at once fall into a condition of collapse, with rapid, thready pulse, which fails to respond to any stimulation; she lies apathetic, with a lack luster look, and dies in two or three days. In another class of cases, on the other hand, the discharge of even 250 cubic centimeters ($\frac{1}{2}$ pint) of pus into the abdomen may be followed by a slowly developing peritonitis, with elevation of temperature, and a pulse rising slowly to 120, 140, and 160.

Abscesses which open into the vagina may discharge their contents completely and the cavity collapse and heal, and the patient regain perfect health.

If the opening is minute through a fistulous tract the discharge only takes place when there is sufficient pressure within to overcome the resistance, and it may continue in this way for months or years, each reaccumulation being characterized by a return of pain, fever, and distention. In some cases the hole cicatrizes over and breaks open afresh each time.

When the abscess opens into the rectum, if the opening is direct and large enough and lies at the bottom of the sac, a rapid and complete recovery may take place. If, on the other hand, the abscess empties into the bowel by a long sinus or by a minute orifice, or if the opening is in the upper part of the ab-

cess, so that the pus only discharges when the sac is full, the discharge may go on indefinitely.

A pelvic abscess opening into the bladder or onto the abdominal wall rarely closes, because the opening lies at a higher level than the sac, and pus can therefore only escape as an overflow or in certain positions of the body; these openings are also always indirectly connected with the sac by a sinus which may pursue a long, tortuous course before reaching the abdominal wall.

Prognosis.—The symptoms, course, and termination of these pelvic inflammatory affections depend upon the species and the virulence of the infecting organisms.

Gonorrheal pyosalpinx usually expends its force upon the uterine tube, and beyond the peri-*o*phoritis and pelvic peritonitis produced by the irritant effects of the toxic products elaborated by the organisms no more extensive damage occurs. The inflammatory condition, however, may be chronic, lasting for years, and is often characterized by exacerbations.

In streptococcus or staphylococcus infections the course of the disease is more rapid, tending to produce a general peritonitis or septicemia. While a considerable percentage of streptococcus cases die, many survive, but are often incapacitated by the accumulation of pus or by the extensive and widespread adhesions remaining after the inflammatory condition has subsided. In about half the chronic cases the organisms die and the pus becomes sterile.

The prognosis is always serious, and a patient with a pelvic abscess is never out of danger, but lives literally over a mine which may explode at any time, when only the most prompt interference can save life.

Diagnosis.—The diagnosis of an abscess involving the uterine tubes or the ovaries, or both, is often easy to make. One of the chief points in establishing it may be the history of an attack of gonorrhea, a septic labor, or miscarriage, since which time the patient has never enjoyed good health; many patients will recall a confinement to bed for one or more weeks with peritonitis.

Many others date their ill health from the first or second month after marriage, even going back to the very week of the marriage, and recalling a more or less profuse irritating leucorrheal discharge with swelling of the internal genitals and dysuria. The outbreak of pelvic peritonitis may then take place at the first menstrual period after marriage. Careful questioning of the husband in these cases will often elicit the information that he was suffering from a slight gleet discharge at the time. The husband of one of my patients actually had a swelled testicle on his wedding day. It is Noeggerath's opinion that no man who has had gonorrhea is ever cured of it.

In other cases there is no such definite history of an initial attack and no sharp line of demarkation between health and disease; the onset is gradual, the pains growing worse and worse with each menstrual period, until a status of invalidism is finally reached.

Following the initial symptoms, the most characteristic features in the natural history of the disease are attacks of peritonitis, confining the patient to bed for days, weeks, or months, often referred to as "inflammation of the

stomach." The patient will often recall that her life was even despaired of at this time.

The general appearance of a patient suffering from an abscess of the appendages varies from a look of complete health to marked emaciation, a sallow complexion, and an expression of constant suffering.

Her attitude and gait as she enters the room are often significant; there is a slight bending of the body over the pelvis, a cautious gait, and a habit of placing the hands on the lower abdomen, keeping up an even pressure on the pelvic viscera to avoid jarring them. This effort is especially marked in stepping over a gutter in crossing the street. I have known a woman to wear a shawl whenever she went out to hide these efforts and the position of her hands.

The differential points in the diagnosis between gonorrhœal and streptococcus cases may be summarized as follows:

GONORRHEAL INFECTION.	STREPTOCOCCUS INFECTION.
Slow in its onset, often preceded by inflammation of the external genitals and urethra.	Onset abrupt, following miscarriage, normal labor, or topical treatments.
Pain localized in one or both ovarian regions.	Pain more general and severe in the lower abdomen.
No signs of general peritonitis.	Usually signs of peritonitis.
Suffers more or less constantly, but may have no fever.	Suffers constantly, and usually has a septic fever.
Temperature 98.5° to 102° F. (38.9° C.).	Temperature 101° to 105° F. (38.3° to 40.5° C.).
Pulse accelerated, but of good quality and volume.	Pulse feebler and more rapid.
Attack lasts five to fifteen days.	Attack seldom lasts less than a month, and may continue three months or more.
Often presents the appearance of good health. Gonococci usually found in cover-slip preparations from the cervical, urethral, or vulvo-vaginal glandular secretions.	Anemic and weak. Gonococci not found in the secretions.
History of marital gonorrhœa.	Husband sound.

A vaginal examination shows that the uterus has lost its natural mobility; sometimes it is solidly wedged in between masses which are felt on one or both sides of the cervix as dense, hard, shapeless, resisting bodies. A stony hardness of the vaginal vault is one of the most characteristic signs of the presence of pus. The position of the fundus often can not be located amid these masses.

The bimanual examination does not at first definitely outline any diseased organs, but simply confirms the discovery made by the vaginal hand, that the pelvic peritoneal floor has become dense and resisting, and that the posterior pelvis is choked with irregular masses.

A continued careful palpation by a trained hand, however, will soon succeed in differentiating several groups of bodies in the pelvis by their location and relative mobility. The first landmark to be established is the body of the womb. This is done by pushing upon the cervix with the vaginal finger and making deep pressure from above until an impulse is felt at the cervix; in this way the fundus can be traced by its direct continuity with the cervix, either in front of it or behind it. The limit of motion in the fixed uterus is small, sometimes only

a few millimeters, but it can be detected by a patient persistence. Masses are now recognized on either side of the uterus and posterior to it, and occasionally straddling it behind, like saddle-bags. Each mass is examined in turn and found filling the posterior half or two thirds of the pelvis on one side, more or less rounded, with a slight mobility of its own quite distinct from that either of the uterus and from the fixed pelvic walls, and it is usually possible to rock it up and down for at least a centimeter.

If the tumor contains pus, a sense of fluctuation may often be best felt by means of the examining finger in the rectum; but if there is but little pus in a thick sac, such as a uterine tube, or a sac surrounded by a dense cellulitis, fluctuation is entirely absent.

Sometimes the pelvic abscess is so large as to form a visible tumor above the symphysis, and a bulging red area in the groin may be due to an imminent rupture.

Occasionally an accumulation of pus on one side presents nothing more than the physical signs of a small ovarian tumor with slight lax adhesions allowing a wide range of mobility, and the absence of all the characteristic evidences of inflammatory reaction may confuse the diagnosis.

In a few instances, however, the diagnosis will be verified in a surprising manner by a free discharge of pus through the cervix, which can be kept up or increased by gentle pressure upon the mass, emptying the abscess more or less completely through the tube, the uterus, and the vagina. Such a gush of pus frequently takes place from the vagina when the abscess sac is grasped and squeezed in the open abdomen during the enucleation.

By the rectal examination in pelvic abscess or densely adherent pyosalpinx the narrow part of the bowel above the ampulla behind the cervix often feels like an auger hole in a board, with rounded edges; above this the tubes and ovaries are felt as more or less fluctuant, bossed, immovable masses, on either side, walling in the rectum.

The temperature is significant where there is a large accumulation of pus, reaching as high as 38.9° to 40° C. (102° F. to 104° F.) or more; in these cases the physical signs also are so distinct as to leave no doubt as to the diagnosis.

The treatment of tubal, ovarian, and tubo-ovarian abscesses is either palliative and expectant, emptying the sac by massage, vaginal incision, and drainage, or enucleation.

In general, the indications establishing the special lines of treatment are as follows: An expectant line of action must be pursued in all cases which are rapidly improving. When there is no manifest improvement, or the change is progressively worse, immediate active interference is the only safe rule. A sac which empties spontaneously through the uterus, or one which can be easily emptied in this way by manipulation, may be treated by massage with a reasonable hope of ultimate complete recovery.

Active surgical interference is the rule in ninety-nine out of every one hundred cases, and this consists either in letting out the pus through the vaginal vault, or in opening the abdomen and removing the sac with or without the

uterus. Wherever it is possible to reach the abscess through the vaginal vault, with or without the aid of an abdominal incision, the patient should first be given the advantage of a trial of this safer method of treatment, by which her pelvic organs are spared. Cases which continue to suffer may afterward submit to the more radical procedure. In patients who are extremely ill, the rapid vaginal operation is often the only one possible under the circumstances.

The urgent indication is always to evacuate the pus; when that is effectively done, the adhesions which are always found are either absorbed or may give rise to no further discomforts. If the patient continues to suffer, an easier and a safer operation may be done at a later date in the absence of pus.

Expectant treatment is limited to a careful observation of the disease, associated with rest and regulation of the bodily functions, and is only applicable in the acute stages of the disease.

In rare cases the pus is wholly discharged through the tubes spontaneously, and complete recovery takes place. Expectancy is necessary in the acute stages of the disease, or one of its exacerbations, on account of the increased danger from a radical operation at this period. While waiting, Nature herself may establish an avenue of discharge at a point favorable for complete evacuation and good drainage.

It is a grave error to hold that as soon as the diagnosis of pelvic abscess is established the next step should be an immediate radical operation.

During the acute stages of the formation of a pelvic abscess the patient must be kept absolutely at rest, the bowels freely open, and ice poultices applied to the abdomen; diaphoretics should be given, and prolonged hot vaginal douches used. Some morphine is necessary to allay the pain. When, under such a *régime*, the abscess points into the vagina or rectum and breaks of itself, a rapid recovery may follow. I have several times ruptured large abscesses in this way simply with the finger while examining the case.

Dilatation of the cervix and curettage have been vaunted as successful in cases of well-defined abscesses to promote the discharge through the uterus, but I have had no experience to enable me to form an opinion.

Evacuation, next to expectancy, is the simplest plan of treatment, and one involving few risks to life in suitable cases. It is accomplished by one of three avenues—the uterus, the vagina, or the rectum. Evacuation through the uterus without operation may be systematically carried out in cases in which it has been found possible in a bimanual examination to squeeze pus out of the sac through the uterus and when the symptoms are not urgent.

Evacuation by incision is the proper mode of treatment in cases pointing into the vagina or rectum.

Simple evacuation by the vagina without enucleation is also indicated even where the abdomen has been opened, and the removal of the adherent tubes and ovaries involve unusual risks to life.

Emptying the Sac by Massage.—Emptying the sac by bimanual compression is particularly adapted to those cases in which the abscess forms a well-defined more or less spherical mass, without much tenderness, and the dense hardness of

the vaginal vault is absent. Success by this form of treatment may be anticipated in cases presenting a history of discharges of pus *per vaginam*. Surrounded by the proper safeguards, this plan of treatment is free from risk, while without due care in avoiding rough handling, and in the absence of a proper selection of cases, there is imminent danger of rupturing the sac into the peritoneal cavity, and so exciting a fresh and even fatal attack of peritonitis.

The relations of the pus sac should first be thoroughly investigated under anesthesia in order to know just where to make the most efficient pressure. Before each massage treatment the vagina must be thoroughly cleansed. The legs are then brought well up and the chest inclined toward the abdomen, producing the most marked relaxation of the abdominal muscles possible. With one hand the abdominal walls are deeply invaginated into the pelvis. When the walls are thin the invagination may be made at any convenient point, but in thick or rigid walls either the linea alba or the linea semilunaris form the most yielding points. The vaginal finger, or the index and middle fingers, now push the vaginal vault behind the cervix, high up and into the back part of the pelvis toward the middle of the sacral hollow. Both hands are thus brought as nearly as possible together behind the tumor; then with a little relaxation of each the strain is relieved, the tactile sense becomes more acute, and the sac is palpated, picked up as it were, by the hands, while a gentle pressure is begun and steadily increased until the sac is squeezed in a direction toward the uterus. The pressure is then relaxed for a moment, and the sac caught again and squeezed in the same direction by a gentle graduated pressure; this process is repeated at intervals for from five to ten minutes, until the contents are milked out through the uterus into the vagina. The success of the maneuver will often be indicated by a free flow of pus out of the vagina over the hand. In case there is no such free discharge, retraction and inspection of the posterior vaginal wall may reveal the presence of the pus.

Such an evacuation should be made once or twice weekly, and the patient kept in bed afterward for several hours or longer if there is any pain or sign of inflammation.

In order to test the value of this treatment as a curative procedure it must be kept up for several months, with rest at the menstrual periods, and the effects judged by the general condition of the patient, together with signs of local improvement, such as relief from pain, and the most important evidence of all, the fact that the sac fills more slowly, or fails at last to fill at all.

Vaginal Incision and Drainage.—The first cases in which I resorted to vaginal puncture were those which came to me in such a critical condition that a radical operation was impossible, and the evacuation of the pus through the vagina was done simply as a temporizing measure with the view of performing a more radical operation later, when the patient had sufficiently recovered to permit it with safety.

The records of the first cases treated in this way showed the most unexpected and gratifying results. Of fifteen cases, eight were permanently relieved without further operation.

Three of these patients were young women (one aged twenty years, another nineteen years, and a third seventeen years) in whom the preservation of the function of the ovaries was of the greatest importance to future health and happiness. Two of these cases were examined two years after operation; in one no evidence of the former disease could be discovered; in the other the appendages were adherent but could be distinctly outlined. In all of the relieved cases the menstrual flow became regular and was unattended by pain.

With these highly satisfactory results as a basis, I extended this method of treatment to a much wider field.

At first only abscesses in which fluctuation could be detected at the vault of the vagina were evacuated by puncture; then cases of dense inflammatory disease, lateral or posterior to the uterus in contact with the vaginal fornix, or walled off from the general peritoneal cavity by adhesions, and finally cases of encysted peritonitis and pyosalpinx, were frequently treated by this means with good results.

Of sixty-five cases treated by vaginal puncture up to Sept., 1896, there were fifty-five cases of pelvic abscess and ten of clearly defined pyosalpinx; in some of these cases there was a pyosalpinx on one side and a hydrosalpinx on the other. In twelve cases there was encysted peritonitis and dense cellulitis. The results in these cases were satisfactory as compared with the higher mortality and slow convalescence in similar cases treated by radical operative measures.

Of the sixty-five cases, thirty-two were cured and two died; of the remainder, some were greatly relieved, while a small proportion were no better. In five cases operation for the enucleation of the diseased structures was performed after the vaginal puncture, when it was found that the patient was only temporarily relieved by this procedure.

The following are the steps of the operation:

1. Cleansing the vagina and cervix.
2. Fixing the point in the vaginal vault for the evacuation.
3. Pressing the vaginal wall well up against the point with the index finger, while the middle finger is introduced into the rectum to protect it from injury.
4. Introduction of a long pair of sharp-pointed scissors on the index finger up to the point of puncture, and plunging the scissors into the abscess in the direction of the axis of the pelvis.
5. Withdrawal of the scissors open, to enlarge the puncture, followed by the introduction and withdrawal of a larger pair of blunt scissors or uterine dilators, making an opening from $2\frac{1}{2}$ to 3 centimeters (1 to $1\frac{1}{4}$ inch) wide.
6. Introduction of the finger, and careful bimanual palpation of the sac wall and surrounding structures, with the finger inside the sac, with a view of discovering and breaking down into any secondary abscesses.
7. Curettage of the living membrane of the sac wall.
8. Irrigation of the cavity.
9. Packing the cavity with iodoform gauze.
10. The after care, consisting in keeping the cavity open, draining freely and clean.

The proper point for puncture of the abscess is posterior to the cervix and in the median line or just to the right or left of it. By the side of the cervix there is danger of wounding the uterine vessels or the ureter. The artery can usually be located by careful palpation against the resisting wall of the sac.

The handle of the scissors affords a good grip, by which the sharp points can be pushed up into the sac in a curved direction toward the second sacral vertebra, or toward the sacral promontory. The operator must take care not to puncture too low down, in the direction of the lower sacral ver-

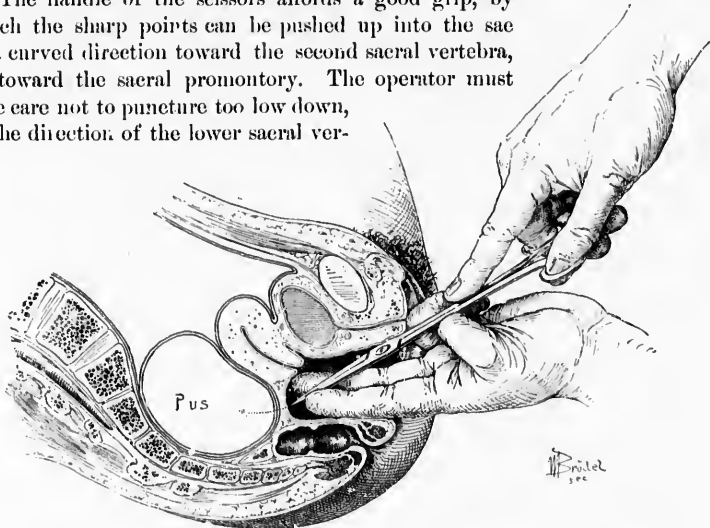


FIG. 386.—OPENING A RETRO-UTERINE PELVIC ABSCESS (PUS) BY PUNCTURING THE POSTERIOR FORNIX WITH A PAIR OF SHARP-POINTED SCISSORS.

The points of the scissors are conducted in the direction of the arrow. It is usually best to insert the middle finger into the rectum to protect it from injury.

tebra, or he may simply transfix the bottom of the cyst and penetrate the rectum.

If the cyst is a little above the vault and too much to the right or the left, this may be corrected by a well-directed pressure made by the hand of an assistant on the lower abdominal wall.

The opening should not be made too much to one side for fear of wounding a ureter.

The position of the uterine artery can always be determined by palpation at the vaginal vault; it is usually felt quite prominent and pulsating against the anterior wall of the sac; knowing its exact position it is safe to enter the sac quite close to it if necessary.

As soon as the sac is entered the blades are easily separated, being now in a free space. If there is much pus present it commonly begins to flow at once. By withdrawing the scissors, keeping the blades open, the hole is torn wider. Stout dilators with parallel blades may next be introduced, or a large pair of blunt scissors may be used as a dilator and withdrawn open as before. The orifice can thus be made fully as broad as Douglas's *cul-de-sac*—from $2\frac{1}{2}$ to 3

centimeters (1 to $1\frac{1}{4}$ inch)—and the pus quickly empties itself through such a wide dependent opening.

The index finger is now easily introduced through this hole, and the size and position and irregularities of the sac explored. The presence of other collections of pus is readily determined by making pressure with the external hand on any doubtful structures, holding them steadily, while they are carefully palpated by the finger inside the sac.

As soon as a well-defined fluctuating mass is felt, if there is no doubt of its being an encysted accumulation, its wall may be broken through with the finger and its contents evacuated through the main abscess cavity. Two or three separate deposits of pus may be released in this way. Great care must be taken not to overlook any such collections, because complete recovery will only follow the evacuation of all the pus in the pelvis.

The empty sac or sacs are now thoroughly irrigated with sterile water, bringing away all the pus and loose tissue *débris*, and a loose pack of washed-out iodoform gauze inserted into the cavity; finally a teaspoonful or more of the iodoform and boric-acid powder (1-7) should be thrown into the vault of the vagina and a loose vaginal gauze pack inserted.

In the case of a large abscess, and especially when it is situated at a distance from the floor of the pelvis, a larger and freer drainage opening is secured by exposing the vaginal vault with specula and making an elliptical incision around and behind the cervix, so as to excise a crescentic piece of the vaginal vault extending up into the peritoneum, as suggested by Dr. G. M. Edebohls. If the edges of the peritoneum are then drawn down and attached to the vaginal tissue,

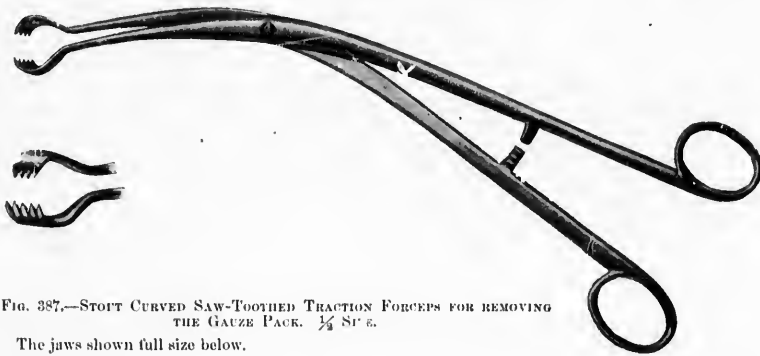

FIG. 387.—STOIT CURVED SAW-TOOTHED TRACTION FORCEPS FOR REMOVING THE GAUZE PACK. $\frac{3}{4}$ 8" L.

The jaws shown full size below.

a perfectly free drain, in which there is no tendency of the edges to drop together, is secured. The first effect of the operation may be a sharp rise in the temperature, as high as 103° to 105° F., which subsides in twenty-four hours.

After establishing free drainage great relief is usually felt at once. If the condition of the patient remains good, the gauze pack in the sac need not be disturbed for three or four days, or longer, when she is brought to the edge of

the bed or table, the posterior vaginal wall retracted, all the gauze removed with a suitable pair of forceps, and the cavity well cleansed with peroxide of hydrogen or boric-acid solution and a fresh pack applied. This cleansing and dressing must be renewed daily, always using speculum and dressing forceps instead of fingers, and carefully avoiding any contamination of the sac wall, for the fact that it has contained pus does not warrant any carelessness as to infection in the after-treatment.

Another way of treating the drain is to withdraw the gauze slowly, taking out 3 or 4 inches every day, and not washing out the sac until it is all removed by about the tenth day.

The patient may rise from her bed and go about the room in eight or ten days if her general condition warrants it.

There is little danger of a free hemorrhage if the operator uses some care in first locating the uterine artery by vaginal touch. In the sixty-five cases I have referred to, hemorrhage, beyond that expected from wounding the vascular vaginal wall, only occurred in two cases, and in both cases it was easily controlled by a firm pack.

Evacuation of the pus into the abdominal cavity must be guarded against as far as possible; but since we have learned that the pus from these cases is so frequently sterile, this appears as a much less serious complication. In nine of the sixty-five cases punctured *per vaginam* the free peritoneal cavity was opened, and in none of them was there any evidence of this accident in the after-symptoms of the patient. When, however, the peritoneal cavity is opened the pus must be most thoroughly removed and the cavity wiped out and packed, and irrigation must be used in small quantities and with the utmost care.

The making of a fecal fistula must be avoided by first examining the rectum to discover its exact relation to the abscess sac, and by keeping one finger in the rectum during the operation to protect it from injury. Notwithstanding these precautions, a small opening may be made, but it will usually heal quickly if the cavity is well packed with gauze, so as to prevent the ingress of fecal matter into the abscess sac. The gauze should be removed daily and the sac well irrigated, followed by the firm application of a fresh pack, with the patient in the knee-breast posture.

The cases most likely to be entirely relieved by vaginal drainage are those where there is a single well-defined collection of pus which can be evacuated completely. When the cellular tissue is more or less honeycombed with multiple abscesses the progress of the case will be slow, and may require repeated puncture on account of the development of the smaller abscesses after the central cavity has been evacuated. In one case five such operations were required before the patient was finally relieved.

A class of cases not likely to be benefitted are those in which there is dense inflammatory tissue without fluctuation, surrounding the rectum, bladder, and ureters. Here the symptoms do not come from the collection of pus, but from the effects of the chronic inflammatory disease. Of the sixty-five cases punctured *per vaginam*, ten were of this class, and beyond the slight relief produced

by the evacuation of a small quantity of pus, the patient experienced no other benefits from the operation.

The cavity contracts day by day in favorable cases, until in a surprisingly short time, sometimes not more than two weeks, a little pit at the vault of the vagina is all that remains. This is finally reduced to a scar, which it may be hard to find at a later date.

Vaginal Incision and Drainage in Acute Cases of Pelvic Inflammation.—A novel plan, proposed by Dr. F. Henrotin (*Trans. Amer. Gyn. Soc.*, 1895, vol. xx, p. 223), on the basis of his experience in twenty-seven cases of acute posterior pelvic inflammatory affections, deserves careful attention. In the absence of further confirmatory evidences it is still impossible to form a satisfactory conclusion and to give this procedure its due position among the other methods of treating suppurating affections. The patient who is suffering from an acute recent infection in its earliest stages is treated by making a semicircular incision posterior to the cervix opening the peritoneum, after which the finger is introduced into the pelvis and used in all further manipulations. With the finger the adherent inflammatory mass is reached, punctured, evacuated, and explored; in the majority of cases an abscess cavity is found. Other foci of inflammation are sought out and opened, and the cavities are then packed with gauze, which is not removed for three, four, or five days, unless the patient's general condition indicates a retention of the secretions.

Following such treatment, the pains and malaise all disappear, and the patients, in the majority of instances, make a rapid recovery.

The author of this plan of treatment also earnestly advocates a thorough curettage of the uterus at the same sitting.

In so far as the pain, tenderness, and elevated pulse and temperature indicate the presence of pus, the general rule may be safely followed and evacuation practiced. Whether it will prove an advantage in the presuppurative stages is still to be determined.

Evacuation through the Rectum.—Evacuation through the rectum is only admissible when there is such a marked area of softening that spontaneous rupture is imminent, and then the opening must be made as low down as possible to secure constant perfect drainage.

Under no circumstances is it allowable to make an opening high up above the constriction between the utero-sacral folds. If Nature makes an opening in such a position, the gases and fecal matter enter the sac and the discharge is kept up for an indefinite period. Where the pointing is high up, or even where an opening already exists at this point, a wide counter-opening should be made through the vaginal vault behind the cervix. The free drainage at this point prevents any accumulation within the sac and allows the higher orifice to close.

Evacuation by the Vagina aided by an Abdominal Incision.—Evacuation of pelvic abscesses by the vagina, controlled by the hand introduced within the abdominal cavity, is called for when the abscess is not so clearly defined as to

admit of operation by the vagina alone, or when upon opening the abdomen the adhesions are found so dense and widespread that an enucleation of the whole mass would be attended with imminent risk to life, or again when the extremely weakened condition of the patient renders drainage safer than enucleation. In the sixty-five cases of pelvic inflammatory disease treated by vaginal puncture an exploratory abdominal section was done in twenty-one.

It is also a better plan of treatment in atypical accumulations of pus, such as deposits around the ligatures and the stump of a previous operation, or where pus pockets are walled in by intestines, or in all cases where the anatomical relations of the septic foci forbid enucleation. Under such conditions if the infected tissues lie in contact with the pelvic floor, a wide opening may be made through the vaginal vault, giving abundant drainage below, and at the same time avoiding injury to the peritoneum by controlling the operation through the hand introduced within the abdomen.

Similarly, if an abscess can not be enucleated after carefully studying its relations through the abdominal incision, the peritoneal cavity is guarded with one hand, while the other carries the sharp-pointed scissors up to the vaginal vault, which is perforated behind the cervix in the direction indicated by the hand within the abdomen. The opening in the vaginal vault is then enlarged, the finger thrust in, and the whole abscess area rapidly broken open into one sac, under the guidance of the hand within.

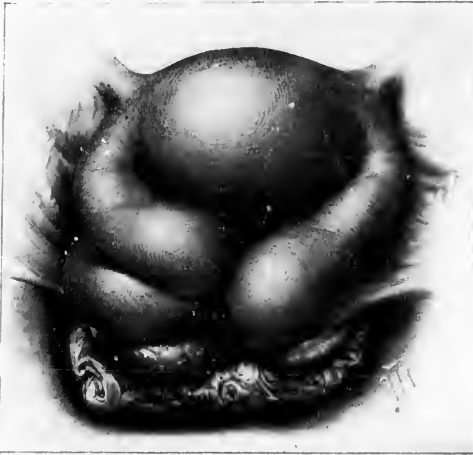

FIG. 388.—ABSCESS OF BOTH FALLOPIAN TUBES TREATED THROUGH AN ABDOMINAL INCISION BY RELEASING, OPENING, AND WASHING OUT THE TUBES, AND THEN DROPPING THEM WITH THE OVARIES ONTO A GAUZE DRAIN LEADING THROUGH THE POSTERIOR FORNIX INTO THE VAGINA. MARCH 4, 1896.

On account of the contamination of the hand holding the scissors, the operator now leaves the patient to the assistant, who closes the abdominal incision and packs the cavity with washed-out iodoform gauze, with the ends brought out into the vagina.

The further treatment of the abscess cavity is to leave the gauze in for several days, when it is removed and the cavity washed out daily; enough gauze is put back after each washing to keep the opening into the vagina from closing before the cavity above has contracted.

One of the worst cases I have ever seen was successfully treated in this way. The patient was in a low typhoid unconscious condition, with a parched brown tongue and pulse at 140. On opening the abdomen the pelvis was found choked

by densely adherent masses which could not be differentiated. It was evident that life could not be saved if the operation was prolonged, so I made a free vaginal opening, and evacuated about 350 cubic centimeters of thick fetid pus. She slowly recovered after several weeks of delirium, and is now, three years after, in good health, without any evidence of pelvic disease.

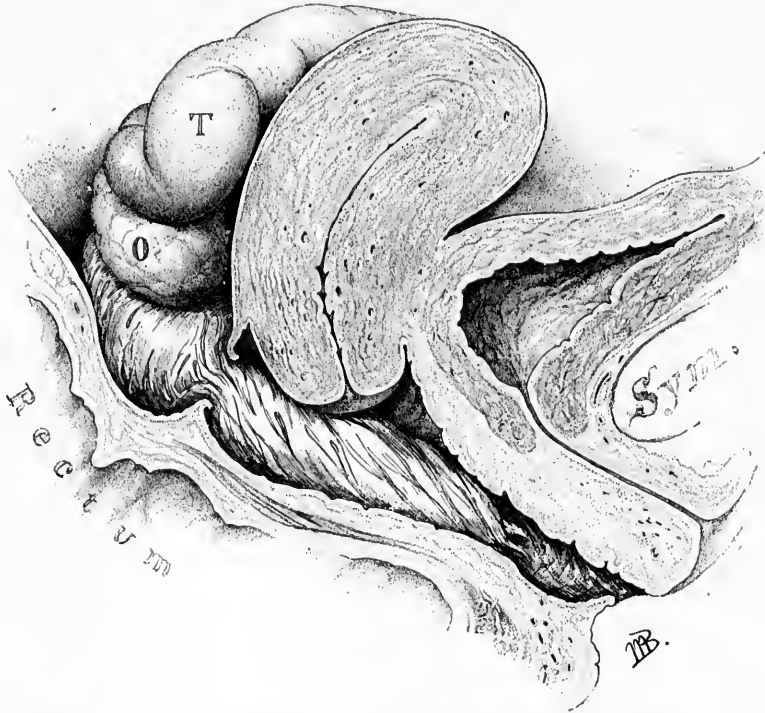


FIG. 359.—SHOWING THE GAUZE DRAIN FILLING THE CUL-DE-SAC BEHIND THE UTERUS AND LEADING DOWN INTO THE VAGINA.

When a pyosalpinx is situated high up in the pelvis and is not in contact with the vaginal vault it may be necessary to free the adhesions and push the pus sac or sacs down into Douglas's *cul-de-sac*, where they may be more easily and safely reached by the vaginal puncture. The following case well illustrates this plan of treatment :

A. C., 4186, March 4, 1896. Chief complaint, severe lower abdominal pains, with recurrent attacks of fever and chills.

She had been married sixteen years and had one child, born eleven years ago after a difficult natural labor. Complete rupture of the recto-vaginal septum occurred, and she was confined to bed for two months with puerperal fever; she has had four operations since in the endeavor to cure the tear, and each time

infection caused a failure. In 1889 she was operated upon for the fifth time successfully.

In Jan., 1896, after exposure to cold she began to have an offensive hemorrhagic discharge, accompanied by chills and fever, and her abdomen became swollen and tender, bowels constipated, defecation very painful. At the beginning of the attack her fever was high and she vomited much bilious matter.

This attack continued throughout February, becoming less and less severe until the present time. The point of greatest tenderness is now in the right iliac region, extending across the abdomen. There is no tympanites, but the abdomen is tender. Micturition is painful, and the urine is loaded with mucus.

Her general condition is one of extreme debility, her tongue is coated, appetite poor, and she is anemic.

Examination.—Vaginal outlet relaxed, uterus anteflexed, cervix bilaterally lacerated. On both sides of the uterus adherent fluctuating fusiform masses.

Diagnosis.—Right ovarian abscess and pyosalpinx; left pyosalpinx and cystic ovary; general pelvi-peritonitis with fresh adhesions to rectum, pelvic walls, broad ligaments, uterus, and pelvic floor.

Complications.—Fresh plastic lymph gluing all organs together and causing free oozing on separating adhesions.

Operation.—Abdominal incision for the purpose of accurately locating the masses which were situated high up in the pelvis, and not in contact with the vaginal fornix, followed by an opening in the posterior wall of the vagina, evacuation of pus, and drainage.

The pelvis was choked with the uterus, pyosalpinx, cystic ovary, and ovarian abscess, adhering to all contiguous structures, and the interspaces were filled with plastic lymph. The adherent organs were detached with difficulty, but without tearing the rectum. An abscess of the ovary, 4 centimeters ($1\frac{1}{2}$ inch) in diameter, ruptured during the separation of the adhesions, discharging pus onto the surrounding gauze; the distended tube was separated from its adhesions to the ovary, and its fibriated end was split open and necrotic material and some pus squeezed out.

The left tube was brought up and treated in the same way, but there was no pus in the left ovary. After freeing the tube from its adhesions the closed extremity was split open and a small amount of pus squeezed out. The vaginal vault posterior to the cervix was then opened and a gauze drain was pulled through from above downward. The tubes and ovaries embraced the uterus behind, touching each other, and filling in the posterior pelvis, with the fibriated extremities lying in Douglas's *cul-de-sac* resting on the gauze drain.

The patient recovered slowly but steadily. The vaginal drain was removed with little difficulty, moistened with a slightly offensive yellowish discharge; after the removal there was no discharge. The post-operative temperature at no time rose above 100° F. (37.8° C.).

She left the hospital five weeks after the operation, and was seen several months later perfectly well and hard at work as a canvassing agent.

Enucleation of Pyosalpinx and Ovarian Abscesses (Salpingo-oöphorectomy).—

In enucleating a pyosalpinx or an ovarian abscess the first step after opening the abdomen is to make a careful inspection of the relations of all the pelvic viscera.

If omental adhesions interfere with the examination they must be separated by catching the omentum close to the adhesion and tearing them loose from their adhering surface with gentle force, or by tying them off.

If the fundus uteri is found at or near its normal position, the fingers then readily glide over the cornua from one side to the other, and palpate the more or less hard nodular masses filling the pelvis on both sides posterior to the broad ligaments.

It is by no means rare for the operator not to be able to discover the uterus at all, because it is so covered over with its diseased lateral structures and inflammatory products, even uniting the bladder to the rectum.

As soon as the diseased tubes or ovaries are located, the relations of each to all the structures with which it lies in contact must be studied separately by sight and by touch, pushing a little here and there to determine the amount of mobility, and noting with care any dense, hard, unyielding attachments, and especially all bowel adhesions.

As a result of this thorough preliminary inspection the operator concludes whether he will or will not be able to make a satisfactory enucleation. It is impossible here to lay down such precise rules as will serve to guide the inexperienced surgeon in all cases, but it is undoubtedly true that operations of this character which appear at first sight, and to a beginner, impossible, are readily performed by a more experienced gynecologist. If the structures can be outlined, and are found to be slightly movable, an enucleation will always be possible; if, on the other hand, they are densely wedged in the posterior pelvis and adhere to the pelvic walls as if frozen there, an enucleation ought never to be attempted; the abscesses must then be evacuated by the vaginal route, aided by one hand in the open abdomen.

If the masses are to be removed, evidences of fluctuation are sought for and the aspirator inserted, so as to draw off the pus into a sterile bottle; cultures should then be taken, and cover-glass preparations made for immediate microscopic examination. The puncture hole should be closed with a single mattress suture. Any pus that escapes accidentally should be taken up at once, and pieces of gauze and sponges should be stuffed down into the pelvis and on all sides above the pelvic brim, so as to protect the adjacent parts from contamination. The sides of the abdominal incision should also be protected throughout the operation by several layers of gauze.

When a large abscess ruptures during an operation, with the pelvis elevated, the patient must at once be let down to a level to prevent the extensive contamination of the intestines.

All intestinal adhesions should be separated under the eye; velamentous adhesions can be pinched off close to the sac, but flat, dense cicatricial adhesions must be dissected off with the knife or scissors, even leaving a part of the outer wall of the abscess adhering to the intestine. If any of the

pyogenic lining membrane of the cyst is left behind, this can be disinfected either by toneling it with pure carbolic acid or by destroying the surface with the cautery, or by scraping it off with a scalpel.

The successful enucleation of the diseased tube and ovary depends upon two factors: A good tactile sense, which constantly differentiates the structures under the fingers and readily recognizes the lines of cleavage between the diseased organs and the adherent peritoneal surfaces, and a knowledge of the usual topographical relations of ovarian and tubal abscesses.

The natural points of cleavage are opposite to the normal anatomical attachments of the tube, along the dorsal and dorso-lateral pelvic walls, and between the two abscess sacs where they touch behind the uterus.

When the cysts are completely covered with dense organized tissue an entrance must sometimes be effected by dissection with the knife, after which the further separation is not so difficult.

By palpating around the dorsal wall of the pelvis a weak spot will usually be found, and then by working one or two fingers down here the split is widened and the cyst may be peeled off from side to side, while the fingers continue to advance on down toward the pelvic floor, at first behind and then under the mass.

As the fingers advance, the separation from side to side is kept up until the mass, freed from the dorsal pelvic wall and the pelvic floor is grasped by the fingers and rolled forward and upward toward the incision, using the upper part of the broad ligament as an axis. This completes the separation of adhesions to the broad ligament. Adhesions at the outer pole of the mass to the rectum or pelvic wall, and at the inner pole to the uterus, are now looked for and separated under inspection.

The whole mass, sometimes as large as the fist, but made up only of tube and ovary, is now brought out of the incision, still retaining its normal attachments to the ovarian hilum and ligament, to the mesosalpinx and cornu uteri, and to the infundibulo-pelvic ligament. As soon as these structures are brought outside, a sponge or loose piece of gauze is packed down into the incision behind the broad ligament to protect and hold back the intestines.

The mass to be amputated should be enclosed in a gauze bag several folds thick the moment it is liberated; this affords a good grasp and protects the hand and the surrounding tissues from the contamination of any escaping pus. The method of ligation and excision of the tube is the same as that described in Chapter XXVI, p. 207.

It will usually be found that the ovary is not diseased itself, but is merely involved in adhesions due to the accident of its position in the pelvis in proximity to the tube; under these circumstances the ovaries should be left in women under forty.

When the disease is bilateral the opposite side is similarly treated.

If persistent oozing is noticed after the enucleation, its source must be sought out and inspected by packing away the intestines with fingers and sponges. A slight, constant oozing from a flat surface on the pelvic floor

may be controlled by a little dried persulphate of iron applied on the finger tip, or the cautery may be used; bleeding from a large vessel must be controlled by ligatures introduced by the needle and carrier. Hemorrhage from a uterine adhesion, or from the side of the uterus where it joins the broad ligament, or from the ovarian hilum, must be controlled by the free use of ligatures through the uterine tissue and through the broad ligament.

Persistent active oozing will occasionally be found to proceed from the outer end of a tube which has been torn in two in the enucleation, or from an adherent piece of the abscess wall left behind. These may be easily removed with forceps or fingers, and the bleeding will cease. Irrigation is indicated where pus has escaped during the operation and there is some probability that the intestines have been more or less contaminated. If the cyst is aspirated before enucleation the liability to contamination is greatly reduced.

The pelvis should now be cleansed with sponges, and then the sides of the incision may be pulled up and as much hot salt solution poured in as the pelvis will hold.

The hot salt solution should be stirred about in the pelvis with the hand or with a sponge on a holder, and the water then sponged out and more poured in; this may be repeated several times, until the surgeon is satisfied that the pus has been well diluted and removed.

After drying out the abdomen the last step is a minute, deliberate inspection of the whole field of the operation to see if the ligatures are all in place and holding well, if all bleeding is checked, and if any intestinal adhesions have been overlooked. It is most important to examine minutely the rectum from the pelvic brim to the pelvic floor in search of a fistulous opening or a rent in the outer coats of the bowel.

The employment of a drain in these cases is of no value and may give rise to serious harm, and it is therefore much better to close the abdomen without drainage unless a septic focus or a much injured bowel has been left behind, when a vaginal drain should be inserted behind the cervix.

In order to prevent the accumulation of fluids in the raw areas left after difficult enucleation of diseased appendages, 500 cubic centimeters of salt solution should be left in the abdominal cavity after operation, and when the patient is returned to her room the bed should be elevated about twenty degrees in order to facilitate the rapid absorption by the lymph channels of the fluids and accumulating serum. The addition of the salt solution dilutes any infectious matter present, and not only hastens its absorption, but also lessens the irritant effects of the toxic products of the bacteria.

When the abdomen is opened for a pelvic abscess and a widespread or a general purulent peritonitis is found, the course pursued by the operator will depend upon the condition of the patient. If she is so weak that she can presumably only stand an operation of the shortest duration, the best plan will be to irrigate rapidly, cleaning out all the accessible pus with a sponge, paying special attention to the pelvic cavity and the renal fossae. If the time is too short to permit the enucleation of the pelvic abscess, this should at least be squeezed

empty and a free drainage opening made into the vagina back of the cervix and the abdomen closed.

When, however, the patient's condition will permit it, the entire abdominal cavity should be washed out and the separate coils of intestines drawn up in an orderly manner and wiped off, and the mesentery cleansed, so that, as far as possible, every trace of pus is removed. It must be remembered that only one third of the intestinal canal lies in contact with the abdominal wall and that there is

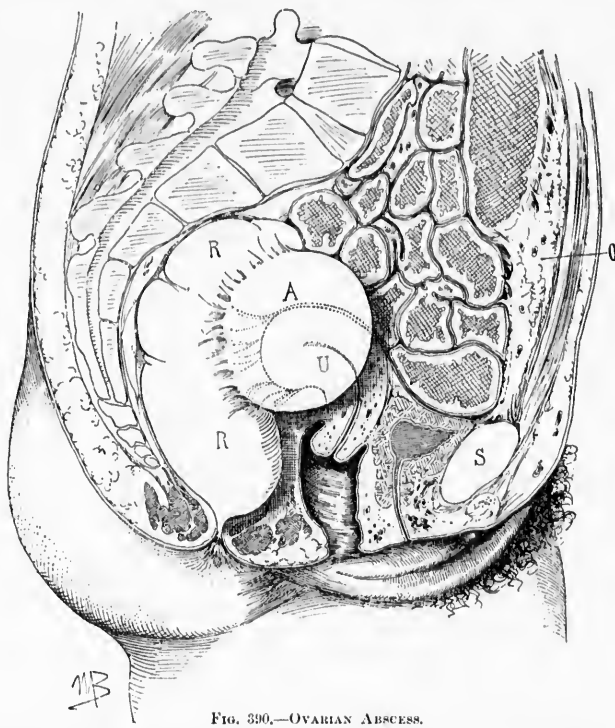


FIG. 390.—OVARIAN ABSCESS.

(A) Densely adherent to the rectum, with retroflexed adherent uterus (U); general pelvic peritonitis of the severest form, involving both tubes and ovaries. Omental adhesions (O) 48 centimeters around the border. Pus in abscess sterile. Enucleation of uterus, tubes, and ovaries. Recovery. Gyn. No. 2325. M. V., June 13, 1894.

an enormous extent of peritoneal surface distributed over the mesentery, so that after simply washing off what is exposed to view through an abdominal incision, much more is left behind which still more urgently demands attention. Liberal gauze drains should then be inserted in the median line leading down into the pelvis and out onto the coils of intestines. The flanks should also be opened and gauze drains put in there to catch any fluids gravitating in that direction. In this way several yards of gauze may be employed and gradually removed in

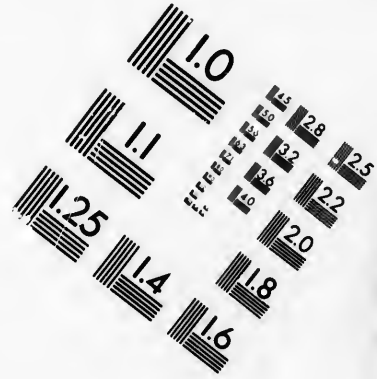
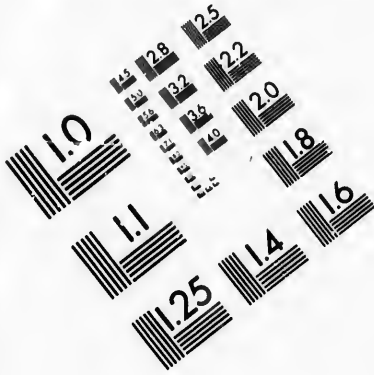
a few days. When the uterus is extensively diseased either by a chronic endometritis or contains numerous myomata, or is cancerous at the same time, as



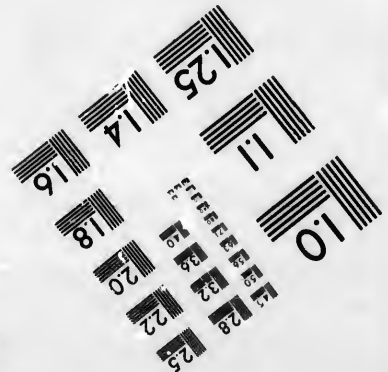



FIG. 391.—DOUBLE PYOSALPINX WITH CARCINOMA OF THE CERVIX.

Showing a case of not uncommon occurrence in which it is necessary to enucleate both tubes and the entire uterus. The pus in both tubes was sterile. No. 398. $\frac{3}{4}$ natural size.

shown in Fig. 391 and Plate XIV, the enucleation should then include the body or the entire uterus with the infected tubes, and the operation should be performed as described in Chapter XXVIII.



**IMAGE EVALUATION
TEST TARGET (MT-3)**



**Photographic
Sciences
Corporation**

23 WEST MAIN STREET
WEBSTER, N.Y. 14580
(716) 872-4503



CHAPTER XXVIII.

HYSTERECTOMY, WITH EXTIRPATION OF OVARIES AND TUBES— ABDOMINAL HYSTERO-SALPINGO-OÖPHORECTOMY.

1. Indications for operation and analysis of one hundred cases.
2. Reasons for removing the uterus.
3. Operation.
4. Complications in one hundred cases.
5. Mortality.

Indications for Operation.—The removal of the uterus with diseased ovaries and tubes by the abdominal route is indicated—

1. Where previous efforts at conservatism have failed.
2. Where the uterus is involved in inflammatory products, buried beneath masses of adhesions, or beneath bladder and rectum adherent together over the top of the uterus.
3. Where, in addition to the extensive lateral disease, the uterus is subinvolved or there is a chronic metritis.
4. Where the incurable disease of the tubes and ovaries is complicated by a uterus containing myomata.
5. In general, where the enucleation *en masse* is technically much easier and therefore safer than the removal of the lateral structures alone.
6. In cancer of the body of the uterus.
7. When both ovaries are the seat of papillary, dermoid, or multilocular cysts.

The diseases of the ovaries and tubes most likely to be found with such a uterus are double pyosalpinx, or pyosalpinx of one side and hydrosalpinx of the other, or double hydrosalpinx, or general posterior pelvic peritonitis binding down the uterus, ovaries, and tubes.

I have found it necessary to remove the uterus, tubes, and ovaries in one hundred cases for the following reasons: For pyosalpinx in 38; for ovarian abscess, 2; for pelvic abscess, involving both tubes and ovaries, 18; for salpingitis and peri-öphoritis, 22; for hydrosalpinx and pelvic peritonitis, 15 (once with dermoid cyst); endometritis, pain, and hemorrhages not relieved by a previous salpingo-öphorectomy, 2; tuberclosis of ovaries and tubes, 3.

Out of sixty-five cases of pelvic abscess treated by a free vaginal incision and drainage I found it necessary at a later date to resort to the radical plan of extirpating uterus, tubes, and ovaries in five cases.

This most radical procedure must be carefully guarded by operating only upon suitable and stringent indica-

tions. In young women, when the ovaries are not diseased, they must be left in the pelvis, confining the enucleation to the tubes and the uterus.

The removal of the uterus with the tubes and ovaries is to be recommended, because without the ovaries it is a useless organ, which may of itself, at a later date, become the source of such serious disturbances as to require its removal. In almost all pelvic inflammatory cases the uterus is traceable as the avenue of

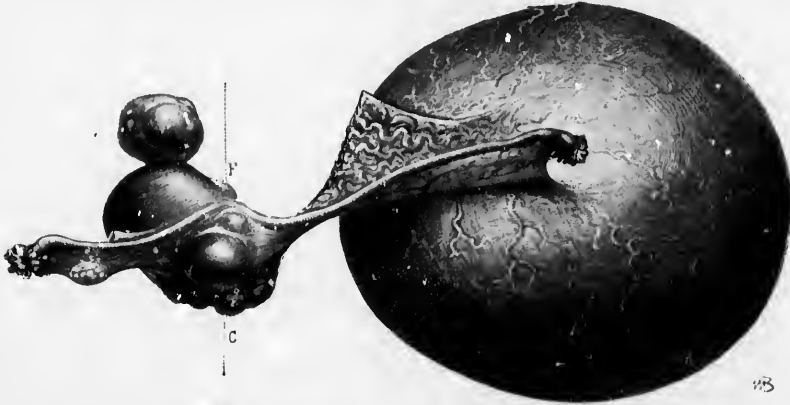

FIG. 392.—EXTIRPATION OF MYOMATOUS UTERUS, OVARIES, AND TUBES WITH A LEFT OVARIAN CYSTOMA.

The uterus is filled with myomata, and the left ovary is converted into a large ovarian cyst. *C*, cervix; *F*, fundus. The dotted line is the median line of the body. No. 443. $\frac{1}{4}$ natural size.

infection, and the retention of an infected subinvolved uterus often insures the persistence of a leucorrhœal discharge, protracted hemorrhages, and a sense of weight and pelvic discomfort, which seriously mar the result of the operation.

In addition to these reasons, many of the uteri operated upon for these conditions are lifted out of beds of adhesions, and when freed present, on the abdominal side, an extensive raw surface which is liable to contract adhesions with contiguous intestines. In a large percentage of cases, too, not only the tubes and the ovaries are infected, but the uterine cornua as well, necessitating at least a partial amputation if the uterus is left behind.

The backward displacement of the uterus onto the pelvic floor when robbed of its adnexa may also cause much distress, and obstruction of the rectum.

If the uterus is not taken out, the pedicles at the top of the broad ligaments are exposed to the right and to the left of it, which is avoided by amputating the uterus in the cervical portion and covering in the whole wound with peritoneum, so as to leave no exposed raw surfaces to contract adhesions. Paradoxical as it may seem, it is easier to take out the uterus with its adnexa than to extirpate densely adherent tubes and ovaries alone. The complete extirpation affords a better view of the entire pelvis, the ligation of the uterine artery gives a better control of hemorrhage, fewer raw areas are left, the operation may be actually of shorter duration, and better drainage is secured if it is called for.

For these important reasons hysterо-salpingo-oöphorectomy is to be preferred to double salpingo-oöphorectomy.

I would only except those cases in which the patient emphatically expresses a desire not to have the uterus removed, and in which there is a small mobile uterine body not involved in the disease.

There exists among surgeons a wide divergence of views regarding the relative advantages of the abdominal and vaginal routes in the extirpation of the uterus and its appendages. I have always held that the abdomen was the best avenue for the following reasons: First and foremost, the operator, upon opening the abdomen, has a chance to inspect the condition of the structures lateral to the uterus and to decide whether or not a conservative course may be safely followed; the abdominal route allows the entire operation to be done under the constant supervision and criticism of the clearest inspection of the entire field; complications such as intestinal adhesions, and particularly adhesion or abscess about the vermiform appendix (attached in twenty-seven out of one hundred of my cases), can be seen and safely dealt with; ligatures are applied with certainty, and hemorrhage is seen and easily controlled; the ureter and bladder are not so liable to injury; and finally the quick, clean recovery following an abdominal operation is far preferable to the sloughing and protracted suppuration and slow healing so common after removing the uterus through the vagina and using clamps on the broad ligaments.

Operation.—The incision is made in the linea alba from 10 to 15 centimeters (4 to 6 inches) long—a shorter cut if the walls are thin, a longer one if they are thick. If the omentum is adherent it is first released, bleeding points tied, and any free fluid carefully removed by means of sponges.

If the intestines do not fall out of the way into the upper part of the abdomen the pelvis should then be further elevated 30 or more centimeters (12 inches) above the table, and the small intestines and any redundant sigmoid lifted out of the pelvic cavity and kept packed away by non-absorbent cotton-gauze pads. The pelvis, thus fully opened to view, is now carefully inspected to determine the extent of the disease on both sides, which side is the worse, and the exact position and relations of the uterus to the inflammatory disease, and whether or not it will be advisable to do a conservative operation.

It has become a mere habit with many operators to exhibit surgical skill (*sic*) by removing uterus, tubes, and ovaries upon various trifling indications, such as a mild pelvic peritonitis with adhesions, a one-sided suppurative salpingitis, etc. The mere mention of such practices carries its own condemnation; the true surgeon will exercise a far higher skill in wisely selecting certain cases for conservatism, and sparing all or as much of the pelvic organs as he deems sound or capable of regeneration and a restored functional activity. To this end an unusual effort should be made in the case of young women by breaking up adhesions, by plastic operations, by resections, and by the liberal use of drainage, counting upon the remarkable restorative powers of youth to preserve to them the possibility of conception and motherhood; or if that is impossible and the tubes must be sacrificed, to preserve menstruation by leaving the uterus and

ovaries; or if the uterus too must be removed, to preserve the ovaries, or one ovary or a piece of an ovary, to obviate as far as possible the distressing sequelæ of the artificial menopause.

The older the patient the less these reasons will have weight; often, too, after long years of invalidism and suffering the patient will insist that she desires above all other things to be rid of her pelvic complaint at all costs; in this case the surgeon will not assume the same risks to save structures he would otherwise feel fully justified in doing. In all cases and at all times the natural bias of the surgeon's mind should be toward a healthy conservatism.

If it is a case of extensive posterior pelvic peritonitis, with long, veil-like adhesions, binding down uterus, ovaries, and tubes, I begin the enucleation by grasping the body of the uterus with a pair of museau forceps and drawing it up toward the lower angle of the incision, putting the adhesions on the stretch. They may yield readily, and if they do I simply strip the whole posterior surface of the uterus free with my fingers, catching up and breaking the bands one by one, as near to the uterus as possible. Next, by pulling the uterus to the right and forward, the adhesions on the left are made tense, so that the tube and ovary may easily be stripped loose and lifted up, freeing the broad ligament; the right side is freed by reversing the movements.

If the adhesions of the posterior surface of the womb do not yield readily to the fingers the scissors must be used. Expose the adhesions by pulling the uterus forward and holding the rectum back by means of a sponge held in the forceps or with the fingers, and then cut them, one after the other, close to the uterus. Adhesions of the ovary and tube to the rectum and pelvic wall may also be severed in this way.

When the adhesions are universal, dense, and close, the surgeon must carefully inspect the whole field before beginning the enucleation at all, in order to effect an entrance at the point of least resistance. This will often be found at the place where the tubes dip down into the posterior pelvis and are lost among the adhesions. By working in first one finger and then two, and stripping from side to side, a purchase is secured upon the adherent uterus and the under surface of the ovary and tube of that side. In this way dense adhesions frequently yield in a direction from below upward, where it seemed impossible to break through them at the pelvic brim.

In severing particularly dense adhesions the principle must always be followed of cutting closer to the organ which is to be removed. Thus, in freeing the uterus from the rectum in a hysterectomy, a piece of the uterus should be left on the bowel rather than risk wounding the rectum by trying to cut exactly between the two.

In another group of cases the uterus, ovaries, and tubes lie completely buried beneath a dense mass of adhesions. Here the uterus may be located by first fixing the position of the rectum and then passing a sound into the bladder to determine its posterior limit, and dissecting carefully with knife and forceps and scissors between these two points. Below the

surface the adhesions often become less dense and can be separated by the fingers, thus opening up a wide area in which the uterus may be found. The dissection is continued until the whole organ with its ovaries and tubes has been freed and elevated out of its bed.

In still another class of cases the rectum is adherent to the bladder, covering in uterus, ovaries, and tubes. This

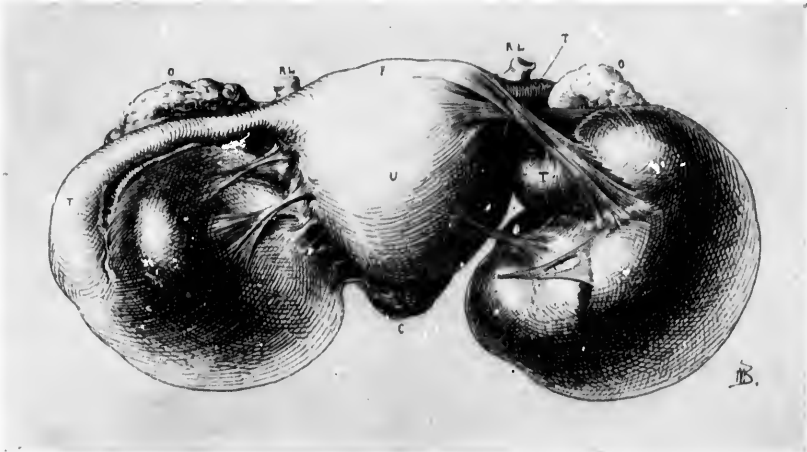


FIG. 393.—HYSTERO-SALPINGO-OÖPHORECTOMY FOR LARGE DOUBLE HYDROSALPINX WITH EXTENSIVE ADHESIONS.

U, uterus; *F*, fundus; *R L*, round ligaments; *T*, uterine tubes; *O*, ovaries. No. 504. $\frac{5}{8}$ natural size.

adhesion may also be broken up and the structures below freed by dissection between the two, pulling the bladder forward and pushing the rectum back so as to make the interval between the two as wide as possible. If a portion of either viscus is to be sacrificed to make the separation, it must be the bladder.

If, on account of their density, it is impossible with safety to break up all the adhesions from above, it is best to proceed at once with the first two steps in enucleation by seeking out the ovarian vessels, which can always be found at the outer extremity of the broad ligament upon lifting up the sigmoid flexure. When these are isolated they should be clamped on the uterine side and ligated on the pelvic side and cut between, the incision being continued in an oblique direction across to the insertion of the round ligament into the uterus. The round ligament is now ligated about 2 centimeters away from the uterus and clamped close to it and divided. By this means the top of the broad ligament is now cut completely through and the adherent tube and ovary may be reached from the front and freed. This is done by first severing them from the broad ligament and working down toward the pelvic floor in front of them, afterward dealing with the adhesions to the pelvic wall by working from below upward.

When in any of these groups of cases the adhesions are all broken up and the uterus with ovaries and tubes set free, I complete the enucleation by the following steps. Beginning, say, on the left side, these will be:

1. Left ovarian vessels ligated and severed.
2. Left round ligament ligated and severed.
3. Vesico-uterine peritoneum freed from left to right and pushed well down with the bladder, exposing the left uterine artery.
4. Left uterine artery and veins tied in the cervical portion.
5. Uterus amputated across cervical portion.
6. Right uterine vessels clamped above the stump.
7. Uterus pulled up and out and right round ligament and ovarian vessels clamped and uterus removed.
8. Ligatures applied in place of the clamps on the right side.
9. Cervical stump closed.
10. Anterior layers of both broad ligaments and vesical peritoneum drawn over the stump and sutured there.

I begin the separation by seeking out the left ovarian vessels at the outer extremity of the broad ligament under the sigmoid flexure. The sigmoid is often found dropped over into the outer extremity of the broad ligament and united to it by numerous adhesions. These may be separated by lifting up the sigmoid, stretching them a little, and severing with scissors. When the vessels are exposed I clamp them on the uterine side and ligate them with a silk ligature passed through the "clear space" on the pelvic side and cut between in an oblique direction across to the round ligament attachment of the uterus. The incision must be far enough from the ligature (at least 1 centimeter) to avoid the risk of its slipping off the stump that is left. I next ligate the round ligament about 2 centimeters ($\frac{3}{4}$ inch) from the uterus and clamp it close to the uterus and sever it too. By these two incisions the top of the broad ligament is laid open.

The line of reflection of the vesical peritoneum on to the uterus begins just below the round ligament and dips down into the pelvis and extends in a concave line across to the opposite side. If not distinguished at once by the marked contrast between the dark-red color of the uterus and the whiter vesical peritoneum, it will be found by lifting up the bladder with forceps and noting the line which marks the limit between the movable portion on the bladder and the fixed portion on the uterus.

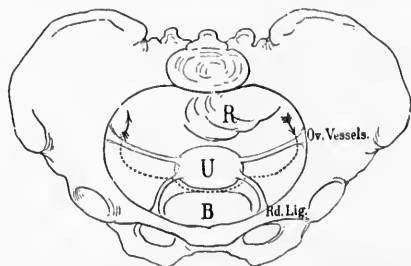


FIG. 394.—OUTLINE SHOWING EXTIRPATION OF THE UTERUS, TUBES, AND OVARIES BY A CONTINUOUS INCISION IN THE DIRECTION OF THE ARROWS, OR THE REVERSE.

In case the ovaries are left, as they must be in a young woman if they are sound, the ligation begins at the tubo-ovarian fimbria, between the tube and the ovary.

There is often found a false line of apparent reflection of the vesical peritoneum high up on the fundus formed by peritoneal adhesions; when this is dissected away from the uterus the real line of reflection is evident.

I now detach the vesical peritoneum along this line, beginning at the left round ligament and continuing the incision in a concave line across the front of the uterus around to the right round ligament. Then, grasping uterus, ovary, and tube in the left hand, or with museau forceps, I draw them strongly upward, outward, and toward the opposite side, while with the right hand I push the vesical peritoneum down off the cervix with a firm sponge held in a pair of forceps. The force of the push and peeling movement with the sponge must fall upon the uterus and not on the bladder. The separation of the bladder from the cervix is easily effected in this way, exposing the uterine arteries and veins low down in the angle between vagina and cervix. After baring the

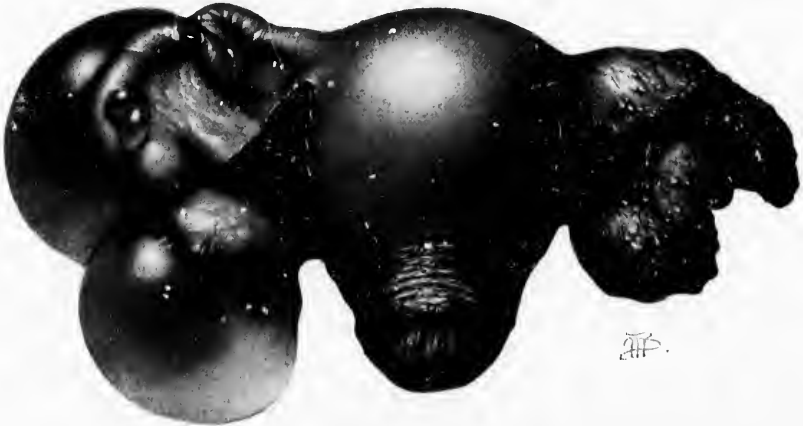

FIG. 395.—EXTIRPATION OF UTERUS, TUBES, AND OVARIES FOR PELVIC PERITONITIS.

The right ovary contains two small Graafian follicle cysts. The left tube and ovary are converted into a ragged mass by the adhesions. $\frac{2}{3}$ natural size.

cervix for about 3 centimeters I take it up between the thumb and the forefinger in front and behind and seek out its lower end, which can be readily distinguished through the vaginal vault. In the same way, palpating at the side of the cervix, I easily recognize the uterine artery by its pulsations. This I now ligate by a medium-sized silk suture, carried beneath the vessels from before backward, low down and close to the cervix. Having now placed all the uterine vessels on the left side under control, I proceed to amputate the cervix with a hysterectomy scalpel or a sharp scalpel, cupping it slightly and angling the cut off on the right side to a little higher level.

While this is being done the uterus is drawn strongly upward, grasped by a gauze pad or museau forceps, keeping the tissues to be cut always under tension, so that as soon as the division of the cervix is completed the two parts

begin to separate until an interval of two or three centimeters exists between them, in which the right uterine vessel may be seen. These are now clamped and controlled a centimeter or more above the cervical stump, and the uterus pulled still farther up until the round ligament is clamped and divided near the fundus; last of all, the ovarian vessels in the ligament near the pelvic brim are clamped and cut, when the enucleation is complete.

As soon as the cervix is cut across it is best to wipe out the canal below with gauze or to push a small piece of iodoform gauze through the canal into the vagina in order to cleanse it; the uterine cavity must also be prevented from emptying its contents over the wound by laying a thick piece of gauze under it.

In dealing with pus cases it is my habit to tie a thick gauze bag over the tube and ovary as soon as they are freed and lifted up, so as to avoid the constant handling and possible distribution of any of their escaping contents over the pelvic peritoneum during the operation.

One of the most signal advantages secured by this method of extirpation is the increased ease with which the enucleation can often be effected by attacking the adherent masses from below instead of in the usual way from above, an advantage similar to that claimed by the operation of vaginal hysterio-salpingo-öophorectomy.

In order to gain this advantage the enucleation must be begun on the side, right or left, which is least adherent, and the opposite side is not touched until the cervix is divided and its vessels clamped; then the enucleation of this side too is effected by beginning behind the broad ligament, but in front of the mass, low down near the pelvic floor, and so working it free from below upward. It is often astonishing how easy it is to roll an adherent mass up and out of the abdominal incision in this way, though the same mass may present grave difficulties with intestinal and other adhesions when attacked from above. Any cystic masses in ovaries or uterine tubes should always be evacuated with an aspirator before freeing them, both in order to protect the peritoneum from their contents as well as to afford more room in dealing with them.

With the removal of the uterus and its attached organs, the cervical stump drops back to the floor of the pelvis.

The right uterine and ovarian vessels are tied with silk and the round ligament with catgut and the forceps removed. In applying the ligature to the uterine vessels care must be taken not to carry the loop deep down beside the cervix, so as to avoid including the ureter. The vessels which are clamped above the cervix can be seen and tied at a safe level above the base of the broad ligament.

There is now seen on the pelvic floor a crescentic denudation, broad in the middle, and tapering to its horns at either pelvic brim, at the stump of the ovarian vessels. In the center lies the cervical stump. I do not in any way disinfect or burn out the cervical canal or the surface of the stump unless

there has been a purulent uterine discharge. It is sufficient simply to wipe the stump out clean with gauze.

I now approximate the surface of the stump for two purposes—to shut off communication with the vagina through the canal, and to check any slight hemorrhage. For this purpose I use from four to six catgut sutures, entering the first suture in the middle of the anterior lip, not including the reflected vesical peritoneum, and bringing it out near the cervical canal, to re-enter behind the canal, and come out again on the posterior peritoneal surface of the stump. This suture is tied tight at once, and brings the lips of the stump together in the middle; it should be left long, to serve as a tractor, to hold the stump within easy reach, while the remaining sutures are introduced on either side of it.

If any bleeding vessels are seen on the surface of the stump, sutures should be passed through the lips in such a manner as to catch and control them when tied. Two or three sutures on each side make an accurate approximation, like the lips of a purse. All the sutures are now cut short and the stump dropped back. The whole raw crescent-shaped area between the peritoneal folds must now be inspected under a good illumination to see if there is any bleeding. If there is, it must be checked, catching the point up with forceps and applying a ligature.

Finally, I unite the anterior peritoneal layers of the broad ligaments and the reflected vesical peritoneum to the posterior peritoneum by a continuous catgut suture, so as to cover in the whole raw area, together with the cervical stump. This suture begins by turning in the ovarian stumps, and pierces the peritoneum at points about 1 centimeter apart. Upon reaching the cervical stump the vesical peritoneum is attached to its posterior peritoneal surface. If this long suture is snugly drawn up each time it is passed, it lifts the peritoneum up in the pelvis, and tends to stop any slight oozing from the edges of the wound.

It is essential, before closing the wound by uniting anterior to posterior peritoneum, to stop all bleeding; if this is not done a hematoma may form which may give rise to an abscess and necessitate the dilatation of the cervix by the vagina to secure its evacuation and drainage. If there is a wide area of cellular tissue exposed, and it tends to ooze, it will be better to close the peritoneum with mattress sutures, so as to let the blood and serum escape and be absorbed.

The pelvis after the extirpation is completed presents to view only the bladder and the rectum with a line of accurately united peritoneum stretching in a concave line between them.

The incision in the abdomen is completely closed and the dressing applied.

Complications.—The complications met with in the inflammatory group of cases of this class are probably more serious than in any other group in abdominal surgery; out of the histories of my one hundred cases the following have been collated:

	Cases.
Omental adhesions in	45
Intestinal adhesions in	52
Adhesions of the vermiform appendix in	27
Sigmoid flexure adhesions in	32
Bladder adhesions in	31
The rupture of a pus sac with the escape of pus into the peritoneal cavity occurred in	27
The intestines were injured in varying degrees from a laceration of the external coat to a complete rupture of all the coats in	24
Old fistulous tracts were found opening into the intestine and requiring suture to close them in	4
A partial obstruction of the intestine existed in	3

It was the fashion to use drainage during the period in which most of these operations were performed, and I must therefore note thirty-one cases drained through the abdominal wound and fifteen drained through the cervix.

The mortality in this entire series amounted to four per cent; one of the deaths was due to an infection entering along the drainage tract, another was caused by peritonitis from the rupture of the intestine at the site of the suture, another was due to a purulent peritonitis, and the fourth came from an intestinal obstruction at the site of an old dense annular cicatrix in the sigmoid flexure.

CHAPTER XXIX.

OVARIOTOMY.

1. Ovarian tumors in general. 1. Kinds of ovarian tumors. 2. Relative frequency. 3. Benign and malignant tumors. 4. The pedicle: (a) Long pedicle. (b) No pedicle at all. (c) Rotation of pedicle. 5. Rupture of a cyst. 6. Clinical course. 7. Diagnosis: (a) Is a tumor present? (b) Is it an ovarian tumor? (c) Of what kind?
2. Multilocular ovarian cyst-adenoma. 1. Pathology: (a) Contained fluid. (b) Pseudomucin. 2. Development. 3. Cause. 4. Symptoms.
3. Papillary tumors of the ovary. 1. Introductory: (a) Forms. (b) Relative malignancy of papillomata and carcinomata. (c) Clinical characteristics. (d) Histology. (e) Diagnosis. 2. Papillary parovarian cyst. 3. Papillary cystic Graafian follicle. 4. Pseudomucinous papillary adenoma. 5. Simple papillary adenoma. 6. Papillary adeno-carcinoma. 7. Papillary cyst-adeno-sarcoma.
4. Carcinomata of the ovary.
5. Dermoid cysts of the ovary.
6. Parovarian cysts. Hydatid of Morgagni.
7. Fibroid tumors of the ovary.
8. Sarcomata of the ovary.
9. Treatment of ovarian tumors. 1. Contraindications to operation. 2. Steps of operation: (a) Median abdominal incision. (b) Evacuation and withdrawal of the cyst. (c) Liberation of all adhesions. (d) Ligation of pedicle. (e) Intraligamentary cysts. (f) Examination of opposite ovary. (g) Cleansing peritoneum, if soiled. (h) Closure of incision.

Ovarian Tumors in General.—The ovary, although but a diminutive organ, is peculiarly rich in cellular elements of various kinds which may give rise to a great variety of tumors; it is difficult also to dissociate mentally the wonderful function of the ovary as a reproductive organ from its marvelous activity as an atypical tissue producer when once its activities have become perverted.

We find, therefore, in the ovary retention cysts, epitheliomata (using the word broadly to include adenomata as well), connective-tissue tumors, fetal inclusion cysts, and parovarian cysts, though the last are not, strictly speaking, ovarian.

The first group—the retention cysts, include:

- Cystic Graafian follicles of large size,
- Cystic corpora lutea, and
- Multiple cystic follicles, usually small in size.

The epithelial group of tumors include:

- The cyst-adenomata, which are the classical ovarian tumors,
- Papillary ovarian tumors, and
- Adeno-carcinomata.

The connective-tissue group is made up of:

- Fibroid tumors of the ovary,
- Myomata, and
- Sarcomata.

Dermoid tumors stand alone as a peculiar group formed by inclusions of a part of the ectoderm during the development of the ovary.

Parovarian cysts, while not strictly belonging to the group of ovarian tumors, are most naturally associated with them for important clinical reasons.

Retention cysts of the ovary are not considered in this chapter, as they have been placed among those affections which are best treated by conservatism. I would also exclude here all of the small and all of the clear-walled parovarian cysts found associated with a sound ovary; these will be found in the chapter on conservatism.

The relative frequency of the different kinds of ovarian tumors varies greatly. Taking 141 cases of large tumors of the ovary differentiated macroscopically in the operating room, they were grouped as follows:

Multilocular ovarian cysts.....	38
Unilocular ovarian cysts.....	36
Parovarian cysts.....	22
Papillary tumors.....	20
Dermoid cysts.....	25

A thorough sifting of this material, however, in the pathological laboratory has served to demonstrate the necessity of a careful microscopical examination in every case; by doing this, small dermoid cysts were discovered where none were suspected on account of their diminutive size, and inflammatory masses were sometimes found to be due to dermoids which had discharged their contents and which only revealed their true character when the minute cell elements were studied.

The group of papillary cysts was also enlarged by a microscopic examination at the expense of the multilocular and the unilocular cysts.

The group of unilocular cysts of the ovary, when more carefully studied, was diminished by the discovery of small cysts in the walls; these tumors were therefore in most instances reclassified among the multilocular cysts; such a reclassification was also made necessary by the frequent discovery of trabeculae on the inner cyst wall. These were clearly the remains of partitions between originally separate cysts which later become fused by pressure and atrophy of the septa or by spontaneous rupture from tension.

In marked contrast, therefore, to the group of tumors classified by their purely macroscopic appearances, I present another group of 138 cases of large ovarian tumors, every one of which was examined microscopically; they were found to be distributed as follows:

Multilocular adeno-cystoma.....	57
Unilocular adeno-cystoma.....	3
Adeno-papilloma.....	27
Adeno-carcinoma.....	9
Sarcoma.....	2
Fibroma.....	4
Dermoid cysts.....	26
Parovarian cysts.....	10

It is only necessary to contrast these two lists to demonstrate the necessity of a searching microscopic examination in every case in order to establish the diagnosis on a scientific footing.

A further most important clinical classification of the ovarian tumors is into benign, malignant, and semi-malignant. It must always be borne in mind that these terms are only clinical expressions and are therefore vague; by a benign tumor is meant one which does not tend to recur when extirpated, as well as one which does not tend to implant itself elsewhere or to invade the tissues; by a malignant tumor is meant one which tends to destroy life by invasion of the surrounding and subjacent tissues, as well as one which distributes its elements by metastases to other parts of the body; a semi-malignant tumor is one which may extend to the adjacent parts by implantation, and then may or may not continue to grow after the removal of the parent tumor.

In general, the multilocular cyst-adenomata, the dermoids, the fibroids, and the parovarian cysts are classified as benign, the papillary tumors as semi-malignant, and the carcinomata and the sarcomata as malignant.

The essential weakness of such a clinical classification is shown histologically by the recognition that many of the cyst-adenomata are in reality papillary tumors, and many of the papillomata belong to the carcinomata, and sometimes even to the sarcomata.

From a practical standpoint all ovarian tumors must be considered as malignant until removed and proved otherwise.

Pedicle.—Ovarian tumors are attached to the broad ligament by the same anatomical structures by which the normal ovary is found attached to it. The base of attachment of the tumor is called its pedicle, and in this pedicle the various anatomical elements differ greatly in their mutual relations, according to the mode of growth of the tumor, whether up into the abdomen or down toward the pelvic floor, according to its length, and according as it has a broad or a narrow insertion.

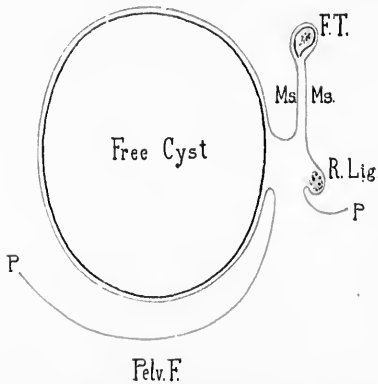


FIG. 396.—DIAGRAM SHOWING THE RELATIONS OF AN OVARIAN CYST TO THE PERITONEUM OF THE PELVIC FLOOR AND BROAD LIGAMENT.

FT., the uterine tube, with its intact mesosalpinx (*Ms.*). The red line (*P, P'*) is the peritoneum, which extends to the hilum of the ovary, but does not cover it.

The anatomical structures concerned are the mesovarium, the utero-ovarian ligament, the mesosalpinx, the uterine tube, and the broad ligament; they deserve careful consideration in each case, because the correct diagnosis in any given case depends upon the recognition of the relationship between the tumor and the broad ligament and

the uterus as established by means of the pedicle; the treatment, also, is simplified or rendered difficult according to the character of the pedicle and the relations of its component structures.

In some instances the mesovarium is pulled out with the utero-ovarian ligament in the form of a long band to form a pedicle 6 or 8 or more centimeters

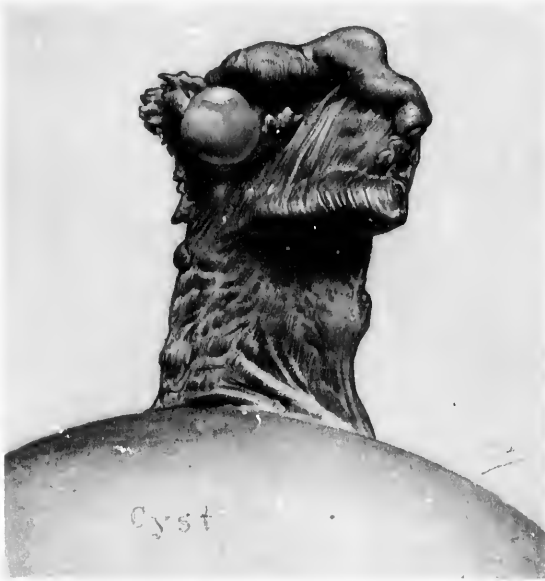

FIG. 397.—LONG PEDICLE OF A PAPILLARY OVARIAN ADENO-CYSTOMA.

The tube is above, with a cyst (hydatid of Morgagni) under its fimbriated extremity. March 8, 1894. No. 202. $\frac{3}{4}$ natural size.

in length (see Fig. 397). At other times the tumor (usually parovarian) develops in the outer part of the mesosalpinx, and the ampullar part of the tube is spread out on its surface. When the whole mesosalpinx is spread apart by the growing tumor, the entire tube is also stretched out on its surface from cornu uteri to fimbriated end, and may be greatly lengthened (see Fig. 398). Continued development in this direction opens up the lower part of the broad ligament, and then raises the pelvic and sometimes the abdominal peritoneum, even as high up as the celiac axis. In broad ligament tumors of this kind the uterus is found lying closely attached on one side.

In marked contrast to these tumors which lie between the layers of the broad ligament, a pseudo-intraligamentary tumor may be found when an ovarian tumor the size of a fist or a child's head is caught in the pelvis under the tube and mesosalpinx which it pushes up before it, so that the mesosalpinx covers the tumor in like a hood; the same effect may also be produced by

adhesions to the broad ligament and mesosalpinx covering in the tumor (Pawlik). (See Fig. 399.)

Rotation of the Pedicle.—Spherical non-adherent cysts with a long pedicle are peculiarly liable to an accidental rotation and strangulation of the pedicle, checking the venous outflow from the tumor and causing hemorrhage into its interior, sometimes large enough to cause the sudden collapse and death of the patient. If the woman survives such an accident and the rotation continues, the entire blood supply may be cut off and the cyst become gangrenous.

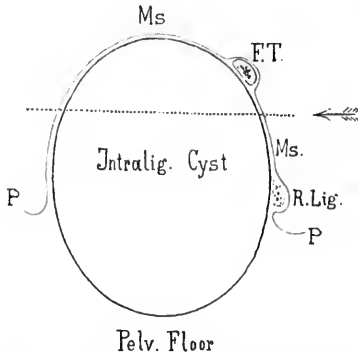


FIG. 398.—DIAGRAM SHOWING THE RELATIONS OF AN INTRALIGAMENTARY CYST TO THE ANTERIOR AND POSTERIOR LAYERS OF THE PERITONEUM OF THE BROAD LIGAMENT.

The red line (*P, P*) is the peritoneum, of which *Ms, Ms* is the mesosalpinx, whose layers are widely separated, while the uterine tube (*FT*) is spread out flat on its surface.

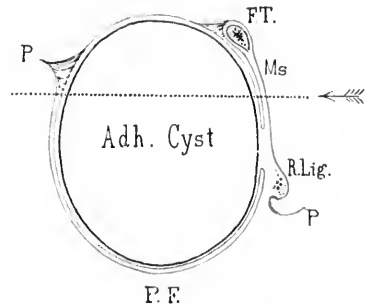


FIG. 399.—ADHERENT CYST OF THE OVARY SHOWING THE MIMICRY OF THE INTRALIGAMENTARY CYST.

The uterine tube (*FT*), the mesosalpinx (*Ms*), and the pelvic peritoneum (*P, P, P*) are adherent to the cyst on all sides. The dotted line and the arrow indicate the level of the pelvic brim.

The symptoms of strangulation are sudden pain, pallor, and sometimes fainting with sudden enlargement of the tumor, which becomes tense and painful.

If the woman survives the first attack the symptoms may be progressive and she is confined to bed, and peritonitis supervenes; later, the cyst, originally free, is found invested on all sides with adhesions. Suppuration may follow, marked by chills and high temperature.

With the cutting off of the blood supply and the pouring out of a hemorrhage into the interior of the cyst, the tumor assumes more the nature of a foreign body, exciting a violent reactive inflammation in all contiguous parts of the peritoneum, and becoming attached to it by vascular adhesions, which in time more or less replace the normal blood supply. In rare cases the pedicle may atrophy and become detached, leaving the tumor to continue a parasitic existence. A remarkable instance of this sort is shown in Fig. 400, in the inset, and in Fig. 403 in the text. There was ascites in the abdomen and extensive peritoneal carcinosis, and the cyst, which could not be removed on this account, was aspirated.

In one of my cases of hemorrhage, figured in the text, there was a large accumulation of blood just above the twisted pedicle and in the walls of the adjacent

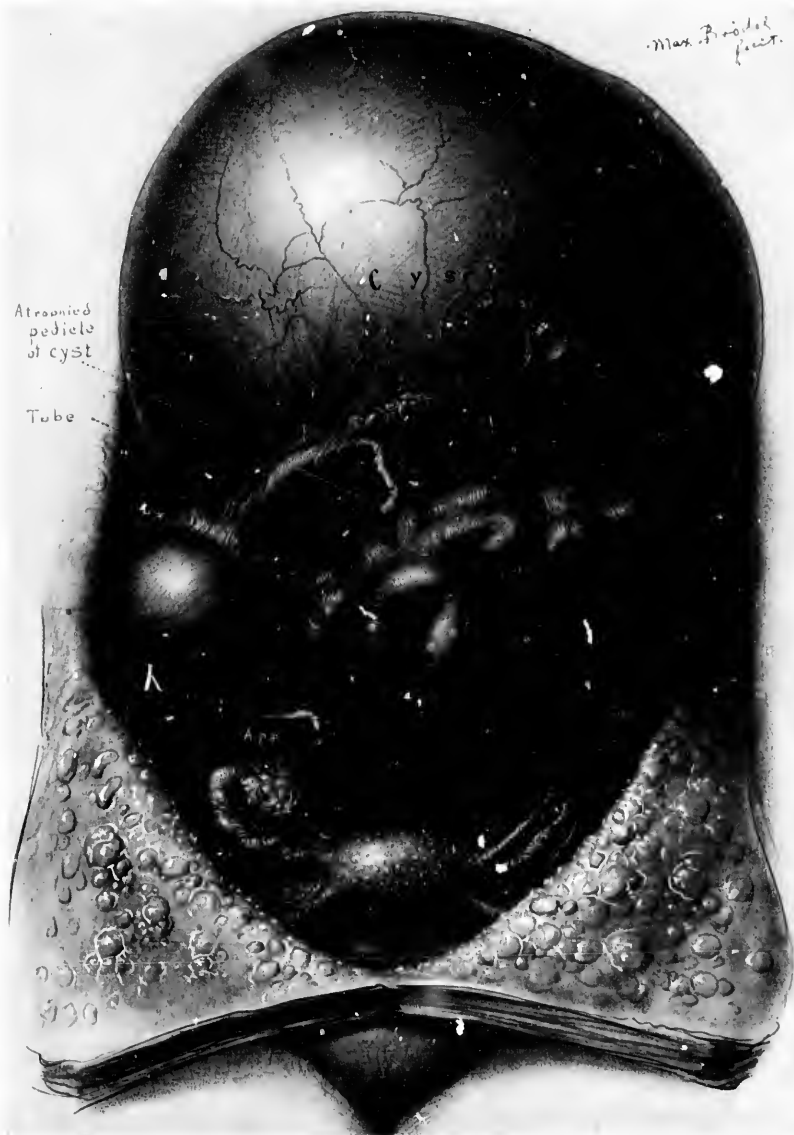

FIG. 400.—PARASITIC OVARIAN CYST OF LEFT SIDE WITH GENERAL PERITONEAL CARCINOSIS.

The cyst is rolled upward, showing its under surface and the atrophied pedicle with the tube. In the place of the left appendage in the pelvis is seen the uterine end of the pedicle of the cyst. Observe the oval opening in the broad ligament; the upper border of this opening is formed by the uterine end of the tube, while the stump of the ovarian ligament is visible through the opening; both stumps merge into the peritoneal covering. The external iliac vessels, right ovary, and tube adherent. Nov. 6, 1897.

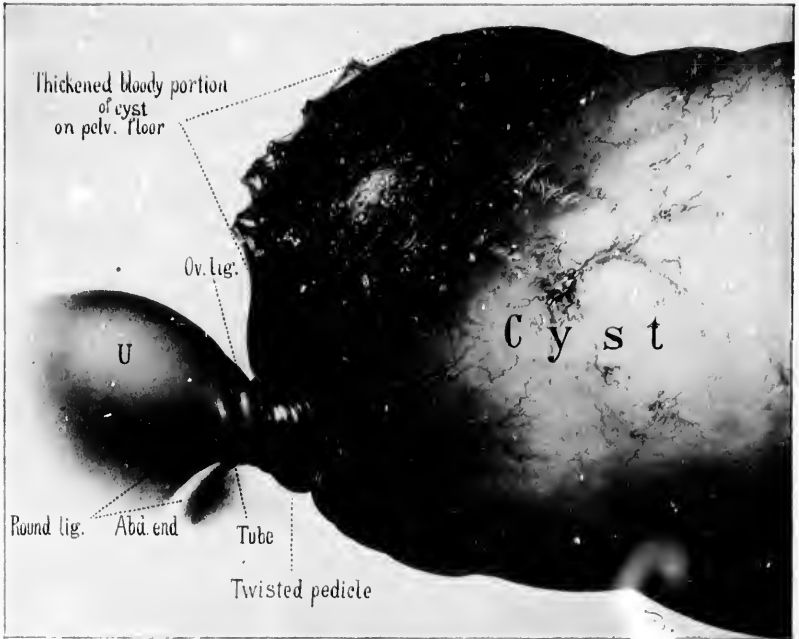


FIG. 401.—LEFT OVARIAN CYST WITH A TWISTED PEDICLE, INCLUDING THE UTERINE TUBE, THE OVARIAN LIGAMENT, AND THE ROUND LIGAMENT.

The area of hemorrhagic infarction is well shown in the pedicle and the adjacent cyst wall. July 16, 1894. No. 2910. $\frac{2}{3}$ natural size.

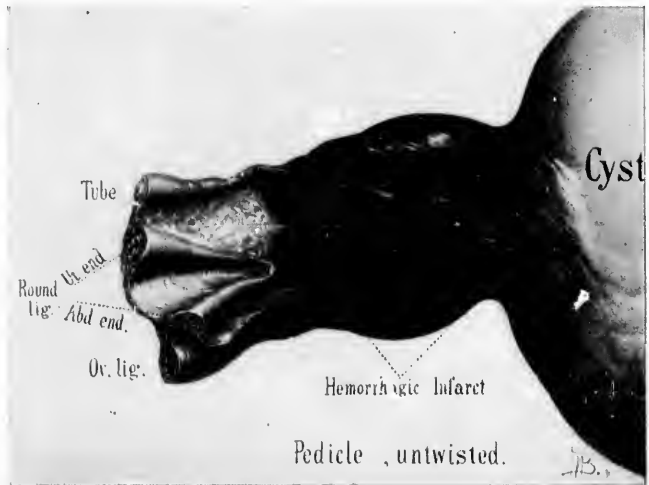


FIG. 402.—PEDICLE UNTWISTED TO SHOW ITS ANATOMICAL ELEMENTS, THE EXTENT TO WHICH THE ROUND LIGAMENT IS INVOLVED, AND THE HEMORRHAGIC INFARCT. $\frac{2}{3}$ NATURAL SIZE.

part of the cyst. In this case the short pedicle in twisting occluded the uterine tube and, what is quite rare, the round ligament was drawn up into the twist.

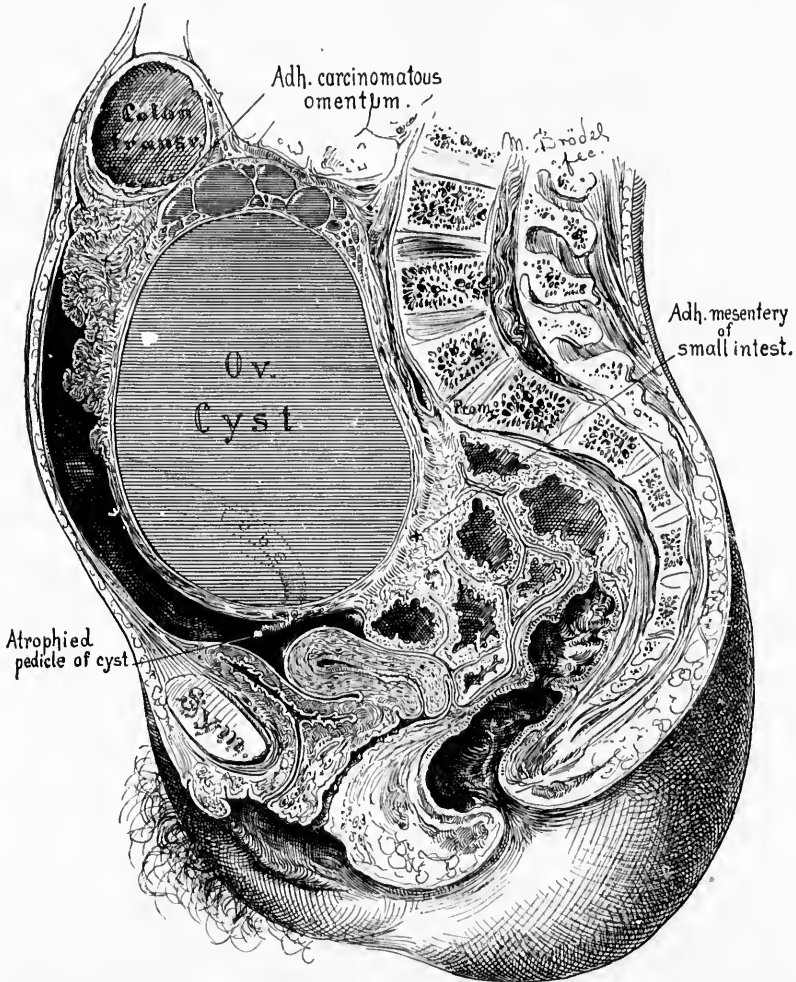


FIG. 403.—THE RELATIONS OF THE PARASITIC MULTILOCULAR OVARIAN CYST SHOWN IN INSET FIG. 400.

The uterus lies below the cyst in the pelvis and totally disconnected from it; the atrophied detached pedicle lies above the bladder. The cyst is, as shown, extensively adherent to the posterior peritoneum, mesentery, colon, and omentum. Nov. 6, 1897. (Autopsy.)

Prof. O. Küstner (*Centrab. f. Gyn.*, 1891, No. 11) believes that the tumors of the right side, as a rule, rotate from left to right, while left ovarian tumors turn from right to left. In four tumors of the right ovary he found the

twisting in every case following this rule, and in six left-sided tumors he found the rule to hold in five cases.

I find two causes for the rotation of cysts. In the first place, large multi-lobular cysts exhibit a notable tendency to the formation of one large cyst cavity, with a number of subsidiary ones, and the tumor will invariably turn until the convex surface of the large cyst comes to lie in relation to the concavity of the distended anterior abdominal wall; this produces a partial rotation which does not tend to increase. I think the cases in which the rotation amounts to or exceeds one turn, found in the spherical tumors the size of a man's head, are for the most part due to the alternate relaxations and contractions of the anterior abdominal walls acting most decidedly on the part of the tumor which is nearest the median line.

Rupture of a Cyst.—Rupture of an ovarian cyst occurs when its walls have been distended and thinned out, or when sufficient force is applied by a blow or by the powerful contraction of the abdominal muscles.

In the polycystic tumors the rupture of one cyst into another is a matter of regular occurrence, and in this way many smaller loculi fuse to form the main cyst cavities so commonly found; the cyst walls are delicate and either rupture by the increased tension of their contents or by absorption of their septa from mutual pressure. Rupture into the abdominal cavity is most apt to occur in the thin-walled cysts, such as some cyst-adenomata and parovarian cysts; because of their thick walls, dermoid tumors are but rarely ruptured unless from a violent blow.

As a result of the severe accidents to which women with large tumors seem peculiarly liable, such as falling down stairs or from a chair, etc., any sort of a cystic tumor may rupture.



FIG. 404.—OVARIAN CYST SHOWING NATURAL PERFORATION AND A TENACIOUS PSEUDOMUCINOUS SECRETION POURING OUT INTO THE ABDOMINAL CAVITY. DEC. 23, 1895. NATURAL SIZE.

The rupture is commonly found as a rent in the capsule, and if this happens to open a large blood vessel, death from intraperitoneal hemorrhage may shortly take place. Fortunately, such an occurrence is rare, and the only effect produced is to pour the cyst contents into the abdominal cavity, where, if it is of a bland nature, as in the case of most parovarian cysts, it is rapidly absorbed and thrown off with an enormous polyuria lasting one or more days. If the fluid is of an irritating nature, a sharp attack

of peritonitis with adhesions may result; when the cyst contains papillary elements, these are disseminated all over the peritoneum, where they con-



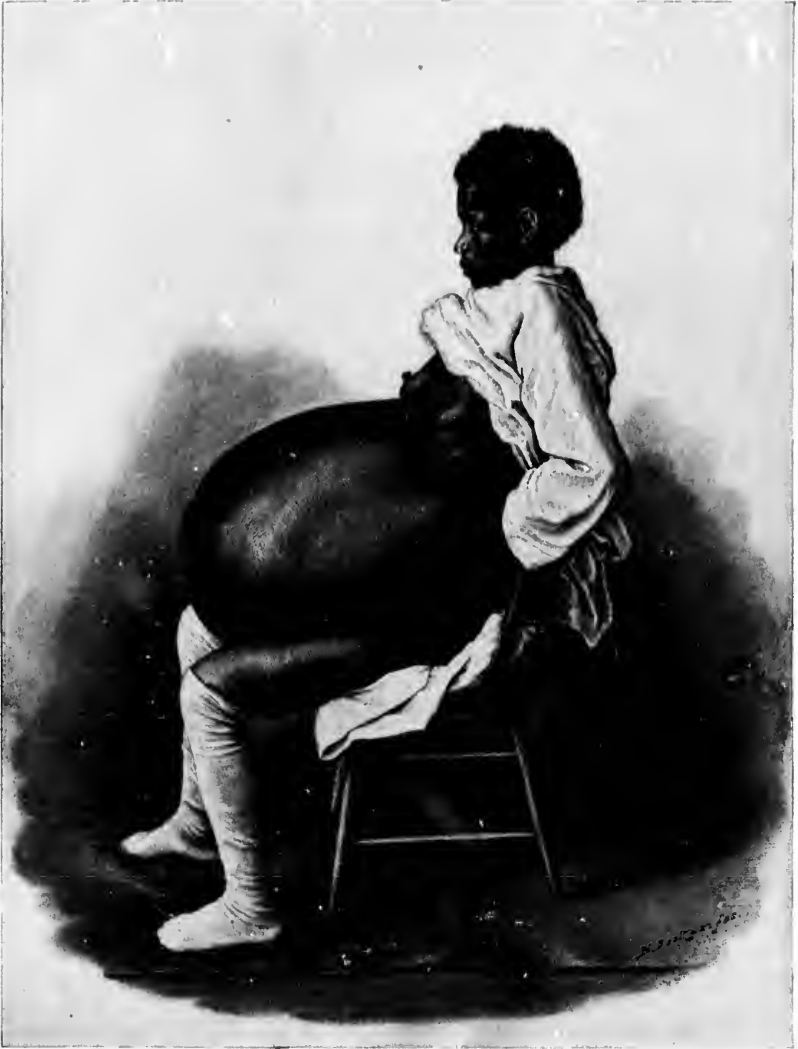

FIG. 405.—LARGE MULTILOCULAR OVARIAN CYST IN A NEGRESS.
Aspiration. Death without operation. Autopsy.

tinue to grow and an ascites forms, and ultimately the patient dies of exhaustion.

After a time the walls of the ruptured cyst retract, forming dense cicatricial bands and exposing and everting any secondary cysts contained within the cavity.

A rare form of rupture is a little pinched-out hole from which the tough pseudo-mucinous fluid slowly oozes out in a tenacious rope.

In one of my cases the hole was plugged from within by a little flaccid cyst seen hanging from the outer surface of the tumor.

Clinical Course.—The tendency of all ovarian tumors is to grow larger, filling first the posterior quadrant of the pelvis of the side from which they spring, then filling the whole pelvis, and finally rising up into the abdomen and gradually encroaching upon its cavity in a direction from below upward.

Tumors weighing over fifty pounds are rare, but well-authenticated cases are recorded in which the weight has exceeded one hundred and fifty pounds.

The smaller tumors displace the uterus at first by pushing it to the opposite side, then by traction on the pedicle they draw it toward the side to which the tumor is attached (see Vol. I, Figs. 73 and 74); if the uterus is adherent it may be drawn up into the abdomen as the tumor enlarges (*ascensus uteri*).

The bladder is displaced, at first becoming gibbous and next expanding upward into the abdomen; when small tumors are adherent or when larger ones press on the pelvic floor and on the brim, the ureters are often compressed, producing a hydronephrosis of low grade.

The rectum is also compressed, and in the large tumors the other intestines are crowded up under the ribs and out at the sides, and digestion is much interfered with.

The largest tumors also find room for their contents by pushing out the abdominal wall until it hangs pendulous, even covering the knees, and by spreading out the margins of the ribs like great wings (*alate chest*). Patients thus afflicted often have marked edema of the legs, and suffer so from the weight and from dyspnea that they rarely leave their bedroom, and are often compelled to live in a chair so as to be able to breathe (see Fig. 405).

Diagnosis.—In making a diagnosis of an ovarian tumor, three questions must be answered when possible: (a) Is there a tumor present? (b) Does it occupy the place of the ovary? (c) What kind of an ovarian tumor is it?

(a) Is there a tumor present? It is usually easy by a vaginal examination to feel the tumor lateral to or behind the uterus, or, if it is large, to see it and to palpate and outline it by percussion.

Patients often mistake tympany for a tumor and appeal to the physician for a decision, usually adding to their complaint the statement that the tumor increases remarkably at times and goes down again. Some cases of tympany do simulate in an extraordinary manner the configuration of an abdomen containing a cystic ovarian tumor; but a little palpation—demonstrating the uniformity of the resistance in all parts of the abdomen, and a few percussion taps over the tumor bringing out the note of resonance all over its surface—serves at once to dispel the illusion.

In the rare case of an ovarian tumor which contains gas and is therefore tympanitic a discrimination between this and intestinal tympany will be made by the fact that the condition of the patient shows that some grave disease exists; an examination also shows that the abdominal enlargement is tympanitic over its most prominent part, but flat at the sides where the resistant areas can be palpated; vaginal examination also reveals the presence of the firm cyst wall and its relations to the uterus.

The greatest difficulty in detecting the presence of a tumor is met with in fat women, and here the embarrassment is twofold, for in the first place the examiner may think that he finds a tumor when there is nothing present but a mass of fat, and in the second place a tumor of medium size may readily escape observation. The best rule to observe in such cases is never to decide that there is a tumor present until indisputable evidence of its existence is secured and it is clearly felt by palpation and outlined by percussion, and above all until its connection with the broad ligament, and so, indirectly, with the uterus, is made manifest by a careful pelvic examination, if need be, under anesthesia.

It is always a good rule where the slightest doubt exists not to give an opinion based upon a single observation, but to see the patient two or more times.

It is equally hazardous when a woman is excessively fat to decide hastily that there is no tumor present, for experience teaches us that obesity in no way hinders the growth of an ovarian cyst. In such a case a doubtful ovarian tumor felt by the abdomen may be felt distinctly by the vagina and by the rectum. The clearest evidence that the patient is not suffering from an ovarian tumor is obtained by giving an anesthetic and then examining the uterus and broad ligaments thoroughly through the emptied rectum, and by palpating and outlining both ovaries.

When an ovarian tumor as large as one or two fists has a long pedicle and slips up into the flank, it may entirely escape observation, unless it is systematically sought for in this position by palpating both flanks between the hands, one placed in front and one behind. This lodgment of a tumor in a flank is most apt to occur and most likely to escape observation when there are two tumors present and the larger one lies prominently under the abdominal wall, easy of access and diagnosis.

(b) *Is the tumor ovarian?* The differential diagnosis of an ovarian tumor from all the other tumors which may be found in the abdominal cavity must be made by discovering in the particular case the presence of certain features characteristic of ovarian tumors, as well as by noting the absence of those features which are peculiar to other kinds of tumors.

The methods of making the diagnosis will also vary according as the tumor is small and still confined to the pelvis, or larger, from the size of a child's head to that of a pregnant uterus at term, or from the size of the uterus at term up to the largest tumors observed.

In order to differentiate an ovarian tumor from abdominal tumors of other

kinds, therefore, the following facts must be borne in mind in making the examination :

The ovarian tumor is dull to percussio*n* over its convexity, and is surrounded by an area of resonance above and at the sides ; it is dull also below, on the side toward the pelvis ; this dull area below points out, as it were, its natural habitat, and may be compared to the trunk of a tree, showing the place from which it has its origin.

The ovarian tumor is attached to the broad ligament by a pedicle which can be felt by the rectum.

It replaces the normal ovary of the side from which it springs.

By finding a normal ovary on one side and none on the other, but in its place a tumor, the diagnosis is made certain.

The conclusion is often easily reached that a tumor is pelvic in its origin, but the more exact nature of the pelvic tumor may not be so easy to determine. The differential diagnosis must here be made between the ovarian and the various uterine and retroperitoneal tumors and an overdistended bladder. I have seen a patient brought a long distance for operation where there was nothing but a distended bladder, relieved at once by passing a catheter. In another case preparations were made for operation upon a parovarian cyst which proved just before the operation to be nothing but a distended bladder. There is something characteristic about the very appearance of an over-full bladder which forms an elongate ovoid in the median line, more prominent just above the symphysis than any ovarian tumor of like size. The invariable custom of passing a catheter just before operation will prevent mortifying mistakes.

Retroperitoneal tumors are usually firm and fixed by a broad base, and their nature becomes evident when the rectum is found lying in front of the tumor.

Pregnancy and uterine tumors are most liable to be confused with ovarian tumors, but such mistakes can occur but rarely if in every instance the examination is properly conducted through the inferior strait and the entire uterus is outlined by vaginal or rectal examination, and if the rule is persisted in of giving an anesthetic and making a minute examination in all doubtful cases.

Tuberculosis and encysted peritonitis may easily be confused with an ovarian tumor, but in both these conditions the enlargement usually exhibits some indefiniteness of outline and peculiar irregular areas of tympany and dullness, the mobility is slight, and the areas of dullness are apt to change from week to week. Tubercles may sometimes be distinctly felt through the thin wall of the rectum.

A large cystic kidney may extend from the diaphragm to the pelvic floor, closely resembling an ovarian tumor, but the fact must ever be borne in mind that the kidney has a tympanitic area in front of it, due to the displaced colon.

A small ovarian tumor must be differentiated from small uterine tumors, tubal tumors, and fecal masses. The ovarian tumor possesses these characteristics : it lies to one side of or behind the uterus, it is usually evidently

cystic from the more or less distinct sense of fluctuation, and is always movable as distinct from the uterus, with which its connection may often be traced by the utero-ovarian ligament on one side. By recognizing these peculiarities in any given case the possibility of the tumor being uterine is excluded. The greatest difficulty is met with when the small ovarian tumor is adherent to the uterus; the tumor is then usually lateral to the uterus, it is fluctuant, and, in addition, the firm uterine body can be outlined independent of the tumor; a careful palpation also shows a slight independent mobility.

A tubal tumor is thin-walled, elongate, sausage-shaped, and often convoluted, and in addition the normal ovary may be felt close by.

Faecal masses, although liable to confuse at the first examination, will not do so when the bowels have been thoroughly evacuated and a high rectal examination is made.

Ovarian tumors of medium size, from that of a child's head to a uterus at term, may best be differentiated, first, by outlining the other abdominal and pelvic organs by palpation and percussio, and so excluding their participation, and then by grasping the cervix with a tenaculum forceps and pulling it down, by which means perceptible traction is made upon the tumor; or by grasping the cervix and pulling it down and then pulling the tumor up in the abdomen, when the hand holding the forceps is seen to respond to the traction.

If a rectal examination is made at this time the tense pedicle may be felt, showing on which side the tumor arises.

Ovarian tumors filling the abdomen need to be distinguished from all other large abdominal tumors, and here the difficulties are greater, because the surrounding area of tympany is not always easily outlined, and the tumor has no free space left in which it can be moved about; it is impossible also either to demonstrate the existence of a pedicle or its position.

The following points will usually be decisive in such cases:

There is a vast dull area over the tumor and at the sides and extending down into the pelvis, but by taking particular pains, tympany may be found far back in the flanks and up under the ribs. The vaginal examination further shows that the uterus is displaced and the pelvis is choked by the tumor.

The surface of the tumor may present characteristic bosses, with evident fluctuation at points; the uterus is intact and displaced, crowded down onto the pelvic floor, or elevated out of the pelvis in front of the tumor, where it may often be felt above the symphysis.

Ascites is sometimes taken for an ovarian tumor, and a mistake is often made when, with the ascites, cystic tumors exist in the pelvis. If the woman has borne children or has relaxed abdominal walls, a form of abdomen may be developed which is almost peculiar to ascites; as the patient lies on her back the walls belly out at the sides and the top is flattened, like a bladder half full of water; this appearance is rarely simulated by a flaccid parovarian cyst.

The area of dullness and tympany in ascites is one of its most important characteristics; the intestines float in the fluid and yield a tympanitic note over

the highest point, while the fluid gravitates downward, giving a dull note in whatever position the patient is placed. This valuable sign is wanting under two conditions: When there is a small amount of ascitic fluid and the colon is distended with gas, we may find tympany in the flanks; and, on the other hand, when the abdomen contains so much fluid that the anterior abdominal wall is pushed out so that the intestines held back by the mesentery can not reach it, the tympanic note is wanting above. In the first case a mistake will be avoided if careful attention is given to the peculiar sense of free fluid conveyed upon palpation, and if the change in the areas of dullness upon change of position of the patient are also noted. When a large ascitic accumulation is present a mistake may still be made, even after careful study of the case, especially when the patient is so ill that a thorough examination is impossible.

I made such an erroneous diagnosis in the case of a colored woman, who was so feeble that she could not lie down, and a vaginal examination had to be omitted. On tapping, what appeared to be a straw-colored ascitic fluid escaped and the abdomen collapsed; no trace of a tumor could be felt (see Fig. 405). She died later of exhaustion, and a multilocular ovarian cyst was found with one enormous sac in front of it. When the ascites is due to a pelvic tumor this will be felt *per vaginam*, while the ascites gives the usual signs at the abdominal examination.

In order to get rid of the unsatisfactory regional terms in common use in our descriptions, I have for the past six years in my teaching designated abdominal tumors as follows: Those descending into the cavity from beneath the ribs I call anatroptic; those ascending from the pelvis, orthotropic; and those pushing out into the abdomen from the flanks as amphitropic, borrowing the terms from the botanic description of the ovule; those which are in the middle of the abdomen, surrounded by an area of resonance on all sides, may be designated mesotropic.

Right or left orthotropic, amphitropic, or anatroptic serve further to designate tumors in the right or left iliac fossæ, the right or left loin, or coming from under the right or left ribs.

(c) What kind of an ovarian tumor is present may sometimes be a difficult question to answer.

In general, the cystic tumors can be easily separated from the solid ones by the marked difference in the resistance, the smaller size of the solid growths, and their frequent association with ascites.

Among the cystic tumors we have to distinguish the adeno-cystomata (the common multilocular ovarian cysts), cystic papillomata, dermoid cysts, parovarian cysts, cysto-carcinomata, and cysto-sarcomata.

A multilocular cyst may sometimes be distinguished by the eye alone, especially when it consists of a number of cysts with well-defined depressions between them, and when the abdominal walls are thin enough to reveal the contour of the growth.

The chief difficulty in differentiating a polycyst is its tendency to form one large cyst which, owing to its spherical form, rotates and adapts itself to the

concavity of the anterior abdominal walls, and so, to palpation, closely resembles a unilocular parovarian cyst. The distinction may often be made by observing that the wall of a polycyst appears thick on palpation and its contents seem to be of more than watery consistence; if a careful search is made in the flanks, irregular bosses may be felt there or high up under the ribs; sometimes a large cyst fills the abdomen, and a careful palpation by the pelvis reveals the presence of a conglomeration of cysts budding off in this direction from the main cyst above. Where the furrows between the separate cysts can not be distinctly made out, a marked difference in the tension between two or more cysts may be discovered by palpation of the tumor in all possible directions.

The fact that a large abdominal tumor fills the pelvis also and possesses an irregular form does not prove that it is polycystic, for these characteristics may be observed in parovarian cysts.

Papillomata can not be diagnosticated when the outgrowths are confined to the interior of cystic tumors. Small superficial papillomata may, however, sometimes be recognized as excrecences plainly felt by the vagina or rectum, and the association of ascites with a small tumor which is often fixed in the pelvis, in the absence of any grave constitutional disturbances, should arouse the suspicion of papillomata. When the disease is more extensive, the pelvis choked, and implantation masses with much ascites are found on the abdominal walls and in the omentum, the diagnosis may be made without difficulty, particularly after tapping, when the contents are much more plainly palpable.

In making a differential diagnosis between dermoids and other tumors these facts must be borne in mind. Küster has shown that the dermoid cyst tends to float up in front of the uterus; it is also a tumor of slow growth, oftenest found in children and young women, and is frequently painful.

The dermoid is usually monocystic, single, not often larger than a man's head, and the fluid fat, on palpation, feels like water or of the consistency of mush.

Parovarian cysts convey the impression, both by the touch and by the uniformity of the abdominal enlargement, that they are unilocular and thin-walled, and although they may have well-defined pedicles, usually they fill out the mesosalpinx at least, and so have a broad base of origin.

Cysto-carcinomata and cysto-sarcomata convey the impression of unilocular cysts often with thick resilient walls; in their earliest stages they present no characteristic features, but later there is ascites, emaciation, and cachexia, and, it may be, metastases.

Among the hard tumors we have to distinguish the solid carcinomata, the fibromata, and some sarcomata.

The fibroid is usually a dense tumor accompanied by ascites and unaccompanied by any serious constitutional depression, in marked contrast to the loss of appetite and strength, the emaciation, cachexia, and edema of the malignant growths.

The carcinoma often involves both ovaries, is hard and nodular, and is found in much younger patients than the fibroma; metastases are, of course, pathognomonic.





W. B. Keen

FIG. 406.—TYPICAL POLYCYSTIC OVARIAN TUMOR, WITH LONG TWISTED PEDICLE.

The larger portion of the ovary (*Ov*) is intact, and the tumor occupies its outer extremity. The abdominal end of the uterine tube lies below the ovary. Jan. 23, 1897. $\frac{1}{2}$ natural size.

Multilocular Ovarian Cyst-adenoma.—The multilocular ovarian cyst-adenoma is the classical tumor of the gynecologist, recognized and operated upon for many years before any clear distinctions as to the microscopical or clinical characters of other ovarian tumors obtained recognition (see Fig. 406).

Pathology.—The ovarian cyst-adenoma owes its origin to a multiplication of the glandular elements of the ovary; these glands become distended with secretion, the fluid accumulating with varying degrees of rapidity to form cysts of all sizes. The cysts are usually unilateral, occurring somewhat more often on the right side than on the left, but they may occur in both ovaries at the same time; six per cent of my cases have been double.

They vary greatly in size, some being not larger than an orange, while others appear as huge masses weighing upward of one hundred pounds; such large tumors, however, are rarely met with any longer, because the patient presents herself for treatment before the cyst can reach such a size and cause much discomfort.

The entire tumor usually lies free in the abdominal cavity and appears as a round or oval mass, with a smooth and glistening surface, irregular in outline, presenting many large or small bosses. These bosses represent the individual cysts, whose walls are pearly white or slightly bluish or pinkish in color; beneath the peritoneum numerous branching blood vessels can be seen radiating out from the main trunks at the pedicle. On section, the appearance usually seen is that of one or more large cysts surrounded by numerous small ones, many of the smaller ones being situated in the walls of the larger ones, for as the cysts enlarge their walls come in contact, and when by the increasing pressure the partitions between them are so thinned as to rupture, the adjoining cysts unite (see Fig. 407). In a recent rupture the remainder of the septum is seen as a perforated diaphragm, later it forms a falciform edge on the cyst wall, and still later appears simply as a ridge or band. More rarely the greater portion of the tumor is formed of masses of small cysts, which, on section, give a honey-combed appearance to the cut surface.

The cyst walls vary from 4 to 5 millimeters in thickness. They are composed of a dense tissue, which here and there may contain areas of calcification and occasionally a dilated Graafian follicle, or a corpus luteum can be demonstrated in a thickened portion of the wall, or irregular, brown, slightly raised patches may be seen which represent the site of old hemorrhages.

The cysts are separated from one another by delicate partitions, and have smooth, glistening inner surfaces which are of a bluish or pinkish hue. Frequently in the largest cysts trabeculae will be seen extending from one side of the cyst wall to the other; these are the remains of old cyst walls. On histological examination, the surface of the tumor may show no epithelial covering, or may be covered by one layer of flat cells. The cyst walls are composed of connective tissue which is arranged in layers parallel to the outer surface, and near the inner surface the tissue is rich in cell elements. The blood supply varies greatly, being sometimes abundant and at other times scanty. There is frequently hemorrhage into the cyst wall, the brown patches seen on the inner sur-

face being the sites of old hemorrhages which have been invaded by connective-tissue cells from the cyst wall, and over which the epithelium is wanting. The cyst walls are also often edematous and may be necrotic in places. Occasionally such ovarian elements as Graafian follicles, corpora lutea, and corpora fibrosa are found scattered throughout the walls. In the vicinity of the pedicle non-stripped muscle fibers may sometimes be demonstrated.

The partitions between the smaller cysts are also composed of connective tissue richer in cell elements than that which forms the outer cyst wall, and in this tissue numerous convoluted glands are seen which are the rudimentary cysts.

The inner surfaces of both the small and large cysts are lined by a single layer of cylindrical epithelium which is often ciliated. The nuclei of these cells are oval or almost flat, and are usually situated immediately on the basement membrane. Some of the cells are swollen and filled with clear contents, resembling goblet cells, and nuclear figures are also occasionally seen. In some of the larger cysts, but more especially in the smaller ones, the walls present a scalloped or convoluted appearance resembling acinous glands.

Calcified areas are common, appearing either as small scales in the fibrous tissue of the walls, or as little granules, which are usually calcified epithelial cells.

An ovarian cyst is not infrequently associated with a dermoid cyst of the opposite side or a parovarian cyst (see Fig. 408).

Contained Fluid.—The fluid in the larger cysts is thinner than that in the smaller ones. It may be grayish yellow, gray, reddish brown, or dark brown in color, the coloring depending to a great extent on the hemorrhages which have taken place in the cyst cavity; the blood is usually distributed equally through the cyst fluid, and clots are rarely found.

The specific gravity of the fluid varies from 1010 to 1030. It contains much albumin, and the microscopical examination reveals desquamated fatty epithelium, and also large cells which are filled with yellowish pigment and which probably have the same origin. Some of the smaller cysts contain a yellowish-white, semi-transparent viscid fluid; others a yellowish transparent, jellylike material, which is but slightly tenacious. The fluid from the smaller cysts, as in the larger ones, contains desquamated epithelium, fat droplets, and detritus. Occasionally a few needle-shaped crystals are seen scattered through the fluid.

The fluid which is present in these cysts has three sources of origin: the secretion from the epithelial cells, the transudation of serum from the blood vessels, and the destruction of cells.

Pseudomucin.—Pseudomucin is one of the most important of the constituents of the glandular ovarian cystomata, and is almost characteristic.

In the days when ovariectomy was exceedingly dangerous great importance was attached to the microscopical and the chemical examination of portions of the cyst fluid removed for diagnostic purposes, and the discovery in this way of the "ovarian cell," the "compound granular cell," and of paralbumin and metalbumin (Scherer), were looked upon as decisive in determining the presence of an ovarian cyst.

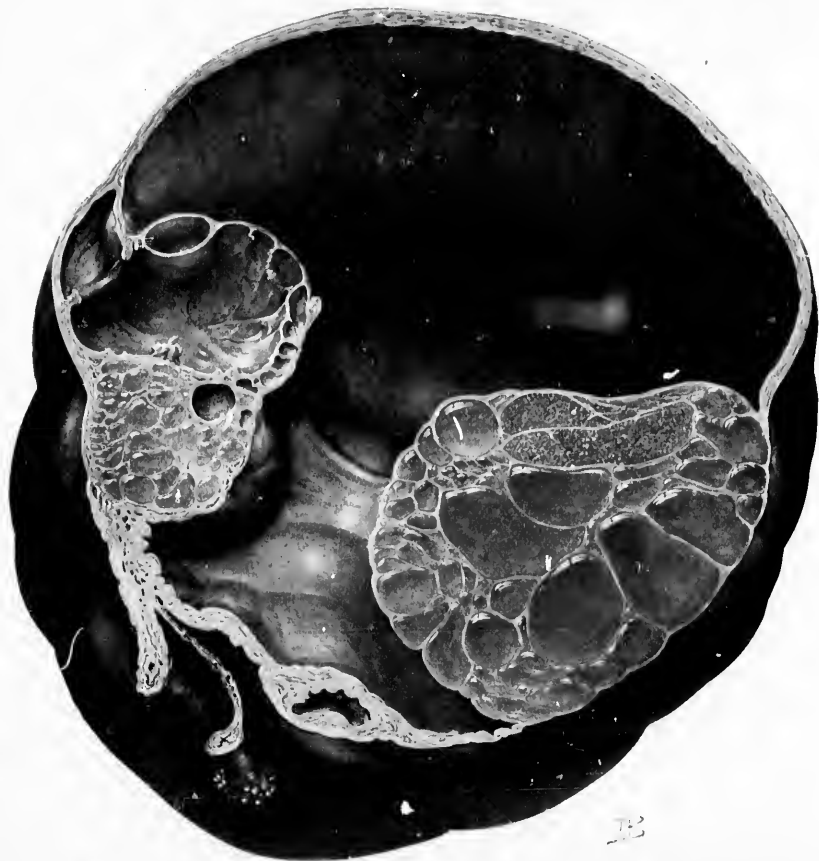

FIG. 407.—MULTILOCULAR OVARIAN CYST, IN WHICH THE SMALLER CYSTS PROJECT INTO THE CAVITY OF THE LARGE ONE, WHICH IN THIS WAY PRESENTS EXTERNALLY THE APPEARANCE OF A MONOCYSTIC TUMOR. The utero-ovarian ligament and the uterine tube are seen cut across below. No. 880. $\frac{3}{4}$ natural size.

The "ovarian cell" has long since disappeared, but paralbumin and metalbumin have kept their place with an identity which has been altered by O. Hammarstein (*Ein Beitr. z. Chemie d. Kystom Flüssigkeiten. Zeits. f. Phys. Chem.*, 1882), who has shown that they do not belong to the albumin group, as at first supposed. While paralbumin is not a chemically pure body, metalbumin, on the other hand, is closely allied to mucin, and to avoid confusion he has given it the name "pseudomucin."

Chemical examination of metalbumin—that is to say, pseudomucin—showed that its chief characteristic was a liability upon boiling with acids to separate a



FIG. 408.—POLYCYSTIC OVARIAN TUMOR AND PAROVARIAN CYST EXISTING ON THE SAME SIDE.
Between the cysts is a firm nodule about the size of a bean. Dec. 19, 1896. Natural size.

carbohydrate; it differs from mucin in its reaction with acetic acid. Pfannenstiel, in a most careful study of this substance in its relation to ovarian cysts (*Arch. f. Gyn.*, Bd. xxxviii, 1890, p. 407), applies to it the term "glycoproteid," because it splits up into an albumin and a sugar.

Pseudomucin is particularly abundant in cysts containing the tough, sticky, mucilaginous substance often capable of being drawn out in long threads; as it is soluble in water, its presence in small quantities can only be recognized by chemical tests, of which the following is one of the simplest practicable (see E. Salkowski, *Practicum der physiologischen und pathologischen Chemie*, 1893, S. 174):

To 25 centimeters of the cyst fluid add 75 centimeters of 95 per cent alcohol. Shake, filter, and wash the residue well with alcohol. Then press out the residue between blotting paper to free it from the alcohol. Next boil the residue

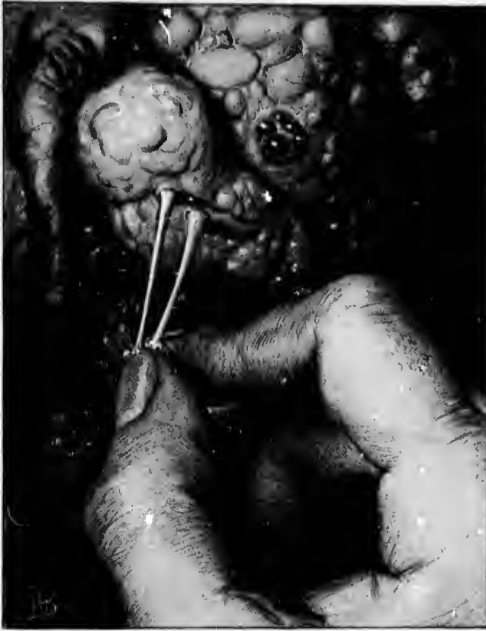

FIG. 409.—MULTIPLE ADENO-CYSTOMATA OF THE OVARY.

Showing the tenacious character of the pseudomucinous contents of the small cysts discharging on the inner surface of a larger one. The two openings seen are not artificial.

in a solution of hydrochloric acid and water (acid 1 pint, water 3 pints). Neutralize the solution with sodium hydrate (15 per cent solution). Then, if a freshly made Fehling's solution precipitates the copper oxide, this shows the presence of the carbohydrate in the cyst fluid, and hence of pseudomucin.

It is also to Pfannenstiel's credit that he has shown that pseudomucin does not result from a colloid degeneration of the cells, as supposed, but that it is a real secretion of the epithelial cells, which goes on indefinitely without cell destruction.

The various stages through which the cells pass in the formation and excretion of pseudomucin may be beautifully seen in a single cyst. The original

epithelial cells lining the cyst walls are short cylinders with a nucleus at the base, and a feebly staining protoplasm (albumin); then we find long cells with a basal nucleus and a still more feebly staining cell body, the first step in the evolution of pseudomucin, which at this stage is evenly distributed throughout the cell body and gives it already a somewhat glassy appearance. The next step is the separation of the pseudomucin from the protoplasm, the pseudomucin lying in the periphery, while the protoplasm is crowded down to the base of the cell, the proportion between the two varying with the amount of pseudomucin excreted; some cells appear to be entirely filled with the pseudomucin. These various stages are all illustrated in Fig. 410.

Pseudomucin is never found in normal ovaries, dropsical Graafian follicles, or in parovarian cysts; it is found in some forms of papillary cysts, and is, as stated, the constant characteristic element in the classical glandular ovarian tumors; it only occurs in ascitic fluids in the presence of a tumor also containing pseudomucin.

Development.—The cysts usually develop and lie free in the abdominal cavity, with a well-marked pedicle formed by the ovarian ligament, the uterine tube, and the broad ligament; and if the tumor is large and exerts much traction, this pedicle will be several inches long. The parovarian is in most cases intact.

Occasionally the development is between the layers of the broad ligament, when they are called intraligamentary cysts; they may then push toward the uterus, toward the bladder, backward into Douglas's *cul-de-sac*, and between the layers of the peritoneum under the cecum and the rectum.

Adhesions between the abdominal viscera and some portion of the cyst are present in a certain proportion of the cases; thus, among thirty-six multilocular cysts which I have operated upon, twenty-two of them presented no adhesions at all, while fourteen were adherent in varying degrees from a few light omental attachments all the way to extensive parietal, intestinal, and pelvic adhesions.

The omentum is more apt to contract adhesions with the cyst wall than any other abdominal organ, and these adhesions may be

in the form of one or more long ribbons attached to the tumor at the lower end, or the whole free border of the omentum may be adherent.

Formerly, when tapping was resorted to, adhesions were found quite uniformly between the abdominal parietes and the cyst wall at the point of puncture. Where the cyst walls are thin and the accumulation of fluid rapid, the wall of the largest cyst may rupture, allowing the contents to escape into the abdominal cavity. Where this occurs, the smaller cysts develop rapidly, project into the rent produced in the large cyst, and eventually completely obliterate it.

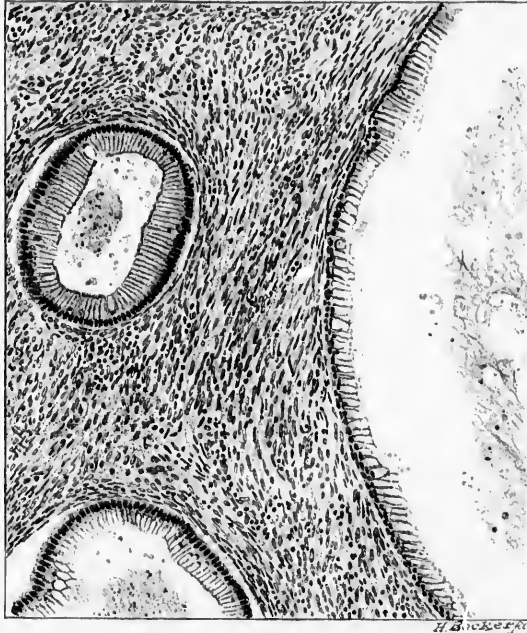


FIG. 410.—THE WALL OF A MULTILOCULAR OVARIAN CYST MAGNIFIED 170 TIMES, SHOWING THE SECRETING GLANDULAR SPACES AND THE METHOD OF FORMATION OF PSEUDOMUCIN.

In the large space on the right the lining epithelial cells are seen in various stages, from those which are markedly granular and contain no pseudomucin, to those in which the cell contents are lighter; and, finally, those in which a goblet cell has been formed full of pseudomucin, and even bursting into the cyst. *Spec. 538.*

The escape of fluid into the abdomen may be followed by a condition called pseudo-myxomatous peritonitis.

The growth of these cysts is usually rapid—in general more rapid than that of the parovarian cysts, although the initial stages are never noted; thus, out of thirty-five cases, the growth is noted as rapid in twenty-three, gradual in seven, and slow in but five, and out of these five two had ruptured and decreased in size and then reappeared. The longest duration noted among my cases was ten years; others were known to have existed for five years, three years, one year and a half, one year, six months, two months, and five weeks.

Cause.—The causation is quite unknown, though age is clearly a strongly predisposing factor, since they are rarely found in girlhood or in old age.

My youngest patient was fifteen years old, and my two oldest seventy-three and seventy-five. The average age of all my cases was forty-two years and six months; this shows the period of strongest predisposition lies near the close of the reproductive period.

The proportion of married to single women was as 3 to 1 in thirty-four cases, and the married women averaged two children each. There is no reason for believing that childbirth has anything to do with causation.

These tumors are usually discovered only after they have become large enough to produce a noticeable distention of the abdomen, and there is a form of abdomen which is characteristic of the large ovarian cysts; the distention is chiefly in the lower abdomen, where the walls are splinted over the tense sac, though the rise from the pubes up to the point of greatest prominence is not so abrupt as in the large spherical myomata. Above this the walls rise and fall with respiration, as shown in Vol. I, Ch. V, Pl. II.

If the cyst is large the flanks are filled out, but they do not sag as in an ascites. The general flattened cylindrical enlargement of the abdomen seen in ascites is wanting.

When the tumor grows large enough the abdominal wall below the umbilicus yields, and the mass falls forward in front of the thighs, or even as low down as the knees.

One of my patients had an ovarian tumor of this kind, weighing one hundred and sixteen pounds, and had not seen her feet or knees for months. Another patient had a large ovarian cyst added to her natural stoutness. (See also Vol. I, p. 83, Fig. 52.)

The average girth of these large tumors, as illustrated by measuring six patients with large ovarian cysts, was 108 centimeters (43.2 inches), the largest measurement being 123 centimeters (49.2 inches); when the circumference exceeds 100 centimeters (40 inches) the measurement does not indicate exactly the size of the tumor, as the subsequent distention is apt to take place downward.

Symptoms.—Pressure symptoms are always produced by the growing tumor sooner or later. Whether they appear early or not depends on the form, consistence, and attachments of the tumor. It is remarkable that in many cases large tumors are carried without any greater inconvenience than the weight. In other cases pressure on the bladder and rectum interferes with their func-



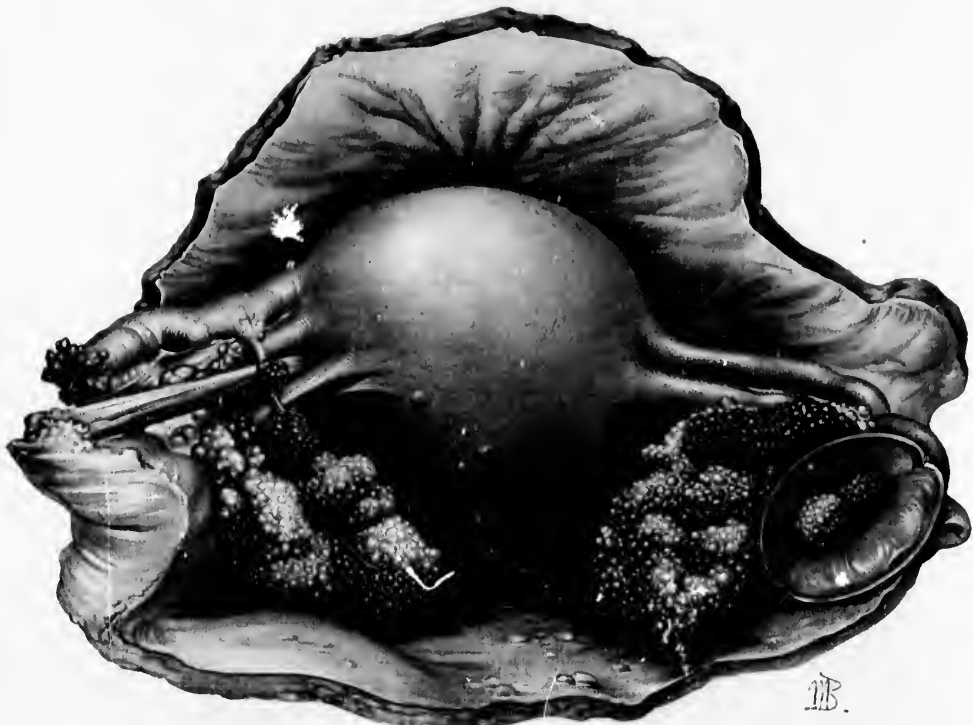

FIG. 411.—PAPILLOMATA OF BOTII OVARIES, SEEN IN SITU FROM BEHIND.

On the left side a series of mulberry masses are seen hanging from a delicate pedicle attached to the Fallopian tube; on the right the ovary is transformed into a mulberry mass, and inside a cyst two masses are seen sprouting. No. 595. Natural size.

tions, and by pressure on one or both ureters, hydronephrosis and hydronephrosis are produced; albumin and casts with dysuria were noted in 50 per cent of my cases. These often disappear within a short time after the operation.

In the large tumors there is often marked interference with digestion, accompanied by flatulence, nausea, and vomiting.

The respiratory and circulatory functions are interfered with by the viscera crowded up under the diaphragm. Other evidences of pressure are the edema of the legs, lower abdomen, and vulva, and the development of the superficial abdominal veins. The distention of the abdomen also produces the red striae physiologically found in pregnancy.

Menstruation was not affected in 50 per cent of my cases; in the others it was irregular, scanty, or even absent, or, on the other hand, excessive.

The general health suffers greatly; in an advanced stage the patient is often extremely emaciated. In only six of my cases was the general health good. The expression, characteristic of the extreme emaciation found in patients with ovarian tumors, has been called the *facies ovariana*.

Pain is not a characteristic symptom. The discomfort produced by the pressure of the large cyst upon the neighboring structures, and usually described as a dull, heavy, dragging sensation, was noted in nineteen of my cases; three spoke of a sharp, cutting pain, and in the remainder no constant pain was complained of. Many women have attacks of pain at longer or shorter intervals, sometimes severe and associated with a slight rise of temperature and a quickened pulse due to a localized peritonitis.

These attacks usually pass off in a few days or a week, leaving behind them more or less extensive adhesions between the cyst and adjacent peritoneal surfaces.

Papillary Tumors of the Ovary.—Papillary tumors of the ovary constitute a well-defined group peculiar in their clinical and microscopical aspects. They are formed by a proliferation of the germinal epithelium, either on the surface of the ovary or in the Graafian follicles or both.

Papillomata were at first classified by Waldeyer as a variety of the ordinary ovarian glandular cystomata (*Archiv. f. Gyn.*, Bd. i, 1870, p. 259). He explained the difference between the clinical appearances furnished by the two classes of tumors by stating that in a cystoma the stimulus of growth fell upon the epithelial elements, which therefore preponderated, while in a papilloma the vascular connective-tissue stroma grew more abundantly, and so pushing out from its bed and covered by epithelium, formed the characteristic papillary trees.

But Olshausen, in 1877, drew a sharp line of differentiation between the papillomatous and the glandular adenomata as totally different one from the other (*Die Krankheiten der Ovarien*, pp. 50–60). Since this time the careful clinical and histological studies of cases by numerous observers, and latterly especially by Dr. J. W. Williams (*Johns Hopkins Reports*, vol. iii, 1892) and by J. Pfannenstiel (*Arch. f. Gyn.*, 1895, p. 507), have not only served to establish the dicta of Olshausen but even to subdivide the generic papilloma into its several well-defined species, of which the following forms are found: Cystoma

parovarii papillare; hydrops folliculi Graafiani papillaris; adenoma papillare pseudomucinosum; adenoma papillare simplex; adeno-carcinoma papillare; adeno-sarcoma papillare.

Out of 138 ovarian tumors of all-kinds operated upon and examined in my own clinic, 30 were papillomata, and these were grouped as follows :

Multilocular adeno-papillo-cystoma (one mixed with sarcoma).....	15
Solid papillomata.....	9
Solid papillo-adeno-carcinoma.....	1
Cystic papillo-adeno-carcinoma.....	2
Parovarian papillomata.....	3

Of these, 21 were unilateral and 9 were bilateral ; in 1 case one ovary contained a cystic papilloma, while the other presented solid papillary masses on the surface.

Before studying the characters of these different kinds of papillomata separately, it will be well to consider them briefly from the broad clinical standpoint of the operator, who is, in fact, too apt to mingle the species under the general term papilloma, without recognizing the well-marked individual characteristics.

Relative Frequency of Papillomata and Carcinomata.
—While the ordinary ovarian cystoma is recognized as a benign growth, the prevailing opinion classifies the papillomata as either malignant or semi-malignant—if I may use such a term—under the impression that they are in some way allied to the carcinomata, into which group they may occasionally pass by a species of degeneration. It must be borne in mind, however, that “malignancy” is but a clinical term, while carcinoma is a purely anatomical expression with a strict scientific significance ; a papilloma has never been demonstrated to have changed into a carcinoma, although from the standpoint of the clinician the frequent association of the two affections in one and the same tumor might well give rise to such a suspicion. The malignancy of the papilloma really refers to a group of symptoms which have nothing in common with the invading destructive tendencies of carcinoma, but are simply the result of its liability to cause extensive ascites and to become distributed and implanted in the form of numerous new foci of growth throughout the peritoneal cavity ; in time symptoms of pressure and obstruction occur, and nutrition is so far interfered with as to produce a condition closely resembling a cachexia. Metastases from the papillomata, in the sense in which they occur in carcinomata, have only been noted in the rarest instances. Well-observed cases are recorded in which papillomatous ovaries have been removed, and numerous implanted papillomatous masses have been noted upon the peritoneum, and yet the patients have recovered and retained perfect health over a period of years without any increase in the growths left behind. A case of K. Thornton's remained free from relapse nine years at the time of publication. In a case of Lomer's (*Centrab. f. Gyn.*, No. 52, 1889) two papillomatous tumors the size of the double fists were removed, leaving warty excrescences scattered over the intestines and the parietal perito-

neum, and four and a half years after the operation no trace of a return of the disease could be detected.

Clinical Characteristics.—The slowness with which some papillomata grow is illustrated by one of my own patients whose abdomen I opened and found full of papillomatous masses choking the pelvis and covering the intestines and abdominal walls.

The tumor masses were so locked in the pelvis and so adherent that extirpation was out of the question, so the fluid was evacuated and the abdomen closed after removing a piece of the growth for microscopic examination. She returned to me in two years so much improved in her general condition, and with the tumors so decidedly movable when examined bimannually, that I re-opened the abdomen in hopes of relieving her, but only to find the conditions about as they had been at the first operation. She died, finally, about three years from the time I first saw her, with the disease in an advanced state.

The manner in which the papillomata implant themselves upon the peritoneum, sprout out into its cavity, and tend to choke its lumen, presents an interesting analogy between tumors of this sort and the intracanalicular adenomata of the breast, which, of course, are to be classed as benign.

In a series of 1,200 abdominal sections for all causes I find 31 papillomata.

Out of 400 ovariectomies Pfannenstiel (*Arch. f. Gyn.*, Bd. xlviii, p. 507) collected 60 papillomata—that is to say, about 15 per cent; and of the 60 papillomata, 29 were bilateral and 26 were located only on one side, in 3 there were indications of the earliest phases of the new growth, and 2 remained uncertain. In 10 out of 89 papillomatous tumors the disease was confined to the surface of the ovary; in 4 out of 60 cases there was a superficial papilloma on one side and on the other a papillary cystoma. This important clinical fact goes to prove that no anatomical distinction can be drawn between papilloma in the ovary and papilloma on the ovary, as has been sometimes attempted.

In about one third of the cystic papillomata, masses are also found on the outer surface of the tumor. A further fact, which tends to do away with the distinction between the solid papillomatous masses growing on the surface of the ovary and those growing within the cysts, is the discovery of Graafian follicles choked with papillomata, which then sprout through the follicle wall and so come to spread out over the surface of the ovary.

The average age of 33 cases treated by me was 42.5 years, the oldest was fifty-six, and the youngest twenty-six.

About a third of the papillomatous cystomata as found at operations are unilocular, but they exhibit for the most part traces of atrophied partitions upon their walls, showing that the one cyst was the result of a fusion of cysts earlier in the history of the growth.

These growths vary in size from little bodies only found under the microscope up to tumors the size of a child's or an adult's head; large tumors like the classical ovarian cysts are rare.

The greatest abundance of papillomatous masses is found in the smaller tumors; in the larger they are apt to be more or less thinly distributed over the

walls and most abundant at the hilum, where the blood supply is richest. One of their chief characteristics is the frequent occurrence of little chalky bodies on the surface or in the tumor walls; these resemble the psammomata described by Virchow, and have been looked upon as a form of degeneration peculiar to this group. Williams has, however, pointed out the fact that they may be found in widely differing conditions, and Pfannenstiel looks upon them as evidences not of degeneration but rather of an excess of nutrition.



FIG. 412.—INNER SURFACE OF A PAPILO-ADENO-CYSTOMA OF THE LEFT OVARY.

Showing papillary masses growing in clusters and in small isolated nodules. March 8, 1894. Path. No. 202. $\frac{3}{4}$ natural size.

The rapidity of the growth varies remarkably. In some cases the tumors seem to develop slowly for months or years, and then begin to increase rapidly in size. Statements made by the patients themselves, however, can only be accepted with due allowances for their powers of observation; quite often it is the sudden accumulation of fluid in the peritoneum which induces the patient to think that the tumor itself has grown rapidly.

Twice I have been able to follow the patient from the time the tumors were small, just felt on the pelvic floor behind the broad ligaments.

In one case (J. H. E., San. 59, Aug. 16, 1893) the mass behind the left broad

ligament was 4 centimeters in diameter, spherical, clearly cystic, and adherent. The patient returned to me after two years, considering herself in fair health, but an examination showed that the pelvis was choked by tumors, now springing from both sides and extending out into the lower abdomen. At the operation I was utterly unable to remove the adherent masses and the numerous implantation nodules, and in five months more the patient died of exhaustion.

In another instance I made an examination for severe pelvic pain associated with an unaccountable weakness, and found small adherent masses behind both broad ligaments; there was no demonstrable ascites, but in three months more the abdomen became enormously distended with fluid, and an operation was for this reason imperative. The fluid was evacuated and the adherent papillary ovarian tumors removed, but numerous small implantation foci peppered over the bladder and pelvic peritoneum were left behind; all went well until the twelfth day, when she suddenly sat up in bed gasping for breath, and then fell back dead from a pulmonary embolus.

In a case (C. K., 2592) operated on Feb. 17, 1894, I removed 17 liters of free fluid. The patient was forty-one years old and complained of continuous emaciation accompanied by an abdominal enlargement. Four months before, her menses had suddenly ceased. She had some pain on defecation, but none at any other time. The abdomen was enormously symmetrically distended by an ascites which lifted the walls so far away from the spine that no tympany could be elicited anywhere below the umbilicus. The circumference was 145 centimeters (58 inches). The superficial veins were distended and there was edema of the skin above the symphysis.

No tumor could be felt by the vagina, but by the rectum I found an irregular ill-defined growth which felt like papillary masses. The abdomen was opened, and after draining out the ascitic fluid two papillary cystic tumors, involving both ovaries, were removed. The left side was easily elevated, but the right had to be separated from dense adhesions to the broad ligament and posterior surface of the uterus. Adhesions were also severed between the bladder and the broad ligament.

The pelvic floor and the rectum were the seat of numerous secondary deposits, eight of which were excised, but the others had to be left, as they covered such a wide space. The patient was discharged in thirty-one days, rapidly regaining strength.

The tumor of the right side was made up of several cysts, bluish-white, but translucent and yellowish in the dependent part (see Fig. 413). On the surface was a pink cauliflower-like excrescence, as seen in the figure, and on the inside the smooth-walled cysts were dotted everywhere with outgrowths of varying sizes. The fluid was thick and tenacious.

I found ascites in eleven of my cases. The fluid is watery, thick, syrupy, glutinous or pseudomucinous; it is oft a glairy, straw-colored, or red or chocolate-colored, due to the admixture of blood.

A patient seen by Dr. M. Sherwood, in Oct., 1896, complained of general weakness without any local symptoms at all; she returned within four months

with the abdomen generally distended, and on making an exploratory incision I found the entire pelvis, both true and false, choked by papillomatous masses, which were beginning to break down extensively in the center. Enucleation was impossible, and she died about a week later of an intense septic peritonitis, produced by rupture of an abscess into the abdominal cavity. Her sister had previously died under my care with the same disease.

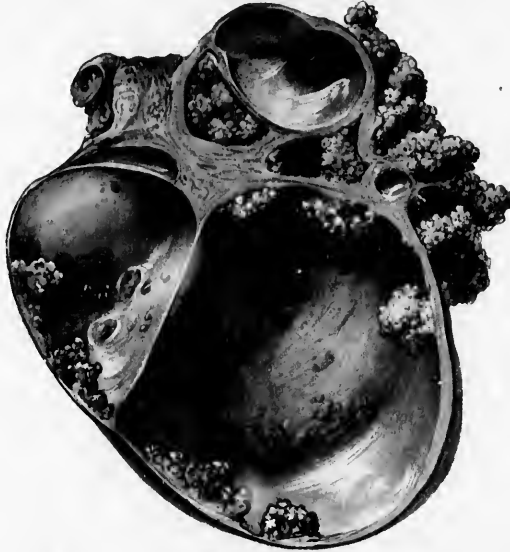
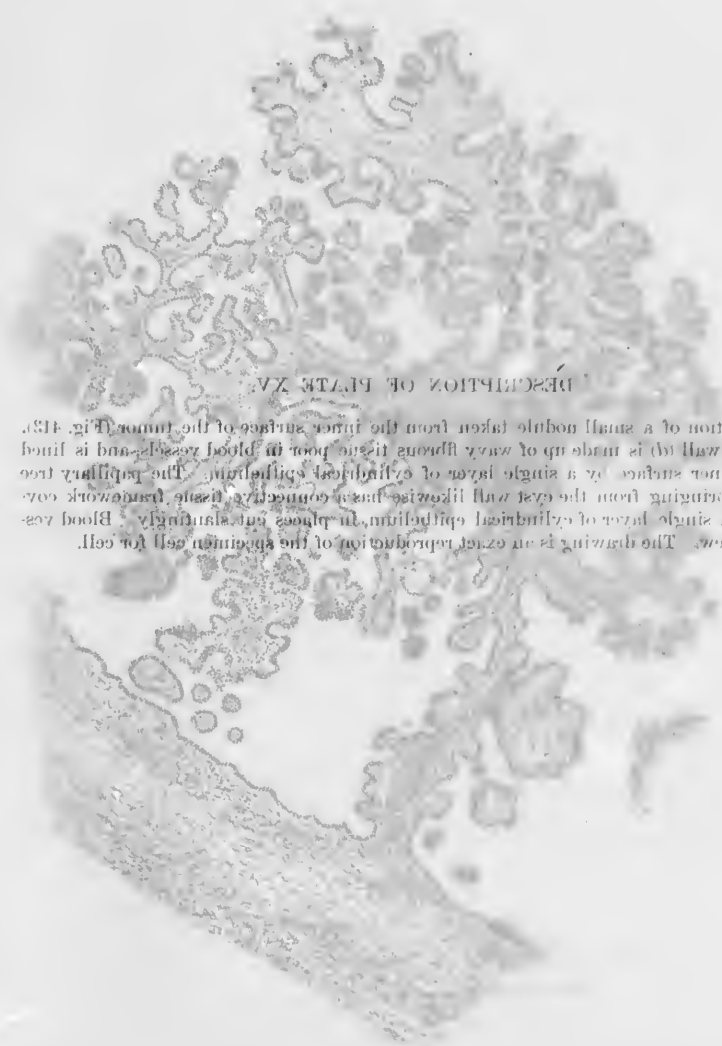

FIG. 413.—CYSTO-PAPILLOMA OF THE OVARY, WITH PAPILLOMATOUS MASSES WITHIN THE CYSTS AS WELL AS ON THE SURFACE.

Both ovaries were involved. No. 174. Natural size.

Histology.—Histologically the papillary excrescences consist of connective tissue covered by epithelium; the connective tissue, however, is but the framework which supports the epithelial growth. An examination of the papilla in its earliest stages shows that it begins by a proliferation of the epithelium, and as this pushes out from the surface and then branches, and branches again, the connective tissue follows it, lying beneath the surface and carrying the blood and lymph vessels. Because of this fact, that the tumor is primarily epithelial in its histogenesis, it might be suitably named a papillary epithelioma, but, as Pfannenstiel suggests, the name epithelioma is so indelibly associated with carcinoma that it is better to call the growth an adenoma. The appearance of papilloma is in fact, in cross-section, that of a tissue everywhere interpenetrated by glands.

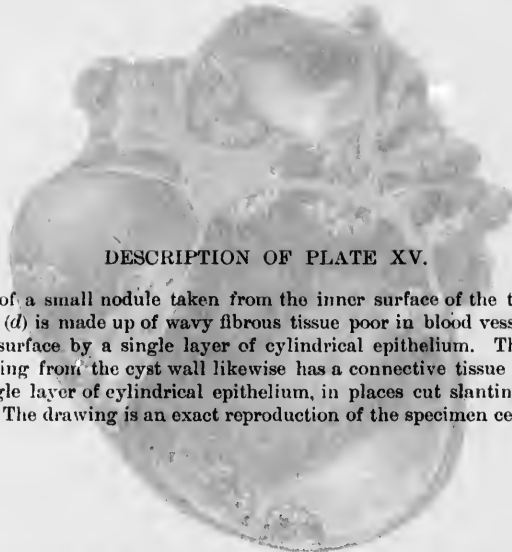
A further clinical distinction may be made between the papillary adenomata in which the epithelial outgrowth is spread out on the surface of the ovary and those in which the epithelial multiplication is in cystic spaces within the ovary;



DESCRIPTION OF PLATE XV.

A section of a small nodule taken from the inner surface of the tumor, fig. 413. The cyst wall (b) is made up of wavy fibrous tissue, and is lined on its inner surface by a single layer of cylindrical epithelium. The papillary tree shown springing from the cyst wall likewise has a connective tissue framework covered by a single layer of cylindrical epithelium, in places substantially as before. The drawing is an exact reproduction of the specimen cell for cell.

with the abdomen generally distended, and on making an exploratory incision I found the ovaries, both free and fixed, checked by papillofistulous masses, which were beginning to break down extensively in the center. Drainage was impossible, and she died about a week later of an acute toxic peritonitis, produced by rupture of an abscess into the abdominal cavity. Her sister had previously died under my care with the same disease.



DESCRIPTION OF PLATE XV.

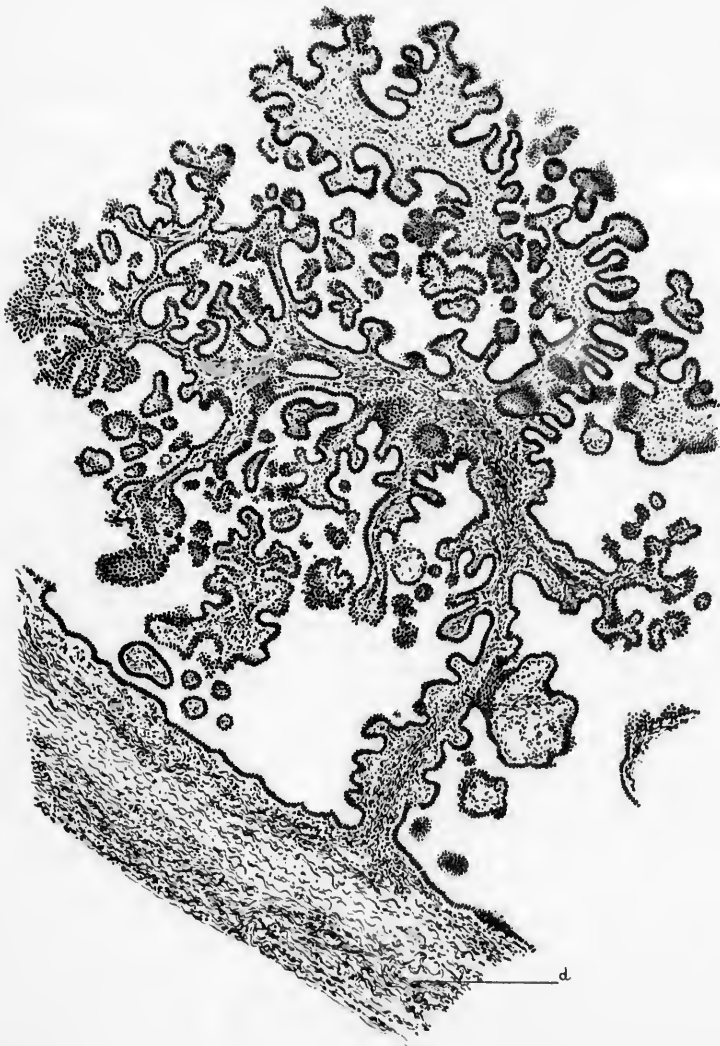
A section of a small nodule taken from the inner surface of the tumor (Fig. 413). The cyst wall (*d*) is made up of wavy fibrous tissue poor in blood vessels, and is lined on its inner surface by a single layer of cylindrical epithelium. The papillary tree shown springing from the cyst wall likewise has a connective tissue framework covered by a single layer of cylindrical epithelium, in places cut spicantly. Blood vessels are few. The drawing is an exact reproduction of the specimen cell for cell.

FIG. 413. SECTION THROUGH A SMALL NODULE TAKEN FROM THE INNER SURFACE OF THE TUMOR. M. B. S. 100 IN PLATE XV. OF PART A.

Pathological Anatomy, Plate XV, Fig. 413.

Histology.—Histologicly the papillary excrescences consist of connective tissue covered by epithelium; the connective tissue, however, is but the framework which supports the epithelial growth. An examination of the papilla in its earliest stages shows that it begins by a proliferation of the epithelium, and as this pushes out from the surface and then branches, and branches again, the connective tissue follows it, lying beneath the surface and carrying the blood and lymph vessels. Because of this fact, that the tumor is primarily epithelial in its histogenesis, it might be suitably named a papillary epithelioma, but, as Pflanzstiel suggests, the name epithelioma is so indubitably associated with carcinoma that it is better to call the growth an adenoma. The appearance of papilloma is in fact, in cross-section, that of a tissue everywhere interpenetrated by glands.

A further clinical distinction may be made between the papillary adenomata in which the epithelial outgrowth is spread out on the surface of the ovary and those in which the epithelial multiplication is in cystic spaces within the ovary;



X 70



these two forms may be distinguished by the suitable names adenoma papillare superficiale and cyst-adenoma papillare.

In sharp and interesting contrast to these glandular epithelial tumors stand a group of little tumors of the ovary in which the connective-tissue elements are greatly in excess of the epithelial; these appear sometimes in the form of a mushroom-like reddish excrescence on the surface of the ovary, apparently sprouting out from a ruptured Graafian follicle. These growths are fully supplied with blood vessels and made up of a mass of connective tissue with just enough epithelium to cover them, and may be suitably termed papillary fibromata.

Diagnosis.—The diagnosis of a papillary tumor can not be made when the papillomata are confined to the interior of an ovarian cyst. The only practical conclusion which can be drawn in reference to such cases is that any ovarian cyst is liable to be papillomatous and therefore malignant, and ought for this reason to be removed as soon as possible.

Monocystic and small nodular ovarian tumors fixed in the pelvis are always more open to suspicion than are the larger polycystic tumors.

A probable diagnosis may be made when such small irregular cystic tumors are found on both sides, adherent to the pelvic floor, especially if they are associated with ascites. The masses lack the density of a pelvic abscess, and are harder and more irregular than a hydrosalpinx.

It is also possible sometimes to feel the papillary masses distinctly through the rectum, and so to make a diagnosis.

When the disease has progressed far enough to produce irregular masses felt through the abdomen with ascites, the diagnosis will rest between carcinoma and papilloma of the peritoneum. I do not know any way of distinguishing them.

The most characteristic symptom is the emaciation and extreme weakness, associated with ascites and ill-defined large masses in the lower abdomen, choking the pelvis.

Often when the disease is entirely masked by an ascites it will be easily outlined through the flaccid abdominal walls after drawing off the fluid.

I would warn against any but the gentlest handling, to avoid the risk of bruising or breaking off pieces of the growth and so provoking hemorrhage. One large tumor had such thin walls that it broke, as soon as I touched it, through the incision, discharging into the peritoneum a brownish fluid full of epithelial cells.

The bloody, syrupy liquid withdrawn from the abdomen is suggestive of papilloma, but I have not found any help from a microscopic examination of it.

Papillary Parovarian Cyst.—Papillary parovarian cysts are rare; the monocystic papillary cyst-adenomata are undoubtedly often mistaken for parovarian cysts under the prevailing tendency to ascribe all monocystic tumors to the parovarium without a critical examination.

Pfannenstiel found three parovarian papillary cysts in forty-eight cases of papillomata; two of them were unilocular, thin-walled cysts as large as the pregnant uterus at term. The contents of the cyst are typical of the parovarian tumors, and on the interior the ciliated epithelium is well preserved. The papillary masses were small and few. In two out of three cases the tumors

were known to have existed for twelve years before the operation, and in no case was there any evidence of malignancy.

Papillary Cystic Graafian Follicle.—In two cases of enlarged Graafian follicles Pfannenstiel found low warty papillae made up of a firm connective-tissue stroma poor in vessels, and covered by a low cylindrical epithelium in one layer. In one case the tumor removed by Fritsch had been found twelve years previously by Spiegelberg. These tumors show no signs of malignancy.

Pseudomucinous Papillary Adenoma.—This group of papillary tumors resembles in external appearance the classical polycystic ovarian cysts and really belongs in the same class with them. They are multilocular in their arrangement, but as a rule the large cyst so often found in other cystonata is wanting, being replaced by a number of small cysts; these contain pseudomucin, varying in consistence with the amount of water contained, and in color from clear, dirty, or yellowish, to brown or greenish.

The tumors, as a rule, have a well-defined pedicle, and show a decided tendency to grow in pairs (over 50 per cent of the cases).

The papillary growths are for the most part confined to the cystic spaces and are more abundant in the neighborhood of the pedicle, where the nutrition is most abundant.

The pseudomucin is a direct secretion from the epithelial cells and not a form of degeneration. The growth of these tumors is slow and not accompanied by marked discomforts; indeed, their tendency is throughout benign, in marked

contrast to the papillary adenomata of the next group, with ciliated epithelium, and to the papillary carcinomata. In seven cases implantations on the peritoneum were found but once, in spite of the presence of papillary excrescences on the surface of the tumor in a number of instances. In the case in which the implantations were found they appeared as little glassy nodules which were not papillary, but resembled those sometimes found with the ordinary ovarian cystomata.

Simple Papillary Adenoma.—

These tumors are often called ciliated papillary tumors, but, as pointed out by Williams, the pres-

ence or absence of cilia does not appear to be important, and the same tumors are often ciliated in some places and not in others.

Over one third of the papillary tumors examined by Pfannenstiel belonged to this group, and in about half of them the tumors were bilateral; in three

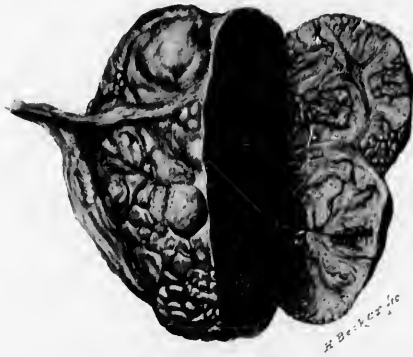

FIG. 414.—SOLID OR FIBROID PAPILLARY ADENOMA OF THE OVARY.

On section the tumor consists of fibrous stroma enclosing alveolar spaces from 0.3 to 1 centimeter in diameter, which are completely filled with branching papillary masses. Color, pinkish gray. Numerous adhesions. Spec. 1265. Natural size.

instances the tumor of one ovary was superficial while the other side presented a papillary cyst-adenoma.

The superficial form attains the average maximum size of a man's fist, and the cystoma, mostly multilocular, grows larger, rarely reaching, however, the size of the pregnant uterus at term.

The contents of the tumors are usually a cloudy, thin serous fluid, never pseudomucinous. Necrosis and the exfoliation of the epithelial cells may produce a yellowish mixture.

The epithelium, ciliated or not, is like that of the normal uterine mucosa.

About half of these tumors have well-defined pedicles, while the other half grow down between the folds of the broad ligament, and, as a rule, do not project free into the peritoneal cavity.

There can be no relapse after complete extirpation, and implanted colonies grow slowly.

Papillary Adeno-carcinoma.—In this group are classed all those tumors which microscopically show a departure from the type in the size, form, and arrangement of the epithelial cells, whether upon the papillæ, or on the inner surfaces of the cyst walls, or in the walls of the tumor itself.

Pfannenstiel found that almost half of his cases were papillary adeno-carcinomata, while in twenty-seven of my own cases I found but two of this kind, a difference which it is difficult to explain.

These tumors are almost exclusively cystic. In one case there was a cysto-carcinoma of one side and a superficial papilloma of the other.

In half the cases the proliferations were found both in the cysts and on the surface, without any evidence of perforation or rupture; hard carcinomatous nodules are often evident in the cyst wall.

In half the cases the tumors were monocystic and more or less spherical, and in the other half they were polycystic.

The picture under the microscope is usually that of an adeno-carcinoma; medullary carcinoma is sometimes seen.

True metastases were observed in six out of twenty cases, in the retroperitoneal and inguinal glands, in the tube, the uterine wall, the stomach, the liver, and the periosteum of the ribs.

In one case there were double ovarian papillary cysto-carcinomata, with carcinoma of the cervix, in a uterus containing numerous myomata.

Peritoneal implantations were found in 30 per cent of the cases—more than twice as often as in the pseudomucinous tumors, and in still further remarkable contrast to the latter group these implantations from the adeno-carcinomata partake of the nature of the mother tumor, and are markedly malignant, distributing themselves widely, and rapidly penetrating into the subjacent tissues. True cachexia is often seen.

Implantations occur only when the papillomata are found in the outer surface of the tumor, or when, as in one case, some of the contents of the tumor escaped into the abdomen during the operation. In this case the patient died a few months later of the peritoneal infection.

About 82 per cent of the patients died of relapse on an average of eight and a half months after the operation, in sharp contrast to the simple adenomata where papillomata were left in the peritoneum, and where the average length of life was three and a half years.

Papillary Cyst-adeno-sarcoma.—Only two cases of this kind are recorded, one by Pfannenstiel (p. 599) and one of my own.

The first case was that of a single woman of forty-seven, from whom an extensive subperitoneal tumor was removed the size of a man's head.

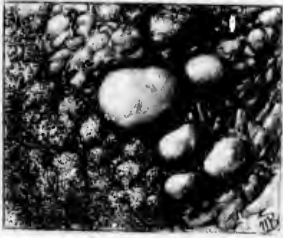
She died four months later, but it could not be ascertained whether she had a relapse. The tumor removed was a unilocular cyst, with a wall in one place 2 centimeters thick, at which point the surface was covered with numerous separate papillary excrescences. On section the tissue appeared homogeneous with some irregular cavities with a smooth wall. The tumor was made up of a vascular connective tissue interpenetrated with round and spindle cells. The papillomata were purely adenomatous in form, delicately constructed and covered with a simple cylindrical epithelium in a single layer, which also sent numerous glandular extensions into the underlying tissue. There was no traceable connection between the papillomata and the sarcoma.

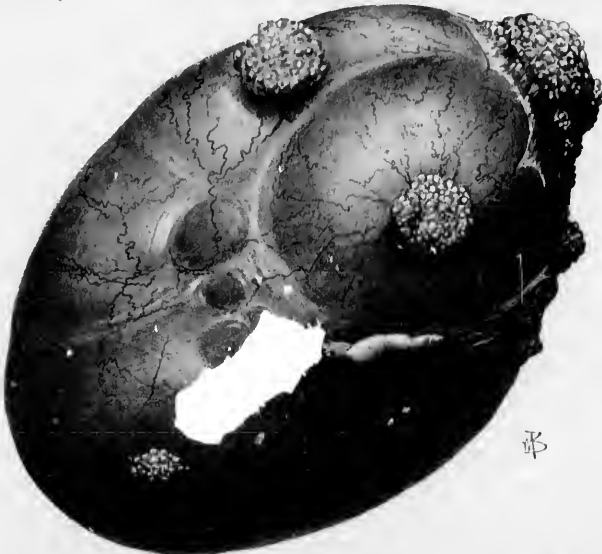

FIG. 415.—ADENO-CARCINOMA (COLLOID CARCINOMA) OF THE OVARY, WITH NUMEROUS CARCINOMATOUS NODULES ON THE EXTERNAL SURFACE OF THE UNRUPTURED CYSTS; SECONDARY GROWTHS IN THE OMENTUM. NO. 328. $\frac{3}{4}$ NATURAL SIZE.

In a rare case occurring in my own clinic a multilocular adeno-papilloma was found associated with sarcomatous nodules in the inner surface of one of the cysts. (See Dr. T. S. Cullen, *Amer. Jour. of Obs.*, vol. xxxiv, 1896.)





X 2

Fig 1

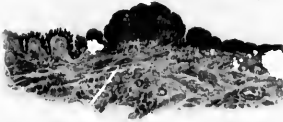
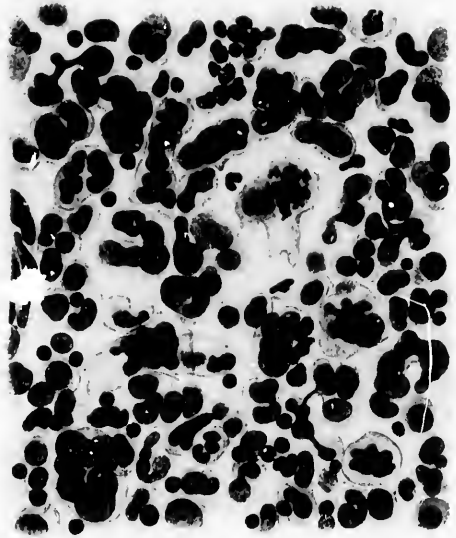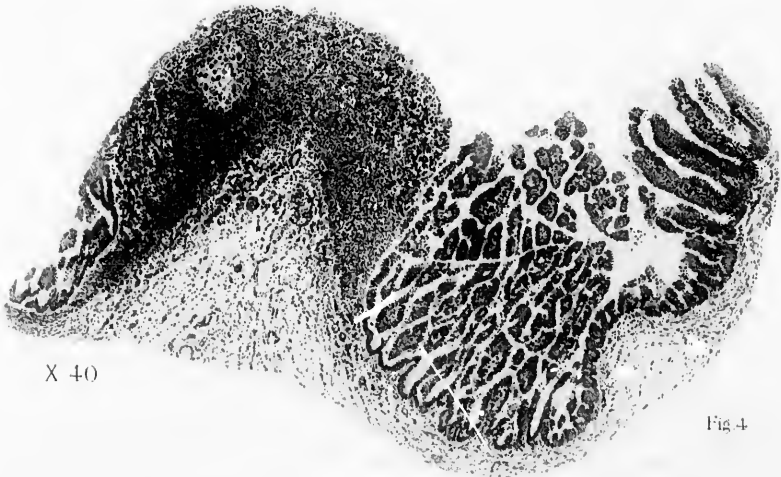


Fig 2



X 570

Fig 3



X 40

Fig 4

The patient, M. G. Mott, was first operated upon three years ago, and was operated upon Oct. 15, 1904 for a second time. She had noticed for the first time six months before. A cyst of the size of a month's fist was removed from the right side close to the uterus, and an interrupted recovery followed. (See Plate XVI.)

Carcinoma of the Ovary.—(Adenocarcinoma.)—The most frequent of all the ovarian diseases. **DESCRIPTION OF PLATE XVI.**

A PAPILLARY OVARIAN CYST EXHIBITING A FEW SARCOMATOUS NODULES.

Fig. 1 represents a portion of the great cyst wall, twice enlarged. In the left lower corner the typical appearance of a papillary cyst is seen, while in the left upper corner and on the right border the smooth but slightly undulating surface of the cyst wall is visible. The sarcomatous masses occupy the center of the field in the form of a large, domelike nodule; to the right and above this a somewhat smaller nodule, and below on the right three more nodules.

Fig. 2 is a cross-section of the same. On the left delicate papillary masses are seen, in the middle a large sarcomatous nodule with smaller ones beside it, and between some of them are a few delicate papillary growths.

Fig. 3 is a highly magnified portion of a sarcomatous nodule. In order to appreciate the size of the cells it is only necessary to contrast them with the small, round, deeply-staining nuclei scattered throughout the tissue, which are the mononuclear leucocytes; the small black mass just above the center of the field is the horseshoe-shaped nucleus of a polymorpho-nuclear leucocyte. The majority of the sarcoma cells have round, oval, or irregularly oval, rather deeply-staining nuclei, and in the nuclei the coarse and fine chromatin granules are easily demonstrable. Surrounding these nuclei is a variable amount of pale staining protoplasm. In the left lower corner is an irregular plaque of protoplasm containing eight nuclei; in the vicinity of the right lower corner an almost circular protoplasmic mass with an irregular, deeply staining nucleus. Just above and to the left of this is an irregular plaque of protoplasm containing a deeply stained nucleus, and to either end of this secondary nuclei are attached by delicate filaments. Scattered throughout the field are numerous similar cells, all showing karyorhexis. A striking cell is seen just above and to the right of the center, markedly irregular in contour, with a distinct nucleus, and containing many coarse granules of chromatin.

Fig. 4 shows a sarcomatous nodule on section, magnified forty times, with the papillomata on either side. The underlying connective tissue is poor in cell elements and contrasts sharply with the superficial sarcoma, whose cells are abundant. The nuclei are round or irregular, and in the pale staining area large.

The following description of the microscopic appearance of the tumor is given by the author:

It is an epithelial growth arising under certain conditions from the ovary, and consists of a primary, in two ways: first, as a direct outgrowth from the surface of the ovary, a germinal, or a papillary cyst, or second, from the interior of the ovary, such as the body of the uterus or the ovary.

The association of carcinoma with the papillary system of the ovary, although unexplained in its etiology, is seen in the natural evolution of the histologically recognizable growth, characterized as they are by an extensive proliferation of atypical "glandular" tissue.

DESCRIPTION OF PLATE XVI

A PAPILLARY OVARIAN CYST EXHIBITING A FEW SARCOMATOUS NODULES

Fig. 1 represents a portion of the great cyst wall, twice enlarged. In the left lower corner the typical appearance of a papillary cyst is seen, while in the left upper corner and on the right border the smooth but slightly undulating surface of the cyst wall is visible. The sarcomatous masses occupy the center of the field in the form of a large, dome-like nodule; to the right and above this a somewhat smaller nodule and below on the right three more nodules.

Fig. 2 is a cross-section of the same. On the left delicate papillary masses are seen in the middle a large sarcomatous nodule with smaller ones beside it and between some of them are a few delicate papillary growths.

Fig. 3 is a highly magnified portion of a sarcomatous nodule. In order to appreciate the size of the cells it is only necessary to contrast them with the small, round, deeply-staining nuclei scattered throughout the tissue, which are the mononuclear leucocytes; the small blue mass just above the center of the field is the nucleus of a polymorphonuclear leucocyte. The majority of the sarcoma cells have round, oval, or irregularly oval, rather deeply-staining nuclei and in the nuclei the coarse and fine chromatin granules are easily demonstrable. Surrounding these nuclei is a variably amount of pale staining protoplasm. In the left lower corner is an irregular plaque of protoplasm containing eight nuclei; in the vicinity of the right lower corner an almost circular protoplasmic mass with an irregular, deeply-staining nucleus. Just above and to the left of this is an irregular plaque of protoplasm containing a deeply stained nucleus and to either end of this secondary nuclei are attached by delicate filaments. Scattered throughout the field are numerous similar cells all showing karyophoresis. A striking cell is seen just above and to the right of the center, markedly irregular in contour with a distinct nucleus and containing many coarse granules of chromatin.

Fig. 4 shows a sarcomatous nodule on section magnified forty times with the papilloma on either side. The underlying connective tissue is poor in cell elements and contrasts sharply with the superficial sarcoma, whose cells are abundant. The nuclei are round or irregular and in the pale staining area large.

The patient (M. G., 3100, Oct. 13, 1894) was sixty-three years old, and was operated upon Oct. 13, 1894, for a tumor which she had noticed for the first time six months before. A cyst about the size of a man's head was removed from the right side close to the uterine cornu, and an uninterrupted recovery followed. (See Plate XVI.)

Carcinoma of the Ovary.—Adeno-carcinoma is the most malignant of all the ovarian diseases.

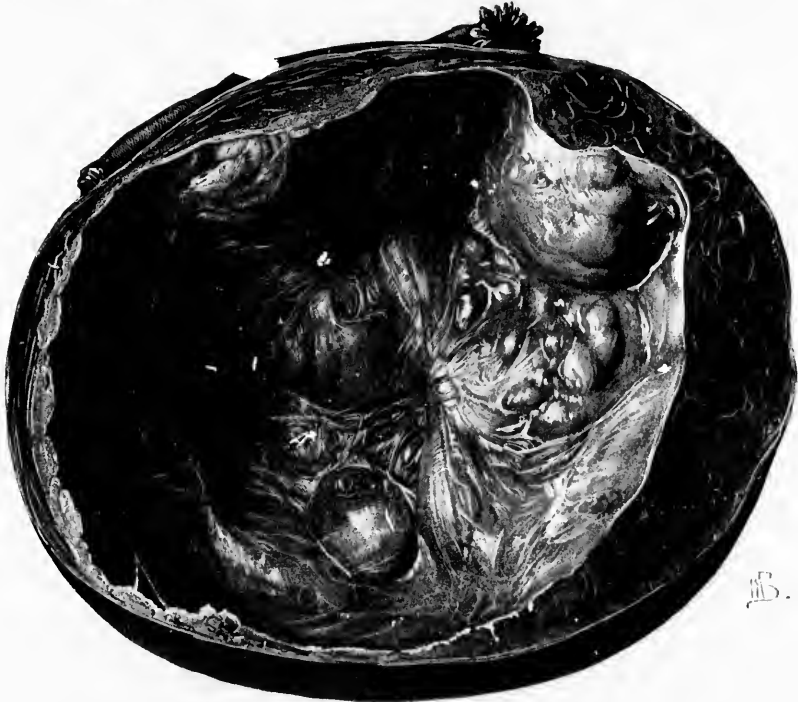

FIG. 416.—CYSTO-CARCINOMA OF THE OVARY OF UNUSUAL FORM.

The walls are thick, and the inner surface of the large cyst is smooth, irregular, nodular, and has no epithelial lining. The uterine tube lies above. No. 344. $\frac{2}{3}$ natural size.

It is an epithelial growth appearing under several forms, either primary—that is, originating in the ovary and constituting the original ovarian tumor—or secondary, in two ways: first, as a degeneration of a glandular ovarian cyst, a dermoid, or a papillary cyst, or second, metastatic from some other organ, such as the body of the uterus or the cervix.

The association of carcinoma with the glandular and the papillary cystoma, although unexplained in its etiology, seems but a natural evolution of these histologically remarkable growths, characterized as they are by an enormous proliferation of atypical "glandular" tissue.

The carcinoma appears in a solid, scirrhous, or in a cystic form, and is found in young patients and after the climacteric.

The epithelium, cylindrical at first, becomes atypical, penetrates the underlying tissues, forms alveoli, and consists of many layers.

Out of thirteen cases of primary ovarian carcinoma occurring in my practice, four were double and nine were single; these were again subdivided into six solid and seven cystic tumors.

There were two cases of papillary cystic carcinoma and one case of papillary solid carcinoma.

The tumors vary in size from small growths scarcely enlarging the ovary to a mass as large as a man's head. The development is rapid, produces metastases in various parts of the body by lymph and blood channels, and invades and destroys the surrounding and subjacent tissues; the omentum is particularly liable to metastases; on the intestine they often appear as round, white, hard, and flat-tipped bodies variously grouped.

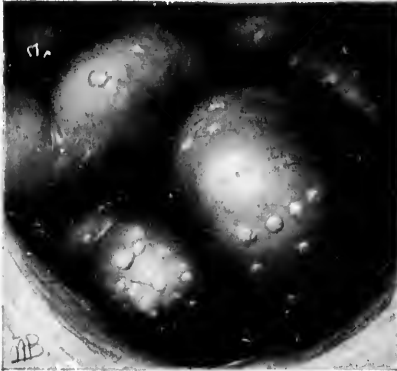


FIG. 417.—FLAT CARCINOMATOUS METASTATIC NODULES OF THE INTESTINES.

Note the tendency to a circular arrangement along the lymphatic vessels. Autopsy Jan. 9, 1897. $\frac{2}{3}$ natural size.

As the disease develops, edema of the legs and cachexia become marked.

Secondary Carcinoma.—There is sufficient clinical evidence to show that the ovary may become the seat of carcinomatous metastases, which partake of the characters of the primitive growth, but this secondary involvement, however, would seem to be rare.

A. Hempel records a case (*Arch. f. Gyn.*, viii, p. 56) in a woman of forty-two in whom ovarian carcinomata of both ovaries were found at the end of pregnancy; a fully developed living child was born, and the patient died a month later of a purulent peritonitis. Both ovaries were found converted into irregular nodular tumors larger than a child's head, and at the pylorus there was a carcinoma of long standing with a perforation 1 centimeter in diameter.

P. Reichel (*Zeits. f. Geb. und Gyn.*, xv, p. 354) shows the remarkable possibility of a metastasis direct from a carcinomatous uterus to the ovary in cases in which the protracted uterine hemorrhages gave satisfactory evidence of the existence of the uterine carcinoma prior to that of the ovary.

He further urges that such a combination is more frequent than is generally believed, and that it should always be borne in mind and looked for in all cases of ovarian carcinoma.

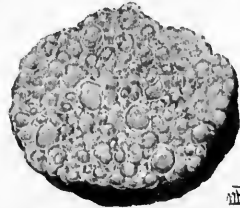


FIG. 419.—ADENO-CARCINOMA OF THE OMENTUM, SEEN IN SECTION. No. 328. NATURAL SIZE. SEE FIG. 418.



FIG. 418.—LARGE ADENO-CARCINOMA (COLLOID CARCINOMA) OF THE OMENTUM, SECONDARY TO CARCINOMA OF THE OVARY; THE FREE BORDER OF THE OMENTUM IS BELOW.

Operation removing omental mass. Recovery. Death some months later. No. 328. $\frac{1}{4}$ natural size.

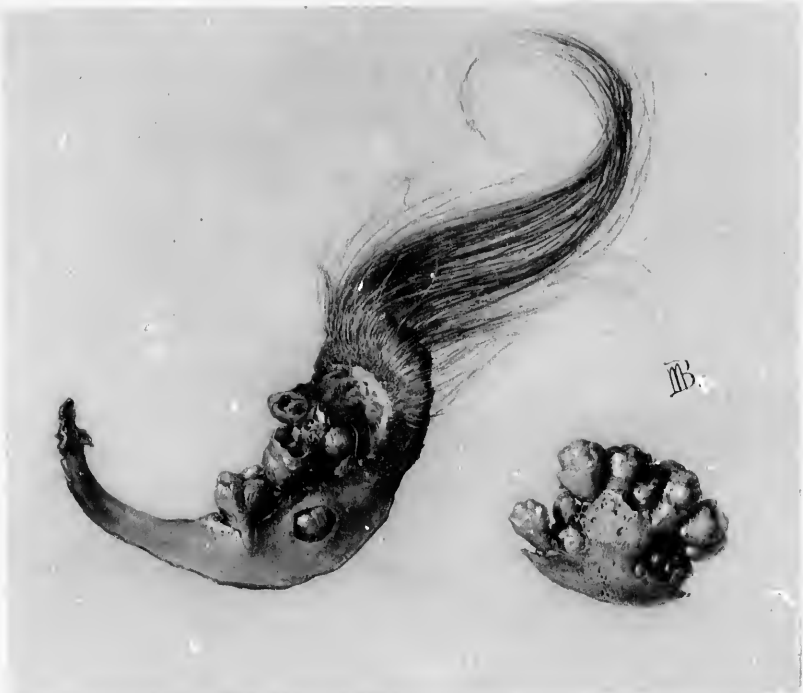

FIG. 420.—RUDIMENTARY JAW FROM A DERMOID CYST CONTAINING MOLAR TEETH, AND WITH A WISP OF BROWN HAIR GROWING FROM ONE EXTREMITY.
On the right is another small piece of dentigerous bone loaded with molar teeth. Case of Dr. Weist. Natural size.

On the other hand, in carcinoma of the body of the uterus the ovaries should be removed too, on account of the possibility of an early metastasis, not yet recognizable to the naked eye.

Dermoid Cysts of the Ovary.—A dermoid ovarian cyst is an ovarian tumor containing some or all of the elements of skin tissue, bones, nerves, and mucous membrane; it is usually unilocular, and exhibits more or less perfectly the epithelial layers of the skin, with sebaceous and sweat glands and hair. Teeth are often found imbedded in the cyst wall, sometimes attached to bone structure, with a well-defined alveolar process closely resembling a part of the lower jaw. Cartilage, nerves, and brain tissue have been found in these cysts, and in one instance nail tissue. A mamma with well-developed nipple has been observed.

The outer covering of the tumor is like that of an ordinary ovarian cyst, and in its general relationships the dermoid cyst is in all respects similar to a unilocular ovarian tumor.

The walls of the cyst are lined by many layers of squamous epithelium, and vary from a thin membrane, almost transparent, to one that is thick and leathery, and the contents are oily, thick, and greasy, sometimes cheesy, due to the

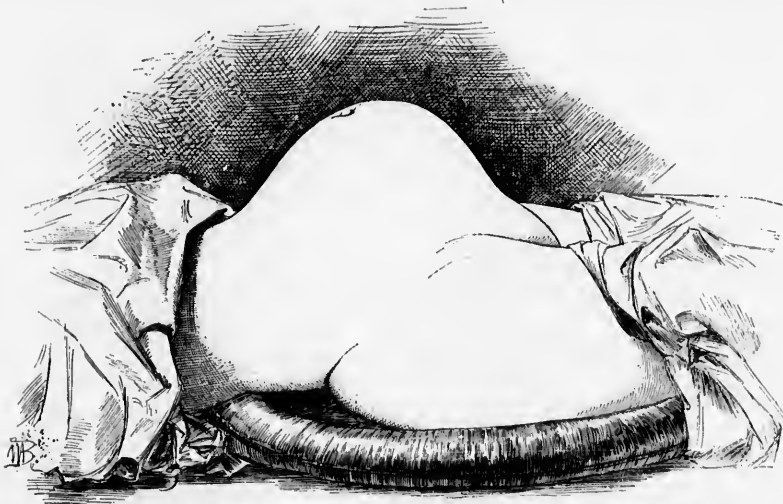


FIG. 421.—CONTOUR OF THE ABDOMEN IN THE CASE OF AN UNUSUALLY LARGE DERMOID CYST. No. 2766.

secretions of the sebaceous glands and fatty degeneration of the epithelial cells. The color of the hair may be either light or dark, and bears no relation to that of the surface of the body. It may be found in large quantities, rolled up loosely in a ball, immersed in fat. Hairs of various lengths are also found growing from the cyst wall, usually not exceeding two feet. In a case reported by Dr. P. F. Munné, of New York, the hair was five feet long.

After removing a dermoid cyst, if the tumor stands in a cool place it be-

comes hard and deep yellow in color; if the contents of a large cyst are allowed to stand, the surface shortly becomes covered with fine feathery flakes of cholesterol crystals.

Dermoid tumors of the ovary are usually limited to one side. In twenty-one cases I had one in which both right and left ovaries were involved, and one in which there were two cysts on the same side. In operating for a dermoid cyst, if the opposite ovary is at all enlarged it must be incised to determine whether a small dermoid may not be concealed within it.

The size of the tumor varies from a little nodule not larger than a distended Graafian follicle to a mass filling the abdomen. One of my cases was but 2 centimeters in diameter, while another contained 10 liters (20 pints) of fluid; they are, however, not often seen much larger than a man's head.

The cause of dermoid tumors has not been satisfactorily explained; the most plausible theory is that of Coluhnheim, who attributes their origin to an inclusion of parts of the outer skin layer (ectoderm) in the ovary during its formation in early fetal life. These misplaced skin elements then naturally begin to grow during the period of greatest ovarian activity, and develop the various skin tissues after an atypical fashion.

In the examination of the clinical history of nineteen of my cases, I find that fourteen women were married and five single. Of the fourteen married women, six were childless, but three of these had had miscarriages. The ages of the patients varied from twenty-one to sixty years, the average being thirty-five years. The growth of the tumor in most cases was slow; one woman had noticed hers for ten years before operation, and others for six or seven years, while another had only known of its presence for three months. Observations as to the slow development can of course only be applied to cases in which the tumor had already attained a size sufficient to produce distention and be felt through the lower abdominal wall. Where the tumor lying in the pelvis was small the patients were unconscious of the existence of any tumor.

Out of seventeen cases the tumors were found eight times on the left side and eight times on the right, and once occupying both left and right sides.

The pedicle varies as in ovarian multilocular tumors. Eight cases were distinctly pediculated, seven had no pedicle at all, and one had a long twisted pedicle turned one and a half time upon itself.

There can be no doubt that dermoid cysts are peculiarly prone to induce attacks of localized peritonitis. This tendency is difficult to explain,

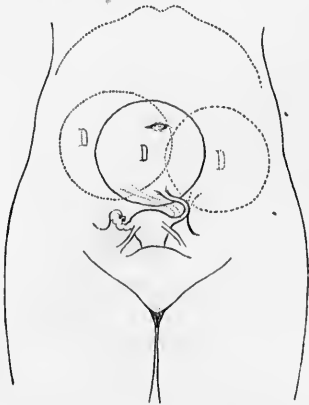


FIG. 422.—LEFT DERMOID CYST OF THE OVARY WITH A LONG PEDICLE.

The cyst (*D*) lay in the median line and could easily be pulled high up in the abdomen or displaced into either flank in the position of the dotted lines. No. 2554.

and seems inherent even in the smallest cysts, which are often found matted in a dense mass of adhesions; on the contrary, however, I have seen a cyst as large as a man's head entirely free from adhesions. I found eight out of nineteen cases not at all adherent, while the other eleven were more or less fixed by adhesions varying from the slight velamentous attachment to the densest fibrous union.

Owing to this liability to provoke attacks of peritonitis involving the immediately surrounding structures, inflammatory disease involving the other ovary and tube is frequently found. This generally consists in adhesions binding down the tube and ovary, often associated with hydrosalpinx (see Fig. 423).

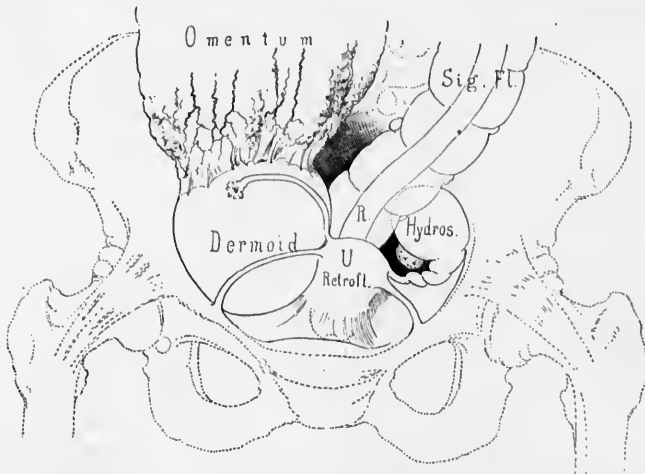


FIG. 423.—COMPLICATED DERMOID CYST OF THE RIGHT OVARY, WITH DENSE ADHESIONS TO THE ENTIRE BREADTH OF THE OMENTUM AND DISPLACEMENT OF THE RIGHT TUBE AND ROUND LIGAMENT.

The uterus is dragged up (ascensus uteri), and on the left side there is a large hydrosalpinx. No. 3120.

Like the ovarian cystoma, the dermoid cyst may become almost completely detached from its natural vascular supply and depend for its existence upon the adhesions formed between it and other organs (see Fig. 424).

I have not been able to note anything characteristic in the menstrual history beyond the fact that sixteen of the nineteen cases complained of pain, generally severe. In three non-adherent cases there was no pain at all, but a distressing bearing-down sensation in the lower abdomen.

About half of all the cases complained of vesical distress varying from a frequent micturition to a severe tenesmus. A marked emaciation is often apparent. One woman lost 40 pounds in six months, and during this time the abdomen reached a circumference of 92 centimeters (36·8 inches).

The prognosis if the tumor is left to grow is bad; in the absence of complications the growth advances until the abdomen is so distended that the

functions of the abdominal, and later of the thoracic, organs are impaired by pressure.

Far more than in the case of ordinary ovarian cysts are these patients liable to attacks of peritonitis resulting in adhesions to all contiguous structures. Suppuration of the cyst is also not uncommon, followed by perforation into bladder (see Vol. I, p. 355, Fig. 225) or bowel. On account of the adenoid elements which they contain, the liability to cancerous degeneration is also great. Hydro-nephrosis and pyelitis may be caused by the pressure of the cyst on one or both ureters. For one or more of these cogent reasons the patient who at first de-

fers an operation will sooner or later be forced to seek surgical relief.

The diagnosis is usually difficult to make. The chief difficulty is in distinguishing a tumor of this sort from an ordinary ovarian tumor. The difference in consistence is of no aid, as the contents of a dermoid cyst are so frequently liquid that they appear on palpation to have about the same consistence as water.

The following points may be borne in mind in making the diagnosis: The dermoid tumor is more or less spherical, usually unilateral, giving the impression of being a monocyst; if large, its growth has been slow. If the patient is young, the chances are in favor of a dermoid. Where attended with inflammatory sequelæ the dermoid is apt to be extremely painful on pressure. The tendency to emaciation must also have its weight in making the diagnosis. Küstner's rule that the dermoid tumor has a remarkable tendency to float out in front of the uterus and lie just behind the abdominal wall was found in five out of twelve of my cases,

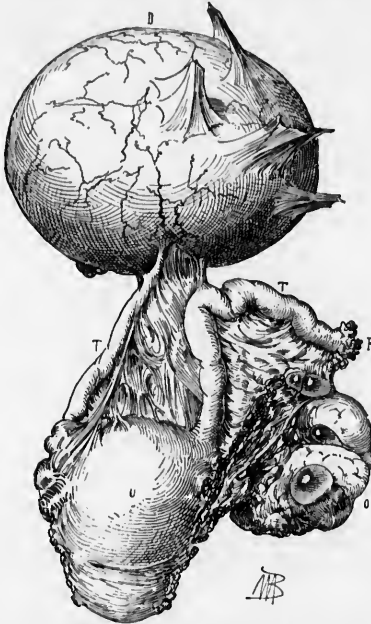


FIG. 424.—RIGHT DERMOID CYST (D) WITH EXTENSIVE ADHESIONS.

Note the displacement and atrophy of the right tube, and the adhesion to and angulation of the left tube. Feb. 2, 1895. No. 584. $\frac{2}{3}$ natural size.

and is therefore a valuable diagnostic point. In one case the diagnosis was unexpectedly made by a vaginal puncture under the impression that the fluctuating sac choking the pelvis and bulging into the vagina was a pelvic abscess. The discharge of fatty matter at once revealed the true nature of the case.

In small monocystic tumors not rising out of the pelvis the dermoid tumor must always enter into the list for a differential diagnosis. When the tumor is adherent and there is a history of pelvic pains lasting some years, and the walls

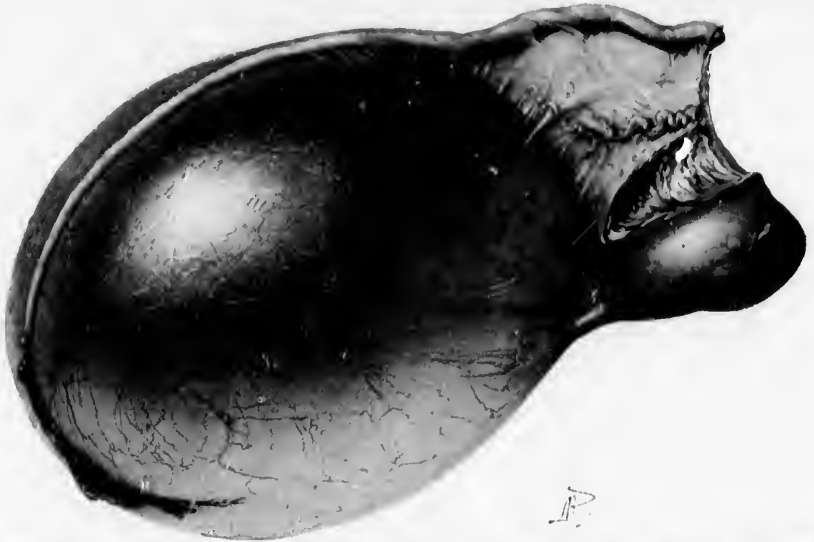

FIG. 425.—PAROVARIAN CYST SITUATED BETWEEN THE AMPULLA OF THE TUBE AND THE OUTER END OF THE OVARY. The rest of the mesosalpinx is intact. The ovary shows a recently ruptured corpus nigrum. Oct. 16, 1895. Natural size.



FIG. 426.—PAROVARIAN CYST, SHOWING ITS TRANSLUCENCY AND THE CHARACTERISTIC RELATIONS OF THE UTERINE TUBE, WHICH IS GREATLY LENGTHENED AND SPREAD OUT ON THE SURFACE OF THE CYST.

There is no mesosalpinx, and the fimbriated end is pulled out longer than the tube itself, and describes an arc sweeping around toward the uterine end of the tube. Note the double set of vessels, superficial and deep. The pedicle is at the area uncovered by peritoneum on the right upper surface. The slightly irregular surface seen on the outline just to the right of the pedicle is the ovary spread out on the surface of the tumor. July 31, 1895. $\frac{3}{4}$ natural size.

of the tumor are evidently thicker than those of a thin Graafian follicle cyst, a probable diagnosis may be made.

Parovarian Cysts.—A parovarian cyst is one originating in the tubular remains of the embryonic Wolffian body, in the layers of the mesosalpinx (see Vol. I, p. 61, Fig. 32), between the uterine tube and ovary; as the cyst continues to grow it either enlarges as a free tumor up into the abdominal cavity, or first down between the layers of the broad ligament and then up into the abdomen, or it may lie altogether behind the peritoneum.

The tubules of the parovarium are one millimeter in diameter or less, and are readily seen by holding the mesosalpinx up to the light while separating the tube from the ovary. Histologically, the tubules are surrounded by several layers of spindle cells, which appear to be non-striped muscular fibers, and they are lined by a single layer of cuboidal or low cylindrical epithelium which is often ciliated.

Parovarian cysts vary in size from a few millimeters to 20 or more centimeters in diameter. If small they may be multiple, but when large they are almost invariably single. These cysts are usually transparent, and are smooth and glistening. As the peritoneum is but loosely connected with the cyst wall by a delicate stroma, it can be readily slid over the surface of the tumor. This is due to the fact that the tubules are situated between the layers of the broad ligament and are but loosely covered by peritoneum. The blood vessels of the peritone-

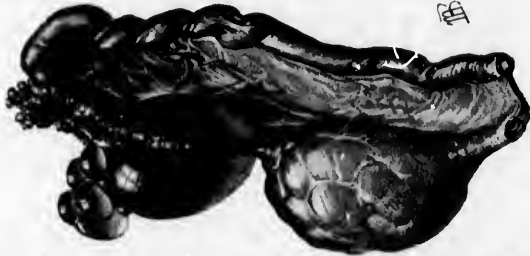


FIG. 427.—PAROVARIAN CYST, WITH SUBSIDIARY CYSTS LYING BENEATH THE TUBO-OVARIAN FIMBRIA, WEIGHING DOWN THE FIMBRIATED END OF THE TUBE AND SEPARATING IT FROM THE OVARY, WHICH IS SEEN ON THE RIGHT, UNDER THE ISTHMUS OF THE TUBE. JULY 3, 1895. NATURAL SIZE.

um have a direction differing from those of the tumor, so that the two well-defined vascular networks are seen crossing each other. The cyst walls are usually thin, and may contain calcareous plates; the inner surface is whitish or pinkish in color, smooth, and glistening; rarely papillary masses spring from the inner wall. The cyst fluid, poor in albumin, is pale and limpid like water, and its specific gravity varies from 1004 to 1006. In those cases, however, where there are papillary masses, or in which hemorrhage has taken place into the cyst, the specific gravity is higher and the color brown, blackish, or yellow. Orth says that he has almost invariably been able to find cilia at some point or other, whether the cyst is large or small. The tumors as they grow tend to separate the layers of the broad ligament more and more and to extend down to the pelvic floor, out toward the rectum or cecum, and up into the abdomen behind the peritoneum. The relations of the tube and the ovary to the cyst are characteristic. The tube is arched over the upper surface of the tumor, and may reach

40 or more centimeters in length. Its fimbriated extremity often adheres to the cyst, but becomes lengthened out and spread apart. The ovary is found as a small flattened prominence on the under or anterior surface of the cyst. It may, however, be included in the cyst walls. The tube and ovary, apart from the flattening, are histologically normal.

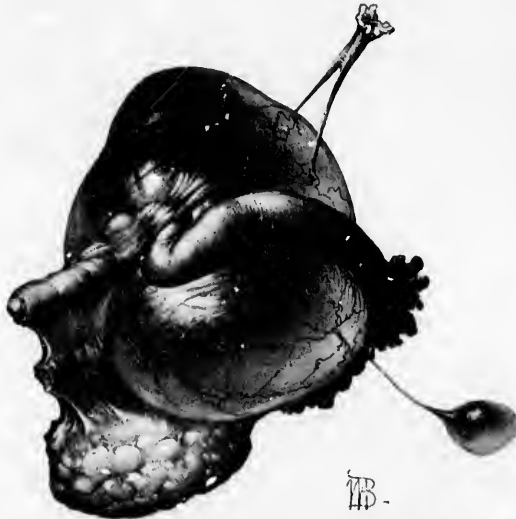

FIG. 428.—PAROVARIAN CYST BULGING OUT ON BOTH SIDES OF THE TUBE AND ATTACHED TO THE ISTHMUS BY BANDS OF ADHESIONS.

The tubo-ovarian fimbria is splinted over the surface of the cyst, and on its upper surface stands out an accessory tube with two pedicles. The hydralid is well shown, and the ovary lies intact beneath the tumor. March 16, 1895. Natural size.

Out of one hundred and fifty cases of cystic tumors of the ovary of all kinds in my own clinic, thirty (20 per cent), including all broad ligament cysts, were parovarian. The average age was thirty-nine years, the two oldest women being seventy-five and seventy-three, and the youngest eighteen. The majority were about thirty-five. The average number of children to the married women was 3.5.

The commonest place for the occurrence of parovarian cysts is under the outer extremity of the tube, separating

the fimbriated end from the ovary as the tumor increases in size, and thus acting as an efficient cause of sterility.

In one case (P. T., No. 604, March 14, 1891) there were two cysts, $2\frac{1}{2}$ centimeters in diameter, in front of the tubo-ovarian fimbria, and a third, 3 centimeters in diameter, at the uterine end of the tube.

These small cysts are almost always sessile and situated plainly between the folds of the broad ligament. In one case, however (L. W., 1171, Jan. 27, 1892), the tumor, about 3 centimeters in diameter, had a pedicle 1.5 centimeter long under the fimbriated end.

The utero-ovarian ligament and the uterine end of the tube are never widely separated, although the tube itself may be lengthened out, in one case 43 centimeters (17.2 inches). It always describes a curved course circling around toward the ovary, which can be found on the surface of the tumor close to the pedicle by means of this ligament. The fact that the parovarian cyst is most likely to spring from the outer part of the parovarium can be shown, even in a large tumor, by lifting up the uterine end of the tube, and exposing this part of

the mesosalpinx, when a part of the parovarium can be seen in it. The simple pediculated parovarian cyst develops from its point of origin up into the abdomen without spreading apart the layers of the broad ligament. The tumor is slow in attaining a large size, and is usually more floccid than the ovarian monoeysts.

The pedicle may be several centimeters long and occupy the breadth of the broad ligament. The ovary is found in the under surface near the uterine end of the tube. Sometimes there is no pedicle, but the tube and the mesosalpinx lie flat on the surface of the cyst, and the ovary near by. The cyst takes often a somewhat cylindrical form, giving the abdomen the appearance of ascites.

A long pedicle may undergo torsion, as in the case of other ovarian tumors. A remarkable instance of torsion of the pedicle, involving the tube and producing a hemorrhagic infarct of both tube and cyst, is shown in Fig. 431.

The most prominent symptoms in my cases necessitating operation were the size of the tumor, and pain in all but three cases, described as dull and bearing down, or paroxysmal and sharp. Adhesions were found in all but four cases.

The diagnosis may often be made by recalling

the fact that the tumor is one of slow growth, has a smooth surface presenting no bosses or evidence of secondary cysts, is apt to be floccid in contrast to the tense ovarian cyst, and when large is symmetrically disposed in the abdomen, which is more flattened or cylindrical than in the case of a tense globular ovarian cyst. The percussion wave is less sharp than in a tensely filled sac, and conveys the impression of a single sac with thin walls.

On opening the abdomen the clear monoeystic accumulation of serum due to an encysted peritonitis must not be mistaken for parovarian or other cysts. These tumors are oftenest found in cases of extensive pelvic peritonitis. An unusually large bleb of this sort is figured in the text (see Fig. 432).

Hydatid of Morgagni (*Appendix sientaris*, Kossmann).—I have seen a variety of interesting affections of the little pediculated vesicular organ which hangs from the anterior surface of the broad ligament at the end of the longitudinal canal of the parovarium, and is sometimes known as the hydatid of Morgagni (see Fig. 428). In no case, however, have I observed any

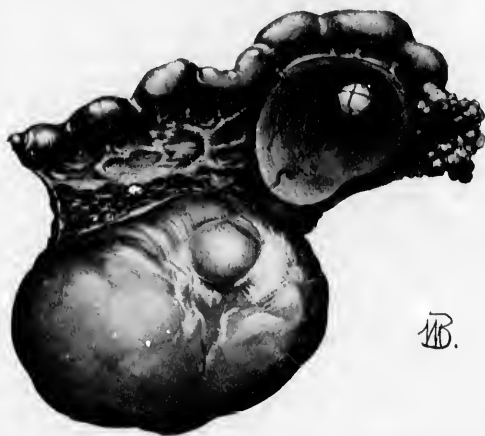


FIG. 429.—CYST OF THE PAROVARIIUM SEPARATING THE AMPULLAR END OF THE TUBE FROM THE OVARY. APRIL 6, 1895. NATURAL SIZE.

condition which could interfere with health. The little organ in question, sometimes oval, sometimes spherical, is about 8 millimeters in diameter; at other times it looks like two vesicles fused together with a slight constriction between them, in which lie the vessels and some of the tissue of the pedicle. The length of the pedicle varies from nothing at all, when the vesicle is sessile on the broad ligament, to one 10 or 12 centimeters long; the average length is about 3 centimeters, when the pedicle is about 2 millimeters in thickness and expanded at the base. The long pedicles are often almost threadlike. The



FIG. 430.—PAROVARIAN CYST.

Showing the mesosalpinx spread out on both sides of the tumor, which is developed more in its outer part, widely separating the tubal ostium from the ovary. The hydatid is seen above. The pedicle lies above the isthmal end of the tube. Path. No. 240. $\frac{2}{3}$ natural size.

little vessels can always be seen ascending the pedicle and distributed over the pellucid surface of the diminutive cyst. When the pedicle is long enough it will often be found hanging over the tubo-ovarian fimbria, between the tubal orifice and the ovary, into the posterior part of the pelvis; this tendency explains the following affection, which I have seen twice: The fimbriated end of the tube has adhered to the tubo-ovarian fimbria, except at a point close up under the tubal orifice, where the pedicle of the hydatid passed under it; by pulling on this pedicle it could be drawn to and fro for a distance of about a centimeter, exhibiting a movement resembling the trochlear muscle of the eye, but, owing to a loose investment of adhesions, it could not be moved beyond this distance; the vesicle hung free on the other side.

I have several times found the pedicle tied in a single knot about its middle without interfering with the circulation.

In one interesting case, an ovarian cyst, figured in the text (Figs. 433 and 434), what was undoubtedly the pedicle of the hydatid was found tied around one of the fimbriae of the uterine tube; the fimbria presented a dead white appearance, there were a few adhesions around the pedicle at the point of constriction, and the hydatid vesicle itself was wanting (Fig. 434). I made a careful drawing of the knot about the fimbria enlarged under a low power, but when the specimen reached the laboratory the knot had pulled out and there remained only a loop with adhesions. I explain the condition found in the following way: A loose knot was formed in the pedicle of the vesicle, which probably hung over the back of the broad ligament; then one of the fimbriae slipped in, was caught in the tie and strangulated, and the vesicle and distal portion of the pedicle, also strangulated, dropped off, leaving the knot fixed by a little adhesive peritonitis, as I found it.

In one case there was a hemorrhagic infarct of the large left hydatid, due to a pedicle several times twisted and almost severed.

In another instance the long pediculated left hydatid was adherent to the sigmoid flexure above the pelvic brim, forming a large loop like a long band of lymph.

Fibroid Tumors of the Ovary.—These are among the rarest of the pelvic tumors, and are characterized by a multiplication of the connective-tissue elements of the ovary at the expense of all the other histological constituents. The entire organ is usually involved, becoming converted into a "fibroid ovary," which may rarely contain degeneration cysts, dilated blood spaces, and lymph spaces.

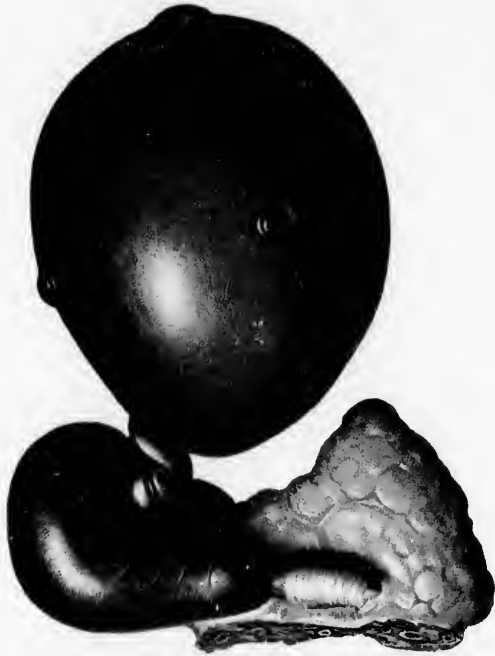

FIG. 431.—PAROVARIAN CYST WITH TWISTED PEDICLE, WITH HEMORRHAGIC INFARCTION OF THE UTERINE TUBE.

The ovary is intact, together with a small portion of the uterine end of the tube. Gyn. No. 1659. Natural size.

The tumor is densely hard, often almost bony in consistence, pinkish or white in color, covered with smooth peritoneum, but divided into lobes by deep and shallow furrows. The fibrous growth is never disposed like a uterine fibroid in a bed from which it can be shelled out; the connection with the ovarian stroma is direct and shows no line of demarcation.

Calcification of fibroid tumors of the ovary occurs in rare instances, forming masses usually small in volume, consisting of the phosphates and carbonates of calcium. The largest mass I have seen was shown to me by Dr. Copeland in Milwaukee, who at my request sent it to Baltimore, where it was carefully examined and described by Dr. J. W. Williams in a valuable monograph

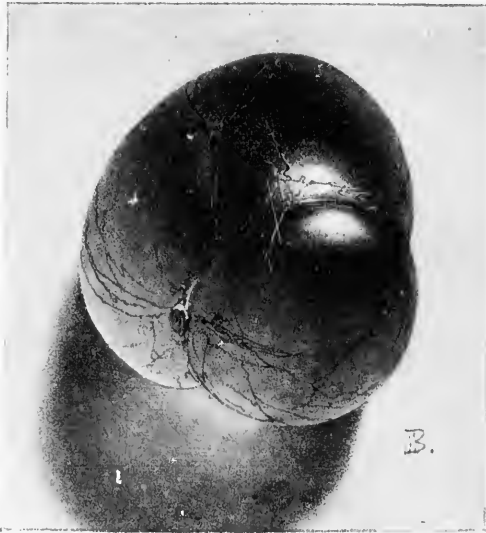

FIG. 432.—SUBPERITONEAL CYST DEVELOPED ENTIRELY FROM THE PERITONEUM.

A type of cyst frequently met with in pelvic inflammatory cases. Natural size.

upon this subject (see *Trans. of the Amer. Gyn. Soc.*, vol. xviii, 1893). The tumor of the right ovary was $7 \times 6 \times 5$ centimeters in diameter, weighed 220 grams, and was like ivory in consistence. I have also seen a calcified corpus luteum in the ovary of an old negress on the dissecting table; the little mass imbedded in the ovary was spherical, white, about 1 centimeter in diameter, covered with little short spicules, and when the shell, about 1 millimeter thick, was broken, the interior was found smooth and filled with a watery fluid.

The specimen figured in the text, given me by Dr. G. S. Peck, of Youngstown, Ohio, is an almond-shaped ovarian "calculus," partly enveloped in a thin fibrous capsule, which microscopically consists of fibrillated tissue poor in nuclei

and containing calcareous particles scattered through it. The stone itself is made up of chalklike material, which Dr. Aldrich upon analysis found to contain a

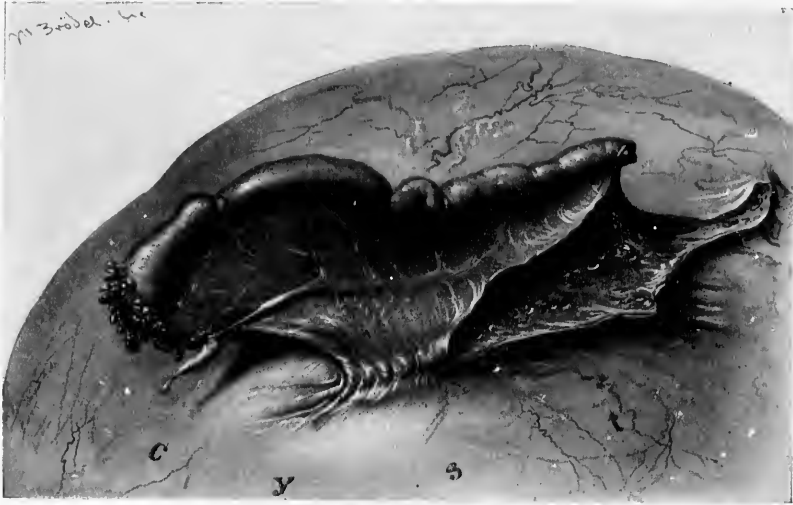

FIG. 433.—THE PEDICLE OF THE HYDATID (APPENDIX VESICULARIS, KOSSMANN) TIED ABOUT THE FREE TUBAL FIMBRIA AT ITS BASE, CLOSE TO THE TUBO-OVARIAN FOLD.

The white thickened fimbria is in marked contrast to the normal red folds above. McGovern, Aug. 23, 1897. Natural size.

large amount of calcium phosphate, with traces of the oxalate and carbonate of calcium, together with traces of magnesium phosphate and organic matter.

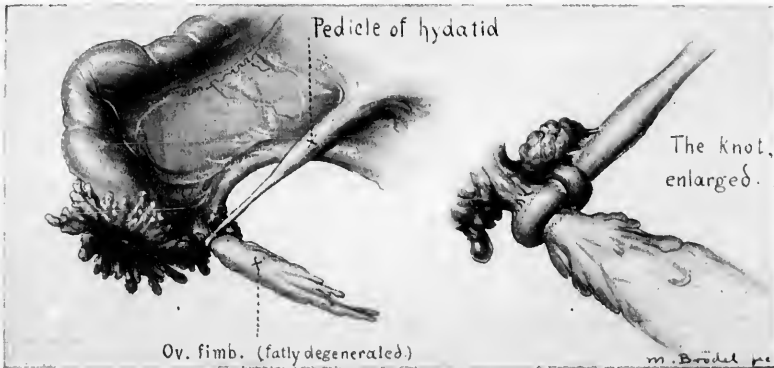

FIG. 434.—SHOWING THE PEDICLE OF THE HYDATID TIED AROUND THE FIMBRIA, ENLARGED; SHOWING ALSO THE APPEARANCE OF THE WHITE FATTY DEGENERATED FIMBRIA.

The right-hand figure shows the adhesion to the pedicle and the knot. Aug. 23, 1897.

The entire ovary is usually involved, and the large tumor preserves the form of a coarse hypertrophy of the ovary.

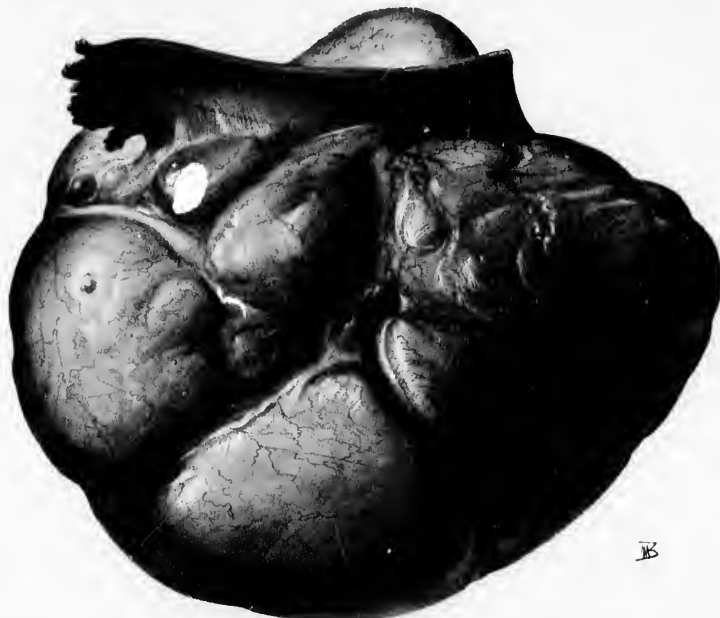


FIG. 435.—FIBROID TUMOR OF THE OVARY.

Showing the coarse enlargement of the ovary, with numerous sulci and vessels coursing over the surface from the hilum. The uterine tube and mesosalpinx are seen above. No. 261. $\frac{2}{5}$ natural size.

Microscopically, ovarian fibroids appear to be made up of a mass of connective tissue with but few muscular bundles and few blood vessels. The fibers have no regular or concentric arrangement, but are interwoven with each other in every direction.

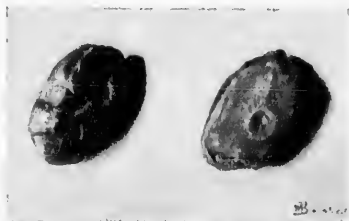

FIG. 436.—CALCULUS OF THE OVARY, SEEN ON ITS TWO SURFACES. CASE OF DR. G. S. PECK. PATH. NO. 1790. NATURAL SIZE.

In twelve hundred abdominal sections I have seen four cases—one in a girl of twenty-two, one in a woman of forty-two, another in a woman of unknown age, and the last in a patient fifty-nine years old.

Loehlein found fibroid ovaries seven times in 172 cases of ovarian tumor; twice they were bilateral.

Ascites is usually present and forms one of the most marked characteristics of the growth, except when it is small; it was present in all of my cases except one, where the tumor was only as large as a walnut.

There is usually no pain referable to the tumor itself, although when large it may make painful pressure on the surrounding parts.

The growth of the tumor is slow, extending over years, and is usually confined to one side; the average size is that of one or two fists. Dr. A. Schachner, of Louisville, operated upon one weighing fourteen pounds, in a colored woman thirty-five years old (*Amer. Jour. Obs.*, vol. xxix, p. 377).

The patient usually applies for relief either because she has discovered a lump in the abdomen which has roused her fears, or because she is burdened by the ascites.

A diagnosis is established by demonstrating the presence of a hard tumor in the pelvis, attached to the broad ligament and accompanied by ascites, without evidence of cachexia.

The small tumor figured in the text (G. Y., San. 211, May 21, 1897) was a fibroid of the ovary, of almost chalky whiteness, with a few fine vessels on its

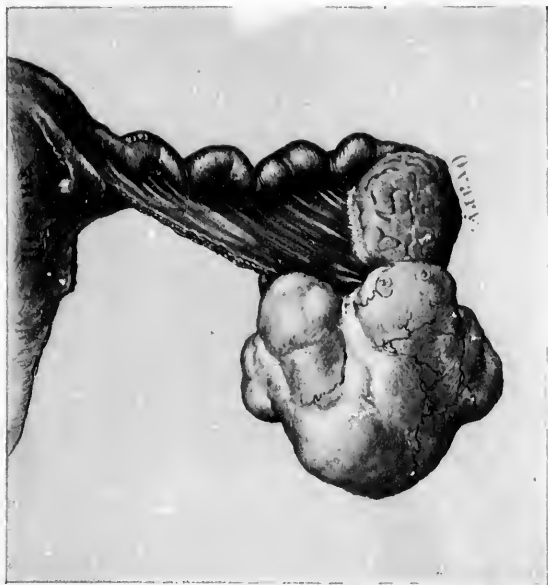


FIG. 437.—PARTIALLY CALCIFIED FIBROMA OF THE RIGHT OVARY.

The tumor springs from the inner border and is chalky white and dense, with a few vessels distributed on the surface. There is a small fibroma of the utero-ovarian ligament which is detached from the ovary. Viewed from behind. Natural size.

surface, and subpyramidal in form; it sprang from the outer end of the ovary, and was associated with a little pediculated fibroid of the utero-ovarian ligament, a small subserous uterine fibroid, and pelvic inflammatory disease. Uterus, tubes, and ovaries were removed by an abdominal incision, and the patient recovered.

Sarcoma of the Ovary.—The sarcomata are among the rarest of all the ovarian tumors; the diagnosis "sarcoma" is often made upon a purely clinical basis when a microscopic examination would show that a majority of these tumors were fibromata.

The sarcomata consist of cells closely resembling the embryonic connective tissue and are subdivided into a number of varieties according to the special character of the cell; we have in this way sarcomata which are round-celled, spindle-celled, and giant-celled. Further varieties are the angio-sarcomata, adeno-sarcomata, and carcino-sarcomata. They are also either cystic or solid.

The gross appearance of a sarcomatous ovary, like a fibroma, may resemble a coarse hypertrophy of the normal organ, which is ovoid, often flattened and lobulated. The surface is usually smooth, whitish, bluish, or flesh-colored,



FIG. 438.—ANGIO-SARCOMA OF THE LEFT OVARY WITH METASTASIS INTO THE UTERUS.

The ovarian tumor on the left side is intimately adherent to the uterus, and made up of fibers running parallel to each other. The uterus is thrice enlarged, and its walls twice the normal thickness and studded with irregular lobulated and round masses, standing out prominently and of a waxy appearance. Portions of the unaffected right ovary and tube can be seen to the right of the uterus. July 7, 1894. Path. No. 372. $\frac{1}{2}$ natural size.

often traversed by large veins, and adherent to all the surrounding structures. The softer tumors tend to break up and bleed freely on handling. On section, the more solid tumors appear white or pink or yellow from fatty degeneration; hemorrhagic areas are also often seen. The softer tumors have a brainlike appearance and feel elastic or springy, and small cyst cavities are often found. In the case of a child twelve years old the brainlike solid elements lay at the hilum, and the capsule of the ovary was lifted up from this by an accumulation of fluid which escaped into the abdominal cavity by a small opening.

Microscopically, the spindle cells are found arranged in irregular bundles extending in every direction.

In the angio-sarcomata the cells are arranged concentrically around the thin-walled blood vessels.

Clinical Characteristics.—Sarcomata of the ovary, like sarcomata of other organs, are most frequently found in early life. J. Bland Sutton has collected twenty cases occurring in children fifteen years of age and younger; the youngest case that I have seen personally I have just referred to; it was a cysto-sarcoma in a girl of twelve, who died of a recurrence about a year after operation.

Out of one hundred ovarian tumors in women over seventy there was one sarcoma.

In a collection of thirty-seven cases made by Olshausen, five were under twenty, nine were between twenty and thirty, eighteen were between thirty and forty, and four between fifty-eight and sixty-seven years. In the younger patients the round-celled form predominates, while the spindle-celled becomes commoner with advancing age.

The tumor is chiefly characterized by its rapidity of growth, and often by the presence of an ascites.

A cystic sarcoma may be so soft that it ruptures under a moderate degree of pressure made in the examination. In one of my cases an extensive hemorrhage took place from such a rupture, and the patient, who was rapidly bleeding to death, barely escaped with her life by a prompt operation and saline infusion under the breasts. (Mrs. C., Dec. 4, 1897.)

Metastases are distributed through the veins and are found in the stomach, peritoneum, pleura, and intestines, while the tumor spreads rapidly by continuity and contiguity of tissue, until the broad ligament, the uterus, and the surrounding parts are infiltrated. Metastases are commonest in the adeno-sarcomata, and least frequent in the spindle-celled form. Death occurs from exhaustion.

The case figured in the text (L. R., 2894, Fig. 438) is an angio-sarcoma of the left ovary, operated upon by me July 7, 1894; the patient was forty-eight years old and the mother of two children. For six months she had suffered from a grinding pain in the left ovarian region, and for the same length of time she noticed a mass growing in the lower abdomen. I found the abdomen much enlarged by a firm bilobate mass and the superficial veins distended. The uterus appeared to be continuous with the mass on its left side.

At the operation the tumor was found so adherent to the pelvic peritoneum that it could not be completely detached, but tore out in peculiar parallel fibers. In order to complete the operation and check the hemorrhage it was necessary to remove the mass with the uterus which was amputated in the cervical portion.

The greatly enlarged uterus was invaded by continuity, and apparently by metastases forming globular, polypoid, and fingerlike masses of a raw-beef color. The ovary formed a reniform mass 16 by 10.5 centimeters (6.4 by 4.2 inches),

adherent on its concave side to the uterus; it was made up of a series of light red and pale fibers looking like muscular tissue; in the center of each fiber, running parallel with it, a blood vessel was found with an inner lining of endothelium, and in places a delicate muscular coat, immediately surrounding which were eight to ten layers of spindle cells parallel to the vessel; in less vascular parts of the tumor the cells did not show any definite arrangement. The surface of the uterine mucosa was intact but atrophic. The patient recovered from the operation and died some months later of a continuance of the growth, which was not entirely extirpated.

Treatment of Ovarian Tumors.—The proper treatment of ovarian tumors is by extirpation as soon after the discovery of the tumor as the physical condition of the patient will permit.

The reason for an early interference with ovarian growths is the impossibility of deciding with certainty that the tumor is not malignant, and still so limited in its extent that it may be successfully removed.

I recall in this connection the case of a healthy active young woman with a little ovarian tumor on the left side not as large as a lemon; she was so well and had such a horror of surgery that I was influenced by her friends to say nothing to her about the tumor, under the proviso that she would remain under observation. When I saw her a year later the pelvis was choked by papillomatous tumors, and with an implantation upon the peritoneum beyond the reach of surgery, and in a few weeks she died.

An apparently harmless cyst may rupture at any moment, and so disseminate the seeds of a carcinoma or papilloma over the peritoneum. By waiting, the further risk is incurred of torsion of the pedicle with hemorrhage, either fatal or so great as to compel an immediate operation under unfavorable circumstances.

With delay, also, inflammatory changes may supervene, adhesions may form, and the cyst itself may suppurate, and an operation, which would have been short and simple at first, is transformed into a protracted one embarrassed by numerous complications. Furthermore, with delay comes exhaustion, interference with the excretory functions of the bowel and bladder, the risks of hydroureter from pressure, and embarrassed digestion, respiration, and circulation.

We must add to these reasons also the mental anxiety of the patient who harbors a tumor, as well as the physical discomforts which must continually increase until the tumor is removed.

All of these cogent reasons for performing the operation at an early date, together with the removal of the great reason for postponement, a high percentage of mortality, justify the present attitude of abdominal surgeons in insisting that there shall be no undue delay when once the diagnosis is clearly established.

The reasons which induced the patients to seek relief was the mere presence of a tumor in forty-four cases, the increasing size of the abdomen in twenty-seven cases, pain in twelve cases, edema, dyspnea, and tachycardia in four cases, and in one case exhaustion and weakness.

Contra-indications to Operation.—The age of the patient does not, as one would suppose, contribute any valid reason for refusing to operate, for out of one hundred women who were over seventy years of age, operated upon by fifty-nine different surgeons, many of them in the early evolutionary years of aseptic surgery, only twelve died. (See *Ovariectomy in the Aged*, by H. A. Kelly and Mary Sberwood. *Johns Hopk. Hosp. Rep.*, vol. iii, p. 509.)

It is important also to note that the number of malignant cases which tend to affect the permanency of the result in this group was surprisingly small.

The classification was as follows:

Nature of Tumor.	No. of Cases.
Multilocular cyst.....	60
Unilocular cyst.....	12
"Cyst".....	7
"Tumor".....	9
Parovarian cyst.....	3
Dermoid cyst.....	2
Taberulous.....	1
Sarcoma.....	1
Fibroid.....	2
Papilloma.....	3
Total.....	100

Remarkably favorable also are the results even in women over eighty years of age, as shown by the collection of eleven cases made by T. B. Sutton (*Surg. Dis. of the Ovaries*, etc., new ed., 1896, p. 175); in the hands of ten operators, every case recovered.

There is also no reason for deferring operation in young children, but rather many cogent reasons for removing the tumor as soon as practicable—in the rapidity of growth, the smaller space and tense walls, and the increased liability to malignancy (sarcoma).

Out of 100 cases in girls fifteen years of age and under, collected by Sutton, in the hands of almost as many different operators, there were 41 simple cysts and adenomata, with 3 deaths; 38 dermoids, with 5 deaths; 21 sarcomata, with 7 deaths.

There is a notable difference in the proportions between the various kinds of tumors in this table and that of the old women, the sarcomata in the children forming nearly 20 per cent of the whole, while but one case of sarcoma is recorded in old women; in the children, too, there is a relative frequency of dermoid tumors, 38 to 100, while in the aged the ratio is but 2 to 100. The increased mortality in youth is due to the sarcomata.

The good or the ill condition of the patient naturally militates for or against the operation, and where the patient is much reduced or is afflicted with any chronic disease of the vital organs, her chances of recovery are not so good; the increased danger, however, will never prevent a conscientious operator from taking necessary risks, on account of a desire to protect his statistical tables.

By assiduous attention, with rest in bed and regulation of the emunctories, a patient whose vital resources seem at first sight depressed below the safety line may often be lifted up above it, and so pass through her operation. Heart disease, except in its advanced form, is a serious disadvantage only in protracted, severe operations, and a slight albuminuria and casts often clear up at once after taking away the tumor.

An uncertain diagnosis too often acts to deter the surgeon from performing an operation, especially where ascites and hard masses are felt in the pelvis or in the abdomen; it is in just this class of cases in which an inexperienced operator often errs and in which the most experienced may occasionally make a wrong diagnosis. All doubtful cases should at least be given the benefit of an exploratory incision, when in some cases the disease will prove not to be carcinoma or papilloma, but tuberculous, and some malignant cases will be found capable of relief by complete extirpation of the growth.

A marked advantage will also be gained in cases in which the disease is not eradicable by taking out the mother tumor whenever this is possible, relieving the pressure of the ascites, and checking the rapidity of the growth. Complete and permanent recoveries from papilloma already distributed over the peritoneum have been noted under these circumstances.

I think there is scarcely an operator of experience who has not been surprised in these ways a number of times.

I have dwelt elsewhere upon the minute preliminary investigation of the patient's physical condition and those general preparations for operation which are so important in securing a good result, and so need not repeat them here (see Chapter XX).

Tapping an ovarian cyst is no longer a justifiable operation, either as a curative measure or to give relief so as to be able to postpone the operation.

It is true that in rare instances a parovarian cyst has not refilled after tapping, but no amount of diagnostic precision can ever assure the operator that in any particular instance the tumor does not contain papillary elements which may soon after become disseminated over the peritoneum, and in tapping tumors of other kinds these risks are still more increased, and associated with them are also the risks of wounding a large blood vessel in the sac wall or of letting out a quantity of its irritating contents to excite a violent peritonitis and add enormously to the difficulties of the subsequent operation.

There is but one class of cases in which I would ever use the trocar to reduce the size of the tumor before operation, and that is where there is an enormous tumor with widely spreading ribs and great dyspnea. A great advantage is gained here if the abdomen can be so far reduced in size, two or three days before the operation, as to allow the respiratory apparatus and the circulation to readjust themselves, to some extent, to the new conditions.

The aseptic technique which controls every part of the operation is fully described in Chapter XX on the general principles common to abdominal operations.

The various operations may be considered under the following heads:

1. A median abdominal incision exposing the tumor.
2. Evacuation and withdrawal of the cyst.
3. Liberation of all adhesions.
4. Ligation of the pedicle.
5. Intraligamentary cysts.
6. Examination of the opposite ovary.
7. Cleansing the peritoneum if it has been soiled by fluid or blood.
8. Closure of the incision.

The patient is put upon a table arranged for the elevation of the pelvis, and, if the tumor is a prominent one, the table is raised but slightly or not at all until the cyst is evacuated of its contents, when it is elevated just enough to cause the small intestines to gravitate up above the upper angle of the incision.

A small median incision is first made, opening the abdomen, at a point a little higher up than in operations for diseases limited to the pelvic cavity, but not quite so high as in the case of large myomatous uteri. Care must be taken, in picking up and cutting the peritoneum, not to cut into the tumor lying in contact with it.

Evacuation of the Cyst.—A point is selected opposite to the incision which is free from large vessels, and while the assistant makes a gentle pressure, keeping the abdominal walls applied to the cyst wall on both sides of the incision, the operator plunges a small knife into the cyst, avoiding vessels, and, instantly withdrawing it, stops the opening with a finger before any of the contents have had time to escape. He then takes up a large glass trocar, armed with a stiff rubber hose, and pushes it through the opening into the cyst, and so discharges its contents. As soon as enough fluid has escaped to make the cyst wall flaccid, it is caught with forceps on both sides and, if there are no adhesions, drawn out of the incision over to one side, and the patient is turned over a little so as to facilitate the free flow of the fluid without risking contaminating the peritoneum. As the cyst goes on collapsing it is caught by successive pairs of forceps and drawn farther and farther out until the whole of it is delivered and the pedicle lies in the incision.

In the case of an ovarian monoecyst or a parovarian cyst, this may often be done without once even exposing the intestines to view.

The operator should carefully avoid soiling his hands with any of the contents of the sac, and the abdominal wall should be wiped off and the tumor covered with gauze while the pedicle is being ligated.

A monoecystic ovary or an ovary with two larger cysts and a number of small ones grouped about the pedicle may be easily delivered in this way through a small incision, but when the tumor contains a thick pseudomucinous secretion which will not run, and when it is made up of a conglomeration of small cysts which can not be emptied in this way, it will be necessary to insert two fingers to lift up the abdominal wall and then to slit it up and down until the opening is large enough to let the tumor out entire by its small diameter.

In the case of a generally adherent suppurating cyst, after making the evacuation as thorough as possible, the edges of the puncture opening should be closed by forceps, and as fast as the tumor is delivered it should be wrapped in folds of gauze to limit the contamination from its contents as much as possible. Fortunately in these cases the micro-organisms are rarely active, otherwise the mortality would be much higher after operation, as some contamination of the peritoneum is often unavoidable.

A parovarian cyst never has the pearly white wall of an ovarian tumor, and may also be distinguished at sight by the two layers of blood vessels crossing each other, one in the peritoneum and one beneath it in the cyst wall proper; the peritoneum is also movable over the cyst.

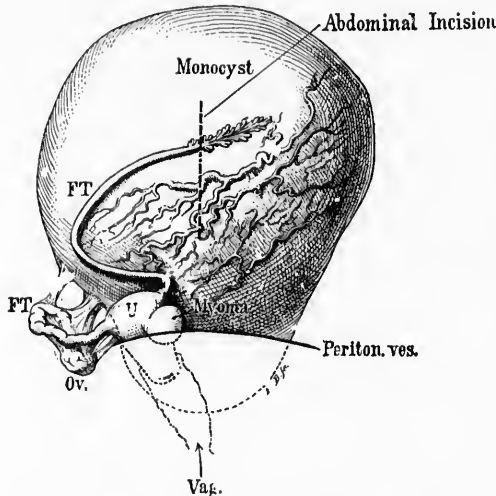


FIG. 439.—MONOCYSTIC TUMOR OF THE LEFT BROAD LIGAMENT.

Showing the tube displaced and spread out on the anterior surface of the tumor, as well as the greatly dilated vessels of the mesosalpinx below the tube. There is also a myoma in the anterior uterine wall, and adhesions to the opposite tube and ovary. The dotted line shows the part of the tumor opposite the abdominal incision. $\frac{1}{4}$ natural size.

as to work rapidly with the utmost freedom, and to wrap the tumor up, as soon as it can be grasped, in abundant gauze, and so handle it in this way.

A soft sarcoma or a papilloma will often begin to break down and bleed frightfully as soon as it is grasped with a view to enucleation. It is useless in such a case to waste valuable time trying to control the bleeding vessels in the friable tissue. The only safe plan is to control at once the main vessels going to the tumor by applying artery forceps to the broad ligament at the pelvic brim, so as to enter the ovarian vessels, and one or two pairs at the uterine cornu to catch the uterine vessels.

In order to get at the broad ligament in this way it may sometimes be neces-

When the tub. and the mesosalpinx are spread out over such a cyst, the mesosalpinx with its large vessels often lies directly under the incision, and it is well in such a case to try to rotate the tumor a little or to draw the incision to one side, or to puncture higher up, so as to avoid injuring these vessels. When the abdomen is filled with an ascites this can usually be recognized just before the peritoneum is opened by its dark, almost black, color.

If the tumor is malignant, a papilloma, a soft sarcoma, or a carcinoma, it is best to make a long incision, so

sary under these circumstances to drag the tumor out boldly by handfuls in the face of an active hemorrhage. In such a case the immediate risk to life overbalances any remoter consideration, such as the contamination of the peritoneum with the tumor elements. After an evacuation of this kind the abdomen must be most carefully washed out and the broad ligament in the bite of the forceps cleansed, lest any bit of the tumor be left behind.

Liberation of Adhesions.—The various ways of dealing with adhesions are similar to those in other affections, and are fully dealt with in the

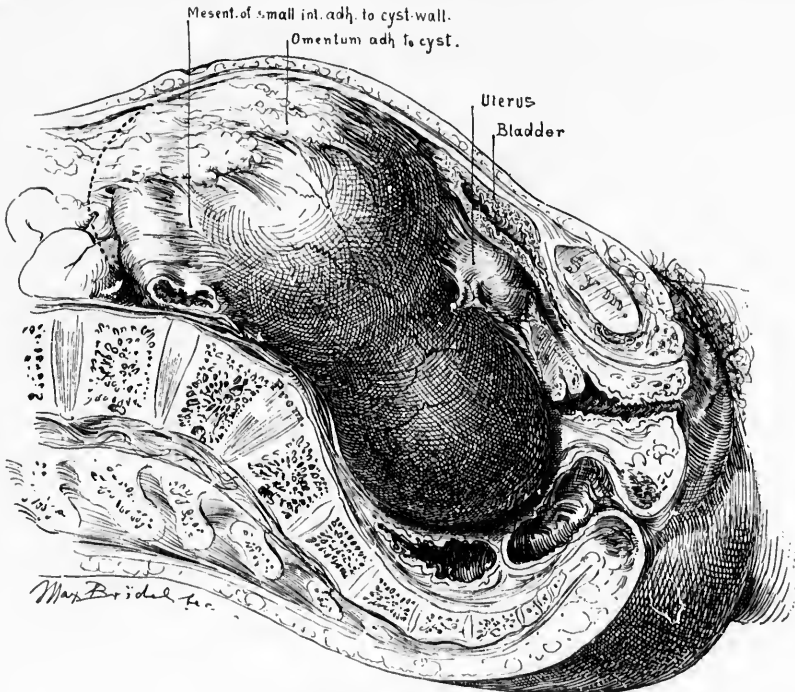


FIG. 440.—SUPPURATING ADHERENT OVARIAN CYST.

Showing extensive attachments to the uterus, bladder, omentum, small intestine, and mesentery. The bladder and the uterus are pulled high up out of the pelvis. Jan. 20, 1897.

chapter on Complications Common to Abdominal Operations. I will here only insist upon a few peculiarities connected with this group of tumors. The adhesions to the abdominal wall which sometimes take in the whole anterior parietes must be detached with deliberate care to avoid dissecting off the peritoneum with the ovarian sac. Such a faulty dissection is usually begun at the incision by starting in the wrong plane of tissues, and it may then be continued onward until, as I have seen done, nearly the whole anterior parietal peritoneum is de-

tached from its cellular base. All ordinary adhesions can usually be separated by pushing the hand with open fingers in between the sac wall and the peritoneum, and opening and closing the fingers with a shearing motion. Any particularly dense adhesions are best dealt with by leaving a portion of the outer fibrous layer of the sac adhering to the abdominal wall. Omental adhesions, if extensive and dense, may be treated by sacrificing the entire omentum up to the transverse colon.

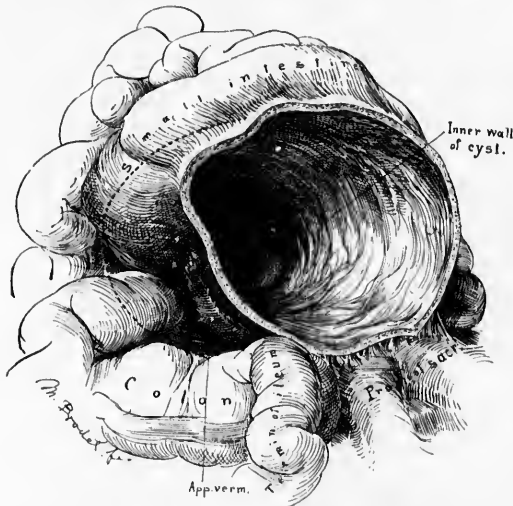


FIG. 441.—SUPPURATING ADHERENT OVIARTIAN CYST.

Showing the relations of that part of the cyst wall which is intimately attached to the small intestine and the mesentery. Jan. 20, 1897.

from the rest and leaving it adherent to the bowel as a protection from the injury which would otherwise be inevitably inflicted in attempting a complete detachment of the entire tumor. This principle may be carried out whether the adhesion is small or large, and is of most avail in enucleating densely suppurating ovarian cysts.

Such a case (E. B. L., 4946, Jan. 20, 1897), extremely complicated, is figured in the text, where a suppurating ovarian cyst filled the pelvis and the lower abdomen and was universally adherent; the ilium from the ileo-cecal valve across to the left side was flattened out over the top of the tumor, which also adhered to its mesentery and over the vertebral column and the great abdominal vessels. A complete separation could not be effected here without resecting the ilium; the complication was met by leaving a cap, consisting of the outer fibrous coat of the tumor, adhering to this entire area. The recovery was uneventful.

Ligation of the Pedicle.—Gauze is placed under and around the pedicle while it is held up, and two or three or more fine silk ligatures are passed

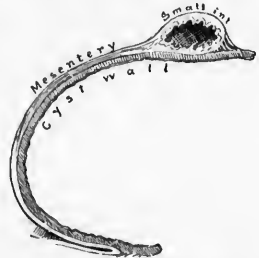


FIG. 442.—CROSS-SECTION OF THE INTESTINAL AND MESENTERIC ATTACHMENT.

Showing the two layers in the cyst wall; the inner layer was stripped off, leaving the outer. Jan. 20, 1897.

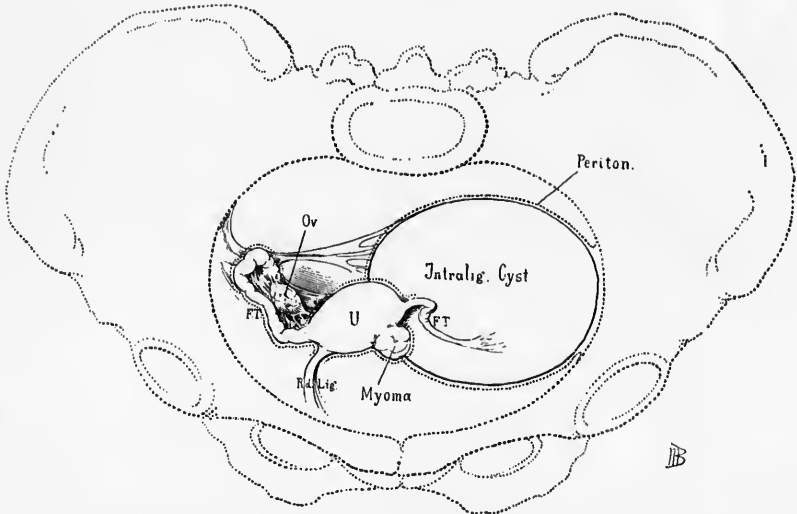


FIG. 443.—DIAGRAM FROM A CASE OF INTRALIGAMENTARY CYST, SEEN FROM ABOVE.

Showing the relations of the separated peritoneal layers of the left broad ligament to the cyst, and the uterine tube (FT) spread out on its surface. The right ovary and tube are adherent, the tube is attached to the cyst. Jan. 5, 1894.

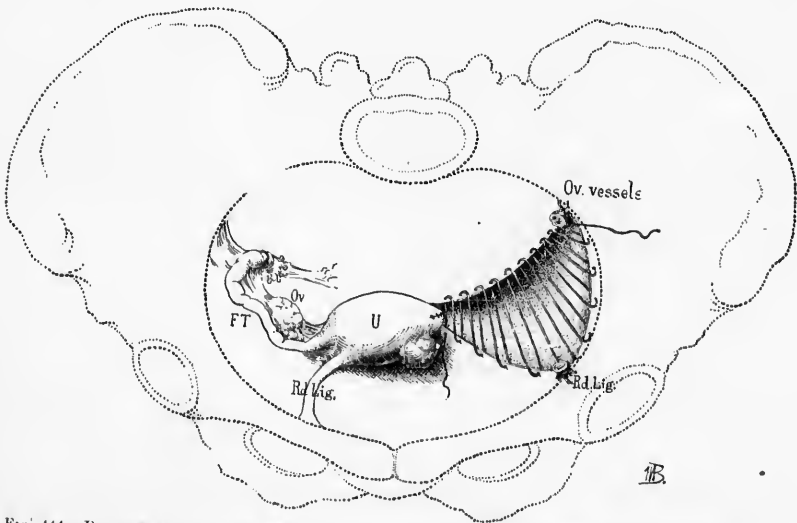


FIG. 444.—DIAGRAM SHOWING THE MANNER OF CLOSING UP THE DEFICIT LEFT BY THE ENCAPSULATION OF AN INTRALIGAMENTARY CYST BY A CONTINUOUS CATGUT SUTURE FROM PELVIC WALL TO UTERINE CORN. Jan. 5, 1894.

through the clear spaces so as to include the vessels which are usually grouped at either border. These should be placed well off from the tumor so as to allow plenty of room to cut the tumor away without shaving it too closely. The utero-ovarian ligament should be ligated separately.

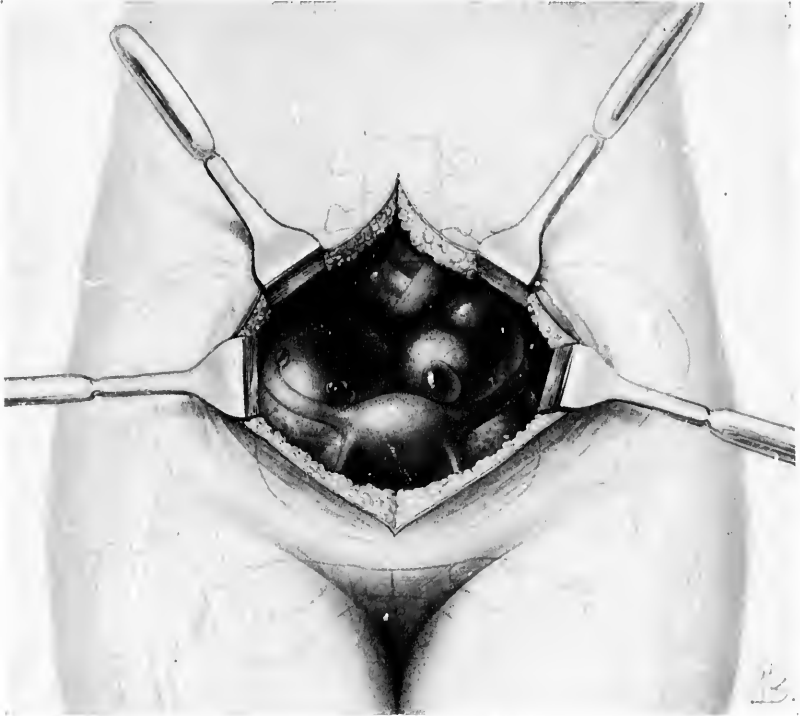

FIG. 445.—INTRALIGAMENTARY GRAAFIAN FOLLICLE CYSTS, SEEN IN SITU. NOV. 24, 1894.

In a young woman it is not necessary to remove the uterine tube unless it is spread out over the surface of the tumor. It is a good plan to burn the pedicle off with a thermo-cautery so as to avoid leaving a raw space behind; the burnt pedicle is much less liable to contract post-operative adhesions with the contiguous structures.

Dr. Skene, of Brooklyn, has devised an electro-cautery which mummifies the stump so that hemorrhage can not take place, and there is no need of using a ligature.

Intraligamentary Cysts.—When the ovarian tumor grows partly free into the abdominal cavity and partly down between the layers of the broad ligament, there is no real pedicle, but the separation may often be easily effected, after ligating the vessels on the side of the pelvic brim and on the uterine side,

by splitting the peritoneum on a line at a level with the pelvic brim and then simply drawing or shelling the tumor out of the loose cellular attachments which still hold it in the pelvis. These investing tissues are, as a rule, not vascular, and ligatures may be generally dispensed with. The top of the broad ligament is then closed in by a continuous catgut suture (see Figs. 443 and 444).

When the entire mass lies beneath the peritoneum the enucleation is more difficult and the difficulties increase in direct ratio with the size of the tumor.

On opening the abdomen in the case of a large retroperitoneal tumor, the posterior and the visceral layers of the peritoneum may be found lying in direct contact with the anterior wall, the pelvic peritoneum is lifted up, the rectum is displaced, and the sigmoid or the colon pushed forward. The ureter is usually behind the growth, and if injured, the injury comes from detaching it from an adherent tumor.

The uterus is displaced by an intraligamentary tumor toward the opposite side, or if there are intraligamentary tumors on both sides, it is crowded between them into the front part of the pelvis.




FIG. 446.—INTRALIGAMENTARY GRAAFIAN FOLLICLE CYSTS. Nov. 21, 1894.

If both sides are affected, it will be easier and better to operate by removing the uterus and tumors together, by ligating the ovarian vessels first on one side, and so opening up the broad ligament and peeling out and rolling one of the

tumors with the uterus up and out of the incision, and controlling the uterine vessels of that side. The uterus is then amputated in its cervical portion, the

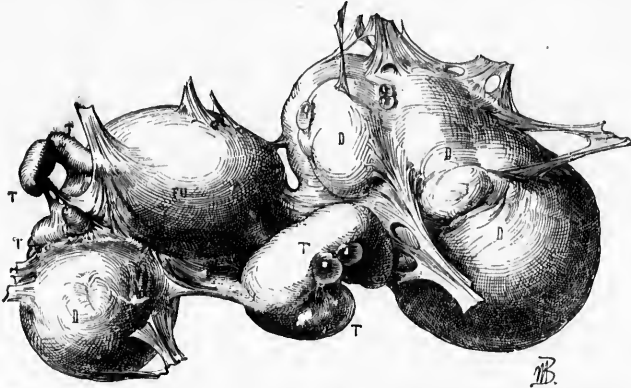

FIG. 447.—MULTIPLE DERMOID CYSTS OF BOTH OVARIES, WITH EXTENSIVE PELVI-PERITONITIS INVOLVING UTERUS, TUBES, AND OVARIES, SEEN FROM ABOVE AND ANTERIORLY.

FU is the fundus uteri. The left ovary consists of a number of cysts (*D, D, D*) covered with adhesions. The left tube was rigid, and distended with pus. The right ovary (*D*) is also covered with adhesions; and the right tube has been amputated by bands of adhesions, so that it consists of three separate portions. Feb. 2, 1895. $\frac{2}{3}$ natural size.

uterine vessels of the opposite side controlled, and the second tumor shelled out easily from below upward; the ovarian vessels are then clamped and the

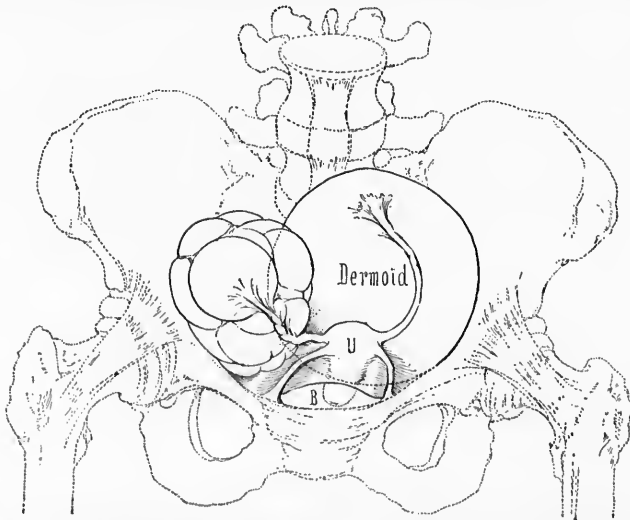


FIG. 448.—LEFT DERMOID CYST AND RIGHT MULTILOCULAR OVARIAN CYST WITH TWISTED PEDICLE. Elevation of the uterus. No. 2766.

whole mass removed, following, in general, the technique used in hysteromyomectomy.

In removing an intraligamentary tumor of one side, it is important to bear in mind that its blood supply continues to be derived from the same channels from which it came while the tumor was still small—that is to say, the ovarian and the terminal branches of the uterine vessels; and if these are patiently sought out and secured at once, there need be but little hemorrhage throughout the operation.

If the tumor is cystic and is made up of one or two larger cysts, the evacuation of the fluid will give the operator more room for his manipulations and the collapsed sac can be pulled on with greater advantage in drawing the tumor out.

In shelling out intraligamentary tumors it is best to avoid using the naked fingers, using in their stead a firm sponge on a handle, with rubber finger stalls covering the finger tips.

After such a tumor is removed the floor of the pelvis is laid bare, and it is a wise and comforting plan always to inspect the ureter throughout its pelvic course, so as to be perfectly sure of its integrity.

C o m p l i c a t e d
C a s e s .—In cases complicated by disease of both ovaries, as in the case of multiple dermoids shown in the text (Fig. 447), or where a dermoid of one side complicates an ovarian cyst of the other (Fig. 448), or where there is an ex-

tensive fibroid degeneration of the uterus (Fig. 449) associated with a fibroid ovary, it is better to do a hysterectomy with an ovariectomy, removing the uterus, tubes, and ovaries in one mass as described above.

The Opposite Ovary.—The opposite ovary ought always to be inspected and a note as to its condition entered in the history. If it is evidently

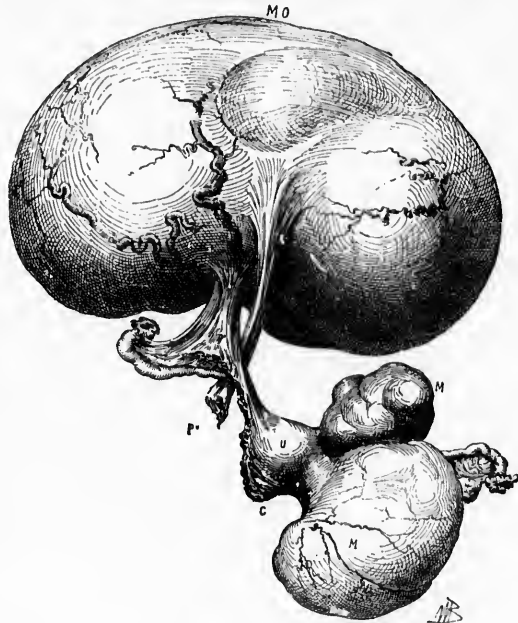


FIG. 449.—FIBROMA OF THE LEFT OVARY (MO), WITH LARGE MYOMATA (M, M) OF THE UTERUS (U).

Note the smooth surface and coarse exaggeration of the form of the ovary, the large vessels and the dense band of adhesion (P) stretching down under its hilum, attaching it to the broad ligament. Jan. 30, 1895. $\frac{1}{2}$ natural size.

diseased it should be removed, too; in a young woman conservatism should always be the ruling principle, and whenever it may be safely applied, a tube or a sound piece of ovary should be retained, even if it be but one tube and the opposed ovary. Resection of the ovary may be practiced in the case of dermoid cysts, and where there is an ovarian cystoma, like that shown in Fig. 406, it would be perfectly proper, if the patient was a young woman, and it was necessary to remove the opposite ovary, to resect the one affected with the cystoma, leaving the portion which appeared macroscopically sound, provided the patient consented to remain under observation for several years (see Chapter XXV).

The methods of cleansing the peritoneum, the question of drainage, and the closure of the incision are discussed in other chapters.



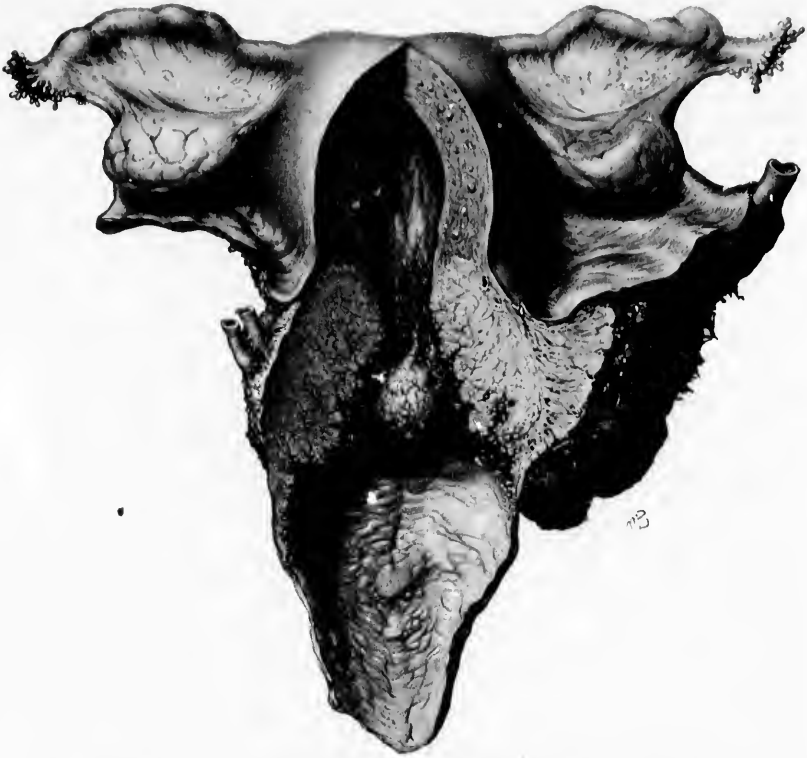

FIG. 450—ADENO-CARCINOMA OF THE CERVIX WITH HYDROURETER OF BOTH SIDES.

The disease stops above abruptly at the junction of the body with the cervix; below, it extends well out into the vaginal vault and the right broad ligament, and involves the entire thickness of the cervix. The right ureter, seen cut across, is converted into a large hydronephros. On the left side two ureters are seen, which were also converted into hydronephroses of lesser degree. Autopsy, June 22, 1896.

CHAPTER XXX.

ABDOMINAL HYSTERECTOMY FOR CARCINOMA AND SARCOMA OF THE UTERUS.

1. Causes.
2. Epithelioma of the cervix. Three stages: 1. Induration. 2. Sloughing. 3. Disappearance. 4. Mode of extension.
3. Adeno-carcinoma of the cervix.
4. Adeno-carcinoma of the body of the uterus.
5. Cancer of the uterus with myoma or tuberculosis.
6. Symptoms.
7. Diagnosis: 1. From subjective symptoms. 2. From touch and inspection. 3. From microscopic examination of scrapings.
8. Treatment: 1. Prevention—rules for. 2. Manner of examining for cancer. 3. The radical operation. *a.* Preparatory treatment. *b.* Technique. *c.* Steps in the operation.
9. Sarcoma of the uterus.

CANCER of the uterus is a malignant disease characterized by an atypical proliferation of the epithelial elements. It is one of the common causes of death among women; according to a computation of W. R. Williams, made in 1896, at least eight thousand women were suffering from cancer of the uterus in England and Wales at the date of writing.

Age.—In fifty-two of my cases of epithelioma of the cervix the following ages were noted:

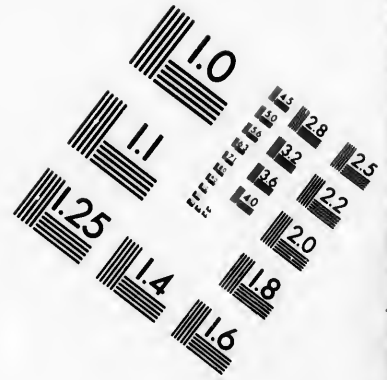
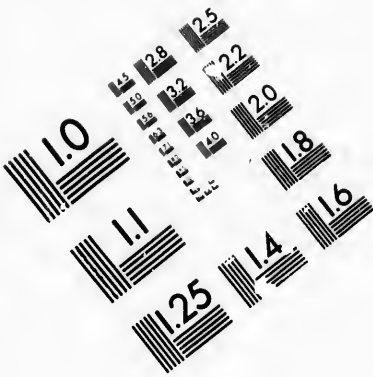
Between 31 and 35 years.....	5 cases.
“ 35 “ 40 “	7 “
“ 40 “ 45 “	19 “
“ 45 “ 50 “	6 “
“ 50 “ 55 “	7 “
“ 55 “ 60 “	4 “
“ 60 “ 62 “	4 “
Total.....	52 cases.

It is clear from this table that epithelioma of the cervix is most common near the menopause, and this induction coincides with the experience of most investigators.

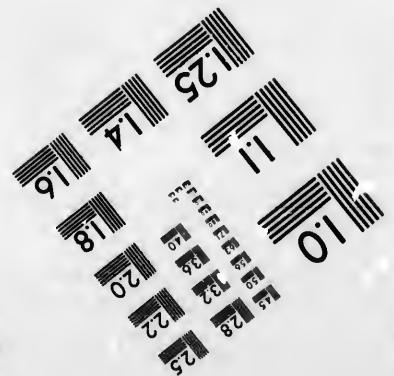


In thirteen of my cases of adeno-carcinoma of the cervix the ages were:

Between 30 and 35 years.....	2 cases.
“ 35 “ 40 “	2 “
“ 40 “ 45 “	1 case.
“ 45 “ 50 “	4 cases.
“ 50 “ 55 “	1 case.
“ 55 “ 60 “	0 “
“ 60 “ 65 “	2 cases.
“ 65 “ 70 “	1 case.

The commonest period of occurrence was between 45 and 50.



**IMAGE EVALUATION
TEST TARGET (MT-3)**



**Photographic
Sciences
Corporation**

23 WEST MAIN STREET
WEBSTER, N.Y. 14580
(716) 872-4503



In estimating the age of patients with adeno-carcinoma of the body, some allowance must be made, as it is impossible to determine with accuracy just when the disease commenced. In thirteen cases the patients' ages were as follows :

	30 years.....	1 case.
Between 35 and 40	"	1 "
" 40 " 50	"	1 "
" 50 " 55	"	5 cases.
" 55 " 60	"	3 "
" 60 " 65	"	2 "
Total.....		13 cases.

The period of most frequency was between fifty and sixty. The average adeno-carcinoma of the body, therefore, occurs (or perhaps it would be better to say makes itself evident) at a later period than either epithelioma or adeno-carcinoma of the cervix.

Causea.—The etiology of cancer is obscure; it has, however, been shown that there is a direct causal relation between cancer of the cervix and the traumatism of childbirth. Cancer of the cervix in unmarried and nulliparous women is extremely rare.

In fifty of the cases of epithelioma of the cervix with accurate data as to marriage and the number of pregnancies, in every instance the patient was married, forty-nine out of the fifty had borne children, and at least half of the patients had had five or more children.

Twelve of the thirteen patients suffering with adeno-carcinoma of the cervix had been pregnant. The thirteenth was unmarried, and gave no history of impregnation.

In eleven cases of adeno-carcinoma of the body it was found that ten were married and one single. From the accompanying tabulation it will be seen that four of them, although married for many years, had never been pregnant. In no case did a woman have more than four children.

	Para.	Mis.
A. married 7 years.....	0	0
D. " 12 "	0	0
A. " 21 "	1	0
G. single	0	0
M. married 24 "	2	0
A. " 33 "	2	5
G. " — "	4	0
A. " 32 "	0	0
P. " 12 "	1	0
S. " — "	0	1
P. " 31 "	0	0

I recall only three cases of cancer of the cervix in nulliparous women in my entire experience, and in one of these the cervix had been forcibly dilated. Dr. T. A. Emmet told me that the only case of cancer of the cervix he had ever seen in a nullipara was also one where forcible dilatation had been practised.

From a histological standpoint the parasitic origin of the disease has been repeatedly asserted, but this is unproven; indeed, many of these so-called parasites have been found to be nothing more than degenerative forms of epithelial cells. It has been repeatedly asserted that there exists a remarkable racial difference between the negroes and the whites in respect to the liability to cancer, and the statement has even been made that the negro is practically immune. This is clearly erroneous according to my statistics, which show a proportion of eight negroes to ninety-one white women.

Cancer or carcinoma of the uterus begins to grow primarily either in or on the cervix or in the body of the organ. This distinction between cancer of the cervix and of the body can always be clearly made with the naked eye in the early stages of the disease, and even remains clear in the most advanced stages in the majority of cases; occasionally, however, in the latest stages, the body is affected in cervical cancer, and, what is rarer, the cervix becomes affected in cancer of the body.

There are three varieties of cancer found in the uterus, each one depending upon the special form of epithelium involved in forming the growth. The vaginal portion of the cervix is covered by squamous epithelium, and from this springs first the epithelioma, the squamous, or flat-celled variety of carcinoma, which preserves this type of growth throughout its entire history and through all its extensions, whatever part of the body it may invade; secondly, the cervical canal and the cervical glands are lined by one layer of very high cylindrical epithelium from which arise the adeno-carcinomata of the cervix, as the name indicates, cancers which preserve

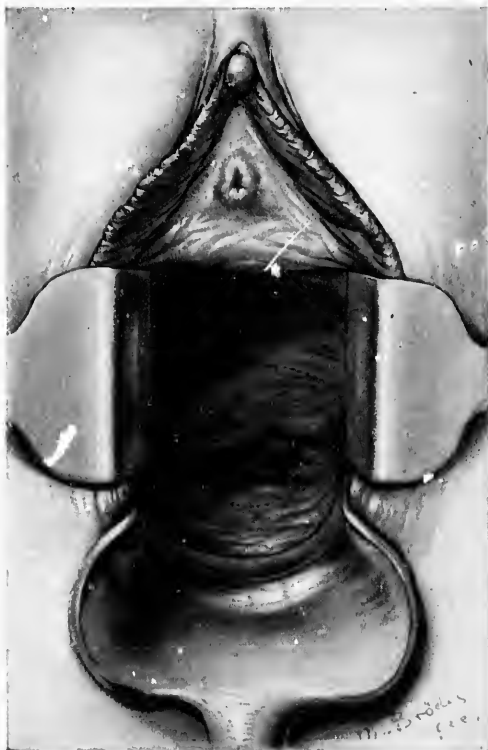

FIG. 45L.—CARCINOMA OF THE CERVIX.

No carcinomatous tissue can be seen at the vaginal vault, and the vaginal tissue has a normal appearance, but the carcinomatous infiltration has extended like a plate of cartilage beneath the vagina over the area included within the dotted lines. Dec. 9, 1896. Natural size.

in their structure, wherever they penetrate, the glandular type; thirdly, the uterine mucous membrane and its glands are lined by a single layer of cylindrical ciliated epithelium; this gives rise to the adeno-carcinomata of the body of the uterus.

Epithelioma of the Cervix.—The clinical picture of cancer of the uterus varies greatly both with the location of the disease and with the stage of advancement.

Epithelioma of the vaginal portion of the cervix may be conveniently divided into three stages; in the earliest of these the cervix shows an area of induration and infiltration with increased vascularity and a glazed appearance, or the tissue may present a slight granular appearance due to small fingerlike projections. The diseased tissue may begin to break down soon and present an excavated area, or it may go on until both lips of the cervix are involved and a mass is formed which fills the whole vagina, and appears to be attached to the vault by a pedicle, closely simulating a pedunculated myoma. The commoner appearance, however, is that of a cauliflower growth with numerous fissures and excrescences, as described by Clark in 1824.




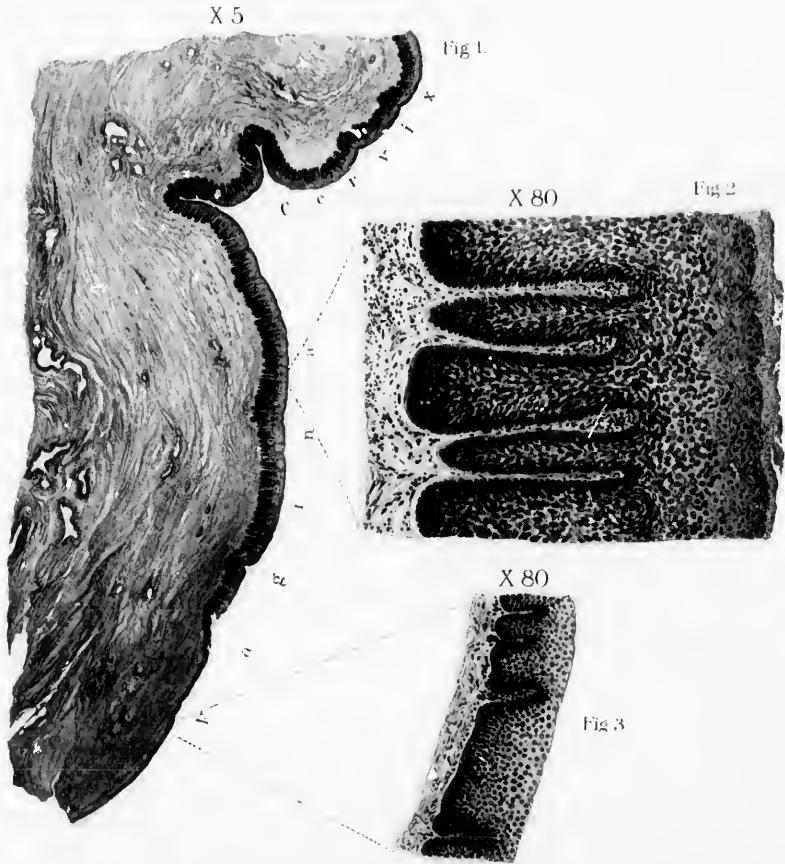
FIG. 452.—EXTENSIVE EPITHELIOMA OF THE CERVIX EXTENDING UP TOWARD THE FUNDUS, THE UPPER PART OF WHICH IS FREE. FOUR PILEBOLITHS IN THE LEFT BROAD LIGAMENT. BUNCHES OF VESICLES ON THE DORSUM OF THE RIGHT TUBE. GYN. PATH. No. 625. $\frac{2}{7}$ NATURAL SIZE.

In the second stage the growth breaks down, bits of tissue slough off, and a portion of the cervix may be wanting, leaving an excavated ulcer with infiltrated edges.

With further advance in the third stage, the entire cervix disappears, leaving in its place a craterous cavity in the vaginal vault covered by necrotic material with hard, irregular walls. With this extension the disease may open up the bladder, the rectum, or the peritoneal cavity, although in the case of the peritoneum the general cavity is almost invariably shut off by a plastic peritonitis.

Beginning with the earliest stages of the disease, the cancer cells may invade the lymphatics, traveling as far as the glands, which then enlarge and in turn become foci for further extension. I am, however, convinced, on the basis of the thorough investigations of all my cases by my associate Dr. T. S. Cullen,





that the irregularity of the lymphatic vessels, especially in the earlier stages of the disease, has been usually overlooked.

The glands which invade the broad muscle from the cervix are the blue group, situated at the pelvic end of the broad muscle of the ilio-psoas etc. In only one of the operable cases of epithelioma which the glands have been described have I found the secondary growth, and in only three of the cases coming to my hands, and when the disease was widespread were the glands the seat of the

DESCRIPTION OF PLATE XVII.

Fig. 1 is from a case of epithelioma of the cervix. The section includes a portion of the cervix and adjacent vaginal mucosa. Both the cervical and vaginal mucosa show marked thickening, but there is no tendency on the part of the epithelium to penetrate into the underlying stroma.

Fig. 2 is a section through the thickened vaginal mucosa. Note that the papillae are much longer than usual, and that the epithelium is about four times its usual thickness.

Fig. 3 represents the normal vaginal mucosa as found a short distance from the thickened mucosa.

This thickening is undoubtedly due to a gradual extension of the epithelioma, but from the section here shown one would not be justified in rendering a diagnosis of epithelioma.

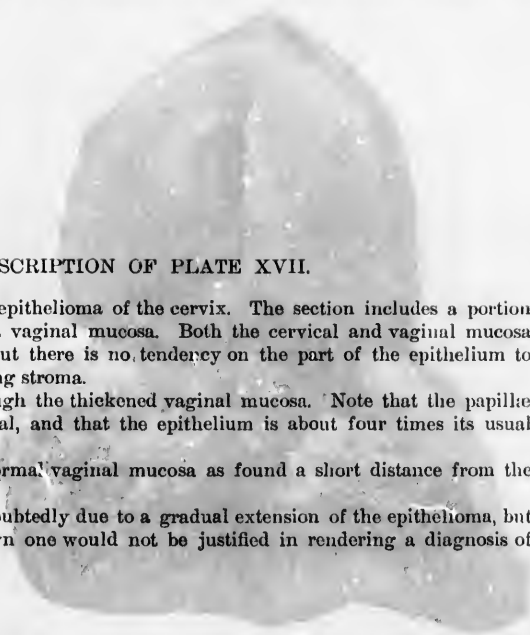


FIG. 1. Epithelioma of the cervix. (See Vol. X, p. 193.)

FIG. 2. Epithelioma of the cervix. (See Vol. X, p. 193.)

divided in the utero-ovarian ligament, and found in the broad muscle. The progress of the disease is often irregular, and the involvement of the body of the uterus is not always from its attachment in the large vessels; toward the end of the disease, however, the growth frequently invades the broad muscle, and stands out in marked contrast to the surrounding normal tissue. On gross examination, the tumor is made up of a network of glistening, fleshy, enclosing spaces from a millimeter to 3 millimeters in diameter, which contain bloody material with a grayish tinge; these are the cancer nodules.

Histologically the appearances are identical with those found in the scrapings removed for diagnosis (see Vol. I, Chapter XIV, p. 193). There is no growth

DESCRIPTION OF PLATE XVII.

Fig. 1 is from a case of epithelioma of the cervix. The section includes a portion of the cervix and adjacent vaginal mucosa. Both the cervical and vaginal mucosa show marked thickening, but there is no tendency on the part of the epithelium to penetrate into the underlying stroma.

Fig. 2 is a section through the thickened vaginal mucosa. Note that the papillae are much longer than usual, and that the epithelium is about four times its usual thickness.

Fig. 3 represents the normal vaginal mucosa as found a short distance from the thickened mucosa.

This thickening is undoubtedly due to a gradual extension of the epithelium, but from the section here shown one would not be justified in rendering a diagnosis of epithelioma.

that the frequency of this lymphatic involvement in the earlier stages of the disease has been unduly exaggerated.

The glands which receive the lymph vessels from the cervix are the iliac group, situated at the pelvic brim just at the bifurcation of the iliac vessels. In only one of the operable cases of epithelioma where the glands have been examined have I found the secondary growth, and in only three of the cases coming to autopsy, and where the disease was widespread, were these glands the seat of metastases.

The common mode of extension of the disease is by the continuity of tissue, and the extension is most rapid in those directions in which the loose meshes of the tissue offer the least resistance; the earliest and most marked evidences of the extension are therefore found at the bases of the broad ligaments, around the vaginal vault, in the connective tissue in-

cluded in the utero-sacral ligaments, and forward and downward under the bladder. The progress of the disease is often arrested at the internal os uteri, and the involvement of the body of the uterus is rarely found in epithelioma in the early stages; toward the end of the disease, however, the body is frequently involved. On section, the growth is yellowish white and waxy, has sharp irregular margins, and stands out in striking contrast to the surrounding sound tissue. On close examination, the cut surface is made up of a network of glistening fibers, enclosing spaces from a pin point to 3 millimeters in diameter, which contain friable material with a yellowish tinge; these are the cancer nests.

Histologically the appearances are identical with those found in the scrapings removed for diagnosis (see Vol. I, Chapter XIV, p. 493). There is an ingrowth



FIG. 453.—INOPERABLE EPITHELIOMA OF THE CERVIX, IN WHICH THE CHIEF INVOLVEMENT IS AT THE INTERNAL OS, WHERE THE UTERUS IS PERFORATED.

In the mucous membrane of the fundus a few epithelial nests were found lying between normal uterine glands. *Gyn. Path.* No. 192, March, 1894. Natural size.

as well as an outgrowth of the squamous epithelium, with epithelial prolongations penetrating the stroma of the cervix in all directions.

Adeno-carcinoma of the Cervix.—Adeno-carcinoma of the cervix originates in the glandular tissue at some point within the external os; in the early stages, on lying open the cervix, a nodular growth is seen involving a part or all of the cervical canal and extending down to the external os, which may show no evidence of disease.

Later in the disease that part which lies nearest the surface breaks down and forms a small ragged cavity whose walls are made up of fine fleshy papillae. The solid part of the growth is yellowish white and is sharply defined from the normal tissue surrounding it.

When the growth begins near the external os, this is soon involved, so that it becomes impossible at a later stage to differentiate, from the macroscopic appearances, between this and the epithelioma just described. The endocervical cancer, in contrast with the epithelioma of the vaginal portion of the cervix, lies closer to the broad ligaments, and hence the earlier invasion.

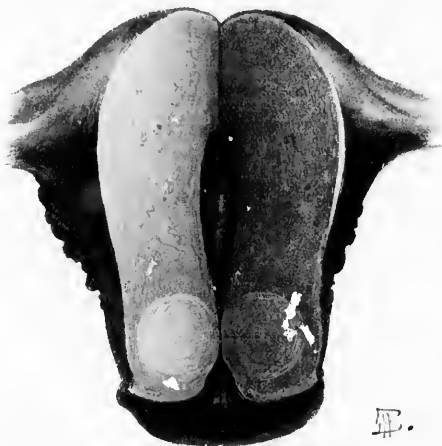

FIG. 454.—ADENO-CARCINOMATOUS NODULE ENTIRELY CONCEALED WITHIN THE CERVIX, IN AN EARLY STAGE OF THE DISEASE.

The diagnosis was made by curettage. Gyn. Path. No. 308. Natural size.

The histological appearances have been described in Vol. I, Chapter XIV, p. 493.

The surface epithelium multiplies and forms new glands, and the glands themselves proliferate and penetrate the tissues in all directions. The growth is an exceedingly rapid one, and is the most malignant of the uterine carcinomata.

Adeno-carcinoma of the Body of the Uterus.—Adeno-carcinoma of the body of the uterus in its early stages is usually localized and the uterus may be sub-normal in size, but as the disease advances the body of the uterus enlarges from a half to three times its normal size. Macroscopically, in its early stages the disease, which usually

begins in the upper part of the uterine cavity, is made up of small papillary and dendritic projections from the general level of the mucosa, while at the same time there is an invasion of the muscular layers. With the advance of the disease the entire uterine cavity fills with masses of fleshy papillary excrescences, and the muscularis is invaded in places all the way through to the peritoneum, so that the uterus is converted into a mere shell filled with the disease which shows but little tendency to break down.

Adeno-carcinoma of the body is a slow growth, sometimes running a course of five years from the initial symptoms; it is further remarkable for the slight tendency it shows to pass beyond the limits of the uterine body, to invade either the cervix below or the parametrium.

The microscopical appearances are those described in Chapter XIV.

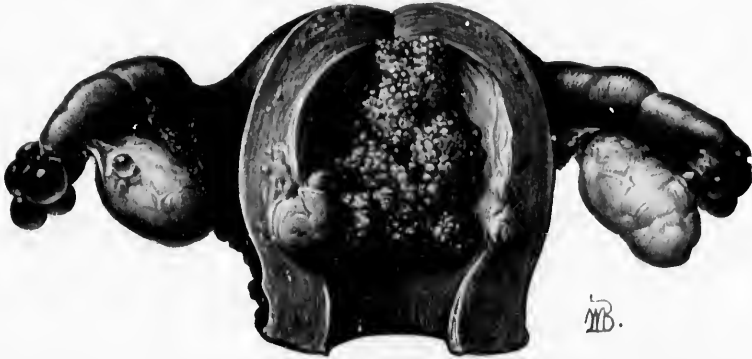

FIG. 455.—ADENO-CARCINOMA OF THE BODY OF THE UTERUS, LIMITED IN ITS DOWNWARD GROWTH BY THE INTERNAL OS.

Note the cystic condition of the ends of the tubes. Small myomata in the wall of the uterus. Gyn. Path. No. 345. Natural size.

The outgrowth of newly-formed glands is greatly in excess of that found in cervical carcinoma.

The general rule holds good that the histological characteristics of the tumor correspond to those of the tissue normally found in the part from which the tumor takes its origin.

Von Rosthorn, Zeller, and others have shown that squamous epithelium is sometimes present in the body of the uterus, and this explains the rare occurrence of epithelioma at this point.

In seventy-six of my cases Dr. Cullen found that fifty-two were epitheliomata, thirteen adeno-carcinomata of the cervix, and eleven adeno-carcinomata of the body of the uterus.

Cancer of the Uterus, with Myoma or Tuberculosis.—Cancer of the uterus is sometimes found associated with myoma or tuberculous; in tuberculous the association appears to be a matter of pure coincidence; it is possible that the reduced state of health brought about by the cancer may prepare the tissues for an easy invasion by the tubercular disease. In myoma the tumor may be at the fundal end of the uterus and the cancer at the cervical end, or again the cancer may be in the body and invade the myomatous tissue, just as it ordinarily invades the normal muscularis.

The chief indication for operation in the case of a large myomatous uterus in rare instances lies in the hemorrhage produced by an undiscovered cancer. I have seen four cases of this kind; in one of them (L. W., 1069, Nov. 23, 1891)

the operation of salpingo-oophorectomy was performed for a myomatous uterus to check severe hemorrhages. These did not cease, and after several months the patient returned for a radical operation, at which the uterus was found filled with the fungating masses of an adeno-carcinoma.

Pregnancy Complicating Carcinoma of the Cervix.—From time to time isolated cases of cancer of the cervix complicating pregnancy have been reported, but for our chief knowledge on the subject we are indebted to Cohnstein, Theillaber, and Olshansen. Scheibe, in an inaugural dissertation published in Halle in 1893, quotes Winckel as having observed 8 cases in 15,000

labors, Sutugin 2 in 9,000, and Stratz 12 in 17,900; in other words, taking all these cases together, a percentage of 0.047. From Cohnstein's statistics we learn that where carcinoma of the cervix and pregnancy coexist the patients are, on an average, much younger than those where carcinoma alone is present. In 127 of the cases cited by Cohnstein 86 were apparently adeno-carcinoma and 41 epitheliomata, but in 5 cases which came under Fehling's personal observation 4 were epi-

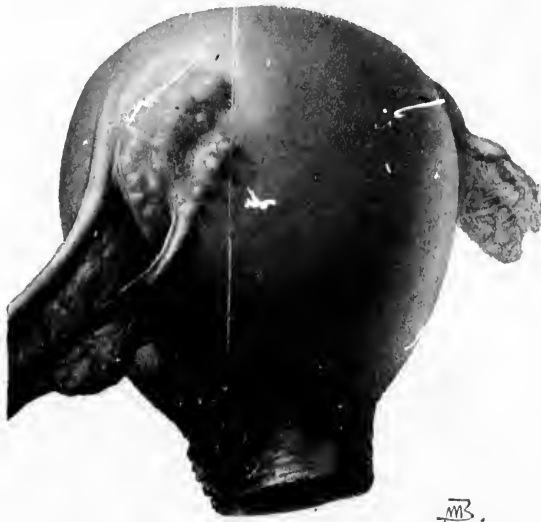

FIG. 456.—ADENO-CARCINOMA OF THE BODY OF THE UTERUS.

Showing large globular uterus filled with the disease; nodules of the extension of the carcinoma through to the peritoneal surface are seen between the left tube and ovary. July 25, 1894. Natural size.

theliomata and 1 an adeno-carcinoma. The clinical history is practically the same as noted in those cases where no pregnancy exists, plus the abdominal enlargement and the swelling of the breasts.

Course of the Pregnancy.—In 29 per cent of Cohnstein's cases the patient either aborted or miscarried. Of those advancing to term the same writer found that 36.2 per cent of the children were born alive, while in Theillaber's cases 47.2 per cent were living at birth. When pregnancy advances to term, labor may come on in the usual way and progress without any untoward symptoms, but in some cases most disastrous results may follow. If the growth is far advanced, deep tears may take place in the hard but friable carcinomatous tissues, and the bladder or rectum may be laid open. In some instances the uterus ruptures; Hermann has reported rupture in 11 out of 180 cases.

Treatment.—Up to the fifth month vaginal or abdominal hysterectomy may be performed. Most operators prefer the vaginal route, as in pregnancy,

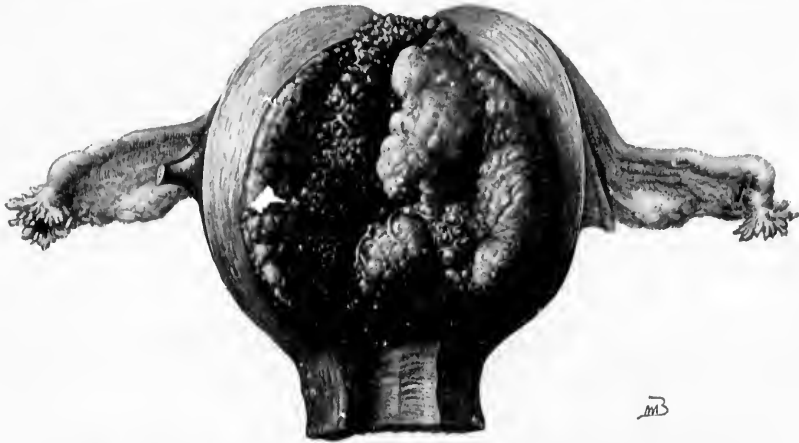

FIG. 457.—ADENO-CARCINOMA OF THE BODY OF THE UTERUS CUT THROUGH THE ANTERIOR WALL.

In spite of the fact that the whole uterine cavity is choked with the disease, it does not invade the cervix. Same as Fig. 456. July 25, 1894. $\frac{3}{4}$ natural size.

the uterus is plastic, and it is possible to reach with ease far out into the broad ligaments, a feat much more difficult in the case of the non-pregnant uterus.

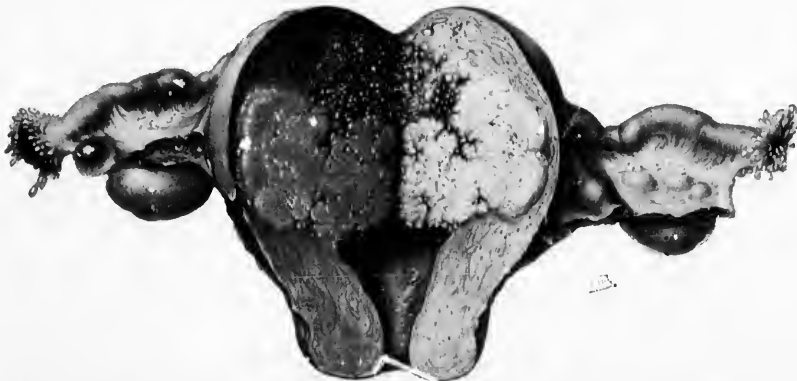


FIG. 458.—ADENO-CARCINOMA OF THE UTERINE BODY, WITH METASTATIC NODULES IN THE LYMPH CHANNELS OF THE LEFT BROAD LIGAMENT AND A NODULE IN THE LEFT ROUND LIGAMENT.

Almost the entire body is converted into a carcinomatous mass, while the cervical portion is free. A large gland, about 2 centimeters in diameter, removed from the pelvic wall showed nothing but hypertrophy.

In the later months Cæsarean section, with entire removal of the uterus, has been the usual procedure, and is my own preference; but recently Fritsch and

others have strongly advocated vaginal hysterectomy. In these cases they first slit the cervix, deliver the child and placenta, and claim that the uterus can then be removed *per vaginam* with great ease.

In inoperable cases, Caesarean section at or near term offers the best chance for the child, and for the mother it is better to continue the operation by amputating the uterus at the cervix; in other words, by performing the Porro-Caesarean operation.

Symptoms.—The chief symptoms of carcinoma are hemorrhage, watery or purulent discharges, and pain.

Hemorrhage is a regular concomitant of some period of the history of the disease, but is not often noted in the early stages; it increases in frequency and severity as time goes on.

It will not be necessary to enter into a disquisition upon the differential clinical signs in all these cases, as the one important difference upon which the diagnosis of cancer depends rests upon the revelation of the cancerous tissue under the microscope.

One of my cases (J. H. A., San., 260, Dec. 13, 1895) was entered for uterine hemorrhages and an adeno-carcinoma found; as the bimanual examination showed that the body of the uterus was not enlarged while the cervix was greatly thickened, the conclusion was drawn that the disease was localized in the cervix. On removing the uterus, however, the fundus was found to be the seat of the neoplasm, while the cervix was extraordinarily enlarged by a cystic degeneration extending from the internal to the external os, but not visible from the vaginal side.

The age at which this disease usually appears renders the patient

unsuspicious, for she attributes it to an irregularity of the menopause, or to a return of the monthly periods, as a sort of a rejuvenation.

Pain, too, is apt to be a late symptom, and is sometimes entirely wanting throughout the disease. The typical distress is a boring, bearing-down, tearing or stabbing pain, which is referred to the lumbar and sacral region, and radiates down the legs and forward into the lower abdomen.

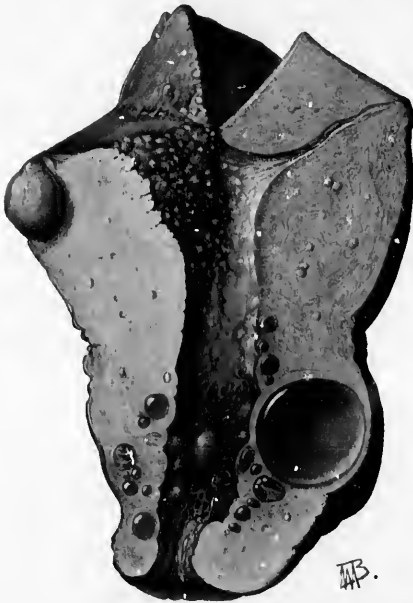

FIG. 459.—LIMITED AREA OF CARCINOMA OF THE FUNDES OF THE UTERUS ON THE LEFT SIDE.

The cervix was greatly enlarged, and was thought from the bimanual examination to be the seat of the disease, on account of the thickening due to numerous cysts in its substance, none of which were visible in the normal vaginal portion. San. Nov. 21, 1895. Natural size.

The watery discharge and leucorrhœa are regular occurrences. The thin ichorous, watery discharge is one of the most characteristic of all the signs of the disease, and sometimes forms the only complaint. Later the discharge becomes purulent, or muco-purulent, or sanguino-purulent, with an offensive odor, when, as a rule, the case is beyond operative interference.

Cachexia and emaciation are not always present, but when found, especially in disease of the cervix, they are almost positive signs that the case is beyond relief.

Diagnosis.—The diagnosis of cancer of the uterus is made from the subjective symptoms, from touch, inspection, and from the microscopic examination of curettings or small pieces of tissue excised from the cervix.

In the later stages of disease the diagnosis is easily made from the symptoms, and by touch and inspection, but in the majority of such cases the affection is too far advanced to admit of a radical cure.

In the earliest stages a diagnosis positive enough to justify a radical operation can not be made without a microscopical examination. In my early experiences, I removed the uterus in four cases where a suspected malignant disease did not exist. It is interesting to note that the first vaginal hysterectomy for cancer in 1814 has been proved by recent study to have been an error of this kind.

The conditions simulating cancer of the uterus are :

1. Hypertrophy of the mucosa with ectropium and induration.
2. Ulceration of the mucous membrane (erosion).
3. Cystic cervical glands.
4. Polypi, which should always be excised and examined microscopically to exclude malignant changes.
5. Submucous myomata.
6. Glandular hypertrophy of the mucous membrane.
7. Endometritis with hemorrhage.

In the later stages of cancer of the cervix the disease forms either a large fungoid, friable mass at the vaginal vault with fetid discharges and frequent hemorrhages, or it forms a craterous opening in the position of the cervix filled with friable material, bleeding on touch. In such cases there can be no doubt as to the diagnosis.

In the case of "eroded," "ulcerated," infiltrated cervixes in which the practitioner is in doubt, he must either secure the advice of a competent gynecologist or excise a wedge of the suspected area, put it in a five-per-cent solution of formalin, and send it to a reliable pathologist for investigation.

In cancer of the body the only reliable method of making the diagnosis is by the microscopic examination of portions of the endometrium removed by curettage.

Treatment.—The treatment of carcinoma of the uterus is either radical or palliative; a radical plan of treatment is adopted in all cases in which the disease is still clearly limited to the uterus and its immediate surroundings, and in

which there is a reasonable hope that it may be completely extirpated. Palliative treatment is adopted for those cases which are beyond radical relief.

One of the most important objects to be attained in the immediate future is an efficient prophylaxis in avoiding the later inoperable stages of the disease.

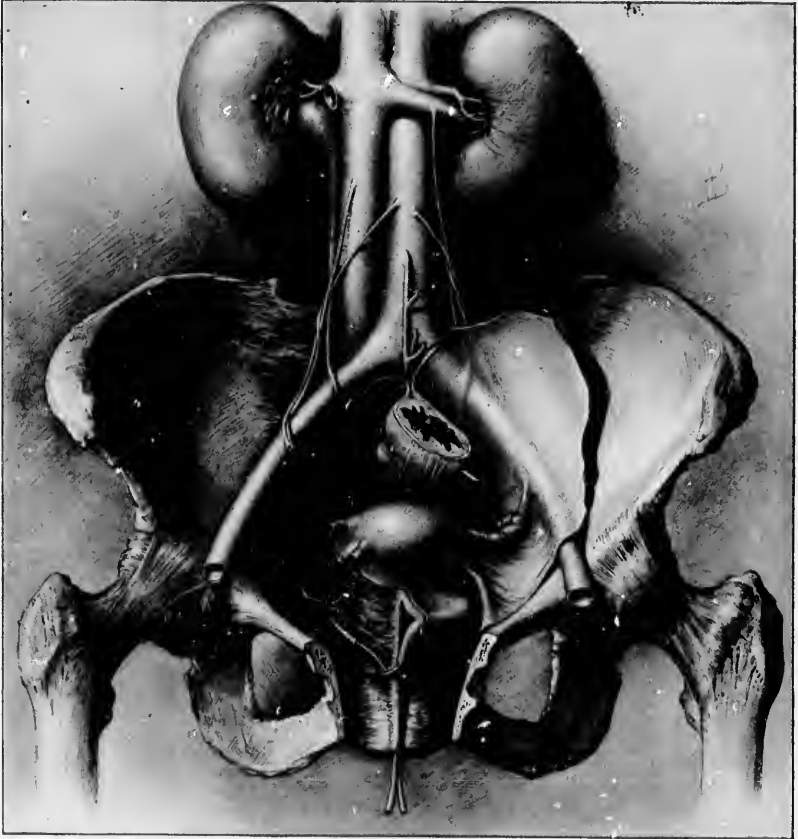


FIG. 460.—OPERATION FOR CARCINOMA OF THE UTERUS.

The ureters are both catheterized in order to make them stand out prominently during the enucleation. On the right side the peritoneum has been removed and the bladder divided so as to show the relations of the ureter to the uterine and pelvic vessels. A part of the pubic rami have also been removed, to expose the structures better to view.

We are not yet in a position to realize anything positive by any process of hygiene or of medication; there is, however, one suggestive fact in the history of carcinoma, and that is its occurrence with such frequency in parous women. This points clearly to a direct relation between the trauma of childbirth and cancerous affections of the cervix, and suggests the need of some

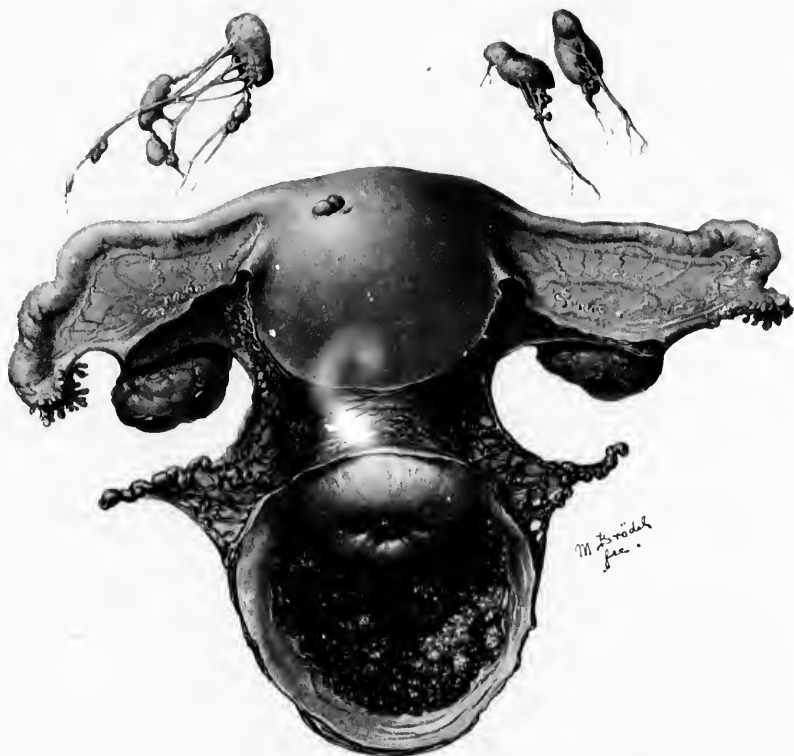

FIG. 461.—CARCINOMA UTERI.

Carcinoma limited to the posterior cervical and the posterior vaginal walls. It has apparently been entirely removed, a narrow band of vaginal mucosa surrounding the margin of advancement downward. The parametrium is apparently free on either side. The right and left pelvic glands with lymph channels removed and shown above. The small nodule in anterior uterine wall are myomata. No extension of carcinoma to the body. Dec. 23, 1895. Anterior view. $\frac{5}{7}$ natural size.

such rules as the following in medical practice (see *New York Med. Jour.*, Oct. 14, 1893):

Rules for the Prevention of Cancer.—1. It is the duty of the obstetrician to see each of his patients at his office from two to three months after confinement, and to examine and carefully record the exact condition of the various pelvic structures, stating accurately just what lesions have been produced by the childbirth.

2. Cervical lacerations should be described with especial care, noting the position and depth of tears and the appearance of the lips. These lacerations require no treatment when the lips are thin, uninfiltated, and lying together. Thick, infiltated, and everted lips, associated with endocervical catarrh, call for depletory treatment followed by repair of the laceration or amputation.

3. Every child-bearing woman who has passed thirty years of age, and whose condition has not been carefully noted in this way, should consult a competent physician. If the cervical lips do not appear sound, she should be kept under observation and be treated, if necessary, or examined at intervals of six or eight months.

4. Every woman of thirty-three or over who has a cervical tear should be examined at least once a year for ten years or longer if the lacerated cervix does not present a perfectly healthy appearance.

5. The community at large should be so trained by the profession that any woman who suffers from an unusual or an atypical uterine hemorrhage, or from any unusual discharge, should at once seek competent advice as to its cause, and the physician should not rest until he has definitely ascertained its source. This rule holds with increased force in the case of women in the forties, when both patients and doctors are so often deluded into a blind waiting for Nature to relieve that which in time proves to be beyond the resources of both Nature and art.

6. These rules apply with special force to patients whose family history shows a liability to cancerous disease.

If these rules were conscientiously observed there can be no doubt but that thousands of lives would be saved yearly in this country alone, for cancer of the uterus is a disease markedly local, and accessible and eradicable in its earliest stages.

I feel that while we are searching for the cause and cure for cancer in all its grades, the line of progress in the immediate future for the gynecologist clearly lies in the direction of prophylaxis and anticipation, either preventing the malady or discovering it in time to eradicate it.

The radical plan of treatment consists in the removal of the entire uterine body, whether the carcinoma is located at the fundal or at the cervical end. The determination that a case is suitable for radical treatment is made after a careful examination of the pelvic organs conducted in the following manner: A digital examination of the vagina is made, and if the vaginal cervix is found apparently normal to the touch and the supravaginal cervix does not seem to be infiltated and enlarged, the carcinoma is then confined to the fundus, the most

favorable site for permanent relief after enucleation. The fundus is then carefully examined bimanually, and if it is found without any adhesions and freely movable the outlook is a good one, in spite of the fact that the body of the uterus may be several times its normal size, and even present nodules of the disease which can be felt on its surface.

If the body is adherent and, in particular, if there are strong intestinal adhesions, and this is associated with cachexia and marked emaciation, the liability of an extension of the disease beyond the uterus is much increased. Even under these circumstances, however, if the patient's general condition will permit it, she should have the benefit of an exploratory incision to determine the character of the adhesions and whether the disease has extended beyond the possibility of extirpation.

When the cervix is affected the determination is somewhat more difficult, as the disease may extend in such a way that its outermost limits can not be accurately determined by the most careful examination.

In investigating a case of cervical carcinoma the various modes of extension of the disease must be borne in mind and each avenue examined in turn; these are:

1. Extension out into the right or the left broad ligaments or into both at once.
2. Extension downward into the vagina.
3. Extension forward into the bladder.
4. Extension backward into the utero-sacral folds and so into the rectum.
5. Extension up into the body of the uterus in rare instances.
6. Metastases into the pelvic glands, rare.
7. Metastases or implantation into the vagina below the focus of the disease, rare.

In the early stages, when the cervix is not much enlarged and the uterus is probably movable, and a rectal examination shows that the broad ligaments are probably clear, the operation may be undertaken without any further investigation.

Later, when the cervix is more extensively diseased, the minutest possible examination should be made before proceeding to operation; if the uterus is fixed in the pelvis and the broad ligaments, one or both, are found hard, thick, and unyielding, pinning the uterus to the pelvic wall, the case may be rejected without further treatment. Whenever this fixation is not found, then a minute categorical investigation should be made, and it is always my own preference to do this by putting the patient under the influence of an anesthetic.

I then inspect the vagina for any evidences of an implantation of the disease low down, or for evidence of the extension of the disease over the vaginal wall in such a superficial form that it might escape the tactile sense if not first recognized by the increased injection shading off into the normal vagina below. In looking into the bladder, the evidences of an early extension in this direction are often evident in the form of a hyperemic area of the base with tints of edematous tissue.

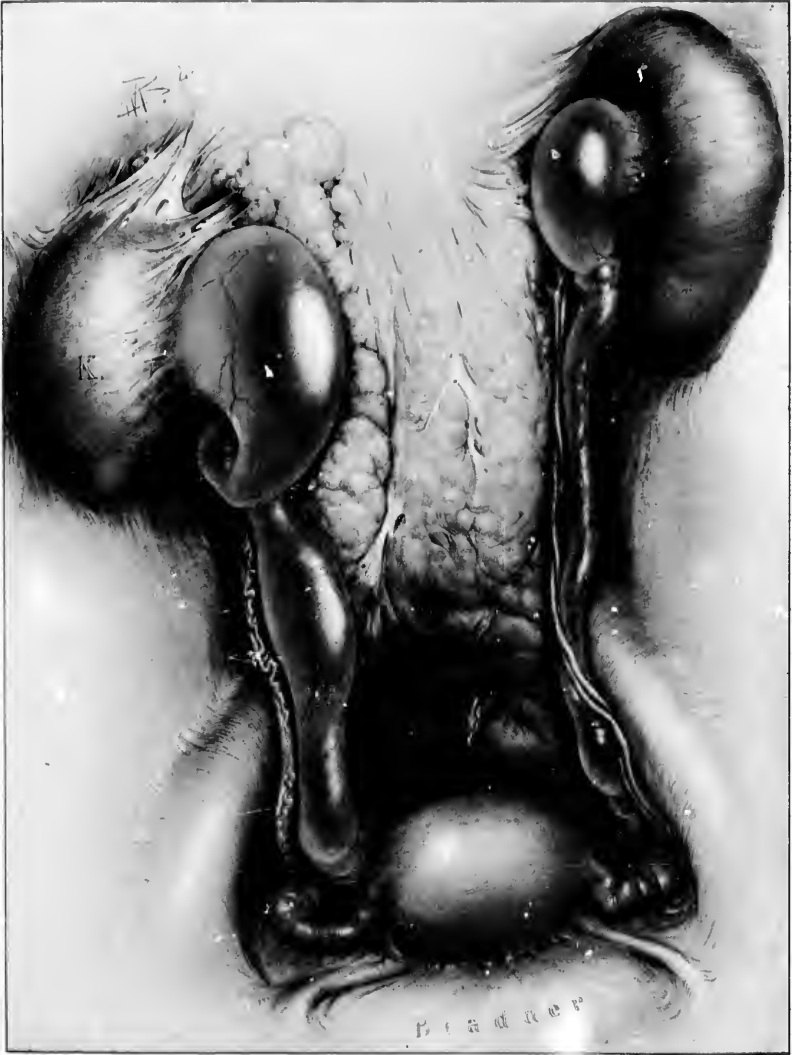

FIG. 462.—DOUBLE HYDROURETER DUE TO ADVANCED CANCER OF THE CERVIX UTERI.

The atrophic and inflammatory changes due to the cancer are plainly visible in the adhesions of the bladder to the uterus, and in the cicatricial tissue and adhesions between the ureters and about the kidneys. Autopsy, March 2, 1896. $\frac{1}{4}$ natural size.

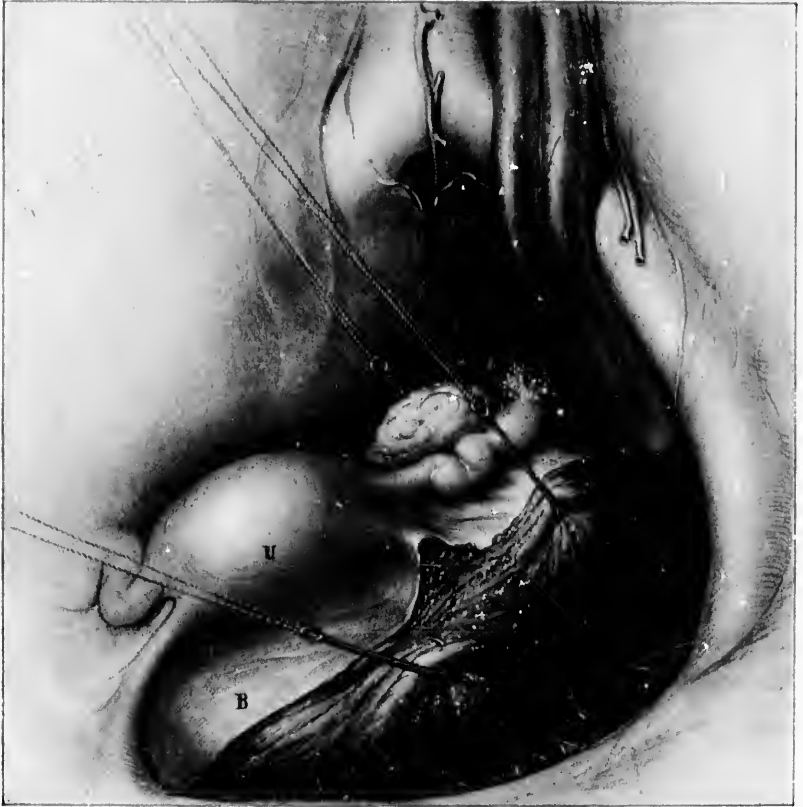

FIG. 463.—Autopsy on a case of carcinoma of the cervix with compression of the ureters, producing hydronephrosis; double ureter on the left and single on the right (faintly seen). The peritoneum is opened and the uterus and bladder pulled to the right, to show the double ureter compressed and kinked at the pelvic floor. Autopsy, June 22, 1896.

By touch, however, the most important information is secured; when the disease is advanced in the vaginal direction the vagina feels shortened and the fornices are obliterated. If the anterior lip alone is involved, the extension may be evident down the anterior vaginal wall, and the hard cervical mass often seems fastened to the bladder.

An extension posteriorly toward the rectum is recognized by the want of mobility of the posterior cervical lip, which seems fastened to the sacrum to which it is sometimes drawn up, and examination through the rectum will show the extent of the disease in this direction.

An extension of the disease upward into the uterine cavity is rare, and usually only occurs in cases so far advanced in other directions that enucleation is impossible; further than this it has no significance, as the entire uterus is removed at the operation.

Extension out into the broad ligaments can only be suitably investigated through the rectum by carrying the index finger well above the ampulla and back of the uterus. The base of each broad ligament must be carefully studied from its cervical to its pelvic attachment; a thick, round, hard mass attached to the cervix and extending out to the pelvic wall in all cases represents the extension of the disease; a slight thickening, and a condition feeling like strings in the broad ligament, scarcely impairing its mobility while probably indicating also extension of the disease, is in some cases due to inflammatory deposits which clear up after the removal of the uterus. In these cases the patient should be given the benefit of doubt. Enlarged glands may sometimes be felt just posterior to the broad ligaments or at the pelvic brim, especially in the bifurcation of the common iliac artery. A glandular metastasis is one of the late sequelae in carcinoma of the uterus, and such a discovery in no way contra-indicates a radical plan of treatment. I have repeatedly taken out enlarged glands in the course of an operation, and in but one instance was any evidence of carcinoma found in them.

In one case of advanced carcinoma of the body I dissected out a hard gland in the right side on the pelvic brim, about 2 centimeters in diameter, which was unhesitatingly pronounced carcinomatous from its macroscopic appearances, but the microscope showed that it was simply a hypertrophy.

In concluding whether or not to operate, the patient should in all cases have the benefit of any reasonable doubt, and the operator must not be too exacting in restricting his indications. I have operated several times where the disease was found so advanced that there could be no reasonable question but that some portion of it was left behind, and this was confirmed by a microscopic examination of the specimen, which showed cancer cells right up to the cut edge of the broad ligament, and yet one of these patients enjoyed perfect health for five years, when the disease reappeared in the glands of the neck; another had a local return after three years of good health, and two others are living, apparently in perfect health, three and four years after the operation.

I am even willing to extend the limit of the scope of the radical operation to cases which manifestly can not be permanently cured, but in which the uterus

can be removed without great difficulty. This may be demanded by the insistence of a patient who is utterly demoralized by the knowledge that she has a cancer and insists upon active measures for her relief, as well as for the purpose of relieving septic symptoms, pyometra, and the risks of hemorrhage.

The disease will often then return in the pelvis without pain, without hemorrhage, and without any extensive breaking down of the tissues; and a tranquil end may be secured either through death from exhaustion or by uremia.

Radical Operation.—The radical operation contemplates the removal of the entire uterus in the hope of eradicating the disease; it is done either by the vaginal or the abdominal routes.

The abdominal route allows a wide dissection of the broad ligaments, with the removal of all the pelvic connective tissue out to the bony walls, as well as the removal of any enlarged glands found in the pelvis or about its brim; it is therefore to be preferred in all cases to the vaginal route where the extirpation is limited to the uterus, and the tissues in its immediate vicinity.

Two objections to the abdominal extirpation are, that it consumes more time, lasting from an hour to an hour and a half, or even two hours, and that it is far more difficult to do than

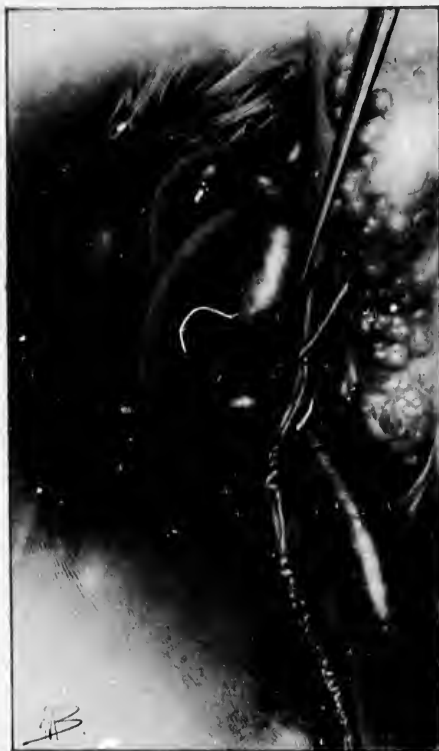


FIG. 464.—THE UPPER HALF OF A HYDRONEPHROTIC KIDNEY, AND HYDRONEPHROSIS FROM COMPRESSION OF THE RIGHT URETER BY A CANCEROUS CERVIX.

The kidney (A) is embedded in adhesions. The kinked ureter is compressed or strictured by the ovarian vessels which cross it at the level of the lower border of the kidney. Autopsy, March 2, 1896. Natural size.

the vaginal operation; the first objection, however, is outweighed by the great advantage of a wider extirpation, and the second will be overcome by practice, developing the requisite technical skill.

Preparatory Treatment.—In addition to rest in bed and such build-up measures as are adopted in all cases where there is a depressed physical condition, it is especially important to secure thorough evacuation of the bowels before proceeding to operation.





Of the various methods the best is, through my eyes, the one described by Thomas XIV. in 1796, in which he cut down externally on the abdomen, at the time the incision is made to discover the extent of the disease. When done, he had good success, but in giving the abdominal incision, the patient is made to die as a necessary step immediately before the operation.

A preliminary operation is now done before operation has the following advantage: The field of operation is one of the greatest, thus, reducing the risk of infection and lowering the danger of inflammation of the peritoneum, the health of the patient during the operation.

There is for an anatomic examination a small, and successful operation which had previously been performed on a patient on whom the extent of the disease discovered at the time.

Operation for Abdominal Hyperplasia of the Uterus. (See Plate XVIII.)
 W. A. Freund (*Path. Soc. Trans.*, 1877, p. 177).
 In removing the uterus, the following steps are taken:

DESCRIPTION OF PLATE XVIII.

Radical operation for cancer of the uterus, showing the locations of the glands removed in a series of cases above the common iliac artery, in the bifurcation and behind the internal iliac artery.

On the left side the method of splitting the peritoneum to expose the glands is demonstrated, while on the right it is opened, laying bare the iliac glands.

Catheters inserted in the ureters cause them to stand out prominently. The stumps of the ligated ovarian vessels and the round ligaments are seen on the outer edge of the peritoneum; the ligated uterine vessels appear deep down on the pelvic floor close to and on the outside of the ureters.

Another advance in the technique of hysterectomy is the removal of the uterus was made by A. Mackenrodt (*Reich. Anzeiger*, 1877, p. 177).
dispositio bei Carcinom. Uter. Zeit. f. Geburt. u. Gynäk., 1877, p. 177.
 The removal of both broad ligaments with the uterus.

The last important step has been taken by the German operator, J. C. Clark (*J. L. B. Hospital*, 1890, p. 177).
 895, and Feb.-March, 1896; L. R. R. *Zeits. f. Geburt. u. Gynäk.*, 1896, p. 177.
 1895, p. 268, and Rumpf, *Z. f. Geburt. u. Gynäk.*, 1896, p. 177.
 192). Each of these operators, with the exception of the first, has performed the operation upon patients who had been operated upon for the uterine glands and the cancer of the uterus, and in his way of doing the operation he has sought to reduce the percentage of relapse.

Ries dwelt especially upon the importance of removing the uterus, broad ligaments, and the iliac glands found in the bifurcation of the common iliac artery and in varying number on both sides of and along the iliac vessels. Rumpf, who was the first to operate upon the uterus, has been followed by extensive dissections, removing the broad ligaments, the paracervical vessels, dissecting out the ureters and much of the pelvic connective tissue below them; in addition

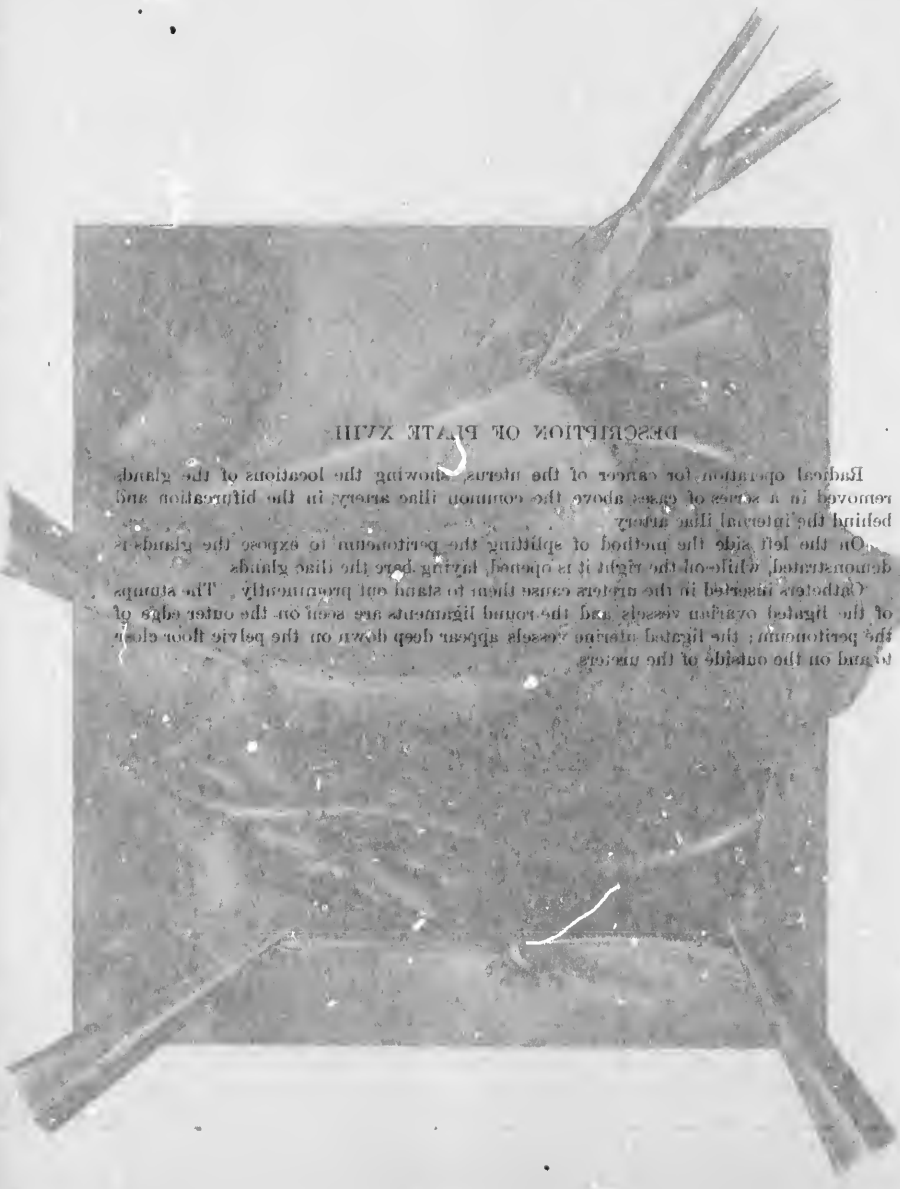to the removal of the uterus, broad ligaments, and the iliac glands found in the bifurcation of the common iliac artery and in varying number on both sides of and along the iliac vessels. Rumpf, who was the first to operate upon the uterus, has been followed by extensive dissections, removing the broad ligaments, the paracervical vessels, dissecting out the ureters and much of the pelvic connective tissue below them; in addition

DESCRIPTION OF PLATE XVII

Radical operation for cancer of the uterus, showing the location of the glands removed in a mass above the common iliac artery in the dissection and behind the internal iliac artery.

On the left side the method of splitting the peritoneum to expose the glands is demonstrated, and on the right it is opened, laying bare the iliac glands.

(Arbiters inserted in the uterus cause them to stand out prominently. The stumps of the ligated ovarian vessels and the round ligaments are seen on the outer edge of the peritoneum; the ligated uterine vessels appear deep down on the pelvic floor close to and on the outside of the uterus.)



If the disease occupies the cervix, a thorough curettage should be done, as described in Chapter XIV, as a rule, a week or ten days before extirpating the uterus, at the time the examination is made to determine the extent of the disease. Where there are good reasons for not giving the anesthetic twice, the curettage may be done as a preliminary step immediately before the extirpation.

A preliminary curettage a week or two before operation has the following advantages: The field of operation is freed of the necrotic tissue, reducing the risks of infection and lessening the danger of implantation of the cancer cells into the healthy tissue during the operation.

Tissue for microscopic examination is secured, and sometimes an operation which had previously seemed feasible is abandoned on account of the extent of the disease discovered at this time.

Operation for Abdominal Hysterectomy for Cancer.—It is not many years since W. A. Freund (*Volk. Sanw. klin. Vortr.*, No. 133, 1878) described a method of removing the cancerous uterus through the abdomen; the mortality following this procedure was, however, so great that few imitators were found. In a case upon which I operated in 1889 I was discouraged from further attempts by the excessive hemorrhage during the operation, and the ligation of a ureter with a fatal result.

A most important step was taken by K. Pawlik (*Internat. klin. Rundschau*, Wien, 1889), who introduced bongies into the ureters so as to mark them out during the removal of the uterus and adjacent pelvic cellular tissue.

My own method of exposing the ureteral orifices by an atmospheric distention of the bladder, and so introducing the bongies under direct inspection, has made Pawlik's plan easily available.

Another advance in the technique of hysterectomy for carcinoma of the uterus was made by A. Mckenrodt (*Beitr. z. Verbess. d. Dauerresultate d. Total-extirpation bei Carcinoma Uteri. Zeits. f. Geburt. u. Gynäk.*, 1894, p. 157) in the removal of both broad ligaments with the uterus.

The last important step has been taken simultaneously and independently by three operators, J. G. Clark (*Johns Hopkins Hospital Bulletin*, July-Aug., 1895, and Feb.-March, 1896; E. Ries *Zeitschr. f. Geburts. u. Gynäk.*, Bd. xxxii, 1895, p. 266, and Rumpf, *Zeitschr. f. Geburts. u. Gynäk.*, Bd. xxxiii, 1895, p. 212). Each of these operators, wishing to establish a parallel between the wide extirpative operations upon cancerous breasts associated with the removal of the axillary glands and the cancer of the uterus, proposed as far as possible to remove the pelvic glands, and in this way to make the operation more thorough and to reduce the percentage of relapses.

Ries dwelt especially upon the importance of removing the uterus, broad ligaments, and the iliac glands found in the bifurcation of the common iliac artery and in varying number on both sides of and along the iliac vessels. Rumpf, who was the first to operate upon the human being, conducted an extensive dissection, removing the broad ligaments, the parametric tissues, dissecting out the ureters and much of the pelvic connective tissue below them; in addition,

Douglas's folds with their neighboring tissues and the floor of Douglas's pouch were also removed with the upper part of the vagina.

The facility and success of the R. Rumpf-Clark operation as developed in my clinic has been greatly enhanced by the passage of catheters into the ureters previous to the operation as before mentioned, converting them for the time into rigid cords, splinted out against the pelvic wall and yet within easy touch, and relieving the operator of the embarrassment arising from any doubt as to their location during the application of the ligatures. These are the steps in the operation :

- (a) Catheterization of the ureters.
- (b) Closing the cervix in carcinoma of the body, or of the vaginal vault in carcinoma of the cervix.
- (c) Thorough disinfection of the vagina, which is then filled with a loose iodoform gauze tampon.
- (d) Elevation of the pelvis and abdominal incision, exposing the field of operation.
- (e) Ligation of the upper parts of both broad ligaments, including the round ligaments.
- (f) Detachment of the vesical peritoneum and of the bladder down to the vaginal vault.
- (g) Ligation of the right and left uterine arteries at their origin at the internal iliac arteries.
- (h) The dissection and freeing of the uterine arteries with all the adjacent cellular tissue from the pelvic wall in toward the vault of the vagina.
- (i) Setting free the ureters which are lifted up and away from the field of operation.
- (j) Ligation of the large uterine veins above and below the ureter out near the pelvic wall.
- (k) Enlarged glands found on the pelvic floor must be taken up with the cellular tissue.
- (l) The uterus, with broad wings of connective tissue, is freed down to its vaginal attachment, and the vagina opened at least 2 centimeters below the lowest limit of the disease, anterior to the cervix, with a thermo-cautery.
- (m) The opening in the vaginal vault is continued around to the right and to the left, clamping any actively bleeding vessels until the uterus is entirely freed.
- (n) As soon as the vagina is incised anteriorly a loose iodoform gauze pack is pushed in, and as soon as the opening is large enough to permit it, the lower part of the uterus and the vaginal vault are enveloped in gauze, so as to prevent any discharge from contaminating the wound area ; the gauze wrap affords an excellent hold for the operator in making traction upon the uterus as it is gradually delivered.
- (o) Bleeding vaginal vessels are controlled by catgut ligatures passed through the vaginal walls but not including the mucosa.
- (p) The entire wound surface is minutely inspected, all oozing vessels con-

trolled by catgut ligatures, and reinforcing ligatures applied to any important vessels where the first ligation seems insecure.

(q) The vesical peritoneum and the peritoneum of the anterior layers of the broad ligaments is drawn back and united by continuous suture to the peritoneum of the posterior layers of the broad ligaments and Douglas's *cul-de-sac*.

(r) If there has been no contamination the abdomen may be closed at once. If, however, there has been some escape of the uterine contents over the wound and into the peritoneum, the pelvic cavity should be thoroughly washed out after letting the patient down to a horizontal position before closing the abdomen.

(s) The vaginal gauze is changed, and a piece of washed-out iodoform gauze passed loosely up between the lips of the wound to give a little support to the sutured peritoneum above, and to avoid any accumulation of fluids within the wound area.

The catheterization of the ureters constitutes one of the most important steps, as by means of the catheters or bougies two valuable objects are attained, as already mentioned: First, the elasticity of the catheter tends to push the ureter out close to the pelvic wall, out of the way of the operation, and second, by means of the catheter, the ureter is converted into a hard cord which can be felt at all times during the enucleation, so insuring its safety from injury.

The best plan is to introduce the catheters before giving the patient the anesthetic, so as to shorten the time of the anesthesia and to avoid the additional shock incident to placing her in the knee-breast position and catheterizing while under the anesthetic. I have several times catheterized the ureters before doing a hysterectomy, without elevating the pelvis at all, by simply directing the speculum down to that part of the bladder where the ureteral orifices would naturally be looked for, and sliding it over the mucous surface until first one orifice is seen and catheterized; then the speculum was withdrawn and re-inserted beside the catheter, and the opposite orifice was sought out and catheterized.

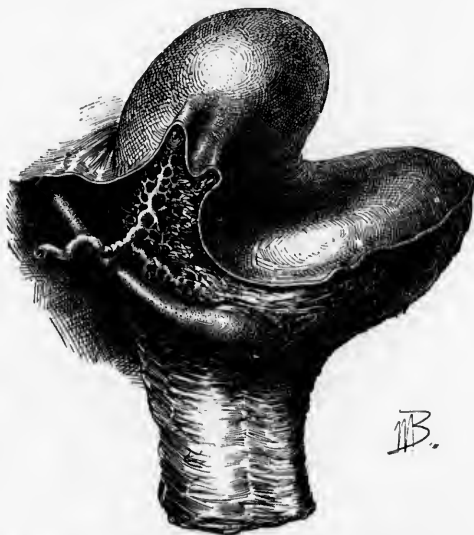

FIG. 465.—THE RELATIONS OF THE URETER AND BLADDER TO THE UTERUS AND VAGINA.

The right ureter is seen crossing under the uterine artery at a little distance from the cervix and entering the collapsed bladder in front. The uterus is above and to the left. The lower part of the figure is made up of vagina on the left and urethra on the right, with a slight sulcus between.

When the broad ligaments are much involved it will sometimes be found impossible to pass the end of the catheter more than 3 or 4 centimeters into the ureter. This would seem to be due to the fact that one of the prime conditions necessary to the passage of the catheter is a certain amount of mobility of the part of the ureter, and when this is impaired by fixation in an inflammatory mass the end of the catheter butts up against the mass and is unable to turn the sharp

angle formed and so to find the lumen. This condition is diagrammatically represented in Fig. 466.

The closure of the cervix by means of stout silk ligatures passed through both lips in the form of mattress sutures is the first step in operation and should never be omitted, as it forms the best means of preventing the escape of cancerous material from the uterus over the wound surface during the enucleation. After tightly tying the ligatures they are cut short, the abdomen is cleansed, the pelvis elevated, and a free abdominal incision made, varying in its length according to the thickness of the abdominal wall and the depth of the pelvis. As a rule, the incision should extend one third or one half way up to the umbilicus, in order to give a perfect exposure of the pelvic viscera and to allow the operator to use his hands with entire freedom in all the manipulations necessary throughout the operation.

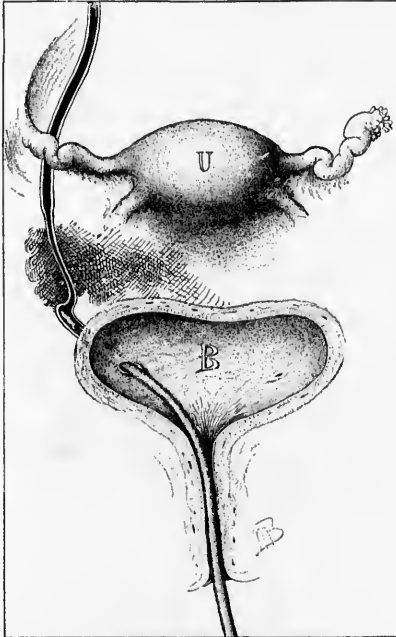


FIG. 466.—DIAGRAM SHOWING WHY THE BOUGIE SOMETIMES REFUSES TO PASS ON UP THE URETER IN CARCINOMA OF THE CERVIX.

The ureter ordinarily yields a little as the bougie passes upward toward the kidney; this movement, by which it accommodates itself to the elasticity of the bougie, is prevented when the ureter is embedded in a carcinomatous mass, and, as a consequence, an angle is formed just at the entrance of the fixed portion, beyond which it is difficult to coax the instrument. Sometimes the ureter is markedly kinked in the neighborhood of the diseased area (see Fig. 463). It is still important, however, to insert the bougie as far as possible, as the position of the point serves to locate the ureter.

and clamps applied to the ovarian vessels and round ligaments on the uterine side, after which the top of the broad ligament is opened by an incision made between the ligatures and clamps. If the case is one of cancer of the cervix the ligatures may be safely applied at a point nearer to the uterus; in advanced cancer of the body, however, it is better to apply them well away from the uterus,

on account of the possibility of cancerous elements being contained in the lymphatics of the upper broad ligament or in the round ligaments. Such a condition is well shown in Fig. 458.

After opening the broad ligament in this way the incision should then be continued on around in front of the uterus to the opposite round ligament, separating the vesical peritoneum from its uterine attachment.

The operator then in a similar manner ligates and opens up the other broad ligament, and pulls up the uterus, while at the same time with a sponge held in the grasp of a pair of forceps he pushes down the vesical peritoneum still further, detaches the bladder, dissecting it loose with a scalpel when it adheres tightly, until it is quite free from the uterus and vaginal vault. Any bleeding vesical vessels may be clamped temporarily or tied with catgut.

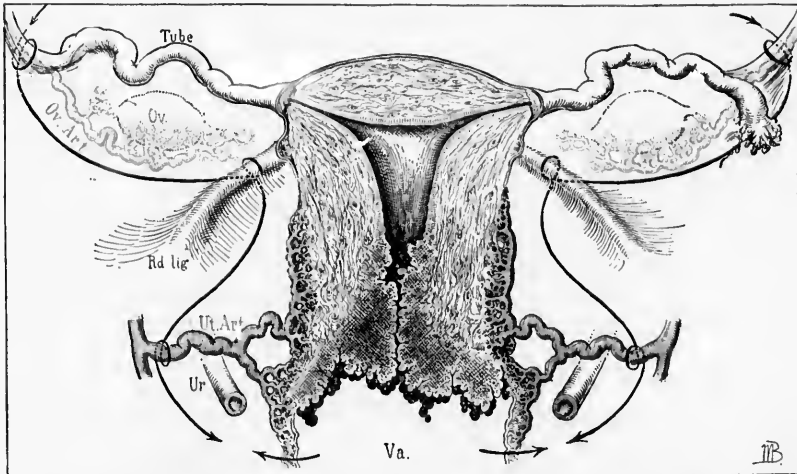


FIG. 467.—OUTLINE DIAGRAM OF THE STEPS OF THE RADICAL OPERATION FOR CANCER OF THE CERVIX.

The incisions are made in the directions indicated by the arrows, following the black lines. The loops indicate the positions of three important ligatures on either side. The vagina (*Va*) may be opened from either side, from within out, as indicated, or from without in. *Ur* is the ureter, behind which the uterine artery is tied.

The succeeding steps in the operation are the most difficult and the most critical, for the operator has now to ligate the uterine arteries at a point distant from the uterus, to free the ureter from its relations to the pelvic connective tissue, to ligate the large uterine veins, and to dissect out, with the lower segment of the uterus, the entire mass of pelvic connective tissue between the cervix and the pelvic walls, sometimes including a chain of large glands.

The best place to ligate the uterine artery is well back in the pelvis at its origin from the anterior branch of the internal iliac; at this point, although not far from the ureter, it lies more parallel to it and is not so difficult to isolate as it is in the neighborhood of the cervix, where it is surrounded by large veins,

and where the ureter crosses beneath it at a right angle. The artery is exposed by separating the anterior and posterior layers of the broad ligament and separating the cellular tissue by a blunt dissection, which is very conveniently done by a three-pronged instrument like a small pitchfork, all the way down to the



FIG. 468.—HYSTERECTOMY FOR CARCINOMA OF THE CERVIX.

The abdomen is incised and the left broad ligament opened up. The stump of the left ovarian vessels is seen at the pelvic brim, and that of the round ligament in front, by the bladder. The uterus is grasped by museau forceps and drawn forcibly to the right, while a blunt dissection is carried on down to the base of the left broad ligament, exposing the uterine artery and tracing it back to its origin in the loose pelvic cellular tissue. The ureter, splinted by a bougie, is plainly seen and felt on the pelvic floor just beneath the uterine artery.

pelvic floor posteriorly, where the artery may be distinctly felt pulsating. The artery may now be easily isolated, lifted up, and ligated with a fine silk ligature passed by means of an aneurism needle; the artery is cut about half a centimeter beyond the ligature and the dissection continued in toward the cervix.

The operator is able to assure himself of the position of the ureter before ligating the uterine artery, either by means of the bougie, or when it has not been possible to introduce the bougie, by simply gathering up the uterine artery and the tissues parallel to it between the thumb and forefinger and letting them slip between the fingers; the flat cordlike sensation of the ureter caught in this way is perfectly characteristic, and it is not necessary to see it to know where it is and to feel assured that it is out of the way of harm.

The uterine artery, tied and divided as described, is now caught by a pair of artery forceps and drawn up, and the dissection of the cellular tissue continued down toward the uterus, at first keeping close to the pelvic wall, so as to leave

no tissue between it and the cervix; during this enucleation the course of the ureter is kept constantly in view, and wherever the dissection encroaches upon it, it is freed without injury. It is especially important not to bruise the coats of the ureter, and not to cut the little tortuous artery on its external surface, in order to avoid the risk of the sloughing of its coats subsequent to the operation and the formation of a uretero-vaginal fistula.

As the dissection is continued on down toward the vaginal vault below the cervix, the detached tissue, which began in a point with the uterine artery, widens out into a broad-based cone, attached to the cervix like a wing.

Down on the floor of the pelvis two or three large veins, often a centimeter in diameter, are exposed and tied; one of these veins is usually found lying below the ureter at a point where it would not be expected, and is therefore more liable to injury before ligation. Care should be taken to ligate the veins both distally and proximally, or at least to clamp them on their distal side.

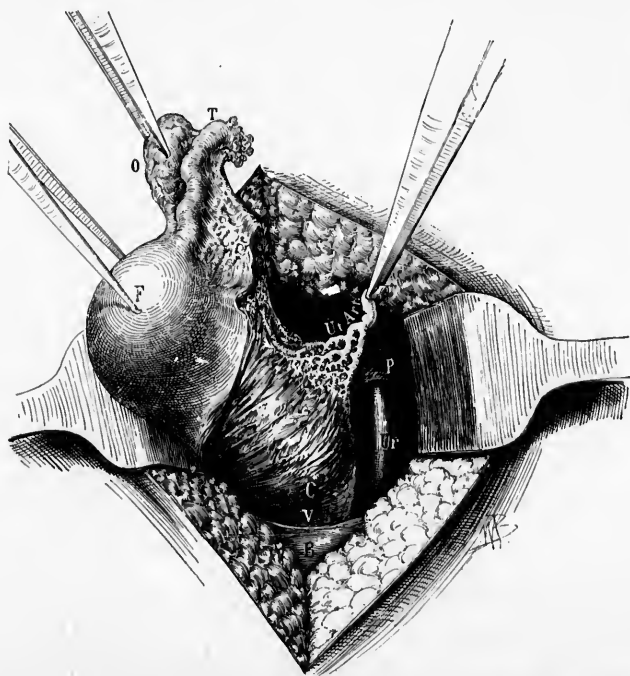


FIG. 469.—The uterus (*F*) is pulled farther to the right, and the uterine artery tied, cut off, and dissected away from the ureter (*Ur*) with a mass of pelvic cellular tissue and glands (not shown). *P*, posterior layer of the peritoneum; *B*, bladder; *C*, cervix; *V*, vagina.

This extensive detachment of the cellular tissue should be completed on both sides before proceeding with the final steps of the enucleation.

Enlarged glands should always be looked for on the pelvic floor and close to

the pelvic wall; they can best be recognized as hard nodules in the soft cellular tissue by the sense of touch; if any are found, they can be dissected out in chains along with the cellular tissue.

The next step is the final one in the enucleation—the amputation of the vaginal vault and the removal of the uterus and as much of the vagina as it is necessary to extirpate with it. When the carcinoma affects the body of the uterus alone the vaginal vault may be opened at any convenient point near the cervix. But when the disease affects the cervix, then the point of amputation of the vagina must be determined with great care at the examination made before the operation; under all circumstances the amputation must be made at least 2 centimeters below the lower margin of the disease. The danger of leaving a considerable portion of a carcinoma extending downward into the vaginal epithelium is well shown in Fig. 451. Before opening the vagina the posterior pelvis must be packed with gauze in such a way as to take up at once any discharges escaping from the wound.

It is my plan always to determine the exact position and the limits of the vagina by percussing it lightly with the forefinger, when it is easily recognized by the tympanic sound.

The vagina is best opened first in front with a thermo-cautery knife at a dull heat, because this checks the bleeding from all but the largest vessels, and so saves a great deal of time which must otherwise be spent in encircling the vagina with ligatures. As rapidly as the vagina is cut through with the cautery its edges are grasped by artery forceps, which serve at the same time to control any hemorrhage.

As soon as a free opening is made into the vagina a loose iodoform-gauze pack is stuffed into it to take up any secretions, and when the separation between the uterus and vagina is carried a little farther still, a gauze pad is bound around the cervical end of the uterus to prevent any contamination of the wound from that source. Should there, however, be contamination, in spite of these precautions, the operator must instantly take a sponge or piece of gauze and wipe off the surface very carefully and thoroughly. Any knife or other instrument used in cutting carcinomatous tissue should be put aside and not used again until sterilized. The specimen removed should be put into a hardening solution at once and carefully studied, devoting particular attention to the cut surfaces. If the disease extends right out to the edge, the probability of a rapid return will, of course, be much greater.

The operator then washes his hands thoroughly, and proceeds to control the vaginal vessels by passing as many catgut ligatures as are needed for the purpose through the outer tissues of the vagina in a direction perpendicular to its long axis.

The pelvis is now carefully examined for other enlarged glands either lying on or under the iliac vessels, at the bifurcation of the common iliac artery, or just above it. Wherever these are found they should be removed. Enlarged glands lying upon the internal or external iliac veins can often be removed only with extreme care and by painstaking dissection. In one instance I found the gland semilunar in form and closely pressing upon the external iliac vein whose

form it had taken; it was only detached by a minute slow dissection, but the separation was finally satisfactorily made. If a vein is torn off at its point of entrance into the external or common iliac veins the opening should be closed

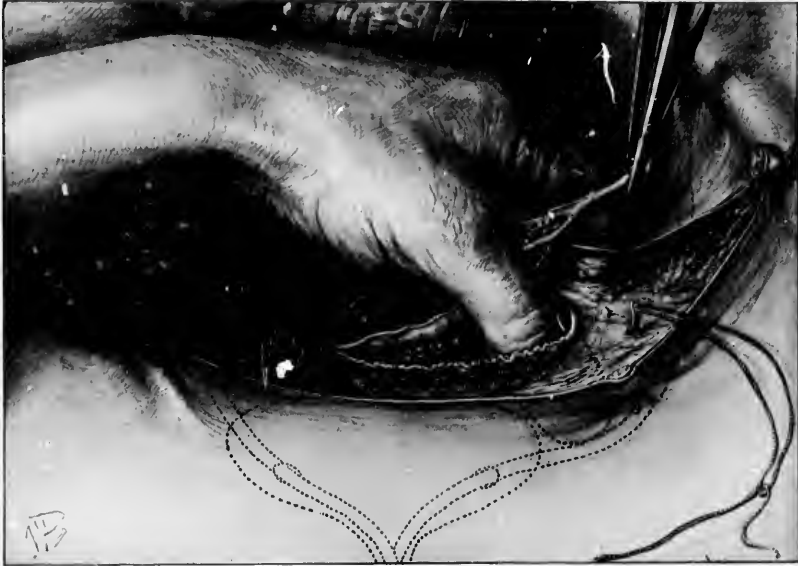


FIG. 470.—After freeing the bladder and dissecting out the left broad ligament, the vaginal vault is opened anteriorly and all hemorrhage controlled by a series of sutures placed as shown in the figure. The bladder and ureters, with bougies, are shown in dotted outlines.

by a fine suture with a fine needle, folding the wall of the vein upon itself, in this way avoiding the necessity of ligating the large trunk with the attendant risk of gangrene below it.

A thorough inspection of the whole area exposed and of all the ligatures applied to important vessels is now made as a distinct and most important step in the operation; in this inspection the operator should assure himself as far as possible as to the thoroughness with which the disease has been extirpated, he should discover any persistently bleeding points and control them with ligatures, and, above all, he should see that all the large vessels are securely tied and should reinforce any doubtful ligatures.

The anterior and posterior semilunar lines of peritoneum which border the wound area in front and behind are now brought together by a continuous cat-gut suture, beginning at the pelvic brim on one side and extending down across the pelvic floor and up to the brim on the opposite side, where the suture is tied.

If the possibility of contamination has been excluded throughout the operation the abdominal incision may now be closed by the three layers of sutures, to the peritoneum, fascia, and skin; but whenever there has been any contamina-

tion from the uterus or vagina the operation should not be concluded without first thoroughly washing out the pelvis with normal salt solution with the patient in a horizontal position.

A loose gauze pack is now pushed up through the vagina and through the opening at its vault to give support to the peritoneum and to drain the wound; at the same time the vagina should be loosely filled with a similar pack.

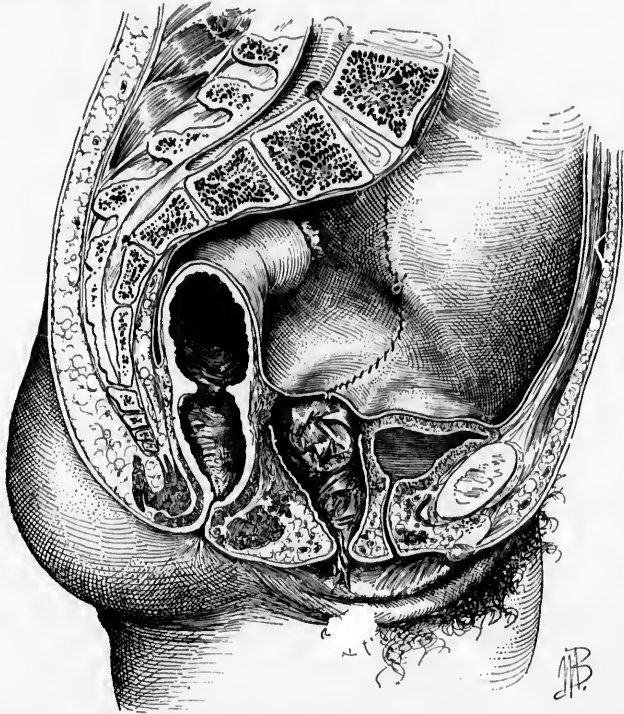


FIG. 471.—SAGITTAL SECTION, SHOWING THE LEFT SIDE OF THE PELVIS, WITH THE OPERATION COMPLETE.

The anterior and posterior peritoneum is united by a continuous catgut suture. The stump containing the ovarian vessels is seen at the pelvic brim, this is usually turned under and concealed; the sutured peritoneum above this has been opened in order to dissect out the enlarged iliac glands. The vaginal vault is not closed, but a gauze pack is placed in the vagina and up under the peritoneum.

Shock from the prolonged operation must be sedulously guarded against by keeping the patient well wrapped in woollens, and with hot-water bottles about her during its performance, by giving hypodermics of strychnin at suitable intervals, by avoiding all unnecessary delay, so as to make the anesthesia as short as possible, and by giving a hot stimulating rectal enema just before she goes off the table.

For anemia and hemorrhage it will be best to infuse from 500 to 800 cubic centimeters of normal salt solution into the cellular tissue under the breast, during or at the close of the operation.

When the operation is complicated by an extension of the disease down the anterior vaginal wall or into the base of the bladder, this may be met by a wider excision at this point, even cutting out, if need be, a large part of the base of the bladder. After completing the enucleation the clean-edged wound in the bladder may then be brought readily together by interrupted sutures of fine silk, passing through all its walls except the mucosa. Care must of course be taken not to injure the ureters at their entrance into the bladder. When the disease extends out laterally or posteriorly onto the rectum farther than the operator has anticipated, the extirpation sometimes becomes a very difficult one. It is particularly hard to make any satisfactory dissection in thickened tissues about the rectum, unless the patient happens to be thin and the pelvis shallow. When

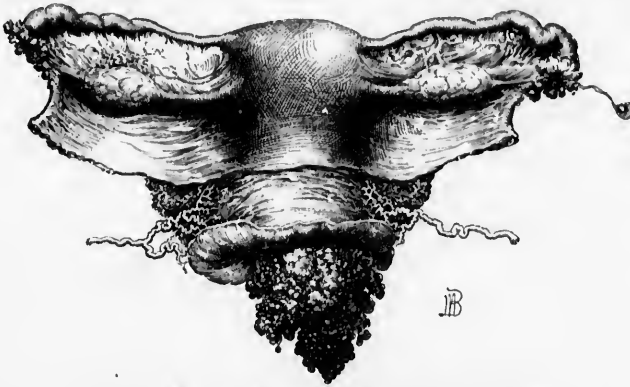


FIG. 472.—EPITHELIOMA OF THE CERVIX IN GRAPELIKE MASS.

Showing the extensive removal of the uterus and broad ligaments by the abdominal method. No. 741. $\frac{3}{8}$ natural size.

there is much lateral infiltration the embarrassment from the hemorrhage in cutting through the infiltrated tissue is sometimes so great that the operator has to abandon all idea of radical relief, and finish the operation the best way he can. I operated upon a case of this kind Oct. 16, 1893. The patient (S. L., 2248) had a large friable carcinoma of the cervix, but no infiltration of the broad ligaments could be felt. On opening the abdomen, strong velamentous adhesions from the sigmoid flexure to the posterior surface of the uterus were freed by dissection with the knife, the left ovary and tube were then dug out of a bed of dense adhesions, and the ovarian vessels ligated and the enucleation begun. The right ovary was also dissected out of a bed of adhesions, and the rectum freed from adhesions binding it over the internal iliac artery. As the operation proceeded, it was found impossible to extirpate the disease in the broad ligaments and to check the free oozing from the diseased tissue which was cut; in order, therefore, to control the entire blood supply going to the part, I ligated both internal iliac arteries at a point 1 centimeter below the bifurcation of the common iliacs. After the ligation all pulsation in the pelvis on both sides

ceased below the ligatures. On the left side the ureter was first located and drawn up and out of the way while the ligature was being passed. On the right side there was a marked hydroureter, but I nicked the peritoneum over the ureter and drew it out toward the median line while the artery was being tied; on con-



FIG. 473.—UTERUS ENUCLEATED PER VAGINAM, TO CONTRAST WITH THE UTERUS ENUCLEATED FROM ABOVE, FIG. 472.

Showing the great difference in the amount of tissue removed.

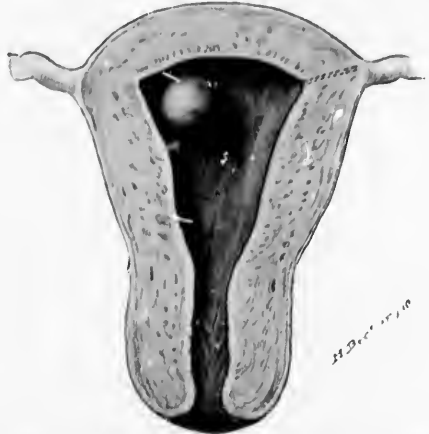

FIG. 474.—SMALL SARCOMA IN THE RIGHT HORN OF THE UTERUS.

Diagnosis made by curettage; hysterectomy, the patient living without recurrence five years after operation.

inning the dissection of the diseased mass this ureter was liberated from a bed of cancerous tissue, involving its course for 5 centimeters. The patient made a good recovery and suffered in no way from the artificial pelvic anemia, and the disease returned so slowly that she lived over two years after the operation.

Sarcoma of the Uterus.—Sarcoma of the uterus is a connective tissue growth of malignant type occurring at all ages.

For clinical convenience, sarcoma of the uterus may be divided into sarcoma originating in the cervix and sarcoma commencing in the body.

Sarcoma of the Cervix.—In rare instances this disease appears like bunches of grapes springing from the cervix, as first described by Spiegelberg in 1879, who reported the case of a girl seventeen years of age. The anterior cervical lip was thickened and enlarged, and covering its margins and surface were oval, yellowish-brown outgrowths, 1 or 2 centimeters in length. These looked like transparent cysts, were easily crushed, and contained a thick, sticky fluid. The girl returned nine months later with the entire vagina filled by the growth, which resembled a hydatiform mole. Weigert, who examined the tissue microscopically, found these cystlike masses covered by a single layer of cylindrical

epithelium, and their interior composed of large, round, spindle-shaped and branching cells, separated from one another by clear spaces.

I have seen but one similar case, in a woman about thirty years of age, where, springing from the cervix and hanging down into and filling the vagina, was a growth resembling a bunch of grapes. In my case amputation of the cervix was followed by a speedy recurrence, invasion of the surrounding tissues, and death.

Dr. J. W. Williams, who has collected these cases, says that in the majority of instances this variety of the disease manifests itself before the twentieth year or after the menopause. In only three cases did it occur between these periods.

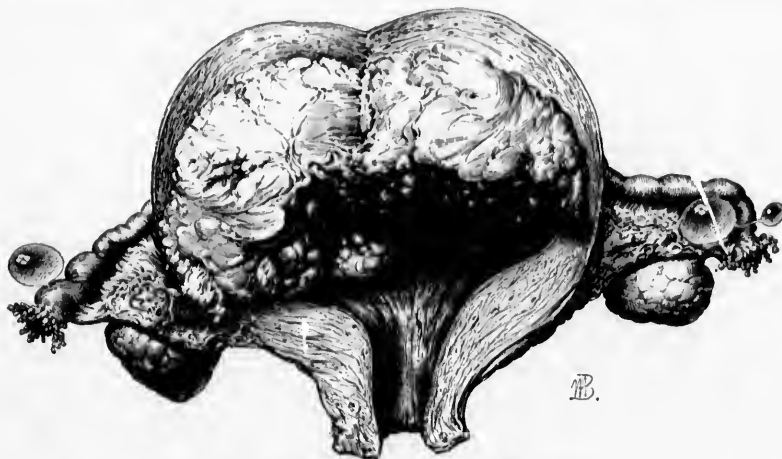


FIG. 475.—SARCOMA OF THE BODY OF THE UTERUS.

The upper two thirds of the uterine body is distended with mulberry-shaped tumor masses resembling brain tissue, and quite vascular. The line of junction with the uterine wall appears sharply defined, but under the microscope metastatic nodules were found in the lymphatics of the left uterine cornu. San. 204, Operation, April 30, 1895. No recurrence, Feb., 1898. $\frac{1}{2}$ natural size.

Spindle-celled Sarcoma of the Cervix.—Only one case of this variety has come under my notice. The patient was thirty-eight years of age, had been married twenty-one years, and was the mother of eight children. Four months before admission she suddenly began to have copious uterine hemorrhages, which gradually ceased, but a watery discharge persisted.

On vaginal examination, the cervix was found to be the seat of a new growth, which was hard, nodular, and filled the entire vaginal vault. The disease was clearly ineradicable, but the excess of tissue was enretted away. Histological examination showed that it was a large spindle-celled sarcoma.

Endothelioma of the Cervix.—This is an exceedingly rare condition, not more than five or six cases having been recorded. In all of our cases of malignant growths of the cervix only one has belonged to this group. The cervix in this case measured 4.5×3.5 centimeters, and was markedly indurated,

while the external os was represented by a craterlike excavation 2.5 × 2 × 2 centimeters. The floor of the excavation was roughened, but there was no evidence of softening or friability until the upper part of the cavity was reached.

On histological examination, the typical picture of an endothelioma was found.

Sarcoma of the Body of the Uterus.—This is a rare disease when compared with adeno-carcinoma of the uterus, as shown by Williams, who in 1894 was able to collect but one hundred and forty-four cases from the literature, including both those arising from the cervix and the body. These sarcomata may be divided into two groups, those affecting the mucosa and those arising in the parenchyma.

The growth usually springs from the upper part of the uterine cavity, and although it may be diffuse in character, is usually sharply defined. If detected

in the early stage (see Fig. 474) it may consist of one rounded or oval nodule, but if larger it may be lobulated, as is well shown in Fig. 475. On cutting the sarcomatous nodule it usually presents a smooth, homogeneous surface not often traversed by broad trabeculae, as seen in adeno-carcinoma.

During the last four years there have been three cases of sarcoma of the body occurring in my clinic, two round-celled and one spindle-celled sarcoma.

Histologically the attention is at once drawn to the large areas of the growth showing practically no necrosis and perfectly preserved. The tissue is composed of a homogeneous mass of cells with little intervening stroma; the cells have round vesicular nuclei and are remarkably uniform in size; traversing the growth are many delicate blood capillaries which ramify in all directions, dividing the tissue up into alveoli. If necrosis takes place it is usually along one margin, the underlying growth remaining intact.

Secondary Sarcoma of the Uterus.—The uterus is occasionally

secondarily involved by a sarcoma of the ovary. In 1894 I operated on a patient where there was a large friable tumor occupying the right side of the pelvis; it penetrated the uterus and formed a large mass in the uterine cavity, while a portion of the growth projected through the external os. Dr. Cullen examined this case and found that it was an angio-sarcoma of the ovary

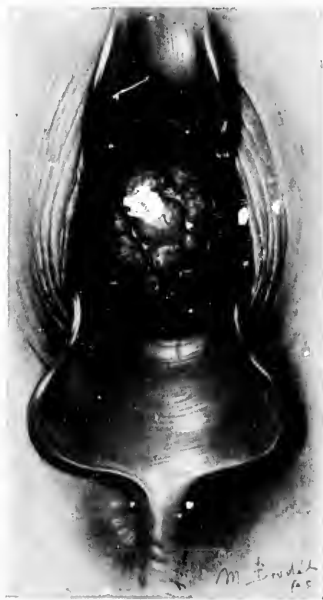

FIG. 476.—SARCOMATOUS NODULE IN THE VAGINA.

Secondary to sarcoma of the uterus and right ovary. Op. Feb. 5, 1896. $\frac{3}{4}$ natural size.

with secondary involvement of the uterus. See *Johns Hopk. Hosp. Bul.*, Dec., 1894.

A second most instructive case occurred in 1896. As seen from an examination of Fig. 476, a lobulated and smooth mass projected from the cervical canal, and Fig. 478 shows that the uterine cavity was also filled with large and small lobules of a new growth. Reference to Fig. 477 shows that the growth



FIG. 477.—SARCOMA OF THE UTERUS (U) AND RIGHT OVARY.

The left ovary (Ov) and tube (T) are intact. The right ovary is converted into a mass of large nodules, choking the pelvis, covered by adhesions, and attached to the omentum, part of which is left on it. Feb. 5, 1896. No. 1054. $\frac{1}{2}$ natural size.

commenced outside of the uterus, and that this organ was secondarily involved. The microscopical examination demonstrated that the growth was a spindle-celled sarcoma, originating in the ovary.

The disease extends by contiguity of tissue, by the veins, and by the lymphatics; the extension is often found in the direction of the vagina, which then contains a number of bluish or reddish nodules of various sizes.

The tendency is to break down late and to discharge blood and watery fluid with the cell *débris*.

The diagnosis is made from a microscopic examination of scrapings or of a piece cut out of the tumor. The patient complains of discomfort and sometimes of hemorrhages, and on examination a uterine tumor is found which under the microscope proves to be a sarcoma. Hemorrhage is by no means a constant symptom; in one of my cases, too far gone for any operation, there had never been any hemorrhage at all.

Cachexia and pain are usually well marked when the growth is large.



FIG. 478.—SARCOMA OF THE UTERUS (SECONDARY TO SARCOMA OF THE OVARY) CUT OPEN IN FRONT.

The sarcoma forms a smooth lobulated mass completely filling the uterine cavity. Over many of the nodules the mucosa is still preserved. Feb. 5, 1896. Path. No. 1054. Natural size.

In another case, operated upon in 1893 and still living, the patient had frequent hemorrhages, and a diagnosis of sarcoma was made from enretted specimens; on removal, a little tumor, 12 millimeters in diameter, was found in the right uterine cornu.

While the naked-eye appearances are often characteristic they may also prove so deceiving that the microscope must be looked upon as the one certain means of making a diagnosis.

In one instance, for example, I was in serious doubt whether the tumor, situated on an inverted fundus, was a myoma or a sarcoma. In general appearance the tumor was slightly lobulated, edematous, friable, and without any

capsule at all; and on detaching it from the fundus an irregular ragged base was left behind. The tissue was pale and waxy and tore in parallel striæ; in short, the tumor to the naked eye closely resembled a sarcoma, but the microscope showed that it was an edematous myoma.

The operation for the extirpation of a sarcomatous uterus consists in a wide enucleation, the same as that for carcinoma just described.

CHAPTER XXXI.

MYOMECTOMY—HYSTERO-MYOMECTOMY.

1. Definition.
2. Clinical characters of fibroid tumors.
3. Kinds and sites of myomata. 1. Submucous. 2. Interstitial, or intramural. 3. Subserous, or subperitoneal. 4. Fibro-cystic tumors.
4. Form peculiarities.
5. Diagnosis. Examination, under anesthesia, if the tumor is small; sounding the length of the uterine cavity.
6. Palliative treatment. 1. Relief of pressure symptoms. 2. Hemorrhage: *a.* Curettage. *b.* Galvanism.
7. Indications for abdominal operations upon the myomatous uterus.
8. Myomectomy. 1. Definition. 2. Cases suitable for. *a.* In general, always the operation of election in young women, in the absence of other complications. *b.* In particular. (1) All pedunculate myomata, where the removal of the tumor will leave a normal uterus. (2) All subserous or interstitial tumors which are well defined in relation to the body of the uterus, whether single or multiple. (3) Multiple small myoma. (4) Broad ligament myomata where the tubes and ovaries are not diseased. (5) Cornual myomata. (6) Submucous myomata too large to take out *per vaginam*. 3. Operation: *a.* Exposure of tumor. *b.* Incision of capsule or pedicle. *c.* Temporary control of hemorrhage. *d.* Enucleation. *e.* Permanent control of hemorrhage—ligature and suture. *f.* Closure of incision, suturing the angles. *g.* Closure of abdominal incision without a drain. *h.* Dangers of the operation—hemorrhage and sepsis. 4. Pedunculate myomata. 5. Subserous, sessile, and interstitial myomata. *a.* Removal of large interstitial myoma without sacrificing any uterine tissue. *b.* Eight subserous and interstitial myoma removed by seven separate incisions. *c.* Cornual myoma. 6. Extirpation of submucous myomata per abdomen.
9. Hystero-myomectomy. 1. Indications for. 2. Operation: *a.* Preliminary preparation. *b.* Opening abdomen. *c.* Delivering tumor. *d.* Ligation of left ovarian vessels and left round ligament. *e.* Detachment of the vesico-uterine fold from side to side, and pushing it down, separating bladder from cervix. *f.* Ligation of left uterine vessels. *g.* Amputation of uterus in cervical portion, leaving a cup-shaped pedicle. *h.* Clamping uterine artery of right side, clamping right round ligament, clamping right ovarian vessels, followed by removal of tumors. *i.* Application of ligatures in place of forceps. *j.* Saturing the stump. *k.* Covering wound area with vesical peritoneum. *l.* Cleansing peritoneal cavity. *m.* Closure of abdomen without drain.
10. Complications of hystero-myomectomy. 1. Complications due to adhesions and affections of surrounding structures. *a.* Inflammatory. (1) Simple adhesions of tubes and ovaries. (2) Hydrosalpinx. (3) Pyosalpinx and abscess of ovary. (4) Encysted peritonitis. (5) Omental adhesions. (6) Parietal adhesions. (7) Adhesions to rectum, sigmoid, colon, and small intestines. (8) Adhesions to vermiform appendix. (9) Adhesions to liver and suspensory ligament. *b.* Tumors of the ovary. (10) Ovarian cystomata. (11) Dermoid cysts. (12) Fibroid ovary. (13) Ovarian hydrocele. (14) Ovarian hematoma. (15) Carcinoma of the ovary. *c.* Diseases of the cervix and uterine mucosa. (16) Cancer of the cervix. (17) Cancer of the uterus associated with myoma. (18) Tuberculosis of the endometrium. 2. Complications due to changes in the tumors themselves. (19) Cysto-myoma. (20) Telangiectatic myoma. (21) Suppurating myoma. (22) Cystic myoma, with twisted pedicle. (23) Adenomyoma uteri diffusum benignum. 3. Complications due to location of tumors. (24) Elevation of tubes and ovaries high out of pelvis. (25) Globular myoma filling pelvis. (26) Myomata wedged in pelvis. (27) Myoma below vesical peritoneum. (28) Myoma below posterior pelvic peritoneum. (29) Myoma in upper part of broad ligament. (30) Myoma in broad ligament proper. (31) Myoma developed antero-laterally, twisting uterus. (32) Myoma developed postero-laterally. (33) Myomata developing under the pelvic peritoneum in several of these positions at once. (34) Myomata displacing the ureters upward. 4. Complications due to pregnancy, ascites, and other causes. (35) Myoma with pregnancy. (36) Myoma simulating pregnancy. (37) Myoma and ascites, feeble heart, nephritis, etc.

Definition.—Myoma of the uterus, fibroid tumor or fibro-myoma of the uterus, is an atypical nodular growth springing from some portion of the uterine



DESCRIPTION OF PLATE XIX.

INJECTED SPECIMEN SHOWING THE VASCULAR SUPPLY OF UTERUS—INTERNAL AND EXTERNAL.

The tumors are embedded in a vascular hypertrophied uterus which is deeply injected. The pedunculate subserous tumor above which has been divided, shows a fascicled arrangement of the large injected vessels surrounding its base on the left side the vessels are seen penetrating the substance of the tumor between its lobes; the distal portion is necrotic. The large internal tumor is seen every where penetrated by small capillaries and there are a few large vessels near the outer margin and the center. There is a remarkable contrast between the vascular supply of the uterus and that of the tumor which is partially subserous. The uterine cavity is further occupied by sessile and pedunculate subserous tumors each of which shows a beautiful vascular coronas; on the free surface of the upper tumor there is a leaf of large vessels. The atrophy of the mucous membrane over these growths is in contrast with the unaltered mucosa of the rest of the uterus. Specimen injected by Dr. J. G. Clark to demonstrate the source of hemorrhages from the uterine mucosa.



CHAPTER XXX

MYOMECTOMY—HYSTERO-MYOMECTOMY

1. Definition
2. Classification of myoid tumors
3. Kinds and locations of myoid tumors. 1. Submucous. 2. Interstitial. 3. Subserous or subperitoneal. 4. Fibrocystic tumors.
4. History of the disease
5. Diagnosis

DESCRIPTION OF PLATE XIX.

6. INJECTED SPECIMEN SHOWING THE VASCULAR SUPPLY OF MYOMATA—SUBMUCOUS, INTERSTITIAL, AND SUBSEROUS.

The tumors are embedded in a vascular hypertrophied uterus which is deeply injected. The pedunculate subserous tumor above, which has been divided, shows a tessellated arrangement of the large injected vessels surrounding its base; on the left side the vessels are seen penetrating the substance of the tumor between its lobules; the distal portion is anemic. The large interstitial tumor is seen everywhere penetrated by small capillaries, and there are a few large vessels near the outer margin and the center. There is a remarkable contrast between the vascular supply of the uterus and that of the tumor which is partially submucous. The uterine cavity is further occupied by sessile and pedunculate submucous tumors, each of which shows a beautiful vascular corona; on the free surface of the upper tumor there is a leash of large vessels. The atrophy of the mucous membrane over these growths is in contrast with the unaltered mucosa of the rest of the uterus. * Specimen injected by Dr. J. G. Clark to demonstrate the source of hemorrhages from the uterine mucosa.

7. Duration of abdominal operation
8. Myomectomy. 1. Definition. 2. Indications. 3. Contraindications. 4. Preparation of patient. 5. Operation. 6. Results. 7. After-treatment. 8. Complications.
9. Myomectomy of the uterus. 1. Submucous. 2. Interstitial. 3. Subserous. 4. Fibrocystic. 5. Results. 6. After-treatment. 7. Complications.
10. Complications of hysteromyomectomy. 1. Hemorrhage. 2. Infection. 3. Adhesions. 4. Sterility. 5. Pain. 6. Shock. 7. Death.

Definition—Myoma of the uterus, fibroid tumor or fibro-myoma of the uterus, is an atypical nodular growth springing from some portion of the uterine





body, usually above the cervix, varying in size from a microscopic node to that of a mass or masses choking the whole abdominal cavity. The tumor is made up of a disorderly interlacement of muscular and connective-tissue fibers, in the larger masses grouped into more or less well-defined spherical nodules.

Between the groups of fibers run arteries, veins, and lymph channels derived from the normal vessels of the uterus, ramifying at first beneath the capsule of the tumor and then plunging directly into its interior. Isolated tumors within the uterine walls are well circumscribed and surrounded by the normal muscular fibers; tumors projecting through the muscular wall become covered on the uterine side by the mucosa, and on the abdominal side by peritoneum.

Clinical Characters of Fibroid Tumors.—Although all myomata probably exist in fetal life in diminutive form, they rarely give evidence of their presence until menstruation has been established for some years. Marked indications of their existence usually occur about middle life, from thirty-five, with increasing frequency, up to forty-five years of age.

The earliest clinical signs are painful menstruation, excessive at the menstrual period, and in married women sterility, and repeated early miscarriages.

The tumors, at first occupying the pelvis, as they grow extend toward the abdomen, and growing slowly do not as a rule attract attention by their size until they have exceeded the capacity of the pelvis, and occasion a symmetrical or nodular enlargement of the lower abdomen evident upon inspection, and still more upon palpation.

The rate of growth is variable; it is sometimes so slow as to require ten, fifteen, and twenty years before the tumor attains the size of a uterus at term. Some of the more vascular myomata, however, may even develop perceptibly within a few months.

With the development of the tumors there is often an enormous hypertrophy of the enveloping uterine muscle; for example, in one case the tumors weighed 1,950 grams and the uterus alone, after they were removed, weighed 625 grams.

Profuse menstrual hemorrhage is the commonest as well as the most striking symptom, and occurs in about fifty per cent of the cases. At the beginning it is apt to be confined to an excessive flow at the period, which lasts from five to eight days; although this weakens the patient at the time, it is readily compensated for in the interim; later, as the tumor enlarges, the flow is of longer duration and becomes more excessive in quantity. By this time menstruation, which has been regular although excessive, becomes more frequent, appearing every three or even every two weeks, and leaves the patient prostrated from excessive loss of blood. The most profound anemia from this cause is not uncommon; the patient's skin becomes peculiarly transparent, of a waxy yellow hue, and she suffers from dyspnea, epistaxis, and palpitation, with a sense of utter weakness. A distinct anemic heart murmur marks the profound changes in the condition of the blood.

Pain is a variable symptom; it is most marked when the uterus contains a number of smaller myomatous masses distributed throughout its walls, when

it is usually menstrual in type and of a distressing, grinding, bearing-down character, often likened to severe protracted labor pains.

Disease of the ovaries and tubes is frequently associated with myoma of the uterus, and both ovaries and tubes are often found bound down in the pelvis by old inflammatory adhesions; in this way hydrosalpinx and pyosalpinx are found. This associated inflammatory disease is often present in connection with small tumors, when the pain is doubtless due more to the inflammation and the tugging on the adhesions than to the presence of the tumors.

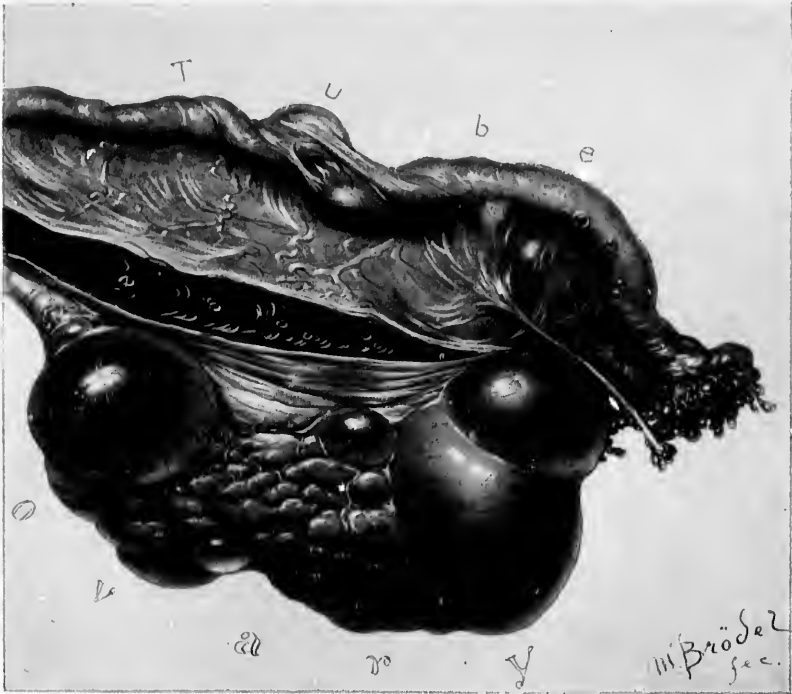

FIG. 479.—GREATLY ENLARGED RIGHT OVARY REMOVED WITH A MYOMATOUS UTERUS WHICH WAS THE SIZE OF A MAN'S HEAD.

At both poles are some large unruptured cysts, and in between a mass of thick cirrhotic ovarian tissue. B., Dec. 6, 1897. Natural size.

The ovaries found in connection with large myomatous uteri often undergo remarkable changes which can scarcely be called disease, although considered by Virchow and others as examples of interstitial oöphoritis and cystic degeneration.

These ovaries are for the most part larger than normal, sometimes peculiarly long and flat; a part of the increase in size is often due to the presence of a number of large unruptured follicles. There is an increase in the number of

the corpora albicantia, with increase in the vascularity and thickening of the vessel walls.

Popow has shown that the changes affect the albuginea (surface of the ovary), the interstitial tissue of the ovary, and the paranehyma (follicles). The interstitial tissue undergoes a marked proliferation, evident in the coarse hypertrophy of the ovary; the follicles are most numerous in some cases and then atrophy (oöphoritis follicularis).

A typical example of these changes seen in an advanced form is shown in Fig. 479, removed with a large myomatous uterus.

Pressure symptoms do not often occur until the tumors are large enough to choke the pelvis, when frequent urination and difficult defecation are common. When a growing tumor becomes incarcerated under the promontory of the sacrum, preventing its escape into the abdomen, these pressure symptoms often become extremely urgent. The examiner must, however, always be on his guard against drawing hasty conclusions from the size and position of the tumor, for it is remarkable how well the rectum is able to maintain a patulous channel under these circumstances. The bladder preserves its function by displacement expanding upward into the lower abdomen, and becoming an abdominal organ.

One of the serious dangers arising from the presence of the larger myomata filling the abdomen, more particularly if they are developed under the pelvic peritoneum, is the production of a hydroureter by pressure at the brim, impairing the function of the kidneys, and inducing hydronephrosis. In a series of one hundred hysteromyomectomies in my clinic, two cases were operated upon on account of periodical attacks of urinary suppression due to pressure on the ureters.

I have seen three cases of pyelonephrosis associated with myomatous uteri where the disease was probably grafted onto a hydronephrosis produced by pressure.

Cancer of the uterus complicating myoma is rare, the malignant disease starting on the uterine mucosa and extending from that point into the myomatous mass. The malignant growth may start either in the cervical or in the corporeal part of the uterus.

Kinds and Sites of Myomata.—One of the most striking and characteristic differences among myomata is the variation in size. All gradations are found, from one the size of a pin head to a mass weighing over a hundred pounds.

The terms large and small may be used in a purely relative sense with regard to the environment of the tumor; for example, we may speak of a uterus not larger than a fist as a small myomatous uterus, but when it is big enough to choke the pelvis and gets wedged in there it is relatively large; if the same uterus escapes into the abdomen it is small in relation to its surroundings, until it attains the size of a seven or eight months' pregnancy, and begins to encroach upon the abdominal viscera.

The mechanical symptoms produced by the smaller tumors are due to pressure on various pelvic organs, while the large tumors often become inconvenient

from their size and weight alone, and in addition derange digestion, deform the thorax, cause difficulty in respiration, and interference with the circulation.

According to the site of the tumor relative to the uterine wall, myomata have long been classified as submucous, interstitial or intramural, subserous or subperitoneal. From a practical standpoint it is important to distinguish these forms, because each is susceptible of a different mode of treatment.

Submucous myomata project into the uterine cavity and are covered over the greater part of their periphery with the uterine mucous membrane. As a result of the growth of the tumor in this direction the uterine cavity becomes proportionately enlarged either in its transverse or in its long axis.



FIG. 1. UTERUS WITH EXTENSIVE MYOMATOUS INVOLVEMENT CHIEFLY INTERSTITIAL AND SUBMUCOUS. Extreme distortion of the uterine cavity. Hystero-myomectomy. Recovery. H. G., March 21, 1901. Natural size.

Interstitial or intramural tumors, situated entirely within the uterine wall, are enveloped on all sides by normal uterine fibers. This form is most apt to become subperitoneal as it grows.

Subserous or subperitoneal tumors develop in the direction of the abdominal cavity and are enveloped for the most part by the peritoneum. Both the subserous and the submucous myomata grow toward the surface and tend to become more polypoid. The submucous tumors may be finally cast off through the cervix into the vagina, while the subserous narrow their attachments down to a thin pedicle and often derive their nutriment from adhesions to other organs.

Fibro-cystic tumors are characterized by an excess of fluid elements, rendering them soft or even fluctuant. This fluid, analogous to serum, is held in enormously dilated lymph channels within the tumor. It coagulates spontaneously on exposure to the air, a clinical feature recognized by the older writers, and considered by them pathognomonic of this variety. This fact, however, is unreliable, because the fluid of a tubercular peritonitis or of a cystic Graafian follicle may also coagulate on exposure. If not extirpated early these tumors often attain an enormous size, larger than any other abdominal growth. In one case reported the mass reached the enormous weight of 195 pounds. Usually the outer covering of the tumor, or of each of the individual component masses, is formed of dense myomatous tissue.

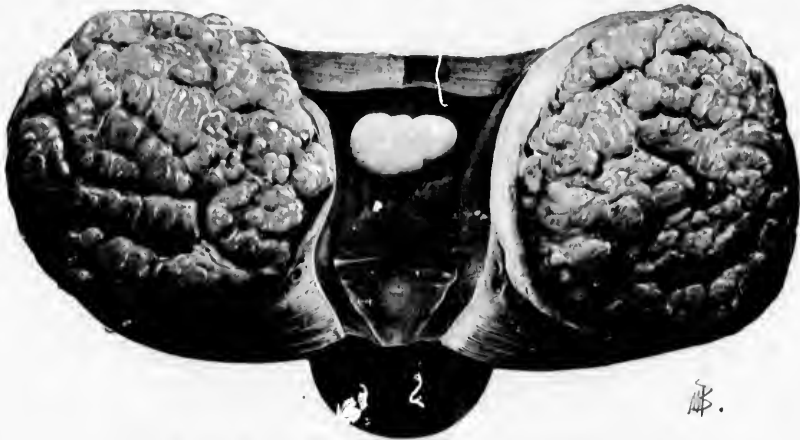


FIG. 481.—MYOMATOUS UTERUS, SHOWING INTERSTITIAL AND SUBPERITONEAL MASSES.

The subperitoneal tumor is half concealed behind the opened cervix. Note the large uterine cavity with a smooth surface presenting a number of translucent vesicles in the lower portion, and on the lower border of the mucous polyp lying within the uterine cavity. Note also the large vessels laid open opposite the internal os uteri. Pl. sh. No. 325. $\frac{7}{8}$ natural size.

The life history of a myomatous tumor is well illustrated by a case which was followed for twenty-seven years, from the time it was first observed to the operation which I performed in May, 1894.

The patient (J. S. S., San. 107), the daughter of a prominent physician, discovered an abdominal tumor in 1867 when in her twenty-seventh year. Two years later she was examined by Dr. Washington L. Atlee, who left the following notes and drawing of the relations of the tumor to the uterus, for which I am indebted to his son-in-law, Dr. J. M. Drysdale, of Philadelphia.

NORFOLK, VA., June 24, 1869.

"To-day I examined Miss ——. She is as large as a lady seven months advanced, shape uniform, tumor round and prominent, hard, non-elastic, movable, not sensitive, crosses both hip bones and upward to the hypochon-

dria. The superior strait of the pelvis is occupied by the same tumor, and in the posterior part the cervix uteri is felt. It is shortened in length, folded against the tumor in front, soft. The sound enters to the distance of eight or nine inches.

“The following diagrams will explain things” (see Fig. 482):

When I saw the patient in May, 1894, twenty-five years later, the abdomen was enormously distended by a great symmetrically disposed tumor, the top of which was 48 centimeters (19 inches) from the level of the bed as she lay on her

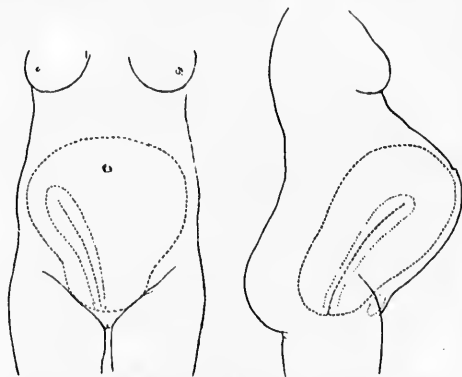


FIG. 482.—These diagrams are copies of sketches made by Dr. Washington L. Atlee in 1869. It is important to note the length of the uterine cavity and the intimate relations of the myoma with the uterine walls. When seen by me twenty-five years later, the uterus was of normal size, and the enormous tumor was attached to the fundus by a pedicle 1 centimeter long.

back. Her circumference at the umbilicus was 128 centimeters (51 inches) and she measured 114 centimeters (45 inches) from umbilicus to ensiform cartilage. Ascitic fluid was felt in the flanks. She had an umbilical hernia with an opening 6 by 7 centimeters (2½ by 3 inches), and a tender, round mass under the right ribs which was a distended gall bladder. She was suffering acutely with renal colic due to suppression of the urine from pressure on the ureters.

At the operation, May 12, the small uterus was found crowded down on the pelvic

floor, and the enormous fibroid mass, weighing 59 pounds, was attached to the anterior uterine wall by a pedicle 1 centimeter long and 3 by 2 centimeters broad, nourished by three enormous arteries ½ centimeter in diameter, coursing superficially over the anterior part of the fundus.

The tumor was extirpated after a long and difficult operation, on account of the numerous vascular ventral adhesions. The gall bladder was also opened and a quantity of pus evacuated.

She made an uninterrupted recovery and is now living in perfect health.

The great interest attached to this case is the entire change in position assumed by a tumor already of great size.

Dr. Atlee's record shows that in 1869 the tumor involved the whole body of the uterus, lengthening out its cavity 9 inches. When I examined it, twenty-five years after, in spite of its immense size, it had become extruded from the grasp of the uterine muscular tissue, and was so far detached from its broad base as to be left with a comparatively small pedicle.

Broad-ligament myomata develop from the lateral wall of the uterus out between the anterior and posterior layers of the broad ligament and

extend down toward the pelvic floor, and are in reality a variety of the subserous form.

When pedunculated, the myomata vary in size from small polyps all the way to huge tumor masses, either submucous or subserous. The pedicle may even be several inches long, but in the subserous form it is rarely over half an inch in length.

Sessile tumors have a broad flat base, often with more than half the growth projecting into the uterine or into the peritoneal cavity.

The number of myomata found in one uterus varies from a single one or several to an indefinite number, when the uterine tissue is converted into a myomatous mass, consisting of a great number of small nodules.

From a practical standpoint the exact location of single tumors, whether cervical or corporeal, is important. With few exceptions it is the fleshy body of the uterus above the neck alone which is involved. When both body and

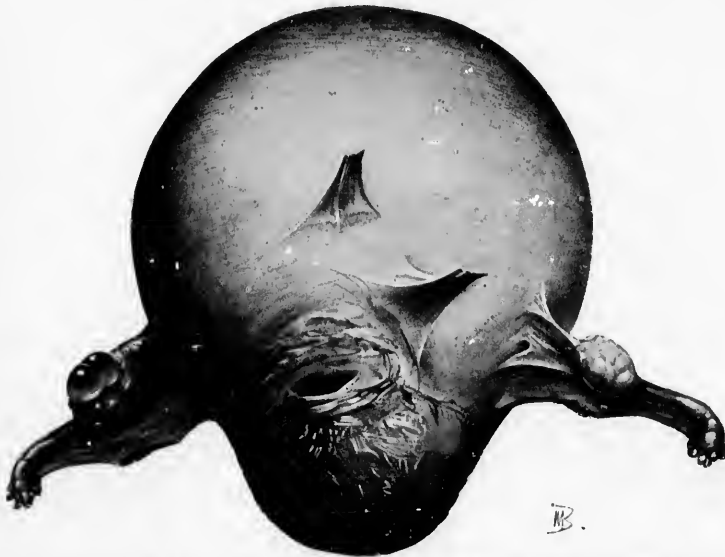

FIG. 483.—GLOBULAR MYOMATOUS UTERUS PRESENTING FORM OF PREGNANT UTERUS AT TERM, WITH ADAPTATION OF THE LOWER PART OF ITS FORM TO THAT OF THE PELVIC CAVITY.

The lower part of the tumor is subperitoneal, and the cervix is displaced up to the level of the pelvic brim. Two peritoneal adhesions are shown above the cervical opening. Seen from behind. Hystero-myomectomy. Recovery. Path. No. 325. $\frac{1}{2}$ natural size.

cervix are involved, the vaginal portion of the cervix is distorted and partially or even entirely obliterated, being represented by a mere dimple on the vaginal wall.

Parasitic myomata are usually pedunculated and depend for a part or the whole of their blood supply upon adventitious vessels of the adjacent

organs. Such tumors are generally large abdominal growths, either entirely detached from the uterus, or connected with it by a small pedicle only, while they are intimately attached to the abdominal walls, intestines, or omentum. Tumors with omental attachments present the most striking characteristics of this group; the omentum forms a fringe around the upper border of the mass, and its congested and tortuous blood vessels are enlarged to the size of goose quills, looking like a cluster of whip cords or a collection of angleworms in the space between the tumor and the transverse colon.

Form Peculiarities.—When unrestrained in its growth a single myoma will assume a more or less spherical form, and retain it until outside influences compel a change. Various restricting influences frequently impress other than a spherical form upon these tumors. Two sets of external forces come into play in this molding process, the hard and the soft parts. Irregular tumor outlines arising from forces within the tumor itself are found when there is a coincident development of a number of these tumors, and when fresh

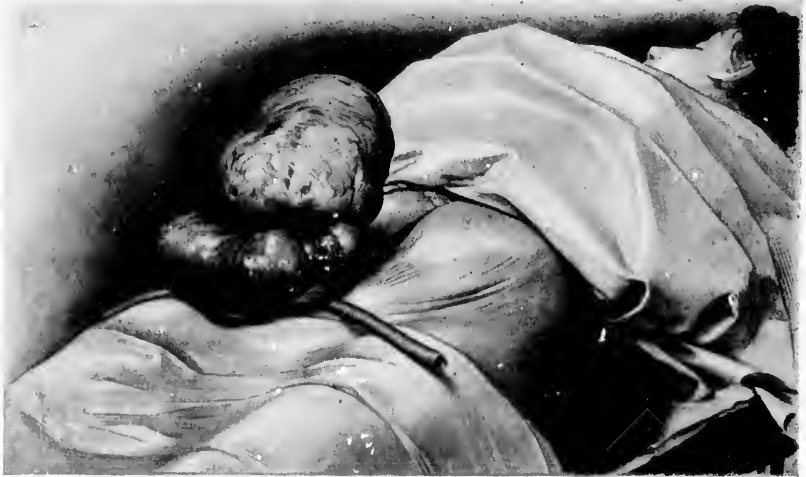

FIG. 484.—MYOMATOUS UTERUS, EXHIBITING A PERFECT CAST OF THE PELVIS.

A rubber ligature has been thrown around the neck of the mass and tied to control the circulation, a procedure no longer employed. The uppermost part of the mass in the picture lay in contact with the pelvic floor, the tumor has therefore been inverted in lifting it out. It is evident that the large upper tumor forms a perfect cast of the sacral curve and the posterior pelvis. Note the irregular masses, in contact with the abdomen just above the rubber tube, which projected out of the pelvis into the abdomen. Hystero-myomectomy. Recovery. Oct. 12, 1892.

nodules bud out on the surface of a tumor, in which case the tumor presents a lobulated or bossed appearance.

The most striking instances of the plastic influence of repeated impacts of the soft parts is represented by the vertical furrows on large tumors due to the pressure of the *linea alba*. The persistence with which the rectum preserves a patulous channel when the pelvis appears to be completely choked is an exam-

ple of the power of a weak force acting with persistent regularity on a more or less resisting body.

A myoma is occasionally detained within the bony pelvis until its cavity is choked with the tumor, which then presents a perfect cast of the posterior part

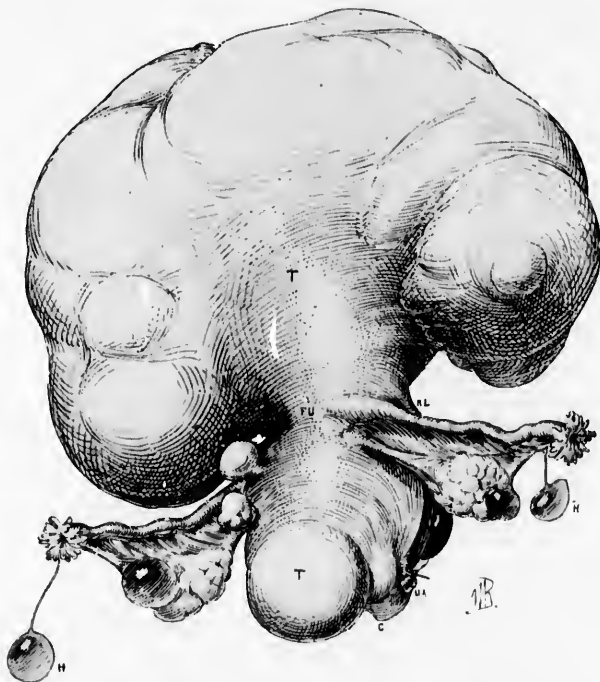


FIG. 485.—LARGE SUPERITONEAL MYOMA, SEEN FROM BEHIND.

Showing remarkable adaptation of form to the vertebral column. *FU*, the fundus of the uterus lay on the sacral promontory, and the mass, *T*, below, lay on the pelvic floor, while *T*, above, lay on the lumbar vertebrae. From *T* to *FU*, to *T*, the form of the tumor is concave, exactly following the vertebral column down to the pelvic floor. The large tumor is also exactly adapted in its form to the lumbar vertebrae from side to side; its concavity thus presents a perfect cast of the lumbar vertebral bodies and the sacral promontory. Hystero-myomectomy. Recovery. Path. No. 498. $\frac{7}{8}$ natural size.

of the pelvis, showing exquisitely the sacral curve and the breadth of the pelvis. The surface appears smooth, but, if examined minutely, slight irregularities due to suppressed budding tumors are evident. This explanation is borne out by the fact that clusters of large spherical nodules often bud out through the superior straight from the main body of the tumor.

Another remarkable evidence of the conformation of myomatous tumors to their environment is seen in the adaptation of some of the larger tumors to the sacral promontory and the projecting bodies of the lumbar vertebrae (see Fig. 485).

Diagnosis.—When a patient complains of painful menstruation, becoming profuse and protracted, and has a history of sterility or early miscarriages, myoma may be suspected. A direct examination to determine the size and shape of the uterus is, however, the only reliable means of deciding the nature of the disease, and in order to detect and locate accurately small tumors, it is necessary to examine the patient under an anesthetic. The inferior lip of the cervix is caught with a corrugated tenaculum or with bullet forceps, and while making traction to draw the uterus down toward the outlet the index finger is carried high up in the rectum above the ampulla. Tumors of small size are felt as little nodules or distinct rounded elevations on the ventral or dorsal surfaces of the womb. I have thus repeatedly detected myomata of less than a half centimeter in diameter high up on the fundus.

I recall one case which had been treated symptomatically twenty-five years for dysmenorrhea and nothing abnormal was detected; when, however, the examination was made under anesthesia *per rectum*, the uterus was found to be full of little myomata.

When the tumor occupies the lower abdomen or fills a large part of the abdominal cavity, more distinct diagnostic signs are observed. The abdomen may have an irregular nodular appearance which is quite characteristic (see Vol. I, Fig. 57), or if the tumor is a symmetrical spherical mass, it often closely simulates a pregnant uterus (see Fig. 483; also Vol. I, Fig. 55). In such a case the history of the long continuance of the growth, often over a period of many years, must be considered in connection with the digital examination in making a diagnosis. One strong peculiarity often present in these myomata is the sharp contour made by the upper border of the tumor as it drops to the chest level with the patient in the dorsal position. The resistance of most myomata to palpation is characteristic—they give the sensation of dense hard unyielding masses; in exceptional cases, however, all the gradations are found from the puttylike through the soft vascular to the fluctuating cystic myomata.

The crucial point in establishing the diagnosis is to determine the relation of the tumor mass to the body of the uterus. This is arrived at by an examination through the vagina in order to determine the position, size, and relations of the cervix to the tumor, and the relations of the tumor to the pelvic cavity. In some cases the cervix projects into the vagina as a rounded knob, and can be traced up to a point where it enters directly into the tumor; in others, the cervix is either completely involved, and is represented simply by a little orifice in the tumor, often drawn high up into the abdominal cavity, or one of its lips remains as a ridge over this orifice, which may be widened into a slit. In cases which present such characteristic signs of myoma, the diagnosis may be made unhesitatingly from the vaginal examination alone. Sometimes the cervix can be traced well above the vaginal vault, and appears to be more or less movable on the surface of the mass

to which it seems to be bound by adhesions. In such cases a rectal examination is required to decide whether the body felt above the vaginal vault and continuous with the vaginal cervix is a small uterus on top of a tumor, or whether it is simply the supravaginal portion of the cervix and the tumor is the enlarged body of the uterus.

In order to make the rectal examination satisfactory, the lower bowel must be emptied by a purgative the night before examination, and by an enema in the morning. The finger introduced into the rectum is assisted by the other hand pressing down through the abdominal walls to determine the size and position of the supravaginal cervix. Particular attention is next given to a study of the relation of the cervix to the tumor by slowly and carefully carrying the finger along the posterior surface of the cervix up to the tumor; this settles the question whether the cervix enters into the tumor or is simply attached to its surface. It must be borne in mind that the distinction between cervix and body is sometimes remarkably emphasized, the body being occupied by the growths, while the cervix remains unaffected and seems to be independent of the tumor. When the cervix is elongated and doubt exists as to whether it is simply a part or the whole of the uterus, the introduction of a flexible sound will settle the doubt by passing directly through the cervical canal and on into the body of the growth.

By grasping the cervix with bullet forceps and drawing it down toward the vaginal outlet, while bimanual palpation is made through the rectum and the abdominal walls, the nature of the connection between the upper limit of the cervix and the mass may be still further determined. A cervix going into the mass will be felt to make a direct pull upon it at the point of entrance, while if the small body above the vagina comprises the whole uterus, it will be drawn down and palpated over its fundus and shown to be attached to the mass simply by adhesions.

Large myomata, except those which are subserous and pedunculate, distort and increase the length of the uterine cavity, and this alteration often constitutes an important factor in establishing the diagnosis.

When the fundus of the uterus can be felt high up on the tumor, or one of the round ligaments is distinguished as a tense cord extending from the main body of the mass down to the inguinal ring, or an enlarged ovary rotated high up and to the front can be distinctly palpated, while the vaginal cervix is felt below, the existence of an elongated uterine cavity is perfectly evident. When none of these landmarks can be recognized with certainty, the length and direction of the cavity can be measured with a flexible hard rubber uterine sound. If the sound does not enter easily under the guidance of the finger, its introduction may be facilitated by catching the cervix and holding it with a pair of bullet forceps.

It is essential during these examinations to observe all the individual peculiarities of the case, which may have an important bearing upon operative treatment or for future comparison to determine whether any changes have occurred; for example, the size of the tumor and the

extent to which it fills the pelvis, whether in one or all directions, should be noted, as well as the condition and size of the cervix and its position, whether in

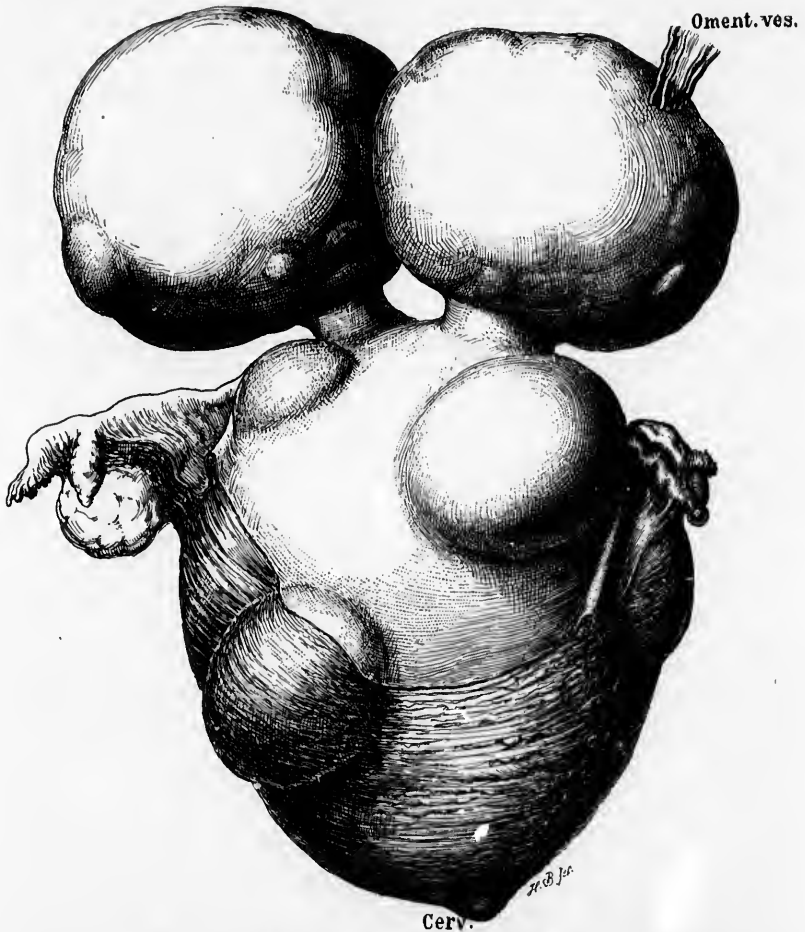


FIG. 486.—PEDUNCULATED MYOMATA, GIVING A PERFECT BALLOTTEMENT. ANTERIOR VIEW.

The uterus contains numerous interstitial and sessile myomata, and on its fundus are two pedunculated tumors about the size of a child's head at seven months. The abdomen was filled with ascitic fluid just sufficient to raise the anterior wall 2 or 3 centimeters away from the tumor on the left. On giving the tumor a slight blow, it disappeared at once, to return again immediately and strike the finger a gentle blow back, perfectly imitating the ballottement of pregnancy. Note the manner in which the enlarged omental vessels plunge directly into the tumor. $\frac{3}{4}$ natural size.

the pelvis or drawn upward into the abdomen. In large tumors the abdominal enlargement should be recorded from the circular measurements of the patient's

body, and a good contour may be made with a flexible leaden tape; the position and size of prominent bosses are also to be described. A sound passed into the bladder will show whether it has suffered any displacement along with the tumor. The degree of mobility of the tumor may be tested by rocking it from side to side and pushing it up from below.

One of the most remarkable myomata I have ever seen exhibited distinctly the sign of *ballotement*, hitherto considered pathognomonic of pregnancy. The abdomen was prominently distended, much in the form of a pregnancy of about eight months, and the uterus was enlarged by two fibroid masses which reached almost to the umbilicus. There was enough ascitic fluid to fill the flanks and occupy the space between the tumors and the abdominal wall. On palpating the abdomen at a point 5 or 6 centimeters above the symphysis nothing was felt, but on making sudden deep pressure through about 4 centimeters of fluid a hard body was encountered which instantly disappeared from touch and returned again one or two seconds later, striking the fingers with a decided blow as it came back.

An accurate means of recording changes in the form of the abdomen, which can be seen but are difficult to describe, is by photography. Two pictures should be taken as the patient lies on the table, a side view and a quartering one, on 4 by 5 plates. It is of assistance in judging the size and relations of the tumor if the umbilicus is shown in the pictures. A picture taken from below looking up toward the chest shows the elevation of the tumor and any asymmetry between right and left sides. A photograph of the tumor after its removal completes the record.

Palliative Treatment.—The treatment of myomata is either expectant, palliative, abortive, or radical. The great majority of myomatous uteri require no treatment whatever; many of the smaller growths produce no symptoms, and their discovery is often purely accidental.

Frequently the patient herself is the first to notice a small abdominal tumor, although I have seen women with a tumor as large as a seven months' pregnancy who did not know it existed. When it is not larger than a three or four months' pregnancy and produces no subjective symptoms no treatment of any kind is called for. A careful examination, however, should be made and the observations recorded, and the patient advised to return for examination at long intervals, so that any changes and the rate of growth may be watched. No surgical treatment should be instituted when a myomatous uterus is complicated by an advanced nephritis, a double pyelonephrosis, or a persistent glycosuria. I mention each of these complications because I have met them.

Relief of Pressure Symptoms.—Discomfort in walking, backache, and a sense of pressure will often be relieved in a small myomatous uterus, where the fundus is retroflexed, by packing the vagina with cotton or wool tampons, or by the use of a pessary, which may even be inserted without replacing the uterus and still do good. When the tumor is large enough to choke the pelvis and does not rise into the abdomen, but is held beneath the sacral promontory, sometimes great relief follows its elevation into the abdomen under

an anesthetic. Care must be taken not to force the displacement unless the mass seems free from adhesions. There is a decided risk in doing this, because the large vessels at the point of attachment of the tumor to the uterus are liable to rupture when the pedicle is friable.

Hemorrhage.—Profuse menstrual hemorrhages with prolonged periods, lasting one, two, or three weeks, often accompany submucous myomata and large myomatous uteri in association with a hypertrophy of the uterine mucosa; this may often be relieved for a long period, or even permanently, by dilatation of the cervix and a thorough eurettege (see Chapter XIV).

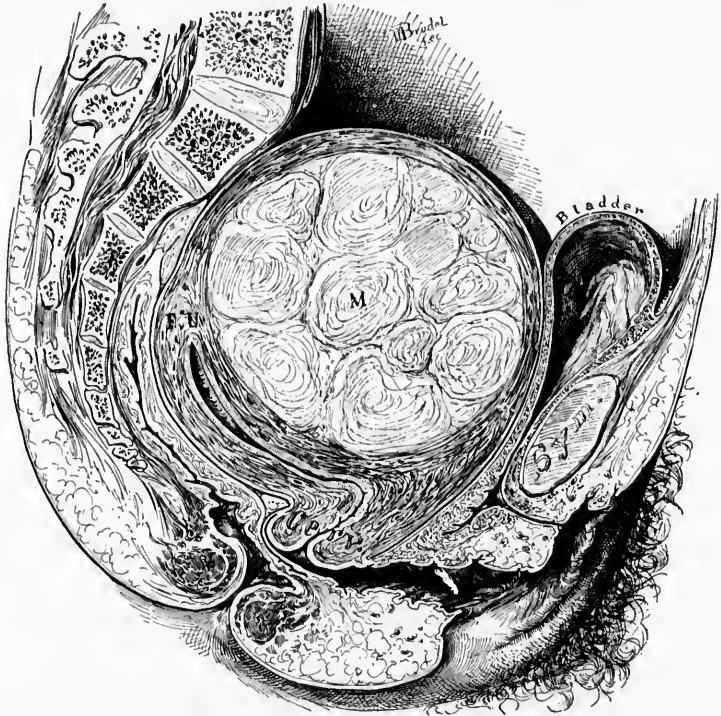


FIG. 487.—LARGE GLOBULAR MYOMA CHOKING THE PELVIS, COMPRESSING RECTUM AND BLADDER, AND FORCING THE BLADDER UP INTO THE ABDOMEN.

Note the retroflexion of the uterus. About half size. Autopsy, Jan. 15, 1897.

There should be no relaxation in the preparatory details, as described in Chapter XIV, as eurettege may be followed by a fatal termination, if great care is not observed in rendering the vagina and cervix as sterile as possible. The posterior vaginal wall is retracted with a Sims or Simon speculum, the anterior lip of the cervix is caught by a pair of bullet forceps, and the uterine sound passed in to determine the length, the direction, and the size of the

uterine cavity. Guided by this information, the smallest uterine dilator is introduced, and the cervix equably stretched in all directions as described. The evidence of the thoroughness of the operation will be shown by the large

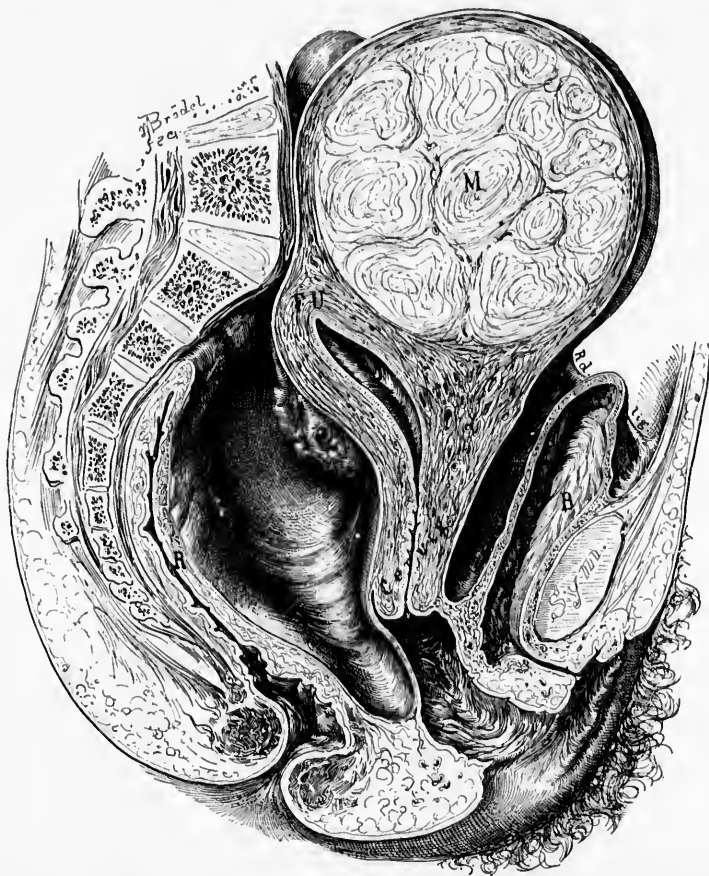


FIG. 488.—The same myoma lifted up into the abdomen out of its bed, showing the hypertrophy of the anterior uterine wall, and the complete detachment of the bladder from the uterus and the upper vagina. Note also the compression of the rectum.

amount of tissue discharged through the os in the form of pale shreds and strips of mucous membrane.

If the cervix is displaced upward it will often be more readily exposed by placing the patient in the left lateral position. In some of these cases, however, the displacement is so great and the uterine canal so distorted that neither sound nor dilator can be introduced, and curettage is utterly impracticable.

Curetage performed under aseptic conditions is free from danger and worthy of a more general use, as it often gives great temporary relief and does not prevent a subsequent radical treatment.

The galvanic electric current, used for the same purpose, is probably the most efficient means of controlling hemorrhage, and producing such permanent surface changes in the uterine mucosa as will tend to prevent its return. The current is applied by introducing a long positive platinum or carbon electrode high up in the uterus, and placing a broad wet cotton or clay negative electrode over the tumor on the abdominal wall.

In this way from 50 to 150 milliamperes are used, the limit being determined by the sensitiveness of the patient. The sittings last from five to ten minutes, and after each the patient should remain an hour or more in bed. The application may be repeated every five or seven days, and usually in the course of two or three months the tendency to hemorrhage entirely disappears.

Drugs are, as a rule, of little or no service in checking hemorrhage. In rare instances an inhibiting effect is exerted by ergotin, in the dose of 1 to 2 grains four times daily.

ABDOMINAL OPERATIONS UPON THE MYOMATOUS UTERUS.

1. General indications for operation.
2. Removal of ovaries and tubes without the tumor.
3. Enucleation of the myomata—myomectomy.
4. Removal of the myomatous uterus, leaving the cervix—hystero-myomec-
tomy.
5. Removal of the myomata with the whole uterus—pan-hystero-myomec-
tomy.

The indications for radical treatment by attacking the myomata directly are absolute and relative. Operation is imperative when the tumor chokes the pelvis and is producing serious symptoms from pressure upon the rectum, bladder, or ureters, or when the tumor occupying the abdomen has reached the size of a seven months' pregnancy or larger, and continues to grow. Here pressure upon the bladder, ureters, intestines, stomach, and diaphragm usually produce their characteristic symptoms, which increase until they are so distressing as to force the removal of the tumor. The extirpation of the tumor is also indicated when the size is great enough to interfere with the patient's occupation. Exhausting hemorrhages also demand radical treatment if curettage and electricity have failed to check the flow.

Relative indications are pain, more or less persistent, causing partial or complete invalidism; this, if not relieved by minor measures, may be so distressing as to necessitate operation. The pain of these cases is often due to a pelvic peritonitis and the associated lesions of the tubes and ovaries.

Troublesome hemorrhages and discomforts of all kinds, reducing the patient to a semi-invalid condition, may also be classed among the relative indications, which must be well weighed before deciding to resort to an operation.

In some patients the constant distress of mind from knowing that they have a tumor forms a valid indication for operation.

Abdominal operations for myomata are contra-indicated when there is grave organic disease of other organs, which will probably within a short time prove fatal. Advanced heart or kidney disease, phthisis, emphysema, and asthma all contra-indicate operation.

In every case the urine should be examined with extreme care to exclude nephritis, pyelonephrosis, and diabetes.

Myomectomy.—Myomectomy is the enucleation of a myoma or fibroid tumor without the sacrifice of any material portion of the uterus; it is thus contrasted with hysteromyomectomy, which is the removal of the uterine body together with the tumor, and with pan-hysteromyomectomy, which is the removal of the entire uterus with its myomata. The defect created by the removal of the tumor is closed in by interrupted sutures uniting the base and the edges of the wound, and leaving a normal uterus functionally perfect. Abdominal myomectomy is one of the most actively conservative of all operative procedures, and is the counterpart of the vaginal extirpation of submucous myomata. (See Chapter XVIII.)

Myomectomy is especially adapted to the treatment of single or of isolated tumors, so disposed that they can be readily excised or shelled out of their beds without undue injury to or loss of the uterine tissue. It should therefore be elected as the proper mode of treatment of all isolated pedunculate, and of many isolated sessile, interstitial, or broad-ligament growths. I have treated in this way a uterus containing as many as nine myomata, each one of which was removed by a separate incision, as well as another containing twelve myomata. No more important advance can be made by the gynecologist in the immediate future than by extending the indications for myomectomy and narrowing the field of hysteromyomectomy, and so saving the uterus wherever possible.

Myomectomy should always be preferred to hysteromyomectomy in a young woman, provided there are no complicating conditions, such as an extreme anemia, in which case the prime indications are to check the hemorrhages and to avoid a protracted operation.

Another contra-indication to myomectomy is the presence of any extensive pelvic inflammatory disease, particularly of pelvic abscesses, or the presence of ovarian or dermoid cysts.

Myomectomy also should not be performed when there exists any grave disease of other abdominal organs or of the thoracic viscera.

When the uterus is larger than a six months' pregnancy the difficulties of closing the wounds made by the removal of the large tumors is so great that for the present the indications for myomectomy have not been extended beyond this limit.

With these few plain limitations, myomectomy, within the proper age limit, must always be the operation of election, and if hysteromyomectomy is performed, definite reasons must be given why the radical instead of the conservative plan of treatment is selected.

Myomatous tumors may be enucleated from the size of a pea up to that of an adult head or larger, in any number, and wherever and however situated or attached.

Categorically stated, cases suitable for abdominal myomectomy are, in general, all single and discrete tumors which can be clearly isolated, and in particular—

(a) All pedunculate myomata, where the removal of the tumor will leave a normal uterus.

(b) All, even the largest, subserous or interstitial myomata which are well defined in relation to the body of the uterus, whether single or multiple.

(c) Multiple small myomata in any number.

(d) Broad-ligament myomata.

(e) A myoma localized at one cornu of the uterus.

(f) Submucous myoma too large to be taken out by the vagina.

In careful hands, with the best technique possible, myomectomy is a safe operation, but an inexperienced, indifferent operator, and one whose technique is slipshod, will inevitably lose many cases from hemorrhage and from sepsis. Under such circumstances the conservative myomectomy is a far more dangerous operation than the more radical hystero-myomectomy.

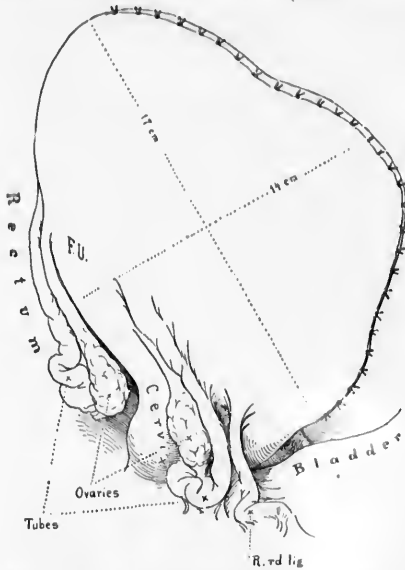


FIG. 489.—UTERUS AFTER EXTIRPATION OF THE MYOMATOUS TUMOR.

Showing great muscular hypertrophy, measuring, when returned to the abdomen, 14×17 centimeters. A row of twenty-nine sutures used in closing the incision in the uterine wall. Jan. 9, 1897. $\frac{2}{3}$ natural size.

Much can be done before the operation to determine whether a myomectomy or a hystero-myomectomy should be performed, by making a thorough examination. Where, for example, the rectal, vaginal, and abdominal examinations show that the tumor springs from the uterus by a well-defined pedicle, and that there are no other tumors in the uterus, the surgeon will be able to assure the patient beforehand that at the operation he will merely remove the tumor, and that there will be no mutilation. Also, when a careful bimanual examination has shown that the uterus is occupied by several well-defined tumors from the size of a walnut to that of a hen's egg, the operator may then anticipate that a myomectomy will be possible, and the same may be said regarding any number of small myomata.

The expectation that a myomectomy will be performed may also be cherished whenever a single myoma is found either laterally, or before or behind the uterus, and the uterine canal is shown by measurement not to be much

lengthened out, for such an examination demonstrates the fact that the tumor springs more from the upper part of the body, where enucleation is always easier. Whenever a mass of myomata, however large, springs from the fundus, and the examination shows that the uterine canal is not at all, or not much lengthened, and the ovaries are low down on the pelvis beside the body of the uterus, the operator may then also expect to remove the mass alone from the fundus by a myomectomy.

With increasing experience in performing myomectomies, after eliminating the possibility of any grave extra-pelvic complications, and assuring himself that there is no extensive pelvic inflammation, the skillful operator will be able to assure all young patients with myomatous uteri which do not rise above the umbilicus that he will in all human probability be able to extirpate the tumors and leave the uterus, ovaries, and oviducts.

The election of an abdominal instead of a vaginal myomectomy for a large submucous tumor is made after determining its size and relations by a vaginal examination, and then estimating the difficulties and dangers of the vaginal route as greater than the abdominal, on account of a contracted cervix and a vaginal outlet, often quite narrow, making it exceedingly awkward to get at the entire mass and bring it away piecemeal.

Operation.—The general principles governing the operation are:

(a) A good exposure of the tumors and the uterus through a free abdominal incision with an elevated pelvis.

(b) The isolation of the tumor (brought outside if possible) by surrounding it with gauze.

(c) The incision around the pedicle or through the capsule, exposing the tumor.

(d) The temporary control of hemorrhage by clamps and compression of the main vascular trunks, as, for example, by placing a ligature around the cervical portion of the uterus.

(e) The enucleation of the tumor from its bed.

(f) The permanent control of hemorrhage by ligatures and buried sutures, and sometimes by ligating the uterine arteries.

(g) The closure of the uterine incisions, giving careful attention to the angles, and seeing that no hemorrhage continues between the sutures.

(h) Closure of the abdominal incision without a drain.

The great danger after the operation is hemorrhage which can only be prevented by a most careful attention to the steps detailed. It is an important rule always to inspect the wounds for hemorrhage, with the table dropped level, before closing the abdomen.

Pedunculate Myomata.—The abdominal incision must be made large enough to get the tumor out by its smallest axis, together with the fundus of the uterus; the intestines are then protected by gauze and an assistant grasps and compresses the uterus tightly just below the pedicle to control the hemorrhage, while the operator rapidly makes an incision around the tumor up on its pedicle from 2 to 3 centimeters from the uterine attachment, closer to the

uterus at the ends, and the mass is removed. Actively bleeding vessels are at once caught by artery forceps. The freest oozing will usually be found at the

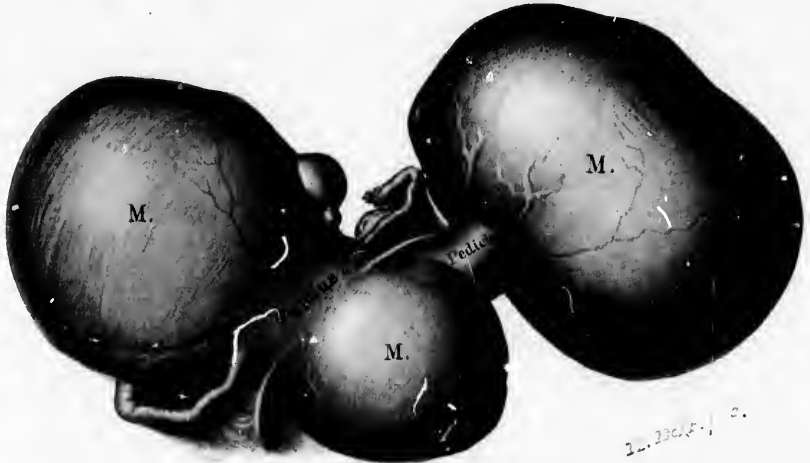

FIG. 490.—MYOMATOUS UTERUS, CONSERVATIVE OPERATION.

Removing three large myomata (*M, M, M*) without sacrificing the uterus. May 11, 1896.

periphery or in the center of the stump, and, owing to the nature of the tissue, it is not possible to pick up bleeding points and throw a ligature about them in



FIG. 491.—CONSERVATIVE TREATMENT OF THE MYOMATOUS UTERUS.

Showing the method of grasping the large posterior tumor and making traction while an oval incision is made not far from its base through the enveloping uterine wall down to the tumor, which is shelled out of its base by traction and dissection.

the ordinary way. The best plan is to control actively bleeding areas down the middle of the pedicle by passing a mattress suture around each one, including the adjacent tissues, and tying it tight. Large vessels at the periphery are best controlled by passing a ligature under the vessel in the uterine tissue a short distance from the edge of the incision.

The opposite sides of the incision are next firmly approximated by a series of interrupted deep catgut sutures. The sutures must be laid so as to make the most pressure on the bleeding points and thus aid in controlling the hemorrhage. Every particle of bleeding must be checked before closing the abdomen.

Subserous Sessile and Interstitial Myomata.—Sessile and interstitial tumors vary in size from masses as large as a uterus five months pregnant down to pealike nodules on the surface or buried in the uterine wall. The larger tumors when interstitial lie encapsulated in a mass of hypertrophied uterine tissue.

The operation for their removal consists in a linear incision through the capsule of peritoneum or uterine tissue, down into the white fibrous tissue of the tumor, grasping the exposed tumor with a pair of stout claw forceps, and elevating it, as it is gradually shelled out of its bed by the fingers, or preferably by some flat blunt instrument, like the handle of a scalpel or closed scissors.

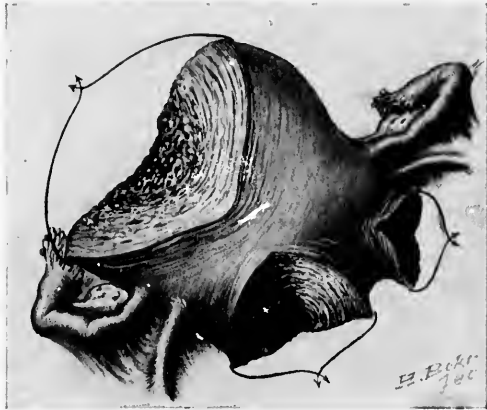


FIG. 492.—Same uterus after removal of the tumors, showing the broad bases of uterine tissue now about to be brought together by buried and interrupted catgut sutures, drawing the lips of the wounds as indicated by the crossed arrows.



FIG. 493.—CULLEN'S MYOMA ENUCLEATOR.

If the uterine cavity is opened it must at once be wiped clean and dry and care taken not to spread its contents over the wound. Interrupted catgut ligatures should be used in closing the cavity. In passing the deep sutures they should reach down to the mucosa, but should not penetrate it.

In one case I tore up the entire uterine mucosa of the anterior wall from cervix to fundus, in the form of a triangular flap; this was closed with a delicate

continuous catgut suture and the rest of the uterine wound, made by the extirpation of a large tumor, was closed in by buried and interrupted sutures. Perfect recovery followed.

In another case I found it necessary to resect at least a third of the uterine cavity.

It may be necessary, if the tumors are large, to control temporarily the uterine circulation by an elastic ligature or a gauze rope twisted around the body of the uterus below the tumor. When the cervical portion of the uterus can be grasped the assistant is able to control the circulation for a while by squeezing it with two hands.

The sutures should be laid with a large curved needle armed with a carrier, which is boldly carried deep down through the uterine tissue from one side of the incision across to the other. Numerous sutures and tight ligation will control the bleeding in all cases. The cavity produced by the enucleation of the tumor must always be closed perfectly from bottom to top, to avoid leaving a dead space with the formation of a blood clot which is liable to become septic. Interrupted buried sutures in one, two, or three tiers will serve to approximate the wound below the surface. Wherever there is bleeding a suture is passed and tied tight. After the wound is well brought together in this way the elastic ligature or the gauze rope is cut to restore the circulation, and additional deep sutures are passed wherever there is any bleeding. At least one tight suture should be placed at each angle of the wound, and, if necessary, beyond the angle, as that is the point most liable to continue bleeding after the abdomen is closed.

The utmost pains must be taken not to handle the structures which are to be left behind any more than is absolutely possible.

The hands of the assistants should be protected by sterilized rubber, thread, or silk gloves. The uterus should be laid open and surrounded with gauze. As soon as the overlying tissue is incised and the tumor exposed and caught with forceps, the lips of the incision should be grasped with gauze pads and worked back off from the tumor as it is being drawn forward. When the tumor is removed it will lessen the risks of sepsis if the operator will tie all the ligatures and sutures with fingers protected by rubber finger stalls.

It will be possible in this way to conduct an extensive myomeetomy from beginning to end without once coming into direct contact with the structures which are to be returned to the abdominal cavity.

An interesting example of what may be done by myomeetomy to conserve the uterus is afforded by the case of M. A. (No. 1576), operated upon Nov. 5, 1892. An incision 10 centimeters long was made through the abdominal walls, and eight subserous and interstitial myomata were removed from the uterus by seven separate incisions. The duration of the operation down to the closure of the abdominal incision was thirty minutes.

The following case shows further what may be done in the way of conservatism: F. E. S., 4055, operated upon Jan. 6, 1896, had a myomatous uterus filling the pelvis and rising well above the brim, about as large as a four and a

half months' pregnancy. *Per vaginam* the cervix seemed to be attached directly at the central portion of the mass, and the fundus could not be felt. The abdomen was opened, and the tumor, which just filled out the pelvis, brought up and out of the incision. The fundus, with tubes and ovaries, lay

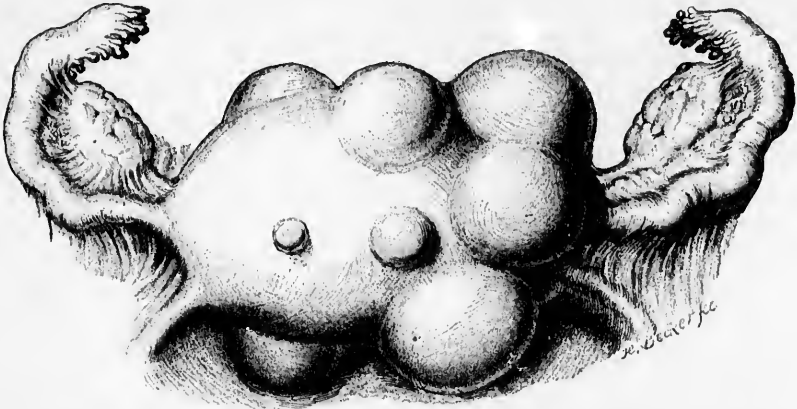


FIG. 494.—MYOMATOUS UTERUS FROM WHICH EIGHT MYOMATA WERE ENUCLEATED BY SEVEN INCISIONS. MAY 11, 1896.

in front of the tumor, which was developed in the lower posterior portion of the uterus. I split the capsule 1 to 2 centimeters thick, and rapidly enucleated a fibroid mass $12 \times 10 \times 10$ centimeters in size, without exposing the uterine cavity at all. The bleeding was free but not excessive, and was controlled by eight to ten pairs of forceps. Several vessels were tied with catgut, and the entire bed of the tumor obliterated by continuous catgut sutures.

The edges of the wound were united by interrupted catgut sutures, and extended, when closed, 15 centimeters from a point beneath the left utero-ovarian ligament downward in the middle line to the pelvic floor. A small myoma, 1.5 by 1.5 centimeter, was also taken out in front of the left cornu. (See also Figs. 494 and 495.)


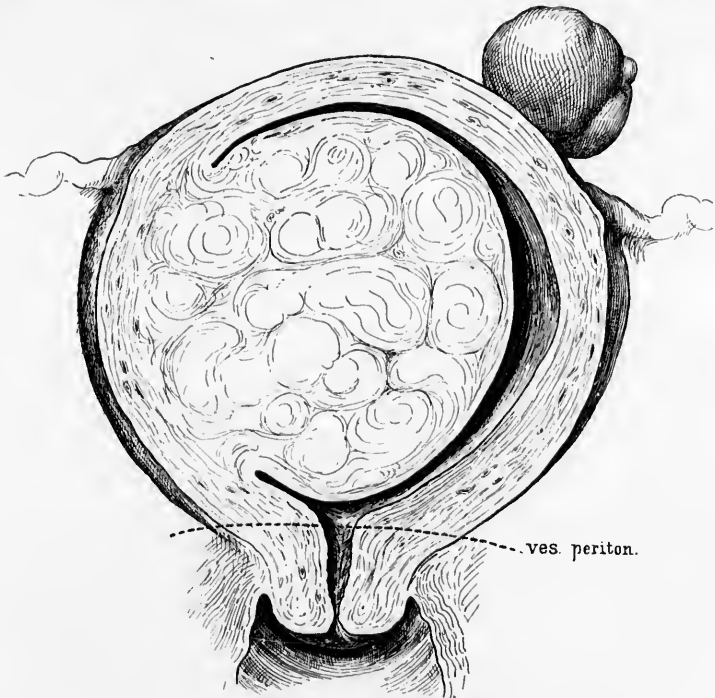


FIG. 495.—UTERUS FROM WHICH EIGHT MYOMATA WERE REMOVED BY SEVEN INCISIONS.

Showing incisions closed by interrupted catgut sutures.

Cornual Myoma.—When a myoma is situated deep in the uterine tissue at one of the cornua, lifting up the uterine tube, the uterus may be saved by

removing the tumor with the tube, and, if need be, the ovary of that side. The circulation of the uterus is controlled either by an elastic ligature around the cervical end, or, better, by tying the uterine artery of that side well below the cornu and ligating the ovarian vessels out near the brim of the pelvis. A small oval incision is then made, to include the uterine end of the tube, exposing the tumor in its bed; the growth is then enucleated, as in a case (S. L., 2500) operated on Jan. 15, 1894, where the tube and ovary of the side where the tumor lay were involved in peritoneal adhesions. The uterine cavity was opened.



F. 496.—LARGE SUBMUCOUS MYOMA.

Adapted to removal by abdominal section by splitting open the uterus and enucleating the tumor, and then sewing up the uterine incision. $\frac{2}{3}$ natural size.

The wedge-shaped flaps left after the enucleation were brought firmly and neatly together and the whole dropped, and the abdomen closed without a drain.

Extirpation of Submucous Myomata per Abdomen.—We owe to Prof. A. Martin, of Berlin, the extension of the field of abdominal myomectomy to the removal of submucous myomata. (See *Cent. f. Gyn.*, July 31, 1886.)

This operation is indicated when the myoma is the size of a child's head or larger, and the entire cervical canal is undilated, or when a part of a large myoma has been extruded through the cervix, leaving a large intra-uterine mass which can not be reached readily through the vagina.

Whenever the tumor can be reached by the vagina it should be removed by morecellation.

Before the operation it is necessary to disinfect the vagina and the uterine cavity by irrigation with a five-per-cent solution of creolin, and then to pack the uterus, if it can be reached, with iodoform or sterilized gauze, to prevent the escape of secretions over the wound surface and into the peritoneal cavity when the uterus is opened from above. If there is a foul uterine discharge, it will be wiser to delay operation until by douches and drainage its character is changed; if an immediate operation is imperative, it will be safest to sew the cervix up tight and remove the entire uterus when the abdomen is opened.

The operation consists in the following steps:

1. Opening the abdomen.
2. Lifting out the uterus onto a gauze napkin, and packing gauze into the posterior pelvis all around the uterus.
3. A temporary rubber ligature around the cervical portion of the uterus to control hemorrhage.
4. Opening the uterine cavity and shelling out the tumor.
5. Closing the uterus by suture and returning it to the abdominal cavity.
6. Closing the abdominal incision.

An incision in the linea alba is made large enough to bring the uterus out onto the abdomen. A thick gauze pad is placed beneath it, and towels or gauze are packed close around its lower portion and down into the incision, to prevent any possible contamination in case any of its contents should escape when it is opened.

A provisional rubber or gauze ligature is thrown about the uterus below the tumor and tied before the uterine incision is made. The position of the pedicle may sometimes be discovered by sliding the uterine walls over the tumor inside of it; the pedicle will be found at the fixed point which refuses to slide.

The incision should be made by preference on the anterior wall, or it may be made across the fundus, away from the pedicle, in the long axis of the uterus, just below the fundus, and it should extend down to the cervix. A few strokes of the knife lays the uterus open from top to bottom, exposing the tumor.

The gauze in the uterus is then taken out with forceps, and a piece of fresh sterilized gauze packed in to protect the margins of the incision, while the tumor is grasped with a sterilized towel or a piece of gauze and peeled from its base by torsion or removed by incising its capsule and peeling it out. The utmost care must be constantly exercised not to let the tumor or any of the contents of the uterine cavity touch the edges of the incision.

In a suppurating myoma such a procedure is rarely if ever justifiable.

The uterine incision is closed by catgut sutures about 1 centimeter apart, entering and emerging about half a centimeter from the margins of the inci-

sion, and carried down to the mucosa, but not entering it. The sutures should be tied as rapidly as possible until all active bleeding is checked. After the deep sutures are tied, any remaining areas of imperfect approximation may be corrected by half-deep sutures of catgut, passing 5 to 8 millimeters into the tissue, as in the Cesarean operation. I prefer to use chromicized catgut at those points which include large vessels.

Infective material having been carefully excluded, the abdominal cavity requires no cleansing. The gauze pads supporting the uterus are removed and the uterus replaced in the pelvic cavity in anteflexion, so as to keep the intestines from coming in contact with the line of incision. The abdominal cavity is then closed, and the after-treatment conducted as usual.

Hystero-myomectomy.—Hystero-myomectomy is the correct name of the operation commonly described at length as “supravaginal hysterectomy for fibroid tumors.” It consists in the removal of a part or the whole body of the uterus with its tumor masses, usually amputated through the cervix.

The history of the evolution of our present methods of treating fibroid tumors of the uterus is deeply interesting, particularly to an American, on account of the important part played by our own surgeons in developing the methods which are now recognized as the best.

This subject has commanded the careful attention of Dr. E. W. Cushing, of Boston (*Ann. of Gyn. and Pædiatry*, 1895, p. 573), and more recently of Dr. C. P. Noble, of Philadelphia, to whose painstaking studies I am particularly indebted for the historical information which follows.

In April, 1845, Dr. W. L. Atlee published a paper in the *Amer. Jour. of the Med. Sci.* entitled *Case of Successful Extirpation of a Fibrous Tumor of the Peritoneal Surface of the Uterus by the Large Peritoneal Section*. The operation was performed in Aug., 1844. From this time on Atlee continued to operate upon fibroid tumors, and he contributed to the literature of the subject throughout his long professional career. He generally operated for the removal of the tumor only, either by the vagina or by abdominal section; but he occasionally did hysterectomy. One of his most important papers was a prize essay published in the *Trans. of the Amer. Med. Assoc.*, 1853, p. 547, and entitled *The Surgical Treatment of Certain Fibrous Tumors of the Uterus, heretofore considered beyond the Resources of Art*.

Dr. Walter Burnham, of Lowell, Mass., operated upon a patient June 26, 1853, with the expectation of removing an ovarian cyst, but the tumor proved to be a fibroid which was extruded from the wound by the act of vomiting and could not be replaced. Burnham therefore had to remove it; he did this by first taking away two pedunculated fibroids to reduce the size, and then passing “a strong double ligature through the neck of the uterus, which was tied on each side; then to make doubly sure against hemorrhage, a ligature was placed around the whole neck.” After this the broad ligaments and cervix were divided and no bleeding followed. The ovaries, which were diseased, were also removed. The cervix was dropped, and the ligatures, brought out at the lower angle of the wound, after the fashion of the day, came away during the fifth

week, and the patient recovered. This was the first recovery after hysterectomy for fibroid tumor. Burnham performed altogether fifteen hysterectomies with three recoveries; the second and third operations were done in 1854 and 1857 (see Dr. J. C. Irish, *Hysterectomy for the Treatment of Fibroid Tumors, Trans. of the Amer. Med. Assoc.*, 1878, p. 447).

Dr. G. Kimball, of Lowell, was the first to perform a deliberate hysterectomy for fibroid tumors of the uterus, having previously made a correct diagnosis. He operated Sept. 1, 1853, upon a patient in a bad condition from protracted uterine hemorrhages. At the operation the cervix was transfixed, each half ligated, and the uterus amputated in the supravaginal portion; the cervix was dropped and the ligatures brought out at the lower angle of the wound. The woman was well eight months later, but the ligatures were still attached (see G. Kimball, *Successful Case of Extirpation of the Uterus, Boston Med. and Surg. Jour.*, May, 1855). According to Bigelow, in 1883, Kimball had performed eleven hysterectomies with six recoveries and five deaths.

Dr. Marey was one of the first to devote particular attention to the method of treating the cervix, and described an improved way of dealing with the pedicle by sewing it across with the cobbler's stitch (*Trans. of the Amer. Med. Assoc.*, 1882, p. 203).

Dr. T. A. Emmet in 1884 (*Principles and Practice of Gynecology*, p. 612) utilized the peritoneum anterior to the uterus to cover the cervical stump in a hysterectomy done for a dermoid cyst of the ovary and a fibro-cystic uterus. In discussing the principles of the operation the important advance thus made in the retroperitoneal treatment of the stump is clearly pointed out.

Dr. M. A. D. Jones, Feb. 16, 1888, performed the first American pan-hysterectomy for uterine fibroid (*New York Med. Jour.*, Aug. 25 and Sept. 1, 1888), originating this form of operation independently of Bardenheuer, whose work was not known at that time in America.

Dr. J. Eastman has indelibly associated his name with the operation of pan-hysterectomy by his pioneer work, and by the invention of new instruments facilitating the operation. His first operation was performed Sept. 21, 1889 (*Indiana Med. Jour.*, 1890, also *Med. Fortnightly*, Jan. 15, 1896).

One of the most revolutionary changes was that devised by Dr. L. A. Stimson, of New York, who proposed and practiced the systematic ligation of the ovarian and uterine arteries in their course as a proper preliminary to hysterectomy (*New York Med. Jour.*, March 9, 1889, and *Med. News*, July 27, 1889). By this simple improvement in the technique the dangerous mass ligatures applied to the broad ligaments were done away with and the risks of sepsis and hemorrhage greatly reduced. Dr. J. R. Goffe (*Amer. Jour. Obs.*, April, 1890, vol. xxiii, p. 372) originated and carried out a well-defined enucleation followed by the complete covering of the cervical stump with peritoneal flaps, which he called "an intra-abdominal but extraperitoneal method of disposing of the pedicle." The first operation was done May 29, 1888, and repeated three times, and then presented before the Obstetric Section of the Academy of Medicine in March, 1890.

While in this way citing and giving credit to American work, I would not slight the admirable work done in France and Germany by such well-known men as Velpeau, Amussat, Bardenheuer, Schröder, Martin, Zweifel, Chrobak, Säinger, Fritsch, and latest of all, Olshausen (see Veit's *Handbuch*, 1897). In England the names of Keith, Thornton, Bantock, Milton, of Cairo, and Heywood Smith are indelibly associated with hysterectomy.

The indications for hysteromyomectomy are, in general—

(a) Discomfort or ill health produced by the tumor, interfering with occupation or comfortable getting about.

(b) All myomata filling the lower abdomen from the size of a six or seven months' pregnancy upward.

(c) Smaller tumors choking the pelvis and pressing injuriously on the rectum or bladder.

(d) Rapid growth of the tumor.

(e) Repeated hemorrhages, which are exhausting to the patient and can not be controlled by simpler means.

(f) Persistent intense dysmenorrhea, seriously affecting the general health, an indication to be accepted only with great caution.

(g) Severe pain, often associated with attacks of peritonitis, and usually due to pelvic peritonitis, tubal and ovarian inflammatory disease, and pelvic abscess.

(h) Myomata complicated by cancer of the uterus, ovarian cysts, dermoid cysts, ovarian fibroids.

I feel it my duty to utter an urgent warning against accepting the simple fact of the presence of a tumor as a sufficient indication for operation. The conscientious operator should always be able to show either that the continued presence of the tumor in some way is a menace to life, or that its presence is incompatible with a comfortable existence.

I have, however, operated two or three times solely on account of the distressed mental condition of the patient, induced by the knowledge that there was a tumor which she could feel in the abdomen. Until the operation was done it was impossible to allay the fears or to persuade the patient to think of anything else but the tumor, and no reasoning had any effect.

The one indication most generally accepted is the large size of the tumor which fills the lower abdomen. Here, on making the incision and exposing the growth, we find the small intestines forced up under the diaphragm and out into the flanks, accounting for the interference with circulation, respiration, and digestion; frequently, too, the ureters are so pressed upon as to cause hydro-ureter and hydronephrosis, and a careful examination of the urine before operation may reveal albuminuria, with hyaline and granular casts. A pyelonephrosis may readily supervene upon the hydronephrosis. Hyaline degeneration of the heart muscle and arterio-sclerosis are sometimes seen in old cases and appear to be caused by the stasis in the circulation due to pressure. When the pressure

is relieved the kidneys often recover, judging by the fact that the albuminuria soon disappears.

Persistent discomfort and protracted severe pains at the menstrual period only become valid indications for an operation when general treatment, such as mild sedatives and hygienic measures, rest, massage, etc., have been faithfully tried, and sufficient time has elapsed to demonstrate the fact that spontaneous relief can not be expected.

Hemorrhages in smaller tumors may often be controlled by eurettege or by galvanism; but in the largest tumors the vaginal cervix is often so small and displaced so high into the abdomen that an intra-uterine application of the electrode is dangerous or impossible.

A firm vaginal pack will also often check hemorrhage at once, and by this means the patient's strength may be husbanded from month to month.

When a soft myoma has been discovered and every subsequent examination at intervals of a few months shows that it is growing rapidly and has reached the size of a four or five months' pregnancy, the operator has valid ground for its removal.

I would call especial attention to the fact that those myomata which are constantly associated with great pain almost invariably belong to the class of complicated cases in which a tubal and ovarian inflammatory disease will also be found. Even pyosalpinx is not an uncommon addition.

The best time to operate is when the patient has been put in the best possible condition her disease will admit of. Women who are enfeebled and worn out should be put to bed and built up for a time. When the monthly period produces great disturbances, the best time to operate is just before an expected period. I have even operated in several instances without disadvantage a day or two after the period had begun.

In operating upon anemic patients unusual precautions must be taken against further loss of blood, to the extent of clamping all the small bleeding vessels in the abdominal walls and controlling at once all oozing from the cellular tissues in the pelvis during the operation. The loss of a few ounces of blood, ordinarily insignificant, suffices in these cases to add to the shock easily induced in the patient's weakened condition.

Wherever a free hemorrhage has occurred in the course of a hysteromyomectomy, enough to give rise to any marked degree of depression, there should be no hesitation in infusing under the breasts a half liter or a liter of normal salt solution (see Chapter XXII, p. 70).

The loss of bodily heat must be avoided in every way by keeping the intestines within the body if possible, or by covering with hot gauze any coils that may be exposed to the air. The body and limbs should be wrapped in blankets and a hot-water bag placed at the feet.

If the pulse begins to run up during the operation it is best to give hypodermics of strychnin, one fortieth of a grain, repeated in doses of one sixtieth of a grain at intervals of half an hour. A stimulant rectal enema of brandy (*spiritus vini gallici*, ℥ ij; *ammonia carbouas*, gr. xx; and hot salt solution, q. s. ad f ℥ vj)

should be given, with the pelvis well elevated, before the patient is lifted from the operating table.

The duration of the entire operation varies from twenty to thirty minutes in easy cases, and from sixty to eighty minutes in the difficult. Operations extending over an hour are apt to produce a decided depression. The duration down to the complete enucleation of the uterus with the tumors lasts from three in the easiest to fifteen or twenty minutes in the most difficult cases; the rest of the time is taken up in the details of the treatment of the wound made by the excision, covering it in with the peritoneum and closing the abdominal incision.

The principal causes of the high rate of mortality following hysterectomy as done by our immediate predecessors were hemorrhage and sepsis. These dangers may now be avoided by following the improved technique recently elaborated.

The technique of hystero-myomectomy includes:

- (a) Preliminary preparation of the field, including the skin and the vagina.
- (b) Opening the abdomen.
- (c) Delivering the tumor if possible.
- (d) Ligation of the ovarian vessels and the round ligament of one side, usually the left, and opening the top of the broad ligament.
- (e) Detachment of the vesico-uterine fold of peritoneum from side to side, and pushing it well down so as to separate the bladder from the cervix.
- (f) Ligation of the uterine vessels of the same side.
- (g) The amputation of the uterus in the cervical portion, leaving a cup-shaped pedicle.
- (h) Clamping the uterine artery of the opposite side, clamping the round ligament, and clamping the uterus with the ovarian vessels, followed by removal of the tumors.
- (i) Applications of ligatures in place of the forceps.
- (j) Suturing the cervical stump.
- (k) Covering the wound area with peritoneum.
- (l) Cleansing the peritoneal cavity.
- (m) Closure of the abdominal incision without a drain.

Hystero-myomectomy without Complications.—Preliminary Preparation.—If the patient is in a reduced condition the operation should be postponed until a maximum improvement has been secured. The preparations immediately preceding the operation have been fully detailed in Chapter XX, p. 9. Especial care must be taken to disinfect the vagina thoroughly.

Opening the Abdomen.—The patient is placed on the table with her pelvis elevated, and an incision from 6 to 20 centimeters ($2\frac{1}{2}$ to 8 inches) long is made over the most prominent part of the tumor, taking care to cut slowly and deliberately, so as not to incise the tumor on opening the peritoneum. I have seen a large vein cut in this way bleed profusely and cause the loss of much valuable time in checking the unnecessary hemorrhage. It is best to open the peritoneum first in the upper part of the incision, so as to avoid the risk of cutting the bladder, which is often raised several inches out of the pelvis. The

exact position of the fundus of the bladder should be determined beforehand with a sound. The hand is then introduced within the abdomen and passed over the tumor on all sides, making an examination which gives an experienced operator in a few seconds an accurate idea as to the character of the operation, and enables him to estimate the mobility and relations of the uterus with its tumors, the presence or absence of adhesions, and particularly the relations of the pedicle to the pelvis, whether broad or narrow, and whether there is any upward displacement of the sigmoid flexure or the bladder. If the tumor is now found to be too large to be delivered, the incision is lengthened by raising its upper angle on two fingers and protecting the peritoneum with a sponge while cutting boldly upward with a knife. Stout angled seissors may be used for the same purpose when the abdominal walls are thin.

Delivering the Tumor.—Tumors limited to the body of the uterus can be readily lifted out of the abdominal cavity at once, and for this reason they constitute a more favorable class for operation, as a natural pedicle is offered by the unaffected cervical part below the mass.

As soon as the tumor escapes, a warm gauze pad should be slipped in under the incision covering the intestines.

In some large multilocular fibrocysts a succession of deliveries of single tumors is necessary before the entire mass lies without the abdomen. Sometimes after a group of large tumors have been lifted

out in this way the pelvis will still be found choked by a tumor which is only dislodged after a prolonged effort. If moderate direct traction on such a mass fails, an assistant should introduce two fingers into the vagina and make strong upward pressure in the axis of the superior strait, setting it free.

Care must be taken not to make such traction on a pedunculate tumor as will result in tearing its pedicle and causing a hemorrhage which might prove troublesome. A large tumor, the size of a child's head, may sometimes be delivered with advantage with obstetrical forceps.

Ligation of the Ovarian Vessels and Round Ligament of One Side.—A fine silk ligature (No. 2) may be used to ligate the ovarian vessels, however large. The outer pelvic extremity of the broad ligament, often swollen by a congeries of large purple veins which cross the pelvic brim under the caecum on the right side and under the sigmoid flexure on the left, is now gathered up between the thumb and forefinger, and the clear space below the vessels sought for, through which a ligature is passed and tied tightly controlling the vessels. It is always surprising to see a bunch of vessels as large as three or four fingers contract down to a mere strand in the bite of a ligature. A second

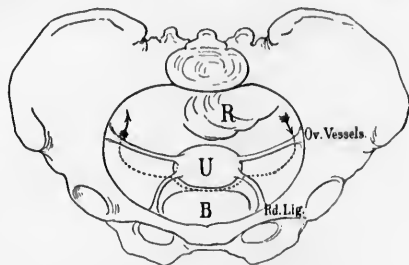


FIG. 497.—SCHEMATIC DIAGRAM.

Showing the line of incision, beginning with the left ovarian vessels and ending with the right, in the extirpation of the myomatous uterus.

ligature or a clamp is applied 4 or 5 centimeters away, toward the uterus, and the vessels cut between the two, at a good distance from the first ligature.

In a woman under forty years of age it is better to leave both ovaries in the pelvis, with or without the uterine tubes; by doing this, although menstruation ceases, the disagreeable symptoms of the artificially induced menopause are avoided. In this case the first and the last ligatures are applied near the horn of the uterus.

The round ligament, often enlarged and vascular, is now lifted up near the uterus and tied with catgut and cut through, and the uterine end clamped.

The top of the broad ligament is opened up by these incisions.

Detaching the Vesico-uterine Peritoneum.—The uterus is now drawn back and the anterior loose peritoneal fold along the curved line of the utero-vesical reflection is cut through from round ligament to round ligament. As the bladder is raised, the loose cellular tissue beneath it is exposed, and it may be still further freed by a rapid dissection with knife or scissors. In ordinary cases there is no bleeding of any moment. The uterus is now pulled well up, while the operator completes the separation of the bladder by taking a sponge, firmly compressed and held in a sponge forceps, and pushing the bladder down with it on all sides, baring the cervical end of the uterus almost or quite down to the vaginal junction. This also brings into view the uterine arteries and veins on the same side of the uterus. Sometimes, when these vessels are not exposed quite clearly enough, they may be brought into better view by drawing the uterus forward and nicking the sharp posterior peritoneal margin behind the cervix.

Ligation of the Uterine Vessels.—The large uterine veins on the side of the uterus are recognized by their dark color, and the smaller cord-like artery can be plainly felt pulsating. These vessels are now securely ligated close to the side of the cervix by a silk ligature, introduced on a large curved needle, passed close to the cervical tissue but not entering it. The uterus is now drawn over toward the other side, and the operator takes a spud and begins the amputation by cutting through the uterine vessels from 6 to 10 millimeters above the ligature. The assistant stands with open artery forceps in hand ready to grasp any bleeding vessel by chance left out of the ligature. The cut vessels above on the tumor side are better clamped or tied in mass to keep the blood from constantly oozing out and obscuring the field of the operation.

The uterus is now completely divided in its cervical portion, at a point just above the vaginal junction, by cutting deliberately through the tissue with a spud or knife, with successive strokes. The cervical canal is usually found about the middle and is recognized by the presence of a little glairy mucus. As soon as this canal is cut across, a pad of gauze several folds thick is laid beneath the upper cut surface to keep any intra-uterine secretions from escaping onto the wound, and the canal below is wiped out. The cutting is now continued across toward the opposite side more slowly, as the little remaining bridge of tissue shows the severance is nearly completed. The bleeding from the cut sur-

face is usually so slight that it may be neglected, or at most one or two forceps only need be applied. It is a good plan when the cervix is nearly divided to cut upward for 1 or 2 centimeters so as to leave behind a thin shell of cervical tissue and expose the opposite uterine vessels at a higher level, where it is much easier to tie them without risk of including the ureter.

Clamping the Opposite Uterine Vessels.—When the last strands of uterine tissue are severed or break, as the uterus is drawn up and out and rolls over more onto its side, the opposite uterine veins and artery come into view. The beginner will expect to find these vessels hugging the

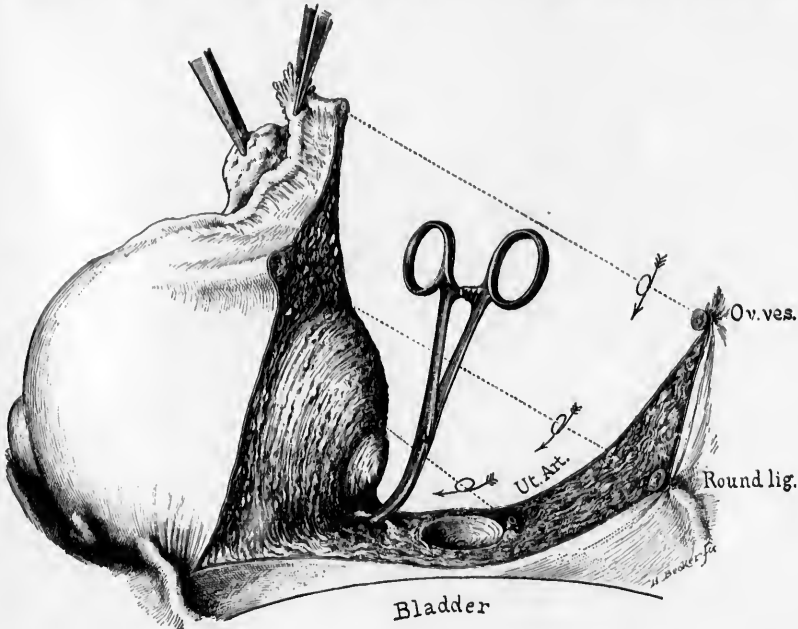


FIG. 498.—THE OPERATION OF HYSTERO-MYOMECTOMY.

By a continuous incision from left to right, ligating or clamping at the points indicated by the arrows; first, the left ovarian vessels (*Ov. ves.*); next, the round ligament, and then the left uterine artery (*Ut. Art.*). Finally the cervix is cut across, and the uterus pulled away until the right uterine vessels are exposed.

uterus tightly, and will be surprised to note the considerable cellular interval which often separates them as they are exposed in this way.

It is best not to clamp them as soon as seen, but to pull the uterus up further until the separation between the cut surfaces amounts to several centimeters. At this higher level the artery, at first not so plainly seen, comes clearly into view and may be clamped by itself, the uterus rolled still more over on its side, and the round ligament clamped close to it and divided, and finally, with a little more traction, the ovarian vessels are seen and clamped and cut, and the whole mass is finally freed and taken away.

The uterine veins often do not bleed when severed in this way; if they do, it is easy to control them with one or two pairs of forceps.

Ligating the Vessels controlled by Forceps.—As soon as the uterus, with the tumor, is lifted away the operator looks over the whole field to see that there is no active hemorrhage going on.

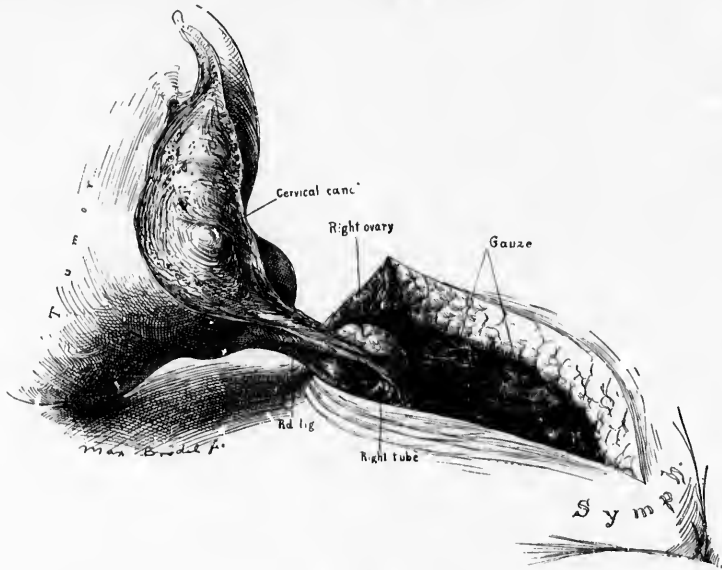


FIG. 499.—THE LAST STEP IN THE ENUCLEATION OF THE MYOMATOUS UTERUS. The mass is rolled out of the abdomen and is now attached only by the round ligament, ovary, and tube.

He then proceeds to tie the vessels on the side controlled by forceps, taking up first the round ligament which is encircled with a catgut ligature; next the ovarian vessels are controlled by transfixing the clear space and tying them with a fine silk ligature. The uterine artery is now drawn up and tied at a point well above the epped stump. This avoids any risk of tying the ureter.

By grasping the cervical stump with a pair of tenaculum forceps it can be pulled up into the abdominal incision within easier reach, bringing with it the uterine vessels, which are then also under better control.

Two ligatures should be placed upon every important vessel, the first tied in the course of the enucleation and the second when the enucleation is completed.

Suturing the Stump.—The next step is to close the stump, but before doing this the operator must look minutely and patiently over the whole field and pick up any minute bleeding points with forceps and tie them with fine catgut. The stump is now closed over the cervical canal by passing from three to five or more catgut sutures in an antero-posterior direction and tying each one as it is passed. If the stump is inclined to ooze at places, this may be

checked by making one of the sutures include that point and tying it tight. In passing these sutures the mucous membrane of the canal must not be included. By this suturing the cup-shaped pedicle is changed into a transverse linear wound. I do not disinfect the cervical canal any more, unless there is such evidence of infection as a discharge of pus from the uterus or a muco-purulent plug in the canal. In this case the canal should be wiped out with gauze as soon as cut across, and afterward dissected out with a narrow sharp knife and forceps.

Covering in the Whole Wound Area with Vesical Peritoneum.—The large loose flap of peritoneum which lies in front of the pedicle and the broad ligaments is now picked up with long rat-tooth forceps and drawn over the stump and attached to the posterior peritoneum from side to side by a continuous intermediate catgut suture; the round ligaments and the pedicles of the ovarian vessels are turned in between the layers of peritoneum, and all that is left of the large wound is a fine line of approximation across the middle of the pelvis, practically converting the pelvis into the male form by the removal of the organs between the rectum and the bladder. This is done by starting the suture at the stump of the ovarian vessels at the brim of the pelvis, and continuing it down across the pelvis and up to the opposite ovarian vessels, as described in Chapter XXVIII.

If there is a large space left in the cellular tissue it will be best to unite the peritoneum with interrupted or mattress sutures, so that any blood which escapes from capillaries will run into the peritoneum and be absorbed instead of forming a hemocele.

Cleansing the Peritoneum.—If the peritoneum has been much soiled by blood in the course of the operation, one or two liters of normal salt solution (0.6 of one per cent) at a temperature of 43.3 C. (110 F.) should be poured into the pelvis and abdominal cavity, and rapidly sponged out until all foreign material has been removed.

Closing the Incision.—The small intestines are drawn into the lower part of the abdomen, and the omentum is sought out and spread between them and the anterior wall.

The abdomen is finally completely closed, without drainage, and dressed as described in Chapter XX, the salt solution enema given, and the patient put to bed.

Mortality.—In one hundred consecutive abdominal hysterectomies, including all kinds of complications, I have lost two cases.

Complications of Hystero-myomectomy.—This operation of hystero-myomectomy varies a great way from the simplest to one of the most complicated difficult procedures in gynecology. Cases like those just described as the type are for the most part easy of operation, and as a rule make a prompt undisturbed recovery. A long list of complications is, however, added when we analyze one hundred consecutive cases, and enumerate all the difficulties encountered. Some of these complications add but slightly, others more, and still others enormously, to the difficulty of enucleation; and when several or more complications of various

sorts exist in the same case, the difficulties are enhanced to an even greater degree. This matter has grown to one of such great importance that I deem it necessary to speak in detail of each of these complicating conditions, first giving a categorical list of all those which are most important.

They are in general of four classes:

1. Complications due to adhesions to and affections of the surrounding structures.

2. Complications brought about by changes in the tumors themselves.

3. Complications due to the positions of the myomatous masses.

4. Complications due to pregnancy, ascites, and other causes in particular.

Complications due to Adhesions and Affections of the Surrounding Structures.—(a) Inflammatory: 1. Simple adhesions of tubes and ovaries. 2. Hydrosalpinx. 3. Pyosalpinx and abscess of the ovary. 4. Encysted peritonitis. 5. Omental adhesions. 6. Parietal adhesions. 7. Adhesions to rectum, sigmoid, colon, and small intestines. 8. Adhesions to vermiform appendix. 9. Adhesions to liver and suspensory ligament.

(b) Tumors of the ovary: 10. Ovarian cystoma. 11. Dermoid cyst. 12. Fibroid ovary. 13. Ovarian hydrocele. 14. Ovarian hematoma. 15. Carcinoma of the ovary.

(c) Diseases of cervix and uterine mucosa: 16. Cancer of the cervix. 17. Cancer of the uterus associated with myoma. 18. Tuberculosis of the endometrium.

Complications due to Changes in the Tumors Themselves.—19. Cysto-myoma. 20. Telangiectatic myoma. 21. Cystic myoma with twisted pedicle. 22. Suppurating myoma. 23. Adeno-myoma uteri diffusum benignum.

Complications due to the Location of the Tumors.—24. Elevation of tubes and ovaries high out of the pelvis. 25. Globular myoma filling pelvis. 26. Myomata wedged in pelvis. 27. Myoma below the vesical peritoneum. 28. Myoma below posterior pelvic peritoneum. 29. Myoma in upper part of broad ligament. 30. Myoma in broad ligament proper. 31. Myoma developed antero-laterally, twisting uterus. 32. Myoma developed postero-laterally. 33. Myomata developing under the pelvic peritoneum in several of these positions at once. 34. Myomata displacing the ureters upward.

Complications due to Pregnancy, Ascites, and Other Causes.—35. Myoma with pregnancy. 36. Myoma simulating pregnancy. 37. Myoma and ascites, feeble heart, nephritis, pyelonephrosis, etc.

Several other conditions may be enumerated, too, which add to the gravity, but, except the last, are beyond the possibility of direct treatment at the time of operation; such are the cases with extreme anemia, rapid feeble heart, valvular heart disease, nephritis, and pyelonephrosis.

1, 2, 3. Adherent Tubes and Ovaries; Hydrosalpinx; Pyosalpinx.—The complications due to inflammatory lesions and adhesions in the surrounding structures must in general be dealt with like similar adhesions under other circumstances, as described in Chapter XX

on General Principles. It is only necessary to speak here first of the frequency with which myomata are complicated by pelvic peritonitis, and, second, of the difficulties of releasing inflamed ovaries and tubes, from the fact that they are often so completely buried behind the tumors, or wedged down into the pelvis, that they are hard to reach without injuring some of the great vascular sinuses in their immediate neighborhood. When they can be got at without special difficulty, an adherent tube and ovary, or a hydrosalpinx, or even a pyosalpinx, may be gently released by gradually working the fingers down between the inflamed structures and the posterior pelvic wall until their under surface is reached, when they are carefully freed from their adhesions to the pelvic floor and walls, and as they are brought up and out of the pelvis, detached also from their broad-ligament adhesions.

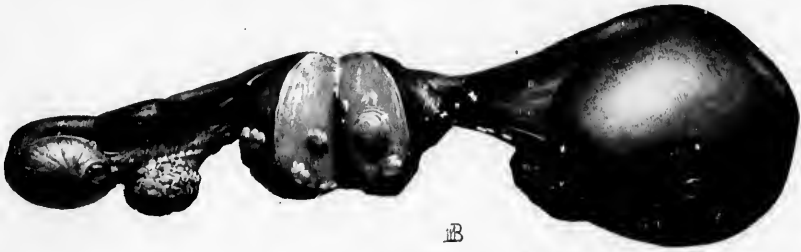

FIG. 500.—COMPLICATED HYSTERO-MYOMECTOMY.

Myomatous uterus with hydrosalpinx on the right side, and a large ovarian cyst on the left side. Hystero-myomectomy. Recovery. Path. No. 245. $\frac{3}{8}$ natural size.

It frequently happens on the left side that these inflamed structures are covered in by an adherent sigmoid flexure, and in order to reach them this must be dissected off by pulling it away from the tumor, so as to expose the cellular interval which is cut with scissors. When the inflamed tube and ovary are hard to reach, either because they are sheltered by the tumor or because they are wedged down in the pelvis, or when the adhesions are so dense that it is dangerous to break them up by touch without the controlling aid of sight, it is best to begin the enucleation by seeking out the ovarian vessels at the outer extremity of the broad ligament and tying them at two points and cutting them between, and then tying off the round ligament in the same way. By this means the top of the broad ligament is opened up and the uterus so far freed that it can be lifted up and out enough to allow free access to the inflamed structures, which can now often be better attacked from the exposed front of the broad ligament.

Where pus is present unusual care must be taken to diminish the risks of infection by aspirating and taking away as much of it as possible, and then protecting the infected structures by abundant gauze until they are removed. The risk of an infection is greater here than in almost any other abdominal operation on account of the wide area of cellular tissue bared between the broad ligaments by the enucleation of the uterus and tumors.

Adhesions, hydrosalpinx, and pelvic abscesses in the right side are best dealt with toward the end of the enucleation; as the uterus is rolled up and out of the pelvis after clamping the right uterine artery, the right adnexa can be easily reached and freed from adhesions under inspection by attacking them from the front.

One of the most complicated cases is shown in Fig. 501.

The patient had a large umbilical hernia, containing a portion of the omentum, which adhered to the edges of the ring; the omentum was also closely

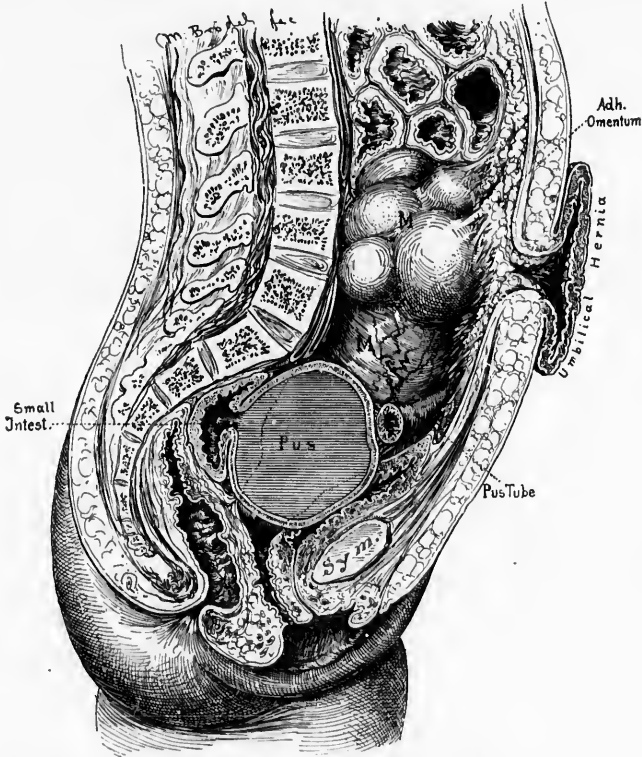


FIG. 501.—COMPLICATED HYSTERO-MYOMECTOMY.

The abdomen is filled with a large myomatous uterus with intestinal and omental adhesions. There is an umbilical hernia, and on the right side of the pelvis a large abscess opening into the small intestine. In front of the abscess lies the uterine tube full of pus. Enucleation. Recovery. R. L. Operation, March 24, 1897.

adherent to the whole front of the large myomatous uterus, which extended from the pelvic floor well above the umbilicus. The adherent bladder was drawn high up out of the pelvis, and over it lay a large thickened uterine tube distended with pus, while on the right side there was a suppurating

ovarian cyst communicating by a fistulous opening with a loop of the small intestine. The proper plan of procedure in such a case is to work with great deliberation until the adhesions are separated sufficiently to allow the myomatous uterus to be handled and to expose the left broad ligament. Gauze should be packed around on all sides to protect the peritoneum and the intestines from contamination, and any accessible sacs of pus should be tapped so that they will collapse, affording more room and obviating the risks of rupture and extensive contamination. After the enucleation the hernia and the intestinal fistula are treated. If the fistula is well closed a drain is not necessary.

4. *Encysted Peritonitis*.—In two cases I have encountered an extensive encysted peritonitis filling the posterior pelvis; in one instance this was not discovered until the adhesions at the brim of the pelvis were broken through and the clear serous fluid gushed out of a pocket lined by peritoneum and extending as far down as the floor of the pelvis. In the other case the fluctuation was so clearly felt *per vaginam* that the diagnosis between an ovarian cystoma and a fibroid uterus remained doubtful, until the abdomen was opened and the myomatous masses were exposed, when the fluctuation was found to be due to the sac of fluid pent up behind the uterus.

5. *Omental Adhesions*.—The omentum often adheres to the larger fibroid uteri, and in many instances its entire free border is attached like a corona to the anterior and upper convex surface of the tumor. The omental vessels in these cases may be greatly enlarged, standing out like whipcords or looking like great bunches of earthworms. These vessels, instead of ramifying on the surface of the tumor, seem to plunge vertically into the substance, and I have shown by injection that while they do contribute some small vessels to the capsule, for the most part they communicate directly with the deeper portions of the mass.

Sometimes all the tissue between the omental vessels disappears, and they stand out like so many separate whipcords from 6 to 10 or 12 centimeters long.

Ordinarily this complication is easily met by tying off the whole omentum with eight or ten fine silk ligatures, taking care not to bunch too many large vessels in one ligature. The difficulties are increased when the distance between the tumor and the transverse colon is so short that there is but little room to work between the two. In one case the whole omentum had disappeared, leaving the colon spread out flat on the surface of the tumor, and sending a number of large vessels into its substance. This difficulty was met by cutting off a thin shell of the capsule of the tumor circumscribing the vascular area, and then folding it in upon itself, and sewing the edges of the strip together.

6. *Parietal Adhesions*.—Adhesions to the abdominal walls are not common, and when they do occur, usually form an unimportant complication. The worst adhesions I have ever seen of this kind were in a case of a large fibroid, in which electricity had been used for a long time. Just under the places where the electric pads had been applied on the right and left sides the adhesions over areas about 10 by 12 centimeters were the densest I have ever seen:

two enormous arteries from 3 to 4 millimeters in diameter coursed prominently under the peritoneum from the lower abdomen to the adherent areas. The difficulty of detaching the tumor, which at first bid fair to be serious, from the constant extensive capillary oozing, was overcome by ligating these arteries in their course low down in the abdomen, and by obliterating with buried sutures the raw areas left after detaching the tumor.

In rare instances the myoma filling the pelvis forms adhesions to the pelvic floor, and the chief difficulties in the operation may arise from the constant oozing from numerous small vessels in the thickened pelvic peritoneum at a point quite remote from the surface. The best way to control the bleeding is to lift up the peritoneum so as to make a fold and then to suture one fold to another until the bleeding points are all under control.

7. *Intestinal Adhesions.*—The sigmoid flexure is more likely to adhere to a tumor than any other part of the intestine, and it is commonly found attached to the top of the broad ligament and the tumor adjacent to it. Its separation is easily effected by lifting it up and dissecting it carefully off from the vessels below, which are plainly seen.

The rectum rarely gives any trouble from adhering directly to the tumor; it is more apt to become attached to the inflamed lateral structures. Adhesions to the rectum low down in the pelvis may, as a rule, be safely left undisturbed.

The colon and small intestines do not often adhere. When they do, if the separation can not be made easily by drawing up the bowel and forming a little interval in the connective tissue binding the structures together, which can be safely cut through, then the important principle is to sacrifice the capsule of the tumor to the bowel by dissecting off a piece around the attached area.

There is, however, one kind of myomatous uterus of which I have seen two examples, where the pelvic adhesions are universal, and the small intestines wherever they touch it are so firmly agglutinated that separation is entirely out of the question. I opened the abdomen in one of these cases four years ago, and concluded, from the red vascular appearance of the softish mass covered with lymph and adherent bowels, that the tumors were malignant; the patient recovered from the exploratory incision and is in fair health to-day. I know of no way of reaching these cases.

8. *Adhesions to the Vermiform Appendix.*—When the appendix adheres to the tumor, a light adhesion may be peeled off, but if the adhesion is dense, or if there is evidence of a coexisting appendicitis, the best plan is to free the tumor on the left side, cut across the cervix, clamp the right uterine artery and roll the tumor out, and then when the right round ligament and ovarian vessels are secured, to clamp off the appendix near the colon, leaving it attached to the tumor. The stump of the appendix is then dealt with as described in Chapter XXXVI.

9. *Adhesions to the Liver and its Suspensory Ligament.*—This complication existed in one of my cases—a large nodular fibroid uterus filling the abdomen. The suspensory ligament bled freely, but the flow was

easily controlled by gathering the bleeding areas together by a catgut suture. Liver adhesions may be treated by passing sutures below the bleeding points and tying them carefully, tight enough to stop the flow, but not tight enough to cut into the liver tissue.

Tumors of the Ovary complicating Fibroid Uteri.—10. Ovarian cystoma. 11. Dermoid cyst. 12. Fibroid ovary. 13. Ovarian hydrocele. 14. Hematoma of the ovary.

I have met each of these conditions as complications of hystero-myomectomy. The first three are rare and merely accidental complications; the fourth is, I believe, unique. The fifth condition is frequently met with, either one or both ovaries containing a large hematoma developing from the corpus luteum.

The best plan of operating is to remove the ovarian tumor and the fibroid uterus together. If the ovarian tumor has a long pedicle, this may be simply clamped and the cyst taken away first; and if it is so large as to be unwieldy, it may be emptied before taking it out together with the uterus. The picture shows a large ovoid fibroid uterus with large dermoid cysts of the left ovary in a patient (J. Q., 3250) operated on Dec. 29, 1894; the whole was removed in one large mass. These operations are difficult only on account of the awkwardness of handling the tumors; their percentage of mortality ought not to be greater than that of simple hystero-myomectomy.

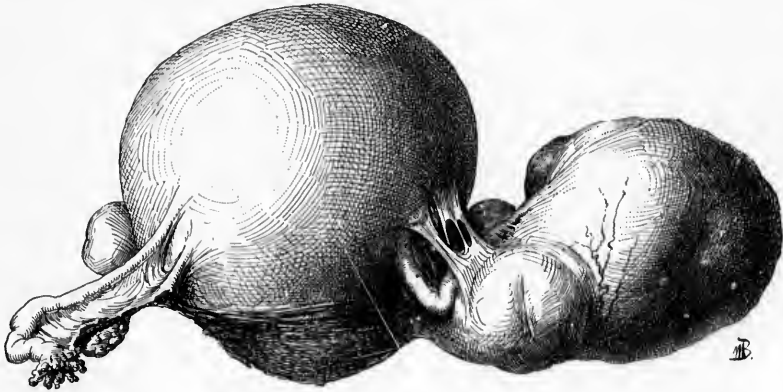


FIG. 502.—GLOBULAR MYOMATOUS UTERUS COMPLICATED BY DERMOID CYSTS OF THE LEFT OVARY. Hystero-myomectomy. Recovery. Dec. 12, 1894. Longest diameter 32 centimeters. $\frac{2}{3}$ natural size.

15. Carcinoma of the Ovary.—I have seen three cases of a cancer of the ovary complicating a large fibroid tumor of the uterus. In one of these cases the pelvic peritoneum was the seat of numerous little sprouting cancerous areas, disseminated from the ovaries. The myomatous uterus was as large as a five months' pregnancy. I took out both ovaries and uterus and evacuated a large amount of ascitic fluid. The patient recovered, but died six months later with ascites and large carcinomatous masses filling the abdomen.

Another case was that of a colored woman (E. M., Path. No. 1009, operated upon Dec. 11, 1895), with a large myoma filling the lower abdomen and rising above the umbilicus, with ascites. The bladder was adherent high up on the anterior face, and on the right side there was a large carcinomatous mass filling the right posterior quadrant and extending back behind the rectum. The extirpation was made from left to right in the usual way, and after exposing the cancerous mass from the front of the right broad ligament it was shelled out of its bed and the enucleation continued up behind the rectum, taking away a good handful of carcinomatous tissue in all. A number of enlarged glands were felt behind the rectum and the lower part of the sigmoid flexure, making a permanent recovery hopeless.

Diseases of the Cervix and Uterine Mucosa.

16. Cancer of the Cervix complicating Myoma.—In rare instances cancer of the cervix, cancer of the uterine mucosa, sarcoma, and tuberculosis of the endometrium have been found complicating myoma of the uterus. When the myomata are insignificant in size and the tuberculosis or the neoplasm is found in an advanced stage, the myoma may be looked upon simply as a complication of the latter. I refer here, however, to instances in which the prominent clinical symptoms are due, or have seemed to be due, to the myomatous condition and the neoplasm has not progressed far. Cancer of the cervix may be discovered upon making a vaginal examination to determine the size and relations of the enlarged uterus; the other conditions, however, are not apt to be suspected unless the uterine mucosa is curetted and a microscopic examination is made.

As a rule, cancer cells are found only when the specimens removed are subjected to a thorough examination. In all such instances panhysterectomy is indicated; in the event of the discovery after the operation, the cervix should be taken out by the vaginal route when the patient has recovered from her first operation.

17. Cancer of the Uterus associated with Myomata.—When we recall the large number of cases of myomata we are called upon to treat, and of the frequency of cancer of the uterus, it would be surprising if the one were not at times associated with the other. The liability of myomatous uteri to cancer is, however, manifestly lessened by the fact that the patient is often sterile and the cervix is spared the traumata of parturition which afford an anatomical basis for the cancer. For the sake of conciseness I divide these cases into three groups:

- (1) Epithelioma of the cervix associated with myoma.
- (2) Adeno-carcinoma of the cervix and myoma.
- (3) Adeno-carcinoma of the body of the uterus with myoma.

In a review of one hundred cases of carcinoma of the uterus, occurring in my wards at the Johns Hopkins Hospital, eight cases were associated with myomata, one case with epithelioma, one case with adeno-carcinoma of the cervix, and six cases with adeno-carcinoma of the body.

In the patient with the epithelioma of the cervix the myoma was small and was not discovered until after removal of the organ.

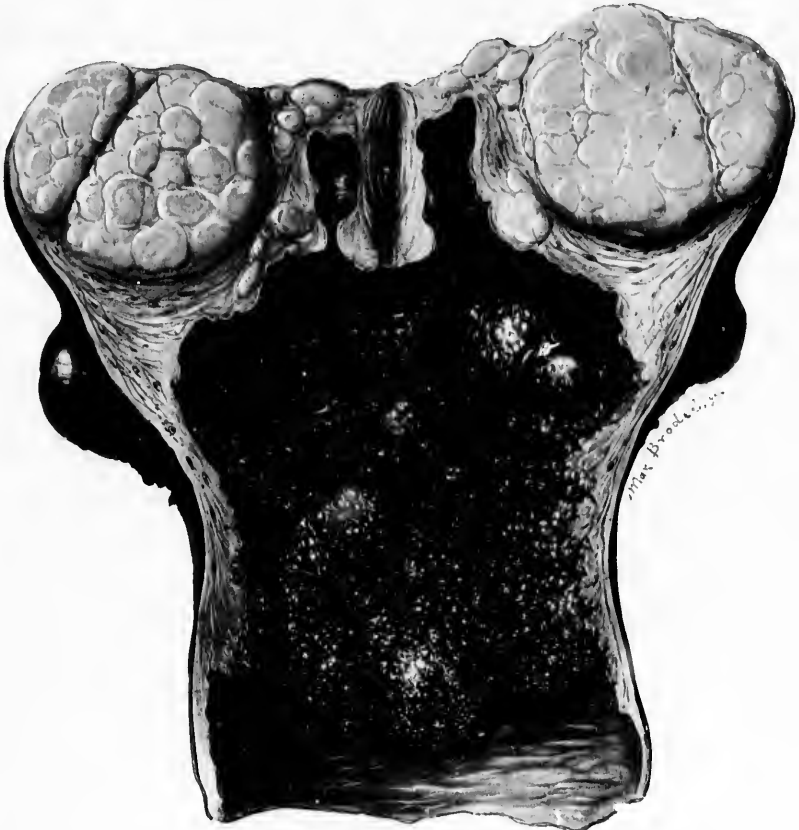

FIG. 503.—MYOMA AND CARCINOMA IN A NEGRESS.

Showing the zones occupied by preference by the two forms of disease. The fundus is converted into a mass of myomatous nodules while the entire lower segment of the uterus has been replaced by carcinomatous vegetations. There are metastases in the inguinal glands as large as an egg. The disease extends through the broad ligaments to the bladder; metastases also exist in the mesenteric, retro-peritoneal, and bronchial glands, as well as in the lungs, pleura, and serosa of the intestines. There is an anemia of all the organs and a fatty degeneration of the liver. Hydroureter. The myomata are not involved in the carcinomatous process. No. 926. Autopsy, March 29, 1897. $\frac{2}{3}$ natural size.

In the adeno-carcinoma of the cervix there were multiple myomata scattered throughout the uterus. The majority of the cases, six out of eight, where the carcinoma was present with myoma, were adeno-carcinomata of the body. The myomata were in some instances subperitoneal, in others interstitial, while in one case a small submucous nodule was present. Probably one of the most interesting cases was one of primary carcinoma of the ovary. The uterus was secondarily involved, and not only was the muscle penetrated in all directions by the new growth, but a large and degenerate myoma showed carcinomatous invasion in numerous places. Although, as has been seen, carcinoma of the uterus is at times associated with myomata, the two diseases represent two dis-

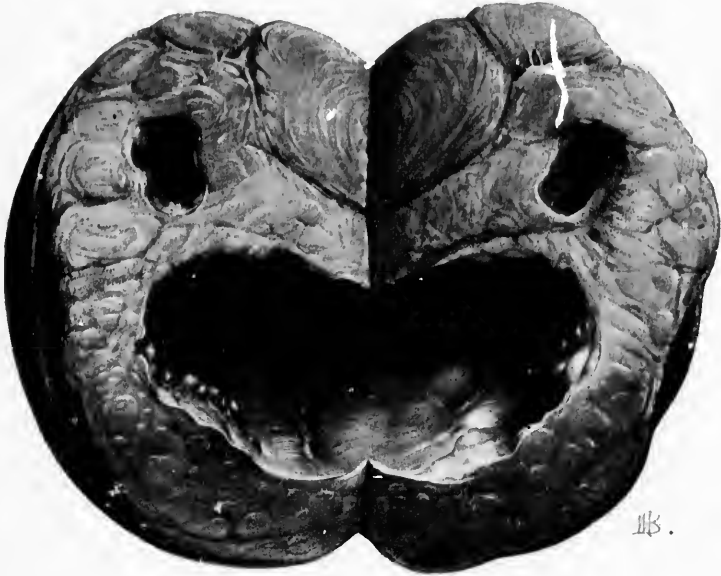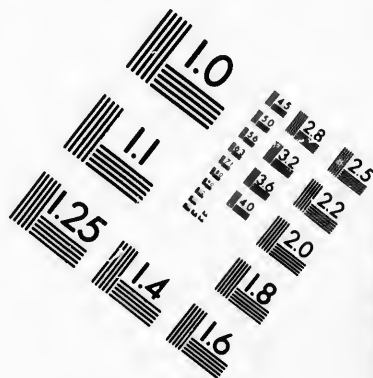
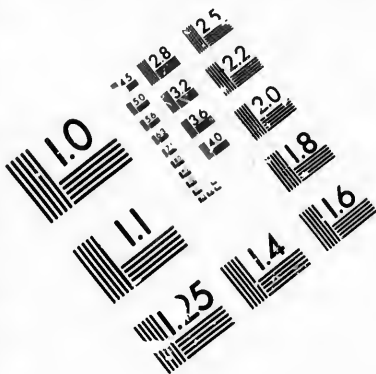


FIG. 504.—MYOMA WITH CYSTIC DEGENERATION.

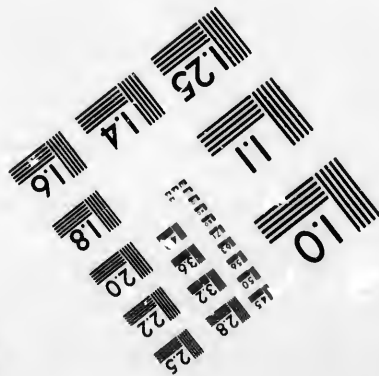
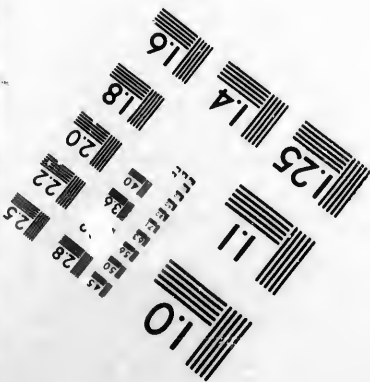


Large cavity, $6 \times 4.5 \times 5$ centimeters, filled with liquid resembling melted butter. The tumor is imbedded in 7 millimeters of the uterine muscular tissue, and its walls are made up of interlacing non-striated muscular fibers. No inflammatory changes found. Hystero-myomectomy. Recovery. Path. No. 347. $\frac{2}{3}$ natural size.

inct processes, in no way dependent the one upon the other, and the presence of the one does not appear to alter the characteristic course of the other.

18. **Tuberculosis of the Endometrium.**—Tuberculosis of the endometrium is exceedingly rare as a complication in the large myomatous uterus. I have met with but one case, and in this the disease was not recognizable to the naked eye, but was readily shown by a microscopic examination occupying the entire mucosa; it extended out into both tubes, which were nodular and caseous but showed no breaking down. A piece removed from this case



**IMAGE EVALUATION
TEST TARGET (MT-3)**



**Photographic
Sciences
Corporation**

23 WEST MAIN STREET
WEBSTER, N.Y. 14580
(716) 872-4503



was used for the plate illustrating tuberculosis of the endometrium, Vol. I, p. 489.

Complications due to Changes in the Tumors Themselves.—There are three principal complications due to alterations in the tumors; these are cystic, vascular, and suppurative changes.

19. **Cysto-myoma.**—The cystic change, as a rule, does not in any way add to the difficulties of operating. Cystic fibroids may be perfectly free and are as easily extirpated as a solid tumor, as will be seen by looking at the figures; some cases, on the other hand, show a tendency to form intimate attachments on all sides, and here the difficulties arise from the adhesions. I had one case of this kind where the cystic tumor choked the pelvis and was everywhere so densely adherent that I was unable to remove it; I tapped the cysts through the vagina several times, removing 3 or 4 liters at each tapping; the patient finally died of exhaustion from the pressure on the viscera.

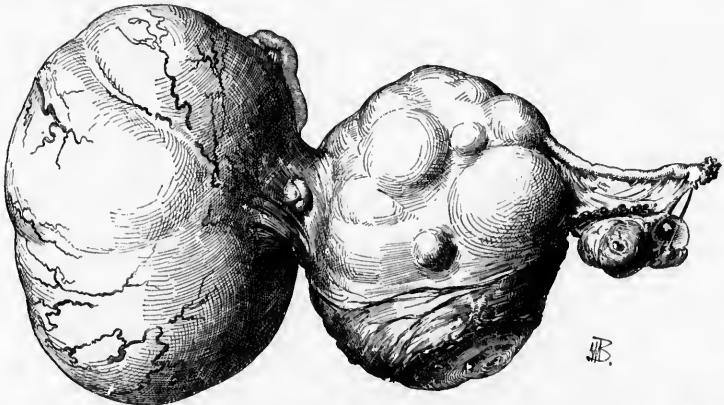


FIG. 505.—LARGE FIBRO-CYSTIC TUMOR OF THE UTERUS ATTACHED BY A BROAD PEDICLE TO A MULTI-NODULAR MYOMATOUS UTERUS.

The right uterine tube is seen in the angle above between the fibro-cyst and the uterus. The hypertrophied ovary is seen on the left side. Hystero-myomectomy. Recovery. Jan., 1895. $\frac{3}{8}$ natural size.

20. **Telangiectatic Myoma.**—The telangiectatic myoma is awkward to handle on account of the great venous sinuses leading out of it, as well as the enormous venous tracts within, any one of which if wounded would immediately deluge the field of operation with blood. A beautiful example of this kind of myoma is shown in section in the colored Plate XX, where the dark vascular areas and the mouths of the cut vessels, which are mostly arteries, are plainly seen in patches. At other places lymph is seen coagulated in the tissues between the myomatous nodules. A tumor of this class often resembles, on section, a large vascular sponge.

21. **Suppurating Myoma.**—I refer under this head to certain rare cases in which the myomatous tumor forms a shell filled with pus. I do not include here those sloughing submucous tumors which discharge *per vaginam*.

DESCRIPTION OF PLATE XX

ANATOMY OF THE UTERUS WITH CERVIX DIVERGENT

The fundus has been divided longitudinally and the picture shows one side of the cut surface, the uterine muscle is seen relaxed on the right side and the uterine horns are seen on the left side.

The groups of cysts scattered throughout the fundus are those usually seen in myometrium. The blood vessels are the most important and are seen in the fundus of the picture. They are cross-sections of groups of blood vessels some of which consist of as many as one hundred vessels. Histologically they are found to be arteries. The wall of the uterus is divided into innumerable tubules and presents the usual appearance.





Such a case (A. S., 3216, Dec. 3, 1894) is figured in the text; the patient had a large intraligamentary mass on the right side with septicæmia, and came to the clinic exceedingly prostrated. (See Fig. 511.)

The tumor had formed dense parietal adhesions and the omentum was attached by its entire free border, together with the cecum, colon, and small intestines on the right side.

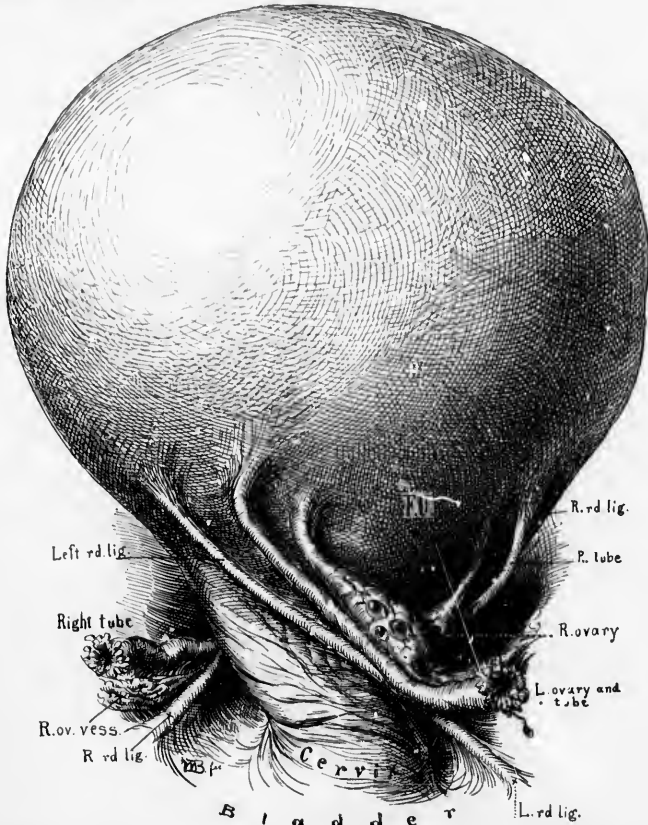


FIG. 506.—TORSION OF THE GLOBULAR MYOMATOUS UTERUS FROM LEFT TO RIGHT, BRINGING THE FUNDUS TO THE FRONT AND THE RIGHT TUBE AND OVARY AROUND TO THE LEFT SIDE.

The tumor occupies the entire anterior uterine wall. Operation. Recovery. $\frac{2}{3}$ natural size. Jan. 9, 1897.

An incision into the abdomen was made 16 centimeters (6 inches) long, the fluctuating myoma tapped, and 4,700 cubic centimeters of yellow pus removed. The great difficulties on the right side were met by first cutting through the left broad ligament and amputating the uterus, and then clamping the right uterine artery just as described in the typical operation. As the uterus and the big col-

lapsed tumor were rolled up and out, the adherent intestines were approached from below and easily separated. The omentum was tied off, and the dense abdominal-wall adhesions treated by leaving on a plaque dissected from the outside of the tumor. The patient recovered and was in good health a year later.

These cases are also quite distinct from those in which there is a suppurative endometritis; I have seen one case in which there existed a pyometra, the uterine cavity containing about 40 cubic centimeters of pus. It is on account of this complication that it is so important to cover up the uterine cavity as soon as it is incised to avoid contamination of the wound.

22. *Cystic Myoma Uteri with Twisted Pedicle.*—Myomatous tumors stand in remarkable contrast to ovarian tumors as regards the rarity with which a twisted pedicle is found. Either the myoma may be pedun-



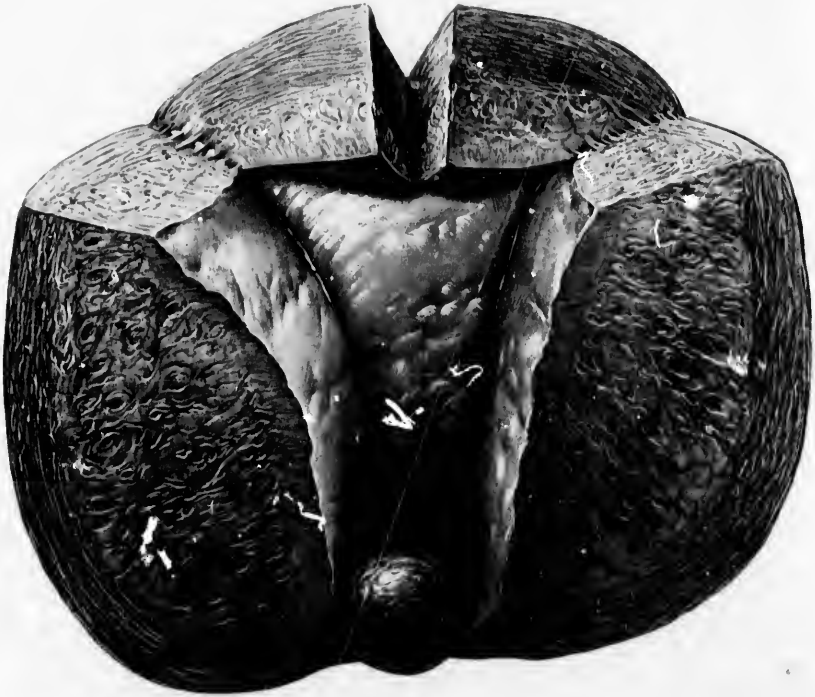
FIG. 507.—TORSION OF THE MYOMATOUS UTERUS. THE UTERUS SEEN IN FIG. 506 UNTWISTED.

Showing the knoblike cervix and the thinned-out supravaginal cervix. Seen from above and from behind the uterus.

culate and twist and contract adhesions, or the body of the uterus with a large myoma of the spherical sort may be revolved on the thinned-out cervix and the broad ligament as a pedicle, as shown in the accompanying illustrations (see Figs. 506 and 507).

Lesser degrees of torsion, as, for example, a quarter of a turn, are not infrequently seen, and are due to slight movements of accommodation of the contained body, the uterus with its tumors, to the containing body, the lower





abdominal cavity. If the containing body is often enlarged, and is often shrunken up, as in the case with the abdominal cavity, it is manifest that the containing body will sooner or later find the field which best fits its form.

The following case is an example of the action of a cystic organ on its pedicle:

A. Y., 148, white, aged 47 (1896). She returned an abdominal enlargement in 1896, which increased gradually for five months, when she began to swell rapidly. She had not suffered any pain and was complained of constipation, flatulency and shortness of breath. Upon making a physical examination the patient was found to have a large, rounded mass in the abdomen; the abdomen was symmetrically enlarged, with tenderness over, pressure high back of navel of the nature of a cystic tumor, which had been gradually enlarged.

Operation, July 3, 1896. Upon section, a large, rounded, pedicled, rounded cystic, the interior was empty. The mass was found to be a large myoma, growing from the right corner of the uterus, and completely filling the abdominal cavity, and the uterus was found to be normal.

DESCRIPTION OF PLATE XXI.

BENIGN ADENO-MYOMA OF THE UTERUS.

The uterus cut open and viewed from the front. A spherical myoma fills the cervical end, and is everywhere penetrated by glands. The divided anterior uterine wall, enormously thickened, is made up of three layers; the inner layer is the uterine mucosa, presenting a smooth, slightly undulating surface; the outermost layer consists of parallel bundles of normal uterine muscular tissue, and between these two layers is one which presents a coarsely reticulate appearance, everywhere penetrated by the uterine glands, which extend as far as the outer muscular layer.

was then performed by a continuous incision from left to right, and a recovery, and the patient made an uneventful recovery.

3. Adeno-myoma Uteri Diffusum Benignum.—On the *Laboratory Report*, vol. vi, p. 133, Dr. F. S. Cullen describes one of my operations, describing a new variety of myoma under the name of "adeno-myoma uteri diffusum benignum." I have also had two more of these benign adeno-myomata. These adeno-myomata are rather more interesting from the pathological and anatomical standpoint, because their true character is not by any means so apparent, as the symptoms do not differ from those of the ordinary myoma.

The treatment differs, in that the operation may be completed like the ordinary myomata on account of the indurated character of the tumor, and the operation is more difficult.

The only operation, therefore, which can be done by some cases of myoma is myomectomy.

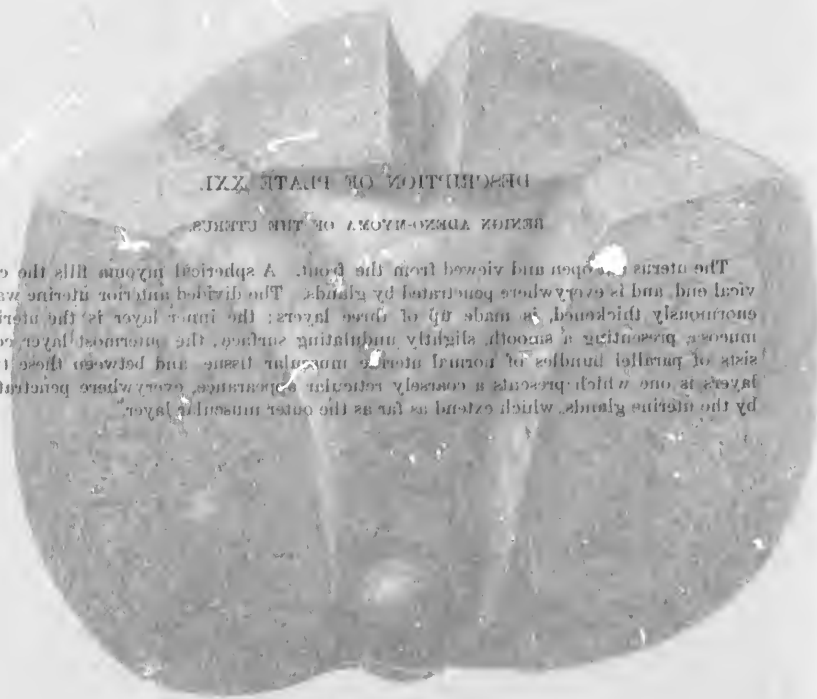
Case I.—Adeno-myoma uteri diffusum benignum. Glandular uterine polyp in cervix. Small uterine polyp and sub-peritoneal myomata. (Plates XXI and XXII).

L. W., admitted to my service, October 1, 1904, aged forty-six, single. Her complaint on admission was in lower part of abdomen, pain and irregular menstruation. Menstruation commenced when she was eleven years of age.

DESCRIPTION OF PLATE XXI.

BENIGN ADENOMA OF THE UTERUS.

The uterus is shown and viewed from the front. A spherical tumor fills the cervical end, and is everywhere penetrated by glands. The divided anterior uterine wall, enormously thickened, is made up of three layers: the inner layer is the uterine mucosa presenting a smooth slightly undulating surface, the innermost layer consists of parallel bundles of normal non-muscular tissue, and between these two layers is one which presents a coarsely reticular appearance, everywhere penetrated by the uterine glands, which extend as far as the outer muscular layer.



abdominal cavity. If the containing body is often changing its shape and is often shaken up, as is the case with the abdominal cavity, it is manifest that the contained body will sooner or later find the bed which best fits its form.

The following case is an example of the torsion of a cystic myoma on its pedicle:

A. Y., 4485, white, aged thirty-nine, first noticed an abdominal enlargement in 1895, which increased gradually for four months, when she began to swell rapidly. She had not suffered any pain and only complained of a smothering sensation and shortness of breath. Upon making a vaginal examination the cervix was found buried in a mass extending up into and filling the abdomen; the abdomen was symmetrically distended, with flabby thick walls, presenting a distinct wave of fluctuation, but a tumor could not be distinctly outlined.

Operation, July 2, 1896, hysteromyomectomy. On opening the peritoneal cavity, the intestines were exposed and found resting upon a cystic myoma, springing from the right cornu of the uterus and completely filling the lower abdominal cavity, and looking like a large multilocular cystoma. The cyst wall was hemorrhagic and flabby, so that the tumor lay like a half-filled bladder upon the posterior abdominal wall. Many of the spaces contained dark, bloody fluid; a few of them contained clear serum. To the left and above the umbilicus the tumor was intimately adherent to the anterior abdominal wall. The pedicle, which was about $\frac{1}{4}$ centimeters long, had two distinct twists from left to right. The adhesions to the abdominal wall were freed and the pedicle cut off close to the uterus. A few catgut ligatures controlled the hemorrhage. The uterus was symmetrically enlarged to the size of a three months' pregnancy, and on both sides a large adherent hydrosalpinx was found. Hystero-salpingo-oöphorectomy was then performed by a continuous incision from left to right without difficulty, and the patient made an uneventful recovery.

23. Adeno-myoma Uteri Diffusum Benignum.—In the *Johns Hosp. Hosp. Rep.*, vol. vi, p. 133, Dr. T. S. Cullen describes one of my cases constituting a new variety of myoma under the name of "adeno-myoma uteri diffusum benignum." I have also had two more cases during the past year. These adeno-myomata are rather more interesting from the pathological than from the clinical standpoint, because their true character can not be recognized before operation, as the symptoms do not differ from those of simple myomata.

The treatment differs in that they can not be enucleated like the simple myomata on account of the intimate connection of the tumor with the uterine muscle.

The only operation, therefore, which can be done in these cases is hysteromyomectomy.

CASE I.—Adeno-myoma uteri diffusum benignum. Glandular uterine polyp in cervix. Small interstitial and subperitoneal myomata. (Plates XXI and XXII.)

L. W., admitted to my service, Oct. 24, 1894, aged forty-six, single.

Her complaint on admission—pain in lower part of abdomen, painful and profuse menstruation. Menstruation commenced when she was eleven years of

age, and was always regular. For the past ten years she has had severe pains in the right ovarian region at the menstrual period. These pains radiated down both limbs, were accompanied by backache, and for the last two years have been so severe that she has been confined to bed for from three to four days at each period. At present the flow lasts from ten days to two weeks, and there is a considerable amount of clotted blood. Her last period ceased one week before admission. Her parents are both living and healthy. One brother died of tuberculosis. With the exception of an attack of diphtheria several years ago, and influenza three years ago, she has always been well.

Present Condition.—The patient is a rather anemic woman and does not appear to be strong. Her tongue is pale and flabby, appetite fair, bowels regular. She is unable to walk much and can not lift heavy weights.

Vaginal Examination.—The outlet is much relaxed, and presenting at the orifice is a hard, irregular mass, which proves to be the cervix. The external os is patulous, admitting the index finger, and projecting from the os is what appears to be a myomatous nodule about the size of a hazelnut. The cone-shaped cervix is continuous with the enlarged uterus, which is apparently freely movable.

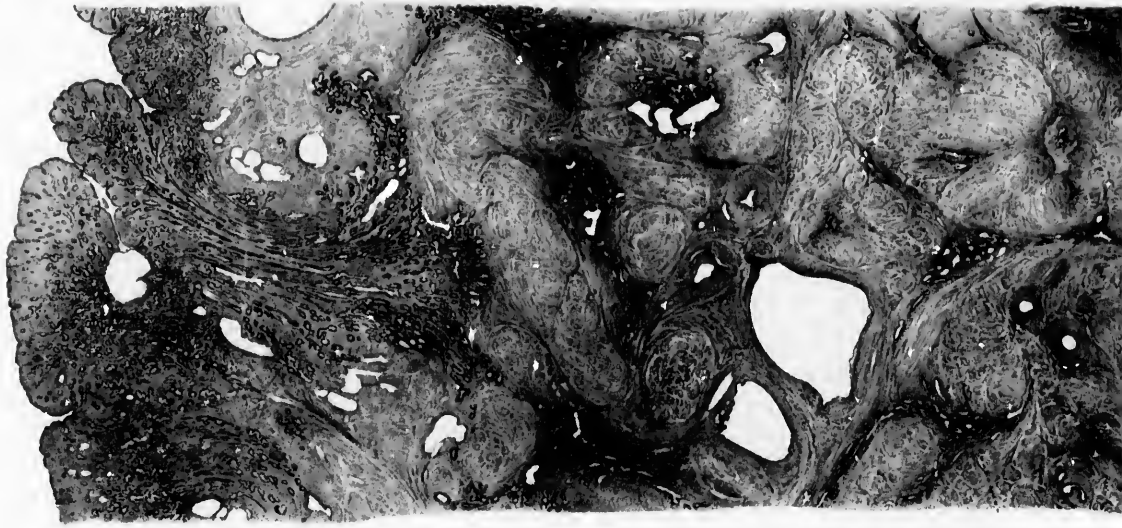Clinical Diagnosis.—Myoma corporis uteri.

Operation, Oct. 31, 1894. On opening the abdomen it was found impossible to raise the uterus out of the pelvis, and the operator was compelled to work in the narrow space between the uterus and the pelvic walls. The ovarian and uterine vessels on both sides were controlled and the uterus amputated. The lips of the stump were then brought together, and, lastly, the peritoneum from the posterior wall sutured to that of the anterior, thereby completely covering over the stump. The patient made an uninterrupted recovery, and was discharged Dec. 1st.

Pathological Report (No. 497).—The specimen consists of the enlarged uterus with its tubes and ovaries intact. The uterus is 13 centimeters long, 12 centimeters broad, and 10 centimeters in its antero-posterior diameter. It is approximately globular, and in its contour resembles a normal but enlarged uterus. Anteriorly it is smooth and glistening, posteriorly over its lower two thirds it is denuded of peritoneum. Situated in the posterior wall in the vicinity of the left uterine cornu are four sessile nodules, which are approximately circular. The largest of these is 2 centimeters in diameter. On section they are whitish in color and are composed of fibers concentrically arranged. They present the usual myomatous picture. The underent surface of the uterus is 12 by 11 centimeters. In the center of this is the cervical opening, which is 1 centimeter in diameter. Projecting from the right side of this opening is a nodule 2.5 centimeters in diameter; this is apparently covered by mucous membrane which is somewhat hemorrhagic.

The anterior uterine wall is 7 centimeters in thickness (Plate XXI); it can be divided into two distinct portions—an outer one, 1 centimeter thick, which resembles normal uterine muscle; the remainder of the wall presents a coarsely



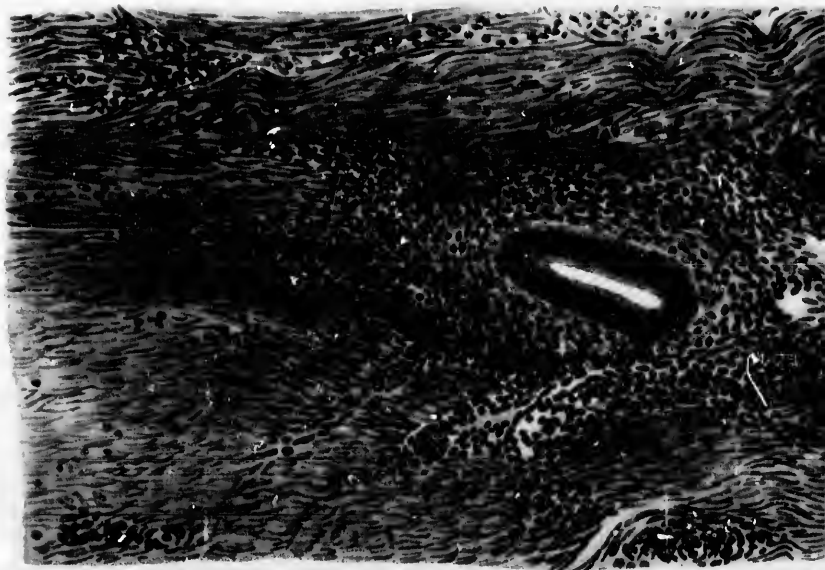

Uterine Mucosa.

X 4.

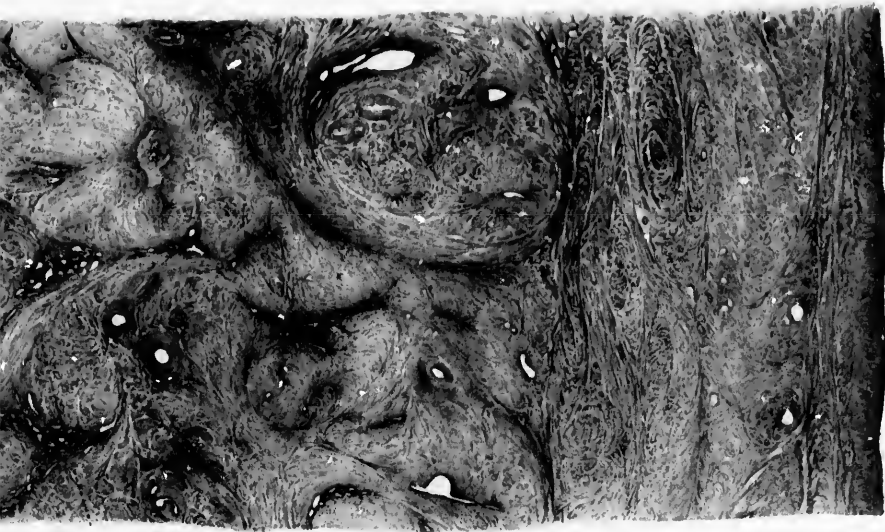Tumor consisting of myomatous muscle and uterine

Fig 1.



X 200

Fig 2.



a

Pathological muscle and uterine glands.
fig. 1.

Normal uterine muscle.

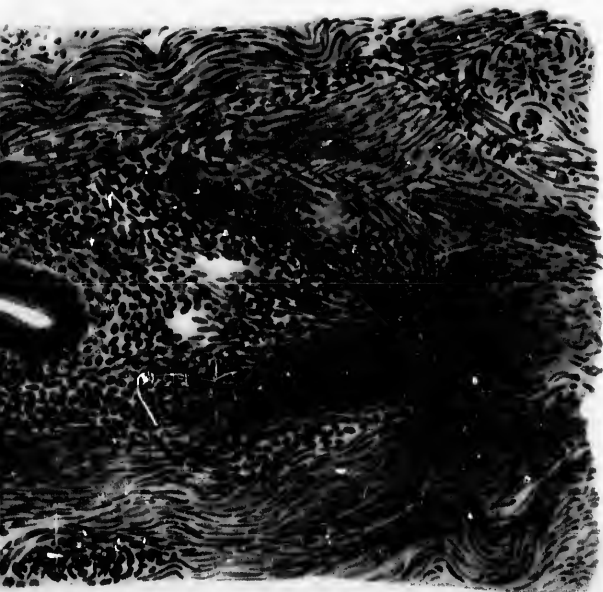


fig. 2.



ted appearance, the striations running in all directions. Throughout this thickened and striated portion of the uterine wall are oval, or elongate, brownish-yellow, homogeneous areas, some of which directly into the uterine muscle. In one or two places small cysts, varying from 1 to 4 millimeters in diameter, can be seen scattered throughout the thickened portion of the uterine wall. The striated appearance can be traced up to the uterine mucosa, and in some places into it. After hardening in Müller's fluid the boundary is clearly between the normal uterine and the thickened striated portion. The uterine muscle being much darker than the striated portion. The diameter of the uterus varies from 5 centimeters in thickness. In some places, but does not present any striation. Situated in the posterior wall are occasional nodules 1

DESCRIPTION OF PLATE XXII.

BENIGN ADENO-MYOMA OF THE UTERUS.

The long section is taken from Plate XXI and magnified four times. To the left is the uterine mucosa with a wavy outline, intact surface epithelium and glands mostly normal; a few glands are dilated. Below the mucosa—that is, to the right in the picture—the glands are seen extending all the way through to the normal uterine muscle on the extreme right; they penetrate the pale muscular bundles, and are surrounded with a darker area of typical stroma of the mucosa. This irregular muscular area also contains numerous dilated gland spaces. Occasional dark patches without lumina are made up of stroma devoid of glands.

The lower figure shows a cross-section of the gland, seen at *a* in the upper figure, magnified two hundred times. The gland is lined by one layer of cylindrical epithelium, and is surrounded by cells having oval vesicular nuclei; it is identical in appearance with a normal uterine gland. Surrounding the stroma of the gland are non-striated muscular fibers, for the most part cut longitudinally.

Side. The uterine tube is 9 centimeters long and 6 millimeters in

Its extremity is patent; the parovarium is intact. The ovary, 4 centimeters in size, is yellowish-white in color and contains a cyst 2.5 centimeters in diameter. The width of the cervix is 2 centimeters in thickness, and the inner os is closed by a firm mass of tissue.

Microscopical Examination.—The uterine wall is composed of several layers of spindle-shaped muscle fibers, some of which are throughout the muscle in places covered by a layer of epithelium. The dilated glands are empty or contain granular material which takes the hematoxylin stain. The surface of the mucosa covering the anterior uterine wall presents in places a wavy outline (Plate XXII, Fig.

DESCRIPTION OF PLATE XXII.

BENIGN ADENOMYOMA OF THE UTERUS.

The long section is taken from Plate XXI and magnified four times. To the left is the uterine mucosa with a wavy outline, intact surface epithelium and glands mostly normal; a few glands are dilated. Below the mucosa—that is, to the right in the picture—the glands are seen extending all the way through to the normal uterine muscle on the extreme right; they penetrate the pale muscular bundles and are surrounded with a darker nest of typical stroma of the mucosa. This irregular muscular nest also contains numerous dilated gland spaces. Occasional dark patches without lumina are made up of stroma devoid of glands.

The lower figure shows a cross-section of the gland, seen as in the upper figure, magnified two hundred times. The gland is lined by one layer of cylindrical epithelium and is surrounded by cells having oval vesicular nuclei; it is identical in appearance with a normal uterine gland. Surrounding the stroma of the gland are non-striated muscular fibers, for the most part cut longitudinally.

striated appearance, the striæ running in all directions. Scattered throughout this thickened and striated portion of the uterine wall are round, oval, or elongate, brownish-yellow, homogeneous areas, some of which merge directly into the uterine mucosa. In one or two places small cysts, varying from 1 to 4 millimeters in diameter, can be seen scattered throughout this thickened portion of the uterine wall. The striated appearance can be traced directly up to the uterine mucosa, and in some places into it. After hardening the specimen in Müller's fluid the contrast is sharp between the normal uterine muscle and the thickened striated portion, the uterine muscle being much darker in color than the striated portion. The posterior wall of the uterus varies from 2.5 to 3.5 centimeters in thickness. It is rather dense, but does not present any coarse striation. Situated in the posterior wall are two interstitial nodules 1 and 1.5 centimeter in diameter; they are pearly white in color and are composed of concentrically arranged fibers.

The uterine cavity is 7.5 centimeters in length, and at the upper part 8 centimeters in breadth. The mucous membrane of the anterior uterine wall varies from 7 to 8 millimeters in thickness, is yellowish white in color, smooth and glistening. In many places, however, it presents ecchymoses in the superficial portions. In the vicinity of the internal os and extending upward for about 2.5 centimeters are three or four longitudinal folds of the mucosa. The depression between these are about 4 or 5 millimeters in depth. The mucosa covering the posterior wall varies from 3 to 4 millimeters in thickness.

Right Side.—The uterine tube is 11 centimeters long and averages 7 millimeters in diameter. Its fimbriated extremity is patent; the parovarium is intact. The ovary measures $8 \times 2.5 \times 1.5$ centimeters, is pale white in color, smooth and glistening. It contains two corpora lutea, the larger of which is 2.5 centimeters in diameter.

Left Side.—The uterine tube is 9 centimeters long and 6 millimeters in diameter. Its extremity is patent; the parovarium is intact. The ovary, $4 \times 4 \times 1$ centimeter in size, is yellowish-white in color and somewhat lobulated. It contains a cyst 2.5 centimeters in diameter. The walls of this are 2 millimeters in thickness, and the inner surface is dirty brown in color.

Histological Examination.—The nodule projecting from the uterine canal (Plate XXI) is composed of non-striated muscle fibers. Its outer surface is in places covered by cylindrical epithelium, but in most places apparently by several layers of spindle-shaped cells like connective tissue. Scattered everywhere throughout the muscle are glandlike spaces varying from a pinpoint to 3 millimeters in diameter. These are lined by one layer of epithelium, which in the smaller glands is of a high cylindrical variety. In the dilated glands, however, it is cuboidal, or has become almost flat. The protoplasm of the cells takes the hematoxylin stain. The nuclei are oval and vesicular, and in many places it is possible to make out the cilia. The glands are empty or contain a granular material which takes the hematoxylin stain. These glands resemble to some extent those of the cervix. The surface of the mucosa covering the anterior uterine wall presents in places a wavy outline (Plate XXII, Fig.

1). Its epithelium is of the high cylindrical variety and is everywhere intact. In a few places it is swollen and somewhat flattened. The glands are moderate in number, are small and round on cross-section, and have an intact epithelium. A few of them are slightly dilated and contain desquamated epithelium. The glands may be traced from 7 to 10 millimeters before any muscular substance is encountered; they then end abruptly or continue into the muscle, where they can in places be traced for at least 1 centimeter; this downgrowth is visible in many places. The stroma of the mucosa is composed of cells whose nuclei vary from oval vesicular, as seen near the surface, to deeply staining ones, as noticed in the depth of the mucosa. In some places the stroma cells have elongate oval nuclei, and it is impossible to distinguish these from muscle fibers. The superficial portions of the stroma show marked hemorrhage which is localized to certain areas. The stroma as a whole does not appear to be very vascular.

The thickened and striated portion of the anterior uterine wall is composed of non-striated muscle fibers, which are for the most part cut longitudinally. The fibers run in all directions, are closely packed together, but are only in a few places concentrically arranged. Scattered throughout this tissue are numerous cells having small, round, deeply staining nuclei which resemble those of lymphoid cells. Under the microscope it is impossible to tell where the coarsely thickened zone ends and the normal uterine muscle commences, as the transition of the one into the other is so gradual. Traversing this thickened portion of the uterine wall are small clusters of glands, precisely similar to those of the uterine mucosa (Plate XXII, Figs. 1, 2). These glands are round or oval and are lined by one layer of cylindrical ciliated epithelium. A few longitudinal sections of the glands are here and there visible. Some of the glands are dilated, one of them reaching 5 millimeters in diameter. The epithelium of the dilated glands is in places somewhat flattened or has entirely disappeared.

In one place two glands are seen opening into a dilated gland. Nearly all of the glands are surrounded by stroma similar to that of the uterine mucosa. A small isolated gland is occasionally found lying directly between the muscle fibers, and a few of the cysts have no stroma surrounding them. The gland invasion can be traced to the point where the coarsely striated tissue joins the uterine muscle. They are most abundant near the uterine mucosa, and gradually diminish as one passes outward. They may be scattered anywhere throughout the myomatous growth, but appear for the most part to occupy the spaces between the muscle bundles. In few places can any concentric arrangement of muscle fibers be made out around the glands. The glands themselves show no evidence of degeneration.

From this description it will be seen that there is a diffuse muscle thickening of the anterior uterine wall, and that there is a downgrowth of normal uterine glands into the newly formed muscle. Along the lower margin of the growth is a typical myomatous nodule 5 millimeters in diameter.

The mucosa covering the posterior uterine wall is normal.

The right tube and ovary are normal.

The left tube is normal. The small cyst of the left ovary has no epithelial lining, hence its exact origin can not be ascertained.

Complications due to the location of the tumors.

These are, perhaps, the most important of all complications of the myomatous uterus. According to the location of the tumors, the operation is easy or difficult. When they are at the fundal end, they can readily be lifted out, the broad ligaments exposed and cut through, when the cervix forms a small pedicle easily dealt with. If, however, the tumors develop underneath the movable pelvic peritoneum, the effect is either to displace the bladder or the rectum and sigmoid flexure, to open out the broad ligaments, to push the uterine body in the opposite direction, or to raise and efface the cervix, so distorting the normal topographical relations. When a number of tumors develop in this way under different parts of the pelvic peritoneum the distortion becomes extreme and at first sight all landmarks seem obliterated. It is just these cases which continue to puzzle even experienced gynecologists, from want of a definite routine plan of handling them. By careful attention to the following detailed descriptions, however, it will be seen that even the most complicated and distorted myomatous uteri may be treated on exactly the same routine plan as the simpler forms.

To make this important point perfectly clear I shall first consider isolated tumors in each of the important situations, and then state what changes are produced when they are found in several of these locations at once.

24. *Elevation of Tubes and Ovaries high out of the Pelvis.*—When the upper part of the body of the uterus is involved the tubes and ovaries and broad ligaments are left low down in the pelvis, or elevated only slightly above the brim, and apart from the handling of the large tumors the operation is not much different from the supravaginal extirpation of a normal uterus.

When the tumors are situated in the body of the uterus below the fundus the enlarging mass carries the lateral structures with it up into the abdomen, and the broad ligaments acquire a vertical instead of their normal horizontal direction. Under these conditions it may be difficult to get at them, and they at first appear to be absent, and replaced by a number of large vessels spread out on the side of the uterus. A closer inspection, however, will show that these vessels come together at the pelvic brim, and upon drawing the uterus to the opposite side they can be exposed, picked up between two fingers, ligated in a bunch with one fine ligature on the pelvic side, and tied or clamped on the uterine side, and the operation begun as usual.

If the sigmoid flexure is raised out of the pelvis, it may be necessary to split the meso-sigmoid on its outer side, and to push the peritoneum down before the vessels can be exposed and tied. Care must always be taken in tying the vessels above the brim of the pelvis not to include a ureter.

25. *Globular Myoma filling the Pelvis.*—The spherical myomata form a distinct group which recur so regularly that they call for a definite plan of dealing with them. When the tumor is just large enough to fill the

pelvis, and arises from the lower part of the body of the womb, the operator will be embarrassed by two things. In the first place, he can not lift the tumor up out of the pelvis and through the incision, and so deal with it easily, even by grasping it with stout forceps and making strong traction; in the second place, he finds that the pelvis is so choked that he can not get room enough between the tumor and the pelvic walls to tie off the broad ligaments, and particularly to get at the uterine artery. I am in the habit of meeting this difficulty by catching the top of the uterus with a museau forceps or a stout bullet forceps on the left side, and then pulling strongly to the right, and rotating the

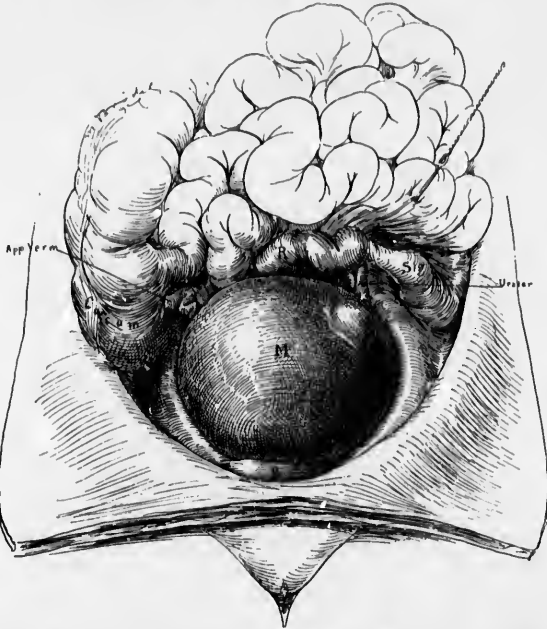


FIG. 508.—PELVIS CHOKED BY A CUP-AND-BALL MYOMA (*M*) COMPRESSING SMALL INTESTINES, BLADDER, RECTUM, VERMIFORM APPENDIX, AND URETERS. SEE FIGS. 487 AND 488.

tumor as it lies in the pelvis so as to bring the top of the broad ligament into view. When the ligament is cut through, by rotating still farther the uterine artery is rolled up, exposed, and tied, when the growth can be lifted out of the pelvis, the cervix cut across, and the operation completed in the usual way.

26. Myomata wedged in the Pelvis.—Incarcerated myomata form a peculiar group of constant recurrence. On opening the abdomen the pelvis is found choked with tumors, the landmarks are difficult to find, and the operator, upon seeing the immobility of the mass, anticipates a prolonged and difficult enucleation. If, however, before beginning the operation he has taken note of the vaginal cervix in front and looks close enough to find out that the



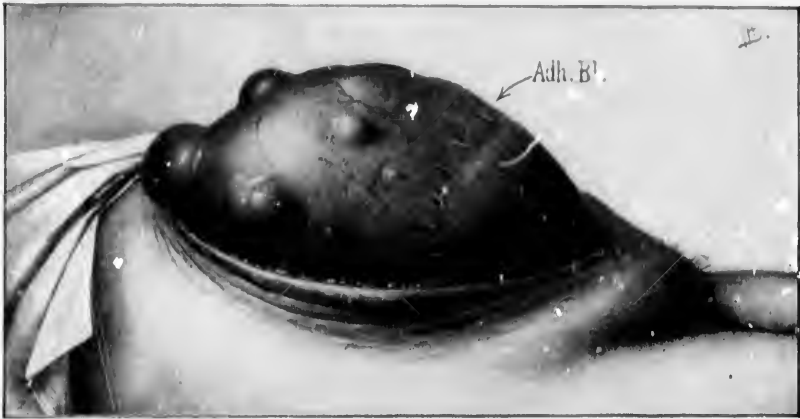

FIG. 509.—LARGE MYOMATOUS UTERUS FILLING THE LOWER TWO THIRDS OF THE ABDOMEN.

Showing the bladder adherent to the uterus and lifted up out of the pelvis with it. This is especially intended to show the difference between the bladder as elevated by its natural anatomical connections and one elevated by adventitious peritoneal adhesions. Hystero-myomectomy. Recovery. Dec. 11, 1895.



FIG. 510.—DISPLACEMENT OF THE BLADDER DUE TO A LARGE MYOMATOUS UTERUS WITH THE FUNDUS AT THE UMBILICUS.

The position of the bladder is indicated by enormous tortuous vessels running parallel to each other down toward the symphysis; the vessels end at the line of reflection of the vesico-uterine peritoneum. Hystero-myomectomy. Recovery. Dec. 14, 1895. $\frac{2}{3}$ natural size.

min masses are wedged into the posterior pelvis, he will be able to rectify the chief source of difficulty by instructing an assistant to push upward on the tumor with two fingers in the vagina, while he himself makes strong traction from above with museum or obstetric forceps; as the tumor is disengaged and extracted from its bed it gives forth a peculiar loud sucking sound, and the whole mass rotates on its transverse axis as it is lifted out of the incision. Such a case is figured in the text (see Figs. 487, 488, and 508). The top part of the mass in the picture is the part which lay on the pelvic floor before it was lifted out. These tumors often present a perfect mold of the posterior part of the pelvis, giving an exact reproduction of the form of the sacrum. All the myomatous nodules seen on section, which in the abdomen would have sprouted out on the surface of the mass forming numerous bosses, are here so compressed by the hard walls of the pelvis as to form a uniformly rounded surface.

Quite another group of complications are introduced when the tumors arise low down on the uterine body or in the cervical region, and as they develop lift up the loose peritoneum so as to raise the pelvic floor. The embarrassment here lies in the fact that at first sight there is no pedicle in view, and the question how to make one is difficult for a novice to answer.

Tumors may develop in this way in front of the uterus, lifting up the vesical peritoneum and possibly the bladder too, or behind the uterus, lifting up the rectum, or on either broad ligament. They may also grow in situations between these four cardinal points or in several of these positions at one and the same time.

As these are the cases which are the hardest to handle, and the ones which give the highest mortality, I will take some pains to dwell on the treatment of all the various forms in detail, and first I will speak of

27. *Myoma below the Vesical Peritoneum.*—If the tumor grows low down on the uterine body just below the line of movable peritoneum, it may then continue to grow out into the cellular space between the vault of the bladder and this line. When the abdomen is opened it looks as if the bladder was raised high up on the anterior face of the uterus, but a closer inspection and a direct palpation show that the lighter-colored movable peritoneum has no underlying bladder, but that the bladder is really still down in the pelvis behind the symphysis.

In other cases, the usual form, the bladder itself goes up into the abdomen with the developing tumor until it reaches even as high as the umbilicus. These cases must be distinguished from still a third class, where the bladder has simply formed adhesions across the top of the uterus, and has been dragged up into the abdomen as the uterus grew in size. The existence of such adhesions may usually be detected by irregularities or breaks in the line of attachment, in addition to the absence of the movable peritoneum with its definite line of attachment clearly reflected onto the uterus. No cases are so liable to serious injury from the very outset as these, for when the bladder is displaced high up in the abdomen by a large myoma the line of reflection of the peritoneum from the abdominal wall over the bladder onto the uterus is also often raised so high that it is

cutting in as usual, unless the operator bears this in mind and makes the opening just below the umbilicus, he is liable to make a hole in the bladder before he knows it. One can not always rely on the sound introduced into the bladder to tell just how high up it extends, for the sound may be stopped by the tumor and not go all the way to the top of the bladder. The bladder may also lie wholly on the anterior face of the tumor, and the relations of the peritoneum to the anterior abdominal wall may remain undisturbed. It is best, therefore, in all large myomata to open the peritoneum at first high up and then to enlarge the opening downward (see Figs. 509 and 510).

After opening the abdomen the chief difficulty in handling an elevated bladder is to free it, so as to be able to get at the cervical part of the tumor, which necessarily lies behind it. This is best done by first tying and cutting the left ovarian vessels and the left round ligament. The operator now carefully seeks out, both by inspection and touch, the line of movable peritoneum crossing the front of the uterus, tracing it all the way from one round ligament to the other and expecting to find it even in a convex line extending high up over the face of a large tumor. He will also often be assisted in locating this line by the numerous deeply congested sinuous vessels of the bladder which begin suddenly just under the reflected peritoneum and run in a parallel course down toward the brim of the pelvis, in marked contrast to the flat uterine vessels above which have no such definite direction.

The incision must always be made above these vesical vessels (see Fig. 510), for if they are cut, great vascular sinuses are opened which are controlled with difficulty even by numerous clamps. If the peritoneal cut from round ligament to round ligament is carefully made just at the line of reflection, as a rule no vessels are severed large enough to need a clamp. After doing this the operator tries to push the bladder down with a sponge. If it sticks he may try a little careful dissection with a spatula or knife or scissors, keeping in the cellular tissue between the bladder and the uterus. The sponge ought not to be used vigorously, for I have seen a hole 4 centimeters in diameter torn in the bladder in this way. But the bladder usually yields, and is slowly pushed or rubbed down off the uterus. If the left ureter is lifted high out of the pelvis, this goes down too with the bladder, and then the uterine arteries come into view and are tied close to the tumor without any risk of including the ureter.

In one of my cases of enormous distorted myomatous uterus I did not examine the situation minutely enough, and thinking I was following the reflected line, I cut boldly from round ligament to round ligament. There was at once a tremendous hemorrhage from the vesical sinuses, and I found I had cut off and left on the uterus a piece of the bladder as large as the palm of my hand. The wound in the bladder was carefully closed with fine interrupted silk sutures down to the mucosa, and the patient made an excellent recovery.

28. Myoma below the Posterior Pelvic Peritoneum.—A myoma in this situation is rare, for, in order to develop under the peritoneum of the pelvic floor behind, the tumor must start in a much more limited portion of the cervix than myomata starting in the subvesical space. In its de-

velopment a tumor in this situation raises the peritoneum posterior to the uterus to the level of the promontory of the sacrum, and even beyond it, obliterating Douglas's *cul-de-sac* and raising the sigmoid flexure with it. In such cases, on opening the abdomen and making the inspection preliminary to enucleation, the operator finds the sigmoid high up in the abdomen spread out flat on the surface of the tumor.

The commonest way in which this condition is brought about is by a tumor growing not exactly from the posterior median part of the cervix, but from a point higher up and to the left. Such a tumor, as it develops, lifts up the posterior layer of the left broad ligament, the peritoneum of the pelvic floor, and the sigmoid flexure.

It is most important to know just how to handle these cases to avoid injury to the sigmoid and the rectum. There are two ways of dealing with this complication—

(1) When the ovarian vessels which run under the sigmoid are so concealed that they can not be picked up and tied, so that the operation may be commenced in the usual way, they can be reached by incising the peritoneum reflected from the sigmoid onto the tumor on its outer side and at some point where there are no vessels, and then introducing the finger into the loose cellular tissue underneath the bowel and carefully working it loose and pushing it down off the convexity of the tumor until the ovarian vessels are exposed.

Sometimes the bowel is so closely attached and there are so many large vessels in the way that it is not safe to free it in this manner, and the second plan is best.

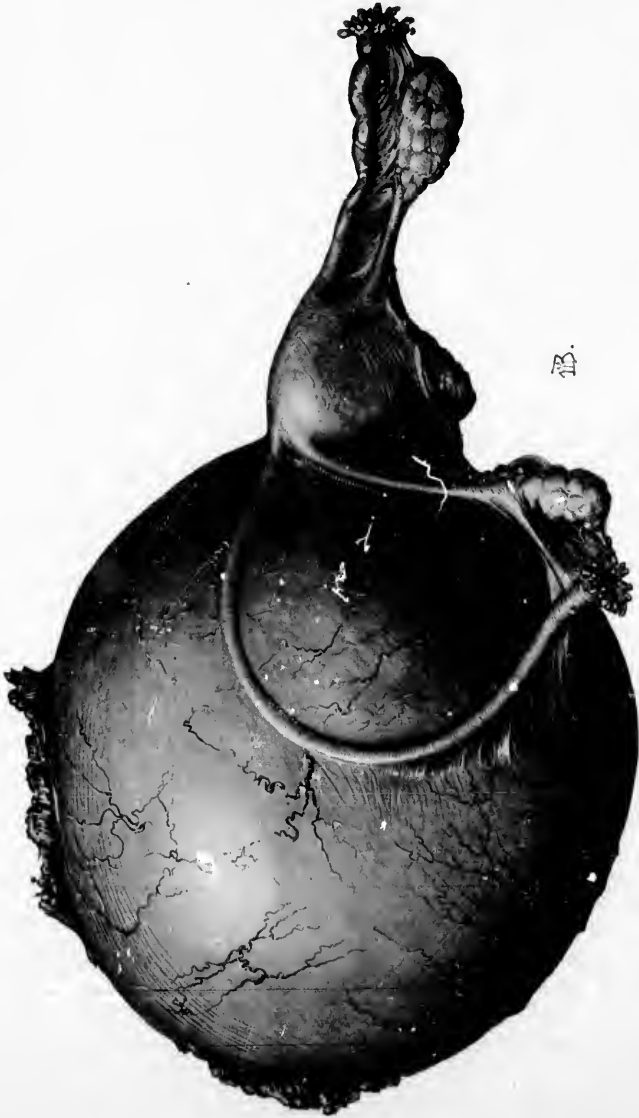(2) The rectal complication is for the time neglected and the ovarian vessels sought out and tied by pulling the mass over to the right and working through the pelvic peritoneum near the brim of the pelvis, or, if need be, by raising the ascending colon and tying them beneath it. They are then divided and the round ligament, which can always be found near the internal inguinal ring, often like a tense bowstring, is next tied and cut, the bladder freed, and the uterine vessels tied as usual.

The next step deals with the complications by cutting across the cervical part of the uterus and so getting at the posterior myoma from in front and below, where it lies in the loose cellular tissue. Its enucleation is now easily effected by rolling it up and out, unwrapping it, as it were, from its peritoneal covering. After doing this and then cutting through the peritoneum reflected from the bowel onto the tumor, it may be from beneath instead of from above, the rectum at once drops into its normal position in the pelvis. The operation may then be completed in the ordinary way.

29. Myoma in the Upper Part of Broad Ligament, and

30. Myoma in the Broad Ligament Proper.—When the tumor develops on either side of the uterus, within the layers of the broad ligament, as it grows it separates the anterior from the posterior layer, raises them up into the abdomen, and pushes the body of the uterus to the opposite side. The amount of disturbance of the normal topographical relations caused by such a

tumor will depend upon its location in the broad ligament. When situated high up, the only effect may be to separate widely the three structures which lie close together at the cornu uteri, the tube, the round ligament, and the ovary,



13.

FIG. 511.—LARGE CYSTIC MYOMA OF THE LEFT BROAD LIGAMENT, FILLED WITH PUS; REMOVED BY HYSTERO-SALPINGO OOPHORECTOMY. The uterus and the right tube and ovary are intact. The left tube and the utero-ovarian ligament are greatly lengthened and spread out on the posterior surface of the tumor, and the mesosalpinx is obliterated. The surface of the tumor is deeply indented and covered with large vessels. All the vessels and to the left on the periphery of the tumor extensive oncetal adhesions are seen. Patient seen Nov., 1896, in perfect health. Path. No. 534. Dec. 3, 1894. $\frac{1}{2}$ natural size.

which are then found spread apart on the surface of the tumor, as shown in Fig. 511.

When the tumor grows farther down in the broad ligament, in addition to parting the round ligament from the tube and the ovary, it also displaces the ovarian vessels at the brim, the sigmoid and the rectum, and the uterine vessels, and often also the bladder. This complication will be recognized by the displacement of these structures.

The treatment of such a mass on the left side is to begin the enucleation by freeing the sigmoid enough to get at and tie and sever the ovarian vessels, and then to tie and cut the round ligament, and to connect these two incisions by just cutting through the peritoneum, which is pushed down toward the pelvic brim. On grasping the tumor and pulling it to the right it is stripped out of its cellular bed and the uterine vessels brought into view in the angle in front, between the tumor and the body of the uterus, where they are tied low down and the cervix cut across and the operation finished as usual.

Too great care can not be taken in these cases to avoid the ureter, which may sometimes be found lifted up into the abdomen over the convexity of the tumor. This is done by making the incision between the ovarian vessels and the uterine end of the round ligament and pushing down the peritoneum as stated. If the ureter is displaced, it goes down into the pelvis with the peritoneal covering of the tumor and is not touched at all. Intraligamentary myomata on the right side require a different sort of treatment. Here the left broad ligament is opened, the bladder freed, and the uterine vessels tied as described in the typical operation; then the cervix is cut across and the uterine vessels on the right side are easily found in the cellular tissue and caught by the side of the cervix.

The intraligamentary mass is now easily shelled out by running the fingers into the loose tissue beneath it, grasping and rolling it up and out, unfolding it from its peritoneal investment, and bringing the broad ligament, and lastly the ovarian vessels, into view. These are clamped, and the enucleation, which at first sight looked difficult, is completed in less than a minute.

31. Myoma situated Antero-laterally, twisting the Uterus. —I have seen one case in which a large myoma had developed under the pelvic peritoneum in the angle between the bladder and the left broad ligament. As the tumor grew and came to occupy a more central position, the uterus was raised high out of the pelvis and rotated at the same time with the bladder attached to it, so twisting the bladder. After freeing the ovarian vessels and the round ligaments I found I could not detach the bladder and push it down, even with the most careful dissection, without tearing its structure, so I abandoned the effort in this direction and further opened up the broad ligament on the left side, until the uterine vessels low down were exposed. I then worked the finger out into the loose cellular tissue in the angle between the vagina, supravaginal cervix, and the bladder, and freed the bladder first at this point, and then continued to strip it loose from its attachments from below upward, reversing the ordinary procedure; the rest of the enucleation was then

easily completed. Care must be taken in following this method to keep close to the uterus so as to avoid the ureter.

32. *Myoma situated Postero-laterally.*—The special point to be noted in myomata developing postero-laterally is the tendency to elevate the rectum and sigmoid flexure when the tumor is located on the left side. This complication will be treated by dissecting off the bowel and ligating the ovarian vessels of that side as already described above.

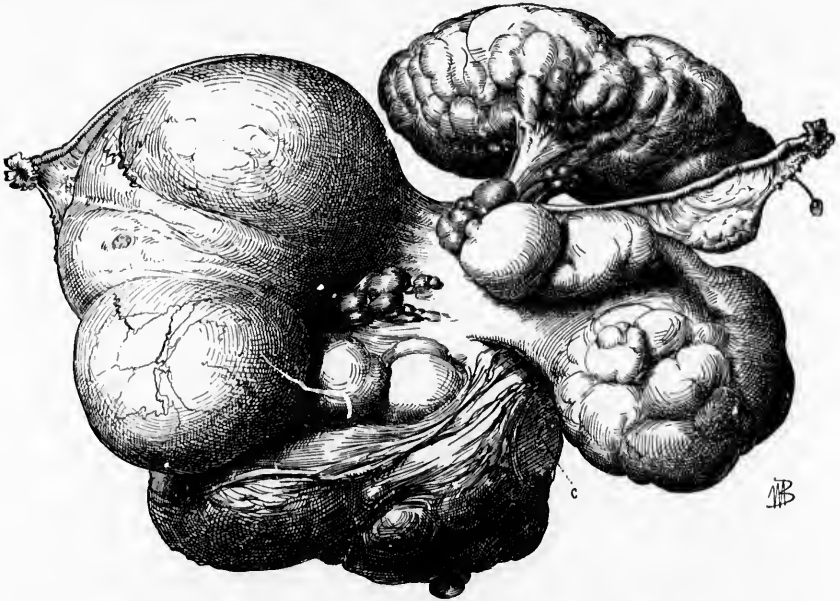


FIG. 512.—MYOMATOUS UTERUS WEIGHING 39 POUNDS, SEEN FROM BEHIND.

Showing the extreme distortion of the uterine body by the tumors occupying every conceivable position. The point of amputation of the cervix is shown at *C*, and the right and left ovaries and tubes are seen above on either side. The left tube is lengthened out and displaced by a large intraligamentary mass. The lower part of the tumor, from a point above the cervix transversely across to the right, was entirely subperitoneal. Hystero-myomectomy. Recovery. Longest diameter 39 centimeters. San. March 16, 1895. $\frac{1}{2}$ natural size.

33. *Myomata situated under the Pelvic Peritoneum in Several of these Positions at Once.*—I have enumerated above (Nos. 28–32) the various positions in which myomata may be found singly beneath the pelvic peritoneum, and dwelt carefully on the special character of the displacements produced and their proper management at the operation; I now wish to speak of a still more complicated class of cases in which the tumors develop in two or more of these situations at once.

In addition to the subperitoneal myomata, large tumors often spring from the body of the uterus above the pelvic peritoneum, producing an irregular complicated mass of growths projecting free into the abdominal cavity, as well as distorting the normal relations of the pelvic organs to the utmost possible de-

gree. These growths afford us some of the largest as well as the most difficult tumors to handle. (See Fig. 512.)

I should note here the fact that the displacement of the entire pelvic floor may also be produced by a single tumor starting at any point in the cervical region, and attaining a size sufficient to lift the body of the uterus high up into the abdomen.

Where the whole pelvic floor is raised in this way, the operator, on opening the abdomen, is apt to find the peritoneum reflected from the anterior abdominal wall over onto the uterus a short distance below the umbilicus; at the sides no broad ligaments are found, but groups of large ovarian vessels course down over the sides of the tumors and disappear below the abdominal peritoneum; one often sees also enormous lymph channels in the same situation, sometimes holding as much as a pint of serum; posteriorly the sigmoid is raised high up,

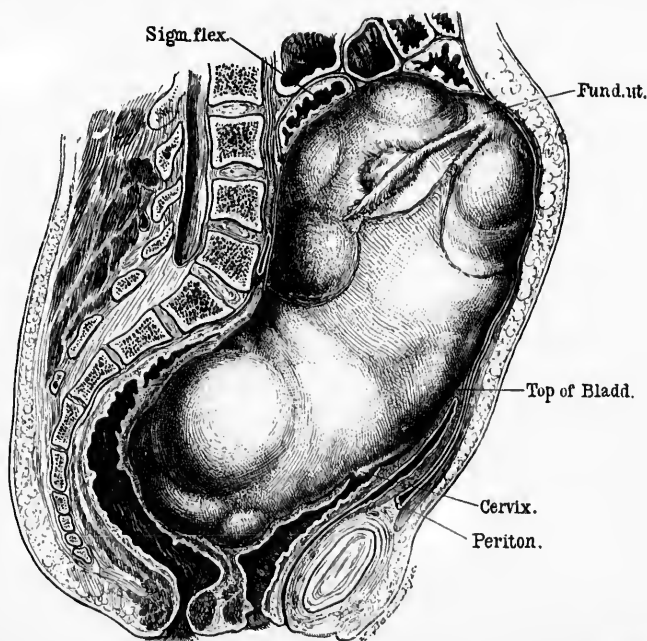


FIG. 513.—COMPLICATED HYSTERO-MYOMECTOMY SHOWING EXTENSIVE SUBPERITONEAL DEVELOPMENT.

The cervix is raised high out of the pelvis, and the bladder has been forced up into the abdomen. The fundus uteri lies high above the umbilicus opposite the displaced sigmoid flexure. The line of reflection of the peritoneum over the side of the tumor is shown. Hystero-myomectomy. Recovery. Feb. 9, 1895.

even above the umbilicus. The whole large mass presents at first sight an appearance well calculated to make the boldest operator hesitate before attacking it, for the part of the uterus covered with the firmly attached peritoneum is often not larger than the palm of the hand, while this area is surrounded on

all sides by the movable peritoneum covering a great tumor mass, and the hard question is, how to commence the operation of removing the growths without cutting large vessels and sacrificing considerable portions of the displaced peritoneum.

These difficulties may all be met by applying the principles developed in the previous sections of this chapter. The sigmoid flexure may often be let down behind by incising its peritoneum, anteriorly or laterally, but never on the median side, at the point of reflection; then the ovarian vessels are carefully sought out and caught in a bunch and tied at a point well above the pelvic brim; next, the round ligament is found and traced up to its uterine attachment and tied; then, continuing the enucleation, the top of the left broad ligament is opened, the vesico-uterine fold of peritoneum is cut through from round ligament to round ligament, and the bladder pushed and dissected down; then the tumor in the left broad ligament is drawn up and to the right until the uterine vessels are exposed and tied and the cervix, which is known by its attachment to the vagina, is cut across; last, the right uterine artery is found and tied, and the large posterior and the right broad ligament masses turned out of their cellular bed by catching them below and rolling them up and out, so that the right round ligament comes into view. When this and the right ovarian vessel are clamped the enucleation is complete.

34. *Myomata displacing the Ureters Upward.*—Among the large myomata described in the last section I have had a number of cases of extreme displacement of one or both ureters. In order to bring this about the tumor must naturally start to grow at some part of the lower uterine segment and then develop below the level of the ureter.

The displaced ureter looks like a large vein or a round ligament. It is often dilated to 1 or 2 centimeters in diameter (hydroureter); it is flattened and whitish in color. It would seem easy at first sight to distinguish this organ from other broad-ligament structures by a simple inspection and by following its course, but such is not the case. I have several times been greatly confused in determining what structure I had in hand. Once, after a painstaking examination, I concluded I was dealing with a large vein on the right side; I tied it in two places and cut between, and then, on passing in a sound, found I had cut the ureter.

After completing the enucleation of the uterus and tumors I made good my error by anastomosing the upper end of the severed ureter into the side of the lower end (uretero-ureterostomy), and the patient recovered.

Another time I discovered that I had tied a ureter by cutting a longitudinal slit in it (ureterotomy) and running in a sound. It was stopped by the ligature, which I at once took off, and no harm resulted.

I show in Fig. 513 a diagram of a myomatous uterus weighing 23½ pounds, where both ureters were lifted high up and out of the pelvis; the right ureter was kinked in two places and raised 6 centimeters above the brim, while the left ureter was arched high up to a point 10 centimeters above the pelvic brim. The cardinal principle in treating this complication is to keep as close as possible to

the uterus throughout the enucleation; this is done, after tying the left ovarian vessels and freeing the vesical peritoneum, by pushing down the peritoneum on the left side and picking up the uterine vessels close to the tumor, or by catching the artery by itself in the cellular tissue; in this way

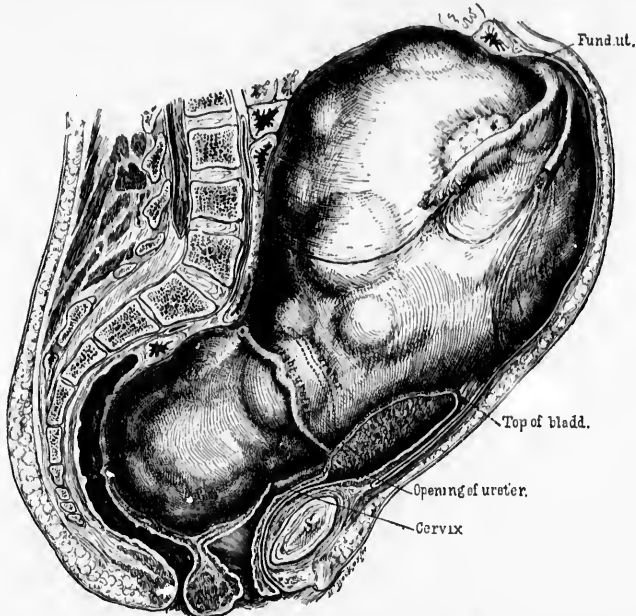


FIG. 514.—COMPLICATED HYSTERO-MYOMECTOMY.

The pelvic peritoneum is displaced high up into the abdomen by the enormous myomatous uterus, as indicated by the line beginning above the bladder and extending up to the round ligament, the oviduct, and ending above the sacral promontory. The fundus lies above and on top of the uterus; above the umbilicus lies the sigmoid flexure, seen in cross section. The bladder lies wholly in the abdomen, and both ureters are displaced above the pelvic brim; the left is indicated in dotted outline. The pelvis is also choked by the tumor, and the cervix lies near the level of the superior strait behind the symphysis. Hystero-myomectomy. Recovery.

the ureter goes down at the side and drops into its normal place. The right ureter is in less danger, as in rolling the tumors up and out it is simply peeled off, and remains behind with the peritoneum which had covered the tumor. In this way the complication is avoided, and the operator does not even need to be aware of the displacement on the right side.

Should a ureter be incised it may be sutured, as described in Chap. XIII.

If a ureter is severed, leaving an end sufficiently long below, the best plan will be to anastomose it (see Figs. 262 and 263, Vol. I, Chap. XIII, pp. 466 and 467).

If it is cut too near the bladder to be anastomosed into itself, the upper end should be turned into the bladder (uretero-cystostomy, see Fig. 260, Vol. I, Chap. XIII, p. 460).

If the ureter is tied in a mass of tissue with the uterine vessels, it will usually do to cut the ligature and retie the vessels and let the ureter alone; but if there is doubt as to the integrity of its inner coats, it will be best to put a flexible ureteral catheter in through the bladder, reaching well up above the point of injury, and to leave it there for two or three days.

Complications due to pregnancy, ascites, and other causes.

35. Myoma with Pregnancy.—The relations of myomata to pregnancy is a question of great practical importance, and the surgeon is often called upon to decide the following questions:

- (a) Whether pregnancy can occur in a given case.
- (b) When pregnancy exists, whether the life of the mother is in danger.
- (c) Whether a living child can be carried and born at term.

It is unusual for a woman with a myomatous uterus of large size to become pregnant, and where there are a number of myomatous masses the patient is apt to abort in from two to four months. Many cases, however, have occurred in which the uterus has carried its additional burden to full or nearly to full term, and a viable child has been born. One of my patients with myomata even became pregnant after fifteen years of married life.

The practice is in general to a too frequent interference with the pregnancy, and in many of the instances of hysteromyomectomy during pregnancy which are reported and figure in the journals, if the patient had been let alone she would have gone on and produced a living child.

The question as to the risk in letting the pregnancy go on to term is to be settled by the size and position of the tumors. Small tumors of the upper part of the uterus do not impede the birth; but when they are attached to the cervical region the important question is whether the tumor is large enough to interfere with the passage of the head, and if it is, whether it can be pushed up from the pelvis out of the way when labor begins.

If the tumor is estimated as too large to let the head go by, the surgeon may then consider whether or not he will be able to enucleate it *per vaginam* several months before the labor.

The child should have the benefit of a doubt, for after labor begins it may still be saved by turning, by the use of the forceps, or by a Porro operation. If the child has died, it may be taken away by craniotomy.

An extra-uterine pregnancy may also exist as a complication in a fibroid uterus.

36. Myoma simulating Pregnancy.—I had a case (V. W., 3198, Nov. 28, 1894) of fibroids which, in size and disposition of the tumors, simulated an advanced abdominal pregnancy (see Fig. 515). The entire mass was 28 centimeters (11 inches) long, and lay transversely in the abdominal cavity. In the left iliac fossa there was a round tumor the size of the head, and a constriction behind it represented the neck. The body of the uterus occupied the position of shoulders, and at the cornu, which was turned toward the anterior abdominal wall, was a peculiar conical fibroid excrescence like the stump of an arm. Behind the uterus, and lying in the right abdomen, a cylindrical mass bellied out

below, and imitated the size and shape of the normal fetal abdomen. The only feature wanting was an attempt to reproduce the lower limbs.

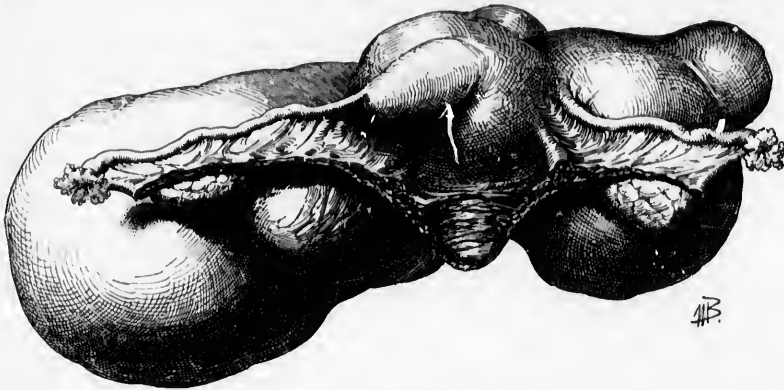


FIG. 515.—MYOMATOUS UTERUS PRESENTING AN EXTRAORDINARY MIMICRY OF A CHILD IN A TRANSVERSE POSITION.

Seen from the front. The supposed head lay on the left side behind the left broad ligament with a well-defined neck back of the uterus. A curious conical nodule extending out under the right uterine tube felt like the arm of the child, while the large mass occupying the right iliac fossa, and seen behind the right broad ligament, had the form of the body from the shoulders down. The longest diameter was 28 centimeters. Path. No. 533. Nov. 28, 1894. Hystero-myomectomy. $\frac{2}{7}$ natural size.

Felt through the abdominal walls, the imitation of a dead fetus at term was exact, and a differential diagnosis was only made by the most careful palpation, recognizing the hardness of the masses and their close attachment to the posterior surface of the uterus, which could be outlined under anaesthesia. The history showed also that they had existed for some years.

37. Myoma and Ascites, Feeble Heart, Nephritis, etc.—Ascites is a complication by no means rare if we take into consideration lesser as well as larger quantities of ascites. We seldom, however, find as much as 1 or 2 liters of serum in the abdomen. The cause of the ascites is not known. One of the most striking cases of this kind I have ever seen was that of a woman from which I removed 7 liters of fluid. The patient was thirty-two years old, and had had two children, the youngest five years old; soon after the birth of this child she noticed a lump in the lower abdomen, which remained stationary for over three years, when, without apparent cause, the abdomen began to enlarge. At the time of her admission into the hospital the abdominal enlargement was uniform, fluctuating, and not tense or tender at any point. The umbilical circumference was $87\frac{1}{2}$ centimeters, and halfway above the umbilicus it was 83 centimeters (see Fig. 486).

Per vaginam, the cervix was found to be jammed down on the pelvic floor by hard uterine tumors filling the pelvis. In the left vault a strong thrill was felt with each pulsation of the uterine artery. Growing from the upper part of the pelvic mass of tumors were two fibroid balls about as large as a fetal head at

the seventh month, $9 \times 6 \times 8$ centimeters, attached by pedicles respectively 1 and $1\frac{1}{2}$ centimeter long and 2×3 and $2\frac{1}{2} \times 2\frac{1}{2}$ centimeters in thickness.

The left mass received three large omental vessels, which appeared to plunge directly into its substance.

Between these short pedicled tumors and the anterior abdominal wall there was a layer of ascitic fluid. On striking the tumor on the left a sharp blow at a point 5 centimeters above the symphysis, it yielded at once and returned in one or two seconds, hitting the fingers a decided blow, and this phenomenon could be felt over an area about 5 centimeters in diameter. The impulse of the blow could also be seen on the abdominal wall on pushing back the tumor and taking the hand away, thus perfectly reproducing ballotement, the diagnostic sign of pregnancy. On giving the mass in the pelvis a decided upward blow by the vaginal finger, a distinct gentle wave could be seen traveling from the symphysis up the abdominal wall.

In excessive anemia the best time to operate is just before an expected period, when a maximum improvement has taken place. In cases of heart disease, nephritis, or other organic lesion, the determination whether or not an operation is advisable will depend, in the first place, upon the relationship believed to exist between the tumor and the visceral lesion. If the tumor aggravates the organic affection or stands in causal relation to it, the operator will be justified in taking risks he would not otherwise assume, with the hope of either ameliorating the condition or at least of checking the advance of the disease. A marked improvement is often especially noticeable in cases which may be supposed from the urinary analysis to be in the earlier stages of nephritis. A pyelonephrosis may be treated by incision and drainage, and then the myoma may be removed. The operation is especially urgent in these cases, as there is apt to be a hydroureter on the opposite side. With the relief of the pressure the normal function of a non-infected kidney may be speedily restored.

CHAPTER XXXII.

OPERATIONS DURING PREGNANCY.

1. Brief historical sketch.
2. Pre-existing pelvic conditions often made manifest by pregnancy.
3. Principles of operation during pregnancy.
4. Indications for operation: (1) Incarcerated uterus. (2) Ovarian, parovarian, and dermoid cysts, and solid tumors of the ovary. (3) Uterine myoma: (a) Rules as to surgical interference. (b) Operation. (4) Cancer of the cervix. (5) Pyosalpinx and ovarian abscess. (6) Appendicitis.

PREGNANCY does not constitute a contra-indication to the performance of any necessary gynecological abdominal operation upon the uterus, tubes, or ovaries. The danger to the life of the mother is not materially increased by the fact that she is pregnant, and abortion does not occur as a rule when the operation does not affect the uterus itself.

This radical reversal of the opinions of our predecessors, who considered all operations especially dangerous in the pregnant state, has been brought about by the advances in surgical technique in general, and in particular by the practical disappearance of sepsis and fever during the recovery from operations (see M. Runge, *Untersuchungen über den Einfluss der gesteigerten mütterlichen Temperatur in der Schwangerschaft auf das Leben der Frucht. Arch. f. Gyn.*, 1877, vol. xii, p. 16).

This important surgical advance was first signaled by Dr. M. D. Mann, of Buffalo, in an elaborate paper published in the *Trans. of the Amer. Gyn. Soc.*, 1883.

The next work of importance was that of Dr. E. Thoman, *Schwangerschaft und Trauma. Zur Frage über die Zulässigkeit chirurgischer Eingriffe bei Schwangeren*, Wien, 1889.

Dr. Mann was able to show that out of eighty-three gynecological operations of all sorts (not abdominal) only sixteen were followed by abortion; and but three mothers died.

Thoman shows that Nature herself first pointed the way by the frequent uncomplicated recoveries of pregnant women from various accidental injuries; he then proves, by sifting all the reported cases out of the surgical literature, that operations of all sorts may be safely undertaken, that operations upon the external genitals and vagina are permissible, and that even up to the date of his publication various abdominal operations had been performed. I have quoted these two papers because of their historical importance; the more recent statistics are still more favorable.

In this connection, too, an important lesson as to the tolerance of the pregnant uterus may be learned from the cases of cattle horn-rip of the abdominal wall, in which protruded intestines were cleansed and returned and the abdomen closed without interrupting the pregnancy. (See Dr. R. P. Harris, *Amer. Jour. of Obst.*, July, 1887, page 682 *et seq.*)

Ovarian and uterine tumors are often noticed for the first time during pregnancy, not so much because they have been stimulated and developed by the physiological changes in the pelvic circulation as on account of the encroachment of the growing uterus, first on the pelvis, and next on the supplementary space of the abdominal cavity. A tumor which may have long been concealed in a spacious cavity now becomes prominent, either from being lifted out of the pelvis within easy touch through the abdominal walls, or because there is no longer room enough in the pelvis or abdomen to harbor both the tumor and the pregnant uterus. The most marked evidence of rapid growth is found in the case of malignant tumors, which may even appear to grow as fast as the uterus itself.

It has been noted in the case of some fibroid tumors that they may increase rapidly in size or become edematous during pregnancy.

Other pelvic conditions, such as adhesions of the uterus, ovaries and tubes, and pelvic abscesses, also often become evident during pregnancy, owing to the changes which occur in the size and position of the uterus, producing traction on adhesions, and rupturing an abscess; or the confined uterus, unable to escape into the abdomen, may make dangerous pressure on the bladder and rectum.

J. Murphy (*Lancet*, 1895, vol. i, p. 148) even had to operate on a pregnant woman on account of collapse due to hemorrhage produced by the rupture of an ovarian adhesion bringing about a rare form of hematocele; about twenty ounces of blood were removed from the abdomen and the bleeding from a torn adhesion to the right ovary checked.

The torsion of the pedicle of an ovarian cyst, with its accompanying symptoms—pain, peritonitis, or collapse—occurs with much greater frequency during pregnancy, and may be the first indication of the existence of a tumor.

Sometimes even large ovarian tumors escape observation in a most surprising way throughout the entire pregnancy, and are only discovered when the uterus is empty and the abdomen remains enlarged; palpation of the entire abdominal cavity is easily practiced early in the puerperium through the flaccid abdominal walls, and a tumor easily discovered and handled which was previously inaccessible.

Although, as I have stated, necessary operations may be safely performed during pregnancy, no cautious surgeon would elect the pregnant state in which to operate, for the risks of abortion, the increased difficulties produced by the presence of an enlarged uterus, and the great vascularity of the parts, must always weigh against doing the operation if it can be safely postponed.

It must also always be remembered that there are two lives to be considered, and the surgeon must strain every effort toward saving both of them when possible. If one must be sacrificed, the mother, with her duties and her established interests in life, must be saved; fortunately, however, such an alternative can not often arise, for the disease which threatens to take the mother's life will also take the child's along with it; for example, a large ovarian tumor producing extreme dyspnea if not relieved will destroy both mother and child.

The conservative surgeon will ever bear in mind the two categories under the one or the other of which all of these cases may be classified:

First, those in which the operation is absolutely necessary to save the mother's life (*indicatio vitalis*).

Second, those in which the operation is elective.

In the interests of the child, small, non-adherent ovarian tumors seen late in pregnancy, which can be watched, and most fibroids of the body of the uterus, should not be interfered with.

The following principles apply alike to all operations during pregnancy:

1. The best time to operate in the interest of both mother and child is in the early months.

2. The thorough vaginal scrubbing and disinfection usual in the preparation for other abdominal operations may be omitted.

3. Take care on opening the abdomen not to injure the enlarged uterus just behind the anterior wall; cutting a large uterine vein would seriously complicate the operation.

4. Be careful throughout to touch and handle the uterus as little as possible. It is best not to lift the uterus out of the abdomen if it can be avoided. If the large uterus must be drawn out in order to reach the tumor, it must be covered with gauze and kept warm by pouring hot water over it frequently.

5. In removing an ovarian or tubal tumor it is of the highest importance that the vessels at both ends of the broad ligament should be tied separately, leaving an interval between; if the vessels are bunched together by interlocking ligatures the risks of hemorrhage are far greater than ordinary.

6. The superficial layers of the uterine tissue may be safely incised and sutured.

7. The body heat should be kept up by hot-water bags and warm blankets, and the intestines should be protected from exposure.

8. A tendency to abort will be best obviated by using enough morphia to keep the patient quiet and free from pain for the first thirty-six hours or longer after operation.

9. The abdominal bandage must be snugly fitted and with great care to give a good firm support to the abdominal walls while the wound is healing.

10. Abortion and maternal death are usually due to sepsis.

Indications for Operation.—An operation is demanded in general when the disease produces much discomfort, threatens life, or renders labor dan-

gerous or impossible, or when the tumor is apparently malignant. Operations during pregnancy may be called for under the following conditions:

- (a) Uterus incarcerated in the pelvis.
- (b) Ovarian cystoma.
- (c) Parovarian cyst.
- (d) Dermoid cyst.
- (e) Solid tumor of the ovary.
- (f) Uterine myoma, sessile, and pedunculated.
- (g) Cancer of the cervix.
- (h) Pyosalpinx and ovarian abscess.
- (i) Appendicitis.

(a) *Incarcerated Uterus.*—I mention here the pregnant retroflexed uterus incarcerated in Douglas's *cul-de-sac*, because the enlarged fundus felt *per vaginam* has been mistaken for a tumor behind the uterus, as in a case of E. Schwartz (*Ann. de Gyn.*, Oct., 1894, p. 241), where the menses were regular and the uterus appeared to be compressed between a tumor filling Douglas's pouch and the symphysis. A celiotomy was done, and the three months' pregnant uterus was found in retroflexion. The flexion was corrected, the abdomen closed, and the patient went to term.

Ordinarily after emptying rectum and bladder the incarcerated uterus can be readily set free by gentle bimannual manipulations of the fundus through the vagina or rectum and the abdominal walls. If the reposition is difficult, it will be facilitated by placing the patient in the knee-breast posture (Singer, *Cent. f. Gyn.*, 1894, p. 174), filling the vagina and rectum with air, and then gently manipulating the fundus in a direction out through the superior strait, bearing in mind the shelf made by the promontory of the sacrum, which offers the only serious mechanical resistance when there are no adhesions present.

If these simple maneuvers do not succeed, the posterior lip of the cervix may be caught with tenaculum forceps and drawn down toward the vaginal outlet, with the patient still in the knee-chest posture; this has the effect of straightening out the uterus, when pressure can be made with better effect on the fundus, which is easily pushed forward into the superior strait by two fingers in the rectum. The cervix is then carried back by the forceps to its normal position in the posterior part of the pelvis, and the fundus pushed farther forward; the forceps are now removed and the patient put in the dorsal position, when the fundus can be brought into marked ante flexion by pushing the cervix back and up toward the promontory with two fingers in the vagina, while the other hand draws the fundus well forward through the abdominal walls.

Buchhold reports a case (*Der prakt. Arzt.*, Band xxxv, No. 2; see Frommel, *Jahresb.*, ix, p. 558) in which an adherent retroflexed uterus was liberated in the fourth month of pregnancy. The patient, thirty-four years old, was suddenly seized with pain in the lower abdomen and sacral region, severe constipation, and difficult urination. An attempt at reposition failed, and in twenty-four hours vomiting and fever set in. The uterus was then liberated by placing the patient under anesthesia and introducing the whole hand into the vagina, and gradually

forcing the fundus up. The effect was to rupture the adhesions and free the uterus; the pain and other disabilities disappeared, and the pregnancy continued to its normal terminus.

If these means fail to right the uterus, and the patient's condition does not contra-indicate it, the abdomen should be opened and the uterus liberated and brought forward (see Michie's case, *Brit. Gyn. Jour.*, Aug., 1895, p. 164).

(b, c, d, e) Ovarian, Parovarian, and Dermoid Cysts, and Solid Tumors of the Ovary.—Ovariectomy as a rule is the simplest and the safest abdominal operation in pregnancy to both child and mother; but its dangers are increased by extensive adhesions, and abortion is liable to be produced by a protracted operation with much manipulation of the uterus. It is but a few years since abortion and puncture were advocated in the treatment of tumors complicating pregnancy; now abortion is no longer practiced, and puncture is limited to those cases in which the patient is actually parturient. A. Martin has even operated with success and prevented a threatened abortion. The importance of the tumor varies with its size, position, and character. A large abdominal tumor, or one which is fixed by adhesions in the pelvis, forces an immediate operation. Bilateral tumors and small hard tumors fixed in the pelvis are malignant in a large percentage of the cases.

W. Heiberg (*Tumor ovarii in graviditate, Cen. f. Gyn.*, No. 26, 1882, p. 405) has shown, in a collection of two hundred and seventy-one cases of ovarian cysts complicating pregnancy which were not interfered with, that over one fourth of the mothers and two thirds of the children died; in marked contrast to this stand the statistics of the cases operated upon during pregnancy.

V. Weiss (*Beitr. z. Chir. Festschr., Th. Billroth*) demonstrated, from a study of one hundred and thirty-three cases of ovariectomy during pregnancy, a maternal mortality of 7.4 per cent.

Dsirne (*Archiv. f. Gyn.*, No. 24, p. 415) collected one hundred and nine cases with 5.9 per cent maternal mortality and 22 per cent abortions. All the cases resulting in death were greatly complicated operations.

F. Mainzer (*Munch. med. Woch.*, No. 48) collected seventeen cases of double ovariectomy. Three times abortion was produced and twice premature labor came on; one mother died, apparently septic. Twelve of the women had a normal labor at term.

In the one hundred and nine cases Dsirne found torsion of the pedicle ten times—that is, in about 9 per cent of the cases.

Tapping the ovarian cyst is unjustifiable in view of the excellent statistics presented by operation, except when the patient is on the eve of or actually in labor, and the pressure exerted by the tumor or the obstruction which it offers to the progress of labor in the pelvis demand immediate relief.

The following case of my own exhibits well the tolerance of the pregnant uterus. Pregnancy of four months in a woman of forty-two after thirteen years' sterility; large ovarian cyst, with hemorrhage; numerous adhesions; operation, cystectomy; recovery, delivery at term.

M. E., 1188, had had three children, the youngest thirteen years ago. Her menstrual periods had continued with slight irregularity up to one week before her entrance into the hospital for the removal of a monoecystic ovarian tumor about the size of a seven months' pregnancy, filling the lower abdomen in the center and rising well above the umbilicus. On opening the abdomen, Feb. 3, 1892, the tumor was found extensively adherent to the abdominal walls as well as over the entire posterior pelvis and to the caput coli. The brownish color of the cyst wall, seen as soon as it was exposed, was the indication of an old extensive hemorrhage into the sac. After tapping the cyst and freeing the adhesions the top of the right broad ligament was tied off and the tumor removed. The small left ovary and tube were adherent to the posterior surface of the uterus, which was in about the fourth month of pregnancy and was crowded over to the left side. After checking the hemorrhage from bleeding points in the pelvis by sutures, the abdomen was irrigated with salt solution and closed without a drain. The patient made a satisfactory recovery, left the hospital in four weeks, and was delivered at term after a normal labor.

Hydrosalpinx and ovarian cyst, H. L., No. 1249, aged nineteen; operation in the third month of pregnancy, recovery, delivery at term without complication.

The patient applied for relief on account of severe lower abdominal pains, loss of weight, constant headache, and a "lump" she had discovered. Her last menses were three months previously. At the operation, Aug. 20, 1894, a right tube and ovary with a large cystic Graafian follicle was freed from adhesions binding it down in the pelvis and removed. The left side was healthy. The pregnancy continued to term.

Parovarian cysts and monoecystic tumors obstructing labor may often be emptied with advantage through the vagina by entering a trocar into the most prominent part.

In one case, S. M. (No. 2561, Jan. 4, 1894), I removed from a patient in the third month of pregnancy a parovarian cyst containing 7 liters of fluid. Two small cysts were also removed from the left parovarium without taking out the tube or the ovary. The pregnancy continued uninterrupted.

Single and double dermoid tumors may also give rise to serious symptoms during pregnancy; the relative frequency of dermoids to ovarian tumors is about as 1 to 13.5. The results of operation are like those in other ovarian tumors.

C. Staudé (*Monatsschr. f. Geb. und Gyn.*, Band ii, Heft 4) reports a case in which he removed in the third month a small generally adherent dermoid without interrupting the pregnancy.

Dr. B. C. Hirst reports an interesting case (*Amer. Jour. of Obst.*, 1895, p. 224) in which it was difficult to distinguish between a possible extra-uterine pregnancy, a retroflexed pregnant uterus, or an ovarian cyst associated with intra-uterine pregnancy. At the operation a dermoid cyst was found on the left side as large as a cocoanut, with one twist in the pedicle. The cyst was removed and the pregnancy continued uninterrupted.

Mr. R. Morrison (*Brit. Gyn. Jour.*, May, 1895, p. 92) removed two dermoid tumors in a woman in the fourth month without interfering with the pregnancy.

Dr. C. Jacobs (*Gaz. méd. de Paris*, 1895, No. 29) removed an ovarian cyst *per vaginam* by incising the posterior *cul-de-sac* with the thermo-cautery, emptying and withdrawing the collapsed sac and controlling the vessels by forceps, which were removed on the third day. The patient was allowed to get up on the fifth day, and the pregnancy continued undisturbed.

I know of no other case like the following, in which I removed a fibroid tumor of the left ovary, June 21, 1893 (A. R., No. 2042), from an unmarried woman of twenty two years, who was six months pregnant. The ovoid mass, 12×7 centimeters, was wedged in the pelvis and could not be displaced by efforts made through the vagina. The cervix was compressed and forced high up behind the horizontal pubic ramus. An abdominal incision 17 to 18 centimeters long was made, and the pregnant uterus lifted out and drawn forward so that the body, covered with hot gauze, rested on the pubes, while the lobulated dense white ovarian mass was extracted from the pelvis and its broad pedicle tied off. Although the entire operation lasted forty-six minutes, and the incision was a long one, and the uterus was handled as described, the patient recovered without the slightest symptom of an abortion and traveled several hundred miles home, where I understand an abortion was practiced two or three months later.

(f) Uterine Myoma.—Scarcely any gynecological question is of greater interest than the proper attitude of the surgeon toward the pregnant myomatous uterus.

The radical views of the profession at large are only too evident from the numerous cases reported in which fibroid uteri have been successfully extirpated in the first six months of pregnancy.

The frequency of pregnancy is well shown by the following statistics of my own cases prepared by Dr. J. H. Durkee: Two hundred and sixty-six married women with myomatous uteri had 542 pregnancies, out of which there were 402 children born at term and 140 miscarriages; the average number of pregnancies was therefore 2.03 per cent.

It often happens that the existence of the myomata is discovered for the first time during pregnancy. This is most liable to occur when the tumors are attached to the anterior surface of the body of the uterus, because, as the womb rises into the abdomen and comes into close contact with the anterior wall, any irregularities or bosses on the surface become conspicuous and are easily felt.

In many cases, after one or more pregnancies, the myomata then grow so rapidly as to fill the lower abdomen in a few years. A form which is met often enough to be characteristic of this class is the single large spherical myoma, choking the pelvis or rising up to the umbilicus, the size of a man's head (see Fig. 483).

The following rules should be observed regarding any surgical interference with the uterus before the last months of pregnancy—that is to say, before the viability of the child:

(a) Always remember that two lives are involved, and, if possible, save both, rejecting all radical measures unless the symptoms are urgent. Mere prophylaxis—that is to say, operating when there are no urgent symptoms on account of dangers which may arise—has no field here.

(b) Small and medium-sized fundal fibroids do not demand operation.

(c) Intraligamentary and subperitoneal cervical fibroids do not demand operation unless of such a size and so located as to encroach upon the pelvic room or the superior strait in such a way as to prevent labor. Pediculated fibroid tumors which can be pushed up into the abdomen do not justify interference during pregnancy.

(d) Interstitial tumors should not be touched if the operation can possibly be avoided, for they require so much handling and suturing of the uterus that abortion almost necessarily follows their removal.

(e) Operation may be demanded on account of extreme pain caused by a fibroid tumor.

(f) Operation may also be called for on account of the rapid growth of the tumors during pregnancy.

(g) Pediculated fibroid tumors (polyps) hanging out of the cervix into the vagina may be removed with safety.

(h) When the patient has gone almost to term, if the fibroid masses are so large as to necessitate a subsequent hysterectomy in case they are left, then it is better to deliver the child by a Cæsarean operation, and to remove the uterus at the same time.

The greatest risk of error in these cases is in removing a uterus with fibroids where the tumors might at a later date be removed without the sacrifice of the uterus. A sessile tumor so placed in the pelvis as to obstruct labor may be removed without much risk of causing abortion. I have performed myomectomy for sessile fibroids before the sixth month three times successfully, and without interrupting the pregnancy in any case.

An example of these operations was M. S. (No. 1249), three months pregnant, myoma about 5 centimeters in diameter, sessile on the posterior surface of the uterus about the cervical junction. At the operation (March 10, 1892), after exposing the tumor by an abdominal incision 8 centimeters long, it was shelled out through an incision in its capsule and the edges of the incision brought together by about eight silk sutures, and the abdomen closed without a drain. The pregnancy continued undisturbed to term.

G. Ainé (see *Nouv. Arch. d'Obs. et de Gyn.*, Sup. No. 4, p. 190) reports an abdominal extirpation of a right intraligamentary tumor removed in the third month without interrupting the pregnancy.

Another instance is recorded by R. Frommel (*Munch. med. Woch.*, No. 14, 1893, p. 262) in which he removed a left-sided intraligamentary myoma. The tumor lay for the most part above the pelvis and filled the superior strait. The enucleation was easy, and, after stopping all the hemorrhage, the walls of the sac were stitched firmly together. The recovery was uninterrupted and the pregnancy went to term.

W. J. Taylor (*Ann. of Gyn. and Ped.*, 1892, p. 92) operated upon an intraligamentary myoma in a twin pregnancy in the fourth month, removing at the same time two small subserous myomata. Drainage was used, and the patient aborted in six days.

Violent abdominal pain was the indication for operation upon a pediculated myoma in the fifth month in a case of Frommel's, where the patient had been unable to leave her bed for three months.

Kirehheimer (*Inaug. Diss.*, Halle, 1895) estimates a mortality of 18·87 per cent in myomeotomy for pediculated fibroids, and 26 per cent in supravaginal amputation of pregnant fibroid uteri, while premature interruption of the pregnancy causes as high a mortality as 40 per cent.

A. L. Stavely (*New York Jour. of Gyn. and Obst.*, June, 1894) has shown that seventeen cases operated on between 1889 and 1894 gave a death rate of 11·75 per cent—results which he rightly attributes to better technique.

When the patient is in the last months of pregnancy and the fibroid uterus is one to require operation, the best plan is to open the abdomen by an incision large enough to lift the uterus with all the tumors outside, and then to clamp all the ovarian vessels near the pelvic brim, using two clamps on each side and cutting between them; the round ligaments are then clamped distally and cut loose, and both broad ligaments pushed down; a rubber ligature thrown tight around the cervical portion of the uterus controls the uterine vessels, while the uterine cavity is opened between the tumors through the thinnest part of the walls and the child extracted. If the bladder is displaced it must be freed and pushed down into the pelvis before placing the provisional ligature around the uterine vessels. A slow operator will do better to liberate the child first, clamping and cutting the cord, and leaving the placenta *in situ*. He may then proceed with a ligation of the vessels and the supravaginal amputation of the uterus as described in Chapter XXVIII. Drainage ought not to be used.

(g) Cancer of the Cervix.—Fortunately for the mother, pregnancy but rarely occurs in a cancerous uterus; the mechanical barrier afforded by the enlarged choked cervix, and the chemical barrier of the infected secretions, seem in most cases to afford a sufficient protection against this accident.

When pregnancy does occur, the increased vascularity and opening up of the lymph channels often causes a rapid advancement of the disease.

The cardinal rule should be, therefore, when a radical operation is possible, to do it at the earliest opportunity in the interest of the mother.

When, on the contrary, the disease is too advanced to offer the hope of its entire enucleation, every effort must be made to save the child by allowing the pregnancy to go on to term, or near it, and delivering the child by Cæsarean section.

The dangers of infection are great after such an operation, and must be provided against by removing as much of the disease as possible, which also gives better vaginal drainage. It is also well to insert into the uterus through the

vagina a drain of washed-out iodoform gauze, and to irrigate the uterus freely on the first appearance of sepsis.

(h) *Pyosalpinx and Ovarian Abscess.*—The distortion, adhesions, and occlusion of the tubes produced by a pelvic abscess are so great that pregnancy but rarely occurs, and then, as a rule, the patient either aborts early or lives in imminent danger from the breaking of the adhesions and the rupture of the abscess as the womb enlarges. It is not long since the general impression prevailed that pregnancy could not occur either in the presence of a pyosalpinx or if the tubes were in a condition to develop a pyosalpinx, but this error has been abundantly disproved by clinical facts. Kaltenbach saw a case of pyosalpinx rupture during the expression of the placenta by Credé's method, with the result of a septic peritonitis and death.

The rule of treatment is in all cases, without exception, either to evacuate the abscess or to extirpate the sac at the earliest possible moment.

When the abscess can be felt in the pelvis behind the uterus, it should be opened, thoroughly cleaned out, and drained through a free incision into the *cul-de-sac*, but when a pyosalpinx has ascended into the abdomen on the growing womb it must be removed by abdominal section.

H. Michie (*Brit. Gyn. Jour.*, Aug., 1895, p. 194) reports two cases of operation for the relief of suppurating appendages during pregnancy.

In one case, a young woman who had ceased to menstruate four months before, suffered from pain in the left iliac region with painful defecation. The uterus was found enlarged, retroverted, and fixed, with a tender swelling behind and to the left side; both appendages were removed by celiotomy, the right inflamed and thickened, and the left containing pus. The uterus was freed and brought forward; the patient recovered and passed through a natural labor at term.

In another case, a multipara, aged forty, both appendages were removed for pyosalpinx between the fourth and fifth months of pregnancy. The patient objected to operation until the symptoms became alarming, when it proved to be too late to be beneficial and she died of acute septic peritonitis on the sixth day.

In a case of Kaltenbach's (R. Kroesing, *Inaug. Diss.*, Halle, 1890) a patient thirty-eight years old, VIII-para, and about seven months pregnant, was suddenly seized with severe intermittent pains in the right lower abdomen, nausea, and fainting spells; four days later an examination showed the presence of resistance and dullness extending from the lower border of the liver to the ileocecal region. The pulse was 120 and the temperature 39° C. On the fifth day after the attack the abdomen was opened in the *linea alba*, and the right tube found much thickened, cyanotic, and dilated, the central point of a marked surrounding peritonitis; there were numerous deposits of lymph on the peritoneum and some exudate in the dependent parts. The vermiform appendix was normal. The friable tube was removed and the patient recovered. She miscar-

ried on the day following the operation, giving birth to a small living female child weighing 1,100 grammes.

In a case operated upon by Dr. H. C. Coe, from three and a half to four months pregnant, the adhesions binding down the pelvic structures were found to be so dense that it was impossible to remove them; a pelvic abscess was then opened and drained through the vagina, and the patient recovered and aborted a month later.

Dr. J. M. Baldy (*Trans. Phila. Co. Med. Soc.*, 1893) operated upon a woman who had been in an insane asylum for menstrual insanity; she was five months pregnant, and had an abscess in the uterine wall, with pyosalpinx on both sides, each containing the same amount of pus—about 30 cubic centimeters. Both tubes and ovaries were removed after freeing numerous adhesions, and the abscess in the uterus, which was opened by separating an adherent omentum, was cleansed, curetted, and sterilized by a bichloride of mercury solution (1 to 1,500), and the edges brought together by silk sutures. The abdomen was closed without drainage, and the patient made an easy convalescence, in spite of a week's insanity, and was delivered at term without any complications.

Suppurating ovarian and suppurating dermoid cysts also occur during pregnancy, and, by the urgency of the symptoms, pain, peritonitis, and elevation of temperature, leave no room for hesitation as to the necessity for immediate operation.

(i) Appendicitis.—Inflammation of the vermiform appendix may occur in pregnancy, as the condition offers no immunity from the disease; an instance of rupture of the vermiform appendix and death during pregnancy was referred to by Clement Godson in the discussion of Mr. Michie's paper (*Brit. Gyn. Jour.*, August, 1895, p. 169).

I have in my own experience seen two cases of pregnant women, both confined to bed by a localized pain and tenderness in the right iliac fossa, and with some elevation of temperature, and presenting a history of previous similar attacks. The diagnosis of appendicitis was made, but no operation was necessary, and both women were delivered at term.

Dr. P. F. Mundé reports a case (*Med. Record*, Dec. 1, 1894, p. 678) of appendicitis occurring in the last month of a first pregnancy. The patient had pain and tenderness in the lower abdomen equally severe in the median line and on both sides, with a temperature of 102° F. (38·9° C.) on the fourth day. On the sixth day "she was seized with atrocious pains in the pelvic region, accompanied by a pronounced chill, and a temperature of 101·5° F.; at the same time labor pains began," and she was delivered of a dead child in about eighteen hours. Twelve hours later decided dullness and acute pain on pressure were found in the right iliac region, without any tenderness or mass near the vaginal vault.

Six days after delivery an abscess walled off by intestines was opened here and drained. After this the recovery was uneventful.

Two instructive cases are also reported by Dr. L. L. McArthur (*Amer. Jour. of Obs.*, Feb., 1895, p. 181), one of them four and a half and the other five

months pregnant; a gangrenous appendix was found in the first case, a dead fetus was expelled the day after operation, and on the following day the mother died of a general peritonitis. In the second case a tumor existed in the right iliac fossa and the right vaginal vault; at the operation the uterus was found to form the inner wall of a fetid abscess; the patient had a miscarriage, and died on the fifth day of peritonitis.

CHAPTER XXXIII.

CESAREAN SECTION.

1. Indications for the operation, absolute and relative.
2. Competitive operations—induction of premature labor, use of forceps, turning, symphyseotomy, craniotomy.
3. The conservative Cesarean operation: 1. Preparation and instruments. 2. The abdominal and uterine incision. 3. Delivery. 4. Clamping the cord. 5. Control of hemorrhage. 6. Delivery of the placenta and membranes. 7. The uterine suture. 8. Cleansing the peritoneum. 9. Closure of the abdominal wound. 10. Duration of the operation. 11. Errors in technique. 12. After care.
4. The Porro-Cesarean operation: 1. Three ways of operating. 2. Operation. *a.* Second method. *b.* Third method—panhysterectomy.

THE Cesarean section is a surgical operation by which the child is delivered from the uterus by an abdominal section. It stands in contrast to all forms of delivery through the vagina, as well as to delivery through the abdomen when the child has escaped into the cavity through a ruptured uterus.

The indications for the Cesarean section are either absolute or relative. The indication is absolute when there is no alternative and delivery *per vias naturales* can not be effected; it is relative when there is a choice between this and various other procedures, such as the induction of premature labor, turning, the use of forceps, symphyseotomy, or craniotomy.

The indication is absolute and the Cesarean section must be performed when there is a living child in a flattened pelvis with a true conjugate diameter of 6.5 centimeters ($2\frac{1}{2}$ inches) or less, or in a generally contracted pelvis of 7 to 7.5 centimeters or less, and in case the child is dead in a pelvis measuring 4.5 centimeters ($1\frac{3}{4}$ inch) or less.

The indication is relative and the Cesarean section enters into competition as an alternative with craniotomy, when the child is alive, when the conjugate diameter runs from 5 or 5.5 to 7.5 centimeters.

Craniotomy must be selected in all cases where the child is dead and the conjugate diameter measures from 4.5 centimeters ($1\frac{3}{4}$ inch) up.

Symphyseotomy competes with the induction of premature labor chiefly in pelvis whose conjugate diameters measure 7 centimeters ($2\frac{1}{2}$ inches) or more. Where the conjugate diameter is less than 7 centimeters it is a hazardous operation, unless the child's head is small.

Turning, followed by immediate delivery, is best limited to cases in which the true conjugate diameter measures from 8.5 to 9.5 centimeters ($3\frac{3}{4}$ to $3\frac{1}{2}$ inches); it may be successful in the case of a small child with dilated cervix and unruptured waters, in flat rachitic pelvis of 7 centimeters ($2\frac{1}{4}$ inches), or in generally contracted pelvis of 7.5 centimeters (3 inches).

The induction of premature labor is performed while the fetus is viable, between the twenty-eighth and thirty-sixth weeks, in pelvis measuring 6.5 to 8 centimeters (2.6 to 3.2 inches) in the conjugate diameter. As I have just said, this procedure enters into competition with symphyseotomy, which should be performed if the parents wish to have a living child.

The Tarnier axis-traction forceps are useful in all cases of contraction of the pelvis of lesser degree.

The relationship between spontaneous labor, a high forceps operation, induced labor, symphyseotomy, and the Cesarean section, in the same woman, is well shown by a case of my own in Philadelphia (K. G.), that of a woman with a flattened pelvis with a true conjugate diameter of 6.5 to 7 centimeters. The first child, born after nineteen hours of difficult labor ended by the forceps, was so severely injured that it died. The second child was a puny girl, born alive, without assistance, after fourteen hours of severe labor pains. The third delivery, May 30, 1888, was a Cesarean section performed by me at the Kensington Hospital for Women, after consultation with Dr. R. P. Harris; the child weighed six pounds and fifteen ounces. The fourth child was delivered by a high application of the forceps by Dr. C. P. Noble, in the Kensington Hospital, after the induction of labor at the thirty-sixth week. This baby weighed five and one thirty-second pounds, and the labor, lasting twenty-seven and a half hours, was characterized by Dr. Noble as extremely difficult. The fifth labor was a symphyseotomy followed by a difficult high application of the forceps; this was also conducted by Dr. Noble. The weight of the baby was eight and a half pounds.

It is manifest, from the statement of the character of each of these labors in a pelvis contracted to this degree, that the two plans of treatment worthy of most consideration as giving the child a maximum chance, without great risk to the mother, are the Cesarean section and symphyseotomy. It is not possible at present to state positively which of these operations will in the future have the precedence under such circumstances as these; my own preference is for the Cesarean section.

The Cesarean operation includes under one name two procedures having in view the same object with regard to the child, but radically different in the effect upon the mother—the conservative “Säuger-Cesarean” operation, preserving the uterus (see *Der Kaiserschnitt*, Leipzig, 1882), and the radical “Porro-Cesarean” operation, completed by a removal of the uterus.

Conservative Cesarean Operation.—The conservative Cesarean operation is to be performed in all cases when the true conjugate diameter measures 6.5 centimeters ($2\frac{5}{8}$ inches) or less, with a living child, and 4.5 centimeters ($1\frac{3}{4}$ inch) with a dead child. This narrowing may be due to a simple deformity in the diameters of the pelvis, or it may be produced by a bony tumor of the sacrum, as in one of my cases (M. S., May 10, 1889), where the pelvic cavity was so filled out with an osteosarcoma that the only remaining space was a narrow ellipse 2 centimeters ($\frac{3}{4}$ inch) in diameter at its widest part (see Fig. 516).

In another case of a simple flat pelvis (E. J., April 17, 1888) the patient had been in labor for two weeks, the waters had ruptured four days before operation, and the lower pelvis was so choked by the swollen, hard, inflamed connective tissue that the inferior strait was practically obliterated and nothing could be distinguished by the vagina; Cesarean section was absolutely necessary to save the mother's life. For an account of the three cases here cited, see *Amer. Jour. Obst.*, March, 1890, vol. xxiii, No. 3. This one was the first successful conservative Cesarean section in Philadelphia after Prof. Gibson's case referred to below.

Another indication is the extensive contraction of the vagina by cicatricial tissue, making the birth impossible *per vias naturales*. This, however, must only be accepted with extreme caution, as successful deliveries have often been effected where the cicatrices seemed impassable.

The best time to operate is at the end of pregnancy, and after labor has been so long in progress that the contraction ring has formed, and, if possible, the cervix is well dilated. It is better that the bag of waters should not be broken, as it facilitates the delivery if the child is taken swimming in the amnion.

Owing to the uncertainty of the precise day of labor and the awkwardness of the hour—often late in the night—and the difficulties of preparation and getting assistance, I have ventured in my own cases to operate at the end of pregnancy without waiting for the pains to come on. In doing this I violated the old-established notion that the woman must be some time in labor in order to insure good uterine contraction afterward, and so to escape the danger of hemorrhage. I met with no such accident, and all the cases did well. I would therefore recommend, whenever the end of pregnancy can be accurately fixed by reference to the cessation of menstruation and measurements of the child, that the operator fix the day and hour himself, and make all his arrangements as for any other operation.

Preparation and Instruments.—Before operating, a careful examination should be made, determining the fact that the child is living, and the exact position of the body and head, as well as the position of the placenta, determined by palpation and auscultation. All necessary pelvic and fetal measurements should be made and recorded at the time the operation is under consideration: distance between anterior superior iliac spines; distance between iliac crests; external conjugate, Baudelocque's diameter, and, when possible, the internal conjugate; distance between trochanters, and, in special cases, measurements at the pelvic outlet. The height of the patient and any deformity must be carefully described, and the length of the flexed child *in utero*, and the estimated biparietal diameter of the head.

The patient should be prepared by diet, regulation of the bowels, and daily warm baths, exactly as for any other abdominal operation.

When the case is one of emergency, all previous preparation may be dispensed with; but in this case extra precautions must be taken in the immediate preparations. Just before the operation, when the patient is completely

anesthetized, the whole abdomen is thoroughly washed and the vagina carefully douched with a ten per cent creolin solution.

The operator stands on one side of the table and opposite to him his first assistant, who gives his closest attention throughout to the uterus and the abdominal and uterine wounds. This necessitates one or two other assistants behind him to hand instruments, needles, ligatures, and sponges. A competent assistant also stands by the operator, ready to take the baby as soon as it is delivered. It will be safer if all the assistants wear rubber gloves throughout, and the operator should do the same if there is the slightest suspicion as to the contamination of his hands.

The vagina is thoroughly cleansed and loosely filled with iodoform gauze when the patient is put upon the operating table.

The Abdominal and Uterine Incision.—An incision about 20 centimeters long is made through the abdominal wall in the linea alba over the most prominent part of the uterine enlargement; this generally falls one third above and two thirds below the umbilicus, or even as much as half above and half below it, when the uterus stands high. Care must be taken not to cut through the abdominal wall too quickly, for fear of cutting the uterus. Even the fetus has been injured in this way by an injudicious stroke.

As soon as the peritoneum is opened the red convex surface of the uterus fills the incision. The assistant now presses the walls on both sides into close contact with the uterus, and keeps up this apposition during the delivery and until the uterus is empty and contracted so as to protect the abdominal cavity from the contamination of the uterine contents. If there is doubt whether the case is already septic or not, it is better to enlarge the abdominal incision so as to bring the uterus outside the body before opening it, taking care to protect the incision and the abdominal cavity behind the uterus with abundant gauze and towels until the uterine wound is closed.

Ordinarily the uterus is incised *in situ*, from the fundus down to the reflection of the vesical peritoneum, which is readily recognized as a white transverse line in the cervical region. The incision should be made as nearly as possible just under the abdominal incision or a little to one side or the other to avoid the placental site, which may be recognized by an increased vascularity or a slight elevation during uterine contraction and a doughy feeling on pressure.

Fritsch, of Bonn, recommends making a transverse incision through the fundus of the uterus.

If the placenta lies directly under the incision (*placenta prævia Cæsariana*), as it does in about half the cases, it will be recognized by the villi pointing into the wound, and care must be taken not to cut its vessels and deplete the circulation of the child. A further objection to cutting through the placental site is the increased amount of hemorrhage.

The thin uterine wall is cut through in one place slowly but deliberately until the dark surface of the uncut amnion appears.

The Delivery of the Child.—The amnion is punctured with a knife, and as the fluid is escaping two fingers are inserted within the uterus, lifting up the edges of the cut while it is enlarged up to the fundus and down to the cervical region, the assistant all the while keeping the abdominal walls pressed in on the collapsing womb. The baby is now grasped by both feet and lifted out through the uterine and abdominal incisions, taking care not to tear the womb by hurrying too much. If an arm is caught by mistake it must be put back and the feet sought for, as an arm delivery necessitates dragging the child out crosswise. If the placenta lies just under the incision in the womb it must not be cut through, but the fingers must be passed to its nearest border and the amnion opened there.

If the labor has been protracted, it will not infrequently happen that the head of the child is so tightly wedged in the pelvis and below the uterine contraction ring that strong traction efforts on the body and feet fail to dislodge it. This difficulty has been experienced over and over again by operators for the past hundred years. If the head does not yield to a moderate traction made upon the legs and body, then the feet should be grasped in one hand just above the ankles while the other grasps the neck and shoulders, guiding the traction which is made with both hands more in the axis of the superior strait. I delivered one baby by grasping the neck and shoulders in this way and at the same time with the middle finger of the same hand pushing down the occiput, which lay in a vertex presentation, while assisting the flexion and traction with the middle finger of the other hand in the mouth. Delay at this point endangers the life of the child, and if the head is not at once freed by these efforts an assistant must insert three fingers into the vagina and push upward on the head at the same time that the traction is being made. To this combined *vis a tergo* and *vis a fronte* the head of any living child is sure to yield.

Clamping the Cord.—In order to shorten the time as much as possible between making the uterine incision and putting in the sutures, I clamp the cord in two places instead of tying it (see *Amer. Jour. of Obst.*, 1894, p. 538) and cut between the forceps, freeing the child, which is handed over to the nurse or to a doctor for resuscitation, if asphyxiated.

Controlling the Hemorrhage.—It has been the custom to prevent hemorrhage during the operation by throwing a rubber ligature around the lower part of the uterus before making the incision, but this is unnecessary, as the hemorrhage, as a rule, is not excessive and may be better controlled by other means. The danger of the ligature is that it predisposes to a subsequent atony of the uterus, and so to post-partum hemorrhage.

It is best not to use many hemostatic clamps, which crush the tissues of the uterine wall. If the incision is made quickly and the child lifted out at once, the uterus begins to contract immediately, diminishing the hemorrhage, which may also be temporarily controlled by the assistant firmly grasping the neck of the uterus with both hands down at the pelvic brim. The pulsations of the uterine arteries can be dis-

tinely felt and the pressure brought to bear directly upon them and kept up as long as desired. The contraction of a flabby uterus may be excited by kneading. The best way to control hemorrhage permanently is by the rapid introduction of the sutures closing the uterine incision.

Delivery of the Placenta and Membranes.—As soon as the child is delivered and the uterus begins to contract firmly, the placenta, if it is not already freed by the uterine contraction, is delivered by grasping it in the open hand and drawing the fingers together and twisting it until it is freed from its base and comes away with the cord and membranes.

Any large pieces of loose decidua left in the uterus should be removed, but time is wasted in picking off little pieces from the walls. I do not consider it necessary to use iodoform powder in the uterus, as has been suggested.

The Uterine Suture.—The uterus, now vigorously contracted and much diminished in size, is lifted out of the abdominal incision and laid on a thick pad of sterilized gauze while the deep and superficial sutures are being introduced. If the abdominal walls are thin and the pelvis narrow, the uterus will lie so close under the incision that it will not be necessary to lift it out to pass the sutures.

The best suture material for the uterus is undoubtedly fine silk. Catgut should never be used, because it is liable to become absorbed and so permit the incision to gape open.

One row of deep interrupted sutures from top to bottom, 1 centimeter apart, is sufficient to close the uterine wound thoroughly. If the woman has been long in labor, or delivery has already been attempted by means of the forceps, there is always an increased liability to sepsis, and

it is better in such a case to use a second row of superficial so-called sero-serous sutures covering in the first row. Each deep suture is passed by a needle armed with a carrier entering 5 to 8 millimeters from the edge of the incision and brought out on the cut surface, on a line between the muscularis and the decidua, to re-enter and emerge at the corresponding points on the opposite side.

Each suture is best tied as soon as passed, bringing the wounded surfaces snugly together, as in that way the bleeding is stopped the quickest. By the



FIG. 516.—CESAREAN UTERUS REMOVED SIX YEARS AFTER OPERATION.

The uterus is laid open on its anterior surface, a little to the right of the cesarean scar, which is seen faintly indicated from fundus down to cervical region. The transverse cut shows the cesarean scar extending in to the uterine mucosa. There is no thinning of the uterine wall. Natural size.

time all the deep sutures are in place, if there is oozing between any of them, it may be checked by passing a few half deep sutures between, and tying them tightly enough to stop the flow; the line of incision now has a slightly blanched appearance. The superficial sutures are next passed over the deep ones, catching the peritoneal covering of the uterus, with a little of the underlying muscularis, and drawing it over the line of the incision, which is completely hidden from sight when they are all tied. In this way a good barrier is formed to limit or at least to delay the advance of a septic process from the uterine toward the abdominal cavity.

Cleansing the Peritoneum.—If the peritoneum has been considerably soiled with blood and amnion, or if the case is doubtfully septic, it is better to flush it out freely with a normal salt solution; otherwise it will do simply to wipe up a little blood and fluid and lay the contracted uterus down in the pelvis and lower abdomen, so that the cavity of the body, the cervix, and the vagina form as nearly as possible a straight line.

I think it is better in doubtful cases not to draw the omentum down over the front of the uterus to keep it away from the abdominal wall, but to use it to protect the intestines. Then if there is any sepsis it is more likely to be localized and to break through the incision.

Adhesions are almost certain to be formed between the uterus and abdominal wall. Mrs. Reybold, twice operated upon by Prof. William Gibson, of Philadelphia, in 1835 and 1837, died at the age of seventy-six years, in 1885, and at the autopsy the fundus of the uterus was found adherent to the upper part of the abdominal cicatrix and drawn out, like a dog's tongue, $4\frac{1}{2}$ inches long (R. P. Harris).

Closure of the Abdominal Wound.—The abdominal wound is closed by fine catgut to the peritoneum, by silver wire tension sutures about 4 centimeters apart and catgut in between, uniting the fascia and the muscles, and a continuous subcuticular catgut suture. If the patient's forces are flagging and it is deemed best to hasten the closure, it is best to use interrupted silkworm-gut sutures, passing each one through all the layers of the wall, except the peritoneum, which is closed separately with catgut.

The Duration of the Operation.—The duration of the operation, especially that part during which the uterus lies open and bleeding, is an important feature in the technique; if the operation is prolonged much over an hour, or even two hours, as has occurred, then none but the strongest patients may be expected to survive the shock, and in the case of those who do survive, sepsis will more readily find an entrance in the depressed devitalized condition. There is no excuse for prolonging the operation longer than thirty or forty minutes, and an expeditious operator will get through in from twenty to twenty-five minutes or even less. There should be no haste at any time, but every step should follow its predecessor in rapid succession, and there should be no delays due to imperfect preparation. As an example of what may be done with proper preparation and good assistance, I quote the records of one of

my operations (E. D., 2412, Jan. 14, 1891, see *New York Medical Journal*, May 2, 1891).

Incision 16 centimeters ($6\frac{1}{2}$ inches) long, begun in abdominal wall.

Fifteen seconds later uterus opened.

Eight hundred to 1,000 cubic centimeters of liquor amnii discharged.

One minute from the commencement the child delivered.

Two minutes from commencement placenta (non-prævia) delivered.

Ten minutes from commencement the uterine wound completely closed by seven deep and eight half deep silk sutures between them.

In twenty-one minutes and forty-five seconds from the beginning the abdomen completely closed and the operation over.

Errors in Technique.—Errors to be avoided in the technique are:

1. The attempt to preserve a uterus which is probably septic and would therefore better be amputated.

2. The use of any antiseptic solutions whatever in the abdominal cavity.

3. Cutting the placenta when it lies under the incision.

4. Grasping the child by the head or arm.

5. Wasting time in picking little shreds of decidua off the uterus.

6. Constricting the neck of the uterus with a rubber ligature.

7. The use of catgut for the deep sutures in the uterus.

8. The use of a continuous suture to close the uterine incision.

9. Drainage of the abdomen.

The After Care.—The abdominal wound is dressed and protected as after any other abdominal section. The lochia usually flows in the normal manner, but should there be any obstruction, with accumulation of clots in the vagina or uterus, these must be cleaned out and the tract washed out with slight force so as not to make any pressure upon the walls of the uterus.

My first case in Philadelphia was thoroughly septic, and would better not have been treated conservatively; owing to the choked condition of the lower part of the pelvis, a mass of fetid clots accumulated in the lower uterine segment, below the contraction ring, where the child's head had laid imbedded. After a few days the vault of the vagina became emphysematous, crackling on touch, and the entire cervix sloughed away; subsequently the uterus became emphysematous and the lower angle of the abdominal wound opened, forming an abdomino-utero-vaginal fistula, which persisted into the next pregnancy.

The bowels should be freely moved on the third day after operation, and the urine drawn only when necessary, and then with the utmost care to avoid infection. It is safer immediately after the operation to withdraw the iodoform gauze from the vagina and use a vulvar pad; every time fresh gauze or cotton is applied under the vulva, and whenever the urine is drawn, about a teaspoonful of iodoform and boric-acid powder (1 to 7) should be dusted well into the vaginal outlet as a preventive against septic invasion from without.

The baby may nurse in from twelve to twenty-four hours—as soon as the effects of the anesthetic have passed off—and may continue to take the

breast as under ordinary circumstances. If the mother is quite feeble it will be well to keep the child in another room at night.

In the third week the patient may sit up a little, and in another week or ten days she may go about her room.

The Porro-Cesarean Operation.—The Cesarean section with the removal of the uterus, the Porro-Cesarean operation (*Dell' amputazione utero-ovarica come complemento di taglio cesareo. Ann. Univ. di med. e chir., Milano, 1876*), showed itself to be a safer procedure than the conservative Säger-Cesarean operation, at a time when all abdominal surgery was dangerous and infection carried off a large percentage of all difficult or prolonged operations. The removal of the uterus with its pedicle fastened in the lower angle of the incision was safer than its preservation, because it left but a small external wound surface, while in the conservative operation the whole uterine cavity forming one big wound remained in direct relation to the peritoneal cavity through the uterine incision. Under these circumstances the removal of the uterus came to be generally recommended as the best plan of treatment of all Cesarean cases. Surgical practice has now changed so much that the two operations have become complementary to each other and no longer rivals in the same field.

The Porro operation must be performed in cases in which some morbid element makes it dangerous to keep the uterus in the body.

1. Where there is good reason to anticipate sepsis, where, for example, the patient is exhausted by a protracted labor, and where manual or instrumental efforts at delivery have been made repeatedly or without due antiseptic precautions.

2. Where there is cancer of the cervix uteri.

3. Where the uterus contains myomatous tumors which block the pelvis or which can not be safely removed by myomectomy.

4. When there is an extensive atresia of the vagina.

5. When there are bilateral ovarian tumors and no sound part of an ovary can be found and left.

6. When the hemorrhage from the placental site is uncontrollable.

The number of suitable cases of this last class, however, will be reduced by avoiding the rubber constricting ligature, and probably by ligating one or both uterine arteries.

The great obstetric genius of Blundell in the early part of this century so clearly appreciated the advantages of a complete extirpation of the uterus that I quote his language as a contribution to the history of the subject:

“In speculative moments I have sometimes felt inclined to persuade myself, the dangers of the Cesarean operation might, perhaps, be considerably diminished by the total removal of the uterus. Rabbits are tender animals, and, bearing many fetuses, have wombs after delivery of great proportion and bulk, indeed nearly large enough to fill the hollow of the hand. If the Cesarean operation be performed on the rabbit in the ordinary way, unless I am much mistaken, it will be found that the animal generally perishes in consequence.

“ But in four rabbits recently delivered I made an opening above the symphysis pubis, and raising the wombs from the abdomen, I elevated them above the aperture, the animal lying in the recumbent position, stretched out at full length. This accomplished, I took a ligature, with a needle on its center, and carrying the point from behind forward I passed it completely through the vagina, afterward cutting the needle away in this manner so as to leave two strong ligatures hanging forth from the aperture. Having applied my ligatures, I tied one on the right side and the other on the left respectively over the Fallopian tube, drawing the threads very firmly, so as completely to cut off all communication with the vagina; and, this part of the operation carefully performed, I took a knife and completely removed the wombs, cutting for this purpose very close upon the ligatures, afterward replacing the parts. This done, after closing the abdominal wound by suture I drew forward the ligatures through the wound till I brought the raw surface left by the removal of the wombs in contact with the abdominal incision internally. By means of the ligature the wound of the vagina and adjacent parts, which must otherwise have been of great extent, being drawn together into a very narrow compass, became not broader than a sixpence, and I trusted that this might promptly contract adhesions with the inner surface of the abdomen. Beyond my hopes the operation succeeded. Of the four rabbits, three recovered, the fourth dying in consequence of the ligatures slipping from their place.

“ Experiments of this kind made upon different animals are much wanted, for the importance of the subject renders multiplication and variety desirable here. Let us think maturely upon facts like these. In performing the Cesarean delivery on the human body perhaps this method of operating may hereafter prove an eminent and valuable improvement.

“ Let it be remembered that in securing the vagina and removing the uterms we are substituting a wound well secured and of smaller extent for one that is larger and not secured by ligature at all.” (*The Principles and Practice of Obstetrics*, James Blundell, London, 1834, pp. 577; 578.)

Three Ways of Operating.—There are three ways of doing this operation, differing in the treatment of the pedicle, only the first of which can, strictly speaking, be called a Porro operation:

The first is to open the uterms and deliver the child, and then to amputate the uterms and fix the pedicle in the lower angle of the abdominal wound.

The second is to deliver the child, amputate the uterms, sew up the stump, cover it with a peritoneal flap, and drop it into the abdomen, which is then closed.

I have had one such case (R. P. S., 8819, Dec. 16, 1893) where the Porro-Cesarean section was made necessary by a large myomatous tumor of the uterms entirely blocking the pelvic canal. The child lived for several days and the mother's recovery was perfectly satisfactory. (See Fig. 517.)

The third is to remove the entire uterms (panhysterectomy), opening the vaginal vault, which is then closed by suture and the pedicle dropped.

Operation.—I would in all cases reject the first method of hysterectomy and select either the second or the third as more in keeping with advanced surgical principles.



FIG. 517.—PORRO-CESAREAN SECTION FOR FIBROID UTERUS AT TERM.

The incision through which the child was extracted is seen in the anterior uterine wall above. The placenta was not removed, and the cord is seen projecting from the cervical end. Path. No. 156. $\frac{3}{8}$ natural size.

When the pregnant uterus is removed for myomata, persistent hemorrhage, or a vaginal atresia, it is better to amputate the cervix, close it by suture, and drop the pedicle in the following manner: The abdomen is opened by an incision large enough to bring the pregnant uterus outside. To prevent the intestines from escaping above, pads of gauze wrung out of a hot normal salt solution are laid over them and under the incision, and the table is elevated just enough to cause them to tend to gravitate upward. The child is then delivered and the enucleation proceeded with. It is not necessary to extract the placenta and the membranes. The ovarian vessels of one side are then tied near the brim of the pelvis and clamped on the uterine side and cut between clamp and ligature.

The round ligament is next tied about 3 centimeters from the uterus and clamped close to it and cut between clamp and ligature.

The ovarian vessels and round ligament of the opposite side are tied and cut in like manner.

The vesical peritoneum is next freed from the uterus, from round ligament to round ligament, and the bladder with its peritoneum pushed well down behind the symphysis.

All this occupies but two or three minutes, and the uterus now remains attached only by its cervical end, well lifted up, and forming a pedicle as large as two or three fingers. The left uterine artery is distinctly felt pulsating, and is tied by passing a silk ligature around it with a needle and carrier. The uterus is then amputated about 1.5 centimeter ($\frac{3}{4}$ inch) above the ligature and the opposite right uterine artery clamped with forceps, before it is divided, at a point well above the pedicle. The uterine vessels on the right side may also be equally well ligated before amputating the cervix.

After the removal of the uterus in this way a ligature is applied to the right uterine artery. The cervical canal is carefully wiped out, and its anterior and posterior lips united by from six to eight catgut sutures, tied tight enough to check any oozing. It is a good precaution to tie all the important arteries a second time with catgut. The anterior layers of the broad ligament and the vesical peritoneum are now drawn over and attached to the posterior layers and the cervical stump by a continuous catgut ligature extending from the pelvic brim of one side to the brim of the other side, completely hiding from view the entire field of the operation. A loose iodoform gauze pack is then placed in the vagina and left there for five or six days.

The third method, that of total extirpation of the uterus, is performed for cancer of the cervix and for a septic uterus, where there have been protracted attempts at delivery and the patient is febrile.

There should be a thorough cleansing of the vagina first, and as much of the cancerous material as can be removed without provoking a serious hemorrhage should be taken away. The vagina is then loosely packed with iodoform gauze.

The uterus is delivered through the incision, the ovarian vessels and round ligaments tied off, and the vesical peritoneum pushed down as just described.

The uterus is now opened and the child delivered, after which the uterus is at once tightly wrapped in towels, to squeeze the edges of the incision well together, as well as to give a good hold and to protect the surgeon's hands and the patient's abdomen from being soiled.

Hemorrhage must be prevented during this more prolonged operation by tying a rubber ligature tightly around the cervix. The important object of the next step in the operation is to enucleate the whole lower segment of the uterus with any infected glands and with as much of the surrounding cellular tissue as possible, without injuring either of the ureters. This has been so carefully described in Chapter XXX, on panhysterectomy for cervical cancer, that I shall not repeat here more than the bare statement that the uterine artery is ligated close to its origin from the internal iliac, and a painstaking dissection is made from this point in toward the uterus on each side, detaching the cellular tissue and the glands, which are finally removed with the cervix. The only safeguard against injuring a ureter is to be constantly aware of its exact position, either by sight or touch, and under no circumstances should mass ligatures be used to control the vessels in the tissues near the vaginal vault.

Having in this way freed the uterus on all sides down to its vaginal attachment before opening the vagina, it is important to provide for the careful pro-

tection of the pelvic peritoneum by packing in gauze on all sides, so that any escaping secretions will be at once taken up. The uterus is now drawn up and the position of the vagina found by palpation, by seeing the longitudinal muscular fibers, and by the clear tympanitic note which it yields on percussion.

As soon as the vagina is cut into anteriorly more iodoform gauze must be stuffed into it to take up any moisture and to limit the chances of contamination. Freely bleeding points in the cut edges must be caught and held by forceps until controlled by sutures.

The anterior and posterior vaginal walls are now brought together with interrupted catgut sutures and the anterior peritoneal folds united to the posterior, as described in the preceding method, completely hiding away the whole field of operation. I think it is best in septic and cancerous cases to lay a small gauze drain under the pelvic peritoneum, and to bring it out into the vaginal tract as a safeguard against any infection lodged in the cellular tissue. The drain may be removed in from four to six days. The vagina must also be filled after the operation with a loose pack of washed-out iodoform gauze.

The further after care does not differ in any important particular from that of an ordinary celiotomy.

Cesarean Section on the Dead.—It is forbidden in Austria to bury a woman dying in the second half of pregnancy without first performing Cesarean section with all the care and technical skill used in operating during life, in hopes of either saving the child, or at least of baptizing it.

Such an operation succeeds only in extremely rare cases in spite of the instances reported in the older literature.

Cesarean section in agonia—that is to say, just before life is extinct—although it increases the chances of the child, offers at best but a forlorn hope, as the extremely reduced condition of the mother for some time before death generally interferes with the proper oxygenation of the fetal blood and so causes its earlier death.

The wiser plan would be, in event of the prospect of the certain death of the mother in the near future, to induce labor a few days before the anticipated event, or even to perform Cesarean section at her urgent request. The great difficulty in the way in such a case is the manifest liability to error in estimating how long the patient still has to live.

Successful cases of Cesarean section *in agonia* saving the child's life have been recorded recently by Runge for brain tumor, by Frank for general burns, by Fehling for basilar meningitis, by Sommerbrodt for fibro-sarcoma cerebri, by Schweiger for gliosarcoma cerebri, and by Hays for cerebral apoplexy (see Schauta, *Lehrb. der gesamt. Gyn.*, 1896, p. 1050). Dr. E. P. Davis, of Philadelphia, delivered a living child immediately after the mother had died of eclampsia (see *Med. News*, Feb. 1, 1896). As, however, Schauta justly says, the improvement of the methods of artificial delivery by the vagina, the rapid dilatation and incisions of the cervix and colpeuryesis of the vagina, with incisions of the perineum associated with turning, has still further limited the field for this rare operation.

CHAPTER XXXIV.

EXTRA-UTERINE PREGNANCY.

1. Definition.
2. Causes: 1. Obstacles within the lumen of the tube by which its caliber is diminished. 2. Diseases of the tube itself and peculiarities in its anatomy or form. 3. Factors acting externally to the tube by which its lumen is encroached upon or obliterated. In particular the causes may be classified as: *a.* Tubal polyps, *b.* Atresia of one tube with external migration of the fertilized ovum from the opposite side, *c.* Persistence of a fetal type of tube, *d.* Diverticula from the lumen of the tube, *e.* Torsion of the tube, *f.* Catarrhal and purulent salpingitis, *g.* Myoma uteri, *h.* Peritoneal bands and adhesions compressing the tube, *i.* Cervico-abdominal fistulae after hysterectomy.
3. Forms of extra-uterine pregnancy—Primary: Interstitial; tubal; ovarian. Secondary: Intra-uterine; abdominal; intraligamentary. Primary tubal may terminate as a mole; tubal abortion; tubo-abdominal; tubo-ovarian; rupture into abdomen; intraligamentary.
4. Criteria of extra-uterine pregnancy: 1. Of a tubal pregnancy. 2. Of an intraligamentary tubal pregnancy. 3. Of an interstitial tubal pregnancy. 4. Of an ovarian pregnancy.
5. Clinical history of an extra-uterine pregnancy without operation: 1. Tubal abortion. 2. Tubal mole. 3. Interstitial pregnancy. 4. Categorical statement of final results.
6. Multiple pregnancy.
7. Repeated extra-uterine pregnancies.
8. Diagnosis: 1. In unruptured cases. 2. In ruptured cases.
9. Mortality: Unruptured sac. Ruptured sac.
10. Treatment: Vaginal incision and drainage. Intraligamentary and pseudo-intraligamentary extra-uterine pregnancy. Operative treatment of advanced extra-uterine pregnancy. Treatment of an interstitial pregnancy. Pregnancy in a rudimentary horn of the uterus.

WHEN the fertilized ovum is arrested at any point between the Graafian follicle and the uterine cavity and there undergoes development, we designate the condition as an extra-uterine or an ectopic pregnancy.

The ovum may be arrested within the ovary or in any portion of the uterine tube from its fimbriated extremity to its interstitial portion inclusive.

Extra-uterine pregnancy is primarily almost always situated in the tube, but may become tubo-ovarian, abdominal, or intraligamentous, or even uterine in the further course of its development. Ovarian pregnancy is one of the greatest gynecological rarities.

Causation.—The factors which lead to the arrest and development of the fertilized ovum within the oviduct are usually of a mechanical nature, by which the downward progress of the ovum from the Graafian follicle to the uterine cavity is impeded.


Such causes may be classified under three heads:

1. Obstacles within the lumen of the tube, by which its caliber is diminished.
2. Diseases of the tubal walls and peculiarities in its anatomy or form.
3. Factors acting externally to the tube, by which its lumen is encroached upon or obliterated.

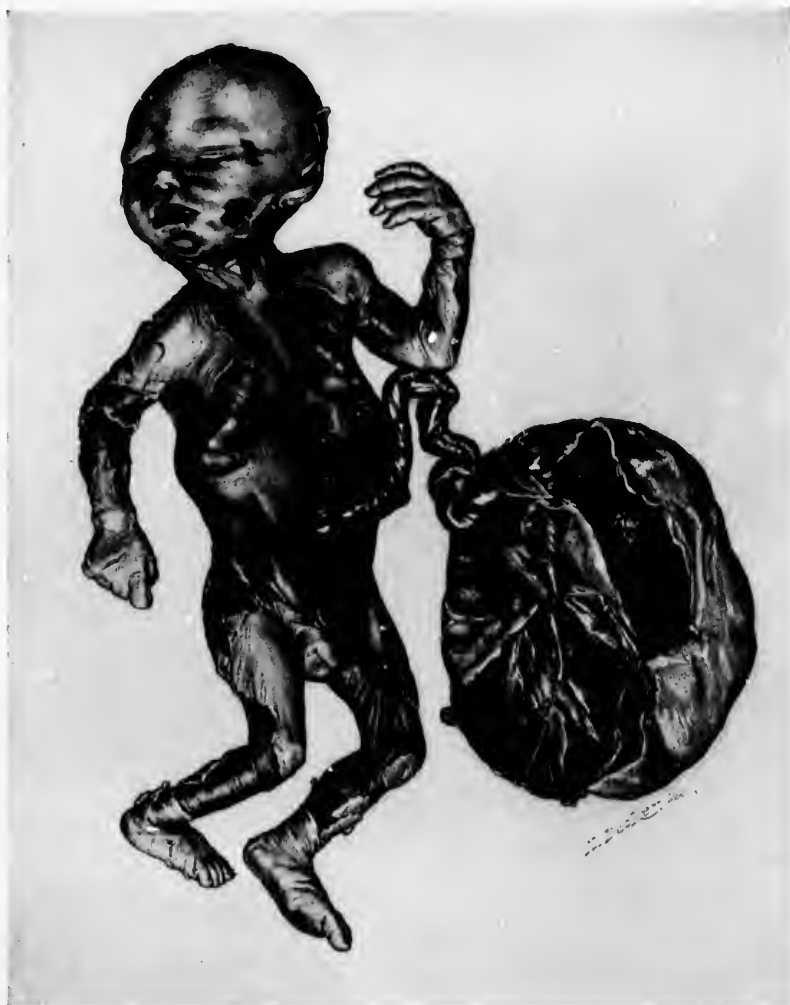

FIG. 518.—EXTRA-UTERINE PREGNANCY GONE SOME SIX OR EIGHT MONTHS BEYOND TERM; FALSE LABOR AND DEATH OF THE CHILD.

The fetus, placenta, and membranes were all removed together. Note the sodden collapsed body and the maceration of the skin which is peeling off, particularly over the body. Operation. Death from streptococcus infection. Measurement from head to rump 30 centimeters. Photo., 625.



In particular the causes may be classified as:

- (a) Tubal polypi.
- (b) Atresia of one tube with external migration of the fertilized ovum or the spermatozoa from the opposite side.
- (c) Persistence of a fetal type of uterine tube (Friend).
- (d) Diverticula from the lumen of the tube (Landau and Williams).
- (e) Torsion of the tube.
- (f) Catarrhal and purulent salpingitis (Tait, Orthmann).
- (g) Myoma uteri (Leopold).
- (h) Peritoneal bands and adhesions, compressing the tube.
- (i) Cervico-abdominal fistula after hysterectomy (Koeberlé and Lecluyse), and perhaps I might add peculiarities of the ovum, such as excessive size, due to twin pregnancy.

The earlier writers upon this subject were greatly hampered in studying the causation of extra-uterine pregnancy by erroneous views as to the place of meeting between the ovum and the spermatozoa; it was formerly supposed that fertilization normally occurred in the upper part of the uterus, and that this was brought about by the antagonistic action of the cilia of the uterine and tubal mucosæ; it was generally believed that the current produced by the cilia of the uterus was directed upward toward the fundus, while the tubal current was directed downward, and that the two met and practically neutralized each other at the upper part of the uterine cavity (Tait, Wyder).

Recent observations by H. Meier have, however, shown that these views are erroneous, and that the current produced by the uterine cilia in women is in exactly the same direction as the tubal current—namely, from above downward—so that the action of the cilia tends to assist the ovum in its downward progress, and to interfere more or less with the upward passage of the spermatozoa, so that if they were not endowed with motility, it is probable that conception would never occur.

Observations upon animals, since the time of Bischoff, have shown that the spermatozoa normally make their way up into the tube, and may even be seen swimming in the peritoneal fluid on the surface of the ovary, where they lie in wait for the ovum.

It has likewise been shown that spermatozoa may retain their vitality for a considerable length of time within the tube; they have been found, for example, in the female bat six months after the last copulation.

These facts would tend to show that fertilization, in the lower animals at least, occurs in the tube, most probably in its upper part, and that the fertilized ovum is carried to the uterus by the action of the tubal cilia.

The observation by Dührssen of spermatozoa in the normal uterine tube of a woman three and a half weeks after the last copulation tend to show that the views just adduced may likewise apply to the human female.

We therefore believe that extra-uterine pregnancy is simply due to some interference with the normal downward passage of the fertilized ovum through the tube.

Tubal Polyp.—The explanation which appealed most strongly to the early investigators was that the ovum was prevented from entering the uterus by some obstruction in the tube, such as a polyp, which partially occluded its lumen. But it is apparent, from the few instances in which such an obstruction has been found in the large number of carefully examined cases, which have been reported during the last few years, that this is a comparatively infrequent cause.

Atresic Tube.—The external migration of the fertilized ovum from one side, which is patulous, to the opposite tube, whose lumen is occluded in some part of its course, offers a satisfactory explanation for a considerable number of cases.

A case operated upon by Dr. H. C. Coe and described by Dr. J. W. Williams affords most convincing proof of this mode of origin. The left uterine tube was the seat of two extra-uterine pregnancies. At its uterine end was a small sac containing the skeleton and calcified remains of a fetus, which completely occluded that portion of the tube, and from the satisfactory history obtained clearly represented the remains of an extra-uterine pregnancy which had occurred twelve years previously, while the lateral end of the tube contained the placenta and the membranes of a four months' pregnancy which had ruptured, allowing the escape of the fetus into the abdominal cavity, where it was found alive at the operation. The left ovary was small and atrophic and presented absolutely no sign of a recent corpus luteum. The right tube presented signs of peri-salpingitis and endo-salpingitis; but its fimbriated extremity was patent, and the right ovary contained a corpus luteum, corresponding in size to the duration of the pregnancy.

It is apparent that the spermatozoa could not in this case have passed the occluded portion of the tube, where the lithopedion was situated; and the absence of a corpus luteum on that side is conclusive evidence that the ovum from which the second recent pregnancy was developed must have come from the opposite side, where there was a distinct corpus luteum; the only plausible explanation, therefore, is that the spermatozoa passed through the right tube, fertilized an ovum from the right ovary, which then migrated to the left tube, passed through its patent fimbriated extremity, and made its way onward until arrested by the lithopedion, where it developed.

It is also theoretically possible for spermatozoa to migrate from the normal to the diseased side, where they may fertilize an ovum, which may pass down the diseased tube to the point of atresia and there develop.

External migration of the ovum occurs comparatively frequently in extra-uterine pregnancy; Dr. Williams has been able to demonstrate it in five out of thirty cases, of which he has accurate pathological records. In all of them the fimbriated extremity of one tube was completely occluded by old inflammatory processes, or the tube was converted into a hydrosalpinx, while the other tube was the seat of the pregnancy, and presented a patent fimbriated extremity. In each case the ovary on the pregnant side presented absolutely no evidence of a corpus luteum, while the ovary corresponding to the occluded tube contained a typical corpus luteum of pregnancy.

Although at first sight such a "migration" (?) of the ovum appears difficult to explain, my observations at the operating table lead me to believe that it may be of tolerably frequent occurrence under ordinary conditions, for I have repeatedly found both tubes and ovaries lying low down behind the uterus, with the fimbriated extremity of the right tube in contact with the left ovary, and *vice versa*.

In one instance I removed the diseased tube on one side and the diseased ovary from the opposite side, leaving behind only the right tube and the left ovary. Pregnancy occurred within a short time and the patient was delivered at term; at a later date an extra-uterine pregnancy occurred and I was obliged to remove the remaining tube.

Persistence of a Fetal Type of the Tube.—The labors of W. A. Freund (*Samml. klin. Vorträge*, 1886, No. 323) have shown that a congenital malformation of the tube has much to do with the production of extra-uterine pregnancy, for the fetal tube has a narrow lumen and is markedly convoluted, thus tending, both by its narrowed caliber as well as by the greater distance which the growing ovum has to travel to reach the uterus, to bring about retention within the tube.

Diverticula.—Diverticula from the lumen of the tube are probably among the most frequent causes. Attention was directed to this condition almost simultaneously by Landau and Rheinstein (*Arch. f. Gyn.*, Bd. xxxix, p. 273) and by J. W. Williams (*Amer. Jour. Med. Sci.*, Oct., 1891).

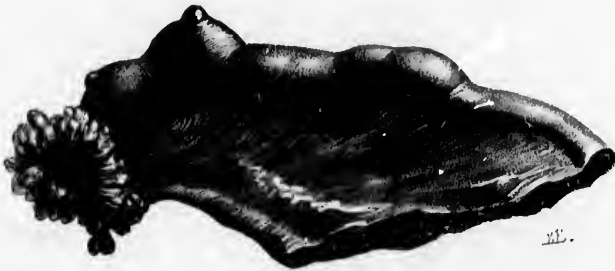

FIG. 519.—TUBAL DIVERTICULA FORMING TWO ROUNDED EMINENCES ON THE UPPER BORDER OF THE AMPULLA.

The peritoneum was intact, while the mucosa of the tube was cleft all the way through, as though the attempt had been made to form two additional tubal orifices. Natural size.

These diverticula are simply little offshoots from the lumen of the tube, which extend into its muscular wall, penetrate it for a greater or lesser distance, frequently running parallel to the tubal lumen, and eventually end blindly as a mere *cul-de-sac* (see Fig. 519). Should a fertilized ovum make its way into such a diverticulum, it would be carried to its blind end by the cilia, there be arrested, and undergo further development. It is apparent that rupture will occur earlier in these cases than when the pregnancy occurs earlier in the main lumen of the tube, for in the former case the pregnancy is separated from the surface of the

tube only by a fraction of the thickness of its wall, instead of by its entire thickness, as when it develops in the main lumen.

It is impossible to make absolute statements as to the frequency of this condition until serial sections of the entire tube have been cut in a large number of cases, which has not yet been done; but it probably occurs frequently; Dr. Williams has been able to demonstrate this mode of development in four and possibly five cases out of thirty specimens which he has examined.

Accessory Ostia.—The accessory tubal ostia (Kossmann, *Zeit. f. Geb. u. Gyn.*, Bd. xxvii, p. 266) act very much as diverticula by breaking the continuity of the walls of the tube, and thus interfering with the normal passage of the ovum toward the uterus. This condition explains only the extra-uterine pregnancies, which occur in the ampullar portion of the tube, where accessory ostia are usually found.

Inflammatory Affections.—Orthmann and Tait believe that inflammatory affections of the tube play a most important part in the causation of extra-uterine pregnancy. Tait thinks that catarrhal salpingitis leads to the pro-



FIG. 520.—TRIPLE TUBAL OSTIA. MARCH 8, 1894. No. 202. NATURAL SIZE.

duction of an extra-uterine pregnancy by the destruction of the ciliated epithelium; this interferes with the normal downward current of the tubal secretion and allows the entrance of spermatozoa, which then fertilize the ovum within the tube, where it undergoes its further development.

The fallacy of this conception has been demonstrated by A. Martin, and it is generally admitted that spermatozoa readily make their way up the tube, in spite of the downward current produced by the cilia, and that fertilization nearly always occurs in the tube; indeed, the careful examination of inflamed tubes shows that the cilia are rarely destroyed, even in well-marked cases of pyosalpinx, and are perfectly preserved in cases of catarrhal salpingitis. When we add to this the fact that cilia are readily demonstrated in nearly every case of tubal pregnancy which has been examined by Dr. Williams or my assistants, it is apparent that some other cause than the destruction of cilia must be invoked to explain the occurrence.

It is more probable that the thickening of the tubal walls, which frequently accompanies marked salpingitis, facilitates the arrest of the fertilized ovum somewhere within the tube by interfering with its peristaltic movements and by choking the lumen.

Purulent Salpingitis on the Affected Side.—In three cases out of thirty Williams found that the pregnant tube was the seat of a purulent salpingitis, and in one other case there was a follicular salpingitis; but he hesitates to state whether the tubal disease played a part in the production of the extra-uterine pregnancy, or was simply an accidental complication.

Pelvic Peritonitis.—Peritoneal adhesions, binding down the tube and restraining its movement, may not infrequently play a part in the production of an extra-uterine pregnancy. We frequently find at operation evidence of old inflammatory disease on both sides, and the history of the patient often points quite clearly to repeated attacks of pelvic peritonitis. In addition to this, the fact is most suggestive that extra-uterine pregnancy frequently occurs in women who have long been sterile.

A dense adhesion stretching across the tube so as to constrict its lumen may likewise be a cause in rare instances. In one of my abdominal operations I found the left tube so constricted by vesical adhesions passing across its isthmus that it was nearly severed, and its lumen almost entirely occluded. A twist in the tube, practically obliterating its lumen, with the pregnancy in its distal pole, was the apparent cause in one of Williams's thirty cases.

Myoma Uteri.—A myoma at the cornu uteri (Leopold) may so distort and compress the lumen of the tube and interfere with its functional activity as to offer a marked obstacle to the downward passage of the fertilized ovum toward the uterus.

The cases of Koeberlé and of Lecluyse (*Bull. de l'Acad. de méd. de Belge*, 1869) may be finally mentioned among the rare and remarkable cases in the annals of extra-uterine pregnancy.

Here, in spite of the removal of the uterus, the spermatozoa passed upward into the abdominal cavity through a cervical fistula, where they fertilized an ovum somewhere in the pelvis, presumably in one of the tubes.

Classification.—A natural classification of the various forms of extra-uterine pregnancy is one based upon the original point of implantation of the fertilized ovum. When it remains and develops where it was first arrested, we designate it as *primary* extra-uterine pregnancy; upon changing its position by rupture or further development it is designated as *secondary*.

The *primary* tubal forms are, according to the site of the ovum, the *interstitial*, the *isthmial*, and the *ampullar*; J. C. Webster further distinguishes an *infundibular* form, which becomes secondarily tubo-ovarian or tubo-abdominal. The *tubo-ovarian* form may develop in an ovarian tube—that is, one whose fimbriated extremity is glued down by adhesions to a limited portion of the ovary (Hennig).

The table here given shows the changes which each of the primary forms may undergo:

Table of Forms of Extra-uterine Pregnancy.

PRIMARY FORMS.	SECONDARY FORMS.
Interstitial may become	{ Intra-uterine. Abdominal (fetus dies). Intraligamentary (fetus dies).
Tubal may become	{ Mole (fetus dies). Abortion (fetus dies). Tubo-abdominal. Tubo-ovarian. Abdominal. Intraligamentary (fetus dies).
Ovarian may become	{ Abdominal (fetus dies).

As I have already stated, ovarian pregnancy is the rarest of all forms (see Leopold, *Arch. f. Gyn.*, Bd. xix, p. 210), and the interstitial form is of infrequent occurrence. Martin found one of the latter in seventy-seven cases. I have never observed an example of either. Almost all cases of tubal pregnancy occur either in the isthmus or ampulla of the tube, and rarely at its fimbriated end. Zweifel distinguishes (see *Arch. f. Gyn.*, Bd. xli) a further form in which the ovum does not enter the lumen of the tube, but becomes attached to the tubo-ovarian fimbria and there develops, in his case it was a pregnancy of about five months; this might in a certain sense even be denominated a primary abdominal pregnancy. In rare instances a tubal pregnancy may develop and reach full term without rupture, but more frequently the sac ruptures into the abdominal cavity or within the folds of the broad ligament, or through the fimbriated end of the tube. The primary abdominal forms have disappeared from our nomenclature since Werth has shown that the classical cases reckoned as such were all tubal in their origin.

A. Martin classifies seventy-seven cases of extra-uterine pregnancy coming under his personal observation, according to the seat of the ovum, as:

Ampullar	48 times.
Isthmial	8 "
Interstitial	1 "
Intraligamentary	7 "
Tubo-ovarian	6 "
Tubo-abdominal	3 "
Ovarian	1 "
Undetermined	3 "

Judging by my own experience, I should say that rupture within the folds of the broad ligament, with intraligamentary or subperitoneo-pelvic development, occurs but rarely; I have observed it only twice in twenty-three cases of extra-uterine pregnancy in one thousand celiotomies.

In several old pelvic inflammatory cases I have found the tube and ovary so enveloped by adhesions, which presented a smooth surface toward the abdominal cavity, that the tubal pregnancy appeared to lie beneath the peritonæum. Such cases may be well designated as pseudo-intraligamentary, and may be differentiated from the true intraligamentary form by the fact that a little patience enables one to separate the adhesions posteriorly and to free the pregna! tube, a procedure manifestly impossible in the true broad-ligament variety.

The statements made by various observers as to the form of extra-uterine pregnancy in any given case are so often based upon an insufficient examination of the structures involved that it is important to keep clearly in mind the various criteria by which the exact form of the extra-uterine pregnancy is established; it is also important that these criteria should be adhered to in the description of a case. It is a matter of curious interest to note that the first bitter discussion in this well-fought field was one of classification, and arose between no less distinguished men than Mauriceau and Regner de Graaf, over a case occurring in 1669. De Graaf insisted that the woman from whom the specimen was received post mortem had died of a ruptured tubal pregnancy, while Mauriceau contended that the pregnancy was not tubal at all, but a hernia of the uterine tissue, and he cited the attachment of the round ligament to the outer side of the sac instead of to the inner side in proof of his position, giving at the same time a clear sketch of the case.

Criteria of a Tubal Pregnancy.—When unruptured, the tumor is in the tube and has a pedicle formed by a part of the tube and the mesosalpinx, holding the same relations to the uterus, broad ligament, and ovary as a hydrosalpinx does; that is to say, the body of the uterus is well defined and separate from the tumor on its inner (median) side, the ovary is found intact, and the layers of the broad ligament are not separated; the round ligament lies on the median side of the tumor.

When the tubal pregnancy is ruptured, if the rupture is recent the fact is evident from the extravasated blood, and an examination of the tube shows the point of laceration; or if the case is one of tubal abortion the fimbriated end is dilated and often choked with firm clots, forming a "tube cast." The tube usually still contains a portion of the ovum, and villi may even be found choking the tear.

The uterus and round ligaments lie toward the median line, the ovary is intact, and the broad ligament is not spread apart.

Criteria of an Intraligamentary Tubal Pregnancy.—Careful observation is necessary to establish the diagnosis of the intraligamentary form of extra-uterine pregnancy, for there is great danger of confusing it with a ruptured intraperitoneal form encapsulated in adhesions. The following are the criteria of differentiation: The tumor occupies the same relations to the broad ligament and the uterus as does an intraligamentary cyst; the mesosalpinx is unfolded, together with the anterior and posterior layers of the broad ligament, and the pelvic peritonæum and even the peritonæum of the ante-

rior abdominal wall has become detached from the cellular tissue and covers the tumor according as the pregnancy is more or less advanced.

The ovary lies somewhere upon the surface of the tumor, flattened or drawn out as much as 6 centimeters, but the ovarian tissue is not distributed over any considerable area, thus affording a differentiation from ovarian pregnancy. The uterus lies closely applied to the tumor, deprived of its broad ligament on the side of the pregnancy, and is pushed over toward the opposite side. The round ligament extends from the *cornu uteri* over the front of the tumor, which lies also in intimate relation with the upper half of the vagina. Muscular tissue is often found abundantly in the sac wall derived from the tube and from the subserous tissue.

Cases of *pseudo-intraligamentary tumors* are liable to be mistaken for this form, because the pregnant ruptured tube and the ovary are often found under a mass of old adhesions, which present a smooth surface toward the abdominal cavity, looking exactly like the posterior layer of the broad ligament. A minute examination of the structures always shows some irregularities in these adhesions, and by testing them, weak points are found where they can be detached and stripped up from the pelvic floor and walls. Furthermore, the ovary, which ought to lie in view in an intraligamentary form, is concealed beneath the adhesions in the pseudo-intraligamentary form. Other evidences of pelvic inflammatory disease also exist.

Criteria of an Interstitial Pregnancy.—This form of ectopic pregnancy is distinguished from the commoner forms by the position of the round ligament on the outer side of the sac, where the uterine tube is also found. The uterus is enlarged and intimately connected with the inner side of the tumor, of which it appears to form an organic part.

The tubo-uterine mass may bulge into the uterine cavity and be separated from it by a small opening or may be freely connected with it. When the fetus escapes into the uterus the placenta stays behind in the wall and communicates with the uterine cavity through the opening.

An interstitial pregnancy is liable to be confused with a pregnancy in a rudimentary horn of the uterus, in which the round ligament is also found on the outer side of the sac. This error will not occur if the uterine body is noted rounded off toward the rudimentary side and the attachment of the pedicle of the tumor, low down on the side of the uterus is observed.

The uterine tube is also inserted lower down on the side of the tumor than it is on the other side. An interstitial pregnancy may also become intraligamentary (Martin, Leopold).

Criteria of an Ovarian Pregnancy.—In this form it is necessary to demonstrate the criteria laid down by Spiegelberg, namely, that the tube is intact and has no organic connection with the gestation sac; that the tumor is connected with the uterus by the utero-ovarian ligament; that the walls of the sac contain Graafian follicles in various places; and that the albuginea of the ovary passes directly into the tumor wall.

Clinical History.—The fertilized ovum once lodged in the tube goes on developing so long as the fetus lives, which may be up to the eighth or ninth month of pregnancy. The first symptoms are identical with those of uterine pregnancy. There is cessation of the menses, morning sickness, uncomfortable sensations and fullness in the breasts, enlargement of the uterus, and discoloration of the vagina. The patient is often impressed with the fact that she is pregnant. A tumor forms to the right or left of the uterus, elastic and painful to touch, which grows from month to month, while the uterus itself enlarges to the size of a two or three months' pregnancy.

Sometimes within the first five or six months the uterus may cast off the decidua vera which has formed in it, either as a complete cast of the interior of the uterine cavity or in pieces. This process is accompanied by a flow of blood from the vagina which is apt to be mistaken for an abortion, and may be so excessive as almost to endanger life.

The tumor continues growing and becomes apparent on one or the other side of the lower abdomen, where it may be discovered for the first time by the patient herself. About the fourth or fifth month, and sometimes earlier, colostrum appears in the breasts.

Attacks of pain and localized peritonitis due to rupture of the sac walls and to hemorrhage from the detachment of some of the villi or of the placenta are frequently observed. These attacks are apt to be sudden and severe, and the pain is often described as "agonizing." When the hemorrhage is sudden and excessive the patient falls in collapse; but, in spite of these alarming symptoms, she may survive a succession of similar attacks and the fetus and sac may continue to develop. The pelvic peritonitis produces adhesions between the sac and the surrounding parts, and is often accompanied by a moderate elevation of temperature.

About the fifth month the fetal movements may be felt, and later the fetal heart sounds and the placental souffle may be heard.

The discharges of blood from the uterus after the escape of the decidua become irregular and are often protracted.

If the fetus survive the risks of rupture, hemorrhage, and the partial detachment of the sac in the early months, false labor, simulating the onset of a miscarriage or a true labor, may occur at any time during the latter months of pregnancy, followed by the death of the child and cessation of its movements, the absorption of the amniotic fluid, and the rapid diminution in the size of the sac. These cases are undoubtedly the "missed labors" of our predecessors (Oldham).

In rare instances the pregnancy advances to full term without any untoward event just as a uterine pregnancy; then at or near term false labor sets in, the fetus dies, and remains behind with the placenta as a foreign body, which may lie undisturbed within the tube for many years, becoming calcified (lithopedion) and converted into adipocere, or it may be skeletonized by the removal of large portions by the phagocytes. In a case cited by Brendel (*Centralb. f. Gyn.*, 1883, p. 649) a dead fetus in the eighth month

was the mechanical cause of an obstinate constipation which lasted four weeks. Cases of ileus have also occurred due to strangulation of the intestines by peritoneal bands. At any date subsequent to the fetal death inflammatory changes may be set up, and the abdominal wall or some of the hollow viscera may be perforated in the discharge of the fetal bones.

The fetus itself may be perfectly formed and well developed, but in a large percentage of cases it is either puny or deformed from insufficient nourishment and undue pressure on certain parts in a constrained position. Kirchoff (*Centrab. f. Gyn.*, 1894, p. 232) found a double fetal monster (thoracopagus) in a left tube ruptured in the fifth week. A large hydramnios resembling an ovarian cyst has been noted (Tenffel, *Arch. f. Gyn.*, Bd. xxii, p. 57).

Torsion and atrophy of the umbilical cord may also occur (see Fig. 521).

The hemorrhage in extra-uterine pregnancy is one of its most characteristic features, and is due, as stated, either to the detachment of some part of the ovum from the tubal wall or to a tear in the wall of the tube unable any longer to accommodate the growing ovum. Hemorrhage may take place into the extra-uterine sac itself, into its walls, into the lumen of the tube, into the abdominal cavity, or between the layers of the peritoneum. Hemorrhage into the tube and by its fimbriated end out into the abdominal cavity, and hemorrhage due to rupture of the tube into the abdominal cavity, are the most important clinical varieties.



FIG. 521.—FETUS AND UMBILICAL CORD FOUND LYING AMONG CLOTS IN ABDOMINAL CAVITY. JANUARY 27, 1896. NATURAL SIZE.

Owing to the tenuity of the tubal walls as they become distended by the growing fetus, rupture frequently occurs early in the pregnancy anywhere from the fourth week to the fourth or fifth month or later. The reason for the thinning out of the wall in one direction more than in another has been the subject of much speculation. Christian Fenger suggests that when the ovum is lodged near the center of the tube surrounded on all sides by its folds it is less likely to rupture than if it lodges down between two folds close to the tubal wall. Landau found in his case of extra-uterine pregnancy lodged in a diverticulum of the tube, that the ovum lay immediately beneath the peritoneum, and the rest of the muscular wall of the tube was almost unchanged.

In a case of my own of right isthmal pregnancy the patient had not even missed a menstrual period when she was suddenly taken with violent pains, interpreted as colic from indigestion, and bled to death in two days from a little mass not larger than a bean, about 1×2 centimeters in size, ruptured on the dorsal surface.

After the rupture of the tube the fetus may escape into the abdominal cavity and continue to develop. The usual course, how-

ever, is the death of the fetus and the formation of an extensive mass of blood clots which may be walled off from the abdominal cavity by intestinal adhesions.

It often happens that the first hemorrhage, even when occurring as early as the second month, proves fatal. This was the condition in the case of an English actress who dropped dead in a *café* in Paris in whom a ruptured extra-uterine pregnancy was found when the viscera were examined under the impression that she had died of poisoning (Chahbazian, *Trans. of the Obs. Soc. of London*, vol. xxiv, p. 157). On the other hand, the patient may die of anemia after a succession of hemorrhages.

The amount of the hemorrhage depends upon the position of the rupture, whether it happens to involve a large blood vessel or not, and the hemorrhage is particularly dangerous when it lies within the placental site. Repeated hemorrhages occur when there is a partial rupture and the ovum continues to grow. The hemorrhage may often be checked temporarily by a clot or by some tufts of placental villi; it is not so likely to prove fatal when it takes place between the layers of the mesosalpinx, and so opens up the broad ligament, becoming extraperitoneal and lying under the pelvic peritoneum.

Not infrequently the pregnancy terminates with the escape and death of the ovum, with the extravasation of blood into the peritoneum, and the entire absorption of the abnormal products, and the case is interpreted by the family physician as simply one of severe colic.

Tubal Abortion.—When the ovum lies in the ampullar end of the tube and becomes detached early in the pregnancy, the successive hemorrhages often accumulate around it and take the shape of the distensible tube (extra-uterine tube cast). The cast formed in this way has somewhat the appearance of a sausage, is cylindrical, from 2 to 3 cen-

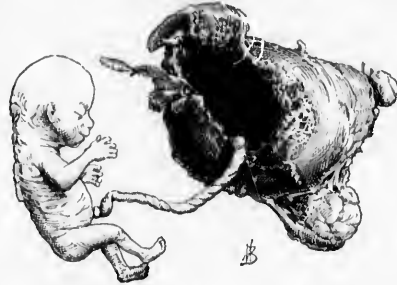


FIG. 522.—EXTRA-UTERINE PREGNANCY. Showing the rupture in the ampulla and the escape of the fetus, which is still attached by its cord; the ovary is intact below the sack. Operation by Dr. Peck, of Youngstown, O. Recovery. $\frac{1}{2}$ natural size.

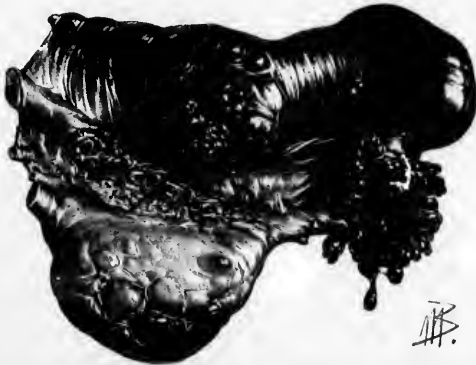

FIG. 523.—RUPTURED LEFT EXTRA-UTERINE PREGNANCY WITH LARGE, FREE INTRAPERITONEAL HEMORRHAGE.

The rupture is at the junction of the ampulla and the isthmus; the rest of the ampulla is dilated and infiltrated down to a narrow neck just behind the fimbriated end. Enucleation; saline infusion. Recovery. Feb. 23, 1895. Natural size.

timeters in diameter and 5 or 6 centimeters in length, and at the outer end which projects from the ampulla it is ragged and broken. These blood casts are often found *in situ*, choking the tube, or lying free in the peritoneal cavity amid a mass of clots; in the latter case they are apt to be broken up in the removal and so not recognized.

In rare instances very little hemorrhage accompanies the tubal abortion, and the fetus and its membranes may be extruded *in toto* through the fimbriated extremity.

In a specimen exhibited by Dr. Edebohls before the New York Obstetrical Society the fetus with its membranes intact was seen in the process of abortion, one half of the ovum being free in the peritoneal cavity, while the other half was firmly grasped by the dilated conical fimbriated end of the tube, like a bud in its calyx.

The fetus, turned into the peritoneal cavity with a mass of clots, by rupture of the sac dies, and the sac becomes walled off by adhesions from the rest of the cavity. Later suppuration may occur, with perforation and discharge of the contents by the rectum, vaginal vault, bladder, or abdominal walls.

Tubal Mole.—A not infrequent termination of tubal pregnancy is the death of the fetus in the intact tube, with marked hemorrhage about it and between its membranes. At the same time the

liquor amnii is absorbed, the blood more or less organized, and a structure produced which is identical with the moles occurring in uterine pregnancy. Such moles may vary markedly in size, according to the age of the pregnancy and the amount of hemorrhages, and may be retained in the tube for an indefinite period.

I have seen two cases of unruptured extra-uterine pregnancy terminate in this way; in the first the pregnancy was four months advanced in the ampullar end of the right tube, and in the second there was a tumor of the isthmal end of



FIG. 524.—EXTRA-UTERINE PREGNANCY.

Showing the thickened tube and adhesions to the tube and ovary. The black mass above the tube is a blood clot forming a perfect tube cast which had been thrown off into the abdominal cavity. Operation. Recovery. Path. No. 417. $\frac{3}{4}$ natural size.

the right tube about the size of a walnut. On cutting through this it was found to consist of a firm old blood clot embraced on all sides by the thin tubal wall.

Interstitial Pregnancy.—When the pregnancy takes place in that part of the tube which lies within the uterine wall, the growing ovum may gradually become extruded into the uterine cavity, while the placenta retains its connection with the sac within the cornu, where it may be found and removed after the delivery of the child by the natural way.

Interstitial pregnancy is peculiarly liable to rupture into the abdominal cavity with an immediately fatal hemorrhage, or it may again rupture between the layers of the broad ligament.

To recapitulate, unless artificially relieved, an extra-uterine pregnancy always terminates fatally to the child, and is frequently fatal to the mother.

The following is a categorical statement of the final results:

1. Development of the fetus within the tube, with false labor and death of the fetus, which is retained as a lithopedion, or is mummified, or discharged with suppuration.
2. Tubal mole.
3. Tubal abortion.
4. Extrusion into the uterus (in the interstitial form), and development to term.
5. Rupture within the folds of the broad ligament, usually with the death of the fetus, in rare instances advancing to term.
6. Rupture into the peritoneal cavity.

- (a) Followed by continued growth of the fetus.
- (b) Death of fetus and mother.

(c) Death of fetus alone with absorption (Leopold, *Archiv f. Gyn.*, xviii, p. 53; experiments on rabbits).

(d) Death of fetus with a succession of hemorrhages ending in (1) suppuration, peritonitis, and maternal death; (2) suppuration and discharge externally by the rectum, by the vagina, by the bladder, or by the abdominal walls.

Multiple Pregnancy.—Numerous observations are recorded in which an extra-uterine and an intra-uterine pregnancy have occurred simultaneously.

The course under such circumstances may be that of an extra-uterine pregnancy with death of the fetus, followed later, it may be several years later, by



FIG. 525.—EXTRA-UTERINE TUBAL MOLE FILLING AND DISTENDING THE AMPULLA.

The isthmus is not affected, and the fimbriated end is not at all distended. There was no free blood in the pelvis. One half of the ovary left. Operation. Recovery. Oct. 20, 1897. Natural size.

an intra-uterine pregnancy (see Coe, *Amer. Jour. Obs.*, 1893, vol. xxvii, p. 855). The uterine pregnancy may then go on to term, or may terminate prematurely in abortion. Inasmuch as the intra-uterine pregnancy is not abnormal, the indications for treatment must depend upon the extra-uterine pregnancy. Out of eighteen cases (see Gutzwiller, *Archiv f. Gyn.*, Bd. xliii, p. 223), ten maternal lives were lost, and of the remaining eight, four were saved by celiotomies. In one case both children were delivered alive, but the mother died. In the case contributed by Gutzwiller the extra-uterine pregnancy advanced to the eighth month and the fetus died after an injury, and the intra-uterine pregnancy began shortly afterward; twelve months after the beginning of the extra-uterine pregnancy it was discovered and operated upon, and the second day after its removal a three-months' fetus was discharged from the uterus.

Spencer Wells made a diagnosis of simultaneous extra-uterine and intra-uterine pregnancy in a case in which there was an enlarged pregnant uterus with a tumor attached to it, by hearing both fetal heart sounds.

In a patient who came under the care of A. L. Galabin (*Trans. of the Obs. Soc. of London*, vol. xxiii, 1881, p. 140) there were two fluctuating tumors separated by a distinct sulcus, one on the right side reaching to the ribs, and one on the left side occupying the left inguinal and iliac regions. Fetal movements and heart sounds and a uterine souffle were heard in the left enlargement only; in the right tumor a hard body could be palpated through the fluid; a significant point in the history was the fact that the patient began to complain suddenly of great pain and faintness, and developed a marked peritonitis. The diagnosis lay between a ruptured ovarian cyst and an extra-uterine fetation combined with an intra-uterine one, and the latter was found at the operation.

The late Dr. H. P. C. Wilson, of Baltimore, had the good fortune to save both the extra-uterine and the intra-uterine child in the case of a woman, twenty-four years old, in her fourth pregnancy. She bore a female child in easy labor April 15, 1880, a month before the calculated time; it was at once evident to both patient and midwife that there was another child present. An examination showed that the tumor in the abdomen was perfectly independent of the uterus, and on auscultating it, fetal heart sounds were detected. The effort was then made to delay operation at least twenty-three days until the full term for the intra-uterine gestation had arrived. The patient had several attacks of colic and laborlike pains, which were quieted by opiates. The operation was done May 11, 1880; the abdomen was opened, and a sac exposed which ruptured under slight manipulation, discharging about 2 liters of amniotic fluid, and a male infant weighing eight pounds was delivered. The child lay well flexed in the abdomen with buttocks down and back turned forward. The sac was sewed to the abdominal incision and drained. The patient died of sepsis ninety hours after the operation.

Chr. Fenger has found two ova in the same tube, and Sanger even found a case of triplets, two of which constituted an intramural twin ovum, while the third was lodged in the ampulla. A number of cases have been reported of extra-uterine pregnancy occurring in both tubes simultaneously.

Repeated Extra-uterine Pregnancies.—Cases are recorded in which an extra-uterine pregnancy has been observed twice in the same woman. Taylor, of Birmingham, had a patient who missed one menstruation, and when six weeks pregnant had a rupture, with the formation of a hematoecle and peritonitis. Two years after, she had a ruptured extra-uterine pregnancy at five weeks, and when the abdomen was opened and the mass removed the scar of the previous rupture was found in the tube.

Olshansen, at the meeting of the Berlin Obstetrical and Gynecological Society, Dec. 13, 1889, exhibited a child in good condition and over a year old, delivered from a right tubal pregnancy. The month before the meeting he had operated successfully a second time upon the mother for a left tubal pregnancy in the fifth week (see *Cent. f. Gyn.*, 1890, p. 67).

Hermann (*Brit. Med. Jour.*, Sept. 27, 1890) removed a ruptured tubal pregnancy, and three years later diagnosed an unruptured pregnancy on the opposite side. Reference has already been made to Coe's case, in which there was an interval of twelve years between the two pregnancies (*Trans. Amer. Gyn. Soc.*, 1893, xviii, p. 268).

F. Schauta (*Lehrb. d. gesammt Gynäkologie*, 1895, p. 681) would explain this accident by the occurrence of a one-sided tubal catarrh offering an obstruction and causing a pregnancy on that side, followed at a later date by a catarrh of the opposite side with a pregnancy on that side.

Diagnosis.—The diagnosis of an extra-uterine pregnancy is usually easy to make. The diagnostic signs vary, however, according to the advancement of the pregnancy and according as the sac is ruptured or unruptured, and the fetus alive or dead.

The two important means of making the diagnosis are the history of the case and the physical examination, either of which may be sufficient alone, but both together often afford a degree of certainty fully as great as that attained in the case of any other abdominal tumor.

The diagnostic signs are the following:

1. Cessation of menstruation.
2. Other signs of pregnancy, such as nausea, changes in the breasts, etc., and certain characteristic signs, often peculiar to the individual.
3. The patient often "feels different" in this pregnancy as compared to previous ones, and suspects that something is wrong.
4. Pains in the pelvis and the presence of a tumor, which is distinct from the uterus and sensitive upon pressure.
5. Sudden severe (agonizing) pain, often coming on during active exertion.
6. Patient is compelled to go to bed with marked anemia or in collapse.
7. Repeated attacks of pain and signs of pelvic peritonitis.
8. Constipation and dysuria.
9. Recurrences of irregular, more or less profuse, menstruation.
10. Discharge of decidual cast.
11. After rupture the patient may have hallucinations, often becomes weak and emaciated, and in some cases there is marked nephritis.

Objective Signs.—1. Uterus enlarged to about the size of a two-months' pregnancy.

2. Formation of a tumor at one or the other side of the uterus.

3. Microscopic demonstration of the decidual nature of cast-off membrane.

4. Contraction of the uterus after casting off the decidua.

5. Occasionally contraction may be felt in the extra-uterine tumor.

6. If the pregnancy continues to develop, the abdomen increases in size and the fetus can be felt with great distinctness through the thin sac wall, and fetal heart sounds are heard.

7. False labor which sets in from the seventh to the tenth month, followed by death of fetus and absorption of amniotic fluid, with rapid diminution in the size of the tumor. The dead fetus and the membranes may then remain in the abdomen innocuous for years, or the sac may suppurate at any period after the death of the fetus, and excite a fatal peritonitis, or discharge the fetal bones through the abdominal walls or into the intestinal canal, bladder, or vagina.

Dr. Routh, of London, has stated that a positive diagnosis may be made if a decidua is cast off from the uterus in the presence of a growing pelvic tumor.

The history of the case often shows that the woman has been sterile for some time—it may be as long as ten or twelve years—and a close investigation generally reveals the fact that there has been some catarrhal process in the uterus and in the tubes with attacks of pelvic peritonitis.

Menstruation, which has been regular, has suddenly ceased for one or more months, when it returns in an irregular way at intervals of two or three weeks, often lasting from ten to fifteen days or more.

It may be difficult to reckon how far the extra-uterine pregnancy has progressed for several reasons. Patients suffering from pelvic inflammatory disease are often irregular in their periods; one of my cases occurred during lactation, and this has been noted before; menstruation sometimes continues for a month or two in spite of the extra-uterine pregnancy, and the irregular menstrual flow common during the first half of the pregnancy is confusing.

In addition to the difficulty of fixing a precise date of onset, there is the added difficulty that the size of the sac does not often correspond to the month of the pregnancy; it may grow rapidly (hydramnios), or it may remain small. When hemorrhages occur in a pregnancy in the fifth or sixth week, it may even appear to be a four or five month's ovum, judged by its size alone. This difficulty, however, does not affect the practical result, for in the first five months the same treatment is employed, whether the pregnancy is reckoned one or two months earlier or later, and at the latter date the fetus can usually be measured and data taken from its size to determine its viability.

Although the diagnosis can be readily made in the majority of cases, occasional instances will occur when the true nature of the malady will be suspected for the first time when the abdomen has been opened and the tube incised and found to contain laminated clots (see Fig. 526).

In all doubtful cases the microscopic examination, showing the presence of placental tissue, chronic villi, and decidual cells, affords the one positive criterion by which the nature of the case is determined beyond a doubt (see Plate XXIII).

The Diagnosis in Unruptured Cases.—When the sac is unruptured the diagnostic factors are not so numerous as in ruptured cases. They are:

Cessation of menstruation for one or more periods, accompanied by nausea and the other signs which lead the patient herself to suspect pregnancy.

Changes in the color of the genital mucous membranes.

The existence of an ovoid tumor to the right or left of the uterus in the position of the uterine tube, usually painful on pressure.

The sac must be handled gently for fear of rupturing it during the examination. Some of the earlier writers thought that a differential diagnosis between extra-uterine and intra-uterine pregnancy could be made by the failure of the extra-uterine sac to contract, but this sign is fallacious, as distinct contractions have been noted.

The uterus may lie in anteversion or in retroflexion, and when the extra-uterine sac becomes larger than an egg the womb is thrust over toward the opposite side.

If the uterine decidua is cast off, or bits may be removed by curettage, this constitutes a sign of the utmost value.

When the fetus dies without rupture of the tube, the absorption of the amniotic fluid, causing a rapid diminution of the size of the sac, is a sign which is almost pathognomonic.

From the third month on, the presence of milk in the breasts.

The first case, as far as I know, in which an unruptured extra-uterine pregnancy was diagnosed and operated upon in America was that of one of my patients in Kensington, Philadelphia, which may serve as a type on account of the characteristic history presented (*Trans. Obst. and Gyn. Society of Balt.*, Jan. 14 and Feb. 11, 1890).

J. B. was twenty-two years old and had been married for three years. She had had one premature still-birth, and one child eleven months before I saw her. She came to me early in December, 1885, stating that her menstruation had been regular up to July, but that she had not menstruated from July until the middle of November, when she discharged something like a piece of flesh. In October she had noticed a painful swelling low down on the right side; the pain was severe and continuous until the menstrual flow came on and relieved it.



FIG. 526.—EXTRA-UTERINE PREGNANCY; CROSS SECTION OF THE TUBAL WALL IN THE AMFELLA.

Showing the placenta on the left and blood clots on the right, choking the tube, which is thinned out in the neighborhood of the clots. Path. No. 417. Natural size.

Upon examination, I found a little milk in the flaccid breasts, and a smooth, tense, elastic ovoid tumor filling the right side of the pelvis anterior to the cervix, which was displaced back into the sacral hollow. The tumor was felt in close contact with the whole anterior vaginal wall; it was moderately movable, and its posterior pole lay close to the right uterine cornu, and felt as if pivoted there. It filled the lower abdomen on the right side halfway up to the umbilicus, and gave a peculiar tense, elastic sensation on pressure. The uterus was small and retroposed, reclining in the sacral hollow.

At her next visit she said she thought she must be pregnant, as she had felt slight movements.

On Dec. 16th, a month after the discharge of the decidua, she had a slight flow without any pain, and on the 12th of January she had a free discharge, lighter in color than normal menstruation, and again on the 8th of March she had a free flow lasting until the 13th. The following note was made on this date: "Uterus small, low down in the hollow of the sacrum. By palpation through the anterior vaginal wall an ovoid, tense cyst is felt on the right side, about 12 centimeters in length by 7 centimeters in breadth. The axis of the cyst lies in the plane of the superior strait; its anterior extremity lies at the symphysis pubis to the right, while its posterior extremity is at the right cornu uteri. A well-defined sulcus lies between the tumor and uterus, which are connected by a short but easily recognizable pedicle. The tumor is very sensitive to pressure. It is very smooth, and has a remarkable elastic feeling like a rubber ball; there is much tenderness on the left side, low down, where there is an indistinct wormlike feeling about the retroposed cornu uteri."

The tumor when first seen had extended out of the pelvis halfway up to the umbilicus, and had therefore markedly diminished in size while under observation.

The diagnosis of an extra-uterine pregnancy was therefore positively made upon the basis of the following signs: Cessation of menstruation for several months, some enlargement of the uterus, the formation of a cystic tumor lateral to the uterus, the appearance of milk in the breasts, the expulsion of a membrane resembling a cast from the uterus, unusual pains in the lower abdomen, a shrinkage of the sac while under observation—a group of signs found in no other condition than extra-uterine pregnancy.

The operation, performed March 20, 1886, in the presence of Dr. R. P. Harris and several other physicians, revealed a right-sided unruptured extra-uterine sac, 10½ centimeters long, developed in about the middle of the uterine tube. The sac was cut open by Dr. C. H. Thomas, when it extruded a shrunken but well-formed male fetus, 12 centimeters long, from vertex to rump.

The patient recovered and became normally pregnant the following month, and I delivered her in January, 1887, after a difficult forceps operation.

Although the diagnosis in an unruptured case may sometimes be easy, mistakes may also occur, especially when the patient is seen but once. I made such an error soon after the case cited above. A young married woman came to me complaining of sudden cessation of menstruation with severe pain in the right

side. On examination, I found an elastic tumor, 5 centimeters in diameter, to the right of a normal uterus, and suspected an extra-uterine pregnancy, but on removal the tumor proved to be a corpus-luteum cyst, and the cessation of menstruation was due to phthisis, which developed rapidly later.

The Diagnosis in Ruptured Cases.—The diagnosis of a ruptured extra-uterine pregnancy depends upon the sudden onset of the severe symptoms, such as extreme pain localized in the pelvis, followed by anemia, and usually associated with a discharge of blood from the uterus, indicating rupture, and often resulting in the formation of a distinct pelvic tumor. The rupture not infrequently occurs while the patient is lying in bed; in other cases the immediate cause of the rupture seems to be some exertion, such as lifting or reaching overhead, as in hanging up clothes, or in working in a garden.

In some instances the immediate loss of blood is so great that the patient falls to the floor unconscious as suddenly as if shot.

The anemia varies from a slight blanching to a deadly pallor. The collapsed, anxious appearance, the thready pulse, and the extreme pain and abdominal tenderness are characteristic, even though there is no tumor or perceptible uterine enlargement.

On making a pelvic examination, the uterus may be found enlarged and the cervix softened. If the blood is fluid and free in the abdominal cavity, it may not be possible to feel it, but in almost all cases a mass of somewhat indefinite outlines and peculiar consistence can be detected posterior to and at one side of the uterus.

When a succession of hemorrhages occurs at intervals of a few hours, several days, or even some weeks apart, each one is marked by a repetition of the symptoms described. Sometimes the first attack is just severe enough to constitute a warning, and the later attacks increase in severity.

After some days or weeks have elapsed the coagula in the pelvis become walled off by adhesions among the intestines, and, with the absorption of some of the fluid elements, the pelvic mass assumes a doughy consistence; it is distinctly impressible by the finger, although no pit is left behind, and it conveys a sense of indistinctness of outline which is quite peculiar.

A rectal examination will sometimes show the presence of clots of blood in the pelvis, which can be felt breaking up under the finger.

When the pregnancy is advanced the difficulty is not so much the diagnosing of a pregnancy as the determination whether it is extra-uterine or intra-uterine; the diagnosis is best made by putting the patient under anesthesia and grasping the cervix with forceps and carefully drawing down the uterus toward the vaginal outlet while palpating its outlines through the rectum. If the entire uterus can be distinctly outlined in this way the ovum is clearly extra-uterine. Error is far more apt to arise from mistaking a normal pregnancy for an extra-uterine pregnancy. When the amniotic fluid is scant and the uterine walls are thinned out almost to the consistence of wet blotting

paper, the impression of an extra-uterine pregnancy conveyed by palpating through thin abdominal walls may be almost irresistible. A skillful vaginal and bimanual examination will, however, correct the diagnosis. It must never be forgotten that the patient may present an extra-uterine and an intra-uterine pregnancy at the same time. The milk in the breasts and the linea nigra are found in the extra-uterine as well as in a normal pregnancy.

A pregnancy in one horn of a bicornute uterus will be distinguished by the lop-sided shape of the enlarged unimpregnated horn, as well as by the low, broad connection of the sac with the cervical end of the uterus.

An error in the diagnosis of a ruptured extra-uterine pregnancy in the early months is most likely to occur in the case of a pelvic abscess. In one of my cases at the Johns Hopkins Hospital there was cessation of menstruation and an irregular return, with sudden severe pain in the right side, followed by similar attacks; the patient was compelled to go to bed, and showed a decided pallor. There was a slight elevation of the temperature. The examination revealed an irregular, tender mass to the right of the uterus, free from the density usually found in pelvic abscess; a diagnosis of extra-uterine pregnancy was made, but the operation proved the case to be one of simple pelvic abscess.

It must be borne in mind that a good percentage of the cases of ruptured extra-uterine pregnancy sooner or later become infected and form a pelvic abscess, in which case, of course, both conditions exist simultaneously. The presence of some old blood clots evacuated with the pus will at the most suggest the nature of the original affection, and the microscopical examination of the villi will set the diagnosis at rest.

A remarkable and, I believe, a unique case was one in which one of my patients suffering from membranous dysmenorrhœa passed a complete cast of the uterine cavity; the next month she became pregnant in the uterine tube, and again passed a perfect decidua of the uterus; both of these casts were kept and put into my possession. She was not conscious of any abnormality in her condition until she suddenly felt an agonizing pain in the lower abdomen and fell to the floor in the bathroom; these attacks of pain were repeated with decided temperature elevation and a marked pallor developed. At the examination I found the uterus embedded in hard, irregular, inflammatory masses filling the pelvis, in no way resembling the ordinary type of an early ruptured extra-uterine pregnancy. The diagnosis of extra-uterine pregnancy was, however, made from the history and confirmed by operation.

Diagnosis of Interstitial Pregnancy.—The diagnosis in a case of interstitial pregnancy may offer considerable difficulties. I have frequently observed a peculiar condition of the uterus in the early months of a pregnancy terminating normally, which might easily be mistaken for an interstitial extra-uterine pregnancy.

In each instance the softening and the enlargement of the uterus was confined to one of the apices, leaving the rest of the uterine body firm and unchanged. The impression conveyed to the examining finger was that of a cyst



DESCRIPTION OF PLATE XXIII

STATION OF BLOOD CLOT, DEPENDANT CELLS, AND PLACENTAL VILLI.
DIAGNOSIS OF EXTRA-UTERINE PREGNANCY BY MICROSCOPIC EXAMINATION—DEMON-

FIG. 1 (Gyr. Path. No. 417, Tubal Pregnancy) is a cross-section of a tube about 1 1/2 centimeter from its uterine extremity. Attached to the outer surface are two vascular adhesions; the muscular coats are somewhat thickened; the tubal folds in many places are normal, but several of them, especially those to the left of the center, and lying free between the folds is considerable blood. Below and just to the left of the center, and lying free in the tube, is a pear-shaped body; the base of this is composed of blood divided off into segments of variable size; the upper part is composed of convoluted folds. The inner center around this pear-shaped body with the

FIG. 2 is a further enlargement of the upper part of the pear-shaped body with the adjoining tubal folds. The fold above and to the left shows an indication of its vessel, while the stroma of the tube folds is wrinkled and filled by a homogeneous material, probably due to a distention of the lymph channels. A similar condition is present in the fold immediately above the pear-shaped body. The remaining folds are normal, and all have a normal epithelial covering.

The pear-shaped body consists of an outer and solid portion and an inner portion composed almost entirely of blood. The outer portion consists of a myocardium, the one and presents a convoluted or wavy outline, and the outer surface is covered by two layers of cells in inner and well-defined layer with round or oval vesicular nuclei, and an outer layer, where the protoplasm of one cell can not be distinguished from that of the surrounding ones; in other words, the protoplasm of the outer row forms a regular ribbon. The nuclei are round or oval and stain very deeply. This is the syncytium. Above and to the right, some of these folds, which are the young placental villi, have been cut transversely, and the outer row of cells is tending to form the so-called "placental giant" cells. No trace of the fetus was found.

paper, the impression of an extra-uterine pregnancy conveyed by palpation, through the abdominal walls may be almost irresistible. A skillful vaginal and bimanual examination will, however, correct the diagnosis. It must not be forgotten that the possibility may present an extra-uterine pregnancy and an intra-uterine pregnancy at the same time. The rule is to be true and true to the facts as they are found in the extra-uterine as well as in the intra-uterine.

A pregnancy in the extra-uterine uterus will be characterized by the fact that the embryo is implanted in the wall of the extra-uterine uterus, and the extra-uterine end of the uterine tube is not dilated.

DESCRIPTION OF PLATE XXIII.

DIAGNOSIS OF EXTRA-UTERINE PREGNANCY BY MICROSCOPIC EXAMINATION—DEMONSTRATION OF BLOOD CLOT, DECIDUAL CELLS, AND PLACENTAL VILLI.

FIG. 1 (Gyn. Path. No. 417, Tubal Pregnancy) is a cross-section of a tube about 1.5 centimeter from its uterine extremity. Attached to the outer surface are two vascular adhesions; the muscular coats are somewhat thickened; the tubal folds in many places are normal, but several of them, especially those to the left of the center, have markedly engorged blood vessels, as indicated by the red coloring, while lying free between the folds is considerable blood. Below and just to the left of the center, and lying free in the tube, is a pear-shaped body; the base of this is composed of blood divided off into segments of variable size; the upper part is composed of convoluted folds. The interest centers around this pear-shaped body.

FIG. 2 is a further enlargement of the upper part of the pear-shaped body with the adjoining tubal folds. The fold above and to the left shows an injection of its vessels, while the stroma at the base of the three folds is rarefied and filled by a homogeneous vacuolated substance that takes the eosin stain. This is probably due to a dilatation of the lymph channels. A similar condition is present in the fold immediately above the pear-shaped body. The remaining folds are normal, and all have a normal epithelial covering.

The pear-shaped body consists of an outer and solid portion and an inner portion composed almost entirely of blood. This outer portion consists of a myxomatous tissue, and presents a convoluted or wavy outline; and the outer surface is covered by two layers of cells, an inner and well-defined layer, with round or oval vesicular nuclei, and an outer layer, where the protoplasm of one cell can not be distinguished from that of the surrounding ones; in other words, the protoplasm of the outer row forms a regular ribbon. The nuclei are round or oval and stain very deeply. This is the syncytium. Above, and to the right, some of these folds, which are the young placental villi, have been cut transversely, and the outer row of cells is tending to form the so-called "placental giant" cells. No trace of the fetus was found.

Diagnosis of Intermittent Pregnancy. The diagnosis in cases of intermittent pregnancy may present some difficulties. I have frequently observed a peculiar condition of the uterus in the early months of pregnancy, terminating normally, which could easily be mistaken for an extra-uterine pregnancy.

In such cases, the softening and enlargement of the uterus was confined to the upper part, leaving the rest of the uterine body firm and unchanged. The impression conveyed to the examining finger was that of a case

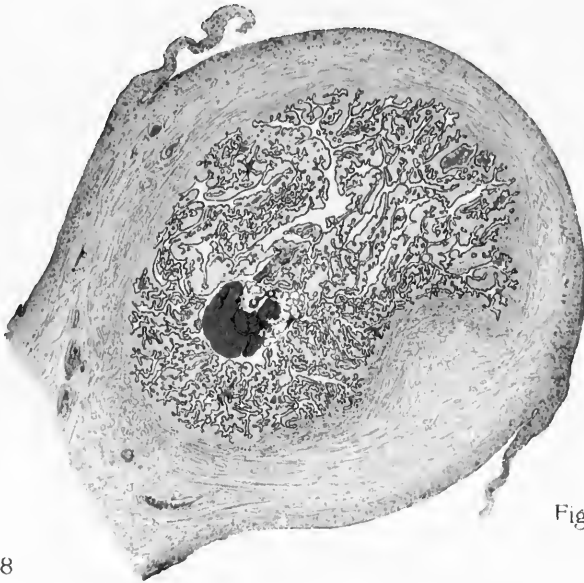


Fig 1

X 8

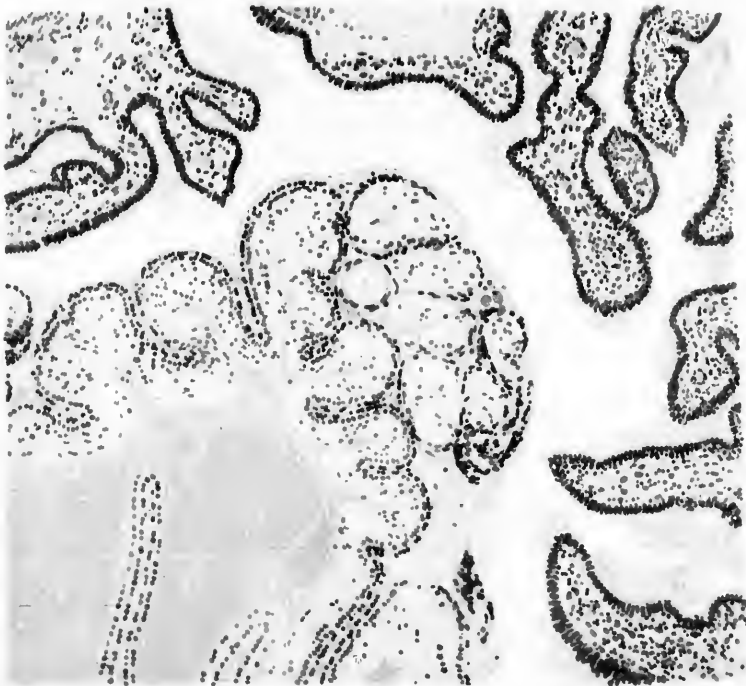

Fig 2.

X120



from 5 to 10 centimeters in diameter, situated up in one corner of the uterus. A remarkable feature of this form of pregnancy is the fact that it is often associated with more or less severe pain.

In one case under anesthesia the right side of the uterus in its upper half was converted into a fluctuating sac 10 centimeters in diameter, while it was surrounded on the left side and below by firm uterine tissue; the distinction between the sac and the rest of the uterus was so well marked that under anesthesia the tumor was thought to be situated in the tube close to the uterus, and after a most careful bimanual examination I concluded that there was a distinct but narrow interval between them. This patient had suffered the most intense pain throughout her pregnancy. On opening the abdomen I found a large spherical reddish sac bulging out from the left cornu of the uterus, soft and fluctuating, and in one place above and in front there was an area of the sac, 3 x 3 centimeters in size, so thin as to be almost transparent. The tubes and the ovaries were normal. I closed the abdomen after passing a sound into the uterus and rupturing the membranes, and the ovum was discharged soon after by the vagina.

In six other cases I have been able to diagnose this condition, and in each one the sequel has proved the correctness of the diagnosis. In one instance a physician brought his wife from Iowa for operation, with the diagnosis of extra-uterine pregnancy; she had a cystic tumor growing in the left upper cornu uteri, representing a five months' pregnancy, while the rest of the uterus was firm and unchanged. Her suffering had been so great as to confine her almost constantly to bed. I gave my opinion that the pregnancy was intra-uterine of this peculiar form, and would terminate normally; it did so four months later.

If my interpretation of these cases is correct, this condition affords an explanation of some of the cases reported as extra-uterine pregnancy becoming intra-uterine with or without the assistance of the electric current. On the other hand, the objection may be offered that these cases are in reality interstitial pregnancies with an ovum simply lodged very near to the uterine cavity and becoming intra-uterine with the increase in the size of the ovum, as interstitial pregnancies not infrequently do.

The characteristics of this peculiar form of apical pregnancy are—

That one apex or one half of the uterus enlarges and softens without the participation of the rest of the organ.

That this is most marked in the early months, but observable as late as the fifth or sixth.

That the pregnancy is painful, the patient often complaining of an amount of suffering never felt before during other normal pregnancies.

That the pregnancy terminates normally.

Mortality.—The mortality of extra-uterine pregnancy when uninterfered with is 68·8 per cent, according to Schauta, reckoned on a basis of two hundred and forty-one cases. This estimate does not include those early cases in which a rupture takes place without severe symptoms and the patient complains only of

colic and goes to bed for a short time, exhibits no pallor, and the blood is soon absorbed.

Veit reckons the mortality in cases in which a hematocele has formed as high as from 25 to 28 per cent.

In the early months the death is almost invariably due to hemorrhage; later it is caused by a septic peritonitis or the rupture of the sac into the bowels.

Treatment.—On account of the imminent danger to the life of the mother, the extra-uterine pregnancy in the early months must be looked upon much as a malignant growth (Werth), and it is only from the seventh month of pregnancy, when the child is viable, that it has any claims to consideration.

The proposal to defer the active treatment of an extra-uterine pregnancy in its early stages in the interests of the child is simple sentimentality. A. Martin has shown that 36.9 per cent out of two hundred and sixty-five cases of extra-uterine pregnancy recovered under an expectant plan of treatment, but that 76.7 per cent out of five hundred and fifteen cases recovered under operative treatment; in the hands of a good operator the mortality would not exceed five or six per cent.

The plans of treatment differ so widely early and late in the pregnancy that I shall deal with them separately.

In the first six months of pregnancy the one important practical consideration is how best to remove the abnormal products.

In the early months, when about 76 per cent of the cases are observed, the plan of treatment is either by an abdominal or by a vaginal section, the former enucleating and the latter draining the sac.

Celiotomy.—The operation differs widely in its details according to the anatomical relations and the complications found; the fetus and the sac may, for example, develop in the tube out in the direction of the abdominal cavity, and are therefore pedunculate, or they may develop within the layers of the broad ligament; again the sac may have ruptured or may be suppurating.

The operation is either radical, removing the fetus, placenta, membranes, and sac, or it is conservative, evacuating the sac of its contents and removing as much as possible of the extravasated blood without sacrificing either the tube or the ovary.

The general principles of the radical operation are these: An abdominal incision. Separation of adhesions enveloping the sac. Removal of blood, fetus, membranes, placenta, and sac. Checking of all hemorrhage. Complete closure of the abdomen without drainage in aseptic cases.

When the sac is ruptured and clots have formed, drainage by the vagina without opening the abdomen, as well as in suppurating cases.

In all cases of active hemorrhage from any part of the sac the cardinal rule is to open the abdomen at once and to control the uterine and ovarian arteries at points beyond the sac.

Active hemorrhage from the sac wall has been temporarily controlled by compression of the abdominal aorta.




FIG. 527.—EXTRA-UTERINE PREGNANCY; TUBAL ABORTION.

The bleeding is checked by a large coagulum distending and thinning out the tube; the frimbriated opening is greatly distended, but the greater diameter of the clot in the ampulla prevents its escape. Wall of tube averaging one millimeter in thickness. Operation. Recovery, July 7, 1896. Natural size.

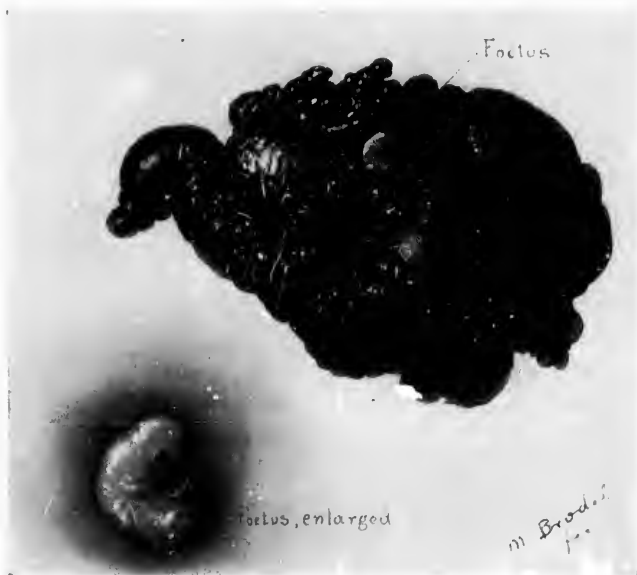

FIG. 528.—COAGULEM TURNED OUT.

Showing a cast of the tube extending up into the isthmus. On its surface lies the foetus. Natural size.



When a diagnosis of an unruptured extra-uterine sac is made, the operation should be performed with as little delay as possible. The technique of such an operation differs but little from that of the extirpation of an ovarian tumor or a hydrosalpinx. The adhesions, if they exist, are usually not difficult to separate; care must be taken not to rupture the sac for fear of profuse hemorrhage; if this accident occurs, or if the sac is so thin as to make rupture almost certain, it is well as a preliminary step to clamp and control the ovarian vessels out at the pelvic brim and the uterine vessels at the cornu, in this way controlling the circulation of the sac, which is then leisurely removed, the vessels all ligated, the pedicle dropped, and the abdomen closed without a drain.

The patient should be kept absolutely quiet and stimulated, and in all cases of anemia half a liter of normal salt solution should be injected into the cellular tissue under each breast. The importance of this injection can not be overestimated; the collapsed patient rapidly revives as the vessels fill with the solution, and the pulse gaining in volume diminishes in frequency. Patients have been successfully operated upon in profound collapse, but I would rather wait a few hours, in some cases, if there are any decidedly encouraging signs of improvement, to gain the maximum effect from stimulation, and then do the operation.

The duration of the anesthesia should be as short as possible.

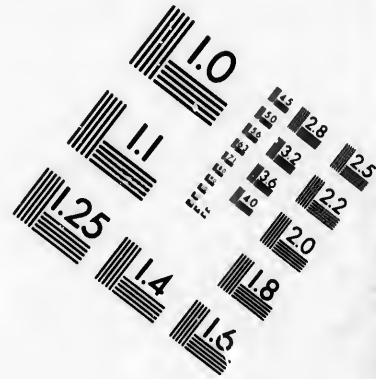
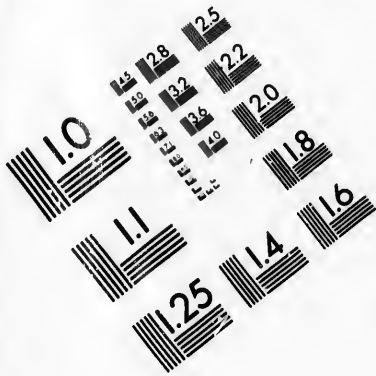
In preparing the field of operation the assistants must not make much pressure at the vaginal vault or on the lower abdomen for fear of exciting more hemorrhage.

A moderate elevation of the pelvis is an advantage during the operation in keeping the blood more in the upper part of the body and in the heart.

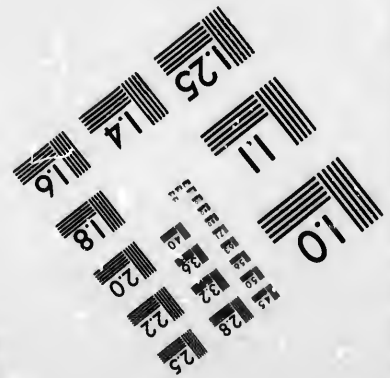


The first indication of the hemorrhage may be found in the discoloration of the skin above the symphysis, or in the greenish and bluish color of the fat seen on making the incision, in older cases; in a recent case the subperitoneal fat may be stained dark by the extravasated blood, or it may be seen through the peritoneum before opening it.

As a rule, when the peritoneum is opened, the liquid blood commences to flow out, and the patient should be let down almost to a level to facilitate the evacuation. I have seen the blood, when extravasated in large quantities, under such tension that it spurted up several feet into the air as soon as the peritoneum was incised.

A free incision should be made from 10 to 15 centimeters long, so as to get at the disease with as little delay and difficulty as possible. The blood should be removed by handfuls or with a ladle, the operator all the while keeping his eyes directed into the pelvis to note whether there is any active hemorrhage going on; if there is none, he may carefully clean the field and expose the structures before proceeding to enucleate them. If, however, there is any evidence of active bleeding, as shown by bright blood welling up in the pelvis as



**IMAGE EVALUATION
TEST TARGET (MT-3)**



**Photographic
Sciences
Corporation**

23 WEST MAIN STREET
WEBSTER, N.Y. 14580
(716) 872-4503



fast as the clots are ladled out, the operator should not delay in order to get a better exposure, but should at once thrust his hand down into the pelvis in the midst of the clots and grasp the uterus. Taking the uterine body as a guide,




FIG. 529.—EXTRA-UTERINE PREGNANCY (LIGHT), WITH TUBAL ABORTION.

The inside of the tube is covered with laminated blood clots, some of which adhere to the wall, which averages two millimeters in thickness. The peritoneal surface of the tube is coated with cylindrical epithelium. No placental villi found. Corpus luteum in same ovary. May 28, 1894. Path. No. 315. Natural size.

he then feels out onto the broad ligament along the tubes on one side and on the other, until he detects the extra-uterine mass; this is then grasped boldly and drawn up and strong clamps applied, by touch alone, on the uterine side and on the side toward the brim of the pelvis. In the event of uncertainty, two clamps should be put on each side, one at each uterine cornu and one at

each pelvic brim. After controlling the circulation in this way, the rest of the enucleation may be conducted more leisurely. Before the patient is taken from the table a hot stimulating rectal enema should be given, with the pelvis well elevated, containing thirty grains of carbonate of ammonia, three ounces of brandy, and three eggs beaten up in a liter of normal salt solution.

All blood clots should be carefully laid in one dish together, and all blood washed out of the abdominal cavity should be kept and a careful search made for the fetus. In the majority of the very early cases this will not be found, being doubtless removed by the phagocytes; in some cases, however, a minute body, best recognized by a black speck, the eye, such as is shown in Fig. 527, will be found; in other instances a little bit of flesh with a black spot and some broken bits will represent the tender diminutive fetus as seen in Fig. 530.

When the sac is walled off by adhesions there is no active hemorrhage, and the first efforts of the operator after opening the abdomen will be directed toward releasing the adherent omentum and adherent bowel until the concealed sac and coagula are set free for enucleation; in just this class of cases, however, I desire to recommend a conservative plan of treatment, and that is—



FIG. 530.—OPERATION FOR RUPTURED EXTRA-UTERINE PREGNANCY.

Showing the bits of the little fetus removed and found concealed in the clots. The means of recognizing the head was the little piece of flesh with a black spot indicating the eye. May 9, 1896. Natural size.

Vaginal Incision and Drainage.—This is the best plan in all old cases where there have been repeated hemorrhages with the formation of a well-defined immovable mass which can be felt through the vaginal vault. They are the cases which usually come to the clinic with a history of pains spreading out over several weeks or some months. Sometimes the accumulation bulges well down through Douglas's *cul-de-sac* into the vagina, but is oftener felt best through the rectum, distending one side of the posterior pelvis and extending across the median line. The vaginal incision practiced in such cases is quite different from the similar procedure recommended for the extraction of a fetus lodged in the pelvis in the later months of extra-uterine pregnancy, or for the evacuation of a suppurating sac.

The advantages of vaginal drainage are :

1. The tubes and ovaries are both preserved.
2. By this avenue the coagula, escaped membranes, placenta, and fetus, if found, are removed usually without opening the general peritoneal cavity.
3. The vaginal method is free from danger, if the operator is prepared to open the abdomen at once in case of unexpected hemorrhage.
4. It is quickly performed, consuming no time in making and closing the incision.
5. It avoids dealing with such a serious complication as intestinal adhesions.

The dangers of the vaginal incision are :

1. Active uncontrollable hemorrhage from the sac.
2. The risk of opening an adherent intestine or of puncturing the rectum.
3. The possibility of the sac wall breaking down and so opening up an avenue for the infection of the peritoneal cavity.

Out of twelve cases treated in this way at the Johns Hopkins Hospital I was forced to open the abdomen immediately, in one instance, in order to check a hemorrhage from the sac which started up as soon as I had cleaned out the coagula, and which persisted in oozing through into the vagina in spite of the pressure of a carefully applied pack. Prof. M. D. Mann, of Buffalo, has lost a life under similar circumstances, in which the abdomen was not opened.

Two of these cases were treated by a combined abdominal and vaginal operation—that is to say, after the abdomen had been opened the adhesions were found to be so numerous that the enucleation bid fair to be one of unusual risk to life, so the sac was evacuated and drained through the vagina, all the while conducting the operation under the guidance of the eye and with a hand within the abdomen defining the upper limits of the sac and protecting the abdomen from intrusion from below. In this way a complete evacuation was secured with good drainage into the vagina; the abdomen was closed without a drain and an uninterrupted recovery followed.

I have seen a sac opened through the vagina and emptied of its contents close down completely without suppuration.

Method of Operating.—A thorough bimanual examination should be made beforehand both by vagina and by the rectum, if necessary under

anesthesia, in order that the operator may know exactly the relations of the sac to the uterus, rectum, broad ligaments, and Douglas's pouch. All preparations should be made for an abdominal operation in case it should become necessary on account of hemorrhage. After properly cleansing the parts, the posterior vaginal wall is retracted and the posterior lip of the cervix is caught with tenaculum forceps and drawn a little downward and forward so as to give a wider space between the rectum and cervix for the puncture or incision.

If the sac is at all prominent, or can be distinctly felt in the vaginal vault behind the cervix, the operator simply marks with his index finger the point for puncture on the median line, two or three centimeters back of the cervix; then introducing a pair of sharp-pointed straight scissors to that point, he pushes them boldly through the peritoneo-vaginal septum, at the same time giving the blades an upward turn so as to keep them in the direction of the axis of the pelvis. If the pelvic curve is not followed, there is risk of the scissors transfixing the sac and perforating the rectum posterior to it.

When the lower limits of the sac are not well defined, it is a good rule to protect the bowel by keeping the middle finger in the rectum, touching the lower border while the index finger of the same hand rests upon it in the vagina; the scissors controlled in this way will easily keep the right direction.

As soon as the points penetrate the sac, as shown by a lessened resistance, if the blades are spread a little apart, some dark blood will be seen to ooze out into the vagina, indicating the correctness of the diagnosis.

By withdrawing the blades open, the hole in the vault is torn large enough to let in the index finger for the purpose of palpating the lower part of the sac; if this is free a larger pair of scissors is introduced and withdrawn open, followed by uterine dilators. In this way a transverse opening is made in the vaginal vault 2.5 to 3 centimeters in breadth. The bleeding from the torn edges of the opening has never been great enough to render it necessary to apply a ligature or suture, or to make it advisable to use a cautery knife in making the opening.

The clots which begin to escape at once must now be evacuated by introducing the first and second fingers and hooking them down. The other hand, making counter-pressure above, greatly aids the fingers working in the sac by bringing all parts of its walls successively within reach. Only gentle force must be used in detaching clots from the walls. After a portion of the coagula has been removed the escape of the remainder will be aided by washing out the sac freely with warm water and using the blunt round point of the glass nozzle carefully over the inner walls.

In the case of a tubal abortion, I have been able to recognize the condition by introducing a finger into the end of the tube, as well as by several large clots with a peculiar rounded-off surface which formed a cylindrical mass when put together. When the evacuation is complete the entire inner surface of the sac should be explored and its relations to the uterus, the pelvic walls, and its inequalities investigated; if possible, the opposite side should be felt also.

The gauze drain is now put in. A long piece of sterilized washed-out iodoform gauze, about 6 centimeters wide, is slowly pushed up into the sac with the packer, until the sac is loosely filled and the opening into the vagina kept wide apart.

A loose pack is left in the vagina and the patient is then put to bed. The pack may be left in place for from three to five or seven days, when it is then taken out and a fresh pack put in. As soon as there is any suppuration or odorous discharge the pack must be removed and the sac washed out daily with a saturated borie-acid solution or a 2 per cent carbolic-acid solution, and just enough gauze put back in the opening to keep it from closing rapidly. In the course of two or three weeks the whole sac has contracted down to the opening and closes spontaneously.

In one of my cases where the irrigation was managed by the nurse, the point of the douche nozzle perforated the sac wall and several of the douchings for two days, of a liter each of the borie-acid solution, were run into the peritoneal cavity.

The patient was brought onto the operating table a second time in a collapsed condition, under the impression that she had a concealed hemorrhage; the abdomen was opened, a large quantity of milky fluid found and washed out, and drains inserted in the median line and in each flank, as well as in the vagina, and she made a good recovery.

In a similar case, Prof. Zweifel, was not so fortunate (see *Arch. f. Gyn.*, Bd. xli, p. 1). Here the assistant pushed the irrigating tube into the peritoneal cavity to one side of the cyst, and the patient, with the sac already infected, died of a violent septic peritonitis.

None of the cases operated upon in this way in the Johns Hopkins Hospital died. I lost one case outside, for which the operation was in no way responsible. The patient had a nephritis with incontinence of urine, and had lain for six days in a comatose state, with contracted pupils and closed eyes, moaning and crying out in an inarticulate way. She had constant elevation of temperature—from 99° to 101° F. By vaginal puncture almost a liter of clots was removed with a quantity of liquid blood. The peritoneal cavity was not opened. The sac was drained with gauze, and she was put to bed in the same condition as when she was lifted onto the table. The nephritis advanced, and she died five days later, with a flat abdomen and without any signs of a local reaction following the operation. Such a history is, in fact, eminently calculated to demonstrate the advantages of the operation by the vaginal route, for the patient could not have survived an abdominal operation, and if she was to be given any chance at all for her life it must have been by some such simple way as this.

The average age in the eleven cases was twenty-nine years, and four patients had never borne a child. In two instances the vagina was opened and the sac drained after opening the abdomen.

Treatment of Intraligamentary and Pseudo-intraligamentary Extra-uterine Pregnancy.—True intraligamentary extra-uterine pregnancy is rare, as I have stated; most cases called intraligamentary are in reality pseudo-intraligamentary.

The proper mode of treatment in these cases is to evacuate and drain the sac extraperitoneally, either by the vagina or above Poupart's ligament. If the peritoneum is opened with a view to extirpating the sac, and it is then found broad-based and sessile on the pelvic floor or lifting up the peritoneum of the anterior abdominal wall, the evacuation should be by the vagina, if the sac is prominent enough to be easily felt there. When the sac elevates the peritoneum of the anterior abdominal wall so as to be easily accessible from the front, an incision should be made just above Poupart's ligament, the peritoneum lifted up, the sac opened and cleared out, and a gauze drain inserted.

If the abdomen has been opened, these manipulations are all easily made under the guidance of the hand, within the abdomen, without opening the peritoneum overlying the sac. After evacuating and draining the sac the abdominal incision is closed. I have treated two cases in this way in the third month of pregnancy without sacrificing any of the pelvic organs.

Treatment of Advanced Extra-uterine Pregnancy.—In advanced extra-uterine pregnancy the treatment will differ according as the fetus is living or dead, and the operator has to deal with a placental circulation which is still active, or with one which is plugged by well-organized thrombi. So long as the circulation in the placenta continues, the operation may be full of danger on account of the excessive hemorrhage produced by every effort made to detach the placenta. When the placental site is on the tubal wall, on the abdominal wall, on the uterus, or on the broad ligament, it may be possible to control the hemorrhage by ligating the large vessels going into the sac, or by passing ligatures deeply into the surrounding tissues on all sides of the site of attachment.

If the danger of removal of the entire live placenta is too great, owing to its widespread attachment over the intestines and the large vessels going to it which can not be tied, the cord is simply tied as short as possible, and an extensive washed-out iodoform gauze drain packed over its site; the discharge of the placenta then takes place piecemeal at a later date. But the danger to life is excessive on account of the possible infection of the large mass, associated with the excessive uncontrollable secondary hemorrhage due to the breaking down of the recent thrombi.

The attempt has been successfully made of tying off the cord and closing the abdomen and leaving the placenta in, and trusting to the aseptic character of the operation to avoid a subsequent infection.

After the death of the child the placental circulation still continues active, and the bruit may be heard for a period of one or two weeks. Unless the symptoms are urgent it is better in such cases to wait several weeks to give the thrombi a chance to become well organized. The detachment of the placenta will not then be associated with any risk.

If the child is viable the operation should be performed without waiting for the pregnancy to complete its term, as false labor may set in at any time and the child's life be lost. There is also the further disadvantage in waiting, that with the absorption of the liquor amnii in the last months the fetus is often seriously pressed upon by surround-

ing parts, tending to produce deformity and to interfere with its nutrition. This fact, together with the early stage at which many of the fetuses are delivered, accounts for the excessive mortality among the extra-uterine viable fetuses.

The operation, when the fetus is viable, consists in the most painstaking preliminary preparations and in precautions throughout to maintain a rigid asepsis.

I would insist upon the operator and his assistants wearing rubber gloves throughout the operation as an added safeguard against infection.

The abdomen is opened and the fetus, if it lies free among the intestines, is delivered and the cord tied. If it is still enclosed in an unruptured sac this is opened at the thinnest point and it is removed, and any bleeding vessels in the sac wall clamped.

The sac is then inspected to determine whether or not its complete removal is possible. Extensive intestinal adhesions to the sac wall may be dealt with either by peeling them off or tying them, or by leaving considerable portions of the sac on the intestines, and controlling the hemorrhage from the cut edges by the cautery or by many fine ligatures. Bleeding should always be controlled, as far as possible, by ligating the uterine and ovarian vessels of the affected side.

When, however, the placenta lies spread out over the intestines or the large pelvic vessels, it will be better simply to tie the cord and drop it, and to pack the placental area with gauze and await its slow expulsion piecemeal.

Whenever it is possible, when drainage is used, the sack wall should be stitched to the lower part of the incision, so as to exclude the peritoneal cavity from the drained area within the sac (marsupialization).

The accompanying table of operations for ectopic viable fetuses has been prepared by my friend Dr. R. P. Harris, of Philadelphia. (See pages 458 and 459.)

The cases have been separated into two groups, in order not to confuse the statistics by mixing the earlier ones, without any or with only imperfect asepsis, with the later ones, in which the aseptic precautions were much better observed.

When the extra-uterine fetus has been dead for several weeks and the placental bruit has disappeared, the gravity of the operation, in the absence of other complications, is greatly lessened, and it becomes analogous to the removal of an adherent ovarian or dermoid cyst. A complete extirpation of the sac in this way has been possible in each of the three cases of extra-uterine pregnancy operated upon in my clinic where the fetus had died during the seventh and in two cases where it had died during the ninth month of the pregnancy. In all five cases there were no unusual difficulties in the way of the enucleation.

Under these circumstances the abdomen is opened, the adhesions separated, and the sac and its contents removed. The chief risks come from the large incision which it is necessary to make, associated with the prolonged exposure and the handling of the intestines; these dangers must be guarded against by keeping the patient warm with hot-water bottles and well covered with blankets under the sheets, and by protecting the intestines from undue exposure by large pieces of gauze wrung out of hot water.

PROGRESSIVE

Ectopic Viable Fetuses delivered

OPERATIONS AND RESULTS IN 80 YEARS.

Recoveries, 9 in 37.

No.	Date.	Operator.	Locality.	Result to Woman.	Result to Child.	Period of Gestation.	Time of Survival of Child.
1.	Nov., 1809.	Müller.	Halbeau, Germany.	Recovered.	Lived.	9 months.	(?)
2.	Aug. 29, 1813.	Brükert.	Berlin.	Died.	"	9 "	Well at 4 years.
3.	Dec. 7, 1814.	Novara.	Porto Maurizio.	"	"	9 "	(?)
4.	1827.	Mattfeld.	Tübingen.	"	"	9th month.	(?)
5.	Mar. 1, 1841.	Haufl.	Kirehheim.	"	Alive.	35 weeks.	50 hours.
6.	1852.	Lazzati.	Milan.	"	"	9 months.	Did not breathe.
7.	Mar. 27, 1863.	Koehleré.	Strassburg.	"	"	9 "	24 hours.
8.	Apr. 21, 1864.	Greenhalgh.	London.	"	"	9 "	1 hour.
9.	Mar. 3, 1870.	Sale.	Aberdeen, Mississippi.	"	Lived.	9 "	6 months.
10.	Oct. 5, 1872.	Scott.	London.	"	Alive.	30 weeks.	To second day.
11.	Aug. 14, 1875.	Jessop.	Leeds.	Recovered.	Lived.	33 or 34 weeks.	11 months.
12.	Mar. 5, 1877.	Spiegelberg.	Breslan.	Died.	"	40 "	3 "
13.	May 27, "	Smith.	London.	"	Alive.	9 months.	30 to 40 minutes.
14.	Nov. 5, "	Gervis.	London.	"	"	36½ weeks.	6 hours.
15.	Aug. 19, 1878.	Fraenkel.	Breslan.	"	"	33½ "	24 "
16.	May 29, 1879.	Sehroeder.	Berlin.	"	Lived.	34 "	Well at 6 months.
17.	Dec. 19, "	Vedeler.	Christiania, Norway.	"	Alive.	35 "	To second day.
18.	Jan. 10, 1880.	Litzmann.	Kiel.	"	"	39½ "	15 minutes.
19.	Feb. 1, "	Tait.	Birmingham.	"	Lived.	9 months.	Living at 15 years.
20.	May 11, "	Wilson.	Baltimore.	"	"	9 "	18 months.
21.	July 26, "	Netzel.	Stockholm.	"	Alive.	9 "	48 hours.
22.	" 9, 1881.	Martin.	Berlin.	Recovered.	"	7 "	Did not breathe.
23.	" 13, "	Beisone.	Bariaseo, India.	Died.	Lived.	9 "	Living in 1895.
24.	Feb. 15, 1882.	Hildebrandt.	Königsberg.	"	"	9 "	
25.	Oct. 3, "	"	"	"	Alive.	34½ weeks.	Did not breathe.
26.	June 6, 1885.	Williams.	London.	Recovered.	"	35th week.	A few minutes.
27.	Nov. 4, "	Lazarewitch.	Kharkof, Russia.	"	Lived.	9 months.	26 days.
28.	Jan. 26, 1886.	Stadfeldt.	Copenhagen.	Died.	"	9 "	7 months.
29.	Oct. 19, "	Champneys.	London.	"	Alive.	7th month.	A few minutes.
30.	Mar. 30, 1887.	Jos. Price.	Camden, N. J.	"	"	7½ months.	4 hours.
31.	May 29, "	Trenb.	Leyden.	Recovered.	Lived.	8½ "	Well at 7½ years.
32.	June 26, "	F. Spnath.	Hamburg.	Died.	Alive.	8 "	24 hours.
33.	Oct. 29, "	Breisky.	Vienna.	Recovered.	Lived.	8 "	19 days.
34.	Mar. 22, 1888.	Lebec.	Paris.	Died.	Alive.	8 "	24 hours.
35.	July 10, "	Eastman.	Indianapolis.	Recovered.	Lived.	8 "	8 months 13 days.
36.	Oct. 12, "	Egon Braun.	Vienna.	Died.	"	8½ "	
37.	Nov. 1, "	Olshausen.	Berlin.	Recovered.	"	8½ "	Well at one year.

Of the first 20 there were 2, and of the first 30, there were 5 maternal recoveries. Of the 37 there were saved less than 26 per cent. Case 22 set the example of saving life by excising the pregnancy as a tumor. Under improved methods there has been a gradual diminution of mortality for seventeen years; this has made the operation less dreaded and more frequently performed, as is shown in the second half of the tabular record.

IMPROVEMENT.

under Celiotomy, 1800-1896.

OPERATIONS AND RESULTS IN 10 YEARS.

Recoveries, 27 in 40 = 67½ Per Cent.

No.	Date.	Operator.	Locality.	Result to Woman.	Result to Child.	Period of Gestation.	Time of Survival of Child.
38.	Feb. 11, 1889.	Carl Braun.	Vienna.	Recovered.	Alive.	9 months.	12 hours.
39.	" 27, "	Olshausen.	Berlin.	"	"	8½ "	1½ hour.
40.	Sept. 22, "	Negri.	Venice.	"	"	8 "	18 hours.
41.	Oct. 9, "	Peauce Gonld.	London.	<i>Died.</i>	"	12 "	Signs of life.
42.	Feb. 4, 1890.	Geo. Rein.	Kieff.	Recovered.	Lived.	37 weeks.	Living in 1894.
43.	Apr. 25, "	Galabin.	London.	<i>Died.</i>	"	7 to 8 months.	6 weeks.
44.	June 16, "	Chrobak.	Vienna.	Recovered.	Alive.	7½ "	24 hours.
45.	" 24, "	Taylor.	Birmingham.	"	Lived.	9 "	5 months.
46.	Aug. 16, "	Negri.	Venice.	<i>Died.</i>	Alive.	8 "	2 days.
47.	" 21, "	Schoonen.	Antwerp.	Recovered.	"	8 "	A few minutes.
48.	Feb. 2, 1891.	Schneider.	Berlin.	"	"	7 "	3 hours.
49.	" 12, "	Gnéniot.	Paris.	<i>Died.</i>	"	7½ "	¼ hour.
50.	June 6, "	Frommel.	Erlangen.	Recovered.	Lived.	9 "	4 months.
51.	" 16, "	Stevenson.	Cape Colony.	"	Alive.	8½ "	48 hours.
52.	Nov. 19, "	Von Strauch.	Moscow.	"	"	9 "	Breathed and died.
53.	Apr. 27, 1892.	Handfield- Jones.	London.	<i>Died.</i>	Lived.	2500h day.	Alive at 3 months.
54.	" 29, "	Sippel.	Frankfort On- the-Main.	"	"	7 months.	5 days.
55.	Oct. 23, "	M. Price.	Philadelphia.	Recovered.	"	10 "	Well in 1897.
56.	Dec. 29, "	Marehand.	Paris.	<i>Died.</i>	"	36 weeks.	8 months.
57.	Apr. 15, 1893.	Szeguireff.	Moscow.	"	"	8 months.	18 "
58.	May 12, "	Urban.	La Bouverie.	Recovered.	"	9 "	"
59.	Aug. 25, "	McNutt.	Oakland, Cal.	<i>Died.</i>	Alive.	9 "	A few minutes.
60.	" 29, "	E. Regnier.	Vienna.	Recovered.	"	9 "	Did not breathe.
61.	Sept. 11, "	Ronenglia.	Modena.	"	Lived.	7½ "	23 days.
62.	Oct. 15, "	Trenb.	Leyden.	"	Alive.	8½ "	50 hours.
63.	Dec. 2, "	Hofmeier.	Wurzburg.	"	"	9 "	Did not breathe.
64.	" 14, "	Gnéniot.	Paris.	<i>Died.</i>	Lived.	9 "	16 days.
65.	Jan. 13, 1894.	Culling- worth.	London.	"	"	8 "	7½ months.
66.	April 4, "	Werner.	Pittsburg.	Recovered.	"	8½ "	4 days.
67.	Sept. 4, "	Potherat.	Paris.	"	"	(?)	(?)
68.	" 14, "	Toumay.	Brussels.	"	Alive.	9 "	2 hours.
69.	Nov. 24, "	Eakins.	Queensland.	<i>Died.</i>	Lived.	8½ "	(?)
70.	Dec. 10, "	Geo. Rein.	Kieff.	Recovered.	"	30 weeks.	Alive at a month.
71.	Feb. 3, 1895.	Pestalozza.	Florence.	"	"	9 months.	" in March, 1895.
72.	May 2, "	Pinard.	Paris.	"	"	7 "	" in July, 1895.
73.	Sept. 29, "	Tauffer.	Budapest.	"	"	9 "	" at 58 days.
74.	(?)	Bond.	Leicester.	"	"	7½ "	Living at 5 months.
75.	Feb. 26, 1896.	Hardie.	Brisbane, Aus- tralia.	"	"	8 "	Alive 6 hours.
76.	" " "	Chrobak.	Vienna.	"	"	9 "	Living at 4 weeks.
77.	Nov. 7, "	Ayers.	New York.	<i>Died.</i>	"	7 "	Living 3 weeks.

Of the last 20 there were 15 recoveries. Of the 5 that died, only one can be attributed properly to the celiotomy. Case 59 was delirious when operated on and died delirious; case 64 died of peritonitis; case 65 had the placenta closed in and died in twenty-six days; case 69 removed her dressings, became fly-blown, and died on the sixteenth day; case 77 was quickly operated on, lost very little blood, but died the next day.

Drainage ought not to be used unless the case is septic at the time of operation. I lost one of my early cases where I removed a seven months' fetus which had lain dead and perfectly aseptic for four months in the abdomen of a colored woman, by a streptococcus infection which undoubtedly entered the

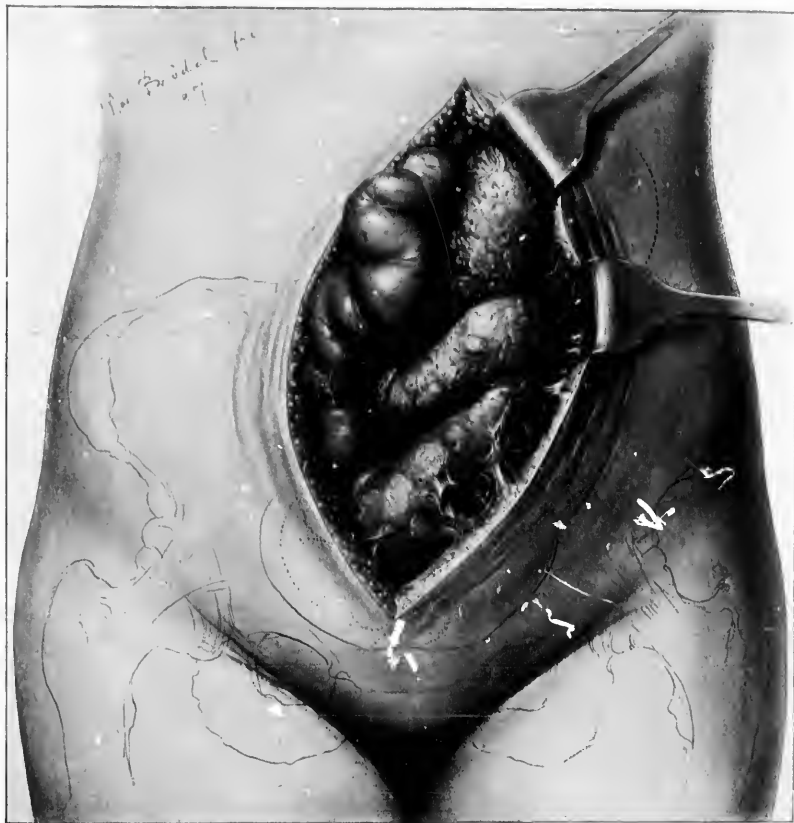

FIG. 531.—LITHOPEDEON LYING UNDISTURBED IN THE ABDOMINAL CAVITY.

The strong adhesions holding it in place and its position are well shown. The patient was a colored woman forty-five years old who had had her last child when thirty-eight; four years before entering the clinic she became pregnant, with all the usual signs, and was taken with perfectly normal labor pains at the expected time. Dr. Barnum, who saw her two months later, recognized an abdominal pregnancy. The mind of the patient was unbalanced, and she would not allow any interference until after four years had passed. Operation by Dr. Clark. Recovery. B. H., Aug. 14, 1896.

abdomen by the drainage-tube openings. It is far safer to trust the large adherent area and numerous bits of tied-off tissues with their ligatures to the closed cavity than to run the slightest risk of infection from without where there is so much dead space.





FIG. 532.—LITHOPEDION REMOVED FROM THE ABDOMINAL CAVITY FOUR YEARS AFTER A FALSE LABOR.

The placental attachment is in the right uterine tube. The fetus has been freed from the enveloping adhesions and lifted out of the abdomen. Note the posture and the peculiar membrane covering all the features and inequalities of the body. There is a deposit of calcareous salts in the envelope and in the skin; the rest of the skin is leathery and converted into adipocere.

A typical case illustrating the difficulties of an extra-uterine pregnancy with a dead fetus advanced beyond term is that of A. L. (No. 191), operated on May 6, 1890.

The patient was a negress twenty-eight years old, pregnant for the first time. Three years before her pregnancy she had had a severe pelvic peritonitis. It was impossible to fix the exact date of her pregnancy, which must have been about four months advanced at the end of May, 1889, when her menses came on profusely and lasted forty-five days, until July 10th; the flow appeared again in August, October, and December, 1889, and in February, 1890.

Since June, 1889, she had been more or less ill, spending much time in bed, feeling weak and prostrated, and suffering from a "misery" in the abdomen and back. An enlargement of the abdomen was noted in July, 1889, and it continued to increase in size up to October, when it began steadily to decrease. She had nothing like a false labor.

Examination showed a large resisting mass, moderately tender on pressure, extending from the left hypochondrium to the pelvic floor, surrounded above and at the sides by a tympanitic area. The uterus, of normal size, lay in front of it, right latero-flexed, and the cervix was extremely soft. I could move the mass above 3 or 4 centimeters to the right and to the left. The *Linea nigra* was well developed, from 1 to 15 millimeters broad below the umbilicus; *linea albicantes* were well marked on the left side below the umbilicus.

The breasts were flaccid and showed numerous lines concentric with the nipple area, which was deeply pigmented; a little milk was easily squeezed from them.

By palpation of the abdominal mass the angular prominences of the body of a child could be felt, but the head could not be detected; the end lying in the pelvis gave the same uncertain sensation one so often recognizes when the breech presents and never noted in a head presentation. No fetal heart sounds or placental bruit could be heard.

At the Operation.—An incision was made 12 centimeters long, and afterward extended 3 centimeters above the umbilicus, exposing a mottled grayish and reddish sac intimately united by adhesions to all the surrounding structures. The adhesions to the abdominal walls were separated without much hemorrhage by running the fingers in between the sac and the parietal peritoneum with a sheering movement. The omentum was then found so intimately adherent over the anterior surface of the sac that it had to be tied off in its entire breadth close to the colon. After freeing the omentum in this way the upper pole of the cyst was exposed, grasped, and drawn down into the incision; it was now evident for the first time during the operation that the tumor was a fully developed dead fetus lying with its back to the abdominal wall and its face buried in adhesions up in the left hypochondrium.

The adhesions which bound the child on all sides to the intestines and posterior abdominal wall were no longer vascular, and were severed freely after lifting up the child and so making them long enough to cut without injury to the attached structure.

A broad mass of adhesions, extending from the shoulder of the child over onto the posterior abdominal wall, looked much like a shawl thrown over it; this was tied off and the child entirely freed above.

The placenta was then found rolled up in a large ball-like mass under its ventral surface, with adhesions in all directions which were easily separated. The point of origin of the sac at the right cornu uteri was now clearly demonstrable, and the right tube with its ovary was removed with the entire mass. About 50 cubic centimeters of blood was lost throughout. The abdomen was closed, according to the technique at that time, with drainage, and the patient recovered.

The vaginal route has been repeatedly used with success for the removal of a dead fetus in which the fetal head could be distinctly felt in the recto-uterine pouch. It is indicated in all cases in which suppuration has already set in, and the fetus or any part of the sac can be felt through the vaginal vault. But this mode of treatment should not be followed when the fetus is not felt distinctly in the pelvis and when the placenta is recognized there by its spongy feel.

Important objections to the vaginal plan of treatment are the difficulty of removing a large fetus without extensively tearing the soft parts at the vaginal vault cases, and the impossibility of doing more than simply removing the fetus; the sac and the placenta can only be extracted under the most favorable circumstances. Under ordinary circumstances a drain must be inserted and the seundines must be left to come away later with the suppuration of the sac.

The general plan of the vaginal operation can not be better described than by following the account of a case treated in this way by Christian Fenger (*Amer. Jour. of Obst.*, vol. xxiv, 1891, p. 418).

The patient, twenty-eight years of age, became pregnant after a single coitus in March, 1886; a month later she experienced dragging pains in the right iliac region. Menstruation continued regularly until June, after which it ceased until Nov. 25th. In June she noticed an enlargement of the right side of the abdomen, which increased in size without pain.

In November she had a bloody discharge which continued until March, 1887, a year after the conception.

She was examined the last of January, 1887, when the outlines of a fetus could be plainly felt through the abdominal walls; the head lay in the left iliac fossa, and the body was inclined upward to the right. No fetal heart sounds could be detected, but the placental bruit was quite plainly heard at a point 3 inches below the umbilicus and a little to the left.

The patient had never been conscious of any fetal movements, and had no idea she was pregnant. She had an attack of chicken-pox about the end of February, 1887; on March 2d the vaginal discharge ceased, and on March 6th the placental souffle was inaudible.

Dr. Fenger operated March 13, 1887, removing a fully developed fetus through the vagina, with the patient in the lithotomy position. A median incision was made down through the perineum to enlarge the field of operation,

and with the index finger resting on the tumor in the rectum a transverse incision was made posterior to the cervix with a cautery knife. Upon opening the sac a moderate amount of almost clear fluid escaped, and the head of the fetus presented in the opening. As it was too large to be delivered intact, craniotomy was performed, and portions of the cranial bones were removed with bone scissors. The head with the rest of the body was then delivered with comparative ease.

A digital examination showed that the placenta was attached high up in the left iliac fossa and adherent on all sides. The sac was then irrigated and two large rubber drainage-tubes inserted.

In three days the discharge had become fetid. Irrigation was frequently used. On the eleventh day a small piece of placenta came away, and on the seventeenth day an examination showing that the margins of the placenta were free; it was broken up and completely removed with the fingers. On the following day all odor had disappeared, and in a week more the patient was allowed to get out of bed. In six weeks after operation menstruation reappeared; the patient was discharged from the hospital in four months with a uterus normal in size but adherent to the left side of the pelvis.

Treatment of an Interstitial Pregnancy.—If an interstitial pregnancy is discovered before rupture, a gentle effort should be made to open the sac wall into the uterine cavity by dilating the cervix and using a sound.

If the abdomen has been opened the same maneuver may be carried out more effectively and with less danger by grasping the sac with the abdominal hand, and so directing the movements of the sound introduced into the uterus.

If the sac has already ruptured and the patient's condition is fairly good, the effort may be made to save the structures by clearing the sac out and suturing the rupture.

Any active hemorrhage should be controlled, either by immediate ligation of the ovarian and uterine arteries of that side, or in a more serious case by first controlling the circulation by throwing a rubber ligature around the body of the uterus below the sac until the vessels going to it are tied.

Complications.—The ectopic gestation may be complicated in a variety of ways other than by the natural frequently recurring difficulties, such as hemorrhage, adhesions, and suppuration.

One of the commonest complications met with is a peculiar tendency to mental aberration, first noted by Dr. Joseph Price.

Another complication which I have noted and find mentioned by various surgeons is a liability to nephritis; one of my cases, which had gone three months over term and was operated upon on an emergency by Dr. H. Robb, died within twenty-four hours with an advanced nephritis and fatty degeneration of the liver.

Another of my cases operated upon by Dr. H. Robb was complicated by an appendicitis. The patient was a negress, admitted to the hospital with a small rapid pulse, an elevated temperature, marked dyspnea, and constant vomiting. The abdomen was symmetrically distended, prominent in the mid-

dle, indistinctly fluctuating, and tender on pressure. Her mental condition was peculiarly dull. Her last menstruation was seven weeks before, but no more exact history could be obtained. The uterus was somewhat enlarged, and there was clearly fluid in the pelvis, but no mass could be felt. The breasts contained some milk. By means of a hypodermic syringe some dark bloody fluid was drawn off in the median line of the abdomen, and a diagnosis of extra-uterine pregnancy was made; the fluid contained a pure culture of colon bacilli, and for this reason a perforation of the intestine was suspected.

At the operation a stream of blood spouted 7 inches high out of the abdominal incision, and the right tube was found ruptured in the isthmus.

The patient died the following day, and at the autopsy a perforation of the vermiform appendix was found with a circumscribed abscess and general peritonitis.

In several instances the extra-uterine pregnancy has been found complicated by an ovarian tumor of the opposite side.

A. Martin has seen one case in which there was torsion of the pedicle of an extra-uterine sac.

Pregnancy in a Rudimentary Horn of the Uterus.—Closely allied to the extra-uterine gestations are those cases in which the pregnancy occurs in a rudimentary horn of the uterus. This malformation is due to the failure of Müller's ducts to coalesce in their upper portion in early fetal life, and the uterus in such a case bifurcates at some point above the vagina. One side may develop into a large gibbous uterine body with a normal tube and ovary, while the other remains rudimentary; the undeveloped side is either connected with the cervix by a fine canal, or completely shut off, but remains in open communication with its own tube and ovary, which are normally developed.

The muscular band which unites the rudimentary half of the uterus with the cervix is about 1 centimeter in breadth and from 3 to 7 centimeters long.

When a canal exists, however fine, communicating with the vagina, the pregnancy may occur at any time in the rudimentary horn.

If, however, the band of connection between the rudimentary horn and the uterus is atresic, then the pregnancy can only occur by the migration of an impregnated ovum from the normal side, or by a similar migration of the spermatozoa.

Pregnancy occurs in a rudimentary horn of the uterus most frequently between the ages of twenty and thirty, and often in women who have previously borne children from the better developed side.

The tendency of this form of pregnancy is to rupture at a somewhat more advanced stage than in tubal pregnancy—that is, from the fourth to the fifth month. The rupture is most apt to occur at the thinnest point near the origin of the tube, and the amount of blood extravasated is large; in these respects the pregnancy resembles the tubo-ovarian form. In some instances, however, the pregnancy has advanced to full term; it may be characterized by intermittent pains throughout. At or near term pains set in, and for several days the patient



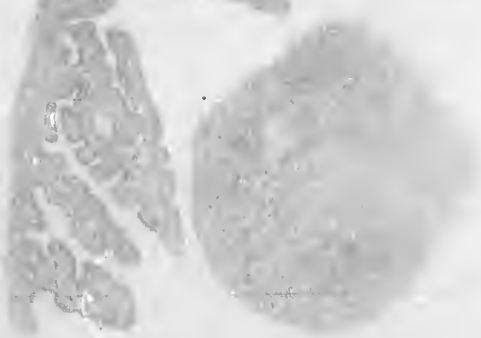
DESCRIPTION OF PLATE XXIV.

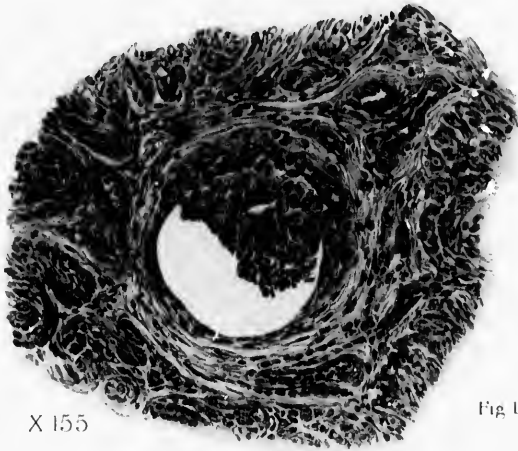
FIG. 323. PREGNANCY IN A RUMINANTIA DUCT TUBERIN HORN. MAGNIFIED SECTION OF

Fig. 1 is a section through Miller's duct at point c. The epithelial lining has dropped off; the underlying stroma cells are swollen, have proliferated, project into and partially obliterate the lumen. The individual cells resemble decidual cells. External to the stroma are cross-sections of muscle fibers.

Fig. 2 is a section through the right tube in a Fig. 323. It represents a segment of the tube at this point. The tubal folds are normal, and have an intact epithelial covering. The cavity of the tube contains many cells; the majority of these have small round deeply staining nuclei. Scattered throughout this mass of cells are some giant cells.

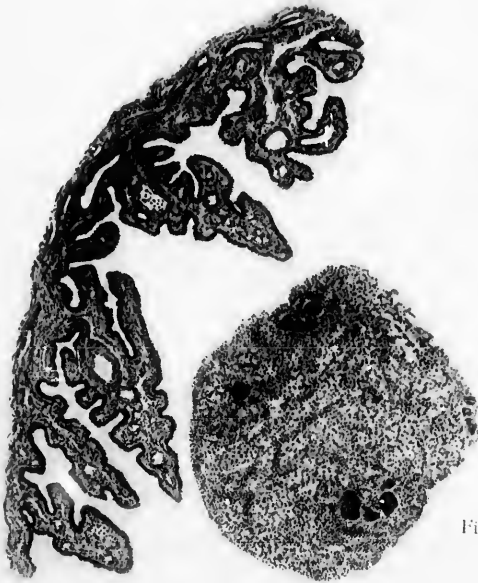Fig. 3 represents two of the giant cells seen in Fig. 2 highly magnified; surrounding these are some of the cells that are seen as small dots in Fig. 2. One giant cell is irregularly oval and has scattered throughout its protoplasm numerous vesicular nuclei. Some are oval others are triangular. The second giant cell is elongated and the nuclei are similar to those of the one described. The giant cells are cross-sections of the so-called placental giant cells, surrounding them are typical decidual cells and small round cells.





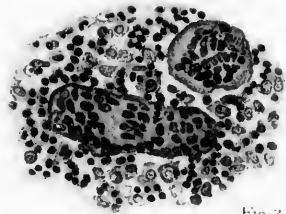
X 155

Fig 1



X 70


Fig 2



X 300

Fig 3





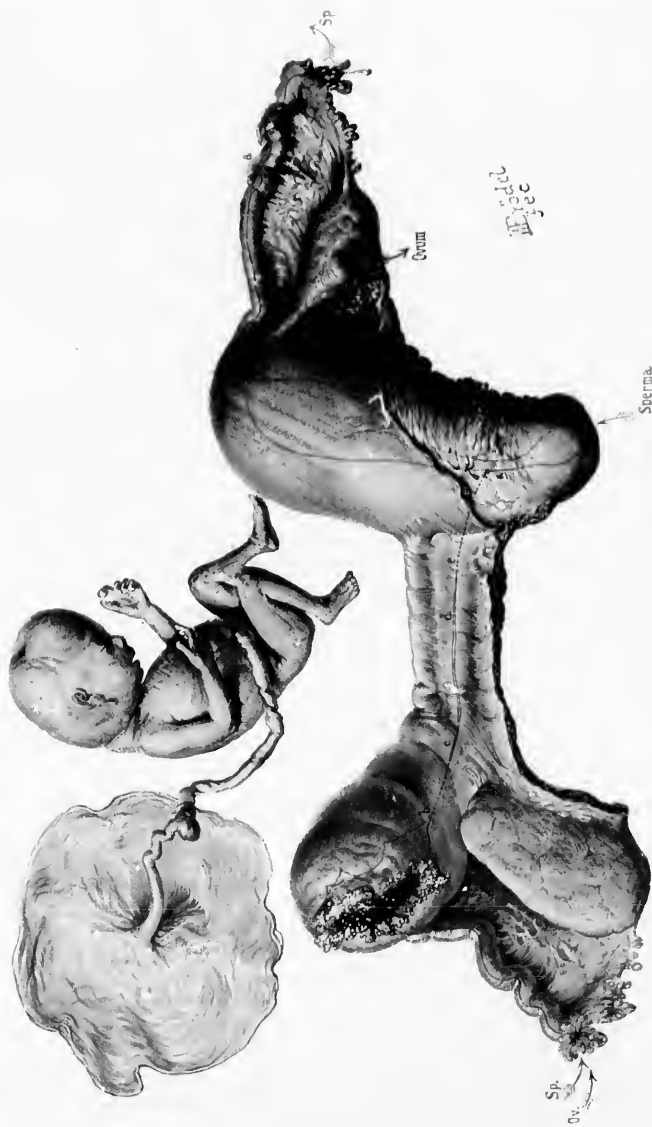


FIG. 533.—PREGNANCY IN A RUDIMENTARY LEFT UTERINE HORN; RUPTURE; DEATH.

The specimen is viewed from behind. To the right is the well-developed uterus, which, after reaching the internal os, deviates to the right side. Attached to the right tube, which is normal. The ovary is of the usual size, and at its inner and lower portion is the corpus luteum of pregnancy. Springing from the left side of the uterus at the internal os is a muscular band; on tracing this to the left it merges into the rudimentary uterine horn. On the posterior surface of this horn is a long slit representing the point of rupture. Protruding through the rent are placental remains. The left tube passes off from the outer side of the rudimentary horn. The left ovary is flattened. The *r-s* line on the well-developed uterus indicates the size of the uterine cavity. The line *b, c, d, e* indicates the course of the left Müller's duct. Between *c* and *d* it contains a haemion; where it is represented by dotted lines it consists of a solid muscular cord. Above the specimen are the placenta and fetus drawn in natural size. Natural size.

passes through a false labor, productive at the utmost of a bloody vaginal discharge.

The developed half of the uterus is enlarged and contains a well-formed decidua which sooner or later is cast off.

In one instance in which the pregnancy terminated after several months without rupture, at an autopsy many years later an abscess was found in the rudimentary horn containing fetal bones.

In another case the fetal bones were found, covered with lime salts, on the pelvic floor, and there was a well-defined scar in the rudimentary uterus.

An accurate diagnosis is always difficult to make. If the case is seen after rupture there will usually be no time to go into greater detail than to determine the existence of an intrapelvic hemorrhage due to an abnormal pregnancy.

If the case is seen before rupture, at an early date, two signs will be of value in determining the character of the pregnancy: the first is the fact that the developed side deviates at an angle of from forty to sixty degrees from the normal position; the second is the fact that the pregnant horn is found by a rectal examination to be connected with the uterus by a broad band which is attached at the lower part of the uterine body.

The treatment is that of an extra-uterine pregnancy. If rupture has occurred, the abdomen should be opened and the rudimentary uterus removed with the ovum.

If rupture has not occurred, and the pregnancy is still in the first six months, it is best to extirpate it in the same way. After the sixth month, in view of the lessened dangers of rupture, the operation may be postponed, keeping the patient under close observation all the while, until the child is viable, when the abdomen should be opened, the child delivered, and the undeveloped uterus and tube removed completely; the ovary should not be removed.

The operation itself does not offer any special difficulties, as the tumor has a well-defined pedicle, and all the vessels supplying it are within easy reach. After opening the abdomen and protecting the intestines, the sac is lifted out and the ovarian vessels of that side tied near the pelvic brim; the round ligament is next tied, and the top of the broad ligament opened and its fold separated until the uterine artery is exposed below the sac; this is then ligated and the sac removed.

The layers of the broad ligament are now approximated with a continuous catgut suture, and the abdomen closed without a drain.

An interesting case of this kind occurred in my practice in the summer of 1894, when I was called in consultation as to the advisability of an operation upon a woman presenting all the symptoms of a ruptured extra-uterine pregnancy. I was absent at the time, and she died of internal hemorrhage; the specimens and notes have been furnished by Dr. G. W. Wilkins, of Baltimore.

She was a German, twenty-nine years old, married, and had had one child several years before. She subsequently had had two attacks of severe pain on the left side, called "ovaritis."

The menses were always regular until Aug. 28, 1894, when, after three months of amenorrhea, she began having uterine contractions accompanied by agonizing pelvic pains, with rectal and vesical tenesmus and marked abdominal tenderness.

There was no vaginal discharge; a tumor the size of an orange could be felt to the left of and behind the uterus. The pains continued two days, when they suddenly ceased, and she experienced a period of calm, followed by fainting, extreme pallor, and cold sweats, with a small, feeble pulse, and evident distention of the abdomen.

A sound was then introduced into the uterus, which was found to be 10 centimeters in length and empty. The patient died six hours after the onset of the fainting spell.

At the autopsy the abdomen was found to contain 4,000 cubic centimeters of blood, and a three to four months' fetus with its investing membrane, connected by its cord with a rudimentary left uterine horn, was floating in the peritoneal cavity. The left tube and ovary were slightly adherent (see Fig. 533).

The specimen was examined by Dr. T. S. Cullen, whose pathological report I use in abstract.

At the autopsy a well-developed right-horned uterus was found, to which a pregnant rudimentary left horn was attached by a muscular band. This pregnant left horn had ruptured. The corpus luteum was on the right side opposite to the pregnancy.

Microscopically, the well-developed right uterus was shown to possess typical decidua, and the right tube contained remains of the placenta lying free in its lumen; the cells of the corpus luteum in the right ovary closely resembled normal decidual cells. The pedicle joining the two horns at the cervix contained a canal blind at both ends and 5 millimeters in diameter, lined with a single layer of cylindrical epithelium resting on a delicate stroma; external to this was a circular muscular coat, and covered again by longitudinal muscular fibers (see Plate XXIV).

The only possible explanation of the location of the pregnancy was by a migration of the ovum and spermatozoa out through the right side and over into the left by way of the abdominal cavity.

An almost identical case is described by C. Ruge (*Zeitschr. f. Geb. und Gyn.*, Bd. ii, 1878, p. 27), in which the rudimentary right horn was ruptured and the corpus luteum was found in the left ovary.



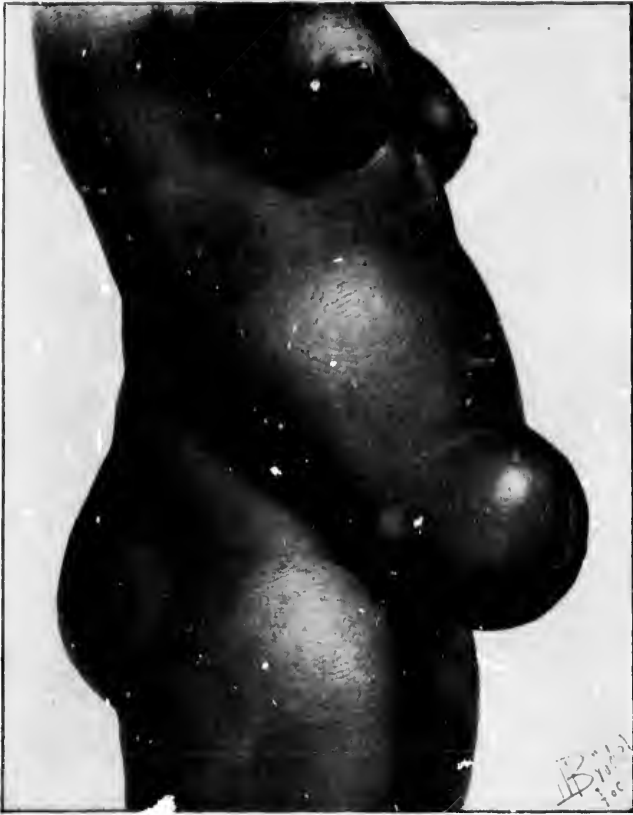

FIG. 584.—HERNIA OF THE PREGNANT UTERUS IN THE NEGRESS.

The uterus has escaped through a ventral hernia, due to a celiotomy, May 3, 1894, of which the scar is plainly seen. The patient went to term and was delivered of a living child by a normal labor. A. R., Gyn. No. 1390, Dec. 5, 1895.

CHAPTER XXXV.

THE RADICAL CURE OF HERNIA.

1. Definition and varieties.
2. Etiology and mechanism.
3. Pathology.
4. Treatment: 1. In general. 2. Special forms. *a.* Hernia in the linea alba. *b.* Umbilical hernia. *c.* Inguinal hernia. *d.* Ovarian hernia and hernia of the uterine tube. *e.* Femoral hernia.

Introductory.—An abdominal hernia is formed by a protrusion of some part of the abdominal viscera through a natural or an acquired opening in some portion of the abdominal walls.

A great variety of herniæ may arise in this way, many of them of rare occurrence; strictly speaking, we should also include under this title the various pelvic herniæ, such as prolapsus uteri, obturator hernia, etc. It is my intention, however, to dwell only upon the treatment of the commoner forms which occur in the anterior abdominal parietes, through the oblique, transverse, and recti muscles and their fasciæ, as well as under Poupart's ligament; that is to say, umbilical, ventral, inguinal, and femoral herniæ.

Causes of Hernia.—The essential factor in the production of these herniæ is a deficiency in the fibrous aponeurosis which gives strength to the abdominal walls; if this deficiency is a congenital one, the hernia may be noted soon after birth; if, on the other hand, the wall is merely weak, the rupture may then develop as soon as stress is put upon it by posture and by any form of exercise which tends to increase the intra-abdominal pressure; it is for this reason that hernia is more frequently found in the laboring classes.

The umbilical ring and the inguinal canals are by nature the weakest points in the abdominal walls; but the umbilicus is well protected against this danger by its position high up in the abdominal wall, where it is least liable to feel the force of pressure.

In the linea alba nature has provided against the possibility of hernia under all ordinary conditions by the strong interlacement of the bundles of fibrous tissue from the conjoined tendons of the muscles of both sides. This advantageous arrangement is sacrificed whenever a median incision is made into the abdominal cavity, never to be restored by any approximation, however perfect, followed by union, however good; and when the apposition of these tissues after an operation is inaccurate, or the line of union is weakened by suppuration, hernia is especially liable to occur.

The so-called ventral hernia noted after repeated pregnancies is in reality nothing more than a diastasis of the recti muscles with a thinning out of

this fibrous layer; it is therefore not a true hernia, but a pouching out of a large portion of the abdominal wall in consequence of overstretching.

The formation of a hernia commonly depends upon the following factors:

1. The existence of a weak point in the abdominal wall through which some portion of the viscera may be forced out to form a sac.

2. The near presence of a viscus—generally either omentum or intestines, or both—which may act as a wedge to drive the weak point ahead of it and enter the hernial sac to form its contents.

3. The application of an intra-abdominal pressure from within outward by means of the muscular abdominal walls acting upon the contained viscera; in this way the viscus lying nearest the weak point is forced against it, and if its form permits, it enters it as a plug.

4. The continued or the repeated actions of the intra-abdominal pressure cause the weak spot to yield further, and so push the viscera out into a pocket under the skin. The neck of the hernial sac is formed by the surrounding layer of fibrous tissue, and the sac itself is that part of the peritoneum and subperitoneal tissue which lies between the neck and the skin.

It is evident that under ordinary circumstances hernia is most liable to occur in those parts which are most dependent, and upon which the omentum and small intestines continually lie while the abdominal muscles are in active exercise.

It is safe to say that inguinal and femoral hernia, due to muscular effort, depend upon the erect position for their production, while if the ancestral position on all fours were still the natural one, umbilical hernia would be the commonest form.

Another cause of hernia is an increase in the contents of the abdominal cavity, stretching and subjecting all parts of the abdominal wall to a pressure from within outward. Umbilical hernia commonly owes its origin to such a change in the relation between container and contents, and is oftenest observed in fat women. An umbilical hernia is also often seen where it otherwise would never have occurred, when the intra-abdominal pressure is greatly increased by the presence of an ascites; it is indeed one of the characteristic marks of an ascitic accumulation. In these cases it is, as a rule, only an interesting clinical sign and free from any danger; the umbilicus stands out dark in color, forming a little cushiony eminence, and upon pressing on it the fluid is felt shooting through the narrow opening into the abdomen, and the finger can often be pushed into the ring; as soon as the pressure is withdrawn the cushion forms again.

This sign is seen with a smaller amount of ascitic fluid than otherwise would be the case when the abdomen is occupied by a tumor of considerable size, and inasmuch as ascitic accumulations are quite constantly observed with papillary ovarian tumors, the umbilical eminence is suggestive and a sign of some value. Once in a while little papillary masses find their way into the sac and grow there, and so give a clue to the diagnosis.

In one case of this kind my patient, some days after tapping for a large ascitic accumulation, had a strangulated intestinal hernia upon which I operated, cutting the ring larger and releasing the bowel. She recovered, and died about a year later of the advance of the papillary disease.

Light is thrown upon the mechanism of the formation of a hernial sac by a study of the multiple omental herniæ found projecting through the holes of the glass drainage-tube, at one time so much used in abdominal surgery. Here, as I have often had occasion to observe, a minute portion of the omentum slips into one of the holes whose lumen becomes choked; this produces a stasis in the circulation, and, while arterial blood is still pumped in, the venous blood can not escape and the hernial mass swells and becomes edematous and so keeps pulling upon its neck and dragging in more and more of the omentum, until the tube is entirely choked or the mass finally becomes gangrenous.

In a hernia in the abdominal wall the mechanism is somewhat similar; a bit of omentum or part of the wall of the bowel slips through the weak spot in the fibrous tissue; beyond this point there is no pressure or constriction; the consequence is that with the impeded circulation the beginning hernial mass swells, forming a marked neck, where it traverses the fibrous tissue, and so exercises traction and makes it easy for more and more of the viscera to push out into the sac.

If the constriction is tight, gangrene may take place; on the other hand, it may be just sufficient to impede the circulation; or if the neck stretches, the compression at this point will be but slight and the viscera may slip to and fro, even returning spontaneously when the patient lies down.

The commonest content of the sac is the omentum, which often completely fills it and, by its adhesions to the neck and to the sac walls, prevents the ingress of any other organ, in this way curing the hernia after a fashion by plugging it up. The frequency with which the omentum is found employed in this way makes it evident that this is undoubtedly one of its important uses. This natural cure is made surer if in addition to the omentum a serous exudate forms within the sac, filling it to the limit of its capacity.

Such a hernia when it produces no symptoms may just as well be let alone; often, however, the pain accompanying this condition necessitates an operation.

The only other organs quite constantly found in abdominal herniæ are loops of the small intestine; wherever the hernia contains portions

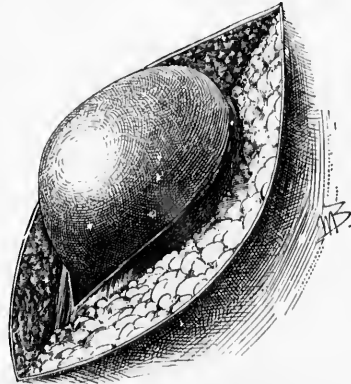


FIG. 535.—GENERAL PRINCIPLES OF THE RADICAL OPERATION FOR HERNIA.

The abdominal pillars and fascia divided and the hernial sac protruding. The sac is then either returned or cut off at the neck.

of the bowel, operation should be resorted to on account of the constant risk of strangulation, gangrene, and death.

An operation upon a hernia is always indicated when the patient is liable to attacks of vomiting and has pain in the region of the hernia, and finds it at times difficult to reduce (replace) the contents of the sac. I have seen patients who were subject to these attacks every few weeks followed by immediate relief after the reduction of the hernia, which they had learned to do themselves. Sooner or later such herniæ are pretty sure to become strangulated, and the strangulation may lead to a fatal result before an operation can be performed.

FIG. 536.—GENERAL PRINCIPLES OF THE RADICAL OPERATION FOR HERNIA.

The sac returned and the kangaroo tendon or silk-worm gut or silver-wire mattress sutures laid through the fascia, including also the muscle, when possible, on both sides.

contra-indications as grave cardiac lesion, advanced nephritis, asthma, or great obesity exist.

Obese patients often suffer from fatty heart, as a consequence of which they are subject to attacks of dyspnea or asthma. In the event of an operation they take the anæsthetic badly; the anæsthesia is apt to be prolonged, and their convalescence is often marked by an exaggeration of the dyspnea and by irregularity of the heart's action; they also show a diminished resistance to infection, and so may die quickly from peritonitis.

For these reasons I advise against operation in excessively fat women if it is possible to make them comfortable by supporting bandages or trusses. Too often, however, the indications for operation are so urgent that it must be done. The unusual dangers of the operation should always be fully explained to the relatives or the patient, in order to relieve the surgeon from an undue weight of responsibility.

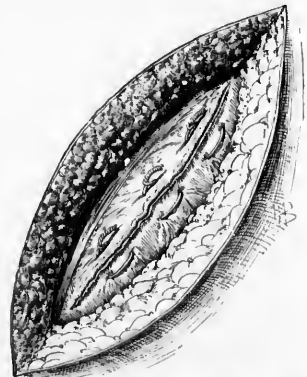

FIG. 537.—GENERAL PRINCIPLES OF THE RADICAL OPERATION FOR HERNIA.

Silver-wire mattress sutures drawn up, twisted, and the ends turned down, completely closing the hernial orifice.

Out of 355 cases of hernia operated upon in Dr. W. S. Halsted's clinic there were—

		Male.	Female.
Inguinal	309	274	35
Umbilical and ventral.	21	6	15
Femoral.	25	11	14
Total	355	291	64

Treatment in General.—The broad lines of the treatment of all forms of herniæ through the fibrous aponeurosis of the abdominal wall are similar—viz.: (1) to cut through the skin and open the sac; (2) to reduce the hernia, if necessary cutting the ring; (3) to dissect out and expose the fibrous ring or the canal; (4) to remove the sac and close the peritoneum; (5) to close the fibrous ring or the canal with buried sutures, always embracing the muscular tissue if possible; and (6) to close in the fat and the skin.




FIG. 538.—GENERAL PRINCIPLES OF THE RADICAL OPERATION FOR HERNIA.
The mattress suture tied. Note the puckering of the fibrous lamella and the inclusion of the muscle.

The points absolutely essential in the treatment are to catch and bring together the fibrous and adjacent muscular tissues stout enough to withstand any pressure which may be put upon them subsequently from within, and to approximate the tissues with a suture material which is non-irritating and at the same time is strong enough to bind them together until firm union has taken place.

A careful dissection well back into the tissue surrounding the ring yields satisfactory material for the new wall, and the use of buried silver wire or silkworm-gut sutures answers the second.

With this general statement as to the principles, it remains to apply them to the particular forms of hernia, with such comments as the special conditions call for.

Hernia in the Linea Alba.—

Hernia in the linea alba, when it occurs, is a direct sequence of an abdominal section, and owes its origin to the division of the fibrous interlacement of the strong fascia overlying the recti muscles, followed by imperfect union after the operation.

Such a hernia can generally be prevented by proper suturing after operation, as described in Chapter XX, p. 40.

It is oftenest found in those cases where for motives of expediency a drain has been inserted in the lower part of the wound, keeping a portion of the walls apart, or where the convalescence has been complicated by suppuration in the



FIG. 539.—GENERAL PRINCIPLES OF THE RADICAL OPERATION FOR HERNIA.
Interrupted gut sutures passed, but not yet tied, in the intervals between the mattress sutures of silkworm gut or silver wire.

abdominal wall. This gap fills in with a plug of fibrous tissue and constitutes a weak point ready to yield when pressure is brought to bear upon it.

The size of such a ventral hernia varies from one not larger than the end of a finger to a mass including most of the intestines. A hernia small at the start may grow to an immense size; marked discomforts are often entailed, but the risk to life is not great. I have, however, seen one case where the patient died of strangulation twenty-seven years after ovariectomy (see Chapter XXXVII).

Before operating, the patient should be examined lying on her back with knees drawn up. The hernia is grasped on the two sides and its contents manipulated until they are all returned to the abdominal cavity. Omental and intestinal adhesions to the sac wall may prevent a complete reduction; sometimes this can not be done before opening the sac.

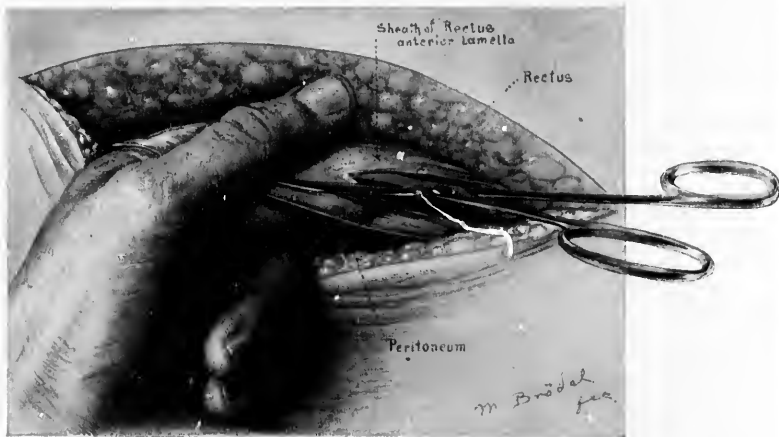

FIG. 540.—OPERATION FOR A VENTRAL HERNIA.

The incision in the median line has exposed the thick fascia covering the rectus; this is grasped between the thumb and forefinger, protecting the peritoneum and guiding the scissors, which are then used to split the fascia all around the hernial ring, exposing the muscle.

After returning the contents the hole in the wall is easily felt, and when it is large the whole hand may be slipped into the abdomen and the most perfect palpation of the abdominal and pelvic viscera made with only the thin skin and the peritoneum intervening, like a glove. The edges of the round or oval ring feel distinct and sharp, but it is important to note that the area of fibrous tissue which must be dissected out in operating is much greater than the manifest thin margin of the ring outlined in this way. The radical operation for this form of hernia is therefore always more extensive than one would naturally expect it to be.

Operation.—The operation is begun by making an oval incision, cutting out the old scar with all of the relaxed wrinkled skin covering the hernial sac. The incision is made most cautiously through the skin and the thinned-out sub-

cutaneous tissues on all sides, and the peritoneum is picked up between two forceps and opened with extreme care. A rapid bold method of incising will risk cutting an adherent coil of intestine often found surprisingly close to the surface.

Two fingers are now introduced within the peritoneum, and under their guidance the peritoneum is cut through on all sides to correspond with the incision in the skin; in this way an oval piece is removed and the abdomen is opened. Intestinal and omental adhesions are commonly found and must be looked for as soon as the peritoneum is opened. Omental adhesions can usually be freed by pulling upon them. Intestinal adhesions must be dealt with more carefully. These are generally attached to the wall by a loose web of tissue, and can be dissected loose by drawing upon them a little and cutting the adhesions with scissors. When all these adhesions are freed it is important to look for more within the abdomen adjacent to the ring, and to separate them in like manner, until all the coils of intestines are freed from any abnormal attachments.

A gauze napkin is now laid upon the intestines within the abdomen to keep them out of the way while the fibrous ring is being dissected out.

The edges of a fibrous ring will be found occupying the whole adjacent area between the skin and the peritoneum, and, in places where it is not clearly seen, overlying fatty and loose fibrous tissue should be dissected off, laying it bare. The fibrous ring thus

bared is not the tissue which must be brought together to close the hernia, but is merely a mass of dense connective tissue which covers in the recti muscles and the true abdominal fascia overlying them.

The next step is to dissect off this tissue and to expose the recti muscles below and the fascia above them. This may be done either by catching up a bit of the tissue with forceps and cutting it off in strips with scissors, or by lifting up the muscle,




FIG. 542.—MATTRESS SUTURES UNITING THE RECTI MUSCLES AND THEIR OVERLYING FASCIA.

The sutures, as a rule, embrace more tissue than is shown in the figure.

which can be easily palpated, and splitting the overlying scar tissue with scissors, as shown in Fig. 540. The underlying muscle is often found pale and atrophic. In the upper and lower angles of the opening the dissection must be carried deeper than at the sides in order to reach layers of fibrous tissue strong enough to hold firmly together when united by suture.

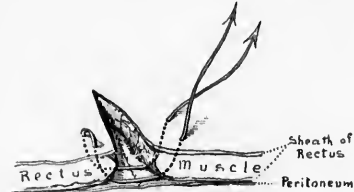

FIG. 541.—TISSUES GRASPED BY THE MATTRESS SUTURES IN CLOSING THE HERNIA.

More muscle should be embraced than is shown in the figure.

After surgical preparation the wound presents an entirely different appearance from that which it first exposed, for now the natural layers of the abdominal wall,



FIG. 543.—INCARCERATED UMBILICAL HERNIA IN A FAT WOMAN, REMOVED AT AUTOPSY.

The patient had anemia and fatty degeneration of the viscera, affecting chiefly the heart, liver, and kidneys. The hernia was bi-lobed, the size of a child's head, and the skin over it was tense and red. The sac contained omentum and a part of the transverse colon twenty centimeters long. Old fibrous bands passed from the ring at the neck of the sac to the contents at their entrance. Age, fifty-three. Autopsy 881. $\frac{2}{3}$ natural size.

the peritoneum, the muscles, the fascia, and the skin are all clearly brought to view by the clean dissection.

The hernia is now closed by a separate suture of each of its layers. The peritoneal layer is brought together first from top to bottom by a continuous suture of catgut.

The fibrous layer, together with the recti muscles, most important of all, is now united by a series of silver-wire or silkworm-gut mattress sutures.

The strong fibrous tissue on either side, somewhat retracted beneath the skin and fat, is first caught with several pairs of artery forceps and drawn out. The stout silver-wire mattress sutures are now drawn through the fascia and the underlying muscle by a carrier, so that one embraces about 1 centimeter of the tissue, and is situated about 2 centimeters distant from the last suture. The suture enters and emerges at about 8 or 10 millimeters from the edge of the cut.

After the sutures are all in place they are taken up in turn, each end in a pair of forceps, and tied or twisted and cut off, and the ends of the silver wire

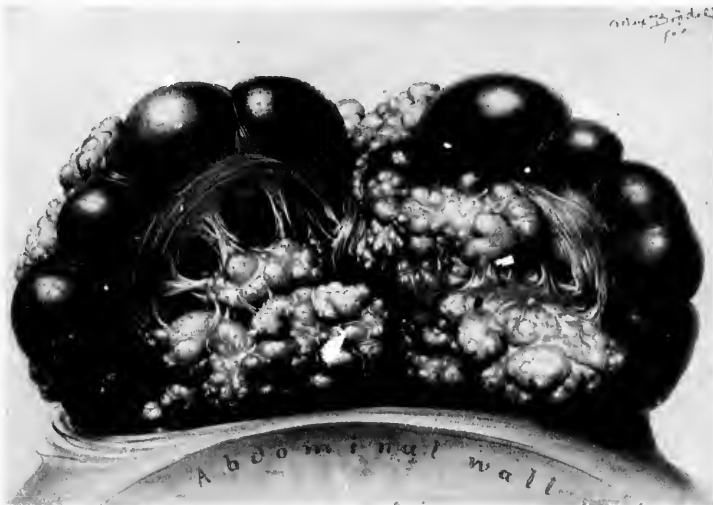

FIG. 544.—THE HERNIAL SAC REMOVED.

Showing the contents, the omentum loaded with fat, the transverse colon, and appendices epiploicæ. $\frac{2}{3}$ natural size (see Fig. 543).

turned down to one side. Catgut sutures are then placed between the permanent ones, leaving no loophole for the escape of the intestines. By this means a firm closure is effected strong enough to act as an effectual barrier against any tendency of the intra-abdominal pressure to force the intestines out again.

Small bleeding vessels in the upper part of the wound are now tied with fine catgut before closing the skin. If there is a thick layer of subcutaneous fat it should be approximated with a continuous catgut suture.

The skin is now united with a subcuticular catgut suture, and the abdominal dressing applied.

It will be safe after such a union of the fibrous tissue to allow the patient to rise from her bed in fourteen days, but any strain on the recti should be avoided if possible for several months.

Umbilical Hernia.—An umbilical hernia is one which takes place at the umbilical ring; it owes its origin to a natural weakness in the abdominal wall at the site of the cicatrix left by the umbilical cord. There is always a natural separation of the recti muscles at this point and a close approximation of the peritoneum and the skin, surrounded by a dense ring or cylinder of fibrous tissue.

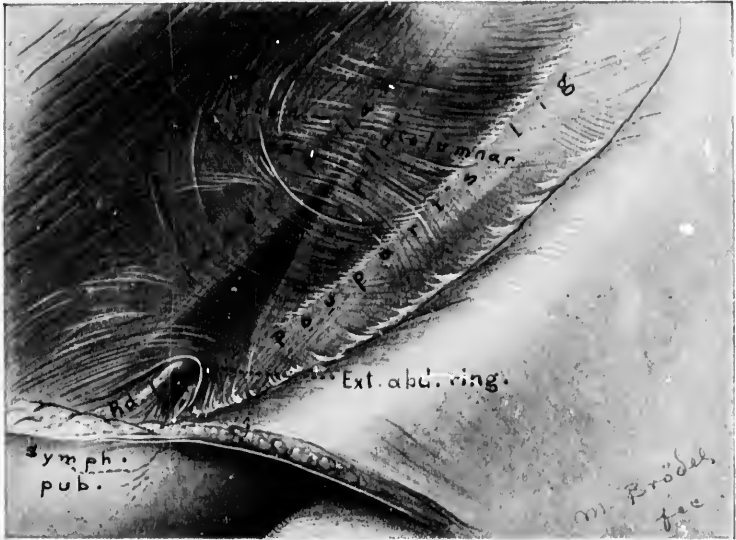

FIG. 545.—ANATOMY OF THE INGUINAL CANAL.

The skin and fat turned back, exposing the aponeurosis of the external oblique muscle. Showing also its triangular division over the inguinal canal, the opening below for the exit of the round ligament (external ring), the relations to Poupart's ligament, and the intercolumnar fibers binding together the inner and outer pillars.

Owing to the location of this naturally weak point, under ordinary conditions the abdominal viscera are not brought to bear directly upon it during the action of the intra-abdominal pressure. In addition to this, the free border of the omentum and the small intestines occupy the lower part of the abdomen, leaving the flat upper part of the omentum with the colon and the stomach in apposition to the umbilicus; these structures from their very form are less liable to enter the opening.

When, however, by the increase of fat in the abdomen the mutual relations of the viscera are disturbed and the relations between the abdominal walls and

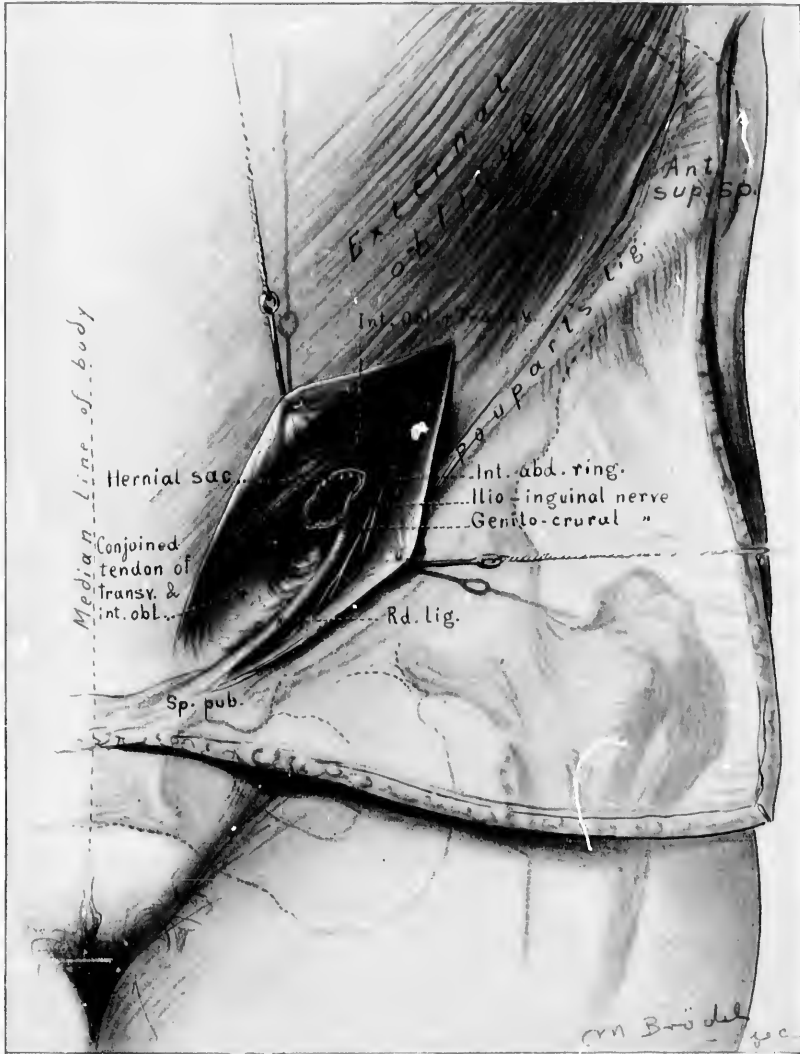


FIG. 546.—ANATOMY OF THE INGUINAL CANAL IN ITS DEEPER LAYERS.

Exposing the intercolumnar fibers and the aponeurosis of the external oblique muscle divided and turned back, showing the internal ring above and the oblique direction of the inguinal canal, which is somewhat dilated by the neck of a hernial sac, shown cut off. The upper border of the canal is formed by the internal oblique and transversalis muscles, which curve around the inner side of the sac to make the conjoined tendon forming the lower wall of the canal. The round ligament is seen against the outer sac wall, and the genito-crural and ilio-inguinal nerves lie to the outside of this again.

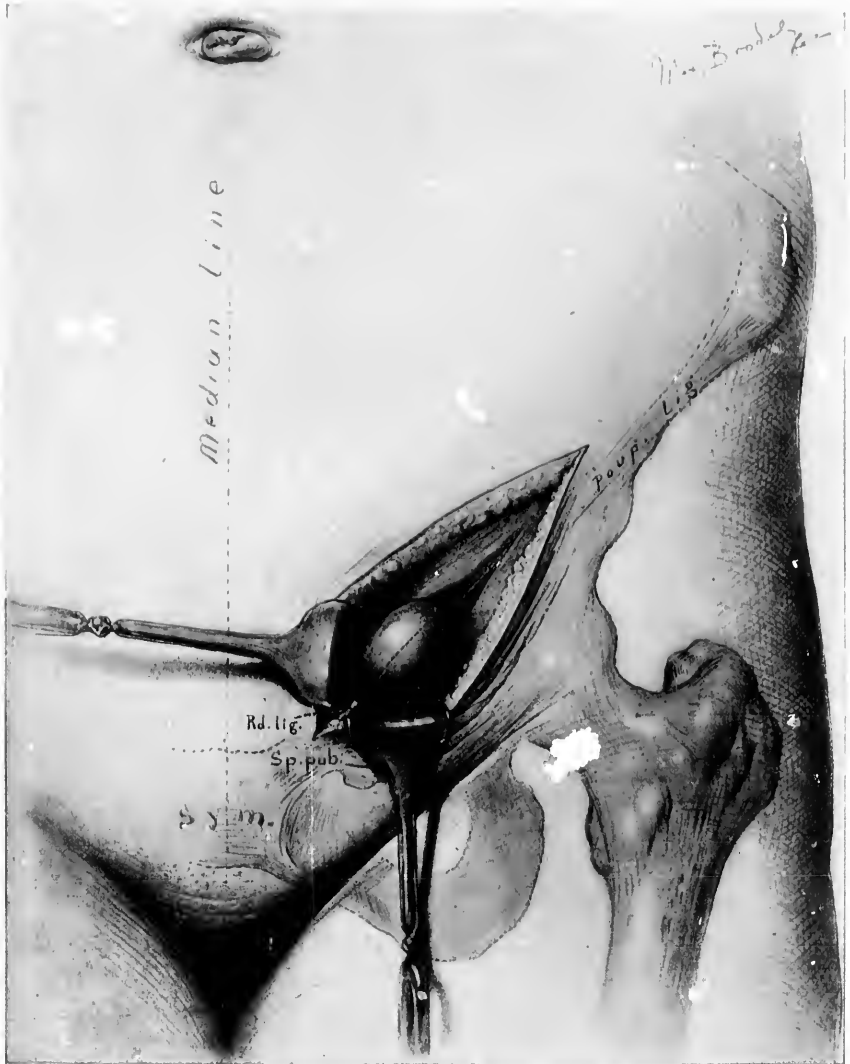


FIG. 547.—FIRST STEP IN THE OPERATION FOR INGUINAL HERNIA.

Showing the sac, after division of the skin and subcutaneous fat, separating the pillars of the aponeurosis of the external oblique muscle. The dotted line indicates the next step, the incision exposing the sac. The round ligament is seen in the lower angle of the wound; it lies above this posterior to and at the outer side of the sac.

their contents are altered, creating the need for more room, the needed space is often found by forcing the viscera out under the skin at the navel, the weakest point in the wall, and so establishing a supplementary cavity, as it were. This sac or cavity may become so large that all the small intestines, and the cecum with its vermiform appendix, colon, and sigmoid, are accommodated in it.

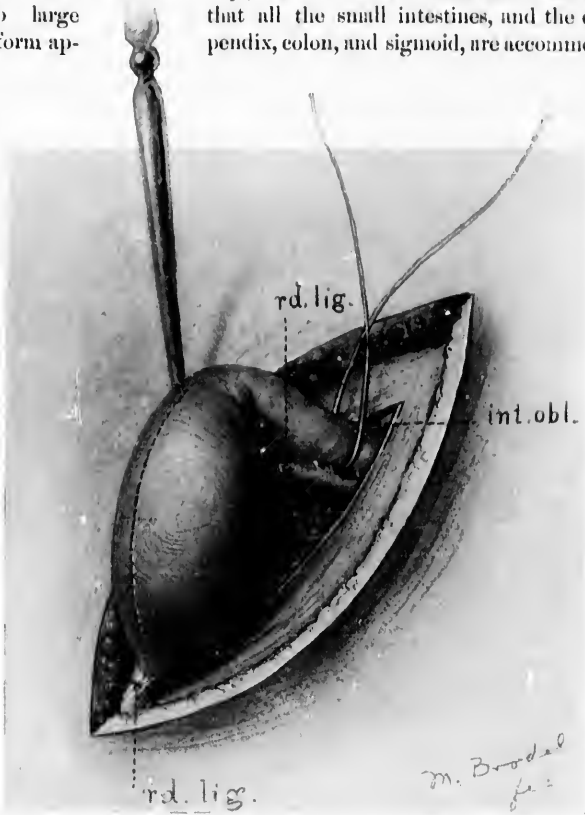


FIG. 548.—SECOND STEP.

Showing the sac, together with the round ligament, exposed and drawn out of the wound; a provisional ligature above, not including the round ligament, fixes the site of the amputation of the sac. The dotted line indicates the position of the next incision (see Fig. 549.)

Umbilical hernia occasionally occurs as the result of prolonged labor accompanied by powerful contractions of the abdominal walls, when the stress of the pressure may be felt in the upper part of the abdominal cavity which now contains the omentum.

Operation.—An operation for an umbilical hernia must do one of two things, both designed to obviate the risk of an intestinal strangulation at the neck of the sac.

1. To effect a radical cure by uniting the fibrous walls by suture in all cases in which the contents of the hernial sac can be put back without dangerously increasing the intra-abdominal pressure.

2. To make the opening so large that no longer will there be any danger of strangulation in those cases in which the contents of the sac are voluminous, and the abdomen so contracted and adjusted in size to the remaining viscera, that the hernia is put back with difficulty, and retained in the abdomen at the expense of a greatly increased intra-abdominal pressure.

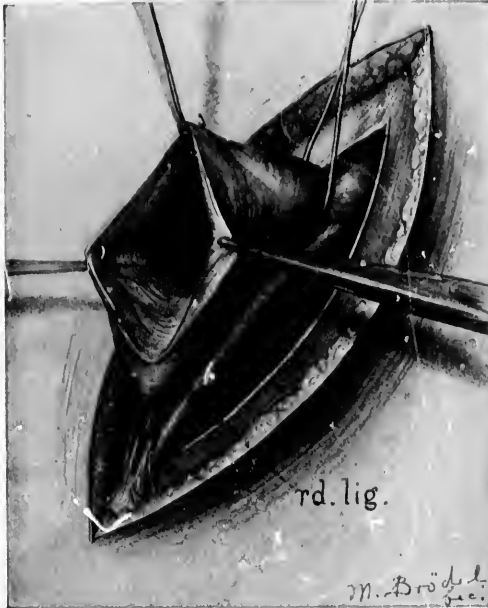


FIG. 549.—THIRD STEP.

The sac incised, as indicated in the last figure, exposing its contents, which are reduced; the sac is then loosened from its surrounding attachments and from the round ligament and excised close to the provisional ligature.

The fibrous ring in a small hernia must now be dissected away, exposing the edges of the recti muscles; any extruded peritonem lining the sac or sacculi must also be removed with seissors and forceps. The opening is then closed by several mattress sutures of silkworm gut laid close together, so as to bring the muscles and the fascia on the right and the left sides into snug apposition; after this the subcutaneous fat is united, and then the skin is closed with a subcuticular catgut suture.

I have found it necessary to relieve several large umbilical hernie by opening the sac and simply pushing the finger between the peritonem and the lower border of the ring and cutting the ring down from 3 to 6 centimeters in the me-

The radical cure is effected by excising the redundant skin and peritoneal pouches which are found in large hernie, and cautiously opening the sac; the adherent omentum and intestines must next be carefully freed from the walls and drawn out of any of the subsidiary sacs or loculi often found; they are then replaced in the abdomen and held there by a gauze pad.

A good-sized cuff of peritonem is then freed, dissected off from the inner surface of the ring, and turned into the abdomen, and the gauze taken out and the peritonem closed by a continuous catgut suture.

dian line in a direction toward the symphysis. I have done this in cases where the intestines had to be forced back into the abdomen and persistently re-escaped, and the effort to hold them there by closing the abdomen put them under too great tension. After the operation it is of the utmost importance to give firm support to the lateral walls of the abdomen by a snug bandage extending from the lower ribs down over the hips; this prevents lateral tension upon the sutures.

Inguinal Hernia.—Of two hundred and forty-four cases of inguinal hernia operated upon by my colleague Dr. W. S. Halsted, only twenty-seven occurred in women.

The infrequency of inguinal hernia in women as compared with men is due largely to the difference in occupation of the two sexes.

Childbearing is not an etiological factor in the production of inguinal hernia, because the strong impact of the abdominal walls in labor falls upon the large gravid uterus which occupies the lower abdomen and keeps away the smaller organs, the omentum, and the intestines.

Another reason why inguinal hernia is more frequent in men than in women is the difference in the contents of the inguinal canal. In man the inguinal canal carries the spermatic cord, accompanied by its arteries and often large dilated veins, while in woman there is only the small round ligament with a few tiny vessels.

This form of hernia is most likely to be produced in women by lifting heavy tubs or buckets, washing clothes in a stooping posture, and sweeping.

The hernia may vary in size all the way from a pointing at the internal inguinal ring, or an ovoid swelling filling the canal, to a large pendulous mass extending down into the labium majus.

The symptoms produced are a sense of weakness or of discomfort, with pain when the hernia is in the canal. Strangulation does not often occur. I had one case, however, in which a diverticulum from the side of the bowel was caught and strangulated, and an abscess formed beside it (*hernia Littrici*). This was incised by the attending physician, who unfortunately laid open the bowel at the same time, leaving a fecal fistula. At the operation which I was called upon to perform subsequently it was necessary to dissect out the whole sac and cut off the diverticulum of the bowel at the junction with the sound intestine, which was then sutured. This was followed by a complete recovery. In a similar case in a man with a fecal fistula in the scrotum, after dissecting out the diseased tissues I closed the opening in the lateral wall of the bowel by suturing a right testicle over it on all sides.

The general principles of the operation are the same as in the operation for a hernia in the *linea alba*, making the necessary changes to adapt the steps to the altered anatomical conditions.

There are two ways of getting at an inguinal hernia: first, in those cases in which the hernia exists as a complication of some other abdominal affection



FIG. 550.—FOURTH STEP.
The closure of the neck of the sac with mattress sutures before allowing it to retract into the abdomen.

which needs celiotomy, the easiest way to reach it is, after the abdomen has been opened, to introduce two fingers of the left hand, and to locate the position of the hernia either by the exit of the round ligament through the wall, or by the weak spot readily felt above Poupart's ligament; the thinned-out inguinal canal is pushed forward with the fingers until it makes a decided prominence on the skin surface. Taking the scalpel in the other hand, the operator now cuts down through the

skin, subcutaneous fat, aponeurosis of the external oblique muscle into the canal, the fingers from injury.



FIG. 551.—FIFTH STEP.

Shows the closure of the inguinal canal with silver-wire mattress sutures and the disposition of the round ligament, which is brought out between the first and second sutures directly under the skin and subcutaneous fat. The internal oblique and the transversalis muscles are seen along the upper margin of the canal. Each suture transfixes the aponeurosis of the external oblique and the internal oblique and transversalis muscles above and Poupart's ligament below. The loops of the sutures are pocketed, especially the lower ones, where the tension is greater. The round ligament is not detached more than is necessary.

Sutures are then introduced in the manner to be described. If the hernia sac is small there is no necessity of excising it, as the operation will be quite as effective without this step.

The method elaborated by Halsted (*Johns Hopk. Hosp. Bul.*, vol. i, Dec., 1889; *The Radical Cure of Hernia*) and Bassini (*Arch. f. klin. Chir.*, Bd. xl, 1890; *Ueber die Behand. der Leistenbr.*) for the radical cure of inguinal hernia

insures the greatest number of satisfactory results, and I shall follow this quite closely in my description.

In the male the spermatic cord and its artery must be carefully preserved from injury during the operation, and so placed in a new canal as to avoid compression of the cord. Atrophy of the testicle only takes place when the veins are excised or injured.

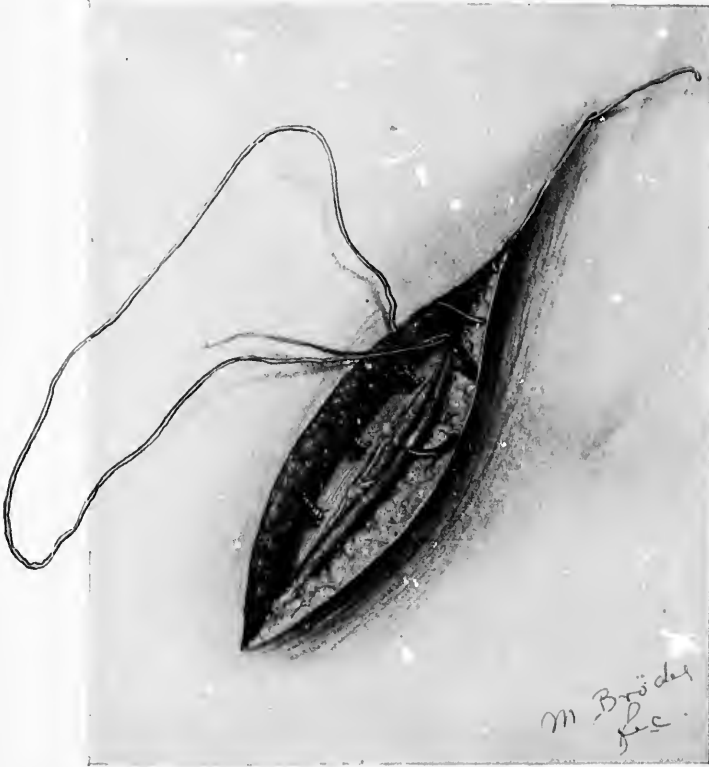

FIG. 552.—SIXTH STEP.

The mattress sutures have been drawn up and twisted and the subcutaneous fat and skin are being closed over the round ligament by a subcuticular continuous suture.

In women the round ligament, which takes the place of the spermatic cord, is smaller and unimportant, and may be safely transixed by the sutures.

If the round ligament is densely adherent to the sac, as is often the case in strangulated or in incarcerated hernia, I do not attempt to isolate it, but prefer to excise it with the sac.

Operation.—An incision is made at an angle of about 25 degrees above Poupart's ligament, and from 2 to 3 centimeters distant from it, beginning at

the spine of the pubes and extending upward and outward beyond the internal abdominal ring.

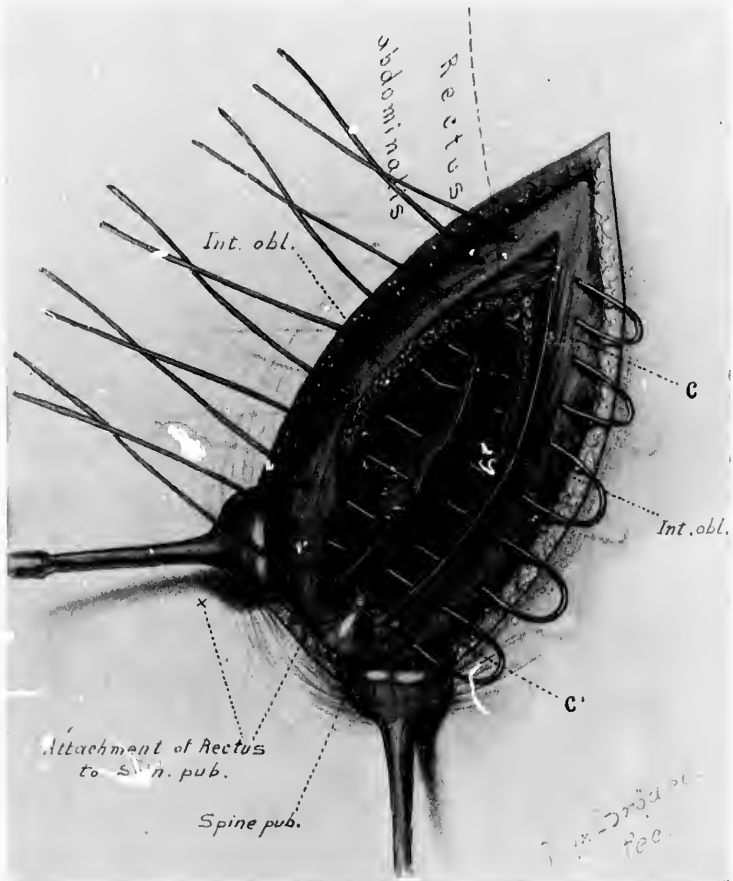


FIG. 553.—OPERATION FOR THE RADICAL CURE OF A LARGE INGUINAL HERNIA WHERE THE CONJOINED TENDON IS DEFICIENT.

This deficit is substituted by the rectus muscle. The interrupted silver-wire sutures are seen in place ready to approximate the left rectus with its sheath to Poupart's ligament, in the manner shown. Note the puckering to be produced by the two lower sutures to gain more tissue. *C, C'*, round ligament cut off in the drawing for the sake of clearness; this emerges between the first and second sutures.

The skin, subcutaneous fat, and intercolumnar fascia are divided in order (see Fig. 547), and the aponeurosis of the external oblique muscle is divided and dissected down to its junction with Poupart's ligament.

The sac is found lying between the lower border of the internal oblique muscle and Poupart's ligament. If the sac is free it is separated from the

round ligament and opened at its apex; if the omentum or intestines are in the sac they will usually drop back into the abdominal cavity of their own weight, or they can be gently returned with a piece of gauze.

The sac is then laid freely open and closed just outside the internal abdominal ring with two or three mattress sutures of fine silk. The sac should not be ligated *en masse*, but in sections, in order to prevent strangulation of so much peritoneum, as well as to avoid the slipping of the mass ligature.

The neck of the sac is divided about 1 centimeter distal to the constricted point, and allowed to drop back into the abdominal cavity (see Fig. 550).

Mattress sutures of silver wire (No. 24) are now introduced through the aponeurosis of the external oblique muscle and the internal oblique muscle appearing in the wound, and transfixing the round ligament, thence into Poupart's ligament, and back through the same structures to form the square. These sutures are placed 1 centimeter apart down to the spine of the pubes (see Fig. 551).

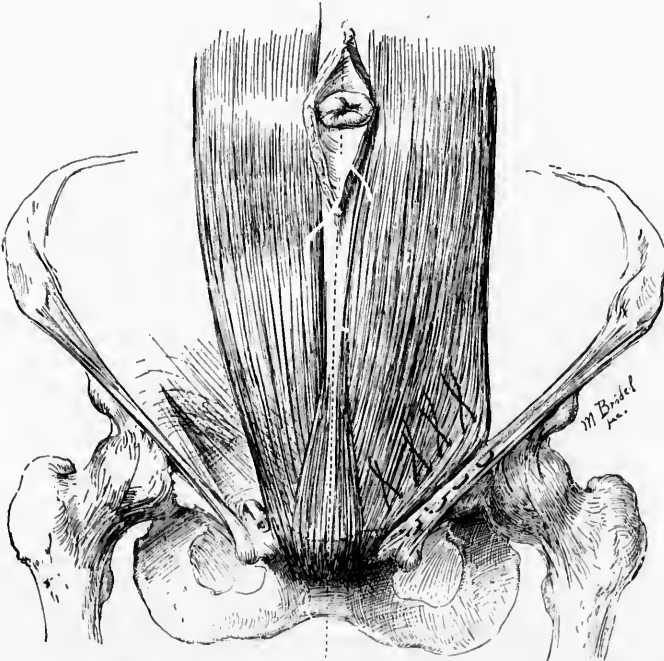


FIG. 554.—SHOWING THE FACILITY WITH WHICH THE RECTUS MUSCLE, RELEASED FROM ITS SHEATH, CAN BE DRAWN OVER AND ATTACHED TO POUPART'S LIGAMENT, COVERING IN THE ENTIRE INGUINAL CANAL.

After the sutures are drawn up, bringing the divided aponeurosis into snug apposition, they are twisted five times and turned to one side upon the aponeurosis, pointing slightly downward.

The aponeurosis of the muscle is neatly closed with a continuous catgut suture, after which the fat is brought into apposition and the skin is closed with a subcutaneous catgut suture.

In large herniæ, in which the conjoined tendon is obliterated or so relaxed as to be useless in closing the opening, Bloodgood's method of transplantation and suture of the rectus to fill in the deficit, strengthening the wall by the inclusion of muscular tissue, may be employed with advantage (see *Johns Hosp. Hosp. Rep.*, 1898). (See Figs. 553 and 554.)

The rectus is secured by a vertical incision through its sheath laterally about 5 centimeters long, beginning just above the pubes. The sutures, which unite the transplanted muscle to Poupart's ligament as far out as the position of the transplanted round ligament, catch both the muscle and its overlying sheath in addition to the other tissues.

Ovarian Hernia.—Hernia of the ovary, of the uterine tube, and of the ovary and the tube together, and of the uterus, of the bladder, and, on the right side, of the vermiform appendix, are also observed.

The ovarian hernia may occur alone or in conjunction with the tube, or the tube alone may be found in the sac, and with any of these unusual forms of hernia the omentum and the intestines may also be found. In a large experience I have myself seen but two cases of hernia of the ovary, both associated with congenital malformations, and out of twenty-seven cases of hernia in women, Halsted had but two, both of which were brought on in middle life by a strain, and in each the tube and the ovary were found.

It is important to recognize the existence of these unusual forms of hernia, not only for the sake of attaining as much diagnostic precision as possible, but because of the altered nature of the operation and the special treatment required. An adherent inflamed vermiform appendix may require removal; if the presence of the bladder in the sac is not recognized it may be incised or torn, and a vesico-abdominal fistula be the result; it is important to determine with regard to the ovary and the uterine tube whether they are sound and to be returned to the abdominal cavity or whether they are diseased and to be removed.

Etiology.—Ovarian and tubal hernia may be either congenital or acquired; the tube is always found in the sac with the ovary in congenital forms, but when the tube is found alone in the sac the hernia is usually acquired.

Out of 38 cases of ovarian hernia collected by English, 27 were inguinal, 9 femoral, and 1 an obturator and ischiatic hernia. Out of 67 cases of ovarian hernia, 27 were accompanied by enterocele; these observations, made by Langton (*St. Barth. Hosp. Rep.*, 1882), were for the most part upon children.

The congenital cases are, as a rule, bilateral, and are largely, as in my own cases, associated with malformation of the genitals, atresia of the vagina, absence of the uterus, and a unicorn or a bicornute uterus; the natural explanation of such herniæ seems to be that the canal of Nuck is persistent, and then that the round ligament acting as its homologue in the male, the gubernaculum testis, conducts the ovaries down the inguinal canal. It does this easily, as the

restrain of the attachment to a normally developed uterus is wanting. In the acquired cases it is probable that the long, movable tube enters a pre-existing sac first, and drags the ovary in with it. A hernia of the uterus occurs usually after the menopause.

An ovary in such a situation may undergo any of the alterations to which it is liable in the normal situation. It may become adherent, or converted into masses of cysts, or hemorrhagic, or it may form a dermoid or a multilocular cystoma or a sarcoma.

Symptoms.—The tumor in the inguinal canal is usually painful, either periodically at the menstrual periods or constantly with monthly exacerbations. It is most suggestive when a little girl who has had an indolent swelling in the groin reaches puberty and the lump suddenly becomes painful.

The patient is sometimes entirely incapacitated for work, and one of my own cases figured in the text (Fig. 555) complained especially on going upstairs. In a case of Deneux (*Recherches sur les hernies de l'ovaire*, 1813) the pain during pregnancy became unbearable, and a patient of Leopold's, who had a hernia of a rudimentary left uterine horn with the ovary and the tube, suffered so much that she attempted several times to commit suicide. A patient of Beigel's, with double ovarian femoral herniæ, experienced the most intense pain in the ovary during coitus.

On account of this sensitiveness it is usually impossible to wear a truss.

The inguinal swelling is usually tender on pressure, producing a characteristic sickening sensation similar to that experienced when a prolapsed ovary is pressed upon behind the cervix.

At the menstrual period the tumor swells decidedly, even doubling its size.

Pregnancy may occur even when both ovaries are in the inguinal canals; pregnancy may also take place in a uterus which lies in a hernial sac, as in Scanzoni's case of a woman who acquired a small hernia when thirty years old by lifting a heavy wine cask. The tumor was small, irreducible, and swelled perceptibly at the menstrual periods. After an attack of typhoid fever it became as large as a man's fist; on making a vaginal examination the cervix could not be felt, and the vagina was found pulled up into a long, narrowing canal. She had previously borne two children, and she conceived a third time in the hernial uterus, which swelled as large as two fists, when she aborted and the swelling was quickly reduced. Within a year she conceived again, and the tumor grew as large as a man's head and covered the pubes, when pain set in and there was retention of urine. A catheter was now passed into the uterus and some warm water injected, and a dead fetus and the placenta were expelled. After-pains were felt in the tumor. She made a good recovery, and the swelling diminished and became less painful.

It must not be forgotten that the omentum and the intestines may also enter into the hernial sac, and so tend to mask the symptoms arising from the presence of the ovary.

Diagnosis.—The diagnosis of hernia of the ovary is easy in the presence of the characteristic signs detailed, and difficult in their absence.

The history shows that the patient has had a small ovoid lump in the groin, it may be from childhood. At the time of puberty the lump becomes suddenly painful at the menstrual periods, when it swells decidedly. It is hard, generally movable, and sensitive on pressure. If it has existed since childhood, the fact that the enlargement is bilateral is especially suggestive of ovarian hernia.

Upon making an examination of the genitals, a malformation will often be found.

All of these peculiarities serve to distinguish an ovarian hernia from an epiplocele (omental hernia), enterocele, lipoma, or an encysted peritonitis.

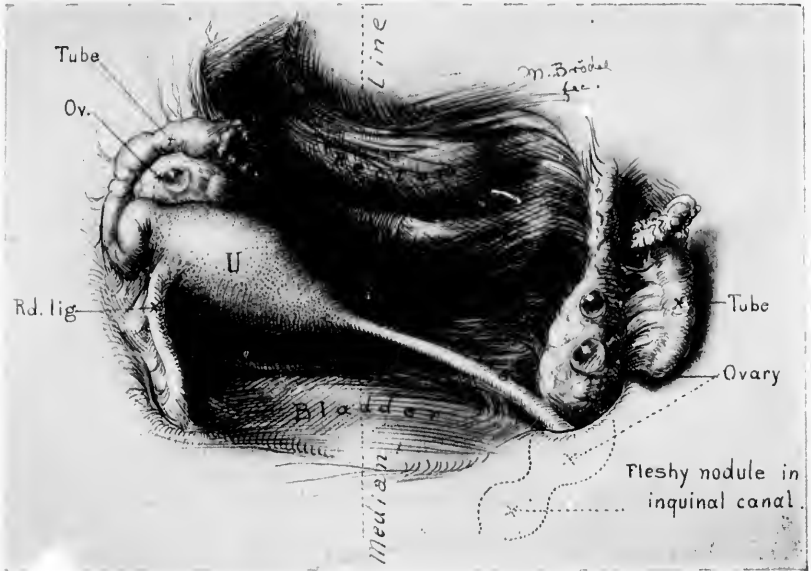


FIG. 555.—PARTIAL HERNIA OF THE LEFT OVARY.

The short tube close by, lying over the superior strait, has no uterine connection. The uterus is displaced markedly to the right side. The right ovary and tube are normal. Nov. 1, 1897.

Upon making an examination of internal pelvic organs, which would better be done under anesthesia, in addition to the characteristic sign afforded by the malformation of the vagina and uterus in other cases, in hernia of one side the uterus is found with one horn pulled decidedly toward that side (torsion); upon pulling on the cervix with a tenaculum forceps the inguinal tumor is displaced, and on letting the cervix go it returns again to its place. Further, a bimanual examination shows the absence of the ovary from the side on which the hernia is found, and if the uterus is pulled down and the utero-ovarian ligament is felt it can then be traced out toward the inguinal canal.

When there is a double ovarian hernia with a well-developed uterus, the latter is pulled up and fixed behind the pubis, much as if there had been an extreme shortening of the round ligaments.

As Cruveilhier has pointed out, the occasional presence of the uterus or a part of it in the sac is due to its organic connection with the tube and the ovary, which descend first with a part of the broad ligament, and if the traction is continued it is only a question of the size of the orifice of the sac and the mobility of the uterus how soon the latter will enter it.

F. Krug (*Amer. Jour. Obs.*, 1890, p. 606) made a diagnosis of hernia of the uterus before operation in a young woman eighteen years old who had a swelling five inches in diameter in the left inguinal region in which two hard, movable masses could be felt, one large and pear-shaped, and the other, distinct from it, about the size of a walnut. The cervix was found close behind the symphysis, and any movement given to it was at once communicated to the pear-shaped mass. This mass could also be pushed out of the canal into the abdomen, and on further investigation, grasping it on all sides with the thumb and the index finger of one hand in the vagina and in the rectum, and the other hand above over the inguinal canal, the uterus could be handled so as to leave no doubt as to its identity and its presence in the canal; the diagnosis was verified by operation.

Treatment.—The treatment is similar to that of other inguinal herniæ. If the presence of the tumor is the occasion of persistent or severe periodical discomforts the inguinal canal should be laid open, the ovary and the tube, and it may be the uterus, exposed, any adhesions freed, and the organs returned to the pelvis, the sac removed, and the inguinal canal closed in the manner described.

If the ovary is much enlarged or has become converted into a tumor of any sort it will then be best to pull it out and tie off the broad ligament carefully with a number of fine silk sutures and to remove the ovary, letting the pedicle drop back into the abdomen.

In one of my cases of hernia of one ovary (see Fig. 555) the left ovary entered the canal only partially, in such a way as to produce a marked constriction between the middle and the outer third at a point corresponding to the internal inguinal ring. There had been no symptoms whatever referable to the ovary, and on opening the abdomen I found the uterus, contrary to the rule, markedly displaced toward the right side, with a well-developed right tube, ovary, and round ligament, and a fairly well-developed right uterine body; but the left cornu was anomalous and communicated, by what appeared to be a long round ligament, with the inguinal canal, in which lay a part of the well-developed ovary and beyond it a little fleshy nodule, looking like a rudimentary uterus. The left uterine tube was short, and ended in a little blunt stump, as shown. I pulled the ovary, with the nodule, out of the canal, with the intention of sewing up the internal inguinal ring from within, but it took so much traction to get it out that I could not sew up the ring without severing its connections, so I concluded the operation by stitching the ovary on all sides to the ring, in

the position on which I found it, so as to prevent the entrance of any of the other abdominal viscera into the canal.

The patient recovered and has suffered no inconvenience from her condition.

Femoral Hernia.—This variety of hernia is comparatively common in women, and is peculiarly liable to strangulation; over 60 per cent of the cases were strangulated, and three of these were gangrenous, according to Bloodgood's statistics from the Johns Hopkins Hospital.

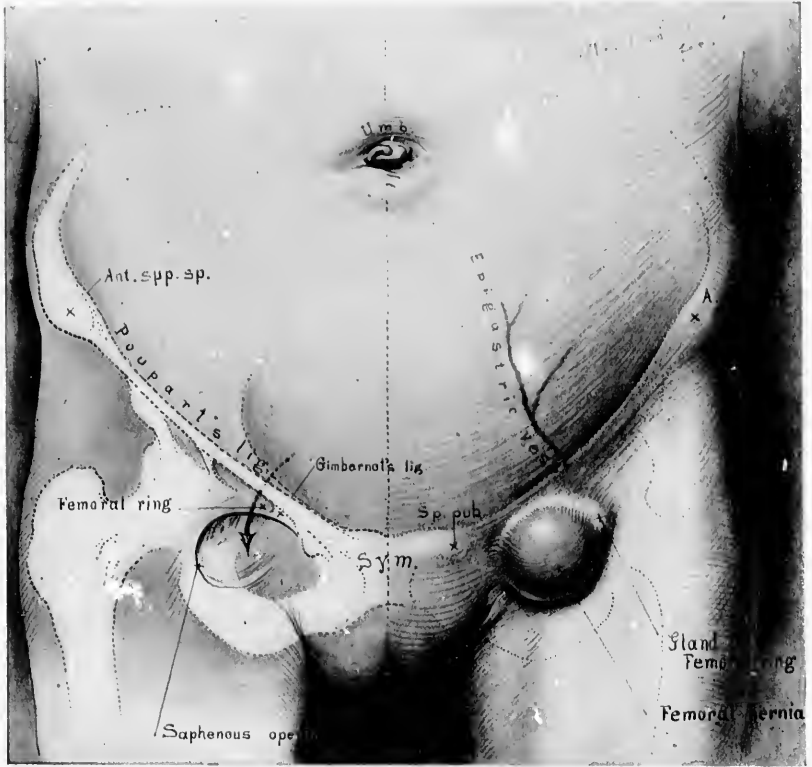


FIG. 556.—LEFT FEMORAL HERNIA.

Showing the characteristic form and position of the hernial sac beneath Poupart's ligament. A small gland is seen on the upper outer border of the sac. On the right side the topography of a femoral hernia is shown; the arrow indicates the direction taken by the hernia beneath Poupart's ligament and out through the saphenous opening. The various important landmarks are shown. II. Ward II. Nov. 20, 1897.

There are various methods of treatment of femoral hernia, and, unless the hernia is large, they are all followed by a large percentage of successes.

In gynecological cases in which I have had occasion to open the abdomen for some pelvic disease I have found stitching the sac from within successful.

After the abdomen is opened I locate the femoral ring, and then with the abdominal incision well lifted up with retractors, the pelvis being elevated, I am able to close effectually the femoral ring without great difficulty. As a rule, the hernial sac is small, and I make no attempt to dissect it out. The first mattress silk suture is introduced from above down through Poupart's ligament, close to the external iliac vein, which can be seen and felt, then on through the pubic portion of the fascia lata, and back again through Poupart's ligament. One or two sutures is sufficient to close the ring effectually. The utmost care must be taken to avoid injuring the external iliac vein.

In cases where the abdomen is not opened an external incision is made over the hernia, usually perpendicular to Poupart's ligament, and extending up to this structure, but not dividing it. After exposing the sac, it is ligated in the same way as an inguinal hernia, and excised. One mattress suture is passed through Gimbernat's ligament above and the pubic portion of the fascia lata below. Care must be observed not to cut or prick the saphenous vein.

A satisfactory way of treating femoral hernia is to excise the sac as described above, and then to pack a small piece of gauze into the canal, removing it gradually within ten days; this causes the canal to close by scar tissue.

In one of my cases (H. S., 5111, March 20, 1897), after opening the abdomen I slipped a sterilized glass ball into the right femoral sac, which it filled, and then sutured the peritoneum over it in two layers. Recovery followed without any discomfort, and there has been no tendency of the hernia to return since. The ball can be felt bimanually with two fingers pushing up through the anterior vaginal wall, while the other hand pushes down from above just over the right Poupart's ligament.

CHAPTER XXXVI.

INTESTINAL COMPLICATIONS.

1. The commonest intestinal complications found in gynecological work involve: 1. Rectum, sigmoid, and ileum (Groups D and E). 2. Vermiform appendix and head of the colon. 3. Adhesions are found high up in the abdomen, in ovarian cysts, and fibroid uteri. 4. General adhesions of bowels among themselves.
2. Kinds of intestinal complications: 1. Flat or velamentous adhesions. 2. Fistule. 3. Strictures. 4. Peritoneal bands.
3. Treatment of adherent bowel: 1. By clipping adhesions with scissors. 2. By leaving a piece of an ovary or fibroid tumor on the bowel. 3. Special cases cited of adhesions to uterus, to myomata, to ovarian cysts, to pelvic abscesses.
4. Removal of the vermiform appendix.
5. Suture of the intestines: 1. Fibrous coat of the intestine; ileum, cecum, and rectum compared. 2. Cleanliness in operating. 3. Tear of the peritoneal muscular coat. 4. Operation when the lumen of the bowel is opened. 5. Operation when the rectum is injured.
6. Anastomoses: 1. Side-to-side anastomosis. 2. End-to-end anastomosis. 3. End-to-side anastomosis. 4. Heo-cccal anastomosis. 5. Anastomosis buttons.
7. Artificial anus—colostomy.

Even the gynecologist who practices his specialty in the narrowest sense and confines his attention to the pelvic organs alone is liable in the course of any abdominal operation to meet with intestinal complications associated with the gynecological ailment, and he is particularly liable to meet with a well-defined group of intestinal complications which stand in the direct relation of effect and cause to the disease he has undertaken to treat. It is absolutely necessary, therefore, for the well-equipped gynecologist to be prepared to meet all such emergencies, and to know by what plans he may sometimes avoid injuring the bowel, or how to make a necessary injury as limited as possible in its extent, and how, on the other hand, to deal with the gravest intestinal lesions which can occur.


The commonest and the most serious complications are found associated with pelvic inflammatory affections, and involve those portions of the intestinal tract which lie normally within the pelvis or above its brim and in contact with the inflamed pelvic structures—that is to say, the rectum, the lower part of the sigmoid flexure, and the ileum, which naturally drops into the posterior pelvis or lies like a lid on top of it (Groups D and E in Fig. 21, Vol. I, p. 51); next in order come the vermiform appendix, the head of the colon, and the displaced transverse colon.

In the case of large tumors encroaching on the upper abdominal cavity, such as dermoid cysts, and some ovarian cysts, particularly those with a twisted pedicle and those which are suppurating, adhesions may be contracted with intestines far higher up than usual, involving the transverse colon and

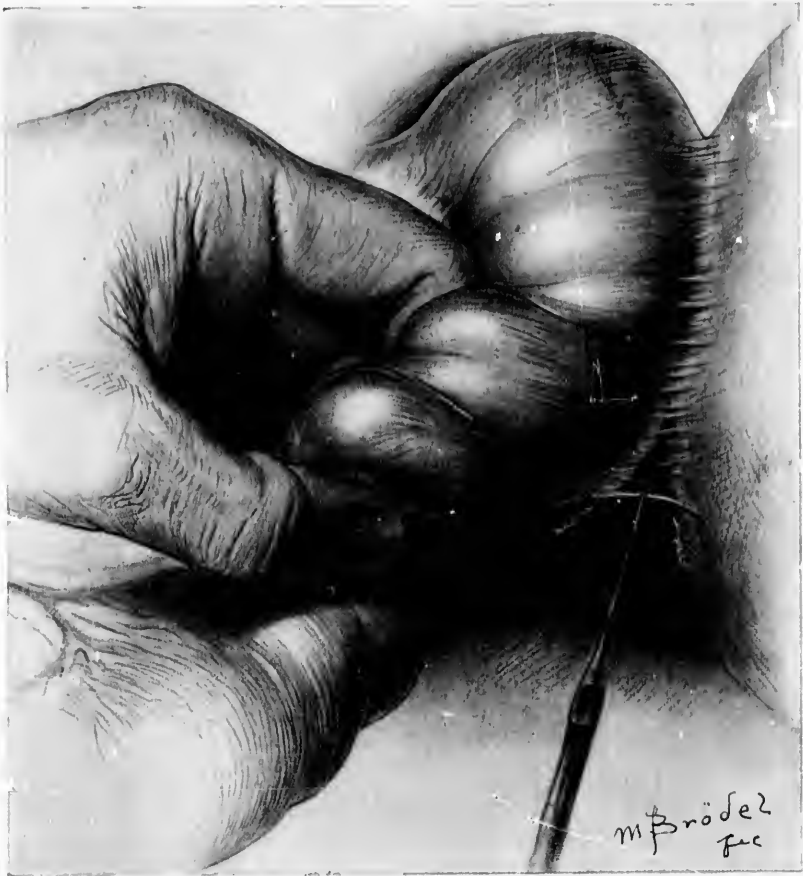

FIG. 557.—METHOD OF DEALING WITH INTESTINAL ADHESIONS WHERE AN INTERVAL CAN BE DEVELOPED BETWEEN THE BOWEL AND THE ADHERENT SURFACE BY SLIGHT TRACTION.

As each adhesion is divided, the next one beyond it is stretched for division.



Groups A, B, and C (*ut supra*). The same thing is true of large fibroid tumors in the abdomen. Under these circumstances the area covered by the intestinal adhesions is often far greater than is possible in disease limited to the pelvis.

In cancer of the ovary and in tuberculous of pelvic origin adhesions between adjacent loops of intestines and the diseased area are common concomitants, but these conditions rarely admit of any operative treatment, nor, indeed, do they call for it.

Another form of intestinal adhesions which demands particular notice is a more or less general agglutination of the bowels among themselves, the sequel of a peritoneal storm which has passed over, the patient surviving the peritonitis, which leaves the bowels everywhere mutually attached. When the abdominal cavity is opened, the separate loops are often difficult to distinguish, but in their place is found what appears to be a flattish red sac, presenting over its surface numerous slight irregularities and whitish streaks; this sac, without careful study, might easily be mistaken for a collapsed tumor. By watching a little while, or tapping the sac smartly with the finger, a vermicular wave is started which shows the presence of the intestine. Sometimes these adhesions are loose and velamentous, and would be easily separated if it were not for their great extent.

An inquiry into such a patient's history will often show that she has not suffered in any way from intestinal cramps or obstruction. I have seen several cases of tubercular peritonitis where all the intestines were adherent and appeared as if covered with a thick sheet of wet gray blotting paper, and yet there were no signs of any interference with the function of the bowel. The rule may therefore be laid down that when the intestines are widely adherent, without displacement of any of the loops, operative interference is not always necessary. On the contrary, a well-intended interference in these cases may bring about the very result the operator wishes to avoid, for the raw separated surfaces easily form new attachments, and one or more loops of the bowel may be caught the second time and detained in a vicious position.

The symptoms of obstruction or intestinal tormina must be the gauge by which to determine whether extensive adhesions ought or ought not to be separated.

Various Kinds of Intestinal Complications.—The kinds of intestinal complications met with are adhesions, either flat or velamentous, peritoneal bands, intestinal strictures, anastomoses between the loops of bowels, and fistulæ.

Adhesions are more apt to be found as the remains of more or less generalized attacks of peritonitis; if the interval between the attack and the operation is but a short one, the adhesions will be found far more extensive than at a later date, provided the cause has ceased to act, for even an extensive peritonitis with widespread adhesions may, after a few months, leave scarcely any trace of its existence behind, and any lingering adhesions will be most apt to be found near the focus of the disease.

The complete manner in which extensive peritoneal adhesions may clear up has often been demonstrated at an operation for a ventral hernia arising from the use of a gauze drain after an abdominal operation. It is well known that extensive adhesions form around such drains if they are left in for a few days, and yet upon opening the abdomen subsequently to operate upon the hernia following the use of the drain, the peritoneum has been repeatedly found entirely free from adhesions of any sort.

The same observation has been made regarding the adhesions surrounding the drain used after removal of the vermiform appendix, and even in the case of the extensive adhesions of a tubercular peritonitis.

In cases of pelvic inflammatory disease characterized by repeated attacks of peritonitis, between the attacks some of the plastic lymph is absorbed, but there is each time a residuum which forms adhesions about the diseased tube or ovary, continually becoming denser.

On the other hand, in cases of fresh acute peritonitis the formation of adhesions progresses at an equal pace with the extension of the disease. When the peritonitis is old, and urgent symptoms arise, everything may be done by operation to divide the adhesions and relieve the disease, but in the recent cases, while the inflammation is acute and progressive, unless the symptoms are most pressing, as a rule the adhesions should not be dealt with directly, but the effort should be made by cleansing the abdomen, or washing it out, or if need be, by extensive vaginal drainage, to cut short the infective process or to diminish its intensity.

The manner in which the adhesions surround a septic focus in the pelvis clearly shows that the agglutination of the loops of the intestines is one of nature's safeguards against any sudden invasion of septic material into the peritoneal cavity, for we constantly find a shading off in the density of the adhesions, which are lightest at a distance from the focus, and with any extension of the septic process a barrier of this sort is kept in front as an advance guard, efficiently protecting the general abdominal cavity. In old cases with general pelvic adhesions a barrier of dense adhesions is sometimes found covering in the pelvis—so dense that the bowel can not be detached without tearing it; below this barrier protecting the abdominal cavity, the adhesions may be so much lighter that the organs once exposed can be freed without special difficulty or risk of rupture. Knowing this fact, it is easy, for example, to enucleate the diseased adherent structures on one side by first cutting across the cervical portion of the uterus and then stripping them loose from below upward, instead of following the usual method of releasing them from above downward.

Loose velamentous and fibrinous adhesions are oftenest found and most widespread in their distribution, as well as the least dangerous. They are most troublesome when limited to a particular region or to a few coils of intestines; in such cases the interference with peristalsis may be marked, and the patient may suffer constantly from colic. Outside of the pelvis such areas of adhesions are oftenest found in the right lower abdomen, with the vermiform appendix as a center. If this occurs as the sequel of an operation, the hope

may always be indulged that with patience and the lapse of time absorption will take place and the pain cease; I have seen this happen repeatedly. At the same time it is sometimes one of the nicest points in abdominal surgery to distinguish between such a case, where there may be a constant but slow improvement, and one which will not improve, where an operation is ultimately inevitable and the patient is losing strength with the delay. Dense flat adhesions of the bowel are found affecting those loops of intestines which lie directly in contact with a highly septic focus, and the destructive alterations in the lumen of the intestine are often so great that a detachment without opening its lumen may be impossible. In many instances the history of the case shows that such adhesions mark the spot where an abscess has at some time ruptured through and discharged by the bowel; in other cases again the abscess is actually on the point of discharging, and but a thin diaphragm in the intestinal wall prevents the pus from escaping, and all that may be wanted to break the barrier is the pressure of the operator's hand as he grasps the abscess to enucleate it.

In this way fistulae arise, and the question whether or not they will remain permanent depends upon the size, position, and character of the contents of the abscess. Fistulae of this sort commonly discharge directly into the bowel, and are fortunately lacking the long, thick-walled sinus adherent on all sides sometimes found in other intestinal fistulae.

In two thousand celiotomies I have seen three instances of fistulae opening into the cecum; one was a large suppurating ovarian monoeyst, another a small dermoid cyst, and the third a pelvic abscess densely adherent in every direction. (E. B., Feb. 15, 1896, No. 4146½).

In two instances (one of them M. L. N., 1824, March 1, 1893) I have seen a spontaneous anastomosis between loops of the ileum, looking like a little bridge of bowel between them not more than a centimeter in diameter and only a few millimeters long; in dividing this bridge, the mucosa of the bowel pointed out on each side from an opening 3 or 4 millimeters in diameter.

Stricture of the bowel caused by a neoplasm or the result of an old chronic ulceration may be found at any point. I have seen long tubular strictures in the ileum near the valve, and again in the rectum at any point from the brim of the pelvis down to the rectal ampulla. A remarkable annular stricture caused by the constant compression of the neck of the sac of an incarcerated ventral hernia is figured in Chapter XXXVII.

Stricture of the rectum between the utero-sacral folds and just above them is so often found associated with pelvic inflammatory diseases that it must be looked upon as peculiarly a gynecological ailment. When the inflammation on one side extends across the pelvis, or when both sides are involved and abut against each other behind the uterus, the distensibility of the bowel is often interfered with.

The stricture may be seen by putting the patient in the knee-chest posture and inspecting the rectum from the ampulla up: just back of the cervix the bowel presents a contracted opening often not much more than a centimeter in

diameter; on making a digital examination, as the finger leaves the ampulla it enters a rigid contracted tube. The rule is for a rapid recovery to take place when the disease is removed, but when all the coats of the rectum have been involved in the inflammatory process the stricture may remain permanent, and it is remarkable how well a woman can get along with a stricture of the rectum which is not more than 3 or 4 millimeters in diameter.

Dense or delicate fibrous bands stretching from one part of the abdomen or pelvis to another part, or from intestine, uterus, bladder, or omentum to the abdominal or pelvic walls, are not often found. Their presence is always fraught with the danger of an incarceration and strangulation of a loop of the bowel beneath the band; to obviate this risk all such bands must be divided.

Treatment of Adherent Bowels.—The question how to deal with adherent bowels is of the utmost importance, and one in which the skill and experience of the operator may be brought into the fullest play, to avoid dangerous accidents, or to deal with such accidents when they do occur; the greatest risk, that of infection, arises when the cavity of the bowel is opened.

I shall speak first of the methods of avoiding injury to the wall of the intestine—that is, of avoiding the necessity of using an intestinal suture—and second of the various ways of suturing the bowel when it is injured.

Slight, superficial, and velamentous adhesions can always be severed by clipping them with scissors, or if there is not enough of an interval between the adherent organs to cut safely, one may be formed by making traction on the bowel. In this way a flat adhesion may be made to develop an interval of a few millimeters, in which it may be cut with safety (see Fig. 557).

In detaching a womb adherent in this way to the rectum, the uterus is pushed forward with the middle finger and the rectum is drawn back with the index finger, developing the interval, while the other hand does the cutting with the scissors. A flat adhesion which will not pull out may often still be severed by a careful dissection with a scalpel or the very tip ends of the scissors snipping little bits of tissue at a time.

Dense adhesions which are not amenable to these simpler plans of treatment may often be handled best by leaving a piece of the organ on the bowel covering the adherent area.

The operator may need to deal in this way with adhesions (1) to the uterus, (2) to myomata, (3) to ovarian cysts, and (4) to pelvic abscesses.

1. When a dense adhesion exists between the posterior wall of the uterus and the intestine, and it can not be freed without risk of opening the bowel, the best way to deal with it will be the following, which I have adopted in several instances with success: After freeing the bowel on all sides down to the fixed point, which is usually a small area not more than a centimeter or two in

diameter, an incision into the uterine wall is made on all sides close to the adhesion, about a millimeter in depth, and then by careful dissection with a sharp scalpel a thin layer of the uterus is dissected off and left adhering to the bowel, which is now free. The oozing from the raw spot on the bowel is always trifling, and that from the uterus may be checked by a few interrupted catgut sutures passed so as to draw the peritoneal edges of the wound together, and tied tight enough to control the flow.

2. When the bowel presents a dense adhesion to any part of a myomatous tumor the same principle may be applied with great freedom by dissecting off a thin layer of the capsule of the tumor and leaving it adherent to the intestine. There need be no fear of the tumor developing again from this area, for in the first place such a piece of the tumor has no power whatever of regeneration, and, moreover, the capsule is usually made up of the stretched-out and muscular envelope derived from the uterine tissue, and not of the tumor proper.

3. In the case of most ovarian cysts the dense white outer capsule of the tumor may be stripped off and left attached here and there to densely adherent coils of the intestines without risk; this would not be safe, however, with papillary and malignant tumors.

A case I am about to cite serves well to illustrate the application of this life-saving principle on an extensive scale. The patient (E. B. L., 4946, Jan. 20, 1897), a feeble elderly woman, was suffering from an ovarian tumor filling the lower abdomen and about the size of a six months' pregnancy. On opening the abdomen, about 30 centimeters of the ileum was found plastered on top of the tumor from the ileo-cecal valve across to the left side; the adhesion was a flat one, involving the inferior half of the bowel, and so intimate that any attempt at separation would have injured the bowel and necessitated a resection of the entire adherent portion. With a view to ligating the main vascular trunks of the tumor, and so preventing the hemorrhage from adhesions, I began by enucleating the pelvic portion of the tumor from a bed of adhesions and tying its pedicle off at the pelvic brim and the uterine cornu; in the course of this enucleation 700 cubic centimeters of thick yellow pus were evacuated, and the collapsed sac was finally drawn out of the abdominal incision, adherent only around the brim of the posterior part of the pelvis, and over the great vessels at the sides and above the brim, up as far as the mesentery, to which it was also densely adherent from the vertebral column out to the bowel, which was spread out over it as described. As these adhesions could not be separated without risk of injuring beyond repair such vital structures as the aorta, vena cava, superior hemorrhoidal and mesenteric vessels, as well as the ileum, I overcame the difficulty by leaving in all of the adherent outer capsule of the tumor. To do this, I made a circular incision on all sides about a centimeter from the attached edge and from a millimeter to a millimeter and a half deep, continuing the dissection bluntly with the handle of the scalpel back under the mesentery from below and from above, until the entire inner surface of the cyst was removed in one piece.

The tendency on the part of the capsule of the tumor to tear through into the more superficial layers was checked by the frequent use of the

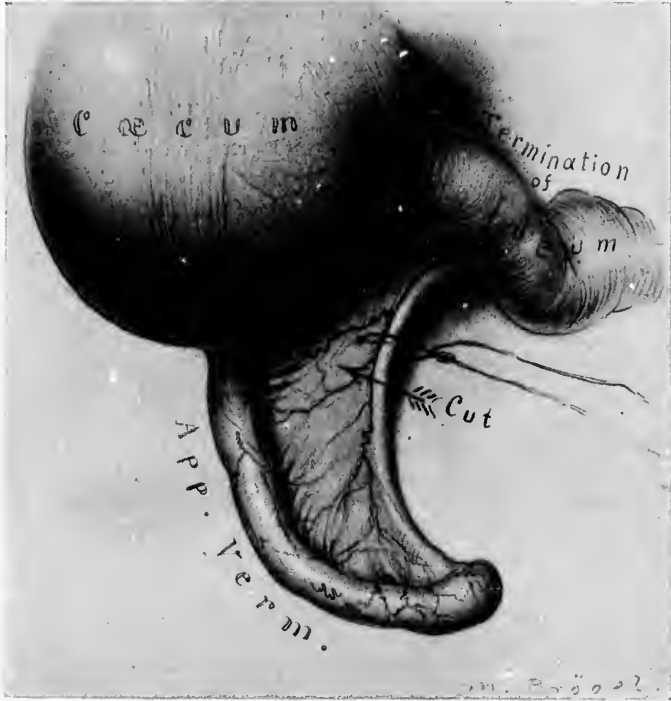


FIG. 558.—FIRST STEP IN THE OPERATION FOR APPENDICITIS.

The appendix and mesenterium freed and the first ligature applied controlling the vessels of the mesenterium, exclusive of the branch which goes to the base of the appendix. The incision is made in the direction of the arrow.

scissors or scalpel. The cap of the outer surface of the tumor—that is to say, the albuginea of the ovary, which was left behind—was as large as an ordinary sleeping-cap; it did not bleed at all, and was simply dropped into the abdomen with its anterior and posterior walls lying in contact, and the abdomen was closed without a drain. The convalescence was entirely undisturbed.

4. When the bowel adheres to a pelvic abscess the same plan of treatment may be applied; in this group of cases, however, it will often be necessary to cut out the entire thickness of the abscess wall over an area corresponding to the adhesion to the bowel, and then either to scrape off the inner lining of the membrane or to burn it off, so as to eliminate the risk of infection from this source.

Removal of the Vermiform Appendix.—In every abdominal section the vermiform appendix should be picked up and inspected and its condition noted in writing on the patient's history.

The frequency of the occurrence of adhesions of the vermiform appendix to inflammatory structures in the pelvis appears to me to be one of the strongest indications for the abdominal route in dealing with cases of this class.

In the series of one hundred hystero-salpingo-oöphorectomies, the vermiform appendix was adherent in twenty-seven cases, and in seven cases required removal on account of the extensive disease in this structure.

In order to remove the appendix it is freed and, with the head of the colon, brought outside the abdominal incision and laid on a gauze pad. The appendix is then lifted up near the colon and its mesentery tied off with one or two single fine silk ligatures, including all its vessels; the mesenteriolum is then cut through down to the root of the appendix. A circular incision is now made through the peritoneum surrounding the appendix about 2 centimeters from the large bowel, and by pulling on its lower end and using the point of the knife or a little blunt instrument to peel back the peritoneum, a cuff 1 centimeter long is turned up onto the colon. The muscular and mucous coats are now tied tightly with fine silk close under the reflected cuff and close to the colon, and another ligature is placed lower down after milking back its contents, so as to prevent any escape of fecal matter upon severing the appendix. The appendix is now divided half a centimeter beyond the proximal ligature. The free end is removed or the end adhering to the tumor is carefully wrapped in gauze and dropped for a time. The stump shows a small tract of everted mucosa pointing beyond its ligature; this is cleansed with a bit of cotton and sterilized with pure carbolic acid, taking

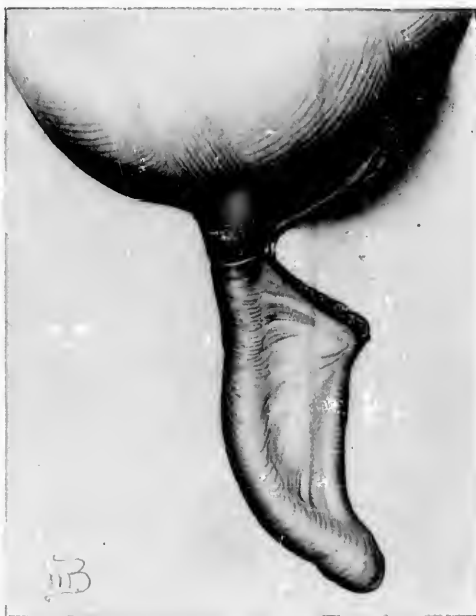

FIG. 559.—SECOND STEP IN THE OPERATION FOR APPENDICITIS.
The mesenteriolum cut through and the peritoneum and external muscular coat of the appendix circumscribed.

care not to let any of it run onto the peritoneum. The reflected peritoneal cuff is now drawn down over the little stump and turned in so as to bring the

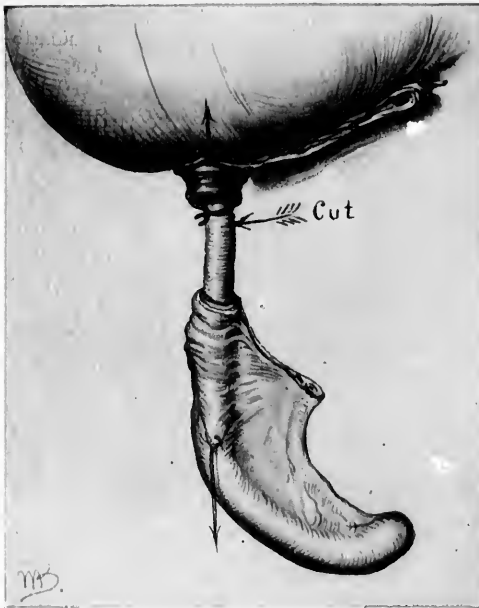

FIG. 560.—THIRD STEP IN THE OPERATION FOR APPENDICITIS.

The cuff of peritoneum and external muscular coat turned up onto the cecum and a fine silk ligature applied to the stripped appendix, consisting now only of circular muscular fibers and mucosa. The ligature must be applied as close as possible to the cecum. The appendix is then amputated just beyond the ligature, and the little area of exposed mucosa distal to it sterilized with pure carbolic acid.

envelope for the stump. Where this can not be effected it is better to throw a silk ligature around the entire appendix, tying it tightly, and then to cut it off beyond the ligature, sterilizing the end and covering it with the peritoneum by suturing a fold of the colon over it. This method is satisfactory, and is advocated in all cases by some surgeons. It is not necessary to cut off the appendix flush with the colon unless it is diseased throughout; in some cases the ulceration extends out into the cecum and it may be necessary to remove the neighboring part of the bowel which should then be closed with mattress sutures.

The pelvic operation is now completed, taking care not to infect the peritoneum with the adherent end of the appendix wrapped in gauze.

Suture of the Intestines.—Intestinal suture is required (1) when any part of the muscular coats of the bowel has been torn in separating adhesions, (2) when

the reflected peritoneal margins together, when it is sutured from side to side with a continuous overlapping fine silk suture threaded in a straight needle. The stump of the appendix now appears like a little tit on the cecum, or it lies almost hidden between the cecal folds. The end of the appendix is finally completely put out of sight in an extraperitoneal pocket by a catgut suture catching it and passing through the sides of the little triangular opening at the base of the mesentericohum; upon tying the suture, the stump is drawn down between the layers of the peritoneum, which are also approximated at the same time.

In some cases where there is extensive suppuration of the appendix, or where its peritoneal coat is friable, it may not be possible to obtain a peritoneal

the lumen of the bowel is opened, (3) when there is a stricture of the bowel which endangers life, or (4) when there is an intestinal fistula.

Needle and Sutures.—The best needles for the intestinal suture are either a long, slender one with a round point and without cutting edges, called a straw needle, size No. 8, and milliners' needles, sizes No. 9 or No. 10, which are longer than the ordinary cambric needles, or a little round curved French needle with an eye opening with a little spring at the end.

In suturing the rectum where the coat of the bowel is thick, a small, curved, flat needle with a carrier, and held in a needle holder, may be used with advantage.

The finest silk thread is used—black, iron-dyed, or white. Each thread is about 30 centimeters long and threaded directly through the eye of the needle. If the straight needles are used, it is best to have about thirty of them threaded ready for any operation and preserved rolled up in a towel (see Fig. 565). The threads do not get tangled if they are drawn through the towel a few times in parallel rows. The needles are stuck in in a row, as practiced by Dr. W. S. Halsted.

The sterilization of the sutures is effected by rolling them up in the towel, pinning another towel about them, and placing them in the steam sterilizer. After sterilization they are dried out thoroughly and put away. This plan of keeping them dry is better than the practice of immersing them in alcohol or in juniper oil.

The Fibrous Coat of the Intestine.—The most valuable contribution which has as yet been made to intestinal surgery is the demonstration by Dr. W. S. Halsted of the fact that the essential feature in any suturing or anastomotic operation is the employment of the submucous intestinal coat. This is an exceedingly tough fibrous membrane, airtight and water-tight; it is the "skin" in which sausage meat is stuffed. It is, moreover, the coat of the intestine from which "cat-gut" is made.

Halsted has shown (see *Circular Suture of the Intestine: An Experimental Study*, *Am. Jour. of the Med. Sci.*, Oct., 1887; see also *Intestinal Anastomosis*, *Johns Hopkins Hosp. Bull.*, No. 10, Jan., 1891) that the taking up of the serous or of the serous and the muscular coats in the suture is insufficient to assure the permanency of the hold, but, on the other hand, "a delicate thread of this tissue (the submucous coat) is very much stronger and better able to hold a stitch than is a coarse shred of the entire thickness of the muscular and serous




FIG. 561.—AFTER AMPUTATION AND STERILIZATION THE STUMP IS ALLOWED TO RETRACT (SEEN IN FAINT OUTLINE) WITHIN THE CUFF OF PERITONEUM.

coats." In fifteen experiments, including eighteen circular sutures of the intestine made by Halsted, all succeeded.

The importance of this discovery has been demonstrated by the experiments of W. Edmunds and Charles A. Ballance in the Brown Institution (see *Obs. and*

Esper. on Intestinal and Gastro-intestinal Anastomosis, Medico-chirurgical Transactions, vol. lxxix, London, 1896). I have made some measurements similar to those of Edmunds and Ballance, and present the figures in the text in order to show the position and relative thickness of this fibrous layer in the small and in the large intestines. It is evident from the figures that it is relatively quite a stout tissue, especially in the rectum, where it attains its maximum development.

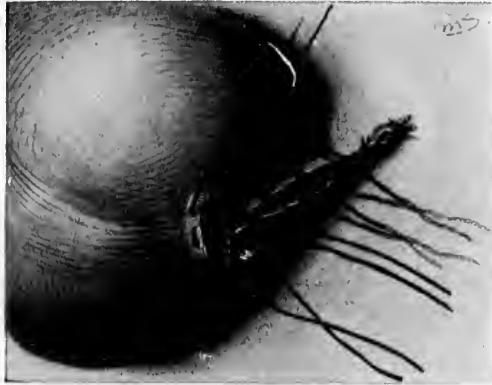

FIG. 562.—CLOSURE OF THE PERITONEAL CUFF OVER THE STUMP BY MATTRESS AND INTERRUPTED SUTURES.

Partial closure of the mesenteriolium, using interrupted or mattress sutures.

The practical question is how this fibrous layer can be recognized in passing the sutures. This is done by pushing the needle vertically through the wall of the intestine after transfixing the serous and mucous coats. On reaching the fibrous layer it at once meets with a considerable resistance, which becomes still greater if the needle is passed horizontally through its meshes. It is not difficult with experience to turn the sharp point so as to pick up a shred of this fibrous layer each time without ever entering the lumen of the bowel.

Simple interrupted, mattress, and continuous sutures may be used. The simple interrupted suture should only be used in the rectum or for a short clean cut in the small bowel. The continuous rectangular suture may be applied occasionally to longer straight tears. The mattress suture is the surest of all and is always used in anastomosing.




FIG. 563.—INVERSION AND EXTRAPERITONEAL DISPOSAL OF THE LITTLE BUTTONLIKE STUMP BENEATH THE CONTIGUOUS MARGINS OF THE MESENTERIOLIUM.

This is accomplished by passing a suture, as shown, and tying it, in this way turning the stump in.

The mattress and the continuous sutures enter and emerge on the serous surfaces, and so serve to turn in the edges of the bowel. Care must be taken not to roll in too much of an edge in this way in order to avoid a large flange projecting into the lumen.

Cleanliness.—When the lumen of the bowel is opened the operator must immediately try to avoid the escape of any of its contents onto the peritoneum. This will be done by bringing the bowel outside the incision whenever it is possible, and laying it upon gauze pads while the opening is being closed.



FIG. 564.—CURVED INTESTINAL NEEDLE, ORDINARY SIZE.
The eye is split open at the end and barbed, as shown, for the insertion of the thread.




FIG. 565.—HALSTED'S METHOD OF PRESERVING THE INTESTINAL NEEDLES, THREADED AND STERILIZED, IN A TOWEL. $\frac{1}{2}$ ACTUAL SIZE.

If the injury is extensive and the operation is to be a long one, as in an anastomosis, it will be best to shut off any communication with the upper and lower bowel by passing a piece of rubber tubing through the mesentery at a convenient distance above and below the field of operation and fastening it with a single tie, or a piece of wood shaped like a toothpick may be thrust through the mesentery and a rubber band stretched across the bowel. The bowel should then be irrigated with salt solution and its mucous surfaces cleansed with peroxide of hydrogen.

As soon as the discovery is made that a part of the bowel is injured which can not be lifted out in this way, it will be best to surround it at once on all sides with gauze pads to protect the peritoneum while the injury is being repaired.

Tear of the Peritoneal and Muscular Coats.—A tear of the muscular coat always calls for suture. A simple continuous suture of catgut or of fine silk may be used, taking in the peritoneum and the torn muscularis; this should be applied in such a way as both to restore the muscle to its position and to avoid narrowing the lumen of the bowel.

When the Lumen of the Bowel is Opened.—If the bowel is opened by a cut or a small hole this may be closed either by interrupted, mattress, or a continuous rectangular suture, entering but not perforating the fibrous layer; the mattress and interrupted sutures ought to be placed close together, at intervals not greater than 1 or 2 millimeters. A little hole in the bowel may be closed snugly by a rectangular or a purse-string suture.

When the Rectum is Injured.—When the rectum is torn open the difficulties of getting at the field of operation are much greater than elsewhere,

but, on the other hand, the remarkable thickness of this part of the bowel makes it much easier to suture it and to bring the edges of the tear into accurate apposition. I prefer in this case to use interrupted sutures placed close together and passed with a small curved needle and a fine silk carrier. A straight needle can not be used with advantage, because there is not room enough deep down in the pelvis to push it in and draw it through. It is most necessary in these

cases not to constrict the lumen of the bowel, as the suturing will not stand the pressure of formed fecal matter accumulating on the proximal side of the stricture.

In these rectal cases the tear is most apt to occur during the enucleation of inflammatory masses from the pelvis, and in that event the bowel

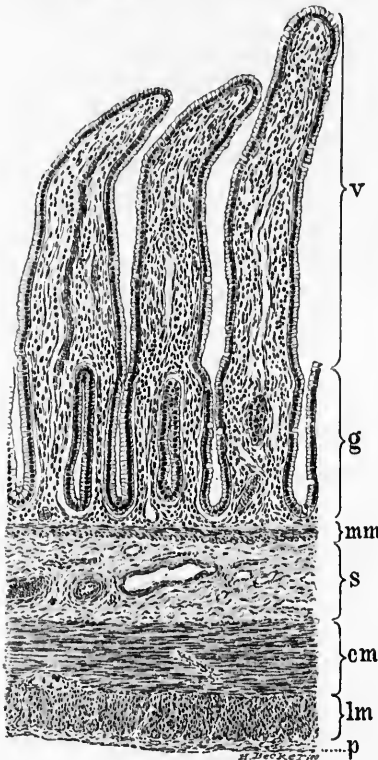


FIG. 566.—HUMAN SMALL INTESTINE MAGNIFIED ONE HUNDRED TIMES TO SHOW THE RELATIVE THICKNESS OF THE VARIOUS COATS.

p, the peritoneum; *lm*, the longitudinal and *cm* the circular muscular coats; *s* is the fibrous coat, and *mm* the muscularis mucosae; *g* marks the glands, and *v* the long villi.

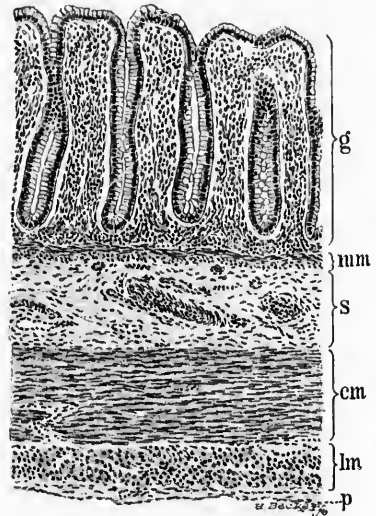


FIG. 567.—A SECTION OF THE COLON MAGNIFIED ONE HUNDRED TIMES.

Showing (*s*) the fibrous coat about as thick as the circular muscular coat and of about the same thickness as in the small intestine. The letters are the same as in the last figure.

may be torn into or torn across flush with the hardened infiltrated pelvic floor. It is not possible to suture together the torn surfaces under these conditions, and the first step taken must be to dissect out and set free enough of the lower part of the bowel to secure good tissue which can be joined to the upper end without traction.

In rectal tears opening the lumen of the bowel, except in well-closed small wounds with healthy surrounding tissues, it is always safer to make a free opening in the vaginal vault posterior to the cervix, and to put in a washed-out iodoform gauze drain for several days or a week.

In one instance (J. S., 357, Sept. 2, 1890) in which the muscular coats of the rectum were torn through in a triangular shape from the pelvic floor to the brim, with the base of the tear at the floor, I covered in the large denuded area by suturing the uterine, in retroposition, to the bowel on each side with a continuous suture (*Johns Hopk. Hosp. Rep.*, vol. iii, 1894, p. 413).

In another case (M. P., 5014, Feb. 13, 1897) the rectum was torn completely across at the pelvic floor, the end being held together only by the mesenteric border. There was no discharge or odor from the bowel, which was scarcely detected amid the mass of pelvic adhesions. The torn surfaces were repaired in the following way: The lower end of the rectum was dissected out and freed from the bed of adhesions on the pelvic floor, and then united to the upper end by a series of thirty interrupted fine silk sutures passed with a small curved needle

and a carrier, beginning at the floor of the pelvis at the left side and extending obliquely upward on the right side to the level of the second sacral vertebra. Each suture penetrated the coats of the bowel down to the mucosa, and the distance between them was about 2 millimeters. A small gauze drain was passed through the vaginal vault. Perfect recovery ensued, without fistula.

Lateral Anastomosis.—If the bowel is gangrenous, or is strictured to such an extent as to threaten the life or the health of the patient, it will be necessary to establish a communication between the sound lumen above and below, in this way anastomosing the bowel to itself and bridging over the diseased area.

A simple and much practiced form of anastomosis is by the approximation of the lateral surfaces with an opening between them, and the best plan of operation is Halsted's, which I shall closely follow throughout in my description (see Figs. 569 to 573).

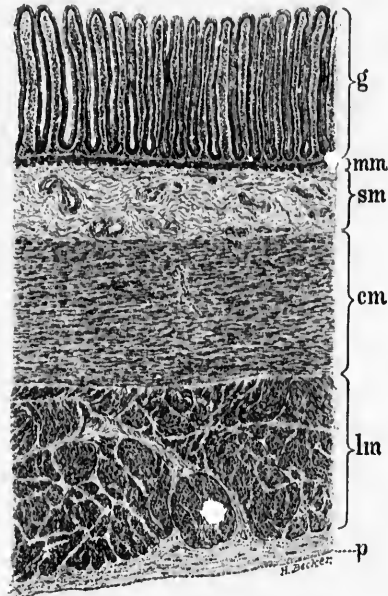


FIG. 568.—COMPARE THIS DRAWING OF THE COATS OF THE RECTUM SEEN IN CROSS-SECTION AND ONLY MAGNIFIED TWENTY-FIVE TIMES, WITH THE PRECEDING PICTURES MAGNIFIED ONE HUNDRED TIMES.

The fibrous coat (*sm*) is almost four times, the circularis about eight times, and the longitudinalis about sixteen times, as thick as in the bowel higher up. Spec. 1024.

First the upper piece of bowel is brought down beside the lower, and from six to eight mattress sutures applied on the side toward the mesentery,




FIG. 569.—LATERAL ANASTOMOSIS.

The ends of the bowel closed, and mattress sutures introduced on the lower side.

and drawn up and tied, as shown in the figures. Two lateral sutures are then applied at either end, so as to curve the line of approximation forward; these are now tied, and an anterior row of sutures is next laid, completing an oval figure, as shown. Before tying these they are



FIG. 570.—LOWER ROW OF SUTURES TIED AND THE LATERAL SUTURES APPLIED, TWO AT EACH END.

drawn apart in order to cut generous openings into the bowel on both sides, so as to effect the anastomosis; the openings must be large enough to allow for the subsequent contraction. As soon as this is done all the sutures are tied and the operation is completed. The duration of this operation in skilled hands is from eight to ten minutes.

End-to-end Anastomosis.—In end-to-end anastomosis after Halsted's method (see *Circular Suture of the Intestine, Amer. Jour. of the Med. Sci.*, Oct., 1887), the mattress sutures are used to bring the opposed edges into accurate apposition on all sides. The bowel must present an even edge and must not project

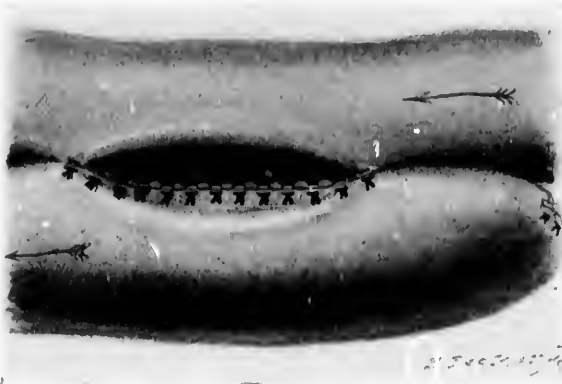


FIG. 571.—THE LATERAL SUTURES TIED ALSO, MAKING A POCKET.

beyond its mesentery upon which it depends for nutrition. The sutures are laid about 2 millimeters apart, as nearly as possible in a straight line around the bowel, and all of them are put in place before a single one is tied; each suture is made to penetrate but not to perforate the fibrous layer of the gut close to its

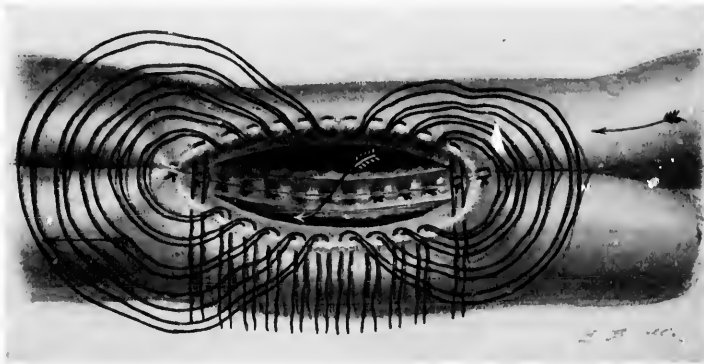


FIG. 572.—REMAINING SUTURES IN PLACE READY TO COMPLETE THE UNION ON ALL SIDES.

The bowel is now freely opened between the upper and lower layer of sutures, establishing the anastomosis in the direction of the arrows.

margin, in order to avoid turning in a broad flange toward the lumen of the bowel to act as an obstruction (see Figs. 574 to 577). On account of the diffi-

culty of accurate approximation at the mesenteric border a painstaking attention must be given to each stitch as it is laid; the union at this point will be further

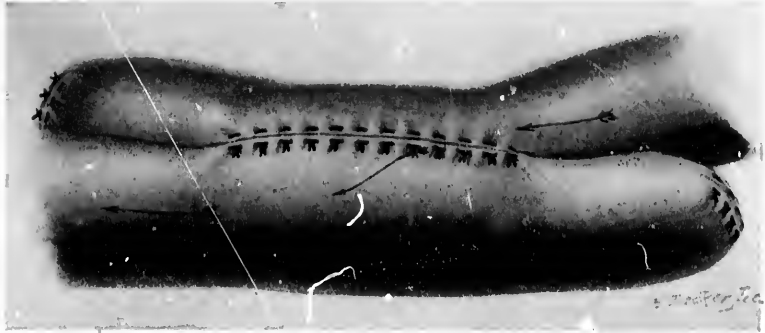

FIG. 573.—LATERAL ANASTOMOSIS COMPLETED, ALL THE SUTURES TIED.

The fecal current now freely follows the course indicated by the arrows.

facilitated by selecting a spot for the resection which is free from fat and large vessels. A good resection is characterized by good union on all sides, and further by the absence of post-operative adhesions about it.

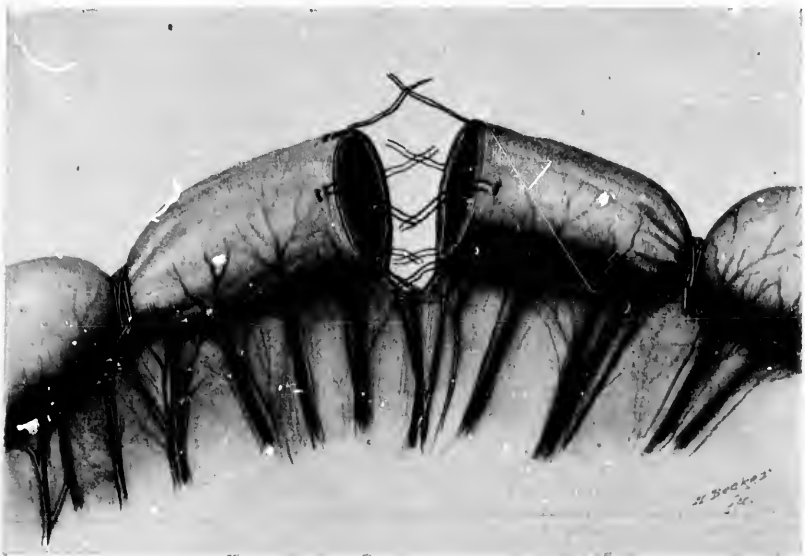

FIG. 574.—END-TO-END ANASTOMOSIS WITHOUT ARTIFICIAL AIDS.

Presection sutures in place and about to be tied.

The sutures are tied and the slit in the mesentery closed, taking care not to interfere with its circulation, and the operation is completed. If the row of




FIG. 575.—PRESECTION SUTURES TIED.

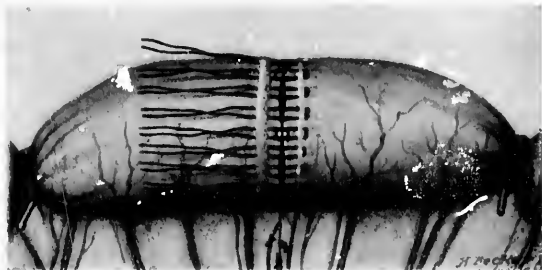


FIG. 576.—MATTRESS SUTURES IN PLACE.

circular sutures has been well applied there is no need of a second row to reinforce them.

Circular Suture of the Intestine with the Use of Inflated Rubber Cylinders.—

Owing to the flaccidity of the bowel, its tendency to contract at the cut edges, and a possible difference in the lumina of the two ends to be brought together, the process of adjustment of the resected ends just described may sometimes present considerable difficulties, interfering with the accuracy of the apposition, and therefore introducing an element of uncertainty. All these difficulties have been obviated by the invention of an inflatable rubber cylinder which is introduced into the bowel, as shown in the inset cut; upon this the ends are easily and accurately brought together, and just before the last stitches are tied, the air is let out and the cylinder withdrawn (see Halsted in the *Phil. Med. Jour.*, Jan. 8, 1898). This method of suture is so simple and so satisfactory that, before operating upon human beings, every surgeon should familiarize himself with it by repeatedly practicing upon dogs until a series of successful results are obtained (see Figs. 578 to 585).

The method of using the cylinder is as follows: In the first place, before resecting the intestine, its blood supply should be carefully studied with reference not only to the placing of the ligatures but also of the stitches, and each stitch should be so placed that the circulation, up to the very edge of the cut, should be interfered with as little as possible.

The intestine is first caught by the presection sutures (see Figs. 578 and 579), and it is immaterial whether they enter the lumen of the bowel or not, as they




FIG. 577.—SUTURES ALL TIED, SHOWING ACCURATE APPROXIMATION OF THE DIVIDED ENDS OF THE BOWEL.

are finally cut off into the bowel. The figures show also the method of ligating the mesenteric vessels taken from life.

The intestine should then be divided with scissors as close to the presection sutures as possible; two of the sutures are then tied, and the collapsed rubber cylinder pushed into the bowel with forceps, so that one half lies in each end and the inflation tube comes out in the middle.

In Fig. 581 the three presection sutures are shown tied, and a supplementary fourth stitch (*b*) is introduced; this is cut later to facilitate the withdrawal of the bag.

The bag is now inflated with air until the intestine is distended to its normal caliber.

The mesenteric stitch (*a*) (see Figs. 581 to 584) is the first and most important of the mattress or permanent sutures; by it the submucosa is picked up four times (as indeed by all the mattress stitches), and the mesentery is perforated twice; by placing the stitch as shown in the figures the mesenteric border is

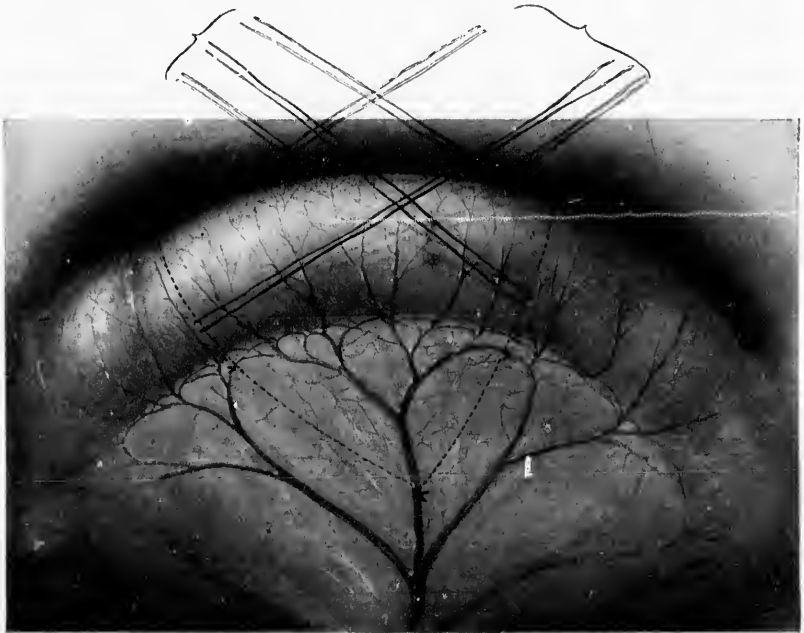


FIG. 578.—CIRCULAR SUTURE OF THE INTESTINE.

Showing the first step in the introduction of the presection sutures, six in number. These serve, when the bowel is resected, to baste the ends together, as it were, facilitating the subsequent application of the mattress sutures which secure accurate union throughout. The area to be excised is included within the dotted lines; this must always be carefully selected with reference to the arrangement of the blood vessels, so as to secure vessels going to the cut edges, and at the same time to avoid including any vessels in the subsequent suturing, as shown in the figure. Note the ligatures applied to vessels before dividing the intestine.



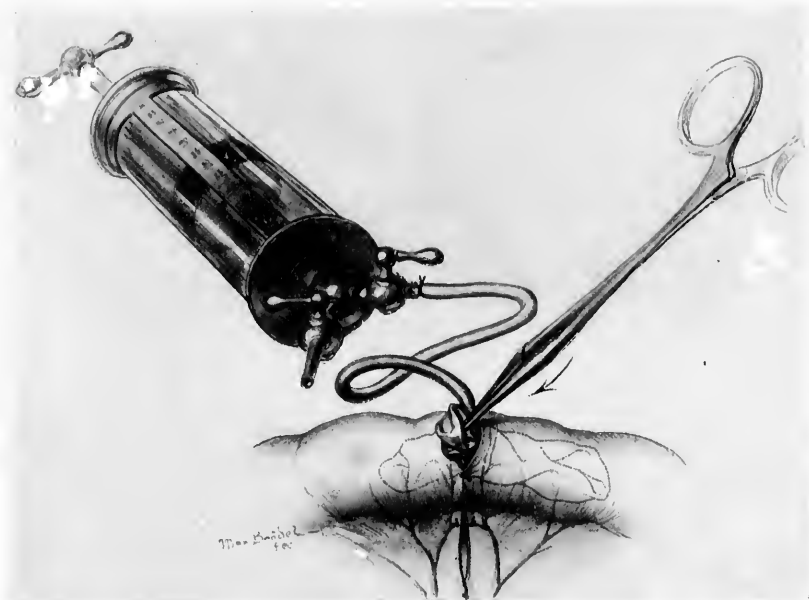


FIG. 580.—THE INTRODUCTION OF THE COLLAPSEL RUBBER CYLINDER BETWEEN THE PRESECTION SUTURES.

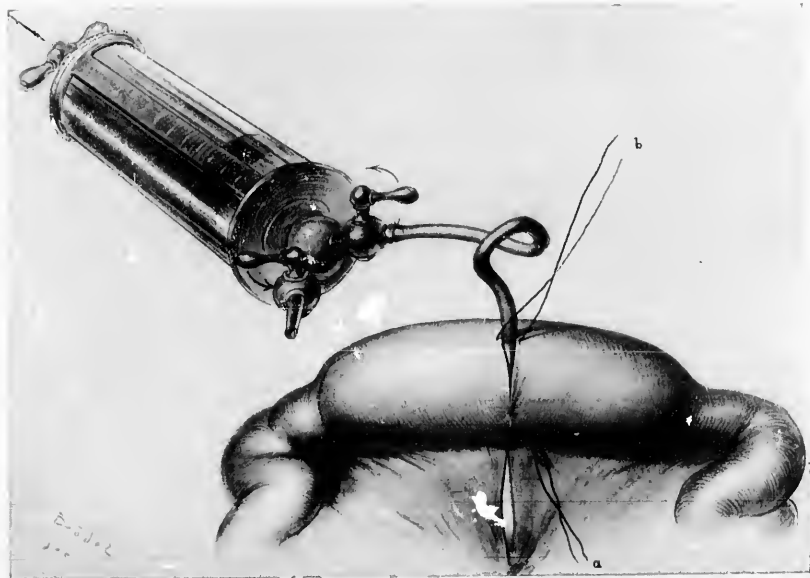


FIG. 581.—AFTER TYING THE THREE PRESECTION SUTURES AND INSERTING THE RUBBER BAG A FOURTH STITCH, *b*, IS INSERTED.

The cylinder inflated and a fourth suture inserted near the tube.

turned in, and the bowel is brought snugly and evenly together at the very point which is apt to be the weakest in the series.

From ten to twelve mattress sutures are now placed around the intestine, from mesenteric border to mesenteric border, taking care not to occlude a single vessel by passing under or over them, as the case may be. All of the

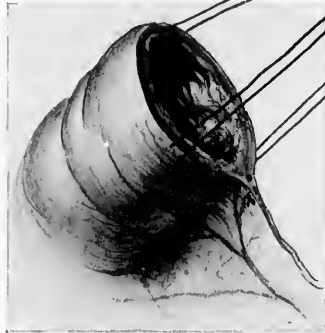


FIG. 579.—ONE OF THE DIVIDED ENDS OF THE INTESTINE.

With its presection sutures ready to be drawn over and roughly approximated to the opposed end. Both sets of presection sutures are applied in exactly corresponding positions, and, owing to the fact that they are turned in by the next set of sutures, it makes no difference even if they penetrate all the coats of the bowel; note the position of the two ligated vessels on the very edge of the mesentery.

one case in which an anastomosis of the upper end of the bowel into the side of the lower end was necessary (see *Johns. Hosp. Hosp. Bull.*, Feb., 1895). The patient (B. W. M., 1161) had a long tubular stricture of the rectum extending from the ampulla up to the sigmoid flexure, and in operating for a pelvic inflammation with dense adhesions the contracted bowel was mistaken by her physician for a uterine tube and cut off; the ends of the bowel were brought out at the abdominal incision, and she recovered with an artificial anus.

About two months later, Oct. 20, 1894, I extirpated, by a most difficult dissection, the uterus, tubes, and ovaries buried in a mass of adhesions; as the patient was rapidly collaps-

ing under or over them, as sutures except the mesenteric are passed before tying them, and if any suture takes up more than the submucosa and enters the bowel and pricks the cylinder, this is at once known by the escape of the air, and the suture must be taken out and a fresh cylinder put in.

After the sutures are passed and the bag is withdrawn, they are tied and cut off short and the bowel snugly united on all sides.

The use of the inflated rubber cylinder not only prevents the escape of the bowel contents, but it also preserves the intestine from the constriction of a clamp and from handling by an assistant. Perhaps the greatest advantage of the method, however, is the easy adaptation secured in lumina of various sizes, which must be brought together.

End-to-side Anastomosis — Sigmoido-proctostomy.—I have had but




FIG. 582.—THE MESENTERIC MATTRESS SUTURE DEvised BY MITCHELL AND HUNNER.

Showing how it is passed to secure accurate apposition of the bowel on the side where the union is most difficult to obtain. Each time the suture is introduced it takes up a bit of the submucosa.

ing, I completed the operation hastily by closing the distal end of the stricture, incising the ampulla, and pulling the sigmoid end of the bowel down into the incision, which it fitted snugly, and holding it there by traction sutures brought out at the anus in the grasp of forceps.

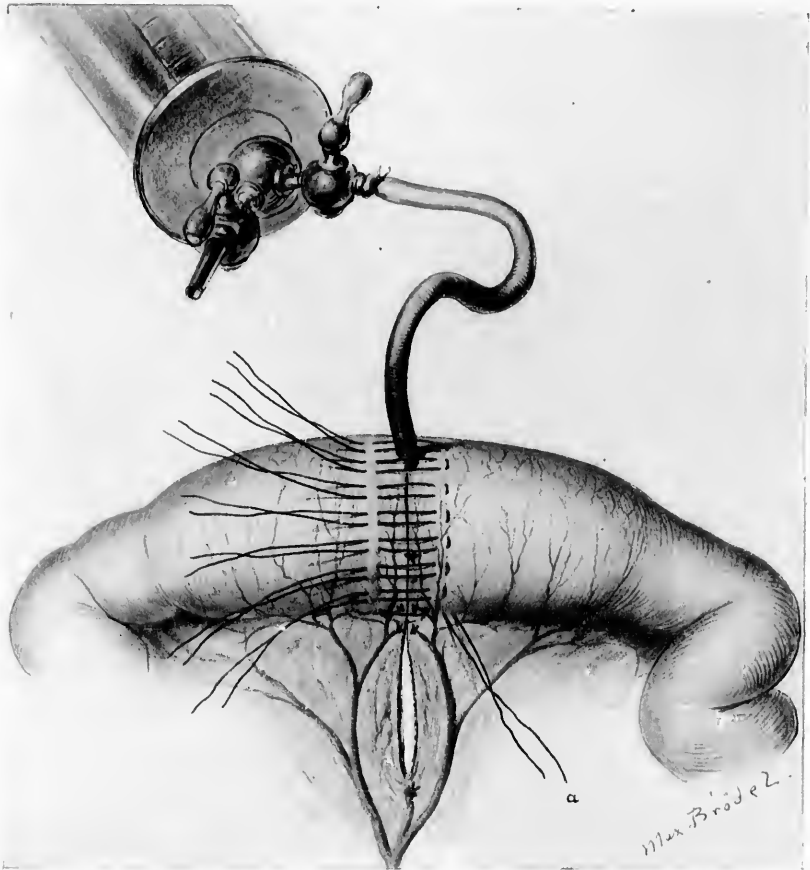


FIG. 583.—FROM TEN TO TWELVE MATTRESS SUTURES ARE INTRODUCED, AS SHOWN, AND THE TYING BEGUN WITH THE MESENTERIC SUTURE *a*.

Great care is taken not to include any of the vessels in a suture, as is shown by passing the needle under one vessel and over another.

One essential feature was wanting to the permanent success of the operation, and that was the suture of the peritoneal surfaces of the entering and receiving bowel. With the rough-and-ready plan of treatment adopted the patient lived for three months and had normal bowel movements. The autopsy showed that

the upper part of the bowel had retracted, leaving a cavity lined by mucous membrane between it and the ampulla.

Ileo-cecal Anastomosis.—A case of fibroid tumor of the ovary (M. F., 2237½, Oct. 7, 1893) was complicated by tight strictures of the ileum, causing peritonitis and the ejection of matter from the mouth having a fecal odor. On opening the abdomen two strictures were found in the ileum, one 18 centimeters above the ileo-cecal valve, and the other 12 centimeters above this—

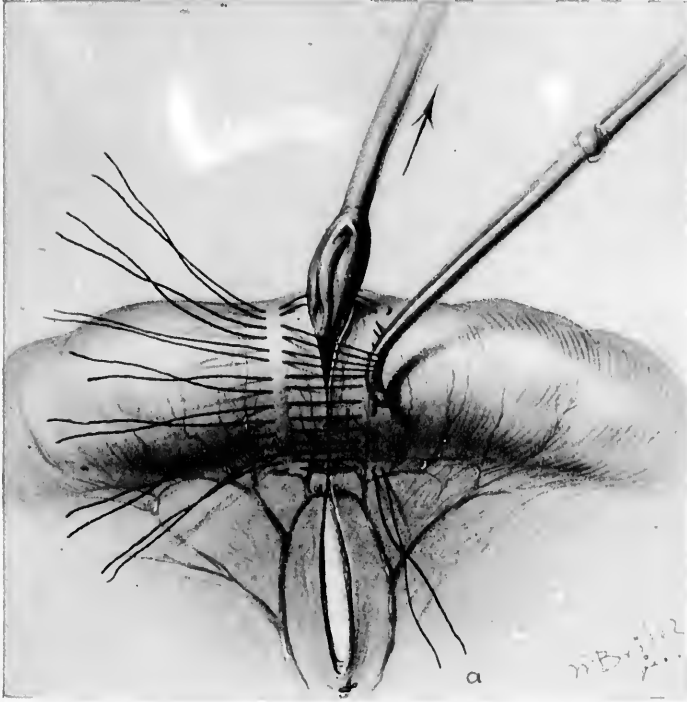


FIG. 584.—NOW THAT THE SUTURES ARE ALL INTRODUCED, TWO OF THEM ARE SEPARATED TO ALLOW THE DEFLATED BAG TO BE WITHDRAWN.

that is, 30 centimeters distant. The gut between the valve and the first stricture was flat and contracted down to 1.5 centimeter in diameter.

The portion between the strictures was distended with fluid, and was spindle-shaped, deeply injected, its surface covered with a light grayish lymph.

Each of the strictures appeared as a little spherical nodule 1 centimeter in diameter, to which the lumen of the bowel suddenly contracted. In the angle between the nodules and the bowel a little pus had accumulated, and from the lower nodule a thick mass extended up the mesentery 2 to 3 by 6 centimeters.

The extreme dense contraction made any attempt to establish even a small lumen through the strictures hopeless, so an anastomosis was made between the distended ileum above the strictures and the cecum, turning the strictured part of the bowel up and flexing it on itself so as to bring them together. The bowels moved naturally and there was no leakage, and a complete recovery followed. In this way the portions above and below the strictures came into approximation most easily; the ileum and the colon could not be so easily drawn together on account of the rigid strictured portion between, which would not bend easily in the opposite direction.

The anastomosis was effected by bringing the bowel outside and laying it on pads of gauze. A continuous rectangular silk suture, 5 centimeters long, was then passed, uniting the ileum to the head of the cecum below the line of intended anastomosis, and including all the layers of the bowel down to the mucous coat. Immediately above this a series of mattress sutures were applied and continued all the way around the line of intended anastomosis. Then the sutures

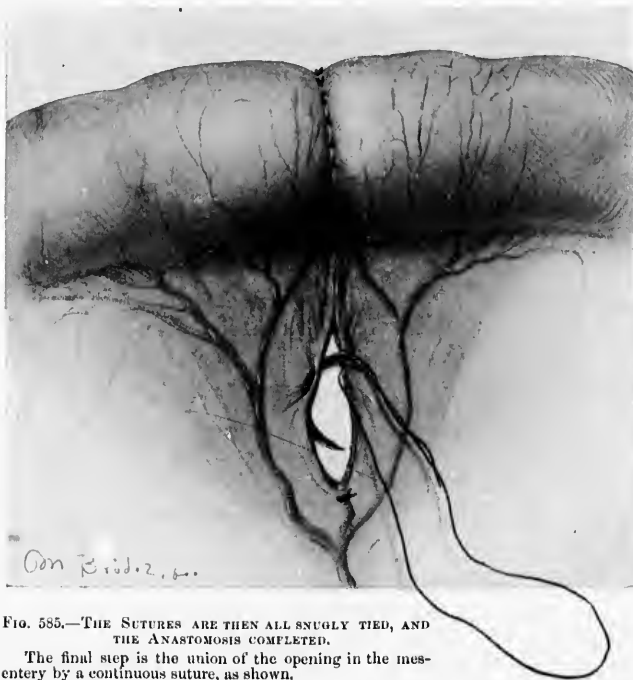


FIG. 585.—THE SUTURES ARE THEN ALL SNUGLY TIED, AND THE ANASTOMOSIS COMPLETED.

The final step is the union of the opening in the mesentery by a continuous suture, as shown.

underneath were drawn up and tied, bringing serous surface snugly against serous surface. The sutures on top, still united, were now drawn apart, and the ileum and cecum cut open from end to end between for a distance of about

4 centimeters. The ileum, which contained a large quantity of fluid, was clamped with the fingers, while the cecum, containing only gas, collapsed. Finally, on tying the top sutures, the anastomosis was effected.

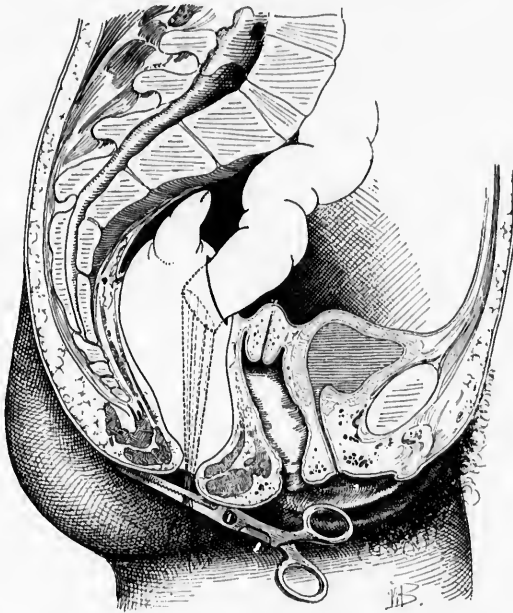


FIG. 586.—ANASTOMOSIS OF THE SIGMOID INTO THE AMPULLA OF THE RECTUM, AFTER REMOVAL OF THE UPPER PART OF THE RECTUM, WITH THE UTERUS, TUBES, AND OVARIES.

The sigmoid should be attached to the rectum by sero-serous sutures.

The original continuous suture was now carried all the way around so as to include the inner line of mattress sutures on all sides. A gauze drain was put in for a few days on account of the existing peritonitis.

Anastomosis Buttons.—The best of all mechanical devices for a rapid and accurate anastomosis of the bowel is the well-known anastomosis button of Dr. J. B. Murphy, of Chicago.

My own preference is always for suturing, which yields the best results in good hands. The objections urged against the suture, as contrasted with mechanical devices, are that it takes a long time to put the sutures in and get them tied, and that the approximation by suture is often inaccurate. All of these objections are disposed of if the operator will take sufficient pains to practice first upon the cadaver and then upon dogs to test the effectiveness of his work; furthermore, the chief sources of discrepancy in the results of suture methods disappear if Halsted's fibrous layer is borne in mind and if the sutures are

applied closely enough. With practice also the time consumed in suturing becomes much less.

The chief objections to the button are that it is a heavy piece of metal, that it gives at best but a small anastomotic hole liable to extreme contraction, and that if not made or selected with extreme care the pressure between the opposed surfaces is sometimes great enough to cause sloughing.

Artificial Anus—Colostomy.—When an ineradicable malignant disease of the uterus or of the ovaries chokes the pelvis so as to produce an obliteration of the lumen of the rectum, it will often be found necessary to make an artificial anus to prevent the patient from dying from simple obstruction of the bowels. By this procedure frightful pain may be relieved immediately, life prolonged many months, and euthanasia secured.

The best place to make the opening is under the left anterior superior iliac spine over Poupart's ligament; but if the disease involves the upper part of the rectum, it will be better to do the operation on the right side and so avoid the necessity of repeating it.

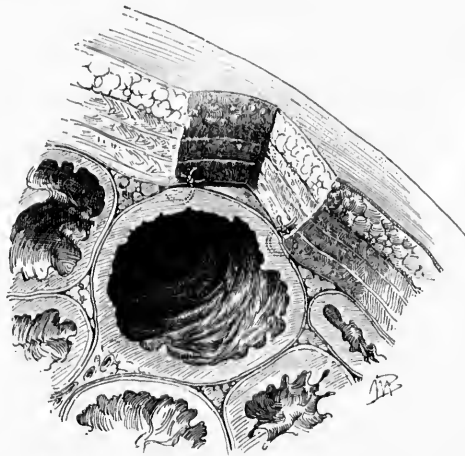


FIG. 587.—MAKING A SIGMOID ANUS IN OCCLUSION OF THE LOWER BOWEL.

The figure shows a vertical section through the wound with two of the sutures uniting the viscerals to the parietal peritoneum. K. C. March 23, 1896.

The accompanying illustrations (Figs. 587 and 588) show how to operate: A funnel-shaped incision 6 to 8 centimeters long is made through skin, fat, muscles, and peritoneum, about 3 centimeters above and parallel to Poupart's ligament, beginning just below the iliac spine. The sigmoid is usually found just under the incision and is sutured to the peritoneum and subperitoneal tissue by interrupted sutures of fine silk placed close together, each one penetrating the fibrous layer of the bowel. The free surface of the bowel, covering an oval

area about 2×4 centimeters should in this way be made to fill in the bottom of the incision.

One of two plans may now be adopted: either the skin margins may be turned in and united to the muscular layer and the exposed bowel opened its

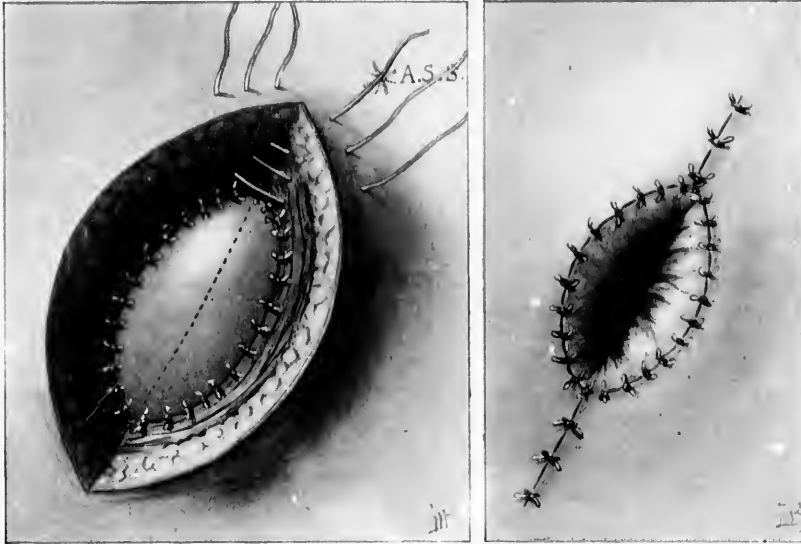


FIG. 588.—MAKING A SIGMOID ANUS.

A. S. S., the left anterior superior spine of the ilium. In the first picture the skin and muscles are divided and the bowel caught and attached on all sides to the peritoneum by a sero-serous suture. A few silkworm-gut sutures are introduced at each end (at the upper end in the picture) to diminish the size of the wound. The bowel is then opened in the dotted line and sutured to the skin surface, as shown in the second picture.

full length the next day with the cautery knife after peritoneal union has occurred, or the bowel may be incised at once and its mucous lining drawn out and attached to the skin margin, which is closed in at the ends, as seen in the figure.

The subsequent care is mainly that of cleanliness.

CHAPTER XXXVII.

THE MORE REMOTE RESULTS OF ABDOMINAL OPERATIONS.

1. Introductory. Moral questions involved.
2. Scarcity of literature on remote results.
3. Anatomical changes due to operation: 1. Hernia. 2. Suppuration. 3. Fistulae and sinuses.
 4. Enlargement and tenderness of scar.
 5. Intestinal adhesions.
4. Encysted peritonitis.
5. Local changes: 1. Changes in the vagina. 2. Changes in the uterus.
6. Menstruation.
7. Artificial menopause.
8. Insanity.

THE surgeon must ever bear in mind that his relationship to his patient is not dissolved with the simple successful performance of an operation. His responsibility in each individual case may be summed up in the following manner:

1. He is called upon to decide whether the symptoms the patient complains of are dependent upon pelvic lesions or are merely coincident with them.
2. Whether the pelvic ailment is sufficient to justify operation.
3. Whether the remote sequelae of operative interference may not be even more distressing to the patient than the present pains.

I can not dwell at length upon all of these topics. The first will be found fully discussed by A. Hegar (*Die Zusammenhang der Geschlechtskrankheiten mit nervoesen Leiden u. die Castration bei Neurosen*, pp. 83, Stuttgart, 1885), as well as in a suggestive paper by Dr. H. C. Coe (*New York Polyclinic*, May 15, 1896), entitled *Symptomatic versus Anatomical Cure after Gynecological Operations*.


One of the reasons why it is difficult to get at some of the remote results of such an operation as castration, for instance, from the moral standpoint is that women are naturally reticent about matters of sex. Again it must be remembered that many of these operations are performed upon poor women and those of the lower classes who are ignorant and wholly unused to protesting against injury of any sort, and who accept life as it comes (see Dr. Sarah E. Post, *N. Y. Med. Jour.*, Sept. 24, 1887).

In weighing the effects of castration we dare not leave out of sight the common feeling that this particular operation is a degradation to women, and that "the majority of physicians and all laymen look upon women deprived of their ovaries as unsexed." (See Dr. William Goodell, *The Effect of Castration on Women and Other Problems in Gynecology*, *Medical News*, Dec. 9, 1893.)



FIG. 589.—POST-OPERATIVE INTRA-ABDOMINAL HERNIA.

Strangulation and gangrene of the ileum, incarcerated in a band of adhesion. Death. The lower picture shows the size and form of the constricting band after the intestine was lifted out. Case of Dr. Burgess.



My own continued experience only serves to confirm my opinion that the castration of women is often a direct cause of domestic unhappiness, and that it has been repeatedly used by men as a good reason for breaking off engagements, and for the violation of marriage vows, and the abandonment of wife and children.

The husband of one of my patients, a highly educated clergyman, wrote, ten years after the operation, in the following terms upon the ethical side of this operation and its effects upon the married life :

“While ovariectomy does not destroy sexual desire nor the pleasure of cohabitation, yet the removal of the organs of motherhood causes a serious obstacle to the affections due a wife, for in depriving a woman of the possibility of children there is taken from the home the unifying power of parental love; and no high-souled affection can be sustained by mere sexual pleasure where the hope of children is taken away, and every Christian husband who understands God’s chief purpose in marriage—namely, reproduction of species—can not justify marriage as merely the means of sexual gratification. As a husband I believe that neither lifelong helplessness nor anything short of impending death justifies ovariectomy, if with the diseased organ or organs remaining there could be the remotest reasonable hope of children. For the woman pain of body is preferable to the anguish of soul attendant upon the destruction of the hope of becoming a mother; and as a man I should in my present light conscientiously decline to marry the best of women from whom had been taken the sacred fountain of motherhood. As a priest I believe that the absence of that function excludes the right of marriage, and if performed after marriage its absence takes away the right of sexual cohabitation except where that act is needful to prevent mental impurity or the sins of adultery or fornication.” (See *Amer. Jour. of Obs.*, vol. xxvii, No. 2, 1893.)

Economically, the effect of castration upon thousands of women in the prime of life has already been raised in France, where the population is decreasing.

Scarcity of Literature on Remote Results.—It is surprising to find in the great body of gynecological literature so little reference of any sort to the remoter results of the various operations, either moral or physical. The surgeons who study their cases for several years after operation in order to learn the effects of extirpation of the pelvic organs are rare.

One of the first systematic investigations of this sort was made by T. Spencer Wells, of London (*Ovarian and Uterine Tumors*, 1882), in his tabulation of one thousand cases of ovariectomy, where he presented in a separate column a statement as to the subsequent condition, showing that he had conducted a correspondence with all of his patients with a view to tracing their histories over a period of some years.

We ought now, with a greater lapse of time and an abundance of cases, to be in a position to answer all important questions as to the relationship between the various abdominal diseases and the remote sequelæ induced by the operative invasion of the peritoneal cavity. An inquiry into the more distant physical effect of the operation possesses far more than a purely scientific value. It is a

question of the highest practical import to each individual patient to know in what way her future life is liable to be affected by any proposed surgical procedure. In the first place she will wish to know what measure of relief may be expected, and in the second how far her physiological functions may be altered, and whether the operation demands any sacrifices, the most conspicuous of which are an incurable sterility and the loss of sexual function.

A decision as to the permanent result can only be recorded after studying a long series of cases for several years after operation, for the remote sequelæ are often masked at first by the distraction afforded by the various temporary discomforts which form a part of every convalescence; moreover, the patient can not justly estimate her new status until she has been restored to her habitual surroundings under the new conditions for some months.

Such an investigation will follow two lines: first, as to the purely objective or anatomical changes; and, second, as to the subjective results bearing upon the relief afforded or new discomforts entailed by the operation.

I do not propose to make an exhaustive investigation of this subject; indeed, in some other parts of this book some phases of the remote sequelæ are especially emphasized, particularly in the chapters on Carcinoma, Hernia, and Suspension of the Uterus.

From a broad humanitarian standpoint one of the queries most interesting to the surgeon is, How many invalidated women are restored again to an active healthful life by surgical treatment? All women, for example, with large tumors are more or less disabled in all the relations of life, and every successful operation for their removal adds years of useful life. It was computed that Sir Spencer Wells, by his successful ovariectomies, gave back a sum total of thousands of years of life to women, not to mention the numerous children born to those in whom he was able to conserve one ovary.

I have selected for an inquiry into the remoter results a hundred cases of chronic pelvic inflammatory disease, a class of patients in whom the subjective symptoms are most marked and the need of operative relief is often greatest. The operations were all radical and the methods of operation were those of five and six years ago, and therefore not so perfect as at present, and the questions in each case were answered at a period of from two to three years after operation. Out of the 100 women I find that 63 per cent were entirely relieved by the operation, 16 per cent expressed themselves as greatly relieved, 16 per cent were partially relieved, while 4 per cent were in the same condition as before, and one woman was worse after the operation than before it.

If drainage had not been so extensively used as it was at that time the percentage of cures would have been much greater.

An increase in weight in this group of cases is almost synonymous with the general improvement, for sixty-nine of these women gained in weight while twenty remained as before, eleven lost weight, and forty-seven out of the sixty-nine reported a gain varying from sixteen to twenty-eight pounds.

Anatomical Changes.—The incision in the abdominal wall is the one feature common to all celiotomies, and it is a question of importance to determine what permanent disadvantages may arise from it. The four chief disturbances liable to occur at a later date from the incision are hernia, suppuration, marked enlargement of the scar, and a tender scar.

Hernia is one of the most distressing sequelæ, causing the patient constant discomfort when erect, limiting to a great degree her activity, and even endangering life from incarceration of the bowel in the sac. I have seen a patient seventy-five years old die from a strangulated incarcerated hernia, the sequel of an ovariectomy performed by Dr. John Atlee, of Lancaster, Pa., twenty-seven years ago. The patient was bedfast after her operation from Oct., 1869, to Feb., 1870, on account of the suppuration of the abdominal wound, and on get-

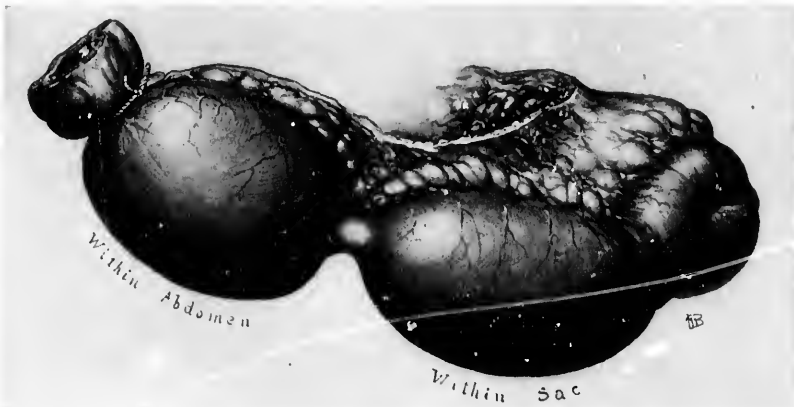


FIG. 590.—STRANGULATED HERNIA IN A PATIENT 75 YEARS OLD, DUE TO OVIARTOMY 27 YEARS BEFORE.

The intestines within the abdomen, proximal to the sac, were greatly distended, and there was moderate distention within the sac, but at the neck of the sac the bowel was narrowed down to a little yellow rigid tube almost without a lumen.

ting up she had a large incarcerated ventral hernia. She suffered from frequent mild attacks of obstruction until the final severe attack of complete obstruction in which I saw her. She was then vomiting fecal matter, and while under the anesthetic, being prepared for an operation on the irreducible hernia, she suddenly poured out such a deluge of fecal matter into her throat and nose that she died at once of suffocation. At the post-mortem examination, which was now made in place of the operation, a large ventral hernia was opened with two principal loculi; in the left was about a foot of adherent strangulated bowel, which was atrophic and narrowed down by the prolonged pressure to a centimeter in diameter at the neck of the sac; a part of the omentum in the sac was gangrenous.

Hernia is caused by several factors, of which the commonest is an infection causing the wound to fill in slowly with scar tissue; it was far more frequent in

the days when the abdomen was habitually drained after all operations, for the opening left by the removal of the glass tube or piece of gauze granulated and left a weak point in the walls liable to give way at a later date.

Hernia is also due to failure in bringing the fasciæ into accurate apposition by good suturing; in the early days the one object clearly before the mind of the operator was simply to hold one side of the incision over against the opposite side by a series of interrupted sutures passing through all the layers. With the knowledge that the strength of the lower abdominal wall lies in the fascia in front of the recti muscles has come more accurate methods of suturing this layer, and correspondingly fewer herniæ.

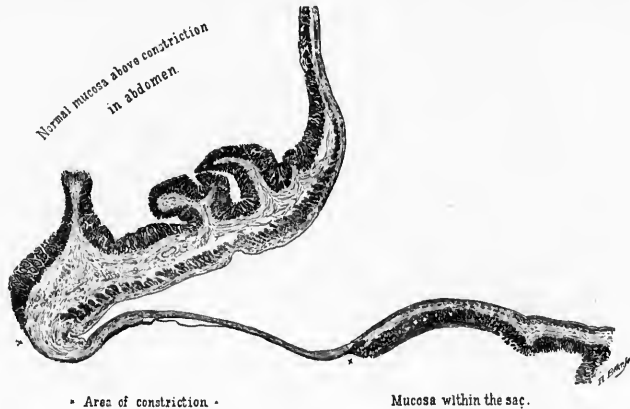


FIG. 591.—A SECTION THROUGH THE CONSTRICTED PORTION OF THE BOWEL SHOWN IN FIG. 590.

Showing the extraordinary thinning of its coats almost to complete severance. The mucosa of the bowel within the abdomen was normal, while within the sac it was much atrophied in common with the remaining coats. In the ring the mucosa had disappeared.

Hernia is more frequent in women who become much stouter after operation, in whom the intra-abdominal pressure is increased.

In rare instances a loop of the bowel slips under a band of lymph and becomes strangulated, causing speedy death unless discovered and relieved by operation (see Fig. 589).

I found eight cases of hernia in one hundred of my cases of pelvic inflammatory disease; these include a variety of plans of suturing and an excessive use of drainage. The number of herniæ under the present methods of suture and the abandonment of drainage will not, I think, amount to more than one in a hundred, and then only in those cases when there has been suppuration in the abdominal walls. In confirmation of this, Dr. W. W. Russell notes a remarkable decrease in the number of hernia cases returning to the Johns Hopkins Hospital Dispensary within the past three years. Since the use of the silver-wire suture in closing the fascia but three cases in all have returned with ventral herniæ, and it is significant to note that there was an infection of the abdominal wound in each case while still in the hospital.

Suppuration of the wound at a date later than a year is rare, though occasionally a little pustule forms on the scar and continues to discharge until one of the fascial sutures is removed.

Fistulæ and sinuses are now of rare occurrence. They were invariably the result of infected drainage tracts and sutures, and were most frequently associated with extensive inflammatory disease of the appendages. Fecal fistulæ are at times caused by infected sutures lying in contact with the bowel, ulcerating their way into its lumen. Deep-seated persistent sinuses are also due to sutures. Such tracts may discharge for months and years, until the suture is taken out or comes away, when they often close spontaneously.

Enlargement of the Scar.—If the patient gains weight rapidly and the girth of the abdomen increases, the scar will yield from side to side until it becomes one or two or more centimeters broad; it is often pitted and pigmented and unsightly. I know of nothing to improve this condition, and do not believe that the bandage is of any material assistance. Some observers have noted the formation of a large keloid in the scar.

Tender Scar.—Soreness and shooting pains in the scar are common while the wound is young and pink; in nervous patients the tenderness may persist for years. Relief will be best attained by gentle massage and by arranging the clothing so as to avoid all direct pressure on the sensitive area.

Alteration in the position of the intestines is perhaps the most constant of all the changes induced by the removal of pelvic viscera; additional loops of the intestines drop into the pelvis to fill the vacated space, producing a pelvic enterocele. For the normal intestinal relations see Vol. I, Chapter IV.

Adhesions of the omentum and intestines over the inner peritoneal surface of the incision, although often discovered in opening the abdomen some years after the original operation, can scarcely be classified among the late sequelæ, as they denote simply the persistence of a condition which must have been brought about shortly after the operation. Such adhesions of the intestines, or short omental adhesions, which drag down the transverse colon and pull the stomach down with it, have repeatedly been found to explain persistent pain in the lower abdomen, tormina, nausea, and frequent vomiting.

The release of the adhesions with an aseptic closure of the abdominal incision has been followed by immediate relief of all the symptoms.

The vermiform appendix may become involved in post-operative adhesions, attaching it to the pedicle left in the pelvis and causing severe pain in the right iliac fossa, with attacks simulating appendicitis. I operated on a patient of this kind whose right ovary had been removed three years before by Dr. Hunter Robb; I removed an inflamed left ovary and the uterus, together with the appendix, which hung over into the pelvis and was firmly adherent at its end to the pedicle on the right side. Dr. Hunter McGuire, of Richmond, has also operated upon two cases of appendicitis originating in this way, one of them being a former patient of my own, from whom I removed the appendages for inflammatory disease.

Encysted peritonitis following a recovery complicated by sepsis sometimes persists for months or a year or more, especially after operations for pelvic inflammatory diseases. Mutually adhering loops of intestines wall off a part of the pelvis, usually to the right or the left side behind the broad ligament, and in this sac a quantity of clear serum accumulates; sometimes as much as half a liter of fluid is found. As the sac becomes tense it can readily be palpated both by the vagina and by the abdomen, and yields the signs of an independent cystic tumor. The patient may have fever, slight chills, a quickened pulse, and severe pain, and is only relieved by evacuation of the sac.

Local Changes.—Following the extirpation of both ovaries, the uterus and vagina undergo the same atrophic changes we see after the natural cessation of menstruation.

Glaevecke (*Archiv. f. Gyn.*, Bd. xxv) divides the changes in the vagina produced by castration into three stages:

First, a hyperemia, which shows a marked injection of the mucosa, soon becoming soft and swollen; the normal secretion is increased, and at times an appearance is produced similar to pregnancy. This condition usually lasts but a few months.

Second, the vagina begins to shrink, becomes pale, and shows a few deep brownish-red patches, especially about the urethral orifice; occasionally the whole vagina is studded with them. The patches do not disappear on pressure, and they are probably due to hemorrhages from rupture of the atrophic vessels by coition. This stage may last from one to five years.

The third stage is one of general atrophy. The mucous membranes become white and anemic, the red spots fade, and the color finally becomes a uniform grayish red. The vagina shortens, its lumen becomes narrower, and its walls stiffer. Coitus is sometimes impossible on account of the marked decrease in size; occasionally a slight vaginal prolapsus may appear.

I have also seen a severe persistent granular colpitis.

The changes in the uterus are regularly found, and are more marked than in the other structures. The decrease in size begins soon after the removal of the ovaries, and progresses rapidly and uniformly throughout the whole organ, which soon becomes harder, stiffer, and less vascular. Any erosion of the cervix rapidly disappears, and a catarrh may cease without treatment.

Menstruation.—During the period when the tubes and ovaries only were removed on account of inflammatory disease, menstruation not infrequently persisted, either appearing at the usual time or as an irregular uterine hemorrhage; but since it has been the rule to remove the uterus with the tubes and ovaries in all cases where it is necessary to remove the appendages the cessation of the menstrual function has been in most cases immediate and absolute. I know of two cases of persistent cervical menstruation after a supravaginal amputation of uterus, tubes, and ovaries, one a patient of Dr. W. E. Ashton and one of my own. Various reasons were wont to be assigned for a regular persistence of menstruation, but it is probable that in every instance some ovarian tissue is left.

Out of seventy-nine of my cases of inflammatory disease of the appendages, investigated by Dr. W. W. Russell from two to three years after the operation, he found that forty-six of them ceased menstruating at once, twenty-three continued to have a regular flow for several years, while nine had irregular hemorrhages at intervals of from one to twelve months.

I have several times been obliged to open the abdomen on account of severe dysmenorrhea and pelvic pain after removal of the tubes and ovaries, and in each case have found little nodules the size of a pea or larger at either uterine cornu, or attached to the stump on the broad ligament. These masses have invariably proved to be made up of ovarian tissue showing follicles and corpora

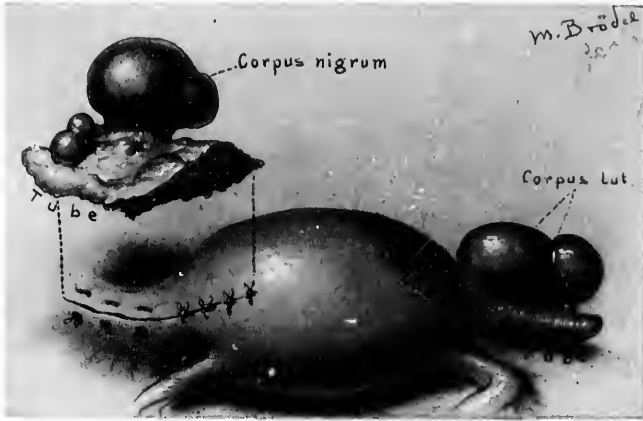


FIG. 592.—SHOWING THE ENDS OF THE TUBES AND PIECES OF THE OVARY LEFT AFTER AN IMPERFECT OPERATION.

The patient came to my clinic, and I reopened the abdomen and found two yellow corpora at the left cornu, with most of the isthmus of the tube and a large corpus nigrum and small corpora lutea and a piece of the tube on the right side. Both masses were excised as indicated by the dotted line at the left cornu, and the wound sutured as shown at the right cornu. L. B., Oct. 28, 1893. Natural size.

lutea, and in one case a long piece of the tube was also found with the bit of ovary at the left cornu. In these cases the persistent menstruation was evidently due to an imperfect operation.

Artificial Menopause.—The menopause artificially produced by the removal of the ovaries usually creates the most distressing disturbances with which we have to deal in the after-care of our patients. They resemble the symptoms occurring at the natural change of life, except that in most cases they are greatly exaggerated.

The first discomforts are generally noted after the time for the first period has passed, and they usually run a course of from eighteen months to two years; exceptionally I have known them to continue for five years or even longer. Not all patients suffer these attacks in like intensity; as a general rule, neurasthenic women seem to suffer the most, and the nearer the patient is to her natural menopause the less the severity of the symptoms.

Waves of heat and flushes are the commonest sequelæ, coming often at variable intervals of a few minutes only or several hours; they pass over the whole body like a wave of hot air; the face may become visibly reddened, and there is a transient cardiac palpitation and sometimes a sense of giddiness. Each attack lasts from half a minute to several minutes.

After the flushing, the skin is often bedewed with a gentle perspiration, and a sense of relaxation and exhaustion is felt; in rarer instances the perspiration is profuse enough to saturate the nightdress, leaving the patient cold and shivering.

A case referred to me by the operator (S. T. W., aged thirty-five, Feb. 16, 1897), affords a good picture of these distressing psychic sequelæ. Both ovaries were removed eight months before, the recovery being complicated by profuse suppuration in the abdominal wound. She had previously always been of a notably cheerful disposition. Suddenly, about two weeks after the operation, a deep gloom came over her "like a flash of lightning," and she was fully persuaded that she was dying; she had at the same time "a giving away cold feeling which lasted three days." She has been since then extremely nervous, and suffers from a confusion of ideas and inability to concentrate her mind. She has lost all confidence in herself and all interest in life, and never has her old sense of buoyancy, nor does she care as before for reading and music. She has "untold miserable feelings, almost amounting to torture." Her face is blotched, and she has itching of the head and nose and anesthesia of the hands and face. Flushes are not troublesome and headaches not marked. I found on making an examination that the vagina was uniformly injected, rose-red, and bathed with a whitish discharge; the cervix was normal and the fundus large, antverted, and not sensitive.

Many patients are distinctly benefited at this time and the severity of the attacks modified by taking bitter tonics. I would particularly recommend the following pill taken three times a day: Strych. sulph., gr. $\frac{1}{30}$; atropia sulph., gr. $\frac{1}{300}$; ext. columbo, gr. 1.

Some patients after complete cessation of the menstrual period have typical menstrual molimina at the time menstruation would have appeared; these symptoms usually disappear in a few months. Recently experiments, the results of which are as yet uncertain, have been made to obviate these symptoms by implanting small portions of ovarian tissue in the abdominal incision.

I have for these reasons left the ovaries in in all my cases of hysteromyomectomies in women under forty, and have noted in each case that the patients did not experience such distressing sequelæ.

Schmalzfuss (*Zur Castration bei Neurosen, Archiv f. Gyn., Bd. xxvi, No. 1*) divides the neuroses into three groups:

1. Symptoms referred to the lumbar section of the spinal cord, such as throbbing and pain in the back, pain in the iliac region, pain extending from the back to the abdomen and radiating down the thighs, pressure in the pelvis, downward tugging, anesthesia and hyperæsthesia of the vagina and vulva, and pain on urination and defecation.

2. Besides those mentioned, other neurotic symptoms appear which are referred to different parts of the body, such as cardialgia, pressure in the epigastrium, sensation of fullness, belching, vomiting, and globus.

3. A distinct neuropathic condition, general pain, vaso-motor disturbances, vicarious menstruation, respiratory, gastric, and intestinal attacks of various sorts, cramps, and epileptiform convulsions.

Many of these results are often due to inflammatory sequelæ and adhesions forming after the operation.

Insanity.—Insanity is the most appalling of all the sequelæ which may follow a gynecological operation; there is, however, nothing peculiar in this association, for it also occurs after operations in general surgery, and indeed has been observed to follow a simple fracture (Dr. F. J. Shepherd, of Montreal), and even the use of an anesthetic without any operation at all. One of my cases, a colored girl, became insane after an aseptic abortion. It has often been noted after such simple plastic operations as repair of the vaginal outlet. I have seen six cases of insanity following perineal operations, one of whom died in acute mania; another case, operated upon for lacerated cervix and a relaxed vaginal outlet, committed suicide after returning home by drinking pure carbolic acid. A colored woman, a case of curettage for carcinoma of the cervix, died in an insane asylum.

I have seen insanity after abdominal operations in eight cases out of something over two thousand abdominal sections—that is, an average of one half of one per cent—

An analysis of a series of cases shows—

1. That the attack of insanity may immediately follow the operation (one case), or be developed at an interval of from a few days to several weeks.

2. That the attack is not due to a septic poison is shown by the simple uncomplicated recovery as far as the field of operation is concerned.

3. That it does not arise from the occurrence of bad sequelæ of any sort connected with the operation, such as exhaustion from hemorrhage, or a protracted operation, or severe suffering after the operation.

4. That the insanity may follow any, even the simplest operation, or even no operation at all. Insanity is more frequent after simple than after grave operations. The removal of ovaries and tubes, and with the removal the ablation of their function, does not appear to stand in any causative relation.

5. Exfoliative cystitis was the symptom most prominent in one of my patients. Dr. C. P. Noble, of Philadelphia, has noted excessive irritability of the bladder in several of his cases of post-operative insanity.

6. Patients most apt to become insane after operation are for the most part women who have been excessively apprehensive about the result of operation or its effect on their minds, also neurotic and hysterical women.

7. A most marked predisposition exists in women who have been previously melancholy and insane, and any patient with this blot in her history should only be operated upon in case of urgent necessity, and with the fullest explanation to the family as to the risk incurred.

8. Recovery may take place in a few weeks or only after several years. There is, as a rule, a slow progression from worse to better, from greater to less violence and noisiness; at other times the first symptoms of improvement are intervals of lucidity which increase in frequency and duration. Not infrequently the insanity is permanent.

Of my own eight cases, five recovered completely, two remained insane, and one committed suicide after her return home.

Dr. C. P. Noble has furnished me with an analysis of sixteen cases occurring in his practice; six of these were insane or had had delusions before the operation, two of whom recovered, while in four the mental condition remained unchanged. In six other cases the mental condition was normal before operation; these were followed either by delusions or by hysterical mania, and all recovered. In the remaining four cases there had been attacks of hystero-epilepsy before the operation; two of these patients were cured, one continued to have attacks, and the remaining one had true epilepsy.

Two other kindred questions worthy of careful consideration are these: whether gynecological ailments can act as the provoking causes of insanity, and whether it is possible to cure or ameliorate the condition of insane patients by treating such gynecological ailments as they may have.

In the Maryland Hospital for the Insane, Dr. George H. Rohe found local lesions demanding operation in forty out of one hundred women (*Jour. of the Amer. Med. Ass.*, Oct. 12, 1895).

"In thirty of these, abdominal section with removal of the uterine appendages was practiced. Two cases were subjected to primary vaginal total extirpation of uterus and appendages. In two repair of the lacerated cervix was done. In six the guardians of the patients would not consent to operation. Of the thirty abdominal sections there were cured physically and mentally, ten; decidedly improved, four; unimproved, thirteen; died, three.

"Of three secondary vaginal hysterectomies, which are included among the thirteen unimproved after removal of the appendages, one was cured and two remained as before. Of the two primary total extirpations, one was cured and the other so much improved as to give strong hope of ultimate mental recovery. The two trachelorrhaphies both recovered, mentally and physically.

"The final results of the operations at present are, therefore, cured (physically and mentally), fourteen; improved, five; unimproved, twelve; died, three. Total, thirty-four."

Dr. Rohe goes on to discuss the indications as follows:

"In what class of cases is an operation indicated? Where there is local disease discoverable on examination. The mental symptoms themselves are no guide. Mania, melancholia, confusional insanity, hystero-epilepsy, have all been cured. The same forms of mental disturbance have sometimes not been benefited. In consecutive dementia and in epilepsy, where brain deterioration has already occurred, no improvement can be looked for in the psychic symptoms. I believe that in some cases of epilepsy where there is pelvic irritation an early removal of the source of the irritation would be of benefit to the patient. In

all cases, however, where local disease exists, appropriate treatment is indicated irrespective of the mental condition. Thus all three of the cases who died were of dementia, two consecutive to epilepsy. In all of these there was abundant local disease to demand interference. In one there were large pus tubes and ovarian abscesses matting all the pelvic organs into a mass infiltrated with pus. In another there was an intraligamentous cyst as large as an orange. The third case was a large fibroid tumor.

"Twelve of the recovered cases have been discharged and all but one are alive, and, so far as I have been able to ascertain, remain in physical and mental health. Two are still under observation in the hospital.

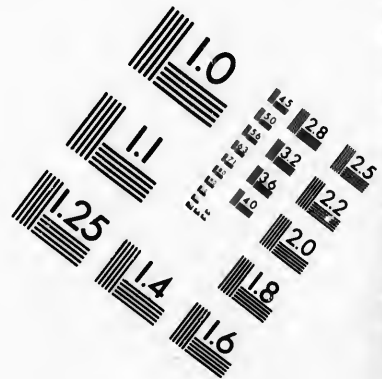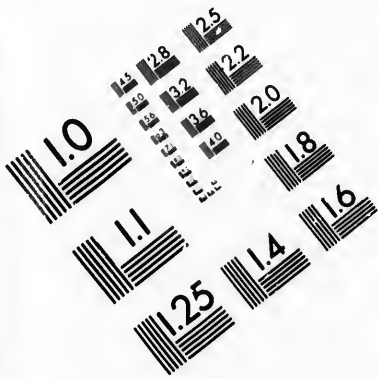
"The clinical variety of mental disturbance in the recovered cases was: puerperal insanity (mania), four; melancholia, six; mania, three; hystero-epilepsy, one. Total, fourteen.

"In the cases in which complete recovery did not follow the operative measures, there were of melancholia, two; mania, five; puerperal insanity (mania), one; dementia (including four of epilepsy), seven (three deaths); paranoia, two; hysterical insanity, two; adolescent insanity, one. Total, twenty.

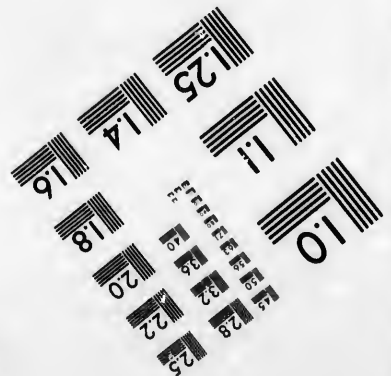
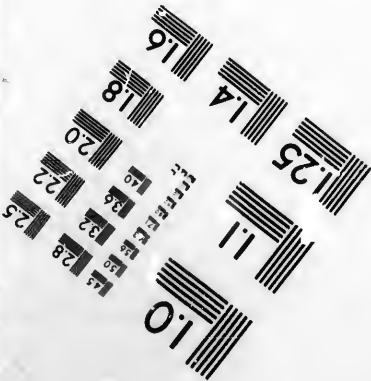


"The number of my cases is too small to allow one to draw any conclusions, but if anything of practical value can be deduced from them, it is that puerperal insanity, melancholia, and simple mania offer the best chances of cure from the proper treatment of local lesions in the pelvis. Of course it may be said that these forms of mental disorder are just those which yield in the majority of cases to the usual methods of management of insanity. In seven of the cases, however, the insanity had lasted over eighteen months before any treatment directed to the local lesion had been instituted. In a case of hystero-epilepsy the patient had been in the hospital seven years, and one of the cases of puerperal insanity had been four and a half years insane. I am convinced that earlier operation in appropriate cases would very largely increase the proportion of recoveries."

Dr. W. P. Manton, of Detroit, Mich., who was the first gynecologist in the country to be appointed on the staff of an insane asylum, summarizes his experience in the following words in a letter dated Dec. 17, 1896:

"During the past ten years or so a very large number of insane women have passed under my observation in the various institutions with which I am connected, and I have had opportunities to do the various abdominal, vaginal, etc., operations, and note their effect. We long ago came to the conclusion that the idea of restoring the sick mind to health as the result of gynecological operative interference should be abandoned. Such operations are therefore now undertaken solely for the relief of somatic conditions. An operation may act as one of the factors in bringing about a mental cure, but I believe that it must always be done early, and associated with such other treatment in the way of medicines, food, quiet, rest, etc. After degenerative processes have occurred in the brain, I believe that it is useless to look for mental cure. I can say this, however: I have never operated on an insane woman yet, no matter to what extent dementia has gone on, without some relief to the mental condition and a decided im-



**IMAGE EVALUATION
TEST TARGET (MT-3)**



**Photographic
Sciences
Corporation**

23 WEST MAIN STREET
WEBSTER, N.Y. 14580
(716) 872-4503



provement in the personal comfort of the patient. I have always been very conservative regarding operative measures undertaken in insane cases, and believe that we can not be too cautious in this respect.

“It is our aim, at the Eastern Asylum at least, to discharge ‘cured’ patients with all their bodily ailments relieved as far as possible.”

CHAPTER XXXVIII.

ON THE CONDUCT OF AUTOPSIES, THE MAKING OF PROTOCOLS, AND THE PRESERVATION OF TISSUES FOR MICROSCOPIC EXAMINATION IN GYNECOLOGICAL PRACTICE.

1. Importance of autopsies in cases of death in gynecological practice.
2. Method of conducting an autopsy: 1. External inspection. 2. Central nervous system (brain and spinal cord). 3. Abdominal viscera. 4. Thoracic organs, pleura, lungs, pericardium, heart, etc. 5. Intestines. 6. Pelvic organs. 7. Spleen, gall bladder, stomach, liver, mesentery. 8. Urinary and genital organs. 9. How to close up a body. 10. Description of the findings at an autopsy.
3. Preservation of tissues for microscopic examination. 1. Fixing agents: *a.* Strong alcohol. *b.* Müller's fluid. 2. Other methods of fixing: *a.* With corrosive sublimate. *b.* With formalin.
4. Protocol I. Death without operation. J. J., Feb. 1, 1890.
5. Protocol II. Death six days after operation. M. E. S., Jan. 27, 1893.
6. Protocol III. Death over fifty-one days after a minor operation. M. II., March 30, 1893.

Importance of Autopsies in Cases of Death in Gynecological Practice.—When a death occurs in his gynecological practice the physician can usually, with the aid of a little tact, overcome the objections of the friends of the deceased and secure permission for the making of an autopsy. On the importance of studying the exact nature of the lesions in every case of death, whether occurring independently of operation or subsequent to operative interference, it is superfluous to insist here. The list of morbid processes and of surgical accidents is so long, and the variations which are possible in any individual disease are so manifold, that after one has taken advantage of every opportunity for observation offered at a large hospital he is compelled to confess that even then he has barely begun to get an insight into the pathology of the uterus and its adnexa.

Methods of conducting an Autopsy.—Whenever it is possible the autopsy should be made by an experienced pathologist, the surgeon, of course, being present to watch each step in the procedure. Taking the clinical history of the case as a guide, it should be the object of the examiner not only to find out the immediate cause of death, but also to explain as definitely as possible the nature, the origin, and the sequence of all the deviations from the normal which may be present in the cadaver. Where, for instance, a patient has died with symptoms of an acute infection, a careful general and special consideration of all the conditions and lesions present must be supplemented by a complete bacteriological examination, in order that we may determine not only the exciting cause of the infection—the micro-organism or micro-organisms concerned—but also the portal of entry through which the bacteria have gained access to the

tissues, the nature of the breach in the normal mechanisms of defense by which this ingress was rendered possible, and finally the conditions underlying the insufficiency in the resisting power of the cells and tissue fluids of the body, which permitted the infection when once in progress to lead to a fatal termination.

An autopsy made with such ends in view is by no means a light task. Not a little time and thought will be required, and if thorough bacteriological and microscopic examinations be made, it may be weeks before the pathologist has completed his investigations and is prepared to pass final judgment upon the case. Too often, even then, a whole series of phenomena will remain unexplained, for in pathology, as in any other science, the work done in the solution of one question usually brings to light the existence of other problems which, for the time being at least, can not be solved.

It is now generally recognized that really thorough and satisfactory autopsies can only be conducted in the special pathological institutions, where the workers can give all their time to pathological work, and the practitioner must be content to approach as nearly as possible to ideal autopsy methods.

The exact course to be followed in a given autopsy necessarily depends to a certain extent upon the attending circumstances—for example, upon the time at one's disposal, upon the extent of the permission obtained from the friends as regards completeness or incompleteness, but more especially upon the nature of the suspected lesions. If through hurry on the part of the friends the cadaver must be delivered within a few minutes, the organs after a quick survey may be removed *en masse* and studied in detail at leisure. If permission for a complete autopsy can not be obtained, the operator may have to be content with the examination of the thoracic and abdominal organs alone. In case of death following an abdominal section, the permission simply to reopen the wound will sometimes be granted when a request for a more complete autopsy is refused. Such incomplete autopsies are always more or less unsatisfactory; nevertheless, in many instances there is much to be learned from them, and on the principle that "half a loaf is better than no bread" it would be a wanton waste of material not to take advantage of these opportunities. In cases of urgency, where no external incision is permitted, one or more organs or pieces of organs can, when desired, be obtained through the rectum. (See H. A. Kelly, *On a Method of Post-mortem Examination of the Thoracic and Abdominal Viscera through Vagina, Perineum, and Rectum, and without Incision of the Abdominal Parities*; *Medical News*, June 30, 1883.)

In order to attain skill in making autopsies there is only one means—long practice. A pathologist, through years of experience, learns to vary his technique and routine according to the nature of the case before him; one, however, who makes only an occasional autopsy will probably do best to follow more or less strictly a definite system, departing from this only when the nature of the lesions renders nonconformity unavoidable. Just as in the clinical examination of a patient by a physician, so in the investigation of diseases at autopsy the rigid adherence to a definite routine leads, in the case of the beginner,

at all events, to the discovery of many abnormalities which otherwise would easily be overlooked.

Of the numerous good methods which have been advised, it matters not much, perhaps, which one is adopted. In any case, the examination begins with a careful inspection of the exterior of the body, the size and general structure are noted, and any abnormal appearances in the skin in connection with the orifices of the body or with the peripheral sense organs are described. As a rule, the central nervous system is next examined, providing the autopsy is to be a complete one, the brain being first removed and afterward the spinal cord. If the examination does not include the central nervous system, the linear incision in the middle line, extending from the supra-sternal notch to the pubes, follows immediately upon the external inspection of the body. As the abdomen is opened and the soft parts are dissected from the ribs, the examiner notes the appearance of the subcutaneous fat, of the muscles, and particularly of the blood in the vessels. After smear coverslip preparations and cultures have been made from the fluid in the peritoneal sac, a careful inspection of the abdominal and pelvic cavities and their contents follows, a part of the examination of the utmost importance to the abdominal surgeon, and one too often hurriedly or carelessly made. In this preliminary inspection of the peritoneal cavity the structures are to be examined as far as possible without handling and, above all, without disturbance of the relations of the different parts to one another. One notes the color, odor, and amount of fluid in the cavity, its consistence and location, and the presence or absence of abnormal constituents in it. It may be necessary to set aside a portion of it in a clean vessel for chemical and microscopical examination. The position of the organs, their color, vascularity, and consistence can, as a rule, be easily determined without disturbing the general relations. If hemorrhage has occurred, the origin and extent of the bleeding must be ascertained, and if extra-uterine pregnancy is suspected the embryo must be carefully sought for.

The accurate and minute examination of the surface of the peritoneum itself can hardly be too strongly insisted upon. Now that the processes of bacterial infection are better understood, the pathologist has learned to look more closely for slight evidences of inflammation in the peritoneum. It is now an established fact that a most virulent infection of the peritoneum, leading in a few hours to death, is, as a rule, accompanied by less marked local and tangible signs than are to be found in those which have had a slower course. Often the only sign of a peritonitis to be made out is an extremely delicate fibrinous deposit which, over limited areas, deadens almost imperceptibly the normal gloss of the peritoneum, or again we may have only a slight injection of the blood vessels in certain places, especially where the individual loops come into contact with one another. In such instances a superficial observation would entirely fail to bring to light a most important pathological change. It is surprising to find how many cases of chronic disease exhibit at autopsy evidences of a final infection which has attacked the peritoneum and has been accompanied by such insignificant phenomena as those just mentioned, and which was not in the least

suspected during life. It is even claimed that an acute bacterial infection of the peritoneum may occur without any associated exudation. Under these circumstances, the practical bearing of which is obvious, an examination by microscopic or cultural methods would alone suffice to make the condition clear. In doubtful cases the examination of the fluid in the peritoneal cavity is of so much interest that one should take care that it is not accidentally neglected.

An infection of the peritoneum being present, its starting point can generally, though not always, be determined. In operative cases the process, by the nature of the lesions, may sometimes be referred to the external wound, to a stitch abscess, or to a drainage-tube; in other cases an infected ligature, the stump of a pedicle, or a wound of the intestinal wall may be held directly responsible. In cases of peritonitis coming to autopsy without operation a careful search will also usually reveal the portal of entrance, whether it be a perforation or fracture of the wall of the stomach, intestine, or appendix, or a simple extension of an infection from another organ (ovary, Fallopian tube, uterus, spleen, liver, or kidney). Sometimes, however, no satisfactory explanation of the etiology is possible, and we are forced to assume an infection through the blood current, or to confess our ignorance of the cause altogether. In cases of advanced renal disease, such as occurs, for example, secondarily to pressure of abdominal tumors on ureters, it is claimed that a peritonitis of purely chemical origin may be present. But it must be remembered that an examination for both living and dead micro-organisms, including the inoculation of animals, would be necessary before the existence of an infection in such a case could be excluded.

Where the peritoneum is secondarily tuberculous or cancerous, a similar systematic study of the possibilities of origin will usually determine the relation of the peritoneal lesions to those in other parts of the body.

Having completed the preliminary inspection of the abdominal cavity and determined the level of the diaphragm upon the two sides, it is customary to proceed to the examination of the organs in the thorax; the pleuræ, pericardium, heart, lungs, larynx, and trachea being examined in turn. If one is not permitted to open the thorax, the examination of the abdominal organs may follow immediately.

Having been freed from the mesentery from the rectum to the duodenum, the intestine is severed at both ends and removed from the body. In order that no fecal matter may escape in doing this, it is better to tie it in two places at both ends, and to cut between the ligatures.

The pelvic organs, ureters, kidneys, and adrenals may be removed together and examined. The spleen, bile duct, duodenum and stomach, liver, gall bladder and pancreas, larger blood vessels, mesentery, lymph glands, and bones are then studied.

It would lead us too far to discuss the various methods employed in the removal and examination of all these organs. A little experience in a good pathological laboratory is of more value than much reading on the subject. If one is familiar with the normal appearance of the different organs and tissues and can

recognize alterations in size, shape, odor, color, and consistence, and in the relation of the different parts and wholes to one another, he will have little difficulty in detecting any abnormalities present.

In order to remove the urinary and genital organs as a whole one may proceed as follows:

The parietal peritoneum lining the pelvic cavity is freed all around from the symphysis pubis to the front of the sacrum behind. The thighs are then well spread apart, and an oval incision is outlined about the external genitals, commencing in front over the root of the clitoris, and being continued on each side to a point just behind the anus. The labia are then seized with one hand and pulled firmly forward and downward, and the incision is continued at the upper angle, with a sharp scalpel or with curved scissors, through the tissues (including the insertions of the corpora cavernosa of the clitoris) into the pelvic cavity. Care must be taken in cutting to keep close to the border of the bone in order not to mutilate the soft parts. The vulva can then be pushed under the symphysis into the cavity of the pelvis, where it is to be grasped with the left hand and lifted as high as possible. The oval incision previously outlined along the sides of the labiæ is now deepened, and with several sweeps of the knife the fatty tissues and muscles on each side of the rectum as well as the ligaments in front of the coccyx can be severed, and the whole mass, including bladder, rectum, external and internal genitalia, can be lifted out and removed, together with the kidneys, adrenals, and uterus.

In continuing the examination of these parts, the organs should be sectioned in such a way that structures will not be too much mutilated should it be desirable to preserve them as museum specimens. The rectum may be split up with scissors along its posterior wall and examined first without being washed and again after a thorough cleansing with water. The bladder can best be opened by an anterior median incision with knife or scissors, passing first through the clitoris and its prepuce, then through the anterior wall of the bladder itself. After the bladder and the ureteral orifices have been carefully inspected, the vagina and uterus can be opened along their anterior walls in the median line. This cut of course divides the bladder completely into two halves. If there be ulceration or neoplastic growths in the bladder, and it be desired to keep its posterior wall entire, the wall of the uterus and vagina can be cut through in the middle line from behind; in this case the incision may either go through the anterior wall of the rectum, dividing it into two halves, or it may be made after dissecting the rectum away from the structures in front of it. The sagittal section of the uterus should extend from the external os to the fundus. In addition, in order to expose the uterine openings of the uterine tubes, two small incisions may be made, extending laterally for a sufficient distance from the upper extremity of the sagittal section. The uterine tubes may be slit up with probe-pointed scissors, beginning at the abdominal ends and passing inward to the uterine orifices. The ovaries may be cut in half from the posterior free surface. The kidneys, after the capsule and external surface have been inspected, are cut into two halves by an incision extending

from the cortex through to the pelvis along the long diameter of the organ. The ureters may be slit up with scissors from the pelvis of the kidney to the mucous membrane of the bladder. They should, however, always be examined *in situ* before the removal of any of the organs; otherwise the situation of a calculus or the relations of a dilatation may be overlooked.

In the case of a death from general infection following a minor operation in which the starting point of the infection is not clear it is advisable to examine every part of the field of operation for the primary seat of the morbid process. A single minute stitch abscess deep down in the perineal tissues may, under certain conditions of lowered vitality, be sufficient to account for the existence of huge multiple pyemic abscesses in various regions of the body.

Where there are no local evidences of infection, and the patient during life has nevertheless shown suspicious clinical symptoms of it, the heart blood should be examined for bacteria in coverslip preparations and by means of cultures. Lesions resulting from a terminal local infection, especially those occurring after operations, are found not infrequently in the intestinal mucous membrane.

In every instance the gut should be cut up along its whole length and closely examined, first without being washed, and next after a thorough cleansing of the mucous surface. If this be done as a matter of routine, one can scarcely overlook a terminal enteritis, nor the intestinal lesions of corrosive sublimate poisoning, a fatality for which the gynecologist and obstetrician are unfortunately occasionally responsible.

How to close up a Body.—Medical men can do much to dissipate the general prejudice of the laity against post-mortem examinations by making the procedure as little objectionable as possible. With care a complete autopsy can be conducted and the body restored to the friends without the slightest evidence of disturbances. Some forethought as to the location of the several incisions, and a little extra care and attention in the drying of the cavities and in the final sewing up and cleansing, are all that is necessary. A body should never be closed up with large quantities of fluids remaining in the cavities, but these should be thoroughly dried and filled with sawdust or cotton waste. If there is any tendency to putrefaction, the addition of a small quantity of some disinfectant, such as sublimate or carbolate of lime, will be of service.

Description of the Findings.—An accurate description of the findings at each autopsy should be dictated, if possible, while the procedure is in progress, or at any rate immediately afterward, while the details are still fresh in the mind of the examiner, and the record should be kept for future reference.

The anatomical diagnosis can be confirmed and afterward added to by means of a microscopic examination of the frozen sections of the fresh tissue, and of sections cut and stained after fixing and hardening. It should be finally completed by a consideration of the results of the bacteriological examination.

If the mechanical part of a carefully conducted autopsy is difficult, the description of the organs is even more so. To be of value, the statements must be

precise and comprehensive without being diffuse. Instead of crude guesses at sizes, weights, and measures, the quantities should be accurately determined with rule, scales, or graduated vessels. The clinical statistician knows full well the uselessness of the majority of the autopsy protocols. Statistics at best are precarious structures to build upon, but when they have been compiled from slovenly and inaccurate records they can not fail to be misleading. On the other hand, a series of exact, complete, objective descriptions of autopsies on gynecological cases affords statistics which, when properly compiled and studied, yield deductions to the practical surgeon of very considerable value. The three protocols which are appended have been selected at random, and afford examples of autopsies on patients dying both without operation and after operation.

The Preservation of Tissues for Microscopic Examination.—**Fixing Agents.**

—It is often necessary for the practicing surgeon to submit to a pathologist for examination and diagnosis fragments or masses of tissue removed at operation or at autopsy. In order that the tissues may reach the microscopist in good condition it is essential that they shall be placed soon after excision—the earlier the better—in a fixing solution; that is, one that will kill the tissue cells and retain the structures in a condition as little removed as possible from that under which they existed in the living body.

Uterine scrapings and bits of tumors, well fixed and hardened, when examined by a competent pathologist, frequently throw light on obscure cases which clinical methods have failed to explain. It has been objected that when the clinician is in doubt the pathological report often fails to decide as to the nature of the condition. But while this can not be denied, it is also true that the pathological examination in many instances is absolutely positive, and not infrequently leads to the discovery of a state of affairs entirely unsuspected before by the surgeon. The logic which demands that because they are not always decisive the examination of the pathologist shall be entirely dispensed with, is not unlike the logic of many debtors, who, because they can not meet all their liabilities, prefer to pay no debt rather than to use the means they possess in order to discharge some of them.

Most valuable specimens are repeatedly ruined by surgeons through a want of knowledge of the qualities requisite for a good preserving fluid. Thus it is not uncommon for the pathologist to receive tissues which have been thrown into a small quantity of weak alcohol or into a dilute solution of carbolic acid, where in the course of a short time they are macerated and rendered unfit for thorough and satisfactory examination, if indeed they be not entirely ruined.

If the pathologist is easily accessible, he will always prefer to receive the specimen immediately after removal from the body, before the tissues have been acted upon by any reagents. He can then study the fresh tissues in teased preparations or in frozen sections, and finally choose for himself the fixing fluid which experience has taught him to be best adapted to the particular tissue in question. It is comparatively seldom, however, that circumstances will permit of this immediate delivery of tissues, and the surgeon is compelled to choose for himself a fixing agent.

The fixing agent which for general use may be recommended to the surgeon as safest and least likely to lead to injury of the tissues is strong alcohol. It has many advantages, in that it is easily accessible, acts quickly, and permits of the preservation of comparatively large specimens. Whereas with the finer fixing agents the size of the individual bits of tissue should not exceed from 1 to 2 millimeters square, with strong alcohol pieces of from 1 to 2 centimeters square will usually harden well. Indeed, large masses of tissue, provided they be cut open at intervals of from 1 to 2 centimeters, may be hardened in alcohol quite well, provided the amount of fluid employed be proportionately large. A specimen, small or large, preserved in alcohol requires at least from ten to twenty times its bulk of fluid, and the alcohol should be changed once or twice at intervals of twenty-four hours.

A second hardening solution, the materials for which can be obtained at any druggist's, is the well-known Müller's fluid, which consists of two and a half parts of bichromate of potassium and one part of sulphate of sodium dissolved in one hundred parts of water. Large pieces of tissue—for example, the genital organs *en masse*—can be safely hardened in this fluid, provided that certain precautions are taken. The uterus must be laid open and the mass of tissue so suspended in a large jar of the fluid that as much surface as possible may be exposed to the action of the hardening reagent. The fluid should be changed every day during the first week, afterward every three days until the hardening is complete. The process takes from six to eight weeks at the temperature of a living room, or from two to four weeks in a thermostat at 37° C. (98.5° F.). In warm weather the addition of a few fragments of gum camphor to the fluid prevents the growth of fungi. On account of the frequent changing of the fluid which is necessary, Müller's fluid is less convenient than alcohol for ordinary work.

Other Methods of Fixing.—The preparation and methods of use of solutions used in finer histological work need not now be considered. The formulae and application of Fleming's solution and Hermann's fluid are described in the text-books of microscopic technique. Two methods may perhaps be mentioned here :

1. The method of fixing with corrosive sublimate, which is popular with some surgeons, and, indeed, when successfully carried out, yields excellent results, and
2. The method of fixing with formalin.

In employing the former small bits of tissue, not exceeding 0.5 centimeters (2 inches) square, are immersed immediately after removal from the body in a saturated solution of corrosive sublimate in physiological salt solution (0.6 per cent sodium chloride in distilled water). The tissue remains in the fixing fluid from one to twenty-four hours; it is then hardened in a series of alcohols of gradually increasing strength (33½, 50, 60, 70, 80, 95 per cent).

The second method is of comparatively recent date. The formalin of commerce consists of an aqueous solution of formaldehyde. As a fixing agent for histological purposes it has been found convenient to use a mixture of ten parts of this commercial liquid with ninety parts of water. The pieces of tissue

should be small and should remain in the fluid only for from twelve to twenty-four hours, after which they are further hardened in alcohol.

By the use of this method the blood and tissue cells are well preserved and the specimen is, as a rule, of excellent consistence for cutting.

Death without Operation.—In order to illustrate the foregoing remarks three protocols of autopsies are appended, taken from the records of the Pathological Laboratory of the Johns Hopkins Hospital and University.

PROTOCOL I.—Case dying without operation.

Feb. 1, 1890. J. J., Path. No. 77 (colored), housewife, aged about forty-five.

Anatomical Diagnosis.—Myoma of uterus with central necrosis, dilatation of ureters from pressure, pyelonephritis, chronic passive congestion and emphysema of lungs, displacement of viscera and deformity of thorax in consequence of tumor. General marasmus. Heart hypertrophy with hyaline, calcific, and fatty degeneration.

Exterior.—Body, 150 centimeters (5 feet) in length; emaciated; *rigor mortis* present. Deep depression beneath each clavicle, more marked on the right side; mammae atrophic; the manubrium sunken; a slight elevation corresponding with the articulation of the second rib and sternum, more marked on the right than on the left side. Abdomen enormously distended; a firm tumor mass felt beneath the thin abdominal wall, projecting more on the right. The right buttock, on which the weight of the body has evidently rested, is smaller than the left. The tumor feels firm and smooth, except directly above the pubes, where a hard, slightly movable mass can be felt.

Measurements: From the tip of the ensiform cartilage to symphysis pubis, 40 centimeters; umbilicus displaced to the right 5 centimeters; greatest abdominal circumference, 79.5 centimeters; thoracic, 69 centimeters. In the skin over tumor on the right side, 4 centimeters below and 6 centimeters to the right of the umbilicus, there is a round smooth cicatrix 2.5 centimeters in diameter; on the posterior surface of lower extremities several large, irregular, circumscribed ecchymoses.

Subcutaneous fat slightly developed, muscles pale. Diaphragm on right side in upper portion of second intercostal space, on left at the middle of third rib; the second intercostal space on each side 3 centimeters, the first 2.5 centimeters, wide; the articulation of the second rib with the sternum, on the right side with the body in the dorsal position, almost directly over the articulation of the first, only 1 centimeter below a perpendicular line from the lower portion of the first rib; on the left side this is not so pronounced. The deep cervical veins, particularly those on the right side, more dilated and engorged; right jugular 2.25 centimeters in diameter.

Peritoneal Cavity.—On opening the peritoneal cavity a large smooth tumor mass appears immediately adjacent to the abdominal walls, its surface covered with large tortuous veins with firm adhesions over a small area of tumor surface, corresponding to the cicatrix in the abdominal walls, these adhesions arranged in a more or less crescentic shape; the largest of them, 6 centimeters

in length, is easily broken through. In the middle line of the tumor mass is a white, firm, movable nodule, and similar nodules are present on its upper left side. The extreme superior margin of the tumor corresponds to a line drawn across from the ends of the eighth pair of ribs. On the anterior surface of the tumor is a dark-colored flattened body, partly covered over with a thin membrane, the upper edge of which is thickened; on the right side and lower down a similar body is visible; closer examination shows these bodies to be enlarged and flattened ovaries, covered over in part by the broad ligaments; the right ovary is connected with the adhesions previously described; the left ovary and both uterine tubes and fimbriae are free from adhesions.

The veins in both broad ligaments, especially those in the right, are enormously distended. The growth occupies almost all of the abdominal cavity; all of the small intestines and the greater part of the cælon lie above the tumor. The peritoneum is smooth; the cecum is displaced upward and lies against the gall bladder; the lower portion of the ileum descends beneath the tumor, then turns upward to be inserted into the cecum.

All of the lymphatic vessels in the lower portion of the abdomen enormously dilated and filled with clear, slightly yellowish contents; some of the post-mesenteric lymph vessels measure 5 millimeters in diameter; large dilated lymphatics can be seen along the ureters and over the capsule of the kidney; mesenteric and retroperitoneal lymphatic glands small.

Thoracic Cavity.—The lower border of liver corresponds to tip of ensiform cartilage in median line, elsewhere to lower border of the fifth rib; the lower border of descending innominate veins is $\frac{1}{2}$ centimeter above the sterno-clavicular articulations. Right lung is bound down by tolerably firm adhesions; the left is free; both pleural cavities are dry.

Heart.—Both layers of pericardium smooth; in pericardial cavity a few cubic centimeters of clear serous fluid; in both sides of heart fluid blood and fresh coagula; left ventricle slightly contracted; no valvular distortion; heart's flesh tolerably firm, of a dark-brownish color. In the wall of the left ventricle, in most cases just beneath the endocardium, are numerous small yellowish foci.

Thickness of left ventricle, 17 millimeters; of right, 4 millimeters; length of left ventricle to lower border of aortic valve, 8 centimeters. Endocardium presents a few pale patches. Aorta just above valves measures 62 millimeters in circumference. The entrance to the left coronary artery is slightly dilated. Weight of heart, 260 grammes.

Lungs.—Left lung small, anterior border thin and emphysematous, surface smooth; in the bronchial artery fresh clots; veins normal; bronchi slightly dilated; mucous membrane pale. Posterior and lower portion of lung firm and dense. Right lung arteries contained fresh clots, veins free; bronchi throughout lung much dilated; surface of lung smooth, save for old adhesions; anterior edge pale, emphysematous; posterior and lower portions firm and dense in structure, congested.

Liver.—Gall duct open; liver small; dimensions, 25 × 14 × 6.5 centimeters; surface mottled; on section also mottled, with numerous very pale

areas; otherwise smooth and congested. Gall bladder contains about 25 cubic centimeters of clear, transparent, yellowish bile. Weight, 1,520 grammes.

Spleen.—Spleen measures $10 \times 7 \times 3.5$ centimeters; capsule smooth; on section of a firm dark-brownish color; trabeculae visible. Weight, 110 grammes.

Stomach, intestines, pancreas, and suprarenal capsules normal.

Kidneys.—Left kidney, $17 \times 7 \times 5.5$ centimeters; pelvis dilated. (Pelvis of both kidneys turned to front.) Capsule adherent, surface irregular and lobulated; beneath capsule numerous whitish foci; on section, throughout kidney numerous purulent foci, following line running from pelvis toward cortex; the pyramids flattened, pelvis generally smooth, here and there covered with a fibro-purulent exudation. Ureters dilated, firmly adherent to the posterior surface of the tumor. The dilatation extends only from the point where the ureter separates from the tumor.

Right kidney, $17 \times 6 \times 4.5$ centimeters; dilated. Kidney filled with purulent foci; in general, shows the same condition as left kidney; the ureter is adherent to tumor for a longer distance and the dilated portion is longer than that on the left side.

Uterus and Appendages.—The uterus, 19 centimeters in length, is thin, anteflexed, and extends directly over the anterior surface of tumor. Both Fallopian tubes patent until they reach the tumor, when they become lost in the tumor substance; the right tube can be traced almost into uterus. Both ovaries flattened, the right $6.5 \times 3.5 \times 0.5$ centimeters, the left $5 \times 4 \times 0.75$ centimeters. In the left ovary a large corpus luteum, with a dark-brownish clot 3 centimeters in diameter.

Bladder.—Bladder contracted; contains small amount of milky purulent urine; mucous membrane ecchymosed and of a dark-red color.

Tumor.—The tumor is a large, firm mass, on its posterior surface divided into two distinct lobes by deep depression corresponding to vertebrae. The small tumor, on anterior aspect, which was felt previously, was found to be separated from the rest and growing into the uterus. Tumor, on section, dense, firm, its center occupied by a large triangular cavity, the longest diameter of which is 17 centimeters, at base 11 centimeters; this cavity is filled with clear, slightly blood-stained fluid, and with dense masses of yellowish-white, hard, elastic tissue. The greatest diameter of tumor is 25 centimeters. The small tumor on anterior surface dense, firm, and somewhat opaque.

Microscopic Examination.—Myocardium; left ventricle shows in frozen section numerous smaller and larger opaque foci; in the center of these are small darker masses of irregular shape. Some of these patches measure 1 to 2 millimeters in diameter; others are very minute; the dark patches correspond to fatty degeneration of the muscle fibers; among these are numerous fibers which have a refractive homogeneous appearance.

The fatty degeneration is chiefly in and around the foci containing hyaline fibers, but in places it appears to exist independently of them; on the other hand, foci of hyaline fibers or single hyaline fibers occur with only a few fatty fibers observable in their neighborhood. The refractive material dissolves in

glacial acetic acid rather slowly, rapidly in HCl and HNO₃, without ebullition of gas. As it dissolves, the fibers containing it swell up and lose their highly refractive appearance and look hyaline. The refractive material is insoluble in strong caustic potash or ammonia. On the addition of H₂SO₄, the refractive substance is replaced by masses of crystals or sulphate of lime. The refractive material therefore is impregnated with a lime salt which is not the carbonate. The refractive fibers are brittle and show sharp contours; they break in sharp lines. One of these was noticed in the right ventricle, which was examined in six different places. None found in left auricle (examined in two places). Found in all parts of left ventricle, but appear to be most abundant in upper part near left border. Stained fresh section showed a marked increase of nuclei in and around the clumps of hyaline fibers, which are themselves devoid of nuclei, and often seem broken up. The fatty, calcified foci appear to be most numerous and extensive in that part of the myocardium which is near the pericardium, but they are to be found also near the endocardium. Sections placed in Fleming's solution show well the fatty degeneration which is present around all calcified fibers, but these fibers themselves contain no fatty particles.

On microscopical examination the tumor is found to be a leiomyoma.

Death Six Days after Operation.—PROTOCOL II.—Case of death, Jan. 27, 1893, six days after operation (Jan. 21, 1893). (Abdominal Section.) M. E. A., aged twenty-nine, 1763.

Anatomical Diagnosis.—General peritonitis; stitch abscesses; syphilitic deformity of the liver; gummata in liver; congestion of lungs; chronic diffuse nephritis; amyloid infiltration of kidney, liver, and spleen.

In the median line of the abdomen is a linear incision 10 centimeters (4 inches) long. The lower 3.5 centimeters (1½ inch) of this gapes; on removing the stitches they are found to be covered with pus. Pus can also be squeezed from the stitch holes. The muscle, where exposed, is covered with pus, and at the superior angle of the wound, where the muscular layers are separated from one another, is a small cavity containing pus. The omentum contains a considerable quantity of fat, is injected, and adherent by its outer surface to the abdominal wound; on its inner surface within the pelvis it is adherent to the intestines. Its under surface over the lower third of its extent is intensely injected, edematous, and cloudy from the presence of pus. Along its inferior border it is much swollen and covered with a fibrino-purulent exudate. There are dense masses of fibrin between the coils of intestines in the pelvis and also on the parietal peritoneum corresponding to them. The large intestine occupies the inferior portion of the pelvis, and its coils are more firmly adherent than are those of the small intestine. Over the peritoneal surface of the intestines in general a very delicate deposit of fibrin can be made out. About 20 centimeters (8 inches) above the ileo-cecal valve a loop of intestine 12 centimeters (5 inches) in length is folded upon itself and covered with a thick fibrinous deposit which can be readily stripped off. This deposit commences at the mesenteric border of the gut and extends two thirds of the

way around it. The peritoneal surface beneath the fibrin is deeply injected and roughened.

The peritoneal coat of the lower portion of the descending colon is intensely injected and covered with hemorrhagic masses of fibrin. The gut is everywhere considerably distended and contains fluid yellow feces. The mucous membrane of the small intestine is somewhat injected; opposite the loop above mentioned the injection is especially marked. The mucosa of the large intestine, except that of the rectum, which is congested, is pale. The appendix is bound down at its middle by old adhesions, but is otherwise normal.

Both uterine appendages are missing, being represented by stumps on either side of the uterus. These stumps are covered with hemorrhagic masses of fibrin, and on section are seen to be suffused with blood. The *cul-de-sac* between the uterus and the bladder is lined with a thin layer of fibrin and there are here some old adhesions. On the superior surface of the uterus and between the posterior surface of the uterus and the anterior surface of the rectum similar old adhesions exist. The peritoneum in Douglas's pouch is also covered with fibrin. The cavity of the uterus is normal. The bladder is normal. The mucous membrane of the stomach is pale, except in a few areas where it is congested.

Liver.—The liver weighs 1,600 grammes. Size $25 \times 17 \times 9.5$ centimeters. It is adherent to the abdominal wall and to the diaphragm, and there are large elevated areas with corresponding depressions, which give the organ a lobulated appearance.

The gall bladder is thickened and is bound down by old adhesions.

The liver on section is mottled, congested areas alternating with pale yellow opaque areas. Bands of dense white tissue run between the lobulations, and the portal veins appear to be dilated. Scattered throughout the liver are many minute gray translucent and yellow foci, the largest being 2 millimeters in diameter.

Kidneys.—Combined weight 340 grammes. Both are alike; size $12 \times 6.5 \times 4$ centimeters; capsule strips off readily. The surface is slightly irregular, presenting depressed atrophic areas. The veins beneath the capsule are injected; on section the pyramids are seen to be injected. The cortex averages 8 millimeters in thickness and is pale. The striae are in part obliterated; where present they are very fine. The Malpighian bodies are prominent and red. The whole organ is edematous.

Lungs.—Both lungs are alike; they retract on opening the thorax; they are slightly emphysematous at their margins; elsewhere they are deeply injected. The pleurae are cyanotic. The bronchi are much injected and contain a small amount of tenacious mucus. The blood vessels of the lung are normal. The bronchial glands are deeply pigmented and edematous.

The heart weighs 220 grammes and is apparently normal.

The spleen measures $13.5 \times 8 \times 3$ centimeters. The capsule is adherent in a few places and the organ is firmer than normal. On section the trabeculae are visible; but few Malpighian bodies are visible to the naked eye. The pancreas is apparently normal. The mesenteric glands are swollen and congested.

Microscopic Examination of Frozen Sections.—The liver tissue is divided up into areas of one or of several lobules and occasionally into fractions of a lobule by dense masses of connective tissue. The liver cells are granular, swollen, and often fatty. Circumscribed areas of necrosis of variable size are found; these correspond to the minute foci visible to the naked eye. In some places these areas are surrounded by a zone of fatty cells, but are without a connective tissue capsule; about others there is a distinct zone of connective tissue. Scattered throughout the liver numerous small masses of necrotic cells can be made out. The capillaries running between these contain a good many polymuclear leucocytes. The dense bands of connective tissue which are scattered throughout the liver are often rich in blood vessels, the walls of which present a hyaline, glistening appearance. Stained with Lugol's solution, this glistening material gives the characteristic amyloid reaction.

Kidneys.—The vessels in the pyramids and in some of the glomerular capillaries yield the characteristic amyloid reaction. There is an increase of connective tissue between the tubules, and in foci the capsules of Bowman are thickened. Hyaline casts are present in some of the tubules.

Bacteriological Examination.—Smear coverslip preparations from peritoneum and kidney substance were negative, but tubes of nutrient agar-agar inoculated with the exudate on the peritoneum gave a pure culture of the *staphylococcus pyogenes aureus*. The same organism was found in the subcutaneous portion of the abdominal wound, in a catgut ligature from the deep part of the abdominal wound, and from the omentum just beneath the abdominal incision.

One and five tenths of a cubic centimeter of a forty-eight-hour bouillon culture of this *staphylococcus* introduced into the aural vein of a rabbit caused the death of the animal at the end of five days.

The lung contained a short bacillus with rounded ends, about half as long again as broad. On cultivation on agar-agar, gelatin, acid gelatin, potato, and in litmus milk, it closely resembled the *bacillus coli communis*, but was not positively identified. Culture tubes inoculated from the kidney, spleen, and liver remained sterile.

Death Fifty-one Days after a Minor Operation.—PROTOCOL III.—A case in which the symptoms of infection due to a minor operation became manifest only after the lapse of six weeks' time, when the external wound was healed.

Abstract of Clinical History.—M. H. (1805), colored, aged fifty-eight; previously healthy; the mother of ten children; catamenia always regular. The present trouble began about three years before admission, when the patient noticed a protrusion between the external genitals, slowly increasing in size. It was at first painful to the touch, but could be kept up by wearing a bandage. She had had constant pains in the back and had to rise five or six times during the night to urinate. Her bowels were regular.

She was examined Jan. 26, 1893, by Dr. Kelly, and considered too feeble for operation. She improved, however, and on Feb. 7, 1893, the resident physician operated for prolapse, performing perineorrhaphy and removing the cervix.

She did well until March 22d, when she was first noticed to have peculiar twitching movements. Respiration was difficult, and there was slight nausea but no headache. Examination of the urine at this time showed a large amount of albumin and hyaline, granular, and blood casts. For two days she improved, but died on March 30th.

Autopsy (Dr. L. F. Barker) nine hours after death.

Anatomical Diagnosis.—Recent operation on cervix and perineum; local infection of deep perineal tissues; secondary general infection, with *Staphylococcus pyogenes aureus*, miliary abscesses in heart muscle, kidneys, and intestines; arterio-sclerosis; chronic passive congestion; pulmonary edema; pulmonary emphysema; pneumoconiosis; infarction of spleen; acute splenic tumor; chronic diffuse nephritis; acute nephritis; ovarian cystomata; cyst of broad ligament; fibrous atrophy of the ovaries; cholelithiasis.

Exterior.—Body 151 centimeters long. Rigor mortis partial in upper extremities, complete in lower. Body well nourished. No edema of the ankles. Diaphragm on right side at fifth interspace; left side, at sixth rib. Peritoneal cavity dry. Omental fat abundant. Liver margin 4 centimeters below free border of ribs. Spleen does not pass costal margin. Cartilages of ribs somewhat calcified. Beneath visceral layer of pericardium, over surface of left ventricle, 3 centimeters from base, is a minute grayish-white opaque area $1\frac{1}{2}$ millimeter in diameter which extends 2 millimeters into the myocardium. The fat in the epicardium is much increased, particularly along the interventricular border.

The Heart.—Weight, 420 grammes; blood inside bright red. On the endocardium of the left ventricle, in that portion corresponding to septum, between the two ventricles, situated $3\frac{1}{2}$ centimeters below root of aorta, is a grayish-yellow slightly raised opaque area 5 millimeters in diameter. This area has a tolerably firm, somewhat irregular base of a dark bluish-red color. It extends a distance of 3 millimeters into the myocardium and contains grayish-white pus. Just beneath this in the myocardium is another abscess, 4 millimeters in diameter, filled with grayish-white pus. The rest of the myocardium, which is fairly firm and red, shows several minute purulent foci. Heart valves normal. Diffuse, small, sclerotic patches in aorta. Coronary arteries dilated; they show also a few sclerotic patches. The right pleural cavity contains no excess of fluid. Some old adhesions over upper lobe. Left pleural cavity free from adhesions.

The Lungs.—Surface of right lung smooth except where old adhesions were attached. There is a moderate amount of coal pigment marking off the lobules. On section much frothy fluid escaped, particularly from the upper lobe. The surface of the lung is reddish-brown in color and not granular; the upper lobe edematous. The bronchi are filled with frothy fluid; mucous membrane congested. The right pulmonary artery is almost occluded by a large clot of laminated fibrin, which is firmly adherent to one side of the vessel. The intima shows several small, yellowish-white raised areas. The bronchial glands are deeply pigmented. The left lung does not differ materially from the right;

the edema in it is perhaps not quite so marked. The margins of both lungs are rounded and show many alveoli dilated and filled with air.

The spleen weighs 190 grammes; dimensions, $12 \times 8 \times 2\frac{1}{2}$ centimeters. The organ is generally a bright brownish-red in color. On its surface are two elevated brownish-red areas, one measuring 4 centimeters in diameter. On section the spleen is almost diffuent; pulp abundant; Malpighian bodies invisible. The dark brownish-red areas are wedge-shaped. One has a soft center. The color is not uniform, but mottled red and brown. Many minute grayish-white points can be seen in the pulp.

The kidneys weigh together 460 grammes. The right measures $15 \times 7 \times 5$ centimeters. On its free border is a small sac $1\frac{1}{2}$ centimeter in diameter filled with clear, straw-colored fluid. Capsule is otherwise smooth and can be removed easily. The surface beneath the capsule is pale and shows very numerous single and conglomerate raised and yellowish-white areas, from some of which grayish-white, gelatinous, purulent fluid exudes. On section the kidney is pale and edematous; average thickness of cortex, 6 millimeters; fine markings are obliterated; striae are coarse. Throughout cortex are numerous yellowish-white puriform areas; some just beneath capsule, others deeper in its substance. There is one wedge-shaped, slightly raised reddish-white area measuring at the base 7 millimeters beneath the capsule. In this area are three or four yellowish-white foci. Another intarction, measuring 2 centimeters at its base, has miliary abscesses about it. The majority of the purulent foci are in the cortex, but the pyramids contain many also. Sometimes they form rows running halfway through the length of the pyramid parallel to the tubes and intertubular vessels. The glomeruli are pale and indistinct. The pelvis of the kidney is slightly congested, the pelvic fat abundant. The left kidney measures $13\frac{1}{2} \times 8 \times 5\frac{1}{2}$ centimeters, and shows similar changes to those in the right. Ureters and adrenals normal.

The liver weighs 1,860 grammes; dimensions, $29 \times 18\frac{1}{2} \times 7$ centimeters. Its surface is smooth; consistence fairly firm. On section, grayish-brown in color, slightly mottled. Lobules indistinct. The gall bladder is filled with gall stones, thirty-five in number, averaging in size that of a hazelnut. They are faceted and greenish-brown or blackish-brown in color. The bile is deep greenish-brown in color and thick. The mucous membrane of the gall bladder is normal.

Pancreas normal.

The stomach is large and partially filled with fluid. The mucous membrane shows minute ecchymoses.

In the small intestine the veins are dilated, more in some places than in others, and there are occasional punctiform ecchymoses on the edges of the folds. Throughout the jejunum and ileum, particularly in the latter, for a distance of 100 centimeters above the ileo-cecal valve, there are numerous miliary and conglomerate nodules, which are elevated and have often a hemorrhagic border; they are usually opaque and grayish-yellow in color. Often large numbers of these run in lines along the horizontal axis of the gut, on both sides of and close

to the circular vessels. On section these are seen to contain necrotic material and grayish-yellow pus. There are only a few miliary abscesses in the wall of the large gut. An occasional small abscess can be made out in the fat around the colon. The rectum is normal.

The mucous membrane of the vagina is smooth; in its upper part are two folds held in place by two silkworm-gut ligatures which run through the cervix and vagina. There is no evidence of inflammatory reaction about them.

The uterus is 7 centimeters long, 4 centimeters wide at its widest part, and 3 centimeters antero-posteriorly. Its cavity from fundus to external os measures 6 centimeters. The average thickness of the uterine walls is 8 millimeters. The mucous membrane is smooth and looks normal.

The ligaments of the uterus and its adnexa are very much relaxed and lengthened. The right uterine tube is 4 centimeters ($1\frac{1}{2}$ inch) long; the surface is smooth. The right ovary is small, atrophic, and contains at its outer end a cyst 1 centimeter in diameter filled with clear straw-colored fluid. On section the ovary is very fibrous and in its substance contains a small nodule about the size of a pea, which is filled with shreddy grayish-white material. On the outer surface of the ovary are very numerous minute cysts about the size of a bird shot. They contain serous fluid. There are a number of these also in the broad ligament on this side. The miliary purulent foci are also seen in the broad ligament. The left uterine tube is 5 centimeters (4 inches) long. The left ovary is small, and on its surface and along the surface of the ovarian ligaments are many extremely minute cysts containing serous fluid, like those on the other side. Around the ovarian ligaments and near the uterus are four larger cysts with gelatinous contents about the size of a hazelnut. The pelvic peritoneum is smooth and shows no signs of inflammation. The bladder is normal.

In the perineum are marks of recent stitch holes, and in the perineal tissue, beneath the operation site which extensively shows a healed wound, is a small cavity filled with greenish-yellow pus. Pus can be squeezed from several points in this tissue.

Microscopic Examination.—Coverslips from purulent foci in different parts show very many cocci, chiefly in pairs. They are often biscuit-shaped. Frozen sections of heart muscles generally not fatty. In the white opaque areas the muscle fibers are necrotic, and there are many small round cells accumulated there. The lung shows many dilated alveoli. The alveolar epithelium is swollen. Some coal pigment in perivascular and peribronchial connective tissue. The liver cells are much swollen and are very granular. The central veins are dilated, as are also the capillaries. The liver cells around the central veins are distinctly pigmented, while the cells in the periphery of the lobules are fatty. There is no marked increase in the connective tissue of the liver. In the kidney collections of leucocytes are numerous in the cortex. There are several collections of pus cells along the intertubular vessels in the pyramids. The epithelium of the convoluted tubules is much swollen and granular. Many cells have been desquamated, and the cells left are loosened

from one another. There has also been swelling and desquamation in the collecting tubes. There is some fatty hyaline degeneration in the secreting tubules. The glomerular vessels are dilated. In a few places there is fatty degeneration of the glomerular epithelium. In some areas there is thickening of the capsule of Bowman, and occasionally a completely obliterated Malpighian body can be seen. In these areas the connective tissue is increased about the blood vessels and between the tubules.

The Cultures.—The cultures on Esmarch's agar, from heart's blood, abscess in myocardium, liver, spleen, and kidney, contain colonies of *staphylococcus pyogenes aureus*, but no other bacteria. The colonies are yellow, and in twenty-four hours the color slips showed typical clusters. The agar Esmarch was too crowded to allow one to get at single colonies. Gelatin rolls made from this showed only one variety of micro-organism, which proved to be the same *staphylococcus*, which is slow in liquefying gelatin. At the end of three days there is no liquefaction. At the end of seven days there is liquefaction in the neighborhood of the individual colonies, and fine granular sediment of cocci in the pendant portion of liquefied medium.

INDEX OF CASES FROM THE JOHNS HOPKINS HOSPITAL.


	PAGE
Adeno-carcinoma of uterus with cystic degeneration	314
Adeno-myoma uteri diffusum benignum	385
Angio-sarcoma of ovary	291
Anastomosis between loops of ileum	495
Cesarean section	422
Cesarean section, myoma complicating pregnancy	424
Cancer of ovary, with fibroid uterus	380
Carcinoma of cervix	331
Carcinoma of uterus, with myoma	311
Cornual myoma	362
Cystectomy during pregnancy	408
Cystic myoma with twisted pedicle	385
Dermoid of ovary, with fibroid uterus	379
Emphysema of abdominal wall	127
Extensive tear of rectum at pelvic floor	505
Extra-uterine pregnancy	461
Fecal fistula	124
Femoral hernia	125
Fibroid ovary during pregnancy	491
Fibroid tumor of ovary	409
Fibro-cystic tumor	289
Fibroma of ovary	343
Fistula opening into cecum	174
Hematoma of ovary	495
Hemorrhage	189
Hemorrhage	66
Hydrosalpinx and ovarian cyst during pregnancy	66
Hystero-salpingo-oöphorectomy	408
Ileo-cecal anastomosis	195
Itus due to Trendelenburg position	513
Interstitial myoma	110
Late shock	360
Late shock	59
Lavage	59
Multilocular ovarian cystoma	76
Myoma during pregnancy	182
Myoma of uterus	410
	539

	PAGE
Myoma simulating pregnancy	V. W., 3198, November 28, 1894 400
Myomata, eight, removed by seven incisions	M. A., 1576, November 5, 1892 360
Ovariectomy	J. S., 3333, February 25, 1895 196
Ovariectomy	S. T. W., examination, San., February 2, 1897 526
Papillary cyst-adeno-sarcoma	M. G., 3100, October 13, 1894 275
Papilloma of ovary	A. W., 5069, March 6, 1897 174
Papilloma of ovary	C. K., 2592, February 17, 1894 269
Papilloma of ovary	J. H. E., San. 59, August 16, 1893 968
Papilloma of ovary	L. K. W., 1189, February 10, 1892 174
Parovarian cyst	L. W., 1171, January 27, 1892 282
Parovarian cyst	P. T., 604, March 14, 1891 282
Parovarian cyst during pregnancy	S. M., 2561, January 4, 1894 408
Pelvic abscess	A. C., 4186, March 4, 1896 229
Perineorrhaphy	M. H., 1805, February 7, 1893 544
Peritonitis	M. E. A., 1763, January 21, 1893 542
Pneumonia following operation	L. Y., 2677, March 29, 1894 107
Post-operative septic peritonitis	V. W., 3198, November 8, 1894 84
Purulent hemorrhagic peritonitis	E. E. H., 6589, January 23, 1893 85
Salpingo-oophorectomy	E. D., 3391, March 23, 1895 196
Septic infection	L. F., 2612, March 1, 1894 67
Septicemia	A. M., 3110, April 2, 1894 103
Septicemia	S. W., 3304, November 28, 1894 101
Sigmoido-rectostomy	B. W. M., 1161, October 20, 1894 511
Sudden death from embolus	M. E. H., 2225, September 25, 1893 (admission) 130
Suppurating ovarian cyst	E. B. L., 4946, January 20, 1897 298, 497
Suppurating myoma	A. S., 3216, December 3, 1894 383
Suspension of the uterus	E. B., 2701, April 6, 1894 153
Suspension of the uterus	J. A. H., San. 332, June 26, 1892 158
Tear of rectum	J. S., 332, September 2, 1890 20
Tubercular peritonitis	B. M., 14, October 18, 1889 138
Tubercular peritonitis	K. J., 2597, February 21, 1894 148
Uterus sutured to rectum	J. S., 357, September 2, 1890 505

INDEX OF CASES FROM THE LITERATURE.

Appendicitis during pregnancy	P. F. MUNDÉ 413
Appendicitis during pregnancy	L. L. McARTHUR 413, 414
Cesarean section	E. J., April 17, 1888, H. A. KELLY 417
Cesarean section and symphyseotomy on different occasions in same woman	K. G., May 30, 1888, H. A. KELLY 416
Cesarean section in a case of osteo-sarcoma of pelvis	M. S., May 10, 1889, H. A. KELLY 416
Cesarean section twice	1835-1837, (Mrs. Reybold) WILLIAM GIBSON 421
Dermoid cyst during pregnancy	B. C. HIRST 408
Dermoid cyst during pregnancy	R. MORISON 409
Dermoid cyst during pregnancy	C. STAUDE 408
Dermoid cyst of ovary	C. SCHRÖDER 181
Dermoid cyst of ovary	P. F. MUNDÉ 277
Extirpation of the uterus	G. KIMBALL 365

		PAGE
Extra-uterine pregnancy	H. A. KELLY	445
Extra-uterine pregnancy	H. C. COE	430
Extra-uterine pregnancy	KOEBERLE and LECLUYSE	433
Extra-uterine pregnancy	C. FENGER	462
Extra-uterine and intra-uterine pregnancy	H. P. C. WILSON	442
Extra-uterine and intra-uterine pregnancy	A. L. GALAMIN	442
Fibroid of ovary	A. SCHACHNER	289
Hysterectomy for fibroid tumor	WALTER BURNHAM	364
Hysterorrhaphy	M. A. W., April 25, 1885, H. A. KELLY	149
Intraligamentary myoma with twin pregnancy	W. J. TAYLOR	411
Inguinal hernia in women	W. S. HALSTED	481
Ovarian carcinoma	A. HEMPLE	276
Ovarian cyst with pregnancy	C. JACOBS	409
Ovariectomy during pregnancy	J. M. BALDY	413
Panhysterectomy for uterine fibroid	M. A. D. JONES	365
Papillary cyst-adeno-sarcoma	PFANNENSTIEL	274
Papilloma of ovary	LOMER	266
Papilloma of ovary	K. THORNTON	266
Pregnancy in rudimentary horn of uterus	G. W. WILKINS	465
Pyosalpinx in pregnancy	KALTENBACH	412
Pregnancy following conservatism	B. F. BAER	190
Pregnancy following conservatism	A. P. DUDLEY	189
Pregnancy following conservatism	B. MACMONAGLE	190
Pregnancy following conservatism	W. M. POLK	188, 191
Pregnancy following conservatism	A. SIPPLE	191
Removal of fibroid tumor	W. J. ATLEE	364
Suppurating appendages during pregnancy	H. MICHE	412



I N D E X .

- Abdominal dressing, 42.
 hysterectomy for carcinoma and sarcoma of
 the uterus, 305.
 incision, 12.
 operations upon the myomatous uterus, 354.
- Abscess, pelvic, forms of, 209.
- Accessory ostia, 432.
- Adeno-carcinoma of cervix, 310.
 of body of uterus, 310.
 of ovary, 275.
- Adeno-myoma uteri diffusum benignum, 385.
- Adherent Fallopian tubes, 183.
 tubes and ovaries, 374.
- Adhesions, methods of dealing with, 17, 493.
 to myomata, 497.
 to ovarian cysts, 497.
 to pelvic abscesses, 498.
 to uterus, 496.
- Amputation of diseased tubes, 186.
- Anastomoses:
 end to end, 507.
 end to side, 511.
 ileo-cecal, 513.
 lateral, 505.
- Anastomosis buttons, 515.
- Anatomical changes due to operation, 521.
- Appendical adhesions, 21.
- Appendicitis, 499.
 with pregnancy, 413.
- Artificial anus, 516.
 menopause, 525.
- Atresia of one tube with external migration of
 the fertilized ovum from the opposite side,
 430.
- Autopsy, methods of conducting, 531.
 how to close up a body, 536.
- Bacillus coli communis, 83.
 laetis aërogenes, 211.
- Bandage, 45.
- Bathing after operation, 45.
- Bimanual compression of pus sac, 221.
- Bowels after operation, 51.
- Cesarean section, 415.
 competitive operations:
 craniotomy, 415.
 premature labor, 416.
 symphysectomy, 415.
 turning, 415.
 use of forceps, 416.
 conservative Cesarean operation, 416.
 in agonia, 427.
 indications for, 415.
 on the dead, 427.
 Potro-Cesarean operation, 423.
- Cancer of the uterus, with myoma or tuberculo-
 sis, 311.
 of the uterus, associated with myomata, 380.
- Carcinoma of ovary, 275, 379.
 of cervix, with pregnancy, 411.
 of the uterus, 305.
- Care of wound, 44.
- Castration for extreme dysmenorrhea, 195.
- Catheterization after operation, 51.
 of the ureters, 323.
- Changes in vagina due to operation, 524.
 in uterus due to operation, 524.
- Chemical test to determine the presence of pseu-
 domucin, 261.
- Charts:
 analysis of urine, 5.
 chart showing high pulse rate with recovery,
 72.
 chart showing relative time of continuance of
 fever after operation for tubercular peri-
 tonitis, with and without drainage, 146.
 composite chart of cases of tubercular peri-
 tonitis not drained, 146.
 composite charts showing the average range
 of pulse and temperature for ten days after
 operation, 54.
 composite urinary chart of one hundred cases,
 with and without saline enemata, 50.
 malarial chart, 75.
 pneumonia chart, 108.
 recovery in tubular peritonitis showing the

- characteristic defervescence after operation without drainage, 147.
 stitch-hole abscess chart, 115.
 temperature and pulse chart (general sepsis from local vaginal infection), 102.
 temperature and pulse chart (septic peritonitis, following myomectomy), 86.
 typical temperature and pulse chart (septicemia from purulent peritonitis), 103.
- Cleansing the abdomen, 10.
 Clear space, 108, 241.
 Closure of the incision, 40.
 Colostomy, 516.
 Complications arising after abdominal operations, 56.
 Conservative operations on the tubes and ovaries, 163.
 importance of conserved structures, 165.
 limitations of, 171.
 objections to, 172.
 on the ovary, 173.
 on the uterine tubes, 183.
 reasons for, 164.
 Cornual myoma, 361.
 Course of an inflammatory process, 213.
 Cultures, 548.
 Curettage, 352.
 Cystic myoma uteri with twisted pedicle, 384.
 Cysto-myoma, 382.
 Cysts of the corpus luteum, 180.
- Dermoid cyst, 379, 406.
 cysts of ovary, 181, 277.
 Diet lists, 47.
 Diverticula from the lumen of the Fallopian tube, 431.
 Drainage:
 - after operation for tubercular peritonitis, 147.
 - cases to be drained, 37.
 - function of the peritoneum under normal and pathological conditions, 30.
 - how to put in and take out a drain, 37.
 - mechanism of absorption of fluids and solid particles in the peritoneal cavity, 33.
 - objections to, 3...
 - of tubal abscesses, 187.
 - physiology of, 29.
 - prevention and removal of infection without drainage, 36.
- Egg albumen, 47.
 Elevation of tubes and ovaries by myomata, 389.
 Emphysema of abdominal wall, 127.
 Emptying, cleansing, or sterilization of inflamed tubes, 185.
 the sac by massage, 221.
- Encysted peritonitis, 377, 524.
 Endothelioma of the cervix, 393.
 Enlargement and tenderness of scrot, 523.
 Eriocoele, 523.
 Eucleation of pyosalpinx and ovarian abscess, 231.
 Epithelioma of cervix, 308.
 Evacuation by vagina aided by an abdominal incision, 227.
 through the rectum, 227.
 Examination of the patient, 2.
 Exposure of field of operation, 14.
 Excision of diseased or strictured tubes, 187.
 Extirpation of submucous myomata per abdomen, 364.
 Extra-uterine pregnancy, 187, 428.
 causes of, 438.
 complicated cases of, 463.
 criteria of, 435.
 diagnosis of, ruptured and unruptured, 443.
 forms of, 433.
 interstitial, 441, 463.
 intraligamentary and pseudo-intraligamentary, 455.
 mortality of, 449.
 multiple pregnancy, 441.
 operations for, early and late, 450.
 repeated, 443.
 treatment of advanced, 456.
 vaginal incision and drainage, 453.
- Facial expression, 53.
 Fehling's solution, 5, 262.
 Femoral hernia, 490.
 Fermentation and septic fevers, 97.
 Fermentation fever, 99.
 Fibrocystic tumors, 343.
 Fibroid tumor, clinical character of, 339.
 tumors of the ovary, 285, 379.
 Fistula, 495.
 fecal, 121.
 urinary, 120.
 Fistulae and sinuses, 523.
 Fixing agents, 537.
 Fleming's solution, 538.
 Food, 47.
 Forceps labor, 416.
 Formalin, 538.
 Function of the peritoneum under normal and pathological conditions, 30.
- Galvanism, 354.
 General principles and complications common to abdominal operations, 1.
 Globular myoma filling pelvis, 389.
 Gonococcus, 210.

- Graafian cysts, 177.
 follicles, 177.
- Health of surgeon, 1.
 Heller's nitric-acid test, 5.
- Hematoma of the ovary, 181, 379.
- Hemorrhage, 24.
 from revivata, 352.
 second - y, 61.
- Hermann's fluid, 538.
- Herula, the radical cure of, 467.
 femoral, 490.
 inguinal, 481.
 in the linea alba, 471.
 moles of origin, 467.
 operations for radical cure of, 467.
 umbilical, 476.
- Hoffman's anodyne, 77.
- Hydatid of Morgagni, 293.
- Hydrops tubae profluens, 202.
- Hydrosalpinx, 374.
 follicularis, 203.
 simplex, 199.
- Hysterectomy :
 abdominal, for carcinoma and sarcoma of the
 uterus, 305.
 analysis of one hundred cases of, 245.
 complications of, 244.
 mortality of, 245.
 with extirpation of ovaries and tubes—ab-
 dominal hysterio-salpingo-oöphorectomy, 236.
- Hystero-myometomy, 338, 355, 364.
 with complications, 373.
 without complications, 368.
- Hysteropexy, 149.
- Hysterorrhaphy, 149.
- Hystero-salpingo-oöphorectomy, 236.
- Heus, 109.
- Illumination of the field, 17.
- Incision, 12.
 closure of, 12.
 exploratory, 12.
 in fat women, 12.
 length of, 12.
- Incarcerated pregnant uterus, 406.
- Inflammatory affections as a cause of extra-
 uterine pregnancy, 432.
- Infusion, 70.
- Inguinal hernia, 481.
- Injuries to bladder and ureters, 23.
- Insanity, 527.
- Internal secretion of ovary, 165.
- Interstitial myomata, 342.
 pregnancy, 441, 463.
- Intestinal adhesions, 378, 523.
 Intestinal anastomosis, 505.
 Intestinal complications, 402.
 Intestinal needles, 501.
 Intestinal sutures, 501.
- Intestines :
 circular suture of, with the use of inflated
 rubber cylinders, 509.
 fibrous coat of, 501.
 suture of, 500.
 tear of peritoneal and muscular coats of,
 503.
- Intraligamentary cysts, 300.
- Irritability of bladder and decrease in urinary
 secretion, 49.
- Leaving piece of an organ on bowel, 497.
- Ligation of the pedicle, 24.
- Liver, adhesions to, 378.
- Local changes due to operation, 524.
- Manual reduction of retroflexion, 150.
- Mechanism of the absorption of fluids and solid
 particles in the peritoneal cavity, 33.
- Menstruation, 524.
- Micrococcus laeucolatus, 211.
- Moral questions involved in gynecological
 operations, 518.
- Morphia, 46.
- Müller's fluid, 538.
- Multilocular ovarian cyst adenoma, 259.
- Multiple pregnancy, 441.
- Myoma below posterior pelvic peritoneum, 392.
 below vesical peritoneum, 391.
 developed antero-laterally, 395.
 developed postero-laterally, 396.
 developing under pelvic peritoneum in several
 positions at once, 396.
 displacing ureters upward, 398.
 in broad ligament proper, 393.
 in upper broad ligament, 393.
 simulating pregnancy, 400.
 wedged in pelvis, 390.
 with ascites, feeble heart, etc., 401.
 with pregnancy, 400, 409.
- Myoma uteri causing extra-uterine pregnancy,
 433.
- Myomata, 338.
 diagnosis of, 348.
 kinds and sites of, 341.
 operation for, 354.
 palliative treatment of, 351.
- Nausea, 46, 75.
- Nephritis, 118.
- Normal salt solution, infusion of, 70.
- Nutrient enemata, 61.

- Omental adhesions, 18, 377.
 Opening or resection of closed tubes, 185.
 Operation for abdominal hysterectomy for cancer, 321.
 Operations during pregnancy, 403.
 Osteomalacia, 167.
 Ovarian abscess, *loc.*
 adhesions, 176.
 Ovarian cystoma, 182, 379, 406.
 Ovarian feeding, 168.
 Ovarian hernia, 486.
 Ovarian hydrocele, 379.
 Ovarian tumors in general, 246-379.
 benign and malignant, 248.
 clinical course of, 253.
 diagnosis of, 253.
 kinds of, 246.
 pathology of, 247.
 relative frequency of kinds, 247.
 treatment of, 292.
 Ovariectomy, 246.
 during pregnancy, 407.

 Pain, excessive, 78.
 Papillary adeno-carcinoma, 273.
 Papillary adenoma, 272.
 Papillary cyst-adeno-sarcoma, 274.
 Papillary cystic Graafian follicle, 272.
 Papillary parovarian cyst, 271.
 Papillary tumors of the ovary, 265.
 Parasitic myomata, 345.
 Parietal adhesions, 377.
 Parovarian cysts, 175, 248, 281, 406.
 Pedicle, 248.
 ligation of, 298.
 rotation of, 250.
 Pedunculate myomata, 357.
 Pelvic abscess, 209.
 natural terminations of, 217.
 Pelvic peritonitis, 433.
 Peritoneal bands, 494.
 bands and adhesions due to pelvic peritonitis
 compressing the Fallopian tube, 433.
 Peritonitis, 79.
 post-operative septic, 82.
 traumatic or plastic, 80.
 Persistence of a fetal type of Fallopian tube,
 431.
 Pessaries, 150.
 Phlebitis, 126.
 Phthisical facies, 138, 142.
 Placenta prævia Cesariana, 418.
 Pleurisy, 106.
 Pneumonia, 107.
 Porro-Cesarean operation, 423.
 Position in bed, 45.

 Post-mortem examination, 531.
 Pregnancy, cases of, after conservative opera-
 tions, 188.
 operations during, 403.
 Pregnancy and tubercular peritonitis, 137.
 Pregnancy and ovarian tumors, 255.
 Pregnancy complicating carcinoma of the cer-
 vix, 312.
 Pregnancy in a rudimentary horn of the uterus,
 404.
 Premature labor, 416.
 Preparation of patient for operation, 7.
 of surgeon and assistants, 11.
 Preservation of tissues for microscopic examina-
 tion, 537.
 Pressure symptoms, 341.
 Prevention and removal of infection without
 drainage, 36.
 Provens Zenkeri, 211.
 FALLOPII I, J. J., 539.
 II, M. E. A., 542.
 III, M. II., 544.
 Pseudomucin, 260.
 Pseudo-mucinous papillary adenoma, 272.
 Pulse, 53.
 peculiarities of, 71.
 Purgatives, 81, 113.
 Pyæmia, 105.
 Pyosalpinx, 212, 374.
 and ovarian abscess, with pregnancy, 412.

 Rectal adhesions, 19.
 Rectum, injury of, 503.
 Regeneration of inflamed tissues, 170.
 Relative frequency of papillomata and carcino-
 mata, 266.
 importance of uterus, ovaries, and tubes, 171.
 Release of adherent tubes, 183.
 Remote results of abdominal operations, 518.
 Resection of relaxed outlet, 150.
 Retroflexion, 145.
 Rotation of pedicle, 250.
 Rules for the prevention of cancer, 317.
 Rupture of a cyst, 252.

 Saline enema, 48.
 purge, 52.
 Salpingitis, catarrhal and purulent, 432, 433.
 Salpingo-ostophorectomy, simple, 193.
 Salpingo-ostophorectomy for hydrosalpinx and
 adherent tubes and ovaries, 199.
 Salt solution, 70, 71.
 Sarcoma of the cervix, 332.
 of the ovary, 290.
 of the uterus, 332, 334.
 Scarcity of literature on remote results, 519.

- Scutetus bandage*, 43.
 Secondary hemorrhage, 61.
 Sedatives, 46.
 Septic intoxication, 99.
 Septicæmia, 101.
 Shock, 57.
 Special diets, 48.
 Spermin, 166.
 Spindle-celled sarcoma of the cervix, 333.
Staphylococcus aureus, 83.
 aureus and *albus*, 211.
 Stitel-hole abscess, 114.
Streptococcus pyogenes, 83, 211.
 Strictures, 495.
 Sub-mucous myomata, 362.
 Sarcous or sub-peritoneal myomata, 342.
 Sudden death, 125.
 Suppression of urine, 119.
 Suppuration, 114, 523.
 causes of, 210.
 Suppurating myoma, 382.
 ovarian cyst, 298.
 Suspension of the uterus, 149.
 Sutures, removal of, 53.
 Symphysectomy, 415.

 Table of ectopic viable fetuses delivered by celiotomy, 458, 459.
 of forms of extra-uterine pregnancy, 434.
 showing bacteriological examination of pus from ovaries and tubes, 212.
 showing effect of castration upon the composition of urine, 167.
 Tabulated symptoms of traumatic and septic peritonitis, 90.
 Telangiectatic myoma, 382.
 Temperature, 52.
 and pulse charts, 54, 72, 75, 86, 102, 163, 164, 115.
 variations in, 73.

 Thirst after operation, 48.
 Toilet after operation, 45.
 Torsion of the Fallopian tube, 433.
 Transplantation of the ovary, 168.
 Treatment of ovarian tumors, 292.
 Tubal abortion, 439.
 mole, 440.
 polyps, 430.
 Tubercle bacillus, 134, 142.
 Tubercular peritonitis, 134.
 Tuberculosis and ovarian tumors, 255.
 of the endometrium, 381.
 Tubo-ovarian cysts, 204.
 Turning, 415.
 Tympanitis, 77.

 Umbilical hernia, 476.
 Urinalysis, 3.
 Uterine myoma, 409.
 Uterine scrapings, 142.

 Vaginal drainage and enucleation for pyosalpinx, ovarian abscess, tubo-ovarian abscess, and pelvic abscess, 208.
 Vaginal incision and drainage for extra-uterine pregnancy, 453.
 Vaginal incision and drainage for pelvic abscess, 222.
 Ventral hernia, 467.
 Ventrofixation, 149.
 Vermiform appendix, adhesions to, 378.
 removal of, 499.
 Vesical adhesions, 23.
 Vetter current adapter, 17.
 Visitors, proper dress and conduct of, 11.
 Vomiting, 75.

 Washing out stomach, 76.
 Wound, dressing of, 53.