

---

---

SOME REMARKS ON THE SYMPTOMS AND OPERATIVE TREAT-  
MENT OF BRONCHOCELE ESPECIALLY IN RELATION  
TO GRAVES' DISEASE.

BY

FRANCIS J. SHEPHERD, M.D.,

Professor of Anatomy, McGill University, Montreal ; Senior Surgeon to the Mont-  
real General Hospital.

---

*Reprinted from the Montreal Medical Journal, December, 1899.*

---

---



SOME REMARKS ON THE SYMPTOMS AND OPERATIVE  
TREATMENT OF BRONCHOCELE, ESPECIALLY IN  
RELATION TO GRAVES' DISEASE.\*

BY

FRANCIS J. SHEPHERD, M.D.,

Professor of Anatomy, McGill University, Montreal; Senior Surgeon to the Montreal General Hospital.

I have been asked this evening to say something about the symptoms and treatment of goitre, both of the ordinary and exophthalmic variety, and also the malignant form.

*Simple Goitre* usually commences as a small kernel like mass in one or other of the lobes of the thyroid, and gradually increases in size as the years go on. Sometimes both sides of the gland are affected and also the isthmus, but in this country at any rate the unilateral variety is the most common. This form is usually encysted, and the cysts may be multiple or single, and may contain clear or blood-stained fluid, or the contents may be solid or semi-solid, colloid material. A cyst which has suddenly become larger from hæmorrhage very often when it is tense simulates a solid growth. In addition to these two forms of goitre we have cases where the gland is uniformly enlarged,—the interstitial or parenchymatous form. This kind is seen chiefly in young girls, especially at the time of puberty, and generally disappears in a few months; it increases markedly before the menstrual periods, and is often, when not of the soft, vascular variety, benefited by the administration of thyroid extract and iodides. In all these forms of goitre the general health is apt to be affected, the patients are more or less nervous, are subject to breathlessness on exertion owing to pressure of the growth on the trachea and sometimes tachycardia, in fact, some of the encysted solid forms are subjects of a kind of pseudo-Graves' disease produced by the growth.

---

\* Read before the Montreal Medico-Chirurgical Society, June 12th, 1890.

The relief afforded by removal of the growth is often very marked, as the following case illustrates :—

Mrs. H., widow, aged 35, a telegraph operator, consulted me December, 1894 ; a delicate, highly nervous woman, with some exophthalmos, has had enlargement of her neck since childhood. Seven years ago the growth suddenly enlarged, but the enlargement lessened for a time on application of an ointment. The increase was accompanied by palpitation of the heart and great nervous excitability, from that time the gland enlarged until last summer, when it grew much more rapidly. Of late has had frequent attacks of tachycardia, and is very nervous, so much so, that she had to give up her occupation. She has great difficulty in breathing, especially when she has to exert herself. In this case the left lobe was the larger, but both lobes extend from the hyoid bone to the clavicle. The growth seemed to consist of a number of cysts, fluid and solid. Operation was performed, and the patient got rapidly well ; all nervousness and tachycardia disappeared, her eyes became normal, and she was able to resume her work.

I have many such cases in my note-book. Here we have symptoms produced by increase of thyroid tissue of the nature of Graves' disease, and perhaps pressure also has something to do with it. I have quite recently operated on a case sent me by Dr. Birkett where pressure from enlargement of the right lobe of the thyroid caused contraction of the pupil on that side, and well-marked ptosis. Operation in this case is too recent to state results, but when I last saw her, ten days after the operation the ptosis was certainly less marked.

The symptoms of Graves' disease are familiar to you all ; the highly nervous, excitable individual, with prominent eyes, enlarged, soft, vascular thyroid, rapid pulse, tremors, and often pyrexia,—symptoms which are produced by taking thyroid internally. Such cases are the exactly opposite of myxœdema, due to loss or absence of thyroid tissue. Here the patient is dull, sleepy, has a stupid expression of face, low pulse and body temperature, dry, thick skin, with loss of hair. The patient sits about stupidly idle and sleeping most of the day. One disease is the exact opposite of the other—the former due to too much thyroid and the latter to too little. The exactly opposite conditions in these two diseases seem to me to prove the theory that too much thyroid is the cause of all that group of symptoms called exophthalmic goitre or Graves' disease, and the cases I have seen of Graves' disease which *commenced* with enlargement of the thyroid, and where the severity of the symptoms increased *pari passu* with the continued enlargement of the gland, also tend to prove the theory that increase of thyroid tissue is followed by symptoms of Graves' disease, and when the increased tissue is removed the patient's health returns to normal, the symptoms of Graves' disease gradually disappearing. The following case illustrates this :—

Miss L., æt 20, first noticed enlargement of the thyroid some years ago. Both sides were enlarged, and the gland continued enlarging. A short time after the enlargement commenced, nervous symptoms developed, such as tachycardia, tremors, etc. These increased in severity, so that on the slightest exertion her pulse was almost uncountable. Then came ophthalmos with persistent pyrexia and œdema of the lower extremities; there was also great difficulty in breathing, especially on exertion. When I saw her in 1896 she was a pale, anæmic girl, very thin, with exophthalmos and a rapid pulse—140 to 200—she was excessively nervous, had tremors, some fever and œdema of the lower extremities. Both lobes of the gland were considerably enlarged; the enlargement, whilst on both sides, was not the usual vascular, spongy enlargement of Graves' disease, but seemed to be made up of a separate solid cyst in each lobe. I advised operation, which was performed November, 1896. Menucleated from each lobe by separate incisions a solid cyst the size of a small orange full of colloid contents. The patient rapidly recovered from the operation, and was sent home in about ten days much better. I had a letter from her doctor May 18th, 1899, in which he says:—"I am pleased to tell you she is in excellent health; the respiratory trouble is of the past; the exophthalmos, the tachycardia, the anæmia and pyrexia are no more present, and she is perfectly well."

In other cases, although the symptoms may not be marked, yet the relief from operation is almost as great.

Jennie R., æt 24, has, since she was fifteen years old, had enlargement of the thyroid. It commenced as a small round growth in the right side, and gradually grew to its present size. For some years, owing to tachycardia and breathlessness, she has not been able to walk any distance or to go upstairs; for some years has had exophthalmos. When I saw her early in January of this year she was an anæmic girl with prominent eyes, a very nervous manner, and rapid pulse. She had a very large swelling, which was round and smooth, extending from the sternum to the hyoid bone, and this swelling went under the sternomastoid. It was not fluctuating, soft, and did not appear to be vascular. I looked upon the case as one of large colloid cyst, and recommended operation. This was performed January 27th, 1899, and the tumour, as expected, turned out to be a colloid cyst. Hæmorrhage was quite free, and a number of ligatures had to be applied, the superior thyroid being ligated. Recovery was complicated by a continuous high temperature (101° F.) and a very rapid pulse (180-200), following immediately on the operation. The discharges from the wound were tested, and found perfectly sterile. It was supposed that this was a case of thyroid intoxication, which has been described by several writers. On giving free vent to the discharges from the wound, which were thin and watery, the tempera-

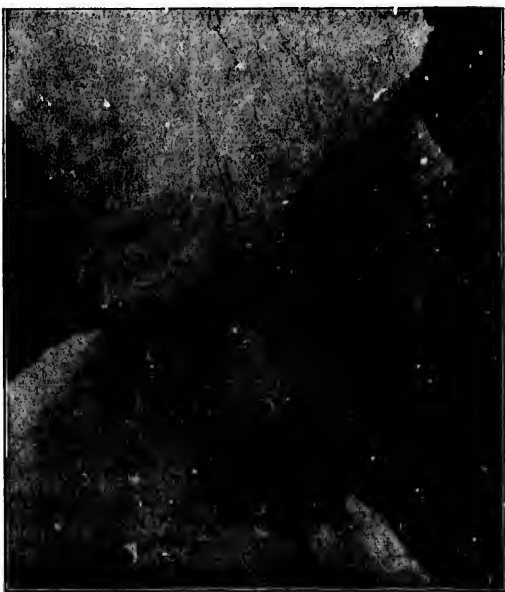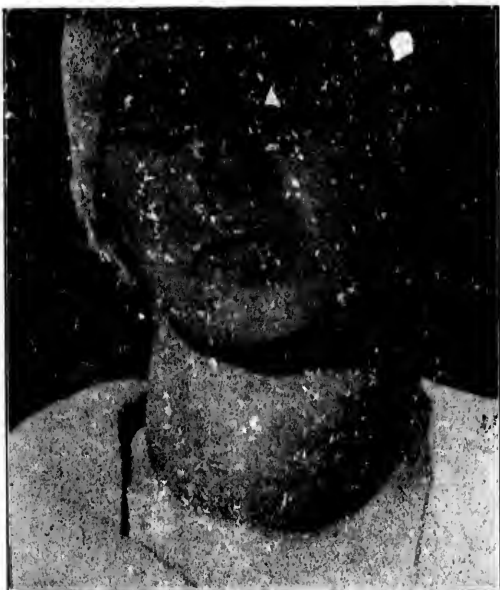ture and pulse rapidly subsided, and the patient recovered completely. I heard from her on the 15th May. She says :—" I have begun to feel like a different person, and just wonder how I ever put in such a miserable existence as I did the last five years. You would scarcely recognize me as the same person. My heart does not palpitate as it did before the operation." (See accompanying plates.)

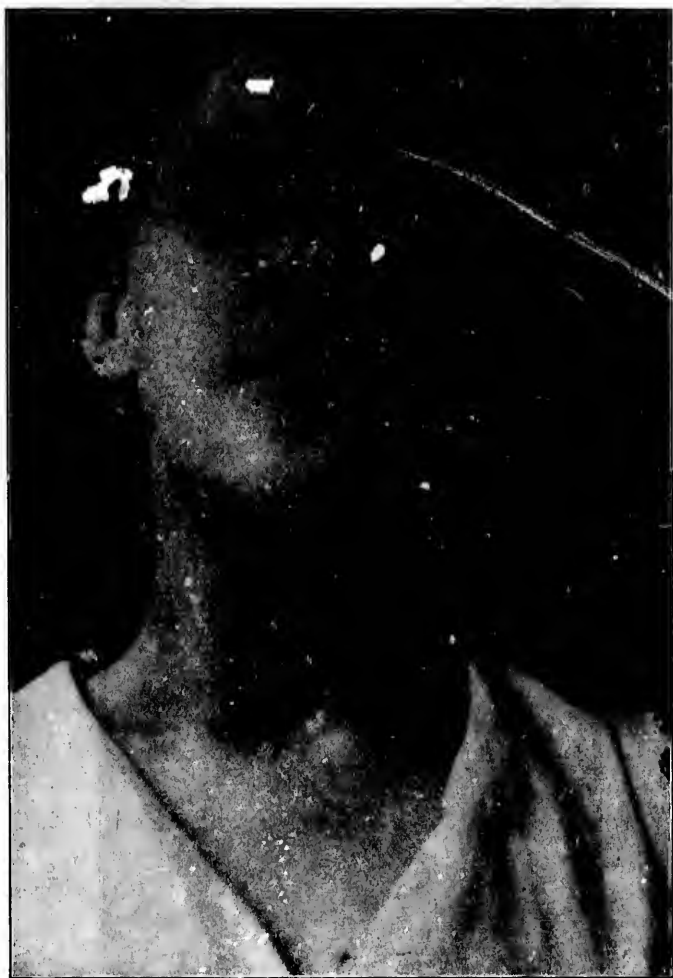
I think these cases sufficiently prove that increase of thyroid tissue can produce a group of symptoms very much resembling Graves' disease. Now, these symptoms in my experience only come on in encysted cases with solid cysts. In cysts with fluid contents I have never seen them, so pressure can be but a small factor in the production of these symptoms.

In cases of true Graves' disease the improvement after operation is not so great. During the past four or five years I have operated on several cases, removing one-half of the enlarged thyroid. Although in these cases there has been improvement, still it is not so rapid or so marked as in those cases where the disease in the gland is localised. In one of my recent cases, operated on in February last, the patient had all the chief symptoms of Graves' disease, such as tremors, tachycardia, pyrexia, etc., and a very large vascular thyroid. Operation relieved, and her general health was much improved, but she writes me (May 23rd) that the nervousness still continues, though the tachycardia and exophthalmos are much better, and the remaining half of the gland is much smaller. In cases of true Graves' disease operation is not without danger. It seems that the danger is chiefly due to the anæsthetic ; so much is this so, that Kocher has given up general anæsthesia in these cases and resorts to local anæsthesia by cocaine. Even with local anæsthesia the operation is a dangerous one, and in Kocher's last 15 cases of operation in Graves' disease, two died.

It is my custom to advise operation in all rapidly growing goitres, especially if they be tumours of the solid form. If there be dyspnœa, the operation is urgently needed, but even if there is no dyspnœa it is well to advise removal of those which are of recent formation and rapidly increasing in size, by early excision, that the serious train of symptoms which is characteristic of Graves' disease will be avoided.

*Operative Procedures.* It is always well to be guided by the kind of case in choosing the form of operation. In the simple cystic case, where the cysts are large and not more than one or two in number, I invariably enucleate by the method I have described before, a simple incision over the cyst through skin and muscles down to the gland, tying the anterior jugular if it be seen. When the gland is reached, it is incised down to the bluish-white capsule of the cyst. The recognition of this capsule is most important, and when reached the cyst can







be easily turned out. It has been my practice to open the cyst and evacuate its contents so that it then can be pulled out of a small opening, and any vessels which bleed can be easily seized as they are torn in separating the cyst. In some cases of adherent cyst the separation is very difficult, but in fluid cysts the vascularity is not so great, nor is there so apt to be an adherent capsule. In the solid, colloid, encysted growths the enucleation is more difficult owing to the greater vascularity. It is important here to get into the proper capsule, preferably the deeper one, for the superficial one is often covered with the ramifications of blood-vessels. Even in these cases, before enucleating I open the tumour and remove some of its contents; when this is done, the subsequent extraction is much less difficult. In diffuse cases or interstitial cases and the true vascular thyroid of Graves' disease, in malignant disease or where the cysts are multiple and small, or where the growth is very large, I prefer now to excise the gland. In Graves' and the interstitial cases only one lobe is excised. In these cases I make use of an incision along the inner border of the sternomastoid to near the upper border of the sternum, and then continue the incision transversely as far as necessary. Here the most important point is the free opening of the capsule of the gland. As soon as the capsule is divided the gland can be delivered and the vessels tied without much difficulty. The superior thyroid artery should first be secured, then the gland thrown up and over to the opposite side. The inferior thyroid artery should be tied and not cut, and then recurrent laryngeal nerve looked for and carefully separated. It runs up the posterior part of the gland, when the gland is enlarged it appears as if it entered it. The branches of the inferior thyroid artery with which it entwines should be cut near the gland, and also the veins which accompany these branches. I have cut the nerve once, and it was immediately sutured; the function has been partially recovered since.

*The After Treatment.* In the cases where enucleation has been performed there may be free oozing from the bed in which the cyst lay, and to prevent extensive oozing I pack this with strips of aseptic gauze, which I remove on the second day. In the cases where a portion of the gland has been removed a drain is inserted for 24 hours. The wound is closed with horse-hair sutures, and ordinary dry dressings applied. Usually the enucleation cases are discharged from hospital in a week or ten days.

The advantage of the enucleation method in suitable cases is the ease with which the operation is performed, the absence of risk of myxœdema and the fact that the recurrent laryngeal nerve is never injured. The disadvantages are the chance of recurrence of the growth, the tendency to oozing after operation, this oozing occasionally going on to secondary

hæmorrhage. In nearly fifty cases of enucleation, I have had recurrence in two cases—in one on the opposite side, and in the other a very small cyst on the side that had previously been operated on. Both came to me of their own accord to have the cysts removed while they were small. Secondary hæmorrhage I have seen three times—once in a young man who afterwards told me that he never had a tooth pulled without its bleeding for a week, and the other two were in women who had an apparent tendency to bleed. The blood oozed into the cavity which was left by the removal of the tumour, and only attracted notice when the breathing became difficult. In these cases the gauze had been removed too soon, for, after removal on the second day there was a good deal of oozing. In such cases the gauze should have been replaced for another 24 hours.

Should secondary hæmorrhage occur the wound should be laid open, the clots turned out, and the cavity firmly packed with sterile gauze. Swabbing out with tincture of the perchloride of iron in the more severe cases will arrest the hæmorrhage.

The cases I have seen all recovered promptly, and the scar left did not appear to be any greater than that left after union by first intention.

I have seen many malignant cases, but have only operated on three. All subsequently died of recurrence of the disease in the lungs. Unless the tumour is removed very early there is little hope of permanent relief. In all the cases I have seen the gland had been enlarged for years before it took on a malignant action.

I have only seen one case of the so-called thyroid intoxication after operation on a bronchocele. It is supposed that during operation much handling of the gland promotes excessive absorption of the fluid, and that after operation the cut surface of the gland exudes so much thyroid juice that if it is not evacuated it is absorbed and intoxicates the individual. Such cases are known by an excessively high temperature and rapid pulse after operation, at the same time that the wound is sterile. In the case I saw, the patient had a continuous temperature of 104° F. for nearly three days, and an uncountable pulse. The secretions from the wound were repeatedly examined, and were always found sterile. She made a good recovery. Some deaths from this cause are reported by Horsley of London and Paul of Liverpool.

The accompanying plates are reproduced through the courtesy of the *Annals of Surgery*, in the November number of which this article appeared.



