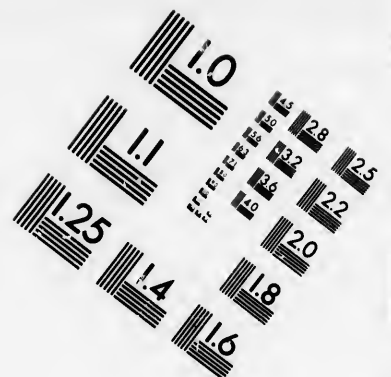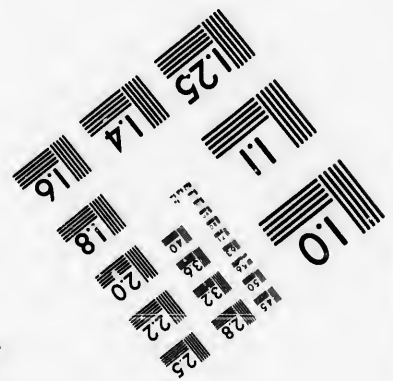



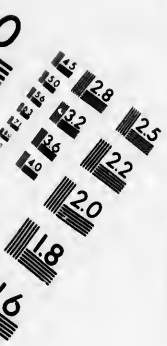


**IMAGE EVALUATION
TEST TARGET (MT-3)**



**Photographic
Sciences
Corporation**

23 WEST MAIN STREET
WEBSTER, N.Y. 14580
(716) 872-4503



**CIHM/ICMH
Microfiche
Series.**

**CIHM/ICMH
Collection de
microfiches.**



Canadian Institute for Historical Microreproductions / Institut canadien de microreproductions historiques



© 1986

Technical and Bibliographic Notes/Notes techniques et bibliographiques

The Institute has attempted to obtain the best original copy available for filming. Features of this copy which may be bibliographically unique, which may alter any of the images in the reproduction, or which may significantly change the usual method of filming, are checked below.

L'Institut a microfilmé le meilleur exemplaire qu'il lui a été possible de se procurer. Les détails de cet exemplaire qui sont peut-être uniques du point de vue bibliographique, qui peuvent modifier une image reproduite, ou qui peuvent exiger une modification dans la méthode normale de filmage sont indiqués ci-dessous.

- | | |
|--|---|
| <input checked="" type="checkbox"/> Coloured covers/
Couverture de couleur | <input type="checkbox"/> Coloured pages/
Pages de couleur |
| <input type="checkbox"/> Covers damaged/
Couverture endommagée | <input type="checkbox"/> Pages damaged/
Pages endommagées |
| <input type="checkbox"/> Covers restored and/or laminated/
Couverture restaurée et/ou pelliculée | <input type="checkbox"/> Pages restored and/or laminated/
Pages restaurées et/ou pelliculées |
| <input type="checkbox"/> Cover title missing/
Le titre de couverture manque | <input checked="" type="checkbox"/> Pages discoloured, stained or foxed/
Pages décolorées, tachetées ou piquées |
| <input type="checkbox"/> Coloured maps/
Cartes géographiques en couleur | <input type="checkbox"/> Pages detached/
Pages détachées |
| <input type="checkbox"/> Coloured ink (i.e. other than blue or black)/
Encre de couleur (i.e. autre que bleue ou noire) | <input checked="" type="checkbox"/> Showthrough/
Transparence |
| <input type="checkbox"/> Coloured plates and/or illustrations/
Planches et/ou illustrations en couleur | <input type="checkbox"/> Quality of print varies/
Qualité inégale de l'impression |
| <input type="checkbox"/> Bound with other material/
Relié avec d'autres documents | <input type="checkbox"/> Includes supplementary material/
Comprend du matériel supplémentaire |
| <input type="checkbox"/> Tight binding may cause shadows or distortion
along interior margin/
La reliure serrée peut causer de l'ombre ou de la
distortion le long de la marge intérieure | <input type="checkbox"/> Only edition available/
Seule édition disponible |
| <input type="checkbox"/> Blank leaves added during restoration may
appear within the text. Whenever possible, these
have been omitted from filming/
Il se peut que certaines pages blanches ajoutées
lors d'une restauration apparaissent dans le texte,
mais, lorsque cela était possible, ces pages n'ont
pas été filmées. | <input type="checkbox"/> Pages wholly or partially obscured by errata
slips, tissues, etc., have been refiled to
ensure the best possible image/
Les pages totalement ou partiellement
obscurcies par un feuillet d'errata, une pelure,
etc., ont été filmées à nouveau de façon à
obtenir la meilleure image possible. |
| <input type="checkbox"/> Additional comments:/
Commentaires supplémentaires: | |

This item is filmed at the reduction ratio checked below/
Ce document est filmé au taux de réduction indiqué ci-dessous.

10X	14X	18X	22X	26X	30X
<input type="checkbox"/>	<input type="checkbox"/>	<input type="checkbox"/>	<input checked="" type="checkbox"/>	<input type="checkbox"/>	<input type="checkbox"/>
12X	16X	20X	24X	28X	32X

The copy filmed here has been reproduced thanks to the generosity of:


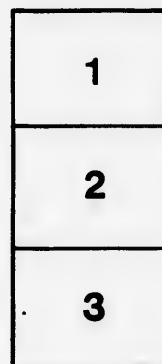
Medical Library
McGill University
Montreal

The images appearing here are the best quality possible considering the condition and legibility of the original copy and in keeping with the filming contract specifications.

Original copies in printed paper covers are filmed beginning with the front cover and ending on the last page with a printed or illustrated impression, or the back cover when appropriate. All other original copies are filmed beginning on the first page with a printed or illustrated impression, and ending on the last page with a printed or illustrated impression.

The last recorded frame on each microfiche shell contains the symbol \rightarrow (meaning "CONTINUED"), or the symbol ∇ (meaning "END"), whichever applies.

Maps, plates, charts, etc., may be filmed at different reduction ratios. Those too large to be entirely included in one exposure are filmed beginning in the upper left hand corner, left to right and top to bottom, as many frames as required. The following diagrams illustrate the method:



L'exemplaire filmé fut reproduit grâce à la générosité de:

Medical Library
McGill University
Montreal

Les images suivantes ont été reproduites avec le plus grand soin, compte tenu de la condition et de la netteté de l'exemplaire filmé, et en conformité avec les conditions du contrat de filmage.

Les exemplaires originaux dont la couverture en papier est imprimée sont filmés en commençant par le premier plat et en terminant soit par la dernière page qui comporte une empreinte d'impression ou d'illustration, soit par le second plat, selon le cas. Tous les autres exemplaires originaux sont filmés en commençant par la première page qui comporte une empreinte d'impression ou d'illustration et en terminent par la dernière page qui comporte une telle empreinte.

Un des symboles suivants apparaît sur la dernière image de chaque microfiche, selon le cas: le symbole \rightarrow signifie "A SUIVRE", le symbole ∇ signifie "FIN".

Les cartes, planches, tableaux, etc., pouvant être filmés à des taux de réduction différents. Lorsque le document est trop grand pour être reproduit en un seul cliché, il est filmé à partir de l'angle supérieur gauche, de gauche à droite, et de haut en bas, en prenant le nombre d'images nécessaires. Les diagrammes suivants illustrent la méthode.

errata
to

pelure,
on à



32X

R- 544-38/65/R/8/25 Alloway, Thomas Johnston

MCC C.
DUPLICATE
PRIMARY



CANCER [ENCEPHALOID] OF THE KIDNEY
DURING CHILDHOOD.

BY

T. JOHNSON ALLOWAY, M.D., L.R.C.S. AND P., Edinburgh,

Consulting Physician Montreal Dispensary; Attending Physician Department for
Diseases of Women, West End Free Dispensary, Montreal.

Reprinted from THE AMERICAN JOURNAL OF OBSTETRICS AND DISEASES
OF WOMEN AND CHILDREN, Vol. XVI., Nos. VIII. & IX., 1883.

NEW YORK :

WM WOOD & CO., PUBLISHERS, 56 & 58 LAFAYETTE PLACE.

1883.

CANCEL

I

T. JOHNS

Consulting

Reprinted

OF W

WM WO

PRIMARY
CANCER [ENCEPHALOID] OF THE KIDNEY
DURING CHILDHOOD.


BY

T. JOHNSON ALLOWAY, M.D., L.R.C.S. AND P., Edinburgh,

Consulting Physician Montreal Dispensary; Attending Physician Department for
Diseases of Women, West End Free Dispensary, Montreal.

Reprinted from THE AMERICAN JOURNAL OF OBSTETRICS AND DISEASES
OF WOMEN AND CHILDREN, Vol. XVI., Nos. VIII. & IX., 1883.

NEW YORK :
WM WOOD & CO., PUBLISHERS, 56 & 58 LAFAYETTE PLACE.
.1883.



PRIMARY CANCER (ENCEPHALOID) OF THE KIDNEY DURING CHILDHOOD.

THE following case of cancer of the right kidney has been of some interest to me from its extreme rarity in childhood, and it may also be interesting, on that account, to others.

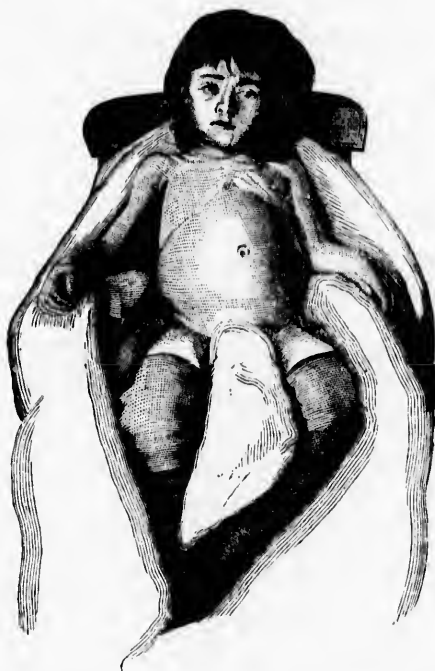Ellen W., aged five years, is of English parentage. Both father and mother are vigorous and have always enjoyed good health. Upon careful inquiry, however, it appears that a paternal aunt of the patient, when about six years of age, caused considerable interest to be manifested in her by several prominent London physicians concerning the growth of a tumor in her right side, and that, although she had visited several hospitals in that great metropolis, the parents could not obtain a definite diagnostic opinion concerning its precise nature. The tumor, however, is said to have disappeared after lasting about two years, although it had in that period of time obtained such a size as to cause quite a deformity, which was apparent in a photograph submitted to me. Further than this, there is a record of an excellent family history on both mother's and father's side. My patient was the second child in a family of three, and has always been in good health, with the exception of a rather severe attack of eutero-colitis in the hot summer of 1879, and, about a year ago, of an attack of remittent fever, which lasted about three weeks, *and was accompanied with diarrhea*. She never had scarlatina.

The first manifestation of her recent illness occurred last December (1882), in the appearance of "a lump on her right side," as her father expressed it. He stated that the child was not sick, but that he felt anxious about this *lump*, as she had fallen down stairs, three months previous, and had struck the very side in question against an upright post during her descent. She com-

4 ALLOWAY: *Primary Cancer of the Kidney.*

plained at the time of the accident of nothing more than children usually do under such circumstances, and it was only recalled to mind by the appearance of the present tumor in the right side.

Physical examination revealed an ovoid tumor extending from the lower margin of the liver to within an inch of the crest of ilium. This tumor occupied such a position that, if a lateral-medial section of the body were made, the line of section would pass half an inch behind the posterior margin of the tumor. It was very hard and movable both by the hand, and by the action of the diaphragm during respiration.



Gentle manipulation caused no pain whatever. At this time, the tumor could be grasped in its middle with fingers and thumb, and lifted and moved about quite freely without pain or inconvenience to the little patient. Percussion gave a continuous dull note from the upper margin of the liver to the lower point of tumor, and from this it was concluded that close adhesions existed between it and the lower margin of liver. The patient was apparently in good health; the excretory organs performed their respective functions in a normal way. The urine was carefully examined with negative results. Her appetite was good. She

slept well. Her skin was clear, and she had the appearance of a plump well-nourished child. She would play and romp about as usual with other children. Towards evening, she would complain slightly to her mother of cramps or "pains in her belly."

Jan. 11th. Saw patient again. Tumor increasing in size, chiefly towards the middle line of abdomen, and downwards toward ilium. Patient not quite so lively. She would complain suddenly of pain at play, making her peevish. Appetite still good, nutrition good, bowels regular, and urine normal.

Jan. 22d. Found a distinct systolic bruit, heard loudest over maximum elevation of tumor, gradually fading in intensity posteriorly toward the spine, and anteriorly toward the epigastrium. In both of these situations, it was plainly audible, but had a distant character, while over point of greatest elevation of growth it appeared as if quite near the surface. The heart was now slightly displaced upward and to the left. Pulse increased slightly in rapidity. Temperature normal. Urine still normal.

Jan. 26th. Dr. Raddieh saw the patient with me to-day. The growth was much increased in size since last visit, and a decided feeling of fluctuation was now quite evident throughout the entire growth. At this time, there was a general enlargement of the whole abdomen becoming apparent. The arterial bruit so distinctly heard the week previous is no less distinct, and is now distant in character. The patient is beginning to show signs of emaciation. There is now noticed a prominence or bulging on the *left* side of the vertebral column at about the level of the first, second, and third lumbar vertebræ. This was thought to be due to involvement of other postperitoneal glands of that side.

Feb. 1st. Dr. R. P. Howard saw the case with me, and after a careful examination agreed with us in inclining towards the diagnosis of encephaloid cancer, as far as it was possible to judge at the present existing stage of the disease. The tumor now seemed to increase in almost every direction, and especially so toward the epigastrium, where a decided prominence with skin tension was apparent. The whole abdominal contents seemed as if in one great mass and moved together. There was no tympanitic note on percussion to be obtained, except along the anterior axillary line of left side; all to the right of this was of wooden dullness. There is very little pain or annoyance caused by examinations. She can stand up with assistance, but cannot walk any longer with comfort. She has to be carried about. Heart is considerably displaced upwards, and to the left side, pulse very rapid. Prominence of left side behind is increasing. Bowels move once a day, and urine normal. The bruit in tumor can no longer be heard at any point.

February 5th. Respiration, 24; pulse, 120; temperature normal. Measurements of abdomen were as follows:

At nipple.....	20 $\frac{1}{4}$ inches.
Xiphoid cartilage.....	22 "
Eighth cartilage.....	23 $\frac{1}{2}$ "
Maximum elevation.....	24 "

6 ALLOWAY: *Primary Cancer of the Kidney.*

Umbilicus.....	23 inches.
Extreme lateral length of tumor.....	5 $\frac{1}{2}$ "
Tumor extends to left of umbilicus....	2 "

Apex of heart-beat at fourth interspace, one-half an inch outside left nipple. Superficial veins very prominent on surface of abdomen.

February 22d. Measured at

Nipple.....	21 $\frac{1}{2}$ inches.
Xiphoid cartilage.....	23 "
Eighth rib.....	24 "
Maximum elevation.....	26 $\frac{1}{2}$ "
Umbilicus.....	26 "

Apex heart-beat one inch outside left nipple and one-quarter inch below level of it. Respiration audible behind no lower than one-quarter of an inch below inferior angle of scapula.

Patient becoming very restless at night, and complains of soreness in front when lifted. Pulse rapid; temperature normal. Bowels very much constipated, moving only once every four or five days. No jaundice.

March 5th. Patient unable to leave cot. She is much emaciated. Pulse 154. Diarrhea set in last night. Urinates very frequently, passing but a small quantity at a time. Apex heart-beat now one and a half inches outside left nipple, and on a level with it. She has not vomited since beginning of December. There is no edema of extremities or other parts of body, and has never had any during illness. Has never exhibited uremic symptoms.

March 12th. Fearfully emaciated. Can only rest on back, with both arms extended backwards over her head, her hands grasping the iron bars at head of the bed. In this position, she seems to obtain the largest possible abdominal and thoracic area by producing traction upon the chest-walls from without. Under these circumstances, the heart and lungs have more freedom of action, and the patient consequently feels more comfort than in any other position. No further change took place until the 16th, when death occurred from asthenia.

Autopsy.—Dr. Osler's Report: The body was greatly emaciated; abdomen distended; superficial veins not much dilated. When opened, a large tumor was seen filling the greater part of the abdominal cavity, and closely attached to the right side. The omentum was adherent, the cecum attached to the lower end, and the ascending colon passed along the left border. The pylorus lay upon the upper end, and the duodenum was flattened upon the left side of the mass. The tumor was retroperitoneal, and peeled out easily, bringing with it aorta and inferior vena cava, which were deeply imbedded in the hinder part. The mass had a rounded outline, broad above, with a concave left border, which presented several very soft lobulated portions overhanging the groove in which the cecum and colon lay. The right border was more solid, and at the lower part showed a small remnant of the kidney surface. The growth has perforated the capsule, and pro-

ected in large, soft masses, some of which were hemorrhagic. The last inch of the abdominal aorta was surrounded by the tumor, the left iliac was pervious, the right was filled with thrombi, and the wall eaten away. The inferior cava could be traced in the mass for about an inch and a half, and just above the bifurcation was obliterated, the walls in close contact. Section of the mass showed it to be made of a soft cerebri-form tissue interspersed with extravasated blood. At the right border there was a trace of kidney substance in the form of a thin shell. The ureter was occluded. The pelvic and renal vessels were infiltrated with the neoplasm.

On microscopic examination, the soft, grayish-white substance was found to be composed of small round cells with but little stroma. Towards the right border of the mass where it was firmer, the soft cerebri-form substance was inclosed in denser strands.

Remarks.

In considering some of the more interesting details in connection with the above case, I think it would be well to discuss them, as points of interest, in a short review of the literature of the subject as recorded up to the present time.

Nothing of any value was written upon cancer of the kidney, with the exception of G. König's "Treatise upon Diseases of the Kidney" in 1826, and that of Wilson, of London, in 1817, until after the year 1830. Cruveilhier was probably the first writer of note, closely followed by Rayer, who put the disease on a sound foundation. After this came the classic works of Walshe, and then of Lebert, who distinguished so clearly between primary and secondary forms of cancer of the kidney. Ebstein and Roberts are also well-known authors on this subject. Rowe, of Cincinnati, records a very interesting case in the *AMERICAN JOURNAL OF OBSTETRICS*, April, 1881.

Of the different species of cancer found in the human body, encephaloid (fungus hematodes) is the one almost invariably found in the kidney. Its chief physical characters as a neoplasm consists in its soft, pulpy, vascular condition; it is frequently the site of extensive hemorrhages, cavities are formed in the mass, containing large quantities of blood mixed with cancerous detritus which flows freely from the cavities when opened or broken into during the post-mortem examination. The whole organ may become infiltrated uniformly, and when it does so, the enlargement is regular. But we also have the formation of nodules of disease growing from a particular part

or end of the kidney, and encroaching upon the ground of a neighboring organ, which gives on palpation the idea of an irregular shaped tumor, and adds very materially to the difficulty of diagnosis. This disease always begins in the cortical substance, and gradually involves the pyramids. The whole growth is surrounded by and contained within a strong fibrous membrane. In about sixty (60) per cent of all reported cases, there have been found secondary deposits elsewhere. The seats of these deposits have been the lymphatic glands in the hilus of the kidneys, the vertebral, and mesenteric glands. The liver and lungs were also affected, but not so often.

In considering the etiology of the disease it is a remarkable fact that among traumatism an injury, such as a blow or fall, is often the starting-point in the history. Chamel, in 1829, refers to a case originating from a blow, in which the anterior wall of the abdomen was destroyed by the disease. Bright gives the history of a young woman who, several months previous to her death from cancer, had experienced a fall down-stairs, and dated her disease from that time. Another case, of a boy, who dated his suffering from a kick in the left side; he afterwards died from medullary cancer of the left kidney. A very interesting case is recorded of a lady who died of carcinoma of the kidney eighteen years after a severe fall on the stairs. Immediately after the accident, she had a severe attack of hematuria, and in the course of six months a tumor became evident as a swelling under the margin of the right ribs. In my own case was experienced a severe fall down-stairs, three months before the first appearance of the growth, but there was no hematuria or other evidence of internal injury. Traumatism may play a certain rôle as an exciting cause in these cases; yet, why should it not be constant, and do so in all cases; instead of which we have such injury followed in one case by nephritis, in another by perinephritis, and another by malignant disease. These are pure clinical facts, inexplicable unless we fall back on the doctrines of individual predisposition.

The earlier writers looked upon cancer of the kidney during childhood as a curiosity from its rarity, but more extended research has taught us that it is found chiefly in the extremes of life—early childhood and old age—while the periods of life

between these points enjoy a remarkable immunity from it. It is said that males are more prone than females—of twenty-four children fifteen were boys and nine girls, and the disparity is still greater with adults. This disproportion may be accounted for by the marked preference shown by cancer for the organs of generation in the female.

In cancer of the kidney, there are two distinct symptoms almost always met with—an *abdominal tumor and hematuria*. Roberts asserts that in all fatal cases one or both of these symptoms are invariably present. Of sixty-four cases sixty-one had a large abdominal tumor, and the remaining three had hematuria; and it is noteworthy that in *all children* who have died from this disease there was an *enormous* abdominal tumor present. These tumors, as a rule, represent the largest, as a variety, which are met with in children. They begin in the loins between the ribs and the crest of the ilium, they increase upwards and downwards, and to the front towards the navel. Percussion within this area elicits a dull note, provided there is not part of the intestine between the tumor and the abdominal wall. But, as a rule, this *is* the case; and in the case of the right kidney being affected, the ascending colon and cecum are generally found on the outer side of the tumor, and as the growth enlarges, the ascending colon is pushed forward, and is found running obliquely across the growth from right to left. Here, of course, we would get a clear tympanitic note.

In my case, the bowel ran along on the left side of the growth in its entire length, and at no place crossed it. Therefore, there was an important diagnostic sign wanting, though, towards the end, such a displacement of the bowel was, however, considered possible, and would account for the uninterrupted dull note obtained. In the case of the left kidney when it is affected, the same condition obtains. Here the descending colon, and often part of the small intestines, cross or lie right in front of the tumor, separating it from the abdominal wall. It is quite true, however, that the intestines can cross the tumor and still elicit a dull note on percussion, from the fact of it being so compressed that it becomes a mere flattened band, and in some cases has been felt as such through the abdominal walls. These tumors are generally firmly fixed by adhesion, and are not influenced by the movement of the diaphragm.

In my case, however, the tumor was remarkably movable, both by palpation and the action of the diaphragm during respiration, without causing the patient pain or inconvenience. This point is important, from the fact that there is a case reported in the London *Lancet* (March 18th, 1865), in which the diseased kidney was so movable or wandering that it was taken for an ovarian tumor. The usual elasticity of these growths on palpation, amounting sometimes to a sense of fluctuation, carries with it a deception for which we cannot be too much "upon our guard" in making a diagnosis. It is probably conveyed to the hand by the general softening process taking place in the growth as it enlarges, and by the formation of secondary cysts or cavities, chiefly on the surface of the principal growth, filled with a semi-fluid cellular substance which is capable of conveying a wave-like impression on palpation.

We come now to a very interesting, and I may say almost unique, symptom in the case; *a loud blowing systolic murmur* heard all over the tumor. This phenomenon first attracted my attention about the end of the third week of attendance, when the tumor was still hard. It continued to be audible, though gradually fading in intensity, until the tumor became soft and fluctuating, when it disappeared altogether. Its disappearance at this time was probably due to the non-transmission of sound through so extensive a semi-fluid mass, as there was certainly no evidence of the complete occlusion of the main vessel. This symptom we must regard as one of peculiar interest. To judge it from first impressions occurring to an observer not over cautious in giving an opinion, it would very probably be diagnosticated as an aneurism of one of the abdominal vessels, and I think the error would bear some fairly pardonable features in it. Ballard reports a case in *Transactions of Pathological Society*, 1859, in which the murmur was so loud that it was diagnosed as an aneurism of the renal artery. Bristow also reports a case (*Med. Times and Gaz.*, 1854, ii., 395) in which a similar phenomenon was present. It may be remarked, however, that in each of the above instances there was also a distinct pulsation, which could not be obtained in this case. The direct cause of this murmur is difficult to decide upon. It may be due to direct pressure upon the aorta, or from the blood current acting upon a partially occluding thrombus situated on

the wall of the vessel. If these views are correct one would expect to have this symptom more often recorded than it has been, and probably it would have been were it more carefully looked for at the beginning of the disease.

We now come to the consideration of the other distinctive symptom, *hematuria*. It will be remembered that, although the most careful investigation was made in regard to this symptom, it never occurred from first to last. This is important from the fact that the patient's illness dated from a severe fall with direct injury to the *right* loin; and that in about fifty per cent of all cases reported, hematuria was noticed at some period of the illness. In the cases which received direct violence to the part, the hemorrhage was generally noticed at the time of the accident, and lasted in some cases but a short while, and not reappearing before death. Then again it may be intermittent, appearing for a few days, disappearing, and then in a few days reappearing again. In other cases again, it does not appear until within a few weeks of death. When hematuria is noticed in the early stages, it is undoubtedly a sign of great value, and should give us food for thought; but it must not be forgotten that it is also present in other diseases of the urinary tract. It may also be present with a tumor in the left side and not be due to renal cancer, for profuse hematuria often occurs in leukaemic patients. When hematuria is absent it is thought to be due to complete occlusion of the ureter of affected kidneys, either by pressure or by extension of the disease into it. In Van Denburg's case (*AM. JOURNAL OF OBST.*, October, 1881, 993), the urine was free from blood and other abnormal ingredients throughout the entire period of disease. This case of Van Denburg's, I may remark in passing, teaches us a very important lesson in another respect, namely, the necessity for giving very guarded opinions in respect to these abdominal tumors in children. His first consultant declared emphatically that it was a case of hepatitis, "just as sure as if he had the liver in his hand." Further council decided it was a case of *non-malignant* tumor of a cystic nature. Paracentesis was performed, withdrawing six to eight ounces of albuminoid fluid. *Hooklets of the echinococcus could not be found.* Again fresh council was obtained, and a larger needle used under chloroform, which resulted in the diagnosis of "multiple cystic tu-

mor." The patient died, and at the autopsy it turned out that the liver, which was accused of being the cause of all the trouble in so many different ways, and by so many experienced diagnosticians, *was perfectly healthy*, and that that little deceiving neighbor of it, the kidney, was the organ at fault.

The reaction of the urine in my case, it will be remembered, was normal, as it generally is in these cases, except when admixed with blood, and then, as a matter of course, we get albumen. But albuminuria without hematuria is rare, pyuria and nephritis being excluded. Uremic symptoms are also exceedingly rare, for the obvious reason that, so long as the other kidney remains healthy, there can be no retention in the blood of the poisonous constituents of the urine, which it is the function of the kidneys to excrete. The urine in this case was not examined microscopically, it being well known that as an aid in the diagnosis of cancer it is of uncertain and questionable reliability. Moore records a case (*Medico-Chirg. Trans.*, xxxv.), in which he found roundish caudate cells, and in many other recorded instances of the discovery of cancer cells there is no proof of the supposed cancer elements being other than epithelial cells from the renal pelvis and ureters. Halle states that in a few instances of renal cancer, he has found deposits of uric acid as well upon discharged flocculi of cancer tissue, as upon the waste substances obtained at the autopsy. But the discovery of certain cell-forms in the urine is of no value in the diagnosis of cancer. The symptom which can only be recorded as significant is the discovery of *cancer particles with an alveolar structure*. Roberts says: "It must be remembered that cancer cells which would find their way into the urine must have come from broken down and degenerated parts of the growth, and to identify them in their changed condition is more than he has ever been able to accomplish."

A symptom very variable in its degree of intensity is *pain*. In this case it never amounted to more than that which would cause the patient to say "my belly is sore." In some cases, however, it is described as being agonizing; while in others again it has been entirely wanting until near the end. Its absence, however, is not of sufficient significance to exclude the existence of renal cancer.

Gastric symptoms are generally prominent. In this case

there had been nausea and vomiting in the beginning of the disease, but after it ceased it did not return. In some cases the appetite is voracious, accompanied with increased thirst. In this case there was anorexia from the beginning to the end. There was no jaundice or tinting of the skin of any nature. No anasarca which might be expected with thrombosis of the vena cava; probably the compensatory circulation of the return blood through the extensive anastomosis formed by the superficial cutaneous veins prevented its occurrence. In remarking upon the duration of the disease, it may be said that it is much shorter in children than in adults. But it is exceedingly difficult to be definite upon this point, as the beginning of the disease cannot be fixed with certainty. In very debilitated children a few weeks may see the end, while in others, six to thirteen months. Ebstein says he has seen but one case of cancer of the kidney in a child which lasted as long as two years. It is, however, erroneous, as maintained by Walshe and Lebert, that the renal cancer runs a more rapid course than other visceral cancers. The contrary, in fact, is established, namely, that as a rule death is longer delayed in renal cancer than in primary cancer of any other internal organ. The mean duration of cancer of the pylorus, of the liver, lung, or brain is under thirteen months, or thereabout. This tolerance on the part of the kidney may be accounted for by the duplication of the organ; when one kidney becomes disabled, the other takes on a compensatory hypertrophy, and does the work of its diseased fellow. The advantage of much room being afforded the enlarging organ, in virtue of its situation, is also obvious.

As the prognosis of this disease is decidedly bad, invariably fatal, the treatment consists in the employment of such therapeutic measures as will tend to relieve distressing symptoms. I may say that the removal of cancerous kidney is a procedure which I don't think is regarded as sound by scientific surgeons. Walcott extirpated a cancerous kidney which he had taken for a hepatic cyst; the growth weighed two and a half pounds, and the patient survived the operation just two weeks.

