

**Technical and Bibliographic Notes/Notes techniques et bibliographiques**

The Institute has attempted to obtain the best original copy available for filming. Features of this copy which may be bibliographically unique, which may alter any of the images in the reproduction, or which may significantly change the usual method of filming, are checked below.


L'Institut a microfilmé le meilleur exemplaire qu'il lui a été possible de se procurer. Les détails de cet exemplaire qui sont peut-être uniques du point de vue bibliographique, qui peuvent modifier une image reproduite, ou qui peuvent exiger une modification dans la méthode normale de filmage sont indiqués ci-dessous.

- Coloured covers/  
Couverture de couleur
- Covers damaged/  
Couverture endommagée
- Covers restored and/or laminated/  
Couverture restaurée et/ou pelliculée
- Cover title missing/  
Le titre de couverture manque
- Coloured maps/  
Cartes géographiques en couleur
- Coloured ink (i.e. other than blue or black)/  
Encre de couleur (i.e. autre que bleue ou noire)
- Coloured plates and/or illustrations/  
Planches et/ou illustrations en couleur
- Bound with other material/  
Relié avec d'autres documents
- Tight binding may cause shadows or distortion along interior margin/  
La reliure serrée peut causer de l'ombre ou de la distortion le long de la marge intérieure
- Blank leaves added during restoration may appear within the text. Whenever possible, these have been omitted from filming/  
Il se peut que certaines pages blanches ajoutées lors d'une restauration apparaissent dans le texte, mais, lorsque cela était possible, ces pages n'ont pas été filmées.
- Additional comments:/  
Commentaires supplémentaires:

- Coloured pages/  
Pages de couleur
- Pages damaged/  
Pages endommagées
- Pages restored and/or laminated/  
Pages restaurées et/ou pelliculées
- Pages discoloured, stained or foxed/  
Pages décolorées, tachetées ou piquées
- Pages detached/  
Pages détachées
- Showthrough/  
Transparence
- Quality of print varies/  
Qualité inégale de l'impression
- Includes supplementary material/  
Comprend du matériel supplémentaire
- Only edition available/  
Seule édition disponible
- Pages wholly or partially obscured by errata slips, tissues, etc., have been refilmed to ensure the best possible image/  
Les pages totalement ou partiellement obscurcies par un feuillet d'errata, une pelure, etc., ont été filmées à nouveau de façon à obtenir la meilleure image possible.



This item is filmed at the reduction ratio checked below/  
Ce document est filmé au taux de réduction indiqué ci-dessous.

10X	14X	18X	22X	26X	30X
<input type="checkbox"/>	<input type="checkbox"/>	<input type="checkbox"/>	<input type="checkbox"/>	<input checked="" type="checkbox"/>	<input type="checkbox"/>
12X	16X	20X	24X	28X	32X



672

RESEARCHES IN FEMALE PELVIC  
ANATOMY



RESEARCHES  
IN  
FEMALE PELVIC ANATOMY

BY  
J. CLARENCE WEBSTER, B.A., M.D., M.R.C.P.ED.

ASSISTANT TO THE PROFESSOR OF MIDWIFERY AND DISEASES OF WOMEN AND  
CHILDREN IN THE UNIVERSITY OF EDINBURGH.

EDINBURGH AND LONDON:  
YOUNG J. PENTLAND

1892

EDINBURGH: PUBLISHED FOR THE ROYAL COLLEGE OF PHYSICIANS BY YOUNG J. PENTLAND,  
11 TEVIOT PLACE; AND 38 WEST SMITHFIELD, LONDON, E.C.

TO  
PROFESSOR A. R. SIMPSON,  
PRESIDENT,  
AND THE  
FELLOWS OF THE ROYAL COLLEGE OF PHYSICIANS OF EDINBURGH,  
IN RECOGNITION OF THEIR EFFORTS TO PROMOTE SCIENTIFIC RESEARCH IN MEDICINE,  
AND  
IN ACKNOWLEDGMENT OF THE GENEROUS ENCOURAGEMENT WHICH THE AUTHOR  
HAS RECEIVED FROM THEM,  
THIS WORK IS DEDICATED.





## PREFACE

HITHERTO, in the text-books, the descriptions of the anatomical changes in the pelvis met with during the puerperium have been of a very imperfect nature, and have been made from the ordinary method of post-mortem examination as well as from physical examination of the living subject. As the most important changes are those of altered relationships, it is evident that neither of these methods of study can be trusted to furnish exact information. In order to gain the most correct idea of topographical relationship, one must make use of the sectional method. As yet only three<sup>1</sup> cadavera have been fully investigated by means of frozen sections, two of which, the one described by Barbour and the other by Stratz, had *deformed* pelves. The third is a five-and-a-half days case of Barbour's, in which, unfortunately, the pelvic contents were septic.

I am now able, in this volume, to describe in detail the anatomical conditions found in the pelves of women who died of diseases causing no alteration in pelvic relationships, on the 1st, 2nd, 3rd, 4th, 6th, and 15th days of the puerperium. The details have been obtained both from Sectional and Dissectional study. In each case the whole pelvis, or pelvis and abdomen, was frozen without any disturbance of the parts. Sections were made, drawn, and described, and the slabs, after soaking for a little in spirit, dissected.

<sup>1</sup> Pirogoff and Legendre have also published two sections, but without the anatomical details requisite for our inquiry.

My chief aim has been to observe accurately, and to describe with faithfulness, the great mass of facts which have come under my observation. The work of investigation has been carried out in the Laboratory of the Royal College of Physicians. The majority of the plates have been drawn by myself from nature, the rest being done by Mr. J. T. Murray. The photographs were made with the aid of Mr. J. H. Paterson, the Laboratory-Assistant. Plates XXIII. XXIV. are copied, with the kind permission of Dr. Savage, from his work, *The Surgery, Surgical Pathology, and Surgical Anatomy of the Female Pelvic Organs*. To the officials of the Laboratory I am deeply indebted for the facilities granted me for the prosecution of my work; and I wish especially to acknowledge the unfailing kindness which I have received from the Curator of the Laboratory, Dr. J. Batty Tuke. To Dr. Freeland Barbour I desire to express my deepest obligations, since it was through his generosity that I obtained, when his assistant, most of the specimens. For one of the specimens I am indebted to Professor A. R. Simpson. Part of "The Beginning of the Puerperium" section was described by me in a paper published conjointly with Dr. Barbour in the *Laboratory Reports R.C.P.E.*, Vol. II. I give this part here, together with the rest of the description (as it was my own work), in order to complete my series. All the cases were seen and examined by me during life.

J. CLARENCE WEBSTER.

EDINBURGH, October 1892.

# TABLE OF CONTENTS.

## PART I.

### THE ANATOMY OF THE FEMALE PELVIS DURING THE PUERPERIUM.

	PAGE
1. THE BEGINNING OF THE PUERPERIUM . . . . .	1
2. THE SECOND DAY . . . . .	10
3. THE THIRD DAY . . . . .	19
4. THE FOURTH DAY . . . . .	26
5. THE SIXTH DAY . . . . .	34
6. THE FIFTEENTH DAY . . . . .	48
7. RÉSUMÉ . . . . .	55


## PART II.

### THE FEMALE PELVIC FLOOR.

INTRODUCTION . . . . .	73
1. THE MEANING OF THE TERM "PELVIC FLOOR" . . . . .	74
2. THE FLOOR STUDIED BY DISSECTION . . . . .	76
3. THE FLOOR STUDIED BY FROZEN SECTIONS . . . . .	91
4. THE FLOOR IN RELATION TO PREGNANCY . . . . .	93
5. THE FLOOR IN RELATION TO LABOUR . . . . .	94
6. THE FLOOR IN RELATION TO PROLAPSUS UTERI . . . . .	106

## PART III.


THE FEMALE PELVIS IN THE BEGINNING OF THE FIFTH MONTH OF PREGNANCY . . . . .	113
BIBLIOGRAPHY . . . . .	125
INDEX . . . . .	127




## ILLUSTRATIONS

PLATE

1. Vertical Mesial Section.	Beginning of Puerperium				<i>Facing page 2</i>
2. Transverse	do.	do.	do.	"	4
3. Vertical Oblique	do.	do.	do.	"	6
4. Vertical Mesial	do.	Second Day	do.	"	10
5. Transverse	do.	do.	do.	"	14
6. Pelvis seen from above.	do.	do.	do.	"	16
7. Vertical Mesial Section.	do.	Third Day	do.	"	20
8. Coronal	do.	do.	do.	"	22
9. Vertical Mesial	do.	Fourth Day	do.	"	26
10. Transverse	do.	do.	do.	"	30
11. Pelvis seen from above.	do.	do.	do.	"	32
12. Vertical Mesial Section.	do.	Sixth Day	do.	"	34
13. Coronal Sections.	do.	do.	do.	"	38
14. Do.	do.	do.	do.	"	40
15. Do.	do.	do.	do.	"	42
16. Uterus and Ovaries.	do.	do.	do.	"	46
	Pelvis seen from above.	Beginning of Puerperium	do.	"	46
17. Vertical Mesial Section.	do.	Fifteenth Day	do.	"	48
18. Transverse	do.	do.	do.	"	52
19. Ovaries and Tubes.	do.	do.	do.	"	52
20. Inner Surface of Uterus.	do.	Beginning of	do.	"	62
21. Full-time Placenta.	do.	Maternal Surface	do.	"	62
22. Vertical Mesial Section.	do.	Contracted Pelvis.	Stratz's case	"	65
	Do.	do.	Kyphotic do. Barbour's case	"	65
23. Dissections of the Pelvic Floor.	do.	Savage's	do.	"	78
24. Do.	do.	do.	do.	"	80
25. Vertical Mesial Section.	do.	Beginning of Fifth Month of Pregnancy	do.	"	115
26. Cast of Amniotic Cavity.	do.	do.	do.	"	117



RESEARCHES IN FEMALE PELVIC  
ANATOMY







$6\frac{1}{4}$  in. In the upper part, for a distance of  $2\frac{1}{8}$  in., it measures from before backwards  $\frac{5}{8}$  in.; below this for nearly 2 in. it measures only  $\frac{3}{16}$  in.; near the lower end of this narrow part is seen a pouching backwards for  $\frac{5}{16}$  in., due to a folding of the posterior wall. Below this narrow portion the cavity has a much greater antero-posterior measurement than elsewhere, due to the deep curved pouching in front and behind, between the body of the uterus and the cervix; the anterior portion is  $\frac{1}{8}$  in. deep, and the posterior  $\frac{9}{16}$  in. Below this the length of the canal between the lips of the cervix is  $\frac{7}{16}$  in. *The Upper Uterine Segment* is in its upper part moulded on the bodies of the sacral vertebræ. Its wall is pale grey with a pinkish tinge over the greater part most marked near the cavity and in the lower part. The periphery is paler than the central mass of the wall.

The anterior wall differs in appearance from the posterior; it is paler and has fewer vessels visible; its inner surface is smooth. The posterior wall is darker and contains a great many vessels (all closed) especially towards its inner part; its inner surface is shaggy, marking the area of attachment of the placenta for a distance of  $3\frac{1}{2}$  in.

At a distance of about  $\frac{2}{3}$  in. from the outer surface of the upper part of the anterior wall is seen a row of closed venous sinuses. They extend around the fundus and are seen in the posterior wall for a short distance. In the lower part of the anterior wall they extend gradually inwards. Outside these sinuses is a longitudinally-striated band of muscle extending around the upper two-thirds of the body of the uterus, becoming wider below and passing into the structure of the lower part of the body. Inside this band the course of the fibres cannot be determined in the upper part of the body, so compact and firm is the tissue. In the lower part, however, the walls have a spongy appearance, the interstices in the anterior wall being smaller, and extending nearer the cervix than in the posterior wall. The lower part of the body is marked by an abrupt change in thickness about the level of the sacral outlet where it passes into the lower uterine segment; at the point of junction (especially in the posterior wall) it appears folded as if by the pressure of the great mass of the body of the uterus from above.

*The Lower Uterine Segment* is seen between the cervix and upper uterine segment. Its exact length cannot be made out because the position


PLATE I.

FIRST DAY OF PUERPERIUM.


*Five Minutes after Delivery.—Vertical Mesial Section.*

(Reduced by  $\frac{1}{3}$ .)

- a. Promontory.
- b. Symphysis Pubis.
- c. Fundus Uteri.
- d. Closed sinus in uterine wall.
- e. Uterine Cavity containing blood clot.
- f. Placental site.
- g. Bladder.
- h. Retraction ring.
- i. Lower Uterine Segment.
- j. Anterior fornix.
- k. Cavity of Uterus above Cervix.
- l. Cervix.
- m. Upper part of Vagina.
- n. Lower " "
- o. Perineum.
- p. Utero-Vesical Pouch.
- q. Pouch of Douglas.







of the *os internum* is not known. Its thickness in its narrowest part is  $\frac{3}{8}$  in. in the anterior wall and  $\frac{1}{8}$  in. in the posterior wall. It is evidently of greater length in front than behind. It widens out above into the body of the uterus, and below into the cervix. On the posterior wall next the cavity is seen a longitudinal striation passing into the cervix.

*The Cervix* has to a certain extent its pre-parturient condition as far as shape is concerned. Its exact extent is not evident because the position of the *os internum* and *os externum* cannot be exactly made out. It appears somewhat flattened from above downwards. The anterior lip has a rough spongy appearance and is coarsely striated in its upper part. Its greatest vertical thickness, parallel with the canal, is  $\frac{1}{2}$  in. The greatest vertical thickness of the posterior lip is  $\frac{5}{8}$  in.; it has a more compact appearance than the anterior lip, being more densely striated and with little spongy structure.

The least thickness of tissue between the uterus and symphysis is  $\frac{3}{16}$  in. (behind the upper part of the symphysis). One half is extra-peritoneal tissue, the rest serum in the peritoneal cavity. Between the lower uterine segment and the anterior fornix is vaginal wall tissue of  $\frac{1}{4}$  in. thickness. Between the uterus and the last lumbar and first sacral vertebræ the thickness is  $\frac{3}{2}$  in.; below, it increases as far as the last sacral, where it measures  $\frac{3}{8}$  in. and consists almost wholly of rectum.

*The Vagina* has its walls apart below the anterior fornix. The orifice of the vulva measures 3 in. from the perineum to the clitoris. The walls are somewhat stretched, the anterior one being considerably crumpled; they are congested.

*The Bladder* lies behind the lower part of the symphysis pubis, compressed from above downwards so that its antero-posterior axis is almost at right angles to the brim. The upper surface is slightly concave. The average thickness of the wall is  $\frac{1}{4}$  in. The cavity is a mere slit concave above, of which two-thirds lie in front of the urethral opening. The upper part of the wall near its anterior end forms a slight projection which moulds the wall of the uterus in contact with it, while immediately in front of the bladder is a projection of the uterus into a pouching of the parietal peritoneum.

*The Urethra* is sigmoid. Its walls are dense and more coloured than

the surrounding connective tissue. Its length is  $1\frac{3}{8}$  in. The orifice is  $\frac{1}{8}$  in. below the symphysis in line with the vertical mesial axis.

*The Perineum* is intact, though flabby. It is 1 in. from before backwards at the base. It passes upwards, gradually becoming thinner.

*The Rectum* is cut into from the anus for a distance of about 6 inches. In its upper part it contains a small quantity of liquid fæces. It is compressed by the uterus and its walls are pale. Above the cavity extending above the brim is seen the meso-rectum compressed between the uterus and the bone.

*The Peritoneum* descends to form the utero-vesical pouch in front, the lowest point being 2 in. below the brim. The pouch is quite closed. The anterior wall of the uterus for an inch above the brim is in contact with the anterior abdominal wall. Above this, as far as the posterior wall, it is in relation to the intestines. Behind, the pouch of Douglas is quite closed, thus shutting out all intestines from the posterior part of the pelvis; its lowest point is  $4\frac{1}{4}$  in. below the brim.

#### TRANSVERSE SECTION (Left Half). (Plate II.)

This section passes in front immediately below the symphysis pubis in front, and behind through the sacrum below the junction of its upper two vertebræ; laterally the acetabulum is divided.

*The Uterus* occupies the greater part of the cavity of the pelvis, all the other structure being closely packed between it and the bony wall. The antero-posterior diameter of the uterus in the middle line is  $3\frac{1}{2}$  in., of which  $\frac{1}{4}$  in. is cavity. The latter extends for  $\frac{5}{8}$  in. to the left of the middle line, where its greatest antero-posterior depth is  $\frac{3}{8}$  in.; it is filled with dark-coloured blood-clot.

The *anterior* wall at the deepest part of the cavity is  $1\frac{1}{2}$  in. thick, and the posterior  $1\frac{5}{8}$  in.; the latter is slightly moulded by the rectum, to the left of which the thickness of the wall is 2 in. From the cavity to the broad ligament the thickness is  $1\frac{1}{8}$  in., and opposite the centre of the acetabulum  $1\frac{1}{6}$  in. The great mass of the wall is pale with a pinkish tinge; around the cavity there is a deep pink tinge.




PLATE II.

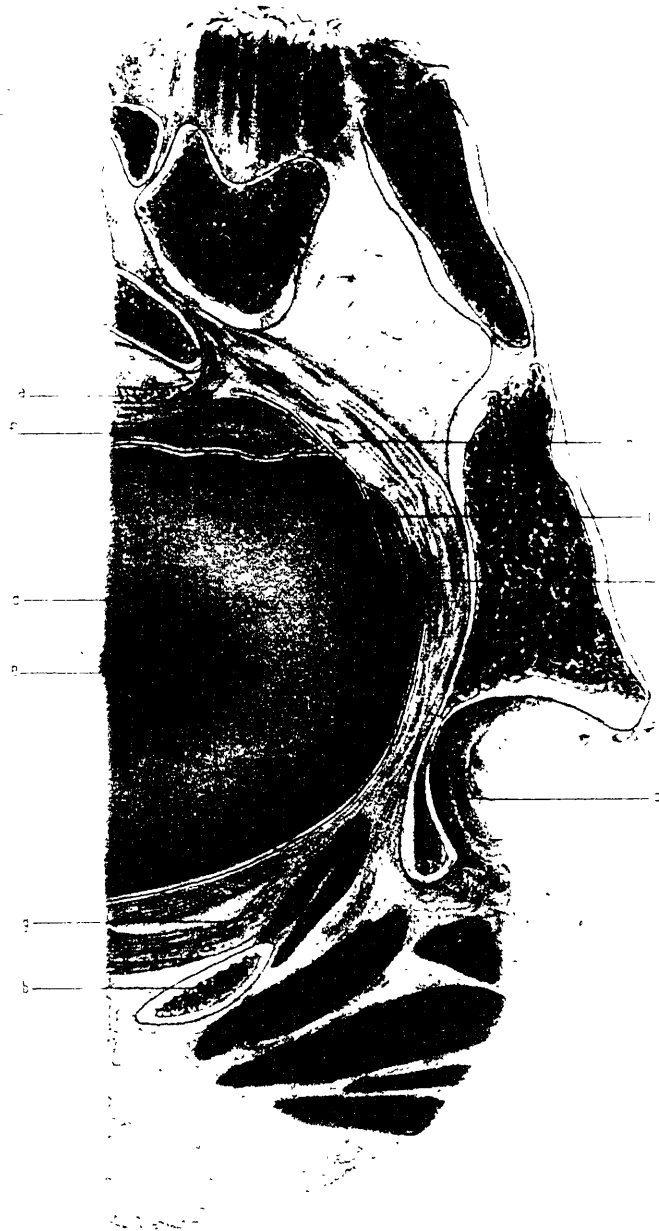
FIRST DAY OF PUERPERIUM.

*Transverse Section. Left Half.—Face of Lower Slab.*

(Reduced by  $\frac{1}{3}$ .)

- a.* Upper margin of Third Sacral Vertebra.
- b.* Left descending Ramus of Pubes, immediately below Symphysis.
- c.* Left Acetabulum.
- d.* Uterus.
- e.* Uterine Cavity.
- f.* Rectum.
- g.* Bladder.
- h.* Ureter.
- i.* Fold of posterior layer of Left Broad Ligament.
- j.* Broad Ligament tissues with closed vessels compressed by Uterus.







No open vessels are seen at all, though in the broad ligament and in the uterine wall adjacent to it several closed ones are visible.

The thickness of tissue, chiefly meso-rectum, between the uterus and sacrum in the middle line is  $\frac{1}{4}$  in., between the uterus and ala of the sacrum it is 1 in., of which half is the flattened-out and almost empty rectum, the other half being extra-peritoneal fat and connective tissue containing nearly closed vessels.

Between the uterus and the pelvic wall at the reflection of the anterior layer of the broad ligament the thickness is  $\frac{5}{16}$  in., consisting of connective tissue fat and a thin layer of muscle (obturator int.); opposite the middle of the acetabulum there are  $\frac{3}{16}$  in. of extra-peritoneal connective tissue, and  $\frac{5}{8}$  in. between the uterus and pubes, of which  $\frac{1}{2}$  in. is bladder.

*The Peritoneum* is cut both in front and behind the uterus. The reflection of the anterior layer of the broad ligament takes place  $1\frac{1}{8}$  in. behind the posterior wall of the acetabulum; that of the posterior layer  $\frac{5}{8}$  in. behind it. At the latter point a tongue-like projection is seen in the peritoneal cavity pointing backwards; it is a section across a fold of the posterior layer of the broad ligament. The rectum is seen to be partly covered by it.

*The Broad Ligament* has very little extent between uterus and pelvis; its tissues are greatly compressed between the uterus and the pelvic wall.

*The Bladder* is cut through immediately above its widest part, and extends  $1\frac{1}{2}$  in. to the left of the middle line. (Half-an-inch lower in the pelvis it extends  $2\frac{1}{8}$  in. to the left.) It is separated from the pubes by fat and connective tissue of the thickness of  $\frac{5}{16}$  in. in the middle line.

*The Rectum* lies on the left of the body of the sacrum, compressed from before backwards. It moulds the posterior uterine wall.

*The Internal Iliac Vessels* are seen behind the rectum, partly closed.

*The Ureter* lies immediately under the parietal peritoneum to the left of the rectum; immediately in front of it are seen some foldings of the utero-sacral ligament.

## VERTICAL OBLIQUE SECTION (Plate III.)

This section passes at right angles to the plane of the brim through the ilium immediately in front of the sacro-iliac joint on the right side, and on the left side through the ilio-pectineal eminence. The coccyx is divided obliquely at the junction of its second and third vertebræ. This section, it will be observed, passes almost through the plane of the right-oblique diameter of the pelvis.

*The Uterus* occupies the greater part of the pelvic cavity. The great mass of the body is pale with a pinkish tinge—the left half is paler than the right; the latter being the site of the placental attachment. In contrast with the smooth firm mass of the upper part of the body is noticed the spongy nature of the lower part, especially on the left side. The lower uterine segment and cervix are of a deep reddish-purple colour.

The width of the body, at the brim level, is 4 in.; opposite the middle of the acetabulum  $3\frac{3}{4}$  in. Its highest point is on the right of the middle line,  $1\frac{3}{4}$  in. above the brim; in the middle line it is  $1\frac{3}{16}$  in. above,  $1\frac{1}{2}$  in. to the left it is  $1\frac{7}{16}$  in. above, and then slopes suddenly down, until at the brim it is only  $\frac{1}{8}$  in. from the bone. On the right,  $1\frac{7}{16}$  in. from the middle line, it also slopes down, and at the level of the brim it is 1 in. from the side wall of the pelvis, the space being occupied by the greatly compressed broad ligament and tissues lining the pelvic wall. The greatest vertical height is  $4\frac{7}{8}$  in. at a point  $1\frac{3}{4}$  in. to the right of the middle line.

The thickness of the wall measures at the fundus (the thinnest part)  $1\frac{5}{16}$  in.; at the level of the brim on the left side,  $2\frac{1}{2}$  in.; opposite the middle of the acetabulum on the left side,  $2\frac{1}{4}$  in.; an inch and a quarter below the brim,  $1\frac{1}{2}$  in.; at the brim on the right side,  $1\frac{5}{16}$  in.; opposite the middle of the acetabulum on the right side,  $1\frac{1}{4}$  in., and opposite the left extremity of the middle division of the uterine cavity, 1 in.

*The cervix*, a quarter of an inch to the right of the middle line, is  $\frac{1}{2}$  in. thick; towards the right it continues of this thickness for  $\frac{3}{4}$  in., when the wall of the uterus suddenly thins to  $\frac{5}{16}$  in.; towards its left side

PLATE III.

FIRST DAY OF PUERPERIUM.

*Vertical Oblique Section.—Face of Posterior Slab.*

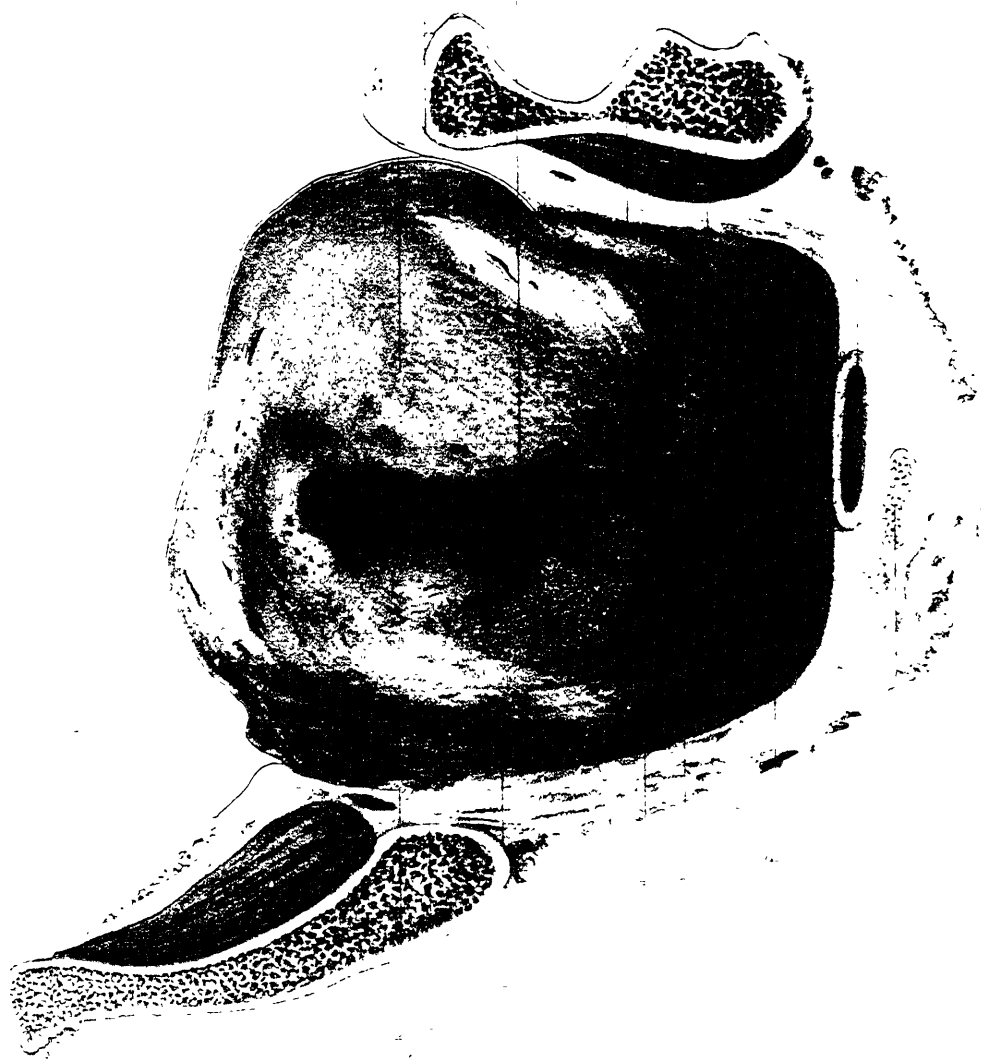
(Reduced by  $\frac{1}{3}$ .)


The Section is made at right angles to the brim, passing almost through the plane of the Right Oblique Diameter.

- a. Right Ilium immediately in front of Sacro-Iliac Synchondrosis.
- b. Left Ilio-pectineal eminence.
- c. Junction of Second and Third Coccygeal Vertebra.
- d. Uterus.
- e. Uterine Cavity.
- f. Cervix.
- g. Closed Vessels in Uterine Wall near Parametrium.
- h. Vagina.
- i. Rectum.
- j. Ureter.
- k. Peritoneum.









it slightly thins, and  $\frac{7}{16}$  in. from the middle line it passes into the body of the uterus.

At the fundus,  $\frac{1}{4}$  in. from the surface, are a series of closed sinuses. They extend on the left side around to the middle of the acetabulum, gradually passing inwards, so that opposite the upper margin of the acetabulum they are  $\frac{5}{8}$  in. from the surface. Lower down are seen the compressed vessels at the junction of the broad ligament. On the right side the sinuses cannot be traced so far down.

*The Cavity of the Uterus* does not appear as continuous in this section, but is in three divisions. The upper of these measures  $2\frac{3}{8}$  in. vertically, and has an average breadth of  $\frac{1}{3}$  in.; it slopes from above downwards and inwards, being at its upper end  $\frac{3}{8}$  in. from the vertical mesial plane, and at the lower end only  $\frac{1}{16}$  in. Its right edge is shaggy, indicating placental attachment. The left edge is smooth. In the cavity is dark blood clot. The middle portion of the cavity is in the form of a curved transverse slit, the concavity being downwards; about two-thirds is on the right of the vertical mesial plane. The right extremity is  $\frac{1}{8}$  in. lower than the left.

The *lower* portion is separated from the middle by a transverse projecting bit of posterior wall  $\frac{7}{16}$  in. thick. It has the form of a transversely-curved slit 2 in. wide, the greatest part of which is on the right of the middle line, the concavity being directed upwards. Its smallest vertical measurement is  $\frac{3}{32}$  in., a short distance to the right of the middle line. It gets wider towards each end.

*The Vagina* is cut obliquely. In the middle line it is  $\frac{1}{4}$  in. below the bottom of the pouch of Douglas. Its walls are in apposition. The posterior wall, below the outer end of the right lateral fornix, is  $\frac{3}{16}$  in. thick. As it passes to the left it gets thinner, but becomes thicker again below the left lateral fornix. It has a striated appearance, the striæ passing from side to side. The vaginal slit is bow-shaped, the concavity at each side being directed upwards.

*The Rectum* is behind the vagina, and is compressed from before backwards. It lies almost entirely on the left of the middle line, its inner third lying in front of the coccyx.

*The broad ligaments* are greatly compressed between the uterus and the pelvic wall, the vessels being closed.

*The Peritoneum* on the right side descends nearly to the brim, and on the left  $\frac{5}{8}$  in. below it.

*The Ureter* on the right side is  $\frac{5}{8}$  in. below the brim, and  $\frac{9}{16}$  in. from the bony wall; on the left side it is  $2\frac{1}{8}$  in. below the brim and  $\frac{5}{8}$  in. from the bone.

#### THE SPECIMEN AS A WHOLE (Plate XVI.)

*The Left Ovary* lies between the left side of the uterus and the pelvic wall. It is not at all visible on looking into the pelvis from above. Its upper surface rests against the uterus and looks forwards, inwards and only slightly upwards. The lower surface rests upon the rectum, upon the pelvic wall adjacent to it, and also upon a piece of the broad ligament which is folded on itself outside the attachment of the ovary. The posterior free border lies against the left edge of the rectum. The lowest part of the ovary is the uterine end. It joins the wall of the uterus directly, just behind the reflection of the posterior layer of the broad ligament at a point  $2\frac{1}{4}$  in. to the left of the vertical mesial plane of the body,  $1\frac{1}{16}$  in. behind the posterior margin of the left acetabulum, and  $\frac{7}{16}$  in. behind a plane passing through the anterior superior iliac spines at right angles to the plane of the brim. The ovarian ligament is spread out on the uterine wall, a little below the brim level.

The outer end of the ovary lies above, behind and internal to the inner end. The greatest part of the ovary lies above the brim.

*The Left Fallopian Tube* arises from the side of the uterus just above the brim nearly an inch behind the anterior surface. It passes at first backwards and downwards for half-an-inch, then upwards and outwards for the same distance, and then backwards and inwards above the ovary until it reaches the fold between the rectum and sigmoid flexure, where the fimbriated end stops touching both these structures as well as the ovary.

The outer part of the tube thus lies in the iliac fossa in a space formed externally by the parietal peritoneum; posteriorly by the junction of the rectum and sigmoid flexure, and internally by the uterine wall. It thus

completely covers the ovary, preventing it from being seen from above. The fimbriated end lies  $2\frac{1}{4}$  in. posterior to a plane passing through the anterior superior iliac spines at right angles to the brim, and  $1\frac{3}{8}$  in. below the highest part of the iliac crest. It is the highest part of the tube.

*The Left Broad Ligament* arises as a ridge of peritoneum in connection with mesentery of the sigmoid flexure in the left iliac fossa.

It runs downwards and forwards towards the brim, its outer surface lying against the parietal peritoneum. About  $\frac{1}{2}$  inch below the brim the layers separate widely, the posterior passing downwards to enter into the formation of the pouch of Douglas, the anterior passing forwards to form the utero-vesical pouch. Where it is reflected to the uterus, the peritoneum is arranged in numerous fine folds.

*The Right Ovary* lies between the uterus and side wall of the pelvis in a plane nearly  $\frac{1}{2}$  in. anterior to that in which the left ovary lies. It is more vertical in position and on a higher level than the left. Its inner end is attached to the uterus, immediately above the brim.

The free border looks backwards, so that the normal upper surface looks inwards, resting against the uterus.

The outer surface rests against the upper part of the broad ligament which is folded behind it.

*The Right Fallopian Tube* arises from the uterus about half-an-inch in front of the origin of the left tube and at a little higher level. It passes outwards and backwards external to the ovary. The fimbriated end curves inwards behind the ovary and touches the uterus.

*The Right Broad Ligament* has much the same arrangement as that of the left side.

*The Peritoneum* of the anterior wall of the pouch of Douglas is thrown into a large number of folds which run from the uterus upwards and outwards. They are seen also on the posterior wall of the uterus, and likewise of the pelvis, but much smaller.

Among the first-mentioned folds are the *Utero-sacral ligaments*, but it is impossible accurately to distinguish these.

*The Peritoneum* of the posterior part of the *utero-vesical pouch* is also considerably wrinkled as well as the anterior layers of the broad ligaments.

## THE SECOND DAY OF THE PUERPERIUM.

*Clinical Note.*—The labour was normal. Eclampsia, due to Bright's disease, developed soon after delivery, leading to death in about thirty-six hours.

### VERTICAL MESIAL SECTION (Plate IV.)

*Bony Pelvis.*—This section passes through the symphysis pubis, the last lumbar vertebra, the sacrum and coccyx. The symphysis is not quite parallel with the upper part of the sacrum, but diverges from above downwards. The sacrum and coccyx measure  $6\frac{1}{2}$  in. in length; they form together a well-marked curve forwards.

Diameters:—

Brim (anatomical) . . . . .	5 in.
„ (obstetrical) . . . . .	$4\frac{5}{8}$ „
Cavity . . . . .	$5\frac{3}{8}$ „
Outlet (sacral) . . . . .	5 „
„ (coccygeal) . . . . .	$4\frac{1}{8}$ „

The pelvic floor projection measures  $2\frac{3}{8}$  in. The umbilicus is opposite the junction of the third and fourth lumbar vertebræ.

*Uterus.*—The uterus is divided in its whole length. It occupies the great part of the pelvis.

The length of the whole uterus is 7 in.

„ „ body is about  $4\frac{7}{8}$  „

„ „ cervix is about  $2\frac{1}{8}$  „

„ „ uterine cavity is  $6\frac{1}{8}$  „

The highest point of the fundus above the brim is  $1\frac{5}{8}$  in. The greatest width of the body is  $3\frac{3}{4}$  in. at a point  $2\frac{5}{16}$  in. below the fundus, opposite the symphysis and first sacral vertebra. In the upper half of the body the anterior wall is slightly thinner than the posterior; in the lower half the


PLATE IV.

SECOND DAY OF PUERPERIUM.

*Vertical Medial Section.*


(Reduced by  $\frac{1}{3}$ .)

- a. Promontory.
- b. Symphysis Pubis.
- c. Fundus Uteri.
- d. Cavity of Uterus.
- e. Os Externum.
- f. Rectum.
- g. Pouch of Douglas.
- h. Utero-Vesical Pouch.
- i. Bladder.
- j. Urethral Orifice.









posterior is thinner than the anterior. The fundus is  $\frac{7}{8}$  in. thick, being thinner than any other part of the body save the lower part of the posterior wall. The anterior wall in its thickest portion measures  $1\frac{3}{4}$  in. ; it scarcely diminishes towards the lower end, so that just above the *os internum* it measures  $1\frac{1}{2}$  in. The thickest part of the posterior wall is 2 in., below this point it gradually diminishes until just above the *os internum* it is  $\frac{3}{4}$  in.

The body is flexed forwards markedly on the cervix at less than a right angle, the point of flexion being the level of the *os internum*. There is no well-marked line of division between the body and the cervix. No lower uterine segment can be distinguished.

The body of the uterus is of solid consistence and of a pink purplish colour. Next the cavity both walls are for a short distance darkly blood-stained. Numerous vessels are seen nearly closed. Around the fundus, about  $\frac{3}{8}$  in. from the peritoneal covering, is seen a row of nearly closed sinuses, which can be traced for a short distance on both anterior and posterior walls.

Outside this layer is seen a longitudinally striated band of muscle, becoming wider as it passes downwards, and gradually disappearing in the coarser, more network-like, structure of the lower part of the body.

*The Cervix* has a somewhat spongy appearance, especially in the anterior wall, being more striated longitudinally. As a whole it is more deeply stained than the body, especially in its lowest part.

The anterior wall is thicker than the posterior; the *os externum* is  $3\frac{1}{4}$  in. below the brim and  $1\frac{1}{8}$  in. above the coccygeal outlet.

*The Cavity* of the uterus from the *os externum* passes upwards and backwards almost parallel with the brim as far as the *os internum*; it then passes forwards almost at right angles to the vertical axis of the abdomen, near the fundus curving downwards and forwards. The wall is rougher over the placental area than in any other part. A thin blood-clot lies in the upper part of the cavity.

The distance of the uterus from the pelvic wall :—

1. Behind the upper part of the symphysis  $\frac{3}{8}$  in.
2. At the promontory . . . . .  $\frac{1}{4}$  „
3. At the *os internum* . . . . .  $\frac{5}{16}$  „

*The Vagina* is a closed slit, and is greatly elongated, being almost 5 in. Its walls are congested. The anterior fornix is  $\frac{3}{8}$  in. deep, the posterior,  $1\frac{1}{8}$  in.

*The Perineum* is intact, rather flabby, and congested. The lower part of the pubic segment is greatly congested.

*The Bladder* lies compressed from above by the uterus. It is empty. The walls average  $\frac{3}{8}$  in. in thickness. The upper surface is slightly sinuous. The anterior wall bulges downwards in front of the urethra. The cavity is > shaped, the anterior limb being much longer than the posterior, and almost in line with it.

Its apex lies at the junction of the upper fourth and lower three-fourths of the symphysis. The junction of the urethra and bladder is  $1\frac{3}{8}$  in. below the brim and just above the sacral outlet.

The walls are pinkish brown, the anterior wall being somewhat congested. The urethra is  $1\frac{1}{2}$  in. long, and curves from above downwards and forwards as a wavy slit.

There is a thin band of extra-peritoneal fat and connective tissue between the bladder and the back of the symphysis; behind the lower part of the latter it becomes triangular in shape.

*The Rectum* is divided from the anus as far as the brim. The cavity is opened in several places. The anus is directed downwards and backwards, not quite at right angles to the brim conjugate. It was closed. The opening seen in the section was made by a bit of cotton wool used to distend it. The cavity is closed save in the lower part. Its walls are of a dark greyish-green colour, the connective tissue outside them being of a pinkish tinge.

*The Peritoneum* descends in front of the uterus to form the utero-vesical pouch, the bottom of the latter being  $2\frac{1}{4}$  in. below the brim. The pouch is empty and closed. The anterior surface of the uterus is in contact with the upper surface of the bladder, and above that organ with the peritoneum of the anterior abdominal wall as high as the middle of the fundus, where the uterine wall comes into relation with intestines—both great and small—as far back as the promontory.

The peritoneum descends behind the uterus to form the pouch of

Douglas, the lowest point of which is 4 in. below the brim. The pouch is closed and empty, the uterus as high as the brim compressing the rectum against the posterior wall of the pelvis.

#### TRANSVERSE SECTION (Plate V.)

This section passes through the middle of the symphysis, through the 1st sacral vertebra and through the acetabula. The section is at a slightly higher level on the left than on the right side.

*The Uterus* is rounded, and occupies the greater part of the pelvic cavity, the extra-uterine tissues being compressed between its outer surface and the bony wall of the pelvis.

The colour of the uterus is darker than in the specimen at the beginning of the puerperium or in that at the end of third day.

The central part of the wall is dark pink-brown. Towards each side it is more deeply coloured red-purple, many partly opened vessels being seen containing blood. Near the broad ligament several large sinuses are seen nearly closed. In the anterior and posterior parts of the wall a few are also seen about  $\frac{3}{8}$  in.— $\frac{1}{2}$  in. from the peritoneal surface; internal to these, however, in the rest of the wall no large sinuses are seen.

The cavity is a sigmoid slit running transversely; its right extremity contains a bit of clot. It is situated nearer the posterior than the anterior surface of the uterus, and nearer the right than the left side. (This wall is cut slightly obliquely, however.)

From its right end to the side of the uterus the thickness is  $1\frac{5}{16}$  in.

Do. left                      do.                      do.                       $1\frac{3}{4}$  „

#### *Extra-Uterine Measurements* :—

1. From the uterus to the bony wall of the pelvis in its middle line in front, the thickness measures 1 in.
2. From the uterus to the bony wall of the pelvis in the middle line behind, its thickness measures  $\frac{3}{8}$  in.
3. From the uterus to the bony wall of the pelvis opposite both acetabula, its thickness measures  $\frac{1}{4}$  in.

4. From the uterus to the bony wall of the pelvis opposite the right sacro-iliac joint its thickness measures  $\frac{7}{16}$  in.
5. From the uterus to the bony wall of the pelvis opposite the left sacro-iliac joint its thickness measures  $\frac{3}{4}$  in.

*The Rectum* lies compressed between the posterior surface of the uterus and the sacrum. Its cavity, a mere slit, is  $1\frac{1}{8}$  in. in width, almost the whole of which is on the right of the middle line. Passing to the left is seen the mesentery of the rectum continuous with the extra-peritoneal tissues.

*The Broad Ligaments* at this level are practically obliterated. Their peritoneal layers are widely separated, their tissue being compressed between the uterus and the wall of the pelvis. The mass of the contracted uterus appears to extend on each side as far as the side wall of the pelvis, thereby separating the peritoneal layers of the ligaments, so that they can scarcely be said to have any lateral extent whatever, being reflected from the uterus to the side walls directly.

On the right side of the pelvis the antero-posterior measurement between the layers is  $1\frac{1}{2}$  in., and on the left side 1 in. The layers on the right side are reflected in a plane a little anterior to the reflection of those on the left side. The extra-uterine tissues are considerably blood-stained, several vessels being seen partly distended with blood.

*The Ureters* are cut across, lying behind the parietal peritoneum. The right one is immediately in front of, and in line with, the right sacro-iliac joint; the left one is further back, being  $\frac{1}{2}$  in. nearer the middle of the sacrum than the right ureter.

#### THE SPECIMEN AS A WHOLE (Plate VI.)

The intestines and great omentum are in relation to the upper surface of the uterus. The caput cæcum rests upon the outer part of the fundus on the right side, reaching inwards to within  $\frac{1}{2}$  in. of the middle line; it also rests upon the ovary and Fallopian tube of the same side, both the uterus and appendages being moulded by it, though it is only distended with flatus.


PLATE V.

SECOND DAY OF PUERPERIUM.

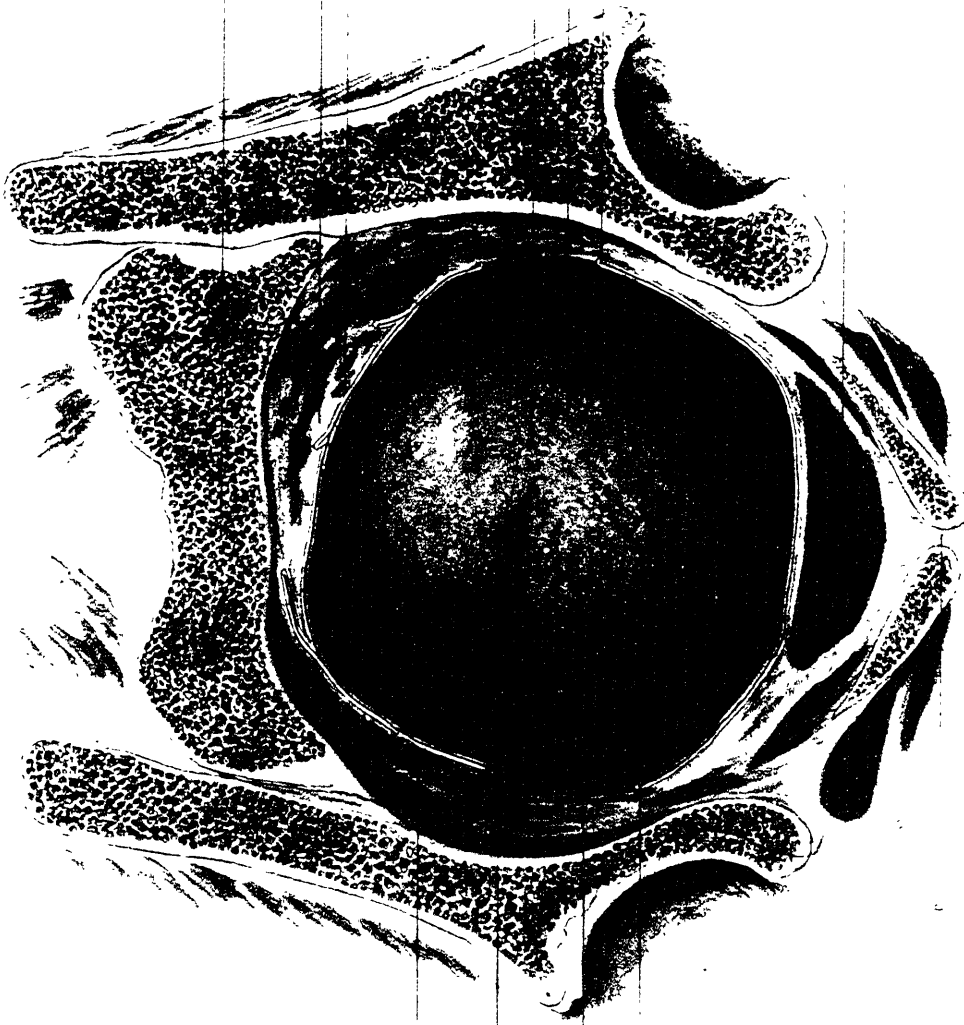
*Transverse Section.—Face of Lower Slab.*

(Reduced by  $\frac{1}{3}$ .)

- a. First Sacral Vertebra.
- b. Symphysis Pubis.
- c. Uterus.
- d. Uterine Cavity.
- e. Compressed Broad Ligament.
- f. Rectum.
- g. Ureter.
- h. Peritoneum.
- i. Bladder.









The vermiform appendix lies against the upper part of the right broad ligament (infundibulo-pelvic) and internal to it; its tip touches the posterior extremity of the ovary.

The middle part of the fundus is covered by the transverse colon and omentum, while on the left is found a fold of the sigmoid flexure. The small intestines only touch a small portion of the posterior wall of the uterus above the brim behind the great omentum and transverse colon.

At the promontory the rectum curves to the left for two inches, completely filling up the space between the left ovary, uterus, and posterior pelvic wall, and then passes upwards, becoming the sigmoid flexure.

*The Right Ovary* lies packed in a space between the sloping right side of the uterus and the side wall of the pelvis above the brim. Its long axis is directed from before backwards, inwards, and slightly upwards. Its most anterior point is  $\frac{1}{2}$  in. in front of a plane passing through the anterior superior iliac spines at right angles to the brim, and is  $1\frac{1}{4}$  in. from the vertical mesial plane of the pelvis; it is attached to the side of the uterus at a point  $1\frac{3}{10}$  in. behind the attachment of the right Fallopian tube. The posterior end is 2 in. from the vertical mesial plane of the pelvis.

The surfaces of the ovary look inwards and outwards, the normal under surface being inwards. The inner surface lies against the uterus just below the junction of the fundus with its posterior and lateral walls. The outer surface is more irregular, being moulded by the structures lying against it; these structures are from above downwards the caput cæcum coli, the vermiform appendix, the right infundibulo-pelvic ligament, the right Fallopian tube, and the right broad ligament.

The highest point of the ovary is  $\frac{1}{2}$  in. above the brim; the lowest is just above the brim.

*The Right Fallopian Tube* arises from the side of the uterus close to the anterior wall, slightly below the brim and 2 in. below the highest point of the fundus. It bends sharply upwards, and curves backwards, upwards, and then outwards for half-an-inch. It then turns sharply inwards and is directed backwards, lying partly in front of and partly outside the ovary.

Externally it is in relation to the pelvic wall, while above it is flattened by the caput cæcum coli.

*The Right Broad Ligament* in its highest part is a thin fold of peritoneum which arises from the junction of the posterior part of the cæcum with the iliac fossa at a point  $1\frac{1}{8}$  in. from the vertical mesial plane of the pelvis. It passes forwards and slightly downwards for  $1\frac{1}{4}$  in. as a ridge  $\frac{3}{8}$  in. high, and then becoming still more developed, passes more in a downward direction into the true pelvis. Below the ovary the anterior layer passes forwards, almost parallel with the brim, arches over the round ligament, and then passes to the bladder and anterior pelvic wall. There is thus formed behind the round ligament a saucer-shaped pouch in which lies the crumpled upper loose portion of the ligament. The posterior layer below the ovary passes downwards and slightly backwards to enter into the formation of the pouch of Douglas. The distance between the diverging layers has been well shown in the transverse section. The part of the ligament above the attachment of the ovary is of much the same thickness as in the non-pregnant woman, and is freely movable. It is crumpled up and lies packed between the uterus and pelvic wall. Several narrow foldings of the peritoneum are seen below the level of the ovary where the reflection takes place from the uterus to the wall of the pelvis.

*The Right Round Ligament* starts from the uterus at the junction of its anterior and lateral walls. It passes outwards in line with the anterior wall just above the brim, and then turns backwards and upwards towards the abdominal wall.

*The Right Utero-Sacral Ligament* arises from the uterus about  $\frac{7}{8}$  in. external to the vertical mesial plane of the pelvis, and opposite the upper part of the third sacral vertebra. It passes upwards and outwards to the side wall, its length being not more than  $\frac{5}{4}$  in., and it is folded between the uterus and the pelvic wall.

*The Left Ovary* has not the same relations to the left half of the pelvis that the right ovary had to the right half.

The most posterior part of the right ovary was the free edge. The most posterior part of the left ovary is its junction with the broad ligament; its free edge is turned forwards against the left Fallopian tube.

PLATE VI.

SECOND DAY OF THE PUERPERIUM.

FIG. 1.—Left half of Pelvis from above. (Reduced.)

- a.* Last Lumbar Vertebra.
- b.* Symphysis Pubis.
- c.* Fundus Uteri.
- d.* Appendages.
- e.* Sigmoid Flexure.

FIG. 2.—Right half of Pelvis seen from above. (Reduced.)

- a.* Last Lumbar Vertebra.
- b.* Fundus Uteri.
- c.* Appendages.


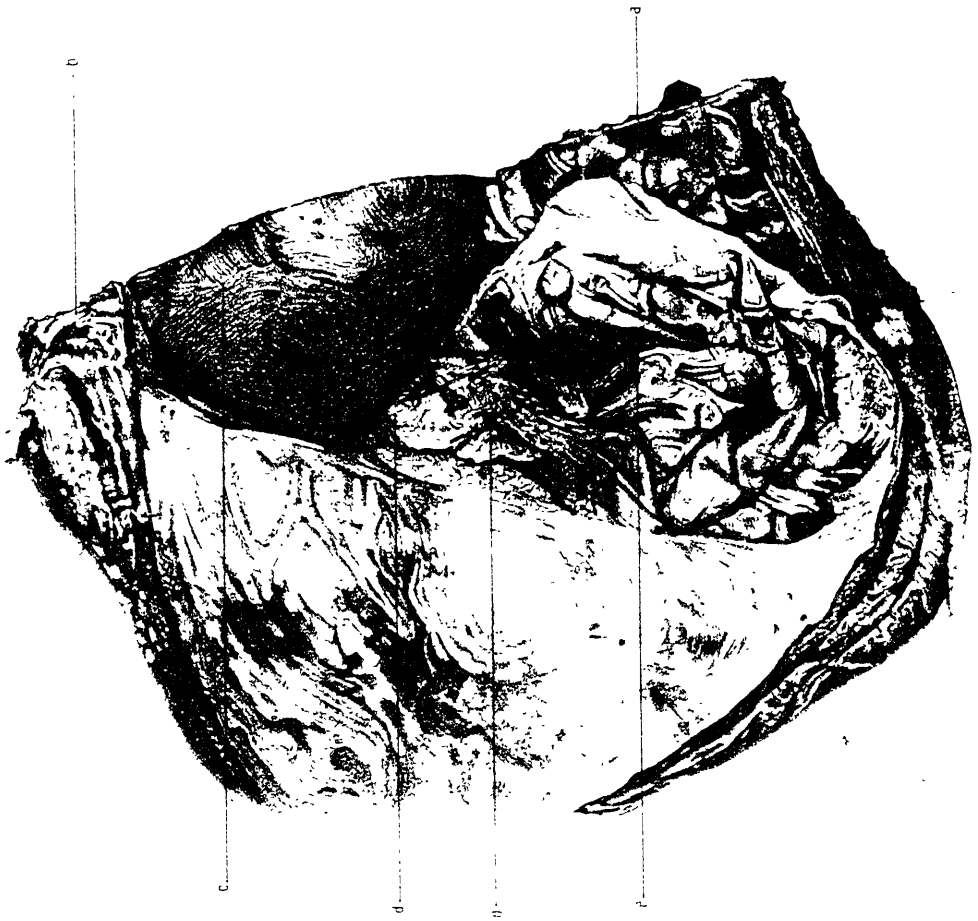



Fig 2



Fig. 1







The general direction of the long axis, as viewed from above, is in a line passing from before backwards, outwards, and upwards. The normal upper surface is turned downward and lies against the posterior layer of the left broad ligament, between the Fallopian tube and ovary. It looks downwards, outwards, and forwards.

The normal upper surface looks upwards as a whole. Its anterior third resting against the uterus looks upwards; the posterior two-thirds looks upwards, inwards, and backwards, and is in relation to a fold of the sigmoid flexure, being, together with an adjacent part of the uterus, covered by it and moulded by the *appendices epiploicae*.

The whole ovary is somewhat lower than that of the right side, and also a little posterior to it. The inner end is attached to the uterus  $1\frac{1}{8}$  in. behind the left Fallopian tube, as was the case with the right ovary.

*The Left Fallopian Tube* arises from the junction of the anterior and left lateral walls of the uterus at a point in the pelvis  $\frac{1}{2}$  in. behind the origin of the right tube. It passes backwards for  $\frac{1}{2}$  in. lying against the uterus, then curves upwards, backwards, and outwards against the free border of the forward-turned ovary, and finally passes outwards, lying on the peritoneum of the iliac fossa external to the mesentery of the sigmoid flexure.

On the right side the fimbriated end of the tube lay in front of the ovary against the upper surface of the uterus.

*The Left Broad Ligament* arises in the iliac fossa under the sigmoid flexure, being continuous with the mesentery of the sigmoid flexure. It passes downwards, forwards, and inwards towards the uterus. The free part above the attachment of the ovary is not crumpled as on the other side. Its anterior surface lies against the pelvic wall, its posterior against the ovary and sigmoid flexure.

Below the ovary the posterior layer passes directly downwards to enter into the formation of the pouch of Douglas. The anterior layer descends a little lower than on the right side before turning forwards to curve over the round ligament, and then to pass forwards over the bladder and to the wall of the pelvis.

*The Left Round Ligament* arises from the uterus close to the anterior

surface under the inner end of the tube, on a plane in the pelvis posterior to the origin of the right round ligament, and a little lower. It passes directly upwards, being packed between the uterus and the pelvic wall.

*The Left Utero-Sacral Ligament* arises from the uterus nearly opposite the lower edge of the third sacral vertebra about  $1\frac{1}{2}$  in. external to the vertical mesial plane of the pelvis. It passes upwards and outwards for about an inch. It is somewhat on the stretch and is packed between the uterus and pelvic wall.

*The Peritoneum* covering the uterus near the reflection of the broad ligament of both sides is thrown into a great number of folds running in a vertical direction.

*The Bladder* lies slightly more in the left than in the right half of the pelvis.

## THE THIRD DAY OF THE PUERPERIUM

*Clinical Note.*—The patient died early on the third day after delivery, of Acute Yellow Atrophy.  
She was near full time.

### VERTICAL MESIAL SECTION (Plate VII.)

*Bony Pelvis.*—The pelvis is above the normal size, the conjugate of the brim being especially increased.

Diameters:—

Brim (anatomical conjugate)	5 $\frac{1}{8}$ in.
,, (obstetrical conjugate)	5 ,,
Cavity (antero-posterior diameter)	4 $\frac{3}{4}$ ,,
Outlet (sacral conjugate)	4 $\frac{5}{8}$ ,,
,, (coccygeal conjugate)	4 $\frac{3}{8}$ ,,

There is a slight projection of the junction of the upper two sacral vertebrae. The vertical length of the symphysis is 1  $\frac{1}{2}$  in. and its greatest thickness  $\frac{3}{4}$  in. The length of the sacro-coccygeal curve is 6  $\frac{7}{8}$  in.

*Uterus.*—The uterus is divided in its whole length. It is somewhat pear-shaped, anteflexed, and occupying a large part of the pelvic cavity.

*The Body* is about at right angles to the inlet, the fundus being the highest part—1  $\frac{3}{8}$  above the anatomical conjugate of the brim. The lowest part is the posterior cervical wall which is 4  $\frac{1}{8}$  in. below the brim.

The length of the whole uterus (Fundus to O. E.) = 6  $\frac{3}{8}$  in.

,, ,, body	= 4 $\frac{3}{8}$ ,,
,, ,, cervix	= 2 ,,
,, ,, uterine cavity	= 5 $\frac{5}{8}$ ,,

The greatest antero-posterior thickness is 3  $\frac{9}{8}$  in. about an inch below the brim. The fundus measures nearly an inch in thickness, being the thinnest part of the body-wall. The anterior wall is thicker than the

posterior; the thickest part of the former is  $1\frac{7}{8}$  in. and of the latter  $1\frac{1}{2}$  in. The anterior wall passes more abruptly into the cervix; the posterior thins out gradually into it. There is no appearance of a retraction-ring nor of a lower uterine segment.

The posterior wall of the cervix is thinner than the anterior (? partly due to pressure).

The body has a solid appearance, and is of a dark pinkish yellowish grey in greater part. The periphery is of a darker shade. Around the upper part of the cavity the body wall is blood-stained.

In the walls several closed vessels can be distinguished. There is a row around the periphery  $\frac{3}{8}$  in. from the peritoneal surface. Around the fundus, however, the blood-stained area and wall adjacent to it has a spongy appearance due to the numerous vessels in it (placental area).

*The Cervix* is more deeply congested than the body. It is of coarser texture also. The arrangement of the muscular fibres cannot be made out with the naked eye. Around the periphery is seen a longitudinally striated appearance. This is seen also somewhat in the cervix.

The *os externum* is  $3\frac{1}{2}$  in. below the brim and just above the outlet.

The cavity is a closed slit save near the fundus, where there is a small space containing blood-clot. Its direction from the *os externum* is upwards and backwards, and then upwards and forwards, the concavity looking to the front.

*Relations.*—Behind the uterus are the rectum, meso-rectum, and sigmoid flexure; in front, the bladder and abdominal wall; above, the intestines. The part nearest the sacrum is that opposite the junction of the upper two sacral vertebræ, the distance being  $\frac{3}{16}$  in. Its point nearest to the symphysis is just behind the upper part, the distance being  $\frac{3}{4}$  in.

*Bladder.*—The bladder is in a partly contracted condition, and lies pressed on by the body of the uterus. The wall averages  $\frac{7}{16}$  in. in thickness. It is of a greyish-pink colour, the inner aspect being irregular in outline. Its upper limit is  $\frac{7}{16}$  in. below brim conjugate; its lower is a little above the outlet. The cavity is nearly empty; it does not form a > with the urethra, but is oblong, the length being  $1\frac{3}{8}$  in., and the width  $\frac{3}{8}$  in.

PLATE VII.

THIRD DAY OF PUERPERIUM.


*Vertical Mesial Section.*

(Reduced by  $\frac{1}{3}$ .)

- a. Promontory.
- b. Symphysis Pubis.
- c. Uterus.
- d. Cavity of Uterus.
- e. Bladder.
- f. Os Externum.
- g. Utero-Vesical Pouch.
- h. Rectum.
- i. Vagina.

L







The upper surface is straight and at right angles to the brim, being in close relation to the uterus; anteriorly there is a thin layer of fat under the peritoneum.

The anterior wall is curved and in relation to the retro-pubic fat. The posterior surface is attached to the cervix by rather loose connective tissue which appears compact from the pressure of the uterus.

*The Urethra* joins the bladder at a point  $2\frac{1}{4}$  in. below the brim. It runs downwards and forwards, being slightly sigmoid-shaped, ending  $\frac{1}{2}$  in. in front of the vertical axis of the symphysis,  $\frac{5}{8}$  in. below the conjugate of the outlet. Its length is  $1\frac{1}{8}$  in. It is about parallel with the brim conjugate.

*Vagina*.—The vagina is a closed slit in its upper part, but is gaping below. Its anterior wall is about  $2\frac{1}{8}$  in. in length, and its posterior  $2\frac{3}{4}$  in. The latter wall below the anterior margin of the cervix bends backwards on itself.

*The Perineal Body* measures  $1\frac{3}{8}$  in. vertically, and  $\frac{3}{4}$  in. across the base.

*The Rectum*.—The rectum is divided from the lower part of the 3rd sacral vertebra down to the anus. As far down as the tip of the coccyx it contains some fæces; below this its cavity is closed save near anus. (The anus was distended with a little cotton wool before freezing.) The anus looks downwards and backwards. It is not at right angles to the brim conjugate, but forms an acute angle anteriorly with it. (The rectum above the lower part of the 3rd sacral vertebra crosses to the right half of the pelvis.) Opposite the brim it is seen as it passes from the right to the left side of the pelvis to become the sigmoid flexure; its mesentery joins the posterior pelvic wall opposite the lower part of the 1st sacral vertebra.

*Peritoneum*.—The lowest point of the pouch of Douglas is  $4\frac{1}{8}$  in. below the brim. It does not reach below the level of the posterior fornix. The lowest part of the utero-vesical pouch is  $2\frac{3}{8}$  in. below the brim.

*Connective Tissue, etc.*—The triangular pad of fat and loose connective tissue behind the lower end of the symphysis is not so well marked as in some of the other cases. One or two closed sinuses are seen in it,

and one partly filled in its lower part. Below the symphysis the tissue is congested.

Continuous upwards behind the symphysis is a thin layer which joins a large triangular mass behind the upper part of the bone—the lower limit of the extra-peritoneal fat of the abdominal wall. The retro-peritoneal tissue on the posterior pelvic wall is so compressed that the vessels are empty.

#### CORONAL SECTION (Plate VIII.)

This cuts the pelvis a little behind the acetabula, the iliac wings being divided above, and the tip of the coccyx below. The width of the cavity is  $5\frac{1}{4}$  in.

*Uterus.*—The uterus occupies the greater part of the pelvic cavity. Its greatest vertical measurement is  $5\frac{1}{4}$  in., its transverse at the brim is 4 in. The highest point is 2 in. above the brim. The organ is slightly nearer the left than the right side of the pelvis. This is probably due to the partly distended rectum which lies mostly in the right half of the pelvis.

The great mass of the wall is yellowish-grey with a light brownish tinge; the periphery is of a darker shade. Around the cavity is seen dark red-purple staining. Around the upper part, and in the upper part of each lateral wall—especially on the left side—are seen numerous closed vessels (evidently in relation to placental area). In the greater part of the right lateral wall no vessels can be seen save in the upper part where they are completely closed; near the parametric tissue on each side other vessels are seen. The cervix is congested especially around the cavity. The *cavity of the body* has been so cut as to appear horseshoe-shaped, the open part being below. The transverse part is  $1\frac{1}{4}$  in. wide; the lower parts extend down for about  $1\frac{1}{4}$  in. The *cervical canal* is divided in its upper part; it appears as an irregular transverse slit  $1\frac{3}{8}$  in. across, the left end being slightly higher than the right.

*Relations.*—On the right side with rectum, ovary, and broad ligament; on the left with pelvic wall and sigmoid flexure; above with intestines.

*Rectum.*—The rectum is seen in two places. The lower part is divided


PLATE VIII.

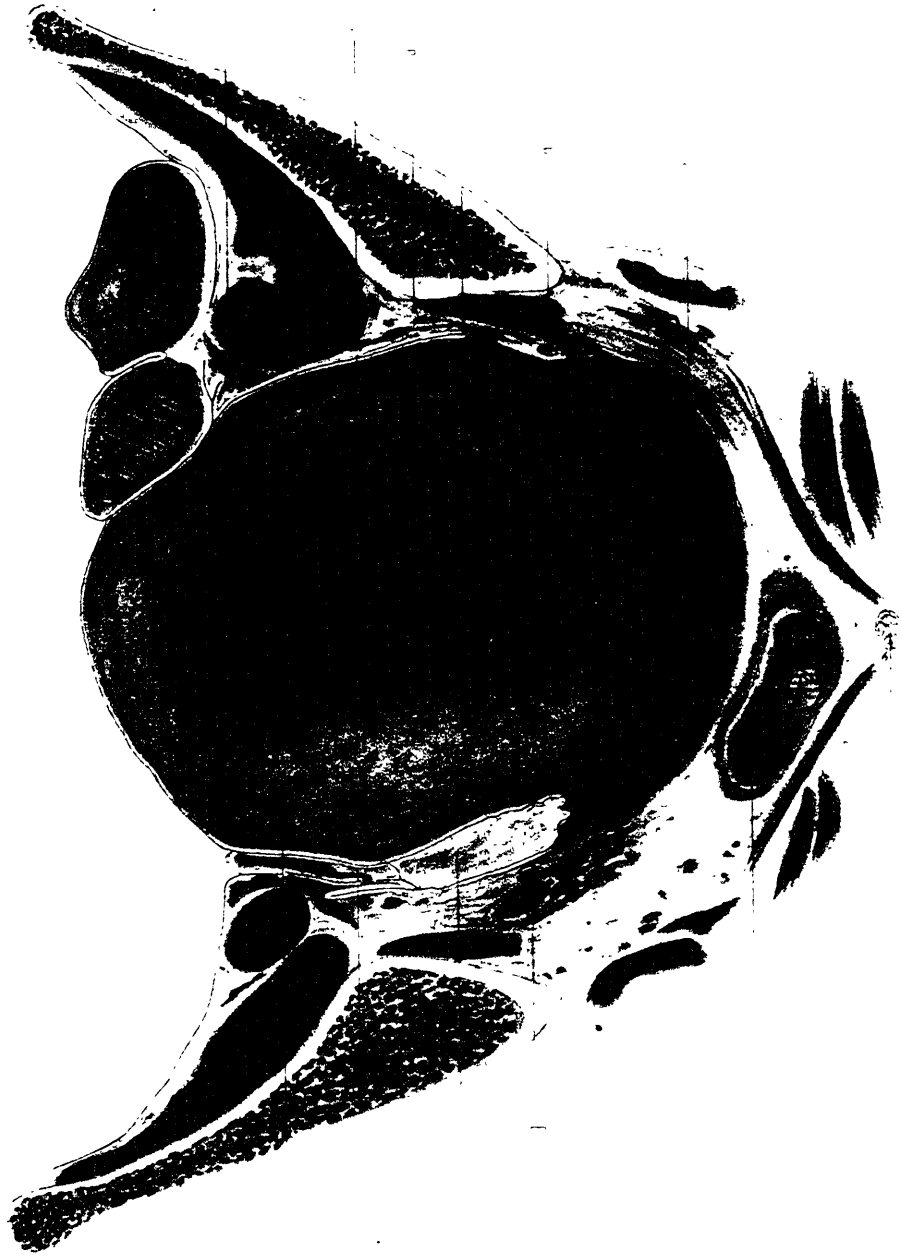THIRD DAY OF PUERPERIUM.


*Coronal Section.—Face of Posterior Slab.*

(Reduced by  $\frac{1}{3}$ .)

- a. Ilium a little behind Acetabulum.
- b. Tip of Coccyx.
- c. Uterus.
- d. Uterine Cavity.
- e. Vagina.
- f. Rectum.
- g. Ureter.
- h. Ovary.
- i. Rectum.
- j. Upper part of Left Broad Ligament.
- k. Peritoneum.







as it lies embedded in the connective tissue lining the posterior pelvic wall. Its upper wall is connected by loose tissue with the cervix uteri. (This appearance, it is to be observed, is exceptional. In most cases, in such a section, the pouch of Douglas, the vagina, or both, would be seen dividing the rectum from the uterus. In this case, however, the pouch of Douglas does not dip as low as usual, nor the posterior fornix as high, hence the continuity of the anterior rectal wall with the cervix.) Its width is  $1\frac{7}{8}$  in., being chiefly on the right of the middle line; its greatest thickness is  $\frac{3}{4}$  in., mainly due to faeces. The highest part of the rectum is seen, not divided, but with its wall merely shaved, lying in the peritoneal cavity to the right of the uterus. Its vertical extent is  $1\frac{3}{8}$  in., and its transverse  $\frac{3}{8}$  in. This is the highest part of the rectum in the right half of the pelvis. It crosses behind the uterus, appearing in the left iliac fossa as the sigmoid flexure, of which two folds are seen.

*Peritoneum.*—The peritoneum is seen covering the upper part of the uterus. Its point of reflection to the pelvic wall takes place, on the right side  $1\frac{1}{4}$  in. below the brim, and on the left side  $\frac{7}{8}$  in. below. At its reflection on the former side it is somewhat wrinkled; it passes up the pelvic wall where, above the brim, it is reflected to the right broad ligament which is partly divided. On the left side it passes upwards, and above the psoas is reflected on to the sigmoid flexure; immediately internal to this is seen a fold—the upper part of the left infundibulo-pelvic ligament.

*Connective Tissue, Ligaments, etc.*—The parametric tissue on both sides is of greater extent owing to the pouch of Douglas not dipping as low as it normally does. It is compressed by the uterus, though on the left side to a greater degree because the uterus is more pressed against that side. The sinuses on the left side are quite closed, but contain some blood on the other side. The parametrium forms with the sacral segment a large extent of tissue, extending from the coccyx to the ilium.

*The Right Broad Ligament* is seen, in small part, above the brim with the ovary internal to it. A small bit of the *left broad ligament*

is seen as a mere fold internal to the psoas muscle, as it runs backwards and upwards to join the meso-sigmoidea.

*The Right Ovary* is compressed between the uterus and the right pelvic wall, with the broad ligament. Its attachment to the latter is cut through in two places. It measures vertically  $1\frac{1}{4}$  in. Its average thickness is  $\frac{1}{3}$  in.

*The Right Ureter* is cut across  $1\frac{1}{2}$  in. below the brim, and  $\frac{7}{8}$  in. internal to the pelvic wall.

*The Left Ureter* is  $1\frac{5}{8}$  in. below the brim  $\frac{1}{2}$  in. internal to the pelvic wall.

#### GENERAL DESCRIPTION

*Right Tube and Ovary.*—These structures lie between the side of the uterus and the side wall of the pelvis, being in relation externally to the broad ligament and to the peritoneum covering the psoas muscle and extra-pelvic connective tissue at the brim level. They lie partly above and partly below the brim, the ovary being chiefly above.

The *Tube* starts from the uterus just below the brim opposite the middle of the acetabulum. It curves upwards and backwards for  $1\frac{1}{2}$  in. and then turns forwards resting on the inner part, touching the uterus internally, the ovary posteriorly, and the psoas externally.

The *Ovary* stands vertically, its free border being turned forwards, lying  $\frac{1}{4}$  in. behind the uterine end of the tube. Its normal inferior surface is internal and rests against the uterus. The normal superior surface rests against the broad ligament and pelvic wall. The line of attachment to the broad ligament is somewhat vertical (*vide* Coronal Section).

The *Ovarian ligament* is very short, the ovary coming very close to the uterus.

*Left Tube and Ovary.*—These structures lie a little higher and more anterior in the pelvis than the tube and ovary of the other side.

The *Tube* starts from the uterus opposite a point just in front of the acetabulum, at the brim level. It passes downwards for  $\frac{1}{2}$  in., then upwards and backwards between the ovary and parietal



peritoneum. It then curves forwards over to the ovary and ends in front of this body.

The *Ovary* has almost the same relation to the broad ligament and uterus as on the other side. The hilum is not so vertical, but passes upwards and forwards somewhat obliquely. The inner part of the ovary is very close to the uterus, the *ovarian ligament* being shorter than on the other side.

*Round ligaments.*—The *right ligament* arises from the uterus a little below and in front of the origin of the tube. It curves upwards and backwards, forming a well-marked ridge in the anterior layer of the broad ligament. It crosses the brim a little behind the middle of the acetabulum having the tube internal to it.

The *left ligament* curves more upwards than the other and crosses the brim a little in front of the other.

The *Utero-Sacral ligaments* cannot be distinguished from several folds of peritoneum in the pouch of Douglas.

The *Peritoneum* covering the uterus is wrinkled especially near the broad ligaments and on the posterior walls. The parietal peritoneum in the *pouch of Douglas* is also wrinkled considerably. The wrinkles are small save in the latter place where they are much better marked. The lowest point of the pouch of Douglas is seen in vertical mesial section.

*Bladder.*—This organ lies chiefly below the brim behind the pubes. It is in a partly contracted condition, being nearly empty. Its highest point is seen in vertical mesial section; from this level it slopes downwards and backwards. Its upper surface is smooth; but the outer border together with the adjacent parietal peritoneum is considerably wrinkled. (These wrinkles probably disappear in the distended condition.)

The inner wall is markedly rugous. The cavity is widest in its posterior part, extending  $1\frac{1}{4}$  in. to the left and  $1\frac{1}{2}$  in. to the right of the middle line.

*Rectum.*—The lower part of the rectum is more in the right than in the left half of the pelvis. At the middle of the 3rd sacral vertebra where the lower part of the meso-rectum is attached, it crosses to the right entirely and then at the brim passes across to the left side behind the uterus.

## THE FOURTH DAY OF THE PUERPERIUM

*Clinical Note.*—The patient died of Bright's disease about eighty hours after delivery.

### VERTICAL MESIAL SECTION (Plate IX.)

*Bony Pelvis.*—This section is made through the last lumbar vertebra, the sacrum and coccyx and the symphysis pubis. The symphysis pubis measures  $1\frac{1}{2}$  in. vertically and  $\frac{5}{8}$  in. transversely across its middle. The sacrum is straight in its upper part, but the last vertebra, together with the coccyx, forms a well-marked curve forwards; the length from the promontory to the tip of the coccyx is 6 in. following the curve of the bone.

The junction of the 1st and 2nd sacral vertebræ bulges forwards somewhat, more than is normally the case.

Diameters :—

Brim (anatomical)	. . .	$4\frac{1}{8}$ in.
„ (obstetrical)	. . .	$3\frac{7}{8}$ „
Cavity	. . .	$4\frac{1}{8}$ „
Outlet (sacral)	. . .	$4\frac{3}{4}$ „
„ (coccygeal)	. . .	4 „

The pelvic floor projection measures  $2\frac{3}{8}$  in. The umbilicus is opposite the junction of the 3rd and 4th lumbar vertebræ.

*The Uterus* occupies the greater part of the pelvis. It has been cut through in the whole of its extent vertically.


The length of the whole uterus	is	$7\frac{1}{8}$ in.
„ „ body	„	$5\frac{1}{8}$ „
„ „ cervix	„	2 „
„ „ uterine cavity	}	$6\frac{1}{4}$ „
from os externum to fundus		


PLATE IX.

FOURTH DAY OF PUERPERIUM.

*Vertical Mesial Section*

(Reduced by

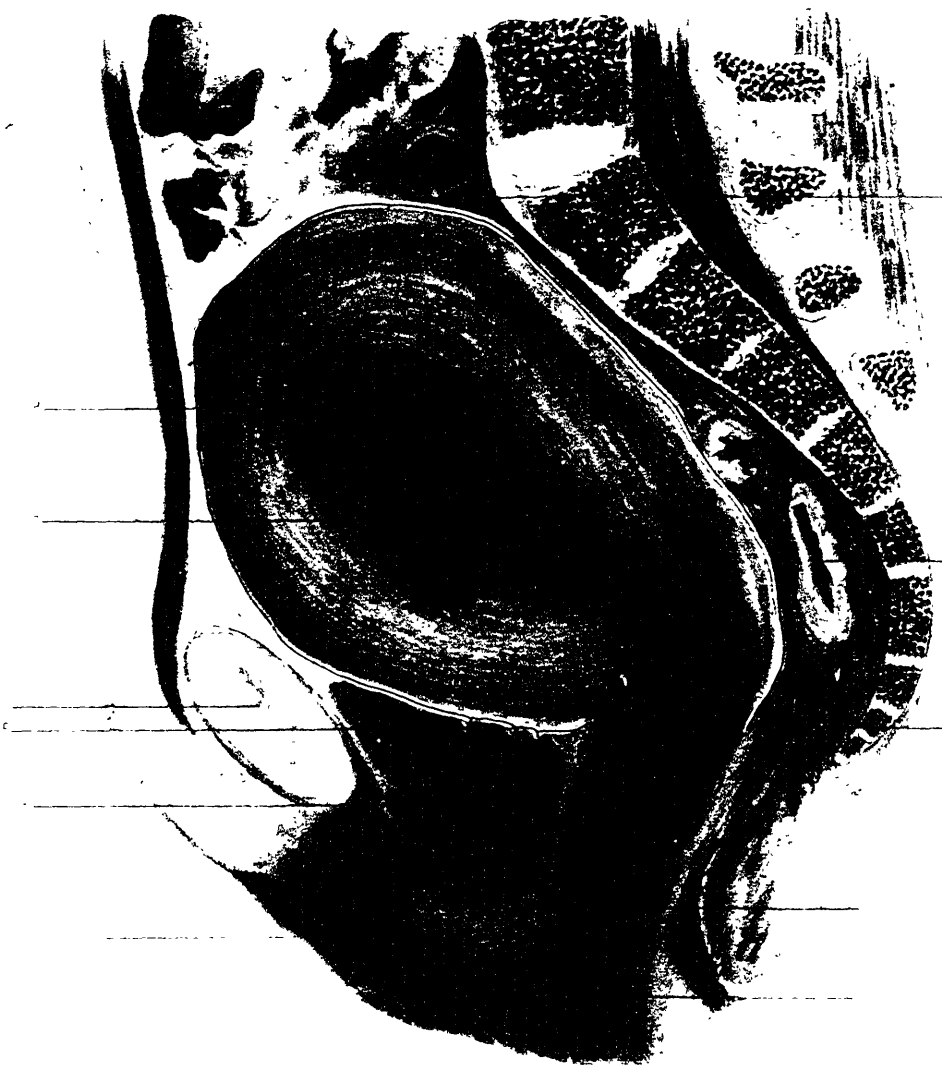- 
- a. Promontory.
  - b. Symphysis pubis.
  - c. Uterus.
  - d. Uterine Cavity.
  - e. Os Externum.
  - f. Utero-Vesical Pouch.
  - g. Pouch of Douglas.
  - h. Rectum.
  - i. Vagina.
  - j. Urethral Orifice.
  - k. Bladder.




*[Faint, illegible mark or signature]*

A

PLATE IX.





The highest point of the fundus above the brim is  $1\frac{3}{4}$  in. The greatest width of the body is opposite the 1st sacral vertebra and upper part of the symphysis,  $3\frac{1}{2}$  in. The anterior wall is thicker as a whole than the posterior; its thickest portion is opposite the junction of the 1st and 2nd sacral vertebræ and the middle of the symphysis, being 2 in. The thickest portion of the posterior wall is  $1\frac{3}{4}$  in. The thinnest part of the whole body is at the fundus, where it measures  $\frac{7}{8}$  in. Below its thickest part the posterior wall diminishes in thickness gradually passing into the cervix.

In the anterior wall, in a line joining the middle of the symphysis and the middle of the 3rd sacral vertebra, is a sudden diminution in its thickness, the wall in its inner part appearing folded.

The uterus is anteflexed, the body being bent forwards on the cervix at right angles, the flexion occurring at the os internum.

There is no well-marked line of distinction between the body and cervix.

No lower uterine segment can be distinguished. The body is of solid consistence and is very firm, the great mass of the walls being pale yellowish-grey with darker areas, especially near the periphery. Near the cavity the appearance is quite different. The posterior wall and fundus is deeply blood-stained for a thickness of about  $\frac{1}{4}$  in.; the anterior, however, is coloured in a much wider extent. The anterior wall was probably the seat of the placenta.

Around the periphery is a lighter yellow longitudinally striated band of muscle. In the posterior wall it is most prominent, measuring  $\frac{1}{4}$  -  $\frac{3}{8}$  in. It is somewhat narrower at the fundus and on the upper part of the anterior wall; at about the middle of the latter it spreads out into the rest of the muscle, and can be followed no farther down as a distinct band. Internal to this band, the upper part of the body appears smooth to the naked eye, the lower fourth presents somewhat of a network-like structure, only visible, however, on close examination.

No open vessels are seen anywhere in the wall. It is practically bloodless.

*The Cervix* appears flattened from before backwards. Its walls diminish

slightly in thickness from above downwards. The vaginal portion is in close contact with the vaginal walls. It is more deeply coloured than the body, being more blood-stained, especially in the lower portion where there is marked congestion. Its periphery is of lighter colour than the central portion.

In structure it seems coarsely longitudinally striated, with a spongy appearance in its lowest part. Of the two walls, the anterior is thicker than the posterior. The width between the fornices is  $1\frac{7}{8}$  in.; this is, of course, an oblique measurement through the cervix and does not represent the antero-posterior diameter of the cervix at the level of the roof of the fornices. The os externum is  $1\frac{5}{8}$  in. below the coccygeal outlet, the os internum about  $\frac{1}{4}$  in. above it.

*The Cavity* of the uterus is closed and empty; its lining wall is not shaggy, but has rather a smooth outline. The distance of the uterus from the pelvic wall measures:

- a. Behind upper part of symphysis . . .  $\frac{1}{8}$  in.
- b. Opposite the 1st sacral vertebra . . .  $\frac{1}{8}$  „

below this it gradually increases, until opposite the 1st coccygeal vertebra it is nearly 1 in.

*The Vagina* is closed in its upper part, but  $\frac{1}{4}$  in. below the anterior fornix the walls are separated, the anterior wall appearing very crumpled.

*The Perineum* is intact but flabby. It is wider at its base than in the non-pregnant woman.

The lower part of the pubic segment as well as the perineum is considerably congested.

*The Bladder* lies partly above, partly below the outlet. It appears considerably pushed down by the uterus. The cavity is almost empty, and scarcely appears > shaped, the posterior limb being greatly obliterated by pressure from above. The upper surface is flat, being in close relation to the lower part of the anterior wall of the body of the uterus; an inch and a quarter from the anterior extremity there is a sharp folding inwards of the upper wall.

The apex of the organ is immediately below the middle of the





symphysis pubis. Its junction with the urethra is  $\frac{3}{4}$  in. below the outlet. (About one-half the whole body lies behind it.) The wall has a yellowish-brown spongy appearance and is somewhat blood-stained at the base.

*The Urethra* is markedly sigmoid-shaped, being  $1\frac{1}{2}$  in. in length.

There is a thin band of connective tissue and fat behind the upper part of the symphysis, continuous above with the extra-peritoneal connective tissue of the abdominal wall and, below, with the bladder behind the lower part of the symphysis. That part above the bladder is bloodless, that below is deeply congested, as is the adjoining part of the base of the bladder.

The thickness of tissue from the lower margin of the sub-pubic ligament to the vagina in line with the vertical axis of the pubes is  $1\frac{3}{4}$  in.

*The Rectum* is divided for  $5\frac{1}{2}$  in. Its cavity, which is empty, is exposed in four places, the highest part seen being opposite the junction of the 2nd and 3rd sacral vertebræ; above this point is seen its mesentery.

The walls are greenish-brown, all the vessels in connection with the tissue surrounding them being closed.

The anus is directed downwards and backwards, not quite at a right angle to the conjugate of the brim. It was quite closed. (The opening seen in the section was due to a small piece of cotton-wool being placed in it before freezing.)

*The Peritoneum* descends in front of the uterus for  $2\frac{7}{8}$  in. below the brim. The utero-vesical pouch is closed, and above the bladder the anterior wall of the uterus is in contact with the peritoneum covering the back of the symphysis and the anterior abdominal wall, no intestines lying between.

Behind, the peritoneum descends to form the pouch of Douglas, the lowest point of which is 4 in. below the brim, nearly as low as the outlet. The pouch is closed, the posterior wall of the uterus being in relation to the posterior wall of the pelvis and to the rectum.

The fundus is in relation to the intestine.

## TRANSVERSE SECTION (Plate X.)

This section passes through the middle of the symphysis in front, and through the junction of the 1st and 2nd sacral vertebræ behind, and through the acetabula on the sides.

*The Uterus* occupies the great part of the cavity of the pelvis. Its greatest transverse measurement is  $4\frac{1}{4}$  in., its greatest antero-posterior being  $3\frac{1}{2}$  in., immediately to the right of the middle line. In structure it appears firm and compact, the surface having a smooth appearance.

It is around the cavity deeply blood-stained, elsewhere of a pale yellowish-grey colour with a pinkish tinge here and there. The periphery is darker than the rest of the pale area. Several sinuses are seen firmly closed and containing no blood.

The cavity is a transverse slit  $1\frac{3}{8}$  in. wide, situated rather nearer the anterior than the posterior surface of the uterus and slightly sinuous from side to side. Its walls are smooth and there is a small quantity of blood-clot lying between them. The general direction of the cavity from side to side is almost in line with the transverse diameter of the pelvis, so that the uterus can scarcely be said to have any rotation; if anything, the left side is slightly turned towards the back.

The thickness of the wall is about the same on each side, being  $1\frac{1}{8}$  in.

The extra-uterine tissues are compressed between the uterus and the pelvic wall, and are thus rendered nearly bloodless.

The distance between the uterus and pelvic wall varies in different places:—

a.	In the middle line in front	it is $\frac{3}{16}$ in.
b.	"    "    behind	" $\frac{1}{8}$ "
c.	Opposite the right sacro-iliac joint	" $\frac{9}{16}$ "
d.	"    left    "	" $\frac{7}{16}$ "
e.	"    middle of the right acetab.	" $\frac{1}{4}$ "
f.	"    "    left    "	"    " $\frac{3}{16}$ "

*The Rectum* lies entirely on the right of the middle line. Its walls are compressed from before backwards so that its cavity is a mere transverse


PLATE X.


FOURTH DAY OF PUERPERIUM.


*Transverse Section.—Face of Lower Slab.*

(Reduced by  $\frac{1}{4}$ .)

- a. Upper part of Second Sacral Vertebra.
- b. Middle of Symphysis pubis.
- c. Sacro-Iliac Synchondrosis.
- d. Uterus.
- e. Peritoneum.
- f. Ureter.
- g. Rectum.
- h. Broad Ligament compressed.
- i. Uterine Cavity.







slit. Its mesentery passes to the left, being continuous with the extra-peritoneal connective tissue.

*The Broad Ligaments* are so disposed that, while their antero-posterior measurement is increased, they have scarcely any transverse measurement whatever. The uterine wall compresses them against the tissues, lining the side wall of the pelvis. The distance between the anterior and posterior layers of the right ligament is  $1\frac{5}{8}$  in., and between those of the left 1 in.

The anterior layers are reflected on to the pelvic wall at about the same level on both sides, viz. near the posterior border of the acetabulum.

*The Vessels* seen are branches of the internal iliac.

They are almost closed. The tissues immediately around them are stained with blood which has oozed from them after the section was made.

*The Ureters* are seen internal to the vessels, lying immediately under the parietal peritoneum. The right one lies  $\frac{1}{2}$  in. behind the reflection of the posterior layer of the right broad ligament; the left lies farther back, near the middle line of the sacrum.

#### THE SPECIMEN AS A WHOLE (Plate XI.)

*The Right Ovary* lies in a depression between the side of the uterus and the pelvic wall, being altogether above the brim.

The normal outer end is directed forwards so that the organ lies turned upside down. The normal superior surface rests against the uterus at the junction of the fundus and side wall, the normal inferior surface—now uppermost—is covered by intestines.

Its most anterior point is almost opposite a line passing transversely through the middle of the fundus, its posterior extremity being almost opposite the posterior surface of the uterus.

The anterior end is  $1\frac{1}{4}$  in. behind a vertical plane passing transversely through the pubes at right angles to the brim and  $\frac{1}{2}$  in. above the brim; it is  $\frac{3}{8}$  in. in front of a plane perpendicular to the brim passing through the anterior superior iliac spines. It slopes downwards and backwards. Its length is  $1\frac{1}{2}$  in.; its width  $\frac{1}{4}$  in.

*The Right Fallopian Tube* starts from the junction of the fundus and

side wall of the uterus about  $\frac{1}{2}$  in. below the top of the fundus and near the front of the uterus. It passes forwards against the uterus for  $\frac{1}{2}$  in. and then turns back on itself, passing outwards in front of the ovary against the pelvic wall for 2 in. The fimbriated end turns inwards and ends on the upper surface of the ovary.

*The Right Broad Ligament* has its highest point of attachment a little above the brim in a plane  $\frac{1}{4}$  in. anterior to the promontory. The free part above the ovary is folded on itself in front of and outside that body. In this part it has about the same thickness as in the non-pregnant condition. It passes downwards and forwards crossing the brim behind the acetabulum, and immediately below the brim widens out. The anterior layer passes forwards and curves over the round ligament thus forming a pouch behind this structure.

The posterior layer passes almost directly downwards into the pouch of Douglas. The tissue of the ligament is pressed against the pelvic wall between its anterior and posterior layers. Just below the brim its width is  $1\frac{1}{2}$  in.

Below the tube the peritoneal layers which appear partly to cover the outer surface of the uterus are very loose, many folds being seen. This condition has probably been brought about through the uterus having, as it were, forced itself at the sides into the ligament, thereby altogether altering the normal appearance of the ligament.

This appears more evident because the normal inner end of the ovary is attached to the side of the uterus.

The uterus is by this arrangement to a considerable extent fixed against the pelvic wall and is very little movable.

*The Right Round Ligament* starts from the uterus at the junction of the anterior and lateral walls at a point  $\frac{1}{4}$  in. lower than the origin of the Fallopian tube. It curves downwards, then upwards and then forwards to the abdominal wall.

There is a well-marked pouch immediately behind it in the anterior layer of the broad ligament, and in it the inner part of the right Fallopian tube lies.

*The Right Utero-Sacral Ligament* consists of a few thin folds of peri-



PLATE XI.

FOURTH DAY OF PUERPERIUM.

FIG. 1.—Left half of Pelvis seen from above. (Reduced.)

- a.* Promontory.
- b.* Symphysis Pubis.
- c.* Fundus Uteri.
- d.* Appendages.
- e.* Sigmoid Flexure turned back.

FIG. 2.—Right half of Pelvis seen from above. (Reduced.)

- a.* Promontory.
- b.* Appendages.
- c.* Vermiform Appendix.
- d.* Caput Cæcum Coli.


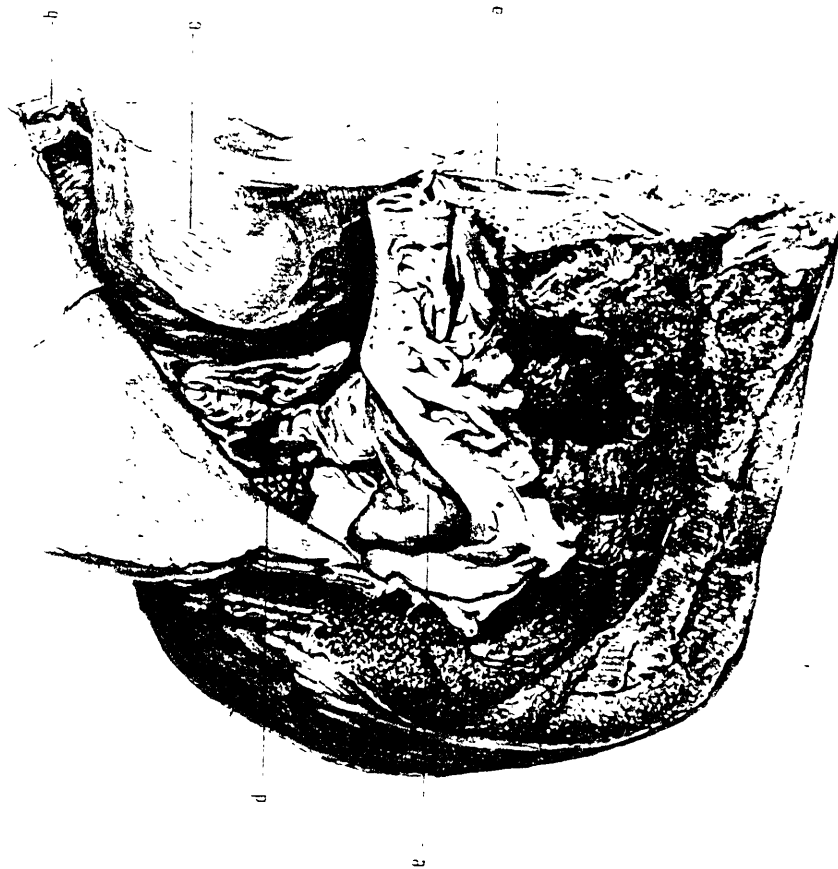



Fig 2.



Fig 1.



1



toneum about 1 in. in length. Its highest point is the parietal attachment—opposite the middle of the 3rd sacral vertebra.

It passes downwards and inwards, being folded on itself, and is attached to the back of the uterus about an inch from the middle line just about opposite the flexion in the uterus seen in the vertical mesial section.

*The Left Ovary and Fallopian Tube* bear almost the same relation to the left half of the uterus and pelvic wall as those already described bear to the right half. The only differences are as follows:—

They are on a slightly anterior plane as a whole. The ovary is slightly larger than the right. The fimbriated end of the tube lies not upon but alongside the ovary.

*The Left Broad and Round Ligaments* are arranged much the same as on the right side.

The left utero-sacral ligament is attached to the wall of the pelvis at a higher level.

*The Bladder* is compressed from above by the body of the uterus. Its upper surface has a very steep inclination from before backwards. Its highest point is seen in the vertical mesial section. The cavity extends  $1\frac{3}{4}$  in. to the left and  $1\frac{1}{2}$  in. to the right of the middle line—its widest part, near the base.

The peritoneum over the posterior part of the upper surface is very loosely attached.

## THE SIXTH DAY OF THE PUERPERIUM

*Clinical Note.*—The patient died of acute lobar pneumonia.

### VERTICAL MESIAL SECTION (Plate XII.)

*Bony Pelvis.*—The pelvis is of the justo-major type.

Diameters:—

Brim (anatomical conjugate)	.	.	.	5 $\frac{3}{8}$ in.
„ (obstetrical conjugate)	.	.	.	5 $\frac{1}{8}$ „
Cavity (antero-posterior diameter)	:	.	.	5 $\frac{1}{8}$ „
Outlet (sacral conjugate)	.	.	:	4 $\frac{7}{8}$ „
„ (coccygeal conjugate)	.	.	.	4 $\frac{1}{16}$ „

The vertical length of the symphysis is 1 $\frac{1}{2}$  in. and its greatest thickness  $\frac{11}{16}$  in. The length of the sacro-coccygeal curve is 6 $\frac{1}{2}$  in. The junction of the upper two sacral vertebræ is somewhat more prominent than normal, though scarcely of sufficient degree to give to the pelvis the condition of “double promontory.”

*Uterus.*—The uterus occupies the cavity of the pelvis, being entirely below the level of the conjugate of the brim, the posterior wall near the fundus coming to within  $\frac{3}{16}$  in. of this line.

The organ is markedly anteflexed; the body forming with the cervix an angle slightly less than a right angle, and lying almost in a line with a diameter joining the middle of the symphysis with the middle of the third sacral vertebra. The fundus lies behind the symphysis, separated from it only by the thickness of the apposed upper and lower bladder walls; the junction of the body and cervix is the most posterior part, and is  $\frac{13}{16}$  in. from the third sacral vertebra, being separated from it by the rectum.

The upper part of the cavity has been divided for a distance of 3 in.


PLATE XII.

SIXTH DAY OF PUERPERIUM.

*Vertical Mesial Section.*

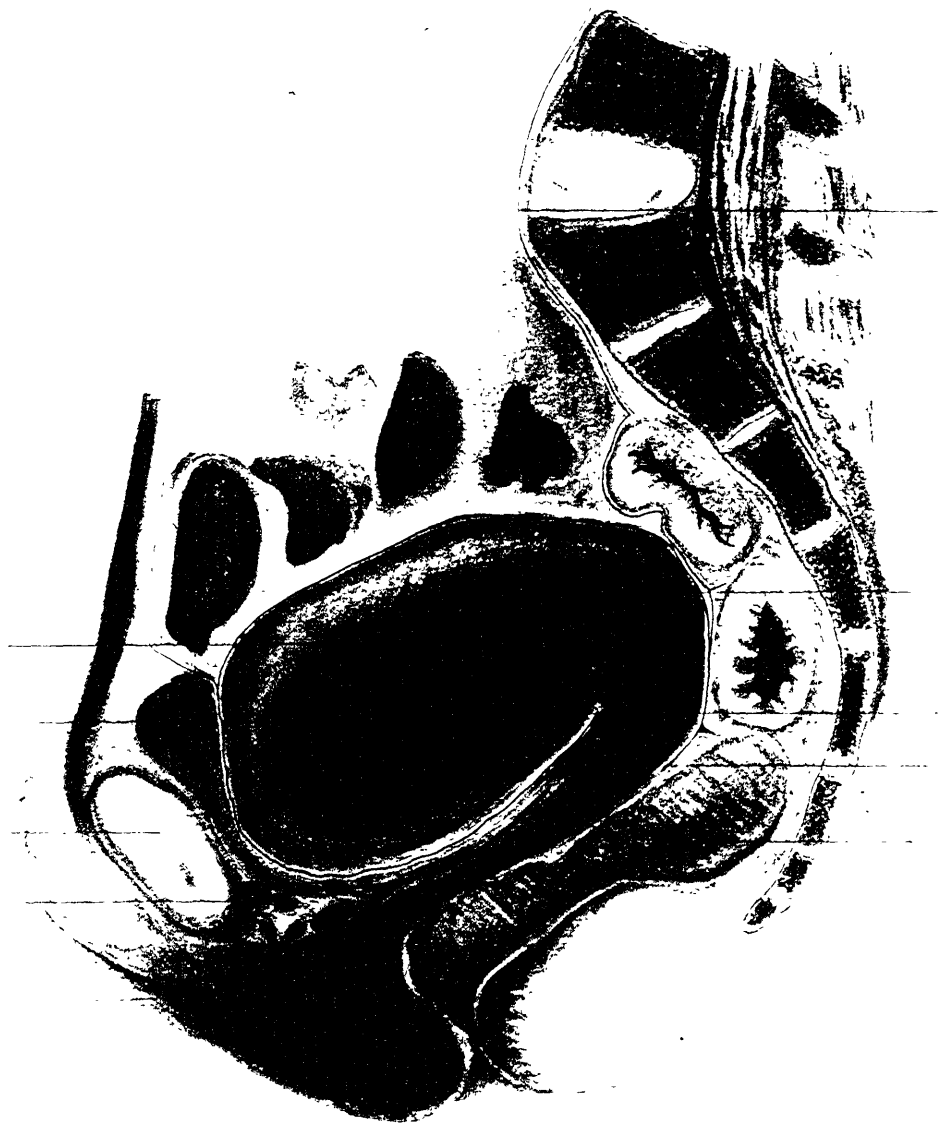(Reduced by  $\frac{1}{3}$ .)


- a. Promontory.
- b. Symphysis pubis.
- c. Uterus.
- d. Bladder.
- e. Uterine Cavity.
- f. Utero-Vesical Pouch.
- g. Pouch of Douglas.
- h. Rectum with fæces.
- i. Retro-pubic tissues with sinuses.
- j. Urethral Orifice.



12







It is a closed wavy slit. (The remaining portion lies to the right of the middle line.)

The greatest thickness of the uterus is about 1 in. below the fundus where it measures  $2\frac{5}{16}$  in., of which the anterior wall measures  $1\frac{1}{2}$  in. and the posterior  $1\frac{3}{8}$  in. The anterior is in its whole extent thicker than the posterior; both diminish in thickness towards the cervix. The thickness of the fundus is  $\frac{5}{8}$  in., that of the cervix opposite the utero-vesical pouch is  $\frac{7}{8}$  in. There is no well-marked line of distinction between the body and cervix, nor is there any lower uterine segment.

*The Body* has a firm solid appearance in its greater part, the posterior wall, the fundus, and the peripheral portion of the anterior wall being of a light brownish-grey colour. The inner part of the anterior wall is deeply blood-stained, forming a marked contrast to the posterior wall, which is very slightly stained near the cavity. In the blood-stained area of the anterior wall as well as outside it are numerous partly closed vessels containing blood. In the posterior wall scarcely any vessels are seen whatever, save a very few small ones completely closed near the cavity. This increased vascularity in the anterior wall is explained by the fact that the placenta was situated on that wall. Extending around the fundus is a row of closed vessels about  $\frac{3}{16}$  in. from the peritoneal surface.

Around the peripheral part of the body of the uterus is seen a faint longitudinal striation about  $\frac{3}{16}$  in. thick; internal to this however the arrangement of the muscle cannot be described. On close examination it has a fine network-like appearance.

*The Cervix* is cut in its left half, the cavity not being divided. It appears somewhat compressed between the body and the rectum. It is darker in colour than the posterior wall of the body and is of coarser texture. It is somewhat longitudinally striated.

*Relations.*—The anterior wall for half-an-inch above the utero-vesical pouch touches the cervix, but in the rest of its length, together with the fundus, is in close relation to the concave upper surface of the bladder. The posterior wall is covered with intestines (not drawn in plate); its lower end, together with the cervix, touching the rectum.

The *Vagina* is sigmoid-shaped and is a closed slit in the great part of

its length; near the vulva it gapes somewhat. The anterior wall is about 3 in., and the posterior 4 in. The walls are of a red tinge, the posterior wall being of a darker shade than the anterior. The left lateral fornix has been divided. The perineum is fairly well preserved and is deeply congested.

The *Bladder* lies almost entirely within the pelvic cavity; its lowest point being  $\frac{1}{4}$  in. above the outlet and its highest  $\frac{1}{16}$  in. above the anatomical conjugate of the brim. Its upper and lower walls are in apposition in nearly their whole extent. Immediately behind the top of the symphysis is a small quantity of urine. The walls are relaxed and flaccid.

(During the illness the patient suffered a good deal from distension due to paralysis of the bladder and dribbling of urine; as the patient said she was making water all right, the real condition was only found out the day before death.) Their average thickness is scarcely  $\frac{1}{8}$  in. The upper surface is deeply concave owing to the pressure of the uterus. The cavity with the urethra has the  $\succ$  shape, the anterior limb being  $2\frac{3}{8}$  in. and the posterior  $1\frac{1}{2}$  in. in length.

*Urethra.*—The Urethra is  $1\frac{1}{2}$  in. in length and is sigmoid-shaped. Its junction with the bladder takes place at a point  $2\frac{3}{8}$  in. below the conjugate of the brim. The external orifice is situated  $\frac{1}{2}$  in. below the symphysis,  $\frac{1}{4}$  in. anterior to its vertical mesial axis.

*Rectum.*—The rectum is cut in three parts. The lower extends from the anus upwards and backwards as far as the sacro-coccygeal junction; it is  $3\frac{1}{2}$  in. in length and is filled with greenish-yellow fæces. The middle portion is oval shaped and lies opposite the lower two sacral vertebræ, being partly distended with fæces. Between it and the lower portion is seen a thin bridge of the wall tissue. In the upper portion the walls are nearly in apposition; it lies opposite the 2nd and 3rd sacral vertebræ and is continuous above with its mesentery.

The *Anus* is nearly closed. It looks downwards and backwards. It is at right angles to a line joining the top of the symphysis with the junction of the upper two sacral vertebræ, and also to the vagina.

*Peritoneum.*—The lowest part of the utero-vesical pouch as regards the conjugate of the brim is the point of reflection of the peritoneum from the

uterus to the bladder; it is  $2\frac{1}{8}$  below. As regards the erect posture, however, the lowest part is the upper surface of the bladder, a short distance behind the lower part of the symphysis. The lower part of the pouch of Douglas is  $3\frac{1}{2}$  in. below the brim conjugate. Both pouches are completely closed. The reflection of the peritoneum on to the anterior abdominal wall takes place at the level of the conjugate of the brim, though, as regards the erect posture, at a point  $\frac{3}{4}$  in. above the symphysis.

*Connective tissue, etc.*—Behind the lower end of the symphysis pubis is a well-marked triangular pad of fat, loose in texture and containing several partly filled venous sinuses. A thin layer of fascia and fat passes from it behind the symphysis to join a large mass of retro-peritoneal fat and connective tissue above. The anterior wall of the bladder is intimately connected with this tissue. Behind the bladder are what appear to be solid tissues connecting that organ with the cervix. This appearance is due to its compression by the body of the uterus; in reality it is loose in texture.

The urethra and the lower bladder wall behind it are firmly joined to the anterior vaginal wall.

The perineum and rectal wall are firmly united to the posterior wall as far up as a point  $\frac{3}{4}$  in. below the pouch of Douglas; above this the connection is somewhat looser. The rectum appears in close union with the fat and connective tissue behind it. The ano-coccygeal body is a well-marked mass measuring  $2\frac{1}{4}$  in. from before backwards and  $1\frac{3}{8}$  in. in its greatest vertical thickness.

#### CORONAL SECTION A (Plate XIII.)

This section is made immediately behind the symphysis, just shaving the lower part of the posterior surface. (The drawing is that of the anterior face of the posterior slab.<sup>1</sup>) The rami of the pubic bones are cut anterior to the obturator foramen.

*Uterus.*—A portion of the right half of the fundus is seen as it bulges forwards against the bladder.

*Bladder.*—The anterior limb has been divided. The anterior wall

<sup>1</sup> In all the Coronal Sections the face of the posterior slab has been drawn and described.

is cut through obliquely behind the lower part of the symphysis. It is closely joined to the pubic bones as high as the brim. Above the brim it passes into the posterior wall which runs transversely for  $2\frac{1}{2}$  in. The inner surface of the latter wall is seen on the left of the uterus, while below the uterus it is cut across as it lies against the anterior bladder wall. In the right half of the section, therefore, the bladder cavity is a mere slit, while in the left half it appears somewhat pear-shaped, a small quantity of urine being in the left corner. Above the bladder wall is seen the suprapubic retro-peritoneal fat with which it is continuous.

*Urethra.*—It is seen  $\frac{7}{8}$  in. below the lowermost portion of the bladder cavity. Its wall is transversely oval-shaped, being of a pale flesh colour. Above it is attached to the retro-pubic connective tissue and fat, and below to the vaginal wall.

*Vagina.*—The vagina is divided near its lower end. Its vertical measurement is greater than the transverse. The walls are seen to be greatly folded. Surrounding it on each side is erectile tissue from which the sphincter vaginæ cannot be distinguished. Extending in from the rami is seen, on each side, a thin fleshy mass. These are the *erectores clitoridis*.

*Connective tissue, etc.*—The retro-pubic tissue is seen above the urethra. It is of considerable extent and contains several filled venous sinuses. In the upper part two denser portions can be made out, viz. the anterior *true ligaments* of the bladder. The retro-pubic tissue is closely united with the bones at the sides; the junction of the bladder with the bones being less firm.

#### CORONAL SECTION B (Plate XIII.)

This section passes through a plane posterior to section A, not quite parallel to it. It is  $\frac{3}{8}$  in. behind the latter at the brim, but  $\frac{5}{8}$  in. behind it at the perineum. It passes through the obturator foramen on each side in front of the acetabulum.

Width of both inlet and outlet cut across is about  $3\frac{1}{2}$  in.

*Uterus.*—The uterus lies partly above but mainly below the brim.

PLATE XIII.

SIXTH DAY OF PUERPERIUM.

FIG. 1.

*Coronal Section A.—Face of Posterior Slab.*

(Reduced by  $\frac{1}{3}$ .)


- a. Ramus of Pubes immediately behind Symphysis.
- b. Right half of Fundus Uteri.
- c. Bladder cavity.
- d. Urethra.
- e. Lower end of Vagina.
- f. Bulb of Vestibule and Sphincter Vaginae.
- g. Anterior true ligaments of Bladder.
- h. Anterior part of Perineum.

FIG. 2.

*Coronal Section B.—Face of Posterior Slab.*


(Reduced by  $\frac{1}{3}$ .)

- a. Ascending Ramus of Pubes  $\frac{3}{8}$  in. behind plane of Coronal Section A and above Obturator foramen.
- b. Descending Ramus of Pubes  $\frac{5}{8}$  in. behind plane of Coronal Section A.
- c. Uterus.
- d. Cavity of Uterus.
- e. Urethra.
- f. Vagina.
- g. Bladder.









It is rotated so that the right side lies above and the left side below the brim. It is nearer the right than the left pelvic wall, approaching to within  $\frac{3}{16}$  in. of the former and  $\frac{1}{2}$  in. of the latter.

The transverse diameter is 3 in., and its greatest antero-posterior  $2\frac{1}{16}$  in. The anterior wall is thicker than the posterior, being in the middle  $1\frac{1}{4}$  in., while the latter is  $\frac{3}{4}$  in.

The posterior wall and the peripheral portion of the anterior wall have a solid appearance, being of a light brownish-grey colour; the inner part of the anterior wall is of a dark red-black colour (wall to which placenta was attached).

Only one or two closed vessels are seen in the posterior wall, but in the anterior wall and on the right side are seen many vessels partly closed, giving to the wall a coarse spongy appearance.

The *Cavity* is a transverse wavy closed slit measuring  $1\frac{5}{8}$  in. The anterior wall near it is slightly stained with blood.

*Relations.*—The anterior wall, save for half-an-inch near the right border where it rests against the pelvic wall, is in close relation with the upper surface of the bladder. The greater part of the posterior wall is covered with intestines; on the left side it rests against the bladder.

*Bladder.*—The bladder is cut transversely just in front of the junction with the urethra. Its upper limit on the right side is a point  $\frac{1}{4}$  in. below the brim, and on the left side  $\frac{5}{8}$  in. above it. Its upper surface is deeply concave in relation to the uterus which rests upon it. The walls are in apposition, save on the left side, where there is a very little urine; they are thin and apparently not contracted. The width of the bladder, following its curve, is  $5\frac{5}{8}$  in.

The *Urethra* lies  $\frac{1}{4}$  in. below the bladder, and appears as a small transverse curved slit with the concavity uppermost. Its wall is somewhat oval-shaped from side to side, the sphincter muscle being here cut across, and appears of a light fleshy colour. Above, it is connected to the bladder by rather firm connective tissue, and below it is intimately joined to the anterior vaginal wall.

*Vagina.*—The vagina appears somewhat H shaped. The lateral limbs

of the  $H$  are not straight but bent, the concavity looking outwards. The lateral walls are slightly folded.

The width of the transverse part is  $\frac{7}{8}$  in.

„ each lateral limb is about  $\frac{5}{8}$  „

*Peritoneum.*—The arrangement of the peritoneum is very simple. It covers the uterus and the upper surface of the bladder, passing from the latter to the pelvic wall.

*Connective Tissue, etc.*—The thin strong layer of the pelvic fascia is seen lining the obturator internus on each side. About  $1\frac{1}{4}$  in. below the brim is seen a layer passing inwards between the bladder and vagina. The tissue underneath the bladder is dark in colour and contains numerous filled venous sinuses. The tissues of the perineal body are of a uniform brownish colour, so that it is impossible to distinguish muscle from connective tissue.

*Muscles.*—The *obturator internus* is well shown. From the inner surface of the pelvic fascia lining it, immediately below the vesical layer above referred to, arises the *levator ani* of each side; they pass downwards and inwards below the vagina, sending a slip above it, however, towards the urethra, meeting in the perineal body. The *transversus perinei* on each side is also seen passing inwards from the margin of the obturator foramen to the perineum, where it blends with the other muscles in the middle line.

#### CORONAL SECTION C (Plate XIV.)

This section is nearly parallel with Section B. It divides the acetabula near their posterior margins. The sides of the pelvic cavity slope slightly inwards from brim to outlet.

*Uterus.*—The uterus shows here the same rotation that was noticed in Section B, only in a less marked degree. It is also nearer the right than the left side of the pelvis. Its highest point is the posterior wall near the middle line, where it is  $\frac{1}{2}$  in. above the brim. Its right side is  $\frac{3}{8}$  in. from the right wall of the pelvis, its left side  $\frac{3}{4}$  in. from the left wall. The greatest thickness between its anterior and posterior peritoneal surface is  $2\frac{7}{16}$  in.; and its transverse diameter is  $3\frac{3}{4}$  in.


PLATE XIV.


SIXTH DAY OF PUERPERIUM.


*Coronal Section C.—Face of Posterior Slab.*

(Reduced by  $\frac{1}{3}$ .)

- a. Posterior part of Acetabulum.
- b. Uterus.
- c. Uterine Cavity.
- d. Vessels in wall opposite placental site.
- e. Peritoneum.
- f. Bladder.
- g. Round Ligament.
- h. Rectum with fæces.
- i. Sinuses in para-vaginal tissues.
- j. Right Fallopian Tube.
- k. Right Ovary.
- l. Parietal pelvic fascia.
- m. Vagina.









The cavity measures nearly 2 in. across, and is a closed slit.

The general appearance of the walls is much the same as in Section B; the posterior wall shows more blood-staining near the cavity.

*Relations.*—The greater part of the anterior wall rests upon the upper surface of the bladder; to the right of the bladder it rests against the pelvic wall.

The greater part of the posterior wall is in relation to intestine (not drawn in plate); on the right side, however, it is in relation to the right ovary for about an inch.

*Bladder.*—The bladder lies compressed from above downwards. Its walls are in apposition save at each side where there is a little urine. It is symmetrically placed in the pelvis in this section, approaching to about  $\frac{5}{16}$  in. from the bony wall, and being  $1\frac{1}{4}$  in. below the brim on each side. From side to side it measures  $4\frac{1}{2}$  in., being slightly curved, the concavity being uppermost. The posterior wall, covered with peritoneum, has the uterus in relation to it. The anterior wall in its middle half is firmly united to the anterior vaginal wall and on each side to the paravaginal tissue which is continuous with that lining the pelvic wall and with that external to the rectum.

*Vagina.*—The vagina appears as a transverse slit slightly wavy from side to side. On the right side it approaches a little nearer to the bony wall than on the left; above, the anterior wall is firmly joined to the bladder; below, the posterior wall is in firm union with the rectum.

*Rectum.*—The rectum appears somewhat compressed from above downwards. It measures transversely  $2\frac{1}{2}$  in., and from before backwards in the middle line  $\frac{5}{8}$  in. It contains some fæces.

The upper wall is firmly joined to the posterior vaginal wall; its lower wall is embraced by the *levator ani*; on each side it is in firm union with the tissues internal to the obturator internus.

*Right Broad Ligament.*—This ligament is seen passing from the right side of the uterus at the brim. It is seen to lie external to and above the ovary, containing the Fallopian tube in its free edge. The anterior and lower portion close to the uterus is formed by the *Round Ligament*. The

tissues of this broad ligament are somewhat compressed near the uterus and contain several closed vessels.

*Left Broad Ligament.*—This is not so well formed as the other. The part seen in the section consists mainly of *round* ligament. The small fold seen near the uterus represents the upper free margin of the broad ligament (contains no tube). The *round* ligament runs outwards and upwards, passing to pelvic wall  $\frac{5}{8}$  in. from the uterus. It disappears for a little behind the level of the section and then appears a little higher, cut obliquely, on its way to the internal abdominal ring.

The parietal layer of the pelvic fascia on both sides is well seen, lining the obturator internus. Its visceral layers cannot well be made out.

Internal to it is connective tissue which joins it to the bladder, vagina, and rectum.

*Right Ovary.*—This ovary is attached to the posterior surface of the broad ligament  $\frac{3}{8}$  in. from the uterus; it is bent inwards on the inner part of the ligament and right side of the posterior uterine wall. The central part is red stained, the periphery pale. Several small Graafian follicles are seen.

*Right Tube.*—This is cut obliquely, lying near free margin of broad ligament.

There is no appearance of an ovary and tube on the left side.

#### CORONAL SECTION D (Plate XV.)

This section is about parallel with section C. It passes through the brim  $1\frac{7}{8}$  in. behind the ilio-pectineal eminence, and through the outlet just in front of the coccyx. The brim at this level is opposite the upper margin of the second sacral vertebra; its width is  $5\frac{1}{2}$  in. The section also passes behind the utero-vesical pouch and in front of the pouch of Douglas.

*Uterus.*—The cervix and posterior part of the body are divided. The rotation of the organ, already referred to, is here also noticed. More of it is situated in the right than in the left half of the pelvis. How much this is caused by the distended rectum it is impossible to say. The right border of the uterus is  $\frac{1}{2}$  in. below the brim, the left border  $1\frac{5}{8}$  in. below it. The highest part of the posterior wall lies just within the brim.


PLATE XV.


SIXTH DAY OF PUERPERIUM.


*Coronal Section D.—Face of Posterior Slab.*

(Reduced by  $\frac{1}{3}$ .)

- a.* Ilium divided  $1\frac{7}{8}$  in. behind Ilio-pectineal eminence.
- b.* Body of Uterus.
- c.* Cavity of Uterus.
- d.* Cervix Uteri.
- e.* Cervical Canal.
- f.* Vagina.
- g.* Rectum with fæces.
- h.* Ureter.
- i.* Sinuses, in parametric tissues.







The general appearance of the body resembles that seen in the other coronal sections, except that the anterior wall is divided near the lower end of the placental area and shows very few vessels. Towards the right broad ligament several vessels are seen, partly filled with blood; on the right side a few closed ones are seen.

*The Cervix* is cut obliquely. It is darker in colour and coarser in texture than the body. It is somewhat compressed from below and the left by the rectum, so that it appears rather asymmetrical. It thus seems to take part in the general rotation of the uterus, its cavity being on the right of the middle line. Its canal is cut into near the *os externum* and appears as a transverse slit  $\frac{5}{8}$  in. wide with a depression in the middle of the anterior wall. The width between the lateral fornices is  $1\frac{3}{4}$  in.

*Vagina*.—The vagina appears as a closed slit running transversely and being curved, the concavity looking upwards. Its direction is not quite transverse, but somewhat slanting from the left fornix downwards towards the right, owing to the pressure of the rectum. Following the curve it measures 2 in. The left fornix is  $\frac{3}{16}$  in. higher in the pelvis than the right.

*Peritoneum*.—This is seen on the posterior uterine wall and reflected from it to the pelvic wall.

*Rectum*.—The rectum lies chiefly on the left of the middle line. Its lower part has been divided. It is considerably distended with faeces especially in its left half. Its width is  $3\frac{1}{8}$  in. It seems undoubtedly to be pushing the uterus towards the right side. Its walls are in intimate connection with the surrounding tissues of the sacral segment. The junction with the vagina is rather loose. Under it is seen muscular tissue—the levator ani of each side.

*Connective Tissue, Ligaments, etc.*—The section passes below the level of the reflection of the anterior layer of the broad ligaments. It shows the continuity of the parametric tissue with that adjacent to the lateral fornices and with that on the pelvic wall. On the left side this tissue is wider and looser than on the other side. Its vessels are more distended. On the right side the corresponding tissue is somewhat compressed, apparently through the pressure exerted by the rectum.

*Ureters.*—The right is seen under the peritoneum external to the uterus, half internal to the pelvic wall and slightly below the brim. The left is seen cut more obliquely  $\frac{7}{8}$  in. internal to pelvic wall and  $\frac{7}{8}$  in. below the brim.

#### GENERAL DESCRIPTION (Plate XVI.)

*Uterus.*—The uterus is somewhat pear-shaped, the body being markedly anteflexed on the cervix. It lies nearer the right than the left side of the pelvis, this condition being more marked at the cervix and lower part of the body than at the fundus. (This is probably chiefly due to the presence of fæces in the rectum.) It is also rotated so that the right border is higher than the left. Though in the Vertical Mesial Section it lies below the conjugate of the brim, the Coronal Sections show that it is above the upper limit of the true pelvis as regards the transverse diameter of the brim. (It is very probable that the uterus would be entirely below the inlet of the pelvis were the rectum empty.)

The vertical mesial section does not give the entire length of the uterus, because the lowermost portion of the cervix lies to the right of the middle line. The whole length really is  $5\frac{1}{8}$  in., of which the body measures  $3\frac{1}{2}$  in. The length of the whole cavity is  $4\frac{5}{8}$  in.

*Bladder.*—This organ lies perfectly flaccid and nearly empty. The thinness of the walls is to be associated with the paralysis from which the patient suffered. Its great size is to be noted.

*Rectum.*—The manner in which the lower part of the rectum, when containing fæces, can displace the uterus is well brought out.

*Left Broad Ligament.*—This ligament arises from the side of the uterus, its highest point of attachment being near the fundus just behind the level of Coronal Section B. For 1 in. its free margin runs downwards on the side of the uterus as a mere ridge  $\frac{1}{4}$  in. in height. Thence it runs outwards and backwards and upwards crossing the brim  $1\frac{1}{2}$  in. behind the middle of the ilio-pectineal eminence. The posterior layer is greatly wrinkled as it passes downwards to the pouch of Douglas.

*The Round Ligament* arises from the side of the fundus, runs down the side of the uterus for 1 in., and then passes outwards and upwards, crossing



the brim just behind the middle of the ilio-pectineal eminence. It is to be noted that, save at its uterine end, this ligament, as it passes from the uterus to the pelvic wall, forms in reality the upper free margin of the broad ligament, that part of the broad ligament which normally is above the round ligament and which contains the Fallopian tube, being practically non-developed and represented as a mere ridge behind and below the level of the round ligament.

No *infundibulo-pelvic ligament* exists whatever on the left side.

*Left Ovary.*—No trace of this body can be found in the pelvis after the most careful dissection. Whether it is in the abdomen, *i.e.* undescended, it is impossible to say, the upper part of the abdomen not having been removed from the cadaver. All that we can say with certainty is that the left ovary does not lie below the level of the last lumbar vertebra.

*Left Fallopian Tube.*—No part of this exists whatever outside the uterus. That part of the broad ligament normally occupied by it is a mere narrow ridge. In the uterine wall, extending from the left upper angle of the uterine cavity, it can be traced for about  $\frac{3}{16}$  in., ending blindly in the uterine muscle. It admits only a fine probe. (For the further consideration of these malformations, *vide* p. 46.)

*The Left Utero-Sacral ligament* arises from the back of the uterus about opposite the middle of the 3rd sacral vertebra. It runs as a peritoneal fold outwards, upwards, and slightly backwards to the pelvic wall for  $1\frac{1}{2}$  in., being pressed a little forwards by the distended left part of the rectum.

*Right Broad Ligament.*—This ligament stands out in striking contrast to that of the left side, being well formed. It crosses the brim about  $1\frac{1}{2}$  in. behind the middle of the ilio-pectineal eminence. The upper portion, containing the Fallopian tube, is turned inwards with the tube and ovary.

The *round ligament* arises from the uterus opposite the origin of the left ligament and crosses the brim a little behind the plane in which the left one crosses it. It lies below the upper free margin of the broad ligament which contains the Fallopian tube of this side.

*Right Ovary.*—This body lies behind the broad ligament, being turned with the upper part of the latter inwards. Its normal under surface rests on the inner end of the broad ligament and outer part of the posterior wall of the uterus. Its line of attachment to the broad ligament measures  $1\frac{1}{2}$  in. ; from the hilum to its free margin it measures  $1\frac{1}{2}$  in., and from side to side it also measures  $1\frac{1}{2}$  in. Its greatest thickness is at its central part, where it measures  $\frac{5}{8}$  in. ; it thins out towards the periphery.

*Right Fallopian Tube.*—This tube passes from the uterus opposite the highest point on the uterus of the broad ligament of the opposite side. It runs backwards and outwards, curving up above the brim, and then passing inwards and a little forwards, resting upon the ovary.

*The Right Utero-Sacral Ligament* is a little higher at its uterine end than on the other side, and is shorter.

The condition of the internal genitals here met with is extremely rare. In this case there can be no doubt that we have to do with a well-formed uterus. It is impossible to say, on examining it with the eye, wherein it differs from an ordinary uterus in the corresponding stage of puerperium. The round ligaments are attached just as in a normal pelvis. The uterus differs from a normal one in that the left Fallopian tube is only represented by a short tube in its wall running outwards from the left upper angle of the body cavity.

Outside the uterus the tube is only represented by a narrow ridge, the upper edge of the broad ligament. There is not even a solid string to represent it as may be found in some malformed conditions of the tubes. Absence of an ovary, according to Olshausen, is usually associated with a mal-development of the corresponding half of the uterus, though *in some cases* it is not. If not, there is usually found some defect in the Fallopian tube, *e.g.* its inner end is alone developed, the outer being rudimentary or obliterated. In this case it is evident that the lower ends of the Müllerian ducts have united as far as they normally do. The upper half of the left one has not developed into the left Fallopian tube. From the entire absence of even a solid string of tissue in the upper edge of the broad ligament, it is probable that from the first there was either a non-development of the upper parts of the original solid rod which afterwards should

PLATE XVI

FIGS. 1 and 2.

SIXTH DAY OF PUERPERIUM.

FIG. 1.—Posterior part of left half of Pelvis with left half of Uterus, seen from above. (Reduced.)

- a.* Fundus Uteri.
- b.* Mal-developed left Broad Ligament without Tube or Ovary.
- c.* Sigmoid Flexure.
- d.* Pouch of Douglas.

FIG. 2.—Posterior part of right half of Pelvis with right half of Uterus, seen from above. (Reduced.)

- a.* Fundus Uteri.
- b.* Pouch of Douglas.
- c.* Well-formed Appendages.

FIG. 3.

FIRST DAY OF PUERPERIUM.

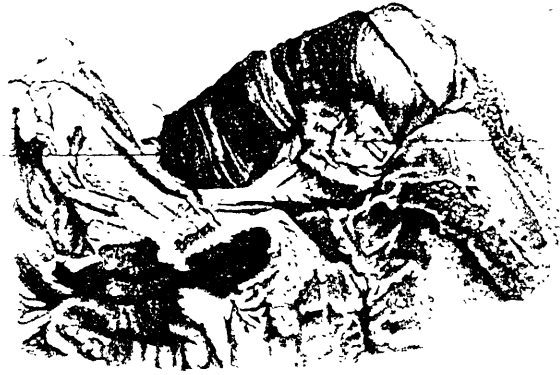Left half of Pelvis, seen from above. (Reduced.)

- a.* Last Lumbar Vertebra.
- b.* Fundus Uteri.
- c.* Appendages.
- d.* Sigmoid Flexure.

b

c

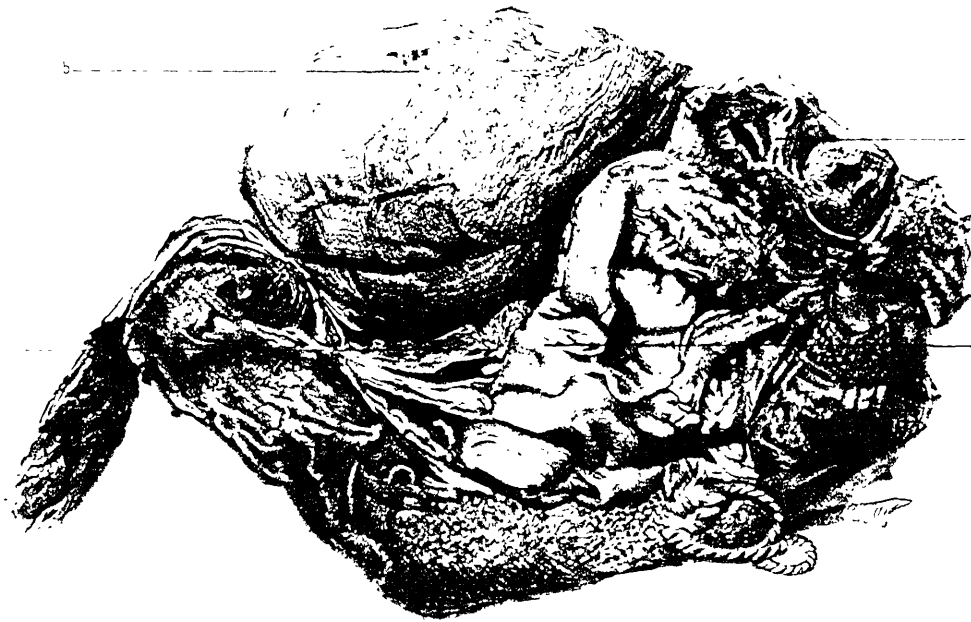Fig 2




Fig



Fig. 3.





develop into the Müllerian duct, or else such a rudimentary development that the duct in its upper part was not formed.

Olshausen, however, thinks that most of these cases in which the ovary and outer end of the tube are absent may be explained by their constriction as a result of having been caught in an adhesion or through torsion.

In this case the facts are not in keeping with such an explanation. The whole tube outside the uterus is absent. The broad ligament in its upper part is undeveloped, it is smooth and shows no adhesions.

Where the ovary is in this case one cannot say. Careful dissection shows that it is not in the pelvis. Unfortunately, the abdomen was not examined to see if, as is often the case in such conditions, the organ was undescended.

The right tube and ovary do not seem to be more enlarged than is ordinarily the case in pregnancy.

## THE FIFTEENTH DAY OF THE PUERPERIUM.

*Clinical Note.*—The patient died of heart disease on the fifteenth day after delivery.

### VERTICAL MESIAL SECTION (Plate XVII.)

*Bony Pelvis.*—The last lumbar vertebra, the sacrum, and coccyx, are divided mesially behind, and the symphysis pubis in front. The symphysis measures  $1\frac{1}{2}$  in. in vertical extent and  $\frac{1}{2}$  in. in width across its widest part.

The sacrum and coccyx together measure  $6\frac{3}{8}$  in., and form a well-marked curve from above downwards and forwards.

Diameters :—

Brim (anatomical)	.	.	.	$4\frac{7}{8}$ in.
„ (obstetrical)	.	.	.	$4\frac{3}{4}$ „
Cavity	.	.	.	$4\frac{13}{16}$ „
Outlet (sacral)	.	.	.	$4\frac{1}{2}$ „
„ (coccygeal)	..	.	.	$3\frac{7}{8}$ „

The pelvic floor projection measures 1 in.

*Uterus.*—The uterus lies well back in the pelvis, and is retroflexed. The highest point is  $\frac{2}{3}\frac{1}{2}$  in. below the brim level.

The greatest antero-posterior measurement of the body is  $2\frac{9}{16}$  in. ; at the bottom of the utero-vesical pouch it is  $1\frac{1}{8}$  in.

The length of the whole uterus is  $3\frac{3}{4}$  in.

„	„	body	„	$2\frac{1}{2}$ „
„	„	cervix	„	$1\frac{1}{4}$ „

The length of the cavity cut through is  $3\frac{1}{16}$  in., the lower two-thirds being a mere slit, the upper third being  $\frac{2}{3}$  in. across and containing a greenish fluid. The highest part of the cavity is not seen in this section, however




PLATE XVII.

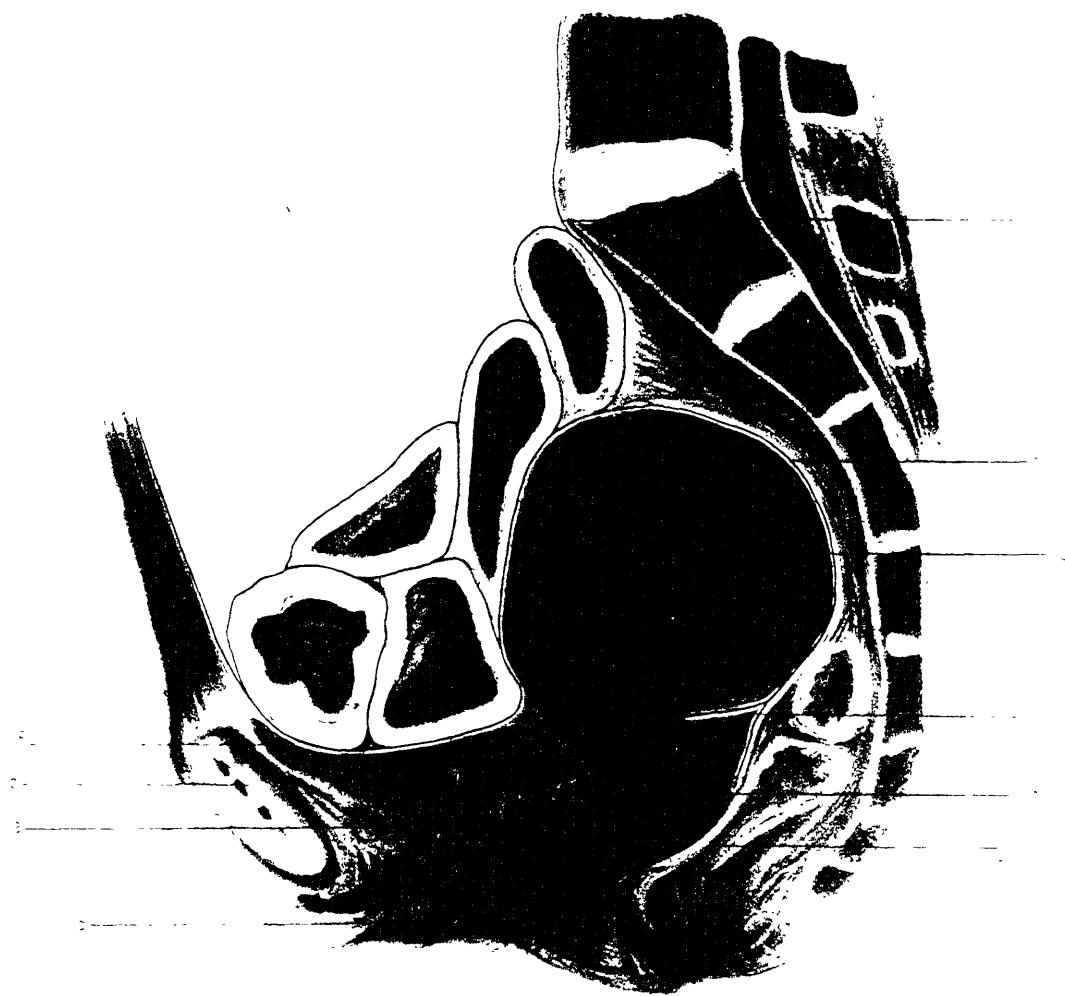
FIFTEENTH DAY OF PUERPERIUM.


*Vertical Mesial Section.*

(Reduced by  $\frac{1}{3}$ .)

- a. Promontory.
- b. Symphysis Pubis.
- c. Fundus Uteri.
- d. Cavity of Uterus.
- e. Os Externum.
- f. Bladder.
- g. Urethral Orifice.
- h. Bit of Right Utero-Sacral Ligament.
- i. Posterior Fornix.
- j. Rectum.







(a quarter of an inch to the right of the plane of the section, it extends to within  $\frac{3}{8}$  in. of the outer surface of the fundus).

The antero-posterior diameter of the cervix at right angles to its canal at the level of the anterior fornix is  $1\frac{1}{4}$  in. of which  $\frac{3}{8}$  in. is the anterior wall and the rest the posterior. The widest part of the cervix is nearest the vagina, due probably to its being pressed against the sacral segment; above this it gradually narrows until, opposite the point of flexion of the posterior wall, it measures  $\frac{3}{4}$  in.

The uterus appears of compact structure and is of a dark reddish-black colour, but towards the outer surface it is of a lighter red-purple tinge. The cervix is softer in consistence than the body.

The point of flexion of the uterus is opposite the lower part of the fifth sacral vertebra,  $2\frac{7}{8}$  in. below the brim. The sulcus which is formed in the posterior wall by the flexion is  $\frac{5}{8}$  in. deep.

The distance of the uterus from the pelvic wall at different points is as follows:—

a. Behind the lower part of the symphysis	. 2 in.
b. Opposite the third sacral vertebra	. $1\frac{5}{8}$ "
c. „ coccyx	. 1 "

No lower uterine segment can be made out.

*The Vagina* in its upper part is closed. The anterior fornix is  $\frac{1}{8}$  in. deep, the posterior is very much deeper.

A quarter of an inch below the anterior fornix the vaginal walls are separated, being about  $\frac{5}{8}$  in. apart. The posterior wall appears bulged downwards and backwards by the cervix. Both walls are of a dark-red colour.

*The Perineum* is somewhat compressed from above downwards. Its height is about  $1\frac{1}{8}$  in.; the antero-posterior diameter at its base is  $1\frac{3}{16}$  in. Above is the recto-vaginal septum  $\frac{1}{4}$  in. across of which slightly more than half is anterior rectal wall.

*The Bladder* lies entirely below the brim, the highest point being just below the upper margin of the symphysis pubis. It is empty, the upper surface being concave. The average thickness of the wall is  $\frac{3}{16}$  in., it is slightly thicker behind than in front.

The cavity with the urethra forms a > shape, the anterior limb being  $1\frac{1}{2}$  in., the posterior  $\frac{3}{8}$  in. The urethra is slightly sigmoid in shape and passes downwards and forwards parallel to the lower part of the anterior vaginal wall; its length is  $1\frac{1}{4}$  in.

Its orifice is  $2\frac{1}{8}$  in. below the brim and  $\frac{1}{8}$  in. behind the vertical mesial axis of the pubes.

Above, the bladder is in relation to the intestines which fill the utero-vesical pouch. Behind it is connected to the cervix by connective tissue of loose structure. The distance from the bottom of the utero-vesical pouch to the anterior fornix is  $1\frac{3}{16}$  in.

In front is a well-marked triangular portion of fat and connective tissue separating it from the pubes.

*The Peritoneum* descends in front of the uterus to a point  $1\frac{3}{4}$  in. below the brim. The utero-vesical pouch is of considerable size because of the retroflexed condition of the uterus, and is filled with intestines.

Behind it descends to form the pouch of Douglas, the lowest point of which is  $3\frac{3}{4}$  in. below the brim.

The tongue-like projection of the uterus below the sulcus is partly formed by the lower end of the right utero-sacral ligament.

*The Rectum* in almost its whole extent is closed. The lower end together with the anus was opened up a little by means of cotton wool placed in it before freezing. The lower end is directed downwards and backwards almost at right angles to the brim. One inch from the anus the direction changes, the bowel passing upwards and backwards, following the curve of the coccyx and sacrum. The highest point of the cavity seen is opposite the junction of the fourth and fifth sacral vertebræ. Below this point it is cut in two places; above it is seen the meso-rectum continuous with the connective tissue lining the wall of the pelvis; the average thickness being as far up as the junction of the second and third sacral vertebræ  $\frac{3}{8}$  in.; above this it widens out until opposite the middle of the first sacral vertebra it suddenly appears thinner. In this tissue several partly closed vessels are seen.

## TRANSVERSE SECTION (Plate XVIII.)

This section passes in front, just below the symphysis pubis, behind through the junction of the second and third sacral vertebræ; and laterally through the acetabula.

*The Uterus* on section appears rounded. It is dark-red around the cavity, but paler towards the periphery, especially on the sides. The transverse diameter is  $2\frac{5}{8}$  in. The portion of cavity opened up is somewhat triangular in shape. The thinnest part of the wall is towards the back (fundus).

The thickness between the uterus and the pelvic wall is as follows:—

1. At the middle of the sacrum it is  $\frac{1}{4}$  in. and consists of extra-peritoneal fat and connective tissue.
2. Opposite the right-sacro-iliac joint  $\frac{5}{8}$  in., of which half is pyriformis muscle and the rest extra-peritoneal fat and connective tissue.
3. Opposite the posterior edge of the right acetabulum  $1\frac{1}{8}$  in., of which  $\frac{1}{2}$  in. is obturator internus muscle and the rest connective tissue, etc., continuous with the base of the broad ligament.
4. Opposite the anterior edge of the right acetabulum  $1\frac{1}{2}$  in., of which  $\frac{3}{4}$  in. is also parametric tissue.
5. Opposite left sacro-iliac joint 1 in., of which  $\frac{5}{8}$  in. is ovary and extra-peritoneal connective tissue and the rest pyriformis muscle.
6. Opposite the posterior edge of the left acetabulum  $1\frac{5}{8}$  in., of which  $\frac{5}{16}$  in. consists of obturator internus muscle and the rest parametric tissue.
7. Opposite the anterior edge of the left acetabulum  $1\frac{3}{4}$  in., of which  $\frac{1}{2}$  in. is obturator internus.

In the parametric and paravesical tissue on the left side is seen a considerable amount of blood-stained tissue due to the oozing of blood from the thawing blood in the partly filled vessels.

On the right and left sides in the outer part of the uterine wall and its adjacent parametric tissue in front of the peritoneum of the pouch of Douglas are seen several closed vessels.

The anterior third of the uterus is in relation to the base of the broad

ligaments (parametric tissue) and to the bladder. The connective tissue joining it to the latter is of loose structure and is continuous with the tissue lining the pelvic wall at the side of both viscera.

The peritoneal surface of the uterus (the posterior two-thirds) is on the left side in close contact with the ovary for a distance of  $1\frac{1}{8}$  in., behind this for an inch with the rectum, and to the right of this with the tissues lining the pelvic wall, continuous in front with the parametric tissue.

*The Bladder* is cut obliquely through its body so that the walls appear thicker than they are. The section passes through the junction of the urethra and cavity. Its transverse width is 2 in. The cavity is curved from side to side, the concavity looking backwards. The distance of the urethra from the pubes at this level is  $1\frac{3}{8}$  in.

*The Vagina* is cut into on each side of the middle line in front of the bladder. It is of a greenish colour (due to post-mortem changes).

*The Peritoneum* is only seen forming the pouch of Douglas. It covers the posterior two-thirds of the uterus. Its reflection from the uterus on the left side is a little in front of the corresponding point on the right side. On the latter side it is about 1 in. behind a line passing through the centre of the ilio-pectineal eminences, and on the left  $\frac{3}{4}$  in. posterior to the same line. Lying in the anterior part of the pouch on left side is the prolapsed and enlarged left ovary.

#### THE SPECIMEN AS A WHOLE (Plate XIX.)

*The Right Ovary* lies with its long axis vertical. Its surfaces look inwards and outwards. Its length is  $1\frac{1}{2}$  in. and its width  $\frac{1}{8}$  in. The inner surface in its lower fourth rests against the uterus; above this it is in contact with the intestines. The outer surface rests against the parietal peritoneum as well as against the right infundibulo-pelvic ligament, which is folded forwards against the pelvic wall.

As a whole the ovary lies  $\frac{1}{4}$  in. behind the posterior margin of the right acetabulum. The lower (inner) end is  $\frac{1}{4}$  in. above the brim, the upper about  $\frac{3}{4}$  in. above the brim.

*The Right Fallopian Tube* passes from the side of the uterus close to




PLATE XVIII.

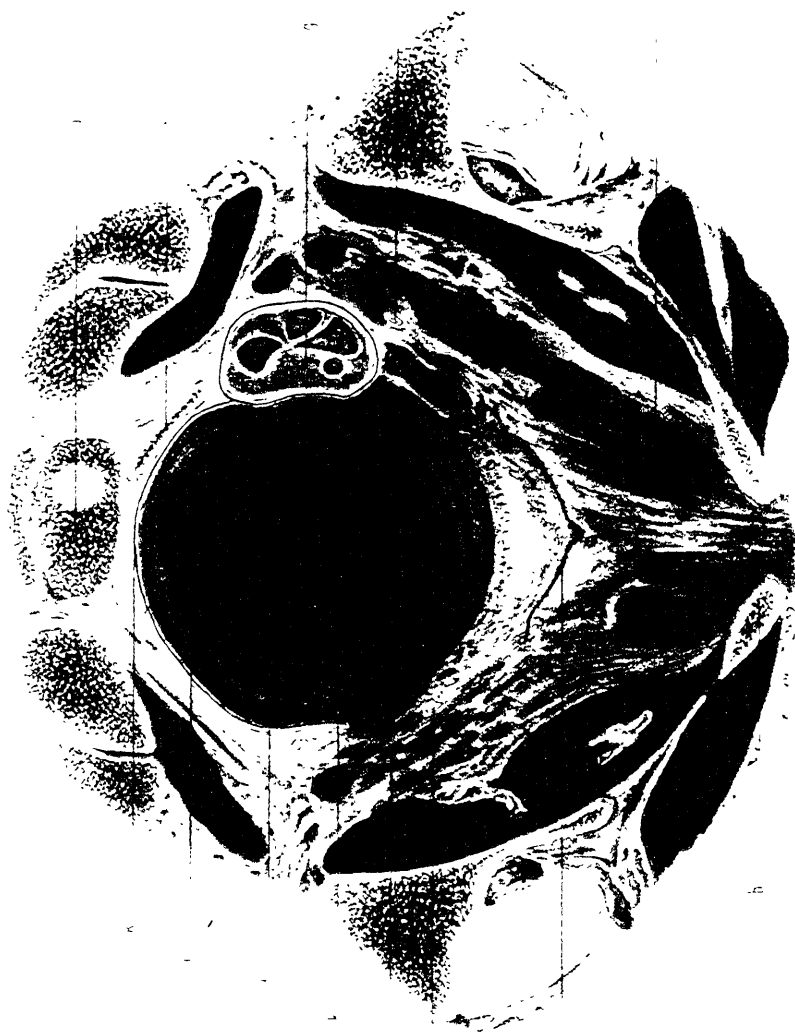
FIFTEENTH DAY OF PUERPERIUM.

*Transverse Section.—Face of Lower Slab.*

(Reduced by  $\frac{1}{3}$ .)

- a. Junction of Second and Third Sacral Vertebrae.
- b. Descending Rami of Pubes immediately below Symphysis.
- c. Uterus.
- d. Uterine Cavity.
- e. Parametrium.
- f. Rectum.
- g. Diseased Ovary.
- h. Ureter.
- i. Bladder.
- j. Vagina.
- k. Peritoneum.








PLATE XIX.

FIFTEENTH DAY OF PUERPERIUM.

FIG. 1.—Upper part of right half of Pelvis with intestines removed.  
(Reduced.)

- a.* Promontory.
- b.* Symphysis Pubis.
- c.* Fundus Uteri.
- d.* Fallopian Tube turned forwards.
- e.* Ovary.

FIG. 2.—Upper part of left half of Pelvis with intestines removed.  
(Reduced.)

- a.* Promontory.
- b.* Symphysis Pubis.
- c.* Fundus Uteri.
- d.* Fallopian Tube.
- e.* Rectum.
- f.* Ovary.


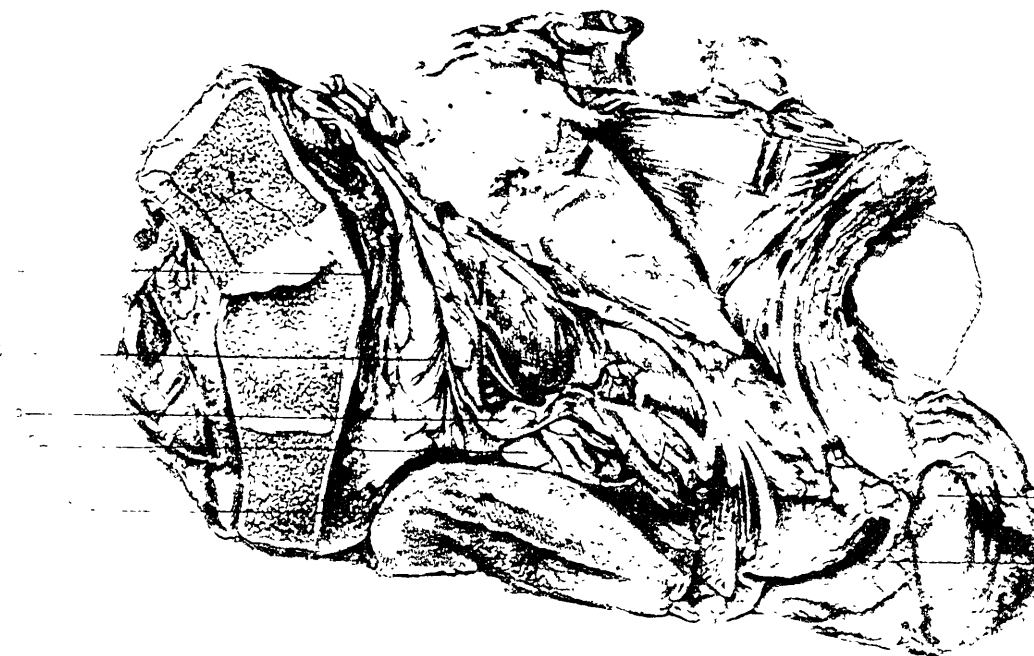



Fig 1



Fig 2







its anterior surface, and extends upwards, outwards, and then slightly downwards for 1 in. lying against the ovary. It then bends suddenly forwards and inwards, the fimbriated end lying in the outer part of the utero-vesical pouch and covered by intestines.

*The Right Broad Ligament* arises as a mere ridge about 2 in. above the brim in the right iliac fossa at a point about  $2\frac{5}{8}$  in. behind a plane perpendicular to the brim passing through the anterior superior iliac spines, and about 2 in. below the level of the highest part of the iliac crest. It runs downwards and forwards, gradually increasing in size, crossing the brim behind the acetabulum about opposite the right anterior superior iliac spine. It then passes downwards and forwards, the anterior layer going to form the bottom of the utero-vesical pouch, and to be reflected to the anterior abdominal wall, the posterior passing gradually downwards and backwards to enter into the formation of the pouch of Douglas.

*The Right Utero-Sacral Ligament* is a well-marked band  $1\frac{3}{8}$  in. in length which forms a distinct shelf in the pouch of Douglas. Its upper end is  $\frac{7}{8}$  in. to the right of the vertical mesial line of the sacrum,  $\frac{1}{4}$  in. above the junction of the fourth and fifth sacral vertebræ. It runs downwards and inwards and is attached to the back of the uterus from the right edge as far in as the middle line (in *V. M. S.* it was seen). Its under surface rests against the posterior parietal peritoneum, its upper is in contact with the retroflexed body of the uterus.

*The Left Ovary* lies in the true pelvis, its highest point being immediately below the brim. It is enlarged, being 2 in. in length,  $1\frac{3}{8}$  in. in width, and  $\frac{3}{4}$  in. in thickness. It contains several small cysts.

Its direction is in a line downwards and backwards. Its lower end is  $\frac{1}{2}$  in. from the bottom of the pouch of Douglas. The outer surface lies against parietal peritoneum and rectum, the inner against the uterus.

The ovary is adherent to the left utero-sacral ligament and to the parietal peritoneum by four delicate bands, varying from  $\frac{3}{4}$  in. to 1 in. in length, and of the thickness of pedicle silk. They are pale and fibrous. They lie folded up underneath the ovary.

*The Peritoneum* on the back of the uterus is wrinkled transversely for a considerable extent.

*The Left Fallopian Tube* passes outwards and forwards from the uterus for half-an-inch, and then turns backwards and upwards for an inch. It then bends sharply forwards, lying between the second part and the ovary.

*The Left Broad Ligament* arises  $1\frac{1}{4}$  in. above the brim,  $3\frac{1}{4}$  in. below the highest part of the iliac crest, and  $2\frac{1}{8}$  in. behind a plane at right angles to the brim passing through the anterior superior iliac spines. It runs downwards and forwards, being arranged as on the other side. It crosses the brim at a point slightly in front of the place where the right ligament crosses it.

*The Left Utero-Sacral Ligament* is a double fold  $1\frac{1}{2}$  in. in length. Its upper end is about  $\frac{3}{4}$  in. external to the vertical mesial line of the sacrum and opposite the junction of the fourth and fifth sacral vertebræ. It runs inwards and downwards forming a double shelf, and is attached to the back of the uterus opposite the attachment of the right ligament.

## RÉSUMÉ.

FROM these detailed facts we gain important information regarding the state of the pelvis and its contents after labour is over, as well as during the first part of the puerperium.

### UTERUS.—AT THE BEGINNING OF PUERPERIUM.

The uterus is at this period several times larger than in the nulliparous condition. It occupies the greater part of the pelvic cavity, the fundus being only  $1\frac{1}{4}$  in. above the brim. Measured vertically the highest part of the uterus is about  $4\frac{3}{4}$  in. above the top of the symphysis. (In the living person the height of the uterus should never be referred to the umbilicus, because of the ill-defined position of the latter owing to the laxity of the abdominal wall left after labour.) This agrees with the average height found by Charpentier<sup>1</sup> in the living subject. Other authors give a little lower figure as the average, Lusk<sup>2</sup> making it  $4\frac{1}{3}$  in. It is easy to understand how, in measuring this distance on the living subject, too short a suprapubic height might be given; it is usual in such cases to measure from the symphysis by pushing in the abdominal wall until the hand rests on the bone; in this way the thickness of the abdominal wall pressed against the symphysis may be left out of account, and hence the measurement be not perfectly accurate. An error of  $\frac{1}{3}$  to  $\frac{1}{2}$  in. might thus easily arise. As a whole the uterus is anteverted, there being no flexion between the cervix and body; the fundus is directed slightly backwards owing to the pressure of the intestines against its anterior part. This is not the most common position of the fundus at the end of the third stage; it usually appears rounded, and is directed to the front against the anterior abdominal

<sup>1</sup> *Traité des Accouchements*, vol. i. p. 516.

<sup>2</sup> *The Science and Art of Midwifery*, p. 244.

wall (as in the Second day case). In this case the uterus when felt through the abdominal wall did not have the so-commonly-described "cricket ball" shape. This shape, which is usually found after labour, is really caused by the rounded fundus of the anteverted uterus lying above the pubes (well seen in the Second day case). Clinically, we know that the "cricket ball" is not always felt. The explanation of this would seem to be the flattening of the fundus (as in this case) from before backwards. There can be no doubt that in normal conditions the uterus at the beginning of the puerperium is anteverted or, it may be, anteflexed, the long axis of the body being practically at right angles to the brim.

Three parts can be distinguished in the uterine wall, viz.—

Upper Uterine Segment.

Lower Uterine Segment.

Cervix.

*Upper Uterine Segment.*—This forms the great mass of the uterus. Its walls, owing to retraction and contraction, are thick and have a compact appearance; it can be moulded, however, by the structures against which it rests. It is of a pale grey pink, darker opposite the placental site. Its vessels are quite closed, the tissues appearing practically bloodless. One would judge that in this condition very little blood could circulate in the wall. That this supposition is undoubtedly true has been proved by the experiments of Helme on a sheep's uterus. He finds that during contraction the uterus is paler, while the amount of blood flowing through it is diminished; the muscle becomes relatively anæmic.<sup>1</sup>

*Lower Uterine Segment.*—This still exists, though very much shorter than during labour. It is best marked in the anterior wall of the uterus when it appears scarcely more than half-an-inch in length. Above, it passes abruptly into the thick upper uterine segment, while below it suddenly joins the well-marked cervix. Posteriorly it is not so thin, and passes more gradually into the upper uterine segment above and the cervix below. There exists a well-marked retraction ring. This is not the same as the retraction ring of labour. It is relatively nearer the cervix, i.e. the

<sup>1</sup> "Physiology of the Uterus," *Laboratory Reports R.C.P.E.*, vol. iii.

upper uterine segment of labour has been added to inferiorly by the amount of the lower uterine segment taken up into it.

*Cervix.*—The cervix, though quite thick, is not restored to the pre-parturient condition. It is considerably flattened from above downwards, though this is probably partly due to the pressure of the upper uterine segment. Its cavity is partly also everted. It is congested, and thus stands out in sharp contrast with the body of the uterus. It is impossible clinically to define *with accuracy* either the *os externum* or *os internum*, especially the latter, hence the long tables of measurements of the cervical and body cavity given by Milsom,<sup>1</sup> Sinclair,<sup>2</sup> Autefage,<sup>3</sup> Charpentier,<sup>4</sup> and E. Martin,<sup>5</sup> are not accurate. These writers have made the mistake of supposing that the prominent lower edge of the retraction ring was the *os internum*. The latter point in the early puerperium cannot be placed with accuracy even after the most careful microscopic examination, because of the transitional nature of the epithelium lining the uterus at its level. There is another reason why these cavity measurements are fallacious. The folding between the upper uterine segment and the cervix is not taken into account. The actual length, therefore, of the cavity of the uterus will be greater than that obtained by the use of a sound or hystrometer. This fallacy is well brought out in Plate I.

Matthews Duncan,<sup>6</sup> in speaking of the measurements made in the living woman, says that in a body so soft and yielding as the cervix uteri, we cannot pretend to minute exactness, because the measurement may be easily changed, even by a change of position of the part measured. (When he wrote this in 1869 it was believed that the lower uterine segment was a part of the cervix.)

The resistant ring described by authors, *e.g.* Lusk,<sup>7</sup> as constituting a well-marked boundary between the *corpus* and *cervix uteri*, and called by them the *os internum*, is in reality the lower edge of the retraction ring. It is of course the boundary between the upper and lower uterine segment only, not between the cervix and the rest of the uterus.

<sup>1</sup> *Thèse. Lyon*, 1880.

<sup>2</sup> *Amer. Gyn. Trans.*, 1879, 1881.

<sup>3</sup> *Thèse. Paris*, 1869.

<sup>4</sup> *Op. cit.*, p. 520.

<sup>5</sup> *Die Neigungen u. Beugungen d. Gebärmutter*, Berlin, 1866.

<sup>6</sup> *Mechanism of Natural and Morbid Parturition*, Edin., p. 276.

<sup>7</sup> *Op. cit.*, p. 243.

To appreciate the change which has been brought about in the uterine wall, it is interesting to compare this early puerperium case with a second stage of labour case described by Dr. Barbour and myself,<sup>1</sup> in which the cervix is greatly thinned out, and the retraction ring  $3\frac{1}{4}$  in. from the *os externum*.

The uterus as a whole is symmetrically placed in the pelvic cavity, though the fundus is higher above the brim in its right than in its left half. It is generally believed that, after the third stage in a normal pelvis and with empty bladder and rectum, the uterus is central and not deflected to one or other side. Clinical observations by Börner<sup>2</sup> and Croom<sup>3</sup> seem to show that in some cases it lies nearer to one side of the pelvis than the other. Out of sixty cases Croom found that in four the uterus was nearer the left, while in ten it was nearer the right side of the pelvis. I have found that, by clinical observation, it is very difficult to measure accurately the distance between the uterus and the bony wall in the early puerperium. If, as in my case, the fundus be most prominent on one side, one is apt to conclude that the uterus as a whole is deflected to that side, whereas asymmetry of the fundus may be coexistent with a central position of the uterus as regards the pelvic cavity. Also, in examining a large number of women, unless one is careful to include only those who have had a perfectly normal pelvic condition, error is sure to arise because of the deviations of the uterus due to previous cellulitis or perimetritis. The position of the patient also is important. As Croom<sup>4</sup> has shown, the results will not be the same when examination is made in the dorsal position, as when it is made in the lateral position.

There was no rotation in my specimen. That this is not always the case, even in an empty condition of bladder and rectum, is now well established. Croom found in forty cases that ten only were rotated, while Börner found that out of sixty-four cases fourteen were rotated. The latest statistics on this point are those of Kehrer,<sup>5</sup> who found that out of one hundred cases thirty were rotated, twenty-four to the right and four to the left. In the majority of cases the rotation is to the right, *i.e.* the anterior

<sup>1</sup> *Lab. Rep. R.C.P.E.*, vol. ii. plate 3.

<sup>3</sup> *The Bladder*, Edin., 1884.

<sup>4</sup> *Op. cit.*, p. 60.

<sup>2</sup> *Ueber den puerperalen uterus*, Graz, 1875.

<sup>5</sup> *Müller's Handbuch d. Geb.* 1888, *bd. i.* p. 532.

surface of the uterus looks to the front and right. Neither of these authors, however, gives the amount of rotation. Spiegelberg<sup>1</sup> says it is only slightly twisted. This is an exceedingly difficult point to ascertain with accuracy on the living person. It is best determined in the cadaver by means of frozen sections, the parts having been undisturbed.

#### AFTER THE FIRST DAY.

On the fourth day the uterus is still partly in the pelvis and partly in the abdomen. On the sixth day it has become lowered somewhat, and, though it is considerably above the brim laterally, it appears in vertical mesial section just below the brim conjugate. In this case, however, owing to the faeces in the rectum, the uterus is somewhat higher than it would have been with an empty condition of the bowel. It is impossible to trace a gradual sinking of the fundus in these sections. We must bear in mind that there are individual differences in the size of the uterus and the pelvis in the various cases.

In the descriptions of puerperal uteri removed from the body published by different authors, Barbour<sup>2</sup> was not able in the early puerperium to trace a gradual diminution in the length of the uterus corresponding to the successive days. He explained this by the existence of pathological conditions in most of the cases affecting involution. It is evident, however, that with uteri removed from the body, there is apt to be a considerable amount of error in comparing measurements made in different cases and by different observers. The amount of disturbance of parts caused by removal from the body is not inconsiderable, and varies with different observers. The measurements which most approach accuracy are those taken after frozen sections have been made.

On the fifteenth day the uterus is entirely a pelvic organ. When exactly this condition is brought about one cannot yet say. Some authors<sup>3</sup> place it at about the tenth day. It is interesting to note the retroflexion. That this is a very common condition in the puerperium is now well

<sup>1</sup> *Text-Book of Mid.*, Eng. Trans., vol. i. p. 297.

<sup>2</sup> *The Anatomy of Labour and its Clinical Bearing*, p. 118.

<sup>3</sup> Lusk, *op. cit.*, p. 245.

recognised. It is found in perfectly normal cases, and usually returns to a state of anteflexion.

In all these cases, *i.e.* after the first day, the uterine wall cannot, from its naked-eye appearance, be divided into the three portions noticed at the beginning of the puerperium, *viz.* Upper and Lower Segments and Cervix. Owing to the retraction of the uterine muscle continuing after the end of the third stage, the lower segment is more and more taken up into the thick portion above it, so that, in my sections, by the thirty-sixth hour after delivery it is completely obliterated, the body of the uterus and the cervix being a continuous whole gradually diminishing in thickness from above downwards.<sup>1</sup> It is impossible to define with accuracy the *os internum*. We can place it fairly correctly by noting the point of flexion, the level of attachment of the utero-sacral ligaments, and the point of reflection of the peritoneum from the uterus to the bladder. (In my early puerperium cases the utero-vesical pouch is abnormally high.) One can therefore say that the following table is approximately correct:

Case.	Cervix.	Body.	Whole Uterus.	Cavity.
	in.	in.	in.	in.
Beginning of Puer.			7 $\frac{7}{8}$	6 $\frac{1}{2}$
2nd Day . . .	2 $\frac{1}{8}$	4 $\frac{7}{8}$	7 $\frac{1}{8}$	6 $\frac{3}{8}$
3rd Day . . .	2	4 $\frac{3}{8}$	6 $\frac{3}{8}$	5 $\frac{5}{8}$
4th Day . . .	2	5 $\frac{1}{8}$	7 $\frac{1}{8}$	6 $\frac{1}{8}$
6th Day . . .	1 $\frac{5}{8}$	3 $\frac{1}{2}$	5 $\frac{1}{8}$	4 $\frac{5}{8}$
15th Day . . .	1 $\frac{1}{4}$	2 $\frac{1}{2}$	3 $\frac{1}{4}$	3 $\frac{3}{8}$

These specimens would thus seem to show that for some time after labour the cervix may be double the normal nulliparous length. The shortening which takes place in it is coincident with that which takes place in the body, though probably not *pari passu*. This diminution is scarcely perceptible for the first three or four days, but has become quite marked by the sixth day, and well pronounced by the fifteenth day. Statements are made in the books regarding the decrease in the size of the uterus, based

<sup>1</sup> The "firm attachment of the peritoneum" which Hofmeier and others give as marking the upper limit of the lower segment, is not available in the frozen condition.



upon clinical observations and instrumental measurements on the living subject. Owing, however, to the fallacies associated with these methods (already pointed out), we cannot depend upon them. Lusk<sup>1</sup> says that a diminution in the size of the uterus is apparent in the course of the first twenty-four hours; Winckel,<sup>2</sup> that the decrease commences as early as twelve hours afterwards, and that there is a daily decrease in length of 2.6 c.m.

Frozen sections do not in any way tend to support these views, but are more in agreement with Heschl<sup>3</sup> who says that the change does not begin until at least the fourth day.

What now is to be said regarding the naked-eye appearances of the uterus?

(a.) *On Section.*—For four days at least the sections have the appearance of contracted and anæmic non-striped muscle. The vessels are closed and can scarcely be distinguished save under the placental site. On the sixth day the uterus has a darker red appearance, the vessels being more filled with blood and more easily distinguished. On the fifteenth day it is of a dark reddish colour. Of my cases the third day uterus is paler than any of the others. There is no sign of the extremely fatty appearance which Spiegelberg<sup>4</sup> says becomes so well marked by the fifth to the eighth day, nor could any fat globules be removed. Neither after thawing took place did I find that the texture was extremely soft and friable. It was compact and rather to be described as of a spongy nature, fairly easily indented with the finger, the indentation, however, disappearing. It was certainly more easily torn than either the non-pregnant or the pregnant uterus. The cervix is softer than the body and is somewhat congested.

(b.) *Outer Surface.*—The peritoneum is wrinkled over a considerable part of the uterus. The wrinkling is especially marked near the broad ligaments and in the pouch of Douglas. It results of course from the diminution in the size of the uterine musculature as a result of contraction and retraction taking place to a relatively greater degree than the shrinking of its peritoneal covering. There is, in other words, a disproportion in their

<sup>1</sup> *Op. cit.*, p. 244.

<sup>2</sup> *Text-book of Mid.*, Eng. Trans., p. 198.

<sup>3</sup> *Zeitsch. d. K.K. Ges. d. Aertze zu Wien*, 1852, p. 228.

<sup>4</sup> *Op. cit.*, p. 292.

retractile powers, the superabundant peritoneum when the uterus has changed from its pregnant to its post-partum condition, being arranged over the uterus in a series of folds. By the sixth day the wrinkling has largely disappeared save near the junction of the broad ligaments.

The shape of the uterus viewed either from the front, the back, or the side, is somewhat pyriform, diminishing in thickness from above downwards. In some cases the posterior wall is well rounded, the anterior being more flattened, but in other cases these conditions are reversed.

The puerperal uterus differs in this respect from the normal non-pregnant uterus in which the posterior wall is always more rounded than the anterior. It usually returns to the normal condition during the puerperium.

(c.) *Inner Surface* (Plate XX.)—The specimen from which this description was taken was removed from a patient who died of lung disease on the first day of the puerperium. Cut longitudinally through the anterior wall and laid open, it presented the following appearance:—

Three areas can be distinguished:

1. *The Placental Site*.—This occupies the posterior, the left lateral, and part of the anterior wall. It is somewhat lemon-shaped, the length being  $4\frac{1}{2}$  in. and the greatest breadth  $2\frac{3}{4}$  in. The area would be nearly that of an average adult man's palm, measuring  $11\frac{1}{2}$  sq. in. In colour it is dark red with a purplish appearance in places. It is more ragged and irregular than the rest of the inner surface, and shows the openings of torn blood-sinuses.

2. *Site of Attachment of Membranes*.—This is larger than the placental portion, is not so deeply coloured, being of a red-brown colour, and not so ragged. Towards the cervix it is smoother than in its upper part. Small shreds of decidual tissue are adherent all over it. This smoother part represents that part of the body wall which formed the Lower Uterine Segment. Küstner,<sup>1</sup> Thiede,<sup>2</sup> Barbour,<sup>3</sup> and others have shown by microscopic study that the surface of this segment differs from that of the Upper Uterine Segment in having scantier and more elongated gland spaces and smaller decidual cells. It is transitional in nature.

<sup>1</sup> *Das untere Uterin segment*, Jena, 1882.    <sup>2</sup> *Zeitsch. f. Gyn.*, bd. iv. s. 210.    <sup>3</sup> *Op. cit.*, p. 125.


PLATE XX.

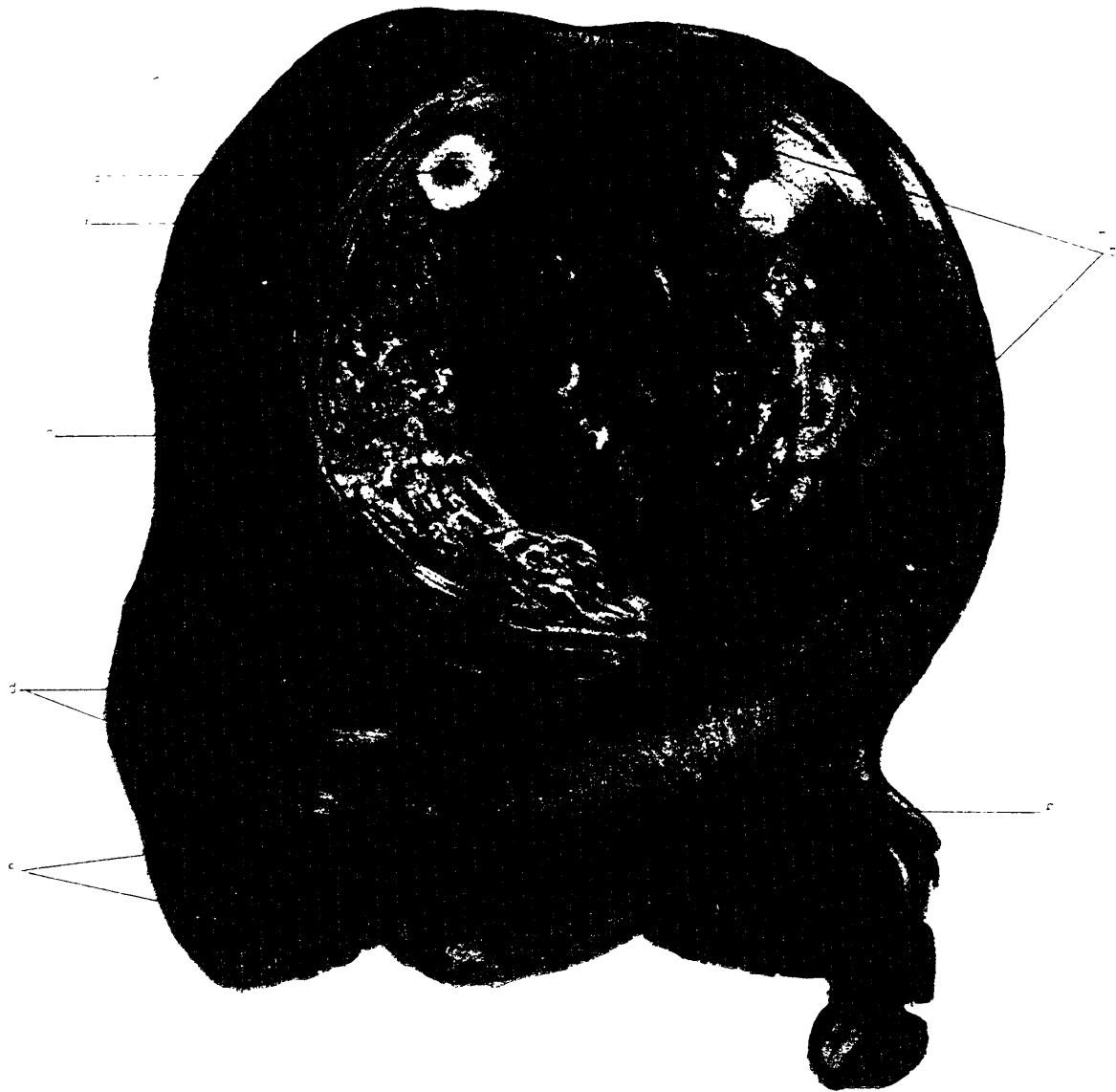
FIRST DAY OF PUERPERIUM.

*Three Hours after Delivery. Uterine Cavity laid open by a  
Vertical Cut through Anterior Wall.*

(Reduced by  $\frac{1}{3}$ .)

- a. Opening of Fallopian Tubes with smooth area around them.
- b. Placental site.
- c-d. Site of attachment of Membranes.
- e. Cervix deeply congested.
- c. Upper Uterine Segment.
- d. Lower Uterine Segment.
- f. Laceration in Cervix.










PLATE XXI.


(Reduced by  $\frac{1}{3}$ .)

Maternal Surface of Placenta which was attached to the Uterus  
represented in Plate XX.









In this area are seen the openings of the Fallopian tubes. Around each of these is an area, about  $\frac{1}{2}$  in. square and perfectly smooth, to which no decidua shreds are adherent; this seems to indicate that the membranes were not attached to the wall in the immediate vicinity of the tubal openings.

3. *Cervical Area.*—Two parts can be distinguished in this area, viz. a lower and an upper portion. The lower, about  $1\frac{1}{8}$  in. in vertical extent, is comparatively smooth with ridges here and there, due probably to the remains of the arbor vitæ. It is deeply congested, and ecchymoses are seen below the surface. The lower edge is irregular, and on the left side is seen a tear.

The upper portion is of a light bluish-grey with ridges seen on it here and there. It becomes gradually continuous with the non-placental site of the body cavity, there being no well-marked line of distinction between the two.

(It is interesting to compare the placental site with the placenta from the same case (Plate XXI.)). This is rounded in form with an average diameter of about 6 in. Its area is about 28 sq. in. There has evidently been brought about a great disproportion between the area of the placenta and the site of its former attachment to the uterus.

*The relation of the Uterus to the extra-uterine tissues, and to the pelvis.*—In a pelvis of average size at the beginning of the puerperium, the uterus fills the greater part of the pelvic cavity and compresses the extra-uterine tissues. This compression is especially marked between the uterus and the bony wall, and to a much less extent inferiorly owing to the softening and relaxation of the fascial and muscular tissues of the pelvic floor. In consequence of this condition of the parts, the intra-pelvic tissues have their blood circulation interfered with to a considerable extent, those parts of the pelvic floor which are least affected, e.g. sub-pubic tissues, vaginal walls, and perineum, being congested, the tissues between the uterus and the pelvic wall, however, being anæmic, having their vessels closed or nearly closed.

The effect of contraction and retraction of the uterus on its blood circulation has already been referred to. The effect of the compression of the organ as a whole on the tissues outside it is to further interfere with the flow of blood to itself; the ovarian and the uterine arteries as well as

the uterine branches of the vaginal arteries are, owing to the rearrangement of the broad ligaments, twisted, and at the same time compressed against the bony wall by the uterus. The only part of the uterus which is not anæmic is the cervix.

It is neither retracted nor contracted in the same degree as the body, nor is it subject to much compression; at the same time it is in close relation to the vascular vaginal walls and para-vaginal tissues which have been so recently engorged with blood, and may therefore become deeply congested.

Owing to the very slight diminution in the size of the uterus, this condition of things, as my sections show, is kept up for three or four days. As a result bleeding from the inner surface of the uterus is greatly interfered with, both through the interference of contraction and retraction with the intra-mural circulation, and also through the mechanical pressure of the uterus as a whole upon the broad ligaments and the tissues lining the pelvic wall containing the vessels passing to it. An enormous influence must be exerted by this greatly altered blood supply in the way of initiating or stimulating those retrogressive changes which bring about the involution of the organ, whatever those changes may be.

Further, the condition of the cervix helps us to understand why after labour there is so often bleeding as a result of even the small tears which take place in it, and why, if the laceration has extended into the parametric and para-vaginal tissues, so rich in venous sinuses, there may be very serious hæmorrhage. Should this not be checked by the ordinary means, *i.e.* hot or cold antiseptic douche, it is evident that pressure of the uterus from above will tend to diminish the flow of blood to the cervix by compressing it, while the introduction of a firm rectal or vaginal plug might in some cases be used as a resisting structure against which the lacerated part could be more firmly compressed. During the last two years I have made careful observations regarding post-partum hæmorrhage as a result of torn cervix in a considerable number of cases, and I have found it to be most profuse and most difficult to stop in women with abnormally large, *e.g.* justo-major, kyphotic, or with abnormally contracted pelvis, *e.g.* rickety. The reason of this is clear if we examine sections made of such

PLATE XXII

FIG. 1.

Vertical Mesial Section of a Contracted Pelvis, from a woman who died  $\frac{1}{2}$  hour after delivery. (Stratz.) (Reduced.)

- |                             |                             |
|-----------------------------|-----------------------------|
| <i>a.</i> Umbilicus.        | <i>e.</i> Tip of Coccyx.    |
| <i>b.</i> Retraction Ring.  | <i>f.</i> Urethra.          |
| <i>c.</i> Cervix.           | <i>g.</i> Urethral orifice. |
| <i>d.</i> Posterior fornix. |                             |

FIG. 2.

Vertical Mesial Section of a Kyphotic Pelvis, from a woman who died  $1\frac{1}{2}$  hour after delivery. (Barbour.) (Reduced.)

- |                                 |                            |
|---------------------------------|----------------------------|
| <i>a.</i> Small intestines.     | <i>j.</i> Cervical canal.  |
| <i>b.</i> Last lumbar vertebra. | <i>k.</i> Cellular tissue. |
| <i>c.</i> Uterus.               | <i>l.</i> Bladder.         |
| <i>d.</i> Peritoneum.           | <i>m.</i> Vein.            |
| <i>e.</i> Placental site.       | <i>n.</i> Symphysis pubis. |
| <i>f.</i> Uterine cavity.       | <i>o.</i> Urethra.         |
| <i>g.</i> Rectum.               | <i>p.</i> Cellular tissue. |
| <i>h.</i> Pouch of Douglas.     | <i>v.</i> Vagina.          |
| <i>i.</i> Cervix.               | <i>w.</i> Anus.            |




Fig 1

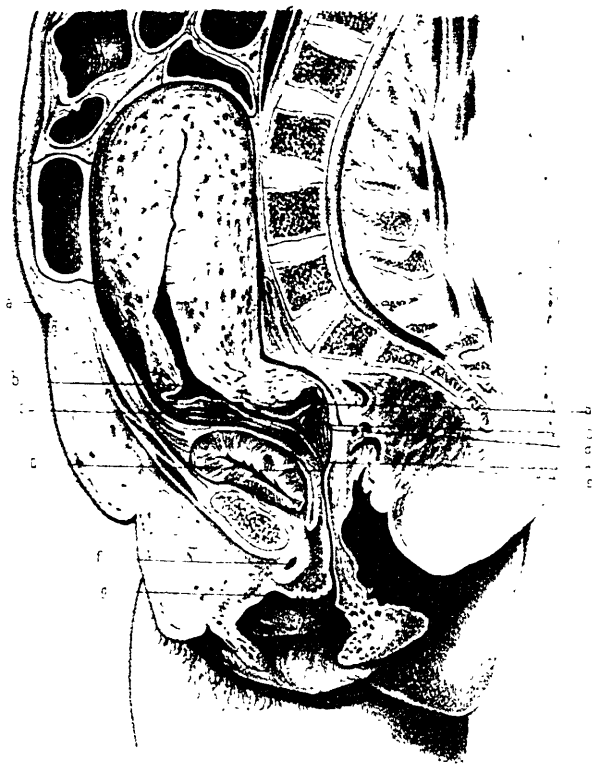
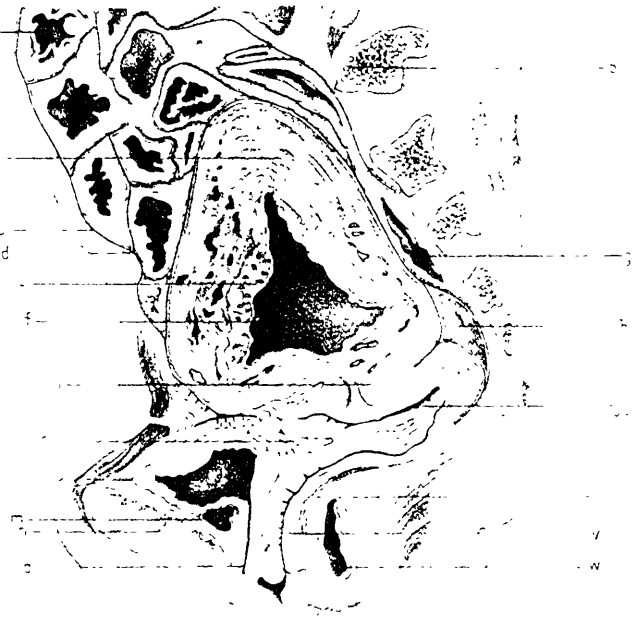


Fig 2







pelvis. Barbour's section<sup>1</sup> of a *kyphotic* pelvis (1½ hour puerperium) shows that the uterus in no way acts as a plug owing to the great size of the upper part of the pelvic cavity, and the condition is undoubtedly more favourable to excessive bleeding. (This very case died of post-partum hæmorrhage.) In a well-marked *rickety* pelvis, as Stratz's section shows us (½ hour puerperium), the uterus cannot sink down into the pelvis, but remains to a large extent above the brim. The cervix and lower uterine segment as well as the tissues adjacent to them are put on the stretch, and thus these parts tend to become greatly congested. (This case also died of post-partum hæmorrhage.) (Plate XXII.)

## BLADDER.

In all my cases the bladder is empty, or nearly so. They show that after labour it returns to practically the same shape that it had before labour. It varies as to its position in different cases, being depressed more in some than in others. Immediately after labour it may lie at the level occupied by it during pregnancy, or even partly lower; this depends mainly upon the softening and stretching of its supports, which takes place during pregnancy and labour. As the puerperium progresses a gradual elevation takes place. I can find nothing to support the statement of Halliday Croom<sup>2</sup> that after the labour "the bladder is on a *higher* level than during pregnancy."

The conditions which affect the lie of the viscus are:

1. Softening and stretching of its supports.
2. Intra-abdominal pressure.
3. Weight of the uterus.

The first of these probably varies considerably in different cases.

In none of my cases is it exactly central in the pelvis. It is slightly deflected either to the right or left side. From the relation of the bladder to the uterus it is evident that its distension with urine must cause the uterus to be less anteverted, *i.e.* must make the fundus take a higher position. Probably, also, the uterus will be raised as a whole.

<sup>1</sup> *Atlas of the Anat. of Labour*, 1889.

<sup>2</sup> *Op. cit.*, p. 55.

The elevation of the fundus found some hours after delivery is due in most cases to the filling of the bladder. Filling of the lower part of the rectum also raises the uterus, though in a less marked degree. The influence of this condition of the rectum in changing the position of the uterus is well shown in my Sixth day case.

#### VAGINA.

The vagina is larger in all its dimensions after labour than before. The vertical mesial sections show that it may return after the third stage to its normal sigmoid shape.

In the early puerperium, in its upper part only are the walls in apposition, the lower part gaping considerably, the lower part of the anterior vaginal wall bulging downwards; it returns during the puerperium to the more normal condition. My Sixth day case shows that on transverse section the vaginal cavity in its upper part is a transversely-curved slit, the concavity looking upwards; in its middle part it is somewhat H shaped, and in its lower part a vertical slit, the walls not being quite in apposition however. The vaginal cavity, in the earliest case, *i.e.* immediately after delivery, in its upper part has the usual transverse direction. In the lower part, however, owing to the stretching, the direction seems to be more vertical, the side walls tending to approximate to one another.

*Perineal Body.*—In none of my cases was there any special tearing of the perineum. The sections show that in spite of the great stretching of this part, it may return almost to the pre-parturient shape, though it is soft and, as a whole, lower in position. As the puerperium advances it becomes firmer and more compact.

*Pelvic Floor Projection.*—Its measurement in my cases is given in the following table:—

First Day.	Second Day.	Third Day.	Fourth Day.	Sixth Day.	Fifteenth Day.
2 in.	1 $\frac{7}{8}$ in.	1 $\frac{5}{8}$ in.	2 $\frac{1}{8}$ in.	1 $\frac{1}{2}$ in.	1 in.

After labour we thus see that the projection is greater than in the nulliparous condition, when, according to Foster,<sup>1</sup> it is very little more than 1 in.

Compared with the measurements made in cases of pregnancy and labour by Dr. Barbour and myself,<sup>2</sup> it is found to be less than it was during the second stage, and about the same as, or a little greater than, it was in advanced pregnancy.

#### BROAD LIGAMENTS.

The upper part, with tube and ovary, has much the same appearance as in the pregnant condition, being freely movable, and having its layers separated only by a small amount of tissue. It is larger than in the non-pregnant woman. The lower part is quite different; it has scarcely any width whatever, because the uterus has extended between its layers almost to the side walls of the pelvis. The peritoneal layers are considerably wrinkled, and the tissues between them are compactly pressed between the uterine and pelvic walls. In fact, in sections it is very difficult to say, with the naked eye, where uterine muscle stops and broad ligament tissue begins. At the end of labour the highest part can be traced as a ridge which arises in the iliac fossa passing downwards and forwards, getting larger, and crossing the brim, its layers gradually getting wider until about  $\frac{1}{2}$  in. below the brim the anterior layer passes to the bladder, the posterior descending to form the pouch of Douglas.

As the puerperium advances the ligaments gradually return to their normal nulliparous condition.

#### TUBES AND OVARIES.

At the commencement of the puerperium they lie almost entirely above the brim on each side, packed in between the uterus and the pelvic wall, and covered with intestines, having descended from the position occupied by them at the beginning of labour.<sup>3</sup>

<sup>1</sup> *Am. Jour. of Obst.*, vol. xiii. p. 30.

<sup>2</sup> *Lab. Rep. R.C.P.E.*, vol. ii. pp. 16, 43.

<sup>3</sup> Barbour, *op. cit.*; Barbour and Webster, *op. cit.*

The ovary and tube, though in all my early puerperium cases packed in between the uterus and pelvic wall, do not always bear the same relation to one another and to the uterus. This variation is due to the mobility of the upper free portion of the broad ligaments. This mobility chiefly affects the tubes, allowing them to lie either in front of, or behind, their point of attachment to the uterus, and folded in various ways. The ovaries, however, have a much more limited range of movement, less than that possessed by them either in the non-pregnant or pregnant woman. Before labour they are still separated from the wall of the uterus, the ovarian ligament being well marked.<sup>1</sup> After labour, however, owing to lateral extension of the retracted and contracted uterus into the broad ligaments, the ovaries get to lie closer to the uterine wall, their inner ends appearing to be attached to it directly, the ovarian ligaments being practically obliterated, having become spread out on the wall of the uterus. The ovary, thus fixed at its uterine end, is only capable of moving around this fixed point; the outer free end may thus be found in front, above, behind, or below the attached end. In no case of mine are the relations the same on both sides. The appendages, also, may be a little higher on one side than on the other. During the first four days at least they do not become lowered to any marked extent. When they reach their normal position we do not yet know. In my Fifteenth day case on one side, both tube and ovary are pathologically lowered, the ovary having formed adhesions with the parietal peritoneum in the pouch of Douglas; on the other side, the tube lies partly above and partly below the brim, about  $\frac{3}{4}$  of the corresponding ovary being above it. In this case, however, the uterus is retroflexed.

*The Bearing of these facts upon the Credé method of expelling the  
Placenta and Post-partum shock.*

The Credé method was originally introduced as a means of separating and expelling the placenta and membranes immediately after the birth of the child. The term has since come to be used in a wider sense, embracing those cases where the placenta has become partially separated,

<sup>1</sup> Barbour, *op. cit.*; Barbour and Webster, *Lab. Rep. R.C.P.E.*, vol. ii. pp. 13, 27.

or where, entirely separated, it still lies in the uterus and upper part of the vagina, and where suprapubic compression and depression of the uterus are employed in order to completely deliver it. Credé's method of grasping the uterus was to place the thumb behind the symphysis and the fingers in front of the promontory, *i.e.* the hand is placed antero-posteriorly *quâ* the pelvis.

Recently Haig Ferguson<sup>1</sup> and Newell<sup>2</sup> have criticised this method of grasping the uterus, saying that, on account of the rotation of the uterus, the ovaries are in danger of being compressed between the fingers and the uterine wall, and that, as a result, a condition of shock is apt to be induced in the patient. The former writer has studied clinically three cases of this so-called "post-partum shock," the latter "one or two cases." It seems to me that their explanation of the cause of this condition is open to criticism both on clinical and anatomical grounds.

A. *Clinical*.—(1) So widely employed is the Credé method, it is remarkable that these are the only cases on record of the occurrence of this condition.

(2) In all these cases, the women were *neurotic*, and there is no reason against supposing that the condition of shock may have been to a large extent produced as a result of the mere Credé manipulation, *apart from any compression of the ovaries*. While the exact relation of shock to psychical and physical causes is not yet clearly defined, we do know that these causes vary greatly in their power of affecting different individuals. Separately or conjointly they may produce shock in all its degrees. There is no doubt, according to Sir Wm. MacCormac<sup>3</sup> and others, that in persons of a *neurotic* temperament the very slightest lesion or pain may lead to shock. It is not too much to suppose, therefore, that compression of the uterus alone in a neurotic woman might lead to shock.

(3) There is one condition, however, which renders the uterus exquisitely sensitive to pressure, *viz.* inflammation. Mere pressure of a finger on an old perimetritic patch may cause a woman great suffering. The

<sup>1</sup> *Obstet. Trans.*, vol. xiv. p. 103.

<sup>2</sup> Leonardi's *Illus. Med. Jour.*, Detroit, July 1890.

<sup>3</sup> Quain's *Dict. of Med.*, p. 1427.

firm compression of a uterus in this condition, sufficient in amount to expel the placenta, undoubtedly causes very great pain, and might easily lead to shock in a neurotic patient.

(4) There may have been a diseased condition of the tube or ovary, or of both, on one side, as a result of which they may have been displaced or enlarged and, therefore, squeezed by the compressing hand. The great pain caused by the compression of an inflamed ovary is a well-recognised fact in gynecological examination. At the Cowgate Dispensary I have seen two cases with symptoms somewhat resembling these described by Ferguson and Newell resulting from the ordinary bi-manual examination of neurotic women with old-standing ovaritis.

There is no doubt that in operations for diseased appendages a condition of shock is sometimes produced, apart from loss of blood. This is attributed by Ferguson to rough handling of the ovary. If he be right, we should find this a very common complication in laparotomies, since, in the majority of operations for removal of the appendages, especially where there is much matting-down of them from inflammatory adhesions, the ovaries are pretty roughly handled. Moreover, one would expect to find shock common in those cases where part of the ovary is left behind embraced by a ligature; yet, as far as I know, it has not been particularly noticed in these cases. After any abdominal operation that has been severe and protracted and accompanied with much loss of blood, shock is liable to occur.

B. *Anatomical*.—The relations of the pelvic organs during the third stage have not yet been studied in the cadaver. Thiede,<sup>1</sup> Stratz,<sup>2</sup> and Benckiser,<sup>3</sup> have studied the uterus of that period, but removed from the body; topographical descriptions of the pelvis, however, are as yet wanting. We do not know the position of the ovaries exactly during that period, nor whether the rotation of the uterus is increased or diminished. We must depend upon clinical examination and upon certain facts known regarding the condition of the parts before and after the third stage. Ferguson bases his hypothesis largely upon the rotation

<sup>1</sup> *Op. cit.*

<sup>2</sup> In Schroeder's *Der Schwang. u. Kreis. Ut.*, Bonn, 1886.

<sup>3</sup> *Zur Anat. d. Ger. u. unt. Uterinseg.* Benckiser u. Hof, 1887.

which is found in the uterus during pregnancy. He says that "the transverse axis of the uterus lies in the right oblique diameter"; I have not been able to find any facts in support of this statement. It is more commonly believed, as Spiegelberg<sup>1</sup> says, that the rotation is usually a slight one, and that it varies according to the amount of distension of the sigmoid flexure and rectum. Ferguson says that this rotation is accompanied by the moving backwards of the right ovary and the moving forwards of the left, so that they lie practically in a plane passing vertically through the right oblique diameter of the pelvis. The published cases, studied by frozen sections, do not uphold this statement. In the Eighth month pregnancy case<sup>2</sup> described by Barbour and myself, in which the uterus was rotated to the right, the right ovary lay in the iliac fossa  $1\frac{1}{2}$  in. behind the anterior superior iliac spine, and  $\frac{1}{2}$  in. below the crest; the left one lay in an almost corresponding position.

In the case<sup>3</sup> where labour was just commencing, where also there was right rotation, it was the *left* ovary and not the right which was most posterior; it lay, in fact, in a vertical plane passing through the left oblique diameter of the pelvis. In our Second Stage case,<sup>4</sup> where the uterus was also rotated to the left, the right ovary lay a little anterior to the left one, because of the disposition of the upper parts of the broad ligaments, the right being turned forwards so that its anterior surface lay against the uterus, the left being turned back.

In Barbour's First Stage case,<sup>5</sup> in which his transverse sections show scarcely any rotation whatever, the right ovary lies anterior to the plane occupied by the left.

These facts, acquired by the sure method of frozen sections, certainly teach us that, practically, *the ovaries do not take up definite positions corresponding to the rotation of the pregnant uterus on its long axis.* As these cases demonstrate, the ovary in pregnancy is not attached directly to the uterus but through the ovarian ligament. It, like the tube, owing to the mobility of the upper free part of the broad ligament, can thus move, independent of the uterus, through a considerable range.

<sup>1</sup> *Op. cit.*, p. 71.      <sup>2</sup> *Op. cit.*, p. 13.

<sup>3</sup> *Op. cit.*, p. 30; plate VII. fig. 2.

<sup>4</sup> *Op. cit.*, plate V. fig. 2.

<sup>5</sup> *Op. cit.*, plate IV.

After the third stage, as my cases show, while the pre-parturient mobility of the ovary is diminished because of the practical obliteration of the ovarian ligament, it is still sufficient to allow the organ to be arranged in various positions. It is found packed between the side of the pelvis and the uterus, and, while one may lie somewhat anterior to the other, in no case do they lie in an oblique diameter of the pelvis. It is different with the tubes, however; they have a wider range of movement and may be found lying chiefly with the ovary, or they may be stretched out considerably in front or behind it. As has already been said, the uterus is not rotated or only to a slight extent in the majority of early puerperium cases; this rotation scarcely affects the lie of the ovaries to a greater extent than in pregnancy and labour.

Being as yet in want of facts derived from anatomical study regarding the position of the uterus and appendages *during* the third stage, and not being able clinically to determine these with accuracy, we are compelled to judge of the probable relation of the parts from what we know of the conditions during pregnancy, labour, and the puerperium. We have no reason to believe that rotation of the uterus is any more marked during the third stage or that the ovaries have any more a fixed position, than during these other periods.

As far as we know, then, there can be no safer grasp of the uterus than an *antero-posterior* one *quâ* the pelvis, as Credé first pointed out. The safest grasp is that in which the hands are placed with their radial edges together, their thumbs being in front of the vertebræ, and the fingers opposite the middle line of the body in front. So far as my cases show, the ovaries could not be compressed, in normal conditions, by this method of manipulating the uterus.



# THE FEMALE PELVIC FLOOR

## INTRODUCTION

DURING the last decade in Obstetrical and Gynecological science the views which have been most prominent, in the Edinburgh School at least, regarding the structure of the Pelvic Floor and its relation to pregnancy, parturition, and certain pathological conditions, *e.g. prolapsus uteri*, are those which have been gained from the study of the pelvis by means of frozen sections.

While the praises of the Sectional Method have been heard on all sides during these years, scarcely a note of warning has been raised as to the *limitations* of this method and the *fallacies* that may arise from its employment.

That the non-observance of these limitations has led to the establishment of erroneous conclusions as to the nature of the pelvic floor I hope to be able to show in the following pages.

During the last three and a half years I have examined, both by sectional and dissectional methods, twenty-one pelvis in the following condition, viz.

- (a) Ten from the fifth month of foetal life up to puberty.
  - (b) One in a non-pregnant adult.
  - (c) One in the fifth month of pregnancy.
  - (d) One in the eighth month of pregnancy.
  - (e) One in the first stage of labour.
  - (f) One in the second stage of labour.
  - (g) Six in the puerperium.
- } Published with Barbour.<sup>1</sup>

<sup>1</sup> *Lab. Reports R.C.P.E.*, vol. ii.

The conclusion to which I have come regarding the relative value of the sectional and dissectional methods is, that for *topographical relations* alone is sectional anatomy of chief value; whereas, for all other purposes, for learning the exact structure of a part of the body, the attachments and complex arrangements of the tissues of which it is composed, the older method of dissection is of prime importance.

The advantages of the sectional method may be stated in the words of Barbour, whose experience in this department is extensive.

He says<sup>1</sup> that sections render the body "practically transparent. We thus come to learn the exact relations of the parts to each other and to the surface landmarks. We see them; nothing is left to conjecture. It is not too much to say that before the days of sectional anatomy the representations of these relations were more or less successful products of the imagination; witness the fact that not a single drawing of the pelvic contents previously given was true to nature." It is evident, therefore, that the best results will be obtained from the combined employment of both methods.

The large stock of facts which I have accumulated in the course of my investigations will, I hope, lead to a truer understanding of the pelvic floor than at present exists. I shall consider the subject under the following heads:—

The meaning of the term "Pelvic Floor."

The Floor studied by Dissection.

The Floor studied by Frozen Sections.

The Floor in relation to Pregnancy.

The Floor in relation to Labour.

The Floor in relation to "Prolapsus Uteri."

#### THE MEANING OF THE TERM "PELVIC FLOOR."

The term "Floor" is not a good one, since it leads one to think of the floor of a house, *e.g.* a rigid partition running transversely between walls. Consequently in looking for a floor in the pelvis we are apt to seek for

<sup>1</sup> *The Anatomy of Labour and its Clinical Bearing*, Edinburgh, p. 7.

something which has the character of a house floor. The pelvic floor has no such structure. It is not a rigid partition, nor does it run transversely. It is elastic and movable, varying in its thickness, its nature, and its slope at various parts, while it runs across a very irregularly shaped space—the outlet of the bony pelvis. It is composed of a variety of tissues, differing in their consistence, their strength, and the firmness of their attachment to the bony wall. The *great purpose* of the pelvic floor, as a floor, is undoubtedly to sustain the weight of the great mass of abdominal viscera or, in other words, to resist the intra-abdominal pressure. As Hart<sup>1</sup> has shown, an increase in the intra-abdominal pressure, a weakening of the floor, or both these conditions combined, may lead to a hernial protrusion of the floor just as corresponding conditions in the abdominal wall produce a similar result.

In strict anatomical accuracy, therefore, it must be admitted that all those structures in connection with the pelvic outlet which help to resist and support this pressure, and whose removal would be a source of weakness, must be considered as forming a part of the floor. While sectional anatomy is of the greatest value in demonstrating the nature of the floor as a whole, there can be no doubt that dissectional work is the only method we possess of analysing its constituent elements and the part they play in resisting the intra-abdominal pressure. Neither Hart nor Symington has, it seems to me, given at all sufficient prominence to this method of study in their papers on the pelvic floor, formulating their conclusions almost entirely from the examination of sections.

According to Hart,<sup>2</sup> whose views have been mainly followed during the last ten years, the floor is composed of those tissues which close the outlet of the pelvis, being bounded by skin externally and by peritoneum internally, the uterus and appendages being removed. He divides it into an anterior part called the pubic segment, and a posterior part called the sacral segment, the line of division between the two being the vaginal slit. Studied in vertical mesial section, the former is seen to be triangular in shape, loose in texture, loosely attached to the pelvis and to include the structures lying between the symphysis and the vaginal slit,

<sup>1</sup> *The Structural Anatomy of the Female Pelvic Floor*, 1880.

<sup>2</sup> *Op. cit.*

being chiefly composed of bladder, urethral and anterior vaginal walls; the latter, strong in structure, embraces the tissues between the vaginal slit and posterior bony wall, firmly dovetailed into the sides of the latter. Symington,<sup>1</sup> on the other hand, considers "that the rectum and the bladder, like the uterus, should not be regarded as parts of the pelvic floor, but as organs resting upon it." He further says, that "the anterior part of the pelvic floor is composed of firm tissue, and is connected as strongly with the anterior part of the pelvic wall as is the sacral segment with the sacrum and coccyx." He also says that only the lower half of the vagina is in the pelvic floor. Both of these authors have formed these different conclusions from their study of the pelvis by frozen sections.

#### THE FLOOR STUDIED BY DISSECTION. (Plates XXIII. XXIV.)

Dissection is of prime importance, and should precede all other methods of studying the floor, for by it alone do we gain a true knowledge of the nature of the floor and of the complex arrangement of the structures composing it. I shall describe these structures singly, and discuss the value of each in regard to the support and strength given by it to the floor.

##### *A. Pelvic Fascia.*

This structure is, undoubtedly, of the very greatest value in resisting the intra-abdominal pressure at the pelvic outlet.

1. *Parietal Layer.*—In front this layer, a strong aponeurotic membrane for the most part, is continued across the sub-pubic arch, as the so-called "posterior layer of the triangular ligament." Its lower border blends with the base of the so-called "anterior layer of the triangular ligament" (triangular ligament proper)<sup>2</sup> which is attached at its apex to the sub-pubic ligament, by its base to the superficial fascia and central point of the perineum, and by its sides to the pubic arch. It is perforated by the urethra and vagina, and is thereby considerably weakened. This layer is never recognised as a distinct membrane in frozen sections because it is so

<sup>1</sup> "A contribution to the normal Anatomy of the Female Pelvic Floor," *Edin. Med. Jour.*, March 1889.

<sup>2</sup> Cunningham, *The Dissector's Guide*, Edin. 1880.

blended with adjacent structures ; it certainly forms part of the pelvic floor, strengthening its anterior part, helping to support and steady the urethra and vagina as well as the perineum. In the posterior part of the pelvis the parietal layer plays a less important part in helping to bridge across the greater and lesser sacro-sciatic notches. Here the great and small sacro-sciatic ligaments are the most important supports, though the parietal fascia internal to them and attached to them is an additional source of strength. (I do not think that the importance of the sacro-sciatic ligaments in regard to the mechanism of labour has been sufficiently noticed. From their position and strength they must influence considerably the course of the various parts of the foetus as they appear successively at the pelvic floor in labour. As the coccyx is driven downwards and backwards they must also be considerably stretched.)

2. *Visceral Layer*.—This layer and its divisions are scarcely noticed by most writers in obstetrics. The pelvic fascia is generally studied in the dissecting-room in the male ; its arrangement in the female is not usually dwelt on to any considerable extent.

There can be no doubt that it forms an important resisting structure to the intra-abdominal pressure.

What is its disposition? In the greater part of its extent it springs from the parietal layer along the *white line*. This *white line* passes around the pelvic wall from the ischial spine behind to a point on the posterior surface of the symphysis pubis, a little above its lower end. The visceral layer passes inwards, on each side, upon the upper surface of the *levator ani* to the lateral walls of the bladder, vagina, and rectum, where it divides into four layers:—

(a) *Vesical layer*.—This layer turns upwards upon the lower lateral aspect of the bladder, forming the "*lateral true ligament of the bladder*." It is in firm union with the bladder-wall, and thins as it passes upwards over the bladder, to be continuous with the corresponding layer of the opposite side.

(b) *Vesico-vaginal layer*.—This layer, thin but strong, passes between the bladder and the anterior vaginal wall, being in firm union with both, and being continuous with the corresponding layer of the opposite side.

At its posterior part it blends with the connective tissue which attaches the posterior part of the bladder to the neck of the uterus.

(c) *Recto-Vaginal layer*.—This layer passes between the vagina and the anterior wall of the lower part of the rectum. Except for a short distance behind the upper part of the vagina, the union between this layer and the vaginal and rectal walls is very firm. Below it is continuous with the strong connective tissue elements of the perineal body. It is continuous with the corresponding layer of the opposite side.

(d) *Rectal layer*.—This layer passes behind the rectum, attached to its walls, and joins the corresponding layer of the opposite side. It is prolonged downwards as a thin layer towards the lowest part of the gut, being, of course, internal to the *levator ani*.

These layers in sections are not always made out with ease as distinct fascial structures on account of their intimate blending with surrounding parts. They are more readily made out by dissection when traced from their parietal origin inwards in the uncut pelvis.

They are of great significance, and are undoubtedly of chief importance in *slinging the bladder, the vagina, and the lower part of the rectum in the pelvis*. In most obstetrical works I find no mention of them whatever.

(e) *Anterior visceral layer*.—Further, the arrangement of the visceral fascia in the anterior part of the pelvis is of considerable importance. Here the visceral layer, arising from the back of the lower part of the pubes on each side of the middle line, above the point of origin of the anterior fibres of the *levatores ani* as well as the attachment of the parietal fascia, passes backwards as two strong bands above them and on each side of the urethra to become blended with the anterior surface of the bladder. These are the *anterior true ligaments of the bladder*. Between them is a space filled with loose connective tissue and fat, continuous below with the retropubic fat and above with the suprapubic or retro-peritoneal fat.

(f) *Anal fascia*.—Lastly, there is a thin aponeurotic membrane, which arises from the parietal fascia along the white line under the attachment of the *levator ani* and passes downwards, closely attached to the muscle and blending with the corresponding layer of the other side and with the other connective tissue elements of the perineum. In front it is attached to the

PLATE XXIII

(From Savage.)

FIG. 1.

Pelvic Fascia from above. (Reduced.)

- R. Rectum.
- V. Vagina.
- B. Bladder.
- b, c. Parietal Fascia.
- d. Recto-vesical Fascia.

FIG. 2.

Superficial Dissection of Perineum.  
(Reduced.)

- A. Anus.
- V. Vagina.
- C. Clitoris.
- T. Tuber Ischii.
- c. Obturator Coccygeus.
- d. Deep layer of Perineal Fascia.
- k. Ischio-Pubic Ramus.

FIG. 3.

Deep Dissection of Perineum. (Reduced.)

- A. Gluteus Maximus.
- L. Great Sacro-Sciatic Ligament.
- S. Deep layer of Perineal Fascia.
- m. Anterior layer of Triangular Ligament.
- p. Posterior " " "
- b. Base of Triangular Ligament.
- c. Anal Fascia.

FIG. 4.

Triangular Ligament from the front.  
(Reduced.)

1. Clitoris.
2. Suspensory Ligament.
3. Crus Clitoridis.
4. Sub-pubic Ligament.
5. Dorsal Vein of Clitoris.
6. Posterior layer of Triangular Ligament.
7. Transversus Perinei.
8. Outer Layer of Triangular Ligament.






Fig 2



Fig 4

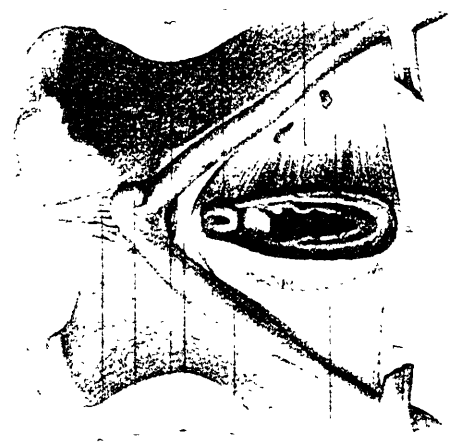


Fig 1


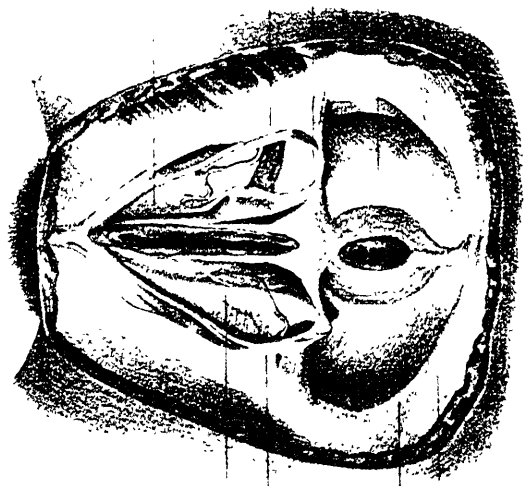



Fig 3.





posterior layer of the triangular ligament (parietal pelvic fascia).<sup>1</sup> This layer is called by some the *anal fascia*, and by others the aponeurosis of the *levator ani*.

### B. Superficial Fascia.

Under the skin, over all the lowermost part of the pelvic floor, is a well-marked layer of superficial fascia. Towards the skin it consists of fine fibrous trabeculæ containing a large quantity of fat which is most abundant behind and on each side of the anus; over the tuberosities of the ischium, this superficial fascia becomes tough and stringy,<sup>2</sup> the fibrous septa being thicker and stronger, attaching the skin to the bone. *The deep layer* is of more importance, being dense and aponeurotic, and giving considerable strength to the pelvic floor through its attachments. *Anteriorly* it is attached to the lower edge of the pubic and ischial rami, extending back almost to the tuberosities; *posteriorly* it blends in the perineum with the base of the triangular ligament.

### C. Pelvic Muscles entering into the Floor.

*Levatores Ani*.—These muscles together form a muscular diaphragm with the concavity upwards. They are usually described as being of chief value in strengthening the pelvic floor. That they are the most important muscles in the floor is true; but on account of their thinness it seems to me that they cannot *per se* exercise a very great influence in resisting the intra-abdominal pressure. Savage<sup>3</sup> divides each into two portions, viz. the *pubo-coccygeus* and the *obturator-coccygeus*. Symington<sup>4</sup> has well described the arrangement and functions of these.

*The pubo-coccygeus* passing on each side, from the back of the pubes to the last two pieces of the coccyx, act as sphincters of the lower part of the vagina and the anal canal, and tend to draw upwards and forwards the perineal body and coccyx. A few fibres blend with the urethral and vaginal walls, others turn inwards in the perineal body in front of the

<sup>1</sup> *The Amer. Syst. of Gyn. and Obst.*, vol. i. p. 227.

<sup>2</sup> Cunningham, *op. cit.*, p. 5.

<sup>3</sup> *The Surgery, Surgical Pathology, and Surgical Anatomy of the Female Pelvic Organs*, London, 1882.

<sup>4</sup> *Op. cit.*, p. 59.

*internal sphincter* of the anus; behind the anus there is a blending of some fibres of opposite sides.

The *obturator coccygeus*, the main part of the muscle, arises from the white line between the pubes and the ischial spine. It runs backwards, downwards, and inwards to the sides of the coccyx. With these should be associated the thin *coccygei muscles* which arise from the ischial spines and small sacro-sciatic ligaments and are inserted into the sides of the last sacral and the coccygeal vertebræ. They have no direct action upon the pelvic viscera. They help to fill in the sides and posterior part of the pelvic outlet; they resist somewhat the intra-abdominal pressure, and they can elevate the coccyx after it has been bent downwards.

This is quite different from the ordinary impression which the student has regarding the arrangement of these muscles. It is usually understood that the great mass of the *levator ani* arising from the white line passes downwards and inwards and, while being attached behind to the coccyx, mainly converges towards the middle line, where it blends with the muscle of the opposite side in the perineal body and behind the anus. Coronal sections are largely to blame for giving this false impression. For example, Hart and Barbour,<sup>1</sup> in their description of a coronal section of Barbour's passing through the *obturator internus* muscle, describe the *levator ani* as arising from the white line and as passing down to be inserted into the perineal body. The truth is that the main part of the muscle arising from the white line passes backwards to be attached to the coccyx and lower part of the sacrum, and meets the corresponding portion of the opposite side in the middle line, only at the tip of the coccyx. It is the anterior and smaller portion, the so-called *pubo-coccygeus*, which alone, by means of its attachment to the urethral and vaginal walls and by its blending with the corresponding muscles of the opposite side in the perineum and behind the anus, helps to strengthen the pelvic outlet across the middle line. Its outer fibres are, of course, parallel to and continuous with the *obturator coccygeus*, and hence the utterly erroneous impression which the coronal sections give of the *levator ani* arising from the white line and being inserted into the perineum. The presence of the vaginal slit is a great

<sup>1</sup> *Man. of Gyn.*, p. 48.

PLATE XXIV.

(From Savage.)

FIG. 1.

Front of Pelvis from within. (Reduced.)

1. Anterior true Ligaments of Bladder.
2. Pubo-Coccygeus.
3. Obturator Coccygeus.
4. Pudic Vein.
5. Venous Plexus.
6. Posterior layer of Triangular Ligament.
7. Pubo-Coccygeus.

FIG. 3.

Muscular part of Floor from above.  
(Reduced.)

- A. Acetabulum.
- B. Neck of Bladder.
- R. Rectum.
- P. Symphysis.
- C. Coccyx.
- S. Sacrum.
1. Anterior true Ligaments of Bladder.
2. Pubo-Coccygeus.
3. Obturator Coccygeus.
4. White Line.
5. Coccygeus.
7. Pyriformis.
8. Obturator Internus.

FIG. 2.

Levator Ani from above. (Reduced.)

1. Pubo-Coccygeus.
2. Obturator Coccygeus.
3. Coccygeus.
4. Origin of Levator Ani from Bone.
5. Coccyx.
6. Median Raphé.
- B. Bladder.
- V. Vagina.
- R. Rectum.

FIG. 4.

Muscular part of Floor from below.  
(Reduced.)

1. Clitoris.
2. Deep Fascia.
3. Crus Clitoridis.
4. Erector "
5. Bulbo-Cavernosus.
7. Transversus Perinei Superficialis.
8. Sphincter Ani Externus.
9. Pubo-Coccygeus.
10. Obturator Coccygeus.
11. Coccygeus.
- V. Vagina.
- G. Gluteus Maximus.




Fig 2.



Fig 4.

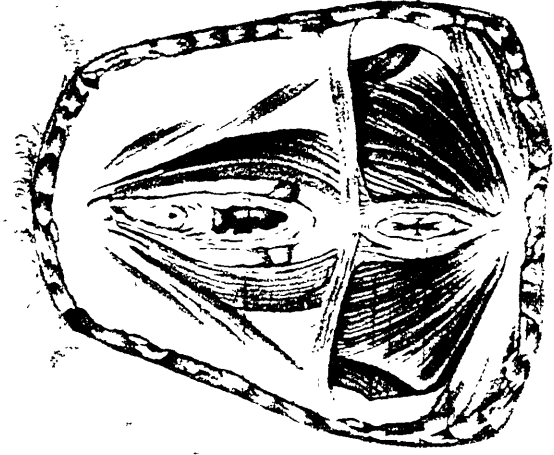




Fig 1



Fig 3



0  
1  
2  
3  
4  
5  
6  
7  
8  
9  
A  
B  
C  
D  
E  
F  
G  
H  
I  
J  
K  
L  
M  
N  
O  
P  
Q  
R  
S  
T  
U  
V  
W  
X  
Y  
Z





source of weakness to this muscle. The value of the *levator ani* to the pelvic floor has, indeed, no doubt, been greatly overstated. Kelly<sup>1</sup> goes so far as to describe the muscular part of the floor as its principal strength. If one imagine the visceral portions of the pelvic fascia and the anal fascia removed, it is not difficult to realise the comparative weakness of the muscular diaphragm in supporting the intra-abdominal pressure.

The other muscles of the pelvic floor play a very small part in strengthening it. The *transversus perinei* is a very small muscle, very difficult to define<sup>2</sup> and less developed in the female than in the male.

The *sphincter vaginae* helps, in a very small degree, to strengthen the floor through its sphincter action on the vagina (though, according to Symington,<sup>3</sup> this is very slight, its main action being merely to compress the vestibular bulb) as well as through its attachment to the clitoris in front and to the central point of the perineum behind.

The *sphincter ani* in the same way helps by its sphincter action on the anus as well as through its attachment to the central point of the perineum in front and the tip of the coccyx behind.

The *compressor urethrae* or *transversus perinei profundus*, arising from the inner aspect of the junction of the rami of the pubes and ischium, passes in front of the urethra and behind the vagina, being also attached to their walls, and blends with the corresponding muscle of the opposite side.

These four muscles are very small, and while undoubtedly helping to consolidate and strengthen the floor, play but a minor part in this capacity.

*Gluteus Maximus*.—The lower part of this muscle as it passes downwards and forwards from the side of the coccyx over the ischial tuberosity is a source of strength to the pelvic floor in its posterior and outer part.

#### D. Viscera and Passages connected with Pelvic Floor.

Certain viscera are connected with the floor; certain passages pierce the floor. Are they to be described as forming part of the floor? Hart<sup>4</sup> describes the bladder and urethra, the vagina and the rectum as forming

<sup>1</sup> *Amer. Syst. of Gyn. and Obst.*, vol. ii. p. 71.

<sup>2</sup> *Cunningham, op. cit.*, p. 43.

<sup>3</sup> *Op. cit.*, p. 60.

<sup>4</sup> *Op. cit.*

part of the floor, the uterus and appendages resting upon it. Symington<sup>1</sup> differs from Hart in saying that the upper part of the bladder, the upper part of the vagina, and the rectum are not a part of the floor. Ranney and Foster<sup>2</sup> differ from Hart in including the uterus.

Putting aside for the present all considerations regarding parturition, prolapsus uteri, the action of pessaries, etc., let us ascertain the truth from a purely anatomical standpoint.

*Bladder.*—This organ, independent of its being empty or filled, cannot but be considered as having a very intimate connection with the anterior part of the floor. *Per se* it does not resist the intra-abdominal pressure; *through its connections*, and those of the urethra, by which it is slung in the pelvis, it does perform this function to a very considerable extent.

These connections are as follows :

*Fascial*—

- Anterior and lateral *true* ligaments.
- Vesico-vaginal layer of the visceral pelvic fascia.
- Triangular ligament.

*Muscular*—

- Pubo-coccygeus division of levator ani.
- Transversus perinei profundus.

*Ordinary Connective Tissue*—

- That connecting it with the bony wall and the structures in immediate relation to the bladder and urethra.

*Peritoneal*—

- False ligaments (unimportant).

*Other structures*—

- Urachus.
- Obliterated hypogastric arteries.
- Ureters.

Of all these, its connections with the pelvic wall through the visceral layers of the pelvic fascia are the most important.

<sup>1</sup> *Op. cit.*

<sup>2</sup> "The Mechanical Action of Pessaries," *Am. Gyn. Trans.*, 1881.

Symington<sup>1</sup> and Croom<sup>2</sup> urge that the bladder should be regarded as resting upon the pelvic floor. The anatomy of the parts shows that it is embedded in the floor. Further, they say that because the organ fills and empties it cannot be considered as part of the floor. Is not this objection of the nature of a quibble? Are the anatomical connections not the same in all conditions of the bladder? If between two posts we tie a rope forming a kind of suspension bridge, and then cutting the rope in two attach between the ends a strong bag which can be filled and emptied; is the bag, because it is hollow, and capable of being filled and emptied, not to be considered as forming part of the bridge?



The analogy is a fair one. The bladder is simply a bag slung between the walls of the anterior and lower part of the pelvis.

*Vagina.*—The wall of this passage is slung in the pelvis by fascial and muscular attachments and is thereby made to form an intimate portion of the pelvic floor.

These attachments are as follows :

*Fascial*—

- Triangular ligament which it pierces.
- Vesico-vaginal layer of visceral pelvic fascia.
- Vagino-rectal layer.

*Muscular*—

- Pubo-coccygeus division of levator ani.
- Sphincter vaginae.
- Transversus perinei profundus.

*Ordinary Connective Tissue*—

- That connecting it with the bony wall.

<sup>1</sup> *Op. cit.*

<sup>2</sup> *Op. cit.*, p. 69.

*Secondary—*

Through its very firm junction with the urethra, the base of the bladder and the lower part of the rectum, it is supported by the attachments of these structures.

The analogy made in reference to the bladder will apply here again. Symington<sup>1</sup> is unwarranted, I think, in making the greater portion of the vaginal wall worthy of a place in the pelvic floor, and at the same time excluding the upper portion of the vaginal wall. His coronal section, passing through this portion, has evidently misled him as to the wider relationships of the vagina. That the upper part of the vagina is less strongly united to the bladder and rectum than the lower and larger part is to the structures in front and behind it, cannot be disputed. These connections are of small importance, *in re* the part they play in the pelvic floor. It is its lateral attachments to the pelvic wall, by means of the fascial structures of the floor, which are of chief importance. I quite admit, however, that the vesico-vaginal and recto-vaginal layers are thinner and weaker in their upper part than elsewhere.

*Rectum.*—Most of the authors already quoted are not precise in their reference to this structure. All are agreed that the lower portion of the wall of the gut forming the anus is an intimate part of the floor. It is disputed as to where the upper limit ends. The so-called *first part* of the rectum—that part provided with a mesentery—must be excluded. The *second part*, which extends from the first part to the tip of the coccyx and resting against the sacrum, coccyx, obturator-coccygeus part of the levator ani, and the coccygeus itself, to all of which it is attached, cannot be considered as forming a part of the pelvic floor, since the intra-abdominal pressure tends to push it, not out of the pelvis, but against the bony posterior wall.

From the coccyx downwards the wall is a part of the pelvic floor, its attachments being as follow:

*Fascial—*

Recto-vaginal layer of visceral pelvic fascia.

Rectal layer

<sup>1</sup> *Op cit.*, p. 55.

*Muscular—*

Pubo-coccygeus portion of levator ani.

Sphincter ani.

*Connective tissue—*

That connecting it with surrounding parts and with the bony wall.

*Secondary—*

Through its attachments to the posterior vaginal wall and perineum.

The lowest part of the rectum, therefore, is, like the vagina, a tube slung between the sides of the pelvis by the fascial tissues of the floor, supported by certain muscles as well as by the vaginal and perineal attachments.

It must be borne in mind that the gut is quite closed unless distended by flatus or fæces.

*Uterus.*—Has this organ no claim to be considered part of the pelvic floor? According to Hart it has not. He says<sup>1</sup> that it merely *rests* on the floor, not being *suspended*. He compares it to the male bladder, which he regards as resting upon the pelvic floor, its ligaments having nothing to do with its support. This statement is opposed to all the teaching of anatomists. I can find no one who at all agrees with him in this view. It is sufficient to quote from Sir William Turner<sup>2</sup>:—“Passing to the bladder are two important membranes which, together with its vessels and ducts, retain it in position. These membranes are the peritoneum and the pelvic fascia.” Hart strenuously contends that *the female bladder* is a portion of the pelvic floor, and it is impossible to understand why he should not place the *male organ* in the same category, since they are both attached to the bony wall in practically the same manner. His comparison of the uterus to bladder is, therefore, from his point of view, a bad one.

What, now, are the connections of the uterus?

1. *In the Fetus.*—The common origin of the uterus and vagina from

<sup>1</sup> *Obstetrical Transactions*, Edin., vol. xiv. p. 24.

<sup>2</sup> *Introduction to Human Anatomy*, Edin., 1882, p. 794.

the fusion of the lower parts of the Müllerian ducts must be remembered. In the third and fourth months there is no distinction between the uterus and vagina.<sup>1</sup> After this the uterine wall gradually becomes thicker, especially in the cervical portion, while a vaginal portion at the same time develops. The important fact to be noted, however, is that while the uterus is, in the foetus, relatively higher than in the adult condition, in other respects it has relations the reverse of those existing in the adult condition.

Thus, in the foetus, the cervix is both very much longer, as well as wider than the body—exactly the reverse of the adult condition. In the foetus the thickness of the cervix in proportion to the pelvic diameter is relatively greater than in the adult condition. In the foetus there is relatively much less of the uterus covered with peritoneum than in the adult. The broad ligaments are, therefore, in the foetus, relatively very small.

The cervix, which forms  $\frac{3}{4}$  of the whole uterus, is, save on its posterior surface where it is covered with peritoneum, firmly embedded in the fascial and connective tissue structures, below the peritoneum. In front it is attached to the bladder which extends across the pelvis from side to side, the vesico-vaginal layer of pelvic fascia passing between them and being connected with both; laterally it is connected with the pelvic wall. From its large size, relative to the width of the pelvic cavity, it is relatively nearer the wall than in the adult condition. In several of my cases, from being somewhat nearer one side than the other, the attachment is very short, and the cervix is practically fixed in position.

*In the foetus and new-born child it is evident, therefore, that the pelvic floor is relatively thicker, and occupies more of the pelvis than in the adult. The greater portion of the uterus—the cervix—is also, in the early period of life, an intimate part of the floor.*

2. *In the Adult.*—The change from the foetal to the adult condition is characterised by a marked increase in the length and width of the body in relation to the cervix of the uterus. The greater part of the

<sup>1</sup> Quain's *Anatomy*, Tenth Ed., vol. i. pt. i. p. 124.

organ is now covered with peritoneum, the broad ligaments being in relation to much more of the uterus than in early life. Owing also to the great growth of the pelvis, the cervix relative to the pelvic cavity is very much smaller than in the foetus, and is relatively, therefore, at a farther distance from its walls.

What, then, are the adult attachments of the uterus?

*Fascial—*

Posterior part of vesico-vaginal layer of visceral pelvic fascia.

*Connective tissue—*

That attaching cervix to bladder.

That attaching cervix to side walls of pelvis (parametric).

That attaching body to pelvis in the fold of the broad, utero-sacral and round ligaments.

*Muscular—*

Non-striped muscle in the broad, round, utero-sacral and utero-vesical ligaments.

*Secondary—*

Through its connection with the bladder and the vagina, which are, as already seen, slung in the pelvis.

What importance is to be attached to these various connections?

The vesico-vaginal layer of pelvic fascia has not directly much influence in supporting the uterus since it is very thin at its posterior limit, blending with the tissue joining the bladder and cervix.

The tissue between the bladder and cervix, though described as being loose in nature, is yet sufficient to unite them intimately. It is, indeed, partly through this junction that the pubic segment is elevated during labour by the upward tension of uterine retraction, though, of course, the tension tells mainly on the vaginal wall, with which the uterine muscle is directly continuous.

Schultze<sup>1</sup> points out that this connection is very rarely disturbed. He says that, "not only does the uterus closely follow the posterior wall of the bladder in the movements due to the variations in the quantity

<sup>1</sup> *The Pathology and Treatment of Displacements of the Uterus*, Eng. Trans., London, p. 2.

of urine contained in it, but the bladder also follows the anterior wall of the uterus so closely, when the latter organ is displaced or enlarged, that the relation of the posterior bladder wall to any tumour in or above the pelvis is of great diagnostic importance whenever there is any doubt as to the share the uterus has in the formation of the tumour."

The connective tissue between the cervix and pelvic wall on each side is loose in nature. Non-striped muscle is found in it.

What, now, is to be said regarding the broad ligaments? Have they nothing to do with the support of the uterus? The peritoneal covering is of very little practical importance in serving this purpose. Within this covering, however, is fibro-muscular and elastic tissue<sup>1</sup> which can be traced as bands in several places running from the uterus to the pelvic wall. The upper part of the ligament, which is freely movable, containing the tube and ovary, can have nothing to do with supporting the uterus. If one exercise the slightest downward pressure on the uterus in the cadaver, it is found that a line of resistance is formed in the broad ligament running from near the cervix upwards and outwards towards its upper parietal attachment. The same thing is found during pregnancy and the puerperium. In pregnancy the suspending action of the ligaments is very evident.

Sir William Turner<sup>2</sup> says that they act as lateral ligaments for the organ.

In the non-pregnant woman, in normal conditions, this may scarcely at all be present, and it may serve merely to steady the uterus, but if the other supports of the uterus be removed, or intra-abdominal pressure be increased, then the ligaments are stretched and endeavour to support the organ.

In the operation of vaginal extirpation of the uterus, after the organ has been separated from its vesical and vaginal connections, although the vagina be distended as widely as possible, the uterus does not tend to fall down, but is kept in position by its ligamentous attachments.

If at this stage the uterus be pulled down to the vulva and then let go, it is instantly drawn up again. Indeed, the difficult part of the operation is the ligaturing of these structures and the removal of the uterus from them.

<sup>1</sup> Coe, *op. cit.*, p. 216.

<sup>2</sup> *Op. cit.*, p. 841.



The utero-sacral and the utero-vesical ligaments act in much the same manner as the broad ligaments, *i.e.* they are in a condition of somewhat *elastic tension*. A. R. Simpson<sup>1</sup> has emphasised the fact that in the normal condition the uterus may be pulled down to the vulva with ease. He says that "in general the organ must descend so far as to bring the os clear through the vulva before the utero-sacral ligaments are put on the stretch. It is when these become quite tense that the patient has any sensation of special discomfort." This is undoubtedly true regarding parous women, but in nulliparæ one has to exercise more force, and even then can rarely draw the uterus so far down as in parous women.

It is the elastic nature of the broad and utero-sacral ligaments that allows the uterus to be drawn down, and which helps partly to draw it up again. (As already mentioned, this may take place even when the vaginal and bladder attachments are gone.)

Inflammation in the ligaments renders them less elastic and makes it difficult or impossible to draw down the uterus.

Where the tönicity has disappeared, and they have become stretched and thinned, it is always a very easy matter to pull down the uterus. Luschka<sup>2</sup> has considered the utero-sacral ligaments of such importance that he has given the name of *Muscularis retractor uteri* to the muscular tissue within them, and he says that they "determine and secure the normal position of the lower end of the uterus." It is objected by some that such thin folds cannot have much strength. The observations of Küstner<sup>3</sup> on this point are worthy of special note. He has made a special microscopic study of the utero-sacral folds, and he says that while in the free portion of the fold there is very little muscle, at its lateral attachment there is a dense flat muscular bundle. He considers this almost equal in strength to the round ligaments.

Coe<sup>4</sup> says that they commonly relax under the influence of an anæsthetic. It is to be noted also that the utero-sacral ligaments run backwards from the uterus in a direction practically parallel with the vagina. Through this

<sup>1</sup> *Contrib. to Obstet. and Gyn.,* Edin., p. 191.

<sup>2</sup> *Anat. d. Menschl. Beckens,* p. 360.

<sup>3</sup> *Die Normale und Path. Lagen u. Beweg. des Uterus,* p. 44.

<sup>4</sup> *Op. cit.,* p. 221.

tension they undoubtedly also act through the cervix on the vagina, helping to keep up its upper end. Foster<sup>1</sup> indeed, says that the vagina, attached to the bone in front through its connections, forms with the utero-sacral ligaments through the medium of the cervix an antero-posterior beam of considerable power.

The vaginal attachment is, it seems to me, a very important support of the uterus. The vagina is slung in the pelvis by the fascial layers around it, and by its attachment to the bladder, urethra, etc. The uterus being attached to the upper end of its wall is, in consequence, also supported.

Schultze corroborates this view. He says<sup>2</sup> that the fixation of the vagina and its immediate surroundings is an essential factor in securing the position of the uterus.

It is rather remarkable that Hart should place no value whatever on the supporting or even steadying power of these ligaments in the non-pregnant condition, but that he should, when explaining the action of the retracting uterine wall on the pelvic floor during labour, say<sup>3</sup> that, as a result of the longitudinal muscle-bundles which pass into them from the uterus, they afford *external fixed points for uterine action*, whereby during the pains the uterus is steadied. Surely this steadying and fixing power must be no inconsiderable one.

From an anatomical standpoint it is evident therefore :

*a.* That the uterus does not merely rest upon the pelvic floor as a chair or table rests upon a house floor, as Hart<sup>4</sup> says it does, but that, through its cervical portion, it is embedded in and forms part of the pelvic floor.

*b.* That, being suspended by its vaginal and bladder attachments, by the broad and utero-sacral ligaments, it, therefore, as part of this suspension bridge arrangement, helps to resist the intra-abdominal pressure in the same manner though not in the same degree as the bladder. This resistance is less than that offered by the fascial layers lower in the pelvic floor.

<sup>1</sup> *Amer. Gyn. Trans.*, 1881.

<sup>2</sup> *Op. cit.*, p. 1.

<sup>3</sup> *Obstet. Trans.*, Edin., vol. xiv. p. 65.

<sup>4</sup> *Ib.*, vol. v. pt. 2, p. 65.

## THE FLOOR STUDIED BY FROZEN SECTIONS.

The vertical mesial section shows, undoubtedly, in the non-pregnant woman, with parts intact, the appearance first described by Hart.<sup>1</sup>

The pelvic floor stretches from pubes to sacrum broken only by the urethra, vagina, and anus. The vagina is a closed slit running practically parallel with the brim, and may be considered as dividing the floor into two parts—the pubic and sacral segments. Excluding the uterus, the former has a triangular shape and the latter an irregular quadrilateral shape.

Hart describes the former as consisting of bladder, urethra, anterior vaginal wall, and bladder-peritoneum. Its attachment to the pubes is a loose one, being separated from it by a pyramidal mass of fat; the posterior bladder wall is loosely attached to the anterior vaginal wall, while the urethra and anterior wall are closely blended.

He describes the sacral segment as consisting of rectum, perineum, posterior vaginal wall, and "strong resistant muscular and tendinous tissue"; the posterior vaginal wall and anterior rectal wall are loosely connected, as far down as the apex of the perineal body.

From these data he generalises as follows:

"The pubic segment is loose in texture, has only a loose bony attachment anteriorly, and will evidently permit of mobility in an up and down direction. The sacral segment is made up of dense tissue, is strong in structure, has a strong dovetailed attachment to the sacrum, and is only movable downwards when it revolves round the sacrum and coccyx as a whole." The weakness in the floor, due to the presence of the vagina, is in the virgin practically of no importance. The pubic segment cannot slip past the sacral because it is firmly pressed against it, the pressure acting at right angles to the vagina.

These are the data upon which Hart has chiefly based his explanation of the mechanism of parturition, and to a considerable extent that of prolapsus uteri.

<sup>1</sup> *Obstet. Trans., Edin., vol. v. pt. 2, p. 65.*

Where are the fallacies in this view of the floor?

A false impression as to the anatomical nature of the floor is given as well as of its mechanics.

a. The floor is only divided into these segments by the width of the vagina. The average width varies between, say 1 in. and  $1\frac{2}{3}$  in.; the average width of the pelvic outlet is 5 in. The pelvic floor is, therefore, only divided into a pubic and a sacral segment in  $\frac{1}{4}$  or  $\frac{1}{5}$  of its width.

b. Hart's description leaves out of account entirely the strong fascial layers which I have already described, and which are so intimately connected to form the fascial framework of the floor. He describes strong tendinous and muscular tissues in the sacral segment, leaving them entirely out of account in the pubic segment. I have already shown that the visceral layers of the pelvic fascia are most strongly developed in the anterior part of the pelvic floor, while the *pubo-coccygeus* portion of the *levator ani* and the *transverse perinei profundus* have certainly as much influence in the anterior part as in the posterior part of the floor. Hart's description takes no notice either of the triangular ligament or of the important layer of deep superficial fascia under the skin.

These omissions are due to the fact that in sections these fascial structures appear so blended with the tissues about them that they are not distinguished.

c. Though in the middle line the bladder is separated from the lower part of the symphysis by loose cellular tissue and fat, behind the upper part it is close to the bone and more firmly attached. Certainly on each side, as my section (plate XIII.) shows, it is more closely united with the bone. My section as well as Symington's<sup>1</sup> shows that undoubtedly the pubic segment is firmly attached to the lower margin of the pubes. The loose cellular tissue surrounding the bladder has not the first part to play in allowing of or limiting the movements of that organ. *It is its fascial attachments—its true ligaments.* The range of movement of which the bladder is capable is in reality chiefly the range possessed by these ligaments.

All changes in position in the pubic segment, likewise, depend primarily

<sup>1</sup> *Obstet. Trans.*, Edin., vol. v. pt. 2, pp. 51, 60.

upon the range of movement and elasticity of its *fascial* attachments to the bone, secondarily of its muscular and other attachments.

Hart dwelt upon the "loose nature" of the pubic segment and its "loose attachment" to the bone as necessary in explaining the disposition of the segments of the floor in Braune's Second Stage case. Such an explanation might be necessary were the pubic segment drawn up to the extent Hart thought it to be. (The nature and mechanism of the changes during parturition I shall discuss under the heading on page 95.)

d. The description of the pubic segment as resting upon the sacral segment is a conclusion based entirely upon the fallacious conception of the pelvic floor which the vertical mesial section gives, and is entirely out of keeping with the structure of the floor as determined by dissection. The two segments are intimately connected; the fascial and muscular suspensory arrangement of the floor is common to both. The artificial division of the floor is not at all necessary, and is only of service in aiding us to comprehend more clearly the changes which take place during labour.

#### THE FLOOR IN RELATION TO PREGNANCY.

During pregnancy there is considerable softening of the tissues of the floor. This is of great importance in facilitating the disturbance and stretching of the parts occasioned by parturition. As regards the disposition of the floor as a whole, the chief change is that attendant upon the increased weight of the pregnant uterus, but partly also upon the softening of the tissues.

In order to determine the amount of sinking of the floor thus caused, I have carefully studied two *cadavera*, the one in the fifth month of pregnancy,<sup>1</sup> and the other in the eighth month,<sup>2</sup> as well as the other cases previously published. I have arranged in tabular form the facts acquired by measurements in regard to the following points:

1. The pelvic floor projection and skin distance between the coccyx and the lower border of the symphysis pubis.
2. The change in the position of the urethral orifice.

<sup>1</sup> *Lab. Rep. R.C.P.E.*, vol. iv.

<sup>2</sup> Barbour and Webster, *Lab. Reports R.C.P.E.*, vol. ii.

3. The change in the position of the junction of the urethra with the bladder (base of bladder).

4. Thickness of the tissue between the lower margin of the symphysis and the vagina in line with the vertical axis of the former.

5. The depth of the utero-vesical pouch of peritoneum.

6. The position of the anterior and posterior lips of the cervix.

The following table shows that during pregnancy the pelvic floor projection is increased as well as the skin distance from coccyx to symphysis; that the base of the bladder, the urethral orifice, the cervix, the bottom of the utero-vesical pouch, are lower than in the nulliparous condition. All these facts show that the pelvic floor is bulged downwards somewhat during pregnancy.

TABLE.

	Nullipara.	Webster's 5 mo. Preg.	Barbour and Webster's 8 mo. Preg.	Braune's 9 mo. Preg.
	In.	In.	In.	In.
Pelvic floor proj. . . . .	1	$1\frac{5}{8}$	2	$3\frac{3}{4}$
Skin dis. from Coc. to Sym. . . . .	$5\frac{3}{10}$	$5\frac{1}{2}$	$6\frac{1}{2}$	10
Dist. of Ureth. Or. below brim . . . . .	$2\frac{3}{8}$	$2\frac{5}{8}$	$2\frac{5}{8}$	$2\frac{3}{4}$
Dist. of Ureth. Or. below Sym. . . . .	$\frac{1}{4}$	1	$1\frac{1}{4}$	$1\frac{1}{4}$
Dist. of junct. of Blad. and Urethra below brim . . . . .	$2\frac{1}{4}$	3	$2\frac{1}{2}$	$2\frac{3}{4}$
Thick. of Tissue bet. Pub. and Vag. . . . .	$\frac{5}{8}$	$1\frac{1}{8}$	$1\frac{3}{8}$	$1\frac{3}{4}$
Depth of Ut. Ves. Pouch below brim . . . . .	$2\frac{1}{4}$	$2\frac{3}{16}$	$2\frac{3}{8}$	$2\frac{3}{8}$
Dist. of O. E. below brim post. . . . .	$2\frac{1}{2}$	4	$3\frac{7}{16}$	$3\frac{1}{2}$
Dist. of O. E. below brim ant. . . . .	$2\frac{1}{2}$	4	$3\frac{7}{16}$	$3\frac{5}{8}$
Dist. of O. I. below brim ant. . . . .	$2\frac{1}{4}$	$3\frac{1}{8}$	$2\frac{3}{4}$	$2\frac{3}{8}$
Dist. of O. I. below post. . . . .	$2\frac{1}{4}$	$3\frac{1}{8}$	$2\frac{3}{4}$	$2\frac{3}{8}$

For sake of comparison I have added the corresponding measurements in the nullipara.

## THE FLOOR IN RELATION TO LABOUR.

The disposition of the pelvic floor during the progress of labour has been the subject of recent discussion. Hart,<sup>1</sup> from a study of the vertical mesial section of Braune's Second Stage case, arrived at the following conclusions:

1. The pubic segment is hauled up partly above the brim by the upward tension of uterine retraction.
2. The sacral segment is driven downwards.
3. The bladder is lifted up above the symphysis and stripped of its peritoneum.
4. The urethra is elongated.

Symington,<sup>2</sup> on the other hand, thinks that "the pubic segment is pushed downwards and forwards under the pubic arch," and "that the bladder is the only part of Hart's pubic segment that is not depressed."

There is thus a very decided difference of opinion between these two authors. From the careful study of two *cadavera*,<sup>3</sup> the one in the first stage of labour, the other in the second stage, as well as of cases published by Barbour,<sup>4</sup> Winter,<sup>4</sup> Chiari,<sup>4</sup> and Saexinger,<sup>4</sup> since Hart's work was written, I am in a position to show that Symington's views are entirely erroneous, and that Hart's views as to the drawing-up of the pubic segment are correct as to the method by which this takes place, though not correct as to the extent of elevation which takes place.

The method adopted by me in investigating this question was the following: I arranged the vertical mesial sections in order according to the degree to which labour had proceeded, and measured corresponding points in the floor in the various sections in reference to the anatomical brim conjugate and also to the symphysis.

In this way one can follow throughout labour the changes in position taken up by these various points. By making a diagram, placing in it the

<sup>1</sup> *The Structural Anatomy of the Female Pelvic Floor*, p. 14.

<sup>2</sup> *Op. cit.*, p. 61.

<sup>3</sup> Published in conjunction with Dr. Barbour, *Lab. Reports R.C.P.E.*, vol. ii.

<sup>4</sup> Vide *Bibliography*.

points according to the measurements obtained and joining the corresponding points, one might graphically represent with considerable exactness the direction and extent of movement of each point.

The measurements were made in reference to the following :

1. The pelvic floor projection and skin distance between the coccyx and the lower border of the symphysis.
2. Change in the position of the urethral orifice.
3. Change in the position of the junction of the urethra with the bladder (base of bladder).
4. Thickness of the tissue between the lower margin of the symphysis and the vagina in line with the vertical axis of the former.
5. The depth of the utero-vesical pouch of peritoneum.
6. The position of the os externum and os internum.
7. Changes in the relation of the junction of urethra and bladder (base of bladder), and the cervix to the pubes and to one another.

TABLE I.

PELVIC FLOOR PROJECTION AND SKIN DISTANCE FROM COCCYX TO LOWER MARGIN OF SYMPHYSIS.

Stage.	Whose Section.	Pelvic Floor Projection.	Skin Dis. from Coccyx to Sym.
Nullipara	Average	In. 1	In. 5 $\frac{1}{4}$
Pregnancy, 5th mo.	Webster's	1 $\frac{5}{8}$	5 $\frac{1}{2}$
" 8th "	Barbour and Webster's	2	6 $\frac{1}{2}$
" 9th "	Braune's	3 $\frac{3}{4}$	10
First Stage	Barbour and Webster's	1 $\frac{3}{4}$	6 $\frac{1}{2}$
"	Winter's	2 $\frac{1}{4}$	6 $\frac{1}{2}$
"	Schroeder's	3 $\frac{1}{2}$	8 $\frac{1}{2}$
"	Barbour's	1 $\frac{1}{2}$	5 $\frac{1}{2}$
Second Stage	Braune's	3 $\frac{5}{8}$	9 $\frac{1}{2}$
"	Chiari's	2 $\frac{1}{2}$	7 $\frac{1}{4}$
"	Barbour and Webster's	2	6 $\frac{1}{2}$

(In the other published sections the coccyx is not indicated, so that accurate measurements cannot be made.)



This table (I.) shows that in the early-part of the first stage there is scarcely any change; that in the first part of the second stage, while the bag of membranes persists, the pelvic floor projection is probably increased; and that later, while the head is low down it is diminished because of the coccyx being pushed downwards and backwards.

The following table (II.) shows that the urethral orifice in the first stage

TABLE II.  
CHANGE IN THE POSITION OF THE URETHRAL ORIFICE.

Stage.	Whose Case.	Distance in front of the Vertical Axis of Pubes.	Distance below Brim.	Distance below Lower Edge of Symphysis.
Nullipara	Average	In. $\frac{1}{4}$	In. $2\frac{1}{4}$ - $2\frac{1}{2}$	In. $\frac{1}{4}$
Pregnancy, 5th mo.	Webster's	$\frac{1}{4}$	$2\frac{5}{8}$	1
" 8th "	Barbour and Webster's <sup>1</sup>	$\frac{1}{4}$	$2\frac{3}{8}$	$1\frac{1}{4}$
" 9th "	Braune's	$1\frac{1}{4}$	$2\frac{1}{4}$	$1\frac{1}{4}$
First Stage	Schroeder's	1	$2\frac{1}{4}$	$3\frac{3}{8}$
"	Barbour and Webster's	$\frac{3}{4}$	$2\frac{1}{4}$	$\frac{5}{8}$
"	Winter's	$\frac{3}{4}$	$2\frac{3}{8}$	$\frac{1}{2}$
"	Barbour's	$\frac{3}{4}$	$2\frac{3}{8}$	$\frac{3}{4}$
Second Stage	Braune's	$1\frac{1}{8}$	2	$\frac{1}{2}$
"	Chiari's	$(\frac{1}{2})$	( $2\frac{3}{4}$ )	$(\frac{7}{8})$
"	Barbour and Webster's	$2\frac{1}{4}$	$2\frac{1}{4}$	$\frac{1}{4}$

of labour is on a somewhat higher level, and that it is not anterior (probably slightly posterior) to the position occupied by it at the end of pregnancy; that, during the second stage, it occupies a still higher level; and that, while an abnormally long persisting bag of membranes may cause it to appear scarcely moved at all backwards, in the more normal condition of the parts it is posterior to the plane occupied by it during the first stage. These facts are not in accordance with the theory of the pushing downwards and forwards of the pubic segment.

<sup>1</sup> Bladder partly distended.

TABLE III.

CHANGE IN THE POSITION OF THE JUNCTION OF THE URETHRA WITH THE BLADDER.

Stage.	Whose Case.	Distance below Brim.	Distance behind Vertical Axis of Symphysis.
Nullipara	Average	In. $2\frac{1}{4}$	In. $\frac{5}{8}$
Pregnancy, 5th mo.	Webster's	3	$\frac{5}{8}$
" 8th "	Barbour and Webster's	$2\frac{1}{4}$	$\frac{1}{4}$
" 9th "	Braune's	$2\frac{3}{4}$	$\frac{1}{4}$
First Stage	Schroeder's	$2\frac{7}{8}$	$\frac{1}{2}$
"	Barbour and Webster's	$2\frac{1}{4}$	$\frac{1}{2}$
"	Winter's	$2\frac{3}{8}$	$\frac{1}{2}$
"	Barbour's	$2\frac{5}{8}$	$\frac{1}{4}$
Second Stage	Braune's	$2\frac{1}{4}$	Just about in line with
"	Chiari's	$1\frac{1}{2}$	$\frac{1}{2}$
"	Barbour and Webster's	$1\frac{3}{4}$	$\frac{1}{2}$

This table shows that the lowest part of the bladder, viz. the point of entrance of the urethra, is, during the early part of the first stage, scarcely altered in position (being neither raised nor pushed forwards), but that during the second stage it is considerably elevated.

TABLE IV.

THICKNESS OF TISSUE BETWEEN LOWER MARGIN OF PUBES AND VAGINA IN LINE WITH VERTICAL AXIS OF PUBES.

Stage.	Whose Case.	Thickness of Tissue.
Nullipara	Average	In. $\frac{5}{8}$
Pregnancy, 5th mo.	Webster's	$1\frac{1}{4}$
" 8th "	Barbour and Webster's	$1\frac{3}{8}$
" 9th "	Braune's	$1\frac{1}{4}$
First Stage	Schroeder's	$1\frac{1}{8}$
"	Barbour and Webster's	$1\frac{3}{8}$
"	Winter's	$1\frac{1}{8}$
"	Barbour's	$1\frac{1}{8}$
Second Stage	Braune's	$\frac{1}{2}$
"	Chiari's	$\frac{1}{2}$
"	Barbour and Webster's	$\frac{1}{2}$

This table shows that the thickness of this tissue, during labour, is not increased, as it certainly would be were there a pushing downwards of the pubic segment.

TABLE V.

## DEPTH OF UTERO-VESICAL POUCH OF PERITONEUM BELOW BRIM.

Stage.	Whose Section.	Distance below Brim.
Nullipara	Average	In. 2 $\frac{1}{4}$
Pregnancy, 5th mo.	Webster's	2 $\frac{3}{8}$
" 8th "	Barbour and Webster's	2 $\frac{1}{4}$
" 9th "	Braune's	2 $\frac{3}{8}$
First Stage	Winter's	1 $\frac{1}{8}$
"	Barbour and Webster's	2 $\frac{1}{4}$
"	Schroeder's	1 $\frac{3}{8}$
"	Barbour's	2 $\frac{1}{8}$
Second Stage	Braune's	Above Brim.
"	Chiari's	"
"	Barbour and Webster's	"

This table shows that the utero-vesical pouch is not made to descend when labour commences, but is, on the contrary, elevated, *i.e.* stripped upwards from the bladder, and that from a very early stage of labour.

[TABLE VI.]

TABLE VI.

## POSITION OF OS EXTERNUM AND OS INTERNUM.

Stage.	Whose Case.	Distance below Brim Anteriorly.	Distance below Brim Posteriorly.
	<i>a. Os Externum.</i>		
Nullipara	Average	In. $2\frac{1}{2}$	In. $2\frac{1}{2}$
Pregnancy, 5th mo.	Webster's	4	4
" 8th "	Barbour and Webster's	$3\frac{7}{8}$	$3\frac{7}{8}$
" 9th "	Braune's	$3\frac{1}{8}$	$3\frac{1}{2}$
First Stage	Schroeder's	$3\frac{1}{2}$	$4\frac{1}{8}$
"	Barbour and Webster's	$3\frac{1}{2}$	$3\frac{1}{2}$
"	Winter's	$3\frac{1}{4}$	$3\frac{7}{8}$
"	Barbour's	$3\frac{1}{2}$	$3\frac{1}{2}$
Second Stage	Braune's	$1\frac{1}{4}$	$3\frac{1}{4}$
"	Chiari's	1	$2\frac{1}{4}$
"	Barbour and Webster's	$1\frac{1}{4}$	$1\frac{1}{4}$
	<i>b. Os Internum.</i>		
Nullipara	Average	$2\frac{1}{4}$	$2\frac{1}{4}$
Pregnancy, 5th mo.	Webster's	$3\frac{1}{8}$	$3\frac{1}{8}$
" 8th "	Barbour and Webster's	$2\frac{1}{4}$	$2\frac{1}{4}$
" 9th "	Braune's	$2\frac{3}{8}$	$2\frac{2}{3}$
First Stage	Winter's	$2\frac{3}{4}$	3
"	Barbour and Webster's	$2\frac{5}{8}$	$2\frac{2}{3}$
"	Schroeder's	$3\frac{1}{2}$	4

These tables show that during the first stage, although the cervix is thinned and taken up (well marked in Schroeder's section), so that the os internum is moved further away from the os externum, it is really at a lower level than before labour began. This is chiefly true of the posterior wall, where the taking-up is most marked; the tables show it to be on a considerably lower level. The anterior wall is only slightly depressed in its upper part, due to the pressure of the uterine contents on its softened structure. The lower level occupied by the posterior wall

is due to the same cause plus greater thinning-out of it, as well as of the posterior lower uterine segment.

The tables also show that during the second-stage the os externum is higher in position. It is impossible to trace the os internum during the second stage, as its position has not been determined in the sections.

It is to be noticed that the cases of labour which I have included in these tables are those in which the full time had been reached, and in which the head or breech presented. In Barbour and Webster's Eighth Month pregnancy case only did the breech present, but there is no reason to suppose that the measurements would differ to any extent from similar cases with the head presenting.

Saexinger's case of labour at the end of the eighth month I have not included, although in such a case it is most probable that the conditions are similar to those in a full-time labour. An examination of his vertical mesial section gives us the following facts, viz.—

1. The pelvic floor projection is only  $2\frac{1}{8}$  in., while the skin distance from the coccyx to the lower margin of the symphysis is  $6\frac{1}{2}$  in.

2. The urethral orifice is at a higher level than in any of the other first stage cases, being about the same distance in front of the vertical axis of the pubes, and only  $\frac{1}{4}$  in. below the symphysis.

3. The point of junction of the urethra and bladder is higher than in any other of the first stage cases, and nearer the pubes than in the majority of them.

4. There is less thickness of tissue between the lower margin of the symphysis and the vagina than in any of the others.

5. The utero-vesical pouch is much higher, being, indeed, above the brim.

6. The os externum is higher.

These facts greatly strengthen the deductions already made, as well as others to be presently made, from the measurements of the full-time cases given in my tables.

We are now in possession of a sufficient number of cases to enable us to trace the movement of the pelvic floor during a considerable part of the first stage and through nearly the whole of the second stage.

We have as yet no section of a late ninth month first stage, but its want will scarcely be felt in our study of this process, with the facts already possessed by us.

It is evident that the beginning and continuation of labour would be accompanied with a pushing downwards of the pubic and the sacral segments by the advancing child, were there no restraining force acting at the same time. We have seen that there is, however, no pushing down of the pubic segment during the first stage, because—

1. The urethral orifice is neither inferior nor anterior to the position occupied by it immediately before labour.
2. The junction of the urethra and bladder (a point certainly in the pubic segment) is not at a lower level.
3. The thickness of the tissue between the lower margin of the pubes and the vagina is not increased but is rather diminished.
4. The anterior cervical wall, as a whole, is not at a lower level.

There must, therefore, be from the very commencement of labour some force acting in opposition to that which tends to push down the pubic segment. This restraining force is undoubtedly, as Hart has pointed out, the upward traction exercised by the contracting uterus on the lower uterine segment and cervix through the attachment of the latter to the bladder and vagina by means of connective tissue. This upward traction is, however, from the first also counteracted by the thinning-out of the lower uterine segment and cervix, so that it barely serves during the early part of the first stage to keep the pubic segment in its pre-parturient position. There are, as it were, three forces in operation, viz.—

- a. The upward traction of the uterus.
- b. The downward pressure of the uterine contents.
- c. The thinning-out of the lower uterine segment and cervix (although it is scarcely exact to call this last a *force*).

For a time in the first stage these so oppose one another that the pubic segment is not moved at all. With the advance of this stage the upward traction of the uterus becomes stronger, and the pressure of its contents on the pubic segment weaker, as the sacral segment is more and more pushed on from above, and gradually actual elevation of the

pubic segment begins. As we follow its movement during the second stage we find it still continues to be elevated, because the sections show :

1. That the point of junction of the urethra and the bladder is higher in the pelvis and nearer the brim.
2. That the urethral orifice is higher in position.
3. That the thickness of tissue between the lower margin of the pubes and the vagina is greatly diminished.
4. That the os externum is much higher in position.

Having thus established the fact that the pubic segment is elevated, we may now consider more minutely some details of the process.

Though for a time in the early part of the first stage there is no actual elevation of the pubic segment on account of the antagonism between the forces acting upon it, we find taking place from the first an actual elevation of the utero-vesical pouch, caused by the stripping of the peritoneum from the posterior part of the upper surface of the bladder by means of the upward traction of the uterus.

If we compare Tables V. and VI. b, we find that, whereas in pregnancy the os internum and the bottom of the utero-vesical pouch are the same distance below the brim (in vertical mesial section), in the first stage sections the latter is at a higher level. This change must be accounted for by the fact that the thinning-out and elongation of the lower uterine segment take place chiefly immediately above the cervix.

When, after a time, the uterine traction becomes stronger, the cervix is gradually elevated, and with it that part of the bladder (the posterior wall) which is attached to it. Then the upper and posterior walls of the bladder are made to slide upwards and forwards over the base. Then the base in its turn, together with the rest of the posterior part of the pubic segment, moves in the same direction.

This process goes on until the bladder lies behind and partly above the pubes, its cavity being continuous below with the upper part of the urethra, and parallel to the posterior surface of the pubes, and also to the cervix which lies close behind it. The changes in relation of the

cervix and junction of urethra with bladder to one another and to the pubes are well brought out in the following table :

Stage.	Whose Case.	Distance of Junction of Urethra with Bladder behind the Vertical Axis of the Symphysis.	Distance of Cervix from Axis of Pubes.
Nullipara	Average	In. $\frac{5}{8}$	In. 2
Pregnancy, 5th mo.	Webster's	$\frac{5}{8}$	$1\frac{1}{2}$
" - 8th "	Barbour and Webster's	$1\frac{1}{2}$	$1\frac{11}{16}$
" 9th "	Braune's	$1\frac{1}{4}$	$1\frac{3}{8}$
First Stage	Schroeder's	$\frac{1}{2}$	1
"	Barbour and Webster's	$\frac{1}{2}$	$1\frac{7}{8}$
"	Winter's	$\frac{1}{2}$	$1\frac{3}{4}$
Second Stage.	Braune's <sup>1</sup>	(Just about in line with it)	$\frac{1}{2}$
"	Chiari's <sup>1</sup>	$(\frac{3}{8})$	$\frac{11}{16}$
"	Barbour and Webster's	$\frac{3}{8}$	$\frac{11}{16}$

Accompanying the uterine traction are two other conditions which help to force the pubic segment forwards against the bone, viz. the stiffening and passing forwards of the uterine wall during the pains and the compression by the head after it has descended through the dilated cervix into the pelvic cavity. At this stage, I believe, the head does push the pubic segment, but pushes it upwards and forwards, and this is due to the strong upward and forward resistance of the sacral segment against the head.

The bladder is not at all drawn up into the abdomen to the degree hitherto supposed; the greatest part of it lies in the pelvis. In Braune's second stage case its highest point is  $\frac{3}{4}$  in. above the brim conjugate, in Chiari's 1 in., and in Barbour and Webster's  $1\frac{3}{8}$  in. In the latter, it is to be observed, labour is further advanced than in the other cases; here the position of the organ was well determined, the great mass of it lay behind the pubes having a transverse breadth of nearly five inches.

In both Braune's and Chiari's cases the urethral opening of the bladder

<sup>1</sup> Although Braune and Chiari do not mark the upper limit of the urethra, we may almost exactly place it in their plates by measuring the length of the canal. We now know that the urethra is not elongated in labour.



is lower than in Barbour and Webster's case. The explanation of these differences is to be found, most probably, in the unusual duration of the bag of membranes in an unbroken condition in the former two; the downward and forward pressure exerted by it resists somewhat the upward traction of the uterus by pushing the anterior part of the pubic segment against the pubes.

It seems to me, therefore, that from the facts obtained by a careful study of all the cases hitherto published, we are justified in concluding beyond doubt—

1. That the pubic segment is not at all pushed downwards during labour.
2. That, on the contrary, it is elevated, and mainly by the upward traction of the uterus, as Hart first pointed out.
3. That this traction is at work from the very commencement of labour, but that owing to opposing forces it does not begin to raise the segment before the first stage has advanced for a certain period; it is not, however, till the second stage that its effects are marked. The segment is not made to slide up by reason of its supposed loose attachment to the bone.

If the tables be examined it will be seen that the lower and anterior portion of the segment is very little raised; the main elevation is in the upper and posterior part, *e.g.* junction of bladder and vagina with cervix. This part is elevated and moved to the front, *i.e.* it may be described as moving in the arc of a circle whose centre is the line of attachment to the lower part of the pubes of the anterior visceral layer of the pelvic fascia or anterior true ligaments of the bladder. In the general softening of the tissues these ligaments probably take part, and so may be a little stretched.

4. That, in the second stage, the advancing child helps to compress the pubic segment thus moved forwards, and that when low down in the pelvis, the upward and forward resistance of the sacral segment increases still more the pressure.

5. That the greater part of the bladder is not drawn above the pubes, as Hart thought it to be, but that it really remains behind the pubes, only a small portion being above it; the walls are then anterior and posterior, the urethral opening being at or near the most dependent part.

6. That the urethra is not elongated during labour.

7. That the peritoneum is stripped from a large part of the bladder.
8. That the elevation of the pubic segment may be somewhat retarded by long persistence of the bag of membranes.
9. That the sacral segment is driven down.
10. That the parametric and para-vaginal connective tissues are greatly stretched during labour.

#### THE FLOOR IN RELATION TO PROLAPSUS UTERI.

Hart's description of the nature and mechanism of this affection is based chiefly upon the view of the pelvic floor obtained by a study of coronal and transverse sections.<sup>1</sup> Examined in this way, he finds that a ring of loose connective tissue can be traced in the pelvic floor running in the following direction; beginning behind the pubes as the retropubic fat, it passes back on each side, on the inner aspect of the *obturator internus* and upper portion of the *levator ani*, and then between the posterior vaginal and anterior rectal wall. This ring divides the pelvic floor into

(a) *The entire displaceable portion*, consisting of bladder, urethral and vaginal walls, with the uterus and appendages resting upon it.

(b) *The entire fixed portion*, consisting of all outside the inner aspect of the *levator ani* and all behind the posterior aspect of the posterior vaginal wall.

The loose tissue between these is a line of weakness.

The entire displaceable portion is supported by the entire fixed portion. In prolapsus uteri the former is driven down past the other, this line of weakness forming the "line of cleavage" between the two.

Is Hart's division of the pelvic floor in this way in keeping with the anatomical details furnished by dissection? Does such an important line of weakness exist in the pelvis? Yes, *if we leave out of consideration the pelvic fascia*, as Hart has done. There is no doubt whatever that there is in the pelvis, as I have already pointed out, loose tissue behind the pubes, at the sides of the bladder, vagina, and rectum, and between the upper part of the vagina and the rectum. Hart's description, however, gives one the

<sup>1</sup> *Op. cit.* *Topographical and Sec. Anat. of the Female Pelvis*, Edin., 1885.

erroneous impression that this tissue is the sole link between the structures internal and those external to it, and that because of *its weakness* it is possible for the internal to slide down upon the external. The important structures which have been overlooked are the visceral layers of the pelvic fascia, forming ligaments for bladder and urethra, for vagina and rectum, as well as the triangular ligament, the deep superficial fascia and the anal fascia which blend with one another in the perineum, and also with some of the visceral layers, thus binding together inferiorly the structures described as "entire displaceable," and those described as "entire fixed." Verily, the pelvic floor described without the pelvic fascia ranks on the same footing as a house described without foundations, girders, or rafters.

It is as if we were to make a transverse section of a barrel *between the hoops* and then to describe the whole barrel as consisting of a series of cylindrically arranged staves (without reference to the very important though few and small hoops).

The truest idea of the pelvic floor is gained when we consider it as having a strong fascial framework in which are suspended bladder, vagina, uterus, and rectum, and having in connection with it certain muscular structures which give additional strength. The floor thus as a whole resists intra-abdominal pressure, the anterior and posterior parts of the floor being intimately connected by the fascial and muscular tissues. Anatomically, therefore, it can be proved that the so-called "displaceable portion" does not merely *rest* on the "fixed portion" in such a manner as that, when the support of the latter is gone, the former falls down. Clinically also, it seems to me, the facts are against this view. Many cases of perineum ruptured even into the anus are not followed by prolapse; whereas, if Hart were correct, in every case, owing to the loss of support, this should occur.

Prolapse of the bladder, urethra, and vagina with the uterus, in reality, it will be found, depend upon the power that the fascial and other tissues suspending them between the bony pelvic walls possess of resisting intra-abdominal pressure. If the former be weakened, or the latter increased, or both these conditions be combined, prolapsus occurs.

The nature and mechanism of prolapsus uteri is still a very disputed

question. There are certain points, however, which are granted by everybody. These are as follows :

Prolapse may be acute, subacute, or chronic ; the last is by far the most common variety, and is the form ordinarily referred to under this term. It is extremely rare in women who have never been pregnant. It is rare in women who are in good circumstances and lead a comfortable life, even though they are multiparæ.<sup>1</sup> It is common among poor hard-working women.

The influence of pregnancy and labour on the floor is as follows :—Its tissues are softened and stretched by the increased intra-abdominal pressure as well as during the birth of the child, when it may also be torn. After labour the floor bulges down more because of this stretching. Among the poor, women usually rise too soon from bed and begin too early to do such work as lifting, carrying, etc. Hence the greater tendency to a prolapse of the floor among them.

What part does the perineum play ? There is no doubt that it is usually found to be more or less ruptured. Thomas,<sup>2</sup> who described the perineal body as a wedge supporting the anterior part of the floor, said that the destruction of the wedge resulted in the prolapse. This is no longer believed in. Hart says that rupture of the perineum is rupture of the "entire fixed segment," and that thus the "entire displaceable" portion can be driven down more easily. That rupture of the perineum favours prolapse when other causes are in operation is undoubtedly true. It does so, however, not because a supporting wedge is removed, according to Thomas, nor because a supporting segment of the floor is weakened. These mechanical explanations are not in keeping, as I have shown, with the anatomy of the floor. Neither is it, as is so often said, because the junction of the *levator ani* is torn through. In an ordinary mesial tear passing even into the anus, only a small part of the *pubo-coccygeus* can be torn, viz. those fibres which are deflected inwards to the perineum from the main mass of the muscle which passes back on each side of the middle line to the coccyx. The most important structures torn through are the various fascial

<sup>1</sup> Schultze, *The Pathology and Treatment of Displacements of the Uterus*, Eng. Trans. 1888, p. 277.

<sup>2</sup> "The Female Perineum ; its Anat., Phys., and Path.," *Am. Jour. of Obst.*, April 1880.

tissues which meet in the perineum—a point which has been entirely overlooked.

These are the following :

1. Triangular ligament—anterior and posterior layers.
2. Recto-vaginal visceral layer.
3. Anal fascia.
4. Deep superficial fascia.

It is evident that such a rupture must lead to a weakening of the suspensory framework of the floor, especially in its anterior half.

The tearing of the small muscles, *e.g.* *transversus perinei profundus*, *transversus perinei*, *sphincter vaginae*, and *sphincter ani*, gives them afterwards but a small share in the support of the floor, though their loss is of minor importance when compared with that of the fascial structures.

In many women, chiefly among the well-to-do, who undergo little physical exertion, these losses may be present for a long time and yet no prolapse occur. This is because the rest of the suspensory framework is sufficient to resist the normal intra-abdominal pressure. If in such, however, chronic bronchitis supervene, the result may be that a prolapse occurs because the intra-abdominal pressure is too strong for the weakened floor. It is well known that there may be congenital deficiency of the perineum without prolapsus. One interesting case is recorded<sup>1</sup> by Prochownik, in which a girl lived in this condition until she was nearly twenty. She then, however, was put to very hard physical exertion for seven months, and the result was a prolapse.

Now as to the nature of the prolapse. Hart says that the uterus has nothing to do with it, the condition being really a hernia of which the uterus forms part of its covering. Schultze, on the other hand, in his classical work on the subject, says,<sup>2</sup> that the essential part of the affection is a descent of the whole uterus, the direct cause being the relaxation of its essential attachments—the utero-sacral ligaments, giving rise to the retroversion, which is always, according to him, the preliminary stage of a prolapse. Hart does not mention the utero-sacral ligaments as having any

<sup>1</sup> *Archiv f. Gyn.*, vol. xvii. p. 326.

<sup>2</sup> *Op. cit.* p. 273.

part to play whatever, and he says that the retroversion occurs during the progress of the prolapse.

Hart says that, first of all, the floor in front of the anterior rectal wall is driven down—the anterior vaginal wall from below upwards, followed by the uterus and then by the posterior vaginal wall from above downwards. Tension on the cervix is caused, and hence retroversion results. Schultze,<sup>1</sup> however, says that the displacement backwards which results from relaxation of the utero-sacral folds leads to the prolapse of the anterior vaginal wall, not the latter to the former; this displacement diminishes to one-half or one-third the distance which previously separated the uterine and pelvic insertions of the vagina, and so forces the anterior vaginal wall with the bladder to bulge into the lumen of the canal. He thinks that the part which the anterior vaginal wall plays in dragging down the uterus is over-estimated; though not proven, he says that it is most probable that the first descent of the uterus is not thus brought about.

These differences of opinion are certainly very great. The exact truth is, I believe, to be found midway between them. The mechanism is not the same in all cases.

1. Prolapsus in early life is rare, but when it does occur it is undoubtedly a condition connected with weakening of the floor. In fact the whole floor may be prolapsed, *e.g.* as in a case of a child, recorded by Breisky,<sup>2</sup> where bladder, vagina, uterus, perineum, and rectum were prolapsed. Prolapsus of the uterus alone in childhood is undoubtedly one of the rarest conditions, though it and the vagina are more favourably placed than in the adult condition, being more vertical in the pelvis.

2. Prolapsus uteri may occur, the uterus remaining anteverted or anteflexed. Even Schultze admits this, though he says it is rarely met with. Breisky<sup>3</sup> figures a case by Schroeder.

(In fairness, however, it must be said that possibly the anteverted position was brought about, in these cases, after the prolapse had been completed.)

There can be little doubt that prolapse with the uterus lying anteverted can only be referred to weakening of the floor. In a normal condition of

<sup>1</sup> *Archiv f. Gyn.*, p. 274.    <sup>2</sup> *Cyclop. of Obst. and Gyn.*, vol. x. p. 269.    <sup>3</sup> *Op. cit.*, p. 85.

the floor with the uterus lying to the front, Schultze himself says<sup>1</sup> that the intra-abdominal pressure only tends to make the organ more decidedly anteverted, and that this opposes a tendency to prolapse; abnormal anteversion, he says, is an absolute bar to its occurrence.

3. Most cases of prolapse undoubtedly have the mechanism described by Hart, *i.e.* the anterior vaginal wall and bladder descend first, the lowest part appearing first, followed by the cervix and lastly by the posterior vaginal wall, its lowest part appearing last.

Against Hart's views are the following facts:

1. Prolapse may occur more or less rapidly in nulliparæ where the pelvic floor has hitherto been sound and strong, as a result of falls or sudden lifts of heavy weights, etc.

2. Cases of traumatic retroversion in nulliparæ have been sometimes found to be followed by prolapse of the uterus.

3. In some cases of chronic prolapsus the anterior vaginal wall does not descend first, but the uterus, dragging after it the vaginal walls.

4. Cases of cystocele are not necessarily accompanied by prolapse of the uterus.

The only satisfactory manner in which these differences can be explained is by admitting that there are various kinds of prolapsus in the pelvic floor. My conclusions I would state in the following propositions:

1. The pelvic floor, as a whole, is a suspensory structure closing the outlet, having let into its substance bladder and urethra, vagina and uterus and rectum. It is in this way weakened.

2. The floor may be prolapsed as a whole (rarely) as in children, due to weakness of the floor as a whole.

3. The anterior vaginal wall and bladder may prolapse alone (cystocele), due to weakness of their supports.

4. The posterior vaginal wall may alone prolapse on account of weakening of its connections.

5. The posterior vaginal wall and anterior rectal wall may together prolapse (rectocele), due to weakening of their supports.

6. The uterus alone may be the first to prolapse, dragging after it the

<sup>1</sup> *Cyclop. of Obst. and Gyn.*, vol. x. p. 271.

parts of the floor attached to it. It must not be forgotten that the uterus has less strong attachments to the rest of the floor and to the bony wall than either the bladder, vagina, or lower part of the rectum. It has no strong fascial layer attaching it to the pelvis. Its connections are more elastic in nature than those of the other structures mentioned, and they may alone become weakened. Retroversion or retroflexion usually results primarily from this. If the retro-displacement be partial, so that the uterus lies in line with the long axis of the vagina, the position is favourable to the prolapse. If, however, the fundus be driven further back so that a marked retro-displacement is produced, the tendency to prolapse is removed (Schultze).

7. In the majority of cases of prolapse we have to do with a descent of the anterior part of the floor in which the bladder, vagina, and uterus participate. These are the numerous cases which occur in working women who have had their pelvic floor damaged during labour, who rise too soon from bed, go to work too soon, and perform duties which increase their intra-abdominal pressure.

The condition produced is, indeed, a hernia of a considerable part of the floor. The question as to whether the uterus drags down the anterior vaginal wall and bladder, or these structures the uterus, or which is the first to be prolapsed, is of secondary importance. In the puerperium the attachments of all these structures are weakened as a result of previous softening, stretching, or tearing; further, the uterus is usually retro-displaced during the latter part of this period. Increased intra-abdominal pressure tends to drive down the weakest part of the floor, the part which is most dependent, *i.e.* the lower part of the vagina making its appearance first beyond the normal pelvic floor projection, in almost every case. This is what one would expect from the study of the puerperal pelvis. My sections show that after labour there is usually some bulging of the lower part of the vagina and bladder. This is a very common clinical observation also. That the lower part of the posterior vaginal wall is the last to appear is to be explained by its firm attachment to the other tissues of the perineum.



THE FEMALE PELVIS IN THE BEGINNING OF THE  
FIFTH MONTH OF PREGNANCY.

*Clinical Note.*—The patient suffered from a dermoid tumour of the left ovary, enlarged to about the size of a man's brain by recent hæmorrhage, resulting from a twisted pedicle. It was removed by Dr. Berry Hart.<sup>1</sup> The patient made good progress for a week, but on the ninth day died of cardiac failure.

*Method of Study.*—The pelvis, as well as the abdomen, was removed from the cadaver intact, and was frozen in the usual manner.<sup>2</sup> A vertical mesial section was cut, drawn, and described, after which the contents of the amniotic cavity were removed and a cast of the cavity made in plaster of Paris. A cast of the fœtus was also taken. The specimen was then placed in spirit and studied in detail after a few days.

VERTICAL MESIAL SECTION (Plate XXV.)

*Bony Measurements*

Brim—Conjugate (anatomical) . . .	4 $\frac{1}{4}$ in.
„ (obstétrical) . . .	4 „
Cavity—Conjugate . . .	4 $\frac{3}{8}$ „
Outlet—Conjugate (sacral) . . .	3 $\frac{7}{8}$ „
„ (coccygeal) . . .	4 $\frac{1}{4}$ „

Vertical length of symphysis is one and a half inches, of sacrum and coccyx six inches.

Pelvic floor projection is one and five-eighth inches.

The umbilicus is opposite the junction of the third and fourth lumbar vertebræ.

*Uterus.*—Occupies the main part of the pelvic cavity and extends also above the brim. It is in close contact with surrounding structures. Above the brim the anterior wall lies against the abdominal parietes and

<sup>1</sup> To Dr. Hart's great kindness I am indebted for the specimen.

<sup>2</sup> *Lab. Reports R.C.P.E.*, vol. ii. p. 3.

higher up against the intestine. The fundus and upper part of the posterior wall are also in relation to the intestine. The highest point of the uterus is two and three-quarter inches above the brim. Below the brim the anterior wall presses against the pubes and the upper wall of the bladder, the posterior wall touching from above downwards the upper part of the sacrum, the upper part of the rectum and a dermoid tumour of the right ovary which lies in the pouch of Douglas.

The lower part of the cervix is in close contact with the vaginal walls.

The *os externum* is four inches below the brim, and the *os internum* three and one-eighth inches.

The vertical mesial circumference of the whole uterus is sixteen and a half inches.

The *body* is of firm consistence and of a pink-grey colour, that part with the placenta being slightly darker. On close examination the muscle shows a finely striated appearance, chiefly in a longitudinal direction. Several closed vessels are seen in the upper portion of the body, being especially numerous opposite the placenta. In the lower portion of the body very few vessels are seen.

Though there is no definite point at which the body can be divided into an *upper* and *lower uterine segment*, it is very evident that this distinction can be made out—the upper portion of the uterine wall being considerably thicker than the lower portion, the passage from one to the other being gradual. On the anterior wall the difference is best marked, the point of division being about four and three-quarter inches above the cervix, or one and a half above the symphysis; on the posterior wall the change takes place lower down—about three-quarters of an inch nearer the cervix.

The average thickness of the *upper uterine segment* is nearly half an inch; that of the *lower uterine segment* being in the anterior wall three-sixteenths, and in the posterior one-quarter inch. Near the cervix both walls thicken slightly as they pass into the cervix.

The *cervix* is darker in colour and coarser in texture than the body, being an inch in length. The anterior and posterior walls are in apposition at the lower end of the canal, but in the rest of its extent slightly separated,


PLATE XXV.

THE FEMALE PELVIS IN THE BEGINNING OF THE FIFTH MONTH OF PREGNANCY.


*Vertical Mesial Section.*

(Reduced by  $\frac{1}{3}$ .)

- |                                |  |
|--------------------------------|--|
| <i>a.</i> Level of Umbilicus.  | <i>k.</i> Junction of Upper and Lower Uterine<br>Segments of posterior wall. |
| <i>b.</i> Fundus uteri.        | <i>l.</i> Bit of Rectum.   |
| <i>c.</i> Placenta.            | <i>m.</i> Arm of foetus.   |
| <i>d.</i> Liquor Amnii.        | <i>n.</i> Dermoid tumour of right ovary.                                     |
| <i>e.</i> Venous Sinus.        | <i>o.</i> Foetal heart.  |
| <i>f.</i> Umbilical Cord.      | <i>p.</i> Pouch of Douglas.  |
| <i>g.</i> Symphysis pubis.     | <i>q.</i> Rectum.  |
| <i>h.</i> Utero-vesical pouch. | <i>r.</i> Os internum.   |
| <i>i.</i> Bladder.             | <i>s.</i> Os externum.   |
| <i>j.</i> Promontory.          | <i>t.</i> Anterior fornix.   |







the upper end of the canal being funnel-shaped; it contains mucus. Both walls are of much the same thickness, the posterior being, if anything, slightly thicker.

The *placenta* is on the anterior wall, being mostly on the *upper* but partly on the *lower uterine segment*. It is of a dark red-purple colour. It is three-quarters of an inch in its greatest thickness—just above its centre; it thins more markedly towards the lower end.

The *membranes* are seen as a thin lining on the wall of the uterus and crossing the os internum.

The *liquor amnii*, the cord, the arms and thorax of the foetus cut transversely, are well shown.

The *peritoneum* in front descends to a point two and three-sixteenth inches below the brim, and behind three and one-quarter inches below it.

Over the *lower uterine segment* anteriorly it is loosely attached, but posteriorly it is closely attached, just as it is to the upper uterine segment.

The *bladder* is empty. It lies partly above, partly below the conjugate of the outlet. The upper surface is concave and in relation with the anterior uterine wall. It is in front closely attached to the back of the pubes, there being no well-defined retropubic triangular pad of fat between them. A thin layer of fat covers the anterior portion of the upper surface, and is continuous with a well-marked layer passing upwards to the abdominal wall. The upper wall below the utero-vesical pouch is connected to the uterus by very loose cellular tissue. The cavity is a mere slit.

The *urethra* lies entirely below the outlet; it is sigmoid-shaped, one and three-eighth inches in length. The junction of urethra and bladder lies three inches below the brim.

The *vagina* has much less of the sigmoid curve than it normally has. The anterior and posterior walls are in apposition, save near the vulva.

The *rectum* is divided from the anus as far as the lower end of the sacrum. A small section of the upper portion of the gut is also seen near the lower end of the first sacral vertebra.

On examining the specimen, after it had been a few days in spirit, further information was gained.

The *uterus* is slightly nearer the right than the left side of the pelvis in its upper part.

The *bladder* slopes from below upwards and to the right, the highest point not being seen in vertical mesial section, being one and a half inches to the right of the symphysis and a quarter of an inch above the brim.

The *left broad ligament* cannot be well described, owing to the contraction of the upper part as a result of the removal of the left dermoid ovarian tumour.

The *right broad ligament* in its upper part is somewhat dragged downwards by the right ovarian tumour.

The *right dermoid ovarian tumour* is about the size of a turkey's egg and lies in the pouch of Douglas, being compressed from before backwards. It contains the ordinary yellowish, fatty-looking contents, with hair, skin, and a few small bones, and from its plasticity is made to appear somewhat flattened between the uterus and the sacrum. No normal-looking piece of ovary could be detected, neither was any *corpus luteum* to be found.

#### CAST OF AMNIOTIC CAVITY (Plate XXVI.)

The cast was taken after the foetus and liquor amnii had been removed, the placenta and membranes being left *in situ*.

Viewed from the front and back it has the general shape of a pear flattened from before backward, the broad end being lowermost. Viewed from the side it is also pyriform, the sides being compressed from before backwards; the anterior surface is markedly convex, the posterior slightly convex below and concave in its upper part. The small antero-posterior diameter of the upper part is due to the flattening of the upper part of the uterus from before backwards, and also to the space occupied by the placenta on the upper part of the anterior wall. The left half of the cast is thicker than the right.

The posterior surface shows a flattening in its lower part chiefly on the right side, caused by the dermoid tumour in the pouch of Douglas; in its upper part is seen a hollow due to the pushing inwards of the uterine wall



PLATE XXVI

THE FEMALE PELVIS IN THE BEGINNING OF THE FIFTH  
MONTH OF PREGNANCY.

*Cast of Amniotic Cavity. (Reduced.)*

Fig. 1.

Anterior Aspect.

- a. Fundus uteri.
- b. Placental area.
- c. Os internum.

Fig. 2.

Left Lateral Aspect.

- d. Fundus uteri.
- e. Promontory mark.
- f. Os internum.




Fig. 2.

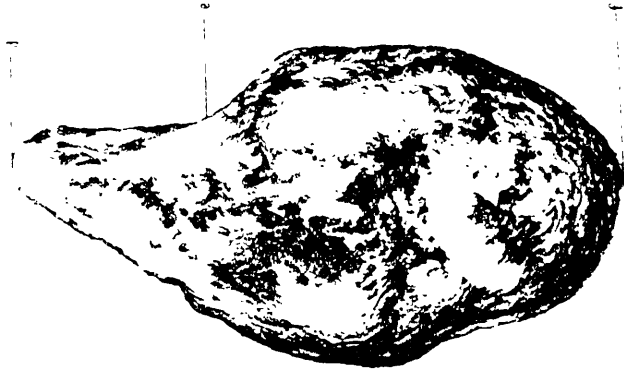




Fig. 1.





by the promontory. On the anterior surface is seen the mark of the placenta occupying somewhat less than half the area of the surface; it is oval in shape, the long axis being almost vertical and measuring four and a half inches, the transverse measuring three and a quarter inches, while the circumference measures twelve and a quarter inches.

The water displacement of the whole cast is 610 c.c. The surface area of the whole cast is about sixty-five square inches. The placental area measures about eleven and three-quarter inches.

## CAST OF FŒTUS.

The parts of the frozen foetus removed from the amniotic cavity were placed together, and cast in plaster. The attitude is one of flexion, though not of extreme degree, the limbs showing a considerable degree of extension at all the joints. The water displacement of the cast is 210 c.c.

## RÉSUMÉ.

The *pelvic floor projection* is one and five-eighth inches. If this be compared with the projection in other cases, we find that it is greater than in the nulliparous condition, and less than in the later months of pregnancy.

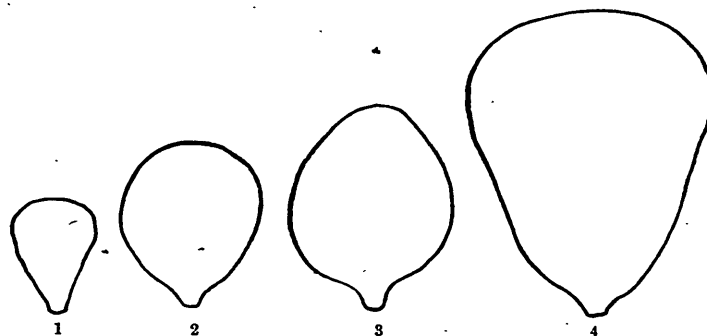
Stage.	Whose Case.	Pelvic floor Projection.	Skin distance from Coccyx to Symphysis.
		In.	In.
Nullipara	Average	1	5 $\frac{1}{4}$
Five months Preg.	Webster	1 $\frac{5}{8}$	5 $\frac{1}{2}$
Eight months "	Barbour and Webster	2	6 $\frac{1}{2}$
Nine months "	Braune	3 $\frac{3}{4}$	10
" "	Braune and Zweifel	2 $\frac{3}{4}$	7 $\frac{1}{2}$

The *uterus* has the following characteristics worthy of note. Its longest diameter is the vertical, which measures from os externum to fundus about seven and three-quarter inches; the greatest width is five inches, and the greatest antero-posterior diameter four inches. In the frozen state there is seen to be a flattening of the uterus from before backwards. In its upper part this is evidently due to the pressure of the anterior abdominal wall, and in the lower to the dermoid tumour in the pouch of Douglas. The

irregularity of outline of the wall is due to the pressure of neighbouring structures against it, chiefly the symphysis and promontory.

The cast of the cavity shows these points, and also brings out the fact that the uterus near the fundus, in both its transverse and antero-posterior diameters, is smaller than that part situated just above the cervix. When the parts were examined after thawing took place, the pressure of the anterior abdominal wall being removed, it was found that, when viewed from the side, the antero-posterior measurements of the upper and lower poles of the uterus were more nearly equal than they appeared to be in the frozen state. The fact that the upper portion of the uterus is not of larger bulk than the lower is worthy of note.

At the beginning of pregnancy the pyriform shape of the uterus, with



OUTLINE OF UTERUS SEEN FROM THE FRONT.

1, At the beginning of pregnancy. 2, During the third and fourth months. 3, At the beginning of the fifth month. 4, At the end of pregnancy.

its wide upper and narrow lower portion, is well recognised. A similar shape is again found late in pregnancy, as frozen sections and casts made by Dr. Barbour and myself show.<sup>1</sup> It is, also usually taught that, after the very early months, the uterus becomes spherical in shape. In this five months case the uterus is neither spherical, nor pyriform as in the later months. It seems, indeed, to be in an intermediate position. The longest diameter is the vertical one. The antero-posterior diameter is greatest just below the middle of the body. Of special interest, however, is the shape of the body as seen from the front. It differs from the pyriform and spheroidal shapes of the early months, as well as from the pyriform of the late months; it has indeed a pyriform appearance, with, however, *the widest part lowermost*

<sup>1</sup> *Lab. Reports R.C.P.E.*, vol. ii. p. 1.

and not uppermost, as is the case in the late months. The foregoing diagrams represent the uterus as seen from the front at various stages of pregnancy.

Whether this is the normal shape at the beginning of the fifth month can only be demonstrated by frozen sections and casts of other cases. In this case it is possible that the presence of the tumours may have somewhat modified the growth of the uterus, though one cannot definitely settle this point. Even, however, allowing for the pressure on the lower uterine segment by the small tumour in the pouch of Douglas, it is evident that the transverse diameter of the upper part of the uterus is at least *not greater* than that of the lower part (thus differing greatly from the condition in early and late pregnancy); there seems, indeed, to be no doubt that in this case the lower diameter is wider than the upper.

If the uterus be compared with that of an eight months pregnancy case,<sup>1</sup> it is evident that there is a marked preponderance in size, in the latter, of the upper portion of the uterus over the lower; in fact, the casts seem to show that, from the beginning of the fifth month onwards, the increase in size of the uterus takes place almost entirely in its upper portion.

The differentiation of the wall into lower and upper segments is well marked. It is, indeed, much better defined than in the other frozen sections of pregnant women already published. In the latter (which are in the late stages of pregnancy), the upper uterine segment is much thinner than in the present case. Here the thickness of this part is about the same as the wall of the non-pregnant uterus. As regards the lower uterine segment, this case agrees with the others in having that of the anterior wall thinner than the posterior, but differs from them in the great extent to which it is developed. Anteriorly, the apparent junction of the upper and lower segments is more than four inches above the cervix (at this point there is a sinus in the wall—?circular sinus); below this level the peritoneum is loosely attached, while above it, it is very firmly attached. Posteriorly, the lower uterine segment is not so well marked off from the upper; the peritoneum covering it is firmly attached save in the lowermost portion.

<sup>1</sup> *Lab. Reports R.C.P.E.*, vol. ii. p. 7.

In none of the other published cases is the lower uterine segment of such a length as in this case. In a uterus at full time, described by Bayer,<sup>1</sup> it measured three and one-eighth inches (8 cm.); in another it measured three and one-sixteenth inches (7.5 cm.) Hofmeier<sup>2</sup> has also found it to measure two and three-quarter inches (7 cm.) in two full-time cases.

Is the extreme degree of development of the lower uterine segment in this case abnormal or only unusual? In Barbour's table,<sup>3</sup> describing all the uteri in which the segment has been described, the greatest variations are found to exist. For example, in Benckiser's four months case, the firm attachment of the peritoneum is one and three-eighth inches (3.5 cm.) above the cervix, whereas in Bayer's it is opposite the upper end of the cervix. There is no reason to doubt that the present condition is but one of many variations found.

Possibly the firm attachment of the peritoneum may not mark the upper limit of the segment, though, indeed, it is exactly opposite the junction of the thick upper and thin lower uterine segments. In some cases described by Bandl, it was a little above the upper end of the lower segment.

It is possible, also, that the uterine wall to which the lowest bit of the placenta is attached is not lower but upper segment, and it may be only the commencement of the thinning of that part of the wall because of the placental attachment. In the other frozen sections the placental part of the wall is much thinner than in the present case. Allowing for this possible explanation of part of the thinning, there would still remain a lower segment of exceptional length—the longest of any recorded case.

It is very evident that the cervix does not enter into the formation of the lower segment; it is of much the same size as in the nulliparous condition. A careful study of all the vertical mesial frozen sections in published cases shows that in the later months the cervix is as large as in the early period, being only somewhat compressed from above downwards, so that it appears slightly shorter and thicker. This condition is chiefly due to the pressure of the softened uterus against the sacral segment of the pelvic floor; the softening becomes even more marked as pregnancy

<sup>1</sup> *Morph. d. Gebärmutter*, 1885.

<sup>2</sup> *Das untere Uterinsegmentes*, etc., 1886.

<sup>3</sup> *The Anat. of Labour*, etc., 1889.



advances. Owing to the continued hyperæmia there may even be some increased growth.

Much of the discussion as to the relation of the cervix to the lower segment has arisen from the study of uteri removed from the body; in this way flattening of the cervix occurs, so that its normal shape is completely altered. Moreover, a microscopic study of the mucous membrane cannot decide the question; the passage of the cervical mucous membrane into the decidua of the lower segment is not abrupt but gradual, and no well-defined os internum can be made out. Of much greater value is the examination of the muscular tissue, that of the lower segment being arranged in a series of plates, mostly longitudinally arranged, that of the cervix being a felted network of bundles.

The *peritoneum* has a somewhat unusual arrangement. In front, the bottom of the utero-vesical pouch is not as low in relation to the cervix and bladder as is generally the case; behind, also, the bottom of the pouch of Douglas is above the level of the posterior fornix, not reaching down between the rectum and upper part of the posterior vaginal wall as it does in the great majority of cases. The dip of the utero-vesical pouch below the brim is two and three-sixteenth inches, and that of the pouch of Douglas three and a quarter inches. If these measurements be compared with corresponding ones in the nullipara, there is found to be very little difference.

The peculiarity in this case is not that the pouches are unusually high, but that the uterus is exceptionally low in the pelvis. It is probable that the peritoneum has not descended with the uterus as the latter has sunk down, and has been consequently separated from its lowest attachments. The tissue below the utero-vesical pouch, between the bladder and lower uterine segment, is very delicate and loose, and would easily allow of this separation.

The reflection of the peritoneum, from the anterior abdominal wall to the bladder, is exceptional. In most nulliparous cases, the highest point of the bladder is in the middle line, either above or below the upper margin of the symphysis, the outer edge sloping downwards and outwards on each side behind the pubic bones.

In this case, however, the bladder is inclined obliquely from below upwards and to the right, the highest point being a quarter of an inch above the brim, and one and a half inches to the right of the symphysis.

The disposition of the pelvic peritoneum during pregnancy has not yet been definitely settled. Regarding its lateral arrangement it is clear that, during the progress of gestation, as the uterus increases in its transverse and vertical diameters, the peritoneum on each side of the pelvis is considerably elevated. This has been well demonstrated by Barbour and Polk.

Regarding the arrangement in front and behind there is considerable uncertainty. Polk<sup>1</sup> declares that the peritoneum is lifted up so that (while in the non-pregnant condition a line drawn from the centre of the symphysis to the junction of the third and fourth sacral bones corresponds to its lowest portion in front of the uterus and behind, except the pouch of Douglas), at the end of pregnancy, and before the uterus has fallen, its lowest level (excepting the pouch of Douglas) is at a line from the centre of the symphysis to the promontory.

This statement is not in accord with the evidence furnished by frozen sections. Polk formed his conclusions from dissectional work—an unreliable method in determining topographical relationships especially in investigating pregnancy, because, owing to the increased softening of the pelvic tissues in that condition, they are very readily stretched and compressed, the normal position of parts being easily altered.

Most of the frozen sections of nulliparæ show that the peritoneum reaches a lower level than that indicated by Polk.

In regard to the changes during pregnancy, though we cannot speak with absolute certainty, owing to the lack of a sufficient number of frozen sections, yet we have sufficient facts at our disposal to disprove the statements made by Polk and others. Variations are doubtless found, just as in the nulliparous condition. If we measure the dip of the peritoneal pouches below the brim of the present five months case, in Barbour and Webster's eight months case, and in Braune's full-time case, we find that the pouches are as low as in the nullipara, or even lower. In a six months case of Barbour's (unpublished) it is three-quarters of an inch lower (I leave out of

<sup>1</sup> *New York Med. Journ.*, vol. xxxv. p. 560.

consideration the full-time cases of Waldeyer, and Braune and Zweifel, the first having a fractured pelvis and the other an unusual arrangement of the bladder).

The changes in the anterior attachments of the peritoneum during pregnancy have always been described in relation to the uterus and the bladder. The growing uterus elevates the peritoneum, it is usually said, stripping it from the bladder; the pouch of Retzius, therefore, as well as that of Douglas, must reach a higher level as pregnancy advances. This conclusion is contradicted, we find, by frozen sections.

As regards the stripping of the bladder, we find, certainly, that this does take place in pregnancy, though, as the sections show, the amount varies in different cases. From a study of the frozen sections, it seems to me that the hitherto attributed cause, viz. the elevation of the peritoneum by the growing uterus, is not the main cause. The growth-changes in the uterus in the latter half of pregnancy, as I have already indicated, affect chiefly its upper and not its lower part. It is difficult to see how these changes can disturb the peritoneal relations of the pouches of Douglas and Retzius. The explanation is rather that the bladder is stripped away from the peritoneum by the sinking of the pelvic floor; owing to the very delicate loose connective tissue joining the bladder and peritoneum, the latter does not follow the posterior part of the former in its downward descent.

Usually the bulging of the floor is most marked near the end of the pregnancy, and Waldeyer's and Braune's sections show a great part of the bladder uncovered. In Barbour and Webster's eight months case, where the bladder is not so pushed down, there is scarcely any stripping of the peritoneum. In this five months case, where the bladder is very low, a considerable portion has lost its peritoneum.

The variations that are found in the different cases may have normally existed in the non-pregnant condition, but they are, no-doubt, partly due to the fact that the peritoneum of the utero-vesical pouch is more or less folded in different cases. Whatever be the cause of the stripping of the bladder, the extent of the stripping must depend upon the number and size of these folds to be unfolded.

As regards the pouch of Douglas, there is no elevation in its central portion throughout the whole of pregnancy.

The explanation of the low position of the uterus is not evident. The frozen sections of full-time cases show as much sinking, while in the eight months case it is nearly as low. It is usually taught that this extreme degree is only normally met with at the end of gestation. It may be that the sinking is progressive from about the middle of pregnancy, being, in some cases, very marked long before term. In this case, it must not be forgotten, the presence of the tumours may have something to do with the low position.

The coexistence of pregnancy and double ovarian tumour, though rare, has been noticed in several cases. Sometimes, as here, it is impossible to find ovarian tissue, while no corpus luteum may be found.

## BIBLIOGRAPHY

- AUTEFAGE, Thèse, Lyon, 1880.
- BÖRNER, Ueber d. puerp. Uterus, 1875.
- BENCKISER, Zur Anat. d. Cer. u. unteruterin seg., 1882.
- BREISKY, Cyclop. of Obstet. and Gyn., vol. x. 1889.
- BARBOUR, The Anat. of Lab. and its Clin. Bear., 1889; Atlas of Anat. of Lab., 1889.
- BRAUNE, Die Lage d. Uterus und Foetus am Ende d. Schwang., 1872.
- BRAUNE U. ZWEIFEL, Gefrierdurchsch. durch d. Korp. e. Hochschwang. geführt, 1890.
- BARBOUR AND WEBSTER, Anat. of Advanced Preg. and of Lab.; Lab. Reports R.C.P.E., vol. ii.
- BANDL, Ueber d. Verhalten d. Uterus u. Cervix in d. Schwangerschaft u. während d. Geburt, 1876.
- BAYER, Morphologie d. Gebärmutter, etc., 1885.
- CHARPENTIER, Traité d. Accouch., 1883.
- CROOM, The Bladder, 1884; Obstet. Trans., Edin., vol. xiv.
- COE, Amer. Syst. of Gyn. and Obstet., 1887.
- CHIARI, Ueb. d. topogr. Verhält. d. Gen., etc., 1885.
- CUNNINGHAM, The Dissector's Guide, 1880.
- DUNCAN, Mechanism of Nat. and Morbid Part., 1875.
- FOSTER, Am. Jour. of Obst., vol. xiii.; Am. Gyn. Trans., 1881.
- FERGUSON, Obstet. Trans., Edin., vol. xiv.
- HART, Obstet. Trans., Edin., vol. v.; Obstet. Trans., Edin., vol. xiv.; The Struct. Anat. of Fem. Pelv. Floor, 1880; Topog. and Sect. Anat. of the Fem. Pelv., 1885.
- HART AND BARBOUR, Man. of Gyn., 1890.
- HELME, Lab. Rep. R.C.P.E., vol. iii.
- HESCHL, Zeitsch. d. K. K. Ges. d. Aertze zu Wien, 1852.
- HOFMEIER, Das unt. Uterinseg. in Anat. u. Physiolog. Beziehung, 1886.
- KEHRER, Müller's Handbuch d. Gyn., 1888.
- KÜSTNER, Das Unt. Ut. Seg., 1882; Die Normal u. Path. Lag. u. Beweg. d. Uterus.
- KELLY, Ain. Syst. of Gyn. and Obst., 1887.
- LUSCHKA, Die Musc. am Boden d. Weib. Beck., 1861.
- LUSK, The Science and Art of Mid., 1892.
- MARTIN, E., Die Neig. u. Beug. d. Gebärmut., 1866.
- MILSOM, Thèse, Lyon, 1880.
- MACCORMAC, Quain's Dict. of Med., 1883.
- NEWELL, Leonard's Illus. Med. Jour., Detroit, 1890.
- OLSHAUSEN, Die Krankh. d. Ovarien, 1886.
- POLK, Observations upon the Anat. of the Female Pelvis; N.Y. Med. Journ., vol. xxxvi.
- PROCHOWNIK, Arch. f. Gyn., vol. xvii.
- RANNEY AND FOSTER, Am. Gyn. Trans., 1881.

- SCHROEDER, Der Schwang. u. Kreis. Ut., 1886.
- SAEYINGER, Gefrierdurchsch. einer Kreis,  
1888.
- SCHULTZE, The Path. and Treat. of Displac. of  
the Ut., Eng. Trans., 1888.
- SIMPSON, A. R., Contrib. to Obstet. and Gyn.,  
1880.
- SAVAGE, The Female Pelvic Organs, 1882.
- STRATZ, Schroeder's "Der Schwang. u. Kreis.  
Ut., 1886."
- SYMINGTON, Edin. Med. Jour., March 1889.
- SPIEGELBERG, Text Book of Mid., Eng. Trans.,  
1888.
- THIEDE, Zeitschr. f. Gyn., bd. iv.
- TURNER, Introd. to Hum. Anat., 1882.
- THOMAS, Am. Jour. of Obstet., 1880.
- WINCKEL, Text Book of Mid., Eng. Trans.,  
1890.
- WALDEYER, Medianschnitt einer Hochsch. etc.,  
1886.
- WINTER, Zwei Medianschnitt durch Gebärende,  
etc., 1889.

## INDEX

### I. THE ANATOMY OF THE FEMALE PELVIS DURING THE PUERPERIUM.

#### *Beginning of Puerperium—*

Bladder, 3, 5.  
Broad ligaments, 5, 8, 9.  
Dissectional, 8.  
Extra-uterine measurements, 3, 5.  
Fallopian tubes, 8, 9.  
Ovaries, 8, 9.  
Peritoneum, 4, 5, 8, 9.  
Rectum, 4, 5, 7.  
Transverse section, 4.  
Ureters, 5, 8.  
Ut.-sac. and round ligaments, 9.  
Uterus, 1, 4, 6.  
Vagina, 3, 7.  
Vertical mesial section, 1.  
,, oblique section, 6.

#### *Fourth Day—*

Bladder, 28, 33, 35.  
Broad ligaments, 31, 33.  
Dissectional, 31.  
Extra-uterine measurements, 28, 30.  
Fallopian tubes, 31, 33.  
Ovaries, 31, 33.  
Peritoneum, 29, 32.  
Rectum, 29, 30.  
Transverse section, 30.  
Ureters, 31.  
Ut.-sac. and round ligaments, 32, 33.  
Uterus, 26, 30.  
Vagina, 28.  
Vertical mesial section, 26.

#### *Fifteenth Day—*

Bladder, 49, 52.  
Broad ligaments, 53, 54.  
Dissectional, 52.  
Extra-uterine measurements, 49, 51.

Extra-peritoneal tissues, 51.  
Fallopian tubes, 52, 54.  
Ovaries, 52, 53.  
Peritoneum, 50, 52, 53.  
Rectum, 50.  
Transverse section, 51.  
Ureters, 52.  
Ut.-sac. and round ligaments, 53, 54.  
Uterus, 48, 51.  
Vagina, 49, 52.  
Vertical mesial section, 48.

#### *Résumé—*

Bladder, 65.  
Broad ligaments, 67.  
Fallopian tubes, 67.  
Ovaries, 67.  
Pelvic floor projection, 66.  
Perineum, 66.  
Post-partum shock, 69.  
Relation of anatomical facts to Credé manipulation, 70.  
Vagina, 66.

#### *Uterus, 55, 59.*

Cavity, 60, 62.  
Cervix, 57, 64.  
Diminution in size, 59.  
Inner wall, 62.  
In contracted pelves, 65.  
In enlarged pelves, 65.  
Lower uterine segment, 56, 62.  
Outer surface, 61.  
Relation to extra-uterine tissues, 63.  
,, pelvic wall, 63.  
Rotation, 58.  
Upper uterine segment, 56, 60.

*Second Day—*

Bladder, 12, 18.  
 Broad ligaments, 14, 16, 17.  
 Dissection, 14.  
 Extra-peritoneal tissues, 14.  
 Extra-uterine measurements, 11, 13.  
 Fallopian tubes, 15, 17.  
 Ovaries, 15, 16.  
 Peritoneum, 12, 18.  
 Rectum, 12, 14.  
 Transverse section, 13.  
 Ureters, 14.  
 Ut.-sac. and round ligament, 16, 17, 18.  
 Uterus, 10, 13.  
 Vagina, 12.  
 Vertical mesial section, 10.

*Sixth Day—*

Bladder, 36, 37, 39, 41, 44.  
 Broad ligaments, 42, 43, 44, 45.  
 Coronal section, 37, 38, 40, 42.  
 Dissection, 44.  
 Extra-uterine measurements, 34.  
 Extra-peritoneal tissues, 37, 38, 40, 43.  
 Fallopian tubes, 42, 45, 46.  
 Malformed int. genitals, 46.

Ovaries, 42, 45, 46.  
 Peritoneum, 36, 40, 43.  
 Rectum, 36, 41, 43, 44.  
 Ureters, 44.  
 Ut.-sac. and round ligaments, 42, 44, 45.  
 Uterus, 34, 37, 38, 40, 42, 44.  
 Vagina, 35, 38, 39, 41, 43.  
 Vertical section, 34.

*Third Day—*

Bladder, 20, 25.  
 Broad ligaments, 23.  
 Coronal section, 22.  
 Dissection, 24.  
 Extra-peritoneal tissues, 20, 21, 23.  
 Extra-uterine measurements, 20.  
 Fallopian tubes, 24.  
 Ovaries, 24, 25.  
 Peritoneum, 21, 23, 25.  
 Rectum, 21, 22, 25.  
 Ureters, 24.  
 Uterus, 19, 22.  
 Ut.-sac. and round ligaments, 25.  
 Vagina, 21.  
 Vertical mesial section, 19.

## II. THE FEMALE PELVIC FLOOR.

Anal fascia, 78.  
 Broad ligaments, relation of, 88.  
 Dissectional view, 76.  
 Etiology of prolapsus uteri, 108.  
 Fallacies in sectional study, 92, 107.  
 Floor in relation to parturition, 94  
 " " pregnancy, 93.  
 " " prolapsus uteri, 106.  
 Meaning of term "Floor," 74.

*Muscles of Floor, 79.*

Gluteus max., 81.  
 Levator ani, 79.  
 Sphincter ani, 81.  
 " vagina, 81.  
 Transversus perinei, 81.  
 " " profund., 81.  
 Nature of prolapsus uteri, 109.  
 Parietal pelvic fascia, 76.  
 Sacro-sciatic ligaments, 77.

Sectional study of floor, 91.  
 Superficial fascia, 79.  
 Triangular ligaments, 76.  
 Ut.-sac. ligaments, 89, 90.  
 Varieties of prolapsus uteri, 111

*Visceral pelvic fascia, 76.*

Anterior layer, 76.  
 Rectal " 78.  
 Recto-vaginal layer, 78.  
 Vesical " 77.  
 Vesico-vaginal " 77.

*Viscera and Passages connected with Floor, 81.*

Bladder, 82, 92.  
 Rectum, 84.

*Uterus, 85.*

In adult, 86.  
 In foetus, 85.  
 White line, 77.

M



III. THE FEMALE PELVIS IN THE BEGINNING OF THE FIFTH MONTH  
OF PREGNANCY.

- |  |                                  |
|--|----------------------------------|
| Bladder, 115, 116.                         | Peritoneum, 115, 121.            |
| Broad ligaments, 116.                      | Placenta, 115, 117.              |
| Cast of amniotic cavity, 116.              | Shape of Uterus, 113.            |
| ,, fetus, 117.                             | Umbilicus, 113.                  |
| Cervix uteri, 114, 120.                    | Upper uterine segment, 114, 119. |
| Double ovarian tumour with pregnancy, 124. | Uterus, 113, 116, 118.           |
| Lower uterine segment, 114, 119.           | Vertical mesial section, 113.    |
| Pelvic floor projection, 117.              |                                  |

Handwritten marks including a large bracket-like shape and a small 'c'.

## YOUNG J. PENTLAND'S RECENT PUBLICATIONS.

Third, Enlarged, and thoroughly Revised Edition, 8vo, Cloth, pp. xx. 652. Illustrated with 195 Coloured Plates from Original Drawings. Price 25s.

**PRACTICAL PATHOLOGY. A Manual for Students and Practitioners.** By GERMAN SIMS WOODHEAD, M.D., F.R.C.P.Ed., Director of the Laboratories of the Royal Colleges of Physicians (London) and Surgeons (England).

Third Edition, Revised and Enlarged, 8vo, Cloth, Gilt Top, pp. xx. 644. With Woodcut and 9 double-page Coloured Illustrations. Price 21s.

**DISEASES OF THE SKIN: A Manual for Students and Practitioners.** By W. ALLAN JAMIESON, M.D., F.R.C.P.Ed., Extra Physician for Diseases of the Skin, Edinburgh Royal Infirmary; Consulting Physician, Edinburgh City Hospital; Lecturer on Diseases of the Skin, School of Medicine, Edinburgh. [*Pentland's Medical Series—Vol. I.*]

In Press, Second Edition, 8vo. To be Illustrated with many additional Coloured Plates from Original Drawings.

**DISEASES OF THE EYE: A Practical Treatise for Students of Ophthalmology.**

By GEORGE A. BERRY, M.B., F.R.C.S.Ed., Ophthalmic Surgeon, Edinburgh Royal Infirmary; Senior Surgeon, Edinburgh Eye Dispensary; Lecturer on Ophthalmology, Royal College of Surgeons, Edinburgh. [*Pentland's Medical Series—Vol. II.*]

8vo, pp. xvi. 640. With Coloured Illustrations from Original Drawings. Price 25s.

**DISEASES OF THE THROAT, NOSE, AND EAR.** By P. M'BRIDE, M.D., F.R.C.P.Ed., Lecturer on the Diseases of the Ear and Throat, Edinburgh School of Medicine; Aural Surgeon and Laryngologist, Royal Infirmary, Edinburgh; Surgeon, Edinburgh Ear and Throat Dispensary. [*Pentland's Medical Series—Vol. III.*]

2 vols. large 8vo, Cloth, pp. xvi. 1008. Illustrated with Maps and Charts. Price 31s. 6d.

**GEOGRAPHICAL PATHOLOGY: An Inquiry into the Geographical Distribution of Infective and Climatic Diseases.** By ANDREW DAVIDSON, M.D., F.R.C.P.Ed., late Visiting and Superintending Surgeon, Civil Hospital, and Professor of Chemistry, Royal College, Mauritius.

Large 8vo, pp. xxviii. 772. With 404 Illustrations. Price 31s. 6d.

**THE PARASITES OF MAN AND THE DISEASES WHICH PROCEED FROM THEM.** A Text-book for Students and Practitioners. By RUDOLF LEUCKART, Professor of Zoology and Comparative Anatomy, Leipsic. Translated from the German, with the co-operation of the Author, by WILLIAM E. HOYLE, M.A. (Oxon.), M.R.C.S., F.R.S.E. "Natural History of Parasites in General." "Systematic Account of the Parasites Infesting Man." "Protozoa—Cestoda."

Large 8vo, Cloth, pp. xvi. 600. With 147 Illustrations, some coloured. Price 30s.

**THE REFRACTION AND ACCOMMODATION OF THE EYE AND THEIR ANOMALIES.** By E. LANDOLT, M.D., Professor of Ophthalmology, Paris. Translated under the Author's supervision by C. M. CULVER, M.A., M.D., formerly Clinical Assistant to the Author; Member of the Albany Institute, Albany, N.Y.

Large 8vo, Cloth, pp. xvi. 783. Price 25s. Illustrated with 226 Wood Engravings, and 68 pages of Lithograph Plates, exhibiting 91 Figures—317 Illustrations in all.

**DISEASES OF THE HEART AND THORACIC AORTA.** By BYROM BRAMWELL, M.D., F.R.C.P.Ed., Lecturer on the Principles and Practice of Medicine, and on Practical Medicine and Medical Diagnosis, in the Extra-Academical School of Medicine, Edinburgh; Assistant Physician, Edinburgh Royal Infirmary.

8vo, Cloth, pp. xvi. 270. With 116 Illustrations. Price 14s.

**INTRACRANIAL TUMOURS.** By BYROM BRAMWELL, M.D., F.R.C.P.Ed., Lecturer on the Principles and Practice of Medicine in the Extra-Academical School of Medicine, Edinburgh; Assistant Physician to the Edinburgh Royal Infirmary.

In one Volume, Royal 4to, Extra Cloth. Price 63s. net.

**ATLAS OF VENEREAL DISEASES: A Series of Illustrations from Original Paintings, with Descriptions of the Varied Lesions, their Differential Diagnosis and Treatment.** By P. H. MACLAREN, M.D., F.R.C.S.E., Surgeon, Edinburgh Royal Infirmary; formerly Surgeon in charge of the Lock wards, Edinburgh Royal Infirmary; Examiner in the Royal College of Surgeons, Edinburgh.

8vo, Cloth, pp. xii. 122. Illustrated with Engravings and numerous Coloured Illustrations. Price 10s. 6d.

**LEAD POISONING IN ITS ACUTE AND CHRONIC FORMS. The Goulstonian Lectures delivered in the Royal College of Physicians, March, 1891.** By THOMAS OLIVER, M.A., M.D., F.R.C.P., Professor of Physiology, University of Durham; Physician to the Royal Infirmary, Newcastle-on-Tyne.

8vo, Cloth, pp. xvi. 104. With 34 full-page Coloured Plates from Original Drawings. Price 16s.

**HYDATID DISEASE IN ITS CLINICAL ASPECTS.** By JAMES GRAHAM, M.A., M.D., Late Demonstrator of Anatomy, Sydney University; Medical Superintendent, Prince Alfred Hospital, Sydney.

8vo, Cloth, pp. xvi. 1080. Illustrated with Charts. Price 24s.

**THE PRINCIPLES AND PRACTICE OF MEDICINE. Designed for the Use of Practitioners and Students of Medicine.** By WILLIAM OSLER, M.D., F.R.C.P., Professor of Medicine in the Johns Hopkins University; Physician-in-chief to the Johns Hopkins Hospital, Baltimore.

YOUNG J. PENTLAND,

EDINBURGH: 11 TEVIOT PLACE.

LONDON: 38 WEST SMITHFIELD, E.C.

## YOUNG J. PENTLAND'S RECENT PUBLICATIONS.

Large 8vo, Cloth, pp. xvi. 700. With 178 Fine Engravings, many in Colour. Price 18s.  
**CLINICAL TEXT-BOOK OF MEDICAL DIAGNOSIS.** For Physicians and Students. By OSWALD VIERORDT, M.D., Professor of Medicine at the University of Heidelberg. Translated, with the Author's permission, from the Second Enlarged German Edition, by FRANCIS H. STUART, M.D., Member of the Medical Society of the County of Kings, New York.

Second Edition, Handsome 8vo, Cloth, pp. 700. With 239 Wood Engravings. Price 18s.  
**THE SCIENCE AND ART OF OBSTETRICS.** By THEOPHILUS PARVIN, M.D., LL.D., Professor of Obstetrics and Diseases of Women and Children in the Jefferson Medical College, Philadelphia.

In two very Handsome Imperial 8vo Volumes, containing about 1600 Pages. Price 50s. net.  
**THE NATIONAL MEDICAL DICTIONARY:** Including English, French, German, Italian and Latin Technical Terms used in Medicine and the Collateral Sciences, and a Series of Tables of useful data. By JOHN S. BILLINGS, A.M., M.D., LL.D. Harv. and Edin., D.C.L. Oxon., Member of the National Academy of Sciences, Surgeon, U.S.A., etc. With the Collaboration of W. O. ATWATER, M.D.; FRANK BAKER, M.D.; C. S. MINOT, M.D.; JAMES M. FLINT, M.D.; R. LORINI, M.D.; WASHINGTON MATTHEWS, M.D.; S. M. BURNETT, M.D.; J. H. KIDDER, M.D.; H. C. YARROW, M.D.; WILLIAM LEE, M.D.; W. E. COUNCILMAN, M.D.

**REPORTS FROM THE LABORATORY OF THE ROYAL COLLEGE OF PHYSICIANS, EDINBURGH.** Edited by J. BATTY TUKE, M.D., G. SIMS WOODHEAD, M.D., and D. NÖEL PATON, M.D.

VOLUME FIRST, 8vo, Cloth, pp. 212, with 23 full page Plates, and 19 Engravings. Price 7s. 6d. net.

VOLUME SECOND, 8vo, Cloth, pp. xiv. 280, with 43 full page Plates, consisting of Lithographs, Chromo-Lithographs, and Micro-Photographs. Price 10s. 6d. net.

VOLUME THIRD, 8vo, Cloth, pp. xii. 304, with 11 Plates and Folding Charts. Price 9s. net.

VOLUME FOURTH, 8vo, Cloth, pp. xii. 254. With 25 Plates and Folding Charts. Price 10s. 6d. net.

18mo, pp. xvi. 293, in Flexible Leather Binding, for the Pocket. Price 6s. 6d.

**PRESCRIBING AND TREATMENT IN THE DISEASES OF INFANTS AND CHILDREN.** By PHILIP E. MUSKETT, late Surgeon to the Sydney Hospital; formerly Senior Resident Medical Officer, Sydney Hospital.

Crown 8vo, Cloth, pp. xvi. 376. With 101 Illustrations, some coloured. Price 10s. 6d.  
**PHYSICAL DIAGNOSIS. A Guide to the Methods of Clinical Investigation.** By G. A. GIBSON, M.D., D.Sc., F.R.C.P.Ed., Lecturer on the Principles and Practice of Medicine in the Edinburgh Medical School; Examiner on Medicine and Clinical Medicine in the University of Glasgow; and WILLIAM RUSSELL, M.D., F.R.C.P.Ed., Pathologist to the Royal Infirmary of Edinburgh, Lecturer on Pathology and Morbid Anatomy in the Edinburgh Medical School.

[Pentland's Students' Manuals.]

Crown 8vo, Cloth, pp. xvi. 226. Price 6s.  
**SURGICAL ANATOMY: A Manual for Students.** By A. MARMADUKE SHEILD, M.B. Cantab., F.R.C.S., Senior Assistant Surgeon; Aural Surgeon and Teacher of Operative Surgery, Charing-Cross Hospital.

[Pentland's Students' Manuals.]

Crown 8vo, Cloth, pp. xvi. 642. With 32 pages of Illustrations. Price 12s. 6d.  
**OUTLINES OF ZOOLOGY.** By J. ARTHUR THOMSON, M.A., Lecturer on Zoology, School of Medicine, Edinburgh.

[Pentland's Students' Manuals.]

Crown 4to, Extra Cloth, Gilt Top. With 70 Plates, exhibiting over 400 Figures. Price 12s. 6d.  
**ILLUSTRATIONS OF ZOOLOGY. Invertebrates and Vertebrates.** By WILLIAM RAMSAY SMITH, B.Sc., Demonstrator of Anatomy, Edinburgh School of Medicine, Minto House, late Senior Assistant to the Professor of Natural History, University of Edinburgh; and J. STEWART NORWELL, B.Sc.

8vo, Cloth, pp. xii. 102. With 4 Illustrations. Price 5s.  
**SUPPURATION AND SEPTIC DISEASES. Three Lectures delivered at the Royal College of Surgeons of England.** By W. WATSON CHEYNE, M.B., F.R.C.S., Hunterian Professor; Surgeon to King's College Hospital; Examiner in Surgery at Edinburgh University.

8vo, Cloth, pp. xii. 223. With 7 Illustrations. Price 9s.  
**ELEMENTS OF PHARMACOLOGY.** By Dr. OSWALD SCHMIEDEBERG, Professor of Pharmacology, and Director of Pharmacological Institute, University of Strassburg. Translated, under the Author's supervision, by THOMAS DIXSON, M.D., Lecturer on Materia Medica in the University of Sydney, N.S.W.

Crown 8vo, Cloth, pp. xvi. 216. With Coloured Plate and 29 Wood Engravings. Price 5s.  
**HANDBOOK OF OBSTETRIC NURSING.** By F. W. N. HAULTAIN, M.D., F.R.C.P.Ed., Physician to the Royal Dispensary; late Clinical Assistant to Physician for Diseases of Women, Royal Infirmary, Edinburgh; and J. HAIG FERGUSON, M.B., F.R.C.P.Ed., Physician to the New Town Dispensary; late Resident Physician, Royal Maternity Hospital, Edinburgh.

YOUNG J. PENTLAND,

EDINBURGH: 11 TEVIOT PLACE.

LONDON: 38 WEST SMITHFIELD, E.C.

