

**CIHM
Microfiche
Series
(Monographs)**

**ICMH
Collection de
microfiches
(monographies)**



Canadian Institute for Historical Microreproductions / Institut canadien de microreproductions historiques

© 1997

The copy filmed here has been reproduced thanks to the generosity of:

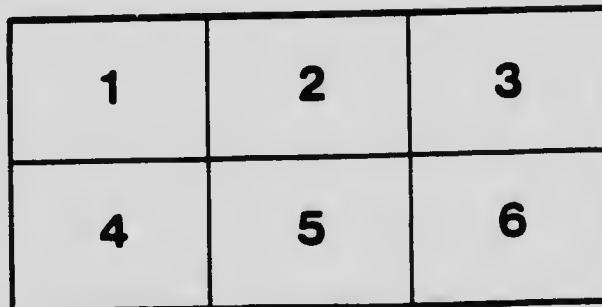
McMaster University
Hamilton, Ontario

The images appearing here are the best quality possible considering the condition and legibility of the original copy and in keeping with the filming contract specifications.

Original copies in printed paper covers are filmed beginning with the front cover and ending on the last page with a printed or illustrated impression, or the back cover when appropriate. All other original copies are filmed beginning on the first page with a printed or illustrated impression, and ending on the last page with a printed or illustrated impression.

The last recorded frame on each microfiche shall contain the symbol \rightarrow (meaning "CONTINUED"), or the symbol ∇ (meaning "END"), whichever applies.

Maps, plates, charts, etc., may be filmed at different reduction ratios. Those too large to be entirely included in one exposure are filmed beginning in the upper left hand corner, left to right and top to bottom, as many frames as required. The following diagrams illustrate the method:



L'exemplaire filmé fut reproduit grâce à la générosité de:

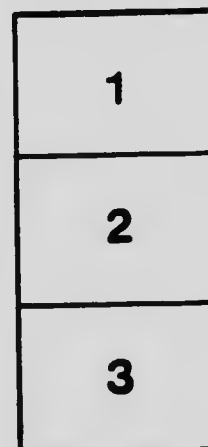
McMaster University
Hamilton, Ontario

Les images suivantes ont été reproduites avec le plus grand soin, compte tenu de la condition et de la netteté de l'exemplaire filmé, et en conformité avec les conditions du contrat de filmage.

Les exemplaires originaux dont la couverture en papier est imprimée sont filmés en commençant par le premier plat et en terminant soit par la dernière page qui comporte une empreinte d'impression ou d'illustration, soit par le second plat, selon le cas. Tous les autres exemplaires originaux sont filmés en commençant par la première page qui comporte une empreinte d'impression ou d'illustration et en terminant par la dernière page qui comporte une telle empreinte.


Un des symboles suivants apparaîtra sur la dernière image de chaque microfiche, selon le cas: le symbole \rightarrow signifie "A SUIVRE", le symbole ∇ signifie "FIN".

Les cartes, planches, tableaux, etc., peuvent être filmés à des taux de réduction différents. Lorsque le document est trop grand pour être reproduit en un seul cliché, il est filmé à partir de l'angle supérieur gauche, de gauche à droite, et de haut en bas, en prenant le nombre d'images nécessaire. Les diagrammes suivants illustrent la méthode.



MICROCOPY RESOLUTION TEST CHART

(ANSI and ISO TEST CHART No. 2)



5.0

5.6

6.3

7.1

8.0

9.0

10.0

11.2

12.5

14.0

16.0

18.0

20.0

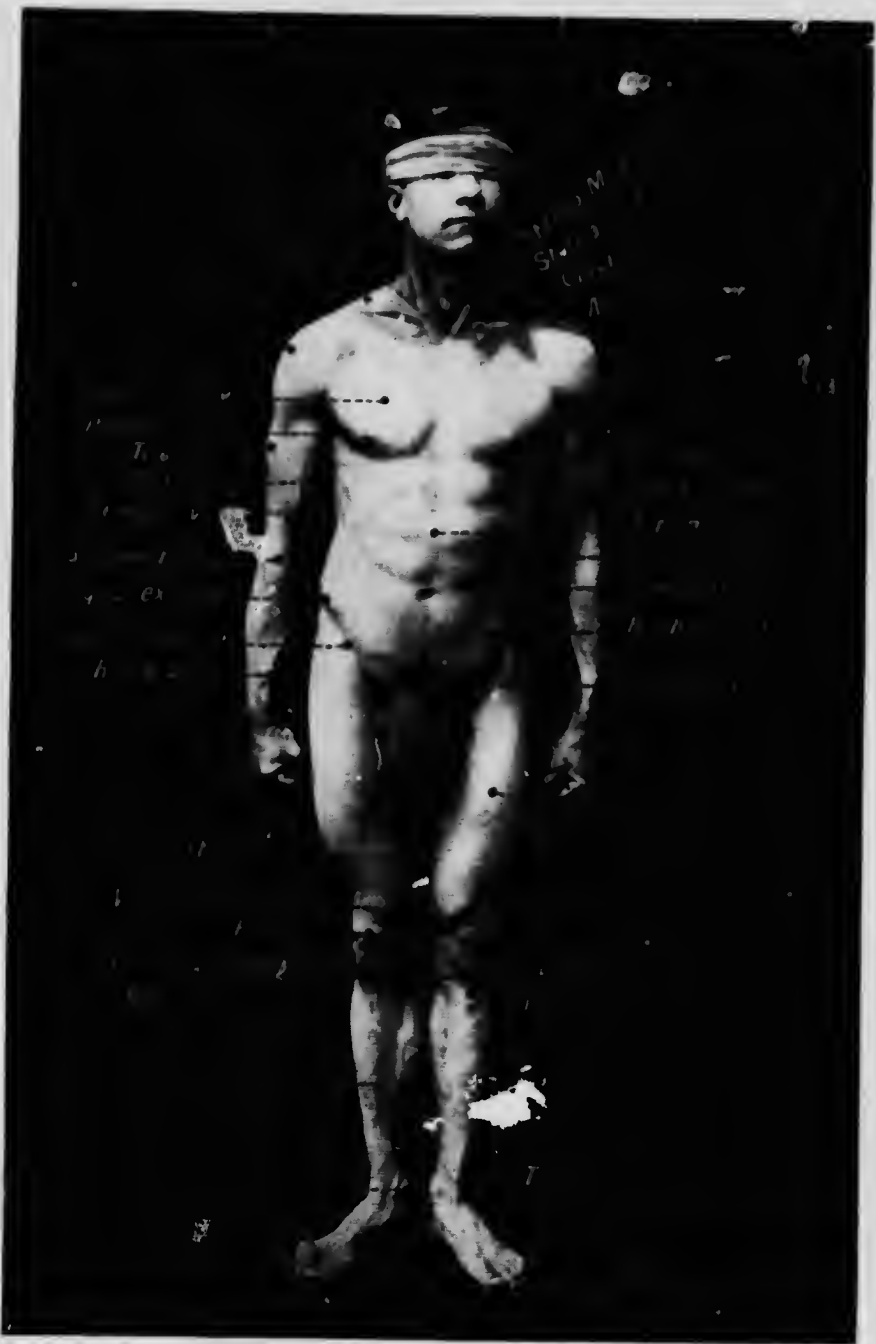

APPLIED IMAGE Inc

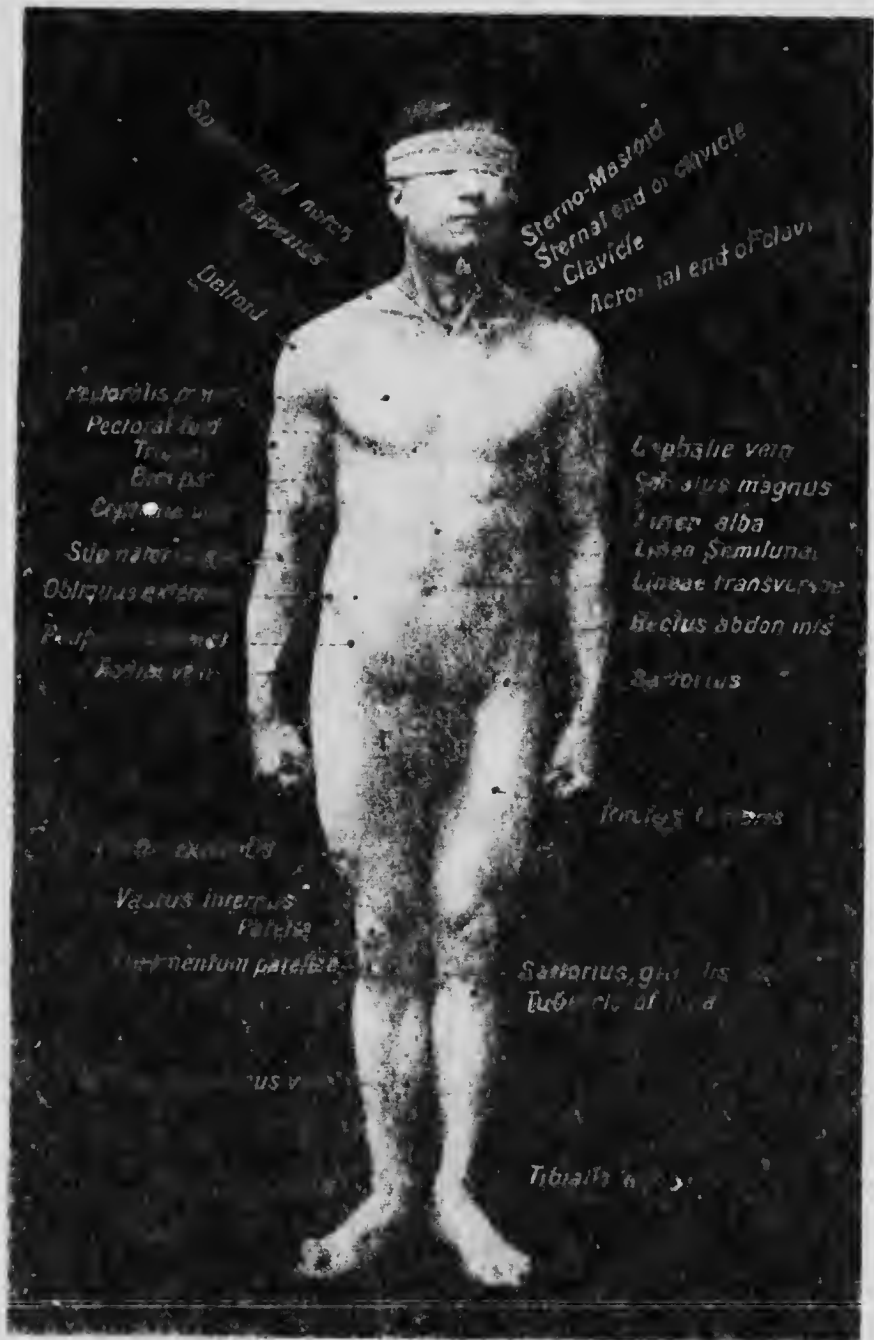
1653 East Main Street
Rochester, New York 14609 USA
(716) 482-0300 - Phone
(716) 288-5989 - Fax

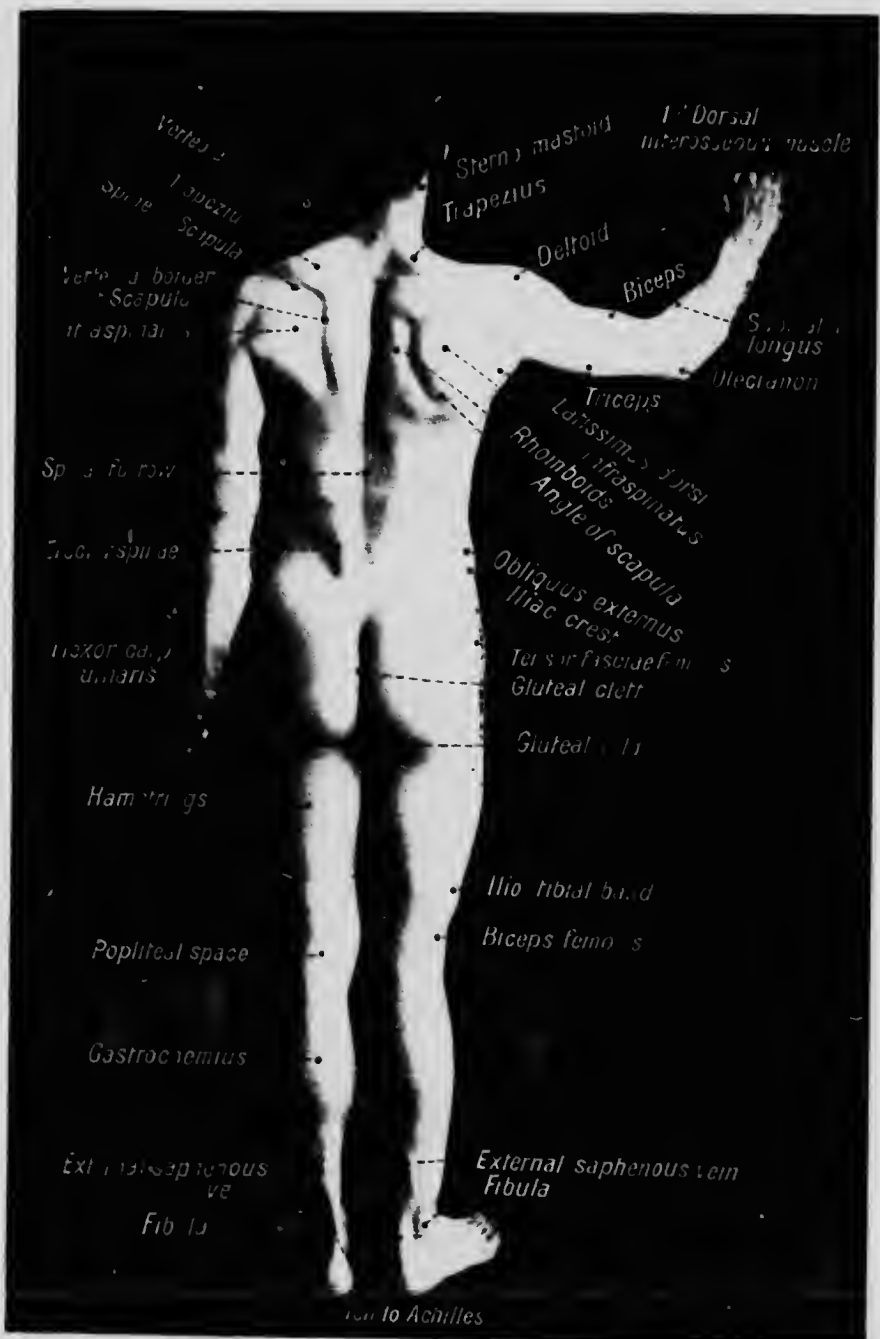
LANDMARKS AND SURFACE MARKINGS
OF THE HUMAN BODY













LANDMARKS AND
SURFACE MARKINGS OF
THE HUMAN BODY

BY

L. BATHE RAWLING

M.B., B.C. (CANT.), F.R.C.S. (ENG.)

SURGEON WITH CHARGE OF OUT-PATIENTS, DEMONSTRATOR OF PRACTICAL AND OPERATIVE SURGERY, LATE SENIOR DEMONSTRATOR OF ANATOMY AT ST. BARTHOLOMEW'S HOSPITAL; LATE ASSISTANT-SURGEON TO THE GERMAN HOSPITAL, DALSTON; LATE HUNTERIAN PROFESSOR. ROYAL COLLEGE OF SURGEONS, ENGLAND, ETC.

WITH THIRTY-ONE ILLUSTRATIONS

FIFTH EDITION

TORONTO
THE MACMILLAN COMPANY OF CANADA, LTD.

1913

Copyright.

PREFACE
TO THE FIFTH EDITION

FROM the fact that the fourth edition was disposed of within one year, it would appear to me obvious that but little alteration or addition is necessitated for this edition ; the text has been adhered to, but the illustrations have been improved.

L. BATHE RAWLING.

16, MONTAGU STREET,
PORTMAN SQUARE, W.
1912



CONTENTS

	PAGE
CHAPTER I	
THE HEAD AND NECK	I
CHAPTER II	
THE UPPER EXTREMITY	19
CHAPTER III	
THE THORAX	34
CHAPTER IV	
THE ABDOMEN	47
CHAPTER V	
THE LOWER EXTREMITY	70
APPENDIX	
THE LENGTH OF VARIOUS PASSAGES, TUBES, ETC.	86
THE WEIGHT OF SOME ORGANS	88
THE OSSIFICATION AND EPIPHYSES OF THE BONES OF THE UPPER AND LOWER EXTREMITIES	89
INDEX	92

ILLUSTRATIONS

FIGS.					
1 and 2. Cranio-cerebral Topography	-	-	-	<i>To face p.</i>	4
3 and 4. The Side of the Neck	-	-	-	"	14, 15
5. The Front of the Neck	-	-	-	"	18
6. The Front of the Arm and Forearm	-	-	-	"	20
7. The Elbow and Back Region	-	-	-	"	23
8. The Elbow Region	-	-	-	"	24
9. The Veins of the Arm and Forearm	-	-	-	"	24
10 and 11. The Palm of the Hand	-	-	-	"	26
12. The Back of the Wrist	-	-	-	"	28
13. The Back of the Arm and Forearm	-	-	-	"	30
14. The Shoulder and Arm	-	-	-	"	31
15. The Heart, Great Vessels, Kidney, and Ureter	-	-	-	"	36
16 and 17. The Pleural Sacs, Lungs, etc.	-	-	-	"	41, 42
18. The Abdominal and Thoracic Planes	-	-	-	"	50
19. The Alimentary Canal	-	-	-	"	56
20. The Liver, Anterior Abdominal Wall, etc.	-	-	-	"	62
21 to 24. The Thigh and Leg	-	-	-	"	70, 74
25 and 29. The Region of the Ankle and Foot	-	-	-	"	77-80

LANDMARKS AND SURFACE MARKINGS OF THE HUMAN BODY

CHAPTER I

THE HEAD AND NECK

CRANIO-CEREBRAL TOPOGRAPHY

ONLY those surface markings will be given which are of practical value, and, as far as possible, each landmark will be rendered independent of any other, as by such means any given structure can be rapidly depicted on the surface, the important question of time and of space rendering the more complicated systems, in which it is necessary to map out a network of intersecting lines in order to fix the position of any single structure, of little surgical value. It is necessary, however, to recognize first certain important bony points, etc.

The *nasion*, situated at the base of the nose at the
Fig. i., 1. central point of the naso-frontal suture.

The *inion*, or *external occipital protuberance*,
Fig. i., 2. a projection, variable in size, which can be readily felt on the occipital bone, immediately above the nuchal furrow.

A line uniting these two points over the vertex of the skull corresponds in direction to the *mesial longitudinal fissure of the brain*, to the upper attached margin of the

falx cerebri, and to the *superior longitudinal venous sinus*. This sinus originates in the region of the foramen cæcum, just anterior to the crista galli, and broadens out rapidly as it passes backwards towards the internal occipital protuberance, which lies at the same level as the previously mentioned external protuberance. It then turns sharply to the right, forming the right *lateral sinus*. The left lateral sinus derives its blood mainly from the *straight sinus*, which receives, at the anterior margin of the tentorium cerebelli, the great vein of Galen, the main efferent trunk of the deep nuclear cerebral veins. The line drawn as above from the nasion to the inion also corresponds in direction to the occasionally persistent *metopic suture* between the two halves of the frontal bone, and to the *sagittal suture* between the two parietal bones.

The frontal bone is separated off from the two parietal bones by the *coronal suture*, and the point of junction of the coronal and sagittal sutures is known as the *bregma*, the site of the foetal anterior fontanelle, an opening which is normally closed by the end of the second year. Between the parietal and occipital bones the *lambdoid suture* lies; and at the junction of the sagittal and lambdoid sutures the posterior fontanelle is situated, closed at or soon after birth. The point of junction of the last two sutures is known as the *lambda*. This point lies about $2\frac{1}{2}$ inches above the inion or external occipital protuberance. About 1 inch from its posterior superior angle, and close to the sagittal suture, the parietal bone is perforated by a small foramen, and a line uniting the two foramina crosses the sagittal suture at a point known as the *obelion*. The parietal bone is outwardly bulged at a point rather above its centre, forming the *parietal eminence*, especially marked in the foetal

Fig. i., 13.

Fig. i., 11.

skull, and indicating the point at which the single ossific nucleus makes its appearance.

Turning now one's attention to the lateral aspect of the skull, the *inferior temporal crest* should be examined. This crest crosses the parietal bone

rather below the junction of the middle and lower thirds, cutting off the vault proper above from the temporal fossa below. The ridge is often so feebly developed in this region that it may be necessary to verify its position by tracing it backwards from the region of the external angular frontal process, at which level the crest is always well marked. The temporal muscle arises from the inferior temporal crest and from the temporal fossa below, whilst

the overlying fascia, the temporal fascia, gains attachment to the *superior temporal crest*—a feebly developed ridge which runs above and parallel to the inferior crest. To avoid confusion, it is perhaps necessary to add that the inferior temporal crest is quite distinct from the infratemporal crest, which forms the lower margin of the temporal fossa, and separates off that fossa from the zygomatic fossa.

The *external angular frontal process* articulates with the frontal process of the malar bone, and the articulation between the two processes is easily felt at the upper and outer border of the orbital cavity.

The *malar tubercle*, a small prominence to be felt along the posterior border of the frontal process of the malar bone, a short distance below the fronto-malar suture.

The *zygomatic process* of the temporal bone should be traced backwards towards the ear, and an examination of the skull will show that this process divides in front of the

ear into three roots, the anterior merging into the eminentia articularis, the middle helping in the formation of the post-glenoid process, whilst the posterior or upper root **Fig. ii., 13, 14** sweeps backwards above the external auditory **Fig. i., 17.** meatus to become continuous with the suprameatal and supramastoid crests, and to blend with the posterior curved end of the temporal crest. The *suprimeatal crest* is of special surgical importance, as it forms the upper boundary of Macewen's suprimeatal triangle, and also indicates fairly accurately the lower level of the cerebrum in this situation.

The *lateral sinus* describes a gentle curve from the **Fig. i., 16.** external occipital protuberance to the upper **Fig. ii., 9.** and posterior part of the base of the mastoid process, finally curving downwards towards, though not reaching to, the apex of that process. The degree of upward curve is subject to a good deal of variation, and the sinus frequently presents a lesser upward convexity than was the case in the specimen from which the illustration was taken.

The *lower limit of the cerebrum* can, with sufficient **Fig. i., 17,** accuracy, be mapped out in the following **17, 17.** manner: A point is taken in the median antero-posterior line about $\frac{1}{2}$ inch above the nasion, and from this point a line is drawn outwards which lies about $\frac{1}{2}$ inch above, and follows the curve of the upper border of the orbit. This line is carried backwards as far as the level of the external angular frontal process, then curving upwards and backwards towards the *Sylvian point* (see next page). The temporo-sphenoidal lobe sweeps now downwards and forwards towards the posterior border of the malar bone, and then lies practically on a level with the upper border of the zygoma. At and behind the ear

a
e
t
y
-
n
e
e
l

FIG. I.

1. The nasion.
2. The inion.
3. The mid-point between nasion and inion.
4. The Rolandic fissure.
5. The superior temporal crest.
6. The inferior temporal crest.
7. The Sylvian point.
8. The anterior horizontal limb of the Sylvian fissure.
9. The vertical limb of the Sylvian fissure.
10. The posterior horizontal limb of the Sylvian fissure.
11. The parietal prominence.
12. The malar tubercle.
13. The lambda.
14. The first temporo-sphenoidal sulcus.
15. The external parieto-occipital sulcus.
16. The lateral sinus.
- 17, 17, 17. The level of the base of the cerebrum.
18. The external auditory meatus.
- 19, 19. Reid's base line.

CRANIO-CEREBRAL TOPOGRAPHY

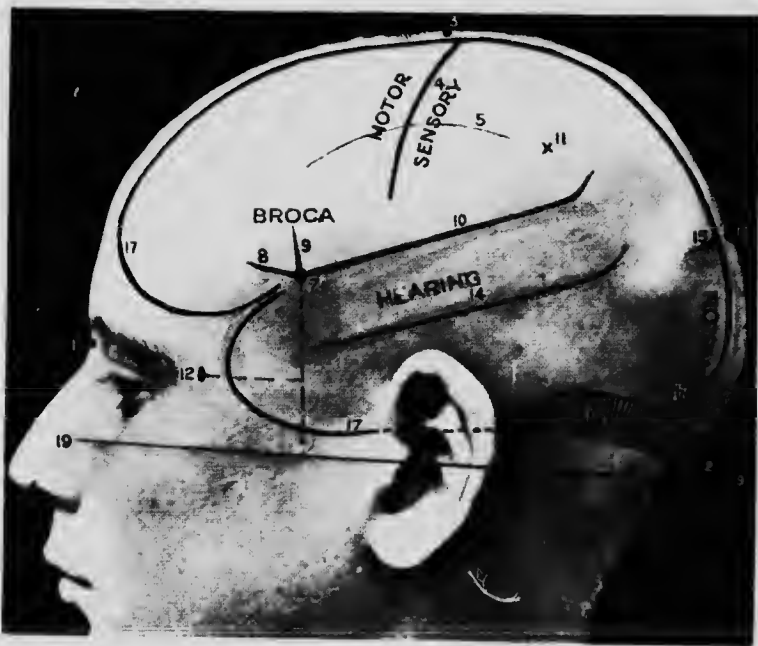
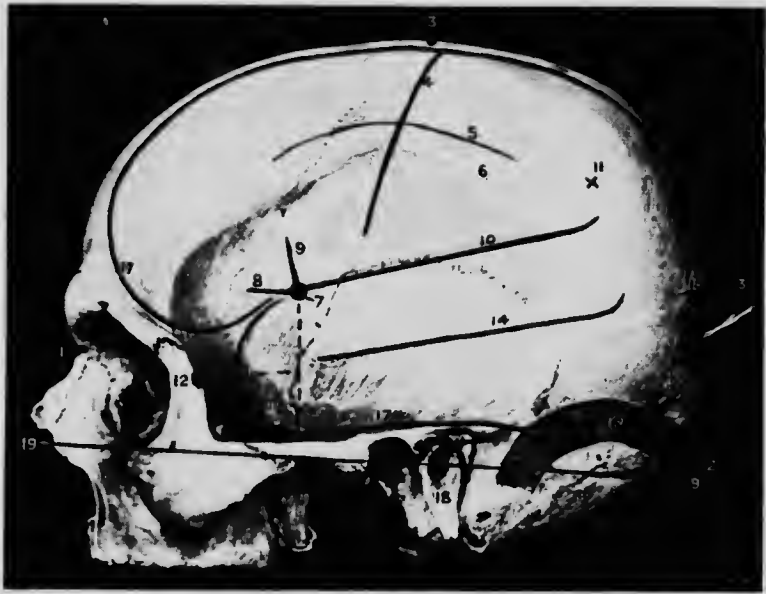


FIG. 1.

To face p. 4.





FIG. II.

- 1, 1. Reid's base line.
- 2, 2. A line parallel to the above at the level of the supra-orbital margin.
3. The middle meningeal artery.
4. The anterior branch.
- 5, 5, 5. The three sites for trephination.
6. The posterior branch.
7. The site for trephination.
8. The point for trephining to reach the descending horn of the lateral ventricle.
9. The lateral sinus.
10. The inion.
11. The mastoid process.
12. Macewen's suprameatal triangle.
- 12*a*. The mastoid antrum.
- 12*b*. The facial nerve.
13. The suprameatal and supramastoid crests.
- 14, 14. The temporal crest.
15. The temporal fossa.
16. The external angular frontal process.
17. The tendo-oculi attachment.
18. The lachrymal groove.

CRANIO-CEREBRAL TOPOGRAPHY

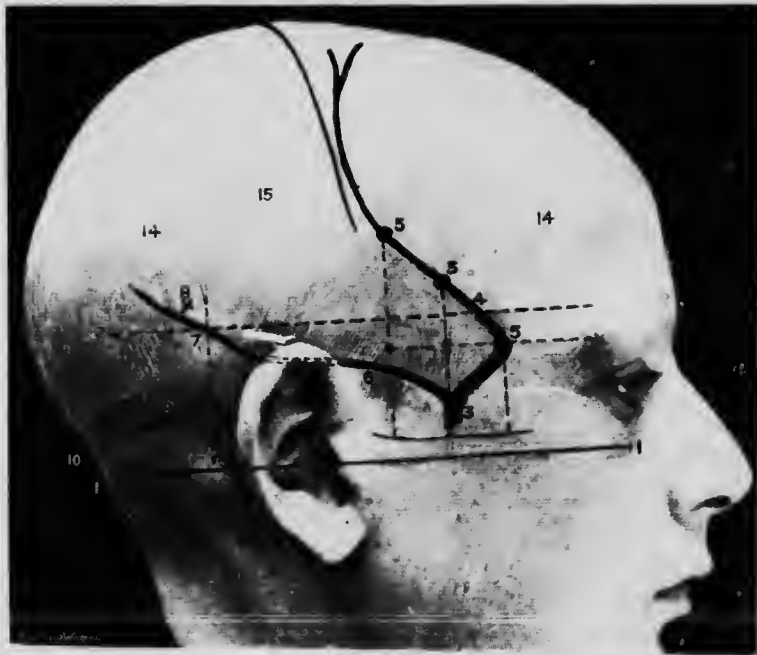
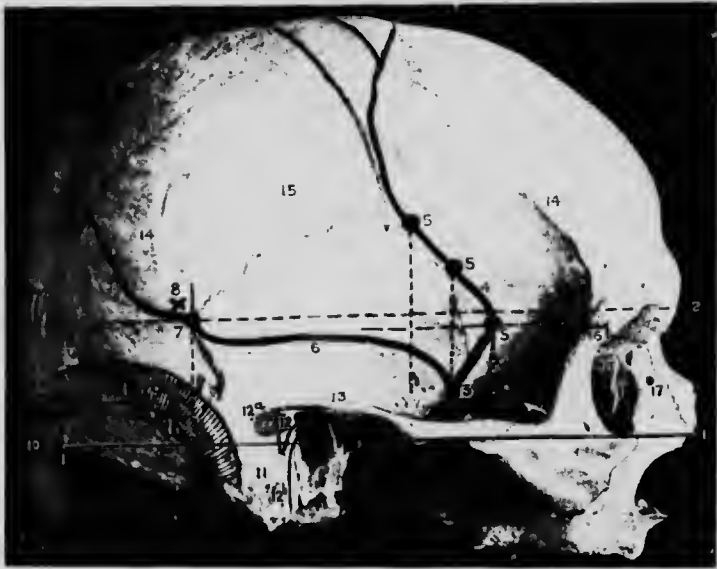


FIG. II.

To follow Fig. I.

the cerebrum lies flush with the suprameatal and supra-mastoid crests, and subsequently follows the curve of the lateral sinus from the base of the mastoid process to the external occipital protuberance.

The lateral sinus is, to a large extent, walled in by the *tentorium cerebelli*, a membrane separating the cerebrum and cerebellum one from the other. The *sinus curve*, therefore, corresponds not only to the position of the lateral sinus, but also represents the outer attachment of the *tentorium cerebelli*, and the interval between the cerebrum above and the cerebellum below.

Reid's base line is drawn backwards from the lower border of the orbit to the middle of the external auditory meatus, and, when further produced, the line will be found to fall just below the level of the inion, and to lie almost entirely below the level of the lateral sinus. This line is utilized by some surgeons in trephining the skull, distances being measured along this line and points taken above or below, according to the seat of the lesion.

The *Sylvian point* represents the site of divergence of the three limbs of the Sylvian fissure. It lies $1\frac{1}{4}$ inches behind the external angular frontal process, and $1\frac{1}{2}$ inches above the upper border of the zygoma. The main posterior horizontal limb of the Sylvian fissure passes backwards and upwards from the Sylvian point to a second point situated $\frac{3}{4}$ inch below the most prominent part of the parietal bone.

The vertical limb is directed upwards for about $\frac{3}{4}$ inch, whilst the anterior horizontal limb passes forwards for about the same distance.

The Sylvian point corresponds also to the anterior pole

of the *island of Reil* and to the *middle cerebral artery*, as that vessel lies deeply embedded in the anterior part of the Sylvian fissure.

To mark out the *external parieto-occipital fissure* and the *Fig. i., 12-* first *temporo-sphenoidal* or *parallel sulcus*, it is necessary to find two bony points—the malar tubercle and the lambda. A line uniting these two points corresponds in its posterior part to the external parieto-occipital sulcus, and in its middle third to the first temporo-sphenoidal sulcus.

The *Rolandic fissure*.—Take a point $\frac{1}{2}$ inch behind the centre of a line drawn across the vertex of the skull from the nasion to the inion, and from this point draw a line downwards and forwards for $3\frac{1}{2}$ to 4 inches, at an angle of $67\frac{1}{2}^\circ$ (three-quarters of a right-angle) to the median antero-posterior line. In front of this sulcus is the precentral or ascending frontal convolution, an area better known as the *Rolandic* or *motor area*. The main centres here situated correspond, from above downwards, to the movements of the *lower extremity*, *upper extremity* and *face* of the opposite side of the body.

The superior temporal crest cuts across the Rolandic line at the junction of its lower and middle thirds. It may be regarded as the line of demarcation between the upper extremity area above and the face area below.

On the left side of the head, that part of the brain which is included in the obtuse angle between the anterior and posterior horizontal limbs of the Sylvian fissure is known as *Broca's area* (the motor speech centre).

The *middle meningeal artery*, a branch of the internal maxillary, enters the skull through the foramen spinosum, and divides, after a short and variable course across the

middle fossa of the skull, into two main trunks. The seat of bifurcation usually corresponds to a point just above the centre of the zygoma.

Fig. ii., 3.

The anterior branch is not only the larger of the two, but it is also more liable to injury, since it is protected in the temporal region by a comparatively thin osseous barrier.

Fig. ii., 4.

The danger zone in the course of this branch may be mapped out by taking three points:

Fig. ii., 5.

5, 5.

(1) 1 inch behind the external angular frontal process, and 1 inch above the zygoma.

(2) $1\frac{1}{2}$ inches behind the external angular frontal process, and $1\frac{1}{2}$ inches above the zygoma.

(3) 2 inches behind the external angular frontal process, and 2 inches above the zygoma.

A line uniting these three points indicates, therefore, that part of the anterior division of the middle meningeal artery which is most liable to injury.

The anterior division of the vessel will be exposed by trephining over any of these three points, but it is generally preferable to choose the highest point, as by such means the posterior border of the great wing of the sphenoid is avoided;* and, as an additional reason, it should be added that, in the position of points 1 and 2, the artery frequently runs in an osseous canal. After trephining over the upper point, the bone can be chipped away in a downward and forward direction, if such an exposure of the artery is deemed necessary.

The *posterior branch of the artery* passes almost horizontally backwards, parallel to the zygoma and to the supramastoid crest, and it can be exposed

Fig. ii., 6.

* N.B.—This point will be better understood by reference to the base of the skull.

by trephining over a point where a vertical line drawn upwards from the posterior border of the mastoid process cuts another line drawn backwards from the supra-orbital margin parallel to Reid's base line.

The *lateral ventricles*.—The descending cornu of the lateral ventricle may be tapped by trephining $1\frac{1}{4}$ inches above Reid's base line and $1\frac{1}{4}$ inches behind the external auditory meatus. The trocar should be directed towards the summit of the opposite ear, the ventricle being reached within 2 inches from the surface (Keen).

The *basic fossæ*.—"There is no external sign to indicate the situation of the fossæ of the skull. In general, however, it may be said that the anterior fossa extends as far back as the anterior end of the zygoma; that the middle fossa lies between this and the mastoid process, and the posterior includes all the base behind the process" (Eisendrath).

The *mastoid antrum* may be exposed by trephining in *Macewen's suprameatal triangle*, a space which is bounded above by the backward continuation of the upper root of the zygoma (the supramastoid crest), behind by a vertical line drawn upwards from the posterior border of the external auditory meatus, and below and in front by the *suprameatal spine*, a prominent bony process which assists in the formation of the posterior superior quadrant of the external auditory meatus. In this triangle there is usually a well-marked depression, the *supramastoid fossa*. The supramastoid crest not only indicates the uppermost possible limit of the mastoid antrum, but, as has already been stated, it corresponds also to the level of the base of brain in

this situation. The crest, therefore, represents the level of the *tegmen antri*, and, in mastoid explorations, the scene of operation must be confined to an area below this crest. In the adult the antrum usually lies at a depth of $\frac{1}{2}$ to $\frac{3}{4}$ inch from the surface.

The *lateral sinus* lies posterior and nearer to the surface, whilst the *facial nerve* pursues its course in front and on a deeper plane.

The *parotid gland* occupies the space which is bounded above by the zygomatic arch, behind by the auricle and the mastoid process, and below by a line drawn from the angle of the jaw to the apex of the mastoid process. In front, the gland extends a variable distance over the anterior surface of the *masseter* muscle. This muscle passes downwards and backwards from the lower border of the zygomatic arch to be attached to the outer surface of the descending ramus and angle of the lower jaw. When the teeth are clenched, the anterior border of the muscle is easily defined, a well-marked line of demarcation being so formed between the masseter muscle behind and the buccinator in front.

Stensen's duct, the duct of the parotid gland, corresponds to the middle third of a line drawn from the lower border of the tragus of the ear to a point situated half-way between the ala of the nose and the red line of the upper lip. At the anterior border of the masseter muscle the duct dips inwards, through the buccinator muscle, to open on the buccal mucous membrane, opposite the second molar tooth of the upper jaw.

The *transverse facial artery*, a branch of the superficial temporal, runs inwards parallel to and immediately below the zygoma, lying above the level of Stensen's duct.

The *facial nerve*, after emerging from the stylo-mastoid foramen, curls round the condyle of the jaw, and traverses the substance of the parotid gland, in which part of its course it divides into numerous branches. The general transparotid course of the nerve and the direction of its buccal branch may be indicated by a line drawn forwards parallel to and below Stenson's duct from the lobule of the ear.

The *inferior dental nerve* may be exposed by trephining over the ascending ramus of the lower jaw, midway between the anterior and posterior borders, and on a level with the last molar tooth. In this manner, the nerve, accompanied by the corresponding artery, is exposed as it enters the inferior dental canal.

The *tonsil* corresponds in position to a point situated just above and in front of the angle of the lower jaw.

The *borders of the bony orbit*.—The following bones assist in the formation of the orbital margin :

Above, the frontal bone.

Externally, the external angular frontal process and the malar bone.

Below, the malar bone and the superior maxilla.

Internally, the nasal process of the superior maxilla and the internal angular frontal process.

The *tendo oculi and nasal duct*.—By alternate forcible closure and opening of the lids, the internal tarsal ligament, or *tendo oculi*, can be felt passing to its insertion into the nasal process of the superior maxilla. Immediately below the tendon, at the junction of the inner and lower walls of the orbital cavity, is the depression for the lachrymal sac, which narrows below into the *nasal duct*.

The duct passes downwards, backwards and slightly outwards, to open into the anterior part of the inferior meatus of the nose under cover of the inferior turbinated bone. The duct is about $\frac{1}{2}$ inch long.

The *supra-orbital, infra-orbital, and mental foramina*.—

Figs. iii., v., 1-3. At the junction of the inner and middle thirds of the supra-orbital margin, the supra-orbital notch or foramen may be felt, and a line drawn downwards from this foramen through the interval between the two lower bicuspid teeth will pass through both infra-orbital and mental foramina. The former foramen lies $\frac{1}{4}$ to $\frac{1}{2}$ inch below the orbital margin, whilst the latter (in the adult) lies midway between the alveolar and inferior borders of the lower jaw.

The *frontal sinuses* are very variable in extent. They occupy the space between the inner and outer tables of the frontal bone, above the base of the nose and above the inner half of the supra-orbital margin. The sinus communicates with the nasal cavity by means of a narrow channel, the *infundibulum*, which opens into the middle meatus of the nose under cover of the middle turbinated bone, on a level with the inner margin of the palpebral fissure.

The *antrum of Highmore* usually occupies the greater part of the interior of the superior maxilla, and opens into the *hiatus semilunaris*, a depression which lies under cover of the middle turbinated bone. The opening is, however, situated at so high a level that pus only escapes into the nose when the antrum is practically full. Two teeth are, on the other hand, closely related to the antrum—namely, the second bicuspid and the first molar—the sinus usually extending downwards in the interval between the two labial and single palatal fangs of the latter

tooth. The removal of either of these teeth, followed up by any necessary upward boring, will efficiently drain the sinus.

The sinus may also be drained by everting the upper lip and puncturing the outer wall through the canine fossa, a depression lying above the canine tooth.

The *sphenoidal sinus* occupies the greater part of the body of the sphenoid, and opens into the sphenoidal recess, a space lying above and behind the superior turbinated bone.

The sinuses of the nose and their efferent channels :

The sphenoidal sinus = sphenoidal recess.

The posterior ethmoidal cells = superior meatus.

The anterior ethmoidal cells	}	= middle meatus.
The middle ethmoidal cells		
The frontal sinus		
The antrum of Highmore		

The nasal duct = inferior meatus.

The Triangles of the Neck.

The lateral aspect of the neck is divided by the sternomastoid muscle into two triangles—anterior and posterior.

The *anterior triangle* is bounded in front by the middle line of the neck, behind by the anterior border of the sternomastoid muscle, and above by the lower border of the ramus of the jaw.

The space so marked out is divided into three smaller triangles by the digastric muscle and by the anterior belly of the omo-hyoid :

Fig. iv., 17. (1) The *submaxillary* triangle, above the digastric muscle, containing the submaxillary gland.

Fig. iv., 19. (2) The *muscular* triangle, anterior to the omo-hyoid muscle.

(3) The *carotid* triangle, bounded above by the posterior belly of the digastric, behind by the anterior border of the sterno-mastoid muscle, and in front by the anterior belly of the omo-hyoid. In this triangle the common carotid bifurcates, and the external carotid gives off most of its branches.

The *posterior* triangle is bounded in front by the posterior border of the sterno-mastoid, behind by the anterior border of the trapezius, and below by the middle third or fourth of the clavicle. The triangle is subdivided by the posterior belly of the omo-hyoid, which cuts off the small *subclavian* triangle below from the more extensive *occipital* triangle above.

The Vessels and Nerves.

The *carotid arteries* correspond in direction to a line from the sterno-clavicular joint to the hollow between the angle of the jaw and the mastoid process. The *common carotid* usually bifurcates at the level of the upper border of the thyroid cartilage (fourth cervical vertebra), the external carotid subsequently lying superficial to and slightly to the inner side of the internal carotid. The *omo-hyoid* muscle (upper belly) crosses the common carotid at the level of the cricoid cartilage, and in this situation the artery may be compressed against the prominent anterior tubercle of the transverse process of the sixth cervical vertebra (Chassaignac's tubercle).

The *superior thyroid* artery arises from the external carotid in the carotid triangle, immediately above the level of the upper border of the thyroid cartilage, and, turning downwards under cover of the anterior belly of the omo-hyoid muscle, is directed

towards the apex of the lateral lobe of the thyroid gland.

The *lingual artery* arises midway between the level of the upper border of the thyroid cartilage and the great cornu of the hyoid bone, and enters the submaxillary triangle by passing deep to the posterior belly of the digastric muscle. The artery so gains the upper border of the hyoid bone, and runs inwards for a short distance parallel to that bone under cover of the hyo-glossus muscle.

The *facial artery* arises opposite the great cornu of the hyoid bone, and also enters the submaxillary triangle by passing deep to the posterior belly of the digastric. In this triangle the artery lies deeply embedded in the substance of the submaxillary salivary gland, and then enters on its facial course by curling round the inferior border of the lower jaw immediately anterior to the masseter muscle, about $1\frac{1}{2}$ inches in front of the angle of the jaw. The vessel then passes upwards towards the inner canthus of the eye, there terminating as the "angular artery."

The *occipital artery* arises from the outer side of the external carotid artery in the upper part of the carotid triangle, and passes upwards and backwards, under cover of the posterior belly of the digastric muscle, towards the interval between the mastoid process and the transverse process of the atlas. At the apex of the posterior triangle the artery is joined by the great occipital nerve (posterior primary division of the second cervical nerve), the two structures then passing upwards on to the vault of the skull.

The *posterior auricular artery* arises from the external carotid, immediately above the posterior belly of the

thyroid

level of

great

sub-

the

very so

is in-

under

f the

le by

igas-

deeply

ivary

ound

erior

f the

ards

the

the

otid

ards,

igas-

stoid

the

the

the

sing

rnal

the

THE SIDE OF THE FACE AND NECK

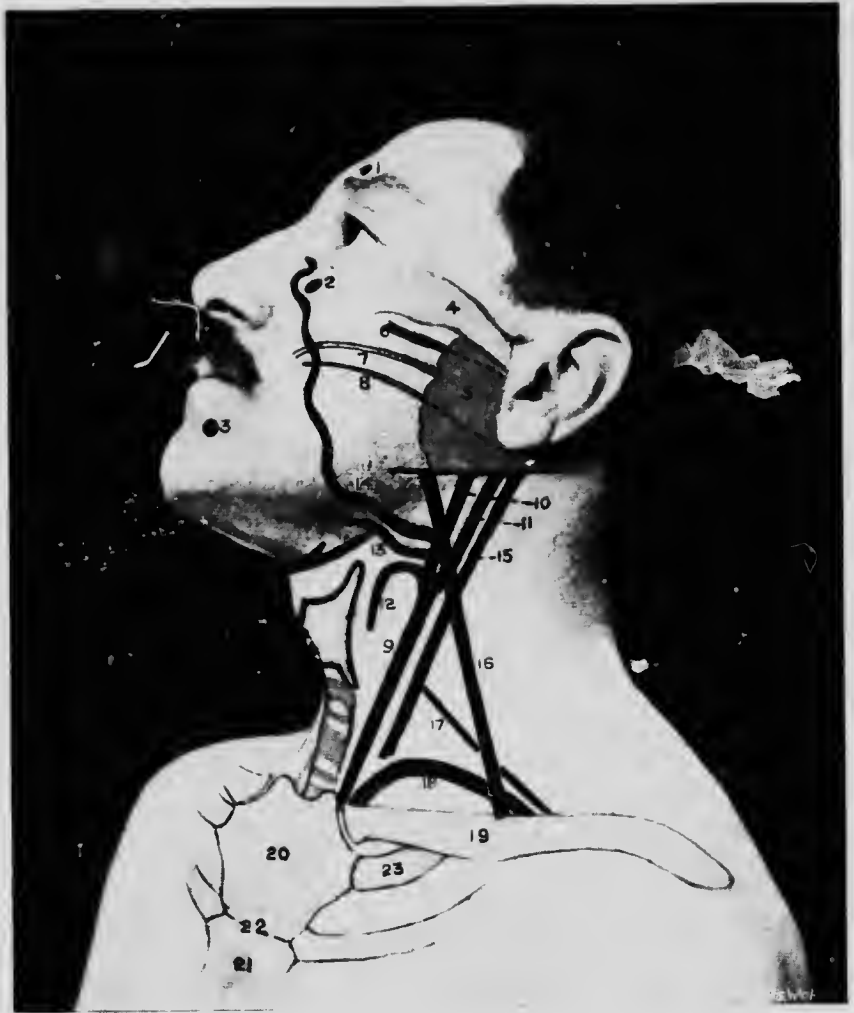

FIG. III.

- | | |
|--|--|
| <ol style="list-style-type: none"> 1. The supra-orbital foramen. 2. The infra-orbital foramen. 3. The mental foramen. 4. The zygoma. 5. The parotid gland. 6. The transverse facial artery. 7. Stensen's duct. 8. The facial nerve. 9. The common carotid artery. 10. The external carotid artery. 11. The internal carotid artery. 12. The superior thyroid artery. | <ol style="list-style-type: none"> 13. The lingual artery. 14. The facial artery. 15. The internal jugular vein. 16. The external jugular vein. 17. The upper limit of the brachial plexus. 18. The subclavian artery. 19. The clavicle. 20. The manubrium sterni. 21. The gladiolus sterni. 22. The angle of Ludwig. 23. The first costal cartilage. |
|--|--|

To face Fig. IV., pp. 14, 15.

THE SIDE OF THE FACE AND NECK

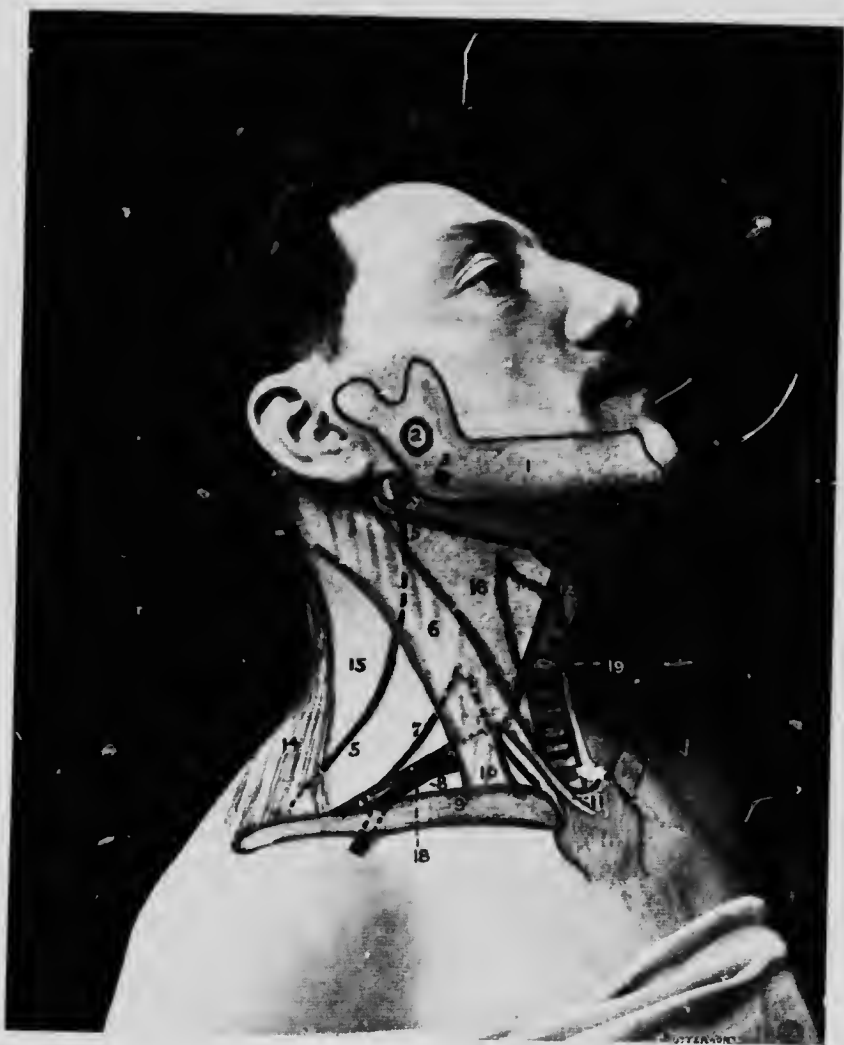

FIG. IV.

1. The inferior maxilla.
2. The inferior dental nerve.
3. The tonsil.
4. The transverse process of the atlas.
5. The spinal accessory nerve.
6. The sterno-mastoid muscle.
7. The upper limb of the brachial plexus.
8. The third part of the sub-clavian artery.
9. The clavicle.
10. The clavicular head of the sterno-mastoid muscle.
11. The sternal head of the sterno-mastoid muscle.
12. The digastric muscle.
13. The omohyoid muscle.
14. The trapezius muscle.
15. The posterior triangle.
16. The carotid triangle.
17. The submaxillary triangle.
18. The subclavian triangle.
19. The muscular triangle.

To face Fig. III., pp. 14, 15.



digastric muscle, and passes backwards parallel to the upper border of that muscle, through the lower part of the parotid gland, to the depression between the cartilage of the concha of the ear and the mastoid process. Here the artery is joined by the posterior auricular nerve—a branch of the facial.

The *superficial temporal artery* arises in the substance of the parotid gland as one of the two terminal branches of the external carotid. It crosses the base of the zygomatic process of the temporal bone, immediately in front of the tragus of the ear, and is accompanied by the auriculo-temporal nerve, a sensory branch of the third division of the fifth cranial nerve.

The *subclavian artery* (cervical course) is represented by a curved line from the sterno-clavicular joint to the mid-point of the corresponding clavicle, the convexity of the line extending upwards into the supraclavicular fossa about $\frac{3}{4}$ to 1 inch above the clavicle. In marking out this vessel, the shoulders should be well depressed.

The artery passes behind the scalenus anticus muscle, the second part of the artery being covered by that muscle. The outer border of the scalene muscle usually corresponds to the outer border of the sterno-mastoid muscle, and consequently the third part of the subclavian artery is represented by that part of the curve which lies between the outer border of the sterno-mastoid muscle and the mid-point of the clavicle.

The subclavian artery ends anatomically at the outer border of the first rib.

The *external jugular vein* is formed just behind the angle of the jaw by the junction of the posterior division of the temporo-maxillary trunk with the posterior auricular vein.

The vessel so formed passes downwards and backwards, superficial to the sterno-mastoid muscle, towards the middle of the clavicle, above which the vein pierces the deep fascia to join the subclavian vein.

The *internal jugular vein* runs parallel and external to the internal and common carotid arteries, and therefore presents a similar surface marking to that already given for those arteries.

The *vagus nerve* passes downwards in the carotid sheath, behind and between the carotid arteries and the internal jugular vein.

The *cervical sympathetic trunk* also lies in the line of the carotid arteries, being placed behind the carotid sheath. The *superior cervical ganglion* is situated in front of the transverse processes of the second and third cervical vertebræ; the *middle ganglion* overlies the corresponding process of the sixth vertebra; whilst the *inferior ganglion*, which is frequently fused with the first thoracic, lies behind the first part of the subclavian artery, between the transverse process of the seventh cervical vertebra and the neck of the first rib.

The *phrenic nerve* is formed below the level of the hyoid bone by branches from the anterior primary divisions of the third, fourth and fifth cervical nerves, and passes downwards and slightly inwards towards the sternal end of the clavicle. At the level of the cricoid cartilage the nerve lies midway between the anterior and posterior borders of the sterno-mastoid muscle.

The *spinal accessory nerve* crosses the transverse process of the atlas, a bony prominence to be felt immediately below and in front of the apex of the mastoid process.

The nerve enters the substance of the sterno-mastoid Fig. iv., 4, at the junction of the upper and second quarters along the anterior border of the muscle, 5, 5. emerging from the posterior border of the muscle at the junction of the upper and middle thirds. The point of emergence is, however, subject to some variation, and the nerve may enter the posterior triangle of the neck at a somewhat lower level, pursuing subsequently a downward and backward course towards the anterior border of the trapezius muscle, beneath which muscle it sinks.*

The *superficial cervical plexus*.—Take a point midway along the posterior border of the sterno-mastoid muscle, and from this point draw three lines:

1. Upwards towards the lobe of the ear = the great auricular nerve (2 and 3 C.).
2. Upwards along the posterior border of the sterno-mastoid muscle = small occipital nerve (2 C.).
3. Forwards towards the middle line of the neck = the transverse cervical nerve (2 and 3 C.).

By producing these three lines in a downward direction, the descending branches of the plexus are roughly indicated.

Thus the great auricular produced = the supraclavicular nerve; the small occipital produced = the suprasternal nerve; the transverse cervical produced = the supra-acromial nerve. The three descending trunks are derived from the third and fourth cervical nerves, and all the branches of this plexus arise from the anterior primary divisions of their respective nerves.

* Another surface-marking for the *spinal accessory nerve*.—Draw a line from a point midway between the tip of the mastoid process and the angle of the jaw to the middle of the posterior border of the sterno-mastoid muscle, and thence across the posterior triangle to the anterior border of trapezius.

The *brachial plexus*.—The upper limit of the nerve-trunks which form this plexus is represented by a line drawn from the mid-point between the anterior and posterior borders of the sterno-mastoid muscle at the level of the cricoid cartilage to a second point situated just external to the mid-point of the clavicle. The lowest cord lies behind the third part of the sub-clavian artery.

The *rima glottidis*, which in its front part is laterally bounded by the true vocal cords, lies opposite the mid-point along the anterior border of the thyroid cartilage.

The *epiglottis*, though fixed below to the thyroid angle immediately above the point of attachment of the true vocal cords, extends upwards to above the level of the body of the hyoid bone.

A suicidal cut-throat frequently involves the thyro-hyoid space, and the epiglottis may be severed from its thyroid attachment.

The *isthmus of the thyroid gland* crosses the trachea about $\frac{1}{2}$ to $\frac{3}{4}$ inch below the cricoid cartilage.

The structures in the *middle line of the neck*:

- (1) Passing down from the jaw to the body of the hyoid bone, the two genio-hyoid muscles lie each side of the middle line. They are placed, however, deep to the mylo-hyoid muscles, which are directed downwards and inwards to the median raphé and to the body of the hyoid bone.
- (2) The body of the hyoid bone. (3) The thyro-hyoid space. (4) The thyroid cartilage. (5) The crico-thyroid space. (6) The cricoid cartilage. (7) The upper two or three tracheal rings. (8) The isthmus of the thyroid gland. (9) The trachea. (10) The suprasternal notch.

THE FRONT OF THE NECK

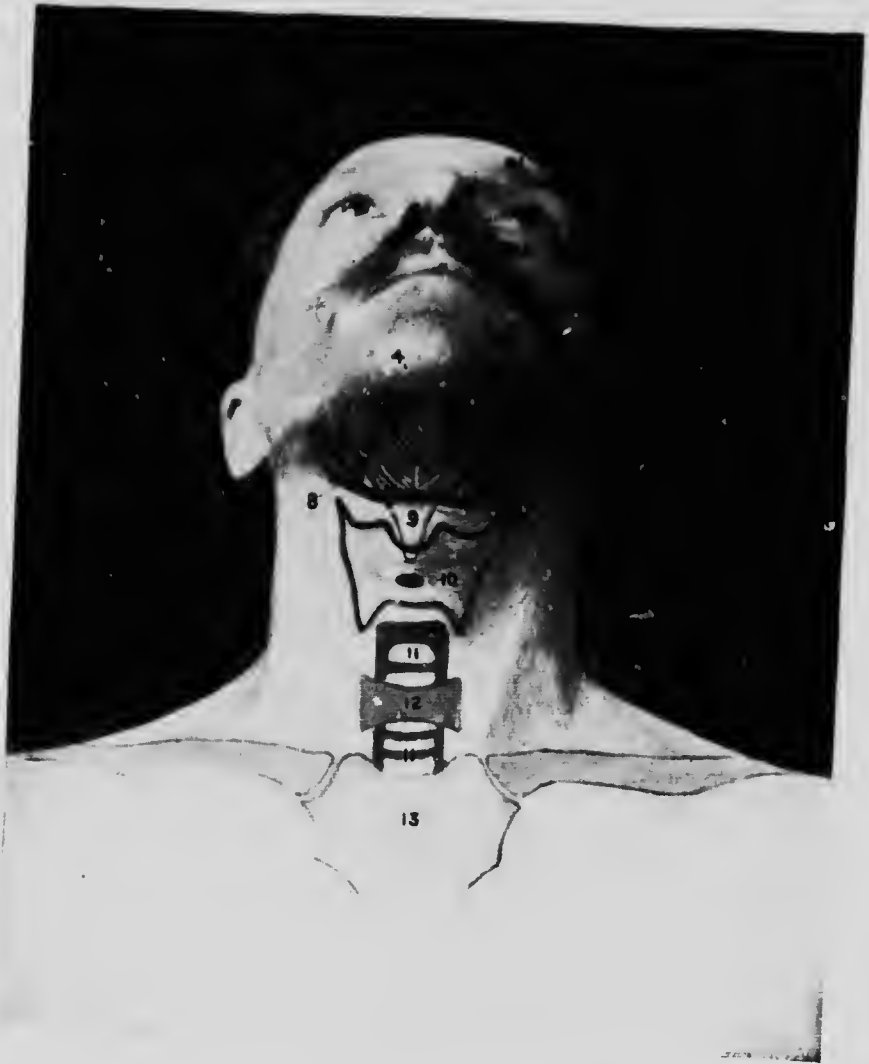

FIG. V.

- | | |
|--|----------------------------|
| 1. The supra-orbital foramen. | 7. The hyo-glossus muscle. |
| 2. The infra-orbital foramen. | 8. The hyoid bone. |
| 3. The mental foramen. | 9. The epiglottis. |
| 4. The genio-hyoid muscle (deep to the mylo-hyoid muscle). | 10. The thyroid cartilage. |
| 5. The digastric muscle. | 11. The trachea. |
| 6. The mylo-hyoid muscle. | 12. The thyroid isthmus. |
| | 13. The sternum. |

To face p. 13.



CHAPTER II

THE UPPER EXTREMITY

IN this chapter, and in that on the lower extremity, the reader's attention is mainly directed to those bony prominences and muscular or tendinous elevations which lie in the region of the joints, since these form the more important landmarks which aid in the representation of the arteries, nerves, etc., of the limbs. The muscular masses, which complete the symmetry of the arm or leg between the joints, are only mentioned where necessary, a fair general knowledge of the anatomical structure of the body being assumed.

The *shoulder region*.—The acromial process, the spine of the scapula and the clavicle, being subcutaneous throughout their whole length, can readily be palpated from end to end. The clavicle should first be examined from its blunted sternal extremity to the acromio-clavicular joint. The inner third of the shaft is rounded and presents a marked forward convexity, whilst the outer third of the bone is flattened from before backwards and shows a concave anterior border. At the outer end of the bone a slight elevation can usually be felt on the superior surface, and immediately external to this is the acromio-clavicular joint, the long axis of which lies in the antero-posterior direction.

The acromial spine is narrow at about its centre, broadening out towards the vertebral border of the scapula, and forming there a smooth triangular surface, over which glides the tendinous part of the trapezius. Externally, the spine terminates in the upward curved acromial process, at the anterior border of which an oval facet is situated for articulation with the clavicle. The supra- and infra-spinatus muscles fill up the depressions or fossæ which lie in relation to the spine of the acromion.

The clavicle is also bounded above and below by depressions, little evident in fat subjects, but most marked when, as the result of pathological or physiological conditions, fat is feebly represented. The supra-clavicular or subclavian triangle is dealt with in the first chapter. The *infraclavicular space* is bounded above by the clavicle, below by the clavicular head of the pectoralis major muscle, internally by the costal cartilage of the first rib, and externally by the anterior border of the deltoid muscle. The floor is formed by the subclavius muscle and the costo-coracoid membrane. In the outer part of the space the coracoid process may be felt, the apex of the process lying under cover of the anterior border of the deltoid muscle. In favourable cases, the pulsation of the axillary artery (Part I.) may be detected below the clavicle, as this vessel runs downwards from the outer border of the first rib. The bulky deltoid muscle, arising from the clavicle and from the acromial process and spine, is, so to speak, pushed outwards by the underlying head and great tuberosity of the humerus, so producing the normal rounded appearance of the shoulder. This outward displacement of the muscle is taken advantage of by Hamilton in the diag-

Fig. xiii., 1.

Fig. xiii., 2.

Fig. iv., 18.

Fig. vi., 3.

Fig. xiv., 5.

THE FRONT OF THE ARM AND FOREARM

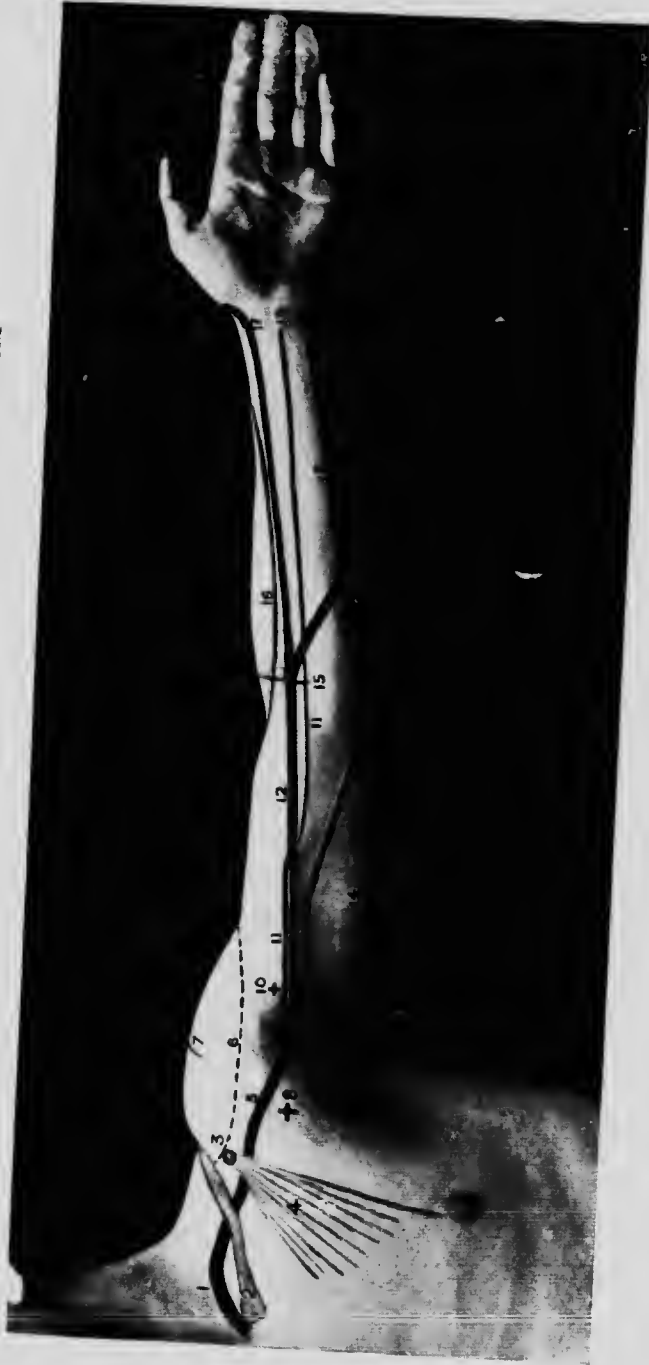

FIG. VI.

1. The subclavian artery.
2. The clavicle.
3. The coracoid process.
4. The pectoralis minor.
5. The axillary artery.
6. The anterior border of the deltoid.
7. The circumflex nerve and arteries.
8. The anterior axillary fold.
9. The posterior axillary fold.
10. The coraco-brachialis prominence.
11. The median nerve in the arm.
12. The brachial artery.
13. The ulnar nerve in the arm.
14. The triceps muscle.
15. The level of the head of the radius.
16. The radial nerve.
17. The radial artery.
18. The ulnar artery.
19. The median nerve in the forearm.
20. The ulnar nerve in the forearm.



nosis of a dislocation of the shoulder-joint, as, after such an injury, the humerus is drawn inwards by the pectoralis major, latissimus dorsi and other muscles to such a degree that a ruler placed along the outer side of the arm will be in contact with the acromion process and the external humeral condyle at one and the same time. In the normal condition, this is not possible.

To measure the *length of the humerus*, the tape-measure **Fig. xiv., 4**, should be carried from the lower margin of the acromial process to the external condyle of the humerus. The lesser tuberosity of the humerus is always difficult to identify, but it can usually be distinguished lying rather below the mid-point of a line uniting the coracoid process and the great tuberosity of the humerus, the arm being well everted and the elbow in contact with the side of the body.

Between the two tuberosities is the *bicipital groove*, in which runs the long tendon of the biceps muscle. The groove may be represented by a line, about 2 inches long, which runs downwards from the tip of the acromial process, parallel to the long axis of the humerus.

The *upper epiphysis* of the humerus includes the head and both tuberosities, and the epiphysial line runs transversely, at right angles to the long axis of the humerus, at the lower border of the great tuberosity.

The *axilla*.—To examine this space, the elbow should be supported, and the patient instructed to relax all muscles. The anterior wall is formed by the major and minor pectoral muscles, and by the costo-coracoid membrane. The pectoralis major alone forms the anterior fold of the axilla, and does not extend as far downwards as the posterior fold, whilst its rounded appearance results from the twisting of the fibres **Fig. vi., 8**.

of the pectoral muscle before their insertion into the outer bicipital ridge. The posterior wall is formed mainly by the subscapularis muscle overlying the ventral surface of the scapula, the axillary border of which bone can be made out by deep palpation from the inferior angle below to the head above. The rounded posterior fold of the axilla results from the fact that the latissimus dorsi curls round the *Fig. vi., 9.* *teres major* muscle from behind forwards in *Fig. xiii., 7.* order to reach its insertion into the floor of the bicipital groove. The narrow outer boundary of the axilla corresponds to the upper part of the shaft and to the head of the humerus, and in this situation, in a well-developed arm, two prominent longitudinal folds are seen, *Fig. vi., 10.* the anterior of which corresponds to the coracobrachialis and biceps (short head) muscles, whilst the *Fig. vi., 11.* more posterior fold results from the projection *13.* of the neuro-vascular bundle. The head of the humerus and of the scapula can be felt at the upper and posterior part of the axilla, the second rib on the inner side, and the coracoid process in front. The head of the humerus looks in the same direction as the internal condyle of the humerus. The inner wall of the axilla is formed by the upper part of the lateral wall of the thorax, which is here clothed by the serrations of the serratus magnus muscle.

The *axillary lymphatic glands* are arranged in three main groups, all converging towards the apex of the axilla :

(a) The *pectoral* set, running upwards and outwards under cover of the outer border of the pectoral muscles and draining the anterior and lateral aspects of the chest-wall and the abdomen above the level of the umbilicus.

(b) The *subscapular* set, running upwards along the axillary border of the subscapularis muscle, and draining

r
y
e
e
e

the lateral and posterior aspect of the chest above the level of the umbilicus.

(c) The *brachial and axillary* set, running upwards in the line of the axillary vessels, and draining the whole of the upper extremity.

The *elbow region*.—When the forearm is extended, a

Fig. vii., line joining the internal and external condyles

1-3. of the humerus cuts across the tip of the ole-

cranon process, which bony prominence lies well to the inner side of the mid-point of the intercondyloid line.

When the forearm is flexed, the olecranon moves downwards, and by uniting the three bony points a triangle is

Fig. xiii., formed. Immediately below the external con-

5, 8. dyle the head of the radius is felt "lying in the

valley behind the supinator longus" (Holden). The humero-radial articulation is transverse, but the humero-

ulnar articulation slopes obliquely downwards and inwards, and consequently, whilst the external condyle is

about $\frac{3}{4}$ inch above the humero-radial joint, the internal condyle lies rather more than 1 inch above the line of the humero-ulnar articulation.

The junction of the *diaphysis* and *lower epiphysis* of the humerus corresponds to a transverse line drawn across

the humerus immediately above the tips of the condyles. The bony points on the outer side of the joint are generally

obscured in those cases where there is considerable effusion into the elbow-joint, the synovial membrane bulging out-

wards below the external condyle of the humerus and between that process and the olecranon process. Under

similar conditions, there is also an outward projection of the synovial membrane between the olecranon and the

internal condyle of the humerus, obscuring the deep depression that normally exists in that situation—a de-

9. The interiliac plane (highest point of iliac crests).

10. The site for lumbar puncture.

11. The iliac crests.

Fig. five p. 21.

7. The filum terminale.

7a. The termination of the filum near the tip of the coccyx.

8. The transpyloric plane.

6a. The termination of the theca at the level of the 3rd sacral vertebra, just below a line drawn transversely between the two posterior superior iliac spines.

5. The spinal cord.

5a. The termination of the cord at the level of the transpyloric plane (1st lumbar vertebra).

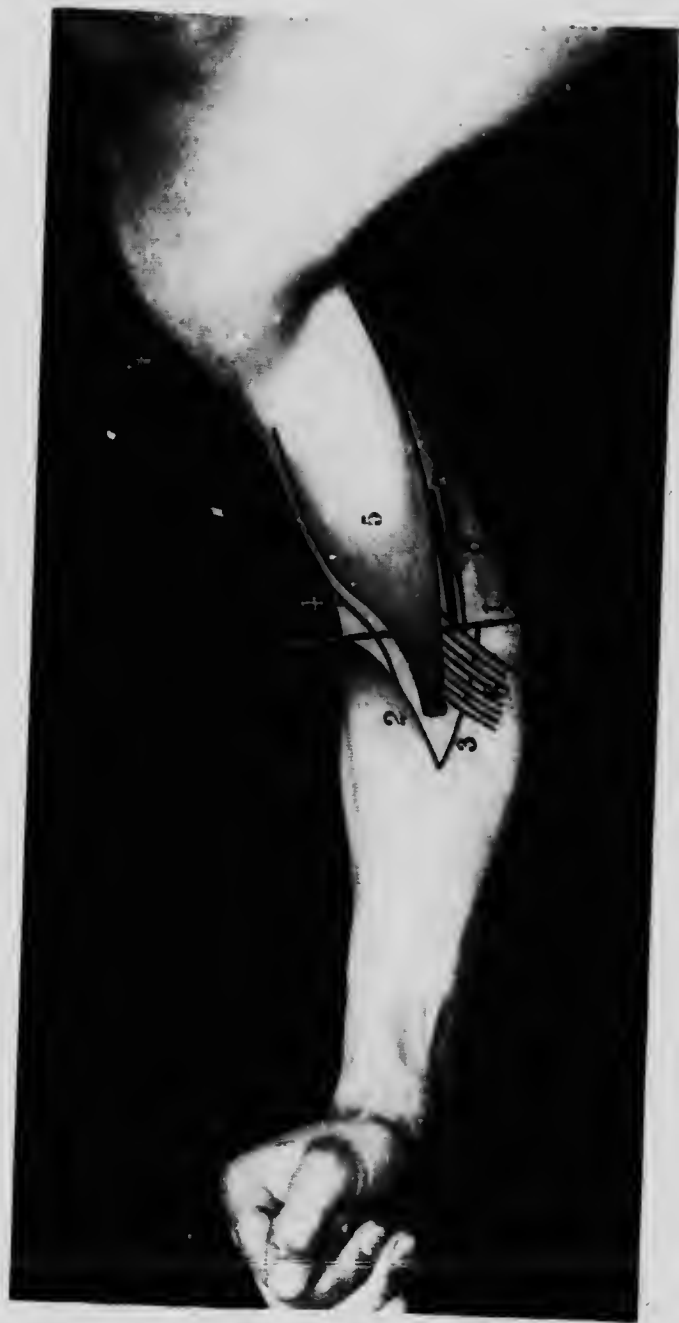1. The theca vertebralis.

pression at the base of which the ulnar nerve can be rolled beneath the finger.

In front of the elbow is the *antecubital triangle*, the base of which corresponds to a line drawn across the front of the elbow between the two humeral condyles, whilst the inner and outer boundaries are formed respectively by the pronator radii teres and supinator longus muscles. This triangular space is vertically subdivided by the biceps tendon, on either side of which a depression exists, the inner and outer *bicipital sulci*. In the outer sulcus the musculo-spiral nerve divides into its two terminal branches, radial and posterior interosseous, whilst the median nerve and the brachial artery lie in the inner sulcus, the artery intermediate between the tendon and the nerve. The artery and nerve are, however, obscured in the lower part of the inner sulcus by the overlying bicipital fascia, which can be traced inwards to the pronator region, whilst its upper free margin presents a well-marked crescentic edge which looks upwards and inwards.

The *superficial veins* in front of the bend of the elbow are arranged in the form of a letter **M**, the radial, median and ulnar veins being received from below, whilst two main efferent vessels, the cephalic and the basilic, carry the blood upwards. The *basilic vein* passes upwards in the superficial fascia, along the inner side of the arm, and pierces the deep fascia about half-way between the axilla and the internal condyle, and at the foramen so produced in the deep fascia the internal cutaneous nerve emerges to become superficial. The *epitrochlear*

THE ELBOW REGION



1. The intercondyloid line.
2. The supinator longus.
3. The pronator radii teres.

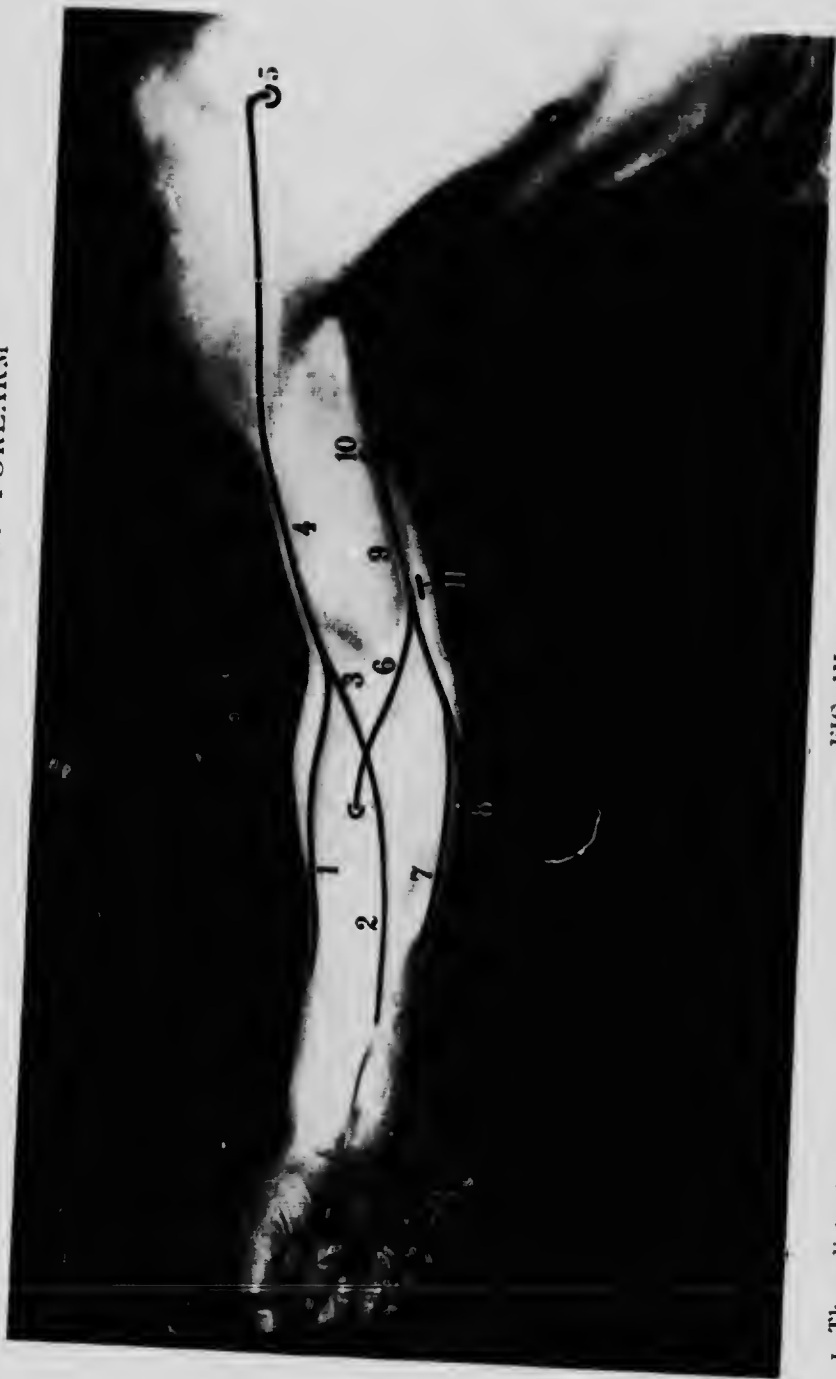
FIG. VIII.

4. The musculospiral nerve.
5. The biceps.
6. The bicipital fascia.

7. The brachial artery.
8. The median nerve.




THE VEINS OF THE ARM AND FOREARM



1. The radial vein.
2. The median and median-profundus veins.
3. The median-cephalic vein.
4. The cephalic vein.

FIG. 1X.

5. The point at which the cephalic vein pierces the costo-coracoid membrane.
6. The median-basilic vein.
7. The anterior ulnar vein.
8. The posterior ulnar vein.
9. The basilic vein.
10. The point at which the basilic vein pierces the deep fascia.
11. The epitrochlear gland.



gland lies in close connection with the median basilic or basilic veins above and in front of the internal condyle.

Fig. ix., 11.

The *cephalic vein* can be traced upwards along the outer side of the arm as far as the groove between the deltoid and pectoralis major muscles. In the interval between these two muscles the vein lies embedded, and eventually pierces the costo-coracoid membrane in the infraclavicular region to open into the axillary vein.

Fig. ix., 4.

Fig. ix., 5.

THE REGION OF THE WRIST AND HAND.

Two tendons only are conspicuous at the front of the wrist—the palmaris longus in the middle line, and the flexor carpi radialis to the outer side of the palmaris longus. The flexor carpi ulnaris can, however, be distinguished by palpation along the ulnar border of the forearm, and can be traced downwards to its insertion into the pisiform bone. Between the palmaris longus and the flexor carpi ulnaris the main mass of the flexor sublimis digitorum lies. Two transverse creases are seen in this situation, the upper of which roughly corresponds to the level of the radio-carpal joint, whilst the lower represents almost exactly the upper limit of the anterior annular ligament.

Fig. x.,
2, 1.

Fig. x.,
4, 5.

Fig. x., 6.

Just external to where the flexor carpi radialis tendon cuts across the two transverse creases there is a depression, in the floor of which the lower end of the radius and the tubercle of the scaphoid bone may be felt. The radial artery crosses this space in a downward and outward direction. The trapezium lies at the lower limit of the depression, immediately below and external to the scaphoid tubercle.

Fig. xi., 4.

Fig. xi., 3.

The prominent pisiform bone can be distinguished by tracing downwards the tendon of the flexor carpi ulnaris muscle, and posterior to this bone both cuneiform and unciform bones are situated. A finger's breadth below and external to the pisiform bone deep palpation will verify the position of the hook of the unciform bone.

The *anterior annular ligament* is attached to four bony points, two on the radial side, the scaphoid tubercle and the ridge on the trapezium, and two on the ulnar side, the pisiform and the hook of the unciform. The upper limit of the ligament corresponds to the lower of the two transverse creases in front of the wrist, whilst the inferior limit of the ligament lies about $\frac{3}{4}$ inch below.

The *flexor synovial sheaths*.—The flexor longus pollicis, the flexor sublimis and the flexor profundus digitorum all pass beneath the anterior annular ligament. In this situation the flexor sublimis consists of four tendons, of which the medius and annularis lie superficial to the tendons which pass to the index and little fingers. The profundus consists of two parts only, the tendon to the index-finger being alone differentiated off from the main mass. Beneath the ligament these tendons are surrounded by two synovial sheaths, one for the flexor longus pollicis and one for the remaining tendons plus the median nerve. The sheaths extend upwards about 1 inch above the upper limit of the ligament, and therefore the same distance above the lower transverse crease in front of the wrist. The flexor longus pollicis sheath is continued downwards to the insertion of the tendon into the distal phalanx of the thumb. The main sheath broadens out below the liga-

Fig. xi., 1.

Fig. xi., 2.

Fig. xi., 5.

Fig. xi., 6.

Fig. xi.

Fig. xi.,
6, 6.

FIG. X.

1. The flexor carpi radialis.
2. The palmaris longus.
3. The ulnar artery.
4. The flexor carpi ulnaris.
5. The pisiform bone.
6. The transverse creases of the wrist.
7. The superficial branch of the ulnar artery.
8. The deep branch of the ulnar artery.
9. The superficial palmar arch.
10. The deep palmar arch.
11. The digital branches of the superficial palmar arch.
12. The superficialis volæ.

FIG. XI.

1. The pisiform.
2. The unciform.
3. The trapezium.
4. The scaphoid tuberosity.
5. The anterior annular ligament.
- 6, 6. The flexor longus pollicis sheath.
- 7, 7. The main flexor synovial sheath.
8. The distal flexor synovial sheaths.
9. The continuation of the main sheath along the little finger.

THE PALM OF THE HAND

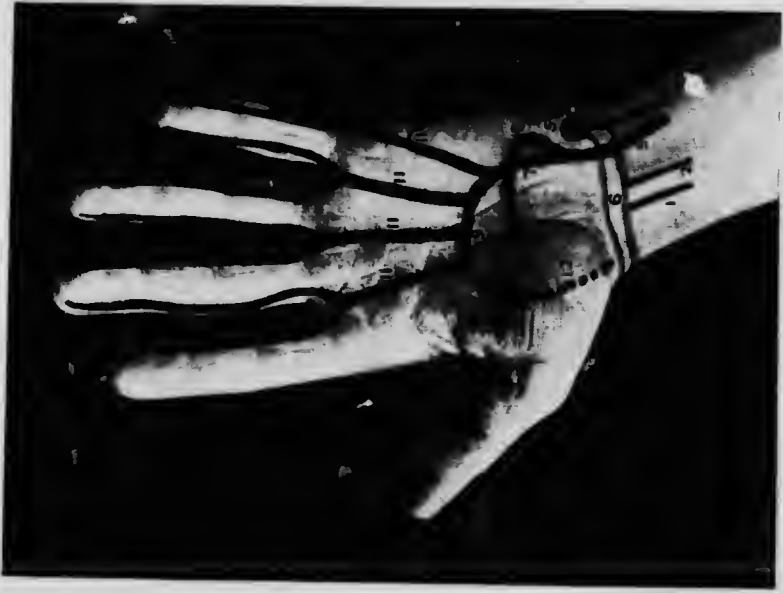

FIG. X.



FIG. XI.



ment, and though generally continued onwards to the end of the little finger, the major portion terminates at the level of the upper transverse crease of the palm. The flexor tendons to the fore, middle and ring fingers also possess more distally distinct synovial sheaths, which extend from the terminal phalanges of the fingers upwards to the necks of the metacarpal bones, a level corresponding roughly to the lower transverse crease of the palm.

A distance of $\frac{1}{2}$ inch separates the main synovial sheath above from the more distal segments below.

On the outer side of the wrist the most marked feature is the "anatomical snuff-box," a space bounded on the radial side by the tendons of the extensor ossis metacarpi and primi internodii pollicis muscles, and on the ulnar side by the tendon of the extensor secundi internodii pollicis.

In the floor of the space the styloid process of the radius is felt, this prominence lying fully $\frac{1}{2}$ inch below the level of the corresponding process of the ulna, and also on a slightly more anterior plane. Immediately below the radial styloid process the scaphoid bone lies, most prominent when the hand is well adducted. Below this, again, the trapezium and the bases of the first and second metacarpals are to be felt.

On the dorsum of the hand there is a well-marked elevation, most noticeable when the wrist is fully flexed, due to the projection of the bases of the second and third metacarpal bones, the styloid process of the latter bone being especially prominent.

Immediately above this elevation there is a depression where the tendons of the extensor carpi radialis longior and breviar are felt as they pass to their insertion into the bases of the second and third metacarpal bones.

Near the middle of the posterior aspect of the lower end of the radius a tubercle can generally be distinguished, *the radial tubercle*, separating the extensor secundi internodii pollicis on the inner side from the tendon of the extensor carpi radialis breviar, which lies more external.

The *posterior annular ligament*, about $\frac{3}{4}$ inch broad, extends from the lower part of the outer border of the radius to the styloid process of the ulna and the carpal bones below the ulna. The ligament has, therefore, a downward and inward direction, and beneath it pass the extensor tendons. These occupy distinct compartments, and possess synovial sheaths as under :

1. One compartment and synovial sheath for the extensor ossis metacarpi and extensor primi internodii pollicis.
2. One for the extensor carpi radialis longior and breviar.
3. One for the extensor secundi internodii pollicis.
4. One for the extensor communis digitorum and extensor indicis.
5. One for the extensor minimi digiti.
6. One for the extensor carpi ulnaris. The extent of the synovial sheaths is indicated in the diagram, where the radial artery is also depicted as it crosses the "anatomical snuff-box" towards the base of the first interosseous space, at which level the vessel dips down between the two heads of the first dorsal interosseous muscle to complete the deep palmar arch.

Fig. xii. 1.

Fig. xii. 2.

Fig. xii. 3.

Fig. xii. 5.

Fig. xii. 6.

Fig. xii. 7.

Fig. xii. 8.

Fig. xii.,
9, 10.

THE BACK OF THE WRIST

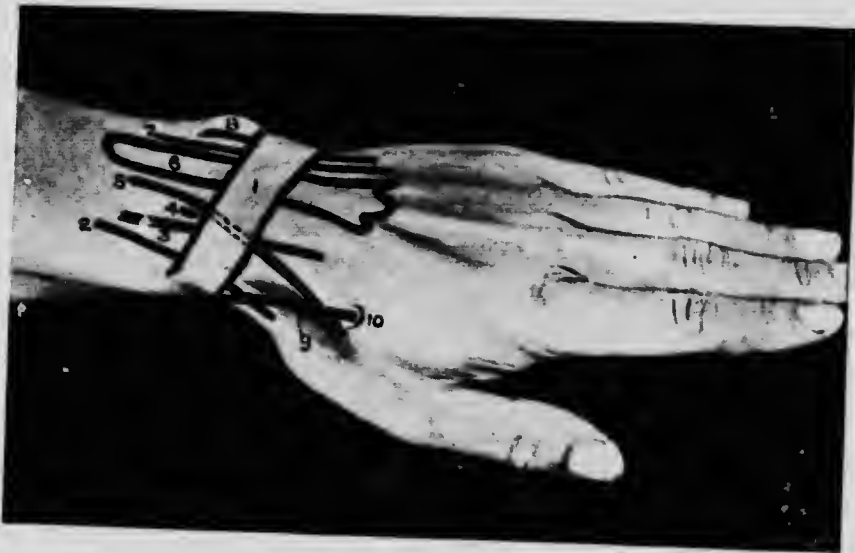


FIG. XII.

1. The posterior annular ligament.
4. The radial tubercle.
- 2, 3, 5-8. The compartments and synovial sheaths of the extensor tendons (see text).
9. The radial artery, crossing the "anatomical snuff-box."
10. The base of the first interosseous space.

To face p. 23.



VESSELS, ETC., OF THE UPPER EXTREMITY.

The *axillary artery* extends from the outer border of the first rib to the lower margin of the *teres major* muscle. When the arm is held out at right angles to the long axis of the body, and the palmar surface of the hand turned upwards, the artery corresponds in direction to a line drawn from the middle of the clavicle to the junction of the anterior and middle thirds of the outer axillary wall at the outlet of that space. At its termination the artery and the accompanying nerves—the neuro-vascular bundle—form a projection which lies behind that due to the *coraco-brachialis* and *biceps* (short head) muscles.

Fig. vi.,
10-13.

The artery is divided into three parts by the *pectoralis minor* muscle, which muscle can be represented by a triangle, the base corresponding to the anterior extremities of the third, fourth and fifth ribs, whilst the apex is situated at the end of the coracoid process.

Fig. vi., 4.

The *brachial artery*.—The arm and forearm being held in the position already indicated as necessary in order to map out the axillary artery, the brachial artery corresponds to a line drawn from the outer wall of the axillary outlet at the junction of its anterior and middle thirds to the mid-point in front of the bend of the elbow at the level of the head of the radius.

Fig. vi., 15

At the last point the artery bifurcates into radial and ulnar arteries.

The *radial artery* extends from the middle of the bend of the elbow at the level of the head of the radius to the radial side of the tendon of the *flexor carpi radialis* muscle just above the base of the thumb. The artery then crosses the "anatomical

Fig. vi., 17.

Fig. xii.,
9. 10.

snuff-box" towards the base of the first interosseous space.

The *ulnar artery* in the lower two-thirds of its course accompanies and lies to the radial side of the ulnar nerve (see "*ulnar nerve in the forearm*," p. 32). The upper third of its course is represented by a line which passes obliquely upwards and outwards to the middle of the bend of the elbow at the level of the head of the radius.

The *superficial palmar arch* is formed by the anastomosis of the superficial division of the ulnar artery with the superficialis volæ, or with some other branch of the radial artery. The convexity of the arch looks towards the fingers, and lies on a level with the lower border of the outstretched thumb. Occasionally the arch extends lower down, reaching as far as the upper of the two transverse creases on the palmar aspect of the hand.

The *deep palmar arch*, formed by the anastomosis of the radial artery with the deep branch of the ulnar, lies about one finger's breadth above the level of the superficial palmar arch.

The *digital branches* of the superficial palmar arch pass downwards in the intervals between the metacarpal bones to within $\frac{1}{2}$ inch of the digital clefts, where the vessels bifurcate to run along the adjacent sides of the fingers.

The *circumflex nerve and the posterior circumflex artery* both pass backwards through the quadrilateral muscular space, and curl round the surgical neck of the humerus towards the outer and front aspect of the shoulder region. The artery anastomoses with the anterior circumflex artery, and the level of the arterial

THE BACK OF THE ARM AND FOREARM



1. The acromion spine.
2. The acromion process.
3. The circumflex nerve and arteries.
4. The insertion of the deltoid.
5. The external condyle of the humerus.

FIG. XIII.

6. The musculo-spiral nerve.
7. The posterior fold of the axilla.
8. The radius.
9. The posterior interosseous nerve.
10. The radial nerve.

To face p. 30.





THE SHOULDER AND ARM

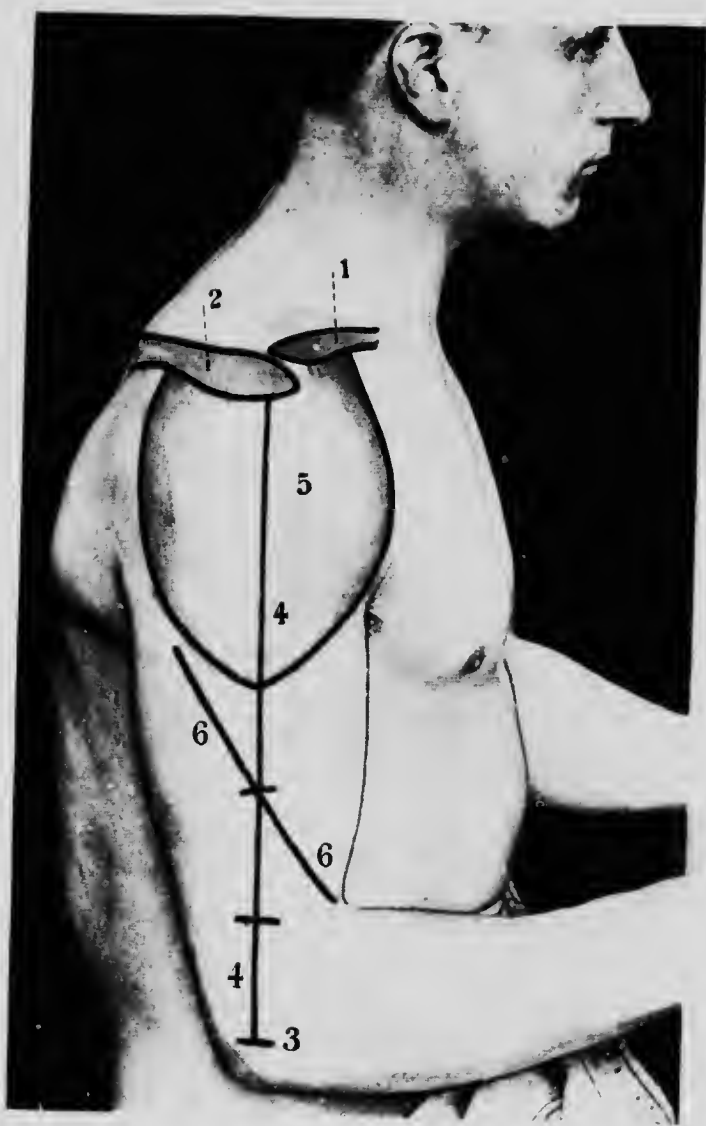


FIG. XIV.

1. The clavicle.
2. The acromion process.
3. The external condyle of the humerus.
4. Hamilton's line.
5. The deltoid muscle.
6. The musculo-spiral nerve.

To face 30.

circle so formed, and of the posterior circumflex nerve, may be represented by a line drawn at right angles to the shaft of the humerus from a point just above the centre of the deltoid muscle.

The *musculo-cutaneous nerve* usually pierces the inner aspect of the coraco-brachialis muscle about 1 to 2 inches below the coracoid process. It then runs downwards and outwards, deep to the biceps muscle, towards the outer bicipital sulcus, at which level it becomes cutaneous. The course of the nerve in the arm can, therefore, be roughly indicated by a line from the coracoid process above to the outer bicipital sulcus below.

The *musculo-spiral nerve*, accompanied by the anterior branch of the superior profunda artery, pierces Fig. xiii., 6. the external intermuscular septum of the arm, Fig. xiv., 6. from behind forwards, at the junction of the upper and middle thirds of a line drawn from the insertion of the deltoid muscle to the external condyle of the humerus. Below this point the nerve passes downwards and inwards to the outer bicipital sulcus, where it bifurcates into its two terminal branches. Above the point at which the nerve pierces the external intermuscular septum, the course of the nerve may be represented by a curved line drawn upwards and inwards to the junction of the upper arm with the posterior fold of the axilla.

The *radial nerve*, a branch of the musculo-spiral, arises Fig. vi., 16 in the outer bicipital sulcus, and passes vertically Fig. xiii., 10. down the forearm, accompanying, and lying to the outer side of, the radial artery in its middle third. At the junction of the middle and lower thirds of the forearm, the nerve turns round the outer border of the radius under cover of the supinator longus tendon, to be distributed to the back of the wrist and hand.

The *posterior interosseous* nerve arises from the musculospiral in the outer bicipital sulcus, and curls round the neck of the radius in the substance of the supinator brevis muscle, emerging from the posterior border of that muscle 2 inches below the head of the radius. It then passes vertically down the posterior aspect of the forearm, lying about midway between the inner and outer borders, and terminating in a gangliform enlargement at the posterior aspect of the wrist.

The *median nerve in the arm*.—This nerve accompanies the brachial artery, and therefore presents a similar surface marking. It is necessary, however, to bear in mind that the nerve crosses the artery superficially from above downwards and from without inwards.

The *median nerve* in the forearm passes vertically downwards from the inner bicipital sulcus to the front of the wrist, there lying to the ulnar side of the flexor carpi radialis and under cover of the palmaris longus tendon. The nerve then passes under the anterior annular ligament to the palm.

The *ulnar nerve* in the upper third of the arm lies along the inner side of the brachial artery. It then leaves that vessel, and, accompanied by the inferior profunda artery, passes downwards and backwards to reach the hollow between the internal condyle and the olecranon process.

The *ulnar nerve* in the forearm corresponds in direction to a line drawn from the internal condyle of the humerus to the radial side of the pisiform bone. In front of the wrist the nerve lies to the radial side of the tendon of the flexor carpi ulnaris muscle, and subsequently passes superficial to the anterior annular ligament to its palmar distribution.

The *palmar fascia* is triangular in shape, the apex being attached to the anterior annular ligament between the thenar and hypothenar eminences, whilst the base corresponds to the proximal ends of the four inner fingers.

THE CREASES OF THE PALM AND FINGERS.

The upper transverse crease on the palmar aspect of the hand lies just below the normal limit of the superficial palmar arch, but at the level of the lower limit of the main flexor synovial sheath. The lower crease crosses the necks of the metacarpal bones, and corresponds to the upper limit of the distal flexor synovial sheaths.

The metacarpo-phalangeal joints lie about half-way between the distal crease of the palm and the proximal crease of the fingers. The middle and distal creases on the palmar aspect of the fingers correspond fairly accurately to the respective interphalangeal joints. The "knuckles" are formed by the heads of metacarpal bones.

CHAPTER III

THE THORAX

THE majority of the thoracic viscera are depicted on the surface in relation to the costal cartilages, ribs and intercostal spaces, and it is therefore necessary to lay stress on certain important points :

1. That the twelve ribs are divided into two groups :
(a) *True* ribs, seven in number, articulating by means of their costal cartilages with the mesial sterno-xiphoid bone ;
(b) *False* ribs, five in number, all falling short of the middle line, the upper three attached to the costal cartilage of the rib above, the lower two *not* articulating with the transverse process of the corresponding vertebra, and the anterior extremities *not* attached to the costal cartilage of the rib above. These last two ribs are therefore known as "floating ribs."

2. That the first rib lies mainly under cover of the clavicle, but that its costal cartilage can generally be palpated with ease as it lies below the sternal end of the clavicle.

3. That the first interspace which can be felt to the outer side of the sternum *is* the first interspace. This axiom may appear at first sight to be quite unnecessary, but it is in reality not uncommon for students to regard the first space which can be felt as the second interspace.

4. That the second costal cartilage articulates in front at the angle of Ludwig with the adjoining parts of the manubrium and gladiolus.

Fig. iii.,
20-22.

5. That the seventh costal cartilage articulates with the adjoining parts of the gladiolus and xiphoid cartilage.

Fig. xvii.

6. That the anterior extremity of the ninth costal cartilage corresponds almost exactly to the point where the *linea semilunaris* cuts the costal arch.

Fig. xx.

7. That the twelfth rib is liable to great variation in size, frequently being so insignificant that it cannot be felt at all. It is, therefore, often advisable to count from above in fixing any particular rib.

8. That the intercostal spaces, in consequence of the downward and forward obliquity of the ribs, are wider in front than behind.

The female *mamma*, when well developed, extends upwards to the second rib, inwards to the outer border of the sternum, downwards to the sixth or seventh rib, and outwards to the mid-axillary line. The true glandular substance is, however, less regular in disposition, prolongations passing in various directions. Of these, the most important is the so-called "axillary prolongation," which is directed upwards and outwards along the anterior fold of the axilla.

The *nipple* usually corresponds to the fourth interspace. It is variable in position, and not infrequently overlies the fourth rib. In the female the nipple lies just below, and external to, the apex or central point of the breast.

Fig. xv.

The *heart* lies opposite the middle four dorsal vertebrae, and the projection of its anterior

Fig. xv.,
1-4.

surface upon the front of the chest wall may be indicated in the following manner.

Take the following four points :

1. The lower border of the second left costal cartilage about 1 inch from the left border of the sternum.
2. The upper border of the third right costal cartilage $\frac{1}{4}$ to $\frac{1}{2}$ inch from the right border of the sternum.
3. The lower border of the sixth right costal cartilage $\frac{3}{4}$ inch from the right border of the sternum.
4. The fifth left interspace $1\frac{1}{2}$ inches below and just internal to a line drawn vertically downwards from the nipple. If any abnormality exists with regard to the position of the nipple, this last point may be fixed with greater accuracy by taking a point in the fifth left interspace nearly 4 inches from the middle line.

The apex beat—the point of maximum impulse of the left ventricle against the chest wall—lies in the fifth left interspace $1\frac{1}{2}$ inches below and $\frac{1}{2}$ inch internal to the nipple, or $3\frac{1}{2}$ inches from the middle line. The position of the apex beat, therefore, does not exactly represent the outermost limit of the left ventricle. The above four points should now be joined in the following manner :

Points 1 and 2 by a straight line.

Points 2 and 3 by a curved line, the heart reaching the greatest distance from the middle line, $1\frac{1}{2}$ inches, in the fourth interspace.

Points 3 and 4 by a line presenting a slight downward convexity, and cutting across the middle line in close relation to the xiphisternal junction.

Points 1 and 4 by a line presenting a fairly well marked convexity to the left. In the illustration this line is drawn rather too straight.

FIG. XV.

N.B.—In this and in other figures in which the costal cartilages are depicted the numbered references do *not* refer to the corresponding cartilages. These are numbered for general convenience only.

- 1-4. The four points of the heart.
5. The auricular area.
6. The ventricular area.
7. The left ventricle.
8. The apex beat.
9. The pulmonary valve.
10. The pulmonary artery.
11. The aortic valve.
12. The mitral valve.
13. The tricuspid valve.
14. The ascending aorta.
15. The aortic arch.
16. The innominate artery.
17. The right and left common carotid arteries.
18. The right and left subclavian arteries.
19. The right and left subclavian veins.
20. The right and left internal jugular veins.
21. The right and left innominate veins.
22. The superior vena cava.
23. The inferior vena cava.
24. The abdominal aorta.
25. The coeliac axis.
26. The superior mesenteric artery.
27. The renal arteries.
28. The inferior mesenteric artery.
29. The common iliac arteries.
30. The internal iliac arteries.
31. The external iliac arteries.
32. The kidney.
33. The ureters.
34. The ovary.

THE HEART, GREAT VESSELS, KIDNEY, AND
URETER

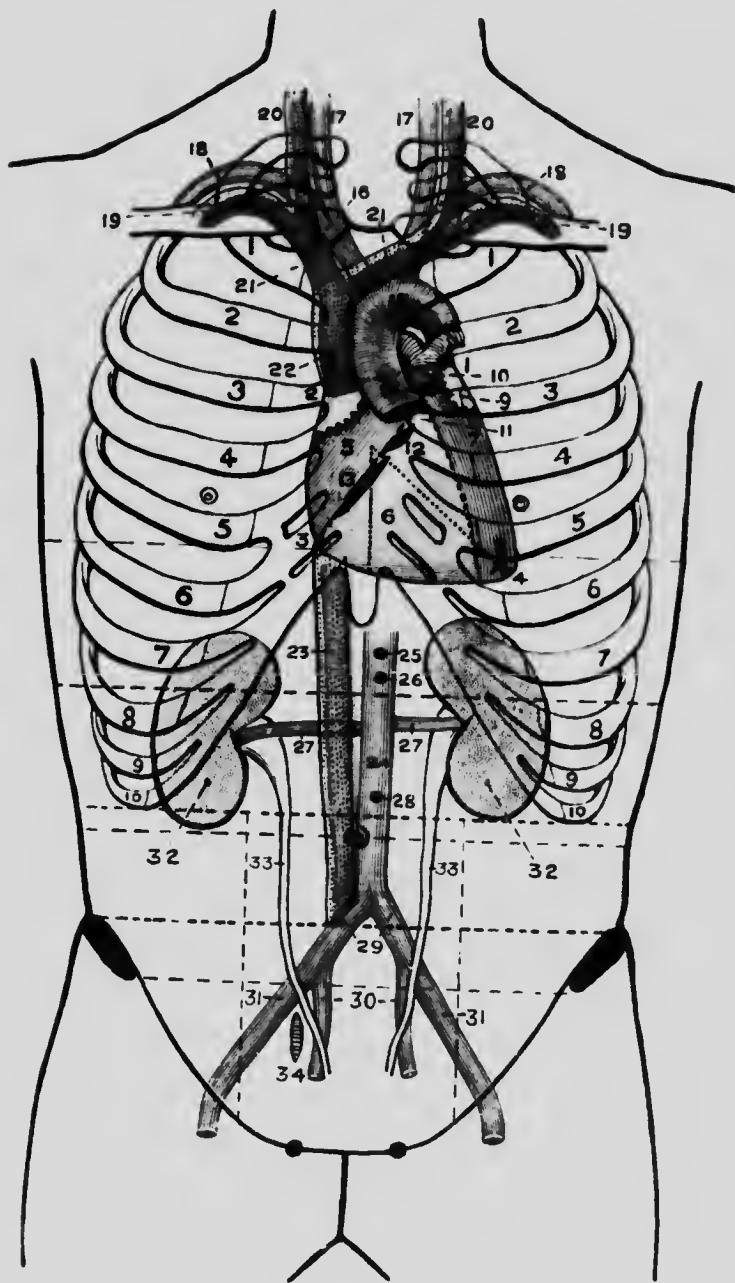


FIG. XV.

To face p. 36.

A line joining Points 1 and 3 divides this cardiac area into two parts, which roughly correspond to the *auricular* area above and to the right, and the *ventricular* area below and to the left. This ventricular area is occupied mainly by the right ventricle, whilst a narrow strip along the left border represents that part of the left ventricle which comes to the surface.

Fig. xv., 5.

Fig. xv., 6.

Fig. xv., 7.

The four points given above for marking out the projection of the heart on the anterior thoracic wall may be simplified by taking and joining the following four points :

1. The upper border of the third right chondro-sternal junction.
2. The lower border of the second left chondro-sternal junction.
3. The lower border of the sixth right chondro-sternal junction.
4. The position of the apex beat.

By uniting these four points, the heart is mapped out for most practical purposes with sufficient accuracy.


THE VALVES OF THE HEART.

1. The *pulmonary* valve is situated at the highest level, and lies opposite the upper border of the third left costal cartilage, close to its junction with the sternum.
- Fig. xv., 9.
2. The *aortic* valve lies just below and internal to the pulmonary valve at the lower border of the third left costal cartilage at its junction with the sternum.
- Fig. xv., 11.
3. The *mitral* or left auriculo-ventricular valve is situated behind the left half of the sternum at the level of the fourth chondro-sternal junction.
- Fig. xv., 12.



MICROCOPY RESOLUTION TEST CHART

(ANSI and ISO TEST CHART No. 2)



APPLIED IMAGE Inc

1653 East Main Street
Rochester, New York 14609 USA
(716) 482 - 0300 - Phone
(716) 288 - 5989 - Fax

4. The *tricuspid* or right auriculo-ventricular valve lies very obliquely behind the sternum at the level of the fourth interspace and the anterior extremities of the fifth costal cartilages, extending downwards and to the right almost as far as the sixth chondro-sternal junction.

Fig. xv.,
13.

THE AORTA AND OTHER VESSELS, ETC.

The *ascending aorta*, 2 to 2½ inches long, arises behind the left border of the sternum at the level of the third costal cartilage, and passes upwards and to the right towards the right border of the sternum at the level of the second costal cartilage.

Fig. xv.,
14.

The *aortic arch* is directed backwards and to the left, the upper limit lying about 1 inch below the suprasternal notch, or half-way between that notch and the angle of Ludwig. The arch becomes the descending aorta at the left side of the lower part of the body of the fourth dorsal vertebra.

Fig. xv.,
15.

The *descending thoracic aorta*, 7 to 8 inches long, passes onwards through the posterior mediastinum, and pierces the diaphragm at the level of the twelfth dorsal vertebra. The site of diaphragmatic perforation is represented on the surface by a point situated just to the left of the middle line, two fingers' breadth above the transpyloric plane.*

The *innominate artery*, 1½ to 2 inches long, arises from the aortic arch in the middle line 1 inch below the suprasternal notch, and passes upwards and to the right to the right sterno-clavicular articulation, at which level it bifurcates into its two terminal branches.

Fig. xv.,
16.

The *left common carotid* (thoracic course) arises from

* Any "planes" mentioned in this chapter will be explained in the chapter on the abdomen.

the aortic arch on a posterior plane to, and slightly to the left of, the trunk of the innominate artery, and passes upwards and to the left to the left sterno-clavicular articulation.

Fig. xv.,
17.

The *left subclavian artery* (thoracic course) arises from the aortic arch on a posterior plane to, and slightly to the left of, the thoracic part of the left common carotid artery, and passes almost vertically upwards behind the left border of the sternum to the left sterno-clavicular joint.

Fig. xv.,
18.

The *superior mediastinum* is bounded above by the plane of the thoracic inlet and below by a plane which passes backwards from the angle of Ludwig in front to the lower border of the fourth dorsal vertebra behind (Ludwig's plane).

Fig. xviii.

The *pulmonary artery* arises opposite the upper border of the third left costal cartilage at its junction with the sternum, and passes backwards and slightly upwards to its bifurcation, which takes place opposite the second left costal cartilage.

Fig. xv.,
10.

The *internal mammary artery* arises from the first part of the cervical course of the subclavian artery, and passes almost vertically downwards behind the corresponding sterno-clavicular joint. In its further thoracic course, the artery lies $\frac{1}{2}$ inch external to the outer border of the sternum, bifurcating opposite the sixth costal cartilage or the sixth interspace into the *musculo-phrenic* and *superior epigastric* arteries. The former vessel curves outwards, following the line of the costal arch, whilst the latter passes onwards to enter the sheath of the rectus abdominis muscle.

Fig. xx., 8.

Fig. xx.,
9, 10.

The *left innominate vein*, 3 inches long, is formed opposite the left sterno-clavicular joint, and passes to the

right, slightly overlapping the upper part of the aortic arch, and occupying the greater part of the space between the summit of the arch below and the suprasternal notch above.

Fig. xv.,
21.

The *right innominate vein* is formed at the right sternoclavicular joint, and passes obliquely downwards and inwards to meet the corresponding vein of the opposite side at the lower border of the first right costal cartilage close to its junction with the sternum.

Fig. xv.,
21.

The *superior vena cava*, formed by the junction of the above two veins, is directed almost vertically downwards from the lower border of the first right costal cartilage close to its junction with the sternum, to open into the right auricle of the heart at the level of the upper border of the third right chondrosternal junction.

The *inferior vena cava* enters upon its short intrathoracic course by passing through the quadrate opening of the diaphragm at the level of the eighth dorsal vertebra, opening into the right auricle of the heart opposite the fifth right interspace and the adjoining part of the sternum.

Fig. xv.,
23.

The *vena azygos major* drains the whole thoracic wall, except the first space on the right side and the upper three spaces on the left. It opens into the superior vena cava at the level of the lower part of the second right interspace, curling round the root of the right lung in order to reach its destination.

The main *aortic intercostal* vessels occupy the subcostal groove of a rib as they pass round the chest wall, lying between the corresponding vein above and the nerve below.

c
e
w

o-
n-
ng
st
m.
ne
ly
st
he
he
ro-

cic
ng
th
art
art

all,
ree
ava
er-
to

stal
ing
rve

THE PLEURAL SACS, LUNGS, ETC.

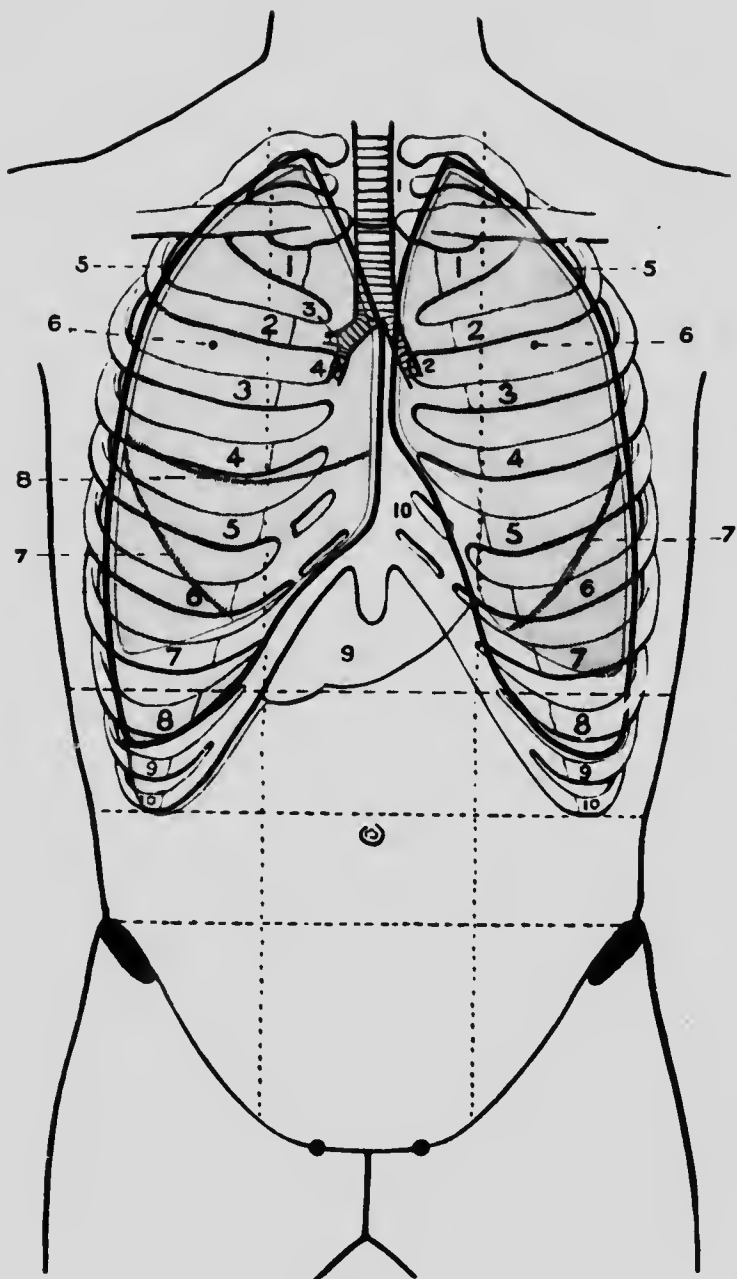


FIG. XVI.

- | | |
|--|---|
| <p>1. The trachea.
 2. The left bronchus.
 3. The eparterial bronchus.
 4. The hyparterial bronchus.
 5, 5. The pleurae.
 6, 6. The lungs.</p> | <p>7, 7. The main oblique fissure of the lungs.
 8. The small transverse fissure of the right lung.
 9. The liver.
 10. Area of superficial cardiac dullness.</p> |
|--|---|

THE PLEURA AND LUNGS.

1. The *pleural sacs*.—When the shoulders are depressed, Fig. xvi., 5. the two clavicles lie practically at right angles Fig. xvii., 4. to the long axis of the body, and in this position the apices of the pleural sacs extend into the supra-clavicular region, lying about $1\frac{1}{2}$ inches above the clavicle under cover of the clavicular head of the sterno-cleido-mastoid muscle.

The anterior margin of each sac sweeps downwards and inwards behind the corresponding sterno-clavicular joint, the two sacs converging towards the angle of Ludwig, at which level they meet one another just to the left of the middle line. They then pass vertically downwards parallel to one another as far as the level of the fourth chondro-sternal junction.

The right sac passes onwards in the same straight line to the sixth or seventh chondro-sternal articulation, and then sweeps round the anterior, lateral and posterior aspects of the chest wall, cutting across—

- (1) The upper part of the eighth costal cartilage in the lateral vertical line ;
- (2) The tenth rib in the mid-axillary line ;
- (3) The eleventh rib in the line of the inferior angle of the scapula ;
- (4) The twelfth rib at the outer border of the erector spinæ muscle.

The obliquity of the twelfth rib causes the pleura to fall below the level of the inner half of the rib, the pleura in this last part of its course being directed inwards towards the spine of the twelfth dorsal vertebra.

The *left pleura*, from the level of the fourth left chondro-sternal articulation, sweeps obliquely outwards and down-

wards behind the costal cartilages of the fifth, sixth and seventh ribs to the eighth costal cartilage in the lateral vertical plane. Beyond this point the left pleura follows the same general direction as the right sac, descending, however, to a slightly lower level.

The lowest limit reached by the two pleural sacs is situated in the mid-axillary line, the sacs there cutting across the tenth rib about 2 inches above the costal margin, which is in this situation usually represented by the tip of the eleventh rib.

Difficulty is sometimes experienced in endeavouring to verify the position of the twelfth dorsal spine, and in such cases the pleural reflection behind the mid-axillary region may be represented by a line which passes almost transversely backwards toward the median posterior line from the tenth rib in the mid-axillary line.

The two sacs are for the most part separated from one another by the width of the vertebral bodies—
 Fig. xvii., 4. about $1\frac{1}{2}$ inches. In the lower part of the posterior mediastinum, however, the right sac approaches the median line.

2. The *lungs* may be mapped out in part by lines similar to those given for the pleural sacs. The apex of the upper lobe of each lung extends into the supra-
 Fig. xvi., 6. clavicular region, and the anterior margins
 Fig. xvii., 5. converge towards the angle of Ludwig, cutting obliquely across the corresponding sterno-clavicular joint.

The two anterior borders do not, however, meet at the angle of Ludwig, for the right lung on reaching the middle line passes vertically downwards as far as the level of the sixth or seventh chondro-sternal junction, whilst the left lung runs down behind the left border of the sternum to the junction of the fourth costal cartilage with the sternum.

THE PLEURAL SACS, LUNGS, ETC.

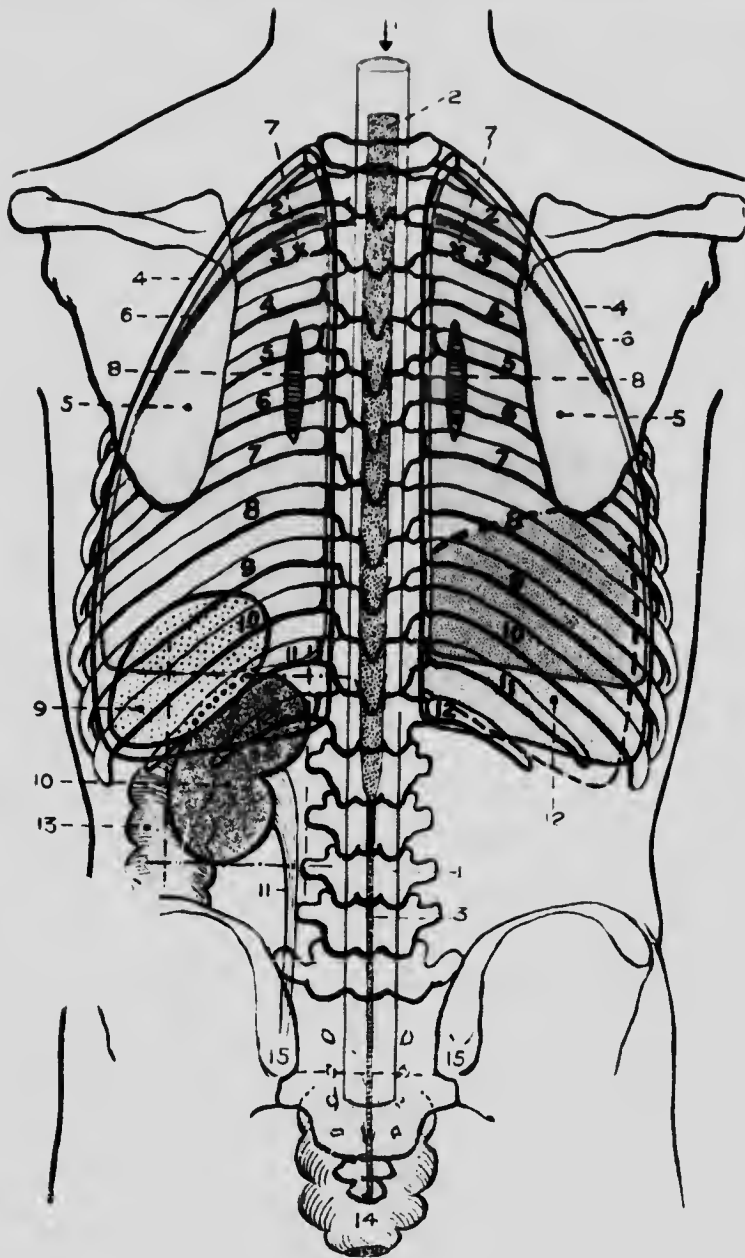


FIG. XVII.

- | | |
|--|---|
| 1, 1. The spinal dural sheath. | 9. The spleen. |
| 2. The spinal cord. | 10. The left kidney in Morris's quadrilateral.* |
| 3. The filum terminale. | 11. The ureter. |
| 4, 4. The pleurae. | 12. The liver. |
| 5, 5. The lungs. | 13. The descending colon. |
| 6, 6. The main oblique fissures of the lungs. | 14. The rectum. |
| 7, 7. The apex of the lower lobe of the lungs. | 15. The posterior superior iliac spine. |
| 8, 8. The roots of the lungs. | |

* The transverse processes of the first and second lumbar vertebrae should be drawn in such a manner as to come into contact with the inner border of the kidney.



The *right lung*, from the level of the sixth or seventh chondro-sternal junction, sweeps outwards, cutting across—

- (1) The sixth costal cartilage in the lateral vertical line
- (2) The eighth rib in the mid-axillary line;
- (3) The tenth rib in the line of the inferior angle of the scapula, and finally passing inwards towards the tenth dorsal spine.

The *left lung*, from the outer border of the sternum at the level of the fourth chondro-sternal articulation, passes outwards for a short distance along the lower border of the fourth costal cartilage, and then turns downwards and inwards in a curved direction to the sixth costal cartilage in the lateral vertical plane. The lung then sweeps round the chest wall, following a course similar to that already indicated as pursued by the right lung, the left lung lying, however, at a slightly lower level.

Stress should, perhaps, be laid on the fact that, as the lower border of each lung sweeps round the antero-lateral, lateral, and posterior aspects of the chest wall, from the sixth costal cartilage in front to the tenth dorsal spine behind, the course pursued is practically transverse to the long axis of the body.

It will be convenient to here put in a tabulated manner the *comparative lower levels of the right pleura and lung*. Starting in each case at the right chondro-sternal junction, the pleura and lung may be represented by lines which traverse the chest wall, cutting across the

- (1) Lateral vertical line at the eighth costal cartilage (pleura)—sixth costal cartilage (lung).
- (2) Mid-axillary line at the tenth rib (pleura)—eighth rib (lung).
- (3) Scapular line at the eleventh rib (pleura)—tenth rib (lung).

- (4) And sweeping in towards the twelfth dorsal spine (pleura)—tenth dorsal spine (lung).

The numbers to be remembered are, therefore, 6, 8, 10, 11, and 12 for the *pleura*, and 6, 6, 8, 10, 10 for the *lung*.

On the left side, the levels are similar with two main exceptions—(a) the lung and pleura sweep outwards so as to leave a part of the heart uncovered (see "*superficial cardiac dulness*"), (b) both lung and pleura descend to a slightly lower level.

The Lower Limit of the Lung, the Pleura, and the Liver in the Right Mid-axillary Line.

- (1) The lung corresponds to the eighth rib.
 (2) " pleura " " tenth rib.
 (3) " liver " " costal margin, or even lower.

The fissures of the lungs.—The main fissure of each lung is indicated by a curved line which starts behind Fig. xvi., 7. at the level of the second dorsal spine, the apex of the main lower lobe of each lung, therefore, being situated immediately below and external to this dorsal spine. When the arms fall naturally to the side of the body, the line representing the main fissure cuts across the infraspinous surface of the scapula, and crossing then the fifth rib in the mid-axillary line, terminates in front at the inferior border of the lung at the level of the sixth chondro-costal junction. When the arms are extended above the head, the inferior angle of the scapula slides upwards and outwards on the chest wall. In this position the main fissure is represented by a line from the second dorsal spine which passes downwards and outwards to the inferior angle of the scapula, and then forwards to the termination of the fissure at the inferior border of the lung.

The smaller or upper fissure of the right lung separates off from the main fissure in the mid-axillary line, and passes almost transversely forwards along the lower border of the fourth rib and costal cartilage to the anterior border of the lung. It is thus manifest that the anterior aspect of the chest, above the level of the sixth costal cartilage, corresponds to the upper two lobes of the right lung and to the upper lobe of the left lung, whilst the posterior aspect of the chest below the level of the second dorsal spine corresponds to the right and left main lower lobes.

The *apices of the upper and lower lobes*.—It will be here in place to again lay stress on the fact that the apex of the upper main lobe lies about 1 inch above the clavicle in the supraclavicular fossa, under cover of the clavicular head of a well-developed sterno-cleido-mastoid muscle, and that the apex of the lower lobe lies immediately below and external to the spine of the second dorsal vertebra.

The *roots of the lungs* lie opposite the spines of the fourth, fifth, and sixth dorsal vertebræ, and the bodies of the fifth, sixth, and seventh vertebra. They may be so represented, lying also midway between the median posterior line and the vertebral border of the scapula, the arms hanging loosely from the shoulders.

The *areas of deep and superficial cardiac dulness*.—
 1. The area of *deep cardiac dulness*, quadrate in form, corresponds to the complete area already mapped out as representing the projection of the heart on to the anterior aspect of the chest wall.

2. The area of *superficial cardiac dulness*, more or less triangular in shape, corresponds to that part of the heart which is not covered by the thin anterior margin of the

lung. This area can, with sufficient accuracy, be defined **Fig. xvi., 10.** as a triangular space, the left border being **Fig. xv.** formed by a line from the fourth left chondro-sternal articulation to the apex beat of the heart in the fifth left interspace, the right border by a line which passes downwards along the middle of the sternum from the level of the anterior extremities of the fourth to the seventh costal cartilages, and the base by a line which passes outwards from the level of the seventh costal cartilage to the position of the apex beat.

A reference to Figs. xiv. and xv. will make it evident that *paracentesis of the pericardium* can be performed, without injury to pleura or lung, in the fifth left intercostal space. The internal mammary artery runs vertically downwards about $\frac{1}{2}$ inch from the outer border of the sternum, and the needle should, therefore, be inserted through the fifth intercostal space about 1 inch from the outer border of the sternum.

The *trachea and bronchi*.—The trachea, $4\frac{1}{2}$ inches long, **Fig. xvi., 1.** commences immediately below the cricoid cartilage, on a level with the sixth cervical vertebra, and passing downwards through the superior mediastinum, bifurcates opposite the level of the lower part of the body of the fourth dorsal vertebra (Ludwig's plane).

The two bronchi diverge, the left being the longer **Fig. xvi., 2,** and the narrower. The tendency of foreign **3, 4.** bodies to pass more frequently into the right bronchus is explained by the fact that the septum between the two bronchi is placed to the left of the middle line of the trachea. The right bronchus, previous to the giving-off of the eparterial bronchus, is less obliquely inclined than the left bronchus, though subsequently it follows much the same course.

The greater obliquity of the left bronchus accounts also for the fact that the left pulmonary artery tends to lie at the higher level, whilst the right pulmonary artery lies below the level of the corresponding bronchus.

The *œsophagus*, 9 inches long, also commences at the level of the cricoid cartilage, and passing downwards through the superior and posterior mediastina, pierces the diaphragm at the level of the tenth dorsal vertebra, entering the stomach at the level of the eleventh vertebra.

The entrance of the *œsophagus* into the stomach may be indicated by taking a point on the seventh left costal cartilage $\frac{1}{2}$ inch away from the left side of the xiphisternal junction.

The *thoracic duct*, 15 to 18 inches long, commences as the receptaculum chyli, a spindle-shaped sac which lies opposite the bodies of the first and second lumbar vertebræ, and between the thoracic aorta on the left and the vena azygos major on the right. It may be represented on the surface by an oval enlargement placed just to the right of the middle line, occupying the upper two-thirds of the space between the transpyloric (first lumbar) and subcostal (third lumbar) planes.

The efferent duct pierces the diaphragm through the aortic orifice opposite the twelfth dorsal vertebra, and passes almost vertically upwards through the posterior mediastinum, just to the right of the middle line, as far as the lower part of the fourth dorsal vertebra (Ludwig's plane). The duct now crosses behind the *œsophagus* to the left of the middle line, and then again passes vertically upwards through the superior mediastinum and into the neck as far as the level of the transverse process of the seventh cervical vertebra.

Finally, the duct curls outwards and downwards to open
Fig. xx., 7. into the angle between the internal jugular and
subclavian veins of the left side. The duct
drains the whole of the lymphatic area of the body, except
the right side of the head and neck, the right arm, the
right side of the thorax and the convexity of the liver, the
lymphatics from these regions draining into a smaller duct
which opens into the angle between the right internal
jugular and subclavian veins.

CHAPTER IV

THE ABDOMEN

THE anterior aspect of the trunk (*i.e.*, thorax and abdomen) is divisible into right and left halves by a *median vertical plane* from the middle point at the suprasternal notch above to the symphysis pubis below. Each half is again divided by a *lateral vertical plane* which is drawn parallel to the median plane, half-way between that plane and the anterior superior iliac spine. Prolonged downwards, this lateral plane crosses Poupart's ligament rather nearer to the inner than to the outer end. Prolonged upwards, it crosses the clavicle about midway between the median point at the suprasternal notch and the acromio-clavicular joint.

That part of the lateral vertical plane which traverses the mammary region is sometimes called the "mammary plane," that part which crosses the clavicle the "clavicular plane," and the downward prolongation which cuts across Poupart's ligament the "Poupart plane."

The clavicular, mammary, and Poupart planes are, however, continuous, and they together form the *lateral vertical plane*, which is chosen in preference to the mid-Poupart plane of many anatomists, since it is measured from the median plane to a fixed bony point. Two vertical planes only will be consequently retained in the subdivision of the anterior aspect of the trunk, the *median and lateral vertical planes*.

The median plane can be bisected by a horizontal plane which is on the same level as the body of the first lumbar vertebra. This plane so constantly cuts across the pyloric end of the stomach that it is called the *transpyloric plane*, and it will be found that not only does this plane lie half-way between the suprasternal notch and the symphysis pubis, but that it also lies midway between the umbilicus and the sterno-xiphoid junction. It is, therefore, not necessary to expose the whole of the anterior aspect of the trunk in order to verify the position of the transpyloric plane, a plane of the greatest value in defining the position of several abdominal viscera.*

The point at which the *median vertical* and *transpyloric planes* intersect has been suitably called the "central point," and the point of intersection of the *lateral vertical* and *transpyloric planes* may be tentatively called the "lateral central" or "paracentral" point. This latter point usually corresponds to the anterior extremity of the ninth costal cartilage.

The distance between the "central point" and the top of the symphysis pubis is bisected by a horizontal plane which passes through the tubercles of the iliac crests, the *intertubercular plane*, a plane corresponding to the level of the body of the fifth lumbar vertebra. It has also been suggested that the distance between the "central point" and the suprasternal notch should likewise be bisected by a plane, the *thoracic plane*, which crosses the gladiolus at the level of some part of

* N.B.—Most of the "planes" mentioned in the text were first put forward by Dr. C. Addison, Lecturer and Senior Demonstrator of Anatomy, St. Bartholomew's Hospital, to whom the credit is due.

THE ABDOMINAL AND THORACIC PLANES

Level of hard palate = first cervical.
 Level of free margin of upper teeth = second cervical.
 Level of hyoid bone = second to third cervical.
 Level of upper part of thyroid cartilage = fourth cervical.
 Level of cricoid cartilage = sixth cervical.

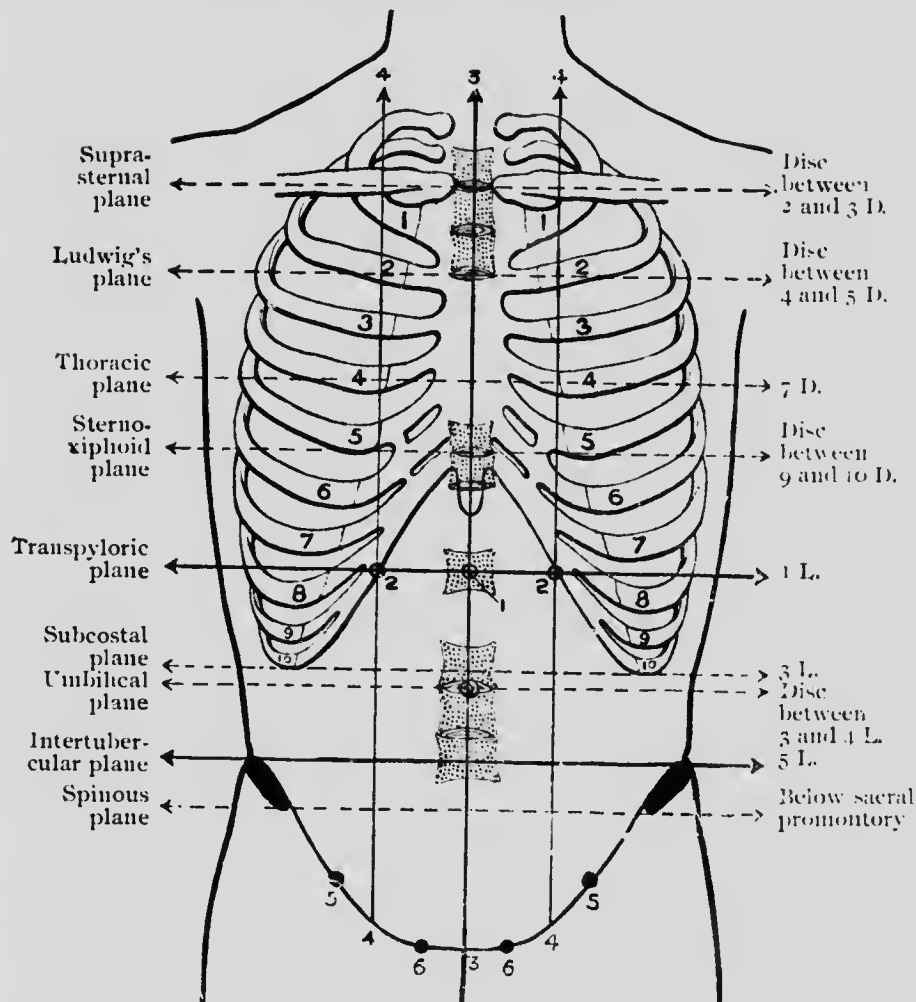



FIG. XVIII.

1. 1. The central point.
- 2, 2. The lateral central or paracentral point.
- 3, 3. The median vertical plane.
- 4, 4. The lateral vertical plane.
- 5, 5. The mid-Poupart point.
- 6, 6. The pubic spines.



the anterior extremities of the fourth costal cartilages.

Fig. xviii. This plane is, however, of little value, and is merely mentioned as completing the symmetrical subdivision of the median vertical plane into four equal parts.

The following planes are, therefore, chosen as the most scientific in the subdivision of the anterior aspect of the trunk :

Two vertical planes—(1) The median ; (2) the lateral.

Three transverse planes—(1) The intertubercular ; (2) the transpyloric ; (3) the thoracic.

Two important points are also named—(1) The central point ; (2) the lateral central point.

The abdominal regions mapped out by the intersection of the transpyloric and intertubercular planes with the lateral vertical planes receive the same nomenclature as in the older methods of regional subdivision of the abdomen. These regions are nine in number :

1. Right hypochondriac. 2. Epigastric. 3. Left hypochondriac. 4. Right lumbar. 5. Umbilical.
Fig. xviii. 6. Left lumbar. 7. Right iliac. 8. Hypogastric. 9. Left iliac.

OTHER TRANSVERSE PLANES, WITH THEIR CORRESPONDING VERTEBRAL LEVELS.

(a) The *suprasternal plane*, on a level with the disc between the second and third dorsal vertebræ.

Fig. xviii. (b) *Ludwig's plane* (junction of manubrium and gladiolus), on a level with the disc between the fourth and fifth dorsal vertebræ

(c) The *sterno-xiphoid plane* (junction of sternum and xiphoid cartilage), on a level with the disc between the ninth and tenth dorsal vertebræ.

(d) The *subcostal plane*, on a level with the lower part of the third lumbar vertebra.

(e) The *umbilical plane*, on a level with the disc between the third and fourth lumbar vertebræ.

(f) The *spinous plane*, drawn between the two anterior superior iliac spines, and usually falling below the level of the sacral promontory.

The *lineæ semilunares* correspond to the outer border of the rectus abdominis muscle, and extend, with a slight outward convexity, from the pubic spine below to the tip of the ninth costal cartilage above (the lateral central point).

The *lineæ transversæ* result from the tendinous inter-sections in the rectus abdominis muscle. They are three in number, and are situated—(1) at the level of the umbilicus; (2) midway between the umbilicus and the xiphoid cartilage; (3) immediately below the xiphoid cartilage.

The *semilunar fold of Douglas*, representing the lower limit of the posterior lamella of the rectus sheath, lies about half-way between the umbilicus and the upper border of the pubic symphysis.

The *umbilicus* usually lies 1 to 1½ inches above the intertubercular plane, and corresponds to the level of the disc between the third and fourth lumbar vertebræ. The umbilicus is, however, so constant in position that the umbilical plane is rejected as often as possible in favour of a more definite and scientific plane.

The *iliac spines and crest*.—When the body is in the dorsal recumbent position, the anterior superior iliac spine is usually visible to the eye, and no palpation is needful in order to fix its position. In the

obese, however, it is generally necessary to trace forward the iliac crest to its anterior termination. By tracing the iliac crests in a backward direction the "iliac tubercles" will be found, lying about 2 to 2½ inches behind the anterior superior spines, and a line uniting these two tubercles (the intertubercular plane) corresponds to the level of the fifth lumbar vertebra. Still further backward, the posterior superior iliac spines will be found at the posterior termination of the iliac crest. A line which joins the posterior superior iliac spines cuts across the spine of the second sacral vertebra.

The *pubic spine* lies at the outer limit of the pubic crest. In the male, it is advisable to invaginate the scrotum in order to locate the position of this spine; whilst in the female, owing to the prominence of the mons veneris, it is usually necessary to abduct the thigh, to feel for the rounded tendon of the adductor longus muscle, and to trace this tendon up to its origin from a depression on the pubic bone, which is situated immediately below and internal to the pubic spine.

In the erect position of the body the symphysis pubis is nearly horizontal, the inner or pelvic surface looking upwards and only slightly backwards, whilst the external surface faces downwards and a little forwards. The pubic crest is therefore practically directed forwards and the pubic arch backwards. A knife inserted horizontally backwards immediately above the pubic symphysis would pass above the upper limit of the prostate gland and below the promontory of the sacrum; whilst if directed horizontally backwards below the symphysis pubis, it would pierce the prostate near its centre and pass below the level of the tip of the coccyx.

The *inguinal canal*.—In the adult this canal is about ^{Fig. xx., 10,} $1\frac{1}{2}$ inches long, and extends from the internal ^{19.} *abdominal ring*, to the external abdominal rings. The *internal abdominal ring*, a funnel-shaped prolongation of the transversalis fascia, is situated $\frac{1}{2}$ inch above the mid-point of Poupart's ligament. The *external abdominal ring*, ^{Fig. xx., 17,} ^{17.} formed by the splitting of the aponeurosis of ^{18.} the external oblique muscle, is triangular in shape, the base directed downwards and inwards and opening up immediately above the pubic spine, whilst the apex is directed upwards and outwards.

Petit's triangle.—This triangle is bounded in front by the posterior border of the external oblique, and behind by the anterior border of the latissimus dorsi muscle, whilst the base is formed by part of the iliac crest. The external oblique is inserted into the anterior half of the iliac crest, and the base of the triangle corresponds to 1 to 2 inches of the bone behind the mid-point of the crest. The triangle is subject to great variation in size, the two bounding muscles converging rapidly above to form the apex of the triangle. The floor is formed by the internal oblique muscle.

THE ALIMENTARY CANAL.

The *stomach*.—Capacity about 2 pints. The *cardiac orifice* lies opposite the eleventh dorsal vertebra, ^{Fig. xix., 2,} and is situated about 4 inches away from the surface. It corresponds in position to a point on the seventh costal cartilage $\frac{1}{2}$ inch away from the outer border of the sterno-xiphoid junction. The seventh costal cartilage is the lowest of the series of cartilages which articulate in front with the mesial sterno-xiphoid bar, and forms, therefore, the upper lateral boundary of

the epigastric triangle. The *pyloric orifice* lies opposite the first lumbar vertebra, and corresponds in position to a point in the transpyloric plane just to the right of the middle line.

The *lesser curvature* is represented by a curved line, convexity to the left, uniting the above two points. The *greater curvature*, in the moderately distended condition of the stomach, ascends to the lower border of the left fifth costal cartilage and rib, lying immediately above and behind the apex of the heart. Sweeping then downwards, the greater curvature usually cuts the left costal margin at some part of the ninth costal cartilage, and finally curves upwards and inwards to the pylorus. The upper limit of the fundus of the stomach corresponds to the level of the left dome of the diaphragm.

The *duodenum*.—Total length, about 10 inches. Part 1 = 2 inches; part 2 = 3 to 4 inches; part 3 = 4 to 5 inches.

The pyloric orifice of the stomach lies opposite the first lumbar vertebra, and the first part of the duodenum is directed backwards, with a slight inclination upwards, to the right side of the body of the first lumbar vertebra.

Part 2 descends, on the right side of the median vertical plane, from the level of the first lumbar vertebra (transpyloric plane) to the level of the third lumbar vertebra (subcostal plane). The third part of the duodenum passes almost transversely across the middle line at the level of the subcostal plane, and having reached the left side of the middle line, ascends sharply to the *duodeno-jejunal flexure*, which is placed on a level with the second lumbar vertebra, just below the transpyloric plane, and 1 to 1½ inches to the left of the middle line. The duodenum is subject to great variation

in position, and the description given merely represents the average situation of this loop of the small gut. The pyloric orifice of the stomach and the duodeno-jejunal flexure are both fairly constant in position, and between these two more or less fixed points the gut describes a loop which varies both in shape and in extent.

The *pancreas*.—The head of the pancreas occupies the concavity of the duodenal loop, the body crossing the middle line at the level of the first and second lumbar vertebræ, and occupying, therefore, the upper two-thirds of the space between the transpyloric (first lumbar) and subcostal (third lumbar) planes. The tail of the pancreas extends to the left as far as the hilum of the spleen.

The *small intestine* is about 23 feet in length, the upper two-fifths being known as the jejunum, the lower three-fifths as the ileum.

The *mesenteric attachment* of the small gut extends from a point 1 to $1\frac{1}{2}$ inches to the left of the middle line, and just below the transpyloric plane (duodeno-jejunal flexure), to the junction of the right lateral vertical and intertubercular planes. The line drawn between these two points should pass at first obliquely outwards and downwards to the right iliac fossa, curving finally outwards to the region of the ileo-cæcal valve.

The *ileo-cæcal valve* is placed opposite the junction of the right lateral vertical and intertubercular planes.

The *cæcum* is about $2\frac{1}{2}$ inches long, and the long axis of the sac is directed downwards, forwards, and inwards. This blind end of the large gut lies below the level of the intertubercular plane, and occupies the right iliac fossa and part of the right half of the hypo-gastric region.




FIG. XIX.

- 1, 1. The œsophagus.
2. The stomach.
3. The pylorus.
- 4, 4, 4. The three parts of the duodenum. 4'. The pancreas.
5. The duodeno-jejunal flexure.
6. The attachment of the mesentery of the small intestine.
7. The ileo-cæcal valve.
8. The cæcum.
9. The vermiform appendix.
10. The ascending colon.
11. The hepatic flexure.
12. The splenic flexure.
13. The descending colon.
14. The iliac colon.
15. The ilio-pelvic colon.
16. The gastro-hepatic omentum.
17. The foramen of Winslow.
18. The common bile-duct.

N.B.—The transverse colon has been intentionally omitted.

THE ALIMENTARY CANAL

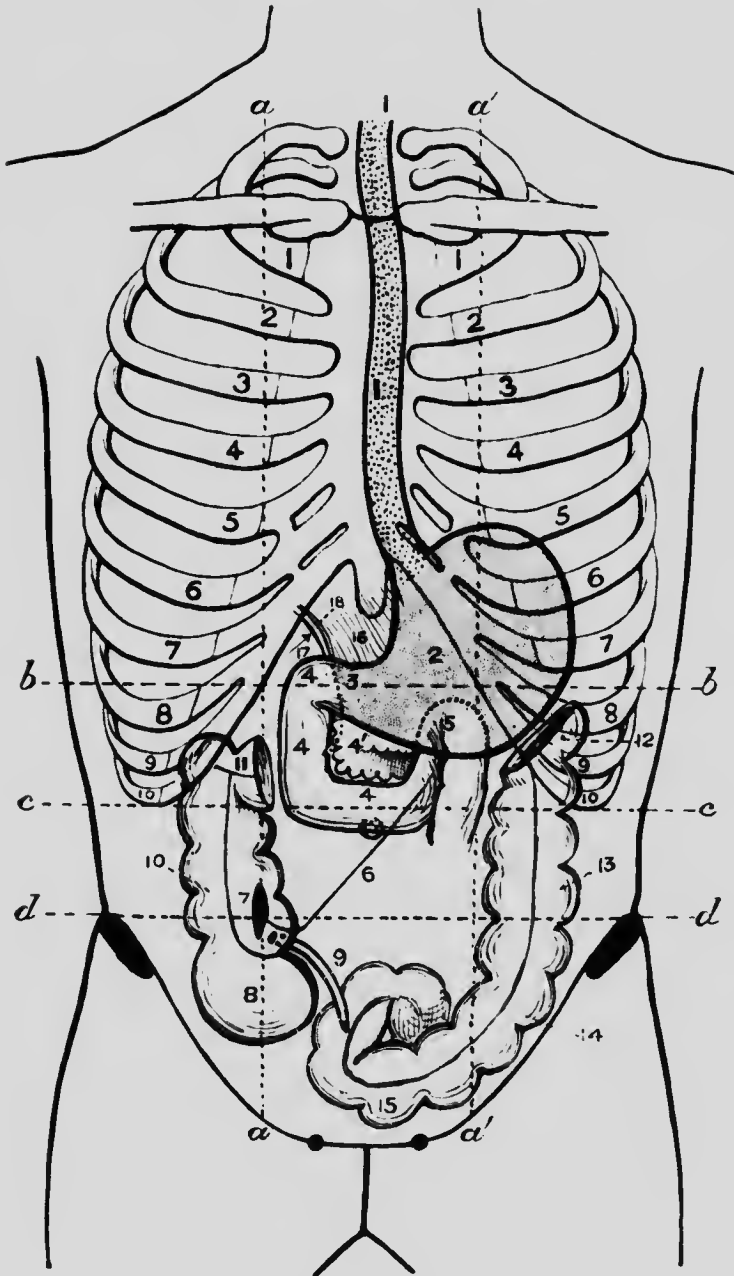



FIG. XIX.

a, a, and a', a' = the lateral vertical planes.
b, b. The transpyloric plane.
c, c. The subcostal plane.
d, d. The intertubercular plane.

To face p. 56.



The *vermiform appendix*.—The opening of the appendix into the cæcum is situated just below and internal to the junction of the right lateral vertical and intertubercular planes, at the top right-hand corner of the hypogastric region. The surface marking of the cæcal orifice of the appendix does not coincide with McBurney's point, which is situated at the junction of the outer and middle thirds of a line drawn from the right anterior superior iliac spine to the umbilicus. This point represents the usual seat of maximum pain on palpation in an attack of appendicitis. The appendix is usually 3 to 4 inches long, and, according to Testut, is in 40 per cent. of cases directed downwards and inwards, overhanging the pelvic brim, whilst in 26 per cent. of cases only is it directed upwards and inwards (towards the spleen). Stress should be laid on the fact that the ileo-cæcal valve and the cæcal orifice of the appendix are both situated on the postero-internal aspect of the cæcum.

The *ascending colon* passes upwards from the level of the intertubercular plane to the upper part of the ninth right costal cartilage, the gut there turning on itself to form the *hepatic flexure*. In its upward course the ascending colon lies almost entirely to the right of the right lateral vertical plane.

The *transverse colon* extends from the *hepatic flexure* on the right to the *splenic flexure* on the left. The former flexure corresponds to the ninth costal cartilage, whilst the latter reaches upwards as high as the eighth. In between these two points the gut varies greatly in direction in different subjects. Most commonly the gut passes almost transversely from one side to the other, crossing the middle line at about the level of the second

lumbar vertebra. It also crosses the second part of the duodenum, and lies, therefore, usually above the umbilical plane. In the diagram the two flexures are depicted, but the intervening portion of the gut has been intentionally omitted.

The *descending colon* passes almost vertically downwards from the region of the splenic flexure to the level of the posterior part of the iliac crest, below which level it becomes known as the *iliac colon*. The descending colon lies wholly to the left of the left lateral vertical plane.

The operation of lumbar colotomy is now seldom performed, but it is nevertheless necessary to indicate the position of the descending colon on the posterior aspect of the trunk. It corresponds in direction to a line drawn vertically upwards to the tip of the last rib, from a point situated $\frac{1}{2}$ inch behind the mid-point along the iliac crest between the anterior and posterior superior iliac spines.

The *iliac and pelvic colon*.—Between the termination of the descending colon at the level of the iliac crest, and the beginning of the rectum proper at the level of the third piece of the sacrum, the large gut describes so varied a course that no definite detailed account can be given of its surface marking. It may, however, be briefly described as passing downwards and inwards from the level of the iliac crest, parallel to Poupart's ligament, as far as the left side of the pelvic brim (the *iliac colon*). The gut then forms a great loop (the *pelvic colon*), which sweeps over to the right side of the pelvic brim, turning on itself to become the rectum at the level of the third sacral vertebra.

The *rectum*.—A line which unites the two posterior

superior iliac spines crosses the spinous process of the second sacral vertebra. The rectum begins at the level of the third sacral vertebra, and may be indicated on the surface by drawing in the gut as starting about $\frac{1}{2}$ to $\frac{3}{4}$ inch below the above-mentioned line, and extending downwards, following the curves of the sacrum and coccyx, to the anal orifice, which is placed about 2 inches below the level of the tip of the coccyx.

The dura mater enclosing the spinal cord (see "*spinal cord*") reaches downwards to the level of the third sacral vertebra. The spinal dura, therefore, terminates at the same level as the rectum begins, a point to be borne in mind in those operations carried out in the sacral region for the exposure of a growth involving the gut in the neighbourhood of the ilio-pelvic and rectal junction.

THE KIDNEY

(Length, $4\frac{1}{2}$ inches; breadth, $2\frac{1}{2}$ inches; thickness, $1\frac{1}{2}$ inches; weight, $4\frac{1}{2}$ ounces).

(a) *Anterior surface marking.*—The two kidneys are obliquely placed in such a manner that the superior poles lie $1\frac{1}{2}$ to 2 inches, and the inferior poles $2\frac{1}{2}$ to 3 inches, distant from the middle line. The left kidney lies at a slightly higher level than its fellow, and the hilum is placed just below and internal to the junction of the transpyloric and left lateral vertical planes; or, in other words, the hilum of the left kidney lies just internal to the anterior extremity of the ninth costal cartilage. The upper pole lies half-way between the sternoxiphoid and transpyloric planes, whilst the lower pole corresponds to the tenth costal plane. The right kidney does not ascend to quite such a high level, and the inferior pole

lies opposite the umbilical plane. The hilum of this kidney also lies just below the level of the hilum of the opposite kidney.

(b) *Posterior surface marking—Morris's quadrilateral.*—
 Fig. xvii., 10. Two vertical lines are drawn at a distance of 1 inch and $3\frac{1}{2}$ inches respectively from the median posterior line, and two horizontal lines are drawn outwards at the level of the spinous processes of the eleventh dorsal and third lumbar vertebræ. In the quadrilateral so marked out, the kidneys are drawn, care being taken to place the long axis of each kidney in the required oblique direction.

THE URETERS

(Length, 10 inches).

(a) *Anterior surface marking.*—The ureter passes nearly
 Fig. xv., 33. vertically downwards from the hilum of the kidney (just below and internal to the junction of the transpyloric and lateral vertical planes), and dips into the true pelvis in close relation to the bifurcation of the common iliac artery. This vessel bifurcates into internal and external iliacs at the junction of the upper and middle thirds of a line drawn from a point $\frac{1}{2}$ inch below and to the left of the umbilicus (the aortic bifurcation) to a second point situated half-way between the anterior superior iliac spine and the symphysis pubis. This apparently complicated surface marking for the ureter will be rendered more easy by a reference to the diagram. The right ureter generally dips into the pelvis just below the bifurcation of the common iliac artery.

(b) *Posterior surface marking.*—The course of the ureter
 Fig. xvii., 11. on the posterior aspect of the trunk can be represented by a line drawn vertically upwards

from the posterior superior iliac spine to the level of the spinous process of the second lumbar vertebra.

The *ovary* lies in the angle between the internal and external iliac arteries, immediately below the pelvic brim and anterior to the ureter.

Fig. xv,
34.

The *urachus* is directed upwards from the apex of the bladder, at the upper border of the pubic symphysis, to the umbilicus.

Fig. xx.,
15.

ABDOMINAL VESSELS.

The *abdominal aorta*.—The thoracic aorta enters the abdominal cavity by passing beneath the middle arcuate ligament of the diaphragm at the level of the twelfth dorsal vertebra. The vessel then changes its name, and the abdominal aorta passes vertically downwards as far as the left side of the body of the fourth lumbar vertebra, at which level it bifurcates into the two common iliac arteries. The course of the vessel may be mapped out on the surface by taking a point about two fingers' breadth above the transpyloric plane and slightly to the left of the middle line, and by drawing a line vertically downwards to a second point situated $\frac{1}{2}$ inch below and to the left of the umbilicus.

The first large vessel which arises from the abdominal aorta is the *cœliac axis*. This trunk is given off at the level of the twelfth dorsal vertebra, and divides, after a course of about $\frac{1}{2}$ inch, into three main trunks—the hepatic, splenic, and coronary or gastric arteries.

The *superior mesenteric* (level of disc between the twelfth dorsal and the first lumbar vertebræ) follows next, springing from the anterior aspect of the aorta immediately above the transpyloric plane.

Fig. xv.,
26.

The *renals* (level of the first lumbar vertebra) pass outwards from the lateral aspect of the aorta immediately below the level of the transpyloric plane.

Fig. xv.,
27.

The *inferior mesenteric* (level of the third lumbar vertebra) arises from the left side of the main trunk at about the level of the subcostal plane.

Fig. xv.,
28.

The *common iliac artery* corresponds to the upper third of a line drawn from a point $\frac{1}{2}$ inch below and to the left of the umbilicus to a second point situated half-way between the anterior superior iliac spine and the symphysis pubis. The *external iliac artery* corresponds in direction to the lower two-thirds of this line.

Fig. xv.,
29.

Fig. xv.,
31.

The *deep epigastric artery* is given off from the external iliac just as that vessel passes under Poupart's ligament half-way between the anterior superior iliac spine and the symphysis pubis. The epigastric artery then passes upwards and inwards along the inner side of the internal abdominal ring towards a point situated $\frac{1}{2}$ inch to 1 inch outside the umbilicus, entering the rectus sheath at the level of the semilunar fold of Douglas.

Fig. xx.,
20.

This vessel forms the outer boundary of *Hesselbach's triangle*, the inner boundary of this space being formed by the linea semilunaris of the same side, and the base by Poupart's ligament. Each triangle is vertically subdivided into two parts by the obliterated hypogastric artery, on either side of which herniæ may protrude.

Fig. xx.,
16.

The *inferior vena cava* is formed by the junction of the two common iliac veins on the right side of the body of the fifth lumbar vertebra, about 1 inch below and $\frac{1}{2}$ inch




FIG. XX.

- 1, 1. The diaphragm.
2. The liver.
3. The gall-bladder.
4. The ligamentum teres.
5. The receptaculum chyli.
6. The thoracic duct.
7. The venous termination of the duct.
8. The internal mammary artery.
9. The superior epigastric artery.
10. The musculo-phrenic artery.
11. The rectus abdominis muscle.
- 12, 12. The linæ semilunares.
- 13, 13, 13. The linæ transversæ.
14. The semilunar fold of Douglas.
15. The urachus.
16. Hesselbach's triangle.
- 17, 17. The internal abdominal ring.
- 18, 18. The external abdominal ring.
- 19, 19. The inguinal canal.
20. The deep epigastric artery.

THE LIVER, ANTERIOR ABDOMINAL WALL, ETC.

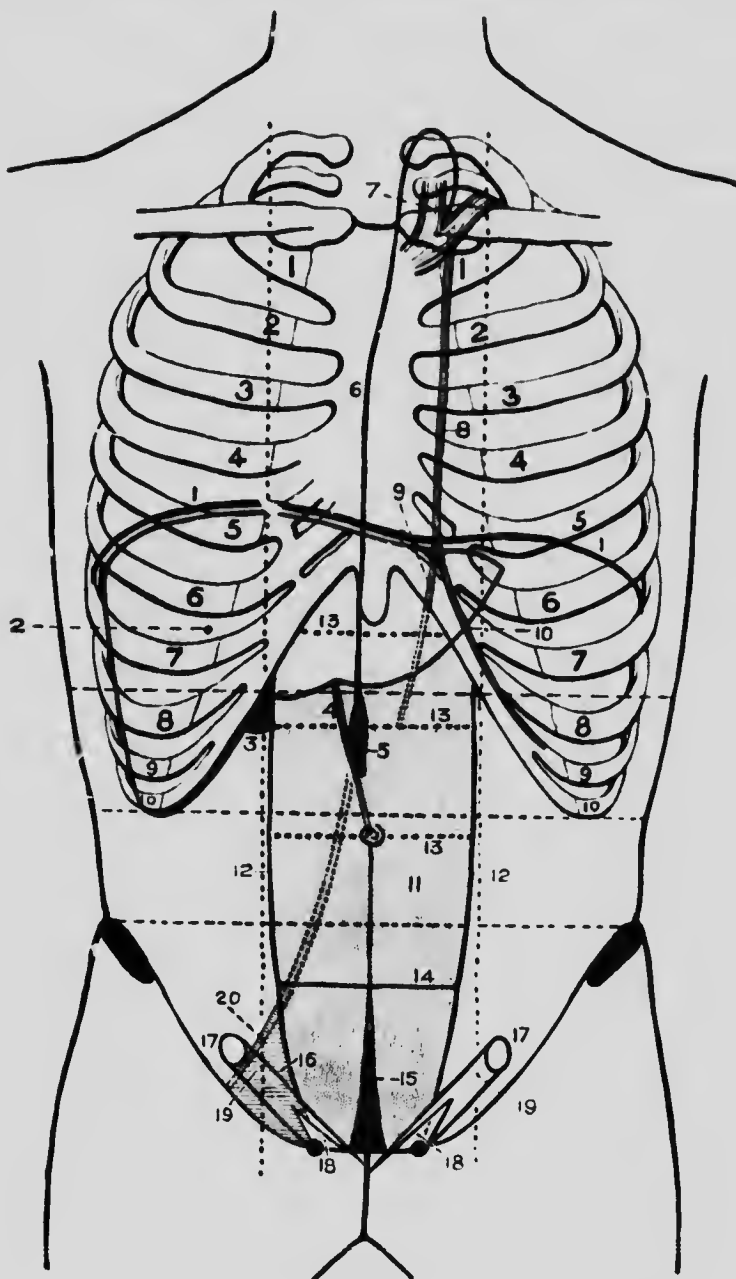


FIG. XX.

Tejue p. 62.

Vertical text or markings along the left edge of the page, possibly bleed-through from the reverse side or a scanning artifact.

to the right of the umbilicus. The vein passes upwards
 Fig. xv.,
 23. to pierce the quadrate opening of the diaphragm
 at the level of the eighth dorsal vertebra,
 entering the right auricle of the heart opposite the fifth
 right interspace and the adjoining part of the sternum.

THE LIVER.

The anterior border can be mapped out by drawing a
 curved line from a point in the fifth left
 Fig. xx., 2. interspace $3\frac{1}{2}$ inches from the middle line (the
 position of the apex of the heart), the line cutting the
 left costal margin at the tip of the eighth costal cartilage
 and the right costal margin at the tip of the ninth costal
 cartilage. Between these two latter points, the anterior
 border of the liver crosses the middle line half-way between
 the umbilicus and the sterno-xiphoid junction (=trans-
 pyloric plane), whilst a notch to the right of the middle
 Fig. xx., 4. line indicates the hepatic attachment of the
ligamentum teres, which passes from that notch
 downwards and inwards to the umbilicus.

Beyond the tip of the ninth right costal cartilage the
 anterior border of the liver follows the lower limit of the
 costal arch, descending sometimes even below that level,
 Fig. xvii.,
 12. and after cutting across the twelfth rib, ascends
 towards the level of the eleventh dorsal spine.

The *upper limit of the liver* is indicated by a line starting
 Fig. xx. as before in the fifth left interspace $3\frac{1}{2}$ inches
 from the middle line, and ascending slightly as
 it passes to the right. This line cuts across the sixth
 Fig. xvii.,
 12. right chondro-sternal articulation, the upper
 border of the right fifth costal cartilage in the
 right lateral vertical plane, the sixth rib in the mid-axillary

line, sweeping thence just below the angle of the scapula towards the eighth dorsal spine.

The *gall-bladder*.—The fundus projects from under the anterior border of the liver in the angle between the tips of the ninth and tenth costal cartilages and the outer border of the rectus abdominis muscle.

The *diaphragm*.—On ordinary inspiration the right dome of the diaphragm corresponds in level to the lower part of the fourth right interspace, whilst the left dome ascends to the lower part of the fifth left rib and costal cartilage.

THE COMMON BILE-DUCT. ETC.

The *gastro-hepatic omentum*, passing upwards from the lesser curvature of the stomach to the transverse fissure of the liver, presents a free edge, which downwards and to the right, and which forms the anterior boundary of the foramen of Winslow, the channel of communication between the greater and the lesser peritoneal sacs. The free edge of this omentum further contains (between its two layers of peritoneum) three important structures :

1. The common bile-duct to the right.
2. The hepatic artery to the left.
3. The portal vein behind and between the two former structures.

In mapping out any of these structures, it is, therefore, advisable to first draw in the lesser curvature of the stomach, the pylorus, the three parts of the duodenum, and the pancreas. The pylorus occupies such a definite position in the transpyloric plane that all these structures are easily and quickly drawn in. The free margin of the lesser omentum should be represented as a curved line

passing upwards and to the right for $1\frac{1}{2}$ to 2 inches from the duodeno-pyloric junction. The *portal vein* is formed behind the head of the pancreas by the union of the superior mesenteric and splenic veins, and passes upwards to the transverse fissure of the liver behind the first part of the duodenum, and in the free edge of the lesser omentum.

The *hepatic artery*, a branch of the cœliac axis, passes upwards from the upper border of the first part of the duodenum, in the free edge of the lesser omentum, to the transverse fissure of the liver.

The *common bile-duct* is 3 inches long, and is formed
Fig. xix., by the union of the hepatic and cystic ducts.

18. It passes downwards in the free edge of the gastro-hepatic omentum, behind the first part of the duodenum, behind the head of the pancreas, and opens on the inner and posterior aspect of the second or descending part of the duodenum.

THE SPLEEN.

The long axis of the spleen corresponds to the tenth
Fig. xvii., rib, and the viscus extends upwards to the
9. upper border of the ninth rib, and downwards to the lower border of the eleventh rib. The upper and inner pole lies $1\frac{1}{2}$ to 2 inches away from the tenth dorsal spine, whilst the lower or anterior pole reaches as far forwards as the mid-axillary line.

THE SPINAL CORD.

The spinal cord extends from the foramen magnum to
Fig. vii., 5. the lower border of the first lumbar vertebra
Fig. xvii, (transpyloric plane). The cord follows the
2. curves of the vertebral column, and presents

also two enlargements, the *intumescencia cervicalis* and *lumbalis*. The former swelling lies between the third cervical and second dorsal vertebræ, the latter between the ninth and twelfth dorsal vertebræ. Near its termination the cord tapers away as the *conus medullaris*.

The *filum terminale*, the prolongation of the cord, is continued onwards from the lower part of the body of the first lumbar vertebra to near the tip of the coccyx, at which level it blends with the periosteum lining that bone.

The *theca vertebralis*, or dural sheath, extends as low as the third sacral vertebra, at which level it is pierced by the *filum terminale*.

A line uniting the two posterior superior iliac spines cuts across the second sacral spine, and the dural sac, therefore, terminates about $\frac{1}{2}$ inch below the level of this interspinous line. At the third month of intra-uterine life the cord extends the whole length of the vertebral canal, whilst at birth it reaches as low down as the third lumbar vertebra.

A reference to Fig 7 will show that cerebro-spinal fluid might be withdrawn from the thecal canal anywhere between the termination of the cord at the level of the transpyloric plane and the base of the sacrum. A line drawn across the back, at right angles to the long axis of the body, at the level of the highest part of the iliac crests, cuts across the median posterior line at the level of the interspace between the laminæ of the second and third or third and fourth vertebræ. It is at this point, or rather to one side of this point, that *lumbar puncture* is carried out.

Fig. vii., 7.
Fig. xvii.,
3.

Fig. vii., 6.
Fig. xvii.,
1, 1.

g. vii., 10.
Fig. xvii.,
15.

THE PERINEUM.

A brief account only will be given, as, though the landmarks are most important, the tendency is great to drift into the question of surgical applied anatomy, a pitfall which the writer is most anxious to avoid.

The *perineum* is, in shape, roughly quadrilateral, the lateral boundaries being formed in front by the diverging rami of the pubis and ischium, and behind by the ischial tuberosity and the *gluteus maximus* muscle. The anterior and posterior angles of the space are formed respectively by the symphysis pubis and the tip of the coccyx. The subpubic angle is obtuse in the female and acute in the male. In the female, also, the ischial tuberosities are further apart and slightly everted. The *perineum* is divided into two areas by a line drawn between the anterior part of the ischial tuberosities, thus forming—

- (a) The *genital* area.
- (b) The *anal* area.

This transverse line passes about 1 inch in front of the anus, and represents the level of the two transverse perinei muscles, the posterior border of the triangular ligament, and the line along which Colles's fascia is reflected round the posterior border of the two transverse perinei muscles to become continuous with the posterior border of the triangular ligament. The "*central tendinous point of the perineum*:" corresponds to the middle of this line, and forms the point of attachment of several muscles.

(a) The *genital area*.—In the *male*, this area is divided into two lateral triangles by the median antero-posterior prominence of the bulb of the penis (*corpus spongiosum*). The two crura of the penis (*corpora cavernosa*) diverge as

they pass backwards towards the tuberosity of the ischium, and the main pudic vessels lie under cover of these erectile organs. The triangle is completed behind by the transversus perinei muscle. All the above-mentioned erectile structures and muscles lie superficial to the triangular ligament.

In the *female*, this area is practically cut into two lateral triangles by the orifice of the vagina, each side of which lies the bulb of the vestibule, an organ of erectile tissue, corresponding developmentally to the male corpus spongiosum. More superficially, the two labia majora converge towards the mons veneris in front, whilst, on the mesial aspect of the labia majora, the labia minora converge towards the clitoris, between which body and the vaginal margin a smooth triangular space exists, the *vestibule*. At the junction of the vagina and the vestibule the *urethra* opens.

Vaginal examination.—Passing along the posterior vaginal wall the finger enters the superior fornix, the upper part of which is in *direct relation with the peritoneal cavity* (Douglas's pouch). Along the anterior wall the smaller anterior fornix is first encountered, this cul-de-sac not being directly related to the peritoneal cavity, and immediately above this the *os uteri* may be examined. Bimanually, much information can usually be gained with regard to the size and position of the uterus, the condition of the uterine appendages, the contents of Douglas's pouch, etc.

(b) *The rectal area.*—This area is divided into two lateral parts by a line drawn from the "central point of the perineum" to the tip of the coccyx, and the examining fingers may, in thin subjects, be made to sink deeply into each lateral recess (the ischio-rectal fossæ), being

then in relation with the rectum and levator ani muscle on the inner side, the ischial tuberosity and the obturator internus muscle on the outer side, the transverse perinei muscle in front, and the gluteus maximus and great sacro-sciatic ligament behind.

Rectal examination.—If the forefinger be gently inserted into the rectum, definite resistance is offered by the external and internal sphincters, the latter aided by contraction of the levator ani muscle. Further on the finger enters the dilated ampullary portion of the rectum, meeting, perhaps, further obstruction from Houston's valves. When insinuated as far as possible, the palmar aspect of the distal phalanx will, in the male, be in contact with the vasa deferentia and the vesiculæ seminales, the middle phalanx with the prostate gland, and the proximal phalanx with the sphincters, which intervene between the finger and the triangular ligament and the spongy and membranous parts of the urethra. Posteriorly, the hollow of the sacrum and the coccyx can be fully explored. It is most important to bear in mind that the peritoneum is reflected from the rectum on to the *upper third of the vagina in the female, and on to the vesiculæ seminales, about 1 inch above the upper limit of the prostate gland, in the male.*

In *children*, since the true pelvis is but little developed and the later pelvic viscera are practically abdominal, a rectal examination enables one to explore all the lower abdominal viscera, including the bladder.

CHAPTER V

THE LOWER EXTREMITY

THE pubic spine, the iliac crest, the anterior and posterior superior iliac spines, and the iliac tubercles have all been previously alluded to and located. It has also been stated that a line uniting the two posterior superior iliac spines cuts across the spine of the second sacral vertebra. Below this line the remaining sacral spines and the coccyx are easily felt, though the coccyx itself is more readily verified by inserting the forefinger into the rectum whilst the thumb is placed over the bone externally.

The region of the hip.—(a) Posterior and external aspect. The great trochanter of the femur and the ischial tuberosity must now be examined. The latter process lies under cover of the lower part of the gluteus maximus muscle, whilst the trochanter is subcutaneous in its lower part, and covered over in front and above by the insertion of the gluteus medius muscle.

The trochanter is more or less quadrilateral in shape, fading off into the shaft of the femur below, and presenting a well-marked posterior border; the highest point of the trochanter corresponds to the posterior superior angle of the quadrilateral. When the body is in the erect position, there is a well-marked depression situated above and behind the great trochanter,




FIG. XXI.

1. The iliac crest.
2. The posterior superior iliac spine.
3. The sacrum.
4. The second sacral spine.
5. The coccyx.
6. The piriformis muscle.
7. The ischial tuberosity.
8. The sciatic artery and the ischial spine.
9. The great trochanter of the femur.
10. The gluteal artery.
11. Nélaton's line.
12. The great sciatic nerve.
13. The internal popliteal nerve.
14. The external popliteal nerve.
15. The biceps tendon.
16. The semimembranosus muscle.
17. The semitendinosus muscle.
18. The outer head of the gastrocnemius muscle.
19. The inner head of the gastrocnemius muscle.
20. The posterior tibial artery and nerve.
21. The external saphenous vein.

THE BACK OF THE THIGH AND LEG

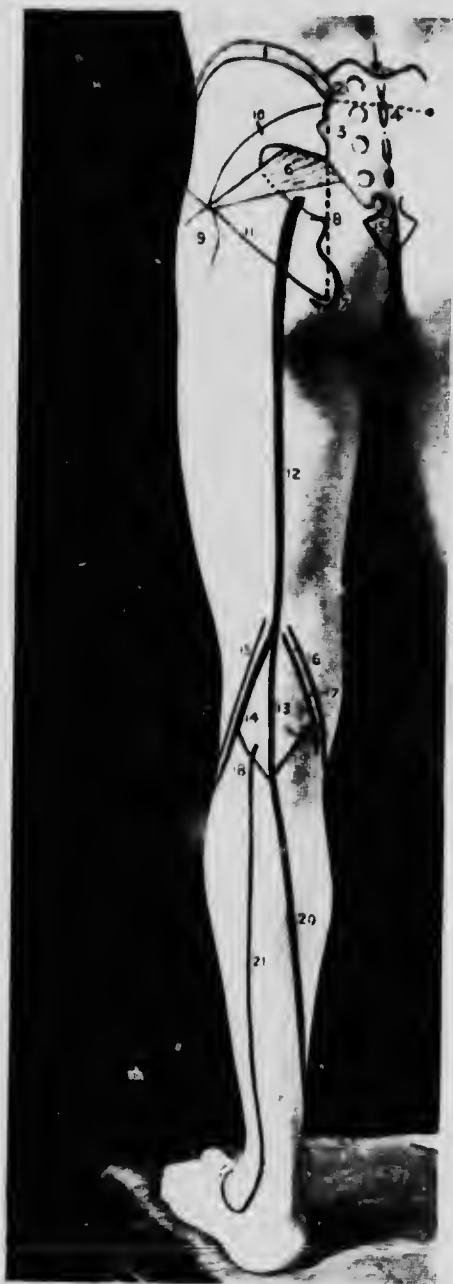

FIG. XXI.

To face p. 53





FIG. XXII.

1. The iliac crest.
2. The pubic spine.
3. Poupart's ligament.
4. The anterior crural nerve.
5. The common femoral artery.
6. The common femoral vein.
7. The crural canal.
8. The superficial femoral artery.
9. Vastus externus.
10. Vastus internus.
11. The upper limit of the synovial membrane of the knee-joint.
12. The patella.
13. The ligamentum patellæ.
14. The tubercle of the tibia.
15. The internal tuberosity of the tibia.
16. The external tuberosity of the tibia.
17. The head of the fibula.
18. The internal saphenous vein.
19. The anterior tibial artery.
20. The anterior tibial nerve.
21. The musculo-cutaneous nerve.
22. The dorsalis pedis artery.
23. The dorsal venous arch.

THE FRONT OF THE THIGH AND LEG



FIG. XXII.

To follow Fig. XXI.

which becomes less marked when, as the result of disease or disuse, the gluteus maximus undergoes atrophic changes. The fold of the nates does not correspond to

the lower border of the gluteus maximus muscle, as it crosses almost transversely the lower oblique fibres of that muscle. This fold also becomes less distinct when the glutei muscles degenerate. The head and neck of the femur form with the shaft of that bone an angle of 125 to 130 degrees.

Nélaton's line.—“ If in the normal state you examine Fig. xxi., 11. the relation of the great trochanter to the other Fig. xxiii., 6. bony prominences of the pelvis, you will find that the top of the great trochanter corresponds to a line drawn from the anterior superior iliac spine of the ilium to the most prominent point of the tuberosity of the ischium. This line also runs through the centre of the acetabulum. The extent of displacement in dislocation or in fracture is marked by the projection of the trochanter behind and above this line ” (Nélaton).

Bryant's triangle.—When the patient is in the dorsal Fig. xxiii., 4. recumbent position, draw a line round the body at the level of the anterior superior iliac spine, and from this line drop a perpendicular to the top of the great trochanter. To complete the triangle, draw a line from the anterior superior iliac spine to the top of the trochanter. When the trochanter is displaced upwards the perpendicular line is diminished in length as compared with the sound side, and when it undergoes a backward displacement the spino-trochanteric line is relatively increased in length.

(b).—Anterior and internal aspect. The lower extremity is demarcated from the abdomen by a well-marked furrow, the *inguinal groove*. This corresponds to the situation

of *Poupart's ligament*, the recurved lower border of the obliquus externus abdominis muscle. This ligament, as it passes from the anterior superior iliac spine to the pubic spine of the same side, forms the upper boundary of *Scarpa's triangle*, a space which is best demonstrated **Fig. xxiv.,** when the thigh is flexed, abducted, and everted.

3, 4. The sartorius muscle is then thrown into action and the outer boundary of the space so shown. If the hand be now placed on the upper and inner aspect of the thigh and the limb be sharply adducted, a rounded tendon at once becomes noticeable. This is the adductor longus, which forms the inner boundary of Scarpa's triangle.

The outwardly directed adductor longus and the inwardly curving sartorius converge to form the apex of the triangle.

The floor of the space is formed from without inwards by the iliacus, psoas, pectineus and adductor longus muscles. In the superficial fascia which overlies this region, numerous lymphatic glands are situated, and it will here be convenient to briefly discuss their general arrangement. The *superficial lymphatic glands* are placed in three main groups:

(1) The *oblique or inguinal glands*, running parallel to and below Poupart's ligament, and draining the anterior aspect of the abdomen below the level of the umbilicus, the lower half of the side and back, the gluteal region, and the upper and outer part of the thigh.

(2) The *vertical or femoral glands*, running with the long internal saphenous vein, and draining the greater part of the inner aspect of the foot, leg, and thigh.

(3) The *pubic glands*, situated below and external to the pubic spine, and draining mainly the external genitals, perineum, and anus.

The deep fascia presents an opening, the *saphenous opening*, for the transmission of the long saphenous vein to the common femoral vein. This foramen is oval in shape, being 1 inch long and $\frac{1}{2}$ to $\frac{3}{4}$ inch broad, the long axis vertical. The central point of the opening is situated $1\frac{1}{2}$ inches below and $1\frac{1}{2}$ inches external to the pubic spine.

Beneath the deep fascia overlying Scarpa's triangle, certain important structures are situated, such as the common, superficial femoral, and profunda femoris arteries, the corresponding veins, and the anterior crural nerve. These will all be dealt with later, the femoral ring alone needing here further definition.

The *femoral ring*, through which a femoral hernia commonly escapes from the abdominal cavity, lies below the inner part of Poupart's ligament, and external to the pubic spine. A good way to define the ring with precision is that recommended by Holden: "Feel for the pulsation of the common femoral artery, allow $\frac{1}{2}$ inch on the inner side for the femoral vein, then comes the femoral ring." The crural or femoral ring presents the following boundaries: To the inner side is Gimbernat's ligament; to the outer side is the femoral vein; in front is Poupart's ligament; behind is the pectineus muscle and the horizontal ramus of the os pubis.

Hunter's canal, a more or less triangular muscular channel for the transmission of the superficial femoral artery, occupies the middle third of the antero-internal aspect of the thigh. During forcible contraction of the thigh muscles, Scarpa's triangle may be seen to be continued downwards as a shallow depression between the extensor and adductor muscles, this furrow

corresponding to the position of the canal in question. The anatomical boundaries of the canal are (1) vastus internus externally, (2) adductor longus and magnus behind, (3) sartorius and a strong fascial band between the adductors and vastus internus in front and internal.

The canal transmits the superficial femoral vein and artery, the long internus saphenous nerve (anterior crural), and the nerve to the vastus internus (anterior crural).

In order to *compare the length* of the lower extremities the bones should be placed parallel to one another, and the tape-measure carried from the anterior superior iliac spine to the tip of the internal malleolus of the tibia of

Fig. xxiv., 16. the same side. The distance between these two points may be subdivided, if necessary, by marking out, on the inner aspect of the knee, the trans-

Fig. xxiv., 17. verse line which indicates the level of the femoro-tibial articulation. The lengths of the femur and of the tibia are thus separately estimated.

The *region of the knee*.—The biceps tendon forms the upper and outer boundary of the popliteal space, and under cover of this tendon, on its inner or popliteal aspect, a cord-like structure is felt, the external popliteal or peroneal nerve. This intimate relation of tendon and of nerve must be remembered in

Fig. xxi., 14. the operation of tenotomy of the biceps tendon

Fig. xxiii., 11. If the biceps tendon be now traced downwards the head of the fibula is reached, this process lying below, external, and on a posterior plane to the outer tuberosity

of the tibia. The styloid process of the head

Fig. xxiii., 9. of the fibula projects upwards from the posterior part of the head, and in front of this the rounded long external lateral ligament of the knee-joint can be traced upwards to its femoral attachment. In front of




FIG. XXIII.

1. The iliac crest.
2. The anterior superior iliac spine.
3. Poupart's ligament.
4. Bryant's triangle.
5. Nélaton's line.
6. The great trochanter.
7. The ilio-tibial band.
8. The outer tibial tuberosity.
9. The head of the fibula.
10. The biceps tendon.
11. The peroneal nerve.
- 12, 12. The anterior tibial nerve.
13. The musculo-cutaneous nerve.
- 14, 14. The anterior tibial artery.
15. The dorsalis pedis artery.
16. The external saphenous vein.
17. The venous arch.

THE SIDE OF THE THIGH AND LEG

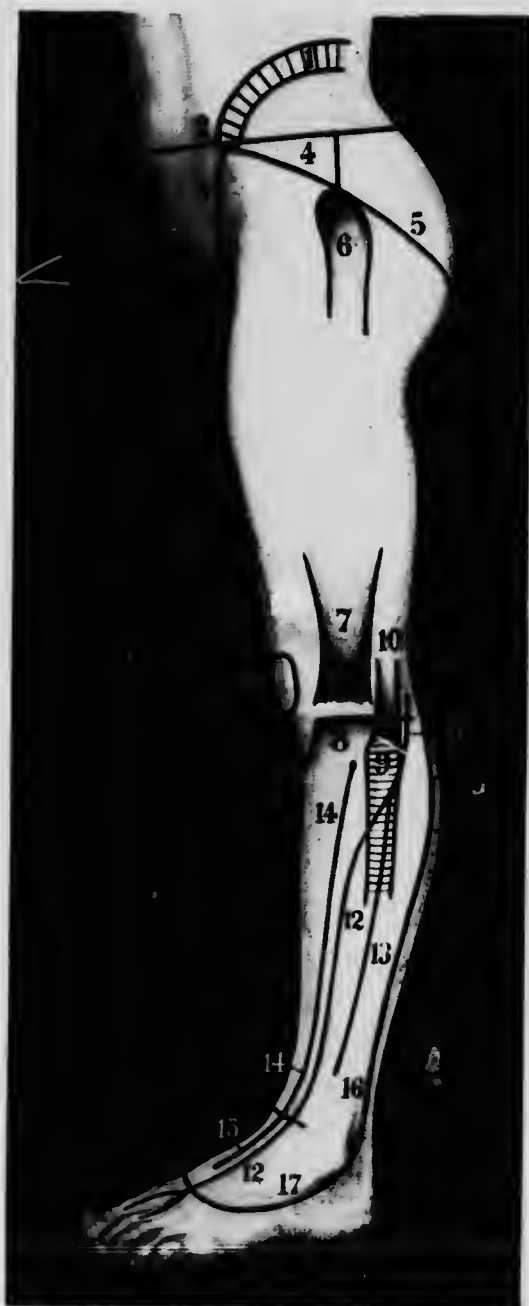

FIG. XXIII.

To face p. 74.



FIG. XXIV.

1. The anterior superior iliac spine.
2. The pubic spines.
3. The sartorius muscle.
4. The adductor longus muscle.
5. The anterior crural nerve.
6. The common femoral artery.
7. The common femoral vein.
8. The femoral ring.
9. The saphenous opening.
- 10, 10, 10. The internal or long saphenous vein.
11. The profunda femoris artery.
12. The superficial femoral in Scarpa's triangle.
13. The superficial femoral in Hunter's canal.
14. The adductor magnus tendon.
15. The adductor tubercle.
16. The lower epiphysial line of the femur.
17. The line of the knee-joint.
18. The gracilis, sartorius, and semitendinosus muscles.
19. The internal saphenous nerve.
20. The posterior tibial artery.
21. The internal plantar artery.
22. The external plantar artery.
23. The anterior tibial nerve.

THE SIDE OF THE THIGH AND LEG

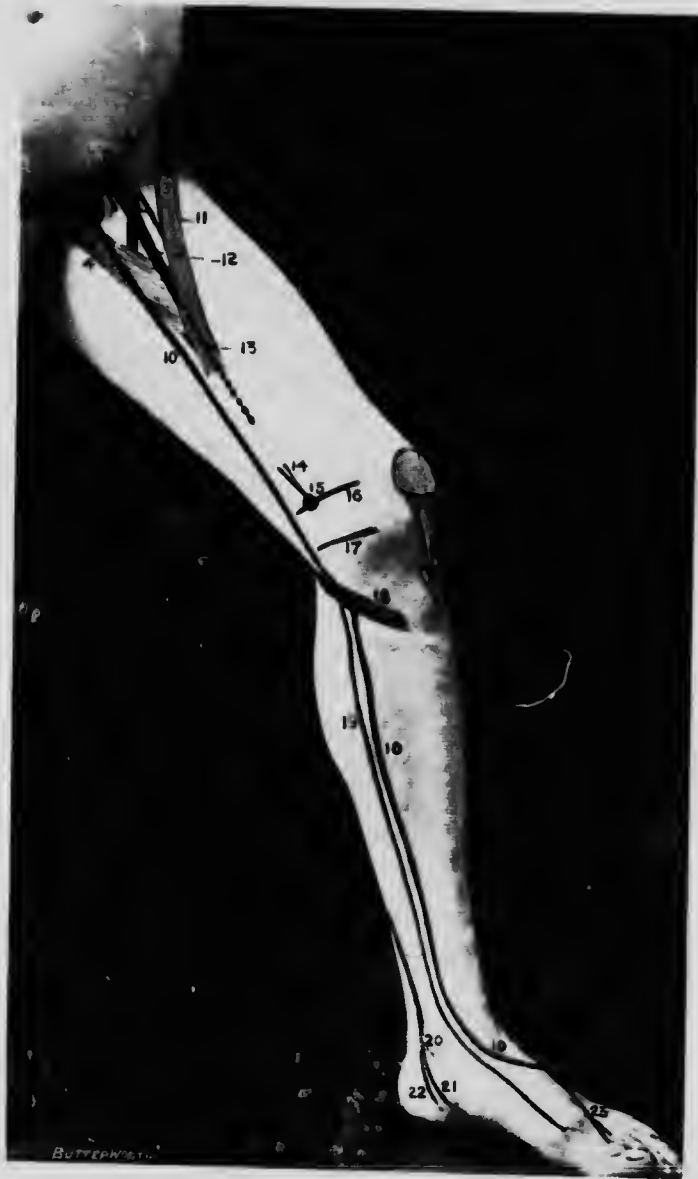


FIG. XXIV.

To follow Fig. XXI.

the biceps tendon there is a depression which is bounded anteriorly by the broad ilio-tibial band. Two well-marked tendons bound the popliteal space on the upper and inner side, the semimembranosus and semitendinosus. The latter is the more external, the more superficial, and the narrower, and the long rounded tendon can be traced some distance up into the thigh. The semimembranosus tendon lies to the inner side of the semitendinosus and on a deeper plane. The broad tendon can be traced downwards to its insertion into the inner and posterior aspect of the internal tuberosity of the tibia. On the inner aspect of the knee the tendon of the gracilis muscle and the lower part of the sartorius muscle form a fairly well-marked prominence, the individual muscles being, however, usually incapable of clear definition owing to their flattened shape. Between these tendons and the prominent vastus internus muscle a depression exists, and by deep palpation the adductor magnus tendon may be felt lying under cover of the inner margin of the vastus internus muscle. By tracing this tendon downwards to its insertion the *adductor tubercle* is reached. This tubercle corresponds also to the level of the *lower epiphysial line* of the femur.

The sartorius and gracilis muscles, though not easily defined on the inner side of the knee, form, together with the semitendinosus muscle, a fairly well-marked elevation below the internal tuberosity of the tibia, which is directed downwards, forwards, and outwards.

The ligamentum patellæ narrows off as it passes from the inferior border of the patella to the tibial tuberosity, and on each side of the ligament

depressions exist, in the lower part of which the inner and outer tuberosities of the tibia are readily felt.

The *prepatellar bursa* extends from the middle of the patella to the tibial tubercle. Laterally, the bursa falls just short of the patellar border.

The *synovial membrane* of the knee-joint extends upwards Fig. xxii., about three fingers' breadth above the upper border of the patella when the leg is in the extended position, reaching up under the vastus internus to a slightly higher level than on the other side. Laterally, the synovial membrane extends to near the inner and outer margins of the femoral condyles, whilst the lower limit is situated just above the tubercle of the tibia. When the joint is distended with fluid the outline of the joint cavity becomes marked, and the depressions which normally exist each side of the patellar ligament become obliterated.

The *ankle and foot*.—The external malleolus projects Fig. xxvii., about $\frac{1}{2}$ inch below the internal, and also lies on a more posterior plane. The ankle-joint corresponds in level to a point about $\frac{1}{2}$ inch above the tip of the internal malleolus.

About 1 inch below and $\frac{1}{2}$ inch in front of the styloid process of the external malleolus is the *peroneal tubercle*, Fig. xxv., which separates the peroneus brevis above from the longus below. The two peronei tendons, when traced upwards, are found to pass behind the external malleolus. About 1 inch in front of the peroneal tubercle is the prominent styloid process of the base of the fifth metatarsal bone, to which the peroneus brevis is attached. Between the peroneal tubercle and the base of the fifth metatarsal bone the cuboid bone may be felt, grooved on its outer and under




FIG. XXV.

INTERNAL ASPECT OF FOOT AND ANKLE.

1. The tibialis anticus.
2. The internal malleolus.
3. The tibialis posticus.
4. The tubercle of the scaphoid.
5. The flexor longus digitorum.
6. The sustentaculum tali of the os calcis.
7. The flexor longus hallucis.
8. The tendo Achillis.
9. The head of the astragalus.
10. The joint between the scaphoid and the internal cuneiform.
11. The joint between the first metatarsal bone and the internal cuneiform.
12. The metatarso-phalangeal joint.

EXTERNAL ASPECT OF FOOT AND ANKLE.

13. The external malleolus.
14. The head of the astragalus.
15. The head of the os calcis.
16. The peroneus tertius.
17. The base of the fifth metatarsal bone.
18. The peroneus brevis.
19. The peroneus longus.
20. The peroneal tubercle of the os calcis.
21. The tendo Achillis.
22. The extensor longus digitorum.

THE REGION OF THE ANKLE AND FOOT

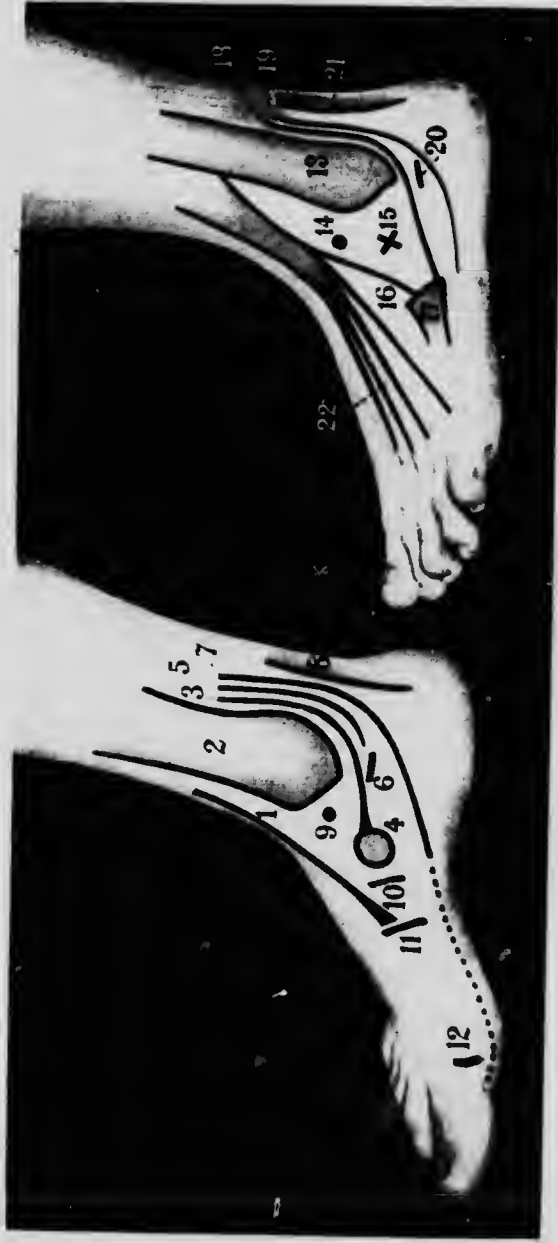

FIG. XXV.

To face p. 77.

aspect by the peroneus longus tendon. The tendon crosses the plantar aspect of the foot in a forward and inward direction, to be inserted into the outer aspect of the base of the first metatarsal bone. Immediately in front of

the external malleolus there is a well-marked depression, which is bounded in front by a prominence due to the fleshy mass of the extensor brevis digitorum, and above by the tendon of the peroneus tertius.

Fig. xxv., 14. If the floor of this depression be examined, the head of the astragalus will be felt above and to the inner side, and the head of the os calcis below and to the outer side.

Fig. xxv., 15. Between the two malleoli in front of the ankle-joint four tendons can be felt. The most prominent and the innermost is the tendon of the tibialis anticus muscle. External to this follow the extensor longus hallucis, the extensor longus digitorum and the peroneus tertius. When the foot is well extended, the head of the astragalus can also be identified lying under cover of the extensor tendons.

Immediately below the internal malleolus is the *sustentaculum tali*, grooved on its under aspect by the flexor longus hallucis tendon, and between the sustentaculum and the internal malleolus the tibialis posticus and flexor longus digitorum pass.

Fig. xxv., 6. The tibialis posticus tendon can be traced upwards behind the internal malleolus and downwards to the scaphoid tuberosity, to which process the tendon gains its main attachment. In front of the internal malleolus there is another depression, which lies below the line of the tibialis

Fig. xxv., 3, 5.

Fig. xxv., 3.

Fig. xxv., 4.

anticus tendon, and here the head of the astragalus can again be felt, especially prominent when the foot is well everted. About 1 inch below Fig. xxv., 1. and in front of the internal malleolus the Fig. xxv., 9. tuberosity of the scaphoid bone forms the Fig. xxv., 4. most prominent bony point on the inner side of the foot, and a line which joins the tip of the internal malleolus, the head of the astragalus, and the scaphoid tubercle, normally presents a slight upward convexity.

In flat-foot, the head of the astragalus undergoes a downward displacement, and the line uniting the three bony points becomes straight, or even downwardly convex.

A line drawn almost transversely across the foot from a point just behind the scaphoid tubercle indicates the level of the *mid-tarsal joint*.

Fig. xxv., 10, 11. In front of the scaphoid tuberosity, the internal cuneiform and the first metatarsal bones may be located and verified.
Fig. xxv., 11, 12.

Behind the ankle-joint, the tendo Achillis is placed, the tendon being at its narrowest at a point about $1\frac{1}{2}$ inches above its insertion into the posterior part of the os calcis. When distended with fluid, the synovial membrane of the ankle-joint bulges outwards, so as to obliterate the depressions that normally lie between the tendo Achillis and the two malleoli.
Fig. xxv., 8, 21.

The *anterior annular ligament of the ankle*.—The upper portion of this ligament, about 1 inch broad, Fig. xxvi., 3. extends transversely across the ankle from tibia to fibula. It presents two compartments only, one for the tibialis anticus, and one for Fig. xxvi., 6. the remaining extensor tendons. The former tendon alone possesses a synovial sheath.

THE REGION OF THE ANKLE AND FOOT

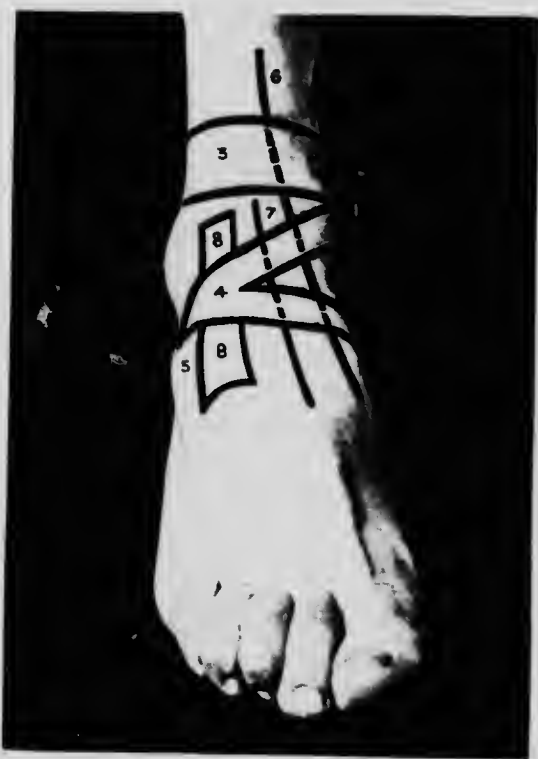

FIG. XXVI.

1. The internal malleolus.
2. The external malleolus.
3. The transverse band of the anterior annular ligament.
4. The Y-shaped band of the anterior annular ligament.
5. The head of the os calcis and the extensor brevis digitorum.
6. The tibialis anticus synovial sheath.
7. The extensor longus hallucis synovial sheath.
8. The extensor longus digitorum and peroneus tertius synovial sheath.

To face p. 72.

THE REGION OF THE ANKLE AND FOOT

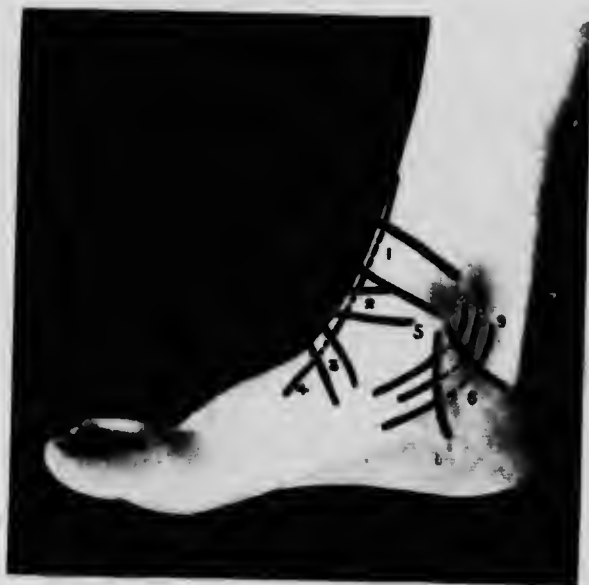

FIG. XXVII.

1. The transverse band.
- 2, 3. The upper and lower limbs of the Y-shaped part of the anterior annular ligament.
4. The tibialis anticus synovial sheath.
5. The internal malleolus.
6. The internal annular ligament.
7. The tibialis posticus synovial sheath.
8. The flexus longus digitorum synovial sheath.
9. The flexor longus hallucis synovial sheath.

To face p. 79.

The lower portion of the ligament is Y-shaped, the **Fig. xxvi., 4.** single limb arising from the upper and outer **Fig. xxvi., 5.** aspect of the head of the os calcis in close connection with the origin of the extensor brevis digitorum muscle. The upper limb of the divided portion becomes attached to the internal malleolus, whilst the lower limb sweeps over to the scaphoid tuberosity and to the inner side of the foot. The extensor communis digitorum and **Fig. xxvi., 8, 8.** the peroneus tertius pass under the single undivided limb, and possess in this situation a common synovial sheath; whilst the extensor longus **Fig. xxvi., 6, 7.** hallucis and the tibialis anticus pass through separate compartments in each limb of the divided portion of the ligament, and each tendon in so doing is surrounded by a synovial sheath, that enveloping the tibialis anticus tendon being continuous with the sheath already alluded to as enclosing the tendon under the transverse portion of the ligament.

The *internal annular ligament* is triangular in shape, the **Fig. xxvii., 6.** apex being attached to the internal malleolus, and the base to the lower margin of the os calcis. From the deep aspect of the ligament septa are given off which form separate compartments for the **Fig. xxvii., 7, 8, 9.** passage of the tendons of the tibialis posticus, flexor longus digitorum, and flexor longus hallucis muscles, each tendon having its own synovial sheath. These three sheaths extend for about 1 inch above the upper limit of the annular ligament; and although the sheath enveloping the tibialis posticus reaches almost as far forwards as the scaphoid tuberosity, the other two sheaths usually terminate about $\frac{1}{2}$ inch **Fig. xxix., 3, 3, 3.** below the inferior margin of the ligament. The flexor longus hallucis and flexor longus

digitorum have, again, distinct synovial sheaths just before their insertion into the distal phalanges of the toes, these sheaths, however, being very variable, and rarely extending further backwards than the heads of the metatarsal bones.

The *external annular ligament* is less definite in shape, and can only be described as a broad band passing from the external malleolus to the lower margin of the os calcis.

Fig. xxviii., Beneath it two tendons pass, the peroneus 4, 5, 6. longus and brevis. These two tendons possess a common synovial sheath, which extends upwards 2 to 3 inches above the tip of the external malleolus, and downwards as far as the "peroneal tubercle," where the sac divides into two, one part accompanying the peroneus brevis to near the base of the fifth metatarsal bone, the other extending forwards to the outer and under aspect of the cuboid bone. The peroneus longus is also usually enclosed in a synovial sheath in the last inch or so of its course, previous to its insertion into the outer aspect of the base of the first metatarsal bone.

THE VESSELS AND NERVES OF THE LOWER EXTREMITY.

The *gluteal artery* emerges from the great sacro-sciatic notch, above the pyriformis muscle, at the Fig. xxi., 10. junction of the inner and middle thirds of a line drawn from the posterior superior iliac spine to the top of the great trochanter of the femur of the same side.

The *sciatic artery* may be ligatured at a point which lies Fig. xxi., 8. just external to the junction of the middle and lower thirds of a line drawn from the posterior superior iliac spine to the outer part of the ischial tuberosity of the same side. This line also cuts across

THE REGION OF THE ANKLE AND FOOT

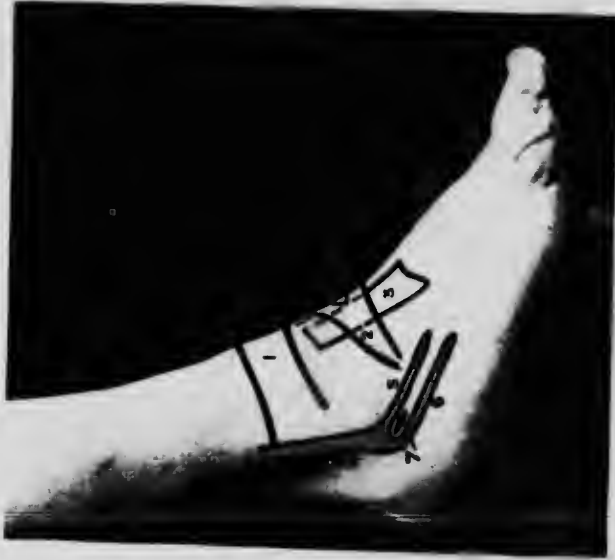

FIG. XXVIII.

1. The transverse limb.
2. The stem of the Y-shaped part of the anterior triangular ligament.
3. The extensor longus digitorum and peroneus tertius synovial sheath.
4. The peroneus longus and brevis synovial sheath.
5. The peroneus brevis sheath.
6. The peroneus longus sheath.
7. The peroneal tubercle.

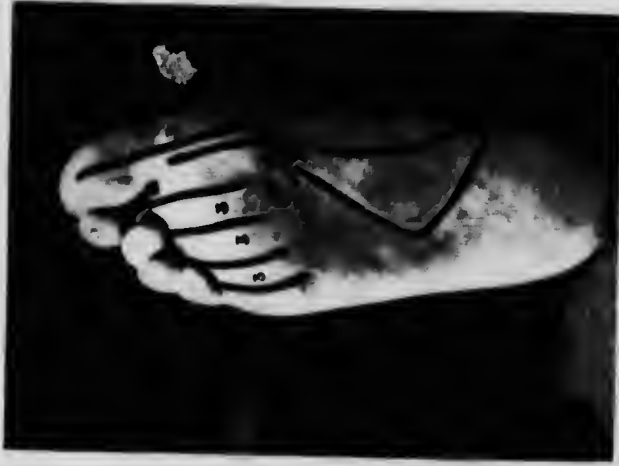

FIG. XXIX.

1. The lateral plantar artery.
2. The medial plantar artery.
3. The distal flexor synovial sheaths.

the *posterior inferior iliac spine* and the tip of the *ischial spine*, whilst the *internal pudic artery* lies immediately internal to the seat of election for ligation of the sciatic artery.

The *common and superficial femoral arteries*.—With the thigh flexed, everted, and slightly abducted, these vessels correspond in direction to a line drawn from a point midway between the anterior superior iliac spine and the symphysis pubis to the adductor tubercle of the femur below.

Fig. xxiv., 6. The upper $1\frac{1}{2}$ inches of this line = the common femoral artery.

Fig. xxiv., 6, 12. The upper third = the common and superficial femoral arteries in Scarpa's triangle.

Fig. xxiv., 6, 12, 13. The upper two-thirds = the complete common and superficial femoral arteries.

Fig. xxiv., 13. The middle third = the superficial femoral artery in Hunter's canal.

The *popliteal artery* enters the upper angle of the popliteal space (from the inner side) by passing between the femur and the adductor magnus tendon. The vessel at first passes obliquely outwards and downwards to the mid-point of the space, and then changes direction by passing vertically downwards as far as the lower border of the popliteus muscle, at which level it bifurcates into anterior and posterior tibial arteries. The point of bifurcation corresponds to the level of the tubercle of the tibia.

The *anterior tibial artery*.—The course of this vessel may be indicated by a line drawn from a point just below the level of the tibial tubercle, and midway between the outer tuberosity of the tibia and the head of the fibula, to a second point in front of the ankle midway between the two malleoli, at which

Fig. xxii., 19.

Fig. xxiii., 14, 14.

level the artery lies between the tendons of the extensor longus hallucis and longus digitorum muscles.

Fig. xxii., 22. The anterior tibial artery is continued on-
 Fig. xxiii., 15. wards as the *dorsalis pedis* as far as the base of the first interosseous space.

The *posterior tibial artery* starts at the lower border of
 Fig. xxi., 20. the popliteus muscle as one of the terminal branches of the popliteal artery. It can be represented by a line which starts at the inferior angle of the popliteal space, on a level with the tubercle of the tibia, and which passes downwards and inwards to the mid-point between the posterior border of the internal malleolus and the inner border of the os calcis. At this level it lies under cover of the internal annular ligament, and bifurcates in this situation into the internal and
 Fig. xxiv., 20 22. external plantar arteries. Behind the internal malleolus the posterior tibial artery lies between the tendons of the flexor longus hallucis and longus digitorum muscles, but on a slightly superficial plane.

The *internal plantar artery* passes forwards to the cleft between the first and second toes, whilst
 Fig. xxix., 2. the more important *external plantar artery* is first directed forwards and outwards towards the base of the fifth metatarsal bone, and then, changing direction, passes forwards and inwards to the base of the
 Fig. xxix., 1. first interosseous space, forming in this latter part of its course the *deep plantar arch*. It anastomoses with the *dorsalis pedis* artery, which dips downwards between the two heads of the first dorsal interosseous muscle.

The *external saphenous vein* arises from the outer side of
 Fig. xxiii., 16, 17. the venous arch on the dorsum of the foot, passing upwards behind the external malleolus and along the outer and back part of the leg to the middle

of the popliteal space, where it pierces the deep fascia to open into the popliteal vein. It is accompanied in the greater part of its course by the *external saphenous nerve*, which extends forwards on the outer side of the foot as far as the tip of the little toe.

The *internal saphenous vein* arises from the inner side of the venous arch found on the dorsum of the foot. It passes upwards in front of the internal malleolus, along the inner side of the leg and knee, behind the internal condyle of the femur, and its further upward course in the thigh is indicated by a line drawn from the adductor tubercle to the saphenous opening. Attention has previously been drawn to the elevation below the internal tuberosity of the tibia which is formed by the sartorius, gracilis and semitendinosus muscles, and below this prominence the saphenous vein is accompanied by the *internal saphenous nerve*, a branch of the deep division of the anterior crural. The saphenous nerve runs down the leg with the vein, in front of the internal malleolus of the tibia, and extends as far forwards as the ball of the great-toe. In the thigh the nerve crosses in front of the superficial femoral artery from without inwards, and accompanies that artery throughout the whole length of Hunter's canal.

The *anterior crural nerve* emerges from under cover of Poupart's ligament, about half-way between the anterior superior iliac spine and the pubic spine. The nerve lies nearly $\frac{1}{2}$ inch external to the common femoral artery, and the same distance external to the femoral sheath.

The *great sciatic nerve* makes its exit from the pelvis through the great sacro-sciatic notch below the piriformis muscle. The nerve emerges

from under cover of the lower border of the gluteus maximus muscle just to the inner side of the mid-point between the ischial tuberosity and the great trochanter of the femur. The nerve corresponds in direction to the upper two-thirds of a line drawn downwards from the above point to the middle of the popliteal space below. At the junction of the middle and lower thirds of the thigh the great sciatic nerve divides into its two terminal branches, internal and external popliteal.

The *small sciatic nerve* lies in the same line as the great sciatic, but extends downwards as far as the inferior angle of the popliteal space.

The *internal popliteal nerve* crosses the popliteal artery superficially from without inwards; its onward continuation, the *posterior tibial nerve*, and the two terminal branches of the posterior tibial nerve, the *internal and external plantars*, all have the same surface marking as the corresponding arteries. Two points, however, need to be borne in mind: first, the posterior tibial nerve crosses the corresponding artery superficially from within outwards and downwards and, secondly, the internal plantar nerve is relatively much more important than the corresponding artery.

The *external popliteal or peroneal nerve* was last seen to lie under cover of the biceps femoris tendon at the upper and outer boundary of the popliteal space. The nerve follows the tendon downwards to the head of the fibula, and curls round to the antero-external aspect of the leg about 1 inch below the head of that bone, dividing there into its two terminal branches, anterior tibial and musculo-cutaneous.

The *anterior tibial nerve* passes downwards and inwards to join the corresponding artery, lying external to the

Fig. xxi., 13.

Fig. xxi., 20.

Fig. xxi.,

14, 15.

Fig. xxiii.,

10., 11.

Fig. xxiii.,

12, 13.

upper third of the artery, superficial to the middle third,
 Fig. xxii., and external again to the lower third. The
 20. nerve extends forwards along the outer side
 Fig. xxiii., of the dorsalis pedis artery as far as the cleft
 12. between the first and second toes, the con-
 tiguous sides of which toes it supplies.

The *musculo-cutaneous nerve*, running down in the sub-
 stance of the peronei muscles, becomes cuta-
 Fig. xxii., neous below the middle of the leg. It then
 21. Fig. xxiii., passes obliquely downwards and inwards across
 13. the anterior annular ligament, to be distributed to the
 greater part of the dorsum of the foot.

APPENDIX

THE LENGTH OF VARIOUS PASSAGES, TUBES, ETC.

THE spinal cord, 16 to 18 inches.

The trachea, $4\frac{1}{2}$ inches.

The right bronchus, 1 inch.

The left bronchus, $1\frac{1}{2}$ to 2 inches.

The pharynx, $4\frac{1}{2}$ inches.

The œsophagus, 9 to 10 inches.*

The stomach :

Capacity, about 2 pints.

Length, 10 inches.

Width, 4 to 5 inches.

Duodenum, 8 to 10 inches.

Bile-duct, 3 inches.

Small intestine, 23 feet.

Jejunum, upper two-fifths.

Ileum, lower three-fifths.

Appendix, 3 to 4 inches.

Cæcum, $2\frac{1}{2}$ inches.

Ascending colon, 8 inches.

Transverse colon, 20 inches.

Descending colon, 4 to 6 inches.

* The distance from the teeth to the cardiac orifice of the stomach is about 16 to 17 inches.

- Iliac colon, 5 to 6 inches.
Pelvic colon, 16 to 18 inches.
Rectum, 5 to 6 inches.
Anal canal, 1 to 1½ inches.
Crural canal, ½ inch.
Inguinal canal, 1½ inches.
Receptaculum chyli, 1 to 2 inches.
Thoracic duct, 16 to 18 inches.
Kidney, 4½ inches by 2½ inches by 1½ inches.
Ureter, 10 inches.
Male urethra, 8 to 10 inches.
 Prostatic, 1 to 1½ inches.
 Membranous, anterior wall, ¾ inch.
 ,, posterior wall, ½ inch.
 Spongy and penile, 6 to 8 inches.
Testis, 1½ inches by 1 inch by ¾ inch.
Seminiferous tubules, 2 to 3 feet.
Canal of the epididymis, 19 to 20 feet.
Vas deferens, 16 to 18 inches.
Ovary, 1 inch by ½ inch.
Fallopian tubes, 4 to 4½ inches.
Uterus, 3 inches by 2 inches by 1 inch.
Vagina, anterior wall, 3 inches.
 ,, posterior wall, 4 inches.
Female urethra, 1 to 1½ inches.

THE WEIGHT OF SOME ORGANS.

The brain : Male, 50 ounces ; female, 45 ounces.

The lungs : Together, 42 ounces ; right, 22 ounces ; left, 20 ounces.

The heart : Male, 10 to 12 ounces ; female, 8 to 10 ounces.

The liver, 50 to 60 ounces.

The kidneys, $4\frac{1}{2}$ ounces.

The suprarenals, 1 to 2 drachms.

The prostate, 6 drachms.

The testis, 6 to 8 drachms.

The ovary, 1 to 2 drachms.

The spinal cord, $1\frac{1}{2}$ ounces.

The pancreas, 2 to 4 ounces.

The spleen, 7 ounces.

THE OSSIFICATION AND EPIPHYSES OF THE BONES OF THE UPPER AND LOWER EXTREMITIES.

Certain epiphyses and epiphysial lines have been alluded to in the text, and the following table, compiled from Gray's "Anatomy," has consequently been appended.

(a) THE UPPER EXTREMITY :

The clavicle :

1 centre for the shaft (in membrane) in the fourth to fifth week (i.u.l).*

1 centre for the sternal end in the eighteenth to twentieth year.

Union between the two in the twenty-fifth year.

The scapula :

1 centre for the body in the eighth week (i.u.l).

1 centre for the coracoid process in the first year.

1 centre for the base of the coracoid process	} between the fifteenth and eighteenth years.
2 centres for the acromial process	
1 centre for the vertebral border	
1 centre for the inferior angle	

The humerus :

1 centre for the shaft in the eighth week (i.u.l).

1 centre for the head in the first year.

1 centre for the great tuberosity in the third year.

1 centre for the small tuberosity in the fourth year.

Head and tuberosities unite together in the fifth year and with the shaft in the twentieth year.

1 centre for the internal condyle in the fifth year.

1 centre for the trochlear in the twelfth year.

1 centre for the capitellum in the second year.

1 centre for the external condyle in the thirteenth year.

The last three unite together to form an epiphysis, which unites with the shaft in the seventeenth year, the internal condyle joining separately in the eighteenth year.

The radius and ulna :

1 centre for the shaft of the radius in the eighth week (i.u.l).

1 centre for the shaft of the ulna in the eighth week (i.u.l).

* i.u.l. = intra-uterine life.

1 centre for the lower end of the radius in the second year—union at twenty.

1 centre for the lower end of the ulna in the fourth year—union at twenty.

1 centre for the upper end of the radius in the fifth year—union at sixteen.

1 centre for the upper end of the ulna in the tenth year—union at sixteen.

The carpus :

All the bones are cartilaginous at birth. The first centre of ossification appears in the os magnum and the last in the pisiform.

The metacarpus and phalanges :

1 centre for the shaft of the metacarpal and the shaft of the phalanx in the eighth week (i.u.l.).

1 centre for the head of the metacarpal bone and the base of the phalanx in the third year.

Union between diaphyses and epiphyses in the twentieth year.

The thumb metacarpal is an exception to the rule, a well-marked epiphysis always appearing at the base. This bone, therefore, resembles a phalanx in its mode of ossification, though an epiphysis is not infrequently seen at the head of the bone also.

(b) THE LOWER EXTREMITY :

The os innominatum :

Three main primary centres for ilium, ischium, and pubis, appearing respectively in the second, third, and fourth months (i.u.l.). The three parts of the bone are separated at first by the Y-shaped acetabular cartilage.

Five secondary centres appear about puberty for the crest, symphysis pubis, anterior inferior iliac spine, ischial tuberosity, and the acetabular cartilage. These unite at about the twenty-fifth year.

The femur :

1 centre for the shaft in the fifth week (i.u.l.).

1 centre for the lower end in the ninth month (i.u.l.)—union with shaft in the twentieth year.

1 centre for the head in the first year—union with shaft in the eighteenth year.

1 centre for the great trochanter in the fourth year.

1 centre for the small trochanter in the fourteenth year.

The patella :

1 centre in the third year.

The tibia and fibula :

- I centre for the shaft of the tibia in the seventh week (i.u.l.).
- I centre for the shaft of the fibula in the eighth week (i.u.l.).
- I centre for the upper end of the tibia in the first year—union at twenty.
- I centre for the upper end of the fibula in the fourth year—union at twenty-five.
- I centre for the lower end of the tibia in the second year—union at eighteen.
- I centre for the lower end of the fibula in the second year—union at twenty.

The tarsus :

The os calcis, astragalus and cuboid alone have centres of ossification at birth, these appearing respectively in the sixth, seventh, and ninth months. The os calcis possesses a secondary centre, appearing about the tenth year, for its posterior surface.






The metatarsus and phalanges :

Centres appear as in metacarpus, etc.



MICROCOPY RESOLUTION TEST CHART

(ANSI and ISO TEST CHART No. 2)



APPLIED IMAGE Inc

1653 East Main Street
Rochester, New York 14609 USA
(716) 482 - 0300 - Phone
(716) 288 - 5989 - Fax

INDEX

- ABDOMINAL AORTA**, 61
 planes, 50
 regions, 51
Acromial spine and process, 19, 20
Acromio-clavicular joint, 19
Adductor magnus tendon, 75
 tubercle, 75
Anal canal, length of, 87
"Anatomical snuff-box," 27, 28, 29
Ankle region, 76
Antecubital space, 24
Anterior annular ligament (ankle),
 78
Anterior annular ligament (wrist),
 25, 26
Anterior crural nerve, 83
 tibial artery, 81
 tibial nerve, 84
 triangle of neck, 12
Antrum of Highmore, 11
Aortic arch, 38
 intercostals, 40
 valve, 37
Apex beat, 36
Apices of lung, 45
Appendix, 57
 length of, 86
Ascending aorta, 38
 colon, 57
 length of, 86
Astragalus, 77
Auricular area, 37
Auriculo-temporal nerve, 15
Axilla, 21
Axillary artery, 20, 29
 lymphatics, 22

Base of brain, 4
Basic fossæ, 8
Basilic vein, 24
Biceps femoris, 74
 humeri, 21, 24
Bicipital fascia, 24
 groove, 21
 sulci, 24
Bile-duct, 64
 length of, 86
Bony points of elbow, 23
Brachial artery, 24, 29
 plexus, 17

Bregma, 2
Broca's area, 6
Bronchi, 46
 length of, 86
Bryant's line and triangle, 71
Bulb of penis, 67
 of vestibule, 67

Cæcum, 56
 length of, 86
Canal of epididymis, 87
Cardiac orifice, 54
Carotid arteries, 13
 triangle, 13
 tubercle, 13
Central point, 50
 tendinous point of perineum,
 67, 68
Cephalic vein, 24, 25
Cerebellum, 5
Cerebrum, 4
Cervical sympathetic, 16
Circumflex nerve and artery, 30
Clavicle, 19
Clitoris, 68
Coeliac axis, 61
Colles's fascia, 67
Common bile-duct, 64, 65
 carotid artery, 38
 femoral artery, 81
 iliac artery, 62
Conus medullaris, 66
Coraco-brachialis fold, 22, 29
Coracoid process, 20
Coronal suture, 2
Coronary artery, 61
Creases of palm and fingers, 33
 of wrist, 25
Cricoid cartilage, 18, 47
Crura of penis, 67
Crural canal, 73
 length of, 87
Cuboid bone, 76
Cuneiform bone, 26
Curvatures of stomach, 56

Deep cardiac dulness, 45
 epigastric artery, 62
 palmar arch, 30
 plantar arch, 82

- Deltoid, 20
 Descending aorta, 38
 colon, 58
 length of, 87
 Diaphragm, 64
 Digital arteries, 30
 Dorsalis pedis artery, 82
 Douglas's fold, 43, 53
 pouch, 68
 Duodeno-jejunal fold, 55
 Duodenum, 55
 length of, 86
 Dura mater, 59, 66

 Elbow region, 23
 Epiglottis, 18
 Epiphyses, 89
 Epiphysal line of humerus, 21, 23
 of femur, 75
 Epitrochlear gland, 25
 Extensor tendons of foot, 64
 of wrist, 28
 External abdominal ring, 54
 angular frontal process, 3
 annular ligament (foot), 80
 carotid artery, 10
 iliac artery, 62
 jugular vein, 15
 lateral ligament (knee), 74
 parieto-occipital fissure, 6
 plantar artery and nerve, 82,
 84
 popliteal nerve, 74, 84
 saphenous vein and nerve,
 82, 83

 Facial artery, 14
 nerve, 9, 10
 Fallopian tubes, length of, 87
 False ribs, 34
 Falx cerebri, 2
 Female urethra, length of, 87
 Femoral canal and ring, 73
 Fibula, 74
 Filum terminale, 66
 First costal cartilage and rib, 34
 First interspace, 34
 Fissures of lung, 44
 Flexor carpi radialis, 25, 29
 ulnaris, 25
 sublimis, 25, 26
 synovial sheaths, 26, 27
 Floating ribs, 34
 Fontanelle, anterior, 2
 posterior, 2
 Foot region, 76
 Foramen of Winslow, 64
 Fornices of vagina, 68
 Frontal sinus, 11

 Gall-bladder, 64
 Gastro-hepatic omentum, 64

 Genital area, 67
 Gluteal artery, 60
 Gluteus maximus, 70
 Gracilis, 75
 Great auricular nerve, 17
 occipital nerve, 14
 sciatic nerve, 83

 Hamilton's test, 20
 Hand region, 25
 Heart, 35
 Hepatic artery, 61, 64, 65
 flexure, 57
 Hesselbach's triangle, 62
 Hip region, 70, 71
 Houston's valves, 68
 Humerus, head of, 20, 22
 Hunter's canal, 73

 Ileo-cæcal valve, 56
 Iliac colon, 58
 length of, 87
 crest, 52
 spines, 52, 53
 tubercles, 53
 Ilio-pelvic colon, 58
 length of, 87
 Ilio-tibial band, 75
 Inferior dental nerve and artery,
 10
 mesenteric artery, 62
 temporal crest, 3, 4
 vena cava, 40, 62
 Infraclavicular space, 20
 Infra-orbital foramen, 11
 Inguinal canal, 54
 length of, 87
 groove, 71
 Inion, 1
 Innominate artery, 38
 veins, 39, 40
 Intercostal space, 35
 Internal abdominal ring, 54
 annular ligament (foot), 79
 carotid artery, 13
 jugular vein, 16
 mammary artery, 39
 plantar artery and nerve, 82,
 84
 popliteal nerve, 84
 pubic artery, 81
 saphenous nerve, 83
 vein, 83
 Intertubercular plane, 50, 53
 Ischial spine, 81
 tuberosity, 70
 Ischio-rectal fossæ, 68
 Island of Reil, 5

 Kidney, 59
 length and weight of, 87

- Knee region, 74
 Knuckles, 33

 Labia majora and minora, 67
 Lachrymal sac, 10
 Lambda, 2
 Lambdoid suture, 2
 Larynx, 18
 Lateral sinus, 2, 4, 5, 9
 ventricles, 8
 vertical plane, 49
 Length of femur and tibia, 74
 of humerus, 21
 Ligamentum patellæ, 75
 teres, 63
 Lineæ semilunares, 52
 transversæ, 52
 Lingual artery, 14
 Liver, 63
 weight of, 88
 Ludwig's angle, 35
 plane, 51
 Lumbar puncture, 66
 Lungs, 42
 weight of, 88

 Macewen's triangle, 4, 8
 Malar tubercle, 3
 Mamma, 34
 Masseter muscle, 9
 Mastoid antrum, 8
 McBurney's point, 57
 Median nerve, 24, 32
 vertical plane, 49
 Mental foramen, 11
 Mesentery of small intestine, 56
 Mesial fissure of brain, 1
 Metacarpo-phalangeal joint, 33
 Metopic suture, 2
 Middle cerebral artery, 5
 meningeal artery, 6, 7
 Mid-tarsal joint, 78
 Mitral valve, 37
 Mons vereris, 67
 Morris's quadrilateral, 60
 Muscular triangle, 12
 Musculo-cutaneous nerve (arm), 31
 (leg), 85
 Musculo-phrenic artery, 39
 Musculo-spiral nerve, 24, 31

 Nasal duct, 10
 Nasion, 1
 Natal fold, 71
 Nélaton's line, 71
 Ninth costal cartilage, 35, 50, 59
 Nipple, 35

 Obelion, 2
 Occipital artery, 14
 nerve (great), 14
 (small), 17

 Oesophagus, 47
 Occipital condyle, 23
 Omo-hyoid muscle, 13
 Orbit, boundaries of, 10
 Os calcis, 77
 Os uteri, 68
 Ovary, 61, 87, 88

 Palmar fascia, 33
 Palmaris longus, 32
 Pancreas, 56
 weight of, 88
 Paracentesis of pericardium, 46
 Paracental point, 50
 Parietal eminence, 2
 Parieto-occipital sulcus, 6
 Parotid gland, 9
 Pectoralis major and fold, 21
 minor, 29
 Pelvic colon, 58
 length of, 87
 Pericardium, 46
 Perineum, 67
 Peroneal nerve, 74, 84
 tendons, 76, 80
 tubercle, 76, 80
 Petit's triangle, 54
 Pharynx, 11
 length of, 86
 Phrenic nerve, 16
 Pisiform bone, 25, 26
 Plantar arch, 82
 Pleura, 41
 Popliteal artery, 81
 space, 74
 Portal vein, 64
 Posterior annular ligament
 (wrist), 28
 auricular artery and nerve, 14
 inferior iliac spine, 81
 interosseous nerve, 21, 32
 superior iliac spine, 53
 tibial artery and nerve, 82, 84
 triangle, 13
 Poupert's ligament, 71
 Prepatellar bursa, 76
 Prostate gland, 53
 weight of, 88
 Pubic spine, 53
 Pudic vessels, 67
 Pulmonary artery, 39
 valve, 37
 truncus, 55
 Pyriformis muscle, 80

 Radial artery, 25, 28, 29
 nerve, 24, 31
 tubercle, 28
 Radius, 23
 Receptaculum chyli, 47, 87
 Rectal area, 67, 68
 examination, 69

- Rectum, 58
 length of, 87
 Reid's base line, 5
 Renal artery, 62
 Rima glottidis, 18
 Rolandic area, 6
 fissure, 6
 Roots of lung, 45

 Sagittal suture, 2
 Saphenous opening, 73
 Sartorius, 75
 Scalenus anticus, 15
 Scaphoid bone (carpus), 25
 (tarsus), 77, 78
 Scarpa's triangle, 72
 Sciatic artery, 80
 nerve (great), 83
 (small), 84
 Semilunar fold of Douglas, 52
 Semimembranosus, 75
 Semiferous tubules, length of, 87
 Semitendinosus, 75
 Shoulder region, 19
 Sinuses of nose, 12
 Small intestine, 56
 occipital nerve, 17
 sciatic nerve, 84
 Sphenoidal sinus, 12
 Spinal accessory nerve, 16
 cord, 65
 length and weight, 86, 88
 Spinous plane, 52
 Spleen, 65
 Splenic artery, 61
 flexure, 57
 Stenson's duct, 9
 Sterno-mastoid, 12
 Sterno-xiphoid plane, 52
 Stomach, 54
 Styloid process of radius and ulna, 27
 Subclavian artery, 15, 39
 triangle, 13
 Subcostal plane, 52
 Submaxillary gland and triangle, 12
 Subpubic angle, 67
 Superficial cardiac dulness, 45
 cervical plexus, 17
 femoral artery, 81
 lymphatics of arm, 22
 of leg, 72
 palmar arch, 30
 temporal artery, 15
 Superior epigastric artery, 39
 longitudinal sinus, 2
 mediastinum, 39
 mesenteric artery, 61
 temporal crest, 3, 6

 Superior thyroid artery, 13
 vena cava, 40
 Supra-acromial nerve, 17
 Supraclavicular nerve, 17
 Suprameatal crest and spine, 3, 8
 fossa, 8
 Supra-orbital foramen, 11
 Suprarenals, weight of, 88
 Suprasternal nerve, 17
 plane, 52
 Sustentaculum tali, 77
 Sylvian fissure, 5
 point, 5
 Sympathetic chain and ganglia, 16
 Symphysis pubis, 53
 Synovial membrane of knee, 76
 sheaths of ankle, 78, 79
 of wrist (extensor), 28
 (flexor), 26

 Tegmen antri, 9
 Temporo-sphenoidal sulcus, 6
 Tendo Achillis, 78
 oculi, 10
 Tendons of ankle region, 76
 of wrist, 25
 Tentorium cerebelli, 5
 Testis, length and weight, 87, 88
 Theca vertebralis, 66
 Thoracic aorta, 38
 duct, 47
 plane, 50
 Thyroid isthmus, 18
 Tibial tuberosities, 74
 Tibialis anticus, 77
 posticus, 77
 Tonsil, 10
 Trachea, 18
 Transpyloric plane, 50, 55
 Transverse cervical nerve, 17
 colon, 57, 86
 creases of palm, 33
 of wrist, 25
 facial artery, 9
 Transversus perinei, 67
 process of atlas, 16
 Trapezium, 25
 Triangles of neck, 12
 Triangular ligament, 67
 Tricuspid valve, 38
 Trochanter of femur, 70
 True ribs, 34
 Tuberosities of humerus, 20
 of tibia, 74

 Ulnar artery, 24, 30
 nerve, 32
 Umbilical plane, 52
 Umbilicus, 52
 Unciform bone, 26
 Urachus, 61

- Ureter, 60, 87
Urethra, male, 87
 female, 87
Uterus, dimensions of, 87
Vagina, examination of, 68
 dimensions of, 87
Vagus nerve, 16
Valves of heart, 37
Veins of elbow, 24
- Vena azygos major, 40
Ventricular area, 36
Vermiform appendix, 57
Vestibule, 68
Vocal cords, 18
Wrist-joint, 25
Wrist region, 25
Zygomatic process, 3

