

STUDIES FROM THE ROYAL VICTORIA HOSPITAL
MONTREAL. Vol. I. No. I. (OPHTHALMOLOGY, I.)

THE PRIMARY INTRADURAL TUMOURS
OF THE
OPTIC NERVE.
(FIBROMATOSIS NERVI OPTICI.)

BY

W. GORDON M. BYERS, M.D.,
ASSISTANT OCUList AND AURIST, ROYAL VICTORIA HOSPITAL;
DEMONSTRATOR IN OPHTHALMOLOGY, MCGILL UNIVERSITY.

AUGUST, 1901.

PRINTED BY
J. A. CARVETH & CO.,
TORONTO.

s
a
g
c
w
q
a

CONTENTS :		PAGE.
INTRODUCTORY, - - - - -		3
REPORT OF CASES STUDIED BY THE WRITER, - - - - -		-
Case I., - - - - -		7
Case II., - - - - -		12
Discussion of the two Cases, - - - - -		18
ETIOLOGY of Intradural Tumours of the Optic Nerve, - - - - -		20
GROSS ANATOMY, - - - - -		22
THE INTRACRANIAL CONNECTIONS of Intradural Tumours, - - - - -		25
MICROSCOPICAL ANATOMY, - - - - -		28
The Relationship of the Various Forms of Intradural Tumour, - - - - -		30
The Relationship of Intradural to other Tumours, - - - - -		33
SYMPTOMATOLOGY, - - - - -		-
Exophthalmos, - - - - -		36
Functional Disturbances of the Optic Nerve, - - - - -		39
Muscular Anomalies, - - - - -		43
Palpation, - - - - -		44
Minor Signs, - - - - -		45
Summary, - - - - -		48
DIAGNOSIS, - - - - -		50
PROGNOSIS, - - - - -		51
TREATMENT, - - - - -		52
ANALYTICAL TABLES of Recorded Cases, - - - - -		58-73
BIBLIOGRAPHY, - - - - -		74-82

INTRODUCTORY.

A TREATISE on tumours of the optic nerve, written at the present time, is practically a resumé of the work which has been done on the subject during the 19th century. Not until 1816 do we meet with something tangible in the report of *Scarpa*,¹⁰³ who described an orbital growth which sprang apparently from the external sheath of the optic nerve and was removed without injury to the function of the eye. To *Wishart*,¹ of Edinburgh, whose report has so long lain forgotten upon the shelf, belongs certainly the honour of having clearly described the first example of that form of growth which forms the subject of this paper, and somewhat open to question as *Scarpa's* case is, it might perhaps be more reasonable to date the commencement of our exact knowledge of

the subject from 1833, the year in which the report of the Scottish surgeon was published.

Goldzieher,¹⁵ 1873, was the first to treat the subject of primary tumours of the optic nerve under a general heading, though *von Graefe*,¹⁶ 1864, in discussing the features of his first two cases, had already, with the insight of genius, drawn a clear clinical picture of these growths and laid down the diagnostic points which are still the mainstay of the profession in their recognition.

A still further advance in the development of the subject was brought about when *Leber* drew the attention of ophthalmologists to the necessity of adopting a more exact classification of the tumours affecting the optic nerve. First broached at the meeting of the Ophthalmologische Gesellschaft of 1874* *Leber*'s views find full expression in his later classic article¹⁷ on this subject, where, instead of an indiscriminate massing together of cases, one finds for the first time an orderly classification of the neoplasms affecting the optic nerve.

Since *Leber*'s time the subject has been enriched by a large number of excellent pathological and clinical reports and several *general* treatises, among which are to be mentioned especially those of—*Willemer*,¹⁸ *Vossius*,¹⁹ *Huc*,²⁰ *Hessdörffer*,²¹ *Ewetzki*,¹¹² *Wolfheim*,³¹ *Jocqs*,¹²⁶ *Ayres*,³⁶ *Sattler*,⁹⁷ *Roudie*,¹⁴⁶ *Gloor*,¹¹⁹ *Thiery*,¹⁴⁷ *Braunschweig*,⁷⁴ *Salzmann*,⁷⁵ *Finlay*,¹²³ *Scalinci*,⁹⁰ *Bullar* and *Marshall*,⁹² *Axenfeld* and *Busch*,⁹³ *Collins* and *Marshall*⁹². This work as a whole reflects the advances which have been made in surgery and pathology during the last quarter of a century.

Leber (l.c.), after clearly distinguishing between the *primary* tumours of the optic nerve and the *secondary* growths or those which involved it by extension from contiguous parts; and after classifying the neoplasms according as to whether they affected the (1) Intraocular, (2) Intraorbital, or (3) Intracranial division of the nerve, separated the tumours of the second mentioned class into the *true* or *genuine* (*eigentlich*), or those encapsuled by the dural sheath, and the *false* (*uneigentlich*) or those which sprang from the external aspect of this structure or the immediately adjacent tissue.

*Klin. Mon. Bl. für Augen, Vol. xii, p. 443.

This paper deals only with the *genuine* tumours of Leber's classification though a slightly different nomenclature has been adopted. In place of the terms "True" and "False" which appeared to us somewhat arbitrary, inasmuch as both classes of growth spring primarily from the nerve, we have substituted the words "*Intradural*" and "*Extradural*," the better to define the real point of difference in the situation of the neoplasms.

It was my intention at first to take up the whole subject of growths of the optic nerve, but with the progress of the work it was decided to deal only with that portion of them already indicated. The reason for this was not only that this class holds easily the first place in clinical importance and interest, but because it was thought that pathologically it could be shewn that these tumours, though differing in many respects, were in reality *but varying manifestations of one underlying process*.

In order to secure accuracy it was determined to employ original articles as far as possible, and to select as material only those cases which were undoubtedly intradural in situation.

While working in this way it became evident that the bibliography of the subject was in an annoyingly inaccurate and incomplete condition. This was seen to have arisen from the employment by former writers of abstracts instead of original articles, and it was interesting to trace the typographical errors in one paper, *e.g.*, that of Jocqs,¹²⁶ through a series of succeeding monographs.

Special care has been taken, therefore, in this paper to make the bibliographical lists, which have been brought forward only as far as 1900, as accurate as possible, and in order to render this part of the work more valuable to future workers, references have been given not only to the tumours under discussion, but also to the cases which have been excluded because of doubt or because they fell under other headings. Still further to add to the reliability of the bibliographical section, I have affixed a dagger sign (†) to those few (6) references which I was unable to verify by access to primary sources, and to increase its usefulness, I have inserted an asterisk (*) wherever the original article was accompanied by illustrations.

I should like here to express my warm thanks to Professor Adami, in whose laboratory at the Royal Victoria Hospital, the histological portion of this work was carried through, for the encouragement which I have received at his hands during the preparation of this paper, but especially for the direct assistance he has given me in the elaboration of the ideas in this article concerning the nature of and the relationship between the various forms of tumours met with. To Dr. Buller for pathological specimens and the permission to use them, and to Dr. Shirres for help with that part of the work which came within his special field of neuro-pathology, I am very grateful. My thanks are also due to Miss Charlton for kind assistance at the McGill Medical Library, to Major Merrill for courteous permission to make use of the incomparable Surgeon-General's Library at Washington, and to Dr. Patrick, Mr. Hamilton White and my brother, Mr. Roddick Byers for the preparation of illustrations.

REPORT OF CASES STUDIED BY THE WRITER.

Before proceeding to discuss the question in its general aspects, I will introduce here the report of two cases of primary intradural tumours, which, together with the pathological portion of that read before the American Ophthalmological Society in 1899 by Dr. Buller, make up the material which forms the basis of my work on this subject.

The first case was originally reported by Dr. Buller in 1886, but as the communication has not generally found its way into the literature, I have inserted verbatim the remarks made at the time of the presentation of the growth before the Montreal Medical Society.²⁰ They are as follows:—

"This growth was removed on the 16th of April from the orbit of a little girl 7 years of age. The history of the case and the objective signs were sufficiently distinctive to warrant a diagnosis of tumour of the optic nerve before the operation for its removal was undertaken. The child was well developed and in excellent health. About six months previously, an undue prominence of the right eye was noticed and this had slowly increased. Two months previously the vision was tested by a physician and the eye found to be entirely blind, just as it was when I first saw it on the 15th of April.



FIG. 1.

8 Primary Intradural Tumours of the Optic Nerve.

The amount and character of the proptosis can be pretty well estimated by a glance at this photograph (see fig. 1), taken the same day. The protrusion was considerable and always directly forward; the movements of the eyeball were slightly impaired but not more so in one direction than another. No signs of any deep-seated inflammatory process existed, nor was there pulsation, bruit, or change in degree of proptosis from placing the head in such a position as would favour congestion of the parts. The ophthalmoscope showed a greatly swollen nerve and unilateral choked disc; this, with the complete and early blindness were strong points in the diagnosis. I hoped to be able to remove the growth and retain the eyeball in position, so, after dividing the attachment of the inner rectus and passing the finger between this muscle and the eyeball, it was easy to feel the enormously swollen nerve and trace it to the optic foramen where it was removed with curved scissors and afterwards separated from the eyeball. There was only moderate bleeding, and as far as manipulative procedure was concerned, it would have been easy to return the eyeball, but, on finding that the pulpy growth over the sheath of the nerve extended right up to the optic foramen, I thought the chances of preventing a recurrence of the tumour would be improved by the free application of chloride of zinc paste to the orbit, and under these circumstances deemed it useless to attempt to save the eyeball. Accordingly, the eye was removed and the zinc paste applied.

The child made a good recovery and returned home in two weeks after the operation."

Although it is now (1901) fifteen years since the removal of the growth, the patient is active and well.

Full anatomical description of the tumour was not made at the time, and the accompanying pathological report is my excuse for giving the case a new publicity. The eye and tumour had been preserved by Dr. Buller in Müller's fluid.

Macroscopically, the tumour was slightly spindle-shaped in appearance, measuring 25 mm. in length by 14 mm. in breadth at its point of greatest thickness, which was situated at or near its middle point, in other words, $12\frac{1}{2}$ mm. from either end. The mass was everywhere surrounded by a smooth dense capsule, having an even thickness throughout of about 0.5 mm. This structure was undoubtedly the *dural sheath* of the optic nerve and could be readily stripped off from the rest of the tumour, leaving exposed an uneven, but smooth, almost shiny, surface.

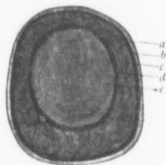


FIG. II.

On *Transverse section* of the tumour from 8-10 mm. behind its bulbous end (fig. 2), it was seen that the tissue immediately underneath the outer sheath (a) was somewhat dense and firm, forming a more or less distinct but quite inseparable outer rind (b) to the layer of new tissue (c), which seemed to blend inwards with the visibly thickened pial sheath (d). This intervaginal tissue was composed of a groundwork of homogeneous substance intersected by fibrous septa running in every direction, and surrounded the noticeably enlarged optic nerve (e) in a crescentic manner. On one side of the nerve, this new tissue layer had a thickness of 7 mm. ; but it gradually diminished in extent, so that at a point directly opposite the first it had a breadth of barely 0.5 mm. The position of the optic nerve was therefore very eccentric, but it was impossible to determine along which of its borders the above layer had mostly developed.



FIG. 3.

On *Longitudinal section*, a different appearance was presented (fig. 3). A few millimeters from the cerebral end of the tumour, the optic nerve had a diameter of 10 mm. while at this point the subvaginal tissue was not present. More posteriorly, the nerve showed a slight rounding off, and no doubt still further decreased in size as it passed through the optic foramen. From the point of greatest thickness forward the diameter of the nerve gradually diminished, while on the other hand the encircling stratum became increased. It was plainly seen that the optic nerve proper attained its greatest thickness near the optic foramen, while the subvaginal tissue was mostly developed along the anterior $\frac{3}{4}$ ths of the tumour.

Microscopically. One saw first of all in the periphery the dural sheath composed of dense bands of wavy fibrous tissue with a rich mingling of elastic fibrils, seen especially well after staining by Unna's and Weigert's methods. Its outer surface showed the same evidence of stasis as noted later on in connection with the sclerotic, while inwards it blended imperceptibly with the tissue occupying the distended subdural space. This latter (see fig. iv.) was composed of irregular flowing masses of connective tissue, which formed a meshwork of varying coarseness. In places it was made up of loose irregular bundles, in others of delicately branching cells, which suggested the myxoma. Promiscuously scattered over the whole field, were rounded and oval cells, and altogether the microscopical appearances were those of *retiform tissue*. Inwards, the pia mater was seen greatly hypertrophied,

10 *Primary Intradural Tumours of the Optic Nerve.*

but it too, like the dural sheath, passed indiscernibly into the subdural overgrowth with which it was identical in structure.

The increase in the size of the nerve proper, was due to enlargement of the fasciculi and of the interfascicular connective tissue.

The spaces between the nerve bundles were occupied by a meshwork of branching connective tissue identical in every respect with that in the subvaginal space. The texture of this hypertrophied tissue, how-



FIG. IV.

ever, was loose and it appeared as if the individual fibres had been pressed apart to form clefts of varying size (fig. 5); while between the outer surface of many of the nerve bundles and the inner surface of the perineurium existed large clear spaces, which surrounded the fasciculi to a varying degree (fig. 5). These appearances were attributed to dilatation of the lymph spaces within the nerve stalk.

The nerve bundles maintained for the most part their usual shape but were very evidently increased in size. This enlargement was due to an increase in the intrafascicular connective tissue (endoneurium), which formed a fine honey-combed fabric, the cells of which, as shown by Van Gieson and Pal-Weigert, were found to be entirely free from any nerve elements proper.

The vessels in the newly formed tissue were comparatively few in number, possessed relatively thick walls, and exhibited a tendency to arrange themselves in clusters or groups. The vascular structures present, however, were engorged with blood as were also the vessels of the rest of the nerve; and the tissues generally, outside the fasciculi, were infiltrated with large numbers of extravasated red blood cells.

There were marked changes in connection with the *globe*. The outer layers of the sclerotic were everywhere swollen and œdematous, but more especially at the posterior pole where the whole surface of the eyeball was covered by masses of loose, curling, hyperplastic fibrous tissue in which were seen numerous blood extravasations and pigment masses derived therefrom. In keeping with this, the vessels of the



FIG. v.

sclerotic, more especially those situated in the superficial layers, were greatly distended and engorged. The iris and ciliary body were the site of a most marked œdema and proliferation of pigment cells, and these conditions were especially seen about the vessels and between the bundles of the ciliary muscle. The changes in the nerve head were those common to post-neuritic atrophy.

To sum up briefly, the chief points concerning the tumour under discussion are as follows :

(1) The growth in relation to the nerve was primary in origin and intradural in situation. (2) The tumefaction was altogether due to a simple hyperplasia of all the connective tissue structures of the nerve, the sensory elements being entirely absent. (3) There were well marked signs of dilatation of the lymph spaces of the nerve stalk, and of stasis within the globe and in the subvaginal lymph space and that of Tenon.

CASE II.

The second case was that of a young woman, who had emigrated to Canada from England. She was first seen when 17 years of age at the Montreal General Hospital by Dr. J. J. Gardner, lecturer on Ophthalmology at McGill University, to whom I am greatly indebted for the notes relating to the girl's condition at the date of her first examination. They are as follows:—

"Dec. 19, 1889; patient had perfect eyesight until two years ago when she accidentally discovered that the left eye was blind. Always a fairly healthy girl and has had no pain in the eye. About—months later the eyeball began to protrude, and this has been increasing more rapidly of late. The movements are impeded in all directions except down; the upward excursion is much diminished; pupils equal, $3\frac{1}{2}$ to 4 mm.; left pupil does not react to light, but contracts and dilates as a reflex from the right. L. V. = no. pl.; no pulsation in eyeball; no apparent heart trouble. T.—2.

Ophthalmoscopic: On closing the right eye, the left pupil dilates and allows a good view of the fundus to be obtained. Media clear, optic disc much swollen (5.0 D.), veins full and tortuous, arteries small, edges of disc obliterated, not much change about the macula. R. V. = 20/50, no improvement."

Dr. Buller subsequently removed the orbital tumour described at the end of this report. The eyeball was for a time preserved in situ but had to be removed later on.

In July following (1890), the patient was readmitted to the General Hospital for recurrence in the same orbit; the house surgeon's note at that time was as follows:

July 9, 1890: Dr. Buller removed contents of orbit; much hæmorrhage. The tumor (recurrence) filled the inner and upper parts of the orbit.* Periosteum firmly adherent and removed with difficulty. Arterial ends touched with the actual cautery; cavity stuffed with strips of lint soaked in carbolic oil; one at the back (apex) covered with chloride of zinc paste."

The patient made a gradual recovery from this operation and was discharged from the Hospital Aug. 1, 1890, "apparently cured."

In 1899, nine years after the removal of the orbital growth, Dr. Gardner informed me of the girl's presence in a Home for Incurables on the outskirts of the city. I was able to follow the case for several weeks, but as no marked change occurred in the girl's condition during this time, I shall be able to embody my several notes in one report.

*This growth was also found, but was so dried that nothing could be made of it microscopically.

The patient was very small of stature and poorly developed for a woman of twenty-five years; her weight was only sixty-seven pounds. She lay down a great deal with her body bent and her legs drawn up, and when sitting on a chair turned around and leant upon its back with her head drooping. The skin of the body generally was dry, while upon the limbs there existed a scaly, ichthyoid condition, especially marked over the dorsal aspect of the toes, knees and the insteps. The supra-clavicular glands were palpable on both sides of the neck, but not markedly enlarged; no other glandular swellings. No changes in the cardio-vascular, (pulse 100 to 110) the respiratory, (except the nasal condition) or the genito-urinary systems.

The patient masticated her food badly and towards the end experienced difficulty in swallowing; vomiting attacks came on at times, but nearly always after the ingestion of food; the bowels were constipated.

The patient was extremely irritable, difficult to manage, and very unclean in her habits; the higher cerebral functions were almost entirely abolished. She seemed to know the members of her family in an indefinite sort of way and the matron of the institution when she placed her keys in the patient's hands. The mental condition, however, varied from time to time. On my second visit, while the patient was being photographed, she said in a thick, indistinct voice, "Am I in the bath-room or in the dining room." "I'll fix you," "I'll pay you back;" and on examining her nose, during which time she struggled violently, "Oh, I'll pay you back." She also said, "Put the shawl over me," and when it was adjusted, "Put it right." On my other visits, however, her mind was by no means so lucid.

The power of all four limbs was intact; but the patient seemed to have lost the art of co-ordination. When taking her on to the verandah she had to be supported on both sides and acted exactly like a baby learning to walk.

Sensation was everywhere intact except over the area supplied by the left supra-orbital nerve, where a pin could be pushed deeply in without the patient evincing the least sign of pain, although responding violently to pricking in other parts of the body. The sense of smell was undoubtedly intact on both sides. Examination of the nose showed a thick muco-purulent discharge from the left side and blocking of the passages by numerous mucous polypi. The pharynx was normal.



FIG. VI.

14 *Primary Intradural Tumours of the Optic Nerve.*

The lt. lower lid was rounded and prominent and of a dusky red color. (See Fig. vi.) On palpation this was felt to be due to a tumour mass intimately attached to and extending upwards from the lower orbital margin, the skin of the lid being adherent to its surface. There was very marked entropion of the upper lid, the outer surface of which lay in close contact with the upper aspect of the tumour, while a purulent discharge came away from the inner angle. The external appearances of the right eye were normal in every respect, movements perfect in all directions, cornea and media clear, sensation everywhere intact, but the pupil was dilated and fixed and the ophthalmoscope showed a condition of advanced atrophy of the optic nerve. V. = O. Tn.

The face was noticeably drawn to the right side in a state of rest, markedly so when the patient attempted to speak or cry out; the creases of the left side of the face were obliterated, *i.e.*, left facial paralysis. (Fig. vi.)

There was absolute deafness on both sides. The ears were completely filled with cerumen, but on account of the behaviour of the patient the obstruction could not be entirely removed and inspection of the drums was impossible. Apart from this, however, there was no doubt of the inability of the patient to appreciate sounds of any kinds.

The sense of taste seemed intact, the patient appreciating certain kinds of food, especially Bologna sausage which her brother brought her.

How far the vomiting, difficulty in swallowing, and position of the head, were due to central disturbance, it was impossible to decide. The sphincters acted properly; the knee jerks were intact, possibly exaggerated. The patient died June 27, 1899. The matron informed me that the day previous the girl had been seized by a choking attack from which she entered into a comatose condition and passed quietly away as if in sleep.

Dr. Adami very kindly performed the partial post mortem examination which was carried out; the following is a brief outline of the conditions present:

Slight rigidity and very apparent emaciation; cutaneous and orbital conditions as noted *ante mortem*. The circumference of the skull, measuring from the glabella to the external occipital protuberance = $19\frac{7}{8}$ ". The scalp was everywhere separated easily from the cranium, and in so doing the occipital bone was found to swell out behind beyond the general level of the skull. On the right side the supra-orbital notch was normal, but on the left side this structure possessed a diameter of $\frac{3}{8}$ " and through it projected a dense mass of thickened tissue surrounding the nerve which could not itself be recognized.

The thickness of the skull varied considerably; over the occipital area it was comparatively thin and transparent, while in the parietal region it possessed a moderate density, and in the middle of the left frontal bone measured $\frac{1}{4}$ " in thickness. Along a line $\frac{1}{2}$ " to the right of the sagittal suture the frontal bone was found excavated, the depression being filled by greatly enlarged Pacchionian bodies, while over the middle aspect of the external surface of the forehead, but to a less extent on the right than on the left, relatively large osteophytes were present.

The left orbit was bathed in foul, thick, greenish pus and the floor was so necrotic and eaten away that the cavity stood in communication with the antrum of Highmore, which exhibited the same long standing purulent inflammation.

The dura mater in general was markedly thickened but showed towards the left frontal region marked thinning and erosion. Scattered here and there in this structure, but especially developed on each side of the longitudinal sinus, in the frontal region, and over the lower and anterior parts of the temporo-sphenoidal lobes at the base, were dense, firm nodules of varying size, which were situated both on the internal and external surfaces of the dura mater, penetrated into the brain substance, and tore the cerebral material on their removal. One of these growths situated on the outer surface of the right parietal region measured $10 \times 8 \times 5$ mm. high.

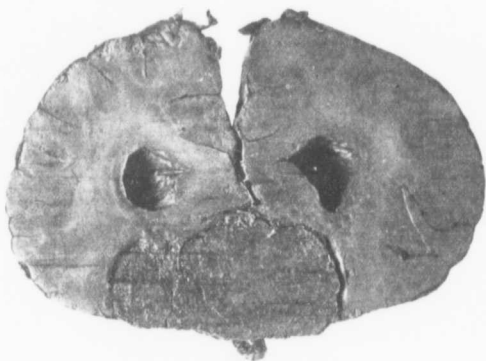


FIG. VII.

Examination of the brain revealed a large neoplasm lying upon and destroying many of the structures of the base. Anteriorly, it began on either side of the bulbous portion of the olfactory nerve which it involved, and extending backwards filled in the whole area between the inner surfaces and tips of the temporal convolutions. All trace of the structures in this vicinity (the optic chiasm, the anterior perforating space, corpora albicantia, infundibulum, optic tracts and pituitary body) were completely obliterated by the growth. More posteriorly the tumour extended on either side of the crus cerebri and pons, compressing the latter structure in such a way that its ventro-dorsal diameter was much increased, its lateral breadth on the other hand reduced to the thickness of little more than $\frac{1}{3}$ in the mid-pontal region. Still further back the growth spread out on the middle peduncle, flocculus, and amygdaloid convolution of the cerebellum.

16 *Primary Intradural Tumours of the Optic Nerve.*

At its posterior extremity the tumour extended beneath nearly the whole of the under surface of the cerebellum, while more anteriorly it completely hid from view the origin of the 5th, 7th and 8th nerves.

The very considerable displacement of the brain substance caused by the atypical growth of the brain tumour can be demonstrated best by the study of a series of transverse sections of the cerebrum. These were made in the following situations :

1. $\frac{3}{4}$ " in front of the optic chiasm.
2. $\frac{1}{2}$ " behind the tip of the temporal lobe.
3. Immediately behind the corpora albicantia.
4. Through the centre of the tegmentum of the crura.

The term, displacement of the brain substance, is used because the tissue of the cerebrum was not at all infiltrated by the neoplasm from which it seemed indeed everywhere sharply demarcated.

Studying the sections in detail, the following are the conditions made out :

1. In Section 1, (see Fig. VII.) the growth is found to occupy the whole of the area extending from the under surface of the corpus callosum and anterior horns of the lateral ventricles to the base of the brain.

2. Practically the same condition is present. Large masses extend from the base right up to the floor of the lateral ventricles, push laterally into the temporal convolutions, and destroy the anterior part of the island of Reil on the left side.

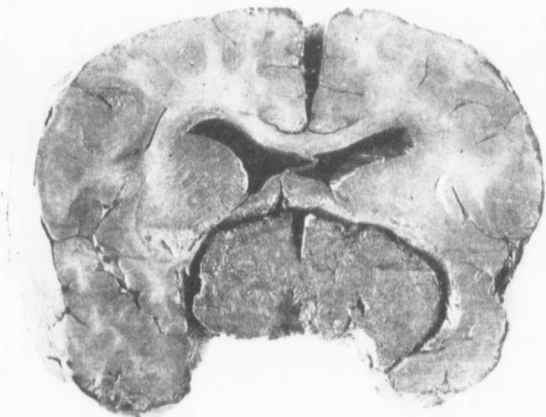


FIG. VIII.

3. The tumour mass (Fig. VIII.) is again seen lying between the floor of the lateral ventricles and the sides of the temporal convolutions

especially pressing into and destroying the latter structures on the left side. On this half of the brain also the caudate nucleus is markedly atrophied and only a few fibres of the internal capsule can be made out.

4. Here the basal tumour is no longer seen but the choroid plexus in the descending horn of the lateral ventricle has become the seat of the growth. In the left side the optic thalamus is greatly atrophied especially the pulvinar and again only a few fibres of the internal capsule can be made out. The third ventricle is very much contorted and altered in shape on account of the atrophy and displacement of the large basal ganglia on the left side.

5. In this section, dilatation of the posterior and descending horns of the left lateral ventricle is very noticeable and in this position the choroid plexus, the outer fringe of which has become especially involved by the neoplasm, forms a large rounded mass the size of one's little finger and can be seen descending into the postero-descending horn.

The cerebellum itself was not attacked by the growth but only pressed upwards and displaced.

Microscopically the growth was composed of characteristic sarcoma cells for the most part of the spindle shaped variety, which in general showed a tendency towards an alveolar arrangement. What lent the neoplasm its peculiar character, however, was the presence of the so-called "onion-bodies," often arranged in groups in different parts of the field. These structures were composed of a few more or less rounded cells, centrally situated, which were surrounded by others flatter in character and arranged in concentric layers. Very often the central areas of these bodies were seen to stain palely and to undergo calcareous degeneration, and not infrequently the last mentioned condition went on to involvement of the whole structure. The "sand-bodies" thus formed became frequently detached from the surrounding tissue, and dropping out during the process of mounting, left free spaces which were lined by endothelial cells.

The character of the growth was practically the same in all the parts affected (brain, orbit and dura mater); only perhaps in the intracranial portion were the "sand bodies" more numerous. The neoplasm apparently did not extend into the substance of the supra-orbital nerve but only surrounded that structure. Unfortunately, owing to the specimen (supra-orbital nerve) being lost during the summer cleaning at the laboratory, the finer conditions here could not be more fully studied.

After a long search I was rewarded by finding the original tumour, and the recurrent growth. They were both, however, so dried up that we were unable to recognize with certainty any details under the microscope.

As regards the general form of the original tumour, the conditions were clearly defined, and there was no doubt whatever of its belonging to the primary intradural neoplasms of the optic nerve.

The antero-posterior, transverse, and vertical measurements of the growth were about equal, namely 22 mm. As usual, the capsule was formed by the dural sheath, the core by the optic nerve and its sheath, and between these structures was situated the intervaginal overgrowth. The capsule of the tumour was not everywhere intact, a noticeable piece being absent near the posterior end of the growth. The course of the

18 *Primary Intradural Tumours of the Optic Nerve.*

nerve through the enlargement was slightly eccentric, corresponding to the difference in the development of the arachnoidal overgrowth, and it gradually increased in size from before backwards. In front, the nerve was sharply defined, measuring 5+5 mm. Behind, where its dimensions were, as nearly as could be made out, 7+8 mm., it was less clearly differentiated from the surrounding tumour mass. It was not possible to determine the various surfaces of the growth, nor indeed to say with absolute certainty which was the anterior and which the posterior end of the tumour.

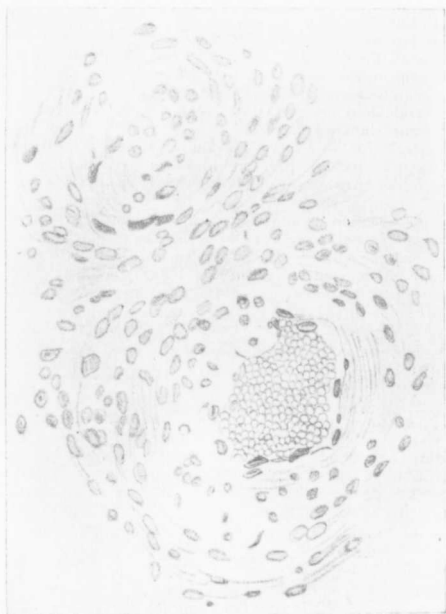


FIG. IX.

Now-a-days it has been recognized that the majority of Psammomata are either of the nature of angio-sarcomata, angio-fibromata or endotheliomata, and these various forms of tumour are closely allied. It may further be noted that the

psammomata and endotheliomata are tumours peculiarly characteristic of the membranes of the brain.

What is of importance here is that we have a tumour of the sarcomatous type, and even acknowledging this to be an endothelioma, or in other words one of the most slowly growing of sarcomatous tumours, it is scarce possible to believe that the tumour of the optic nerve was primarily of this nature. It is more than we are, with our present knowledge, prepared to believe, that a tumour of sarcomatous nature could exist for ten years in connection with the brain and the optic nerve; or in other words we are forced to conclude either that the tumour found at the autopsy was of relatively recent development and had no connection with the original disturbance for which the eye was enucleated, or, on the other hand, that if there be a relationship between the original tumour and those discovered post mortem, then that original tumour was of a strictly benign type, and only after the course of long years, the portion not removed took upon itself more sarcomatous and more malignant growth.

The history of the case certainly favors this latter view, as obviously there had been long continued disturbance at the base of the brain. Hence it is reasonable to suppose that here primarily we had to deal with a condition resembling that seen in the first case, a condition which I have termed "Fibromatosis," and that eventually in the course of years the proliferation of the endothelial elements became the prominent feature, and the tumour took on the characters described in the text. That seems in every respect the natural conclusion, and arriving at this conclusion, we recognize that the second case belongs to the same order as the first, and incidentally that such an endotheliomatous tumour formation may be grafted upon the more fibromatous condition.

Examining the sections, I am strongly of opinion that the endotheliomatous development has been primarily in connection with the lymphatics; the blood vessel shewn in Fig. IX. would appear to be only secondarily involved. This growth then in connection with the lymphatics of the part may be associated or compared with the marked dilatation and disturbance of the lymphatics seen in the first case.

ETIOLOGY

In general, the observations made in this section only confirm those of previous writers. Notwithstanding that practically all cases are now-a-days brought before the notice of the profession,* tumours of the optic nerve must still be placed among the rarities of eye surgery. Locality appears to be of no effect, though Dr. Buller's experience in Montreal has been rather unique, he having observed three cases in a material of now about 50,000 patients.

As regards the *age* of the patients at the time *when the disease first made its appearance*, the following table, representing an analysis of 85 cases in which the facts are stated, shews the number of those attacked at the different periods of life to be as follows:—

Between the 1st and 5th years	32 cases.
" " 5th " 10th "	20 "
" " 10th " 15th "	15 "
" " 15th " 20th "	9 "
" " 20th " 25th "	5 "
" " 25th " 30th "	3 "
" " 30th " 65th "	1 "

It will be noticed that only four of the 85 cases occurred after the 25th year, and in general the table shews how essentially this condition is a disease of early life. Probably in others, but almost certainly in the cases of Ritterich,⁸ von Forster,²⁵ Rampoldi,¹¹ Vossius,³⁸ Salzer,⁷¹ Braunschweig,⁷⁴ and Buller,⁶⁶ where the onset was well within the first year, is the condition to be looked upon as *congenital* in origin.

As regards *sex*, of the 95 cases in which the fact is noted, 39 (41%) were males, and 56 (59%) were females, and, touching the frequency of the eye affected, an analysis of 94 reports gives 42 (45%) to the right side, and 52 (55%) to the left.

There is undoubtedly a tendency, therefore, *for females to be affected oftener than males, and the left nerve more frequently than the right.*

Very interesting is the part played apparently by *traumatism* in the production of these tumours, and the fact affords another example of the unexplained relationship which is occasionally stated to exist between injuries and cell overgrowth. In 13 instances among the tumours under discussion,

*The cases referred to by Dr. Reeve of Toronto (Trans. Amer. Ophth. Soc., '99, p. 518), occurred in the Clinic of Dr. Lloyd Owen, Birmingham, Eng., but have not as yet, I think, found their way into the literature.

the growth was attributed to an injury, which in nine cases (Duboué,⁵ Szokalski,⁷ Ritterich,⁸ von Graefe,¹² Grüning,²² Knapp,³² Ayres,⁵⁶ Lagrange,⁶³ and Golowin¹⁰¹), was in connection with the head or temporal region; in three more (Huc,³⁷ Perls and Loch,⁴⁷ Brailey²⁴), with the eyeball itself, and in one last instance (Quaglino,¹⁴) was of the nature of a penetrating wound of the orbit.

The number of cases, too, in which the condition is stated to have followed some *febrile disturbance or infectious disease*, is too large to be merely accidental. In some instances the relationship is hardly to be doubted. Thus for example, Lidell's⁶ patient had an attack of parotitis (mumps), in the spring of 1850, but while the swelling of the right gland subsided, that of the left persisted. In the latter part of the same summer, the eyelids of the affected side became swollen and remained so for two or three months. Finally, four or five months after the palpebral trouble had subsided, the patient noted that the sight of the left eye was failing, and six months later exophthalmos made its appearance. In Christensen's²¹ case, the disease followed upon a febrile illness of two weeks duration, which was thought possibly to have been of the nature of a localized meningitis, while the condition manifested itself in Sym's⁵⁸ child, during an attack of pertussis and in Vossius'³⁸ second patient was looked upon as a sequela of the same disease. Lastly, in the instances of Pflüger,³⁶ Vossius,³⁸ Parissoti and Despagnet,⁴⁴ Burnett⁵³ and Ellinger,⁹⁴ a relationship was noted between the tumour and measles (probably), ophthalmia neonatorum, typhoid, complicated during convalescence by a stye, la grippe, and stomatitis aphthosa respectively.

Finally, it may be mentioned that in the case of Schlodtmann,⁹⁸ the condition seemed to follow upon childbirth, and as regards case 2 of this paper and the patients of Christensen,²¹ Hessdörffer,⁴² and Burnett,⁵³ the new growth was associated with an ill developed condition of the body as a whole.

PATHOLOGICAL ANATOMY.

GROSS ANATOMY.—The intradural tumours of the optic nerve, though varying in minor details, possess in general, a very characteristic structure.

It necessarily follows from our classification that in every instance the *capsule* is formed by the dural sheath. As a rule, this structure as it surrounds the tumour, forms a uniform covering varying from 0.5 to 1 mm. in thickness, which can be readily stripped away from the structures beneath; but as a common exception the capsule is thickened and adherent as it passes over the surface of the enlargement, or, on the other hand, thinned and attenuated, even—though rarely, to the extent of perforation (Alt,²⁶ Rockliffe²⁷). In a case which the writer studied for Dr. Buller,²⁸ there was present in addition to the clearly defined dural sheath, and external to it, a second less dense and shaggier capsule, which was looked upon as the layer of fascia normally present between the optic nerve and the orbital fat.

These intradural tumours of the optic nerve vary considerably in *size*, and generally speaking, this depends upon the length of the period of development, though it frequently happens that a *discrepancy exists between the symptoms present and the size of the growth*. The tumour of Seggel¹³ was so small as to cause no appreciable bulging of the nerve, while on the other hand the specimens of Lidell⁶ and Kunachowitch⁴³ had attained the dimensions of a goose egg.

A considerable difference is also present in the *form* of these growths, depending upon the situation and extent of the new tissue growth in the subvaginal space as well as upon the changes in the nerve proper. What is generally the case is, that a *piece of normal or uniformly enlarged optic nerve exists between the globe and a more or less marked swelling upon the posterior two-thirds or three-fourths of the nerve*, and the commonest appearance produced is that of a pear, Indian club, leg of mutton or nuts of different kinds. In not a few instances the normal spiral curve of the anterior part of the nerve is considerably exaggerated and the tumour then looks like the classic Horn of Plenty. Braunschweig²⁴ is not correct in saying that the reverse condition is "common," in which the greatest development is along the anterior part of the nerve, and a pedicle extends between it and the optic foramen.

The only cases which conform with certainty to this type are those of Lawson,⁵⁴ Grüning,⁵⁵ Taylor,⁷³ and Rockliffe,⁷⁵ and the last mentioned seems to have been the only one in which the optic nerve was absolutely normal. In numerous instances on the other hand, the swelling has extended the whole length of the nerve with the zone of maximum development falling somewhere in the middle third of its course. The enlargement has been characterized in this case as spindle, sausage or egg-shaped in appearance. In only two instances, those of Lidell⁶ and Goldzieher¹⁸ (Case 1.) has a small pedicle of optic nerve existed at both ends of an enlargement centrally situated.

The *core* of these enlargements is formed by the nerve proper and its pia mater, while between these structures and the dural sheath in the distended subdural space, a layer of cell-over-growth is present in every instance. The behaviour of the nerve core and its surrounding new-tissue stratum varies considerably, however, in different cases. Though many intermediate stages are met with, the following arrangements are to be seen in studying the growths in longitudinal section :—

1. The new tissue stratum, mostly developed over the central part of the optic nerve, ceases to exist at either end, while the nerve proper—normal or nearly so—anteriorly and posteriorly expands considerably in the central region of the swelling, *e.g.*, Goldzieher,¹⁸ Case 1.

2. The optic nerve runs unchanged or uniformly enlarged through the whole course of the growth, which occupies as usual the subdural space in varying degree, *e.g.*, Salzmann,⁷⁶ (Case 1) Schiess-Gemuseus,⁵⁵ Buller.⁶⁰

3. The nerve proper gradually increases in size to the optic foramen, the subdural stratum on the other hand develops more as the globe is approached. Buller,⁵⁰ Byers, and Sattler.⁵⁷

4. The tumour stratum is developed along the whole or posterior part of the nerve, while the nerve proper, normal or nearly so for some distance, expands fan-like and is lost in the growth. Sichel,¹⁵ Salzmann⁷⁶ (2), Vernon,⁴¹ Burnett,⁸³ Knapp,³⁸ Willemer⁷⁹ (3), etc.

5. The nerve proper and subdural stratum developed mostly anteriorly, become normal or nearly so at the optic foramen. Taylor,⁷³ Rockliffe,⁷⁵ Lawson.⁵⁴

A study of these longitudinal sections simply shews us that while in a certain few cases the growth is entirely confined to the orbital portion of the optic nerve, in the great majority of instances the excised tumour is *incomplete* and must necessarily have been connected with a remaining portion within the cranium. It also teaches us that while in a large percentage of cases changes both within and without the *nerve proper* go hand in hand, yet in a very limited number of examples this structure may be more or less spared.

Though the nerve proper forms the core of these tumours, its course throughout the enlargement is often an *eccentric* one. Both on longitudinal and transverse section, but especially the latter, the nerve is seen lying to one side in more or less close contact with the dural sheath, and the new tissue stratum, filling in the remaining space, has a crescentic shape.

The data of the reports with regard to this matter are too meagre to enable one to form a general rule. It has been frequently noted that the outline of the nerve was less clearly defined opposite the position of the greatest development of the subdural mass, and this tallies with the microscopical finding that the changes in the septa are more marked at this point.

As regards the *consistence* of these tumours, they vary from dense and firm to soft and fluctuating masses, though as a rule they possess an elastic feeling of varying degree. In the same growth one frequently finds considerable variation in consistence in different parts and the latter condition is especially noted where, as is frequently the case, *cyst-like spaces* are present. These cavities contain a viscid glairy fluid which has generally been regarded (though probably wrongly so) as mucin and which escapes on section or from rupture during the operation.

The *colour* of the tumours is generally spoken of as yellowish, greyish red, or reddish-grey. On section the nerve proper is distinguishable both by a slightly different tint and by its striated appearance. Hæmorrhagic spots in different localities are among the commonest macroscopical findings. Quite frequently an increase in the length of the intra-orbital part of the optic nerve has been noted. Normally this structure measures according to Weiss³¹ 20-30 mms., but it often exceeds this length and has even attained a length of 55 mm. (Willemer).³²

THE INTRACRANIAL CONNECTIONS OF THE INTRADURAL TUMOURS.

Thus far as regards the orbital aspect of these tumours. A more careful study of the subject, however, affords abundant evidence to shew that *in a very large percentage of these cases the process which brings about tumefaction of the orbital portion of the nerve is by no means limited to this structure, but extends in reality to a very much larger field.* The facts which go to prove this statement are briefly as follows :

1. A large number of reports record that a portion of the orbital tumour was left in the optic foramen in spite of the fact that the growth had been excised as close as possible to the entrance to the skull. In other words, only a part of a larger growth had been removed.

2. In studying the macroscopical appearances of the excised orbital growths, one is struck at the outset by the fact that in a great many instances there is an incompleteness in their structure which can only be accounted for on the supposition of an unexcised complementary portion within the skull.

3. The literature affords us a number of instances in which a post mortem examination revealed the intracranial conditions so soon after the excision of the orbital growth that the possibility of an extension backwards of the orbital neoplasm into the cranial cavity is altogether excluded on account of the shortness of the period which elapsed between the primary operation and the after death examination.

In those cases of this group where intracranial growths were also found it must be clear that one has to deal either with a single growth only developing at one and the same time within the orbit and within the cranial cavity, or else with a primary and secondary growth which had arisen during the life time of the patient. The latter, however, is but a modification of the former statement, for the extension may have occurred as well from the side of the brain as that from the orbit. It is interesting to study the records in these cases, which have been subjected to post mortem examination. They are as follows :*

*Heymann's case is here included though both the orbital and intracranial conditions were only made known at the P. M. examination. Szokalski's case is excluded because the interval between the P. M. exam. and the patient's death does not remove the possibility of an intracranial recurrence as was actually the case in the orbit.

26 *Primary Intradural Tumours of the Optic Nerve.*

CASE 1. (HEYMANN)³ Patient died of Pulmonary Tuberculosis at the age of 19; a tumour had existed since earliest childhood, but the conditions within the skull were absolutely normal.

CASE 2. (ROUX)⁴ Patient died of Meningitis "some days" after the operation, but no evidences of intracranial growth were present.

CASE 3. (DUBOUE)⁵ Death from Meningitis on the 8th day following the removal of the orbital tumour. Post mortem examination showed the apex of the orbit occupied by an unexcised portion of growth, and within the skull enlargement of the optic nerve of the same side to within 4-5 mm. of the chiasm.

CASE 4. (RITTERICH)⁶ Death from Meningitis 41 hours after operation. The intracranial portion of the optic nerve of the same side as well as the chiasm were greatly enlarged.

CASE 5. (VON GREFE)¹² Death from Meningitis 13 days after operation. In addition to the usual signs of purulent Meningitis it was seen that the chiasm and for the most part both optic nerves were involved in a growth 2 cm. long by 2.5 cm. broad. This neoplasm was connected on the one hand with a second growth which extended backwards as far as the pons, and on the other with a still larger mass which had grown upwards and greatly displaced the overlying cerebral structures.

CASE 6. (MAUTHNER-SCHOTT)²⁷ Death from Meningitis seven days after operation. The postmortem examination showed a large tumour 5.5 cm. long, by 4-4.5 cm. broad, which was situated beneath both frontal lobes and covered in great part the longitudinal fissure of the brain. The tumour was so situated upon the under surface of the chiasm that the whole of the right optic nerve had disappeared in its substance: and the whole of the chiasm, except a small strip of its posterior margin, appeared covered by the mass.

CASE 7. (WILLEMER)²⁹ In addition to signs of purulent meningitis, specially marked in places, the chiasm as a whole was seen to be markedly thickened and fibrous-like, though the optic tracts were apparently normal in structure. The right optic nerve was only slightly thickened within the skull, but a short distance after its exit through the optic foramen it rapidly increased in size and 1-1½ cm. from the globe had a diameter of 12 mm. A gradual diminution of 7 mm. followed upon this and then occurred a second enlargement involving at least 8 mm. of the optic nerve. The greatest diameter of this swelling was 9 mm. Transverse section of the orbital enlargement showed the usual conditions. In the smaller swelling there was slight increase in the size of the optic nerve and hyperplasia of the tissue of the sub-vaginal space, while the larger swelling was due to a marked increase in size of the optic nerve, here surrounded by a crescentic layer of new tissue growth (4.5-5.5 mm.), which was more marked on the nasal side. The condition here was in fact that of a *second typical primary intradural tumour of the optic nerve.*

The left optic nerve immediately after its exit from the chiasm had a diameter of 7 mm., then occurred a short spindle-shaped enlargement with a maximum diameter of 11 mm. Immediately in front of this the nerve entered that part of the tumour which had been connected with the orbital mass and which, together with a large overgrowth from its upper surface, pressed upwards into the horn of the

lateral ventricle. The intraorbital tumour of the left side was pear-shaped and possessed the usual typical arrangement of a primary intradural growth of the optic nerve.

CASE 8. (HUC-RICHET)³⁷ Death from Meningitis nine days after operation. In front of the chiasm just as the nerve entered the optic foramen a tumour of the size of a bean was seen situated upon its upper surface, almost over the margin of the anterior cerebral fossa. This second tumour was placed in such a way as to form with the orbital tumour a sort of *bisac*, the anterior part of which was much more voluminous than the posterior.

CASE 9. (ADAMÜCK)³² Death from Meningitis eleven days after operation. The intracranial growth was directly continuous with the orbital tumour through the medium of newly formed tissue situated in the dilated optic foramen. In general the shape of the neoplasm was that of an hour-glass. Beyond the isthmus the intracranial portion of the tumour reached the size of a large hen's egg and this half, like that within the orbit, consisted essentially of altered optic nerve. The new growth had also involved the chiasm, this structure being almost entirely destroyed and drawn towards the tumour, which had pressed into the lateral ventricle and developed further in this region.

CASE 10. (KALT)³⁹ Patient died of Meningitis ten days after operation. Kalt found at the base of the brain a flattened tumour, roughly quadrilateral in shape, which appeared to have started in the chiasm.

From a study of these records it is remarkable to note how extensive in the majority of instances are the connections of the primary intradural tumours. In *only two* of the cases was the tumefaction limited to the orbital portion of the nerve; in the remaining eight, there were more or less well marked changes within the skull. More precisely, among these eight, we find in two instances enlargement of the intracranial portion of the nerve in front of the chiasm and in three more involvement of the same structure as well as the chiasm. The cases of Willemer and von Gräfe showed that the chiasm and both optic nerves had participated in the process, while in the instance of Kalt, the growth appears to have sprung only from the chiasm.

It will be noticed how purely the process seems to have been limited to the chiasm and the parts extending from it anteriorly.

It is rare, now-a-days, on account of the great advances that have been made in surgical cleanliness, for patients to come to the post mortem table, but there is no reason for disbelieving that the above records are not fairly indicative of the condition of affairs generally existing in these cases. From this evidence, therefore, and by reason of the facts which we have previously mentioned, we feel fully justified in

concluding that *in a very large percentage of cases, the primary intradural tumours of the optic nerve constitute but a part of a neoplasm more or less widely affecting other structures within the skull.*

It might be urged that these cases came to the post mortem table soon after operation, because the process was already so generalized that the general health of the patient was impaired and, as a consequence, these post mortem records do not represent the true proportion of cases in which there is involvement of the nerve beyond the optic foramen. It will, however, be noted that in every case, death cannot be ascribed to this cause, but was due in 9 instances to meningitis secondary to operation and in the remaining one to pulmonary tuberculosis.

MICROSCOPICAL ANATOMY.—In studying the microscopical details of these tumours, one is confused at the outset by the large number of different terms which have been used to characterize the conditions present. This heterogeneity can be best comprehended by a glance at the following table which gives in a classified manner the anatomical diagnosis of all the intradural tumours heretofore reported :—

Endothelioma	2
Fibroma	4
Lymphangiectasique Fibrome	1
Fibromyxoma	2
Fibro-nuclear tumour	1
Fibro sarcoma	6
Fibro-myxo-sarcoma	4
Glioma	6
Glio-myxoma	1
Glio-myxo-sarcoma	1
Glio-sarcoma	3
Hyperplasia of connective tissue	1
Myxoma	8
Myxo-fibroma	7
Myxo-sarcoma	30
Neuroma	5
Sarcoma	8
" Elastic neuroglia	1
" Tubular-angio	1
" Endothelial	1
" Angio-myxo	1
Scirrhous Carcinoma	1
Not designated	2
" (connective tissue tumours)	3
Total, - - -	100

The complexity is not so great, however, as it would seem at first sight. We have to remember that the history of these tumours is older than our modern pathological conceptions and technique, and that the diagnosis has been incorrect in numerous instances because of the imperfectly developed examination methods of the time. By a process

of reasonable exclusion and fair inference, our diversified list can be considerably simplified.

Thus, for instance, the term "*neuroma*" was applied indiscriminately by earlier writers to every tumour growing in connection with the nerves of the body, not only on account of their association with these structures, but because it was thought they were composed of real nerve tissue. With the advance of time, however, it was shewn that a proliferation of true nervous elements did not, in the great majority of cases, enter into the constitution of so-called neuromata, but that, in fact, the growths consisted entirely of an overgrowth of the connective tissue structures of the nerve. To these tumours now, the term "false neuroma" was applied in contradistinction to the "true neuromata" in which a proliferation of nerve elements proper occurred. In the domain of ophthalmology since Vossius,¹⁶ with more perfect reagents, showed that the tumour designated neuroma by Perls,¹⁷ was in reality a myxo-sarcomatous growth, the former term has never again been applied to these neoplasms, and we may I think reasonably infer that the other cases were mesoblastic in nature.

So, too, in regard to the *Gliomata*. Until within comparatively recent times neuroglia was confused with the fibrous connective structures of the nerve and the gliomata were thought to originate in mesoblastic tissue and to be closely allied to the sarcomata. With the work of His, Cajal and von Lenhossek pathology learnt to distinguish between mesoblastic and epiblastic tumours of the nervous system, but even then considerable confusion existed and the term "glioma" was often given a loose application. With the appearance of Mallory's and Weigert's stains in 1895, a new and more certain means of diagnosis was given to the profession, and while we can overlook the incorrect nomenclature previous to that date, we cannot now a-days accept the diagnosis of glioma without the evidence of these reagents.

In reading carefully through the cases of glioma of the optic nerve reported up to the present time, we find little evidence against and much in favor of believing that they were also in every instance mesoblastic in nature.

Taking the smaller group of *Glio-sarcomata*, we feel even more fully justified in believing them to have been entirely of

mesoblastic origin. Practically all modern writers are agreed that the term "gliosarcoma" is a misnomer and ought to be discarded. "von Lenhossek states clearly the absurdity involved when he says that from a histogenic point of view (and that is the only one we may properly use in such a matter) it is impossible that a sarcoma can at the same time be a glioma, since these cells are differently derived, in the one case from mesoblast, in the other from epiblast. It is conceivable that a glioma and a sarcoma might occur side by side, but we have no reason to suppose that this actually does so nor do we have any analogy to such a process in the other forms of new growth."*

Taylor¹⁹, after a careful critical review of the literature, declares that the term Gliosarcoma should be dropped as unscientific and misleading in its significance. The same misapprehension of the nature of neuroglia led to the use of the terms *glio-myxo-sarcoma* and *glio-myxoma* for growths which were undoubtedly wholly mesoblastic in nature.

As regards the case of Szokalski⁷, there can be no doubt of the incorrectness of the term *scirrhus cancer*, for the writer says distinctly that his growth originated in the perineurium, and that the enlargement and destruction of the nerve structures was undoubtedly due to the extraordinary development of the fascicular connective tissue—that is to say, the growth was of the nature of fibrous connective tissue.

By means of this process of exclusion we are able to simplify our primary list very appreciably, for although the nomenclature is still varied, *our growths are common in this, that they are in every instance essentially mesoblastic in nature.* This fact has been previously enunciated by Braunschweig²⁴ and others, but it has a new significance in the light of our recent knowledge as to the true nature of neuroglia.

THE RELATIONSHIP OF THE VARIOUS FORMS OF INTRADURAL TUMOURS.

Objections have now and then been raised to the diversity of terms in use to describe these growths and attempts have been made to bring them all under one special heading. One has only to read the literature slightly, however, to find how difficult it has been for workers to hit upon any one term to

* Extracted from Taylor's paper; reference follows.

describe these tumours and how many writers have found satisfaction only in the employment of compound words.

The fact of the matter is that *these tumours do not correspond to any one special type of growth, but that we have constantly represented in one and the same specimen, several phases of developing connective tissue.* The proper conception of these tumours is found, we think, in comparing them with sections of *elephantiasis* of the subcutaneous tissues. Here we find conditions closely resembling those in the optic nerve (bundles of fibrous tissue, masses of growing cells, areas of œdema and mucoid degeneration, and dilatation of the lymph spaces), and the same difficulty in bringing the condition under any one special heading. So striking is the similarity occurring between the changes in the two conditions that we feel that the primary tumours of the optic nerve should be brought into that somewhat motley and ill-defined class of connective tissue overgrowth which finds place in pathology under the heading of *Fibromatosis*.

Studying this condition of fibromatosis more closely, we find that while we have here to deal essentially with an overgrowth of white connective tissue, this exuberance is markedly protean in character. Thus where the process is very gradual we have firm dense fibrous tissue with relatively few nuclei to be recognized in its substance, whereas in the commonest form of elephantiasis, we have primarily an obstruction to the lymph flow and a marked myxœdematous infiltration of the accompanying well developed connective tissue, which is thus divided up into strands or bundles. The latter condition suggests strongly the real myxoma and is often mistaken for myxomatous change or interstitial mucoid degeneration of the parts. At other times where there is a more rapid cell growth we find an almost imperceptible transition into the sarcomatous or myxosarcomatous type with the liability to the assumption of malignant properties.

Looking into the various recorded cases of these intradural tumours of the optic nerve, we cannot fail to be struck by the fact that *it is exactly this series of changes which we encounter either alone or variously admixed.* The whole series in fact is here included, and while the cases which have been designated in part or entirely myxomatous, are greatly in the ascendency this is entirely accounted for by the early and often

profound stasis which occurs both in the lymphatic and venous channels of the orbital portion of the nerve. That the condition here, however, is in reality one of *adema* and not true myxomatous tissue is proven, first of all, by local appearances, first appreciated by Schiess-Gemuseus⁵⁵ * and by the *negative reactions to mucin* which have been obtained by Vossius⁵⁶, Salzmann⁵⁷, Delius⁵⁸ and other investigators. In short, this negative reaction to mucin shews that we are not dealing with a myxomatous development but with a myxœdmatous change, or more correctly with that infiltration of the tissues with somewhat inspissated serum which is a characteristic feature in ordinary elephantiasis brought about by lymphatic obstruction.

One possible exception has to be made to the above statement. There are a few recorded cases which are of a somewhat different type, although, if we may judge aright, neoplasms of this nature are being more and more recognized as curiously closely allied to the connective tissue tumours. We refer to the *endotheliomata* of which the cases of Alt,⁵⁶ Taylor⁷³ and Kalt⁶⁹ are examples and with which our own case seems nearly akin. What the reason is we do not know, but while occasionally that proliferation of cells which forms an embryonic or sarcomatous connective tissue tumour, is most marked as arising from tissue immediately outside a lymph or blood vessel, in other cases it is not the surrounding connective tissue but the endothelial cells lining the blood and more especially the lymph vessels, which take on excessive growth. It is not surprising, therefore, that the arachnoidal "Balkenwerk," richly lined as it is with endothelial cells should occasionally form a starting point for this form of tumour. I have already referred to this matter in discussing our second case (vide p. 18).

Indefinite then as the term fibromatosis may be, it well defines in a general way all the changes that occur in the tumours under discussion. These growths are not myxosarcomata or fibrosarcomata, else should we have *secondary manifestations* of these growths. But primary tumours of the optic nerve do not give rise to metastases, and while occasionally local recurrences have been noted this is easily explained on

*Professor Schiess-Gemuseus (p. 257 l. c.) in summing up the microscopical appearances of the *subdural tissue* in his first case, remarks as follows: "There was present at many points a peculiar œdematous infiltration of the tissues as well as genuine spaces corresponding to the lymph clefts which were filled with fluid."

the well known fact of the tendency of fibromatosis towards local malignancy.

When primary tumours of the optic nerve cause death, it is, I believe, never because of the spreading backward of the orbital tumour but through *the continued growth of an intracranial portion of the neoplasm which coexists with the orbital tumour and which is not removed at the time of operation.*

Premising then in conclusion that I would include these tumours among the fibromatoses, and mentioning the personal equation of the individuals in whom they grow, as another factor which would tend to produce various rates of increase on the part of the cellular constituents, I find my views fully expressed in the words of Dr. Swan M. Burnett,⁵³ namely, "*That these growths are essentially the same in structure and development, the differences in their microscopical appearances, as described, being due to the various periods at which they were examined, the various stages of their growth or development and the personal equation of the observer.*"

THE RELATIONSHIP OF THE INTRADURAL TUMOURS TO OTHER FORMS OF GROWTH.

Other very important points in connection with the pathology of these tumours are the situation and distribution of the newly formed tissue and the condition of the fibres of the nerve proper.

Macroscopically, as well as microscopically, we find as a rule, to which there is no exception, the subdural space occupied by the newly formed tissue which arises in this situation from the arachnoid or pial sheath of the nerve. The capsule formed by the dural sheath is generally spared and is certainly never the starting point of the growth in this situation. This is made clearer if we think of the tumour as springing also from the intracranial portion of the nerve, for here the two innermost layers only are present, the dural sheath not becoming an envelope until its exit from the optic foramen.

Within the nerve proper we find as a rule an active participation of the connective tissue structures which must be regarded as occurring *simultaneously* with the overgrowth in the subdural space. In the case of Salzmänn⁷⁵ (Case 1) the septa were stated to be apparently normal, while in that of Schiess-Gemuseus⁵⁵ only slight hypernucleation was noted.

But instances like these, in which the changes are so slightly marked, are exceptional. Very commonly, in keeping with the macroscopical appearance, there is little or no alteration in the pedicle of nerve so commonly present, but as one approaches the area of tumefaction one finds a gradually increasing participation on the part of the connective tissue structures. In some instances the changes are largely restricted to the septa, while in others the participation of the peri and endoneurium goes hand in hand and the general appearance is more or less that of the normal, only on a larger scale.

In other cases again and especially where the overgrowth has taken on a malignant tendency, the local appearances are more or less destroyed on account of the infiltration of the parts by the newly formed cells.

As regards the *nerve fibres*, these structures are found to undergo very early and marked degeneration, for in a large percentage of cases, even with modern staining reagents, they are found to be entirely absent. This pathological finding affords a satisfactory explanation of the early loss of vision noted.

The pathological changes in connection with the surface of the globe and optic nerve and the significance thereof have been discussed elsewhere. The changes in the papilla exhibit no special points of difference from those which are generally present in the "choked" and atrophied conditions of this structure.

If now we seek to establish the *relationships* of these tumours with other forms of new growth, we are compelled to place them, as Goldmann⁴⁵ has done before us, in the same category as the *false neuromata*. In the one as in the other *an overgrowth of the connective tissue structures is responsible for the tumefaction of the nerves* and in both conditions the cellular proliferation is stamped by that protean character of which we have already spoken. That the nerve fibres in the tumours of the opticus undergo so early a degeneration is fully explained by the changes brought about by the special anatomical conditions in the nerve and so constitutes only an apparent point of difference between the two affections. It is true that we have to recognize a certain want of clinical association between these growths and false neuromata affecting

the other nerves of the body, but this is probably due to the difference in the time of development or in the anatomical structure of the parts, rather than in the underlying process at work. And, moreover, the lack of association is not absolute, as stated by Goldmann, for the optic nerve was involved also in Prudden's⁴⁹ case of multiple fibromata. Add to this certain points of clinical resemblance between the two forms of tumour and we feel that the changes shew that they are at least intimately related, if indeed they are not identical in character.

To go further back to the *cause* of these tumours we were struck at the outset, as Rohmer⁶⁵ was, by the close association of the sites of development of the new tissue overgrowth with the lymph clefts of the nerve and on observing evidences of actual stasis in these structures* we were prepared for a while to believe that we had here, as in macro-glossia, to deal with a local disturbance of the lymph system, congenial in origin or secondary to trauma or infectious disease. But with a later conception of the wider field of tumours of the optic nerve, it was necessary to be more sceptical of this hypothesis, until, at any rate, our knowledge of the intracranial portions of these growths became more complete.

*For description of these changes see Case 1 of this report. The cystlike spaces so commonly noted in connection with these tumors, represent probably only localized exaggerations of the dilatation described.

SYMPTOMATOLOGY.

The primary tumours of the optic nerve have as their most striking symptom that of orbital growths in general, namely:—

1. EXOPHTHALMOS, and it is this condition which, in a large percentage of the cases, first attracts the attention of patient or friends and leads to the seeking of medical advice. Three features of the proptosis deserve special consideration.

A. THE DIRECTION OF THE EXOPHTHALMOS: von Graefe¹⁰ laid it down as a general characteristic that the proptosis caused by these growths was direct or in the line of the axis of the orbit as opposed to that produced by other orbital neoplasms, which had the effect of making the globe deviate in one direction or another. von Graefe's views were based upon two cases in which the bulging was in the line of the orbital axis, and upon theoretical grounds which seemed highly plausible; but Jocqs,¹⁰⁶ after carefully studying the matter, came to the conclusion that it was far from certain that these growths always produced so typical an exophthalmos. A glance at the following table will shew the various directions in which the proptosis, is stated to have taken place in the cases reported upon up to date:—

Forwards.....	14
Forwards and Upwards.....	1
Forwards, Upwards and Inwards.....	7
Forwards, Upwards and Outwards.....	7
Forwards and Inwards.....	3
Forwards and Outwards.....	3
Forwards and Downwards.....	8
Forwards, Downwards and Outwards.....	20
Forwards, Downwards and Inwards.....	5
Proptosis (direction not stated).....	27
Not accompanied by Exophthalmos.....	4
Total.....	102

It is unfortunate that the number of negative answers is so large, but considering the 63 cases in which the direction of the proptosis is precisely stated we find, if we allow that in the examples where the eye protruded forward, forward and outward, and forward, outward and downward, the exophthalmos coincided more or less closely with the line of the axis of the orbit, that 37 or 58.7% of the cases conform to von Graefe's rule, while 26 others (42.6%) in taking up the remaining positions are to be looked upon as exceptions. It is impossible, of course, to form any definite opinion regarding the cases in which it is simply

stated that proptosis was present, without any mention being made of the direction of the bulging. It is probable that the greater number of these were more or less direct, else had the fact been otherwise noted. Granting even this, the exceptions still form a large percentage of the cases, and we must conclude therefore that *while proptosis in or about the orbital axis is somewhat characteristic, too much stress is not to be put upon it as a sign of primary tumours of the optic nerve.*

B. THE DEVELOPMENT OF THE PROPTOSIS: This feature, expressive for the most part of the rate of growth of the tumour, is, in the great majority of instances, *slow and evenly progressive*; exceptions to the rule are comparatively few in number. In the cases of Narkiewicz-Joko,¹⁹ Vossius,⁴⁶ Hessdörffer,⁴⁷ and Braunschweig⁷⁴ (3rd), the onset of the exophthalmos was *rapid*; in the instance of Wishart,¹ the proptosis developed quickly during the first year and then remained stationary in degree; in Frothingham's³⁷ second growth, the proptosis "became very marked in a short time after long persisting in a slight degree;" and the relations of Vossius'³⁸ first patient gave a history of very marked increase in the exophthalmos having occurred during a single night. Buller,⁶⁶ Rampoldi,³⁴ Willemer⁷⁰ (1st), Gardner (this paper), and De Vincentiis,⁸⁴ also noted accelerated augmentation of the proptosis at different periods of its development. In the last mentioned instance, the increase seemed to follow the examination by palpation.

Variations in the degree of the exophthalmos were observed in Vossius'⁴⁶ third patient and the same phenomena, at the time of the menstrual periods, were noted by Norton⁶⁶ and Brailey.⁷⁴ The most remarkable instance of this kind, however, is that reported by Axenfeld and Busch,⁹³ where marked differences in the degree of bulging of the globe occurred, accompanied at one time by pyrexia and swelling behind the angle of the jaw, at another, by fever, vomiting and pain in the affected eye.

C. THE PAINLESS CHARACTER OF THE EXOPHTHALMOS: This feature of the disease was clearly recognized by Lidell⁶ in 1860, but it remained for von Graefe¹⁰ (1864) to dignify the symptom by a general application, and to point out its value in differentiating between the closely invested tumours of the optic nerve and those growths which were marked by a tendency to invade the deeper structures of the orbit.

A study of the greatly enlarged literature of to-day goes to confirm the observations of these writers. In a certain few cases the onset of the exophthalmos has been preceded or accompanied by pain and other somewhat inexplicable symptoms. Thus for instance the loss of vision and proptosis in Tailor's⁷³ patient were preceded by violent pain in the eye and neighbouring regions of the head in association with photophobia and swelling of the lids. In Rothmund's⁹ case, pain seemed to be present at the onset but disappeared entirely later on. In Frothingham's³³ second patient, the exophthalmos and loss of sight came on "some time after severe frontal headache, heavy feelings over the eyes, and slight orbital pain" and the case was marked throughout by "constant dull pain" in the affected organ. In the instance recorded by Alt,²⁶ severe headaches in the circumorbital region preceded epileptic seizures and the intense pain in the eye led the patient to seek medical advice.

A few more writers note the presence of similar *bizarre* symptoms occurring in the course of the disease. Lawson, Sr's³⁴ second patient suffered from "headache, frontal and behind the ear on his left side at times;" while in the instance of Quaglino,¹⁴ a persistent hemicrania was accompanied by well marked Tinnitus Aurium. For five years, Norton's⁵⁶ patient had "much sharp pain in the orbit extending to the back of the head and down to the stomach," while Aub's⁴³ case was attacked eight or ten times by severe pain in the head which lasted sometimes for two hours and was accompanied by dizziness and throbbing sensations in the eye.

In quite a number of instances (15), the disease has been marked by severe pain of a neuralgic character, referable to the branches of the 5th nerve and appearing for the most part in the later stages of the disease.

In general, however, and especially in the early periods of development, *the tumours are singularly free from pain, which at no time is of that distinctively orbital type characteristic of malignancy.* If I may change the tense and convert special into general remarks, the facts are fully summed up in the following words of Lidell⁶:—

No pain is occasioned by the tumour until it becomes so large as to press upon the ophthalmic branches of the 5th nerve that run along the walls of the orbit, and the larger the

tumour becomes and the greater its pressure upon these nerves, the severer becomes the pain. The pain does not seem to be in the tumour itself so much as in the neighbouring parts which are invaded mechanically by the morbid growth.

The *cause* of the exophthalmos is to be found first of all in the displacement produced by the tumour itself. This will not explain the whole matter, however, for, as has been pointed out before, the size of the growth is by no means always in direct proportion to the degree of proptosis. A second factor is to be found undoubtedly in congestive changes which result from pressure upon the vessels of the orbit, and signs of which are frequently seen in the pathological examination of these tumours. This view finds confirmation in a consideration of cases like those of Norton⁶⁶ and Brailey⁶⁷ where increase of the exophthalmos was noted at the menstrual periods, or that of Strawbridge⁶⁸ where the proptosis came on apparently as the result of labor.

The cases marked by variation of degree or rapid acceleration might be explained as caused in the above way, or as resulting from the changes immediately noted.

As a possible third factor may be mentioned here again the appearances noted in connection with the eyeball of Case 1 of this report and to a less extent with that reported by Dr. Buller.⁶⁹ In both specimens there were conditions present on the outer surface of the globe and dural sheath of the nerve which could only be accounted for on the supposition of a *stasis in Tenon's capsule and the supra vaginal lymph space of the optic nerve*. Müller⁷⁰ is the only writer I can find who has described similar changes in connection with the eyeball, though Steffan⁷¹ whose case, because of some doubt as to its real nature, has been excluded from this paper, long ago attributed rapid acceleration of the exophthalmos in his patient to a sudden effusion into the lymph space of Tenon.

2. EVIDENCES OF PROFOUND AND EARLY DISTURBANCE OF THE FUNCTION OF THE OPTIC NERVE: These are in part *subjective (loss of vision)*, in part *objective (ophthalmoscopic)* in character, and constitute for the oculist the most striking and significant feature of this special form of orbital tumour.

A. LOSS OF VISION: Of the 89 cases in which the state of vision was accurately noted 62 or 69% were *absolutely blind*

in the affected eye at the time of the first examination, and in very many of these there was a history that the sight had been lost for some time.

Of the remaining 27 cases five, (A. Lawson⁸¹ (apparently), Ayres⁸² (1st), Hessdörffer,⁸³ Hulke⁸⁴ and von Graefe,¹²) had bare perception of light left, one (Collins and Marshall⁸⁵) perceived hand movements only, and four (Vossius,⁸⁶ Pflüger,⁸⁶ Willemer⁸⁷ (3rd) and Goldzieher)⁸⁸ could but count fingers at 8, 6, 1 and 15-16 feet respectively. In four more the state of vision, though expressed in general terms only, was evidently very poor. Thus for instance, Heymann's⁸¹ case had "slight vision" and Ritterich's⁸⁸ "some vision," which was lost entirely 2½ years later; while DeVincentiis⁸⁴ states that it was "greatly reduced," and von Graefe¹² that the eye was "amblyopic." On the other hand, Szokalski's⁸⁷ case had "fairly good vision" as had those of Schiess-Gemuseus,³³ ½ to ⅔, Rockcliffe⁸² 6/18 J. I.; Braunschweig²⁴ (4th) 5/36, Ellinger⁸⁴ 6/10, Schiess⁸⁶ (3rd) ½-⅓.

In three instances only (Wiegmann,⁸⁷ Axenfeld & Busch,⁸⁵ and Guaran⁸⁹) was the sight *normal* at the time of the first examination, but in the second mentioned case vision sank from 1 to 0.8 two days before the removal of the growth. Finally in the case of Braunschweig²⁴ (2nd), Norton,⁸⁶ Scalinci,⁸⁹ and Schiess⁸⁶ (2nd), vision was reduced respectively to 1/60, 1/200, 5/60 and 16/200.

How profound are the visual disturbances in connection with these tumours will be readily appreciated from the foregoing remarks. We have already seen that 69% of the cases had not even perception of light at the first examination, but the profundity of the changes in sight may perhaps be more fully realized by stating that at the period above mentioned about 87% of the patients had less than 1/10 (6/60) of the normal acuity of vision.

To be mentioned here are the *variations in visual acuity* which have occurred in the individual cases at different periods. The most remarkable example of this kind is that reported by Schiess-Gemuseus.³³ At the first examination in July, 1885, the vision was made out to be from ½ to ⅔; in January, 1886, it sank to ⅓ only to rise again to ½ the normal. Still later, in September, 1866, the patient's acuity of sight equalled 2/7, but during the following nine days which preceded the

operation it rapidly diminished to 1/200-2/200. The changes in the patient's power of vision were attributed by Schiess-Gemuseus to variations in the degree of stasis in the lymph spaces of the nerve. Similar phenomena though of less marked degree were also noted by Norton⁶⁶ and Ayres³⁷ (1st).

As regards the *field of vision* in these cases the records are too few to permit of any definite conclusions. Rockliffe⁷⁷ suggested that this procedure might be employed in order to obtain a more exact idea of the situation of the growth, but in this author's own case and that of Braunschweig⁷⁸ (4th), the constriction was of a concentric character. On the other hand in the instance of Schiess-Gemuseus⁵⁵ where the field of vision was of an irregular character, the nerve was exceptionally free from change. This point will have to be more fully gone into before any reliable data can be obtained, and there will always be the matter of age in the way of obtaining accurate records in every case.

B. OPHTHALMOSCOPIC CHANGES: Of the 82 cases in which the condition of the fundus is described, three (Sichel¹⁵, Vossius⁵⁹ and Veron⁴¹) showed *simple atrophy* of the disc without any signs of previous inflammation; 34 *optic neuritis*, for the most part of a pronounced character, and 36 *post-neuritic atrophy* or consecutive atrophy in course. That is to say, marked changes were present in the nerve head in 89% of the patients.

In the instances of Szokalski,⁷ Guaran⁵⁹ and A. Lawson,⁹³ *fulness of the retinal veins* was the only ophthalmoscopic change noted at the first examination, but in the second mentioned case, optic neuritis was made out at a later date and Lawson saw a descending atrophy after a lapse of five weeks. In only three instances (Knapp,³⁹ Hulke⁶⁰ and Frothingham³³), was the fundus noted to be *normal*, though in the first mentioned instance optic neuritis made its appearance while the patient was under observation. Seggel's³³ case presented a picture typical of thrombosis of the central retinal artery and this was seen afterwards to be due entirely to the position and action of the new growth.

Of other ophthalmoscopic changes, *partial detachment of the retina* was observed in four instances. In Straub's⁶⁰ case it manifested itself as "scarcely visible folds in the swollen membrane" while in Salzer's⁷¹ patient there were two small

detachments extending out into the retina for a short distance from the temporal and upper margins of the papilla respectively. In Taylor's⁷¹ patient, the retina was raised at points some distance from the papilla and in the second case of Collins and Marshall⁶⁹ the clinical picture from the presence of a detachment resembled that of a sarcoma of the choroid.* Goldzieher¹⁸ ascribed the microscopical detachment of the retina in his second case, which he was unable to diagnose previous to enucleation on account of a diffuse opacity of the cornea, to the mechanical action of a stasis in the veins of the retina bringing about an increased tortuosity of their structures, and Braunschweig⁷⁴ would explain all these cases in this way.

Hæmorrhages, for the most part slight, along the course of the vessels and in the vicinity of the optic disc, are mentioned by Guarán⁶⁹, Taylor⁷¹, Wolfheim⁵¹, Hessdörffer⁴⁸ and Collins and Marshall⁶⁹, but in the case of Lagrange⁶⁵, they were so extensive as to obscure the whole fundus.

Lastly, it may be mentioned that in the cases of Schiess-Gemuseus⁵⁵ and Braunschweig⁷⁴ (1st) there were present in the macular area dots of fatty degeneration which resembled more or less strongly the changes found in retinitis of the albuminuric type.

The ophthalmoscopic and visual disturbances call for a few special remarks. It is probable that in every case the overgrowth is such as to completely retard the flow of lymph in the intervaginal space and we are not surprised, therefore, that the increased pressure produced in this way should bring about so often the condition of "*choked disc*." That this single factor, however, will not suffice always as a complete explanation is witnessed by the cases in which the fundi were normal or showed only an atrophy of a simple or descending nature.

It is noteworthy that in the cases of Frothingham⁶³ and Hulke⁶², where no ophthalmoscopic changes were present, the pathological examination showed that a full half inch or more of normal nerve was preserved anteriorly and it would seem, therefore, that the ophthalmoscopic changes varied somewhat with the distribution of the newly formed tissue. If the growth remains localized to the central end of the nerve, the intra-ocular portion, possibly from non-implication of the central

* Messrs. Collins and Marshall in their article compare this with another overlooked case of Brailley's in Vol. II. of the Transactions to which I have not access at this time.

vessels, does not go on to the condition of choked disc and we have a *simple descending atrophy from pressure and nutritional changes behind.*

Further in a modified way we get atrophic changes occurring first in the posterior part of the nerve, where as we have seen the tumour is mostly developed, and choked disc making its appearance later from extension of the growth forwards. This *modus operandi* probably holds true in a large number of cases and explains the clinical fact that in primary tumours of the optic nerve *the vision is not infrequently entirely lost when the changes in the nerve head are only such as would lead us to expect a certain amount of sight to be still present.*

The want of relationship here between the visual disturbances and ophthalmoscopic changes is important and is the reverse of that which marks the choked disc of cerebral neoplasms, where, as is well known, the vision is often surprisingly better than the conditions in the fundus would lead us to expect.

3. MUSCULAR ANOMALIES: It is somewhat difficult on account of the vagueness of the reports, to determine with accuracy the degree of movement in all cases; but in 77 instances at least, the data are sufficiently clear for purposes of analysis. From a practical point it is only necessary to separate the cases into two classes, namely, (a) those in which movement was unimpaired, and (b) those in which noticeable restriction of one or more of the excursions of the globe was present. In the one class we find 35 instances in which for all intents and purposes, the movements of the globe were normal, while in the second division there are 42 cases in which there was marked impairment of the ocular movements varying from noticeable diminution in one direction to complete immobility of the eye.

We may infer from this that while non-impairment of the ocular movements is not so common perhaps as von Graefe¹⁰ supposed, still as compared with other orbital growths, *freedom of the musculature of the eye is present in a relatively large percentage of cases of primary intradural tumours of the optic nerve*, and must therefore be looked upon as more or less characteristic of these neoplasms.

On theoretical grounds one is surprised not to find this feature more common. The new growth is in nearly every instance absolutely contained by its dural sheath capsule and the globe is allowed more or less freedom of action on account of the pedicle of comparatively normal nerve which commonly exists between the eyeball and the point of greatest swelling. But other factors such as congestive conditions of the orbital tissues, doubling of the nerve upon itself and its protrusion between the globe and the orbital walls, pressure upon the ocular muscles, or even fatty degeneration of these structures (Jocqs)¹⁰⁶ come into play, and bring about a fixity of the globe in such a large percentage of the cases that the occurrence of free movement is greatly diminished.

Of interest are the cases where *strabismus* appeared in connection with the growth of these tumours; the literature mentions the condition as having occurred 22 times. As regards the time of appearance, of the 20 cases in which this point is noticed in 9 the squint manifested itself before the exophthalmos, in 7 it occurred simultaneously with the protrusion of the eye and in 4 after the exophthalmos had developed. In 5 cases the external rectus was involved (convergent strabismus), in 7 the internal rectus (divergent strabismus), and in one the superior rectus (strabismus deorsumvergens). In only 4 instances, however, was *diplopia* complained of by the patients. Jocqs¹⁰⁶ attributes the condition to the deviation of the globe produced by the growing tumour and accounts for the infrequency of diplopia as the result of the tender years of many of the patients and the well known tendency for early loss of vision to occur in these cases. This purely mechanical view, however, does not explain the case of Christensen¹¹ where the levator palpebrae was involved with the internal rectus.

4. PALPATION: In a large number of instances this yields helpful information. While on 6 occasions this procedure was entirely negative in its results and on 18 more very indefinite as regards the information obtained, in 30 instances palpation revealed a growth, which could, with considerable certainty, be said to have some connection with the optic nerve. In a certain few cases a diagnosis could apparently have been made

by this manipulation alone. Aub⁴ for instance was able to make out on the one hand, the attachment of the nerve to the back of the eyeball, and on the other, could trace this structure into an oval shaped enlargement which extended backwards into the apex of the orbit. *Generally speaking, the higher the degree of proptosis and the greater the amount of deviation of the globe, the more likely is one to gain information from this procedure.* On a few occasions the conditions have been made out very fully with the patient under an anæsthetic, and generally at the commencement of the operation, the finger introduced through the preparatory conjunctival opening, has defined the existing conditions with satisfactory exactness. Palpation rarely caused discomfort to the patient. In four instances, however, (Duboué,⁵ Lidell,⁶ Ritterich⁷ and Pflüger⁸) the procedure was distinctly productive of pain; but as regards the first three mentioned only in the later stages of the disease.

MIXOR SIGNS.

While the above are to be looked upon as the cardinal signs of the disease, there are still a large number of widely different conditions, occurring in connection with these growths, which though for the most part of secondary importance yet require systematic mention.

(A). THE GENERAL HEALTH of these patients, is for the most part strikingly out of keeping with the local condition. In only 10 cases was the state of the patient's general health unsatisfactory, and in 6 of these this was due to a condition of simple anæmia. Rockliffe⁹ is the only writer who notes loss of flesh, his patient having fallen off 2½ stones in 15 months; the other authors simply note that their patients had a sickly appearance. As was mentioned under Etiology, four patients were physically undersized, while the case of von Forster¹⁰ showed strumous swelling of the glands of the neck.

(B). CEREBRAL MANIFESTATIONS: These are extremely interesting and probably resulted from the tumour growth within the skull, some process which produced the condition, or some congenital cerebral insufficiency associated with the causative factor of the cellular proliferation. In Higgen's¹¹ case symptoms of *idiocy* appeared along with the other manifestations of the disease, though after the oper-

ation the patient became a "rather sharp, intelligent child." In Braunschweig's⁵⁴ first patient there was present a slight degree of idiocy which found expression in noticeable difficulty in speech. Dr. Buller's⁵⁶ patient had a severe attack of general *convulsions*, accompanied by loss of consciousness at the age of four, and while after that illness the boy had no actual convulsive seizures he was subject to attacks of fear or terror, which were accompanied by action on the part of the muscles of deglutition. One of Sattler's⁵⁷ patients had frequent attacks of convulsions and bronchial catarrh. Three years after the onset of the exophthalmos and following a severe attack of pain in the circumorbital region, Alt's⁵⁸ patient was seized with epileptic convulsions which increased so much in severity as to recur several times in a single day. The man's condition was greatly ameliorated by the removal of the neoplasm.

Dizziness occurring in the later stages of the disease and in association with pain about the orbit, was noted by Holmes⁵³ and Johnson,⁴⁵ and in both instances the condition was aggravated by stooping. Vertigo coexisted with throbbing sensations in the eye in Aub's⁵¹ patient and the same symptom in association with orbital pain, a heavy feeling over the eyes and frontal headache preceded the onset of exophthalmos and loss of vision in Frothingham's⁵² second case. The last mentioned author notes also that his first patient was "nervous and fitful by spells." Here may be mentioned, perhaps, the partial deafness on the same side as the tumour in Lidell's⁵ case which disappeared entirely after operation and the *tinnitus aurium* of Quaglino's¹⁴ patient which was associated with amenorrhœa and right sided hemiplegia.

(C.) CHANGES IN CONNECTION WITH THE GLOBE :

(i.) *Increased tension* or secondary glaucoma was noted by Middlemore², Sichel¹⁵, Forster²⁵, Taylor⁷¹, Salzmann⁷⁸, Lawson, Sr.³⁴ and Wiegmann⁷⁷, though in the last mentioned case the condition was but transitory. *Diminished tension* on the other hand was determined by Ayres³⁶ (T.—1), Ellinger²⁴ (Tn. to—1) and Gardner, this paper (T.—2).

(ii.) Highly characteristic of these tumours is the antero-posterior flattening which occurs as the result of the pressure of the growth and brings about a *hypermetropic state* of the refraction of the eye. This condition occurred in 21 of the collected cases and will probably be more commonly observed

in the future; it is so frequently present that it ought to suggest at least the presence of a growth behind the posterior pole of the eyeball. In the first case mentioned by Collins and Marshall⁶⁰, the hypermetropia increased under observation from 4 to 9 D. The antero-posterior flattening has been made out after the removal of the eyeball (von Graefe) or verified at this time (Goldzieher⁵² and Sichel⁵³).

(iii.) *Cornea*. Changes in this structure are of comparatively frequent occurrence. In eight cases (Lidell⁵, Szokalski⁷, von Graefe⁵⁴, Quaglino⁵⁴, Forster⁵⁵, Willemer⁵² (2nd), Hessdörffer⁵⁷ and Germann⁵⁷), *ulceration* of the cornea was noted, and, although not definitely stated, perforation of the cornea probably occurred in the instances of Poncet⁵⁵ and Adamück⁵² where the eyeball, completely collapsed, was found on the anterior extremity of the tumour. In six other instances, (Kunachowitch⁴⁸, Johnson⁴⁵, Salzmann⁵⁸, Delius⁵¹, Kalt⁵⁹, Buller⁶⁰) the corneal trouble might perhaps be very properly described as a *keratitis*. What the "diffuse opacity" was in Goldzieher's⁵² case which prevented an examination of the fundus it is impossible to say.

In all of these cases the inflammation occurred, so far as can be ascertained only after the lids were no longer able to completely protect the cornea, and in that part of it which was especially exposed, namely, the lower portion. The involvement, therefore, of the cornea is to be looked upon as a triumph of micro-organisms over the epithelial cells of this structure, lowered in vitality from undue exposure to outside influences. von Forster⁵⁵, who demonstrated complete anaesthesia in his case, sought to give a trophic basis to the ulcerative process, but if this were true we should not expect to find the inflammation so uniformly limited to the exposed portion of the cornea. Finally it may be mentioned that suppurative keratitis has been the cause of the destruction of the globe in several cases where this structure was retained in position after the removal of the tumour.

(iv.) *Iris and Lens*: There is nothing peculiar in the pupillary reactions. With complete blindness the pupil only reacts consensually and remains of normal size, or more or less dilated. The latter condition occurs also where contraction occurs sluggishly or even actively (Noering⁶¹) to direct stimulation. In two cases (Ritterich⁵ and Willemer⁵²) the pupils were contracted and fixed.

No changes have at any time been noted in connection with the lens.

(D.) LIDS AND CONJUNCTIVA: As the proptosis increases the upper lid becomes more and more stretched and thinned and sooner or later a condition of *lagophthalmos* is produced. When the proptosis is very great, luxation behind the globe may occur spontaneously or as a result of manipulation. Occasionally well marked venous obstruction and œdema of these structures are present. The peculiar behaviour of the lids at the onset of the disease in the case of Lidell⁶ has been already mentioned in the section on Etiology.

The changes in the conjunctiva are quite unimportant. Occasionally slight hyperæmia and œdema were present where the circulation was obstructed, and injection and chemosis in cases of involvement of the cornea.

(E.) ORBIT AND OPTIC FORAMEN: In the cases of Lidell⁶, Szokalski⁷, Poncet¹³ and Kunachowitch¹⁴, where the growth attained considerable size, dilatation of the orbit was noted. In the last mentioned instance, the orbital capacity was almost double the normal, while in the former the changes were so marked as to produce distinct facial asymmetry. Willemer¹⁵ and Szokalski⁷ noted dilation of the optic foramen at the post mortem examination, while Johnson¹³ was able to insert his little finger into this structure at the time of the operation. In the last mentioned case also the "examination of the orbit discovered that its floor, thinned and eroded from pressure, had broken through during the operation." In Hessdörffer's¹² case the tumour was adherent to the floor of the orbit for a short distance and after the "subperiosteal exenteration" a perforation was found in this structure leading into the antrum of Highmore. It will be remembered that the orbit in the second case of this paper stood, through advanced necrosis of its floor, in free communication with the cavity of the superior maxilla.

Finally, to recapitulate what has been laid down in this section, the following are to be looked upon as the distinguishing signs of primary tumours of the optic nerve:—

1. Exophthalmos: Painless and slow in development and tending somewhat to coincide with the line of the axis of the orbit.
2. Profound and early disturbance of the function of the optic nerve as shown by a reduction of vision, often

greater than marked ophthalmoscopic changes in the intra-ocular portion of the nerve would lead us to expect.

3. A palpable tumour in the position of the optic nerve, non-adherent to the orbital wall, and especially to be made out in high degrees of bulging or deviation of the globe, or under an anæsthetic.

4. Relatively good movement on the part of the globe owing to comparatively infrequent impairment of the musculature of the eye.

5. A hypermetropic state of the eyeball brought about by the pressure of the tumour upon the posterior surface of the globe.

DIAGNOSIS.

The diagnosis of a tumour of the optic nerve necessitates first of all the determination of the presence of an orbital neoplasm, and this implies simply the routine differentiation between this condition and the other affections of the orbit and neighbouring cavities with which it is commonly contrasted and which need not here be specially mentioned.

As proptosis gives us the principal clue to the presence of an orbital growth, so *an associated early and profound reduction of vision* indicates more than any other symptom, the presence of a tumour of the optic nerve. Taken together these two symptoms alone, *unilateral and slowly developing exophthalmos with early amaurosis*, are almost in themselves proof positive of the presence of the condition under discussion, but if in addition one has, as is frequently the case, *marked changes in the papilla*, the diagnosis of a tumour of the optic nerve is practically certain.

How important a sign is amaurosis is evident from the fact that it is only in those cases where a certain amount of vision is maintained that the diagnosis is uncertain. The difficulty in coming to a right conclusion here rises with the acuity of vision and a point is reached where it is practically impossible to distinguish these tumours from other orbital neoplasms.

Under such circumstances, a consideration of the other symptoms present will probably make it possible in every instance to diagnose a deep-seated orbital growth and in these cases, Krænlein's operation is indicated as offering a certain method of confirmatory diagnosis and the best procedure for the extirpation of the tumour. So pronounced, as a rule, however, are the symptoms of these growths that difficulty in their clinical differentiation must be present only in a very small percentage of the cases.

It is very questionable if the intradural can always be differentiated from the extradural growths of the optic nerve. On the one hand the maintenance of fairly good vision in a few of the intradural growths makes it impossible to distinguish these tumours from other orbital neoplasms, and on the other hand some of the cases of extradural growths (Knapp,¹⁰⁸ Dusaussay,¹¹⁰ Ewetzki,¹¹² Brailey¹¹³) have presented a group of symptoms really indistinguishable from those of

the intradural tumours. Leber's classification of tumours arising from the orbital division of the nerve seems more justified on pathological than on clinical grounds.

PROGNOSIS.

If the conclusions arrived at in this paper be correct, the prognosis in primary tumours of the optic nerve is to be looked upon as more serious than it has hitherto been regarded. *The danger is not from recurrence in the strict sense of the term, but from the continued development of the intracranial portion of the tumour which it is impossible to remove at the time of the operation.* In a certain number of cases, the condition is localized, as we have seen, to the orbital division of the nerve and in these instances the operation will prove successful. It may also be that the removal of the orbital portion of the nerve may in some way retard or stop the growth within the skull, and certain it is that these tumours are characteristically slow in their rate of development, but it is highly probable that in the majority of these cases the unexcised cerebral portion continues on its course of development and sooner or later brings about the death of the patient.

The literature affords us 12 instances where signs of an intracranial neoplasm occurred after the operation and on the other hand only 8 cases are known positively by record, to have continued in a good state of health beyond five years. We are still greatly in need of details concerning cases which have been dealt with a number of years previously before the matter can be definitely settled, but so far as our studies lead us we must conclude that the outlook in general is to be regarded as extremely grave.

TREATMENT.

In spite of the fact that in the great majority of these cases it is highly probable that the extirpation of the growth was incomplete, in only 5 instances (Szokalski,⁷ Goldzieher¹³ (3rd), Brailey,¹⁴ Salzer¹⁵ and Byers) have local recurrences been recorded. The fact of the matter is, the fibromatosis underlying the formation of these growths, rarely shews a tendency to malignancy even in its local form. When we consider further that in the large percentage of these cases, the part of the optic nerve immediately next the eyeball is normal and that it is quite possible in practically all cases to separate thoroughly the posterior pole of the globe from the neoplasm, we find good reason for attempting in every instance the highly desirable step of maintaining the globe in position.

It might be urged that in attempting to save the eyeball, this structure would be an impediment in the way of the perfect removal of the growth, but as a matter of fact it need not be, and under any circumstances if the tumour extends into the optic foramen, as it generally does, our ordinary operative procedures will not suffice to entirely extirpate the neoplasm. Fully isolated as these tumours are by their fibrous capsule, and rarely shewing a tendency to malignancy, exenteration of the orbit as a primary operation seems entirely contraindicated in these cases.

The argument that the retained eyeball would present a serious obstacle to the diagnosis of recurrence is not of much value, because in the first place this condition rarely occurs and in the second place it is not possible that the secondary growth could attain to any considerable size without giving rise to fresh displacement of the globe. The question therefore has got to be as Schlotdmann¹⁶ says, *not shall we preserve or sacrifice the eyeball, but how best shall we maintain the globe in position.*

As is well known, Scarpa¹⁰³ (1816) and Critchett¹⁰³ (1852) removed tumours of the optic nerve with preservation of the eyeball; but the real commencement of the modern conservative movement was in 1874, when Professor Knapp,¹⁰³ of New York, presented to the Ophthalmologische Gesellschaft, at Heidelberg, a specimen of a primary extradural tumour (carcinoma) of the optic nerve, which he had removed while

leaving the globe in situ. The operation as described by Professor Knapp at that time was as follows:

"The lids were held open by an ordinary wire speculum, and then with a pair of strabismus scissors I made an opening through the conjunctiva and Tenon's capsule between the rectus superior, rectus internus and obliquus superior until I felt the bared tumour with my index finger. Guided always by my left index finger I now cut around the whole of the tumour, separated it from the sclerotic, sectioned it from the optic nerve, first at its ocular end and then at its orbital end, and finally, with the flat of the scissors, pried out the tumour, somewhat larger than a walnut in size, which now lies before you."

Not long afterwards Dr. Emil Grüning,²² of New York, following the example of his former "chief," successfully removed for the first time, a primary *intradural* tumour of the optic nerve, and since the meeting at Heidelberg, in 1874, Professor Knapp's example has been followed on twenty different occasions, namely, by Grüning,²² Alt,²⁶ Mauthner-Schott,²⁷ Strawbridge,²⁸ Knapp,³² Schiess-Gemuseus,³³ Lagrange,⁶³ Rohmer,⁶⁵ Norton,⁶⁶ Sattler,⁶⁷ Graefe⁷⁴ (two cases), Fuchs⁷⁶ (two cases), Adamück,⁸¹ DeVincentiis,⁸⁴ Schiess-Gemuseus,⁸⁶ Kalt,⁸⁹ Scalinci,⁹⁰ and Buller (this paper).

I do not include here the cases where for one reason or another the attempt to save the eyeball was given up during the course of the operation, though they shew us, nevertheless, some of the difficulties in the way of procedure. Thus, for instance, Sichel¹⁵ abandoned his intention of saving the globe because he found that the internal rectus was lost in the growth 15 cm. from the eyeball, while Leber,³⁸ Ayres,⁵⁶ and Buller⁸⁶ sacrificed the eye through fear lest they would not entirely remove the growth. Leber also enucleated for the same reason and in order to obtain better drainage after the operation, and Johnson⁴⁵ and von Garnier⁶¹ because of the large size of their tumours.

It will be noticed that Professor Knapp removed his tumour through the conjunctival opening without cutting any of the muscular attachments and it is well known that those who came after him introduced changes in the operation, such as tenotomy of one or more recti, external canthotomy, etc. The principle, however, has remained the same throughout and we must question the right of Lagrange⁶³ to designate his alterations "A New Procedure."

As one of the most completely described modifications of Prof. Knapp's operation, it may be useful, however, to enumerate here the various steps advocated by Lagrange.⁵³

External canthotomy is first performed and then a suture passed through each lid in order to hold them easily apart. The bulbar conjunctiva is now dissected up in its outer third and the external rectus tenotomised, a suture being passed through its anterior extremity to keep it in view. With the index finger and a director the neoplasm is next everywhere isolated and the eyeball turned inwards so as to disengage the orbit. The growth, separated from the muscles, is now secured with a ligature passed around the tumour by means of a Cooper's needle and then knotted. Afterwards guided by the finger the optic nerve is sectioned close to the optic foramen by means of strong curved scissors, and in doing this Lagrange says it is possible to avoid wounding the ophthalmic artery. Traction upon the suture previously attached to the growth will now withdraw it from the orbit and bring the posterior pole of the globe into view when it can be thoroughly separated from the neoplasm. Lastly, the external rectus is re-united and the lids and conjunctiva are brought together after stoppage of the hæmorrhage, lavage of the orbit with antiseptics, and the insertion of a small tube for drainage.

The last phase in the development of this subject and that which is now exciting considerable interest, was entered upon when Braunschweig⁵⁴ in 1893 introduced into ophthalmology, for the treatment of tumours of the optic nerve, a brilliant operation which had previously been devised by Krönlein⁵⁵ for "the extirpation of deep-seated lateral orbital tumours and in particular orbital dermoids." The steps of this operation which were first given out in 1887, were described by the author in the following words:

Skin Incision : The incision begins in the temporal region at the point where the *linea semicircularis* of the frontal bone is distinctly felt through the skin, in other words, about 1 cm. above the *margo supra-orbitalis*, and extends downwards along the outer orbital margin as a slight curve with the convexity forwards, to the level of the upper margin of the zygomatic process of the malar bone, where it turns backwards and ends in the middle of this structure.

The skin incision is then carried down to the bone along the outer orbital margin, and through this periosteal incision the whole of the periosteum is separated from the lateral orbital wall by means of a raspatory, a proceeding easy of accomplishment. The point of the raspatory is then passed downwards to the inferior orbital fissure in order to fix the spot where the converging bony incisions presently described meet one another.

Bony Incisions : The osteoplastic resection includes the whole of the outer orbital margin (*process. zygomaticus oss. front.* and *process. front. oss. zygomatic.*) and that part of the outer wall which lies between this limit and the inferior orbital fissure (*pars orbitalis oss. zygomatici* and

anterior part of the *ala temporalis oss.sphenoid.*). The piece of bone to be temporarily removed has therefore the shape of a wedge whose base is formed by the outer orbital margin (*process.zygom.oss.front.* and *process.front.oss.zyg.*), and whose apex ends at the anterior part of the inferior orbital fissure.

The bony incisions are best made with a sharp chisel without any further "Preparation" and especially without loosening the natural connections to which, together with the skin flaps, falls the work of nourishing the separated piece of bone during the early period of healing. First of all, the *processus zygomaticus* of the frontal bone is chiselled transversely through above the distinctly visible and palpable *sutura zygomatico-frontalis*, and the bony incision continued forward in a direct though oblique line through the lateral orbital wall to the raspatory in the inferior orbital foramen. Following this the *processus frontalis* of the malar bone is chiselled horizontally through close to its base and the incision likewise continued into the fissure.

When this has been done, the bony piece thus made free, together with the skin, fasciæ and muscle flaps of the temporal region, can be so far turned outwards that the entrance to the orbit in its lateral part appears free. The operation is usually easily and quickly performed; after successful removal of the tumour, the skin and soft parts are replaced and held in position by sutures and healing follows without difficulties or disfigurement.

Following the example of Braunschweig,⁷⁴ who adopted this procedure for the removal of two cases of primary intradural tumour of the optic nerve, the operation has been performed for the same condition by Ellinger,⁹⁴ Axenfeld and Busch,⁹⁵ and Golowin,¹⁰¹ making a total in all of 5 cases.

It remains now to determine if possible which of the foregoing procedures is the better.

Studying the fate of the eyeball in the 20 cases operated on by Knapp's method, we find that in two instances the globe had to be removed 36 hours and 3 days respectively after the operation on account of orbital cellulitis, while Alt²⁶ was forced to do an enucleation 4 hours after the primary interference because of the unbearable pain caused by severe post-operative hæmorrhage. In the patients of Strawbridge²⁵ and Knapp,³² the eye passed into a state of phthisis bulbi following keratitis, while Braunschweig⁷⁴ enucleated the globe on account of a large perforation of the cornea. Salzmann²³ states, that 4½ years after the operation the globe of his first patient had shrunk to the size of a pea and in his second case the eyeball became atrophic under slight inflammatory manifestations. In the second patient in this report, the eyeball was removed on account of the orbital recurrence. We have therefore 9 instances in which the after result was

distinctly bad, though the case of Mauthner-Schott⁵⁷ and Kalt⁵⁸ can hardly be taken into account in determining the effect of the procedure.

On the other hand, 11, or 55% of the cases were successful, if by that is meant the simple preservation of the globe in situ. While Adamück⁵¹ simply states that 4½ months after the operation the globe remained in position, apparently the patients of Grüning⁵² (eye in good state of preservation 25 years later), Schiess-Gemuseus⁵³ (eye of good form 8 years after the operation), Norton⁵⁶ (globe normal in position and direction with only slight limitation of movement and faint opacity of the cornea 18 months later), and Schlodtmann⁵⁵ (eyeball perfectly free in movements and practically normal in position 18 months after the operation), are the only cases in which the after results can be regarded as entirely satisfactory from a cosmetic point of view.

All the remaining cases were more or less marred by some noticeable defect. Thus for instance Rohmer⁵⁵ states that six months after operation the globe in his case was slightly atrophied and in a position of slight convergence, while in Sattler's⁵⁷ patient there was hypotony (T—1), very marked limitation of movement and convergent strabismus. Braunschweig's⁷⁴ second case showed healed opacity of the cornea and a deviation up and out which was to be corrected later by operation; DeVincentiis'⁸⁴ a faint corneal cicatrix and partial paralysis of the superior oblique; Schiess-Gemuseus'⁷⁶ divergence and slight post-inflammatory scarring of the cornea, and Scalinci's⁹⁰ slight enophthalmos.

The method of Krönlein has so far undoubtedly yielded better results, though we are not yet in a position to determine the matter definitely on account of the paucity of reports. In all the cases so far recorded the globe has remained in position* and the cornea uninvolved, and if perhaps there seems to be a tendency towards marked restriction of movement (Golowin¹⁰³ and Braunschweig, 2nd⁷⁴), and enophthalmos (Ellinger⁸¹, Golowin) the results on the whole, but especially as regards the cases of Axenfeld and Busch⁹⁵ and Ellinger, must be regarded as satisfactory.

*Recently Domela-Nieuwenhuis in an admirable paper has shewn that Krönlein's operation has been equally successful in conditions other than those under discussion, the globe being subsequently retained in situ in 100% of the cases. Beitrage z. Klin. Chir. 1900, Pts. 2 and 3. See also Oph. Rev. 1/01 p. 7.

Theoretically as well as practically the arguments appear to be in favor of Krönlein's procedure. It is true that the operation is of a more serious nature than professor Knapp's and leaves behind a scar; but these count for little. The operation can still hardly be called a major one and the resulting cicatrix with modern asepsis is of slight moment. On the other hand the method affords a better view of the orbit, especially in its deeper parts, and enables one, therefore, to take away the largest possible amount of growth. Further, it does not sever the connection of the eyeball with the muscles, and offers a much better chance of preserving the anterior ciliary arteries intact. Finally the cornea is protected and free from injury during the course of the operation and *the conjunctival sac, contaminated as it certainly is in a large per centage of cases by pyogenic organisms, is not brought into communication with the easily infected deeper structures of the orbit.*

In a word, so far as we can see now, Krönlein's operation seems admirably adapted for this special field of surgery and the proceeding will probably find much larger scope in the years to come.

58 Primary Intradural Tumours of the Optic Nerve.

No.	Author.	Age, Sex, Eye Affected.	Etiology and History of Onset.	Present Condition.	Operation.	Anatomical Diagnosis.	After Result.
1	WISHART. 1831.	13 F. R.	Onset of exophthalmos 2 years ago; increase noted; no pain.	Considerable proptosis; tumour felt on palpation.	Exenteration of orbit.	"Tumour of firm consistency resembling cerebral substance, probably of a malignant nature."	No recurrence after a year.
2	MIDDLEMORE. 1838.	3 M. L.	Fulness of the left eye since birth; slight strabismus and loss of sight.	Slight proptosis; amaurosis of some duration on account of three mos. increase of exophthalmos and involvement of optic nerve (and secondary glaucoma?) noted.	Removal of eye-ball and tumour. Growth incomplete.	Tissue resembled that of meningeal fibrous, i.e. fibro-lymphoma.	About 1 year later no local recurrence, but tumour on right hand, arm and leg.
3	HEYMANN. 1842.	19 M. R.	Disease began in the "best" eyes of childhood, and was marked by divergent strabismus, diplopia, very gradual diminution of vision, discharges from the eyes, upwards and outwards, and absence of pain.	Downward exotropia of globe restricted; pupil active; enough vision left to permit recognition of diplopia shortly before death.	The patient died of pulmonary tuberculosis at age of 19 years. Eye removed after death.	Neurinoma, meningio-epithelioma of cranial portion of optic. Intracranial nerve and meninges involved.	
4	ROUX. 1844.	13 or 14 M. L.	Onset "some years" previous; progressive increase painless.	Exophthalmos; complete loss of vision.	Exstirpation of eye-ball and tumour.	Neurinoma (in cerebello-ocular suitable term).	Death "some days" later in hospital. In cranial portion of nerve not involved.
5	DUBOUE. 1850.	14 F. R.	Exophthalmos fell away upon contusion of right side of head, occurring in far back; could be remembered. Consequent strabismus, which was from time to time; more severe headaches last six months.	Considerable proptosis; convergent strabismus; amaurosis. In exophthalmos, but not in strabismus, deep pains on palpation of eyeballs (achrymal gland outwards).	Removal of eyeball, retrobulbar tumour, and smaller masses, this removed in a second operation. Resembling organized blood-clots.	Neurinoma.	Death from meningitis 8 days after operation. P.M. exam. showed apex of optic nerve containing section of orbital enlargement and intracranial part of o. n. measuring 4 mm. x 0.5 mm. of chiasm.

No.	Author.	Age, Sex, Affected.	Etiology and History of Onset.	Present Condition.	Operation.	Anatomical Diagnosis.	After Result.
6	LIDELL, 1866.	20 F. L.	Swelling of eyelids, failure of vision, and exophthalmos, gradually increasing successively upon an attack of epidemic parotitis; ulceration of cornea and formation of fungoid pains noted later on.	Large protruding orbital mass, regular in shape, capsular, and containing a culent connective of cord carrying remains of coarctation on its apex. Orbit greatly distended.	Exenteration of orbit; lids left in situ.	Neuroma.	Patient in good health fourteen and a half years after operation. Partially blind, left eye disappeared after removal of tumour.
7	SZOKALSKI, 1864.	4 M. L.	Disease attributed to inflammation of meninges four or five months previously.	Slight proptosis, moderate dimming of vision, dilated veins, unimpaired movement. During two months of disease, exophthalmos, conjunctival symptoms (objective and subjective), and irritability of eye observed to prevail under observation.	Excision of eyeball and tumour.	Scirrhous Carcinoma.	Large orbital recurrence of meningitis, followed by meningitis and death. Tumour, four of same nature upon intracranial portion of optic foramen and orbit distended.
8	RITTERICH, 1864.	4 M. L.	Slight forceps injury to orbit, occurred at birth. Onset of exophthalmos at age of 4 months.	Marked exophthalmos and proptosis, slight in all directions. Amniotic rods; pupil contracted and lacrimal secretion of right eye diminished.	Excision of eyeball and tumour.	Sarcoma.	Death at hours after the operation. The eyeball was removed. The tumour showed chiasm greatly enlarged and intracranial portion of optic foramen distended throughout its whole extent.
9	ROHMUND, JR., 1865.	15 F. L.	Complete loss of vision at age of 3 years; onset of exophthalmos about 6 months previous to this.	Large, prominent orbital tumour, movable and covered with hyperæmic membrane, remains of opaque cornea existed.	Excision of tumour.	Myxoma.	Recovery; ultimate result not known.
10	VON GREFFE, 1864.	73 M. R.	Onset with diplopia 2 yrs. previously; soon after gradually increasing exophthalmos, and increase of double vision with failure of vision; involvement of cornea with pain in the last few weeks.	Exophthalmos (3 $\frac{1}{2}$) in direction of orbital axis; impaired movements of eyeballs; asymmetrical swelling of optic disc; central corneal ulcer.	Excision of eyeball and tumour.	Myxoma.	Recovery; ultimate result not stated.

60 *Primary Intradural Tumours of the Optic Nerve.*

No.	Author.	Age, Sex, Affected.	Etiology and History of Onset.	Present Condition.	Operation.	Anatomical Diagnosis.	After Result.
11	VON GREEF. 1864.	24 F. L.	Trouble began at age of 12 years. Strabismus, G. found, proptosis and neuro-retinitis. Amblyopia, G. found. Gradual increase of exophthalmos during next 5 yrs.	Exophthalmos (?), more G. found in every direction; proptosis in K. post-neuritic atrophy. V. - pl.	Excision of eyeball and tumour.	Myxo-sarcoma.	Recovery; further not stated.
12	VON GREEF. 1866.	6 F. L.	Divergent strabismus, exophthalmos and loss of vision appearing gradually from birth, occurring at the age of three.	Exophthalmos (8") in direction of orbital axis; optic atrophy, G. found; neuro-retinitis in pl. only; under chloroform to be cut to pass into tumour.	Excision of eyeball and tumour.	(a) Optic nerve tumour—glomus; (b) growth—(glomus)-sarcoma. (V. F. - chow).	Death from meningitis 15 days after operation. Growth found post-mortem.
13	SEGEL. 1875.	49 M. L.	Patient incidentally called attention to blindness of his left eye, while under condition of unconsciousness, during a paralytic attack of the braine of left cheek.	Amaurosis; neuro-retinitis; arteries contracted; optic atrophy; G. found; periphery small haemorrhages outer margin of papilla; appearance of papilla also absent in end-bolism.	None; tumour found at post-mortem examination.	"Sarcoma of glomus" of optic nerve 2.5" behind its entrance into sclerotic).	Pneumonia cause of death.
14	QUARLES- MANFREDI 1874.	24 F. R.	Failure of vision, diplopia, exophthalmos, headache and vomiting, commenced one month after a penetrating wound of the orbit.	Five years later enormous proptosis, anisometropia, optic atrophy and ulceration of cornea; G. found behind the eye; marked ears and amenorrhoea present during course of disease.	Excision of eyeball and tumour.	Myxoma.	Died from intracranial operation. P. M. Examination not permitted.
15	SICHEL FILS. 1871.	16 F. L.	Onset at age of seven of convergent strabismus and gradually increasing exophthalmos and failure of vision.	Proptosis; movements greatly impaired; primary atrophy optic nerves; hyaline membrane below a.c.; increased tension.	Excision of eyeball and tumour (removal apparently incomplete).	Myxoma hyaline size 6x4x1 mm. in places containing albumen bodies.	No recurrence after 3 years.

Analytical Tables.

No.	Author.	Age, Sex, Eye Affected.	Etiology and History of Onset.	Present Condition.	Operation.	Anatomical Diagnosis.	After Result.
16	NARKEWICZ-JOKO. 1872.	11 F. R.	Rapid onset of exophthalmos without pain.	Proptosis: optic neuritis.	Excision of eyeball and tumour.	Tumour consisted of two parts respectively new-born choroid and myxoma lacunare.	Recovery.
17	PERLS-LOCH. 1873.	9 F. R.	At age of seven congenit strabismus and proptosis appeared three months after a blow upon the eye.	Exophthalmos: impaired movements: amaurosis: optic neuritis.	Excision of eyeball and tumour.	Neurama Verum (Perls)-Myxosarcoma (Yossus).	No recurrence five months after operation.
18	GOLDZIEHER. 1873.	10 M. L.	Exophthalmos "recently" noted by school master.	Moderate proptosis: movements limited in all directions: optic neuritis: hypermetropia Vision - Fingers 15-16.	Excision of eyeball and tumour.	Fibroma-myxosarcoma.	No recurrence after a year.
19	GOLDZIEHER. 1873.	4½ ? R.	Prominence of eye noted six months previously.	Exophthalmos: tumour formation: movements of globe restricted: diffuse opacity of cornea.	Excision of eyeball and tumour.	Glioma showing characteristic glioneuritic tissue.	Rapid convalescence: further not known.
20	GOLDZIEHER. 1873.	4 ? L.	No statement	Forward and downward displacement of globe: marked limitation of movements: extensive degeneration of retina at posterior pole	Excision of eyeball and tumour.	Myxosarcoma. (Endothelial) cell-nests also present; papilla invaded; optic nerve of parts of retina invaded.)	A year later orbital recurrence; limitation of field of vision and atrophy of optic nerve of parts of retina. Eight years later total blindness, partial paralysis and transient blindness noted.
21	CHRISTENSEN. 1875.	5½ F. R.	Six months previously divergent strabismus, developed after febrile illness, which lasted two weeks. Complete loss of vision noted for two months	Forward and outward displacement of globe: total blindness: optic neuritis: amaurosis: post-neuritic atrophy: ptosis: child poorly developed.	Excision of eyeball and tumour.	Hyperplasia of connective-tissue sheath probably caused by extension of localized meningitis	No recurrence about a year later.

No.	Author.	Age, Sex, Eye Affected.	Etiology and History of Onset.	Present Condition.	Operation.	Anatomical Diagnosis.	After Result.
22	GRÜNING. 1876.	34 F. L.	At the age of twenty blow upon left side of head from a fall; two years later vision reduced to perception of light; four years after this onset of exophthalmos and complete loss of sight. Pain.	Proptosis in direction of axis of orbit; amaurosis; optic atrophy; movements of globe good.	Excision of tumour with preservation of globe.	Myxoma.	Twenty-five years later no recurrence; eyeball in good condition.
23	HOLMES. 1877.	10½ F. R.	Onset of exophthalmos towards end of patient's tenth year; blindness of affected eye noted some time later.	Exophthalmos in direction of axis of orbit; movements free; amaurosis; post-neuritic atrophy.	Excision of eyeball and tumour operation incomplete).	Myxo-Fibroma. (Knapp).	No recurrence after two years.
24	BRAILEY. 1877.	62 F. L.	Six months after a blow on the eye from a fist exophthalmos noted; twelve months after the injury vision entirely lost	Proptosis; limitation of movement in all directions; choked disc; amaurosis.	Excision of eyeball and tumour.	Fibroma.	End of two months orbital recurrence suspected.
25	VON FORSTER. 1878.	1½ M. K.	Nine months previously onset of strabismus and gradually developing exophthalmos.	Proptosis; limitation of movements; ulceration of totally anaesthetic cornea; palpable tumour; intraocular tension increased; optic neuritis; albuminuric-like changes in macular area; amaurosis.	Exenteration of orbit (including periosteum).	Fibro-nuclear tumour.	No recurrence about two years later.
26	ALT. 1878.	31 M. L.	Onset at age of twenty-five of exophthalmos, complicated, three years later, by epileptic seizures. Complete loss of vision for one year.	Proptosis; slight diminution of movement; optic atrophy; amaurosis.	Excision of eyeball and tumour. Attempt to preserve globe unsuccessful on account of severe hæmorrhage.	Endothelioma.	Recovery; epileptic seizures fewer after operation.
27	MAUTHNER-SCHOTT. 1878.	31 F. K.	Gradually increasing, painless exophthalmos for two years.	Proptosis; movements intact; amaurosis; post-neuritic atrophy; hypermetropia.	Excision of tumour with preservation of eyeball; globe subsequently removed on account of orbital cellulitis.	Glio-sarcoma.	Death from meningitis seven days after operation. P. M. showed large intracranial tumour.

No.	Author.	Age, Sex, Eye Affected.	Etiology and History of Onset.	Present Condition.	Operation.	Anatomical Diagnosis.	After Results.
28	STRAWBRIDGE, 1878.	24 F. R.	Right hemiplegia and limitation of vision for number of years. Total blindness for four years; Exophthalmos (coming on after confinement) for three years.	Exophthalmos; palpable tumor; amaurosis; hypermetropia; post-neuritic atrophy.	Extirpation of tumour with preservation of eyeball. (Perforation of cornea on tenth day and subsequent atrophy of globe.)	Glioma.	Some time later there was a post-neuritic atrophy in left eye, and "cerebral symptoms indicating central lesion."
29	WILLEMER, 1879.	6 F. R.	Onset of exophthalmos and limitation of vision 2½ years previously.	Marked proptosis; divergence of eyeballs; limitation of movement; amaurosis; optic neuritis.	Excision of eyeball and tumour.	Myxo-sarcoma.	Recovery.
30	WILLEMER, 1879.	4½ F. L.	At age of 4½ years, onset of convulsive seizures. In following year, during attack of typhoid, proptosis of eyeball, and later strabismus.	Exophthalmos; limitation of movement; amaurosis; post-neuritic atrophy; cloudiness of cornea; limitation of optic nerve of other side.	Excision of eyeball and tumour.	Myxo-sarcoma.	Death from meningitis 9 days after operation. Large intracranial growth found at P. M. examination.
31	WILLEMER, 1879.	14 F. L.	One and a half years gradual development of exophthalmos and diplopia.	Proptosis; limitation of movement; amaurosis; hypermetropia; V. f. n. - gers' r.	Excision of eyeball of orbit.	Myxo sarcoma.	No recurrence 15 months later.
32	KSAPP, 1879	2 M. R.	Protrusion of eye and failure of vision came on soon after a fall.	Exophthalmos; optic neuritis; mobility unimpaired.	Excision of tumour with preservation of eyeball. (A week later central ulcer of cornea developed, with shrinking of globe.)	Myxomatous gliosarcoma.	About nine months later choked disc on left side and signs of intracranial growth.
33	HIGGINS, 1879	5 F. L.	Two years previously proptosis and divergent strabismus. Loss of vision noted for months. Condition gradually improved, with other symptoms.	Exophthalmos; amaurosis; strabismus; slight restriction of movements.	Excision of eyeball and tumour.	Fibroma.	Mental condition of child improved after operation. No recurrence four months later.

64 *Primary Intradural Tumours of the Optic Nerve.*

No.	Author.	Age, Sex, Eye Affected.	Etiology and History of Onset.	Present Condition.	Operation.	Anatomical Diagnosis.	After Results.
34	RAMPOLDI 1886.	4 F. L.	Slowly and painlessly development upwards and downwards; rapid increase noted during last month; vision affected early in life.	Very marked proptosis; downward deviation; amaurosis.	Excision of eyeball and tumour.	Glio-sarcoma.	Recovery.
35	POSCET 1884.	16 F.	Onset of exophthalmos at age of three; development slow and painless; vision was entirely lost in tenth year.	Large orbital tumor, covered with conjunctiva and carrying degenerated bone; non-adherent to walls of dilated orbit.	Excision of tumour (after preliminary puncture).	Myxoma fastid.	Recovery.
36	PFLÜGER. 1884.	9 F. L.	Age of seven; febrile attack of 15 months, followed by slowly developing proptosis.	Esophthalmos; restriction of upward and outward movements; post-neuritic atrophy; V-fingers 2	Excision of eyeball and tumour.	Fibro-sarcoma.	Recovery; no note as to ultimate result.
37	HCC (RICHTER) 1882.	7 M. L.	Difficulty in walking; loss of vision and exophthalmos attributed to blow on eye from a stick two years previously.	Protruded proptosis; slow upward and outward movements; post-neuritic atrophy.	Excision of eyeball and tumour.	Fibro-sarcoma.	Death from meningitis 6 months after operation. P.M. exam showed intracranial portion of optic nerve also involved.
38	VOSSUS. 1882.	23 M. L.	Some weeks after birth peculiar appearance of face; exophthalmos developed after mild attack of opthalmia. One year previous onset of exophthalmos; eight days after a fall.	Esophthalmos; amaurosis; optic neuritis; movements good	Excision of eyeball and tumour.	Myxo-sarcoma.	No recurrence after three years.
39	VOSSUS 1882.	8 M. L.	Exophthalmos said to have followed whooping cough in year previous.	Esophthalmos; simple atrophy of optic nerve; some limitation of movement.	Excision of eyeball and tumour.	Myxo-sarcoma.	No recurrence eight months later.

No.	Author.	Age, Sex, Affected.	Etiology and History of Onset.	Present Condition.	Operation.	Anatomical Diagnosis.	After Result.
40	HULKE, 1882.	49 F. R.	Progressive loss of sight and increasing proptosis of globe since sixth year.	Extreme exophthalmos and great reduction of thalamicoscopic appearances.	Excision of eyeball and tumour.	Sarcoma.	Recovery; later result not stated.
41	VEROS, 1893	18 M. ?	For three years exophthalmos, pain and failure of vision.	Proptosis; limitation of movement of eyeball; trochlear atrophy of optic nerve; amaurosis.	Excision of eyeball and tumour.	Myxoma (undergoing fibroid change).	Recovery.
42	HESSELBERGER, 1893	18 F. L.	Rapidly increasing proptosis; sudden onset of complete blindness; colour spectra noted.	Exophthalmos; conjunctival atrophy; retinal haemorrhages; amaurosis; silver degeneration; movements of globe free.	Subperiosteal excision; perforation found in orbital floor.	Elastic neuroma.	No recurrence after five months.
43	AUER, 1884.	? F. ?	Exophthalmos and gradual loss of vision for several months; headache, dizziness and throbbing sensations in the eye.	Proptosis; slight optic neuritis (no swelling); conjunctival atrophy; felt to pass into retrobulbar tumour.	Excision of eyeball and tumour.	Myxo-sarcoma (ALT).	Recovery.
44	PARENTHY- DESPAGNET, 1884.	37 F. R.	Twenty years previously proptosis developed after an attack of typhoid, commencing with a proptosis by a size of right upper eyelid.	Exophthalmos; limitation of movement; optic atrophy; hypermetropia; conjunctival atrophy; palpable tumour; epiphora.	Excision of eyeball and part of growth. Fourteen weeks of tumour (excision of orbit).	Fibroma.	Death from ? meningitis two days after operation.
45	JOHNSON, PROBORN, 1885.	17 F. L.	Onset of exophthalmos at age of six; six months later eye found to be blind.	Marked exophthalmos; conjunctival atrophy; amaurosis; palpable tumour.	Excision of eyeball and tumour. External cauthotomy	Myxo-sarcoma.	No recurrence twenty months after operation.
46	VOSSLER, 1885.	50 F. L.	Dilatation of pupil and proptosis for four days; later proptosis increased; later variations in degree of protrusion noted.	Exophthalmos; palpable tumour; optic neuritis; conjunctival atrophy and amaurosis.	Excision of eyeball and tumour.	Myxo-sarcoma.	Recovery.

66 *Primary Intradural Tumours of the Optic Nerve.*

No.	Author.	Age, Sex, Eye Affected.	Etiology and History of Onset.	Present Condition.	Operation.	Anatomical Diagnosis.	After Result.
47	LAWSON, SR. 1885.	17 F. L.	No statement.	Marked bulging of eye and protrusion of ophthalmos; amaurosis.	Excision of eyeball and tumour.	Fibro-sarcoma.	Recovery.
48	KUNACHOWITZ. 1885.	18 F. R.	Onset of exophthalmos at age of eight; vision lost for more than three years.	Enlargement proptosis amaurosis; movements slightly impaired; optic dilatation of orbit.	Excision of eyeball and tumour.	Fibro-cellular and hamor- rhagic.	Recovery.
49	STRAUB. 1886.	11 M. R.	Slowly increasing exoph- thalmos for one year.	Proptosis; amaurosis; optic neuritis; palpable tumour.	Excision of eyeball and tumour.	Glioma.	No recurrence after ten months.
50	BULLER. 1886.	7 F. R.	Onset of proptosis six months; receding exoph- thalmos; at least two months.	Exophthalmos; slight proptosis; amaurosis; movements; amaurosis; optic neuritis.	Excision of eyeball and tumour.	Fibroma tosis nervi optici.	Patient still living.
51	WOLFFHID. 1887.	8 M. L.	Gradual development of proptosis.	Exophthalmos; optic neuritis; hemorrhages and proptosis; palpable tumour.	Excision of eyeball and tumour.	Myo-sarcoma.	
52	FROTSHINGHAM 1887.	7 M. R.	Exophthalmos, and total blindness noted for one month.	Proptosis; optic neuritis; amaurosis; scrophulous enlargement of cervical glands.	Excision of eyeball and tumour.	Round-cell sar- coma.	No recurrence after five years.
53	FROTSHINGHAM. 1887.	19 F. L.	"Some time" after attack of frontal headache, ver- tigo, and vomiting, consist- ing of left side, exoph- thalmos and loss of vision noted.	Proptosis (rapid increase noted); amaurosis with- out proptosis; optic neuritis; change; constant dull pain in eye.	Excision of eyeball and tumour.	Round-cell sar- coma.	No recurrence at time of reporting.
54	LAWSON, SR. 1888.	12 M. L.	Exophthalmos noted for two months.	Proptosis; movements good; post-nervitic atrophy; V-p1.	Excision of eyeball and tumour.	Sarcoma, under- going myxoma- tous degenera- tion. (Lawford).	Patient well five months later.

No.	Author.	Age, Sex, Eye Affected.	Etiology and History of Onset.	Present Condition.	Operation.	Anatomical Diagnosis.	After Result.
55	SCHIESS, GERMSEUS 1888.	12 $\frac{1}{2}$ F. R.	Onset of exophthalmos three years previously. Very marked variations in acuity of vision noted from time to time.	Prominent displacement of globe; limitation of movement; optic neuritis; fatty changes in macula; vision rapidly before operation.	Excision of tumour with preservation of eyeball.	Myo-sarcoma.	Eyeball successfully preserved. No recurrence a few months later.
56	AYRES, 1889.	12 M. R.	Optic neuritis and amblyopia, with subsequent partial improvement of vision and amaurosis.	Exophthalmos in addition to symblepharon. Movements unimpaired.	Excision of eyeball and tumour.	Small round-cell sarcoma.	Patient still living in May, 1900 (Ayres).
57	AYRES, 1889.	24 F. R.	Proptosis and loss of vision apparently due to fall on back of head at age of eight years.	Exophthalmos; optic atrophy; movements normal; amaurosis.	Excision of eyeball and tumour.	Myo-sarcoma.	Died from typhoid six weeks after operation (Ayres).
58	SYM, 1889.	3 F. L.	Onset during attack of whooping cough one year previously. Pain and failure of general health later on.	Exophthalmos; amaurosis; palpable tumour.	Excision of eyeball and tumour.	Sarcoma.	Improvement of general health a few weeks after operation.
59	GUARAN, 1889.	41 M. R.	Onset of exophthalmos without cause over a year previous.	Fulness of retinal veins, going on later to papillitis and amaurosis. Vision very slightly affected. Proptosis; limitation of movement.	Excision of eyeball and tumour.	Fibro-sarcoma.	Recovery.
60	SCHIESS, GERMSEUS 1890.	36 F. R.	Failure of vision for three years. One year previous to operation optic neuritis; proptosis six months later; proptosis and slight limitation of movement.	Exophthalmos; optic neuritis; limitation of movement; diplopia; palpation negative.	Excision of eyeball and tumour.	Fibro-sarcoma.	One year later no recurrence, but traumatic ptosis remained.
61	VON GARBEK, 1891.	15 F. R.	Gradually increasing proptosis and failure of vision for one year.	Proptosis and optic neuritis with maintenance of good movement.	Excision of eyeball and tumour.	Myo-sarcoma.	No recurrence after three years.

68 *Primary Intradural Tumours of the Optic Nerve.*

No.	Author.	Age, Sex, Eye Affected.	Etiology and History of Onset.	Present Condition.	Operation.	Anatomical Diagnosis.	After Result.
62	KESLER, 1892.	5 L.	Onset of proptosis at age of one and a half years. No cause.	Ephthalmalms; limitation of movement; optic neuritis; amaurosis (or very poor V).	Excision of eyeball and tumour.	Fibros-myxo-sarcoma.	Recovery.
63	LAGRANGE, 1891.	13 M. L.	Ephthalmalms and total blindness noted for three months. History of internal haemorrhages almost entirely absent at the region at age of ten or eleven.	Marked exophthalmos; amaurosis; "profuse retinal haemorrhages almost entirely absent at the papilla.	Excision of eyeball and tumour.	Myxo-sarcoma.	Five months later no recurrence. Corneal ulceration and protrusion of globe after operation.
64	NOERING, 1892.	3 F. L.	Prominence of eye noted for six months.	Ephthalmalms; hypermetropia; slight optic neuritis.	Excision of eyeball and tumour.	Fibros-Sarcoma.	No signs of recurrence nine months later.
65	ROHMER, 1892.	15 F. R.	Deviation of right eye noticed for two months.	Ephthalmalms; convergent strabismus; optic neuritis; hypermetropia; palpable tumour.	Excitation of tumour with preservation of eyeball.	"Fibrous lymphangio-ectasisque."	No recurrence eight months after operation. Slight wasting of globe six months later.
66	NORTON, 1892.	30 F. R.	Gradually increasing proptosis for past ten or fifteen years. Orbital pain for five years.	Exophthalmos; post-neuritic atrophy; greatly impaired vision.	Excitration of tumour with preservation of eyeball.	Myxoma (microscopical examination not made).	Preserved eyeball in excellent condition eighteen months later.
67	SATTLER, 1892.	3 F. R.	Onset with strabismus at age of one year. Strabismus later gradually increasing. History of frequent attacks of convulsions.	Ephthalmalms with good mobility; optic neuritis; amaurosis.	Excitration of tumour with preservation of eyeball.	Myxo-fibroma.	Six months later eyeball, slightly shrunken, in a normal position and convergent.
68	SATTLER, 1892.	7 M. R.	Divergent strabismus at age of two years. Early loss of vision.	Proptosis; papillitis; amaurosis.	Excision of eyeball and tumour.	Myxo-fibroma.	Recovery.
69	SATTLER, 1892.	4 F. L.	No history; orbital pain during last few weeks.	Enormous proptosis; movements greatly restricted; optic atrophy; amaurosis.	Excision of eyeball and tumour.	Myxo-fibroma.	No recurrence fourteen months later.

No.	Author.	Age, Sex, Eye Affected.	Etiology and History of Onset.	Present Condition.	Operation.	Anatomical Diagnosis.	After Result.
70	SATTLER. 1892.	Adult ? R. & L.	"Atrophy of both optic nerves for a long time during life."	No other symptoms of optic nerve tumours present.	Condition found <i>post mortem</i> .	t	
71	SALZER. 1892.	1½ M. L.	3 months after birth strabismus noted by parents. In last few weeks increase of muscular condition and onset of proptosis.	Exophthalmos: limitation of movement; optic neuritis; partial detachment of retina; amaurosis.	Excision of eyeball and tumour.	Tubular angio-sarcoma.	About seven weeks later exenteration of orbit for recurrence. Three months after above second recurrence and signs of intracranial growth.
72	ROCKLIFFE. 1893.	20 M. L.	Gradually increasing proptosis since age of eighteen or nineteen.	Exophthalmos: moderate reduction of vision; optic neuritis? Movements free.	Excision of eyeball and tumour.	Glioma (Treacher Collins).	No recurrence over six years later (Br. Med. Jour., 1899, p. 1419).
73	TAILOR. 1893.	18 F. ?	Severe pain referable to first division of fifth nerve ushered in loss of vision, soon ending in complete blindness. Later onset of proptosis. History of blow at age of seven.	Exophthalmos: eyeball in glaucomatous condition; amaurosis; movements restricted.	Excision of eyeball and tumour.	Endothelioma.	Recovery: signs of recurrence end of a year.
74	BRAUNSCHWEIG. 1893.	7 M. L.	Gradually increasing exophthalmos for five or six years.	Proptosis: post-neuritic atrophy; amaurosis; limitation of movements; hypermetropia; mild degree of idiocy.	Excision of tumour, with preservation of eyeball. (Globe subsequently removed because of extensive ulceration of cornea.)	Myxo-sarcoma.	No recurrence after six years.
75	BRAUNSCHWEIG. 1893.	15 F. R.	Slowly increasing proptosis, without pain and gradual loss of vision for two years.	Exophthalmos, with limitation of all movements; optic neuritis; great reduction of vision; irregular constriction of field of vision.	Excision of tumour with preservation of eyeball.	Myxo-sarcoma.	Three years later no recurrence; globe in good condition, but only fair position.
76	BRAUNSCHWEIG. 1893.	1½ M. L.	Towards end of first year of life onset of strabismus and rapidly developing proptosis. Latterly loss of memory and convulsions.	Exophthalmos; amaurosis; post-neuritic atrophy; hypermetropia; limitation of movements; symptoms of intracranial growth.	Excision of tumour, with preservation of eyeball (Kronlein's operation).	Myxo-sarcoma.	Death four weeks after operation apparently from intracranial tumour. Eyeball remained in situ.

70 *Primary Intradural Tumours of the Optic Nerve.*

No.	Author.	Age, Sex, Eye Affected.	Etiology and History of Onset.	Present Condition.	Operation.	Anatomical Diagnosis.	After Result.
77	BRUNSCHWEIG, 1893.	44 M. L.	Proptosis and failure of vision for one and a half years.	Exophthalmos; restriction of vision; optic neuritis; marked impairment of vision; concentric narrowing of field of vision.	Excision of tumour of eyeball (Klein's operation).	Myxo-sarcoma.	Three months later eyeball in excellent position.
78	SALZMANN, 1893.	5 F. ?	No statement.	Ditto.	Excision of tumour with preservation of eyeball.	Myxo-sarcoma.	44 years later no recurrence; eyeball shrunken to size of pea.
79	SALZMANN, 1893.	46 M. ?	Failure of vision noted for twenty-five years; proptosis for nine months.	Exophthalmos; amaurotic atrophy of optic nerve.	Excision of tumour of eyeball.	Myxo-sarcoma.	34 years later no recurrence; eyeball atrophic.
80	SALZMANN, 1893.	9 F. L.	Blindness of left eye with proptosis for one year.	Marked exophthalmos; optic neuritis; spotted opacity and vascularization of retina; photophobia, etc.	Excision of eyeball and tumour.	Myxo-sarcoma.	No recurrence 44 years after operation.
81	ADAMICK, 1893.	17 F. K.	Exophthalmos existed several years and developed gradually without pain.	Marked proptosis; movements normal; amaurotic atrophy; palpable tumour.	Excision of tumour with preservation of eyeball.	Glioma.	34 months later no recurrence; globe in position.
82	ADAMICK, 1894.	35 M. L.	Failure of vision in fourth year, followed by gradual blindness in fifth year. Latterly headache and orbital pain.	Large cylindrical tumour bulging from distal end of optic nerve; remains of globe; other parts covered by thick, white, opaque, opalescent exudate; seated fluctuation; pain.	Excision of tumour.	Myxo-sarcoma.	Death from meningitis 11 days after operation.
83	BURNETT, 1894	7 M. L.	Proptosis and failure of vision apparently followed by gradual blindness (at age of four or five) and were associated with irregular action of heart.	Exophthalmos; restriction of movements; proptosis; amaurotic atrophy; palpable tumour.	Excision of eyeball and tumour.	Mesoblastic (no special designation).	Death from intracranial glioma 15 months after operation. Clinical picture of primary tumour of optic nerve was repeated in right eye.

No.	Author.	Age, Sex, Eye Affected.	Etiology and History of Onset.	Present Condition.	Operation.	Anatomical Diagnosis.	After Result.
84	DR VINCENTS. 1894.	10-12 M. R.	Onset of proptosis noted four years previously; gradually increased; gradually greatly diminished.	Exophthalmos; limitation of movements; post-operative; great relief; limitation of vision.	Excision of tumour with preservation of eyeball.	Myxo-sarcoma.	One year later no recurrence; eyeball in normal position even after advancement of internal rectus.
85	ARHLSTROM. 1894.	? R. ?	Onset of proptosis over three years previous; vision at first good; gradually diminished; protrusion of head and over right eye in last few months.	Exophthalmos; slight limitation of all movements; post-neuritic atrophy; supraorbital neuralgia.	Excision of eyeball and tumour.	Fibro-myxo-sarcoma.	Recovery.
86	SCHLESS. GEMUSEUS. 1895.	14 M. L.	Exophthalmos and failure of vision for two years.	Proptosis; limitation of movements; post-neuritic atrophy; hypermetropia.	Excision of tumour with preservation of eyeball.	Fibroma.	Globes remained in situ but in divergent position. Small corneal cicatrix.
87	WIEGMANN. 1895.	5 F. L.	Proptosis for eight months. Daily recurring headache, especially over left eye.	Exophthalmos; strabismus; deorsum vergens; progressing optic atrophy; sarcoma; trabecular glaucoma.	Excision of eyeball and tumour.	Fibro sarcoma.	No recurrence six months later.
88	MÜLLER. 1896.	8 M. L.	No statement.	Ditto.	Excision of eyeball and tumour.	Myxo-sarcoma.	Recovery.
89	KALT. 1897.	5 M. R.	Gradually increasing proptosis for two years.	Exophthalmos; movements almost entirely conserved; slight opacity lower part of cornea.	Excision of tumour with preservation of eyeball.	Sarcoma endothelial.	Suppuration; eyeball removed three days later; death ten days after operation.
90	SCALIN. 1897.	13 M. R.	Exophthalmos and reduction of vision noted for four years.	Noticable exophthalmos; post-neuritic atrophy. V _{OD} : H 3.5 D.	Excision of tumour with preservation of eyeball.	Myxo-sarcoma.	About three years later no signs of recurrence; but Klobé not shrunken. T.
91	DELLUS. 1898.	13 M. R.	Onset of exophthalmos two years previously; six months later marked reduction of vision noted.	Marked proptosis; limitation of movement; eyeball protruding; under anaesthetic; superficial keratitis; amaurosis.	Excision of eyeball and tumour.	Myxo-sarcoma.	No recurrence one year later.

No.	Author.	Age, Sex, Eye Affected.	Etiology and History of Onset.	Present Condition.	Operation.	Anatomical Diagnosis.	After Result.
92	BULLER- MARSHALL 1898.	36 F. L.	Proptosis and failure of vision noticed for five years.	Exophthalmos; amaurosis; movements normal; pallor of optic disc; no change in vessels.	Excision of eyeball and tumour.	Glioma.	Recovery. No recurrence three and one-half years later. (<i>Br. Med. Jour.</i> , 1899, p. 1419.)
93	LAWSON, JR. 1898.	2 F. L.	Loss of vision noted for about 3 months. Increase in proptosis, descending optic atrophy, limitation of movements, etc., came on under observation.	Exophthalmos; limitation of movement; optic atrophy.	Exenteration of orbit.	Myxo-fibroma.	The child was quite well fourteen months after operation
94	ELLINGER, 1899.	10 F. L.	Strabismus and proptosis apparently followed stomatitis aphthosa 2 years previously.	Exophthalmos; movements good; palpable tumour; post-neuritic atrophy.	Excision of tumour with preservation of eyeball. (Kronlein's operation).	Myxo-sarcoma.	Three months after operation globe in excellent position.
95	AYENFELD- BUSCH. 1899.	11 F. R.	Periodical attacks of headache, accompanied by sensations of heat and cold, and vomiting for 6 to 8 months; onset of proptosis, with headache.	Picture unusual; proptosis varied in degree; at one time increase with pyrexia and swelling behind angle of jaw; at another with pain in eye, vomiting and pyrexia; recent optic neuritis; sudden reduction of vision, etc.	Excision of tumour with preservation of eyeball. (Kronlein's operation).	Myxo-sarcoma.	One year later no recurrence; globe in good position.
96	BULLER, 1899.	6 M. R.	Onset with strabismus about age of 3 months; proptosis noted soon afterwards; at age of 4 rapid increase in exophthalmos and convulsive seizures; mental condition afterwards weak.	Exophthalmos with good movement; post-neuritic atrophy; marginal keratitis.	Excision of tumour and eyeball.	Fibromatosis nervi optici.	Dr Silver, family physician, reports that child died ten months after operation. Symptoms characteristic of intracranial growth.
97	GERMANN, 1899.	18 F. L.	Slowly increasing proptosis and failure of vision for 2 years.	Exophthalmos; movements only slightly impaired; amaurosis; post-neuritic atrophy; corneal cicatrix downward.	Excision of tumour and eyeball.	Angio-sarcoma with partial myxomatous degeneration.	Recovery.

No.	Author.	Age, Sex, Eye Affected.	Etiology and History of Onset.	Present Condition.	Operation.	Anatomical Diagnosis.	After Result.
98	SCHLODTMANN 1899	30 F. L.	In patient's 30th year gradually increasing loss of vision, with hemicrania, nausea, vomiting and giddiness, came on after confinement; exophthalmos appeared later	Exophthalmos in line of orbital axis; limitation of movement; amaurosis; post-neuritic atrophy; from O.D. to macula connective-tissue band, result of ancient hæmorrhage; hypermetropia	Excision of tumour with preservation of eyeball.	Myxo fibroma.	18 months after operation no recurrence; eyeball in good position, with perfect movement.
99	COLLINS-MARSHALL. 1899	5 M. R.	Gradually increasing proptosis and failure of vision for 8 months.	Exophthalmos; post-neuritic atrophy; V-hand movements; hypermetropia increasing under observation.	Excision of eyeball and tumour.	Not designated.	Recovery.
100	COLLINS-MARSHALL. 1899.	46 F. R.	Failure of vision for 9 months.	Proptosis; amaurosis; free movement; detachment of retina; retinal hæmorrhages	Exenteration of orbit.	Ditto.	Died 2½ years later; enormous intracranial growth found post-mortem.
101	GOLOWIN. 1899	4 M. R.	Onset of exophthalmos 1 month after fall upon forehead, which occurred 10 months previously.	Proptosis with relatively good movement; optic neuritis; amaurosis; palpable tumour.	Excision of tumour with preservation of eyeball. (Kronlein's operation.)	Fibro-myo-sarcoma.	6 months later no recurrence globe preserved; but sunken and adducted; movement slight
102	BYERS. 1901.	17 F. L.	Loss of vision noted at age of 15; some months later onset of proptosis	Proptosis; impaired movements in all directions except down; optic neuritis; amaurosis.	Excision of tumour with preservation of eyeball.	Fibromatosis neuro-optic.	Orbital recurrence six months later; death from intracranial growth about 10 years later.

BIBLIOGRAPHY.

I. PRIMARY INTRADURAL TUMOURS OF THE OPTIC NERVE.

- (1) WISHART : A case of extirpation of the eyeball. *Edinburgh Med. and Surg. Jour.*, XL, p. 274* 1833.
- (2) MIDDLEMORE : Extirpation of the eye on account of a tumour developed within the optic sheath. *London Med. Gazette*, XXII, p. 897* 1838.
- (3) HEYMANN : De neuromata nervi optici. Inaugural Dissertation, Berlin, 1842†; also Böhm "Das Schielen und der Sehnenschnitt in seinen Wirkungen auf Stellung und Sehkraft der Augen," Berlin, 1845, p. 448,* and abstract by Wilde, *Dublin Quart. Jour. Med. Sc.*, III, p. 231.
- (4) ROUX : Tumeur intraorbitaire, etc., etc., *Gazette des hôpitaux*, 1844, p. 362.
- (5) DOUBOUÉ : Nevrome du nerf optique droit, *Bull. de la Soc. Anatom. de Paris*, XXXIV, p. 178, 1859.
- (6) LIDELL : A case of neuroma of the optic nerve. *N.Y. Jour. of Med.*, VIII, p. 151, 1860* : also as pamphlet (N.Y. 1860), abstracted by Noyes in his "Diseases of the eye" 2nd Ed. p. 738 : also fully given in *Ranking's "Extracts,"* XXXII, p. 107.
- (7) SZOKALSKI : Tumeur squirrhus-cancereuse du nerf optique, *Annales d'oc.*, XLVI, p. 43, 1861.
- (8) RITTERICH : Case 1 under "Neubildungen," Weitere Beiträge Zur Vervollkommnung der Augenheilkunst, Leip. u. Heid. *C. F. Winter*, 1861, p. 57.*
- (9) ROTHMUND, JR. : Neurom (cystöse Degeneration) des Sehnerven, *Klin. Mon-Bl. für Augen.*, I, p. 261, 1863.* Abstract *Ann. d'oc.*, LI, p. 108.
- (10-11) VON GRAEFE : Zur Casuistik der Tumoren. *Archiv für Oph.*, X, p. 193, 1864.
- (12) VON GRAEFE : Tumor orbitae et cerebri. *Archiv für Oph.*, XII, p. 100.
- (13) SEGGER : Über plötzliche Erblindungen, *Bayer. Aerz-Intelligenz-Bl.*, XVII, p. 171.
- (14) QUAGLINO-MANFREDI : (a) Contribuzione alla storia clinica dei tumori dell'occhio. osservazione III. *Annali di Ottamologia*, I, p. 27, 1871, (Quaglino) (b) Missoma del nervo ottico, esame anatomico. *Ann. di Ottal.*, I, p. 337, 1871* (Manfredi). See also *Annal. d'oc.*, LXV, p. 252 and LXVIII, p. 71 for abstracts.
- (15) SICHEL : Note sur les tumeurs de l'orbite et principalement sur le myxome du nerf optique. *Gaz. heb. de Med. et de Chir.*, VIII, p. 165, 1871 ; also *Annal. d'oc.*, LXV, p. 279 and *R.O.H. Repts.*, p. 272, 1871.

*The asterisk indicates that the article in question is accompanied by illustrations.

†The dagger indicates that the article has not been studied by the author in the original.

- (16) NARKIEWICZ-IOKO: Case in Medical report of Lubomirskiego Oph. Institute. *Gazeta Lekarska*, XIII, p. 804, 1872; also *Nagel's Jahresbericht*, 1872, p. 363.
- (17) PERLS-LOCH: (a) Ein Fall von Neuroma verum; *Archiv für Oph.*, XIX, p. 287* (Perls) (b) *Inaugural Dissertation*, Greifswald, 1874 (Loch).
- (18-20) GOLDZIEHER: Die Geschwülste des Sehnerven, *Archiv für Oph.*, XIX, p. 119.
- (21) CHRISTENSEN: Tumor nervi optici. *Hosp. Tid. Kjøbenh.*, 1875, 2 R, II, p. 817. Abstract *Nagel's Jahresbericht*, 1875, p. 386.
- (22) GRÜNING: A case of myxoma of the optic nerve; removal of growth with preservation of the eyeball. *Archives of Oph.*, V, p. 508; also *Archiv für Augenheilk.*, VI, p. 35.
- (23) HOLMES: Thirteen cases of ocular tumour with a case of tumour of the optic nerve, etc. *Archives of Oph.*, VI, p. 291, 1877.
- (24) BRAILEY: Fibrous tumour of the optic nerve. *R.O.H. Repts.*, IX, II, p. 231, 1877.
- (25) vox FORSTER: Zur Kenntniss der Orbitalgeschwülste, deren Ausgangspunkte und Fortpflanzungsbahnen. *Archiv für Oph.*, XXIV, p. 103, 1878.*
- (26) ALT: A case of endothelioma of the intervaginal space of the optic nerve, etc. *Arch. of Oph.*, VI, p. 367, 1878. Translation *Arch. für Augen*, VII, p. 40.
- (27) MAUTHNER-SCHOTT: (a) Gliosarcom Nervi optici et cerebri. *Wiener Med. Presse*, XIX, p. 111, 1878 (Mauthner). (b) Mittheilungen über Erkrankungen des Opticus (Gliosarcom des rechten opticus) *Archiv für Augen*, VII, p. 81, 1878* (Schott).
- (28) STRAWBRIDGE: Tumour of the optic nerve; its removal without enucleation of the eyeball. *Tr. Am. Oph. Soc.*, 1878, p. 383.
- (29-31) WILLEMER: Über eigentliche d.h. sich innerhalb der äusseren Scheide entwickelnde Tumoren des Sehnerven. *Inaug. Diss. Göttingen*, 1879* and (same title) *Archiv für Oph.*, XXV, p. 189, 1879.*
- (32) KNAPP: Tumour of the optic nerve. *Tr. Amer. Oph. Soc.*, 1879, p. 557.*
- (33) HIGGINS: Tumour of the optic nerve. *Br. Med. Jour.*, 1879, p. 616.
- (34) RAMPOLDI: Gliosarcome du nerf optique. *Compte rendu du Cong. internat. d'oph. Milan*, 1880, p. 333.* See especially *Annali di ottal.*, Vol. X, p. 121.*
- (35) PONCET: Myxome fasciculé du nerf optique. *Archiv d'oph.*, I, p. 616, 1881.*
- (36) PFLÜGER: Fibrosarcom nervi optici. *Bericht der Augenklinik in Bern über das Jahr*, 1880, p. 45.
- (37) HUC: Essai sur les tumeurs du nerf optique. *Thèse de Paris*, 1882.* See also *Paris Méd.*, VII, p. 529, 1882.

- (38-39) VOSSIUS : Das Myxosarcom des Nervus opticus ; Beitrag zur Lehre von den wahren d.h. innerhalb der äusseren Scheide sich entwickelnde Sehnervengeschwülsten *Arch. für Oph.*, XXVIII, p. 33.*
- (40) HULKE : On a case of spurious neuroma of the optic nerve. *Oph. H. Repts.*, X, p. 293, 1882.
- (41) VERON : Myxo-fibrome du nerf optique, etc. *Recueil d'oph.*, V, p. 32.
- (42) HESSDÖRFFER : Über eine wahre Opticusgeschwulst. *Inaug. Diss. Würzburg*, 1883.
- (43) AUB : Two cases of orbital tumours. *Am. Jour. Oph.*, I, p. 243, 1884.
- (44) PARISOTTI-DESPAGNET : Fibrome du nerf optique. *Rec. d'Oph.*, VI, p. 720* and VII, page 218 (additional note).
- (45) JOHNSON-PRUDDEN : Myxo-Sarcoma of the optic nerve with hyaline degeneration. *Arch. of Oph.*, XIV, p. 151.*
- (46) VOSSIUS : Über Sehnervengeschwülste. *Berlin. Klin. Woch.*, XXII, p. 199, 1885.* Abstract *Phil. Med. Times*, XVI, p. 46.
- (47) LAWSON, SR. : Tumours of optic nerve. *Diseases and Injuries of the Eye*, 5th ed., p. 238, 1885.*
- (48) KUNACHOWITCH : † Myxoma of optic nerve. *Medit. Obozrainic*, XXIV, p. 293, 1885. See Jocqs' Thèse (126) for French translation.
- (49) STRAUB : Die Geschwülste des Nervus opticus. *Archiv. für Oph.* XXXII, p. 206, 1886 (Subdivision of a paper entitled "Die Gliome des Sehorgans.")
- (50) BULLER : Tumour of the optic nerve. *Canada Med. and Surg. Jour.* XV, p. 306, 1886 ; also *Phil. Med. News*, 1886, p. 555, and this paper.
- (51) WOLFHEIM : Über die eigentlichen Sehnervengeschwülste. *Inaugural Dissertation. Königsberg*, 1887.*† See Ayres (56).
- (52-53) FROTHINGHAM : Two cases of tumour of the optic nerve. *Jour. of Amer. Med. Assoc.*, IX, p. 741* 1887. See also *Archiv. d'Oph.*, 1887, p. 480.
- (54) LAWSON, SR. : A case of tumour of the optic nerve, *R. O. H. Repts.*, XII, p. 1-6*, 1888.
- (55) SCHIESS-GEMUSEUS : Totales Myxosarcom des Opticus, extirpiert mit Erhaltung des Bulbus. *Arch. für Oph.*, XXXIV, p. 226-240,* 1888. (Finished report of a case in the *Bericht der Augenheilanstalt in Basel* for 1886, p. 53).
- (56) AYRES : Tumours of the optic nerve, with report of two original cases. *Jour. Amer. Med. Assoc.*, XIV., p. 325-331, 1890. also *Amer. Jour. Oph.*, VII, p. 69-87, and separate pamphlet (R. Clarke & Co., Cincinnati, 1890, 38, 8*).
- (58) SYM : On tumours of the optic nerve. *Brit. Med. Jour.*, Sept 1889, p. 717. Also *Oph. Review*, VIII, p. 306, 1889.
- (59) GUARAN : Fibro-sarcome du nerf optique. *La Normandie Med.*, IV, p. 385, 1887.

- (60) SCHIESS-GEMUSEUS: Tumor nervi optici; Exstirpation mit bleibender Heilung. *Augenheilanstalt in Basel; Jahresbericht für 1889*, Basel 1890, p. 55.
- (61) VON GARNIER: Ein Fall von Myxosarcom des Opticus. *Klin. Mon. Bl. für Augen.*, XXIX, p. 208-217,* 1891.
- (62) KESSLER: Intervaginaal fibro-sarcom van den nervus opticus. *Weekblad V.H.Neder. Tijdsch. v. Genees*, XXVII, p. 781,* 1891.
- (63) LAGRANGE: (a) Sarcome du nerf optique; extirpation totale du nerf sans ablation du globe oculaire. *Mem. et Bull. Soc. de Med. et Chir. de Bordeaux*, 1892, p. 352-362. Same report in *Journ. de Med. de Bord.*, XXXI, p. 149-150, 1891. Further pathological study of this case under "Note sur un cas de myxosarcome du nerf optique" in *Journ. de Med. de Bord.*, XXXII, p. 78-80, 1892, and also as "Note anatomopathologique sur un cas du myxosarcome du nerf optique" in *Bull. Soc. d'Anatom. et Phys. de Bord.*, XIII, p. 30-34, 1892.
- (b) Complete report of above in paper "De la conservation du globe oculaire dans l'ablation des Tumeurs du nerf optique; description d'un procédé nouveau," *Cong. Franc. de Chir. proc. verb.*, VI, p. 189, 1892, (*The best reference to use*). Resumé of above in *Gazette d'Hop.*, LVI, p. 435, 1892.
- (64) NOERING: Über einen Fall von Fibrosarcom des nervus opticus. *Inaug. Diss. Königsberg*, 1892.
- (65) ROHMER: Observation de fibrome lymphangiectasique du nerf optique. *Bull. et Mem. de la Soc. franc. d'Oph.*, May, 1892.* Also *Arch. d'Oph.* XII, p. 554* 1892 (same title).
- (66) NORTON: The removal of a tumour of the optic nerve with preservation of the eye. *Arch. of Oph.*, XXI, p. 356,* 1892.
- (67) SATTLER: Über die eigentlichen Sehnerventumoren und ihre chirurgische Behandlung. *Beiträge zur Chir. Festschrift Th. Billroth's Geburtstag*, 1892, p. 314.*
- (71) SALZER: Über ein primäres tubulöses Angiosarcom des Sehnerven. *Arch. für Oph.*, XXXVIII, p. 33.*
- (72) ROCKLIFFE: Notes on a case of tumour of the optic nerve. *Trans. Oph. Soc., U. K.*, XIII, p. 101*, 1893; also *Lancet*, p. 1444*, 1893.
- (73) TAILOR: Endotelioma dell guaine del nervo ottico. *Lav. d. Clin. Oc. d. r. Univ. di Napoli*, 1891-1893, 111, p. 147-173*; also (same title), *Ann. di Ottal.*, 1894, XXIII, p. 18-50.*
- (74) BRAUNSCHWEIG: Die primären Geschwülste des Sehnerven. *Archiv. für Oph.*, XXXIX, p. 1-93,* 1893.
- (78) SALZMANN: Studien über das Myxosarcom des Sehnerven. *Archiv. für Oph.*, XXXIX, p. 94-130,* 1893.
- (81) ADAMÜCK: Zur Frage über den Einfluss der Choroidea auf die Ernährung der Retina. *Archiv für Augenheilkunde*, XXVII, p. 256, 1893.

- (82) ADAMÜCK: Zwei Fälle von Neubildungen (des Nervus opticus und der Orbita) mit letalem Ausgang. *Archiv für Augenheilk.*, XXXVIII, p. 129.
- (83) BURNETT: Tumour of the intervaginal space of the optic nerve sheath. *Trans. Amer. Oph. Soc.*, 1894, p. 81-91.*
- (84) DEVINCENTHIS: Sull asportazione di un tumore del nervo ottico con conservazione del bulbo, etc. *Atti. d. r. Accad. Med. Chir. di Napoli*, XLVIII, 256-262; also (same title), *Lav. di Clin. Oc. d. r. Univ. di Napoli*, IV, 175-180, 1895; also (later note) Stato dell'occhio e suoi annessi nell'infermo operato da un anno di asportazione di un tumore del. n. ottico. *Atti. d. r. Acc. Med. Chir. di Napoli*, XLIX, 219-221, 1895.
- (85) AEHLSTROM: Tumor nervi optici. *Beiträge zur Augenheilk.*, 11, p. 526,* 1894.
- (86) SCHIESS GEMUSEUS: Fibroma Nervi optici, operiert mit Erhaltung des Bulbus. *Augenheilkunst in Basel: Bericht über das Jahr. 1894.* Basel, 1895, p. 57.
- (87) WIEGMANN: Ein Fall von primärem Fibrosarcom des Sehnerven. *Klin. Mon. Bl. für Augen.*, XXXIII, p. 272, 1895.
- (88) MÜLLER: Über einen Fall von Sehnervengeschwulst. *Inaug. Dissertation Jena*, 1896.*
- (89) KALT: Sarcome endothelial du nerf optique. *Rec. d'Oph.*, XIX, 135-139, 1897; also *Annal. d'Oc.*, CXXII, p. 277-299.
- (90) SCALINCI: Di un mixo-sarcoma del nervo ottico asportata con conservazione del bulbo. *Lav. d. Clin. oc. d. r. Univ. di Napoli*, V, p. 121-171,* 1897.
- (91) DELIUS: Über einen Fall von primärer eigentlichen Sehnervengeschwulst. *Inaug. Diss. Tübingen*, 1898.*
- (92) BULLAR-MARSHALL: Tumour of the optic nerve. *Trans. Oph. Soc. U.K.*, XIX, p. 110, 1898-'99.
- (93) LAWSON (Arnold): A case of myxo-fibroma of the optic nerve sheath. *Tr. Oph. Soc. U. K.*, XIX, p. 123, 1898-'99.*
- (94) ELLINGER: Myxosarcom des Sehnerven operiert nach Krönlein mit Erhaltung des Bulbus. *Zeitschr. für Augen*, I, p. 48, 1899.*
- (95) AXENFELD-BUSCH: Ein Beitrag zur klinischen Symptomatologie und zur Histologie des primären Myxosarcoms des Sehnerven sowie zur operativen Behandlung desselben nach der Krönleinschen Methode. *Archiv für Augenheil.* XXXIX, p. 1-21, 1899.*
- (96) BULLER: A case of primary tumour of the optic nerve. *Tr. Amer. Oph. Soc.*, 1899, p. 510*
- (97) GERMANN: Zur Casuistik der Tumoren des Sehnerven; Angiosarcom mit theilweiser myxomatöser Degeneration. *Klin. Mon. Bl. für Augenheil.*, XXXVII, p. 319, 1899*: Abstract in *Zeitschr. für Augenheil.*, III, p. 543, from *Westnik oftalm.* No. 6, 1899.

- (98) SCHLODTMANN: Über die Exstirpation retrobulbärer Tumoren mit Erhaltung des Augapfels und das klinische Verhalten der Bulbi nach der Operation. *Festschrift f. A. von Hippel* (Halle, Karl Marhold) 1899.*
- (99-100) COLLINS-MARSHALL: Two cases of primary neoplasm of the optic nerve. *Tr. Oph. Soc. U. K.*, XX, p. 156, 1900*. See also *B. M. J.*, 1899, p. 1419, and Marshall. "Further note on a case of Optic nerve tumour previously reported to the society." *Tr. Oph. Soc. U. K.*, 1900, p. 164.
- (101) GOLOWIN:† Krönlein's Operation in einem Fall von Sehnerventumor. *Westnik oftalmol.*, No. 4-5, 1899. Abstract: *Zeit. für Augenheilk.* III, p. 544 (used in this paper.)

II. PRIMARY EXTRADURAL TUMOURS OF THE OPTIC NERVE.

- (103) SCARPA † (1816): Case quoted by Demarquay. *Traité des Tumeurs de l'orbite*. Paris 1860. See also Joëqs (126).
- (104) WARDROP (1834): *Morbid Anatomy of the human eye*. Vol. II, p. 169, (plate XVII, Fig. I), 2nd ed., London, 1834.
- (105) CRITCHETT (1852): Fibrous tumour within the orbit protruding the eye—extirpation—recovery. *Med. Times and Gaz.*, V, (new series), p. 465.
- (106) BILLROTH (1872): Psammon—Sarcoma (Virchow) of the orbit. *Billroth's Clinical Surgery, a translation for New Sydenham Soc. by Dent*, 1881, p. 116.
- (107) NEUMANN (1872): Über Sarcome mit endothelialen Zellen etc. *Arch. der Heilk.*, 4-5, p. 310-313, 1872.*
- (108) KNAPP (1874): A case of carcinoma of the outer sheath of the optic nerve removed with preservation of the eyeball. *Klin. Mon. Bl. für Augen*, XII, p. 439, 1874, also *Archiv. Oph. and Otol.*, IV, p. 323,* and *Arch. Augenheilk. u. Ohr.*, IV, p. 209.
- (109) SAVARY (1874): Notes cliniques (tumeur de l'orbite). *Annal d'oc.*, LXXII, p. 214.
- (110) DUSAUSSAY-RICHET (1875): (a) Sarcome angiolithique du nerf optique gauche—ablation—meningite de la convexité—contracture—mort. *Soc. Anatom. de Paris*, 1875, I, p. 211-217 (Dusaussay). (b) Richet (same title). *Rec. d'Oph.*, 1875, 2s. II, 295-302.
- (111) CHENANTAIS (1879): Tumeur du nerf optique et de l'orbite (nevrome medallaire ou sarcome à cellules nerveuse). *Bull. de la Soc. Anatom. de Nantes*, 1879, p. 48.
- (112) EWETZKI (1882): Ein Fall von Endotheliom der äussern Sehnervenscheide. *Archiv für Augenheilk.*, XII, p. 16, 1882-1883.
- (113) LAWSON (1882): On a case of sarcoma springing from the sheath of the optic nerve, etc. *R. O. H. Repts.*, X, p. 296, 1882.*

- (114) PEABODY (1883): Sarcoma of right optic nerve. *Med. Rec.*, N. Y., XXIII, p. 216.
- (115) BRAILEY (1886): Sarcoma springing from the dural sheath of the optic nerve. *Tr. Oph. Soc. U. K.*, VII, p. 120.*
- (116) SUTPHEN (1889): Sarcoma of the optic nerve noticeable chiefly for its size and shape. *Tr. Amer. Oph. Soc.*, 1889, p. 457.
- (117) SALTZMANN (1890): Sarcoma of the sheath of the optic nerve. *Finska lakarsällsk. handl.*, XXX, p. 490[†]; abstracts *Annals of Surg.*, 1890, II, p. 219; *N. Y. Med. Jour.*, LIII, p. 82.
- (118) LAGRANGE (1894): Un cas de myxo-sarcome des gaines du nerf optique. *Jour. de Med. de Bord.*, XXIV, p. 73; also *Gaz. d'hop. d'Toulouse*, 1894, VIII, p. 147.

III. PRIMARY INTERDURAL TUMOUR OF THE OPTIC NERVE.

- (119) GLOOR: Zur Lehre von den Opticustumoren. *Inaug. Dis. Basel*, 1892.[†]

IV. TUMOURS EMBODIED IN PREVIOUS ARTICLES ON GROWTHS OF THE ORBITAL DIVISION OF THE OPTIC NERVE, BUT EXCLUDED FROM THIS PAPER FOR VARIOUS REASONS.

(a) BECAUSE DOUBTFUL AS TO THEIR ESSENTIAL NATURE, SITUATION, ETC.‡

- (120) MONTEATH: *Translation of Weller's Manual* (foot note). Vol. I, page 109, 1821; also Mackenzie, *Diseases of the Eye* 1st Ed., 1830, and subsequent editions.
- (121) GALEZOWSKI: Etude ophthalmoscopique sur les alterations du nerf optique, etc., *Thèse de Paris*, 1865, p. 175.
- (122) HORNER: *Corresp. Bl. für Schweizer-Aerzte*, Sitzung von Ap. 1871, I, p. 108.
- (123) VON RECKLINGHAUSEN: Über die multiplen Fibroma der Haut, etc., *Festschrift*, 1882.¹
- (124) STEFFAN: *Augenheilstalt in Frankfurt a. m.*, 1873-74, p. 33-36 (? Inflammatory).
- (125) PUF AHL: *Beiträge zur prakt. Augenheilk.*, III, 1878, p. 63,† (not accompanied by pathological report).
- (126) JOCQS: Des Tumeurs du nerf optique. *Thèse de Paris*, 1887. (Growth unfortunately so lacerated during the operation that exact relations could not be made out. The Thèse itself is not surpassed in point of excellence by any monograph on the subject.)
- (127) BUFFUM: *Jour. Oph. Otol. and Laryngol.*, I, p. 44, 1889.

‡Included here also are all the other early cases quoted by Demarquay, Schuchardt (145), and Finlay (128), which are only of historical value.

- (128) FINLAY: *Archives of Oph.*, XXIV., p. 224, 1895. ("The tumour had been cut up into a number of small semi-cylindrical pieces, it being impossible to determine the topographical relation in which they stood to one another.")
- (129) RING: *Arch. of Oph.*, XXV, p. 51. (Concerns an orbital tumour, which sprang possibly from the sheath of the optic nerve in an anophthalmic patient).
- (130) BOURGEOIS: *Annal. d'Oc.*, CX, p. 289, Oct. 1893.
- (131) DARIER:** *Annal d'Oc.*, CXI, p. 285 and CXII, p 322, 1894.
- (132) VALUDE:** Extirpation d'une tumeur du nerf optique par l'opération du Krönlein. *La Clin. Oph.*, 1899, No. XIV, p. 160-161.
- (133) SCHOLDTMANN: Case II, l. c. 98. (The growth was of a curious nature and is carefully and fully reported. It is somewhat difficult to classify but evidently does not belong to the tumours discussed in this paper. S. characterizes the neoplasm as a "Cystoid optic-sheath tumor, the central part of which arose from the arachnoid, the peripheral capsule from the dura." The former showed a marked sarcomatous type, while in the latter fibrous tissue predominated.)
- (134) SCHLODTMANN: Case III., l. c., ("whether the tumour arose from the optic nerve stalk or its sheath is uncertain.")

(b) BECAUSE PROBABLY SECONDARY IN NATURE.

- (135) ARMAIGNAC: *Jour. de Med. de Bord.*, 1878, p. 104.
- (136) KROHN: *Klin. Mon. Bl. fur Augen.*, X, p. 103, 1872¹: (Metastatic?).
- (137) REICH: *Archiv. fur Oph.*, XXII., p. 103-110, 1876.
- (138) TEILLAIS: *Jour de Med. de l'ouest*, XV, p. 74-78, 1881.
- (139) TILLIAUX: *Gaz. des hôp.*, Paris, LX, p. 161-163, 1887; also *Rec. d'Oph.*, 1887, 38, IX, p. 65-72.
- (140) RISLEY: *Tr. Amer. Oph. Soc.*, VII, p. 526, 1896.

(c) BECAUSE INTRACRANIAL IN SITUATION.

- (141) MICHEL: *Archiv. fur Oph.*, XIX, p. 145-164² (closely allied to the growths discussed in this paper and associated with elephantiasis of the leg).
- (142) SCHOTT: *Archives of Oph.*, VI, p. 276.

(d) BECAUSE INTRAOCULAR IN SITUATION.

- (143) JACOBSON: *Archiv. fur. Oph.*, X, p. 55, 1864.

**The identity of the cases thus marked is not fully established by the details contained in the articles cited.

V. OTHER GENERAL MONOGRAPHS DEALING WITH TUMOURS OF THE OPTIC NERVE.

- (144) KNAPP: On tumours of the optic nerve. *Tr. Internat. Med. Congress*, Phil., 1876, p. 905.
- (145) SCHUCHARDT: Die intraorbitalen Geschwülste des Sehnerven. *Schmid's Jahrbucher*, 222, 1880, p. 185.
- (146) ROUDIE: Étude sur les sarcomes du nerf optique. *Thèse de Bordeaux*, 1891-92.
- (147) THIERY: De l'extirpation des Tumeurs du nerf optique sans enucleation du globe oculaire. *Thèse de Nancy*, 1892.

VI. MISCELLANEOUS REFERENCES.

- (148) GOLDMANN: Beiträge zur Lehre von den Neuromen. *Beiträge zur Klin. Chir.*, X, Heft I.
- (149) PRUDDEN: Contributions to the structure and clin. history of the multiple neuroma. *Am. Jour. Med. Sc.*, Vol. LXXX, p. 134, 1880.
- (150) TAYLOR: A contribution to the study of human neuroglia. *Jour. Exp. Med.*, III, p. 611, 1897.
- (151) WEISS: Ueber Länge u. Krümmung des orbitalen Stückes des Sehnerven, etc. *Ber. Klin. Woch.*, XXII, p. 863, 1885.
- (152) KRÖNLEIN: Zur Pathologie und operativen Behandlung der Dermoidcysten der Orbita. *Beiträge zur Klin. Chir.*, IV, 1887.
- (153) LEBER: Die Krankheiten der Netzhaut und des Sehnerven. *Handbuch der gesamten Augenheilkunde*. Graefe and Saemisch, Bd. V, p. 910, 1877.