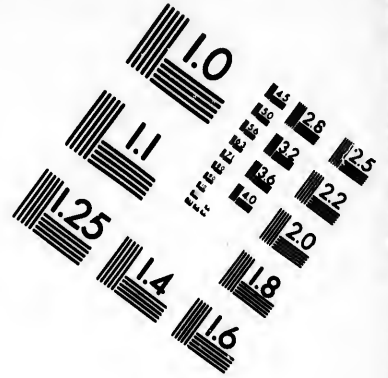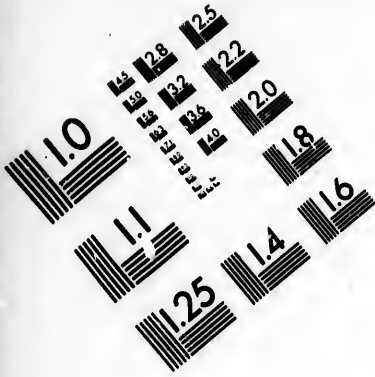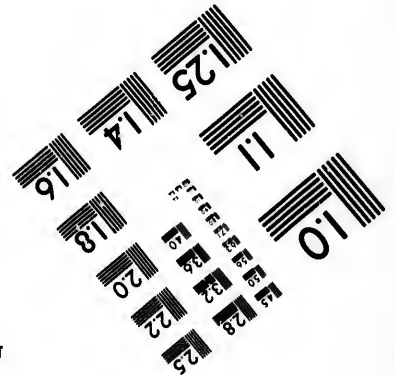
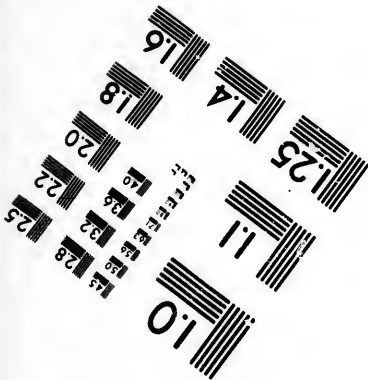
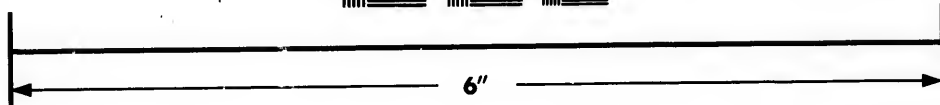



**IMAGE EVALUATION
TEST TARGET (MT-3)**



**Photographic
Sciences
Corporation**

23 WEST MAIN STREET
WEBSTER, N.Y. 14580
(716) 872-4503

15 128 125
16 132 122
17 20
18

**CIHM/ICMH
Microfiche
Series.**

**CIHM/ICMH
Collection de
microfiches.**



Canadian Institute for Historical Microreproductions / Institut canadien de microreproductions historiques

10
11

© 1985

Technical and Bibliographic Notes/Notes techniques et bibliographiques

The Institute has attempted to obtain the best original copy available for filming. Features of this copy which may be bibliographically unique, which may alter any of the images in the reproduction, or which may significantly change the usual method of filming, are checked below.

L'Institut a microfilmé le meilleur exemplaire qu'il lui a été possible de se procurer. Les détails de cet exemplaire qui sont peut-être uniques du point de vue bibliographique, qui peuvent modifier une image reproduite, ou qui peuvent exiger une modification dans la méthode normale de filmage sont indiqués ci-dessous.

- Coloured covers/
Couverture de couleur
- Covers damaged/
Couverture endommagée
- Covers restored and/or laminated/
Couverture restaurée et/ou pelliculée
- Cover title missing/
Le titre de couverture manque
- Coloured maps/
Cartes géographiques en couleur
- Coloured ink (i.e. other than blue or black)/
Encre de couleur (i.e. autre que bleue ou noire)
- Coloured plates and/or illustrations/
Planches et/ou illustrations en couleur
- Bound with other material/
Relié avec d'autres documents
- Tight binding may cause shadows or distortion
along interior margin/
La reliure serrée peut causer de l'ombre ou de la
distorsion le long de la marge intérieure
- Blank leaves added during restoration may
appear within the text. Whenever possible, these
have been omitted from filming/
Il se peut que certaines pages blanches ajoutées
lors d'une restauration apparaissent dans le texte,
mais, lorsque cela était possible, ces pages n'ont
pas été filmées.
- Additional comments:/
Commentaires supplémentaires:

- Coloured pages/
Pages de couleur
- Pages damaged/
Pages endommagées
- Pages restored and/or laminated/
Pages restaurées et/ou pelliculées
- Pages discoloured, stained or foxed/
Pages décolorées, tachetées ou piquées
- Pages detached/
Pages détachées
- Showthrough/
Transparence
- Quality of print varies/
Qualité inégale de l'impression
- Includes supplementary material/
Comprend du matériel supplémentaire
- Only edition available/
Seule édition disponible
- Pages wholly or partially obscured by errata
slips, tissues, etc., have been refilmed to
ensure the best possible image/
Les pages totalement ou partiellement
obscurcies par un feuillet d'errata, une pelure,
etc., ont été filmées à nouveau de façon à
obtenir la meilleure image possible.

This item is filmed at the reduction ratio checked below/
Ce document est filmé au taux de réduction indiqué ci-dessous.

10X	12X	14X	16X	18X	20X	22X	24X	26X	28X	30X	32X
						✓					

The copy filmed here has been reproduced thanks to the generosity of:

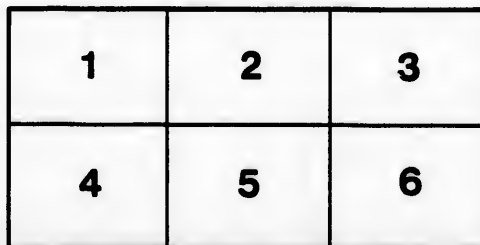
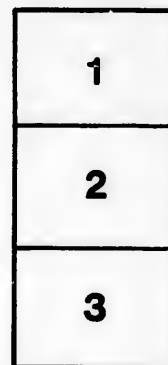
Medical Library
McGill University
Montreal

The images appearing here are the best quality possible considering the condition and legibility of the original copy and in keeping with the filming contract specifications.

Original copies in printed paper covers are filmed beginning with the front cover and ending on the last page with a printed or illustrated impression, or the back cover when appropriate. All other original copies are filmed beginning on the first page with a printed or illustrated impression, and ending on the last page with a printed or illustrated impression.

The last recorded frame on each microfiche shall contain the symbol \rightarrow (meaning "CONTINUED"), or the symbol ∇ (meaning "END"), whichever applies.

Maps, plates, charts, etc., may be filmed at different reduction ratios. Those too large to be entirely included in one exposure are filmed beginning in the upper left hand corner, left to right and top to bottom, as many frames as required. The following diagrams illustrate the method:



L'exemplaire filmé fut reproduit grâce à la générosité de:

Medical Library
McGill University
Montreal

Les images suivantes ont été reproduites avec le plus grand soin, compte tenu de la condition et de la netteté de l'exemplaire filmé, et en conformité avec les conditions du contrat de filmage.

Les exemplaires originaux dont la couverture en papier est imprimée sont filmés en commençant par le premier plat et en terminant soit par la dernière page qui comporte une empreinte d'impression ou d'illustration, soit par le second plat, selon le cas. Tous les autres exemplaires originaux sont filmés en commençant par la première page qui comporte une empreinte d'impression ou d'illustration et en terminant par la dernière page qui comporte une telle empreinte.

Un des symboles suivants apparaîtra sur la dernière image de chaque microfiche, selon le cas: le symbole \rightarrow signifie "A SUIVRE", le symbole ∇ signifie "FIN".

Les cartes, planches, tableaux, etc., peuvent être filmés à des taux de réduction différents. Lorsque le document est trop grand pour être reproduit en un seul cliché, il est filmé à partir de l'angle supérieur gauche, de gauche à droite, et de haut en bas, en prenant le nombre d'images nécessaire. Les diagrammes suivants illustrent la méthode.

**ANEURYSM OF THE ASCENDING PORTION OF THE AORTIC ARCH,
LEADING TO EXTERNAL RUPTURE.**

BY

JAMES STEWART, M.D.,


Professor of Medicine, McGill University ; Physician to the Royal Victoria
Hospital.

and

J. G. ADAMI, M.A., M.D.,

Professor of Pathology, McGill University ; Pathologist to the Royal Victoria
Hospital.

(Reprinted from the Montreal Medical Journal, November, 1896.)



ANEURYSM OF THE ASCENDING PORTION OF THE AORTIC
ARCH, LEADING TO EXTERNAL RUPTURE.

WITH A NOTE ON TRACHEAL TUGGING.

BY

JAMES STEWART, M.D.,

Professor of Medicine, McGill University; Physician to the Royal Victoria
Hospital,

AND

J. G. ADAMI, M.A., M.D.,

Professor of Pathology, McGill University; Pathologist to the Royal Victoria
Hospital.

The subject of these notes will be remembered by some as having been one of the cases exhibited by one of us (J. S.) at the recent meeting of the Canada Medical Association in this City.

The history of the patient is very full, he having been in the hospital for long periods during the last two years, and very full notes of his case have been taken by Drs. Reilly, McCarthy and Nicholls. The most important points in connection with the history are as follows:

The patient, 49 years old at the time of his death, was born in Nova Scotia and gave rather a full history of circulatory disease in his family. Thus his father, who is said to have had heart disease, died at the age of 58, from the effects of overstraining himself. His father's mother had heart disease, but lived to a good old age: her father again died suddenly from heart failure. The patient entered the navy at 16, and served there until he was 25 years old. During this period he lived a life of considerable excess. He drank freely, contracted syphilis at 22, and gonorrhoea at 27. He left the navy and entered government service, and for the last twenty-four years has continued in that employment, leading a clerical and literary life.

In July, 1893, after excessive mental work he began to suffer from stabbing pains in the right and left breasts. These varied in situation, severity and course. At night they changed according to the side he lay upon, appearing in the right breast when he lay upon the right side. There were also frequent pains running from the heart to the shoulders and spreading down the arms, more especially down the right arm. There were other pains from the centre of the back under the right axilla and over the right shoulder. It will be noted that

these pains were mainly on the right side and so differed from similar pains which may accompany coronary disease.

The August and September of this year, 1893, were spent at the seaside and here the pains disappeared, but they returned upon his return to work. The patient, it may be added, was of a nervous, excitable temperament, easily depressed and at times most melancholic. Alcoholic stimulants were now ordered with the result that he became an inebriate, and in December, 1893, his condition was such that he underwent the "Gold Cure." This apparently had the desired effect, but the general condition of the patient became steadily worse, so that by June, 1894, he had to give up work. The following month, he entered one of the large Boston hospitals, where, misled apparently by the neurotic temperament of the patient, a diagnosis was made of nervous prostration. From the hospital he went the following month to Nova Scotia, and here, with rest, his condition improved, and in September he was able to return to work. Already according to the patient, a slight prominence was noticeable over the sternum; this gradually enlarged. It should be added that it was already in the spring of this year that the patient had suffered from wheezing respiration and paroxysmal coughs. In November, 1894, his condition was so bad that he entered the Royal Victoria Hospital, Montreal. Upon admission, there was a prominence over the chest from the second to the seventh rib, highest over the centre of the sternum. On the left side there were two small tumours, just at the edge of the sternum between the second and third, and the third and fourth ribs; the area was distinctly red with definite pulsation and heaving expansile impulse. The dullness present extended rather more to the right side, namely, half inch to the left and two inches to the right of the sternum. There was a systolic murmur over the tumour, tracheal tugging was present and the patient experienced some slight difficulty in swallowing.

The arteries were atheromatous and tension was higher on the right side. There were diminished breath sounds over the right lung with wheezing during deep inspiration. Upon December 1st, 1894, the small pulsating tumours on the left side had united. Upon Dec. 6th, definite erosion through the sternum and through the third rib on the left side were made out. Upon the 19th, straining at stool led to definite increase of the pulsation and redness of the tumour. The pains during this month were evanescent. Towards the end of the month, the skin had assumed a bronze tinge over the whole tumour with two reddened areas, one over the centre of the sternum, the other and smaller to the left of the same. In January the tumour

continued to grow slowly, but by March, 1895, it was noticed to be slowly lessening in diameter, measuring 4 instead of 6 inches across. The patient continued in the hospital until May, when he was discharged, showing distinct improvement in his condition since January. The diagnosis then made was Aneurysm of the Ascending Arch.

In March of this year he was in the hospital again, for a few days, for examination, and then went home, returning on the 13th August. Upon re-admission he complained of transient pains, as before, in the pectorals and shooting down the right arm, then again in the back below the shoulder blades. Arcus senilis was now well marked. There was no dyspnoea save on exertion and save that when lying upon his back the patient experienced a smothering sensation. The right radial was rather stronger than the left. The transverse diameter of the tumour had increased from 4 to 5½ inches. The skin over it was shining and glazed, there was a harsh blowing systolic murmur heard over the chest in front, faint at the apex. There was, as before, tracheal tugging, and the breath sounds on the right side were feeble. There was no difference between the pulses, at the beginning of September. The tumour steadily enlarged and upon the 8th, the skin over the apex began to give way, there being one or two small cracks from which blood oozed in small quantities. On the next day the skin over the apex looked as though the aneurysm might burst at any moment. The patient now was discharged at his desire. He was seen at home by Dr. Reilly every other day. He lived nearly four weeks after his discharge, until October 5th. Then taking his tea in bed, sitting up, the tumour suddenly burst, the blood pouring out of the upper portion of the prominence, and in a moment he was dead.

The condition of the subject when he came down out of the post-mortem room is admirably shown by the accompanying photograph. The body was that of a somewhat emaciated adult of spare frame; the conical bulge occupied the centre of the chest, having a transverse diameter of 14.3 cm. or about six inches. The skin over the cone was rather discoloured, having a brownish tinge. The truncated apex of the cone had its centre in the line joining the two nipples, and it formed a circular, fungating, blood-stained mass 5 cm. in diameter, projecting 3 cm. above the level of the surrounding skin. A probe could be passed easily into this mass towards what, taking the head as north, might be described as N.W. by W. portion of the periphery, and later examination showed that the fungating mass was devoid of skin, and was in fact, a thick layer of blood-stained fibrin, which, until the fatal moment, had acted as a shield, preventing rupture.

A small cicatrix was seen at the junction of the glans and skin.

The chest was opened carefully, so that the whole of the aneurysm and attached tissues might be taken out *en masse*. The ascending portion of the aorta presented large flattened fibroid, almost cartilagenous plaques beginning immediately above the sinuses of Valsalva. 2.5 cm. above the valves began the sacculated aneurysm, proceeding abruptly by a sharp but smoothly rounded edge out of the aorta. The mouth of the sac was 6.5 cm. across in longitudinal diameter, by 4.5 in transverse. The fibroid thickening of the aortic intima was especially thick anteriorly along what formed the lower lip of the aneurysm.

This aneurysm was given off from the front of the ascending aorta, very slightly to the right; it was noticeable that the upper edge of the opening was 2.5 cm., or about an inch below the orifice of the innominate artery. Just beyond the upper edge of the mouth, the aorta measured 9.5 cm. in circumference, that is to say, that almost immediately beyond the sac the aorta was but little larger than normal. The sac was of great size from before, backwards; when emptied after removal, it measured 8 cm. in depth. At the sternal attachment it was 11 cm. from above downwards, beginning 3 cm. below the upper border of the sternum; in breadth it was 9 cm. The outer walls of the sac were formed of the pleuræ on either side and above, save in the middle line where there was solid mediastinal tissue; below the greatly expanded parietal pericardium formed the outer wall. The sac was filled with fairly loose clot in the main not laminated. Even in the outer portion where this formed the thickest layer, it had a comparatively recent appearance, and was so deeply stained with pigment that lamination could not be recognized. Portions of the eroded sternal edges could be felt protruding into the sac on the right side; on the left they were covered over. The main erosion or sternal orifice extended in the mid-sternal region from below the level of the third chondrocostal articulation to above the level of the 5th.

The rest of the aorta showed general slight dilatation with an atheromatous condition similar to that already described. The innominate, left carotid, and left sub-clavian arteries were not implicated in the aneurysm, nor again did they show any aneurysmal dilatation, either at their origins or along their course; their walls were however, distinctly thickened. The heart showed, first, an extensive hydropericardium, the cavity containing a perfectly clear limpid serum. There was no valve disease. The main feature of the organ was the hypertrophy and dilatation of the right ventricle and

with this a definite dilatation of the pulmonary artery, the circumference of which immediately above the valve was 9.3 cm.

The reason for this condition appeared clear when the lungs were examined; these were found retracted, and while the upper lobes were slightly emphysematous, the lower lobes were in a state of partial collapse with congestion. The small size of the lung and the obstruction of the pulmonary circulation were evidently due to the large mass of the aneurysm filling up so large a portion of the thoracic cavity. It should be added that both upper lobes presented adhesion to the wall of the aneurysmal sac and no where else. Further, it is to be noticed that there was no adhesion between the sac and either the trachea or the bronchi; nor upon examination did any of the main air tubes show distortion from pressure.

The points of more especial importance in connection with this case are:

1. The position.—In general, aneurysms of the ascending arch are situated and expand mainly to the right. In this case, although the aneurysmal sac began an inch and more above the valves, the rupture had occurred in the anterior wall, slightly it is true to the right, but very slightly, and the expansion had been in the median area of the chest so that the erosion of the sternum was central. Indeed there was an accessory but well marked erosion on the left side in the region of the third left chondrocostal articulation.

2. The second point to be noticed is that in this case there had been from time to time a marked difference in the two radial pulses, which with the other symptoms might well have led to a diagnosis of aneurysm originating much higher up the arch. It must be kept in mind that difference in the two radials is by no means diagnostic. In this case the regions of the innominate and the left subclavian were well outside the region of the aneurysm, and the difference in the two pulses here, must, as in other cases in which no aneurysm is found to exist, be ascribed in the main to the arterio-sclerotic changes, affecting the two trunks to a different extent. There is, however, another possibility in this case, namely, that the aneurysm, adherent as it was to the chest wall, did undoubtedly bring about malposition of the aorta, and this malposition may have so affected or distorted the orifice of either the innominate or the left sub-clavian as to impede the passage of blood and of the blood-wave down one or other vessel.

3. The third point of some value is brought out in connection with the sign of tracheal tugging. It is generally taught now a-days, that tracheal tugging affords a sure indication of aneurysm of the trans-

verse portion of the aorta, and as I showed recently to the Society, in a case of aneurysm of this nature, dilation of the transverse arch does undoubtedly lead easily to the production of this sign, and accomplishes this by pressing upon the lower end of the trachea and the left bronchus as this passes underneath the arch. In the case before us there was no aneurysm of the transverse arch, and further there was no adhesion of the aneurysm of the ascending portion to either trachea or bronchus, and yet there was at least two years history of distinct tracheal tugging obtainable. The motion of the larynx and trachea must have, it seems to me, been brought about by the downward pressure of the large aneurysmal sac upon the lungs and smaller bronchi with each distension of the sac following upon the heart-beat. This case teaches us, therefore, to recognize that tracheal tugging may be a sign of aneurysm of the ascending aorta as well as one of aneurysm of the transverse arch.

4. As to the termination of this case.—External rupture is one of the more uncommon terminations of a thoracic aneurysm. According to Crisp's Tables this occurred six times in 136 cases of aneurysm of the ascending arch which he found recorded.

