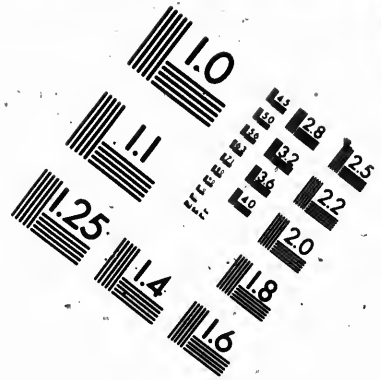
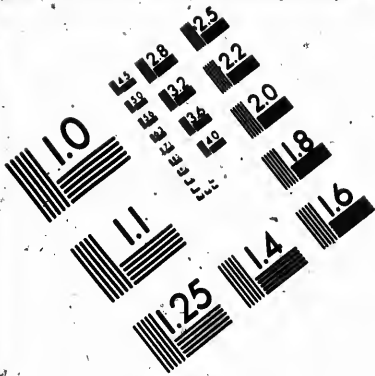




**IMAGE EVALUATION
TEST TARGET (MT-3)**



**Photographic
Sciences
Corporation**

23 WEST MAIN STREET
WEBSTER, N.Y. 14580
(716) 872-4503

**CIHM
Microfiche
Series
(Monographs)**

**ICMH
Collection de
microfiches
(monographies)**



Canadian Institute for Historical Microreproductions / Institut canadien de microreproductions historiques

© 1992

Technical and Bibliographic Notes / Notes techniques et bibliographiques

The Institute has attempted to obtain the best original copy available for filming. Features of this copy which may be bibliographically unique, which may alter any of the images in the reproduction, or which may significantly change the usual method of filming, are checked below.

L'Institut a microfilmé le meilleur exemplaire qu'il lui a été possible de se procurer. Les détails de cet exemplaire qui sont peut-être uniques du point de vue bibliographique, qui peuvent modifier une image reproduite, ou qui peuvent exiger une modification dans la méthode normale de filmage sont indiqués ci-dessous.

- Coloured covers/
Couverture de couleur
- Covers damaged/
Couverture endommagée
- Covers restored and/or laminated/
Couverture restaurée et/ou pelliculée
- Cover title missing/
Le titre de couverture manque
- Coloured maps/
Cartes géographiques en couleur
- Coloured ink (i.e. other than blue or black)/
Encre de couleur (i.e. autre que bleue ou noire)
- Coloured plates and/or illustrations/
Planches et/ou illustrations en couleur
- Bound with other material/
Relié avec d'autres documents
- Tight binding may cause shadows or distortion along interior margin/
La reliure serrée peut causer de l'ombre ou de la distorsion le long de la marge intérieure
- Blank leaves added during restoration may appear within the text. Whenever possible, these have been omitted from filming/
Il se peut que certaines pages blanches ajoutées lors d'une restauration apparaissent dans le texte, mais, lorsque cela était possible, ces pages n'ont pas été filmées.
- Additional comments: /
Commentaires supplémentaires:

- Coloured pages/
Pages de couleur
- Pages damaged/
Pages endommagées
- Pages restored and/or laminated/
Pages restaurées et/ou pelliculées
- Pages discoloured, stained or foxed/
Pages décolorées, tachetées ou piquées
- Pages detached/
Pages détachées
- Showthrough/
Transparence
- Quality of print varies/
Qualité inégale de l'impression
- Continuous pagination/
Pagination continue
- Includes index(es)/
Comprend un (des) index
- Title on header taken from: /
Le titre de l'en-tête provient:
- Title page of issue/
Page de titre de la livraison
- Caption of issue/
Titre de départ de la livraison
- Masthead/
Générique (périodiques) de la livraison

This item is filmed at the reduction ratio checked below/
Ce document est filmé au taux de réduction indiqué ci-dessous.

10X	14X	18X	22X	26X	30X
<input type="checkbox"/>	<input type="checkbox"/>	<input type="checkbox"/>	<input checked="" type="checkbox"/>	<input type="checkbox"/>	<input type="checkbox"/>
12X	16X	20X	24X	28X	32X

The copy filmed here has been reproduced thanks to the generosity of:

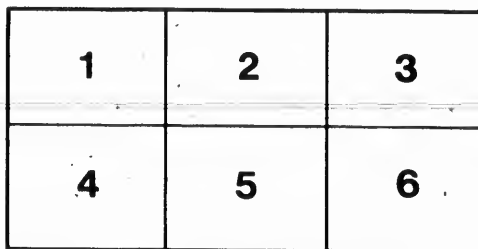
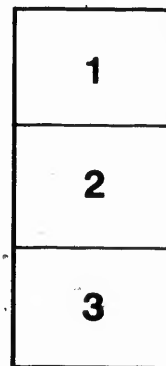

Harold Campbell-Vaughan Memorial Library
Acadia University

The images appearing here are the best quality possible considering the condition and legibility of the original copy and in keeping with the filming contract specifications.

Original copies in printed paper covers are filmed beginning with the front cover and ending on the last page with a printed or illustrated impression, or the back cover when appropriate. All other original copies are filmed beginning on the first page with a printed or illustrated impression, and ending on the last page with a printed or illustrated impression.

The last recorded frame on each microfiche shall contain the symbol \rightarrow (meaning "CONTINUED"), or the symbol ∇ (meaning "END"), whichever applies.

Maps, plates, charts, etc., may be filmed at different reduction ratios. Those too large to be entirely included in one exposure are filmed beginning in the upper left hand corner, left to right and top to bottom, as many frames as required. The following diagrams illustrate the method:



L'exemplaire filmé fut reproduit grâce à la générosité de:

Harold Campbell-Vaughan Memorial Library
Acadia University

Les images suivantes ont été reproduites avec le plus grand soin, compte tenu de la condition et de la netteté de l'exemplaire filmé, et en conformité avec les conditions du contrat de filmage.

Les exemplaires originaux dont la couverture en papier est imprimée sont filmés en commençant par le premier plat et en terminant soit par la dernière page qui comporte une empreinte d'impression ou d'illustration, soit par le second plat, selon le cas. Tous les autres exemplaires originaux sont filmés en commençant par la première page qui comporte une empreinte d'impression ou d'illustration et en terminant par la dernière page qui comporte une telle empreinte.

Un des symboles suivants apparaîtra sur la dernière image de chaque microfiche, selon le cas: le symbole \rightarrow signifie "A SUIVRE", le symbole ∇ signifie "FIN".

Les cartes, planches, tableaux, etc., peuvent être filmés à des taux de réduction différents. Lorsque le document est trop grand pour être reproduit en un seul cliché, il est filmé à partir de l'angle supérieur gauche, de gauche à droite, et de haut en bas, en prenant le nombre d'images nécessaire. Les diagrammes suivants illustrent la méthode.

THE TREATMENT
OF
ANEURISM OF THE ARTERIA INNOMINATA
BY LIGATURE OF THE
RIGHT COMMON CAROTID ARTERY.

MONTREAL:

ANDREW A. DE MEYER, MEDICAL CHURCHMAN'S OFFICE, 45 St. Francois Street.

SCAPULA UNIVERSITY LIBRARY

THE UNIVERSITY OF CHICAGO

THE HISTORY OF THE UNITED STATES

BY CHARLES A. BEAMAN

THE UNIVERSITY OF CHICAGO PRESS

Prof. Campbell, M.D.
with the kind efforts
of W. C. C.

THE TREATMENT

OF


ANEURISM OF THE ARTERIA INNOMINATA.

BY LIGATURE OF THE

RIGHT COMMON CAROTID ARTERY.

MONTREAL:

Printed at the MEDICAL CHRONICLE OFFICE, 42 St. Francois Xavier
Street.



43926

A

to
co
for
ag
of
vis
bu
op
th
no
ra
wh
to
Si
up
ho
co
up
m
im
an
te
no
w
18

ject
Pro
Un
sar
Ch

THE TREATMENT
OF
ANEURISM OF THE ARTERIA INNOMINATA,
BY LIGATURE OF
THE RIGHT COMMON CAROTID ARTERY*.

The treatment of aneurism by the Brasdorean operation is peculiar to modern surgery. Sixty years ago it was unknown. Its earliest record is in the "Recueil periodique de la Société de Médecin de Paris" for 1799. It is there stated that after a lengthened consultation upon an aged citizen, afflicted with an inguinal aneurism of great size, two-thirds of the members, among whom were Allan, Brasdor, Boyer, and Corvisart, advised tying of the femoral artery. The ligature was applied, but no benefit was obtained, and the tumor enlarged. In this case the operator was Deschamps, and in proclaiming the fact, he informs us, that although he was the first to put it into practice, the principle was not his own, but emanated with the gentleman by whose name the operation is now conventionally distinguished. He says: "I am the first who has been bold enough to undertake this operation, but not the first to propose it, for a long time ago the late Brasdor first proposed it orally." Since then it has been performed not only upon the femoral, but also upon the subclavian and carotid arteries. With what frequency is, however, unascertainable, for its statistics have been variously and incompletely registered. In Velpeau's Operative Surgery, the operations up to 1845 inclusive, are numbered at 19; and in Erichsen's Surgery, a much later work, they are reduced to 17; while both statements are so imperfect, that each notices examples not comprehended by the other, and neither includes instances of inguinal aneurism. The opinions entertained of its merits have also been conflicting. Mr. A. Burns' denounced it as "absurd in theory" and "ruinous in execution;" but he was too hasty and generalized from the issue of a single case, for up to 1811, when he wrote, Deschamps was without a rival." Seventeen

*Re-printed from the *Medical Chronicle* for March, 1856, being observations on this subject, with a case, communicated to that Journal by WILLIAM WRIGHT, M.D., L.R.C.S.E., Professor of Materia Medica, University of McGill College; Consulting Physician to the University Lying-in-Hospital; Physician to the General Hospital, to the Montreal Dispensary, to the Ladies' Benevolent Institution, to the House of Refuge, and to the House of Charity, Montreal; Member of the Surgical Society of Ireland, &c.

years afterwards, Mr. Wardrop published a small treatise on aneurism which was almost altogether confined to the cure of the innominata variety, by the ligature of the subclavian or carotid arteries. In this *brochure*, six cases were described, two of operation upon the former, and four upon the latter vessel, and in reference to them the author observed, "I consider the operation of tying one or both of the branches of that vessel (innominata,) on the distal side of the tumor, likely to become an operation of great utility, and in an especial manner applicable." The views of their immediate successors, as seen by the light of the original writers, display a party tendency. Mr. B. Phillips, in 1831, doubted whether the operation had ever been successfully performed; and M. Tarral, in 1834, with more truth on his side, declared, in direct contradiction, that the operation had been "completely successful," and was "indisputably established." Subsequently more modified expressions were ventured, and the profession, generally, became chary in their encomiums. The animus thus manifested grew with time, so that at the present day Pirrie's conclusion may be received as a correct reflection of popular estimation, that "certainly this mode of treatment has not gained the favorable opinion of the profession." The reasons for this might readily be shown, but these, with further general considerations, would be too obtrusive in a communication intended to consider the question of operation, *solely*, as it relates to aneurism of the innominata, treated by ligature of the right common carotid artery.

This question may be profitably examined from points of view different to those customarily adopted; from views that will enable us to ascertain whether in cases of failure the result be due to inadequacy of the operation to accomplish the purposes for which it was performed—or to dangers incurred by the ligature, independantly of the cause necessitating its application—or to the prejudicial influence of other circumstances co-existent with the aneurism. And thus we may, secondarily, determine whether the operation can be justifiably resorted to in any case, or whether it should be wholly proscribed from future repetition.

Hitherto there have only been recorded, in English periodicals, 10 cases of aneurism of the innominata, treated by ligature of the right common carotid. In accordance with the objects above expressed these may be arranged under 3 classes. 1stly. Cases in which the operation was successful, and the patient survived three months or longer. 2ndly: Cases in which the operation was successful, but death ensued within three months after. 3rdly. Cases in which the operation was unsuccessful. In these distinctions the word *successful* is used in reference to the alterations produced by the ligature upon the aneurism—to the obliteration of its cavity by contained fibrin, and the arrest of circulation from

it thro
havin
Three
second
the lo
their
that i
These
Dida
moy
phis
of suc
time,
stabil

Lang
Ope

1. Lavi
aft

2. 20

3. 7 m

T
mon
mor
pres

A
mee
tum
has
eve
the
end
fied
bec
late
in t
red
the

it through the carotid—these being received as tokens of the operation having fulfilled the immediate objects for which it was undertaken. Three months are selected as a period of division between the first and second classes because it is sufficiently long to allow of recovery from the local effects of the operation, and because before danger ceases, on their account the cause of death becomes embarrassed with the possibility that it may depend upon, or be in some way connected with them. These assumptions are supported by the authorities of Wardrop and Diday, the former says, "whenever coagulation of the blood in the tumor does take place, then the cure of aneurism may be said to be accomplished." And the latter has fixed upon four months as the turning point of success or failure—for the reason given above, I have reduced the time, and because an additional month only serves to afford a little more stability to the changes previously established.

CLASS I.

Length of Life after Operation.	Delay in separation of Ligature.	Local Accidents	Arrest of Circulation from Sac to Carotid.	Mode of Obliteration of Aneurism.	Surgeon.	Year.
1. Living 9 years after.	Cut away on 7th day.	Obclusive inflammation of arteries of right arm.	Perfect.	Fibrillation.	Evans, St Derby.	1828
2. 20 months.	31st day.	None.	Do.	Do.	Morrison of Banane Ayras.	1834
3. 7 months.	26th day.	None.	Do.	Do.	Mott of New York	1839

These are the only cases that fall under this class, and their testimony on behalf of the operation is certainly favorable, but to set forth more fully the effects of the ligature upon the disease than can be expressed, in a table, the following question may now be examined:—

In what condition is the aneurism placed by the operation? The immediate effects have been rather dissimilar in different cases—thus the tumor has been evidently diminished, (Mott) while in the majority there has been no appreciable decrease in its size. In none has enlargement ever been produced, thus disproving an opinion entertained by some that the operation might induce such an over-distention of the sac as would end in rupture. The pulsations have also, at first, been variously modified; generally speaking they were not lessened, but on one occasion became unusually violent (Morrison). These primary effects sooner or later, after the first day, were succeeded by signs of increasing hardness in the tumor, weakness in its pulsations, obscurity of its expansions, and reduction of its bulk. These latter changes are highly interesting, for they denote that the solidification of the aneurism is proceeding. The

earliest case which allows of any conclusion concerning the inception of this action is one by Mr. Fergusson, reported in the *London Medical and Surgical Journal* for 1841. The patient died 7 days after the carotid was tied, and yet the innominatal tumor, Mr. F. says, "was found to be nearly filled with pretty firm clots of fibrin . . . similar to such as are met with in aneurismal sacs," and different to the post mortem shreds called polypi. Another important fact to know is, that coagulation goes on as surely and as rapidly as if the ligature had been applied around the vessel on the cardiac side of the tumor. This is strongly corroborated by the case last cited. The eminent surgeon in his recital adds that the clots were not only aneurismal, but were like those that would be found "about the same period after the Hunterian operation has been performed." The occurrence of the foregoing changes is inviolable. I have not met with any case in which they had not supervened. At a period still more remote than the last referred to, the external tumor is found to have completely disappeared, and the *visible* signs of aneurism cease to be discoverable. This was strikingly obvious in the cases above tabulated—in Evan's case the tumor was as large as a walnut, and, in Mott's, the size of a pigeon's egg, yet in both its disappearance was perfect—in Mott's, 26 days after the operation, and in Evan's, rather more slowly; in Morrison's the subsidence was not so complete, or, rather, was not so pronounced, as there was a concurrent aneurism of the right carotid between the ligature and the tumor. It may readily be conceived that simultaneous alterations connected with the aneurism in the chest are advancing, and from analogy it were easy to describe them, but, as a matter of fact, there are no actual observations by which they can be demonstrated. The circumstances above specified—increasing hardness, and decreasing volume—render it highly probable that the changes begun progress, and that advanced phases of organization occur in the fibrinous clot, similar to those noticed in aneurisms cured by either compression, or the Hunterian operation, or other method. In Morrison's case, the longest-lived in which a post mortem was held, the arteria innominata was found contracted to within twice its proper bulk, instead of a "large tumor in the neck where it extended from the chest," the coagulum consisted of *dense fibrous laminae*, and the vessel was studded with spiculæ of ossific matter. From the preceding data the following inferences may be drawn:—

1. Ligature of the carotid artery reduces the volume of innominatal aneurism.
2. This operation causes the obliteration or occlusion of the sac.
3. This result is due to the fibrillation of blood arrested in its circulation.

4.
ope

As

61

60

43

47

TH
been
affor

De

conn
natal
lower
term
by th
takal
sels o
clude
artery
comp
afford
pervi
to the
nature
not be
issue
not be
ration
dange
that v
hæmo
contra
coarct

4. This process ensues as favorably as when induced by any other operation, either artificial or natural.

CLASS II.

Age.	Time of Death after Operation.	Cause of Death.	State of Aneurism After Death.	Surgeon.	Year.
61	4 Hours.	Organic Syncope.	More than half filled with consolidated fibrin.	Key of London.	1830.
56	7th Day.	Pneumonia.	Sac diminished in size, and filled with clots of fibrin.	Ferguson of London.	1841.
48	19th Day.	Pneumonia.	Sac slightly diminished, and filled with a mass of stratified fibrin, weighing 8½ oz.	Campbell of Montreal.	1846.
47	66th Day.	Ulceration of Sac into Trachea--Bronchus.	Tumor diminished. Coagulation had occurred, but subsequently had broke down from pus of inflamed Sac.	Hutton.	

These cases, it will be seen, substantiate the deductions that have just been made. But they are chiefly interesting from the information they afford, in reply to the question:—

Does the operation entail any special dangers? These cases, taken in connexion with others in which the carotid artery was tied for innominate aneurism, prove that four-tenths of the operations have been followed by an early death. In the three that are first detailed, the fatal termination is to be referred to interruption in the circulation, produced by the obliteration of the vessel. In Mr. Key's case this was unmistakably evident. In it there was an abnormal conformation of the vessels of the neck, which, had it been previously known, would have precluded the operation. The brain was freely supplied by only a single artery, and, as it afterwards appeared, this was the one ligatured. The compensation which under the normal disposition would have been afforded for its obstruction was withheld, for the vessels that remained pervious were so strictured that an insufficient supply of blood was sent to the brain, and syncope or asthenia supervened of an irremediable nature. The aneurism was not the cause of death, for had this lesion not been present, and had the same operation been executed, a similar issue must have followed. The death, then, was due to the operation, not because it was an operation for aneurism, but because it was an operation upon the common carotid artery—not on account of any special danger entailed by the aneurism, but on account of a common accident that would have been as surely met, had the vessel been tied for hæmorrhage or any other cause. It were equally absurd to suppose the contrary, as to believe the aneurism was instrumental in producing the coarctation of the left carotid and vertebral arteries that existed. In the

same manner the two deaths that next follow are to be ascribed to pneumonia induced by ligature of the common carotid—essentially to the ligature, and not to any influence caused by the coincidence of aneurism. Without this explanation, it must be assumed that death was, in some way, caused by the aneurism, as for instance, by the changes underwent, since the tumor, from being soft, mobile, and yielding, was converted into a hard, incompressible and ponderous mass; and in this latter state would exert, as might be supposed, by its presence in the chest, an amount of pressure on the contiguous organs of which it was incapable in the fluid condition. The details, however, of the cases do not agree with such a view. In Mr. Fergusson's case the pneumonia was confined to the middle lobe of the *left* lung, while the rest of the pulmonary structure was perfectly healthy, and the tumor had not pressed upon either the lungs or their nerves, nor had it displaced the bronchi. In Dr. Campbell's, again, the tumor had produced compression, but it was upon the superior part of the right lung which was simply condensed in substance, while the inflammation was seated, not there, but, in the *left* lung, "posteriorly and inferiorly," where there was no pressure at all. The truth these facts teach, is what was to be expected; for in the abstract, the pernicious influence of the tumor was alike both before and after the operation, since aside from its density, its positive bulk and occupation of space were similar at both times. The history, too, of intra-thoracic tumors, generally, evinces no tendency to the production of pneumonia. When, also, thoracic aneurisms are left to take their course, pneumonia is neither a complication nor a termination. Upon these grounds it may be concluded that the aneurisms were not the cause of death. Returning, then, to the original proposition; it may be asked, as the alternative,—is there any reason for considering the ligature to have been the sole cause of death? All precedent is in favor of the affirmative. Pneumonia after operations, of every sort, is a common event. From an analysis of 62 autopsies, given in the *Medico-chirurgical transactions*, Vol XXVI, of persons on whom capital operations had been performed, 39 presented signs of pneumonia more or less advanced. But this fact is especially applicable to the common carotid; since after it has been tied, for whatever cause, pneumonia is of frequent occurrence, probably ranking, in point of accident after the cerebral sequelæ; so much is this disease, then, to be expected that Mr. Miller, in his *Practice of Surgery*, specially warns the operator against it, he says, "after the operation congestion of the lungs with its baneful consequences must be guarded against." Mr. Erichsen likewise refers to the prevalence of pneumonia after deligation of the common carotid, indiscriminately, and in briefly summing up the theories assigned for

scribed to pneu-
 essentially to the
 of aneurism.
 h was, in some
 ges underwent,
 , was converted
 this latter state
 in the chest, an
 it was incapable
 es do not agree
 onia was confin-
 of the pulmonary
 not pressed upon
 the bronchi. In
 sion, but it was
 ply condensed in
 , but, in the left
 'pressure at all.
 d; for in the ab-
 -like both before
 ositive balk and
 e history, too, of
 to the production
 left to take their
 mination. Upon
 ms were not the
 sition; it may be
 sidering the liga-
 ent is in favor of
 sort, is a common
 e Medico-chirur-
 apital operations
 more or less ad-
 common carotid;
 monia is of fre-
 quence after the cere-
 d that Mr. Miller,
 tor against it, he
 h its baneful con-
 likewise refers to
 common carotid,
 ories assigned for

this circumstance, considers it most likely owing to a derangement in the functions of the brain, and medulla oblongata induced by a disturbed state of the encephalic circulation. His opinion seems probable and perhaps the peculiarity of the left lung being affected after ligature of the right artery, as in the above cases, may be attributed to the same agency as that whereby palsy is made to occur on a side of the body opposite to the one in which the cerebral lesion exists. With these arguments before us the two cases of pneumonia must be placed in the same category with the first. And, I believe, had the same operation been performed upon the same individuals, on any other account, than aneurism, the same result would have ensued. The last case in the above list varies somewhat from the foregoing, there inflammation attacked the aneurismal sac, leading to suppuration with ulceration; and of their consequences, the patient died. Yet, in the end, it falls in with them. The death is distinctly referable to the ligature—not because it was applied upon any novel principle or in any unusual mode—not that, by carrying out Brasdor's proposal, the aneurism was rendered more accessible to inflammation, than had the Hunterian plan been followed—nor that a more adverse modification was induced in the circulation than had the vessel been obliterated elsewhere; but because such a result is one of the accidents of arterial deligation when practised for the cure of aneurism. Proceeding from causes which the Surgeon cannot apprehend when present, much less predicate when absent; and supervening alike whether the ligature be on the distal or cardiac side of the tumor. This latter and most important averment is easily supported. If we search the statistics of carotid aneurisms treated by tying the vessel between the sac and the heart, we find Mr Norris in the American Journal Medical Sciences, 1847, referring to 33 cases of the disease thus treated, and informing us, that of 13 deaths, in 6 the sac was ulcerated; he does not state in how many it had been inflamed, but the number must have been considerably more than the last: for Mr. Solly in a lecture, on carotid aneurism treated by cardiac ligature, reported in the *Lancet* for 1854, and *Medical Chronicle* vol. I., alludes, as he observes, to "the most important cases" recorded; and of 9 there mentioned, the sac was inflamed in 5, and in each, as in Hutton's, the issue was fatal, while in a sixth arteritis occurred and induced death, so that in only one third was there neither inflammation of the sac nor vessel. Surely, then, the Brasdorean are not more amenable to this evil than the Hunterian operations. In conclusion it may be inferred—

1. The early deaths, occurring after the right carotid artery has been tied for innominatal aneurism, have been due to the consequences of the operation.

2. These are referrible to the ligature and similar to those, ordinarily, produced under other conditions.

3. No special dangers have been entailed by the aneurism having been the cause of deligation.

4. It is not more injurious to tie the vessel on the distal than on the cardiac aspect of the sac.

CLASS III.

The preceding seven cases, without exception, are instances that fibrillation has been instituted after the operation, and proceeded to a length compatible with the duration of life, so that the immediate object of the ligature was attained; but in the remaining class of facts, the usual blood changes in the sac have not occurred, or having begun have not continued, the aneurism has become larger, and a second operation been demanded, thus suggesting the inquiry:—

Why has the operation failed? To this last class I have only found three cases belonging. Their details are too dissimilar to admit of parallel arrangement, but they may be taken up *seriatim*. The first failure happened to Mr. Fearn, of Derby. The aneurism sprang from the right side of the innominate, and involved the arch. The right carotid was tied. The patient, a female of 28, recovered from the effects of the ligature, no bad symptom ensued, but the aneurism was not obliterated. Two years afterwards, the subclavian was deligated, she having all along suffered, as before the operation, from the symptoms of aneurism, and they being, then, still urgent. The reason of the failure of the carotid ligature is thus given by Mr. F.:—"I entertain but little doubt that a permanent cure would have been effected by the first operation, had she not exposed herself to every sort of excitement likely to prevent such a result, as it was there can be no question her life was saved by it."—*Lancet* 1838-39 So that the case is not so negative as it, at first sight, appeared, but lends its countenance to the operation. For while Mr. F.'s opinion sanctions the supposition that had more prudence been observed by the patient, the case would have taken its place among the first class; the report proves that the operation on the carotid is not rendered more dangerous by the plus addition of an innominate aneurism, and thereby corroborates the inferences last drawn that, in reality, deligation was the same in effect as if there had been no aneurism in existence. The next case leads to similar conclusions.

Mr. Wickham, of Winchester, relates, in the Medico-Chirurgical transactions, that R. C. had an aneurism which arose from nearly half of the innominate, forming a sac that arched to the top of the thyroid cartilage, and a swelling the size of a hen's egg, externally, over the cla-

ilar to those, ordi-

aneurism having

the distal than on

are instances that
and proceeded to a
that the immediate
remaining class
occurred, or having
come larger, and a
e inquiry:—

I have only found
lar to admit of par-
s. The first failure
rang from the right
e right carotid was
e effects of the liga-
was not obliterated.
she having all along
s of aneurism, and
ilure of the carotid
t little doubt that a
st operation, had she
y to prevent such a
as saved by it.”—
as it, at first sight,
n. For while Mr.
more prudence been
its place among the
e carotid is not ren-
nominatal aneurism,
that, in reality, deli-
o aneurism in exist-

lico-Chirurgical trans-
m nearly half of the
of the thyroid car-
rnally, over the cla-

vicle. There was also extreme dilatation, and ossific degeneration of the thoracic aorta. On the 25th September, 1839, the right carotid was tied. On the 14th day, the ligature came away; the tumor was evidently lessened although pulsations continued. He left the Hospital against the wishes of the Surgeon; the tumor then rapidly increased, attained double its former size, and he suffered so much from dyspnoea that 69 days after the first operation, the subclavian was tied. The report says by the latter his life was prolonged 76 days, and that before it was undertaken “he appeared to be almost at his last gasp from suffocation, and great fears were entertained lest he should expire under the operation.” The further details, as in the former case, are here omitted from being irrelevant to the question under inquiry. The failure of the carotid deligation is not accounted for; it may have been that after having left the Hospital too early, he resumed his usual avocations and old habits, before the fibrinous changes in the sac were strong enough to resist the excitement of circulation, induced by his premature indulgences. Thus assimilating the case to the former one.

The third case in this class is usually disregarded, because its principal details are unknown, and no opinion can be formed either of the extent of the disease, or of the effect of the treatment upon it. In the *Lancet*, for 1834-35, it is simply stated that a man had a prominent and frightful tumor of the neck, which was *supposed* to be an aneurism of the innominate, and was menacing rupture; the right carotid was tied by Mr. Scott. The upper part of the swelling, *sometime* after the operation, appeared to have diminished, and afterwards the sac opened, probably from having inflamed, and a quickly fatal hemorrhage ensued. No post mortem was allowed. These cases, then, are not calculated to originate any unfavorable impression against the real merit of the operation. But leaving this:—the question of failure may now be examined in a more general way. If we are to judge from 6 of the 10 cases of innominate aneurism, of which we have the fullest particulars, we shall not entertain much hope for the ultimate preservation of an individual similarly circumstanced; for their character is of a hopeless nature, it appearing that although the operation be perfectly successful, yet life cannot be enjoyed any great length of time afterwards, in consequence of the destructive influence of kindred morbid causes with which the aneurism is associated. A patient may, therefore, survive the dangers of the ligature, and surmount every circumstance connected with it, the occlusion of the sac may also be most satisfactory; yet other agencies are at work, from which he cannot escape, as they are not remediable. Nearly all cases of this aneurism, operated upon, have been complicated with disease of the aorta of the class of disorganizing inflammations; frequently, too,

with distinct aneurisms in the chest; and, occasionally, in addition, with heart disease. Thereby affording proof of the activity of an aneurismal diathesis, and of a formative tendency to arterial disease. A morbid state which must infallibly shorten life; and even sooner than it otherwise might, because conjoined with the disordered innervation and its impairment of vital function, that ensues after obliteration of the carotid artery. That these cases possess this unfortunate combination is shown in the subscribed statement:—

Peculiarity of Aneurism.	Complication of Aneurism.	Surgeon.
Mentioned above	1. Arch aorta ossified and dilated. 2. ossification of aortic valves.	Morrison.
Size of small orange involving the arch	1. Aneurism aorta. 2. Concretion of left carotid. 3. Small size of both vertebrae	Key.
Innominate at origin size of aorta. formed a large swelling against sternum, and extern. another the size of an orange	1. Dilatation of aorta. 2. Compression of par vagum, and recurrent laryngeal nerves	Fergusson.
Tumor over sterno-clavicle articulation size of a large egg. Tumor in chest size of a heart	1. Aneurism of arch aorta. 2. Dilatation of the thoracic aorta. 3. Ossific degeneration of ascending aorta. 4. Slight hypertrophy left ventricle.	Campbell. Fearn.
Mentioned above	Involvement of arch aorta.	Wickham.
Extended from innominate to upper part of thyroid cartilage	1. Dilatation thoracic aorta, with 2. Calcareous degeneration.	

Of the remaining four no account can be given of their complications, as in Evan's case, the man was alive at last report, in Mott's no mention is made of state of heart or aorta, and in the remaining two the facts are unknown. So that exclusive of these, there are six of complications with aortic disease, &c., to which the remarks preceding the statement apply. That morbid complications interfere with a salutary termination is evidenced by contrasting the results that have followed Brasdor's operation in innominate aneurism with those that have succeeded it in cases of aneurism of the root of the carotid uncomplicated by any other vascular abnormality. Of this latter variety there are five *bona fide* cases, and one supposed case; of the former 3 were complete recoveries, 1 was successful so far as the aneurism was concerned, and in only 1 was there no improvement. The comparison just drawn also suggests that were an aneurism of the innominate placed under as favorable conditions as one of the carotid, the chances of life would be materially lengthened, and be on a par with those afforded by the latter. For this purpose, the sac should be confined to the upper part of the vessel or near its bifurcation, spring from the left segment of the artery, and be unimplicated with disease of the aorta or heart, or with aneurism of the aorta. A combination so fortuitous will, however, be of great rarity, and altogether exceptional to the rule. If then, past experience is to form a guide, we must conclude that although this operation may successfully obliterate the aneurism, yet it is proble-

ly, in addition, with
ity of an aneurismal
ase A morbid state
er than it otherwise
ervation and its im-
ation of the carotid
ombination is shown

Case.	Surgeon.
1. Dilatation of the aorta.	Morrison.
2. Dilatation of the aorta.	Key.
3. Dilatation of the aorta.	Fergusson.
4. Dilatation of the aorta.	Campbell.
5. Dilatation of the aorta.	Fearn.
6. Dilatation of the aorta.	Wickham.

their complications, as
Mott's no mention is
ing two the facts are
of complications with
ceding the statement
a salutary termination
ollowed Brasdor's ope-
e succeeded it in cases
ed by any other vas-
five *bona fide* cases, and
e recoveries, I was suc-
in only 1 was there no
suggests that were an-
ble conditions as one of
lengthened, and be on
rpose, the sac should be
bifurcation, spring firm
ned with disease of the
ombination so fortuitous
ceptional to the rule. If
conclude that although
eurism, yet it is proble-

matical, whether this circumstance will delay death, and that the existence of morbid accompaniments with the aneurism should preclude the ligature of the carotid. Unless some very urgent reason should arise, as the peril from instant rupture of the external tumor, when even though the forbidding complications co-exist, the operation may be performed, as the probability is it will then lengthen life. Such an advantage was evidently obtained in Wickham's case, where death which was momentarily anticipated before the artery was tied, did not occur till two months after the operation. And again the mean duration of life after the vessel was tied, in the cases examined, has been four and a half months. The inferences deducible from the foregoing are:—

1. Failures of carotid deligation to obliterate innominate aneurisms are attributable to individual irregularities.
2. Failures of carotid deligation to lengthen life in innominate aneurism, exclusive of the accidents of the ligature, are principally referrible to co-existent disease of the heart, or aorta, or aortic aneurism.
3. The operation should not be attempted in cases where there is a complication with these morbid states.

4. Unless there be imminent danger of death from rupture of the sac, &c.

5. The most promising case for the operation is when the innominate is most like a simple carotid aneurism.

And lastly, this operation may be compared with others for the cure of the same affection. These are:—1. Deligation of the arteria innominata on the cardiac side; 2. Ligature of both the carotid and subclavian arteries; 3. Tying the subclavian artery; and 4. Securing the arteria innominata on the distal side. The first is either impracticable under the circumstances of the case, or if practicable, inevitably fatal. It has been proscribed by Velpeau and others. In the second the operation varies as to whether both vessels be tied simultaneously or on separate occasions. The simultaneous ligature has been executed but once, and then under very unlucky auspices; it having been found post mortem, that the only pervious artery supplying the brain was the left vertebral. From the deligation not being feasible in any other than the third part of the subclavian's course, it follows as there will still be active circulation of blood through the tumor, and from it through the principal branches of the subclavian artery, which are all given off from this vessel before it extends beyond the scaleni muscles, that at most there

will be but a fractional addition to the stasis of blood caused by occlusion of the carotid; and when, for this trifling gain, so many additional dangers are risked, the dangers of a double instead of a single ligature, it does not seem warrantable to incur them for the trivial, perhaps, doubtful advantage acquired. The ligature of these vessels on separate occasions has been practised twice, but in addition to what has been just stated which is now equally applicable, it may be objected that the procedure reduces the case down to a single operation, since before the second is performed the collateral circulation will have become developed, and thus counteract all other advantages except those immediately secured by the first. Thirdly. Tying the subclavian artery alone, this is, of course, open to the objections just raised against this vessel when ligatured simultaneously with the carotid. By obliterating the carotid half the volume of blood that entered the aneurism is obstructed, whereas, by occluding the subclavian a check is only given to one-sixth, *i. e.*, one-third the amount destined for passage through the vessel, this important difference depending upon the carotid being a long trunk, giving off no branches between the sac and ligature, while the subclavian gives off all its largest branches between these two points. Lastly, tying the arteria innominata on the distal side—this is equivalent in impropriety to the first variety. According to writers, it would be the true Brasdorean method, for they have divided the distal operation into, 1 the Brasdorean, and 2 the Wardropian; but the distinction is unfounded, for in cases requiring it the first cannot be performed, as the encroachments of the tumor in both innominatal and inguinal aneurisms leave no space for the ligature of the end of the innominata or of the common femoral, so that in both a divisional branch, either carotid or superficial femoral, must be tied. Moreover, there is no authority for thus limiting M. Brasdor's proposal, for so far as is known, he intended it to be executed upon the principle expounded by Mr. Wardrop in his self-styled "new operation." And in conclusion it may be inferred:—

1. The ligature of the right carotid possesses advantages over alternative operations which entitle it to preference in practice.

2. Opinions as to the probable benefit of carotid deligation in innominatal aneurism, founded upon the results of tying the subclavian artery or both subclavian and carotid arteries cannot hold good.

From the inferences of the antecedent discussion, it may be concluded, as a secondary deduction, that there exists abundant justification to warrant a surgeon in again treating innominatal aneurism by ligature of the right common carotid artery; nay, more, that in certain cases he

would
having

The
tested
that o
extern
expect
—the
sac w
accide
the re
equall
rism o
post m
operat
tion, t
racter

Pier
day, 2
advice

The
lars th
border
the cla

caused by occlusion of so many additional vessels by a single ligature, it is, perhaps, doubtful whether on separate occasions it has been just stated that the procedure recommended is the second is preferred, and thus developed, and thus completely secured by the operation. This is, of course, a great advantage when ligatured at the carotid half the vessel is obstructed, whereas, in one to one-sixth, *i. e.*, through the vessel, this being a long trunk, ligature, while the operation in these two points. This is equivalent in the operation into, 1 the operation is unfounded, for in the encroachments of the vessels leave no space for the common femoral, so the superficial femoral, or thus limiting M. It is to be executed as self-styled "new"

advantages over alternative practice.

ligation in innominate the subclavian artery good.

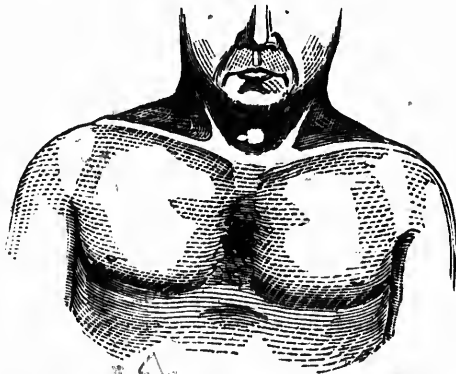
It may be concluded that the justification to aneurism by ligature is in certain cases he

would be deserving of censure if he permitted his patient to die without having been afforded the benefits of the operation.

The correctness of many of the foregoing statements is strikingly attested by the following case which occurred to me last autumn. It was that of a septuagenarian, having an innominate aneurism which pointed externally, and so superficially that its spontaneous rupture was hourly expected—the carotid artery was tied—life was prolonged three months—the aneurism underwent reduction in size—fibrillation occurred—the sac was occluded, and circulation from it to the artery ceased—no local accident interfered obnoxiously—death was caused by cerebral disease, the result of the ligature—no event happened that would not have equally followed, had the ligature been cardiac instead of distal—aneurism of the arch, and other evidences of arterial disease, were ascertained post mortem—and the relations of the aneurism proved that no other operation would have been as useful as the one executed—and, in addition, the case presented some unusual features, giving it a singular character. The details, as noted at the time, are these:—

Pierre Bridor was brought to the Montreal General Hospital on Saturday, 29th September, 1855, by Mr. Picault, a medical student, for my advice concerning a supposed aneurism at the root of the neck.

The tumor was situated in the episternal cervical pit; having for pillars the cleido-mastoid muscles, and being interposed between the lower border of the thyroid gland, and a line drawn across the sternal ends of the clavicles. Although fixed, it could be slightly displaced, as, laterally,



by manipulation, and, anteriorly, by efforts of deglutition. Its position was relatively affected by changes in the state of the neck; during flexion, its lower segment touched the superior border of the sternum, but when the head was thrown back, these parts were separated by a finger's breadth of intervening space. It had the appearance of two swellings united in one, of which the largest was hemispherical, the size of a split peach—and the smallest ovoidal, like an almond kernel; in reference to the mesian line, the former was nearly symmetrical, while the latter was on the right side, and, by its superaddition, destroyed the circularity, which, otherwise, the outline would have had. The entire tumor measured, vertically, $1\frac{1}{2}$ inches, and transversely $2\frac{1}{4}$ inches, its central axis projected about $1\frac{1}{2}$ inches from the superficies of the neck. Its surface was uniformly smooth, and rounded; the investing skin had a lurid red color, and the centre spot presented an aspect of pointing, being greatly attenuated, slightly excoriated, and seemingly on the eve of bursting: in short, it looked like a ripe abscess, and misled by this *facies futua*, the patient had been treating it with poultices. Moreover, it felt soft, and fluctuated most distinctly. But again, it pulsated forcibly; the pulsations were, everywhere, equable—as marked around the periphery as over the summit, and no variations could be discovered in their force, by producing the displacements above mentioned. It expanded with each contraction of the heart, and subsided during the diastole. A *bruit de soufflet* was heard proceeding from it; although the murmur was limited to the sides, and only heard when the stethoscope was pressed rather firmly against them, and it was not accompanied by any *fremissement*, or thrill. The swelling, by direct compression, carefully applied, was, in great part, emptied of its contents, and pressure upon the right carotid artery rendered it pale, diminutive, and flaccid, in consequence of syncope, which was also induced by this operation. It was first noticed on the 23rd September, and was then as big as the top of his finger, it subsequently enlarged day by day until it had reached the dimensions above detailed; it had begun with the same softness and compressibility it now possessed, and it had never been hot, nor tender, nor painful, although for a few days before its development, the skin, *in situ*, seemed unusually red.

Having next examined the chest I found the top piece of the sternum dull on percussion, and I heard throughout this space a strong pulsation which was loudest along the superior border, clearly distinct from the cardiac sounds, and most faint towards the region of the heart. No decided *bruit de soufflet* could be distinguished, but there was near the right sterno-clavicular articulation, the modification of sound that often,

by aug
was ra
also, r
more h
weake
of the

He
with la
he had
wh-n
asthm
month
their a
largem
comple
been tr
rally o
seanty
neck h
had a c
previo
extend
but ret
t on h
already
by pain
right s
their g
or as h
cutane
infra-c
No suc

In th
with
thoroug
of the i
the Ho
the me
tumor
death i
left al
the rig

tion. Its position
the neck; during
er of the sternum,
re separated by a
appearance of two
spherical, the size
mond kernel; in re-
symmetrical, while
tion, destroyed the
e had. The entire
rseely 2½ inches, its
ificies of the neck.
e investing skin had
aspect of pointing,
emingly on the eve
and misled by this
ultices. Moreover,
it pulsed forcibly;
ked around the peri-
e discovered in their
oned. It expanded
during the diastole.
ough the murmur was
pe was pressed rather
y any fremitus,
refully applied, was,
pon the right carotid
consequence of syn-
t was first noticed on
p of his finger, it sub-
the dimensions above
nd compressibility it
nder, nor painful, al-
e skin, *in situ*, seemed

piece of the sternum
ace a strong pulsation
ly distinct from the
of the heart. No de-
there was near the
on of sound that often,

by augmentation, passes into a bruit. The right infra clavicular region was rather duller than the corresponding one of the opposite side; here, also, respiration was generally weaker, and over the costal cartilages more blowing than natural. The pulse of the right wrist was somewhat weaker than that of the left one, but no difference was noted in the beats of the two carotids.

He was 70 years of age, by trade a hatter, a stout strong-built man, with large head, short neck and capacious chest. During his long life he had been seldom seriously ill. His chief ailments began a year ago, when he experienced a difficulty of breathing, which he believed was asthma, since then he had been liable to paroxysms that supervened monthly, and after continuing for a few days left him as well as before their accession. The first seizure was accompanied with dropsical enlargement of the abdomen and limbs, that lasted for six months and then completely disappeared. Ever after the first asthmatic attack he had been troubled with cough, which was never very annoying, and generally of slight character. It was attended with the expectoration of a scanty frothy mucus sputum, but at no time with hæmoptysis. His neck had a tendency to "tippet shape," the base was puffy, pitted and had a doughy feel, with an obscure crepitus on being pressed. A month previously a swelling commenced in the submaxillary region and rapidly extended over the neck; after persisting for a few days it went down, but returned in two or three week's time; and at the date of examination had so far declined as to present a mere trace over the clavicles, as already stated. When these tumefactions ensued they were accompanied by pains, which he took to be rheumatic; the latter were mostly felt in the right shoulder and spread thence upwards along the neck. When at their greatest height, he, also, suffered from a sensation of cephalic tension, or as he said his head felt as if it had been jammed into a tin case. The cutaneous venules were slightly varicose in the external part of the right infra-clavicular and mammary regions and axillary side of that arm. No such appearance visible on left side.

In the course of the afternoon I returned to the Hospital in company with Dr. Campbell, our Professor of Surgery. This gentleman, after a thorough investigation of the tumor, felt convinced that it was an aneurism of the innominata, and at his suggestion a consultation of the medical staff of the Hospital was called for next morning. There was a full attendance of the members, and all present were unanimous in diagnosing the external tumor to be aneurismal; and prognosticating the certainty of the man's death in, perhaps, a few hours, or at furthest, in a few days if he was left alone to his fate. After a mature deliberation it was resolved that the right common carotid artery should be tied on the morrow.

October 1, Noon.—THE OPERATION.—The patient was placed on the operating table, in the recumbent posture, with his neck extended and face inclined to the left side. An incision was commenced behind the angle of the jaw on the right side of the neck, in front of the sternomastoid, and continued downwards, nearly parallel to the anterior border of that muscle, for the extent of three inches, so that its termination approached the circumference of the tumor. The skin and subjacent cellulo-adipose membrane having been divided; the platysma myoides came into view and was cut through upon a director by a button-pointed bistoury; a small nervous twig (superficialis colli) appearing across the centre of the wound was purposely incised. A deep stratum of fascia was then divided in the same way as the muscle had been, and exposed several large veins below, which were carefully displaced and retracted; more fatty membrane next presented itself and was cautiously cut through. After which the sheath of the vessels was seen and opened in the usual manner. The wound, having been gradually decreased in length at each successive division, had now a triangular shape, the apex being upon the vessels. The needle was dipped, and as it was entering a large vein rolled forwards, but this having been held aside, the instrument was passed from without inwards; the structure, however, it surrounded proved to be the pneumogastric nerve which lay anterior to the artery instead of in its usual position. The needle was disengaged and reintroduced, but in the direction of from within outwards, when the primitive carotid artery was at once secured. Having assured myself the vessel was isolated from its neighbouring associates, I now firmly tied it by a reef knot: one end of the ligature was cut off and the other allowed to depend from the wound. The wound was closed by a stitch and a couple of straps of adhesive plaster, as well as by a bandage turned round the top of the chest. Scarcely any blood was lost, the drops that did flow proceeded from the integumental incisions as no hæmorrhage occurred during the subsequent manipulations. Upon opposing together the sides of the vessel, a sort of epileptoid seizure was induced, but it was only of momentary duration. After tightening the ligature there was a total absence of pulsation in the temporal and other branches of the external carotid; there was also an appreciable alteration in the tumor, as it became less tense and pulsated more feebly. Chloroform was not administered, and the suffering was endured with remarkable fortitude and suppression of feeling.

4 P. M.—Tumor pulsating strongly, rather larger, particularly in the night; but owing to participation in general vascular excitement for his pulse is 92 and fuller, and he is feverish. While returning from the theatre to the ward he vomited a little, but since then he has been

Compo
a vein
and co
Liq. p
gitalis
he had
ability
solid.

2nd
sations
little l
free;
added
solid;
finger
if it
dent.

lanced
produc
ingly a
not mo
his life

3rd,
and th
to be a
ripplin
water;
now, n
with s
feels r
out dis
upper
remov
jelly a
serum
swelli
not gr
ation,
ated w
tissues
fused,
pulsati

was placed on the neck extended and extended behind the front of the sternum to the anterior border at its termination skin and subjacent platysma myoides by a button point- i) appearing across A deep stratum of muscle had been, and fully displaced and itself and was causing vessels was seen being gradually had now a triangular was dipped, and as it being held aside, the structure, however, which lay anterior the needle was disengaged within outwards, red. Having assured my associates, I now was cut off and the wound was closed by a suture as well as by a bandage. No blood was lost, the arterial incisions as no manipulations. Upon epileptoid seizure was After tightening the the temporal and other an appreciable alteration pulsated more feebly and was endured with

ger, particularly in the vascular excitement. While returning from since then he has been

Composed and has had an hour's sleep. ℥xii . of blood were drawn from a vein of the bend of the elbow. Lint soaked in the following lotion and covered with oiled silk, was constantly applied to the tumor. ℞ Liq. plumbi diacet ℥ss ; acid tannic ℥ss ; aquæ Oss. And ℞ tinct digitalis, vini antimonial ana ℞x ; quaque secunda hora—which mixture he had been taking during the past 24 hours. Absolute rest and tranquillity enjoined. 9 P. M.—Tumor seems less prominent and more solid. No other change.

2nd October, 12 A. M.—Tumor appears rather more diffused. Pulsations becoming weaker. Pulse not so strong and only 82. Dozed a little last night, head is slightly giddy; skin still rather warm; bowels free; no pain anywhere. Two drops of tr. aconite (U. S. Ph.) to be added to each dose of mixture. 7 P. M.—Tumor certainly feels more solid; skin over centre very thin, candid, dry, and partly fissured, the finger can invert it by gentle pressure without feeling any pulsation, but if it cause more than a slight depression above stated, becomes evident. Pulse fuller, firmer, and 86. A vein near the inner ankle was lanced and about ℥x of blood allowed to escape; faintness was not produced either by this or the former venesection. To use fluids as sparingly as possible—ordinary drink to be water flavored with wine, and not more than ℥i ss of latter in the day; he has been, for last years of his life, accustomed daily to take whiskey and wine freely.

3rd, noon.—About 7 a. m. the centre of the apex of the tumor cracked, and there escaped, from beneath a scale of cuticle, a quantity (supposed to be a few drachms) of a fluid which the House Surgeon, who watched it rippling away, describes as very thin, clear, transparent, yellowish and watery, it has since continued to ooze out, though more thinly, and that now, noon, seen by myself, has the characters above stated, and is identical with serum. The aneurism is, in consequence, less tense and prominent, feels much harder and throbs more feebly. Wound was dressed without disturbing him from the dorsal decubitus: it looked very well, the upper part appeared to be united by primary adhesion; the stitch was removed. Posture not to be changed. Diet to consist of calf's foot jelly and strong beef tea, with corn starch. 7 P. M.—The leakage of serum continued during the greater part of the afternoon, leaving the swelling so reduced that the latter now consists of a central rising not greater in circumference than a shilling piece, with a lateral elongation, the residual site of the former tumor is firm and marked by indurated welt like borders feeling like solid lymph in the sub-integumental tissues; visible pulsation still easily seen in all aspects and generally diffused, tangible pulsation also very evident by palpation, and lastly, audible pulsation is as distinct as before the sac opened; the cutaneous disco-

loration has been gradually fading with the disappearance of the Intumescence. Patient feels well and has no cause of complaint; bowels open; pulse rather weaker, but of frequency last specified.

4th, Noon.—The flow of serum has been gradually decreasing; pretty firm pressure can be made over the aneurismal debris, with no other effect than the extrusion of drops of serum; the central flake of cuticle has separated, exposing a minute slough; the fluid that escapes is a little darker, and more viscid, than previously, but its other characters are unchanged. 6, P.M.—Progressing satisfactorily.

5th, Noon.—The serum that now escapes is slightly opalescent, as it mixes, during its transit, with a little pus secreted by the ulceration around the slough; wound looks well; pulse, 78. Stethoscopic signs, over sternum, unchanged; they are more superficial and sonorous than the cardiac, and easily distinguishable from them. 6, p.m.—He broke through restraint, and I found him sitting up, eating his supper, and supported in bed. An egg a day added to former diet.

6th—Slough detaching. Complains of pains along the right side of neck and head. Pulse 78. Substitute for former lotion, ℞ alumin ʒiiss., spt. lavend. co. ʒij., Aquæ. Oss. 9, P.M.—Appears to be progressing favourably.

7th, 9, A.M., (Sunday).—Cervical pulsations have been weakening and becoming less extensive. No change in those over the sternum. Slough came away, exposing an ulcer the size of a shirt-button, through which, by pressure on surrounding parts, drops of serum may still be extruded. Wound dressed; its appearance is favorable. Pains not so acute, but has an uneasy feeling in the right ear. 5½, P.M.—Had chicken to-day.

8th, Noon.—The external aneurism has been gradually disappearing, the former indurated elevations have been subsiding, in loco the parts feel soft, and are somewhat depressed. Ulcer healthy. Pains continue, they are remitting in severity, becoming worse at 9 or 10 at night, and continuing severe till the morning; they prevent his sleeping soundly, and are confined entirely to the right side. He sleeps well in the day-time.

9th.—Visible pulsation, only perceptible when he is sat up in bed—it is then quite obvious in the old situation, although the vestiges of the original tumor have been removed. A little serum still escapes; it has a reddish tint to-day. Appetite good, and relishes food. Pulse 72, regular and normal. Not wishing to incur the "explosive effects" of digitalis, the mixture was replaced by one containing ipecacuanha and citrat potass.

10th—The episternal cervical pit has now an excavated appearance,

is soft,
with d
through
extent
rectly
the oth
and ki
I felt s
was, o
follow
lower
ness in
tion ha
12th
13th
ed thr
tion of
parativ
abated
the rig
men, s
64. A
Dose a
ch. iij.
14th
15th
pector
integu
and al
gular,
wine.
in che
felt si
hyd. e
16th
less in
where
ng sca
17th
prostra
hot sw
respira

rance of the Intumescence; bowels open;

gradually decreasing; small debris, with no central flake of the fluid that escapes. but its other characteristics.

ently opalescent, as it is by the ulceration. Stethoscopic signs, normal and sonorous than 6, p.m.—He broke up his supper, and sup-

ing the right side of motion, & alumin 3iss., is to be progressing

ve been weakening the over the sternum. shirt-button, through scarum may still be extensible. Pains not so bear. 5½, P.M.—Had

gradually disappearing, ting, in loco the parts healthy. Pains continue, 9 or 10 at night, and his sleeping soundly, sleeps well in the day-

ne is sat up in bed—it the vestiges of the orifices still escapes; it has a good food. Pulse 72, regressive effects" of digesting ipecacuanha and

excavated appearance,

is soft, and, apparently, of normal structure, yet it still pulsates, though with diminished energy. The ulcer has contracted to a minute opening, through which a probe may be passed along a fistula of nearly two inches extent, in a direction of first backwards to the mesial line, and then directly downwards; this fistula was discovered by Dr. Holmes, who, with the other physicians of the Hospital, manifested a lively interest in the case, and kindly visited the patient from time to time. On probing this trajet, I felt strong impulses communicated to my fingers, and the instrument was, on each occasion, sensibly elevated. No escape of blood or fluid followed these explorations. Wound in upper part completely healed, lower part suppurating. 5, P.M.—Pains rather worse; has some uneasiness in chest, but no cough, nor dyspnœa. His old cough and expectoration have been gradually leaving him since the day of operation.

12th.—Passed a good night.

13th.—Seized last evening with dyspnœa and cough, which continued throughout the night, but relieved this morning, after the expectoration of a large quantity of pituitous phlegm. He is now, noon, comparatively easy, but does not feel as well as usual, and the cough, though abated, continues. Right side of chest feels tight, and respiration around the right nipple is harsh, and abrupt; has some uneasiness in the abdomen, and last alvine evacuation was unusually copious and loose. Pulse 64. Adde misturæ ʒviij. ut supra; tinct. lobeliæ 3iss.; tinct. corii ʒj. Dose as before. Sinapism over right side, and pulv. ipecac. co. gr. v., ch. iij. i quaque quarta hora.

14th.—Rather better: pulse 60.

15th, 12 a.m.—No return of dyspnœa; cough still troublesome; expectoration seroalbuminous, frothy, and more scanty; slight œdema of integuments at base of neck; complains greatly of the pain in the ear and about the face and neck on the right side; pulse only 57, firm, regular, and compressible. Appetite failing; sleeps well; ordered ʒiv. wine. 5 p.m. Complained of some dysphagia, also of a void sensation in chest, which he says, although he did not mention it before, have been felt since operation, and been gradually increasing. R doveri gr. iij, hyd. c. creta gr. ij.; quaque 2 da hora. Pergat. in usu mist.

16th.—Better; pectoral symptoms improved; slept well, and pains less intense; wound healed throughout, except at inferior commissure, where ligature emerges; fistulous opening still patulous, and discharging scantily; pulsation in episternal pit has been growing fainter.

17th.—Much worse. The change set in last night. Noon: Greatly prostrated; face sunken and suffused; pulse 52, small and weak; has not swallowed anything for some hours, as he says the passage is closed; respiration noisy; sonorous rales, in various modifications, heard over the

front of both lungs, but loudest over the right side; voice, though weak, not otherwise altered, and has at no time deviated from ordinary character; cough occasional and short; expectoration scanty; intelligence unaffected; had no sleep last night; bowels open; urine natural. In lieu of former mixture—R tr. cinchon. co. ℥ij., spt. ammon. arom., spt. cinnam. co. aa ʒvi., aquæ ℥ivss., m. ft. mist. Sig. coch. maj., secund quaque hora. ℥iv. brandy in addition to wine. To be given liquors as punch and negus. Sinapism to chest. 2 p.m. Visited him with Dr. Campbell, He had not swallowed anything since I last saw him. There was, now, a disposition to sopor, slowness and impediment in articulation, slight involuntary twitches in fingers of right hand. Other symptoms unchanged. At Dr. C.'s advice, a blister was put on the nape of the neck, and mustard applied to the feet; the other measures were continued. Wound looked well, and no signs seen of suppuration in its vicinity. 5½ p.m. More somnolent; did not know his friends this afternoon; right half of mouth is more dependant than the left; moans considerably; coughs but seldom; no heat of scalp; pulse 55. Has taken the medicine and some of the brandy, but refuses nourishment. Enema terebinth statim. Omit pulv.

18th, Noon.—Better; conscious and no tendency to stupor, complains of malaise, and of old pains in particular, feels very unwell, pulse 48 stronger, no muscular twitches, otherwise no alteration. Rept sinapism, blistered surface to be dressed with cerat sabin. 5½ p.m.—Swallowed nourishment for the first time this afternoon since this last attack, its ingestion required a double effort; respiration tranquil, and physical signs less loud. Make brandy into egg flip.

19th, Noon.—Dysphagia lessened; appears much as formerly described; pulse weaker and 46. Had an enema terebinth this morning. 6 p.m.—Has since had two stools. Cough troublesome, expectoration difficult; respiration over both lungs harsh and rough, but much loudest over right, no distinct bronchitic rale; increasing thirst and heat of skin; pain continues severe, Add spts. sulph. æther. co. ʒvj to mixt.

20th, Noon.—Symptoms generally ameliorated, no pyrexial tendency. Slept a few hours last night. Pulse 52, rather fuller. 6 p.m. Has been using a full share of nutriment for last two days, strength augmenting, as now he gets out of bed, with assistance, to sit on the night chair. Pulse 48, margins of wound red and swollen.

22nd.—Paralytic symptoms mentioned on the 18th have been becoming generally developed, and now hemiplegia is decidedly manifest: loss of balance in corresponding features; left half of face blank and lengthened; left half of lips pendulous and apposed, while right contracted and open; during a strong expiration the left cheek is puffed out

like
of le
side
com
Puls
ed th
24
won
it op
exce
Omi
day,
25
skin
no in
old p
senin
31
but
statu
requ
reuch
the
befor
have
trou
ible.
ou c
nues
has s
chan
No
when
india
7th
has l
and l
visite
9th
him t
paral
11
excit

voice, though weak, from ordinary chascanty; intelligence fine natural. In lieu mon. arom., spt. cinch. maj., second quab. be given liquors as visited him with Dr. last saw him. There ment in articulation, d. Other symptoms on the nape of the measures were contipation in its vicifriends this afternoon; left; moans consider- 55. Has taken the nourishment. Enema

y to stupor, complains very unwell, pulse 48 eration. Rept sinap . 5½ p.m.—Swallow since this last attack, tranquil, and physical

ch as formerly describ- inth this morning. 6 ome, expectoration dif- gh, but much loudest thirst and heat of skin; o. 3vj to mixt.

, no pyrexial tendency. lér. 6 p.m. Has been , strength augmenting, sit on the night chair.

18th have been becom- s decidedly manifest : half of face blank and posed, while right con- b left cheek is puffed out

like a bag; cannot close the left fingers as firmly as the right; motion of left extremities abbreviated; arm more feeble than leg; says, that side feels dead; sensibility is slightly blunted; special senses not affected; complains of tickling and irritation in the throat; slept well last night. Pulse 56. The usual difference felt in the two radials now more marked than formerly.

24th.—A small abscess that had been forming in the track of the wound burst this morning, and discharged about 3ij of laudable pus; it opened about the middle of the wound, which is now entirely closed except in that spot, and at the inferior angle where the ligature is. Omit. mist. and let him have gr. 1½ quinin, in solution, three times a day, with 3ss co. Tr. eardam. Simple dressing to neck.

25th.—The ulcer has healed, and the fistulous opening is at length skinned over. Pulse 47. Feels stronger; appetite good; sleeps well; no intellectual derangement; no heat of scalp nor febrile disorder. The old pains of the ear, neck, and face, though daily present, have been lessening.

31st.—Since last report his articulation was, for a few days impeded, but it is growing more distinct, the other paralytic symptoms are *in statu quo*. Has latterly had a tendency to costiveness, and yesterday required a dose of castor oil. Slowness of pulse persists; it seldom has reached 50, thought to day it is 53, occasionally it has seemed to be of the same volume and force in both wrists, unlike the usual condition before stated. Does not complain of pain in ear, nor face, nor neck which have hitherto persisted more or less since first mentioned. Cough not troublesome; pulsation in episternal cavical pit has ceased to be perceptible. Skin of this part has become chafed from chin being usually bent on chest, and thus keeping opposed folds in contact. Wound continues discharging at two points, inflammatory turgescence of borders has subsided. Blister on neck has been allowed to heal. No further change.

November 2nd.—Left Hospital, with consent, and returned home, where I continued my attendance. Ligature put on the stretch by india-rubber tape to facilitate its separation.

7th.—No important change has taken place; except that the pulse has been gradually rising, and is now 60, perhaps from his sitting up and being near a warm stove, which is the position he is found in when visited.

9th.—Greatly agitated yesterday by domestic matters, which caused him to pass a restless night. Pulse 64; surface hot; cough troublesome; paralysis as at last report.

11th.—Recovered from the mental annoyance, and the consequent excitement has passed off.

13th.—Ligature removed: in attempting to draw it away it broke, and rather strangely, on examining the wound attentively, a small white projection was found in the aperture left by the healing of the abscess, and this projection appearing to be also thread was pulled when the remainder of the ligature was extracted; the latter contained a distinct noose, which was the presenting part,—clearly showing the ligature had separated internally from the artery sometime previously. Hemiplegia appears rather improved; he can bend his elbow, and raise the arm of the affected side to a level with the top of his shoulder; and can partially clench his hand, but he cannot make the fingers touch the palm; while sitting he can move the leg and bend the knee, but in walking the leg drags; facial distortion not more pronounced than when last noticed; appetite moderate and general health good. Pulse 60.

26th.—Hemiplegic symptoms have grown worse; unable to walk unsupported; mental faculties decaying, is very troublesome, peevish and passionate; sometimes talks a little silly. Complains of pains in right ear, and over corresponding side of neck and head having returned and with distressing acuteness. Of late has suffered from urgent thirst. Exhibits no febrile symptoms. When visited is generally sitting up, eating his dinner.

Dec. 5.—Continuing worse, confined to bed in dorsal decubitus, unable to help himself, seemingly much exhausted, loss of power over left arm and leg is complete; urine escapes, involuntarily; bowels sluggish; pulse small, weak and slow; tongue when protruded comes against left corner of mouth. Cont quin, wine, brandy, and nourishment; together with an occasional dose of ol ricini when required.

7th.—So much improved in feeling that he sat up and used food. Paralysis as before, articulation more difficult.

10th.—Another bad turn similar to that of the 5th instant, but he is now, in addition, soporose and there is a tendency to stertor in respiration; bowels costive; pulse feeble. Habt ol ricini 3ij.

12th.—Improved; more wakeful and attempts to reply to questions asked him; but, from the loss of articulation, his meaning cannot be understood. Has latterly been taking very little nourishment.

17th.—Has had involuntary startings of paralysed extremities; bowel not been opened for the last 3 or 4 days. Habt ol ricini 3ij.

19th.—Return of drowsiness; paralysed parts still retain sensation though in a weakened degree; muscular startings occasionally observed; respiration is rather blowing, and while he expires left cheek swells out. Bowels now only moved when he is given the oil.

23rd.—Sleeps most of the time; when awake is very thirsty, takes hardly any nourishment; pulse barely appreciable, there is an ossifica-

tion
now
26
but h
tion
light
27
N
therl
With
disse
stern
usua
other
large
infer
great
were
were
and c
about
sion

BR
alter
round
was i
it cor
rated
its pr
this v
was
The
remo
tenin
spher
absce
cornu
im ne
subst
not la
just

tion of the vessel which prevents the beats from being distinctly felt, now that the blood current is so weak.

26th.—Has been gradually failing. Lies on his back in a torpid state, but he may be easily aroused and sometimes wakes up moaning, respiration is tranquil, and the pupils are not dilated and obey the stimulus of light.

27th.—He died this morning at an early hour.

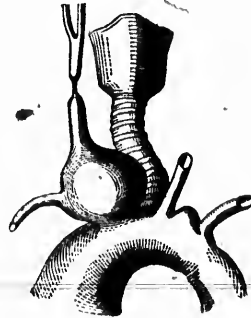
NECROPSY, 2½ P. M.—Present: Drs. Holmes, Campbell, Fraser, Sutherland Scott, McCallum, and Craik; Messrs. Kirkpatrick and Picault. With the assistance of Drs. Scott and McCallum the neck was carefully dissected and the cavity of the chest fully exposed. Between the sterno-mastoids, the subcutaneous cellular tissue was condensed and unusually adherent. The episternal cervical pit presented no tumor, nor other morbid condition. Behind the first bone of the sternum was a large globular aneurism which had caused the heart to be displaced inferiorly. After observing the relations of parts; the heart with its great vessels, as well as the wind-pipe, together with the aneurism, were all removed *en masse* and taken home for closer study. The lungs were rather voluminous but not emphysematous, they had a dark color and contained a large quantity of black blood which was chiefly settled about their posterior parts. Laterally the pleuræ had contracted adhesion to the sides of the great vessels connected with the heart.

BRAIN.—The right hemisphere appeared larger than the left, and was altered in shape; the anterior extremity, especially, being fuller and rounder. Upon section four abscesses were discovered in it—the largest was in the *centrum ovale* sinus, occupying the anterior and middle lobes, it contained about 3 ij. ss. of pus. Its outer wall was very thin, separated from the pia mater by only a few lines of cerebral substance; by its pressure it caused a displacement and atrophy of contiguous parts—this was especially obvious with regard to the corpus striatum, which was flattened and narrowed; the optic thalamus was also changed. The pus was thick, of a green color, fetid, and, in part, clotty; upon its removal, the inner surface of the cavity appeared very smooth and glistening, as if lined by a serous membrane—the cavity was irregularly spheroidal, and had no communication with the lateral ventricle. The abscess next in size was in the posterior lobe, to the outer side of the cornu, but distinct from it, it held about 3 ss. of pus of same character; immediately below it, but completely isolated by a stratum of cerebral substance, was the third abscess, it was of still smaller capacity, and was not larger than a small marble. The last was in form like a bean, and just about as bulky; it was situated externally to, and behind the, cor-

pora quadragemina. The fluid in each had the same character, and was like that described as found in the first; and the wall of each had a similarly worn appearance, rendering it as smooth, as if lined by a membrane. The medullary matter around these abscesses was firm, and rather indurated, particularly the portions which seemed to have been most encroached upon, as the outer wall of the largest abscess, this was, in its thinnest part, almost coriaceous; otherwise the brain substance was remarkably healthy; no fluid found in the ventricles; no unusual congestion of the veins; the membrane was healthy; there seemed to be some slight serous effusion beneath the arachnoid over the left hemisphere, but it was very slight, and not decided. The right crus cerebri appeared to be more diffuent than ordinary, but the change was only in its medullary exterior, and had not destroyed the original white color. No alteration in pons, medulla oblongata, cerebellum, nor elsewhere.

The parts removed having been dissected by my friend, Dr. MacCallum, and myself, the following additional facts were noticed:—

ANEURISM.—The aneurism began in a dilatation of the arteria innominata at its origin; and this enlargement, as it ascended, became so great that the vessel had given way, and a sac had been formed, partly by the arterial coats, and partly by surrounding textures. Its sac was formed anteriorly and superiorly; by, firstly, the right sterno-hyoid and sterno-thyroid muscles, which were attenuated and flattened, and were bound to the analagous muscles of the opposite side by the deep layer of the cervical fascia, which was, here, strongly condensed, and much thickened; secondly, by a submuscular stratum of fat in considerable abundance; and, thirdly, by subjacent cellular tissue in a condensed state. Posteriorly, and elsewhere, the sac was formed of the expanded coats of the innominatal artery, which were thinned, and covered by a consistent layer of adipose tissue. The right carotid and subclavian



arter
swel
vesse
in th
The
verti
part
this
havin
was
part
super
half
and d
the la
relati
nerve
the p
laryn
face
lar m
was f
centr
throu
the b
existe
with
canal
mass,
tendin
Ri
inche
tende
of cor
the re
gradu
the p
firm,
super
above
tid, b
taine

ame character, and
 wall of each had a
 s if lined by a mem-
 was firm, and rather
 have been most en-
 erness, this was, in its
 n substance was re-
 ; no unusual conges-
 e seemed to be some
 the left hemisphere,
 us cerebri appeared
 as only in its medul-
 l white color. No
 nor elsewhere.
 y friend, Dr. MacCal-
 e noticed :—
 of the arteria inno-
 ascended, became so
 been formed, partly
 textures. Its sac was
 ight sterno-hyoid and
 d flattened, and were
 e by the deep layer of
 ondense, and much
 fat in considerable
 ssive in a condensed
 med of the expanded
 ed, and covered by a
 rotid and subclavian

arteries arose from about the middle of the outer circumference of the swelling; they were, here, somewhat dilated, particularly the first vessel, each forming an infundibulum which, by diffusion, was lost in the general envelope, and also contributed towards its formation. The aneurism formed a tumor of a spheroidal shape; its longest or vertical axis measured $2\frac{1}{4}$ inches, its transverse $1\frac{1}{4}$ inches in the widest part; its greatest circumference was a little more than 6 inches; above this it became gradually rounded, and was lost in a superior segment, having no outlet; below this it grew more slender, and most inferiorly was only $4\frac{1}{4}$ inches in girth. It was placed obliquely across the lower part of the trachea, the inferior extremity pointing to the left, and the superior to the right side; the main body of the tumor was on the right half of the trachea. The tumor and trachea were separated by a firm and dense layer of fat; in the back part of the former was a groove where the latter had rested. The aneurism, posteriorly, had also the following relations from without inwards:—superior intercostal artery, phrenic nerve and internal mammary artery, while more posterior to these was the pneumogastric nerve, and curving round the swelling the recurrent laryngeal branch; its external border was connected to the inner surface of the superior lobe of the right lung, by transverse bands of cellular membrane. The aneurism was solid; and upon division its cavity was found filled with a hard mass of indurated fibrin, disposed in concentric laminæ, and of a buffy light red color. The only communication through the aneurism was a channel, admitting a bougie, through which the blood flowed from the aorta into the subclavian; and a small fissure existed on the exterior of the tumour at the junction of the sterno-hyoid with the sterno-thyroid, and nearly in the mesian line. It led into a canal directed downwards and backwards, situated within the fibrinous mass, nearer to the anterior than the posterior wall of the sac, and extending nearly across from the one to the other.

RIGHT COMMON CAROTID ARTERY.—This vessel was intercepted $2\frac{1}{4}$ inches from its origin, it gradually tapered to this limit, as a firm distended, slightly flattened cord; but here its place was occupied by a strip of condensed areolar membrane, which connected the former part with the rest of the artery; beyond this band, the artery began pointed, and gradually swelled out into its usual form and calibre. The interior of the portion below the band, was filled with a clot of lymph, which was firm, truncated, reddish, fibrillated, and adherent to the inner wall; the superior portion was occupied, for nearly an inch, by a similar plug, but above this point, the artery terminated in the external and internal carotid, both of which branches were pervious, although the former contained, at its origin, a delicate clot, measuring three lines in length, and

extending from the rest. The sheath of the vessels was confused, and not distinguishable at the place where the artery was defective; a short distance above and below this, it was thickened and adherent to the outer coat of the vessel; and still further upwards and downwards, it was remarkably well defined, but scarcely abnormal. The pneumogastric nerve proceeded between the internal jugular vein and artery, from behind forwards, and continuing to be directed anteriorly, it lay in front of the latter inferiorly, and was separated from it for the distance of two lines; it next approached the sac, became flattened, running, in this condition, over the right segment of the aneurism, and leaving the latter opposite the commencement of the subclavian, where it gave off the recurrent, and then proceeded onwards in its usual course. The internal jugular vein was external to the artery and nerve, and on a higher level than either; its lower part was directed more anteriorly than usual, it impinged on the top of the tumor, ran over its external circumference, united with the subclavian, and the continuation (*vena innominata*) passed across the tumor, and joined its fellow of the opposite side.

AORTA.—The *ascending* portion was considerably dilated, being 5½ inches in circumference across its inner surface. The lining membrane was scabrous from atheromatous deposits, some of which were disposed in an annular form resembling ring worms. The *Arch* was aneurismal and extensively degenerated. The dilatation was principally obvious between the left carotid and left subclavian arteries, where it rose up like a bladder; it also, conspicuously, involved the anterior and posterior walls of the arch just above its commencement; circularly the arch, here, measured 6½ inches when flaccid. In the upward protrusion there was a fibrous clot, looking like placental structure, of a buff colour, variegated with red, reaching as low down as the innominate opening, and connected to the contiguous surface by delicate trabeculæ; a second clot of similar appearance, but much smaller, was, also, found attached to the upper part, a little further forward. The lining membrane was variously diseased, in part eaten away by minute erosions; in one place looking like an ulcer, there being an irregularly ragged solution of continuity, in the lining membrane, which was walled round by a raised fungoid border, having for its floor the middle coat, stained of a dark red color; and measuring 1½ inch by 1 inch; elsewhere the inner membrane was irregularly thickened and atheromatous, here rosily stained and there morbidly white. The *descending* aorta was, also, in a state of atheromatous degeneration.

HEART.—Aortic valves normal, but the ostium ossific and studded with bony plates; mitral valve fibroid, base encircled with calcareous deposits of coralline shape. Both these valves close perfectly, and preclude

regur-
ventri-
cious-
ascert-

The
fellow
blanc-
toms-
rived
tomic-
—the
culati-
varied
the su-
constr-

I. T
that of
Of 8 c
was di-
tremity
muscle
and ou-
one-th
ternal,
is desc-
the tra-
All the
ever, th
this sit-
it acco-
aneuris-
wise tr-
with li-
taken u-
tion.

Surger-
itself
proceed-
of the
from th
ring to
resemb

regurgitation of fluid. Tricuspid and pulmonic valves healthy. Left ventricle hypertrophied, its wall being seven lines thick; no over capacity of its cavity; left auricle slightly thickened. No further lesions ascertained.

The characters that chiefly distinguish the preceding case from its fellows are as follows:—the situation of the external tumor—the resemblance of the latter to an abscess—the modification of its direct symptoms—the initiatory redness—the inadequacy of the acoustic signs derived from the chest—the slightness of the remote symptoms—the anatomical difficulties of the operation—the external opening of the aneurism—the fistula to which it led—the symptoms of deranged cerebral circulation as witnessed in hemiplegia, ushered in by pseudo-coma, and varied before death by intercurrent stupor and vigillium—and, lastly, the subsequent discovery of abscesses in the brain, and of a peculiarly constructed aneurism. Each of these calls for a few remarks.

I. The situation of the tumor appears peculiar when contrasted with that of others, before quoted, in which this circumstance is precisely stated. Of 8 cases of innominate aneurism treated by carotid deligation: in five it was directly above the right sterno-clavicular articulation, or inner extremity of the clavicle, and behind the lower end of the sterno-mastoid muscle; when large it projected so as to be visible on both the tracheal and outer borders of the muscle. In one it proceeded outward about one-third along the right clavicle. In another it was still more external, and was seated over the middle of this bone. And in the last it is described as “immediately above the sternum, bounded laterally by the trachea and tracheal margin of the sterno-cleido-mastoid muscle.” All these exhibit a lateral position. In the case I have described, however, the situation was mesian in the episternal cervical pit. But while this situation was exceptional to that seen in cases similarly treated, it accords with what has been observed in other cases of innominate aneurism, which have either not been operated upon, or have been otherwise treated; for if their records be examined, examples will be met with like the one in question. This central situation is occasionally taken up by aneurism of the aorta, either of the arch or ascending portion. Dr. V. Mott, in his remarks upon aneurisms, (*Velpeau's Operative Surgery*, vol. 1, p. 278,) says:—“When an aneurismal tumor shews itself above the upper bone of the sternum, it happens as often that it proceeds from the aorta as from the innominate.” *Blakiston (Diseases of the Chest*, p. 135) describes a case of sacculated aneurism that sprang from the arch of the aorta, and caused a suprasternal tumor; on referring to it, the reader will remark that the latter bears many points of resemblance to the one in the case above detailed. It is an important

matter to be able to distinguish whether aneurism pointing in this part arise from the innominate or aorta; as if it be the former, operative interference may be justifiable, while if it be the latter, such procedure is inadmissible. In some cases this diagnosis cannot be made during life, but in others, of a less, obscure kind, a correct conclusion may be formed—and perhaps in future cases the following differential arrangement may be found useful. It refers merely to the distinction of the tumor in the episternal cervical pit, and not to the diagnosis of the aneurisms generally.

INNOMINATAL.

Most frequent.
Development more rapid.
Unilateral.
Inclined to the right.
Proceeds from the right to the mesian line.
Attachment expanded.
Basis dextrolateral.
Occupies whole length of inner segment of innominate.
Signs of aortic aneurism absent or doubtful.
Dullness greatest about the sterno-clavicular joint.
The remote symptoms of aneurism confined to, or chiefly observed in, the right side of the body.

It is expected that an exception may be met with to one or more of these distinctions, for they are only intended, like other diagnoses, to apply to the generality of cases. Besides the above vessels (innominate and aortic) it is just possible, that through great rarity, an aneurism might be produced in a similar situation, either by a lateral diversion of the root of the right common carotid, or by the thyroid, middle or inferior, artery communicating with the cavity of an abscess. Such cases would be characterized by their own individual features, as the higher locality of the tumor, &c., as well as by an absence of the positive characters of innominate aneurism.

II. The likeness of the superficial swelling to an abscess was striking, and it is, therefore, not strange the patient should have mistaken it for one. In other cases this resemblance has been so strong, as even to have deceived surgeons themselves. Mr. Norris (*op. cit.*) has published two such instances in which the sac was incised, one of which happened to the late Mr. Liston. This error, for the most part, only happens where the more prominent symptoms of aneurism are absent: such as equable expansion and declination of the sac, synchronously with the systole and diastole of the heart; collapse of the sac, upon pressure of the artery on its cardiac side; emptying the sac by direct manipulation; inability to remove pulsation by displacement, &c.; should cardinal signs like these be absent then, indeed, a wrong diagnosis may be venial. While, however, it is true that an aneurism may be considered to be an abscess, the converse does not necessarily follow, as is unconditionally

AORTIC.

Less common.
Formation more gradual.
Symmetrical.
Equi-distant from either side;
Ascends mesially.
Attachment pedunculated.
Basis inferior.
From a part of the arch between the innominate and left carotid.
Signs of aortic aneurism invariable and evident.
Dullness greatest over centre of manubrium.

The remote symptoms of aneurism occur at least in the first instance on the left side.

stated in some hand-books, (e.g., Erichsen,) and I believe it may be asserted that *an abscess cannot be mistaken for an aneurism.*— For that could only occur when an abscess possessed the most distinctive of the signs of aneurism as those just specified; while experience shows that such attributes are never present. An abscess may pulsate and thus simulate an aneurism, but this is merely a suggestive sign of aneurism, and unless accompanied by the cardinal signs is never considered to be conclusive in its indication. An abscess is more likely to be mistaken for an aneurism in its earlier stage than when fully matured. Lancisi (De aneurysmatibus, 1728,) bears witness to the correctness of this proposition in the following decisive words:—"For whatever pulsatile power an abscess may be supposed to possess, yet its pulsation only lasts until pus is generated when it ceases." Owing probably to the hard fibrinous exudation of the first period being capable of exercising a degree and kind of pressure upon contiguous vessels, which the purulent secretion of the latter is unable to accomplish. Occasionally, however, a few exceptions are observed where an abscess in the fluid condition does pulsate, but these are so uncomplicated as not to embarrass the diagnosis. And from them the practical conclusion follows; that swellings in the neck, though soft, liquid, fluctuating and pulsating, if deficient in every other mark of aneurism; may be safely treated as abscesses.

III. Some of the direct signs of aneurism, or those proceeding immediately from the sac, were deficient; as the absence of thrill and indistinctness of bruit. This peculiarity is to be ascribed to the nature of the aneurism; it was of the species known as sacculated or false, and still more appropriately called by Petit, aneurism by effusion, the latter appellation implying that, the blood escapes or is effused from the artery to which it returns after having circulated through an intermediate sac. In every such aneurism, according to this eminent surgeon, who wrote in 1736, thrill is rarely perceptible and bruit is seldom, or else but indistinctly perceived. He also mentions another distinguishing feature, that further identifies the above case with this class—it is that in aneurism by effusion, the enveloping "integument assumes a brownish or leaden tint, as if there was a bruise." These observations, also, go to show that Petit, more than 100 years ago, was positively in advance of the knowledge entertained on his subject at the present day. Contrast, for example, with his clear observations the remarks on diagnosis between true and false aneurisms, as stated by Chelius, and which are so inapplicable as to have drawn forth the comments of even his editor, Mr. South. The

discoloration last noticed generally supervenes when the swelling becomes superficial, and the surface takes on a species of inflammatory action.

IV. The redness of the skin that preceded the swelling may be explained by assuming that, when the arterial dilatation first gave way, it left a very minute opening and that through this chink a little blood escaped, and was impelled upwards into the sub-integumental tissue, where, upon becoming extravasated, it stained the superimposed skin; being produced in short, after the manner of an ordinary bruise. Swelling succeeded gradually, because the tense, unyielding nature of the thoracic fascia had to be overcome; and this obstacle only yielded to frequent repetitions of the systolic impulses, that had caused rupture. When at length it yielded, a diverticulum of blood was forced with sufficient momentum to protrude forward the episternal cervical pit. This is the way in which some cases of false aneurism are developed at the bend of the elbow after venesection. And it is also the origin of some cases of dissecting aneurisms, as is thus described in Jones and Sieveking's *Pathological Anatomy*:—"We sometimes meet with small ecchymoses under the lining membrane of the aorta in the dead body, which indicate the commencement of this form of aneurism. A minute, and, sometimes, imperceptible fissure in the inner coat allows of the permeation of a small quantity of blood, and the first step having occurred a succession of similar deposits may soon cause a greater accumulation, and necessarily a coincident separation of the coats."

V. The acoustic signs did not indicate, correctly, the existent state of the heart and large vessels. The principal abnormality heard was a strong pulsation, which was double or formed of two strokes, and denoted by two sounds. These, in special character, resembled the cardiac sounds, but differed from them in being more superficial and more sonorous; they appeared to be loudest about the right superior angle of the sternum, and grew progressively fainter as they were examined at remoter spots. So that, including the heart's region, there were present in the chest *two distinct centres of pulsation*, which Dr. Stokes has informed us, is the simplest expression of physical diagnosis in aneurism. The distinction between these aneurismal sounds was not very obvious till after the operation, when they exactly simulated the *bruit de choc* of some French auscultators,—the greater clearness at this period may be referred to the improved conducting power of the sac after fibrillation of its blood had occurred. With the pulsation there was no distinct *bruit de soufflet*. And thus the general rule in thoracic aneurism was

prese
was
it, an
cums
more
to the
was,
only
lity, a
or the
was o
sive o
clusio
canno
and D
ceptib
to som
ly sim
aortic
cernin
seem a
left ve
any br
the mi
base.
any m
direct
mitral
but hy
one cas
mur is
due to
plane.
agreein
whethe
ry is us
VI. M
mote sy
the cerv
and alo
mor, sh

preserved; but an exception to it might have been expected, for the tumor was compressed, posteriorly, by the trachea which had left its mark upon it, and, anteriorly, in a less degree by the clavicle and sternum. Circumstances which, in the opinion of some Pathologists, would be causes more than competent to educe murmur. Over the point corresponding to the passage of blood, from the sac through the left subclavian, there was, however, an approximation to a bruit. The above signs, at most, only denoted a thoracic aneurism. And did not imply its precise locality, as, for aught they shewed, this may have been the ascending aorta, or the arch, or the innominata, &c.; they did not indicate whether there was only one, or more than one, aneurism;—and they were inexpressive of the actual size of the aneurism. Thus substantiating the conclusions of various observers, as Dr. Mott, who contend that stethoscopy cannot declare the true seat of aneurisms about the root of the neck, and Dr. Stokes who has said that an “extremely weak, almost imperceptible impulse, may attend even a large aneurism of the aorta.” But to some, the signs present may appear still more vague, since they closely simulated those heard in gouty aortitis, permanent patency of the aortic valves, &c. There was a still greater lack of intelligence concerning the state of the heart. The impulse of this organ did not seem abnormal, and yet there was a considerable hypertrophy of the left ventricle;—the sounds were not accompanied with nor replaced by any bruit, and yet the aortic ostium was inlaid with bony plates and the mitral valve was fibroid in its flaps, as well as calcareous round its base. The latter negation is easily understood, as the report shows, had any murmurs existed, they must have been of the “obstructive” or direct kind for no regurgitation had taken place. Now of these a diastolic mitral murmur is the rarest of rare sounds; Laennec knew of no instance, but hypothetically inferred the presence of a bruit, and up to 1848 only one case has been recorded, and that is by Andry. Systolic aortic murmur is on the contrary of common prevalence; its absence was probably due to the ostium being smooth as the deposits were laminated and plane. And lastly, the roughened aorta did not cause a murmur, thus agreeing with the observations of Hamerjak of Prague, who doubts whether a bruit will arise from a roughened aorta, although the contrary is usually believed among English and American auscultators.

VI. In comparing the above case with others, the slightness of the remote symptoms is at once evident. In it pressure upon the branches of the cervical plexus produced pains like rheumatism in the right shoulder and along the neck;—instead of, as in others, dull aching pain in the tumor, sharp neuralgia in the arm, side of face and head, shoulder and top of

st. Pressure on the air passages provoked paroxysmal attacks of asthma,—instead of continued dyspnoea: the laryngeal irritation, from pressure on the recurrent laryngeal nerve, was signified by a short persistent cough, scanty mucus sputum, and no change of voice,—instead of dry cough, paroxysmal cough, (tussis clangosa), sero-mucus expectoration, laryngeal stridor, and hoarse, husky, or whispering voice. Pressure on the vena innominata caused a tendency to tippet-shaped neck—instead of œdema in the right side of the face and neck, the front of the chest and arm; a varicose state of the cutaneous veins in the external half of the infra-clavicular and mammary regions, and axillary side of the right arm,—instead of an enlargement of the superficial veins of the neck, right half of the chest and arm forming a continuous mesh of knotty swollen big veins; no change of features—instead of staring, protuberant eyes, with lips, nose, and countenance of a livid hue. Pressure on the œsophagus had, at first, caused no dysphagia,—instead of great and extreme difficulty of swallowing. And pressure on the subclavian artery had made a variation in the two pulses, but it was slight—instead of strongly marked. The moderation of these effects may have been owing to the feebleness of the compression exerted by the aneurism, and this, in turn, may have depended upon the peculiar direction of the latter.

VII. An unusual relation of the pneumogastric nerve to the carotid artery and jugular vein, was observed at the point of deligation. The nerve was on a plane more anterior than that occupied by the vessels, and although, thus, the most superficial of the contents of the sheath, it still preserved its median situation as usual. It is more than probable that instead of being an original conformation, this relation was accidentally produced by the aneurism. As from the protrusion of the tumor forwards, and the position of the nerve on its anterior face, the nerve was drawn away from the direction that it would have otherwise occupied. Hence it appeared, on dissection, to be passing downwards in a diagonal line from behind to the front, and the vessels not undergoing a corresponding displacement, the alteration in relation necessarily occurred. The possibility of an aneurism thus causing an anatomical deviation is an important fact, inasmuch as its knowledge prepares the surgeon for modifications it may necessitate in the usual performance of his operation. In the above case the difficulty was obviated by introducing the needle in a reverse manner to that commonly directed.

VIII. The most unique circumstance, in the above case, was the external opening of the aneurism. As had been predicted, before the lapse of many hours the episternal tumor opened—exactly 43 hours after the

open
seru
utili
of th
with
aneu
as e
trate
ism,
sary
induc
but u
tiate
kind
swel
cuati
This
verin
fulles
(stern
reduc
this p
lation
attemp
abbrev
amoun
pari p
easy t
which
so tha
of the
was th
branou
tially f
rietes
there c
IX.
proxim
section
tegume
interve
interior

operation—but instead of an issue of blood with its fatal consequences, serum alone escaped, and safety followed. This event established the utility of the ligature, by indicating the perfect way in which the blood of the sac had coagulated, after the operation; a solid clot remained within and unmixed serum drained away. I can find no record of aneurism terminating similarly, so that the above case may be regarded, as exhibiting a fact in pathological knowledge not previously demonstrated. It has frequently been observed, that after operations for aneurism, the clot was remarkably firm, and it has been received as a necessary belief, that the forcible action causing this result must have induced, as a cotemporaneous result, a thorough separation of serum; but until the above incident, this opinion had probably not been substantiated by any ocular proof, or by an experimentum crucis of a positive kind. Contrary to what might have been expected, the episternal swelling completely disappeared, and left no trace behind, after the evacuation of the serum, neither corrugated sac, nor partially filled tumor. This peculiarity appears to have been dependant upon the muscular covering of the aneurism. Before deligation the sac, being then in fullest size, caused the greatest distention of the surrounding muscles (sterno hyoid and sterno thyroid); as long as its volume remained un-reduced, the latter parts were incapable of exerting their tonicity, since this power was overborne by the force of the constantly recurring circulation. When, however, this last was weakened, by coagulation and its attendant serous discharge, then tonicity came into play, the muscles abbreviated themselves, and the sac was by so much diminished. As the amount of drain augmented, the contraction of the sac increased and, *pari passu*, its capacity was unavoidably decreased. It is, therefore, easy to understand that in the closer approximation of sarcous elements, which these changes imply that the peculiarity mentioned was produced, so that there was a complete adaptation preserved between the capacity of the sac and the bulkiness of its contents, for as the latter lessened so was the former decreased. Had, however, the wall been simply membranous, then the evacuation of the serum must have left the sac partially filled, or, in other words, too large for the contained clot; and its parietes not being resilient must have partially collapsed, and, consequently, there could not have been the complete disappearance which did occur.

IX. At the spot where these muscles first touch each other upon approximation, a small fissure, as has been stated, was found during dissection; it corresponded with an opening, observed during life, in the integument, to which the exterior of the sac was intimately connected by intervening cellular tissue, and it led into a minute canal seated in the interior of the aneurismal clot. This was the course which the probe

followed, when first introduced, on the 18th October. The canal only extended through a part of the coagulum, and its floor was formed by very dense resisting fibrin. Its formation may be referred either to force used in the introduction of the probe while the fibrin was not yet thoroughly consolidated; or to the insertion of the instrument between two concentric laminae of fibrin, which were, at the time, somewhat separated by interposed serum. The latter of these reasons is the more likely, from the circumstance of the fibrin, underneath, not having been penetrated so as to draw blood from the artery immediately below, for had the clot been actually pierced, the probability is the same force would have rendered the perforation complete throughout. It is, also, for the above reason, more probable that it was a natural channel accidentally discovered, than one forcibly produced, and it may have so happened that the probe was inserted into the conduit along which the extruded serum separated from the consolidating fibrin. The features, we have been considering, exhibit proof of the perfectness of fibrillation; of course this effect was due to the ligature,—but how far the topical applications resorted to, may have been adjuvant in establishing or strengthening it, is not easy to determine. It does not seem proper to deny them any merit, nor to suppose they were wholly nugatory, for it is well known that under favorable circumstances chemical agents become powerful inspissants. Guerin, in 1779, mentioned cases of encysted or mixed aneurism, which were cured by applying to the tumor compresses soaked in cold lead lotions; by administering to the patient acid drinks of ʒj of the eau du rabel to the pint of diluent; by keeping the patient perfectly quiet; and by favoring the action of the refrigerants, by a suitable regimen; and finally by avoiding all compression.

X. The opinions entertained, at the present day, of the danger to the brain from cutting off its supply of blood through even one carotid, are diametrically opposed to those maintained by distinguished surgeons of a later period, and even by some not many years back, as Sir A. Cooper, Mr. S. Cooper, Mr. Miller and Mr. Wardrop. The first observes, "the carotid may be tied without injuring the functions of the brain," and the latter in Costello's Cyclopædia of Practical Surgery remarks, "no one now (1841) entertains the slightest fear for the intellect and other functions of the brain," after obliterating the carotid. Of the extreme liability to occur of the result here denied, there can be now no doubt raised; and aware of this fact, the question arises,—how far should the danger it entails, form an objection to the ligature of the carotid artery in innominate aneurism. To this I think these words of Dr. Cheever's designed by him to be of general application, are a complete reply—

"That the facts are to be considered as not rendering at all doubtful the

prol
sent
insta
thre
prov
in w
caus
num
stan
stan
toms
XI
hith
the v
I thi
and
1.
tion,
2.
part
3.
4.
versic
tion o
with
5.
whic
6.
curri
7.
porar
8.
appea
9. J
ralys
10.
short
In a
diness
menta
occurr
whic

The canal only was formed by either to force was not yet instrument be- at the time, of these reasons underneath, not y immediately lity is the same oughout. It is, natural channel t may have so ong which the The features, ess of fibrilla- far the topical hing or streng- to deny them is well known ome powerful mixed aneur- sses soaked in ks of 3j of the ient perfectly a suitable re-

danger to the e carotid, are (l surgeons of Sir A. Cooper, serves, " the rain," and the ks, " no one d other func- extreme lia- ow no doubt r should the rotid artery r. Cheever's olete reply— doubtful the

propriety of the operation in the majority of the cases in which it is at present had recourse to, but as strongly discountenancing it in nearly all instances where the disease for which it is employed does not positively threaten the patient's existence." (London Med. Gazette.) Statistics prove that cerebral symptoms happen to one of about every eight cases in which carotid deligation is practised, and that they are the most common cause of death in fatal cases, constituting two and one-third of the whole number. Yet, notwithstanding this frequency, as well as the circumstance of their repeated occurrence after the Hunterian operation, the instance above described contains the first record of fatal cerebral symptoms having followed the Brascorean operation for innominate aneurism.

XI. With a view to determine the character of the cerebral disorder, hitherto witnessed, after ligature of the carotid for the cure of aneurism the various reports as given by Norris (*op. cit.*) have been examined, and I think the following species may be identified; in which the prominent and frequent occurrence of paralysis is remarkable.

1. Symptoms of phrenitis. Happening a few hours after the operation, and disappearing in health.

2. Immediate apoplexy: (within twenty-four hours after deligation) partial recovery, but death before many days.

3. Slight convulsions, ending in recovery.

4. Simple cerebral disorder—variously exemplified; as in loss or perversion of one or more special senses, error of common sensation, dilatation of one pupil, dysphagia, feeling of bewilderment: unaccompanied with general paralysis, and not producing death.

5. Vague symptoms of cerebral disturbance, preceeding paralysis, which latter seen on fourth day.

6. Paralysis confined to one extremity. Of temporary duration; occurring on the eight day, and disappearing four days afterwards.

7. Paralysis more general, and ushered in by drowsiness. Also temporary.

8. Paralysis preceeded by convulsions, and by stupor. Convulsions appearing 1½ hours after operation; stupor lasting two days.

9. Immediate hemiplegia, symptoms persistent, death early. (Paralysis first seen an hour after the operation, and fatal on the fifth day.)

10. Temporary hemiplegia—slow in accession, slight in development, short in duration, and ending in recovery.

In addition, twitchings, tremblings, &c., have been noticed with giddiness, &c., but usually they have ushered in paralysis, or, after a momentary duration, passed off without any fulfillment. When paralysis occurred, it was exhibited on the side of the body opposite to that on which the artery had been tied; but when other symptoms, they were

displayed irregularly. In the case I have reported, the semeiological features were different to the foregoing both in kind and in arrangement. The first marks of cerebral disturbance were observed on the 6th day after the operation, as pains along the right side of the head; afterwards an uneasy feeling in the right ear; on the 13th day, evidences of pulmonary congestion, or dyspnoea, cough, pituitous sputum, copious expectoration; next day, slowness of the pulse, only counting 60 beats a minute, at a later period, the pulse fell to 46, and during the rest of the time, it fluctuated between this number and 64. On the 17th day, a paroxysm set in, as it were, from encephalic oppression, and signified by adynamic phenomena, as gravescent stupor, difficulty of articulation, involuntary twitches in the fingers, &c.; out of this fit, hemiplegia arose, first visible in the lips; after a few hours the patient gradually regained intelligence, and recovered from all the previous symptoms, except the paralytic, and he endured the latter till 70 days longer, when he expired.

XII. The symptoms that immediately ushered in the hemiplegia were of a comatose nature. The occurrence of lethargy, after closure of the carotid, has been long known. The Arabians called this vessel "the apoplectic vein," thus connecting it directly with this peculiar state of the sensorium. Avicenna remarked that, when these vessels were tied, sense and motion were instantly lost. And nearly every ancient writer, Grecian or Roman, from that time forwards, referred to the same circumstance, either in acquiescence or denial. The history of the above case reminds one of paralysis from extravasated blood, by showing that apoplexy was followed by hemiplegia. Out of 14 published cases I can only find two that bore any resemblance to it. In one, reported by Magendie, on the sixth day the patient was attacked with loss of consciousness; "very slow" pulse; irregular respiration, occasionally, noisy; with every mark of approaching dissolution. Some time after, (when not stated,) hemiplegic symptoms supervened. The other particulars are entirely dissimilar. The second is by Macaulay and is somewhat analogous to the last. In the remaining 12 cases the clinical histories are so imperfect, that no correct information can be obtained as to the proportionate frequency of the symptoms under consideration. In some it is distinctly stated, that the antecedents of hemiplegia were of a different character to the preceeding, and in others no allusion of any kind occurs.

XIII. As the case advanced, there were superadded to the ordinary symptoms of hemiplegia, indications of decay of the mental faculties, of disorder of the assimilative functions, and of impairment of excretion; there was no affection of the special senses and no febrile distur-

banc
and
last
of w
gene
ness,
cana
powe
whic
anxic
into
the d
lesion
exhib
thirst
lowe
XI
of a t
The h
the o
while
degre
both
soon
tion.
ally e
The r
flam
in pre
I am
cribed
believ
their
were
For a
before
suppu
toms
not a
quanti
thalam
ago, w

semeiological arrangement. On the 6th day; afterwards pulsations of pulsions. ex- ing 60 beats a the rest of the On the 7th sion, and sig- nity of articu- his fit, hemi- the patient all the pre- latter till 70

hemiplegia after closure and this vessel this peculiar these vessels ly every an- referred to The history asated blood, Out of 14 bance to it. ent was at- ular respira- dissolution. upervened. by Macau- ing 12 cases mation can otoms under ecedents of and in others

the ordinary al faculties, t of excre orile distur

bance: but a more singular event than these, was an intercurrent stupor and vigillium. This remarkable alternation was noticed during the last three weeks of existence. The stupor was associated with signs of weakened volition, sensation, and apparently great exhaustion. It generally lasted for 36 or 48 hours, was always connected with costiveness, and usually passed away after a free evacuation of the intestinal canal. A sort of reaction then occurred, the patient became wakeful, power and feeling returned, this continued so for about 3 days during which the appetite would be good, he would sit up in bed, talk and enter anxiously upon personal matters. It was observed that with each relapse into drowsiness, the symptoms of paraplegia became more marked, as if the drowsiness were attended with periodical exacerbations of the central lesion. And again as the recoveries became repeated, the last, in order, exhibited greater signs of sympathetic disturbance than its predecessor, thirst became more urgent, the desire for food lessened, the pulse lowered in strength, &c.

XIV. The cerebral lesions to be expected after ligature of the carotid are of a two-fold kind, those from 1st. inanition, and 2nd. overstimulation. The hemisphere corresponding to the occluded artery is anæmic, whilst the opposite one is over-vigorous; upon the first there is a deficient, while upon the second there is an increased pressure, from the altered degree of fulness of the blood vessels. The effects proceeding from both these conditions are sometimes only temporary, because they are soon remedied by a new or compensatory arrangement of the circulation. At other times, however, serious changes of structure are gradually established, and a sure foundation is laid for permanent disorder. The morbid states hitherto recorded have been congestion, simple inflammation, atrophy, and softening. The case described stands alone, in presenting a new cerebral lesion—abscesses—after carotid deligation. I am not aware of any reported case in which a similar result is described. Indeed, it is so far different, from what is usual, that some might believe the abscesses were not consequent upon the ligature, and that their occurrence in the right hemisphere was a mere coincidence. They were not bordered by softening and had all the characters of chronicity. For anything that appeared to the contrary, their origin may have been before the day of the operation. Like many other cases of encephalic suppuration, there was a remarkable immunity from the ordinary symptoms of phrenitis; a truth which is sometimes so forcibly declared, that not a single symptom of head derangement exists although pus in large quantity is present all the while. The alteration in form and size of the thalamus opticus, and corpus striatum are interesting, and a few years ago, when the connexion between these parts and the extremities was

more admitted than at present, they would be considered as affording a sufficiently obvious explanation of the occurrence of the hemiplegia.

XV. The peculiarities of the aneurism have already furnished several points for observation. Another, of equal interest, is the lateral disposition the tumor possessed. This circumstance, I think, has a practical bearing on the question of operation, and fitly forms a conclusion to this communication. It would seem that the success of carotid deligation must be influenced by the side or segment of the artery from which the aneurism proceeds. If it be the left, as in the case referred to, there will be every prospect of success from the operation, since the introduction of blood into the sac is derived from the current destined for this vessel; if, however, the aneurism were dexolateral, then the same benefit cannot be afforded, as the supply is furnished by the subclavian. Therefore, under the latter circumstance, ligature of the last named vessel should prove more advantageous than of the carotid. And again, were the aneurism equal on either side of the innominata, or a symmetrical dilatation, then the only hope of a certain and sure stasis of blood would be afforded by tying both branches. And lastly, the bearing may be noted which the case, now reviewed, has upon the question of operation, as that question was left by cases published before its time.

It has, then, borne its testimony to the feasibility of the operation; to the propriety of its performance in suitable cases; to the correctness of the inferences formerly drawn,—and thereby has increased the weight of the arguments upon which they depended: it has shewn that ligature of the carotid artery will cause the solidification and reduction of innominal aneurism; that the operation is not more dangerous than ligature of the same vessel, performed for any other cause; and that by it, life may be prolonged if not saved when there is no other expedient to which recourse can be had. Thus disproving the truth of the allegations, particularly expressed, against the operation, to wit., the charge of Miller, that Wardrop's (!) procedure contains in itself the elements of failure (Principles of Surgery); and the conclusion of Erichsen, who says, from the facts no surgeon would be again justified in tying the carotid in innominal aneurism (Art and Science of Surgery). And, finally, by the observations it has originated, this case affords the following propositions, as to the cases requiring or negating carotid deligation:—

1. Cases most suitable:—those of uncomplicated innominal aneurism.
2. Cases imperatively requiring:—innominal aneurism with imminent danger from external rupture of sac, pressure on trachea, &c.

3.
segm
4.
near
5.
aorti

as affording a
hemiplegia.

inished several
lateral disposi-
as a practical
conclusion to
carotid deliga-
ry from which
ferred to, there
the introduc-
ined for this
e same bene-
e subclavian.
st named ves-
l again, were
symmetrical
blood would
ring may be
on of opera-
time.

operation; to
correctness of
the weight of
gature of the
innominatal
ature of the
life may be
o which re-
tions, popu-
Miller, that
(Principles
m the facts
innominatal
the obser-
positions, as

aneurism.


with immi-
, &c.

3. Cases most favorable:—when the aneurism proceeds from the left segment or anterior circumference of the artery.

4. Cases less advantageous:—those in which the external tumor is nearest the middle of the clavicle.

5. Cases contra-indicating:—complications with aortic aneurism, aortic disease, &c., unless excepted by extreme urgency.





22

23