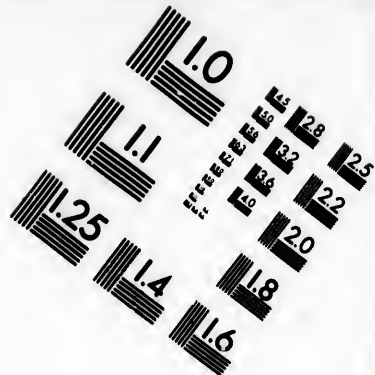
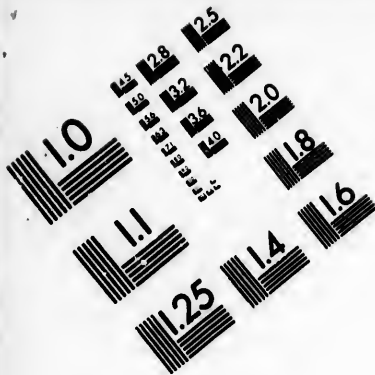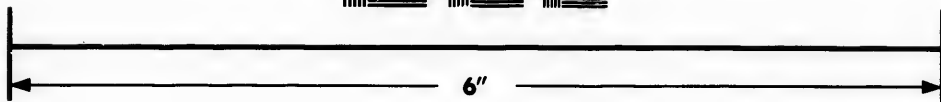



**IMAGE EVALUATION
TEST TARGET (MT-3)**



**Photographic
Sciences
Corporation**

23 WEST MAIN STREET
WEBSTER, N.Y. 14580
(716) 872-4503

28
25
22
20
18

**CIHM/ICMH
Microfiche
Series.**

**CIHM/ICMH
Collection de
microfiches.**



Canadian Institute for Historical Microreproductions / Institut canadien de microreproductions historiques

11
01

© 1986

Technical and Bibliographic Notes/Notes techniques et bibliographiques

The Institute has attempted to obtain the best original copy available for filming. Features of this copy which may be bibliographically unique, which may alter any of the images in the reproduction, or which may significantly change the usual method of filming, are checked below.

L'Institut a microfilmé le meilleur exemplaire qu'il lui a été possible de se procurer. Les détails de cet exemplaire qui sont peut-être uniques du point de vue bibliographique, qui peuvent modifier une image reproduite, ou qui peuvent exiger une modification dans la méthode normale de filmage sont indiqués ci-dessous.

- | | |
|--|--|
| <input checked="" type="checkbox"/> Coloured covers/
Couverture de couleur | <input type="checkbox"/> Coloured pages/
Pages de couleur |
| <input type="checkbox"/> Covers damaged/
Couverture endommagée | <input type="checkbox"/> Pages damaged/
Pages endommagées |
| <input type="checkbox"/> Covers restored and/or laminated/
Couverture restaurée et/ou pelliculée | <input type="checkbox"/> Pages restored and/or laminated/
Pages restaurées et/ou pelliculées |
| <input type="checkbox"/> Cover title missing/
Le titre de couverture manque | <input checked="" type="checkbox"/> Pages discoloured, stained or foxed/
Pages décolorées, tachetées ou piquées |
| <input type="checkbox"/> Coloured maps/
Cartes géographiques en couleur | <input type="checkbox"/> Pages detached/
Pages détachées |
| <input type="checkbox"/> Coloured ink (i.e. other than blue or black)/
Encre de couleur (i.e. autre que bleue ou noire) | <input checked="" type="checkbox"/> Showthrough/
Transparence |
| <input type="checkbox"/> Coloured plates and/or illustrations/
Planches et/ou illustrations en couleur | <input type="checkbox"/> Quality of print varies/
Qualité inégale de l'impression |
| <input checked="" type="checkbox"/> Bound with other material/
Relié avec d'autres documents | <input type="checkbox"/> Includes supplementary material/
Comprend du matériel supplémentaire |
| <input type="checkbox"/> Tight binding may cause shadows or distortion
along interior margin/
La reliure serrée peut causer de l'ombre ou de la
distorsion le long de la marge intérieure | <input type="checkbox"/> Only edition available/
Seule édition disponible |
| <input type="checkbox"/> Blank leaves added during restoration may
appear within the text. Whenever possible, these
have been omitted from filming/
Il se peut que certaines pages blanches ajoutées
lors d'une restauration apparaissent dans le texte,
mais, lorsque cela était possible, ces pages n'ont
pas été filmées. | <input type="checkbox"/> Pages wholly or partially obscured by errata
slips, tissues, etc., have been refilmed to
ensure the best possible image/
Les pages totalement ou partiellement
obscurcies par un feuillet d'errata, une pelure,
etc., ont été filmées à nouveau de façon à
obtenir la meilleure image possible. |
| <input type="checkbox"/> Additional comments:/
Commentaires supplémentaires: | |

This item is filmed at the reduction ratio checked below/
Ce document est filmé au taux de réduction indiqué ci-dessous.

10X	14X	18X	22X	26X	30X
<input type="checkbox"/>	<input type="checkbox"/>	<input type="checkbox"/>	<input checked="" type="checkbox"/>	<input type="checkbox"/>	<input type="checkbox"/>
12X	16X	20X	24X	28X	32X

The copy filmed here has been reproduced thanks to the generosity of:

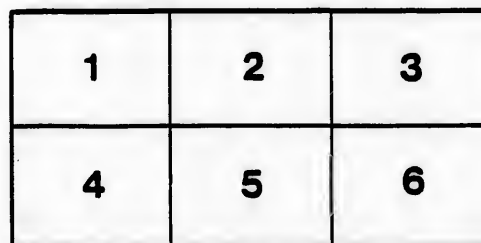
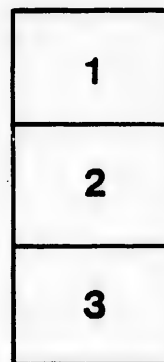
Medical Library
McGill University
Montreal

The images appearing here are the best quality possible considering the condition and legibility of the original copy and in keeping with the filming contract specifications.

Original copies in printed paper covers are filmed beginning with the front cover and ending on the last page with a printed or illustrated impression, or the back cover when appropriate. All other original copies are filmed beginning on the first page with a printed or illustrated impression, and ending on the last page with a printed or illustrated impression.

The last recorded frame on each microfiche shall contain the symbol \rightarrow (meaning "CONTINUED"), or the symbol ∇ (meaning "END"), whichever applies.

Maps, plates, charts, etc., may be filmed at different reduction ratios. Those too large to be entirely included in one exposure are filmed beginning in the upper left hand corner, left to right and top to bottom, as many frames as required. The following diagrams illustrate the method:



L'exemplaire filmé fut reproduit grâce à la générosité de:

Medical Library
McGill University
Montreal

Les images suivantes ont été reproduites avec le plus grand soin, compte tenu de la condition et de la netteté de l'exemplaire filmé, et en conformité avec les conditions du contrat de filmage.

Les exemplaires originaux dont la couverture en papier est imprimée sont filmés en commençant par le premier plat et en terminant soit par la dernière page qui comporte une empreinte d'impression ou d'illustration, soit par le second plat, selon le cas. Tous les autres exemplaires originaux sont filmés en commençant par la première page qui comporte une empreinte d'impression ou d'illustration et en terminant par la dernière page qui comporte une telle empreinte.

Un des symboles suivants apparaîtra sur la dernière image de chaque microfiche, selon le cas: le symbole \rightarrow signifie "A SUIVRE", le symbole ∇ signifie "FIN".


Les cartes, planches, tableaux, etc., peuvent être filmés à des taux de réduction différents. Lorsque le document est trop grand pour être reproduit en un seul cliché, il est filmé à partir de l'angle supérieur gauche, de gauche à droite, et de haut en bas, en prenant le nombre d'images nécessaire. Les diagrammes suivants illustrent la méthode.

ails
du
modifier
une
page

rata
o

pelure,
à

32X



RE
C
V. S. P.
PREFACE
CONTENTS
LIST OF ILLUSTRATIONS
ABBREVIATIONS
SYMBOLS
UNITS
CONVERSION TABLES
INDEX
SE



THE SURGICAL TREATMENT OF CERTAIN FORMS
OF BRONCHOCELE, WITH REPORTS OF
SIXTEEN CASES.¹

By FRANCIS J. SHEPHERD, M.D., C.M.,

OF MONTREAL,

PROFESSOR OF ANATOMY AND LECTURER IN OPERATIVE SURGERY IN MCGILL
UNIVERSITY; SENIOR SURGEON TO THE MONTREAL GENERAL HOSPITAL.

THE surgical treatment of bronchocele has always excited great interest among surgeons, but it is only since the introduction of antiseptic methods that surgeons have been able to perform operations on tumors of the thyroid with any measure of success.

The continental surgeons, especially those of Switzerland, where disease of the thyroid is so common, have done much to perfect our methods in the surgical treatment, and to such men as Socin, Reverdin, and Kocher much credit is due. My experience in the surgical treatment of bronchocele has been small compared with that of these men, who count their cases by the hundreds; but, although the number of cases operated on by me only reaches sixteen, still, I have learned something, and this is my excuse for inflicting a paper upon you.

The method I have adopted is that of enucleation or "shell-ing out," and the more experience I have the more I am convinced that this is the true method to practise in all cases of encapsulated or cystic tumors of the thyroid, and these are seen infinitely more commonly than the diffuse or angiomatous forms. In fact, nineteen out of twenty cases of diseased thyroid, and perhaps more, can be treated in this way.

This method of operating was adopted first by Juillard, Rott-

¹ Read before the Ontario Medical Association, June 5, 1895.

man, and others, but to Professor Socin belongs the credit of first systematizing the operation and bringing it prominently before the profession. The advantages of this procedure are many: first, the rapidity and comparative bloodlessness of the operation; second, the fact that only the diseased portion of the gland is removed, so that no danger of serious after-results, such as cachexia strumipriva, need be feared; and, thirdly, the comparative safety of the method and the absence of the risk of wounding the recurrent laryngeal nerve.

I have not as yet operated on any of the enormous goitres, which are seen so commonly in Switzerland and occasionally in French Canada, for I have never been able to induce such cases to submit to operation, as I could not promise that it would be entirely without danger. However, I have operated on cases of considerable size, where the growth extended over the vessels at the root of the neck and beneath the clavicle. In several cases the tumor reached from the hyoid bone to the clavicle and went well past the middle line of the neck.

The most favorable cases for operation are those in which only one side of the gland is affected, for in such cases the enlargement is most likely to be of the cystic variety. Of course, all enlargements or tumors of the thyroid are not suited to this form of treatment. For instance, all those cases of diffuse enlargement of the gland, malignant and inflamed goitres, as well as those vascular bronchoceles associated with Graves's disease, need either to be treated by exsection or ligature of the thyroid arteries. In the diffuse form Kocher has obtained good results¹ by feeding with thyroid extract.

In many of these cases the enlarged gland has been greatly diminished by the administration of twenty drops of tincture of iodine, three times a day, a treatment advocated by Condet, of Geneva, nearly seventy-five years ago. Again, Professor Kocher has seen these diffuse enlargements disappear almost entirely or sensibly decrease by the patient remaining in hospital without any treatment at all.

¹ Correspondenz Blatt für Schweizer Aerzt, January, 1895.

The enlargements of the thyroid to which I allude as suitable for treatment by enucleation are the cystic and colloid forms,—the latter is usually encapsulated, though the capsule may at times be of the thinnest. The fluid tumors usually contain a dark yellowish-brown material, which on microscopical examination shows large numbers of cholesterine crystals, and large round cells containing fatty globules. Sometimes the color of the fluid is light yellow and glairy in consistency, and other times the fluid is very dark in color, containing coffee-grounds-looking material, due, no doubt, to hæmorrhages.

In the solid tumors the material is mostly colloid and almost colorless. On microscopical examination it is found that the solid and semisolid tumors have a distinct fibrous capsule, and are composed of vesicles filled with colloid matter, and these vesicles are usually lined with cubical epithelium. There is often evidence of the coming together of vesicles by atrophy of the intervening wall. The cyst wall is often made up of several layers between which atrophied gland tissue is found. The cystic forms, which are by far the most numerous, were formerly treated by injections, setons, and even incisions.

Mayo Robson,¹ a few years ago, in a paper on "Cysts of the Thyroid," advocated antiseptic incision and stitching the edge of the cysts to the skin, scraping out the interior of the cysts and draining, and after-packing with zinc lotion and lint.

He reported two successful cases treated in this way. Injections were always dangerous, and severe phlegmonous inflammations often followed; setons frequently led to septic infection, and both forms of treatment were very uncertain.

These cases are much better treated by enucleation, as recommended by Socin. The operation can be made aseptic, and usually only requires the skill which a general surgeon, used to various operations, easily acquires.

All cases, however, are not simple, and any one who has operated often will occasionally come upon a difficult case, and for this he must always be prepared; the most simple cases often proving most troublesome from unexpected hæmorrhage, etc.

¹ Lancet, January 22, 1887.

In the cases I have operated on there has been no mortality, the great majority recovered and went out of hospital within a week.

The simplest cases for operation are those where the cyst is single; where there are several cysts which are situated in both lobes, then the difficulties increase, for after enucleating a large cyst or solid tumor one frequently finds there are several others deeper down, which can only be reached by cutting the posterior wall of the cavity from which the last one has been taken. This occurred in Cases IV, IX, and XII.

Again, in some cases the cyst wall is so thin and friable that it cannot be enucleated, but has to be picked off, piece by piece, each tearing of the sac opening up large veins, which bleed furiously, such a case I had in No. XI, and to stop the hæmorrhage I had to tie the inferior thyroid artery and vein. In other cases the cyst wall is so adherent to the surrounding gland tissue that shelling it out without tearing large blood-vessels is exceedingly difficult, and sometimes impossible.

In these cases I have found that if the tumor be cystic, tapping the cyst and evacuating some of the contents, whether fluid or semisolid, allows it to be drawn out, and then the cyst wall can be peeled off from the gland tissue with the fingers or a raspator, much as an adherent ovarian cyst is peeled off from its surrounding structures; should a vessel come into view, it is easily tied. Thus the operation is made one which is almost entirely external to the neck.

In my first three or four cases I was astonished at the ease with which enucleation was accomplished, and with what slight hæmorrhage, and I thought the operation was a very simple one; but in my next case the cyst wall was strongly adherent to its surrounding gland tissue and intimately associated with large blood-vessels, which were torn every time a piece of cyst wall was peeled off, with the result that the loss of blood was considerable, and the time required greater than before; then it was that the idea of partially evacuating the cyst occurred to me.

My next case was one of colloid tumor with adherent capsule. I tried to shell out the cyst with my finger, but only succeeded

in tearing some large blood-vessels, so I opened the capsule, rapidly turned out its contents, and then, the tension being relieved, I easily pulled out the capsule, peeling it off from the surrounding gland tissue as it was delivered, and leaving a cavity behind lined by a number of large tortuous veins which looked like the gnarled roots of an old oak. Since then, whenever I have had any difficulty in shelling out the tumor, I invariably evacuate some of its contents, then easily deliver the growth, and as it is delivered peel it off from the surrounding tissue.

Many of these growths extend down below the sternum and clavicle, being separated from the great vessels at the root of the neck by a very thin layer of gland tissue. In such cases the voice is often altered, the patient has occasional attacks of difficult breathing, and sometimes there is difficulty in swallowing.

Where the tumor is unilateral and can be pushed upward and outward beneath the sterno-mastoid muscle there is no difficulty in breathing or swallowing, and the unsightliness of the tumor is the only reason for operation.

In many cases the gland has very slowly increased in size for years without giving trouble, when suddenly it begins to increase very rapidly, this causes pain and discomfort and induces the patient to seek relief.

I may say that in many cases where the growth gave rise to no symptoms, except great nervousness, yet after removal the patient's general health improved greatly. All my cases, with one exception, were in women; they submitting much more readily to operation than men, for they have more regard for their personal appearance, besides the affection is more common in women than men.

My method of operation is as follows:

Anæsthetic.—In my first cases I always had chloroform administered, with the idea that in chloroform anæsthesia there was less congestion of the veins, and hence less danger of hæmorrhage; but one of my colleagues, when about to operate on a large thyroid cyst, lost a patient from chloroform-poisoning, the patient dying before the operation was commenced. Since then

I have used ether exclusively, and found that the congestion of the vessels was a bug-bear, which had only existence when the ether was given badly.

Operation.—The neck having been thoroughly cleansed, an incision is made some three or four inches long, directly over the tumor; after cutting through the skin and fascia, the depressor muscles of the thyroid are reached, and if the tumor be large, they are very thin and hardly noticed. In any case they should be incised in the same line as the skin. Over the muscles and deep fascia is often seen running the anterior jugular vein, which is sometimes very large, this when met with should be divided between two ligatures. After cutting through the depressor muscles the gland is come upon; it looks much like muscle, but bleeds freely when cut. Some glands, of course, are much more vascular than others. A small incision should be made through the gland tissue and at a greater or lesser depth, the capsule of the tumor is come down upon: this is recognized by its bluish-white color, but it requires some experience to know when the proper layer is reached. Reverdin says, truly enough, "Whenever you are doubtful, you are not on the growth." When the capsule of the tumor is reached the incision in the gland should be enlarged, and with the aid of the finger the tumor should be rapidly enucleated; if the separation is easy or there is no hæmorrhage then the enucleation may be continued until the whole growth is freely separated. To deliver the cyst, the incision in the gland must be further enlarged.

This sometimes leads to free bleeding, which can be controlled by T-forceps or by the application of the thermo-cautery. Sometimes the gland tissue does not bleed at all, being often so thin that it appears to be part of the capsule of the tumor.

I used formerly to incise the gland more freely than I do at present, then I always endeavored to shell out the cyst or tumor. Now, if it does not come out easily, I incise it and evacuate some of its contents, in this way the tension is relaxed and the gland comes out of its bed, and, as it is delivered, the sac is peeled off easily from the surrounding gland tissue without any loss of blood.

Should there be many large vessels about the capsule these can be peeled off, or if they tear they can be tied then and there; as I said before, this proceeding makes the operation extra- instead of intracervical.

Having enucleated the cyst, others are searched for through the cavity left behind, and if found, treated in the same way; all the bleeding-points being secured, the cavity is packed with iodoform gauze, and the end of the strip of gauze allowed to protrude through the lower angle of the wound. I formerly used a drainage-tube, but the gauze acts as a good drain, and at the same time, by its pressure, arrests hæmorrhage; the skin wound is now sutured with sterilized horse-hair sutures. Where the drain protrudes, a suture of silkworm gut is introduced and left untied. Next day the wound is dressed, the gauze removed, and the opening closed with the silkworm-gut suture. The horse-hair is used, because it is cheap, elastic, easily sterilized, and is removed much more easily than silkworm gut.

In the first dressing I never wash out, or, in fact, use water or antiseptics for cleansing the wound; I merely apply sterilized or antiseptic dressings and place a bandage over them. I allow and even encourage the patients to get up on the second day, if so inclined; by doing so I believe they recover more quickly; at the end of the week I remove the stitches, and next day, in nearly all my cases, the patient is discharged. Occasionally after the operation I have seen a very rapid pulse and high temperature; but if the wound looks normal I pay no attention to these symptoms, and they seem to have no injurious effect on the course of the convalescence, being due probably to the disturbance of the gland at the time of operation.

It is extraordinary how rapidly healing takes place after these operations, even when a huge cyst has been removed. My patients have rarely remained in hospital more than a week; the vascularity of the parts and the fact that the cellular tissue planes are not interfered with might to some extent account for this.

Some of the smaller cysts seem to give more pain than the larger ones. In several cases patients have come for operation on account of the pain and discomfort caused by the tumor and not for dyspnœa and dysphagia.

In this operation, as only the diseased part is removed, there is no fear of any ill consequences following the excision.

Appended will be found the notes of sixteen cases operated on since 1883, most of them, however, have been treated in the last two years.

Dr. Bradley, under the direction of Professor Adami, has made microscopical sections of some of the removed cysts, and appended to several of the later reports are the results of their investigations.

CASE I.—*Cyst of Right Lobe of Thyroid in a Boy aged Ten Years; Wound of the Internal Jugular Vein;*¹ *Recovery.*—P. F., aged ten years, December 18, 1883, was seen in consultation with Dr. Simpson for a small tumor on right side of neck. Three years before a small growth was noticed in right side of neck which was supposed to be an enlarged gland, this grew steadily until it reached its present size, has never caused any pain or other trouble.

On examining the neck a growth the size of a large egg is seen opposite the thyroid cartilage and going under the right sterno-mastoid; it is smooth and fluctuates, moves with the thyroid during deglutition, and, although freely movable, gives the impression that it is attached deeply posteriorly.

Operation.—December 19, 1883. Chloroform was given and an incision three inches long made over the tumor; the tumor was easily exposed and enucleation by the finger was attempted without success; curved scissors were then used, and just as the last portion of the deeper attachment was being severed there was a sudden gush of blood; the bleeding was immediately arrested by the finger and the bleeding-point seized with artery forceps. It was found that the internal jugular vein had been opened, so it was tied in two places and cut through between the ligatures, the wound was closed with catgut sutures and drained with a rubber tube. Patient rapidly recovered, leaving hospital well on the tenth day. Pulse on second day was 116, and temperature 100.5° F.

CASE II.—*Small Solid Cyst of Right Lobe of Thyroid; Enucleation; Recovery.*—Miss C., aged thirty years. Admitted October 22, 1889. A strong, robust woman; unmarried. Has suffered for some

¹ In this case I know now I never reached the proper cyst wall, and had I done so the jugular could not have been wounded.

years from a painful swelling in right side of neck. Has been growing slowly for nine years, and at times caused dyspnoea and dysphagia, voice slightly altered. Six months ago grew more rapidly and became painful. On examination a small tumor is seen, size of a large walnut, connected with the right lobe of the thyroid. It reaches down to the right sterno-clavicular articulation and is quite movable.

Operation.—October 29, 1889 Ether administered. Incision over tumor, some large veins tied, gland tissue thin, but very vascular. The capsule of tumor easily detected and separated from the surrounding gland tissue with a considerable amount of hæmorrhage. The cyst contained colloid material and blood clot, and appeared to be connected with the right half of the isthmus. A drainage-tube was introduced and wound closed with silkworm-gut sutures. Drainage-tube removed next day and wound closed and redressed. Stitches removed on seventh day; exit on eighth. No temperature and very slight elevation of pulse.

CASE III.—*Large Cyst of Left Lobe of Thyroid which extended Down under the Clavicle and had been growing for some Years.*—Mrs. J. L., aged forty years. Operation by enucleation December 17, 1889. Rapid recovery. (The case-book containing the notes of this case has been lost, and the above is extracted from my private operation book.)

CASE IV.—*Two Large Colloid Cysts of Right Thyroid Lobe; Enucleation; Recovery.*—Maggie C., aged thirteen years, native of Canada. Admitted into hospital, February 20, 1893, with a hard movable tumor in the centre of the neck below the thyroid cartilage. A year ago first noticed enlargement of neck, it remained same size for some months, but latterly has grown rapidly. Always has been healthy. No pain or discomfort felt from the growth.

Operation.—February 23, 1893. Incision as usual over tumor. Came down rapidly on the growth, and shelled it out without much bleeding. After the first cyst was removed another was felt deeper down, this was also cut down upon through the cavity occupied by the first and removed easily by enucleation and without hæmorrhage. The first tumor was the size of a large walnut, and the second somewhat smaller. The cysts were filled with fairly solid colloid material. Both tumors turned out to be connected with the right lobe of the thyroid.

In this case subcutaneous sutures were used and no drainage. Next day temperature rose to 105° F. and gradually fell to normal on

the sixth day. No suppuration. Patient discharged and the sutures still in on March 18, the fifteenth day.

CASE V.—*Large Cyst in Right Lobe of Thyroid, containing Gelatinous Fluid; Enucleation; Recovery.*—Amanda M., native of Canada, aged twenty-nine years. Admitted into hospital July 5, 1893, with large cystic bronchocele.

Enlargement first noticed five years ago, and has grown steadily until four months ago, when she had a miscarriage. Since then it has grown very fast. Has never caused any pain or interfered with breathing or swallowing. Wishes operation on account of unsightliness of the neck. Is in good health, but of a nervous excitable temperament. On the right side of the neck, extending from the thyroid cartilage to beneath the sterno-mastoid and from the hyoid bone to the clavicle, is a large globular swelling, smooth, painless, and non-fluctuating. The tumor moves with the thyroid cartilage on swallowing. The left lobe of thyroid is normal. Heart's action very rapid.

Operation.—July 7, 1893. Chloroform was administered. An incision was made over the tumor. The anterior jugular vein came into view and was cut between two ligatures. After cutting through the depressor muscles the gland was come down upon. It was non-vascular and had the appearance of a cyst wall. Several layers were cut through before the proper cyst wall was reached, and then the tumor was rapidly enucleated by means of the operator's finger alone; before complete enucleation was accomplished, the cyst wall ruptured and a lot of gelatinous, dark-green fluid escaped. Very little hæmorrhage resulted. A huge cavity was left and through its posterior walls the carotid vessels could be seen pulsating. The cavity was irrigated with a solution of 1-5000 of sublimate solution, the skin wound closed with a subcutaneous suture, a drain being left at the lower angle,—sterilized dressing applied. Next day tube was removed, the dressings being saturated with serous oozing. On the sixth day after operation the subcutaneous suture was pulled out and the patient went home. Some weeks later she was shown at a meeting of the Montreal Medico-Chirurgical Society in splendid health and with the nervous condition much less marked.

CASE VI.—*Large Cystic Bronchocele of Left Lobe of Thyroid; Recovery.*—Cordelia M., unmarried, aged twenty-three years, native of Montreal, was admitted to the General Hospital September 2, 1893, with enlargement of the neck. Tumor first appeared eight years ago, enlarging gradually. It has never been painful, nor has

there ever been difficulty in swallowing or breathing, but she has great shortness of breath on exertion, which may be due to condition of anæmia, which is marked in her case.

On examining the throat a large tumor was seen on the right side, extending from the top of the thyroid cartilage to the suprasternal notch. This has all the characteristics of a cystic bronchocele, fluctuates, moves upward on swallowing, and is freely movable laterally.

Operation.—September 29, 1893. Chloroform administered, and an incision made directly over the tumor, some three inches long. The anterior jugular vein tied, the muscles divided and separated, and then the gland came into view. This had the appearance of the cyst wall, but on incision several layers of fibrous (?) tissue were cut through, and then the bluish-white wall of the cyst appeared. The cyst was then partially enucleated with the finger, and was found to extend deeply down beneath the clavicle. It was firmly attached on its posterior wall to the gland tissue. While enucleating the cyst it burst, discharging its thick, brownish, fluid contents. The attached portion of the cyst wall was now rapidly freed by scalpel and the cyst removed. In the bottom of the cavity that was left the carotid vessels were seen pulsating. There was very free oozing, which was partially arrested by sponge pressure and a douche of hot sublimate solution, 1-5000. The wound was closed with a subcutaneous silk suture, a drain being left at the lower angle of the wound. Usual dressings applied. Next day tube was removed and wound closed, though dressings were saturated with serous oozing.

October 3. Subcutaneous suture removed; wound quite healed.

October 7. Patient discharged from hospital eight days after the operation with wound soundly healed.

CASE VII.—*Colloid Cyst of Left Thyroid Lobe; Enucleation; Recovery.*—Rachel L., unmarried, aged twenty-seven years; French Canadian. Admitted into hospital July 30, 1894, for tumor of neck. Has always been healthy. First noticed a small, hard lump in the middle line of neck below the cricoid cartilage eight years ago, which has been growing slowly ever since. Latterly it has become very painful. Has never had dyspnoea or dysphagia.

The enlargement is on the left side, and is about the size of a lemon, reaching from upper margin of the thyroid cartilage to the sternum. It is quite movable, feels soft, and does not fluctuate, and ascends with deglutition. No dyspnoea; no exophthalmos.

Operation.—August 2, 1894. Chloroform administered. Usual

incision over the tumor made. The gland was come down upon and incised; here considerable bleeding took place. When the capsule of cyst was reached enucleation was attempted, but the bleeding was furious, so the cyst was immediately opened and its contents shelled out, and then the capsule was carefully dissected out with finger and knife, the vessels being tied as cut. The cavity, from which there was free oozing, was packed with iodoform gauze, the end of the strip of gauze being brought out at lower end of wound. The wound was then closed with horse-hair sutures and dressed as usual. The cyst contained colloid material and very little fluid. Next day the dressings were soaked with serous discharge. The gauze was removed and the wound closed.

Patient had normal temperature and pulse. Stitches removed and patient discharged well, August 11, the ninth day after operation.

CASE VIII.—*Large Colloid Bronchocoele of Left Side, very Adherent; Recovery.*—Bella E., aged twenty-nine years, English Canadian. Admitted into the Montreal General Hospital, September 20, 1894, with enlarged thyroid.

Seven years ago first noticed the neck commencing to enlarge on the left side. The tumor has always been soft and movable. Grew slowly until a year ago, when it rapidly increased. Has had all kinds of local applications. Tumor causes a great deal of discomfort and aches at times severely. Patient is of a highly nervous temperament, and loses a great deal of blood at every menstrual period. There is a large tumor of the thyroid on the left side, reaching from the middle line well under the sterno-mastoid muscle and from the upper border of the thyroid cartilage to the clavicle and beneath it. The tumor is soft and does not fluctuate, ascends with the cartilage during deglutition, and is freely movable. Right half of the gland is normal.

Operation.—September 21, 1894. Ether given. Incision some three inches long over the growth and the gland exposed. Over the gland coursed some very large veins which were ligatured. When the capsule of the tumor was reached, it was found that attempted enucleation caused great bleeding, and that the finger did not easily get around the growth, so the tumor was cut into, and its contents, which consisted of solid colloid material, were shelled out. Then the capsule was carefully pulled out of the wound, and as it came out the adhesions were separated, and if a vessel was torn, as often happened, it was immediately tied. In this way the whole capsule was removed, leaving behind a cavity lined with huge blood-vessels. This

cavity extended below the clavicle and behind the sternum. As there was considerable oozing from the cavity, it was packed with iodoform gauze. The wound was closed with horse-hair sutures and was dressed with sterilized gauze and cotton and a bandage applied. The gauze was brought out at the lower end of the wound, a silkworm-gut suture being left untied.

Next day gauze was removed and wound closed. Stitches removed on the 26th, and patient discharged well with wound soundly healed on the 28th, the seventh day after operation.

I have occasionally seen the patient since, and she is in much better general health and suffers much less from nervousness.

CASE IX.—*Multiple Colloid Cysts of both Lobes of Thyroid Gland; Removal by Enucleation; Recovery.*—Mrs. H., widow, aged thirty-five years; English Canadian; telegraph operator. Admitted into hospital, December 16, 1894, for enlarged thyroid. Is a delicate-looking woman, highly nervous, and with some exophthalmos. She has had an enlargement of the neck since childhood. Seven years ago the enlargement suddenly increased, but disappeared again on the application of an ointment. This increase was accompanied by palpitation of the heart and great nervous excitability. From that time the gland has slowly enlarged until last summer, when the growth was much more rapid. Latterly has difficulty of breathing on exertion. The neck is larger during menstruation and when she laces tightly.

On examination of the neck it is found that the left lobe is the larger, but both lobes extend from the hyoid bone to the clavicle. The enlargement seems to be due to a number of solid growths in the thyroid gland. Several very hard nodules are felt in the left lobe. Patient latterly has been unable to do her work, chiefly on account of nervousness.

Operation.—December 17, 1894. Ether administered. On cutting down on the left side over the growth one or two large veins had to be ligated, and on cutting through a thin layer of gland the capsule of the largest cyst was reached, and this was easily shelled out. Several other cysts were now felt, and through the posterior wall of the cavity left by the large one several smaller cysts were rapidly enucleated with considerable hæmorrhage, which was controlled by tampons. A number of very small cysts the size of beans were now shelled out, and the cavities packed with iodoform gauze. An incision was then made over the right half of the gland, and

here a number of small solid tumors were found, and some with very adherent capsules had to be dissected out. One or two were evidently very old, being quite cartilaginous. There was considerable bleeding, which was controlled by pressure and ligature. Iodoform gauze was freely used to pack the cavities, and the wounds were closed with horse-hair sutures. Next day gauze was removed, and on the eighth day stitches were taken out and patient discharged well.¹

In this case, on the evening of the operation, the pulse rose to 140, and continued as high as 120 for four days, the temperature rising to 101.5° F. the second day, but there was no suppuration, and union was complete in a week.

Pathological report by Dr. Bradley, of the McGill Pathological Laboratory. Sections show vesicles filled with colloid, in general of large size. Between the large-sized ones are occasional very small vesicles, which also contained colloid material. No appearance of colloid in the lymphatics.

In several places there is evidence of the coming together of vesicles by atrophy of intermediate wall, and small processes are seen standing out as in emphysematous lungs.

The epithelium of the vesicles is greatly flattened, consisting of little else than small rounded nuclei. The colloid is homogeneous, each vesicle contains a few large round cells with much protoplasm.

CASE X.—Diffuse Enlargement of both Lobes of the Thyroid; Excision of Left Lobe and Isthmus.—Marie F., aged twenty years, French Canadian, was admitted into hospital, January 15, 1895, for enlarged thyroid.

History.—The enlargement of thyroid commenced five or six years ago, on the right side and shortly afterwards on the left. The growth increased very slowly at first, but during the past year its increase has been rapid, and more so during the past month. At times has paroxysmal attacks of dyspnoea, but no nervousness or palpitation of the heart. Menstruation has been profuse and painful and has occurred every three weeks. No exophthalmos.

Present Condition.—Appears to be a healthy, well-nourished girl. Neck much enlarged, more on right side; this enlargement connected with the thyroid; no distinct tumor can be made out; the whole gland apparently affected with diffuse hypertrophy. The enlargement reaches upper border of thyroid cartilage to sterno-clavicular articu-

¹ I have seen her several times since, and she tells me her health has much improved, and that she is now able to attend to her business without fatigue.

lation of both sides, and the whole growth about the size of a medium-sized orange.

Operation.—January 18, 1895. Ether administered. An incision made three inches long to inner side of right sterno-mastoid muscle and over the tumor, and after tying some large veins the gland was reached and incised; as expected, there was no encapsuled tumor, but the whole gland was evenly enlarged. It was not very vascular. The isthmus was very much hypertrophied and it pressed on the trachea. After first tying the superior thyroid arteries and veins and then the inferior thyroid branches as they entered the gland, the right half of the thyroid was dissected out, care being taken to avoid injuring the recurrent laryngeal nerve on that side. The isthmus was then freed with a knife from the trachea, to which it was firmly adherent, and was tied off with a strong catgut ligature. The right half of the gland and isthmus were removed without hæmorrhage. The wound was closed with horse-hair suture and drained with a small rubber tube. Next day tube was removed and wound redressed. The temperature went up to 103° F., and pulse to 120, and this was the first case in which I had any suppuration. By the end of the week the temperature had fallen to normal, and the patient was sent out on the sixteenth day with wound firmly healed. The next week she returned with a small sinus which had opened, and through which protruded a small ligature. This was removed and the sinus closed.

Pathological report by Dr. Bradley. Sections show densely-packed vesicles in general below normal size, with, however, occasional larger vesicles.

Epithelium cubical, almost coalescent in some cases; these here and there show a clear, free, internal margin. Colloid material much shrunken, so that large, clear vacuoles appear between the narrower central mass and the epithelium. Occasional hæmorrhages, both interstitial and intervesicular. Between some of the lobules great development of hyaline fibrous tissue, with atrophy of peripheral vesicles.

CASE XI.—*Colloid Cysts of Right Lobe of Thyroid; Profuse Hæmorrhage; Ligature of the Thyroid Arteries and subsequent Sloughing of the Right Half of Gland; Recovery.*—Mrs. S., aged fifty-six years, native of and has always lived in Ontario, entered a private ward in the Montreal General Hospital, January 22, 1895, for an enlargement of right lobe of thyroid. (Patient is a spare, wiry woman, of an excessively nervous temperament, skin somewhat jaundiced.)

First noticed an enlargement of the thyroid ten years ago ; while crossing the Atlantic was violently sea-sick, and shortly after she noticed a small lump in right side of neck. This has been growing steadily ever since. The growth has been more rapid in the last three months. At first the tumor was very movable, but recently has become more fixed. It still moves with deglutition. Last year, for the first time, patient had some difficulty in swallowing, and this has continued ever since when solid food is taken. Respiration has never been interfered with, but the tumor has often been painful. The tumor is about the size of a small orange ; patient has an enlarged liver which has existed for some years, and soon after its commencement was said to be due to malignant disease ; had ascites at one time. Her health has never been robust.

Operation.—January 24, 1895. Ether administered. Usual incision over the tumor and sac soon reached. Over its surface coursed a number of large veins, which were tied. The sac itself was so friable that it was found impossible to shell it out, and the solid contents were evacuated and found to consist of a reddish-brown material. The capsule was now removed piecemeal from the gland tissue to which it was firmly adherent. The sac was so friable and the parts about so vascular that considerable difficulty was experienced in arresting the hæmorrhage. At the bottom of the cavity left by the cyst another smaller one was discovered, and, as there was still considerable bleeding, it was thought proper before removing the second tumor to ligate the inferior thyroid artery, and the second cyst was removed without any hæmorrhage, the wound was closed with horse-hair sutures after packing the cavity from which the large cyst was taken with iodoform gauze.

Next day the iodoform gauze was removed and the wound closed. On January 26, temperature had risen to 103° F., and the wound was discharging a thin sero-pus. Pulse rapid. During the next week the evening temperature averaged 102° F., and the dressings were removed and lead lotion was applied. There was considerable swelling and pain. Wound opened, and through the opening one could see a quantity of sloughing gland tissue, which was removed in large pieces daily. This went on until the whole right half of the thyroid came away. Patient also had all this time a troublesome cough. As soon as all the slough came away patient's temperature became normal, and she rapidly improved, and left the hospital with a small sinus on February 14, 1885, the eighteenth day after operation.

Pathological Report.—The majority of the vesicles have no lumen, being simply clumps of cells with nuclei tending to be peripheral. Some contain dense colloid material with brown stain. In a few this material shows a definite concentric arrangement. Epithelium around these is of a very irregular depth, many contain clear, transparent crystals (seen both after staining with carmine and hæmatoxylin). These crystals are relatively large, and vary in shape from almost a perfect square to rhomboid with occasional truncated cubes.

Some periarteritis. Small hæmorrhages into the substance with areas in which the capillaries are greatly dilated and the vesicles relatively far apart.

The whole appearance is that of undeveloped vesicles. Probably atrophy, though, for that, there is peculiarly little relative increase of fibrous stroma. The case looks like one of adenoma.

CASE XII.—*Two Cysts in Right Lobe of Thyroid; Enucleation; Recovery.*—Mrs. G., aged twenty-five years, native of the Province of Quebec, was admitted into the hospital, April 11, 1895, for a swelling of neck.

First noticed enlargement on right side of the neck six years ago; growth was small, but slowly increased until a year ago, when it grew rapidly and seemed to change its position, growing more towards the sternum. At first there was no pain or inconvenience, but during last year or two has had difficulty in breathing, and also dryness of throat, and difficulty in swallowing. She has also been in a highly nervous and excitable condition for some time past, and has lost flesh lately. Has a brother with a similar enlargement of the neck.

On examination the right lobe of the thyroid is found to be much enlarged, owing to a tumor which can be distinctly made out; this growth is very movable and reaches from the sternum to the middle of the thyroid cartilage. It is non-fluctuating, and appears to be about the size of a Tangarine orange.

Operation.—April 15, 1895. Incision over tumor. Anterior jugular vein tied, the gland incised, and cyst reached. It was found impossible to easily enucleate the cyst, so some of its contents, which consisted of a thick greenish-brown fluid, were evacuated, and then the opening closed with forceps. The cyst was easily lifted out with the lower part of the thyroid and peeled off gradually from the surrounding gland tissue and blood-vessels; through the cavity left another cyst about half the size of the first could be felt, which was cut down upon, its contents (brownish fluid) evacuated, and the cap-

sule removed, as in the previous one. The hæmorrhage from this latter enucleation was somewhat free, but was stopped by packing with iodoform gauze.

Next day gauze was removed. The stitches were taken out on the sixth day, and she was discharged with a soundly-healed wound on the seventh day. This patient never had a temperature or pulse over 100.

Pathological Report.—(Dr. Bradley.) Fluid of cyst contains a large number of cholesterine crystals, hæmotoxilin crystals, and large round cells containing fatty globules; fluid is of a glairy consistency and of a yellowish-brown color. Cyst wall is made up of several layers of fibrous tissue with occasional short imperfect layers, containing numerous small nuclei. On the inner surface are numerous fairly well developed vesicles with distinct epithelium somewhat flattened, and some are multiple, as if due to the coming together of several. In addition small fibroid areas with atrophy of gland tissue and scattered deposits of calcareous material are seen.

CASE XIII.—*Colloid Cyst of Right Lobe of Thyroid; Enucleation; Recovery.*—Emily L., aged twenty-three years, native of Quebec, was admitted into hospital, April 15, 1895, for enlarged thyroid.

Three years ago patient first noticed a lump in the neck the size of a filbert; it was situated to the right of the median line below the thyroid cartilage; grew very slowly until last year, when it suddenly increased in size. Has never caused any pain or inconvenience, and she wishes it removed because it is unsightly. She has always enjoyed perfect health. Two female cousins have similar enlargements of the neck.

On examining neck the tumor is found to be confined to the right lobe of the thyroid, is freely movable, is chiefly situated beneath the sterno-mastoid muscle, and is most easily pushed upward and outward. It is about the size of a lemon and feels somewhat solid.

Operation.—April 26, 1895. Ether administered. Usual incision over the tumor, tied the anterior jugular vein, and after cutting through the depressors of the hyoid the gland was reached. It was found to be somewhat more vascular than usual. The cyst was situated deep in its substance, and nearly a quarter of an inch of gland had to be incised before the capsule of the tumor was come down upon. As it would not readily "shell out," the capsule was opened

and some of its solid contents evacuated, and as the cyst was delivered it was peeled off from the surrounding tissue as in the other cases. The sac was very thin and very adherent. There was considerable bleeding after the cyst was extirpated, so the cavity was packed with iodoform gauze. The cut edges of the incision in the gland bled freely, and the thermo-cautery had to be used to stop the bleeding. Skin wound closed with horse-hair sutures. Next day pulse went up to 104, and temperature to 102° F. The gauze was removed and the loose ligature tied. There was no more rise of temperature, and the wound was firmly united on the sixth day, when the stitches were removed, and next day she went to her home in the country.

Pathological Report.—(Dr. Bradley.) Cyst wall formed of several layers of fibrous tissue with intermediate partial layers of atrophied gland tissue, vesicles of colloid material, average one-half of Winkel's ocular micrometer.

CASE XIV.—*Cyst of Left Lobe of Thyroid; Enucleation; Recovery.*—Lizzie C., aged twenty-one years, native of Montreal, was admitted into hospital, May 4, 1895, for enlargement of left lobe of thyroid.

First noticed swelling of neck in May, 1894; grew slowly until three months ago, when it rapidly increased. Has always been freely movable, especially on swallowing. Tumor never gave rise to any pain or dyspnoea, and she wishes operation solely on account of the unsightliness of the growth. Patient, although she never has been ill, is very anæmic, and is troubled a good deal with shortness of breath and palpitation. On examining the neck, a swelling is seen on the left side opposite the lower border of the thyroid cartilage, is partially under the sterno-mastoid muscle. It reaches to near the sternum and is about the size of a hen's egg. The tumor is well defined, movable, and feels like a solid growth.

Operation.—May 6, 1895. Ether administered. Usual incision over the tumor, the anterior jugular vein tied, the gland incised to the depth of one-eighth of an inch, and the bluish-white capsule of the cyst reached. It did not "shell out" easily, so an incision was made into it and some dark yellowish-brown fluid evacuated with clots of blood. The opening was closed with forceps and the tumor came out easily; as it came out its attachments to the surrounding gland tissue were freed and the adherent vessels tied. The cyst wall

appeared to be composed of several layers of tissue arranged in a tessellated manner. After delivery of the cyst the bleeding was quite free, but after securing some of the vessels and packing the cavity with iodoform gauze the bleeding was controlled. The wound was closed with horse-hair sutures. Next day gauze was removed and opening closed. On the fifth day the stitches were removed, and on the sixth day patient went home with the wound soundly healed. She had no elevation of temperature except 100° F. on first day after operation. Pulse never went over 100.

Pathological Report.—Shows cyst wall formed of fibrous tissue and compressed vesicles. Shows also fibrous tissue growing between the vesicles that are in the gland itself and adjoining the wall. Vesicles measure from three to forty divisions of Winckel's micrometer.

CASE XV.—*Cyst of Left Lobe of Thyroid; Enucleation; Recovery.*—Mrs. J., aged thirty years, native of Dublin, Ireland, has been in Canada fifteen years. A large, stout, healthy-looking woman, was admitted into the hospital, May 12, 1895, for enlargement of left lobe of thyroid. Enlargement commenced twelve years ago, and has been growing slowly ever since. Has caused her a great deal of pain, is especially painful when she lies on the right side. Dyspnoea has been present for years, and has been worse, especially on exertion, during the last four months. Swallowing somewhat difficult, and patient has to eat very slowly. The tumor appears to be about the size of a small orange, reaching from the upper border of the thyroid cartilage to within an inch of the sternum. Moves with deglutition. When in its usual position is chiefly beneath the sterno-mastoid. Feels hard and nodular.

Operation.—May 13, 1895. Ether administered. Incision over tumor and to inner side of sterno-mastoid muscle. Two large veins tied, and when gland was reached several veins of large size were seen running over it; these were ligated. The gland was incised and cyst wall reached. This was found to be very dense and adherent, so the cyst was tapped and some straw-colored fluid evacuated, and the cyst lifted out and separated from the surrounding adherent gland tissue with raspatory and knife.

Several very dense nodules seemed to be outgrowths of the larger cyst. Not much bleeding. Cavity packed with iodoform gauze and wound closed with horse-hair sutures. Next day gauze removed and wound closed. On the sixth day, May 20, the sutures were removed and patient left hospital well. No pain and feeling much better.



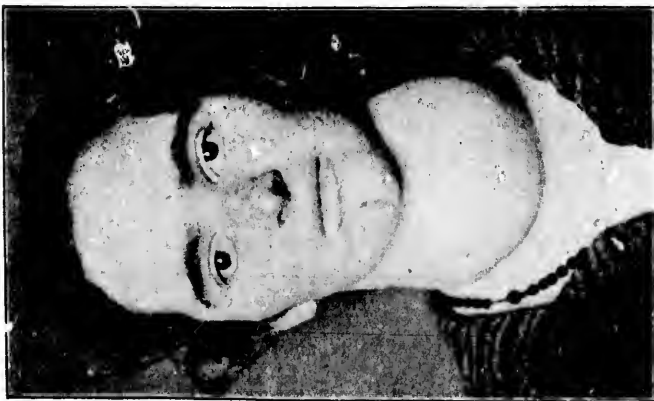


FIG. 1.—Front view before operation.

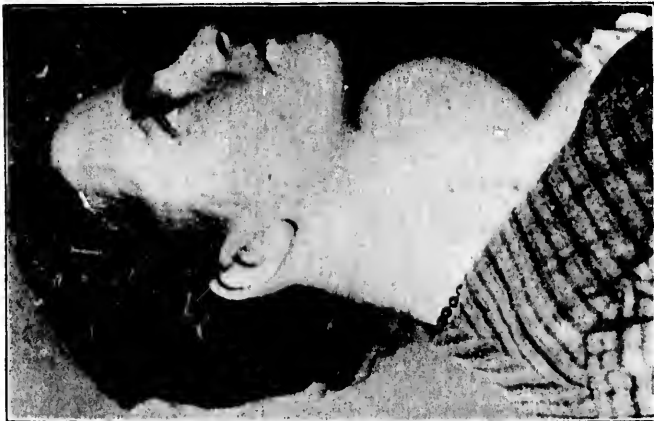

FIG. 2.—Side view before operation.

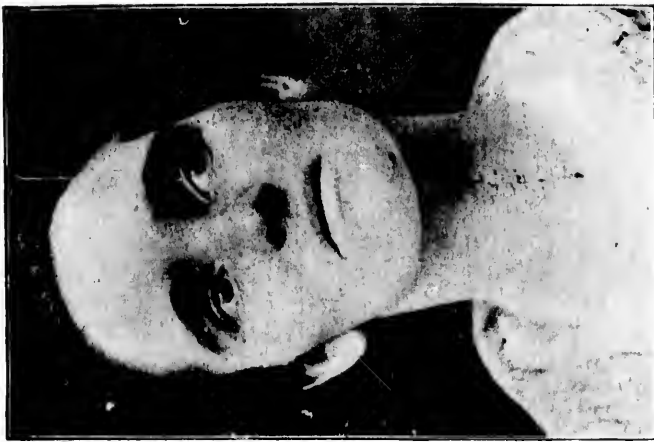

FIG. 3.—Seven days after operation.

CYSTIC TUMOR OF THYROID GLAND. (CASE XVI OF DR. SUEBIER'S SERIES.)

CASE XVI.—*Large Cystic Tumor of the Left Lobe of Thyroid; Enucleation; Recovery.*—(This case occurred after the reading of this paper.) Mary McL., native of Province of Quebec, aged nineteen years, entered the Montreal General Hospital, June 4, 1895, for tumor of thyroid.

Patient has always been healthy, but of late has been very anæmic. Six years ago she first noticed an enlargement in the middle line of neck, smooth and elastic.

During the first six months it did not grow, then for the next two years it grew slowly, latterly it has increased much more rapidly. Never has caused any pain, but she is very breathless when walking, and cannot talk and walk at the same time, breathless also on reading aloud.

Patient is a well-nourished young woman of a fair complexion and showing signs of anæmia. No exophthalmos; temperature 99.2° F.; pulse 80; respiration 24.

Over the region of the thyroid is a large, smooth, elastic swelling, larger on the left than the right side. This swelling reaches from one sterno-mastoid muscle to the other, and from the hyoid bone to the sternum it fluctuates and appears to be made up of two cysts, one small one on the right side, and the larger on the left side of the neck.

Operation.—June 7, 1895. Ether was administered and an incision was made over the most prominent part of the tumor on the left side. Some large veins tied and the gland reached and incised. The bluish-gray wall of the cyst was easily recognized, and, as the cyst was a very large one, it was incised and some of its contents evacuated.

These consisted of dark-brown fluid, somewhat thickish in consistency; about twelve ounces were evacuated and then the cyst was pulled out with the surrounding gland and gradually peeled off from the adherent tissue. The capsule was somewhat vascular and was attached on its posterior wall, from which were growing several small adenoid tumors the size of walnuts. After some trouble the cyst was completely enucleated and a number of bleeding points were secured in the huge cavity that was left behind. It was found that the whole swelling was one large cyst, and that the appearance of a second cyst on the right side was due to a constricting band. The cavity was packed with iodoform gauze and the wound closed, except at its lower end, with horse-hair sutures.

Next day the gauze was removed and a considerable quantity of bloody serum evacuated. The lower end of wound from which the gauze protruded was closed with a suture. As there was some temperature and swelling, on the third day the dressings were removed and some bloody serum evacuated with a grooved director. On the sixth day the sutures were removed, and wound was found to be firmly healed. In this case the temperature rose to 103° F., the day after operation, but gradually fell to normal on the sixth day. Patient sat up on the second day and felt well and slept well. The temperature possibly was due to the tension caused by the serum as well as to the disturbance of the gland, but there was no evidence of sepsis throughout the case.

Pathological Report.—(Dr. Johnston.) Sections through the cyst wall and solid portion of the cyst show epithelium arranged in the small, round alveoli characteristic of thyroid tissue. The cells on the walls of the cyst are flattened, swollen, and show colloid changes.

