

**CIHM
Microfiche
Series
(Monographs)**

**ICMH
Collection de
microfiches
(monographies)**



Canadian Institute for Historical Microreproductions / Institut canadien de microreproductions historiques

© 1997

Technical and Bibliographic Notes / Notes techniques et bibliographiques

The Institute has attempted to obtain the best original copy available for filming. Features of this copy which may be bibliographically unique, which may alter any of the images in the reproduction, or which may significantly change the usual method of filming, are checked below.

L'Institut a microfilmé le meilleur exemplaire qu'il lui a été possible de se procurer. Les détails de cet exemplaire qui sont peut-être uniques du point de vue bibliographique, qui peuvent modifier une image reproduite, ou qui peuvent exiger une modification dans la méthode normale de filmage sont indiqués ci-dessous.

- Coloured covers/
Couverture de couleur
- Covers damaged/
Couverture endommagée
- Covers restored and/or laminated/
Couverture restaurée et/ou pelliculée
- Cover title missing/
Le titre de couverture manque
- Coloured maps/
Cartes géographiques en couleur
- Coloured ink (i.e. other than blue or black)/
Encre de couleur (i.e. autre que bleue ou noire)
- Coloured plates and/or illustrations/
Planches et/ou illustrations en couleur
- Bound with other material/
Relié avec d'autres documents
- Tight binding may cause shadows or distortion along interior margin/
La reliure serrée peut causer de l'ombre ou de la distorsion le long de la marge intérieure
- Blank leaves added during restoration may appear within the text. Whenever possible, these have been omitted from filming/
Il se peut que certaines pages blanches ajoutées lors d'une restauration apparaissent dans le texte, mais, lorsque cela était possible, ces pages n'ont pas été filmées.
- Additional comments: /
Commentaires supplémentaires:

- Coloured pages/
Pages de couleur
- Pages damaged/
Pages endommagées
- Pages restored and/or laminated/
Pages restaurées et/ou pelliculées
- Pages discoloured, stained or foxed/
Pages décolorées, tachetées ou piquées
- Pages detached/
Pages détachées
- Showthrough/
Transparence
- Quality of print varies/
Qualité inégale de l'impression
- Continuous pagination/
Pagination continue
- Includes index(es)/
Comprend un (des) index
- Title on header taken from: /
Le titre de l'en-tête provient:
- Title page of issue/
Page de titre de la livraison
- Caption of issue/
Titre de départ de la livraison
- Masthead/
Générique (périodiques) de la livraison

This item is filmed at the reduction ratio checked below/
Ce document est filmé au taux de réduction indiqué ci-dessous.

10X	14X	18X	22X	26X	30X
<input type="checkbox"/>	<input type="checkbox"/>	<input type="checkbox"/>	<input checked="" type="checkbox"/>	<input type="checkbox"/>	<input type="checkbox"/>
12X	16X	20X	24X	28X	32X

The copy filmed here has been reproduced thanks to the generosity of:

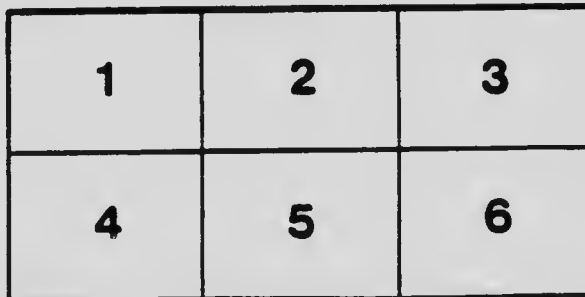
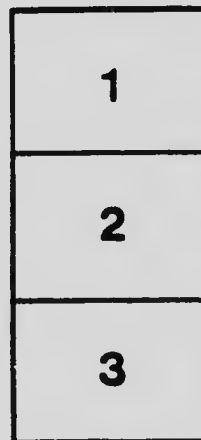
University of Toronto
Gerstein Science Information Centre

The images appearing here are the best quality possible considering the condition and legibility of the original copy and in keeping with the filming contract specifications.

Original copies in printed paper covers are filmed beginning with the front cover and ending on the last page with a printed or illustrated impression, or the back cover when appropriate. All other original copies are filmed beginning on the first page with a printed or illustrated impression, and ending on the last page with a printed or illustrated impression.

The last recorded frame on each microfiche shall contain the symbol \rightarrow (meaning "CONTINUED"), or the symbol ∇ (meaning "END"), whichever applies.

Maps, plates, charts, etc., may be filmed at different reduction ratios. Those too large to be entirely included in one exposure are filmed beginning in the upper left hand corner, left to right and top to bottom, as many frames as required. The following diagrams illustrate the method:



L'exemplaire filmé fut reproduit grâce à la générosité de:


University of Toronto
Gerstein Science Information Centre

Les images suivantes ont été reproduites avec le plus grand soin, compte tenu de la condition et de la netteté de l'exemplaire filmé, et en conformité avec les conditions du contrat de filimage.


Les exemplaires originaux dont la couverture en papier est imprimée sont filmés en commençant par le premier plat et en terminant soit par la dernière page qui comporte une empreinte d'impression ou d'illustration, soit par le second plat, selon le cas. Tous les autres exemplaires originaux sont filmés en commençant par la première page qui comporte une empreinte d'impression ou d'illustration et en terminant par la dernière page qui comporte une telle empreinte.

Un des symboles suivants apparaîtra sur la dernière image de chaque microfiche, selon le cas: le symbole \rightarrow signifie "À SUIVRE", le symbole ∇ signifie "FIN".

Les cartes, planches, tableaux, etc., peuvent être filmés à des taux de réduction différents. Lorsque le document est trop grand pour être reproduit en un seul cliché, il est filmé à partir de l'angle supérieur gauche, de gauche à droite, et de haut en bas, en prenant le nombre d'images nécessaire. Les diagrammes suivants illustrent la méthode.



MICROCOPY RESOLUTION TEST CHART
 NATIONAL BUREAU OF STANDARDS
 STANDARD REFERENCE MATERIAL 1010a
 (ANSI and ISO TEST CHART No. 2)



THE ESSENTIALS
OF
MORBID HISTOLOGY



MP
G

THE ESSENTIALS
OF
MORBID HISTOLOGY

FOR THE USE OF STUDENTS

BY

ALBERT S. GRÜNBAUM

M.A., M.D., F.R.C.P., D.P.H.


PROFESSOR OF PATHOLOGY IN THE UNIVERSITY OF LEEDS
EXAMINER IN PATHOLOGY IN THE UNIVERSITY OF LONDON
EXAMINER IN COMPARATIVE PATHOLOGY IN THE UNIVERSITY OF DUBLIN

*WITH 22 COLOURED PLATES
AND 139 OTHER ILLUSTRATIONS*

THE MACMILLAN COMPANY OF CANADA, LTD.

TORONTO

1912



TO MY WIFE



PREFACE

THIS book follows the lines of Professor Schäfer's *Essentials of Histology*, which the student is assumed already to possess and to know. The main difficulty in writing any book for the use of students, especially a practical book, lies, of course in choosing between what is essential and what is accessory and the choice offers a wide range for difference of opinion. The author feels that he is likely to be accused of many errors of judgment in this respect. He has been guided mainly by the principle that difficulty should not be the criterion for determining what a student should or should not do or be given, but rather the importance or general applicability of each observation to a general knowledge of pathological processes. The book is intended to assist the teaching of "general" rather than "special" pathological anatomy.

The illustrations are, for the greater part, from drawings made by Miss A. Kelley specially for this book. They are from specimens of which the majority have been given out in class. While essential features have here and there been emphasised, the drawings are in no sense diagrammatic. Two have been borrowed from Dejerine and André-Thomas, *Mémoires de la Moelle Epinière* and four from Oppenheim's *Lehrbuch der Nervenkrankheiten*, Figs. 69, 90, 103 and 164. For the loan or gift of specimens the author is indebted to various friends, especially

to Mr. W. W. Adanson, M.B., Miss Chambers, M.D. and Mr. M. J. Stewart, M.B. He also owes much to the numerous existing text books on the subject.

The arrangement, order and length of the lessons can naturally be varied to suit individual requirements, for there is no strictly logical sequence which can be adopted as a standard.

It will be gathered that no pretence of completeness is made or assumed and the utility of the book will probably be measured by the extent of its parallelism with each teacher's own preconceptions.

CONTENTS

CHAPTER	PAGE
I. THE CELL - - - - -	1
II. CELL DEGENERATIONS - - - - -	6
III. CELL DEGENERATIONS (<i>continued</i>) - - - - -	12
IV. CIRCULATORY DISTURBANCES, CONGESTION, THROMBOSIS, INFARCT, HAEMORRHAGE - - - - -	15
V. INJURY AND REPAIR - - - - -	23
VI. INFLAMMATION - - - - -	27
VII. SPECIFIC INFLAMMATIONS - - - - -	37
VIII. ATROPHY AND HYPERTROPHY, GROWTH - - - - -	43
IX. NEW GROWTHS (EPITHELIAL - - - - -	45
X. NEW GROWTHS (EPITHELIAL <i>continued</i>) - - - - -	54
XI. NEW GROWTHS (CONNECTIVE TISSUE) - - - - -	63
XII. NEW GROWTHS (<i>continued</i>) - - - - -	73
XIII. RESPIRATORY SYSTEM - - - - -	80
XIV. RESPIRATORY SYSTEM (<i>continued</i>) - - - - -	88
XV. THE HEART - - - - -	96
XVI. THE HEART (<i>continued</i>), THE BLOOD-VESSELS - - - - -	102
XVII. THE ALIMENTARY SYSTEM - - - - -	109

CHAPTER	PAGE
XXVIII. THE ALIMENTARY SYSTEM (<i>continued</i>), THE IN- TESTINES - - - - -	117
XIX. THE LIVER - - - - -	124
XX. THE PANCREAS, THE SPLEEN - - - - -	136
XXI. THE KIDNEY - - - - -	140
XXII. THE BLADDER, THE MALE GENITAL ORGANS -	147
XXIII. THE FEMALE GENITAL ORGANS - - - - -	153
XXIV. THE DUCTLESS GLANDS - - - - -	165
XXV. THE BLOOD - - - - -	173
XXVI. THE SEROUS MEMBRANES - - - - -	176
XXVII. THE LYMPHATIC GLANDS, THE BONES - - - - -	183
XXVIII. THE MUSCLES, THE NERVES - - - - -	190
XXIX. THE CENTRAL NERVOUS SYSTEM - - - - -	193
XXX. THE SPINAL CORD - - - - -	201
APPENDIX—METHODS - - - - -	209
INDEX - - - - -	213

PAGE
17
24
36
40
47
53
65
73
76
83
90
93
101
109
113

LIST OF ILLUSTRATIONS

FIG.	PAGE
1. Mitosis. Uterine glands and stroma. Endometritis - -	2
2. Mitosis. Testis (human) - - - - -	3
3A. Mitosis. Liver. Carcinoma - - - - -	4
3B. Mitosis. Mamma. Carcinoma - - - - -	4
4. Cloudy swelling. Liver. Sepsis - - - - -	7
5. Cloudy swelling. Kidney. Burn - (Coloured) to face page	7
6. Lardaceous disease. Liver - - (Coloured) to face page	8
7. Colloid carcinoma of the intestine - - - - -	9
8. Epithelioma showing cell nests - - - - -	10
9. Fatty kidney. Continued chloroform administration (Coloured) to face page	12
10. Fatty liver: phosphorus poisoning (osmic acid) - - -	13
11. Calcification. Artery. Thrombosis - - - - -	14
12. Passive congestion. Liver - - (Coloured) to face page	16
13. Artery. Thrombosis (recent) - - - - -	17
14. Artery. Thrombosis (older) - - - - -	18
15. Infaret. Kidney - - - - -	19
16. Bruise (4 days). Skin of leg and subjacent tissue - -	20
17. Haemorrhage. Pons Varolii - - - - -	21
18. Wound, (surgical), 2 days. Skin - - - - -	25
19. Giant cells. Surgical wound - - - - -	26
20. Inflammation. Early stage. Radium (Coloured) to face page	28
21. Chemical injury (AgNO ₃). Skin - - - - -	30
22. Blister (caused by Radium). Skin - - - - -	31
23. Abscess. Liver - - - - -	32

FIG.	PAGE
24. Ulcer. Skin of leg - - - - - (Coloured) to face page	33
25. Granulation tissue - - - - -	34
26. Glossitis - - - - - (Coloured) to face page	34
27. Diphtheritic inflammation. Trachea. Mucous membrane -	35
28. Syphilitic inflammation. Chancre of penis - - - - -	38
29. Syphilitic inflammation. Gumma of liver - - - - -	39
30. Tuberculous inflammation. Lymphatic gland - - - - -	40
31. Tubercle of liver - - - - -	41
32. Actinomycotic inflammation. Liver - - - - -	42
33. Muscular fibres, (a) from non-pregnant ;	44
34. (b) from pregnant uterus	
35. Adenoma. Rectum - - - - -	47
36. Columnar cell carcinoma. Rectum - - - - -	48
37. Fibro-adenoma. Mamma - - - - -	49
38. Carcinoma (scirrhous). Mamma - - - - -	51
39. Carcinoma (encephaloid). Mamma - - - - -	52
40. Wart (papilloma). Skin - - - - -	55
41. Rodent ulcer. Skin - - - - -	57
42. Chronic ulcer becoming epitheliomatous. Skin - - - - -	58
43. Epithelioma. Skin - - - - -	59
43*. Epithelioma, showing cell nests - - - - -	60
44. Metastasis. Cancer. Spleen. Mouse - - - - -	61
45. Fibroma - - - - -	64
46. Myoma. Uterus - - - - -	65
47. Small round cell sarcoma - - - - -	67
48. Large round cell sarcoma - - - - -	68
49. Spindle-celled sarcoma. Rat - - - - -	69
50. Myeloid sarcoma - - - - -	70
51. Melanotic sarcoma - - - - -	71
52. Chondrosarcoma - - - - -	74
53. Myxosarcoma - - - - -	75
54. Naevus (capillary angioma) - - - - -	76
55. Angioma. Liver - - - - -	77
56. Endothelioma (tumour of a rodent) - - - - -	78
57. Chorionepithelioma. Uterus - (Coloured) to face page	78

LIST OF ILLUSTRATIONS.

xiii

PAGE	FIG.	PAGE
33	58. Nose. Mucous polypus - - - - -	81
34	59. Bronchiole. Bronchitis - - - - -	82
34	60. Bronchiole. Bronchiecta - - - - -	83
35	61. Lung. Infaret - - - - -	84
38	62. Lung. Emphysema - - - - -	86
39	63. Lung. Passive hyperaemia and oedema - - - - -	87
40	64. Lung. Lobar pneumonia. Red hepatisation	
41	<i>(Coloured) to face page</i>	89
42	65. Bronchopneumonia - - - - -	91
44	66. Large miliary tubercle. Lung - - - - -	92
47	67. Lung. Anthracosis - - - - -	93
47	68. Anthracosis of lung - - - - -	94
48	69. Heart muscle. Brown atrophy - - - - -	97
49	70. Heart. Fatty degeneration. Pernicious anaemia - - - - -	98
51	71. Heart. Interstitial myocarditis - - - - -	99
52	72. Heart. Chronic myocarditis - - - - -	100
55	73. Vegetation on mitral valve. Endocarditis - - - - -	103
57	74. Endocarditis. Vegetation on mitral valve - - - - -	103
58	75. Heart. Chronic endocarditis, myocarditis and pericarditis -	105
59	76. Cerebral vessel. Chimpanzee. Early endarteritis	
60	<i>(Coloured) to face page</i>	106
61	77. Cerebral vessel. Human. Arteriosclerosis	
64	<i>(Coloured) to face page</i>	106
65	78. Cerebral vessel. Higher magnification	
67	<i>(Coloured) to face page</i>	106
68	79. Artery. Chronic arteritis - - - - -	107
69	79* Artery. Thrombosis (recent) - - - - -	108
70	80. Tongue. Epithelioma - - - - -	110
71	81. Stomach. Subacute granular gastritis - - - - -	111
74	82. Stomach. Chronic atrophic gastritis - - - - -	112
75	83. Ulcer. Stomach - - - - -	113
76	84. Cancer. Stomach - - - - -	114
77	85. Stomach, leather bottle - - - - -	115
78	86. Typhoid. Intestine (small) - - - - -	119
78	87. Tubercle. Intestine (small) - - - - -	120

FIG.	PAGE
88. Appendicitis (early) - - - - -	122
88†. Cloudy swelling. Liver. Sepsis - - - - -	125
88*†. Fatty liver phosphorus poisoning (osmic acid) - - -	126
89. Cirrhosis of Liver. Weigert's elastic stain <i>(Coloured) to face page</i>	127
90. Cirrhosis of Liver. Higher magnification <i>(Coloured) to face page</i>	127
91. Hypertrophic cirrhosis. Liver - - - - -	127
92. Syphilitic cirrhosis. Liver - - - - -	128
93. Acute yellow atrophy. Liver - - - - -	129
94. Pernicious anaemia. Liver. Sclerosis <i>(Coloured) to face page</i>	131
94*. Tubercle of liver - - - - -	130
95. Gumma. Liver - - - - -	131
95*. Syphilitic inflammation. Gumma of liver - - - - -	132
96. Cancer. Liver - - - - -	133
96*. Liver. Carcinoma - - - - -	134
97. Hydatid Cyst. Liver - - - - -	135
98. Fat necrosis and fibrosis. Pancreas <i>(Coloured) to face page</i>	137
99. Cancer. Pancreas - - - - -	137
100. Lardaceous disease (diffuse). Spleen - - - - -	138
101. Kidney. Fatty. Chronic parenchymatous nephritis <i>(Coloured) to face page</i>	141
102. Subacute parenchymatous nephritis - - - - -	142
103. Glomerulus in subacute parenchymatous nephritis - - -	143
104. Subacute interstitial nephritis - - - <i>(Coloured) to face page</i>	142
105. Mixed nephritis - - - - -	144
106. Lardaceous disease in kidney - - - <i>(Coloured) to face page</i>	146
107. Lardaceous disease in kidney. Higher magnification <i>(Coloured) to face page</i>	145
108. Adenoma. Kidney - - - - -	145
109. Cystitis. Bladder - - - - -	148
110. Carcinoma. Bladder - - - - -	149
111. Orchitis - - - - -	150

LIST OF ILLUSTRATIONS.

XV

PAGE	FIG.	PAGE
22	112. Tuberculous epididymis - - - - -	151
25	113. Prostate. Hypertrophy - - - - -	152
26	114. Papilliferous (colloid) cyst of ovary - - - - -	154
	115. Papilliferous cyst of ovary - - - - -	155
27	116. Carcinoma (solid) of ovary - - - - -	156
	117. Dermoid. Ovary - - - - -	157
	118. Gonorrhoeal salpingitis - - - - -	158
27	119. Tuberculosis of Fallopian tube - - - - -	159
27	120*. Uterine glands and stroma. Endometritis - - - - -	160
28	120. Endometritis. Curetting - - - - -	161
29	120†. Myoma. Uterus - - - - -	162
	121. Curetting. Cancer of uterus - - - - -	163
31	122. Simple goitre. Thyroid - - - - -	166
30	123. Exophthalmic goitre. Thyroid - - - - -	167
31	124. Thyroid gland in myxoedema - - - - -	168
32	125. Thyroid. Carcinoma - - - - -	169
33	126. Adrenal. Tubercle - - - - -	170
34	127. Adrenal. Atrophy - - - - -	171
35	128. Skin. Addison's disease - - - - -	171
	129. Hypernephroma (boundary zone). Kidney - - - - -	172
37	Blood Plate - - - - - <i>(Coloured) to face page</i>	174
37	130. Heart. Pericarditis. Organising - <i>(Coloured) to face page</i>	177
38	131. Heart. Chronic pericarditis - - - - -	177
	132. Pleurisy - - - - -	179
41	133. Intestinal wall (portion of). Peritonitis - - - - -	180
42	134. Perihepatitis. (Old) - - - - -	181
43	135. Tattooing. Gland - - - - -	184
42	135*. Tuberculous inflammation. Lymphatic gland - - - - -	184
44	136. Lymphadenoma. Gland - - - - -	185
46	137. Lymphadenoma. Gland - - - - -	186
	138. Rickets. Costosternal junction - - - - -	188
46	139. Peripheral Neuritis - - - - -	191
45	140. Muscle in pseudo-hypertrophic paralysis (osmic acid) - - - - -	192
48	141. Acute suppurative meningitis - - - - -	194
49	142. Tuberculous meningitis - - - - -	196
50		

FIG.		PAGE
143.	Chronic encephalitis. General paralysis - - - -	197
144.	Perivascular infiltration. Cerebral cortex. Chorea -	198
145.	Psaummoma. Dura mater - - - - -	199
146.	Spinal leptomeningitis - - - - -	202
146A.	Syphilitic pachymeningitis - - - - -	203
147.	Acute disseminated myelitis - - - - -	203
148A.	} Anterior Poliomyelitis. Spinal cord - - - -	204
148B.		
149.	Tabes dorsalis (late stage) - - - - -	205
149A.	Cells of dorsal ganglion in various stages of degeneration.	
	Tabes dorsalis - - - - -	206
150.	Primary lateral sclerosis - - - - -	207
151.	Combined sclerosis, idiopathic anaemia - - - - -	207

PAGE
197
198
199
202
203
203
204
205
206
207
207

CHAPTER I

THE CELL

ILLUSTRATIVE PREPARATIONS.

1. Uterine curettings to show somatic mitoses.
2. Primary carcinoma of the liver to show asymmetrical and irregular mitoses.
3. Human testis for heterotype mitoses.
4. Rapidly growing mammary carcinoma for occasional heterotype mitoses and cell inclusions.
5. Mix a drop of blood and an emulsion of micrococci on a slide, cover and incubate for ten minutes. Make a film and stain. Examine the leucocytes for phagocytosis.

THE essential constituents of the normal cell, namely the nucleus and the cytoplasm, are liable to various physiological changes which correspond to their various phases of activity and must not be confused with pathological variations. Thus the nucleus, with its nucleolus, may alter its position, divide or rearrange its chromatin, or vary in its staining reaction.

An alteration in the position of the nucleus is seen in secreting cells when in full physiological activity and is not necessarily evidence of a pathological condition, but in some diseases of the central nervous system eccentricity of the nucleus is a very constant feature and is pathological by reason of the increased frequency of its occurrence.

In **normal** or **somatic** mitosis, the chromatin network takes the form of a definite coil, which in turn divides into a definite number of segments. These segments, or chromosomes, arrange

themselves around the equator of the spindle, assuming a **V**-shape with the apex directed towards the axis of the spindle (Fig. 1). Each chromosome then divides longitudinally into two and the daughter chromosomes, as they are termed, proceed toward opposite poles of the spindle, where each set coalesces and forms

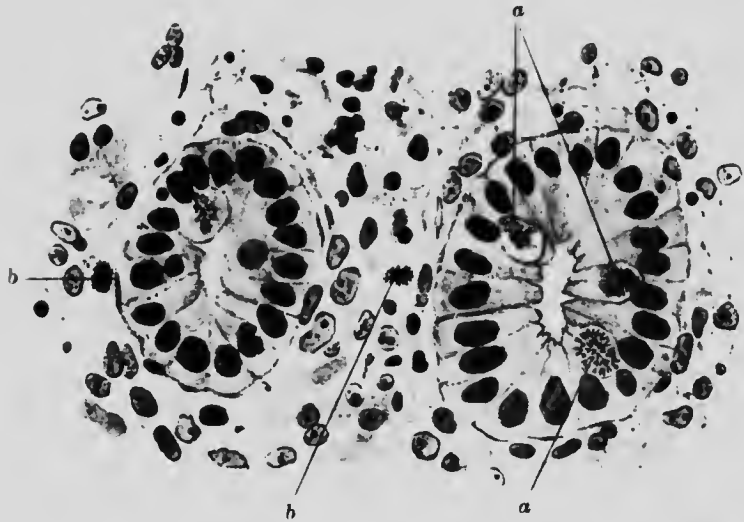


FIG. 1. UTERINE GLANDS AND STROMA. ENDOMETRITIS. ($\times 525$)

- a. Cells of glands showing somatic mitosis. Metaphase. Observe V-shaped chromosomes arranged at right angles to long axis.
- b. Similar condition in cells of stroma. The chromosomes are more closely clustered.

the nucleus of a daughter cell. The number of chromosomes in a cell is not the same for all animals, but is constant for the body cells of animals of the same species. In man it is 32.

In **germinal** or **heterotype** mitosis, which occurs in some of the germ cells, a different form of division is present (Fig. 2). The essential features are:

1. The reduction of the number of chromosomes to one half.
2. Alteration of the shape of the chromosomes, which then form hooks and rings instead of V's.
3. Alteration in the position of the chromosomes, which then tend to lie along the axis of the spindle.

In some **pathological** conditions, one or more of the following abnormalities may be seen in the mitotic figures:

1. Increase in the number of poles.
2. Alteration in the number of chromosomes.
3. Alteration in the form of the chromosomes.

Within limits these changes may be induced artificially, but practically they may be said to occur only in new growths.

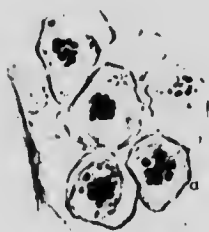


FIG. 2. TESTIS (HUMAN). ($\times 500$)

The cells show heterotype mitosis, and that marked *a* shows the arrangement of chromosomes along the axis of the spindle.

Nuclear figures with three, four or more poles and the same number of spindles are found in rapidly growing tumours. They are probably due to premature division of the centrosome (Fig. 3A). The variation in the number of chromosomes which is seen in some tumours may arise in two ways. An unequal distribution at the time of division will result in more rods passing to one pole than the other, or a double division of the chromosomes causes a genuine total increase in number, so that in man, 64 instead of the normal 32 chromosomes may be found.

In place of the clear cut V-shaped figures with equal arms, the chromosomes may assume the form of a hook with unequal arms, or be otherwise distorted. Not infrequently these distorted forms resemble those found in heterotype mitosis.

Genuine heterotype mitosis also occurs in malignant new growths (Fig. 3B).

Other pathological changes occurring in the nucleus are karyolysis and karyorrhexis. They are both seen in toxic conditions

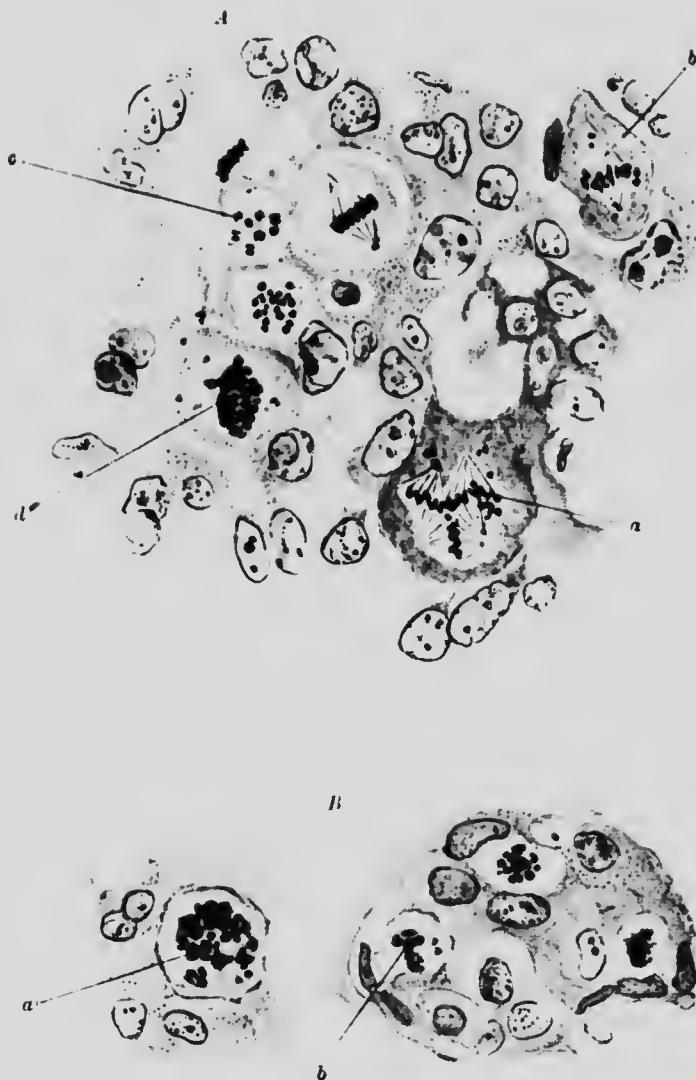


FIG. 3. A. LIVER CARCINOMA. ($\times 750$)

- a.* Cell with tripolar mitosis. Spindle well marked.
- b.* Cell with heterotypoid chromosomes.
- c.* Cell with scattered homotypoid chromosomes.
- d.* Cell with irregularly distributed chromosomes.

B. MAMMA CARCINOMA.

- a.* Cell with irregular distribution of chromosomes.
- b.* Cell showing heterotype mitosis.

and are particularly obvious in the central nervous system. As a result of karyolysis (a gradual solution of chromatin) the nucleus stains more faintly. In karyorrhexis the chromatin substance is broken up into amorphous fragments.

The power to ingest foreign bodies or particles (**phagocytosis**) and the property of amoeboid movement possessed by certain cells, are of great importance under pathological conditions. Neutrophile leucocytes, mononuclear leucocytes, endothelial cells and occasionally cancer cells exhibit these faculties. Phagocytosis is seen most commonly in inflammatory conditions in which many neutrophile leucocytes may be found to have ingested one or more of the attacking micro-organisms. Phagocytosis is a physiological function which may, under pathological circumstances, be either abnormally exerted or—a much more serious condition—entirely lost.

CHAPTER II

CELL DEGENERATIONS

ILLUSTRATIVE PREPARATIONS.

1. Fresh liver cells from a normal and from a febrile case to be teased in normal saline solution and the latter to be examined for cloudy swelling.
2. Kidney from a case of extensive burn to show cloudy swelling of the secreting cells.
3. Kidney stained with methyl violet to show lardaceous change.
4. Colloid cancer of intestine to show colloid (mucoid) change.
5. Epithelioma of the tongue with cell nests to show horny degeneration.

In the typical normal body cell, the protoplasm contains, both in the fresh and in the fixed condition, a faint reticular network called spongioplasm enclosing within its meshes a translucent substance named hyaloplasm. In the secreting and some other body cells, the hyaloplasm contains fine granules, called metaplasmic granules, of which some appear to be essential cell constituents and others the result of cell metabolism. The ordinary classification of these granules is a rough one dependent on the varying affinity of the different groups for particular classes of dyestuffs. The classes are (*a*) *oxyphil* (also called eosinophil or acidophil) granules taking acid or protoplasmic dyes (*e.g.* eosin), (*b*) *basophil*, staining with basic or nuclear stains (*e.g.* methylene blue), (*c*) *neutrophil*, without special affinity for either and (*d*) *amphophil*, staining equally well with both acid and basic dyes.

in
dy
the

oth
ork
ent
her
eta-
cell
The
ent
lar
lled
lyes
(*g.*)
ther
asie

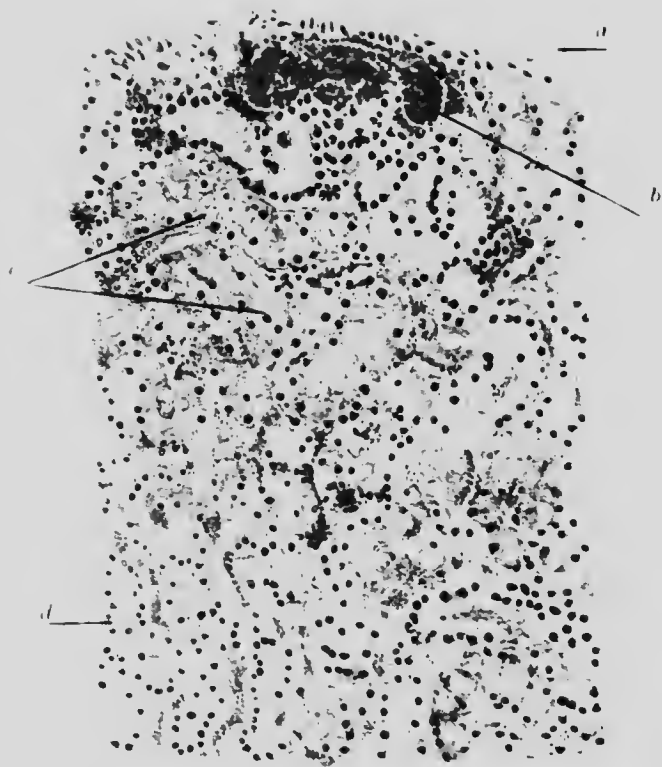


FIG. 5. KIDNEY. Cloudy swelling after burn. (x 100)

- a.* Capsule.
- b.* Congested blood vessel. The capillaries are all over full.
- c.* Vacuolated granular cells, some with, some without, nucleus.

Under pathological conditions the reticular formation may become indistinct or even disappear, the hyaloplasm may become opaque and the essential metaplastic granules vanish. The changes can be classified in the following manner:

Albuminoid Degeneration	{	Degeneration with coagulation of protoplasm	{	parenchymatous (cloudy swelling).
				hyaline. lardaceous. keratinous.
		Degeneration with liquefaction of protoplasm	{	colloid. mucoid.

Glycogenous degeneration.

Fatty degeneration.

Pigmentary degeneration.

It is to be noted that the degenerate cell is not a dead cell nor necessarily a dying cell.

Granular degeneration, or "**cloudy swelling**," occurs in inflammatory or toxic conditions. It is characterised by a fine precipitate of spherical granules, but in badly fixed specimens shows

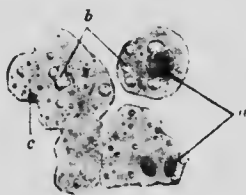


FIG. 4. CLOUDY SWELLING. LIVER. SEPSIS. ($\times 400$)

- a. Nucleus in chromatolysis and fragmentation.
b. Fat globules. c. Granular cytoplasm.

itself merely as an opaque ground-glass appearance in the cell, which itself is swollen and tends to separate from its fellow cells (Fig. 4). The nucleus stains badly, but the cytoplasm stains more deeply than normal with acid dyes (Fig. 5). The

metaplasmic granules disappear from cells undergoing granular degeneration.

Hyaline degeneration occurs usually after acute infections, but it may follow slow intoxications, not necessarily bacterial in origin. It affects the connective tissue of the capillaries and inner coat of the arterioles and occasionally the muscle fibres. No macroscopical changes are evident, but under the microscope the connective tissue fibres are seen to be swollen, homogeneous, transparent and refractile. Commonly the appearance produced is that of a translucent structureless band, containing a few nuclei, surrounding and sometimes obliterating the bore of the affected vessel. With v. Gieson's stain, the hyaline substance stains red, orange or yellow, according to the duration of the condition. Hyaline degeneration is distinguished from lardaceous degeneration by the irregularity of its distribution and by staining in the ordinary way with methyl violet.

Lardaceous degeneration, sometimes called waxy or, erroneously, amyloid degeneration, occurs in chronic infections or toxic conditions, and is characterised macroscopically by an abnormal translucency of the tissue combined with special colour reactions, *e.g.* staining mahogany brown with iodine, or pink with methyl violet. The shape of the organ is not much altered, but the size is increased, the consistency is firmer, and the angles are more rounded than in the normal condition.

The degeneration begins in the intermuscular connective tissue of the arterioles, spreading later to the capillaries, veins and larger arteries. The supporting connective tissue of glandular organs may also be affected with this change.

In the advanced stages when, for instance, the whole of a Malpighian glomerulus is affected, the degeneration can be recognised under the microscope in specimens stained with haematoxylin, but for the early stages, a specific stain, such as methyl violet, is almost indispensable. When thus treated, the degenerate tissue stands out as a homogeneous pink line, streak or mass, regular or irregular, in the dark blue environment of

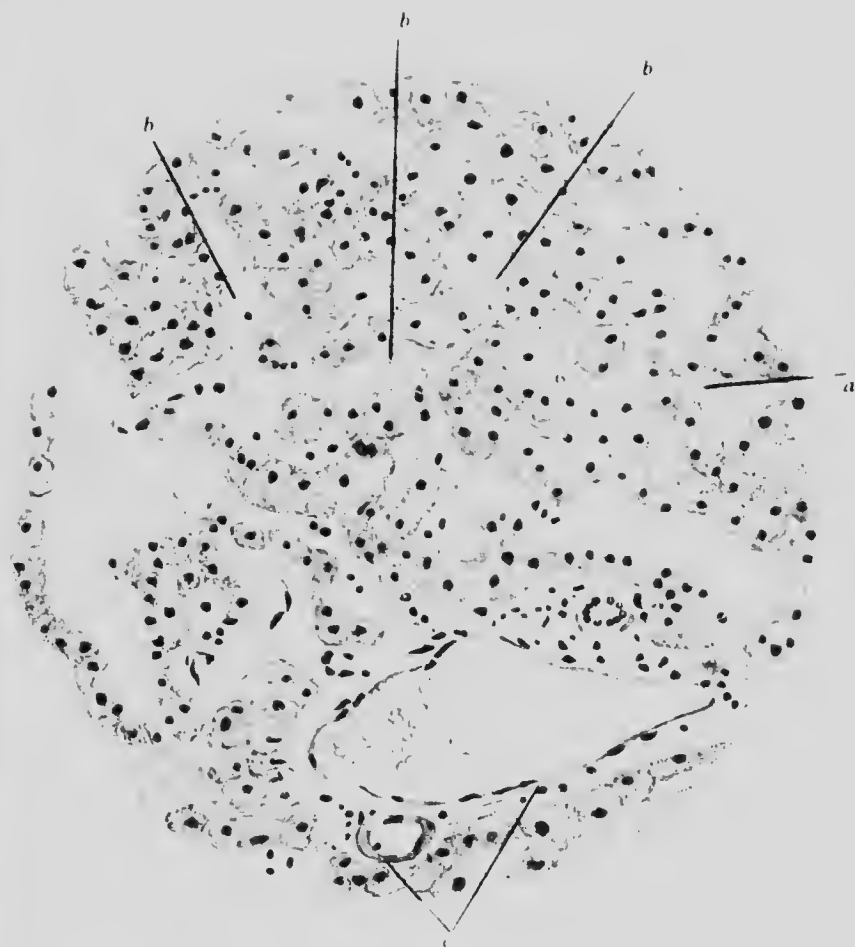



FIG. 6 LIVER. LARDACEOUS DISEASE. (x 225)

- a. Liver cells.
- b. Capillaries totally degenerated.
- c. Vein and arteriole whose walls are partially affected.



the surrounding unaffected tissue (Fig. 6). The tissues in any organ may be attacked, but the order of frequency is liver.

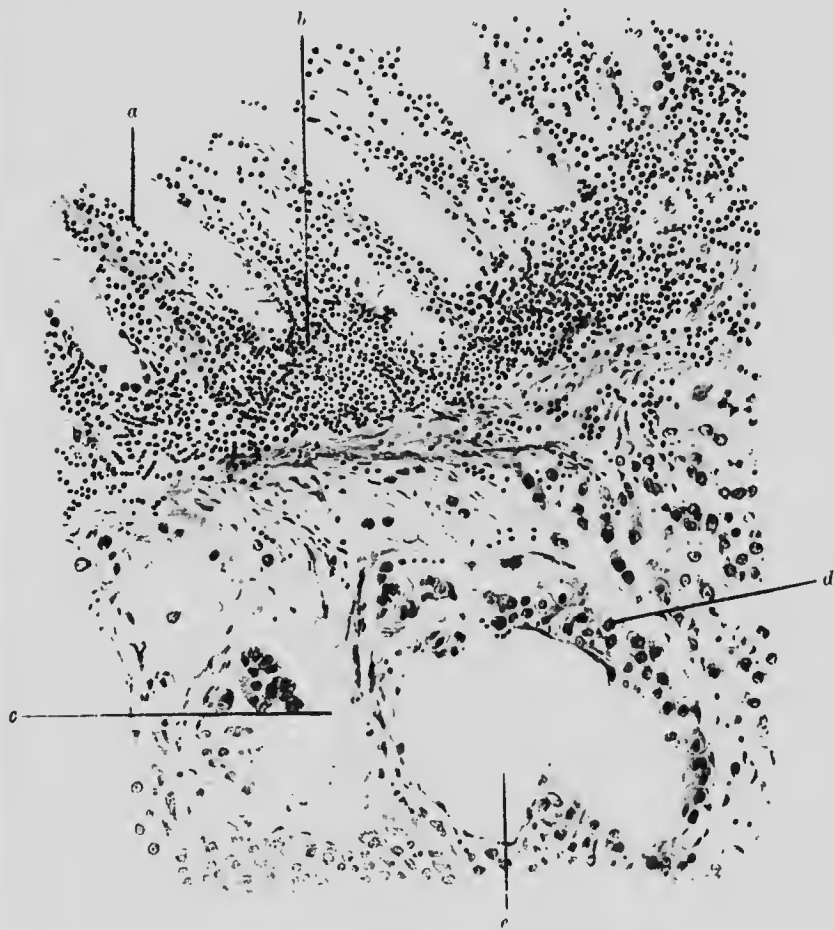

FIG. 7. COLLOID CARCINOMA OF THE INTESTINE. ($\times 200$)

- a.* Mucous membrane with small cell infiltration between the glands.
- b.* Infiltration at base of glands.
- c.* Columnar cells belonging to the growth.
- d.* Cancer cells undergoing colloid degeneration. They are swollen and amorphous or spherical.
- e.* Space in growth containing colloid secretion.

spleen, kidney, intestine and gland. The cells of the parenchyma do not themselves undergo lardaceous degeneration, but they may lose their Altman's granules and even atrophy as the result of pressure.

Mucoid degeneration occurs in connective tissue cells, especially in some diseases of the bone marrow, and in senility. The fat cells are transformed into fibrillated or homogeneous

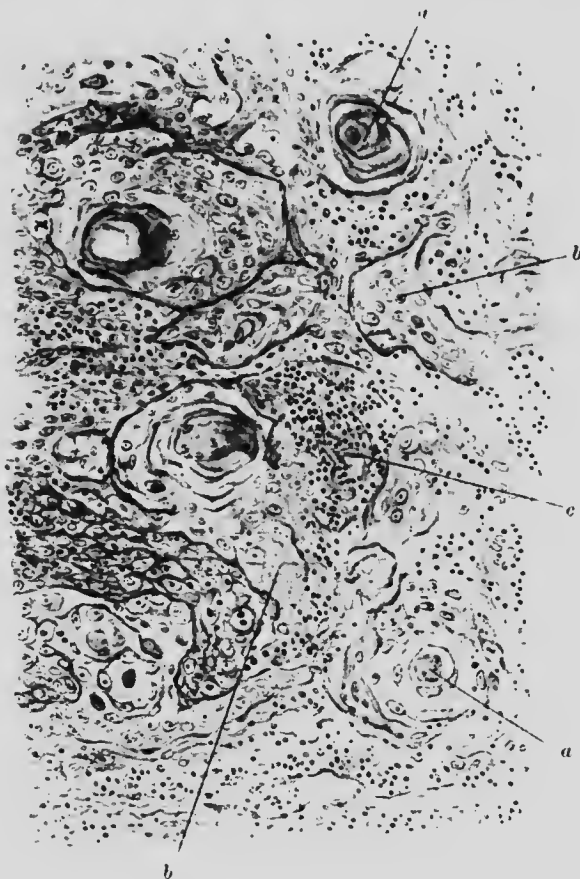


FIG. 8. EPITHELIOMA SHOWING CELL NESTS. ($\times 120$)

- a.* Centre of cell nest, consisting of concentrically arranged, flattened epithelioma cells.
b. Ordinary epithelioma cells. *c.* Area of inflammatory reaction.

translucent material. The change begins at the periphery of the cell, and contiguous cells tend to fuse at their margins.

Myxomatous degeneration differs from mucoid inasmuch as the cell does not itself degenerate but secretes or excretes a special substance. The branching fibroblasts form a network

which is filled with a viscid substance of almost gelatinous consistency, generally homogeneous, but sometimes granular or fibrillated. The cells have faintly staining nuclei, and their ramifying protoplasmic processes frequently anastomose with those of neighbouring cells. Myxomatous degeneration occurs in some chronic inflammatory conditions, *e.g.* in granulation tissue, in myxoedema and, secondarily, in new growths.

Colloid degeneration occurs only in secreting cells. It may be considered to be the result of retention within the cell of its own special secretion with a corresponding loss of cytoplasm. Such cells appear swollen, ill-defined and stain badly. Many of them become detached from the basement membrane and embedded in the secretion (Fig. 7).

Horny degeneration is a physiological process which occurs only in epithelial cells and becomes pathological when occurring in abnormal places or to an excessive extent. Its commencement is indicated by the appearance of highly refractile globules within the affected cells. The cytoplasm loses its reticular structure and stains homogeneously. The keratinisation begins in the cells furthest removed from any blood supply and is usually preceded by their multiplication. In epithelial cancer, the result is the formation of somewhat typical cell nests, which are composed of concentric groups of keratinised cells, often with some refractile globules remaining and staining homogeneously. The nuclei are often degenerate or hardly visible (Fig. 8). A point of importance in this degeneration is that, in the early stages, the included granules have often been mistaken for parasites.

CHAPTER III

CELL DEGENERATIONS—(Continued)

ILLUSTRATIVE PREPARATIONS.

1. Kidney from a case of chloroform poisoning, stained with scarlet R, to show fatty infiltration.
2. Liver in phosphorus poisoning, stained with osmic acid to show fatty degeneration.
3. Artery with partial calcification to illustrate calcareous degeneration.

Fatty degeneration may occur as a primary affection, but is more often a sequel to cloudy swelling. By some it is thought that all intracellular fat is brought to the cell (Fig. 9) and none formed within it, but that if such cell cannot deal with the imported fat, the appearance known as "fatty degeneration" is produced; others believe in the possibility of an intracellular, degenerative formation of fat from the cell substance.

The macroscopical changes are an increase in the size of the organ, grey to yellow colour, greater softness and sometimes a greasy appearance. The distribution of the fat may be regular or patchy. The presence of fat in minute droplets is physiological in some cells, *e.g.* those of the liver, but it becomes pathological if the droplets are too many or too large.

The presence of fat in cells which are usually without it, yet show no other abnormality, is termed **fatty infiltration**. The same term is often applied also to intercellular deposit of fat in non-glandular organs. If, in addition to the abnormal quantity of fat, there are other pathological changes in the cell, the condition

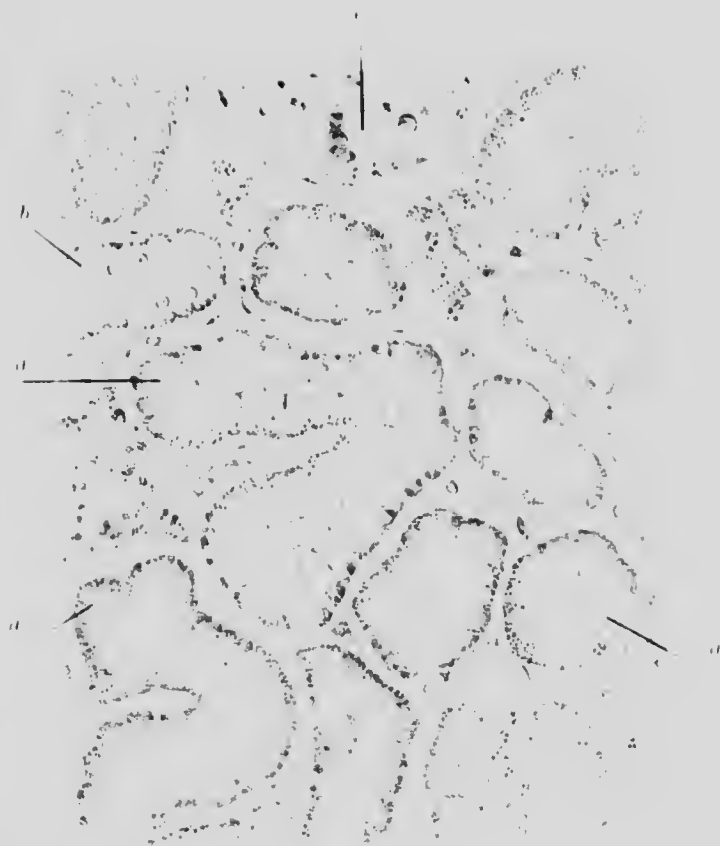


FIG. 9. KIDNEY, FATTY. Continued chloroform anesthesia. (x 250)

All the cells have fine fat droplets at their periphery, showing infiltration of fat from without, stained pink with Scarlet R.

- a. Degenerate cells; nucleus obscured.
- b. Fairly normal cells - nucleus seen.
- c. Glomerulus.



properly known as "fatty degeneration" is present. In either case, the fat seems first to exist as small droplets, which gradually increase in size and flow together to form larger drops until the fat nearly fills the cell (Fig. 10).

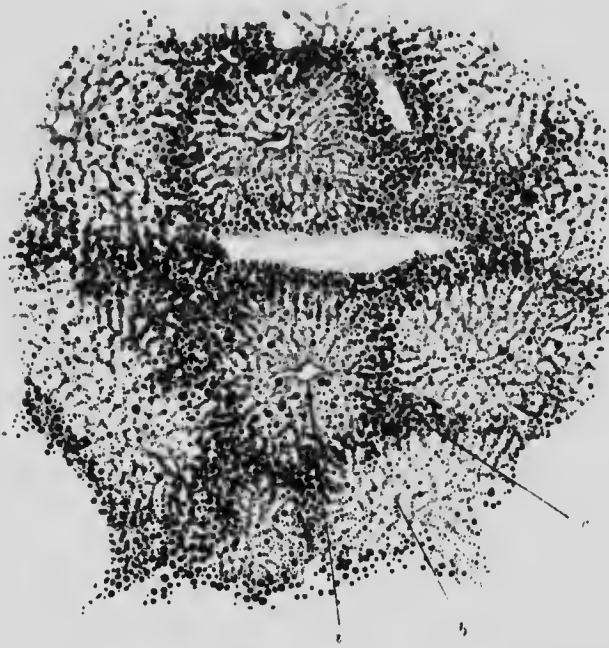


FIG. 10. FATTY LIVER; PHOSPHORUS POISONING (OSMIC ACID). ($\times 30$)

- a.* Central vein. *b.* Columns of cells with small fat droplets.
c. Peripheral cells with large fat droplets.

Glycogenous degeneration is probably of a similar nature to fatty degeneration and is really an infiltration. Glycogen is normally present in many cells, especially those of the liver and muscle. It is also present in leucocytes, in the cells of the kidney, of cartilage, of epithelium and of some tumours. The amount is increased in diabetes and in infectious diseases, whether acute or chronic, especially in the leucocytes. Glycogen is deposited in the form of water-soluble granules and consequently is represented by vacuoles in sections prepared in the ordinary way, but it may be demonstrated in alcohol fixed tissue by

staining with iodine, which colours the granules yellow-brown. The appearance is much like that of fatty degeneration stained with osmic acid, except that the droplets are brown instead of black.




FIG. 11. ARTERY. THROMBOSIS. CALCIFICATION. ($\times 50$)

- a.* Clot.
- b.* Intima, slightly thickened and hardly separable at this point from the thrombus.
- c.* Areas of calcification.
- d.* Middle coat.
- c.* Area of chronic interstitial inflammation.

Calcareous degeneration, or calcification, is a secondary process by which lime salts may be deposited in or around tissues or cells after they have undergone a preceding hyaline or fatty degeneration (Fig. 11). The process is characterised microscopically by the bright, blue-black, homogeneous colour which the calcified tissues assume when stained with haematoxylin.

CHAPTER IV

CIRCULATORY DISTURBANCES. CONGESTION. THROMBOSIS. INFARCT. HAEMORRHAGE

ILLUSTRATIVE PREPARATIONS.

1. Liver showing passive chronic congestion.
2. Kidney to show the edge of an infarct.
3. Lung showing "brown induration."
4. Vein showing a portion of clot adherent to its wall (early stage).
5. Vein with a clot already organising (later stage).
6. Atheromatous artery with clot.
7. Pons with small haemorrhages.

Congestion implies the local stagnation and collection of blood, whether due to increased inflow (active or arterial hyperaemia) or to obstructed outflow (passive or venous hyperaemia) from the part. In the first case the affected area appears warm and red, in the other, blue and cold. The state of pathological active hyperaemia is due to active dilatation of arterioles and capillaries. It usually accompanies the inflammation due to acute infection, such as pneumonia in the lung or an abscess under the skin. It is a relatively transient condition. Passive hyperaemia results from either local obstruction to the outflow or weakness of the circulatory pump. Microscopically, except for the difference in fulness of the arteries and veins respectively, there is at first not much distinction between the two forms, but continuous active hyperaemia may lead to the formation of fibrous tissue or of local hypertrophy; passive hyperaemia only rarely does so, however long it may persist.

The chief microscopical characteristic is the capillary engorgement, not infrequently accompanied by diapedesis of red cells into the neighbouring spaces. When the pressure caused by the overdistension has persisted for some time there may be sufficient degeneration or atrophy of the surrounding cells to cause difficulty in recognising them between the overfull capillaries. This is well seen in passive congestion of the liver (Fig. 12). Persistent congestion also causes macroscopic changes, largely due to the deposit of blood pigment, *e.g.* in the so-called nutmeg liver and brown induration of the lung of heart disease.

Thrombosis means the localised intravascular clotting of blood during life. It is generally preceded by congestion and stagnation, although it may result merely from injury or disease of the vessel wall. The former condition usually produces only a red clot, while the latter produces at first a white, mainly leucocytic clot. In either case the clot may subsequently extend for some distance along the vessel. Under the microscope, the recent clot is seen to be in contact with the vessel wall or just retracted from it, and to consist merely of fibrin with red and white corpuscles and blood platelets, the majority of the latter being on the periphery of the clot (Fig. 11).

Older aseptic clots pass through the process known as organisation, during which they are invaded by leucocytes and endothelial cells travelling along the crevices formed by the contraction of the clot. The leucocytes thus gradually remove the debris, and the formation of capillaries by the endothelial cells ultimately replaces the clot by vascular connective tissue (Figs. 13 and 14). In this way re-establishment of the passage of blood (canalisation of the clot) may be brought about. Subsequent calcareous infiltration is not uncommon.

But an aseptic clot may soften by autolysis and become puriform, and particles may be carried away from it.

In an infected clot the micro-organisms or their toxins hasten the softening process and particles may become detached and carry infection into the general circulation.




FIG. 12. LIVER. PASSIVE CONGESTION. (x 50)

- a.* Central vessel (intralobular vein).
- b.* Peripheral distended capillaries.
- c.* Circumferential layer of little affected hepatic cells.
- d.* Portal canal.

Most of the liver cells are obscured by the distended blood capillaries and the blood within them.

b

c

d

e

Infarction is the state produced in the area of supply of an end artery when the artery is suddenly blocked. This is generally brought about by a piece of detached thrombus or vegetation from a heart valve being carried into a vessel which is too small to let it through. The detached particle is called an "embolus."

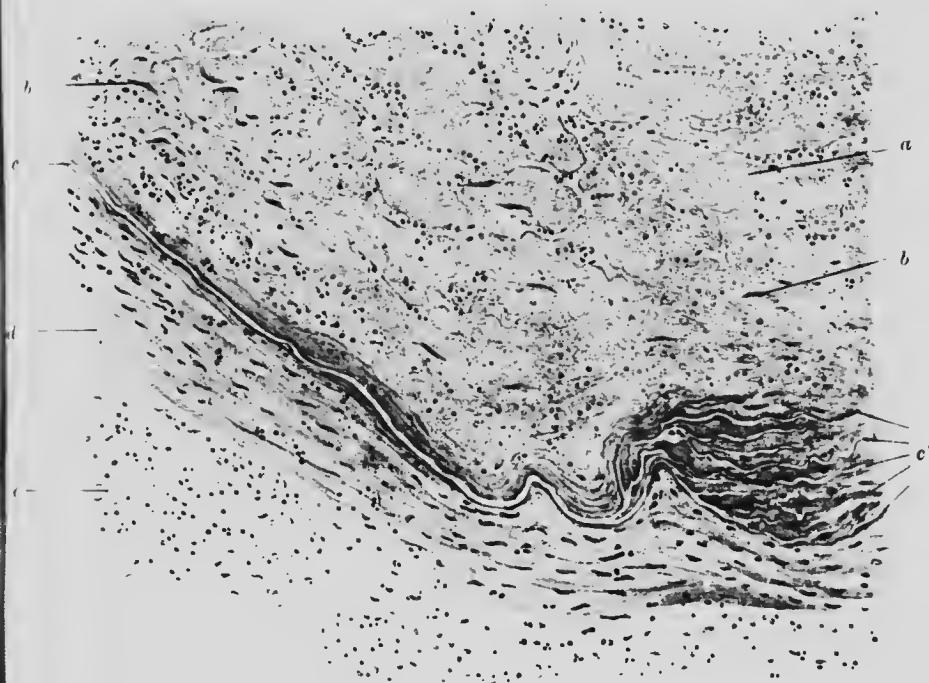


FIG. 13. ARTERY. THROMBOSIS (RECENT). ($\times 150$)

- a. Clot, partly shrunken, the clefts filled with erythrocytes.
 b. Fibroblasts.
 c. Internal elastic lamina split up at c' , into several layers.
 d. Media. e. Adventitia.

The area of tissue affected by the block, after a transient anaemic stage, becomes full of blood from collateral capillary circulation, but the temporarily starved and consequently injured vessel walls allow diapedesis into the surrounding tissues, and what is termed an **haemorrhagic infarct** results. Sometimes the collateral circulation is insufficient, and death of the starved

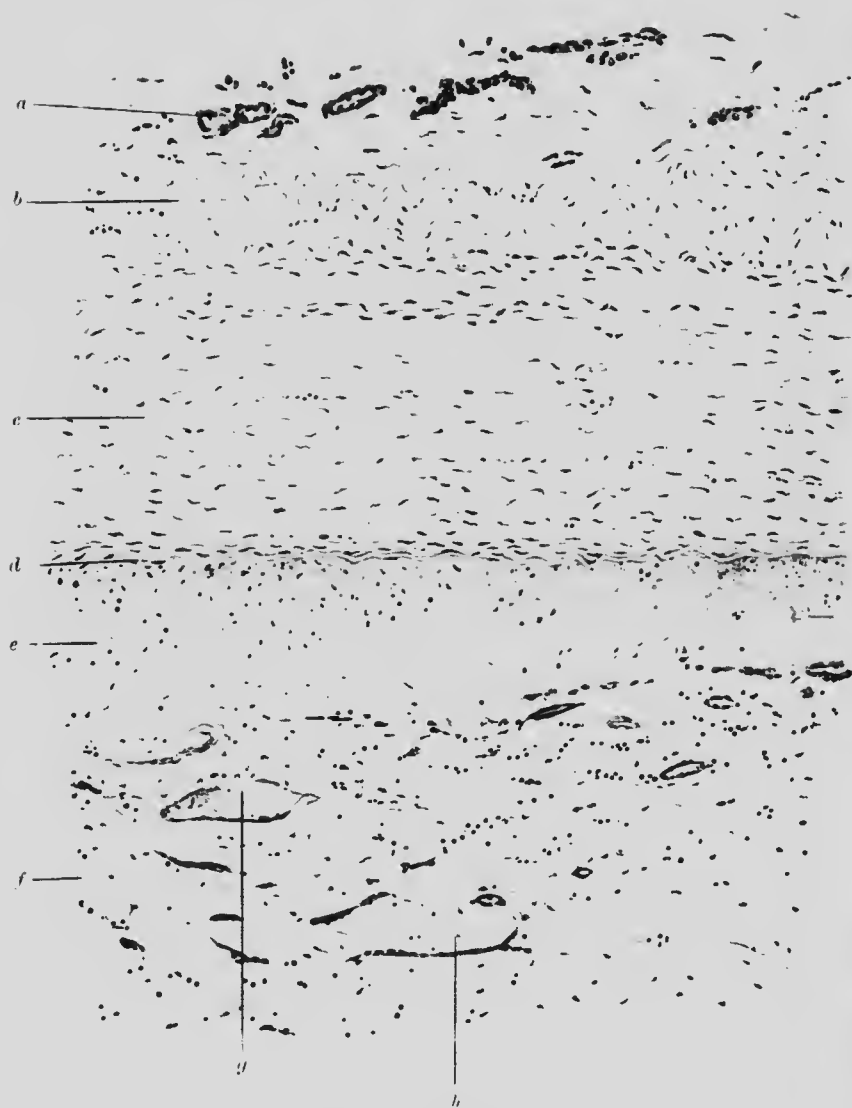

FIG. 14. ARTERY. THROMBOSIS (OLDER). ($\times 120$)

- | | |
|---|--|
| <i>a.</i> Adventitia with vasa vasorum. | <i>c.</i> Swollen and degenerate intima. |
| <i>b.</i> Layer of fibrous tissue. | <i>f.</i> Organised thrombus with |
| <i>c.</i> Media. | <i>g.</i> new blood-vessel and |
| <i>d.</i> Internal elastic layer. | <i>h.</i> developing capillary. |

tissue (necrosis) follows rapidly; this produces the white or (miscalled) anaemic infarct. On the other hand, the collateral circulation may be so good that no condition of infarction results.



FIG. 15. INFARCT. KIDNEY. ($\times 75$)

- | | |
|--|--|
| <i>a.</i> Necrotic kidney tissue. | <i>c.</i> Arteriole with thickened wall. |
| <i>b.</i> Leucocytes of inflammatory zone. | <i>f.</i> Normal tubules. |
| <i>c.</i> Necrosing capsule. | <i>g.</i> Normal capsule. |
| <i>d.</i> Distended vein. | |

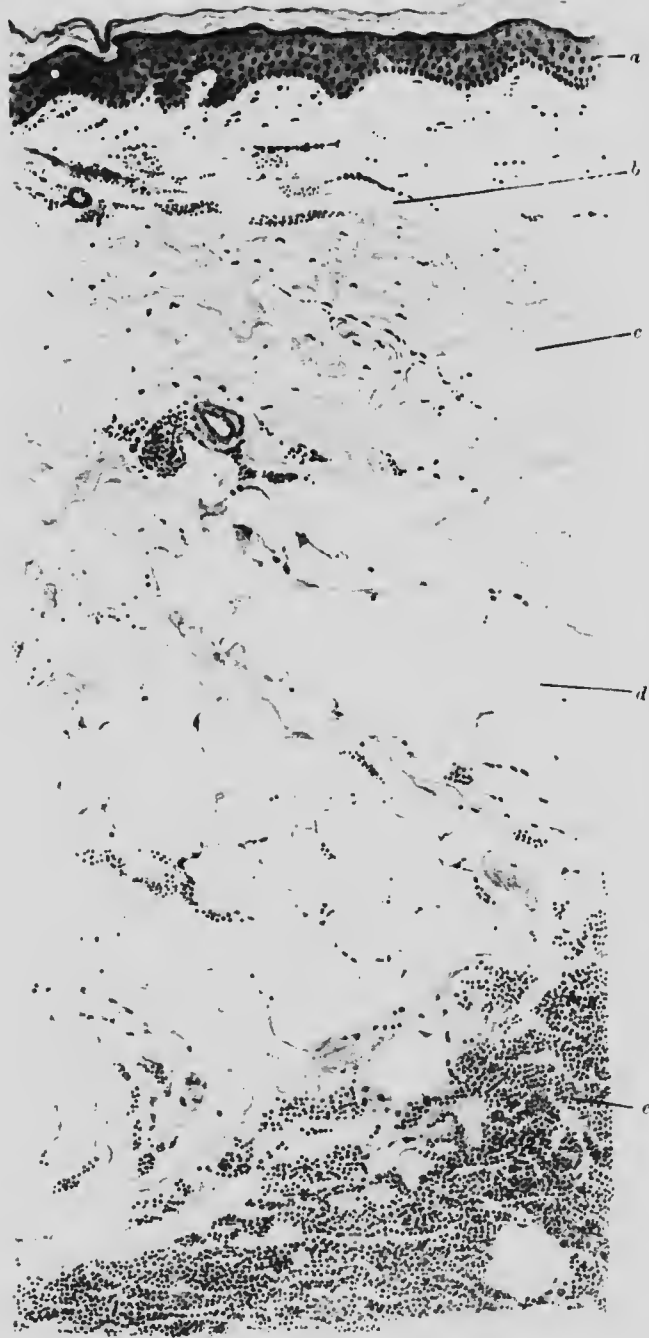


FIG. 16. BRUISE (4 DAYS). SKIN OF LEG AND SUBJACENT TISSUE. ($\times 100$)

- a. Epithelium.
- b. Corium with patches of effused erythrocytes.
- c. Fibrous tissue. Hardly any haemorrhage.
- d. Fat with some haemorrhage.
- e. Considerable haemorrhage among muscle fibres.

An increase in the coagulability of the blood or alteration in the vessel walls may, by thrombosis, lead to the formation of an infarct either by causing complete occlusion of a small artery or by the incomplete blocking of an end artery.

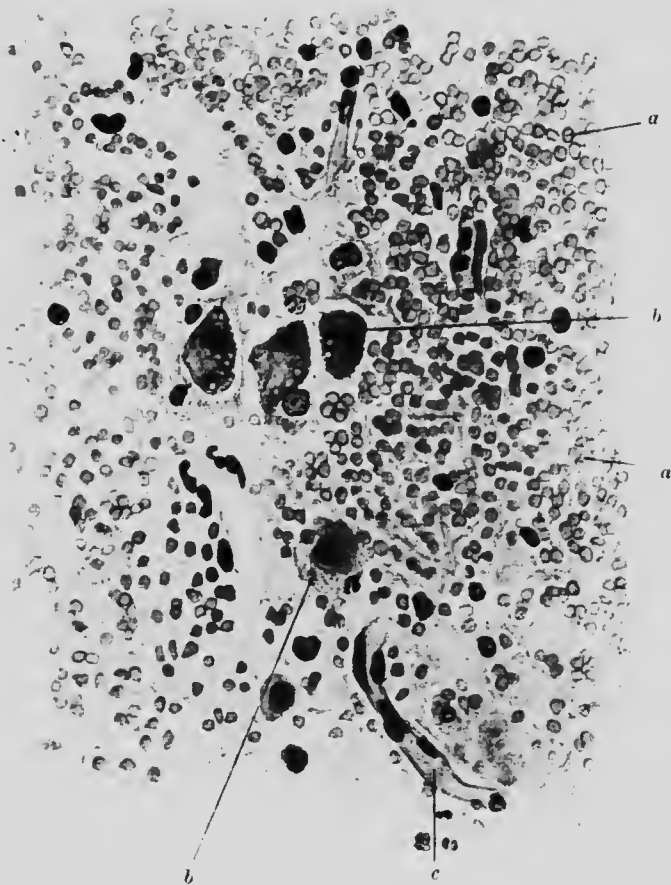

FIG. 17. HAEMORRHAGE. PONS VAROLII. ($\times 400$)

- a.* Effused red corpuscles.
- b.* Nerve cells, partly disintegrated.
- c.* Capillary.

An **infarct** is roughly wedge-shaped, but the outline on the surface of the affected organ is irregular. In the lungs, spleen, alimentary canal and the extremities, infarcts are usually haemorrhagic: in the kidneys and brain they are pale.

The ultimate fate of the infarct depends largely on the nature of the embolus, but, in any case, an anaemic area undergoes necrosis and acts as a foreign body (Fig. 15). A line of inflammation appears round the infarcted area and later it is invaded by leucocytes and new blood-vessels, with the removal of the dead tissue and the formation of connective tissue. This subsequently becomes fibrous, and in contracting leaves a scar on the surface of the organ.

Haemorrhage, apart from open wounds or escape of blood into a cavity, may be the result of injury to a vessel wall from without (trauma), or of weakening of the wall to such an extent that it cannot stand the pressure from within. In either case the blood tends to spread along the lines of least resistance. Substantaneously it travels along the planes of tissue (Fig. 16): in the brain, since the resistance is fairly uniform in all directions, it spreads pretty evenly in all directions from the bleeding centre, plunging up and causing considerable damage to the soft parts in the process (Fig. 17).

CHAPTER V

INJURY AND REPAIR. REGENERATION

ILLUSTRATIVE PREPARATIONS.

1. Skin and subcutaneous tissues showing the effects of a bruise.
2. Skin and underlying tissues showing condition of an aseptic surgical wound after 48 hours.
3. Giant cells around a foreign body (surgical stitch).
4. Human skin showing inflammation produced by exposure to radium for six hours (plasma cells and leucocytes).

INJURY may be effected mechanically (by a cut), chemically by a poison (chloroform), or biologically (by bacteria), although the distinction between the last two is partly artificial, since biological injury is, in most cases, due to chemical products. Usually the damage does not remain localised to the point of application, but becomes diffuse or even multiple, especially when chemical noxae have entered the circulation.

The resulting damage may be primary, the direct effect of the injury, or it may be secondary, a sequel of the primary injury. If the primary injury involve the death or destruction of the affected tissue or cell, no secondary effects can occur in the tissue or cell itself, but it will act as a foreign body and produce secondary effects in the surrounding tissues. In the end necrosis will supervene and the cell-debris will be removed.

Chemical injuries arising from substances introduced into the circulation lead, for the most part, to one or more of the changes described under degenerations: those arising from substances

applied locally are usually accompanied by inflammation and will be treated under that heading.

Of mechanical injuries, a clean incised wound presents the most simple form. It necessarily involves the death of at least such portions of cells as have been separated from their nucleus and these dead debris have to be removed. Consequently there are always slight secondary effects even in wounds healing directly "by first intention."

The pathological changes observed under the microscope in this condition consist of the opening up of tissue spaces previously under adhesive tension. This leads to separation and swelling of cells, interstitial effusion of blood and a slight immigration of leucocytes (Fig. 18). The destroyed cells are replaced, so far as possible, by corresponding cells from the same tissue, but if the injury affect organ tissues which regenerate only with difficulty, the defect will be made good and the repair carried out, chiefly by connective tissue cells.

In general, the greater the destruction of higher, more differentiated tissues, the greater is the tendency towards their substitution by overgrowth of connective tissue, and for immigration of leucocytes to remove the dead cells. The newly formed cells of all the tissues are distinguished by greater size and protoplasmicity, but they soon dwindle to normal size, so that, although an early scar occupies more, a late scar takes up less space than the original wounded tissue. This reduction occurs even in organs containing relatively little connective tissue, because the contracting new connective tissue compresses some organ cells out of existence.

In other words, in a composite tissue, the amount of repair after injury will vary with the power of growth and regeneration of each individual tissue entering into the composition of the whole, and the final composition of the repaired tissue will depend on this power. Therefore, wounds involving epithelial tissues repair less well than wounds involving only connective tissues. Some epithelial cells, *e.g.* nerve cells, when destroyed, are never replaced.

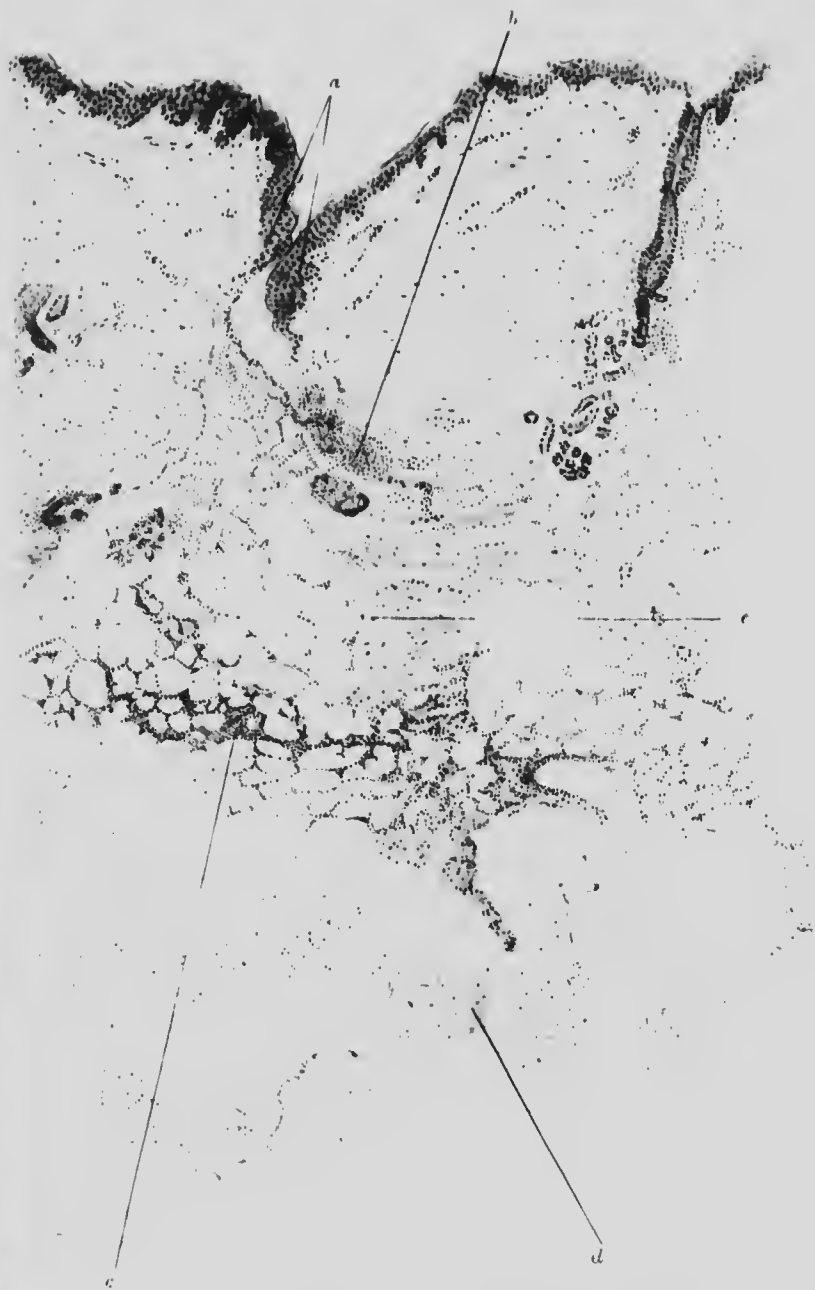


FIG. 18. WOUND (SURGICAL), 2 DAYS. SKIN. ($\times 35$)

- a.* Edges of divided epithelium.
- b.* Collection of leucocytes in corium extending into
- c.* layer of fat with leucocytes.
- d.* Deep muscle layer. *e.* Edge of divided muscle.

Scattered leucocytes are found in many places below the wound. The space between the divided subcutaneous tissues is filled with plasma.

In the process of repair, giant cells or multinucleate cells are often seen; especially around aseptic foreign bodies embedded in the tissues. They are supposed to arise from fusion of

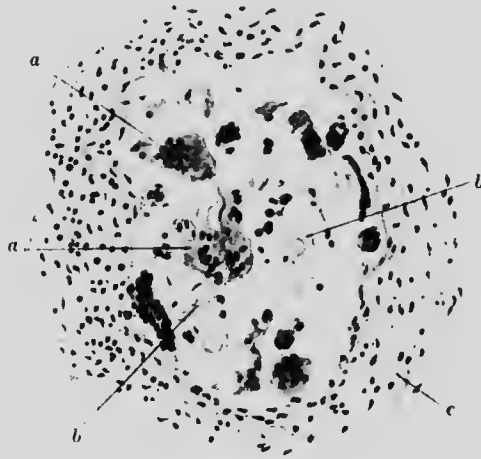


FIG. 19. GIANT CELLS. SURGICAL WOUND. ($\times 150$)

- a.* Giant cells of irregular shape with several scattered nuclei.
- b.* Fragments of silk ligature.
- c.* Surrounding connective tissue.

endothelial cells. They are phagocytic and are endowed with amoeboid movement. They are generally seen in subacute inflammatory conditions, especially around substances difficult of absorption, such as sutures or loose bone (Fig. 19).

CHAPTER VI

INFLAMMATION

ILLUSTRATIVE PREPARATIONS.

1. Human skin showing inflammation produced by exposure to radium for 24 hours (blister).
2. Human skin showing inflammation after a chemical injury (silver nitrate application).
3. Skin of the leg showing ulceration.
4. Trachea showing the membrane formed in diphtheria.
5. Liver showing the formation of a small abscess.
6. Granulation tissue from a polypus of the ear.

THE best definition is that of Grawitz, who calls inflammation "the reaction of irritated and damaged tissues which still retain vitality."

Its manifestations vary, and depend upon different combinations of:

1. Cause. (a) Simple, or (b) septic (infective).
2. Character. (a) Acute, or (b) chronic.
3. Position. (a) In vascular, or (b) in avascular tissue.

A simple aseptic acute inflammation may be caused by the application of chemical irritants (*e.g.* AgNO_3) or by physical action (*e.g.* radium or X-rays). The stage to which the process extends is dependent on the concentration and period of action of the irritant.

If a small quantity (10 mgr.) of radium be applied to the human skin for six hours, and the skin then examined, a faint blush is seen over the area of exposure. Microscopically, the vessels are found dilated and congested, with diapedesis from the capillaries of mononuclear and neutrophile leucocytes into the

perivascular spaces. At the same time plasma cells congregate around the affected capillaries. But with the removal of the irritant the vessels resume their normal calibre, the leucocytes pass away in the lymphatics and the tissues regain their normal appearance. The inflammation does not progress beyond the first stage, although it is to be noted that it extends to some depth downwards, involving the vessels around the sebaceous glands.

If the application of the radium be prolonged to 24 hours, a very different result is found. Macroscopically, the affected area looks as if it had been scalded or burnt and has formed a blister. Microscopically, much more perivascular exudation of leucocytes is found, it has extended deep into the tissues and contains numerous disintegrated leucocytes and fragments of chromatin. The surface epithelium over the area of direct exposure is lifted from the corium, and the intervening space filled with coagulated lymph containing a few leucocytes. The detached epithelial cells and those for a little distance beyond are degenerate and necrotic, but a little further outwards show signs of regeneration. The continuance of the irritation has brought the tissues to a stage in which the process extends independently of the irritant and causes destruction requiring the regeneration of tissue in order to regain the original state. The various stages of inflammation have been passed through very rapidly. But apart from the phenomena described, it is a peculiarity of the inflammation produced by radium and X-rays for it to return again some time after the removal of the irritant and the apparent subsidence of the primary inflammation.

A chemical injury such as the application of solid silver nitrate to the skin produces an inflammation intermediate between the two stages just described. The epithelium actually touched by the chemical is, of course, destroyed at once. Below it, and only in the immediate neighbourhood, a localised exudation of leucocytes and aggregation of plasma cells occurs. A limited destruction of cells follows, and these are soon carried off by the phagocytes that subsequently appear.



FIG. 20 SKIN. INFLAMMATION (Radium 6 hours). (x 350)

- a.* Pointing to red corpuscles in a small blood-vessel, containing numerous polymorphonuclear and mononuclear leucocytes.
- b.* Leucocyte passing through wall of vessel.
- c.* Proliferating endothelium.
- d.* Plasma cells.
- e.* Proliferating perithelial cells.

ce
fo
o
I
a
a
t
f
t

Infective acute inflammation in a vascular area is the most common form and is started usually by the presence of pus-forming organisms brought to the spot either directly by a trauma, or from another part of the body in the blood or lymph stream. In the neighbourhood of this bacterial focus the capillaries and arterioles, after a transient contraction, dilate: the blood stagnates and the leucocytes wander to the wall of the vessel and adhere there. Gradually they insinuate themselves through the wall: first of all, it would appear, the mononuclear leucocytes emerge, but they are soon outnumbered by the polymorphonuclear cells, which proceed to the field of action and establish a cordon around it. Meanwhile the tissue cells on the spot increase in size and activity, and some of them become almost indistinguishable from the immigrant leucocytes (Fig. 20). The cordon thus established may succeed in preventing extension, or it may be itself destroyed. If destroyed, a similar force collects outside, while that destroyed becomes a part of the original lesion. These alternations may be repeated until either the leucocytes and tissues gain the upper hand, or the whole organism succumbs from toxæmia.

If the leucocytic attack is successful early, the diapedesis and immigration cease, the vascular conditions gradually return to normal and the leucocytes disappear. The micro-organisms which caused the inflammation, destroyed by the combined action of the leucocytes and tissue fluids, will also disappear and the tissue itself resume its normal appearance.

If, on the other hand, the contest be prolonged, the immigration of leucocytes may last for some days, during which time a number of leucocytes will be killed. If the number be not too great they may be at once taken up by the accompanying mononuclear cells: otherwise, they will remain in the surrounding fluid and form "pus." Pus is the essential characteristic, in an enclosed area, of an abscess: on a free surface, of an ulcer: in a cavity, of a purulent collection of fluid: on a mucous membrane, of a "membrane" as in diphtheria.

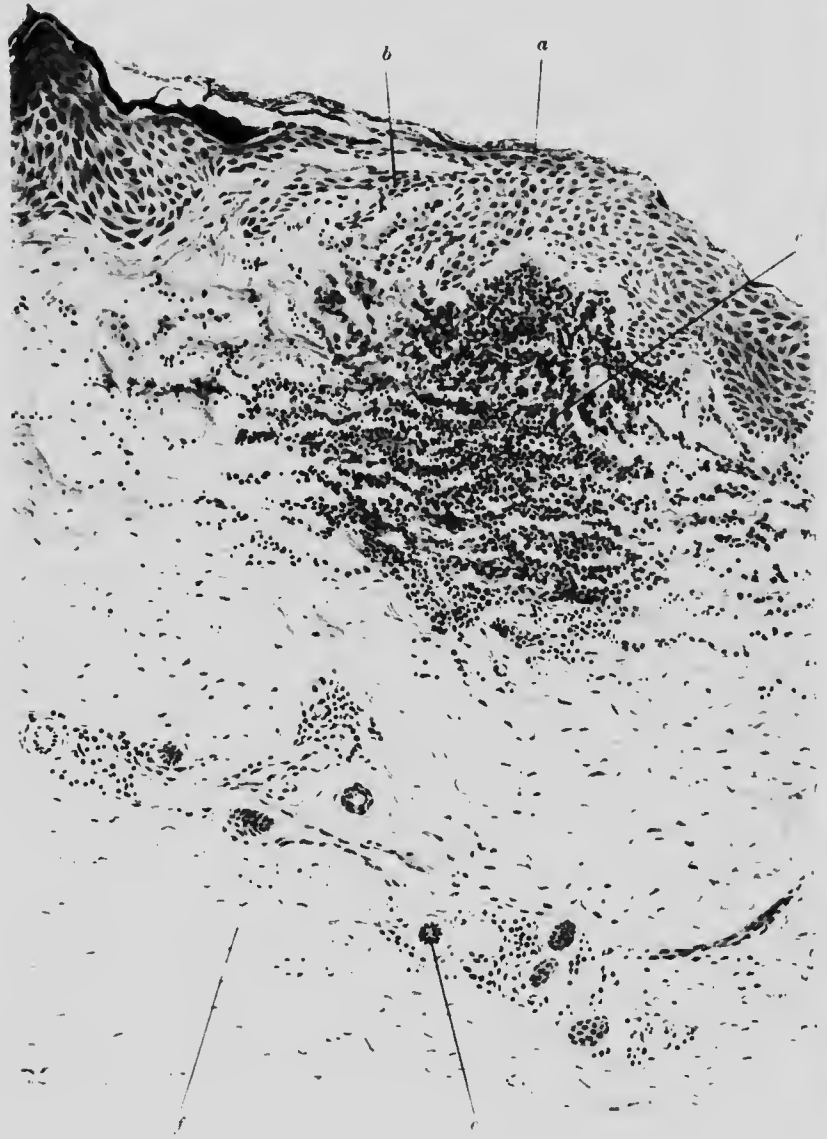

FIG. 21. CHEMICAL INJURY (AgNO_3). SKIN. ($\times 120$)

- a.* Superficial layers stained black with AgNO_3 .
- b.* Swollen epithelium.
- c.* Inflammatory collection of mainly leucocytes with some plasma cells.
- e.* Sweat gland duct.
- f.* Fibrous tissue.

The cell substance of the leucocyte disintegrates after its death and partly disappears, while the chromatin retains its staining property for some time longer, although eventually this property also is lost. As a result, we have in the inflammatory area a



FIG. 22. BLISTER (CAUSED BY RADIUM). SKIN. ($\times 60$)

- a* Superficial epithelium, artificially detached.
- b* Malpighian layer normal here, but at
- c*, showing signs of necrosis and degeneration, which are seen commencing at the point of detachment.
- d*. Coagulum of fluid effused below epithelium and raising it up from the corium.
- e*. Papillae of corium with slight infiltration much more marked at
- f*, and all along the vessels. *g*. Subcutaneous tissue.

structureless necrotic core which will stain diffusely with eosin. It is surrounded by a layer of irregular chromatin debris representing the remains of the nuclei of the leucocytes and tissue cells, and taking a deep haematoxylin stain. Outside is a layer

of healthy phagocytic cells, and beyond this is a layer of newly formed connective tissue containing a few lymphocytes. Outside this last layer the tissues are more or less normal. This limiting

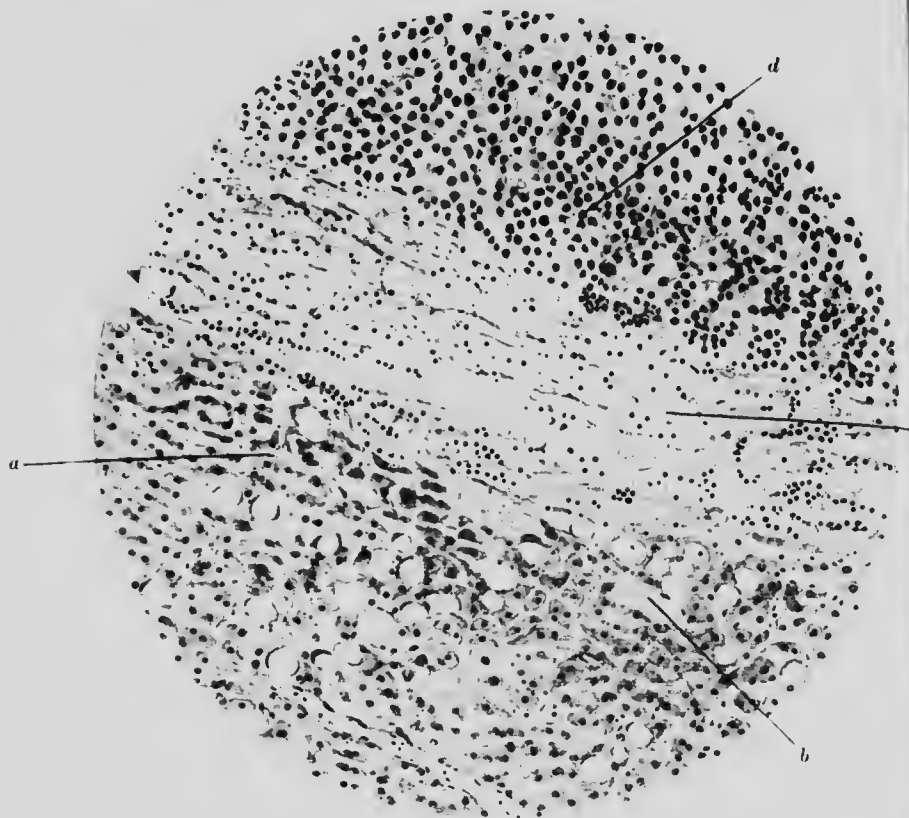


FIG. 23. ABSCESS. LIVER. ($\times 150$)

- a.* Liver cells: some showing fatty degeneration.
- b.* Distended capillary.
- c.* Band of necrotic tissue with a few leucocytes intervening between intact liver tissue and forming a boundary to
- d.* collection of polymorphonuclear leucocytes (pus).

band of connective tissue forms the limit of an abscess when infective inflammation occurs within an organ (Fig. 23).

When inflammation occurs on or just below a free surface, the dead leucocytes and tissue cells together with the exuded fluid, will for the most part escape, leaving a surface denuded of

...y
...d
...g



...en
...he
...id,
...of

...
...
...

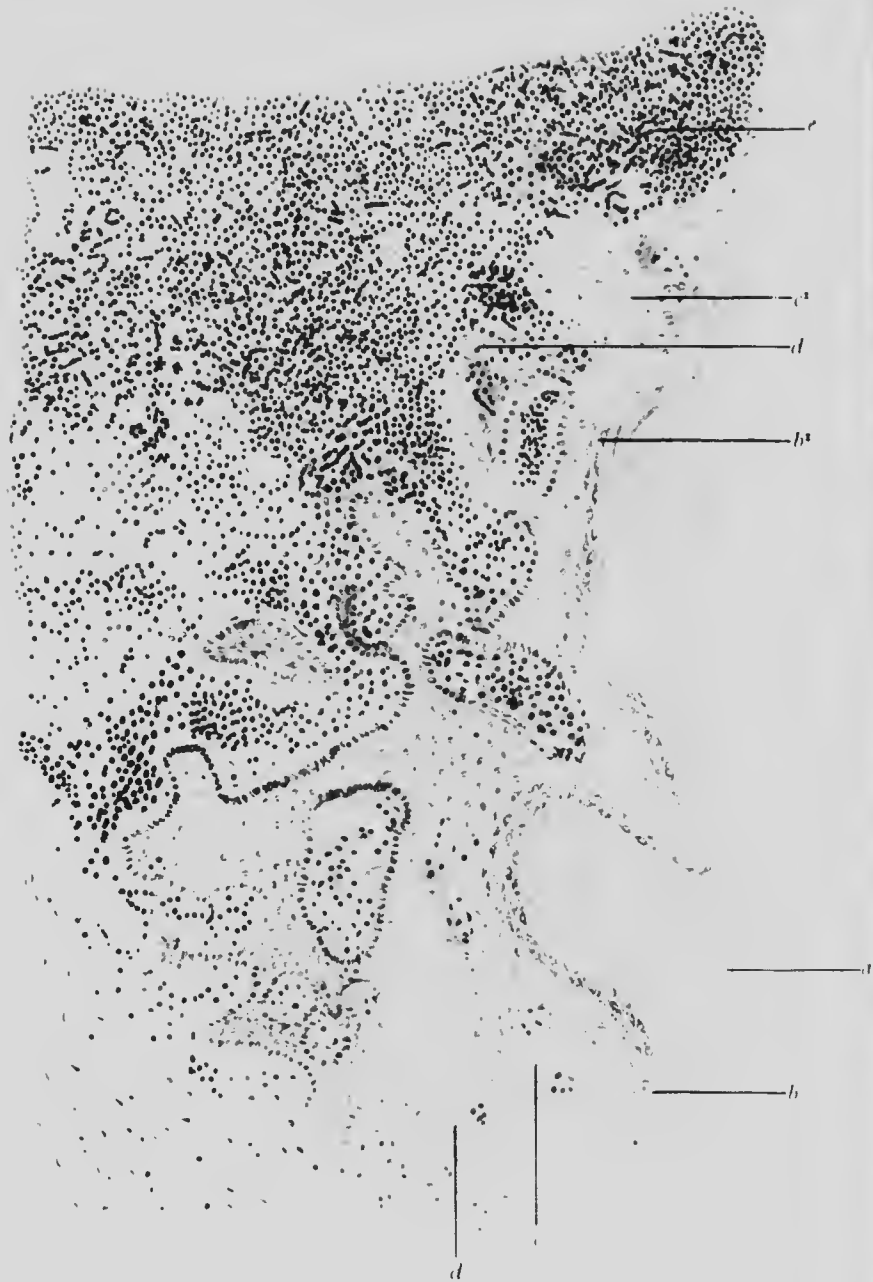

FIG. 24. ULCER, SKIN OF LEG (x 10)

a. Superficial dead epithelium. *b.* Stratum granulosum which near the ulcerated surface at *b'* is gradually disappearing. *c.* Prickle cell layer: widened, with irregular downgrowths. *c'* Necrosed prickle cells. *d.* Basal cell layer which at *d'* is lost near the ulcer proper. *e.* Leucocytes, reaching up to surface of ulcer, undermining the skin beyond and penetrating into tissues of the crum.

epithelium but covered with a layer of fibrin and dead cells of varying thickness.

From serous membranes the dead cells and fluid will fall off and collect in the cavity, but some will adhere to or coagulate on the surface of the membrane, making its surface lustreless and irregular, with patches of coagulated lymph (fibrin + leucocytes) spread over it or tags the roof hanging from it. Inflammation of a secreting membrane, such as in the trachea, is accompanied by necrosis and shedding of the secreting cells, which are then found among the debris in the lumen.

If the individual survive, the tissues recover to a varying extent from the inflammatory process, but some traces usually remain. The inflammation may become chronic and produce gradual destruction of the surrounding structures, which are then replaced by fresh fibrous tissue. This contracts with age and, in so doing, gradually cuts off the nutrition of the surrounding organ parenchyma and thus leads to its ultimate destruction and disappearance. The presence of small collections of lymphocytes is characteristic of chronic inflammation, although they do not bear any direct relation to the absorptive process. Their presence affords some explanation of the recurrence of acute inflammation in places where it has previously been chronic (Fig. 23).

In a dirty wound, or on an ulcerating surface (Fig. 24), an intermediate stage occurs between the inflammation and the completion of repair, namely, the formation of *granulation tissue*. This is composed, in the main, of new formed capillaries and of fibroblasts. Scattered between them are plasma cells, neutrophile leucocytes and lymphocytes. The spaces in the whole loose meshwork are filled with lymph.

The new capillaries arise from pre-existing capillaries. Some of their endothelial cells put out solid buds at right angles to the capillary axis, and these projections, while growing, become gradually hollowed out and unite with other similar buds to form a new capillary loop. The loops tend to run at right angles to the granulating surface and to be parallel to one another.

Granulation tissue is consequently very vascular and tends to bleed very easily.

The *fibroblasts* are young connective tissue cells undergo rapid multiplication, mostly spindle-shaped, and lying with the

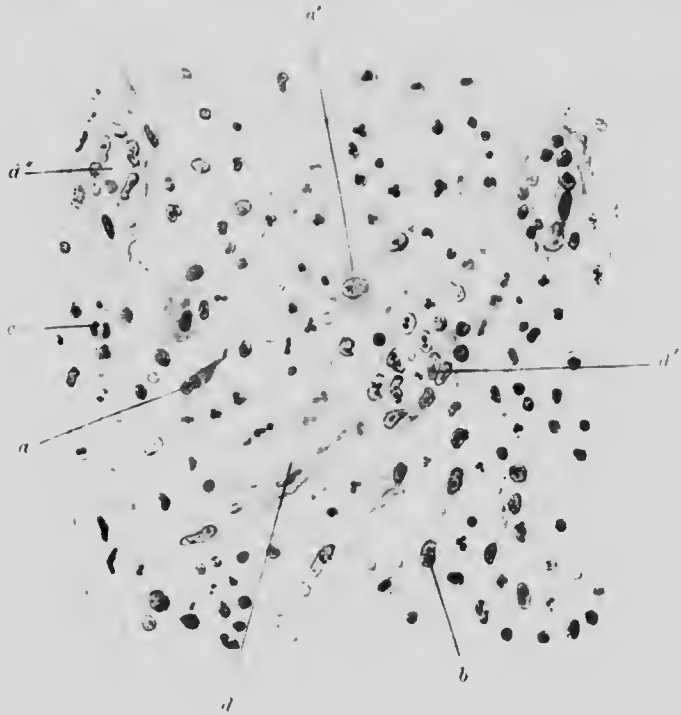

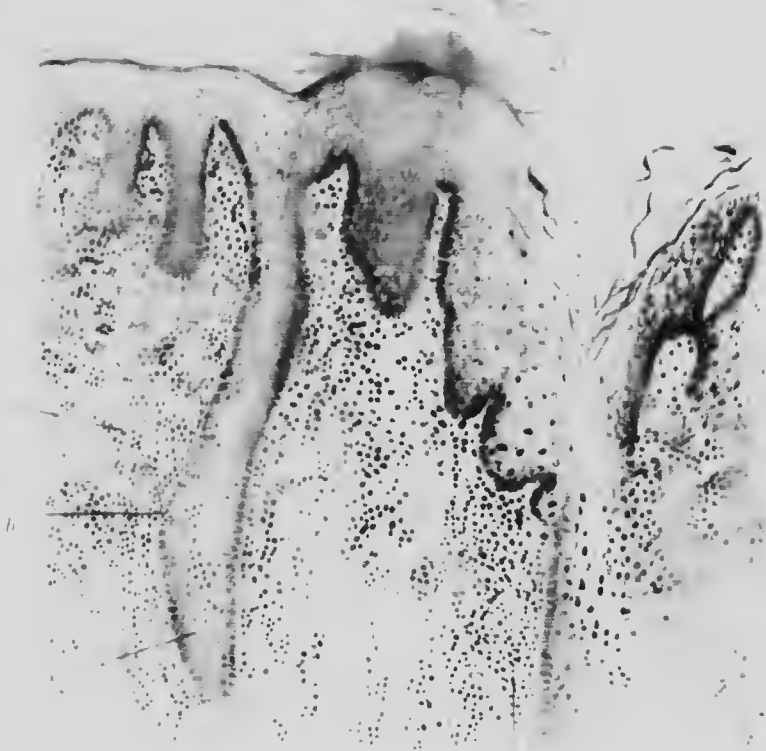FIG. 25. GRANULATION TISSUE. ($\times 250$)

- a. Developed fibroblast.
- a'. Early fibroblast.
- b. Plasma cell.
- c. Developing connective tissue.
- d, d' and d''. Developing blood vessels in various stages.

long axes across the wound. Most of them show mitotic activity (Fig. 25).

The *plasma cells* which occur in many instances of inflammation are ovoid cells with an eccentric nucleus. The chromatin is arranged in segments with a gap opening towards the centre. They contain basophile granules which stain red with Pappenheim's methyl-green pyronin (Fig. 26).

A



B

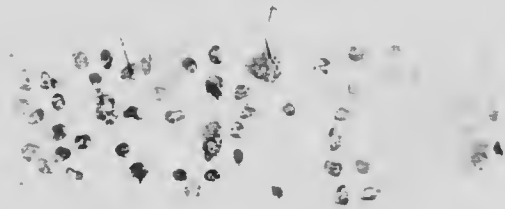



FIG. 26. SYPHILITIC GLOSSITIS. TONGUE. (x 175)

- A. *a.* Epithelial downgrowth with slight neutrophilic leucocyte invasion.
- b.* Breach in the layer of basal cells.
- c.* Collection of plasma cells and leucocytes, the plasma cells being in the majority.
- d.* Capillary.

- B. *b.* Plasma cells. (x 400)
- c.* Mononuclear leucocytes (from the region of *c.* in A.)



Granulation tissue may be quite voluminous and, indeed, forms the main bulk of many polypi on mucous surfaces, such as the nose and the intestine.

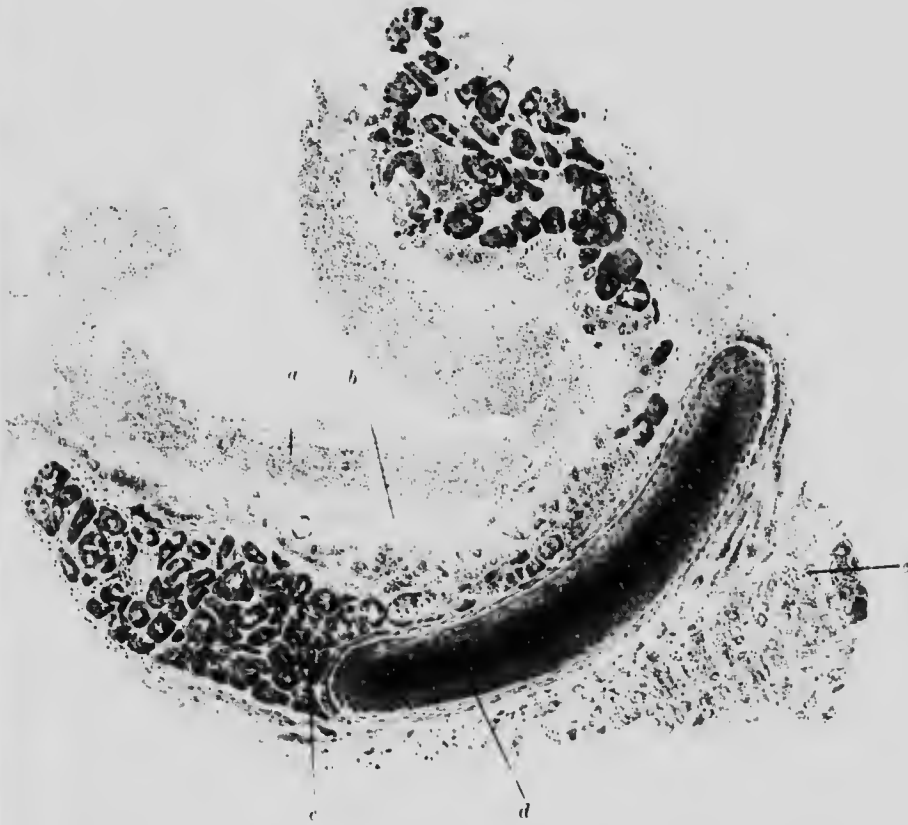

FIG. 27. DIPHTHERITIC INFLAMMATION. TRACHEA. MUCOUS MEMBRANE. ($\times 10$)

- a.* False membrane consisting of leucocytes, fibrin, etc.
- b.* Necrotic mucous membrane. The deeper layers still fairly intact.
- c.* Mucous glands.
- d.* Cartilage.
- e.* Lung tissue partly collapsed.

When inflammation occurs on a secreting membrane such as the trachea, the disintegrated leucocytes, the fibrin and lymph on the surface, and the secretion may unite to form a thick tough layer. This membrane, as it is termed, is strongly adherent to the mucous surface below, and its removal causes bleeding

(Fig. 27). Although particularly characteristic of diphtheritic inflammation of the pharynx and trachea, similar membranes are occasionally found in other situations and due to other causes of inflammation, *e.g.* the effect of corrosive poisons on the mucous membrane of the alimentary canal. When occurring on epithelial surfaces, the inflammation takes place below the epithelium which is lifted off to form part of the membrane.

CHAPTER VII

SPECIFIC INFLAMMATIONS

ILLUSTRATIVE PREPARATIONS.

1. Chancre of the penis.
2. Syphilitic glossitis.
3. Gomma of the liver.
4. Tuberculous lymph gland.
5. Actinomycosis of the liver.

CHRONIC inflammation is distinguished by the more important rôle which the connective tissue cells play as compared with the leucocytes. It may result from either (*a*) preceding acute inflammation, or (*b*) special irritants such as the organisms of syphilis and tubercle, or (*c*) some slowly acting poison like lead or the toxin of gout.

Subacute inflammation is histologically intermediate between the acute and chronic forms, resembling the former in its focal origin and the latter in the part played by the tissue cells.

True chronic inflammation affects the whole organ attacked.

The inflammatory changes occurring in syphilis, tubercle and actinomyces are somewhat characteristic and generally receive a separate description.

Syphilitic inflammation presents both a subacute and a chronic form. In the subacute form, in the absence of ulceration, the inflammatory reaction is characterised by the predominance of mononuclear and plasma cells, and a corresponding absence

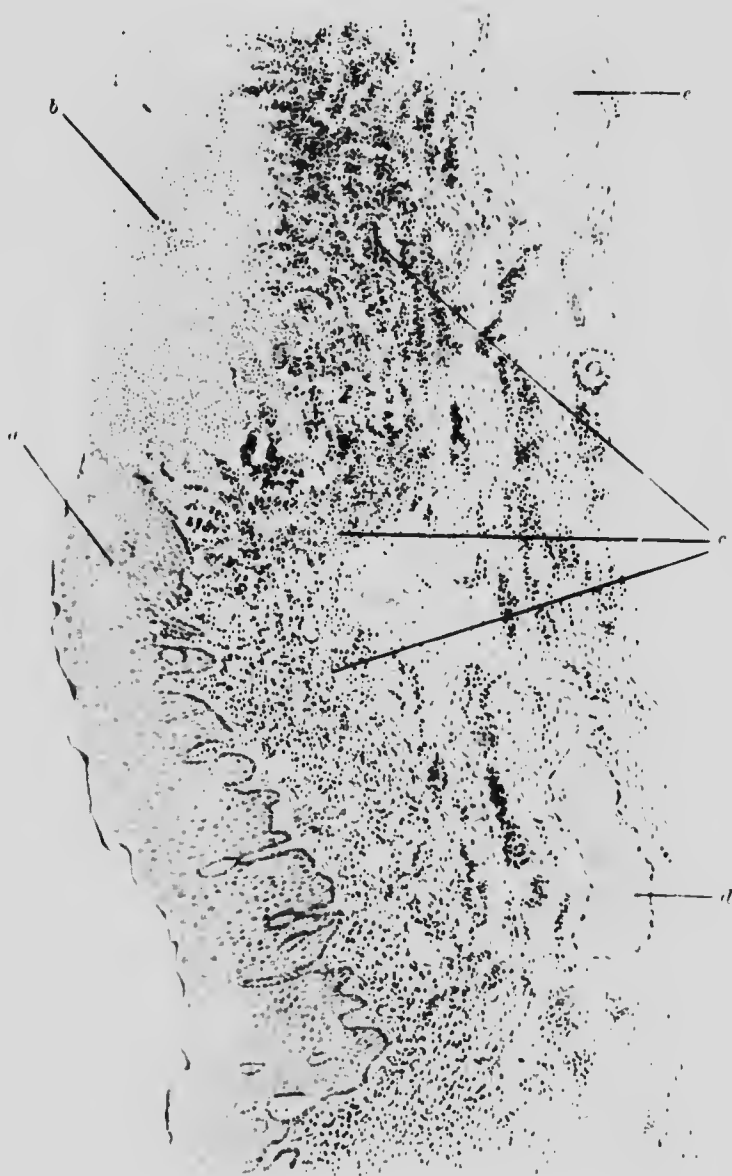

FIG. 28. SYPHILITIC INFLAMMATION. CHANCRE OF PENIS. ($\times 30$)

- | | |
|--|-----------------------------------|
| <i>a.</i> Area of commencing breaking down of epithelium. | <i>b.</i> Ulcerated surface. |
| <i>c.</i> Inflammatory invasion of corium: mainly along lymphatic spaces, with a majority of plasma cells. | <i>d.</i> Distended blood-vessel. |
| | <i>e.</i> Pacinian body. |

of polymorphonuclear leucocytes and lymphocytes (Figs. 20 and 28).

The chronic form probably commences in the same way, but the affected area slowly becomes avascular by reason of the



FIG. 29. SYPHILITIC INFLAMMATION. GUMMA OF LIVER. ($\times 200$)

- a.* Areas of lymphocytic infiltration in
- b.* layers of fibrous tissue surrounding
- c.* central mass of necrotic caseous material, forming main portion of gumma.

fibroid contraction which spreads gradually and concentrically outwards to form a fibrous capsule for the central, structureless and caseous portion: both parts together going to form a "gumma" (Fig. 29).

Tuberculous inflammation is characterised by attacking lymphoid tissue first and this fact influences its histological

features. At first there is an increase in the number of peripherally placed lymphoid cells and then also of the epithelioid cells, but the relative increase of each is very variable. The endothelial cells of the primary focus soon degenerate, but the reaction of the connective tissue and the attempts at cell multiplication lead to the formation of **giant cells**, which occur




FIG. 30. TUBERCULOUS INFLAMMATION. LYMPHATIC GLAND. ($\times 170$)

- a.* Multinucleate giant cell. *b.* Layer of epithelioid cells.
c. Layer of lymphocytes.

generally at the margin of, but may also be found within the necrotic portion. This process is termed **caseation** and results in the formation of a central amorphous granular mass containing tubercle bacilli as well as giant cells. Bacilli may also be found within the giant cells. Surrounding the necrotic edge is a concentric layer of proliferating endothelial (epithelioid) cells, and outside this again are layers of lymphocytes; but the type arrangement is often modified. There are no blood-vessels

within the "tubercle" (Figs. 30 and 31). There may be, of course, numerous tubercles in close proximity to each other, and they frequently fuse.

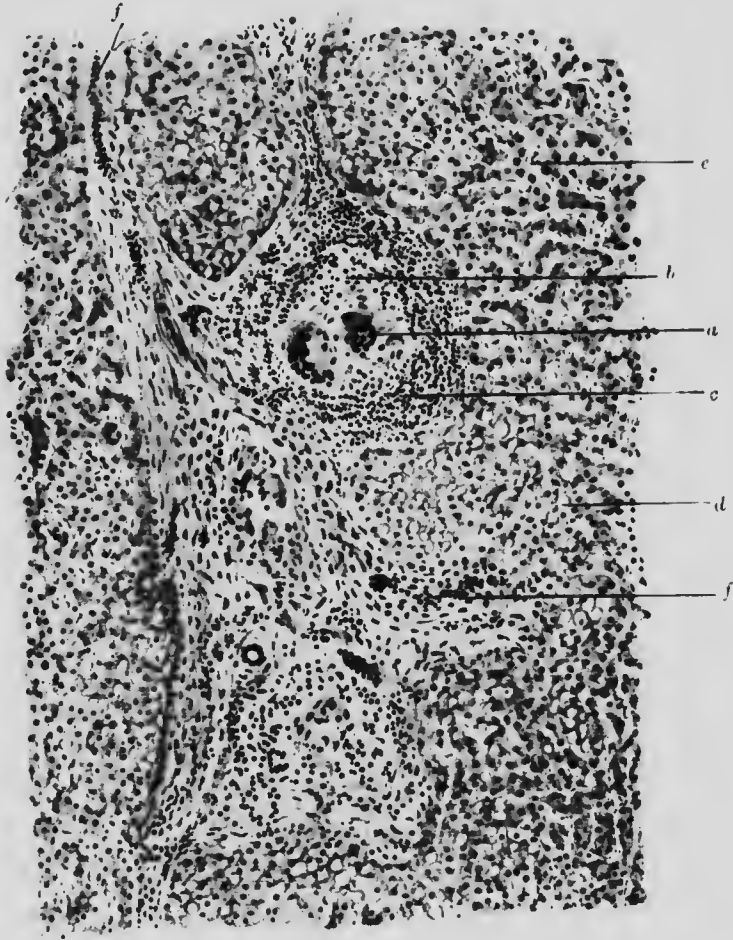


FIG. 31. TUBERCLE OF LIVER ($\times 100$)

- | | |
|--|---------------------------------------|
| <i>a.</i> Giant cells. | <i>c.</i> Outer layer of lymphocytes. |
| <i>b.</i> Surrounding endothelial cells. | <i>d.</i> Fatty liver cells. |
| <i>e.</i> Normal liver cells. | |
| <i>f.</i> Lymphocyte infiltration along Glisson's capsule. | |

Actinomycosis. Except that the "ray fungus" forms the centre of the inflammatory focus, the arrangement resembles that

of tubercle with the addition of many eosinophile cells. In the later stages the condition more resembles an ordinary septic

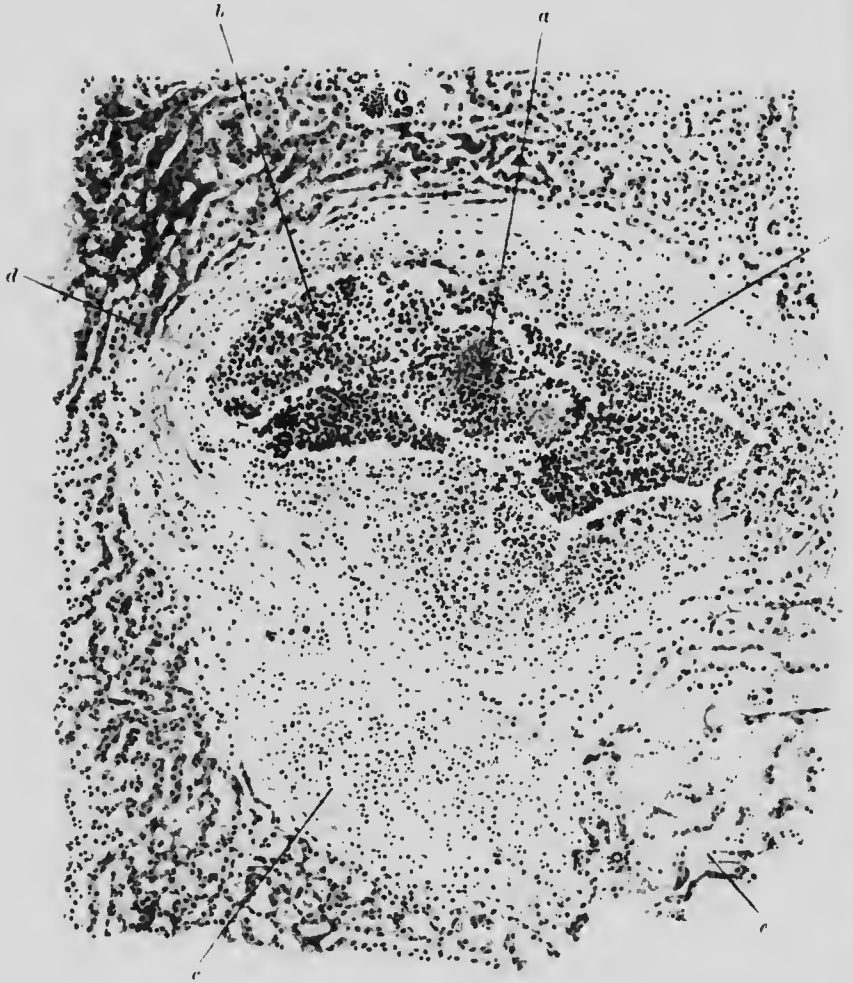


FIG. 32. ACTINOMYCOTIC INFLAMMATION. LIVER. ($\times 90$)

- a.* Ray fungus, surrounded by leucocytes.
- b.* Collection of leucocytes in space around fungus, forming small abscess.
- c.* Fibrous granulation tissue, in part replacing destroyed liver tissue.
- d.* Liver tissue.
- e.* Area of congestion with compressed liver tissue.

abscess (Fig. 32), with the addition of many plasma cells. The macroscopic characters and the granules in the pus are almost more characteristic than the histological features.

CHAPTER VIII

ATROPHY AND HYPERTROPHY. GROWTH

ILLUSTRATIVE PREPARATIONS.

1. Teased muscle fibres from a non-pregnant uterus.
2. Teased muscle fibres from an uterus at full term to show hypertrophy.

PROPERLY speaking, the terms atrophy and hypertrophy are applicable to diminution or increase of the total size of an organ or tissue, while the terms hypoplasia or hyperplasia should be used for corresponding alterations in the size of individual cells. The combination of the two states is the most common condition. Disease, lack of exercise, or supernormal activity are the commonest causes. Both disuse and over-use may be either primary or secondary. Disuse from a fractured bone is primary, from a diseased nerve is secondary. Over-use of the calf muscles in rowing is primary, of the uterus and mammary glands in pregnancy, secondary. Obviously, there is a fundamental difference in causation although the anatomical result may be practically the same (Figs. 33 and 34).

There are certain general facts about the process of growth not histologically demonstrable, which the student should know.

The capacity for growth and consequently for regeneration, varies inversely with the position of the organism in the animal scale. The capacity differs also according to the tissue to be replaced, being greatest in those most exposed to constant wear.

It varies inversely as the age of the organism: growth is obviously more pronounced in youthful than in aged

individuals. Consequently the embryo shows more capacity for regeneration after injury than the adult. Partly, no doubt, this property depends also on the fact that the tendency to multiplication diminishes, as a whole, in proportion to the differentiation



FIGS. 33 and 34. MUSCULAR FIBRES (*a*) FROM NON-PREGNANT, (*b*) FROM PREGNANT UTERUS, DRAWN TO THE SAME SCALE. (Sellheim.)

of the cell and the highly differentiated nerve cell shows little ability to multiply. Thus we find duct cells regenerating where gland cells do not. Moreover, regenerating cells often revert first to the embryonic form when dividing. It follows also that a tissue may be of too complicated a structure for regeneration.

CHAPTER IX

NEW GROWTHS (EPITHELIAL)

ILLUSTRATIVE PREPARATIONS.

1. Adenoma of the rectum.
2. Carcinoma of the rectum.
3. Fibro-adenoma of the mamma.
4. Encephaloid carcinoma of the mamma.
5. Scirrhous carcinoma of the mamma.

Tumours (new growths) generally may be defined as useless independent overgrowths of single tissues. They are divided into two main classes: simple (benign), and malignant. Simple tumours are usually circumscribed, limited in size and often encapsulated: they press on but do not grow into the tissues surrounding them and when removed by operation, they do not tend to recur. Their nutrition is maintained by concomitantly formed blood-vessels.

Malignant tumours are characterised by irregularity of form: absence of capsule: and their extension occurs at the expense and destruction of the neighbouring tissues which they invade. They possess the property of detaching cells which form colonies of similar cells elsewhere (metastases) and when removed they tend to recur.

Benign tumours are called by the name of the tissue in which they arise, with the suffix **-oma**: *e.g.* fibroma, adenoma, and so on.

Malignant tumours arising from epithelial cells (*viz.* from epiblast or hypoblast) are termed carcinomata: those arising from

connective tissue (mesoblast) are called sarcomata. The carcinomata usually have a substantial amount of supporting tissue—the stroma—derived from the connective tissue around their site of origin and growth. This stroma may even form the large portion of a slow growing tumour. The carcinomata are supplied partly with new blood-vessels of ordinary structure, partly with thin walled vessels running an irregular course.

The sarcomata have only a fine intercellular supporting tissue and their blood supply is, in the main, brought by delicate vessels formed only of a single layer of endothelium.

Many believe in a "precancerous stage" of the tissue to be affected, consisting principally of an inflammatory reaction with a breach of limiting structures. In syphilitic glossitis, for example, the wall of basal cells may be broken through by the inflammatory invasion (Fig. 34), and this particular inflammation of the tongue frequently precedes cancer of the tongue.

Certain tissues are more liable to primary carcinomatous growth than others, for instance, the alimentary canal in men, and the sex organs in women. In contrast thereto, primary new growth is less common in the organs where secondary deposits mostly flourish, *e.g.* the liver.

There is no sharp dividing line, either in their histology or physiology, between benign and malignant growths, so that, occasionally and sometimes after an interval of years, a tumour may pass from innocence to malignancy.

Epithelial growths.—New growths of every known type of epithelium (except of nerve cells) occur. The following account gives examples of some of the main varieties.

COLUMNAR CELLS.—Types: (*a*) Adenoma of rectum (polypus).

(*b*) Carcinoma of rectum.

Adenoma of the rectum forms a soft growth projecting into the lumen of the bowel, without ulceration or induration. Microscopically, the mass is composed chiefly of columnar cells with characters very similar to those of the normal mucous membrane,

but staining rather deeper, together with a quantity of granulation tissue. The submucosa is not invaded (Fig. 35).

Carcinoma of the rectum forms a hard or soft growth according to the amount of fibrous tissue present: it is often ulcerated and

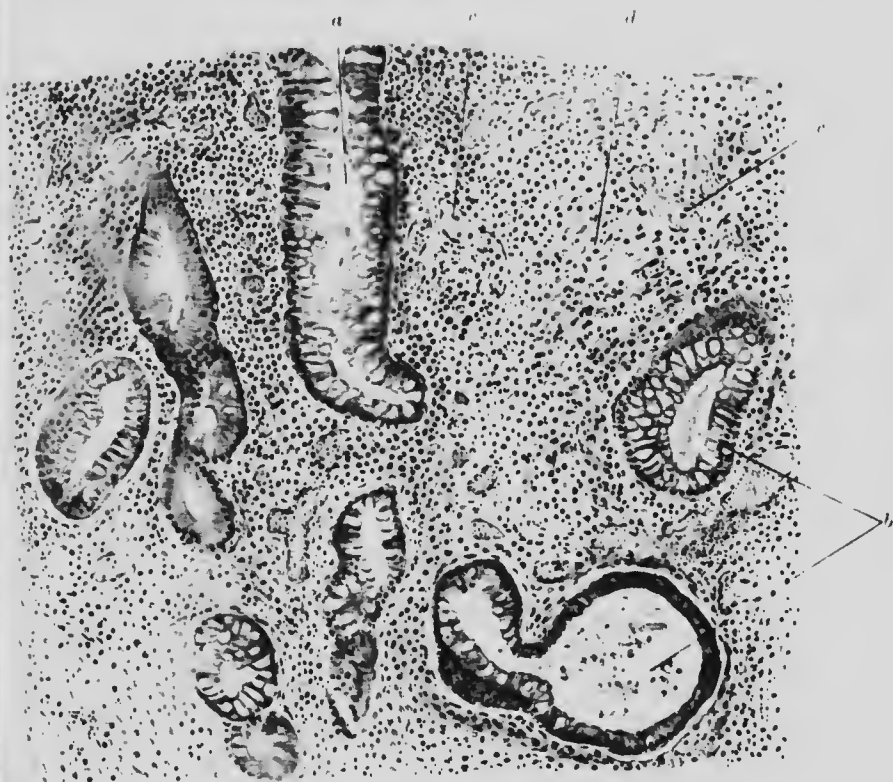


FIG. 35. ADENOMA. RECTUM. ($\times 100$)

- a.* Mucous gland tissue cut longitudinally
- b.* Mucous gland tissue cut transversely.
- c.* Dilated blood vessels.
- d.* Interstitial granulation tissue.

the surrounding tissues are indurated. Microscopically, it is not possible to say to a cell where normal tissue leaves off and cancerous tissue begins, but at the transitional portion the cells become larger and the cytoplasm stains more deeply. The cells are often several layers deep and soon lose their glandular arrangement and grow in projecting, irregular, almost solid masses

which penetrate the submucosa. The normal mucous membrane is undermined and may thus be destroyed by upward as well as

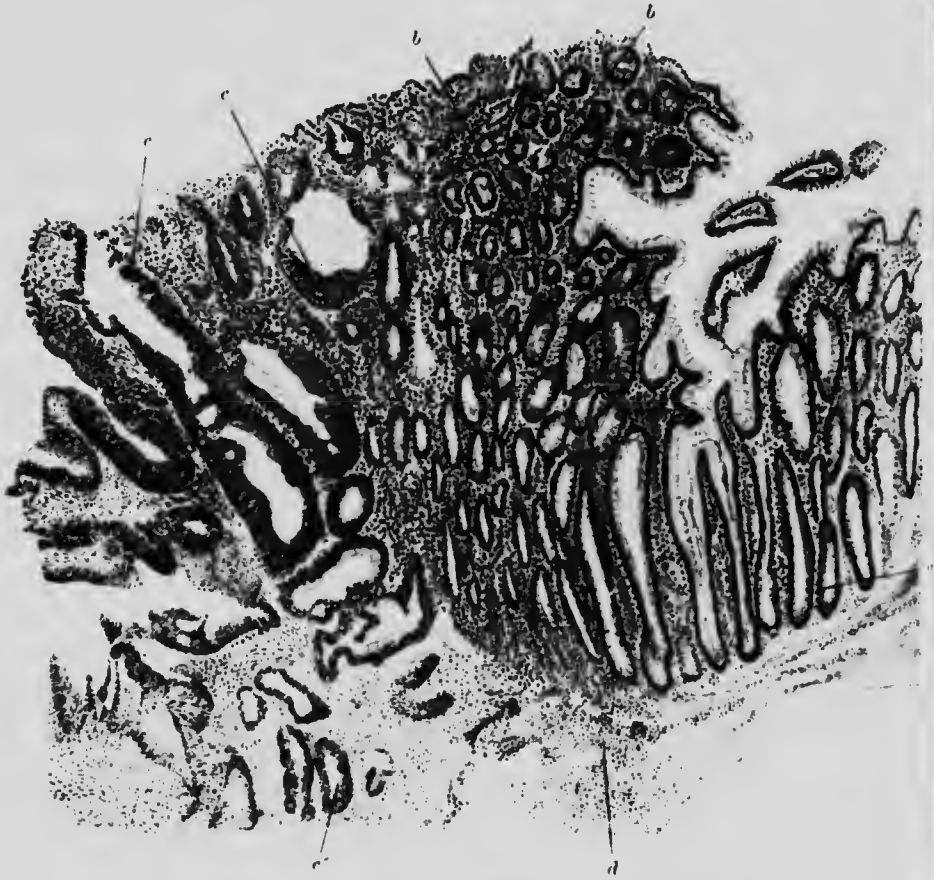


FIG. 36 COLUMNAR CELL CARCINOMA. RECTUM. ($\times 35$)

- a.* Normal cells of glands, cut longitudinally.
- b.* Small celled infiltration around glands cut transversely, near the new growth.
- c.* Carcinoma cells forming irregular glandular masses and at
- d.* penetrating into the submucosa.
- d.* Submucosa.

(The other coats of the rectum are not represented.)

by lateral extension of the growth (Fig. 36). This class of carcinoma is especially liable to colloid degeneration.

There is always some leucocytic infiltration in and around the

growth and a varying amount of fibrous tissue proliferation, but this latter is more marked in growths consisting of

- SPHEROIDAL CELLS.—Types: (*a*) Adenoma of breast.
(*b*) Cancer of breast.

a

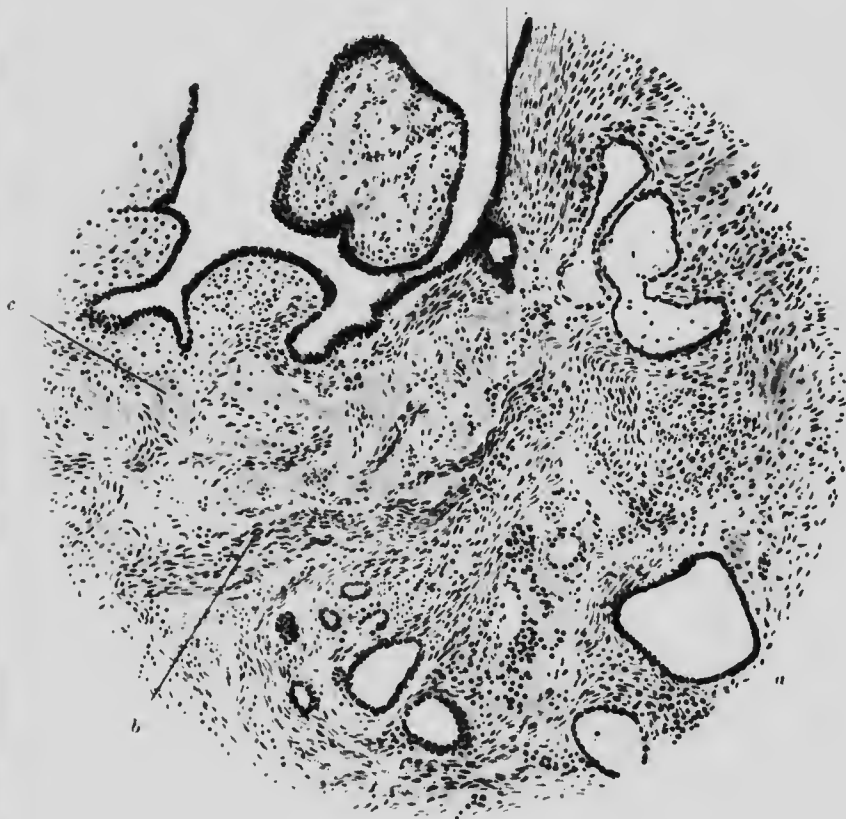

FIG. 37. FIBRO-ADENOMA. MAMMA. ($\times 70$)

- a.* Glandular epithelium which has proliferated around large spaces.
b. Cellular fibrous tissue.
c. Less cellular, fibrous tissue.

The original shape of the cell is cubical and this is seen in many parts of the non-malignant adenoma. The spheroidal shape is mainly due to compression.

Adenoma of the breast forms a capsulated growth, freely movable under the skin, which it does not involve. Microscopically, it is seen to be composed of ordinary mammary gland (including duct) cells and fibrous tissue. The glandular portion does not differ much from normal, except for some irregularity of shape or outline: the lumen of the acini is often distended, and the typical grape-like arrangement of the acini is lost. Nevertheless, the general impression given by the growth is that of regularity. The new portions are not surrounded by inflammatory reaction or infiltration (Fig. 37).

Cancer of the breast forms a nodular or irregular mass beneath the skin to which it is often attached. It is not freely movable like an adenoma and does not possess a capsule. The consistency is rather variable, depending on the predominance in the growth of fibrous or cellular tissue respectively. The relative amounts can easily be demonstrated by immersing a thin slice of the tumour in 5% HNO_3 , when the fibrous tissue will stand out as translucent bands and the epithelial tissue will become more opaque. In common with many other new growths mammary cancer exhibits a tendency to degeneration and necrosis in the central oldest portions, while the margin shows the most active proliferation. Microscopically the necrotic portions look yellow and are of soft creamy consistency and often show the remains of small haemorrhages. The growing margin is of more uniform consistency and vascularity. According as the fibrous or the cellular tissue predominates, the growth is called scirrhus or encephaloid. In both varieties the cells have departed in form from the original, so that their origin is no longer evident. They are roughly cubical, or spheroidal, grouped for the most part in irregular solid masses or columns along lymphatic spaces, sometimes they surround a lumen which contains secretion. The direction of growth is determined in part by the lines of the connective tissue: this is seen especially in the scirrhus variety (Fig. 38). Their cells being placed between the planes of fibrous tissue tend much less than in the encephaloid

tumours to the formation of definite alveoli. Apparently the multiplication of cells is to some extent held in bounds by the fibrous tissue which may contract so much as to pucker the overlying skin. Many of them show mitotic figures which are sometimes irregular.

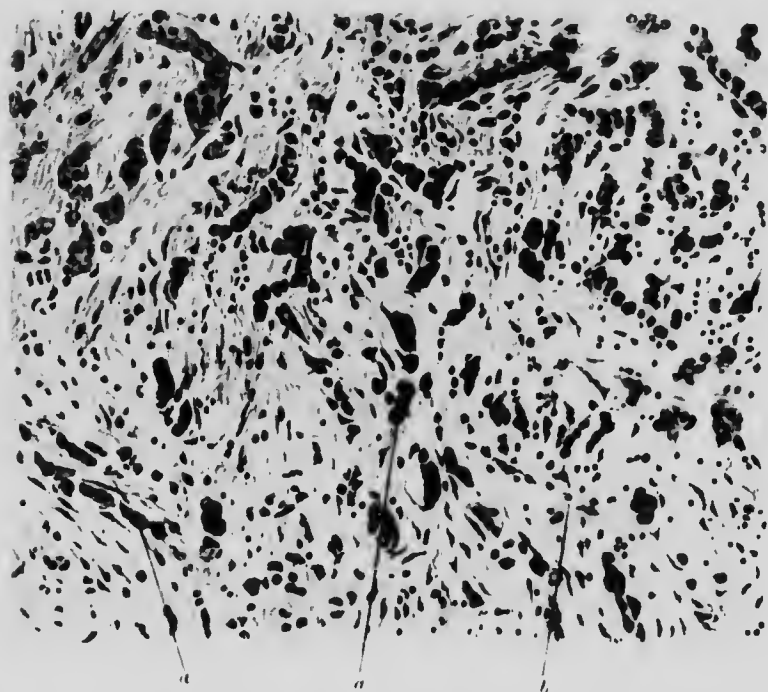


FIG. 38. CARCINOMA (SCIRRHUS). MAMMA. ($\times 100$)

- a. Carcinoma cells, some solitary, mostly in short single file columns, separated by
b. intervening layers of fibrous tissue.

In the encephaloid variety, the groups of cells may form large alveoli, often with a lumen containing the secretion. The amount of intervening connective tissue is relatively small (Fig. 39) and microscopically, the growth is seen to be much more luxuriant and the mitoses far more numerous than in the scirrhous variety. In many places the cancer columns are surrounded or preceded along the growing edge by collections of leucocytes which have emigrated from a neighbouring

blood-vessel. Encephaloid grow more rapidly than scirrhou tumours: for the latter may atrophy even to the extent of disappearance.

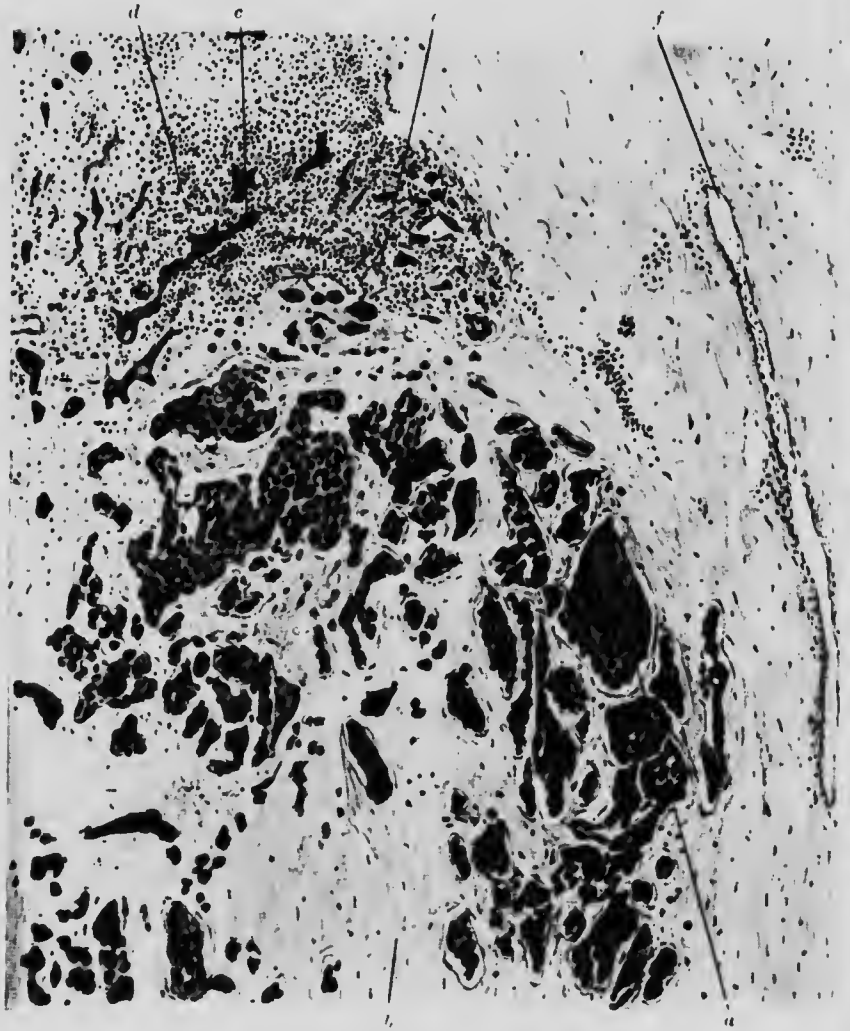

FIG. 39. CARCINOMA (ENCEPHALOID). MAMMA. ($\times 75$)

- | | |
|--|--|
| <i>a.</i> Carcinoma in masses. | <i>b.</i> Fibrous tissue. |
| <i>c.</i> Carcinoma cells at advancing edge of growth. | <i>d.</i> Surrounding leucocytic infiltration. |
| <i>e.</i> Blood-vessel associated with infiltration. | <i>f.</i> Blood-vessel. |

The occasional difficulty in the histological differentiation between innocent and malignant new growths is well illustrated

in mammary cancer especially since it is often preceded by an inflammatory condition of the breast tissue (mastitis). If such an inflammatory reaction be localised or accompanied by an irregular proliferation of gland cells, the condition is to be regarded with suspicion. If irregular mitoses or heterotype mitoses are found, the diagnosis of malignant new growth is practically certain.

It is to be remembered that the process does not take the whole breast simultaneously, but starts from a centre and gradually involves the remaining tissue, so that a negative diagnosis is not justified from the histological examination of a small isolated portion.

CHAPTER X

NEW GROWTHS (EPITHELIAL) (*Continued*)

ILLUSTRATIVE PREPARATIONS.

1. Papilloma of the skin (wart).
2. Rodent ulcer.
3. Epithelioma of the skin following X-ray inflammation.
4. Chronic ulcer of the skin becoming epitheliomatous.
5. Spleen of mouse showing metastatic deposits of new growth.

SQUAMOUS CELLS.—Types: (*a*) Papilloma of the skin and of the bladder,

(*b*) Rodent ulcer,

(*c*) Epithelioma of the skin and of the oesophagus.

The cell is originally flat or polyhedral.

(*a*) **Papilloma** of the skin is the ordinary wart. The skin is thrown into closely apposed folds, forming a sort of talldeland with clefts reaching down to the normal level of the skin. The epithelium covering these papillae is rather deeper and the cells larger than normal, while in the space between the clefts concentric collections of cells, which have undergone horny degeneration, may be found. Some leucocytic infiltration is often seen at the base of a papilla (Fig. 40).

Papilloma of the bladder, owing to the ease with which it can grow into a protected space, presents rather different characters.

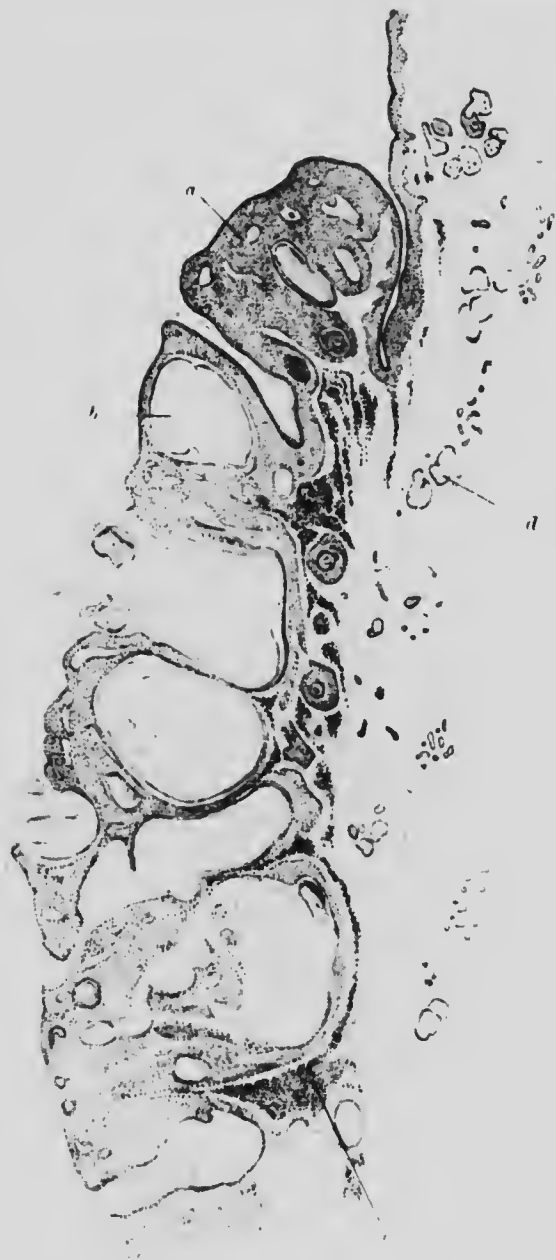

FIG. 10. WART (PAPILLOMA). SKIN. (150)

- a.* Papilla showing considerable thickening of epithelium, with blood vessels and hairs cut across.
- b.* Area in which extensive honey degeneration of epithelium has occurred.
- c.* Leucocytic infiltration at base of a papilla.
- d.* Sebaceous glands.

The cells are mounted on finger-like projections of fine connective tissue and tend to assume a more columnar shape. The papillae are therefore very long and thin and resemble, macroscopically, the intestinal villi, so that this form of tumour is sometimes called villous tumour.

It is characteristic of the papillomata, which are non-malignant tumours, that the epithelial growth extends above the free surface and not below the normal level, so that it neither undermines the epithelium nor invades the sub-epithelial tissues. Bacterial infection appears sometimes to start such growths and not infrequently, probably on account of long-continued irritation, they acquire malignant characters.

Histologically it is not possible to distinguish between congenital papillomata and others, such as those arising from infections, *e.g.* the condylomata and venereal warts due to syphilis and to gonorrhoea.

(b) **Rodent ulcer** arises, not from the surface epithelium but from the cells of the sebaceous glands or external root-sheaths of hairs. It is a typical slightly malignant, slow growing tumour, spreading irresistibly along the surface but not producing any metastases.

Arising below the level of the superficial epithelium, rodent ulcer gradually undermines, destroys and displaces it, causing superficial ulceration in the process. The cells are flattened, oval or polyhedral, smaller than ordinary squamous epithelium and have less cytoplasm: they do not form the cell nests so characteristic of the next variety (Fig. 41).

(c) **Epithelioma** may arise on any surface covered with squamous epithelium and occurs occasionally in places, *e.g.* the gall-bladder, where normally the epithelium is not squamous. It frequently starts at the lines of junction of skin and mucous membrane or on those portions of skin which are especially liable to irritation or periodic destruction or regeneration. A frequent predisposing cause is chronic inflammation, *e.g.* syphilitic

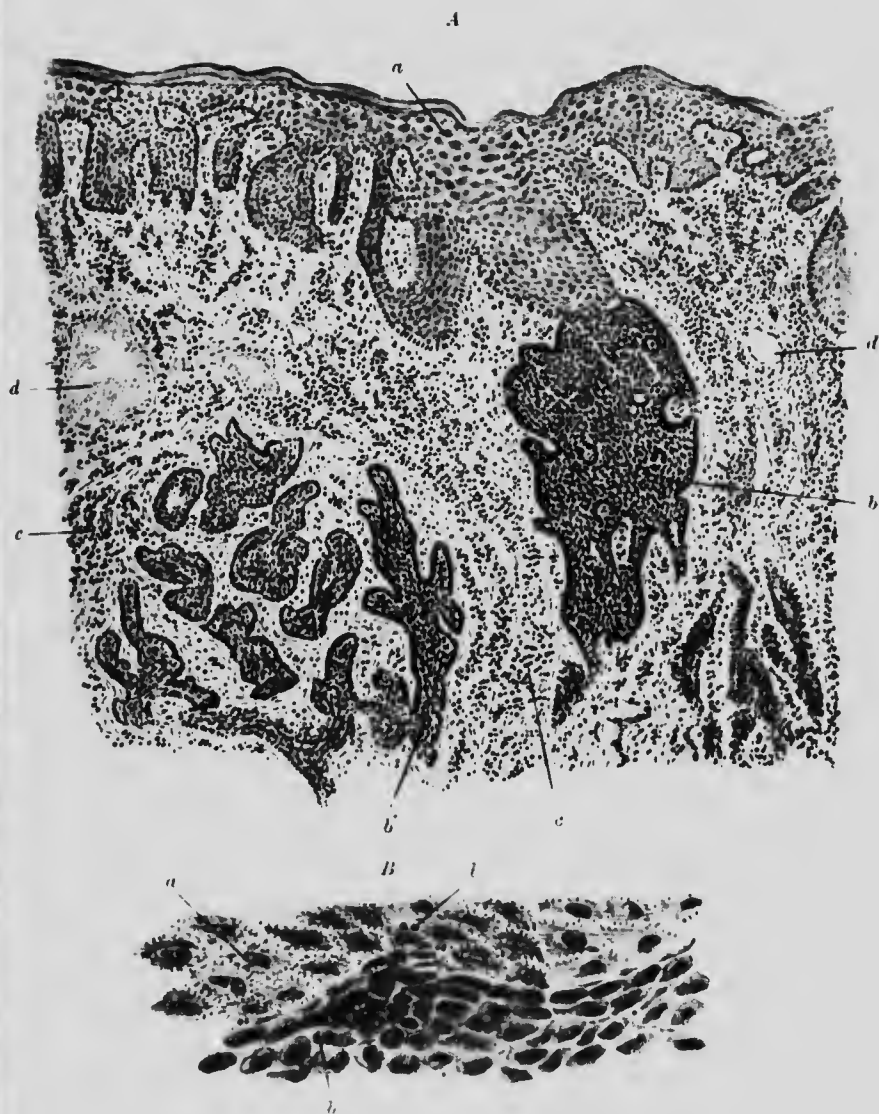


FIG. 41. RODENT FLECK. SKIN. ($\times 30$ and $\times 300$)

- A. *a.* Normal epithelium.
b. Cells of new growth in contact with normal epithelium, but at
b' in detached masses in the subcutaneous tissue.
c. Leucocytic infiltration in connective tissue.
d. Blood vessels.
- B. *a* and *b.* As above. *l.* Leucocytes between epithelial cells

glossitis, smoking, a chronic ulcer (Fig. 42), or dermatitis following exposure to X-rays (Fig. 43).

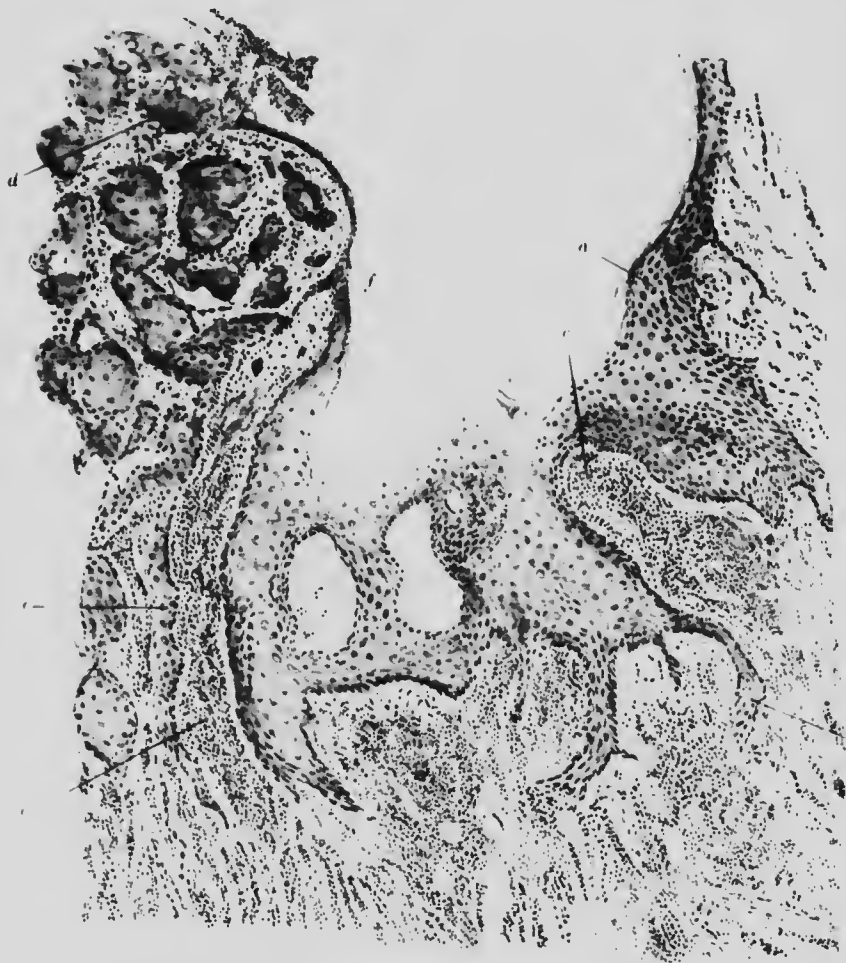


FIG. 12. CHRONIC ULCER BECOMING EPITHELIOMATOUS. SKIN. (130)

- a.* Fairly normal epithelium, sending out at downgrowths irregularly into the corium.
- b.* Inflammatory infiltration between and below the papillae.
- c.* Epitheliomatous cells growing downwards, and at undermining the skin.
- d.* Epithelial layers have degenerated and almost disappeared, and are continuous with the ulcerated surface of the growth.

In the earliest stages there is usually irregular downgrowth and overgrowth of epithelium into the corium: the new cells

spread laterally and upwards so that the superjacent normal epithelium is destroyed, until finally the new growth cells reach the surface. Leucocytic infiltration around and between these new outgrowths and especially around the cell nests mentioned below, is particularly characteristic of epitheliomatous growth.





FIG. 43. EPITHELIOMA. SKIN. ($\times 60$)

- a.* Normal epithelium.
- b.* Growth epithelium in contact with it, and at
- b'* continuous downgrowth, which at
- b''* appears as separate deposits.
- c.* Leucocytic reaction around growth.
- d.* Fibrous tissue.

Infection and ulceration soon follow. Unlike many other new growths, the cells of a squamous epithelioma retain the characteristics of the parent cells fairly well. The shape and the prickles may be kept. One arrangement of cells, namely, the cell nests, consisting of small bodies formed of concentrically arranged horny, flattened, badly-staining cells, quite distinct from their





MICROCOPY RESOLUTION TEST CHART
NATIONAL BUREAU OF STANDARDS
STANDARD REFERENCE MATERIAL 1010a
(ANSI and ISO TEST CHART No. 2)

neighbours, is especially common in epithelioma (Fig. 43*) Very little new stroma is formed, and there are no varieties like the encephaloid and the scirrhus of spheroidal celled cancer

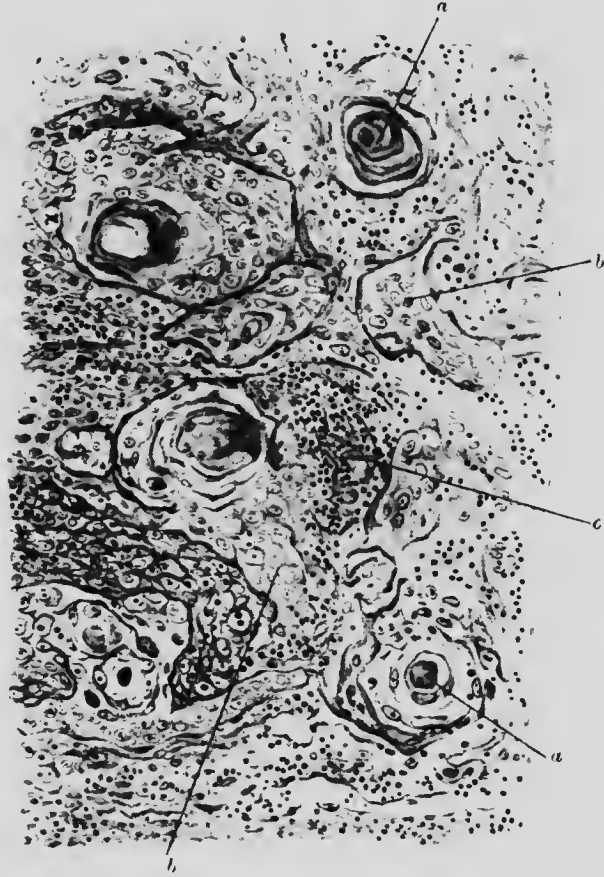


FIG. 43*. EPITHELIOMA SHOWING CELL NESTS. ($\times 120$)

- a.* Centre of cell nest, consisting of concentrically arranged, flattened epithelioma cells.
b. Ordinary epithelioma cells. *c.* Area of inflammatory reaction.

The blood supply is usually good, yet the growths are very liable to bacterial infection. They spread, with varying degrees of malignancy, along the lymphatic channels and metastases are found in the lymphatic glands, and, less commonly, in the internal organs. When occurring on a free, protected surface,

such as the oesophagus, and also on the skin, epithelioma tends to form a heaped-up growth which, in the former case, may obstruct or even occlude the lumen of the affected organ. Like many other new growths, the epitheliomata easily break down and

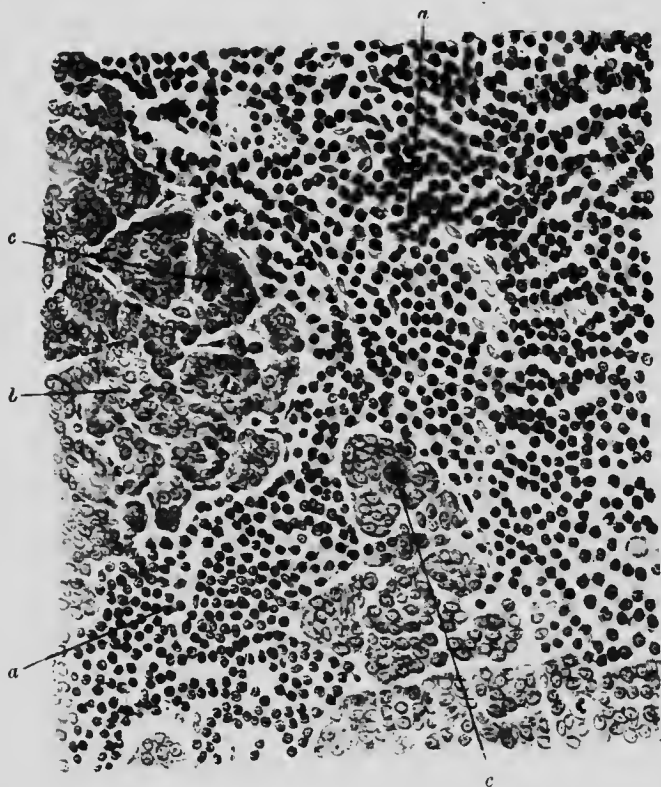


FIG. 44. METASTASIS. CANCER. SPLEEN. MOUSE. ($\times 250$)

- a.* Spleen tissue. *b.* Cancer tissue.
c. Cancer cells showing mitoses.

necrose and, on account of their superficial position, readily ulcerate. Except in animals, the growth usually more than keeps pace with the ulceration and consequently surely, although it may be slowly, increases in size and extent.

The deposition of cancer cells at a distance from the primary growth (**metastases**) is effected by either direct extension of the growth cells, or their conveyance by the blood or the lymph

stream. Although the metastatic deposits generally cause enlargement of the gland or organ in which they grow by reason of their own bulk, they also destroy the organ cells by their pressure. The cells of the tumour and of the organ are in direct contiguity without any attempt at demarcation. Very often the metastatic cells are of a less differentiated type than those of the original growth, although as a rule they reproduce the original characteristics fairly well (Fig. 44).

CHAPTER XI

NEW GROWTHS (CONNECTIVE TISSUE)

ILLUSTRATIVE PREPARATIONS.

1. Fibroma.
2. Myoma of the uterus.
3. Small round cell sarcoma.
4. Large round cell sarcoma.
5. Spindle cell sarcoma.
6. Myeloid sarcoma.
7. Melanotic sarcoma.

THERE is not the same parallelism between the benign and malignant forms of connective tissue tumours that exists in the epithelial group. There are three classes:

(a) The **benign class** formed of differentiated cells which retain their characteristics almost unimpaired and do not vary so much from the normal as the corresponding benign epithelial growths from the type cell. The name in each case is made up of an abbreviation of the name of the tissue with the affix **-oma**, *e.g.* osteoma.

(b) The **malignant class**, the sarcomata proper, composed of cells having embryonic characters. The individual tumours are named according to the size and shape of the cells composing them, *e.g.* spindle cell sarcoma.

(c) The **mixed class**, consisting of tissues of both preceding classes and malignant by reason of inclusion of the second. Compound names are employed for the designation of these

growths, made up from the tissue name with the affix **sarcoma**
e.g. osteo-sarcoma.

The characters of the benign connective tissue tumours are



FIG. 45. FIBROMA. ($\times 200$)

- | | |
|--|------------------------------------|
| <i>a.</i> Thin fibre cut longitudinally. | <i>c.</i> Fibres cut transversely. |
| <i>b.</i> Thick fibres cut longitudinally. | <i>d.</i> Fibres cut obliquely. |
| <i>e.</i> Blood-vessel with definite wall. | |

sufficiently apparent from their names, so that it will suffice to consider only a few of them in any detail.

Fibroma is an encapsulated growth consisting of whorls of fibrous tissue cells, often with rather more, sometimes with rather less than the normal quantity of cytoplasm, producing accordingly

either a soft or hard fibroma (Fig. 45). With v. Gieson's stain, like normal fibrous tissue, the cells are coloured pink, thus distinguishing them from another connective tissue tumour much resembling it, namely:

Myoma is composed of whorls of plain muscle fibres. In microscopical appearance it closely resembles the cellular type of




FIG. 46. MYOMA. UTERUS. ($\times 250$)

- a.* Plain muscle fibres cut longitudinally.
b. Muscle fibres cut transversely.

fibroma and the two tissues are often mixed to form a fibromyoma. The cells may be differentiated by v. Gieson's stain: the muscle fibres stain yellow. The cells are long and thin, with an elongated nucleus. They may be cut at any angle and thus often present a transverse section (Fig. 46).

A very common tumour is the **lipoma**. It has less tendency to malignancy than any other form of growth. It consists

simply of fat and may vary in size from a few grammes to weighing many kilogrammes. It is vascular and soft. Histologically it is like ordinary adipose tissue, but the fat cells are larger than normal; often contain fat crystals and are liable to become angular on account of the close packing. Lipomata are especially liable to degenerate and especially to undergo myxomatous degeneration.

The **chondroma** is a cartilaginous tumour usually occurring where, or near to where, cartilage is normally found (*e.g.* ends of metacarpal bones and phalanges), but also in organs where there is no cartilage (*e.g.* parotid and testis). It forms a capsulated growth. While for the greater part composed of proliferating cartilage cells in a soft hyaline matrix, there are often areas containing calcareous granules.

The **osteoma** is a bony tumour which may occur almost anywhere, but is found most often at the junction of a bone and its cartilage. The bony tissue may be extremely dense and hard, arranged in strata parallel to the surface of the growth, or it may resemble compact or spongy bone, and the microscopical characters correspond to that of the corresponding types of normal bone.

The pure **sarcomata**, that is, the simple new malignant growths arising in connective tissue, are but few in number: the compound sarcomata already mentioned are numerous. Only the first group will be considered here.

They are classified according to their constituent cells, which resemble embryonic cells at various stages:

- (a) **small round cell sarcoma**;
- (b) **large round and mixed cell sarcoma**;
- (c) **spindle cell sarcoma**;
- (d) **myeloid sarcoma**.

The **small round cell sarcoma** forms a soft, fleshy tumour, often of heterogeneous appearance on section, by reason of degeneration or haemorrhage within it. It is well defined

from the surrounding tissues, although without a definite capsule.

Microscopically, as the name indicates, it is composed of small round cells of the embryonic type, which have very little cytoplasm and are rather smaller than the ordinary neutrophile

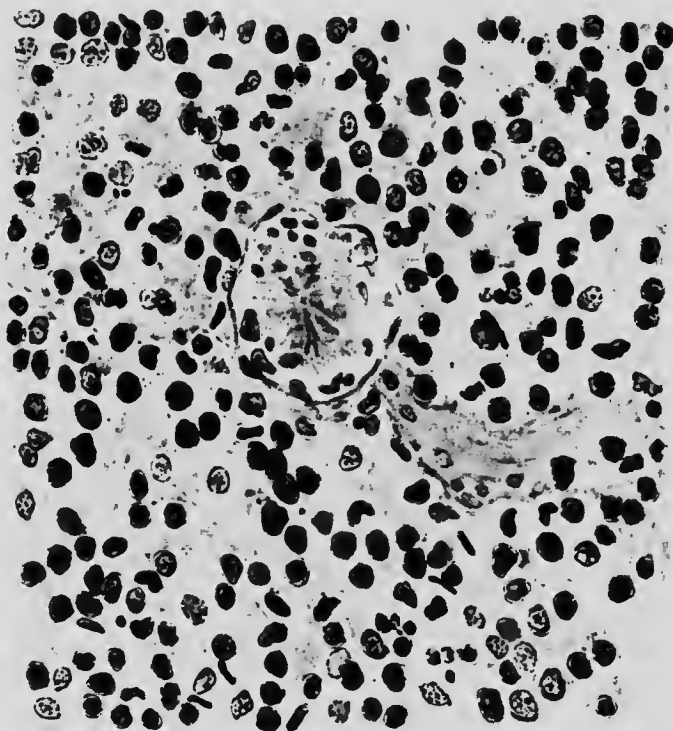


FIG. 47. SMALL ROUND CELL SARCOMA. ($\times 400$)

Consists of small round cells with large nuclei and, in many cases, obvious nucleoli. In the centre is a blood-vessel formed by a single layer of epithelium.

leucocyte. There are many mitoses and a fine intercellular stroma. Many of the blood-vessels have thin single layer walls of the embryonic type. This form of sarcoma occurs, as a primary growth, chiefly in the subcutaneous tissues and the connective tissue of the generative organs, muscles and bones: it is very malignant. Secondary growths usually appear first in the lung, but soon spread to other organs (Fig. 47).

The small round cell sarcoma is sometimes difficult to distinguish from granulation tissue, and vice versa, especially if the specimen be indifferently fixed. The occurrence of several varieties of leucocytes, the evidence of typical new capillary formation and the

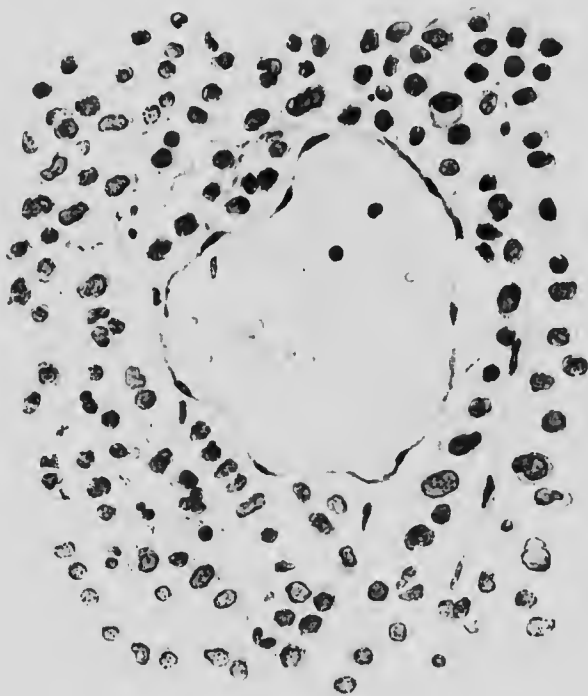


FIG. 48. LARGE ROUND CELL SARCOMA. ($\times 400$)

Large cells, of which some contain more than one nucleus, with fair amount of cytoplasm. Reticulum obvious. Blood-vessel as in Fig. 47. Some extravasated blood is seen.

presence of fibroblasts are in most cases sufficient to distinguish granulation tissue from the cells and stroma of new growth.

(b) The **large round cell**, or **mixed cell sarcoma**, differs from the foregoing in being firmer, composed of larger cells, and showing less malignancy. Cells of elongated shape are present, and some of the cells may contain several nuclei. The arrangement has a tendency to be alveolar (Fig. 48). It occurs in much the same situations as the small cell sarcoma.

(c) In the **spindle cell sarcoma** the cells are more differentiated. They are elongated, have an oval nucleus which takes up nearly the whole breadth of the cell and are arranged in interlacing bundles. Consequently, in microscopic sections, the

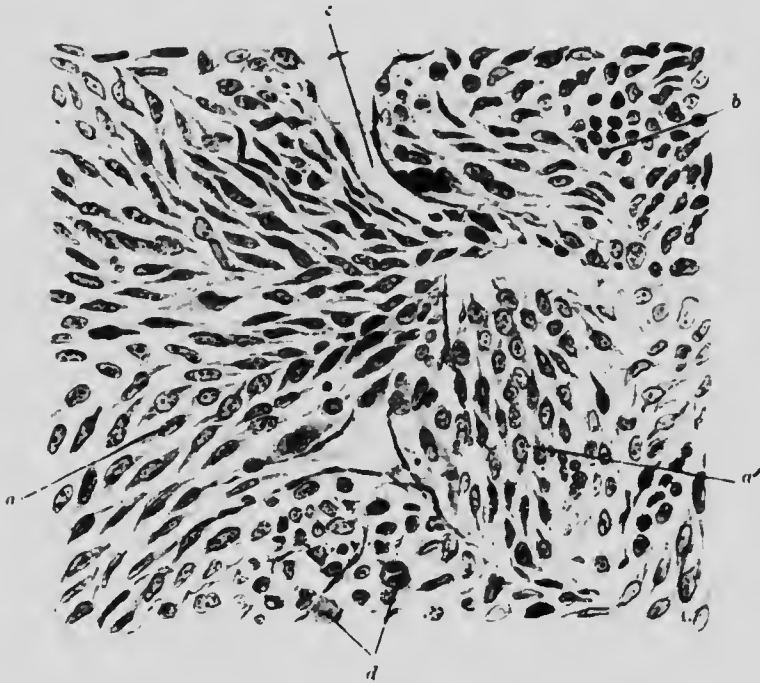


FIG. 49. SPINDLE-CELLED SARCOMA. RAT. ($\times 400$)

- a. Fibres cut longitudinally.
- a'. Fibres cut obliquely.
- b. Fibres cut transversely.
- c. Blood-space lined with single layer of endothelium.
- d. Cells showing mitosis.

cells may be cut at various angles, and differ in appearance accordingly (Fig. 49). The supporting and vascular structure is the same as in the other forms. Two kinds, large and small spindle cell sarcoma, occur: the former is the more malignant.

Although the spindle cell sarcoma may resemble both the myoma and the fibroma, the one is not to be regarded merely as a malignant form of the other, like carcinoma and adenoma of

the rectum. Besides possessing infiltrating properties which the myoma and fibroma have not, the sarcoma is usually composed of shorter and thicker cells and does not possess blood-vessels of the

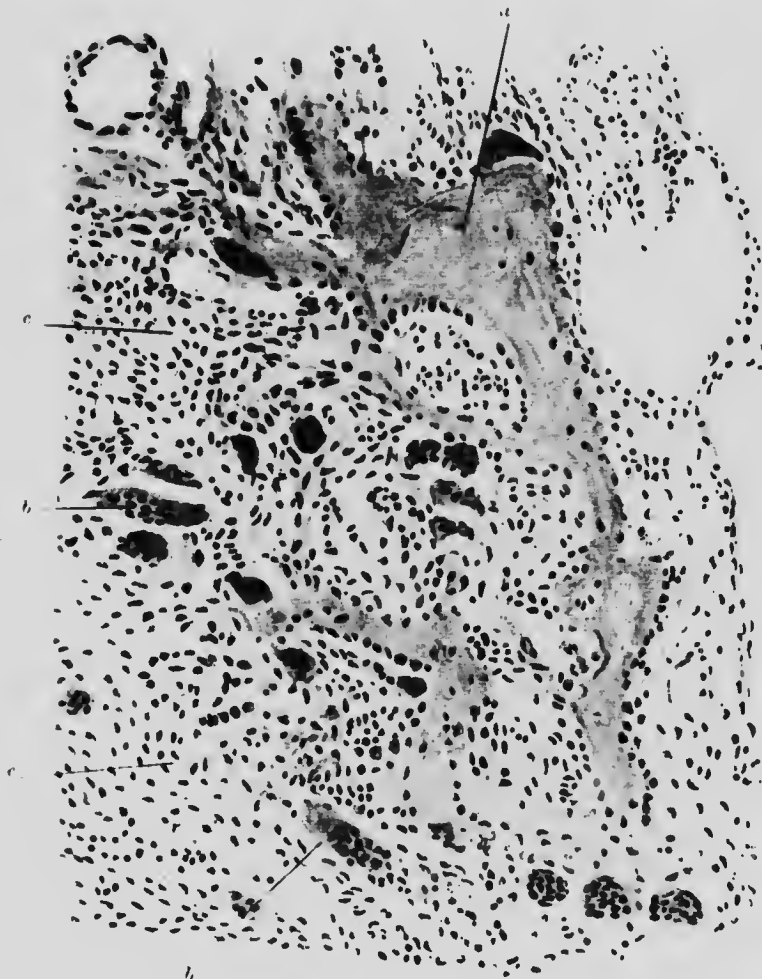

FIG. 50. MYELOID SARCOMA. ($\times 150$)

- a.* Bone. *b.* Giant cells.
c. Ordinary sarcoma spindle cells.

normal type. Occasionally the resemblance is, nevertheless, so great as to make the diagnosis very difficult.

(*d*) The **myeloid**, or **giant cell**, **sarcoma** arises, as the first

name indicates, in connection with the bone marrow and it is essentially a spindle cell sarcoma containing multinucleate cells. The latter are of large size, with scalloped edges and from 9-12 nuclei, placed chiefly in the centre of the cell. Strands of bone may be included. The tumour is very vascular, and the intercellular tissue small in amount (Fig. 50). Its malignancy is comparatively slight.

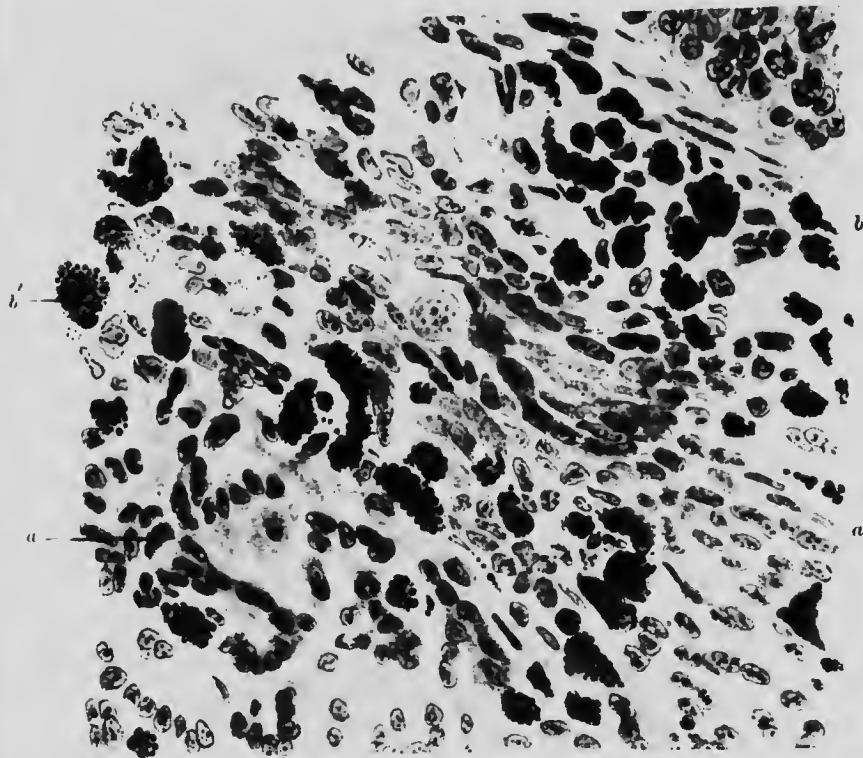


FIG. 51. MELANOTIC SARCOMA. ($\times 400$)

- a.* Pigmentless sarcoma cells, intermediate between round and spindle shape.
- b.* Sarcoma cells containing melanin granules, obscuring the nucleus in most instances, but in
- b',* the nucleus is just visible.

(*c*) The **melanotic sarcoma** is a form of mixed cell sarcoma, most of the cells being slightly spindle-shaped and a variable number of them containing the black pigment, melanin. It is an extremely

malignant form of tumour. The cells of the secondary deposits like many of those in the primary growth, may be quite free from melanin. On the other hand, the pigment may so fill the cell as to obscure entirely the nucleus and the cytoplasm. (Fig. 51).

CHAPTER XII

NEW GROWTHS—(*Continued*)

ILLUSTRATIVE PREPARATIONS.

1. Chondrosarcoma.
2. Myxosarcoma.
3. Angeioma of the skin (naevus).
4. Angeioma of the liver.
5. Endothelioma of the parotid gland.
6. Chorionepithelioma.

THE **chondrosarcoma** is made up partly of chondroma and partly of small cell sarcoma, usually arranged in such a way that one portion is pure chondroma, another pure sarcoma, with an intermediate portion composed of both (Fig. 52). But there is no regularity of arrangement in the tumour as a whole. Small areas of calcification are common. In the same way, in myxosarcoma we have myxomatous and sarcomatous tissue both separate and intermingled (Fig. 53).

Angeiomata occur in two forms: the simple **capillary** and the **cavernous angeioma**. The former, of which the ordinary red birth-mark is an example, is composed mainly of dilated capillaries supported by delicate connective tissue. The proportions of capillary and connective tissue vary very much, and in many specimens (Fig. 54) the dilatation of capillaries is not so marked as the increase of surrounding connective tissue. The perivascular lymphatics are often very prominent. The latter, the cavernous angeioma, is found most frequently in the liver. The

blood spaces or sinuses are very much larger than in the other form. They are lined by a single endothelial layer, but are separated from one another by comparatively thick fibrous trabeculae (Fig. 55).

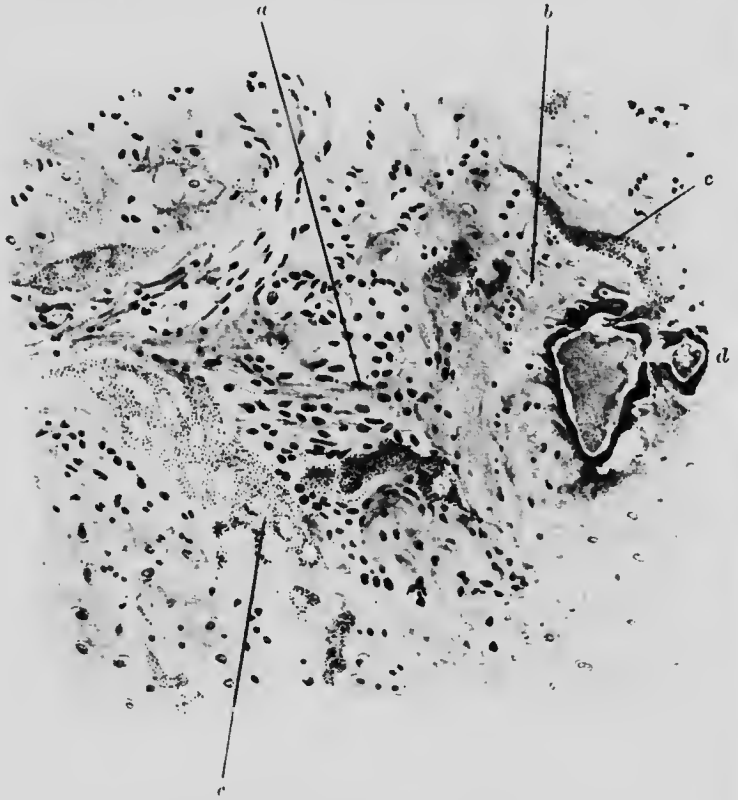


FIG. 52. CHONDROSARCOMA. ($\times 100$)

- | | |
|---|----------------------------|
| <i>a.</i> Sarcoma cells. | <i>b.</i> Cartilage cells. |
| <i>c.</i> Calcification in cartilage cells. | <i>d.</i> Blood-vessel. |

Endothelioma is a form of tumour which is thought to arise from the lining cells of the lymphatics and blood-vessels. While in many respects resembling carcinoma, it is now usually classed among the alveolar sarcomata. The growing edge has a fairly typical appearance: strands of polyhedral cells permeating the connective tissue along its natural cleavage lines (Fig. 56). In other parts it may present resemblances to an encephaloid cancer. One form which arises from and extends along perivascular

lymphatics is often called a **perithelioma**. It presents a characteristic appearance under the microscope: the vessels cut transversely have a wide circular band of new growth cells

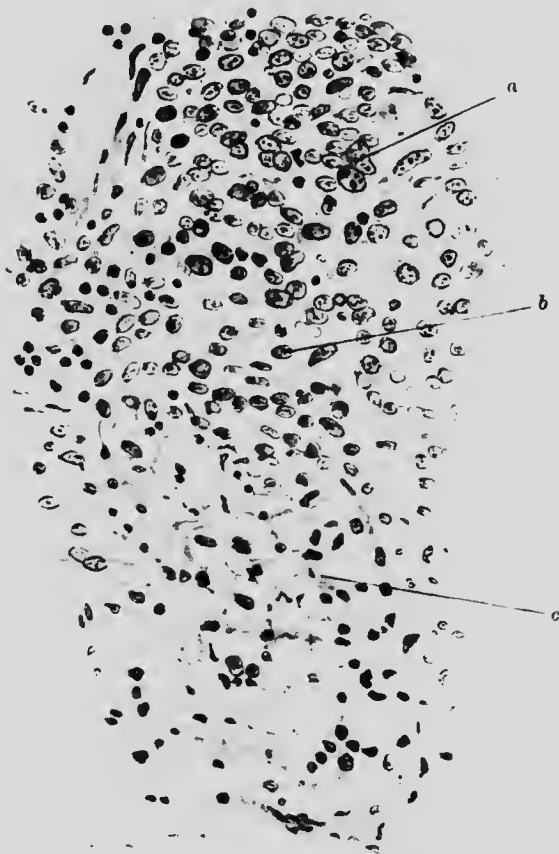

FIG. 53. MYXOSARCOMA. ($\times 250$)

- a. Portion composed of round cells.
- b. Transitional portion: mixed round cells and branched cells.
- c. Myxomatous portion: majority of cells with branched outline and intervening spaces filled with mucoid material.

surrounding them. Another form which arises from serous membranes, *e.g.* peritoneum, pleura, etc., is termed **mesothelioma**. Endothelial growths occur most frequently in the parotid gland and the membranes of the brain. They vary greatly in malignancy and often show it only after having been present for several years.

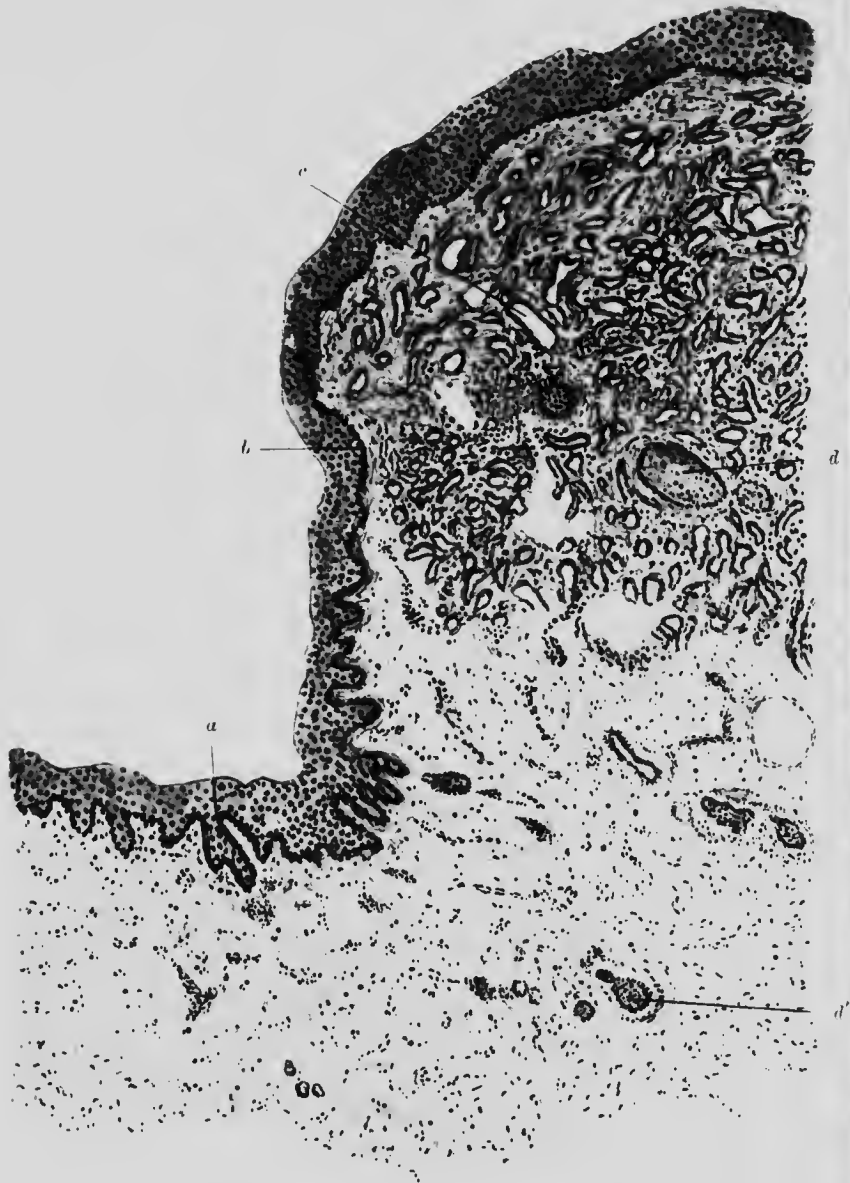

FIG. 54. NAEVUS (CAPILLARY ANGIOOMA). ($\times 30$)

- a.* Normal skin.
- b.* Flattened Malpighian layer.
- c.* Vascular tissue with capillaries of various sizes surrounded by thin fibrous tissue.
- d.* Hair cut transversely.
- d'.* Subcutaneous tissue with various connective tissues.

Chorionepithelioma is a unique form of growth of considerable clinical importance, which ordinarily arises from cells derived from the chorionic villi of the foetus, but grows and produces

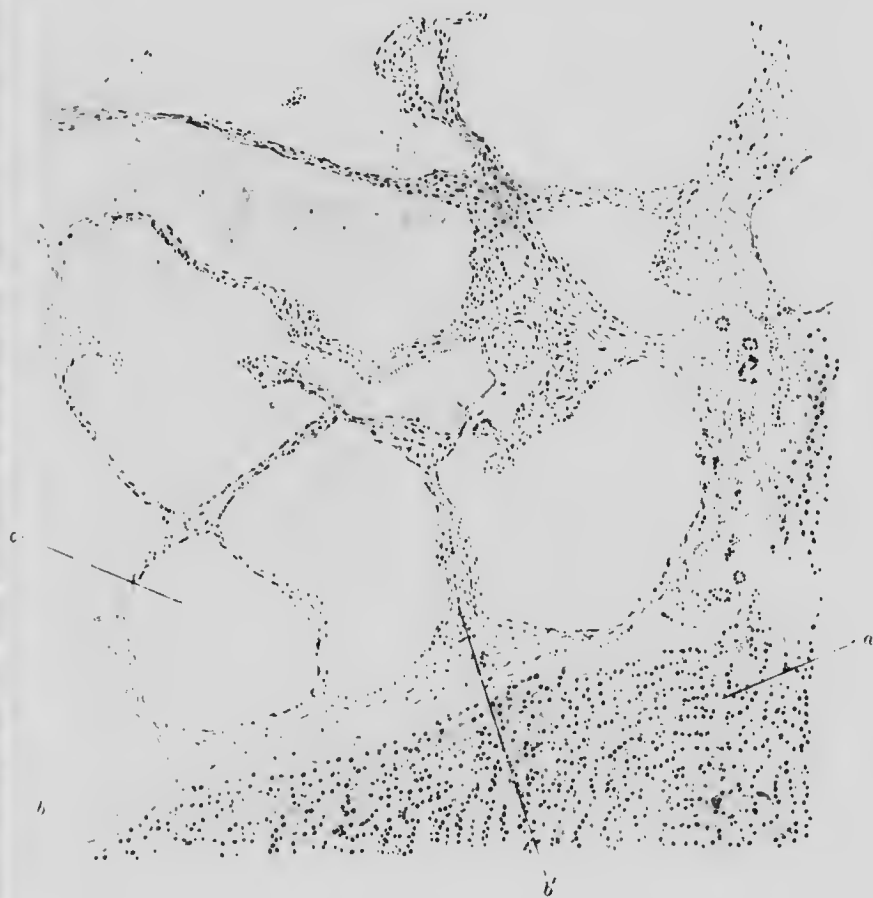

FIG. 55. ANGIOMA. LIVER. ($\times 40$)

- a.* Liver substance.
- b.* Fibrous capsule prolonged at
- c.* and elsewhere into trabeculae separating
- e.* the blood-spaces lined with flattened epithelium.

metastases in the body of the mother. Its favourite site is the uterus, consequent upon an hydatid mole, but it has also been found in other parts of the body and in both sexes. It is very malignant and usually forms multiple metastases very early.

Macroscopically the uterine tumour forms a shaggy mass resembling blood clot, of which it is largely composed, adherent to and invading the uterine wall.

Under a low power there can be made out blood clot, muscle-tissue, and two types of tumour cells: sometimes, also, the normal chorionic villi from which the tumour cells arise.

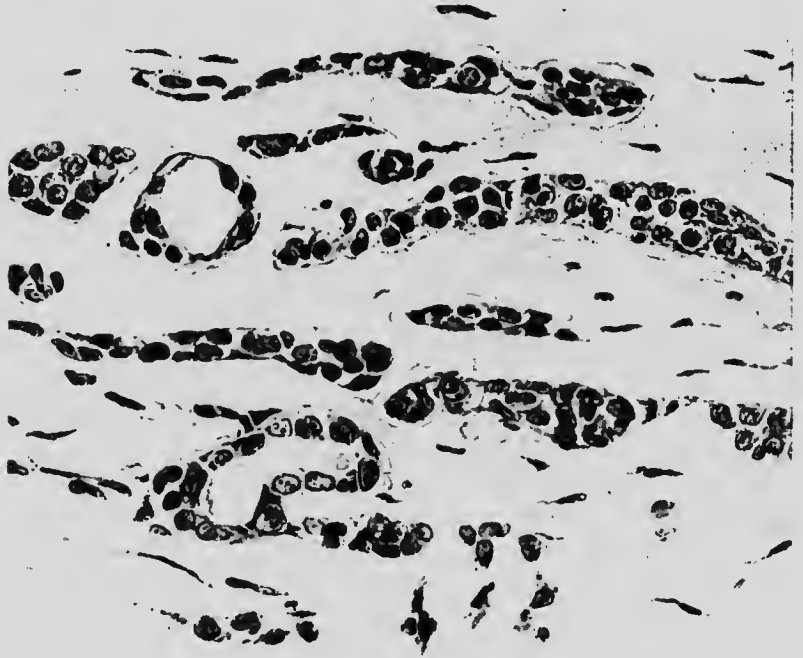

FIG. 56. ENDOTHELIOMA (TUMOUR OF PAROTID). ($\times 350$)

Layers of cells with large oval nuclei and little cell protoplasm, arising in and spreading along lymphatics.

With higher magnification the two types of cell are found to be (*a*) multinucleate masses with deep-staining cytoplasm, and (*b*) close packed collections of clear, vesicular, mononuclear cells. Among the latter mitoses are numerous, but not among the former. Both kinds of cell invade the muscle tissue and the intervening spaces are usually filled with blood. The syncytial (multinucleate) cells are believed to arise from the corresponding cells of the

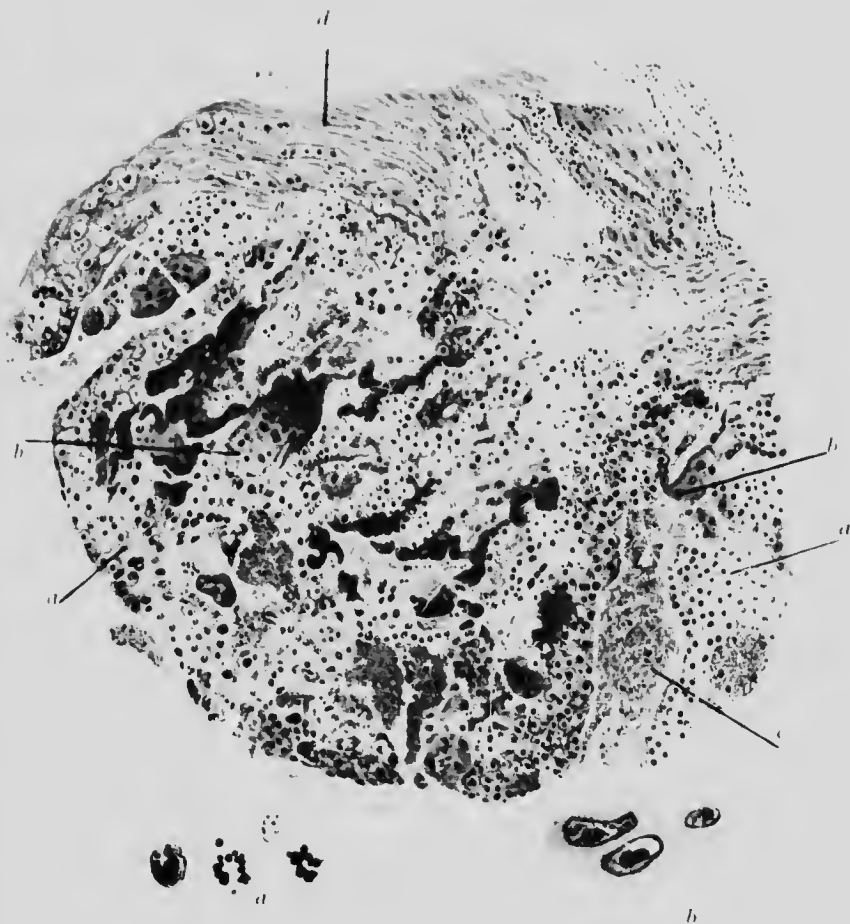



FIG. 57. CHORIONEPITHELIOMA. UTERUS. (x 60)

- a.* Vesicular cells from Langhans' layer.
- b.* Syncytial cells.
- c.* Blood clot.
- d.* Uterine muscle invaded by tumour cells.



chorionic villus and the clear vesicular cells from those of the Langhans' layer of the villus (Fig. 57).

Teratomata are compound tumours formed of tissues from more than one embryonic layer. Consequently they may be composed of almost any combination of organs, connective and epithelial tissues, either in an irregular mixture or arranged to form a more or less complete individual. They are supposed to originate from an aberrant germ cell which has undergone irregular development within the tissues of another individual. It seems too that even the tissues of a teratoma may be the sites of new growth.

CHAPTER XIII

RESPIRATORY SYSTEM

ILLUSTRATIVE PREPARATIONS.

1. Polypus of the nose.
2. Bronchitis.
3. Bronchiectasis.
4. Emphysema of the lung.
5. Passive congestion and oedema of the lung.
6. Infarct of the lung.

THE nose is frequently the seat of acute catarrh and very often of chronic catarrh. The appearances are the same as those seen in the inflammatory conditions of other mucous membranes. Malignant new growths are not common, but so-called mucous polypus in the nose is quite common. The bulk of the polypus is made up of granulation tissue which has undergone mucous degeneration. It is covered by mucous membrane, which sends down projections into the granulation tissue below (Fig. 58).

Acute **bronchitis** results from direct chemical or physical irritation, or by the action of micro-organisms.

The epithelial cells are loosened and then cast off. Some of them are found embedded, together with neutrophile leucocytes, in the preceding excessive secretion of mucus collected in the lumen. All the vessels are dilated and engorged. The sub-epithelial layer is infiltrated with leucocytes and the swollen mucous glands are surrounded by them. The inflammatory process may extend outwards and involve cartilage and muscle (Fig. 59).

The catarrhal condition may become chronic and is then followed by atrophy of the various bronchial structures, by which the wall may be so weakened that **bronchiectasis** results. It is a condition in which the smaller bronchioles are dilated and weakened so as to form receptacles for secretion. It may arise

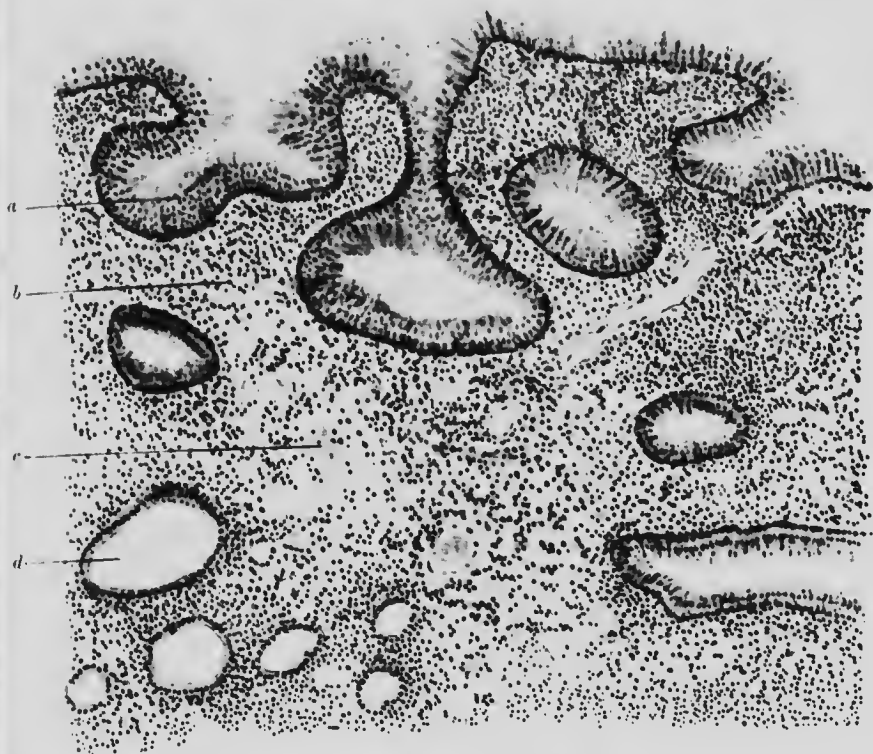


FIG. 58. MUCOUS POLYPUS. ($\times 90$)

- a.* Layer of columnar mucous cells; several layers deep.
- b.* Close granulation tissue: mainly leucocytes.
- c.* Loose granulation tissue.
- d.* Distended new mucous glands.

acutely in young children, but is more often a chronic condition due either to contracting adhesions formed around an inflamed gland or to fibrosis occurring in the lung itself. The macroscopical are thus often more marked than the microscopical appearances. The latter show an irregular wavy outline in the cross-sections of the bronchioles, frequently with a bay at one

end. From a considerable portion of the circumference the epithelium has often disappeared. The blood-vessels in the




FIG. 59. BRONCHIOLE. BRONCHITIS. ($\times 60$)

- a.* Red and white cells in lumen of bronchiole.
- b.* Columnar epithelium detached from basement membrane.
- c.* Layer of distended vessels with some leucocytic infiltration.
- d.* Muscular layer with distended vessels.
- e.* Glandular layer.
- f.* Layer of cartilage.

bronchial wall are congested and the muscular and fibrous layers infiltrated with leucocytes. The lung tissue in the immediate

neighbourhood, although possibly normal for the greater part, will at some point show evidence of fibrotic change (Fig. 60).

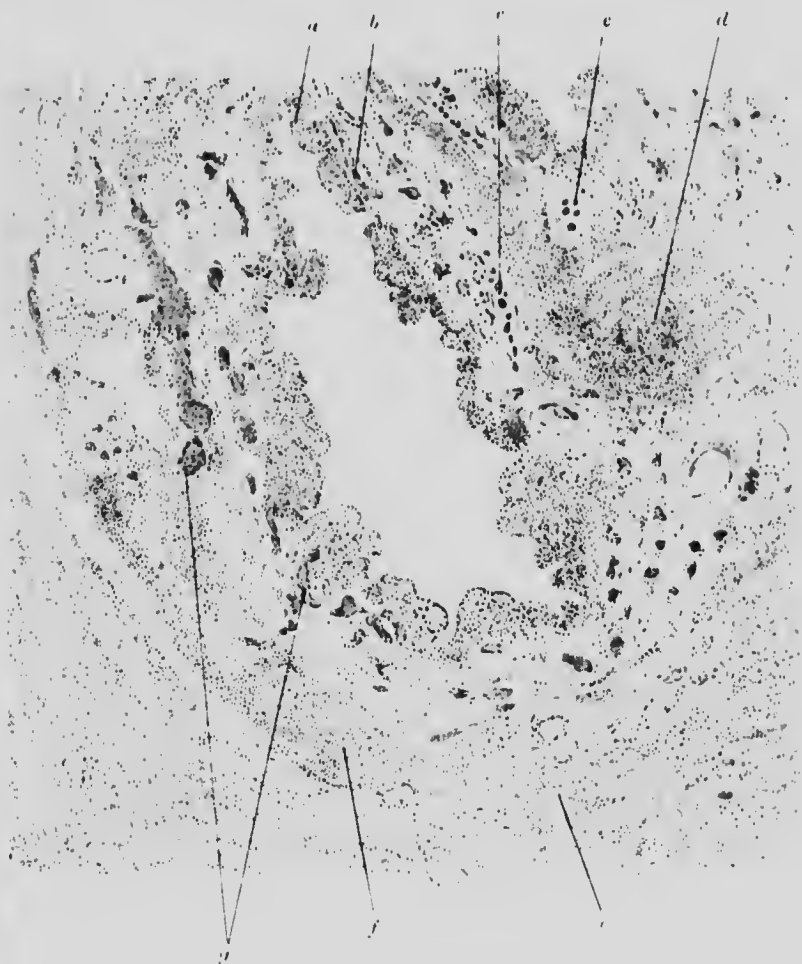


FIG. 60. BRONCHIOLE. BRONCHIECTASIS. ($\times 25$)

- a.* Mucosa, denuded of epithelium and inflamed submucosa.
- b.* Distended vessels.
- c.* Cartilage.
- d.* Inflammation in peribronchial tissue.
- e.* Collapsed lung tissue and haemorrhage.
- f.* Peribronchial inflammatory fibrosis.
- g.* Congested blood-vessels.

The condition of **infarction** results when an artery is blocked in the lung. The influx from surrounding areas is so great that

the distended vessels almost obliterate the air spaces and the alveolar walls are so compressed that they become nearly invisible.

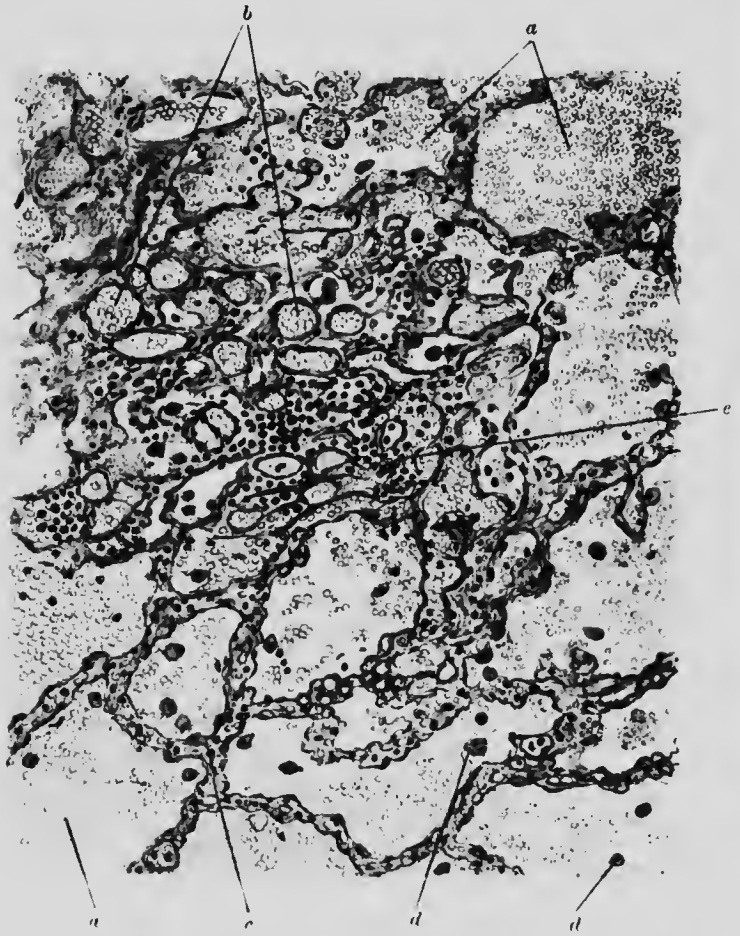


FIG. 61. LUNG. INFARCT. ($\times 90$)

- | | |
|---|------------------------------|
| <i>c.</i> Blood within alveoli. | <i>b.</i> Distended venules. |
| <i>c.</i> Distended interalveolar capillaries. | |
| <i>d.</i> Pigmented cells. | |
| <i>e.</i> Leucocytic perivascular infiltration. | |

This appearance is aided also by the extravasation which occurs into the air spaces.

Consequently, under the microscope, if the section include also an unaffected area of lung, there is a comparatively sharp line of demarcation between it and the infarcted area which, under a low

magnification, appears merely as a mass of dilated vessels and blood, in which a few nuclei belonging to the network of lung tissue may still be traceable (Fig. 61). Later, the infarct may be absorbed like any other clot, together with the necrotic lung tissue.

Collapse of lung may be brought about by external pressure (pleural effusion, growth), and is then called compression atelectasis, or by obliteration of a bronchus or bronchiole, when it is known as absorption atelectasis. On the surface of the lung the collapsed portions appear as slightly depressed, dark blue patches. Microscopically, the approximation of the alveolar walls gives a mistaken impression of considerable cellular proliferation in the collapsed area. In the absorptive form the vessels are abnormally distended: in the compressive they are unusually empty. At the surface of the lung there is often evidence of proliferation and formation of new fibrous tissue, and if the collapse and adhesion of surfaces persist for long, fibrotic changes with the formation of cicatricial tissue ensue.

In ordinary vesicular **emphysema** the converse condition obtains. The air spaces are excessively distended, so that the emphysematous portions of the lung appear abnormally bulky. The interalveolar septa consequently are thinned and the cells flattened. In time, the septa rupture and several alveoli are thrown into one. The elastic fibres also are broken, the capillaries are small, and the other small vessels compressed and empty. The amount of pigment is less than usual, partly because it has been set free and absorbed, and partly because the thinning and stretching process has increased the distance between the granules (Fig. 62).

Except in so-called compensatory emphysema, the condition is hardly ever simple, but is combined with the changes resulting from chronic bronchitis and circulatory disturbances.

Congestion, or passive hyperaemia, results from cardiac or other diseases causing obstruction to the outflow of blood from the lungs and is consequently often accompanied by other changes, apart from the effect on the capillaries and veins. In

the early stages no more than the passive dilatation of the vessels will be found, but the persistent distension and stasis is followed by diapedesis of corpuscles into the surrounding lung, with deposit of blood pigment in the interalveolar septa. Some of the

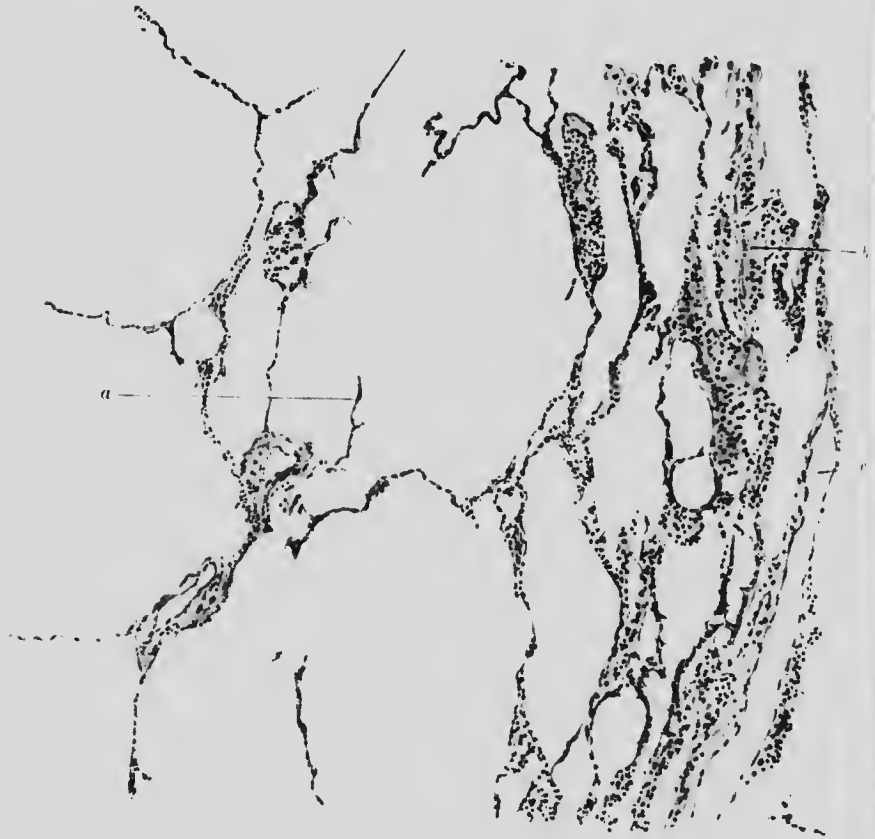


FIG. 62. LUNG. EMPHYSEMA. ($\times 90$)

- a. Torn end of very thin alveolar septum lying in large alveolar space.
- b. Fibrotic area with collapsed alveoli around.
- c. Blood vessel.

alveoli collapse, while the walls of others thicken and proliferate. Desquamating cells are found in the alveoli lying free. In cases due to cardiac disease, characteristic large cells containing pigment are also found in the alveolar lumen (Fig. 63).

Oedema of the lungs is often found in heart disease or following saline infusion. A very watery froth can be expressed by

hand from the lung. Microscopically the capillaries are distended, and the alveoli are filled with granular exudate containing a few



FIG. 63. LUNG. PASSIVE HYPERAEMIA AND OEDEMA. ($\times 230$)

- a.* Distended and tortuous capillary, anastomosing with others; all many times their normal diameter.
- b.* Pigmented cells of heart disease within alveolus.
- c.* Granular material representing coagulated oedematous fluid, distending the alveolus. A few red cells and an occasional leucocyte are also seen.

separated epithelial cells and leucocytes. In cardiac cases there is generally pigment in the perivascular and perilymphatic spaces and a few large pigment cells in the alveoli.

CHAPTER XIV

RESPIRATORY SYSTEM—(Continued)

ILLUSTRATIVE PREPARATIONS.

1. Red hepatisation in lobar pneumonia.
2. Grey hepatisation in lobar pneumonia.
3. Broncho-pneumonia.
4. Anthracosis of the lung.
5. Miliary tubercle of the lung.

Pneumonia is an inflammatory condition of the lung, accompanied by exudation, and may arise primarily in the lung tissue over a large area at one time (lobar or croupous pneumonia), or begin and spread from small bronchial foci (catarrhal or lobular pneumonia, broncho-pneumonia) either by way of the peribronchial tissue into the neighbouring lung substance, or along the smaller air passages into the alveoli.

The causes are very various, but are probably always, either primarily or secondarily, of an infectious nature.

Lobar pneumonia is conventionally divided into four stages: (1) congestion, (2) red hepatisation, (3) grey hepatisation, and (4) resolution. It is probable that stage 3 is omitted when recovery takes place.

(1) Congestion is only a late stage of active hyperaemia. The capillaries are so distended that the alveolar walls look wider than normal and some fibrinous exudate, with a few cast-off cells, is found in the alveolar spaces. The larger vessels, including the arterioles, are also distended. This condition passes into

(2) Red hepatisation, so termed because the semi-solid lung

u-
e
or
ar
i-
g
r
:
d
n
e
r
?
5
5

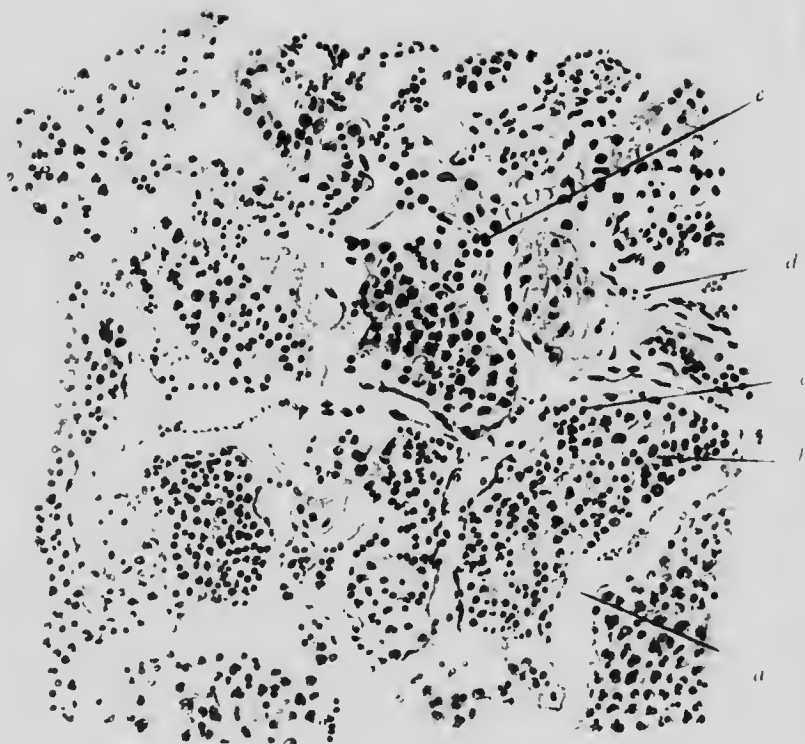


FIG. 61. LUNG. LOBAR PNEUMONIA. Red hepatisation. (x 225)

- a.* Greatly distended capillaries.
- b.* Alveolus distended with fibrin, leucocytes and some erythrocytes.
- c.* Aggregation of lymphocytes.
- d.* Artery cut in longitudinal section.
- e.* Enlarged endothelial cell.

has, when cut into, a certain naked eye resemblance to liver.

Microscopically, the chief additional change to those seen in the first stage, is the great increase in the amount of intra-alveolar fibrin, containing some leucocytes, some red cells, and blood pigment, which collectively fill up the alveoli the relative proportions varying considerably in different alveoli. Where intracapillary, or intralymphatic clotting has occurred, fibrin may be seen also in these vessels (Fig. 64). Sometimes the bands of fibrin are continuous between alveoli through Cohn's stigmata.

If exudation continue

(3) Grey hepatisation results, in which the naked eye colour is due partly to disappearance of the red cells by the emptying of the capillaries by pressure of the exudate and partly to the large number of leucocytes now occupying the alveolar spaces and undergoing fatty change. The fibrin network is beginning to break up and the individual threads are no longer distinct. Mixed with the leucocytes is a considerable quantity of cast-off alveolar cells. In cases which recover, grey hepatisation probably does not occur, but

(4) Resolution follows straight on red hepatisation. The exudate softens and is absorbed or expectorated. Microscopically, the fibrinous network and the cells are seen to be completely broken up, so that the alveolar spaces are gradually emptied, and the lung tissue gradually recovers its former condition. But recovery may also be accompanied by connective tissue proliferation, which fills the alveoli and subsequently becomes fibrous, causing the condition of chronic pneumonia, known as carnification, from its flesh-like appearance.

Broncho-pneumonia is characterised macroscopically by its patchy distribution in the lung: microscopically, the appearance is protean owing to the great variety of agents capable of producing broncho-pneumonia.

Commencing in a bronchiole, the process may spread either along the bronchiole into the alveoli, or by way of the

peribronchial tissue. The first variety is the common type of catarrhal pneumonia, the latter is more apt to follow other acute infectious diseases such as influenza, measles and so on.

The first type begins with inflammation of the bronchial mucous membrane and casting off of its cells, which may then fill up its lumen. If this occur, collapse of the corresponding portion of the lung follows, but it is distended later by the shedding and swelling of the alveolar epithelium, and by the exudation of leucocytes and erythrocytes, almost entirely without the formation of fibrin. The lobular distribution is thus well marked (Fig. 65).

In the peribronchial type, with interalveolar continuity, ordinary pus cells predominate, the blood-vessels are distended, and fibrin is present, so that the appearance approximates to that of lobar pneumonia, and is distinguishable only by reason of its irregularity of distribution.

Sometimes giant cells are found in the exudate.

Tubercle of the lung is an inflammatory process of the broncho-pneumonic type, but set up in so many ways as to produce a great diversity of appearance, although it most probably commences in each case in a lymphatic gland or lymphoid tissue. Tubercles, giant cells and tubercle bacilli are always present, although they may be quite few in number, and require much search to find.

Three principal classes may be distinguished: acute, semi-acute and chronic.

In the acute form, tubercles, as already described, appear simultaneously at many foci in the alveolar walls and, in growing, cause a desquamation of epithelium and a fibrinous deposit. Usually several foci fuse to form the distinct macroscopic conglomerations found in an acute miliary tubercle. In this stage the tubercles are still within the elastic fibres bounding contiguous alveoli, although later they break through into the alveolar space. Life usually continues long enough for central degeneration and caseation of many of the tubercles to take place, but the tubercles are occasionally of uniform size throughout the lung.

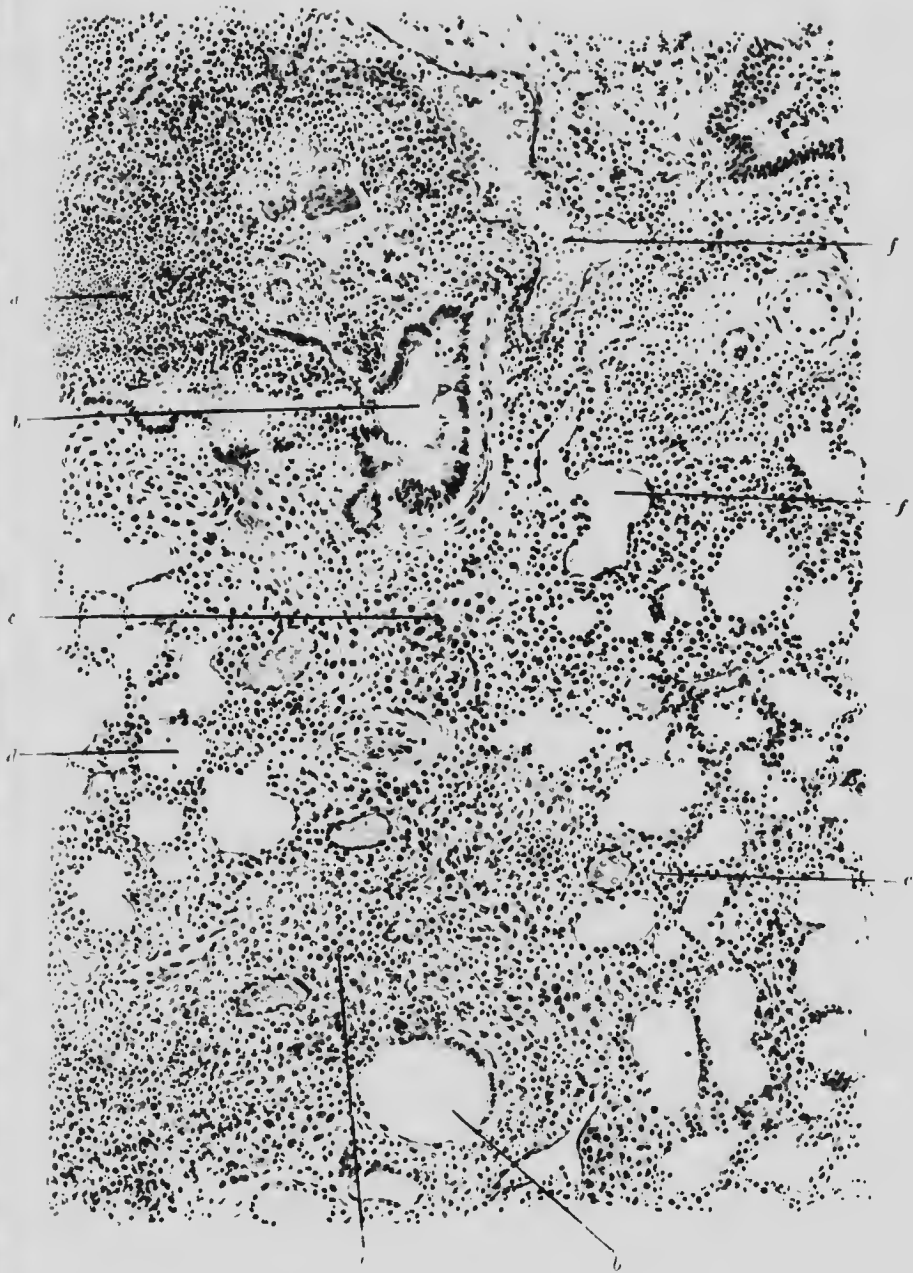


FIG. 65. BRONCHOPNEUMONIA. (· 75)

- a.* Leucocytes in lumen of bronchiole.
- b.* Swollen and partly detached columnar cell layer of bronchiole.
- c.* Exudate into alveoli.
- d.* Comparatively normal alveoli.
- e.* Exudate around vessel and bronchiole.
- f.* Congested blood-vessel.

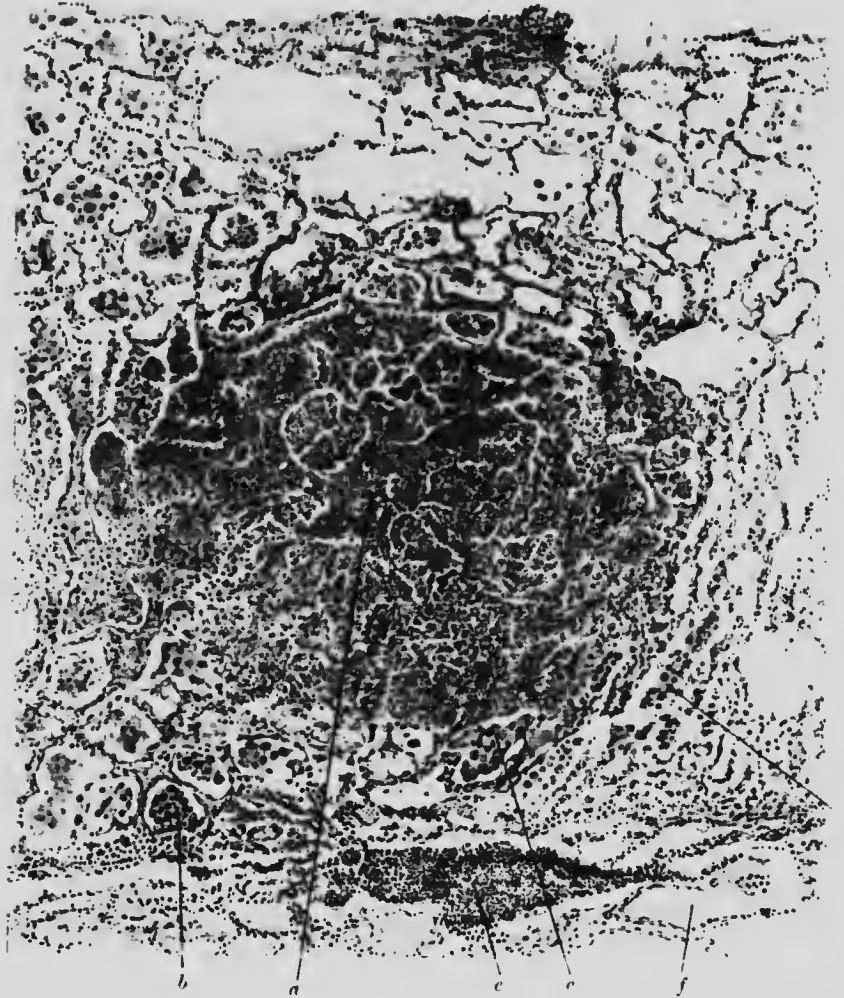


FIG. 66. LARGE MILIARY TUBERCLE. LUNG. ($\times 75$)

- a.* Centre of an area consisting of several alveoli filled with grey caseous material with some nuclear material and leucocytes.
- b.* Proliferation of endothelium of alveolus.
- c.* The same in a later stage.
- d.* The same, beginning degeneration of which (*a*) is the ultimate stage.
- e.* Circumferential inflammation in the neighbourhood of
- f.* blood-vessel.

In the semi-acute form the process starts from lymphoid tissue, generally peribronchial, although sometimes it begins

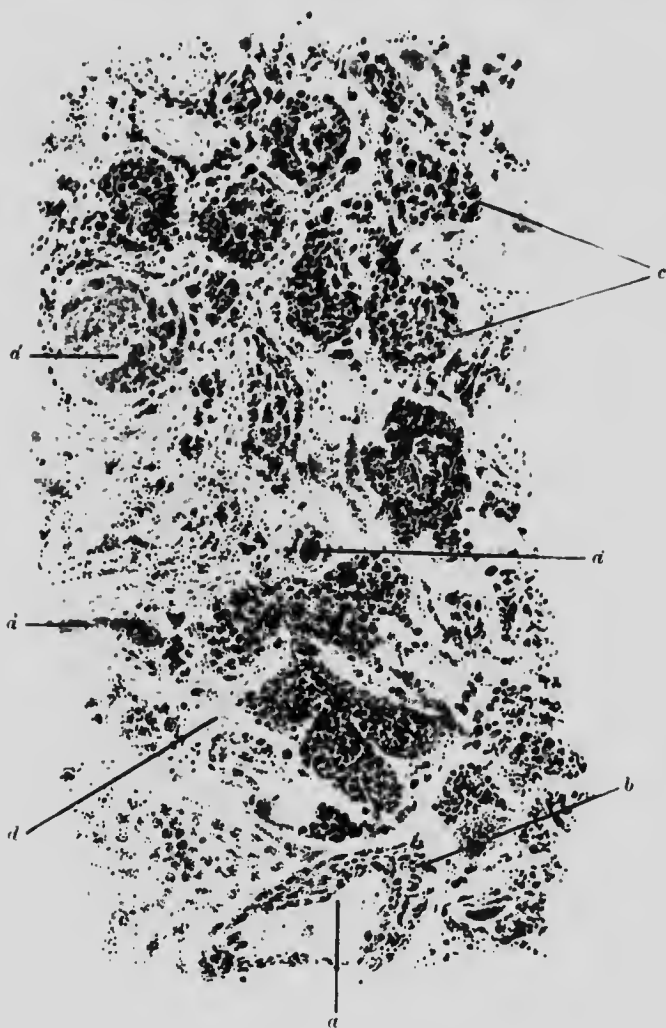


FIG. 67. LUNG. ANTHRACOSIS. ($\times 60$)

- a.* Arteriole with pigment in wall.
- a'.* Distended venules.
- b.* Pigment in perivascular lymphatics.
- c.* Pigment within the alveoli, arranged in lobular fashion.
- d.* Perialveolar fibrous tissue.

endobronchially. It extends further and more slowly than the acute form: there is fusion of tubercles over areas involving many

alveoli, always with a surrounding zone of inflammation. In some instances this zone forms a limiting membrane, its caseous contents break down and are partly absorbed, leaving the typical tuberculous cavity containing dirty mucus and many tubercle bacilli. In this case the tubercles vary very much in size throughout the lung (Fig. 66).

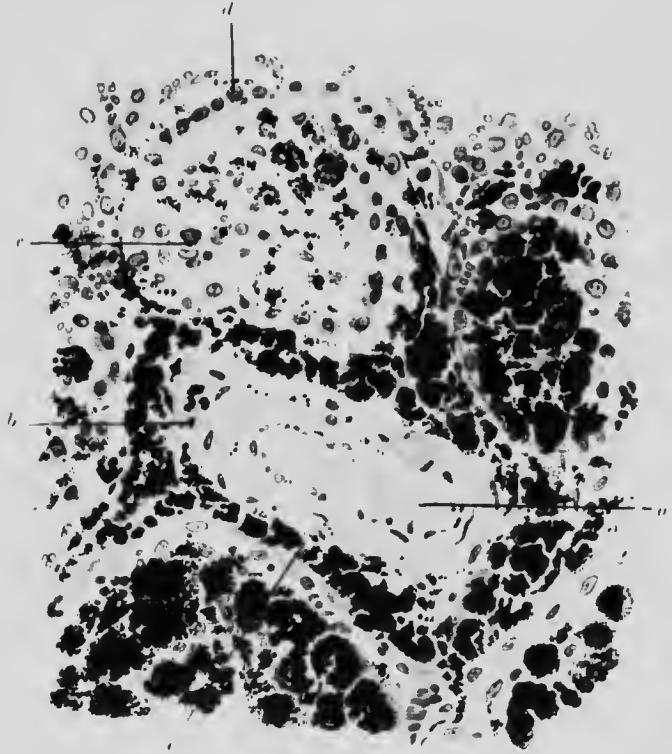


FIG. 68. ANTHRACOSIS OF LUNG. ($\times 400$)

- | | |
|--|---|
| <i>a.</i> Arteriole containing clot. | <i>b.</i> Carbon deposited in its wall. |
| <i>c.</i> Carbon deposit in shed alveolar cells. | |
| <i>d.</i> Alveolar wall. | <i>e.</i> Carbon in lymphatic spaces. |

The chronic form probably results from a limited infection of the sub-acute type, in which the tuberculous material is either absorbed or calcified. The inflammatory reaction then ends in a copious formation of fibrous tissue, which usually contains such pigment as may have been present before and often includes a few giant cells, but is almost devoid of bacilli.

The conditions known as **anthracosis** and **silicosis** are due to unorganised substances inhaled with air and deposited in the lungs. They do not generally remain either at their original site or without effect on the surrounding tissues; the effect varies, however, with the physical rather than the chemical characteristics of the substances.

It would seem, also, that the irritation facilitates bacterial infection, especially that of tubercle. In all cases the chief change is a fibrosis, which generally encloses the irritant.

In the early stages the substance may be found to have a lobular distribution, or it may be perivascular and even enter the muscular layer: later on, it is found included in the layers of connective tissue to the formation of which it has led (Figs. 67 and 68).

The usual irritants are soot and coal dust, stone and metal dust. From the lymphatics the particles may find their way into any part of the organ.

CHAPTER XV

THE HEART

ILLUSTRATIVE PREPARATIONS.

1. Brown atrophy in heart muscle.
2. Fatty degeneration of heart muscle.
3. Chronic myocarditis.
4. Acute interstitial myocarditis.
5. Suppurative myocarditis.

THE **heart** is liable to pathological changes as the result both of age and of disease: the form of change is often identical.

Brown atrophy is of frequent occurrence. It is not really a simple change. It is found in old age and also as an accompaniment to many wasting diseases. It obtains its name from the naked eye appearance of the heart muscle and this, under the microscope, is seen partly to depend on the deposit of brown pigment around and about the nuclei of the muscle fibres, enclosing the nucleus in a sort of double sugar loaf (Fig. 69). In most instances the remainder of the fibre also is affected, as shown by the partial or complete loss of striation, the tendency to fragmentation and by the individual fibres being thinner than normal. At some spots and in some vessels there are indications of chronic inflammation.

Cloudy swelling occurs chiefly in acute febrile diseases, either as a secondary toxic effect or from actual inflammation of the muscle substance. It is often followed by fatty degeneration. Macroscopically, the heart substance is altered in colour, semi-translucent, soft and friable.

Microscopically, in a fresh unstained specimen, the fibres look opaque and granular, with partial or complete loss of striation. The granules are soluble in water or dilute acetic acid. The condition often occurs only quite locally in the fibre. In stained specimens the increase of connective tissue is the most marked feature.

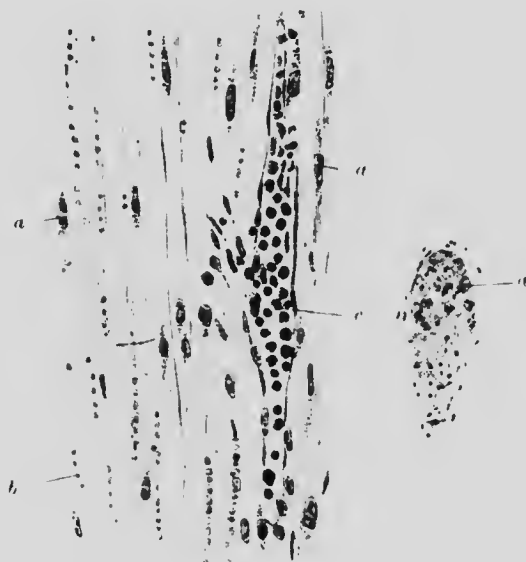


FIG. 69. HEART MUSCLE. BROWN ATROPHY. ($\times 250$)

- a.* Nucleus of muscle fibre surrounded with brown pigment.
- b.* Erythrocytes in capillaries.
- c.* Small blood-vessels abnormally full of leucocytes.

Fatty infiltration of the heart. or "fatty heart," implies merely excessive deposit of fat external to the heart muscle, which may thus be mechanically affected when the fat is much in excess, or infiltrates far below the epicardium. The fat globules are large, packed close together and quite outside the heart muscle, unless it is (as often is the case) has also partly degenerated.

Fatty degeneration occurs as the sequel of many febrile diseases, *e.g.* scarlet fever or such blood diseases as pernicious anaemia, or from the action of some inorganic poisons, *e.g.* phos-

phorus. It may arise also by inflammation spreading from pericardium or endocardium, or from mechanical interference with the vascular supply (atheroma of the coronary arteries). When

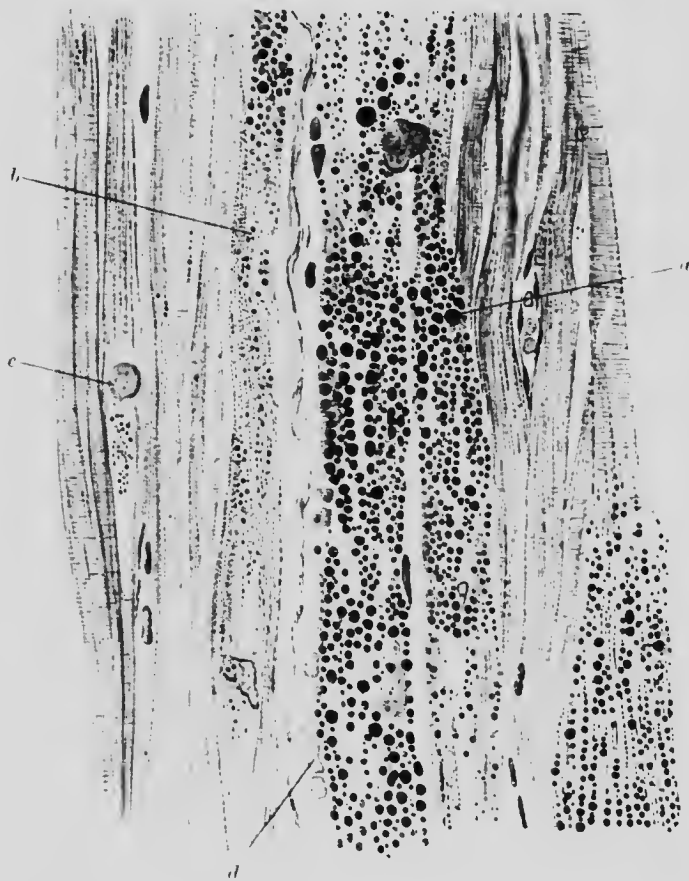

FIG. 70. HEART. FATTY DEGENERATION IN PERNICIOUS ANAEMIA. ($\times 340$)

- a.* Muscle fibres with large fat droplets. Striation lost
b. Muscle fibres with small fat droplets. Striation lost.
c. Swollen nucleus. *d.* Erythrocytes.

visible to the naked eye the fatty change is usually indicated by wavy striations arranged like a tiger's stripes.

Microscopically, under a low power, in a specimen stained with osmic acid, this arrangement, indicating a partial degeneration in each affected fibre, becomes very marked. Under a high power it is seen that some increase of connective tissue has taken place

and fat globules of various sizes, from mere black dust points to globules occupying the whole diameter of the fibre, may be observed within the fibres. Their striation is obscured and may be entirely lost (Fig. 70).



FIG. 71. HEART. INTERSTITIAL MYOCARDITIS. ($\times 100$)

- a.* Area of degenerate muscle fibres, several without nuclei: much infiltration.
- b.* Area of fairly normal fibres: much less infiltration.
- c.* Leucocytes, lymphocytes and plasma cells in intermuscular spaces.

Acute myocarditis occurs generally as a secondary condition by spread from the pericardium. The heart muscle looks red, may be speckled with yellow patches and is friable.

Under the microscope, some fibres are seen to be swollen and opaque, some are quite disintegrated, while others look normal. In the interstices there is considerable exudation of leucocytes, together with proliferation of connective tissue (Fig. 71).

Chronic myocarditis is frequently found as an accompaniment of general diseases with high blood pressure. There is a chronic




FIG. 72. HEART. CHRONIC (FIBROID) MYOCARDITIS (LONGITUDINAL AND TRANSVERSE SECTION). ($\times 100$)

- a.* Zone of fibres, cut transversely, and much intervening fibrous tissue. *a* points to cell with enlarged nucleus.
- b.* Zone of fibres, also with much fibrous tissue, cut longitudinally.
- c.* Zone as *b*, with much less fibrous change.

inflammatory change, characterised at first by an increase of fibrous tissue and later by atrophy of the muscle fibres.

Microscopically, in the early stages there is perivascular infiltration with mononuclear cells and the smaller vessels are dilated. Some of them have thickened walls. The muscle fibres are collected in islets separated by fibrous tissue. They may not be obviously altered, or they may be atrophic, or fatty, especially in areas containing many young fibrous tissue cells with long spindle-shaped nuclei (Fig. 72).

In syphilitic myocarditis, a chronic interstitial inflammation in the perivascular and perimuscular connective tissue, with destruction of muscle fibres, is more common.

CHAPTER XVI

THE HEART—(*Continued*). THE BLOOD-VESSELS

ILLUSTRATIVE PREPARATIONS.

1. Acute endocarditis.
2. Chronic endocarditis.
3. Chronic endo-, myo- and pericarditis.
4. Syphilitic endarteritis in a cerebral vessel (early stage).
5. Syphilitic endarteritis (arteritis obliterans).
6. Atheroma of a cerebral vessel.
7. Kidney to show arterio-sclerosis of its vessels.

Endocarditis may be found in specimens as an acute, or as a chronic process, but the latter is probably always a later stage of a non-fatal acute attack. Its origin is in all cases infective, the variable result depending on the varying virulence of the micro-organisms. In the chronic form it is not always possible to demonstrate bacterial presence.

The ordinary manifestation is a "vegetation" of warty appearance on the congruent edges of the mitral or aortic valves: and very rarely on the tricuspid valve. The inflammation may appear, also, on any part of the auricular or ventricular endocardium as an irregular, rough, red deposit. The size of the vegetation, or the amount of the deposit, is more or less proportionate to the duration of the acute stage of the disease: in the chronic stage it tends to shrink. Microscopically, the process may be divided into two parts: that in the endocardium and that outside it.

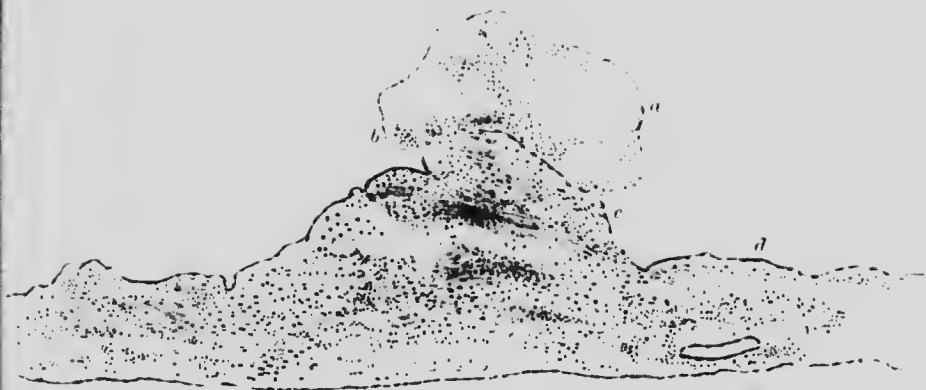

FIG. 73. VEGETATION ON MITRAL VALVE. ENDOCARDITIS. ($\times 25$)

- a.* Blood clot, mostly erythrocytes.
- b.* Collection of leucocytes next endocardium.
- c.* Proliferated endocardial cells.
- d.* Endocardium.
- e.* Proliferated fibrous tissue cells.

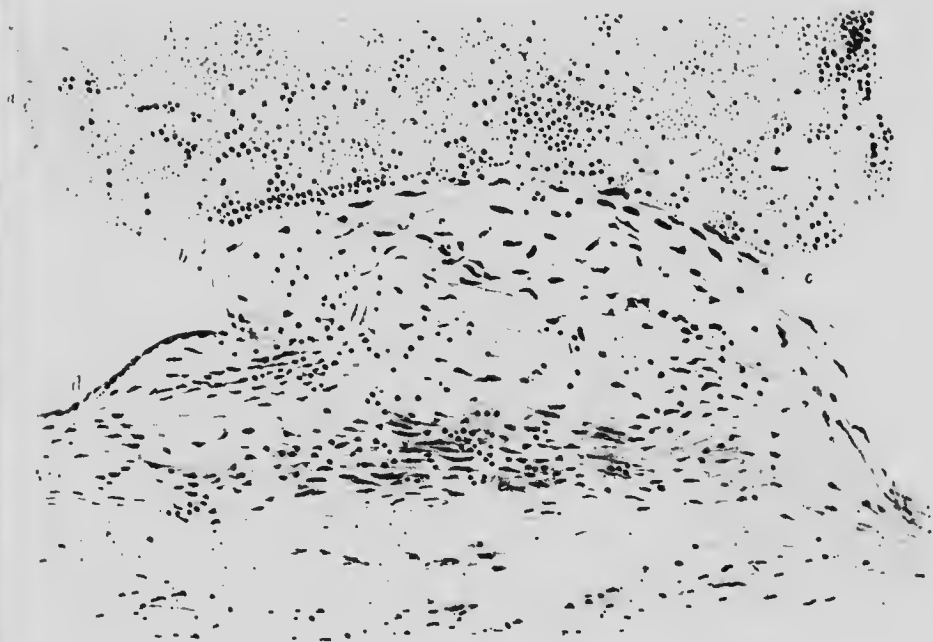

FIG. 74. ENDOCARDITIS. VEGETATION ON MITRAL VALVE. ($\times 200$)

- a.* Blood clot, mostly erythrocytes.
- b.* Collection of leucocytes next endocardium.
- c.* Proliferated endocardial cells.
- d.* Endocardium.
- e.* Proliferated fibrous tissue cells.

In the acute stage the projections (vegetations) are small and of spherical or mulberry shape and consist mainly of fibrin embracing a small number of leucocytes and disintegrating red cells. The whole mass is adherent to the endocardium and at this part the endocardium is swollen and projecting by reason of the proliferation of the subendothelial connective tissue cells (Figs. 73 and 74). With suitable stains micro-organisms can generally be demonstrated on the endothelial surface. If the inflammation occurs near heart muscle there is usually some accompanying myocarditis.

When the condition passes into the chronic stage, the vegetations become larger and more irregular. They become organised and adherent to the heart valve or wall, but remain for a time friable enough for the detachment of fragments to occur. The connective tissue of the valve and of the vegetation become practically continuous. Subsequently lime salts may be deposited under the endothelium, or the newly formed fibrous tissue may undergo atheromatous changes. Microscopically, it will be seen that fibroblasts have taken the place of the leucocytic infiltration which lay between strata of genuine fibrous tissue (Fig. 75).

Blood-vessels.—Disease in the arteries begins in most cases in the inner coat, but in some cases it is said that the middle coat is first affected.

As elsewhere, inflammation in arteries may be acute or chronic, the latter form occurring without clinical or pathological evidence of previous acute inflammation.

Since different arteries vary somewhat in structure, the microscopical appearances resulting from the same process differ. Acute inflammation, arteritis, is uncommon and occurs most often near the commencement of the aorta, either as an extended endocarditis or as a primary acute infection. The affected portion has characteristic raised gelatinous yellow or pink patches, well defined from the unaffected surroundings and there is usually some corresponding external inflammation (periarteritis).

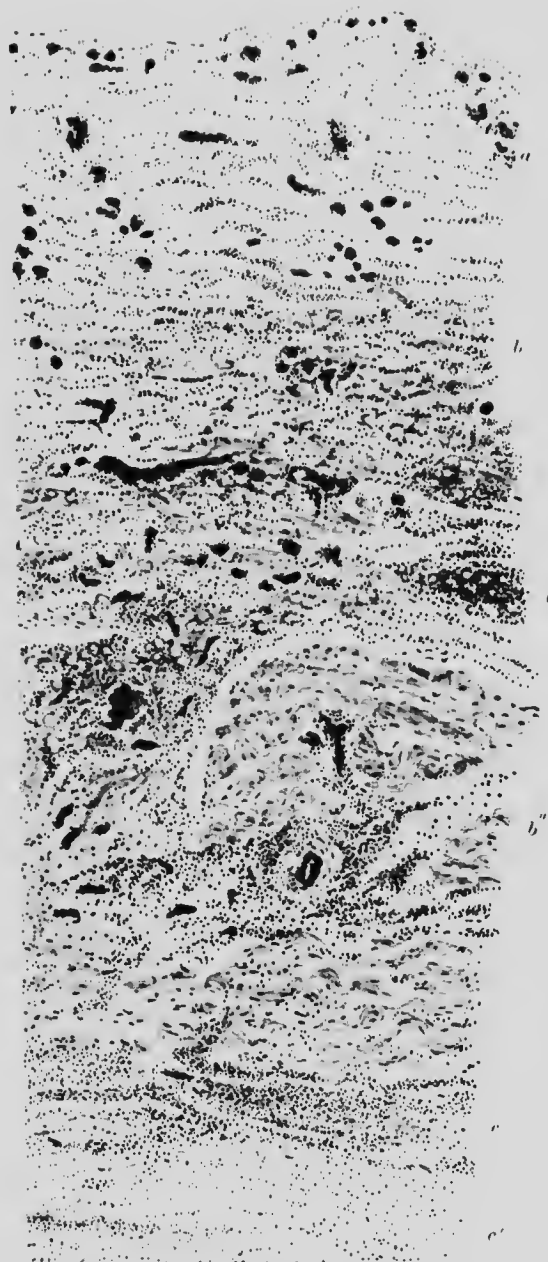


FIG. 75. HEART. CHRONIC ENDOCARDITIS, MYOCARDITIS AND PERICARDITIS. ($\times 30$)

- a.* Thickened pericardium with dilated vessels.
- b, b' and b''.* Heart muscle showing infiltration and some fibrous change.
- c.* Boundary between muscle and endocardium, which at *c'* is thickened and less cellular.

Microscopically, all the layers are seen to be infiltrated with leucocytes, causing separation of the various strata: and there may be some necrotic changes. The intima is chiefly affected and if recovery takes place it undergoes a fibroid change which narrows the lumen of the vessel.

In **arteriosclerosis**, or **atheroma**, also termed chronic endarteritis, the naked eye appearance varies very much according to the age of the lesion. All gradations and varieties may be found, from slightly raised yellow patches with regular edges, to depressed greyish hard areas with a coast line border. The changes seen microscopically are practically limited to the intima. They are bounded externally by the internal elastic lamina where it is present and internally by the endothelium. The distance between these two layers may, by the proliferation of the intima, be increased even by as much as the diameter of the vessel. The new material deposited consists of fresh connective tissue in varying stages of degeneration and is generally arranged in strata according to age, but the various stages are also found intermingled.


The first change consists of an increase in the fibrous tissue cells beneath the intima, accompanied by some small cell infiltration, which gradually spreads for a short distance around the circumference of the vessel and increases in thickness (Fig. 76). On account of this one sided affection of the vessel wall, the condition is sometimes termed endarteritis deformans. Later on, spaces form between this new laminated tissue which are larger towards the outer layers and are filled with either fatty or calcareous material; the latter is often in the form of spiky crystals, staining in part with Scarlet R and thus revealing its fatty nature (Figs. 77 and 78).

In some cases of old standing the changes seem more pronounced in the media and are similar to those already described, except that they take place outside the internal elastic lamina and are accompanied by some periarteritis (Fig. 79).

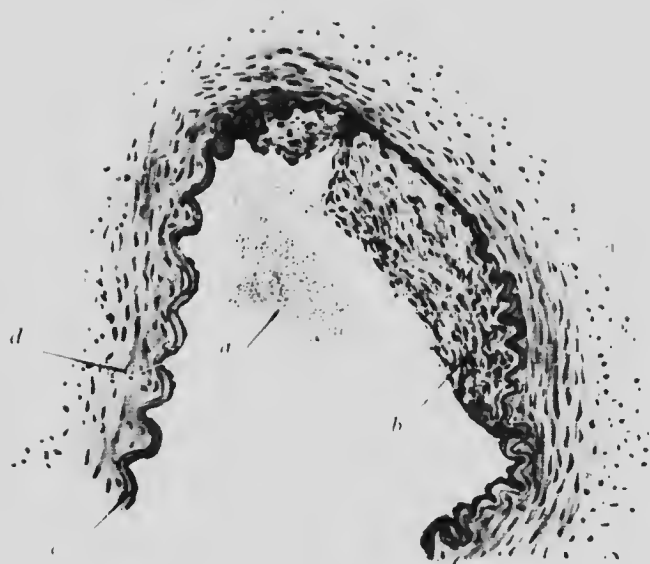

FIG. 76. CEREBRAL VESSEL FROM CHIMPANZEE showing early syphilitic endarteritis. (x 75)

- a.* Blood.
- b.* Much thickened tunica intima.
- c.* Elastic lamina, thinned and straightened where under *b.*
- d.* Muscular coat.



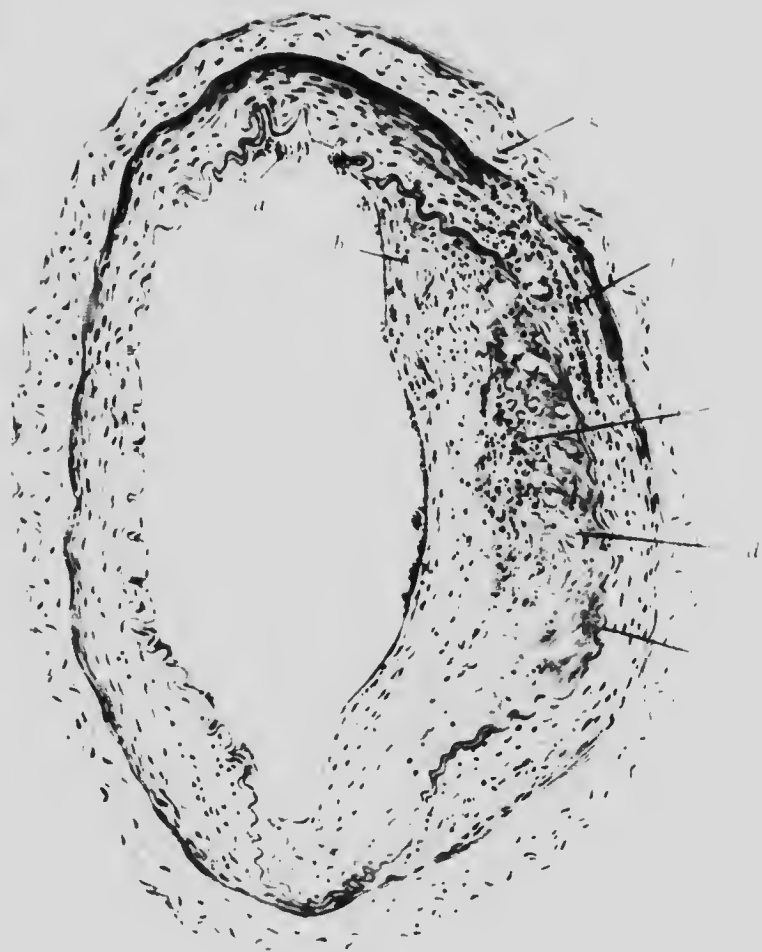


FIG. 77. CEREBRAL VESSEL SHOWING ARTERIOSCKROSIS,
stained with Scarlet R

OX 101

- a. Erythrocytes.
- b. Thickened tunica intima.
- c. Fatty globules, in outermost layers of *b*.
- d. Crystals.
- e. Internal elastic lamina.
- f. Degenerative changes in tunica med.
- g. Tunica adventitia.



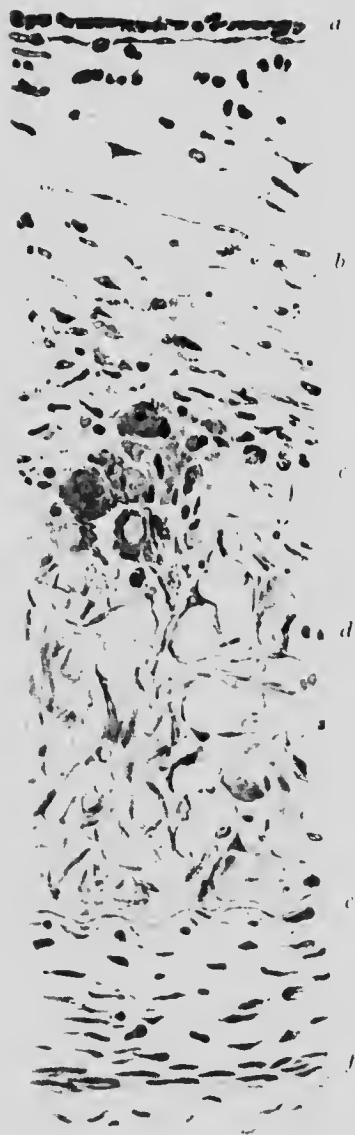


FIG. 78.

Portion of Fig. 77.
Lettering as before.

(x 300)

1870
1871
1872
1873
1874
1875
1876
1877
1878
1879
1880
1881
1882
1883
1884
1885
1886
1887
1888
1889
1890
1891
1892
1893
1894
1895
1896
1897
1898
1899
1900
1901
1902
1903
1904
1905
1906
1907
1908
1909
1910
1911
1912
1913
1914
1915
1916
1917
1918
1919
1920
1921
1922
1923
1924
1925
1926
1927
1928
1929
1930
1931
1932
1933
1934
1935
1936
1937
1938
1939
1940
1941
1942
1943
1944
1945
1946
1947
1948
1949
1950
1951
1952
1953
1954
1955
1956
1957
1958
1959
1960
1961
1962
1963
1964
1965
1966
1967
1968
1969
1970
1971
1972
1973
1974
1975
1976
1977
1978
1979
1980
1981
1982
1983
1984
1985
1986
1987
1988
1989
1990
1991
1992
1993
1994
1995
1996
1997
1998
1999
2000
2001
2002
2003
2004
2005
2006
2007
2008
2009
2010
2011
2012
2013
2014
2015
2016
2017
2018
2019
2020
2021
2022
2023
2024
2025

The internal elastic lamina is affected very early. It may either be straightened out or the fibres may be split up




FIG. 79. ARTERY. CHRONIC ARTERITIS. ($\times 50$)

- a.* Thickened and fibrous intima.
- b.* Haemorrhage between intima and media.
- c.* Necrotic, partly fatty, partly calcified material, below the intima.
- d.* Infiltration of lymphocytes and plasma cells in media.
- e.* Vasa vasorum.

(Fig. 79*) and also reduced in number, their place being taken by ordinary connective tissue.

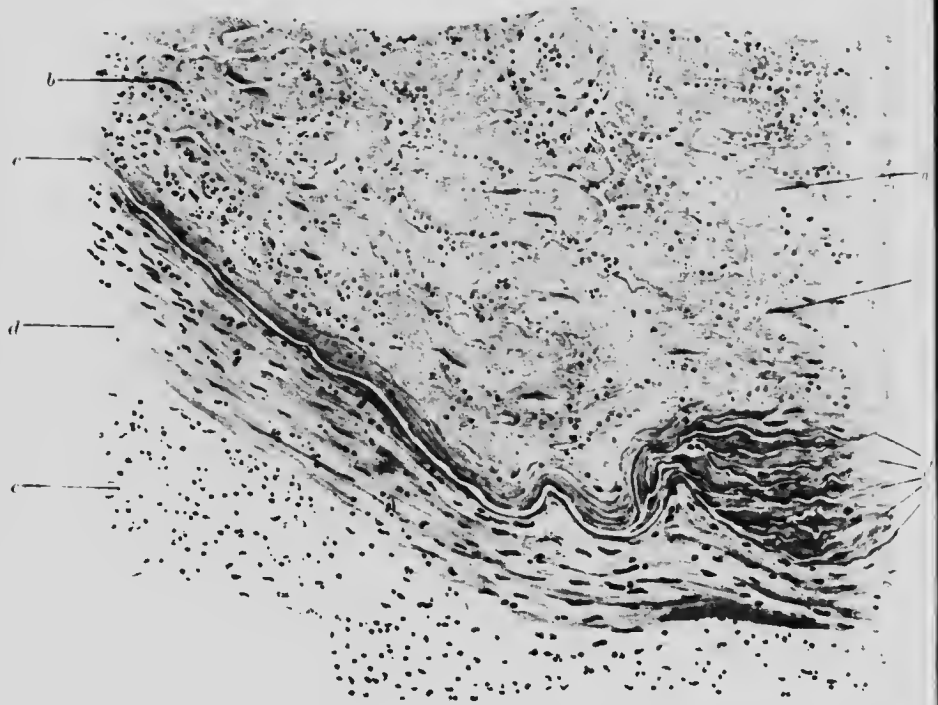


FIG. 79*. ARTERY. THROMBOSIS (RECENT). (150 \times)

- a.* Clot, partly shrunken, the clefts filled with erythrocytes.
b. Fibroblasts.
c. Internal elastic lamina split up at *c'* into several layers.
d. Media. *e.* Adventitia.

In another form, endarteritis obliterans, which is the usual type in syphilis and chronic interstitial nephritis, there is the additional factor of endothelial proliferation.

In consequence the lumen of the vessel is narrowed and may ultimately be obliterated.

CHAPTER XVII

THE ALIMENTARY SYSTEM

ILLUSTRATIVE PREPARATIONS.

1. Epithelioma of the tongue.
2. Stomach showing subacute gastritis.
3. Stomach showing chronic gastritis.
4. Stomach showing ulceration.
5. Stomach showing fibrosis and hypertrophy (leather bottle).
6. Carcinoma of the stomach.

THE **tongue** is subject to inflammation (**glossitis**) and is not infrequently the site of new growth. The processes are related to one another, inasmuch as syphilitic glossitis, or the ulceration resulting from a sharp edge of a tooth, often precedes epithelioma.

In **glossitis** the lower layers of the epithelium are increased in thickness, as well as the stratum of dead superficial cells (leukoplakia). Beneath the epithelium is a condition of chronic inflammation, from which some of the cells may invade the epithelium, breaking through the basal layer and causing a breach in its continuity (Fig. 26).

Epithelioma of the tongue resembles in its general features epithelioma occurring elsewhere, but is specially characterised by the rapid invasion of the muscular planes (Fig. 80).

The **pharynx** is often the seat of chronic inflammation and sometimes of new growth.

The **oesophagus** is not infrequently the seat of epithelioma, which is of the squamous cell type.

Acute inflammation of the stomach, **acute gastritis**, occurs as the result of bacterial infection and the action of poisons. The changes are similar to those seen in other acute inflammatory

conditions of mucous membranes, but they are rarely demonstrable on account of rapid post-mortem changes. Consequently, loss of

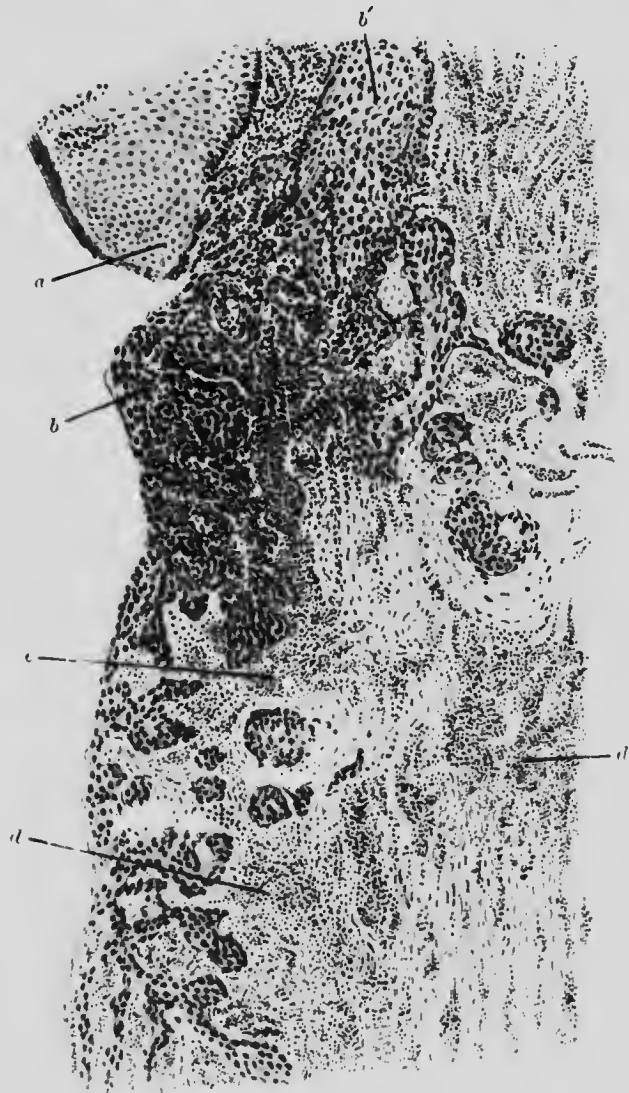


FIG. 80. TONGUE. EPITHELIOMA. ($\times 35$)

- a.* Edge of normal epithelium.
b. Epitheliomatous cells, which at *b* are undermining the normal epithelium.
c. Inflammatory reaction at edge of growth. *d.* Leucocytic reaction in muscle-tissue.

epithelium and evidence of hypersecretion of mucus are the chief features actually observed, together with infiltration into the muscular layers.

Subacute (granular) gastritis is seen especially as a result of alcoholism. Its distinguishing histological feature is the increased distance between individual glands, the space being occupied by a round cell infiltration, which raises the mucous membrane into

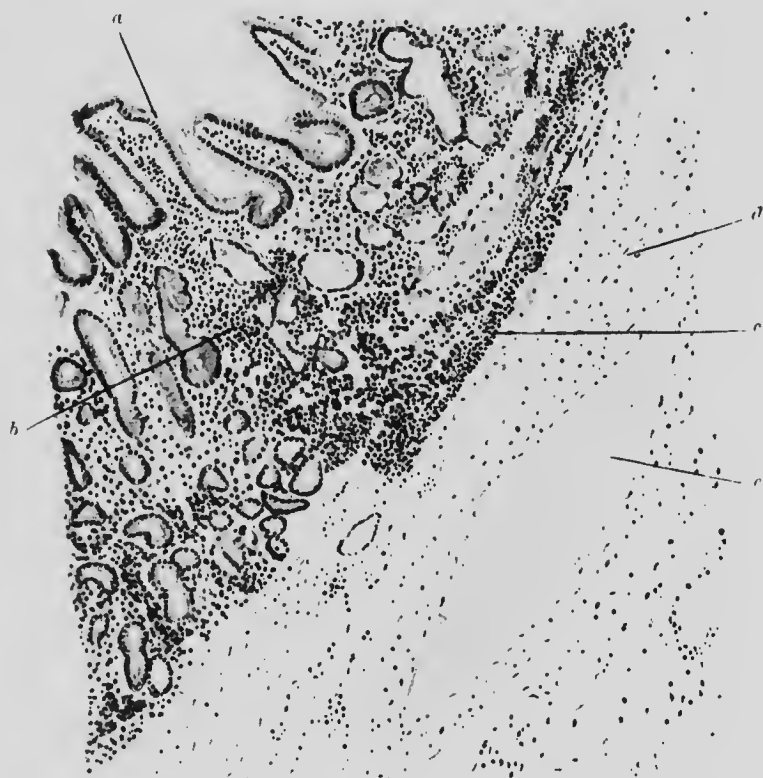


FIG. 81. STOMACH. SUBACUTE GRANULAR GASTRITIS. ($\times 100$)

- a.* Mucous gland enlarged.
b. Interglandular infiltration of neutrophile leucocytes and plasma cells.
c. Submucosal infiltration.
d. Submucosa. *e.* Blood-vessel.

folde and is accompanied by connective tissue proliferation. The glandular substance proper also shows signs of irritation: mitotic figures are more numerous than normal and the remaining glands assume a more mucous type with the formation of many goblet cells (Fig. 81). Finally, atrophy of the mucous membrane and its replacement by connective tissue ensue.

Chronic gastritis exhibits similar features, but atrophy of the mucous glands takes the place of enlargement. The distance between the glands is increased and the space is occupied by new connective tissue or plasma cells and lymphocytes (Fig. 82).

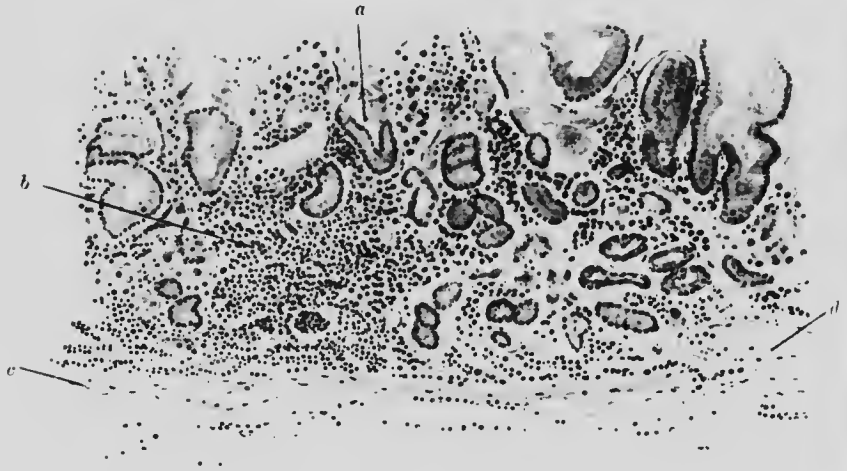


FIG. 82. STOMACH. CHRONIC ATROPHIC GASTRITIS. ($\times 100$)

- a.* Atrophic gland. All the gland tissue is reduced in amount.
b. Exudate of lymphocytes and mononuclear cells.
c. Submucosa. *d.* Blood-vessel.

The extent of tissue involved in **gastric ulcer** and consequently the appearance of the ulcer depend largely upon the duration of the process. The causation is unknown, but thrombosis of a small vessel elsewhere produces a similar result. A circular area of mucous membrane necroses, the edge shading off gradually into normal cells and giving an impression as if the mucous membrane had been shaved off rather steeply. The underlying submucosa is the seat of a chronic inflammation, with destruction of its tissue over a rather smaller area: the loss of substance diminishing through the coats, outwards, to a conical apex (Fig. 83).

Ultimately, the ulcer either perforates, or more often heals, so that only an inconspicuous external scar remains. The stomach wall is thinner and more fibrous than normal at this part, but is covered with apparently normal mucous membrane.

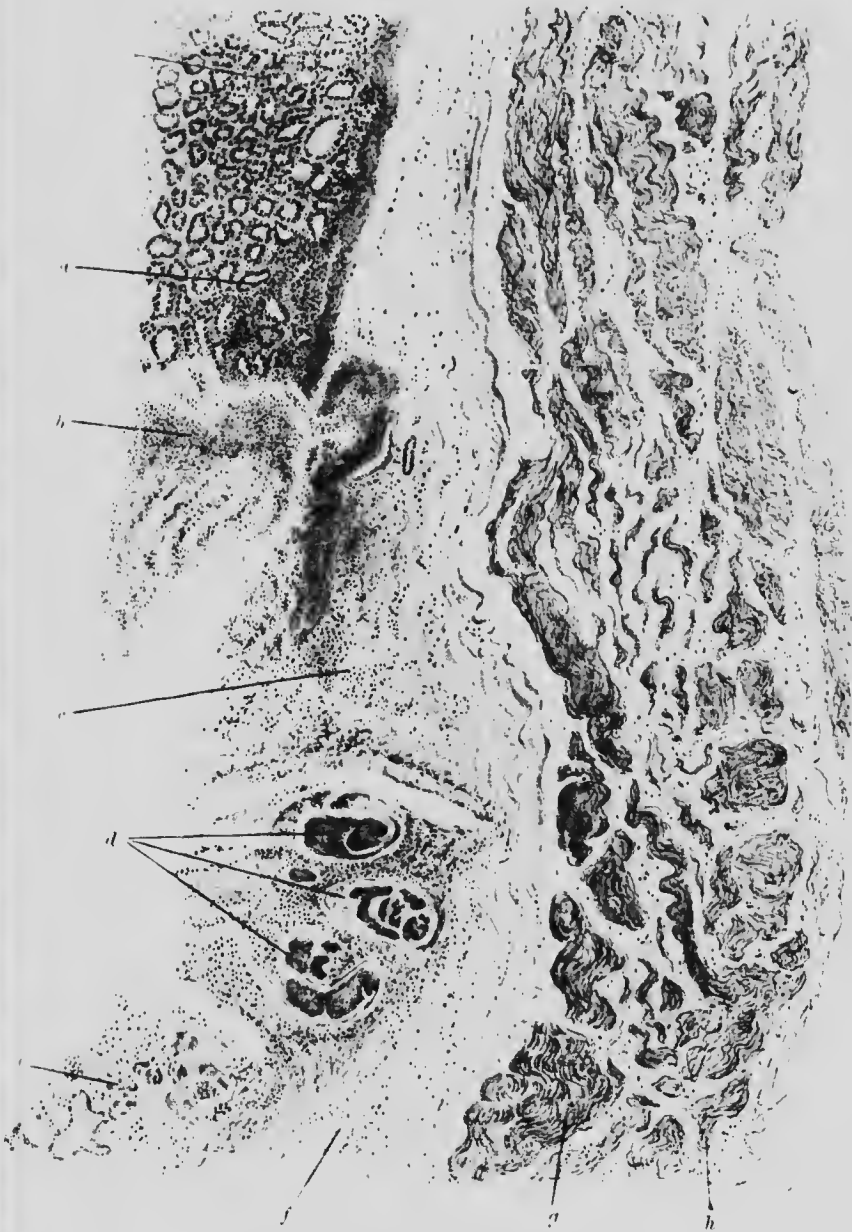


FIG. 83. ULCER. STOMACH. ($\times 20$)

- | | |
|--|--|
| <i>a</i> Fairly healthy glands. | <i>b</i> Debris of necrotic tissue. |
| <i>c</i> Submucosa partly infiltrated and necrotic. | <i>d</i> Thrombosed veins on floor of ulcer. |
| <i>e</i> Glands partly necrotic. | <i>f</i> Submucosa. |
| <i>g</i> and <i>h</i> . Longitudinal and circular muscle fibres. | |

G. H.

H

Congestion, found in chronic heart disease, gives a red colour to the mucous membrane, with the appearances of congestion and catarrhal proliferation of cells as seen elsewhere.

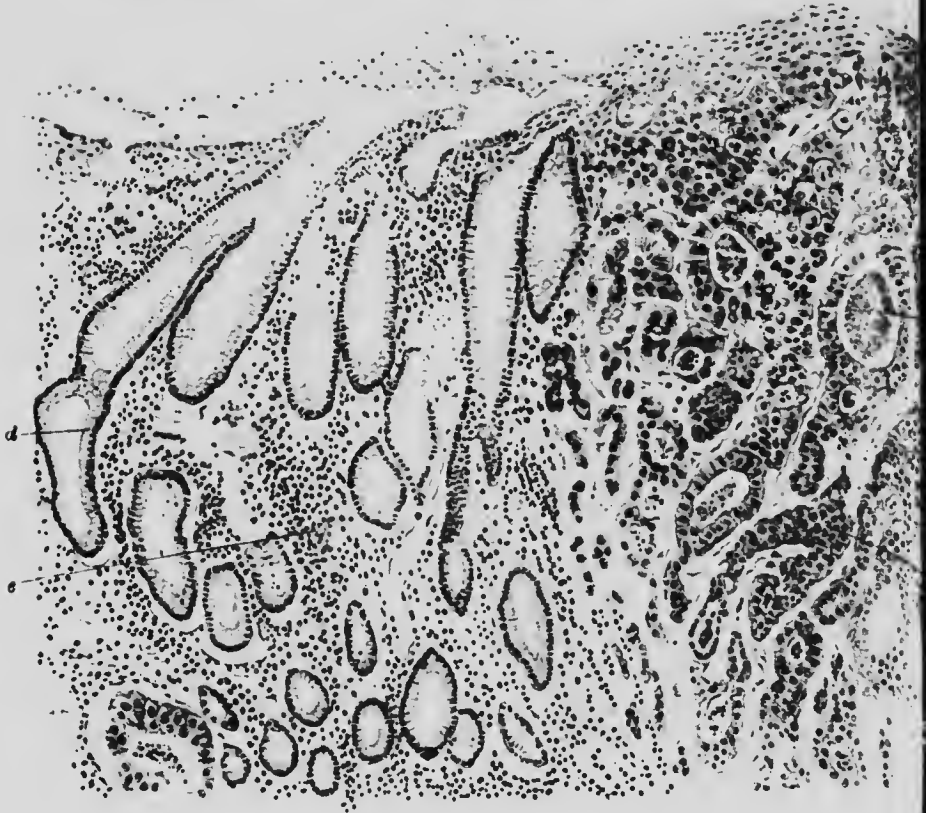


FIG. 84. CANCER. STOMACH. ($\times 100$)

- a. Secretion and flattened superficial cells.
- b. Solid strand of cancer cells
- c. Debris in lumen of a hollow cylinder of cancer cells.
- d. Normal pyloric glands.
- e. Periglandular infiltration

Cancer of the stomach appears often to arise on an old ulcer, but its occurrence is not limited to the ulcer area and it may be found at either end of the stomach, although generally at the pylorus. When arising at the cardiac end the growth is more luxuriant, cauliflower-like and freely ulcerating: at the pyloric end it is circumscribed, fibrous, without or with only limited ulceration.

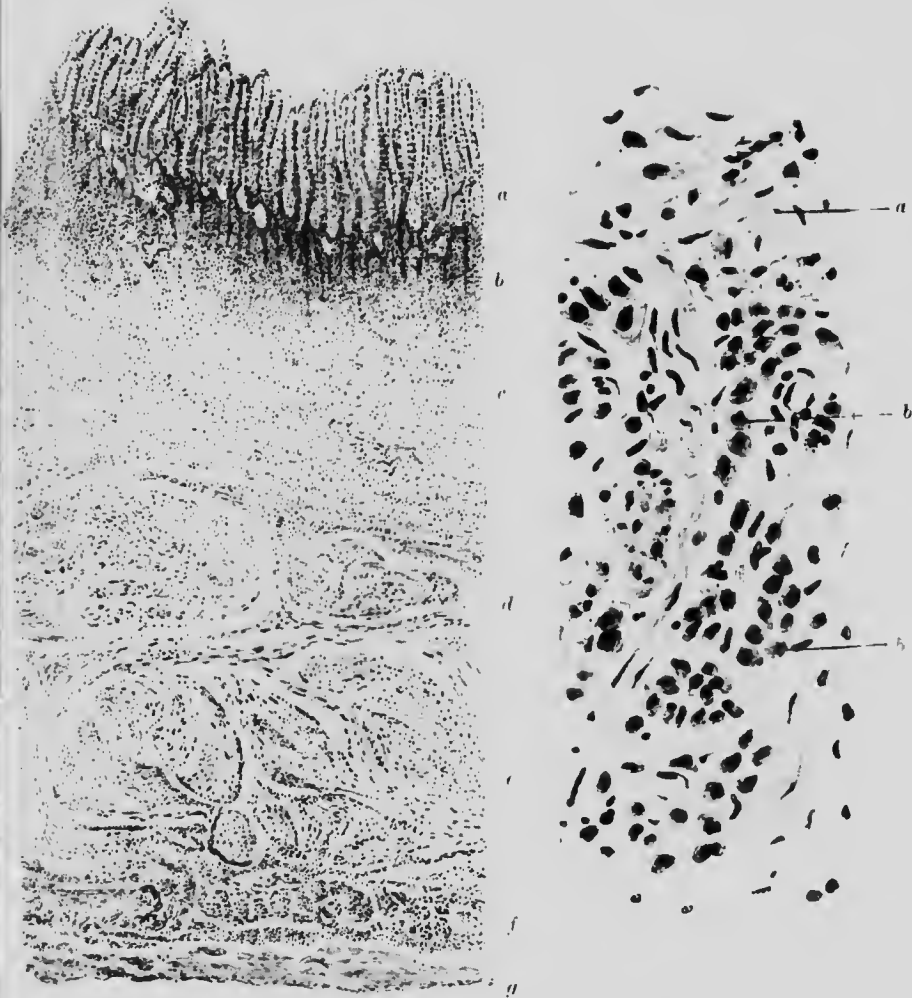


FIG. 85. STOMACH, LEATHER BOTTLE. ($\times 15$ and $\times 400$)

- A.* *a.* Glandular layer extending lower to
b. in the submucosa, which is much infiltrated.
c. Thickened submucosa.
d and *e.* Muscular layers, also thickened.
f. Subperitoneal layer infiltrated.
g. Peritoneum.
- B.* *a.* Fibrous tissue of submucosa.
b. Large gland-like cells in submucosa.

Of course these typical differences are not always present. They are due chiefly to variation in the relative amounts of cellular and fibrous new growth (Fig. 84). Otherwise the appearances are those already described under colonic and colloid carcinoma. The undermining of the mucous membrane by the new growth is small, since it tends to spread and destroy more rapidly along the free surface than elsewhere, but extensive secondary deposits may occur in the walls and glands with but a small primary ulcerated area.

Combined hypertrophy and fibrosis of the stomach occurs in the not uncommon condition of "**leather bottle**" stomach, which is characterised by having a small cavity but very thick and tough walls. Microscopically, the cells of the mucous membrane appear to extend deep down into the submucosa which is thicker than usual and contains an excess of fibrous tissue. The gastric cells in the submucosa are mostly cubical in shape. In addition the muscular coats are hypertrophic and consequently thickened (Fig. 85). By some the condition is held to be a form of carcinomatosis of the stomach.

CHAPTER XVIII

THE ALIMENTARY SYSTEM—(Continued) THE INTESTINES

ILLUSTRATIVE OPERATIONS.

1. Ulcer of intestine
2. Tuberculous ulcer of intestine
3. Appendix in appendix
4. Dysenteric ulcer of intestine

Atrophy of the Intestine—is especially in marantic infants. Macroscopically the wall is thin, transparent and anaemic and usually distended with gas. Microscopically, the mucous membrane is found markedly atrophic and the lymphoid and muscular tissue also reduced.

Lardaceous disease sometimes occurs in the intestine when present elsewhere. It involves the capillaries of the villi, which it thus marks out, although the villi themselves become brittle, denuded of mucous membrane or even broken across.

The small intestine is very subject to inflammation (**enteritis**), which shows the usual naked eye characteristics and, microscopically, loss of epithelium, together with extreme vascular congestion. The cells around the inflamed area become goblet-shaped and distended with mucus. The lymphoid nodules naturally share in the inflammatory process: they are swollen and proliferate rapidly, or, at a later stage, show central necrosis, which, after healing, remains evident as a black pigmented spot.

If the inflammation become chronic, the proliferation of the interglandular connective tissue and the leucocytic infiltration cause deformation and atrophy of the glandular tissue.

Very intense inflammation, such as that caused by metallic poisons, may lead to the formation of a fibrinous membrane over the inner surface of the intestine, but this is unusual.

Two specific inflammations—typhoid and tubercle—are not uncommon in the small intestine. They present very different appearances. Both occur by preference in the Peyer's patches: the former proceeds along the long axis and the latter around the circumference of the bowel.

Typhoid inflammation begins with swelling of the lymphoid tissue, especially of the Peyer's patches, which are raised and look something like a relief map, the mucous membrane over the patch being thrown into wavy folds. Microscopically, in the early stage there is degeneration of the secreting epithelium with proliferation of endothelial cells, especially in the germinal centres, and infiltration with mononuclear cells. These changes, together with the congestion, bring about the swelling of the patch and affect even the lowest layers of the submucosa (Fig. 86). The swelling is followed by sloughing of either a portion or the whole surface of the Peyer's patch or solitary gland. In the latter case the long axis of the ulcer will be parallel to that of the bowel. The floor, formed by granulation tissue and by the circular muscular coat, is smooth: the edges are undermined and ragged. Sometimes the inner muscular coat also is involved and then the outer layer will form part of the overhanging margin. The peritoneum usually shows only microscopical affection.

In a section through the ulcer it will be noted that the mucous membrane over the Peyer's patch, especially at the edge, is infiltrated with small cells and the infiltration extends into the tissues around. On the floor of the ulcer is an upper layer of non-staining debris covering a swollen and infiltrated muscular coat. The depth of the ulcer will determine the occurrence or otherwise of perforation. In the lymphoid tissue, the specific

bacilli, singly or in groups, may be found. Very little scarring or contraction occurs after healing.

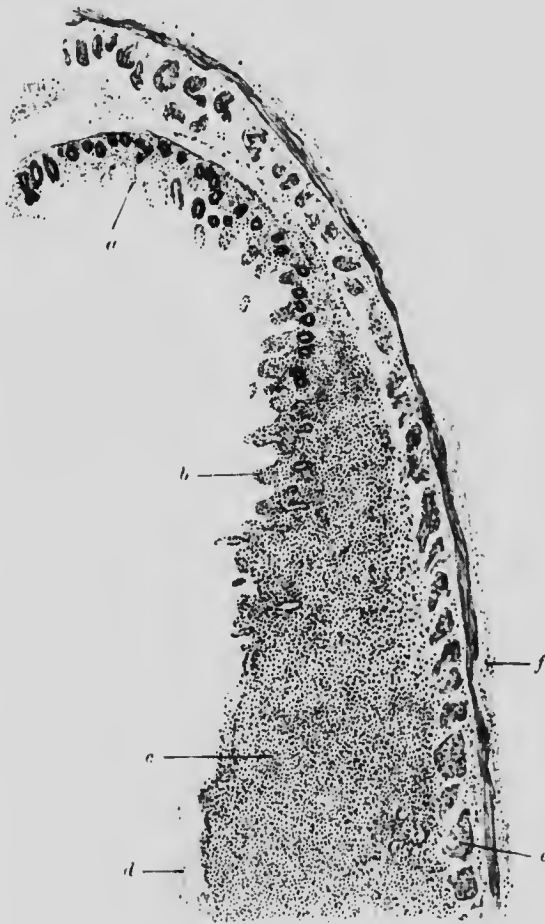

FIG. 86. TYPHOID. INTESTINE (SMALL). ($\times 15$)

- a.* Mucosa. Some gland cells still left.
- b.* Superficial epithelium degenerated; swollen submucosa below.
- c.* Infiltrated lymphoid tissue.
- d.* Debris on surface.
- e.* Muscular layers.
- f.* Peritoneum.

Tuberculous ulcers occur on the same sites as typhoid ulcers, but are not limited to them. A tuberculous ulcer presents a more wavy, swollen margin, extending circularly around the

bowel, and, as generally seen, is the result of the fusion of several small ulcers. These form yellowish, blood-stained patches, with nodules in their floors, which are best seen and recognised as

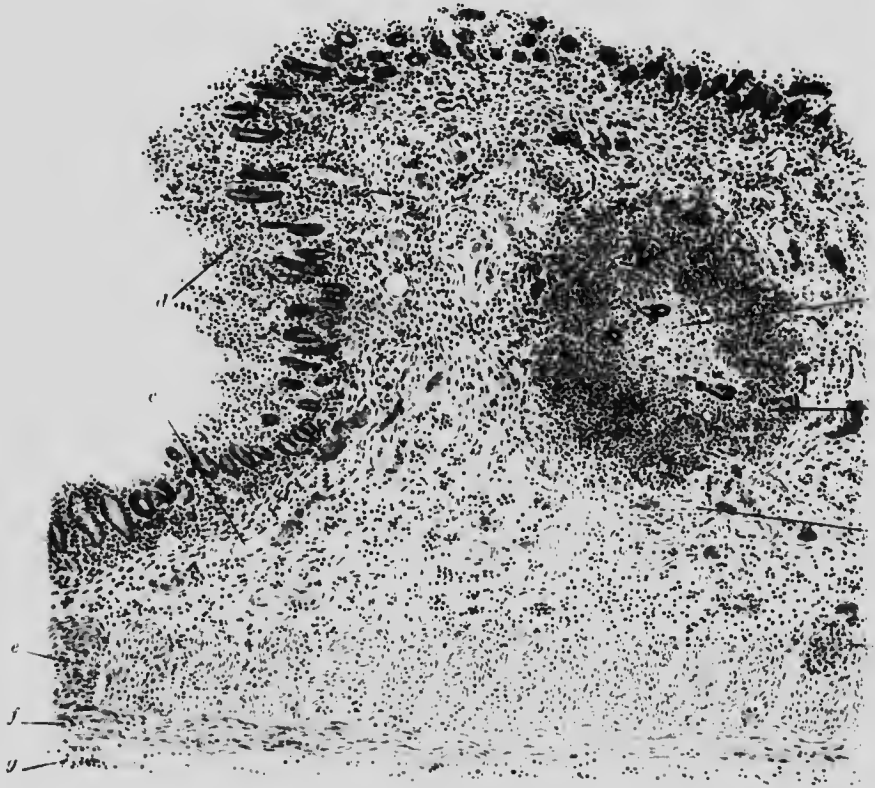


FIG. 87. TUBERCLE IN SMALL INTESTINE. ($\times 35$)

- a.* Caseation in centre of tubercle with giant cells.
- b.* Lymphocytes and endothelial cells.
- c.* Congested blood-vessels.
- d.* Surface epithelium, partly lost.
- e* and *f.* Muscular layers.
- g.* Peritoneal covering, slightly thickened.

tubercles from the peritoneal side. The peritoneum has generally lost its smooth surface and is inflamed. The lymphatics in the neighbourhood stand out as yellowish white lines. Considerable scarring and contraction may occur on healing.

Under the microscope the sides of the ulcer are seen to be nearly vertical and only slightly undercut on the floor. The

sides are formed of folded-in submucosa in which tubercles have formed. Vascular dilatation also contributes to the thickening. The tubercles are in all stages of development; some quite new, others already caseating, while regular giant cell systems are common (Fig. 87). The floor is irregular and knobby, being formed of tubercles resting on the muscular coat. The peritonemum is much thickened and may also contain tubercles.

Dysentery is a form of colitis, whether of bacillary or amoebic origin, and produces in the large intestine numerous shallow ulcers with sharp cut edges and coast line margin.

Microscopically, the bacillary form is characterised by an infiltration with leucocytes of the interglandular spaces and the areas below them and accompanied by destruction of the upper layers of the mucous membrane. This destruction gradually spreads downwards and sideways until the adjacent ulcerating areas fuse. A layer of lymph covers the surface at first, but later this separates together with the necrosed mucous membrane, as a slough, and leaves a suppurating submucosa exposed below. Swelling of lymphoid tissue, ending in necrosis, is also a marked feature.

In the amoebic form there is necrosis without accompanying inflammation and the amoeba may be found undermining the mucous membrane, causing exudation and the formation of minute ulcers which gradually spread and fuse.

The absence of inflammatory reaction and the general necrotic and oedematous condition of the tissues, which stain badly, contrast markedly with the conditions found in bacillary dysentery.

The conditions known as mucous colitis and ordinary ulcerative colitis anatomically resemble bacillary dysentery.

Various new growths, especially **adenoma** and **columnar celled carcinoma** of the annular type, occur in the large intestine and less commonly in the small intestine, but they do not present any special characteristics (Figs. 7 and 36). Sometimes the line of demarcation is not sharp and gives the impression that the growth is spreading by "cancerous

degeneration" of adjacent cells rather than by growth of existent cancer cells and destruction of normal ones. The central portion of the growth usually necroses and forms an ulcer, but adhesions are generally formed with other organs or the body wall before perforation of the intestine takes place.

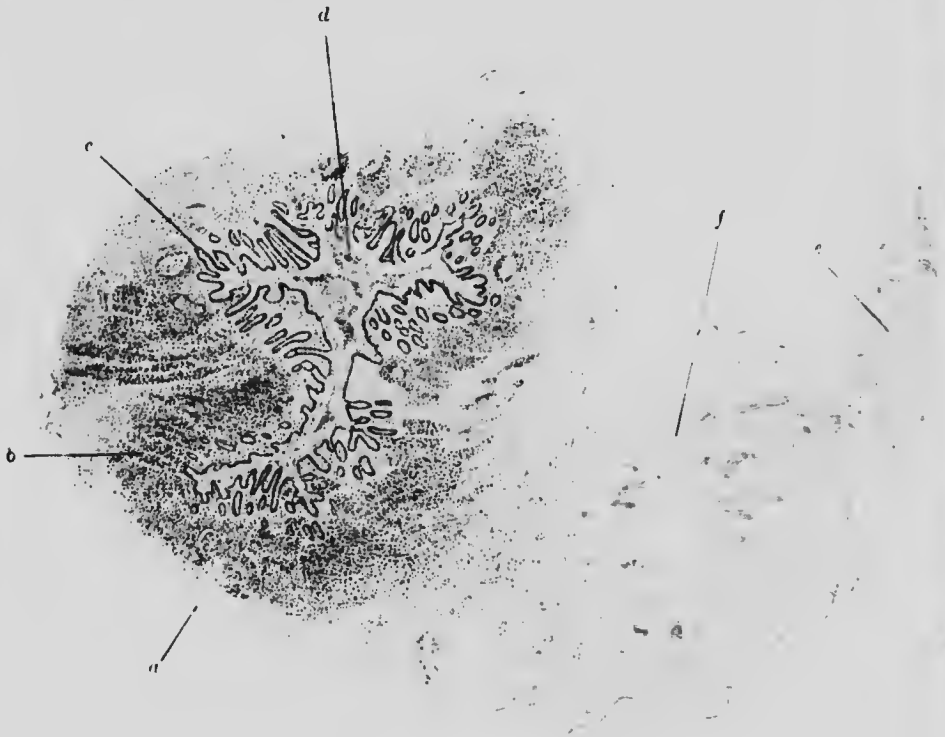


FIG. 88. APPENDICITIS (EARLY). ($\times 10$)

- a. Peritonemum.
- b. Lymphoid tissue with some infiltration.
- c. Mucosa.
- d. Leucocytes and debris in lumen.
- e. Oedematous mesentery.
- f. Congested blood-vessels.

Appendicitis is only an ordinary inflammation, occurring in the intestine and presenting special characteristics due to anatomical structure and position of the appendix.

The lymphoid tissue, which is normally present in relatively large amount in the appendix, is infiltrated with leucocytes and

the mucous membrane swells up so much that the whole lumen and the orifice may be obliterated. This leads to great general enlargement of the appendix (Fig. 88). The inflammatory process frequently spreads to the peritoneal surface, causing the appendix to become adherent. From this stage, regression to a nearly normal condition often occurs. On the other hand, the process may go on to perforation with the formation of an abscess or the supervention of peritonitis.

Although in essence the same, the details of the process vary enough to produce very different clinical pictures. In the early stages the infiltration consists mainly of polymorphonuclear leucocytes: later on, of lymphocytes with much fluid exudation. Destruction of the mucous membrane follows and later the inflammation may either involve successively the coats of the appendix immediately below until perforation occurs, or it may extend superficially along a considerable length of mucous membrane, which then becomes necrotic and gangrenous.

CHAPTER XIX

THE LIVER

ILLUSTRATIVE PREPARATIONS.

1. Liver in ordinary multilobular cirrhosis.
2. Liver in hypertrophic cirrhosis.
3. Liver in syphilitic cirrhosis.
4. Liver in acute yellow atrophy.
5. Liver, stained with potassium ferrocyanide and hydrochloric acid, in pernicious anaemia.
6. Tubercle of the liver.
7. Gamma of the liver.
8. Carcinoma of the liver.
9. Hydatid cyst of the liver.

THE chief **circulatory disturbance of the liver** is passive congestion from obstruction to the flow of blood in the inferior vena cava. The microscopical appearances vary according to the duration of the condition, from simple distension of the central vein and capillaries with blood, to one of vascular dilatation commencing in the middle of the lobule and by pressure causing gradual atrophy of liver cells from the centre outwards. The condition is usually accompanied by fatty degeneration in the zone beyond the congested area. The ill-defined margins of the lobules are broken down and the dilated vessels of several contiguous lobules become directly continuous, so that in the section a lobular arrangement of the blood corpuscles is the most conspicuous feature and there are very few liver cells to be seen. In the latest stages there is usually some increase of

connective tissue and the liver tissue is much reduced in amount (Fig. 12).

Cloudy swelling of the liver cells occurs in most infectious diseases and intoxications. If a fresh specimen be examined the cells are seen to be more spherical than normal, much more granular and perhaps contain an excessive quantity of fat (Fig. 88†).

Fatty deposits occur in the liver under a variety of conditions. Almost any mechanical change in the hepatic circulation or any general disease will produce them. Morphologically, they may be divided into two classes according to the position of the fat and the cells, namely, fatty degeneration and fatty infiltration.

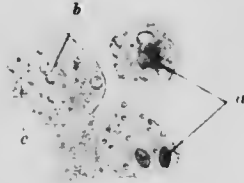


FIG. 88†. CLOUDY SWELLING. LIVER. SEPSIS. ($\times 400$)

- a. Nucleus in chromatolysis and fragmentation.
 b. Fat globules. c. Granular cytoplasm.

The first name implies cellular degeneration into fat: the latter, cellular absorption of fat from the circulation. Both these processes are chronic; but in combination with other changes an acute fatty degeneration also occurs.

In **fatty infiltration**, the peripheral rows of cells of the lobules are chiefly affected. The globules of fat appear as spheres of varying size, some filling up nearly the whole cell and leaving only the flattened nucleus visible at the periphery. The cell outlines are obscured. The process may affect the whole of a lobule or series of lobules so that the liver substance becomes indistinguishable from fat.

Fatty degeneration is often a sequel of cloudy swelling. It results especially from chronic infectious disease. Both the liver itself as well as the constituent cells are reduced in size, so that

h
ll
ot.

u-
b.

-
y
.
n
s
t
s

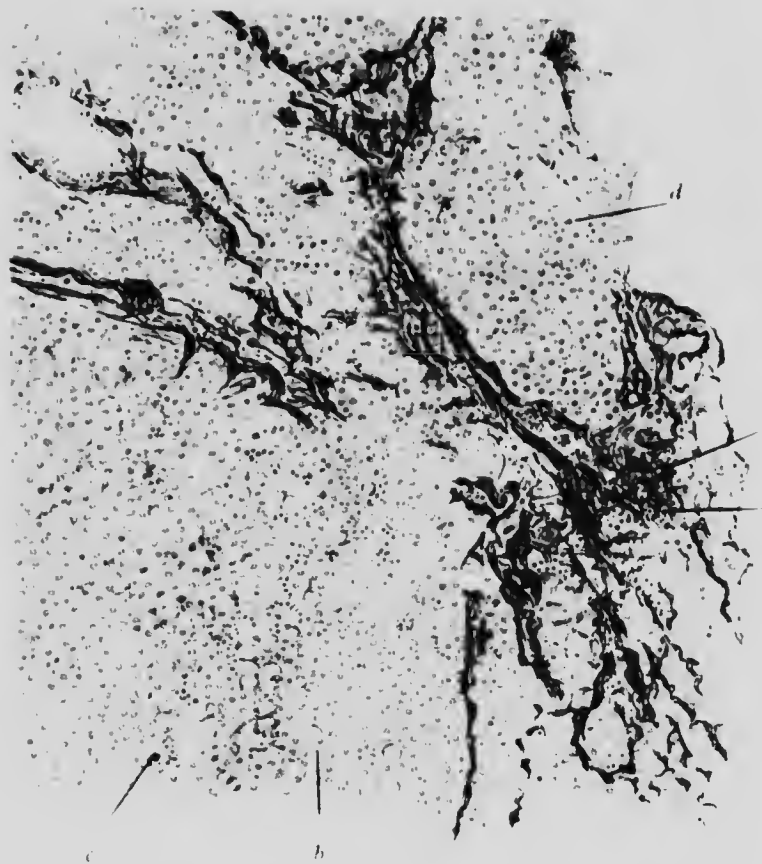

FIG. 89. CIRRHOSIS OF LIVER. Stained with Weigert's elastic stain and safranin. (X 100.)

- a.* Elastic tissue, accompanied by some fibrous tissue, chiefly around portal canals.
- b.* Liver cells undergoing fatty degeneration.
- c.* Erythrocytes, distending the capillaries.
- d.* Normal liver cells.
- e.* Small area of chronic inflammation.



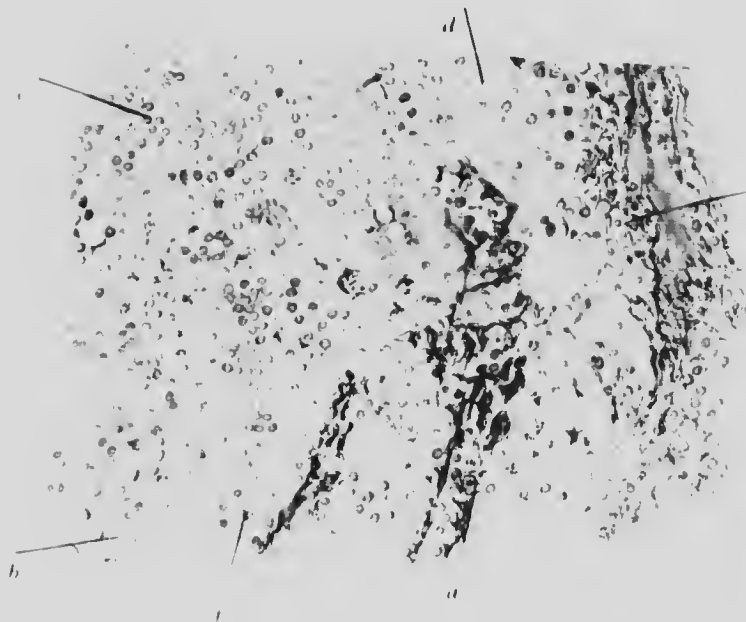


FIG. 90. (x 225)

a. e. As Fig 89.

f. Liver cells with pigment deposited in them.

or elastic tissue spread inwards, cutting off areas consisting of several lobules. The pressure thus occasioned brings about fatty degeneration and atrophy of the peripheral liver cells. The change is usually accompanied by some lymphocytic infiltration and formation of new blood-vessels in the portal canals, while the branches of the portal vein are dilated by the compression of

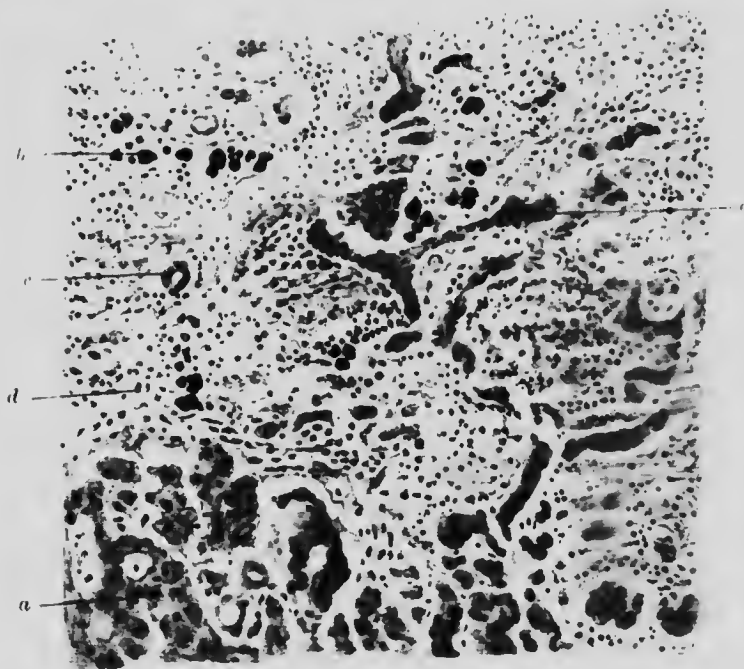


FIG. 91. HYPERTROPHIC CIRRHOSIS. LIVER. ($\times 200$)

- | | |
|--------------------------------------|---------------------------|
| <i>a.</i> Fairly normal liver cells. | <i>c.</i> Bile duct. |
| <i>b.</i> Degenerate liver cells. | <i>d.</i> Fibrous tissue. |
| <i>e.</i> Proliferating liver cells. | |

their tributaries. Strands of cells cut off from the main lobule are very characteristic (Figs. 89 and 90).

In **hypertrophic cirrhosis** the total volume of the liver is increased on account of the considerable excess of connective tissue which more than compensates for the atrophy of liver cells which it brings about. The arrangement of the fibrosis is practically unilobular, but the most characteristic feature of the process is the increase in the number of bile ducts, whence the

condition is sometimes termed "biliary cirrhosis." In part the increase is only apparent and is due to the destruction of liver cells throwing the ducts into greater prominence, but there is also a genuine increase of duct cells. The ducts and many of the liver cells often contain bile pigment (Fig. 91).




FIG. 92. SYPHILITIC CIRRHOSIS. LIVER. ($\times 180$)

- a.* Isolated liver cells surrounded by new connective tissue.
- b.* New fibrous tissue.
- c.* Older fibrous tissue.
- d.* Areas of liver tissue cut off by connective tissue. Nuclei peripheral and deeply staining.
- e.* Normal liver tissue.

In **syphilitic cirrhosis** the arrangement of the fibrous tissue is often described as pericellular, but it usually embraces columns of cells, not lobules. The fibrous tissue is of a fine and delicate variety. This process is seen most often in infants (Fig. 92).

In **acute yellow atrophy** the bulk of the liver is diminished the capsule is wrinkled, and the liver substance for the most part appears structureless, although variegated in some parts by yellow

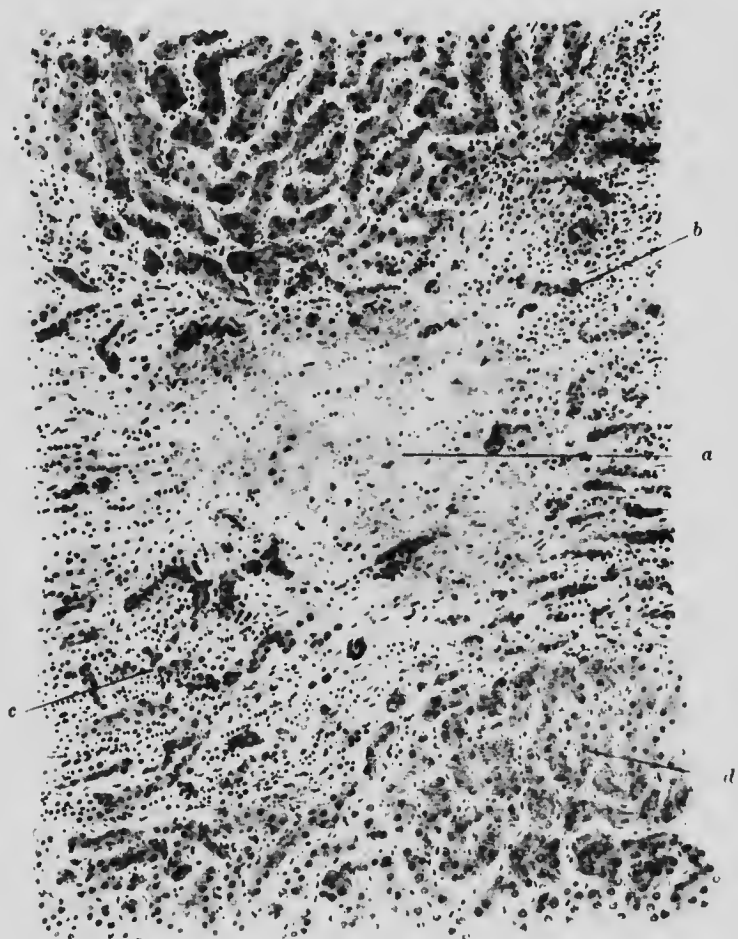

FIG. 93. ACUTE YELLOW ATROPHY. LIVER. ($\times 75$)

- a.* Necrotic amorphous area. *b.* Bile ducts.
c. Isolated clusters of liver cells with surrounding infiltration.
d. Normal liver.

and red patches. Microscopically, there is evidence of inflammation starting from the portal canals. In the lobules many cells have disappeared and their places are taken by amorphous granular material and blood. These are the macroscopical red

areas. The remaining liver cells are bile-stained, atrophic and irregular, but do not show much fatty change. The bile ducts,

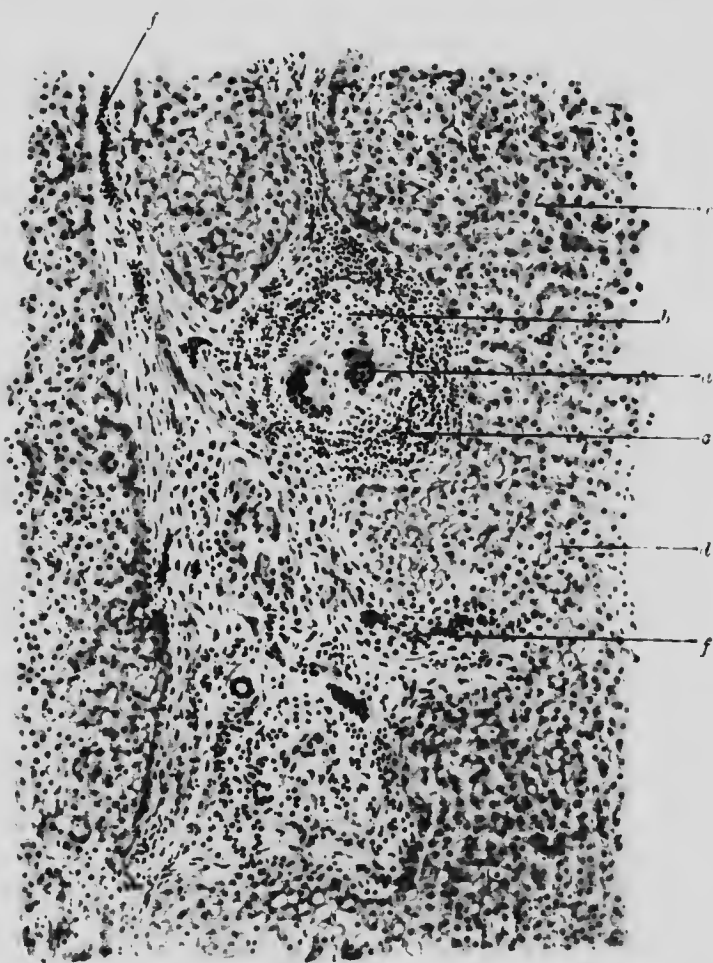


FIG. 94*. TUBERCLE OF LIVER. ($\times 100$)

- | | |
|--|---------------------------------------|
| <i>a.</i> Giant cells. | <i>e.</i> Outer layer of lymphocytes. |
| <i>b.</i> Surrounding endothelial cells. | <i>d.</i> Fatty liver cells |
| <i>c.</i> Normal liver cells. | |
| <i>f.</i> Lymphocyte infiltration along Glisson's capsule. | |

being more resistant, are not so much affected and even show some attempts at regeneration. They are thus prominent objects in the microscopical section (Fig. 93).

nd
nts,

ome
s in




FIG. 96. LIVER. PERNICIOUS ANAEMIA. SIDEROSIS (X 200)

- a. Normal liver cells.
- b. Liver cells with much iron deposit (green).
- c. Portal canal.

In **pernicious anaemia** the liver contains an excess of iron, which may be demonstrated as an intracellular deposit by means of potassium ferrocyanide and hydrochloric acid (Fig. 94).

Tubercle of the liver presents a very typical appearance, the giant cell system, the epithelioid cells and the surrounding layer

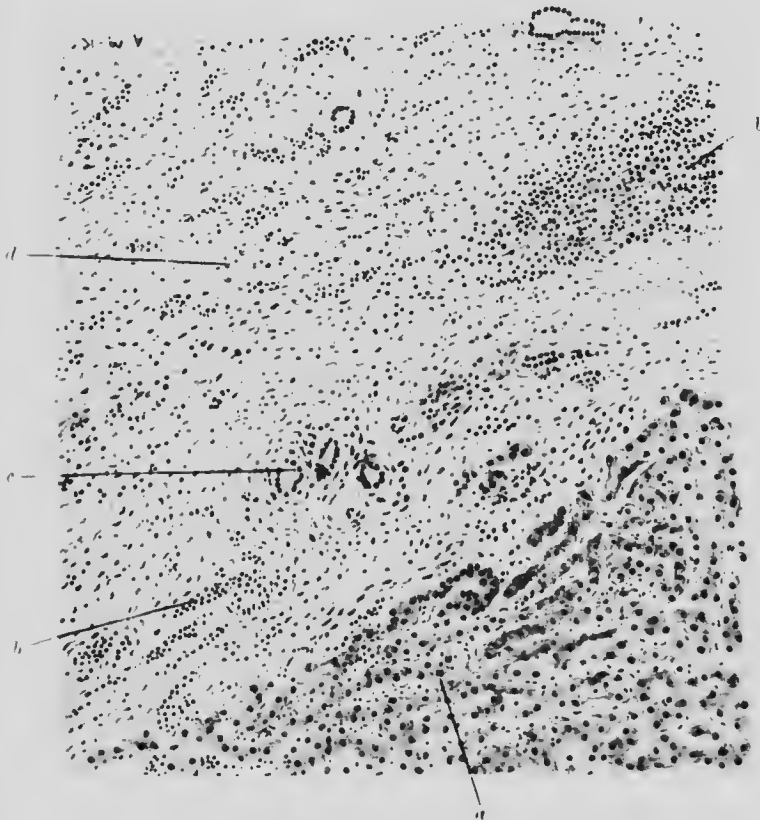


FIG. 95. GUMMA. LIVER. ($\times 100$)

- | | |
|---------------------------------------|---------------------------|
| a. Columns of compressed liver cells. | c. Remains of bile ducts. |
| b. Areas of small cell infiltration. | d. Fibrous tissue. |

of lymphocytes being all present. The liver tissue around is in some places partly compressed and atrophied and thus simulates a capsule: in other parts, the tubercle and the liver substance appear quite continuous (Fig. 94*).

Lardaceous disease of the liver causes a marked increase

in the size and weight of the organ and gives it a translucent appearance on section. The changes, which have already been described (p. 8), occur mainly between the columns of cells and in the smaller vessels (Fig. 6).



FIG. 95*. SYPHILITIC INFLAMMATION. GUMMA OF LIVER. ($\times 200$)

- a.* Areas of lymphocytic infiltration in
- b.* layers of fibrous tissue surrounding
- c.* central mass of necrotic caseous material, forming main portion of gumma.

Gumma of the liver is not often seen before the ensuing stage, but in its commencement it is a localised, highly vascular syphilitic cirrhosis. In the course of its development, the concomitant endarteritis leads to atrophy by causing lack of blood supply, while the simultaneous formation of a fibrous capsule completes the atrophy and causes necrosis of the tissue within

the capsule. The gumma, as ordinarily seen, in the caseating stage, presents a central yellow amorphous mass which takes a pink stain with eosin. This portion is limited by a fibrous capsule of variable thickness from which fibrous bands radiate into the liver substance, causing destruction of many liver cells.

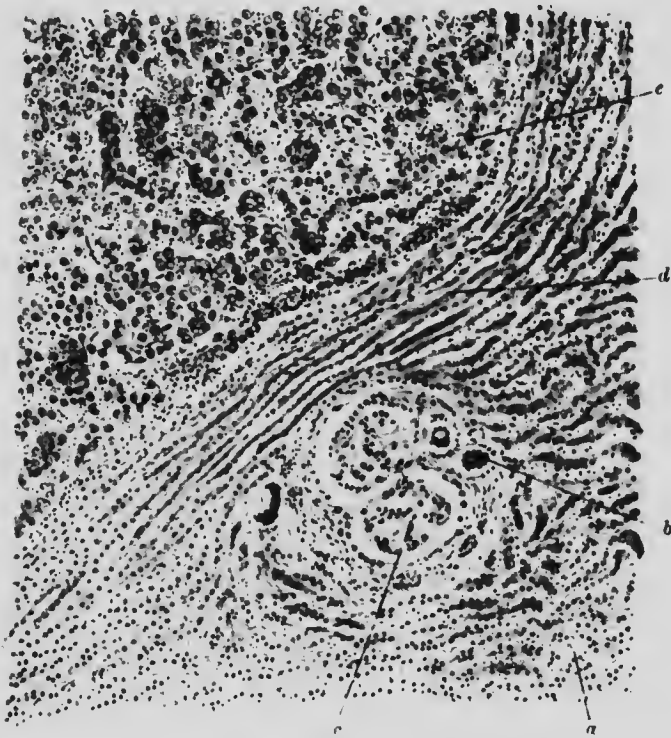


FIG. 96. CANCER. LIVER. ($\times 100$)

- | | |
|---|------------------|
| a. Normal liver. | b. Bile duct. |
| c. Cancer cells within vessels of portal canal. | e. Cancer cells. |
| d. Compressed liver cells. | |

At various points small collections of lymphocytes may be seen, indicating the chronic but continuous nature of the inflammation (Figs. 95 and 95*).

Primary carcinoma of the liver is uncommon. There are two forms: one localised and massive, the other diffuse and always associated with cirrhosis. The histological type of the former is that of malignant adenoma (Fig. 96), while the latter

consists of an irregular scattered growth of atypical liver cells (Fig. 96*).

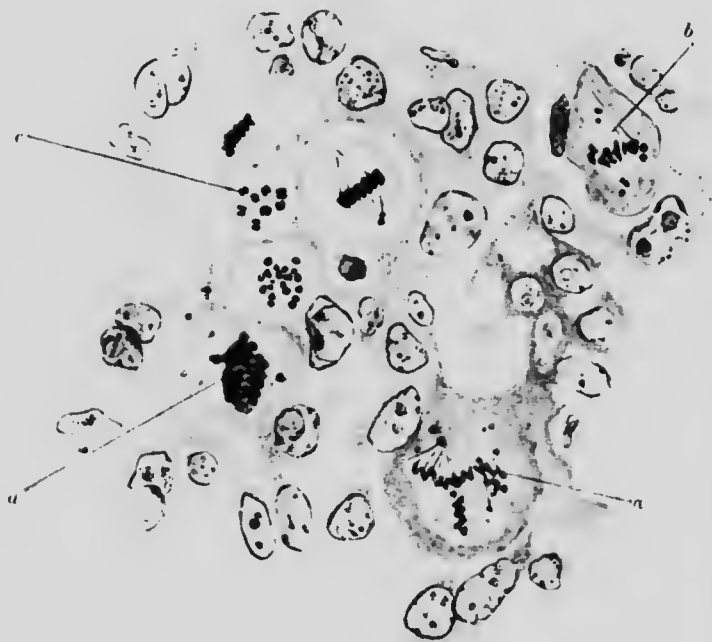

FIG. 96* LIVER, CARCINOMA. ($\times 750$)

- a.* Cell with tripolar mitosis. Spindle well marked.
- b.* Cell with heterotypic chromosomes.
- c.* Cell with scattered homotypic chromosomes.
- d.* Cell with irregularly distributed chromosomes.

The usual cause of **hydatid cyst of the liver** is the echinococcus cysticus, the larval stage of the dog tapeworm, taenia echinococcus. The cyst itself is composed of (*a*) the capsule derived from the hepatic connective tissue, from which the liver cells have disappeared under the pressure of the cyst; (*b*) the ectocyst, which is really the wall of the cyst and is composed of an outer, looser fibrous layer and an inner, hyaline laminated stratum; and (*c*) the endocyst composed of a double layer of cells, from the inner of which the "brood capsules" are developed. The interior is filled with fluid and in it lie the parasites. The head usually

lies near the cyst wall and consists of a small prominent process, the rostellum, with four suckers and a circle of hooklets attached




FIG. 97. HYDATID CYST. LIVER. ($\times 100$)

- a* Liver tissue. *b* Fibrous capsule. *c* Lamellated cyst membrane.
d Endocyst showing outer and inner layers. *e* Points to hooklets of scolex.

to it. The remainder of the parasite is merely a small bladder, attached by a pedicle to the broad capsule (Fig. 97).

CHAPTER XX

PANCREAS. SPLEEN

ILLUSTRATIVE PREPARATIONS.

1. Pancreas showing fibrosis and fat necrosis.
2. Pancreas showing acute necrosis.
3. Spleen, stained with methyl violet, showing lardaceous disease.
4. Spleen showing deposits of lymphadenomatous tissue.

Fibrosis of the pancreas (chronic pancreatitis) is not uncommon in association with general diseases. Macroscopically the lobules look more homogeneous than normal and under the microscope this appearance is seen to be due to the cementing together of the lobules by transparent fibrous bands. Two varieties are distinguishable: the lobular and the acinary fibrosis.

In lobular fibrosis large areas of gland tissue are cut off by broad strands of fibrous tissue from other areas and the islands of Langerhans are not affected. In acinary fibrosis the new connective tissue appears between the individual acini and the islands degenerate. In both cases the normal amount of elastic tissue is usually diminished and some lymphocyte infiltration accompanies the new connective tissue.


In some cases pancreatic necrosis and fat necrosis occur together with fibrosis, probably as the result of auto-digestion, whether brought about by trauma or by obstruction of the common duct and invasion of the pancreatic ducts by bile. The patches of fat necrosis are opaque and white and they

not
ally
the
ting
Two
ary

f by
ands
new
the
astic
tion

ecur
tion,
the
bile.
they





MICROCOPY RESOLUTION TEST CHART
NATIONAL BUREAU OF STANDARDS
STANDARD REFERENCE MATERIAL 1010a
(ANSI and ISO TEST CHART No. 2)

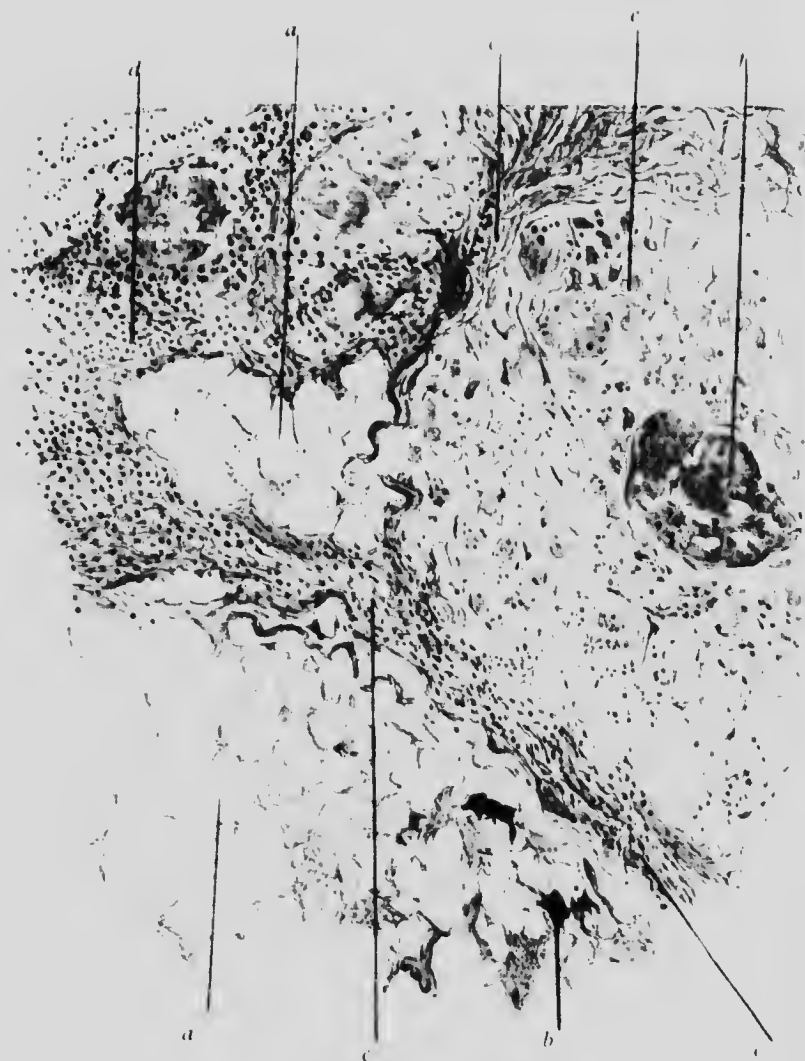

FIG. 98. PANCREAS. FAT NECROSIS AND FIBROSIS. (X 60)

- a.* Area of fat necrosis. The fatty material has been dissolved out but in a few places.
- b.* Some crystals can still be made out.
- c.* Strands of fibrous tissue of varying cellularity.
- d.* Leucocytic infiltration.
- e.* Degenerated pancreatic tissue enclosed in fibrous tissue.
- f.* Comparatively normal area of pancreas.

take on a blue colour when dipped into copper acetate solution. With Nile Blue sulphate they stain blue, not pink like fat. In sections which have not been passed through alcohol the crystals of fatty acid composing the patches may be recognised (Fig. 98). The condition misnamed "haemorrhagic pancreatitis" is a necrosis without inflammation.

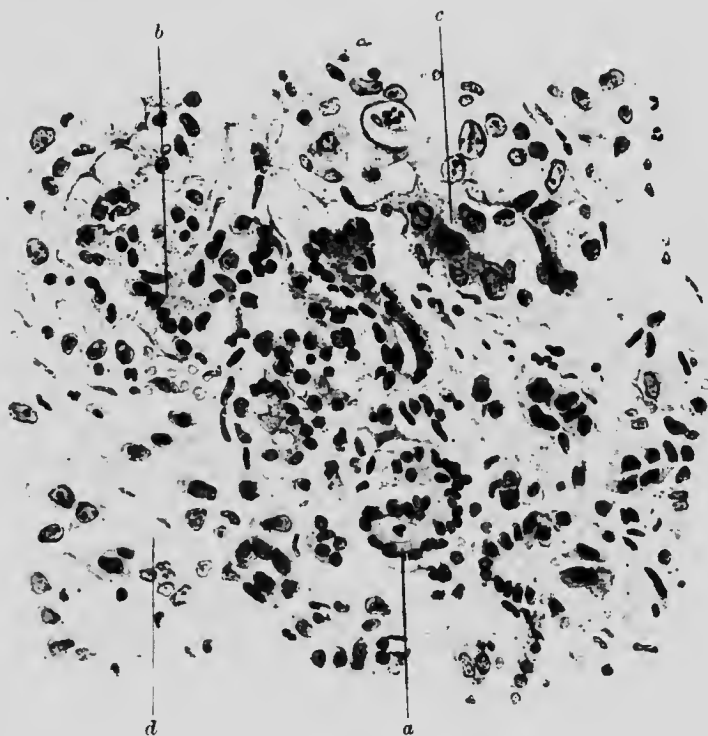


FIG. 99. CANCER. PANCREAS. ($\times 250$)

- | | |
|------------------------------|---------------------|
| a. Normal pancreatic tissue. | c. Carcinoma cells. |
| b. Transitional tissue. | d. Stroma. |

Carcinoma of the pancreas is not very rare. It occurs generally at the head of the pancreas (Fig. 99).

Congenital **syphilitic fibrosis** and **gummata** of the pancreas are found occasionally.

The **spleen** frequently presents changes secondary to acute diseases and characterised chiefly by altered vascularity and proliferation of endothelial cells. The subsequent condition of

fibroid thickening of the capsule and trabeculae is often seen post-mortem.

Lardaceous disease is relatively common in the spleen. It occurs in two forms: (1) patchy, affecting chiefly the Malpighian corpuscles and (2) diffuse, affecting chiefly the splenic pulp.

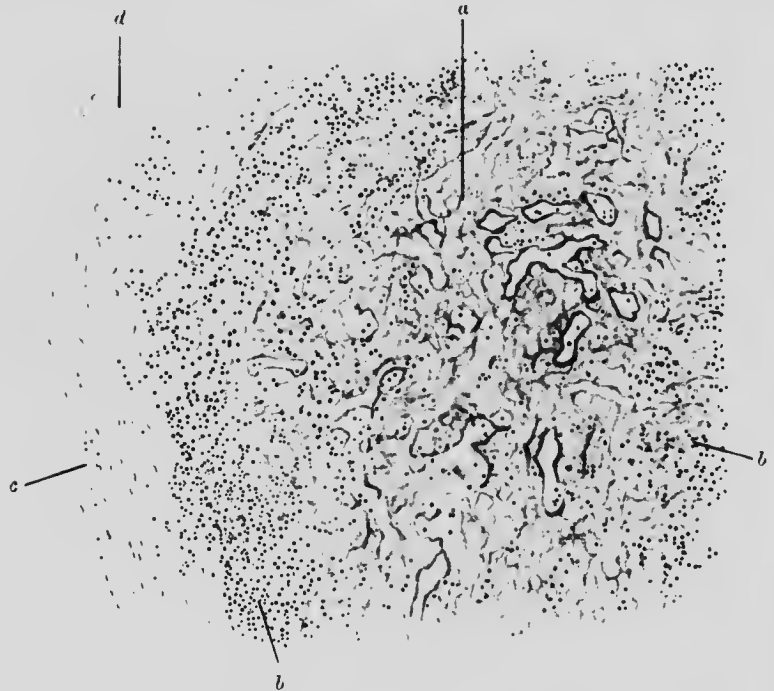


FIG. 100. LARDACEOUS DISEASE (DIFFUSE). SPLEEN. ($\times 120$)

- a.* Degenerated walls of sinuses gradually shading off into
b. normal lymphoid tissue. *c.* Fibrous trabecula.
d. Blood-vessel unchanged.

Corresponding to this distribution we find in methyl-violet stained sections, that in the patchy form the pink-stained material is found almost entirely in the smaller vessels of the Malpighian corpuscle. The central vessel is generally unaffected: the other vessels outside the capsules are only slightly affected and then chiefly in patches in the connective tissue of the middle coats. In the diffuse form the change is much more general and is found in the connective tissue trabeculae immediately surrounding the pulp sinuses (Fig. 100).

Chronic congestion is a common accompaniment of long-standing heart disease or other hindrance to the hepatic or pulmonary circulation. Since the spleen is but little enlarged it follows that the parenchyma must partly have disappeared to make room for the dilated blood-vessels and under the microscope it is seen that the spleen cells are reduced in number.

The spleen is one of the common sites of **infarct**. When recent, the infarct is always haemorrhagic and results from an embolus. Later on it becomes pale and yellow.

Microscopically, in a recent infarct, there is little to see beyond congestion and distension of the blood vessels and sinuses, with some diapedesis. Necrosis follows in the blood-starved area and fibrous tissue replaces the spleen tissue. During the time that the necrotic portion is undergoing absorption, lime salts, cholesterol, haematoidin crystals, etc., may be found in it.

In **leucocythaemia** the number of leucocytes in and consequently the volume of the spleen is considerably increased.

The presence of various types of leucocytes and proliferation of endothelial cells in excess, causing distension of the sinuses, are the chief microscopical characteristics and are generally associated with thickening of the trabeculae.

Secondary **lymphadenoma** in the spleen presents characteristic naked eye appearances, as if pieces of fat were embedded in the spleen substance. These pale areas consist of adenoid tissue. The Malpighian corpuscles and the trabeculae undergo fibroid change.

CHAPTER XXI

THE KIDNEY

ILLUSTRATIVE PREPARATIONS.

1. Acute nephritis in scarlet fever.
2. Subacute parenchymatous nephritis.
3. Chronic parenchymatous nephritis.
4. Mixed chronic nephritis.
5. Chronic interstitial nephritis.
6. Lardaceous disease of the kidney.
7. Adenoma of the kidney.

THE **diseases of the kidney** may affect (*a*) the secreting, (*b*) the vascular and (*c*) the connective tissue. It is rare for only one tissue to be affected, although the process may start in one only. Acute disease begins usually in the glomeruli or the secreting tubules: chronic disease in the larger vessels or the connective tissue. In either case it soon spreads.

Acute glomerular nephritis is a toxic inflammatory condition occurring most often in the later stages of scarlet fever. The lining epithelium of the glomeruli is thickened and the number of nuclei on the capillary tuft increased so as to obscure its outline. The nuclei of the connective tissue are also increased in number and in extreme instances the whole glomerulus may look superficially like a collection of spindle cells. Fatty casts are to be found within some of the tubules. Around the tubules and especially at the entrance of the vessel into the capsule, there is aggregation of leucocytes.

(b)
ly
me
he
he

ion
The
per
its
in
ok
are
nd
ere

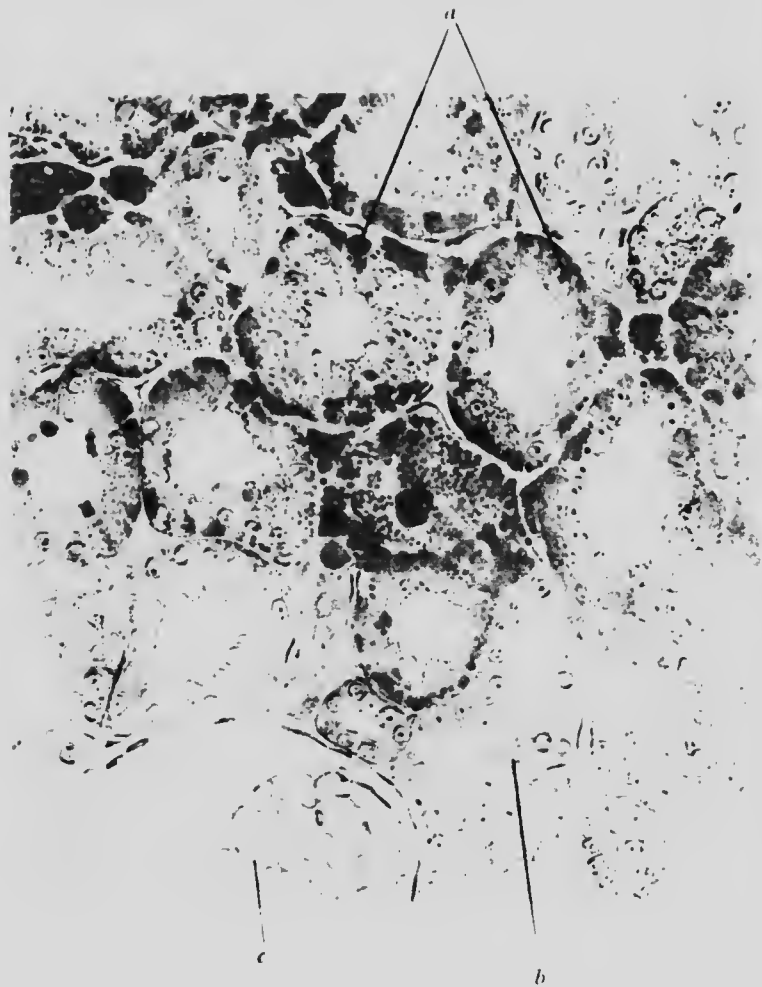


FIG. 101. KIDNEY, FATTY. Chronic parenchymatous nephritis. (x 250)
Stained with Scarlet R

- a.* Tubule cells containing large droplets of fat of varying sizes.
- b.* Comparatively normal cells.
- c.* Glomerulus.

In **acute parenchymatous nephritis** the changes, corresponding to those seen with the naked eye, namely, increase of size, evidence of congestion and widening and fatty appearance of the cortex, are seen with the microscope to affect both the tubules and the glomeruli and to be most marked in the cortex.

In the glomeruli the capillaries are distended with blood. Sometimes the capsule is ruptured and the glomerulus filled with blood which afterwards passes down into the tubules and forms casts. In the tubules there is evidence of cell destruction in various stages: cloudy swelling, granular deposits and fatty changes: sometimes total desquamation, so that many convoluted straight tubules are blocked with dead cells. In places there is hæmorrhage into the interstitial tissue, which also contains an excess of leucocytes. The vascular congestion is general.

Subacute (chronic) parenchymatous nephritis may be consecutive to an acute attack, but is more often a primary affection. The name merely implies that the changes occur mainly, although by no means exclusively, in the parenchyma.

The cortex is abnormally wide by reason of (1) distension of the glomeruli and tubules with exudate and (2) oedema of the interstitial tissue. It is due only in a minor degree to congestion, which, where it occurs, is local and not general. Many of the cells show fatty degeneration (Fig. 101).

The epithelium of the convoluted tubules is flattened yet frothy in appearance and often detached in places from the basement membrane. The lumen is often occupied by a homogeneous cast. In other parts there is evidence of regeneration: the epithelium appears well formed and the nuclei stain well. Many of the tubules will have been irremediably damaged and destroyed and their place taken either by homogeneous albuminous cylinders or, in later stages, by connective tissue (Figs. 102 and 103).

The glomeruli are progressively affected from the kidney capsule inwards: the layer just beneath the capsule is often entirely destroyed.

In **subacute interstitial nephritis**, although the primary changes begin probably in the connective tissue, the secondary changes in the parenchyma may be as marked as those described

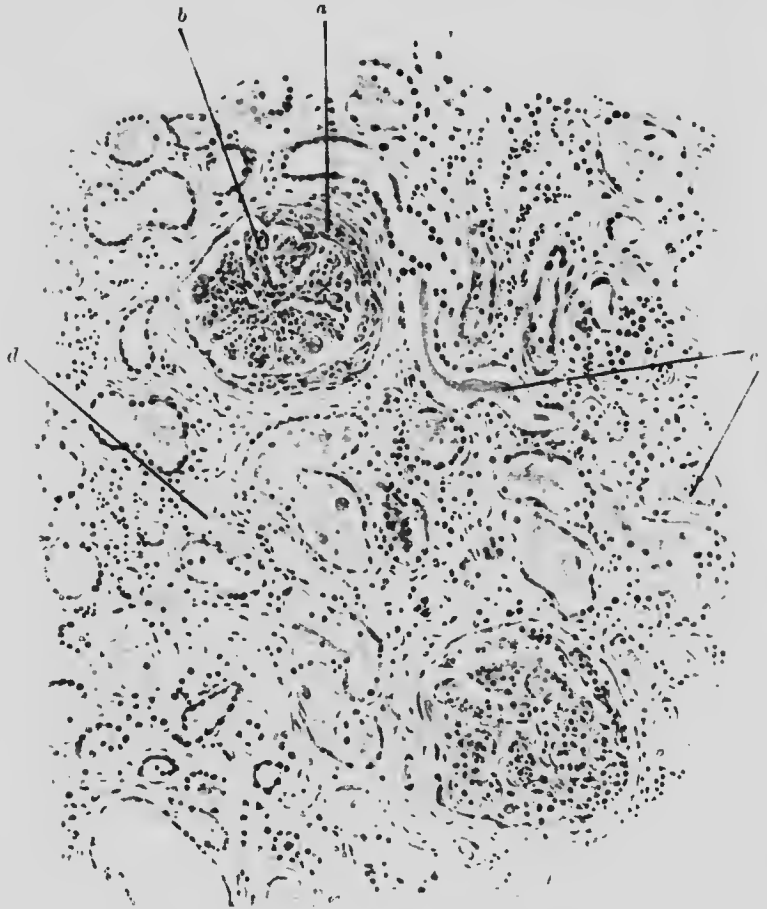


FIG. 102. SUBACUTE PARENCHYMATOUS NEPHRITIS. ($\times 80$)

- a.* Proliferated epithelium of Bowman's capsule.
- b.* Malpighian tuft also proliferated.
- c.* Casts in atrophic tubules.
- d.* Interstitial tissue replacing atrophied tubules.

above. The increase in fibrous tissue is seen best along the course of the interlobular vessels, from which it spreads laterally and involves both tubes and glomeruli.

In the glomeruli there occurs, in addition, proliferation of the

na v
la y
bd

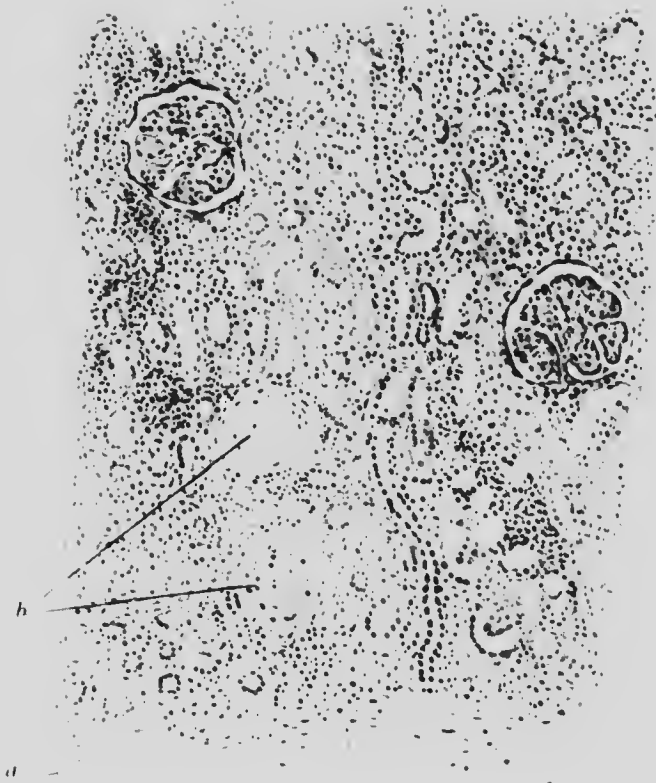

FIG. 104. KIDNEY. Subacute interstitial nephritis. (x 50)

- a.* Capsule somewhat thickened.
- b.* Glomeruli which have undergone total fibrotic change.

the
ally

the

1947
1948
1949
1950
1951
1952
1953
1954
1955
1956
1957
1958
1959
1960
1961
1962
1963
1964
1965
1966
1967
1968
1969
1970
1971
1972
1973
1974
1975
1976
1977
1978
1979
1980
1981
1982
1983
1984
1985
1986
1987
1988
1989
1990
1991
1992
1993
1994
1995
1996
1997
1998
1999
2000
2001
2002
2003
2004
2005
2006
2007
2008
2009
2010
2011
2012
2013
2014
2015
2016
2017
2018
2019
2020
2021
2022
2023
2024
2025

cells of Bowman's capsule, involving usually only a portion of the circumference. The whole capillary tuft may finally become

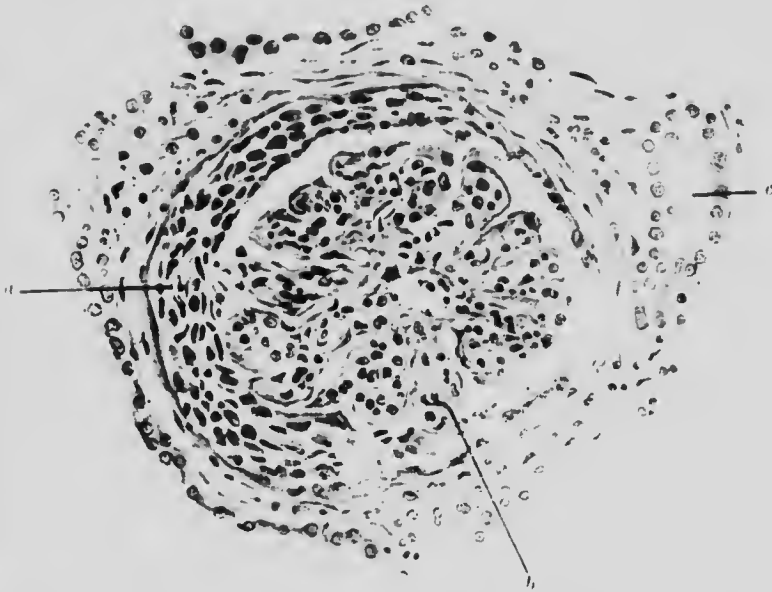


FIG. 103. GLOMERULUS IN SUBACUTE PARENCHYMATOUS NEPHRITIS. ($\times 225$)

- a. Thickened Bowman's capsule, lined by proliferating cells.
- b. Glomerular tuft, somewhat contracted. The covering and lining cells are increased in number.
- c. Convoluted tubule.

fibrous and atrophic. Sometimes the space between it and Bowman's capsule is dilated and filled with fluid, forming a small cyst (Fig. 104).

Chronic interstitial nephritis (contracting granular kidney) is the condition found in the small brown kidney which has an adherent capsule, narrow cortex and obviously diseased vessels.

Microscopically, the tissue seems to be a medley of fibrotic thickened arteries, atrophied glomeruli and fibrous tissue, with localised patches of chronic inflammation. On closer examination, the changes are seen to be most marked in the cortex at the bases of the pyramids. Thence the process spreads inwards,

causing marked irregularity among the straight lines which normally converge towards the apex of the pyramid.

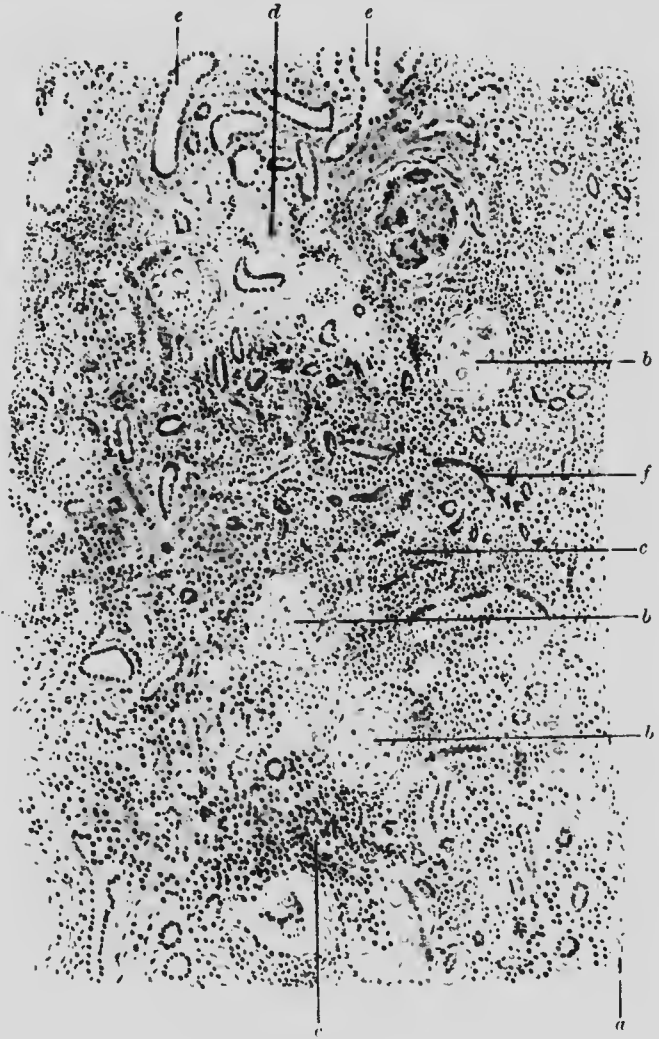


FIG. 105. MIXED NEPHRITIS. ($\times 50$)

- | | |
|---|-------------------------------------|
| <i>a.</i> Kidney capsule. | <i>b.</i> Glomeruli quite fibrotic. |
| <i>c.</i> Interstitial infiltration. | |
| <i>d.</i> Area of atrophied convoluted tubules replaced by connective tissue. | |
| <i>e.</i> Dilated collecting tubules. | <i>f.</i> Tubules containing casts. |

The affected areas are made up of intermingled patches of dense and loose tissue, the former composed mainly of new

paravasalar fibrous tissue and atrophied glomeruli and the latter of distended convoluted and collecting tubules. The free surface is irregular and the capsule thickened.

The lumen of the arteries is much diminished by fibroid thickening and the starved glomeruli connected with them present a hyaline, structureless appearance (Fig. 105).

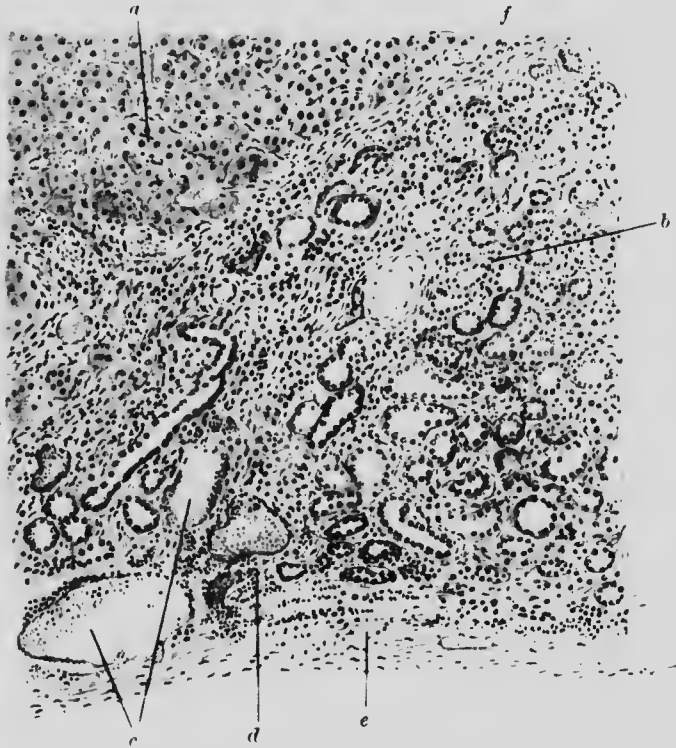


FIG. 108. ADENOMA. KIDNEY. ($\times 75$)

- | | | | |
|--------------|---|-----------|--------------------------|
| <i>a.</i> | Cells of adenomatous portion resembling secreting tubule cells. | <i>c.</i> | Blood-vessels. |
| <i>b.</i> | Kidney substance. | <i>d.</i> | Small cell infiltration. |
| <i>d.</i> | Small cell infiltration. | <i>e.</i> | Capsule of kidney. |
| <i>f, f.</i> | Line of division between adenoma and kidney proper. | | |

In **lardaceous disease** the kidney is enlarged, translucent and of a yellowish-brown colour. As elsewhere, the degeneration begins in the intimal coat of the smaller vessels, but soon involves the capillary tufts. The basement membrane of Bowman's capsule remains conspicuously unaffected. There are often

colloid casts in the tubules. When well marked, the process can be recognised both in unstained specimens and in specimens stained by ordinary methods (Figs. 106 and 107).

New growths in the kidney are not uncommon: the most characteristic are the adenoma and the hypernephroma. The simple adenoma is a non-malignant tumour, composed of a mass of cubical cells like the renal epithelium, arranged roughly in columns or alveoli (Fig. 108). The hypernephroma, although found most frequently in the kidney, is really an adrenal tumour and will be there described. Small fibromata in the pyramids of the kidney are very common.

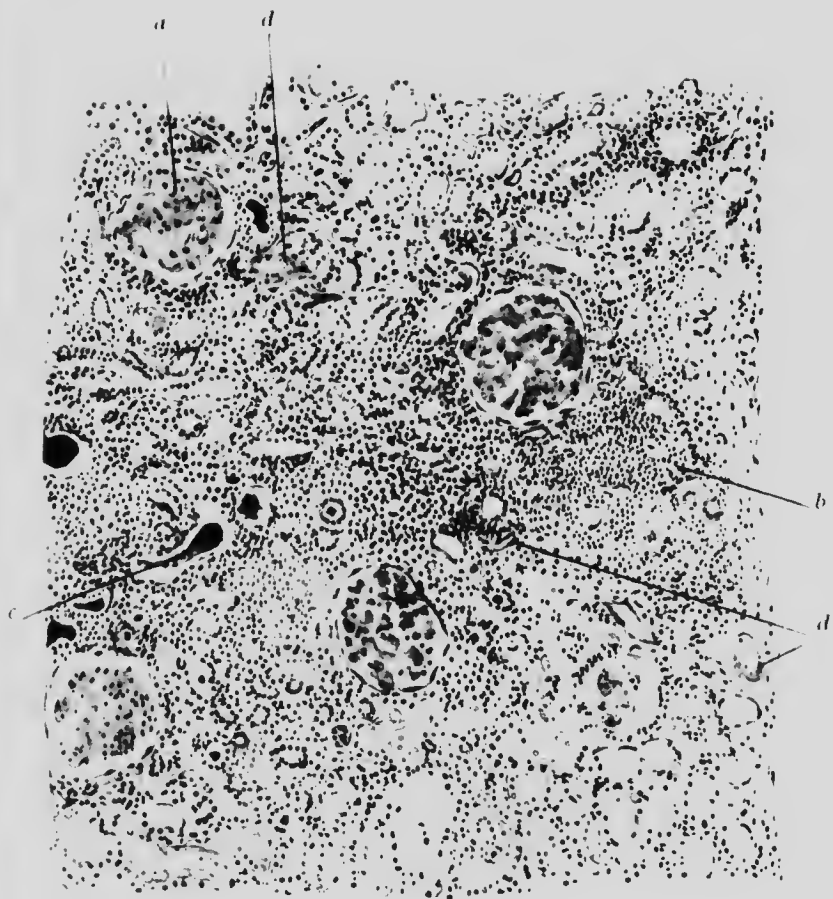


FIG. 106. LARDACEOUS KIDNEY. Stained methyl violet. (x 50)

- a.* Glomerulus in which lardaceous degeneration is complete
- b.* Area of interstitial, chronic inflammation.
- c.* Tubule with epithelium shed, containing cast.
- d.* Small vessels undergoing lardaceous change.



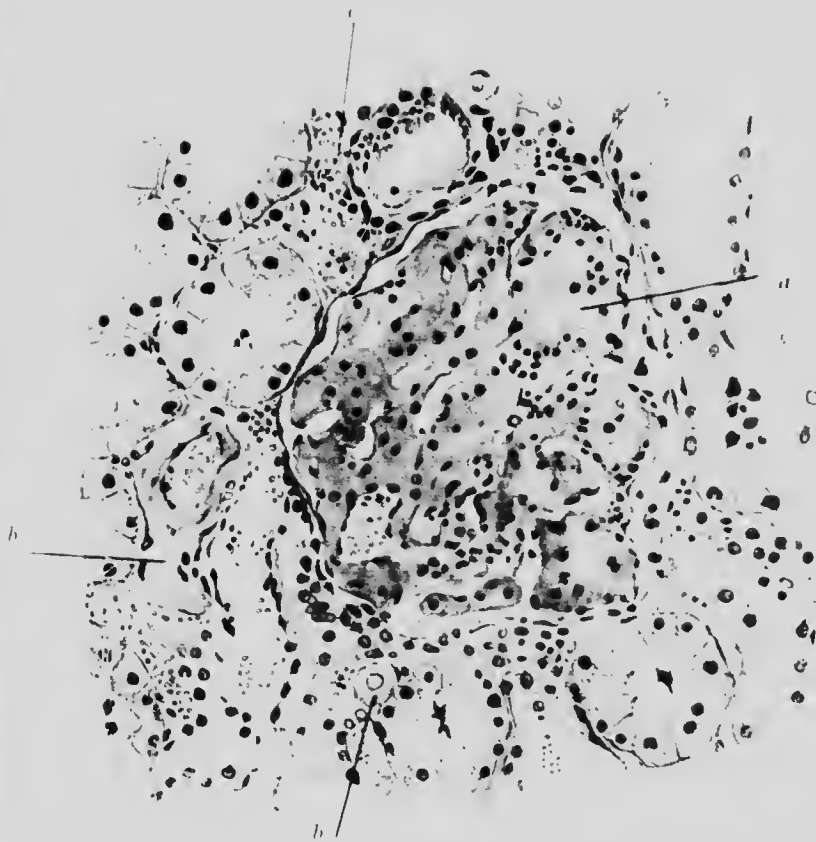



FIG. 107. LARDACEOUS KIDNEY. Stained methyl violet. (x 200)

- a.* Capillary of Malpighian tuft quite degenerated.
 - b.* Vessels which have also degenerated.
 - c.* Erythrocytes.
- Unaltered healthy tissue stained blue.



CHAPTER XXII

THE BLADDER. THE MALE GENITAL ORGANS

ILLUSTRATIVE PREPARATIONS.

1. Inflammation of the bladder (cystitis).
2. Carcinoma of the bladder.
3. Inflammation of the testicle (traumatic).
4. Inflammation of the testicle (gonorrhoeal).
5. Fibrosis of the testicle (syphilitic).
6. Tuberculous disease of the epididymis.
7. Enlargement of the prostate gland.

The **bladder** is subject to hypertrophy of its muscular coats whenever there is serious obstruction to the expulsion of its contents. In such case the urine in the bladder is liable to be bacterially infected and an inflammatory condition (cystitis) to supervene. Cystitis may, of course, occur by direct infection without previous retention of urine, *e.g.* by the use of catheter or extension from other parts of the genito-urinary tract. In either case, the mucous membrane becomes red and swollen. Under the microscope, patches denuded of epithelium are seen, while in other parts the number of layers of epithelial cells may be more than normal. In the submucosa are numerous parallel rows of leucocytic infiltration: and they occur also in the muscular layers, which may be enormously thickened (Fig. 109). In some parts, the epithelium may not yet be thrown off, but is necrotic and looks like a patch of diphtheritic membrane. If

the urine has been alkaline there may be deposits of triphosphate crystals on the mucous membrane.




FIG. 109. CYSTITIS. BLADDER. ($\times 60$)

- a. Epithelium, partly necrotic.
- b. Papilla (slightly infiltrated) with epithelium shed.
- c. \uparrow inflammatory reaction in submucosa.
- d. Blood-vessel. e. Muscular layers.

Tuberculosis of the bladder is not uncommon. The process begins below the epithelium, subsequently breaking through it and forming a lenticular ulcer.

The most common new growth in the bladder is **papilloma**, so-called villous tumour, on account of its resemblance to an aggregation of gigantic intestinal villi. It is composed of branching, finger-like processes of epithelium mounted on a stalk of delicate, extremely vascular connective tissue, which bleeds on very slight provocation. This growth is generally not malignant, but a malignant form (carcinoma) which burrows into the submucosa also occurs (Fig. 110).

Leucocyte infiltration of the bladder is often a marked feature in leukaemia.

The **testis** is subject to atrophy, to various forms of inflammation (simple, tuberculous and syphilitic orchitis and epididymitis) and to new growth.

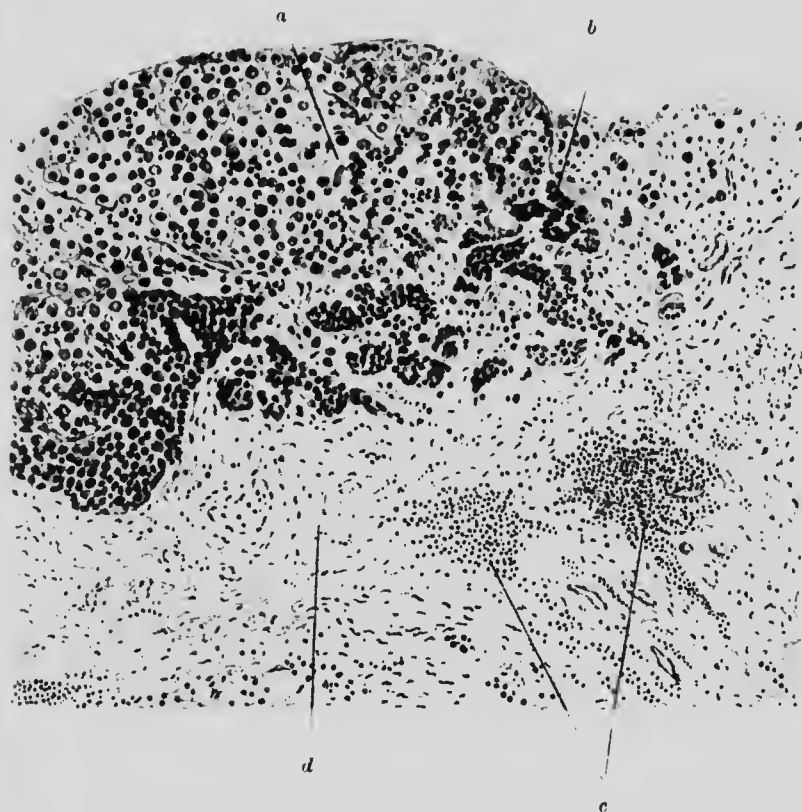


FIG. 110. CARCINOMA. BLADDER. ($\times 60$)

- | | |
|--|------------------------|
| a. Oedematous and degenerate cancer cells. | c. Inflammatory cells. |
| b. Healthy cancer cells. | d. Submucosa. |

Atrophy occurs in old age when the tubules disappear and their place is taken by interstitial connective tissue. Atrophy may also follow injury.

Simple inflammation or **orchitis** follows injury or infection. It presents a characteristic microscopical appearance, each tubule being surrounded by several concentric layers of leucocytic infiltration, which may break into and destroy the tubule

(Fig. 111). Such inflammation may end in abscess formation (especially when it has been brought about by infection, such as gonorrhoea or mumps), or a chronic form of inflammation with fibrous overgrowth may supervene and persist.

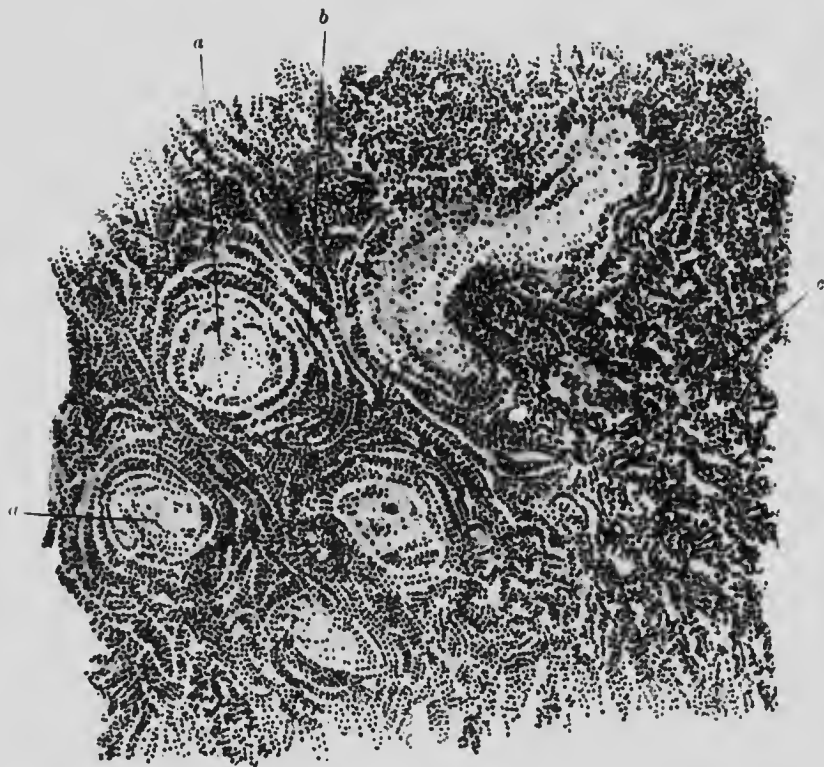


FIG. 111. ORCHITIS. ($\times 100$)

- a.* Seminal tubule with destroyed epithelium.
b. Peritubular inflammation. *c.* Interstitial inflammation.

Tubercle generally occurs in the epididymis, which is then much enlarged. There is usually extensive caseation. As a rule it is secondary to an existing genito-urinary tuberculosis (Fig. 112).

Syphilitic inflammation produces fibrosis of the testicle with compression atrophy of the tubules or gummata which coalesce and destroy the gland.

Tumours of the testis are not uncommon: generally they are malignant and often teratomatous.

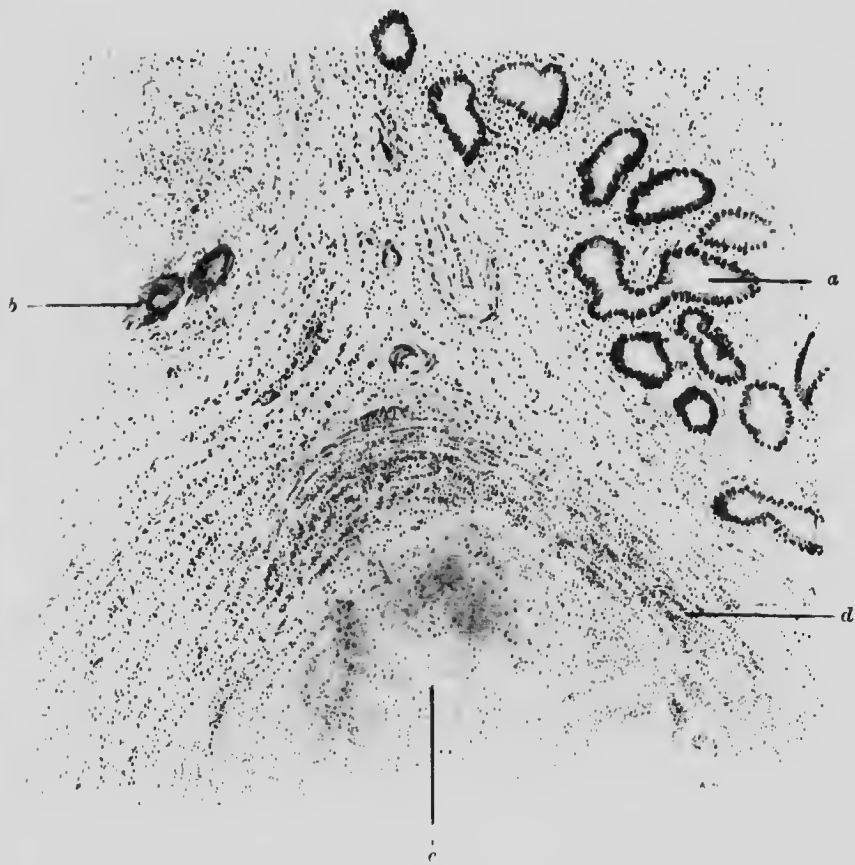


FIG. 112. TUBERCULOUS EPIDIDYMIS. ($\times 40$)

- a.* Normal seminal tubules with slight surrounding infiltration.
- b.* Giant cells.
- c.* Caseating tubercle.
- d.* Endothelial and lymphocytic infiltration at edge of tubercle.

Enlargement is the most common affection of the **prostate** and is due to overgrowth of either the muscular or the glandular portion of the gland, with consequent apparent diminution of the other portion. There may be overgrowth of both portions (Fig. 113).

Abscess of the prostate, often due to gonorrhoea, is not uncommon.

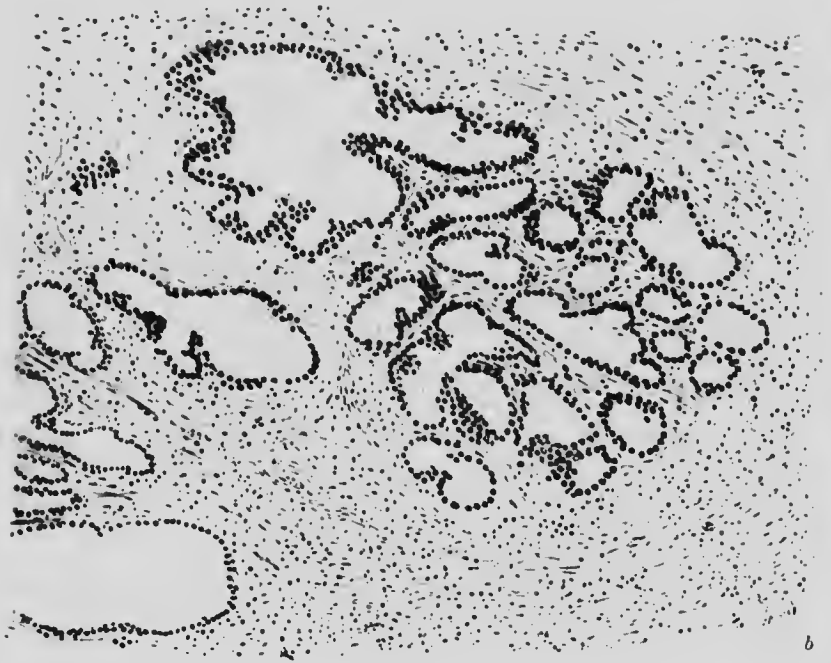


FIG. 113. PROSTATE. HYPERTROPHY. ($\times 100$)

a. Proliferated glandular tissue. *b.* Muscular and fibrous tissue.

Cancer of the prostate is of not infrequent occurrence, but the benign form, adenoma, already mentioned under enlargement, is far more common.

CHAPTER XXIII

THE FEMALE GENITAL ORGANS

ILLUSTRATIVE PREPARATIONS.

1. Multilocular cyst of the ovary.
2. Papillomatous cyst of the ovary.
3. Carcinoma of the ovary.
4. Dermoid cyst of the ovary.
5. Teratoma of the ovary.
6. Salpingitis in gonorrhoea.
7. Salpingitis from tubercle.
8. Endometritis, mainly glandular (curetting).
9. Endometritis, mainly interstitial (curetting).
10. Carcinoma of the uterus (curetting).
11. Carcinoma of the uterine cervix.

THE **ovary** is frequently the site of chronic inflammation and fibrosis, generally the sequel of an acute inflammation due to general or local infection. Replacement of ovarian tissue by fibrous tissue is all that can then be made out microscopically.

The most common affections are cysts and tumours, both malignant and benign.

Simple cysts may result from mere hyperdistension of a follicle. They are often unilocular, although multiple. The lining epithelium is either flat or may even be absent.

Cysts proper of the ovary are always multilocular and lined with columnar epithelium of which portions may be ciliated. The walls of such cysts are either plain or they form papillae and

these papillae may lie so close together as to give the impression of solidity and malignancy. The contents are mostly mucoid in character (Fig. 114). The central portion and base of the papillae is made up of fine connective tissue, varying considerably

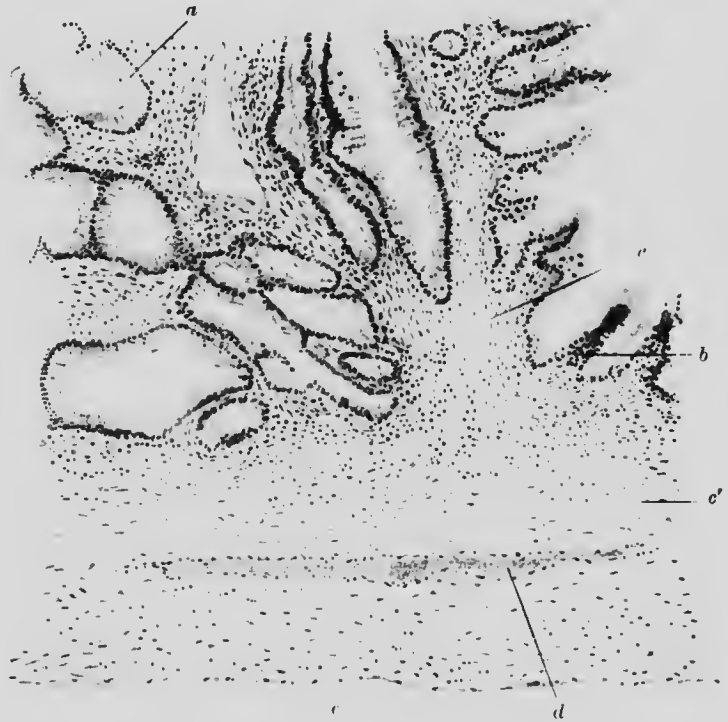


FIG. 114. PAPILLIFEROUS (COLLOID) CYST OF OVARY. ($\times 50$)

- a.* Columnar epithelial lining of a cyst.
- b.* Epithelium thrown into papilliform folds.
- c.* Stroma supporting papilla.
- c'.* Wall of tumour. *d.* Blood-vessel.
- e.* Peritoneal covering.

in density at different places (Fig. 115). Such cystomata may turn out to be malignant with but slight and localised histological evidence thereof.

Solid ovarian carcinomata also occur. The histological type is adenomatous or resembles exaggerated Graafian follicles

(Fig. 116). Secondary deposits from cancer elsewhere are not unusual in the ovary and are then frequently bilateral.

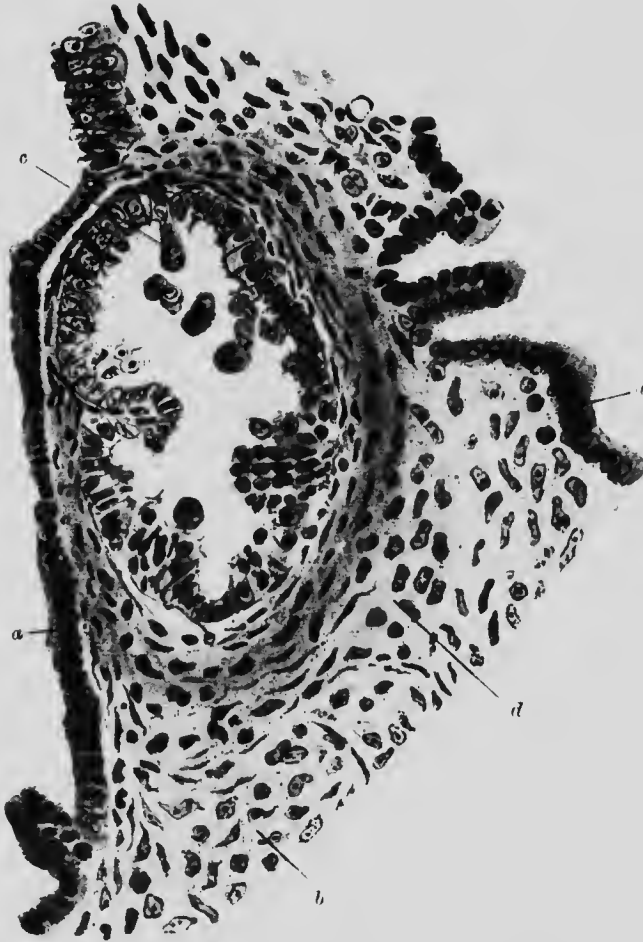


FIG. 115. PAPILLIFEROUS CYST OF OVARY. ($\times 225$)

- a.* Columnar cell covering epithelium of a papilla.
- b.* Supporting stroma.
- c.* Small cyst cut transversely with proliferating irregular epithelium.
- d.* Thickened stroma around.

In **dermoid cysts**, the contents are semi-solid, amorphous and composed of cholesterol and other material. The wall consists of the elements of skin, namely, epithelium, sebaceous glands, hair and occasionally teeth, with an excess of fibrous tissue (Fig. 117).

Cysts containing structures from other layers than the epiblast also arise in the ovary: they should be classed as **teratomata**.

Of the diseases of the **Fallopian tubes** inflammation (**salpingitis**) is the most important pathological condition. The most common causes are gonorrhœa and tubercle.

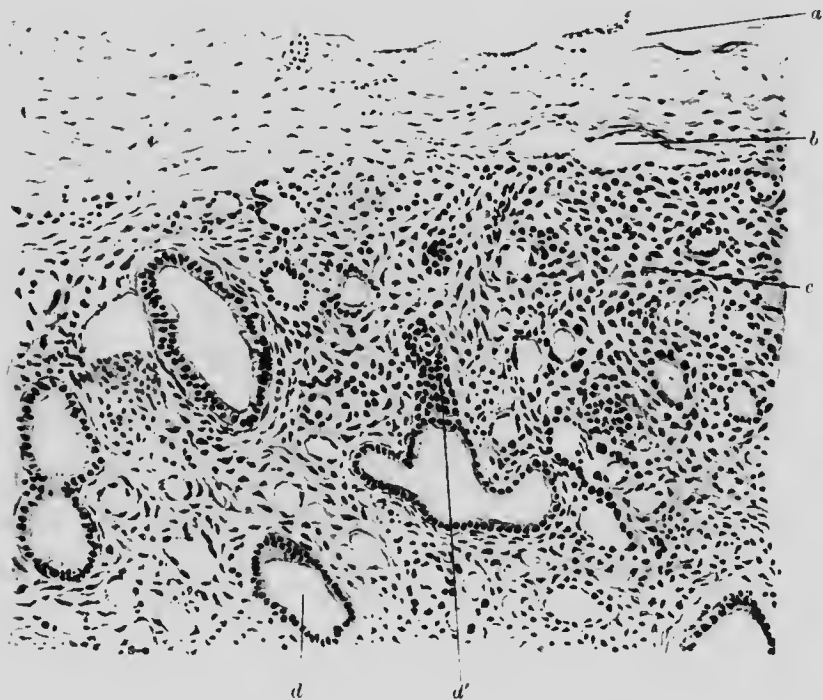


FIG. 116. CARCINOMA (SOLID) OF OVARY. ($\times 75$)

- a.* Thickened capsule of ovary.
b. Blood vessel. *c.* Normal ovarian tissue.
d and *d'*. Cancerous portions becoming cystic.

In **gonorrhœal salpingitis** the lumen of the tube is filled with pus, often causing considerable distension: the folds of mucous membrane below the epithelium are also separated by the infiltration. The inflammation extends throughout the wall on to the peritoneum, but the walls of the tube are not appreciably thickened. Other septic infections may cause similar appearances and the resulting disintegration of the tube, together with the

adhesions to other parts, may make the organ almost unrecognisable both to the naked eye and to the microscope (Fig. 118).

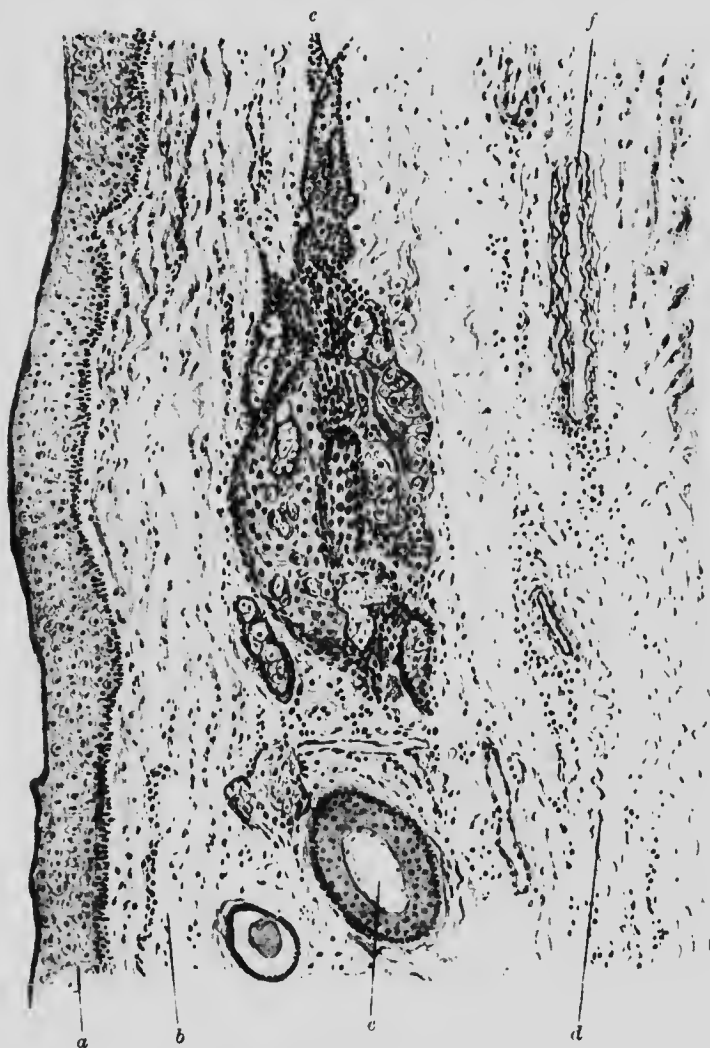


FIG. 117. DERMOID. OVARY. ($\times 80$)

- | | |
|--|----------------------------|
| <i>a.</i> Epithelium. | <i>e.</i> Hair cut across. |
| <i>b.</i> Fibrous tissue. | <i>d.</i> Elastic tissue. |
| <i>c.</i> Mass of mixed epithelium and sebaceous gland tissue. | |
| <i>f.</i> Blood-vessel. | |

In **tuberculous salpingitis**, typical tubercles occur in the mucous membrane and in the muscular layers. The latter are

much thickened (Fig. 119). Tubercles may be present on the peritoneal surface and the inflammation, whatever its form, may

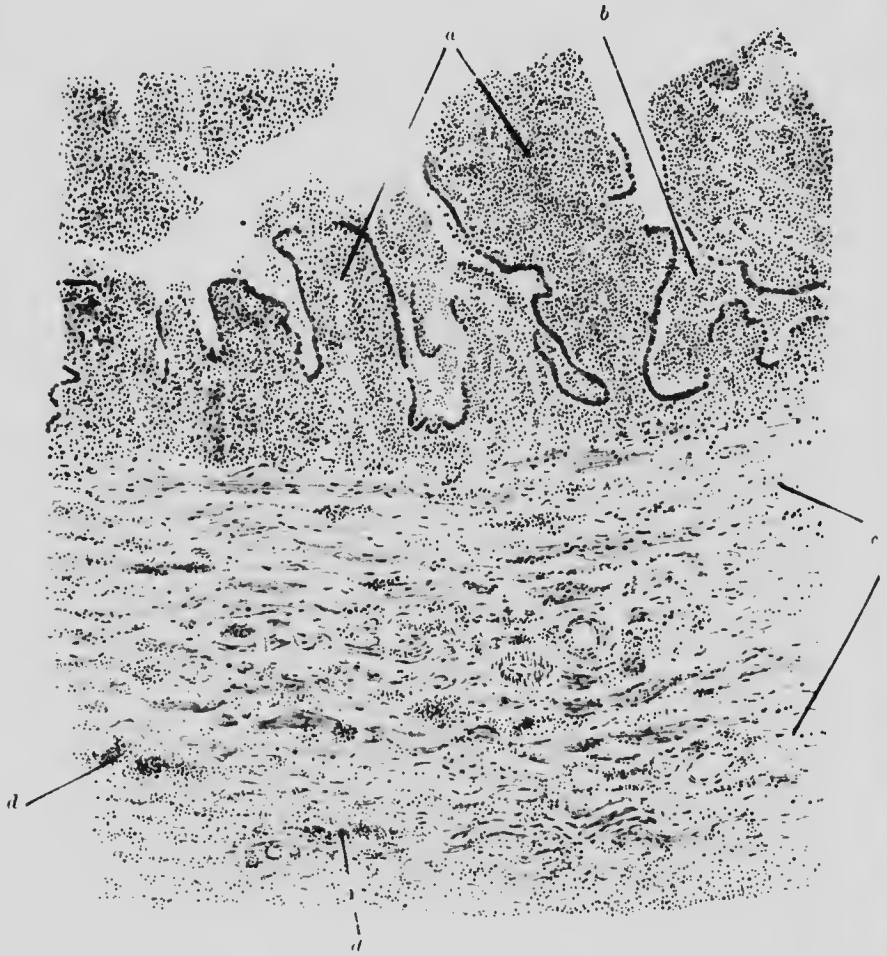


FIG. 118. GONORRHEAL SALPINGITIS. ($\times 100$)

- a.* Mucous membrane, with epithelium partly lost and the stroma of the papillae full of pus.
b. Pus in the lumen of glands. *c.* Muscular wall with
d. local infiltrations of small cells.

spread to the ovary. The inflammatory affections of the female genital organs are of importance mainly by their implication of the peritoneum, leading to the formation of adhesions and their attendant discomforts.

FIG. 119. TUBERCULOSIS OF FALLOPIAN TUBE. ($\times 75$)

- | | |
|---|--------------------------------------|
| <i>a.</i> Mucous membrane. | <i>d.</i> Tubercle in muscular coat. |
| <i>b.</i> Submucosal caseating tubercle. | <i>f.</i> Peritoneum. |
| <i>b'.</i> Tubercles with surrounding inflammation. | |
| <i>c.</i> Thickened muscular coat. | |

The Fallopian tubes are not often the seat of new growths.

Acute purulent inflammation (**metritis**) affects the mucous membrane and whole thickness of the wall of the **uterus**, generally with the production of peritoneal adhesions. In the chronic form there is the usual formation of fibrous tissue with subsequent contraction.

Endometritis is an inflammatory catarrhal condition of the mucous membrane and its accompanying stroma. In a section

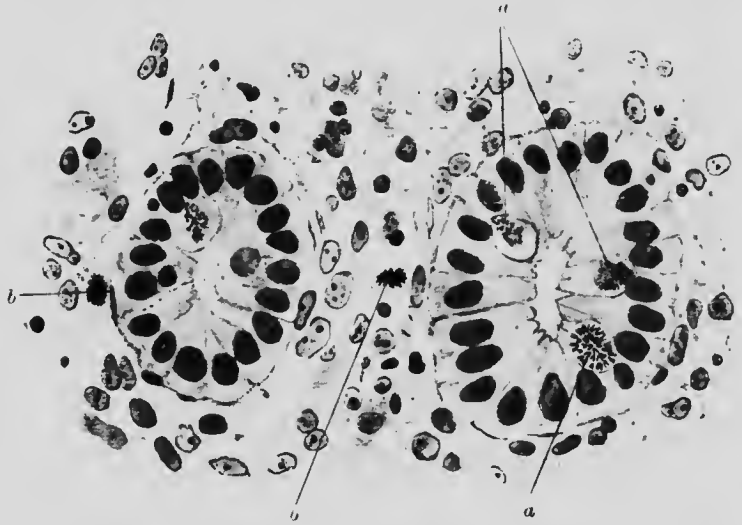

FIG. 120*. UTERINE GLANDS AND STROMA. ENDOMETRITIS. ($\times 525$)

- a. Cells of glands showing somatic mitosis. Metaphase. Observe V-shaped chromosomes arranged at right angles to long axis.
- b. Similar condition in cells of stroma. The chromosomes are more closely clustered.

from a enetting it will be noted that the gland lumen is often distended and contains shed cells, while numerous mitoses indicate considerable proliferation. The stroma shows a loose network with occasional haemorrhages, many mitoses and occasional leucocytic infiltration. According as the glandular or connective tissue proliferation is predominant we get the one or the other type of endometritis. Later on the ordinary results of chronic inflammation supervene, especially the loss of glandular epithelium (Figs. 120 and 120*).

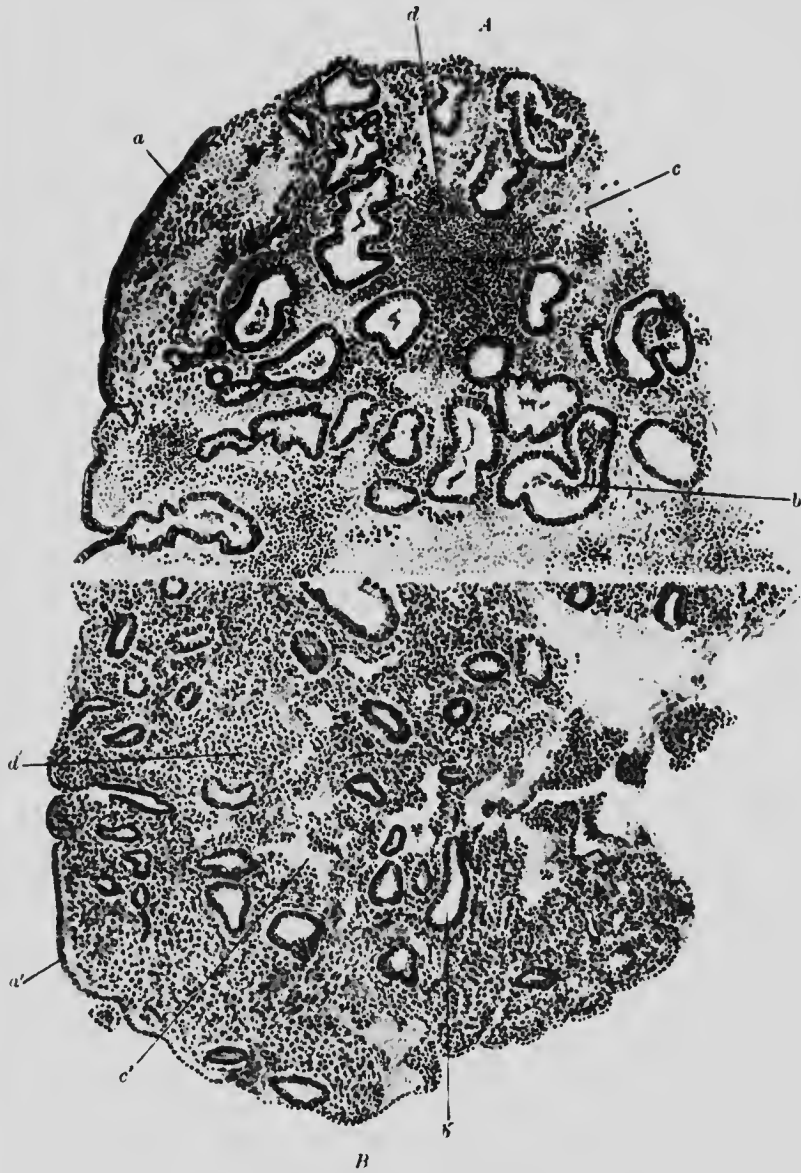


FIG. 120. ENDOMETRITIS. CURETTING. ($\times 50$)

A. MAINLY GLANDULAR FORM.

- | | |
|---|-------------------------------------|
| <i>a.</i> Superficial epithelium. | <i>c.</i> Red blood corpuscles. |
| <i>b.</i> Enlarged and multiplied glands. | <i>d.</i> Collection of leucocytes. |

B. MAINLY INTERSTITIAL FORM.

- | | |
|------------------------------------|--|
| <i>a'.</i> Superficial epithelium. | <i>c'.</i> Red blood corpuscles. |
| <i>b'.</i> Glands. | <i>d'.</i> Considerably increased interstitial tissue. |

G.H.

L

Of new growths in the uterus, myomata in the body and carcinoma of the cervix are the most important.

Myoma and **fibromyoma** are composed of plain muscle or a mixture thereof with fibrous tissue in varying proportions (Fig. 120†). The relative amount of each constituent is made obvious by using v. Gieson's stain. The growths are liable to

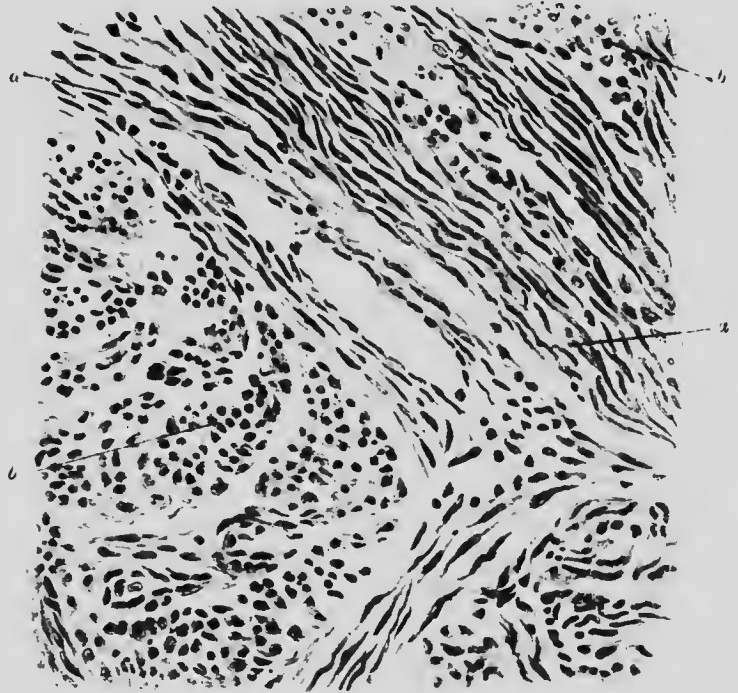


FIG. 120†. MYOMA. UTERUS. ($\times 250$)

- a.* Plain muscle fibres cut longitudinally.
b. Muscle fibres cut transversely.

undergo degeneration and necrosis. One peculiar form, accompanied by haemorrhage, is known as "red degeneration" and is accompanied by acute clinical symptoms.

Cancer in the **vaginal portion** of the cervix is of epitheliomatous type, like the structure of the tissue at its site of origin. It tends to grow irregularly in the so-called cauliflower form, accompanied, as a rule, by much ulceration and destruction of tissue.

In the **supravaginal** portion of the cervix the growth is of adenomatous type, tending to be solid and encephaloid.

Both forms are liable to spread through the substance of the uterus and the supravaginal form may do so without affecting the os uteri visibly for a considerable time.

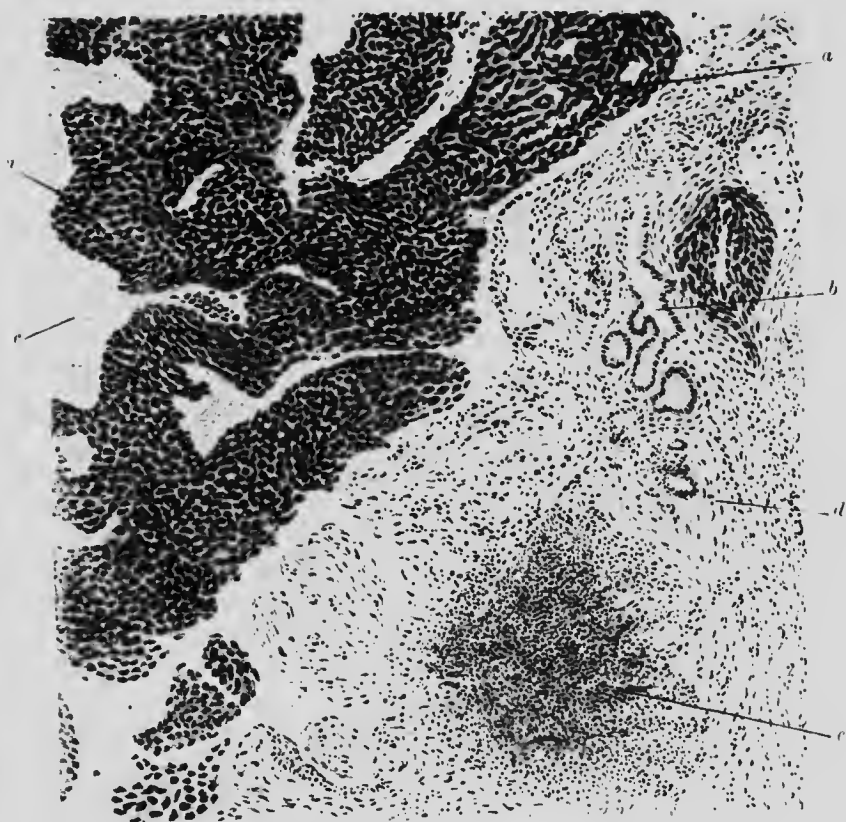


FIG. 121. CURETTING. CANCER OF UTERUS. ($\times 75$)

- | | |
|--|--------------------------|
| <i>a.</i> Cancerous epithelium. | <i>c.</i> Blood-clot. |
| <i>b.</i> Normal glandular epithelium. | <i>d.</i> Muscle fibres. |
| <i>e.</i> Inflammatory area. | |

New growth in the body of the uterus is much less common.

The distinctive features have often, for purposes of diagnosis, to be made out from scrapings of tissue. In the squamous celled growth, the flattened, often diamond-shaped cells, present in large groups, generally make the diagnosis fairly easy. In adeno-

carcinomatous growths, the irregular many layered glands contrast with the more regular overgrowth seen in hypertrophic endometritis. Since in both cases there is often an inflammatory zone, this criterion is of little use in the discrimination of uterine growths (Fig. 121).

ontra t
lom -
zoi s,
teri. e

CHAPTER XXIV

THE DUCTLESS GLANDS

ILLUSTRATIVE PREPARATIONS.

1. Thyroid gland in simple goitre.
2. Thyroid gland in exophthalmic goitre.
3. Thyroid gland in myxoedema.
4. Carcinoma of the thyroid gland.
5. Atrophy of the adrenal gland.
6. Tuberculous disease of the adrenal gland.
7. Carcinoma of adrenal gland (hypernephroma).
8. Skin from a case of Addison's disease.
9. Carcinoma of the pituitary gland.

THE **thyroid gland** may be the seat of (1) non-metabolic hypertrophy (simple hypertrophy), (2) metabolic hypertrophy (exophthalmic goitre), (3) of subactive atrophy (myxoedema) and (4) of new growth (adenoma or cancer).

In **simple goitre** the gland is much enlarged. The enlargement is commonly due to cystic degeneration with the formation of numerous cysts of various sizes, containing either colloid material or altered blood. Either the whole of the gland or one lobe or the isthmus only may be affected. Occasionally the enlargement is partly solid. Corresponding to this, under the microscope there is either an increase of colloid distending the alveoli with very little increase of secreting epithelium or an overgrowth of alveolar epithelium with very little increase of colloid, but most commonly a combination of both processes

(Fig. 122). Dilatation of the blood-vessels or thickening of their walls is often associated with this condition.

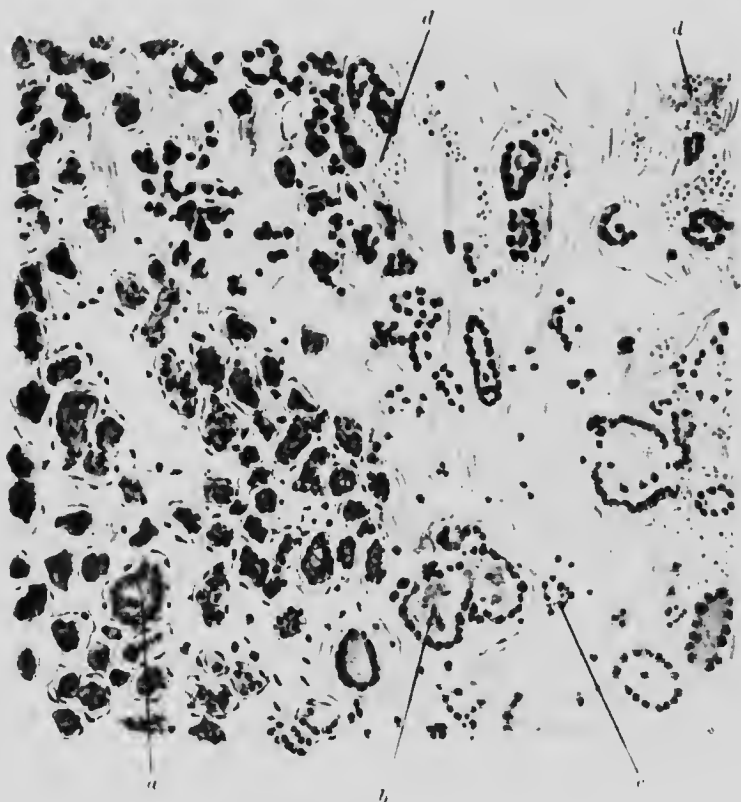


FIG. 122. SIMPLE GOITRE. THYROID. ($\times 100$)

- | | |
|---|----------------------------|
| <i>a.</i> Area of glandular overgrowth. | <i>c.</i> Fibrous tissue. |
| <i>b.</i> Acini distended with colloid. | <i>d.</i> Dilated vessels. |

In **exophthalmic goitre**, such increase in the size of the gland as may be present is due partly to vascular distension and partly to a marked hyperplasia of gland tissue, with some infiltration. The gland is pale and abnormally soft. Cysts are not usually present. On section, the naked eye appearance of the gland resembles that of the pancreas. Owing to the disappearance of colloid, the enlargement is much less than in many cases of simple goitre (Fig. 123). The thymus gland is often still

persistent and enlarged in this condition. Microscopically there is considerable proliferation of epithelium which tends to become arranged like a racemose gland. It is more cubical or columnar



FIG. 123. EXOPHTHALMIC GOITRE. THYROID. ($\times 120$)

- a.* Proliferation of cells forming solid acinus.
- b.* The same in an earlier stage.
- c.* Acinus surrounded by lymphocytic infiltration.
- d.* Granular deposit in lumen of acinus.
- e.* Colloid material becoming granular.

than normal and shows numerous mitoses. The spaces are filled with a material which is more granular and fluid than colloid.

Atrophy of the gland occurs as the result of a progressive chronic inflammatory process which leads to the destruction of

secreting tissue and its replacement by fibrous tissue. Areas of leucocytic infiltration with distended blood-vessels may be found until quite a late stage. Clinically, the condition known as **myxoedema** results. A similar state is produced by operative

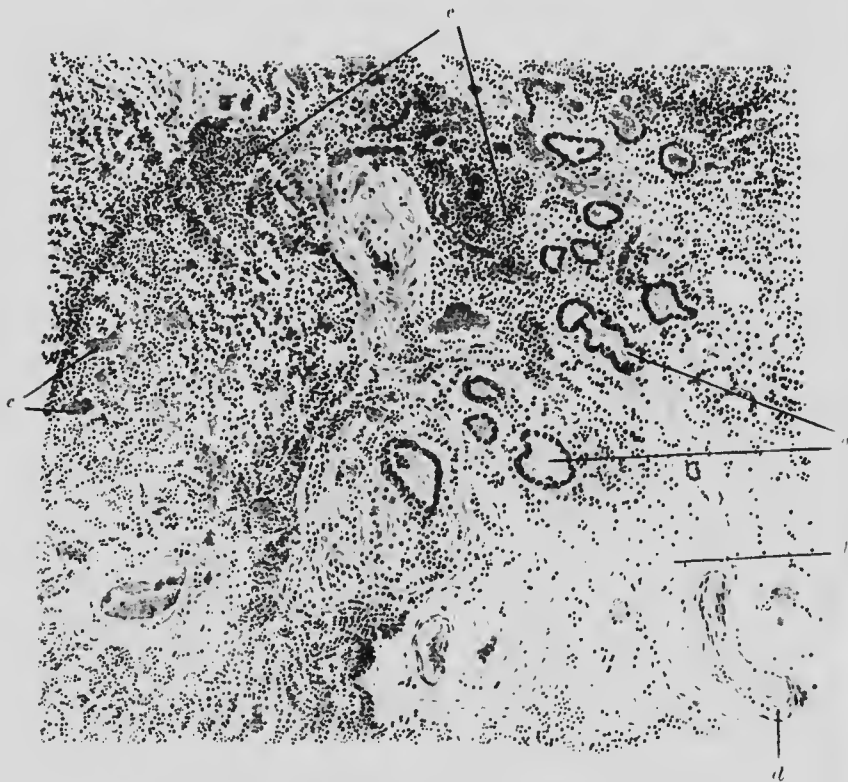


FIG. 124. THYROID GLAND IN MYXOEDEMA. ($\times 100$)

- a.* Remains of gland tissue. Structure still quite evident.
- b.* Fibrous tissue replacing gland tissue.
- c.* Lymphocytic infiltration preceding (*b*).
- d.* Veins much dilated.
- e.* Artery in midst of fibrotic patch.

removal of the whole thyroid or by its congenital absence or atrophy (Fig. 124).

New growth in the thyroid gland is generally benign (**adenoma**), consisting of several small spherical, partly encapsulated growths buried in the substance of the gland and distinguishable from it

microscopically by their greater cellularity. When malignant, there is no capsule, the mode of growth is irregular and penetrative and the cells, instead of being cubical, are spheroidal-shaped and unequal (Fig. 125).




FIG. 125. THYROID. CARCINOMA. ($\times 100$)

- a.* Area of new growth with occasional acinar arrangement.
- b.* Area of solid mass of cells.
- c.* Advancing edge of growth into *d*, connective tissue.
- c.* Blood-vessel.

In the **adrenal gland**, the most common affections are haemorrhage, tuberculous disease, atrophy and new growth.

Tuberculosis of the adrenal gland has only the ordinary features of the process and when so extensive as to cause total

destruction of the glandular tissue (Fig. 126) leads to the same result as **atrophy** following on chronic inflammation. Here the

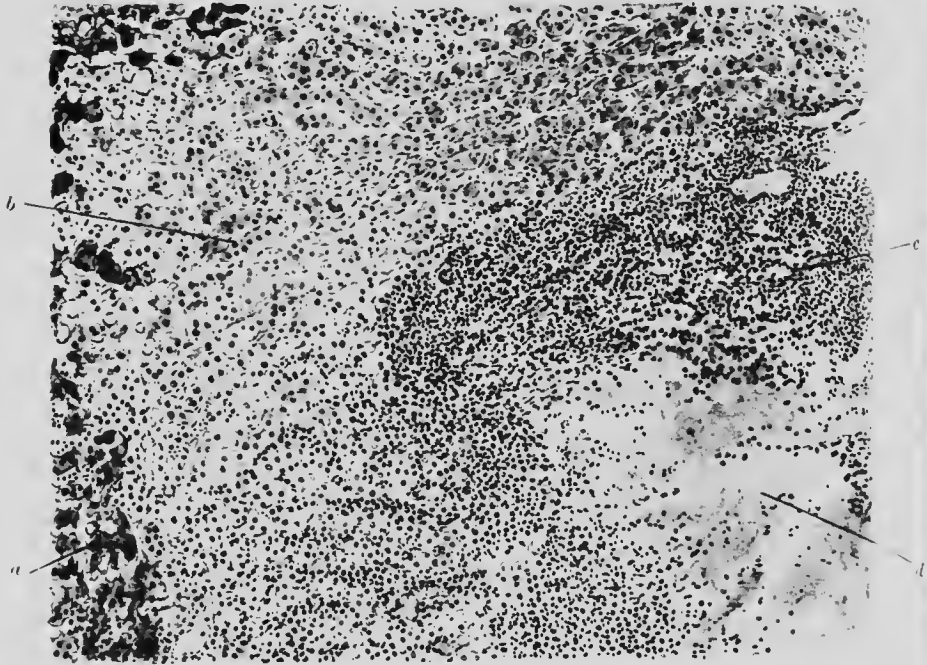


FIG. 126. ADRENAL TUBERCLE. ($\times 75$)

- | | |
|----------------------------|---------------------------------|
| <i>a.</i> Cortical cells. | <i>c.</i> Lymphocytic border of |
| <i>b.</i> Medullary cells. | <i>d.</i> caseous tubercle. |

tubules are reduced in size and the spaces between them occupied with lymphocytes (Fig. 127). Both these pathological states, when bilateral, produce the condition known as Addison's disease. The skin is often discoloured from a deposition of pigment (Fig. 128).

Haemorrhage into both glands is not very uncommon after infectious disease in children and may be so extensive as to destroy the glands and cause death.

Of primary new growths, the **hypernephroma** is the most important, but the adrenal gland is also often the seat of secondary deposits. Although of adrenal origin, hypernephroma is found more often in the kidney than in the gland. When simple, it is often called an adenoma and is composed of a




FIG. 127. ADRENAL ATROPHY. ($\times 60$)

- a.* Thickened capsule.
- b.* Lymphocytic interglandular infiltration.
- c.* Atrophied columns of gland cells.



FIG. 128. SKIN. ADDISON'S DISEASE. ($\times 150$)

- a.* Superficial epithelium.
- b.* Malpighian layer.
- c.* Stratum granulosum, with pigment in cells.
- d.* Corium.

solid mass of cells resembling the cortex of the adrenal gland. When malignant, the tumour forms papilliferous alveoli bearing cubical epithelium on delicate stalks, or it may take a form

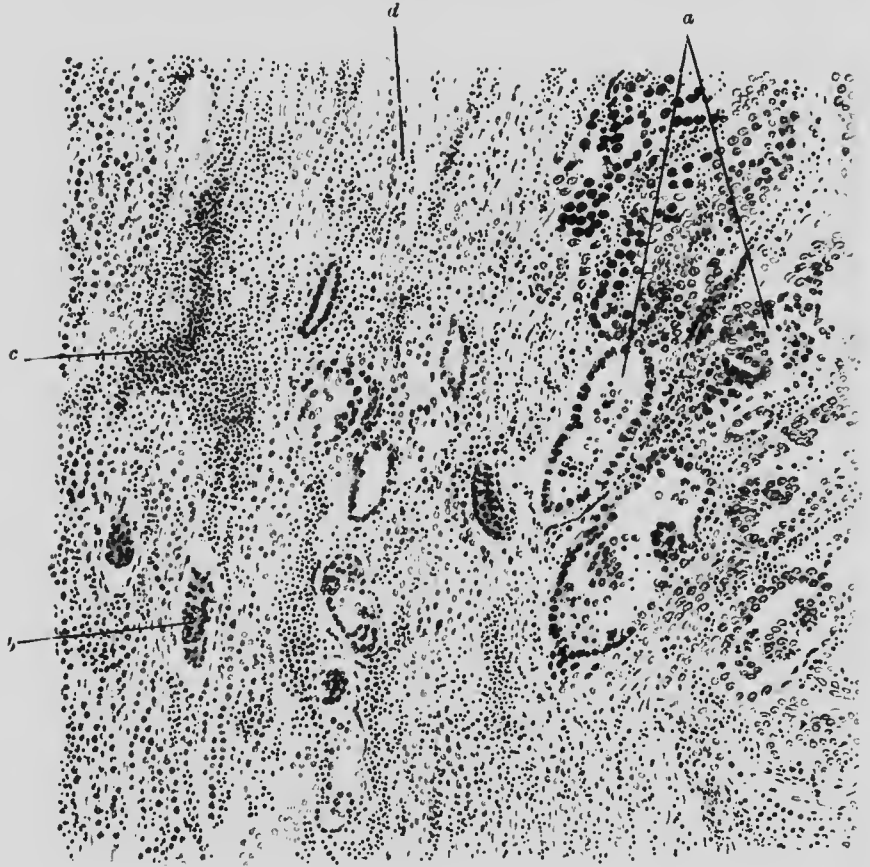


FIG. 129. HYPERNEPHROMA (BOURNEVILLE ZONE). KIDNEY. ($\times 75$)

- | | |
|-----------------------------------|----------------------------------|
| a. Cells of growth. | c. Inflammatory area in kidney. |
| b. Atrophic glomerulus in kidney. | d. Compressed tubules of kidney. |

resembling distended and irregular kidney tubules (Fig. 129). The malignant growth compresses and destroys neighbouring tissues and deposits metastatic growths in other organs.

The **pituitary gland** is sometimes the seat of new growth: both of carcinoma and of sarcoma, of hyperplasia and of fibroid change. These conditions produce marked clinical symptoms.

CHAPTER XXV

THE BLOOD

ILLUSTRATIVE PREPARATIONS.

1. Blood from a case of chlorosis.
2. Blood film from a case of idiopathic anaemia.
3. Blood film from a case of myelogenous leukaemia.
4. Blood film from a case of lymphatic leukaemia (acute and chronic).
5. Blood film from a case of pseudo-leukaemia.

THE pathological alterations in the blood corpuscles may affect their number, shape, size, colour and cellular constituents so far as the changes are anatomically demonstrable. The chief primary diseases of the blood are chlorosis, idiopathic anaemia and leukaemia. Secondary changes occur in other diseases, such as the infectious diseases and lead poisoning.

In **chlorosis** the number of red cells is slightly reduced, the size is not so uniform as in normal blood but the shape remains the same. The haemoglobin is diminished, so that the erythrocytes are of paler colour than normal.

In **idiopathic anaemia** the red cells are diminished in number and they are often deformed as well as diminutive in the stained blood film. Nucleated erythrocytes are not uncommon and the individual cells appear of deeper colour than normal owing to the excess of haemoglobin which each contains.

Red cells may occasionally be seen, in suitably stained specimens, containing blue granules, the so-called basophile degeneration. The colour of such cells is often blue rather

than pink (polychromatophilia), but either of the two conditions, basophilia and polychromatophilia, also occurs independently of the presence of the other. The leucocytes are reduced in number.

In **spleno-medullary leukaemia**, so called because the microscopic changes are seen principally in the spleen and in the bone marrow, the distinctive feature is the occurrence in the circulating blood of cells which normally are found only in the bone marrow, hence their name of "myelocytes." They are immature white cells which, while showing the specific granulation of the class, have a relatively simple nucleus. The neutrophile myelocyte resembles the neutrophile leucocyte but is larger and the nucleus, which instead of being lobed and forming three sides of a square is spherical or oval, occupies a larger proportion of the cell and takes on only a faint stain. In the eosinophile myelocyte the faint stain and relatively simple form of the nucleus also occur. In addition to the increase in number of neutrophile cells and myelocytes there is also an excessive number of mast cells and eosinophile cells present. Thus both the absolute and proportionate numbers of the various leucocytes are profoundly altered.

The red cells undergo a progressive diminution in number during the course of the disease. Immature red cells appear, both normoblasts and megaloblasts. The former has a nucleus and is of normal size or a little smaller; the latter is also nucleated but abnormally large.

In **lymphatic leukaemia** the excess of lymphocytes is the chief feature. In the chronic form the small, and in the acute form the large, lymphocyte predominates. The number is greatest in the chronic cases.

It should be remembered that both myelocytes and excess of lymphocytes may be found in the blood apart from the disease, leukaemia.

The coarsely granular acidophile cells are present in excess (**eosinophilia**) in parasitic diseases, especially those due to worms of various kinds, in some skin diseases and in asthma.

tion
ly c
d i

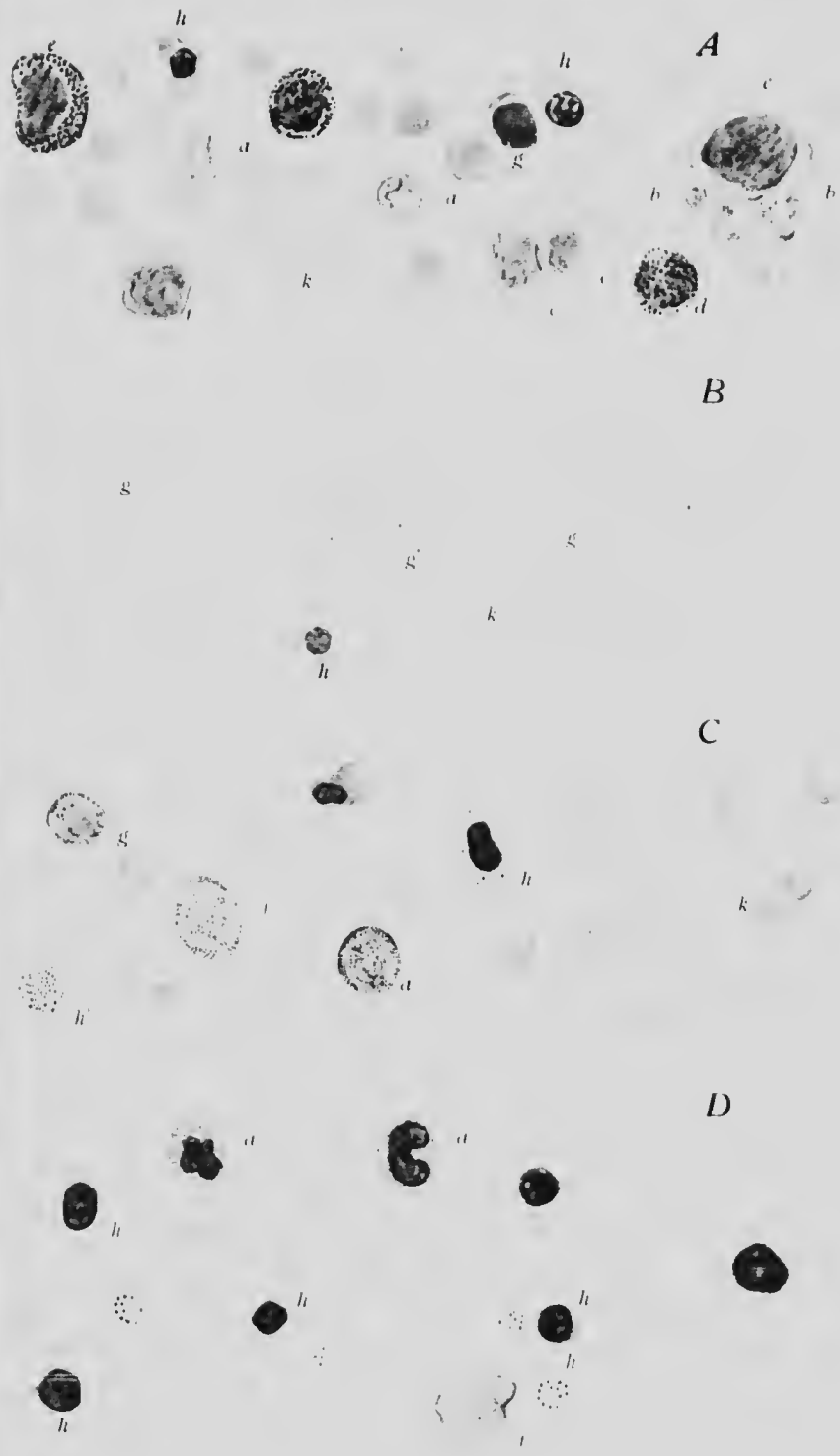
micro
bone
atin
row
white
class
ocyte
elens
pare
and
e the
ocut.
and
and
onate

mber
pear,
elens
also

s the
neute
atet

xcess
the

xcess
orms



DISEASES OF THE BLOOD.

1870
1871
1872
1873
1874
1875
1876
1877
1878
1879
1880
1881
1882
1883
1884
1885
1886
1887
1888
1889
1890
1891
1892
1893
1894
1895
1896
1897
1898
1899
1900
1901
1902
1903
1904
1905
1906
1907
1908
1909
1910
1911
1912
1913
1914
1915
1916
1917
1918
1919
1920
1921
1922
1923
1924
1925
1926
1927
1928
1929
1930
1931
1932
1933
1934
1935
1936
1937
1938
1939
1940
1941
1942
1943
1944
1945
1946
1947
1948
1949
1950
1951
1952
1953
1954
1955
1956
1957
1958
1959
1960
1961
1962
1963
1964
1965
1966
1967
1968
1969
1970
1971
1972
1973
1974
1975
1976
1977
1978
1979
1980
1981
1982
1983
1984
1985
1986
1987
1988
1989
1990
1991
1992
1993
1994
1995
1996
1997
1998
1999
2000
2001
2002
2003
2004
2005
2006
2007
2008
2009
2010
2011
2012
2013
2014
2015
2016
2017
2018
2019
2020
2021
2022
2023
2024
2025

Leucocytosis, viz. an increase in the number of neutrophile leucocytes, is often seen in septic cases, especially in those having an enclosed collection of pus. Mere septicaemia by itself does not lead to so marked a leucocytosis.

Leucopenia, viz. a decrease in the number of leucocytes, is found in a few acute infectious diseases of which enterica and general tuberculosis are the most important.

KEY TO COLOURED PLATE.

A, B AND C, JENNER'S STAIN; D, HAEMATOXYLIN AND EOSIN.

A. SPLENO-MEDULLARY LEUKAEMIA. (×500)

- | | |
|--|----------------------------------|
| <i>a.</i> Neutrophile myelocytes. | <i>f.</i> Large lymphocyte. |
| <i>b.</i> Nearly fully developed neutrophile leucocytes. | <i>g.</i> Small lymphocyte. |
| <i>c.</i> Intermediate myelocytes. | <i>h.</i> Normoblasts. |
| <i>d.</i> Mast cells. | <i>k.</i> Red cells. |
| <i>e.</i> Large neutrophile myelocyte. | <i>l.</i> Eosinophile myelocyte. |

B. LYMPHATIC LEUKAEMIA. (×500)

- | | |
|--|----------------------|
| <i>a.</i> Neutrophile myelocyte. | |
| <i>g.</i> Lymphocytoid cells of various sizes forming the majority of cells. | |
| <i>g'.</i> Large lymphocytoid cell with neutrophile granulations. | |
| <i>h.</i> Nucleated red cell. | <i>k.</i> Red cells. |

C. IDIOPATHIC ANAEMIA. (×500)

- | | |
|--|------------------------------|
| <i>a.</i> Neutrophile myelocyte. | <i>f.</i> Transitional cell. |
| <i>b.</i> Nucleated red cell showing basophile granules (granular degeneration). | |
| <i>h'.</i> Ordinary red cell showing basophile granules. | |
| <i>k.</i> Red cells of various sizes and shapes (poikilocytosis). | |

D. PSEUDOLEUKAEMIA INFANTUM. (×500)

- | | |
|---|--------------------------------|
| <i>a.</i> Degenerate neutrophile leucocytes. | <i>g.</i> Small lymphocyte. |
| <i>f.</i> Large lymphocyte. | <i>h.</i> Nucleated red cells. |
| <i>h'.</i> Red cell with granular degeneration. | |

CHAPTER XXVI

SEROUS MEMBRANES

ILLUSTRATIVE PREPARATIONS.

1. Acute pericarditis in stage of organisation.
2. Chronic fibrinous pericarditis.
3. Acute pleurisy.
4. Acute peritonitis.
5. Chronic perihepatitis.

THE **serous membranes** embrace the pleura, pericardium and peritoneum. Inflammation is the most common lesion. The two layers, of which each of these membranes consists, may either be separated further apart than normal by the presence of an excess of fluid in the cavity which they bound, or in the absence of fluid become adherent and connected by the excessive formation of fibrin. In many cases the ultimate result is the same, for adhesions form after the absorption of the excess of fluid.

Pericarditis, in its acute form, is caused by bacteria or toxins and therefore occurs commonly in the course of certain infective diseases. The phenomena are the same in principle as those seen elsewhere in inflammation. The variations in detail arise chiefly from the fact that the process takes place on a very vascular free surface. Consequently, after the initial stages of congestion and stasis, the exudation of lymph proceeds more rapidly and is greater in amount than in solid tissue. Permanent traces and evidence of previous inflammation nearly always remain after recovery.

n and
ne two
her be
excess
f fluid
ion of
e, for
dd.

toxins
fective
e seen
chiefly
ar free
n and
and is
es and
after




FIG. 130. PERICARDITIS (ORGANISING.) (X 100)

- a.* Heart muscle.
- b.* Fibroid boundary layer.
- c.* Layer of connective tissue cells with
- d.* dilated blood-vessels formed from new capillaries.
- e.* Layer of leucocytes that have come through the new vessels, and fibrin.

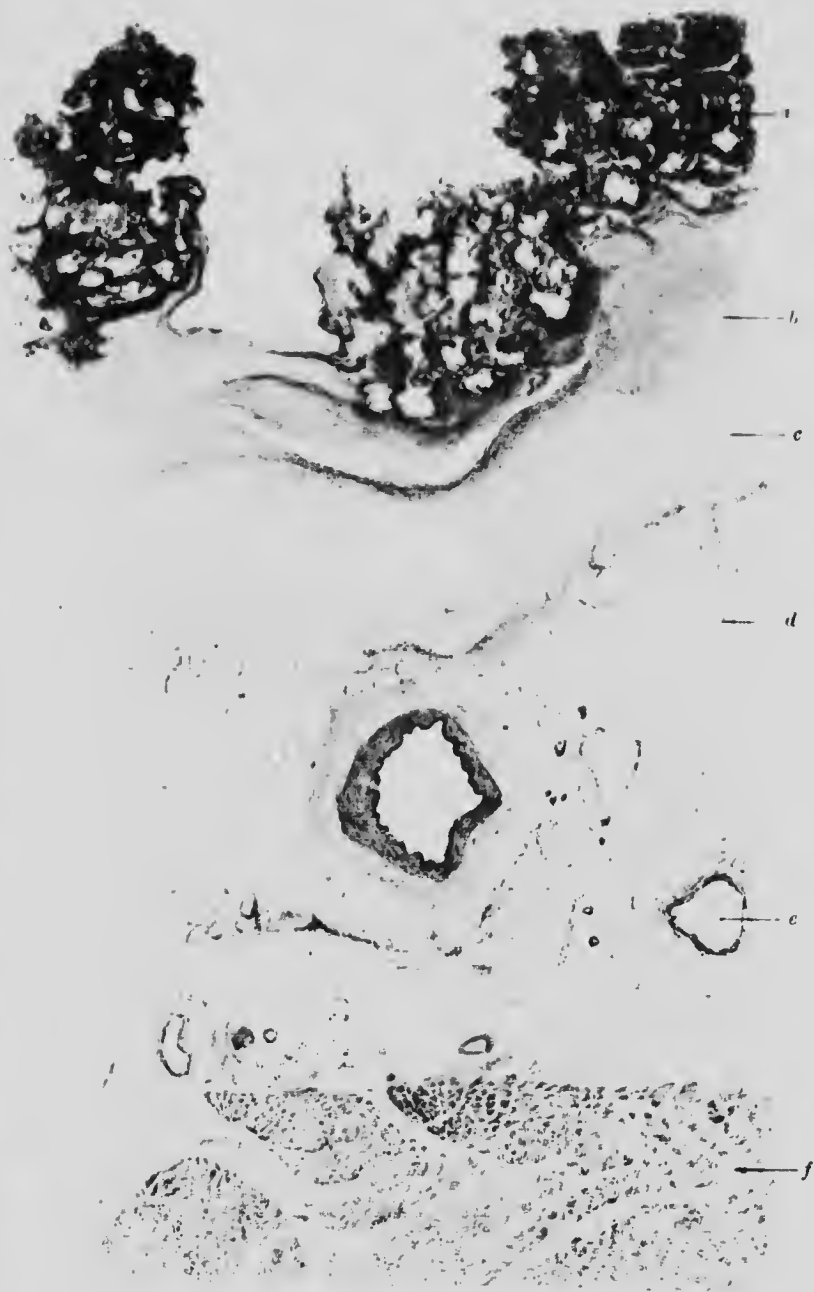


FIG. 131. HEART. CHRONIC PERICARDIITIS. ($\times 10$)

- a.* Papilliform deposit of fibrin.
- b* and *c.* Deposit of fibrin in progressive stages of organisation.
- d.* Enormously thickened pericardium with
- e.* large blood vessels. Myocardium.

G. H.

M

In the most common form—rheumatic pericarditis—a fibrinous lymph (with but few leucocytes) is exuded. The lymph becomes adherent to the epicardium and entangles some leucocytes. The superficial layers of muscle fibres share in the process and show signs of myocarditis, with corresponding histological changes (Fig. 130). The stage of organisation follows and a few days later a section through heart muscle, pericardium and exudate will show the following differentiated layers, arranged from without inwards towards the heart: (*a*) a deeply stained network of fibrin and leucocytes, (*b*) a less deeply stained layer of granular fibrin, more white cells and a few capillaries. The capillaries become generally larger and more numerous as we pass inwards and, together with hyaline material and mononuclear cells, make up the next layer (*c*). In the next stratum (*d*) there is very little fibrin and the capillaries are surrounded with a form of granulation tissue which (*e*) close to the heart muscle contains fibroblasts and new fibrous tissue. Later on the fibrous tissue becomes vascularised. A similar process may go on in the parietal layer of pericardium while the two layers are in contact resulting in an adherent and thickened pericardium. Finally we have (*f*) a layer of myocarditis (Fig. 131).

A similar process takes place in **pleurisy** but here the infection usually passes from the lung to the pleura and on account of the lesser density of lung compared with heart tissue, a greater thickness of lung than of heart tissue is involved (Fig. 132).

In **peritonitis**, by reason of the close apposition of the layers of intestine, the exudate consists mainly of neutrophile leucocytes with comparatively little fluid and fibrin. There is separation of the muscular layers of the intestine by exudate and the individual fibres are swollen (Fig. 133).

After chronic inflammation of very long persistence the peritoneal covering of an organ like the liver (Fig. 134) may become enormously tough and thick. It consists then of very condensed fibrous tissue with very few nuclei and hardly any cytoplasm.




FIG. 132. PLEURISY. ($\times 75$)

- a.* Lung tissue, congested.
- b.* Large vessels in the adjacent pleura.
- c.* More recently formed vessels in external layers of thickened pleura.
- d.* Layer of blood.
- e.* Thick layer of fibrin.
- f.* Thin layer of leucocytes.




FIG. 133. INTESTINAL WALL (PORTION OF). PERITONITIS. ($\times 150$)

- | | |
|--|--|
| <i>a.</i> Layer of fibrin and leucocytes. | <i>c.</i> Dilated capillaries. |
| <i>b.</i> Thickened layer of peritoneum. | <i>d.</i> Swollen connective tissue cells. |
| <i>c.</i> Swollen muscle fibres. | |
| <i>a'.</i> Portion of <i>a.</i> ($\times 400$) | |

In all three cases the process may be suppurative and the cavities be filled with pus. If recovery take place, the serous



FIG. 134. PERIHEPATITIS. (OLD.) ($\times 100$)

- a.* Liver tissue partly replaced by connective tissue.
- b.* Boundary layer of leucocytes.
- c.* Layer of fairly dense new connective tissue.
- d.* Outer layer of more open connective tissue with a few leucocytes.

membrane concerned is much thickened with new connective tissue.

In the peritoneal cavity, the multiplicity of organs leads to many varieties of adhesion.

The other primary affections of the serous membranes are neither numerous nor common.

Tubercle is usually secondary to affection of the neighbouring organ, consequently tuberculous pericarditis is the least common and tuberculous pleurisy the most common.

Of the three membranes the peritoneum is most often affected with new growth. It is nearly always secondary, although colloid cancer and **mesotheliomata** (tumours of similar characters and origin to the endotheliomata) do occur primarily. Occasionally general carcinomatosis, secondary to growth in one of the pelvic organs, is found. It manifests itself as numerous nodules scattered all over the peritoneum.

CHAPTER XXVII

THE LYMPHATIC GLANDS. THE BONES

ILLUSTRATIVE PREPARATIONS.

1. Lymphatic gland in lymphadenoma.
2. Lymphatic gland in the neighbourhood of a tattoo mark.
3. Chondro-sternal junction in rickets.
4. Cartilage and synovial membrane in rheumatoid arthritis.
5. Cartilage and synovial membrane in gout.

THE **lymphatic glands**, being virtually filters, are especially liable to infection and inflammation resulting from processes occurring in their vicinity and to the reception of deposits of foreign bodies or new growth conveyed to them through the lymphatics. In some blood diseases the lymphatic glands show changes which are probably primary and they may also be the seat of primary sarcoma.

Pigmentation is frequently seen in the bronchial glands of town dwellers, miners or others having dusty occupations. After tattooing the pigment is partly carried away to the nearest glands. It is then found mainly within the phagocytes which conveyed it and in the endothelial cells of the gland. It causes proliferation of these cells with ultimate fibrosis (Fig. 135).

Lymphadenitis, or inflammation, is usually the result of bacterial infection, including typhoid and plague bacilli as well as pyogenic organisms. Softening and necrosis of the gland, together with aggregation of the causal organism within its tissues, are the most marked special features of glandular inflammation.

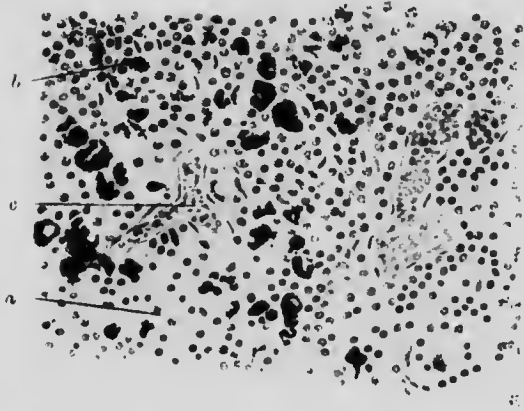


FIG. 135. TATTOOING. GLAND. ($\times 250$)

- a.* Normal gland tissue.
- b.* Gland tissue with pigmentary deposit.
- c.* Dilated capillary.




FIG. 135*. TUBERCULOUS INFLAMMATION. LYMPHATIC GLAND. ($\times 170$)

- a.* Multinucleate giant cell.
- b.* Layer of epithelioid cells.
- c.* Layer of lymphocytes.

Tuberculous infection produces distinctive appearances. Macroscopically, there is yellow caseation or calcification and microscopically, the presence of particularly typical giant cell systems (Fig. 135*). In addition, there is proliferation of the



FIG. 136. LYMPHADENOMA. GLAND. ($\times 100$.)

Showing increase of reticulum tending to fibrosis, with mononuclear and multinuclear giant cells.

reticular cells, generally followed by necrosis and the production of masses of granular, structureless material (caseation).

In **lymphadenoma** (Hodgkin's disease) the lymphatic glands undergo a gradual enlargement without any characteristic changes in the blood. The effects bear resemblance both to tubercle and

to tumour formation. The glands remain discrete, are semi-opaque and partly grey and partly streaky yellow in colour.

Microscopically, the most striking feature is the presence of phagocytic giant cells arising from the endothelium. Some of these cells are mononuclear, some are multinuclear. Large syncytial masses also occur. At first there is an increase of lymphoid

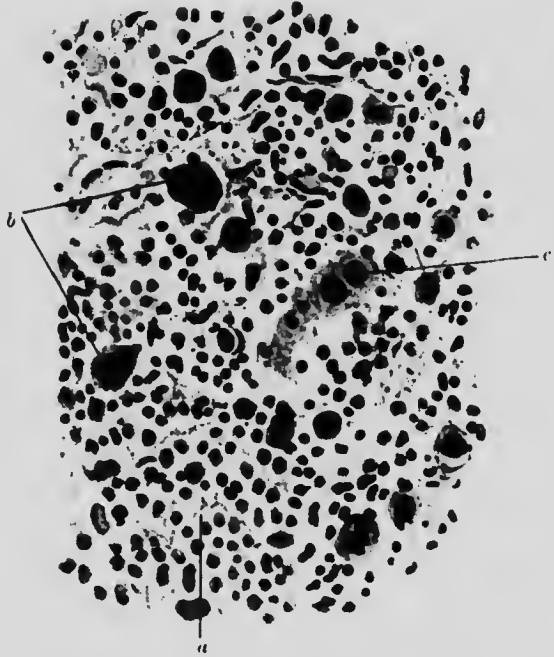


FIG. 137. LYMPHADENOMA. GLAND. FROM OUTER LAYER OF PRECEDING FIGURE. ($\times 250$)

- a.* Lymphoid tissue. *b.* Multinuclear giant cells.
c. Mononuclear giant cells.

tissue but it is soon overtaken by proliferation and subsequent fibrosis of the reticulum (Figs. 136 and 137). In some instances there is an increase in the number of eosinophile cells in the substance of the gland. Finally, the gland becomes quite fibrotic.

Lymphosarcoma is an extremely malignant new growth arising in lymphatic glands. It is characterised by a great multiplication of lymphocytes without corresponding proliferation of

the remainder of the gland tissue, so that, microscopically, the malignant nature is not at once evident. The loss of proportion between the various tissues differentiates it from the enlarged glands due to non-malignant lymphoma. Lymphosarcoma is found most often in the retroperitoneal and mediastinal glands.

Anatomically **ricketts** is seen chiefly at the junction of bone and cartilage in the long bones and ribs and forms nodular swellings in these regions.

Microscopically, we find an irregular overgrowth and intermixture of bone and of cartilage, together with thickening of the periosteum. Between the normal cartilage and the normal bone are four abnormal interdigitating zones. (1) The regular rows of cartilage become disarranged and gradually broken up by (2) a network of partly calcified fibro-cartilage, itself intermingled and continuous with (3) irregular partly ossified trabeculae, which pass on into (4) osteoid tissue with imperfect calcification, arranged in a very open network enclosing large, marrow-filled spaces (Fig. 138).

Under a high power, it will be noted that the individual cells are irregular in size and shape, that in some parts cartilage, calcified cartilage and bone are all mixed up together. An excessive number of osteoblasts appears, especially under the periosteum, forming imperfectly calcified tissue and large blood-vessels may be seen in each zone. The condition appears to be due to the irregular cell proliferation, which gets entirely out of step with the processes of calcification and ossification.

Gout, when it affects the joints, leads to the deposit of an opaque white layer of urates on or beneath the articular surface.

Microscopically, opaque bundles of urate crystals can be seen extending into the cartilage. They are thickest at the edge and gradually thin down as they pass inwards. Around the crystals the cartilage is necrosing. Sometimes the urates act as foreign bodies, so that the signs of inflammation, giant cells and granulation tissue, may then be found in their neighbourhood.

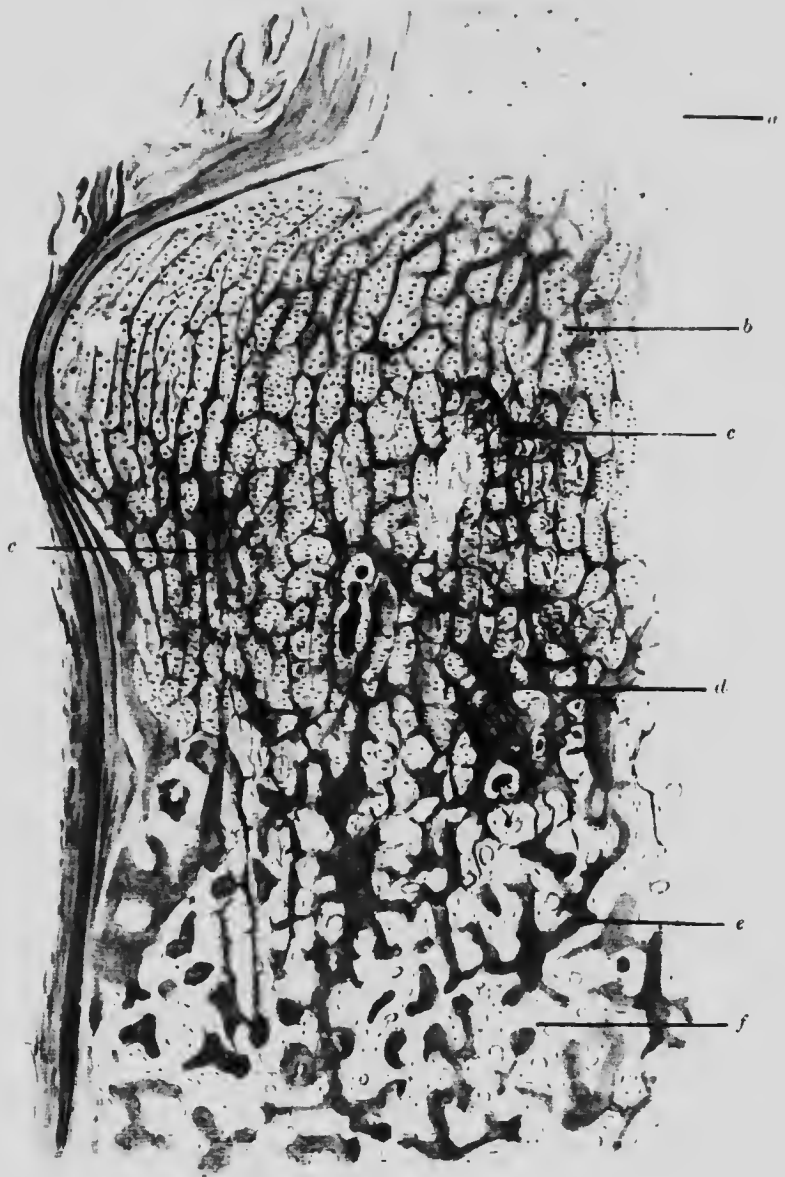


FIG. 138. RICKETS. COSTOSTERNAL JUNCTION. ($\times 10$)

- | | |
|---|-----------------------------------|
| <i>a.</i> Healthy cartilage. | |
| <i>b.</i> Cartilage becoming irregular and broken up lines of commencing calcification. | |
| <i>c.</i> Condition of <i>b</i> , yet more marked. | <i>d.</i> Irregular ossification. |
| <i>e.</i> Irregular osteoid tissue. | <i>f.</i> Irregular bony tissue. |

In **rheumatoid arthritis** two strata of the synovial membrane are distinguishable: a coarser outer stratum of fibrous tissue and a thinner internal one forming the real lining of the joint. The tissue composing the inner stratum has an oedematous appearance and often contains giant cells. The vessel walls are thickened and there is frequently perivascular infiltration with mononuclear leucocytes. In the later stages of eburnation the thin layer of compact bone on the surface becomes worn away with simultaneous production by osteoblasts of new bone below. There are no necrotic changes as in gout.

CHAPTER XXVIII

THE MUSCLES. THE NERVES

ILLUSTRATIVE PREPARATIONS.

1. Muscle fibres in idiopathic muscular atrophy.
2. Muscle fibres in pseudo-hypertrophic paralysis.
3. Muscle fibres showing hyaline degeneration (enteric fever).
4. Nerve fibres in early peripheral neuritis.
5. Nerve fibres in late peripheral neuritis (alcoholic).
6. Nerve fibres in peripheral neuritis (diphtheritic).

INFLAMMATION of nerve (**neuritis**), when not traumatic, is brought about by some poison, organic or inorganic. The extent and amount of the inflammation varies considerably with the different toxins.

Macroscopically, there is sometimes swelling and redness of the nerve trunk with obvious vascular dilatation. The process may be acute or subacute, but the anatomical and histological conditions do not necessarily correspond. In some instances the toxin has a selective action for particular nerves.

In some cases (*e.g.*, Bright's disease, diabetes) there is degeneration of nerve fibres with or without any inflammation. The process begins with breaking up of the axis in intermyelin sheaths and frequently remains limited to the intermyelin sheath so that, although the axis cylinders are disintegrated and reformed, they do not degenerate. The surrounding myelin sheath remains free from infiltration (Fig. 139).

In other cases (e.g. lead and arsenic poisoning) the medullary sheath and the surrounding tissues bear the brunt of the attack. The myelin disintegrates, often over short lengths of nerve only, and the connective tissue around is thickened and infiltrated with leucocytes.

In yet another class of case (e.g. diphtheria, alcoholism) axis cylinder, medullary sheath and surrounding tissue are all

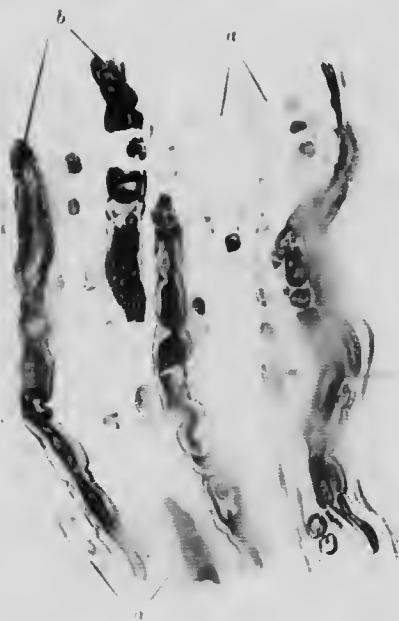

FIG. 139. PERIPHERAL NERVE (×300)

- a. Degenerated nerve fibres, almost completely lost and not taking the stain.
 b. Nerve fibres in various stages of degeneration. Myelin sheath mostly gone and axis cylinders breaking up. Surrounding tissue shows inflammation.

affected. The axis cylinder degeneration begins quite early, but accompanying it, outside the fibres, there is inflammation with proliferation of the cells and nuclei of the tissues around.

In **pseudo-hypertrophic paralysis** the muscles are apparently increased in size, but even the naked eye section shows that the increase is due mainly to fat and not to muscle. Microscopically, large deposits of fat are found between the muscle fibres which

present very great variations in size and in parts have almost disappeared. The fibres may be either larger or smaller than

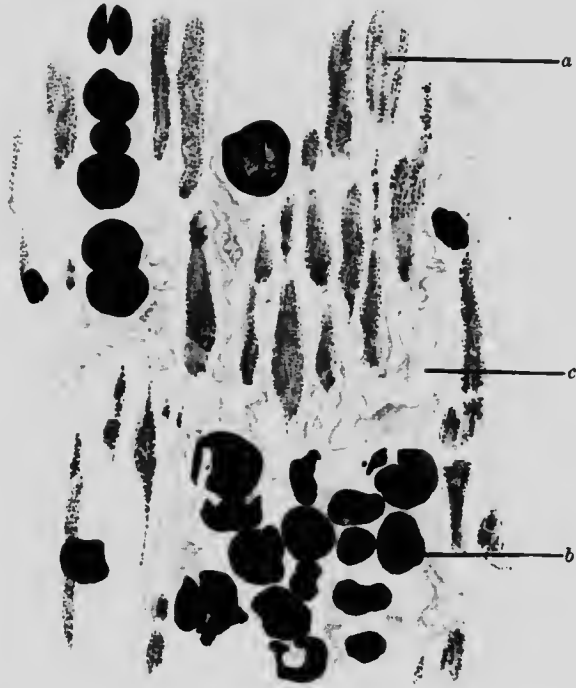

FIG. 140. MUSCLE IN PSEUDO-HYPERTROPHIC PARALYSIS. STAINED WITH OSMIC ACID. ($\times 100$)

- a. Muscle fibres cut longitudinally, in which the fat is deposited in fine droplets. The diameter of the fibres varies considerably.
- b. Large fat droplets in the interstitial tissue.
- c. Overgrowth of fibrous tissue.

normal and are often in a state of fatty degeneration (Fig. 140). Occasionally a degenerated muscle spindle may be seen.

CHAPTER XXIX

THE CENTRAL NERVOUS SYSTEM

ILLUSTRATIVE PREPARATIONS.

1. Acute suppurative meningitis.
2. Tuberculous meningitis.
3. Chronic encephalitis in general paralysis of the insane.
4. Perivascular infiltration in chronic nervous disease (chorea).
5. Tumour of the dura mater (psammoma).

INFLAMMATION of the meninges (meningitis) may be acute or chronic.

When occurring on the dura mater (pachymeningitis) it is usually secondary either to trauma or to infection; the latter may spread from the skull on the outside, or the pia mater on the inside.

The pia mater is much oftener attacked primarily (leptomeningitis).

Serous leptomeningitis is indistinguishable from oedema of the pia mater.

Leptomeningitis with the formation of pus may result from (a) secondary septic infection, *e.g.* from otitis media, (b) acute infectious diseases, *e.g.* cerebrospinal meningitis, influenza or gonorrhoea, (c) tubercle and (d) syphilis.

Naked eye inspection alone is generally unable to distinguish between (a) and (b) and apart from actual demonstration of the responsible organism, there is no great difference in the histological appearance. The subarachnoid space chiefly on the lateral and vertical aspects of the brain and particularly along the course of

the vessels, is filled and then distended with fibrin and leucocytes, between or within which as the case may be the specific organism is often to be found. The vessels also are much distended, while the perivascular spaces, especially in the sulci, are



FIG. 141. ACUTE SUPPURATIVE MENINGITIS. ($\times 35$)

- a.* Large cells. *b.* Small cells in purulent exudate.
c. Layer of large mononuclear and endothelial cells next cerebral cortex, lying in a loose meshwork.
d. Blood-vessels. *e.* Mononuclear cells in sulci.

filled with an outer, denser layer of leucocytes surrounding an inner, looser layer containing a large proportion of new connective tissue.

Usually the adventitia also is infiltrated: the underlying brain tissue only to a slight degree. The pia is not adherent (Fig. 141).

The process is the same along the spinal cord and does not show much tendency to spread along the nerve roots.

Tuberculous meningitis is most intense around the base and along the fissures. It is a semi-acute process in comparison with the septic forms of meningitis. Macroscopically, the distinguishing feature is the occurrence of tuberculous nodules lying on the vessel walls: but they are not always easy to find and see.

Microscopically, the exudate consists of many lymphocytes and epithelioid cells as well as polymorphonuclear cells. The infiltration extends into the vessel walls and into the loose sub-pial tissue. The tubercles are mostly in a state of caseation, the large central necrotic portion being surrounded by layers of epithelioid cells. These tubercles are frequently in connection with the walls of a blood-vessel. Giant cells are rare in the tubercles, while bacilli are usually numerous.

The surface of the brain is generally involved in the process: the pia becomes adherent and under the microscope it may be impossible to see any boundary line between the two kinds of tissue (Fig. 142).

Syphilitic leptomeningitis runs a much more chronic course: the exudate is less cellular and shows the characteristic tendency of syphilis towards fibrosis. As in tubercle, centres of caseation in contact with blood-vessels can be found, but the vessels always show evidence of syphilitic endarteritis. The pia and underlying brain substance may be inseparably fused.

Inflammation of the brain (**Encephalitis**), when an **acute** process arising from infection (influenza, etc.), differs from typical inflammation elsewhere because the leucocytes play a relatively small part. There are two chief forms: haemorrhagic and parenchymatous encephalitis. The first is usually focal and accompanied by haemorrhage into the brain substance, but several foci may be so merged as to cover a considerable continuous area. The second is distinguished more by primary necrosis of nerve cells and substance. In either case, but chiefly in the haemorrhagic form, characteristic epithelioid cells,

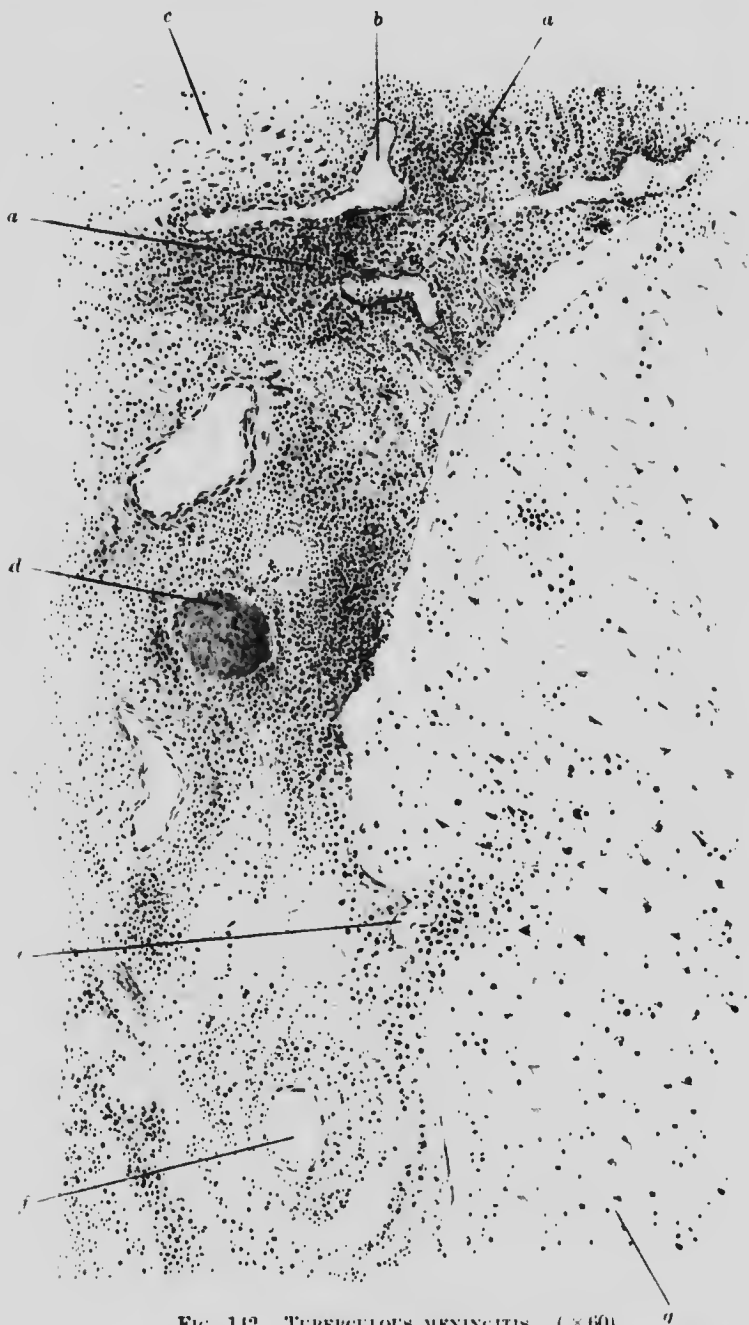

FIG. 142. TUBERCULOUS MENINGITIS. ($\times 60$)

- a.* Lymphocytic infiltration surrounding
- b.* a blood vessel.
- c.* Proliferated endothelial cells.
- d.* Caseating tubercle in proximity to a vessel.
- e.* Pia mater adherent to cerebral cortex.
- f.* Arteriole with inflammatory changes in its walls.
- g.* Cerebral cortex.

sometimes multinucleate, are found in the lesion. Either complete repair or definite scars may be the final result.

The **chronic** forms are more common. The chief causes are syphilis, lead poisoning and tubercle.

Syphilitic encephalitis, the condition found in general paralysis of the insane, is characterised histologically by increase

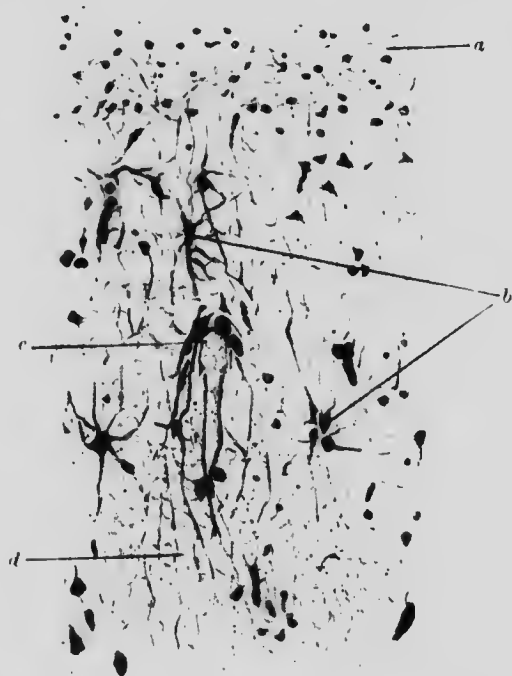


FIG. 143. CHRONIC ENCEPHALITIS. GENERAL PARALYSIS. ($\times 300$)

- a.* Superficial feltwork. *b.* Proliferating glia cells.
c. Proliferating glia cells opposed to capillary.
d. White matter of cortex.

in width of the superficial neuroglial network of the cortex, proliferation of neuroglial cells, perivascular infiltration and nerve cell degeneration. There is always some accompanying leptomeningitis.

The additional superficial feltwork is composed of the processes belonging to neuroglia cells lying some little distance below, so that it appears free of these cells, which are actually much

increased in number. They are often seen in pairs and are frequently placed in apposition to the wall of small blood-vessels (Fig. 143). There is very marked perivascular infiltration with lymphocytes and plasma cells, but it should be remembered that

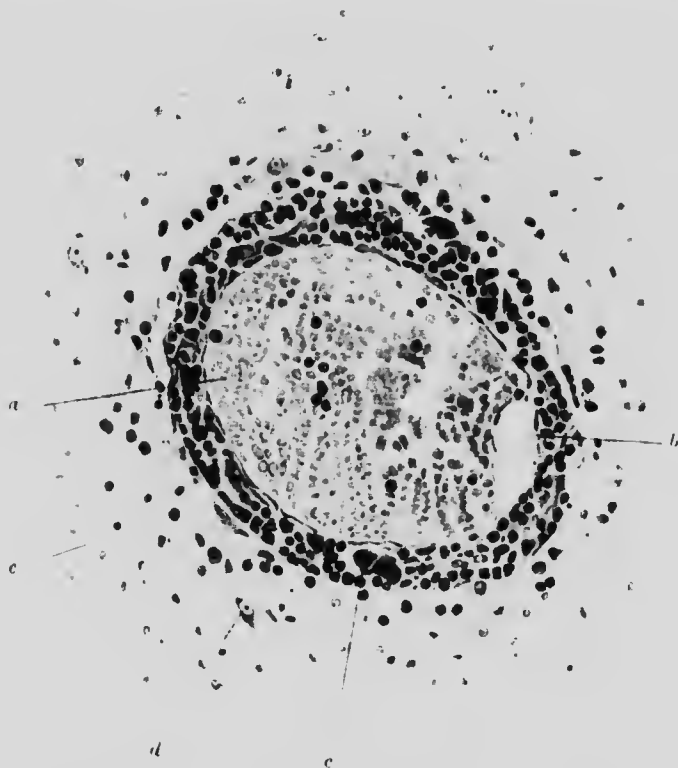


FIG. 144. PERIVASCULAR INFILTRATION. CEREBRAL CORTEX.
CHOREA. ($\times 300$)

- a. Blood within vein.
- b. Space (artificial) between vein and lymphatic.
- c. Cells (mononuclear, plasma, etc.) in perivascular lymphatic.
- d. Cortical cell. e. White matter.

such infiltration is found also in other nervous diseases, *e.g.* chorea (Fig. 144). Degeneration of motor nerve cells and consequent irregularity in their arrangement is a marked feature.

In some cases of **lead poisoning** with cerebral symptoms, a similar condition has been found: in others, there has been

neither perivascular infiltration, neuroglial proliferation nor nerve cell degeneration.

Tertiary syphilis of the brain with the formation of gummata occurs but the gummata present no special features as compared with gummata elsewhere.

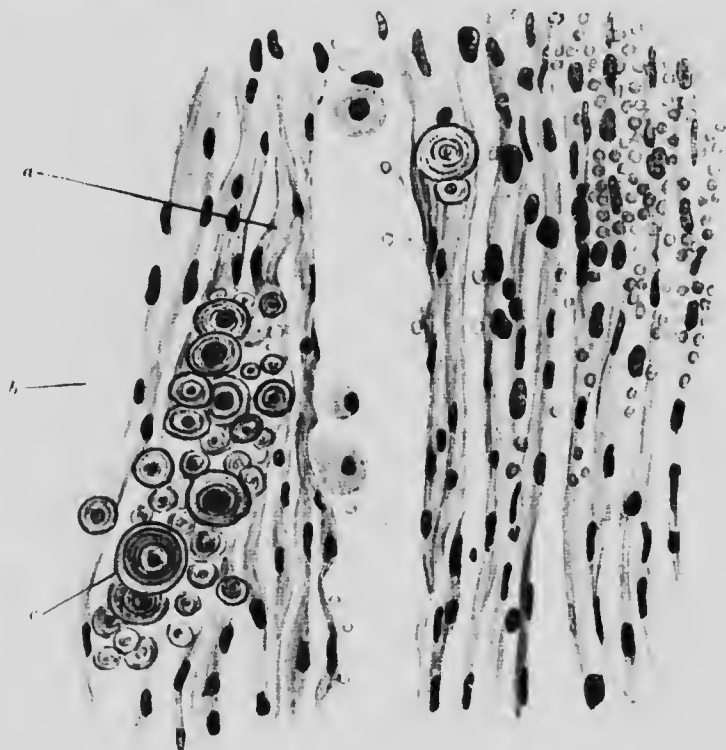


FIG. 145. PSAMMOMA. DURA MATER. ($\times 300$)

- a.* Fibrous tissue. *b.* Red blood corpuscles.
c. Calcareous stratified spherules.

Tuberculous inflammation results in the formation of tubercles in the brain substance. They usually have many giant cells on the periphery, but many of them shade off into the brain substance without any marked epithelioid or lymphocyte layer.

Glioma proper is a non-malignant tumour arising in the white substance of the brain or spinal cord. It is composed of branching neuroglia cells and capillaries.

Not infrequently it is combined with small round cell sarcoma to form a malignant glio-sarcoma.

Psammoma is a form of tumour growing from one of the brain membranes and distinguished by the presence of calcareous spherules, "brain-sand," within it. The growth may be composed mainly of fibrous tissue with brain-sand in the interfibrillar spaces, in which case it is not malignant (Fig. 145): or it may be partly fibrous and partly endotheliomatous, having concentric groups of endothelial cells arranged around a spherule and lying in a matrix of fibrous tissue, and may then form a malignant tumour.

CHAPTER XXX

THE SPINAL CORD

ILLUSTRATIVE PREPARATIONS.

1. Spinal leptomeningitis.
2. Inflammation of the grey matter (acute anterior poliomyelitis).
3. Sclerosis of the dorsal columns (tabes dorsalis).
4. Disseminated sclerosis.
5. Amyotrophic lateral sclerosis.

THE affections of the spinal meninges are similar to those of the brain (Fig. 146). Syphilitic pachymeningitis causes much compression of the spinal cord and leads to considerable degeneration in some of the long tracts (Fig. 146A).

The causes of inflammation of the spinal cord (myelitis) are mostly infective, either primary, or secondary to trauma. Cold and damp are also alleged aetiological factors.

The lesion may begin in either the white or in the grey matter (poliomyelitis), but in any case it does not remain limited to the one or the other portion.

In **acute myelitis**, the cord is abnormally soft and, according to the amount and duration of congestion and extravasation, is in a condition of "red" or "yellow" softening.

Microscopically, the examination of fresh unstained specimens shows much disintegration of the white matter. The myelin sheath is irregular in shape and contains granular droplets. The axis cylinder is also degenerated and placed eccentrically while the amorphous products of degeneration and white cells occupy the

spaces between the fibres. In specimens stained and mounted in the ordinary way (viz. with fat removed) the chief features are the extreme distension and congestion of the vessels in both white

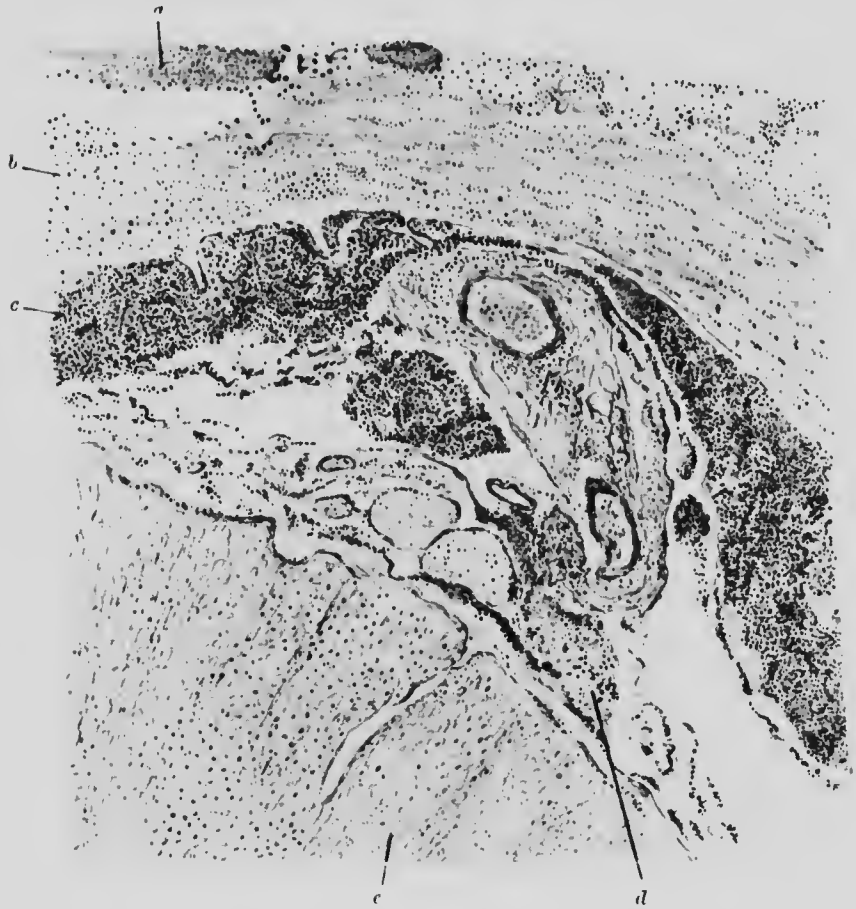

FIG. 146. SPINAL LEPTOMENINGITIS. ($\times 35$)

- a.* Blood.
- b.* Dura mater slightly infiltrated.
- c.* Infiltration of neutrophile leucocytes beneath pia mater.
- d.* Slight infiltration in nerve root.
- e.* White matter of spinal cord.

and grey matter and the infiltration of the perivascular spaces with leucocytes and plasma cells. Apart from these spaces the white cells are not prominent (Fig. 147).

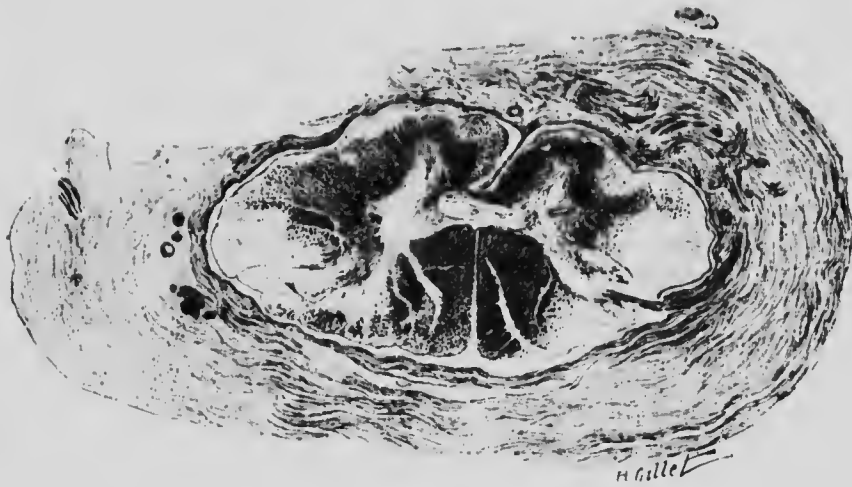


FIG. 146A. SYPHILITIC PACHYMEINGITIS. (From Dejerine and André-Thomas.)

Section of spinal cord at level of 3rd cervical nerve root. There is also degeneration of the periphery of the antero-lateral tract, of the crossed pyramidal tracts and slight degeneration of the dorsal columns.

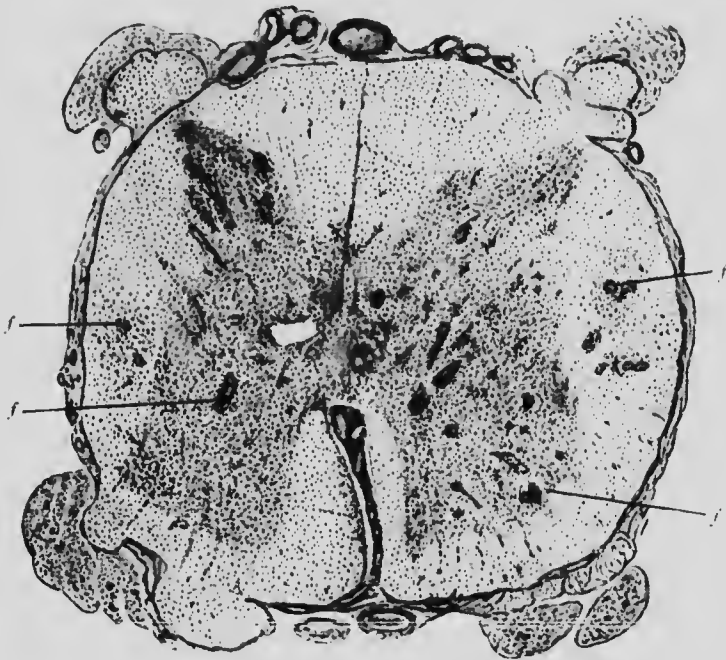


FIG. 147. ACUTE DISSEMINATED MYELITIS. (From Oppenheim.)

f. Foci of leucocytic infiltration.

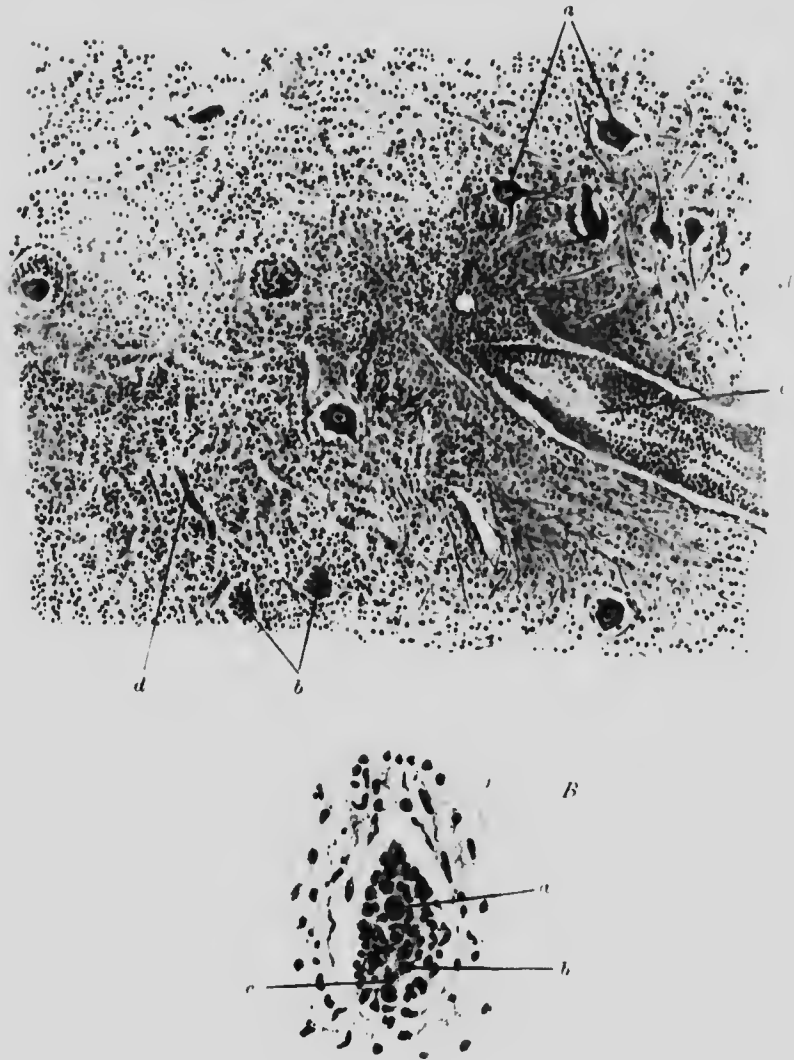


FIG. 148. ANTERIOR POLIOMYELITIS. SPINAL CORD. ($\times 75$)

- A. *a.* Normal nerve cells.
b. Nerve cells surrounded and obscured by infiltrating cells.
c. Vessel with marked perivascular infiltration.
d. Dilated capillary.
- B. *a.* Nucleus of nerve cell whose outline is obscured by
b. mononuclear and *c.* polymorphonuclear cells.

The white matter is partly replaced by amorphous granular material and partly by a proliferation of the glia cells. In most instances there is also spinal meningitis in the neighbourhood of the lesion.

If recovery take place, chronic myelitis with fibrosis and consequent compression and atrophy of the affected portion of the cord ensue.

In **anterior poliomyelitis**, the process is usually restricted to the grey matter of the ventral horn of one side in the lumbar region. The inflammation is of infective origin. Macroscopically, the grey matter appears red and inflamed and frequently some meningitis is visible.

Microscopically, the capillaries around the affected nerve cells are seen to be dilated and congested while their perivascular spaces are so filled with lymphocytes that many cells in the section are obscured. Where the cells are visible they show evidence of chromatolysis and of cytoplasmic degeneration. Leucocytes are scattered about also in the surrounding tissue (Fig. 148).

If the patient recover, the affected horn becomes smaller than the other, on account of the destruction of nerve cells and fibres.

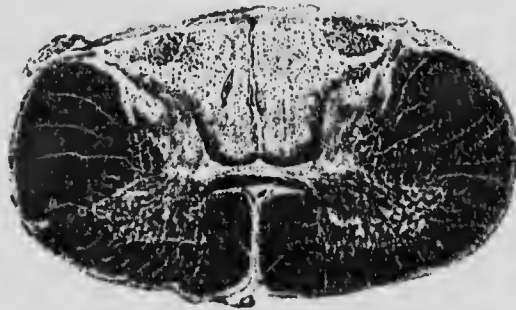

FIG. 149. TABES DORSALIS (LATE STAGE). (From Oppenheim.)

The degeneration embraces almost the whole of the dorsal columns in the cervical region.

The remaining cells in the region show various stages of degeneration, but some, especially the median group, generally remain healthy.

In the **systemic diseases of the spinal cord** the various tracts are affected selectively.

The dorsal columns degenerate in **locomotor ataxy** (*tabes dorsalis*). The degeneration becomes gradually less in ascending the cord from its origin in the lumbar nerve roots, as the afferent fibres draw gradually inwards (Fig. 149). In old-standing

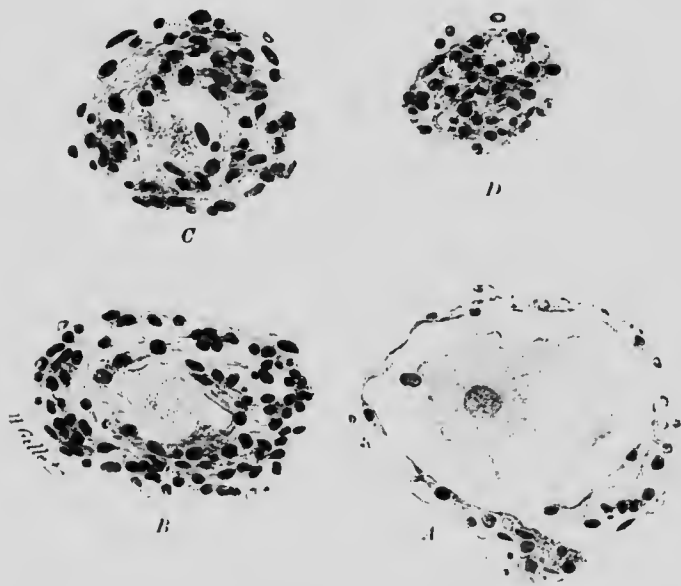


FIG. 149A. CELLS OF DORSAL GANGLION IN VARIOUS STAGES OF DEGENERATION. *TABES DORSALIS*. (From Dejerine and André-Thomas.)

- A. Almost normal cell, slightly retracted from lymphatic capsule.
- B. Partly atrophic cell with multiplication of nuclei of capsule.
- C. The cell is reduced to a mass of pigment. The capsule is a series of concentric layers.
- D. Nothing remains of the cell but a nodule of connective tissue.

cases nearly the whole of the dorsal columns may be affected even quite high up. The cells of the ganglia may be found in various stages of degeneration (Fig. 149A). Both dorsal and lateral columns are affected in **ataxic paraplegia**.

The pyramidal tracts degenerate in **primary lateral sclerosis** (Fig. 150) and both the pyramidal tracts and ventral horn cells

degenerate in **amyotrophic lateral sclerosis**. In some diseases, such as idiopathic anaemia, a combined sclerosis of ascending and

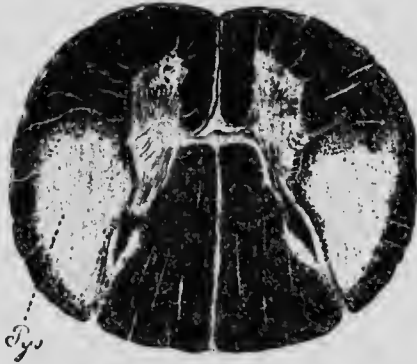

FIG. 150. PRIMARY LATERAL SCLEROSIS. (From Oppenheim.)

The lateral columns (*Pos*) are almost entirely degenerated

descending tracts is found (Fig. 151). Although each of these diseases may be due to a separate toxin, the ultimate histological lesion is much the same in all.

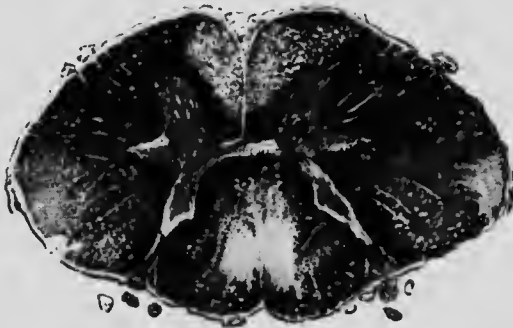


FIG. 151. COMBINED SCLEROSIS, IDIOPATHIC ANAEMIA. (From Oppenheim.)

There is considerable degeneration in the dorsal and both pyramidal tracts.

The process commences with disintegration of axis cylinders and myelin sheath, as in nerve, but not simultaneously in each fibre. It is seen accompanied by a proliferation of neuroglia and the destroyed nervous tissue is in part replaced by neuroglia.

The changes can be made evident by special stains. In the early stages, a transverse section stained by the Marchi method,

shows the affected tract studded with black dots, and the remainder of the normal yellow tinge. The black dots vary in size on account of differences in the size of the fibres and the amount of swelling at various periods of degeneration. In later stages the Weigert haematoxylin stain tinges the sound myelin sheaths black, while the sclerosed areas appear yellow and thus shows how much normal tissue has been affected and has disappeared. The increase in glia tissue fibres can be shown with Weigert's special blue glia stain.

As the name implies, **insular**, or **disseminated sclerosis**, is a disease commencing in several foci, mostly in the spinal cord but also in the medulla and higher centres. It may be termed a transverse disease of the cord in contradistinction to the systemic or longitudinal diseases, because the lesions, speaking generally, are wide and shallow: that is, the degeneration may occupy a considerable area of the cord at any particular level but may extend a very little distance above or below. The foci vary much in size and extent. The disease begins as a primary sclerosis with overgrowth of glia, leading secondarily to the destruction of nerve fibres within and in the neighbourhood only of the affected areas. The results may be demonstrated by the methods indicated above.

APPENDIX

ONLY some of the more special methods for pathological work are mentioned here. For ordinary methods, the student should consult the Appendix to the *Essentials of Histology*.

In preserving tissues for examination it is important that

- (1) they should be obtained as fresh as possible and not have been in contact with water ;
- (2) small pieces of tissue be taken and at least twenty times their volume of fixing fluid be used ;
- (3) where possible, a portion of normal tissue should be included.

The fixing agent to be used will vary according to the special points to be brought out.

For general use a mixture of

Potassium bichromate,	2.5
Sodium chloride,	0.85
Formaldehyde (40 per cent.),	5
Water,	100

is satisfactory.

After 24 hours the mixture is changed for one without the formaldehyde, and again then from day to day.

Zenker's solution or a modification of it, consisting of the above solution, with the addition of 5 per cent. saturated solution of mercuric chloride in 0.85 per cent. NaCl, also gives very good results. Several subsequent changes into 2.5 per cent. potassium bichromate solution should follow after the first 24 hours.

The following staining methods are in frequent use for the demonstration of pathological degenerations and conditions.

1. *Methyl Violet for demonstrating Lardaceous Degeneration.*

(a) Stain section with 0.5 per cent. solution of methyl violet in water for 1-2 minutes.

(b) Wash in water

(c) Differentiate with 2 per cent. acetic acid for 1-2 minutes.

Watch the effect under the low power of the microscope.

(d) Wash free from acid.

(e) Mount in laevulose or glycerine jelly.

By using ammonium molybdate solution (1 per cent.) as a mordant after (d), the colour may be better fixed and mounting in Canada balsam made possible.

2. Scarlet R Stain for Fatty Degeneration.

Use a saturated filtered solution of the dye in a mixture containing equal parts of 70 per cent. alcohol and acetone.

Small pieces of formalin hardened tissue, after bringing up to 70 per cent. alcohol, may be stained in bulk and sections cut subsequently on the freezing microtome or, with more difficulty, cut first and then stained.

The sections may be counter-stained with haematoxylin and cannot, of course, be passed through alcohol, but must be mounted in glycerine jelly or similar medium.

3. Pappenheim's Stain for Plasma Cells.

Saturated watery solutions of methyl green and of pyronin are used, mixed in the proportions of 3-4 parts to 1-1½ parts. To obtain the best results the tissues should be fixed in absolute alcohol.

Rin the stain on to the section on the slide: after two minutes pour off, wash rapidly with water, which removes some of the methyl green stain: differentiate with 1 per cent. resorcin in absolute alcohol, dehydrate and mount in neutral Canada balsam.

The plasma cells are stained bright red and the nuclei blue green.

Heidenhain's Iron Haematoxylin Nuclear Stain.

Use paraffin sections, preferably from material fixed in Hermann's solution or mercuric chloride, and laid on albuminised slides.

After the usual preliminary treatment:

(1) place the slide in 2 per cent. solution of iron alum sulphate for 12-24 hours;

(2) wash in water and then stain with 1 per cent. haematoxylin solution in 10 per cent. alcohol for 12-24 hours;

(3) wash and differentiate in the iron alum solution until the nuclear structures stand out sharply. Use the microscope for this purpose;

- (4) wash for 1-3 hours in running water ;
 (5) dehydrate and mount in the usual way.

The section may be previously counterstained with advantage in a dilute solution of Bordeaux red for 24 hours.

v. Gieson stain for fibrous tissue.

Stain the section in the ordinary way with Ehrlich's haematoxylin or Weigert's haematoxylin. This immerse in or pour on, for a few seconds the following mixture :

Saturated aqueous solution of picric acid,	100 parts.
Saturated aqueous solution of acid fuchsin (added until a deep red colour is obtained, usually)	1 to 3 parts.

Mix and filter.

Wash out very rapidly in water, followed by absolute alcohol. Clear and mount in the usual manner.

The fibrous tissue or tissues that have undergone fibroid degeneration are stained bright pink.

The muscular tissue is stained yellow, and the nuclei nearly black.

Mallory's connective tissue stain.

Stain the sections for 5 minutes or more, in the 5 per cent. aqueous solution of acid fuchsin. Transfer for 20 minutes or longer to the following mixture :

Anilin-blue soluble in water (Gruber),	0.5
Orange G (Gruber),	2.0
Phosphomolybdic acid, 1 per cent. aqueous solution,	100.0

Wash and dehydrate in several changes of 95 per cent. alcohol, clear in xylol or in oleum origani cretici, and mount.

"The fibrillae and reticulum of connective tissue, amyloid, mucus, and certain other hyaline substances stain blue; nuclei, protoplasm fibroglia fibrils, axis cylinders, neuroglia fibres, and fibrin red; red blood corpuscles and myelin-sheaths yellow; elastic fibres pale pink or yellow."

Weigert's Stain for Elastic Fibres.

Make two solutions, containing 1 per cent. and 2 per cent. respectively of fuchsin and of resorcin in distilled water. Mix and boil. While boiling add 25 per cent. of liquor ferri perchlor. Continue boiling for five minutes, stirring all the time. Cool and filter. Boil the precipitate and the filter paper in 200 parts of 94 per cent. alcohol. Remove fragments of paper; cool and filter. Make up to 200 parts again with alcohol and add 4 parts HCl. Do not use for 24 hours.

Sections may be previously stained with lithium carmine or subsequently with safranin. They are placed in the elastic stain for twenty minutes to two hours, the stain washed off with dilute alcohol and are then treated in the usual manner for mounting.

Blood Stains.

Jenner's stain consists of a mixture in the proportions of 12 to 10 of 0.5 per cent. solutions of yellow shade eosin (Grübler's) and of medicinal methylene blue in pure methyl alcohol (Merek's "for analysis").

The dried blood film is fixed and stained in one operation by pouring some of this solution on to the slide, covering with a watch-glass to prevent evaporation and leaving to stain for two to four minutes. The film is then washed with distilled water until of a faint pink colour. Dry with good blotting paper and mount in neutral Canada balsam. The nuclei are coloured blue, the cytoplasm pink, the red cells also pink and the eosinophile and basophile granules scarlet and deep-blue respectively.

Leishman's stain is best bought in powder form. Its preparation is rather lengthy and complicated. A solution of 0.15 per cent. is made in pure methyl alcohol. A few drops are placed on the film and the slide gently rocked. After thirty seconds about double the quantity of distilled water is added to and mixed with the stain. Leave on for five to ten minutes, according to the thickness of the film. Wash with distilled water, leaving a little on for about a minute: dry with blotting paper and mount in Canada balsam.

INDEX

- Abscess, 29, 32.
Actinomyces, 41.
Adenoma of adrenal gland, 170.
 of breast, 49, 50.
 of kidney, 146.
 of prostate, 152.
 of rectum, 46.
 of thyroid gland, 168.
Adrenal gland, 169.
 adenoma of, 170.
 atrophy of, 170.
 haemorrhage into, 170.
 hypernephroma of, 170.
 tuberculosis of, 169.
Anaemia, idiopathic, 173.
 liver in, 131.
Angioma, capillary, 73.
 cavernous, 73.
Anthrax, of lung, 95.
Appendicitis, 122.
Arsenic poisoning, 191.
Arteries, arteriosclerosis, 199.
 arteritis, 104.
 atheroma, 106.
Arthritis, perivascular infiltration in,
 189.
 rheumatoid, 189.
Atrophy, 43.
 acute yellow, of liver, 129.
 brown, of heart, 96.
 from leuse, 43.
 of adrenal gland, 170.
 of intestinal mucous membrane,
 117.
 of thyroid gland, 167.
Benign tumours, 45.
Bladder, 117.
 inflammation of, 117.
 papilloma of, 54, 148.
 papilloma, malignant, of, 148.
 tuberculosis of, 148.
Blister, 28.
Blood, in chlorosis, 173.
 eosinophilia, 174.
 in enterica, 175.
 in idiopathic anaemia, 173.
 in lymphatic leukaemia, 174.
 in septicaemia, 175.
 in spleno-medullary leukaemia, 174.
 leucocytosis, 175.
 leucopenia, 175.
Bones, in rheumatoid arthritis, 189.
 in gout, 187.
 in rickets, 187.
Brain, glioma of, 199.
 gummatous, 199.
 inflammation, acute, 195.
 tuberculous, 199.
 leptomeningitis, 193, 195.
 meningitis, tuberculous, 195.
 proliferation of neuroglia, 197,
 207.
 psammoma of, 209.
Breast, adenoma of, 49, 50.
 cancer of, 49.
 inflammation of, 52.
Bright's disease, 143, 190.
Bronchiectasis, acute, 81.
 chronic, 81.
Bronchitis, 89.
Broncho-pneumonia, 89.
 tuberculous, 99.
Brood capsules, 131.

- Calcareous degeneration, 14.
 Cancer, metastases in, 61.
 of bladder, 147.
 of breast, 49.
 scirrhous, 50.
 encephaloid, 51.
 of liver, 133.
 of oesophagus, 109.
 of pancreas, 137.
 of prostate, 152.
 of rectum, 47.
 of stomach, 114.
 of thyroid, 168.
 of uterus, 162.
 Capacity for growth, 43.
 Carcinomatosis of peritoncum, 182.
 Casation, 40, 94, 135.
 Cast, blood, 141.
 colloid, 146.
 fatty, 140.
 homogeneous, 141.
 Cell, chromosomes, number of, 2.
 shape of, 2.
 cytoplasm, 1.
 degenerations, 7.
 cloudy swelling, 7.
 granular degeneration, 7.
 infiltration, fatty, 12.
 keratinisation, 11.
 mucoid degeneration, 10.
 spongioplasm, 6.
 hyaloplasm, 6.
 karyolysis, 5.
 karyorrhexis, 5.
 mitosis, heterotype, 2, 3.
 normal or somatic, 1.
 nests, 59.
 normal, 1.
 nucleolus, 1.
 nucleus, 1.
 eccentricity of, 1.
 number of poles, 3.
 number of spindles, 3.
 phagocytosis, 5.
 abnormally exerted, 5.
 lost, 5.
 plasma, 34.
 poles of nucleus, 3.
 position of chromosomes, 2.
 Clavate, 37.
 Chlorosis, blood in, 173.
 Chorea, 198.
 Chorionepithelioma, 77.
 hydatid mole, 77.
 Langhans' hyer, 79.
 Chromatolysis in poliomyelitis, 205.
 Chromosomes, 1.
 number of, in cell, 2.
 shape of, in cell, 2.
 Chondrosarcoma, 73.
 Cirrhosis of liver, 126.
 atrophic, 126.
 hypertrophic, 127.
 syphilitic, 128.
 nodule, 127.
 Clot, 16.
 Cloudy swelling, 7.
 of the heart, 96.
 of the liver, 125.
 Colitis, intestines, 121.
 Collapse of lung, 85.
 Colloid degeneration, 11.
 Congestion, 15.
 chronic, of liver, 125.
 of lung, 85.
 of stomach, 114.
 Cystitis, 147.
 Cytoplasm, 1.
 Degeneration, calcareous, 11.
 colloid, 11.
 fatty, 12, 125.
 glycogenous, 13.
 horny, 11.
 hyaline, 8.
 lardaceous, 8.
 myxomatous, 10.
 Diphtheria, meningitis in, 191.
 Disuse of muscles, 43.
 Dysentery, 121.
 Embolus, 17.
 Emphysema, 85.
 Encephalitis, 195.
 perivascular infiltration in, 198.
 syphilitic, 197.
 Encephaloid cancer, 50, 51.
 Endarteritis, 106.
 internal elastic lamina in, 107.
 intima *i.e.*, 106.

- 205.
- Endocarditis, 102.
 acute, 104.
 vegetations in, 102.
- Endocyst in liver, 134.
- Endothelial cells, 40.
- Endothelioma, 74.
- Enteric, blood in, 175.
 intestine in, 118.
- Enteritis, 117.
- Eosinophilia, 174.
- Epithelioma, 56.
 cell nests in, 59.
 of skin, 58.
 of tongue, 109.
- Fat necrosis, 136.
- Fatty degeneration, 12.
- Fibroblasts in inflammation, 34.
- Fibroma, 64.
- Fibrosis of glands, 187.
 after inflammation, 33.
 of pancreas, 137.
 syphilitic, of pancreas, 137.
 unilobular, of liver, 127.
- Fixing agents, 209.
- Ganglia, dorsal, 206.
- Gastric ulcer, 112.
- Gastritis, acute, 109.
 chronic, 112.
 subacute, 111.
- Giant cell sarcoma, 70.
- Giant cells in injury, 26.
 in lymphadenoma, 186.
 in tuberculous inflammation, 30.
- v. Gieson's stain, 65, 211.
- Glands, in lymphadenoma, 186.
 in lymphosarcoma, 187.
 in tubercle, 185.
- Glioma, 199.
- Glossitis, 109.
 syphilitic, 37, 109.
- Glycogenic degeneration, 13.
- Goitre, exophthalmic, 166.
 simple, 165.
- Gout, 187.
 urates in, 187.
- Granular degeneration, 7.
- Granulation tissue, 33, 35.
- Granules in hyaloplasm, 6.
- Growth, capacity for, 43.
- Gumma of brain, 199.
 of liver, 132.
 of pancreas, 137.
 of testis, 150.
- Hæmorrhage, into brain, 22.
 into adrenal gland, 170.
 into subcutaneous tissue, 22.
- Heart, brown atrophy of, 96.
 endocarditis, 102.
 acute, 102.
 chronic, 102.
 fatty degeneration, 97.
 infiltration, 97.
 myocarditis, acute, 99.
 chronic, 100.
 syphilitic, 101.
 pericarditis, 176.
 vegetations in endocarditis, 102.
- Heidenhain's iron hæmatoxylin stain, 210.
- Hepatisation, grey, in pneumonia, 88.
 red, in pneumonia, 88.
- Horny degeneration, 11.
- Hyaline degeneration, 8.
- Hyaloplasm, 6.
 granules in, 6.
- Hydatid cyst, 135.
- Hydatid mole in chorionepithelioma, 77.
- Hyperæmia, 15.
- Hypernephroma of adrenal gland, 170.
 of kidney, 136.
- Hyperplasia, 43.
- Hypertrophy, 43.
 through over-use of muscles, 43.
- Hypoplasia, 43.
- Infarct, 21.
 anæmic, 19.
 hæmorrhagic, 17.
 in lung, 83.
 in spleen, 139.
- Infarction, 17, 83.
 by embolus, 17.
 and necrosis, 49.
- Infiltration, fatty, 12, 125.
 perivascular, 198.

- Inflammation, 27.**
 abscess, 29, 32.
 actinomyces, 41.
 acute, of brain, 195.
 acute endocarditis, 102.
 bladder in, 147.
 blister, 28.
 by chemical injury, 28.
 by nitrate of silver, 28.
 and emulsion, 40.
 causes of, 27.
 chronic, 33, 37, 178.
 cystitis, 147.
 encephalitis, 195.
 syphilitic, 197.
 endocarditis, 102.
 endothelial cells in, 40.
 fibroblasts in, 34.
 granulation tissue, 33, 35.
 infective, 29.
 in lymphoid tissue, 39.
 membrane in diphtheria, 29.
 neuritis, 190.
 orchitis, 149.
 pericarditis, 176.
 peritonitis, 178.
 plasma cells in, 34.
 pleurisy, 178.
 position of, 27.
 produced by radium, 27, 28.
 pus, 29.
 bladder, 147.
 syphilitic, 37.
 in testis, 150.
 tuberculous, 39.
 of brain, 199.
 giant cells in, 40.
injury, 23.
 chemical, 28.
 giant cells in, 26.
 mechanical, 24.
Intestine, 117.
 atrophy of, 117.
 colitis, 121.
 inflammation of, 117.
 in typhoid, 118.
 lardaceous disease, 117.
 metallic poisons, 118.
 Peyer's patches, 118.
 tuberculous ulcers, 119.
 Intestine, villi, 117.
 Iodine stain, 8.
 Iron in liver, 131.
 Irritants of lung, 95.
 Jenner's stain, 212.
 Karyolysis, 5.
 Karyorrhexis, 5.
 Keratinisation, 11.
 Kidney, adenoma of, 146.
 Bright's disease, 190.
 colloid casts in, 146.
 fibromata, 146.
 homogeneous cast, 141.
 hypernephroma, 146.
 lardaceous disease of, 145.
 nephritis, acute glomerular, 140.
 acute parenchymatous, 141.
 chronic interstitial, 143.
 subacute interstitial, 142.
 subacute (chronic) parenchymatous, 141.
 Lamina, internal elastic, 107.
 Langhans' layer in chorionepithelium, 79.
 Lardaceous degeneration, 8.
 Lardaceous disease of intestine, 117.
 of kidney, 145.
 of liver, 131.
 of spleen, 138.
 Large round cell sarcoma, 68.
 Lead poisoning, 198.
 Leishman's stain, 212.
 L. meningitis, 193.
 syphilitic, 195.
 Leucocythæmia, 174.
 spleen in, 139.
 Leucocytosis, 175.
 Leucopenia, 175.
 in enterica, 175.
 in tuberculosis, 175.
 Leukaemia, lymphatic, 174.
 spleno-medullary, 171.
 Liver, acute yellow atrophy, 129.
 brood capsules in, 134.
 cirrhosis, 126.
 atrophic, 126.
 hypertrophic, 127.

- Liver
 cirrhosis
 syphilitic, 128.
 unifolobar, 127.
 cloudy swelling of, 125.
 endocyst, 134.
 fatty degeneration of, 125.
 fatty deposits of, 125.
 gumma of, 132.
 hydatid cyst, 134.
 infiltration, fatty, 125.
 iron in, 131.
 hirsuteous disease, 131.
 pericellular fibrous tissue, 128.
 pernicious anaemia in, 131.
 primary carcinoma of, 133.
 tubercle of, 131.
- Lung, 83.
 anthracosis of, 95.
 collapse of, 85.
 congestion of, 85.
 emphysema, 85.
 irritants of, 95.
 oedema of, 86.
 silicosis of, 95.
 tubercle of, 90.
 acute, 90.
 semi-acute, 93.
- Lymphadenoma, 185.
 fibrosis, 186.
 lymphatic glands in, 185.
 in spleen, 139.
 syncytial masses in, 186.
- Lymphatic glands, 183.
 tuberculous infection, 186.
 lymphadenitis, 183.
 pigmentation of, 183.
- Lymphocytes, 33, 174.
- Lymphoid tissue, 39, 186, 187.
- Lymphosarcoma, 187.
- Mallory's stain, 211.
- Mastitis, 52.
- Membrane in diphtheria, 29.
- Meningitis, tuberculous, 196.
- Mesothelioma, 182.
- Metastases, 45, 61.
- Methyl violet stain, 8, 138, 209.
- Mitosis, chromosomes, 1.
 heterotype, 2, 3.
- Mitosis, normal or somatic, 1.
- Mucoid degeneration, 10.
- Muscle, cloudy swelling of heart, 96.
 paralysis, pseudo-hypertrophic of, 191.
 spindles, 192.
- Myelitis, acute, 201.
- Mycocytes, 174.
- Mycoid sarcoma, 70.
- Myocarditis, syphilitic, 101.
- Myoma, 65.
- Myxoedema, 168.
- Myxomatous degeneration, 10.
- Necrosis, 19.
 fat, 136.
- Nephritis, acute glomerular, 140.
 acute parenchymatous, 141.
 chronic interstitial, 143.
 subacute interstitial, 142.
 subacute (chronic) parenchymatous, 141.
- Neuritis, 190.
- Nose, 80.
- Nucleolus, 1.
- Nucleus, 1.
 eccentricity of, 1.
 number of poles, 3.
 poles of, 3.
- Oedema of lung, 86.
- Oesophagus, cancer of, 109.
- Orchitis, 149.
- Organisation in thrombosis, 16.
- Over-use of muscles, 43.
- Pachymeningitis, 201.
- Pancreas, 136.
 carcinoma of, 137.
 fat necrosis of, 136.
 fibrosis of, 136.
 syphilitic, 137.
 gumma of, 137.
 pancreatitis, chronic, 136.
 "haemorrhagic," 137.
- Papilloma, 54, 148.
 malignant, of bladder, 148.
 of skin, 54.
- Pappenheim's stain, 210.
- Pemphigus, pseudo-hypertrophic, 191.





4.5
5.0
5.6
6.3
7.1
8.0
9.0
10
11.2
12.5



MICROCOPY RESOLUTION TEST CHART
NATIONAL BUREAU OF STANDARDS
STANDARD REFERENCE MATERIAL 1010a
(ANSI and ISO TEST CHART No. 2)

- Pericarditis, 176.
 Pericellular fibrous tissue, 128.
 Perithelioma, 75.
 Peritonitis, 178.
 Perivascular infiltration, in arthritis, 189.
 in chorea, 198.
 in general paralysis, 198.
 Peyer's patches, 118.
 Phagocytosis, 5.
 abnormally exerted, 5.
 lost, 5.
 Pharynx, 109.
 Pigmentation of glands, 183.
 of skin, 170.
 Plasma cells, 34.
 Pleurisy, 178.
 Pneumonia, 88.
 hepatisation, grey, 88.
 red, 88.
 lobar, 88.
 Poisoning, alcohol, 191.
 arsenic, 191.
 lead, 191, 198.
 Poisons, metallic, 118.
 Poliomyelitis, anterior, 205.
 chromatolysis in, 205.
 Polypus of rectum, 46.
 of nose, 80.
 Position of chromosomes, 2.
 Precancerous stage, 46.
 Proliferation of neuroglia, 197, 207.
 Prostate, 151.
 adenoma of, 152.
 cancer of, 152.
 enlargement of, 151.
 Psammoma, 200.
 Pus, 29.
 Radium, inflammation produced by, 27, 28.
 Rectum, adenoma of, 46.
 carcinoma of, 47.
 Regeneration, 43.
 Retroperitoneal glands, 187.
 Rickets, 187.
 Rodent ulcer, 54.
 from sebaceous glands, 56.
 Salpingitis, gonorrhoeal, 156.
 Salpingitis, tuberculous, 157.
 Sarcoma, giant cell, 70.
 large round cell, 68.
 melanotic, 71.
 myeloid, 70.
 small round cell, 66.
 spindle cell, 69.
 Sarcomata, 63, 66.
 Scarlet R stain, 210.
 Scirrhus, cancer of breast, 50.
 Sclerosis, amyotrophic lateral, 207.
 insular, 208.
 primary lateral, 206.
 Sebaceous glands, 56.
 Septicæmia, 175.
 Serous membranes, 176.
 carcinomatosis, 182.
 chronic inflammation, 178.
 tumours, 182.
 Silicosis of lung, 95.
 Skin, papilloma of, 54.
 Small round cell sarcoma, 66.
 Spinal cord, 201.
 ganglia, dorsal, 206.
 locomotor ataxy, 206.
 myelitis, acute, 201.
 poliomyelitis, anterior, 205.
 sclerosis, amyotrophic lateral, 207.
 insular, 208.
 primary lateral, 206.
 Spindle cell sarcoma, 69.
 Spindles, number of, 3.
 Spleen, 137.
 chronic congestion, 139.
 infarct, 139.
 in leucocythæmia, 139.
 in lardaceous disease, 138.
 lymphadenoma in, 139.
 Spongioplasm, 6.
 Stain for connective tissue, 211.
 demonstrating lardaceous degeneration, 209.
 elastic fibres, 211.
 fatty degeneration, 210.
 fibrous tissue, 211.
 nuclei, 210.
 plasma cells, 210.
 Stain, iodine, 8.
 methyl-green and pyronin, 210.
 methyl-violet, 8, 138, 209.

- Stain, scarlet R,** 210.
Stains, for blood, 212.
Stomach, cancer of, 114.
 congestion of, 114.
 gastritis of, 112.
 chronic, 112.
 subacute, 111.
 "leather bottle," 116.
Stroma in new growths, 46.
Synectial masses in lymphadenoma,
 186.
Syphilitic cirrhosis of liver, 128.
 inflammation of the testis, 149.
 the tongue, 109.
 leptomeningitis, 195.
- Teratomata,** 79, 156.
Testis, 149.
 atrophy, 149.
 inflammation of, 149.
 tuberculosis of, 150.
 tumours of, 151.
- Thrombosis,** 16.
 clot, 16.
 organisation, 16.
- Thyroid gland,** 165.
 adenoma of, 168.
 atrophy of, 167.
 cancer of, 169.
 goitre, exophthalmic, 166.
 simple, 165.
 myxoedema, 168.
- Tongue,** 109.
 epithelioma of, 109.
 glossitis, 109.
- Tubercle, in brain,** 199.
 giant cells in, 40.
 leucopenia in, 175.
 of adrenal, 169.
 of bladder, 148.
 of glands, 185.
 of liver, 131.
 of lung, 90.
 chronic, 93.
 acute, 90.
 semi-acute, 93.
 of testis, 150.
- Tuberculous meningitis,** 195.
 ulcer of intestine, 119.
- Tumours,** 45.
 benign, 45.
 malignant, 45.
 of serous membranes, 182.
- Typhoid,** 118.
- Ulcer,** 29.
 gastric, 112.
 rodent, 54.
- Urates, in gout,** 187.
- Uterus, cancer of,** 77, 162.
 inflammation of, 160.
 myoma, 65.
- Vegetations, in endocarditis,** 102.
- Wart,** 54.
- Weigert's stain,** 211.
- Zenker's solution,** 209.



