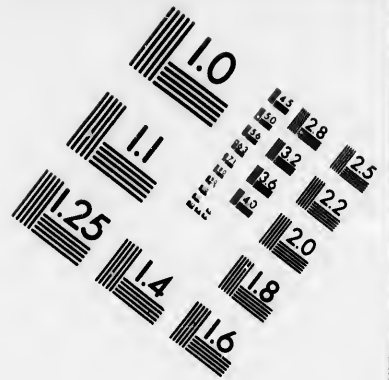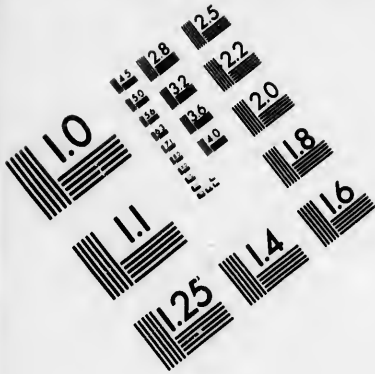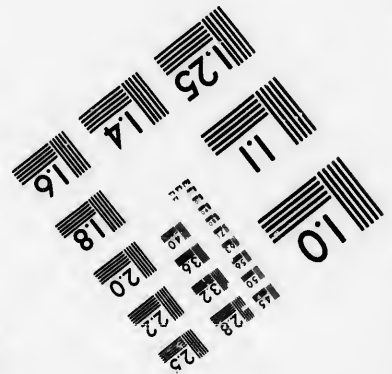




**IMAGE EVALUATION  
TEST TARGET (MT-3)**



**Photographic  
Sciences  
Corporation**

23 WEST MAIN STREET  
WEBSTER, N.Y. 14580  
(716) 872-4503

**CIHM/ICMH  
Microfiche  
Series.**

**CIHM/ICMH  
Collection de  
microfiches.**



**Canadian Institute for Historical Microreproductions / Institut canadien de microreproductions historiques**

**© 1986**

Technical and Bibliographic Notes/Notes techniques et bibliographiques

The Institute has attempted to obtain the best original copy available for filming. Features of this copy which may be bibliographically unique, which may alter any of the images in the reproduction, or which may significantly change the usual method of filming, are checked below.

L'Institut a microfilmé le meilleur exemplaire qu'il lui a été possible de se procurer. Les détails de cet exemplaire qui sont peut-être uniques du point de vue bibliographique, qui peuvent modifier une image reproduite, ou qui peuvent exiger une modification dans la méthode normale de filmage sont indiqués ci-dessous.

- Coloured covers/  
Couverture de couleur
- Covers damaged/  
Couverture endommagée
- Covers restored and/or laminated/  
Couverture restaurée et/ou pelliculée
- Cover title missing/  
Le titre de couverture manque
- Coloured maps/  
Cartes géographiques en couleur
- Coloured ink (i.e. other than blue or black)/  
Encre de couleur (i.e. autre que bleue ou noire)
- Coloured plates and/or illustrations/  
Planches et/ou illustrations en couleur
- Bound with other material/  
Relié avec d'autres documents
- Tight binding may cause shadows or distortion  
along interior margin/  
La reliure serrée peut causer de l'ombre ou de la  
distortion le long de la marge intérieure
- Blank leaves added during restoration may  
appear within the text. Whenever possible, these  
have been omitted from filming/  
Il se peut que certaines pages blanches ajoutées  
lors d'une restauration apparaissent dans le texte,  
mais, lorsque cela était possible, ces pages n'ont  
pas été filmées.
- Additional comments:/  
Commentaires supplémentaires:

- Coloured pages/  
Pages de couleur
- Pages damaged/  
Pages endommagées
- Pages restored and/or laminated/  
Pages restaurées et/ou pelliculées
- Pages discoloured, stained or foxed/  
Pages décolorées, tachetées ou piquées
- Pages detached/  
Pages détachées
- Showthrough/  
Transparence
- Quality of print varies/  
Qualité inégale de l'impression
- Includes supplementary material/  
Comprend du matériel supplémentaire
- Only edition available/  
Seule édition disponible
- Pages wholly or partially obscured by errata  
slips, tissues, etc., have been refilmed to  
ensure the best possible image/  
Les pages totalement ou partiellement  
obscurcies par un feuillet d'errata, une pelure,  
etc., ont été filmées à nouveau de façon à  
obtenir la meilleure image possible.

This item is filmed at the reduction ratio checked below/  
Ce document est filmé au taux de réduction indiqué ci-dessous.

10X	12X	14X	16X	18X	20X	22X	24X	26X	28X	30X	32X
						✓					

The copy filmed here has been reproduced thanks to the generosity of:


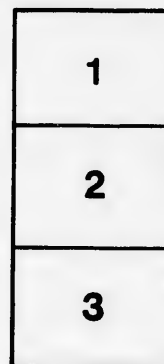
Medical Library  
McGill University  
Montreal

The images appearing here are the best quality possible considering the condition and legibility of the original copy and in keeping with the filming contract specifications.

Original copies in printed paper covers are filmed beginning with the front cover and ending on the last page with a printed or illustrated impression, or the back cover when appropriate. All other original copies are filmed beginning on the first page with a printed or illustrated impression, and ending on the last page with a printed or illustrated impression.

The last recorded frame on each microfiche shall contain the symbol  $\rightarrow$  (meaning "CONTINUED"), or the symbol  $\nabla$  (meaning "END"), whichever applies.

Maps, plates, charts, etc., may be filmed at different reduction ratios. Those too large to be entirely included in one exposure are filmed beginning in the upper left hand corner, left to right and top to bottom, as many frames as required. The following diagrams illustrate the method:



L'exemplaire filmé fut reproduit grâce à la générosité de:

Medical Library  
McGill University  
Montreal

Les images suivantes ont été reproduites avec le plus grand soin, compte tenu de la condition et de la netteté de l'exemplaire filmé, et en conformité avec les conditions du contrat de filmage.

Les exemplaires originaux dont la couverture en papier est imprimée sont filmés en commençant par la première page et en terminant soit par la dernière page qui comporte une empreinte d'impression ou d'illustration, soit par la seconde page, selon le cas. Tous les autres exemplaires originaux sont filmés en commençant par la première page qui comporte une empreinte d'impression ou d'illustration et en terminant par la dernière page qui comporte une telle empreinte.

Un des symboles suivants apparaît sur la dernière image de chaque microfiche, selon le cas: le symbole  $\rightarrow$  signifie "A SUIVRE", le symbole  $\nabla$  signifie "FIN".

Les cartes, planches, tableaux, etc., peuvent être filmés à des taux de réduction différents. Lorsque le document est trop grand pour être reproduit en un seul cliché, il est filmé à partir de l'angle supérieur gauche, de gauche à droite, et de haut en bas, en prenant le nombre d'images nécessaire. Les diagrammes suivants illustrent la méthode.

ire  
détails  
es du  
modifier  
er une  
filmage

es

errata  
to

pelure,  
on à



32X

Rep

Shepherd, F. J.

Jr MacDonnell

7

- F. J. -


REPORT ON SOME  
Anatomical Variations

FOR 1883.

BY  
FRANCIS J. SHEPHERD, M.D.,  
OF MONTREAL, CANADA.

—  
*REPRINT.*  
—

BROOKLYN, N. Y.,  
ANNALS OF ANATOMY AND SURGERY,  
1883.



ON SOME ANATOMICAL VARIATIONS, WITH  
REMARKS ON THEIR MORPHOLOGY.

By FRANCIS J. SHEPHERD, M.D., C.M., M.R.C.S., ENG.,

OF MONTREAL, CANADA,

PROFESSOR OF ANATOMY IN MCGILL UNIVERSITY; SURGEON TO THE  
MONTREAL GENERAL HOSPITAL.

THE variations described below are some of the most interesting that were noticed in the anatomical rooms of McGill University during the winter session, 1882-3.

MENTO-HYOID OR HYO-MENTAL MUSCLE.

Three examples of this muscle were noted; two on the left side and one on the right. It was once seen on both sides of the same subject. In the first case this muscle consisted of a small slip quite distinct from the anterior belly of the digastric. It arose from the lower jaw near the symphysis, internal to the attachment of the digastric, and passed downwards over the mylo-hyoid muscle, to be inserted into the body of the hyoid bone. In this case the left digastric had two anterior bellies, the supernumerary one being given off from the fascia at the level of the hyoid bone.

The other two cases occurred in the same subject. The muscles arose, as usual, from the lower jaw, between the insertions of the digastric, but did not reach the hyoid bone. Spreading out as they descended, they ended in a strong fascia covering the mylo-hyoid, and attached below to the hyoid bone. In the same subject the

right digastric gave off a small slip of muscle which passed beneath the mento-hyoids, and blended with the mylo-hyoid of the opposite side.

MacAlister<sup>1</sup> has fully described this muscle, and considers that it is a differentiated portion of the platysma. He mentions that, in one case, it blended with the genio-hyoid, the intervening portion of mylo-hyoid being absent. The last variety I have described approaches this form, the strong fascia into which the muscle is inserted would represent the subhyoidean septum. The mento-hyoid or hyo-mental exists normally in many animals—*e. g.*, the hippopotamus and bat. Prof. Humphry<sup>2</sup> considers that the anterior belly in man is formed from the middle portion of the hyo-mental, which accounts for its insertion near the symphysis. In the cases of mento-hyoid narrated above, it is the inner portion of the hyo-mental which persists as well as the middle. The shifting insertion of the digastric into the jaw in many of the lower animals, according to Prof. Humphry,<sup>3</sup> is explained by the fact that its anterior belly may be formed by different parts of the hyo-mental in different animals. The hyo-mental (and, of course, the anterior belly of the digastric) is formed from the superficial brachio-cephalic stratum of muscle.

#### DOUBLE STYLO-HYOID.

This anomaly was met with *five* times; twice on both sides of the same subject. In all five cases the extra muscle took the place of the stylo-hyoid ligament, and extended between the styloid process and lesser cornu of the hyoid bone passing beneath the hyo-glossus muscle. This arrangement is found in some of the edentata.

<sup>1</sup> Proceedings Royal Irish Academy, vol. xxv.

<sup>2</sup> Observations in Myology, p. 133.

<sup>3</sup> Loc. cit.



## CHONDRO-SCAPULAR.

This muscle occurred three times; once on both sides of the subject.

The first example met with was on the left side of a muscular male subject. It arose by a round tendon from the costal cartilage of the first rib, soon developed into a large fleshy belly, which, after running parallel to the clavicle for a short distance, crossed beneath it and passed over the subclavian artery, and between the supra-scapular vein and artery; continuing outwards, it ended by being inserted into upper border of the scapula immediately external to the notch, some of its fibres were attached also to the transverse ligament of the notch. In this subject, on the same side (left) there was no trace of a subclavius, and the omo-hyoid muscle arose from the middle of the clavicle. In the same subject, and on the left side, was a mento-hyoid muscle, and the anterior belly of the digastric was double. There was also a levator thyroideæ.

The other two examples of this muscle occurred in a muscular male subject. The course on each side was precisely the same. The muscle arose by a round tendon from the costal cartilage of the first rib, passed *over* the clavicle near its sternal end, and piercing the cervical fascia above the clavicle developed into a well-formed fleshy belly, which crossed the scalenus anticus muscle and third part of the subclavian artery, and was inserted into the root of the coracoid process. On each side the subclavius was of small size. I have now seen seven examples of this muscle, and with the exception of these two (occurring in the same subject), all passed *beneath* the clavicle. In the Norway rat, guinea pig, wombat, etc., this muscle exists as the sterno-scapular. In the horse it is a well-developed muscle. In the first case

described above, it would seem to have embodied the subclavius, as that muscle was absent. In animals without clavicles some authorities consider it the homologue of the subclavius.

#### CLEIDO-OCCIPITAL.

Two examples of this muscle were seen. The first occurred on the right side of a male subject. It arose from the middle of the hinder border of the clavicle, and passed up as a muscular band two centimetres broad, and quite distinct from the sterno-mastoid, to be inserted into the occipital bone, between the trapezius and sterno-mastoid. The second case occurred on the left side of a female subject. It was not so well marked as the foregoing, as immediately before its insertion it blended with the sterno-mastoid. This muscle is well marked in the hedge-hog, mole, etc., and, according to Prof. Wood,<sup>1</sup> corresponds to the cephalo-humeral muscle of many of the lower animals.

#### RECTUS STERNALIS.

On the left side of a male subject a well-marked example of this muscle was seen. The muscle arose from the costal cartilage of the fifth rib by a broad tendinous expansion, passed upwards over the fourth and third costal cartilages to the second, to which it was attached by a few aponeurotic fibres, the main portion, however, was attached to the first costal cartilage, and the inner portion ended in a tendon which, after crossing the first piece of the sternum, became continuous with the inner border of the sterno-mastoid of the opposite side. The muscle was in no way connected with the rectus abdominis, and was superficial to the pectoralis major (see Fig. 1).

<sup>1</sup> Proceedings Royal Society, 1870.

Prof. Turner,<sup>1</sup> in a most interesting essay on this muscle, holds that it is not, as was formerly supposed, homologous with the anterior or pectoral end of the rectus abdominis. The rectus, when prolonged upwards in the lower animals, is always beneath, or rather deeper than the great pectoral muscle. The rectus sternalis of man is always superficial, so Prof. Turner<sup>2</sup> regards it "as an additional rudiment in man of that very im-

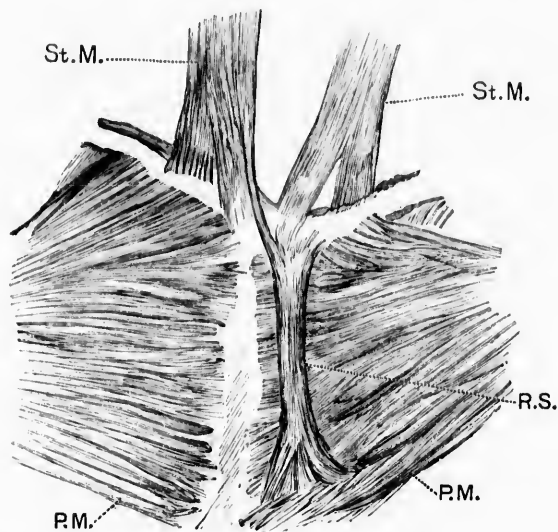


FIG. I. RECTUS STERNALIS MUSCLE.

*R. S.*, rectus sternalis; *St. M.*, sterno-mastoid; *P. M.*, pectoralis major.

portant tegumentary muscle (the panniculus carnosus), though it must be admitted that the human platysma lies on a plane superficial to the fibres of the sternalis in those individuals in whom they co-exist." I have seen one case of rectus sternalis which was continuous with

<sup>1</sup> *Journal of Anatomy and Physiology*, vol. i.

<sup>2</sup> *Loc. cit.*

the platysma, but the case described above was directly continuous with the sterno-mastoid, and some anatomists (Henle, Theile, and others) consider this muscle a continuation downwards of the sterno-mastoid, as in man, when it exists, it is so often connected with the sterno-mastoid. In many mammals the attachments of the sterno-mastoids are continued backwards superficial to the pectoralis major.<sup>1</sup>

Dr. G. E. Dobson<sup>2</sup> looks upon the *musculus sternalis* "as homologous, not with the *panniculus carnosus* lining the integument, but with the sterno-cuticularis (sterno-facialis of the hedge-hog), which is found in many species of mammals springing from the sternum and attached to the deep surface of the *panniculus carnosus* either in front of or behind the anterior extremity." This, however, does not satisfactorily account for its continuation in many cases with the sterno-mastoid.

#### PECTORALIS MINOR.

In three cases this muscle blended with the coraco-brachialis, or more properly speaking, its lower border was inserted into the coraco-brachialis, forming at the point of junction a broad tendinous intersection. It was once seen having no insertion into the coracoid process, but the whole brachial end was fused with the coraco-brachialis for about two inches. This is an approach to the insertion of the pectoralis minor into the humerus, as is seen in *quadrupana* and some of the carnivora.

#### DOUBLE CORACO-BRACHIALIS.

On the right side of a male subject the coraco-brachialis had two insertions: (1) the normal one into the inner side of the middle of the humerus, and (2) a second one

<sup>1</sup> Prof. Turner, loc. cit.

<sup>2</sup> *Journal of Anatomy and Physiology*, October 1882.

into the internal condyle of the humerus. The supernumerary portion arose with the normal muscle from the coracoid process, and consisted of a strong muscular slip which passed down the arm internal to it; after crossing the vessels and nerves of the arm about its middle, the slip became tendinous. This tendon blended internally with a broad aponeurotic band, which covered the internal portion of the triceps muscle and the ulnar nerve, and reached from near the head of the humerus to the internal condyle. The tendon proper of the muscular slip above described continued on, and was inserted into the lower part of the internal condyloid ridge. Prof. Wood<sup>1</sup> has fully described a similar anomaly, and mentions that he has met with three varieties of coracobrachialis muscle in man: (1) The normal arrangement, which he calls the coraco-brachialis proprius; (2) where the muscle is inserted into the internal condyle (coraco-brachialis longus); and (3) the rarest variety where the muscle is inserted into the capsule of the shoulder close to its insertion into the anatomical neck of the humerus, immediately below the lesser tuberosity. This has been described as the coraco-capsularis. Prof. Wood calls it the coraco-brachialis superior vel brevis. All these varieties exist normally in the lower animals. In a bear which I lately dissected, the short and long variety existed. In most of the quadrumana there is a double insertion of this muscle, in the dog and cat the short variety alone exists,<sup>2</sup> and in the guinea pig the median variety only is present, as in man.

## FLEXOR INDICIS.

On the right side of a male subject there was a distinct flexor indicis muscle, separated from the profundus by a

<sup>1</sup> *Journal of Anatomy and Physiology*, vol. i.

<sup>2</sup> Prof. Wood, loc. cit.

well-marked cellular interval. It was of considerable size, and arose from a small portion of the ulna, the interosseous membrane and a portion of the radius internal to the flexor pollicis; there was a well-marked tendinous intersection between it and the flexor pollicis. In the ourang, chimpanzee, and gorilla, there is a distinct flexor indicis.<sup>1</sup>

#### FIBULO-ACCESSORIUS.

This supernumerary muscle arose on both sides of the same subject from the lower fifth of the posterior border of the fibula, its fibres blending with those of the peroneus tertius. its course was then downwards behind the inner margin and posterior to the flexor hallucis, where it ended in a slip and tendon which grooved the astragalus and os calcis, and was enclosed in a separate sheath; it finally ended by being inserted into the deep surface of the long flexor tendon with the accessorius. I have several times seen a similar slip, which arose from the lower part of the tibia (tibio-accessorius), but never before one quite like this. It probably was a differentiated portion of the longus hallucis. Its morphology I am unable to determine.

#### TRIPLE ANTERIOR COMMUNICATING ARTERY.

In the brain of a female subject the two anterior cerebral arteries were connected together by three distinct communicating arteries. They were of small size. I have frequently seen the anterior communicating artery so short that the two anterior cerebrals seemed fused together, but this is the first time I have seen it multiple. The two cerebral arteries in this case were separated by a considerable interval.

#### INTERNAL MAMMARY.

This artery was once seen to come off from the thyroid axis, and it, in another case, gave off the suprascapular.

<sup>1</sup> W. J. Walsham, St Bartholomew's Hospital Reports, 1880.

## ABERRANT ARTERY.

On the left side of a male subject, opposite the insertion of the latissimus dorsi, a large branch was given off from the brachial which passed down the arm internal and parallel to the brachial, and joined it again at the bend of the elbow. The main artery, after receiving the aberrant branch, almost immediately divided into radial and ulnar. The aberrant artery was quite as large as the brachial, which, in this instance, was smaller than usual.

## INTERNAL CIRCUMFLEX FROM THE DEEP EPIGASTRIC.

This occurred on the left side of a male subject. The epigastric arose from the external iliac, about half an inch above Poupart's ligament, and almost immediately gave off the internal circumflex. From this origin the internal circumflex passed beneath Poupart's ligament, within the femoral sheath (being enclosed in the same compartment as the common femoral), and continued down the thigh for nearly two inches, lying between the femoral vein and artery; it then gradually proceeded inwards across the femoral vein to dip down between the pectineus and psoas muscles. Before doing so, it gave off a large branch, corresponding to a portion of the profunda, which was distributed to the adductor muscles (see Fig. 2). The external circumflex was given off directly from the femoral, and the profunda did not come off till the main artery reached the apex of Scarpa's triangle. It was of small size. In a bear which I lately dissected, on both sides the internal circumflex was of large size, and was given off from the external iliac some distance above Poupart's ligament, and continued downwards within the femoral sheath, lying between the vein and the artery; about an inch below Poupart's ligament it proceeded to its destination by dipping down between the vein and artery. I have several times seen the internal circum-

flex and deep epigastric arteries given off from a common trunk, and once I noticed a common trunk for the internal circumflex, epigastric and obturator; but in all cases this occurred *below* Poupart's ligament. This is the first time I have seen this rare anomaly of the internal circumflex arising with the epigastric *above* the ligament. Mr. Arthur

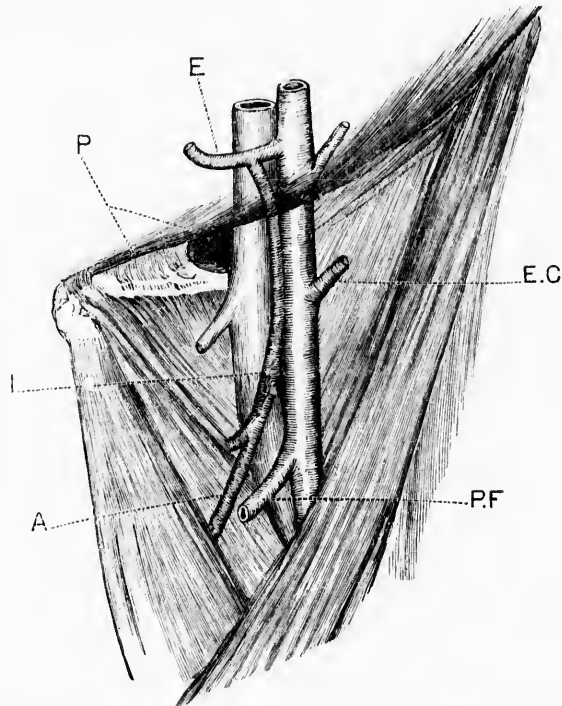


FIG. 2. ABNORMAL ORIGIN OF INTERNAL CIRCUMFLEX ARTERY.

*P.*, Poupart's ligament; *E.*, epigastric artery; *I.*, internal circumflex; *A.*, branch from circumflex to adductor muscles; *E. C.*, external circumflex; *P. F.*, profunda femoris.

Thompson,<sup>1</sup> in a recent number of the *Journal of Anatomy and Physiology*, gives an account of two cases in which there was this unusual arrangement of the arteries. In one case the internal circumflex, after leaving the epigastric, curved

<sup>1</sup> April, 1883.



inwards and downwards, lying internal to the femoral vein and winding to the inner side of the crural ring, where it gave off the external pudic. It then rested on the pectineus muscle, being bound down to it by strong fascia. The artery being in this position would, in the event of a hernia coming down, surround the neck of the sac, and, in case of operation, would be in danger of being wounded. It would, however, be a much simpler matter for the surgeon to secure it than an abnormal obturator.

In Mr. Thompson's second case the common trunk was larger, and crossed the external iliac vein at a point corresponding to the septum, between the compartment for the vein and crural canal, the artery pierced the sheath and split into the deep epigastric and internal circumflex, the latter crossed downwards, being in contact with and to the inner side of the vein. In this case, Mr. Thompson thinks, if a hernia had existed, it would have pushed the artery to the outer side, and the vessel would not have been in any danger should an operation for strangulated hernia have been needed.

#### LEFT SUPERIOR VENA CAVA.

This occurred in an old woman aged 70. The heart was considerably larger than normal, and its right side and the veins emptying into it were full of blood. The right cava and transverse innominate were not much reduced in size or length, and were normally placed. The persistent left cava, or rather the left dual of Cuvier, passed down over the arch of the aorta and root of left lung, pierced the fibrous pericardium and joined the coronary sinus (which was much enlarged), and through it entered the right auricle. The opening into the auricle was of great size. The persistent vein was about the size of a common lead pencil, and received just below the point where the transverse branch was given off a large vein which returned the blood from the upper four intercostal spaces. The azygos veins were nor-

mal. The thyroid veins emptied into the transverse branch. This is the second example I have seen of this anomaly in two hundred and fifty subjects; both occurred in adults. In my other case<sup>1</sup> the persistent vein was much larger. Both specimens are now preserved in the museum of McGill University. This arrangement of the veins is the normal one in birds and some mammals, as, *e. g.*, the rabbit. Mr. Marshall has ably worked out the development of the great veins of the neck, and has fully described the cause of this anomaly. Mr. Walsham<sup>2</sup> has, lately, very fully described a well-marked case of persistent left cava.

#### LARGE OCCIPITAL SINUS.<sup>2</sup>

The right occipital sinus was twice seen, of very large size—quite as large as the ordinary lateral. In both these cases the lateral sinus was so small that it would only admit a probe. J. T. Knott<sup>3</sup> has, lately, fully described the variations of the lateral sinuses.

#### DISPLACED KIDNEYS.

In an elderly female subject, who had borne children, the kidneys were seen two inches lower than normal. The lower end of the left kidney rested on the external iliac artery, the lower end of right in the iliac fossa. The upper end of each kidney was below the last dorsal vertebra. The left kidney received two branches from the aorta—one given off normally entered the hilus, the other was given off from the aorta just above its division and entered the extreme lower end of the kidney. On the right side the renal artery, before entering the hilus, divided into four branches. From the position of the supernumerary renal to the left kidney, I should judge that the left kidney, at any rate, was congenitally misplaced. Both kidneys were firmly fixed in their abnormal position.

<sup>1</sup> Montreal General Hospital Reports, vol. i., 1880.

<sup>2</sup> St. Bartholomew's Hospital Reports, 1880.

<sup>3</sup> Proceedings of International Medical Congress, 1881, vol. i.

