

**CIHM  
Microfiche  
Series  
(Monographs)**

**ICMH  
Collection de  
microfiches  
(monographies)**



**Canadian Institute for Historical Microreproductions / Institut canadien de microreproductions historiques**

**© 1996**

Technical and Bibliographic Notes / Notes techniques et bibliographiques

The Institute has attempted to obtain the best original copy available for filming. Features of this copy which may be bibliographically unique, which may alter any of the images in the reproduction, or which may significantly change the usual method of filming, are checked below.

L'Institut a microfilmé le meilleur exemplaire qu'il lui a été possible de se procurer. Les détails de cet exemplaire qui sont peut-être uniques du point de vue bibliographique, qui peuvent modifier une image reproduite, ou qui peuvent exiger une modification dans la méthode normale de filmage sont indiqués ci-dessous.

Coloured covers/  
Couverture de couleur

Covers damaged/  
Couverture endommagée

Covers restored and/or laminated/  
Couverture restaurée et/ou pelliculée

Cover title missing/  
Le titre de couverture manque

Coloured maps/  
Cartes géographiques en couleur

Coloured ink (i.e. other than blue or black)/  
Encre de couleur (i.e. autre que bleue ou noire)

Coloured plates and/or illustrations/  
Planches et/ou illustrations en couleur

Bound with other material/  
Relié avec d'autres documents

Tight binding may cause shadows or distortion  
along interior margin/  
La reliure serrée peut causer de l'ombre ou de la  
distorsion le long de la marge intérieure

Blank leaves added during restoration may appear  
within the text. Whenever possible, these have  
been omitted from filming/  
Il se peut que certaines pages blanches ajoutées  
lors d'une restauration apparaissent dans le texte,  
mais, lorsque cela était possible, ces pages n'ont  
pas été filmées.

Coloured pages/  
Pages de couleur

Pages damaged/  
Pages endommagées

Pages restored and/or laminated/  
Pages restaurées et/ou pelliculées

Pages discoloured, stained or foxed/  
Pages décolorées, tachetées ou piquées

Pages detached/  
Pages détachées

Showthrough/  
Transparence

Quality of print varies/  
Qualité inégale de l'impression

Continuous pagination/  
Pagination continue

Includes index(es)/  
Comprend un (des) index

Title on header taken from: /  
Le titre de l'en-tête provient:

Title page of issue/  
Page de titre de la livraison

Caption of issue/  
Titre de départ de la livraison

Masthead/  
Générique (périodiques) de la livraison

Additional comments: / Wrinkled pages may film slightly out of focus.  
Commentaires supplémentaires: Copy has manuscript annotations.

This item is filmed at the reduction ratio checked below/  
Ce document est filmé au taux de réduction indiqué ci-dessous.

10x	14x	18x	22x	26x	30x
<input type="checkbox"/>	<input type="checkbox"/>	<input type="checkbox"/>	<input checked="" type="checkbox"/>	<input type="checkbox"/>	<input type="checkbox"/>
12x	16x	20x	24x	28x	32x

The copy filmed here has been reproduced thanks to the generosity of:

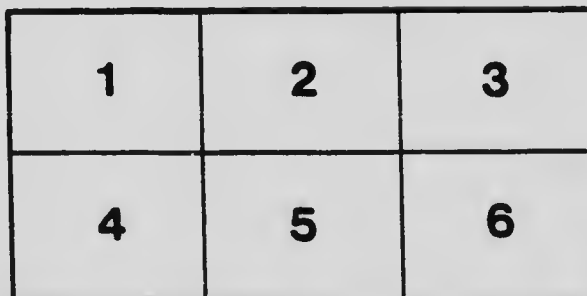
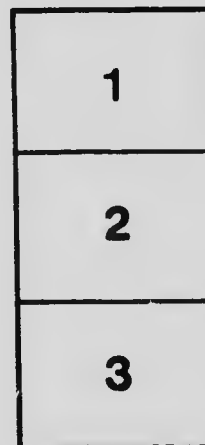

University of Toronto,  
Science & Medicine Library

The images appearing here are the best quality possible considering the condition and legibility of the original copy and in keeping with the filming contract specifications.

Original copies in printed paper covers are filmed beginning with the front cover and ending on the last page with a printed or illustrated impression, or the back cover when appropriate. All other original copies are filmed beginning on the first page with a printed or illustrated impression, and ending on the last page with a printed or illustrated impression.

The last recorded frame on each microfiche shall contain the symbol  $\rightarrow$  (meaning "CONTINUED"), or the symbol  $\nabla$  (meaning "END"), whichever applies.

Maps, plates, charts, etc., may be filmed at different reduction ratios. Those too large to be entirely included in one exposure are filmed beginning in the upper left hand corner, left to right and top to bottom, as many frames as required. The following diagrams illustrate the method:



L'exemplaire filmé fut reproduit grâce à la générosité de:


University of Toronto,  
Science & Medicine Library

Les images suivantes ont été reproduites avec le plus grand soin, compte tenu de la condition et de la netteté de l'exemplaire filmé, et en conformité avec les conditions du contrat de filmage.

Les exemplaires originaux dont la couverture en papier est imprimée sont filmés en commençant par le premier plat et en terminant soit par la dernière page qui comporte une empreinte d'impression ou d'illustration, soit par le second plat, selon le cas. Tous les autres exemplaires originaux sont filmés en commençant par la première page qui comporte une empreinte d'impression ou d'illustration et en terminant par la dernière page qui comporte une telle empreinte.

Un des symboles suivants apparaîtra sur la dernière image de chaque microfiche, selon le cas: le symbole  $\rightarrow$  signifie "A SUIVRE", le symbole  $\nabla$  signifie "FIN".

Les cartes, planches, tableaux, etc., peuvent être filmés à des taux de réduction différents. Lorsque le document est trop grand pour être reproduit en un seul cliché, il est filmé à partir de l'angle supérieur gauche, de gauche à droite, et de haut en bas, en prenant le nombre d'images nécessaire. Les diagrammes suivants illustrent la méthode.



MICROCOPY RESOLUTION TEST CHART  
 NATIONAL BUREAU OF STANDARDS  
 STANDARD REFERENCE MATERIAL 1010a  
 (ANSI and ISO TEST CHART No. 2)

1875

mt.  
M.

A

THE  
DEVELOPMENT OF THE  
HUMAN BODY

A MANUAL OF HUMAN EMBRYOLOGY

BY

J. PLAYFAIR McMURRICH, A.M., PH.D.

PROFESSOR OF ANATOMY IN THE UNIVERSITY OF MICHIGAN

*With Two Hundred and Seventy Illustrations*

83851  
27.9.07

PHILADELPHIA  
P. BLAKISTON'S SON & CO.  
1012 WALNUT STREET

1902

Copyright, 1902,  
BY P. BLAKISTON'S SON & CO.

---

PRESS OF WM. F. FELL & CO.  
1220-24 SANSON STREET  
PHILADELPHIA.

## PREFACE.

The assimilation of the enormous mass of facts which constitute what is usually known as descriptive anatomy has always been a difficult task for the student. Part of this difficulty has been due to a lack of information regarding the causes which have determined the structure and relations of the parts of the body, for without some knowledge of the *why* things are so, the facts of anatomy stand as so many isolated items, while with such knowledge they become bound together to a continuous whole and their study assumes the dignity of a science.

The great key to the significance of the structure and relations of organs is their development, recognizing by that term the historical as well as the individual development, and the following pages constitute an attempt to present a concise statement of the development of the human body and a foundation for the proper understanding of the facts of anatomy. Naturally, the individual development claims the major share of attention, since its processes are the more immediate forces at work in determining the conditions in the adult, but where the embryological record fails to afford the required data, whether from its actual imperfection or from the incompleteness of our knowledge concerning it, recourse has been had to the facts of comparative anatomy as affording indications of the historical development or evolution of the parts under consideration.

It has not seemed feasible to include in the book a com-



plete list of the authorities consulted in its preparation. The short bibliographies appended to each chapter make no pretensions to completeness, but are merely indications of some of the more important works, especially those of recent date, which consider the questions discussed. For a very full bibliography of all works treating of human embryology up to 1893 reference may be made to Minot's *Bibliography of Vertebrate Embryology*, published in the "Memoirs of the Boston Society of Natural History," volume iv, 1893. It is fitting, however, to acknowledge an especial indebtedness, shared by all writers on human embryology, to the classic papers of His, chief among which is his *Anatomie menschlicher Embryonen*, and grateful acknowledgments are also due to the admirable text-books of Minot, O. Hertwig, and Kollmann.

ANATOMICAL LABORATORY,  
UNIVERSITY OF MICHIGAN.  
October 1, 1907.

# CONTENTS.

	PAGE.
INTRODUCTION, .....	17-26
<b>PART I.—GENERAL DEVELOPMENT.</b>	
CHAPTER I.	
The Spermatozoön and Spermatogenesis; the Ovum and Its Maturation and Fertilization, .....	27-53
CHAPTER II.	
The Segmentation of the Ovum and the Formation of the Germ Layers, .....	54-81
CHAPTER III.	
The Development of the External Form of the Human Embryo, ..	82-111
CHAPTER IV.	
The Medullary Groove, Notochord, and Mesodermic Somites, ..	112-127
CHAPTER V.	
The Yolk-stalk, Belly-stalk, and Fetal Membranes, .....	128-160
<b>PART II.—ORGANOGENY.</b>	
CHAPTER VI.	
The Development of the Integumentary System, .....	161-173
CHAPTER VII.	
The Development of the Connective Tissues and Skeleton, .....	174-215
CHAPTER VIII.	
The Development of the Muscular System, .....	216-239
CHAPTER IX.	
The Development of the Circulatory and Lymphatic Systems, ..	240-295
CHAPTER X.	
The Development of the Digestive Tract and Glands, .....	296-333

	PAGE.
CHAPTER XI.	
The Development of the Pericardium and Pleuro-peritoneum, the Diaphragm and the Spleen, .....	334-351
CHAPTER XII.	
The Development of the Organs of Respiration,.....	352-359
CHAPTER XIII.	
The Development of the Urinogenital System and the Supra- renal Bodies,.....	360-393
CHAPTER XIV.	
The Development of the Nervous System,.....	394-453
CHAPTER XV.	
The Development of the Organs of Special Sense,.....	454-500
CHAPTER XVI.	
Post-natal Development, .....	501-518
INDEX, .....	519-527

## LIST OF ILLUSTRATIONS.

FIG.	PAGE.
1. Ovum of New-born Child with Follicle-cells.—(Verrens),.....	19
2. Diagrams Illustrating the Prophases of Mitosis.—(Adapted from E. B. Wilson),.....	21
3. Diagrams Illustrating the Metaphase and Anaphases of Mitosis.— (Adapted from E. B. Wilson), .....	23
4. Human Spermatozoön,.....	28
5. Spermatozoön of Rat,.....	28
6. Diagram showing Stages of Spermatogenesis as seen in Different Sectors of a Seminiferous Tubule of a Rat.—(Modified from von Lenhossek),.....	29
7. Diagram Illustrating the Reduction of the Chromosomes During Spermatogenesis, .....	31
8. Four Stages in the Transformation of a Spermatid into the Spermatozoön of a Rat.—(von Lenhossek), .....	32
9. Section through Portion of an Ovary of an Opossum ( <i>Didelphys virginiana</i> ) showing Ova and Follicles in Various Stages of Development,.....	34
10. Ovum from Ovary of a Woman Thirty Years of Age.—(Nagel),	35
11. Ovary of a Woman Nineteen Years of Age, Eight Days after Menstruation.—(Kollmann), .....	40
12. Section through the Corpus Luteum of a Rabbit, Seventy Hours <i>post coitum</i> .—(Sobotta), .....	41
13. Diagram Illustrating the Reduction of the Chromosomes during the Maturation of the Ovum, .....	44
14. Ovum of a Mouse showing the Maturation Spindle.—(Sobotta),	46
15. Six Stages in the Process of Fertilization of the Ovum of a Mouse.—(Sobotta), .....	48
16. Stages in the Segmentation of <i>Amphioxus</i> .—(Hatschek),.....	55
17. Stages in the Segmentation of <i>Amblystoma</i> .—(Eycleshymer),...	56
18. Four Stages in the Segmentation of the Blastoderm of the Chick.—(Coste), .....	57
19. Diagram Illustrating a Section of the Ovum of a Reptile at a Stage Corresponding to the Blastula of an Amphibian,....	58
20. Four Stages in the Segmentation of the Ovum of a Mouse.— (Sobotta), .....	60
21. Later Stages in the Segmentation of the Ovum of a Bat.—(Van Beneden),.....	61
22. Two Stages in the Gastrulation of <i>Amphioxus</i> .—(Morgan and Hazen), .....	65
23. Transverse Section of <i>Amphioxus</i> Embryo with Five Meso- dermic Pouches.—(Hatschek),.....	66
24. Section through a Gastrula of <i>Amblystoma</i> .—(Eycleshymer),...	67
25. Section through an Embryo Amphibian (Triton) of 2½ Days, showing the Formation of the Gastral Mesoderm.—(Hert- wig), .....	68

FIG.	PAGE.
26. Longitudinal Sections through Embryos of the Gecko, showing Gastrulation.—( <i>Will</i> ), .....	69
27. Diagrams Illustrating the Formation of the Gastral Mesoderm in the Gecko.—( <i>Will</i> ), .....	70
28. Sections of Ova of a Bat showing (A) the Formation of the Endoderm and (B and C) of the Amniotic Cavity.—( <i>Van Beneden</i> ), .....	72
29. A, Side View of Ovum of Rabbit Seven Days Old ( <i>Kölliker</i> ); B, Embryonic Disk of a Mole ( <i>Heape</i> ); C, Embryonic Disk of a Dog's Ovum of about Fifteen Days ( <i>Bonnet</i> ), .....	73
30. Posterior Portion of a Longitudinal Section through the Embryonic Disk of a Mole.—( <i>After Heape</i> ), .....	74
31. Diagram Illustrating Conerescence.—( <i>Duval</i> ), .....	75
32. Transverse Section of the Embryonic Area of a Dog's Ovum at about the Stage of Development shown in Fig. 29, C.—( <i>Bonnet</i> ), .....	76
33. Diagram of a Longitudinal Section through the Embryonic Disk of a Mole.—( <i>Heape</i> ), .....	77
34. Transverse Section through the Embryonic Disk of a Rabbit.—( <i>After Van Beneden</i> ), .....	78
35. Section of Embryo and Adjacent Portion of an Ovum of 1 mm.—( <i>Peters</i> ), .....	82
36. Diagrams to show the Probable Relationships of the Parts in the Embryos Represented in Figs. 28, C, and 35, .....	83
37. Ovum Measuring $6 \times 4.5$ mm. The Left Half of the Chorion has Been Removed to show the Embryo.—( <i>von Spée</i> ), ....	85
38. Embryo 1.54 mm. in Length, from the Dorsal Surface.—( <i>von Spée</i> ), .....	85
39. Diagrams Illustrating the Constriction of the Embryo from the Yolk-sac, .....	86
40. Embryo 2.5 mm. Long.—( <i>Allen Thomson</i> ), .....	87
41. Reconstruction of Embryo 2.11 mm. Long.—( <i>After Eternod</i> ), ..	88
42. Embryo 2.5 mm. Long.—( <i>Kollmann</i> ), .....	89
43. Embryo L <sub>g</sub> , 2.15 mm. Long.—( <i>His</i> ), .....	90
44. Floor of the Pharynx of Embryo B, 7 mm. Long.—( <i>His</i> ), ....	92
45. Embryo L <sub>r</sub> , 4.2 mm. Long.—( <i>His</i> ), .....	93
46. Embryo of from Twenty to Twenty-five Days.—( <i>Coste</i> ), .....	95
47. Embryo 9.1 mm. Long.—( <i>His</i> ), .....	96
48. Embryo Br <sub>2</sub> , 13.6 mm. Long.—( <i>His</i> ), .....	98
49. A, Embryo S <sub>2</sub> , 15 mm. Long (showing Ectopia of the Heart); B, Embryo L <sub>3</sub> , 17.5 mm. Long.—( <i>His</i> ), .....	99
50. Embryo W <sub>t</sub> , 23 mm. Long.—( <i>His</i> ), .....	100
51. Head of Embryo of 6.9 mm.—( <i>His</i> ), .....	102
52. Face of Embryo of 8 mm.—( <i>His</i> ), .....	103
53. Face of Embryo after the Completion of the Upper Jaw.—( <i>His</i> ),	104
54. Embryo 1.34 mm. Long.—( <i>Eternod</i> ), .....	113
55. Diagram of a Longitudinal Section through an Embryo of 1.54 mm.—( <i>von Spée</i> ), .....	114
56. Diagrams showing the Manner of the Closure of the Medullary Groove, .....	115
57. Transverse Sections through Mole Embryos, showing the Formation of the Notochord.—( <i>Heape</i> ), .....	116
58. Transverse Section through the Second Mesodermic Somite of a Sheep Embryo 3 mm. Long.—( <i>Bonnet</i> ), .....	118

LIST OF ILLUSTRATIONS.

ix

FIG.	PAGE.
59. Transverse Section of an Embryo of 2.5 mm. (See Fig. 42) showing on either side of the Medullary Canal a Mesodermic Somite, the Intermediate Cell-mass, and the Ventral Mesoderm.—( <i>von Lenhossek</i> ),.....	119
60. Transverse Section of an Embryo of 4.25 mm. at the Level of the Arm Rudiment.—( <i>Kollmann</i> ),.....	121
61. Diagrams Illustrating the History of the Gastral Mesoderm.—( <i>Modified from Kollmann</i> ),.....	125
62. Diagrams Illustrating the Formation of the Amnion and Allantois in the Chick.—( <i>Gegenbaur</i> ),.....	129
63. Diagrams Illustrating the Formation of the Umbilical Cord, ..	132
64. Transverse Section through the Belly-stalk of an Embryo of 2.15 mm.—( <i>His</i> ), .....	137
65. Transverse Sections of the Umbilical Cord of Embryos of (A) 1.8 cm. and (B) 25 cm.....	140
66. Two Diagrams Illustrating the Formation of Chorionic Villi.—( <i>Peters</i> ), .....	142
67. Two Villi from the Chorion of an Embryo of 7 mm.,.....	143
68. Transverse Sections through Chorionic Villi in (A) the Fifth and (B) the Seventh Month of Development.—( <i>A, which is more highly magnified than B, from Szymonowicz, B from Minot</i> ), .....	144
69. Mature Placenta after Separation from the Uterus.—( <i>Kollmann</i> ), .....	146
70. Section through the Placental Chorion of an Embryo of Seven Months.—( <i>Minot</i> ), .....	147
71. Diagram showing the Relations of the Fetal Membranes,.....	148
72. Surface View of Half of the Decidua Vera at the End of the Third Week of Gestation.—( <i>Kollmann</i> ),.....	149
73. Diagrammatic Sections of the Uterine Mucosa, A, in the Non-pregnant Uterus, and B, at the Beginning of Pregnancy.—( <i>Kundrat and Engelmann</i> ),.....	150
74. Section of an Ovum of 1 mm. A Section of the Embryo Lies in the Lower Part of the Cavity of the Ovum.—( <i>From Strahl, after Peters</i> ),.....	152
75. Section through a Placenta of Seven Months' Development.—( <i>Minot</i> ), .....	154
76. Diagrammatic Section through the Human Placenta at the Middle of the Fifth Month.—( <i>From Hertwig, after Leopold</i> ), <i>Colored,</i> .....	157
77. A, Section of Skin from the Dorsum of Finger of an Embryo of 4.5 cm.; B, from the Plantar Surface of the Foot of an Embryo of 10.2 cm.,.....	162
78. Diagram showing the Cutaneous Distribution of the Spinal Nerves.—( <i>Head</i> ), .....	163
79. Diagram showing the Overlap of the III, IV, and V Intercostal Nerves of a Monkey.—( <i>Sherrington</i> ),.....	164
80. Longitudinal Section through the Terminal Joint of the Index-finger of an Embryo of 4.5 cm.,.....	165
81. Longitudinal Section through the Nail Area in an Embryo of 17 cm.—( <i>Okamura</i> ),.....	166
82. The Development of a Hair.—( <i>Kollmann</i> ),.....	167
83. Lower Surface of a Detached Portion of Epidermis from the Dorsum of the Hand.—( <i>Bluschko</i> ), .....	169
84. Milk Ridge ( <i>nr</i> ) in a Human Embryo.—( <i>Kallius</i> ),.....	170

FIG.	PAGE.
85. Sections through the Epidermal Thickenings which Represent the Mammary Gland in Embryos (A) of 6 cm. and (B) of 10.2 cm.,.....	171
86. Section through the Mammary Gland of an Embryo of 25 cm.—(From Nagel, after Basch),.....	172
87. Portion of the Center of Ossification of the Parietal Bone of a Human Embryo,.....	175
88. Longitudinal Section of Phalanx of a Finger of an Embryo of 3½ Months.—(Szymonowicz),.....	176
89. The Ossification Center of Fig. 88 More Highly Magnified.—(Szymonowicz),.....	177
90. The Ossification Centers of the Femur.—(Testut),.....	179
91. A, Transverse Section of the Femur of a Pig Killed after Having Been Fed with Madder for Four Weeks; B, the Same of a Pig Killed Two Months after the Cessation of the Madder Feeding.—(After Flourens),.....	180
92. Transverse Section through the Intervertebral Plate of the First Cervical Vertebra of a Calf Embryo of 8.8 mm.—(Froriep),.....	181
93. Longitudinal Section through the Occipital Region and Upper Cervical Vertebrae of a Calf Embryo of 18.5 mm.—(Froriep),.....	182
94. A, A Vertebra at Birth; B, Lumbar Vertebra showing Secondary Centers of Ossification.—(Sappey),.....	186
95. A, Upper Surface of the First Sacral Vertebra, and B, Ventral View of the Sacrum showing Primary Centers of Ossification.—(Sappey),.....	187
96. Formation of the Sternum in an Embryo of about 3 cm.—(Ruge),.....	189
97. Sternum of New-born Child, showing Centers of Ossification.—(Gegenbaur),.....	190
98. Reconstruction of the Chondrocranium of an Embryo of 14 mm.—(Levi),.....	191
99. Frontal Section through the Occipital and Upper Cervical Regions of a Calf Embryo of 8.7 mm.—(Froriep),.....	193
100. Diagram showing the Five Branchial Cartilages, I to V,.....	194
101. Occipital Bone of a Fetus at Term,.....	196
102. Sphenoid Bone from Embryo of 3½ to 4 Months.—(Sappey),.....	197
103. Anterior Portion of the Base of the Skull of a 6 to 7 Months' Embryo.—(After von Spee),.....	198
104. The Temporal Bone at Birth. The Styloid Process and Auditory Ossicles are not Represented.—(Poirier),.....	200
105. Diagram of the Ossifications of which the Maxilla is Composed, as seen from the Outer Surface. The Arrow Passes through the Infraorbital Canal.—(From von Spee, after Sappey),.....	203
106. Diagram showing the Categories to which the Bones of the Skull Belong,.....	205
107. The Ossification Centers of the Scapula.—(Testut),.....	207
108. Reconstruction of an Embryonic Carpus,.....	209
109. The Ossification Centers of the Os Innominatum.—(Testut),.....	210
110. Longitudinal Section through the Joint of the Great Toe in an Embryo of 4.5 cm.—(Nicolas),.....	213
111. Cross-sections of Heart-muscle Cells from Pig Embryos of (A) 10 mm. and (B and C) 20 mm.—(Macallum).....	217
112. Cross-section of a Muscle from the Thigh of a Pig Embryo 75 mm. Long.—(Macallum),.....	218

## LIST OF ILLUSTRATIONS.

xi

FIG.		PAGE.
113.	Embryo of 13 mm. showing the Formation of the Rectus Muscle.—( <i>Mall</i> ), .....	223
114.	Perineal Region of Embryos of (A) Two Months and (B) Four to Five Months, showing the Development of the Perineal Muscles.—( <i>Popowsky</i> ), .....	227
115.	Head of Embryos (A) of Two Months and (B) of Three Months showing the Extension of the Seventh Nerve upon the Face.—( <i>Popowsky</i> ), .....	230
116.	Diagram of a Segment of the Body and Limb.—( <i>Kollmann</i> ), ..	234
117.	External Surface of the Os Innominatum showing the Attachment of Muscles and the Zones Supplied by the Various Nerves.—( <i>Bolk</i> ), .....	235
118.	Sections through (A) the Thigh and (B) the Calf showing the Zones Supplied by the Nerves. The Nerves are Numbered in Continuation with the Thoracic Series.—( <i>A after Bolk</i> ), ..	236
119.	Section through the Upper Part of the Arm showing the Zones Supplied by the Nerves.—( <i>Bolk</i> ), .....	237
120.	Transverse Section through the Area Vasculosa of Rabbit Embryos showing the Transformation of Mesoderm Cells into the Vascular Cords.—( <i>van der Stricht</i> ), .....	241
121.	Surface View of a Portion of the Area Vasculosa of a Chick.—( <i>Disse</i> ), .....	242
122.	The Vascular Areas of Rabbit Embryos. In B the Veins are Represented by Black and the Network is Omitted.—( <i>van Bcneden and Julin</i> ), .....	243
123.	Section of a Portion of the Liver of a Rabbit Embryo of 5 mm.—( <i>van der Stricht</i> ), .....	245
124.	Stages in the Transformation of an Erythrocyte into an Erythroplastid.—( <i>van der Stricht</i> ), .....	245
125.	Portion of a Section from the Liver of an Embryo Cat of 2.7 mm. showing a Megacaryocyte Surrounded by Erythrocytes in a Blood-vessel.—( <i>Howell</i> ), .....	247
126.	Diagrams Illustrating the Formation of the Heart in the Guinea-pig.—( <i>After Strahl and Carius</i> ), .....	249
127.	Heart of Embryo of 2.15 mm., from a Reconstruction.—( <i>His</i> ), ..	250
128.	Heart of Embryo of 4.2 mm. seen from the Dorsal Surface.—( <i>His</i> ), .....	250
129.	Heart of Embryo of 5 mm., seen from in Front and Slightly from Above.—( <i>His</i> ), .....	251
130.	Inner Surface of the Heart of an Embryo of 10 mm.—( <i>His</i> ), ..	252
131.	Heart of Embryo of 10.2 cm. from which Half of the Right Auricle has Been Removed, .....	253
132.	Section through a Reconstruction of the Heart of a Rabbit Embryo of 10.1 mm.—( <i>Born</i> ), .....	255
133.	Diagrams of Sections through the Heart of Embryo Rabbits to show the Mode of Division of the Ventricles and of the Auriculo-ventricular Orifice, .....	257
134.	Diagrams showing the Development of the Auriculo-ventricular Valves.—( <i>From Hertwig, after Gegenbaur</i> ), .....	258
135.	Diagrams Illustrating the Formation of the Semilunar Valves.—( <i>Gegenbaur</i> ), .....	259
136.	Reconstruction of Embryo of 2.6 mm.—( <i>His</i> ), .....	261
137.	Diagram Illustrating the Arrangement of the Branchial Vessels, ..	262
138.	Arterial System of an Embryo of 10 mm.—( <i>His</i> ), .....	264



FIG.		PAGE.
139.	Diagram Illustrating the Changes in the Arrangement of the Branchial Arch Vessels,.....	265
140.	Diagram showing the Relations of the Lateral Branches to the Aortic Arches,.....	266
141.	Diagram Illustrating the Development of the Umbilical Arteries,.....	267
142.	The Development of the Vertebral Artery in a Rabbit Embryo of Twelve Days.—( <i>Hochstetter</i> ),.....	269
143.	Embryo of 13 mm. showing the Mode of Development of the Internal Mammary and Deep Epigastric Arteries.—( <i>Mall</i> ),.....	270
144.	Diagrams showing an Early and a Late Stage in the Development of the Arteries of the Arm,.....	273
145.	Diagrams Illustrating Stages in the Development of the Arteries of the Leg,.....	275
146.	Reconstruction of the Head Veins of Guinea-pig Embryos.—( <i>Salzer</i> ),.....	278
147.	Diagrams showing the Development of the Superior Vena Cava,.....	279
148.	Diagrams Illustrating the Transformations of the Omphalomesenteric and Umbilical Veins.—( <i>Hochstetter</i> ),.....	282
149.	A, The Venous Trunks of an Embryo of 5 mm. seen from the Ventral Surface; B, Diagram Illustrating the Transformation to the Adult Condition.—( <i>His</i> ),.....	283
150.	Diagrams Illustrating the Development of the Inferior Vena Cava,.....	285
151.	The Development of the Arm Veins in the Rabbit.—( <i>Hochstetter</i> ),.....	287
152.	The Fetal Circulation.—( <i>From Kollmann</i> ),..... Colored,	289
153.	Diagrams showing the Arrangement of the Lymphatic Vessels in Pig Embryos of (A) 20 mm. and (B) 40 mm.—( <i>Sabin</i> ),.....	292
154.	Developing Lymphatic Gland from the Axilla of an Embryo of Eleven Weeks.—( <i>Chievitz</i> ),.....	293
155.	Reconstruction of the Anterior Portion of an Embryo of 2.15 mm.—( <i>His</i> ),.....	297
156.	Reconstruction of the Hind End of an Embryo 6.5 mm. Long.—( <i>Kcibel</i> ),.....	298
157.	View of the Roof of the Oral Fossa of Embryo showing the Lip-groove and the Formation of the Palate.—( <i>His</i> ),.....	299
158.	Transverse Sections through the Lower Jaw showing the Formation of the Dental Shelf in Embryos of (A) 17 mm. and (B) 40 mm.—( <i>Rose</i> ),.....	301
159.	Section through the First Molar Tooth of a Rat, Twelve Days Old.—( <i>von Brunn</i> ),.....	303
160.	Floor of the Pharynx of Embryos of (A) 7 and (B) 10 mm. showing the Development of the Tongue.—( <i>His</i> ),.....	306
161.	The Floor of the Pharynx of an Embryo of about 20 mm.—( <i>His</i> ),.....	307
162.	Diagram of the Distribution of the Sensory Nerves of the Tongue.—( <i>Zander</i> ),.....	308
163.	An Oblique Section through the Mouth Cavity of an Embryo of about 16 to 17 mm.—( <i>His</i> ),.....	309
164.	The Floor of the Pharynx of an Embryo of 2.15 mm.—( <i>His</i> ),.....	311
165.	Reconstructions of the Branchial Epithelial Bodies of Embryos of (A) 14 mm. and (B) 26 mm.—( <i>Fourneux and Verdun</i> ),.....	313
166.	Thyroid, Thymus and Epithelial Bodies of a New-born Child.—( <i>Groschuff</i> ),.....	315
167.	Diagram showing the Origin of the Various Branchial Epithelial Bodies.—( <i>Kohn</i> ),.....	316

FIG.		PAGE.
168.	Reconstructions of the Digestive Tract of Embryos of (A) 4.2 mm. and (B) 5 mm.—( <i>His</i> ),	318
169.	Reconstruction of Embryo of 20 mm.—( <i>Mall</i> ),	320
170.	Reconstruction of the Intestine of an Embryo of 19 mm. The Figures on the Intestine Indicate the Primary Coils.—( <i>Mall</i> ),	321
171.	Representation of the Coilings of the Intestine in the Adult Condition. The Numbers indicate the Primary Coils.—( <i>Mall</i> ),	322
172.	Cæcum of Embryo of 10.2 cm.,	323
173.	Reconstruction of a Portion of the Intestine of an Embryo of 28 mm., showing the Longitudinal Folds from which the Villi are Formed.—( <i>Berry</i> ),	324
174.	Reconstructions of the Liver Outgrowths of Rabbit Embryos of (A) 5 mm. and (B) of 8 mm.—( <i>Hammar</i> ),	326
175.	Transverse Section through the Liver of an Embryo of Four Months.—( <i>Toldt and Zuckerkandl</i> ),	327
176.	Transverse Sections of Portions of the Liver of (A) a Fetus of Six Months and (B) a Child of Four Years.— <i>Toldt and Zuckerkandl</i> ),	328
177.	Injected Bile Capillaries of Pig Embryos of (A) 8 cm., (B) 16 cm., and (C) of Adult Pig.—( <i>Hendrickson</i> ),	329
178.	Reconstruction of the Pancreatic Outgrowths of an Embryo of 7.5 mm.—( <i>Hell</i> ),	331
179.	Reconstruction of a Rabbit Embryo of Eight Days, with the Pericardial Cavity Laid Open.—( <i>His</i> ),	335
180.	Transverse Sections of a Rabbit Embryo showing the Division of the Parietal Recesses by the Omphalo-mesenteric Veins.—( <i>Ravn</i> ),	336
181.	Reconstruction from a Rabbit Embryo of Nine Days showing the Septum Transversum from Above.—( <i>Ravn</i> ),	337
182.	Diagrams of (A) a Sagittal Section of an Embryo showing the Liver Enclosed within the Septum Transversum; (B) a Frontal Section of the Same; (C) a Frontal Section of a Later Stage when the Liver has Separated from the Diaphragm,	339
83.	Diagram showing the Position of the Diaphragm in Embryos of Different Ages.—( <i>Mall</i> ),	342
184.	Diagram showing the Arrangement of the Mesentery and Visceral Branches of the Abdominal Aorta in an Embryo of Six Weeks.—( <i>Toldt</i> ),	344
185.	Diagrams Illustrating the Development of the Great Omentum and the Transverse Mesocolon.—( <i>Hertwig</i> ),	345
186.	Diagrams Illustrating the Manner in which the Fixation of the Descending Colon (C) takes Place,	346
187.	Diagrams showing the Development of the Great Omentum and its Fusion with the Transverse Mesocolon.—( <i>After Allen Thomson</i> ),	348
188.	Section through the Left Layer of the Mesogastrium of a Chick Embryo of Ninety-three Hours, showing the Origin of the Spleen.—( <i>Tonkoff</i> ),	350
189.	Portion of a Section through an Embryo of the Fourth Week.—( <i>Toldt</i> ),	352
190.	Reconstruction of the Lung Outgrowths of Embryos of (A) 10, (B) 8.5, and (C) 10.5 mm.—( <i>His</i> ),	353

FIG.	PAGE.
191. Diagram of the Final Branches of the Mammalian Lymphatics.— ( <i>Miller</i> ), .....	355
192. Reconstruction of the Opening into the Larynx in an Embryo of Twenty-eight Days, Seen from Behind and Above, the Dorsal Wall of the Pharynx Being Cut Away.—( <i>Kallius</i> ),...	356
193. Reconstruction of the Mesenchyme Condensations which Represent the Hyoid and Thyreoid Cartilages in an Em- bryo of Forty Days.—( <i>Kallius</i> ), .....	357
194. Transverse Section through the Abdominal Region of a Rabbit Embryo of 12 mm.—( <i>Mihalkovicz</i> ), .....	360
195. Transverse Section through Chick Embryo of about Thirty-six Hours, .....	362
196. Transverse Section of the Wolffian Ridge of a Chick Embryo of Three Days.—( <i>Mihalkovicz</i> ), .....	364
197. Urinogenital Apparatus of a Male Pig Embryo of 6 cm.— ( <i>Mihalkovicz</i> ), .....	365
198. Diagrams of Early Stages in the Development of the Meta- nephric Tubules.—( <i>Hayeraft</i> ), .....	367
199. Three Stages in the Development of a Uriniferous Tubule of a Rabbit.—( <i>Hayeraft</i> ), .....	368
200. Transverse Section through the Abdominal Region of an Em- bryo of 25 mm.—( <i>Keibel</i> ), .....	370
201. Reproductive Organs of a Female Embryo of Six Months.— ( <i>Adapted from Mihalkovicz</i> ), .....	372
202. Section through the Testis and the Broad Ligament of the Testis of an Embryo of 5.5 mm.—( <i>Mihalkovicz</i> ), .....	373
203. Diagram of an Epithelial Invagination of the Ovary of a Rabbit. —( <i>von Winzwarter</i> ), .....	375
204. Section of the Ovary of a New-born Child.—( <i>From Gegenbaur,</i> <i>after Waldeyer</i> ), .....	375
205. Diagrams Illustrating the Transformations of the Müllerian and Wolffian Ducts.—( <i>Modified from Huxley</i> ), ... <i>Colored</i> ,	378
206. Reconstruction of the Cloacal Region of an Embryo of 14 mm.— ( <i>Keibel</i> ), .....	382
207. Reconstruction of the Cloacal Structures of an Embryo of 25 mm.—( <i>Adapted from Keibel</i> ), .....	383
208. The External Genitalia of an Embryo of 25 mm.—( <i>Keibel</i> ),...	385
209. Diagrams Illustrating the Descent of the Testis.—( <i>After</i> <i>Hertwig</i> ), .....	389
210. Section through a Portion of the Wolffian Ridge of a Rabbit Embryo of 6.5 mm.—( <i>Aichel</i> ), .....	391
211. Ependymal Cells from the Spinal Cord of an Embryo of 4.25 mm.—( <i>His</i> ), .....	395
212. Diagram showing the Development of the Mantle Layer in the Spinal Cord.—( <i>Schaper</i> ), .....	396
213. Three Sections through the Medullary Canal of an Embryo of 2.5 mm.—( <i>von Lenhossek</i> ), .....	397
214. Cells from the Gasserian Ganglion of a Guinea-pig Embryo.— ( <i>van Gehuchten</i> ), .....	398
215. Transverse Sections through the Spinal Cords of Embryos of ( <i>A</i> ) about Four and a Half Weeks and ( <i>B</i> ) about Three Months.—( <i>His</i> ), .....	402
216. Reconstruction of the Brain of an Embryo of 2.15 mm.—( <i>His</i> ),	404
217. Median Longitudinal Section of the Brain of an Embryo of the Third Month.—( <i>His</i> ), .....	406

FIG.		PAGE.
218.	Transverse Section through the Medulla Oblongata of an Embryo of 9.1 mm.—( <i>His</i> ),	408
219.	Transverse Section through the Medulla Oblongata of an Embryo of about Eight Weeks.—( <i>His</i> ),	409
220.	A, Dorsal View of the Brain of a Rabbit Embryo of 16 mm.; B, Median Longitudinal Section of a Calf Embryo of 3 cm.— ( <i>Mihalkovicz</i> ),	411
221.	Diagram Representing the Differentiation of the Cerebellar Cells.—( <i>Schafer</i> ),	412
222.	Transverse Section of the Thalamencephalon of an Embryo of Five Weeks.—( <i>His</i> ),	415
223.	Dorsal View of the Brain, the Roof of the Lateral Ventricles being Removed, of an Embryo of 13.6 mm.—( <i>His</i> ),	417
224.	Median Longitudinal Section of the Brain of an Embryo of 13.6 mm.—( <i>His</i> ),	419
225.	Median Longitudinal Section of the Brain of an Embryo Calf of 5 cm.—( <i>Mihalkovicz</i> ),	421
226.	Brain of an Embryo of the Fourth Month,	423
227.	Cerebral Hemisphere of an Embryo of about the Seventh Month.—( <i>Cunningham</i> ),	425
228.	Median Longitudinal Section of the Brain of an Embryo of Three Months.—( <i>Mihalkovicz</i> ),	426
229.	Median Longitudinal Section of the Brain of an Embryo of the Fifth Month.—( <i>Mihalkovicz</i> ),	427
230.	Transverse Section through the Medulla Oblongata of an Embryo of 10 mm., showing the Nuclei of Origin of the Vagus (X) and Hypoglossal (XII) Nerves.—( <i>His</i> ),	432
231.	Diagram showing the Sensory Components of the Cranial Nerves of a Fish ( <i>Menidia</i> ).—( <i>Herrick</i> ),	436
232.	Transverse Section through an Embryo Shark ( <i>Scyllium</i> ) of 15 mm., showing the Origin of a Sympathetic Ganglion.—( <i>Onodi</i> ),	442
233.	Diagram showing the Arrangement of the Neurones of the Sympathetic System.—( <i>Adapted from Huber</i> ),	443
234.	Transverse Section through the Spinal Cord of an Embryo of 7 mm.—( <i>His</i> ),	445
235.	Reconstruction of the Sympathetic System of an Embryo of 10.2 mm.—( <i>His, Jr.</i> ),	447
236.	Section of a Cell Ball from the Intercarotid Ganglion of Man.—( <i>From Bohm and Davidoff, after Schafer</i> ),	449
237.	Accessory Sympathetic Organs of Zuckerkandl from a New-born Child.—( <i>Zuckerkandl</i> ),	451
238.	Diagram Illustrating the Relations of the Fibers of the Olfactory Nerve.—( <i>Van Gehuchten</i> ),	456
239.	Diagrams Representing the Development of a Circumvallate Papilla.—( <i>Graberg</i> ),	458
240.	Transverse Section Passing through the Otocyst ( <i>ot</i> ) of Embryos of (A) 2.4 mm. and (B) 4 mm.—( <i>His</i> ),	460
241.	Reconstructions of the Otocysts of Embryos of (A) 6.9 mm. and (B) 10.2 mm.—( <i>His, Jr.</i> ),	461
242.	Reconstruction of the Otocyst of an Embryo of 13.5 mm.—( <i>His, Jr.</i> ),	462
243.	Reconstruction of the Otocyst of an Embryo of 22 mm.—( <i>His, Jr.</i> ),	463

FIG.	PAGE.
244. The Right Internal Ear of an Embryo of Six Months.—( <i>Retzius</i> ),	465
245. Section of the Scala Media of the Cochlea of a Rabbit Embryo of 55 mm.—( <i>Baginsky</i> ),	466
246. Transverse Section through a Semicircular Canal of a Rabbit Embryo of Twenty-four Days.—( <i>Von Kolliker</i> ),	467
247. Diagrammatic Transverse Section through a Coil of the Cochlea, showing the Relations of the Scala.—( <i>From Gerlach</i> ),	468
248. Semi-diagrammatic View of the Auditory Ossicles of an Embryo of Six Weeks.—( <i>Siebenmann</i> ),	470
249. Diagrams Illustrating the Mode of Extension of the Tympanic Cavity Around the Auditory Ossicles,	471
250. Horizontal Section Passing through the Dorsal Wall of the External Auditory Meatus in an Embryo of 4.5 cm.—( <i>Siebenmann</i> ),	473
251. Stages in the Development of the Pinna.—( <i>His</i> ),	475
252. Early Stage in the Development of the Lens in a Rabbit Embryo.—( <i>Rabl</i> ),	477
253. Reconstruction of the Brain of an Embryo of Four Weeks, showing the Chorioid Fissure.—( <i>His</i> ),	478
254. Horizontal Section through the Eye of an Embryo Pig of 7 mm.,	479
255. Sections through the Lens ( <i>A</i> ) of Human Embryo of Thirty to Thirty-one Days and ( <i>B</i> ) of Pig Embryo of 36 mm.—( <i>Rabl</i> ),	481
256. Posterior (Inner) Surface of the Lens from an Adult showing the Sutural Lines.—( <i>Rabl</i> ),	482
257. Radial Section through the Iris of an Embryo of 19 em.—( <i>Szili</i> ),	485
258. Portion of a Transverse Section of the Retina of a New-born Rabbit.—( <i>Falchi</i> ),	487
259. Diagram showing the Development of the Retinal Elements.—( <i>Kallius, after Cajal</i> ),	488
260. Diagrammatic Longitudinal Section of the Optic Cup and Stalk passing through the Chorioid Fissure,	490
261. Transverse Sections through the Proximal Part of the Optic Stalk of Rat Embryos of ( <i>A</i> ) 9 mm. and ( <i>B</i> ) 11 mm.—( <i>Robinson</i> ),	491
262. Reconstruction of a Portion of the Eye of an Embryo of 13.8 mm.—( <i>His</i> ),	493
263. Transverse Section through the Ciliary Region of a Chick Embryo of Sixteen Days.—( <i>Angelucci</i> ),	494
264. Transverse Section through the Ciliary Region of a Pig Embryo of 23 mm.—( <i>Angelucci</i> ),	496
265. Section through the Margins of the Fused Eyelids in an Embryo of Six Months.—( <i>Schweigger-Seidl</i> ),	498
266. Child and Man Drawn to the Same Scale.—( <i>Langer, from the "Growth of the Brain," Contemporary Science Series, by permission of Charles Scribner's Sons</i> ),	502
267. Curves showing the Annual Increase in Weight in ( <i>I</i> ) Boys and ( <i>II</i> ) Girls.—( <i>Stephenson</i> ),	506
268. Longitudinal Section through the Sacrum of a New-born Female Child.—( <i>Fehling</i> ),	509
269. Skin of a New-born Child and of an Adult Man, Drawn to Approximately the Same Scale.—( <i>Henke</i> ),	512
270. Longitudinal Sections of the Head of the Femur of ( <i>A</i> ) New-born Child and ( <i>B</i> ) a Later Stage of Development.—( <i>Henke</i> ),	517

# THE DEVELOPMENT OF THE HUMAN BODY.

## INTRODUCTION.

A little more than sixty years ago (1839) one of the fundamental principles of biology was established by Schleiden and Schwann as the *cell theory*. According to this, all organisms are composed of one or more structural units termed *cells*, each of which, in multicellular organisms, maintains an individual existence and yet contributes with its fellows to the general existence of the individual. Viewed in the light of this theory, the human body is a community, an aggregate of many individual units, each of which leads to a certain extent an independent existence and yet both contributes to and shares in the general welfare of the community.

To the founders of the theory the structural units were vesicles with definite walls, and little attention was paid to their contents. Hence the use of the term "cell" in connection with them. Long before the establishment of the cell theory, however, the existence of organisms composed of a gelatinous substance showing no indications of a definite limiting membrane had been noted, and in 1835 a French naturalist, Dujardin, had described

the gelatinous material of which certain marine organisms (Rhizopoda) were composed, terming it sarcode and maintaining it to be the material substratum which conditioned the various vital phenomena exhibited by the organisms. Later, in 1846, a botanist, von Mohl, observed that living plant cells contained a similar substance, upon which he believed the existence of the cell as a vital structure was dependent, and he bestowed upon this substance the name *protoplasm*, by which it is now universally known.

By these discoveries the importance originally attributed to the cell-wall was greatly lessened and in 1864 Max Schultze reformulated the cell theory, defining the cell as a mass of protoplasm, the presence or absence of a limiting membrane or cell-wall being immaterial. At the same time the spontaneous origination of cells from an undifferentiated matrix, believed to occur by the older authors, was shown to have no existence, every cell originating by the division of a preëxisting cell, a fact concisely expressed in the aphorism of Virchow—*omnis cellula a cellulâ*.

Interpreted in the light of these results, the human body is an aggregate of myriads of cells,\*—*i. e.*, of masses of protoplasm, each of which owes its origin to the division of a preëxistent cell and all of which may be traced back to a single parent cell—a fertilized ovum. But all these cells are not alike, but just as in a social community one group of individuals devotes itself to the performance of one of the duties requisite to the well-being of the community and another group devotes itself to the performance of another duty, so too, in the body,

---

\* It has been estimated that the number of cells entering into the composition of the body of an adult human being is about twenty-six million five hundred thousand millions!

one group of cells takes upon itself one especial function and another another. There is, in other words, in the cell-community a *physiological division of labor*. Indeed, the comparison of the cell-community to the social community may be carried still further, for just as gradations of individuality may be recognized in the individual, the municipality, the state, and the republic, so too in the cell-community there are cells; *tissues*, each of which is an aggregate of similar cells; *organs*, which are aggregates of tissues, one, however, predominating and determining the character of the organ; and *systems*, which are aggregates of organs having correlated functions.

It is the province of embryology to study the mode of division of the fertilized ovum and the progressive differentiation of the resulting cells to form the tissues, organs, and systems. But before considering these phenomena as seen

in the human body it will be well to get some general idea of the structure of an animal cell.

This (Fig. 1), as has been already stated, is a mass of protoplasm, a substance which in the living condition is a viscous fluid resembling in many of its peculiarities egg-albumen, and like this being coagulated when heated or when exposed to the action of various chemical reagents. As to the structure of living protoplasm little is yet known, since the application of the reagents necessary for its accurate study and analysis results in its disintegration or coagulation. But even in the living cell it can be seen that the protoplasm is not a simple homogeneous substance. What is termed a *nucleus* is usually clearly

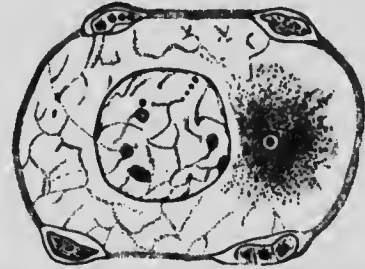


FIG. 1.—OVUM OF NEW-BORN CHILD WITH FOLLICLE-CELLS.—(Mertens.)



discernible as a more or less spherical body of a greater refractive index than the surrounding protoplasm, and since this is a permanent organ of the cell it is convenient to distinguish the surrounding protoplasm as the *cytoplasm* from the nuclear protoplasm or *karyoplasm*.

The study of protoplasm coagulated by reagents seems to indicate that it is a mixture of substances rather than a simple chemical compound. Both the cytoplasm and the karyoplasm consist of a more solid substance, the *reticulum*, which forms a network or felt-work, in the interstices of which is a more fluid material, the *enchylema*.\* The karyoplasm, in addition, has scattered along the fibers of its reticulum a peculiar material termed *chromatin* and usually contains embedded in its substance one or more spherical bodies termed *nucleoli*, which may be simply larger masses of chromatin or bodies of special chemical composition. And, finally, in all actively growing cells there is differentiated in the cytoplasm a peculiar body known as the *archoplasm sphere* in the center of which there is usually a minute spherical body termed the *centrosome*.

It has been already stated that new cells arise by the division of preëxisting ones, and this process is associated with a series of complicated phenomena which have great significance in connection with some of the problems of embryology. When such a cell as has been described above is about to divide, the fibers of the reticulum in the neighborhood of the archoplasm sphere arrange

\* It has been observed that certain coagulable substances and gelatin, when subjected to the reagents usually employed for "fixing" protoplasm, present a structure similar to that of protoplasm, and it has been held that protoplasm in the uncoagulated condition is, like these substances, a more or less homogeneous material. On the other hand, Bütschli maintains that living protoplasm has a foam-structure and is, in other words, an emulsion.

themselves so as to form fibrils radiating in all directions from the sphere as a center, and the archoplasm with its contained centrosome gradually elongates and finally divides, each portion retaining its share of the radiating fibrils, so that two *asters*, as the aggregate of centrosome,

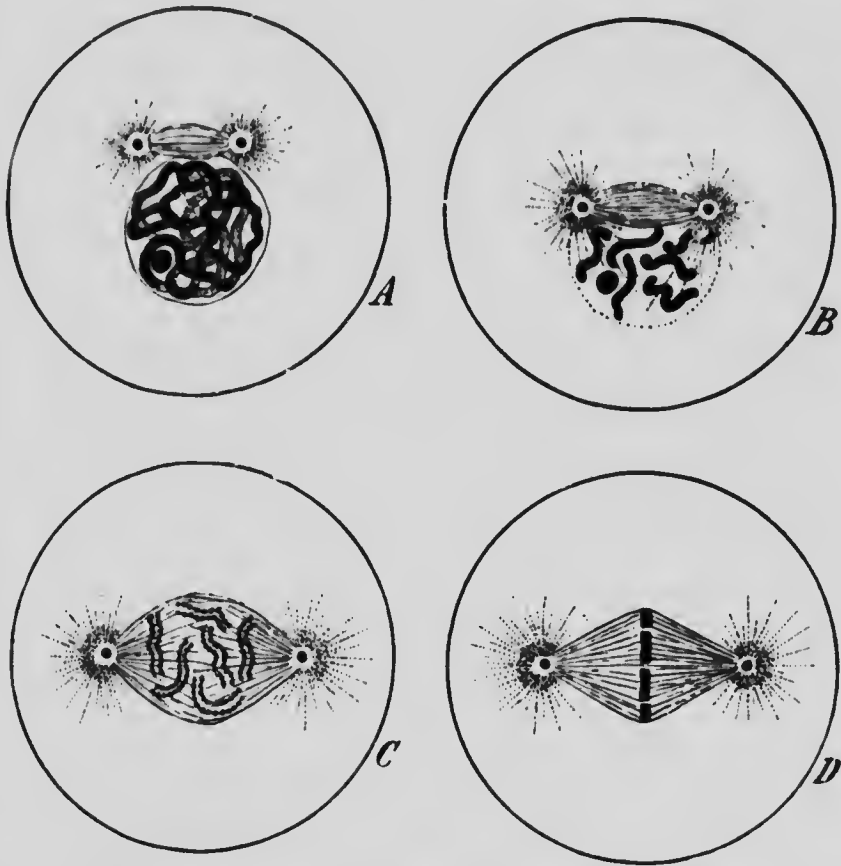


FIG. 2.—DIAGRAMS ILLUSTRATING THE PROPHASES OF MITOSIS.—  
(Adapted from E. B. Wilson.)

sphere, and fibrils is termed, are now to be found in the cytoplasm (Fig. 2, A). • Gradually the two asters separate from one another and eventually come to rest at opposite sides of the nucleus (Fig. 2, C). • In this structure im-

portant changes have been taking place in the mean time. The chromatin, originally scattered irregularly along the reticulum, has gradually aggregated to form a continuous thread (Fig. 2, A), and later this thread breaks up into a definite number of pieces termed *chromosomes* (Fig. 2, B), the number of these being practically constant for each species of animal. Thus, in the mouse, the salamander, and the trout the number of chromosomes is twenty-four; in the ox, the guinea-pig, and man it is sixteen; while in one of the round-worms (*Ascaris*) the number may be as small as four, or even two. It is to be noted that the number is always an even one.

As soon as the asters have taken up their position on opposite sides of the nucleus, the nuclear reticulum begins to be converted into a spindle-shaped bundle of fibrils which associate themselves with the astral rays and have lying scattered among them the chromosomes (Fig. 2, C). To the figure so formed the term *amphiaster* is applied, and soon after its formation the chromosomes arrange themselves in a circle or plane at the equator of the spindle (Fig. 2, D) and the stages preparatory to the actual division, the prophases, are completed.

The next stage, the metaphase (Fig. 3, A), consists of the division, usually longitudinally, of each chromosome, so that the cell now contains twice as many chromosomes as it did previously. As soon as this division is completed the anaphases are inaugurated by the halves of each chromosome separating from one another and approaching one of the asters (Fig. 3, B), and a group of chromosomes, containing half of the total number formed in the metaphase, comes to lie in close proximity to each archoplasm sphere (Fig. 3, C). The spindle and astral fibers gradually resolve themselves again into the reticulum and the chromosomes of each group become irregular

in shape and gradually spread out upon the nuclear reticulum so that two nuclei, each similar to the one from which the process started, are formed (Fig. 3, D). Before all these changes are accomplished, however, a

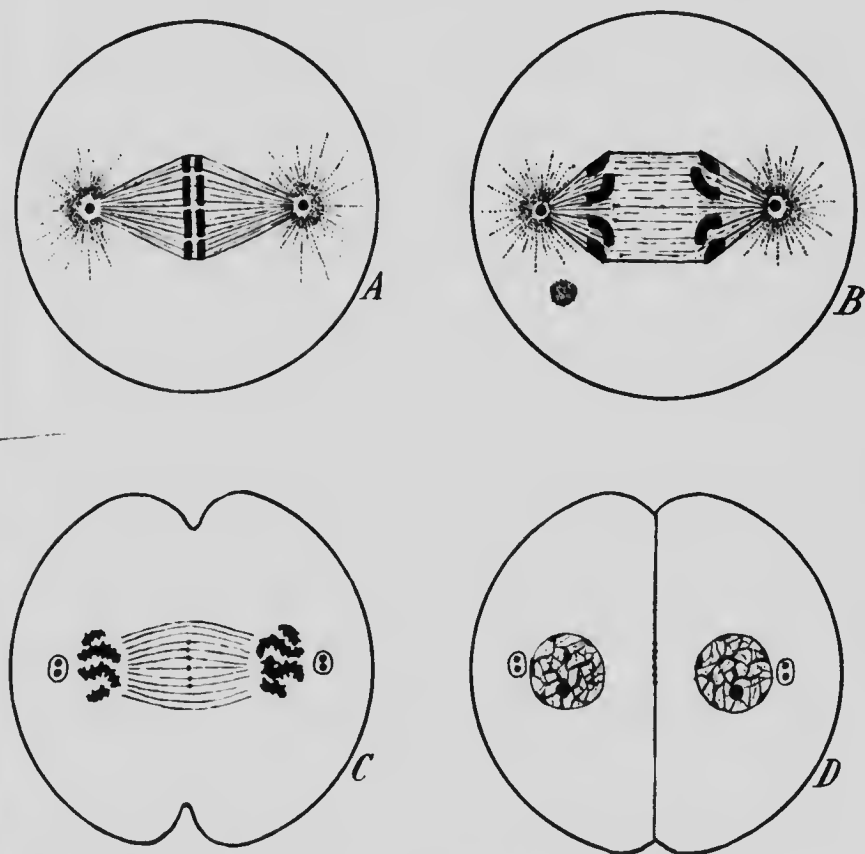
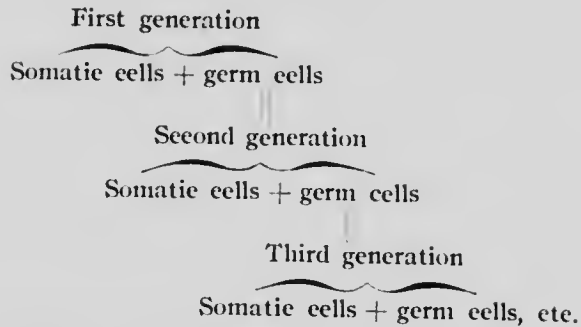


FIG. 3.—DIAGRAMS ILLUSTRATING THE METAPHASE AND ANPHASES OF MITOSIS.—(Adapted from E. B. Wilson.)

constriction makes its appearance at the surface of the cytoplasm (Fig. 3, C) and, gradually deepening, divides the cytoplasm in a plane passing through the equator of the amphiaser and gives rise to two separate cells (Fig. 3, D).

This complicated process, which is known as *karyokinesis* or *mitosis*, is the one usually observed in dividing cells, but occasionally a cell divides by the nucleus becoming constricted and dividing into two parts without any development of chromosomes, spindle, etc., the division of the cell following that of the nucleus. This amitotic method of division is, however, rare, and it seems probable that it occurs, as a rule, only in cells whose reproductive activities are becoming impaired. In actively reproducing cells the mitotic method of division may be regarded as the rule.

Since the process of development consists of the multiplication of a single original cell and the differentiation of the cell aggregate so formed, it follows that the starting-point of each line of individual development is to be found in a cell which forms part of an individual of the preceding generation. In other words, each individual represents one generation *in esse* and the succeeding generation *in posse*. This idea may perhaps be made clear by the following considerations. As a result of the division of a fertilized ovum there is produced an aggregate of cells, which, by the physiological division of labor, specialize themselves for various functions. Some assume the duty of perpetuating the species and are known as the sexual or germ cells, while the remaining ones divide among themselves the various functions necessary for the maintenance of the individual, and may be termed the somatic cells. The germ cells represent potentially the next generation, while the somatic cells constitute the present one. The idea may be represented schematically thus:



It is evident, then, while the somatic cells of each generation die at their appointed time and are differentiated anew for each generation from the germ cells, the latter, which may be termed collectively the *germ-plasm*, are handed on from generation to generation without interruption, and it may be supposed that this has been the case *ab initio*. This is the doctrine of the *continuity of the germ-plasm*, a doctrine of fundamental importance on account of its bearings on the phenomena of heredity.

It is necessary, however, to fix upon some link in the continuous chain of the germ-plasm as the starting-point of the development of each individual, and this link is the fertilized ovum. By this is meant a germ cell produced by the fusion of two units of the germ-plasm. In many of the lower forms of life (*e. g.*, *Hydra* and certain turbellarian worms) reproduction may be accomplished by a division of the entire organism into two parts or by the separation of a portion of the body from the parent individual. Such a method of reproduction is termed *non-sexual*. Furthermore in a number of forms (*e. g.*, bees, Phylloxera, water-fleas) the germ cells are able to undergo development without previously being fertilized, this constituting a method of reproduction known as *parthenogenesis*. But in all these cases *sexual reproduction* also occurs, and in all the more highly organized animals it is the only method which normally occurs;

in it a germ cell develops only after complete fusion with another germ cell. In the simpler forms of this process little difference exists between the two combining cells, but since it is, as a rule, of advantage that a certain amount of nutrition should be stored up in the germ cells for the support of the developing embryo until it is able to secure food for itself, while at the same time it is also advantageous that the cells which unite shall come from different individuals (cross-fertilization), and hence that the cells should retain their motility, a division of labor has resulted. Certain germ cells store up more or less food yolk, their motility becoming thereby impaired, and form what are termed the female cells or *ova*, while others discard all pretensions of storing up nutrition and are especially motile and can seek and penetrate the inert *ova*; these latter cells constitute the male cells or *spermatozoa*. In many animals both kinds of cells are produced by the same individual, but in all the vertebrates (with rare exceptions in some of the lower orders) each individual produces only *ova* or *spermatozoa*, or, as it is generally stated, the sexes are distinct.

It is of importance, then, that the peculiarities of the two forms of germ cells, as they occur in the human species, should be considered.

#### LITERATURE.

- E. B. WILSON: "The Cell in Development and Inheritance." Third edition. New York, 1900.
- O. HERTWIG: "Die Zelle und die Gewebe." Jena, 1893.

PART I.  
GENERAL DEVELOPMENT.

CHAPTER I.

THE SPERMATOZOÖN AND SPERMATOGENESIS; THE OVUM AND ITS MATURATION AND FERTILIZATION.

**The Spermatozoön.**—The human spermatozoön (Fig. 4) is a minute and greatly elongated cell, measuring about 0.05 mm. in length and consisting of an anterior broader portion or head (*k*) and a narrow thread-like tail (*f*). The head measures about 0.005 mm. in length and when viewed from one surface (Fig. 4, A) has an oval outline, though since it is somewhat flattened or concave toward the tip, it has a pyriform shape when seen in profile (Fig. 4, B). The tail consists of several portions. Situated immediately behind the head is a short cylindrical portion measuring 0.006 mm. in length which is termed the *middle-piece* or neck (*m*), and behind this is the *flagellum*, of about the same diameter as the middle-piece but forming about four-fifths (0.04 mm.) of the entire length of the spermatozoön. The axis of the flagellum is formed by a delicate filament which projects somewhat beyond the flagellum, forming what is termed the terminal filament or end-piece (*e*).

In addition to these various parts, the spermatozoa of many mammalia possess a *head-cap* (Fig. 5, *hc*) covering the anterior



end of the head and a *spiral membrane* wound around the flagellum. The presence of these structures has not yet been generally observed in the human spermatozoön, though several observers have claimed the existence of a spiral membrane,



FIG. 4.—HUMAN SPERMATOZOÖN.  
1, Front view, 2, side view of the head; e, terminal filament; k, head; f, tail; m, middle-piece.  
(After Retzius.)

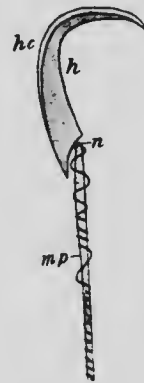


FIG. 5.—SPERMATOZOÖN OF RAT.  
h, Head; hc, head-cap; mp, middle-piece; n, neck.—(Jensen.)

and the head-cap undoubtedly exists in the earlier stages of the development of the spermatozoön, though it may later be lost.

To understand the significance of the various parts entering into the composition of the spermatozoön a study of their development is necessary, and since the various processes of spermatogenesis have been much more accurately observed in such mammalia as the rat

and guinea-pig than in man, the description which follows will be based on what has been described as occurring in these forms. From what is known of the spermatogenesis in man it seems certain that it closely resembles that of these mammals so far as its essential features are concerned.

**Spermatogenesis.**—The spermatozoa are developed from the cells which line the interior of the seminiferous tubules of the testis. The various stages of development cannot

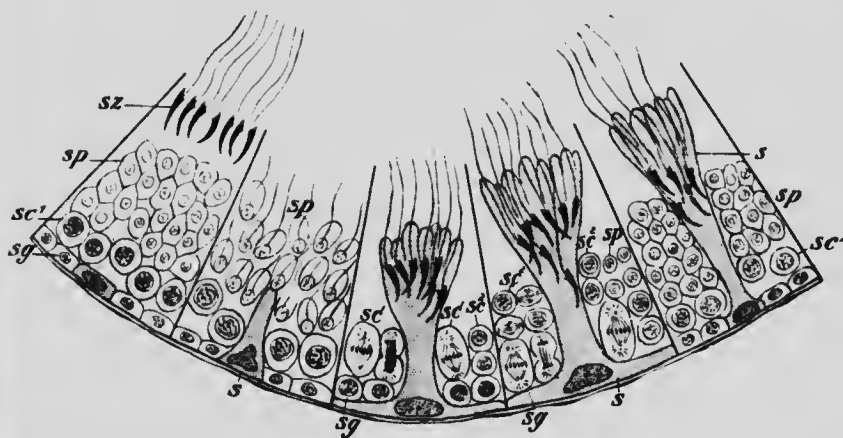


FIG. 6.—DIAGRAM SHOWING STAGES OF SPERMATOGENESIS AS SEEN IN DIFFERENT SECTORS OF A SEMINIFEROUS TUBULE OF A RAT. *s*, Sertoli cell; *sc*<sup>1</sup>, spermatocyte of the first order; *sc*<sup>2</sup>, spermatocyte of the second order; *sg*, spermatogone; *sp*, spermatid; *sz*, spermatozoon —(Modified from von Lenhossek.)

all be seen at any one part of a tubule, but the formation of the spermatozoa seems to pass along each tubule in a wave-like manner and the appearances presented at different points of the wave may be represented diagrammatically as in Fig. 6.

In the first section of this figure four different generations of cells are represented; above are mature spermatozoa lying in the lumen of the tubule, while next the

basement membrane is a series of cells from which a new generation of spermatozoa is about to develop. The cells of this series are of two kinds; the larger one (*s*) will develop into a structure known as a *Sertoli cell*, while the others are parent cells of spermatozoa and are termed *spermatogonia* (*sg*). In the next section the Sertoli cell is seen to have become considerably enlarged, its cytoplasm projecting toward the lumen of the tubule, and in the third section the enlargement has increased to such an extent that the spermatogonia are forced away from the basement membrane, with which the Sertoli cell alone is in contact. In the fourth section the spermatogonia are seen in process of division; one of the cells so formed will persist as a spermatogone, while the other forms what is termed a *primary spermatocyte* (*sc*<sup>1</sup>). The results of the division are seen in the last section, where four spermatogonia are seen again in contact with the basement membrane and above them are four primary spermatocytes. Returning now to the first and second sections, the layer of primary spermatocytes may still be seen, indications of an approaching division being furnished by the arrangement of the chromatin in those of the second section, and in the third section the division is seen in progress, the two cells which result from it being termed *secondary spermatocytes* (*sc*<sup>2</sup>). These cells almost immediately undergo division, as shown in the fourth section, each giving rise to two *spermatids* (*sp*), each of which becomes later on directly transformed into a spermatozoon (*sz*). From the primary spermatocyte there have been formed, therefore, as the result of two mitoses, four cells, each of which represents a spermatozoon.

During these divisions important departures from the typical method of mitosis occur. These departures

have been most thoroughly studied in the lower forms, but it is probable that they are fundamentally similar in the mammalia. It has already been pointed out (p. 22) that the number of chromosomes which appear dur-

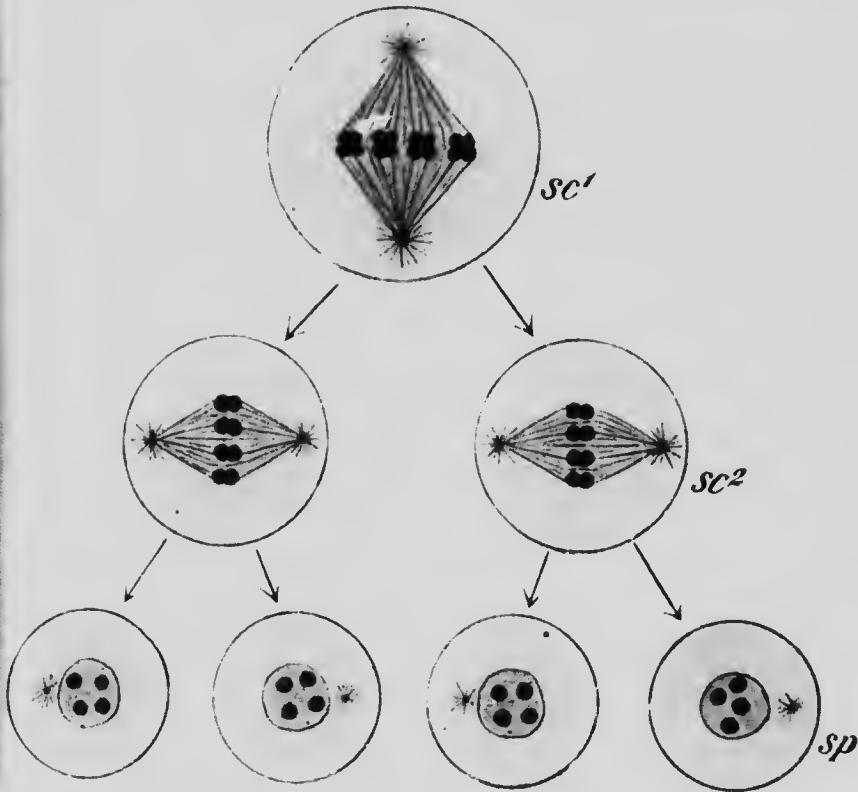


FIG. 7.—DIAGRAM ILLUSTRATING THE REDUCTION OF THE CHROMOSOMES DURING SPERMATOGENESIS.

*sc*<sup>1</sup>, Spermatocyte of the first order; *sc*<sup>2</sup>, spermatocyte of the second order; *sp*, spermatid.

ing the mitoses of the somatic cells is characteristic for the species. In the division of the primary spermatocytes the number of chromosomes which appear is apparently only half the characteristic number, but in reality it is double that number, since each chromosome is

really composed of four elements more or less closely united to form a *tetrad*. During the mitosis each tetrad divides into two *dyads*, one of which passes into each secondary spermatocyte, and these cells undergoing

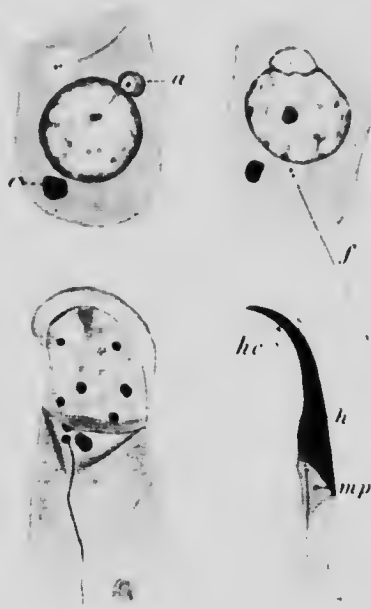

FIG. 8.—FOUR STAGES IN THE TRANSFORMATION OF A SPERMATID INTO THE SPERMATOZOON OF A RAT.

*a*, Archoplasm; *c*, mass of chromatin which is later absorbed; *f*, axial filament; *h*, head; *hc*, head-cap; *mp*, middle-piece.—(von Lenhossek.)

division without the usual reconstruction of the nucleus, each of the dyads which they contain is halved, so that each spermatid receives a number of single chromosomes equal to half the number characteristic for the species. This *reduction of the chromosomes* of the germ cells may be understood from the annexed diagram (Fig. 7), which represents the spermatogenesis of a form whose somatic cells are supposed to contain eight chromosomes.

The transformation of the spermatids into spermatozoa takes place while they are in intimate association with the Sertoli cells, a number of them fusing with the cytoplasm of an enlarged Sertoli cell, as shown in Fig. 6, *s*, and probably receiving nutrition from it. In each spermatid there is present, in addition to the nucleus, an archoplasm sphere from which the centrosomes have migrated so as to lie free in the cytoplasm. The details of the transformation are still to a certain extent under discussion, the view here presented being only one of the

many which have been advanced within recent years. On the fusion of the spermatid with a Sertoli cell, a delicate filament (Fig. 8, *f*), the beginning of the axial filament of the spermatozoon, appears in its cytoplasm, seeming to rise from the centrosome which lies at one end of it. The archoplasm sphere (*a*) and centrosome migrate to opposite sides of the nucleus, which gradually assumes an excentric position, and the archoplasm becomes converted into the head-cap (*hc*) while the centrosomes enlarging form the anterior portion or neck of the middle-piece (*mp*), the remainder of that structure being formed from the axial filament surrounded by a cytoplasmic sheath. As the axial filament lengthens the cytoplasm is drawn out with it to form its sheath, the terminal portion of the filament only projecting beyond the sheath to form the end-piece, and the cytoplasm surrounding the nucleus becomes reduced to an exceedingly delicate layer, so that the head of the spermatozoon (*h*) consists almost entirely of nuclear substance if the head-cap be left out of consideration.

The homologies of the parts of the spermatozoon with those of the spermatid may be presented in tabular form thus:

SPERMATID.	SPERMATOZOÖN.
Nucleus	Head.
Archoplasm.	Head-cap.
Centrosome.	Neck of middle-piece.
	{ Axial filament.
Cytoplasm.	{ Sheath of middle-piece.
	{ Sheath of tail.

The spermatozoon is, then, one of four equivalent cells, produced by two successive divisions of a primary spermatocyte and containing one-half the number of chromosomes characteristic for the species.

**The Ovum.**—The human ovum is a spherical cell meas-

uring about 0.2 mm. in diameter and is contained within a cavity situated near or at the surface of the ovary and termed a *Graafian follicle*. This follicle is surrounded by a capsule composed of two layers, an outer one, the *theca externa*, consisting of fibrous tissue resembling that found

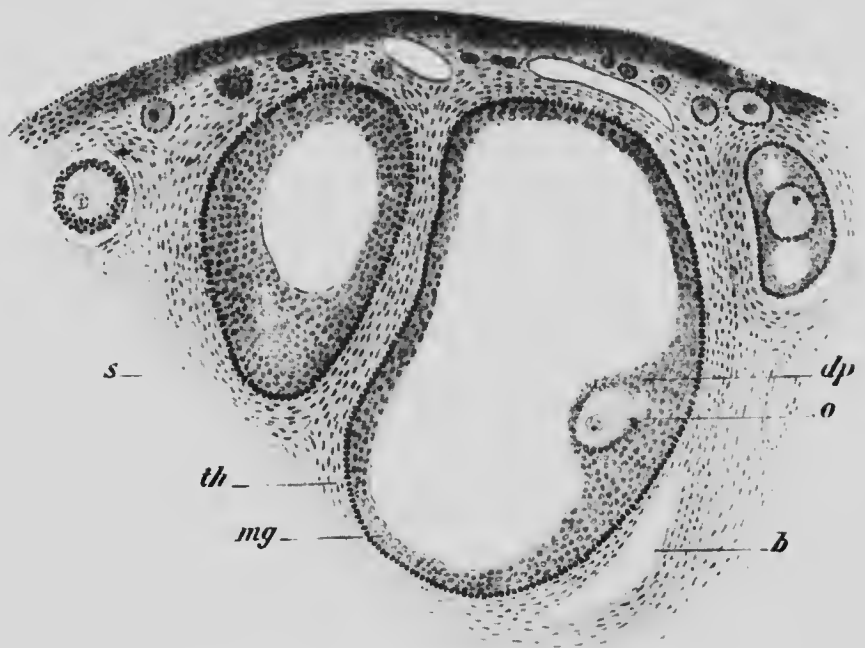


FIG. 9.—SECTION THROUGH PORTION OF AN OVARY OF AN OPOSSUM (*Didelphys virginiana*) SHOWING OVA AND FOLLICLES IN VARIOUS STAGES OF DEVELOPMENT.

*b*, Blood-vessel; *dp*, discus proligerus; *mg*, stratum granulosum; *o*, ovum; *s*, stroma; *th*, theca folliculi.

in the ovarian stroma, and an inner one, the *theca interna*, composed of numerous spherical and fusiform cells. Both the thecæ are richly supplied with blood-vessels, the theca interna especially being the seat of a very rich capillary network. Internal to the theca interna there is a transparent, thin, and structureless *hyaline membrane*, within

which is the follicle proper, whose wall is formed by a layer of cells termed the *stratum granulosum* (Fig. 9, *mg*) and inclosing a cavity filled with an albuminous fluid, the *liquor folliculi*. At one point, usually on the surface nearest the center of the ovary, the stratum granulosum

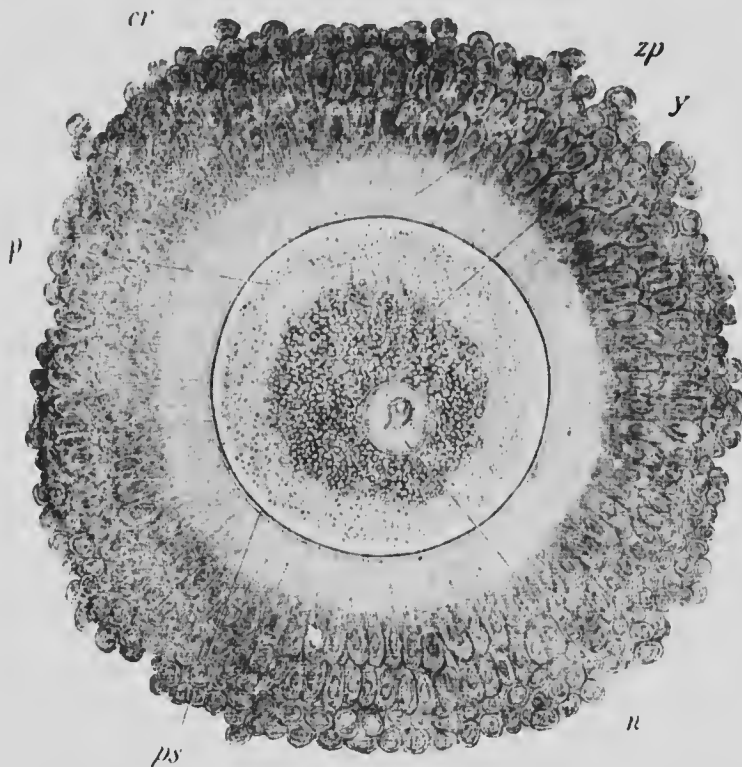


FIG. 10.—OVUM FROM OVARY OF A WOMAN THIRTY YEARS OF AGE. *cr*, Corona radiata; *n*, nucleus; *p*, protoplasmic zone of ovum; *ps*, perivitelline space; *y*, yolk; *zp*, zona pellucida.—(Nagel.)

is greatly thickened to form a mass of cells, the *discus proligerus* (*dp*), which projects into the cavity of the follicle and encloses the ovum (*o*). Usually but a single ovum is contained in any discus, though occasionally two or even three may occur.



The cells of the discus proligerus are for the most part more or less spherical or ovoid in shape and are arranged irregularly. In the immediate vicinity of the ovum, however, they are more columnar in form and are arranged in about two concentric rows, thus giving a somewhat radiated appearance to this portion of the discus, which is termed the *corona radiata* (Fig. 10, *cr*). Immediately within the corona is a transparent membrane, the *zona pellucida* (Fig. 10, *zp*), about as thick as one of the cells of the corona (0.02 to 0.024 mm.), and presenting a very fine radial striation which has been held to be due to minute pores traversing the membrane and containing delicate prolongations of the cells of the corona radiata. Within the zona pellucida is the ovum proper, whose cytoplasm is more or less clearly differentiated into an outer more purely protoplasmic portion (Fig. 10, *p*) and an inner deutoplasmic mass (*y*) which contains numerous fine granules of fatty and albuminous natures. These granules represent the food yolk or deutoplasm, which is usually much more abundant in the ova of other mammals and forms a mass of relatively enormous size in the ova of birds and reptiles. The nucleus of the ovum (*n*) is situated somewhat eccentrically in the deutoplasmic portion of the ovum and contains a single, well-defined nucleolus.

A follicle with the structure described above and containing a fully grown ovum may measure anywhere from five to twelve millimeters in diameter, and is said to be "mature," having reached its full development and being ready to burst and set free the ovum. This, however, is not yet mature; it is not ready for fertilization, but must first undergo certain changes similar to those through which the spermatoeyte passes, the so-called ovum at this stage being more properly a primary oöeyte. But before

describing the phenomena of maturation of the ovum it will be well to consider the extrusion of the ovum and the changes which the follicle subsequently undergoes.

**Ovulation and its Relation to Menstruation.**—As a rule, but a single follicle near maturity is found in either the one or the other ovary at any given time. In the early stages of its development a follicle is situated somewhat deeply in the stroma of the ovary, but during its growth it approaches the surface and eventually forms a marked prominence, only an exceedingly thin membrane separating the cavity of the follicle from the abdominal cavity. This thin membrane finally ruptures, and the liquor folliculi, which is apparently under some pressure while contained within the follicle, rushes out through the rupture, carrying with it the ovum surrounded by some of the cells of the discus proligerus.

The immediate cause of the bursting of the follicle is not yet clearly understood. It has been suggested that a gradual increase of the liquor folliculi under pressure must in itself finally lead to a rupture, and it has also been pointed out that just before the maturation of the follicle the theca interna undergoes an exceedingly rapid development and vascularization which may play an important part in the phenomenon.

Normally the ovum when expelled from its follicle is received at once into the Fallopian tube, and so makes its way to the uterus, in whose cavity it undergoes its development. Occasionally, however, this normal course may be interfered with, the ovum coming to rest in the tube and there undergoing its development and producing a tubal pregnancy; or, again, the ovum may not find its way into the Fallopian tube, but may fall from the follicle into the abdominal cavity, where, if it has been fertilized, it will undergo development, producing an abdominal

pregnancy; and, finally, and still more rarely, the ovum may not be expelled when the Graafian follicle ruptures and yet may be fertilized and undergo its development within the follicle, bringing about what is termed an ovarian pregnancy. All these varieties of extra-uterine pregnancy are, of course, exceedingly serious, since in none of them is the fetus viable.

It was long believed that ovulation was coincident with certain periodic changes of the uterus which constitute what is termed menstruation. This phenomenon makes its appearance at the time of puberty, the exact age at which it appears being determined by individual and racial peculiarities and by climate and other factors, and after it has once appeared it normally recurs at definite intervals more or less closely corresponding with lunar months (*i. e.*, at intervals of about twenty-eight days, the extremes being from twenty-four to thirty-four days) until somewhere in the neighborhood of the fortieth or forty-fifth year, when it ceases.

The structural changes associated with menstruation consist of a preliminary thickening of the walls of the uterus, its mucous membrane and the subjacent tissue becoming highly vascular and eventually congested. Later the walls of the blood-vessels degenerate and permit of an escape of blood here and there beneath the mucous membrane which, in the areas overlying the effused blood, undergoes a fatty degeneration and is desquamated, allowing of the formation of a blood-clot in the cavity of the uterus. The hemorrhagic portion of the process lasts usually from three to five days; at its close a regeneration of the lost portions of the mucous membrane begins, and when this is completed a resting period ensues which persists until near the time of a new menstrual period.

The local structural changes of the uterus are associated

with decided constitutional disturbances. The pulse, blood-pressure, temperature, muscular power, and lung capacity are in general somewhat increased before menstruation and sink immediately before or at the time when the hemorrhage in the uterus begins; immediately before the menstrual period there is also a diminished destruction of the nitrogenous materials of the body, as shown by the amount of nitrogen excreted being less than at other times.

These general changes may well affect the ovary as well as other portions of the body and so contribute to a coincidence of menstruation and ovulation. And, indeed, there seems little question but that the coincidence is of frequent or even usual occurrence. The appearance of menstruation indicates, as a rule, the beginning of fertility, and sterility ensues at the time of the final cessation of the menses. Furthermore, menstruation ceases when pregnancy supervenes, and the cessation persists not only until parturition, but so long as the child remains unweaned, and as a rule ovulation is also in abeyance during the same period. Exceptions, however, have been observed which show that the coincidence of the two phenomena is not invariable, pregnancy, for example, having occurred in young girls who had not yet menstruated, and in forty-two operated cases in which the ovaries and uterus had been removed after menstruation, twelve showed no signs of ovulation as determined by the presence of recently ruptured follicles in the ovaries (Leopold and Mironoff), while in another set of fifty-four cases ovulation appeared to have coincided with menstruation in thirty-nine instances.

From the evidence at present at our disposal it may be stated that in the human species while ovulation generally coincides with menstruation, yet the two phenomena

may, and not infrequently do, occur independently of one another.

**The Corpus Luteum.**—With the setting free of the ovum the usefulness of the Graafian follicle is at an end, and it begins at once to undergo retrogressive changes which result primarily in the formation of a structure known as the *corpus luteum* (Fig. 11). On the rupture of the follicle a considerable portion of the stratum granulosum remains in place, and usually there is an effusion of a greater or less amount of blood from the vessels of the theca interna

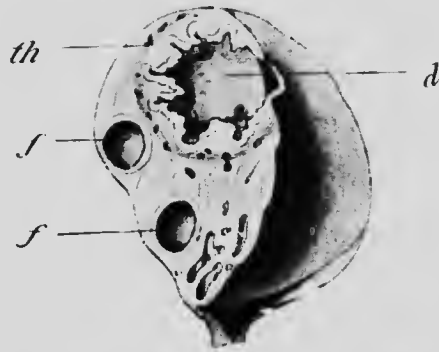

FIG. 11.—OVARY OF A WOMAN NINETEEN YEARS OF AGE, EIGHT DAYS AFTER MENSTRUATION.  
d, Blood-clot; j, Graafian follicle; th, theca.—(Kollmann.)

into the follicular cavity. The split in the wall through which the ovum escaped soon closes over and the cavity becomes filled with cells separated into groups by trabeculae of connective tissue containing blood-vessels (Fig. 12). These cells contain a considerable amount of a peculiar yellow pigment known as *lutein*, the color imparted

to the follicle by this substance having suggested the name *corpus luteum* which is now applied to it.

In later stages there is a gradual increase in the amount of connective tissue present and a corresponding diminution of the lutein cells, the *corpus luteum* gradually losing its yellow color and becoming converted into a whitish, fibrous, scar-like body, the *corpus albicans*, which may eventually almost completely disappear. These various changes occur in every ruptured follicle, whether or not the ovum which was contained in it be fertilized. But

the rapidity with which the various stages of retrogression ensue differs greatly according to whether pregnancy occurs or not, and it is customary to distinguish the corpora lutea which are associated with pregnancy as *corpora lutea vera* from those whose ova fail to be fertilized and which form *corpora lutea spuria*. In the latter the retro-

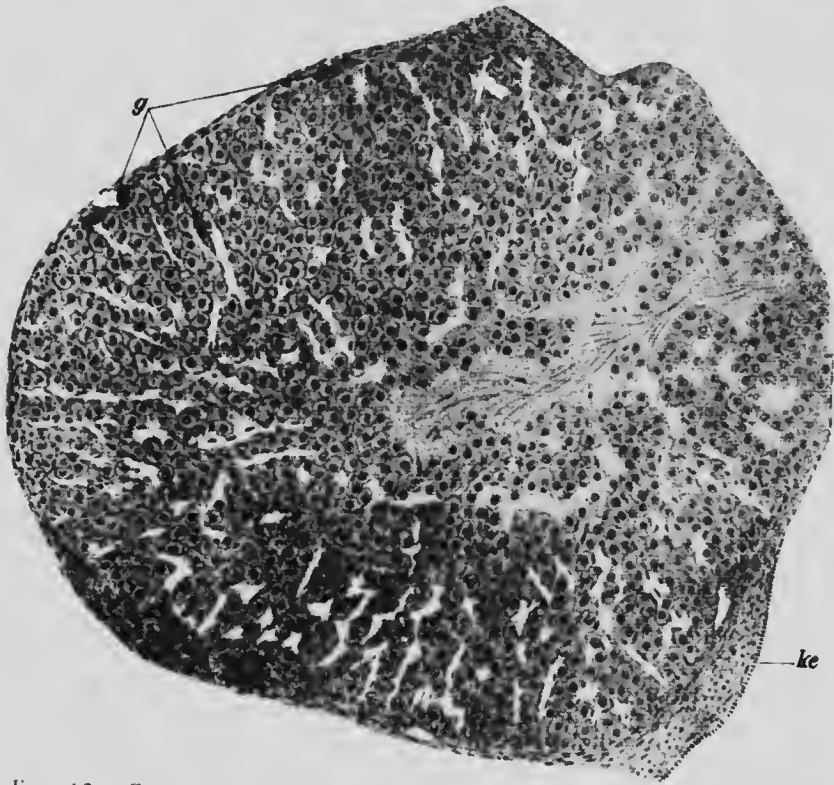

FIG. 12.—SECTION THROUGH THE CORPUS LUTEUM OF A RABBIT, SEVENTY HOURS *post coitum*.

The cavity of the follicle is almost completely filled with lutein cells, among which is a certain amount of connective tissue. *g*, Blood-vessels; *ke*, ovarian epithelium. (Sobotta.)

gression of the follicle is completed usually in about three weeks, while the corpora vera persist throughout the entire duration of the pregnancy and complete their retrogression after the birth of the child.

Two very different views are held as to the origin of the lutein cells. According to one, which may be termed von Baer's view, the cells of the stratum granulosum remaining in the follicle rapidly undergo degeneration and completely disappear, and the lutein cells and connective-tissue trabeculae are formed entirely from the cells of the theca interna, which increase rapidly both in size and number. The other view was first advanced by Bischoff and may be known by his name. It is to the effect that the granulosa cells do not disintegrate, but, on the contrary, increase rapidly in number and become converted into the lutein cells, only the connective tissue and the blood-vessels being derived from the theca interna.

Which of these two views is correct is at present uncertain. The majority of those who have within recent years studied the formation of the human corpus luteum have expressed themselves in favor of von Baer's theory. Sobotta has, however, made a thorough study of the phenomena in a perfect series of mice ovaries and has demonstrated that in that form the lutein cells are derived from the granulosa cells. It would seem strange if the lutein cells had a different origin in two different mammals, and the observations on mice are so thorough that one is tempted to regard different results as being due to imperfections in the series of ovaries studied, important steps in the development of the corpora lutea being thus overlooked. Still the evidence available renders a resistance to the temptation advisable, and the possibility of both views being correct—the one in some cases, the other in others—must be entertained. Indeed, it has very recently been suggested that the rapidity with which the retrogressive changes ensue in small animals compared with larger ones may be sufficient to account for marked differences in the mode of origin of the lutein cells in dif-

ferent cases. If this possibility be accepted, then it may be said that the weight of evidence is in favor of the correctness of von Baer's views in the case of the human species.

**The Maturation of the Ovum.**—Returning now to the ovum, it has been shown that at the time of its extrusion from the Graafian follicle it is not equivalent to a spermatozoon but to a primary spermatocyte, and it may be remembered that such a spermatocyte becomes converted into a spermatozoon only after it has undergone two divisions, during which there is a reduction of the number of the chromosomes to one-half the number characteristic for the species.

Similar divisions and a similar reduction of the chromosomes occur in the case of the ovum, constituting what is termed its *maturation*. The phenomena have not as yet been observed in human ova, and, indeed, among mammals only with any approach to completeness in the mouse (Sobotta); but they have been observed in so many other forms, both vertebrate and invertebrate, and present in all cases so much uniformity in their general features, that there can be little question as to their occurrence in the human ovum.

In typical cases the ovum (the primary oöcyte) undergoes a division in the prophase of which the chromatin aggregates to form half as many tetrads as there are chromosomes in the somatic cells (Fig. 13, *oc*<sup>1</sup>) and at the metaphase a dyad from each tetrad passes into each of the two cells that are formed. These two cells (secondary oöcytes) are not, however, of the same size; one of them is almost as large as the original primary oöcyte and continues to be called an ovum (*oc*<sup>2</sup>), while the other is very small and is termed a *polar globule* (*p*). A second division of the ovum quickly succeeds



the first (Fig. 13,  $oc^2$ ), and each dyad gives a single chromosome to each of the two cells which result, so that each of these cells possesses half the number of chromosomes characteristic for the species. The second division, like

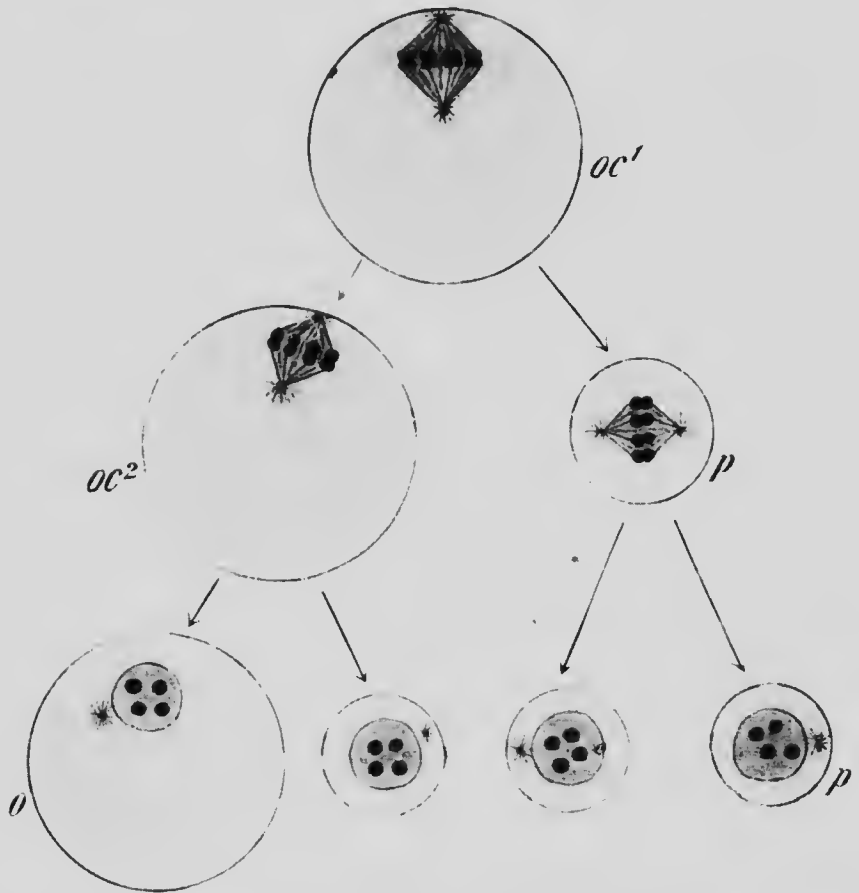
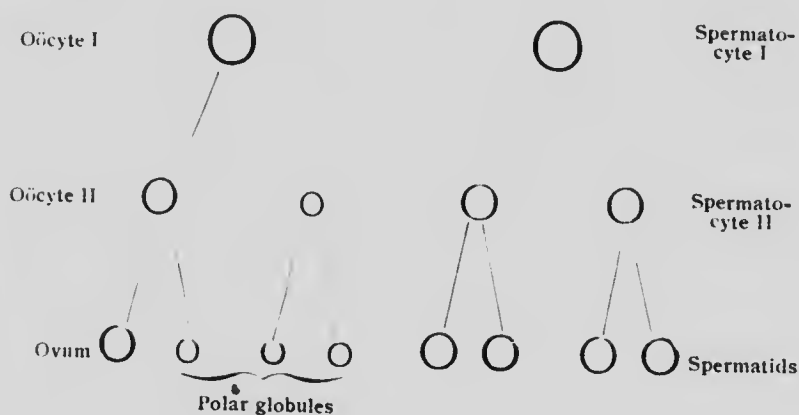


FIG. 13. —DIAGRAM ILLUSTRATING THE REDUCTION OF THE CHROMOSOMES DURING THE MATURATION OF THE OVUM.  
*o*, Ovum;  $oc^1$ , oöcyte of the first generation;  $oc^2$ , oöcyte of the second generation; *p*, polar globule.

the first, is unequal, one of the cells being relatively very large and constituting the mature ovum, while the other is small and is the second polar globule. Frequently the

first polar globule divides during the formation of the second one, a reduction of its dyads to single chromosomes taking place, so that as the final result of the maturation four cells are formed (Fig. 13), the mature ovum (*o*), and three polar globules (*p*), each of which contains half the number of chromosomes characteristic for the species.

The similarity of the maturation phenomena to those of spermatogenesis may be perceived from the following diagram:



In both processes the number of cells produced is the same and in both there is the same reduction of the chromosomes. But while each of the four spermatids is functional, the three polar globules are non-functional, and are to be regarded as abortive ova formed during the process of reduction of the chromosomes only to undergo degeneration. In other words, three out of every four potential ova sacrifice themselves in order that the fourth may have the bulk, that is to say, the amount of nutritive material and cytoplasm necessary for successful development.

In the mouse, which for the present must be taken as type of the mammalia, the majority of ova show an im-

portant departure from the processes just described. The number of chromosomes occurring in the somatic cells of the mouse is apparently twenty-four. The first maturation spindle (Fig. 14) possesses twelve chromosomes, which from analogy with the lower forms may be assumed

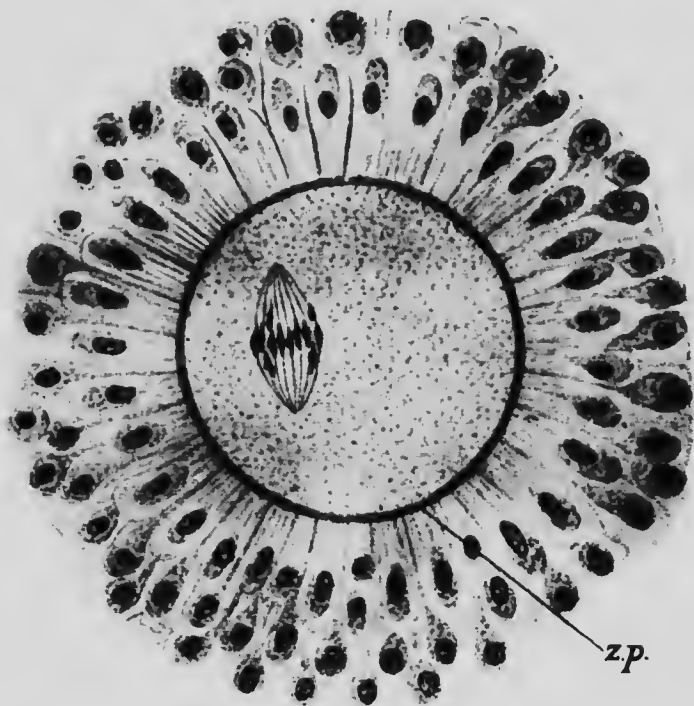


FIG. 14.—OVUM OF A MOUSE SHOWING THE MATURATION SPINDLE. The ovum is enclosed by the zona pellucida (*z.p.*), to which the cells of the corona radiata are still attached.—(*Sobotta*).

to be tetrads, and during the metaphase each chromosome divides transversely, the polar globule receiving twelve chromosomes, presumably dyads, while twelve remain within the ovum. So far the process is essentially typical, but in 90 per cent. of the ova examined this was the only maturation division which took place, only one

polar globule being formed. In the remaining 10 per cent. the second division occurred, the twelve chromosomes again dividing transversely, so that the second polar globule and the ovum each received twelve chromosomes and the reduction was typical.

The occurrence of but one maturation division in an immense majority of ova is difficult to explain and demands further study. Possibly in these ova the supposed tetrads are in reality dyads and the reduction differs only quantitatively from the typical process.

**The Fertilization of the Ovum.**—It is perfectly clear that the reduction of the chromosomes in the germ cells cannot very long be repeated in successive generations unless a restoration of the original number takes place occasionally, and, as a matter of fact, such a restoration occurs at the very beginning of the development of each individual, being brought about by the union of a spermatozoön with an ovum. This union constitutes what is known as the *fertilization of the ovum*.

The fertilization of the human ovum has not yet been observed, but the phenomenon has been repeatedly studied in lower forms, and a thorough study of the process has been made on the mouse by Sobotta, whose observations are taken as a basis for the following account.

The maturation of the ovum is quite independent of fertilization, but in many forms the penetration of the spermatozoön into the ovum takes place before the maturation phenomena are completed. This is the case with the mouse. A spermatozoön makes its way through the zona pellucida and becomes embedded in the cytoplasm of the ovum and its tail is quickly absorbed by the cytoplasm while its nucleus and probably the middle-piece persist as distinct structures. As soon as the maturation divisions are completed the nucleus of the ovum, now

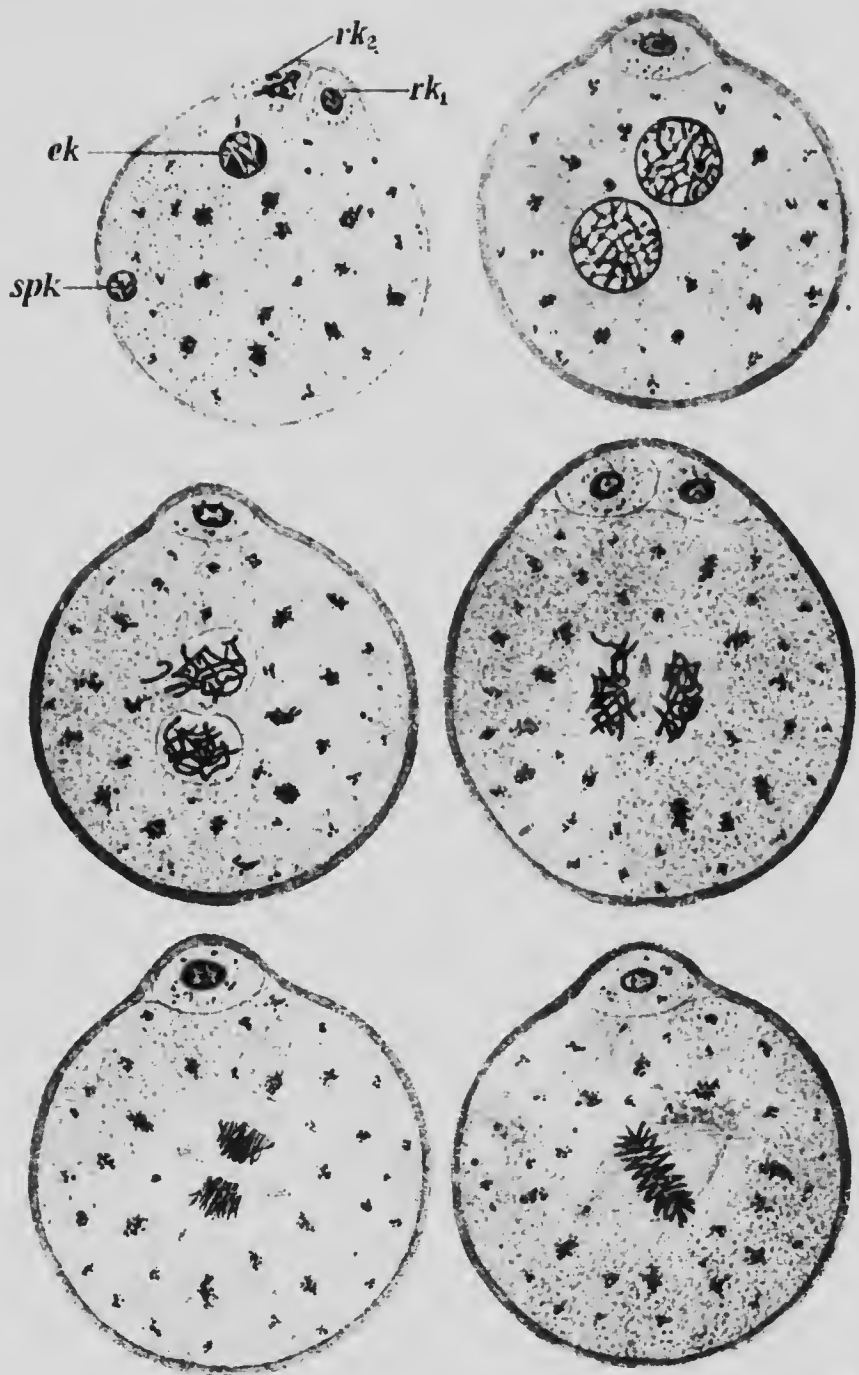


FIG. 15.—SIX STAGES IN THE PROCESS OF FERTILIZATION OF THE OVUM OF A MOUSE.

After the first stage figured it is impossible to determine which of the two nuclei represents the male or female pronucleus. *ek*, Female pronucleus; *rk<sub>1</sub>* and *rk<sub>2</sub>*, polar globules; *spk*, male pronucleus.—(Sobotta.)

termed the *female pronucleus* (Fig. 15, *ck*), migrates toward the center of the ovum, and is now destitute of an archoplasm sphere and centrosome, these structures having disappeared after the completion of the maturation divisions. The spermatozoön nucleus, which, after it has penetrated the ovum, is termed the *male pronucleus* (*spk*), may lie at first at almost any point in the peripheral part of the cytoplasm, and it now begins to approach the female pronucleus, preceded by the middle-piece, which becomes an archoplasm sphere with its contained centrosome and is surrounded by astral rays. The two pronuclei finally come into contact near the center of the ovum, forming what is termed the *segmentation nucleus* (Fig. 15), and the archoplasm sphere and centrosome which have been introduced with the spermatozoön undergo division and the two archoplasm spheres so formed migrate to opposite poles of the segmentation nucleus, an amphiaster forms and the compound nucleus passes through the various prophases of mitosis. Since, in the mouse, the male and female pronuclei have each contributed twelve chromosomes, the equatorial plate of the mitosis is composed of twenty-four chromosomes, the number characteristic for the species being thus restored.

It seems to be a rule that but one spermatozoön penetrates the ovum. Many, of course, come into contact with it and endeavor to penetrate it, but so soon as one has been successful in its endeavor no further penetration of others occurs. The reasons for this are in most cases obscure; experiments on the ova of invertebrates have shown that the subjection of the ova to abnormal conditions which impair their vitality favors the penetration of more than a single spermatozoön (*polyspermy*), and, indeed, it appears that in some forms, such as the common newt (*Diemyctylus*), polyspermy is the rule, only one of

HE

the  
male  
is.—

the spermatozoa, however, which have penetrated uniting with the female pronucleus, the rest being absorbed by the cytoplasm of the ovum.

Fertilization marks the beginning of development, and it is therefore important that something should be known as to where and when it occurs. It seems probable that in the human species the spermatozoa usually come into contact with the ovum and fertilization ensues in the upper part of the Fallopian tubes, and the occurrence of extra-uterine pregnancy (see p. 38) seems to indicate that occasionally the ovum may be fertilized even before it has been received into the tube.

It is evident, then, that when fertilization is accomplished the spermatozoon must have traveled a distance of about twenty-four centimeters, the length of the upper part of the vagina being taken to be about 5 em., that of the uterus as 7 em., and that of the tube as 12 em. A considerable interval of time is required for the completion of this journey, even though the movement of the spermatozoon be tolerably rapid. The observations of Henle and Hensen indicate that a spermatozoon may progress in a straight line at about the rate of from 1.2 to 2.7 mm. per minute, while Lott finds the rate to be as high as 3.6 mm. Assuming the rate of progress to be about 2.5 mm. per minute, the time required by the spermatozoon to travel from the upper part of the vagina to the upper part of a Fallopian tube will be about one and a half hours (Strassman). This, however, assumes that there are no obstacles in the way of the rapid progress of the spermatozoon, which is not the case, since, in the first place, the irregularities and folds of the lining membrane of the tube render the path of the spermatozoon a labyrinthine one, and, secondly, the action of the cilia of the epithelium of the tube and uterus being

from the ostium of the tube toward the os uteri, it will greatly retard the progress; furthermore, it is presumable that the rapidity of movement of the spermatozoön diminishes after a certain interval of time. It seems probable, therefore, that fertilization does not occur for some hours after coition, even providing an ovum is in the tube awaiting the approach of the spermatozoön.

But this condition is not necessarily present, and consequently the question of the duration of the vitality of the sperm cell becomes of importance. Ahlfeld has found that, when kept at a proper temperature, a spermatozoön will retain its vitality outside the body for eight days, and Dührssen reports a case in which living spermatozoa were found in a Fallopian tube removed from a patient who had last been *in coitu* about three and a half weeks previously. As regards the duration of the vitality of the ovum less accurate data are available. Hyrtl found an apparently normal ovum in the uterine portion of the left tube of a female who died three days after the occurrence of her second menstruation, and Issmer estimates the duration of the capacity for fertilization of an ovum to be about sixteen days.

It is evident, then, that even when the exact date of the coitus which led to the fertilization is known, the actual moment of the latter process can only be approximated, and in the immense majority of cases it is necessary to rely upon the date of the last menstruation for an estimation of the probable date of parturition. And by this method the possibilities for error are much greater. It has been seen that ovulation usually, though not invariably, is associated with menstruation, but it is uncertain whether the ovum whose fertilization has resulted in a pregnancy was expelled from its follicle during the last menstrual period which occurred, or during or just pre-



ceding the first omitted period. Both views have been advocated, but it seems probable that the latter case is the more frequent, the fertilized ovum being one which has been expelled from its follicle subsequent to the last menstruation which occurred. The duration of pregnancy is normally ten lunar or about nine calendar months and it is customary to estimate the probable date of parturition as nine months and seven days from the last menstruation. From what has been said, it is clear that any such estimation can be depended upon only as an approximation, the possible variation from it being considerable.

**Superfetation.**—The occasional occurrence of twin fetuses in different stages of development has suggested the possibility of the fertilization of a second ovum as the result of a coition at an appreciable interval of time after the first ovum has started upon its development. There seems to be little room for doubt but that many of the cases of supposed *superfetation*, as this phenomenon is termed, are instances of the simultaneous fertilization of two ova, one of which, for some cause concerned with the supply of nutrition, has later failed to develop as rapidly as the other. At the same time, however, even although the phenomenon may be of rare occurrence, it is by no means impossible, for occasionally a second Graafian follicle, either in the same or the other ovary, may be so near maturity that its ovum is extruded soon after the first one, and if the development of the latter and the incidental changes in the uterine mucous membrane have not proceeded so far as to prevent the access of the spermatozoon to the ovum, its fertilization and development may ensue. The changes, however, which prevent the passage of the spermatozoon are completed early in development and the differences between the normally developed embryo and that due to superfetation will be comparatively small, and will become less and less evident as development proceeds, provided that the supply of nutrition to both embryos is equal.

## LITERATURE.

- E. BALLOWITZ: "Untersuchungen über die Struktur der Spermatozoen," No. 4. *Zeitschr. für wissensch. Zool.*, LII, 1891.
- K. VON BARDELEBEN: "Beiträge zur Histologie des Hodens und zur Spermatogenese beim Menschen," *Archiv für Anat. und Physiol., Anat. Abth., Supplement*, 1897.
- TH. BOVERI: "Befruchtung," *Ergebnisse der Anat. und Entwicklungsgesch.*, I, 1892.
- J. G. CLARK: "Ursprung, Wachstum und Erde des Corpus luteum nach Beobachtungen am Ovarium des Schweines und des Menschen," *Archiv für Anat. und Physiol., Anat. Abth.*, 1898.
- W. HEAPE: "The Menstruation of *Semnopithecus entellus*," *Philosoph. Trans. Royal Soc.*, CLXXXV, 1894.
- W. HEAPE: "The Menstruation and Ovulation of *Macacus rhesus* with Observations on the Changes Undergone by the Discharged Follicle," *Philosoph. Trans. Royal Soc.*, CLXXXVIII, 1897.
- O. HERTWIG: "Vergleich der Ei- und Samenbildung bei Nematoden," *Archiv für mikrosk. Anat.*, XXXVI, 1890.
- M. VON J. HOSSEK: "Untersuchungen über Spermatogenese," *Archiv für mikrosk. Anat.*, LI, 1898.
- F. MEYER: "Ueber Struktur und Histogenese der Samenfäden des Meersehens," *Archiv für mikrosk. Anat.*, LIV, 1899.
- J. E. S. MOORE: "Some Points in the Spermatogenesis of Mammalia," *Internat. Monatsschrift für Anat. und Physiol.*, XI, 1894.
- W. NAGEL: "Das menschliche Ei," *Archiv für mikrosk. Anat.*, XXXI, 1888.
- G. NIESSING: "Die Betheiligung der Centalkörper und Sphäre am Aufbau des Samenfadens bei Säugethieren," *Archiv für mikrosk. Anat.*, XLVIII, 1896.
- J. SOBOTTA: "Die Befruchtung und Furchung des Eies der Maus," *Archiv für mikrosk. Anat.*, XLV, 1895.
- J. SOBOTTA: "Ueber die Bildung des Corpus luteum bei der Maus," *Archiv für mikrosk. Anat.*, XLVII, 1897.
- J. SOBOTTA: "Ueber die Bildung des Corpus luteum beim Kaninchen," *Anat. Hefte*, VIII, 1897.
- P. STRASSMANN: "Beiträge zur Lehre von der Ovulation, Menstruation und Conception," *Archiv für Gynaekol.*, LII, 1896.
- W. WALDEYER: "Eierstock und Ei," Leipzig, 1870.

## CHAPTER II.

### THE SEGMENTATION OF THE OVUM AND THE FORMATION OF THE GERM LAYERS.

**Segmentation.**—The union of the male and female pronuclei has already been described as being accompanied by the formation of a mitotic spindle which produces a division of the ovum into two cells. This first division is succeeded at more or less regular intervals by others until a mass of cells is produced in which a differentiation eventually appears. These divisions of the ovum constitute what is termed its *segmentation*.

The mammalian ovum has behind it a long line of evolution, and even at early stages in its development it exhibits peculiarities which can only be reasonably explained as an inheritance of past conditions. One of the most potent factors in modifying the character of the segmentation of the ovum is the amount of food yolk which it contains, and it seems to be certain that the immediate ancestors of the mammalia were forms whose ova contained a considerable amount of yolk, many of the peculiarities resulting from its presence being still clearly indicated in the early development of the almost yolkless mammalian ovum. To give some idea of the peculiarities which result from the presence of considerable amounts of yolk it will be well to compare the processes of segmentation and differentiation seen in ova with different amounts of yolk.

A little below the scale of the vertebrates proper is a form, *Amphioxus*, which possesses an almost yolkless

ovum presenting a simple process of development. The fertilized ovum of *Amphioxus* in its first division separates into two similar and equal cells, and these are made four (Fig. 16, A) by a second plane of division which cuts the previous one at right angles. A third plane at right angles to both the preceding ones brings about an eight-celled stage (Fig. 16, B), and further divisions result in the formation of a large number of cells which arrange them-

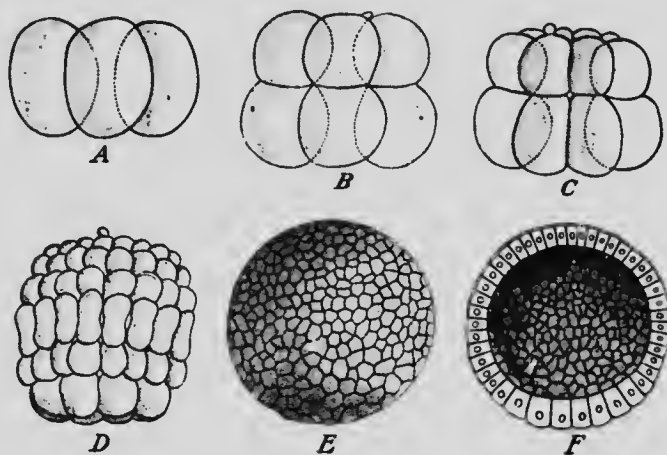


FIG. 16.—STAGES IN THE SEGMENTATION OF *Amphioxus*.

A, Four-celled stage; B, eight-celled stage; C, sixteen-celled stage; D, early blastula; E, blastula; F, section of blastula.—(Hatschek.)

selves in the form of a hollow sphere which is known as a *blastula* (Fig. 16, E).

The minute amount of yolk which is present in the ovum of *Amphioxus* collects at an early stage of the segmentation at one pole of the ovum, the cells containing it being somewhat larger than those of the other pole (Fig. 16, B), and in the blastula the cells of one pole are larger and more richly laden with yolk than those of the other pole (Fig. 16, F). If, now, the segmenting ovum of an Amphibian be examined, it will be found that a very

much greater amount of yolk is present and, as in *Amphioxus*, it is located especially at one pole of the ovum. The first three planes of segmentation have the same relative positions as in *Amphioxus* (Fig. 16), but one of the tiers of cells of the eight-celled stage is very much smaller than the other (Fig. 17, B). In the subsequent




FIG. 17. —STAGES IN THE SEGMENTATION OF *Amblystoma*.—(Eycleshymer.)

stages of segmentation the small cells of the upper pole divide more rapidly than the larger ones of the lower pole, the activity of the latter seeming to be retarded by the accumulation of the yolk, and the resulting blastula (Fig. 17, D) shows a very decided difference in the size of the cells of the two poles.

In the ova of reptiles and birds the amount of yolk stored up in the ovum is very much greater even than in the amphibia, and it is aggregated at one pole of the ovum of which it forms the principal mass, the yolkless protoplasm appearing as a small disk upon the surface of a relatively huge mass of yolk. The inertia of this mass of

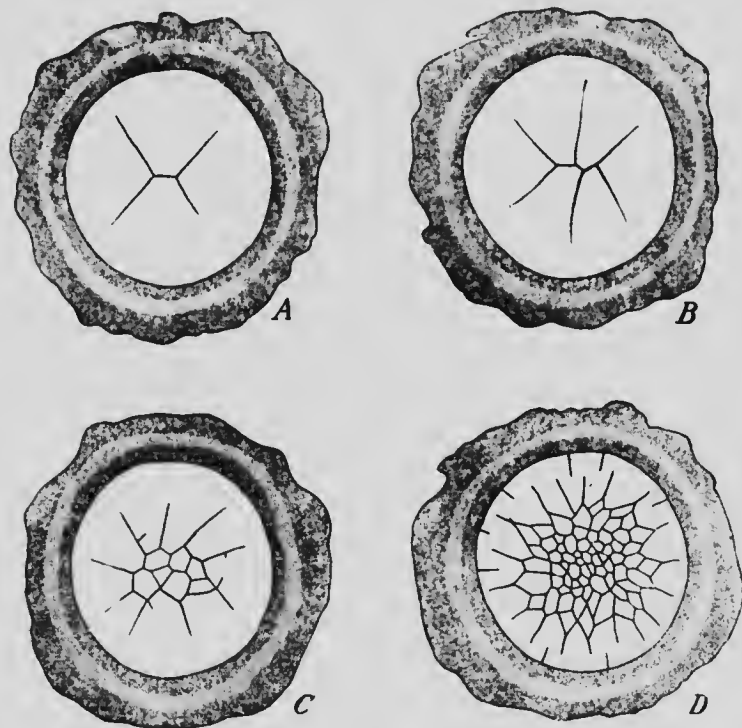


FIG. 18.—FOUR STAGES IN THE SEGMENTATION OF THE BLASTODERM OF THE CHICK.—(Coste.)

nutritive material is so great that the segmentation is confined to the small yolkless disk of protoplasm and affects consequently only a portion of the entire ovum. To distinguish this form of segmentation from that which affects the entire ovum it is termed *meroblastic* segmentation, the other form being known as *holoblastic*.

In the ovum of a turtle or a bird the first plane of segmentation crosses the protoplasmic disk, dividing it into two practically equal halves, and the second plane forms at approximately right angles to the first one, dividing the disk into four quadrants (Fig. 18, A). The third division, like the two which precede it, is radial in position, while the fourth is circular and cuts off the inner ends of the six cells previously formed (Fig. 18, D). The disk now consists of six central smaller cells surrounded by six

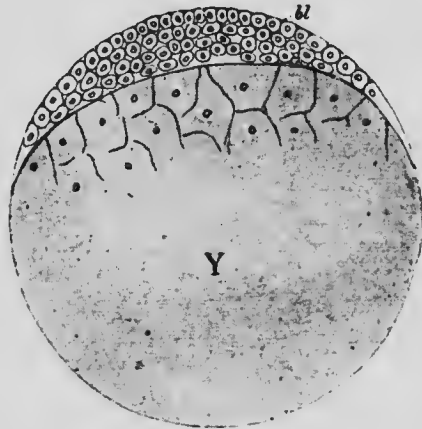


FIG. 19.—DIAGRAM ILLUSTRATING A SECTION OF THE OVUM OF A REPTILE AT A STAGE CORRESPONDING TO THE BLASTULA OF AN AMPHIBIAN.

*bl*, Blastoderm; *Y*, yolk-mass.

larger peripheral ones. Beyond this period no regularity can be discerned in the appearance of the segmentation planes; but radial and circular divisions continuing to form, the disk becomes divided into a large number of cells, those at the center being much smaller than those at the periphery. In the mean time, however, the smaller central cells have begun to divide in planes parallel to the surface of the disk, which, from being a simple plate of cells, thus becomes a discoidal cell-mass.

During the segmentation of the disk it has increased materially in size, extending further and further over the surface of the yolk, into the substance of which some of the lower cells of the discoidal cell-mass have penetrated. A comparison of the diagram (Fig. 19) of the ovum of a reptile at about this stage of development with the figure of the amphibian blastula (Fig. 17, D) will indicate the similarity between the two, the large yolk-mass of the reptile (Y) with the scattered cells which it contains corresponding to the lower pole cells of the amphibian blastula the central cavity of which is practically suppressed in the reptile. Beyond this stage, however, the similarity becomes more obscured. The peripheral cells of the disk continue to extend over the surface of the yolk and finally completely enclose it, forming an *enveloping layer* which is completed at the upper pole of the egg by the discoidal cell-mass, or, as it is usually termed, the *blastoderm*.

Turning now to the mammalia,\* it will be found that the ovum in the great majority is almost or quite as destitute of food yolk as is the ovum of *Amphioxus*, with the result that the segmentation is of the total or holoblastic type. It does not, however, proceed with that regularity which marks the segmentation of *Amphioxus* or an amphibian, but while at first it divides into two slightly unequal cells (Fig. 20), thereafter the divisions become irregular, three-celled, four-celled, five-celled, and six-celled stages having been observed in various instances. Nor is the result of the final segmentation a hollow vesicle or blastula, but a solid mass of cells, termed a *morula*, is formed. This structure is not, however, comparable to the blastula of the lower forms, but corresponds to a stage of reptilian

\* The segmentation of the human ovum has not yet been observed; what follows is based on what occurs in the ovum of the rabbit, mole, and especially of a bat (Van Beneden).



development a little later than that shown in Fig. 19, since, as will be shown directly, the cells corresponding to the blastoderm and the enveloping layer are already present. There is, then, no blastula stage in the mammalian development.

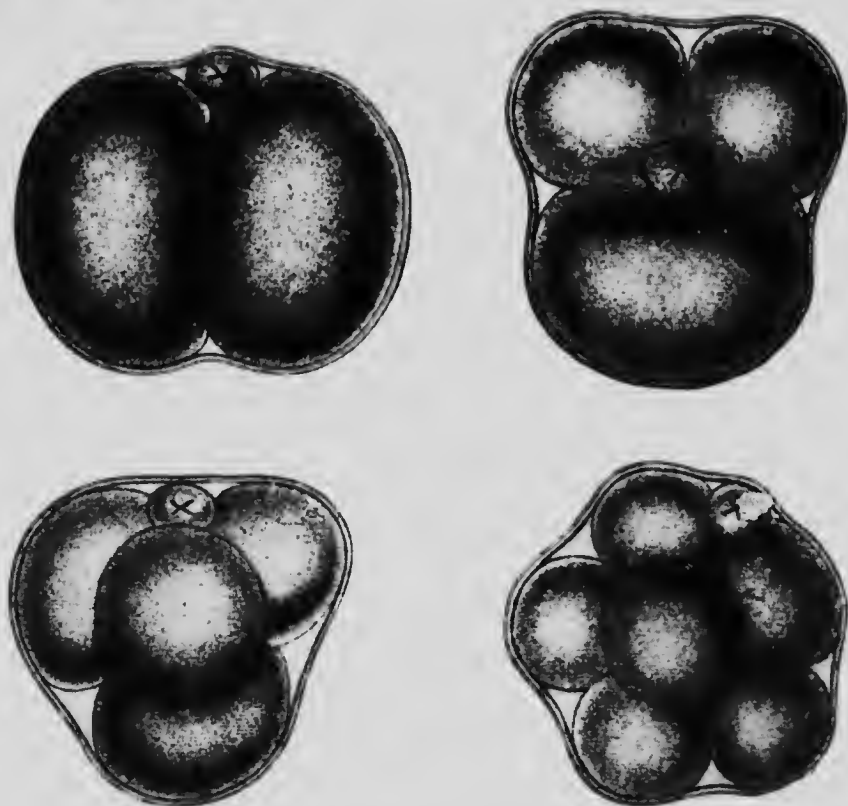


FIG. 20.—FOUR STAGES IN THE SEGMENTATION OF THE OVUM OF A MOUSE.

X, Polar globule.—(Sobotta).

This differentiation now begins by the peripheral cells of the morula becoming less spherical in shape and later forming a layer of flattened cells, the enveloping layer, surrounding the more spherical central cells (Fig. 21, A). In the latter vacuoles now make their appearance, espe-

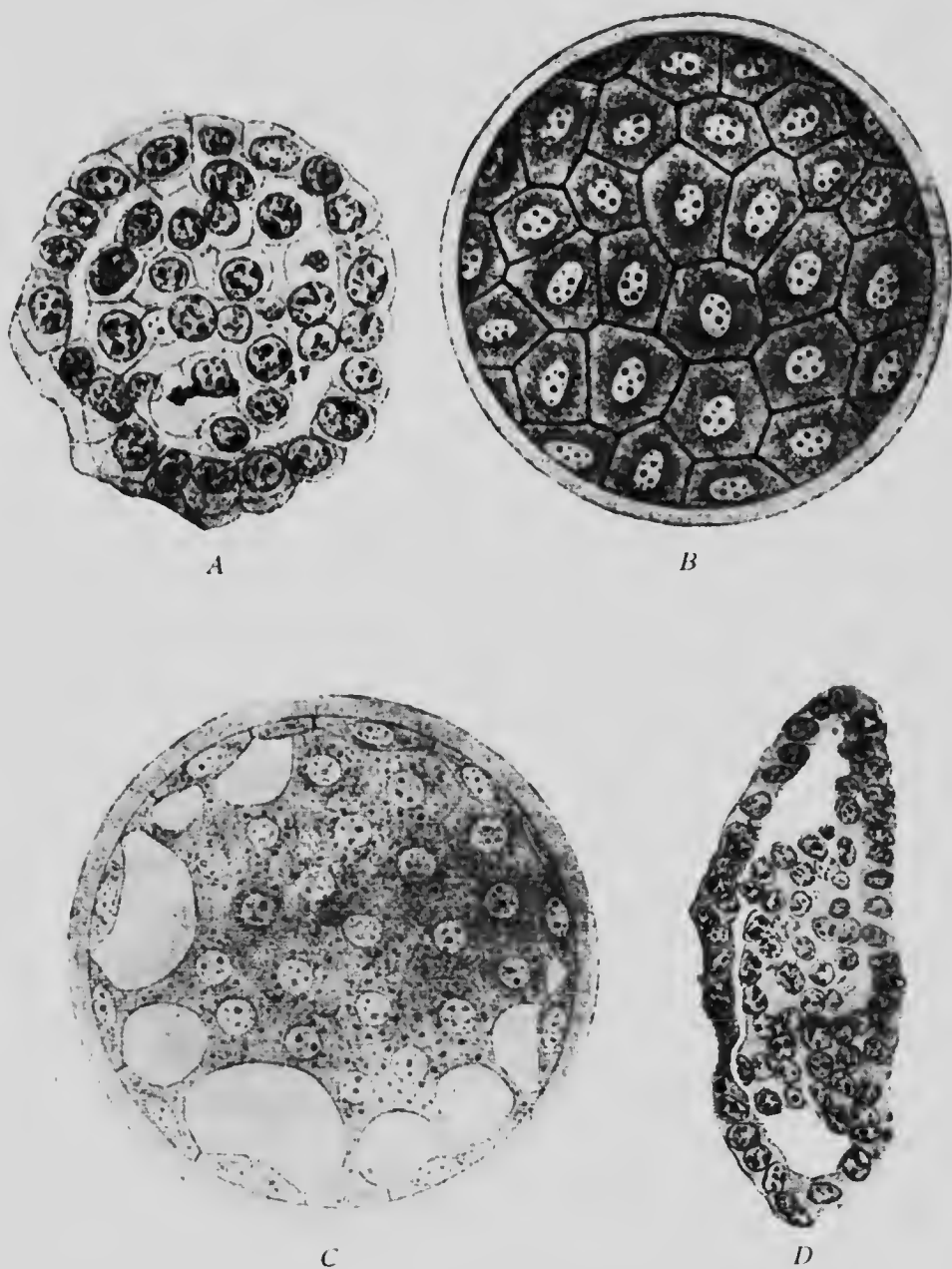


FIG. 21.—LATER STAGES IN THE SEGMENTATION OF THE OVUM OF A BAT.

*A, C, and D are sections, B a surface view.—(Van Beneden.)*

cially in those cells which are nearest what may be regarded as the lower pole of the ovum (Fig. 21, C), and these vacuoles, gradually increasing in size, eventually become confluent, the condition represented in Fig. 21, D, being produced. At this stage the ovum consists of an enveloping layer, enclosing a cavity which is equivalent to the yolk-mass of the reptilian ovum, the vacuolization of the inner cells of the morula representing a belated formation of yolk. On the inner surface of the enveloping layer, at what may be termed the upper pole of the ovum, is a mass of cells projecting into the yolk-cavity and forming what is known as the *inner cell-mass*, a structure comparable to the blastoderm of the reptile. In one respect, however, a difference obtains, the inner cell-mass being completely enclosed within the enveloping cells, which is not the case with the blastoderm of the reptile. That portion of the enveloping layer which covers the cell-mass has been termed *Rauber's covering layer*, and probably owes its existence to the precocity of the formation of the enveloping layer.

It is clear, then, that an explanation of the early stages of development of the mammalian ovum is to be obtained by a comparison, not with a yolkless ovum such as that of *Amphioxus*, but with an ovum richly laden with yolk, such as the meroblastic ovum of a reptile or bird. In these forms the nutrition necessary for the growth of the embryo and for the complicated processes of development is provided for by the storing up of a quantity of yolk in the ovum, the embryo being thus independent of external sources for food. The same is true also of the lower mammalia, the Monotremes, which are egg-laying forms producing ova resembling greatly those of a reptile. When, however, in the higher mammals the nutrition of the embryo became provided for by the attachment of the

embryo to the walls of the uterus of the parent so that it could be nourished directly by the parent, the storing up of yolk in the ovum was unnecessary and it became a holoblastic ovum, although many peculiarities depended on the original meroblastic condition persisted in its development.

*Twin Development*—As a rule, in the human species but one embryo develops at a time, but the occurrence of twins is by no means infrequent, and triplets and even quadruplets occasionally are developed. The occurrence of twins may be due to two causes, either to the simultaneous ripening and fertilization of two ova, either from one or from both ovaries, or to the separation of a single fertilized ovum into two independent parts during the early stages of development. That twin may be produced by this latter process has been abundantly shown by experimentation upon developing ova of lower forms. Each of the two cells of an *Amphioxus* ovum in the early development, if mechanically separated, completes its development and producing an embryo of about half the normal size.

*Double Monsters and the Duplication of Parts*—The occasional occurrence of double monsters is explained by an imperfect separation into two parts of an originally single embryo, the extent of the separation, and probably also the stage of development at which it occurs, determining the amount of fusion of the two individuals constituting the monster. All gradations of separation occur, from almost complete separation, as seen in such cases as the Siamese twins, to forms in which the two individuals are united throughout the entire length of their bodies. The separation may also affect only a portion of the embryo, producing, for instance, double-faced or double-headed monsters or various forms of so-called parasitic monsters; and, finally, it may affect only a group of cells destined to form a special organ, producing an excess of parts, such as supernumerary digits or accessory spleens.

It has been observed in the case of double monsters that one of the two fused individuals always has the position of its various organs reversed, it being, as it were, the looking-glass image of its fellow. Cases of a similar *situs inversus viscerum*, as it is called, have not infrequently been observed in single individuals, and a plausible explanation of such cases regards them as one of a pair of twins formed by the division

of a single embryo, the other individual having ceased to develop and either having undergone degeneration or, if the separation was an incomplete one, being included within the body of the apparently single individual.

**The Formation of the Germ Layers.**—During the stages which have been described as belonging to the segmentation period of development there has been but little differentiation of the cells. In *Amphioxus* and the amphibians the cells at one pole of the blastula are larger and more yolk-laden than those at the other pole, and in the mammals an inner cell-mass can be distinguished from the enveloping cells, this latter differentiation having been anticipated in the reptiles and being a differentiation of a portion of the ovum from which alone the embryo will develop from a portion which will give rise to accessory structures. In later stages a differentiation of the inner cell-mass occurs, resulting first of all in the formation of a two-layered or *diploblastic* and later of a three-layered or *triploblastic* stage.

Just as the segmentation has been shown to be profoundly modified by the amount of yolk present in the ovum and by its secondary reduction, so, too, the formation of the three primitive layers is much modified by the same cause, and to get a clear understanding of the formation of the triploblastic condition of the mammal it will be necessary to describe briefly its development in lower forms.

In *Amphioxus* the diploblastic condition results from the flattening of the large-celled pole of the blastula (Fig. 22, A), and finally from the invagination of this portion of the vesicle within the other portion (Fig. 22, B). The original single-walled blastula in this way becomes converted into a double-walled sac termed a *gastrula*, the outer layer of which is known as the *ectoderm* or *epiblasti*

and the inner layer as the *endoderm* or *hypoblast*. The cavity bounded by the endoderm is the primitive gut or *archenteron*, and the opening by which this communicates with the exterior is the *blastopore*. This last structure is at first a very wide opening, but as development proceeds it becomes smaller, and finally is a relatively small opening situated at the posterior extremity of what will be the dorsal surface of the embryo.

As the oval embryo continues to elongate in its later development the third layer or *mesoderm* makes its ap-

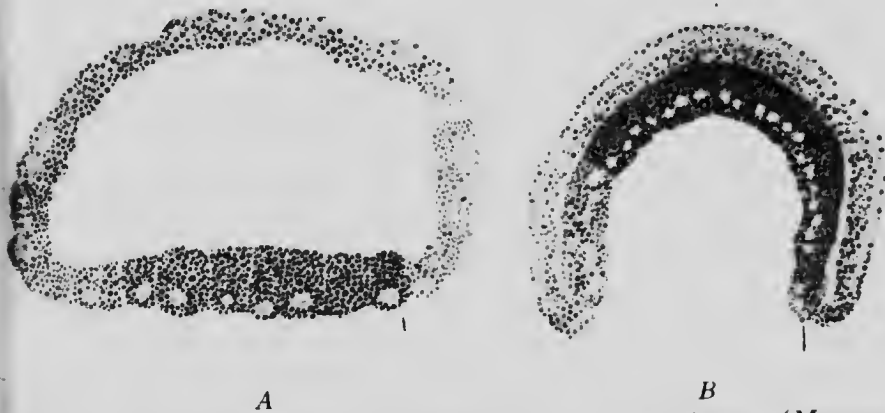

FIG. 22.—TWO STAGES IN THE GASTRULATION OF *Amphioxus*.—(Morgan and Hazen.)

pearance. It arises as a lateral fold (*mp*) of the dorsal surface of the endoderm (*en*) on each side of the middle line as indicated in the transverse section shown in Fig. 23. This fold eventually becomes completely constricted off from the endoderm and forms a hollow plate occupying the space between the ectoderm and endoderm, the cavity which it contains being the *body-cavity* or *cælom*.

In the amphibia, where the amount of yolk is very much greater than in *Amphioxus*, the gastrulation becomes considerably modified. On the line where the large-

and small-celled portions of the blastula become continuous a crescentic groove appears and deepening forms an invagination (Fig. 24, *gc*) the roof of which is composed of relatively small yolk-containing cells while its floor is formed by the large cells of the lower pole of the blastula. The cavity of the blastula is not sufficiently large to allow of the typical invagination of all these large cells, so that they become enclosed by the rapid growth of the ectoderm cells of the upper pole of the ovum over them. Before

this growth takes place the blastopore corresponds to the entire area occupied by the large yolk cells, but later, as the growth of the smaller cells gradually encloses the larger ones, it becomes smaller and is finally represented by a small opening situated at what will be the hind end of the embryo.

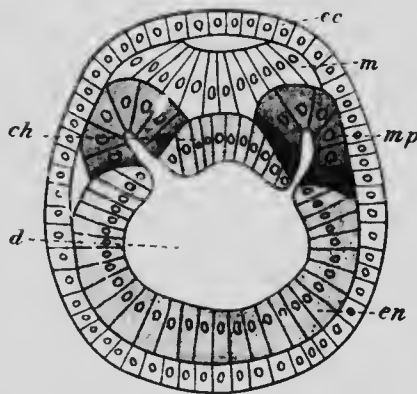


FIG. 23.—TRANSVERSE SECTION OF *Amphioxus* EMBRYO WITH FIVE MESODERMIC POUCHES.

*Ch*, Notochord; *d*, digestive cavity; *ec*, ectoderm; *en*, endoderm; *m*, medullary plate; *mp*, mesodermic pouch.—(Hatschek.)

Soon after the archenteron has been formed a solid plate of cells, eventually splitting into two layers, arises from its roof on each side of the median line and grows out with the space between the ectoderm and endoderm (Fig. 25, *mk*<sup>1</sup> and *mk*<sup>2</sup>) evidently corresponding to the hollow plates formed in the same situations in *Amphioxus*. This is not, however, the only source of the mesoderm in the amphibia, for while the blastopore is still quite large there may be found surrounding it between the endoderm and ectoderm a ring of mesodermal tissue (Fig. 24, *mes*).

As the blastopore diminishes in size and its lips come together and unite, the ring of mesoderm forms first an oval and then a band lying beneath the line of closure of the blastopore and united with both the superjacent ectoderm and the subjacent endoderm. This line of fusion of the three germ layers is known as the *primitive streak*. It is convenient to distinguish the mesoderm of

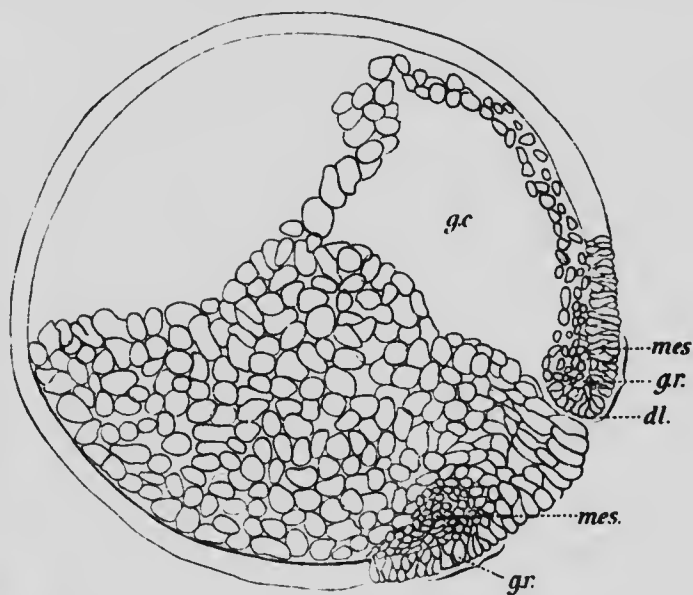


FIG. 24.—SECTION THROUGH A GASTRULA OF *Amblystoma*.  
*dl*, Dorsal lip of blastopore; *gc*, digestive cavity; *gr*, area of mesoderm formation; *mes*, mesoderm.—(*Eyleshymer*.)

the primitive streak from that formed from the dorsal wall of the archenteron by speaking of the former as the *prostomial* and the latter as the *gastral* mesoderm, though it must be understood that the two are continuous immediately in front of the definitive blastopore.

In the reptilia still greater modifications are found in the method of formation of the germ layers. Before the enveloping cells have completely surrounded the yolk-



mass, a crescentic groove, resembling that occurring in amphibia, appears near the posterior edge of the blastoderm, the cells of which, in front of the groove, arrange themselves in a superficial layer one cell thick which may be regarded as the ectoderm (Fig. 26, *ec*) and a subjacent mass of somewhat scattered cells. Later the lowermost cells of this subjacent mass arrange themselves in a continuous layer constituting what is termed the *primary*

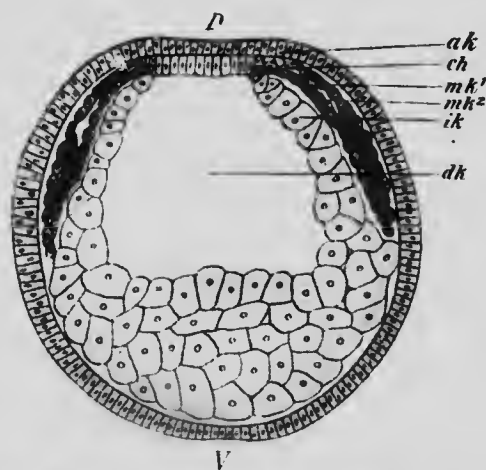


FIG. 25. SECTION THROUGH AN EMBRYO AMPHIBIAN (TRITON) OF 2½ DAYS, SHOWING THE FORMATION OF THE GASTRAL MESODERM. *ak*, Ectoderm; *ch*, chorda endoderm, *dk*, digestive cavity; *ik*, endoderm; *mk*<sup>1</sup> and *mk*<sup>2</sup>, splanchnic and somatic layers of the mesoderm. *D*, dorsal and *V*, ventral. (Holtwig.)

*endoderm* (*en*<sup>1</sup>), while the remaining cells, aggregated especially in the region of the crescentic groove, form the prostomial mesoderm (*prm*). In the region enclosed by the groove a distinct delimitation of the various layers does not occur, and this region forms the primitive streak. The groove now begins to deepen, forming an invagination of secondary endoderm, the extent of this invagination being, however, very different in different species. In the gecko (Will) it pushes forward between the ectoderm and primary endoderm almost to the anterior edge of the

blastoderm, but later the cells forming its floor, together with those of the primary endoderm immediately below, undergo a degeneration, the roof cells at the lateral margins of the invagination becoming continuous with the persisting portions of the primary endoderm. This layer, following the enveloping cells in their growth over the yolk-mass, gradually surrounds that structure so that

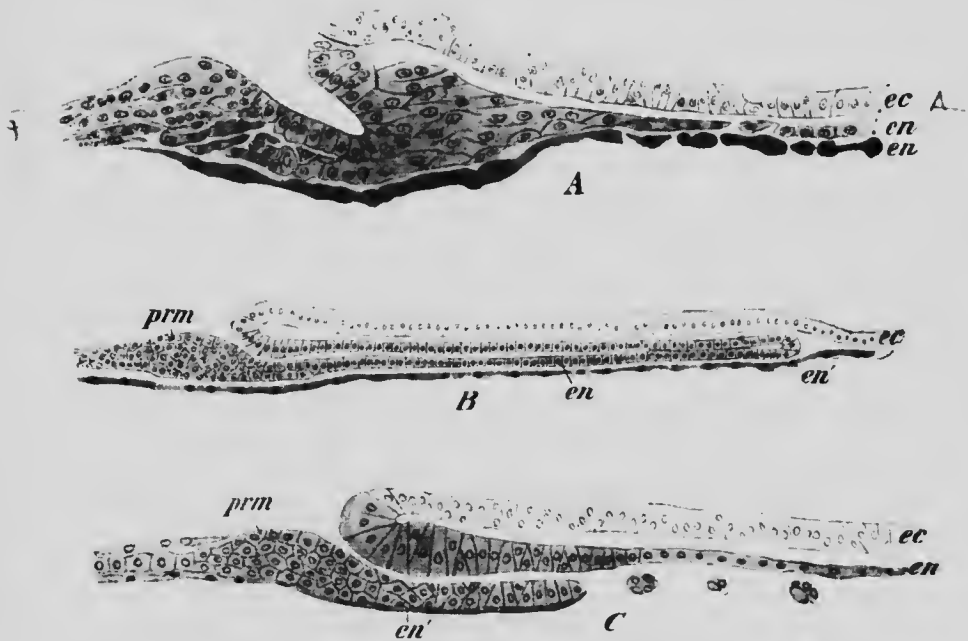


FIG. 26.—LONGITUDINAL SECTIONS THROUGH EMBRYOS OF THE GECKO, SHOWING GASTRULATION.  
*ec*, Ectoderm; *en*, secondary endoderm; *en'*, primary endoderm; *prm*, prostomial mesoderm.—(Will.)

it comes to lie within the archenteron. In some turtles, on the other hand, the disappearance of the floor of the invagination takes place at a very early stage of the infolding, the roof cells only persisting to grow forward to form the dorsal wall of the archenteron. This interesting abbreviation of the process occurring in the gecko indicates the mode of development which is found in the mammalia.

The existence of a prostomial mesoderm in connection with the primitive streak has already been noted, and when the invagination takes place it is carried forward as a narrow band of cells on each side of the sac of secondary endoderm. After the absorption of the ventral wall of the invagination a folding or turning in of the margins of the secondary endoderm occurs (Fig. 27) whereby its

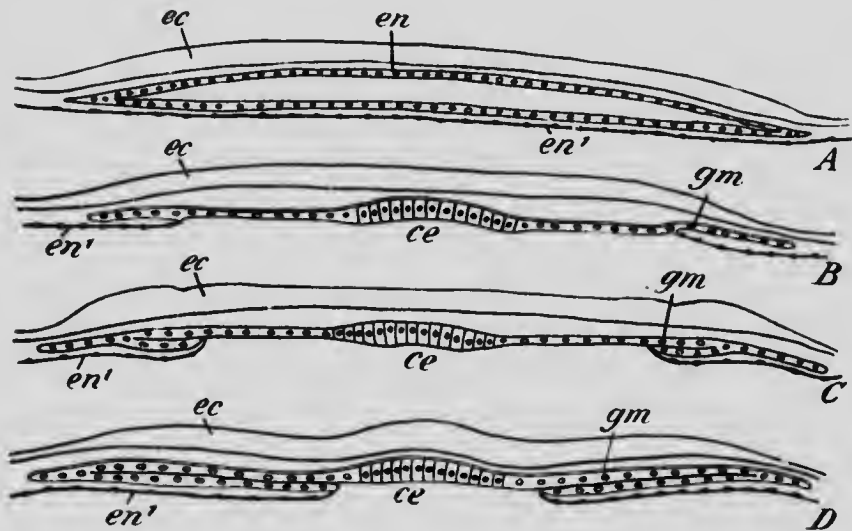


FIG. 27.—DIAGRAMS ILLUSTRATING THE FORMATION OF THE GASTRAL MESODERM IN THE GECKO.

*ce*, Chorda endoderm; *ec*, ectoderm; *en*, secondary endoderm; *en'*, primary endoderm; *gm*, gastral mesoderm.—(Will.)

lumen becomes reduced in size and it passes off on each side into a double plate of cells which constitute the gastral mesoderm. Later these plates separate from the archenteron as in the lower forms. All the prostomial mesoderm does not, however, arise from the primitive streak region, but a considerable amount also has its origin from the ectoderm covering the yolk outside the limits of the blastoderm proper, a mode of origin which serves to explain the phenomena later to be described for the mammalia.

In comparison with the amphibians and *Amphioxus*, the reptilia present a subordination of the process of invagination in the formation of the endoderm, a primary endoderm making its appearance independently of an invagination, and, in association with this subordination, there is an early appearance of the primitive streak, which, from analogy with what occurs in the amphibia, may be assumed to represent a portion of the blastopore which is closed from the very beginning.

Turning now to the mammalia, it will be found that these peculiarities become still more emphasized. The inner cell-mass of these forms corresponds to the blastoderm of the reptilian ovum, and the first differentiation which appears in it concerns the cells situated next the cavity of the vesicle, these cells uniting to form a distinct layer which gradually extends so as to form a complete lining to the inner surface of the enveloping cells (Fig. 28, A). These cells are endodermal and correspond to the primary endoderm of the reptiles.

Before the extension of the endoderm is completed, however, cavities begin to appear in the cells constituting the remainder of the inner mass, especially in those immediately beneath Rauber's cells (Fig. 28, B), and these cavities in time coalesce to form a single large cavity bounded above by cells of the enveloping layer and below by a thick plate of cells, the *embryonic disk* (Fig. 28, C). The cavity so formed is the *amniotic cavity*, whose further history will be considered in a subsequent chapter.

It may be stated that this cavity varies greatly in its development in different mammals, being entirely absent in the rabbit at this stage of development and reaching an excessive development in such forms as the rat, mouse, and guinea-pig. The condition here described is that which occurs in the bat and the mole, and it seems probable, from what occurs in the youngest human embryos hitherto observed, that the processes in man are closely similar.

While these changes have been taking place a splitting of the enveloping layer has occurred, so that the wall of

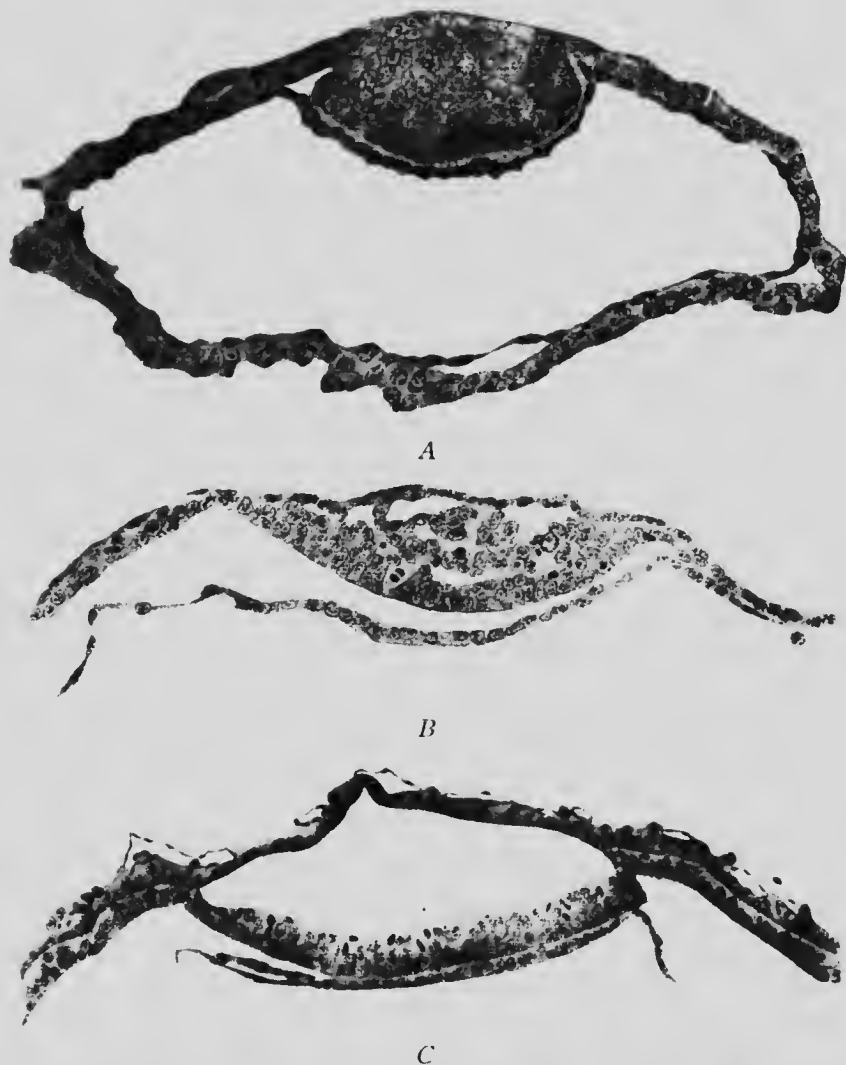

FIG. 28.—SECTIONS OF OVA OF A BAT SHOWING (A) THE FORMATION OF THE ENDODERM AND (B AND C) OF THE AMNIOTIC CAVITY.—(Van Beneden.)

the ovum is now formed of three layers, an outer one which may be termed the *trophoblast*, a middle one which

probably is transformed into the extra-embryonic mesoderm of later stages, though its significance is at present somewhat obscure, and an inner one which is the primary endoderm. In the bat, of whose ovum Fig. 28, C, represents a section, that portion of the middle layer which forms the roof of the amniotic cavity disappears, only the

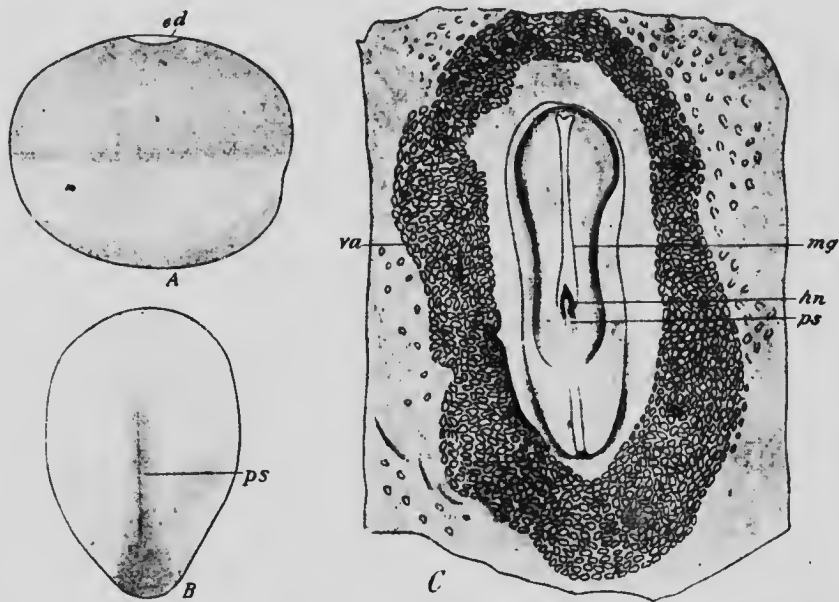


FIG. 29.—A, SIDE VIEW OF OVUM OF RABBIT SEVEN DAYS OLD (Kölliker); B, EMBRYONIC DISK OF A MOLE (Heape); C, EMBRYONIC DISK OF A DOG'S OVUM OF ABOUT FIFTEEN DAYS (Bonnet).  
ed, Embryonic disk; hn, Hensen's node; mg, medullary groove; ps, primitive streak; va, vascular area.

trophoblast persisting in this region, but in another form this is not the case, the roof of the cavity being composed of both the trophoblast and the middle layer.

A rabbit's ovum in which there is yet no amniotic cavity and no splitting of the enveloping layer shows, when viewed from above, a relatively small dark area on the surface, which is the embryonic disk. But if it be looked

at from the side (Fig. 29, A), it will be seen that the upper half of the ovum, that half in which the embryonic disk occurs, is somewhat darker than the lower half, the line of separation of the two shades corresponding with the edge of the primary endoderm which has extended so far in its growth around the inner surface of the enveloping layer. A little later a dark area appears at one end of the embryonic disk, produced by a proliferation of cells in this region and having a somewhat crescentic form. As the embryonic disk increases in size a longitudinal band makes its appearance extending forward in the median line nearly to the center of the disk and represents the primi-

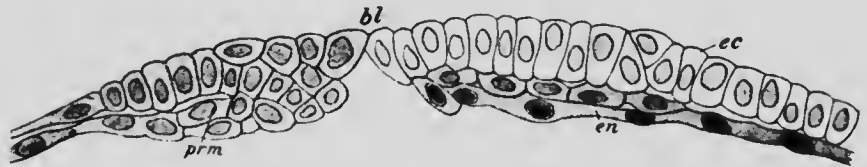

FIG. 30.—POSTERIOR PORTION OF A LONGITUDINAL SECTION THROUGH THE EMBRYONIC DISK OF A MOLE.

*bl*, Blastopore; *cc*, ectoderm; *en*, endoderm; *prm*, prostomial mesoderm.—(After Heape.)

tive streak (Fig. 29, B), a slight groove along its median line forming what is termed the *primitive groove*. In slightly later stages an especially dark spot may be seen at the front end of the primitive streak and is termed *Hensen's node* (Fig. 29, C, *hn*), while still later a dark streak may be observed extending forward from this in the median line and is termed the *head-process* of the primitive streak.

To understand the meaning of these various dark areas recourse must be had to the study of sections. A longitudinal section through the embryonic disk of a mole ovum at the time when the crescentic area makes its ap-

pearance is shown in Fig. 30. Here there is to be seen near the hinder edge of the disk what is potentially an opening (*bl*), in front of which the ectoderm (*ec*) and primary endoderm (*en*) can be clearly distinguished, while behind it no such distinction of the two layers is visible. This stage, then, may be regarded as comparable to the invagination stage of the reptilian ovum, the blastopore being, however, much less developed, and the region behind the blastopore will correspond to the reptilian primitive streak. The later forward extension of the primitive streak is supposed to be due to the mode of growth of the embryonic disk. Between the stages represented in Figs.

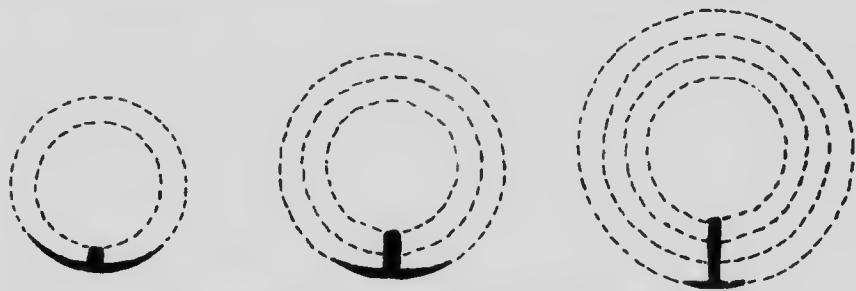


FIG. 31.—DIAGRAM ILLUSTRATING CONERESCENCE. —(Duvál.)

30 and 29, B, the disk has enlarged considerably and as growth proceeded there was a turning in, as it were, of the edges of the disk at its posterior end, whereby the primitive streak would be carried forward and elongated. This process, which is termed *conerescence*, will perhaps be understood more clearly from an inspection of Fig. 31 than from many lines of description. If this process of conerescence really occurs, then the point where the original rudimentary blastopore occurred is now situated far forward upon the embryonic disk, and Hensen's node indicates a proliferation of cells in the vicinity of the blastopore to form the prostomial mesoderm.



As regards the head process, it is a band of cells which grows forward from the region of the blastopore along the median line and replaces the primary endoderm in that situation (Fig. 32, *chp*). It corresponds, therefore, to the dorsal wall of the invagination of secondary endoderm in the reptile, the ventral wall of the invagination not developing at all, a condensation of development already indicated in the turtle (see p. 69). Indeed, in the gecko, the turtle, and the mammal we have three degrees of simplification of a process. In the gecko a sac-like invagination extends nearly to the anterior edge of the embryonic



FIG. 32.—TRANSVERSE SECTION OF THE EMBRYONIC AREA OF A DOG'S OVUM AT ABOUT THE STAGE OF DEVELOPMENT SHOWN IN FIG. 29, C. The section passes through the head process (*Chp*); *M*, mesoderm.—(Bonnet.)

disk and its ventral wall later disappears; in the turtle the invagination is comparatively slight and the useless ventral wall is only partly developed; and, finally, in the mammal (Fig. 33) the invagination is practically non-existent and no ventral wall whatsoever is formed, only the dorsal wall (*ce*) growing forward. It should be stated that in some mammals apparently the most anterior portion of the roof of the archenteron is formed directly from the cells of the primary endoderm, which in this region are not replaced by the head process, but aggregate to

form a compact plate of cells with which the anterior extremity of the head process unites. Such a condition would represent a further modification of the original condition.

As regards the formation of the mesoderm it is possible to recognize both the prostomial and gastral mesoderm in the mammalian ovum, though the two parts are not so clearly distinguishable as in lower forms. It has already been seen that Hensen's node probably indicates the existence of a mass of prostomial mesoderm, and when the head process grows forward it carries with it some of this



FIG. 33.—DIAGRAM OF A LONGITUDINAL SECTION THROUGH THE EMBRYONIC DISK OF A MOLE.

*am*, Amnion; *ce*, chorda endoderm; *ec*, ectoderm; *nc*, neurenteric canal  
*ps*, primitive streak. —(Heape.)

tissue. But, in addition to this, a contribution to the mesoderm is also apparently furnished by the cells of the head process in the form of lateral plates situated on each side of the middle line. These plates are at first solid (Fig. 34, *gm*), but their cells quickly arrange themselves in two layers, between which a cœlomic space later appears.

Furthermore, as has already been pointed out, the layer of enveloping cells splits into two concentric layers, the inner of which seems to be mesodermal in its nature and forms a layer lining the interior of the trophoblast and lying between this and the primary endoderm. This layer is by no means so evident in the lower forms, but is

perhaps represented in the reptilian ovum by the cells which underlie the ectoderm in the regions peripheral to the blastoderm proper (see p. 70).

**The Significance of the Germ Layers.**—The formation of the three germ layers is a process of fundamental importance, since it is a differentiation of the cell units of the ovum into tissues which have definite tasks to fulfil. As has been seen, the first stage in the development of the layers is the formation of the ectoderm and endoderm, or, if the physiological nature of the layers be considered, it is the differentiation of a layer, the endoderm, which has

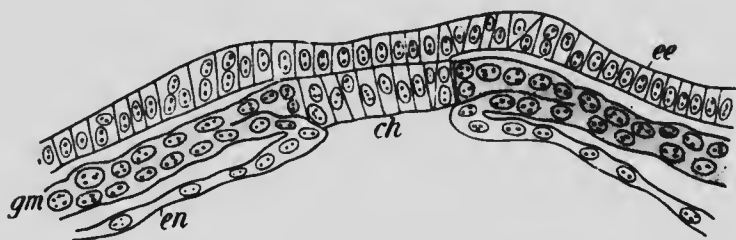


FIG. 34.—TRANSVERSE SECTION THROUGH THE EMBRYONIC DISK OF A RABBIT.  
*ch*, Chorda endoderm; *ee*, ectoderm; *en*, endoderm; *gm*, gastral mesoderm.—(After van Beneden.)

principally nutritive functions. In certain of the lower invertebrates, the class Cœlentera, the differentiation does not proceed beyond this diploblastic stage, but in all higher forms the intermediate layer is also developed, and with its appearance a further division of the functions of the organism supervenes, the ectoderm, situated upon the outside of the body, assuming the relational functions, the endoderm becoming still more exclusively nutritive, while the remaining functions, supportive, excretory, locomotor, reproductive, etc., are assumed by the mesoderm.

The manifold adaptations of development obscure in

certain cases the fundamental relations of the three layers, certain portions of the mesoderm, for instance, failing to differentiate simultaneously with the rest of the layer and appearing therefore to be a portion of either the ectoderm or endoderm. But, as a rule, the layers are structural units of a higher order than the cells, and since each assumes definite physiological functions, definite structures have their origin from each.

Thus from the ectoderm there develop:

The epidermis and its appendages, hairs, nails, epidermal glands, and the enamel of the teeth.

The mucous membrane lining the mouth and the nasal cavities, as well as that lining the lower part of the rectum.

The nervous system and the nervous elements of the sense-organs, together with the lens of the eye.

From the endoderm develop:

The mucous membrane lining the digestive tract in general, together with the epithelium of the various glands associated with it, such as the liver and pancreas.

The lining epithelium of the larynx, trachea, and lungs.

The epithelium of the bladder and urethra.

From the mesoderm there are formed:

The various connective tissues, including bone and the teeth (except the enamel).

The muscles, both striated and non-striated.

The circulatory system, including the blood itself and the lymphatic system.

The lining membrane of the serous cavities of the body.

The kidneys and ureters.

The internal organs of reproduction.

From this list it will be seen that the products of the mesoderm are more varied than those of either of the other layers. Among its products are organs in which in either the embryonic or adult condition the cells are arranged in

a definite layer, while in other structures its cells are scattered in a matrix of non-cellular material, as, for example, in the connective tissues, bone, cartilage, and the blood and lymph. It has been proposed to distinguish these two forms of mesoderm as *mesothelium* and *mesenchyme* respectively, a distinction which is undoubtedly convenient, though probably devoid of the fundamental importance which has been attributed to it by some embryologists.

## LITERATURE.

- R. ASSHETON: "A Reinvestigation into the Early Stages of the Development of the Rabbit," *Quarterly Journ. of Microsc. Science*, xxxvii, 1894.
- R. ASSHETON: "The Development of the Pig During the First Ten Days," *Quarterly Journ. of Microsc. Science*, xli, 1898.
- R. ASSHETON: "The Segmentation of the Ovum of the Sheep, with Observations on the Hypothesis of a Hypoblastic Origin for the Trophoblast," *Quarterly Journ. of Microsc. Science*, xli, 1898.
- E. VAN BENEDEN: "Recherches sur les premiers stades du développement du Murin (*Vespertilio murinus*)," *Anatom Anzeiger*, xvi, 1899.
- R. BONNET: "Beiträge zur Embryologie der Wiederkäuer gewonnen am Schafei," *Archiv für Anat. und Physiol., Anat. Abth.*, 1884 and 1889.
- R. BONNET: "Beiträge zur Embryologie des Hundes," *Anat. Hefte*, ix, 1897.
- G. BORN: "Erste Entwicklungsvorgänge," *Ergebnisse der Anat. und Entwicklungsgesch.*, i, 1892.
- A. C. EYLESHYMER: "The Early Development of Amblystoma with Observations on Some Other Vertebrates," *Journ. of Morphol.*, x, 1895.
- B. HATSCHEK: "Studien über Entwicklung des Amphioxus," *Arbeiten aus dem zoolog. Institut zu Wien*, iv, 1881.
- W. HEAPE: "The Development of the Mole (*Talpa europæa*)," *Quarterly Journ. of Microsc. Science*, xxiii, 1883.
- A. A. W. HUBRECHT: "Studies on Mammalian Embryology II: The Development of the Germinal Layers of *Sorex vulgaris*," *Quarterly Journ. of Microsc. Science*, xxxi, 1890.
- F. KEIBEL: "Studien zur Entwicklungsgeschichte des Schweines," *Morpholog. Arbeiten*, iii, 1893.
- K. MITSUKURI and C. ISHIKAWA: "On the Formation of the Germinal Layers in Chelonia," *Quarterly Journ. of Microsc. Science*, xxvii, 1887.

- E. SELENKA: "Studien über Entwicklungsgeschichte der Thiere," 4tes Heft, 1886-87; 5tes Heft, 1891-92.
- J. SOBOTTA: "Die Befruchtung und Furchung des Eies der Maus," *Archiv für mikrosk. Anat.*, XLV, 1895.
- J. SOBOTTA: "Die Furchung des Wirbelthiereies," *Ergebnisse der Anat. und Entwicklungsgeschichte.*, VI, 1897.
- L. WILL: "Beiträge zur Entwicklungsgeschichte der Reptilien," *Zoolog. Jahrbücher, Abth. für Anat.*, VI, 1893.

CHAPTER III.

THE DEVELOPMENT OF THE EXTERNAL  
FORM OF THE HUMAN EMBRYO.

The youngest human ovum at present known is that described by Peters. It was taken from the uterus of a

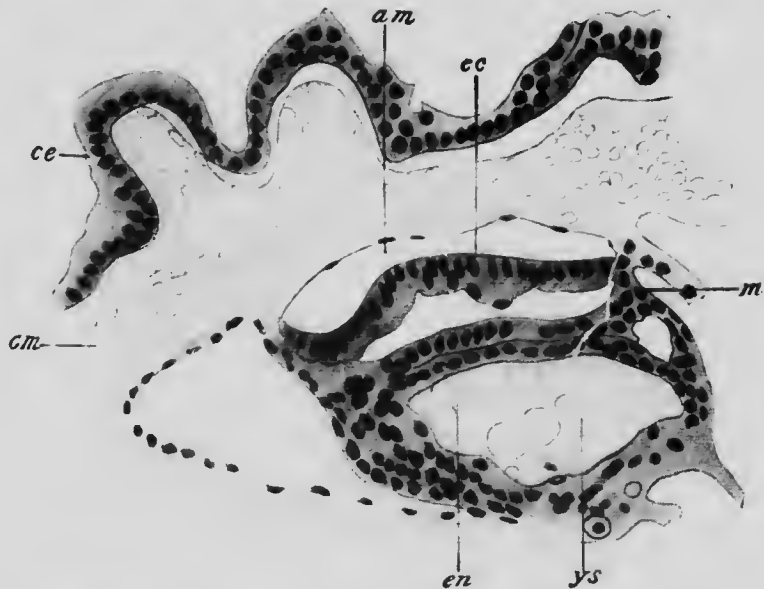


FIG. 35.—SECTION OF EMBRYO AND ADJACENT PORTION OF AN OVUM OF  
1 MM.

*am*, Amniotic cavity; *cc*, chorionic cavity; *cm*, chorionic mesoderm; *ec*, embryonic ectoderm; *en*, endoderm; *m*, embryonic mesoderm; *ys*, yolk-sac.—(Peters.)

woman who had committed suicide one calendar month after the last menstruation, and it measured about 1 mm. in diameter. The entire inner surface of the trophoblast (Fig. 35, *ce*) was lined by a layer of mesoderm (*cm*), which,

on the surface furthest away from the uterine cavity, was considerably thicker than elsewhere, forming an area of attachment of the embryo to the wall of the ovum. In the substance of this thickening was the amniotic cavity (*am*), whose roof was formed by flattened cells, which, at the sides, became continuous with a layer of columnar cells forming the floor of the cavity and constituting the embryonic ectoderm (*ec*). Immediately below this was a

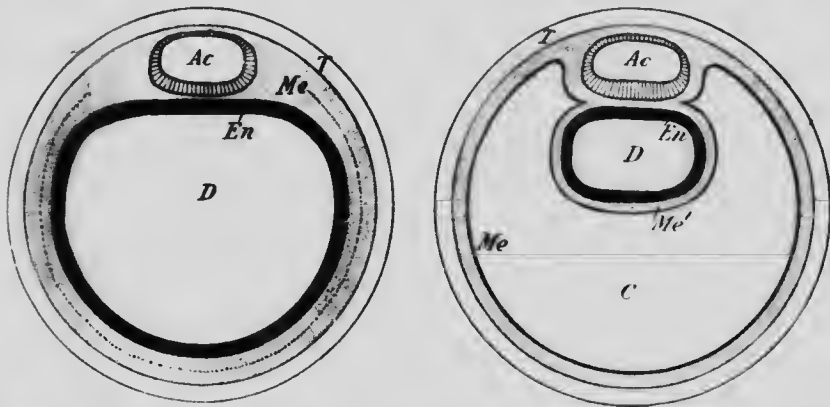


FIG. 36.—DIAGRAMS TO SHOW THE PROBABLE RELATIONSHIPS OF THE PARTS IN THE EMBRYOS REPRESENTED IN FIGS. 28, C, AND 35. *Ac*, Amniotic cavity; *C*, extra-embryonic body-cavity; *Me*, (in figure to the left) mesoderm, (in figure to the right) somatic mesoderm; *Me'*, splanchnic mesoderm; *D*, digestive tract; *En*, endoderm; *T*, trophoblast. The broken line in the mesoderm of the figure to the left indicates the line along which the splitting of the mesoderm occurs.

layer of mesoderm (*m*) which split at the edge of the embryonic disk into two layers, one of which became continuous with the mesodermic thickening and so with the layer of mesoderm lining the interior of the trophoblast, while the other enclosed a sac lined by a layer of endodermal cells and termed the *yolk-sac* (*ys*). The total length of the embryo was 0.19 mm., and so far as its ectoderm and mesoderm are concerned it might be described as a flat disk resting on the surface of the yolk-sac, though



it must be understood that the yolk-sac also to a certain extent forms part of the embryo.

This embryo seems to be in an early stage of the primitive streak formation, before the development of the head process. On comparing it with the ovum of a bat in approximately the stage of development represented in Fig. 28, C, it will be seen to present some important advances (Fig. 36). It seems clear that the yolk-sac is equivalent to what was the cavity of the ovum in the earlier stages, and consequently the cavity (*c*) into which the yolk-sac projects is unrepresented in the bat's ovum. How this cavity is formed can only be conjectured, but it seems probable that it arises by the splitting of the layer of cells which lines the interior of the trophoblast in the bat's ovum (or perhaps by the vacuolization of the central cells of this layer) and the subsequent accumulation of fluid between the two mesodermal layers so formed. However that may be, it seems clear that the size of the human ovum is due mainly to the rapid growth of this cavity, which, as future stages show, is the extra-embryonic portion of the body-cavity, the splitting or vacuolization of the mesoderm by which it is probably formed being the precocious appearance of the typical splitting of the mesoderm to form the embryonic body-cavity which, as will be seen in a subsequent chapter, takes place only at a later stage of development. From now on the trophoblast and the layer of mesoderm lining it may together be spoken of as the *chorion*, the mesoderm layer being termed the chorionic mesoderm.

A human embryo of a somewhat greater age (Fig. 37), measuring about 0.37 mm. in length, has been described by Graf Spee as embryo *v.H.*, and was taken from an ovum estimated to measure 6 by 4.5 mm. in diameter. Notwithstanding the much greater size of the ovum,

which is due to the continued increase in the size of the extra-embryonic coelom, the embryo is but little advanced beyond the stage which the Peters' embryo had reached, and is probably in a late stage of the development of the primitive streak. Confining the attention for the present solely to the embryo and the immediately adjoining parts, it will be seen that the thickening of the chorionic mesoderm which encloses the amniotic cavity has increased in

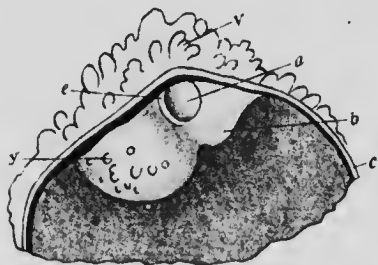


FIG. 37.—OVIUM MEASURING  $6 \times 4.5$  MM. THE LEFT HALF OF THE CHORION HAS BEEN REMOVED TO SHOW THE EMBRYO.  
a, Amniotic cavity; b, belly-stalk; c, chorion; e, embryonic disk; v, chorionic villus; y, yolk-sac.—(von Spee.)

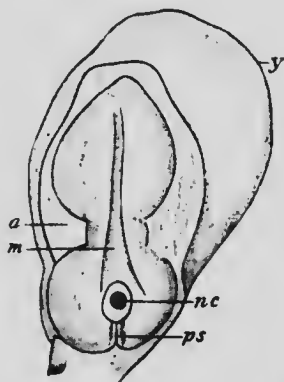


FIG. 38.—EMBRYO 1.54 MM. IN LENGTH, FROM THE DORSAL SURFACE.  
a, Amnion; m, medullary groove; nc, neurenteric canal; ps, primitive streak; y, yolk-sac.—(von Spee.)

size and now forms a pedicle, known as the *belly-stalk* (b), at the extremity of which is the *yolk-sac* (y). Furthermore, the amniotic cavity (a) now lies somewhat eccentrically in this pedicle, being near what may be spoken of as its anterior surface. The embryo still possesses a discoidal form and may still be described as a flat disk floating on the surface of the yolk-sac.

This same general form is preserved in another embryo, known as embryo *Gle*, described by Graf Spee, which

measured 1.54 mm. in length (Fig. 38). In it, however, the more median portion of the embryonic disk has become thicker and is separated from the more peripheral portions by a distinct furrow. From the more median or axial portion the embryo proper will develop, and this portion is now shaped somewhat like the body of a violin and presents at its posterior portion the remains of the primi-

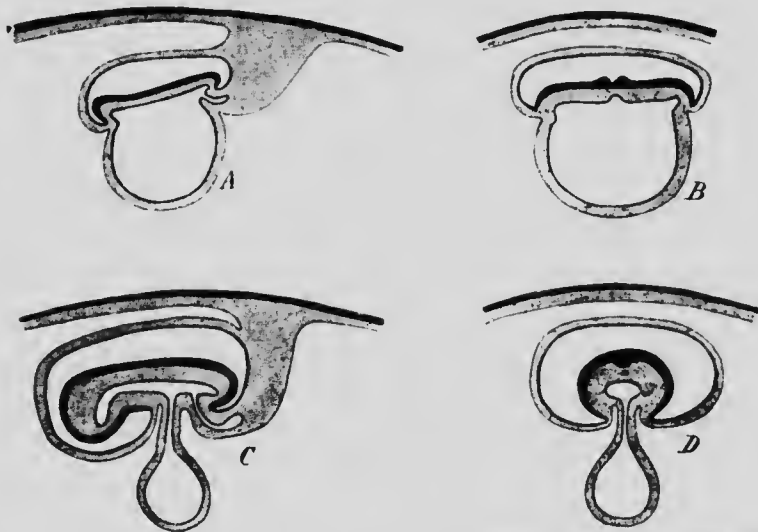


FIG. 39.—DIAGRAMS ILLUSTRATING THE CONSTRICTION OF THE EMBRYO FROM THE YOLK-SAC.

*A* and *C* are longitudinal, and *B* and *D* transverse sections. *B* is drawn to a larger scale than the other figures.

tive streak, near the anterior end of which is a distinct pore, the opening of what is termed the *neurenteric canal* (*nc*), a description of which will be found in a subsequent chapter (p. 112). More anteriorly two longitudinal ridges have appeared, the first indications of which are termed the *medullary folds*.

In later stages a separation or constriction of the embryo from the yolk-sac begins and results in the transformation of the discoidal embryonic portion of the em-

bryonic disk into a cylindrical structure. Primarily this depends upon the deepening of the furrow which surrounds the embryonic area, the edges of this area being thus bent in on all sides toward the yolk-sac. This bending in proceeds most rapidly at the anterior end of the body, as shown in the diagrams (Fig. 39), and least rapidly at the posterior end where the belly-stalk is situated, and produces a constriction of the yolk-sac, the portion of that structure nearest the embryonic disk becoming enclosed within the body of the embryo to form the digestive tract, while the remainder is converted into a pedicle-like portion, the *yolk-stalk*, at the extremity of which is the *yolk-vesicle*. The further continuance of the folding in of the edges of the embryonic area leads to an almost complete closing in of the digestive tract and reduces the opening through which the yolk-stalk and belly-stalk communicate with the embryonic tissues to a small area known as the *umbilicus*.

An embryo which exhibits an early stage in the process of constriction has been described by Allen Thompson and is represented in Fig. 40.\* It measured about 2.5 mm. in length and had reached a stage in which the medullary folds had become very pronounced and their edges had come into contact at one portion, although the anterior and posterior portions of the groove (*mg*) between them

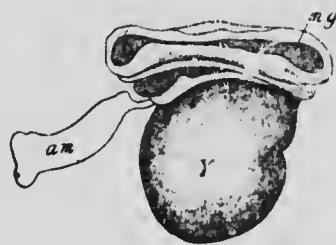


FIG. 40.—EMBRYO 2.5 MM. LONG.  
*am*, Fragment of the torn amnion; *mg*, medullary groove; *Y*, yolk-sac.—(Allen Thompson.)

\* It must be noted that in the figure neither the amnion (except for a small fragment still persisting in front) nor the belly-stalk is represented.

were still widely open. The embryo will be seen from the figure to project somewhat both in front of and behind the yolk-sac, although the greater part of its ventral surface is still formed by that structure. At the sides also it is well separated from the yolk-sac, and resting upon the sac in front is a swelling which represents the heart.

In another embryo (Fig. 41), slightly smaller though

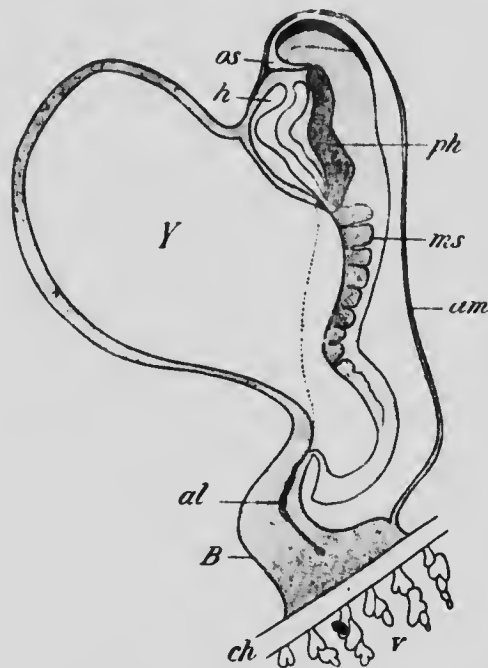


FIG. 41.—RECONSTRUCTION OF EMBRYO 2.11 MM. LONG.

*al*, Allantois; *am*, amnion; *B*, belly-stalk; *ch*, chorion; *h*, heart; *ms*, mesodermic somite; *os*, oral fossa; *ph*, pharynx; *v*, chorionic villi; *Y*, yolk-sac.—(After Eternod.)

evidently older than the preceding one, and described by Eternod, the edges of the medullary folds have not only come into contact throughout the greater portion of their length, but they have fused together, the groove between them being open only in front and behind. On each side of the median line eight somewhat oblong areas are to be

distinguished, caused by a transverse division of the subjacent mesoderm into what are termed *mesodermic somites*

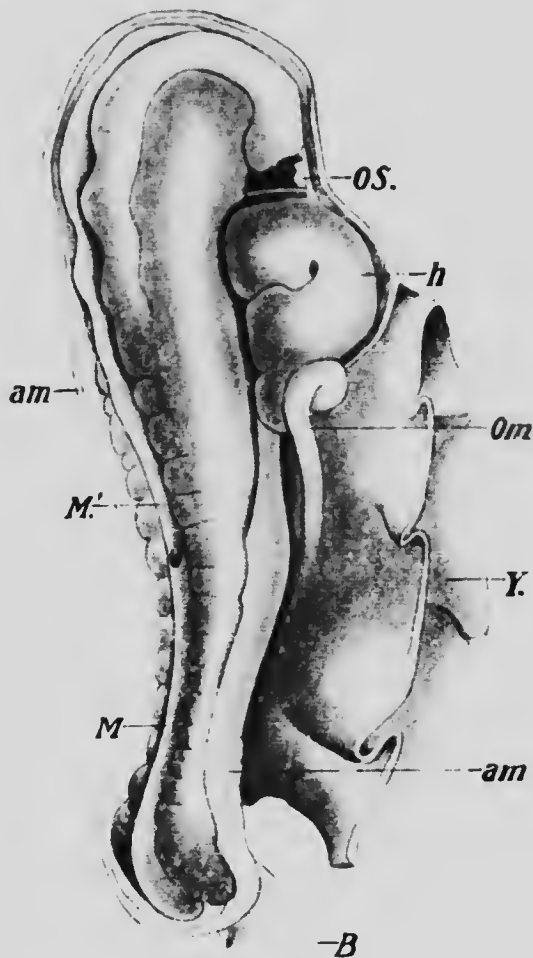



FIG. 42.—EMBRYO 2.5 MM. LONG.

*am*, Amnion; *B*, belly-stalk; *h*, heart; *M*, closed, and *M'*, still open portions of the medullary groove; *Om*, omphalo-mesenteric vein; *OS*, oral fossa; *Y*, yolk-sac. — (Kollmann)

(*ms*), structures which will be described in detail in the succeeding chapter. The separation of the embryo from





MICROCOPY RESOLUTION TEST CHART  
 NATIONAL BUREAU OF STANDARDS  
 STANDARD REFERENCE MATERIAL 1010a  
 (ANSI and ISO TEST CHART No. 2)



the yolk-sac (*Y*) has advanced considerably and the sac shows evident indications of constriction just where it meets the body of the embryo. The head projects more markedly beyond the anterior surface of the yolk-sac and is separated from the region occupied by the heart (*h*)

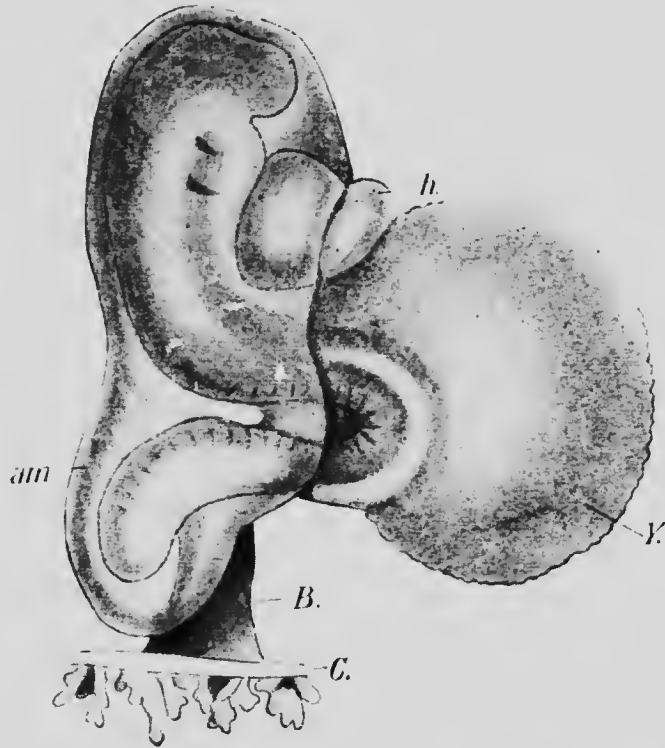


FIG. 43.—EMBRYO Lg. 2.15 MM. LONG.  
*am*, Amnion; *B*, belly-stalk; *C*, chorion; *h*, heart; *Y*, yolk-sac.—(*His.*)

by a deep and well-marked depression, the *oral fossa* (*os*).

In an embryo described by Kollmann (Fig. 42) and measuring 2.5 mm. in length,\* the edges of the medullary folds (*M*) had come into contact throughout their entire

\* The embryo was measured only after having been preserved in alcohol, and the actual length was probably somewhat greater than this.

length, except for a short distance anteriorly ( $M^1$ ), and thirteen mesodermic somites were visible. The constriction of the yolk-sac was even more pronounced than in the preceding embryo and the hind end of the body had become defined, the belly-stalk no longer seeming to be a posterior continuation of the body but arising from the posterior part of the ventral surface. The oral fossa ( $OS$ ) was also more marked, and it may be noticed that the dorsal surface of the body was distinctly concave from before backward, a peculiarity which becomes more pronounced in a later stage and constitutes what is termed the *dorsal flexure*.

This is well shown in an embryo described by His and named by him embryo LXVIII (Lg) (Fig. 43). In it the yolk-sac forms a much smaller portion of the ventral surface than it did in earlier stages, and it has also become distinctly separated from the belly-stalk. The most peculiar feature of this embryo is, however, the dorsal flexure. This is apparently a normal feature and is probably produced by a difference in the rate of growth of the lateral and median portions of the outer layer of the embryonic mesoderm, the former portion failing to keep pace with the growth of the latter, which becomes folded in accommodation to the strain. The flexure is of comparatively short duration, and when once it begins to disappear it seems to do so rapidly, the dorsal concavity suddenly becoming a convexity and the tension of the layer coming into equilibrium in the new position. One other feature is noteworthy in this embryo—namely, the occurrence of two linear vertical depressions a little behind the head region of the embryo; these are the first representatives of a series of *branchial clefts*.

These structures are of great morphological importance,

inasmuch as they determine to a large extent the arrangement of various organs of the head region. They represent the clefts which exist in the walls of the pharynx in fishes, through which water, taken in at the mouth, passes to the exterior, bathing on its way the gill filaments attached to the bars or *arches*, as they are termed, which separate successive clefts. Hence the name "branchial" which is applied to them, though in the mammals they never have respiratory functions

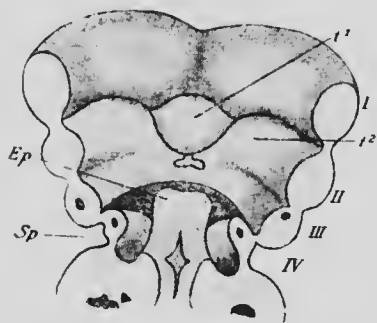


FIG. 44.—FLOOR OF THE PHARYNX OF EMBRYO B, 7 MM LONG.

*Ep*, Epiglottis; *Sp*, sinus praecervicalis; *t*<sup>1</sup>, anterior, and *t*<sup>2</sup>, posterior portions of the tongue; *I*, *II*, *III*, and *IV*, branchial arches. —(*His.*)

to perform, but, appearing, persist for a time and then either disappear or are applied to some entirely different purpose. Indeed, in man they are never really clefts but merely grooves, and corresponding to each groove in the ectoderm there is also one in the subjacent endoderm of what will eventually be the pharyngeal region of the digestive tract, so that in the region of each cleft the ecto-

derm and endoderm are in close relation, being separated only by a very thin layer of mesoderm, while in the intervals between successive clefts a more considerable amount of mesoderm is present (Fig. 44).

In the human embryo four clefts develop in each side of the body and five branchial arches, the last arch lying posteriorly to the fourth cleft and not being very sharply defined along its posterior margin.

As just stated, the clefts are normally merely grooves, and in later development either disappear or are converted into

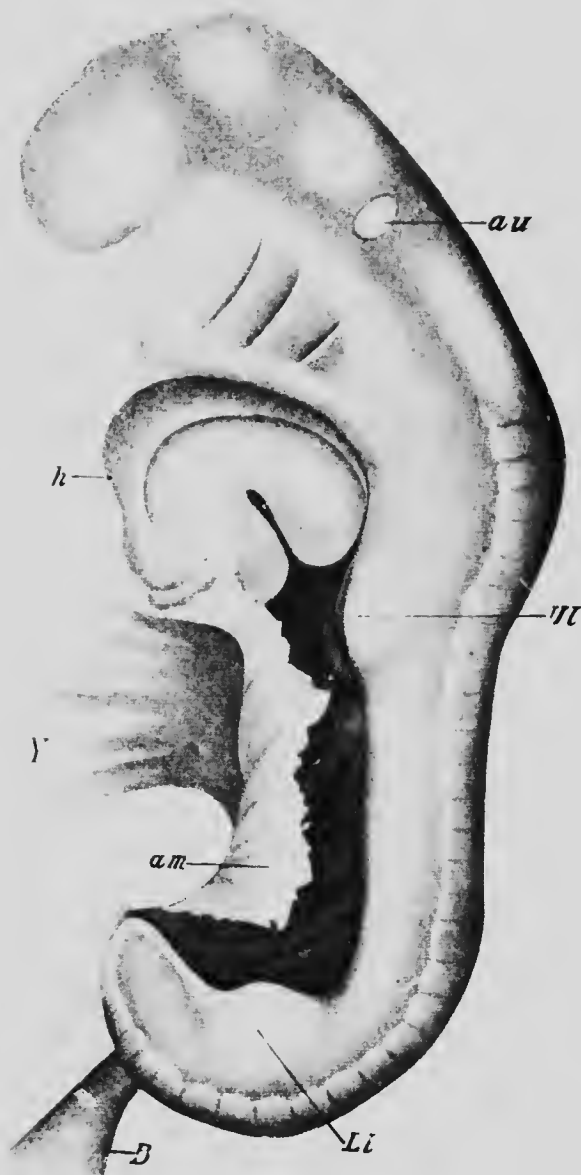


FIG. 45.—EMBRYO Lr, 4.2 MM. LONG.

*am*, Amnion; *au*, auditory capsule; *B*, belly-stalk; *h*, heart; *Li*, lower and *U*, upper limb; *Y*, yolk-sac.—(*His.*)

special structures. Occasionally, however, a cleft may persist and the thin membrane which forms its floor may become perforated so that an opening from the exterior into the pharynx occurs at the side of the neck, forming what is termed a *branchial fistula*. Such an abnormality is most frequently developed from the lower (ventral) part of the first cleft; normally this disappears, the upper portion persisting, however, to form the external auditory meatus and tympanic cavity.

The embryo LXVIII (Lg) just described measured 2.11 mm. in length, this measurement, however, being taken along a straight line and not following the flexure of the body. It does not represent, therefore, the actual length of the body and there is much less difference between it and the next embryo described than is implied by the figures. This embryo (Fig. 45) is also one of those described by His and is known as embryo LXVII (Lr). It measures 4.2 mm. in length and shows an almost complete disappearance of the dorsal flexure so marked in embryo LXVIII. Instead of this, it presents a well-marked ventral bending of both the anterior and posterior portions of the body, so that the dorsal surface is prominently convex in the regions which will later be the nape of the neck and the sacral region, and consequently the convexities may be known as the *neck bend* and the *sacral bend*. Furthermore, there is noticeable a ventral projection of the extreme front end of the body, so that a third convexity occurs anteriorly to the neck bend and may be termed the *head bend*.

The constriction of the yolk-sac has progressed, as has also its separation from the belly-stalk; the mesodermic somites have almost reached their maximum development and are very distinct; the two branchial clefts present in the preceding embryo have increased in size and the third cleft has made its appearance; two

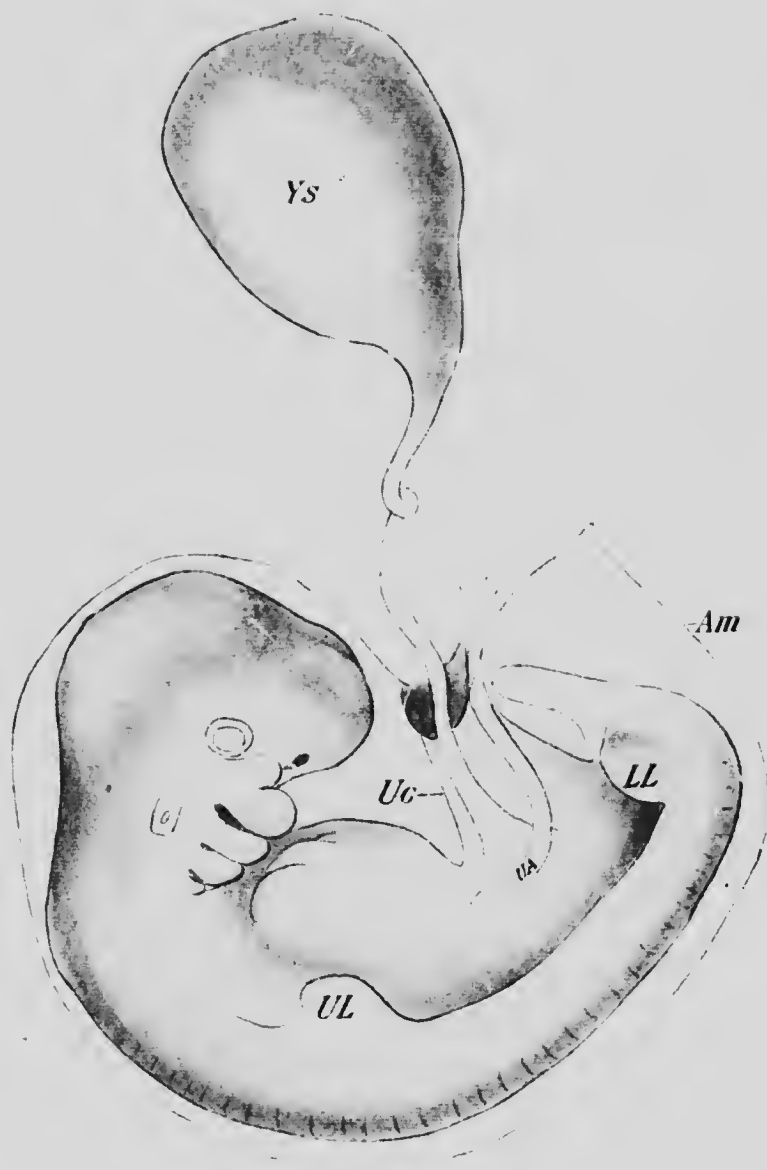


FIG. 46.—EMBRYO OF FROM TWENTY TO TWENTY-FIVE DAYS.  
*Am*, Amnion; *LL*, lower limb; *UA*, umbilical artery; *Uc*, umbilical cord;  
*UL*, upper limb; *Ys*, yolk-sac.—(*Coste.*)

small elevations of the sides of the body, one almost opposite the neck bend and the other opposite the sacral bend, are the first indications of the limbs (*Ul* and *Ll*); and the eyeball and ear vesicle (*au*), which were present though not very evident in earlier stages, are now plainly visible in surface views.

In the next stage—as a type of which an embryo

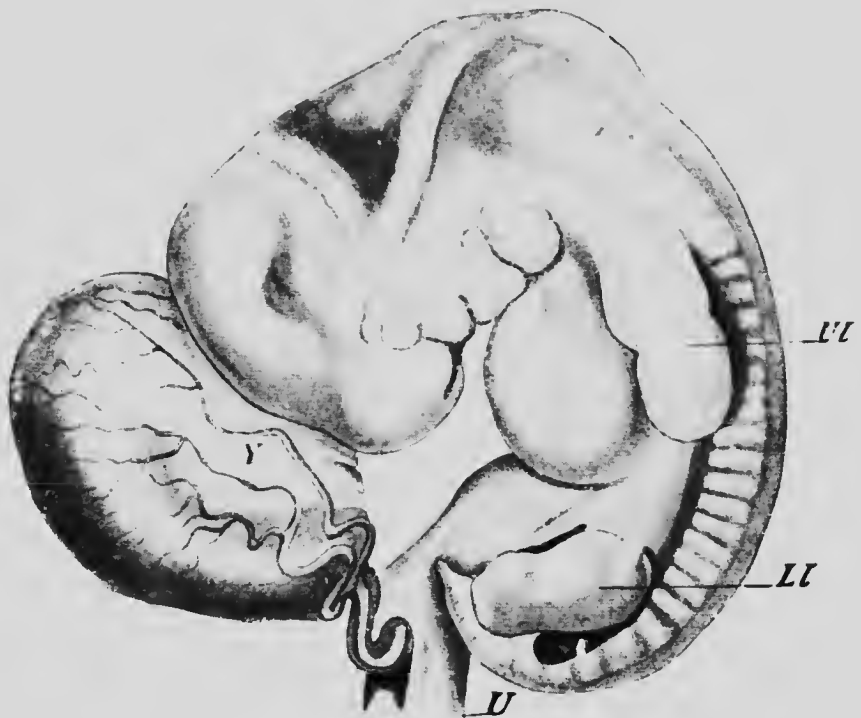


FIG. 47.—EMBRYO 9.1 MM. LONG.

*Ll*, Lower limb; *U*, umbilical cord; *Ul*, upper limb; *Y*, yolk-sac.—(*His.*)

figured by Coste (Fig. 46) may be taken—the three bends of the body mentioned above have greatly increased, so that the head and tail of the embryo are almost in contact and the latter is bent a little toward one side. The closure of the ventral surface of the body is almost completed and

the margins of the umbilicus have begun to be prolonged ventrally so as to enclose the yolk-stalk and belly-stalk in the *umbilical cord*. The yolk-sae has increased considerably in length and the differentiation of its extra-embryonic portions into a yolk-stalk and yolk-vesicle is plainly distinguishable. The limb rudiments have increased somewhat in size, and, in addition to the eyeball and ear vesicle, a third sense-organ has made its appearance in the form of two pits situated on the under side of the anterior portion of the head; these pits are the first indications of the *nasal fossæ*.

The fourth branchial cleft has appeared and those formed earlier have elongated so that they almost reach the mid-ventral line, and from the dorsal part of the anterior border of the first arch a strong process has developed so that the arch on each side is somewhat <-shaped. The upper limb of each V is destined to give rise to the upper jaw, and hence is known as the *maxillary process*, while the lower limb represents the lower jaw and is termed the *mandibular process*.

Leaving aside for the present all consideration of the further development of the limbs and branchial arches, the further evolution of the general form of the body may be rapidly sketched. In an embryo (Fig. 47) from Ruge's collection, described and figured by His and measuring 9.1 mm. in length,\* the prolongation of the margins of the umbilicus has increased until more than half the yolk-stalk has become enclosed within the umbilical cord. The neck and sacral bends are still very pronounced, although

\* This measurement is taken in a straight line from the most anterior portion of the neck bend to the middle point of the sacral bend and does not follow the curvature of the embryo. It may be spoken of as the neck-rump length and is convenient for use during the stages when the embryo is coiled upon itself.



the embryo is beginning to straighten out and is not quite so much coiled as in the preceding stage. At the posterior end of the body there has developed a rather abruptly conical *tail filament*, in the place of the blunt and gradually tapering termination seen in earlier stages, and a well-marked rotundity of the abdomen, due to the rapidly increasing size of the liver, begins to become evident.

In later stages the enclosure of the yolk- and belly-stalks within the umbilical cord proceeds until finally the

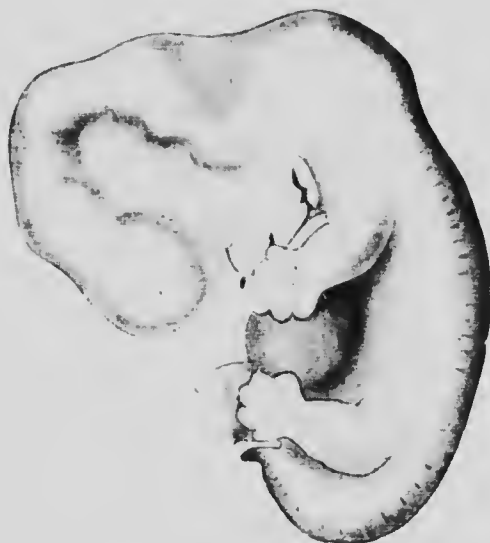

FIG. 48.—EMBRYO Br<sub>2</sub>, 13.6 MM. LONG.—(His.)

cord is complete through the entire interval between the embryo and the wall of the ovum. At the same time the straightening out of the embryo continues, as may be seen in Fig. 48 representing the embryo XLV (Br<sub>2</sub>) of His, which shows also, both in front of and behind the neck bend, a distinct depression, the more anterior one being the *occipital* and the more posterior the *neck depression*; both these depressions are the expressions of changes taking

place in the central nervous system. The tail filament has become more marked, and in the head region a slight ridge surrounding the eyeball and marking out the conjunctival area has appeared, a depression anterior to the nasal fossæ marks off the nose from the forehead, and the external ear, whose development will be considered later on, has become quite distinct. This embryo had a neck-rump length of 13.6 mm.

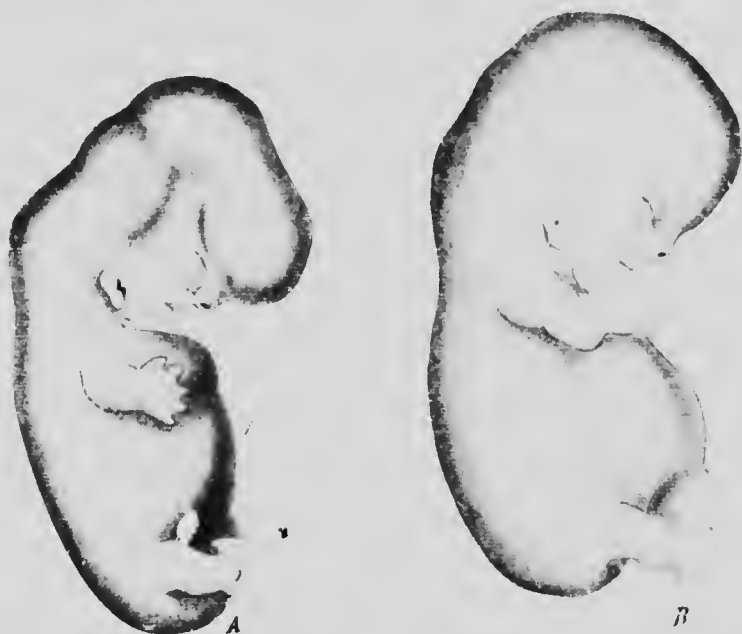

FIG. 49.—A, EMBRYO  $S_2$ , 15 MM. LONG (SHOWING ECTOPIA OF THE HEART);  
B, EMBRYO  $L_3$ , 17.5 MM. LONG.—(His.)

In the embryos xxxv ( $S_2$ ) and xcix ( $L_3$ ) (Fig 49, A and B) of His' collection the straightening out of the neck bend is proceeding, and indeed is almost completed in embryo xcix, which begins to resemble closely the fully formed fetus. The tail filament, somewhat reduced in size, still persists and the rotundity of the abdomen continues to be well marked. The neck region is beginning to be distin-

guishable in embryo xxxv and in embryo xcix the eyelids have appeared as slight folds surrounding the conjunctival area. The nose and forehead are clearly defined by the greater development of the nasal groove and the nose has also become raised above the general surface of the

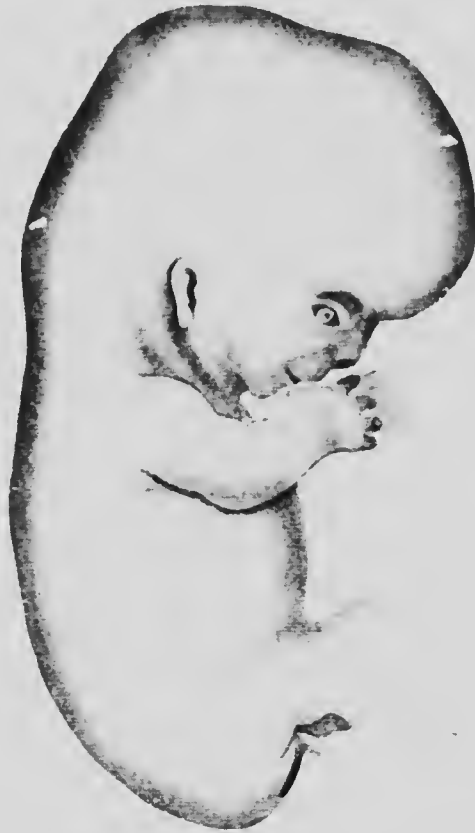

FIG. 50.—EMBRYO Wt, 23 MM. LONG.—(His.)

face, while the external ear has almost acquired its final fetal form. These embryos measure respectively about 15 and 17.5 mm. in length.\*

\* The embryo xxxv presents a slight abnormality in the great projection of the heart, but otherwise it appears to be normal.

Finally, an embryo—again one of those described by His, namely, His LXXVII (Wt) having a length of 23 mm.—may be figured (Fig. 50) as representing the practical acquisition of the fetal form. This embryo dates from about the end of the second month of pregnancy, and from this period onward it is proper to use the term fetus rather than that of embryo. The changes which have been described in preceding stages are now complete and it remains only to be mentioned that the caudal filament, which is still prominent, gradually disappears in later stages, becoming, as it were, submerged and concealed beneath adjacent parts by the development of the buttocks. The incompleteness of the development of these regions in embryo LXXVII is manifest, not only from the projection of the tail filament, but also from the external genitalia being still largely visible in a side view of the embryo, a condition which will disappear in later stages.

**The Later Development of the Branchial Arches, and the Development of the Face.**—In Coste's embryo (Fig. 46) the four branchial clefts and five arches which develop in the human embryo are visible in surface views, but in the Ruge embryo (Fig. 47) it will be noticed that only the first two arches, the first with a well-developed maxillary process, and the cleft separating them can be distinguished. This is due to a sinking inward of the region occupied by the three posterior arches so that a triangular depression, the *sinus præcervicalis*, is formed on each side of what will later become the anterior part of the neck region. This is well shown in an embryo (Pr<sub>3</sub>) described by His which measured 6.9 mm. in length and of which the anterior portion is shown in Fig. 51. The anterior boundary of the sinus (*ps*) is formed by the posterior edge of the second arch and its posterior boundary by the thoracic wall, and

in later stages these two boundaries gradually approach one another so as first of all to diminish the opening into the sinus and later to completely obliterate it by fusing together, the sinus thus becoming converted into a completely closed cavity whose floor is formed by the ectoderm covering the three posterior arches and the clefts separating these. This cavity eventually un-

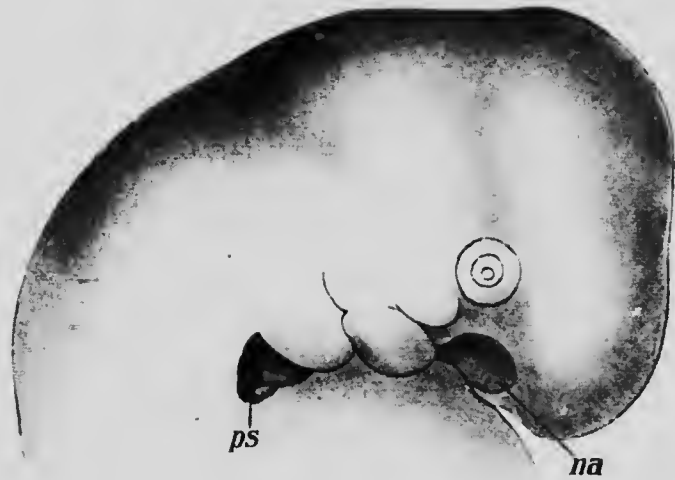


FIG. 51.—HEAD OF EMBRYO OF 6.9 MM.  
*na*, Nasal pit; *ps*, precervical sinus.—(*His.*)

dergoes degeneration, no traces of it occurring normally in the adult, although certain cysts occasionally observed in the sides of the neck may represent persisting portions of it.

A somewhat similar process results in the closure of the ventral portion of the first cleft,\* a fold growing back-

\* See page 94, small type.

ward from the posterior edge of the first arch and fusing with the ventral part of the anterior border of the second arch.

The upper part of the second cleft, however, persists, and, as already stated, forms the external auditory meatus, the pinna of the ear being developed from the adjacent parts of the first and second arches (Figs. 48 and 49).

The region immediately in front of the first arch is

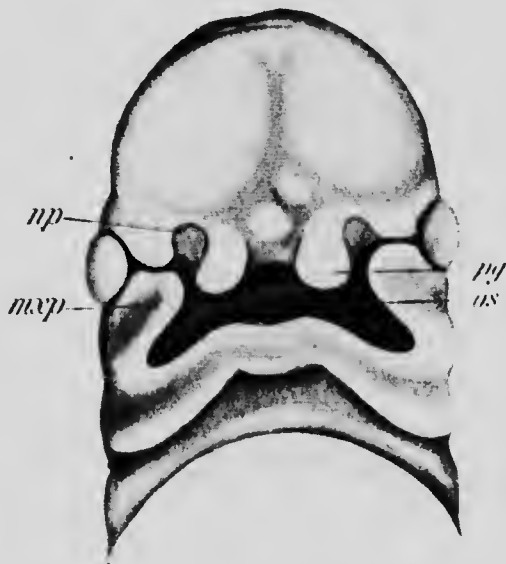


FIG. 52.—FACE OF EMBRYO OF 8 MM.

*mxp*, Maxillary process; *np*, nasal pit; *os*, oral fossa; *pg*, processus globularis.—(*His.*)

occupied by a rather deep depression, the oral fossa, whose early development has already been traced. In an embryo measuring 8 mm. in length (Fig. 52) the fossa (*os*) has assumed a somewhat irregular quadrilateral form. Its posterior boundary is formed by the mandibular processes of the first arch, while laterally it is bounded by the

maxillary processes (*mxp*) and anteriorly by the free edge of a median plate, termed the *nasal process*, which on either side of the median line is elevated to form a marked protuberance, the *processus globularis* (*pg*). The ventral ends of the maxillary processes are widely separated, the nasal process and the *processus globulares* intervening

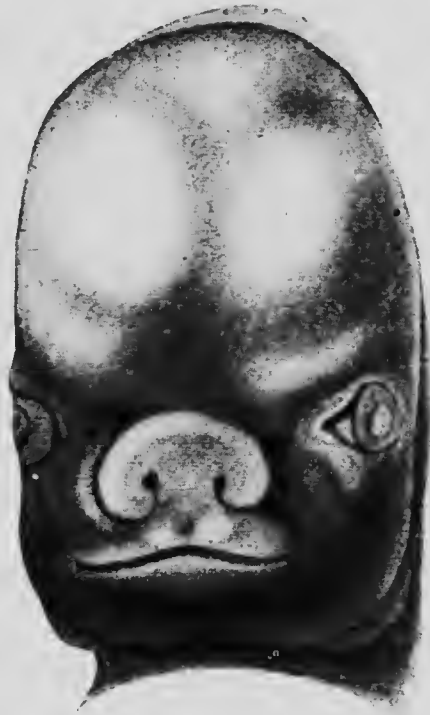

FIG. 53.—FACE OF EMBRYO AFTER THE COMPLETION OF THE UPPER JAW.  
—(*His.*)

between them, and they are also separated from the globular processes by a deep and rather wide groove which anteriorly opens into a circular depression, the *nasal pit* (*np*).

Later on the maxillary and globular processes unite,

obliterating the groove and cutting off the nasal pits—which have by this time deepened to form the nasal fossæ—from direct communication with the mouth, with which, however, they still communicate behind the maxillary processes, an indication of the anterior and posterior nares being thus produced.

Occasionally the maxillary and globular processes fail to unite on one or both sides, producing a condition popularly known as "harelip."

At the time when this fusion occurs the nasal fossæ are widely separated by the broad nasal process (Fig. 53), but during later development this process narrows to form the nasal septum and is gradually elevated above the general surface of the face as shown in Figs. 48-50. By the narrowing of the nasal process the globular processes are brought nearer together and form the portions of the upper jaw immediately on each side of the median line, the rest of the jaw being formed by the maxillary processes. In the mean time a furrow has appeared upon the mandibular process, running parallel with its borders (Fig. 49); the portion of the process in front of this furrow gives rise to the lower lip and is known as the *lip ridge*, while the portion behind the furrow becomes the lower jaw proper and is termed the *chin ridge*.

**The Development of the Limbs.**—As has been already pointed out, the limbs make their appearance in an embryo measuring about 4 mm. in length (Fig. 45) and are at first bud-like in form. As they increase in length they at first have their long axes directed parallel to the longitudinal axis of the body and become somewhat flattened at their free ends, remaining cylindrical in their proximal portions. A furrow or constriction appears at the junction of the flattened and cylindrical portions (Fig. 47), and later a second constriction divides the cylindrical portion



into a proximal and distal moiety, the three segments of each limb—the arm, forearm, and hand in the upper limb, and the thigh, leg, and foot in the lower—being thus marked out. The digits are first indicated by the development of four radiating shallow grooves upon the hand and foot regions, and a transverse furrow uniting the proximal ends of the digital furrows indicates the junction of the digital and palmar regions of the hand or of the toes and body of the foot. After this stage is reached the development of the upper limb proceeds more rapidly than that of the lower, although the processes are essentially the same in both limbs. The digits begin to project slightly, but are at first to a very considerable extent united together by a web, whose further growth, however, does not keep pace with that of the digits, which thus come to project more and more in later stages. Even in comparatively early stages the thumb, and to a somewhat slighter extent the great toe, is widely separated from the second digit (Figs. 49 and 50).

While these changes have been taking place the entire limbs have altered their position with reference to the axis of the body, being in stages later than that shown in Fig. 47 directed ventrally so that their longitudinal axes are at right angles to that of the body. From the figures of later stages it may be seen that it is the thumb (radial) side of the arm and the great toe (tibial) side of the leg which are directed forward; the plantar and palmar surfaces of the feet and hands are turned toward the body and the elbow is directed outward and slightly backward, while the knee looks outward and slightly forward. It seems proper to conclude that the radial side of the arm is homologous with the tibial side of the leg, the palmar surface of the hand with the plantar surface of the foot, and the elbow with the knee.

The limbs are, however, still in the quadrupedal condition, and they must later undergo a second alteration in position so that their long axes again become parallel with that of the body. This is accomplished by a rotation of the limbs around axes passing through the shoulders and hip-joints together with a rotation about their longitudinal axes through an angle of 90 degrees. This axial rotation of the upper limb is, however, in exactly the opposite direction to that of the lower limb of the corresponding side, so that the homologous surfaces of the two limbs have entirely different relations, the radial side of the arm, for instance, being upon the outer side while the tibial side of the leg is the inner side, and whereas the palmar surface of the hand looks ventrally, the plantar surface of the foot looks dorsally.

In making these statements no account is taken of the secondary position which the hand may assume as the result of its pronation; the positions given are those assumed by the limbs when both the bones of their middle segment are parallel to one another.

It may be pointed out that the prevalent use of the physiological terms flexor and extensor to describe the surfaces of the limbs has a tendency to obscure their true morphological relationships. Thus if, as is usual, the dorsal surface of the arm be termed its extensor surface, then the same term should be applied to the entire ventral surface of the leg, and all movements of the lower limb ventrally should be spoken of as movements of extension and any movement dorsally as movements of flexion. And yet a ventral movement of the thigh is generally spoken of as a flexion of the hip-joint, while a straightening out of the foot upon the leg—that is to say, a movement of it dorsally—is termed its extension.

**The Age of the Embryo at Different Stages.**—The age of an embryo must be dated from the moment of fertilization, and from what has been said in previous pages (pp. 50, 51)

it is evident that it must be exceedingly difficult to determine the exact age of any embryo even when the date of the cessation of the menses and the date of the cohabitation which resulted in the pregnancy are known. And, furthermore, not only is the actual date of the beginning of development uncertain, but in the majority of the known human embryos in early stages the time of the cessation of development is also more or less uncertain, since the embryos are abortions and their expulsion need not necessarily have immediately succeeded their death.

These various sources of uncertainty are of especial importance in the early stages of development, when a day more or less means much. But nevertheless it is convenient to have some estimate of the age of such embryos even though it be recognized that any date given is a mere approximation. His has made an estimate of the age of a number of embryos concerning which approximate data were available with results which are stated in the following table:

At 2-2½ weeks	the embryo measures	2.2- 3	mm. in length.
“ 2½-3	“ “	3 - 4.5	mm. “
“ 3½	“ “	5 - 6	mm. “
“ 4	“ “	7 - 8	mm. “
“ 4½	“ “	10 -11	mm. “
“ 5	“ “	13	mm. “

It must be borne in mind, however, that embryos of the same age need not in all cases be of the same length, since conditions of nutrition, etc., will largely determine not only the size of the embryo, but also the amount of its development. And, furthermore, it seems probable that the estimates for age given in the above table may be too small, since there is reason to believe that the earlier stages of development proceed more slowly than do the later ones. Thus, Bischoff found that the embryonic disk in

showed but little differentiation up to the seventh day, while at the tenth day the embryo possessed branchial clefts and mesodermic somites. It would seem from the available data, which are more definite than usual, that a human embryo described by Eternod and measuring only 1.3 mm. in length was very nearly twenty-one days old; and if this estimate be correct then the ages assigned by His to the earlier embryos must be very considerably increased.

As regards the later periods of development, the limits of error for any date become of less importance. His estimates that at the end of the second month when the embryo becomes a fetus, its length is about 25 to 28 mm., and for later periods Schröder gives the following measurements as the average:

3d lunar month, .....	70-90 mm.
4th " " .....	100-170 mm.
5th " " .....	180-270 mm.
6th " " .....	280-340 mm.
7th " " .....	350-380 mm.
8th " " .....	425 mm.
9th " " .....	467 mm.
10th " " .....	490-500 mm.

The data concerning the weight of embryos of different ages are as yet very insufficient, and it is well known that the weights of new-born children may vary greatly, the authenticated extremes being, according to Vierordt, 717 grams and 6123 grams. It is probable that considerable variations in weight occur also during fetal life. So far as embryos of the first two months are concerned, the data are too imperfect for tabulation; for later periods Fehling gives the following as average weights:

3d month, .....	20 grams.
4th " .....	120 "
5th " .....	285 "

6th month, .....	635	grams.
7th " .....	1220	"
8th " .....	1700	"
9th " .....	2240	"
10th " .....	3250	"

## LITERATURE.

- J. BROMAN: "Beobachtung eines menschlichen Embryos von beinahe 3 mm. Länge mit specieller Bemerkung über die bei demselben befindlichen Hirnfalten," *Morpholog. Arbeiten*, v, 1895.
- J. M. COSTE: "Histoire générale et particulière du développement des corps organisés," Paris, 1847-1859.
- A. ECKER: "Beiträge zur Kenntniss der äusserer Formen jüngster menschlicher Embryonen," *Archiv für Anat. und Physiol., Anat. Abth.*, 1880.
- A. C. F. ETERNOD: "Communication sur un œuf humain avec embryon excessivement jeune," *Archives Ital. de Biologie*, xxii, 1895.
- A. C. F. ETERNOD: "Il y a un canal notochordal dans l'embryon humain," *Anat. Anzeiger*, xvi, 1899.
- C. GIACOMINI: "Un œuf humain de 11 jours," *Archives Ital. de Biologie*, xxix, 1898.
- V. HENSEN: "Beitrag zur Morphologie der Körperform und des Gehirns des menschlichen Embryos," *Archiv für Anat. und Physiol., Anat. Abth.*, 1877.
- W. HIS: "Anatomie menschlicher Embryonen," Leipzig, 1880.
- J. JANOSIK: "Zwei junge menschliche Embryonen," *Archiv für mikrosk. Anat.*, xxx, 1887.
- F. KEIBEL: "Ein sehr junges menschlicher Ei," *Archiv für Anat. und Physiol., Anat. Abth.*, 1890.
- F. KEIBEL: "Ueber einen menschlichen Embryo von 6.8 mm. grösster Länge," *Verhandl. Anatom. Gesellsch.*, xiii, 1899.
- J. KOLLMANN: "Die Körperform menschlicher normaler und pathologischer Embryonen," *Archiv für Anat. und Physiol., Anat. Ab., Supplement*, 1889.
- F. P. MALL: "A Human Embryo Twenty-six Days Old," *Journ. of Morphology*, v, 1891.
- F. P. MALL: "A Human Embryo of the Second Week," *Anat. Anzeiger*, viii, 1893.
- F. P. MALL: "Early Human Embryos and the Mode of their Preservation," *Bulletin of the Johns Hopkins Hospital*, iv, 1894.
- C. S. MINOT: "Human Embryology," New York, 1892.
- J. MÜLLER: "Zergliederungen menschlicher Embryonen aus früherer Zeit," *Archiv für Anat. und Physiol.*, 1830.

- H. PETERS: "Ueber die Einbettung des menschlichen Eies und das früheste bisher bekannte menschliche Placentarstadium," Leipzig und Wien, 1899.
- C. PHISALIX: "Étude d'un Embryon humain de 11 millimètres," *Archives de zoolog. expérimentale et générale*, Sér. 2, vi, 1888.
- H. PIPER: "Ein menschlicher Embryo von 6.8 mm. Nackenlinie," *Archiv für Anat. und Physiol., Anat. Abth.*, 1898.
- F. GRAF VON SPEE: "Beobachtungen an einer menschlichen Keimscheibe mit offener Medullarrinne und Canalis neurentericus," *Archiv für Anat. und Physiol., Anat. Abth.*, 1889.
- F. GRAF VON SPEE: "Ueber frühe Entwicklungsstufen des menschlichen Eies," *Archiv für Anat. und Physiol., Anat. Abth.*, 1896.
- ALLEN THOMPSON: "Contributions to the History of the Structure of the Human Ovum and Embryo before the Third Week after Conception, with a Description of Some Early Ova," *Edinburgh Med. and Surg. Journal*, III, 1839. (See also Froriep's *Neue Notizen*, XIII, 1840.)

## CHAPTER IV.

### THE MEDULLARY GROOVE, NOTOCHORD, AND MESODERMIC SOMITES.

In the youngest human embryos known, such as the Peters' embryo and the youngest embryo described by Graf Spee, there is no differentiation of the embryonic disk other than that associated with the formation of the primitive streak. In an embryo described by Eternod and measuring 1.3 mm. in length (Fig. 54) a median longitudinal groove (*m*) has made its appearance, marking out the axis of the disk and forming what is known as the *medullary groove*; and in the older embryo described by Spee (Fig. 38) a longitudinal ridge has appeared on either side of the groove, forming the *medullary folds*.

The two folds are continuous anteriorly, but behind they are at first separate, the anterior portion of the primitive streak lying between them. In forms, such as the Reptilia, which possess a distinct blastopore, this opening lies in the interval between the two, and consequently is in the floor of the medullary groove, and in the mammalia, even though no well-defined blastopore is formed, yet at the time of the formation of the medullary fold an opening breaks through at the anterior end of the primitive streak and places the cavity lying below the endoderm in communication with the space bounded by the medullary folds. The canal so formed is termed the *neurenteric canal* (Fig. 55, *nc*) and is so called because it unites what will later become the central canal of the nervous system with the intestine (enteron). The significance of this

ND

the  
by  
disk  
im-  
and  
itu-  
ing  
the  
by  
her

ind  
mi-  
the  
ing  
s in  
lia,  
at  
ing  
eak  
m-  
ary  
ric  
at  
em  
his

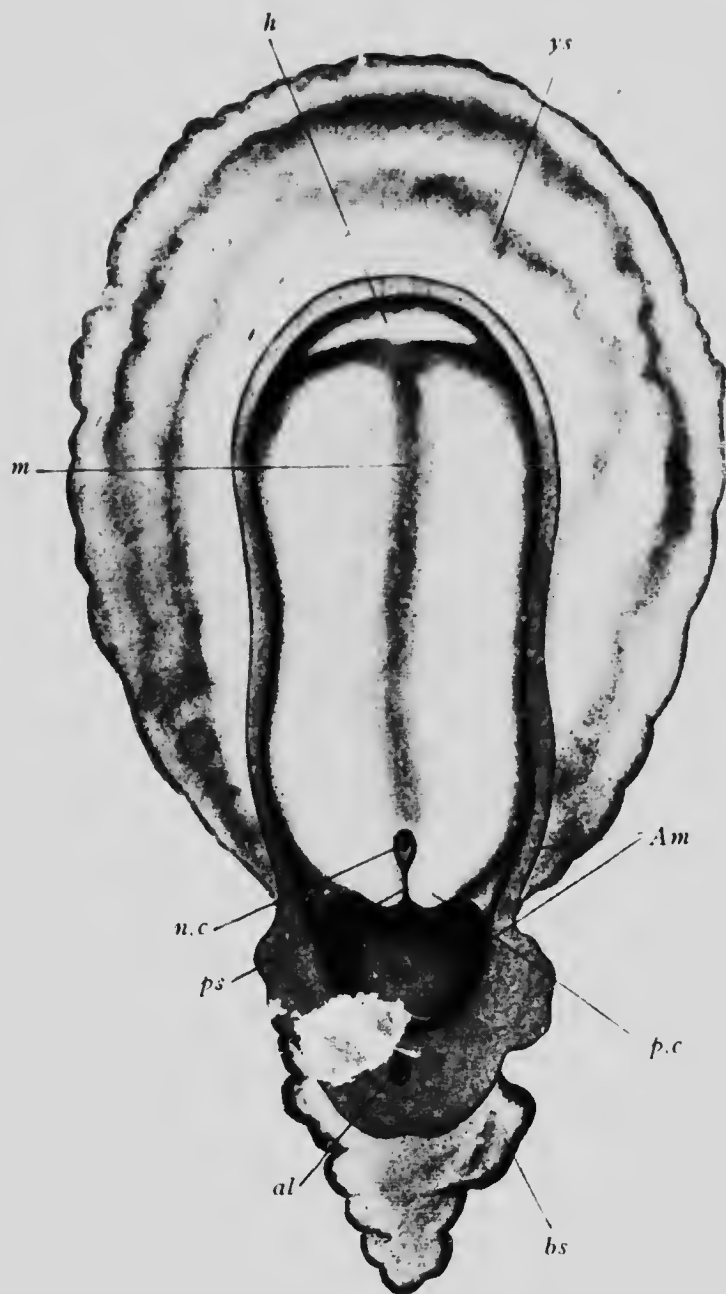


FIG. 54.—EMBRYO 1.34 MM. LONG.

*al*, Allantois; *Am*, amnion, *bs*, belly-stalk; *h*, heart; *m*, medullary groove; *n.c*, neurenteric canal; *p.c*, caudal protuberance; *ps*, primitive streak; *ys*, yolk-stalk.—(*Eternod.*)



canal is somewhat obscure, and it is of very brief persistence, closing at an early stage of development so as to leave no trace of its existence.

As development proceeds the medullary folds increase in height and at the same time incline toward one another

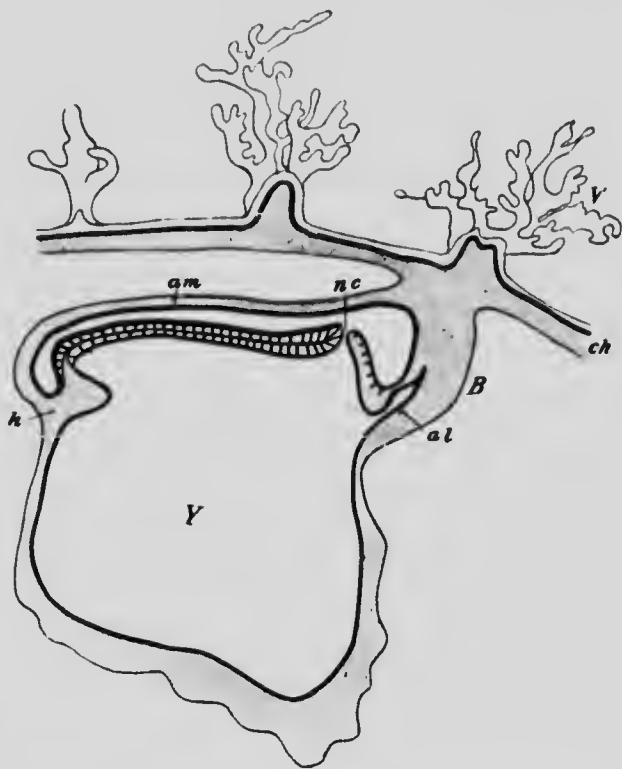


FIG. 55.—DIAGRAM OF A LONGITUDINAL SECTION THROUGH AN EMBRYO OF 1.54 MM.  
*al*, Allantois; *am*, amnion; *B*, belly-stalk; *ch*, chorion; *h*, heart; *nc*, neurenteric canal; *Y*, chorionic villi; *Y*, yolk-sac.—(von Spée.)

(Fig. 40) so that their edges finally come into contact and later fuse, the two ectodermal layers forming the one uniting with the corresponding layers of the other (Fig. 56). By this process the medullary groove becomes converted into a *medullary canal* which later becomes the

central canal of the spinal cord and the ventricles of the brain, the ectodermal walls of the canal thickening to give rise to the central nervous system. The closure of the groove does not, however, take place simultaneously along its entire length, but begins in what corresponds to the neck region of the adult (Fig. 41) and thence proceeds both anteriorly and posteriorly, the extension of the fusion taking place rather slowly, however, especially anteriorly, so that an anterior opening into the otherwise closed canal can be distinguished for a considerable period (Fig. 42).

While these changes have been taking place in the ectoderm of the median line of the embryonic disk, modifications of the subjacent endoderm have also occurred. This endoderm, it will be remembered, was formed by the head process of the primitive streak, and was a plate of cells continuous at




FIG. 56.—DIAGRAMS SHOWING THE MANNER OF THE CLOSURE OF THE MEDULLARY GROOVE.

the sides with the primary endoderm and extending forward as far as what will eventually be the anterior part of the pharynx. Along the line of its junction with the primary endoderm it gives rise to the plates of gastral mesoderm (Fig. 27), while the remainder of it produces an important embryonic organ known as the *notochord* or *chorda dorsalis* and on this account is sometimes termed the *chorda endoderm*.

After the separation of the plates of gastral mesoderm the chorda endoderm, which is at first a flat band, becomes somewhat curved (Fig. 57, A), so that it is concave on its under surface, and, the curvature increasing, the edges of the plate come into contact and finally fuse together (Fig. 57, B), the edges of the primary endoderm at the same time uniting beneath the chordal tube so formed, so this layer becomes a continuous sheet, as it was at its first appearance. The lumen which is at first

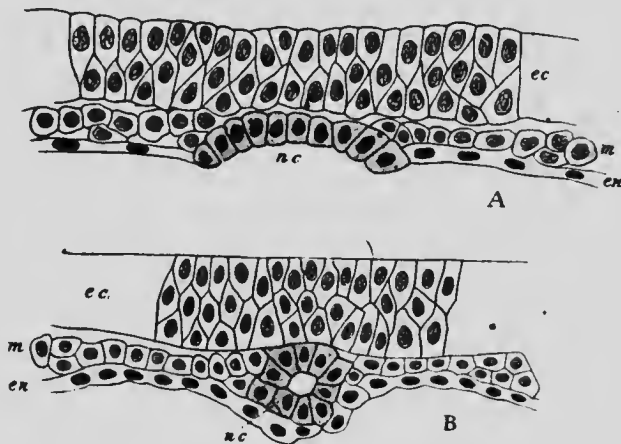


FIG. 57.—TRANSVERSE SECTIONS THROUGH MOLE EMBRYOS, SHOWING THE FORMATION OF THE NOTOCHORD.

*ec*, Ectoderm; *en*, endoderm; *m*, mesoderm; *nc*, notochord.—(Heape.)

present in the chordal tube is soon obliterated by the enlargement of the cells which bound it, and these cells later undergo a peculiar transformation whereby the chordal tube is converted into a solid elastic rod surrounded by a cuticular sheath secreted by the cells. The notochord lies at first immediately beneath the median line of the medullary groove, between the ectoderm and the endoderm, and has on either side of it the mesodermal plates. It is a temporary structure of which only rudiments persist in

the adult condition in man, but it is a structure characteristic of all vertebrate embryos and persists to a more or less perfect extent in many of the fishes, being indeed the only axial skeleton possessed by *Amphioxus*. In the higher vertebrates it is almost completely replaced by the vertebral column, which develops around it in a manner to be described later.

Turning now to the middle germinal layer, it will be found that in it also important changes take place during these early stages of development. The probable mode of development of the extra-embryonic mesoderm and body-cavity has already been described (p. 84) and attention may now be directed toward what occurs in the embryonic mesoderm. In both the Peters embryo and the embryo *v.H* described by von Spee this portion of the mesoderm is represented by a plate of cells lying between the ectoderm and endoderm and becoming continuous at the edges of the embryonic area with both the layer which surrounds the yolk-sac and, through the mesoderm of the belly-stalk, with the chorionic mesoderm (Fig. 35). It seems probable, since there is in these embryos no indication as yet of the formation of the chorda endoderm, that this plate of mesoderm corresponds to the prostomial mesoderm of lower forms. In older embryos, such as the embryo *Gle* of Graf Spee and the younger embryo described by Eternod (Fig. 54), the mesoderm no longer forms a continuous sheet extending completely across the embryonic disk, but is divided into two lateral plates, in the interval between which the ectoderm of the floor of the medullary groove and the chorda endoderm are in close contact (Fig. 34). These lateral plates represent the gastral mesoderm, whose origin has already been described (p. 77), and which apparently supplants the original prostomial mesoderm, whose fate in the human embryo is

at present unknown. The changes which now occur have not as yet been observed in the human embryo, though they probably resemble those described in other mammalian embryos, and the phenomena which occur in the sheep may serve to illustrate their probable nature.

The lateral plates increase in size by the multiplication of the cells which compose them and, in sections, have a somewhat triangular form, the portions nearest the median line of the embryo being much thicker than the more lateral parts. In the region which will later become the

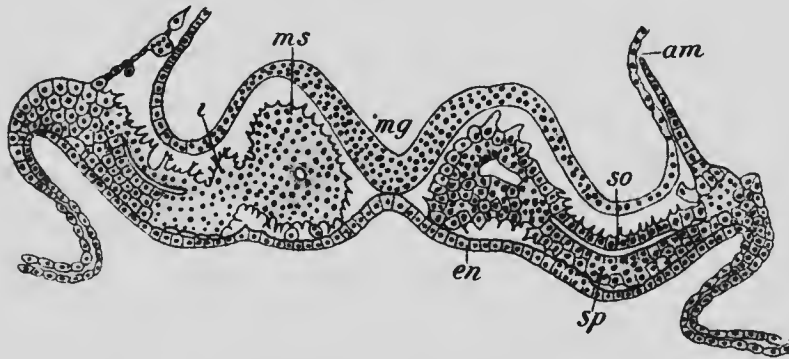


FIG. 58.—TRANSVERSE SECTION THROUGH THE SECOND MESODERMIC SOMITE OF A SHEEP EMBRYO 3 MM. LONG.

*am*, Amnion; *en*, endoderm; *i*, intermediate cell-mass; *mg*, medullary groove; *ms*, mesodermic somite; *so*, somatic and *sp*, splanchnic layers of the ventral mesoderm.—(Bonnet.)

neck of the embryo a longitudinal groove appears upon the dorsal surface of each plate, marking off the more median thicker portion from the lateral parts, and the median portions then become divided transversely into a number of more or less cubical masses which are termed the *protovertebræ* or, better, *mesodermic somites* (Fig. 58, *ms*), structures whose appearance in surface views has already been described (Figs. 41 *et seq.*). The cells of the somites and of the lateral parts, which may be termed the

ventral mesoderm, are at first stellate in form, but later become more spindle-shaped, and those near the center of each somite and those of the ventral mesoderm arrange themselves in regular layers so as to enclose cavities which appear in these regions (Fig. 58). The cavities of the somites first formed become continuous with the cavities contained between the layers of the adjacent ventral mesoderm, but this continuity eventually disappears and

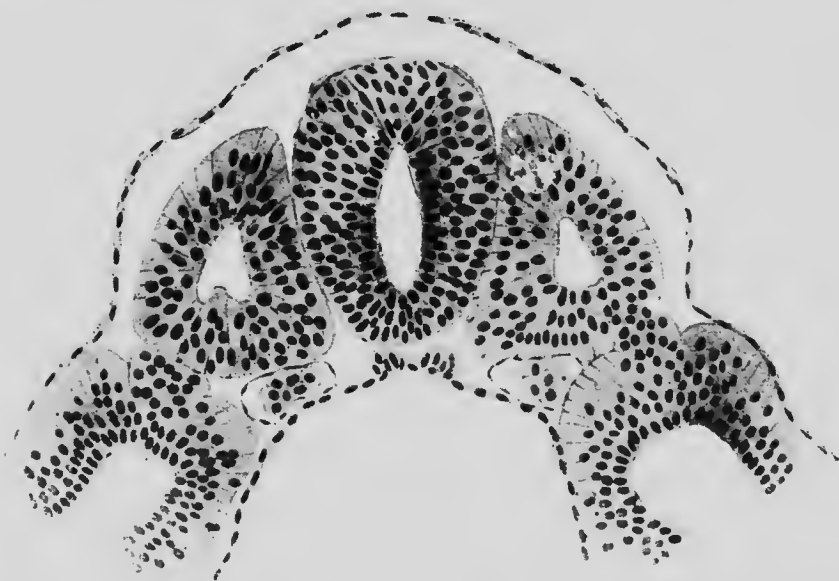


FIG. 59.—TRANSVERSE SECTION OF AN EMBRYO OF 2.5 MM. (SEE FIG. 42) SHOWING ON EITHER SIDE OF THE MEDULLARY CANAL A MESODERMIC SOMITE, THE INTERMEDIATE CELL-MASS, AND THE VENTRAL MESODERM.—(von Lenhossek.)

is not developed in the later formed somites. Each original lateral plate of gastral mesoderm then becomes divided longitudinally into three areas, a more median area composed of mesodermic somites, lateral to this a narrow area underlying the original longitudinal groove which separated the somite area from the ventral mesoderm and which from its position is termed the *intermediate cell*.

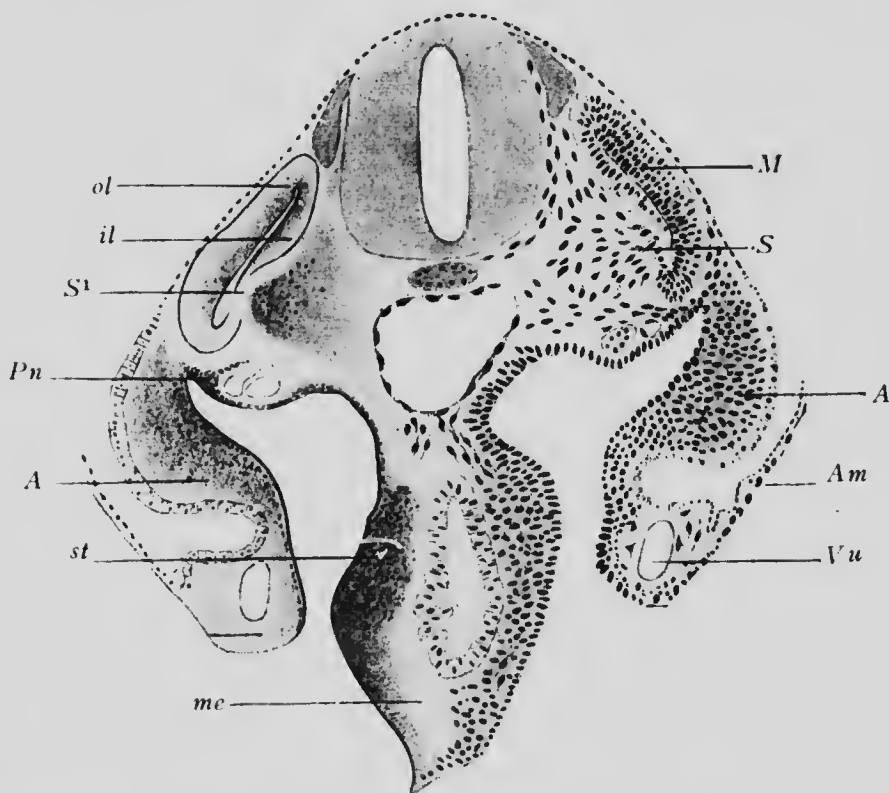
*mass* (Fig. 58, *i*), and, finally, the ventral mesoderm. This last portion is now divided into two layers, the dorsal of which is termed the *somatic mesoderm*, while the ventral one is known as the *splanchnic mesoderm* (Fig. 58, *so* and *sp*; and Fig. 59), the cavity which separates these two layers being the embryonic body-cavity or *pleuroperitoneal cavity*, which will eventually give rise to the pleural pericardial and peritoneal cavities of the adult as well as the cavity of each tunica vaginalis testis.

Beginning in the neck region, the formation of the mesodermic somites proceeds anteriorly and posteriorly until finally there are present in the human embryo thirty-eight pairs in the neck and trunk regions of the body, and, in addition, a certain number are developed in what is later the occipital region of the head. Exactly how many of these occipital somites are developed is not known, but in the cow four have been observed, and there are reasons for believing that the same number occurs in the human embryo.

In the lower vertebrates a number of cavities arranged in pairs occur in the more anterior portions of the head and have been homologized with mesodermic somites. Whether this homology be perfectly correct or not, these *head-cavities*, as they are termed, indicate the existence of a division of the head mesoderm into somites, and although practically nothing is known as to their existence in the human embryo, yet, from the relations in which they stand to the cranial nerves and musculature in the lower forms, there is reason to suppose that they are not entirely unrepresented.

The mesodermic somites in the earliest human embryos in which they have been observed contain a completely closed cavity, and this is true of the majority of the somites in such a form as the sheep. In the four first-formed somites in this species, however, as has already been stated, the somite cavity is at first continuous with the

pleuroperitoneal cavity and only later becomes separated off from it, and in lower vertebrates this continuity of the somite cavities with the general body-cavity is the rule. The somite cavities are consequently to be regarded as



10.—TRANSVERSE SECTION OF AN EMBRYO OF 4.25 MM. AT THE LEVEL OF THE ARM RUDIMENT.

*A*, axial mesoderm of arm; *Am*, amnion; *il*, inner lamella of myotome; *M*, myotome; *me*, splanchnic mesoderm; *S*, sclerotome; *S*<sup>1</sup>, defect in wall of myotome due to separation of the sclerotome; *st*, stomach; *Vu*, umbilical vein.—(Kollmann.)

portions of the general pleuroperitoneal cavity which have secondarily been separated off. They are, however, of but short duration and early become filled up by spindle-shaped cells derived from the walls of the somites, which



themselves undergo a differentiation into distinct portions. The cells of that portion of the wall of each somite which is opposite the notochord become spindle-shaped and grow inward toward the median line to surround the notochord and central nervous system and give rise eventually to the lateral half of the body of a vertebra and the corresponding portion of the vertebral arch. This portion of the somite is termed a *sclerotome* (Fig. 60, *s*), and the remaining part of the medial wall forms a *muscle plate* or *myotome* (*m*) which is destined to give rise to a portion of the voluntary musculature of the body, while the outer wall probably takes part in the formation of the cutis layer of the skin and hence has been termed the *cutis plate*, or *dermatome*.

The intermediate cell-mass in the human embryo, as in lower forms, partakes of the transverse divisions which separate the individual mesodermic somites. From one portion of the tissue of most of the somites (Fig. 60, *pn*) the provisional kidneys or Wolffian bodies develop, this portion of each mass being termed a *nephrotome*, while the remaining portion gives rise to a mass of cells showing no tendency to arrange themselves in definite layers and constituting that form of mesoderm which has been termed mesenchyme (see p. 80). These mesenchymatous masses become converted into connective tissues and blood-vessels.

The ventral mesoderm in the neck and trunk regions never becomes divided transversely into segments corresponding to the mesodermic somites, differing in this respect from the other portions of the gastral mesoderm. In the head, however, that portion of the middle layer which corresponds to the ventral mesoderm of the trunk does undergo a division into segments in connection with the development of the branchial arches and clefts. A

consideration of these segments, which are known as the *branchiomer*es, may conveniently be postponed until the chapters dealing with the development of the cranial muscles and nerves, and in what follows here attention will be confined to what occurs in the ventral mesoderm of the neck and trunk.

Its splanchnic layer applies itself closely to the endodermal digestive tract (Fig. 62, *sp*), which is constricted off from the dorsal portion of the yolk-sac, and becomes converted into mesenchyme out of which the muscular coats of the digestive tract develop. The cells which line the pleuroperitoneal cavity, however, retain their arrangement in a layer and form a part of the serous lining of the peritoneal and other serous cavities, the remainder of the lining being formed by the corresponding cells of the somatic layer; and in the abdominal region the superficial cells, situated near the line where the splanchnic layer passes into the somatic, and in close proximity to the nephrotome of the intermediate cell-mass, become columnar in shape and are converted into reproductive cells.

The somatic layer, if traced peripherally, becomes continuous at the sides with the layer of mesoderm which lines the outer surface of the amnion (Fig. 60) and posteriorly with the mesoderm of the belly-stalk. That portion of it which lies within the body of the embryo, in addition to giving rise to the serous lining of the parietal layer of the pleuroperitoneum, becomes converted into mesenchyme, which for a considerable length of time is clearly differentiated into two zones, a more compact dorsal one which may be termed the somatic layer proper, and a thinner more ventral vascular zone which is termed the *membrana reuniens* (Fig. 61). In the earlier stages the somatic layer proper does not extend ventrally beyond the line which passes through the limb buds and it grows out into these

buds to form an axial core for them (Fig. 61, *Lr*), in which later the skeleton of the limb forms. The remainder of the mesoderm lining the sides and ventral portions of the body-wall is at first formed from the *membrana reuniens*, but as development proceeds the somatic layer gradually extends more ventrally and displaces, or, more properly speaking, assimilates into itself, the *membrana reuniens* until finally the latter has completely disappeared.

It is to be noted that no part of the voluntary musculature of the lateral and ventral walls of the neck and trunk is derived from the somatic layer, nor do the muscles of the limbs arise from the axial core of mesenchyme which passes into them from this layer.\* All the voluntary muscles of the neck, trunk, and limbs are derived from the myotomes which gradually extend ventrally and send out also into the limbs prolongations which completely invest the axial mesenchyme, and it is probable, also, that the ribs are derived from ventral prolongations of the sclerotomes. The probable relations of the various parts derived from the gastral mesoderm may be perceived from the diagrams composing Fig. 61, which represent the conditions obtaining in embryos of different ages.

The appearance of the mesodermic somites is an important phenomenon in the development of the embryo, since it influences fundamentally the future structure of the organism. If each pair of mesodermic somites be regarded as an element and termed a *metamere* or segment, then it may be said that the body is composed of a series of metameres, each more or less closely resembling its fellows, and succeeding one another at regular intervals. Each somite differentiates, as has been stated, into a sclerotome, a myotome, and a cutis plate, and, accord-

---

\* See page 231.

ingly, there will primarily be as many vertebræ, muscle segments, and cutis segments as there are mesodermic somites, or, in other words, the axial skeleton, the voluntary muscles, and the cutis are primarily metameric. Nor is this all. Since each metamere is a distinct unit, it must possess its own supply of nutrition, and hence the primary arrangement of the blood-vessels is also metameric, a

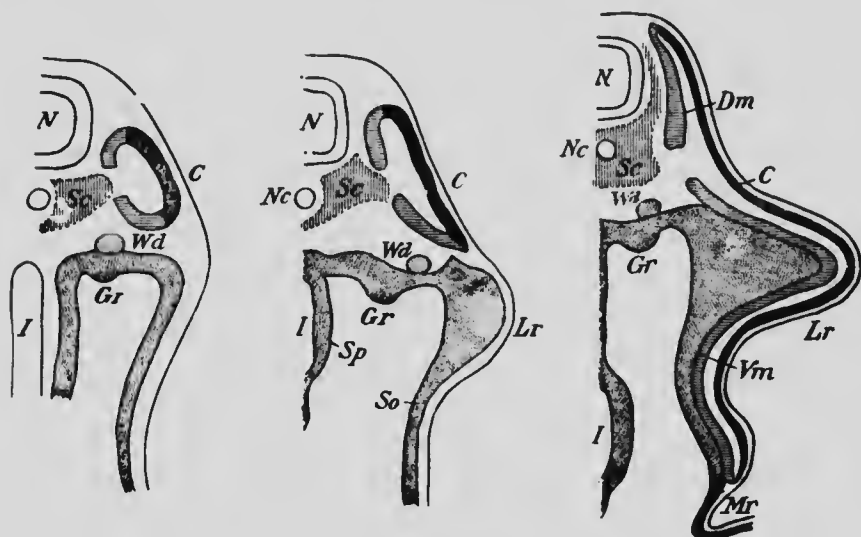


FIG. 61.—DIAGRAMS ILLUSTRATING THE HISTORY OF THE GASTRAL MESODERM.

*C*, Cutis plate; *Dm*, dorsal portion of myotome; *Gr*, genital ridge; *I*, intestine; *Lr*, limb bud; *Mr*, membrana reuniens; *N*, nervous system; *Nc*, notochord; *Sc*, sclerotome; *So* and *Sp*, somatic and splanchnic mesoderm; *Vm*, ventral portion of myotome; *Wd*, Wolffian duct.—(Modified from Kollmann.)

branch passing off on either side from the main longitudinal arteries and veins to each metamere. And, further, each pair of muscle segments and the corresponding cutis plates receive their own nerves, so that the arrangement of the nerves, again, is distinctly metameric.

This metamerism is most distinct in the neck and trunk regions, and at first only in the dorsal portions of these

regions, the ventral portions showing metamerism only after the extension into them of the myotomes. But there is clear evidence that the arrangement extends also into the head, and that this, like the rest of the body, is to be regarded as composed of metameres. It has been seen that in the notochordal region of the head of lower vertebrates mesodermic somites are present, while anteriorly in the præchordal region there are head-cavities which resemble the mesodermic somites in that their walls become converted into muscle tissue, and which may, perhaps, be directly comparable to the somites of the trunk. There is reason, therefore, for believing that the fundamental arrangement of all parts of the body is metameric, but though this arrangement is clearly defined in early embryos, it loses distinctness in later periods of development. The various cutis metameres early unite, so that their primary relations become greatly obscured, and the same is true to a certain extent of the muscle segments and of the blood-vessels; but even in the adult the primary metamerism is clearly indicated in the arrangement of the nerves and of parts of the axial skeleton, and careful study frequently reveals indications of it in highly modified muscles and blood-vessels.

In the head the development of the branchial arches and clefts produces a series of parts presenting many of the peculiarities of metameres, and, indeed, it has been a very general custom to regard them as expressions of the general metamerism which prevails throughout the body. It is to be noted, however, that they are produced by the segmentation of the ventral mesoderm, a structure which in the neck and trunk regions does not share in the general metamerism, and, furthermore, recent observations on the cranial nerves seem to indicate that these branchiomeres cannot be regarded as portions of the head meta-

meres or even structures comparable to these. They represent, more probably, a second metamerism superposed upon the more general one, or, indeed, possibly more primitive than it, but whose relations can only be properly understood in connection with a study of the cranial nerves (see p. 431).

## LITERATURE.

In addition to many of the papers cited in the list at the close of Chapter II, the following may be mentioned:

- W. HEAPE: "The Development of the Mole (*Falpa Europæa*)," *Quarterly Journ. Microsc. Science*, xxvii, 1887.
- F. KEIBEL: "Zur Entwicklungsgeschichte der Chorda bei Säugern (Meerschweinchen und Kaninehen)," *Archiv für Anat. und Physiol., Anat. Abth.*, 1889.
- J. KOLLMANN: "Die Rumpfsegmente menschlicher Embryonen von 13 bis 35 Urwirbeln," *Archiv für Anat. und Physiol., Anat. Abth.*, 1891.
- J. W. VAN WIJHE: "Ueber die Mesodermsegmente des Rumpfes und die Entwicklung des Excretionsystems bei Selachiern," *Archiv für mikrosk. Anat.*, xxxiii, 1889.
- K. W. ZIMMERMANN: "Ueber Kopfhöhlenrudimente beim Menschen," *Archiv für mikrosk. Anat.*, liii, 1898.

## CHAPTER V.

### THE YOLK-STALK, BELLY-STALK, AND FETAL MEMBRANES.

The conditions to which the embryos and larvæ of the majority of animals must adapt themselves are so different from those under which the adult organisms exist that in the early stages of development special organs are very frequently developed which are of use only during the embryonic or larval period and are discarded when more advanced stages of development have been reached. This remark applies with especial force to the human embryo which leads for a period of nine months what may be termed a parasitic existence, drawing its nutrition from and yielding up its waste products to the blood of the parent. In order that this may be accomplished certain special organs are developed by the embryo, by means of which it forms an intimate connection with the walls of the uterus, which, on its part, becomes greatly modified, the combination of embryonic and maternal structures producing what is termed the *decidua*, owing to its being discarded at birth when the parasitic mode of life is given up.

Furthermore, it has already been seen that many peculiar modifications of development in the human embryo result from the inheritance of structures from more or less remote ancestors, and among the embryonic adnexes are found structures which represent in a more or less modified condition organs of considerable functional importance in lower forms. Such structures are the *yolk-stalk*

and vesicle, the amnion, and the allantois, and for their proper understanding it will be well to consider briefly their development in some lower form, such as the chick.

At the time when the embryo of the chick begins to be constricted off from the surface of the large yolk-mass, a fold, consisting of ectoderm and somatic mesoderm, arises just outside the embryonic area, which it completely sur-

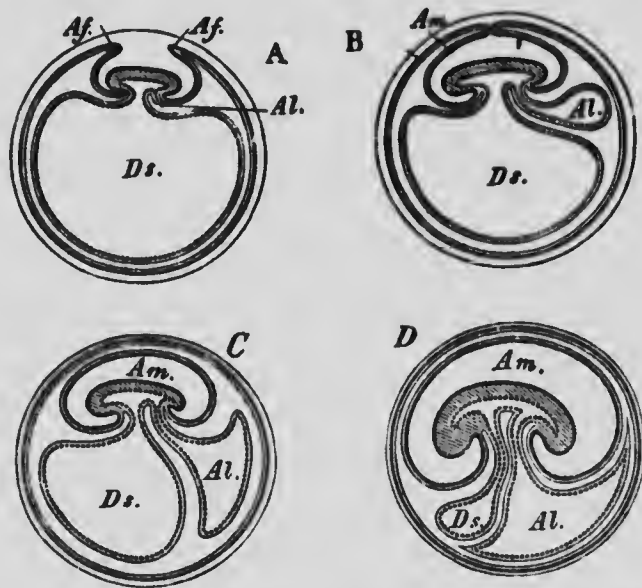


FIG. 62.—DIAGRAMS ILLUSTRATING THE FORMATION OF THE AMNION AND ALLANTOIS IN THE CHICK.

*Af.*, Amnion folds; *Al.*, allantois; *Am.*, amniotic cavity; *Ds.*, yolk-sac.  
—(Gegenbaur.)

rounds. As development proceeds the fold becomes higher and its edges gradually draw nearer together over the dorsal surface of the embryo (Fig. 62, A), and finally meet and fuse (Fig. 62, B), so that the embryo becomes enclosed within a sac, which is termed the *amnion* and is formed by the fusion of the layers which constituted the inner wall of the fold. The layers of the outer wall of the



fold after fusion form part of the general ectoderm and somatic mesoderm which make up the outer wall of the ovum and together are known as the serosa, corresponding to the chorion of the mammalian embryo. The space which occurs between the amnion and the serosa is a portion of the extra-embryonic cœlom and is continuous with the embryonic pleuroperitoneal cavity.

In the ovum of the chick, as in that of the reptile, the protoplasmic material is limited to one pole and rests upon the large yolk-mass. As development proceeds the germ layers gradually extend around the yolk-mass (compare Fig. 62, A-C) and eventually completely enclose it, the yolk-mass coming to lie within the endodermal layer, which, together with the splanchnic mesoderm which lines it, forms what is termed the *yolk-sac*. As the embryo separates from the yolk-mass the yolk-sac is constricted in its proximal portion and so differentiated into a *yolk-stalk* and a yolk-sac, the contents of the latter being gradually absorbed by the embryo during its growth, its walls and those of the stalk being converted into a portion of the embryonic digestive tract.

In the mean time, however, from the posterior portion of the digestive tract, behind the point of attachment of the yolk-sac, a diverticulum has begun to form (Fig. 62, A). This increases in size, projecting into the extra-embryonic portion of the pleuroperitoneal cavity, and pushing before it the splanchnic mesoderm which lines the endoderm (Fig. 62, B and C). This is the *allantois*, which, reaching a very considerable size in the chick, and applying itself closely to the inside of the serosa, serves as a respiratory and excretory organ for the embryo, for which purpose its walls are richly supplied with blood-vessels, the allantoic arteries and veins.

Toward the end of the incubation period both the am-

nion and allantois begin to undergo retrogressive changes, and just before the hatching of the young chick they become completely dried up and closely adherent to the egg-shell, at the same time separating from their point of attachment to the body of the young chick, so that when the chick leaves the egg-shell it bursts through the dried-up membranes and leaves them behind as useless structures.

**The Amnion.**—Turning now to the human embryo, it will be found that the same organs are present, though somewhat modified either in the mode or the extent of their development. A well-developed amnion occurs, arising, however, in a very different manner from what it does in the chick; a large yolk-sac occurs even though it contains no yolk; and an allantois which has no respiratory or excretory functions is present, though in a somewhat degenerated condition. It has been seen from the description of the earliest stages of development that the processes which occur in the lower forms are greatly abbreviated in the human embryo. The enveloping layer, instead of gradually extending from one pole to enclose the entire ovum, develops *in situ* during the stages immediately succeeding segmentation, and the extra-embryonic mesoderm, instead of growing out from the embryo to enclose the yolk-sac, splits off directly from the enveloping layer. The earliest stages in the development of the amnion are not yet known for the human embryo, but from the condition in which it is found in the Peters embryo (Fig. 35) and in the embryo *v.H.* of von Spee (Fig. 37) it is probable that it arises, not by the fusion of the edges of a fold, as in the chick, but by a vacuolization of a portion of the inner cell-mass, as has been described as occurring in the bat (p. 71). It is, then, a closed cavity from the very beginning, the floor of the cavity

being formed by the embryonic disk, its posterior wall by the anterior surface of the belly-stalk, while its roof and sides are thin and composed of a single layer of flattened ectodermal cells lined on the outside by a layer of meso-

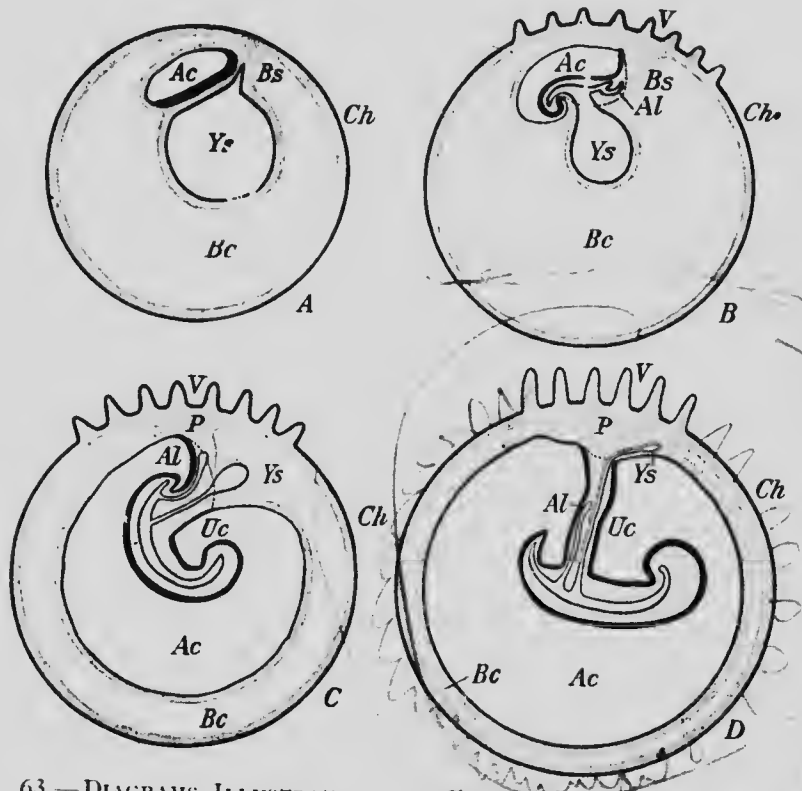


FIG. 63.—DIAGRAMS ILLUSTRATING THE FORMATION OF THE UMBILICAL CORD.

The heavy black line represents the embryonic ectoderm; the dotted line represents the line of reflexion of the body ectoderm into that of the amnion. *Ac*, Amniotic cavity; *Al*, allantois; *Bc*, extra-embryonic coelom; *Bs*, belly-stalk; *Ch*, chorion; *P*, placenta; *Uc*, umbilical cord; *V*, chorionic villi; *Ys*, yolk-sac.

derm continuous with the somatic mesoderm of the embryo and the mesoderm of the belly-stalk (Fig. 63, A).

When the bending downward of the peripheral portions of the embryonic disk to close in the ventral surface of the

embryo occurs, the line of attachment of the amnion to the disk is also carried ventrally (Fig. 63, B), so that when the constriction off of the embryo is practically completed, the amnion is attached anteriorly to the margin of the umbilicus and posteriorly to the extremity of the band of ectoderm lining what may now be considered the posterior surface of the belly-stalk, while at the sides it is attached along an oblique line joining these two points (Figs. 63, B and C, in which the attachment of the amnion is indicated by the broken line).

Leaving aside for the present the changes which occur in the attachment of the amnion to the embryo (see p. 139), it may be said that during the later growth of the embryo the amniotic cavity increases in size until finally its wall comes into contact with the chorion, the extra-embryonic body-cavity being thus practically obliterated (Fig. 63, D), though no actual fusion of amnion and chorion occurs. Suspended by the umbilical cord, which has by this time developed, the embryo floats freely in the amniotic cavity, which is filled by a fluid, the *liquor amnii*, whose origin is involved in doubt, some authors maintaining that it infiltrates into the cavity from the maternal tissues, while others hold that a certain amount of it at least is derived from the embryo. It is a fluid with a specific gravity of about 1.003 and contains about 1 per cent. of solids, principally albumin, grape-sugar, and urea, the last constituent probably coming from the embryo. When present in greatest quantity,—that is to say, at about the beginning of the last month of pregnancy,—it varies in amount between  $\frac{1}{2}$  and  $\frac{3}{4}$  of a liter, but during the last month it diminishes to about half that quantity. To protect the epidermis of the fetus from maceration during its prolonged immersion in the liquor amnii, the sebaceous glands of the skin at about the sixth month of develop-

ment pour out upon the surface of the body a white fatty secretion known as the *vernix caseosa*.

During parturition the amnion, as a rule, ruptures as the result of the contraction of the uterine walls and the liquor amnii escapes as the "waters," a phenomenon which normally precedes the delivery of the child. As a rule the rupture is sufficiently extensive to allow the passage of the child, the amnion remaining behind in the uterus, to be subsequently expelled along with the deciduæ.

Occasionally it happens, however, that the amnion is sufficiently strong to withstand the pressure exerted upon it by the uterine contractions and the child is born still enveloped in the amnion, which, in such cases, is popularly known as the "caul," the possession of which, according to an old superstition, marks the child as a favorite of fortune.

As stated above, the liquor amnii varies considerably in amount in different cases, and occasionally it may be present in excessive quantities, producing a condition known as *hydramnios*. On the other hand, the amount may fall considerably below the normal, in which case the amnion may form abnormal unions with the embryo, sometimes producing malformations. Occasionally also bands of a fibrous character traverse the amniotic cavity and, tightening upon the embryo during its growth, may produce various malformations, such as scars, splitting of the eyelids or lips, or even amputation of a limb.

**The Yolk-sac.**—The development of the yolk-sac in the human embryo, its differentiation into yolk-stalk and yolk-vesicle, and its enclosure within the umbilical cord have already been described. When these changes have been completed, the vesicle is a small pyriform structure lying between the amnion and the chorionic mesoderm, some distance away from the extremity of the umbilical cord (Fig. 63, D), and the stalk is a long slender column of cells extending from the vesicle through the umbilical cord to unite with the intestinal tract of the embryo. The

vesicle persists until birth and may be found among the decidual tissues as a small sac measuring from 3 to 10 mm. in its longest diameter. The stalk, however, early undergoes degeneration, the lumen which it at first contains becoming obliterated and its endoderm also disappearing as early as the end of the second month of development. The portion of the stalk which extends from the umbilicus to the intestine usually shares in the degeneration and disappears, but in about 3 per cent. of cases it persists, forming a more or less extensive diverticulum of the lower part of the small intestine, sometimes only half an inch or so in length and sometimes much larger. It may or may not retain connection with the abdominal wall at the umbilicus, and is known as *Meckel's diverticulum*.

This embryonic rudiment is of no little importance, since, when present, it is apt to undergo invagination into the lumen of the small intestine and so occlude it. How frequently this happens relatively to the occurrence of the diverticulum may be judged from the fact that out of 100 cases of occlusion of the small intestine 6 were due to an invagination of the diverticulum.

In the reptiles and birds the yolk-sac is abundantly supplied with blood-vessels by means of which the absorption of the yolk is carried on, and even although the functional importance of the yolk-sac as an organ of nutrition is almost *nil* in the human embryo, yet it still retains a well-developed blood-supply, the walls of the vesicle especially possessing a rich network of vessels. The future history of these vessels, which are known as the *omphalomesenteric* vessels, will be described later on.

**The Allantois and Belly-stalk.**—It has been seen that in reptilian and avian embryos the allantois reaches a high degree of development and functions as a respiratory and excretory organ by coming into contact with what is comparable to the chorion of the mammalian embryo.

In man it subserves similar functions, but is very much modified both in its mode of development and in its relations to other parts, so that its resemblance to the avian organ is somewhat obscured. The differences depend partly upon the remarkable abbreviation manifested in the early development of the human embryo and partly upon the fact that the allantois serves to place the embryo in relation with the maternal blood, instead of with the external atmosphere, as is the case in the egg-laying forms. Thus, the endodermal portion of the allantois, instead of arising from the intestine and pushing before it a layer of splanchnic mesoderm to form a large sac lying freely in the extra-embryonic portion of the body-cavity, appears in the human embryo before the intestine has differentiated from the yolk-sac and pushes its way into the solid mass of mesoderm which forms the belly-stalk (Fig. 63, A). To understand the significance of this process it is necessary to recall the abbreviation in the human embryo of the development of the extra-embryonic mesoderm and body-cavity. Instead of growing out from the embryonic area, as it does in the lower forms, this mesoderm develops *in situ* by splitting off from the layer of enveloping cells and, furthermore, the extra-embryonic body-cavity arises by a splitting of the mesoderm so formed before there is any trace of a splitting of the embryonic mesoderm (Figs. 36 and 35). The belly-stalk, whose development from a portion of the inner cell-mass has already been traced (p. 85), is to be regarded as a portion of the body of the embryo, since the ectoderm which covers one surface of it resembles exactly that of the embryonic disk and shows an extension backward of the medullary groove upon its surface (Fig. 64). The mesoderm, therefore, of the belly-stalk is to be regarded as a portion of the embryonic mesoderm which has not yet

undergone a splitting into somatic and splanchnic layers, and, indeed, it never does undergo such a splitting, so that there is no body-cavity into which the endodermal allantoic diverticulum can grow.

But this does not account for all the peculiarities of the human allantois. In the birds, and indeed in the lower oviparous mammals, the endodermal portion of the allantois is equally developed with the mesodermal portion, the allantois being an extensive sac whose cavity is filled with fluid, and this is also true of such mammals as the marsupials, the rabbit, and the ruminants. In man, however,

the endodermal diverticulum never becomes a sac-like structure, but is a slender tube extending from the intestine to the chorion and lying in the substance of the mesoderm of the belly-stalk (Fig. 63, D), the greater portion of which is to be regarded as homologous with the relatively thin layer of splanchnic mesoderm covering the endodermal diverticulum of the chick. An explanation of

this disparity in the development of the mesodermal and endodermal portions of the human allantois is perhaps to be found in the altered conditions under which the respiration and secretion take place. In all forms, the lower as well as the higher, it is the mesoderm which is the more important constituent of the allantois, since in it the blood-vessels, upon whose presence the physiological functions depend, arise and are embedded. In the birds and oviparous mammals there are no means by which excreted

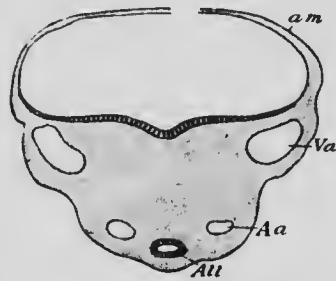


FIG. 64.—TRANSVERSE SECTION THROUGH THE BELLY-STALK OF AN EMBRYO OF 2.15 MM.

*Aa*, Umbilical (allantoic) artery; *All*, allantois; *am*, amnion; *Va*, umbilical (allantoic) vein.—(*His.*)



material can be passed to the exterior of the ovum, and it is, therefore, stored up within the cavity of the allantois, the allantoic fluid containing considerable quantities of nitrogen, indicating the presence of urea. In the higher mammals the intimate relations which develop between the chorion and the uterine walls allow of the passage of excreted fluids into the maternal blood; and the more intimate these relations, the less necessity there is for an allantoic cavity in which excreted fluid may be stored up. The difference in the development of the cavity in the ruminants, for example, and man depends probably upon the greater intimacy of the union between ovum and uterus in the latter, the arrangement for the passage of the excreted material into the maternal blood being so perfect that there is practically no need for the development of an allantoic cavity.

The portion of the endodermal diverticulum which is enclosed within the umbilical cord persists until birth in a more or less rudimentary condition, but the intra-embryonic portions of the allantois reach a greater development, the more proximal portions acquiring a cavity of considerable extent and forming the urogenital sinus and the urinary bladder, while the portion intervening between the apex of the bladder and the umbilicus becomes converted into a solid cord of fibrous tissue termed the *urachus*.

Occasionally a lumen persists in the urachal portion of the allantois and may open to the exterior at the umbilicus, in which case urine from the bladder may escape at the umbilicus.

Since the allantois in the human embryo, as well as in the lower forms, is responsible for respiration and excretion, its blood-vessels are well developed. They are represented in the belly-stalk by two veins and two arteries (Fig. 64), known in human embryology as the *umbilical*

*veins* and *arteries*, which extend from the body of the embryo out to the chorion, there branching repeatedly to enter the numerous chorionic villi by which the embryonic tissues are placed in relation with the maternal.

**The Umbilical Cord.**—During the process of closing in of the ventral surface of the embryo a stage is reached in which the embryonic and extra-embryonic portions of the body-cavity are completely separated except for a small area, the *umbilicus*, through which the yolk-stalk passes out (Fig. 63, B). At the edges of this area in front and at the sides the embryonic ectoderm and somatic mesoderm become continuous with the corresponding layers of the amnion, but posteriorly the line of attachment of the amnion passes up upon the sides of the belly-stalk (Fig. 63 B), so that the whole of the ventral surface of the stalk is entirely uncovered by ectoderm, this layer being limited to its dorsal surface (Fig. 64). In subsequent stages the embryonic ectoderm and somatic mesoderm at the edges of the *umbilicus* grow out ventrally, carrying with them the line of attachment of the amnion and forming a tube which encloses the proximal part of the yolk-stalk. The ectoderm of the belly-stalk at the same time extending more laterally, the condition represented in Fig. 63, C, is produced, and, these processes continuing, the entire belly-stalk, together with the yolk-stalk, becomes enclosed within a cylindrical cord extending from the ventral surface of the body to the chorion and forming the *umbilical cord* (Fig. 63, D).

From this mode of development it is evident that the cord is, strictly speaking, a portion of the embryo, its surfaces being completely covered by embryonic ectoderm, the amnion being carried during its formation further and further from the umbilicus until finally it is attached around the distal extremity of the cord.

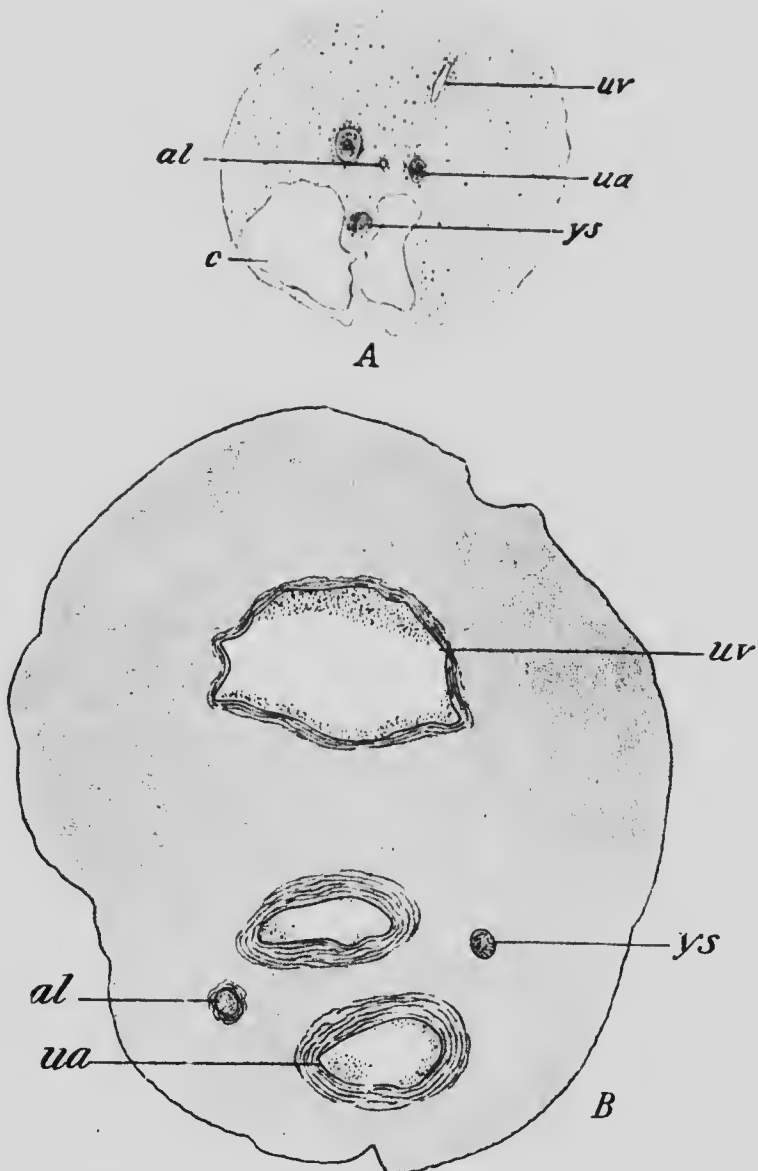


FIG. 65.—TRANSVERSE SECTIONS OF THE UMBILICAL CORD OF EMBRYOS OF (A) 1.8 CM. AND (B) 25 CM.  
*al*, Allantois; *c*, cœlom; *ua*, umbilical artery; *uv*, umbilical vein; *ys*, yolk-stalk.

In enclosing the yolk-stalk the umbilical cord encloses also a small portion of what was originally the extra-embryonic body-cavity surrounding the yolk-stalk. A section of the cord in an early-stage of its development (Fig. 65, A) will show a thick mass of mesoderm occupying its dorsal region; this represents the mesoderm of the belly-stalk and contains the allantois and the umbilical arteries and vein (the two veins originally present in the belly-stalk having fused), while toward the ventral surface there will be seen a distinct cavity in which lies the yolk-stalk with its accompanying blood-vessels. The portion of this cœlom nearest the body of the embryo becomes much enlarged, and during the second month of development contains some coils of the small intestine, but later the entire cavity becomes more and more encroached upon by the growth of the mesoderm, and at about the fourth month is entirely obliterated. A section of the cord subsequent to that period of development will show a solid mass of mesoderm in which are embedded the umbilical arteries and vein, the allantois, and the rudiments of the yolk-stalk (Fig. 65, B).

When fully formed, the umbilical cord measures on the average 55 cm. in length, though it varies considerably in different cases, and has a diameter of about 1.5 cm. It presents the appearance of being spirally twisted, an appearance largely due, however, to the spiral course pursued by the umbilical arteries, though the entire cord may undergo a certain amount of torsion from the movements of the embryo in the later stages of development and may even be knotted. The greater part of its substance is formed by the mesoderm, the cells of which become stellate and form a reticulum, the meshes of which are occupied by connective-tissue fibrils and a mucous fluid which gives to the tissue a jelly-like consistence, whence it has received the name of *Wharton's jelly*.

**The Chorion.**—The umbilical cord, or, more properly, the belly-stalk, places the body of the embryo in communication with the wall of the embryonic vesicle, and this wall, termed the *chorion*, is in contact with the walls of the uterus and becomes specially modified to produce the connection between the embryo and the maternal tissues which is characteristic of all the higher mammalia. It is composed of two layers, an outer ectodermal trophoblast layer and an inner chorionic mesoderm. In the earliest stages it may be presumed that the trophoblast is com-

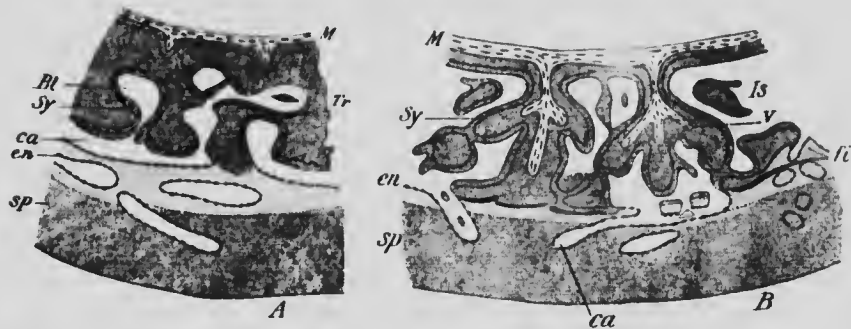


FIG. 66.—TWO DIAGRAMS ILLUSTRATING THE FORMATION OF CHORIONIC VILLI.

*Bl*, Blood-space; *ca*, maternal capillary; *en*, endothelium; *fi*, fibrin; *Is*, intervillous space; *M*, chorionic mesoderm; *sp*, stratum spongiosum; *Sy*, syncytium; *Tr*, trophoblast; *v*, villus.—(Peters.)

paratively thin, as in the bat's ovum, and later becomes a stout layer many cells thick. In the Peters embryo, whose ovum measures only about 1 mm. in diameter, it has already become quite thick and contains numerous blood lacunæ arranged as a network throughout its substance. These lacunæ seem to have been produced by blood extravasated from the maternal vessels penetrating into the substance of the trophoblast and breaking it up into irregular bands and processes (Fig. 66, A), this being possible from the fact that even at this early stage the

ovum is completely embedded in the mucosa of the uterus. In later stages the lacunæ increase in size and unite to form an extensive blood space completely surrounding the embryonic vesicle. Into this blood space the vessels of the uterine walls open, and into it also the irregular processes of the trophoblast project, forming what are termed the *chorionic villi*, the space itself being known as the *intervillous space* (Fig. 66, B).

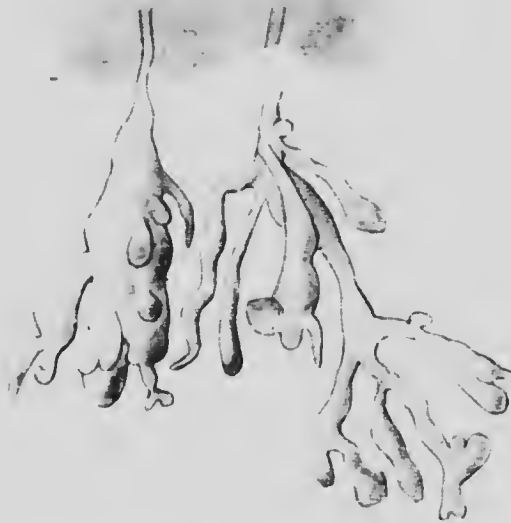

FIG. 67.—TWO VILLI FROM THE CHORION OF AN EMBRYO OF 7 MM.

These villi may at first be developed over the whole surface of the chorion or they may be limited to a broad band situated at what may be termed the equator of the ovum; but whichever arrangement occurs, only those developed from that portion of the chorion to which the belly-stalk is attached undergo further elaboration in later stages, the rest gradually disappearing or remaining only as minute rudiments. It is customary, consequently,

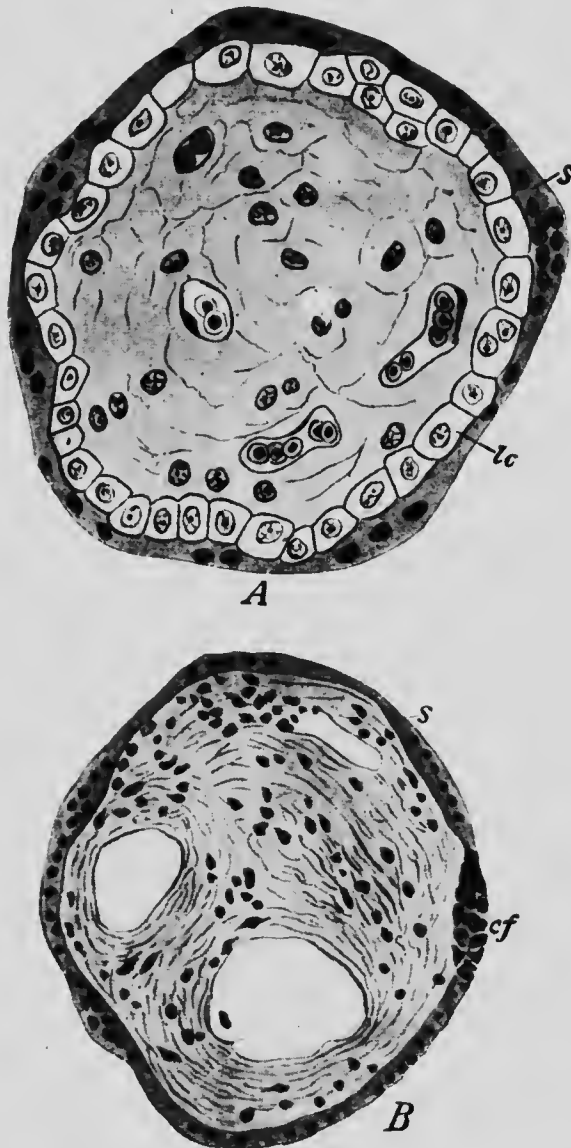


FIG. 68.—TRANSVERSE SECTIONS THROUGH CHORIONIC VILLI IN (A) THE FIFTH AND (B) THE SEVENTH MONTH OF DEVELOPMENT. *cf*, Canalized fibrin; *lc*, Langhans cells; *s*, syncytium.—(A, which is more highly magnified than B, from Szymonowicz; B from Minot.)

to speak of that portion of the chorion in which the development of the villi proceeds as the *chorion frondosum*, to distinguish it from the remaining portion, which is termed the *chorion læve*.

The villi (Fig. 67) at first are irregularly lobed processes formed by a solid mass of trophoblast cells and projecting fully into the intervillous space, a lobe here and there extending completely across the space (Fig. 76) and uniting with the maternal tissues to form roots of attachment. As development proceeds the lobes become much more slender and branch so that each villus assumes a dendritic form. In the mean time, however, processes from the chorionic mesoderm grow out into each villus, extending out even into the terminal branches and forming a central core in which blood-vessels develop, which become continuous with the umbilical arteries and veins. When this has occurred, the ectoderm differentiates into two layers, a superficial one in which the cell-boundaries disappear so that it consists of a continuous layer of protoplasm in which numerous nuclei are embedded (Fig. 68, A, s) and which is termed the syncytium, and an inner one, consisting of well-defined cells arranged in a single layer and termed the Langhans cells (lc).

It may be stated that the exact significance of these two layers is still under discussion, some authors believing the Langhans cells to be mesodermal, while others, admitting that they are ectodermal, maintain the view that the syncytium is really maternal tissue. The view here presented is most in accord with the more recent observations (Minot, Peters).

As development proceeds the villi, which are at first distributed evenly over the chorion frondosum, are separated into groups termed *cotyledons* (Fig. 69), by the growth into the intervillous space of trabeculae from



the walls of the uterus, the villous roots of attachment becoming connected with these septa as well as with the general uterine wall. The ectoderm of the villi also undergoes certain changes with advancing growth, the layer of Langhans cells disappearing except in small areas scattered irregularly in the villi, and the syncytium, though persisting, undergoes local thickenings which degenerate more or less extensively into fibrin-like substance (Fig. 68, B. *cf.*).

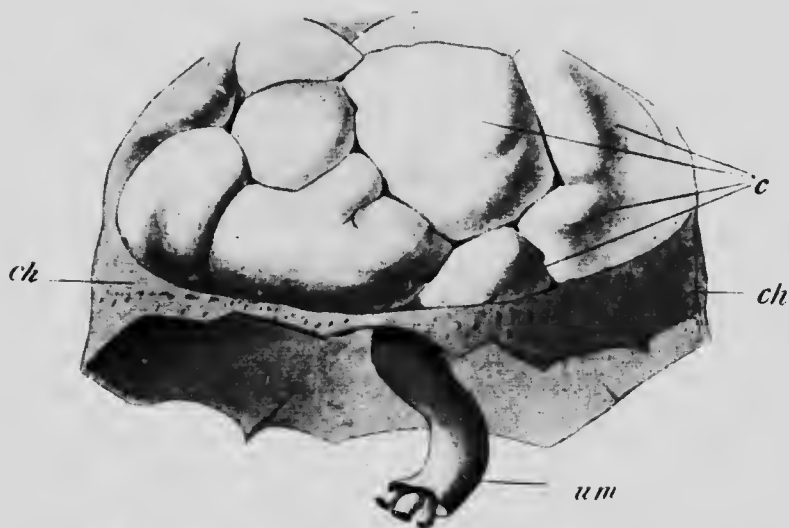


FIG. 69.—MATURE PLACENTA AFTER SEPARATION FROM THE UTERUS.  
*c*, Cotyledons; *ch*, chorion, amnion, and decidua vera; *um*, umbilical cord.—(Kollmann.)

The changes which occur during the later stages of development in the chorion are very similar to those described for the villi. Thus, the mesoderm thickens, its outermost layers becoming exceedingly fibrillar in structure, while the ectoderm differentiates into two layers, the outer of which is syncytial while the inner is cellular, and later still, as in the villi, the syncytial layer degenerates in irregular patches into a peculiar form of fibrin

which is traversed by flattened anastomosing spaces and to which Minot has applied the name canalized fibrin (Fig. 70).

The Decidua.—In connection with the phenomenon of

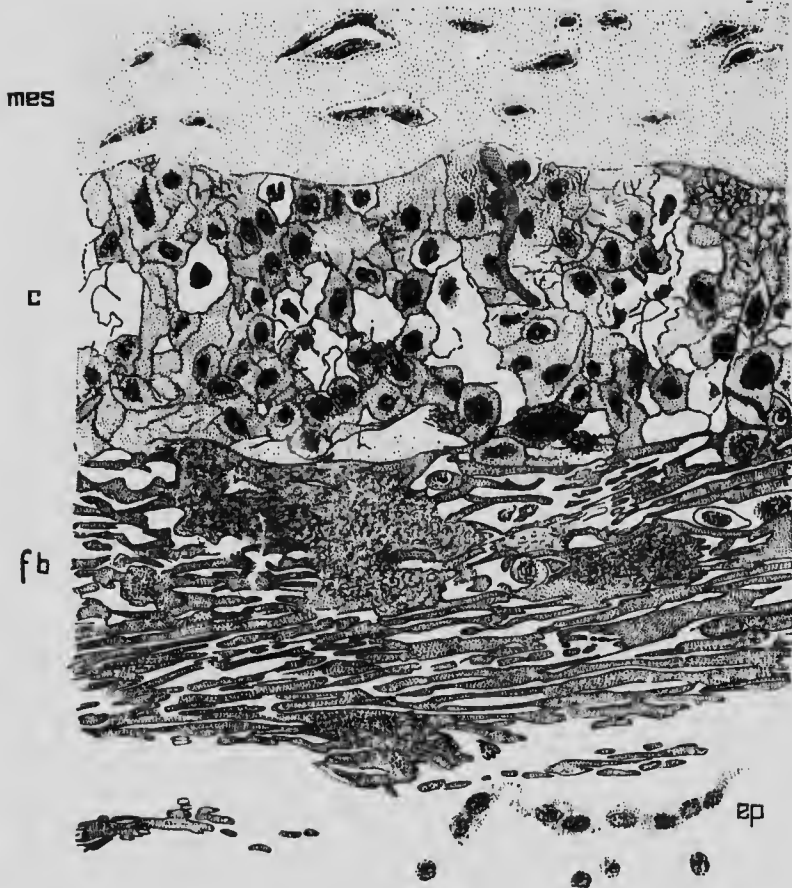


FIG. 70.—SECTION THROUGH THE PLACENTAL CHORION OF AN EMBRYO OF SEVEN MONTHS.

*c*, Cell layer; *cp*, remnants of epithelium; *fb*, fibrin layer; *mes*, mesoderm.—(Minot.)

menstruation periodic alterations occur in the mucous membrane of the uterus. If during one of these periods a fertilized ovum reaches the uterus, the desquamation of

portions of the epithelium does not occur nor is there any appreciable hemorrhage into the cavity of the uterus, the uterine mucosa remains in what is practically the ante-menstrual condition until the conclusion of pregnancy, when, after the birth of the fetus, a considerable portion of its thickness is expelled from the uterus, forming what is

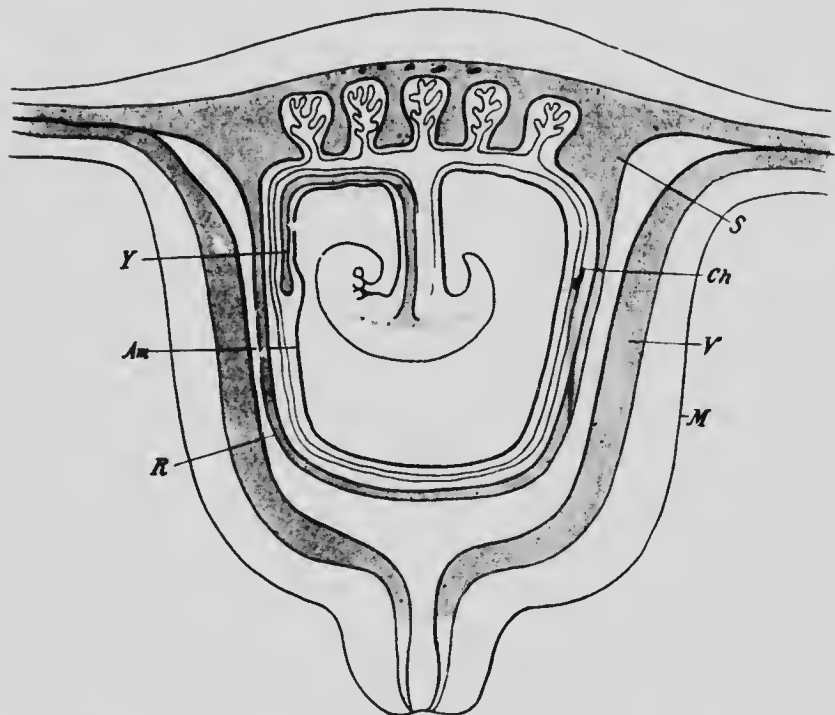


FIG. 71.—DIAGRAM SHOWING THE RELATIONS OF THE FETAL MEMBRANES. *Am*, Amnion; *Ch*, chorion; *M*, muscular wall of uterus; *R*, decidua reflexa; *S*, decidua serotina; *V*, decidua vera; *Y*, yolk-stalk.

termed the *deciduae*. In other words, the sloughing of the uterine mucosa which concludes the process of menstruation is postponed until the close of pregnancy, and then takes place simultaneously over the whole extent of the uterus. Of course, the changes in the uterine mucosa are somewhat more extensive during pregnancy than during

menstruation, but there is an undoubted fundamental similarity in the changes during the two processes.

The human ovum comes into direct apposition with only a small portion of the uterine wall, and the changes which this portion of the wall undergoes differ somewhat from those occurring elsewhere. Consequently it becomes

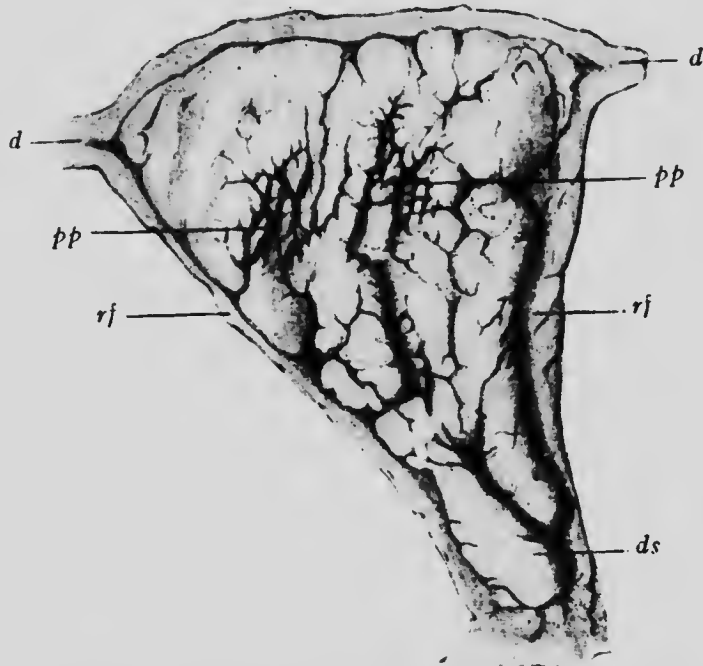


FIG. 72.—SURFACE VIEW OF HALF OF THE DECIDUA VERA AT THE END OF THE THIRD WEEK OF GESTATION.

*d*, Mucous membrane of the Fallopian tubes; *ds*, prolongation of the vera toward the cervix uteri; *pp*, papillæ; *rf*, marginal furrow.—(Kollmann.)

possible to divide the deciduæ into (1) a portion which is not in direct contact with the ovum, the *decidua vera* (Fig. 71, *V*) and (2) a portion which is. The latter portion is again capable of division. The ovum becomes completely embedded in the mucosa, but, as has been pointed

out, the chorionic villi reach their full development only over that portion of the chorion to which the belly-stalk is attached. The decidua which is in relation to this chorion frondosum undergoes much more extensive modifications than that in relation to the chorion læve, and to it the name of *decidua serotina* (Fig. 71, S) is applied, while the rest of the decidua which encloses the ovum is termed the *decidua reflexa* (R).

The changes which give rise to the decidua vera may first be described and those occurring in the others considered in succession.

(a) *Decidua vera*.—On opening a uterus during the fourth or fifth month of pregnancy, when the decidua vera is at the height of its development, the surface of the mucosa presents a corrugated appearance and

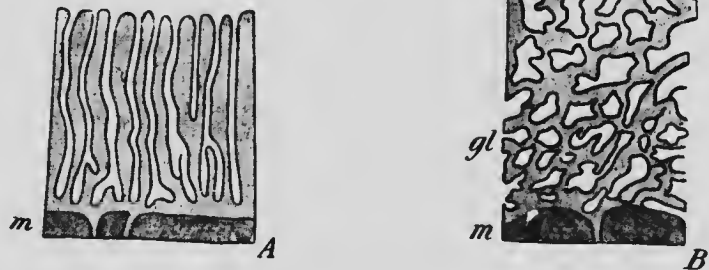


FIG. 73.—DIAGRAMMATIC SECTIONS OF THE UTERINE MUCOSA, A, IN THE NON-PREGNANT UTERUS, AND B, AT THE BEGINNING OF PREGNANCY. c, Stratum compactum; gl, the deepest portions of the glands; m, muscular layer; sp, stratum spongiosum.—(Kundrat and Engelmann.)

is traversed by irregular and rather deep grooves (Fig. 72). This appearance ceases at the internal os, the mucous membrane of the cervix uteri not forming a de-

cidua, and the deciduæ of the two surfaces of the uterus are separated by a distinct furrow known as the *marginal groove*.

In sections the mucosa is found to have become greatly thickened, frequently measuring 1 cm. in thickness, and its glands have undergone very considerable modification. Normally almost straight (Fig. 73, A), they increase in length, not only keeping pace with the thickening of the mucosa, but surpassing its growth, so that they become very much contorted and are, in addition, considerably dilated (Fig. 73, B). Near their mouths they are dilated, but not very much contorted, while lower down the reverse is the case, and it is possible to recognize three layers in the decidua, (1) a *stratum compactum* nearest the lumen of the uterus, containing the straight but dilated portions of the glands; (2) a *stratum spongiosum*, so called from the appearance which it presents in sections owing to the dilated and contorted portions of the glands being cut in various planes; and (3) next the muscular coat of the uterus a layer containing the contorted but not dilated extremities of the glands is found. Only in the last layer does the epithelium of the glands retain its normal columnar form, elsewhere it becomes more or less flattened and shows a tendency toward degeneration.

In addition to these changes, the epithelium of the mucosa disappears completely during the first month of pregnancy, and the tissue between the glands in the *stratum compactum* becomes packed with large, often multinucleated cells, which are termed the *decidual cells*.

After the end of the fifth month the increasing size of the embryo and its membranes exerts a certain amount of pressure on the decidua, and it begins to diminish in thickness. The portions of the glands which lie in the *stratum compactum* become more and more compressed and

finally disappear, while in the spongiosum the spaces become much flattened and the vascularity of the whole decidua, at first so pronounced, diminishes greatly.

(b) *Decidua reflexa*.—The decidua reflexa receives its name from the fact that it was supposed to arise as a fold of the mucous membrane of the uterus and to be reflected

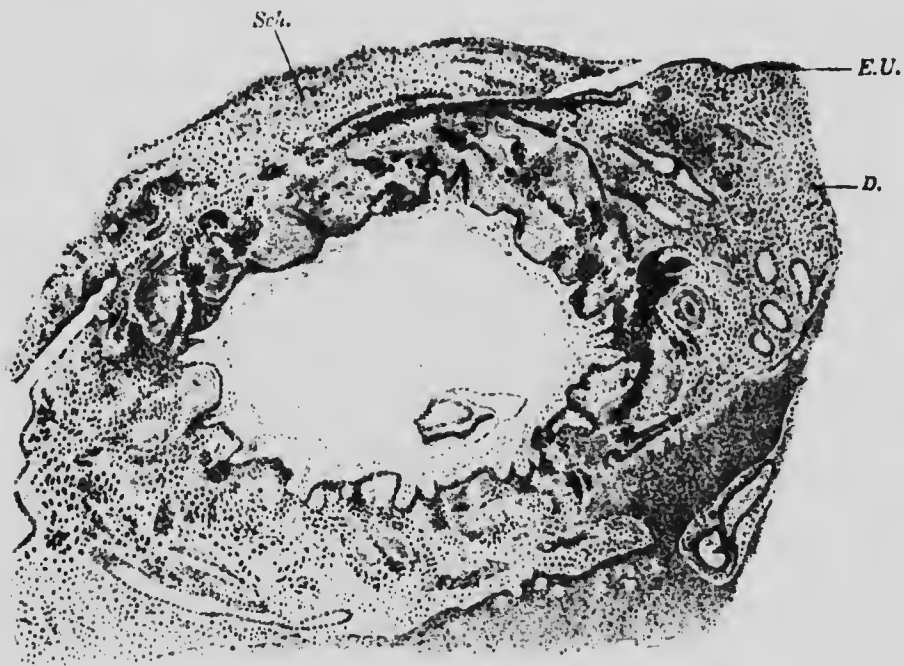


FIG. 74.—SECTION OF AN OVUM OF 1 MM. A SECTION OF THE EMBRYO LIES IN THE LOWER PART OF THE CAVITY OF THE OVUM.

*D*, Decidua; *E.U.*, uterine epithelium; *Sch*, blood-clot closing the aperture left by the sinking of the ovum into the uterine mucosa.  
—(From Strahl, after Peters.)

over the ovum after this had attached itself. Recent observations, however, throw doubt on this mode of origin. Thus, the ovum described by Peters (Fig. 74) was already almost completely enclosed by the reflexa, a small area at one pole being alone exposed. The uterine epithe-

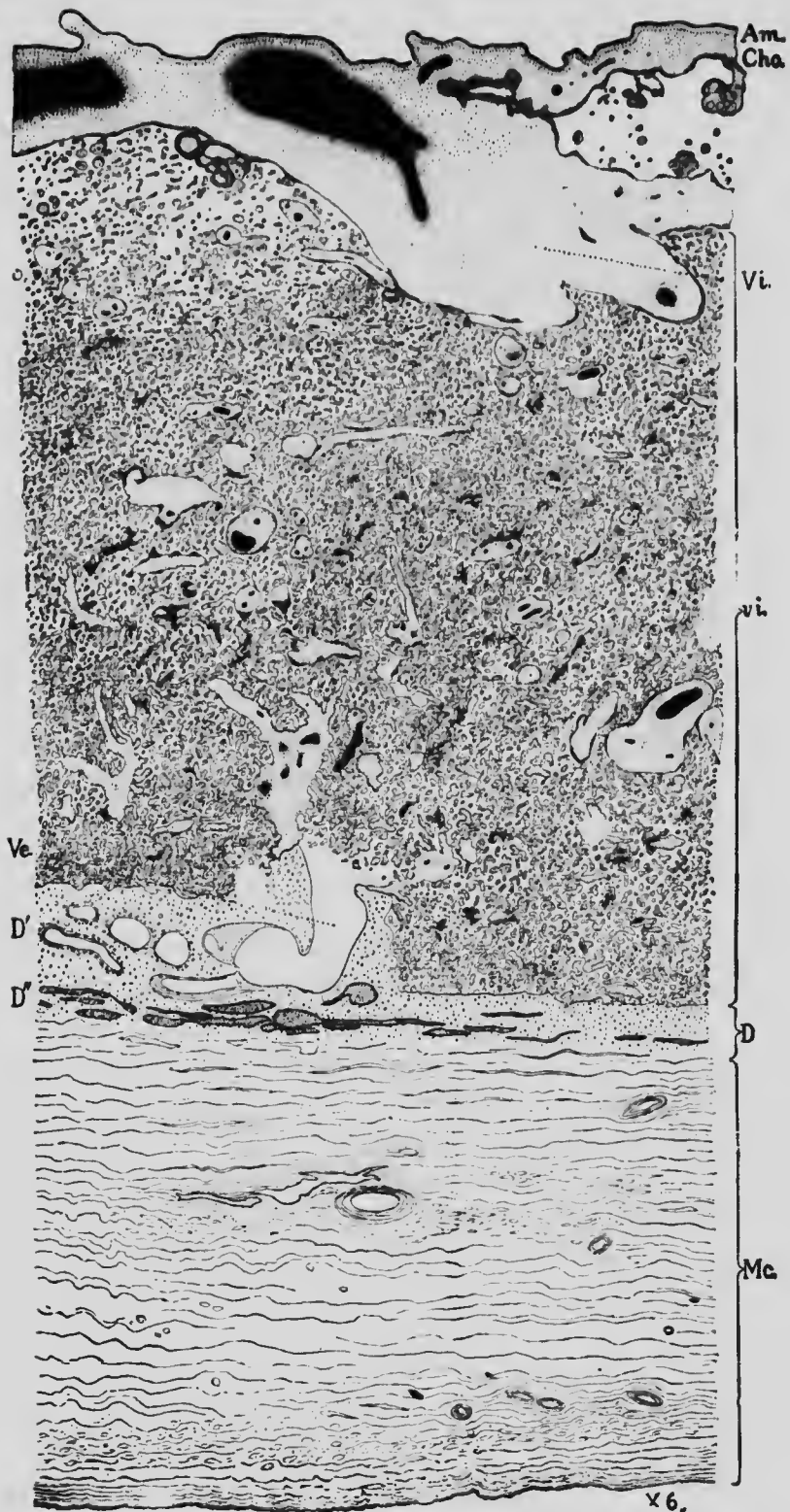
lium around the margins of this unenclosed area was exceedingly thin and had the appearance of being stretched by the growth of the ovum. Peters interprets the condition found in this very early stage by supposing that when the ovum reached the uterus it came into contact with the thickened mucosa at a point where the epithelium had been thrown off and at once proceeded to embed itself in the substance of the mucosa. By the time it reached a diameter of about 1 mm. the ovum was almost completely embedded and the mucosa surrounding it constituted the reflexa. According to this view, which seems to be more in harmony with what has been observed, there is no formation of a fold and no reflection over the surface of the ovum, but the reflexa is due to the ovum becoming embedded in the substance of the mucosa.

As development proceeds the reflexa eventually completely encloses the ovum, the point of union of the edges of the aperture through which the ovum sank into the mucosa being indicated for some time by a scar-like mark.

The general structure of the reflexa is closely similar to that described for the vera, but as the ovum increases in size it becomes thinner and thinner, and at about the fifth month has come into contact with the vera, forming a whitish transparent membrane with no traces of either glands or blood-vessels, and very possibly it eventually degenerates and completely disappears (Minot).

(c) *Decidua serotina*.—The structure of the serotina up to about the fifth month of development is practically the same as that of the vera. It loses its epithelium very early, probably before the attachment of the ovum, and the glands undergo the same changes as in the vera, so that the compactum and spongiosum can be recognized. Beyond the fifth month, however, there is a great differ-





ence between it and the vera, in that, being concerned with the nutrition of the embryo, it does not partake of the degeneration noticeable in the other deciduæ, but persists until birth, forming a part of the structure termed the *placenta*.

**The Placenta.**—This organ, which forms the connection between the embryo and the maternal tissues, is composed of two parts, separated by the intervillous space. One of these parts is of embryonic origin, being the chorion frondosum, while the other belongs to the maternal tissues and is the decidua serotina. Hence the terms *placenta fœtalis* and *placenta uterina* frequently applied to the two parts. The fully formed placenta is a more or less discoidal structure, convex on the surface next the uterine muscularis and concave on that turned toward the embryo, the umbilical cord being continuous with it near the center of the latter surface. It averages about 3.5 cm. in thickness, thinning out somewhat toward the edges, and has a diameter of 15 to 20 cm., and a weight varying between 500 and 1250 grams. It is situated on one of the surfaces of the uterus, the posterior more frequently than the anterior, and usually much nearer the fundus than the internal os. It develops, in fact, wherever the ovum happens to become attached to the uterine walls, and occasionally this attachment is not accomplished until the ovum has descended nearly to the internal os, in which case the placenta may completely close this opening and form what is termed a *placenta prævia*.

If a section of a placenta in a somewhat advanced stage of development be made, the following structures may be

FIG. 75.—SECTION THROUGH A PLACENTA OF SEVEN MONTHS' DEVELOPMENT.

*Am*, Amnion; *cho*, chorion; *D*, layer of decidua containing the uterine glands; *Mc*, muscular coat of the uterus; *Ve*, maternal blood-vessel; *Vi*, stalk of a villus; *vi*, villi in section.—(Minot.)

distinguished: On the inner surface there will be a delicate layer representing the amnion (Fig. 75, *Am*), and next to this a somewhat thicker one which is the chorion (*cho*), in which the degenerative changes already mentioned may be observed. Succeeding this comes a much broader area composed of the large intervillous blood space in which lie sections of the villi (*vi*) cut in various directions. Then follows the stratum compactum of the serotina, next the stratum spongiosum, next the outermost layer of the mucosa (*D''*), in which the uterine glands retain their epithelium, and, finally, the muscularis uteri (*Mc*).

These various structures which enter into the composition of the placenta have, for the most part, been already described, and it remains here only to say a few words concerning the special structure of the serotinal compactum and concerning the origin of the intervillous space and its relations to the villi and the maternal vessels.

From the surface of the compactum processes arise, termed *septa*, which project into the intervillous space, grouping the villi into cotyledons and giving fixation to some of the roots of attachment of the villi (Fig. 75). Throughout the greater extent of the placenta the *septa* do not reach the surface of the chorion, but at the periphery, throughout a narrow zone, they do come into contact with the chorion and unite beneath it to form a membrane which has been termed the *closing plate*. Beneath this lies the peripheral portion of the intervillous space which, owing to the arrangement of the *septa* in this region, appears to be imperfectly separated from the rest of the space and forms what is termed the *marginatus sinus* (Fig. 76).

The probable origin of the intervillous space by the effusion of blood from the maternal vessels into the sub-

*Placenta and Uterus,  
Middle of the Fifth Month.*



FIG. 76.—DIAGRAMMATIC SECTION THROUGH THE HUMAN PLACENTA AT THE MIDDLE OF THE FIFTH MONTH.  
a, Maternal artery; Bp, basal plate; C, intervillous space; CS, stratum compactum; f, prolongation of villi; h<sup>1</sup> and h<sup>2</sup>, roots of attachment of villi; m, chorionic mesoderm; sp, stratum spongiosum; SP, closing plate; z, villus. The fetal portions of the placenta are blue, the maternal black and brown, and the blood spaces pink.—(From Hertwig, after Leopold.)

stance of the trophoblast and the subsequent corrosion of that layer has already been described, and if this be the true method of its development, then it is evident that the fetal villi are in direct contact with the maternal blood contained in the space. The uterine vessels become very much enlarged during pregnancy and those of the serotina communicate freely with the intervillous space, so that a free circulation of the maternal blood through the space occurs. The villi being completely immersed in this constantly renewed blood, an osmotic interchange takes place between the maternal blood of the space and the fetal blood contained in the vessels of the villi, the maternal blood transmitting the nutritive materials necessary for the growth of the embryo and receiving the waste products of the fetal metabolism. And it is only in this manner that the nutrition of the embryo can take place, since nowhere is there a direct communication of the two vascular systems.

It has been maintained by many authors that the intervillous space is lined throughout by a layer of cells continuous with the endothelium of the maternal vessels, so that the fetal blood is separated from the maternal, not only by the fetal tissues of the villi, but also by a layer of maternal tissue (compare what is said in the small print on page 145 concerning the homologies of the ectodermal layers of the villi). The presence of such a layer is certainly what might be expected, since, as Oscar Hertwig has well expressed it, "the employment of spaces lying outside the blood-courses as component parts of the vascular system would be a phenomenon without analogy." It is to be noted that the arteries and veins of the serotina do not communicate by means of capillaries, but by the intervillous space, and this has given rise to the theory that the space is to be regarded as an enormously enlarged capillary, in which case it should be lined throughout by maternal endothelium. Recent observations on the lower mammals, especially the rodents (rabbit, guinea-pig, etc.), seem to show, however, that the space owes its origin to a true effusion of maternal blood, and the evidence furnished

by Peters and van Heukelom from the study of its formation in very early human embryos indicates its origin in the human placenta in the manner described above.

**The Separation of the Decidua at Birth.**—At parturition, after the rupture of the amnion and the expulsion of the fetus, there still remains in the uterine cavity the decidua and the amnion, which is in contact but not fused with the decidua. A continuance of the uterine contractions, producing what are termed the "after-pains," results in the separation of the placenta from the uterine walls, the separation taking place in the deep layers of the spongiosum, so that the portion of the mucosum which contains the undegenerated glands remains behind. As soon as the placenta has separated, the separation of the decidua vera takes place gradually though rapidly, the line of separation again being in the deeper layers of the stratum spongiosum, and the whole of the decidua, together with the amnion, is expelled from the uterus, forming what is known as the "after-birth."

Hemorrhage from the uterine vessels during and after the separation of the decidua is prevented by the contractions of the uterine walls, assisted, according to some authors, by a preliminary blocking of the mouths of the uterine vessels by certain large polynuclear decidual cells found during the later months of pregnancy in the outer layers of the serotina. The regeneration of the uterine mucosa after parturition has its starting-point from the epithelium of the undegenerated glands which persist, this epithelium rapidly evolving a complete mucosa over the entire surface of the uterus.

## LITERATURE.

- S. VAN HEUKELOM: "Ueber die menschliche Placentation," *Archiv für Anat. und Physiol., Anat. Abth.*, 1898.
- W. HIS: "Die Umschliessung der menschlichen Frucht während der frühesten Zeit des Schwangerschafts," *Archiv für Anat. und Physiol., Anat. Abth.*, 1897.
- F. KEIBEL: "Zur Entwicklungsgeschichte der Placenta," *Anat. Anzeiger*, iv, 1889.
- J. KOLLMANN: "Die menschlichen Eier von 6 mm. Grösse," *Archiv für Anat. und Physiol., Anat. Abth.*, 1879.
- J. MERTTENS: "Beiträge zur normalen und pathologischen Anatomie der menschlichen Placenta," *Zeitschrift für Geburtshülfe und Gynaekol.*, xxx and xxxi, 1894.
- C. S. MINOT: "Uterus and Embryo," *Journal of Morphol.*, ii, 1889.
- G. PALADINO: "Sur la genèse des espaces intervilleux du placenta humain et de leur premier contenu, comparativement à la même partie chez quelques mammifères," *Archives Ital. de Biolog.*, xxxi and xxxii, 1899.
- H. PETERS: "Ueber die Einbettung des menschlichen Eies und das früheste bisher bekannte menschliche Placentationsstadium," Leipzig und Wien, 1899.
- C. RUGE: "Ueber die menschliche Placentation," *Zeitschrift für Geburtshülfe und Gynaekol.*, xxxix, 1898.
- F. GRAF SPEE: "Ueber die menschliche Eikammer und Decidua reflexa," *Verhandl. des Anat. Gesellsch.*, xii, 1898.
- J. C. WEBSTER: "Human Placentation," Chicago, 1901.

## PART II.

# ORGANOGENY.

---

### CHAPTER VI.

#### THE DEVELOPMENT OF THE INTEGUMENTARY SYSTEM.

**The Development of the Skin.**—The skin is composed of two embryologically distinct portions, the outer epidermal layer being developed from the ectoderm, while the dermal layer is mesenchymatous in its origin and is formed from the dermatomes of the mesodermic somites.

The ectoderm covering the general surface of the body is, in the earliest stages of development, a single layer of cells, but at the end of the first month it is composed of two layers, an outer one, the *epitrichium*, consisting of slightly flattened cells, and a lower one whose cells are larger and which will give rise to the *epidermis* (Fig. 77, A). During the second month the differences between the two layers become more pronounced, the epitrichial cells assuming a characteristic domed form and becoming vesicular in structure (Fig. 77, B). These cells persist until about the sixth month of development, but after that they are cast off, and, becoming mixed with the secretion of sebaceous glands which have appeared by this time, form a constituent of the vernix caseosa.

In the mean time changes have been taking place in the epidermal layer which result in its becoming several layers



thick (Fig. 77, B), the innermost layer being composed of cells rich in protoplasm while those of the outer layers are irregular in shape and have clearer contents. As development proceeds the number of layers increases and the superficial ones, undergoing a horny degeneration, give rise to the stratum corneum, while the deeper ones become the stratum Malpighii. At about the fourth month ridges develop on the under surface of the epidermis, pro-

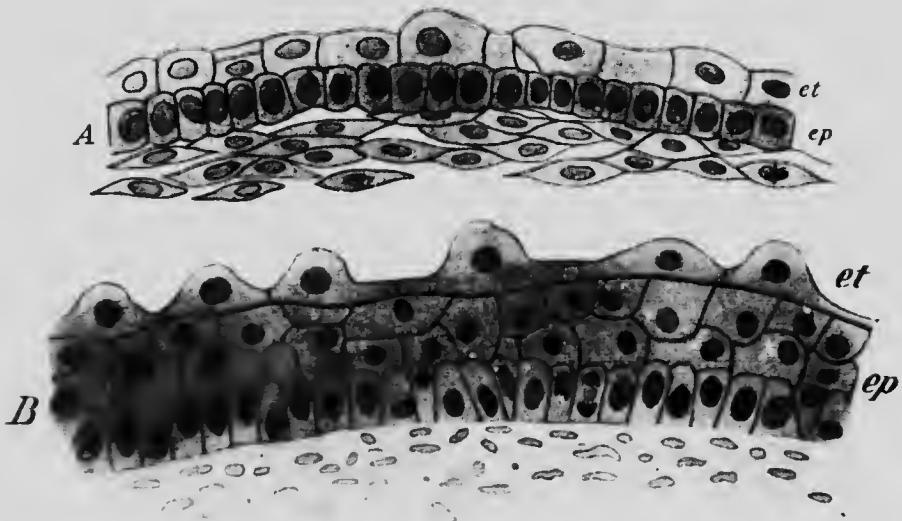


FIG. 77.—A, SECTION OF SKIN FROM THE DORSUM OF FINGER OF AN EMBRYO OF 4.5 CM.; B, FROM THE PLANTAR SURFACE OF THE FOOT OF AN EMBRYO OF 10.2 CM

*et*, Epithelium; *ep*, epidermis

jecting downward into the dermis (Fig. 83), and later secondary ridges appear in the intervals between the primary ones, while on the palms and soles ridges appear upon the outer surface of the epidermis, corresponding in position to the primary ridges of the under surface.

The mesenchyme derived from the dermatomes early loses all traces of its original segmental arrangement and

forms a continuous layer underlying the epidermis. It becomes converted principally into fibrous connective tissue, the outer layers of which are relatively compact, while the deeper ones are looser, forming the subcutaneous areolar tissue. Some of these mesenchymal cells, however, become converted into non-striated muscle-fibers, which for the most part are few in number and associated with the hair follicles, though in certain regions, such as the skin of the scrotum, they are very numerous and form a distinct layer known as the dartos. Some cells also arrange themselves in groups and undergo a fatty degeneration, well-defined masses of adipose tissue embedded in the lower layers of the dermis being thus formed at about the sixth month.

Since the dermal mesenchyme is primarily segmental in character, it might be expected that indications of this original condition might be shown by the distribution of the cutaneous nerves in the adult, even though the boundaries of each dermatome had become indistinct. A study of the cutaneous nerve-supply in the adult realizes to a very considerable extent this expectation, the areas supplied by the various nerves forming

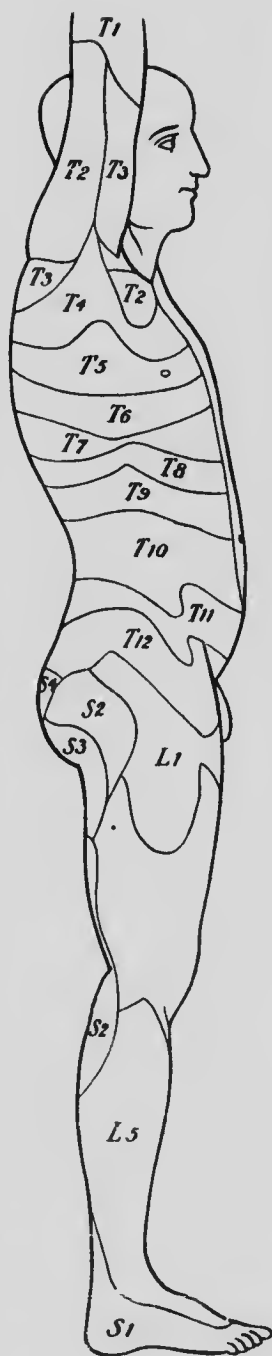


FIG. 78.—DIAGRAM SHOWING THE CUTANEOUS DISTRIBUTION OF THE SPINAL NERVES.—(Head.)

more or less distinct zones, and being therefore segmented (Fig. 78). But a considerable commingling of adjacent dermatomes has also occurred. Thus, while the distribution of the cutaneous branches of the fourth thoracic nerve, as determined experimentally in the monkey (*Macacus*), is distinctly zonal or segmental, the nipple lying practically in the middle line of the zone, the upper half of its area is also supplied or overlapped by fibers of the third nerve and the lower half by fibers of the fifth (Fig. 79), so that any area of skin in the zone is innervated by fibers coming from at least two segmental nerves (Sherrington). And, furthermore, the distribution of each nerve crosses the mid-ventral line of the body, forming a more or less extensive crossed overlap.

And not only is there a confusion of adjacent dermatomes but a dermatome may shift its position relatively to the




FIG. 79.—DIAGRAM SHOWING THE OVERLAP OF THE III, IV, and V INTERCOSTAL NERVES OF A MONKEY.—(Sherrington.)

deeper structure supplied by the same nerve, so that the skin over a certain muscle is not necessarily supplied by fibers from the nerve which supplies the muscle. Thus, in the lower half of the abdomen, the skin at any point will be supplied by fibers from higher nerves than those supplying the underlying muscles (Sherrington), and the skin of the limbs may receive twigs from nerves which are not represented at all in the muscle-supply (second and third thoracic and third sacral).

**The Development of the Nails.**—The earliest indications of the development of the nails have been described by Zander in embryos of about nine weeks as slight thicken-

ings of the epidermis of the tips of the digits, these thickenings being separated from the neighboring tissue by a faint groove. Later the nail areas migrate to the dorsal surfaces of the terminal phalanges (Fig. 80) and the grooves surrounding the areas deepen, especially at their proximal edges, where they form the *nail-folds* (*nf*), while distally thickenings of the epidermis occur to form what have been termed *sole-plates* (*sp*), structures quite rudi-

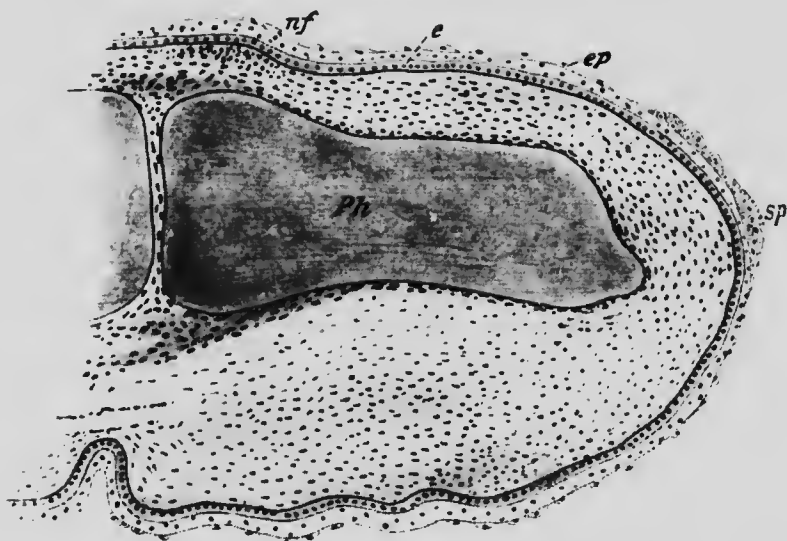


FIG. 80.—LONGITUDINAL SECTION THROUGH THE TERMINAL JOINT OF THE INDEX-FINGER OF AN EMBRYO OF 4.5 CM.  
*e*, Epidermis; *ep*, epitrichium; *nf*, nail fold; *Ph*, terminal phalanx; *sp*, sole plate.

mentary in man, but largely developed in the lower animals, in which they form a considerable portion of the claws.

The actual nail substance does not form, however, until the embryo has reached a length of about 17 cm. By this time the epidermis has become several layers thick and its outer layers, over the nail areas as well as elsewhere, have

become transformed into the stratum corneum (Fig. 81, *sc*), and it is in the deeper layers of this that keratin granules develop in cells which degenerate to give rise to the nail substance (*n*).

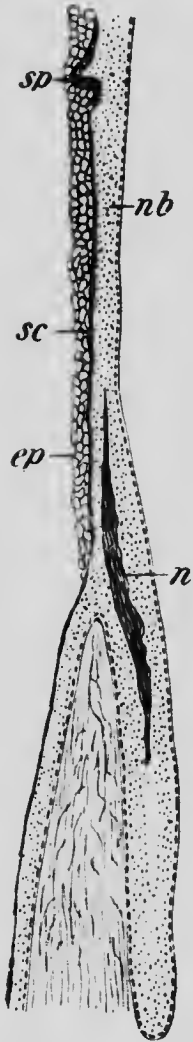


FIG. 81.—LONGITUDINAL SECTION THROUGH THE NAIL AREA IN AN EMBRYO OF 17 CM.

*ep*, Eponychium; *n*, nail substance; *nb*, nail bed; *sc*, stratum corneum; *sp*, sole plate.—(Okamura)

At its first formation, accordingly, the nail is covered by the outer layers of the stratum corneum as well as by the epitrichium, the two together forming what has been termed the *eponychium* (Fig. 81, *ep*). The epitrichium soon disappears, however, leaving only the outer layers of the stratum corneum as a covering, and this also later disappears with the exception of a narrow band surrounding the base of the nail which persists as the *perionychium*.

The formation of the nail begins in the more proximal portion of the nail area and its further growth is by the addition of new keratinized cells to its proximal edge and lower surface, these cells being formed only in the proximal part of the nail bed in a region marked by its whitish color and termed the *lunula*.

The first appearance of the nail areas at the tips of the digits as described by Zauder has not yet been confirmed by later observers, but the migration of the areas to the dorsal surface necessitated by such a location of the primary differentiation affords

an explanation of the otherwise anomalous cutaneous nerve-supply of the nail areas in the adult, this being from the palmar (plantar) nerves.

**The Development of the Hairs.**—The hairs begin to develop at about the third month and continue to be formed during the remaining portions of fetal life. They

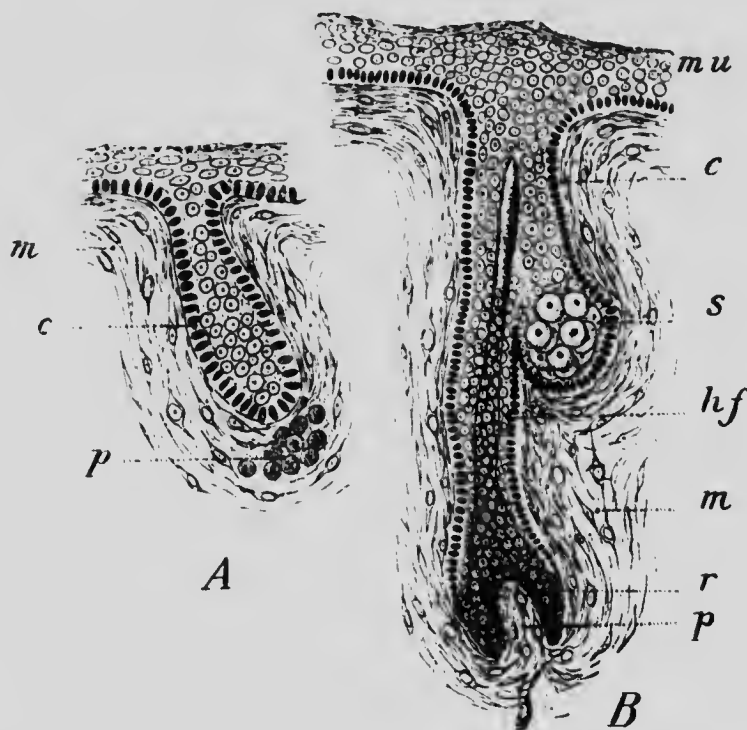


FIG. 82.—THE DEVELOPMENT OF A HAIR.

*c*, Cylindrical cells of stratum mucosum; *hf*, wall of hair follicle; *m*, mesoderm; *mu*, stratum mucosum of epidermis; *p*, hair papilla; *r*, root of hair; *s*, sebaceous gland.—(Kollmann.)

arise as solid cylindrical downgrowths, projecting obliquely into the subjacent dermis from the lower surface of the epidermis. As these downgrowths continue to elongate, they assume a somewhat club-shaped form (Fig. 82), and later the extremity of each club moulds itself

over the summit of a small papilla which develops from the dermis (Fig. 82). Even before the dermal papilla has made its appearance, however, a differentiation of the cells of the downgrowth becomes evident, the central cells becoming at first spindle-shaped and then undergoing a keratinization to form the hair shaft, while the more peripheral ones assume a cuboidal form and constitute the lining of the hair follicle. The further growth of the hair takes place by the addition to its basal portion of new keratinized cells, probably produced by the multiplication of the epidermal cells which envelop the papilla.

From the cells which form the lining of each follicle an outgrowth takes place into the surrounding dermis to form a sebaceous gland, which is at first solid and club-shaped, though later it becomes lobed. The central cells of the outgrowth separate from the peripheral and from one another, and, their protoplasm undergoing a fatty degeneration, they finally pass out into the space between the follicle walls and the hair and so reach the surface, the peripheral cells later giving rise by division to new generations of central cells. During fetal life the fatty material thus poured out upon the surface of the body becomes mingled with the cast-off epitrichial cells and constitutes the white oleaginous substance, the *vernix caseosa*, which covers the surface of the new-born child. The muscles, *arrectores pilorum*, connected with the hair follicles arise from the mesenchyme cells of the surrounding dermis.

The first growth of hairs forms a dense covering over the entire surface of the fetus, the hairs which compose it being exceedingly fine and silky and constituting what is termed the *lanugo*. This growth is cast off soon after birth, except over the face, where it is hardly noticeable on account of its extreme fineness and lack of coloration. The coarser hairs which replace it in certain regions of the

body probably arise from new follicles, since the formation of follicles takes place throughout the later periods of fetal life and possibly after birth. But even these later formed hairs do not individually persist for any great length of time, but are continually being shed, new or secondary hairs normally developing in their places. The shedding of a hair is preceded by a cessation of the proliferation of the cells covering the dermal papilla and by a shrinkage of the papilla whereby it becomes detached from the hair, and the replacing hair arises from a papilla which is probably budded off from the older one before its degeneration and carries with it a cap of epidermal cells.

It is uncertain whether the cases of excessive development of hair over the face and upper part of the body which occasionally occur are due to an excessive development of the later hair follicles (hypertrichosis) or to a persistence and continued growth of the lanugo.

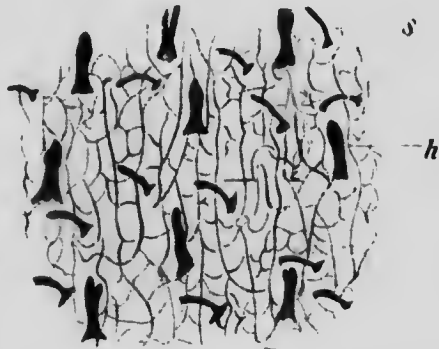


FIG. 83.—LOWER SURFACE OF A DETACHED PORTION OF EPIDERMIS FROM THE DORSUM OF THE HAND.  
*h*, Hair follicle; *s*, sudoriparous gland.  
 —(Blaschko.)

**The Development of the Sudoriparous Glands.**—The sudoriparous glands arise during the fifth month as solid cylindrical outgrowths from the primary ridges of the epidermis (Fig. 83), and at first project vertically downward into the subjacent dermis. Later, however, the lower end of each downgrowth is thrown into coils, and at the same time a lumen appears in the center. Since, however, the cylinders are formed from the deeper layers of the epidermis, their lumina do not at first open upon the



surface, but gradually approach it as the cells of the deeper layers of the epidermis replace those which are continually being cast off from the surface of the stratum corneum. The final opening to the surface occurs during the seventh month of development.

**The Development of the Mammary Glands.**—In the majority of the lower mammals a number of mammary glands occur, arranged in two longitudinal rows, and it has been observed that in the pig the first indication of their

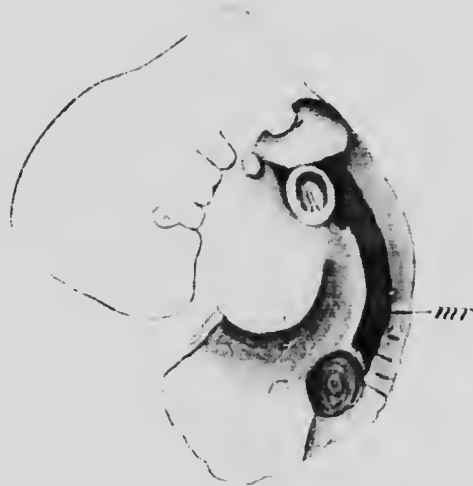

FIG. 84.—MILK RIDGE (*mr*) IN A HUMAN EMBRYO.—(*Kallius*.)

development is seen in a thickening of the epidermis along a line situated at the junction of the abdominal walls with the membrana reuniens (Schulze). This thickening subsequently becomes a pronounced ridge, the *milk ridge*, from which at certain points the mammary glands develop, the ridge disappearing in the intervals. In a human

embryo 4 mm. in length an epidermal thickening has been observed which extended from just below the axilla to the inguinal region (Fig. 84) and was apparently equivalent to the milk line of the pig, and in embryos of 14 or 15 mm. the upper end of the line had become a pronounced ridge, while more posteriorly the thickening had disappeared.

The further history of the ridge has not, however, been yet traced in human embryos, and the next stage of the development of the glands which has been observed is one

in which they are represented by a circular thickening of the epidermis which projects downward into the dermis (Fig. 85, A). Later the thickening becomes lobed (Fig. 85, B), and its superficial and central cells become cornified and are cast off, so that the gland area appears as a depression of the surface of the skin. During the fifth and

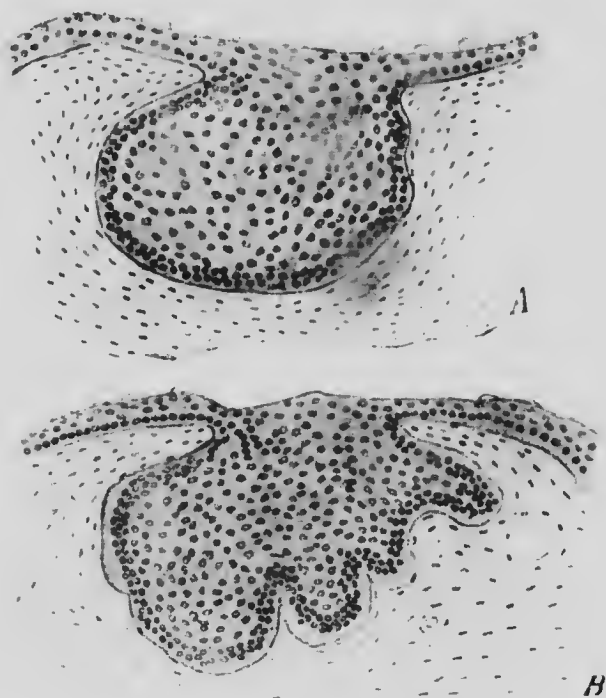


FIG. 85.—SECTIONS THROUGH THE EPIDERMAL THICKENINGS WHICH REPRESENT THE MAMMARY GLAND IN EMBRYOS (A) OF 6 CM. AND (B) OF 10.2 CM.

sixth months the lobes elongate into solid cylindrical columns of cells (Fig. 86) resembling not a little the cylinders which become converted into sudoriparous glands, and each column becomes slightly enlarged at its lower end, from which outgrowths begin to develop to form the acini.

A lumen first appears in the lower ends of the columns and is formed by the separation and breaking down of the central cells, the peripheral cells persisting as the lining of the acini and ducts.

The elevation of the gland area above the surface to form the nipple appears to occur at different periods in different embryos and frequently does not take place until after birth. In the region around the nipple sudoriparous and sebaceous glands develop, the latter also occurring within the nipple area and frequently opening into the extremities of the lacteal ducts. In the areola, as the area surrounding the nipple is termed, other glands,

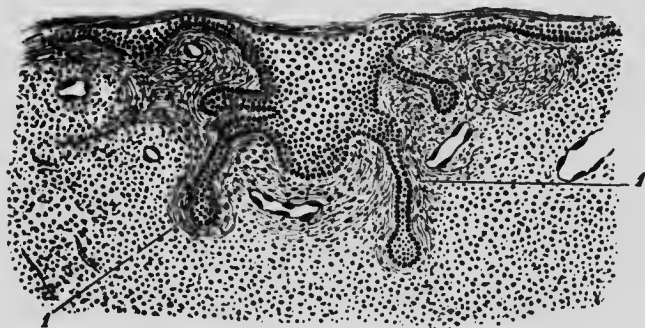


FIG. 86.—SECTION THROUGH THE MAMMARY GLAND OF AN EMBRYO OF 25 CM.  
1, Stroma of the gland.—(From Nagel, after Basch.)

known as *Montgomery's glands*, also appear, their development resembling that of the mammary gland so closely as to render it probable that they are really rudimentary mammary glands.

The further development of the glands, consisting of an increase in the length of the ducts and the development from them of additional acini, continues slowly up to the time of puberty in both sexes, but at that period further growth ceases in the male, while in females it continues for a time and the subjacent dermal tissues, especially the adipose tissue, undergo a rapid development.

The occurrence of a milk ridge has not yet been observed in a sufficient number of embryos to determine whether it is a normal development or is associated with the formation of supernumerary glands (*polymastia*). This is by no means an infrequent anomaly; it has been observed in 19 per cent. of over 100,000 soldiers of the German army who were examined, and occurs in 47 per cent. of individuals in certain regions of Germany. The extent to which the anomaly is developed varies from the occurrence of well-developed accessory glands to that of rudimentary accessory nipples (*hyperthelia*), these latter sometimes occurring in the areolar area of a normal gland and being possibly due in such cases to an hypertrophy of one or more of Montgomery's glands.

Although the mammary glands are typically functional only in females in the period immediately succeeding pregnancy, cases are not unknown in which the glands have been well developed and functional in males (*gynæcomastia*). Furthermore, a functional activity of the glands normally occurs immediately after birth, infants of both sexes yielding a few drops of a milky fluid, the so-called *witch-milk* (*Hexennilch*), when the glands are subjected to pressure.

## LITERATURE.

- R. BONNET: "Die Mammarorgane im Lichte der Ontogenie und Phylogenie," *Ergebnisse der Anat. und Entwicklungsgesch.*, II, 1893.
- J. T. BOWEN: "The Epitrichial Layer of the Human Epidermis," *Anat. Anzeiger*, IV, 1889.
- G. BURCHARD: "Ueber embryonale Hypermastie und Hyperthelie," *Anat. Hefte*, VIII, 1897.
- H. HEAD: "On Disturbances of Sensation with Special Reference to the Pain of Visceral Disease," *Brain*, XVI, 1892; XVII, 1894; and XIX, 1896.
- E. KALLIUS: "Ein Fall von Milchleiste bei einem menschlichen Embryo," *Anat. Hefte*, VIII, 1897.
- T. OKAMURA: "Ueber die Entwicklung des Nagels beim Menschen," *Archiv für Dermatol. und Syphilol.*, XXV, 1900.
- H. SCHMIDT: "Ueber normale Hyperthelie menschlicher Embryonen und über die erste Anlage der menschlichen Milchdrüsen überhaupt," *Morphol.-Arbeiten*, XVII, 1897.
- C. S. SHERRINGTON: "Experiments in Examination of the Peripheral Distribution of the Fibres of the Posterior Roots of some Spinal Nerves," *Philosoph. Trans. Royal Soc.*, CLXXXIV, 1893, and CXC, 1898.
- H. STRAHL: "Die erste Entwicklung der Mammarorgane beim Menschen," *Verhandl. Anat. Gesellsch.*, XII, 1898.

## CHAPTER VII.

### THE DEVELOPMENT OF THE CONNECTIVE TISSUES AND SKELETON.

It has been seen that the cells of a very considerable portion of the somatic and splanchnic mesoderm, as well as of parts of the mesodermic somites, become converted into mesenchyme. A very considerable portion of this becomes converted into what are termed connective or supporting tissues, characterized by consisting of a non-cellular matrix in which more or less scattered cells are embedded. These tissues enter to a greater or less extent into the formation of all the organs of the body, with the exception of those forming the central nervous system, and constitute a network which holds together and supports the elements of which the organs are composed; in addition, they take the form of definite membranes (serous membranes, fasciæ), cords (tendons, ligaments), or solid masses (cartilage), or form looser masses or layers of a somewhat spongy texture (areolar tissue). The intermediate substance is somewhat varied in character, being composed sometimes of white, non-branching non-elastic fibers, sometimes of yellow, branching, elastic fibers; of white, branching, but inelastic fibers which form a reticulum, or of a soft gelatinous substance containing considerable quantities of mucin, as in the tissue which constitutes the Whartonian jelly of the umbilical cord. Again, in cartilage the matrix is compact and homogeneous, or, in other cases, more or less fibrous, passing over into ordinary fibrous tissue, and, finally, in

bone the organic matrix is largely impregnated with salts of lime.

Two views exist as to the mode of formation of the matrix, some authors maintaining that in the fibrous tissues it is produced by the actual transformation of the mesenchyme cells into fibers, while others claim that it is manufactured by the cells but does not directly represent the cells themselves. Fibrils and material out of which fibrils could be formed have undoubtedly been observed in connective-tissue cells, but whether or not these are

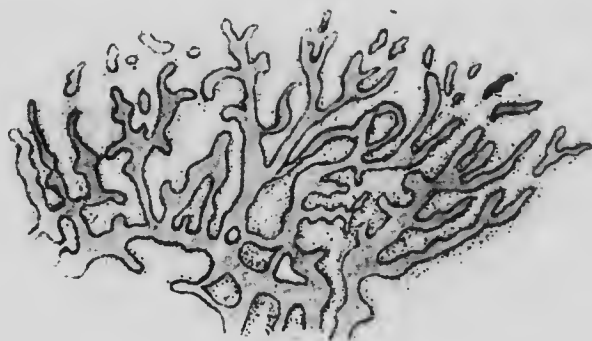


FIG. 87.—PORTION OF THE CENTER OF OSSIFICATION OF THE PARIETAL BONE OF A HUMAN EMBRYO.

later passed to the exterior of the cell to form a connective-tissue fiber is not yet certain, and on this hangs mainly the difference between the theories. Recently it has been held (Mall) that the mesenchyme of the embryo is really a syncytium in and from the protoplasm of which the matrix forms; if this be correct, the distinction which the older views make between the intercellular and intracellular origin of the matrix becomes of little importance.

Bone differs from the other varieties of connective tissue in that it is never a primary formation, but is always

developed either in fibrous tissue or cartilage; and according as it is associated with the one or the other, it is spoken of as membrane bone or cartilage bone. In the development of membrane bone some of the connective-tissue cells, which in consequence become known as *osteoblasts*, deposit lime salts in the matrix in the form of

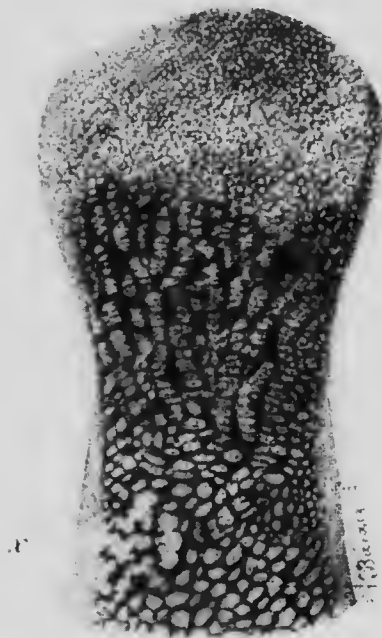

FIG. 88. LONGITUDINAL SECTION OF PHALANX OF A FINGER OF AN EMBRYO OF 3½ MONTHS.  
c, Cartilage trabeculae; p, periosteal bone; po, periosteum; o, ossification center. (Szymonowicz.)

bony spicules which increase in size and soon unite to form a network (Fig. 87). The trabeculae of the network continue to thicken, while, at the same time, the formation of spicules extends further out into the connective-tissue membrane, radiating in all directions from the region in which it first developed. Later the connective tissue which lies upon either surface of the reticular plate of bone thus produced condenses to form a stout membrane, the *periosteum*, between which and the osseous plate osteoblasts arrange

themselves in a more or less definite layer and deposit upon the surface of the plate a lamella of compact bone. A membrane bone, such as one of the flat bones of the skull, thus comes to be composed of two plates of compact bone, the inner and outer tables, enclosing and united to a middle plate of spongy bone which constitutes the diploe.

With bones formed from cartilage the process is somewhat different. In the center of the cartilage the intercellular matrix becomes increased so that the cells appear to be more scattered and a calcareous deposit forms in it. All around this region of calcification the cells arrange themselves in rows (Fig. 88) and the process of calcification extends into the

trabeculæ of matrix which separate these rows. While these processes have been taking place the mesenchyme surrounding the cartilage has become converted into a periosteum (*po*), similar to that of membrane bone, and its osteoblasts deposit a layer of bone (*p*) upon the surface of the cartilage. The cartilage cells now disappear from the intervals between the trabeculæ of calcified matrix, which form a fine network into which masses of mesenchyme (Fig. 89, *pi*), containing blood-vessels and osteoblasts, here and there penetrate from the periosteum, after having broken through the layer of periosteal bone. These masses absorb portions of the fine calcified network and so transform it into a coarse network, the meshes of which they occupy to form the *bone marrow* (*m*), and the osteoblasts which they contain arrange themselves on the surface of the persisting trabeculæ and deposit layers of bone upon their surfaces.

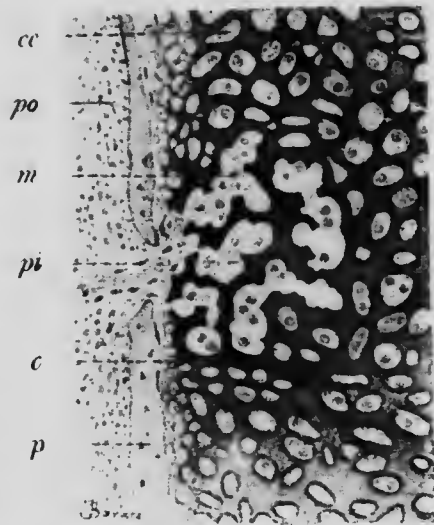


FIG. 89.—THE OSSIFICATION CENTER OF FIG. 88 MORE HIGHLY MAGNIFIED.

*c*, Ossifying trabeculæ; *cc*, cavity of cartilage network; *m*, marrow cells; *p*, periosteal bone; *pi*, interruption of periosteal tissue; *po*, periosteum. (Szymonowicz.)



In the mean time the calcification of the cartilage matrix has been extending, and as fast as the network of calcified trabeculae is formed it is invaded by the mesenchyme, until finally the cartilage becomes entirely converted into a mass of spongy bone enclosed within a layer of more compact periosteal bone.

As a rule, each cartilage bone is developed from a single center of ossification, and when it is found that a bone of the skull, for instance, develops by several centers, it is to be regarded as formed by the fusion of several primarily distinct bones, a conclusion which may generally be confirmed by a comparison of the bone in question with its homologues in the lower vertebrates. Exceptions to this rule occur in bones situated in the median line of the body, these frequently developing from two centers lying one on either side of the median line, but such centers are usually to be regarded as a double center rather than as two distinct centers, and are merely an expression of the fundamental bilaterality which exists even in median structures.

More striking exceptions are to be found in the long bones in which one or both extremities develop from special centers which give rise to the *epiphyses* (Fig. 90, *ep*, *ep'*), the shaft or *diaphysis* (*d*) being formed from the primary center. Similar secondary centers appear in marked prominences on bones to which powerful muscles are attached (Fig. 90, *a* and *b*), but these, as well as the epiphysial centers, can readily be recognized as secondary from the fact that they do not appear until much later than the primary centers of the bones to which they belong. These secondary centers give the necessary firmness required for articular surfaces and for the attachment of muscles and, at the same time, make provision for the growth in length of the bone, since a plate of cartilage

always intervenes between the epiphyses and the diaphysis. This cartilage continues to be transformed into bone on both its surfaces by the extension of both the epiphyseal and diaphyseal ossification into it and, at the same time, it grows in thickness with equal rapidity until the bone reaches its required length, whereupon the rapidity of the growth of the cartilage diminishes and it gradually becomes completely ossified, uniting together the epiphysis and diaphysis.

The growth in thickness of the long bones is, however, an entirely different process, and is due to the formation of new layers of periosteal bone on the outside of those already present. But in connection with this process an absorption of bone also takes place. A section through the middle of the shaft of a humerus, for example, at an early stage of development would show a peripheral zone of compact bone surrounding a core of spongy bone, the meshes of the latter being occupied by the marrow tissue. A similar section of an adult bone, on the other hand, would show only the peripheral compact bone, much thicker than before and enclosing a large marrow cavity in which no trace of spongy bone might remain. The difference depends on the fact that as the periosteal bone



FIG. 90.—THE OSSIFICATION CENTERS OF THE FEMUR.

*a* and *b*, Secondary centers for the great and lesser trochanters; *d*, diaphysis; *ep*, upper and *ep'*, lower epiphysis.—(Testut.)

increases in thickness, there is a gradual absorption of the spongy bone and also of the earlier layers of periosteal bone, this absorption being carried on by large multinucleated cells, termed *osteoclasts*, derived from the marrow mesenchyme. By their action the bone is enabled to reach its requisite diameter and strength, without becoming an almost solid and unwieldy mass of compact bone.

During the ossification of the cartilaginous trabeculae osteoblasts become enclosed by the bony substance, the

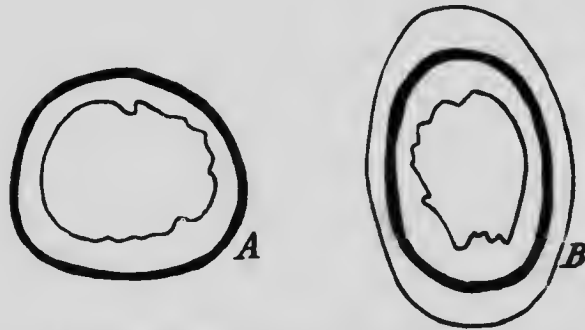


FIG. 91.—A, TRANSVERSE SECTION OF THE FEMUR OF A PIG KILLED AFTER HAVING BEEN FED WITH MADDER FOR FOUR WEEKS; B, THE SAME OF A PIG KILLED TWO MONTHS AFTER THE CESSATION OF THE MADDER FEEDING.

The heavy black line represents the portion of bone stained by the madder.—(After *Flourens*.)

cavities in which they lie forming the *lacunæ* and processes radiating out from them the *canaliculi*, so characteristic of bone tissue. In the growth of periosteal bone not only do osteoblasts become enclosed, but blood-vessels also, the *Haversian canals* being formed in this way, and around these lamellæ of bone are deposited by the enclosed osteoblasts to form Haversian systems.

That the absorption of periosteal bone takes place during growth can be demonstrated by taking advantage of the fact that the coloring substance madder, when consumed with

food, tinges the bone being formed at the time a distinct red. In pigs fed with madder for a time and then killed a section of the femur shows a superficial band of red bone (Fig. 91, A), but if the animals be allowed to live for one or two months after the cessation of the madder feeding, the red band will be found to be covered by a layer of white bone varying in thickness according to the interval elapsed since the cessation of feeding (Fig. 91, B); and if this interval amount to four months, it will be found that the thickness of the uncolored bone between the red bone and the marrow cavity will have greatly diminished (Flourens).

**The Development of the Skeleton.**—Embryologically considered, the skeleton is composed of two portions, the *axial skeleton*, consisting of the skull, the vertebræ, ribs, and sternum, developing from the sclerotomes of the mesodermal somites, and the *appendicular skeleton*, which includes the pectoral and pelvic girdles and the bones of the limbs, and which

arises from the mesenchyme of the somatic mesoderm. It will be convenient to consider first the development of the axial skeleton, and of this the differentiation of the vertebral column and ribs may first be discussed.

**The Development of the Vertebrae and Ribs.**—The mesenchyme formed from the sclerotome of each mesodermic somite grows inward toward the median line and forms a complete investment for the notochord, and, at

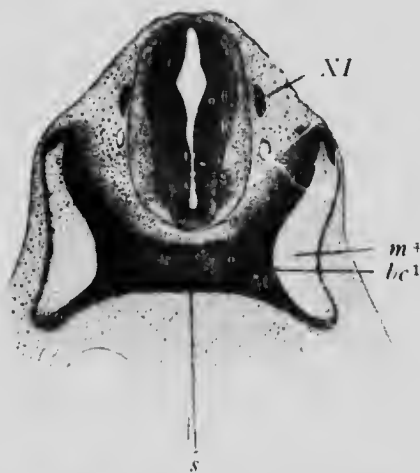


FIG. 92. TRANSVERSE SECTION THROUGH THE INTERVERTEBRAL PLATE OF THE FIRST CERVICAL VERTEBRA OF A CALF EMBRYO OF 8.8 MM.

*bc*<sup>1</sup>, Intervertebral plate; *m*<sup>4</sup>, fourth myotome; *s*, hypochordal bar; *NI*, spinal accessory nerve. (*Froriep.*)

the same time, sends a wing dorsally on each side of the medullary canal, so that this, as well as the notochord, becomes enclosed by a series of mesenchymatous masses, each of which is separated from its predecessor and successor by a plate of more densely arranged mesenchymatous cells (Fig. 92,  $bc^2$ ). These intervertebral plates are

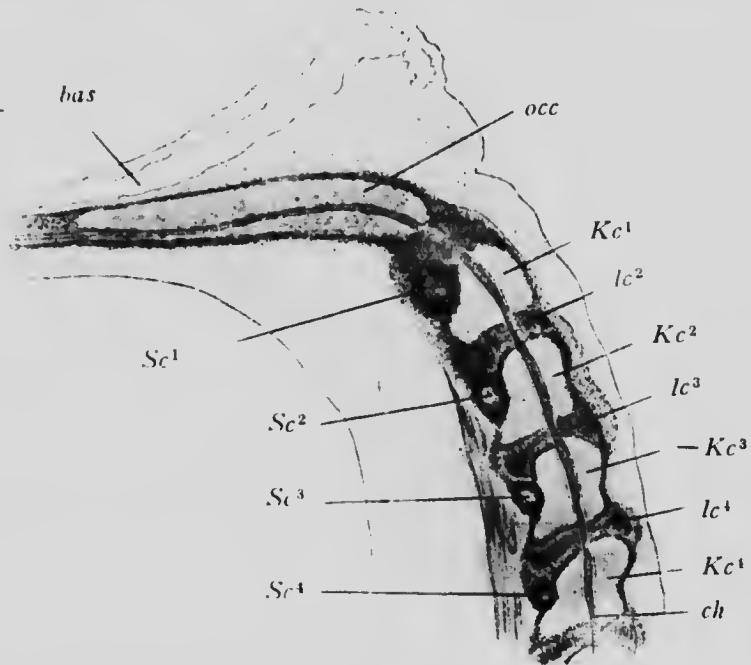



FIG. 93.—LONGITUDINAL SECTION THROUGH THE OCCIPITAL REGION AND UPPER CERVICAL VERTEBRÆ OF A CALF EMBRYO OF 18.5 MM.  
*bas*, Basilar artery; *ch*, notochord;  $Kc^{1-4}$ , vertebral centra;  $lc^{2-4}$ , intervertebral disks; *occ*, basioccipital;  $Sc^{1-4}$ , hypochordal bars.—  
 (Froriep.)

portions of the *intermuscular septa* which occupy the intervals between adjacent mesodermic somites and are formed of cells which have wandered from the anterior and posterior surfaces of the somites. At first, then, the investment of the notochord and medullary canal is by a series of alternating segmental and intersegmental cellular

masses, and the first stage in the development of the vertebræ may be termed the cellular stage.

In the second or cartilaginous stage the mesenchyme becomes converted into cartilage in certain definite regions. The portions of sclerotomic mesenchyme which surround the notochord become chondrified and form the vertebral centra (Fig. 93, *Kc*), these structures being therefore segmental and corresponding in position with a pair of spinal nerves, myotomes and dermatomes. The remaining portions of each vertebra and the ribs are developed in the intermuscular septa, and are therefore intersegmental in position. In the mesial edge of each septum a cartilaginous bar develops, the upper part of which comes into contact with the tip of the corresponding bar of the opposite side to form a *neural arch*, while the lower end becomes connected with its fellow of the other side by a transverse rod of cartilage which lies below the notochord and is termed the *hypochordal bar* (Fig. 93, *Sc*). Furthermore, the ventral edge of each intermuscular septum becomes to a greater or less extent converted into cartilage to form a rib. The neural arches later unite with the centra, their original intersegmental character being thus to a certain extent obscured, but the ribs, which typically alternate with the centra, retain their original position. The hypochordal bars are for the most part merely transitory structures, recalling structures found in the lower vertebrates; in the mammalia they degenerate before the completion of the second stage of development, except in the case of the atlas, whose development will be described later. The cartilages which form the neural arches are at first simple rods, but later a lateral outgrowth develops on each to form a transverse process and upon the ribs a slighter elevation develops to form the tuberculum.





MICROCOPY RESOLUTION TEST CHART  
NATIONAL BUREAU OF STANDARDS  
STANDARD REFERENCE MATERIAL 1010a  
(ANSI and ISC TEST CHART No. 2)



The portions of the sclerotomic mesenchyme which grew up around the medullary canal do not undergo chondrification but become converted into dense fibrous connective tissue, forming the supraspinous and interspinous ligaments and the ligamenta subflava. The portions of the intermuscular septa which immediately surround the notochord and are not concerned in the formation of the hypochordal bars are converted into fibrocartilaginous tissue forming the intervertebral disks (Fig. 93, *lc*), while the anterior and posterior intervertebral ligaments arise from portions of the mesenchyme from which the centra are developed.

Primarily the notochord traverses the entire series of centra and intervertebral disks as a continuous rod, but as the process of chondrification proceeds the portions which traverse the centra gradually become encroached upon and eventually are completely obliterated, while in the intervertebral disks it continues to grow and persists as the masses of pulpy tissue, one of which occupies the center of each disk.

The mode of development described above applies to the great majority of the vertebræ, but some departures from it occur, and these may be conveniently considered before passing on to an account of the ossification of the cartilages. The variations affect principally the extremes of the series. Thus the posterior vertebræ present a reduction of the parts derived from the intermuscular septa, the neural arches of the last sacral vertebræ being but feebly developed, while in the coccygeal vertebræ they are indicated only in the first. In the first cervical vertebra, the atlas, the reverse is the case, for the entire adult vertebra is formed from the intermuscular septum, its lateral masses and posterior arch being the neural arches, while its anterior arch is the hypochordal bar, which persists

in this vertebra only. A well-developed centrum is also formed, however (Fig. 93), but it does not unite with the parts derived from the corresponding intermuseular septum, but during its ossification unites with the centrum of the axis, forming the odontoid process of that vertebra. The axis consequently consists of two segmental and one intersegmental portion, while the atlas consists of one intersegmental portion only.

The extent to which ribs are developed in connection with the various vertebræ also varies considerably. Throughout the cervical region they are very short, the upper five or six being no longer than the transverse processes with the tips of which their extremities unite at an early stage. In the upper five or six vertebræ a relatively large interval persists between the rib and the transverse process, forming the vertebral foramen, through which the vertebral vessels pass, but in the seventh vertebra the fusion is more extensive and the foramen is very small and hardly noticeable. In the thoracic region the ribs reach their greatest development, the upper eight or nine extending almost to the mid-ventral line, where their extremities unite to form a longitudinal cartilaginous bar from which the sternum develops (see p. 189). The lower three or four thoracic ribs are successively shorter, however, and lead to the condition found in the lumbar vertebræ, where they are again greatly reduced and firmly united with the transverse processes, the union being so close that only the tips of the latter can be distinguished, forming what are known as the accessory tubercles. Finally, in the sacral region the ribs are reduced to short flat plates, which unite together to form the lateral masses of the sacrum. They are usually developed only in connection with the first three sacral vertebræ, the last two sacrals and the coccygeals having no ribs.

The limitation of the ribs to the three anterior sacral vertebræ is explained by the fact that primarily the pelvic girdle is in relation only to the last two, whose ribs are consequently suppressed. The rib-bearing sacral vertebræ are really members of the lumbar series and only secondarily come into relation with the iliac bones.

The third stage in the development of the axial skeleton begins with the ossification of the cartilages, and in each vertebra there are typically as many primary centers of ossification as there were originally cartilages. Thus, to take a thoracic vertebra as a type, a center appears in each half of each neural arch at the base of the transverse

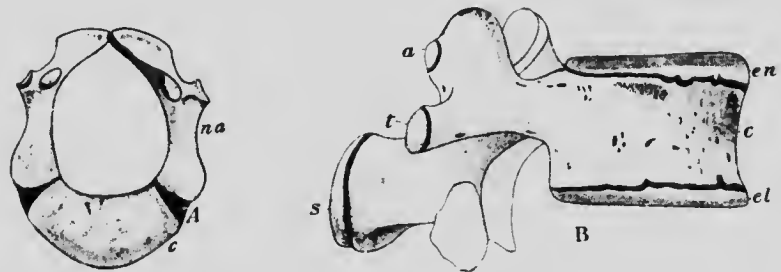


FIG. 94.—A, A VERTEBRA AT BIRTH; B, LUMBAR VERTEBRA SHOWING SECONDARY CENTERS OF OSSIFICATION.

*a*, Center for the articular process; *c*, centrum; *el*, lower epiphysial plate; *en*, upper epiphysial plate; *na*, neural arch; *s*, center for spinous process; *t*, center for transverse process.—(Sappey.)

process and gradually extends to form the bony lamina, pedicle, and the greater portion of the transverse and spinous processes; a double center (see p. 178) gives rise to the body of the vertebra; and each rib ossifies from a single center. These various centers appear early in embryonic life, but the complete transformation of the cartilages into bone does not occur until some time after birth, each vertebra at that period consisting of three parts, a centrum and two halves of an arch, separated by unossified cartilage (Fig. 94, A). At about puberty second-

dary centers make their appearance; one appears in the cartilage which still covers the anterior and posterior surfaces of the vertebral centra, producing disks of bone in these situations, another appears at the tip of each spinous and transverse process (Fig. 94, B), and in the lumbar vertebræ others appear at the tips of the articulating processes. The epiphyses so formed remain separate until growth is completed and between the sixteenth and twenty-fifth years unite with the bones formed from the

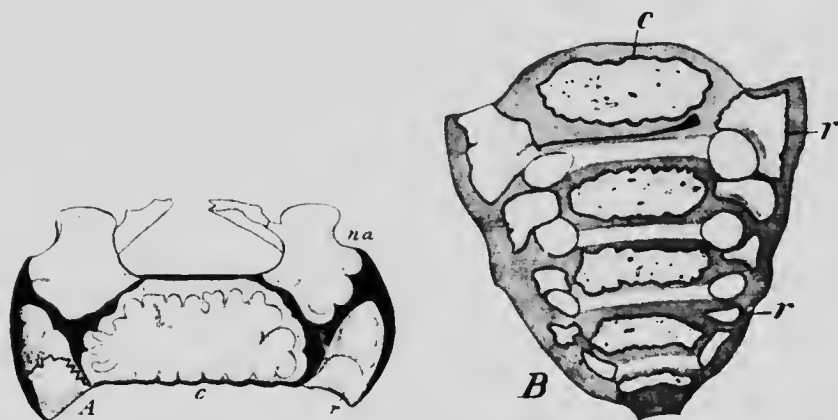


FIG. 95. — A, UPPER SURFACE OF THE FIRST SACRAL VERTEBRA, AND B, VENTRAL VIEW OF THE SACRUM SHOWING PRIMARY CENTERS OF OSSIFICATION.

*c*, Centrum; *na*, neural arch; *r*, rib center.—(Sappey.)

primary centers, which have fused by this time, to form a single vertebra.

Each rib ossifies from a single primary center situated near the angle, secondary centers appearing for the capitulum and tuberosity.

In some of the vertebræ modifications of this typical mode of ossification occur. Thus, in the upper five cervical vertebræ the centers for the rudimentary ribs are suppressed, ossification extending into them from the neural

arch centers, and a similar suppression of the costal center occurs in the lower lumbar vertebra, the first only developing a separate rib center. Furthermore, in the atlas a double center appears in the persisting hypochordal bar, and the centrum which corresponds to the atlas, after developing the terminal epiphysial disks, fuses with the centrum of the axis to form its odontoid process, this vertebra consequently possessing, in addition to the typical centers, one (double) other primary and two secondary centers. In the sacral region the typical centers appear in all five vertebræ, with the exception of rib centers for the last one or two (Fig. 95) and two additional secondary centers give rise to plate-like epiphyses on each side, the upper plates forming the articular surface for the ilium. At about the twenty-fifth year all the sacral vertebræ unite to form a single bone, and a similar fusion occurs also in the rudimentary vertebræ of the coccyx.

The majority of the anomalies seen in the vertebral column are due to the imperfect development of one or more cartilages or of the centers of ossification. Thus, a failure of an arch to unite with the centrum or even the complete absence of an arch or half an arch may occur, and in cases of spina bifida the two halves of the arches fail to unite dorsally. Occasionally the two parts of the double center for the body fail to unite, a double body resulting; or one of the two parts may entirely fail, the result being the formation of only one-half of the body of the vertebra. Other anomalies result from the excessive development of parts. Thus, the rib of the seventh cervical vertebra may sometimes remain distinct and be long enough to reach the sternum, and the first lumbar rib may also fail to unite with its vertebra. On the other hand, the first rib is occasionally found to be imperfect.

**The Development of the Sternum.**—The longitudinal bars which are formed by the fusion of the ventral ends of the anterior eight or nine cartilaginous ribs represent the

future sternum. At an early period the two bars come into contact anteriorly and fuse together (Fig. 96), and at this anterior end two usually indistinctly separated masses of cartilage are to be observed at the vicinity of the points where the ventral ends of the cartilaginous clavicles articulate. These are the *episternal cartilages* (*em*), which later normally unite with the longitudinal bars and form

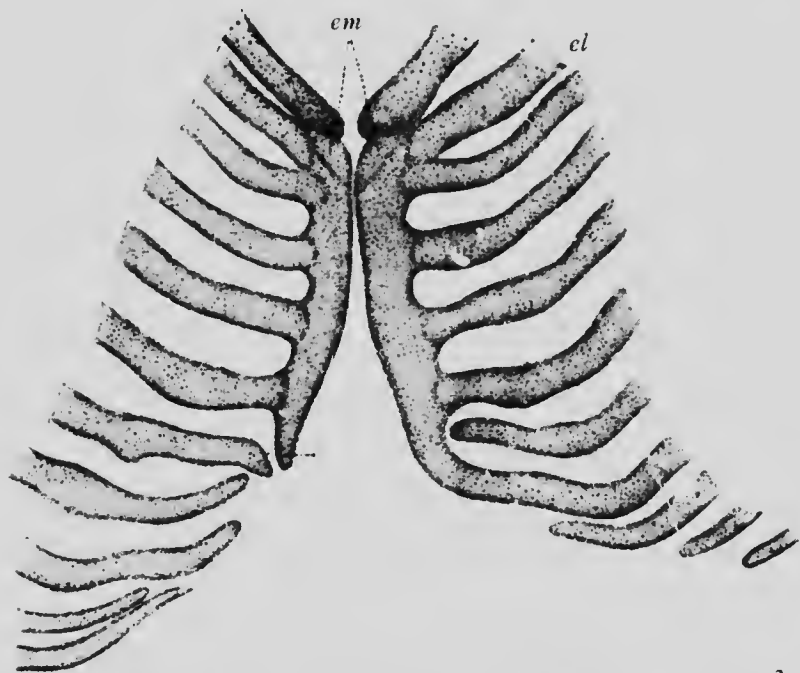


FIG. 96.—FORMATION OF THE STERNUM IN AN EMBRYO OF ABOUT 3 CM.  
*cl*, Clavicle; *em*, episternal cartilages.—(Ruge.)

part of the manubrium sterni, though occasionally they persist and ossify to form the *ossa suprasternalia*. The fusion of the longitudinal bars gradually extends backward until a single elongated plate of cartilage results, with which the seven anterior ribs are united, one or two of the more posterior ribs which originally took part in the formation of each bar having separated. The portions of

the bars formed by these posterior ribs constitute the ensiform process.

The ossification of the sternum (Fig. 97) partakes to a certain extent of the original bilateral segmental origin of the cartilage, but a marked condensation of the centers of ossification also occurs. In the portion of the cartilage which lies below the junction of the third costal cartilages a series of pairs of centers appears just about birth, each

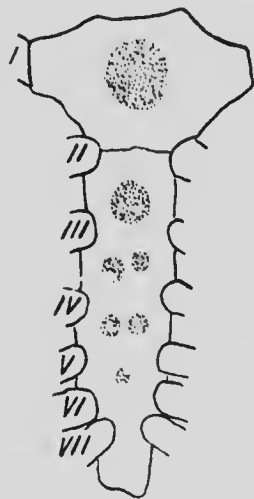


FIG. 97.—STERNUM OF NEW-BORN CHILD, SHOWING CENTERS OF OSSIFICATION.

I to VII, Costal cartilages.  
—(Gegenbaur.)

center probably representing an epiphysial center of a corresponding rib. Later the centers of each pair fuse and the single centers so formed, extending through the cartilage, eventually unite to form the greater part of the gladiolus. In each of the two uppermost segments, however, but a single center appears, that of the lower segment uniting with the more posterior centers and forming the upper part of the gladiolus, while the uppermost center gives rise to the manubrium, which frequently persists as a distinct bone united to the gladiolus by a hinge-joint.

A failure of the cartilaginous bars to fuse produces the condition known as *cleft sternum*, or if the failure to fuse affects only a portion of the bars there results a perforated sternum. A perforation or notching of the ensiform cartilage is of frequent occurrence owing to this being the region where the fusion of the bars takes place last.

The suprasternal bones are the rudiments of a large bone, the episternum, situated in front of the manubrium in the lowest mammalia and reptilia. It furnishes the articular surfaces for the clavicles and is possibly formed by a fusion of the

ventral ends of the cartilages which represent those bones, hence its appearance as a pair of bones in the rudimentary condition.

**The Development of the Skull.**—Little is as yet known, especially in the human embryo, concerning the origin of the mesenchyme from which the mammalian skull is developed, yet, since there is probably a continuation forward into the cranial region of the series of mesodermic somites, it is supposable that these furnish the mesenchyme for the skull, as the more posterior somites furnish material for the vertebrae.

In the earliest stages the human skull is represented by a continuous mass of mesenchyme which invests the anterior portion of the notochord and extends forward beyond its extremity into the nasal region, forming a core for the fronto-nasal process (see p. 104). From each side of this basal mass a wing projects dorsally to enclose the anterior portion of the medullary canal which will later become the cerebral part of the central nervous system. No indications of a segmental origin are to be found in this mesenchyme; as stated, it is a continuous mass, and this is likewise true of the cartilage which later develops in it.

The chondrification occurs first along the median line

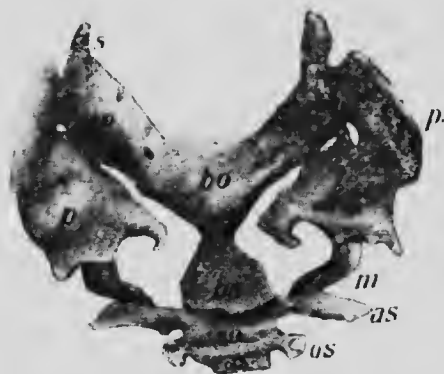

FIG. 98.—RECONSTRUCTION OF THE CHONDROCRANIUM OF AN EMBRYO OF 14 MM.  
*as*, Alisphenoid; *bo*, basioccipital; *bs*, basisphenoid; *co*, exoccipital; *m*, Meckel's cartilage; *os*, orbitosphenoid; *f*, periotic; *ps*, presphenoid; *so*, sellae turcica; *s*, supraoccipital.—(Levi.)



in what will be the occipital and sphenoidal regions of the skull (Fig. 98) and thence gradually extends forward into the ethmoidal region and to a certain extent dorsally at the sides and behind into the regions later occupied by the wings of the sphenoid (*as* and *os*) and the squamous portion of the occipital (*s*). No cartilage develops, however, in the rest of the sides or in the roof of the skull, but the mesenchyme of these regions becomes converted into a dense membrane of connective tissue. While the chondrification is proceeding in the regions mentioned, the mesenchyme which encloses the internal ear becomes converted into cartilage, forming a mass, the *periotic capsule* (Fig. 98, *p*), wedged in on either side between the occipital and sphenoidal regions, with which it eventually unites to form a continuous *chondrocranium*, perforated by foramina for the passage of nerves and vessels.

The posterior part of the basilar portion of the occipital cartilage presents certain peculiarities of development. In calf embryos there are in this region, in very early stages, four separate condensations of mesoderm corresponding to as many mesodermic somites and to the three roots of the hypoglossal nerve together with the first cervical or suboccipital nerve (Froriep) (Fig. 99). These mesenchymal masses in their general characters and relations resemble vertebral centra, and there are good reasons for believing that they represent four vertebræ which, in later stages, are taken up into the skull region and fuse with the primitive chondrocranium. In the human embryo they are less distinct than in lower mammals, but since a three-rooted hypoglossal and a suboccipital nerve also occur in man it is probable that the corresponding vertebræ are also represented. Indeed, confirmation of their existence may be found in the fact that during the cartilaginous stage of the skull the anterior condyloid

foramina are divided into three portions by two cartilaginous partitions which separate the three roots of the hypoglossal nerve. It seems certain from the evidence derived from the embryology and comparative anatomy that the human skull is composed of a primitive unsegmental chondrocranium plus four vertebræ, the latter being added to and incorporated with the occipital portion of the chondrocranium.

Emphasis must be laid upon the fact that the cartilaginous portion of the skull forms only the base and lower portions of the sides of the cranium, its entire roof, as well as the face region, showing no indication of cartilage, the mesenchyme in these regions being converted into fibrous connective tissue, which, especially in the cranial region, assumes the form of a dense membrane.

But in addition to the chondrocranium and the vertebræ incorporated

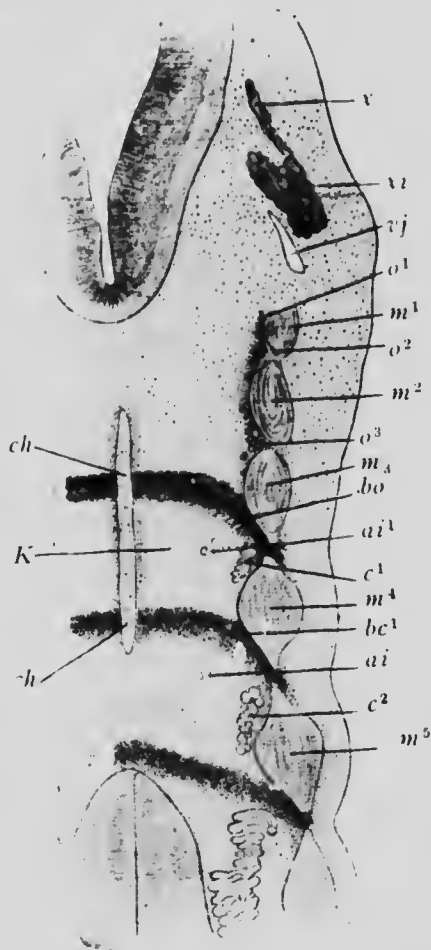


FIG. 99.—FRONTAL SECTION THROUGH THE OCCIPITAL AND UPPER CERVICAL REGIONS OF A CALF EMBRYO OF 8.7 MM.

*ai* and *ai*<sup>1</sup>, Intervertebral arteries; *bc*<sup>1</sup>, first cervical intervertebral plate; *bo*, suboccipital intervertebral plate; *c*<sup>1-2</sup>, cervical nerves; *ch*, notochord; *K*, vertebral centrum; *m*<sup>1-3</sup>, occipital myotomes; *m*<sup>4-5</sup>, cervical myotomes; *o*<sup>1-3</sup>, roots of hypoglossal nerve; *vj*, vagus spinal vein; *x* and *xi*, vagus and spinal accessory nerves. —(Fricke.)

with it, other cartilaginous elements enter into the composition of the skull. The mesenchyme which occupies the axis of each branchial arch undergoes more or less complete chondrification, cartilaginous bars being so formed, certain of which enter into very close relations with the skull. It has been seen (p. 97) that each half of the first arch gives rise to a maxillary process which grows forward and ventrally to form the anterior boundary of the mouth, while the remaining portion of the arch forms the mandibular process. Cartilage appears in the posterior or dorsal part of each maxillary process, and the rod so formed applies itself by its ventral end to the

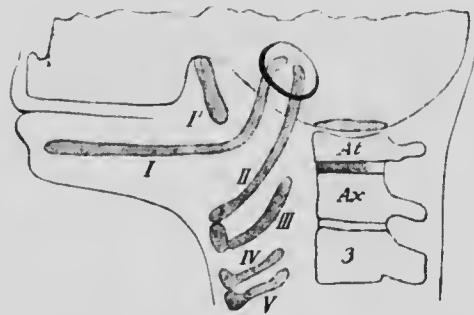


FIG. 100.—DIAGRAM SHOWING THE FIVE BRANCHIAL CARTILAGES, I TO V. I', Internal pterygoid process of the sphenoid; At, atlas; Ax, axis; 3, third cervical vertebra.

under surface of the sphenoid region of the chondrocranium, forming the cartilaginous internal pterygoid plate. The whole of the axis of the mandibular process, on the other hand, becomes chondrified, forming a rod known as *Meckel's cartilage*, and this, at its dorsal end, comes into relation with the periotic capsule, as does also the dorsal end of the cartilage of the second arch. In the remaining three arches cartilage forms only in the ventral portions, so that their rods do not come into relation with the skull, though it will be convenient to consider their further history together with that of the other branchial arch cartilages. The arrangement of these cartilages is shown diagrammatically in Fig. 100.

under surface of the sphenoid region of the chondrocranium, forming the cartilaginous internal pterygoid plate. The whole of the axis of the mandibular process, on the other hand, becomes chondrified, forming a rod known as *Meckel's cartilage*, and this, at its dorsal

By the ossification of these various parts three categories of bones are formed: (1) cartilage bones formed in the chondrocranium, (2) membrane bones, and (3) cartilage bones developing from the cartilages of the branchial arches. The bones belonging to each of these categories are primarily quite distinct from one another and from those of the other groups, but in the human skull a very considerable amount of fusion of the primary bones takes place, and elements belonging to two or even to all three categories may unite to form a single bone of the adult skull. In a certain region of the chondrocranium also and in one of the branchial arches the original cartilage bone becomes ensheathed by membrane bone and eventually disappears completely, so that the adult bone, although represented by a cartilage, is really a membrane bone. And, indeed, this process has proceeded so far in certain portions of the branchial arch skeleton that the original cartilaginous representatives are no longer developed, but the bones are deposited directly in connective tissue. These various modifications interfere greatly with the precise application to the human skull of the classification of bones into the three categories given above, and indeed the true significance of certain of the skull bones can only be perceived by comparative studies. Nevertheless it seems advisable to retain the classification, indicating, where necessary, the confusion of bones of the various categories.

**The Ossification of the Chondrocranium.**—The ossification of the cartilage of the occipital region results in the formation of four distinct bones which even at birth are separated from one another by bands of cartilage. The portion of cartilage lying in front of the foramen magnum ossifies to form a *basioccipital* bone (Fig. 101, *bo*), the portions on either side of this give rise to the two *exo-occipitals*

(*eo*), which bear the condyles, and the portion above the foramen produces a *supraoccipital* (*so*), which represents the part of the squamous portion of the adult bone lying below the superior nuchal line. All that portion of the bone which lies above that line is composed of membrane bone which owes its origin to the fusion of two or sometimes four centers of ossification, appearing in the membranous roof of the embryonic skull. The bone so formed (*ip*) represents the *interparietal* of lower vertebrates and,

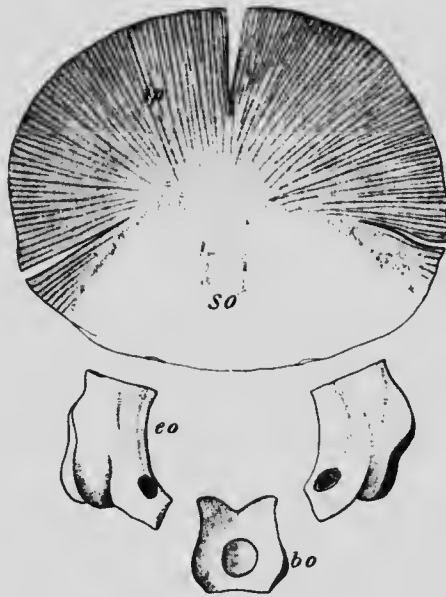


FIG. 101.—OCCIPITAL BONE OF A FETUS AT TERM.  
*bo*, Basioccipital; *eo*, exoccipital; *ip*, interparietal; *so*, supraoccipital.

at an early stage, unites with the supraoccipital, although even at birth an indication of the line of union of the two parts is to be seen in two deep incisions at the sides of the bone. The union of the exoccipitals and supraoccipital takes place in the course of the first or second year after birth, but the basioccipital does not fuse with the rest of the bone until the sixth or eighth year. It will be noticed that no special centers occur for the four occipital ver-

tebræ, these structures having become completely incorporated in the chondrocranium, and even the cartilaginous partitions which divide the anterior condyloid foramen usually disappear during the process of ossification.

In the sphenoidal region the number of distinct bones which develop is much greater than in the occipital region.

In the first place, the basal portion of the cartilage ossifies to form two bones, an anterior or *presphenoid* and a posterior or *basisphenoid* (Fig. 102, *b*), and on each side of each of these an ossification appears giving rise to two lesser wings or *orbitosphenoids* (*os*) and two greater wings or *alisphenoids* (*as*), and an additional center appears on each side of the basisphenoid to form the *lingula* (*l*). In the course of the third month the *lingulae* fuse with the basisphenoid, the orbitosphenoids unite with the presphenoid at about the sixth month, and a little later the presphenoid and basisphenoid unite, the fusion of the alisphenoids with the basisphenoids not taking place until after birth. The centers which give rise to the alisphe-

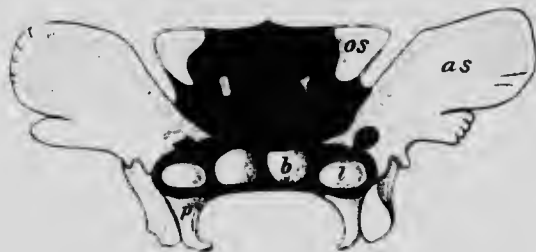

FIG. 102.—SPHENOID BONE FROM EMBRYO OF  $3\frac{1}{2}$  TO 4 MONTHS. The parts which are still cartilaginous are represented in black. *as*, Alisphenoid; *b*, basisphenoid; *l*, lingula; *os*, orbitosphenoid; *p*, internal pterygoid plate.—(Sappey.)

noids extend into the external pterygoid plates, but the internal plates (*p*) are formed by membrane bone which encloses and eventually replaces the pterygoid cartilage derived from the first branchial arch. It seems probable that the upper anterior angle of the alisphenoids arises from a special ossification developing in membrane in this region.

The cartilage of the ethmoidal region of the chondrocranium forms somewhat later than the other portions and consists at first of a stout median mass projecting downward and forward into the fronto-nasal process (Fig.

103, *lp*) and two lateral masses (*lm*), situated one on either side in the mesenchyme on the outer side of each olfactory pit. Ossification of the lateral masses or *ectethmoids* begins relatively early, but it appears in the upper part of the median cartilage only after birth, producing the crista galli and the perpendicular plate, which together form what is termed the *mesethmoid*. When first formed, these three bones are quite separate from one another, the olfactory and nasal nerves passing down between them to

the olfactory pit, but later bony trabeculae begin to extend across from the junction between the crista galli and perpendicular plate to the upper part of the ectethmoids and eventually form a fenestrated horizontal lamella, the cribriform plate.

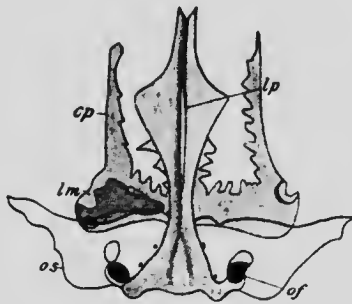


FIG. 103.—ANTERIOR PORTION OF THE BASE OF THE SKULL OF A 6 TO 7 MONTHS' EMBRYO.

The shaded parts represent cartilage. *cp*, Cribriform plate; *lm*, lateral mass of the ethmoid; *lp*, perpendicular plate; *of*, optic foramen; *os*, orbitosphenoid.—(After von Spee.)

The lower part of the median cartilage does not ossify, but a center appears on each side of the median line in the mesenchyme behind and below its posterior or lower border. From these centers two vertical bony plates develop

which unite by their median surfaces below, and above invest the lower border of the cartilage and form the *vomer*. The portion of the cartilage which is thus invested undergoes a certain amount of resorption, but the more anterior portions persist to form the cartilaginous septum of the nose. The vomer, consequently, is not really a portion of the chondrocranium, but is a membrane bone; its intimate relations with the median ethmoidal carti-

lage, however, make it convenient to consider it in this place.

When first formed, the ectethmoids are masses of spongy bone and show no indication of the honeycombed appearance which they present in the adult skull. This condition is produced by the absorption of the bone of each mass by evaginations into it of the mucous membrane lining the nasal cavity. This same process also brings about the formation of the curved plates of bone which project from the inner surfaces of the lateral masses and are known as the superior and middle turbinated bones. The inferior and sphenoidal turbinated bones are developed from special centers but belong to the same category as the others, being formed from portions of the lateral ethmoidal cartilages which become almost separated at an early stage before the ossification has made much progress. Absorption of the body of the sphenoid bone to form the sphenoidal cells, of the frontal to form the frontal sinuses, and of the maxillary to form the antrum of Highmore is also produced by outgrowths of the nasal mucous membrane, all these cavities, as well as the ethmoidal cells, being continuous with the nasal cavities and lined with an epithelium which is continuous with the mucous membrane of the nose.

In the lower mammalia the erosion of the mesial surface of the ectethmoidal cartilages results, as a rule, in the formation of five turbinated plates, while in man but three are usually recognized. Not infrequently, however, the human middle turbinated bone shows indications, more or less marked, of a division into an upper and a lower portion, which correspond to the third and fourth bones of the typical mammalian arrangement. Furthermore, at the upper portion of the nasal wall, in front of the superior turbinate, a slight elevation, termed the *agger nasi*, is always observable, its lower edge being prolonged downward to form what is termed the uncinat process of the ethmoid. This process and the *agger* together represent the first turbinate of the typical arrangement, to which, therefore, the human arrangement may be reduced.



A number of centers of ossification—the exact number is yet uncertain—appear in the periotic capsule during the later portions of the fifth month, and during the sixth month these unite together to form a single center from which the complete ossification of the cartilage proceeds to form the petrous and mastoid portions of the temporal bone (Fig. 104, *p*). The mastoid process does not really form until several years after birth, being produced by the hollowing and bulging out of a portion of the petrous bone

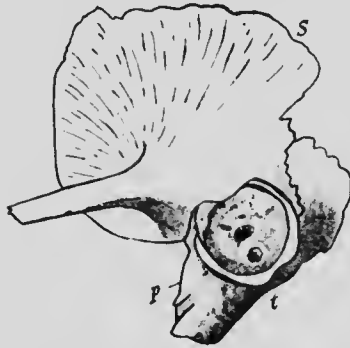

FIG. 104.—THE TEMPORAL BONE AT BIRTH. THE STYLOID PROCESS AND AUDITORY OSSICLES ARE NOT REPRESENTED

*p*, Petrous bone; *s*, squamosal; *t*, tympanic.—(Poirier.)

by outgrowths from the lining membrane of the middle ear. The cavities so formed are the mastoid cells, and their relations to the middle-ear cavity are in all respects similar to those of the ethmoidal and sphenoidal cells to the nasal cavities. The remaining portions of the temporal bone are partly formed by membrane bone and partly from the branchial arch skeleton. An ossification appears in the membrane which forms the side of the

skull in the temporal region and gives rise to a *squamosal* bone (*s*), which later unites with the petrous to form the squamosal portion of the adult temporal, and another membrane bone, the *tympanic* (*t*), develops from a center appearing in the mesenchyme surrounding the external auditory meatus, and later also fuses with the petrous to form the floor and sides of the external meatus, giving attachment at its inner edge to the tympanic membrane. Finally, the *styloid process* is developed from the upper

part of the second branchial arch, whose history will be considered later.

The various ossifications which form in the chondrocranium and the portions of the adult skull which represent them are shown in the following table:

REGION OF CHONDROCRANIUM.	OSSIFICATIONS.	PARTS OF ADULT SKULL.
Occipital, . . . . .	{ Basisoccipital Exoccipitals Supraoccipital	Basilar process. Condyles. Squamous portion above superior nuchal line.
Sphenoidal, . . .	{ Basisphenoid } Presphenoid } Lingula } Alisphenoids } Orbitosphenoids	Body. Greater wings and external pterygoid plates. Lesser wings.
Ethmoidal, . . .	{ Mesethmoid Ectethmoids Inferior turbinate Sphenoidal turbinate	{ Lamina perpendicularis. Crista galli. Nasal septum. Lateral masses. Superior turbinate. Middle turbinate.
Petrotic capsule, . . . . .		{ Petrous. Mastoid.

**The Membrane Bones of the Skull.**—In the membrane forming the sides and roof of the skull in the second stage of its development ossifications appear, which give rise, in addition to the interparietal and squamosal bones already mentioned in connection with the occipital and temporal, to the *parietals* and *frontal*. Each of the former bones develops from a single center, while the frontal is formed from two centers situated symmetrically on each side of the median line and eventually fusing completely to form a single bone, although more or less distinct indications of a median suture, the metopic, are not infrequently present.

Furthermore, ossifications appear in the mesenchyme of the facial region to form the *nasal*, *lachrymal*, and

*malar* bones, the first two arising from single centers of ossification, while each malar possesses three centers which early unite, though occasionally one or more of their lines of union may persist, producing a divided malar.

The vomer, which has already been described, belongs also strictly to the category of membrane bones, as do also the maxillæ and palatines; these latter, however, primarily belonging to the branchial arch skeleton, with which they will be considered.

The purely membrane bones in the skull are, then, the following:

Interparietals, .....	Part of squamous portion of occipital.
Squamosals, .....	Squamous portions of temporals.
Tympanics, .....	Tympanic plates of temporals.
Parietals.	
Frontal.	
Nasals.	
Lachrymals.	
Malars.	
Vomer.	

**The Ossification of the Branchial Arch Skeleton.**—It has been seen (p. 194) that a cartilaginous bar develops only in the dorsal portion of the maxillary process of the first branchial arch. This cartilage becomes invested by membrane bone which gradually replaces the cartilage and eventually fuses with the sphenoid bone to form its internal pterygoid plate. In the more ventral portions of the maxillary process, however, no cartilaginous skeleton forms, but two membrane bones, the palatine and maxilla, are developed in it, their cartilaginous representatives, which are to be found in lower vertebrates, having been suppressed by a condensation of the development. The

*palatine* bone develops from a single center of ossification, but for each *maxilla* no less than five centers have been described (Fig. 105). One of these gives rise to so much of the alveolar border of the bone as contains the bicuspid and molar teeth; a second forms the nasal process and the part of the alveolar border which contains the canine tooth; a third the portion which contains the incisor teeth; while the fourth and fifth centers lie above the first and give rise to the inner and outer portions of the orbital plate and the body of the bone. The first, second, fourth, and fifth portions early unite together, but the third center, which really lies in the ventral part of the fronto-nasal process, remains separate for some time, forming what is termed the *premaxilla*, a bone which remains permanently distinct in the majority of the lower mammals.

Since the condition known as cleft palate results from a failure of the maxillary process to unite with the fronto-nasal process (see p. 105), and since the premaxilla develops in the latter and the maxilla in the former, the cleft passes between these two bones and prevents their union.

The upper end of Meekel's cartilage passes between the tympanic bone and the outer surface of the periotic capsule and thus comes to lie apparently within the tympanic cavity of the ear; this portion of the cartilage divides into two parts which ossify to form two of the bones of the middle ear, the malleus and incus, a description of whose further development may be postponed until a later chap-

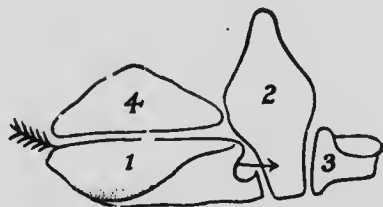


FIG. 105.—DIAGRAM OF THE OSSIFICATIONS OF WHICH THE MAXILLA IS COMPOSED, AS SEEN FROM THE OUTER SURFACE. THE ARROW PASSES THROUGH THE INFRA-ORBITAL CANAL.—(From von Spee, after Sappey.)

ter. The lower half of the ventral portion of the cartilage becomes completely invested by a number of flat membrane bones, which fuse together so as to enclose the cartilage together with the vessels and nerve (inferior dental) which lie beside it. Later the cartilage disappears and a canal containing the vessels and nerve is left traversing the fused bones which represent the horizontal ramus and the lower part of the vertical ramus of the mandible. The upper part of the vertical ramus is formed of membrane bone also, but in this case the bone lies entirely on the outer side of the cartilage, whence the position of the dental foramen on the inner surface of the ramus. The upper half of the ventral portion of the cartilage which corresponds to this upper part of the ramus undergoes a degeneration, forming the speno-mandibular ligament, and, in the later stages of development, cartilage develops, quite independently of the original Meckelian cartilage, at the symphysis, the articular surface, the coronoid process and the angle, and may undergo ossification, becoming eventually united to the membrane bone; these cartilages are to be regarded as secondary epiphysial cartilages.

The upper part of the cartilage of the second branchial arch also lies within the tympanic cavity and ossifies to form the stapes, while the portion of the cartilage immediately ventral to this ossifies as the styloid process of the temporal bone. The succeeding moiety of the cartilage undergoes degeneration to form the stylo-hyoid ligament, while its most ventral portion ossifies as the *lesser cornu* of the *hyoid bone*. The great variability which may be observed in the length of the styloid processes and of the lesser cornua of the hyoid depends upon the extent to which the ossification of the original cartilage proceeds, the length of the stylo-hyoid ligaments being in inverse ratio to the length of the processes or cornua. The *greater*

*cornua* of the hyoid are formed by the ossification of the cartilages of the third arch, and the body of the bone is

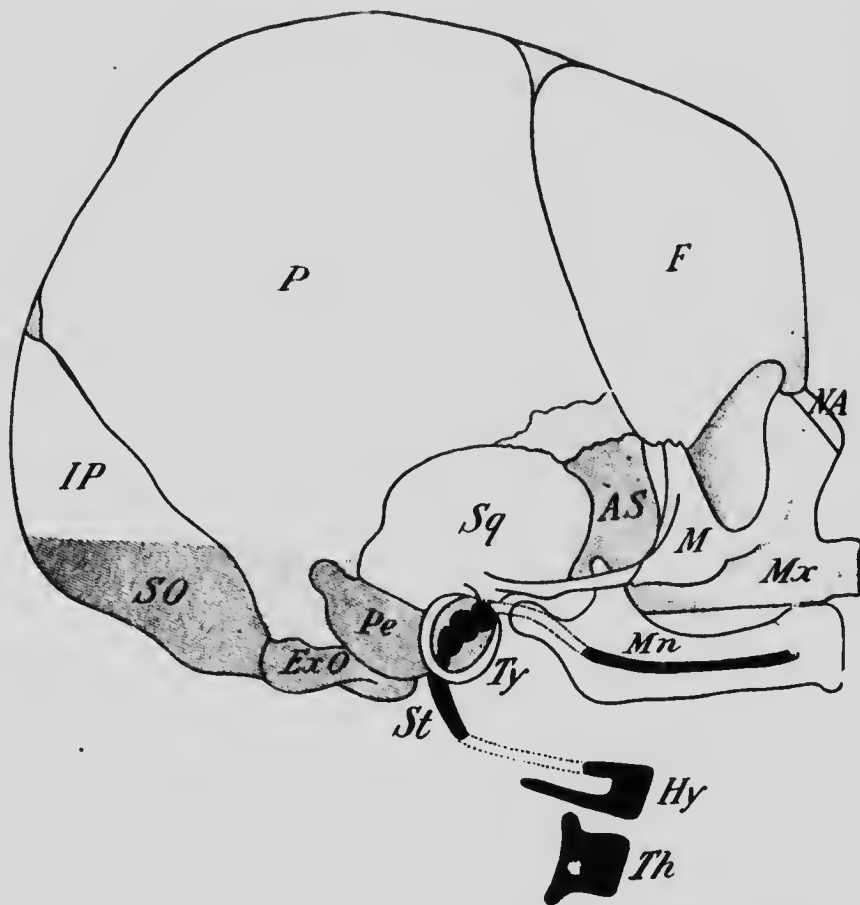


FIG. 106.—DIAGRAM SHOWING THE CATEGORIES TO WHICH THE BONES OF THE SKULL BELONG.

The unshaded bones are membrane bones, the shaded represent the chondrocranium, while the black represent the visceral arch elements. AS, Alisphenoid; ExO, exoccipital; F, frontal; Hy, hyoid; IP, interparietal; M, malar; Mn, mandible; Mx, maxilla; NA, nasal; P, parietal; Pe, periotic; SO, supraoccipital; Sq, squamosal; St, styloid process; Th, thyroid cartilage; Ty, tympanic.

formed from a cartilaginous plate, the *copula*, which unites the ventral ends of the two arches concerned.

Finally the cartilages of the fourth and fifth arches early fuse together to form a plate of cartilage, and the two plates of opposite sides unite by their ventral edges to form the thyroid cartilage of the larynx.

The accompanying diagram (Fig. 106) shows the various structures derived from the branchial arch skeleton as well as some of the other elements of the skull, and a résumé of the fate of the branchial arches may be stated in tabular form as follows, the parts represented by cartilage which becomes replaced by membrane bone being printed in italics, while membrane bones which have no cartilaginous representatives are enclosed in brackets:

	(Maxilla).
	(Palatine).
1st arch, . . . . .	<i>Pterygoid</i> internal pterygoid process of sphenoid.
	Malleus.
	Incus.
	(Spheno-mandibular ligament.
	<i>Mandible</i> .
2d arch, . . . . .	Stapes.
	Styloid process of the temporal.
	Stylo-hyoid ligament.
	Lesser cornu of hyoid.
3d arch, . . . . .	Greater cornu of hyoid.
4th and 5th arches, . .	Thyroid cartilage of larynx.

**The Development of the Appendicular Skeleton.**—While the axial skeleton is formed from the sclerotomes of the mesodermic somites, the appendicular skeleton is derived from the somatic mesenchyme, which is not divided into metameres. This mesenchyme forms the core of the limb bud and becomes converted into cartilage, by the ossification of which all the bones of the limbs, with the possible exception of the clavicle, are formed.

Of the bones of the pectoral girdle the clavicle requires further study before it can be certain whether it is to be regarded as a pure cartilage bone or a combination of

cartilage and membrane ossifications (Gegenbaur). It is the first bone of the skeleton to ossify, its center appearing at about the sixth week of development. The tissue in which the ossification forms has certain peculiar characters, and it is difficult to say whether it is to be regarded as cartilage which, on account of the early differentiation of the center, has not yet become thoroughly differentiated histologically, or as some other form of connective tissue. However that may be, true cartilage develops on either side of the ossifying region, and into this the ossification gradually extends, so that at least a portion of the bone is preformed in cartilage.

The *scapula* is at first a single plate of cartilage in which two centers of ossification appear. One of these gives rise to the body and the spine, while the other produces the coracoid process (Fig.

107, *co*), the rudimentary representative of the coracoid bone which extends between the scapula and sternum in the lower vertebrates. The coracoid does not unite with the body until about the fifteenth year, and secondary centers which give rise to the vertebral edge (*b*) and inferior angle of the bone (*a*) and to the acromion process (*c*) unite with the rest of the bone at about the twentieth year.

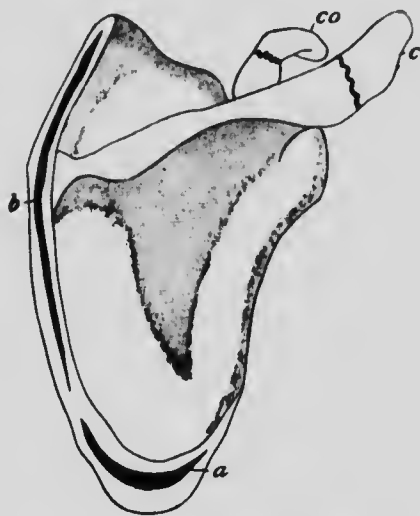

FIG. 107.—THE OSSIFICATION CENTERS OF THE SCAPULA.

*a*, *b*, and *c*, Secondary centers for the angle, vertebral border, and acromion; *co*, center for the coracoid process.—(Testu.)



The *humerus* and the bones of the forearm are typical long bones, each of which develops from a primary center which gives rise to the shaft and has, in addition, two or more epiphysial centers. In the humerus an epiphysial center appears for the head, another for the greater tuberosity, and usually a third for the lesser tuberosity, while at the distal end there is a center for each condyle, one for the trochlea and one for the capitulum, the fusion of these various epiphyses with the shaft taking place between the seventeenth and twentieth years. The *radius* and *ulna* each possess a single epiphysial center for each extremity in addition to the primary center for the shaft, and the ulna possesses also an epiphysial center for the olecranon process.

The embryological development of the *carpus* is somewhat complicated. A cartilage is found representing each of the bones normally occurring in the adult (Fig. 108), and these are arranged in two distinct rows: a proximal one consisting of three elements, named from their relation to the bones of the forearm, *radiale*, *intermedium*, and *ulnare*; and a distal one composed of four elements, termed *carpalia*. In addition, a cartilage, termed the *pisiform*, is found on the ulnar side of the proximal row and is generally regarded as a sesamoid cartilage developed in the tendon of the flexor carpi ulnaris, and furthermore a number of inconstant cartilages have been observed whose significance in the majority of cases is more or less obscure. These accessory cartilages either disappear in later stages of development or fuse with neighboring cartilages, or, in rare cases, ossify and form distinct elements of the carpus. One of them, however, occurs so frequently as almost to deserve classification as a constant element; it is known as the *centrale* (Fig. 108, *c*) and occupies a position between the cartilages of the proximal and distal rows and appar-

ently corresponds to a cartilage typically present in lower forms and ossifying to form a distinct bone. In the human carpus its fate varies, as it may either disappear or unite with other cartilages, that with which it most usually fuses being probably the radiale. There is evidence also to show that another of the accessory cartilages unites with the ulnar element of the distal row, representing the carpale V typically present in lower forms.

Each of the elements corresponding to an adult bone ossifies from a single center with the exception of carpale IV-V, which has two centers, a further indication of its composite character. The relation of the cartilages to the adult bones may be seen from the table given on page 212.

With regard to the metacarpals and phalanges, it need merely be stated that each develops from a single primary center for the shaft and one secondary epiphysial center. The primary center appears at about the middle of the shaft except in the terminal phalanges, in which it appears at the distal end of the cartilage. The epiphyses for the metacarpals are at the distal ends of the bones, except in the case of the metacarpal of the thumb, which resembles the phalanges in having its epiphysis at the distal end.




FIG. 108. RECONSTRUCTION OF AN EMBRYONIC CARPUS.

*c*, Central; *cu*, cuneiform; *lu*, semilunar; *m*, os magnum; *p*, pisiform; *sc*, scaphoid; *t*, trapezium; *tr*, trapezoid; *u*, unciform.

Each *innominate* bone appears as a somewhat oval plate of cartilage whose long axis is directed almost at right angles to the vertebral column and which is in close relation with the fourth and fifth sacral vertebræ. As development proceeds a rotation of the cartilage, accompanied by a slight shifting of position, occurs, so that eventually

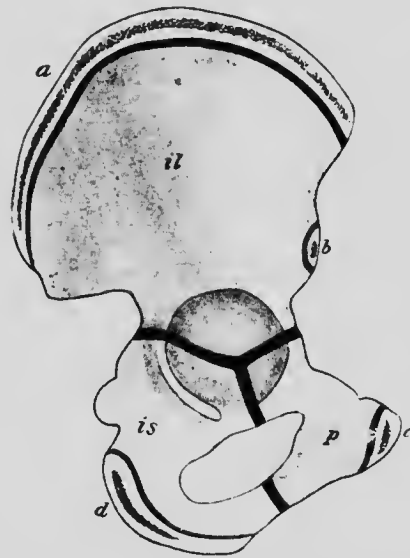

FIG. 109.—THE OSSIFICATION CENTERS OF THE OS INNOMINATUM.

*a, b, c, and d*, Secondary centers for the crest, anterior inferior spine of symphysis, and ischial tuberosity; *il*, ilium; *is*, ischium; *p*, pubis.—(Testut.)

the plate has its long axis almost parallel with the vertebral column and is in relation with the first three sacrals. Ossification appears at three points in each cartilage, one in the upper part to form the *ilium* (Fig. 109, *il*) and two in the lower part, the anterior of these giving rise to the *pubis* (*p*), while the posterior produces the *ischium* (*is*). At birth these three bones are still separated from one another by a Y-shaped piece of cartilage whose three limbs meet at the bottom of the acetabulum, but later a secondary center appears in this cartilage and unites the three bones together. The central part of the lower half each original cartilage plate does not undergo complete chondrification, but remains membranous, constituting the obturator membrane which closes the obturator foramen.

In addition to the Y-shaped secondary center, other

epiphysial centers appear in the prominent portions of the cartilage, such as the pubic crest (Fig. 109, *c*), the ischial tuberosity (*d*), the anterior inferior spine (*b*) and the crest of the ilium (*a*), and unite with the rest of the bone at about the twentieth year.

The *femur*, *tibia*, and *fibula* each develop from a single primary center for the shaft and an upper and a lower epiphysial center, the femur possessing, in addition, epiphysial centers for the greater and lesser trochanters (Fig. 90). The patella does not belong to the same category as the other bones, but resembles the pisiform bone of the carpus in being a sesamoid bone developed in the tendon of the quadriceps extensor cruris. Its cartilage does not appear until the fourth month of intrauterine life, when most of the primary centers for other bones have already appeared, and its ossification does not begin until the third year after birth.

The *tarsus*, like the carpus, consists of a proximal row of three cartilages, termed the *tibiale*, the *intermedium*, and the *fibulare*, and of a distal row of four *tarsalia*. Between these two rows a single cartilage, the *centrale*, is interposed. Each of these cartilages ossifies from a single center, that of the intermedium early fusing with the tibiale, though it occasionally remains distinct as the *os trigonum*, and from a comparison with lower forms it seems probable that the fibular cartilage of the distal row really represents two separate elements, there being, properly speaking, five *tarsalia* instead of four. The fibulare, in addition to its primary center, possesses also an epiphysial center, which develops at the point of insertion of the tendo Achillis.

A comparison of the carpal and tarsal cartilages and their relations to the adult bones may be seen from the following table:

CARPUS.		TARSUS.	
Cartilages.	Bones.	Bones.	Cartilages.
Radiale	Scaphoid	Astragalus	} Tibiale Intermedium Fibulare
Intermedium	Semilunar	Os Calcis	
Ulnare	Cuneiform		
Sesamoid cartilage	Pisiform		
Centrale	Fuses with scaphoid	Navicular	Centrale
Carpale I	Trapezium	Int. Cuneiform	Tarsale I
Carpale II	Trapezoid	Mid. Cuneiform	Tarsale II
Carpale III	Os Magnum	Ext. Cuneiform	Tarsale III
Carpale IV	} Unciform	Cuboid	Tarsale IV
Carpale V			

The development of the metatarsals and phalanges is exactly similar to that of the corresponding bones of the hand (see p. 209).

**The Development of the Joints.**—The mesenchyme which primarily represents each vertebra, or the skull or the skeleton of a limb, is at first a continuous mass, and when it becomes converted into cartilage this also may be continuous, as in the skull, or may appear as a number of distinct parts united by unmodified portions of the mesenchyme. In the former case the various ossifications as they extend will come into contact with their neighbors and will either fuse with them or will articulate with them directly, forming a *suture*.

When, however, a portion of unmodified mesenchyme intervenes between two cartilages, the mode of articulation of the bones formed from these cartilages will vary. The intermediate mesenchyme may in time undergo chondrification and unite the bones in an almost immovable articulation known as a *synchondrosis* (e. g., the sacroiliac articulation); or a cavity may appear in the center of the intervening cartilage so that a slight amount of move-

ment of the two bones is possible, forming an *amphiarthrosis* (e. g., the symphysis pubis); or, finally, the intermediate mesenchyme may not chondrify, but its peripheral portions may become converted into a dense sheath of connective tissue (Fig. 110, *c*) which surrounds the adjacent ends of the two bones like a sleeve, forming the capsular ligament, while the central portions degenerate to form a cavity. The bones which enter into such an articulation are more or less freely movable upon one another and the

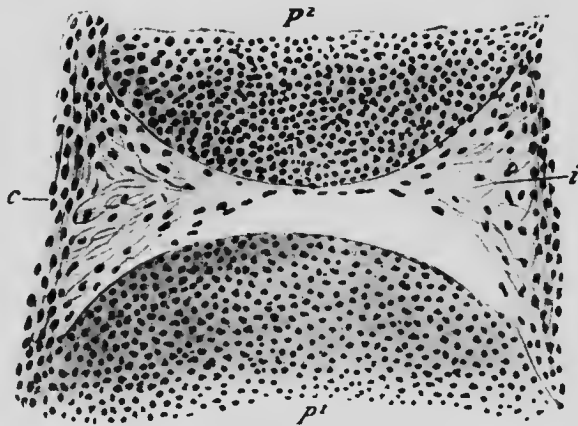


FIG. 110.—LONGITUDINAL SECTION THROUGH THE JOINT OF THE GREAT TOE IN AN EMBRYO OF 4.5 CM.

*c*, Capsular ligament; *i*, intermediate mesenchyme which has almost disappeared in the center;  $p^1$  and  $p^2$ , cartilages of the first and second phalanges.—(Nicolas.)

joint is termed a *diarthrosis* (e. g., the knee- or shoulder-joint).

In a diarthrosis the connective-tissue cells near the inner surface of the capsule arrange themselves in a layer to form a synovial membrane for the joint, and portions of the capsule may thicken to form special bands, the reinforcing ligaments, while other strong fibrous bands, which may pass from one bone to the other forming accessory ligaments, are shown by comparative studies to be in

many cases degenerated portions of what were originally muscles.

In certain diarthroses, such as the temporo-mandibular and claviculo-sternal, the whole of the central portions of the intermediate mesenchyme does not degenerate, but it is converted into a fibro-cartilage, between each surface of which and the adjacent bone there is a cavity. These interarticular cartilages seem, in the sterno-clavicular joints, to represent the sternal ends of a bone existing in lower vertebrates and known as the *precoracoid*, but it seems doubtful if those of the temporo-mandibular joints have a similar significance.

#### LITERATURE.

- A. BERNAYS: "Die Entwicklungsgeschichte des Kniegelenks des Menschen mit Bemerkungen über die Gelenke im Allgemeinen," *Morpholog. Jahrbuch*, iv, 1878.
- E. DURSÝ: "Zur Entwicklungsgeschichte des Kopfes des Menschen und der höheren Wirbelthiere," Tübingen, 1869.
- V. VON EBNER: "Ueber die Beziehungen der Wirbel zu den Urwirbeln," *Sitzungsberichte der kais. Akad. Wien*, cl, 3te Abth., 1892.
- A. FRORIEP: "Zur Entwicklungsgeschichte der Wirbelsäule, insbesondere des Atlas und Epistropheus und der Occipitalregion," *Archiv für Anat. und Physiol., Anat. Abth.*, 1886.
- C. GEGENBAUR: "Ein Fall von erblichem Mangel der Pars aerómialis Claviculae, mit Bemerkungen über die Entwicklung der Clavicula," *Jenaische Zeitschr. für medic. Wissensch.*, i, 1864.
- HENKE AND REYHER: "Studien über die Entwicklung der Extremitäten des Menschen, insbesondere der Gelenkflächen," *Sitzungsberichte der kais. Akad. Wien*, LXX, 1875.
- M. JAKOBY: "Beitrag zur Kenntnis des menschlichen Primordialcraniums," *Archiv für mikrosk. Anat.*, XLIV, 1894.
- H. LÉBOUCQ: "Recherches sur la morphologie du carpe chez les mammifères," *Archives de Biolog.*, v, 1884.
- G. LEVI: "Beitrag zum Studium der Entwicklung des knorpeligen Primordialcraniums des Menschen," *Archiv für mikrosk. Anat.*, LV, 1900.
- F. P. MALL: "The Development of the Connective Tissues from the Connective-tissue Syncytium," *Amer. Jour. Anat.*, i, 1902.
- W. VAN NOORDEN: "Beitrag zur Anatomie der knorpeligen Schädelbasis

- menschlicher Embryonen," *Archiv für Anat. und Physiol., Anat. Abth.*, 1887.
- RAMBAUT ET RENAULT: "Origine et développement des Os," Paris, 1864.
- E. ROSENBERG: "Ueber die Entwicklung der Wirbelsäule und das Centrale carpi des Menschen," *Morpholog. Jahrbuch*, 1, 1876.
- G. RUGE: "Untersuchungen über die Entwicklungsvorgänge am Brustbein des Menschen," *Morpholog. Jahrbuch*, vi, 1880.
- G. THILENIUS: "Untersuchungen über die morphologische Bedeutung accessorischer Elemente am menschlichen Carpus (und Tarsus)," *Morpholog. Arbeiten*, v, 1896.
- P. A. ZACHARIADÉS: "Recherches sur le développement du tissu conjonctif," *Comptes Rendus de la Soc. de Biolog. Paris*, Sér 10, v, 1898.



## CHAPTER VIII.

### THE DEVELOPMENT OF THE MUSCULAR SYSTEM.

Two forms of muscular tissue exist in the human body, the striated tissue, which forms the skeletal muscles and is under the control of the central nervous system, and the non-striated, which is controlled by the sympathetic nervous system and is found in the skin, in the walls of the digestive tract, the blood-vessels and lymphatics, and in connection with the genito-urinary apparatus. In the walls of the heart a muscle tissue occurs which is frequently regarded as a third form, characterized by being under control of the sympathetic system and yet being striated; it is, however, in its origin, much more nearly allied to the non-striated than to the striated form of tissue, and will be considered a variety of the former.

**The Histogenesis of Non-striated Muscular Tissue.**— Non-striated muscular tissue is formed by the direct conversion of mesenchyme cells into muscle-fibers, the exact details of the conversion being as yet unknown. The fibers are sometimes more or less scattered in the general connective tissue or may be grouped into small bundles or into layers. They are formed from the mesenchyme of the dermatomes and from that of the somatic and splanchnic layers of the mesoderm, but never from the myotomes of the mesodermic somites.

The cells from which the heart musculature develops show at first an irregular protoplasmic reticulum (Fig. 111, A) which later becomes regularly arranged so as to

give the cell when viewed in longitudinal section the appearance of being composed of a series of disks arranged in closely approximated rows, each disk being one of the meshes bounded by the reticulum fibers. Later each mesh or disk (Fig. 111, *B*) becomes divided into smaller disks by reticulum trabeculæ which meet in the centers of the original disks, and at the lines along which these secondary trabeculæ meet the reticulum thickens to form a fibril (Fig. 111, *C, f*). The formation of the fibrils begins at the periphery of the cell and proceeds centrally, though even in the adult condition there is an area surrounding

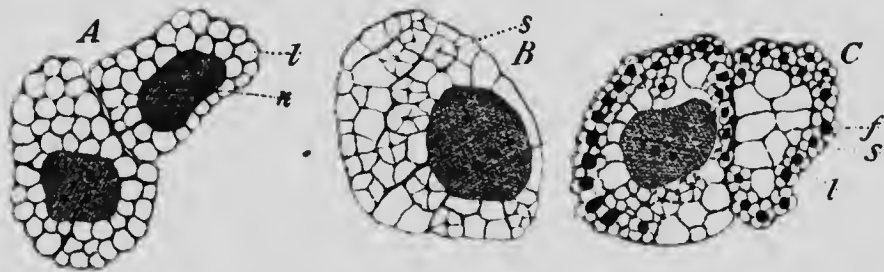


FIG. 111.—CROSS-SECTIONS OF HEART-MUSCLE CELLS FROM PIG EMBRYOS OF (A) 10 MM. AND (B AND C) 20 MM.  
*f*, Fibril; *l*, large disk; *n*, nucleus; *s*, small disk.—(Macallum.)

the nucleus in which they do not develop. The cells so altered arrange themselves at first in bundles distinctly separated from one another, so that the heart-wall has a somewhat spongy appearance, but later the various bundles fuse more or less completely to form a solid mass, the original condition being retained only in the auricular appendices and on the inner surfaces of the ventricles, where the bundles form the columnæ carneæ and musculi papillares.

**The Histogenesis of Striated Muscular Tissue.**—The histogenesis of the striated muscle-fibers resembles very

closely that described as occurring in the heart muscle, with the difference that the fibrils are developed throughout the entire thickness of the cell, the nucleus originally present disappearing, while new nuclei (Fig. 112, *B*), in considerable number, make their appearance at the periphery of the fiber, some of these being possibly formed by a division of the original nucleus. The formation of the fibrils is completed in embryos of about 17 cm. in length, and up to this period the increase in thickness of a muscle

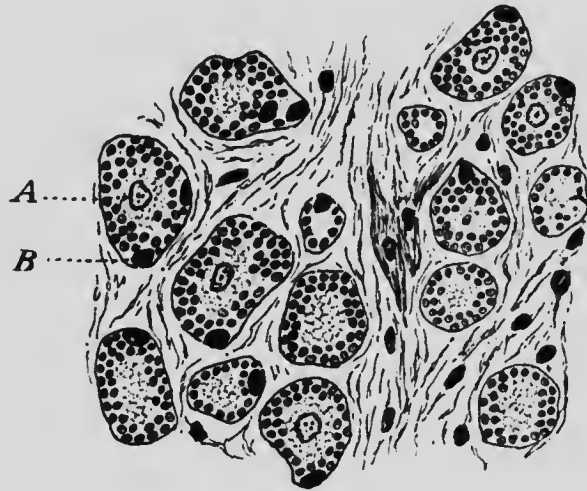


FIG. 112.—CROSS-SECTION OF A MUSCLE FROM THE THIGH OF A PIG EMBRYO 75 MM. LONG.

*A*, Original central nucleus; *B*, new peripheral nucleus.—(Macallum.)

is probably due to a certain extent to an increase in the actual number of fibers, new fibers forming by the division of those already existing. Subsequently, however, this mode of growth ceases, the further increase of the muscle depending upon an increase in size of its constituent elements (Macallum).

**The Development of the Skeletal Muscles.**—It has already been pointed out that all the skeletal muscles of

the body, with the exception of those connected with the branchial arches, are derived from the myotomes of the mesodermic somites, even the limb muscles probably having such an origin, although the cells of the myotomes as they grow out into the limb buds early lose their epithelial arrangement and become indistinguishable from the somatic mesenchyme which forms the axial core of the limb.

The various fibrils of each myotome are at first loosely arranged, but later they become more compact and are arranged parallel with one another, their long axes being directed antero-posteriorly. This stage is also transitory, however, the fibers of each myotome undergoing various modifications to produce the conditions existing in the adult, in which the original segmental arrangement of the fibers can be perceived in comparatively few muscles. The exact nature of these modifications is almost unknown from direct observation, but since the relation between a nerve and the myotome belonging to the same segment is established at a very early period of development and persists throughout life, no matter what changes of fusion, splitting, or migration the myotome may undergo, it is possible to trace out more or less completely the history of the various myotomes by determining their segmental innervation. It is known, for example, that the latissimus dorsi arises from the seventh and eighth\* cervical myotomes, but later undergoes a migration, becoming attached to the lower thoracic and lumbar vertebræ and to the crest of the ilium, far away from its place of origin (Mall), and yet it retains its nerve-supply from the seventh and eighth cervical nerves with which it was originally

\* This enumeration is based on convenience in associating the myotomes with the nerves which supply them. The myotomes mentioned are those which correspond to the sixth and seventh cervical vertebræ.

associated, its nerve-supply consequently indicating the extent of its migration.

By following the indications thus afforded, it may be seen that the changes which occur in the myotomes may be referred to one or more of the following processes:

1. A longitudinal splitting into two or more portions, a process well illustrated by the trapezius and sternomastoid, which have differentiated by the longitudinal splitting of a single sheet and contain therefore portions of the same myotomes. The sterno-hyoid and omohyoid have also differentiated by the same process, and, indeed, it is of frequent occurrence.

2. A tangential splitting into two or more layers. Examples of this are also abundant and are afforded by the muscles of the fourth, fifth, and sixth layers of the back, as recognized in English text-books of anatomy, by the two oblique and the transverse layers of the abdominal walls, and by the intercostal muscles and the triangularis sterni of the thorax.

3. A fusion of portions of successive myotomes to form a single muscle, again a process of frequent occurrence, and well illustrated by the rectus abdominis (which is formed by the fusion of the ventral portions of the last six or seven thoracic myotomes) or by the superficial portions of the erector spinæ.

4. A migration of parts of one or more myotomes over others. An example of this process is to be found in the latissimus dorsi, whose history has already been referred to, and it is also beautifully shown by the serratus magnus and the trapezius, both of which have extended far beyond the limits of the segments from which they are derived.

5. A degeneration of portions or the whole of a myotome. This process has played a very considerable part

in the evolution of the muscular system in the vertebrates. When a muscle normally degenerates, it becomes converted into connective tissue, and many of the strong aponeurotic sheets which occur in the body owe their origin to this process. Thus, for example, the aponeurosis connecting the occipital and frontal portions of the occipito-frontalis is due to this process and is muscular in such forms as the lower monkeys, and a good example is also to be found in the aponeurosis which occupies the interval between the superior and inferior serrati postici, these two muscles being continuous in lower forms. The strong lumbar aponeurosis and the aponeuroses of the oblique and transverse muscles of the abdomen are also good examples.

Indeed, in comparing one of the mammals with a member of one of the lower classes of vertebrates, the greater amount of connective tissue compared with the amount of muscular tissue in the former is very striking, the inference being that these connective-tissue structures (fasciæ, aponeuroses, ligaments) represent portions of the muscular tissue of the lower form (Bardleben). Many of the accessory ligaments occurring in connection with diarthrodial joints apparently owe their origin to a degeneration of muscle tissue, the external lateral ligament of the knee-joint, for instance, being probably a degenerated portion of the peroneus longus, while the great sacro-sciatic ligament appears to stand in a similar relation to the long head of the biceps femoris (Sutton).

6. Finally, there may be associated with any of the first four processes a change in the direction of the muscle-fibers. The original antero-posterior direction of the fibers is retained in comparatively few of the adult muscles and excellent examples of the process here referred to are to be found in the intercostal muscles and the muscles of the

abdominal walls. In the musculature associated with the branchial arches the alteration in the direction of the fibers occurs even in the fishes, in which the original direction of the muscle-fibers is very perfectly retained in other myotomes, the branchial muscles, however, being arranged parallel with the branchial cartilages or even passing dorso-ventrally between the upper and lower portions of an arch, and so forming what may be regarded as a constrictor of the arch. This alteration of direction dates back so far that the constrictor arrangement may well be taken as the primary condition in studying the changes which the branchial musculature has undergone in the mammalia.

It would occupy too much space in a work of this kind to consider in detail the history of each skeletal muscle of the human body, but a statement of the general plan of their development will not be out of place. For convenience the entire system may be divided into three portions--the cranial, trunk and limb musculature; and of these, the trunk musculature may first be considered.

**The Trunk Musculature.**—It has already been seen (p. 124) that the myotomes at first occupy a dorsal position, becoming prolonged ventrally as development proceeds so as to overlap the somatic mesoderm, until those of opposite sides come into contact in the mid-ventral line. Before this is accomplished, however, a longitudinal splitting of each myotome occurs, whereby there is separated off a dorsal portion which gives rise to a segment of the dorsal musculature of the trunk and is supplied by the ramus dorsalis of its corresponding spinal nerve. In the lower vertebrates this separation of each of the trunk myotomes into a dorsal and ventral portion is much more distinct in the adult than it is in man, the two portions being separated by a horizontal plate of connective tissue

extending the entire length of the trunk and being attached by its inner edge to the transverse processes of the vertebræ, while peripherally it becomes continuous with the connective tissue of the dermis along a line known as the lateral line. In man the dorsal portion is also much smaller in proportion to the ventral portion than in the lower vertebrates. From this dorsal portion of the myo-

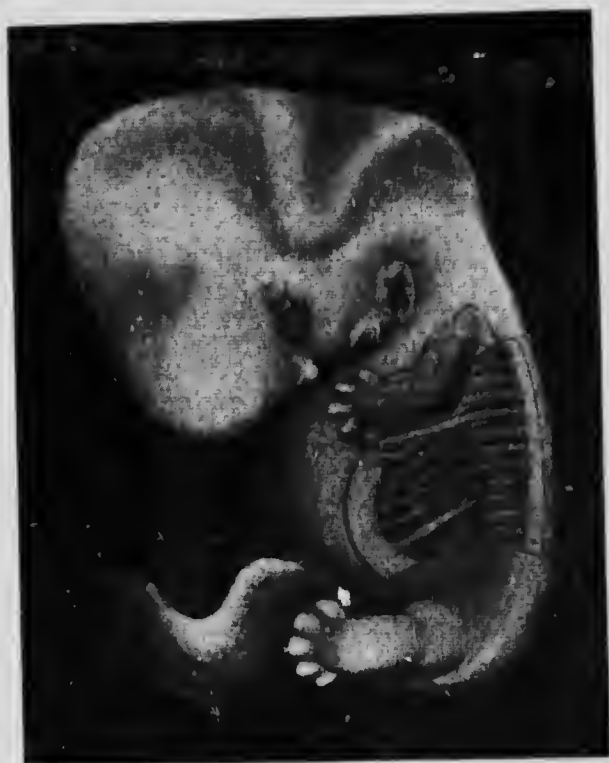

FIG. 113.—EMBRYO OF 13 MM. SHOWING THE FORMATION OF THE RECTUS MUSCLE.—(Mall.)

tomes are derived the muscles belonging to the three deepest layers of the dorsal musculature, the more superficial layers being composed of muscles belonging to the limb system. Further longitudinal and tangential divisions and a fusion of successive myotomes bring about the conditions which obtain in the adult dorsal musculature.



While the myotomes are still some distance from the mid-ventral line another longitudinal division affects their ventral edges (Fig. 113), portions being thus separated which later fuse more or less perfectly to form longitudinal bands of muscle, those of opposite sides being brought into apposition along the mid-ventral line by the continued growth ventrally of the myotomes. In this way are formed the rectus and pyramidalis muscles of the abdomen and the depressors of the hyoid bone, the geniohyoid and genio-hyo-glossus \* in the neck region. In the thoracic region this rectus set of muscles, as it may be termed, is not represented except as an anomaly, its absence being probably correlated with the development of the sternum in this region.

The lateral portions of the myotomes which intervene between the dorsal and rectus muscles divide tangentially, producing from their dorsal portions in the cervical and lumbar regions muscles, such as the longus colli and psoas, which lie beneath the vertebral column and hence have been termed hyoskeletal muscles (Huxley). More ventrally three sheets of muscles, lying one above the other, are formed, the fibers of each sheet being arranged in a definite direction differing from that found in the other sheets. In the abdomen there are thus formed the two oblique and the transversalis muscles, in the thorax the intercostals and the triangularis sterni, while in the neck these portions of some of the myotomes disappear, those of the remainder giving rise to the sealeni muscles, portions of the trapezius and sternomastoid (Bolk), and possibly the hyoglossus and styloglossus. In the abdominal region, and to a considerable extent in the neck also, the various portions of

\* This muscle is supplied by the hypoglossal nerve, but for the present purpose it is convenient to regard this as a spinal nerve, as indeed it primarily is.

myotomes fuse together, but in the thorax they retain in the intercostals their original distinctness, being separated by the ribs.

The table on page 226 will show the relation of the various trunk muscles to the portions of the myotomes.

The intimate association between the pelvic girdle and the axial skeleton brings about extensive modifications of the posterior trunk myotomes. So far as their dorsal portions are concerned probably all these myotomes as far back as the fifth sacral are represented in the erector spinæ, but the ventral portions from the first lumbar myotome onwards are greatly modified. The last myotome taking part in the formation of the reetus abdominis is the twelfth thoracic and the last to be represented in the lateral musculature of the abdomen is the first lumbar, the ventral portions of the remaining lumbar and of the first and second sacral myotomes being devoted to the formation of the musculature of the lower limb.

The ventral portions of the third and fourth sacral myotomes are represented, however, by the levator ani and coccygeus, and are the last myotomes which persist as muscles in the human body, although traces of still more posterior myotomes are to be found in muscles such as the curvator coccygis sometimes developed in connection with the coccygeal vertebræ.

The perineal muscles and the external sphincter ani are also developments of the third and fourth (and second) sacral myotomes. At a time when the cloaca (see p. 296) is still present, a sheet of muscles lying close beneath the integument forms a sphincter around its opening (Fig. 114). On the development of the partition which divides the cloaca into rectal and urinogenital portions, the sphincter is also divided, its more posterior portion persisting as the external sphincter ani, while the anterior part gradually

REGION OF MYOTOME.	ABDOMINAL MUSCLES.	THORACIC MUSCLES.	CERVICAL MUSCLES.	HYOGLOSSAL MUSCLES.
Dorsal, . . . . .	. . . . .	. . . . .	. . . . .	. . . . .
Lateral	Posterior layer of Quadratus lumborum and External oblique	External intercostals		
	Anterior layer of Quadratus lumborum and Internal oblique	Internal intercostals	Scaleni Trapezius in part Sternomastoid in part	Styloglossus? Hyoglossus?
Ventral	Transversalis	Triangularis sterni		
Rectus	Rectus abdominis	. . . . .	Sternohyoid Omohyoid	Geniohyoglossus.
	Pyramidalis		Sternothyroid Thyrohyoid Geniohyoid	

differentiates into the various perineal muscles (Popowsky).

**The Cranial Musculature.**—As was pointed out in an earlier chapter, the existence of distinct mesodermic somites has not yet been completely demonstrated in the head of the human embryo, but in lower forms, such as the elasmobranch fishes, they are clearly distinguishable, and it may be supposed that their indistinctness in man is a secondary condition. Exactly how many of these somites are represented in the mammalian head it is im-

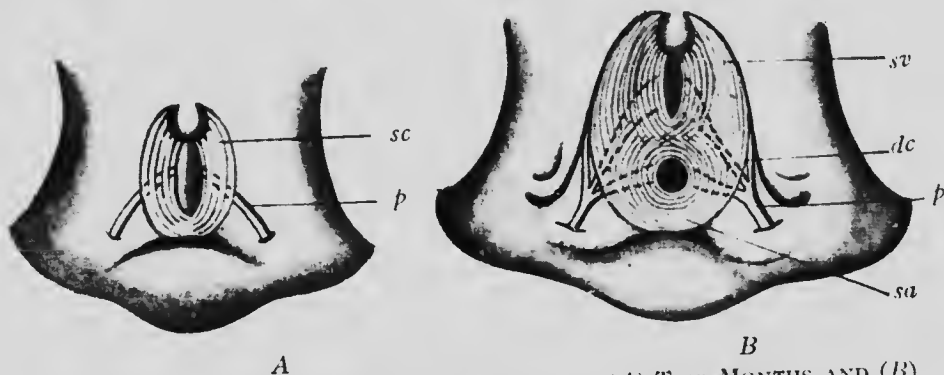


FIG. 114.—PERINEAL REGION OF EMBRYOS OF (A) TWO MONTHS AND (B) FOUR TO FIVE MONTHS, SHOWING THE DEVELOPMENT OF THE PERINEAL MUSCLES.

*dc*, Nervus dorsalis clitoridis; *p*, pudendal nerve; *sa*, sphincter ani; *sc*, sphincter cloacæ; *sv*, sphincter vaginae.—(Popowsky.)

possible to say, but it seems probable, from comparison with lower forms, that there is a considerable number. The majority of them, however, early undergo degeneration, and in the adult condition only three are recognizable, two of which are præoral in position and one post-oral. The myotomes of the anterior præoral segment give rise to the muscles of the eye supplied by the third cranial nerve, those of the posterior one furnish the superior oblique muscles innervated by the fourth nerve, while

from the postoral myotomes the external recti, supplied by the sixth nerve, are developed. The muscles supplied by the hypoglossal nerve are also derived from myotomes, but they have already been considered in connection with the trunk musculature.

The remaining muscles of the head differ from all other voluntary muscles of the body in the fact that they are derived from the branchiomeres formed by the segmentation of the cephalic ventral mesoderm. These muscles, therefore, are not to be regarded as equivalent to the myotomic muscles if their embryological origin is to be taken as a criterion of equivalency, and in their case it would seem, from the fact that they are innervated by nerves fundamentally distinct from those which supply the myotomic muscles, that this criterion is a good one. They must be regarded, therefore, as belonging to a special category, and may be termed *branchiomic* muscles to distinguish them from the myotomic set.

If their embryological origin be taken as a basis for homology, it is clear that they should be regarded as equivalent to the muscles derived from the ventral mesoderm of the trunk, and these, as has been seen, are the non-striated muscles associated with the viscera, among which may be included the striated heart muscle. At first sight this homology seems decidedly strained, chiefly because long-continued custom has regarded the histological and physiological peculiarities of striated and non-striated muscle tissue as fundamental. It may be pointed out, however, that the branchiomic muscles are, strictly speaking, visceral muscles, and indeed give rise to muscle sheets (the constrictors of the pharynx) which surround the upper or pharyngeal portion of the digestive tract. It is possible, then, that the homology is not so strained as might appear, but further discussion of it may profitably be deferred until the cranial nerves are under consideration.

The skeleton of the first branchial arch becomes converted partly into the jaw apparatus and partly into auditory ossicles, and the muscles derived from the correspond-

ing branchiomere become the muscles of mastication (the temporal, masseter, and pterygoids), the mylohyoid, anterior belly of the digastric, the tensor palati and the tensor tympani. The nerve which corresponds to the first branchial arch is the trigeminus or fifth, and consequently these various muscles are supplied by it.

The second arch has corresponding to it the seventh nerve, and its musculature is partly represented by the stylohyoid and posterior belly of the digastric and by the stapedius muscle of the middle ear. From the more superficial portions of the branchiomere, however, a sheet of tissue arises which gradually extends upward and downward to form a thin covering for the entire head and neck, its lower portion giving rise to the platysma myoides and the nuchal fascia which extends backward from the dorsal border of this muscle, while its upper parts become the occipito-frontalis and the superficial muscles of the face (the muscles of expression), together with the fasciæ which unite the various muscles of this group. The extension of the platysma sheet of muscles over the face is well shown by the development of the branches of the facial nerve which supply it (Fig. 115).

The degeneration of the upper part of the third arch produces a shifting forward of one of the muscles derived from its branchiomere, the stylopharyngeus arising from the base of the styloid process. The innervation of this muscle by the ninth nerve indicates, however, its true significance, and since fibers of this nerve of the third arch also pass to the constrictor muscles of the pharynx, a portion of these must also be regarded as having arisen from the third branchiomere.

The cartilages of the fourth and fifth arches enter into the formation of the larynx and the muscles of the corresponding branchiomeres constitute the muscles of the

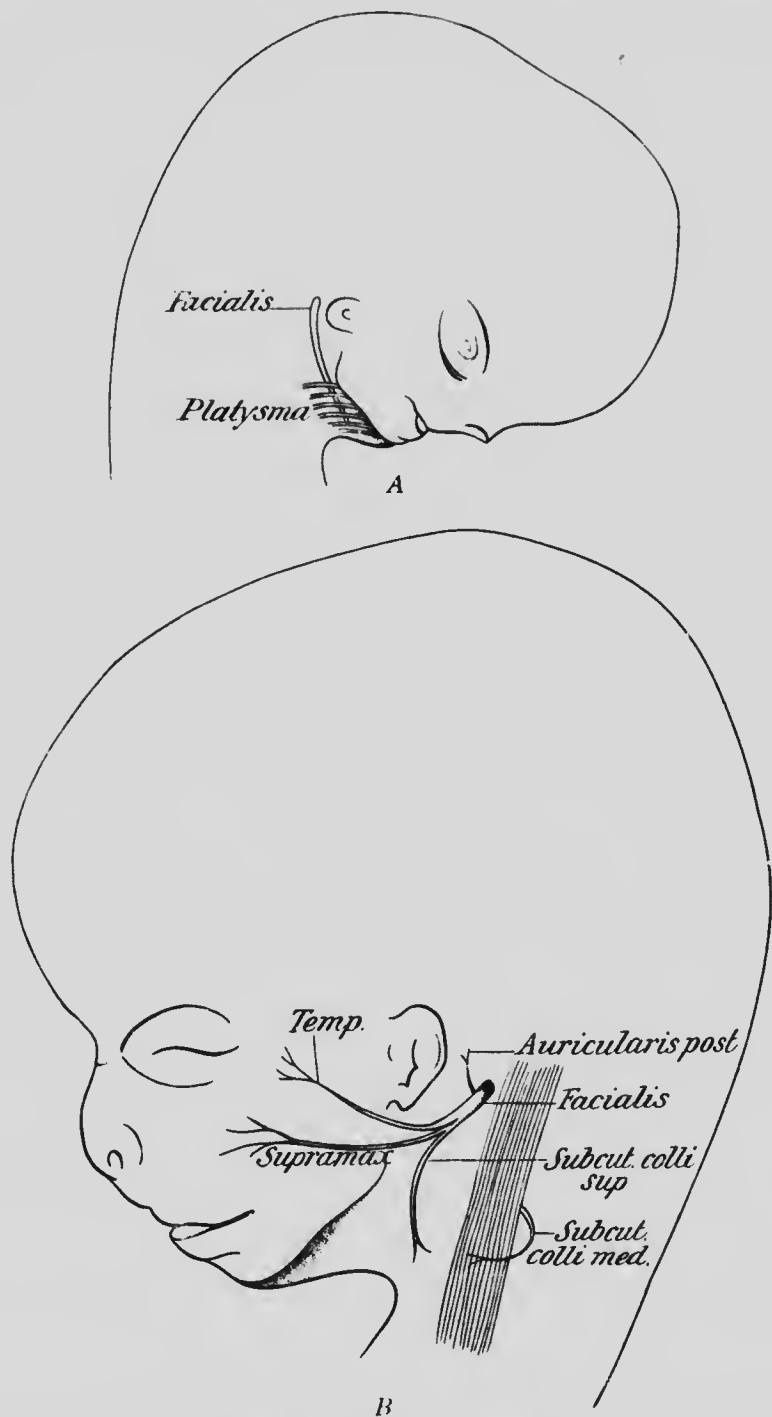


FIG. 115.—HEAD OF EMBRYOS (A) OF TWO MONTHS AND (B) OF THREE MONTHS SHOWING THE EXTENSION OF THE SEVENTH NERVE UPON THE FACE.—(Popowsky.)

larynx, together with the remaining portions of the constrictors of the pharynx and the muscles of the soft palate, with the exception of the tensor. Both these arches have branches of the tenth nerve associated with them and hence this nerve supplies the muscles named. In addition, two of the extrinsic muscles of the tongue, the palatoglossus and chondroglossus, belong to the fourth or fifth branchiomere, although the remaining muscles of this physiological set are myotomic in origin.

Finally, portions of two other muscles should probably be included in the list of branchiomic muscles, these muscles being the trapezius and sternomastoid. It has already been seen that these muscles are partly derived from the cervical myotomes, but they also appear to be innervated in part by the spinal accessory, and since the motor fibers of this nerve are serially homologous with those of the vagus it would seem that the muscles which they supply are probably branchiomic in origin. Observations on the development of these muscles, determining their relations to the branchiomeres, are necessary, however, before their morphological significance can be regarded as definitely settled.

The table on page 232 shows the relations of the various cranial muscles to the myotomes and branchiomeres, as well as to the motor cranial nerves.

**The Limb Muscles.**—In the human embryo the tissue from which the limb muscles develop is indistinguishable in early stages from the core of somatic mesenchyme which gives rise to the limb skeleton. And while it is possible that the muscles may have a common origin with the skeletal tissue, yet it seems more probable that they are really derived from the myotomes, and that the unsegmented and mesenchymatous character of the tissue from which they differentiate is a secondary condition. For it



NERVE.	Third.	Fourth.	Fifth.	Sixth.	Seventh.	Ninth.	Tenth.	Eleventh.
MYOTOMIC MUSCLES.	Superior } recti. Inferior } Internal } Inferior } oblique.	Superior oblique.	.....	External rectus.	.....	.....	.....	.....
BRANCHIOMERIC MUSCLES.	.....	.....	Temporal. Masseter. Pterygoids. Mylohyoid. Digastric (anterior belly). Tensor palati. Tensor tympani.	.....	Stylohyoid. Digastric (posterior belly). Stapedius. Platysma. Occipitofrontalis. Muscle of exproation.	Stylopharyngeus. Constrictors of pharynx (in part).	Constrictors of pharynx (in part). Palatopharyngeus. Levator palati. Azygus uvulae. Muscles of the larynx. Palatoglossus. Chondroglossus.	Trapezius. Sternomastoid.

seems certain that a very considerable amount of condensation of development occurs in the limb muscles; prolongations from the myotomes have been observed extending out into the limb buds in some of the lower vertebrates; and, furthermore, the distribution of the nerves in the limbs of the adult seem to indicate clearly a segmental arrangement of both the muscles and the cutis.

Accepting, then, the idea that the limb muscles are derived from myotomes, it may be supposed that the myotomes of the segments corresponding to each limb, in their growth ventrally, extend outward over the tip of the core of skeletal mesenchyme and return to the side of the trunk in the manner shown in Fig. 116. Each myotome thus gives rise to a portion of both the dorsal and the ventral musculature of the limb and forms a loop, as it were, extending lengthwise over the axis of the limb. Since the first of the myotome loops which pass out into each limb lies along the anterior edge of the limb bud, the musculature derived from it will, in the adult, be situated along the outer side of the arm and the inner side of the leg, because of the opposite rotation which the two limbs undergo during development (see p. 107).

If, now, this loop idea be tested by the distribution of the nerves to the lower limb, it will be found that the first myotome to pass out upon the dorsum of the ilium is the second lumbar, and following that there are met successively, from before backward, the remaining lumbar and the first and second sacral myotomes. The arrangement of these myotomes upon the dorsal surface of the pelvis and the muscles to which they contribute may be seen from Fig. 117. In this portion of their course they represent portions of the dorsal half of the loops, the remaining portions extending downward on the anterior surface of the

leg. Only the sacral myotomes, however, extend throughout the entire length of the limb into the foot, the second lumbar myotome extending down only to about the middle of the thigh, the third to about the knee, the fourth to about the middle of the tibial region, and the fifth as far as the base of the fifth metatarsal bone. Each of these

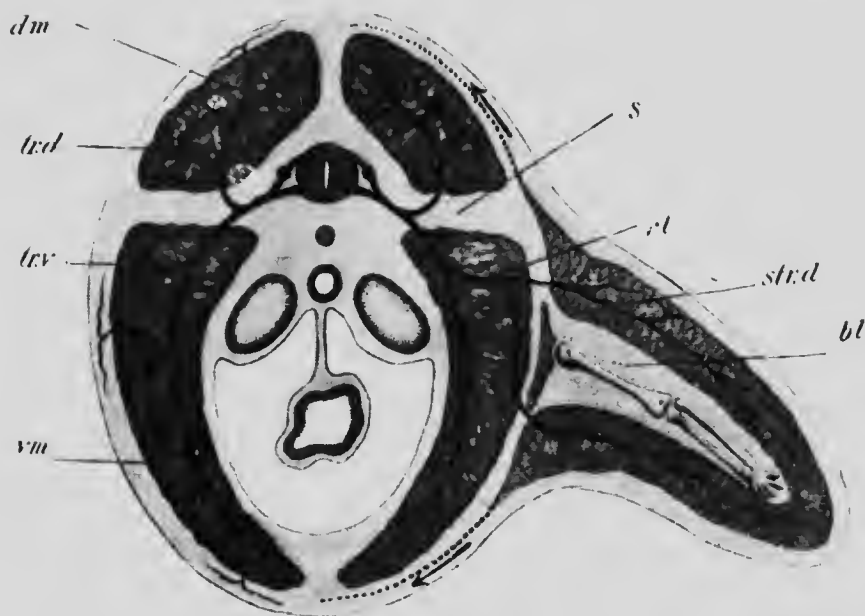

FIG. 116.—DIAGRAM OF A SEGMENT OF THE BODY AND LIMB.

*bl*, Axial blastema; *dm*, dorsal musculature of body; *nl*, nerve to limb; *s*, septum between dorsal and ventral musculature; *st.d*, dorsal layer of limb musculature; *tr.d* and *tr.v*, dorsal and ventral divisions of a spinal nerve; *vm*, ventral musculature of the body.—(Kollmann.)

myotomes at the point indicated bends toward the inner side of the leg and passes upward again on its posterior surface toward the trunk, representing in this portion of its course the ventral portion of the loop. The two sacral myotomes can be traced into the foot, the first giving rise

to the musculature of the inner portion and the second to

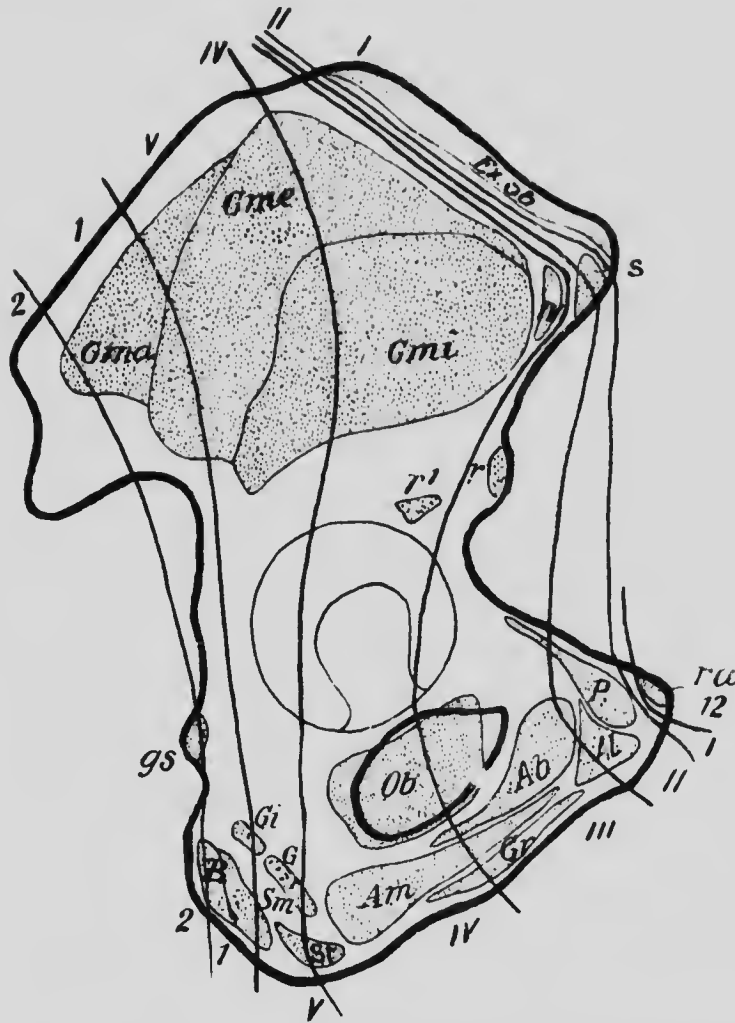


FIG. 117.—EXTERNAL SURFACE OF THE OS INNOMINATUM SHOWING THE ATTACHMENT OF MUSCLES AND THE ZONES SUPPLIED BY THE VARIOUS NERVES.

12, Twelfth thoracic nerve; I to V, lumbar nerves; 1 and 2, sacral nerves.—(Bolk.)

that of the outer portion, and, extending to the tips of the toes, they are reflected upon the plantar surface and so

loop upward on the posterior surface of the leg toward their point of origin from the trunk.

In a transverse section through any part of the limb,

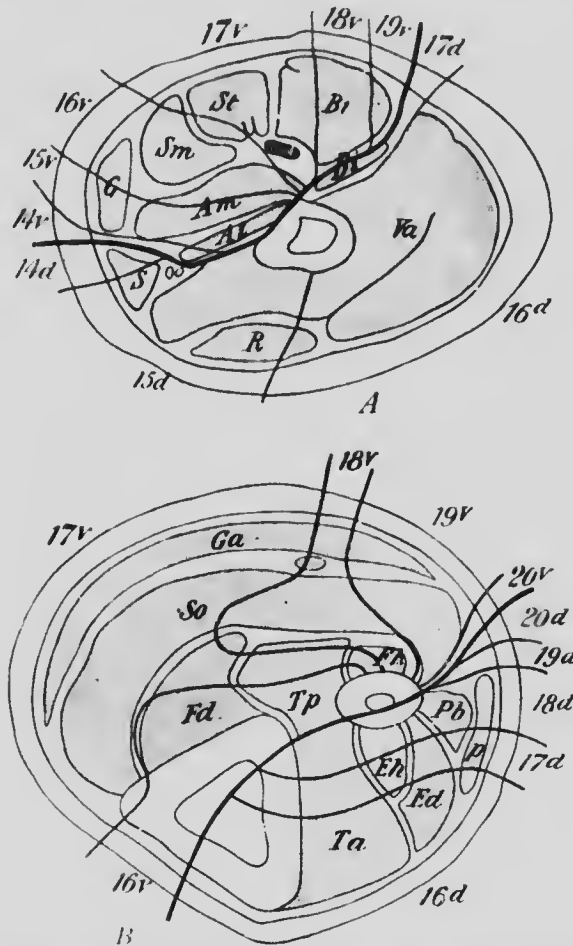


FIG. 118.—SECTIONS THROUGH (A) THE THIGH AND (B) THE CALF SHOWING THE ZONES SUPPLIED BY THE NERVES. THE NERVES ARE NUMBERED IN CONTINUATION WITH THE THORACIC SERIES.—(A after *Bolk.*)

accordingly, each myotome concerned will be cut twice, once in the descending (dorsal) and once in the ascending (ventral) portion of the loop, the arrangement found being

that represented in Fig. 118. The modifications undergone by the various myotomes throughout the course of their loops resemble those already described as occurring in the trunk myotomes. Thus, each of the muscles represented in Fig. 118, *B*, is formed by the fusion of elements derived from two or more myotomes; the soleus and gastrocnemius represent deep and superficial layers formed from the same myotomes by a horizontal (tangential) splitting, these same muscles contain a portion of the second

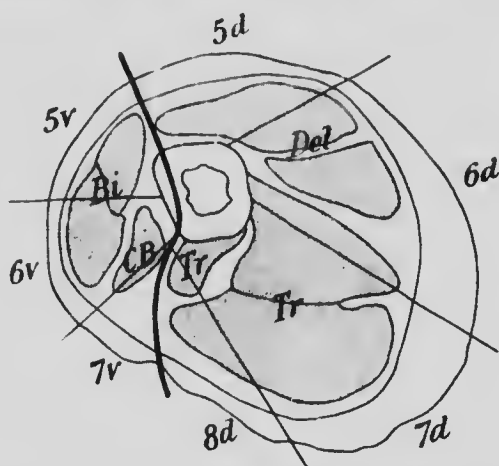


FIG. 119. SECTION THROUGH THE UPPER PART OF THE ARM SHOWING THE ZONES SUPPLIED BY THE NERVES.  
5v to 7v, Ventral branches; 5d to 8d, dorsal branches of the cervical nerves. —(Bolk.)

sacral myotome which overlaps muscles composed only of higher myotomes, and the intermuscular septum between the peroneus brevis and the flexor longus hallucis represents a portion of the third sacral myotome which has degenerated into connective tissue.

A similar arrangement occurs in the myotomes entering into the formation of the musculature of the upper limb. These are the fourth, fifth, sixth, seventh, and eighth cervical and the first thoracic myotomes, and of these only

the eighth cervical and first dorsal extend as far as the tips of the fingers. The arrangement of the myotomes in the upper part of the brachium may be seen from Fig. 119, in connection with which it must be stated that the fourth cervical myotome does not extend down to the level at which the section is taken and that the ventral portion of the loop of the eighth cervical and both portions of that of the first dorsal are represented only by connective tissue in this region.

## LITERATURE.

- C. R. BARDEEN AND W. H. LEWIS: "Development of the Limbs, Body-wall, and Back in Man," *The American Journal of Anat.*, I, 1901.
- K. BARDELEBEN: "Muskel und Fascia," *Jena'sche Zeitschr. für Naturwissenschaft.*, XV, 1882.
- L. BOLK: "Beziehungen zwischen Skelett, Muskulatur und Nerven der Extremitäten, dargelegt am Beckengürtel, an dessen Muskulatur sowie am Plexus lumbosacralis," *Morphol. Jahrbuch*, XXI, 1894.
- L. BOLK: "Rekonstruktion der Segmentirung der Gliedmassenmuskulatur dargelegt an den Muskeln des Oberschenkels und des Schultergürtels," *Morphol. Jahrbuch*, XXII, 1895.
- L. BOLK: "Die Sklerozonie des Humerus," *Morphol. Jahrbuch*, XXIII, 1896.
- L. BOLK: "Die Segmentaldifferenzierung des menschlichen Rumpfes und seiner Extremitäten," I, *Morphol. Jahrbuch*, XXV, 1898.
- W. P. HERRINGHAM: "The Minute Anatomy of the Brachial Plexus," *Proceedings of the Royal Soc. London*, XLI, 1886.
- W. H. LEWIS: "The Development of the Arm in Man," *Amer. Jour. of Anat.*, I, 1902.
- J. B. MACCALLUM: "On the Histology and Histogenesis of the Heart Muscle-cell," *Anat. Anzeiger*, XIII, 1897.
- J. B. MACCALLUM: "On the Histogenesis of the Striated Muscle-fiber and the Growth of the Human Sartorius Muscle," *Johns Hopkins Hospital Bulletin*, 1898.
- F. P. MALL: "Development of the Ventral Abdominal Walls in Man," *Journ. of Morphol.*, XIV, 1898.
- A. MEEK: "Preliminary Note on the Post-embryonal History of Striped Muscle-fibers in Mammalia," *Anat. Anzeiger*, XIV, 1898. (See also *Anat. Anzeiger*, XV, 1899.)
- B. MORPURGO: "Ueber die post-embryonale Entwicklung der quergestreiften Muskel von weissen Ratten," *Anat. Anzeiger*, XV, 1899.

- I. POPOWSKY: "Zur Entwicklungsgeschichte des N. facialis beim Menschen," *Morphol. Jahrbuch*, xxiii, 1896.
- I. POPOWSKY: "Zur Entwicklungsgeschichte der Dammmuskulatur beim Menschen," *Anat. Hefte*, xii, 1899.
- L. RETZI: "Der peripheren Verlauf der motorischen Rachen- und Gaumennerven," *Sitzungsber. der kais. Akad. Wissensch. Wien. Math.-Naturwiss. Classe*, cii, 1893.
- C. S. SHERRINGTON: "Notes on the Arrangement of Some Motor Fibers in the Lumbo-sacral Plexus," *Journal of Physiol.*, xiii, 1892.
- J. B. SUTTON: "Ligaments, their Nature and Morphology," London, 1897.



## CHAPTER IX.

### THE DEVELOPMENT OF THE CIRCULATORY AND LYMPHATIC SYSTEMS.

At present nothing is known as to the earliest stages of development of the circulatory system in the human embryo, but it may be supposed that they resemble in their fundamental features what has been observed in such forms as the rabbit and the chick. In both these the system originates in two separate parts, one of which, located in the embryonic mesoderm, gives rise to the heart, while the other, arising in the extra-embryonic mesoderm, forms the first blood-vessels. It will be convenient to consider these two parts separately, and the formation of the blood-vessels may be first described.

In the rabbit the extension of the mesoderm from the embryonic region where it first appears over the yolk-sac is a gradual process, and it is in the more peripheral portions of the layer that the blood-vessels first make their appearance. They can be distinguished before the splitting of the mesoderm has been completed, but are always developed in that portion of the layer which is most intimately associated with the yolk-sac and consequently becomes the splanchnic layer. The first indication of the vessels is the appearance in the peripheral portion of the mesoderm of cords or minute patches of spherical cells (Fig. 120, *A*). These increase in size by the division of the cells and by their separation from one another (Fig. 120, *B*), a clear fluid appearing in the intervals which separate them. Soon the cells surrounding each cord arrange

themselves to form an enclosing wall, and the cords, increasing in size, unite together to form a network of vessels in which float the spherical cells which may now be known as *erythrocytes*. Viewed from the surface at this stage a portion of the vascular area of the mesoderm would have the appearance shown in Fig. 121, revealing a dense network of canals in which, at intervals, are groups of erythrocytes adherent to the walls, constituting what

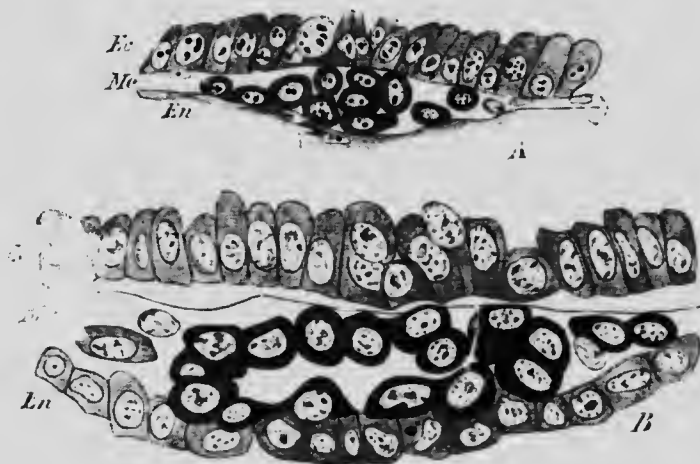


FIG. 120.—TRANSVERSE SECTION THROUGH THE AREA VASCULOSA OF RABBIT EMBRYOS SHOWING THE TRANSFORMATION OF MESODERM CELLS INTO THE VASCULAR CORDS.

*Ec*, Ectoderm; *En*, endoderm; *Me*, mesoderm.—(*van der Stricht*.)

have been termed the *blood-islands*, while in the meshes of the network unaltered mesoderm cells can be seen, forming the so-called *substance-islands*.

At the periphery of the vascular area the vessels arrange themselves to form a *sinus terminalis* enclosing the entire area, and the vascularization of the splanchnic mesoderm gradually extends toward the embryo. Reaching it, the vessels penetrate the embryonic tissues and eventually come into connection with the heart which has

already differentiated and has begun to beat before the connection with the vessels is made, so that when it is made, the circulation is at once established. Before, however, the vascularization reaches the embryo some of

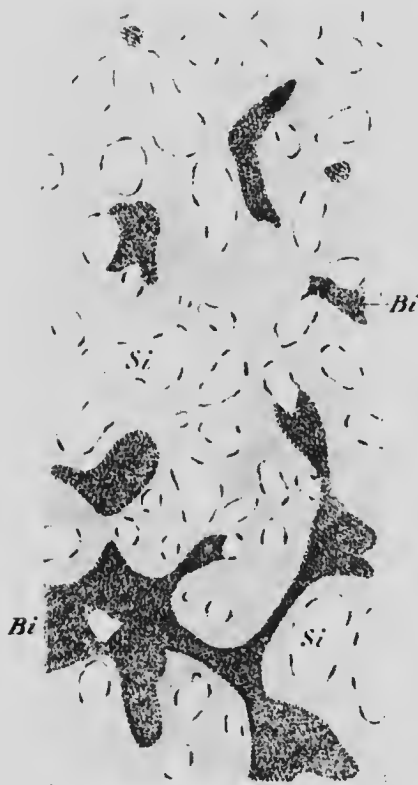

FIG. 121.—SURFACE VIEW OF A PORTION OF THE AREA VASCULOSA OF A CHICK.

The vascular network is represented by the shaded portion. *Bi*, Blood-island; *Si*, substance-island. —(*Dissc.*)

the canals begin to enlarge (Fig. 122, A), producing arteries and veins, the rest of the network forming capillaries uniting these two sets of vessels, and, this process continuing, there are eventually differentiated a single *omphalo-mesenteric (vitelline) artery* and two *omphalo-mesenteric (vitelline) veins* (Fig. 122, B).

In the human embryo the small size of the yolk-sac permits of the extension of the vascular area over its entire surface at an early period, and this condition has already been reached in the earliest stages known and consequently no sinus terminalis such as occurs in the rabbit is

visible. Otherwise the conditions are probably similar to what has been described above, the first circulation developed being associated with the yolk-sac.

**The Formation of the Blood.**—The erythrocytes, which

are the first blood-corpuses, are all nucleated and are for a time the only cells occurring in the blood, though later other cells, arising in tissues exterior to the blood-vessels, make their way into the vessels, forming *leukocytes*. From their very first formation then the red (erythrocytes) and white (leukocytes) blood-corpuses have a different origin, and they remain distinct throughout life, one form never becoming converted into the other.

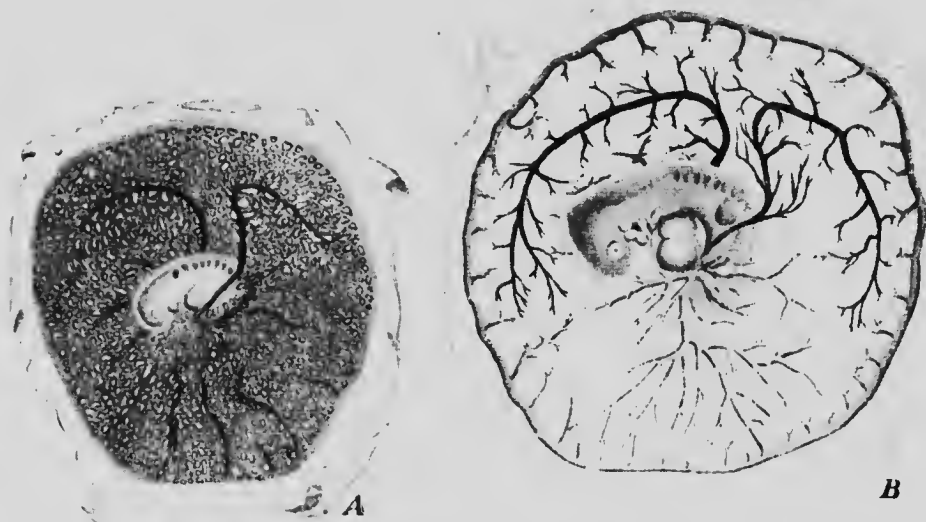

FIG. 122.—THE VASCULAR AREAS OF RABBIT EMBRYOS. IN B THE VEINS ARE REPRESENTED BY BLACK AND THE NETWORK IS OMITTED. — (van Beneden and Julin.)

So long as the formation of blood-vessels is taking place in the extra-embryonic mesoderm, so long are new erythrocytes being differentiated from the mesoderm. But whether the formation of blood-vessels within the embryo results from a differentiation of the embryonic mesoderm *in situ*, or from the actual ingrowth of vessels from the embryonic regions (His), is as yet uncertain, and hence it is also uncertain whether erythrocytes are differentiated

from the embryonic mesoderm or merely pass into the embryonic region from the more peripheral areas. However this may be, it is certain that the erythrocytes increase by division in the interior of the embryo, and that there are certain portions of the body in which these divisions take place most abundantly, partly, perhaps, on account of the more favorable conditions of nutrition which they present and partly because they are regions where the circulation is sluggish and permits the accumulation of erythrocytes. These regions constitute what have been termed the *hæmatopoietic organs*, and are especially noticeable in the later stages of fetal life, diminishing in number and variety about the time of birth. It must be remembered, however, that the life of individual corpuscles is comparatively short, their death and disintegration taking place continually during the entire life of the individual, so that there is a necessity for the formation of new corpuscles and for the existence of hæmatopoietic organs at all stages of life.

In the fetus erythrocytes in process of division may be found in the general circulation and even in the heart itself, but they are much more plentiful in places where the blood-pressure is diminished, as, for instance, in the larger capillaries of the lower limbs and in the capillaries of all the visceral organs and of the subcutaneous tissues. Certain organs, however, such as the liver, the spleen, and the bone-marrow, present especially favorable conditions for the multiplication of the blood-cells, and in these not only are the capillaries enlarged so as to afford resting-places for the corpuscles, but gaps appear in the walls of the vessels through which the blood-elements may pass and so come into intimate relations with the actual tissues of the organs (Fig. 123). After birth the hæmatopoietic function of the liver ceases and that of the spleen

becomes limited to the formation of white corpuscles, though the complete function may be re-established in cases of extreme anæmia. The bone-marrow, however, retains the function completely, being throughout life the seat of formation of both red and white corpuscles, the lymphatic nodes and follicles, as well as the spleen, assisting in the formation of the latter elements.

Until about the second month of development the erythrocytes and leukocytes are the only elements found in the blood, and in the hæmatopoietic organs

they may be observed in active mitosis. In addition other cells, having the same general appearance as the erythrocytes but lacking hæmoglobin, also occur, and



FIG. 124.—STAGES IN THE TRANSFORMATION OF AN ERYTHROCYTE INTO AN ERYTHROPLASTID.—(van der Stricht.)

these, which may be termed *erythroblasts*, produce by division erythrocytes in which hæmoglobin gradually appears. After the second month, however, a third form of blood-elements appears in the form of non-nucleated discs containing hæmoglobin, and these may be termed *erythroplastids*. They are derived from the erythrocytes, whose nuclei, originally

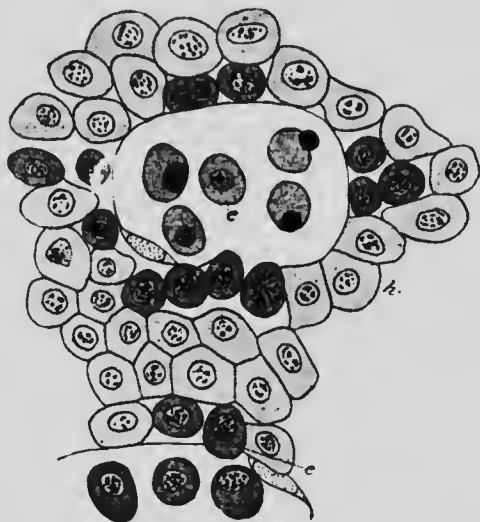


FIG. 123.—SECTION OF A PORTION OF THE LIVER OF A RABBIT EMBRYO OF 5 MM.

*c*, Erythrocytes in the liver substance and in a capillary; *h*, hepatic cells.—(van der Stricht.)

reticular in structure, gradually condense to become spherical, deeply staining masses, and are finally completely extruded from the cytoplasm (Fig. 124). The cast-off nuclei undergo degeneration and phagocytic absorption by the leukocytes, and the masses of cytoplasm pass into the circulation, becoming more and more numerous as development proceeds, until finally they are the only hæmoglobin-containing elements in the blood and form what are properly termed the red blood-corpuscles. In the later fetal and the post-natal stages erythrocytes are to be found only in the red bone-marrow.

In the formation of the new leukocytes there is a tendency for the dividing cells to collect in more or less definite groups which have been termed germ-centers (Flemming). The new cells when they first pass into the circulation have a relatively large nucleus surrounded by a small amount of cytoplasm, and, since they resemble the cells found in the lymphatic vessels, are termed *lymphocytes*. In the circulation the nuclei become larger and the cytoplasm more voluminous and amœboid, the cells being then known as *mononuclear* leukocytes, and transitional forms lead from these to still larger cells with irregularly lobed or branched nuclei, the *polymorphonuclear leukocytes*, while these again seem to lead to *polynuclear* cells. It is probable that these various kinds of cells stand in genetic relation to one another, the polymorphonuclear and polynuclear forms perhaps representing the commencement of the degeneration and breaking down of the elements.

In the fetal hæmatopoietic organs and in the bone-marrow of the adult large, so-called *giant-cells* are found, which, although they do not enter into the general circulation, are yet associated with the development of the blood-corpuscles. These giant-cells as they occur in the bone-

marrow are of two kinds which seem to be quite distinct, although both are probably formed from leukocytes. In one kind the cytoplasm contains several nuclei, whence they have been termed *polycaryocytes*, and they seem to be the cells which have already been mentioned as osteoelasts (p. 180). In the other kind (Fig. 125) the nucleus is single, but it is large and irregular in shape, frequently appearing as if it were producing buds. These *megacaryocytes* appear to be phagocytic cells, having as their

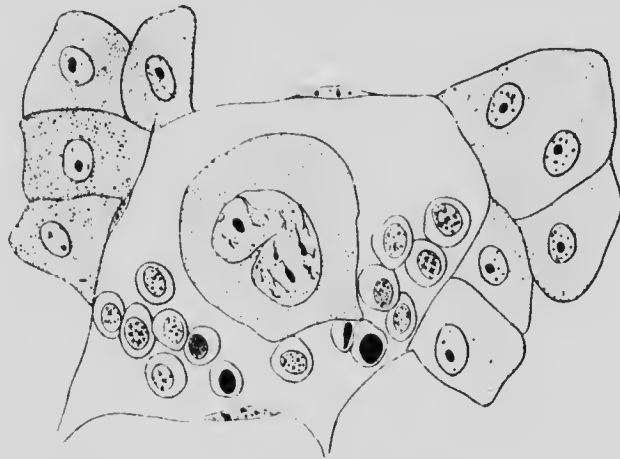


FIG. 125.—PORTION OF A SECTION FROM THE LIVER OF AN EMBRYO CAT OF 2.7 MM. SHOWING A MEGACARYOCYTE SURROUNDED BY ERYTHROCYTES IN A BLOOD-VESSEL.—(Howell.)

function the destruction of degenerated corpuscles and of the nuclei of the erythrocytes.

Little is certainly known as yet as to the origin of the blood-platelets, though the most plausible suggestion is that they are the fragmented nuclei of broken-down leukocytes.

The question of the origin of the various forms of blood-elements is a very difficult one, and the opinions of some observers are very different from some of the statements made above. Thus it has been maintained that the nuclei of the



erythrocytes are not extruded in the formation of erythroplastids, but undergo a degeneration within the original cell; that mesenchyme cells of the marrow become transformed into leukocytes; that the polymorphonuclear and polynuclear leukocytes are not stages leading to disintegration, but represent stages of amitotic division, etc. It is impossible in the limits of the present work to discuss these various ideas and the views which have seemed to be most strongly supported by observations have been chosen for presentation.

✓ **The Formation of the Heart.**—The heart makes its appearance while the embryo is still spread out upon the surface of the yolk-sac, and arises as two separate portions which only later come into contact in the median line. On each side of the body near the margins of the embryonic area a fold of the splanchnopleure appears projecting into the coelomic cavity and within this fold a very thin-walled sac is formed, probably by a splitting off of its innermost cells (Fig. 126, A). Each fold will produce a portion of the muscular walls (*myocardium*) of the heart, and each sac part of its endothelium (*endocardium*). As the constriction of the embryo from the yolk-sac proceeds, the two folds are gradually brought nearer together (Fig. 126, B), until they meet in the mid-ventral line, when the myocardial folds and endocardial sac fuse together (Fig. 126, C) to form a cylindrical heart lying in the mid-ventral line of the body, in front of the anterior surface of the yolk-sac and in what will later be the cervical region of the body. At an early stage the various veins which have already been formed, the omphalo-mesenteries, umbilicals, jugulars, and cardinals, unite together to open into a sac-like structure, the *sinus venosus*, and this opens into the posterior end of the heart cylinder. The anterior end of the cylinder tapers off to form the *aortic bulb*, which is continued forward on the ventral surface of the pharyngeal region and carries the blood away from the heart. The

blood accordingly opens into the posterior end of the heart tube and flows out from its anterior end.

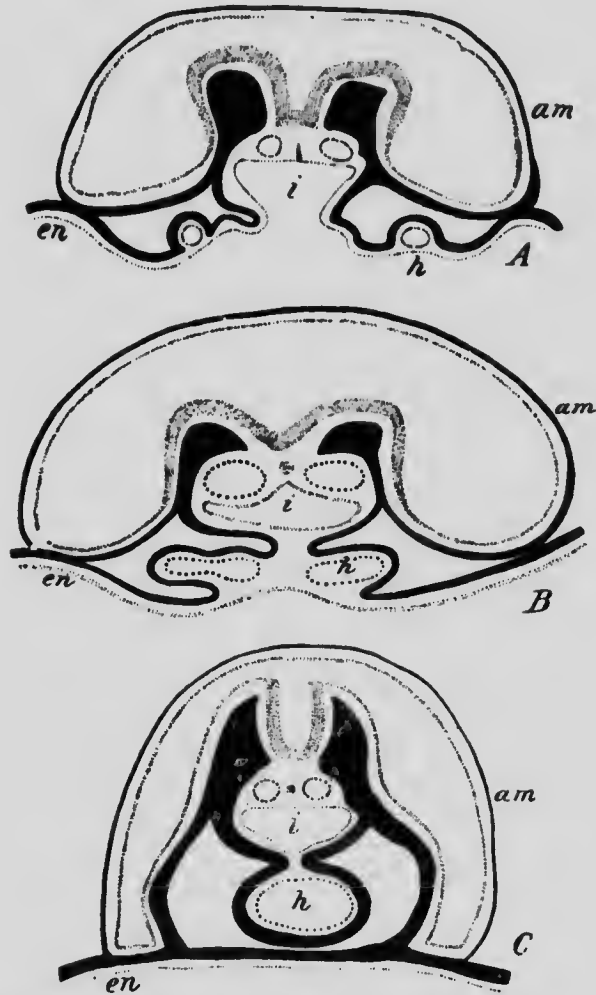


FIG. 126.—DIAGRAMS ILLUSTRATING THE FORMATION OF THE HEART IN THE GUINEA-PIG.

The mesoderm is represented in black and the endocardium by a broken line. *am*, Amnion; *en*, endoderm; *h*, heart; *i*, digestive tract. —(After Strahl and Carius.)

The simple cylindrical form soon changes, however, the heart tube in embryos of 2.15 mm. in length having be-

come bent upon itself into a somewhat S-shaped curve (Fig. 127). Dorsally and to the left is the lower end into which the sinus venosus opens, and from this the heart tube ascends somewhat and then bends so as to pass at first ventrally and then downward and to the right, where it again bends at first dorsally and then anteriorly to pass over into the aortic bulb. The portion of the curve which

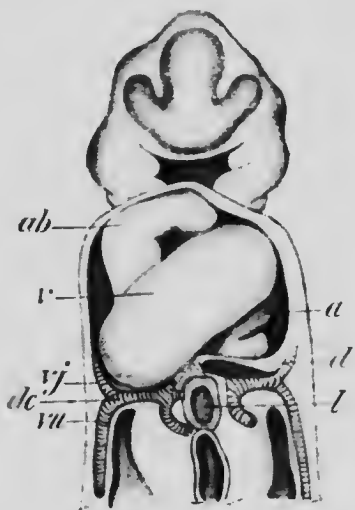


FIG. 127.—HEART OF EMBRYO OF 2.15 MM., FROM A RECONSTRUCTION.

*a*, Auricle; *ab*, aortic bulb; *d*, diaphragm; *dc*, ductus Cuvieri; *l*, liver; *v*, ventricle; *vj*, jugular vein; *vu*, umbilical vein.  
—(His.)

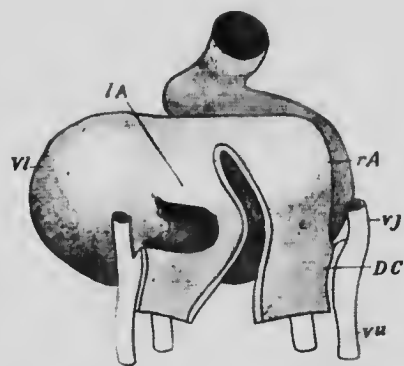


FIG. 128. HEART OF EMBRYO OF 4.2 MM. SEEN FROM THE DORSAL SURFACE.

*DC*, Ductus Cuvieri; *IA*, left auricle; *rA*, right auricle; *vj*, jugular vein; *v*, left ventricle; *vu*, umbilical vein. (His.)

lies dorsally and to the left is destined to give rise to both auricles, the portion which passes from right to left represents the future left ventricle, while the succeeding portion represents the right ventricle. In later stages (Fig. 128) the left ventricular portion drops downward in front of the auricular portion, assuming a more horizontal position, while the portion which represents the right ven-

tricle is drawn forward so as to lie in the same plane as the left.

At the same time two small out-pouchings develop from the auricular part of the heart and form the first indications of the two auricles. As development progresses, these increase in size to form large pouches opening into a common auricular canal (Fig. 129) which is directly continuous with the left ventricle, and as the enlargement of the pouches continues their openings into the canal enlarge, until finally the pouches become continuous with one another, forming a single large sac, and the auricular canal becomes reduced to a short tube which is slightly invaginated into the ventricle (Fig. 130).

In the mean time the sinus venosus, which was originally an oval sac and opened into the auricular canal, has elongated transversely until

it has assumed the form of a crescent whose concavity is in contact with the walls of the auricles, and its opening into the heart has verged toward the right, until it is invaginated entirely within the area of the right auricle. As the enlargement of the auricles continues, the right horn and median portion of the crescent are gradually taken up into their walls, so that the various veins which originally opened into the sinus now open directly into the right auricle by a single opening, guarded by a projecting fold which is continued upon the roof of the auricle as a




FIG. 129.—HEART—EMBRYO OF 1.5 MM., SEEN FROM THE FRONT AND SLIGHTLY FROM ABOVE.

muscular ridge known as the *septum spurium* (Fig. 130, *sp*). The left horn of the crescent is not taken up into the auricular wall, but remains upon its posterior surface as an elongated sac forming the *coronary sinus*.

The division of the now practically single auricular cavity into the permanent right and left auricles begins with the formation of a falciform ridge running dorso-ventrally

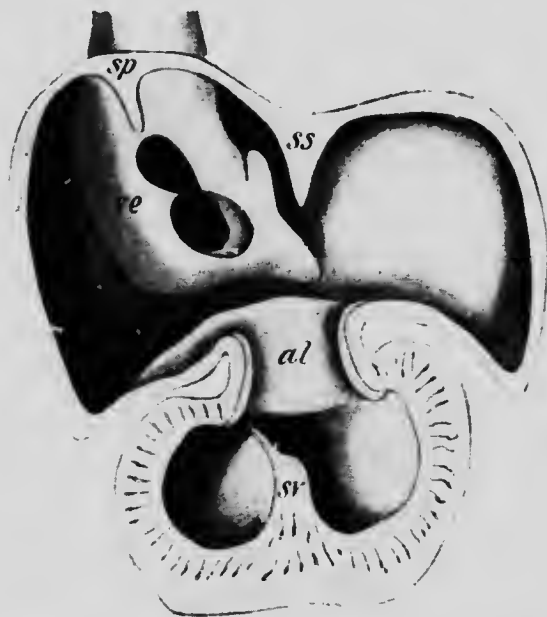


FIG. 130.—INNER SURFACE OF THE HEART OF AN EMBRYO OF 10 MM. *al*, Auriculo-ventricular thickening; *sp*, septum spurium; *ss*, septum primum; *sv*, septum ventriculi; *re*, Eustachian valve.—(His.)

across the roof of the cavity. This is the *auricular septum* or *septum primum* (Fig. 130, *ss*), and it rapidly increases in size and thickens upon its free margin which reaches almost to the upper border of the short auricular canal (Fig. 132). The continuity of the two auricles is thus almost dissolved, but is soon re-established by the formation in the dorsal part of the septum of an opening which

soon reaches a considerable size and is known as the *foramen ovale* (Fig. 131, *fo*). Close to the auricular septum, and parallel with it, a second ridge appears in the roof and ventral wall of the right auricle. This *septum secundum* ( $S_2$ ) is from the beginning very much thicker than the auricular septum, and its free end, arching around the ventral edge and floor of the foramen ovale, becomes continuous with the left lip of the fold which guards the opening of the sinus venosus and with this forms the *annulus of Vieussens* of the adult heart.

When the absorption of the sinus venosus into the wall of the right auricle has proceeded so far that the veins communicate directly with the auricle, the vena cava superior opens into it at the upper part of the dorsal wall, the vena cava inferior more laterally, and below this is the smaller opening of the coronary sinus. The upper portion of the right lip of the fold which originally surrounded the opening of the sinus venosus, together with the septum spurium, gradually disappears; the lower portion persists, however, and forms (1) the *Eustachian valve* (Fig. 131, *Ve*), guarding the opening of the inferior cava and directing the blood entering by it toward the foramen ovale, and (2) the *Thebesian valve*, which guards the opening of the coronary sinus. At first no veins communicate with the left auricle, but on the development of the lungs and the es-

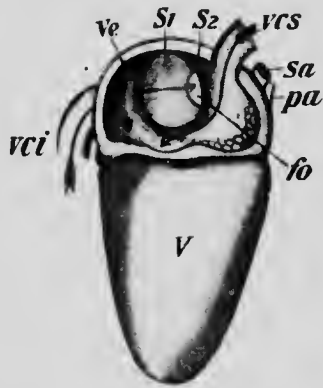


FIG. 131.—HEART OF EMBRYO OF 10.2 CM. FROM WHICH HALF OF THE RIGHT AURICLE HAS BEEN REMOVED.

*fo*, Foramen ovale; *pa*, pulmonary artery;  $S_1$ , septum primum;  $S_2$ , septum secundum; *sa*, systemic aorta; *V*, right ventricle; *vci*, and *vcs*, inferior and superior venae cavae; *Ve*, Eustachian valve.

establishment of their vessels, the pulmonary veins make connection with it. Two veins arise from each lung, and as they pass toward the heart they unite in pairs, the two vessels so formed again uniting to form a single short trunk which opens into the upper part of the auricle (Fig. 132, *Vep*). As is the case with the right auricle and the sinus venosus, the expansion of the left auricle brings about the absorption of the short single trunk into its walls, and, the expansion continuing, the two vessels are also absorbed, so that eventually the four primary veins open independently into the auricle.

While the auricular septa have been developing there has appeared on the dorsal wall of the auricular canal a tubercle-like thickening of the endocardium, and a similar thickening also forms on the ventral wall. These endocardial cushions increase in size and finally unite together by their tips, forming a complete partition dividing the auricular canal into a right and left half (Fig. 132). With the upper edge of this partition the thickened lower edge of the auricular septum unites, so that the separation of the auricles would be complete were it not for the foramen ovale.

While these changes have been taking place in the auricular portion of the heart, the separation of the right and left ventricles has also been progressing, and in this two distinct septa take part. From the floor of the ventricular cavity along the line of junction of the right and left portions a ridge, composed largely of muscular tissue, arises (Figs. 130 and 132), and, growing more rapidly in its dorsal than its ventral portion, it comes into contact and fuses with the dorsal part of the partition of the auricular canal. Ventrally, however, the ridge, known as the *ventricular septum*, fails to reach the ventral part of the partition, so that an oval foramen, situated just below the

point where the aortic bulb arises, still remains between the two ventricles. This opening is finally closed by what

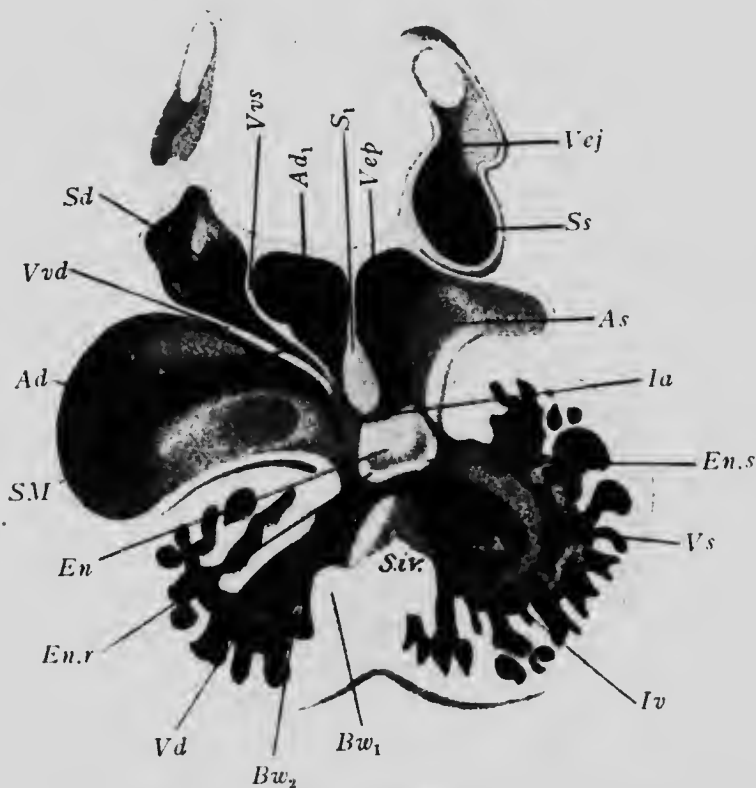


FIG. 132.—SECTION THROUGH A RECONSTRUCTION OF THE HEART OF A RABBIT EMBRYO OF 10.1 MM.

*Ad* and *Ad<sub>1</sub>*, Right, and *As*, left auricle; *Bw<sub>1</sub>* and *Bw<sub>2</sub>*, lower ends of the ridges which divide the aortic bulb; *En*, endocardial cushion; *En.r* and *En.s*, thickenings of the cushion; *Ia*, interauricular and *Iv*, interventricular communication; *s<sub>1</sub>*, septum primum; *Sd*, right and *Ss*, left horn of the sinus venosus; *Siv*, ventricular septum; *SM*, opening of the sinus venosus into the auricle; *Vd*, right and *Vs*, left ventricle; *Vej*, jugular vein; *Vep*, pulmonary vein; *Vvd* and *Vvs*, right and left limbs of the valve guarding the opening of the sinus venosus.—(Born.)

is termed the *aortic septum*. This makes its appearance in the aortic bulb just at the point where the first lateral branches which give origin to the pulmonary arteries (see



p. 264) arise, and is formed by the fusion of the free edges of two ridges which develop on opposite sides of the bulb. From its point of origin it gradually extends down the bulb until it reaches the ventricle, where it fuses with the free edge of the ventricular septum and so completes the separation of the two ventricles (Fig. 133). The bulb now consists of two vessels lying side by side, and owing to the position of the partition at its anterior end, one of these vessels, that which opens into the right ventricle, is continuous with the pulmonary arteries, while the other, which opens into the left ventricle, is continuous with the rest of the vessels which arise from the forward continuation of the bulb. As soon as the development of the partition is completed, two grooves, corresponding in position to the lines of attachment of the partition on the inside of the bulb, make their appearance on the outside and gradually deepen until they finally meet and divide the bulb into two separate vessels, one of which is the pulmonary aorta and the other the systemic aorta.

In the early stages of the heart's development the muscle bundles which compose the wall of the ventricle are very loosely arranged, so that the ventricle is a somewhat spongy mass of muscular tissue with a relatively small cavity. As development proceeds the bundles nearest the outer surface come closer together and form a compact layer, those on the inner surface, however, retaining their loose arrangement for a longer time (Fig. 132). The lower edge of the auricular canal becomes prolonged on the left side into one, and on the right side into two, flaps which project downward into the ventricular cavity, and an additional flap arises on each side from the lower edge of the partition of the auricular canal, so that three flaps occur in the right auriculo-ventricular opening and two in the left. To the under surfaces of these flaps the loosely

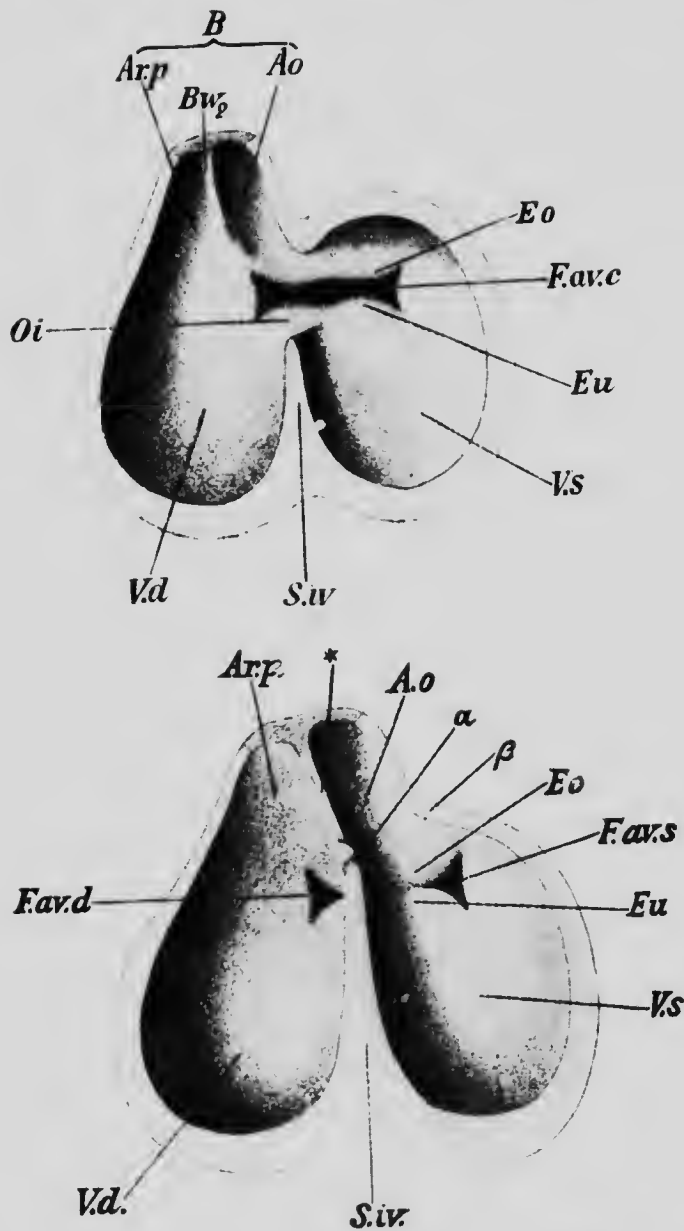


FIG. 133.—DIAGRAMS OF SECTIONS THROUGH THE HEART OF EMBRYO RABBITS TO SHOW THE MODE OF DIVISION OF THE VENTRICLES AND OF THE AURICULO-VENTRICULAR ORIFICE.

*Ao*, Aorta; *Ar.p*, pulmonary artery; *B*, aortic bulb; *Bw<sub>2</sub>*, one of the ridges which divide the bulb; *Eo* and *Eu*, upper and lower thickenings of the margins of the auriculo-ventricular orifice; *Fav.c*, the original auriculo-ventricular orifice; *Fav.d* and *Fav.s*, right and left auriculo-ventricular orifices; *Oi*, interventricular communication; *S.iv*, ventricular septum; *Vd* and *Vs*, right and left ventricles.

arranged muscular trabeculæ of the ventricle are attached, and muscular tissue also occurs in the flaps. This condition is transitory, however; the muscular tissue of the flaps degenerates to form a dense layer of connective tissue, and at the same time the muscular trabeculæ undergo a condensation. Some of them separate from the flaps, which represent the *auriculo-ventricular valves*, and form muscle bundles which may fuse throughout their entire length with the more compact portions of the ventricular walls, or else may be attached only by their ends, forming loops; these two varieties of muscle bundles constitute

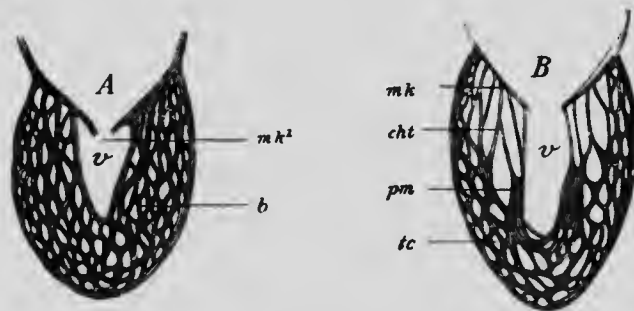


FIG. 134.—DIAGRAMS SHOWING THE DEVELOPMENT OF THE AURICULO-VENTRICULAR VALVES.

*b*, Muscular trabeculæ; *cht*, chordæ tendineæ; *mk* and *mk¹*, valve; *pm*, musculus papillaris; *tc*, columnæ carneæ; *v*, ventricle.—(From Hertwig, after Gegenbaur.)

the *columnæ carneæ* of the adult heart. Other bundles may retain a transverse direction, passing across the ventricular cavity and forming the so-called *moderator bands*; while others, again, retaining their attachment to the valves, condense only at their lower ends to form the *musculi papillares*, their upper portions undergoing conversion into strong though slender fibrous cords, the *chordæ tendineæ* (Fig. 134).

The endocardial lining of the ventricles is at first a simple sac separated by a distinct interval from the myocar-

dium, but when the condensation of the muscle trabeculæ occurs the endocardium applies itself closely to the irregular surface so formed, dipping into all the crevices between the columnæ carneæ and wrapping itself around the musculi papillares and chordæ tendineæ so as to form a complete lining of the inner surface of the myocardium.

The aortic and pulmonary *semilunar valves* make their appearance, before the aortic bulb undergoes its longitudinal splitting, as four tubercle-like thickenings of connective tissue situated on the inner wall of the bulb just where it arises from the ventricle. When the division of the bulb occurs, two of the thickenings, situated on opposite sides, are divided, so that both the pulmonary and systemic aortæ receive three thickenings (Fig. 135). Later the thickenings become hollowed out on the surfaces directed away from the ventricles and are so converted into the pouch-like valves of the adult.

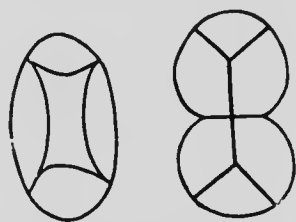


FIG. 135.—DIAGRAMS ILLUSTRATING THE FORMATION OF THE SEMILUNAR VALVES.—(Gegenbaur.)

*Changes in the Heart after Birth.*—The heart when first formed lies far forward in the neck region of the embryo, between the head and the anterior surface of the yolk-sac, and from this position it gradually recedes until it reaches its final position in the thorax. And not only does it thus change its relative position, but the direction of its axes also change. For at an early stage the ventricles lie directly in front of (*i. e.*, ventrad to) the auricles and not below them as in the adult heart, and this primitive condition is retained until the diaphragm has reached its final position (see p. 342).

In addition to these changes in position, important

changes also occur in the auricular septum after birth. Throughout the entire period of fetal life the foramen ovale persists, permitting the blood returning from the placenta and entering the right auricle to pass directly across to the left auricle, thence to the left ventricle, and so out to the body through the systemic aorta (see p. 288). At birth the lungs begin to function and the placental circulation is cut off, so that the right auricle receives only venous blood and the left only arterial; a persistence of the foramen ovale beyond this period would be injurious, since it would permit of a mixture of the arterial and venous bloods, and, consequently, it closes completely soon after birth. The closure is made possible by the fact that during the growth of the heart in size the portion of the auricular septum which is between the edge of the foramen ovale and the dorsal wall of the auricle increases in width, so that the foramen is carried further and further away from the dorsal wall of the auricle and comes to be almost completely overlapped by the annulus of Vieussens (Fig. 131). This process continuing, the dorsal portion of the auricular septum finally overlaps the free edge of the annulus, and after birth the fusion of the overlapping surfaces takes place and the foramen is completely closed.

In a large percentage (25 to 30 per cent.) of individuals the fusion of the surfaces of the septum and annulus is not complete, so that a slit-like opening persists between the two auricles. This, however, does not allow of any mingling of the blood in the two cavities, since when the auricles contract the pressure of the blood on both sides will force the overlapping folds together and so practically close the opening. Occasionally the growth of the dorsal portion of the septum is imperfect or is inhibited, in which case closure of the foramen ovale is impossible.

**The Development of the Arterial System.**—It has been seen that the formation of the blood-vessels begins in the extra-embryonic splanchnic mesoderm surrounding the

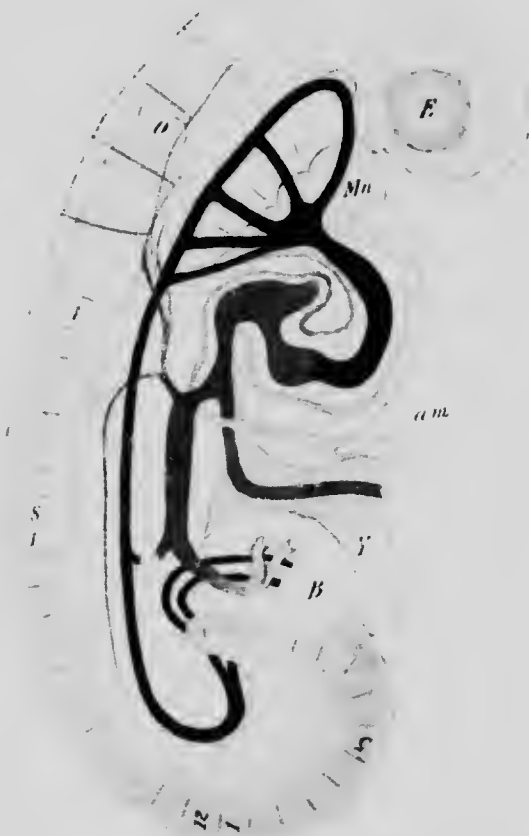


FIG. 136.—RECONSTRUCTION OF EMBRYO OF 2.6 MM.  
*am*, Amnion; *B*, belly-stalk; *E*, optic evagination; *H*, heart; *Mn*, mandibular process; *O*, auditory capsule; *om*, omphalo-mesenteric vein; *v*, umbilical vein; *Y*, yolk-stalk.—(*His.*)

yolk-sac and extends thence toward the embryo. The two original omphalo-mesenteric arteries, entering the body of the embryo along the yolk-stalk, make their way to the dorsal wall of the abdomen, and growing forward

and backward give rise to two longitudinal stems, the representatives of the dorsal aorta. From near the posterior ends of these there arise at an early stage two branches, which pass out along with the allantois into the belly-stalk and so to the chorionic villi, forming the *allantoidean* or *umbilical arteries*, while anteriorly each aorta

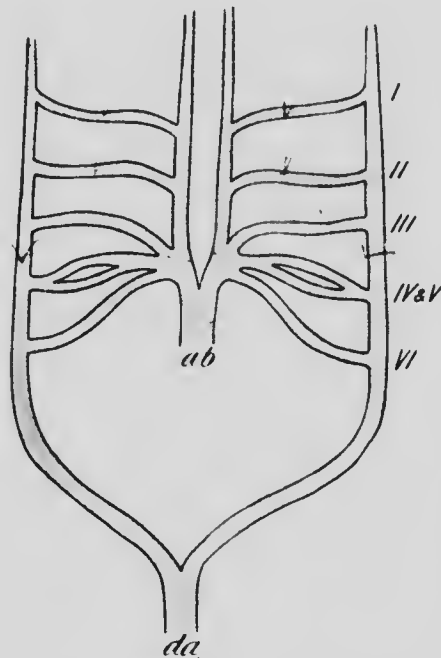


FIG. 137.—DIAGRAM ILLUSTRATING THE ARRANGEMENT OF THE BRANCHIAL VESSELS.

*ab*, Aortic bulb; *da*, dorsal aorta; *I* to *VI*, branchial arch vessels.

sends branches ventrally in the anterior branchial arches and these, uniting together, pass backward along the floor of the pharynx to become continuous with the aortic bulb (Fig. 136). Later the two dorsal aortæ fuse together as far forward as the region of the eighth cervical segment to form a single trunk (Fig. 137), and the left omphalo-mesenteric artery disappears, the right one persisting to form the superior mesenteric artery of the adult. ?

It will be convenient to consider first the history of the vessels which pass ventrally in the branchial arches. Altogether, six of these vessels are developed, the fourth branchial arch possessing a rudimentary one in addition to that which properly belongs to it (Zimmermann), and when fully formed they have an arrangement which may be understood from the diagram (Fig. 137), in which the

vessels are represented as spread out upon a plane surface, the lateral trunks being the dorsal aortæ. This arrangement represents a condition which is permanent in the lower vertebrates. In the fishes the respiration is performed by means of gills developed upon the branchial arches, and the heart is an organ which receives venous blood from the body and pumps it to the gills, in which it becomes arterialized and is then collected into the dorsal aortæ, which distribute it to the body. But in terrestrial animals, with the loss of the gills and the development of the lungs as respiratory organs, the capillaries of the gills disappear and the afferent and efferent branchial vessels become continuous, the condition represented in the diagram resulting.

But this condition is merely temporary in the mammalia and numerous changes occur in the arrangement of the vessels before the adult plan is realized. The first change is a disappearance of the vessel of the first arch, the ventral stem from which it arose being continued forward to form the temporal arteries, giving off near the point where the branchial vessel originally arose a branch which represents the internal maxillary artery, and possibly also a second branch which represents the facial (His). A little later the second branchial vessel also degenerates (Fig. 138), a branch arising from the ventral trunk near its former origin possibly representing the future lingual artery (His), and then the portion of the dorsal trunk which intervenes between the third and fourth branchial vessels vanishes, so that the dorsal trunk anterior to the third branchial arch is cut off from its connection with the dorsal aorta and forms, together with the vessel of the third arch, the internal carotid, while the ventral trunk, anterior to the point of origin of the third vessel, becomes the external carotid, and the portion which in-



tervenes between the third and fourth vessels becomes the common carotid (Fig. 139).

The rudimentary fifth vessel, like the first and second, disappears, but the fourth persists to form the aortic arch, there being at this stage of development two complete aortic arches. From the sixth vessel a branch arises which passes backward to the lungs, and the portion of the vessel of the right side which intervenes between this

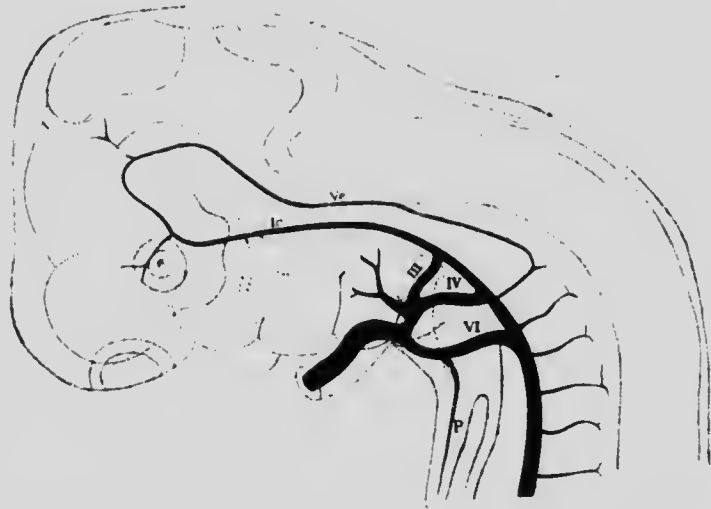


FIG. 138.—ARTERIAL SYSTEM OF AN EMBRYO OF 10 MM.  
Ic, Internal carotid; P, pulmonary artery; Vc, vertebral artery; III to VI, persistent branchial vessels.—(His.)

and the aortic arch disappears, while the corresponding portion of the left side persists until after birth, forming the *ductus arteriosus* (*ductus Botalli*) (Fig. 139). When the longitudinal division of the aortic bulb occurs, the septum is so arranged as to place the sixth arch in communication with the right ventricle and the remaining vessels in connection with the left ventricle, the only direct communication between the systemic and pulmonary vessels

being by way of the ductus arteriosus, whose significance will be explained later (p. 290).

One other change is still necessary before the vessels acquire the arrangement which they possess during fetal life, and this consists in the disappearance of the lower portion of the right aortic arch (Fig. 139), so that the left arch alone forms the connection between the heart and the dorsal aorta. The upper part of the right aortic arch persists to form the proximal part of the right subclavian artery, the portion of the ventral trunk which unites the arch with the aortic bulb becoming the brachio-cephalic (innominate) artery.

From the entire length of the thoracic aorta, and in the embryo from the aortic arches, lateral branches arise corresponding to each segment and accompanying the segmental nerves. The first of these branches arises just below the point of union of the ves-

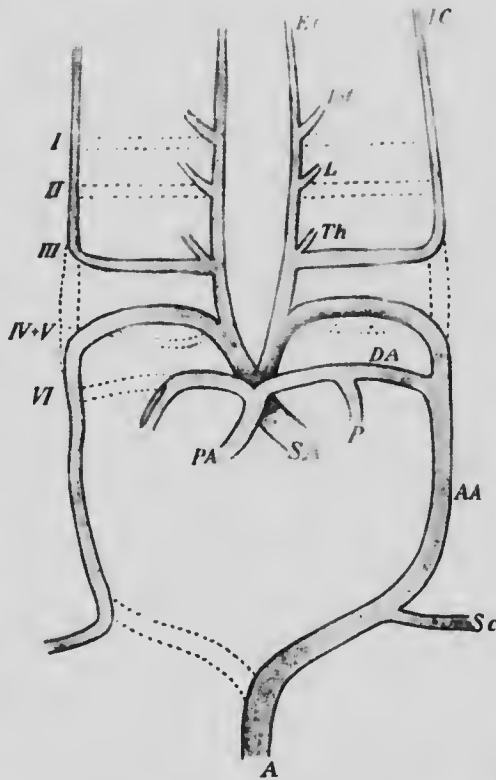


FIG. 139.—DIAGRAM ILLUSTRATING THE CHANGES IN THE ARRANGEMENT OF THE BRANCHIAL ARCH VESSELS.

The broken lines indicate portions of the original vessels which have disappeared. A, Aorta; A.A., aortic arch; D.A., ductus arteriosus; E.C., external carotid; I.C., internal carotid; I.M., internal maxillary; L., lingual; P, pulmonary artery; P.A., pulmonary aorta; S.A., systemic aorta; S.c., subclavian; I to VI, original branchial arch vessels.

sel of the sixth arch with the dorsal trunk and accompanies the hypoglossal nerve (Fig. 140, *h*), and that which accompanies the seventh cervical nerve arises just

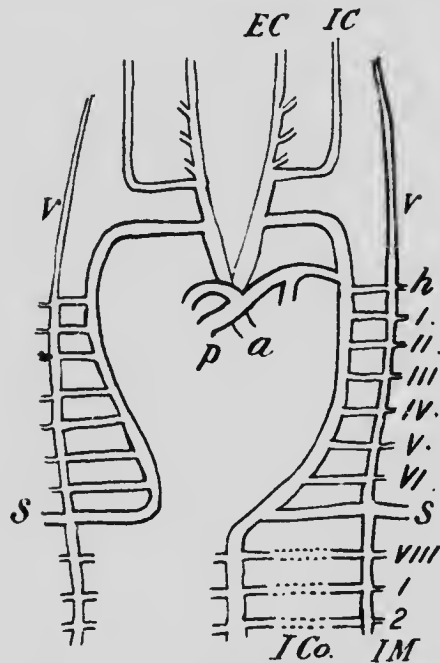


FIG. 140.—DIAGRAM SHOWING THE RELATIONS OF THE LATERAL BRANCHES TO THE AORTIC ARCHES.

*EC*, External carotid; *h*, lateral branch accompanying the hypoglossal nerve; *IC*, internal carotid; *ICo*, intercostal; *IM*, internal mammary; *s*, subclavian; *v*, vertebral; *I* to *VIII*, lateral cervical branches; *1*, *2*, lateral thoracic branches.

above the point of union of the two aortic arches (Fig. 140, *s*), and extends out into the limb bud, forming the subclavian artery.\*

Further down twelve pairs of lateral branches, arising from the thoracic portion of the aorta, represent the intercostal arteries, and still lower four pairs of lumbar arteries are formed, the fifth lumbar being represented by two large branches, the common iliacs, which seem from their size to be the continuations of the aorta rather than branches of it. The true continuation of the aorta is, however, the *art. sacra media*, which represents in a de-

generated form the caudal prolongation of the aorta of other mammals, and, like this, gives off lateral branches corresponding to the sacral segments.

\* It must be remembered that the right subclavian of the adult is more than equivalent to the left, since it represents the fourth branchial vessel + a portion of the dorsal longitudinal trunk + the lateral segmental branch (see Fig. 140).

In addition to the segmental lateral branches arising from the aorta, visceral branches, which have their origin rather from the ventral surface than the sides, also occur. The development of these branches has as yet been but little studied, but it seems probable that they too may show, when their embryonic history has been worked out, a more perfect segmental plan than is discernible from their adult arrangement. The

earliest representative of them is the superior mesenteric artery, whose origin from the left omphalo-mesenteric has already been described. Several other visceral branches occur both in the thoracic and abdominal regions, but they are irregular in their distribution, the unpaired branches of the abdominal region having probably condensed from an original segmental condition to form compound trunks such as the coeliac axis and the inferior mesenteric.

One pair of the visceral branches, the umbilical arteries, require more than a passing notice on account of their embryonic importance. They are formed at a very early stage and arise by a short common trunk from the anterior surface of the aorta (Fig. 141,  $U^1$ ). They pass directly forward on the medial side of the Wolffian duct (see p. 361) to the terminal portion of the intestine, and thence pass out along the sides of the allantois to the chorionic villi. Later there are formed from the aorta just below the origin

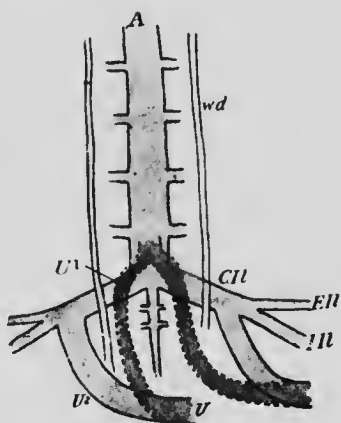


FIG. 141.—DIAGRAM ILLUSTRATING THE DEVELOPMENT OF THE UMBILICAL ARTERIES.

$A$ , Aorta;  $CI$ , common iliac;  $EI$ , external iliac;  $II$ , internal iliac;  $U^1$ , umbilical artery;  $U^2$ , the primary proximal and  $U^2$ , the secondary proximal part of the umbilical;  $wd$ , Wolffian duct.

of the umbilicals, the lateral branches (*c.il*) which become the common iliacs, and from each of these a short branch ( $U^2$ ) arises which passes to the outer side of the Wolffian duct and unites with the umbilical arteries, whereupon the original proximal portions of these arteries disappear and they come to arise from the iliacs instead of directly from the aorta. At birth the portions of the arteries beyond the umbilicus are severed when the umbilical cord is cut, and their intra-embryonic portions, which have been called the *hypogastric arteries*, quickly undergo a reduction in size. The proximal portion of the allantois persists as the urinary bladder, and the proximal portions of the hypogastric arteries remain functional as the superior vesical arteries carrying blood to this viscus, but the portions which intervene between the bladder and the umbilicus become reduced to solid cords forming the obliterated hypogastric arteries of adult anatomy.

In its general plan, accordingly, the arterial system may be regarded as consisting of a pair of longitudinal vessels which fuse together throughout the greater portion of their length to form the dorsal aorta, from which there arise lateral, segmentally arranged somatic branches and ventral visceral branches whose segmental arrangement is less distinct. With the exception of the aortic trunks (together with their anterior continuation, the internal carotids) and the external carotids, no longitudinal arteries exist primarily. In the adult, however, several longitudinal vessels, such as the vertebrales, internal mammary, and epigastric arteries, exist. The formation of these secondary longitudinal trunks is the result of a development between adjacent vessels of anastomoses, which become larger and more important blood-channels than the original vessels.

At an early stage each of the lateral branches of the dor-

sal aorta gives off a twig which passes forward to anastomose with a backwardly directed twig from the next

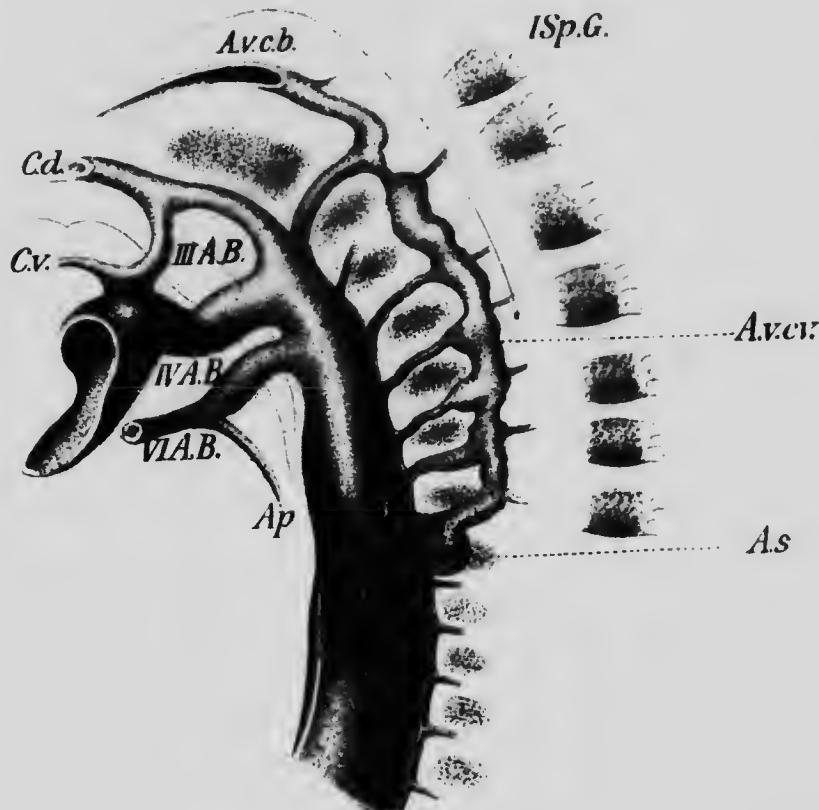


FIG. 142. THE DEVELOPMENT OF THE VERTEBRAL ARTERY IN A RABBIT EMBRYO OF TWELVE DAYS.

III A.B. to VI A.B., Branchial arch vessels; *A.p.*, pulmonary artery; *A.v.c.b.* and *A.v.c.v.*, cephalic and cervical portions of the vertebral artery; *A.s.*, subclavian; *C.d.* and *C.v.*, internal and external carotid; *I.S.p.G.*, spinal ganglion.—(*Hochstetter.*)

anterior lateral branch, so as to form a longitudinal chain of anastomoses along each side of the neck. In the earliest stage at present known the chain starts from the lateral

branch corresponding to the first cervical (suboccipital) segment and extends forward into the skull through the foramen magnum, terminating by anastomosing with the internal carotid. To this original chain other links are added from each of the succeeding cervical lateral branches as far back as the seventh (Figs. 142 and 140). But in the mean time the recession of the heart toward the

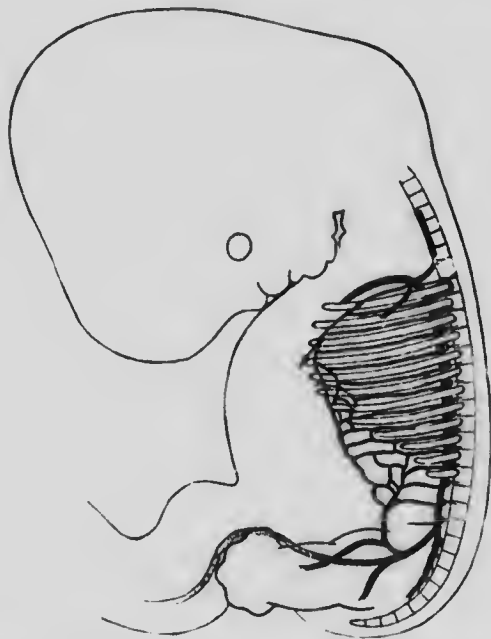


FIG. 143. —EMBRYO OF 13 MM. SHOWING THE MODE OF DEVELOPMENT OF THE INTERNAL MAMMARY AND DEEP EPIGASTRIC ARTERIES.—  
(Mall.)

thorax has begun, with the result that the common carotid stems are elongated and the aortic arches are apparently shortened so that the subclavian arises on the left side almost opposite the point where the aorta was joined by the sixth branchial vessel. As this apparent shortening proceeds, the various lateral branches which give rise to the chain of anastomoses, with the exception of the

seventh, disappear in their proximal portions and the chain becomes an independent stem, the *vertebral artery*, arising from the seventh lateral branch, which is the subclavian.

The recession of the heart is continued until it lies below the level of the upper intercostal arteries and the upper two of these, together with the last cervical branch on each side, lose their connection with the dorsal aorta, and, sending off anteriorly and posteriorly anastomosing twigs, develop a short longitudinal stem, the *superior intercostal*, which opens into the subclavian.

The intercostals and their abdominal representatives, the lumbar and iliacs, also give rise to longitudinal anastomosing twigs near their ventral ends (Fig. 143), and these increasing in size give rise to the *internal mammary* and *deep epigastric* arteries, which together form continuous stems extending from the subclavians to the external iliacs in the ventral abdominal walls. The *superficial epigastrics* and other secondary longitudinal vessels are formed in a similar manner.

**The Development of the Arteries of the Limbs.**—Much information is still required before the complete history of the development of the arteries of the limbs can be written, and at present one must rely largely upon the facts of comparative anatomy and on the anomalies which occur in the human body for indications of what the early development is likely to be. So far as embryological observations go, they confirm the conclusions derived from such sources.

Notwithstanding the fact that the limbs are formed by outgrowths from several segments, there is as yet no evidence to show that a corresponding number of segmental arteries take part in the development of their blood-supply, but it seems that in both limbs the entire arterial sys-



tem is formed from a single lateral branch, that of the upper limb, the subelavian, corresponding to the seventh cervical segment, while that of the lower limb, the common iliac, is probably the fifth lumbar branch. In the simplest arrangement the subelavian is continued as a single trunk along the axis of the anterior limb as far as the carpus, where it divides into digital branches for the fingers. In its course through the forearm it lies in the interval between the radius and ulna, resting on the interosseous membrane, and in this part of its course it may be termed the *arteria interossea*. In the second stage a new artery accompanying the median nerve appears, arising from the main stem or brachial artery a little below the elbow-joint. This may be termed the *arteria mediana*, and as it develops the *arteria interossea* gradually diminishes in size, becoming finally the small anterior interosseous artery of the adult (Fig. 144), and the median, uniting with its lower end, takes from it the digital branches and becomes the principal stem of the forearm.

A third stage is then ushered in by the appearance of a branch from the median which forms the *arteria ulnaris*, and this, passing down the ulnar side of the forearm, unites at the wrist with the median to form a superficial palmar arch from which the digital branches arise. A fourth stage is marked by the diminution of the median artery until it finally appears to be a small branch of the interosseous, the *arteria comes nervi mediani*, and at the same time there develops from the brachial, at about the middle of the upper arm, what is known as the *arteria radialis superficialis* (Fig. 144, *rs*). This extends down the radial side of the forearm, following the course of the radial nerve, and at the wrist passes upon the dorsal surface of the hand to form the *aa. dorsalis pollicis* and *dorsalis indicis*. At first this artery takes no part in the for-

mation of the palmar arches, but later it gives rise to the superficial volar branch, which usually unites with the superficial arch, while from its dorsal portion a perforating branch develops which passes between the first and second

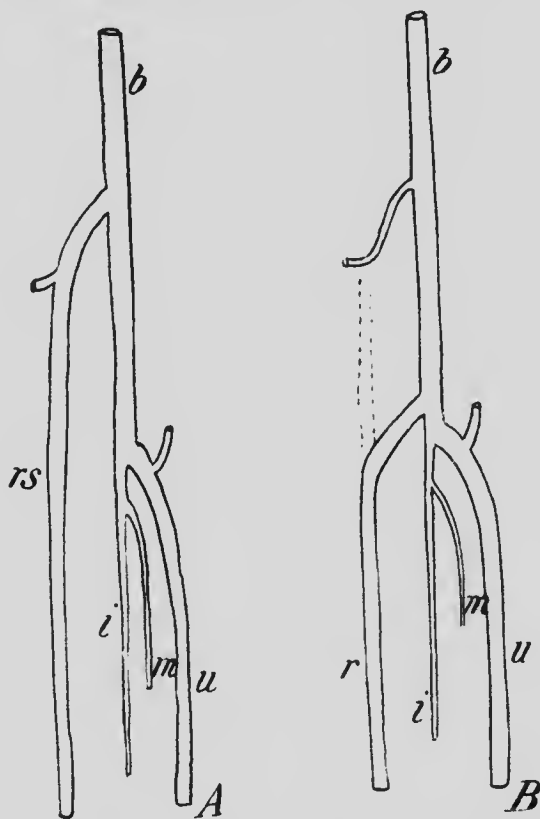


FIG. 144.—DIAGRAMS SHOWING AN EARLY AND A LATE STAGE IN THE DEVELOPMENT OF THE ARTERIES OF THE ARM.  
*b*, Brachial; *i*, interosseous; *m*, comes nervi mediani; *r*, radial; *rs*, superficial radial; *u*, ulnar.

metacarpal bones and unites with a deep branch of the ulnar to form the deep arch. The fifth or adult stage is reached by the development from the brachial below the elbow of a branch (Fig. 144, *r*) which passes downward and outward to unite with the superficial radial, where-

upon the upper portion of that artery degenerates until it is represented only by a branch to the biceps muscle (Schwalbe), while the lower portion persists as the adult radial.

The various anomalies seen in the arteries of the forearm are, as a rule, due to the more or less complete persistence of one or other of the stages described above, what is described, for instance, as the high branching of the brachial being the persistence of the superficial radial.

In the leg there is a noticeable difference in the arrangement of the arteries from what occurs in the arm, in that the principal artery of the thigh, the femoral, does not accompany the principal nerve, the sciatic. This difference is apparently secondary, but, as in the case of the upper limb, it is necessary to rely largely on the facts of comparative anatomy and on anomalies which occur in the human body for an idea of the probable development of the arteries of the lower limb. It has already been seen that the common iliac artery is to be regarded as a lateral branch of the dorsal aorta, and in the simplest condition of the limb arteries its continuation, the anterior division of the internal iliac, passes down the leg as a well-developed sciatic artery as far as the ankle (Fig. 145, *s*). At the knee it occupies the position of the popliteal of adult anatomy, and below the knee gives off a branch corresponding to the anterior tibial (*at*) which, passing forward to the extensor surface of the leg, quickly loses itself in the extensor muscles. The main artery continues downward on the interosseous membrane, and some distance above the ankle divides into a strong anterior and a weaker posterior branch; the former perforates the membrane and is continued down the extensor surface of the leg to form the lower part of the anterior tibial and the dorsalis pedis arteries, while the latter, passing upon the

plantar surface of the foot, is lost in the plantar muscles. At this stage the external iliac is a secondary branch of the common iliac, being but poorly developed and not extending as far as the knee.

In the second stage the external iliac artery increases in size until it equals the sciatic, and it now penetrates the

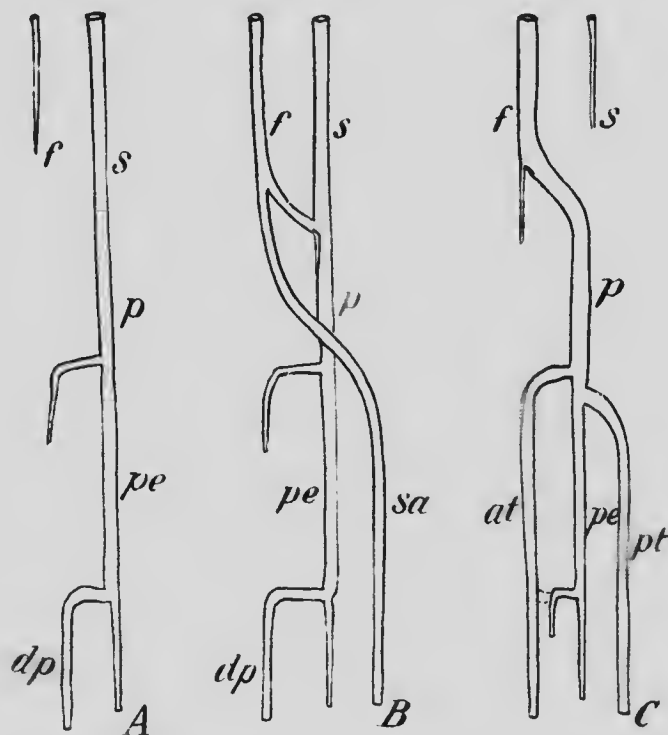


FIG. 145.—DIAGRAMS ILLUSTRATING STAGES IN THE DEVELOPMENT OF THE ARTERIES OF THE LEG.

*at*, Anterior tibial; *dp*, dorsalis pedis; *f*, femoral; *p*, popliteal; *pe*, peroneal; *pt*, posterior tibial; *s*, sciatic; *sa*, saphenous.

adductor magnus muscle and unites with the popliteal portion of the sciatic. Before doing this, however, it gives off a strong branch (*sa*) which accompanies the long saphenous nerve down the inner side of the leg, and passing behind the internal malleolus extends upon the plantar sur-

face of the foot, where it gives rise to the digital branches. From this arrangement the adult condition may be derived by the continued increase in size of the external iliac and its continuation, the femoral (*f*), accompanied by a reduction of the upper portion of the sciatic and its separation from its popliteal portion (*p*). The continuation of the popliteal down the leg is the peroneal artery (*pe*) and the upper perforating branch of this unites with the lower one to form a continuous anterior tibial, the lower connection of which with the peroneal persists in part as the anterior peroneal artery. A new branch arises from the upper part of the peroneal and passes down the back of the leg to unite with the lower part of the *arteria saphena*, forming the *posterior tibial artery* (*pt*), and the upper part of the saphenous becomes much reduced, persisting as the superficial branch of the *anastomotica magna* (*arteria musculo-articularis*) and a rudimentary chain of anastomoses which accompany the long saphenous nerve.

**The Development of the Venous System.**—The earliest veins to develop are those which accompany the first-formed arteries, the omphalo-mesenterics and umbilicals, but it will be more convenient to consider first the veins which carry the blood from the body of the embryo back to the heart. These make their appearance, while the heart is still in the pharyngeal region, as two pairs of longitudinal trunks, the anterior and posterior cardinal veins, into which lateral branches, arranged more or less segmentally, open. The anterior cardinals appear somewhat earlier than the posterior and form the *internal jugular* veins of adult anatomy. They are formed by the union of two stems which convey the blood from the brain. One of these stems is formed by a number of veins which pass backward over the surface of the fore-brain, uniting to

form a stem which follows the course of the facial nerve and unites with the other stem formed by veins from the more posterior portions of the brain and passing outward and downward along with the vagus nerve. The various veins of the fore-brain region later condense to form the *superior longitudinal sinus* (Fig. 146, *sss*), while the stem which they formed becomes the *lateral sinus* (*str*), with which the ophthalmic vein (*vo*) unites. A communication, passing on the median side of the ear capsule, develops between the lateral sinus and the posterior stem, and the original communication disappears, the condition represented in Fig. 146, *B*, being thus acquired. In later stages, as the fore-brain vesicles grow backward, the point of union of the superior longitudinal sinus with the laterals is brought nearer to its adult position, and, at the same time, the portion of the lateral sinus between the communication of the ophthalmic vein and the jugular foramen diminishes in length until it is practically obliterated, the ophthalmics and lateral sinuses meeting at the jugular foramen. The intra-cranial portions of the ophthalmic veins form the *cavernous* and *inferior petrosal sinuses*, the *superior petrosals* being formed later by a communication between the cavernous and lateral sinuses.

Passing backward from the jugular foramen the internal jugular veins unite with the inferior cardinals to form on each side a common trunk, the *ductus Cuvieri*, and then passing transversely toward the median line open into the sides of the sinus venosus. So long as the heart retains its original position in the pharyngeal region the jugular is a short trunk receiving lateral veins only from the uppermost segments of the neck and from the occipital segments, the remaining segmental veins opening into the inferior cardinals. As the heart recedes, however, the jugulars become more and more elongated and the cervi-





1.50

1.56

1.63

1.71

1.80

1.88

1.96

2.04

2.12

2.20

2.28

2.36

2.44

2.52

2.60

2.68

2.76

2.84

2.92

3.00

3.08

3.16

3.24

3.32

3.40

3.48

3.56

3.64

3.72

3.80



MICROCOPY RESOLUTION TEST CHART  
NATIONAL BUREAU OF STANDARDS  
STANDARD REFERENCE MATERIAL 1010a  
(ANSI and ISO TEST CHART No. 2)



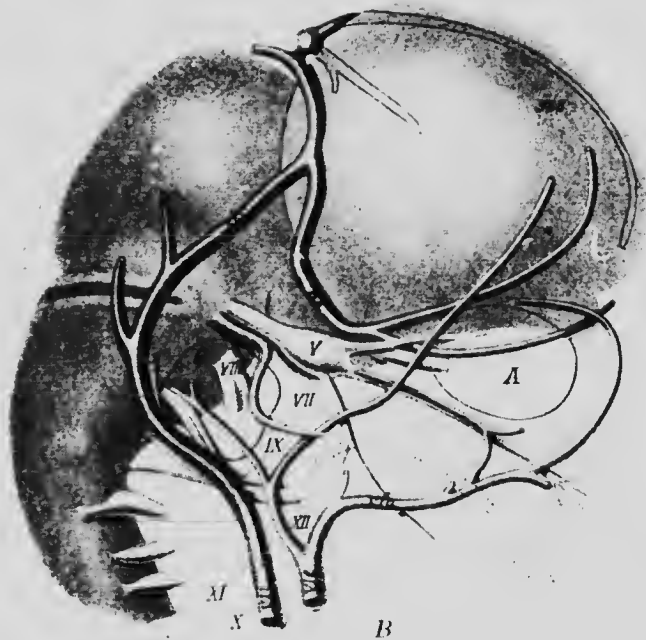
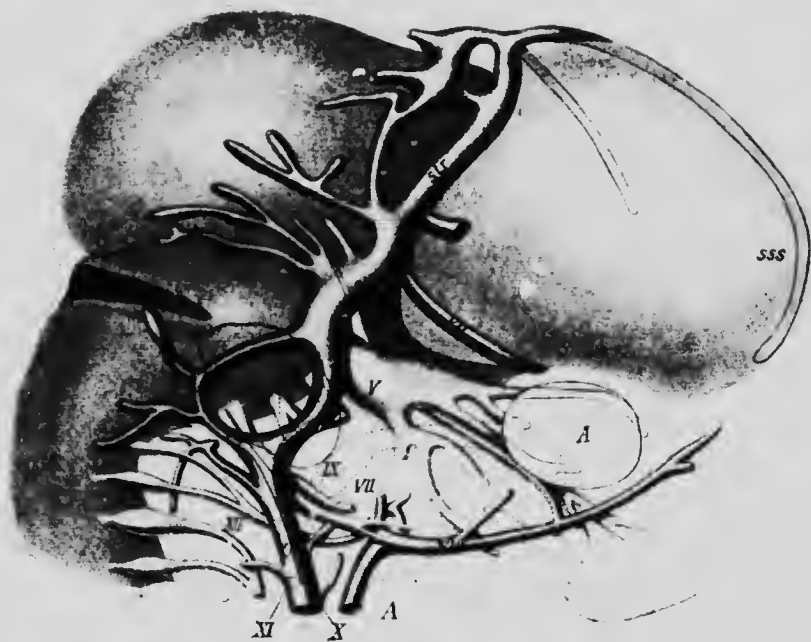


FIG. 146.—RECONSTRUCTION OF THE HEAD VEINS OF GUINEA-PIG EMBRYOS.

A, Eye; G, auditory capsule; sss, superior longitudinal sinus; str, lateral sinus; vfa, facial vein; vj and vji, internal jugular vein; vje, external jugular vein; vo, ophthalmic vein.—(Salzer.)

cal lateral veins shift their communication from the cardinals to the jugulars, until, when the subclavians have thus shifted, the jugulars become much larger than the cardinals. When the sinus venosus is absorbed into the wall of the right auricle, the course of the left Cuvierian duct becomes a little longer than that of the right, and from the left jugular, at the point where it is joined by the left subclavian, a branch arises which extends obliquely

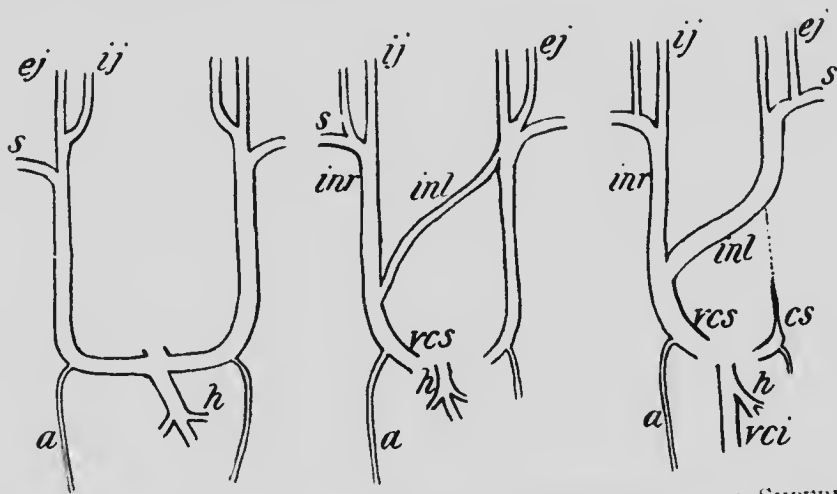


FIG. 147.—DIAGRAMS SHOWING THE DEVELOPMENT OF THE SUPERIOR VENA CAVA.

*a*, Right azygos vein; *cs*, coronary sinus; *ej*, external jugular; *h*, hepatic vein; *ij*, internal jugular; *inr* and *inl*, right and left innominate veins; *s*, subclavian; *vci* and *vcs*, inferior and superior venæ cavae.

across to join the right jugular, forming the left *innominate vein*. When this is established, the connection between the left jugular and Cuvierian duct is dissolved, the blood from the left side of the head and neck and from the left subclavian vein passing over to empty into the right jugular, whose lower end, together with the right Cuvierian duct, thus becomes the *superior vena cava*. The left Cuvierian duct persists, forming with the left horn of the sinus venosus the coronary sinus

The *external jugular vein* develops somewhat later than the internal. The facial vein, which primarily forms the principal affluent of this stem, passes at first into the skull along with the fifth nerve and communicates with the internal jugular system, but later this original communication is broken and the facial vein, uniting with other superficial veins, passes over the jaw and extends down the neck as the external jugular (Fig. 146, *vje*). Later still the facial anastomoses with the ophthalmic at the inner angle of the eye and also makes connections with the internal jugular just after it has crossed the jaw, and so the adult condition is acquired.

It is interesting to note that in many of the lower mammals the external jugular becomes of much greater importance than the internal, the latter in some forms, indeed, eventually disappearing and the blood from the interior of the skull emptying by means of anastomoses which have developed into the external jugular system. In man the primitive condition is retained, but indications of a transference of the intracranial blood to the external jugular are seen in the *emissary veins*.

The inferior cardinal veins, or, as they may more simply be termed, the cardinals, extend backward from their union with the jugulars along the sides of the vertebral column, receiving veins from the mesentery and also the various lateral segmental veins of the neck and trunk regions, with the exception of that of the first cervical segment which opens into the jugular. Later, however, as already described (p. 279), the cervical veins shift to the jugulars, as do also the first and second thoracic (intercostal) veins, but the remaining intercostals, together with the lumbar and sacral, continue to open into the cardinals. In addition, the cardinals receive in early stages the veins from the primitive kidneys (mesonephros), which are exceptionally large in the human embryo, but when they are replaced later on by the permanent kidneys

(metanephros) their veins undergo a reduction in number and size, and this, together with the shifting of the upper lateral veins, produces a marked diminution in the size of the cardinals. These veins persist, however, in part until adult life, forming what are known as the *azygos* and *hemi-azygos veins*, but the changes by which they acquire their final arrangement are so intimately associated with the development of the inferior vena cava that their description may be conveniently postponed until the history of that vein, together with that of the omphalo-mesenteric and of the umbilical veins, has been presented.

The *omphalo-mesenteric veins* are two in number, a right and a left, and pass in along the yolk-stalk until they reach the embryonic intestine, along the sides of which they pass forward to unite with the corresponding umbilical veins. These are represented in the belly-stalk by a single venous trunk which, when it reaches the body of the embryo, divides into two stems which pass forward, one on each side of the umbilicus, and thence on each side of the median line of the ventral abdominal wall, to form with the corresponding omphalo-mesenteric veins common trunks which open into the ductus Cuvieri. As the liver develops it comes into intimate relation with the omphalo-mesenteric veins, which receive numerous branches from its substance and, indeed, seem to break up into a network (Fig. 148, A) traversing the liver substance and uniting again to form two stems which represent the original continuations of the omphalo-mesenteries. From the point where the common trunk formed by the right omphalo-mesenteric and umbilical veins opens into the Cuvierian duct a new vein develops, passing downward and to the left to unite with the left omphalo-mesenteric; this is the *ductus venosus* (Fig. 148, B, DVA). In the mean time three cross-connections have developed between the two

omphalo-mesenteric veins, two of which pass ventral and the other dorsal to the intestine, so that the latter is surrounded by two venous loops (Fig. 149, A), and a connection is developed between each umbilical vein and the corresponding omphalo-mesenteric (Fig. 148, B), that of the left side being the larger and uniting with the omphalo-mesenteric just where it is joined by the ductus venosus so as to seem to be the continuation of this vessel (Fig. 148,

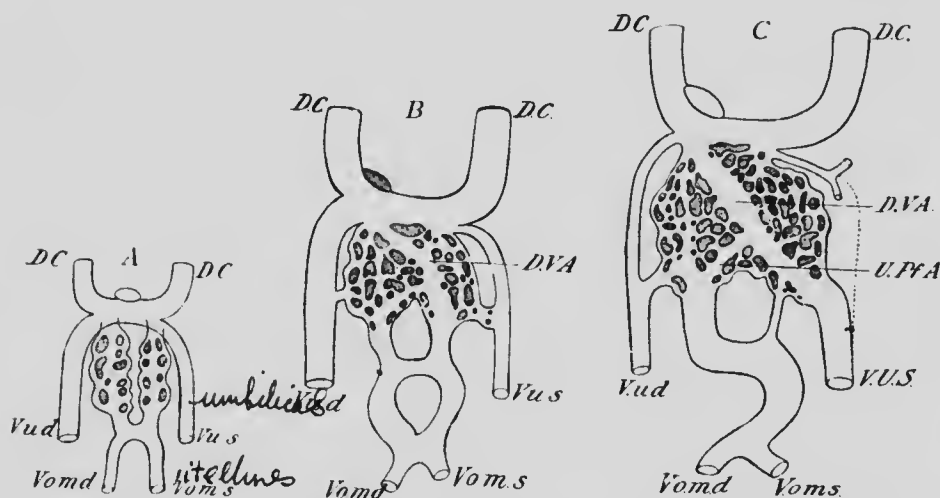


FIG. 148. — DIAGRAMS ILLUSTRATING THE TRANSFORMATIONS OF THE OMPHALO-MESENTERIC AND UMBILICAL VEINS.

*D.C.*, Ductus Cuvieri; *D.V.A.*, ductus venosus; *V.o.m.d* and *V.o.m.s.*, right and left omphalo-mesenteric veins; *V.u.d* and *V.u.s.*, right and left umbilical veins.—(*Hochstetter.*)

C). When these connections are complete, the upper portions of the umbilical veins degenerate (Fig. 149), and now the right side of the lower of the two omphalo-mesenteric loops which surround the intestine disappears, as does also that portion of the left side of the upper loop which intervenes between the middle cross-connection and the ductus venosus, and so there is formed from the omphalo-mesenteric veins the *vena porta*.

While these changes have been progressing the right umbilical vein, originally the larger of the two (Fig. 148, A and B, *V.u.d*), has become very much reduced in size and, losing its connection with the left vein at the umbilicus, forms a vein of the ventral abdominal wall in which the blood now flows from above downward. The left umbilical now forms the only route for the return of

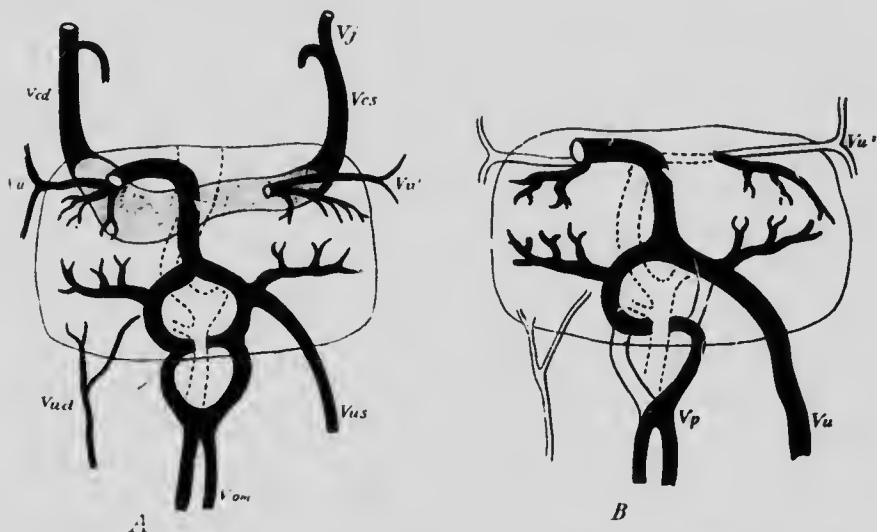


FIG. 149.—A, THE VENOUS TRUNKS OF AN EMBRYO OF 5 MM. SEEN FROM THE VENTRAL SURFACE; B, DIAGRAM ILLUSTRATING THE TRANSFORMATION TO THE ADULT CONDITION.

*Vcd* and *Vcs*, right and left superior venæ cavæ; *Vj*, jugular vein; *V.om*, omphalo-mesenteric vein; *Vp*, vena porta; *Vu*, umbilical vein (lower part); *Vu'*, umbilical vein (upper part); *Vud* and *Vus*, right and left umbilical veins (lower parts).—(His.)

blood from the placenta, and appears to be the direct continuation of the ductus venosus (Fig. 149, C), into which open the *hepatic veins*, returning the blood distributed by the portal vein to the substance of the liver.

Returning now to the cardinal veins, it has been found in the rabbit that the branches which come to them from the mesentery anastomose longitudinally to form a vessel

lying parallel and slightly ventral to each cardinal. These may be termed the *subcardinal veins* (Lewis), and in their earliest condition they open at either end into the corresponding cardinal, with which they are also united by numerous cross-branches. Later, in rabbits of 8.8 mm., these cross-branches begin to disappear and give place to a large cross-branch situated immediately below the origin of the superior mesenteric artery, and at the same point a cross-branch between the two subcardinals also develops. The portion of the right subcardinal which is anterior to the cross-connection now rapidly enlarges and unites with the ductus venosus just where the hepatic veins open into that vessel (Fig. 150, A), and at the same time the lower part of the right cardinal and its connection with the right subcardinal also enlarge, and these three elements straighten out to form a single longitudinal trunk, which, together with the proximal portion of the ductus venosus, constitutes the *vena cava inferior* of the adult.

As soon as the establishment of this vessel is accomplished, the lower portion of the right subcardinal undergoes degeneration, while the left one, diminishing in size, persists as the left suprarenal vein (Hochstetter) (Fig. 150, B, *vsr*). The cross-branch between the two subcardinals persists, however, and by its connection with the left cardinal allows the blood from the lower part of that vein to flow over into the vena cava.

As the permanent kidneys grow forward (see Chap. XIII) they push their way between the aorta and the posterior portions of the cardinal veins, forcing the latter off to the side and interfering with the flow of blood in them, a difficulty which is overcome by the development of a branch from each cardinal, just above the kidney, which passes to the medial side of the ureter to unite again with the cardinal below (Fig. 150, B). As soon as this circle

around the ureter has been established, its lateral limb, which represents part of the original cardinal vein, degenerates, its anterior portion alone persisting to form a part of the renal vein (compare Figs. 150, A and B, *r*). An anastomosis now develops between the right and left cardinals at the point where the iliac veins open into them

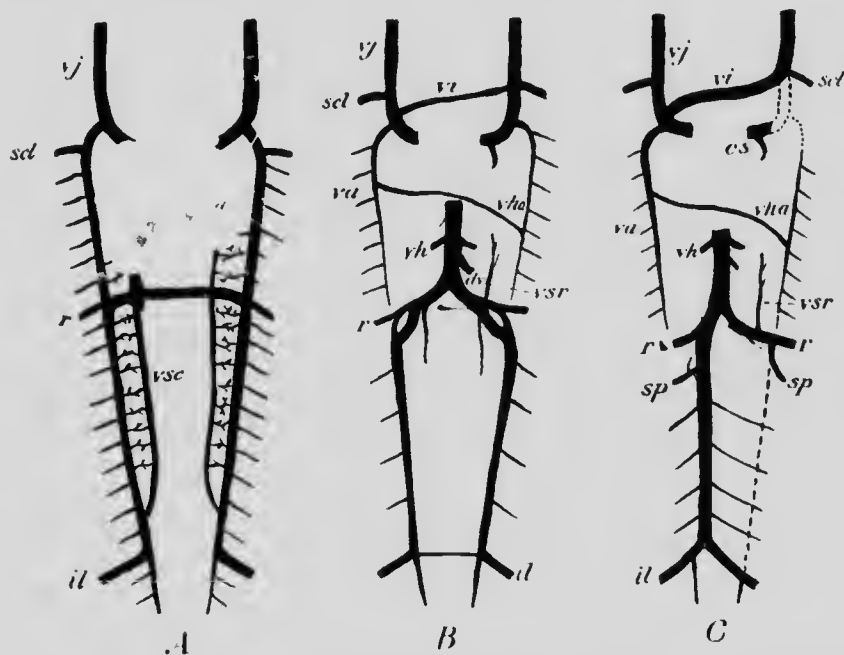


FIG. 150.—DIAGRAMS ILLUSTRATING THE DEVELOPMENT OF THE INFERIOR VENA CAVA.

*cs*, Coronary sinus; *dv*, ductus venosus; *il*, iliac vein; *r*, renal; *scl*, subclavian; *sp*, spermatic; *va*, vena azygos; *vh*, hepatic; *vha*, vena hemi-azygos; *vi*, left innominate; *vj*, jugular; *vsc*, subcardinal; *vsr*, supra-renal.

(Fig. 150, B), and the portion of the left cardinal which intervenes between this anastomosis and the entrance of the spermatic (ovarian) vein disappears, the remainder of it, as far forward as the renal vein, persisting as the upper part of the left spermatic (ovarian) vein, which thus comes to open into the renal vein instead of into the vena cava as



does the corresponding vein of the right side of the body (Fig. 150, C, *sp*). The renal veins originally open into the cardinals at the point where these are joined by the large cross-connection, and when the lower part of the left cardinal disappears, this cross-connection forms the proximal part of the left renal vein, which consequently receives the left suprarenal (Fig. 150, C).

The observations upon which the above description is based have been made most thoroughly upon the rabbit, but it seems probable from the partial observations that have been made that the same changes occur also in the human embryo. It will be noted from what has been said that the inferior vena cava is a composite vessel, consisting of at least four elements: (1) the proximal part of the ductus venosus; (2) the anterior part of the right subcardinal; (3) the cross-connection between the right cardinal and subcardinal; and (4) the posterior part of the right cardinal.

The fate of the anterior portions of the cardinal veins has yet to be considered. When the large cross-connection with the subcardinals has been established, the portions of the cardinals immediately anterior undergo degeneration, so that their anterior portions become quite disconnected from the posterior (Fig. 150, B). They continue to receive the intercostal veins, and the right one, retaining its connection with the ductus Cuvieri, becomes the *vena azygos* (Figs. 150, B and C, *va*), while that on the left side, after developing a cross-connection with its fellow, degenerates at its anterior end, and, so becoming separated from the ductus Cuvieri, is transformed into the *vena hemiazygos* of adult anatomy (Fig. 150, B and C, *vha*).

The ascending lumbar veins, frequently described as the commencements of the azygos veins, are in reality secondary formations developed by the anastomoses of anteriorly and posteriorly directed branches of the lumbar veins.

*The Development of the Veins of the Limbs.*—The development of the limb veins of the human embryo requires further investigation, but from a comparison of what is known with what has been observed in rabbit-embryos it may be presumed that the changes which take place are somewhat as follows. The blood brought to the limbs by the arteries is collected into a marginal vein which surrounds the free edges of the distal portions of the limb (Fig. 151, A) and passes proximally in two stems, one situated on the ulnar (fibular) and the other on the radial

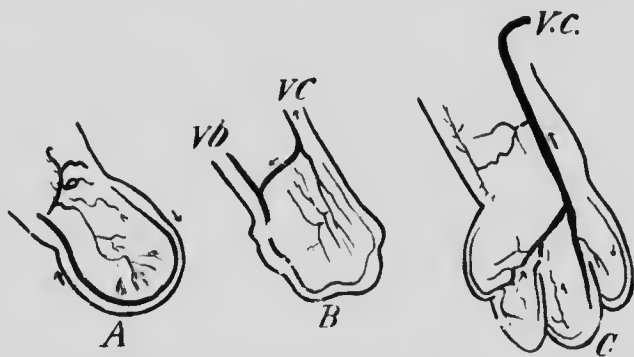


FIG. 151.—THE DEVELOPMENT OF THE ARM VEINS IN THE RABBIT.  
*vb*, Vena basilica; *vc*, vena cephalica. It is to be noted that in the rabbit the basilic vein at one stage (C) is much reduced in size, but is later re-established. (*Hochstetter*.)

(tibial) side. In the anterior extremity the radial vein becomes of less and less importance (Fig. 151, B), and as the digits develop the marginal vein becomes broken up into segments and disappears (Fig. 151, C), while the ulnar vein persists, forming the *basilic vein* (*vb*) of adult anatomy, of which the axillary and subclavian veins are the proximal continuation. All other veins of the arm are secondary or tertiary developments, the *cephalic* (*ve*) and other superficial veins first developing and later the deep veins (*venæ comites*). At first the cephalic vein,

passing over the clavicle, empties into the external jugular, but later it forms a connection with the axillary below the clavicle, the port. above this connection persisting as a small vein known as the jugulo-cephalic.

In the lower limb the changes are somewhat similar, the tibial and marginal veins disappearing, while the fibular persists as the short saphenous and sciatic veins, which are at first continuous. The anterior tibial and long saphenous are of secondary development, while, as in the arm, the deep veins are the latest to form. On the establishment of these last the short saphenous makes connection with the popliteal, while the sciatic, like the corresponding artery, undergoes a marked reduction.

*The Pulmonary Veins.*—The development of the pulmonary veins has already been described in connection with the development of the heart (see p. 254).

*The Fetal Circulation.*—During fetal life while the placenta is the sole organ in which occur the changes in the blood on which the nutrition of the embryo depends, the course of the blood is necessarily somewhat different from what obtains in the child after birth. Taking the placenta as the starting-point, the blood passes along the umbilical vein to enter the body of the fetus at the umbilicus, whence it passes forward in the free edge of the anterior mesentery (see p. 340) until it reaches the liver. Here, owing to the anastomoses between the umbilical and omphalo-mesenteric veins, a portion of the blood traverses the substance of the liver to open by the hepatic veins into the inferior vena cava, while the remainder passes on through the ductus venosus to the cava, the united streams opening into the right auricle. This blood, whose purity is only slightly reduced by mixture with the blood returning from the inferior vena cava, is prevented from passing into the right ventricle by the Eustachian valve,

which directs it to the foramen ovale, and through this it passes into the left auricle, thence to the left ventricle, and so out by the systemic aorta.

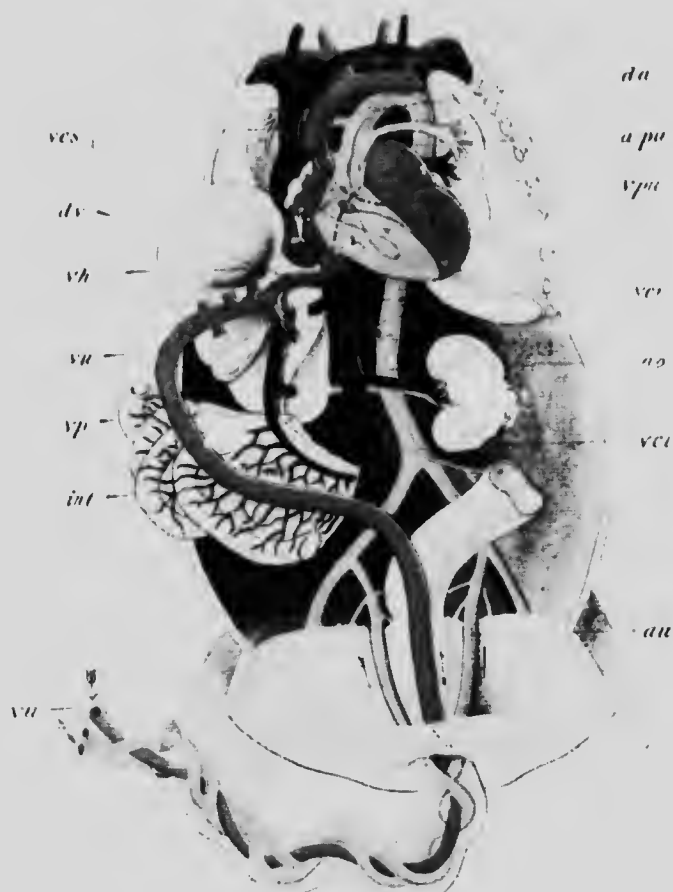

FIG. 152.—THE FETAL CIRCULATION.

ao, Aorta; a.pu, pulmonary artery; au, umbilical artery; da, ductus arteriosus; dv, ductus venosus; int, intestine; vci and ves, inferior and superior vena cava; vh, hepatic vein; v, vena portae; v.pu, pulmonary vein; vu, umbilical vein.—(From Köllmann.)

The blood which has been sent to the head, neck, and upper extremities is returned by the superior vena cava also into the right auricle, but this descending stream

opens into the auricle to the right of the annulus of Vieussens (see Fig. 131) and passes directly to the right ventricle without mingling to any great extent with the blood returning by way of the inferior cava. From the right ventricle this blood passes out by the pulmonary artery, but the lungs at this period are collapsed and in no condition to receive any great amount of blood, and so the stream passes by way of the ductus arteriosus into the systemic aorta, meeting there the placental blood just below the point where the left subclavian artery is given off. From this point onward the aorta contains only mixed blood, and this is distributed to the walls of the thorax and abdomen and to the lungs and abdominal viscera, the greater part of it, however, passing off in the hypogastric arteries and so out again to the placenta.

It will be perceived that although no portion of the body receives absolutely pure placental blood, yet the quality of that which is supplied to the liver, heart, head, neck, and upper limbs is much better than that distributed by the branches arising from the aorta below the union of the ductus arteriosus. Hence it is that the anterior portions of the fetus are much better developed than the posterior.

At birth the lungs at once assume their functions, and on the cutting of the umbilical cord all communication with the placenta ceases. Shortly after birth the foramen ovale closes more or less perfectly, and the ductus arteriosus diminishes in size as the pulmonary arteries increase, and becomes eventually converted into a fibrous cord. The hypogastric arteries diminish greatly, and after they have passed the bladder are also reduced to fibrous cords, a fate likewise shared by the umbilical vein, which becomes converted into the *round ligament* of the liver.

**The Development of the Lymphatic System.**—It has already been seen (p. 243) that the lymphocytes first make their appearance in the tissues surrounding the early blood-vessels, but opinions differ as to their exact origin. According to some observers, they are formed by modification of mesenchyme cells, while others believe that they have evidence that the lymphocytes of the intestinal and tonsillar lymph-nodes are derived from the intestinal and tonsillar epithelium, and quite recently it has been maintained that the epithelial cells which form the thymus body in fishes are directly transformed into lymphocytes. Which view will prove correct must be left for future observations to decide.

The development of the lymphatic vessels has recently been carefully studied in pig embryos and the results obtained have been partially confirmed in human embryos (Sabin). The vessels are first distinguishable in pig embryos of 14.5 mm. as two small sacs or *lymph hearts*, which arise, one on each side, from near the junction of the subclavian and jugular veins, the opening of the sac into the veins being guarded by a valve due to the oblique direction taken by the outgrowth. From each lymph heart branches, which anastomose and radiate in all directions, grow outward toward the skin which they reach in embryos of about 18 mm., and in later stages continue to extend in a radiating manner until they form a subcutaneous network over the anterior half of the body. In the mean time the lymph hearts have separated from their points of origin (Fig. 153, A, *ALH*), with which, however, they remain connected by a duct, and from this a branch grows backward, following the line of the vagus nerve (Fig. 153, A, *TD*). The branch on the left side soon meets with the aorta and, using this as a guide, grows more rapidly than its fellow on the right and becomes the *thoracic duct*,

or, rather, since it divides just before it reaches the aorta and sends a branch backward on either side of that vessel, it gives rise to *two* thoracic ducts (Fig. 153, B).

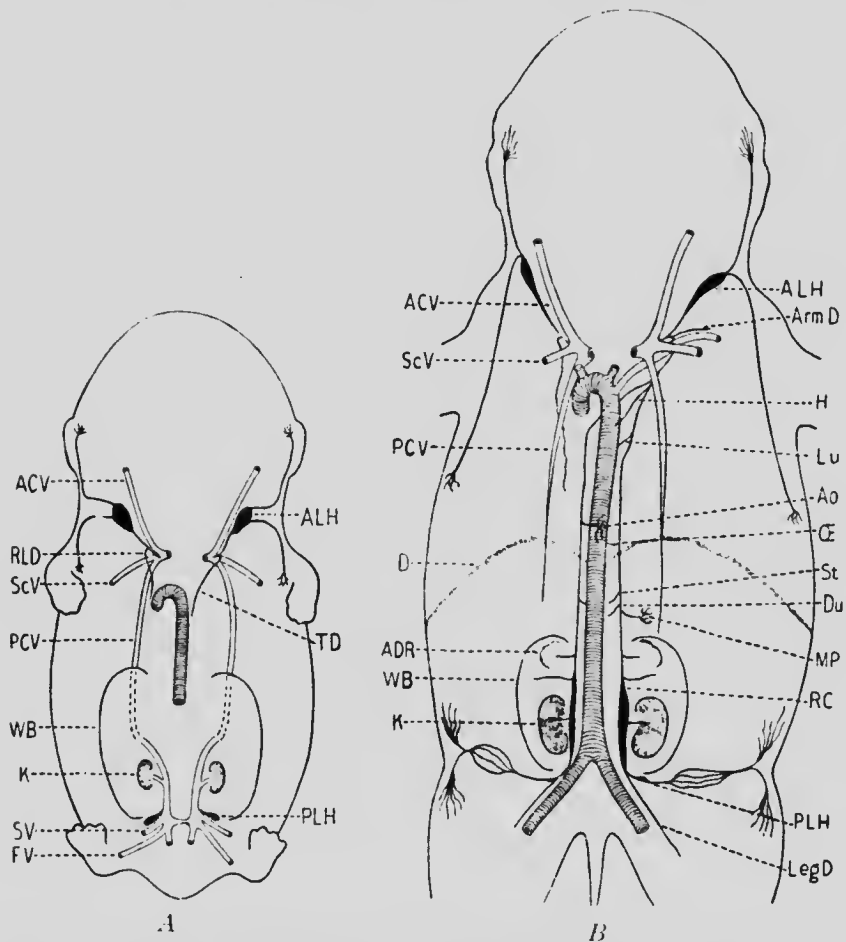


FIG. 153.—DIAGRAMS SHOWING THE ARRANGEMENT OF THE LYMPHATIC VESSELS IN PIG EMBRYOS OF (A) 20 MM. AND (B) 40 MM.

ACV, Jugular vein; ADR, suprarenal body; ALH, anterior lymph heart; Ao, aorta; Arm.D, deep lymphatics to the arm; D, diaphragm; Du, branches to duodenum; FV, femoral vein; H, branches to heart; K, kidney; LegD, deep lymphatics to leg; Lu, branches to lung; MP, branches to mesenteric plexus; (E, branch to oesophagus; PCV, cardinal vein; PLH, posterior lymph heart; RC, receptaculum chyli; RLD, right lymphatic duct; ScV, subclavian vein; SV, sciatic vein; St, branches to stomach; TD, thoracic duct; WB, Wolffian body.—(Sabin.)

In embryos of 20 mm. a second pair of lymph hearts develops at the junction of the sciatic veins with the cardinals (Fig. 153, A, *PLH*), and from these branches grow toward the surface and radiate subcutaneously, similarly to those from the anterior hearts, with which they eventually unite. The thoracic ducts, continuing to elongate backward, dilate opposite the kidneys to form two *receptacula chyli* (Fig. 153, B, *RC*) and still more posteriorly unite with the posterior lymph hearts, which then separate completely from the veins from which they originated.

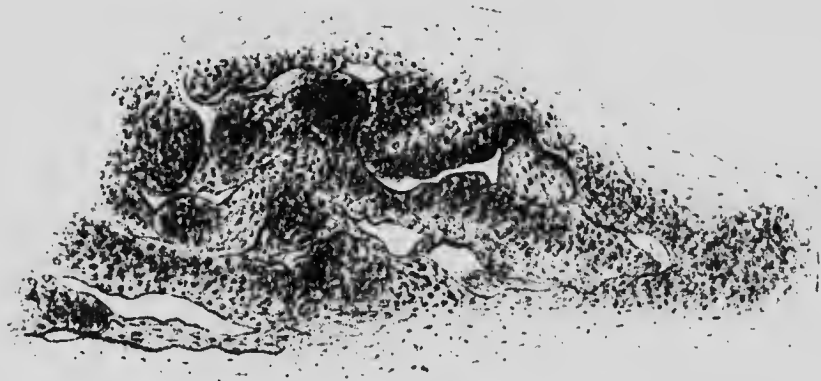

FIG. 154.—DEVELOPING LYMPHATIC GLAND FROM THE AXILLA OF AN EMBRYO OF ELEVEN WEEKS.—(*Chievitz*.)

In later stages branches, arising as outgrowths from the thoracic ducts, gradually invade the mesentery and the various organs, following in general the course of the arteries, as do also the branches which pass to the limbs to form their deep lymphatics; the superficial branches, on the contrary, follow essentially the course of the veins. The lymph hearts gradually elongate as development proceeds and eventually become undistinguishable from the vessels, and at various points in the system minute plexuses arise, around which the adjacent mesenchyme



condenses to form a capsule, the whole constituting a *lymph-node* (Fig. 154).

Up to this stage of the development no valves are present in the vessels, and the development of these has yet to be studied, as has also the final transformation of the condition described into that found in the adult. It seems probable that in human embryos the two thoracic ducts, together with the receptacula chyli, gradually approach one another and finally fuse throughout their entire length to form the single receptaculum and thoracic duct of the adult. The not infrequent occurrence of a partial doubling of the thoracic duct receives a simple explanation if this be the case.

#### LITERATURE.

- E. VAN BENEDEN and C. JULIN: "Recherches sur la formation des annexes fœtales chez les mammifères," *Archives de Biolog.*, v, 1884.
- A. C. BERNAYS: "Entwicklungsgeschichte der Atrioventricularklappen," *Morphol. Jahrbuch*, II, 1876.
- G. BORN: "Beiträge zur Entwicklungsgeschichte des Säugethierherzens," *Archiv für mikrosk. Anat.*, xxxiii, 1889.
- J. H. CHIEVITZ: "Zur Anatomie einiger Lymphdrüsen im erwachsenen und fötalen Zustande," *Archiv für Anat. und Physiol., Anat. Abth.*, 1881.
- J. DISSE: "Die Entstehung des Blutes und der ersten Gefäße im Hühnerrei," *Archiv für mikrosk. Anat.*, xvi, 1879.
- A. C. F. ETERNOD: "Premiers stades de la circulation sanguine dans l'œuf et l'embryon humain," *Anat. Anzeiger*, xv, 1899.
- W. HIS: "Anatomie menschlicher Embryonen," Leipzig, 1880-1882.
- F. HOCHSTETTER: "Ueber die ursprüngliche Hauptschlagader der hinteren Gliedmasse des Menschen und der Säugethiere, nebst Bemerkungen über die Entwicklung der Endäste der Aorta abdominalis," *Morphol. Jahrbuch*, xvi, 1890.
- F. HOCHSTETTER: "Ueber die Entwicklung der A. vertebralis beim Kaninchen, nebst Bemerkungen über die Entstehung der Ansa Vieuroni," *Morphol. Jahrbuch*, xvi, 1890.
- F. HOCHSTETTER: "Ueber die Entwicklung der Extremitätsvenen bei den Amnioten," *Morphol. Jahrbuch*, xvii, 1891.
- F. HOCHSTETTER: "Beiträge zur Entwicklungsgeschichte des Venensystems der Amnioten," *Morphol. Jahrbuch*, xx, 1893.

- W. H. HOWELL: "The Life-history of the Formed Elements of the Blood, Especially the Red Blood-corpuscles," *Journ. of Morphol.*, iv, 1890.
- W. H. HOWELL: "Observations on the Occurrence, Structure, and Function of the Giant-cells of the Marrow," *Journ. of Morphol.*, iv, 1890.
- F. P. MALL: "Development of the Internal Mammary and Deep Epigastric Arteries in Man," *Johns Hopkins Hospital Bulletin*, 1898.
- J. NESBAUM and T. PRYMAK: "Zur Entwicklungsgeschichte der lymphoiden Elemente der Thymus bei den Knochenfischen," *Anat. Anzeiger*, xix, 1901.
- R. RETTERER: "Sur la part que prend l'épithélium à la formation de la bourse de Fabricius, des amygdales et des plaques de Peyer," *Journ. de l'Anat. et de la Physiol.*, xxix, 1893.
- C. RÖSE: "Zur Entwicklungsgeschichte des Säugethierherzens," *Morphol. Jahrbuch*, xv, 1889.
- H. SALZER: "Ueber die Entwicklung der Kopfvenen des Meerschweinchens," *Morphol. Jahrbuch*, xx, 1893.
- P. STÖHR: "Ueber die Entwicklung der Darmlymphknötchen und über die Rückbildung von Darmdrüsen," *Archiv für mikrosk. Anat.*, li, 1898.
- O. VAN DER STRICHT: "Nouvelles recherches sur la genèse des globules rouges et des globules blancs du sang," *Archives de Biolog.*, xii, 1892.
- O. VAN DER STRICHT: "De la première origine du sang et des capillaires sanguins dans l'aire vasculaire du Lapin," *Comptes Rendus de la Soc. de Biolog. Paris*, Sér. 10, ii, 1895.
- ZIMMERMANN: "Ueber die Kiemenarterienbogen des Menschen," *Verhandl. des Xten internat. medic. Congresses*, ii, 1891.

## CHAPTER X.

### THE DEVELOPMENT OF THE DIGESTIVE TRACT AND GLANDS.

The greatest portion of the digestive tract is formed by the constriction off of the dorsal portion of the yolk-sac, as shown in Fig. 39, the result being the formation of a cylinder, closed at either end, and composed of a layer of splanchnic mesoderm lined on its inner surface by endoderm. This cylinder is termed the *archenteron* and has connected with it the yolk-stalk and the allantois, the latter communicating with its somewhat dilated terminal portion, which also receives the ducts of the primitive kidneys and is known as the *cloaca* (Fig. 156).

At a very early stage of development the anterior end of the embryo begins to project slightly in front of the yolk-sac, so that a shallow depression is formed between the two structures. As the constriction of the embryo from the sac proceeds, the anterior portion of the brain becomes bent ventrally and the heart makes its appearance immediately in front of the anterior surface of the yolk-sac, and so the depression mentioned above becomes deepened (Fig. 155) to form the *oral sinus*. The floor of this, lined by ectoderm, is immediately opposite the anterior end of the archenteron, and, since mesoderm does not develop in this region, the ectoderm of the sinus and the endoderm of the archenteron are directly in contact, forming a thin *pharyngeal membrane* separating the two cavities (Fig. 155, *pm*). In embryos of 2.15 mm. this membrane is still existent, but soon after it becomes per-

forated and finally disappears, so that the archenteron and oral sinus become continuous.

Toward its posterior end the archenteron comes into somewhat similar relations with the ectoderm, though a marked difference is noticeable in that the area over which the cloacal endoderm is in contact with the ectoderm to form the *cloacal membrane* (Fig. 156, *cm*) lies a little in front of the actual end

of the archenteric cylinder, the portion of the latter which lies posterior to the membrane forming what has been termed the *post-anal gut* (*p.an*). This diminishes in size during development and early disappears altogether, and the pouch-like fold seen in Fig. 156 between the intestinal portion of the

archenteron and the allantoic stalk (*al*) deepening until its floor comes into contact with the cloacal membrane, the cloaca becomes divided into a ventral portion, with which the allantois and the primitive excretory ducts (*w*) are connected, and a dorsal portion which becomes the lower end of the rectum. This latter abuts upon the dorsal portion of the cloacal membrane, and this eventually ruptures, so that the posterior communication of the archenteron with the exterior becomes established. This rupture, however, does not occur until a compara-

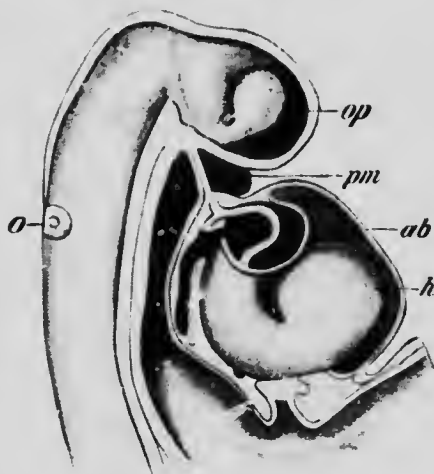


FIG. 155.—RECONSTRUCTION OF THE ANTERIOR PORTION OF AN EMBRYO OF 2.15 MM.

*ab*, Aortic bulb; *h*, heart; *o*, auditory capsule; *op*, optic evagination; *pm*, pharyngeal membrane.—(*His.*)

tively late period of development, until after the embryo has reached the fetal stage; nor does the position of the membrane correspond with the adult anus, since later there is a considerable development of mesoderm around the lower end of the rectum, which bulges out, as it were, the regions immediately surrounding the membrane, pro-

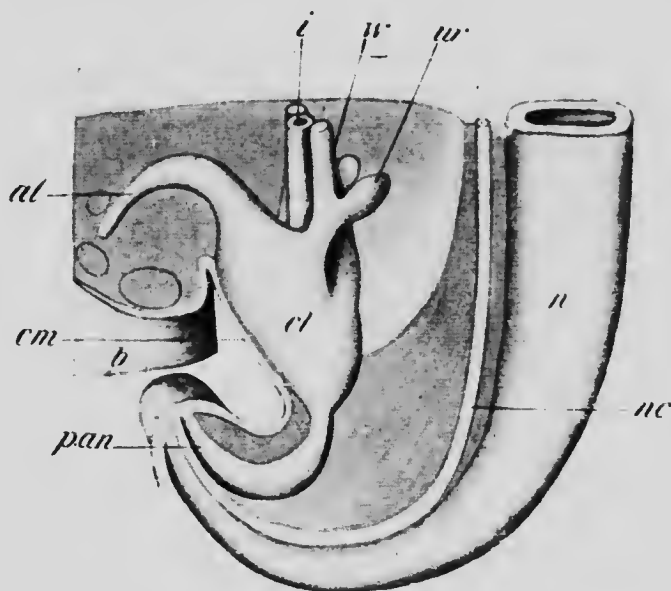


FIG. 156.—RECONSTRUCTION OF THE HIND END OF AN EMBRYO 6.5 MM. LONG.

*al*, Allantois; *b*, belly-stalk; *cl*, cloaca; *cm*, cloacal membrane; *i*, intestine; *n*, spinal cord; *nc*, notochord; *pan*, post-anal gut; *ur*, outgrowth to form ureter and metanephros; *w*, Wolffian duct.—(Keibel.)

ducing a short ectodermal addition to the rectum, the end of which is the definitive anus.

It will be noticed that the digestive tract thus formed consists of three distinct portions, an anterior, short, ectodermal portion, an endodermal portion representing the original archenteron, and a posterior short portion which is also ectodermal. The differentiation of the tract into

its various regions and the formation of the various organs found in relation with these may now be considered.

**The Development of the Mouth Region.**—The deepening of the oral sinus by the development of the first branchial arch and its separation into the oral and nasal cavities by the development of the palate have already been described (p. 103), but, for the sake of continuity in description, the latter process may be briefly recalled. At first the nasal pits communicate with the oral sinus by grooves lying one on each side of the fronto-nasal process, but by

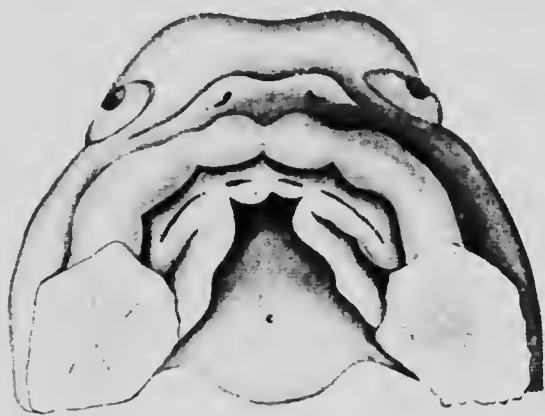


FIG. 157.—VIEW OF THE ROOF OF THE ORAL FOSSA OF EMBRYO SHOWING THE LIP-GROOVE AND THE FORMATION OF THE PALATE.—(His.)

the union of the latter with the maxillary processes this communication is partly interrupted, though the pits still retain connection with the oral sinus behind the maxillary process. At about the fifth week a downgrowth of epithelium into the substance of both the maxillary and fronto-nasal processes above and the mandibular process below, takes place and the surface of the downgrowth becomes marked by a deepening groove (Fig. 157), which separates an anterior fold, the *lip*, from the jaw proper (Fig. 158). From the premaxillary and maxillo-pala-

tine portions of the upper jaw, shelf-like ridges then begin to grow backward and inward, and at about the beginning of the third month these meet in the median line to form the palate, completing the separation of the definitive mouth from the nasal cavity. At the point of meeting of the premaxillary and maxillary shelves a small communication between the two cavities persists for a time, frequently until after birth; it allows passage of the anterior palatine vessels and nerves, and places the organ of Jacobson (p. 457) in communication with the mouth. Later the opening becomes closed over by mucous membrane, but it may be recognized in the dried skull as the foramen incisivum (anterior palatine canal).

Before the formation of the palate begins, a pouch is formed in the median line of the roof of the oral sinus, just in front of the pharyngeal membrane, by an upgrowth of the epithelium. This pouch, known as *Rathke's pouch*, comes in contact above with a downgrowth from the floor of the brain and forms with it the pituitary body (see p. 418).

*The Development of the Teeth.*—When the epithelial downgrowth which gives rise to the lip groove is formed, a horizontal outgrowth develops from it which extends backward into the substance of the jaw, forming what is termed the *dental shelf* (Fig. 158, A). This at first is situated on the anterior surface of the jaw, but with the continued development of the lip fold it is gradually shifted until it comes to lie upon the free surface (Fig. 158, B), where its superficial edge is marked by a distinct groove, the *dental groove* (Fig. 157). At first the dental shelf of each jaw is a continuous plate of cells, uniform in thickness throughout its entire width, but later ten thickenings develop upon its deep edge, and beneath each of these the mesoderm condenses to form a *dental papilla*, over the

surface of which the thickening moulds itself to form a cap, termed the *enamel organ* (Fig. 158, B). These ten papillæ in each jaw, with their enamel caps, represent the teeth of the first dentition.

The papillæ do not, however, project into the very edge of the dental shelf, but obliquely into what, in the lower

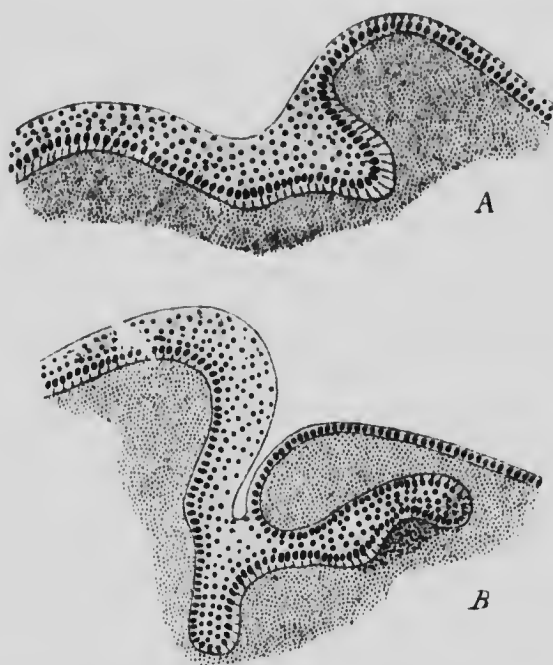


FIG. 158.—TRANSVERSE SECTIONS THROUGH THE LOWER JAW SHOWING THE FORMATION OF THE DENTAL SHELF IN EMBRYOS (A) 17 MM. AND (B) 40 MM.—(Röse.)

jaw, was originally its under surface (Fig. 158, B), so that the edge of the shelf is free to grow still deeper into the surface of the jaw. This it does, and upon the extension so formed there is developed in each jaw a second set of thickenings, beneath each of which a dental papilla again appears. These tooth-germs represent the incisors, canines, and premolars of the permanent dentition. The



lateral edges of the dental shelf being continued outward toward the articulations of the jaws as prolongations which are not connected with the surface epithelium, opportunity is afforded for the development of three additional thickenings on each side in each jaw, and, papillæ developing beneath these, twelve additional tooth-germs are formed. These represent the permanent molars; their formation is much later than that of the other teeth, the germ of the second molar not appearing until about the sixth week after birth, while that of the third is delayed until about the fifth year.

As the tooth-germs increase in size, they approach nearer and nearer to the surface of the jaw, and at the same time the enamel organs separate from the dental shelf until their connection with it is a mere neck of epithelial cells. In the mean time the dental shelf itself has been undergoing degeneration and is reduced to a reticulum which eventually completely disappears, though fragments of it may occasionally persist and give rise to various malformations. With the disappearance of the last remains of the shelf, the various tooth-germs naturally lose all connection with one another.

It will be seen, from what has been said, that each tooth-germ consists of two portions, one of which, the enamel organ, is derived from the ectoderm, while the other, the dental papilla, is mesenchymatous. Each of these gives rise to a definite portion of the fully formed tooth, the enamel organ, as its name indicates, producing the enamel, while from the dental papilla the dentine and pulp are formed.

The cells of the enamel organ which are in contact with the surface of the papilla, at an early stage assume a cylindrical form and become arranged in a definite layer, the *enamel membrane* (Fig. 159, *SEi*), while the remaining

cells (*SEa*) apparently degenerate eventually, though they persist for a time to form what has been termed the *enamel pulp*. The formation of the enamel seems to be

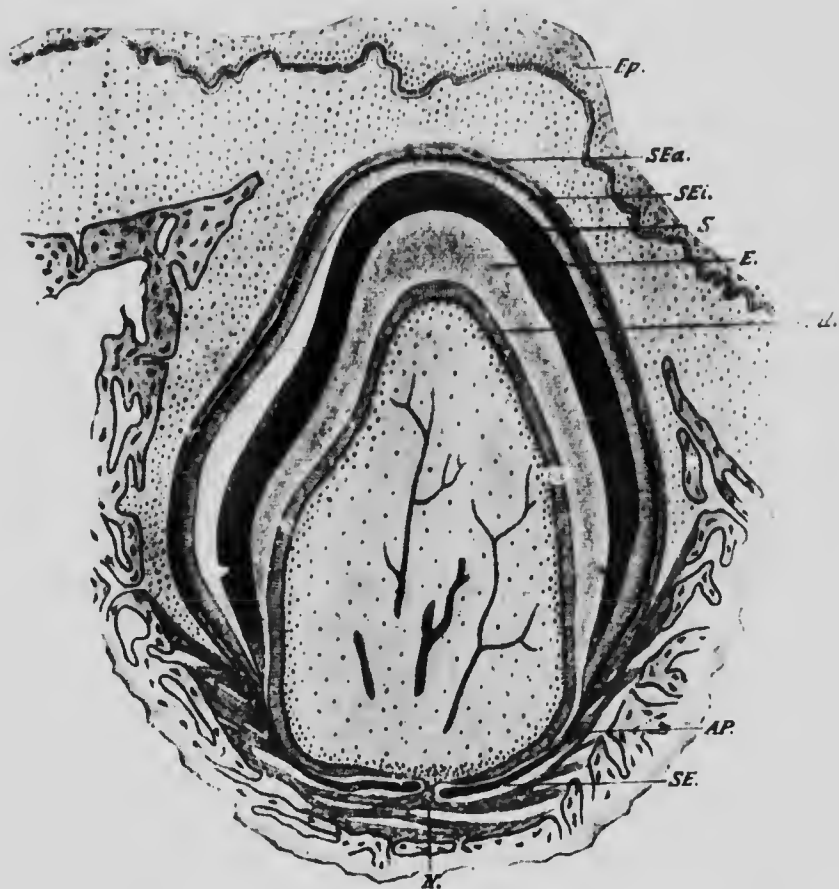


FIG. 159.—SECTION THROUGH THE FIRST MOLAR TOOTH OF A RAT, TWELVE DAYS OLD.

*Ap*, Periosteum; *E*, dentine; *Ep*, epidermis; *Od*, odontoblasts; *S*, enamel; *SEa* and *SEi*, outer and inner layers of the enamel organ; *SE*, portion of the enamel organ which does not produce enamel.—(von Brunn.)

due to the direct transformation of the enamel cells, the process beginning at the basal portion of each cell, and as a result, the enamel consists of a series of prisms, each

of which represents one of the cells of the enamel membrane. The transformation proceeds until the cells have become completely converted into enamel prisms, except at their very tips, which form a thin membrane, the *enamel cuticle*, which is shed soon after the eruption of the teeth.

The dental papillæ are at first composed of a closely packed mass of mesenchyme cells, which later become differentiated into connective tissue into which blood-vessels and nerves penetrate. The superficial cells form a more or less definite layer (Fig. 159, *od*), and are termed *odontoblasts*, having the function of manufacturing the dentine. This they accomplish in the same manner as that in which the periosteal osteoblasts produce bone, depositing the dentine between their surfaces and the adjacent surface of the enamel. The outer surface of each odontoblast is drawn out into a number of exceedingly fine processes which extend into the dentine to occupy the minute dentinal tubules, just as processes of the osteoblasts occupy the canaliculi of bone.

At an early stage the enamel membrane forms an almost complete investment for the dental papilla (Fig. 159), but, as the ossification of the tooth proceeds, it recedes from the lower part, until finally it is confined entirely to the crown. The dentine forming the roots of the tooth then becomes enclosed in a layer of cement, which is true bone and serves to unite the tooth firmly to the walls of its socket. As the tooth increases in size, its extremity is brought nearer to the surface of the gum and eventually breaks through, the eruption of the first teeth usually taking place during the last half of the first year after birth. The growth of the permanent teeth proceeds slowly at first, but later it becomes more rapid and produces pressure upon the roots of the primary teeth. The

roots of these then undergo partial absorption, and so are loosened in their sockets and are readily pushed out by the further growth of the permanent teeth.

The dates and order of the eruption of the teeth are subject to considerable variation, but the usual sequence is somewhat as follows:

## PRIMARY DENTITION.

Median incisors.....	6th to 8th month.
Lateral incisors.....	7th to 9th month.
First molars, .....	Beginning of 2d year.
Canines, .....	1½ years.
Second molars, .....	3 to 3½ years.

The teeth of the lower jaw generally precede those of the upper.

## PERMANENT DENTITION.

First molars, .....	7th year.
Middle incisors, .....	8th year.
Lateral incisors, .....	9th year.
First premolars, .....	10th year.
Second premolars, .....	11th year.
Canines, } .....	13th to 14th years
Second molars, }	
Third molars, .....	17th to 40th years.

In a considerable percentage of individuals the third molars (wisdom teeth) never break through the gums, and frequently when they do so they fail to reach the level of the other teeth, and so are only partly functional. These and other peculiarities of a structural nature shown by these teeth indicate that they are undergoing a retrogressive evolution.

**The Development of the Tongue.**—Strictly speaking, the tongue is largely a development of the pharyngeal region of the digestive tract and only secondarily grows forward into the floor of the mouth. In embryos of about 3 mm. there may be seen in the median line of the floor of the mouth, between the ventral ends of the first branchial arches, a small rounded elevation which has been termed the *tuberculum impar*. In later stages

(Fig. 160, A) this becomes larger and reaches its greatest development in embryos of about 8 mm., after which it becomes less prominent and finally unrecognizable, but before this there has appeared on each side of the floor of the mouth a longitudinal groove, each of which at its anterior end bends medially toward its fellow. By these *alveolo-lingual grooves* an area is marked out in the floor of the mouth which gradually becomes more and more prom-

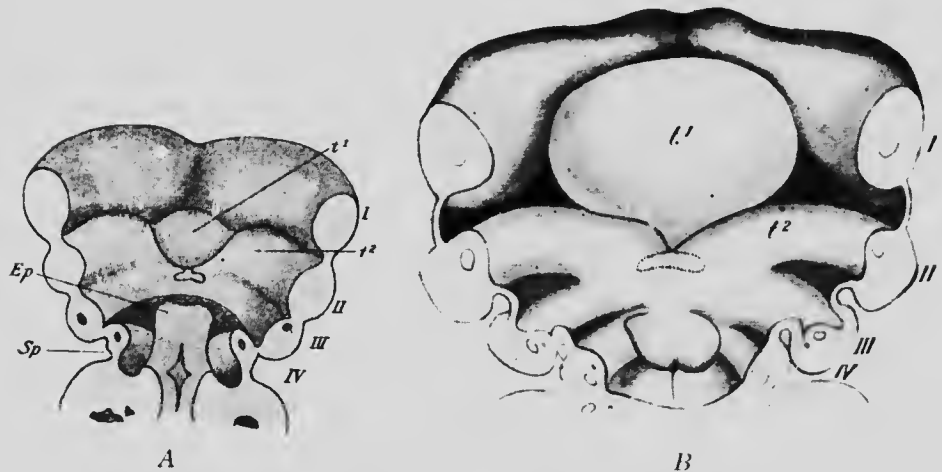


FIG. 160.—FLOOR OF THE PHARYNX OF EMBRYOS OF (A) 7 AND (B) 10 MM. SHOWING THE DEVELOPMENT OF THE TONGUE.

*Ep*, Epiglottis; *Sp*, præcervical sinus; *t<sup>1</sup>* and *t<sup>2</sup>*, median and lateral portions of the tongue; *I* to *IV*, branchial arches.—(*His.*)

inent and rounded upon its oral surface, and forms the anterior portion of the tongue (Fig. 160, B, *t<sup>1</sup>*). This median elevation is bounded at the sides and almost to the median line in front by the alveolo-lingual grooves, and posteriorly it is separated from the anterior edge of the second branchial arch by a distinct V-shaped groove, at the apex of which is a deep circular depression, the *foramen cæcum* (see p. 313).

The posterior portion of the tongue arises as thickenings

of the ventral ends of the second branchial arches, and is consequently a V-shaped structure, into the angle of which the posterior part of the anterior portion of the tongue fits (Fig. 161). The two portions, anterior and posterior, eventually fuse together, but the groove which originally separated them remains more or less clearly distinguishable, the circumvallate papillæ (see p. 458) developing immediately anterior to it.

The tongue is essentially a muscular organ, being formed of a central mass of muscular tissue, enclosed at the sides and dorsally by mucous membrane derived from the floor of the mouth and pharynx. The muscular tissue consists partly of fibers limited to the substance of the tongue and forming the *m. lingualis*, and also of a number of extrinsic muscles, the *hyoglossi*, *geniohyoglossi*, *styloglossi*, *palatoglossi*, and *chondroglossi*. The last two muscles are innervated by the vagus nerve, and the remaining extrinsic muscles receive fibers from the hypoglossal, while the lingualis is supplied partly by the hypoglossal and partly, apparently, by the facial through the chorda tympani. That the facial should take part in the supply is what might be expected from the mode of development of the tongue, but the hypoglossal has been seen to correspond to certain primarily postcranial metameres (p. 192), and its relation to structures taking part in the formation of an organ belonging to the anterior part of the pharynx seems somewhat anomalous. It may be supposed that in the evolution of the tongue the extrinsic muscles, together with a certain amount of the lingualis, have grown into the tongue thickenings from regions situated much further back, for the most part from behind the last branchial arch.

Such an invasion of the tongue by muscles from posterior

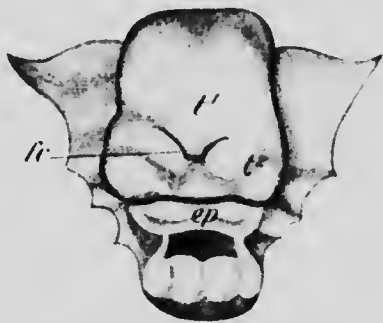


FIG. 161.—THE FLOOR OF THE PHARYNX OF AN EMBRYO OF ABOUT 20 MM.

*ep*, Epiglottis; *fc*, foramen cæcum; *t*<sup>1</sup> and *t*<sup>2</sup>, median and lateral portions of the tongue.—(*His.*)

segments would explain the distribution of its sensory nerves. The anterior portion, from its position, would naturally be supplied by branches from the fifth and seventh nerves, while the posterior portion might be expected to be supplied by the

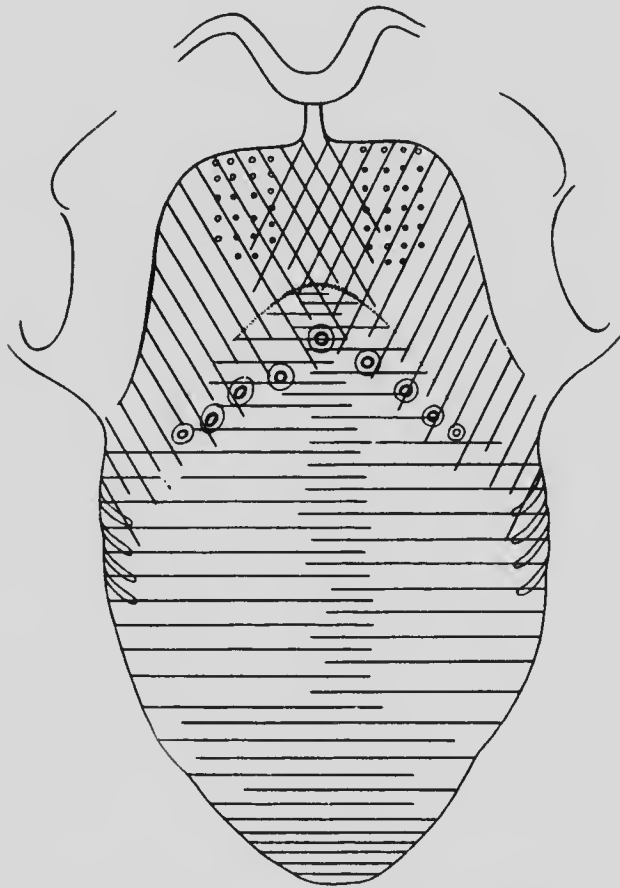


FIG. 162.—DIAGRAM OF THE DISTRIBUTION OF THE SENSORY NERVES OF THE TONGUE.

The area supplied by the fifth (and seventh) nerve is indicated by the transverse lines; that of the ninth by the oblique lines; and that of the tenth by the small circles.—(Zander.)

seventh. There seems, however, to have been a dislocation forward, if it may be so expressed, of the mucous membrane, the sensory distribution of the ninth nerve extending forward upon the posterior part of the anterior portion of the tongue,

while a considerable portion of the posterior portion is supplied by the tenth nerve. The distribution of the sensory fibers of the facial is probably confined entirely to the anterior portion, though further information is needed to determine the exact distribution of both the motor and sensory fibers of this nerve in the tongue.

**The Development of the Salivary Glands.**—In embryos of about 8 mm. a slight furrow may be observed in the floor of the groove which connects the lip grooves of the upper and lower jaws at the angle of the mouth and may be known as the *cheek groove*. In later stages this furrow

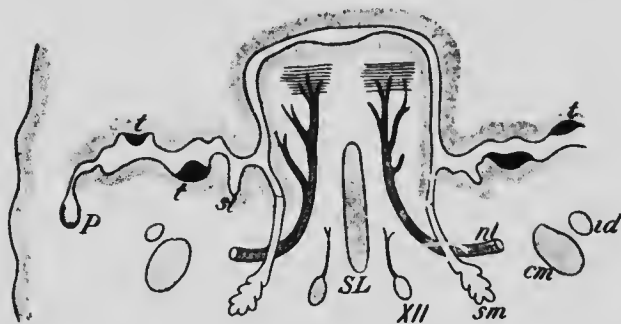


FIG. 163.—AN OBLIQUE SECTION THROUGH THE MOUTH CAVITY OF AN EMBRYO OF ABOUT 16 TO 17 MM.

*cm*, Meckel's cartilage; *id*, inferior dental nerve; *nl*, lingual nerve; *P*, parotid gland; *SL*, septum of the tongue; *sl*, sublingual gland; *sm*, submaxillary gland; *t*, tooth; *XII*, hypoglossal nerve. — (*His*.)

deepens and gradually becomes closed in to form a hollow tubular structure, which in embryos of 17 mm. has separated from the epithelium of the floor of the cheek groove except at its anterior end and has become embedded in the connective tissue of the cheek. This tube is readily recognizable as the *parotid gland* and *Stenson's duct*, and from the latter as it passes across the masseter muscle a pouch-like outgrowth is early formed which probably represents the *socia parotidis*.

The *submaxillary gland* and *Wharton's duct* appear in



embryos of about 13 mm. as a longitudinal ridge-like thickening of the epithelium of the floor of the alveolo-lingual groove (see p. 306). This ridge gradually separates from behind forward from the floor of the groove and sinks into the subjacent connective tissue, retaining, however, its connection with the epithelium at its anterior end, which indicates the position of the opening of the duct. In the vicinity of this there appear in embryos of 24.4 mm. five small bud-like downgrowths of the epithelium, which later increase considerably in number as well as in size, and constitute a group of glands which are generally spoken of as the *sublingual gland*.

As these representatives of the various glands increase in length, they become lobed at their deeper ends, and the lobes later give rise to secondary outgrowths which branch repeatedly, the terminal branches becoming the alveoli of the glands. A lumen early appears in the duct portions of the structures, the alveoli remaining solid for a longer time, although they eventually also become hollow.

It is to be noted that each parotid and submaxillary consists of a single primary outgrowth, and is therefore a single structure and not a union of a number of originally separate parts. The sublingual glands of adult anatomy are usually described as opening upon the floor of the mouth by a number of separate ducts. This arises from the fact that the majority of the glands which form in the vicinity of the opening of Wharton's duct remain quite small, only one of them on each side giving rise to the sublingual gland proper. The small glands have been termed the alveolo-lingual glands, and each one of them is equivalent to a parotid or submaxillary gland. In other words, there are in reality not three pairs of salivary glands, but from fourteen to sixteen pairs, there being usually from eleven to thirteen alveolo-lingual glands on each side.

**The Development of the Pharynx.**—The pharynx represents the most anterior part of the archenteron, that portion in which the branchial arches develop, and in the

embryo it is relatively much longer than in the adult, the diminution being brought about by the folding in of the posterior arches and the formation of the sinus præœervicalis already described (p. 101). Between the various branchial arches, grooves occur, representing the endodermal portions of the grooves which separate the arches. During development the first of these becomes converted into the tympanic cavity of the ear and the Eustachian tube (see Chap. XV); the second disappears in its upper part, the lower persisting as the *groove of Rosenmüller* and the fossa in which the tonsil is situated; while the remaining two disappear, leaving traces of their existence in detached portions of their epithelium which form what are termed the *branchial epithelial bodies*, among which are the thyreoid and thymus glands.

In the floor of the pharynx behind the thickenings which produce the tongue there is to be found in early stages a pair of thickenings passing horizontally backward and uniting in front so that they resemble an inverted U (Fig. 164, *f*). These ridges, which form what is termed the *furcula* (His), are concerned in the formation of parts of the larynx (see p. 355). In the part of the roof of the pharynx which comes to lie between the openings of the Eustachian tubes, a collection of lymphatic tissue takes place beneath the mucous membrane, forming the *pharyngeal tonsil*, and immediately behind this there is formed in the median line an upwardly projecting pouch,

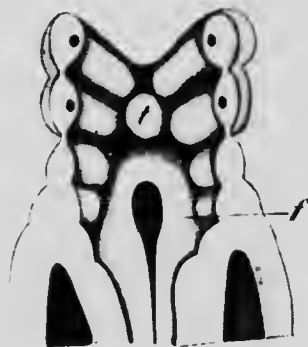

FIG. 164.—THE FLOOR OF THE PHARYNX OF AN EMBRYO OF 2.15 MM.  
*f*, Furcula; *t*, median portion of tongue.—(His.)

the *pharyngeal bursa*, first certainly noticeable in embryos 6.5 mm. in length.

This bursa has very generally been regarded as the persistent remains of Rathke's pouch (p. 300), especially since it is much more pronounced in fetal than in adult life. It has been shown, however, that it is formed quite independently of and posterior to the true Rathke's pouch (Killian), though what its significance may be is still uncertain.

The *tonsils* are formed from the epithelium of the lower part of the second branchial groove. At about the fourth month solid buds begin to grow from the epithelium into the subjacent mesenchyme, and depressions appear on the surface of this region. Later the buds become hollow by a cornification of their central cells, and open upon the floor of the depressions which represent the crypts of the tonsil. In the mean time lymphocytes, concerning whose origin there is a difference of opinion, collect in the subjacent mesenchyme and eventually aggregate to form lymphatic follicles in close relation with the buds. Whether the lymphocytes wander out from the blood into the mesenchyme or are derived directly from the epithelial cells is the question at issue.

The tonsil may grow to a size sufficient to fill up completely the depression in which it forms, but not infrequently a marked depression, the *fossa supratonsillaris*, exists above it and represents a portion of the original second branchial furrow. Another portion of the same furrow is represented by a more or less prominent depression situated posteriorly to the opening of the Eustachian tube on each side and known as the *groove of Rosenmüller*.

*The Development of the Branchial Epithelial Bodies.*—These are structures which arise either as thickenings or as outpouchings of the epithelium lining the lower portions

of the inner branchial furrows. Five pairs of these structures are developed and, in addition, there is a single unpaired median body. This last makes its appearance in embryos of about 3 mm., and gives rise to the major portion of the thyroid body. It is situated immediately behind the anterior portion of the tongue, at the apex of the groove between this and the posterior portion, and is first a slight pouch-like depression. As it deepens, its extremity becomes bilobed, and after the embryo has reached a length of 6 mm. it becomes completely separated from the

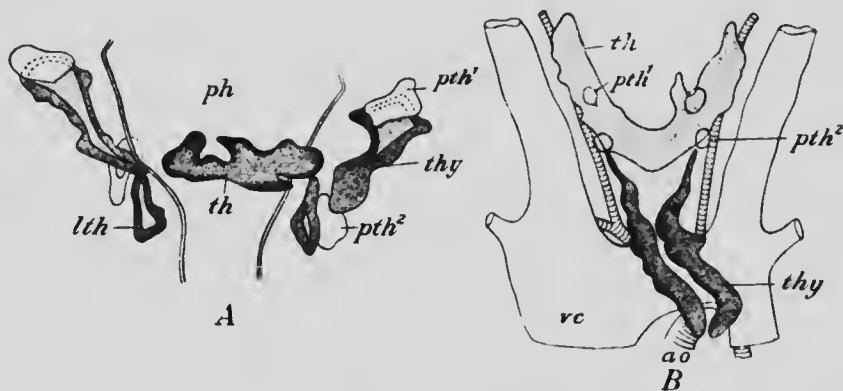


FIG. 165.—RECONSTRUCTIONS OF THE BRANCHIAL EPITHELIAL BODIES OF EMBRYOS OF (A) 14 MM. AND (B) 26 MM.

ao, Aorta; lth, lateral thyroid; ph, pharynx; pth<sup>1</sup> and pth<sup>2</sup>, parathyroids; th, thyroid; thy, thymus; vc, vena cava superior. — (Tourneux and Verdun.)

floor of the pharynx. The point of its original origin is, however, permanently marked by a circular depression, the *foramen cæcum* (Fig. 161, *fc*). Later the bilobed body migrates down the neck and becomes a solid transversely elongated mass (Fig. 165, *th*), into the substance of which trabeculæ of connective tissue extend, dividing it into a network of anastomosing cords which later divide transversely to form follicles. When the embryo has reached a length of 2.6 cm., a cylindrical outgrowth arises from the

anterior surface of the mass, usually a little to the left of the median line, and extends up the neck a varying distance, forming, when it persists until adult life, the so-called *pyramid* of the thyroid body.

This account of the pyramid follows the statements made by recent workers on the question (Tourneux and Verdun); His has claimed that it is the remains of the stalk connecting the thyroid with the floor of the pharynx, and which he terms the *thyreo-glossal duct*.

In addition to this median structure, one of the pairs of the lateral evaginations also take part in the formation of the thyroid body. These are the *lateral thyroids* (Fig. 165, *lth*), and they arise from the posterior wall of the fourth branchial furrow, in embryos of about 8 mm. Separating from the furrow, they migrate backward to fuse in embryos of about 16 mm. with the posterior surface of the lateral portions of the median thyroid. They form, however, only a relatively small portion of the entire thyroid (Fig. 166, *thm IV*).

Two other pairs of bodies enter into intimate relations with the thyroid, forming what have been termed the *parathyroid bodies* (Fig. 165, *pth<sup>1</sup>* and *pth<sup>2</sup>*). One of these pairs arises as a thickening of the anterior wall of the fourth branchial groove and the other comes from the corresponding wall of the third groove. The members of the former pair, after separating from their points of origin, come to lie on the dorsal surface of the lateral portions of the thyroid body (Fig. 166, *pthm IV*) in close proximity to the lateral thyroids, while the latter, passing further backward, come to rest behind the lower border of the thyroid (Fig. 166, *pthm III*). The cells of these bodies do not become divided into cords by the ingrowth of connective tissue to the same extent as those of the thyroids, nor do they become separated into follicles, so that the

bodies are readily distinguishable by their structure from the thyroid.

From the posterior wall of the third branchial groove a pair of evaginations develop, similar to

those which produce the lateral thyroids. These elongate greatly, and growing downward ventrally to the thyroid and separating from their points of origin, come to lie below the thyroids, forming the *thymus gland* (Fig. 165, *thy*). As development proceeds they pass further backward and come eventually to rest upon the anterior surface of the pericardium. The cavity which they at first contain is early obliterated and the glands assume a lobed appearance and become traversed by trabeculae of connective tissue. Lymphocytes,

derived, according to some recent observations, directly from the epithelium of the glands, make their appearance and gradually increase in number until the original epi-

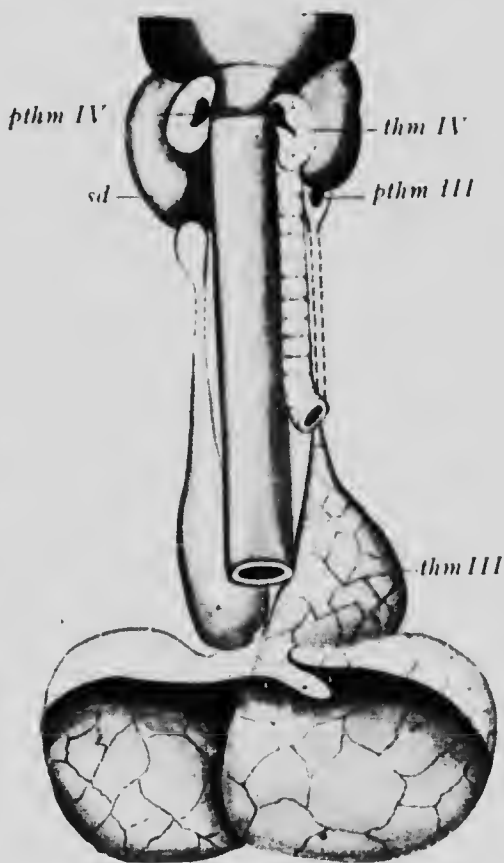


FIG. 166.—THYROID, THYMUS AND EPITHELIAL BODIES OF A NEW-BORN CHILD.

*pthm III* and *pthm IV*, Parathyroids; *sd*, thyroid; *thm III*, thymus; *thm IV*, lateral thyroid. —(Groschuff.)

thelial cells are represented only by a number of peculiar spherical structures, consisting of cells arranged in concentric layers and known as *Hassal's corpuscles*.

The glands persist until about the second year after birth, when they undergo a degeneration into a mass of fibrous and adipose tissue.

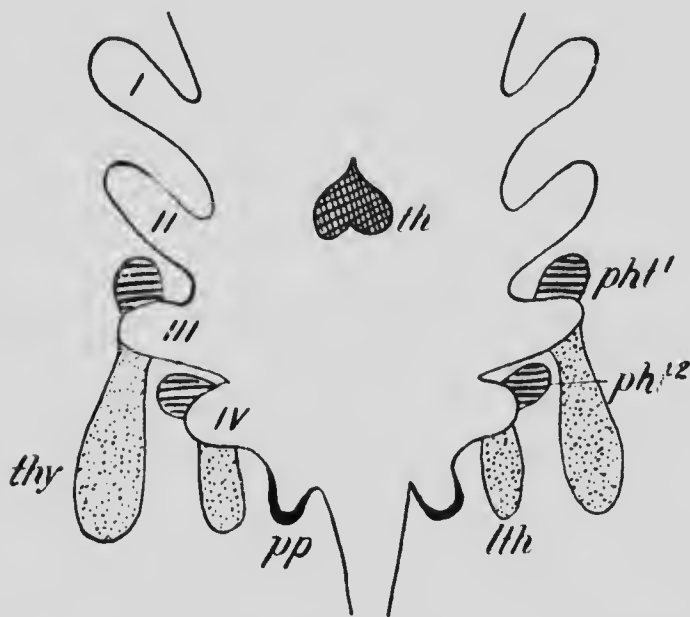


FIG. 167.— DIAGRAM SHOWING THE ORIGIN OF THE VARIOUS BRANCHIAL EPITHELIAL BODIES.

*llh*, Lateral thyreoids; *pp*, postbranchial bodies; *pht¹* and *pht²*, parathyroids; *lh*, median thyreoid; *thy*, thymus; I to IV, branchial grooves. (Kohn.)

Finally, a pair of outgrowths arise from the floor of the pharynx just behind the fifth branchial arch, in the region where the fifth groove, if developed, would occur. These *post-branchial bodies*, as they have been called, usually undergo degeneration at an early stage and disappear completely, though occasionally they persist as cystic structures embedded in the substance of the thyreoid.

The relation of these various structures to the branchial grooves is shown by the annexed diagram (Fig. 167); and from it, it will be seen that the bodies derived from the third and fourth grooves are serially equivalent. Comparative embryology makes this fact still more evident, since, in the lower vertebrates, each branchial groove contributes to the formation of the thymus gland. The terminology used above for the various bodies is that generally applied to the mammalian organs, but it would be better, for the sake of comparison with other vertebrates, to adapt the nomenclature proposed by Grosehuff, who terms each lateral thyreoid a thymus IV, while each thymus lobe is a thymus III. Similarly the parathyroids are termed parathymus III and IV, the term thyreoid being limited to the median thyreoid.

*The Musculature of the Pharynx.*—The pharynx differs from other portions of the archenteron in the fact that its walls are furnished with voluntary muscles, the principal of which are the constrictors and the stylo-pharyngeus. This peculiarity arises from the relations of the pharynx to the branchial arches. It has been seen that in the higher mammalia the dorsal ends of the third, fourth, and fifth branchial cartilages disappear; the muscles originally associated with these structures persist, however, and give rise to the muscles of the pharynx, which consequently are innervated by the ninth and tenth nerves.

**The Development of the Œsophagus.**—From the ventral side of the lower portion of the pharynx an evagination develops at an early stage which is destined to give rise to the organs of respiration; the development of this may, however, be conveniently postponed to a later chapter (Chap. XII).

The Œsophagus is at first a very short portion of the archenteron (Fig. 168, A), but as the heart and diaphragm recede into the thorax it elongates (Fig. 168, B) until it eventually forms a considerable portion of the digestive tract. Its endodermal lining, like that of the rest of the



digestive tract except the pharynx, is surrounded by splanchnic mesoderm whose cells become converted into non-striated muscular tissue, which by the fourth month has separated into an inner circular and an outer longitudinal layer.

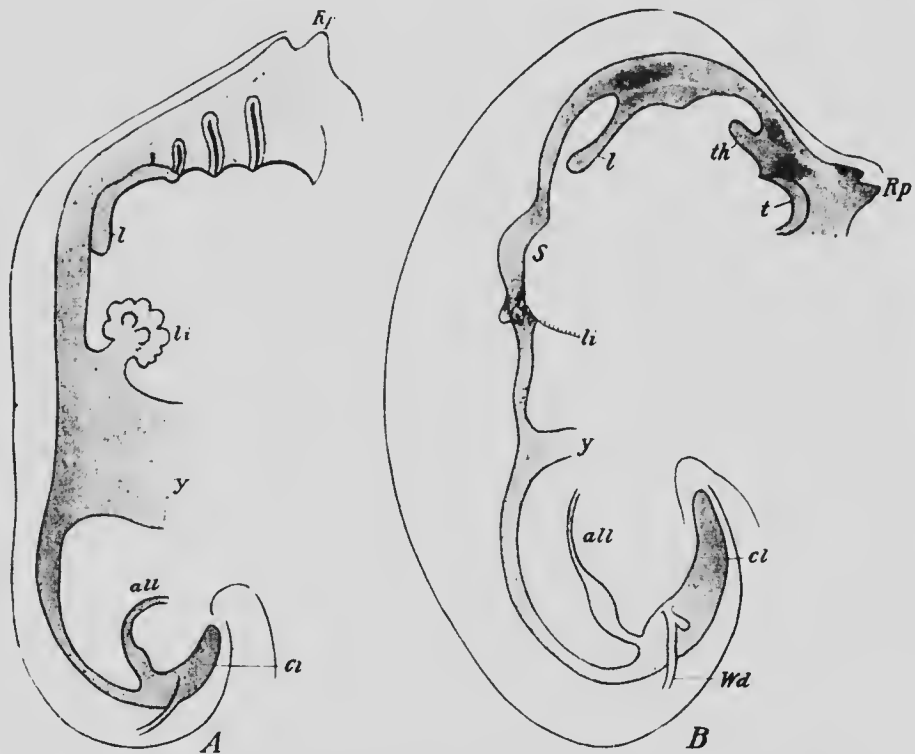


FIG. 168.—RECONSTRUCTIONS OF THE DIGESTIVE TRACT OF EMBRYOS OF (A) 4.2 MM. AND (B) 5 MM.

*all*, Allantois; *cl*, cloaca; *l*, lung; *li*, liver; *Rp*, Rathke's pouch; *S*, stomach; *t*, tongue; *th*, thyroid body; *Wd*, Wolffian duct; *y*, yolk-stalk.—(His.)

**The Development of the Stomach and Intestines.**—By the time the embryo has reached a length of about 3 mm. its constriction from the yolk-sac has proceeded so far that a portion of the digestive tract anterior to the yolk-sac can be recognized as the stomach and a portion posterior as the intestine. At first the stomach is a simple spindle-

shaped enlargement (Fig. 168) and the intestine a tube without any coils or bends, but since in later stages the intestine grows much more rapidly in length than the abdominal cavity, a coiling of the intestine becomes necessary.

The elongation of the stomach early produces changes in its position, its lower end bending over toward the right, while its upper end, owing to the development of the liver, is forced somewhat toward the left. At the same time the entire organ undergoes a rotation about its longitudinal axis through nearly 90 degrees, so that, as the result of the combination of these two changes, what was originally its ventral border becomes its lesser curvature and what was originally its left surface becomes its ventral surface.

Hence it is that the left pneumogastric nerve passes over the ventral and the right over the dorsal surface of the stomach in the adult.

In the mean time the elongation of the œsophagus has carried the stomach further away from the lower end of the pharynx, and from being spindle-shaped it has become more pyriform, as in the adult.

The growth of the intestine results in its being thrown into a loop opposite the point where the yolk-stalk is still connected with it, the loop projecting ventrally into the portion of the œelomic cavity which is contained within the umbilical cord, and being placed so that its upper limb lies to the right of the lower one. Upon the latter a slight pouch-like lateral outgrowth appears which is the beginning of the *cæcum* and marks the line of union of the future small and large intestine. The small intestine, continuing to lengthen more rapidly than the large, assumes a sinuous course (Fig. 169) in which it is possible to recognize six primary coils which may be recognized until ad-

vanced stages of development and even in the adult (Mall). The first of these is at first indistinguishable from the pyloric portion of the stomach and can be recognized as the *duodenum* only by the fact that it has connected with it the duets of the liver and pancreas; as development proceeds, however, its caliber diminishes and it assumes the appearance of a portion of the intestine.

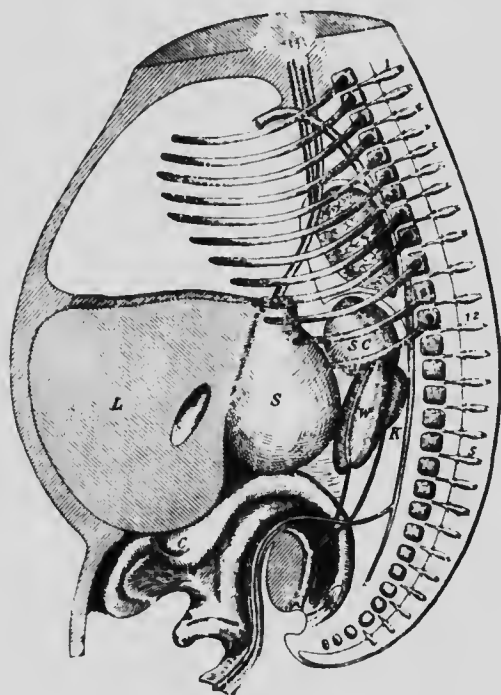


FIG. 169.—RECONSTRUCTION OF EMBRYO OF 20 MM.

C, Cæcum; K, kidney; L, liver; S, stomach; SC, suprarenal bodies; W, mesonephros.—(Mall.)

The remaining coils elongate rapidly and are thrown into numerous secondary coils, all of which are still contained within the cœlum of the umbilical cord (Fig. 170). When the embryo has reached a length of about 40 mm. the coils rather suddenly return to the abdominal cavity,

and now the cæcum is thrown over toward the right, so that it comes to lie immediately beneath the liver on the right side of the abdominal cavity, a position which it retains until about the fourth month after birth (Treves). The portion of the large intestine which formerly projected into the umbilical cœlom now lies transversely across the upper part of the abdomen, crossing in front of the duodenum and having the remaining portion of the small intestine below it. The elongation continuing, the



FIG. 170.—RECONSTRUCTION OF THE INTESTINE OF AN EMBRYO OF 19 MM. THE FIGURES ON THE INTESTINE INDICATE THE PRIMARY COILS. (Mall.)

secondary coils of the small intestine become more numerous and the lower portion of the large intestine is thrown into a loop which extends transversely across the lower part of the abdominal cavity and represents the *sigmoid flexure* of the colon. At the time of birth this portion of the large intestine is relatively much longer than in the adult, amounting to nearly half the entire length of the colon (Treves), but after the fourth month after birth a readjustment of the relative lengths of the parts of the

colon occurs, the sigmoid flexure becoming shorter and the rest of the colon proportionally longer, whereby the cæcum is pushed downward until it lies in the right iliac fossa, the *ascending colon* being thus established.




FIG. 171.—REPRESENTATION OF THE COILINGS OF THE INTESTINE IN THE ADULT CONDITION. THE NUMBERS INDICATE THE PRIMARY COILS.—(Mall.)

When this condition has been reached, the duodenum, after passing downward for a short distance so as to pass dorsally to the transverse colon, bends toward the left and the secondary coils derived from the second and third

primary coils come to occupy the left upper portion of the abdominal cavity. Those from the fourth primary coil pass across the middle line and occupy the right upper part of the abdomen, those from the fifth cross back again to the left lumbar and iliac regions, and those of the sixth take possession of the false pelvis and the right iliac region (Fig. 171).

Slight variations from this arrangement are not infrequent, but it occurs with sufficient frequency to be regarded as the normal. A failure in the readjustment of the relative lengths of the different parts of the colon may also occasionally occur, in which case the cæcum will retain its embryonic position beneath the liver.

The yolk-stalk is continuous with the intestine at the extremity of the loop which extends out into the umbilical cœlum, and when the primary coils become apparent its point of attachment lies in the region of the sixth coil. As a rule, the caliber of the stalk does not increase proportionally with that of the intestine and eventually its embryonic portion disappears completely. Occasionally, however, this portion of it does partake of the increase in size which occurs in the intestine, and it forms a blind pouch of varying length, known as *Meckel's diverticulum* (see p. 135).

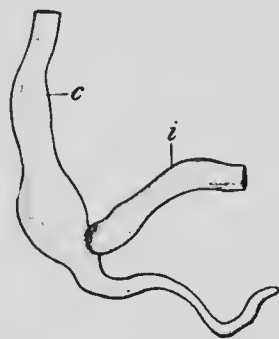


FIG. 172.—CÆCUM OF EMBRYO OF 10.2 CM. c, Colon; i, ileum.

The *cæcum* has been seen to arise as a lateral outgrowth at a time when the intestine is first drawn out into the umbilicus. During subsequent development it continues to increase in size, until it forms a conical pouch arising from the colon just where it is joined by the small intestine. The enlargement of its terminal portion does not keep

pace, however, with that of the portion nearest the intestine, but it becomes gradually more and more distinguished and gives rise to the *vermiform appendix*. At birth the original conical form of the entire outgrowth is still distinguishable, though it is more properly described as funnel-shaped, but later the proximal part, continuing to increase in diameter at the same rate as the colon, becomes sharply separated from the appendix, forming the *cæcum* of adult anatomy.

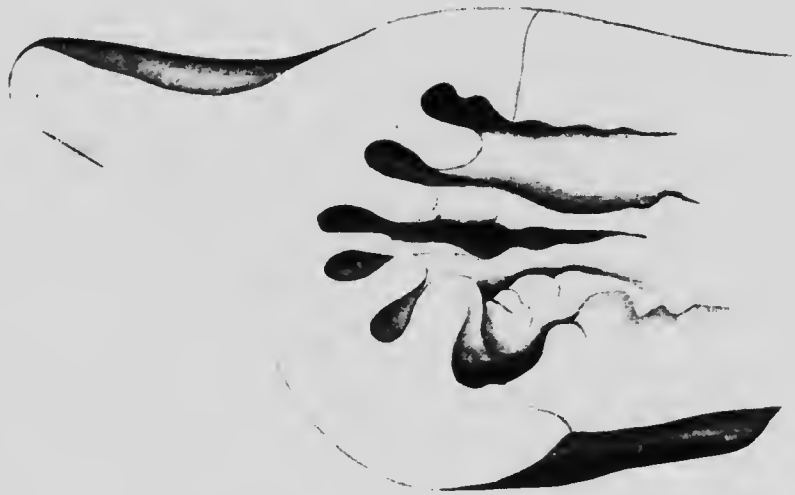

FIG. 173.—RECONSTRUCTION OF A PORTION OF THE INTESTINE OF AN EMBRYO OF 28 MM., SHOWING THE LONGITUDINAL FOLDS FROM WHICH THE VILLI ARE FORMED.—(Berry.)

Up to the time when the embryo has reached a length of 14 mm., the inner surface of the intestine is quite smooth, but when a length of 19 mm. has been reached, the mucous membrane of the upper portion becomes thrown into longitudinal folds, and later these make their appearance throughout its entire length (Fig. 173). Later, in embryos of 60 mm., these folds break up into numbers of conical processes, the villi, which increase in number

with the development of the intestine, the new villi appearing in the intervals between those already present.

A remarkable phenomenon has recently been described as occurring in the duodenum of embryos of about 12.5 mm. It consists in a rapid growth in the thickness of the mucous membrane, whereby the lumen of the intestine immediately below the opening of the hepatic and pancreatic ducts becomes greatly reduced in size and is finally completely obliterated. This condition persists until the embryo has reached a length of 14.5 mm., when the lumen again appears (Tandler). This process is interesting in connection with the occasional occurrence in new-born children of an atresia of the duodenum.

**The Development of the Liver.**—The liver makes its appearance in embryos of about 3 mm. as a longitudinal groove upon the ventral surface of the archenteron just below the stomach and between it and the umbilicus. The endodermal cells lining the anterior portion of the groove early undergo a rapid proliferation, and form a solid mass which projects ventrally into the substance of a horizontal shelf, the septum transversum (see p. 336), attached to the ventral wall of the body. This solid mass (Fig. 174, L) forms the beginning of the liver proper, while the lower portion of the groove, which remains hollow, represents the future gall-bladder (Fig. 174, B). Constrictions appearing between the intestine and both the hepatic and cystic portions of the organ gradually separate these from the intestine, until they are united to it only by a stalk which represents the *ductus communis choledochus* (Fig. 174).

The further development of the liver, so far as its external form is concerned, consists in the rapid enlargement of the hepatic portion until it occupies the greater part of the upper half of the abdominal cavity, its ventral edge extending as far down as the umbilicus. In the rabbit its substance becomes divided into four lobes corresponding



to the four veins, umbilical and omphalo-mesenteric, which traverse it, and the same condition occurs in the human embryo, although the lobes are not so clearly indicated upon the surface as in the rabbit. The two omphalo-mesenteric lobes are in close apposition and may almost be regarded as one, a median ventral lobe which embraces the ductus venosus (Fig. 174, B, *DV*), while the umbilical lobes are more lateral and dorsal and repre-

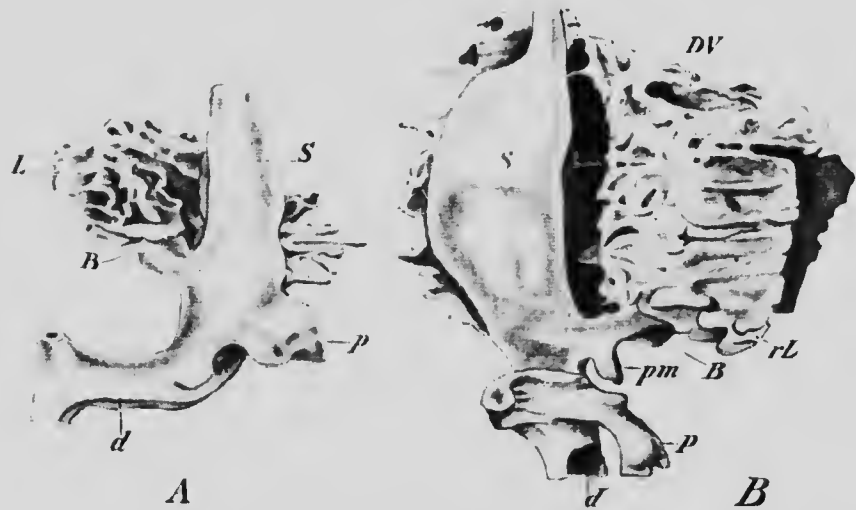


FIG. 174.—RECONSTRUCTIONS OF THE LIVER OUTGROWTHS OF RABBIT EMBRYOS OF (A) 5 MM. AND (B) OF 8 MM.

*B*, Gall-bladder; *d*, duodenum; *DV*, ductus venosus; *L*, liver; *pm*, ventral pancreas; *rL*, right lobe of the liver; *S*, stomach. (*Hammar.*)

sent the right (*rL*) and left lobes of the adult liver. The remaining definitive lobes, the spigelian, quadrate and caudate, are of later formation, the first two standing in relation to the vessels which cross the lower surface of the liver, while the caudate is formed by a portion of the right lobe which arches across the upper part of the ductus venosus.

The ductus communis choledochus is at first wide and

short, and near its proximal end gives rise to a small out-growth on each side, one of which becomes the ventral pancreas (Fig. 178, B, *pm*). Later it elongates and becomes more slender, and the gall-bladder is constricted off from it, the connecting stalk becoming the *cystic duct*. The hepatic ducts are apparently developed from the liver substance and are relatively late in appearing.

Shortly after the hepatic portion has been differentiated its substance becomes permeated by numerous

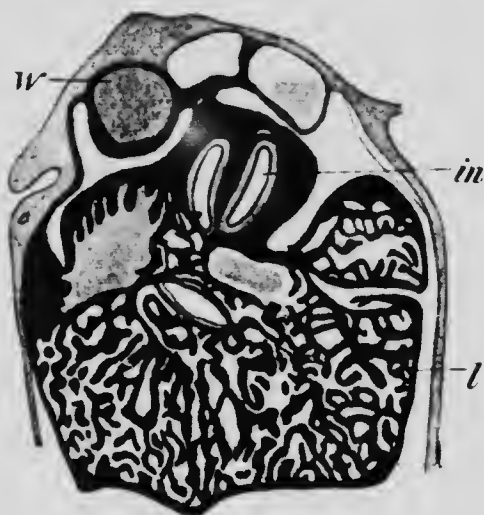


FIG. 175.—TRANSVERSE SECTION THROUGH THE LIVER OF AN EMBRYO OF FOUR MONTHS.

*in*, Intestine; *l*, liver; *W*, Wolffian body.—(Toldt and Zuckerkandl.)

blood-vessels, and so divided into numerous anastomosing trabeculae (Fig. 175). These are at first irregular in size and shape, but later they become more slender and more regularly cylindrical, forming what have been termed the *hepatic cylinders*. In the center of each cylinder, where the cells which form it meet together, a fine canal appears, the beginning of a *bile capillary*, the cylinders thus becoming converted into tubes with fine lumina. This oc-

curls at about the fourth week of development and at this time a cross-section of a cylinder shows it to be composed of about three or four hepatic cells (Fig. 176, A), among which are to be seen groups of smaller cells (*e*) which are erythrocytes, the liver having assumed by this time its hæmatopoietic function (see p. 244). This condition of affairs persists until birth, but later the cylinders undergo an elongation, the cells of which they are composed slip-

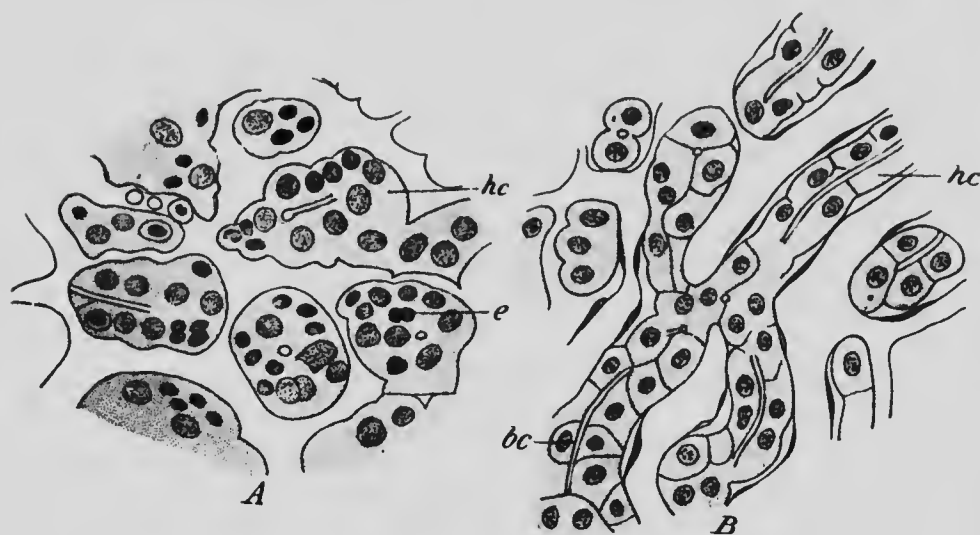


FIG. 176.—TRANSVERSE SECTIONS OF PORTIONS OF THE LIVER OF (A) A FETUS OF SIX MONTHS AND (B) A CHILD OF FOUR YEARS. *bc*, Bile capillary; *e*, erythrocyte; *hc*, hepatic cylinder.—(Toldt and Zuckerkandl.)

ping over one another apparently, so that the cylinders become thinner as well as longer and show for the most part only two cells in a transverse section (Fig. 176, B); and in still later periods the two cells, instead of lying opposite one another, may alternate, so that the cylinders become even more slender.

The bile capillaries seem to make their appearance first in cylinders which lie in close relation to branches of the

portal vein (Fig. 177) and thence extend throughout the neighboring cylinders, anastomosing with capillaries developing in relation to neighboring portal branches. As the extension so proceeds the older capillaries continue to enlarge and later become transformed into *bile-ducts* (Fig. 177, C), the cells of the cylinders in which these capillaries were situated becoming converted into the epithelial lining of the ducts.

The lobules, which form so characteristic a feature of the adult liver, are late in appearing, not being fully de-

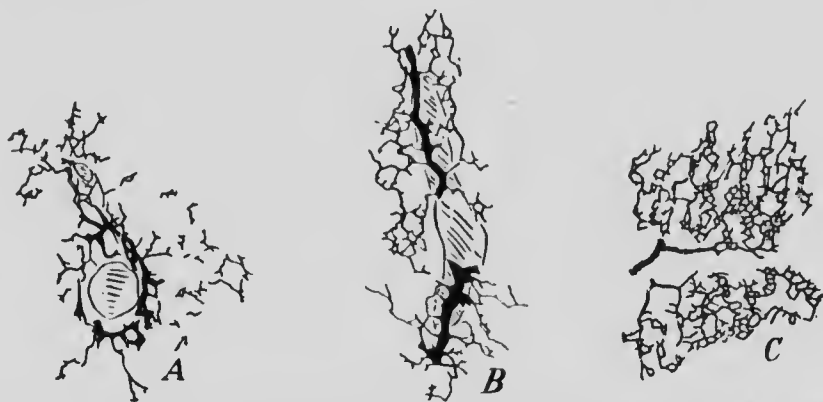


FIG. 177. — INJECTED BILE CAPILLARIES OF PIG EMBRYOS OF (A) 8 CM., (B) 16 CM., AND (C) OF ADULT PIG. — (Hendrickson.)

veloped until some time after birth. They depend upon the relative arrangement of the branches of the portal and hepatic veins; these at first occupy distinct territories of the liver substance, being separated from one another by practically the entire thickness of the liver, although of course connected by the capillaries which lie between the hepatic cylinders. During development the two sets of branches extend more deeply into the liver substance, each invading the territory of the other, but they can readily be distinguished from one another by the fact that the portal branches are enclosed within a sheath of con-

nective tissue (Glisson's capsule) which is lacking to the hepatic vessels. At about the time of birth the branches of the hepatic veins give off at intervals bunches of terminal vessels, around which branches of the portal vein arrange themselves, the liver tissue becoming divided up into a number of areas which may be termed *hepatic islands*, each of which is surrounded by a number of portal branches and contains numerous dichotomously branching hepatic terminals. Later the portal branches sink into the substance of the islands which thus become lobed, and finally the sinking in extends so far that the original island becomes separated into a number of smaller areas or *lobules*, each containing, as a rule, a single hepatic terminal (the *intralobular vein*) and being surrounded by a number of portal terminals (*interlobular veins*), the two systems being united by the capillaries which separate the cylinders contained within the area. The lobules are at first very small, but later they increase in size by the extension of the hepatic cylinders.

Frequently in the human liver lobules are to be found containing two intralobular veins, a condition which results from an imperfect subdivision of a lobe of the original hepatic island.

The liver early assumes a relatively large size, its weight at one time being equal to that of the rest of the body, and though in later embryonic stages its relative size diminishes, yet at birth it is still a voluminous organ, occupying the greater portion of the upper half of the abdominal cavity and extending far over into the left hypochondrium. Just after birth there is, however, a cessation of growth, and the subsequent increase proceeds at a much slower rate than that of the rest of the body, so that its relative size becomes still more diminished (see Chap. XVI). The cessation of growth affects principally the left lobe

and depends upon an actual degeneration of portions of the liver tissue, the cells disappearing completely, while the ducts and blood-vessels originally present persist, the former constituting the *vasa aberrantia* of adult anatomy. These are usually especially noticeable at the left edge of the liver, between the folds of the left lateral ligament, but they may also be found along the line of the vena cava, around the gall-bladder, and in the region of the left longitudinal fissure.

**The Development of the Pancreas.**—The pancreas arises a little later than the liver, as three separate outgrowths, one from the dorsal surface of the duodenum (Fig. 178, *DP*) almost opposite the liver outgrowth, and one on each side from the lower part of the common bile-duct. Of the latter outgrowths, that upon the left side (*Vps*) early begins to degenerate and completely disappears, while that of the right side (*Vpd*) continues its development to form what has been termed the ventral pancreas. Both this and the dorsal pancreas continue to elongate, the latter lying to

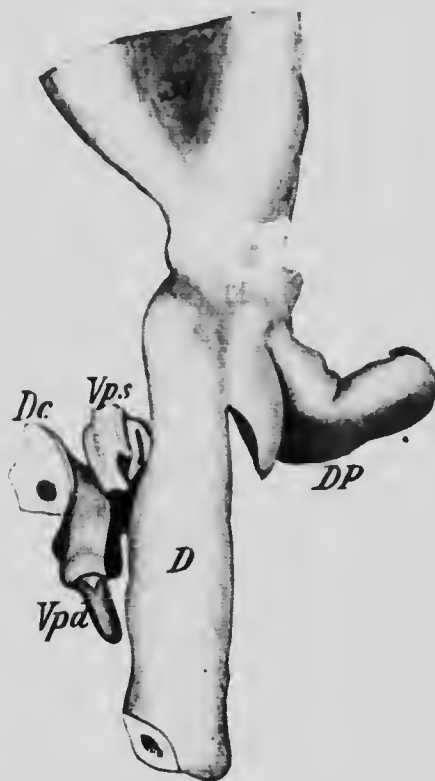


FIG. 178.—RECONSTRUCTION OF THE PANCREATIC OUTGROWTHS OF AN EMBRYO OF 7.5 MM.

*D*, Duodenum; *Dc*, ductus communis choledochus; *DP*, dorsal pancreas; *Vpd* and *Vps*, right and left ventral pancreas.—(Helly.)

the left of the portal vein, while the former, at first situated to the right of the vein, later grows across its ventral surface so as to come into contact with the dorsal gland, with which it fuses so intimately that no separation line can be distinguished. The body and tail of the adult pancreas represent the original dorsal outgrowth, while the right ventral pancreas becomes the head.

Both the dorsal and ventral outgrowths early become lobed, and the lobes becoming secondarily lobed and this lobation repeating itself several times, the compound tubular structure of the adult gland is acquired, the very numerous terminal lobules becoming the secreting acini, while the remaining portions become the ducts. Of the principal ducts, there are at first two; that of the dorsal pancreas, the *duct of Santorini*, opens into the duodenum on its dorsal surface, while that of the ventral outgrowth, the *duct of Wirsung*, opens into the ductus communis choledochus. When the fusion of the two portions of the gland occurs, an anastomosis of branches of the two ducts develops and the terminal portion of the duct of Santorini usually degenerates, so that the secretion of the entire gland empties into the common bile-duct through the duct of Wirsung.

In the connective tissue which separates the lobules of the gland groups of cells, arranged so as to form anastomosing trabeculae, occur. These appear to have no connection with the ducts of the gland, and form what are termed the *areas of Langerhans*. They seem to arise by the separation off of portions of the acini, but what their later history and function may be is as yet uncertain.

#### LITERATURE.

- J. M. BERRY: "On the Development of the Villi of the Human Intestine," *Anat. Anzeiger*, XVI, 1900.

- J. BRACHET: "Recherches sur le développement du pancréas et du foie," *Journ. de l'Anat. et de la Physiol.*, xxxii, 1896.
- J. H. CHEVITZ: "Beiträge zur Entwicklungsgeschichte der Speicheldrüsen," *Archiv für Anat. und Physiol., Anat. Abth.*, 1885.
- K. GROSCHOFF: "Ueber das Vorkommen eines Thymussegmentes der vierten Kiementasche beim Menschen," *Anat. Anzeiger*, xvii, 1900.
- J. A. HAMMAR: "Einige Plattenmodelle zur Beleuchtung der früheren embryonal Leberentwicklung," *Archiv für Anat. und Physiol., Anat. Abth.*, 1893.
- J. A. HAMMAR: "Notiz über die Entwicklung der Zunge und der Mundspeicheldrüsen beim Menschen," *Anat. Anzeiger*, xix, 1901.
- K. HELLY: "Zur Entwicklungsgeschichte der Pancreasanlagen und Duodenalpapillen des Menschen," *Archiv für mikrosk. Anat.*, lvi, 1900.
- W. F. HENDRICKSON: "The Development of the Bile-capillaries as revealed by Golgi's Method," *Johns Hopkins Hospital Bulletin*, 1898.
- W. HIS: "Anatomic menschlicher Embryonen," Leipzig, 1882-1886.
- F. KEIBEL: "Zur Entwicklungsgeschichte des menschlichen Urogenitalapparatus," *Archiv für Anat. und Physiol., Anat. Abth.*, 1896.
- G. KILLIAN: "Ueber die Bursa und Tonsilla pharyngea," *Morphol. Jahrbuch*, xiv, 1888.
- A. KOHN: "Die Epithelkörperchen," *Ergebnisse der Anat. und Entwicklungsgesch.*, ix, 1899.
- F. P. MALL: "Ueber die Entwicklung des menschlichen Darmes und seiner Lage beim Erwachsenen," *Archiv für Anat. und Physiol., Anat. Abth. Supplement*, 1897.
- J. F. MECKEL: "Bildungsgeschichte des Darmkanals der Säugethiere und namentlich des Menschen," *Archiv für Anat. und Physiol.*, iii, 1817.
- C. RÖSE: "Ueber die Entwicklung der Zähne des Menschen," *Archiv für mikrosk. Anat.*, xxxviii, 1891.
- A. SWAEN: "Recherches sur le développement du foie, du tube digestif, de l'arrière-cavité du péritoine et du mésentère," *Journ. de l'Anat. et de la Physiol.*, xxxii, 1896, and xxxiii, 1897.
- J. TANDLER: "Zur Entwicklungsgeschichte des menschlichen Duodenum in frühen Embryonalstadien," *Morphol. Jahrbuch*, xxix, 1900.
- C. TOLDT AND E. ZUCKERKANDL: "Ueber die Form und Texturveränderungen der menschlichen Leber während des Wachstums," *Sitzungsber. der kais. Akad. Wissensch. Wien., Math.-Naturwiss. Classe*, lxxii, 1875.
- F. TOURNEUX AND P. VERDUN: "Sur les premiers développements de la Thyroïde, du Thymus et des glandes parathyroïdiennes chez l'homme," *Journ. de l'Anat. et de la Physiol.*, xxxiii, 1897.
- F. TREVES: "Lectures on the Anatomy of the Intestinal Canal and Peritoneum in Man," *British Medical Journal*, i, 1885.



## CHAPTER XI.

### THE DEVELOPMENT OF THE PERICARDIUM AND PLEURO-PERITONEUM, THE DIA- PHRAGM AND THE SPLEEN.

It has been seen (p. 248) that the heart makes its appearance at a stage when the greater portion of the ventral surface to the intestine is still open to the yolk-sac. The ventral mesoderm splits to form the somatic and splanchnic layers and the heart develops as a fold in the latter on each side of the median line, projecting into the coelomic cavity enclosed by the two layers (Fig. 126, A). As the constriction of the anterior part of the embryo proceeds, the two heart folds are brought nearer together and later meet, so that the heart becomes a cylindrical structure lying in the median line of the body and is suspended in the coelom by a ventral band, the *ventral mesocardium*, composed of two layers of splanchnic mesoderm which extend to it from the ventral wall of the body, and by a similar band, the *dorsal mesocardium*, which unites it with the splanchnic mesoderm surrounding the digestive tract. The ventral mesocardium soon disappears (Fig. 126, C) and the dorsal one also vanishes somewhat later, so that the heart comes to lie freely in the coelomic cavity, except for the connections which it makes with the body-walls by the vessels which enter and arise from it.

The coelomic cavity of the embryo does not at first communicate with the extra-embryonic coelom, which is formed at a very early period (see p. 84), but later when

the splitting of the embryonic mesoderm takes place the two cavities become continuous behind the heart but not anteriorly, since the ventral wall of the body is formed in the heart region before the union can take place. It is possible, therefore, to recognize two portions in the embryonic cœlom, an anterior one, the *parietal cavity* (His), which is never connected laterally with the extra-embryonic cavity, and a posterior one, the *trunk cavity*, which is so connected. The heart is situated in the parietal cavity, a considerable portion of which is destined to become the *pericardial cavity*.

Since the parietal cavity lies immediately anterior to the still wide yolk-stalk, as may be seen from the position of the heart in the embryo shown in Fig. 42, it is bounded posteriorly by the yolk-stalk. This boundary is complete, however, only in the median line, the cavity being continuous on either side of the yolk-stalk with the trunk-cavity by passages which have been termed the *recessus parietales* (Fig. 179, *Bp* and *Rca*). Passing forward toward the heart in the splanchnic mesoderm which surrounds the yolk-stalk are the large omphalo-mesenteric veins, one on either side, and these shortly become so large as to bring the

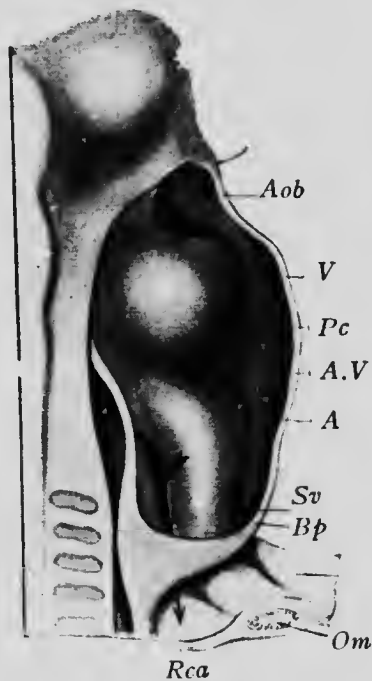


FIG. 179.—RECONSTRUCTION OF A RABBIT EMBRYO OF EIGHT DAYS, WITH THE PERICARDIAL CAVITY LAID OPEN.

*A*, Auricle; *Aob*, aortic bulb; *A.V.*, auriculo-ventricular communication; *Bp*, ventral parietal recess; *Om*, omphalo-mesenteric vein; *Pc*, pericardial cavity; *Rca*, dorsal parietal recess; *Sv*, sinus venosus; *V*, ventricle. —(His.)

splanchnic mesoderm in which they lie in contact with the somatic mesoderm which forms the lateral wall of each recess. Fusion of the two layers of mesoderm along the course of the veins now takes place, and each recess thus becomes divided into two parallel passages, which have been termed the dorsal (Fig. 180, *rpd*) and ventral (*rpv*) parietal recesses. Later the two veins fuse in the upper portion of their course to form the beginning of the sinus venosus, with the result that the ventral recesses become closed below and their continuity with the

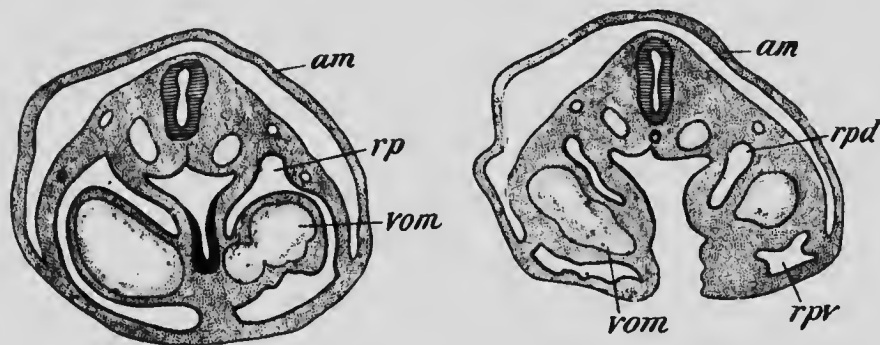


FIG. 180.—TRANSVERSE SECTIONS OF A RABBIT EMBRYO SHOWING THE DIVISION OF THE PARIETAL RECESSES BY THE OMPHALO-MESENTERIC VEINS.

*am*, Amnion; *rp*, parietal recess; *rpd* and *rpv*, dorsal and ventral divisions of the parietal recess; *vom*, omphalo-mesenteric vein. —(Ravn.)

trunk-cavity is interrupted, so that they form two blind pouches extending downward a short distance from the ventral portion of the floor of the parietal cavity. The dorsal recesses, however, retain their continuity with the trunk-cavity until a much later period.

By the fusion of the omphalo-mesenteric veins mentioned above, there is formed a thick semilunar fold which projects horizontally into the coelom from the ventral wall of the body and forms the floor of the ventral part of the parietal recess. This is known as the *septum transversum*.

*sum*, and besides containing the anterior portions of the omphalo-mesenteric veins, it also furnishes a passage by which the ductus Cuvieri, formed by the union of the jugular and cardinal veins, reaches the heart. Its dorsal edge is continuous in the median line with the mesoderm surrounding the digestive tract just opposite the region

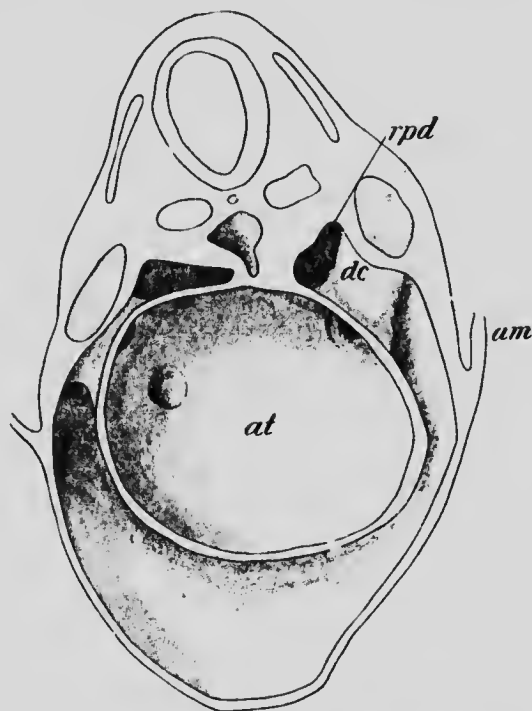


FIG. 181.—RECONSTRUCTION FROM A RABBIT EMBRYO OF NINE DAYS SHOWING THE SEPTUM TRANSVERSUM FROM ABOVE.  
*am*, Amnion; *at*, auricle; *dc*, ductus Cuvieri; *rpd*, dorsal parietal recess.—  
 (Kavn.)

where the liver outgrowth will form, but laterally this edge is free and forms the ventral walls of the dorsal parietal recess. An idea of the relations of the septum at this stage may be obtained from Fig. 181, which represents the anterior surface of the septum, together with the related parts, in a rabbit embryo of nine days.

*The Separation of the Pericardial Cavity.*—The septum transversum is at first almost horizontal, but later it becomes decidedly oblique in position, a change associated with the backward movement of the heart. As the closure of the ventral wall of the body extends posteriorly the ventral edge of the septum gradually slips downward upon it, while the dorsal edge is held in its former position by its attachment to the wall of the digestive tract and the ductus Cuvieri. The anterior surface of the septum thus comes to look ventrally as well as forward and the parietal cavity, having taken up into itself the blind pouches which represented the ventral recesses, comes to lie to a large extent ventral to the posterior recesses. As may be seen from Fig. 181, the ductus Cuvieri, as they bend from the lateral walls of the body into the free edges of the septum, form a marked projection which diminishes considerably the opening of the dorsal recesses into the parietal cavity. In later stages this projection increases and from its dorsal edge a fold, which may be regarded as a continuation of the free edge of the septum, projects into the upper portions of the recesses and eventually fuses with the median portion of the septum attached to the wall of the gut. In this way the parietal cavity becomes a completely closed sac, and is henceforward known as the *pericardial cavity*, the original coelom being now divided into two portions, (1) the *pericardial* and (2) the *pleuro-peritoneal* cavities, the latter consisting of the abdominal coelom together with the two dorsal parietal recesses which have been separated from the pericardial (parietal) cavity and are destined to be converted into the *pleural* cavities.

*The Formation of the Diaphragm.*—It is to be remembered that the attachment of the transverse septum to the ventral wall of the digestive tract is opposite the point

where the liver outgrowth develops. When, therefore, the outgrowth appears, it pushes its way into the substance of the septum, which thus acquires a very considerable thickness, especially toward its dorsal edge, and it furthermore becomes differentiated into two layers, an upper one, which forms the floor of the ventral portion of the pericardial cavity and encloses the Cuvierian duets, and a lower one which contains the liver. The upper layer is comparatively thin, while the lower forms the greater

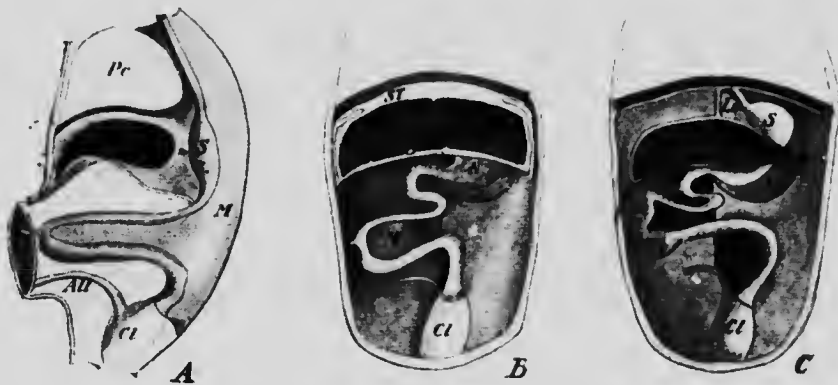


FIG. 182.—DIAGRAMS OF (A) A SAGITTAL SECTION OF AN EMBRYO SHOWING THE LIVER ENCLOSED WITHIN THE SEPTUM TRANSVERSUM; (B) A FRONTAL SECTION OF THE SAME; (C) A FRONTAL SECTION OF A LATER STAGE WHEN THE LIVER HAS SEPARATED FROM THE DIAPHRAGM.

*All*, Allantois; *Cl*, cloaca; *D*, diaphragm; *Li*, liver; *Ls*, suspensory ligament of the liver; *M*, mesentery; *Mg*, mesogastrium; *Pc*, pericardium; *S*, stomach; *ST*, septum transversum; *U*, umbilicus.

part of the thickness of the septum, its posterior surface meeting the ventral wall of the abdomen at the level of the anterior margin of the umbilicus (Fig. 182, A).

In later stages of development the layer containing the liver becomes separated from the upper layer by two grooves which, appearing at the sides and ventrally immediately above the liver (Fig. 182, B), gradually deepen toward the median line and dorsally. These grooves do

not, however, quite reach the median line, a portion of the lower layer of the septum being left in this region as a fold, situated in the sagittal plane of the body and attached above to the posterior surface of the upper layer and below to the anterior surface of the liver, beyond which it is continued down the ventral wall of the abdomen to the umbilicus (Fig. 182, C, *Ls*). This is the suspensory ligament of the liver of adult anatomy, and in the free edge of its prolongation down the ventral wall of the abdomen the umbilical vein passes to the under surface of the liver, while the free edge of that portion which lies between the liver and the digestive tract contains the omphalo-mesenteric (portal) vein, the common bile-duct, and the hepatic artery. The diagram given in Fig. 182 will, it is hoped, make clear the mode of formation and the relation of this fold, which, in its entirety, constitutes what is sometimes termed the *ventral mesentery*.

And not only do the grooves fail to unite in the median line, but they also fail to completely separate the liver from the upper layer of the septum dorsally, the portion of the lower layer which persists in this region forming the *coronary ligament* of the liver. The portion of the lower layer which forms the roof of the grooves becomes the layer of peritoneum covering the posterior surface of the upper layer (which represents the diaphragm), while the portion which remains connected with the liver constitutes its peritoneal investment.

In the mean time changes have been taking place in the upper layer. As the rotation of the heart occurs, so that its auricular portion comes to lie anterior to the ventricle, the Cuvierian ducts are drawn away from the septum and penetrate the posterior wall of the pericardium, the separation being assisted by the continued descent of the attachment of the edge of the septum to the ventral wall of

the body. During this descent, when the upper layer of the septum has reached the level of the fourth cervical segment, a portion of the myotome of that segment becomes prolonged into it and the layer assumes the characteristics of the *diaphragm*, the supply of whose musculature from the fourth cervical nerve through the phrenic is thus explained.

The diaphragm is as yet, however, incomplete dorsally, where the dorsal parietal recesses are still in continuity with the trunk-cavity. With the increase in thickness of the septum transversum, these recesses have acquired a considerable length antero-posteriorly, and into their upper portions the outgrowths from the lower part of the pharynx which form the lungs (see page 353) begin to project. The recesses thus become transformed into the *pleural cavities*, and as the diaphragm continues to descend, slipping down the ventral wall of the body, and drawing with it the pericardial cavity, the latter comes to lie entirely ventral to the pleural cavities. The free borders of the diaphragm, which now form the ventral boundaries of the openings by which the pleural and peritoneal cavities communicate, begin to approach the dorsal wall of the body, with which they finally unite, and so complete the separation of the cavities. The pleural cavities continue to enlarge after their separation and, extending laterally, pass between the pericardium and the lateral walls of the body until they finally almost completely surround the pericardium. The intervals between the two pleura form what are termed the *mediastina* in adult anatomy, the posterior (dorsal) mediastinum, in which the œsophagus lies, being the remains of the median portion of the septum transversum which was attached to the wall of the gut.

The downward movement of the septum transversum



extends through a very considerable interval, which may be appreciated from the diagram shown in Fig. 183. From this it may be seen that in early embryos the septum is situated just in front of the first cervical segment and that it lies very obliquely, its free edge being decidedly

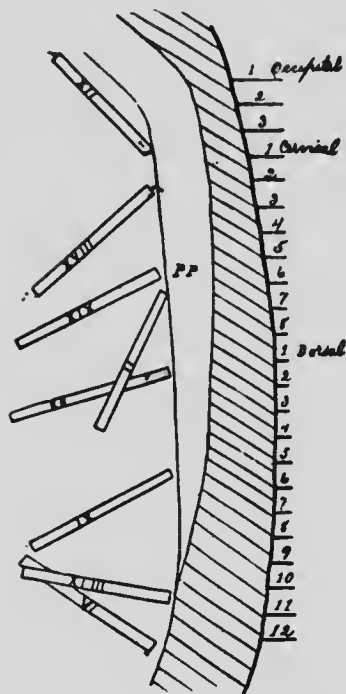


FIG. 183.—DIAGRAM SHOWING THE POSITION OF THE DIAPHRAGM IN EMBRYOS OF DIFFERENT AGES.—(Mall.)

posterior to its ventral attachment. When the downward displacement occurs, the ventral edge at first moves more rapidly than the dorsal, and soon comes to lie at a much lower level. The backward movement continues throughout the entire length of the cervical and thoracic regions, and when the level of the tenth thoracic segment is reached the separation of the pleural and peritoneal cavities is completed and then the dorsal edge begins to descend more rapidly than the ventral, so that the diaphragm again becomes oblique in the same sense as in the beginning, a position which it retains in the adult.

*The Development of the Peritoneum.*—The peritoneal cavity is developed from the trunk-cavity of early stages and is at first in free communication on all sides of the yolk-stalk with the extra-embryonic cœlom. As the ventral wall of the body develops the two cavities become more and more separated, and with the formation of the umbilical cord the separation is complete. Along the

mid-dorsal line of the body the archenteron forms a projection into the cavity and later moves further out from the body-wall into the cavity, pushing in front of it the peritoneum, which thus comes to surround the intestine, forming its serous coat, and from it is continued back to the dorsal body-wall forming the *mesentery*.

It has already been seen that on the separation of the liver from the septum transversum, the tissue of the latter gives rise to the peritoneal covering of the liver and of the posterior surface of the diaphragm, and also to the ventral mesentery. When the separation is taking place, the rotation of the stomach already described (p. 319) occurs, with the result that the portion of the ventral mesentery which stretches between the lesser curvature of the stomach and the liver shares in the rotation and comes to lie in a plane practically at right angles with that of the suspensory ligament, its surfaces looking dorsally and ventrally and its free edge being directed toward the right. This portion of the ventral mesentery forms what is termed the *lesser omentum*, and between it and the dorsal surface of the stomach as the ventral boundaries and the dorsal wall of the abdominal cavity dorsally there is a cavity, whose floor is formed by the dorsal mesentery of the stomach, the *mesogastrium*, the roof by the under surface of the left half of the liver, while to the right it communicates with the general peritoneal cavity dorsal to the free edge of the lesser omentum. This cavity is known as the *lesser sac* of the peritoneum, and the opening into it from the general cavity or *greater sac* is termed the *foramen of Winslow*. Later, the floor of the lesser sac is drawn downward to form a broad sheet of peritoneum lying ventral to the coils of the small intestine and consisting of four layers; this represents the great omentum of adult anatomy (Fig. 187).

Below the level of the upper part of the duodenum the ventral mesentery is wanting; only the dorsal mesentery occurs. So long as the intestine is a straight tube the length of the intestinal edge of this mesentery is practically equal to that of its dorsal attached edge. The intestine, however, increasing in length much more rapidly than the abdominal walls, the intestinal edge of the mesentery soon becomes very much longer than the attached

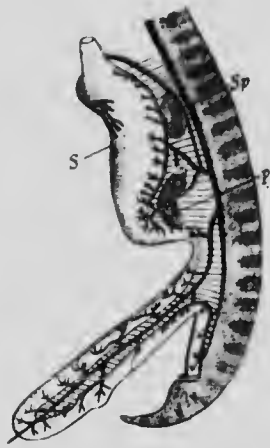

FIG. 184. — DIAGRAM SHOWING THE ARRANGEMENT OF THE MESENTERY AND VISCERAL BRANCHES OF THE ABDOMINAL AORTA IN AN EMBRYO OF SIX WEEKS.

*p*, Pancreas; *S*, stomach; *Sp*, spleen. — (Toldt.)

edge, and when the intestine grows out into the umbilical cœlum the mesentery accompanies it (Fig. 184). As the coils of the intestine develop, the intestinal edge of the mesentery is thrown into corresponding folds, and on the return of the intestine to the abdominal cavity the mesentery is thrown into a somewhat funnel-like form by the twisting of the intestine to form its primary loop (Fig. 185). All that portion of the mesentery which is attached to the part of the intestine which will later become the jejunum, ileum, ascending and transverse colon, is attached to the body-wall at the apex of the funnel, at

a point which lies to the left of the duodenum.

Up to this stage or to about the middle of the fourth month the mesentery has retained its attachment to the median line of the dorsal wall of the abdomen throughout its entire length, but later fusions of certain portions occur, whereby the original condition is greatly modified. One of the earliest of these fusions takes place at the apex

of the funnel, where the portion of the mesentery which passes to the transverse colon and arches over the duodenum fuses with the ventral surface of the latter portion of the intestine and also with the peritoneum covering the dorsal wall of the abdomen both to the right and to the left of the duodenum. In this way the attachment of the *transverse mesocolon* takes the form of a transverse line instead of a point, and this portion of the mesentery

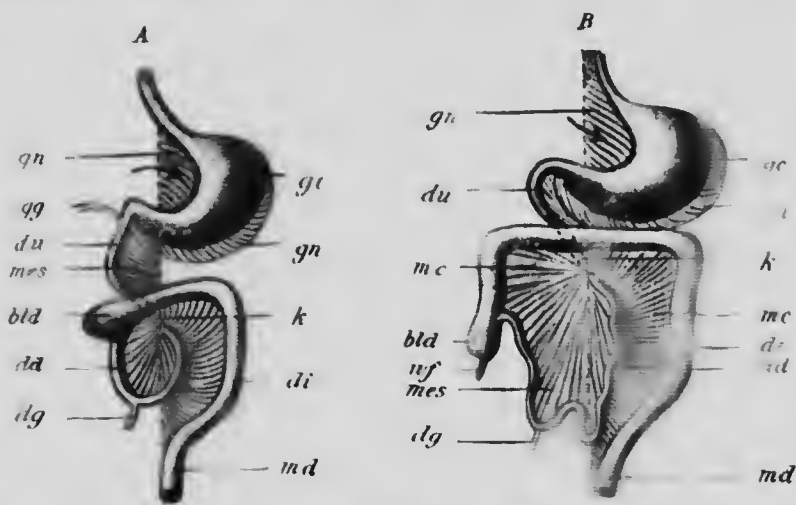


FIG. 185. —DIAGRAMS ILLUSTRATING THE DEVELOPMENT OF THE GREAT OMENTUM AND THE TRANSVERSE MESCOLO.

*bla*, Cæcum; *da*, small intestine; *dg*, yolk-stalk; *di*, duodenum; *gc*, greater curvature of stomach; *gg*, bile duct; *mes*, mesentery; *md*, rectum; *mc*, mesentery; *nf*, vermiform appendix; *o*, omentum; *k*, point where the loops of the intestine cross; *ad*, ascending colon.

divides the abdominal cavity into two portions, the upper (anterior) of which contains the liver and stomach, while the lower contains the remainder of the digestive tract with the exception of the duodenum. By passing across the ventral surface of the duodenum and fusing with it, the transverse mesocolon forces that portion of the intestine against the dorsal wall of the abdomen and fixes it in that position, and its mesentery thereupon degenerates,

becoming subserous areolar tissue, the duodenum assuming the retroperitoneal position which characterizes it in the adult.

The descending colon, which on account of the width of its mesentery is at first freely movable, lies well over to the left side of the abdominal cavity, and in consequence the left layer of its mesentery lies in contact with the parietal layer of the peritoneum. A fusion of these two layers, beginning near the middle line and thence extend-

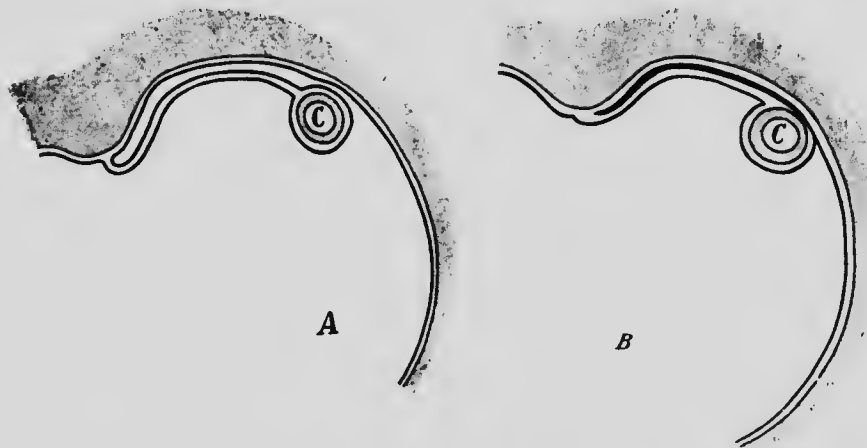


FIG. 186.—DIAGRAMS ILLUSTRATING THE MANNER IN WHICH THE FIXATION OF THE DESCENDING COLON (C) TAKES PLACE.

ing outward, takes place, the fused layers becoming converted into connective tissue, and this portion of the colon thus loses its mesentery and becomes fixed to the abdominal wall. The process by which the fixation is accomplished may be understood from the diagrams which constitute Fig. 186. When the ascending colon is formed, its mesentery undergoes a similar fusion, and it also becomes fixed to the abdominal wall.

The fusion of the mesentery of the ascending and descending colon remains incomplete in a considerable number of cases (one-

fourth to one-third of all cases examined), and in these the colons are not perfectly fixed to the abdominal wall. It may also be pointed out that the cæcum and appendix, being primarily a lateral outpouching of the intestine, do not possess any true mesentery, but are completely enclosed by peritoneum. Usually a falciform fold of peritoneum may be found extending along one surface of the appendix to become continuous with the left layer of the mesentery of the ileum. This, however, is not a true mesentery, and is better spoken of as a mesenteriole.

One other fusion is still necessary before the adult condition of the mesentery is acquired. The great omentum consists of two folds of peritoneum which start from the greater curvature of the stomach and pass downward to be reflected up again to the dorsal wall of the abdomen, which they reach just anterior to (above) the line of attachment of the transverse mesocolon (Fig. 187, A). At first the attachment of the omentum is vertical, since it represents the mesogastrium, but later, by fusion with the parietal peritoneum it assumes a transverse direction, while at the same time the pancreas, which originally lay between the two folds of the mesogastrium, is carried dorsally and comes to have a retroperitoneal position in the line of attachment of the omentum. By this change the lower layer of the omentum is brought in contact with the upper layer of the transverse mesocolon and a fusion and degeneration of the two results (Fig. 187, B), a condition which brings it about that the omentum seems to be attached to the transverse colon and that the pancreas seems to lie in the line of attachment of the transverse mesocolon. This mesentery, as it occurs in the adult, really consists partly of a portion of the original transverse mesocolon and partly of a layer of the great omentum.

By these various changes the line of attachment of the mesentery to the dorsal wall of the body has become some-

what complicated and has departed to a very considerable extent from its original simple vertical arrangement. If all the viscera be removed from the body of an adult and the mesentery be cut close to the line of its attachment, the course of the latter will be seen to be as follows: Descending from the under surface of the diaphragm are the

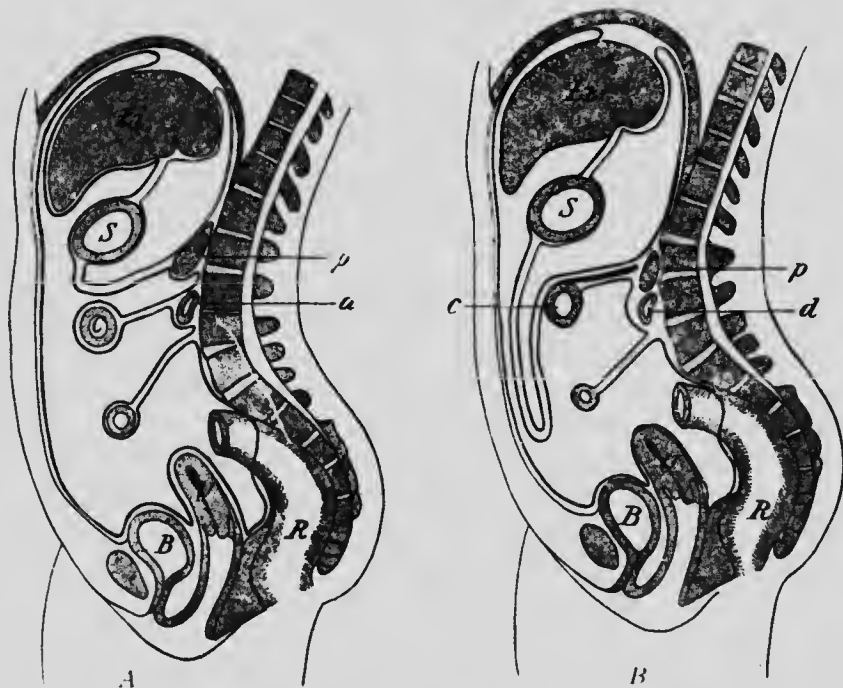


FIG. 187. DIAGRAMS SHOWING THE DEVELOPMENT OF THE GREAT OMENTUM AND ITS FUSION WITH THE TRANSVERSE MESOCOLON.

*B*, Bladder; *c*, transverse colon; *d*, duodenum; *Li*, liver; *p*, pancreas; *R*, rectum; *S*, stomach; *U*, uterus.—(After Allen Thomson.)

lines of attachment of the suspensory ligament, which on reaching the liver spread out to become the coronary and lateral ligaments of that organ. At about the mid-dorsal line these lines become continuous with those of the mesogastrium which curve downward toward the left and are continued into the transverse lines of the transverse

mesocolon. Between these last, in a slight prolongation, there may be seen to the right the cut end of the first portion of the duodenum as it passes back to the dorsal wall of the abdomen, and at about the mid-dorsal line the cut ends of its last part become visible as it passes ventrally again to become the jejunum. From the transverse mesocolon three lines of attachment pass downward; the two lateral broad ones represent the lines of fixation of the ascending and descending colons, while the narrower median one, which curves to the right, represents the attachment of the mesentery of the small intestine other than the duodenum. Finally, from the lower end of the fixation line of the descending colon the mesentery of the sigmoid is continued downward.

**The Development of the Spleen.**—The spleen has generally been regarded as a development of the mesenchyme situated between the two layers of the mesogastrium. To this view, however, recent observers have taken exception, holding that the ultimate origin of the organ is in part or entirely from the cœlomic epithelium of the left layer of the mesogastrium. The first indication of the spleen has been observed in embryos of the fifth week as a slight elevation on the left (dorsal) surface of the mesogastrium, due to a local thickening and vascularization of the mesenchyme accompanied by a thickening of the cœlomic epithelium which covers the elevation. The mesenchyme thickening presents no differences from the neighboring mesenchyme, but the epithelium is not distinctly separated from it over its entire surface, as it is elsewhere in the mesentery. In later stages, which have been observed in detail in pig and other amniote embryos, cells separate from the deeper layers of the epithelium (Fig. 188) and pass into the mesenchyme thickening, whose tissue soon assumes a different appearance from the sur-



rounding mesenchyme by its cells being much crowded. This migration soon ceases, however, and in embryos of forty-two days the cœlomic epithelium covering the thickening is reduced to a simple layer of cells.

The later stages of development consist of an enlargement of the thickening and its gradual constriction from the surface of the mesogastrium, until it is finally united to it only by a narrow band through which the large splenic vessels gain access to the organ. The cells differentiate themselves into trabeculæ and pulp cords, special collections of cells around the branches of the splenic artery forming the Malpighian corpuscles.

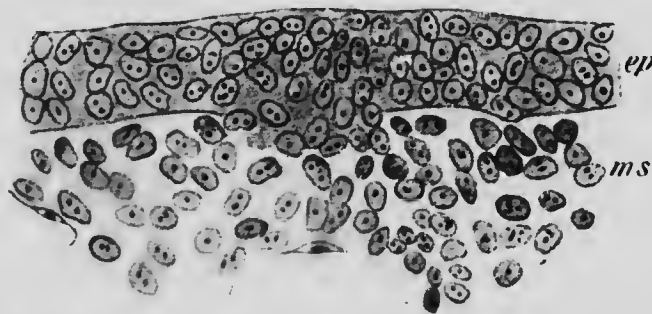


FIG. 188.— SECTION THROUGH THE LEFT LAYER OF THE MESOGASTRIUM OF A CHICK EMBRYO OF NINETY-THREE HOURS, SHOWING THE ORIGIN OF THE SPLEEN.

*ep*, Cœlomic epithelium; *ms*, mesenchyme. (Tonkoff.)

It has already been pointed out (p. 244) that during embryonic life the spleen is an important hæmatopoietic organ, both red and white corpuscles undergoing active formation within its substance. The Malpighian corpuscles are collections of lymphocytes in which multiplication takes place, and while nothing is as yet known as to the fate of the cells which are contributed to the spleen from the cœlomic epithelium, since they quickly come to resemble the mesenchyme cells with which they are associated, yet the growing number of observations indicating an epithelial origin for lymphocytes suggests the possibility that the cells in question may be responsible for the first leukocytes of the spleen.

## LITERATURE.

- A. BRACHET: "Die Entwickelung der grossen Körperhohlen und ihre Trennung von Einander," *Ergebnisse der Anat. und Entwicklungsgesch.*, VII, 1898.
- W. HIS: "Mittheilungen zur Embryologie der Säugethiere und des Menschen," *Archiv für Anat. und Physiol., Anat. Abth.*, 1881.
- F. P. MALL: "Development of the Human Cœlom," *Journal of Morphol.*, XII, 1897.
- E. RAVN: "Ueber die Bildung der Scheidewand zwischen Brust- und Bauchhöhle in Säugethierembryonen," *Archiv für Anat. und Physiol., Anat. Abth.*, 1889.
- A. SWAEN: "Recherches sur le développement du foie, du tube digestif, de l'arrière-cavité du péritoine et du mésentère," *Journ. de l'Anat. et de la Physiol.*, XXXII, 1896; XXXIII, 1897.
- C. TOLDT: "Bau und Wachstumsveränderungen der Gekröse des menschlichen Darmkanals," *Denkschr. der kais. Akad. Wissensch. Wien, Math.-Naturwiss. Classe*, XLI, 1879.
- C. TOLDT: "Die Darmgekröse und Netze im gesetzmässigen und gesetzwidrigen Zustand," *Denkschr. der kais. Akad. Wissensch. Wien, Math.-Naturwiss. Classe*, LVI, 1889.
- W. TONKOFF: "Die Entwickelung der Milz bei den Amnioten," *Archiv für mikrosk. Anat.*, LVI, 1900.
- F. TREVES: "Lectures on the Anatomy of the Intestinal Canal and Peritoneum," *British Medical Journal*, I, 1885

## CHAPTER XII.

### THE DEVELOPMENT OF THE ORGANS OF RESPIRATION.

**The Development of the Lungs.**—The first indication of the lungs and trachea is found in embryos of about 3.2 mm. in the form of a groove on the ventral surface of the œsophagus, at first extending almost the entire length of that portion of the digestive tract. As the œsophagus

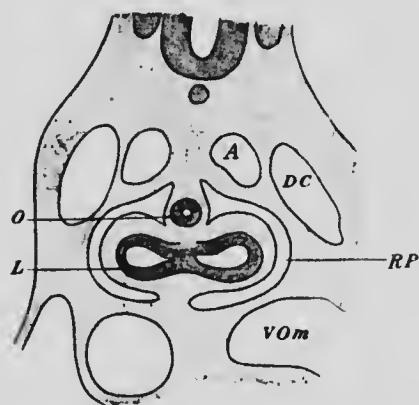


FIG. 189. — PORTION OF A SECTION THROUGH AN EMBRYO OF THE FOURTH WEEK.

*A*, Aorta; *DC*, ductus Cuvieri; *L*, lung; *O*, œsophagus; *RP*, parietal recess; *Vom*, omphalo-mesenteric vein.— (Toldt.)

lengthens the lung groove remains connected with its upper portion (Fig. 168, A), and furrows which appear along the line of junction of the groove and the œsophagus gradually deepen and separate the two structures (Fig. 168, B). The separation takes place earliest at the lower end of the groove and thence extends upward, so that the groove is transformed into a cylindrical pouch lying ventrad of the œsophagus

and dorsad of the heart and opening with the œsophagus into the terminal portion of the pharynx.

Soon after the separation of the groove from the œsophagus its lower end becomes enlarged and bilobed,

and since this lower end lies, with the œsophagus, in the median attached portion of the dorsal edge of the septum transversum, the lobes, as they enlarge, project into the dorsal parietal recesses (Fig. 189), and so become enclosed within the peritoneal lining of the recesses which later become the pleural cavities.

The lobes, which represent the *lungs*, do not long remain simple, but bud-like processes arise from their cavities, three appearing in the right lobe and two in the left (Fig.

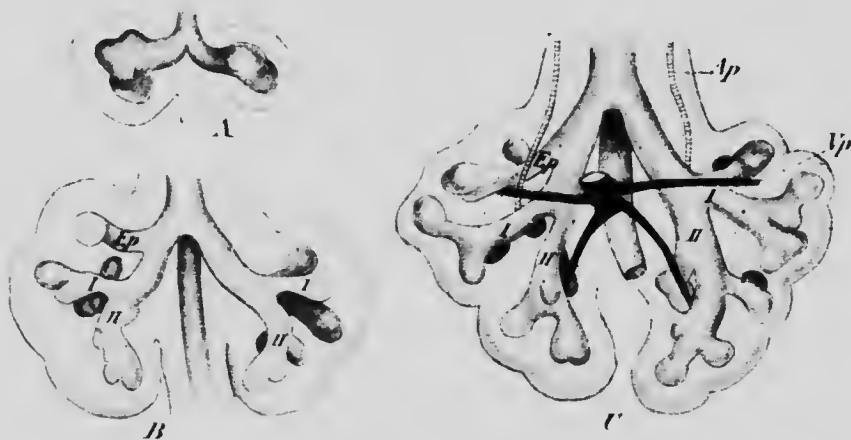


FIG. 190.—RECONSTRUCTION OF THE LUNG OUTGROWTHS OF EMBRYOS OF (A) 10, (B) 8.5, AND (C) 10.5 MM.

*Ap*, Pulmonary artery; *Ep*, apical bronchus; *Vp*, pulmonary vein; *I-II*, primary bronchi.—(*His.*)

190, A), and as these increase in size and give rise to additional outgrowths, the structure of the lobes rapidly becomes complicated (Fig. 190, B and C). In the formation of new outgrowths the terminal enlarged part of each process divides as if to give rise to two equal bronchi, but later as the new bronchi elongate, one grows more rapidly than the other and places itself so as to be in the line of the stem from which it arose, its fellow seeming to be a lateral branch from it. As a result of this method of growth a

main bronchus traversing the entire length of the lung is formed, and into it there open numerous lateral branches, which may be termed secondary bronchi, arranged in a more or less definite and similar manner in the two lungs. The main stem of the pulmonary artery traverses the lung lying to the outer side of the main bronchus, and since certain of the secondary bronchi arise ventral and others dorsal to the line of the artery it is possible to recognize series of ventral and dorsal bronchi. These alternate more or less regularly with one another, the dorsal bronchi standing higher than the ventral and in the human lung there are usually four ventral bronchi, while the number of the dorsal ones is frequently reduced to three by the failure of the one corresponding to the third ventral to develop.

The first dorsal bronchus of the left side differs from that of the right side in that it arises from the first ventral bronchus instead of from the main stem, a condition with which is associated the fusion of the upper and middle lobes of the left lung to a single lobe.

The secondary branches elongate and give rise to lateral branches just as do the main bronchi, and of these tertiary bronchi one, which arises from the second ventral bronchus or from the main bronchus in its neighborhood, is of especial importance, since, especially in the right lung, in which it is usually better developed than in the left, it frequently forms the main stem for a fourth lobe, which, from its position, is termed the *infracardial lobe*.

At first the amount of mesenchyme which separates the various branches is comparatively great, but as the branchings continue, the growth of the mesenchyme fails to keep pace with it, so that in later stages the terminal enlargements are separated from one another by only very thin partitions of mesenchyme in which the pulmonary vessels form a dense network. The final branchings of

each ultimate bronchus or bronchiole results in the formation at its extremity of from three to five enlargements, the *atria* (Fig. 191, *A*), from which arise a number of *air-sacs* or *alveoli* (*s*) whose walls are pouched out into slight diverticula, the *air-cells*. Such a combination of atria, air-sacs, and air-cells constitutes a lobule, and each lung is composed of a large number of such units.

The greater part of the original pulmonary groove becomes converted into the *trachea*, and in the mesenchyme surrounding it the incomplete cartilaginous rings develop at about the eighth or ninth week. The cells of the epithelial lining of the trachea and bronchi remain columnar or cubical in form and become ciliated at about the fourth month, but those of the epithelium of the air-sacs become greatly flattened and constitute an exceedingly thin layer of pavement epithelium.

**The Development of the Larynx.**—The opening of the upper end of the pulmonary groove into the pharynx is situated at first just behind the fourth branchial furrow and is surrounded anteriorly and laterally by the  $\Omega$ -shaped ridge already described (p. 311) as the furcula, this separating it from the posterior portion of the tongue (Fig. 164). The anterior portion of this ridge, which is apparently derived from the ventral portions of the third branchial arch, gradually increases in height and forms the

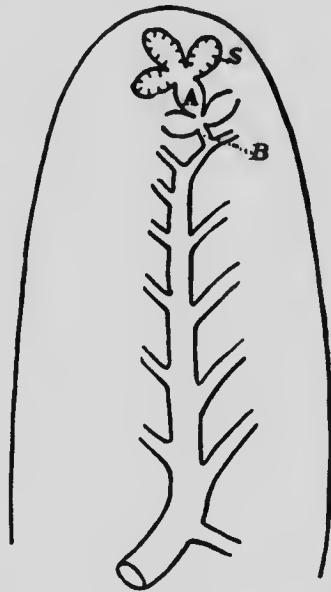


FIG. 191.—DIAGRAM OF THE FINAL BRANCHES OF THE MAMMALIAN BRONCHI. *A*, Atrium; *B*, bronchus; *S*, air-sac.—(Miller.)

*epiglottis*, while the lateral portions, which pass posteriorly into the margins of the pulmonary groove, form the *arytenoid ridges*. When the pulmonary groove separates from the œsophagus, the opening of the trachea into the pharynx is somewhat slit-like and is bounded laterally by the arytenoid ridges, whose margins present two elevations which may be termed the cornicular and cuneiform tubercles (Fig. 192, *co* and *cu*, and Fig. 161). The opening is, how-

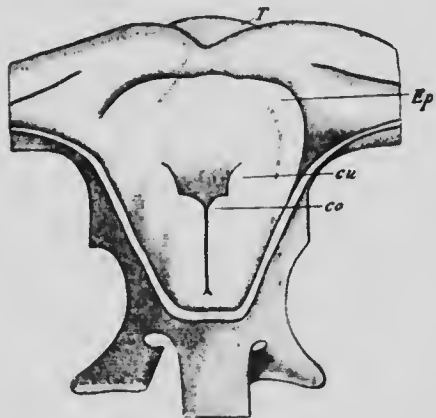


FIG. 192.—RECONSTRUCTION OF THE OPENING INTO THE LARYNX IN AN EMBRYO OF TWENTY-EIGHT DAYS, SEEN FROM BEHIND AND ABOVE, THE DORSAL WALL OF THE PHARYNX BEING CUT AWAY.

*co*, Cornicular, and *cu*, cuneiform tubercle; *Ep*, epiglottis; *T*, unpaired portion of the tongue.—(Kallius.)

ever, for a time, almost obliterated by a thickening of the epithelium covering the ridges, and it is not until the tenth or eleventh week of development that it is re-established. Later than this, at the middle of the fourth month, a linear depression makes its appearance on the mesial wall of each arytenoid ridge, forming the beginning of the *ventricle*, and although at first the depression lies horizontally its lateral edge later

bends anteriorly, so that its surfaces look outwards and inwards. The lips which bound the opening of the ventricle into the laryngeal cavity give rise to the *vocal cords*.

The cartilages of the larynx can be distinguished during the seventh week as condensations of mesenchyme which are but indistinctly separated from one another. The *thyroid cartilage* is represented at this stage by two lateral plates of mesenchyme, separated from one another both

ventrally and dorsally, and each of these plates undergoes chondrification from two separate centers (Fig. 193). These, as they increase in size, unite together and send prolongations ventrally which meet in the mid-ventral line with the corresponding prolongations of the plates of the opposite side, so as to enclose an area of mesenchyme into which the chondrification only extends at a later period, and occasionally fails to so extend, producing what is termed a foramen thyroideum.

The mesenchymal condensations which represent the *cricoid* and *arytenoid* cartilages are continuous, but each



FIG. 193.—RECONSTRUCTION OF THE MESENCHYME CONDENSATIONS WHICH REPRESENT THE HYOID AND THYROID CARTILAGES IN AN EMBRYO OF FORTY DAYS.

The darkly shaded areas represent centers of chondrification. *c.ma*, Greater cornu of hyoid; *c.mi*, lesser cornu; *Th*, thyroid cartilage. —(Kallius.)

arytenoid has a distinct center of chondrification, while the cartilage of the cricoid appears as a single ring which is at first open dorsally and only later becomes complete. The epiglottis cartilage resembles the thyroid in being formed by the fusion of two originally distinct cartilages, from each of which a portion separates to form the cuneiform cartilages (*cartilages of Wrisberg*), while the corniculæ laryngis (*cartilages of Santorini*) are formed by the separation of a small portion of cartilage from each arytenoid.



The formation of the thyroid cartilage by the fusion of two pairs of lateral elements finds an explanation from the study of the comparative anatomy of the larynx. In the lowest group of the mammalia, the Monotremata, the four cartilages do not fuse together and are very evidently serially homologous with the cartilages which form the cornua of the hyoid. In other words, the thyroid results from the fusion of the fourth and fifth branchial cartilages. The cricoid, in its development, presents such striking similarities to the cartilaginous rings of the trachea that it is probably to be regarded as the uppermost cartilage of that series, but the paired arytenoids and the epiglottis are possibly representatives of the sixth and seventh pairs of branchial cartilages, structures which occur with great constancy in the lower vertebrates. The epiglottis possibly represents the sixth pair of cartilages and the arytenoids the seventh (Gegenbaur).

These two last arches have undergone almost complete reduction in the mammalia, the cartilages being their only representatives, but, in addition to the cartilages, the fourth and fifth arches have also preserved a portion of their musculature, part of which becomes transformed into the muscles of the larynx. Since the nerve which corresponds to these arches is the vagus, the supply of the larynx is derived from that nerve, the superior laryngeal nerve probably corresponding to the fourth arch, while the inferior (recurrent) answers to the fifth.

The course of the recurrent laryngeal nerve finds its explanation in the relation of the nerve to the fourth branchial artery. When the heart occupies its primary position ventral to the floor of the pharynx, the inferior laryngeal nerve passes transversely inward to the larynx beneath the fourth branchial artery. As the heart recedes the nerve is caught by the vessel and is carried back with it, the portion of the vagus between it and the superior laryngeal nerve elongating until the origins of the two

laryngeal nerves are separated by the entire length of the neck. Hence it is that the right recurrent nerve bends upward behind the right subclavian artery, while the left curves beneath the arch of the aorta (see Fig. 139).

## LITERATURE.

- E. GÖPPERT: "Ueber die Herkunft der Wisbergsehen Knorpels," *Morphol. Jahrbuch*, XXI, 1894.
- W. HIS: "Zur Bildungsgeschichte der Lungen beim menschlichen Embryo," *Archiv für Anat. und Physiol., Anat. Abth.*, 1887.
- E. KALLIUS: "Beiträge zur Entwicklungsgeschichte des Kehlkopfes," *Anat. Hefte*, IX, 1897.
- E. KALLIUS: "Die Entwicklung des menschlichen Kehlkopfes," *Verhandl. der Anat. Gesellsch.*, XII, 1898.
- A. NARATH: "Der Bronchialbaum der Säugethiere und des Menschen," *Bibliotheca Medica*, Abth. A, Heft 3, 1901.

## CHAPTER XIII.

### THE DEVELOPMENT OF THE URINOGENITAL SYSTEM AND THE SUPRARENAL BODIES.

The excretory and reproductive systems of organs are so closely related in their development that they must be considered together. They both owe their origin to the mesoderm which constitutes the intermediate cell-mass, this, at an early period of development, becoming thickened so as to form a ridge projecting into the dorsal por-

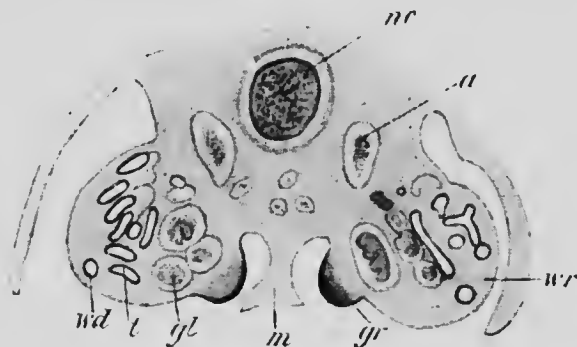


FIG. 194—TRANSVERSE SECTION THROUGH THE ABDOMINAL REGION OF A RABBIT EMBRYO OF 12 MM.

*a*, Aorta; *gl*, glomerulus; *gr*, genital ridge; *m*, mesentery; *nc*, notochord; *t*, tubule of mesonephros; *wd*, Wolffian duct; *wr*, Wolffian ridge.—*(Mihalkovicz.)*

tion of the cœlom and forming what is known as the *Wolffian ridge* (Fig. 194, *wr*). The greater portion of the substance of this ridge is concerned in the development of the primary and secondary excretory organs, but on its mesial surface a second ridge appears which is destined to give rise to the ovary or testis, and hence is termed the *genital ridge* (*g*).

The development of the excretory organs is remarkable in that three sets of organs appear in succession. The first of these, the *pronephros*, exists in a very rudimentary condition in the human embryo, although its duct, the *pronephric* or *Wolffian duct*, undergoes complete development and plays an important part in the development of the succeeding organs of excretion and also in that of the reproductive organs. The second set, the *mesonephros* or *Wolffian body*, reaches a considerable development during embryonic life, but later, on the development of the final set, the definitive kidney or *metanephros*, undergoes degeneration, portions only persisting as rudimentary structures associated for the most part with the reproductive organs.

**The Development of the Pronephros and the Pronephric Duct.**—The first portions of the excretory system to make their appearance are the pronephric or Wolffian ducts, and these develop as thickenings of the lateral parts of the intermediate cell-masses. At first the thickenings form solid cords of cells (Fig. 195, *wd*), but later a lumen appears in the center of each cord, which thus becomes converted into a canal. In early stages the cords, toward their posterior ends, may undergo a secondary fusion with the immediately overlying ectoderm (Martin) and may thereby present the appearance of having arisen from that layer, but when fully developed the ducts lie in the substance of the Wolffian ridges (Fig. 194, *wd*), their anterior ends being situated well forward in the region occupied by the heart, whence they extend backward to open on the ventral part of the lateral walls of the cloaca (Fig. 156).

The pronephros appears in embryos of about 3 mm. as two tubular invaginations of the cœlomic epithelium into the substance of each Wolffian ridge, in the region in which the anterior end of the Wolffian duct is found (Janhosik).

The tubules do not proceed to complete development, making no connection with the duct, and indeed the anterior one hardly deserves to be termed a tubule, since it is a solid cord of cells, continuous at one extremity with the cœlomic epithelium. The posterior one is, however, a hollow tubule ending blindly at one extremity, while at the other it communicates with the cœlomic cavity, the opening being termed a *nephrostome*. Opposite these rudimentary tubules there arises from the root of the mesentery a process which projects freely into the cœlom toward the nephrostomes. This probably represents a rudimen-

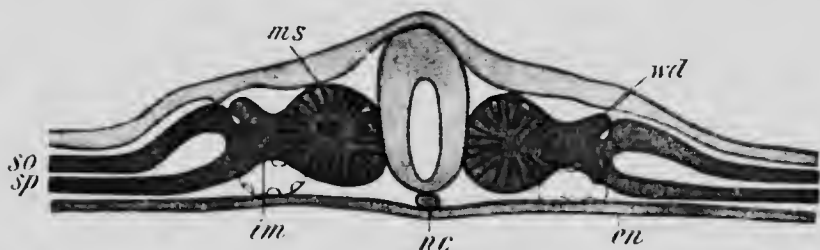


FIG. 195.—TRANSVERSE SECTION THROUGH CHICK EMBRYO OF ABOUT THIRTY-SIX HOURS.

*en*, Endoderm; *im*, intermediate cell mass; *ms*, mesodermic somite; *nc*, notochord; *so*, somatic, and *sp*, splanchnic mesoderm; *wd*, Wolffian duct.—(Waldeyer.)

tary free glomerulus, into which branches from the aorta may project.

Nothing is known as to the further development of these pronephric tubules and glomeruli, but it seems probable that they are merely transitory structures which disappear completely at an early stage of development (see p. 391).

A similar but more perfectly developed pronephros has been described in other mammals, such as the rabbit and rat, and is of constant occurrence in all the lower vertebrates. In these the pronephric tubules, which may be six (in the lamprey) or more in number on each side, are primarily arranged segment-

ally, and open by one extremity into the anterior portion of the Wolffian duct and by the other into the coelomic cavity, and, furthermore, each tubule has corresponding to it a glomerulus which lies freely in the coelomic cavity in the vicinity of the nephrostome. By these free glomeruli and by the possession of nephrostomes the tubules of the pronephros are distinguished from those of the mesonephros in the higher vertebrates, and since both these peculiarities are represented in the two pairs of tubules described above as occurring in the 3 mm. human embryo, there seems to be little room for doubt but that they are representatives of a rudimentary pronephros.

It has been very generally supposed that the tubules of the mesonephros, which develop in the segments succeeding those which contain the pronephros, were serially homologous with the pronephric tubules. Doubts have recently been aroused against this theory (Rückert, Wheeler). Important structural differences exist in the two sets of tubules, and since even in the lowest vertebrates the pronephros seems to be a rudimentary structure, it has been held not improbable that in the ancestors of the vertebrates it was a much more perfectly developed organ, extending back into the region occupied by the mesonephros in existing vertebrates. As the mesonephros developed the pronephros underwent degeneration, portions of its tubules persisting, however, and uniting to form a continuous canal, the pronephric duct, a structure for which, otherwise, it is difficult to find a satisfactory explanation. The fact that in lower forms the duct seems to develop as a number of separate parts which later become continuous lends in favor of this hypothesis, but in opposition to it is the observation that the lower portion of the duct in several species of mammals arises from the ectoderm (von Spee, Flemming): It seems, however, to be established that in the majority of the lower vertebrates it is of purely mesodermal origin, and its connection with the ectoderm in the mammalia is therefore very probably due to a secondary fusion (Martin).

**The Development of the Mesonephros.**—The pronephric duct does not disappear with the degeneration of the pronephric tubules, but persists to serve as the duct for the mesonephros and to play an important part in the development of the metanephros also. In the regions of the Wolffian ridge which lie posterior to the pronephros there

appear in embryos of between 3 and 4 mm. a number of coiled tubules whose origin has not yet been sufficiently elucidated in human embryos. In lower mammals they arise by some of the cells of the Wolffian ridge aggregating together to form solid cords, which are entirely unconnected with the cœlomic epithelium and at first also with the Wolffian (pronephric) duct. These cords acquire a lumen and at one end connect with the duct, while near the other end a condensation of the mesoderm of the ridge

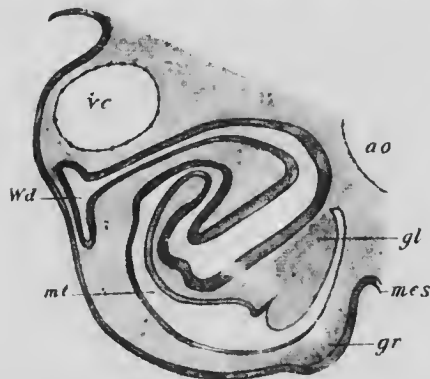


FIG. 196.—TRANSVERSE SECTION OF THE WOLFFIAN RIDGE OF A CHICK EMBRYO OF THREE DAYS.

*ao*, Aorta; *gl*, glomerulus; *gr*, genital ridge; *mes*, mesentery; *mt*, mesonephric tubule; *vc*, cardinal vein; *Wd*, Wolffian duct. (Mihalkovicz.)

occurs to form a glomerulus into which a vessel extends from the neighboring aorta. The tubules rapidly increase in length and become coiled, and the glomeruli project into their cavities, pushing in front of them the wall of the tubule so that the whole structure has the appearance represented in Fig. 196.

It seems probable that primarily the mesonephric cords are arranged segmentally, a single pair occurring in each segment of the body behind the pronephros as far back, probably, as the pelvic region, and hence the intermediate cell-mass from which the Wolffian ridge is formed may properly be regarded as composed of nephrotomes, even though no surface indications of segmentation are to be seen in it. The correspondence of the tubules with the myotomes becomes, however, early disturbed, partly as the result of differences in growth of the two structures,

but especially because a number of secondary and tertiary tubules develop in connection with each of the primary ones. Exactly how these additional tubules arise is a little uncertain, some observers maintaining that they are formed from the substance of the Wolffian ridge in the same manner as the primary tubules with which they later

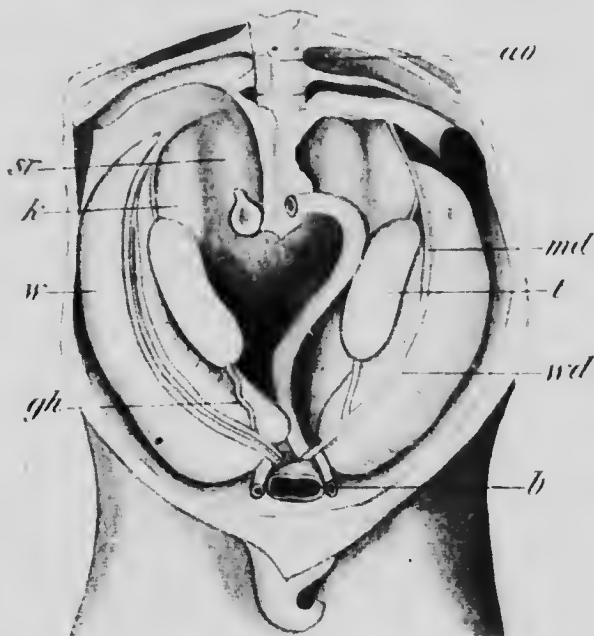


FIG. 197.—URINOGENITAL APPARATUS OF A MALE PIG EMBRYO OF 6 CM. *ao*, Aorta; *b*, bladder; *gh*, gubernaculum of Hunter; *k*, kidney; *md*, Müllerian duct; *sr*, suprarenal body; *t*, testis; *w*, Wolffian body; *wd*, Wolffian duct.—(Mihalkovicz.)

become connected (Mihalkovicz), while others hold that they are formed by the splitting of the primary tubules or as buds from these (Braun, Janhosik).

By the formation of these additional tubules and the continued elongation of all, whereby they become thrown into numerous convolutions, the Wolffian ridge becomes a somewhat voluminous structure, projecting markedly



into the cœlomic cavity (Fig. 197). It is attached to the dorsal wall of the body by a distinct mesentery and has in its lateral portion, embedded in its substance, the Wolffian duct, while on its mesial surface anteriorly is the but slightly developed genital ridge (*t*). This condition is reached in the human embryo at about the sixth or seventh week of development, and after that period the mesonephros undergoes rapid degeneration, so that at about the sixteenth week nothing remains of it except the duct and a few small rudiments whose history will be given later.

**The Development of the Metanephros.**—The metanephros arises as an outgrowth from the dorsal surface of the Wolffian duct, shortly before its entrance into the cloaca (Fig. 156). The outgrowth is of a tubular form and, as it elongates, it comes to lie dorsal to the mesonephros, its anterior end enlarging and becoming lobed and also becoming surrounded by a condensation of mesenchyme which has been termed the *metanephric blastema*. The outgrowth, which represents the *ureter*, makes its appearance in embryos of about 5 mm., but its anterior end does not reach its final position in the neighborhood of the suprarenal body until the third month of development.

The development of the tubules of the metanephros has been studied most thoroughly in the rabbit, and the description which follows is based on what occurs in that animal. The extremity of the ureter early begins to branch within the substance of the blastema, and in embryos of twelve days it has given rise to two or three branches which branch again, each of the terminal branches ending in a distinct enlargement, a primary renal vesicle, which lies in the cortical portion of the blastema which by this time has formed a capsule for itself (Fig. 197, A). In embryos one day older each of the renal

vesicles has given rise to two or three prolongations which are coiled upon themselves in an S-shaped manner and represent urinary tubules (Figs. 198, B, and 199, A). In what would correspond with the lower loop of the S, a collection of mesenchyme appears into which at a later stage branches penetrate from the renal artery, producing a glomerulus, the wall of the tubule in this region becoming exceedingly thin to form a capsule of Bowman (Fig. 199, B, *bc*). At first the glomerulus lies close to the surface of the kidney, but as development proceeds it is gradually carried deeper into the cortical portion by the elongation of the portion of the tubule intervening between the glomerulus and the primary renal vesicle. This elongation affects at first the upper limb of the S, which is represented by the loop of Henle in the adult kidney, the portion between the loop and the glomerulus forming the first, and that between the loop and the renal vesicle the second, convoluted tubule (Fig. 199, C).

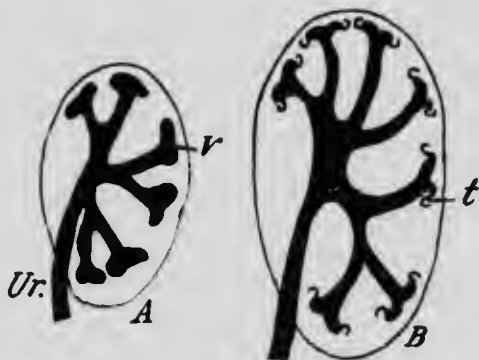


FIG. 198.—DIAGRAMS OF EARLY STAGES IN THE DEVELOPMENT OF THE METANEPHRIC TUBULES.

*t*, Urinary tubule; *Ur*, ureter; *v*, renal vesicle.—(Haycraft.)

In the mean time new tubules have arisen from the vesicle and have undergone a development similar to what occurs in the earlier formed ones, and the formation of new tubules continues until a large number has been produced from each renal vesicle, these eventually elongating to form the collecting tubules (Fig. 199, C). Up to the

time when the urinary tubules begin to develop there is no pelvis to the kidney, the ureter extending well toward the center of the blastema before beginning to branch and the branches thence extending to the cortex (Fig. 198). As soon as the tubules appear, however, the formation of the pelvis begins by what has been described as an evagination of the primary branches of the ureter to form a common cavity, a process which is beginning to

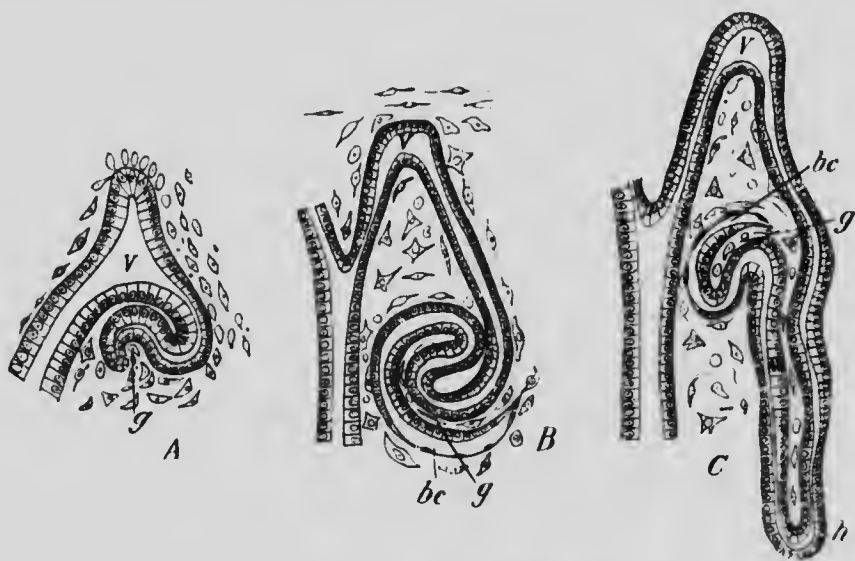


FIG. 199.—THREE STAGES IN THE DEVELOPMENT OF A URINIFEROUS TUBULE OF A RABBIT.  
bc, Bowman's capsule; g, glomerulus; h, loop of Henle; v, renal vesicle.  
—(Haycraft.)

manifest itself in the stage shown in Fig. 198, B, and which is continued until the secondary branches are also taken up into the cavity, into which the various collecting tubules then open separately.

At about the tenth week of development the surface of the human kidney becomes marked by shallow depressions into lobes, of which there are about eighteen, one corre-

sponding to each of the groups of tubules which arise from the same renal vesicle. This lobation persists until after birth and then disappears completely, the surface of the kidney becoming smooth.

From what has been said above it will be seen that the tubules of the metanephros are all derived from the original outgrowth which arises from the Wolffian duct; the tissue of the metanephric blastema gives rise only to the connective tissue and vessels of the kidney. It was at one time maintained that the ureters and collecting tubules were alone developed from the outgrowth, and that the tubules were formed independently in the blastema and only later united with the collecting tubules. The view presented above seems, however, to more nearly represent the actual processes of development.

**The Development of the Müllerian Duct and of the Genital Ridge.**—At the time when the Wolffian body has almost reached its greatest development a second longitudinal duct makes its appearance in close proximity to the Wolffian. This is known as the Müllerian duct (Fig. 200, *Md*). Its development is preceded by the appearance of a distinct ridge or fold upon the ventral surface of the Wolffian body, extending from the under surface of the diaphragm above to the urogenital sinus below and containing in the lower portion of its course the Wolffian duct (Fig. 197). Near the anterior end of the mesonephros there grows into this fold an evagination from the peritoneum covering the Wolffian ridge and by the proliferation of the cells at its tip this evagination gradually extends downward in the substance of the ridge, and in embryos of 22 mm. has reached the urogenital sinus. As they approach the sinus, the right and left evaginations or Müllerian ducts gradually approach one another and finally fuse together to form a single tube in the lower part of their course, but they remain distinct above, each tube retaining its original opening into the peritoneal cavity.

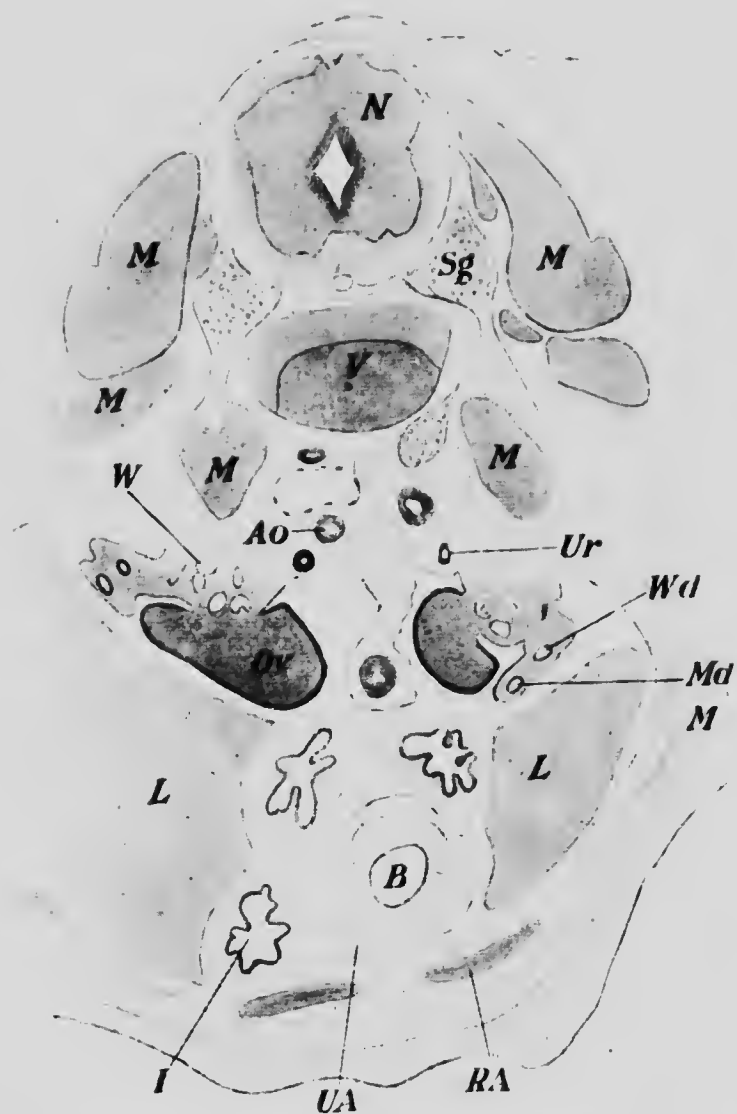



FIG. 200.—TRANSVERSE SECTION THROUGH THE ABDOMINAL REGION OF AN EMBRYO OF 25 MM.

Ao, Aorta; B, bladder; I, intestine; L, liver; M, muscle; Md, Müllerian duct; N, spinal cord; Or, ovary; RA, rectus abdominis; Sg, spinal ganglion; UA, umbilical artery; Ur, ureter; v, vertebra; W, Wolffian body; Wd, Wolffian duct.—(Keibel.)

The first indication of the appearance of the genital ridge is the assumption of a high columnar form by the epithelial cells of the upper part of the mesial surface of the Wolffian ridge, and shortly after this thickening of the epithelium has appeared a condensation of the underlying mesenchyme occurs (Fig. 194). At first the ridge is of insignificant dimensions compared with the more voluminous Wolffian body, but as the degeneration of the latter proceeds the relative size of the two structures becomes reversed and the genital ridge forms a marked prominence attached to the surface of the Wolffian ridge by a fold of peritoneum which becomes the *mesovarium* in the female and the *mesorchium* in the male. The fold which surrounds the Wolffian body becomes transformed on the degeneration of that structure into the *broad ligament*, the transverse position of which in the adult is due to the fusion of the lower portions of the Müllerian ducts, and since the genital ridges lie primarily to the median side of the ducts, they come to be attached by their mesentery to the dorsal surface of the broad ligament. The relations of the broad ligaments and mesorchia in the male become profoundly modified by the descent of the testes into the scrotum, a process to be described later (p. 388.)

From each genital ridge a prolongation of mesenchyme extends downward in the mesentery of the ridge, nearly parallel with the Müllerian duct, with which it comes into contact at the point where the two ducts fuse and thence is continued downward and forward between the folds of the broad ligament to be attached to the ventral wall of the abdomen in the inguinal region. The upper part of this prolongation of the genital ridge represents the *ligament of the ovary* and its lower part the *ligamentum teres* of the female (Fig. 201), while in the male the entire structure forms what is known as the *gubernaculum testis*.





MICROCOPY RESOLUTION TEST CHART  
NATIONAL BUREAU OF STANDARDS  
STANDARD REFERENCE MATERIAL 1010a  
(ANSI and ISO TEST CHART No. 2)



Although the histological differentiation of the genital ridge proceeds along similar lines in both sexes until about the fifth or sixth week, it seems convenient to consider separately the entire process of differentiation as it occurs in each sex.

*The Development of the Testis*—The earliest sign of development visible in the testis is a multiplication of the

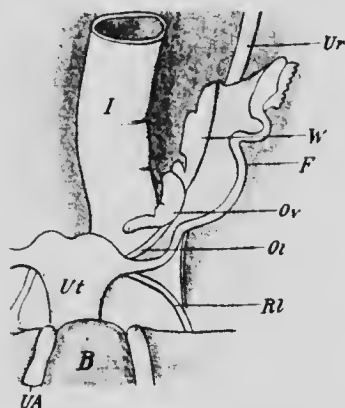


FIG. 201.—REPRODUCTIVE ORGANS OF A FEMALE EMBRYO OF SIX MONTHS.

*B*, Bladder; *F*, Fallopian tube; *I*, intestine; *Ol*, ovarian ligament; *Ov*, ovary; *Rl*, round ligament; *UA*, umbilical artery; *Ur*, ureter; *Ut*, uterus; *W*, Wolffian body (epöphoron). —(Adapted from Mihal-kovicz)

epithelial cells to form a thick layer, into the under surface of which deep bays extend from the subjacent mesenchyme, producing the appearance of cords of cells extending into the mesenchyme from the epithelium. These cords (Fig. 202, *cc*) consist of two kinds of cells, (1) elongated cells with a small amount of protoplasm, the epithelial cells, and (2) large spherical cells with more abundant, clear protoplasm, and termed sexual cells.

While the development is at this stage,—that is, at about the fourth or fifth week,—a structure makes its

appearance which serves to characterize the organ as a testis. This is a layer of connective tissue which grows in between the superficial and deep layers of the epithelium and gradually extends around the entire organ to form the *tunica albuginea*. Shortly after its appearance the cords of cells become broken up into more or less spherical masses by the growth into them of the surrounding mesen-

chyme, and into the substance of the testis there grow from the capsules of Bowman in the neighboring portions of the mesonephros cords of cells which form what are known as the *medullary cords* (Fig. 202, *mc*). One of these cords comes into relation with each of the spherical masses derived from the epithelium, and the cells of each mass, both the epithelial and the sexual, arrange themselves in a layer surrounding the enclosing wall of mesenchyme, al-

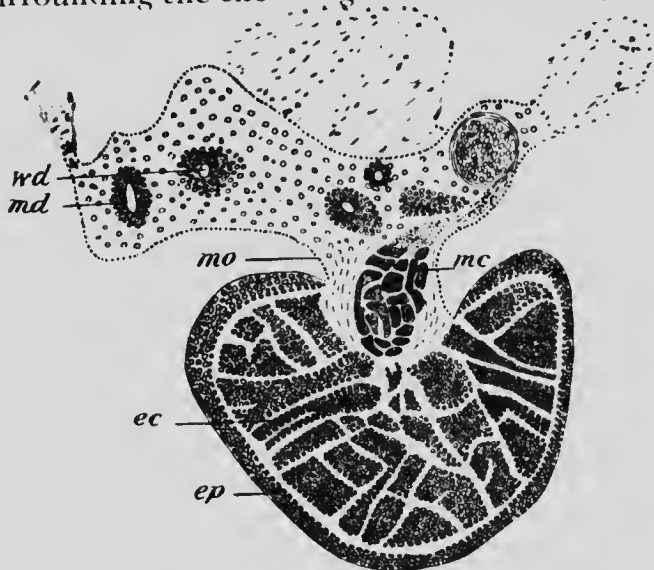


FIG. 202.—SECTION THROUGH THE TESTIS AND THE BROAD LIGAMENT OF THE TESTIS OF AN EMBRYO OF 5.5 MM.

*ec*, Epithelial cords; *ep*, epithelium; *mc*, medullary cords; *md*, Müllerian duct; *mo*, mesorchium; *wd*, Wolffian duct. (Mihalkovicz.)

though no lumen as yet occurs in any of them. This condition is reached at about the sixth week, and from this time onward until the approach of puberty, the changes which occur are limited to a growth in length of the medullary cords and epithelial masses, lumina not appearing in them until shortly before puberty.

As this period approaches the final differentiation of the testis is completed. A lumen appears in each epithelial

mass, which thus becomes a tubule, and the medullary cords are also transformed into tubules. The sexual cells begin to multiply and assume the form of spermatogonia (see p. 30), while the epithelial cells become transformed into Sertoli cells (Benda). There is some difference of opinion as to whether the medullary cords take any part in the formation of the seminiferous tubules of the adult testis; the probability seems to be in favor of the view that they do not, the *seminiferous tubules* being derived from the epithelial cords alone, while the medullary cords give rise to the *tubuli recti* and the capsules of Bowman from which they arise to the *rete testis*.

*The Development of the Ovary.*—The development of the ovary starts off on the same general lines as that of the testis, although there are important differences in the details. Two distinct elements are concerned, as in the case of the testis—namely, cords of cells derived from the epithelium of the genital ridge and prolongations from the uppermost tubules of the mesonephros; but the relations of the two elements and their differentiation are very different in the ovary.

The ovarian epithelial cords when fully developed consist of three well-defined portions: (1) a lower rather cylindrical portion, (2) an intermediate short and greatly thickened portion, and (3) an outer short cylindrical portion or neck (Fig. 203). Each cord so constituted corresponds to one of the epithelial cords of the testis, but whereas in the latter epithelial and sexual cells occur throughout the entire length of the cord, in the ovary the sexual cells are found only in the intermediate enlargement. At an early stage the lower cylindrical portions of the ovarian cords become separated from the intermediate portions by connective tissue and form what have been termed the medullary cords, though it is clear that

they are not homologous with the structures so named in the testis.

After this separation the intermediate portion of each cord is penetrated by bands of mesenchyme in such a manner that it becomes divided into secondary cylindrical cords known as *Pflüger's cords* (Fig. 204), and these latter again become divided transversely into rounded masses, the *Graafian follicles*, each of which contains, as a rule, but a single sexual



FIG. 203.—DIAGRAM OF AN EPITHELIAL INVAGINATION OF THE OVARY OF A RABBIT.

*ep*, Ovarial epithelium; *e*, intermediate enlargement containing germ cells; *i*, proximal cylindrical portion; *me*, medullary cord.—(von Winthaler.)

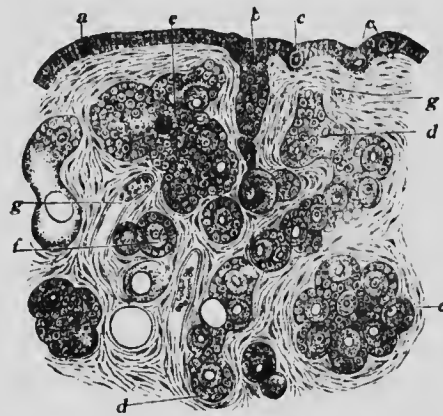


FIG. 204.—SECTION OF THE OVARY OF A NEW-BORN CHILD.

*a*, Ovarial epithelium; *b*, proximal part of an epithelial cord; *c*, germ cell in epithelium; *d*, intermediate enlargement of an epithelial cord; *e*, group of germ cells enclosed in a follicle; *f*, single germ cells with follicles; *g*, blood-vessel.—(From Gegenbaur, after Waldeyer.)

cell which is enclosed within a mass of epithelial cells, the whole being surrounded by a condensed zone of

mesenchyme, which eventually becomes richly vascularized and forms the *theca folliculi* (Fig. 9). The epithelial cells in each follicle are at first comparatively few in number and closely surround the sexual cell (Fig. 204, *c*) which is destined to become an ovum, but in certain of the follicles they undergo an increase by mitosis, becoming extremely numerous, and later secrete a fluid, the liquor folliculi, which collects at one side of the follicle and eventually forms a considerable portion of its contents. The follicular cells are differentiated by its appearance into the *stratum granulosum*, which surrounds the wall of the follicle, and the *discus proligerus*, in which the ovum is embedded (Fig. 9, *dp*), and the cells which immediately surround the ovum, becoming cylindrical in shape, give rise to the *corona radiata* (Fig. 10, *cr*).

The elements derived from the mesonephros which correspond to the medullary cords of the testis do not reach as extensive a development as in that organ and, indeed, do not really penetrate into the substance of the ovary, but form a network, the *rete ovarii*, lying in the mesovarium along the line of its junction with the ovary. In some mammals, such as the rabbit, they come into contact with the so-called ovarian medullary cords, the similarity to the conditions obtaining in the testis being thus greatly increased.

**The Transformation of the Mesonephros and the Ducts.**  
—At one period of development there are present, as representatives of the urinogenital apparatus, the Wolffian body (mesonephros) and its duct, the Müllerian duct, and the developing ovary or testis. Such a condition forms an indifferent stage from which the development proceeds in one of two directions according as the genital ridge becomes a testis or an ovary, the Wolffian body in part undergoing degeneration and in part persisting to form

organs which for the most part are rudimentary, while in the female the Wolffian duct also degenerates except for certain rudiments and in the male the Müllerian duct behaves similarly.

*In the Male.*—It has been seen that the upper portion of the Wolffian body, in giving rise to the medullary cords of the testis, enters into very intimate relations with that organ and may be regarded as divided into two portions, an upper genital and a lower excretory. In the male the genital portion of the body persists in its entirety, serving as the efferent ducts of the testis, which, beginning in the spaces of the rete testis, already shown to represent the capsules of Bowman, open into the upper part of the Wolffian duct and form the globus major of the *epididymis*. The excretory portion undergoes extensive degeneration, a portion of it persisting as a mass of coiled tubules ending blindly at both ends, situated near the head of the epididymis and known as the *paradidymis* or *organ of Giralde*s, while a single elongated tubule, arising from the portion of the Wolffian duct which forms the globus minor of the epididymis, represents another portion of it and is known as the *vas aberrans*.

The Wolffian duct is retained complete, the portion of it nearest the testis becoming greatly elongated and thrown into numerous coils, forming the body and globus minor of the epididymis, while the remainder of it is converted into the *vas deferens* and the *ductus ejaculatorius*. A lateral outpouching of the wall of the duct to form a longitudinal fold appears at about the third month and gives rise to the *vesicula seminalis*, the lateral position of the outgrowth explaining the adult position of the vesiculæ lateral to the vasa deferentia.

With the Müllerian duct the case is very different, since it disappears completely throughout the greater part of its



*sinus pocularis*, which is usually prolonged upward into a short cylindrical pouch known as the *uterus masculinus*, though it corresponds to the vagina rather than to the uterus of the female.

*In the Female.*—In the female the genital portion of the mesonephros, though never functional as ducts, persists as a group of ten to fifteen tubules, situated between the two layers of the broad ligament and in close proximity to the ovary; these constitute what is known as the *epoöphoron* (*parovarium* or *organ of Rosenmüller*). The tubules are straight at the ends nearest the ovary, but at the other ends where they are somewhat coiled, they open into a common duct which represents the upper end of the Wolffian duct. Near this rudimentary body is another, also composed of tubules, representing the remains of the excretory portion of the mesonephros and termed the *paroöphoron*. So far as the mesonephros is concerned, therefore, the persisting rudiments in the female are comparable to those occurring in the male.

As regards the ducts, however, the case is different, for in the female it is the Müllerian ducts which persist, while the Wolffians undergo degeneration, a small portion of their upper ends persisting in connection with the epoöphora, while their lower ends persist as straight tubules lying at the sides of the vagina and forming what are known as the *canals of Gärtner*. The Müllerian ducts, on the other hand, become converted into the *Fallopian tubes*, and in their lower portions into the *uterus* and *vagina*. From the margins of the openings by which the Müllerian ducts communicate with the cœlom projections develop at an early period and give rise to the *fimbriæ*, with the exception of the one connected with the ovary, the *fimbria ovarica*, which is the upper persisting portion of the original genital ridge, its lower portion, below the ovary, being represented by the ovarian and inguinal



ligament already described. It has been seen that the lower portions of the Müllerian ducts fuse together to form a single canal, and it is from this that the uterus and vagina are differentiated, the histological distinction of the two portions commencing to manifest itself at about the third month. During the fourth month the vaginal portion of the duct becomes flattened and the epithelium lining its lumen fuses so as to completely occlude it and, a little later, there appears near its lower opening a distinct semicircular fold attached to its dorsal margin. This is the *hymen*, a structure which seems to be represented in the male by the *veru montanum*. The obliteration of the lumen of the vagina persists until about the sixth month, when the cavity is re-established by the breaking down of the central epithelial cells.

The diagram, Fig. 205, illustrates the transformation from the indifferent condition which occurs in the two sexes, and that the homologies of the various parts may be clearly understood they may also be stated in tabular form as follows:

INDIFFERENT STAGE.	MALE.	FEMALE.
Genital ridge, . . . . .	Testis. Gubernaculum.	Fimbria ovarica. Ovary. Ovarian ligament. Round ligament.
Wolffian body, . . . . .	Globus major of epididymis. Paradidymis. Vasa aberrantia.	Epoöphoron. Paroöphoron. . . . . .
Wolffian ducts, . . . . .	Body and globus minor of epididymis. Vasa deferentia. Ejaculatory ducts.	Collecting tubules of epoöphoron. . . . . . Canals of Gärtner.
Müllerian ducts, . . . . .	Sessile hydatid. Uterus masculinus.	Fallopian tubes. Uterus. Vagina.

In addition to the sessile hydatid, a *stalked hydatid* also occurs in connection with the testis, and a similar structure is attached to the fimbriated opening of each Fallopian tube. The significance of these structures is uncertain, though it has been suggested that they are persisting rudiments of the pronephros.

A failure of the development of the various parts just described to be completed in the normal manner leads to various abnormalities in connection with the reproductive organs. Thus there may occur a failure in the fusion of the lower portions of the Müllerian ducts, a bihorned or bipartite uterus resulting, or the two ducts may come into contact and their adjacent walls fail to disappear, the result being a median partition separating the vagina or both the vagina and uterus into two compartments. The excessive development of the fold which gives rise to the hymen may lead to a complete closure of the lower opening of the vagina, while, on the other hand, a failure of the Müllerian ducts to fuse may produce a biperforate hymen.

**The Development of the Urinary Bladder and the Urogenital Sinus.**—So far the relations of the lower ends of the urinogenital ducts have not been considered in detail, although it has been seen that in the early stages of development the Wolffian and Müllerian ducts open into the sides of the ventral portion of the cloaca; that the ureters communicate with the lower portions of the Wolffian ducts; that from the ventral anterior portion of the cloaca the allantoic duct extends outward into the belly-stalk; and, finally (p. 297), that the cloaca becomes divided into a dorsal portion, which forms the lower part of the rectum, and a ventral portion, which is continuous with the allantois and receives the urinogenital ducts (Fig. 206). It is the history of this ventral portion of the cloaca which is now to be considered.

It may be regarded as consisting of two portions, an anterior and a posterior, the line of insertion of the urinogenital ducts marking the junction of the two. The anterior or upper portion is destined to give rise to the urinary

bladder (Fig. 206, *b*), while the lower one forms what is known for a time as the urogenital sinus (*sg*). The bladder, when first differentiated, is a tubular structure, whose lumen is continuous with that of the allantois, but after the second month it enlarges to become more sac-like, while the intra-embryonic portion of the allantois degenerates to a solid cord extending from the apex of the bladder to the

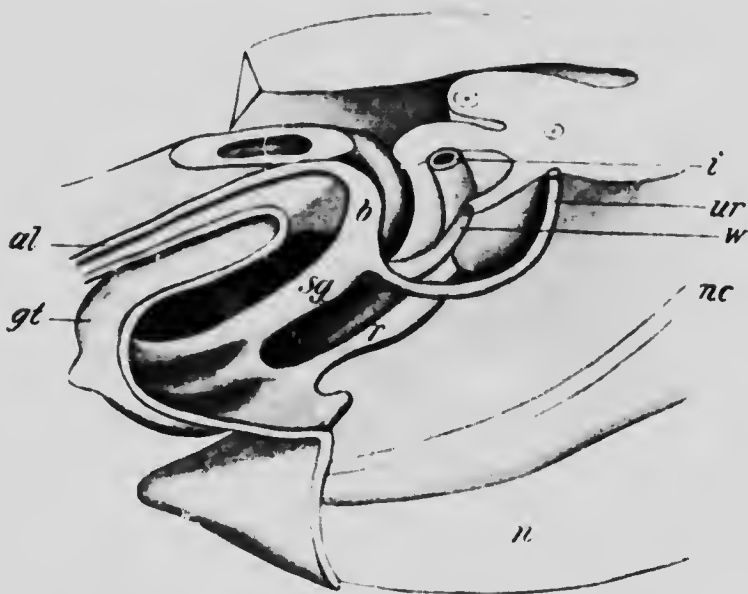


FIG. 206.—RECONSTRUCTION OF THE CLOACAL REGION OF AN EMBRYO OF 14 MM.

*al*, Allantois; *b*, bladder; *gt*, genital tubercle; *i*, intestine; *n*, spinal cord; *nc*, notochord; *r*, rectum; *sg*, urogenital sinus; *ur*, ureter; *w*, Wolffian duct.—(Kcibel.)

umbilicus and is known as the *urachus*. During the enlargement of the bladder the terminal portions of the urogenital ducts become taken up into its walls, a process which continues until finally the ureters and Wolffian ducts open into it separately, the ureters opening to the sides of and a little anterior to the ducts. This condition is reached in embryos of about 14 mm. (Fig. 206), and in

later stages the interval between the two pairs of ducts is increased (Fig. 207), resulting in the formation of a short canal connecting the lower end of the bladder which receives the ureters with the upper end of the urogenital sinns, into which the Wolffian and Müllerian ducts open. This connecting canal represents the *urethra* (Fig. 207, *ur*), or rather the entire urethra of the female and the

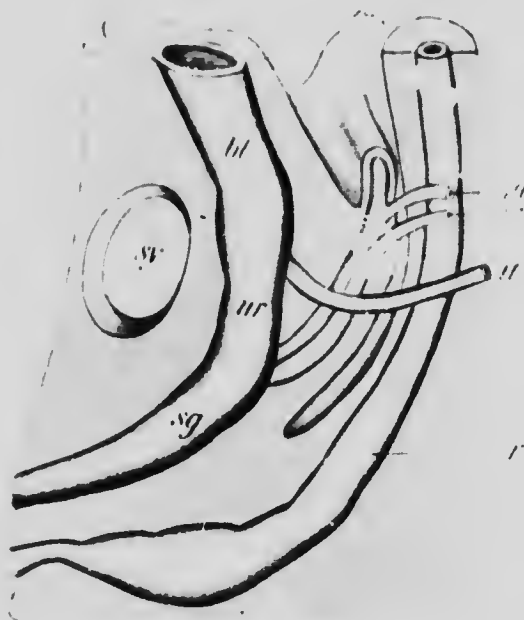


FIG. 207. RECONSTRUCTION OF THE CLOACAL STRUCTURES OF AN EMBRYO OF 25 MM.

*bl*, Bladder; *m*, Müllerian duct; *r*, rectum; *sg*, urogenital sinus; *st*, symphysis pubis; *u*, ureter; *ur*, urethra; *w*, Wolffian duct.—(Adapted from Keibel.)

proximal part of that of the male, since a considerable portion of the latter canal is still undeveloped (see p. 386). From this urethra there is developed, at about the third month, a series of solid longitudinal folds which project upon the outer surface and separate from the urethra from above downward. These represent the tubules of the

*prostate gland* and are developed in both sexes, although they remain in a somewhat rudimentary condition in the female. The muscular tissue, so characteristic of the gland in the adult male, is developed from the surrounding mesenchyme at a later stage.

The urogenital sinus is in the early stages also tubular in its upper part, though it expands considerably below, where it is closed by the cloacal membrane. This, by the separation of the cloaca into rectum and sinus, has become divided into two portions, the more ventral of which closes the sinus and the dorsal the rectum, the interval between them having become considerably thickened to form the *perineal body*. In embryos of about 17 mm. the urogenital portion of the membrane has broken through, and in later stages the tubular portion of the sinus is gradually taken up into the more expanded lower portion, until finally the entire sinus forms a shallow depression, termed the *vestibule*, into the upper part of which the urethra opens, while below are the openings of the Wolffian (ejaculatory) ducts in the male or the orifice of the vagina in the female. From the sides of the lower part of the sinus a pair of evaginations arise toward the end of the fourth month and give rise to the *glands of Bartholin* of the female or the corresponding *Cowper's glands* in the male.

**The Development of the External Genitalia.**—At about the fifth week, before the urogenital sinus has opened to the exterior, the mesenchyme on its ventral wall begins to thicken, producing a slight projection to the exterior. This eminence, which is known as the *genital tubercle* (Fig. 206, *gt*), rapidly increases in size, its extremity becomes somewhat bulbously enlarged (Fig. 208, *gl*) and a groove, extending to the base of the terminal enlargement, appears upon its vestibular surface, the lips of the groove forming two well-marked *genital folds* (Fig. 208, *gf*). At about the

tenth week there appears on either side of the tubercle an enlargement termed the *genital swelling* (Fig. 208, *gs*), which is due to a thickening of the mesenchyme of the lower part of the ventral abdominal wall in the region where the inguinal ligament is attached, and with the appearance of these structures the indifferent stage of the external genitals is completed.

In the female the growth of the genital tubercle proceeds rather slowly and it becomes transformed into the *clitoris*, the genital folds becoming prolonged to form the



FIG. 208.—THE EXTERNAL GENITALIA OF AN EMBRYO OF 25 MM.  
*a*, Anus; *gj*, genital fold; *gl*, glans; *gs*, genital swelling; *p*, perineal body.  
 —(Keibel.)

*labia minora*. The genital swellings increase in size, their mesenchyme becomes transformed into a mass of adipose and fibrous tissue and they become converted into the *labia majora*, the interval between them constituting the *vulva*.

In the male the early stages of development are closely similar to those of the female; indeed, it has been well said that the external genitals of the adult female resemble those of the fetal male. In early stages the genital tubercle elongates to form the *penis* and the integument which covers the proximal part of it grows forward as a fold

which encloses the bulbous enlargement or *glans* and forms the *prepuce*, whose epithelium fuses with that covering the glans and only separates from it later by a cornification of the cells along the plane of fusion. The genital folds meet together and fuse, converting the vestibule and the groove upon the vestibular surface of the penis into the terminal portion of the male urethra and bringing it about that the vasa deferentia and the uterus masculinus open upon the floor of that passage. The two genital swellings are at the same time brought closer together, so as to lie between the base of the penis and the perineal body and, eventually, they unite together to form the *scrotum*, the line of their junction being indicated by the median raphe. The mesenchyme of which they were primarily composed differentiates into the same layers as are found in the wall of the abdomen and a peritoneal pouch is prolonged into them from the abdomen, so that they form sacs into which the testes descend toward the close of fetal life (see p. 388).

The homologies of the portions of the reproductive apparatus derived from the cloaca and of the external genitalia in the two sexes may be perceived from the following table:

	MALE.	FEMALE.
	Urinary bladder.	Urinary bladder.
	Proximal portion of urethra.	Urethra.
	Cowper's glands.	Glands of Bartholin.
Urogenital sinus, . . .	The rest of the urethra.	Vestibule.
Genital tubercle, . . .	Penis.	Clitoris.
Genital folds, . . . . .	Prepuce.	Labia minora.
Genital swellings, . . .	Scrotum.	Labia majora.

It is stated above that the layers which compose the walls of

the scrotum are identical with those of the abdominal wall. This may be seen in detail from the following scheme:

ABDOMINAL WALLS.	SCROTUM.
Integument.	Integument.
Superficial fascia	Dartos.
External oblique muscle.	Intercolumnar fascia.
Internal oblique muscle.	Cremasteric fascia.
Transversalis muscle.	Infundibuliform fascia.
Peritoneum.	Tunica vaginalis.

Numerous anomalies, depending upon an inhibition or excess of the development of the parts, may occur in connection with the external genitalia. Should, for instance, the lips of the groove on the vestibular surface of the penis fail to fuse, the penial portion of the urethra remains incomplete, constituting a condition known as *hypospadias*, a condition which offers a serious bar to the fulfilment of the sexual act. If the *hypospadias* is complete and there be at the same time an imperfect development of the penis, as frequently occurs in such cases, the male genitalia closely resemble those of the female and a condition is produced which is usually known as *hermaphroditism*. It is noteworthy that in such cases there is frequently a somewhat excessive development of the uterus masculinus, and a similar condition may be produced in the female by an excessive development of the clitoris. Such cases, however, which concern only the accessory organs of reproduction, are instances of what is more properly termed *spurious hermaphroditism*, true hermaphroditism being a term which should be reserved for possible cases in which the genital ridges give rise in the same individual to both ova and spermatozoa. Such cases are of exceeding rarity in the human species, although occasionally observed in the lower vertebrates, and the great majority of the examples of hermaphroditism hitherto observed are cases of the spurious variety.

**The Descent of the Ovaries and Testes.**—The positions finally occupied by the ovaries and testes are very different from those which they possess in the earlier stages of development, and this is especially true in the case of the testes. The change of position is partly due to the rate of growth of the inguinal ligaments being less than that



of the abdominal walls, the reproductive organs being thereby drawn downward toward the inguinal regions where the ligaments are attached. The attachment is to the bottom of a slight pouch of peritoneum which projects a short distance into the substance of the genital swellings and is known as the *canal of Nuck* in the female, and in the male as the *vaginal process*.

In the female a second factor combines with that just mentioned. The relative shortening of the inguinal ligaments acting alone would draw the ovaries toward the inguinal regions, but the fusion of the lower ends of the Müllerian ducts, since the inguinal ligaments are united with these (see p. 371), produces a traction toward the median line, so that the organs come to lie finally in the true pelvis.

With the testes the case is more complicated, since in addition to the relative shortening of the inguinal ligaments, there is an elongation of the vaginal processes into the substance of the genital swellings. Three stages may be recognized in the descent of the testes. The first of these depends on the slow rate of elongation of the inguinal ligaments or gubernaculum. It lasts until about the fifth month of development, when the testes lie in the inguinal region of the abdomen, but during this month the elongation of the gubernaculum becomes more rapid and brings about the second stage, during which there is a slight ascent of the testes, so that they come to lie a little higher in the abdomen. This stage is, however, of short duration, and is succeeded by the stage of the final descent, which is characterized by the elongation of the vaginal processes of the peritoneum into the substance of the scrotum (Fig. 209, A). Since the gubernaculum is attached to the bottom of the process, and since its growth has again diminished, the testes gradually assume again

their inguinal position, and are finally drawn down into the scrotum, slipping down between the walls of the vaginal processes and the infundibuliform fascia, which, together with the other layers composing the scrotal wall, are differentiated at about this time.

The condition which is thus acquired persists for some time after birth, the testicles being readily pushed upward into the abdominal cavity along the cavity by which they descended. Later, however, the size of the openings

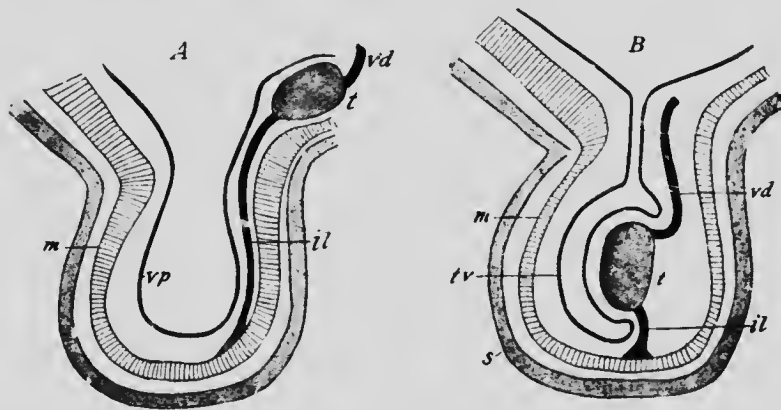


FIG. 209.—DIAGRAMS ILLUSTRATING THE DESCENT OF THE TESTIS.  
*il*, Inguinal ligament; *m*, muscular layer; *s*, skin and dartos of the scrotum; *t*, testis; *tv*, tunica vaginalis; *vd*, vas deferens; *vp*, vaginal process of peritoneum.—(After Hertwig.)

of the vaginal processes into the general peritoneal cavity becomes greatly reduced, so that each process becomes converted into an upper narrow neck and a lower sac-like cavity (Fig. 209, B), and, still later, the walls of the neck portion fuse and become converted into a solid cord, while the lower portion, wrapping itself around the testis, becomes the *tunica vaginalis* (*tv*). By these changes the testes become permanently located in the scrotum. During their descent the testes are drawn downward out of the mesenteries, the mesorchia, in which they were origi-

nally enclosed, and these structures flatten out and disappear, and, since the remains of each Wolffian body, the epididymis, and the upper part of each vas deferens, together with the spermatic vessels and nerves, are drawn down into the scrotum with each testis, the mesenterial fold comparable to the broad ligament of the female also practically disappears, becoming converted into a sheath of connective tissue which encloses the vas deferens and the vessels and nerves, binding them together into what is termed the *spermatic cord*.

In the text-books of anatomy the spermatic cord is usually described as lying in an *inguinal canal* which traverses the abdominal walls obliquely immediately above Poupart's ligament. So long as the lumen of the neck portion of the vaginal process of peritoneum remains patent there is such a canal, placing the cavity of the tunica vaginalis in communication with the general peritoneal cavity, but the cord does not traverse this canal but lies outside it in the retroperitoneal connective tissue. When, however, the neck of the vaginal process disappears, a canal no longer exists, although the connective tissue which surrounds the spermatic cord and unites it with the tissues of the abdominal walls is less dense than the neighboring tissues, so that the cord may readily be separated from these and thus appear to lie in a canal.

**The Development of the Suprarenal Bodies.**—The suprarenal bodies make their appearance at an early stage, while the Wolffian bodies are still in a well-developed condition, and they are situated at first to the medial side of the upper ends of these structures (Fig. 197, *sr*). Their final relation to the metanephros is a secondary event, and in merely a topographic relation, there being no developmental relation between the two structures.

Their development has been very variously described. In the Mammalia they arise by the proliferation of cells situated at the extremities of invaginations of the coelomic epithelium into the Wolffian ridge (Fig. 210), the groups

of cells so formed from the several invaginations later uniting together to form a relatively large organ. The invaginations resemble closely in appearance and position the tubules and funnels of the pronephros (see p. 361), and they have recently (Aichel) been regarded as representing funnels belonging to the mesonephros. One of the characteristics of the mammalian mesonephros is that it possesses no nephrostomes, but in the lower vertebrates such structures do occur, and it is possible that the invaginations of the coelomic epithelium which give rise to the suprarenals may be representatives of certain meso-

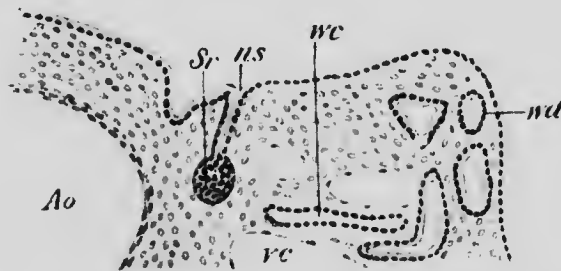


FIG. 210.—SECTION THROUGH A PORTION OF THE WOLFFIAN RIDGE OF A RABBIT EMBRYO OF 6.7 MM.

Ao, Aorta; ns, nephrostome; Sr, suprarenal body; vc, cardinal vein; wc, tubule of Wolffian body; wd, Wolffian duct.—(Aichel.)

nephric funnels which have failed to unite with the tubules and have undergone a secondary transformation.

That the suprarenals are primarily connected with the mesonephros becomes exceedingly probable from the fact that similar structures, known as the *accessory suprarenals of Marchand*, not infrequently occur between the layers of the broad ligament of the female and in the vicinity of the epididymis in the male and are developed from the degenerating tubules of the epoöphoron or paroöphoron, and presumably from the corresponding structures in the male.

It is doubtful, however, if the entire mass of the suprarenal organs is derived from the constituents furnished by the mesonephros, although this is the view maintained by the most recent investigator of the subject (Aichel). In the fully formed organs a clear distinction obtains between the cortical and medullary portions, and earlier observers very generally maintained that the latter was derived from cells which separated from the neighboring ganglia of the sympathetic nervous system. Strong support is afforded to this view by the close connections which exist between the organs and the sympathetic nervous system in the adult condition, and also by the fact that the cells of the medullary substance possess a strong affinity for chromium salts, assuming a distinctly brown color when treated with solutions of these salts. The same chrom-affine nature is characteristic of the cells of certain other organs, such as the intercarotid ganglia and Zuckerkandl's organs (see p. 450), whose origin from the sympathetic system seems to be beyond question.

It is probable, therefore, that the suprarenal organs are formed by a combination of two constituents, one of which, derived from the mesonephros, forms the cortical portion of the organs, while the other, having its origin from the sympathetic ganglia, gives rise to the medullary portion. The mesenchyme in the vicinity of each organ condenses around it to form a capsule, and the organs in later stages receive a rich blood-supply.

#### LITERATURE.

- O. AICHEL: "Vergleichende Entwicklungsgeschichte und Stammesgeschichte der Nebennieren," *Archiv für mikrosk. Anat.*, LVI, 1900.
- O. FRÄNKEL: "Beiträge zur Lehre vom Descensus testicularum," *Sitzungsber. des kais. Akad. Wissensch. Wien, Math.-Naturwiss. Classe*, CIX, 1900

- J. B. HAYCRAFT: "The Development of the Kidney in the Rabbit," *Internat. Monatsschrift für Anat. und Physiol.*, XII, 1898.
- J. JANOSIK: "Histologisch-embryologische Untersuchungen über das Urogenitalsystem," *Sitzungsber. der kais. Akad. Wissensch. Wien, Math.-Naturwiss. Classe*, xci, 1887.
- F. KEIBEL: "Zur Entwicklungsgeschichte des menschlichen Urogenitalapparatus," *Archiv für Anat. und Physiol., Anat. Abth.*, 1896.
- J. B. MACALLUM: "Notes on the Wolffian Body of Higher Mammals," *Amer. Journ. of Anat.*, I, 1902.
- E. MARTIN: "Ueber die Anlage der Urniere beim Kaninchen," *Archiv für Anat. und Physiol., Anat. Abth.*, 1888.
- H. MEYER: "Die Entwicklung der Urnieren beim Menschen," *Archiv für mikrosk. Anat.*, xxxvi, 1890.
- G. VON MIHALKOVICZ: "Untersuchungen über die Entwicklung des Harn- und Geschlechtsapparates der Amnioten," *Internat. Monatsschrift für Anat. und Physiol.*, II, 1885.
- V. NAGEL: "Ueber die Entwicklung des Urogenitalsystems des Menschen," *Archiv für mikrosk. Anat.*, xxxiv, 1889.
- W. NAGEL: "Ueber die Entwicklung des Uterus und der Vagina beim Menschen," *Archiv für mikrosk. Anat.*, xxxvii, 1891.
- W. NAGEL: "Ueber die Entwicklung der innere und äussere Genitalien beim menschlichen Weiber," *Archiv für Gynäkol.*, xlv, 1894.
- G. PALLIN: "Beiträge zur Anatomie der Prostata und der Samenblasen," *Archiv für Anat. und Physiol., Anat. Abth.*, 1901.
- A. SOULIÉ: "Sur la migration des Testicules," *Comptes Rendus de la Soc. de Biol. Paris*, Sér 10me, II, 1895.
- A. SOULIÉ: "Sur le nécanisme de la migration des testicules," *Comptes Rendus de la Soc. de Biol. Paris*, Sér 10me, II, 1895.
- F. TOURNEUX: "Sur le développement et l'évolution du tubercule genital chez le fœtus humain dans les deux sexes," *Journ. de l'Anat. et de la Physiol.*, xxv, 1889.
- S. WEBER: "Zur Entwicklungsgeschichte des uropoetischen Apparates bei Säugern, mit besonderer Berücksichtigung der Urniere zur Zeit des Auftretens der bleibenden Niere," *Morphol. Arbeiten*, VII, 1897.
- P. WENDELER: "Die fötale Entwicklung der menschlichen Tuben," *Archiv für mikrosk. Anat.*, xlv, 1895.
- H. VON WINIWARTER: "Recherches sur l'ovogenèse et l'organogenèse de l'ovaire des Mammifères" (Lapin et Homme), *Archives de Biol.*, xvii, 1900.

## CHAPTER XIV.

### THE DEVELOPMENT OF THE NERVOUS SYSTEM.

**The Histogenesis of the Nervous System.**—The entire central nervous system is derived from the cells lining the medullary groove, whose formation and conversion into the medullary canal has already been described (p. 114). When the groove is first formed, the cells lining it are somewhat more columnar in shape than those on either side of it, though like them they are arranged in a single layer; later they increase by mitotic division and arrange themselves in several layers, so that the ectoderm of the groove becomes very much thicker than that of the general surface of the body. While its tissue is in this condition the lips of the groove unite, and the subsequent differentiation of the canal so formed differs somewhat in different regions, although a fundamental plan may be recognized. This plan is most readily perceived in the region which becomes the spinal cord, and may be described as seen in that region.

Throughout the earlier stages, the cells lining the inner wall of the medullary tube are found in active proliferation, some of the cells so produced arranging themselves with their long axes at right angles to the central canal and extending throughout the entire thickness of the wall to form a supportive framework (Fig. 211), while others, whose destiny is for the most part not yet determinable, and which therefore may be termed *indifferent cells*, occur in the meshes of this framework. At this

stage a transverse section of the medullary tube shows it to be composed of two well-defined zones, an inner one immediately surrounding the central canal and composed of the indifferent cells and the bodies of the supportive or *ependymal cells*, and an outer one consisting of the branched prolongations of the ependymal cells. This outer layer is termed

the *marginal velum* (Randsschleier) (Fig. 211, *mv*). The indifferent cells now begin to wander outward to form a definite layer, termed the *mantle layer*, lying between the marginal velum and the bodies of the ependymal cells (Fig. 212), and when this layer has become well established the cells composing it begin to divide and to differentiate into (1) cells termed *neuroblasts*, destined to become

nerve-cells, and (2) others which appear to be supportive in character and are termed *neuroglia cells* (Fig. 212, B). The latter are for the most part small and have their cell-bodies drawn out into very numerous and exceedingly slender processes, which ramify among the neuroblasts, these, on the other hand, being larger and each




FIG. 211.—EPENDYMAL CELLS FROM THE SPINAL CORD OF AN EMBRYO OF 4.25 MM.

*mv*, Marginal velum.—(His.)



early developing a single strong process which grows out into the marginal velum and is known as an *axis-cylinder*. At a later period the neuroblasts also give rise to other processes, termed *dendrites*, more slender and shorter than the axis-cylinders, branching repeatedly and, as a rule, not extending beyond the limits of the mantle layer.

The axis-cylinder processes of the majority of the neuro-

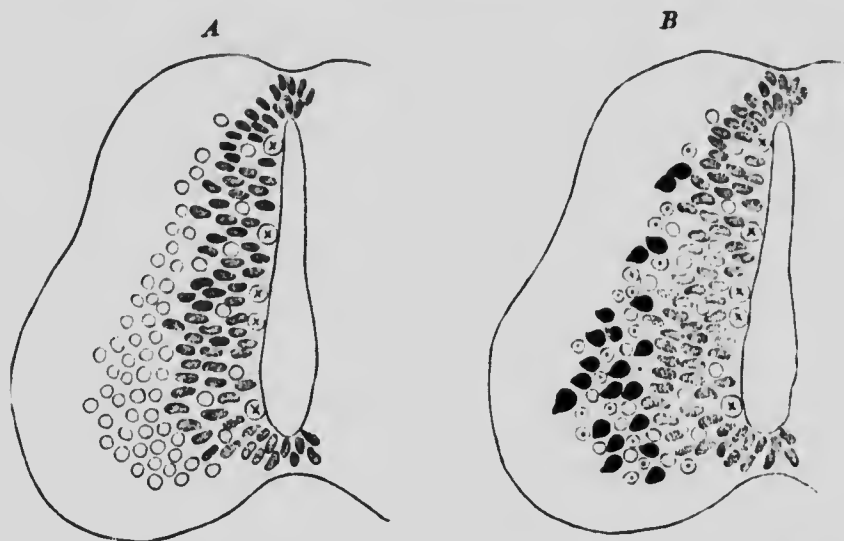


FIG. 212.—DIAGRAMS SHOWING THE DEVELOPMENT OF THE MANTLE LAYER IN THE SPINAL CORD.

The circles, indifferent cells; circles with dots, neuroglia cells; shaded cells, germinal cells; circles with cross, germinal cells in mitosis; black cells, nerve-cells.—(Schaper.)

blasts on reaching the marginal velum bend upward or downward and, after traversing a greater or less length of the cord, re-enter the mantle layer and terminate by dividing into numerous short branches which come into relation with the dendrites of adjacent neuroblasts. The processes of certain cells situated in the ventral region of the mantle zone pass, however, directly through the

marginal velum out into the surrounding tissues and constitute the *ventral nerve-roots* (Fig. 215).

The *dorsal nerve-roots* have a very different origin. In embryos of about 2.5 mm., in which the medullary canal is only partly closed (Fig. 42), the cells which lie along the line of transition between the lips of the groove and the general ectoderm form a distinct ridge readily recognized in sections and termed the *neural ridge*

(Fig. 213, A). When the lips of the groove fuse together the cells of the crest unite to form a wedge-shaped mass, completing the closure of the canal (Fig. 213, B), and later proliferate so as to extend outward over the surface of the canal (Fig. 213, C). Since this proliferation is most active in the regions of the crest which correspond to the mesodermic somites there is

formed a series of cell masses, arranged segmentally and situated in the mesenchyme at the sides of the medullary canal (Fig. 200). These cell-masses represent the *posterior root ganglia*, and certain of their constituent cells, which may also be termed neuroblasts, early assume a fusiform shape and send out a process from each extremity. One of these processes, the axis-cylinder, grows inward toward the medullary canal and penetrates

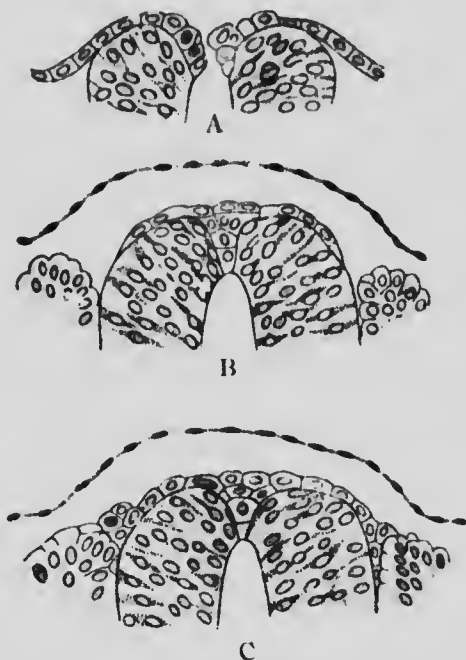


FIG. 213.—THREE SECTIONS THROUGH THE MEDULLARY CANAL OF AN EMBRYO OF 2.5 MM.—(von Lenhossek.)

its marginal velum, and, after a longer or shorter course in this zone, enters the mantle layer and comes into contact with the dendrites of some of the central neuroblasts. The other process extends peripherally and is to be regarded as an extremely elongated dendrite. The processes from the cells of each ganglion aggregate to form a nerve, that formed by the axis-cylinders being the posterior root of a spinal nerve, while that formed by the dendrites soon unites with the ventral nerve-root of the corresponding segment to form the main stem of a spinal nerve.

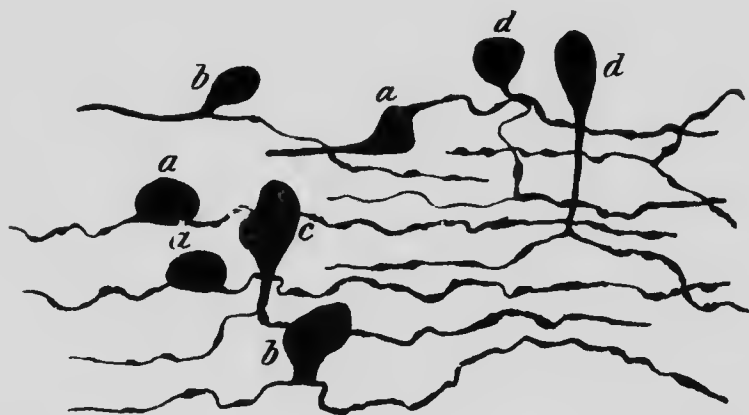


FIG. 214.— CELLS FROM THE GASSERIAN GANGLION OF A GUINEA-PIG EMBRYO.

*a*, Bipolar cell; *b* and *c*, transitional stages to *d*, T-shaped cells. (van Gehuchten.)

There is thus a very important difference in the modes of development of the two nerve-roots, the axis-cylinders of the ventral roots arising from cells situated in the wall of the medullary canal and growing outward (centrifugally), while those of the dorsal root spring from cells situated peripherally and grow inward (centripetally) toward the medullary canal. In the majority of the dorsal root ganglia the points of origin of the two processes of each bipolar cell gradually approach one another and eventually

come to arise from a common stem, a process of the cell-body which thus assumes a characteristic T form.

From what has been said it will be seen that each axis-cylinder is an outgrowth from a single neuroblast and is part of its cell-body, as are also the dendrites. Consequently there is strong embryological evidence in support of the *neurone theory*, which regards the entire nervous system as composed of separate units, each of which corresponds to a cell and is termed a neurone. Doubts have recently been thrown on the complete individuality of the neurones in the adult (Apathy, Bethe), but both from the embryological and physiological standpoints their primary distinction seems to be established.

By the development of the axis-cylinders which occupy the meshes of the marginal velum, that zone increases in thickness and comes to consist principally of nerve-fibers, while the cell-bodies of the neurones of the cord are situated in the mantle zone. No such definite distinction of color in the two zones as exists in the adult is, however, noticeable until a late period of development, the *medullary sheaths*, which give to the nerve-fibers their white appearance not beginning to appear until the fifth month and continuing to form from that time onward until after birth. The origin of the myelin which composes the medullary sheaths is as yet uncertain, although the more recent observations tend to show that it is picked out from the blood and deposited around the axis-cylinders in some manner not yet understood. Its appearance is of importance as being associated with the beginning of the functional activity of the nerve-fibers.

Various theories have been advanced to account for the formation of the medullary sheaths. It has been held that the myelin is formed at the expense of the outermost portions of the axis-cylinders themselves (von Kölliker), and, on the other hand, it has been regarded as an excretion of the cells which compose the primitive sheaths surrounding the fibers (Ranvier), a theory which is, however, invalidated by the fact that myelin

is formed around the fibers of the central nervous system which possess no primitive sheaths. As stated above, the more recent observations (Wlassak) indicate its exogenous origin.

It has been seen that the central canal is closed in the mid-dorsal line by a mass of cells derived from the neural crest. These cells do not take part in the formation of the mantle layer, but become completely converted into ependymal tissue, and the same is true of the cells situated in the mid-ventral line of the canal. In these two regions, known as the *roof-plate* and *floor-plate* respectively, the wall of the canal has a characteristic structure and does not share to any great extent in the increase of thickness which distinguishes the other regions (Fig. 215). In the lateral walls of the canal there is also noticeable a differentiation into two regions, a dorsal one standing in relation to the ingrowing fibers from the dorsal root ganglia and known as the *dorsal zone*, and a ventral one, the *ventral zone*, similarly related to the ventral nerve-roots. In different regions of the medullary tube these zones, as well as the roof- and floor-plates, undergo different degrees of development, producing peculiarities which may now be considered.

**The Development of the Spinal Cord.**—Even before the lips of the medullary groove have met a marked enlargement of the anterior portion of the canal is noticeable, the region which will become the brain being thus distinguished from the more posterior portion which will be converted into the spinal cord. When the formation of the mesodermic somites is completed, the spinal cord terminates at the level of the last somite, and in this region still retains its connection with the ectoderm of the dorsal surface of the body; but in that portion of the cord which is posterior to the first coccygeal segment the histological differentiation does not proceed beyond the stage

when the walls consist of several layers of similar cells; the formation of neuroblasts and nerve-roots ceasing with the segment named. After the fourth month the more differentiated portion elongates at a much slower rate than the surrounding tissues and so appears to recede up the spinal canal, until its termination is opposite the second lumbar vertebra. The less differentiated portion, which retains its connection with the ectoderm until about the fifth month, is, on the other hand, drawn out into a slender filament whose cells degenerate during the sixth month, except in its uppermost part, so that it comes to be represented throughout the greater part of its extent by a thin cord composed of pia mater. This cord is the structure known in the adult as the *filum terminale*, and lies in the center of a leash of nerves occupying the lower part of the spinal canal and termed the *cauda equina*. The existence of the cauda is due to the recession of the cord which necessitates for the lower lumbar, sacral and coccygeal nerves, a descent through the spinal canal for a greater or less distance, before they can reach the intervertebral foramina through which they make their exit.

In the early stages of development the central canal of the cord is quite large and of an elongated oval form, but later it becomes somewhat rhomboidal in shape (Fig. 215, A), the lateral angles marking the boundaries between the dorsal and ventral zones. As development proceeds the sides of the canal in the dorsal region gradually approach one another and eventually fuse, so that this portion of the canal becomes obliterated (Fig. 215, B) and is indicated by the dorsal longitudinal fissure in the adult cord, the central canal of which corresponds to the ventral portion only of the embryonic cavity. While this process has been going on both the roof- and the floor-plate have become depressed below the level of the general surface of

the cord, and by a continuance of the depression of the floor-plate—a process really due to the enlargement and consequent bulging of the ventral zone—the ventral fissure is produced, the difference between its shape and that of the dorsal fissure being due to the difference in its development.

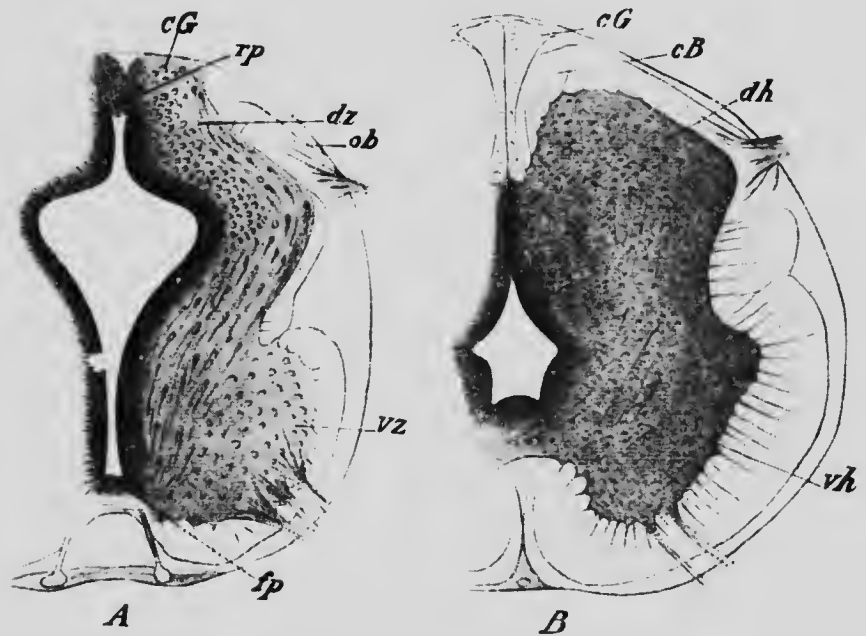


FIG. 215.—TRANSVERSE SECTIONS THROUGH THE SPINAL CORDS OF EMBRYOS OF (A) ABOUT FOUR AND A HALF WEEKS AND (B) ABOUT THREE MONTHS.

*cB*, Column of Burdaeh; *cG*, column of Goll; *dh*, dorsal horn; *dz*, dorsal zone; *fp*, floor-plate; *ob*, oval bundle; *rp*, roof-plate; *vh*, ventral horn; *vz*, ventral zone.—(*His.*)

The development of the mantle layer proceeds at first more rapidly in the ventral zone than in the dorsal, so that at an early stage (Fig. 215, A) the anterior horn of gray matter is much more pronounced, but on the development of the dorsal nerve-roots the formation of neuroblasts in the dorsal zone proceeds apace, resulting in the formation

of a dorsal horn. A small portion of the zone, situated between the point of entrance of the dorsal nerve-roots and the roof-plate, fails, however, to give rise to neuroblasts and is entirely converted into ependyma. This represents the future *column of Goll* (Fig. 220, A, cG), and at the point of entrance of the dorsal roots into the cord a well-marked oval bundle of fibers is formed (Fig. 215, A, ob) which, as development proceeds, creeps dorsally over the surface of the dorsal horn until it meets the lateral surface of the column of Goll, and, its further progress toward the median line being thus impeded, it insinuates itself between that column and the posterior horn to form the *column of Burdach* (Fig. 215, B, cB).

Nothing definite is as yet known concerning the development of the other columns which are recognizable in the adult cord, but, from what is known of the adult anatomy, it seems certain that the crossed and pyramidal tracts are composed of fibers which grow downward in the meshes of the marginal velum from neuroblasts situated in the cerebral cortex, while the direct cerebellar tract and the fibers of the ground-bundles have their origin from cells of the mantle layer of the cord.

The myelination of the fibers of the spinal cord begins between the fifth and sixth months and appears first in the columns of Burdach, and about a month later in the columns of Goll. The myelination of the great motor paths, the crossed and direct pyramidal tracts, is the last to develop, appearing toward the end of the ninth month of fetal life.

**The Development of the Brain.**—The enlargement of the anterior portion of the medullary canal does not take place quite uniformly, but is less along two transverse lines than elsewhere, so that the brain region early becomes divided into three *primary vesicles* which undergo further differentiation as follows. Upon each side of the anterior vesicle an evagination appears and becomes converted into a club-shaped structure attached to the ventral portion of the vesicle by a pedicle. These evaginations (Fig. 216,



*op*) are known as the *optic evaginations*, and being concerned in the formation of the eye will be considered in the succeeding chapter. After their formation the antero-lateral portions of the vesicle become bulged out into two

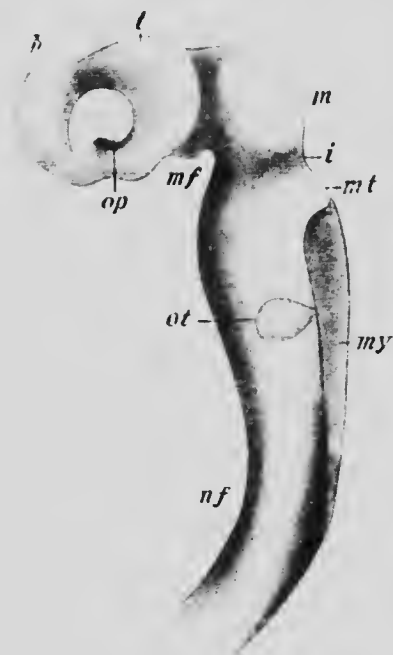


FIG. 216. — RECONSTRUCTION OF THE BRAIN OF AN EMBRYO OF 2.15 MM.

*h*, Hemisphere; *i*, isthmus; *m*, mesencephalon; *mf*, mid-brain flexure; *mt*, metencephalon; *my*, myelencephalon; *nf*, neck flexure; *ot*, otic capsule; *op*, optic evagination; *t*, thalamencephalon.—(*His.*)

protuberances (*h*) which rapidly increase in size and give rise eventually to the two *cerebral hemispheres*, which form, together with the portion of the vesicle which lies between them, what is termed the *telencephalon* or *fore-brain*, the remainder of the vesicle giving rise to what is known as the *diencephalon* (thalamencephalon) or *between-brain* (Fig. 216, *t*). The middle vesicle is bodily converted into the *mesencephalon* or *mid-brain* (*m*), but the posterior vesicle differentiates so that three parts may be recognized: (1) a rather narrow portion which immediately succeeds the mid-brain and is termed the *isthmus* (*i*); (2) a portion whose roof and floor give rise to the cerebellum and pons respectively,

and which is termed the *metencephalon* or *hind-brain* (*mt*); and (3) a terminal portion which is known as the *medulla oblongata*, or, to retain a consistent nomenclature, the *myelencephalon* or *after-brain* (*my*). From each of these six divisions definite structures arise whose relations to

the secondary divisions and to the primary vesicles may be understood from the following table and from the annexed figure (Fig. 217), which represents a median longitudinal section of the brain of a fetus of three months.

	Myelencephalon	Medulla oblongata (I).
1st Vesicle, . . . .	Metencephalon	{ Pons (II 1).
		{ Cerebellum (II 2).
	Isthmus	{ Superior peduncles of the cerebellum (III).
		{ Crura cerebri (posterior portion).
2d Vesicle, . . . .	Mesencephalon	{ Crura cerebri (anterior portion) (IV 1).
		{ Corpora quadrigemina (IV 2).
	Diencephalon	{ Pars mammillaria (V 1).
		{ Optic thalamus (V 2).
3d Vesicle, . . . .	Telencephalon	{ Epiphysis (V 3).
		{ Infundibulum (VI 1).
		{ Corpus striatum (VI 2).
		{ Olfactory bulb (VI 3).
		{ Hemispheres (VI 4).

But while the walls of the primary vesicles undergo this complex differentiation, their cavities retain much more perfectly their original relations, only that of the first vesicle sharing to any great extent the modifications of the walls. The cavity of the third vesicle persists in the adult as the *fourth ventricle*, traversing all the subdivisions of the vesicle that of the second, increasing but little in height and breadth, constitutes the *iter*; while that of the first vesicle is continued into the cerebral hemispheres to form the *lateral ventricles*, the remainder of it constituting the *third ventricle*, which includes the cavity of the median portion of the telencephalon as well as the entire cavity of the diencephalon.

During the differentiation of the various divisions of the brain certain flexures appear in the roof and floor, and to a certain extent correspond with those already described as occurring in the embryo. The first of these flexures to appear occurs in the region of the mid-brain, the first vesicle being bent ventrally until it comes to lie at practically a right angle with the axis of the mid-brain. This may be termed the mid-brain flexure (Fig. 216, *mf*)

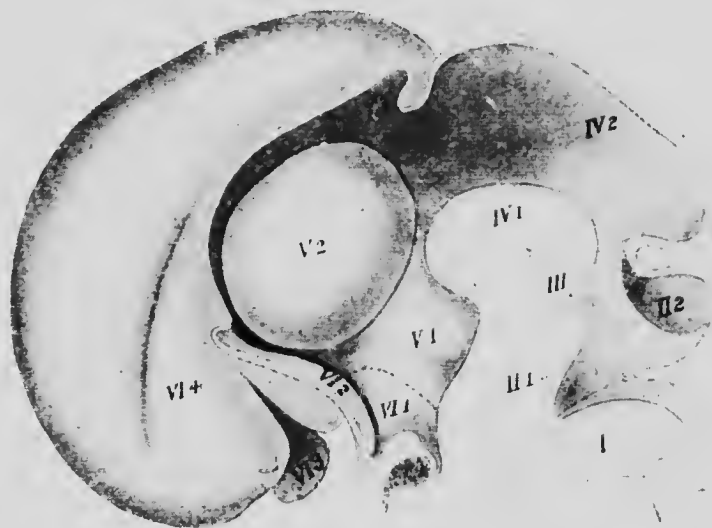


FIG. 217.—MEDIAN LONGITUDINAL SECTION OF THE BRAIN OF AN EMBRYO OF THE THIRD MONTH.—(*His.*)

and corresponds with the head-bend of the embryo. The second flexure occurs in the region of the medulla oblongata and is known as the neck flexure (Fig. 216, *nf*); it corresponds with the similarly named bend of the embryo and is produced by a bending ventrally of the entire head, so that the axis of the mid-brain comes to lie almost at right angles with that of the medulla and that of the first vesicle parallel with it. Finally, a third flexure occurs in the region of the metencephalon and is entirely peculiar

to the nervous system; it consists of a bending ventrally of the floor of the hind-brain, the roof of this portion of the brain not being affected by it, and it may consequently be known as the *pons flexure*.

In the later development the pons flexure practically disappears, owing to the development in this region of the transverse fibers and nuclei of the pons, but the mid-brain and neck flexures persist, though greatly reduced in acuteness, the axis of the anterior portion of the adult brain being inclined to that of the medulla at an angle of about 134 degrees.

*The Development of the Myelencephalon.*—In its posterior portion the myelencephalon closely resembles the spinal cord and has a very similar development. More anteriorly, however, the roof-plate (Fig. 218, *rp*) widens to form an exceedingly thin membrane, the *posterior velum*; with the broadening of the roof-plate there is associated a broadening of the dorsal portion of the brain cavity, the dorsal and ventral zones bending outward, until, in the anterior portion of the after-brain, the margins of the dorsal zone have a lateral position, and are, indeed, bent ventrally to form a reflected lip (Fig. 218). The portion of the fourth ventricle contained in this division of the brain becomes thus converted into a broad shallow cavity, whose floor is formed by the ventral zones separated in the median line by a deep groove, the floor of which is the somewhat thickened floor-plate. About the fourth month there appears in the roof-plate a transverse groove into which the surrounding mesenchyme dips, and, as the groove deepens in later stages, the mesenchyme continued within it becomes converted into blood-vessels, forming the *chorioid plexus* of the fourth ventricle, a structure which, as may be seen from its development, does not lie within the cavity of the ventricle, but is

separated from it by the portion of the roof-plate which forms the floor of the groove.

In embryos of about 9 mm. the differentiation of the dorsal and ventral zones into ependymal and mantle layers is clearly visible (Fig. 218), and in the ventral zone the marginal velum is also well developed. Where the fibers from the sensory ganglion of the vagus nerve enter the dorsal zone an oval area (Fig. 218, *fs*) is to be seen which is evidently comparable to the oval bundle of the

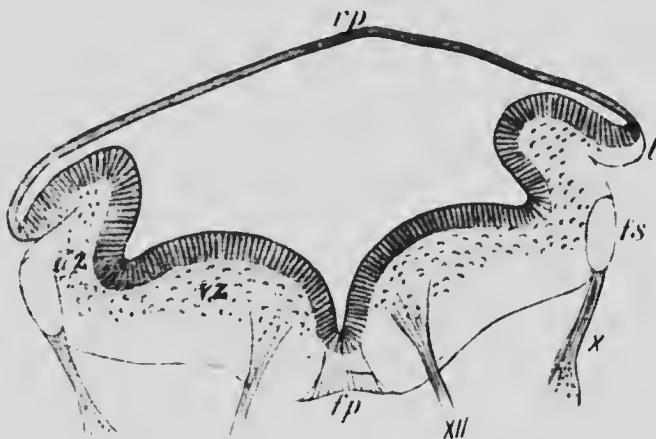


FIG. 218.—TRANSVERSE SECTION THROUGH THE MEDULLA OBLONGATA OF AN EMBRYO OF 9.1 MM.

*dz*, Dorsal zone; *jp*, floor-plate; *fs*, fasciculus solitarius; *l*, lip; *rp*, roof-plate; *vz*, ventral zone; *X* and *XII*, tenth and twelfth nerves.—(His.)

cord and consequently with the column of Burdach. It gives rise to the *solitary fasciculus* of adult anatomy, and in embryos of 11 to 13 mm. it becomes covered in by the fusion of the reflected lip of the dorsal zone with the sides of the myelencephalon, this fusion, at the same time, drawing the margins of the roof-plate ventrally to form a secondary lip (Fig. 219). Soon after this a remarkable migration ventrally of neuroblasts of the dorsal zone begins. Increasing rapidly in number the migrating cells pass on

either side of the solitary fasciculus toward the territory of the ventral zone, and, passing ventrally to the ventral portion of the mantle layer, into which fibers have penetrated and which becomes the *formatio reticularis* (Fig. 219, *fr*), they differentiate to form the *olivary body* (*ol*).

The thickening of the floor-plate gives opportunity for fibers to pass across the median line from one side to the other, and this opportunity is taken advantage of at an early stage by the axis-cylinders of the neuroblasts of the

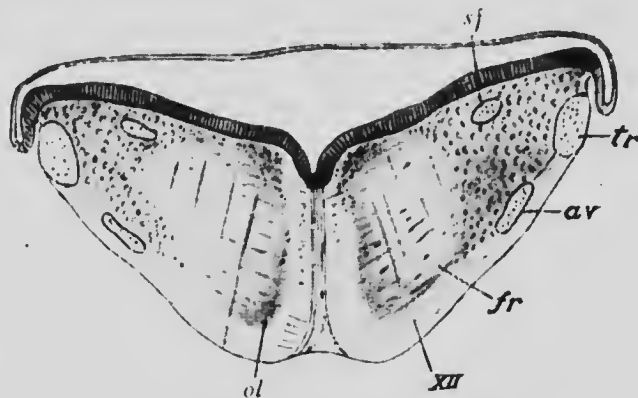


FIG. 219.—TRANSVERSE SECTION THROUGH THE MEDULLA OBLONGATA OF AN EMBRYO OF ABOUT EIGHT WEEKS.

*av*, Ascending root of the trigeminus; *fr*, reticular formation; *ol*, olivary body; *sf*, solitary fasciculus; *tr*, restiform body; XII, hypoglossal nerve. —(*His.*)

ventral zone, and later, on the establishment of the olivary bodies, other fibers, descending from the cerebellum, decussate in this region to pass to the olivary body of the opposite side. In the lower part of the medulla fibers from the neuroblasts of the nuclei of Goll and Burdach, which seem to be developments from the mantle layer of the dorsal zone, also decussate in the substance of the floor-plate; these fibers, known as the *arcuate fibers*, pass in part to the cerebellum, associating themselves with fibers ascending from the spinal cord and with the olivary fibers

to form a round bundle situated in the dorsal portion of the marginal velum and known as the *restiform body* (Fig. 219, *tr*).

The principal differentiations of the zones of the myelencephalon may be stated in tabular form as follows:

Roof plate, . . . . .	Posterior velum.
	Nuclei of termination of sensory roots of
	} cranial nerves.
Dorsal zones, . . . . .	Nuclei of Goll and Burdach.
	} The olivary bodies.
	Nuclei of origin of the motor roots of cranial
Ventral zones, . . . . .	} nerves.
	} The reticular formation.
Floor-plate, . . . . .	The median raphe.

*The Development of the Metencephalon and Isthmus.*—Our knowledge of the development of the metencephalon, isthmus, and mesencephalon is by no means as complete as is that of the myelencephalon. The pons develops as a thickening of the portion of the brain floor which forms the anterior wall of the pons flexure, and its transverse fibers are well developed by the fourth month (Mihal-koviez), but all details regarding the origin of the pons nuclei are as yet wanting. If one may argue from what occurs in the myelencephalon, it seems probable that the reticular formation of the metencephalon is derived from the ventral zone, and that the median raphe represents the floor-plate. Furthermore, the relations of the pons nuclei to the reticular formation on the one hand, and its connection by means of the transverse pons fibers with the cerebellum on the other, suggest the possibility that they may be the metencephalic representatives of the olivary bodies and be formed by a migration ventrally of neuroblasts from the dorsal zones.

The cerebellum is formed from the dorsal zones and roof-plate of the metencephalon and is a thickening of the

tissue immediately anterior to the front edge of the posterior velum. This latter structure has in early stages a rhomboidal shape (Fig. 220, A) which causes the cerebellar thickening to appear at first as if composed of two lateral portions inclined obliquely toward one another. In reality, however, the thickening extends entirely across the roof of the brain (Fig. 220, B), the roof-plate probably being invaded by cells from the dorsal zones and so giving rise to the *vermis*, while the lobes are formed directly from the dorsal zones. During the second month a groove appears on the ventral surface of each lobe,

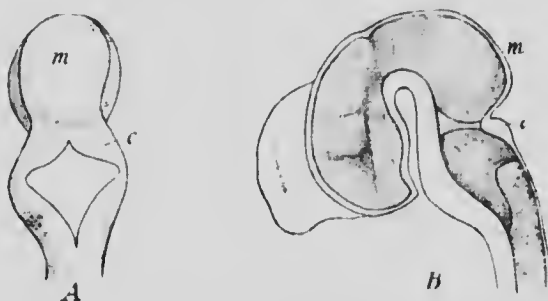


FIG. 220. A, DORSAL VIEW OF THE BRAIN OF A RABBIT EMBRYO OF 16 MM.; B, MEDIAN LONGITUDINAL SECTION OF A CALF EMBRYO OF 3 CM. c, Cerebellum; m, mid-brain.—(Mihalkovicz.)

marking out an area which becomes the *flocculus*, and later, during the third month, transverse furrows appear upon the vermis dividing it into five lobes, and later still extend out upon the lobes and increase in number to produce the lamellate structure characteristic of the cerebellum.

The histogenetic development of the cerebellum at first proceeds along the lines which have already been described as typical, but after the development of the mantle layer the cells lining the greater portion of the cavity of the ventricle cease to multiply, only those which are



situated in the roof-plate of the metencephalon and along the line of junction of the cerebellar thickening with the roof-plate continuing to divide. The indifferent cells formed in these regions migrate outward from the median line and forward in the marginal velum to form a superficial layer, known as the *epithelioid layer*, and cover the entire surface of the cerebellum.

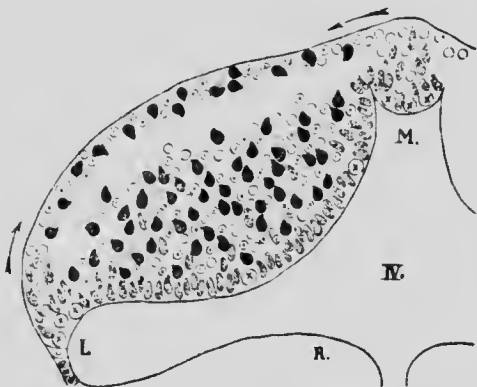


FIG. 221. — DIAGRAM REPRESENTING THE DIFFERENTIATION OF THE CEREBELLAR CELLS.

The circles, indifferent cells; circles with dots, neuroglia cells; shaded cells, germinal cells in mitosis; circles with cross, germinal cells; black cells, nerve-cells. *L*, Lateral recess; *M*, median furrow, and *R*, floor of *IV*, fourth ventricle.—(Schaper.)

The cells of this layer, like those of the mantle, differentiate into neuroglia cells and neuroblasts, the latter for the most part migrating centrally at a later stage to mingle with the cells of the mantle layer and to become transformed into the *granular cells* of the cerebellar cortex. The neuroglia cells remain at the surface, however, forming the principal constituent of the outer or, as it is now termed, the

*molecular layer* of the cortex, and into this the dendrites of the *Purkinje cells*, probably derived from the mantle layer, project. The migration of the neuroblasts of the epithelial layer is probably completed before birth, at which time but few remain in the molecular layer to form the *stellate cells* of the adult. The origin of the dentate and other nuclei of the cerebellum is at present unknown, but it seems probable that they arise from cells of the mantle layer.

The nerve-fibers which form the medullary substance of

the cerebellum do not make their appearance until about the sixth month, when they are to be found in the ependymal tissue on the inner surface of the layer of granular cells. Those which are not commissural or associative in function converge to the line of junction of the cerebellum with the pons, and there pass into the marginal velum of the pons, myelencephalon, or isthmus as the case may be.

The dorsal surface of the isthmus is at first barely distinguishable from the cerebellum, but as development proceeds its roof-plate undergoes changes similar to those occurring in the medulla oblongata and becomes converted into the *anterior velum* and *valve of Vieussens*. In the dorsal portion of its marginal velum fibers passing to and from the cerebellum appear and form the superior peduncle of the cerebellum (*brachium conjunctivum*), while ventrally fibers, descending from the more anterior portions of the brain, form the *crura cerebri*. Nothing is at present known as to the history of the gray matter of this division of the brain, although it may be presumed that its ventral zones take part in the formation of the *tegmentum*, while from its dorsal zones the nuclei of the *brachia conjunctiva* are possibly derived.

The following table gives the origin of the principal structures of the metencephalon and isthmus:

Roof-plate, . . . . .	{ Posterior velum.	Anterior velum.
	{ Vermis of cerebellum.	Valve of Vieussens.
	{ Lobes of cerebellum.	Brachia conjunctiva
	{ Flocculi.	
Dorsal zones, . . . . .	{ Nuclei of termination of sensory roots of cranial nerves.	
	{ Pons nuclei.	
	{ Nuclei of origin of motor roots of cranial nerves.	Posterior part of crura cerebri.
Ventral zones, . . . . .	{ Reticular formation.	Posterior part of teg- mentum.
Floor-plate, . . . . .	{ Median raphe.	Median raphe.

*The Development of the Mesencephalon.*—Our knowledge of the development of this portion of the brain is again very imperfect. During the stages when the flexures of the brain are well marked (Figs. 216 and 217) it forms a very prominent structure and possesses for a time a capacious cavity. Later, however, it increases in size less rapidly than adjacent parts and its walls thicken, the roof- and floor-plates as well as the zones, and, as a result, the cavity becomes the relatively smaller canal-like iter. In the marginal velum of its ventral zone fibers appear at about the third month, forming the anterior portion of the crura cerebri, and, at the same time, a median longitudinal furrow appears upon the dorsal surface, dividing it into two lateral elevations which, in the fifth month, are divided transversely by a second furrow and are thus converted from corpora bigemina (in which form they are found in the lower vertebrates) into *corpora quadrigemina*.

Nothing is known as to the differentiation of the gray matter of the dorsal and ventral zones of the mid-brain. From the relation of the parts in the adult it seems probable that in addition to the nuclei of origin of the oculomotor and trochlear nerves, the ventral zones give origin to the gray matter of the tegmentum, which is the forward continuation of the reticular formation. Similarly it may be supposed that the corpora quadrigemina are developments of the dorsal zones, as may also be the *red nuclei*, whose relations to the superior peduncles of the cerebellum suggest a comparison with the olivary bodies and the nuclei of the pons.

A tentative scheme representing the origin of the mid-brain structures may be stated thus:

Roof-plate, .....	(?)
Dorsal zones, .....	{ Corpora quadrigemina. Red nuclei.
Ventral zones .....	{ Nuclei of origin of the third and fourth nerves. Anterior part of tegmentum. Anterior part of crura cerebri.
Floor plate, .....	Median raphe.

*The Development of the Diencephalon.*—A transverse section through the diencephalon of an embryo of about five weeks (Fig. 222) shows clearly the differentiation of this portion of the brain into the typical zones, the roof-plate (*rp*) being represented by a thin-walled, somewhat folded area, the floor-plate (*fp*) by the tissue forming the floor of a well-marked ventral groove, while each lateral wall is divided into a dorsal and ventral zone by a groove known as the *sulcus Monroi*

(*Sm*), which extends forward and ventrally toward the point of origin of the optic evagination (Fig. 223, +). At the posterior end of the ridge-like elevation which represents the roof-plate is a rounded elevation (Fig. 223, *p*) which, in later stages, elongates until it almost reaches the dermis, forming a hollow evagination of the brain roof known as the *pineal process*. The distal extremity of this process enlarges to a sac-like structure which later becomes lobed,

and, by an active proliferation of the cells lining the cavities of the various lobes, finally becomes a solid structure, the *pineal body*. The more proximal portion of the evagination, remaining hollow, forms the *pineal stalk*, and the entire structure, body and stalk, constitutes what is known as the *epiphysis*.

The significance of this organ in the Mammalia is doubtful. In the Reptilia and other lower forms the outgrowth is double,

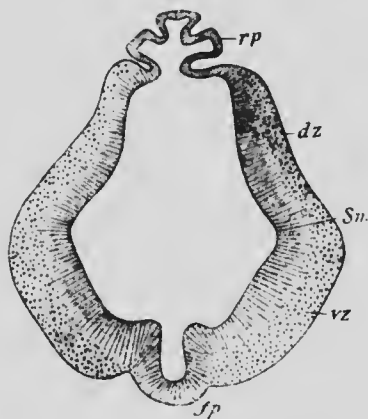


FIG. 222.—TRANSVERSE SECTION OF THE THALAMENCEPHALON OF AN EMBRYO OF FIVE WEEKS.

*dz*, Dorsal zone; *fp*, floor-plate; *rp*, roof-plate; *Sm*, sulcus Monroi; *vz*, ventral zone.—(*His.*)

a secondary outgrowth arising from the base or from the anterior wall of the primary one. This anterior evagination elongates until it reaches the dorsal epidermis of the head, and, here expanding, develops into an unpaired eye, the epidermis which overlies it becoming converted into a transparent cornea. In the Mammalia this anterior process does not develop and the epiphysis in these forms is comparable only to the posterior process of the Cephalia.

In addition to the epiphysial evaginations, another evagination arises from the roof-plate of the first brain vesicle, further forward, in the region which becomes the median portion of the telencephalon. This *paraphysis*, as it has been called, has been observed in the lower vertebrates and in the Marsupials (Senka), but up to the present has not been found in other groups of the Mammalia. It seems to be comparable to a chorioid plexus which is evaginated from the brain surface instead of being invaginated as is usually the case. There is no evidence that a paraphysis is developed in the human brain.

The portion of the roof-plate which lies in front of the epiphysis represents the velum interpositum of the adult brain, and it forms at first a distinct ridge (Fig. 223). At an early stage, however, it becomes reduced to a thin membrane upon the surface of which blood-vessels, developing in the surrounding mesenchyme, arrange themselves at about the third month in two longitudinal plexuses, which, with the subjacent portions of the velum, become invaginated into the cavity of the third ventricle to form its *chorioid plexus*.

The dorsal zones thicken in their more dorsal and anterior portions to form massive structures, the *optic thalami* (Figs. 217, V2, and 223, *ot*), which, encroaching upon the cavity of the ventricle, transform it into a narrow slit-like space, so narrow, indeed, that at about the fifth month the inner surfaces of the two thalami come in contact in the median line, forming what is known as the *middle or soft commissure*. More ventrally and posteriorly another thickening of the dorsal zones occurs, giving rise on each

side to the *pulvinar* of the thalamus and to an *external geniculate body*, and two ridges extending backward and dorsally from the latter structures to the thickenings in the roof of the mid-brain which represent the anterior corpora quadrigemina, give a path along which the nerve-fibers which constitute the *anterior brachia* pass.

From the ventral zones what is known as the *sub-thalamic region* develops, a mass of fibers and cells whose relations and development are not yet clearly understood, but which may be regarded as the forward continuation of the tegmentum and reticular formation. In the median line of the floor of the ventricle an unpaired thickening appears, representing the *corpora albicantia*, which during the third month becomes divided by a median furrow into two rounded eminences; but whether these structures and the posterior portion of the *tuber cinereum*, which also develops from this region of the brain, are derivatives of the ventral zones or of the floor-plate is as yet uncertain.

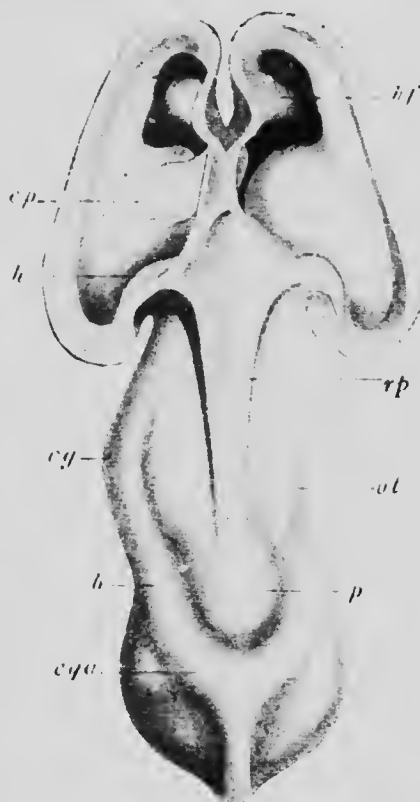


FIG. 223.—DORSAL VIEW OF THE BRAIN, THE ROOF OF THE LATERAL VENTRICLES BEING REMOVED, OF AN EMBRYO OF 13.6 MM.

*b*, Anterior brachium; *cg*, external geniculate body; *cp*, chorioid plexus; *cqa*, anterior corpus quadrigeminum; *h*, hippocampus; *hf*, hippocampal fissure; *ot*, optic thalamus; *p*, pineal body; *rp*, roof-plate.—(His.)

Assuming that the albicaulia and the tuber cinereum are derived from the ventral zones, the origins of the structures formed from the walls of the diencephalon may be tabulated as follows:

Roof-plate, .....	{	Velum interpositum
		Epiphysis.
Dorsal zones, .....	{	Optic thalami.
		Pulvinares.
		External geniculate bodies.
Ventral zones, .....	{	Subthalamie region.
		Corpora albicaulia.
		Tuber cinereum (in part).
Floor-plate, .....		Tissue of mid-ventral line.

*The Development of the Telencephalon.*—For convenience of description the telencephalon may be regarded as consisting of a median portion, which contains the anterior part of the third ventricle, and two lateral outgrowths which constitute the cerebral hemispheres. The roof of the median portion undergoes the same transformation as does the greater portion of that of the diencephalon and is converted into the anterior part of the velum interpositum (Fig. 224, *vi*), which anteriorly passes into the anterior wall of the third ventricle, the *lamina terminalis (lt)*, a structure which is to be regarded as formed by the union of the dorsal zones of opposite sides, since it lies entirely dorsal to the anterior end of the sulcus Monroi. From the ventral part of the dorsal zones the optic evaginations are formed, a depression, the *optic recess (or)*, marking their point of origin.

The ventral zones are but feebly developed, and form the anterior part of the subthalamie region, while at the anterior extremity of the floor-plate an evagination occurs, the *infundibular recess (ir)*, which elongates to form a funnel-shaped structure known as the *hypophysis*. At its extremity the hypophysis comes in contact during the fifth week with the enlarged extremity of Rathke's pouch

formed by an invagination of the roof of the oral sinus (see p. 300), and applies itself closely to the posterior surface of this (Fig. 217) to form with it the *pituitary body*. The anterior lobe at an early stage separates from the mucous membrane of the oral sinus, the stalk by which it was attached completely disappearing, and toward the end of the second month it begins to send out processes from its walls into the surrounding mesenchyme and so

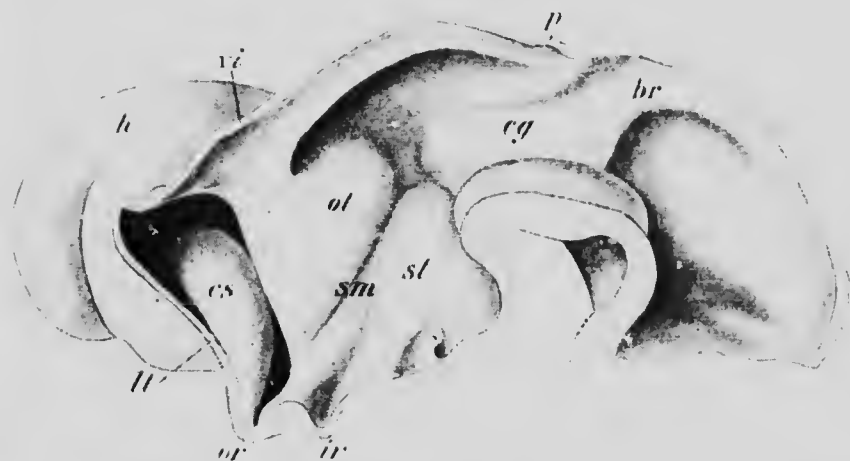


FIG. 224.—MEDIAN LONGITUDINAL SECTION OF THE BRAIN OF AN EMBRYO OF 13.6 MM.

*br*, Anterior brachium; *cg*, corpus geniculatum externum; *cs*, corpus striatum; *h*, cerebral hemisphere; *br*, infundibular recess; *h*, lamina terminalis; *or*, optic recess; *ot*, optic thalamus; *b*, pineal process; *sm*, sulcus Monroi; *st*, subthalamic region; *vi*, velum interpositum.—(*His.*)

becomes converted into a mass of solid epithelial cords embedded in a mesenchyme rich in blood and lymphatic vessels. The cords later on divide transversely to a greater or less extent to form alveoli, the entire structure coming to resemble somewhat the parathyroid bodies (see p. 314), and, like these, having the function of producing an internal secretion. The posterior lobe, derived from the brain, retains its connection with that



structure, its stalk being the *infundibulum*, but its terminal portion does not undergo such extensive modifications as does the anterior lobe, although it is claimed that it gives rise to a glandular epithelium which may become arranged so as to form alveoli.

The cerebral hemispheres are formed from the lateral portions of the dorsal zones, each possessing also a prolongation of the roof-plate. From the more ventral portion of each dorsal zone there is formed a thickening, the *corpus striatum* (Figs. 224, *cs*, and 217, VI 2), a structure which is for the telencephalon what the optic thalamus is for the diencephalon, while from the more dorsal portion there is formed the remaining or *mantle* (*pallial*) portions of the hemispheres (Figs. 224, *h*, and 217, VI 4). When first formed, the hemispheres are slight evaginations from the median portion of the telencephalon, the openings by which their cavities communicate with the third ventricle, the *foramina of Monro*, being relatively very large (Fig. 224), but, in later stages (Fig. 217), they increase more markedly and eventually surpass all the other portions of the brain in magnitude, overlapping and completely concealing the roof and sides of the diencephalon and mesencephalon and also the anterior surface of the cerebellum. In this enlargement, however, the foramina of Monro share only to a slight extent, and consequently become relatively smaller (Fig. 217), forming in the adult merely slit-like openings lying between the lamina terminalis and the optic thalami and having for their roof the anterior portion of the velum interpositum.

The velum interpositum,—that is to say, the roof-plate,—where it forms the roof of the foramen of Monro, is prolonged out upon the dorsal surface of each hemisphere, and, becoming invaginated, forms upon it a groove. As the hemispheres, increasing in height, develop a mesial

wall, the groove, which is the so-called *chorioid fissure*, comes to lie along the ventral edge of this wall, and as the growth of the hemispheres continues it becomes more and more elongated, being carried at first backward (Fig. 225), then ventrally, and finally forward to end at the tip of the temporal lobe. After the establishment of the grooves the mesenchyme in their vicinity dips into them, and, developing blood-vessels, becomes the *chorioid plexuses* of the lateral ventricles, and at first these plexuses grow much more rapidly than the ventricles, and so fill them almost completely. Later, however, the walls of the hemispheres gain the ascendancy in rapidity of growth and the plexuses become relatively much smaller. Since the portions of the roof-plate which form the chorioid fissures are continuous with the velum interpositum in the roofs of the foramina of Monro, the chorioid plexuses of the lateral and third ventricles become continuous also at that point.

The mode of growth of the chorioid fissures seems to indicate the mode of growth of the hemispheres. At first the growth is more or less equal in all directions, but later it becomes more extensive posteriorly, there being more room for expansion in that direction, and when further extension backward becomes difficult the posterior extremities of the hemispheres bend ventrally toward the base of the cranium, and, reaching this, turn forward to form the temporal lobes. As a result the cavities of the

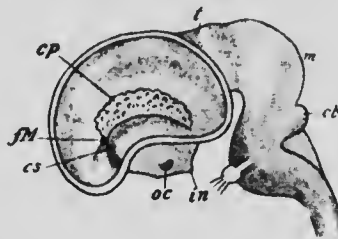


FIG. 225.—MEDIAN LONGITUDINAL SECTION OF THE BRAIN OF AN EMBRYO CALF OF 5 CM.

*cb*, Cerebellum; *cp*, chorioid plexus; *cs*, corpus striatum; *fM*, foramen of Monro; *in*, hypophysis; *m*, mid-brain; *oc*, optic commissure; *t*, posterior part of the thalamencephalon.—(Mihalkovicz.)

hemispheres, the lateral ventricles, in addition to being carried forward to form an anterior horn, are also carried backward and ventrally to form the lateral or descending horn, and the corpus striatum likewise extends backward to the tip of each temporal lobe as a slender process known as the tail of the caudate nucleus. In addition to the anterior and lateral horns, the ventricles of the human brain also possess posterior horns extending backward into the occipital portions of the hemispheres, these portions, on account of the greater persistence of the mid-brain flexure (see p. 406), being enabled to develop to a greater extent than in the lower mammals.

The scheme of the origin of parts in the telencephalon may be stated as follows:

	MEDIAN PART.	HEMISPHERES.
Roof-plate, . . . . .	{ Anterior part of Velum interpositum.	{ Floor of chorioidal fis- sure. Pallium.
Dorsal zones, . . . . .	{ Lamina terminalis. Optic evaginations.	{ Corpus striatum. Olfactory bulbs (see p. 427).
Ventral zones, . . . . .	{ Anterior part of sub- thalamic region. Anterior part of tuber cinereum.	

*The Convolution of the Hemispheres.*—The growth of the hemispheres to form the voluminous structures found in the adult depends mainly upon an increase of size of the pallium. The corpus striatum, although it takes part in the elongation of each hemisphere, nevertheless does not increase in other directions as rapidly and extensively as the pallium, and hence, even in very early stages, a depression appears upon the surface of the hemispheres where the corpus is situated (Fig. 226). This depression is

the *fossa Sylvii*, and for a considerable period it is the only sign of inequality of growth on the outer surfaces of the hemispheres. Upon the mesial surfaces, however, at about the time that the chorioid fissure appears, another linear depression is formed dorsal to the chorioid, and when fully formed extends from in front of the foramen of Monro to the tip of the temporal lobe (Fig. 228, *h*). It affects the entire thickness of the pallial wall and consequently produces an elevation upon the inner surface, a projection into the cavity of the ventricle which is known as the *hippocampus*, whence the fissure may be termed the *hippocampal fissure*. The portion of the pallium which intervenes between this fissure and the chorioid forms what is known as the *dentate gyrus*.

Toward the end of the third or the beginning of the fourth month two prolongations arise from the fissure just where it turns to be continued into the temporal lobe, and these, extending posteriorly, give rise to the *parieto-occipital* and *calcarine* fissures. Like the hippocampal, these fissures produce elevations upon the inner surface of the pallium, that formed by the parieto-occipital early disappearing, while that produced by the calcarine persists to form the *calcar* (*hippocampus minor*) of adult anatomy.

The three fissures just described, together with the

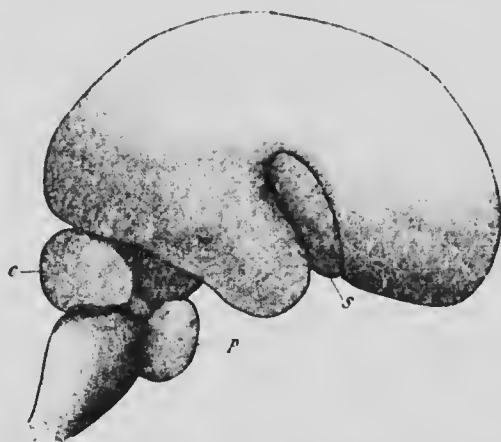


FIG. 226.—BRAIN OF AN EMBRYO OF THE FOURTH MONTH.

*c*, Cerebellum; *p*, pons; *s*, Sylvian fossa.

chorioid and the fossa of Sylvius, are all formed by the beginning of the fourth month and all affect the entire thickness of the wall of the hemisphere, and hence have been termed the *primary* or *total fissures*. Until the beginning of the fifth month they are the only fissures present, but at that time secondary fissures, which, with one exception, are merely furrows of the surface of the pallium, make their appearance and continue to form until birth and possibly later. Before considering these, however, certain changes which occur in the neighborhood of the Sylvian fossa may be described.

The fossa is at first a triangular depression situated above the temporal lobe on the surface of the hemisphere. During the fourth month it deepens considerably, so that its upper and lower margins become more pronounced and form projecting folds, and, during the fifth month, these two folds approach one another and eventually cover in the floor of the fossa completely, the groove which marks the line of their contact forming the *Sylvian fissure*, while the floor of the fossa becomes known as the *island of Reil (insula)*.

The first of the secondary fissures to appear is the *calloso-marginal*, which is formed about the middle of the fifth month on the mesial surface of the hemispheres, lying parallel to the anterior portion of the hippocampus fissure and dividing the mesial surface into the *gyri marginalis* and *fornicatus*. A little later, at the beginning of the sixth month, several other fissures make their appearance upon the outer surface of the pallium, the chief of these being the fissure of *Rolando*, the *intra-parietal*, the *pre-* and *post-central*, and the *temporal* fissures, the most ventral of these last running parallel with the lower portion of the hippocampal fissure and differing from the others in forming a ridge on the wall of the ventricle

termed the *collateral eminence*, whence the fissure is known as the *collateral*. The position of most of these fissures may be seen from Fig. 227, and for a more complete description of them reference may be had to text-books of descriptive anatomy.

In later stages numerous tertiary fissures make their appearance and mask more or less extensively the sec-

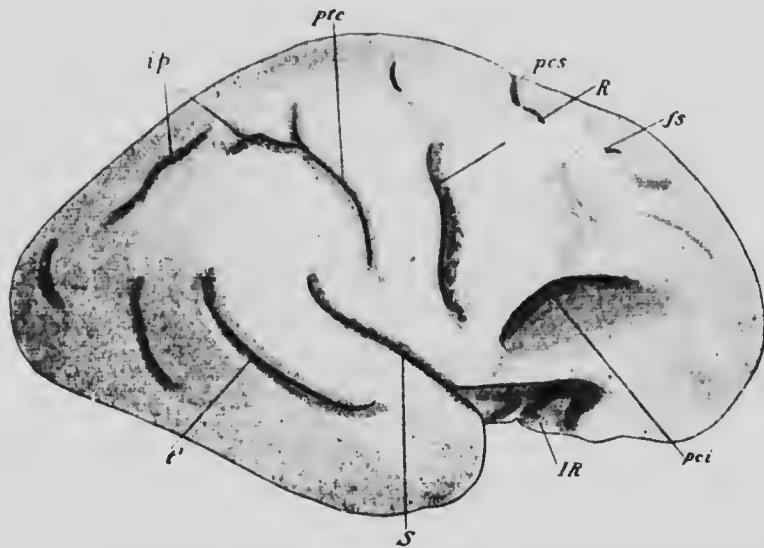


FIG. 227.—CEREBRAL HEMISPHERE OF AN EMBRYO OF ABOUT THE SEVENTH MONTH.

*s*, Superior frontal fissure; *ip*, intraparietal; *IR*, island of Reil; *pci*, inferior pre-central; *pcs*, superior pre-central; *ptc*, post-central; *R*, Rolandic; *S*, Sylvian; *t<sup>1</sup>*, first temporal.—(Cunningham.)

ondaries, than which they are, as a rule, much more inconstant in position and shallower.

*The Corpus Callosum and Fornix.*—While these fissures have been forming, important structures have developed in connection with the lamina terminalis. Up to about the fourth month the lamina is thin and of nearly uniform thickness throughout, but at this time it begins to thicken at its dorsal edge to form a mass which is triangular in

section and connects the mesial surfaces of the two hemispheres. The ventral angle of the thickening later separates slightly from the rest and fibers appear in it, converting it into the *anterior commissure*, and the remainder of the thickening, continuing to increase in size with the increase of the hemispheres, forms a mass of considerable

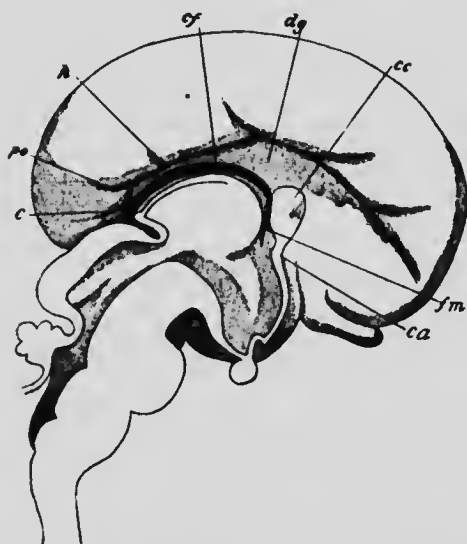


FIG. 228.—MEDIAN LONGITUDINAL SECTION OF THE BRAIN OF AN EMBRYO OF THREE MONTHS.

*c*, Calcarine fissure; *ca*, anterior commissure; *cc*, corpus callosum; *cf*, chorioidal fissure; *dg*, dentate gyrus; *fm*, foramen of Monro; *h*, hippocampal fissure; *po*, parieto-occipital fissure.—(Mihalkovicz.)

size, still retaining its triangular shape and having its apex directed posteriorly. In the dorsal portion of the triangle fibers extend across from the pallium of one hemisphere to that of the other and form the *corpus callosum*, while in its ventral edge other fibers extend from the hippocampus to the lamina terminalis, and, descending in that structure, pass posteriorly in the floor of the third ventricle toward the corpora albicantia. These fibers constitute the pillars of the *fornix*, whose peculiar course in the adult brain may be understood by a consideration of the rotation of the hemispheres during growth which results in the formation of the temporal lobe (see p. 421).

The portion of the triangle included between the callosum and the fornix remains thin and forms the *septum*

size, still retaining its triangular shape and having its apex directed posteriorly. In the dorsal portion of the triangle fibers extend across from the pallium of one hemisphere to that of the other and form the *corpus callosum*, while in its ventral edge other fibers extend from the hippocampus to the lamina terminalis, and, descending in that structure, pass posteriorly in the floor of the third ventricle toward the corpora albicantia. These fi-

*lucidum*, and a split occurring in the center of this gives rise to the so-called *fifth ventricle*, which, from its mode of formation, is a completely closed cavity and is not lined with ependymal tissue of the same nature as that found in the other ventricles.

Owing to the very considerable size reached by the thickening of the lamina terminalis whose history has just been described, important changes are wrought in the adjoining portions of the mesial surface of the hemispheres. Before the development of the thickening the gyrus dentatus and the hippocampus extend forward into the anterior portion of the hemispheres (Fig. 228), but on account of their position they become encroached upon by the enlargement of the lamina terminalis, with the result that the hippocampus becomes practically obliterated in that portion of its course which lies in the region occupied by the corpus callosum, its fissure in this region becoming known as the *callosal fissure*, while the corresponding portions of the dentate gyrus become reduced to narrow and insignificant bands of nerve-tissue which rest upon the upper surface of the corpus callosum and are known as the *striæ of Lancisi*.

*The Olfactory Lobes.*—At the time when the cerebral

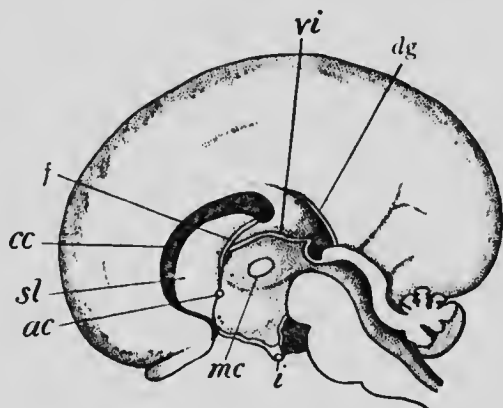


FIG. 229.—MEDIAN LONGITUDINAL SECTION OF THE BRAIN OF AN EMBRYO OF THE FIFTH MONTH.

ac, anterior commissure; cc, corpus callosum; dg, dentate gyrus; f, fornix; i, infundibulum; mc, middle commissure; sl, septum lucidum; vi, velum interpositum.—(Mihalkovicz.)



hemispheres begin to enlarge—that is to say, at about the fourth week—a slight furrow, which appears on the ventral surface of each anteriorly, marks off an area which, continuing to enlarge with the hemispheres, gradually becomes constricted off from them to form a distinct lobe-like structure, the *olfactory lobe* (Fig. 217, VI 3). In most of the lower mammalia these lobes reach a very considerable size, and consequently have been regarded as constituting an additional division of the brain, known as the *rhinencephalon*, but in man they remain smaller, and although they are at first hollow, containing prolongations from the lateral ventricles, the cavities later on disappear and the lobes become solid. Each lobe becomes differentiated into two portions, its terminal portion becoming converted into the club-shaped structure, the olfactory bulb and stalk, while its proximal portion gives rise to the olfactory tracts, the trigone, and the anterior perforated space.

*Histogenesis of the Cerebral Cortex.*—A satisfactory study of the histogenesis of the cortex has not yet been made. In embryos of three months a marginal velum is present and probably gives rise to the stratum zonale of the adult brain; beneath this is a cellular layer, perhaps representing the mantle layer; beneath this, again, a layer of nerve-fibers is beginning to appear, representing the white substance of the pallium; and, finally, lining the ventricle is an ependymal layer. In embryos of the fifth month toward the innermost part of the second layer cells are beginning to differentiate into the large pyramid cells, but almost nothing is known as to the origin of the other layers recognizable in the adult cortex, nor is it known whether any migration, similar to what occurs in the cerebellar cortex, takes place. The fibers of the white substance do not begin to acquire their myelin sheaths until

toward the end of the ninth month, and the process is not completed until some time after birth (Flechsig), while the fibers of the cortex continue to undergo myelination until comparatively late in life (Kaes).

**The Development of the Spinal Nerves.**—It has already been seen that there is a fundamental difference in the mode of development of the two roots of which the typical spinal nerves are composed, the ventral root being formed by axis-cylinders which arise from neuroblasts situated within the substance of the spinal cord, while the dorsal roots arise from the cells of the neural crests, their axis-cylinders growing into the substance of the cord while their dendrites become prolonged peripherally to form the sensory fibers of the nerves. Throughout the thoracic, lumbar and sacral regions of the cord the fibers which grow out from the anterior horn cells converge to form a single nerve-root in each segment, but in the cervical region the fibers which arise from the more laterally situated neuroblasts make their exit from the cord independently of the more ventral neuroblasts and form the roots of the spinal accessory nerve (see p. 438). In the cervical region there are accordingly three sets of nerve-roots, the dorsal, lateral, and ventral sets, the last being not quite equivalent to the similarly named roots of the more posterior nerves.

In a typical spinal nerve, such as one of the thoracic series, the dorsal roots as they grow peripherally pass downward as well as outward, so that they quickly come into contact with the ventral roots with whose fibers they mingle, and the mixed nerve so formed soon after divides into two trunks, a dorsal one, which is distributed to the dorsal musculature and integument, and a larger ventral one. The ventral division as it continues its outward growth soon reaches the dorsal angle of the pleuro-peri-

toneal cavity, where it divides, one branch passing into the tissue of the body-wall while the other passes into the splanchnic mesoderm. The former branch, continuing its onward course in the body-wall, again divides, one branch becoming the lateral cutaneous nerve, while the other continues inward to terminate in the median ventral portion of the body as the anterior cutaneous nerve. The splanchnic branch forms a ramus communicans to the sympathetic system and will be considered more fully later on.

The conditions just described are those which obtain throughout the greater part of the thoracic region. Elsewhere the fibers of the ventral divisions of the nerves as they grow outward tend to separate from one another and to become associated with the fibers of adjacent nerves, giving rise to plexuses. In the regions where the limbs occur the formation of the plexuses is also associated with a shifting of the parts to which the nerves are supplied, a factor in plexus formation which is, however, much more evident from comparative anatomical than from embryological studies.

**The Development of the Cranial Nerves.**—During the last thirty years the cranial nerves have received a great deal of attention in connection with the idea that an accurate knowledge of their development would afford a clue to a most vexed problem of vertebrate morphology, the metamerism of the head. That the metamerism which was so pronounced should extend into the head was a natural supposition, strengthened by the discovery of head-cavities in the lower vertebrates and by the indications of metamerism seen in the branchial arches, and the problem which presented itself was the correlation of the various structures belonging to each metamere and the determination of the modifications which they had undergone during the evolution of the head.

In the trunk region a nerve forms a conspicuous element of each metamere and is composed, according to what is known as Bell's law, of a ventral or efferent and a dorsal or afferent root. Until comparatively recently the study of the cranial nerves has been dominated by the idea that it was possible to extend the application of Bell's law to them and to recognize in the cranial region a number of nerve pairs serially homologous with the spinal nerves, some of them, however, having lost their afferent roots, while in others a dislocation, as it were, of the two roots had occurred.

The results obtained from investigation along this line have not, however, proved entirely satisfactory, and facts have been elucidated which seem to show that it is not possible to extend Bell's law, in its original form at least, to the cranial nerves. It has been found that it is not sufficient to recognize simply afferent and efferent roots, but these must be analyzed into further components, and when this is done it is found that in the series of cranial nerves certain components occur which are not represented in the nerves of the spinal series.

Before proceeding to a description of these components it will be well to call attention to a matter already alluded to in a previous chapter (p. 127) in connection with the segmentation of the mesoderm of the head. It has been pointed out that while there exist "head-cavities" which are serially homologous with the mesodermal somites of the trunk, there has been imposed upon this primary cranial metamerism a secondary metamerism represented by the branchiomeres associated with the branchial arches, and, it may be added, this secondary metamerism has become the more prominent of the two, the primary one, as it developed, gradually slipping into the background until, in the higher vertebrates, it has become to

a very considerable extent rudimentary. In accordance with this double metamerism it is necessary to recognize two sets of cranial muscles, one derived from the cranial myotomes and represented by the muscles of the eyeball, and one derived from the branchiomic mesoderm, and it is necessary also to recognize for these two sets of muscles two sets of motor nerves, so that, with the dorsal or

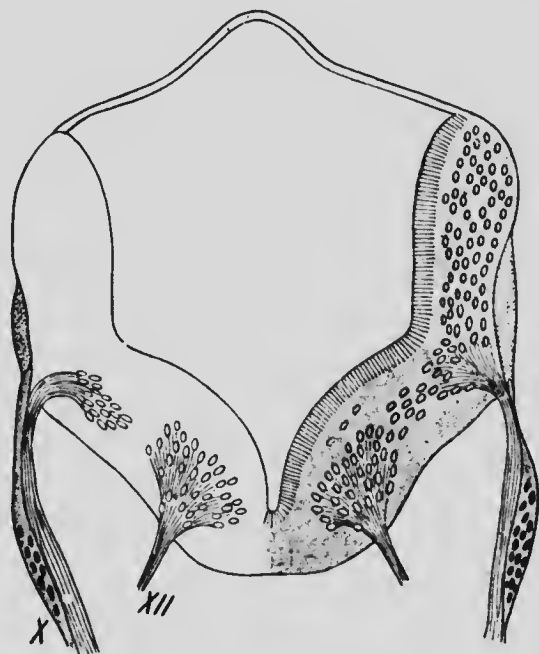


FIG. 230.—TRANSVERSE SECTION THROUGH THE MEDULLA OBLONGATA OF AN EMBRYO OF 10 MM., SHOWING THE NUCLEI OF ORIGIN OF THE VAGUS (X) AND HYPOGLOSSAL (XII) NERVES.—(His.)

sensory nerve-roots, there are altogether three sets of nerve-roots in the cranial region instead of only two, as in the spinal region.

These three sets of roots are readily recognizable both in the embryonic and in the adult brain, especially if attention be directed to the cell groups or nuclei with which they are associated (Fig. 230). Thus there can be recog-

nized: (1) a series of nuclei from which nerve-fibers arise, situated in the floor of the fourth ventricle and iter close to the median line and termed the ventral motor nuclei; (2) a second series of nuclei of origin, situated more laterally and in the substance of the formatio reticularis, and known as the lateral motor nuclei; and (3) a series of nuclei in which afferent nerve-fibers terminate, situated still more laterally in the floor of the ventricle and forming the dorsal or sensory nuclei. None of the twelve cranial nerves usually recognized in the text-books contain fibers associated with all three of these nuclei; the fibers from the lateral motor nuclei almost invariably unite with sensory fibers to form a mixed nerve, but those from all the motor nuclei form independent roots, while the olfactory and auditory nerves alone, of all the sensory roots (omitting for the present the optic nerve), do not contain fibers from either of the series of motor nuclei. The relations of the various cranial nerves to the nuclei may be seen from the following table, in which the + sign indicates the presence and the — sign the absence of fibers from the nuclear series under which it stands:

NUMBER.	NAME.	VENTRAL MOTOR.	LATERAL MOTOR.	SENSORY.
I.	Olfactory.	—	—	+
III.	Oculomotor.	+	—	—
IV.	Trochlear.	+	—	—
V.	Trigeminus.	—	+	+
VI.	Abducens.	+	—	—
VII.	Facial.	—	+	+
VIII.	Auditory.	—	—	+
IX.	Glossopharyngeal.	—	+	+
X.	Vagus.	—	+	+
XI.	Spinal Accessory. }			

Two nerves—namely, the second and twelfth—have been omitted from the above table. Of these, the second or optic nerve undoubtedly belongs to an entirely differ-

ent category from the other peripheral nerves, and will be considered in the following chapter in connection with the sense-organ with which it is associated (see especially p. 489). The twelfth or hypoglossal nerve, on the other hand, really belongs to the spinal series and has only secondarily been taken up into the cranial region in the higher vertebrates. It has already been seen (p. 192) that the bodies of four vertebræ are included in the basioccipital bone, and that three of the nerves corresponding to these vertebræ are represented in the adult by the hypoglossal and the fourth by the first cervical or suboccipital nerve. The dorsal roots of the hypoglossal nerves seem to have almost disappeared, although a ganglion has been observed in embryos of 7 and 10 mm. in the posterior part of the hypoglossal region (His), and probably represents the dorsal root of the most posterior portion of the hypoglossal nerve. This ganglion disappears, as a rule, in later stages, and it is interesting to note that the ganglion of the suboccipital nerve is also occasionally wanting in the adult condition. The hypoglossal roots are to be regarded, then, as equivalent to the ventral roots of the cervical spinal nerves, and the nuclei from which they arise lie in series with the cranial ventral motor roots, a fact which indicates the equivalency of these latter with the fibers which arise from the neuroblasts of the anterior horns of the spinal cord.

The equivalents of the lateral motor roots may more conveniently be considered later on, but it may be pointed out here that these are the fibers which are distributed to the muscles of the branchiomeres. In the case of the sensory nerves a further analysis is necessary before their equivalents in the spinal series can be determined. For this the studies which have been made in recent years of the components entering into the cranial nerves of the

amphibia (Strong) and fishes (Herrick) must supply a basis, since as yet a direct analysis of the mammalian nerves has not been made. In the forms named it has been found that three different components enter into the formation of the dorsal roots of the cranial nerves: (1) fibers belonging to a general cutaneous or somatic sensory system, distributed to the skin without being connected with any special sense-organs; (2) fibers belonging to what is termed the *communis* or viscerosensory system, distributed to the walls of the mouth and pharyngeal region and to special organs found in the skin of the same character as those occurring in the mouth; and (3) fibers belonging to a special set of cutaneous sense-organs largely developed in the fishes and known as the organs of the lateral line.

The fibers of the somatic sensory system converge to a group of cells, situated in the lateral part of the floor of the fourth ventricle, and forming what is termed the trigeminal lobe, and also extend posteriorly in the substance of the medulla (Fig. 231), forming what has been termed the ascending root of the trigeminus and terminating in a column of cells which represents the forward continuation of the posterior horn of the cord. In the fishes and amphibia fibers belonging to this system are to be found in the fifth, seventh, and tenth nerves, but in the mammalia their distribution has apparently become more limited, being confined almost exclusively to the trigeminus, of whose sensory divisions they form a very considerable part. Since the cells around which the fibers of the ascending root of the trigeminus terminate are the forward continuations of the posterior horns of the cord, it seems probable that the fibers of this system are the cranial representatives of the posterior roots of the spinal nerves, which, it may be noted, are also somatic in their distribution.





great superficial petrosal; and also, probably, by the lingual branch of the trigeminus. Furthermore, since the mucous membrane of the palate is supplied by branches from the trigeminus which pass by way of the sphenopalatine (Meekel's) ganglion, and the same region is supplied in lower forms by a palatine branch from the facial, it seems probable that the palatine nerves of the mammalia are also to be assigned to this system.\* If this be the case, a very evident clue is afforded to the homologies of the system in the spinal nerves, for since the sphenopalatine ganglion is to be regarded as part of the sympathetic system, the sensory fibers which pass from the viscera to the spinal cord by way of the sympathetic system (p. 443) present relations practically identical with those of the palatine nerves.

Finally, with regard to the system of the lateral line, there seems but little doubt that it has no representation whatsoever in the spinal nerves. It is associated with a peculiar system of cutaneous sense-organs found only in aquatic or marine animals, and also with the auditory and possibly the olfactory organs, the former of which are certainly and the latter possibly primarily parts of the lateral line system of organs. The organs are principally confined to the head, although they also extend upon the trunk, where they are followed by a branch from the vagus nerve, the entire system being accordingly supplied by cranial nerves. In the fishes, in which the development of the organs is at a maximum, fibers belonging to the system are found in all the branchiomic nerves and

---

\* The fact that the palatine branches are associated with the trigeminus in the Mammalia and with the facial in the Amphibia is readily explained by the fact that in the latter the Gasserian and geniculate ganglia are not always separated, so that it is possible for fibers originating from the compound ganglion to pass into either nerve.

all converge to a portion of the medulla known as the *tuberculum acusticum*. In the Mammalia, with the disappearance of the lateral line organs there has been a disappearance of the associated nerves, and the only representatives of the system which persist are the auditory and olfactory nerves.

The table given on page 433 may now be expanded as follows, though it must be recognized that such an analysis of the mammalian nerves is merely a deduction from what has been observed in lower forms, and may require some modifications when the components have been subjected to actual observation:

NERVE.	VENTRAL MOTOR.	LATERAL MOTOR.	SOMATIC SENSORY.	VISCERAL SENSORY.	LATERAL LINE.
I.	—	—	—	—	+
III.	+	—	—	—	—
IV.	+	—	—	—	—
V.	—	+	+	+	—
VI.	+	—	—	—	—
VII.	—	+	—	—	—
VIII.	—	—	—	—	—
IX. } X. } XI. }	—	+	—	+	—
XII.	+	—	—	—	—
Spinal.	+	(?)	+	+	—

An additional word is necessary concerning the spinal accessory nerve, for it presents certain interesting relations which possibly furnish a clue to the spinal equivalents of the lateral motor roots. In the first place, the neuroblasts which give rise to those fibers of the nerve which come from the spinal cord are situated in the dorsal part of the ventral zones and in the adult in the lateral horn of the cord. As the nuclei of origin are traced anteriorly they will be found to change their position some-

what as the medulla is reached and eventually come to lie in the reticular formation, the most anterior of them being practically continuous with the motor nucleus of the vagus. Indeed, it seems probable that certain nerve roots belonging to the vagus set, which occur in the lower vertebrates immediately behind the motor roots of the vagus and are termed the *spino-occipital* nerves (Fürbringer), are incorporated in the spinal accessory of higher forms and constitute the portion of that nerve which supplies the sternomastoid and trapezius muscles.

It is believed that the white rami communicantes, which pass from the spinal cord to the thoracic and upper lumbar sympathetic ganglia arise from cells situated in the dorso-lateral portions of the ventral horns, and since these rami are lacking in the region in which the spinal accessory occurs, it would seem that this nerve may represent the white rami of the cervical segments. The temptation is great to carry this line of homology to its conclusion, and to regard the cranial lateral motor roots as equivalent to the white rami of the cord, and the temptation is intensified when it is recalled that there are both embryological and topographical reasons for regarding the branchiomeric muscles, to which the cranial lateral motor nerves are applied, as equivalent to the visceral muscles of the trunk. But in view of the fact that a sympathetic neurone is always interposed between a white ramus fiber and the visceral musculature, while the lateral motor fibers connect directly with the branchiomeric musculature, it seems advisable to await further studies before yielding to the temptation.

As regards the actual development of the cranial nerves, they follow the general law which obtains for the spinal nerves, the motor fibers being outgrowths from neuroblasts situated in the walls of the neural tube, while the

sensory nerves are outgrowths from the cells of ganglia situated without the tube. In the lower vertebrates a series of ganglia, known as the *suprabranchial ganglia*, are developed from the ectoderm along a line corresponding with the level of the auditory invagination, while on a line corresponding with the upper extremities of the branchial clefts another series occurs which has been termed that of the *epibranchial ganglia*, and with both of these sets the cranial nerves are in connection. In the mammalia these structures have not yet been sufficiently studied, but from the general relationship of the suprabranchial ganglia it seems probable that they are associated with the lateral line nerves and are consequently represented in the mammalia only by the ganglia of the auditory nerve.

From what has been said above it is clear that the usual arrangement of the cranial nerves in twelve pairs does not represent their true relationships with one another. The various pairs are serially homologous neither with one another nor with the typical spinal nerves, nor can they be regarded as representing twelve cranial segments. Indeed, it would seem that comparatively little information with regard to the number of myotomic segments which have fused together to form the head is to be derived from the cranial nerves, for while there are only four of these nerves which are associated with structures equivalent to the mesodermic somites of the trunk, a much greater number of head cavities or mesodermic somites has been observed in the cranial region of the embryos of the lower vertebrates, Dohrn, for instance, having found nineteen and Killian eighteen in the cranial region of *Torpedo*. Furthermore, it is not possible to say at present whether the branchiomeres and their associated nerves correspond with one or several of the cranial mesodermic somites, or whether, indeed, any correspondence whatever exists.

In early stages of development a series of constrictions have been observed in the cranial portion of the neural tube and have been regarded as indicating a primitive segmentation of that structure. The *neuromeres*, as the intervals between successive constrictions have been termed, seem to correspond with the cranial nerves as usually recognized and hence cannot be re-

garded as primitive segmental structures. They are more probably secondary and due to the arrangement of the neuroblasts corresponding to the various nerves.

#### The Development of the Sympathetic Nervous System.—

From the embryological standpoint the distinction which has been generally recognized between the sympathetic and central nervous systems does not exist, the former having been found to be an outgrowth from the peripheral ganglia of the latter. This mode of origin has been observed with especial clearness in the embryos of some of the lower vertebrates, in which masses of cells have been seen to separate from the posterior root ganglia to form the ganglia of the ganglionated cord (Fig. 232). In the mammalia, including man, the relations of the two sets of ganglia to one another is by no means so apparent, since the sympathetic cells, instead of being separated from the posterior root ganglion *en masse*, migrate from it singly or in groups, and are therefore less readily distinguishable from the surrounding mesodermal tissues.

To understand the development of the sympathetic system it must be remembered that it consists typically of three sets of ganglia. One of these is constituted by the ganglia of the ganglionated cord (Fig. 233, *GC*), the second is represented by the ganglia of the prævertebral plexuses (*PVG*), such as the cardiac, solar, hypogastric, and pelvic, while the third or peripheral set (*PG*) is formed by the cells which occur throughout the tissues of probably most of the visceral organs, either in small groups or scattered through plexuses such as the Auerbach and Meissner plexuses of the intestine. Each cell in these various ganglia stands in direct contact with the axis-cylinder of a cell situated in the central nervous system, probably in the lateral horn of the spinal cord or the corresponding region of the brain, so that each cell forms the

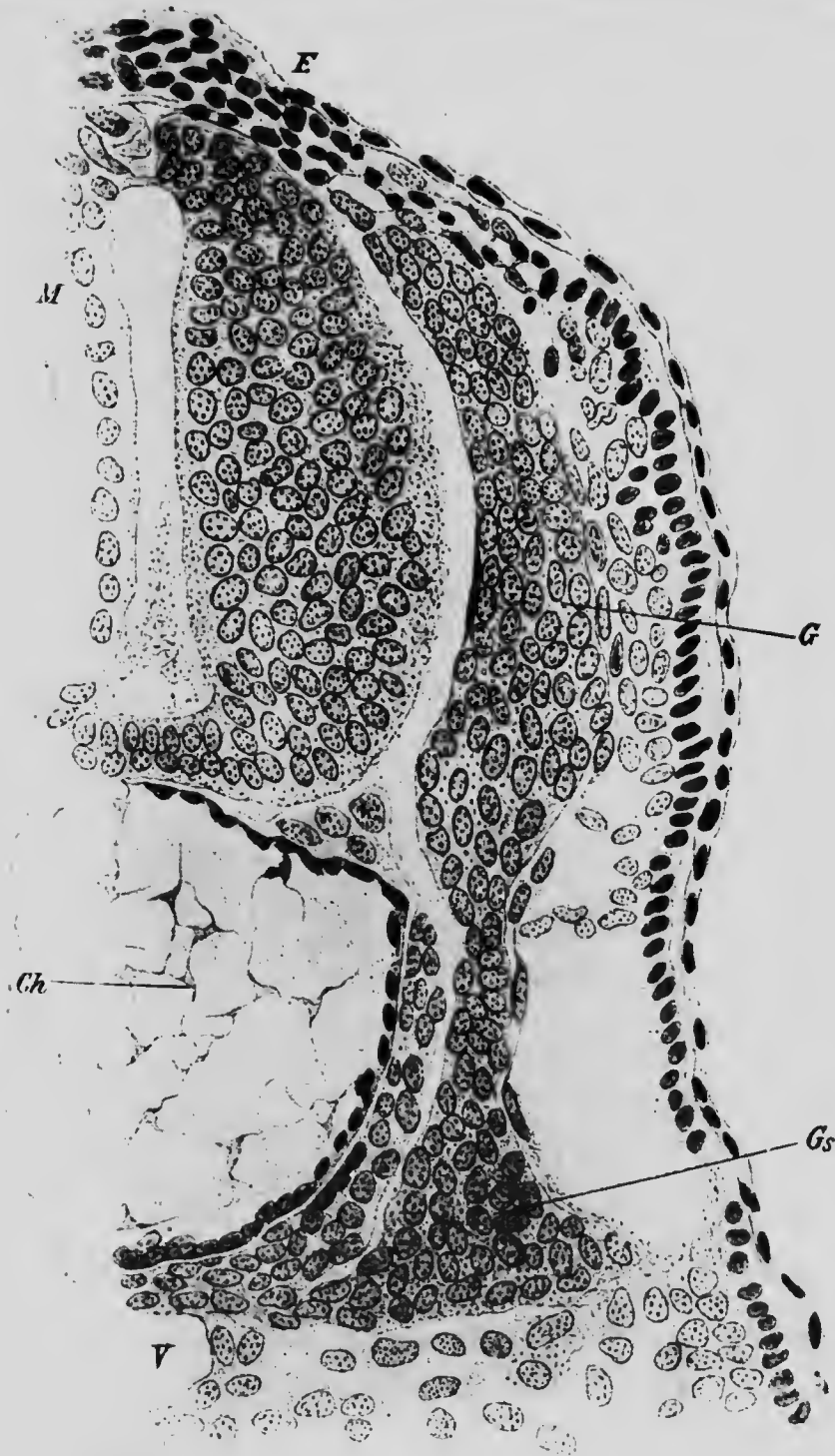


FIG. 232.—TRANSVERSE SECTION THROUGH AN EMBRYO SHARK (*Scyllium*) OF 15 MM., SHOWING THE ORIGIN OF A SYMPATHETIC GANGLION. *Ch.* Notochord; *E*, ectoderm; *G*, posterior root ganglion; *Gs*, sympathetic ganglion; *M*, spinal cord.—(Onodi.)

terminal link of a chain whose first link is a neurone belonging to the central system (Huber). Throughout the thoracic and upper lumbar regions of the body the central system neurones form distinct cords known as the *white rami communicantes* (Fig. 233, *WR*), which pass from the spinal nerves to the adjacent ganglia of the ganglionated cord, some of them terminating around the cells of these ganglia, others passing on to the cells of the prævertebral ganglia, and others to those of the peripheral

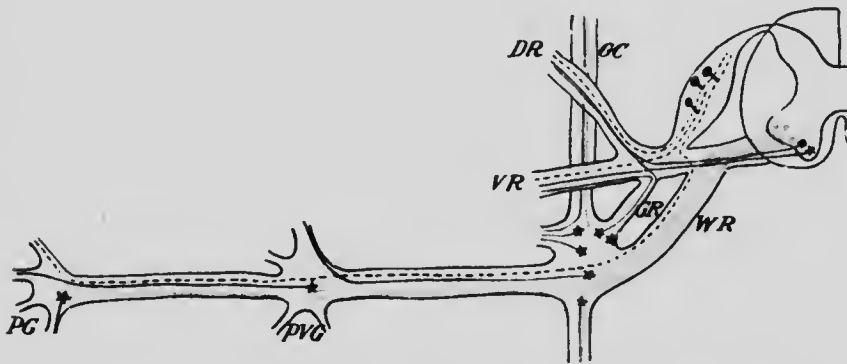


FIG. 233.—DIAGRAM SHOWING THE ARRANGEMENT OF THE NEURONES OF THE SYMPATHETIC SYSTEM.

The fibers from the posterior root ganglia are represented by the broken black lines; those from the anterior horn cells by the solid black; the white rami by red; and the sympathetic neurones by blue. *DR*, Dorsal ramus of spinal nerve; *GC*, ganglionated cord; *GR*, gray rami communicans; *PG*, peripheral ganglion; *PVG*, prævertebral ganglion; *VR*, ventral ramus of spinal nerve; *WR*, white rami communicans.—(Adapted from Huber.)

plexuses. In the cervical, lower lumbar and sacral regions white rami are wanting, the central neurones in the first-named region probably making their way to the sympathetic cells largely by way of the spinal accessory nerves, while in the lower regions they may pass down the ganglionated cord from higher regions or may join the prævertebral and peripheral ganglia directly without passing through the proximal ganglia. In addition to these white



rami, what are known as *gray rami* also extend between the proximal ganglia and the spinal nerves; these are composed of fibers, arising from sympathetic cells, which join the spinal nerves in order to pass with them to their ultimate distribution.

The brief description here given applies especially to the sympathetic system of the neck and trunk. Representatives of the system are also found in the head, in the form of a series of ganglia connected with the trigeminus and facial nerves and known as the ciliary (lenticular), spleno-palatine, otic, and submaxillary ganglia; and, as will be seen later, there are probably some sympathetic cells which owe their origin to the root ganglia of the pneumogastric and glossopharyngeal nerves. There is nothing, however, in the head region corresponding to the longitudinal bundles of fibers which unite the various proximal ganglia of the trunk to form the ganglionated cord.

The first indications of the sympathetic system are to be seen in a human embryo of about 7 mm. As the spinal nerves reach the level of the dorsal edge of the body-cavity, they branch, one of the branches continuing ventrally in the body-wall, while the other (Fig. 234, *w*) passes mesially toward the aorta, some of its fibers reaching that structure, while others bend so as to assume a longitudinal direction. These mesial branches represent the white rami communicantes, but as yet no ganglion cells can be seen in their course. The cells of the posterior root ganglia have already, for the most part, assumed their bipolar form, but among them there may still be found a number of cells in the *neuroblast* condition, and these (Fig. 234, *s*), wandering out from the *ganglia*, give rise to a column of cells standing in relation to the white rami. At first there is ~~no~~ indication of a segmental arrangement

of the cells of the column (Fig. 235), but at about the seventh week such an arrangement makes its appearance in the cervical region, and later, extends posteriorly, until the column assumes the form of the ganglionated cord.

Before, however, the segmentation becomes marked,



FIG. 234.—TRANSVERSE SECTION THROUGH THE SPINAL CORD OF AN EMBRYO OF 7 MM.

*c*, Notochord; *g*, posterior root ganglion; *m*, spinal cord; *s*, sympathetic cell migrating from the posterior root ganglion; *wr*, white ramus.—*(His.)*

thickenings appear at certain regions of the cell column, and from these, bundles of fibers may be seen extending ventrally toward the viscera. The thickenings represent certain of the prævertebral ganglia, and later cells wander out from them and take a position in front of the aorta.

In an embryo of 10.2 mm. two ganglionic masses (Fig. 235, *pc*) occur in the vicinity of the origin of the omphalo-mesenteric artery (*am*), one lying above and the other below that vessel; these masses represent the ganglia of the solar plexus and have separated somewhat from the ganglionated cord, the fiber bundles which unite the upper mass with the cord representing the greater and lesser splanchnic nerves (*sp*), while that connected with the lower mass represents the connection of the cord with the superior mesenteric ganglion. Lower down, in the neighborhood of the umbilical arteries, is another enlargement of the cord (*bg*), which probably represents the inferior mesenteric and hypogastric ganglia which have not yet separated from the cell column.

In the cervical region a similar origin of the ganglion cells of the cardiac plexus from the cell column seems to obtain. In embryos of about 7 mm. fibers may be seen extending from the column toward the heart, and, entering into close relationship with descending branches from the vagus, they form a plexus, the ganglia of which are composed of cells which have wandered from the cell column.

The elongated courses of the cardiac sympathetic and splanchnic nerves in the adult receive an explanation from the recession of the heart and diaphragm (see p. 259 and 342), the latter process forcing downward the solar plexus, which originally occupied a position opposite the region of the ganglionated cord from which the splanchnic nerves arise.

The cells which occur in the peripheral plexuses have, in a similar manner, wandered out from their original position in the cell column. In 10 mm. embryos groups of such cells have been observed both in the lesser and greater curvatures of the stomach (Fig. 235, \*), where they become connected with a plexus formed by fibers from the vagus nerves (*rv*). The wandering of sympa-

thetic cells into the walls of the intestine has also been observed, and they form at first a single layer in the mesoderm of the intestinal wall, only later, on the differentiation of the muscle layers, becoming separated into the two

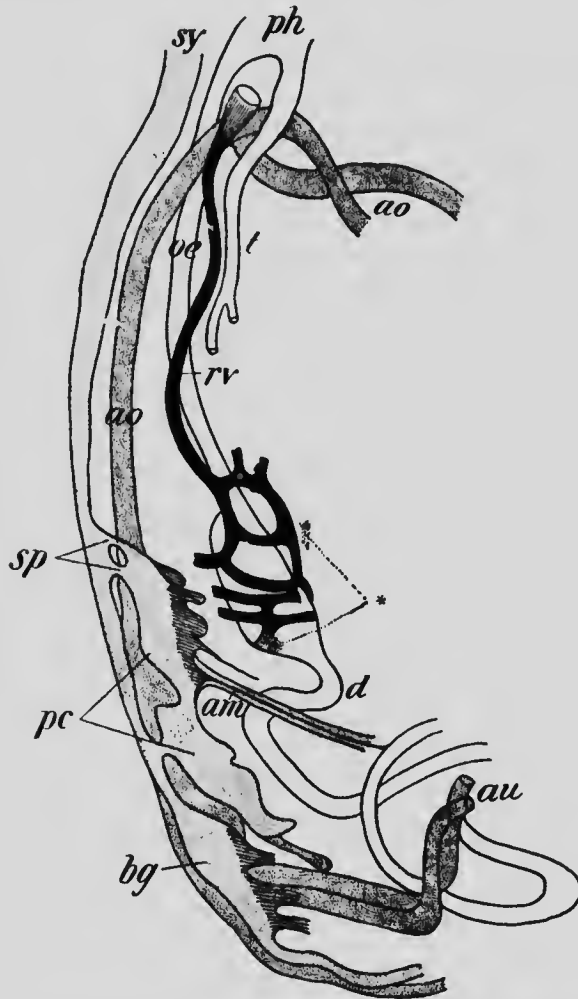


FIG. 235.—RECONSTRUCTION OF THE SYMPATHETIC SYSTEM OF AN EMBRYO OF 10.2 MM.

*am*, Omphalo-mesenteric vein; *ao*, aorta; *au*, umbilical artery; *bg*, ganglionic mass representing the pelvic plexus; *d*, intestine; *oe*, œsophagus; *pc*, ganglia of the coeliac plexus; *ph*, pharynx; *rv*, right vagus nerve; *sp*, splanchnic nerves; *sy*, ganglionated cord; *t*, trachea; \*, peripheral sympathetic ganglia in the walls of the stomach.—(*His, Jr.*)

layers which constitute the plexuses of Auerbach and Meissner. Similarly cells reach the heart by wandering in some cases along fibers of the vagus, although they really come from the cervical region of the ganglionated cord, and, having in their wandering met with fibers of the vagus, make use of them as paths by which they may reach their destination.

As regards the cephalic sympathetic ganglia, the observations of Remak on the chick and Kölliker on the rabbit show that the ciliary, sphenopalatine, and otic ganglia arise by the separation of cells from the Gasserian ganglion, and from their adult relations it may be supposed that the cells of the submaxillary and sublingual ganglia have similarly arisen from the geniculate ganglion of the facial nerve. Evidence has also been obtained from human embryos that sympathetic cells are derived from the ganglia of the vagus and glossopharyngeal nerves, but, instead of forming distinct ganglia in the adult, these, in all probability, associate themselves with the first cervical ganglia of the ganglionated cord.

**Accessory Organs of the Sympathetic System.**—In addition to the various sets of ganglia which clearly belong to the sympathetic system, there occur throughout the body, in various regions, certain peculiar organs which are closely associated with the same system both in their origin and in their adult relations, but whose exact physiological significance is as yet problematical.

*The Ganglia Intercarotica.*—These structures, which are frequently though incorrectly termed *carotid glands*, are small bodies about 5 mm. in length, which lie usually to the mesial side of the upper ends of the common carotid arteries. They possess a very rich arterial supply and stand in intimate relation with the branches of an inter-

carotid sympathetic plexus, and, furthermore, they are characterized by possessing as their specific constituents markedly chromaffine cells (see p. 392), among which are scattered stellate cells resembling the cells of the sympathetic ganglia.

They have been found to arise in pig embryos of 44 mm. by the separation of cells from the ganglionic masses seat-

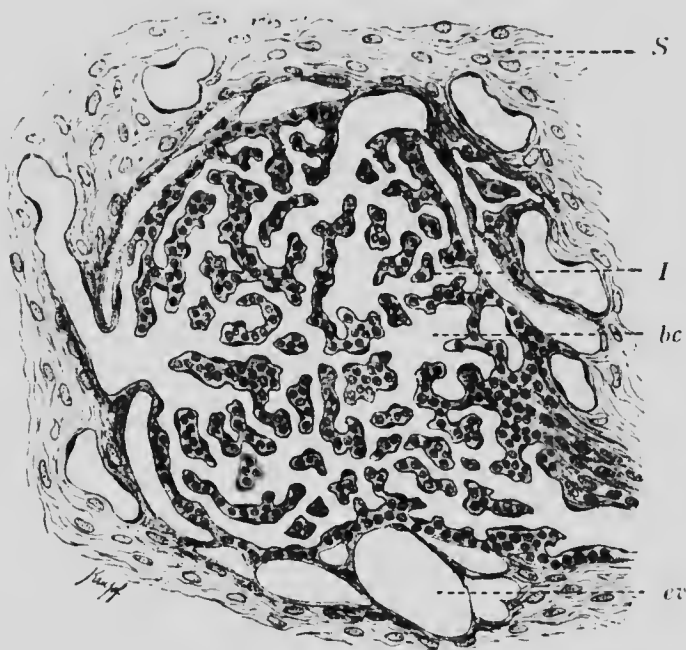


FIG. 236.—SECTION OF A CELL BALL FROM THE INTERCAROTID GANGLION OF MAN.

*bc*, Blood capillaries; *cv*, efferent vein; *S*, connective-tissue septum; *I*, trabeculae.—(From Bohm and Davidoff, after Schaper.)

tered throughout the intercarotid sympathetic plexuses. These cells, which become the chromaffine cells, arrange themselves in round masses termed cell balls, many of which unite to form each ganglion, and in man each cell ball becomes broken up into trabeculae by the blood-vessels (Fig. 236) which penetrate its substance, and the

individual balls are separated from one another by considerable quantities of connective tissue.

Some confusion has existed in the past as to the origin of this structure. The mesial wall of the proximal part of the internal carotid artery becomes considerably thickened during the early stages of development and the thickening is traversed by numerous blood lacunæ which communicate with the lumen of the vessel. This condition is perhaps a relic of the branchial capillaries which in the lower gill-breathing vertebrates represent the proximal portion of the internal carotid and has nothing to do with the formation of the intercarotid ganglion, although it has been believed by some authors (Schaper) that the ganglion was derived from the thickening of the wall of the vessel. The fact that in some animals, such as the rat and the dog, the ganglion stands in relation with the external carotid and receives its blood supply from that vessel is of importance in this connection.

The thickening of the internal carotid disappears in the higher vertebrates almost entirely, but in the Amphibia it persists throughout life, the lumen of the proximal part of the vessel being converted into a fine meshwork by the numerous trabeculæ which traverse it. This carotid labyrinth has been termed the carotid gland, a circumstance which has probably assisted in producing confusion as to the real significance of the intercarotid ganglion.

*The Organs of Zuckerkandl.*—In embryos of 14.5 mm. there have been found, in front of the abdominal aorta, closely packed groups of cells which resemble in appearance the cells composing the ganglionated cord, two of these groups, which extend downward along the side of the aorta to below the point of origin of the inferior mesenteric artery, being especially distinct. These cell groups give rise to the ganglia of the prævertebral sympathetic plexuses and also to peculiar bodies which, from their discoverer, may be termed the organs of Zuckerkandl. Each body stands in intimate relation with the fibers of the sympathetic plexuses and has a rich blood-supply,

resembling in these respects the intercarotid ganglia, and the resemblance is further increased by the fact that the specific cells of the organ are markedly chromaffine.

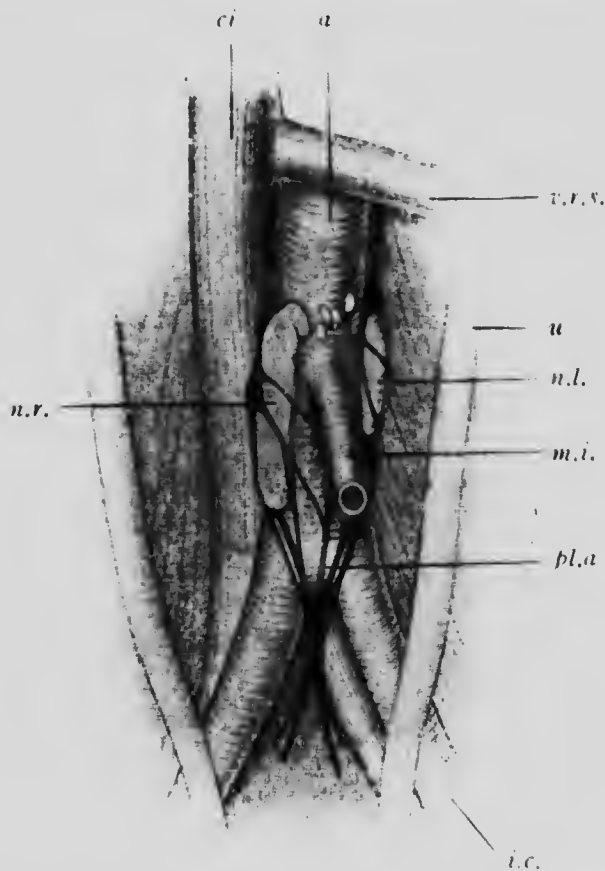


FIG. 237.—ACCESSORY SYMPATHETIC ORGANS OF ZUCKERKANDL FROM A NEW-BORN CHILD.

*a*, Aorta; *ci*, inferior vena cava; *i.c.*, common iliac artery; *m.i.*, inferior mesenteric artery; *n.l.* and *n.r.*, left and right accessory organs; *pl.a.*, aortic plexus; *u.*, ureter; *r.r.v.*, left renal vein. —(Zuckerkandl.)

At birth the bodies situated in the upper portion of the abdominal cavity have broken up into small masses, but the two lower ones, mentioned above, are still well defined (Fig. 237). Even these, however, seem to disappear later



on and no traces of them have as yet been found in the adult.

*The Coccygeal or Luschka's Ganglion.*—In embryos of about 15 cm. there is to be found on the ventral surface of the apex of the coccyx a small oval group of polygonal cells, clearly separated from the surrounding tissue by a mesenchymal capsule. Later, connective-tissue trabeculæ make their way into the mass, which thus becomes divided into lobules, and, at the same time, a rich vascular supply, derived principally from branches of the *arteria sacra media*, penetrates the body which thus assumes the adult condition, in which it presents a general resemblance to the intereartotid ganglion.

There are as yet no direct observations determining the origin of the specific cells of this coccygeal gland, but the evidence available points to their derivation from the sympathetic system. They appear in the position which should be occupied by the terminal portion of the sympathetic cord, and from the time when they first become recognizable onward they are connected with sympathetic fibers. The probability is that, like the cells of the other organs described above, they are derived from sympathetic ganglia.

#### LITERATURE.

- W. HIS: "Zur Geschichte des menschlichen Rückenmarkes und der Nervenwurzeln," *Abhandl. der königl. Sächsischen Gesellsch., Math.-Physik. Classe*, XIII, 1886.
- W. HIS: "Zur Geschichte des Gehirns sowie der centralen und peripherischen Nervenbahnen beim menschlichen Embryo," *Abhandl. der königl. Sächsischen Gesellsch., Math.-Physik. Classe*, XIV, 1888.
- W. HIS: "Die Formentwicklung des menschlichen Vorderhirns vom Ende des ersten bis zum Beginn des dritten Monats," *Abhandl. der königl. Sächsischen Gesellsch., Math.-Physik. Classe*, XV, 1889.
- W. HIS: "Histogenese und Zusammenhang der Nerven-elemente," *Archiv für Anat. und Physiol., Anat. Abth., Supplement*, 1890.

- W. HIS, JR.: "Die Entwicklung des Herznervensystems bei Wirbelthieren," *Abhandl. der konigl. Sächsischen Gesellsch., Math. Physik. Classe*, XVIII, 1893.
- W. HIS, JR.: "Ueber die Entwicklung des Bauchsymplicus beim Huhnchen und Menschen," *Archiv für Anat. und Physiol., Anat. Abth., Supplement*, 1897.
- C. J. HERRICK: "The Cranial and First Spinal Nerves of Menidia. A Contribution upon the Nerve Components of the Bony Fishes," *Journ. of Comp. Neurol.*, IX, 1899.
- C. J. HERRICK: "The Cranial Nerves and Cutaneous Sense-organs of the North American Silmroid Fishes," *Journ. of Comp. Neurol.*, XI, 1901.
- G. C. LEBER: "Four Lectures on the Sympathetic Nervous System," *Journ. of Comp. Neurol.*, XII, 1897.
- J. H. JAKOBSSON: "Beiträge zur Kenntnis der fetalen Entwicklung der Steissdrüse," *Archiv für mikrosk. Anat.*, LIII, 1899.
- A. KOHN: "Ueber den Bau und die Entwicklung der sog. Carotisdrüse," *Archiv für mikrosk. Anat.*, LVI, 1900.
- M. VON LENNOSSEK: "Die Entwicklung der Ganglienanlagen bei dem menschlichen Embryo," *Archiv für Anat. und Physiol., Anat. Abth.*, 1891.
- F. MARCHAND: "Ueber die Entwicklung des Balkens im menschlichen Gehirn," *Archiv für mikrosk. Anat.*, XXXVII, 1891.
- V. VON MIHALKOVICZ: "Entwicklungsgeschichte des Gehirns," Leipzig, 1877.
- A. D. OSODI: "Ueber die Entwicklung des sympathischen Nervensystems," *Archiv für mikrosk. Anat.*, XXVII, 1886.
- G. RETZIUS: "Das Menschenhirn," Stockholm, 1896.
- A. SCHAPER: "Die frühesten Differenzierungsvorgänge im Centralnervensystem," *Archiv für Entwicklungsmechanik*, V, 1897.
- O. S. STRONG: "The Cranial Nerves of Amphibia," *Journal of Morphol.*, X, 1895.
- R. WLESSAK: "Die Herkunft des Myelins," *Archiv für Entwicklungsmechanik*, VI, 1898.
- E. ZUCKERKANDL: "Ueber Nebenorgan: des Sympathicus im Retroperitonealraum des Menschen," *Verhandl. Anat. Gesellsch.*, XV, 1901.

## CHAPTER XV.

### THE DEVELOPMENT OF THE ORGANS OF SPECIAL SENSE.

Like the cells of the central nervous system, the sensory cells are all of ectodermal origin, and in lower animals, such as the earthworm, for instance, they retain their original position in the ectodermal epithelium throughout life. In the vertebrates, however, the majority of the sensory cells relinquish their superficial position and sink more or less deeply into the subjacent tissues, being represented by the posterior root ganglion cells and by the sensory cells of the special sense-organs, and it is only in the olfactory organ that the original condition is retained. Those cells which have withdrawn from the surface receive stimuli only through an overlying cell or cells, and in certain cases these transmitting cells are not specially differentiated, the terminal branches of the sensory dendrites ending among ordinary epithelial cells or in such structures as the Pacinian bodies or the end-bulbs of Krause situated beneath undifferentiated epithelium. In other cases, however, certain specially modified superficial cells serve to transmit the stimuli to the peripheral sensory neurones, forming such structures as the hair-cells of the auditory epithelium or of the taste-buds.

Thus three degrees of differentiation of the special sensory cells may be recognized and a classification of the sense-organs may be made upon this basis. One organ, however, the eye, cannot be brought into such a classification, since its sensory cells present certain developmental

peculiarities which distinguish them from those of all other sense-organs. Embryologically the retina is a portion of the central nervous system and not a peripheral organ, and hence it will be convenient to arrange the other sense-organs according to the classification indicated and to discuss the history of the eye at the close of the chapter.

**The Development of the Olfactory Organ.**—The general development of the nasal fossa, the epithelium of which contains the olfactory sense cells, has already been described (pp. 97 and 104), as has also the development of the olfactory lobes of the brain (p. 427), and it remains to consider here merely the formation of the olfactory nerve and the development of the rudimentary organ of Jacobson.

*The Olfactory Nerve.*—Very diverse results have been obtained by various observers of the development of the olfactory nerve, it having been held at different times that it was formed by the outgrowth of fibers from the olfactory lobes (Marshall), from fibers which arise partly from the olfactory lobes and partly from the olfactory epithelium (Beard), from the cells of an olfactory ganglion originally derived from the olfactory epithelium but later separating from it (His), and, finally, that it was composed of the prolongations of certain cells situated and, for the most part at least, remaining permanently in the olfactory epithelium (Disse). The most recent observations on the structure of the olfactory epithelium and nerve indicate a greater amount of probability in the last result than in the others, and the description which follows will be based upon the observations of His, modified in conformity with the results obtained by Disse from chick embryos.

In human embryos at the fourth week the cells lining the upper part of the olfactory pits show a distinction into ordinary epithelial and sensory cells, the latter, when fully

formed, being elongated cells prolonged peripherally into a short but narrow process which reaches the surface of the epithelium and proximally gives rise to an axis-cylinder process which extends up toward and penetrates

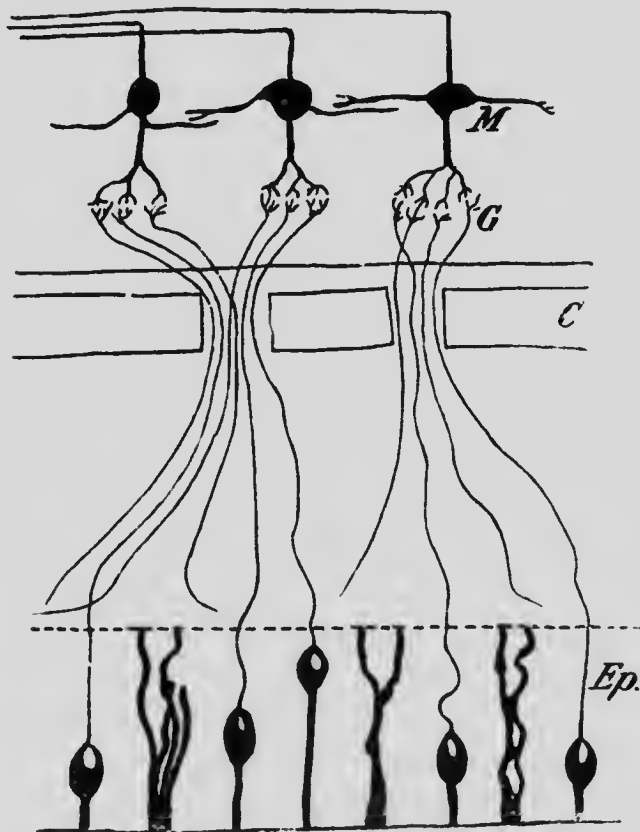


FIG. 238.— DIAGRAM ILLUSTRATING THE RELATIONS OF THE FIBERS OF THE OLFACTORY NERVE.

*Ep.*, Epithelium of the olfactory pit; *C*, cribriform plate of the ethmoid; *G*, glomerulus of the olfactory bulb; *M*, mitral cell.—(Van Gehuchten.)

the tip of the olfactory lobe to come into contact with the dendrites of the first central neurones of the olfactory tract (Fig. 238). These cells constitute a neuro-epithelium and in later stages of development retain their epithelial

position for the most part, a few of them, however, withdrawing into the subjacent mesenchyme and becoming bipolar, their peripheral prolongations ending freely among the cells of the olfactory epithelium. These bipolar cells resemble closely in form and relations the cells of the embryonic posterior root ganglia, and thus form an interesting transition between these and the neuro-epithelial cells.

*The Organ of Jacobson.*—In embryos of three or four months a small pouch-like invagination of the epithelium covering the lower anterior portion of the median septum of the nose can readily be seen. This becomes converted into a slender pouch, 3 to 5 mm. long, ending blindly at its posterior extremity and opening at its other end into the nasal cavity. Its lining epithelium resembles that of the respiratory portion of the nasal cavity, and there is developed in the connective tissue beneath its floor a slender plate of cartilage, distinct from that forming the septum of the nose.

This organ, which may apparently undergo degeneration in the adult, and in some cases completely disappears, appears to be the representative of what is known as Jacobson's organ, a structure which reaches a much more extensive degree of development in many of the lower mammals, and in these contains in its epithelium sensory cells whose axis-cylinder processes pass with those of the olfactory sense cells to the olfactory bulbs. In man, however, it seems to be a rudimentary organ, and no satisfactory explanation of its function has as yet been advanced.

The olfactory neuro-epithelium, considered from a comparative standpoint, seems to have been derived from the system of lateral line organs so highly developed in the lower vertebrates. In higher forms the system, which is cutaneous in character, has disappeared except in two

regions where it has become highly specialized. In one of these regions it has given rise to the olfactory sense cells and in the other to the similar cells of the auditory apparatus.

**The Organs of Touch and Taste.**—Nothing is yet known concerning the development of the various forms of tactile organs, which belong to the second class of sensory organs described above.

*The Organs of Taste.*—The remaining organs of special sense belong to the third class, and of these the organs of taste present in many respects the simplest condition. They are developed principally in connection with the

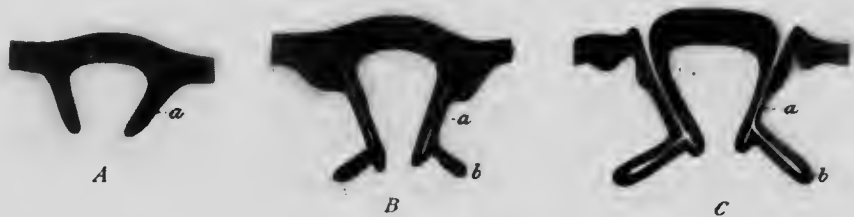


FIG. 239.—DIAGRAMS REPRESENTING THE DEVELOPMENT OF A CIRCUMVALLATE PAPILLA.

*a*, Valley surrounding the papilla; *b*, von Ebner's gland.—(Graberg.)

circumvallate and foliate papillæ of the tongue, and of the former one of the earliest observed stages has been found in embryos of 9 cm. in the form of two ridges of epidermis, lying toward the back part of the tongue and inclined to one another in such a manner as to form a V with the apex directed backward. From these ridges solid downgrowths of epidermis into the subjacent tissue occur, each downgrowth having the form of a hollow truncated cone with its basal edge continuous with the superficial epidermis (Fig. 239, A). In later stages lateral outgrowths develop from the deeper edges of the cone, and about the same time clefts appear in the substance of the original

downgrowths (Fig. 239, B) and, uniting together, finally open to the surface, forming a trench surrounding a papilla (Fig. 239, C). The lateral outgrowths, which are at first solid, also undergo an axial degeneration and become converted into the *glands of Ebner* (*b*), which open into the trench near its floor. The various papillæ which occur in the adult do not develop simultaneously, but their number increases with the age of the fetus, and there is, moreover, considerable variation in the time of their development.

The taste-buds are formed by a differentiation of the epithelium which covers the papillæ, and this differentiation appears to stand in intimate relation with the penetration of fibers of the glossopharyngeal nerve into the papillæ. The buds form at various places upon the papillæ, and at one period are especially abundant upon their free surfaces, but in the later weeks of intrauterine life these surface buds undergo degeneration and only those upon the sides of the trench persist, as a rule.

The foliate papillæ do not seem to be developed until some time after the circumvallate, being entirely wanting in embryos of four and a half and five months, although plainly recognizable at the seventh month.

**The Development of the Ear.**—It is customary to describe the mammalian ear as consisting of three parts, known as the inner, middle, and outer ears, and this division is, to a certain extent at least, confirmed by the embryonic development. The inner ear, which is the sensory portion proper, is fundamentally an ectodermal structure, secondarily becoming deeply seated in the mesodermal tissue of the head, while the middle and outer ears, which provide the apparatus necessary for the conduction of the sound-waves to the inner ear, are modified portions of the anterior branchial arches. It will be con-



venient, accordingly, in the description of the ear, to accept the usually recognized divisions and to consider first of all the development of the inner ear, or, as it is better termed, the *otocyst*.

*The Development of the Otocyst.*—In an embryo of 2.4 mm. a pair of pits occur upon the surface of the body about opposite the middle portion of the hind-brain (Fig. 240, A). The ectoderm lining the pits is somewhat thicker than is the neighboring ectoderm of the surface of the body, and, from analogy with what occurs in other vertebrates, it seems probable that the pits are formed by the invagination of localized thickenings of the ectoderm.

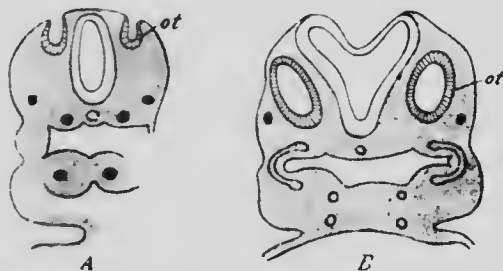


FIG. 240. TRANSVERSE SECTION PASSING THROUGH THE OTOCYST (*ot*) OF EMBRYOS OF (A) 2.4 MM. AND (B) 4 MM.—(*His.*)

The mouth of each pit gradually becomes smaller, until finally the invagination is converted into a closed sac (Fig. 240, B), which separates from the surface ectoderm and becomes enclosed within the subjacent mesoderm. This sac is the *otocyst*, and in the stage just described, found in embryos of 4 mm., it has an oval or more or less spherical form. Soon, however, in embryos of 6.9 mm., a prolongation arises from its dorsal portion and the sac assumes the form shown in Fig. 241, A; this prolongation represents the *ductus endolymphaticus*, and, increasing in length, it soon becomes a strong club-shaped process, projecting considerably beyond the remaining portions of the

otocyst (Fig. 241, B). In embryos of about 10.2 mm. the sac begins to show certain other irregularities of shape (Fig. 241, B, *sc*). Thus, about opposite the point of origin of the ductus endolymphaticus three folds make their appearance, representing the *semicircular canals*, and as

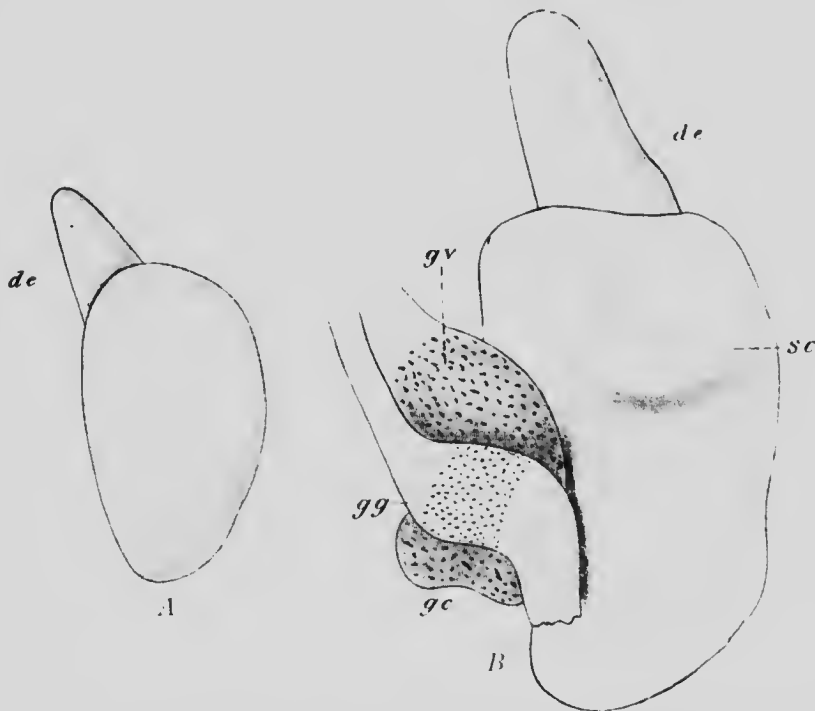


FIG. 241.—RECONSTRUCTIONS OF THE OTOCYSTS OF EMBRYOS OF (A) 6.9 MM AND (B) 10.2 MM.

*de*, Endolymphatic duct; *gc*, ganglion cochleare; *gg*, ganglion geniculatum; *gv*, ganglion vestibulare; *sc*, horizontal semicircular canal.—(*His, Jr.*)

they increase in size the opposite walls of the central portion of each fold come together, fuse, and finally become absorbed, leaving the free edge of the fold as a crescentic canal, at one end of which an enlargement appears to form the *ampulla*. The transformation of the folds into canals takes place somewhat earlier in the cases of the two

vertical than in that of the horizontal canal, as may be seen from Fig. 242, which represents the condition occurring in an embryo of 13.5 mm.

A short distance below the level at which the canals

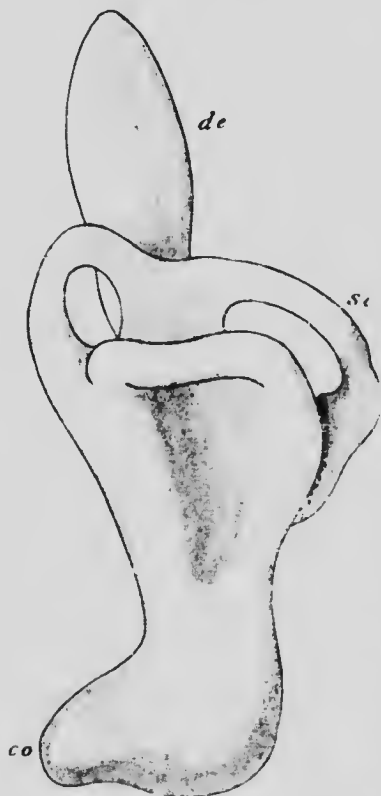


FIG. 242.—RECONSTRUCTION OF THE OTOCYST OF AN EMBRYO OF 13.5 MM.

*co*, Cochlea; *de*, endolymphatic du.; *sc*, semicircular canal. —(His, Jr.)

communicate with the remaining portion of the otocyst a constriction appears, indicating a separation of the otocyst into a more dorsal portion, which becomes the *utricle*, and a more ventral one. Later, the ventral portion of the latter begins to be prolonged into a flattened canal which, as it elongates, becomes coiled upon itself and also becomes separated by a constriction from the portion of the otocyst from which it arises. The latter is the representative of the adult sacculus (Fig. 243, *s*), while the coiled canal (*co*) forms the *scala media* of the *cochlea* and the constricted portion of the otocyst, which unites the *scala* and the *sacculus*, becomes the *canalis reuniens*. The constriction which marks the line of separation of the *utricle* (*ut*) and *sacculus* is converted into a narrow canal with which the *ductus endolymphaticus* connects, and hence it is that, in the adult, the connection between these two portions of the otocyst

seems to be formed by the ductus dividing proximally into two limbs, one of which is connected with the utricle and the other with the saccule.

When first observed in the human embryo the auditory ganglion is closely associated with the geniculate ganglion of the seventh nerve (Fig. 241, B), the two, usually spoken of as the acustico-facialis ganglion, forming a mass

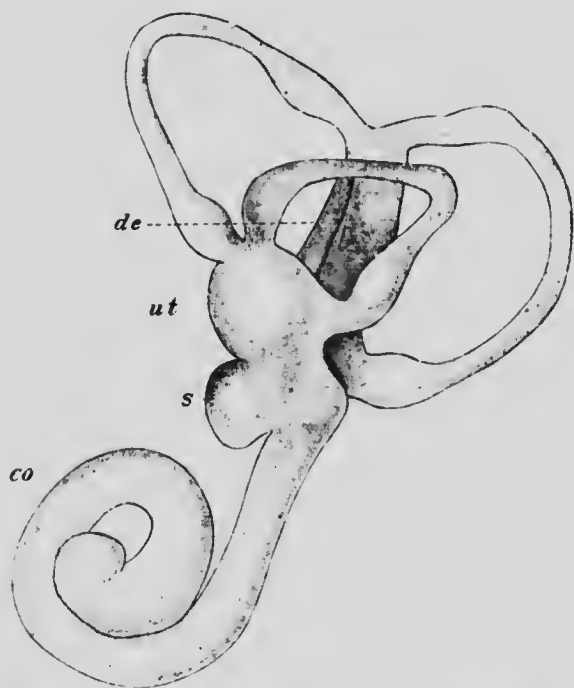


FIG. 243. —RECONSTRUCTION OF THE OTOCYST OF AN EMBRYO OF 22 MM. *co*, Cochlea; *de*, endolymphatic duct; *s*, saccule; *ut*, utricle.—(His, Jr.)

of cells lying in close contact with the anterior wall of the otocyst. The origin of the ganglionic mass has not yet been traced in the mammalia, but it has been observed that in cow embryos the geniculate ganglion is connected with the ectoderm at the dorsal end of the first branchial cleft (Froriep), and it may perhaps be regarded as one of

the epibranchial ganglia (see p. 440), and in the lower vertebrates a union of the ganglion with a suprabranchial ganglion has been observed (Kupfer), this union indicating the origin of the auditory ganglion from one or more of the ganglia of the lateral line system.

At an early stage in the human embryo the auditory ganglion shows indications of a division into two portions, a more dorsal one, which represents the future *ganglion vestibulare*, and a ventral one, the *ganglion cochleare*. The ganglion cells become bipolar, in which condition they remain throughout life, never reaching the T-shaped condition found in most of the other peripheral cerebrospinal ganglia. One of the prolongations of each cell is directed centrally to form a fiber of the auditory nerve while the other penetrates the wall of the otocyst to enter into relations with certain specially modified cells which differentiate from its lining epithelium.

In the earliest stages the ectodermal lining of the otocyst is formed of similar columnar cells, but later over the greater part of the surface the cells flatten down, only a few, aggregated together to form patches, retaining the high columnar form and developing hair-like processes upon their free surfaces. These are the sensory cells of the ear. In the human ear there are in all six patches of these sensory cells, an elongated patch (*crista acustica*) in the ampulla of each semicircular canal (Fig. 244, *cr*), a round patch (*macula acustica*, *mu*) in the utriculus and another (*ms*) in the sacculus, and, finally, an elongated patch which extends the entire length of the scala media of the cochlea and forms the sensory cells of the organ of Corti.

In connection with this last patch certain adjacent cells also retain their columnar form and undergo various modifications, giving rise to a rather complicated structure

whose development has been traced in the rabbit. Along the whole length of the scala media the cells resting upon that half of the basilar membrane which is nearest the axis of the cochlea, and may be termed the inner half, retain

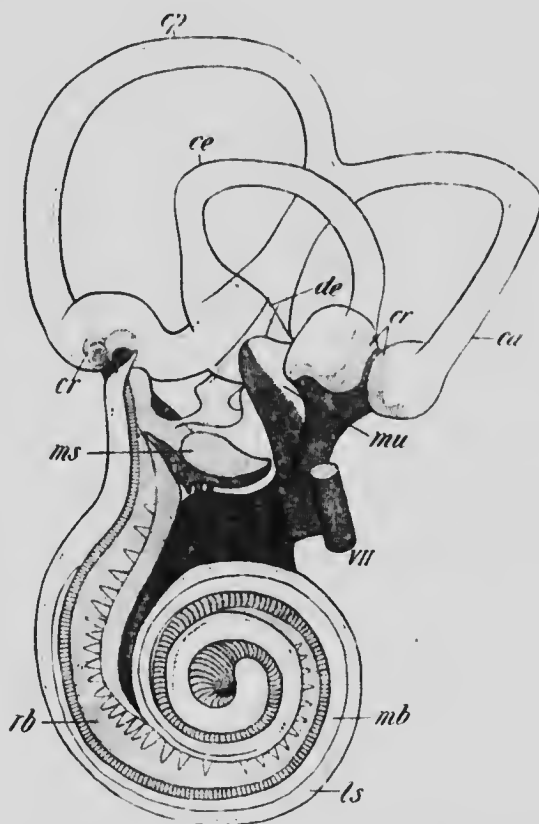



FIG. 244.—THE RIGHT INTERNAL EAR OF AN EMBRYO OF SIX MONTHS. *ca*, *ce*, and *cp*, anterior, external, and posterior semicircular canals; *ca*, crista acustica; *de*, endolymphatic duct; *ls*, spiral ligament; *mb*, basilar membrane; *ms* and *mu*, macula acustica sacculi and utriculi; *rb*, basilar branches of the cochlear nerve.—(Retzius.)

their columnar shape, forming two ridges projecting slightly into the cavity of the scala (Fig. 245). The cells of the inner ridge, much the larger of the two, give rise to the *membrana tectoria*, either as a cuticular secre-





1.5

1.6

1.8

2.0

2.2

2.5

2.8

3.2

3.6

4.0

4.5

5.0

5.6

6.3

7.1

8.0

9.0

10

11.2

12.5

14

16

18

20

22.4


25

28

32

36

40



MICROCOPY RESOLUTION TEST CHART  
NATIONAL BUREAU OF STANDARDS  
STANDARD REFERENCE MATERIAL 1010a  
(ANSI and ISO TEST CHART No. 2)



tion or by the artificial adhesion of long hair-like processes which project from their free surfaces (Ayers). The cells of the outer ridge are arranged in six longitudinal rows (Fig. 245, 1-6); those of the innermost row (1) develop hairs upon their free surfaces and form the inner hair cells, those of the next two rows (2 and 3) gradually become transformed on their adjacent surfaces into chitinous sub-

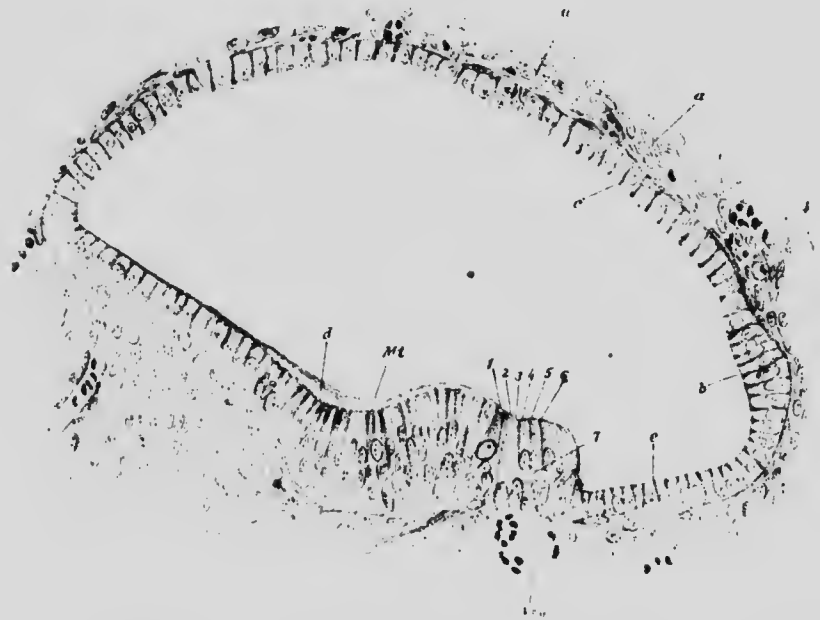


FIG. 245.—SECTION OF THE SCALA MEDIA OF THE COCHLEA OF A RABBIT EMBRYO OF 55 MM.

*a*, Mesenchyme; *b* to *c*, epithelium of scala media; *M.t.*, membrana tectoria; *V.s.p.*, vein; 1 to 7, organ of Corti.—(Baginsky.)

stance and form the rods of Corti, while the three outer rows (4 to 6) develop into the outer hair cells. It is in connection with the hair cells that the peripheral prolongations of the cells of the cochlear ganglion terminate, and since these hair cells are arranged in rows extending the entire length of the scala media, the ganglion also is

drawn out into a spiral following the coils of the cochlea, and hence is sometimes termed the spiral ganglion.

While the various changes described above have been taking place in the otocyst, the mesoderm surrounding it has also been undergoing development. At first this tissue is quite uniform in character, but later the cells immediately surrounding the otocyst condense to give rise to a fibrous layer (Fig. 246, *cp*) while more peripherally they become more loosely arranged and form a somewhat gelatinous layer (*s*),

and still more peripherally a second fibrous layer is differentiated and the remainder of the tissue assumes a character which indicates an approaching conversion into cartilage. The further history of these various layers is as follows. The inner fibrous layer gives rise to the connective-tissue wall which supports the ectodermal lining of the various portions of the otocyst; the gelatinous layer undergoes a degeneration to form a lymph-like fluid known as the perilymph, the space occupied by the fluid being the perilymphatic space; the outer fibrous layer becomes perichondrium and later periosteum; and the procartilage undergoes chondrification and later ossifies to form the petrous portion of the temporal bone.

The gelatinous layer completely surrounds most of the otocyst structures, which thus come to lie free in the peri-

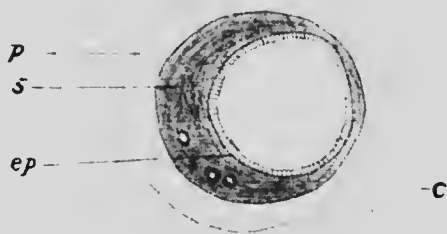


FIG. 246.—TRANSVERSE SECTION THROUGH A SEMICIRCULAR CANAL OF A RABBIT EMBRYO OF TWENTY-FOUR DAYS.

*c*, Perilymphatic space; *cp*, fibrous membrane beneath the epithelium of the canal; *p*, perichondrium; *s*, spongy tissue.—(Von Kolliker.)

lymphatic space, but in the cochlear region the conditions are somewhat different. In this region the gelatinous layer is interrupted along two lines, an outer broad one where the connective-tissue wall of the scala media is directly continuous with the perichondrium layer, and an inner narrow one, along which a similar fusion takes place with the perichondrium of a shelf-like process of the cartilage, which later ossifies to form the *lamina spiralis*.

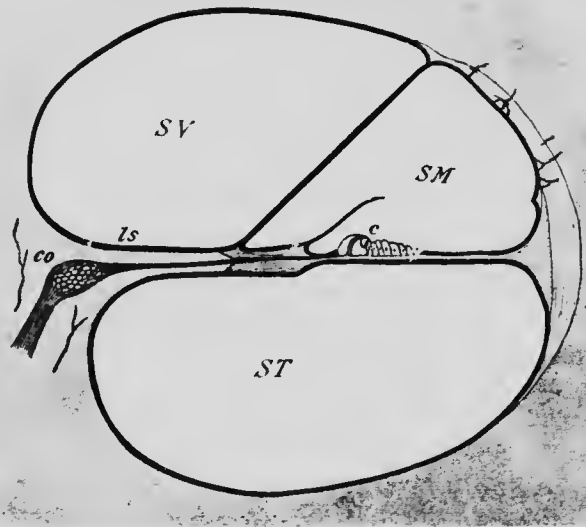


FIG. 247.—DIAGRAMMATIC TRANSVERSE SECTION THROUGH A COIL OF THE COCHLEA, SHOWING THE RELATIONS OF THE SCALÆ.

c, Organ of Corti; co, ganglion cochleare; ls, lamina spiralis; SM, scala media; ST, scala tympani; SV, scala vestibuli.—(From Gerlach.)

Consequently throughout the cochlear region the perilymphatic space is divided into two compartments which communicate at the apex of the cochlea, while below one, known as the *scala vestibuli*, communicates with the space surrounding the saccule and utricle, and the other, the *scala tympani*, abuts upon a membrane which separates it from the cavity of the middle ear and represents a portion

of the outer wall of the petrous bone where chondrification and ossification have failed to occur. This membrane closes what appears in the dried skull to be an opening in the inner wall of the middle ear, known from its shape as the *fenestra rotunda*; another similar opening, also closed by membrane in the fresh skull, occurs in the bony wall opposite the utricular portion of the otoecyst and is known as the *fenestra ovalis*.

*The Development of the Middle Ear.*—The middle ear develops from the upper part of the pharyngeal groove which represents the endodermal portion of the first branchial cleft. This becomes prolonged dorsally and at its dorsal end enlarges to form the tympanic cavity, while the narrower portion intervening between this and the pharyngeal cavity represents the Eustachian tube.

To correctly understand the development of the tympanic cavity it is necessary to recall the structures which form its boundaries. Anteriorly to the upper end of the first branchial pouch there is the upper end of the first arch, and behind it the corresponding part of the second arch, the two fusing together dorsal to the tympanic cavity and forming its roof. Internally the cavity is bounded by the outer wall of the cartilaginous investment of the otoecyst, while externally it is separated from the upper part of the ectodermal groove of the first branchial cleft by the thin membrane which forms the floor of the groove.

It has been seen in an earlier chapter that the axial mesoderm of each branchial arch gives rise to skeletal structures and muscles. The axial cartilage of the ventral portion of the first arch is what is known as Meckel's cartilage, but in that portion of the arch which forms the roof and anterior wall of the tympanic cavity, the cartilage becomes constricted to form two masses which later

ossify to form the *malleus* and *incus* (Fig. 248, *m* and *i*), while the muscular tissue of this dorsal portion of the arch gives rise to the *tensor tympani*. Similarly, in the case of the second arch there is to be found, dorsal to the extremity of the cartilage which forms the styloid process of the adult, a narrow plate of cartilage which forms an investment for the facial nerve (Fig. 248, *VII*), and dorsal to

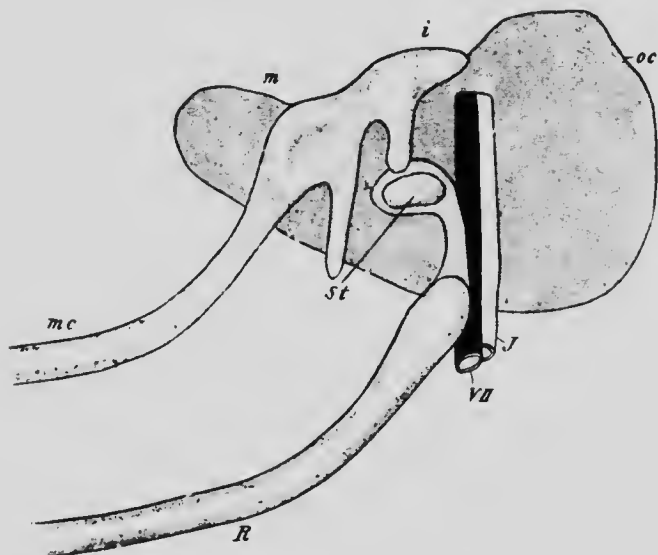


FIG. 248.—SEMI-DIAGRAMMATIC VIEW OF THE AUDITORY OSSICLES OF AN EMBRYO OF SIX WEEKS.

*i*, Incus; *J*, jugular vein; *m*, malleus; *mc*, Meckel's cartilage; *oc*, capsule of otocyst; *R*, cartilage of the second branchial arch; *st*, stapes; *VII*, facial nerve.—(Siebenmann.)

this a ring of cartilage (*st*) which surrounds a small artery and represents the *stapes*, in connection with which a muscle, termed the *stapedius*, develops.

Since, as has already been stated, the two arches meet dorsally above the primitive tympanic cavity, the structures just mentioned lie embedded in the mesenchyme forming the roof of the cavity, as does also the chorda

tympani, a branch of the seventh nerve, as it passes into the substance of the first arch on the way to its destination. The mesenchyme in which these various structures are embedded is rather voluminous (Fig. 250), and after the end of the seventh month it becomes converted into a peculiar spongy tissue, which, toward the end of fetal life, gradually degenerates, the tympanic cavity at the same time expanding and wrapping itself around the ossicles and the muscles attached to them (Fig. 249). The bones and their muscles, consequently, while appearing in the adult to traverse the tympanic cavity, are really completely enclosed within a layer of epithelium continuous with that lining the wall of the cavity, while the handle of the malleus and the chorda tympani lie between the epithelium of the outer wall of the cavity and the fibrous mesoderm which forms the tympanic membrane.

The extension of the tympanic cavity does not, however, cease with its replacement of the degenerated spongy mesenchyme, but toward the end of fetal life it begins to invade the substance of the temporal bone by a process similar to that which produces the ethmoidal cells and the

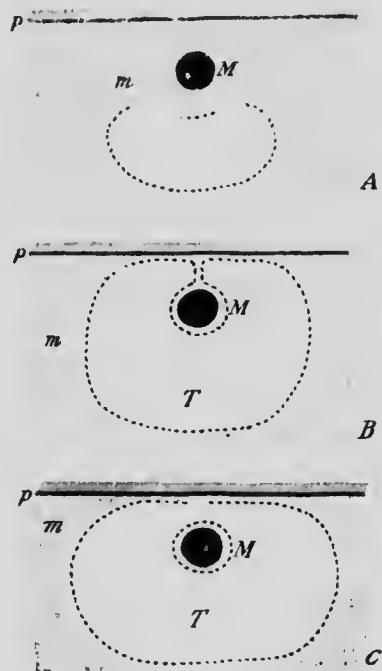


FIG. 249.—DIAGRAMS ILLUSTRATING THE MODE OF EXTENSION OF THE TYMPANIC CAVITY AROUND THE AUDITORY OSSICLES.

*M*, Malleus; *m*, spongy mesenchyme; *p*, inner surface of the periotic capsule; *T*, tympanic cavity. The broken line represents the epithelial lining of the tympanic cavity.

other osseous sinuses in connection with the nasal cavity (see p. 199). This process continues for some years after birth and results in the formation in the mastoid portion of the bone of the so-called *mastoid cells*, which communicate with the tympanic cavity and have an epithelial lining continuous with that of the cavity.

The lower portion of the diverticulum from the first pharyngeal groove which gives rise to the tympanic cavity becomes converted into the Eustachian tube. During development the lumen of the tube disappears for a time, probably owing to a proliferation of its lining epithelium, but it is re-established before birth.

In the account of the development of the ear-bones given above it is held that the malleus and incus are derivatives of the first branchial (mandibular) arch and the stapes of the second. This view represents the general consensus of recent workers on the difficult question of the origin of these bones, but it should be mentioned that nearly all possible modes of origin have been at one time or other suggested. The malleus has very generally been accepted as coming from the first arch, and the same is true of the incus, although some earlier authors have assigned it to the second arch. But with regard to the stapes the opinions have been very varied. It has been held to be derived from the first arch, from the second arch, from neither one nor the other, but from the cartilaginous investment of the otocyst; or, finally, it has been held to have a compound origin, its arch being a product of the second arch while its basal plate was part of the otocyst investment. Recent observations seem to place its independence of the otocyst investment beyond doubt, in which case its origin from the second arch seems fairly certain.

*The Development of the Tympanic Membrane and of the Outer Ear.*—Just as the tympanic cavity is formed from the endodermal groove of the first branchial cleft, so the outer ear owes its origin to the ectodermal groove of the same cleft and to the neighboring arches. The dorsal and most ventral portions of the groove flatten out and

disappear, but the median portion deepens to form at about the end of the second month, a funnel-shaped cavity which corresponds to the outer portion of the external auditory meatus. From the inner end of this a

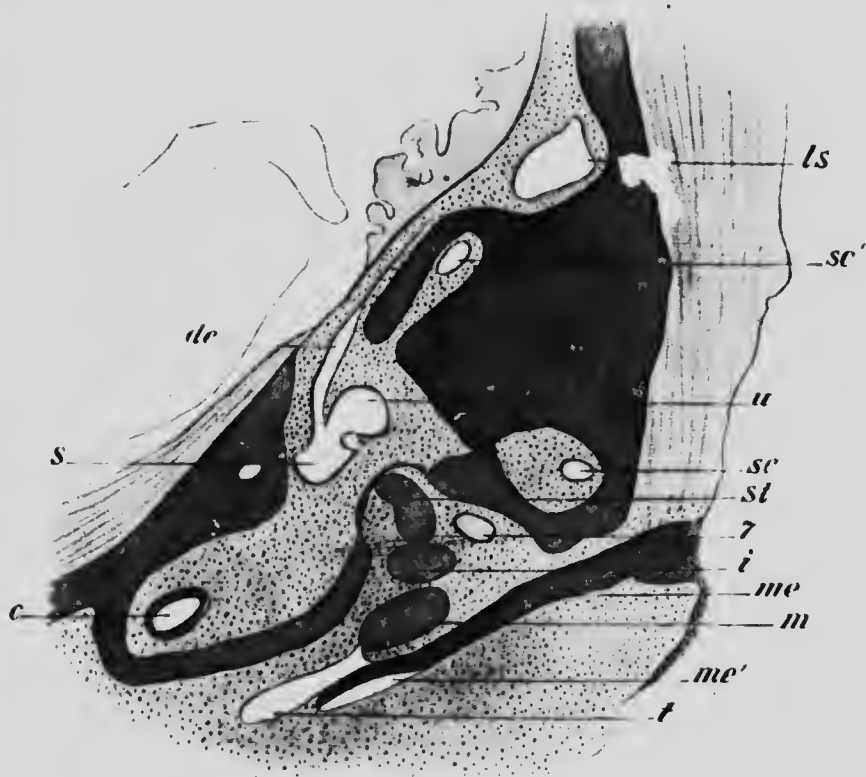


FIG. 250.—HORIZONTAL SECTION PASSING THROUGH THE DORSAL WALL OF THE EXTERNAL AUDITORY MEATUS IN AN EMBRYO OF 4.5 CM. *c*, Cochlea; *de*, endolymphatic duct; *i*, incus; *ls*, lateral sinus; *m*, malleus; *me*, meatus auditorius externus; *me'*, cavity of the meatus; *s*, sacculus; *sc*, horizontal semicircular canal; *sc'*, posterior semicircular canal; *st*, stapes; *t*, tympanic cavity; *u*, utricle; 7, facial nerve.—(Siebenmann.)

solid ingrowth of ectoderm takes place, and this, enlarging at its inner end to form a disk-like mass, comes into relation with the gelatinous mesoderm which surrounds the malleus and chorda tympani. At about the seventh



month a split occurs in the disk-like mass (Fig. 250), separating it into an outer and an inner layer, the latter of which becomes the outer epithelium of the tympanic membrane. Later, the split extends outward in the substance of the ectodermal ingrowth and eventually unites with the funnel-shaped cavity to complete the external meatus.

The tympanic membrane is formed in considerable part from the substance of the first branchial arch, the area in which it occurs not being primarily part of the wall of the tympanic cavity, but being brought into it secondarily by the expansion of the cavity. The membrane itself is mesodermal in origin and is lined on its outer surface by an ectodermal and on the inner by an endodermal epithelium.

The *pinna* owes its origin to the portions of the first and second arches which bound the entrance of the external meatus. Upon the posterior edge of the first arch there appear about the end of the fourth week two transverse furrows which mark off three tubercles (Fig. 251, A, 1-3) and on the anterior edge of the second arch a corresponding number of tubercles (4-6) is formed, while, in addition, a longitudinal furrow, running down the middle of the arch, marks off a ridge (*c*) lying posterior to the tubercles. From these six tubercles and the ridge are developed the various parts of the *pinna*, as may be seen from Fig. 251. The most ventral tubercle of the first arch (1) gives rise to the *tragus*, and the middle one (5) of the second arch furnishes the *antitragus*. The middle and dorsal tubercles of the first arch (2 and 3) unite with the ridge (*c*) to produce the *helix*, while from the dorsal tubercle of the second arch (4) is produced the *antihelix* and from the ventral one (6) the *lobule*. It is noteworthy that at about the third month of development the upper and posterior portion of

the helix is bent forward so as to conceal the antihelix; is at just about a corresponding stage that the pointed form of the ear seen in the lower mammals makes its appearance, and it is evident that, were it not for the forward bending, the human ear would also be assuming at

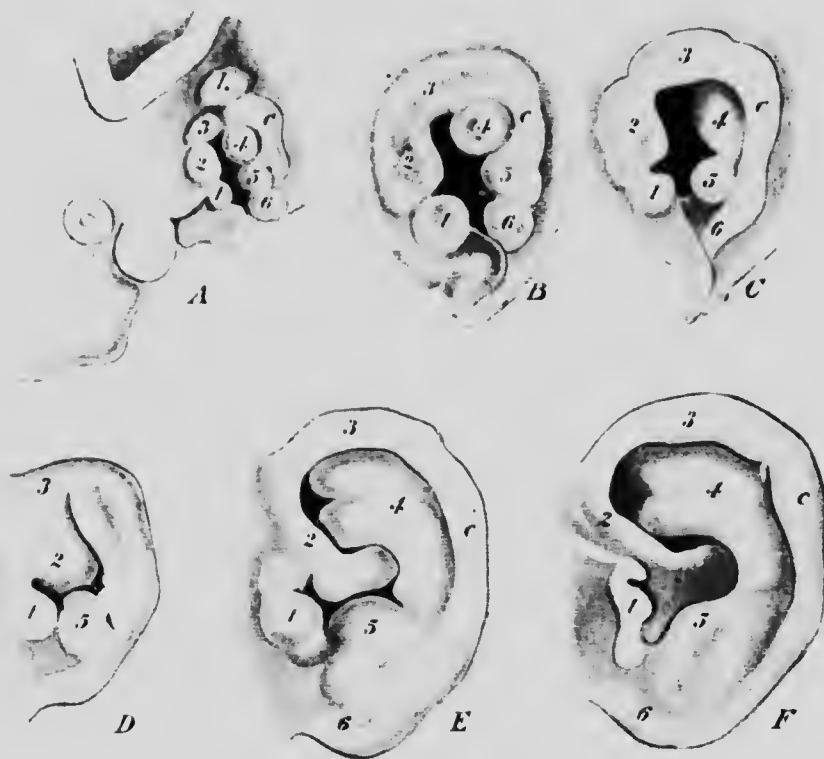


FIG. 251.—STAGES IN THE DEVELOPMENT OF THE PINNA. A, Embryo of 11 mm.; B, of 13.6 mm.; C, of 15 mm.; D, at the beginning of the third month; E, fetus of 8.5 cm.; F, fetus at term.—(His.)

this stage a more or less pointed form. Indeed, there is usually to be found upon the incurved edge of the helix, some distance below the upper border of the pinna, a more or less distinct tubercle, known as *Darwin's tubercle*, which seems to represent the point of the typical mammalian

ear, and is, accordingly, the morphological apex of the pinna.

There seems to be little room for doubt that the otoeyst belongs primarily to the system of lateral line sense-organs, but a discussion of this interesting question would necessitate a consideration of details concerning the development of the lower vertebrates which would be foreign to the general plan of this book. It may be recalled, however, that the analysis of the components of the cranial nerves described on page 437 refers the auditory nerve to the lateral line system.

**The Development of the Eye.**—The first indications of the development of the eye are to be found in a pair of hollow outgrowths from the side of the first primary brain vesicle, at a level which corresponds to the junction of the dorsal and ventral zones. Each evagination is directed at first upward and backward, and, enlarging at its extremity, it soon shows a differentiation into a terminal bulb and a stalk connecting the bulb with the brain (Fig. 216). At an early stage the bulb comes into apposition with the ectoderm of the side of the head, and this, over the area of contact, becomes thickened and then depressed to form the beginning of the future *lens* (Fig. 252).

As the result of the depression of the lens ectoderm, the outer wall of the optic bulb becomes pushed inward toward the inner wall, and this invagination continuing until the two walls come into contact, the bulb is transformed into a double-walled cup, the optic cup, in the mouth of which lies the lens (Fig. 254). The cup is not perfect, however, since the invagination affects not only the optic bulb, but also extends inward on the posterior surface of the stalk, forming upon this a longitudinal groove and producing a defect of the ventral wall of the cup, known as the *chorioidial fissure* (Fig. 253). The groove and fissure become occupied by mesodermal tissue, and in this, at

about the fifth week, a blood-vessel develops which traverses the cavity of the cup to reach the lens and is known as the *arteria hyaloidea*.



FIG. 252.—EARLY STAGE IN THE DEVELOPMENT OF THE LENS IN A RABBIT EMBRYO.

The nucleated layer to the left is the ectoderm and the thicker lens epithelium, below which is the outer wall of the optic evagination; above and below between the two is mesenchyme.—(Rabl.)

In the mean time further changes have been taking place in the lens. The ectodermal depression which represents

it gradually deepens to form a cup, the lips of which approximate and finally meet, so that the cup is converted into a vesicle which finally separates completely from the ectoderm (Fig. 254), much in the same way as the otocyst does. As the lens vesicle is constricted off, the surrounding mesodermal tissue grows in to form a layer between it and the overlying ectoderm, and a split appearing in the layer divides it into an outer thicker portion, which represents the *cornea*, and an inner thinner portion, which

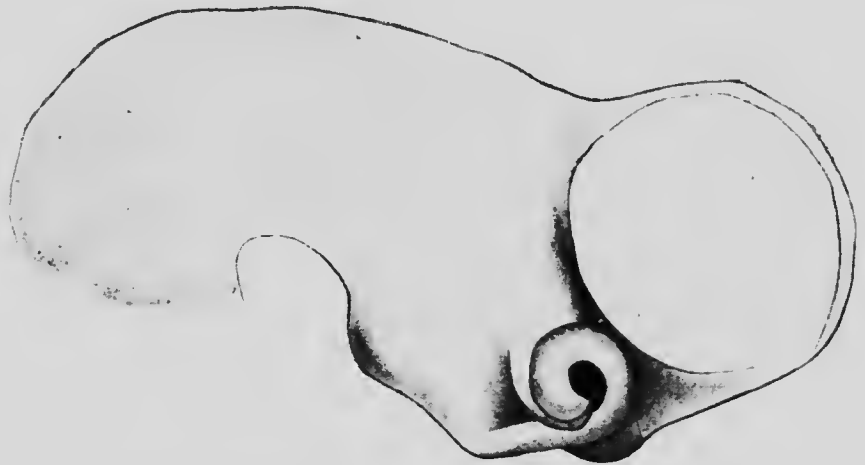

FIG. 253.—RECONSTRUCTION OF THE BRAIN OF AN EMBRYO OF FOUR WEEKS, SHOWING THE CHORIOID FISSURE.—(His.)

covers the outer surface of the lens and becomes highly vascular. The cavity between these two portions represents the *anterior chamber* of the eye. The cavity of the optic cup has also become filled by a peculiar tissue which represents the *vitreous humor*, while the mesodermal tissue surrounding the cup condenses to form a strong investment for it, which is externally continuous with the cornea, and at about the sixth week shows a differentiation into an inner vascular layer, the *chorioid coat*, and an outer denser one, which becomes the *sclerotic coat*.

The various processes resulting in the formation of the eye, which have thus been rapidly sketched, may now be considered in greater detail.

*The Development of the Lens.*—When the lens vesicle is complete, it forms a more or less spherical sac lying be-

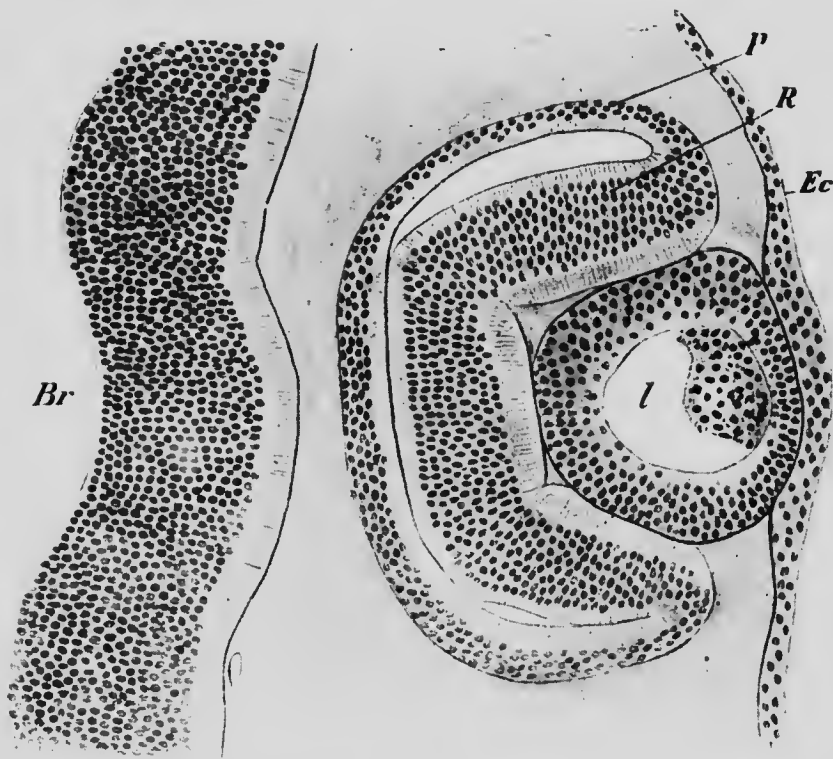


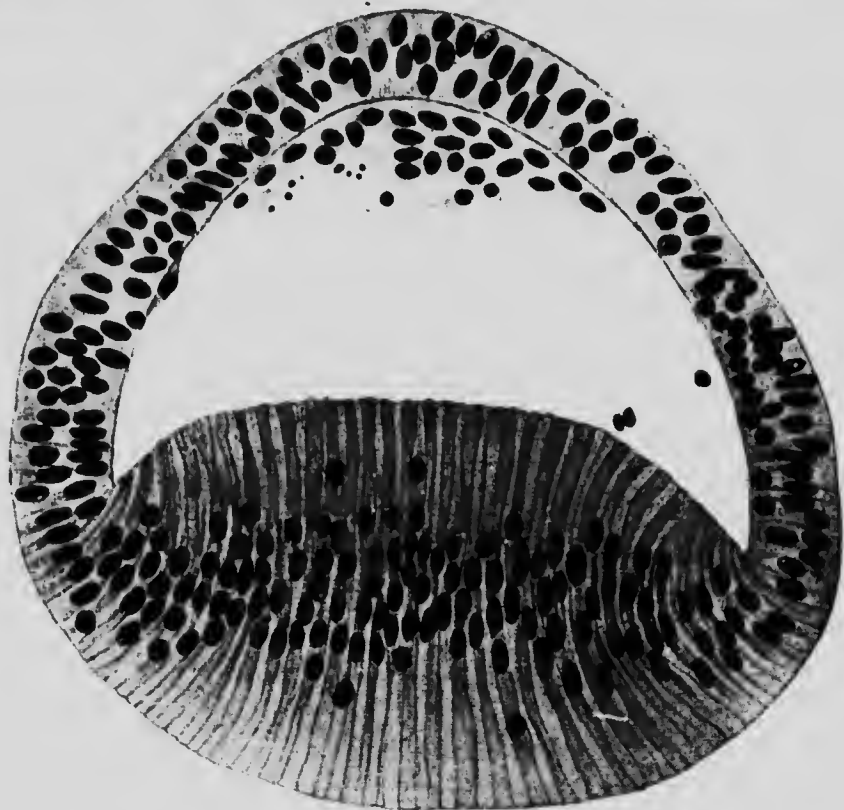
FIG. 254.—HORIZONTAL SECTION THROUGH THE EYE OF AN EMBRYO PIG OF 7 MM.

*Br*, Thalamencephalon; *Ec*, ectoderm; *l*, lens; *P*, pigment, and *R*, retinal layers of the retina.

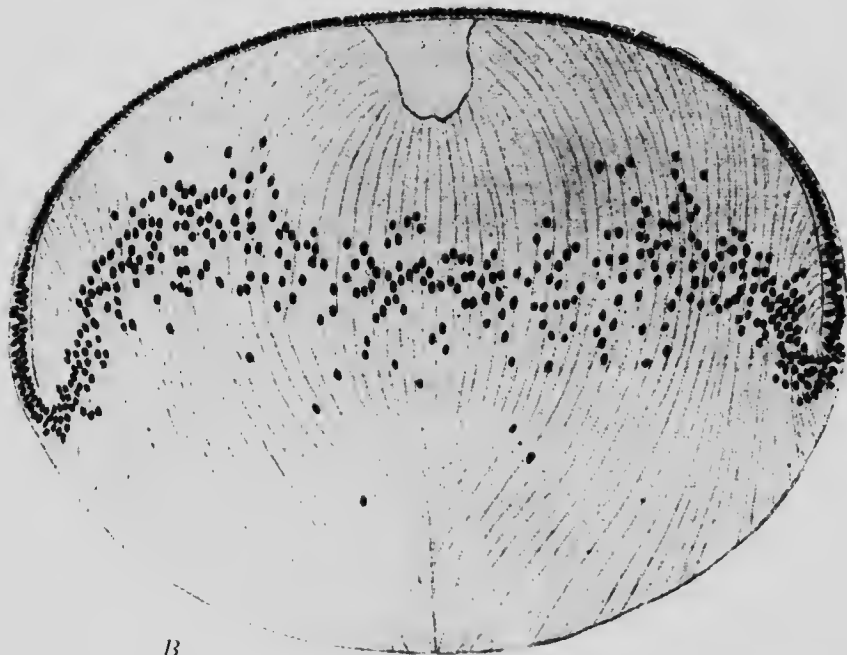
neath the superficial ectoderm and containing in its cavity a few cells, either scattered or in groups (Fig. 254). These cells, which have wandered into the cavity of the vesicle from its walls, take no part in the further development of the lens, but early undergo complete degeneration, and

the first change which is concerned with the actual formation of the lens is an increase in the height of the cells forming its inner wall and a thinning out of its outer wall (Fig. 255, A). These changes continuing, the outer half of the vesicle becomes converted into a single layer of somewhat flat cells which persist in the adult condition to form the *anterior epithelium* of the lens, while the cells of the posterior wall form a marked projection into the cavity of the vesicle and eventually completely obliterate it, coming into contact with the inner surface of the anterior epithelium (Fig. 255, B).

These posterior elongated cells form, then, the principal mass of the lens, and constitute what are known as the *lens fibers*. At first those situated at the center of the posterior wall are the longest, the more peripheral ones gradually diminishing in length until at the equator of the lens they become continuous with and pass into the anterior epithelium. As the lens increases in size, however, the most centrally situated cells fail to elongate as rapidly as the more peripheral ones and are pushed in toward the center of the lens, the more peripheral fibers meeting below them along a line passing across the inner surface of the lens. The disparity of growth continuing, a similar sutural line appears in the outer surface beneath the anterior epithelium, and the fibers become arranged in concentric layers around a central core composed of the shorter fibers. In the human eye the line of suture of the peripheral fibers becomes bent so as to consist of two limbs which meet at an angle, and from the angle a new suturing line develops during embryonic life, so that the suture assumes the form of a three-rayed star. In later life the stars become more complicated, being either six-rayed or more usually nine-rayed in the adult condition (Fig. 256).



A



B

FIG. 255.—SECTIONS THROUGH THE LENS (A) OF HUMAN EMBRYO OF THIRTY TO THIRTY-ONE DAYS AND (B) OF PIG EMBRYO OF 36 MM.—(Rabl.)



As early as the second month of development the lens vesicle becomes completely inverted by mesodermal tissue in which blood-vessels are developed in considerable numbers, whence the investment is termed the *tunica vascu-*




FIG. 256.—POSTERIOR (INNER) SURFACE OF THE LENS FROM AN ADULT SHOWING THE SUTURAL LINES.—(Rabl.)

*losa lentis* (Fig. 264, *tv*). The arteries of the cunic are in connection principally with the hyaloid artery of the vitreous humor (Fig. 262), and consist of numerous fine branches which envelop the lens and terminate in loops

almost at the center of its outer surface. This tunic undergoes degeneration after the seventh month of development, which time the lens has completed its period of most active growth, and, as a rule, completely disappears before birth. Occasionally, however, it may persist to a greater or less extent, the persistence of the portion covering the outer surface of the lens, known as the *membrana pupillaris*, causing the malformation known as *congenital atresia of the pupil*.

In addition to the vascular tunic, the lens is surrounded by a non-cellular membrane termed the *capsule*. The origin of this structure is still in doubt, some observers maintaining that it is a product of the investing mesoderm, while others hold it to be a product of the lens epithelium.

*The Development of the Optic Cup.*—When the invagination of the outer wall of the optic bulb is completed, the margins of the resulting cup are opposite the sides of the lens vesicle (Fig. 254), but with the enlargement of the lens and cup the margins of the latter gradually come to lie in front of—that is to say, upon the outer surface of—the lens, forming the boundary of the opening known as the pupil. The lens, consequently, is brought to lie within the mouth of the optic cup, and that portion of the latter which covers the lens takes part in the formation of the *iris* and the adjacent *ciliary body*, while its posterior portion gives rise to the *retina*.

The chorioidal fissure normally disappears during the sixth or seventh week of development by a fusion of its lips, and not until this is accomplished does the term cup truly describe the form assumed by the optic bulb after the invagination of its outer wall. In certain cases the lips of the fissure fail to unite perfectly, producing the defect of the eye known as *coloboma*; this may vary in its

extent, sometimes affecting both the iris and the retina and forming what is termed coloboma iridis, and at others being confined to the retinal portion of the cup, in which case it is termed coloboma chorioideæ.

Up to a certain stage the differentiation of the two layers which form the optic cup proceeds along similar lines, in both the ciliary and retinal regions. That layer which represents the original internal portion of the bulb becomes thinner as the cup increases in size, and becomes also the seat of a deposition of dark pigment, whence it may be termed the *pigment layer* of the cup; while the other layer—that formed by the invagination of the outer portion of the bulb, and which may be termed the *retinal layer*—remains much thicker (Fig. 254) and in its proximal portions even increases in thickness. Later, however the development of the ciliary and retinal portions of the retinal layers differs, and it will be convenient to consider first the history of the ciliary portion.

*The Development of the Iris and Ciliary Body.*—The first change noticeable in the ciliary portion of the retinal layer is its thinning out, a process which continues until the layer consists, like the pigment layer, of but a single layer of cells (Fig. 257), the transition of which to the thicker retinal portion of the layer is somewhat abrupt and corresponds to what is termed the *ora serrata* in adult anatomy. In embryos of 10.2 cm. the retinal layer throughout its entire extent is readily distinguishable from the pigment layer by the absence in it of all pigmentation, but in older forms this distinction gradually diminishes in the iris region, the retinal layer there acquiring pigment and forming the *uvea*.

When the anterior chamber of the eye is formed by the splitting of the mesoderm which has grown in between the superficial ectoderm and the outer surface of the lens, the

peripheral portions of its posterior (inner) wall are in relation with the ciliary portion of the optic cup and give rise to the stroma of the ciliary body and of the iris (Fig. 257) this latter being continuous with the tunica vasculosa lentis so long as that structure persists (Fig. 264). In embryos of about 14.5 cm. the ciliary portion of the cup

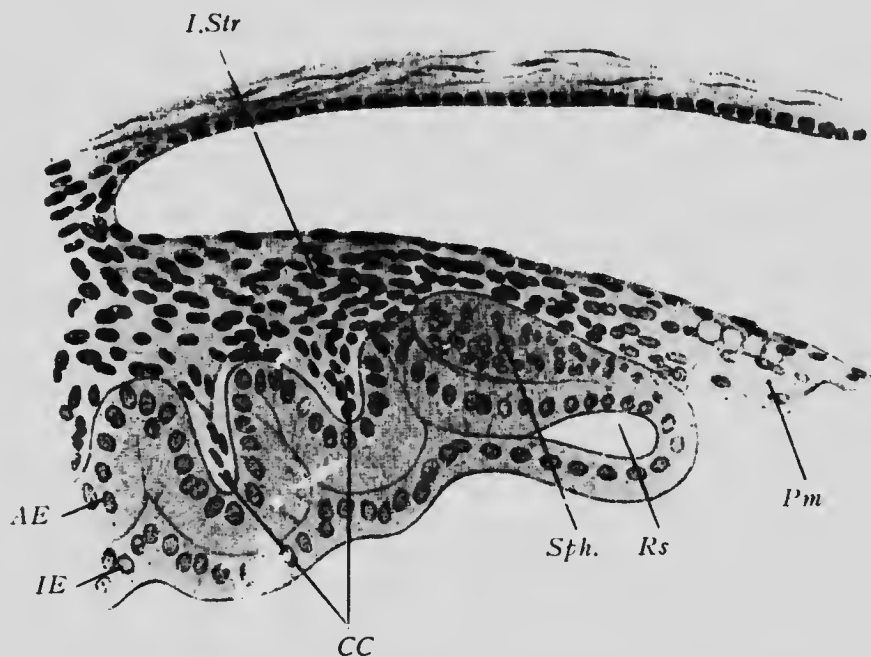


FIG. 257.—RADIAL SECTION THROUGH THE IRIS OF AN EMBRYO OF 19 CM.

*AE*, Pigment layer; *CC*, ciliary folds; *IE*, retinal layer; *I.Str*, iris stroma; *Pm*, pupillary membrane; *Rs*, marginal sinus; *Sph*, splincer iridis.—(*Szili*.)

becomes thrown into radiating folds (Fig. 257), as if by a too rapid growth, and into the folds lamellæ of mesoderm project from the stroma. These folds occur not only throughout the region of the ciliary body, but also extend into the iris region, where, however, they are but temporary structures, disappearing entirely by the end of the

fifth month. The folds in the region of the corpus ciliare persist and produce the *ciliary processes* of the adult eye.

Embedded in the substance of the iris stroma in the adult are non-striped muscle-fibers, which constitute the *sphincter* and *dilatator iridis*. It has long been supposed that these fibers were differentiated from the stroma of the iris, but recent observations have shown that they arise from the cells of the pigment layer of the optic cup, the sphincter appearing near the pupillary border (Fig. 257, *sph*) while the dilatator is more peripheral.

*The Development of the Retina.*—Throughout the retinal region of the cup the pigment layer, undergoing the same changes as in the ciliary region forms the pigment layer of the retina (Fig. 258, *p*). The retinal layer increases in thickness and early becomes differentiated into two strata (Fig. 254), a thicker one lying next the pigment layer and containing numerous nuclei, and a thinner one containing no nuclei. The thinner layer, from its position and structure, suggests an homology with the marginal velum of the central nervous system, and probably becomes converted into the nerve-fiber layer of the adult retina, the axis-cylinder processes of the ganglion cells passing into it on their way to the optic nerve. The thicker layer similarly suggests a comparison with the mantle layer of the cord and brain, and in embryos of 38 mm. it becomes differentiated into two secondary layers (Fig. 258), that nearest the pigment layer (consisting of smaller and more deeply staining nuclei, probably representing the rod and cone and bipolar cells of the adult retina, while the inner layer, that nearest the marginal velum, has larger nuclei and is presumably composed of the ganglion cells.

Little is as yet known concerning the further differentiation of the nervous elements of the human retina, but the

history of some of them has been traced in the cat, in which, as in other mammals, the histogenetic processes take place at a relatively later period than in man. Of the histogenesis of the inner layer the information is rather scant, but it may be stated that the ganglion cells are the earliest of all the elements of the retina to become recog-




FIG. 258.—PORTION OF A TRANSVERSE SECTION OF THE RETINA OF A NEW-BORN RABBIT.

*ch*, Chorioid coat; *g*, ganglion-cell layer; *r*, outer layer of nuelei; *p*, pigment layer.—(*Falchi*.)

nizable. The rod and cone cells, when first distinguishable, are unipolar cells (Fig. 259, *a* and *c*), their single processes extending outward from the cell-bodies to the external limiting membrane which bounds the outer surface of the retinal layer. Even at an early stage the cone cells (*a*) are distinguishable from the rod cells (*c*) by their

more decided reaction to silver salts, and at first both kinds of cells are scattered throughout the thickness of the layer from which they arise. Later, a fine process grows out from the inner end of each cell, which thus assumes a bipolar form (Fig. 259, *b* and *d*), and, later still, the cells gradually migrate toward the external limiting

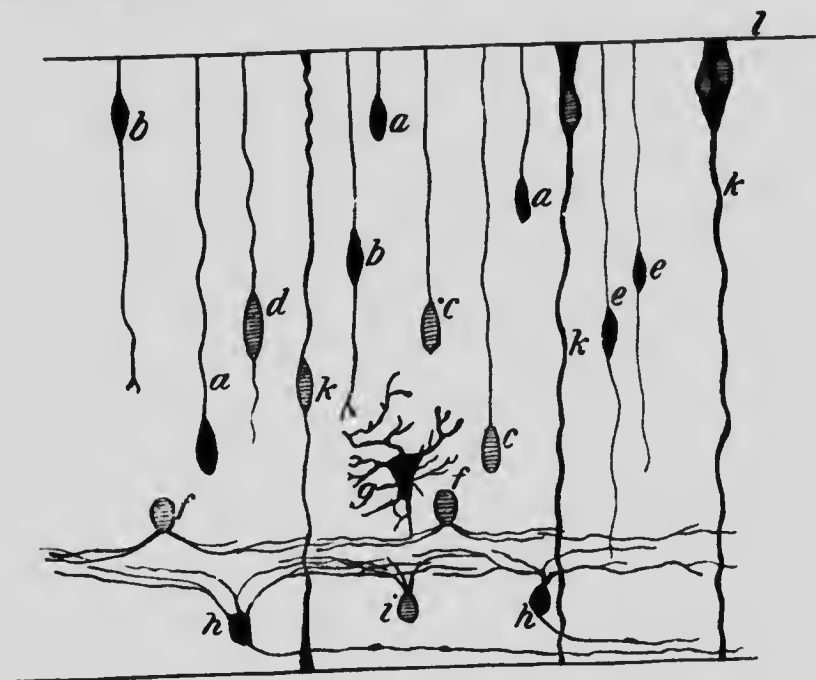


FIG. 259.—DIAGRAM SHOWING THE DEVELOPMENT OF THE RETINAL ELEMENTS.

*a*, Cone cell in the unipolar, and *b*, in the bipolar stage; *c*, rod cells in the unipolar, and *d*, in the bipolar stage; *e*, bipolar cells; *f* and *i*, amacrin cells; *g*, horizontal cells; *h*, ganglion cells; *k*, Müller's fiber; *l*, external limiting membrane.—(Kallius, after Cajal.)

membrane, beneath which they form a definite layer in the adult. In the mean time there appears opposite the outer end of each cell a rounded eminence projecting from the outer surface of the external limiting membrane into the pigment layer. The eminences over the cone cells are larger than those over the rod cells, and later, as both in

crease in length, they become recognizable by their shape as the rods and cones.

The bipolar cells are not easily distinguishable in the early stages of their differentiation from the other cells with which they are mingled, but it is believed that they are represented by cells which are bipolar when the rod and cone cells are still in a unipolar condition (Fig. 259, *e*). If this identification be correct, then it is noteworthy that at first their outer processes extend as far as the external limiting membrane and must later shorten or fail to elongate until their outer ends lie in what is termed the outer granular layer of the retina, where they stand in relation to the inner ends of the rod and cone cell processes. Of the development of the amacrine (*f, i*) and horizontal cells (*g*) of the retina little is known. From their position in new-born kittens it seems probable that the former are derived from cells of the same layer as the ganglion cells, while the horizontal cells may belong to the outer layer.

In addition to the various nerve-elements mentioned above, the retina also contains neuroglial elements known as Müller's fibers (Fig. 259, *K*), which traverse the entire thickness of the retina. The development of these cells has not yet been thoroughly traced, but they resemble closely the ependymal cells observable in early stages of the spinal cord.

*The Development of the Optic Nerve.*—The observations on the development of the retina have shown very clearly that the great majority of the fibers of the optic nerve are axis-cylinders of the ganglion cells of the retina and grow from these cells along the optic stalk toward the brain. Their embryonic history has been traced most thoroughly in rat embryos (Robinson), and what follows is based upon what has been observed in that animal.

The optic stalk, being an outgrowth from the brain, is at



first a hollow structure, its cavity communicating with that of the third ventricle at one end and with that of the optic bulb at the other. When the chorioid fissure is developed, it extends, as has already been described, for some distance along the posterior surface of the stalk and has lying in it a portion of the hyaloid artery. Later, when the lips of the fissure fuse, the artery becomes enclosed within the stalk to form the *arteria centralis retinae* of the adult (Fig. 262).

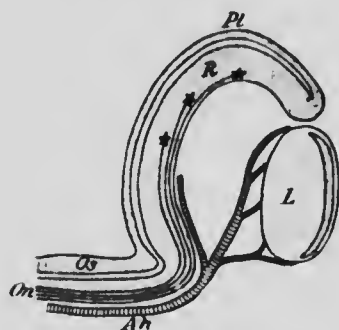


FIG. 260.—DIAGRAMMATIC LONGITUDINAL SECTION OF THE OPTIC CUP AND STALK PASSING THROUGH THE CHORIoid FISSURE.

Ah, Hyaloid artery; L, lens; On, fibers of the optic nerve; Os, optic stalk; Pl, pigment layer, and R, retinal layer of the retina.

the original cavity of the distal portion of the stalk becomes obliterated, and at the same time the ventral and posterior walls of the stalk are brought into continuity with the retinal layer of the optic cup, and so opportunity is given for the passage of the axis-cylinders of the ganglion cells along those walls (Fig. 260). At an early stage a section of the proximal portion of the optic stalk (Fig. 261, A) shows the central cavity surrounded by a number of nuclei representing the mantle layer, and surrounding these a non-nucleated layer resembling the marginal velum and continuous distally with the similar layer of the retina. When the ganglion cells of the latter begin to send out their axis-cylinder processes, these pass into the retinal marginal velum and converge in this layer toward the bottom of the ciliary fissure, so reaching the ventral wall of the optic stalk, in the velum of which they may be distinguished in rat embryos of 4 mm., and still more

clearly in those of 9 mm. (Fig. 261, A). Later, as the fibers become more numerous, they gradually invade the lateral and finally the dorsal walls of the stalk, and, at the same time the mantle cells of the stalk become more scattered and assume the form of connective-tissue (neuroglia) cells, while the original cavity of the stalk is gradually obliterated (Fig. 261, B). Finally, the stalk becomes a solid mass of nerve-fibers, among which the altered mantle cells are scattered.

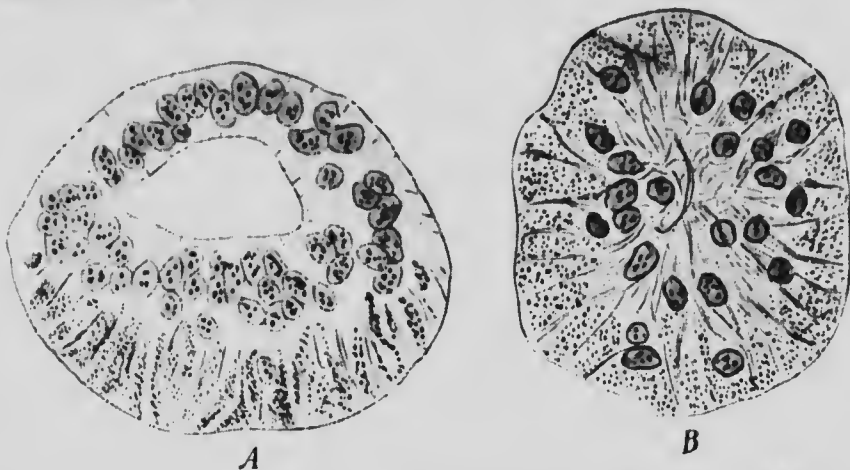


FIG. 261.—TRANSVERSE SECTIONS THROUGH THE PROXIMAL PART OF THE OPTIC STALK OF RAT EMBRYOS OF (A) 9 MM. AND (B) 11 MM. (Robinson.)

From what has been stated above it will be seen that the sensory cells of the eye belong to a somewhat different category from those of the other sense-organs. Embryologically they are a specialized portion of the mantle layer of the medullary canal, whereas in the other organs they are peripheral structures either representing or being associated with representatives of posterior root ganglion cells. Viewed from this standpoint, and taking into consideration the fact that the sensory portion of the retina is formed from the invaginated part of the optic bulb, some light is thrown upon the inverted arrangement of the retinal elements, the rods and cones being directed away from the source of light. The normal relations of the mantle layer and marginal velum are retained in the retina, and the latter

serving as a conducting layer for the axis-cylinders of the mantle layer (ganglion) cells, the layer of nerve-fibers becomes interposed between the source of light and the sensory cells. Furthermore, it may be pointed out that if the differentiation of the retina be imagined to take place before the closure of the medullary canal,—a condition which is indicated in some of the lower vertebrates,—there would be then no inversion of the elements, this peculiarity being due to the conversion of the medullary plate into a tube, and more especially to the fact that the retina develops from the outer wall of the optic cup. In certain reptiles in which an eye is developed in connection with the epiphysial outgrowths of the diencephalon, the retinal portion of this pineal eye is formed from the inner layer of the bulb, and in this case there is no inversion of the elements.

A justification of the exclusion of the optic nerve from the category which includes the other cranial nerves has now been presented. For if the retina be regarded as a portion of the central nervous system, it is clear that the nerve is not a nerve at all in the strict sense of that word, but is a tract, confined throughout its entire extent within the central nervous system and comparable to such groups of fibers as the direct cerebellar or fillet tracts of that system.

*The Development of the Vitreous Humor.*—It has already been pointed out (p. 477) that a blood-vessel, the hyaloid artery, accompanied by some mesodermal tissue makes its way into the cavity of the optic cup through the chorioid fissure. On the closure of the fissure the artery becomes enclosed within the optic stalk and appears to penetrate the retina, upon the surface of which its branches ramify. In the embryo the artery does not, however, terminate in these branches as it does in the adult, but is continued on through the cavity of the optic cup (Fig. 262) to reach the lens, around which it sends branches to form the tunica vaseulosa lentis.

According to some authors, the formation of the vitreous humor is closely associated with the development of this artery, the humor being merely a transudate from it, while others have maintained that it is a derivative of the

mesoderm which accompanies the vessel, and is therefore to be regarded as a peculiar gelatinous form of connective tissue. In the mammalian eye it is difficult to determine the relative merits of these two views, but the fact that in the lower vertebrates—the birds, for example—the vitreous humor forms at a time when the optic cup contains neither mesoderm cells nor blood-vessels indicates a probability that neither of them is quite sufficient to explain the observed phenomena. Recently it has been suggested that it is to the retinal cells that one must look

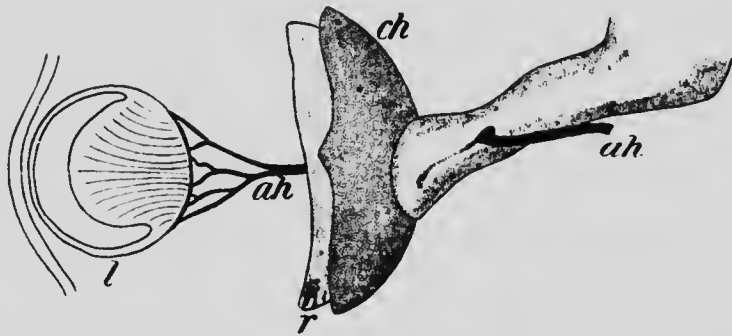


FIG. 262.—RECONSTRUCTION OF A PORTION OF THE EYE OF AN EMBRYO OF 13.8 MM.

ah, Hyaloid artery; ch, chorioid coat; l, lens; r, retina.—(His.)

for the formation of the humor (Rabl), and further observations along this line are desirable.

Over the surface of the vitreous humor a structureless membrane, known as the *hyaloid membrane*, is formed, apparently by a condensation of the vitreous humor or as a secretion of the retinal cells, and in the more anterior portions of the humor fibers appear, extending across from the ciliary processes to become continuous with the capsule of the lens (Fig. 263, *sl*). These fibers increase in number in later stages and represent the *suspensory ligament* of the lens (*zonula Zinnii*), and spaces which occur

between the fibers enlarge to produce a cavity traversed by scattered fibers and known as the *canal of Petit*.

After about the third month the portion of the hyaloid artery which traverses the vitreous humor begins to undergo degeneration, and during the last month of development it disappears altogether, the only trace of its existence at birth being a more fluid consistency of the axis of

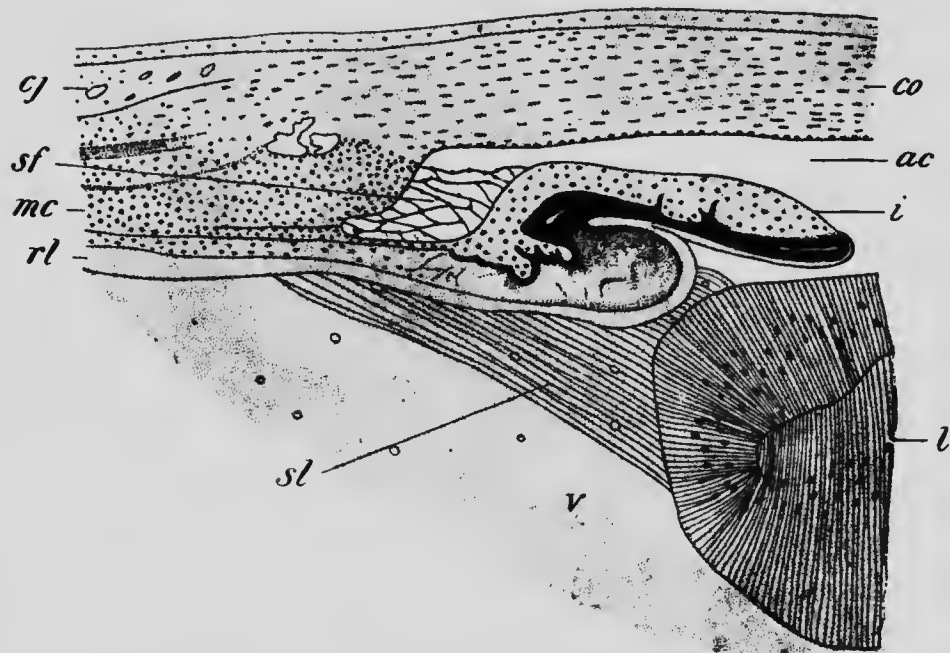


FIG. 263. —TRANSVERSE SECTION THROUGH THE CILIARY REGION OF A CHICK EMBRYO OF SIXTEEN DAYS.

*ac*, Anterior chamber of the eye; *cj*, conjunctiva; *co*, cornea; *i*, iris; *l*, lens; *mc*, ciliary muscle; *rl*, retinal layer of optic cup; *sf*, spaces of Fontana; *sl*, suspensory ligament of the lens; *v*, vitreous humor.—(Angelucci.)

the vitreous humor, this more fluid portion representing the space originally occupied by the artery and forming what is termed the *hyaloid canal* (*canal of Cloquet*).

*The Development of the Outer Coat of the Eye, of the Cornea, and of the Anterior Chamber.*—Soon after the

formation of the optic bulb a condensation of the mesoderm cells around it occurs, forming a capsule. Over the inner portions of the optic cup the further differentiation of this capsule is comparatively simple, resulting in the formation of two layers, an inner vascular and an outer denser and fibrous, the former becoming the *chorioid coat* of the adult eye and the latter the *sclerotic*.

More externally, however, the processes are more complicated. After the lens has separated from the surface ectoderm a thin layer of mesoderm grows in between the two structures and later gives place to a layer of homogeneous substance in which a few cells, more numerous laterally than at the center, are embedded. Still later cells from the adjacent mesenchyme grow into the layer, which increases considerably in thickness, and blood-vessels also grow into that portion of it which is in contact with the outer surface of the lens. At this stage the interval between the surface ectoderm and the lens is occupied by a solid mass of mesodermal tissue (Fig. 264, *co* and *tv*), but as development proceeds, small spaces filled with fluid begin to appear toward the inner portion of the mass (*ac*), and these, increasing in number and size, eventually fuse together to form a single cavity which divides the mass into an inner and an outer portion. The cavity is the *anterior chamber* of the eye, and it has served to separate the *cornea* (*co*) from the *tunica vasculosa lentis* (*tv*), and, extending laterally in all directions, it also separates from the cornea the mesenchyme which rests upon the marginal portion of the optic cup and constitutes the stroma of the iris. Cells arrange themselves on the corneal surface of the cavity to form a continuous endothelial layer, and the mesenchyme which forms the peripheral boundary of the cavity assumes a fibrous character and forms the *ligamentum pectinatum iridis*, among the fibers

ersed  
loid  
un-  
lop-  
xist-  
is of

*co*  
*ac*  
*i*



OF A

is; l,  
es of  
or.—

ting  
ning

the  
the

of which cavities, known as the *spaces of Fontana* (Fig. 263, *sf*), appear. Beyond the margins of the cavity the corneal tissue is directly continuous with the sclerotic, beneath the margin of which is a distinctly thickened portion of mesenchyme resting upon the ciliary processes and forming the stroma of the ciliary body, as well as

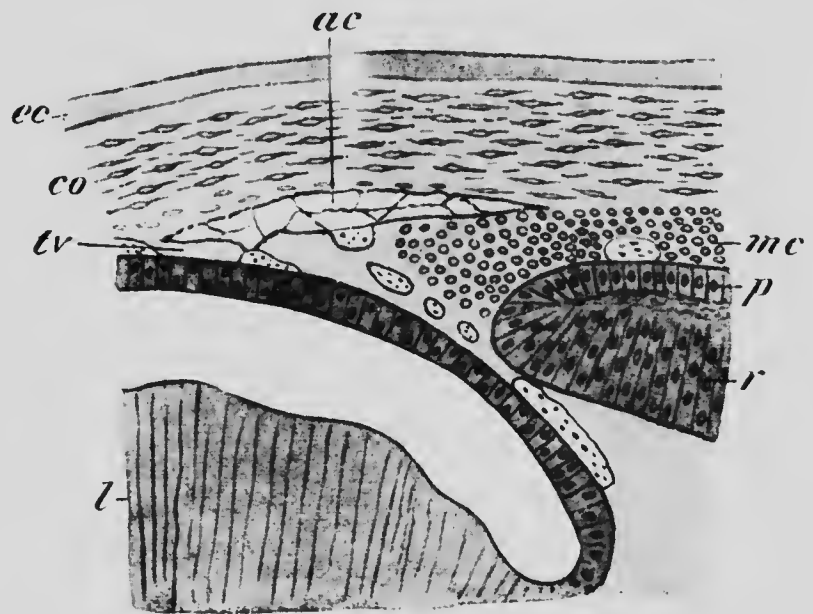


FIG. 264.—TRANSVERSE SECTION THROUGH THE CILIARY REGION OF A PIG EMBRYO OF 23 MM.

*ac*, Anterior chamber of the eye; *co*, cornea; *ec*, ectoderm; *l*, lens; *mc*, ciliary muscle; *p*, pigment layer of the optic cup; *r*, retinal layer; *lv*, tunica vasculosa lentis.—(Angelucci.)

giving rise to the muscle tissue which constitutes the *ciliary muscle* (Figs. 263 and 264, *mc*).

The ectoderm which covers the outer surface of the eye does not proceed beyond the stage when it consists of several layers of cells, and never develops a stratum corneum. In the corneal region it rests directly upon the corneal tissue, which is thickened slightly upon its outer

surface to form the *membrane of Bowman*; more peripherally, however, a quantity of loose mesodermal tissue lies between it and the outer surface of the sclerotic, and, together with the ectoderm, forms the *conjunctiva* (Fig. 263, *cj*).

*The Development of the Accessory Apparatus of the Eye.* — The *eyelids* make their appearance at an early stage as two folds of skin, one a short distance above and the other below the cornea. The center of the folds is at first occupied by indifferent mesodermal tissue, which later becomes modified to form the connective tissue of the lids and the tarsal cartilage, the muscle tissue probably secondarily growing into the lids as a result of the spreading of the platysma over the face, the orbicularis palpebrarum apparently being a derivative of that sheet of muscle tissue.

At about the beginning of the third month the lids have become sufficiently large to meet one another, whereupon the thickened epithelium which has formed upon their edges unites and the lids fuse together, in which condition they remain until shortly before birth. During the stage of fusion the eyelashes (Fig. 265, *h*) develop at the edges of the lids, having the same developmental history as ordinary hairs, and from the fused epithelium of each lid there grow upward or downward, as the case may be, into the mesodermic tissue, solid rods of ectoderm, certain of which early give off numerous short lateral processes and become recognizable as the *Meibomian glands* (*m*), while others retain the simple cylindrical form and represent the *glands of Moll*. When the eyelids separate, these solid ingrowths become hollow by a breaking down of their central cells, just as in the sebaceous and sudoriparous glands of the skin, the Meibomian glands being really modifications of the former glands, while the



glands of Moll are probably to be regarded as specialized sudoriparous glands.

A third fold of skin, in addition to the two which produce the eyelids, is also developed in connection with the eye, forming the *plica semilunaris*. This is a rudimentary

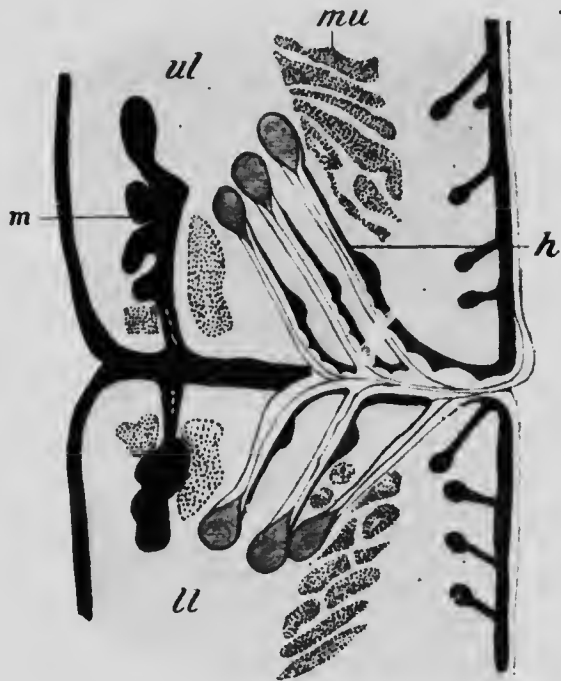


FIG. 265.—SECTION THROUGH THE MARGINS OF THE FUSED EYELIDS IN AN EMBRYO OF SIX MONTHS.

*h*, eyelash; *ll*, lower lid; *m*, Meibomian gland; *mu*, muscle bundle; *ul*, upper lid.—(Schweigger-Seidl.)

third eyelid, representing the nictitating membrane which is fairly well developed in many of the lower mammals and especially well in birds. In man a number of glands develop in its substance, forming a small reddish nodule known as the *caruncula lachrymalis*.

The *lachrymal gland* is developed at about the third

month as a number of branching outgrowths of the ectoderm into the adjacent mesoderm along the outer part of the line where the epithelium of the conjunctiva becomes continuous with that covering the inner surface of the upper eyelid. As in the other epidermal glands, the outgrowths and their branches are at first solid, later becoming hollow by the degeneration of their axial cells.

The *lachrymal* or *nasal duct* is developed in connection with the groove which, at an early stage in the development (Fig. 52), extends from the inner corner of the eye to the olfactory pit and is bounded posteriorly by the maxillary process of the first visceral arch. The epithelium lying in the floor of this groove thickens toward the beginning of the sixth week to form a solid cord, which sinks into the subjacent mesoderm, though retaining connection with the ectoderm at either end; its upper end is continuous with the ectoderm of the edge of the upper eyelid, while the lower one is united with that of the olfactory pit. Later, the solid cord acquires a lumen, and from its palpebral end a bud arises which unites with the ectoderm of the edge of the lower eyelid and produces the lower limb of the lachrymal canal.

## LITERATURE.

- A. ANGELUCCI: "Ueber Entwicklung und Bau des vorderen Uvealtraetus der Vertebraten," *Archiv für mikrosk. Anat.*, XIX, 1881.
- B. BAGINSKY: "Zur Entwicklung der Gehörschnecke," *Archiv für mikrosk. Anat.*, XXVIII, 1886.
- I. BROMAN: "Die Entwicklungsgeschichte der Gehörknöchelchen beim Menschen," *Anat. Hefte*, XI, 1898.
- S. RAMON Y CAJAL: "Nouvelles contributions a l'étude histologique de la rétine," *Journ. de l'Anat. et de la Physiol.*, XXXII, 1896.
- J. DISSE: "Die erste Entwicklung der Riechnerven," *Anat. Hefte*, IX, 1897.
- J. GRABERG: "Beiträge zur Genese des Geschmacksorgans der Menschen," *Morphol. Arbeiten*, VIII, 1898.
- J. A. HAMMAR: "Zur allgemeinen Morphologie der Schlundspalten des

- Menschen. Zur Entwicklungsgeschichte des Mittelohrraumes, des äusseren Gehörganges und des Paukenfelles beim Menschen," *Anat. Anzeiger*, xx, 1901
- HEERFORDT: "Studien über den *Musc. dilatator pupillæ* sammt Angabe von gemeinschaftlicher Kennzeichen einiger Fälle epithelialer Musculatur," *Anat. Hefte*, xiv.
- J. HEGETSCHWEILER: "Die embryologische Entwicklung des Steigbügels," *Archiv für Anat. und Physiol., Anat. Abth.*, 1898.
- W. HIS, JR.: "Die Entwicklungsgeschichte des Acustico-Facialisgebietes beim Menschen," *Archiv für Anat. und Physiol., Anat. Abth., Supplement*, 1897.
- V. VON MIHALKOVICZ: "Nasenhöhle und Jacobson'sches Organ. Eine morphologische Studie," *Anat. Hefte*, xi, 1898.
- C. RABL: "Ueber den Bau und Entwicklung der Linse," *Zeitschrift für wissenschaft. Zoologie*, LXII and LXV, 1898; LXVII, 1899.
- A. ROBINSON: "On the Formation and Structure of the Optic Nerve and Its Relation to the Optic Stalk," *Journal of Anat. and Physiol.*, xxx, 1896.
- SIEBENMANN: "Die ersten Anlagen vom Mittelohrraum und Gehörknöchelchen des menschlichen Embryo in der 4 bis 6 Woche," *Archiv für Anat. und Physiol., Anat. Abth.*, 1894.
- A. SZILI: "Zur Anatomie und Entwicklungsgeschichte der hinteren, Irisschichten, mit besonderer Berücksichtigung des *Musculus sphincter iridis* des Menschen," *Anat. Anzeiger*, xx, 1901.
- F. TUCKERMAN: "On the Development of the Taste Organs in Man," *Journal of Anat. and Physiol.*, xxiv, 1889

## CHAPTER XVI.

### POST-NATAL DEVELOPMENT.

In the preceding pages attention has been directed principally to the changes which take place in the various organs during the period before birth, for, with a few exceptions, notably that of the liver, the general form and histological peculiarities of the various organs are acquired before that epoch. Development does not, however, cease with birth, and a few statements regarding the changes which take place in the interval between birth and maturity will not be out of place in a work of this kind.

The conditions which obtain during embryonic life are so different from those to which the body must later adapt itself, that arrangements, such as those connected with the placental circulation, which are of fundamental importance during the life *in utero*, become of little or no use, while the relative importance of others is greatly diminished, and these changes react more or less profoundly on all parts of the body. Hence, although the post-natal development consists chiefly in the growth of the structures formed during earlier stages, yet the growth is not equally rapid in all parts, and indeed in some organs there may even be a relative decrease in size. That this is true can be seen from the annexed figure (Fig. 266), which represents the body of a child and that of an adult man drawn to the same scale. The greater relative size of the head and upper part of the body in the child is very marked, and the central point of the height of the

child is situated at about the level of the umbilicus, while in the man it is at the symphysis pubis. This excessive development of the upper portions of the body of the child is largely due to the nature of the blood-supply during fetal life, when, as may be seen by reference to Fig. 152, the blood passing to the head, neck, arms and upper por-

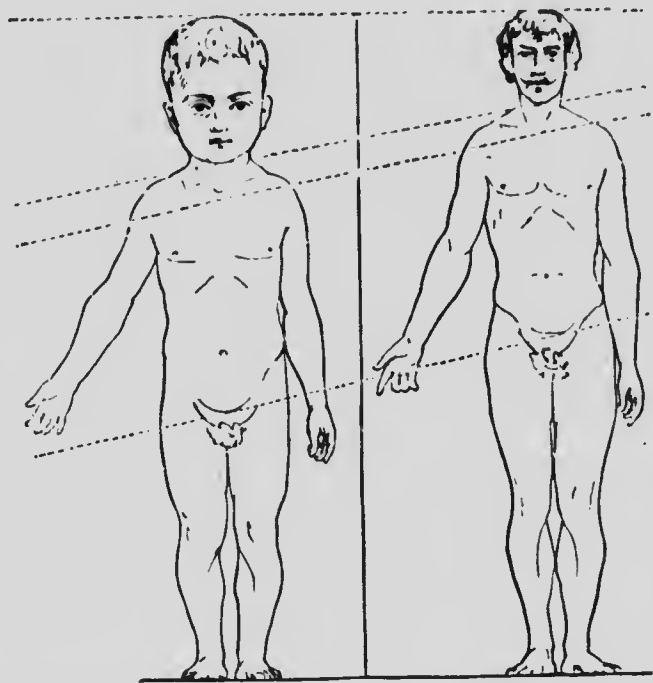


FIG. 266.—CHILD AND MAN DRAWN TO THE SAME SCALE.—(Langer, from the "Growth of the Brain," Contemporary Science Series, by permission of Charles Scribner's Sons.)

tions of the thorax leaves the aorta before the ductus arteriosus opens into it, and is therefore practically unmixed with venous blood, while throughout the rest of the body the supply is largely diluted with blood from the right side of the heart.

That there is a distinct change in the geometric form of

the body during growth is also well shown by the following consideration (Thoma). Taking the average height of a new-born male as 500 mm., and that of a man of thirty years of age as 1686 mm., the height of the body will have increased from birth to adolescence  $\frac{1686}{500} = 3.37$  times. The child will weigh 3.1 kilos and the man 66.1 kilos, and if the specific gravity of the body with the included gases be taken in the one case as 0.90 and in the other as 0.93, then the volume of the child's body will be 3.44 liters and that of the man's 71.08 liters, and the increase in volume will be  $\frac{71.08}{3.44} = 20.66$ . If, now, the increase in volume had taken place without any alteration in the geometric form of the body, it should be equal to the cube of the increase in height; this, however, is  $3.37^3 = 38.27$ , a number well-nigh twice as large as the actual increase.

But in addition to these changes, which are largely dependent upon differences in the supply of nutrition, there are others associated with alterations in the general metabolism of the body. Up to adult life the constructive metabolism or anabolism is in excess of the destructive metabolism or katabolism, but the amount of the excess is much greater during the earlier periods of development and gradually diminishes as the adult condition is approached. That this is true during intrauterine life is shown by the following figures, compiled by Donaldson:

AGE IN WEEKS.	WEIGHT IN GRAMS.	AGE IN WEEKS.	WEIGHT IN GRAMS.
0 (ovum)	0.0006	24	635
4	—	28	1220
8	4	32	1700
12	20	36	2240
16	120	40 (birth)	3250
20	285		

From this table it may be seen that the embryo of eight weeks is six thousand six hundred and sixty-seven times as heavy as the ovum from which it started, and if the increase of growth for each of the succeeding periods of four weeks be represented as percentages, it will be seen that the rate of increase undergoes a rapid diminution after the sixteenth week, and from that on diminishes gradually but less rapidly, the figures being as follows:

PERIODS OF WEEKS,	PERCENTAGE INCREASE	PERIODS OF WEEKS,	PERCENTAGE INCREASE.
8-12	400	24-28	92
12-16	500	28-32	39
16-20	137	32-36	32
20-24	123	36-40	45

That the same is true in a general way of the growth after birth may be seen from the table on page 505, representing the average weight of the body in English males at different years from birth up to twenty-three (Roberts) and also the percentage rate of increase.

Certain interesting peculiarities in post-natal growth become apparent from an examination of this table. For while there is a general diminution in the rate of growth yet there are marked irregularities, the most noticeable being (1) a rather marked diminution during the eleventh and twelfth years, followed by (2) a rapid acceleration which reaches its maximum at about the sixteenth year and then very rapidly diminishes. These irregularities may be more clearly seen from the following charts, which represent the curves obtained by plotting the annual increase of weight in boys (Chart I) and girls (Chart II). The diminution and acceleration of growth referred to

above are clearly observable, and it is interesting to note that they occur at earlier periods in girls than in boys, the diminution occurring in girls at the eighth and ninth years and the acceleration reaching its maximum at the thirteenth year.

YEAR.	NUMBER OF CASES.	WEIGHT IN KILOGRAMS.	PERCENTAGE INCREASE.
0	451	3.2	
1		(10.8)	(238)
2	2	14.7*	(36)*
3	41	15.4	4.8*
4	102	16.9	9.7
5	193	18.1	7.1
6	224	20.1	11
7	246	22.6	12.4
8	820	24.9	10.2
9	1425	27.4	10.
10	1464	30.6	11.5
11	1599	32.6	6.5
12	1786	34.9	7.
13	2443	37.6	7.7
14	2952	41.7	10.9
15	3118	46.6	11.7
16	2235	53.9	15.7
17	2496	59.3	10.
18	2150	62.2	4.9
19	1438	63.4	1.9
20	851	64.9	2.5
21	738	65.7	1.2
22	542	67.0	1.9
23	551	67.0	0.

Considering, now, merely the general diminution in the rate of growth which occurs from birth to adult life, it

\* From a comparison with other similar tables there is little doubt but that the weight given above for the second year is too high to be accepted as a good average. Consequently the percentage increase for the second year is too high and that for the third year too low.

It may be mentioned that the weights in the original table are expressed in pounds avoirdupois and have been here converted into kilograms, and further the figures representing the percentage increase have been added.



becomes interesting to note to what extent the organs which are more immediately associated with the metabolic activities of the body undergo a relative reduction in weight. The most important of these organs is un-

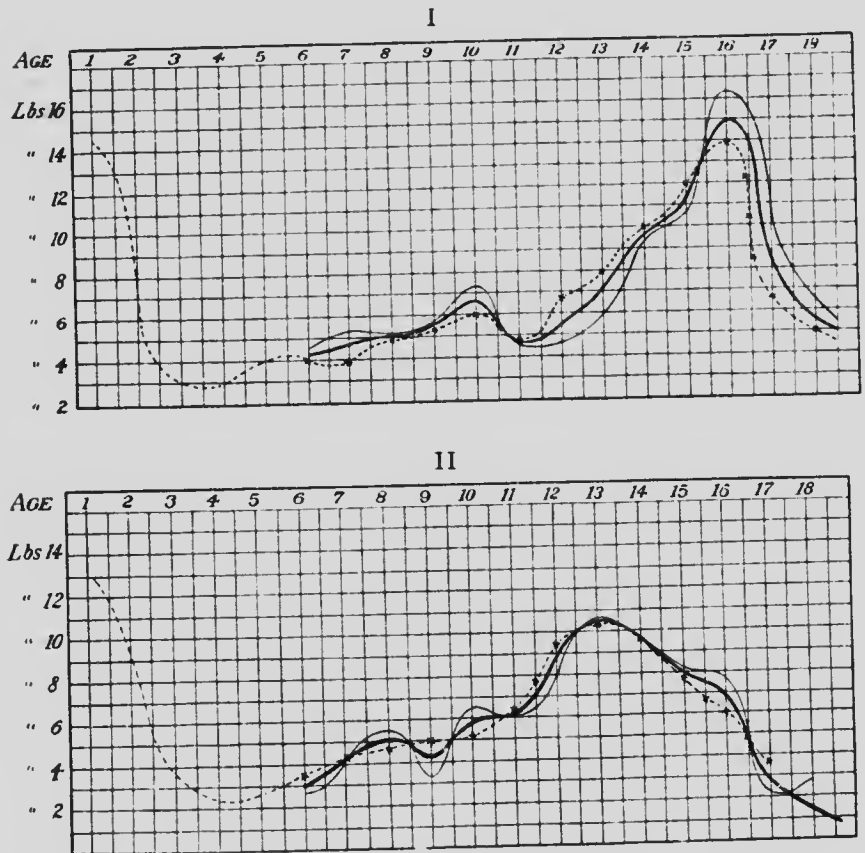


FIG. 267.—CURVES SHOWING THE ANNUAL INCREASE IN WEIGHT IN (I) BOYS AND (II) GIRLS.

The faint line represents the curve from British statistics, the dotted line that from American (Bowditch), and the heavy line the average of the two. Before the sixth year the data are unreliable.—(Stephenson.)

doubtedly the liver, but with it there must also be considered the thyroid and thymus glands, and probably the suprarenal bodies. In all these organs there is a marked

diminution in size as compared with the weight of the body, as will be seen from the following table (H. Vierordt), which also includes data regarding other organs in which a marked relative diminution, not in all cases readily explainable, occurs:

## ABSOLUTE WEIGHT IN GRAMS

## NEW-BORN AND ADULT.

LIVER.	THY- REOID.	THY- MUS.	SUPRAREN- AL BODIES.	SPLEEN.	HEART.	KID- NEYS.	BRAIN.	SPINAL CORD.
141.7	4.85	8.15	7.05	10.6	23.6	23.3	381.0	5.5
1819.0	33.8	26.9	7.4	163.0	300.6	305.9	1430.9	39.15

## PERCENTAGE WEIGHT OF ENTIRE BODY

## NEW-BORN AND ADULT.

LIVER.	THY- REOID.	THY- MUS.	SUPRAREN- AL BODIES.	SPLEEN.	HEART.	KID- NEYS.	BRAIN.	SPINAL CORD.
4.57	0.16	0.26	0.23	0.34	0.76	0.75	12.29	0.18
2.75	0.05	0.04	0.01	0.25	0.46	0.46	2.16	0.06

On the other hand, the remaining organs, when compared with the weight of the body, either show an increase or remain practically the same.

## ABSOLUTE WEIGHT IN GRAMS.

## NEW-BORN AND ADULT.

SKIN AND SUBCU- TANEOUS TIS- SUES.	SKELETON.	MUSCULA- TURE.	STOMACH AND INTES- TINES.	PANCREAS.	LUNGS.
611.75	425.5	776.5	65	3.5	54.1
11765.0	11575.0	28732.0	1364	97.6	994.9

## PERCENTAGE OF BODY-WEIGHT.

## NEW-BORN AND ADULT.

SKIN AND SUBCU- TANEOUS TIS- SUES.	SKELETON.	MUSCULA- TURE.	STOMACH AND INTES- TINES.	PANCREAS.	LUNGS.
19.73	13.7	25.05	2.1	0.11	1.75
17.77	17.48	43.40	2.06	0.15	1.50

From this table it will be seen that the greatest increment of weight is that furnished by the muscles, the percentage weight of which is one and three-fourths times as great in the adult as in the child. The difference does not, however, depend upon the differentiation of additional muscles; there are just as many muscles in the new-born child as in the adult, and the increase is due merely to an enlargement of organs already present. The percentage weight of the digestive tract, pancreas, and lungs remains practically the same, while in the case of the skeleton there is an appreciable increase, and in that of the skin and subcutaneous tissue a slight diminution. The latter is readily understood when it is remembered that the area of the skin, granting that the geometric form of the body remains the same, would increase as the square of the length, while the mass of the body would increase as the cube, and hence in comparing weights the skin might be expected to show a diminution even greater than that shown in the table.

The increase in the weight of the skeleton is due to a certain extent to growth, but chiefly to a completion of the ossification of the cartilage largely present at birth. A comparison of the weights of this system of organs does not, therefore, give evidence of the many changes of form which may be perceived in it during the period under

consideration, and attention may be drawn to some of the more important of these changes.

In the spinal column one of the most noticeable peculiarities observable in the new-born child is the absence of the curves so characteristic of the adult. These curves

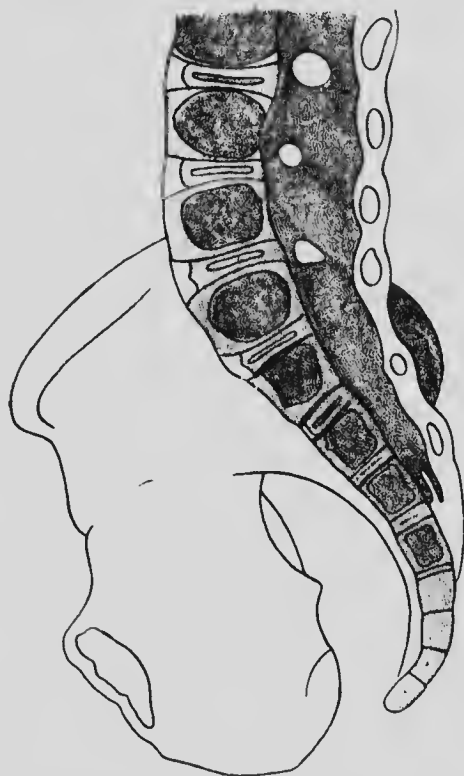


FIG. 26c.—LONGITUDINAL SECTION THROUGH THE SACRUM OF A NEW-BORN FEMALE CHILD.—(Fehling.)

are due partly to the weight of the body, transmitted through the spinal column to the hip-joint in the erect position, and partly to the action of the muscles, and it is not until the erect position is habitually assumed and the musculature gains in development that the curvatures become pronounced. Even the curve of the sacrum, so

marked in the adult, is but slight in the new-born child, as may be seen from Fig. 268, in which the ventral surfaces of the first and second sacral vertebræ look more ventrally than posteriorly, so that there is no distinct promontory.

But, in addition to the appearance of the curvatures, other changes also occur after birth, the entire column becoming much more slender and the proportions of the lumbar and sacral vertebræ becoming quite different, as may be seen from the following table (Acby):

LENGTHS OF THE VERTEBRAL REGIONS EXPRESSED AS PERCENTAGES OF THE ENTIRE COLUMN.

AGE.	CERVICAL.	THORACIC.	LUMBAR.
New-born child, . . . . .	25.6	47.5	26.8
Male 2 years, . . . . .	23.3	46.7	30.0
“ 5 “ . . . . .	20.3	45.6	34.2
“ 11 “ . . . . .	19.7	47.2	33.1
“ adult, . . . . .	22.1	46.6	31.6

The cervical region diminishes in length, while the lumbar gains, the thoracic remaining approximately the same. It may be noticed, furthermore, that the difference between the two variable regions is greater during youth than in the adult, a condition possibly associated with the general more rapid development of the lower portion of the body made necessary by its imperfect development during fetal life. The difference is due to changes in the vertebræ, the intervertebral disks retaining approximately the same relative thickness throughout the period under consideration.

The form of the thorax also alters, for whereas in the adult it is barrel-shaped, narrower at both top and bottom than in the middle, in the new-born child it is rather conical, the base of the cone being below. The difference

depends upon slight differences in the form and articulations of the ribs, these being more horizontal in the child and the opening of the thorax directed more directly upward than in the adult.

As regards the skull, the processes of growth are very complicated. Cranium and brain react on one another, and hence, in harmony with the relatively enormous size of the brain at birth, the cranial cavity has a relatively greater volume in the child than in the adult. The fact that the entire roof and a considerable part of the sides of the skull are formed of membrane bones which, at birth, are not in sutural contact with one another throughout, gives opportunity for considerable modifications, and, furthermore, the base of the skull at the early stage still contains a considerable amount of unossified cartilage. Without entering into minute details, it may be stated that the principal general changes which the skull undergoes in its post-natal development are (1) a relative elongation of its anterior portion and (2) an increase in the relative height of the superior maxillæ.

If a line be drawn between the central points of the occipital condyles, it will divide the base of the skull into two portions, which in the child's skull are equal in length. The portion of the skull in front of a similar line in the adult skull is very much greater than that which lies behind, the proportion between the two parts being 5:3, against 3:3 in the child (Froriep). There has, therefore, been a decidedly more rapid growth of the anterior portion of the skull, a growth which is associated with a corresponding increase in the dorso-ventral dimensions of the superior maxillæ. These bones, indeed, play a very important part in determining the proportions of the skull at different periods. They are so intimately associated with the cranial portions of the skull that their

increase necessitates a corresponding increase in the anterior part of the cranium, and their increase in this direction stands in relation to the development of the teeth, the eight teeth which are developed in each maxilla (including the premaxilla) in the adult requiring a longer bone than do the five teeth of the primary dentition, these again requiring a greater length when completely developed than they do in their immature condition in the newborn child.

But far more striking than the difference just described is that in the relative height of the cranial and facial

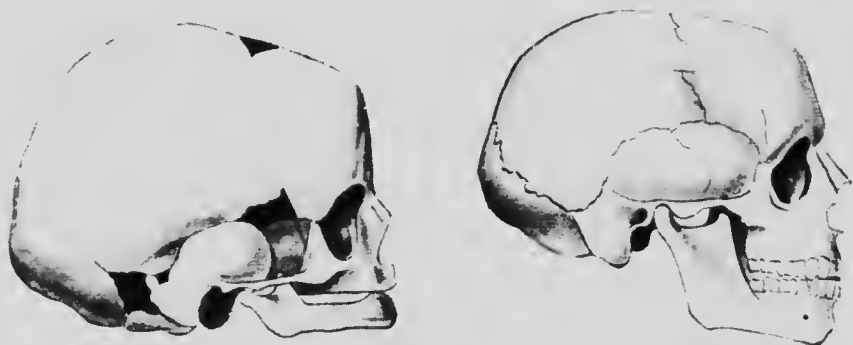


FIG. 269.—SKULL OF A NEW-BORN CHILD AND OF AN ADULT MAN, DRAWN TO APPROXIMATELY THE SAME SCALE.—(Henke.)

regions (Fig. 269). It has been estimated that the volumes of the two portions have a ratio of 8:1 in the newborn child, 4:1 at five years of age, and 2:1 in the adult skull (Froriep), and these differences are due principally to changes in the vertical dimensions of the superior maxillæ. As with the increase in length, the increase now under consideration is, to a certain extent at least, associated with the development of the teeth, these structures calling into existence the alveolar processes which are practically wanting in the child at birth. But a more

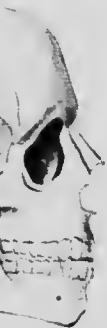important factor is the development in the maxillæ of the antra of Highmore, the practically solid bodies of the bones becoming transformed into hollow shells. These cavities, together with the sinuses of the sphenoid and frontal bones, which are also post-natal developments, seem to stand in relation to the increase in length of the anterior portion of the skull, serving to diminish the weight of the portion of the skull in front of the occipital condyles and so relieving the muscles of the neck of a considerable strain to which they would otherwise be subjected.

These changes in the proportions of the skull have, of course, much to do with the changes in the general proportions of the face. But the changes which take place in the mandible are also important in this connection, and are similar to those of the maxillæ in being associated with the development of the teeth. In the new-born child the horizontal ramus is proportionately shorter than in the adult, while the vertical ramus is very short and joins the horizontal one at an obtuse angle. The development of the teeth of the primary dentition, and later of the three molars, necessitates an elongation of the horizontal ramus equivalent to that occurring in the maxillæ, and, at the same time, the separation of the alveolar borders of the two bones requires an elongation of the vertical ramus if the condyle is to preserve its contact with the glenoid fossa, and this, again, demands a diminution of the angle at which the rami join if the teeth of the two jaws are to be in proper apposition.

In the bones of the appendicular skeleton secondary epiphysial centers play an important part in the ossification, and in few are these centers developed prior to birth, while the union of the epiphyses to the main portions of the bones takes place only toward maturity.

ante-  
direc-  
teeth,  
la (in-  
longer  
, these  
devel-  
e new-

cribed  
facial



G, DRAWN

the vol-  
the new-  
the adult  
ncipally  
superior  
ase now  
st, asso-  
ructures  
hich are  
a more



The dates at which the various primary and secondary centers appear, and the time at which they unite, may be seen from the following table:

## UPPER EXTREMITY.

BONE.	APPEARANCE OF PRIMARY CENTER.	APPEARANCE OF SECONDARY CENTERS.	FUSION OF CENTERS.
Clavicle, . . . .	<i>6th week.</i>	(At sternal end) 17th year.	20th year.
Scapula, . . . .			
Body, . . . . .	<i>8th week</i>	{ 2 acromial 15th year. 2 on vertebral border 16th year.	} 20th year.
Coracoid, . .	1st year.		
		{ Head 1st year. Great tuberosity 3d year. Lesser tuberosity 5th year.	} 20th year.
Humerus, . . . .	<i>8th week.</i>		
		{ Trochlea 10th year. Outer condyle 14th year.	} 17th year.
Ulna, . . . . .	<i>8th week.</i>		
		Distal epiphysis 4th year.	18th year.
Radius, . . . . .	<i>8th week.</i>	Proximal epiphysis 5th year.	17th year.
		Distal epiphysis 2d year.	20th year.
Os magnum, . .	1st year.	.....	.....
Unciform, . . .	2d year.	.....	.....
Cuneiform, . .	3d year.	.....	.....
Semilunar, . .	4th year.	.....	.....
Trapezium, . .	5th year.	.....	.....
Scaphoid, . . .	6th year.	.....	.....
Trapezoid, . . .	8th year.	.....	.....
Pisiform, . . . .	12th year.	.....	.....
Metacarpals, .	<i>8th week.</i>	3d year.	20th year.
Phalanges, . .	<i>8th-10th week.</i>	3d-5th years.	17th-18th year.

The dates in italics are before birth.

LOWER EXTREMITY.

BONE.	APPEARANCE OF PRIMARY CENTER.	APPEARANCE OF SECONDARY CENTERS.	FUSION OF CENTERS.
Ilium, . . . . .	<i>3d month.</i>	Crest 15th year. Anterior inferior spine 15th year.	} 22d year.
Ischium, . . . . .	<i>3d-4th month.</i>	Tuberosity 15th year	
Pubis, . . . . .	<i>4th month.</i>	Crest 18th year.	} 20th year.
Patella, . . . . .	Cartilage appears at <i>4th month.</i>	Ossification in 3d year.	
Femur, . . . . .	<i>7th week.</i>	Head 1st year. Great trochanter 4th year. Lesser trochanter 13th- 14th year.	19th year. 18th year.
Tibia, . . . . .	<i>8th week.</i>	Condyle <i>9th month.</i> Head <i>end of 9th month.</i> Condyle <i>9th month.</i> Distal end 2d year.	21st year. 21st-25th year. 21st year. 18th year.
Fibula, . . . . .	<i>8th week.</i>	Upper epiphysis 5th year. Lower epiphysis 2d year.	21st year. 20th year.
Astragalus, . . . . .	<i>7th month.</i>	.....	.....
Calcaneum, . . . . .	<i>6th month.</i>	10th year.	16th year.
Cuboid, . . . . .	A few days after birth.	.....	.....
Scaphoid, . . . . .	4th year.	.....	.....
Cuneiform, . . . . .	1st year.	.....	.....
Metatarsals, . . . . .	<i>8th week.</i>	3d year.	20th year.
Phalanges, . . . . .	<i>8th-10th week.</i>	4th-8th years.	.....

The dates in italics are before birth.

So far as actual changes in the form of the appendicular bones are concerned, these are most marked in the case of the lower limb. The ossa innominata alter somewhat in their proportions after birth, a fact which may conveniently be demonstrated by considering the changes which occur in the proportions of the pelvic diameters, although it must be remembered that these diameters are greatly influenced by the development of the sacral curve. Taking the conjugate diameter of the pelvic brim as a unit for comparison, the antero-posterior (dorso-ventral) and transverse diameters of the child and adult have the following proportions (Fehling):

DIAMETER.		NEW-BORN FEMALE.	ADULT FEMALE.	NEW-BORN MALE.	ADULT MALE.
Brim.	{ Conjugata vera, . . . . .	1.00	1.00	1.00	1.00
	{ Transverse, . . . . .	1.19	1.292	1.20	1.294
Cavity.	{ Antero-posterior, . . . . .	0.96	1.19	0.91	1.18
	{ Transverse, . . . . .	1.01	1.151	0.99	1.14
Outlet.	{ Antero-posterior, . . . . .	0.91	1.05	0.78	1.07
	{ Transverse, . . . . .	0.83	1.154	0.84	1.153

It will be seen from this that the general form of the pelvis in the new-born child is that of a cone, gradually diminishing in diameter from the brim to the outlet, a condition very different from what obtains in the adult. Furthermore, it is interesting to note that sexual differences in the form of the pelvis are clearly distinguishable at birth; indeed, according to Fehling's observations, they become noticeable during the fourth month of intra-uterine development.

The upper epiphysis of the femur is entirely unossified at birth and consists of a cartilaginous mass, much broader than the rather slender shaft and possessing a deep notch upon its upper surface (Fig. 270). This notch marks off the great trochanter from the head of the bone, and at this stage of development there is no neck, the head being practically sessile. As development proceeds the inner upper portion of the shaft grows more rapidly than the outer portion, carrying the head away from the great trochanter and forming the neck of the bone. The acetabulum is shallower at birth than in the adult and cannot contain more than half the head of the femur; consequently the articular portion of the head is much less extensive than in the adult.

It is a well-known fact that the new-born child habitually holds the feet with the soles directed toward one another, a position only reached in the adult with some difficulty, and associated with this supination or inversion there is a pronounced extension of the foot (*i. e.*, flexion upon the leg as usually understood; see p. 107), it being difficult to flex the child's foot beyond a line at right angles with the axis of the leg. These conditions are due apparently to the extensor and tibialis muscles being relatively

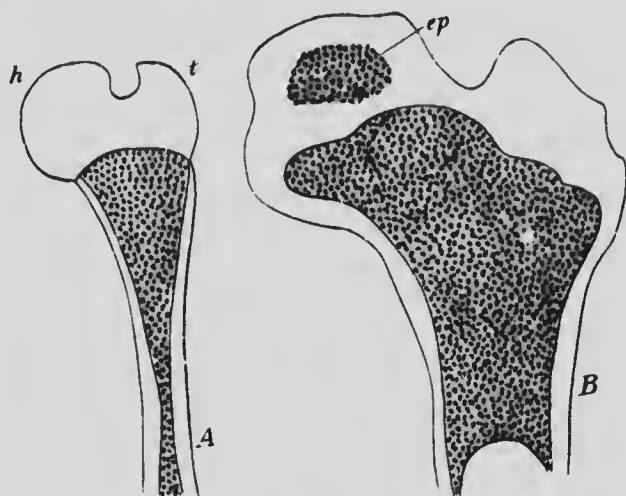


FIG. 270. —LONGITUDINAL SECTIONS OF THE HEAD OF THE FEMUR OF (A) NEW-BORN CHILD AND (B) A LATER STAGE OF DEVELOPMENT.  
*ep*, Epiphysial center for the head; *h*, head; *t*, trochanter.—(Henke.)

shorter and the opposing muscles relatively longer than in the adult, and with the elongation or shortening, as the case may be, of the muscles on the assumption of the erect position, the bones in the neighborhood of the ankle-joint come into new relations to one another, the result being a modification of the form of the articular surfaces, especially of the astragalus. In the child the articular cartilage of the trochlear surface of this bone is continued onward to a considerable extent upon the neck of the bone, which comes into contact with the tibia in the extreme

extension possible in the child. In the adult, however, such extreme extension being impossible, the cartilage upon the neck gradually disappears. The supination in the child brings the astragalus in close contact with the inner surface of the os calcis and with the sustentaculum tali; with the alteration of position a growth of these portions of the calcaneum occurs, the sustentaculum becoming higher and broader, and so becoming an obstacle in the way of supination in the adult. At the same time a greater extent of the outer surface of the astragalus comes into contact with the outer malleolus, with the result that the articular surface is considerably increased on that portion of the bone. Marked changes in the form of the astragalo-scaploid articulation also occur, but their consideration would lead somewhat further than seems desirable.

#### LITERATURE.

- C. AEBY: "Die Altersverschiedenheiten der menschlichen Wirbelsäule," *Archiv für Anat. und Physiol., Anat. Abth.*, 1879.
- W. CAMERER: "Untersuchungen über Massenwachsthum und Längenwachsthum der Kinder," *Jahrbuch für Kinderheilkunde*, xxxvi, 1893.
- H. H. DONALDSON: "The Growth of the Brain," London, 1895.
- H. FEILING: "Die Form des Beckens beim Fötus und Neugeborenen und ihre Beziehung zu der beim Erwachsenen," *Archiv für Gynäkol.*, x, 1876.
- W. HENKE: "Anatomie des Kindersalters," *Handbuch der Kinderkrankheiten (Gerhardt)*, Tübingen, 1881.
- C. HENNIG: "Das kindliche Becken," *Archiv für Anat. und Physiol., Anat. Abth.*, 1880.
- C. HÜTER: "Anatomische Studien an den Extremitätengelenken Neugeborener und Erwachsener," *Archiv für patholog. Anat. und Physiol.*, xxv, 1862.
- W. STEPHENSON: "On the Relation of Weight to Height and the Rate of Growth in Man," *The Lancet*, ii 1888.
- R. THOMA: "Untersuchungen über die Grösse und das Gewicht der anatomischen Bestandtheile des menschlichen Körpers," Leipzig, 1882.
- H. VIERORDT: "Anatomische, Physiologische und Physikalische Daten und Tabellen," Jena, 1893.
- H. WELCKER: "Untersuchungen über Wachsthum und Bau des menschlichen Schädels," Leipzig, 1862.

## INDEX.

### A.

After-birth, 159  
 After-brain, 404  
 Agger nasi, 199  
 Allantois, 130, 135  
 Alveolo-lingual glands, 310  
     groove, 306  
 Amitotic division, 24  
 Amnion, 129  
 Amniotic cavity, 71  
 Amphiarthroses, 213  
 Amphiaser, 22  
 Annulus of Vieussens, 253  
 Anterior commissure, 426  
 Antihelix, 474  
 Antitragus, 474  
 Antrum of Highmore, 199  
 Anus, 298  
 Aortic arch, 264  
     bulb, 248  
     septum, 255  
 Appendicular skeleton, 181, 206  
 Archenteron, 65, 296  
 Archoplasm, 20  
 Arcuate fibers, 409  
 Areas of Langhans, 332  
 Arrectores pilorum, 168  
 Arteries, 261  
     allantoidean, 262  
     anastomotica magna, 276  
     anterior tibial, 274, 276  
     aorta, 262  
     brachiocephalic, 265  
     branchial, 262  
     carotid, 263  
     centralis retinae, 490  
     coeliac axis, 267  
     dorsalis indicis, 272  
         pedis, 274  
         pollicis, 272  
     epigastric, 271  
     external iliac, 275  
     facial, 263  
     femoral, 276  
     hyaloid, 476

### Arteries:

hypogastric, 268  
 iliac, 266  
 inferior mesenteric, 267  
 innominate, 265  
 intercostal, 266  
 internal mammary, 271  
 internal maxillary, 263  
 interosseous, 272  
 lingual, 263  
 lumbar, 266  
 median, 272  
 median sacral, 266  
 omphalo-mesenteric, 242  
 peroneal, 276  
 popliteal, 274  
 posterior tibial, 276  
 radial, 272  
 saphenous, 275  
 sciatic, 274  
 subclavian, 265, 266  
 superior intercostal, 271  
     mesenteric, 262  
     vesical, 268  
 temporal, 263  
 ulnar, 272  
 umbilical, 262, 267  
 vertebral, 271  
 vitelline, 242  
 Arytenoid cartilages, 357  
 Aster, 21  
 Atresia of duodenum, 325  
     of pupil, 483  
 Auditory ganglion, 464  
 Auerbach, plexus of, 448  
 Auricular septum, 252  
 Auriculo-ventricular valves, 258  
 Axial skeleton, 181  
 Axis-cylinder, 396

### B.

Bartholin, glands of, 384  
 Belly-stalk, 85, 135  
 Bile-capillaries, 327

- Bladder, 381  
 Blastoderm, 59  
 Blastopore, 65  
 Blastula, 55  
 Blood, 242  
 Blood-islands, 241  
 Blood-vessels, 240  
 Body-cavity, 65  
 Bone, cartilage, 176  
   development of, 176  
   growth of, 178  
   membrane, 176  
 Bone-marrow, 177  
 Bones:  
   alisphenoid, 197  
   atlas, 184  
   axis, 185  
   basioccipital, 195  
   carpal, 208  
   clavicle, 206  
   coecyx, 188  
   coracoid, 207  
   ectethmoid, 197  
   ethmoid, 197  
   femur, 211, 517  
   fibula, 211  
   frontal, 201  
   humerus, 208  
   hyoid, 204  
   ilium, 210  
   incus, 203, 470, 472  
   innominate, 210, 515  
   interparietal, 196  
   ischium, 210  
   lacrimal, 201  
   lingulae, 197  
   malar, 202  
   malleus, 203, 470, 472  
   mandible, 204  
   maxilla, 203  
   mesethmoid, 198  
   metacarpal, 209  
   metatarsal, 212  
   nasal, 201  
   occipital, 195  
   orbitosphenoids, 197  
   palatine, 203  
   parietal, 201  
   patella, 211  
   phalanges, 209, 212  
   precoracoid, 214  
   premaxilla, 203  
   presphenoid, 197  
   pubis, 210  
   radius, 208  
   ribs, 183, 185  
   sacrum, 188, 509  
   scapula, 207  
   sphenoid, 196  
   squamosal, 200  
   stapes, 204, 470, 472  
   sternum, 188  
   supraoccipital, 196  
   suprasternal, 189  
   tarsal, 211, 517  
   temporal, 200  
   tibia, 211  
   turbinated, 199  
   tympanic, 200  
   ulna, 208  
   vertebrae, 181, 510  
   vomer, 198  
 Bowman, membrane of, 497  
 Brain, 403  
 Branchial arch skeleton, 202  
   clefts, 91, 101  
   epithelial bodies, 312  
   fistula, 94  
 Branchiomeres, 123  
 Burdach, column of, 403
- C.
- Cæcum, 323  
 Calcar, 423  
 Calcarine fissure, 423  
 Callosal fissure, 427  
 Calloso-marginal fissure, 424  
 Canalis reuniens, 462  
 Carotid gland, 448  
 Cartilage bone, 177  
 Caruncula lacrymalis, 495  
 Cauda equina, 401  
 Cavernous sinus, 277  
 Cell, 17  
 Cell-theory, 17  
 Centrosome, 20  
 Cerebellum, 410  
 Cerebral convolutions, 422  
   cortex, 428  
   hemispheres, 408, 418  
 Chin ridge, 105  
 Chondrocranium, 192, 195  
 Chorda dorsalis, 115  
   endoderm, 115  
 Chordæ tendinæ, 258  
 Choroid coat of eye, 478, 495  
   plexus, 407, 416, 421  
 Choroidal fissure, 421, 476

Chorion, 84, 142  
 frondosum, 145  
 læve, 145  
 Chromaffine cells, 392  
 Chromatin, 20  
 Chromosomes, 22  
 reduction of, 32  
 Ciliary body, 485  
 ganglion, 444, 448  
 Circumvallate papillæ, 458  
 Cleft palate, 203  
 sternum, 190  
 Clitoris, 385  
 Cloaca, 296  
 Cloacal membrane, 297  
 Cloquet, canal of, 494  
 Coccygeal ganglion, 452  
 Cochlea, 462, 467  
 Cœlom, 65  
 Collateral eminence, 425  
 fissure, 425  
 Coloboma, 483  
 Colon, 321  
 Columnæ corneæ, 258  
 Concrecence, 75  
 Conjunctiva, 497  
 Connective tissue, 174  
 Cornea, 478, 495  
 Corniculæ laryngis, 357  
 Corona radiata, 36, 376  
 Coronary sinus, 252  
 Corpora albicantia, 417  
 quadrigemina, 414  
 Corpus albicans, 40  
 callosum, 426  
 luteum, 40  
 striatum, 420  
 Corti, organ of, 464  
 Cotyledons, 145  
 Cowper, glands of, 384  
 Cricoid cartilage, 357  
 Cristæ acusticæ, 464  
 Crura cerebri, 413  
 Cuneiform cartilages, 357  
 Cutis plate, 122  
 Cytoplasm, 20

## D.

Darwin's tubercle, 475  
 Decidua reflexa, 152  
 scrotina, 153  
 vera, 150  
 Deciduæ, 128, 147, 159

Dendrites, 396  
 Dental groove, 300  
 papillæ, 300  
 shelf, 300  
 Dentate gyrus, 423, 427  
 Dentine, 304  
 Dermatome, 122, 164  
 Diaphragm, 338  
 Diaphysis, 178  
 Diarthrosis, 213  
 Dienecephalon, 404, 415  
 Discus proligerus, 35, 376  
 Dorsal flexure, 91  
 zone, 400  
 Duct of Santorini, 332  
 of Stenson, 309  
 of Wharton, 309  
 of Wirsung, 332  
 Ductus arteriosus, 264  
 Botalli, 264  
 communis choledochus, 325  
 Cuvieri, 277  
 ejaculatorius, 377  
 venosus, 281  
 Duodenum, 320

## E.

Ear, 459  
 Ebner, glands of, 459  
 Ectoderm, 64  
 Embryonic disc, 71  
 Enamel, 301  
 Endocardium, 248  
 Endoderm, 65  
 Endolymphatic duct, 460  
 Enveloping layer, 59  
 Ependymal cells, 395  
 Epiblast, 64  
 Epibranchial ganglia, 440  
 Epidermis, 161  
 Epididymis, 377  
 Epiglottis, 356  
 Epiphyses, 178  
 Epiphysis cerebri, 415  
 Episternal cartilages, 189  
 Epitrichium, 161  
 Eponychium, 166  
 Epoöphoron, 379  
 Erythroblasts, 245  
 Erythrocytes, 241  
 Erythroplastids, 245  
 Eustachian tube, 472  
 valve, 253



Extrauterine pregnancy, 38  
 Eye, 476  
 Eyelids, 497

## F.

Fallopian tubes, 379  
 Fasciculus communis, 436  
   solitarius, 426  
 Fenestra ovalis, 469  
   rotunda, 469  
 Fertilization of ovum, 47  
 Fetal circulation, 238  
 Fifth ventricle, 427  
 Filum terminale, 401  
 Fimbria ovarica, 379  
 Flocculus, 411  
 Floor-plate, 400  
 Foliate papillæ, 459  
 Fontana, spaces of, 496  
 Foramen cæcum, 306  
   incisivum, 300  
   of Winslow, 343  
   ovale, 253  
 Fore-brain, 404  
 Formatio reticularis, 409  
 Fornix, 426  
 Fossa supratonsillaris, 312  
 Frontal sinuses, 199  
 Furcula, 311

## G.

Gall-bladder, 325  
 Ganglionated cord, 445  
 Gärtner, canals of, 379  
 Gastral mesoderm, 67  
 Gastrula, 64  
 Geniculate bodies, 417  
 Genital folds, 384  
   ridge, 360, 371  
   swellings, 385  
   tubercle, 384  
 Germ cells, 24  
   plasma, 25  
 Germinal layers, 64, 78  
 Giant cells, 247  
 Giraldes, organ of, 377  
 Goll, column of, 403  
 Graafian follicle, 34, 375  
 Gray rami, 444  
 Growth of body, 502  
 Gubernaculum testis, 371  
 Gynæcomastia, 173

Gyrus fornicatus, 424  
   marginalis, 424

## H.

Hæmatopoietic organs, 244  
 Hair, 167  
 Harclip, 105  
 Haversian canals, 180  
 Head bend, 94  
   cavities, 120, 440  
   process, 74, 76  
 Heart, 248  
 Helix, 474  
 Hensen's node, 74  
 Hermaproditism, 387  
 Highmore, antrum of, 199  
 Hind-brain, 404  
 Hippocampal fissure, 423  
 Hippocampus, 423  
   minor, 423  
 Holoblastic segmentation, 57  
 Hyaloid canal, 494  
 Hydatid of Morgagni, 378  
   stalked, 381  
 Hymen, 380  
 Hypertelia, 173  
 Hypertrichosis, 169  
 Hypoblast, 65  
 Hypochordal bar, 183  
 Hypophysis cerebri, 418  
 Hypospadias, 387

## I.

Infundibulum, 420  
 Inguinal canal, 390  
 Insula, 424  
 Interarticular cartilages, 214  
 Intercarotid ganglia, 448  
 Intermediate cell mass, 119  
 Intermuscular septa, 182  
 Intervertebral discs, 184  
 Intestine, 319  
 Intraparietal fissure, 424  
 Iris, 485  
 Isthmus, 404, 413  
 Iter, 405

## J.

Jacobson, organ of, 457  
 Joints, 212

## K.

Karyokinesis, 24  
 Karyoplasma, 20  
 Kidney (see *Metanephros*), 366

## L.

Labia majora, 385  
   minora, 385  
 Lachrymal duct, 499  
   gland, 498  
 Lamina spiralis, 468  
   terminalis, 418  
 Lancisi, striae of, 427  
 Langhans, areas of, 33  
   cells of, 145  
 Lanugo, 168  
 Larynx, 355  
 Lateral sinus, 277  
   thyreoids, 314  
 Lens, 476, 479  
 Lenticular ganglion, 444  
 Leukocytes, 243  
 Ligaments:  
   broad, 371  
   capsular, 213  
   coronary, 340  
   external lateral, of knee, 221  
   great sacro-sciatic, 221  
   infraspinous, 184  
   inguinal, 388  
   intervertebral, 184  
   ovarian, 371  
   pectinatum iridis, 495  
   round, of liver, 290  
   spleno-mandibular, 204  
   subflavan, 184  
   supraspinous, 184  
   suspensory, of lens, 493  
   suspensory, of liver, 340  
   teres, of ovary, 371  
 Limbs, 105  
 Lip ridge, 105  
 Lips, 299  
 Liquor annui, 133  
 Liver, 325  
 Lungs, 352  
 Lunula, 166  
 Luschka's ganglion, 452  
 Lymph hearts, 291  
   nodes, 294  
 Lymphatics, 291  
 Lymphocytes, 246, 291

## M.

Maculae acusticae, 464  
 Mammary glands, 170  
 Mandibular process, 97  
 Mantle layer, 395  
 Marchand, accessory suprarenals of,  
   391  
 Mastoid cells, 472  
   process, 200  
 Maturation of ovum, 43  
 Maxillary process, 97  
 Meatus auditorius externus, 473  
 Meckel's cartilage, 194  
   diverticulum, 135 323  
 Mediastina, 341  
 Medulla oblongata, 404  
 Medullary canal, 114  
   folds 36, 112  
   groove, 112  
   sheath, 399  
 Megacaryocytes, 247  
 Meibomian glands, 497  
 Meissner, plexus of, 448  
 Membrana pupillaris, 483  
   reuniens, 123  
   tectoria, 465  
 Membrane bone, 176  
 Menstruation, 38  
 Meroblastic segmentation, 57  
 Mesencephalon, 404, 414  
 Mesenchyme, 80  
 Mesenteriole, 347  
 Mesentery, 342  
 Mesocardium, 334  
 Mesocolon, 345  
 Mesoderm, 65  
 Mesodermic somites, 89, 118  
 Mesogastrium, 342  
 Mesonephros, 363  
 Mesoneurium, 371, 389  
 Mesothelium, 80  
 Mesovarium, 371  
 Metamere, 124  
 Metanephros, 366  
 Metencephalon, 404, 410  
 Metopic suture, 201  
 Midbrain, 404  
 Middle commissure, 416  
 Milk ridge, 170  
 Mitosis, 24  
 Moderator bands, 258  
 Moll, glands of, 497  
 Monro, foramen of, 420  
   sulcus of, 415

- Monstrosities, 63  
 Montgomery's glands, 172  
 Morgagni, hydatid of, 378  
 Morula, 59  
 Mouth cavity, 299  
 Müllerian duct, 369  
 Muscle plate, 122  
 Muscles:  
     biceps femoris, 221  
     branchiomic, 225  
     chondroglossus, 231  
     ciliary, 496  
     coccygeus, 225  
     constrictores pharyngis, 229,  
         231  
     cranial, 227  
     curvator coccygis, 225  
     digastric, 229  
     diator iridis, 486  
     dorsal, 223  
     erector spinæ, 220  
     external rectus, 228  
     gastrocnemius, 237  
     geniohyoglossus, 224  
     geniohyoid, 224  
     hyoglossus, 224  
     hyposkeletal, 224  
     intercostal, 220, 224  
     laryngeal, 229  
     latissimus dorsi, 219  
     levator ani, 225  
     limb, 231  
     longus colli, 224  
     masseter, 229  
     mylohyoid, 229  
     obliqui abdominis, 220, 224  
     occipito-frontalis, 221, 229  
     omohyoid, 220  
     palatoglossus, 231  
     perineal, 227  
     peroneus longus, 221  
     platysma, 229  
     psoas, 224  
     pterygoid, 229  
     pyramidalis, 224  
     rectus abdominis, 220, 224  
     scaleni, 224  
     serrati postici, 221  
     serratus magnus, 220  
     skeletal, 218  
     soleus, 237  
     sphincter ani, 225  
     sphincter cloacæ, 225  
     sphincter iridis, 486  
     stapedius, 229, 470  
 Muscles:  
     sterno-mastoid, 220, 224, 231  
     styloglossus, 224  
     stylohyoid, 229  
     stylopharyngeus, 229  
     superior oblique, 227  
     temporal, 229  
     tensor palati, 229  
     tensor tympani, 229, 470  
     transversus abdominis, 220, 224  
     trapezius, 220, 224, 231  
     triangularis sterni, 224  
 Muscular tissue, 216  
 Musculi papillares, 258  
 Myelencephalon, 404, 407  
 Myelin, 399  
 Myocardium, 248  
 Myotome, 122
- N.
- Nail fold, 165  
 Nails, 164  
 Nasal duct, 499  
     fossæ, 97  
     process, 104  
 Neck bend, 94  
     depression, 98  
 Nephrostome, 362  
 Nephrotome, 120  
 Nerve roots, 397  
 Nerves:  
     cranial, 430  
     hypoglossal, 434  
     olfactory, 455  
     optic, 489  
     recurrent laryngeal, 358  
     spinal, 429  
         accessory, 429, 438  
         spino-occipital, 439  
         splanchnic, 446  
         superior laryngeal, 358  
 Nervous system, 394  
 Neural arch, 183  
     ridge, 397  
 Neurenteric canal, 86, 112  
 Neuroblasts, 395  
 Neuroglia, 395  
 Neuromeres, 440  
 Neurone theory, 399  
 Non-sexual reproduction, 25  
 Notochord, 115  
 Nuck, canal of, 388  
 Nucloli, 20  
 Nucleus, 19

## O.

- Oecipital depression, 98  
 Odontoblasts, 304  
 Œsophagus, 317  
 Olfactory lobes, 427  
 Olivary body, 409  
 Omentum, greater, 343, 347  
   lesser, 343  
 Oöcyte, 43  
 Optic cup, 476, 483  
   thalami, 416  
 Ova serrata, 484  
 Oval fossa, 90, 103  
 Osteoblasts, 176  
 Osteoclasts, 180, 247  
 Otic ganglion, 444, 448  
 Otoeyst, 460, 476  
 Ovaries, descent of, 387  
 Ovary, 374  
 Ovulation, 37  
 Ovum, 33, 376  
   fertilization of, 47  
   maturation of, 43  
   segmentation of, 53

## P.

- Palate, 299  
 Pancreas, 331  
 Paradidymis, 377  
 Paraphysis, 416  
 Parathyroids, 3 4  
 Parietal cavity, 335  
 Parieto-occipital fissure, 423  
 Paroöphoron, 379  
 Parovarium, 379  
 Parthenogenesis, 25  
 Penis, 385  
 Pericardial cavity, 338  
 Perilymph, 467  
 Perincal body, 384  
 Perionyx, 166  
 Periosteum, 176  
 Periotic capsule, 192, 200  
 Peritoneum, 342  
 Petit, canal of, 494  
 Petrosal sinus, 277  
 Pflüger's cords, 375  
 Pharyngeal bursa, 312  
   membrane, 297  
   tonsil, 311  
 Pharynx, 310  
 Pineal body, 415  
 Pinna, 474

- Pituitary body, 419  
 Placenta, 155  
   fœtalis, 155  
   prævia, 155  
   uterina, 155  
 Pleural cavities, 341  
 Pleuro-peritoneal cavity, 120, 338  
 Plica semilunaris, 498  
 Polar globules, 43  
 Polycaryocytes, 247  
 Polymastia, 173  
 Polyspermy, 49  
 Post-anal gut, 297  
 Post-branchial bodies, 316  
 Post-central fissure, 424  
 Posterior root ganglia, 397  
 Precentral fissure, 424  
 Prepuce, 386  
 Primitive streak, 67, 68, 74  
 Processus globularis, 104  
 Pronephric duct, 361  
 Pronephros, 361  
 Pronuclei, 49  
 Prostate gland, 384  
 Prostomial mesoderm, 67  
 Protoplasm, 18  
 Protovertebra, 118  
 Pulvinar, 417

## R.

- Rathke's pouch, 300  
 Rauber's covering layer, 62  
 Receptaculum chyli, 293  
 Recessus parietales, 335  
 Rectum, 297  
 Red nucleus, 414  
 Reil, island of, 424  
 Restiform body, 410  
 Rete ovarii, 376  
   testis, 374  
 Retina, 486  
 Rhinencephalon, 428  
 Rolando, fissure of, 424  
 Roof-plate, 400  
 Rosenmüller, groove of, 312  
   organ of, 379

## S.

- Sacral bend, 94  
 Salivary glands, 309  
 Santorini, cartilages of, 357  
   duct of, 332

- Sarcodae, 18  
 Sclerotic coat, 478, 495  
 Sclerotome, 122  
 Scrotum, 386  
 Sebaceous glands, 168  
 Segmentation nucleus, 49  
   of ovum, 54  
 Semicircular canals, 461  
 Semilunar valves, 259  
 Semiferous tubules, 374  
 Septum lucidum, 426  
   transversum, 336  
 Sertoli cells, 30  
 Sexual reproduction, 25  
 Sinus pocularis, 379  
   præcervicalis, 101  
   terminalis, 241  
   venosus, 248  
 Situs inversus viscerum, 63  
 Skeleton, 181  
 Skin, 101  
 Skull, 191, 511  
 Socia parotidis, 309  
 Soft commissure, 416  
 Solar plexus, 446  
 Sole plate, 165  
 Solitary fasciculus, 408  
 Somatic cells, 24  
   mesoderm, 120  
 Spermatid, 30  
 Spermatocyte, 30  
 Spermatogenesis, 29  
 Spermatogonia, 30  
 Spermatozoa, 27  
 Splenoidal cells, 219  
 Sphenopalatine ganglion, 444, 448  
 Spinal cord, 400  
 Splanchnic mesoderm, 120  
 Spleen, 349  
 Stenson's duct, 309  
 Sternum, cleft, 190  
 Stomach, 318  
 Stratum granulosum, 35, 376  
 Sublingual ganglion, 448  
   gland, 310  
 Submaxillary ganglion, 444, 448  
   gland, 309  
 Substance islands, 241  
 Subthalamie region, 417  
 Sudoriparous glands, 169  
 Sulcus of Monro, 415  
 Superfetation, 52  
 Superior longitudinal sinus, 277  
 Suprabranchial ganglia, 440  
 Suprarenal bodies, 390  
 Suprarenals, accessory, 391  
 Suture, 212  
 Sylvian fissure, 424  
   fossa, 423  
 Sympathetic system, 441  
 Synchondrosis, 212
- T.**
- Tail filament, 98  
 Taste, organs of, 458  
 Teeth, 300  
 Tegmentum, 413  
 Telencephalon, 404, 418  
 Temporal fissures, 424  
   lobe, 421  
 Testes, descent of, 388  
 Testis, 372  
 Thalamencephalon, 404  
 Thebesian valve, 253  
 Thoracic duct, 291  
 Thymus gland, 315  
 Thyreo-glossal duct, 314  
 Thyroid body, 313  
   cartilage, 356  
 Tongue, 305  
 Tonsils, 312  
 Touch, organs of, 458  
 Trachea, 355  
 Tragus, 474  
 Trophoblast, 72  
 Tuber cinereum, 417  
 Tuberculum impar, 305  
 Tubuli recti testis, 374  
 Tunica albuginea, 372  
   vaginalis, 389  
   vascularis, 482  
 "Tween-brain, 404  
 Twins, 63  
 Tympanic cavity, 469  
   membrane, 474
- U.**
- Umbilical cord, 97, 139  
 Umbilicus, 87  
 Uraachus, 138, 382  
 Ureter, 366  
 Urethra, 383  
 Urinogenital system, 360  
 Urogenital sinus, 382  
 Uterus, 379  
   masculinus, 379

Utriculus, 462  
Uvea, 484

## V.

Vagina, 379  
Vaginal process, 388  
Vas aberrans, 377  
  deferens, 377  
Veins:  
  anterior tibial, 288  
  ascending lumbar, 286  
  azygos, 286  
  basilic, 287  
  cardinal, 280  
  cephalic, 287  
  emissary, 280  
  external jugular, 280  
  facial, 280  
  hemiazygos, 286  
  hepatic, 283  
  inferior cava, 284  
  innominate, 279  
  internal jugular, 276  
  jugulo-cephalic, 288  
  omphalo-mesenteric, 242, 281  
  ovarian, 285  
  portal, 282  
  renal, 285  
  sciatic, 288  
  spermatie, 285  
  subcardinal, 284  
  superior cava, 279  
  suprarenal, 284  
  umbilical, 281  
  vitelline, 242  
Velum, anterior, 413  
  interpositum, 416  
  marginal, 395  
  posterior, 407  
Ventral zone, 400

Ventricle, fourth, 405  
  lateral, 405  
  third, 405  
Ventricular septum, 254  
Vermiform appendix, 324  
Vermis, 411  
Vernix caseosa, 134, 168  
Vern montanum, 380  
Vesiculæ seminales, 377  
Vicussens, annulus of, 253  
  valve of, 413  
Villi, chorionic, 143  
  intestinal, 324  
Vitreous humor, 492  
Vocal cords, 356  
Vulva, 385

## W.

Wharton's duct, 309  
  jelly, 141  
White rami, 443  
Wirsung's duct, 332  
Witch milk, 173  
Wolfian body, 361  
  duct, 361  
  ridge, 360  
Wrisberg, cartilages of, 357

## Y.

Yolk-sac, 83, 130, 134  
Yolk-stalk, 87, 130  
Yolk-vesicle, 87

## Z.

Zona pellucida, 36  
Zonula Zinnii, 493  
Zuckerkanal, organs of, 450

