

**CIHM/ICMH
Microfiche
Series.**

**CIHM/ICMH
Collection de
microfiches.**



Canadian Institute for Historical Microreproductions / Institut canadien de microreproductions historiques

© 1986

Technical and Bibliographic Notes/Notes techniques et bibliographiques

The Institute has attempted to obtain the best original copy available for filming. Features of this copy which may be bibliographically unique, which may alter any of the images in the reproduction, or which may significantly change the usual method of filming, are checked below.

L'Institut a microfilmé le meilleur exemplaire qu'il lui a été possible de se procurer. Les détails de cet exemplaire qui sont peut-être uniques du point de vue bibliographique, qui peuvent modifier une image reproduite, ou qui peuvent exiger une modification dans la méthode normale de filmage sont indiqués ci-dessous.

- ☒ Coloured covers/
Couverture de couleur
- ☐ Covers damaged/
Couverture endommagée
- ☐ Covers restored and/or laminated/
Couverture restaurée et/ou pelliculée
- ☐ Cover title missing/
Le titre de couverture manque
- ☐ Coloured maps/
Cartes géographiques en couleur
- ☐ Coloured ink (i.e. other than blue or black)/
Encre de couleur (i.e. autre que bleue ou noire)
- ☐ Coloured plates and/or illustrations/
Planches et/ou illustrations en couleur
- ☒ Bound with other material/
Relié avec d'autres documents
- ☐ Tight binding may cause shadows or distortion
along interior margin/
La reliure serrée peut causer de l'ombre ou de la
distorsion le long de la marge intérieure
- ☐ Blank leaves added during restoration may
appear within the text. Whenever possible, these
have been omitted from filming/
Il se peut que certaines pages blanches ajoutées
lors d'une restauration apparaissent dans le texte,
mais, lorsque cela était possible, ces pages n'ont
pas été filmées.
- ☐ Additional comments:/
Commentaires supplémentaires:

- ☐ Coloured pages/
Pages de couleur
- ☐ Pages damaged/
Pages endommagées
- ☐ Pages restored and/or laminated/
Pages restaurées et/ou pelliculées
- ☒ Pages discoloured, stained or foxed/
Pages décolorées, tachetées ou piquées
- ☐ Pages detached/
Pages détachées
- ☒ Showthrough/
Transparence
- ☐ Quality of print varies/
Qualité inégale de l'impression
- ☐ Includes supplementary material/
Comprend du matériel supplémentaire
- ☐ Only edition available/
Seule édition disponible
- ☐ Pages wholly or partially obscured by errata
slips, tissues, etc., have been refilmed to
ensure the best possible image/
Les pages totalement ou partiellement
obscurcies par un feuillet d'errata, une pelure,
etc., ont été filmées à nouveau de façon à
obtenir la meilleure image possible.

This item is filmed at the reduction ratio checked below/
Ce document est filmé au taux de réduction indiqué ci-dessous.

10X	14X	18X	22X	26X	30X
<input type="checkbox"/>	<input type="checkbox"/>	<input type="checkbox"/>	<input checked="" type="checkbox"/>	<input type="checkbox"/>	<input type="checkbox"/>
12X	16X	20X	24X	28X	32X

The copy filmed here has been reproduced thanks to the generosity of:

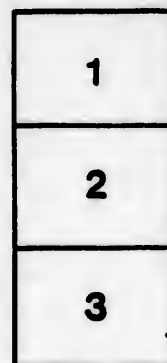
Medical Library
McGill University
Montreal

The images appearing here are the best quality possible considering the condition and legibility of the original copy and in keeping with the filming contract specifications.

Original copies in printed paper covers are filmed beginning with the front cover and ending on the last page with a printed or illustrated impression, or the back cover when appropriate. All other original copies are filmed beginning on the first page with a printed or illustrated impression, and ending on the last page with a printed or illustrated impression.

The last recorded frame on each microfiche shall contain the symbol \longrightarrow (meaning "CONTINUED"), or the symbol ∇ (meaning "END"), whichever applies.

Maps, plates, charts, etc., may be filmed at different reduction ratios. Those too large to be entirely included in one exposure are filmed beginning in the upper left hand corner, left to right and top to bottom, as many frames as required. The following diagrams illustrate the method:



L'exemplaire filmé fut reproduit grâce à la générosité de:

Medical Library
McGill University
Montreal

Les images suivantes ont été reproduites avec le plus grand soin, compte tenu de la condition et de la netteté de l'exemplaire filmé, et en conformité avec les conditions du contrat de filmage.

Les exemplaires originaux dont la couverture en papier est imprimée sont filmés en commençant par le premier plat et en terminant soit par la dernière page qui comporte une empreinte d'impression ou d'illustration, soit par le second plat, selon le cas. Tous les autres exemplaires originaux sont filmés en commençant par la première page qui comporte une empreinte d'impression ou d'illustration et en terminant par la dernière page qui comporte une telle empreinte.

Un des symboles suivants apparaîtra sur la dernière image de chaque microfiche, selon le cas: le symbole \longrightarrow signifie "A SUIVRE", le symbole ∇ signifie "FIN".


Les cartes, planches, tableaux, etc., peuvent être filmés à des taux de réduction différents. Lorsque le document est trop grand pour être reproduit en un seul cliché, il est filmé à partir de l'angle supérieur gauche, de gauche à droite, et de haut en bas, en prenant le nombre d'images nécessaire. Les diagrammes suivants illustrent la méthode.

ails
du
odifier
une
nage

rrata
o

pelure.
n à

32X



A CASE OF CHOLECYSTENTEROSTOMY PERFORMED
WITH MURPHY'S BUTTON; DEATH FROM
HÆMORRHAGE ON FOURTH DAY.

By FRANCIS J. SHEPHERD, M.D., C.M.,

OF MONTREAL,

SURGEON TO THE MONTREAL GENERAL HOSPITAL; PROFESSOR OF ANATOMY AND
LECTURER ON OPERATIVE SURGERY IN MCGILL UNIVERSITY.

OWING to the fact that we only read of the successful cases in which Murphy's button has been used, it seems to me fitting that the following fatal case from a hitherto not much noticed cause should be placed on record. The button was made by J. J. Ryan, of Chicago, and was a No. 1 of the series.

Mrs. J. F., aged thirty-six years, came to me in August, 1894, complaining of jaundice and a swelling in right side of abdomen. She gave the following history:

In January, 1893, had a severe attack of fever, which was followed by jaundice and a very uncomfortable feeling along the right side of the abdomen. Later this feeling developed into a severe pain. After lasting four months the jaundice disappeared entirely.

During the winter of 1894 she again had pains in the right side of the abdomen but no jaundice. These pains were described as of a gnawing character. In June, 1894, was troubled with indigestion, nausea, and vomiting, continuous high temperature, and with pains in right side of the abdomen. In July of this year first noticed a lump in right hypochondriac region and a continuous soreness, which was relieved by hot applications. The lump itself was freely movable and not at all tender to the touch. This lump has been continually increasing in size.

On examination patient was found to be deeply jaundiced, much emaciated, and on examining her abdomen a large pyriform swelling was felt on the right side, continuous with the liver and extending down below the umbilicus. It was elastic and freely movable, and

was dull on percussion, the dull note being continuous with the liver dulness.

Having decided that the tumor was an enlarged gall-bladder, operation was recommended and agreed to. She was admitted into the Montreal General Hospital, and operation was performed August 30. Incision over tumor, which was, as diagnosed, a distended gall-bladder. This was incised, and nearly a pint of bile evacuated, with some very small gall-stones. The obstruction in the common duct was then sought for, and a hard lump found the size of a small almond near the entrance of the duct into the duodenum, and some lumps higher up, which it was supposed might be enlarged glands. The lump near the pancreas was thought might be the obstructing stone; so padded forceps were used to break it up, without result. It was then decided to sew the gall-bladder to the skin incision and insert a drain.

The case progressed well, all the bile, of course, coming through the tube. The patient soon got an appetite, gained flesh, and lost her yellow color. She went home September 29, with the bile still flowing from the wound.

It was suggested that at some future time a cholecystenterostomy might be performed if the bile fistula did not close. The stools were slightly colored.

In three months, November 28, she returned, saying she had never felt better in her life, and she looked strong and robust, having gained considerably in weight since she left the hospital. Her bowels had been irregular, in fact inclined to diarrhœa. She said she was tired of having a continual discharge of bile, and desired the operation I had mentioned to her when she left the hospital in September.

I agreed to perform a cholecystenterostomy, and decided to make use of a Murphy button.

Operation December 3, 1894, assisted by Dr. Armstrong. An incision was made inside the first one, and the bladder was seen attached to the abdominal wall. On examining the site of the lump previously felt, one came down on a large mass, the size of one's fist, which apparently involved the head of the pancreas and duodenum. Being now certain that the case was one of malignant disease, and that all measures for relief could only be temporary, it was decided to unite the gall-bladder with the colon instead of the duodenum, as being easier and more rapid and quite as beneficial. The button was introduced without very much difficulty, the purse-string suture being

first inserted. Owing to the thickness of the gall-bladder there was some puckering, and the parts did not come together without considerable pressure on the button. At one point in the colon where the button could be seen easily through the bowel, a few Lembert sutures were placed. It was decided not to close the fistulous opening which had existed during the past three months, as it was felt this would close of itself after free communication was established between the gall-bladder and bowel. On dropping back the bowel and gall-bladder with the button, there was no pulling or tension, and the parts seemed to be in accurate apposition and to lie comfortably. The wound was closed with layers of buried sutures.

The patient went on well for four days, felt bright, and was cheerful; no sickness, no abdominal distress, and good pulse. There was also no bile discharging from the fistulous opening.

On the morning of the fourth day some blood was noticed oozing through the dressings. This seemed to come from the fistula leading to the gall-bladder and also from the abdominal wound. The blood was bright red, and on squeezing the abdomen gently a huge clot was forced out of the gall-bladder. This was carefully packed with iodoform gauze, and the abdominal wound examined and some stitches removed. Here was also found a blood-clot, but on its removal no further hæmorrhage was apparent.

The same evening my house surgeon called me up, saying my patient was again bleeding freely from the wound. On reaching the hospital I found her much blanched, sighing, and almost pulseless. Blood was rapidly oozing from the fistulous opening and wound. It was decided to reopen the wound and arrest the hæmorrhage if possible. On opening the abdomen a large clot was found about the seat of the anastomosis, and the gall-bladder was distended with blood-clot. There were found no signs of sepsis, the peritoneal cavity being perfectly normal. On examination of the button anastomosis the origin of the hæmorrhage was at once found. The button had cut through the thick and friable gall-bladder and could be easily seen. The hæmorrhage came entirely from the gall-bladder. To remove the button the tissues of bowel and bladder had to be incised and the button unscrewed. Feeling that it would be useless to reinsert the button, it was decided to sew up the incisions in the gall-bladder and colon, and to allow things to remain as they were before operation. The wound in the colon was closed easily enough, but that in the gall-bladder, owing to the friability of the structure, with

greater difficulty. The abdominal wound was closed and dressings applied. By this time the patient was in a very weak condition with the pulse hardly perceptible; so an intravenous injection of saline solution was given with good effect, increasing the volume of the pulse and reducing it to 140.

Next morning patient was going on very well, but towards mid-day another oozing of blood took place, and she gradually sank and died that evening.

Only a partial post-mortem could be obtained, but it was found that the obstruction to the common duct was due to carcinoma of the head of the pancreas. Near the duodenum were numerous glands enlarged and infiltrated. The gall-bladder was full of bile-stained blood-clot, and there was a large clot in the lesser sac.

Since the above was written I have read Dr. Murphy's paper,¹ in which he says that the operation of cholecystenterostomy in malignant disease is very unsatisfactory, as several deaths occurred in eight operations, none, so far as I can make out, from hæmorrhage, though it is well known that the tendency to hæmorrhage in those suffering from carcinoma is very great.

Dr. Murphy also says that now, when he finds a large carcinoma of the pancreas, duct, or neck of the gall-bladder, he abandons the operation. No doubt before long we will find out the limits of the application of the button. Its use ought certainly to be avoided in cases of obstruction due to malignant disease.

¹ Philadelphia Medical News, February 9, 1895.

rs
h
e
e

i-
d
d
ne
ds
ed

's
er-
al
ke
cy
at.
ar-
he
out
er-
nt

