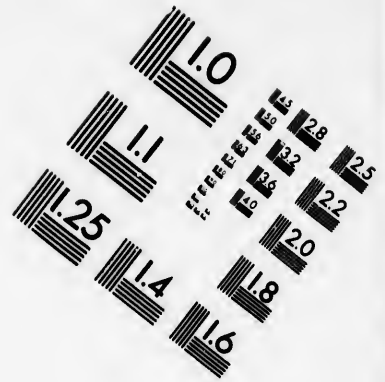
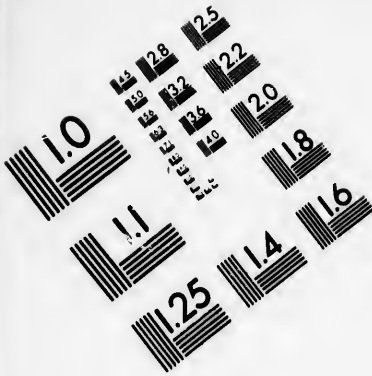


**IMAGE EVALUATION
TEST TARGET (MT-3)**



**Photographic
Sciences
Corporation**

23 WEST MAIN STREET
WEBSTER, N.Y. 14280
(716) 872-4503

**CIHM
Microfiche
Series
(Monographs)**

**ICMH
Collection de
microfiches
(monographies)**



Canadian Institute for Historical Microreproductions / Institut canadien de microreproductions historiques

© 1993

Technical and Bibliographic Notes / Notes techniques et bibliographiques

The Institute has attempted to obtain the best original copy available for filming. Features of this copy which may be bibliographically unique, which may alter any of the images in the reproduction, or which may significantly change the usual method of filming, are checked below.

L'Institut a microfilmé le meilleur exemplaire qu'il lui a été possible de se procurer. Les détails de cet exemplaire qui sont peut-être uniques du point de vue bibliographique, qui peuvent modifier une image reproduite, ou qui peuvent exiger une modification dans la méthode normale de filmage sont indiqués ci-dessous.

Coloured covers/
Couverture de couleur

Covers damaged/
Couverture endommagée

Covers restored and/or laminated/
Couverture restaurée et/ou pelliculée

Cover title missing/
Le titre de couverture manque

Coloured maps/
Cartes géographiques en couleur

Coloured ink (i.e. other than blue or black)/
Encre de couleur (i.e. autre que bleue ou noire)

Coloured plates and/or illustrations/
Planches et/ou illustrations en couleur

Bound with other material/
Relié avec d'autres documents

Tight binding may cause shadows or distortion along interior margin/
La reliure serrée peut causer de l'ombre ou de la distorsion le long de la marge intérieure

Blank leaves added during restoration may appear within the text. Whenever possible, these have been omitted from filming/
Il se peut que certaines pages blanches ajoutées lors d'une restauration apparaissent dans le texte, mais, lorsque cela était possible, ces pages n'ont pas été filmées.

Additional comments: /
Commentaires supplémentaires:

Coloured pages/
Pages de couleur

Pages damaged/
Pages endommagées

Pages restored and/or laminated/
Pages restaurées et/ou pelliculées

Pages discoloured, stained or foxed/
Pages décolorées, tachetées ou piquées

Pages detached/
Pages détachées

Showthrough/
Transparence

Quality of print varies/
Qualité inégale de l'impression

Continuous pagination/
Pagination continue

Includes index(es)/
Comprend un (des) index

Title on header taken from: /
Le titre de l'en-tête provient:

Title page of issue/
Page de titre de la livraison

Caption of issue/
Titre de départ de la livraison

Masthead/
Générique (périodiques) de la livraison

This item is filmed at the reduction ratio checked below /
Ce document est filmé au taux de réduction indiqué ci-dessous.

10x	12x	14x	16x	18x	20x	22x	24x	26x	28x	30x	32x
<input type="checkbox"/>	<input type="checkbox"/>	<input type="checkbox"/>	<input type="checkbox"/>	<input type="checkbox"/>	<input type="checkbox"/>	<input checked="" type="checkbox"/>	<input type="checkbox"/>	<input type="checkbox"/>	<input type="checkbox"/>	<input type="checkbox"/>	<input type="checkbox"/>

The copy filmed here has been reproduced thanks to the generosity of:


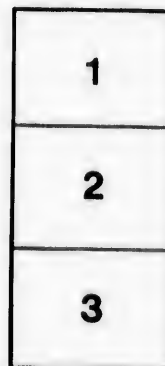
National Library of Canada

The images appearing here are the best quality possible considering the condition and legibility of the original copy and in keeping with the filming contract specifications.

Original copies in printed paper covers are filmed beginning with the front cover and ending on the last page with a printed or illustrated impression, or the back cover when appropriate. All other original copies are filmed beginning on the first page with a printed or illustrated impression, and ending on the last page with a printed or illustrated impression.

The last recorded frame on each microfiche shall contain the symbol \rightarrow (meaning "CONTINUED"), or the symbol ∇ (meaning "END"), whichever applies.

Maps, plates, charts, etc., may be filmed at different reduction ratios. Those too large to be entirely included in one exposure are filmed beginning in the upper left hand corner, left to right and top to bottom, as many frames as required. The following diagrams illustrate the method:



L'exemplaire filmé fut reproduit grâce à la générosité de:

Bibliothèque nationale du Canada

Les images suivantes ont été reproduites avec le plus grand soin, compte tenu de la condition et de la netteté de l'exemplaire filmé, et en conformité avec les conditions du contrat de filmage.

Les exemplaires originaux dont la couverture en papier est imprimée sont filmés en commençant par le premier plat et en terminant soit par la dernière page qui comporte une empreinte d'impression ou d'illustration, soit par le second plat, selon le cas. Tous les autres exemplaires originaux sont filmés en commençant par la première page qui comporte une empreinte d'impression ou d'illustration et en terminant par la dernière page qui comporte une telle empreinte.

Un des symboles suivants apparaîtra sur la dernière image de chaque microfiche, selon le cas: le symbole \rightarrow signifie "A SUIVRE", le symbole ∇ signifie "FIN".

Les cartes, planches, tableaux, etc., peuvent être filmés à des taux de réduction différents. Lorsque le document est trop grand pour être reproduit en un seul cliché, il est filmé à partir de l'angle supérieur gauche, de gauche à droite, et de haut en bas, en prenant le nombre d'images nécessaire. Les diagrammes suivants illustrent la méthode.

7



CASES OF OVARIOTOMY.

BY

KENNETH N. FENWICK, M.A., M.D.,

Prof. Obstetrics and Diseases of Women and Children, Royal College of Physicians and Surgeons, and Women's Medical College, in affiliation with Queen's University, Kingston; Member of the Royal College of Surgeons, England; Fellow of the Obstetrical Society, Edinburgh; and Surgeon to the Kingston General Hospital.

*Printed by J. Smith
Kingston.*

RC401
P3
no. 0726
~~P333~~



National Library
of Canada

Bibliothèque nationale
du Canada



Canada

K

as
wh
and
sup
for
ope
an e
are t
anti
In
chlo
out v
abdo
excep
carele
In
catgu
rectus
better
Tho...

CASES OF OVARIOTOMY.

—BY—

KENNETH N. FENWICK, A.M., M.D., M.R.C.S. ENG., F.O.S. EDIN.,

PROF. OBSTETRICS AND GYNECOLOGY, ROYAL COLLEGE AND WOMEN'S
MEDICAL COLLEGE, KINGSTON.

The following cases present some points of interest to the profession as illustrating an operation where dexterity is only gained by experience; where so many complications occur that the patience, presence of mind, and courage of the operator are put to the test, and it is reasonable to suppose that greater success should follow when the operation is performed with facilities and experience to aid the operator. Most of these operations were done in the Kingston General Hospital, where we have an efficient staff of trained nurses, and where the operator and the staff are thoroughly imbued with the necessity of thorough cleanliness and antisepsis.

In all the cases ether was the anæsthetic except in No. 10, where chloroform was preferred for several reasons. Antisepsis was carried out very carefully in all, and in every case of recovery union of the abdominal wound took place by first intention without a drop of pus, except in No. 3 and No. 8, and in both of these the cause was traced to carelessness in the preparation of the solution of bichloride.

In every case the abdominal wound was closed by the continuous catgut suture, beginning at the peritoneum, then the sheath of the rectus, and finally the skin, a method which I am satisfied is infinitely better than the interrupted suture, and which I first saw done by Dr. Thomas, of New York. In all the cases the pedicle was tied with silk,

which was cut short and dropped. A drainage tube was not employed in any of the cases, although I would be inclined to use in suitable cases simply a strip of antiseptic gauze, as I saw two years ago used by Dr. Hahn of Berlin, and in Albert's clinic at Vienna.

CASE 1.—Mrs. B., aged 36, married eleven years; no children; no miscarriages; always regular. About eight years ago first complained of pains in the abdomen, and was then informed by her physician that she had a tumor. About two years ago she moved to Kingston, and upon examination I found a tumor in the right side of the abdomen about the size of a child's head, hard and evidently containing fluid. At that time there were no indications of its fibroid character, and I had the impression that it was ovarian, but as the symptoms were not urgent an operation was not suggested. She soon after this moved to Carleton Place, where the tumor rapidly became larger, and as the pain, distension, and vomiting became very troublesome, she was tapped to give temporary relief. The cyst very rapidly refilled, and four weeks afterwards, the symptoms becoming very distressing, she came to Kingston to have the tumor removed. On admission to the hospital she was hardly able to retain any food; the abdomen was very fully distended, tense, and marked by veins; she suffered constant pain in her side; and her face had an expression of hopeless anguish. The next day she was etherized in a room heated to 80°, and an incision four inches long was made, cutting through the structures until the cyst was reached, when a sound was introduced to feel for adhesions, which were slight and easily freed. She was then turned on her right side and the cyst punctured with an ordinary curved trocar, when sixteen quarts of a greenish-yellow fluid were removed, the cyst walls being gradually drawn out and a solid mass as large as two fists, which was attached to the upper border of the fundus of the uterus and the right broad ligament. An endeavor was made to tie this broad pedicle with silk in sections, but was found impossible, so the ligature was tied and left in. It was then sewed with silver wire, using the cobbler's stitche, as recommended by Emmet. The cyst walls and solid mass were then cut away about an inch from the ligature and the stump seared with thermo-cautery, touched with perchloride of iron, and dropped into the peritoneal cavity. The latter was carefully swabbed out and the

wound closed. She suffered severely from shock for a few hours, but soon recovered, and the next day her pulse was 120, temp. 100°, and resp. 33. Her condition remained favorable, and she left for home in three weeks in good spirits.

CASE 2.—Mrs. J. S., *æ*t. 44. Had one child. For over a year noticed a tumor beginning on left side. At time of operating the tumor was the size of a seven months' pregnancy. Having been properly prepared the usual incision was made three inches long, the cyst tapped with an ordinary trocar, and the clear fluid removed. The cyst was found to be multilocular, so after removing sufficient fluid to draw the sac out through the incision, and being free from adhesions, the pedicle was tied and dropped, the abdominal wound closed, and the usual dressing of bichloride gauze, absorbent cotton, and bandage applied. Her recovery was rapid, no elevation of temperature, and she left for her home in two weeks.

CASE 3.—Miss Sarah N., *æ*t. 27. A little over a year ago she had cystitis and a great deal of pain in right iliac region. On examination I found the right ovary enlarged and cystic, about the size of the fist, and as the symptoms were evidently due to this, advised its removal. On opening the abdomen the left ovary was found to be cystic also, and it first came in sight at the wound. In trying to remove it the cyst burst, so its pedicle was tied and the tumor removed. The right ovarian cyst, which was tougher, was removed entire, the pedicle tied and dropped, and the peritoneal cavity thoroughly sponged out. She made a rapid recovery, with no elevation of temperature, but considerable pain, which I thought was largely due to her nervous temperament. The abdominal wound took three weeks to heal, owing to some defect in the preparation of the bichloride solution. The pain and cystitis have quite subsided since.

CASE 4.—Miss M. J. W. About three years before the operation she took a severe pain in her right side after a long walk, and a few months after this she noticed some abdominal enlargement, but could not remember exactly when it began. Some months after this she was tapped and eighteen pints of fluid removed. She was subsequently, at intervals of six months, twice tapped again, the fluid being highly albuminous and containing cholesterolin. A few months after this she returned,

and I determined to try and remove it. On opening the abdomen the cyst appeared to be divided into two parts by a fibrous partition running obliquely across it, but as it was so firmly adherent to the anterior and lateral wall of the abdomen, I decided not to risk completing the operation, so I closed the wound, and in two weeks she was up and around again. The cyst was afterwards tapped in two places, above and below the site of the partitions, when a large quantity of thick oily amber-colored liquid was got from one cyst, and three quarts of thin greenish fluid from the other.

CASE 5.—Mrs. E. O., *æ*t. 46. Three years ago first noticed a tumor in right iliac region. On examination I felt a hard tumor about the size of an infant's head, with some fluctuation. It had every appearance of being fibro-cystic, especially as the cavity of the uterus was abnormally deep, and menorrhagia was marked. Dr. McLean of Michigan, who examined it with me at this time, also agreed with its being fibro-cystic of the uterus, and advised letting it alone. The subsequent history only shows how impossible it is to be quite sure of the nature of these tumors until the abdomen is opened. Some months after this, the tumor becoming very large and troublesome, and fluctuation being everywhere present, I determined to operate. Some slight adhesions to the omentum were found, and after evacuating the cyst the tumor was found to be a fibro-cystic of the ovary with a large hydrosalpinx. The tying of the pedicle was therefore a matter of difficulty. She did fairly well until the third day after the operation, when the pulse began to fail and she gradually sank and died. On post mortem examination the ligature was found to have slipped and allowed some oozing, which, although very little blood was found, no doubt this, added to the shock of the operation, caused the fatal result.

CASE 6.—Mrs. C., *æ*t. 55. Never had any children. Two years before the operation noticed abdominal enlargement. On examination I diagnosed an ovarian cyst, and on using a fine aspirator found it to contain colloid matter. She had had an attack of peritonitis a few weeks before, and now as she suffered so much discomfort she urgently desired some relief, and preferred to run the risks, which she was told were greatly against success. On coming down to the cyst found recent adhesions in every direction, which broke down easily, and some

firm adhesions which had to be tied and cut. When the pedicle had been tied and cut, the colloid matter sufficiently scooped out to allow the removal of the cyst, the bowels were so glued together as to remain above and leave a cavity before occupied by the cyst. The wound was then closed, but she only survived the shock about an hour.

CASE 7.—Mrs. J. C., *æt.* 32. Never had any children. About two years before noticed abdominal enlargement. The operation, which was done in Picton, was very simple, and was entirely completed in twenty-five minutes; the fluid was clear and watery; there were no adhesions; the pedicle, which was small, was tied and dropped; and her recovery was rapid and complete.

CASE 8.—Mrs. N., *æt.* 35. Has had several children. Suffered for years from ovarian dysmenorrhœa, and as every remedy failed I advised removal of the ovaries. On opening the abdomen I found the uterine and ovaries so firmly bound down by adhesions like bands of fibrous tissue that it was impossible to raise the ovaries from their bed, so, for fear of serious consequences, I abandoned their removal and closed the wound. She recovered in ten days without any trouble, except some pus in the abdominal wound, which took three weeks to heal.

CASE 9.—Mrs. J. D., *æt.* 34. Never had any children. Three or four years ago she noticed abdominal enlargement, and on admission to hospital was prepared for operation. On opening the abdomen the cyst wall was noticed to be unusually vascular. A large amount of greenish fluid was removed by the trocar, and on drawing out the cyst walls it was found to be a fibro-cystic attached to the fundus of the uterus. The opening in cyst was then sewed up, and it was replaced in abdominal cavity. It should have been opened up, stitched to abdominal wound and drained. However, she recovered quickly without any bad symptom, but I have had to tap her several times since.

CASE 10.—Mrs. E. S., *æt.* 30. Had three children. Suffered severely from pelvic pain, menorrhagia, and dysmenorrhœa. As the pain had become unbearable, and no remedy had any effect, I advised removal of the ovaries. The operation was simple and presented no difficulties. She recovered so as to be up in two weeks, but soon developed chills and pain, and died about a month after the operation. On post mortem examination found an abscess at seat of one of the ligatures.

CASE 11.—Ann B., æt. 32. A prostitute and addicted to masturbation. Has suffered for years from abdominal pain. I advised removal of the tubes and ovaries, which was done in the usual way. Recovery was rapid and complete.

CASE 12.—Mrs. J. C., æt. 52. Has had two children. Has suffered intensely from dysmenorrhœa and menorrhagia. The uterus was very large and hard, the cavity four inches deep, and the organ was tender. It seemed like interstitial fibroid, and the question whether the operation should be vaginal hysterectomy or removal of the ovaries resulted in choosing the latter as safer and likely to remove the trouble. The abdomen having been opened it was found quite impossible to raise the ovaries near enough to the wound to ligate, so after a great effort they were freed from adhesions and the wound closed. The effect of this was remarkable, as she rapidly recovered and has had no pain since, now six months, although the uterus is still as large as before and she has occasional attacks of cystitis.

CASE 13.—Mrs. F., æt. 35. Never had any children. Has had an abdominal tumor for thirteen years. On opening the abdomen and inserting a trocar into the cyst a thin sebaceous matter came away with difficulty. A dermoid cyst was at once diagnosed, the opening was enlarged with a knife until the hand could be inserted, when the contents, which consisted of sebaceous matter, hair, and bones, were scooped out. The cyst was multilocular, and after breaking through partitions the other cysts were emptied in the same way. Several adhesions between the cyst and abdominal wall were broken down with the hand, while two firmer bands were tied and cut. The abdominal wound had to be enlarged to fully six inches to remove the remainder of the cyst. The pedicle, which was broad, was tied in sections and dropped. The abdomen was washed out with a weak hot solution of bichloride, thoroughly sponged out, and the abdominal wound closed. There was hardly any shock, and recovery was rapid and complete. The operation lasted sixty-five minutes, and the tumor must have weighed altogether about thirty-five pounds.

CASE 14.—Mrs. Z., æt. 42. Has suffered severely from ovarian dysmenorrhœa for past three years. Electricity had been tried for several weeks, but failed to relieve the pain, so laparotomy was advised. I re-

moved the left ovary only, as the pain was all felt in left side, and the right ovary seemed to be healthy. The left ovary contained a thick-walled cyst looking like a degenerated Graffian follicle. The temperature never reached 100° and she made a rapid recovery.

