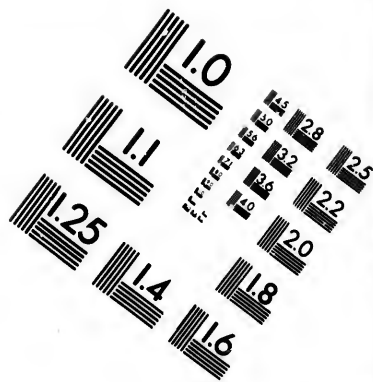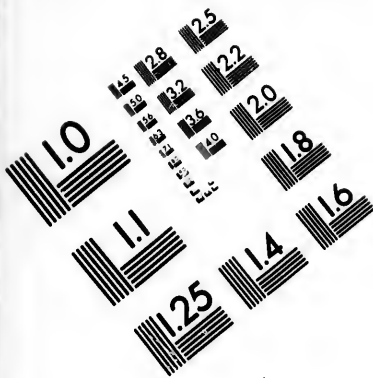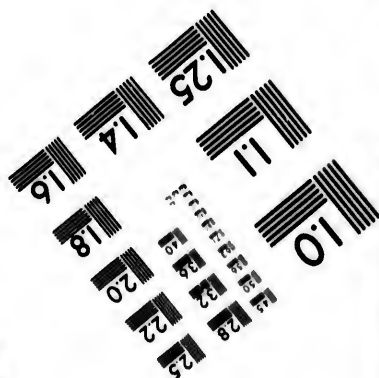





**IMAGE EVALUATION  
TEST TARGET (MT-3)**



**Photographic  
Sciences  
Corporation**

23 WEST MAIN STREET  
WEBSTER, N.Y. 14580  
(716) 872-4503

15 28 25  
12 13 22  
14 20  
18  
5

**CIHM/ICMH  
Microfiche  
Series.**

**CIHM/ICMH  
Collection de  
microfiches.**



**Canadian Institute for Historical Microreproductions / Institut canadien de microreproductions historiques**

10  
01

**© 1985**

Technical and Bibliographic Notes/Notes techniques et bibliographiques

The Institute has attempted to obtain the best original copy available for filming. Features of this copy which may be bibliographically unique, which may alter any of the images in the reproduction, or which may significantly change the usual method of filming, are checked below.

L'Institut a microfilmé le meilleur exemplaire qu'il lui a été possible de se procurer. Les détails de cet exemplaire qui sont peut-être uniques du point de vue bibliographique, qui peuvent modifier une image reproduite, ou qui peuvent exiger une modification dans la méthode normale de filmage sont indiqués ci-dessous.

- Coloured covers/  
Couverture de couleur
- Covers damaged/  
Couverture endommagée
- Covers restored and/or laminated/  
Couverture restaurée et/ou pelliculée
- Cover title missing/  
Le titre de couverture manque
- Coloured maps/  
Cartes géographiques en couleur
- Coloured ink (i.e. other than blue or black)/  
Encre de couleur (i.e. autre que bleue ou noire)
- Coloured plates and/or illustrations/  
Planches et/ou illustrations en couleur
- Bound with other material/  
Relié avec d'autres documents
- Tight binding may cause shadows or distortion  
along interior margin/  
La reliure serrée peut causer de l'ombre ou de la  
distortion le long de la marge intérieure
- Blank leaves added during restoration may  
appear within the text. Whenever possible, these  
have been omitted from filming/  
Il se peut que certaines pages blanches ajoutées  
lors d'une restauration apparaissent dans le texte,  
mais, lorsque cela était possible, ces pages n'ont  
pas été filmées.
- Additional comments:/  
Commentaires supplémentaires:

- Coloured pages/  
Pages de couleur
- Pages damaged/  
Pages endommagées
- Pages restored and/or laminated/  
Pages restaurées et/ou pelliculées
- Pages discoloured, stained or foxed/  
Pages décolorées, tachetées ou piquées
- Pages detached/  
Pages détachées
- Showthrough/  
Transparence
- Quality of print varies/  
Qualité inégale de l'impression
- Includes supplementary material/  
Comprend du matériel supplémentaire
- Only edition available/  
Seule édition disponible
- Pages wholly or partially obscured by errata  
slips, tissues, etc., have been refilmed to  
ensure the best possible image/  
Les pages totalement ou partiellement  
obscurcies par un feuillet d'errata, une pelure,  
etc., ont été filmées à nouveau de façon à  
obtenir la meilleure image possible.

This item is filmed at the reduction ratio checked below/  
Ce document est filmé au taux de réduction indiqué ci-dessous.

10X	14X	18X	22X	26X	30X
<input type="checkbox"/>	<input type="checkbox"/>	<input type="checkbox"/>	<input checked="" type="checkbox"/>	<input type="checkbox"/>	<input type="checkbox"/>
12X	16X	20X	24X	28X	32X

The copy filmed here has been reproduced thanks to the generosity of:


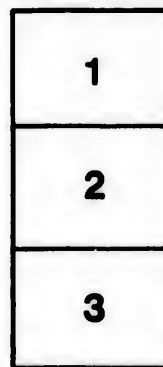

Medical Library  
McGill University  
Montreal

The images appearing here are the best quality possible considering the condition and legibility of the original copy and in keeping with the filming contract specifications.

Original copies in printed paper covers are filmed beginning with the front cover and ending on the last page with a printed or illustrated impression, or the back cover when appropriate. All other original copies are filmed beginning on the first page with a printed or illustrated impression, and ending on the last page with a printed or illustrated impression.

The last recorded frame on each microfiche shall contain the symbol  $\rightarrow$  (meaning "CONTINUED"), or the symbol  $\nabla$  (meaning "END"), whichever applies.

Maps, plates, charts, etc., may be filmed at different reduction ratios. Those too large to be entirely included in one exposure are filmed beginning in the upper left hand corner, left to right and top to bottom, as many frames as required. The following diagrams illustrate the method:



L'exemplaire filmé fut reproduit grâce à la générosité de:

Medical Library  
McGill University  
Montreal

Les images suivantes ont été reproduites avec le plus grand soin, compte tenu de la condition et de la netteté de l'exemplaire filmé, et en conformité avec les conditions du contrat de filmage.

Les exemplaires originaux dont la couverture en papier est imprimée sont filmés en commençant par le premier plat et en terminant soit par la dernière page qui comporte une empreinte d'impression ou d'illustration, soit par le second plat, selon le cas. Tous les autres exemplaires originaux sont filmés en commençant par la première page qui comporte une empreinte d'impression ou d'illustration et en terminant par la dernière page qui comporte une telle empreinte.

Un des symboles suivants apparaîtra sur la dernière image de chaque microfiche, selon le cas: le symbole  $\rightarrow$  signifie "A SUIVRE", le symbole  $\nabla$  signifie "FIN".

Les cartes, planches, tableaux, etc., peuvent être filmés à des taux de réduction différents. Lorsque le document est trop grand pour être reproduit en un seul cliché, il est filmé à partir de l'angle supérieur gauche, de gauche à droite, et de haut en bas, en prenant le nombre d'images nécessaire. Les diagrammes suivants illustrent la méthode.

e  
détails  
s du  
modifier  
r une  
image

es

errata  
to

pelure.  
on à

32X

Stomach  
Dyspepsia  
Gastric  
2000  
Surge

Osler, William  
+  
McCrae, Thomas

616.33

OSLER  
LIBRARY

C. 2. 212.

[Reprinted from the Special Number on Gastric Diseases, PHILADELPHIA  
MEDICAL JOURNAL, February 3, 1900.]

### LATENT CANCER OF THE STOMACH.

By WILLIAM OSLER, M.D., AND THOMAS MCCRAE, M.B.,  
of Johns Hopkins Hospital.

IN a study of 150 consecutive cases of carcinoma of the stomach in the medical department of the Johns Hopkins Hospital, we have been very much interested in a group in which the disease was unsuspected during life. As Welch remarks, it is rare to find cancer of the stomach in an apparently healthy man dying of accident. The latent cases are most frequently met in old persons, in whom the symptoms may be very slight, or absent, or they are mistaken for the ordinary dyspeptic complaints of the aged. Even after the most thorough examination it may not be possible to reach a diagnosis. In obscure cases, particularly with dyspepsia and emaciation, the possibility of latent carcinoma should be borne in mind.

There are three groups of cases of latent carcinoma of the stomach:

1. A very small one in general hospitals, a very large one in almshouses and asylums, comprising cases in which the symptoms are those of a gradual enfeeblement without any indication of local disease—as Oliver Wendell Holmes puts it, in the "One Hoss Shay," "a general flavor of mild decay, but nothing local."

2. Cases in which, with an absence of gastric symptoms, the lesions of associated disease seem sufficient to account for the condition. In this group were 4 of our cases. In 2 the diagnosis of nephritis was made; 1 had advanced pulmonary tuberculosis with pneumothorax, and the fourth showed profound anemia with multiple venous thrombi. The following is a summary of these cases:

**CASE I.**—*Diagnosis of nephritis, arteriosclerosis and pleurisy; no gastric symptoms.*

No. 22. A. G., Hospital Nos. 2454 and 3251, male, aged 61 years, first admitted January 22, 1891, complaining of short-

ness of breath. A history of dyspnea, for some years. He had frequent attacks at night, and any ordinary exertion was difficult. With this he has had frequent cough. He had little appetite and the bowels had been loose.

Examination: Dyspnea, cyanosis, and edema. The arteries were very sclerotic. There was fluid in the left pleural cavity; over 600 cc. were withdrawn. The heart's action was rapid, with gallop rhythm; on January 20, 900 cc. were withdrawn from the left pleura, and the following day a friction-rub was heard in the left axilla. There were albumin and tube casts in the urine. The dyspnea gradually lessened, and by February 16 his condition was much improved.

The patient remained in the hospital until April 29; on discharge he was still slightly cyanotic, but the dyspnea had gone. There was slightly impaired resonance on the left side of the chest. There was nothing noteworthy about the abdomen. During his stay there were no gastric symptoms and the general condition of the patient improved.

*Second admission*, May 19, 1891, three weeks later. He looked very ill, cyanosed, and with dyspnea and hiccough. The pulse was scarcely perceptible. On May 23, 260 cc. of fluid were withdrawn from the left pleural cavity. His condition remained much the same until death on June 5, 1891. There was no complaint of any gastric symptoms. The temperature was practically normal during both admissions. There was no loss of weight on the second admission, and the nephritis and arteriosclerosis seemed to account for the symptoms, and no stomach-symptoms were present to draw attention to that organ.

*Autopsy* showed carcinoma of the stomach and esophagus, there being an elevated tumor-mass 7 by 2 cm., which was half in the stomach. The center was ulcerated. There was chronic diffuse nephritis, arteriosclerosis, aortic and mitral insufficiency, and chronic pericarditis. There was pleural exudate with a fibrinous pleurisy over an infarction in the right lung. There were no metastases. Thrombi were present in both sides of the heart and in the pulmonary artery.

**CASE II.**—*General edema; albumin and granular and hyaline tube casts in urine, rapid emaciation; vomiting at onset, but none during his stay in hospital; diagnosis of nephritis.*

No. 73. T. C., Hospital No. 10,234, male, aged 61, admitted June 26, 1894, complaining of swelling of the legs. His family history was negative. He gave a history of an attack like the present 20 years ago, which lasted for 2 months. He then had both edema and dyspnea. In the last 5 years he had gradually lost over 40 pounds. His present illness began about 5 weeks before with persistent vomiting which lasted for one week. Swelling of the legs then appeared, and the vomiting stopped. He was able to keep at work until 4

days before admission. His appetite has been good, and the bowels regular. Examination showed marked emaciation and fairly general edema. There was slight dullness over the right base. The abdomen was distended, tympanitic in the elevated and dull in the dependent portions, but it was held so tensely that attempts at palpation were not satisfactory. The urine was of dark color. Specific gravity 1012, showed a faint trace of albumin and contained hyaline and granular casts. The temperature was slightly elevated. The edema increased and the patient died on July 4.

*Autopsy* showed a large scirrhous cancer involving nearly the whole of the stomach, and extending to the esophagus. The stomach was adherent to all surrounding structures. The growth extended through to the peritoneum at places. There were secondary growths in the glands and liver.

CASE III.—*Tuberculosis and pneumothorax, all the symptoms those of chronic consumption; no stomach symptoms.*

No. 71.—J. A., Hospital No. 10,050, male, aged 41 years, admitted June 7, 1894, complaining of pain in the chest and cough. His family history was tuberculous. He had been very healthy previously. His present illness dated back about six months, though for some time before he had been troubled with a cough. This became worse, he had sharp pain in the left chest and several attacks of hemoptysis. For five months he had diarrhea, with the passage of mucus and blood in the stools. He has not had any appetite. There has been much loss of flesh. There was no history of any stomach-symptoms.

*Examination* showed great emaciation. There was clubbing of the fingers. There were marked signs on both sides of the thorax, both on percussion and auscultation. Pneumothorax was present on the left side. The abdomen looked natural, was nowhere tender and was negative on palpation. The temperature was only slightly elevated. The patient rapidly sank and died on June 11.

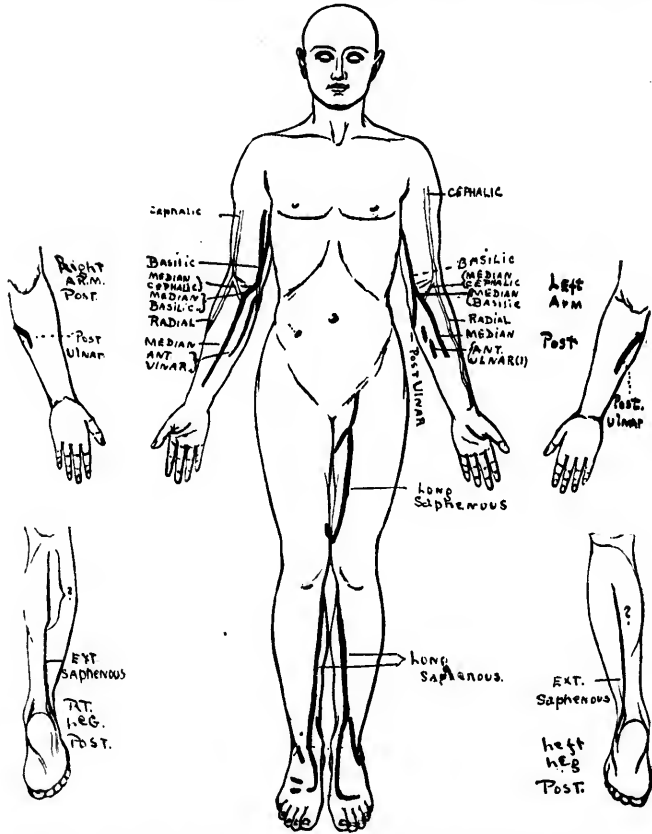
*Autopsy* showed cancer of the lesser curvature of the stomach with secondary growths in the lymph-glands and liver. The mass measured 6 by 5 cm. It was soft and fungoid in character. The pylorus was free. There was tuberculosis in both lungs and pneumothorax on the left side. Tuberculous ulceration of the large and small intestine was also found.

CASE IV.—*Multiple thrombi of superficial cutaneous veins; profound and progressive anemia; no gastric symptoms.*

No. 64. G. N., Hospital No. 9131, male, aged 50, admitted January 31, 1894, complaining of weakness and pains in the arms and legs. His family and previous history were normal. The present illness, which began four weeks before, he attributed to exposure, wet and cold. He had a chill fol-

lowed by fever, which lasted some days. Pain then began in each leg and then in the arms. These were sharp, made worse by movement and there was a great tenderness of the muscles on pressure. There was not any edema, but great weakness. The appetite was poor. The bowels were regular.

Examination showed no marked general change, except



pallor and sallowness. The thorax was normal. On examination there was epigastric tenderness and marked resistance of the abdominal walls. Neither the spleen nor liver was enlarged. Many of the superficial veins of both the arms and legs were represented by firm hard cords. These thrombosed veins were somewhat sensitive. A portion of



one of these veins in the arm was removed. The thrombus was soft and could be squeezed out. Cultures made from it were negative. The chart shows the remarkable extent of the thrombosis:

Blood—Hemoglobin .....	39%.
Red corpuscles.....	2,300,000.
White corpuscles .....	6,000.

On February 10 edema appeared in the left leg. Very many of the superficial veins showed thrombosis. The left foot felt as warm as the right. On February 15 edema began in the right leg. The left femoral vein could be felt as a firm cord.

The anemia increased, the blood-count on February 16 being:

Hemoglobin .....	22%.
Red corpuscles... ..	1,716,000.
White corpuscles.....	29,000.

The differential count showed 89% of polymorphonuclears. No nucleated red corpuscles were seen.

The patient gradually sank and died on February 18, 1894. His temperature was constantly somewhat elevated. There were no stomach-symptoms.

*Autopsy* showed cancer of the pylorus with secondary involvement of lymph-glands, gastrohepatic, anterior mediastinal and subclavicular, and the liver. The mass occupied the lesser curvature and did not involve the whole pylorus, so that the orifice was not narrowed. There were also multiple venous thrombi.

This remarkable case excited very special interest, more particularly the unusual number of thrombi in the superficial veins, and their association with great tenderness in the muscles. Though we spoke of the possibility of malignant disease, yet there was no positive evidence obtained. He was not given a test-meal, as there were really no features whatever pointing to the stomach.

3. Cases in which the metastases completely mask the primary disease.

*CASE V.—Paraesthesia in feet; symptoms of ataxia; gradual paraplegia; headache; marked pain in neck; development of a tumor in the right side of the pelvis; no stomach symptoms. Autopsy; primary carcinoma of lesser curvature of the stomach; secondary masses in the abdominal glands, the right ilium and the femur.*

No 106. J. W., male, white. Hospital No. 14,944. Aged 40 years. Admitted January 10, 1896, complaining of inability to walk and pain in the neck and legs. His history

was negative and he had been healthy until his present attack.

*Present illness* began about 8 months before with peculiar sensations as of "pins and needles" in the feet. In about 2 months the weakness in the legs had so increased that he was unable to walk. Sensation was almost absent in the feet. Headache and pains in the neck had been severe. There had not been any special stomach symptoms, although he had vomited occasionally.

*Examination* showed emaciation and marked pallor. The abdomen was practically negative in the upper part. A mass was felt deeply in the right iliac fossa, which was palpable per rectum and involved the bony parts of the pelvis. There was great wasting of the legs with absence of the kneejerks. Blood-examination showed hemoglobin 48% ; red corpuscles, 2,432,000.

The patient had severe pain which required large amounts of morphin. The tumor of the right pelvis increased in size. He lost ground in every way. In February he developed marked mental symptoms with ideas of persecution, etc. Death followed on March 14, 1896.

*Autopsy* showed primary carcinoma of the lesser curvature of the stomach. The stomach was of normal size and on the anterior wall in the region of the lesser curvature was an area of new growth 6 cm. in diameter. There was no ulceration. Histologically, the growth was a colloid carcinoma. There were secondary growths in the abdominal glands and in the right ilium and femur. Unfortunately, the spinal cord was not examined.

*CASE VI.—Pains in the right arm and right side of neck, with wasting of the muscles of the right arm ; inequality of the pupils ; development of nodular masses on the ribs ; diagnosis of cancer, but primary disease not suspected ; no gastric symptoms. Autopsy showed cancer of lesser curvature of the stomach ; a nodular mass compressing the brachial plexus ; metastases in tenth dorsal and first lumbar vertebrae.*

No. 124. G. K., Hospital No. 17,993, male, aged 39 years, admitted December 1, 1896, complaining of pain through the right shoulder and back, with loss of sensation in the right forearm. His family-history was negative. He had had malaria every year for eight years past and pains in the shoulders and back, thought to be rheumatic. The most severe of these attacks was 18 months before, during which he spent two weeks in bed. Since then he has been very well and able to work. His occupation, an ironfitter, involved much heavy lifting. He never had any stomach or bowel trouble ; at times for many years he has had shortness of breath on exertion.

The present illness began in August, 1896, with coughing and profuse expectoration. Pain soon came on in the right

side, close to the shoulder, and was severe enough to make him give up work. The cough soon left him, but the pain remained. It gradually went down the right arm. It was constant and described as boring in character. It was worse on movement. About one week before admission he noticed a loss of sensation in the forearm, and at the same time he lost power in the right arm, so that since then he has not been able to use it. The pain and weakness has also extended to his back, so that he had difficulty in raising himself up in bed. The legs were not affected. There was no history of any injury. There had not been any stomach-symptoms. The bowels had been constipated. He had lost nearly 20 pounds in weight and much strength.

Examination showed fair nutrition. The patient remained usually on the left side, he seemed to suffer much pain and objected to changing his position or sitting up, on account of the pain it caused. There were prominences on the 4th, 5th, 7th, 8th, and 12th ribs, not attached to the skin, but to the bones. They were very tender, had a slightly elastic, but not fluctuated feeling. Examination of the thorax was negative. There was no dulness over the manubrium. The abdomen was flat, the muscles were held somewhat rigidly, so that palpation was difficult. There was marked wasting of the muscles of the right arm, and loss of power. There seemed to be some disturbance of sensation over the ulnar surface of the left arm, but the results were not constant. There was distinct inequality of the pupil, the left being larger. They both reacted to light and on convergence. Ophthalmoscopic examination was negative. The patient held himself very stiffly when asked to sit up, and the mobility of the head downward was much impaired. There was no pain on pressure over the spine. There was no general glandular enlargement.

Blood—Hemoglobin.....	92%.
Red corpuscles.....	5,752,000.
White corpuscles.....	13,000.

The patient had severe pain, and frequently required morphin hypodermically. He lost weight and strength. The masses on the ribs gradually increased in size, and became more tender. On December 26 it was noted that the abdomen was very tense, and moderately distended. No other abdominal symptoms were present. The leukocytes increased and were 22,000 on the 26th. A differential count showed 85% of polymorphonuclear. The patient generally sank, and died on December 30. During his stay he took nourishment fairly well. There was no complaint or sign of any gastric trouble.

The case was regarded as probably one of primary neoplasm in the thorax with secondary deposits on the

ribs and probably in the vertebrae. The absence of history of any gastric trouble and of any signs during his stay in the hospital, did not call for special attention to the stomach, and no test-breakfast was given. The abdominal examination was always negative, except that the muscles were held tensely. As the patient was difficult of examination this did not perhaps arouse the attention it should have done. The true condition was not suspected.

*Autopsy* showed cancer of the stomach. The lesser curvature was converted into a rigid mass over which the omentum was closely bound. The growth extended along the posterior wall. It did not involve the cardia or pylorus. On section all the coats were infiltrated. The mucous membrane was smooth, white, and opaque. Near the pylorus was an ulcerated area 3 by 3 cm. on the posterior wall. There were metastases in the lungs, bronchial, pericardial axillary and abdominal lymph-glands, ribs, skull, and vertebrae. There was compression of the bronchial plexus by a tumor-nodule. The vertebral metastases were in the first and tenth dorsal and first lumbar.

*CASE VII.—Onset of illness with ascites; two months later aspiration of bloody fluid; recurrence of ascites with swelling of the legs; drainage of peritoneum; recognition of malignant disease of the stomach. Autopsy showed extensive cancer of the stomach.*

No. 141. A. H., male, Hospital No. 21,173, aged 59 years; admitted November 9, 1897, complaining of 'dropsy.' His family history was negative. He had been a moderate drinker and denied syphilis.

*Present illness* began four months previously with swelling of the abdomen. This increased gradually and at the end of two months he was tapped by his physician, who drew off a large amount of bloody fluid. Soon after the abdomen began to enlarge again and this continued until the present admission. With this swelling of the legs came on. There had been some pain in the lower abdomen. His appetite had varied. He had occasional vomiting of mucus but no blood. The bowels had been irregular. There had been great frequency of micturition.

*Examination* showed emaciation but not cachexia. The thorax was negative. The abdomen was distended symmetrically. Movable dulness and fluctuation were obtained. The liver-dulness began at the fifth rib in the right nipple line and only extended a distance of 4 cm. Its edge could not be felt. There was edema of the legs, genitalia and lower trunk.

The case was suggestive in some ways of cirrhosis of the liver, although the history of bloody fluid being obtained on previous tapping pointed to malignant growth. The absence of any stomach-symptoms seemed against a primary growth there. The patient required tapping and it was thought best to do this by an exploratory exploration.

*Operation.*—On the abdominal cavity being opened a bloody turbid fluid was obtained. A mass was found in the stomach and secondary deposits over the peritoneum. The fluid showed numerous red corpuscles and leukocytes. There were also large cells many times the size of a leukocyte, some of which contained more than one nucleus. No signs of karyokinesis were seen. Certain groups of cells were found which were very suggestive of masses of cancer-cells. After the operation a firm mass was to be felt in the left hypochondrium. In the right hypochondrium several nodules were felt. The patient was much easier after the operation, but died suddenly on December 5, 1897.

*Autopsy* showed colloid carcinoma of the stomach along the lesser curvature from the cardia to the pylorus. The pylorus was converted into a dense ring and the growth extended for a short distance into the duodenum. The esophagus was invaded but the cardiac orifice was not narrowed. The omentum and peritoneum were involved. The stomach was adherent to the liver, spleen and diaphragm. The growth extended through the diaphragm to the pleura.

In reviewing this interesting series of cases, and particularly in the study of the autopsy records, one is astonished to notice how extensive and widespread the disease may be with practically no symptoms. In three of the cases a very large part of the stomach was involved, in two the cardiac orifice, and in two the pylorus. In one instance the growth involved the esophagus, and in one to a slight extent the duodenum. In three instances there was ulceration, and in five metastases were present.

Oster Niche

FW

7

082

v. 4

1900-1907

no. 212

THE  
**Philadelphia Medical Journal**

(WEEKLY)

---

DR. GEORGE M. GOULD, Editor.

---

Published solely in the interest of the profession and medical science.

Absolutely free from influences of manufacturing or publishing houses.

No secret articles advertised under any conditions.

Greater amount of medical literature for the money than given by any other medical journal.

Contains the most valuable original articles from leading medical writers, and latest American and foreign medical news.

Editorial utterances are untrammelled; articles are not accepted or rejected for business reasons, its columns being uninfluenced by related commercial interests.

Contains under Department of "Latest Literature" abstracts each week from all the more important weekly and monthly journals, from which can be obtained a view over the entire range of the most recent medical literature, European and American. This department alone obviates the necessity of physicians subscribing to numerous other journals.

**\$3.00 PER ANNUM**

