

**CIHM
Microfiche
Series
(Monographs)**

**ICMH
Collection de
microfiches
(monographies)**



Canadian Institute for Historical Microreproductions / Institut canadien de microreproductions historiques

© 1996

Technical and Bibliographic Notes / Notes techniques et bibliographiques

The Institute has attempted to obtain the best original copy available for filming. Features of this copy which may be bibliographically unique, which may alter any of the images in the reproduction, or which may significantly change the usual method of filming, are checked below.

L'Institut a microfilmé le meilleur exemplaire qu'il lui a été possible de se procurer. Les détails de cet exemplaire qui sont peut-être uniques du point de vue bibliographique, qui peuvent modifier une image reproduite, ou qui peuvent exiger une modification dans la méthode normale de filmage sont indiqués ci-dessous.

Coloured covers/
Couverture de couleur

Covers damaged/
Couverture endommagée

Covers restored and/or laminated/
Couverture restaurée et/ou pelliculée

Cover title missing/
Le titre de couverture manque

Coloured maps/
Cartes géographiques en couleur

Coloured ink (i.e. other than blue or black)/
Encre de couleur (i.e. autre que bleue ou noire)

Coloured plates and/or illustrations/
Planches et/ou illustrations en couleur

Bound with other material/
Relié avec d'autres documents

Tight binding may cause shadows or distortion
along interior margin/
La reliure serrée peut causer de l'ombre ou de la
distorsion le long de la marge intérieure

Blank leaves added during restoration may appear
within the text. Whenever possible, these have
been omitted from filming/
Il se peut que certaines pages blanches ajoutées
lors d'une restauration apparaissent dans le texte,
mais, lorsque cela était possible, ces pages n'ont
pas été filmées.

Coloured pages/
Pages de couleur

Pages damaged/
Pages endommagées

Pages restored and/or laminated/
Pages restaurées et/ou pelliculées

Pages discoloured, stained or foxed/
Pages décolorées, tachetées ou piquées

Pages detached/
Pages détachées

Showthrough/
Transparence

Quality of print varies/
Qualité inégale de l'impression

Continuous pagination/
Pagination continue

Includes index(es)/
Comprend un (des) index

Title on header taken from: /
Le titre de l'en-tête provient:

Title page of issue/
Page de titre de la livraison

Caption of issue/
Titre de départ de la livraison

Masthead/
Générique (périodiques) de la livraison

Additional comments: / Pagination is as follows: p. 11-258, [1]-16.
Commentaires supplémentaires: Copy has manuscript annotations.

This item is filmed at the reduction ratio checked below/
Ce document est filmé au taux de réduction indiqué ci-dessous

10x	14x	18x	22x	26x	30x
<input type="checkbox"/>	<input type="checkbox"/>	<input type="checkbox"/>	<input type="checkbox"/>	<input checked="" type="checkbox"/>	<input type="checkbox"/>
12x	16x	20x	24x	28x	32x

The copy filmed here has been reproduced thanks to the generosity of:




Academy of Medicine Collection
The Toronto Hospital

The images appearing here are the best quality possible considering the condition and legibility of the original copy and in keeping with the filming contract specifications.

Original copies in printed paper covers are filmed beginning with the front cover and ending on the last page with a printed or illustrated impression, or the back cover when appropriate. All other original copies are filmed beginning on the first page with a printed or illustrated impression, and ending on the last page with a printed or illustrated impression.

The last recorded frame on each microfiche sheet contain the symbol \rightarrow (meaning "CONTINUED"), or the symbol ∇ (meaning "END"), whichever applies.

Maps, plates, charts, etc., may be filmed at different reduction ratios. Those too large to be entirely included in one exposure are filmed beginning in the upper left hand corner, left to right and top to bottom, as many frames as required. The following diagrams illustrate the method:



L'exemplaire filmé fut reproduit grâce à la générosité de:

Academy of Medicine Collection
The Toronto Hospital

Les images suivantes ont été reproduites avec le plus grand soin, compte tenu de la condition et de la netteté de l'exemplaire filmé, et en conformité avec les conditions du contrat de filmage.


Les exemplaires originaux dont la couverture en papier est imprimée sont filmés en commençant par le premier plat et en terminant soit par la dernière page qui comporte une empreinte d'impression ou d'illustration, soit par le second plat, selon le cas. Tous les autres exemplaires originaux sont filmés en commençant par la première page qui comporte une empreinte d'impression ou d'illustration et en terminant par la dernière page qui comporte une telle empreinte.

Un des symboles suivants apparaîtra sur la dernière image de chaque microfiche, selon le cas: le symbole \rightarrow signifie "A SUIVRE", le symbole ∇ signifie "FIN".

Les cartes, planches, tableaux, etc., peuvent être filmés à des taux de réduction différents. Lorsque le document est trop grand pour être reproduit en un seul cliché, il est filmé à partir de l'angle supérieur gauche, de gauche à droite, et de haut en bas, en prenant le nombre d'images nécessaire. Les diagrammes suivants illustrent la méthode.

Atlas and Text-Book
of Human Anatomy

Sobotta-Mc Murrich



ATLAS AND TEXT-BOOK
OF
HUMAN ANATOMY

BY
DR. JOHANNES SOBOTTA
PROFESSOR OF ANATOMY IN THE UNIVERSITY OF WÜRZBURG

EDITED, WITH ADDITIONS, BY
J. PLAYFAIR McMURRICH, A.M., Ph.D.
PROFESSOR OF ANATOMY IN THE UNIVERSITY OF MICHIGAN

VOLUME I
BONES, LIGAMENTS, JOINTS, AND MUSCLES

With 320 Illustrations, Mostly in Colors

PHILADELPHIA AND LONDON
W. B. SAUNDERS COMPANY
1906

Copyright, 1906, by W. B. Saunders Company

PRESS OF
W. B. SAUNDERS COMPANY
PHILADELPHIA

EDITOR'S PREFACE.

There can be no question as to the value of a good Atlas of Anatomy as an aid to the acquisition and retention of correct ideas regarding the structure of the human body and the relations of its various parts. Anatomy, at least the descriptive part of it, is learned only when one can call up a mental picture of the part in question, and volumes of description will do less to furnish a correct picture than will a single dissection or the inspection of an accurate illustration. This is especially true as regards relational anatomy, and without an accurate knowledge of the relations of parts the student or practitioner will find himself sadly at sea in his application of Anatomy to diagnosis and treatment.


To both the student and the practitioner, therefore, a good Atlas must prove a great boon to the one in enabling him to impress upon his mind what he has seen in the laboratory, without recourse to the pernicious "quiz-compend," which is but a Tantalus cup, to the other in recalling the mental image more or less blurred by time. The present Atlas, with its wealth of accurate illustrations and its thorough though concise descriptive text, is presented to English-speaking students and practitioners in the full confidence that it will prove of the greatest value to them.

The work of the Editor in adapting the Atlas for English readers has largely been confined to changes in the nomenclature and in the arrangement of the text. In the original German edition the text and Atlas were separate volumes, the Atlas proper being provided with a descriptive epitome of the parts represented in the various figures. It has seemed best, both to the publisher and to the Editor of the present edition, to unite the text and Atlas in a common volume, much repetition being thereby avoided and the result being still a volume of convenient size. The translation of the German text has been done by Dr. W. Hersey Thomas.

As to the nomenclature employed, it is essentially that proposed by the Basel Committee on Anatomical Nomenclature, the terms being, however, for the most part Anglicized. In the section on Myology the Latin terms have been retained throughout, since usage has already made many of them familiar in their classical form and it seemed preferable, for uniformity's sake, to use that form for all. A few terms may be found somewhat unfamiliar to English-speaking students of anatomy, and when these are used the more familiar term has been added in parentheses. The adoption of a uniform code of nomenclature is of such great importance that the slight inconvenience which the present generation may experience in the temporary use of a double set of names for a few structures will be more than counterbalanced by the advantages which a universal terminology will eventually offer.

THE EDITOR.

UNIVERSITY OF MICHIGAN, *April 10, 1906.*



AUTHOR'S PREFACE.

When I was invited by the publishers to prepare an atlas of descriptive anatomy at a time when good atlases were in abundance and the wants of the preceding decennium had been largely supplied, I did not accept without due reflection as to the demand for such a work. I believed that this demand could be best tested by having students use the existing atlases in their dissections. This test demonstrated, not only the possible popularity of an appropriate work, but in many respects emphasized the necessity of preparing an atlas which would be handy, practical, not too comprehensive, provided with illustrations true to nature, and specially adapted for the use of medical students in the dissecting room.

My first thought, consequently, was to prepare an atlas which would supply the practical wants of both the student and the physician. It is not an atlas for the finished anatomist. The admirable atlas of Toldt contains a vast number of well-chosen illustrations, but it is so comprehensive that it is difficult for the student to pick out what he actually needs, and, owing to its high price and the fact that many of its illustrations are not true to nature, it has not met with great favor from the student body. In the present atlas the aim has been to limit the material to what is absolutely necessary.

The first volume has been compiled as an atlas especially adapted for use during dissection, and the illustrations have consequently been arranged to conform to the usual methods of instruction in anatomy. The fundamental principle of the work has been to avoid any unusual presentation of the subject which would make the recognition of well-known relations more difficult for the beginner.

To the best of my knowledge this is the first anatomical atlas in which multicolor lithography has been employed. Almost the entire myology has been illustrated in this manner; of the thirty-four plates in this volume, thirty were made by this method and the remaining four by the so-called three (four) color process. The other illustrations were made by the so-called half-tone method, the complete adaptability of which is abundantly demonstrated by the pictures. Additional explanatory figures and diagrams have been reproduced by simple line-etching. No woodcuts have been employed, since the failure of the latter method to produce illustrations true to life has been distinctly shown by several of the newer anatomical atlases. It leaves entirely too much to the discretion of the wood-engraver, whereas the photomechanical method of reproduction depends entirely upon the impression made upon the photographic plate by the original drawing.*

* It has been claimed for the woodcut that many designations may be cut in the matrix, so that reference lines are not necessary. To my mind, this advantage is not of much value, since it is quite a limited one. Lithography allows of a much freer subsequent addition of the designations to whatever extent they may seem desirable, and when small they are not so illegible as they frequently are in the woodcut. Since it is undoubtedly true that a large number of reference lines are inelegant and confusing, they have been made in as few instances as possible, and where many designa-

In order to insure the accuracy of the illustrations, all of the preparations were photographed and the photograph was made exactly the same size as the intended illustration, lenses of the longest possible focal length being employed to avoid perspective distortion.* In the great majority of the illustrations photographs were employed as the basis of the drawings; Figs. 167 to 171 are direct reproductions of photographs, and Figs. 178 and 181 were made from photographs which had been touched up. Only a few illustrations are diagrammatic, and in such instances it has been so stated in the titles.

The illustrations produced by the half-tone method have been made much clearer by the use of a number of colors. A buff color has been employed for the bones in the pictures of the joints and of the muscles, and various colors have been used for the different bones of the skull and in the topographic views of the cranium.† No illustration has been omitted which would make the relations of the parts more readily understood. Microscopic and topographic anatomy have been disregarded to a certain extent, although enough has been given to serve as an outline for the subsequent volumes, which will be more topographic than descriptive in character. The parts have been designated according to the Basel nomenclature.

The original drawings for this Atlas were executed by Messrs. K. Hajek and A. Schmitson.‡ The former gentleman, who will also furnish the illustrations for the subsequent volumes, has performed his difficult task with such special aptitude and cleverness that the remaining volumes promise to be even better and to exhibit still greater uniformity in the method of production.

A number of the specimens from which the illustrations were made are in the collection of the Anatomical Institute (Würzburg), and I take this occasion to express my special thanks to Professor Stöhr for his permission to employ them in this work. The majority of the joint preparations, all of the muscle dissections and some of the bones, I have myself prepared for the Atlas. In addition to the photographed specimens, other dissections have been made and compared, so that every illustration in the book has an individual character, with the exception that marked anomalies have been corrected. The muscles have been given a bright red color such as they exhibit in a fresh body after they have been exposed for a short time, although less intense tones have been selected than those of the natural muscular and fatty tissues.

The publishers have spared nothing to make the illustrations excel those of all other works in character and to equal if not exceed those of the majority in number. In spite of this, however, the price of the work is much lower than that of most other atlases.

THE AUTHOR.

tions were necessary they have been distributed over several figures. In some instances explanatory outline etchings have been appended with the designations inscribed thereon. In the lithographic plates the inscriptions have been made by a second impression.

* In a few cases in which perspective distortion was feared even when lenses of the longest focal lengths were employed, the subject was photographed to one-half the size of the desired illustration and the photograph was subsequently enlarged.

† In carrying out this idea the same bone has always been represented by the same color; for example, the palate bone in blue, the ethmoid in orange.

‡ About ten of the illustrations in the Atlas were sketched by W. Freytag, drawing master in the University, and subsequently completed by Mr. Hajek.

CONTENTS

	PAGE		PAGE
Introduction	17	THE SKELETON OF THE HEAD (Continued)	
Osteology	19	The Nasal Bone.....	65
GENERAL OSTEOLOGY	19	The Vomer.....	65
SPECIAL OSTEOLOGY	22	The Maxilla.....	66
THE SKELETON OF THE TRUNK	22	The Palate Bone.....	66
The Vertebral Column.....	22	The Zygomatic Bone.....	70
The True Vertebrae.....	22	The Mandible.....	71
The Cervical Vertebrae.....	23	The Hyoid Bone.....	73
The Thoracic Vertebrae.....	26	The Orbital Cavities.....	73
The Lumbar Vertebrae.....	27	The Nasal Cavity.....	76
The False Vertebrae.....	28	The Roof of the Oral Cavity, the Hard	
The Sacrum.....	28	Palate.....	78
The Coccyx.....	30	The Pterygopalatine Fossa.....	78
The Vertebral Column as a Whole.....	30	The Infratemporal Fossa.....	79
The Development of the Vertebral Col- umn.....	31	The Sutures of the Skull.....	79
The Ribs.....	32	The Skull of the New-born.....	81
The Sternum.....	34	THE SKELETON OF THE EXTRIMITIES	82
The Thorax.....	35	THE SKELETON OF THE UPPER EXTREMITY ..	83
The Development of the Ribs and of the Sternum.....	35	The Shoulder Girdle.....	83
Variations in the Skeleton of the Trunk....	35	The Scapula.....	83
THE SKELETON OF THE HEAD	36	The Clavicle.....	85
The Anterior Aspect of the Skull.....	36	The Humerus.....	85
The Lateral Aspect of the Skull.....	37	The Ulna.....	87
The External Surface of the Base of the Skull.....	39	The Radius.....	88
The Internal Surface of the Base of the Skull.....	41	The Bones of the Hand.....	89
The Superior Aspect of the Skull.....	44	The Carpal Bones.....	89
The Inner Aspect of the Cranial Vault or Calvaria.....	44	The Metacarpal Bones.....	91
The Bones of the Skull.....	44	The Bones of the Fingers.....	92
The Cranial Bones.....	45	The Sesamoid Bones of the Hand.....	92
The Occipital Bone.....	45	The Skeleton of the Hand as a Whole....	92
The Sphenoid Bone.....	47	THE SKELETON OF THE LOWER EXTREMITY ...	93
The Temporal Bone.....	51	The Pelvic Girdle.....	93
The Parietal Bone.....	50	The Innominate Bone.....	93
The Frontal Bone.....	60	The Femur.....	97
The Ethmoid Bone.....	62	The Patella.....	99
The Inferior Turbinate Bone.....	64	The Tibia.....	99
The Lachrymal Bone.....	64	The Fibula.....	101
		The Bones of the Foot.....	101
		The Tarsal Bones.....	102
		The Talus.....	102
		The Calcaneus.....	103
		The Navicular Bone.....	103
		The Cuboid Bone.....	104

	PAGE		PAGE
THE SKELETON OF THE LOWER EXTREMITY		THE JOINTS AND LIGAMENTS OF THE FOOT	137
The Cuneiform Bones.....	104	The Joints of the Foot.....	137
The Five Metatarsal Bones.....	105	The Ligaments of the Tarsus.....	139
The Bones of the Toes.....	105	Myology	142
The Sesamoid Bones of the Foot.....	106	GENERAL MYOLOGY	142
The Skeleton of the Foot as a Whole.....	106	SPECIAL MYOLOGY	144
Syndesmology	107	THE MUSCLES OF THE TRUNK	144
GENERAL SYNDESMOLOGY	107	The Muscles of the Back.....	144
Synarthroses.....	107	The Short Muscles of the Neck.....	155
Diarthroses.....	108	The Fasciæ of the Back.....	156
SPECIAL SYNDESMOLOGY	110	The Abdominal Muscles.....	157
JOINTS AND LIGAMENTS OF THE VERTEBRAL COLUMN	110	The Abdominal Fasciæ.....	163
The Connections of the Vertebral Bodies.....	110	The Diaphragm.....	164
The Intervertebral Articulations.....	111	The Thoracic Muscles.....	166
The Ligaments of the Vertebral Column.....	111	The Pectoral Fasciæ.....	170
The Articulations of Sacrum and Coccyx.....	113	The Muscles of the Neck.....	171
The Articulation of the Upper Two Cervical Vertebrae with Each Other and with the Occiput.....	113	The Prevertebral Cervical Muscles.....	176
The Articulations of the Ribs with the Vertebral Column and with the Sternum.....	116	The Fasciæ of the Neck.....	177
THE ARTICULATIONS AND LIGAMENTS OF THE HEAD	117	THE MUSCLES OF THE HEAD	177
The Temporomandibular Articulation.....	118	The Muscles of the Face and of the Scalp.....	178
The Independent Ligaments of the Head.....	118	The Fasciæ of the Head.....	184
The Ligaments of the Hyoid Bone.....	119	THE MUSCLES OF THE UPPER EXTREMITY	185
THE JOINTS AND LIGAMENTS OF THE UPPER EXTREMITY	119	The Muscles of the Shoulder.....	186
The Sternoclavicular Articulation.....	119	The Muscles of the Upper Arm.....	188
The Acromioclavicular Articulation.....	120	The Muscles of the Forearm.....	191
The Ligaments of the Scapula.....	120	The Muscles of the Hand.....	198
The Shoulder-joint.....	121	The Muscles of the Thenar Eminence.....	199
The Elbow-joint.....	122	The Muscles of the Hypothenar Eminence.....	200
The Distal Radio-ulnar Joint and the Interosseous Membrane.....	123	The Interossei and Lumbricales.....	200
THE JOINTS AND LIGAMENTS OF THE HAND	124	The Relations of the Extensor Tendons and their Sheaths beneath the Dorsal Carpal Ligaments.....	203
The Joints of the Carpus.....	124	The Extensor Tendons of the Fingers.....	204
The Carpal Ligaments.....	126	The Tendons and Synovial Sheaths of the Flexor Tendons in the Palm.....	205
The Finger-joints.....	127	The Fasciæ of the Upper Extremity.....	207
THE JOINTS AND LIGAMENTS OF THE PELVIC GIRDLE	128	The Most Important Bursæ of the Upper Extremity.....	208
The Pelvic Ligaments, Synarthroses and Diarthroses.....	128	THE MUSCLES OF THE LOWER EXTREMITY	209
The Independent Ligaments of the Pelvis.....	129	The Muscles of the Hip.....	210
The Pelvis as a Whole.....	130	The Muscles of the Thigh.....	214
The Hip-joint.....	131	The Muscles of the Leg.....	219
The Knee-joint.....	133	The Muscles of the Foot.....	224
The Articulations of the Tibia and Fibula.....	136	The Synovial Sheaths of the Foot.....	229
		The Fasciæ of the Lower Extremity.....	231
		The Most Important Bursæ of the Lower Extremity.....	233
		INDEX	237

PAGE
 ..137
 ..137
 ..139
 ..142
 ..142
 ..144
 ..144
 ..144
 ..155
 ..156
 ..157
 ..163
 ..164
 ..166
 ..170
 ..171
 ..176
 ..177
 ..177
 ..178
 ..184
 ..185
 ..186
 ..188
 ..191
 ..198
 ..199
 ..200
 ..200
 ..200
 ..203
 ..204
 ..204
 ..205
 ..207
 ..208
 ..209
 ..210
 ..214
 ..210
 ..224
 ..220
 ..231
 ..233
 ..237

ATLAS AND TEXT-BOOK OF HUMAN ANATOMY.

INTRODUCTION.

Human anatomy treats of the structure of the human body, in contrast to physiology, which treats of function, and it is usually subdivided into general anatomy and special anatomy. General anatomy is practically synonymous with histology, and treats of the structure of the component parts of the body.

Special anatomy is usually termed descriptive or systematic anatomy, since it consists of the simple description of the different parts and systems of the body. It is consequently composed of a number of subdivisions: Osteology, treating of the bones; Syndesmology, treating of the joints and ligaments; Myology, treating of the muscles; Splanchnology, treating of the viscera; Angiology, treating of the vessels; Neurology, treating of the nervous system; and of the description of the organs of special sense and of the skin.

Descriptive anatomy, considered from the special standpoint of the mutual relations of the individual parts, is termed topographic anatomy, and that branch of anatomy which has to do with the development of the body is designated Embryology.

To indicate the relations of the different parts of the body to each other or to the body in general, certain technical expressions are employed. In describing the position of a structure it is always to be assumed that the body is in the erect posture. The median plane divides the body into two almost similar halves,* since man, like the majority of animals, is bilaterally symmetrical. Any plane of the body which is parallel to the median plane is termed *sagittal* (from the sagittal suture, see page 79); those which pass through the body horizontally are termed *horizontal* or *transverse*, while vertical planes at right angles to the median plane are known as *frontal* planes, since they are parallel to the forehead. If a part is situated nearer to the median plane, it is designated *internal* or *medial*; while if it is more remote, it is said to be *external* or *lateral*. The direction toward the median plane is spoken of as *inward* and the opposite direction as *outward*.

The words *internal* and *external* are also employed in reference to the cavities of the body

* Although the bilateral symmetry is not complete in the adult body, it is perfect during embryonic life.

or to the inner or outer surface of a portion of the body; in this connection it is frequently better to substitute the word superficial for external, and deep for internal. *Above* and *below*, like all other designations, refer to the erect position of the body, and this direction may be frequently better indicated by the terms *cranial* and *caudal*. *In front* and *behind* refer to the anterior and posterior surface of the body, but this relation may be more accurately expressed by *ventral* and *dorsal*.

Special additional designations are to a certain extent necessary for the extremities. In this connection, *proximal* means nearer to the trunk and *distal* more remote. In the forearm it is preferable to use the words *radial* and *ulnar* instead of outer and inner, since during pronation (see page 123) the inner side is directed outward and vice versa; and since the palm of the hand and the sole of the foot are designated respectively as the volar and plantar surfaces, the words *volar* and *plantar* are used to indicate the position of parts situated upon the corresponding surfaces.

OSTEOLOGY.

GENERAL OSTEOLOGY.

The greater portion of the skeleton of the human body is composed of bones, the remainder consisting of cartilages, and since the bones consist largely of lime salts they are much firmer than the cartilages, which, though hard, are nevertheless flexible. The parts of the skeleton are either paired or single, the latter being in the minority.

The **bones** of the human body vary greatly in their form, shape, and size. The largest bone is the thigh bone or femur; the smallest are the sesamoid bones of the hand and the auditory ossicles. According to form, we usually distinguish between *long* or *tubular bones*, *broad* or *flat bones*, and *short bones*, while bones possessing air-containing cavities are also called *pneumatic bones*.

The **long bones** have in general a cylindrical shape and are found only in the extremities. With few exceptions, they consist of a middle portion or *shaft* (*diaphysis*) and of two ends or *extremities* (*epiphyses**). The shaft contains a cavity, the *medullary cavity*, which is filled with bone-marrow, and it is on this account that these bones are also termed *tub.* bones. The bony substance of their shaft surrounds this medullary cavity and, on account of its firm structure, is known as the compact substance, in contradistinction to a less dense spongy substance, which consists of a fine network and forms the greater portion of the extremities of the bones with the exception of a very thin outer compact layer of cortical substance.

The long bones of the human body are found only in the skeleton of the extremities. They are as follows: the clavicle, the humerus, the radius, the ulna, the five metacarpal bones, the bones of the fingers and toes, the femur, the tibia, the fibula, and the metatarsal bones. The ribs are classified with the flat bones.

The **broad** or **flat bones** are markedly flattened in one direction and have the shape of flat or curved plates. Their central portion consists of spongy bone, the cortex being formed, however, by a more or less thick layer of compact cortical substance. In many instances they are provided with well-marked processes. In the flat bones of the skull the spongiosa is known as the *diploë*, while the layers of compact substance are designated as the outer and inner vitreous tables. The flat bones of the human body are: the sternum, the scapula, the innominate bones, the ribs, and many of the cranial bones.

The **short bones** have an irregular form and no one of their diameters greatly exceeds the others. They consist almost entirely of spongy tissue, their compact cortical layer being frequently very thin. They are frequently associated in groups, as in the carpus and tarsus. The

* The terms epiphyses and extremities are not, as a rule, synonymous, since the portions of the bones designated as extremities usually contain portions of the diaphysis as well.

most important short bones of the human body are: the true vertebræ, the carpal bones, the tarsal bones, the patella, and the sesamoid bones.

In addition to the long, flat, and short bones there are a number which cannot be classified in any of the three categories. These are designated as **irregular bones**; as a rule, they represent transition forms between the broad and flat bones, as in the cases of the sacrum and of many of the cranial bones. Among the latter there are also some—for example, the temporal bone and the occipital bone—which in a portion of their extent are typical flat bones, while in their remaining portions they would be regarded as belonging to the group of the short or irregular bones.

All the varieties of bones may possess prominences which take the form of projections, ridges, and processes of the most varied shapes. According to their size and form, they are designated as *tubercles*, *tuberosities* (rough, more or less pronounced projections), *spines*, *crests* (rough lines or projecting ridges), *processes*, *condyles* (also termed condyloid or articular processes), *epicondyles* (*i. e.*, projections situated above the condyles), and *outgrowths* (*apophyses*). In a similar manner many bones possess excavations (*foveæ* or *fossæ*), impressions, grooves, furrows (*sulci*), notches (*incisuræ*), perforations (*foramina*), slits (*hiatus*), and canals. The enlarged rounded ends, particularly of the long bones, are frequently called *heads*, while the constriction situated beneath them is known as the *neck*. All bones possess larger or smaller foramina for the entrance of the nourishing blood-vessels; these are known as the *nutrient foramina*, and are particularly large in the shafts of the larger long bones, where they lead into a *nutrient canal*, which extends into the medullary cavity.

The bones of the human body are usually studied in the macerated condition, *i. e.*, after their soft parts have been removed by putrefaction. The bones of the living body and of the dead subject, however, consist not only of bony substance, but also of a series of soft tissues, some of which partly resist putrefaction, so that the "entire bone" is composed of the following constituents: (1) The actual bony tissue; (2) the periosteum; (3) the articular cartilage; (4) the bone-marrow; and (5) the nutrient vessels and nerves.

The macerated bone represents not only the bone-ash, *i. e.*, the calcium salts of the bone, but also contains other organic constituents. The bone substance consists chemically of almost two-thirds inorganic, and of a little more than one-third organic material; the latter is chiefly gelatin or ossein, and may be demonstrated in the form of the so-called bone-cartilage by extracting the calcium salts with acids. The inorganic constituents of bone are, calcium carbonate (about 85.5 per cent.), calcium phosphate (about 9 per cent.), calcium fluoride (about 3.5 per cent.), and magnesium phosphate (about 1.75 per cent.), and may be demonstrated by heating the dried bone to incandescence. Both the bone cartilage and the calcined bone retain the original shape of the bone from which they were obtained, the organic and the inorganic constituents being intimately intermingled.

The actual **bony tissue** appears in two modifications, which pass into each other, however, without demarcation—the compact substance and the spongy substance. The former has a dense and apparently quite uniform structure, while the spongy substance consists of a fine network of bony trabeculae, which at first sight seem to be without definite arrangement.

In reality, however, the architecture of the spongy substance is by no means irregular. Its parts are arranged in such a manner as to produce a firm and resistant structure with the greatest possible saving in weight, and a careful examination of its trabeculae and plates will

show that they are placed so as to lie in the direction of the greatest pressure or muscular traction exerted upon the bone, and every bone or part of a bone formed of spongy substance contains, consequently, several intersecting systems of trabeculae which cross each other mostly at right angles (Figs. 167 to 171).

Almost nowhere in the body do we find bony tissue uncovered, as it is enveloped either by articular cartilage or by periosteum. Articular cartilage covers the ends of two bones forming a joint, as in the extremities of most of the long bones; the remainder of the bone is enveloped by periosteum, a fibrous connective-tissue structure of varying thickness, which is of great importance for the nourishment, growth, and regeneration of the bone. Articular cartilage is hard but elastic, and consists of the so-called hyaline cartilage. Its thickness varies greatly in different bones, being sometimes only the fraction of a millimeter or in other cases amounting to several millimeters. (For the more minute structure of bone, periosteum, articular cartilage, and bone-marrow, see Sobotta's "Histology," Saunders' "Medical Hand Atlases.")

The **bone-marrow** appears in two varieties, the red and the yellow. The yellow marrow is really fat tissue, and is found in the medullary cavity of the long bones of the adult, while in young individuals these spaces are filled by red marrow, a soft vascular structure, which is also situated in the finer medullary spaces of the adult bone between the spongy trabeculae.

The vessels nourishing the bone are found chiefly in the medullary cavity and periosteum, but they also occur in the bony tissue itself. The nerves, on the contrary, are found principally in the periosteum, the bony tissue having no nerves, and the articular cartilage neither nerves nor vessels.

In certain regions of the human body, even in the adult condition, portions of the skeleton are formed by **cartilage**, as at the anterior extremities of the ribs, and since cartilage is elastic and flexible, it plays quite a different functional rôle from that of bone. These cartilages are enveloped by a connective-tissue covering, the *perichondrium*.

With reference to the development of bone, two varieties of bone formation are recognizable. The great majority of the bones are laid down in cartilage at a certain stage of fetal development, and these bones, which are thus preformed in cartilage, stand in contrast with those which are formed by the direct ossification of connective tissue, the so-called membranous bones, examples of which are to be found in the majority of the flat cranial bones and in many of the facial bones. (For a minute description of the processes of ossification, see Sobotta's "Histology," Saunders' "Medical Hand Atlases.")

During the transformation of the cartilaginous into the bony skeleton,—a process which begins early but proceeds slowly and lasts very long, usually not being completed until the twenty-fifth year,—so-called centers of ossification appear in the cartilaginous portions of the skeleton. These centers may be single (short bone) or, as is usually the case, multiple, and sometimes they occur in relatively large numbers and are somewhat irregularly arranged (as in the sternum). Usually, however, particularly in the long bones of the extremities, the center for the future shaft of the bone, the diaphysal center, appears first, while the ends or epiphyses still remain cartilaginous, and each epiphysis later develops at least one and frequently several separate centers of ossification (the exceptions are given upon page 92), which not only appear at a much later period than the diaphysal center, but long after birth are still separated from the center for the diaphysis by a layer of cartilage. This is termed the epiphysal line (*synchondrosis epiphyscos*), and it finally disappears and the bone becomes ossified throughout.

SPECIAL OSTEOLOGY.

The human skeleton may be separated into three chief divisions: (A) The skeleton of the trunk; (B) the skeleton of the head; (C) the skeleton of the extremities.

From the standpoint of embryology and evolution the skeleton should be divided into: (1) The axial skeleton, *i. e.*, the vertebral column with its adnexa and the greater part of the base of the skull; (2) the appendicular skeleton, *i. e.*, the skeleton of the extremities; and (3) the membrane and visceral bones, *i. e.*, the flat bones of the cranial vault and the facial bones, and those portions of the skeleton which represent the visceral or branchial skeleton of the lower vertebrates.

The skeleton of the trunk is formed by the vertebral column and its appendages (the ribs and the sternum), the skeleton of the head is represented by the skull, and the skeleton of the extremities is further subdivided into the skeleton of the upper and that of the lower extremity.

THE SKELETON OF THE TRUNK.

The principal portion of the skeleton of the trunk is the *vertebral column*, which is composed of a series of parts, the *vertebræ*. A typical vertebra consists of a *body* and of *arches*, these latter being subdivided into a posterior or dorsal and an anterior or ventral arch. The posterior or dorsal arches surround the spinal cord, while the anterior or ventral arches, in the form of the ribs, are well developed only in the thoracic portion of the vertebral column and are rudimentary in the remaining vertebrae; they surround the vegetative cylinder of the body, the intestine. While the dorsal arches are firmly united with the bodies of the vertebrae, the ribs are paired bony arches articulating with the thoracic vertebrae behind and anteriorly with a special bone, the breast-bone or *sternum*.

The entire series of the vertebrae form the spine or vertebral column, and the thoracic vertebrae with the ribs and the sternum form the *thorax*. The skeleton of the trunk consequently consists of the vertebral column together with the thorax.

THE VERTEBRAL COLUMN.

THE TRUE VERTEBRÆ.

In the vertebral column two main subdivisions may be recognized. One subdivision is formed by the *true vertebrae*, the other by the *false vertebrae*, the former being separate bones connected by ligaments and joints, while the latter are united by bony tissue to form larger bones. The entire human spinal column consists of thirty-two to thirty-five vertebrae; of these, twenty-four are true vertebrae and eight to eleven are false vertebrae. The true vertebrae may be separated into three subdivisions: (1) The cervical vertebrae; (2) the thoracic or dorsal vertebrae; and (3) the lumbar vertebrae. There are seven cervical, twelve thoracic, and five lumbar vertebrae.

A typical vertebra is composed of: (1) The body; (2) the vertebral arch; and (3) a number of processes.

The body (Figs. 1 and 2) is composed of spongy substance enclosed by a thin layer of cortical compact bone. It presents a superior and an inferior plane or curved surface, an anterior surface markedly convex from side to side and slightly concave from above downward, and a posterior surface which is concave in both directions. The posterior surface usually presents one or more large nutrient foramina and, with the vertebral arch, completes the enclosure of the spinal foramen (*foramen vertebrale*). The arch consists of somewhat firmer tissue than the body and forms from a half to three-quarters of a circle. The portion continuous with the body on each side is known as the pedicle or root (*radix arcus vertebræ*) (Fig. 1), and presents a notch upon both its upper and its lower surface (*the superior and inferior vertebral notches*) (Fig. 2), the notches of contiguous vertebræ (*the inferior notch of the upper vertebra and the superior one of the lower vertebra*) together forming an *intervertebral foramen* which communi-

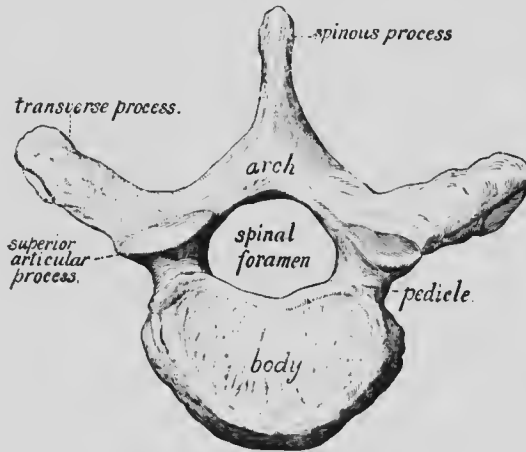


FIG. 1.—A vertebra seen from above.

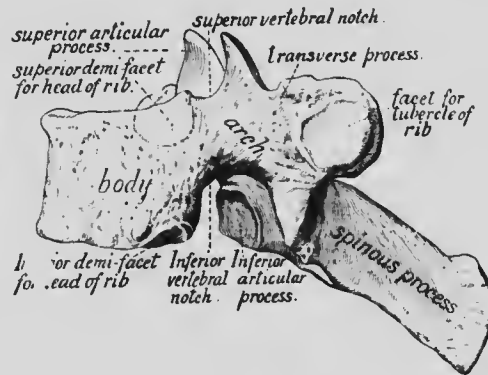


FIG. 2.—A vertebra seen from the side.

cates with the spinal canal. The superior intervertebral notch is usually the shallower; the inferior one the deeper.

The processes of the vertebræ consist of the articular processes (Fig. 2), for the purpose of articulation with neighboring vertebræ, and the spinous (Fig. 2) and transverse processes (Fig. 1), which serve as points of attachment for the muscles. Every typical vertebra possesses four articular processes, two superior and two inferior, and these bear articular surfaces which are correspondingly named. Of the remaining processes, the spinous process is single, while the transverse processes are paired.

THE CERVICAL VERTEBRÆ.

Of the seven cervical vertebræ, the two uppermost ones, the first or *atlas*, and the second or *axis* (*epistrophæus*), show marked deviations from the type. They are also known as "rotatory" vertebræ, in contradistinction to the remaining vertebræ (*flexion vertebræ*).

The general characters of the cervical vertebræ (Figs. 4, 5, and 6) are as follows: The

FIG. 4.—The cervical vertebræ seen from behind and partly from the side ($\frac{1}{2}$).

FIG. 5.—The fifth cervical vertebra seen from above ($\frac{1}{2}$).

FIG. 6.—The seventh cervical vertebra seen from above ($\frac{1}{2}$).

FIG. 7.—The atlas seen from above ($\frac{1}{2}$).

FIG. 8.—The axis seen from above ($\frac{1}{2}$).

bodies are relatively small, low, oblong (or quadrilateral with rounded corners), and they increase in size from above downward. The bodies are smaller than in any other region of the spine, and their upper surfaces are concave from side to side and slightly convex from before backward, while the lower surfaces are concave from before backward and slightly convex from side to side. As a consequence of this, the upper surface of every vertebra projects laterally beyond the body of the vertebra next above (Figs. 3 and 4).

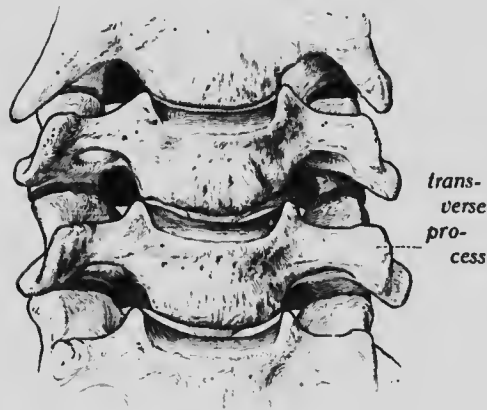


FIG. 3.—Cervical vertebræ seen from in front.

The arches of the cervical vertebræ (Fig. 5) are of medium height and arise by a pedicle which is directed outward and backward. Together with the body, the arch surrounds a spinal foramen which is very wide, especially in its transverse diameter. The articular processes (with the exception of those of the upper two vertebræ) are placed obliquely, so that the plane of the articulation passes from above downward and from before backward, and the articular surfaces are consequently in a middle position between a horizontal and a frontal plane, those nearer the skull approaching the horizontal position, and those nearer the thoracic vertebræ the frontal plane.

The transverse processes (Figs. 5 and 6) of all the cervical vertebræ are perforated by a large round foramen (*foramen transversarium*), a peculiarity which distinguishes the cervical from all other vertebræ. Furthermore, the ends of the transverse processes are prolonged into two tubercles separated by a groove (*sulcus nervi spinalis*) (Fig. 5), situated upon the surface of the transverse process.

The anterior root of the transverse process, which passes directly outward from the body of the vertebra and is separated from the posterior root by the *foramen transversarium*, the *sulcus nervi spinalis*, and the constriction between the two tubercles, is known as the costal process (*processus costarius*), and represents a rudimentary rib adherent to the true transverse process which is represented by the posterior root. This costal process is occasionally independent, especially in the seventh cervical vertebra, and forms then a cervical rib.

The spinous processes (Figs. 4 and 5) are for the most part small, somewhat downwardly inclined, and distinctly bifid at their apices.

From the third to the sixth the cervical vertebræ are typical. The seventh (Fig. 6) is distinguished by possessing a long spinous process which is not bifid and is directed downward,

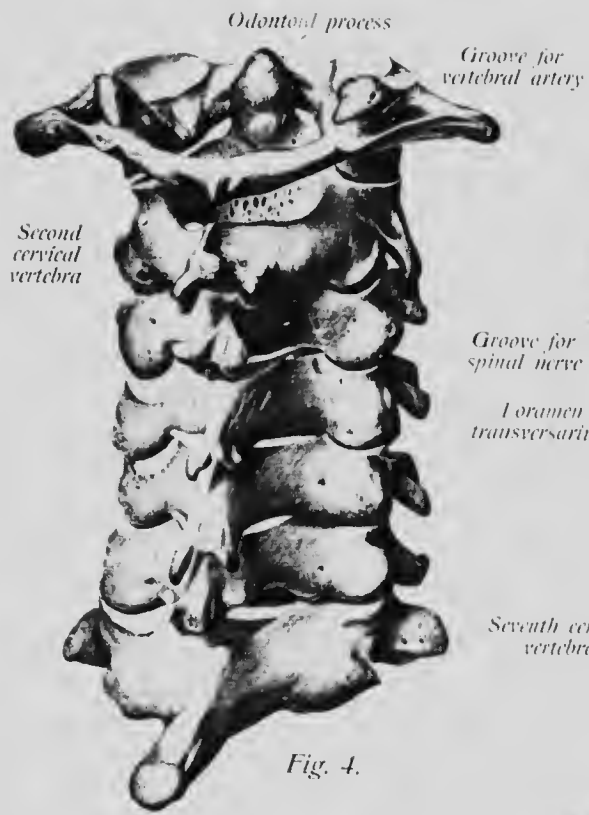


Fig. 4.

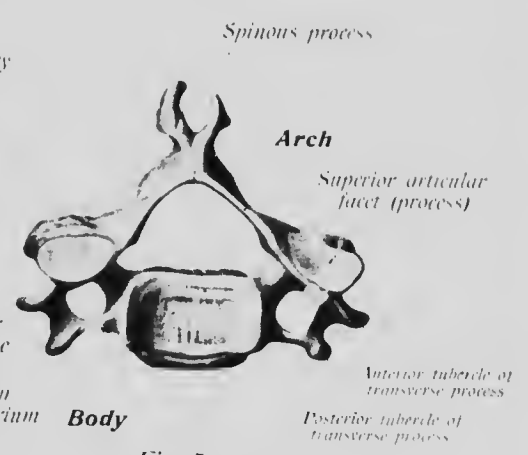


Fig. 5.

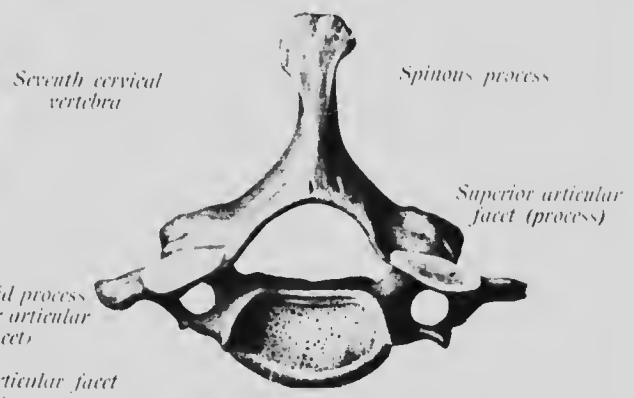


Fig. 6.

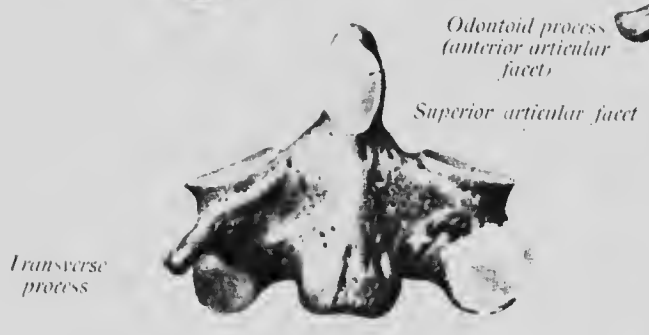


Fig. 8.

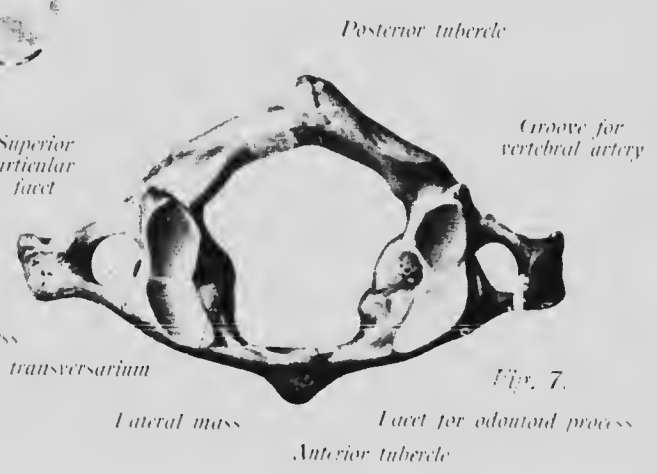



Fig. 7.



and in these respects the form of the vertebra approaches that of the thoracic vertebrae. Its spinous process is the uppermost one discoverable by palpation, and the bone is therefore also known as the *vertebra prominens*. The anterior tubercle of its transverse process is either entirely or almost entirely absent, and the foramen transversarium is usually smaller than in the other cervical vertebrae.

The first cervical vertebra, or **atlas** (Figs. 4 and 7), is characterized by a series of negative peculiarities. The body is absent, but in its place we find an *anterior arch*, opposite the customary *posterior arch* which the bone also possesses. The spinous process is also wanting, its place being taken by a prominence known as the posterior tubercle, corresponding to which there is an anterior tubercle upon the anterior arch. Finally, instead of articular processes, it possesses two upper and two lower articulating surfaces, and both the superior and the inferior vertebral notches are absent.

In the atlas there are distinguishable therefore an anterior arch, a posterior arch, and the connecting *lateral masses*, which are the strongest portions of the bone. The anterior arch is shorter and weaker but higher than the posterior one; anteriorly (ventrally) it presents a slight projection, the anterior tubercle; posteriorly (dorsally, *i. e.*, toward the spinal canal) a round shallow articular surface (*jovea articularis dentis*), for articulation with the odontoid process or *dens* of the axis (the second cervical vertebra).

The posterior arch of the atlas bears upon its posterior surface a short projection, the *posterior tubercle*, a rudiment of the spinous process, and is the lowest of all the arches of the cervical vertebrae (and in fact of all the vertebrae). It is flat and broad, however, and presents upon its upper surface near the pedicle a furrow which is sometimes shallow and sometimes broad and deep, and which is occupied by the vertebral artery. This groove is not infrequently bridged over and converted into a foramen or short canal with a rough inner margin.

The inner portion of each lateral mass of the atlas (*tuberositas atlantis*) projects markedly into the anterior part of the spinal canal, so that the latter is converted into a smaller anterior compartment, for the reception of the odontoid process of the axis, and a larger posterior compartment. This posterior compartment is really the spinal foramen and contains the spinal cord. Upon the upper surfaces of the lateral masses are the upper articular surfaces for the reception of the occipital condyles. These surfaces are bean-shaped and, corresponding to the convexity of the condyles, they are concave from anteriorly and within to posteriorly and without. In the middle they are constricted and occasionally divided. On the under surface of the lateral masses are found the inferior articular surfaces which serve for articulation with the second cervical vertebra and resemble the similar surfaces of the other vertebrae more than do the superior articular surfaces, possessing plane, but slightly inclined (almost horizontal) surfaces.

The transverse processes exhibit the same characteristics as the transverse processes of all the cervical vertebrae, but are larger. Like the others, each possesses a foramen transversarium, but the sulcus nervi spinalis and the tubercles are absent.

The second cervical vertebra (Figs. 4 and 8), or **axis** (*epistrophicus*), so called because the occiput and the atlas rotate upon it, is on the whole a typical cervical vertebra, except that its body has adherent to it the original body of the atlas, which forms the *odontoid process* (*dens*

FIG. 9.—The tenth to the twelfth thoracic and the first and second lumbar vertebræ seen from the side and slightly from behind ($\frac{3}{4}$).

FIG. 10.—The tenth thoracic vertebra from above ($\frac{1}{2}$).

FIG. 11.—The sixth thoracic vertebra from the side ($\frac{1}{2}$).

FIG. 12.—The third lumbar vertebra seen from above ($\frac{1}{2}$).

epistrophei) and projects into the anterior compartment of the spinal foramen of the atlas. This odontoid process is cone-shaped with a rounded apex, and presents an anterior facet for articulation with the anterior arch of the atlas and a posterior articular facet which is not always distinct. Instead of articular processes the upper part of the body presents corresponding articular surfaces for connection with the atlas; these surfaces are slightly convex and but a trifle inclined from the horizontal.

The spinous process (Fig. 4) is fairly well developed and always distinctly bifid; the transverse processes, on the contrary, are smaller than those of the atlas and their tubercles and sulci nervi spinalis are likewise absent, although there is usually a shallow groove for the second spinal nerve on each side behind the superior articular facet. The inferior articular processes are more inclined than the superior ones, and already show the characteristics of those of the flexion vertebræ.

The foramina transversaria of the articulated cervical vertebræ form a canal for the passage of the vertebral artery and vein (the former runs through the upper six only). The markedly developed anterior tubercle of the transverse process of the sixth cervical vertebra is known as the carotid tubercle or tubercle of Chassaignac (*tuberculum caroticum*).

THE THORACIC VERTEBRÆ.

On account of the independent development of the ribs in the thoracic region, we find no fused costal rudiments in the thoracic vertebræ such as occur throughout the remainder of the true vertebræ, and the thoracic vertebræ are consequently of the purest type.

Their bodies (Figs. 9, 10, 11, and 21) increase in size and height from above downward. In the upper thoracic vertebræ their surfaces are elliptical, like those of the cervical region, but as we pass downward they become rounder, then cordiform, and finally reniform in the lower members of the series, which approximate the form of the lumbar vertebræ. And not only do the bodies become larger, but their lateral diameter especially is increased as they gradually approach the form of the lumbar vertebræ. Their contiguous surfaces are almost perfectly flat. The spinal foramen (Fig. 10) is not only absolutely, but even relatively smaller than that of the cervical vertebræ, and in the upper members of the series it is rounded, while in the lower it is rather triangular. The upper and lower margins of the bodies each present, immediately in front of the pedicles, a demifacet for the head of a rib (Fig. 11). The first and the two (or three) lowest vertebræ, however, show deviations from this arrangement, the former having an entire facet upon the upper margin, and each of the latter (Fig. 9) presenting an entire facet toward the middle of the body of the vertebra.

The articular surfaces for the heads of the ribs are placed on two adjacent thoracic vertebræ in such a manner that each vertebral margin does not receive exactly one half of the articulation, but toward the lower end of the series more than half, and then two-thirds of the entire surface occurs upon the lower vertebra until the eleventh, and occasion

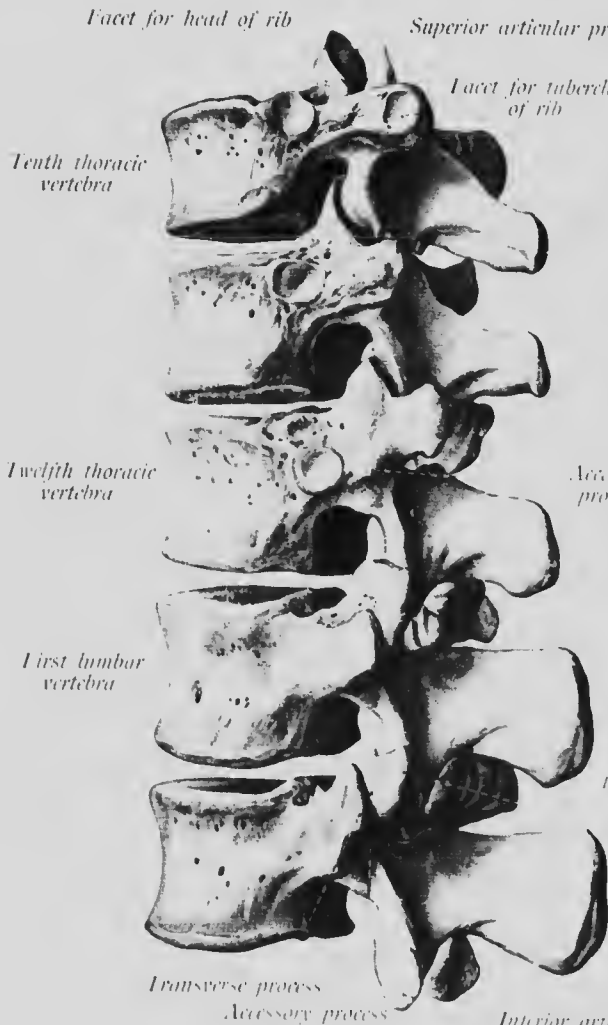


Fig. 9.

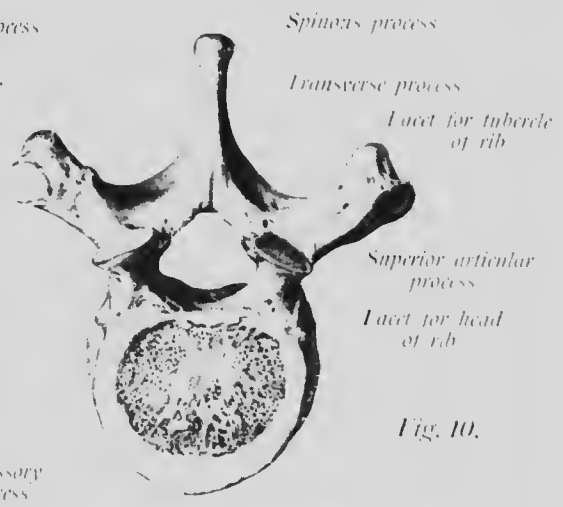


Fig. 10.



Fig. 11.

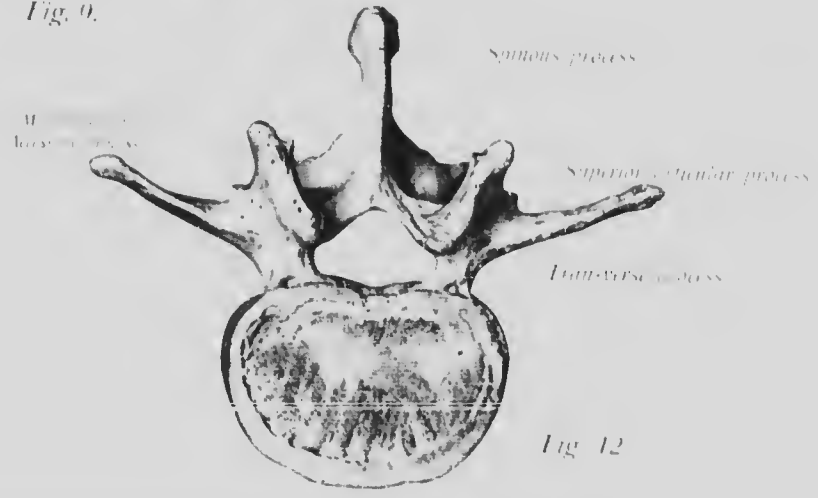



Fig. 12.



ally the tenth also, possesses an entire costal facet (Fig. 23). Those vertebrae which possess an entire facet have typically no inferior facet.

The arches of the thoracic vertebrae (Fig. 10) are high and thick. The articular processes, with the exception of those of the twelfth vertebra, lie almost in the frontal plane and are placed so that the almost round and slightly concave inferior surfaces look forward, while the slightly convex superior ones look backward, the surfaces forming part of a thick cylinder the axis of which lies in front of the vertebral body. The superior processes are very prominent, while the inferior ones project but slightly.

The long transverse processes (Fig. 10) are strongly developed. They are directed backward as well as outward, and have thickened club-shaped extremities. The anterior surface of this thickening usually presents an approximately circular, slightly concave articular facet, for the accommodation of the tubercle of a rib; this facet is wanting, however, in the eleventh and twelfth vertebrae (Fig. 9), and the transverse process of the latter often shows a variable development, frequently consisting of several irregular tubercles.

The spinous processes (Figs. 9, 10, and 23) are long and three-sided, and are directed obliquely downward, one border looking upward and one surface downward. Those of the middle vertebrae of the series overlap each other like the shingles of a roof (Fig. 23). That of the twelfth vertebra (Fig. 9) resembles those of the lumbar vertebrae.

The twelfth thoracic vertebra (and sometimes the eleventh also) is the only one that can be designated as atypical, since it exhibits several characteristics of the lumbar vertebrae (the shape of the spinous process, body, and spinal foramen, the position of the articular processes and the appearance of the accessory and mammillary processes upon the rudimentary transverse processes). The facet for the head of the rib alone shows the true nature of the twelfth thoracic vertebra, just as the facets upon the bodies (and transverse processes) are the surest points of identification for the thoracic vertebrae in general.

THE LUMBAR VERTEBRÆ.

The lumbar vertebrae (Figs. 9, 12, 21, and 23) are the largest of the true vertebrae. The bodies in particular are large, very high and broad, and have plane reniform surfaces, *i. e.*, they are convex anteriorly and concave posteriorly. The anterior surface is distinctly concave from above downward and convex from side to side, so that the upper and lower surfaces of the bodies are considerably broader than their middle portions. Also the bodies of the lower lumbar vertebrae at least (and especially of the fifth) are distinctly higher anteriorly than posteriorly (Fig. 23).

The arches of the lumbar vertebra (Fig. 12) are strongly developed and very high, but show no further peculiarities; the spinal foramina are small and approximately triangular. The articular processes are well formed and project markedly both above and below, and the articular surfaces are slightly curved and are almost in the sagittal plane, the concavity of the upper surfaces looking backward and inward while the convexity of the lower ones is directed forward and outward. The surfaces represent sections of a large hollow cylinder, whose axis is situated, not in front of the vertebral bodies, as in the thoracic region, but behind them (behind the spinous process), and the inferior processes of each vertebra are consequently overlapped laterally by the superior processes of the next succeeding one. The inferior processes of the fifth vertebra are united with the upper articular processes of the sacrum (see page 29).

- FIG. 13.—The sacrum seen from behind (dorsal surface) ($\frac{3}{4}$).
 FIG. 14.—The sacrum seen from in front (pelvic surface) ($\frac{3}{4}$).
 FIG. 15.—The sacrum seen from above (base) ($\frac{3}{4}$).
 FIG. 16.—Horizontal section of the sacrum at the level of the second sacral foramina ($\frac{3}{4}$).
 FIG. 17.—Median longitudinal section through a sacrum, showing the synchondroses between the individual vertebræ ($\frac{3}{4}$).
 FIG. 18.—The sacrum and coccyx seen from the side ($\frac{3}{4}$).
 FIG. 19.—The coccyx seen from in front ($\frac{1}{2}$).
 FIG. 20.—The coccyx seen from behind ($\frac{1}{2}$).

The transverse processes of the lumbar vertebræ (Fig. 10) are long, directed almost at a right angle from the spinal column, and distinctly compressed from before backward. They represent rudimentary lumbar ribs and are therefore really the costal processes,* while a small projection situated at the base of the "transverse process," the *accessory process* (Figs. 9 and 12), corresponds to the transverse process of the thoracic vertebræ. This accessory process is characteristic for the lumbar vertebræ, and although sometimes poorly marked, it usually appears even in the twelfth thoracic vertebra. The superior articular processes of the lumbar vertebræ also exhibit another round roughened protuberance, the *mammillary process* (Figs. 9 and 12).

The spinous processes (Figs. 9 and 12) are very strong and high and are distinctly compressed from side to side. They extend directly backward and show a slight thickening at their apices.

THE FALSE VERTEBRÆ.

The false vertebræ, which are variable in number, form two bones, the sacrum and the coccyx.

THE SACRUM.

The sacrum is that portion of the vertebral column which is connected with the pelvic girdle and completes the latter posteriorly; it consequently forms a portion of the pelvis itself.

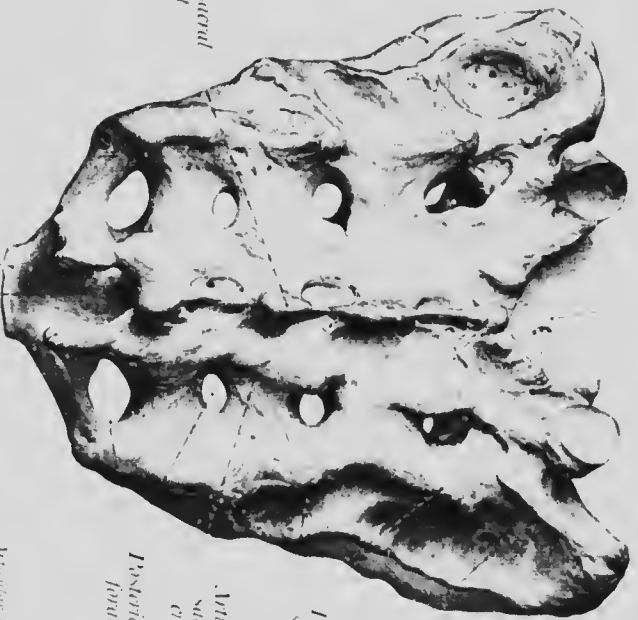
It is a broad, curved, moderately flat, shovel-shaped bone (Figs. 13 and 14), which is broad and thick above, and narrow and thin below (Fig. 18). In it there may be distinguished an anterior relatively smooth surface, concave in both the sagittal and transverse directions, and known as pelvic surface, because it looks toward the pelvic cavity, and a posterior extremely rough dorsal surface. The broad upper surface of the sacrum is called the base and the lower angle the apex.

The pelvic surface presents a number of transverse ridges, usually four, which connect four pairs of irregular rounded foramina known as the anterior sacral foramina. The ridges correspond to the junctions of the five originally separate sacral vertebræ of which the bone is composed, while the sacral foramina indicate the junctions of the bodies with the lateral processes (costal and transverse processes). The anterior sacral foramina communicate pos-

* These processes occasionally form so-called abdominal or lumbar ribs.

Superior articular process

Sacral canal



Angular
syrinx

Median sacral
crest

Fig. 13.

Apex of sacrum

Sacral
hiatus
Sacral
cornu

Posterior
sacral
foramina

Lateral
sacral
crest

Angular
sacral
crest

Sacral
tubercle

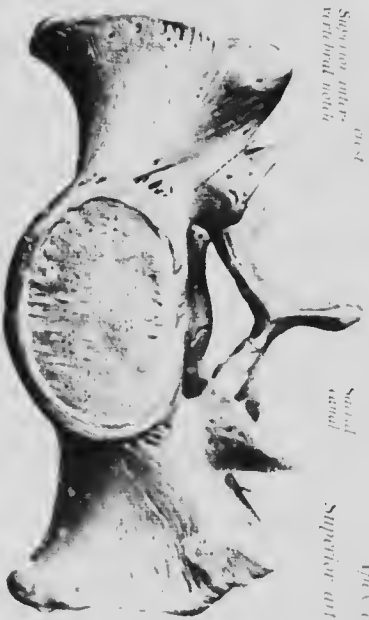Transverse
line

Sacral
cornu

Median sacral crest

Widular crest

Superior
rotational notch

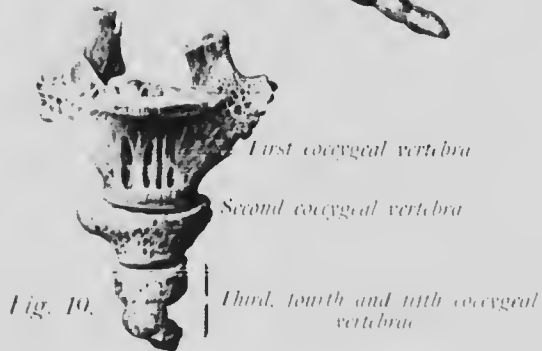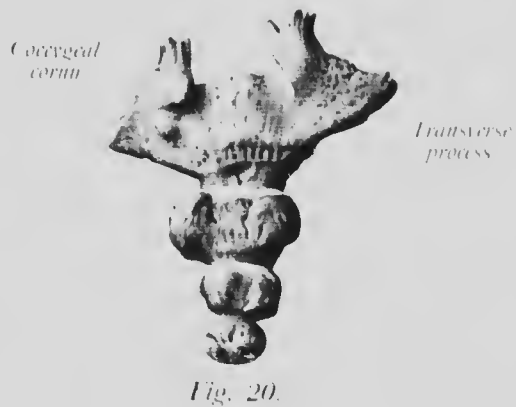
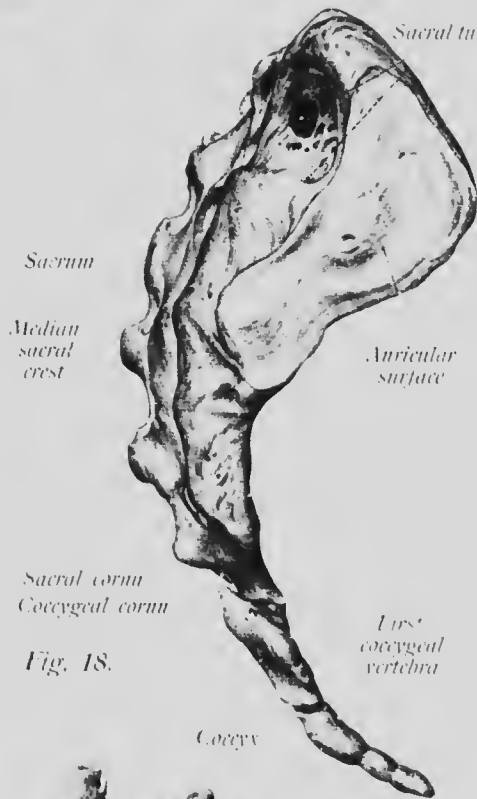
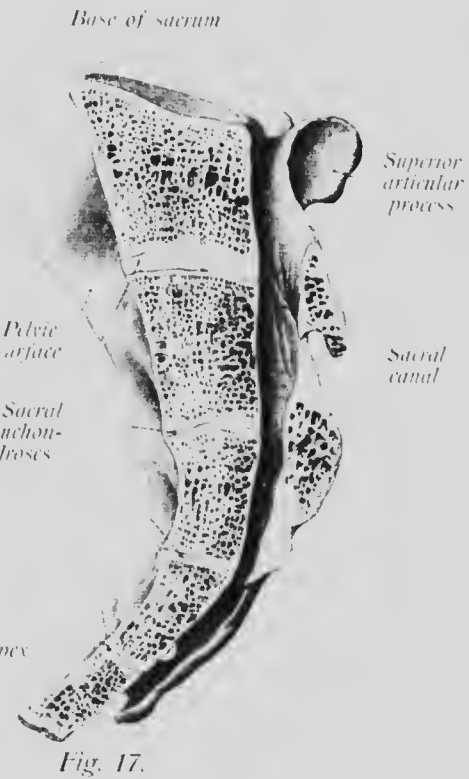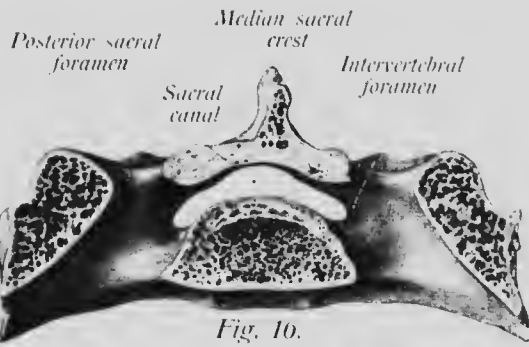



Sacral
canal
Superior articular process
Lateral process

Fig. 14

Fig. 15.







teriorly with the spinal canal and extend laterally as grooves which gradually become shallower and are finally lost upon the lateral masses of the bone.

The portions of bone situated external to the sacral foramina and which are particularly well developed in the upper part of the sacrum, where they articulate with the pelvic girdle, are designated as the lateral masses (*partes laterales*) (Fig. 15). Their lateral surfaces exhibit large ear-shaped articular surfaces, known as the *auricular surfaces*, which articulate with the pelvic bones, and occur chiefly upon the first, to a limited extent upon the second, and even upon the third sacral vertebra (Fig. 18). Behind the auricular surfaces there is an irregular rough impression, the *sacral tuberosity* (Fig. 13), which is united by a ligament with a similarly named part of the pelvic bone (see page 95). At the junction of the base of the sacrum and the pelvic surface there is a feebly marked line, the sacral portion of the ileopectineal line (*linea terminalis*), which separates the true from the false pelvis.

The upper surface of the sacrum (Fig. 15) also possesses a slightly uneven surface intended for articulation with the lower surface of the fifth lumbar vertebra. The form of this surface exactly fits the corresponding surface of the body of the fifth lumbar vertebra and exhibits all the characteristics of a lumbar vertebra, including a superior vertebral notch and a superior articular process.

The dorsal surface of the sacrum (Fig. 13) has four pairs of rounded foramina which exactly correspond in their position to the anterior ones. In addition, it exhibits a series of parallel, rough, frequently interrupted ridges, a median single ridge, and two rows of paired ridges. The median ridge, known as the *crest*, consists of the more or less fused spinous processes of the five sacral vertebrae, and is more pronounced than the lateral ridges. These (Fig. 13) are separated by the posterior sacral foramina, the inner ridge known as the *articular crest* and the outer one as the *lateral crest*. The former is, as a rule, the least pronounced of all the ridges, and is formed by the fusion of the articular processes of the sacral vertebrae, only two of these processes on each side retaining a certain degree of independence, the superior processes of the first vertebra and the inferior ones of the fifth. The former lie at the base of the sacrum and are called the *superior articular processes* of the sacrum; they articulate with the inferior articular processes of the last lumbar vertebra and are equally well formed. Their articular surfaces are placed midway between the sagittal and the frontal plane. The articular crest is continued downward on each side over the apex of the sacrum and usually projects beyond it as a horn-like process called the *sacral cornu*. This process is the modified lowermost articular process, and is united by ligaments to a similar process on the coccyx.

The lateral sacral crest is to be regarded as formed by the fusion of the transverse processes and forms a rough ridge which is occasionally interrupted.

The sacrum is traversed throughout its length by a canal (Fig. 17) which is the direct continuation of the spinal canal and is known as the *sacral canal*. It is tolerably wide in the upper part of the sacrum, but rapidly diminishes in both its sagittal and transverse diameters as it descends. It terminates externally between the sacral cornua as the *sacral hiatus* (Fig. 13), and is connected with the anterior and posterior sacral foramina by four short transverse canals, the *intervertebral foramina* (Fig. 16).

The posterior wall of the sacral canal is formed essentially by the completely fused arches

FIG. 21.—The vertebral column seen from in front ($\frac{1}{3}$).

FIG. 22.—The vertebral column seen from behind ($\frac{1}{3}$).

FIG. 23.—The vertebral column seen from the left side ($\frac{1}{3}$).

of the sacral vertebræ. The intervertebral foramina correspond to the similar structures in the true vertebræ; but in the latter there are no openings comparable to the sacral foramina, at least not in the bony spinal column. This is due to the fact that the spinal nerves divide into an anterior and a posterior branch within the sacral canal instead of outside of the spinal canal as in the true vertebræ, or, to go back a step further, it is due to the fact that whereas throughout the series of true vertebræ the ribs or costal processes remain distinct from one another, in the sacrum the costal processes, which are represented in the lateral masses, fuse together and also unite with the transverse processes, so that the intervertebral canals are closed at their outer ends.

The apex of the sacrum presents an elliptical surface for articulation with the coccyx, and at its sides there is a shallow notch which is converted into a foramen by the transverse process of the first coccygeal vertebra and the connecting ligaments (see page 113).

THE COCCYX.

The coccyx (Figs. 18, 19, and 20) is a small bone of variable length formed by the fusion of four or five (rarely three or six) quite rudimentary vertebræ (*vertebræ caudales*). The first vertebra alone shows some vertebral characteristics, since there can be recognized in it indications of transverse processes as well as of the upper articular processes which are transformed into the *coccygeal cornua*. The transverse processes also frequently appear in the second vertebra in the shape of feeble indistinct projections, but the remaining coccygeal vertebræ are irregular, rounded pieces of bone. None of the coccygeal vertebræ possesses a trace of vertebral arches or of a spinous process, and the individual vertebræ are united either by syndesmoses or (more rarely) by bony tissue.

The sacrum shows typical sexual differences, since it is broader, shorter, and less curved in the female than in the male. Not infrequently the first sacral vertebra remains partly or even entirely independent (*the lumbosacral vertebra*), and the first coccygeal vertebra frequently fuses with the sacrum, in which case the sacral and coccygeal cornua are also united by bony tissue.

THE VERTEBRAL COLUMN AS A WHOLE.

The vertebral column is completed by its ligamentous connections and particularly by the intervertebral discs situated between the bodies of the vertebræ (see page 110). If the bony vertebral column be observed from the side (Fig. 23), its marked curvature at once becomes apparent. This curvature is manifold, the cervical portion of the column being convex anteriorly, the thoracic portion markedly concave anteriorly, the lumbar portion decidedly convex anteriorly, and the sacrum concave anteriorly. At the junction of the lumbar portion with the sacrum, where the convexity of the former passes into the concavity of the latter there is a marked angulation called the *promontory*. The curvatures of the vertebral column are subject to individual variation.

*Cervical
vertebrae*

*Thoracic
vertebrae*

*Lumbar
vertebrae*

Sacrum



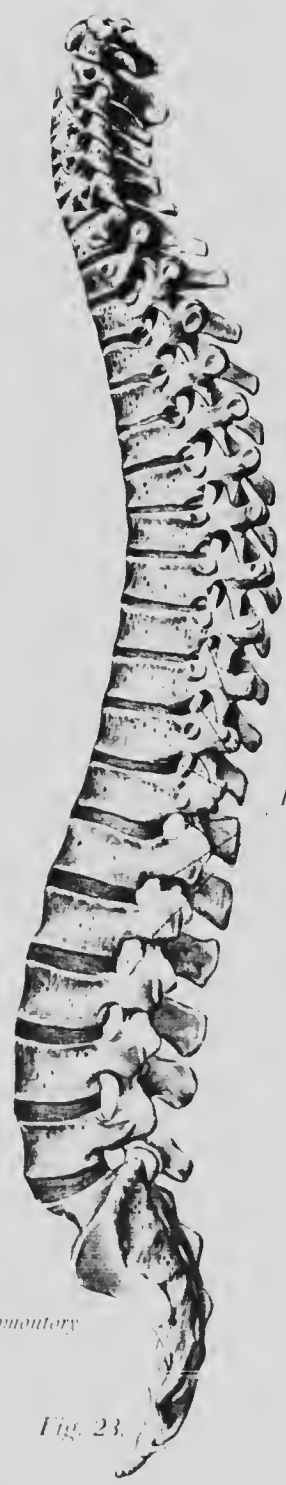Coccyx

Fig. 21.




Promontory

Fig. 22.



*Intervertebral
foramina*

Fig. 23.



In viewing the vertebral column from in front (Fig. 21) it will be noticed that the sacrum is by far the broadest part of the spine. From here upward the vertebral column becomes smaller until the fifth thoracic vertebra is reached, whence it commences to enlarge as it ascends. In the upper cervical region the column again decreases in size, but the atlas is broader than the bones which lie below it. A study of the profile of the spinal column (Fig. 23) shows, however, that its greatest thickness is found in the lumbar region.

Just as the anterior surface of the vertebral column is completed by the intervertebral discs between the bodies of the individual vertebrae, so too the spaces between the arches are similarly filled by ligamentous tissue. These spaces are largest in the lumbar region and between the two upper cervical vertebrae (Fig. 22), in the latter instance because the arch of the atlas is extremely low.

The spinal canal (*canalis vertebralis*), formed by the spinal foramina of the individual vertebrae, has not, therefore, a uniform bony boundary even in the region of the true vertebrae, but at intervals is covered in only by membranous structures. It communicates laterally with the intervertebral foramina (Figs. 23 and 36), each of which is formed by two vertebrae; above it is continuous with the cranial cavity; and its lower end is formed by the *sacral hiatus*, which, however, is almost completely closed by ligaments.

There are twenty-three pairs of intervertebral foramina, six in the cervical region (see page 26), twelve in the thoracic region, and five in the lumbar region. Those in the lumbar region are the largest, while those situated between the cervical vertebrae are the smallest; between the atlas and the occiput there are no intervertebral foramina whatever, and those between the atlas and axis are only partially limited by bone. The lowermost intervertebral foramen lies between the fifth lumbar vertebra and the upper surface of the sacrum. The intervertebral foramina in the cervical region are exactly between the transverse processes, while in the thoracic and lumbar regions they are in front of them (Fig. 23).

THE DEVELOPMENT OF THE VERTEBRAL COLUMN.

As far as the development of the bony vertebral column is concerned, each vertebra arises from three centers of ossification, one for the body and one for each half of the vertebral arch. Ossification commences at the end of the second month of embryonic life, the centers for the arches appearing somewhat earlier than those for the body and also giving rise to the different vertebral processes. In addition to these chief centers, accessory centers develop considerably later, at the age of puberty or even subsequently, and appear as flat discs on the apices of the spinous and transverse processes, on the mammillary processes of the lumbar vertebrae, and on the upper and lower surfaces of the vertebral bodies. These epiphyses do not unite with the remainder of the vertebra until the growth of the body has been completed.

In the first year of life the two centers for the vertebral arches unite, in the third year the arches become joined to the bodies, while the epiphyses remain distinct until the twenty-fifth year.

In the atlas the center for the body is wanting. The anterior arch remains cartilaginous for a long time, not ossifying until the first year, and not uniting with the posterior arch until the fifth or sixth year. The two centers for the posterior arch remain separated until the third year.

In the axis there is a center for the body and a similar one (originally double) for the odontoid process. Both unite in the third year.

The sacral vertebrae ossify in a similar manner to the true vertebrae. In each there is a single center for the body, two for each arch, epiphyseal plates, and special ventral centers corresponding to the sacral ribs. The body and arches of the fifth sacral vertebra unite first (second year) and then follows the union of the body and arches of the first vertebra (fifth and sixth year), while bony union between the bodies does not occur until the twenty-fifth year or later. In the coccyx the first vertebra is ossified at birth, the last one not until the twentieth year.

FIG. 24.—The first rib of the right side seen from above and from the side ($\frac{3}{4}$).

FIG. 25.—The second rib of the right side seen from above and from the side ($\frac{3}{4}$).

FIG. 26.—The posterior extremity of the seventh rib of the right side seen from behind and partly from below ($\frac{3}{4}$).

FIG. 27.—The seventh rib of the left side seen from behind ($\frac{3}{4}$).

FIG. 28.—The seventh rib of the left side seen from within ($\frac{3}{4}$).

THE RIBS.

The ribs (*costæ*) belong to that limited group of skeletal segments which remain partly cartilaginous throughout life. Attention may first be directed to the bony ribs, of which there are twelve pairs (Figs. 24 and 30), corresponding to the number of the thoracic vertebrae.

The ribs are not tubular bones, but flat bony strips of considerable length. Those in the middle of the series are quite uniform in shape, only the upper and lower ones showing certain deviations.

In a typical rib the following parts may be recognized:

1. The *head*, the posterior (vertebral) slightly thickened end. It presents an *articular surface* (Fig. 27), which is opposed to the bodies of the vertebrae, and is marked by a median ridge, the *crest*, which divides it into an upper and a lower articular surface for the two vertebral bodies with which it articulates.

2. The *neck*, a constriction situated external to the head (Fig. 28). Its upper margin is formed by a ridge, *crest of the neck*, which is separated from the body of the rib by a rough eminence, the *tubercle*, presenting a facet for articulation with the transverse process of a thoracic vertebra.

3. The *body*, the longest part of the rib. This is placed vertically and is distinctly flattened from without inward, so that an external and an internal surface may be recognized; near the tubercle it presents a rough surface, the *angle* of the rib (Fig. 28). The rib is at first directed outward, backward, and downward, but at the costal angle it turns upon itself and passes forward. On the inner surface of the lower margin of the body there is a groove, the *costal groove* (Fig. 28), which gradually becomes shallower as it approaches the anterior costal extremity, and causes the lower margin of the rib to be sharp while the upper one is more rounded. At its anterior extremity, the body of the rib presents a roughened, somewhat shallow surface for the reception of the costal cartilage.

The typical ribs are the third to the tenth, the first two and the last two exhibiting certain peculiarities. The first rib (Fig. 24) is short and broad; it is not placed vertically but almost horizontally, so that an upper and a lower surface may be recognized in its posterior portion, and an upper or outer and a lower or inner surface in its anterior portion. Its head has no crest, since the first rib usually articulates with the body of the first thoracic vertebra only and not with two adjacent vertebrae, and its angle coincides with the tubercle. Near the anterior extremity of its body there is a low rough protuberance, known as the *scalene tubercle* or *tubercle of Lisfranc*, for the insertion of the scalenus anticus muscle, and behind this tubercle



Fig. 20.




Fig. 24.



Fig. 25.

Lamina
sella



Fig. 27.

Body

Fig. 28.

Uggo

Small vertical text on the left margin, possibly a page number or reference.

th
b
I
b
i
a
o
c
e
a
t
v
I
r
(
p
h
s
r
a
r
l
l
a
t
t
a
c
c
c
b

there is a broad shallow groove, the *subclavian groove*, for the subclavian artery, and close beside this groove a roughened surface for the insertion of the scalenus medius muscle.

The second rib (Fig. 25) resembles the first and, at the same time, the typical ribs as well. It is longer than the first rib, but its posterior portion shows the same peculiar torsion of the body, so that one surface looks outward and upward while the other is directed downward and inward. The position of its anterior extremity is typical, and it possesses a capitular crest, although the tubercle and angle still coincide. A roughness, the tuberosity, serves for the origin of one, or sometimes two digitations of the serratus magnus muscle.

The eleventh (Fig. 29) and especially the twelfth ribs (Fig. 30) are short and but slightly curved. The crests of the head are wanting and the tubercles have no articular surface, being either merely indicated or entirely absent. The costal sulci, especially that of the twelfth rib, are very indistinct or almost wholly wanting.

The bony ribs increase in length from the first to the seventh and then decrease downward to the twelfth. The lower ribs present a curvature which corresponds to that of the thoracic wall and is known as the surface curvature. It is only in the cases of the first and the posterior portion of the second ribs that the outer (lower) border corresponds to the thoracic wall.

By torsion curvature is meant the torsion of the ribs upon their axes. Such a torsion is found in the first and second ribs, since they pass from a horizontal into an oblique plane, but a certain amount of torsion also occurs in the middle (typical) ribs as their anterior extremities pass from a vertical to an oblique plane, so that the upper margin is directed posteriorly. On the other hand, only the anterior extremities of the two lower ribs are vertical, the posterior extremities having their upper border directed backward (Fig. 35).

The **costal cartilages** connect the bony ribs with the sternum, but it is only in the upper seven ribs that the sternal connection is a direct one (Fig. 34). The eighth, ninth, and tenth ribs have a common cartilage which is continuous with that of the seventh, and the eleventh and twelfth ribs have free ends with short cartilaginous apices. Consequently *true* and *false ribs* may be recognized, the true ribs being the first to the seventh and the false ones the eighth to the twelfth. The eleventh and twelfth ribs are also termed *floating ribs*.

The costal cartilages are flat, are placed vertically like the ribs, and their margins are rounded, possessing neither grooves nor ridges. Their length rapidly increases from the first to the seventh and then decreases markedly, the eleventh and especially the twelfth ribs having merely cartilaginous apices; the first costal cartilage is also very short but broad. The cartilages, particularly of the middle ribs, become distinctly wider as they pass toward the sternum.

The first and second cartilages are inclined slightly downward toward the sternum (from above downward and from without inward), the third is exactly horizontal, and from the fourth downward there is an increasing inclination from below upward and from without inward (Fig. 34). The cartilages of the sixth to the tenth ribs are often quite broad and articulate with each other by variously formed processes passing upward and downward; they form synchondroses or, as is usually the case, diarthroses, and by their union there is formed an arch like lower border for the thorax, the *costal arch*.

FIG. 29.—The eleventh rib of the right side seen from behind (½).

FIG. 30.—The twelfth rib of the right side seen from behind (½).

FIG. 31.—The sternum seen from in front (½).

FIG. 32.—The sternum seen from the left side (½).

THE STERNUM.

The breast-bone, or *sternum*, is a single, flat, oblong bone. It lies approximately in the frontal plane and forms the middle portion of the anterior wall of the thorax, and by its articulation with the clavicles, it completes the shoulder girdle anteriorly. It is composed (Fig. 31) of three distinctly separated portions placed one above the other, an upper broad handle, the *manubrium*, a middle piece, the *body* or *gladiolus*, and a lower piece, the *xiphoid process*. The three portions are either separated by cartilage or are united by bone; the former condition prevails between the manubrium and the body (*synchondrosis sternalis*), while the latter obtains between the body and the xiphoid process. At the synchondrosis between the manubrium and the body there is usually quite an obtuse angle, open posteriorly, the *angulus sterni* (*angle of Louis*). The sternum is not exactly in the frontal plane, but is placed somewhat obliquely, so that the upper end is considerably nearer to the vertebral column than the lower one, a relation which is also partly due to the curvature of the vertebral column (see page 14).

The *manubrium* is considerably broader than the body of the bone, and is broadest above and narrowest below; its anterior surface is slightly convex, and the posterior surface slightly concave. The upper margin presents three rounded notches, a median shallow *interclavicular* or *jugular notch*, and two lateral deeper *clavicular notches*, which are covered with cartilage and accommodate the sternal ends of the clavicles. Immediately below each clavicular notch there is a notch (Fig. 32) upon the lateral margin of the sternum for the reception of the broad costal cartilage of the first rib, which is joined to the sternum in this situation by a synchondrosis, and each side of the lower end of the manubrium presents a demifacet, for articulation with the cartilage of the second rib.

The *body* is usually narrowest above, gradually widening as it descends, until it attains its greatest breadth in its lower third, and then rapidly narrowing again as it approaches the xiphoid process; it is occasionally, however, of uniform width throughout. Its nearly flat anterior (ventral) surface is called the *planum sternale*, and sometimes presents transverse lines (Fig. 34) which indicate the original fusion of several parts situated one above the other.

At the margins of the body (Fig. 32) are found notches for the cartilages of the six lower true ribs, that for the second rib being situated at the junction of the manubrium and the body, that for the sixth rib on the lower margin of the body, and that for the seventh in the angle between the body and the xiphoid process. The notches for the fifth, sixth, and seventh ribs lie close together, and the fourth notch is situated below the middle of the entire bone.

The *xiphoid process* varies greatly in shape and size. It is always markedly narrower than the body, often partly or even wholly cartilaginous, and it is sometimes perforated. The female sternum is usually shorter and broader than that of the male.




Fig. 29.



Fig. 30.

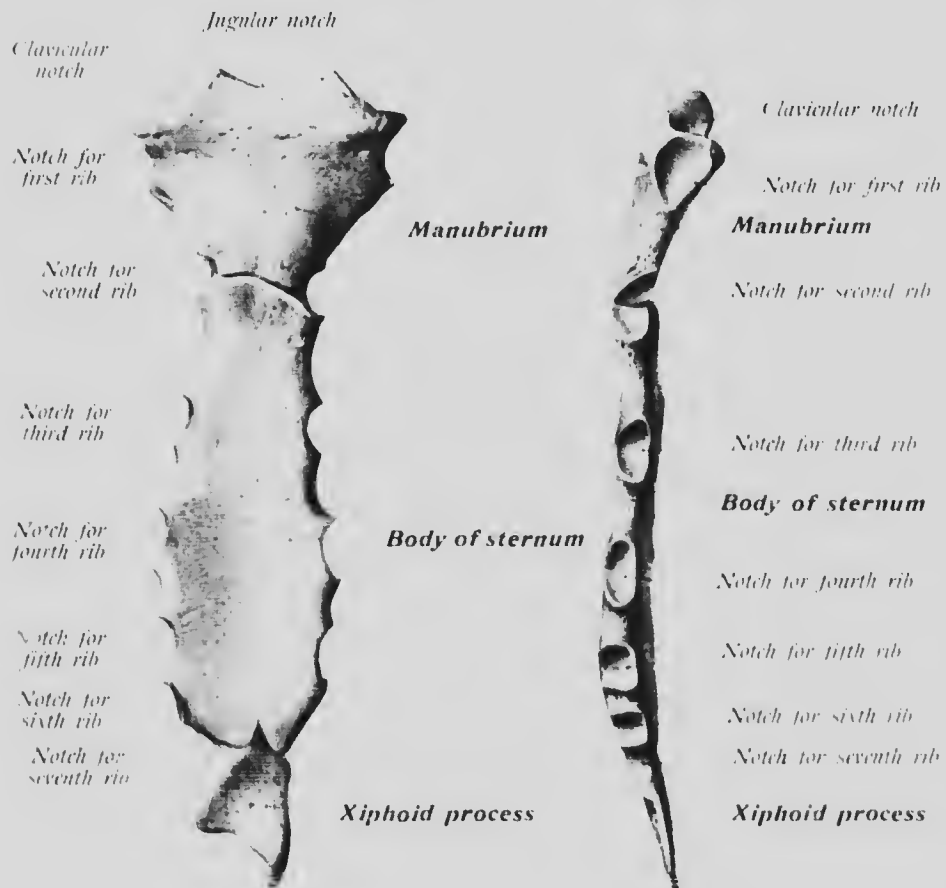


Fig. 31.

Fig. 32.



THE THORAX.

The thorax (Figs. 32 to 36) is formed by the twelve thoracic vertebrae, the twelve pairs of ribs, and the sternum, and is an approximately conical cavity, wide open above and below, and with the apex directed upward.

In it there may be recognized an upper opening and a much larger lower one. The superior thoracic aperture is formed by the first thoracic vertebra, the first rib, and the upper margin of the manubrium. Like the cross-section of the thorax, it is reniform in shape (on account of the projecting vertebral bodies), and is placed not horizontally but obliquely, being directed downward and forward so that at the end of expiration, the upper margin of the sternum usually corresponds to the junction of the second and third thoracic vertebrae.

The inferior aperture is of very irregular form on account of the notches situated between the costal margins and the lower end of the sternum. It is bounded posteriorly by the twelfth thoracic vertebra, by the twelfth and then by the eleventh rib, and anteriorly by the costal margins and the xiphoid process of the sternum. The angle between the costal margin and the xiphoid process is known as the *subcostal* or *inrasternal angle*.

The anterior wall of the thorax, formed by the sternum and the costal cartilages, is considerably shorter than the posterior one, formed by the vertebral column. Above the difference amounts to the height of two entire vertebrae, while below it is usually (according to the length of the xiphoid process) equal to three, since the lower end of the xiphoid process ordinarily is opposite the ninth thoracic vertebra. The lateral wall formed by the ribs is still longer than the posterior one (Fig. 35), the lower margin of the twelfth rib extending downward to the level of the second lumbar vertebra. On either side of the bodies of the vertebrae, which project markedly into the thoracic cavity, there is a broad groove, the *pulmonary groove*. The transverse or frontal diameter of the thorax is considerably larger than the sagittal or sternovertebral one.

The spaces situated between the ribs are known as the *intercostal spaces*, and are eleven in number, the lowermost one, that between the eleventh and twelfth ribs, being very short. Their direction naturally corresponds exactly to that of the adjacent ribs, but they are considerably wider than these structures, especially in front between the cartilages.

THE DEVELOPMENT OF THE RIBS AND OF THE STERNUM.

The ossification of the ribs takes place chiefly from a center which appears in the body of the rib simultaneously with the centers of the vertebrae. Some time after puberty epiphyseal centers appear for the heads and tubercles, and these do not fuse with the main portion of the bone until after the twenty-fifth year.

The manubrium of the sternum is usually formed from a single nucleus, while the body is developed from a number of nuclei (four to thirteen), which are frequently arranged in two more or less distinct longitudinal rows. As a rule, there is but one center for the xiphoid process. Ossification of the sternum does not begin until the fourth or sixth month of embryonic life, and in the xiphoid process not until from the sixth to the twentieth year.

VARIATIONS IN THE SKELETON OF THE TRUNK.

Supernumerary vertebrae are sometimes present, particularly in the lower portion of the vertebral column (sacrum, lumbar vertebrae). Not infrequently ribs are formed from the costal processes of the seventh cervical and of the last lumbar vertebrae, and are designated as cervical and lumbar ribs respectively. The last lumbar vertebra sometimes

FIG. 33.—The thorax together with the left shoulder girdle, seen from behind ($\frac{1}{3}$).

FIG. 34.—The thorax together with the left shoulder girdle, seen from in front ($\frac{1}{3}$).

FIG. 35.—The skeleton of the trunk, divided by a medium longitudinal section, together with the shoulder and pelvic girdles, seen from the left side ($\frac{1}{3}$).

FIG. 36.—The skeleton of the trunk, divided by a median longitudinal section, together with the shoulder and pelvic girdles, seen from the median line ($\frac{1}{3}$).

develops a broad mass which unites with the sacrum and is to be regarded as a sacral rib (lumbosacral vertebra, see page 30), and the posterior arch of the atlas and the portions representing the arches of the sacral vertebrae sometimes fail to ossify, so that the spinal canal remains open posteriorly (rhachischisis).

The ribs frequently fork near the costochondral articulations, the two portions so formed usually uniting again, so that a fenestration of the rib is produced.

Foramina are not rare in the sternum and one is frequently found in the xiphoid process. At the upper end of the manubrium, at the sides of the interclavicular notch, two small bones which are termed *episternal bones* occasionally occur.

THE SKELETON OF THE HEAD.

The sum total of the bones of the head is designated as the *skull* or *cranium*, and this portion of the skeleton differs from the others in that all of its constituents, with the exception of the lower jaw, are firmly united even in the macerated condition (the exact nature of the union is described under "Syn-desmology," page 107), so that special means are required to separate the individual bones from each other, and such a separation is not usually successful if the individual is too old. A skull the bones of which have been isolated, is known as a disarticulated skull.

The completely formed adult skull is an extremely complicated structure, some of the individual parts being united in such a manner that it is quite difficult to recognize them. Some bones, indeed, are scarcely visible in the perfect skull, owing to the fact that they are to a great extent covered or overlapped by the other cranial bones. Before describing the individual cranial bones it will be advantageous to consider briefly the skull as a whole, in order to obtain an idea of the topography of the individual cranial bones and of their chief component parts. The skull will therefore be studied first from in front, then from the side, from below (without the inferior maxilla), and from above, looking downward upon the great cranial cavity which encloses the brain, and finally the outer and inner aspects of the cranial vault will be considered.

THE ANTERIOR ASPECT OF THE SKULL.

If the anterior aspect of the skull (Figs. 37 and 38) be examined, it will be seen that the bony forehead (*frons*) is formed by the vertical portion of the *frontal bone*, and that toward the vertex a slightly serrated suture, the *coronal suture*, separates the vertical plate of the frontal from the two *parietal bones*. The frontal bone also forms the upper margin of the orbit, and at the outer margin of the orbit it is separated from the contiguous *zygomatic* or *malar bone* by a suture, the *zygomatico-frontal suture*. The process of the frontal bone articulating with the zygomatic bone in this situation is known as the *external angular* or *zygomatic process*. To either side of the frontal bone will be observed the anterior inferior or *sphenoidal angle* of the

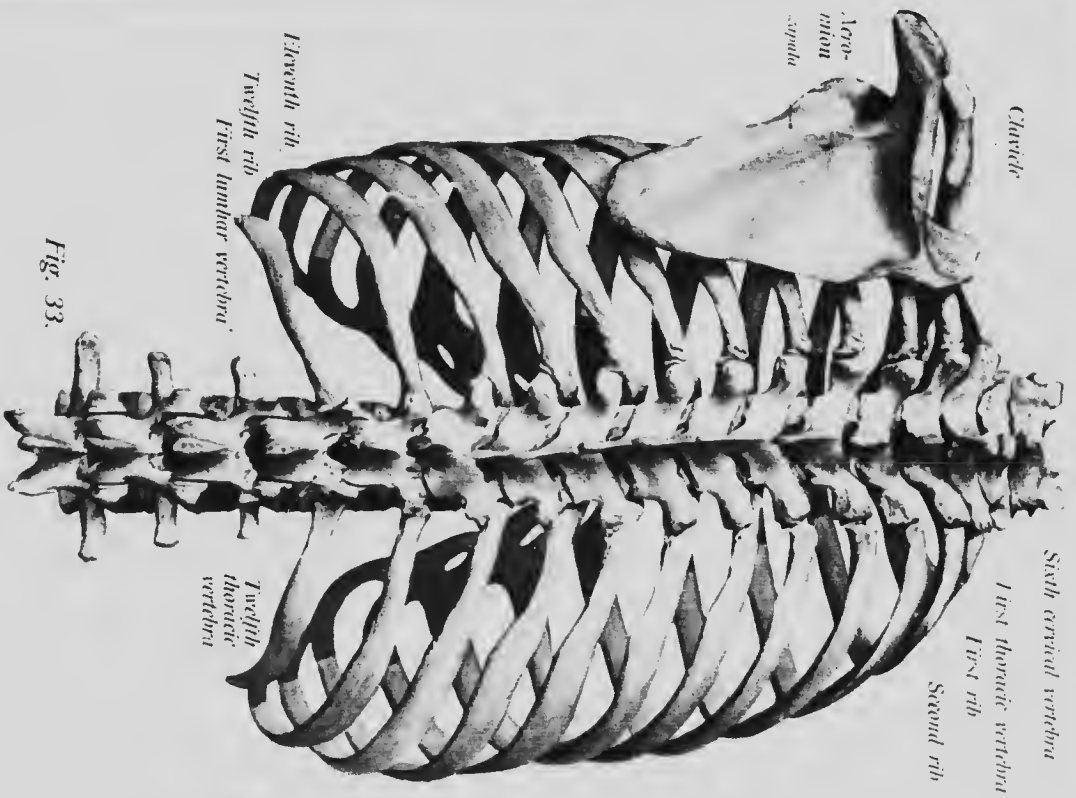


Fig. 33.

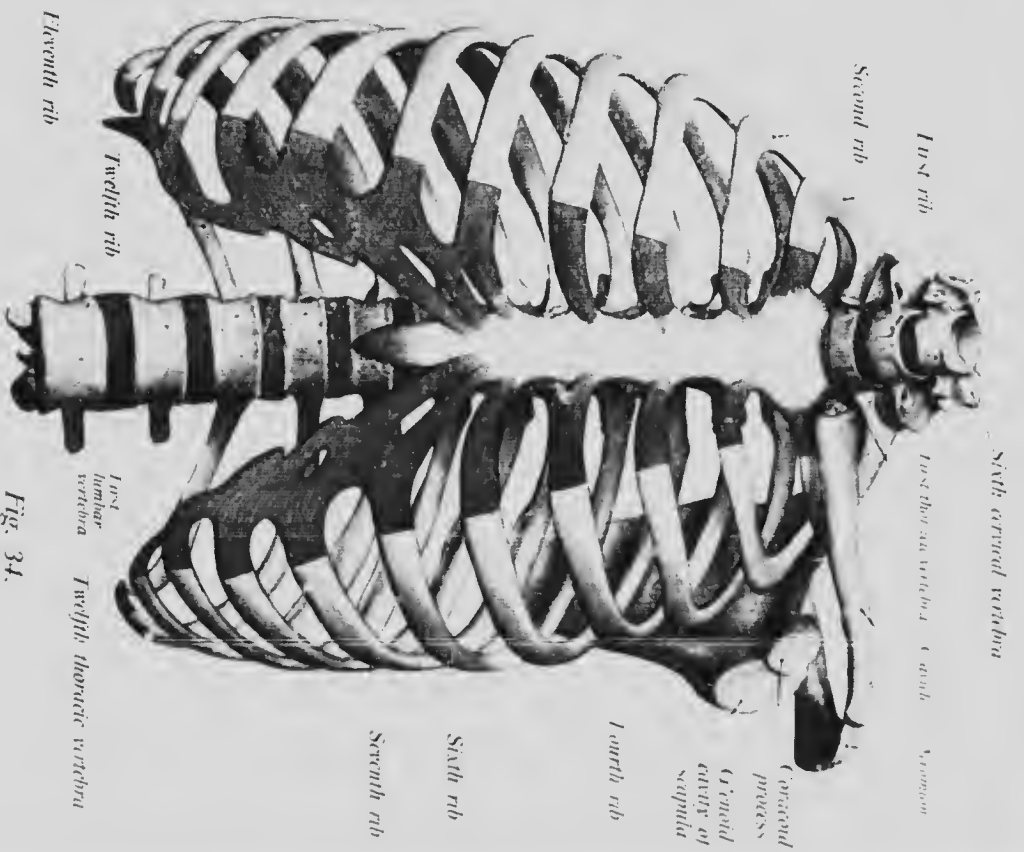
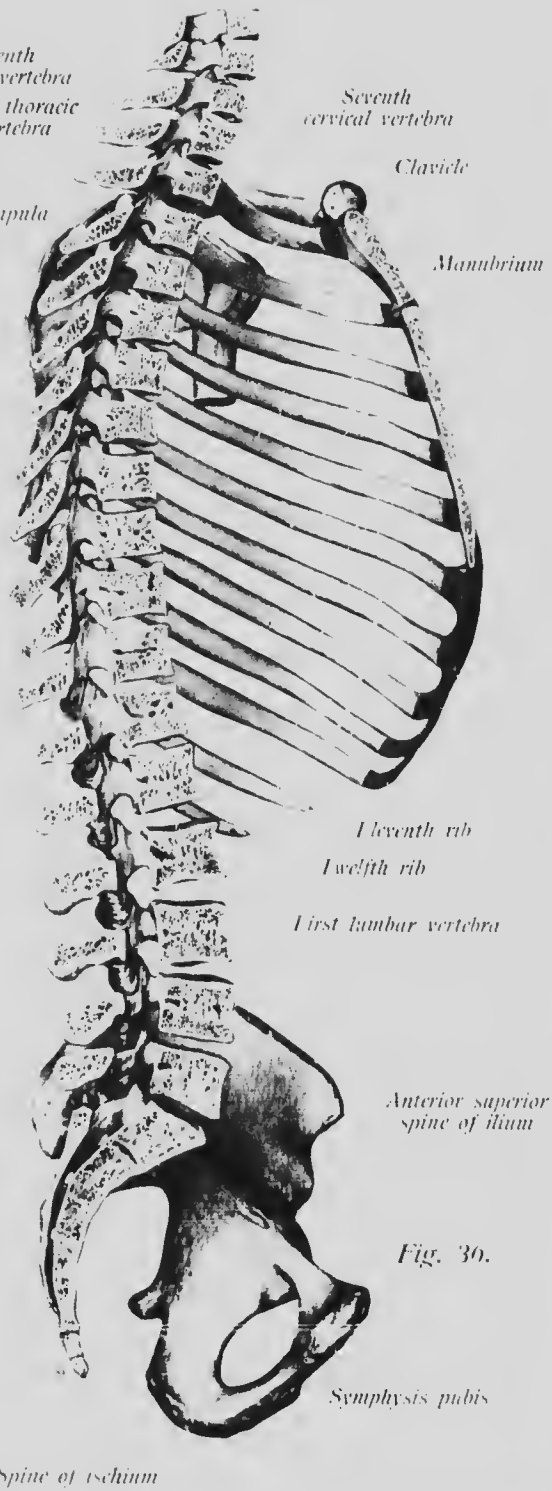
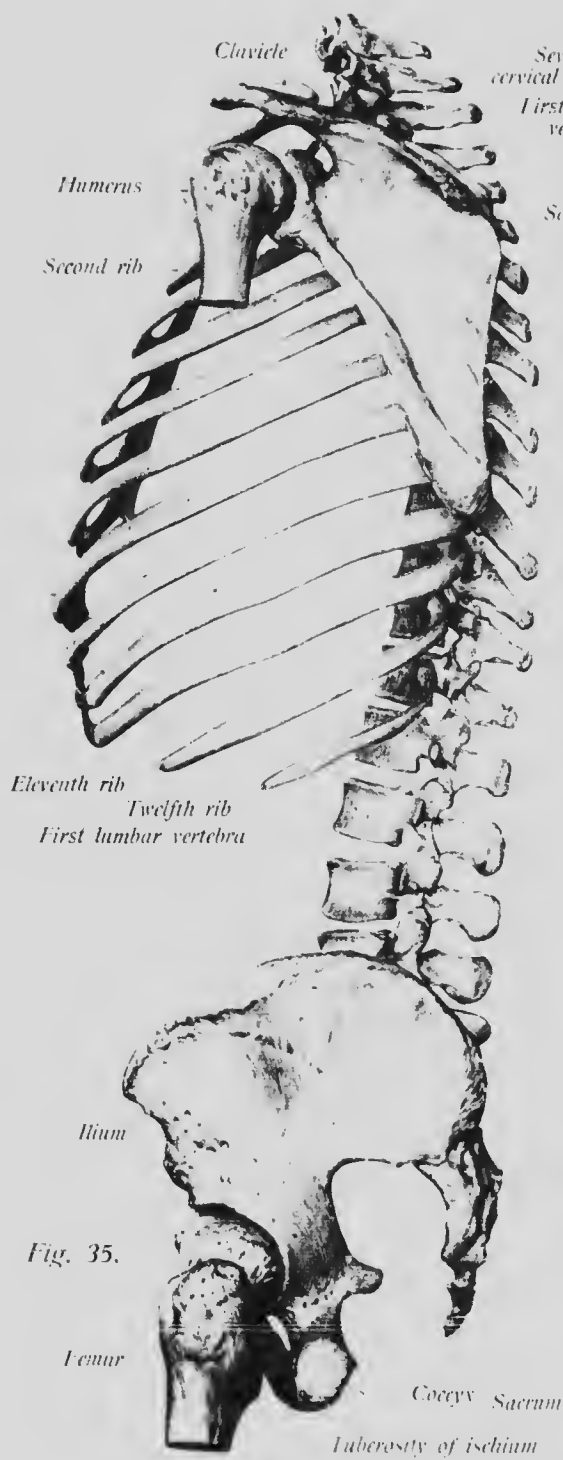


Fig. 34.



parietal bone, which is separated from the greater wing of the *sphenoid bone* by the *spheno-parietal suture*. A portion of the *temporal bone* is also visible on the anterior aspect of the skull.

Below the vertical plate of the frontal bone are the large orbital cavities, the greater portion of whose roofs are formed by the orbital plates of the frontal bone, which articulate with the orbital surface of the greater wings of the sphenoids, the intervening suture being the *spheno-frontal suture*; they are separated from the lesser wing of the sphenoids by the *superior orbital fissure (sphenoidal fissure)*. The *sphenozygomatic suture* is situated in the outer wall of the orbit between the greater wing of the sphenoid and the zygomatic bone, the latter forming a part of the outer wall of the orbit, as well as the outer and a portion of the lower margin of the orbit.

The bony bridge of the nose is placed between the two orbital cavities, and in this situation the frontal bone articulates on either side with three bones which, from within outward, are the *nasal bone*, the *nasal or frontal process* of the maxilla, and the *lachrymal bone*. The intervening sutures are called the *naso-frontal*, the *naso-maxillary*, and the *frontolachrymal* sutures.

The two nasal bones, which form the main portion of the bony bridge of the nose, are separated from each other by the *internasal suture*, and from the nasal process of the maxilla by the *nasomaxillary suture*. They form the upper boundary of the anterior nares (*apertura piriformis*), which are bounded throughout the rest of their circumference by the two *maxillae*. These two bones are separated in the median line by the *intermaxillary suture*, and the frontal or nasal process of each is separated from the corresponding nasal bone by the *nasomaxillary suture*, and borders externally upon the lachrymal bone (for a detailed description see the orbital cavity, page 73). The maxilla also forms the inner half of the floor of the orbit and of the inferior orbital margin, the *inferior orbital (sphenomaxillary) fissure*, in the floor of the orbit separating the maxilla from the greater wing of the sphenoid.

Below the inferior orbital margin, in the body of the maxilla, is the *infraorbital foramen*, and in the anterior nares can be seen the bony *nasal septum*,* and also the *nasal conchae (turbinated bones)*, particularly the inferior ones, which project from the outer wall of the nasal fossae. At the junction of the intermaxillary suture with the lower margins of the anterior nares there is a bony spine, the *anterior nasal spine*. The *zygomaticomaxillary suture* separates the maxilla from the zygomatic bone, whose malar surface is visible in the anterior view of the skull. The lower portion of the maxilla forms the tooth-bearing *alveolar process*.

Finally there is the *mandible* or lower jaw. Its middle portion or body presents a foramen, the *mental foramen*, and the tooth-bearing *alveolar portion*; to either side (and somewhat shortened in the figure) the *ramus*.

THE LATERAL ASPECT OF THE SKULL.

The lateral aspect of the skull (Figs. 39 and 40) contains a number of bones which have been already considered in the description of the anterior cranial region. Above and anteriorly we observe that the frontal bone is separated from the parietal bone by the *coronal suture*, and from the greater wing of the sphenoid by the *spheno-frontal suture*. The *zygomatico-frontal suture* separates the zygomatic process of the frontal bone from the *frontosphenoidal process*

* The anterior portion of the nasal septum is cartilaginous.

of the zygomatic bone, and the *temporal ridge* commences at the zygomatic process of the frontal bone and passes backward in a curved manner over the frontal and parietal bones.

Behind the frontal bone is seen almost the entire parietal bone. It is limited anteriorly by the coronal suture and is separated from the occipital bone posteriorly by the *lambdoid suture*. Its lower border articulates with the greater wing of the sphenoid by the *sphenoparietal suture*, with the squamous portion of the temporal bone by the *squamosal suture*, and with the mastoid portion of the temporal bone by the *parietomastoid suture*.

The only portion of the *occipital bone* visible in the lateral view of the skull is its *squamous portion*, which is separated from the mastoid process of the temporal bone by the *occipitomastoid suture*.

Below the frontal and parietal bones, the temporal surface of the greater wing of the sphenoid is visible. It is separated from the zygomatic bone anteriorly by the *sphenozygomatic suture*, and from the squamous portion of the temporal bone posteriorly by the *sphenosquamosal suture*.

The first portion of the *temporal bone* to attract attention in the lateral aspect of the skull is the squamous portion, from which a long process, the *zygomatic process*, passes almost horizontally forward to articulate with the short temporal process of the zygomatic bone by the *zygomatico-temporal suture*; the two processes together forming the zygoma or *zygomatic arch*. The origin of the zygomatic process of the temporal bone marks the termination of the inferior temporal line as it passes from the parietal to the temporal bone.

Below the inferior temporal line there is upon the lateral surface of the skull a slightly depressed area, the *planum temporale*, formed by the temporal and parietal bones, the greater wing of the sphenoid, and a small portion of the frontal bone. In the zygomatic region the *planum temporale* deepens into the temporal fossa.

The portion of the temporal line situated upon the temporal bone forms approximately the anterior boundary of a second portion of the temporal bone visible in the lateral view of the skull, the *mastoid portion*, which derives its name from a strong conical protuberance, the *mastoid process*.

A third portion of the temporal bone to be seen in the lateral cranial region is the *tymppanic portion*, and is situated immediately below the root of the zygoma, forming the outer and lower circumference of the large opening of the bony external auditory meatus (*meatus acusticus externus*).

In looking at the skull from the side, the malar surface of the zygomatic bone is directed toward the observer. In the lateral aspect of the maxilla there may be observed (as in the anterior view) the anterior nasal spine, the frontal process, the nasomaxillary suture by which it articulates with the nasal bones, and the alveolar process, which is directed toward the similarly named portion of the mandible.

In the lower jaw we see the body with the mental foramen, and almost at right angles with the body, the ramus, the upper portion of which is divided by a deep notch, the *sigmoid notch*, into two processes, the coronoid and the condyloid processes. The articular surface of the condyloid process rests in a fossa of the temporal bone situated below the root of the zygoma, the *mandibular or glenoid fossa*.



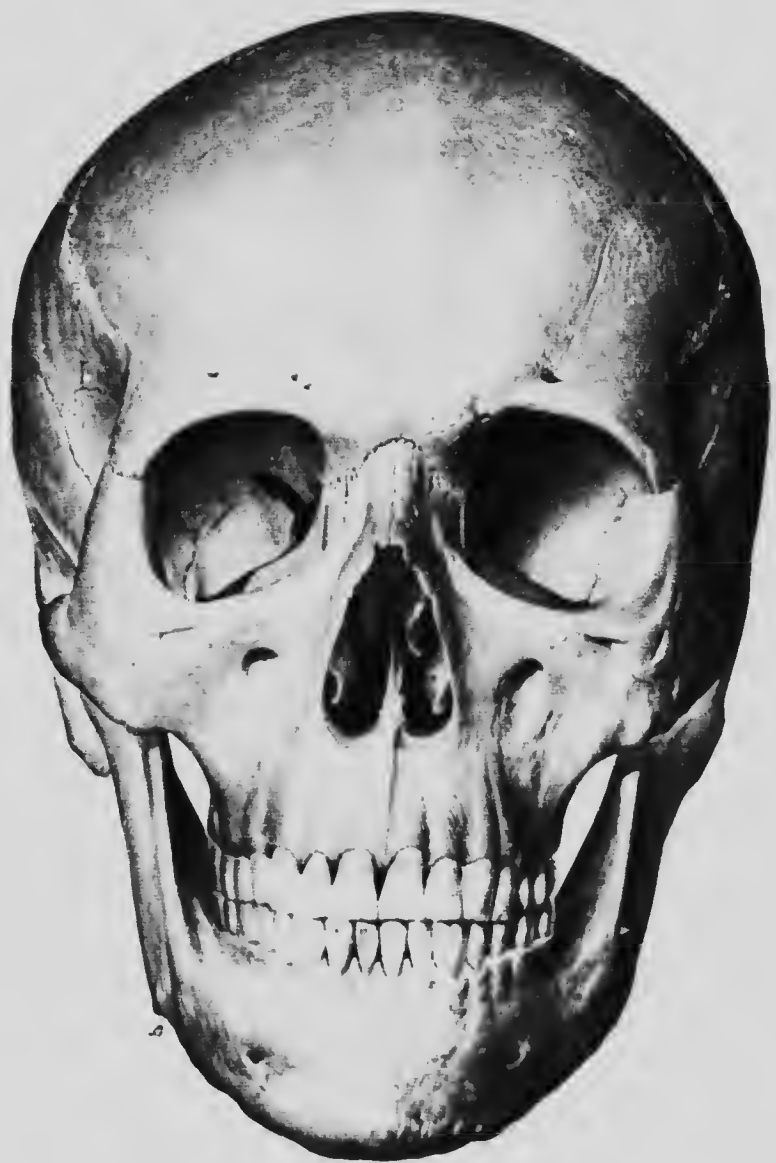


Fig. 37.

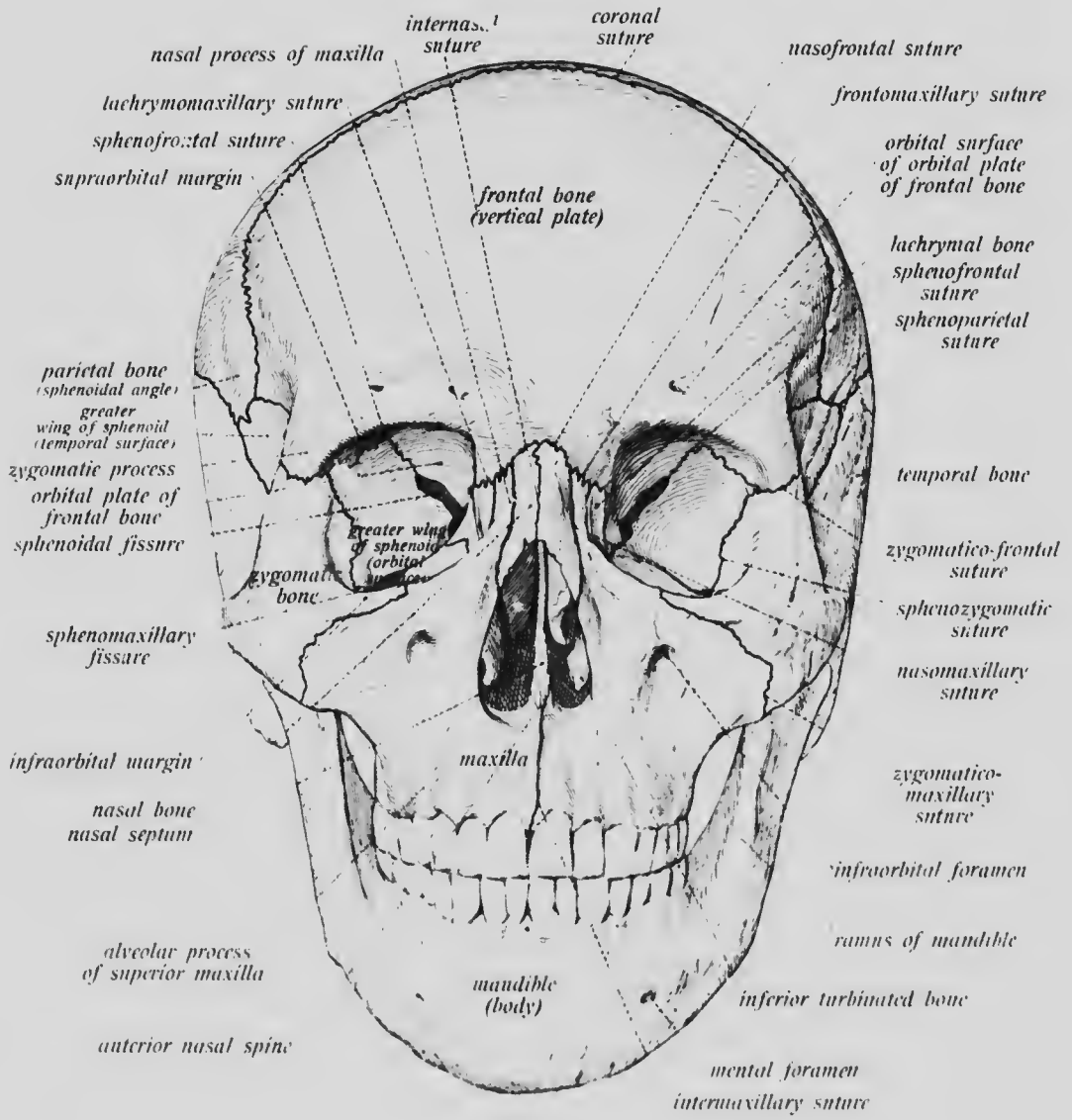


Fig. 38.

Figs. 37 and 38. The skull seen from in front ('').

In fig. 38 the frontal bone is violet, the maxilla yellow, the sphenoid green, the parietals brown, the lacrymals and vomer pink, the ethmoid orange, the zygomatic pink streaked, the mandible blue streaked and the nasals and temporals white.

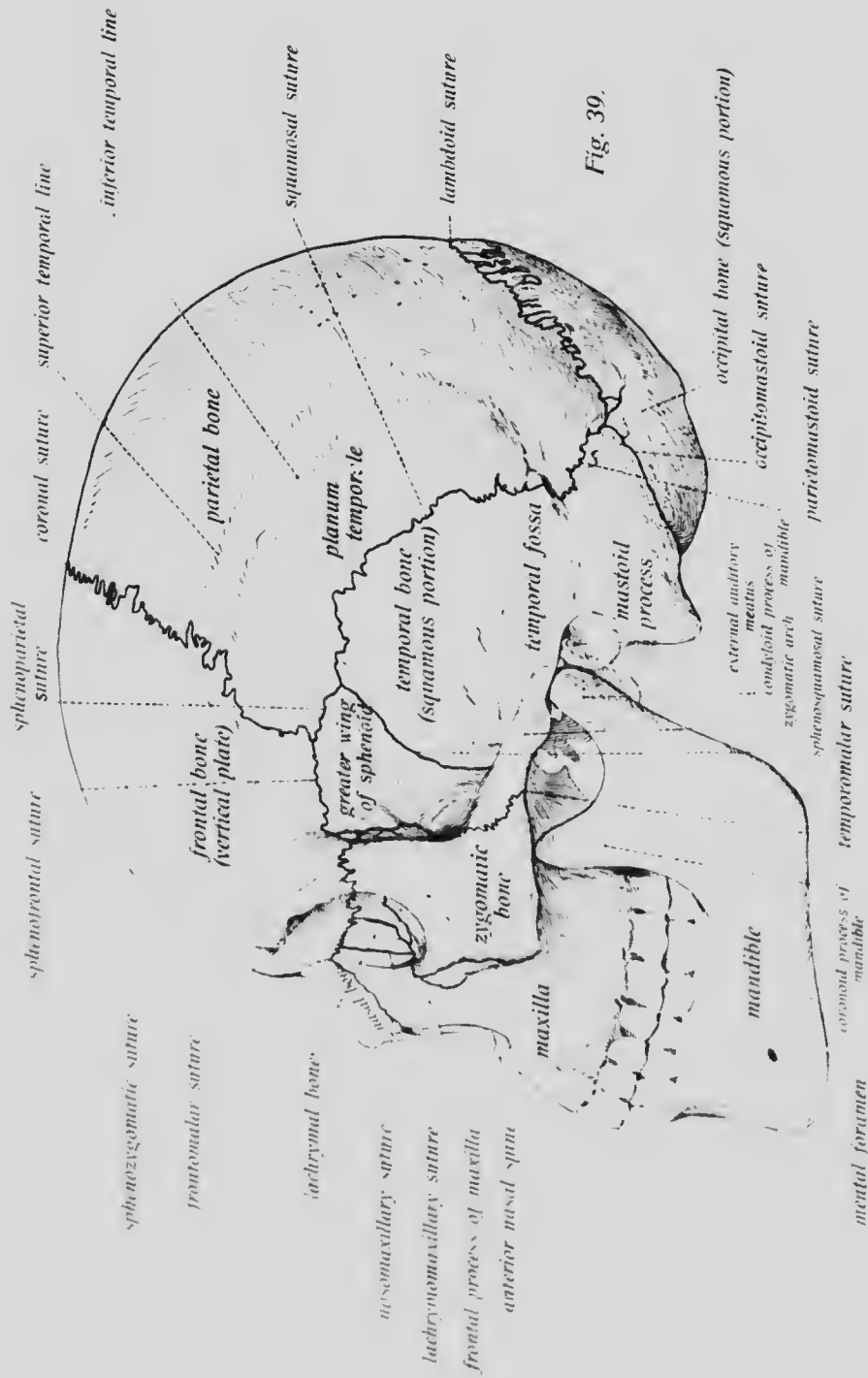


Fig. 39.

Figs. 39 and 40. The skull seen from the left side ($\frac{4}{6}$).

In fig. 39 the various bones are colored as in fig. 38 and in addition the occipital in blue.

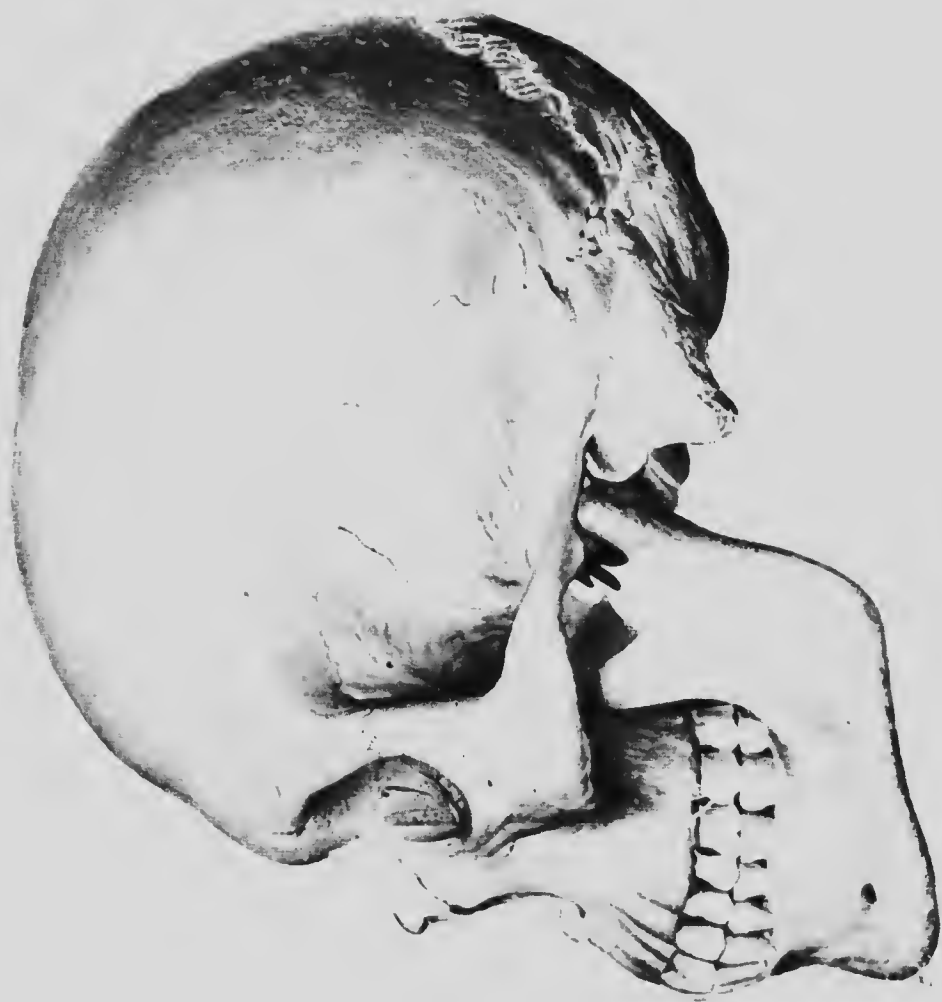


Fig. 40.



THE EXTERNAL SURFACE OF THE BASE OF THE SKULL.

The inferior aspect of the human skull, exposed by the removal of the lower jaw, presents an extremely irregular surface (Figs. 41 and 42), and is termed the external surface of the base of the skull, *basis cranii externa*, to distinguish it from the internal surface which forms the floor of the cranial cavity.

Passing from before backward, there may be noticed first the bony plate of the hard palate, which is bounded externally by the alveolar process of the maxilla and the upper row of teeth. It forms the bony partition separating the oral and nasal cavities, is composed of two bones upon either side, the *palatine process* of the maxilla, forming its anterior two-thirds to three-quarters, while the posterior third or fourth is furnished by the *horizontal portion* of the palate bone. It is traversed in the median line by the *median palatine suture*, the anterior extremity of which contains the *incisive foramen*, a pit-like depression, which leads to a canal of the same name. The palate bones are separated from the palatine processes of the maxilla by the *transverse palatine suture*, and at the posterior extremity of the median palatine suture, the two bones terminate in a spine, the *posterior nasal spine*. The posterior free margins of the horizontal plates of the palate bones form the lower boundary of the posterior nares or *choana*, the posterior outlets of the bony nasal fossae.

To the outer side of the hard palate is seen the short, broad *zygomatic process* of the maxilla, which articulates with the malar bone by means of the *zygomaticomaxillary suture*. There is also to be seen the anterior extremity of the *inferior orbital* or sphenomaxillary fissure between the upper jaw and the greater wing of the sphenoid bone. The zygomatic arch, formed by the junction of the *zygomatic process* of the temporal bone with the *temporal process* of the zygomatic bone, is distinctly visible.

A large portion of the external surface of the base of the skull is formed by the *sphenoid bone*. The greater wings are almost entirely visible and are limited posteriorly and externally by the *sphenosquamosal suture*, their foreshortened temporal surfaces, already noticed in the lateral view of the skull, being seen to unite with the infratemporal surfaces, which are actually situated in the base of the skull, at a distinct angle marked by a rough ridge, the *infratemporal crest*.

The posterior margin of this infratemporal surface is separated from the contiguous petrous portion of the temporal bone by the *sphenopetrosal fissure*, which is continuous internally with an irregular foramen, the *foramen lacerum*. The extreme postero-external angle of the greater wing of the sphenoid, the *spine*, is directed toward the temporal bone, and presents a round opening, the *foramen spinosum*, which leads into the cranial cavity and transmits the middle meningeal artery. In front of this is a larger oval aperture, the *foramen ovale*, through which the mandibular division of the trigeminal nerve emerges from the cranial cavity.

In the middle of the base of the skull a part of the body of the sphenoid bone is visible between the two greater wings, but its anterior portion is partly concealed. It will be observed that the posterior margin of the bony nasal septum, which in this preparation represents the *septum choanarum*, is formed by the *vomer*, which articulates with the body of the sphenoid by means of a broad base, known as the *ala vomeris*.

A strong process, the *pterygoid process*, which is divided lengthwise into two plates, projects

downward from the body of the sphenoid. The broader, larger, external plate is termed the *external pterygoid plate*, and the narrower internal one, the *internal pterygoid plate*, terminates below in a small hook-like process, the *hamular process* (*hamulus pterygoideus*). The pterygoid process of the sphenoid bone articulates in this situation with the horizontal plate of the palate bone and also with a process of this bone, its *tuberosity* (*processus pyramidalis*), which is directed backward and outward and fills the gap between the external and internal pterygoid plates, consequently aiding in the formation of the *pterygoid fossa*, which occupies the interval between the two plates.

In the palate bone, at its junction with the pterygoid process of the sphenoid, there is a larger anterior foramen, the *greater palatine foramen*, and usually several smaller posterior openings, the *lesser palatine foramina*.

The posterior half of the external surface of the base of the skull is formed by the two temporal bones and by the occipital bone. All the four portions of which the temporal bone is composed are visible, namely, the inferior surfaces of the *petrous portion*, of the *mastoid portion*, and of the *tympanic portion*, and a part of the *squamous portion*. The apex of the petrous portion lies in an irregularly shaped opening, the *foramen lacrum*; it is separated from the sphenoid bone anteriorly by the *sphenopetrosal fissure* and from the occipital bone posteriorly by the *petro-occipital fissure*. The mastoid portion articulates with the occipital bone by means of the *occipitomastoid suture*.

Of the squamous portion, one sees mainly the zygomatic process (forming a portion of the *zygomatic arch*) and the *mandibular fossa*, which accommodates the condyloid process of the mandible and presents anteriorly the *articular eminence*. Of the mastoid portion, there is to be seen the mastoid process (*processus mastoideus*), which has a deep groove, the *digastric fossa* (*incisura mastoidea*), upon its inner surface, and, at the side of the occipitomastoid suture, an opening, the *mastoid foramen*. The tympanic portion, with the *meatus auditorius externus*, is placed between the mastoid process and the mandibular fossa, and in front of it there is a fissure, the *Glaserian fissure* (*fissura petrotympanica*).

There are many foramina and fossæ upon the very rough and irregular lower surface of the petrous portion of the temporal bone. Slightly to the inner side and in front of the mastoid process is the pointed *styloid process*, between the mastoid and styloid processes there is an opening, the *stylomastoid foramen*; to the inner side of the styloid process there is a rather deep depression, the *jugular fossa*, leading into the cranial cavity through an irregular opening, the *jugular foramen*; and to the inner side and in front of the jugular fossa there is a round opening, the external orifice of the *carotid canal*.

The *occipital bone* forms the large remaining portion of the external surface of the base of the skull. In the adult skull it is united with the sphenoid so that its basilar portion is continuous anteriorly with the body of the sphenoid bone without demarcation. Posteriorly the *basilar portion* forms the anterior margin of the *foramen magnum*, while the portions of bone external to this foramen, known as the *lateral portions*, present the two large *occipital condyles*, by means of which the skull articulates with the first cervical vertebra or atlas. The base of each condyle is perforated by a short canal, the *hypoglossal* or *anterior condyloid canal*, while the termination of a similar canal, the *condyloid* or *posterior condyloid*, is visible behind the condyle.

med the
minates
erygoid
e palate
directed
plates,
between

ere is a
posterior

vo tem-
bone is
portion,
petrous
om the
teriorly
means

of the
of the
e is to
e fossa
re, an
ternus,
re is a

face of
mastoid
is an
r deep
ng, the
ening,

base of
inuous
basilar
ternal
means
myle
nation

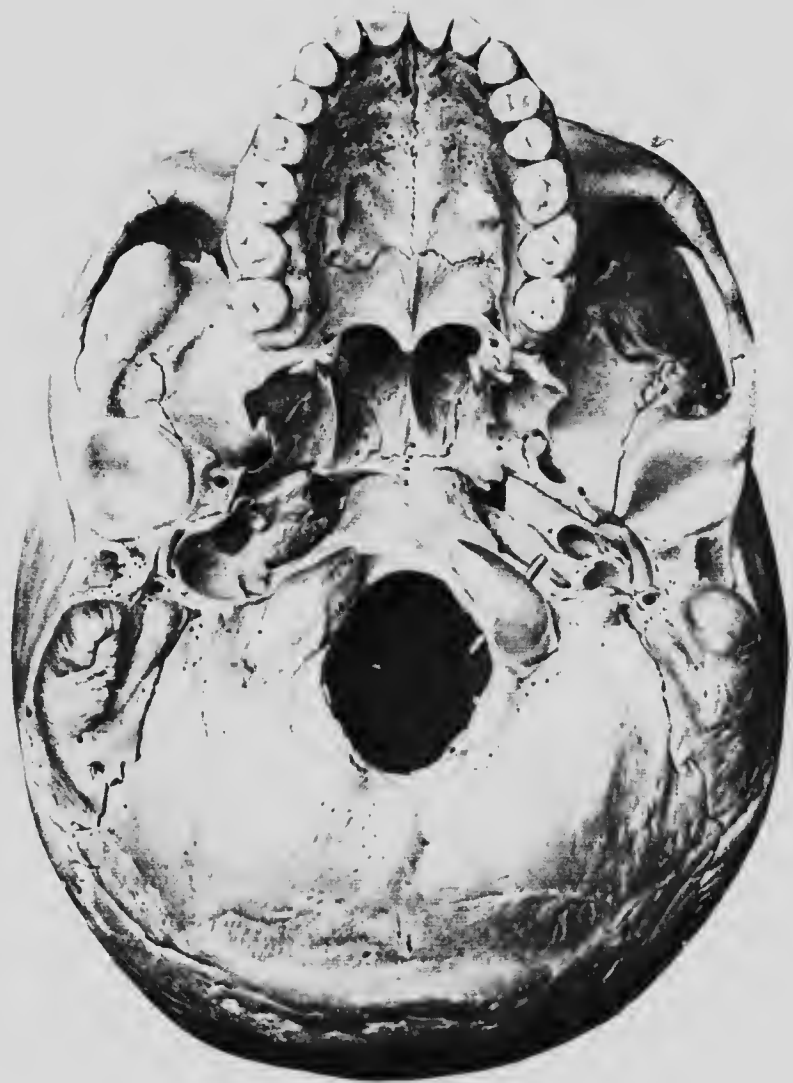


Fig. 41.

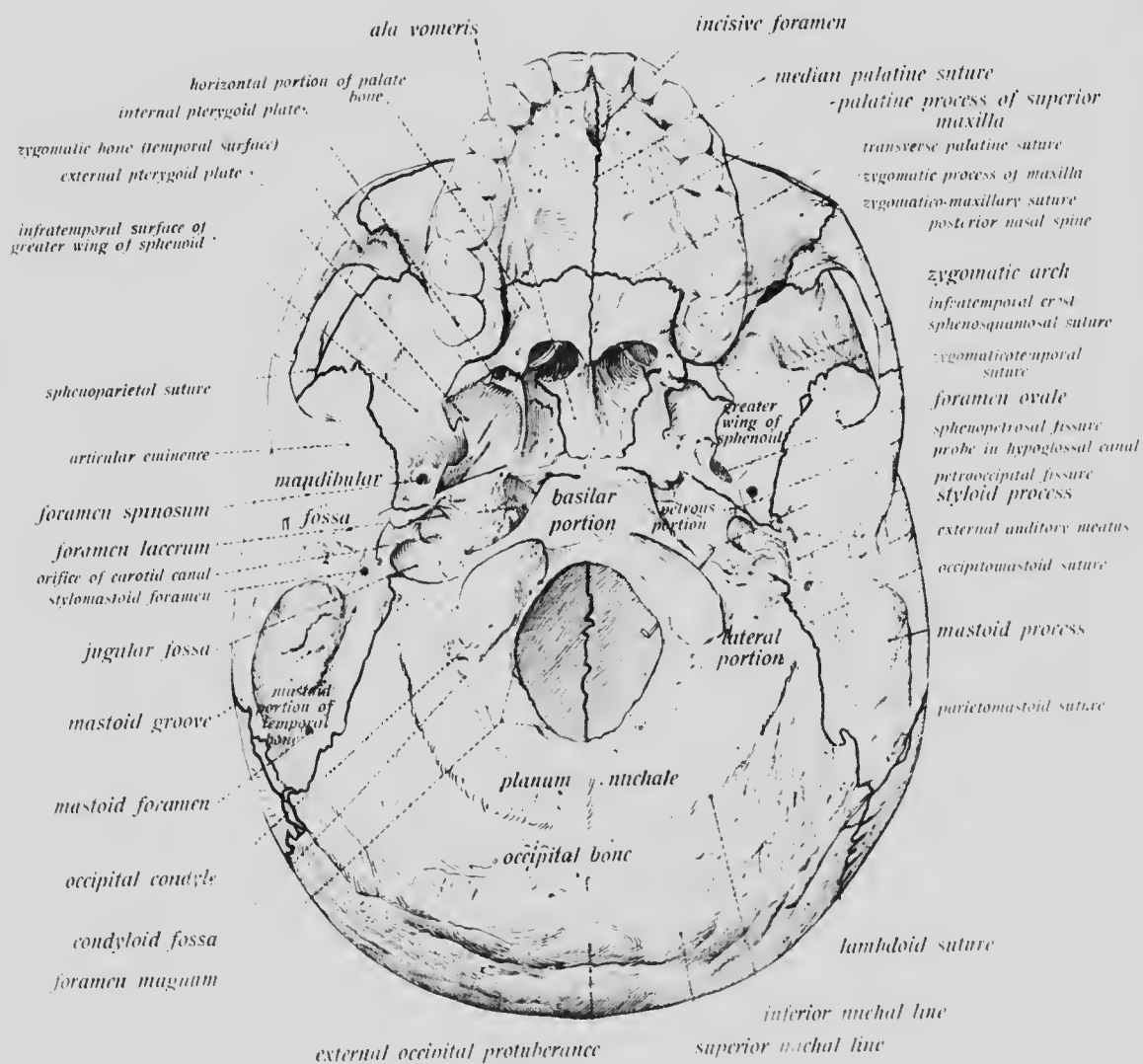


Fig. 42.

Figs. 41 and 42. The skull seen from below, the outer surface of the base (¹).

In fig. 42 the various bones are colored as in fig. 38 except that the occipital is yellow streaked with red and the palatines are blue.

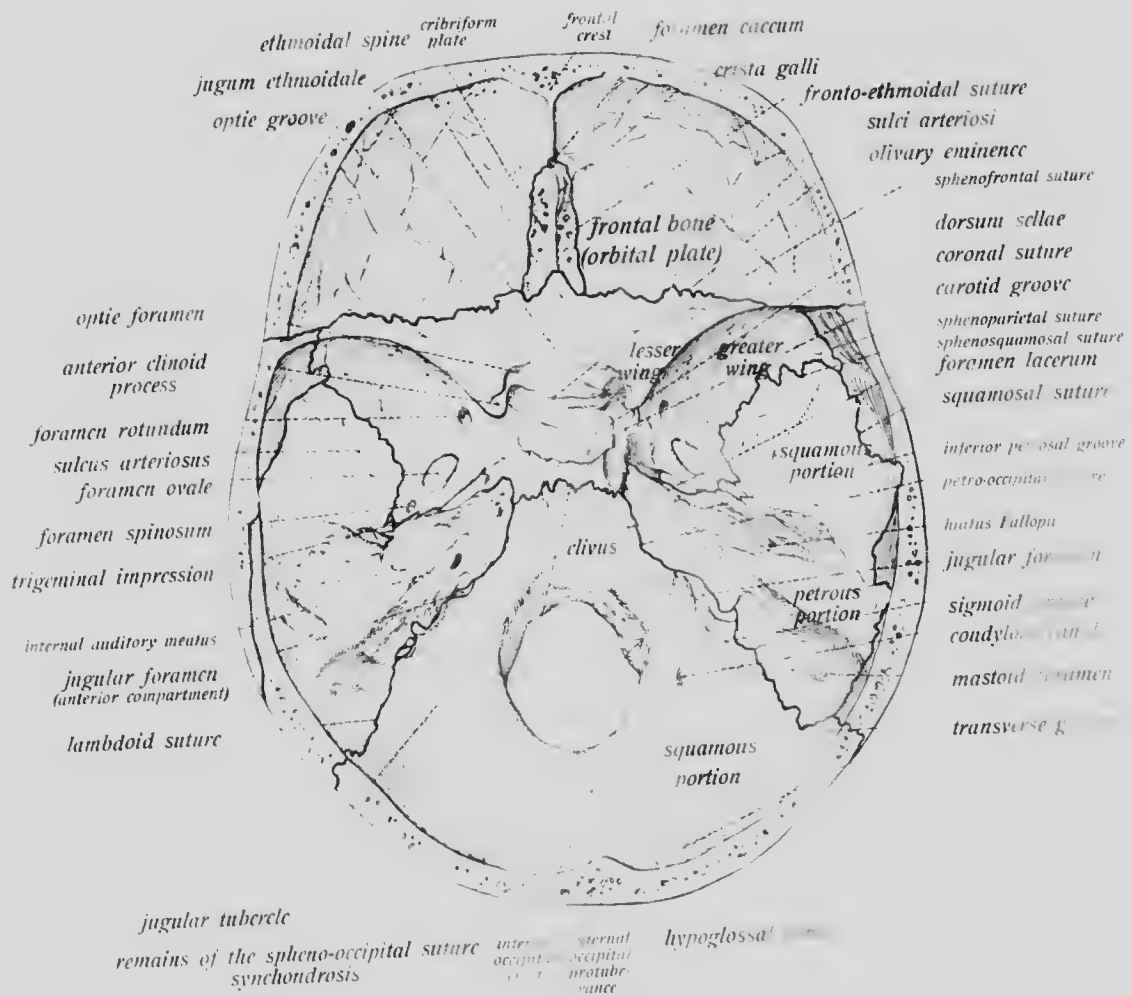


Fig. 43.

Figs. 43 and 44 The inner surface of the base of the skull. In fig. 43 the various bones are shown as in fig. 38.

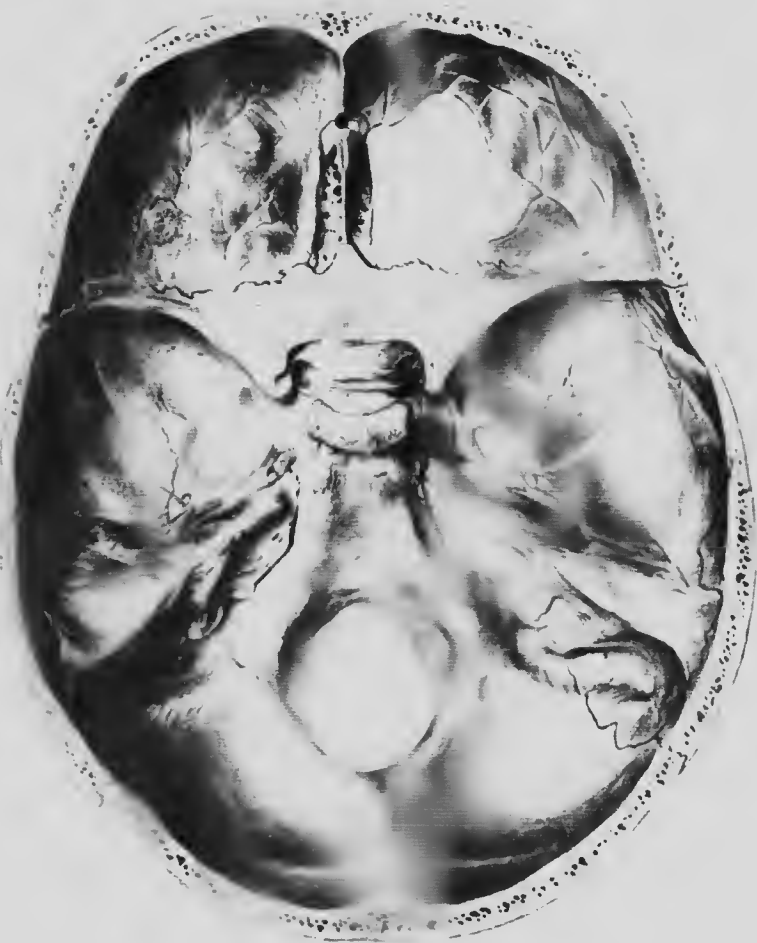

Fig. 44.



There is further to be observed the entire nuchal surface (*planum nuchale*) of the squamous portion and a foreshortened portion of the *planum occipitale*, the boundary between the two portions being formed by a rough line, the *superior nuchal*, which extends laterally from the central *external occipital protuberance*. Below the upper line, the nuchal surface is crossed by the *inferior nuchal line*.

THE INTERNAL SURFACE OF THE BASE OF THE SKULL.

By the internal surface of the base of the skull (Figs. 43 and 44) is understood the floor of the cranial cavity which is exposed by sawing horizontally through the bony cranium and removing the calvarium. It is concave, and contains the so-called cranial fossæ, of which there are recognized an *anterior*, a *middle*, and a *posterior fossa* (Fig. 45). All three fossæ meet in a saddle-like elevation, the *sella turcica*, which is a portion of the body of the sphenoid bone and is situated somewhat anteriorly to the middle of the cranial cavity.

The **anterior cranial fossa** is relatively flat. The greater portion of its floor is formed by the orbital plates of the frontal bone (Figs. 43 and 44), whose upper surfaces are directed toward the cranial cavity and are known as the *cerebral surfaces*. They present peculiar elevations and corresponding depressions, called respectively *cerebral juga* and *digitate impressions*, and they also present grooves for blood-vessels. The two halves of the frontal bone are separated anteriorly by a ridge, the *frontal crest*, which commences at a foramen, the *foramen cæcum*, and posteriorly the orbital plates of the frontal bone articulate with the lesser wings of the sphenoid by the *sphenofrontal suture*.

Lying between the two orbital plates of the frontal bone and extending from the foramen cæcum to the sphenoid bone there is a thin bony plate, characterized by being perforated by numerous foramina. It is the *cribriform plate* of the *ethmoid bone*, and it presents in its median line a comb like elevation, the *crista galli*, and articulates with the frontal bone by means of the *fronto-ethmoidal suture*.

In the median line behind the cribriform plate of the ethmoid is seen the *jugum sphenoidale* of the sphenoid bone with the *ethmoidal spine*, and to either side are observed the *lesser wings* of the bone, these latter arising from either side of the body of the sphenoid by two roots which enclose an opening, the *optic foramen*. Near the *sella turcica*, the lesser wing of either side projects into the middle cerebral fossa as a short, slightly curved, hook like process, the *anterior clinoid process*.

The **middle cranial fossa** is much deeper and larger than the anterior one, and is divided into two halves by a marked median elevation, the *sella turcica*. In this there may be recognized the high back of the saddle, the *dorsum sellæ*, with the *hypophysial fossa* in front of it, and, still further anteriorly, the *olivary eminence (tuberculum sellæ)*. In front of the latter is a groove, the *optic groove (sulcus chiasmatis)*, and a second groove, the *carotid groove*, is situated on each side of the *sella turcica*. A short distance behind the *dorsum sellæ* we find the *spheno-occipital synchondrosis*, a slightly serrated line which indicates the boundary between the body of the sphenoid and the occipital bone and is the remains of the synchondrosis originally separating the two bones (see page 47).

To the outer side of the sella turcica we see the cerebral surface of the greater wing of the sphenoid bone, which is separated from the overlying lesser wing of the sphenoid by the *superior orbital* or *sphenoidal fissure*. The remaining boundaries of this surface are the same as those seen on the external surface of the base of the skull, namely, the *sphenoparietal* and *sphenosquamosal sutures*, the *foramen lacerum* or *sphenopetrosal fissure*. Near its origin from the body, the greater wing of the sphenoid bone contains three orifices; the *foramen rotundum*,

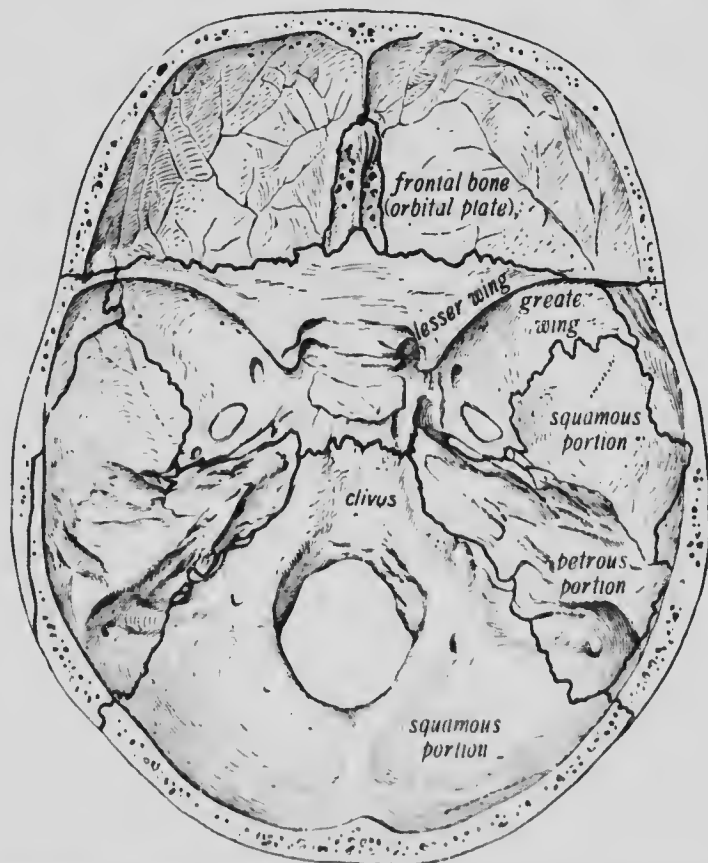


FIG. 45.—The inner surface of the base of the skull; the anterior fossa is colored blue, the middle fossa white, and the posterior fossa pink.

directed obliquely anteriorly and leading into a short canal, the *foramen ovale*, and the *foramen spinosum*.

In addition to the greater wing of the sphenoid bone, the floor of the middle cranial fossa is formed by the cerebral surface of the squamous portion of the temporal bone and by the anterior surface of the petrous portion, the posterior surface of the petrous portion and the mastoid portion helping to form the floor of the posterior cranial fossa. The boundaries of the temporal

bone in the middle fossa are also similar to those observed upon the external surface of the base of the skull, namely, the *sphenosquamosal* and *squamosal sutures* and the *foramen lacerum*.

Upon the cerebral surface of the squamous portion of the temporal, commencing at the foramen spinosum, there is a groove, the *sulcus arteriosus*, which is continued by manifold ramifications upon the inner surface of the cranial vault. Upon the apex of the petrous portion, which is in contact with the body of the sphenoid, there is a shallow depression, the *trigeminal impression* for the Gasserian ganglion, and at about the middle of its anterior surface there is a slit-like opening, the *hiatus canalis facialis (hiatus Fallopii)*, while upon its superior margin there runs a shallow groove, the *superior petrosal groove*.

The **posterior cranial fossa** is the largest of all. Its floor is formed by only the occipital and temporal bones, the boundaries between which in the posterior fossa are the *petro-occipital fissure*, the *jugular foramen*, and the *occipitomastoid suture*.

Upon the posterior surface of the petrous portion of the temporal bone there is a large, round, irregular opening, the *internal auditory meatus (porus acusticus internus)*.

The *jugular foramen*, situated between the temporal and occipital bones, is formed in the following manner. Each of the two bones possesses a corresponding notch which is so subdivided that the jugular foramen consists of a smaller anterior and of a larger posterior compartment, the former giving passage to the glosso-pharyngeal, pneumogastric, and spinal accessory nerves; the latter to the internal jugular vein.

In the posterior fossa the mastoid portion of the temporal bone exhibits a curved groove, the *sigmoid groove*, which begins at the posterior compartment of the jugular foramen and is at first situated on the lateral portion of the occipital bone, passing in a curve around the *jugular process*, which is directed toward the temporal bone. In the mastoid portion of the temporal bone is the inner (cerebral) orifice of the *mastoid foramen*, and at the junction of the temporal, parietal, and occipital bones, where the lambdoid and occipitomastoid sutures become continuous, the sigmoid groove bends at almost a right angle into the *transverse groove*, so that the posterior inferior angle of the parietal bone, the *mastoid angle*, also aids in its formation. The transverse groove passes across the inner surface of the squamous portion of the occipital bone as a markedly shallower groove to a median crucial elevation, the *crucial eminence*, whose center forms the *internal occipital protuberance*.

The cerebral surface of the occipital bone forms by far the greater portion of the floor of the posterior fossa. Its *basilar portion* forms a portion of the so-called *clivus*, a steep bony incline passing from the back of the sella turcica to the border of the foramen magnum; the anterior portion of the clivus is formed by that part of the body of the sphenoid which is situated anterior to the original sphenoccipital synchondrosis. At the outer side of the clivus there is the shallow, *inferior petrosal groove*, which is formed by the junction of the occipital and temporal bones in the petro-occipital fissure.

The lateral portions of the occipital bone, situated to either side of the foramen magnum, present two rounded projections upon their cerebral surface, the *jugular tubercles*, whose bases are traversed by the previously mentioned hypoglossal or anterior condyloid canal, and behind the jugular process (usually in the beginning of the sigmoid groove) is situated the internal extremity of the condyloid canal.

FIG. 46.—The skull seen from above ($\frac{1}{2}$).
 X = foramen parietale.

FIG. 47.—The inner surface of the roof of the skull (calvarium) ($\frac{1}{2}$).

The posterior margin of the round *foramen magnum*, situated in the middle of the posterior fossa, is formed by the squamous portion of the occipital, which exhibits, below the transverse groove, two concave depressions, the *inferior occipital fossæ*, which are separated by a median ridge, the *internal occipital crest*.

THE SUPERIOR ASPECT OF THE SKULL.

The superior aspect of the skull (Fig. 46) is much less complicated. It shows only four bones, the vertical portion of the frontal, the large surfaces of the two parietals, and the apex of the squamous portion of the occipital. The visible sutures are the coronal suture, the sagittal suture, separating the parietal bones throughout their entire length, and the lambdoid suture, which forms an obtuse angle with the sagittal suture. In the parietal bone, on either side of the sagittal suture and at about the junction of the third and fourth quarters, there is an orifice, the *parietal foramen*, and the foreshortened *temporal line* can also be seen.

THE INNER ASPECT OF THE CRANIAL VAULT OR CALVARIA.

The inner surface of the cranial vault (Fig. 47) corresponds to the outer surface with slight differences. It presents the same bones, frontal, parietal, and occipital, and the same sutures, the coronal, sagittal, and lambdoid. Upon the inner surface of the sagittal suture we find a shallow groove, the *sagittal groove*, which commences at the crest of the frontal bone and passes backward over the parietal to the occipital bone. The cerebral surfaces of all the bones of the cranial vault show vascular grooves, the *sulci arteriosi*; they are found in greatest numbers upon the parietal bone and, next in frequency, upon the frontal bone. Small inconstant depressions, often of inconsiderable depth and situated particularly along the sagittal suture, are designated as the *foveolæ granulares* or *Pacchionian depressions*.

THE BONES OF THE SKULL.

After this consideration of the skull as a whole we turn to the description of the individual bones of the skull. These may be divided into two groups: (1) the bones of the cranium (*cranium cerebrale*), and (2) the bones of the face (*cranium viscerale*). The cranial bones are the *occipital* bone, the *sphenoid* bone, the two *temporal* bones, the two *parietal* bones, the *frontal* bone, and the *ethmoid* bone. The facial bones are the *nasal* bones, the *lacrimal* bones, the *vomer*, the *inferior turbinated bones* (*conchæ nasales inferiores*), the *maxilla*, the *palate* bones, the *zygomatic* bones, the *mandible*, and the *hyoid* bone.

The bones of the skull may also be classified according to the method of their development (see page 21), and from this standpoint they are quite heterogeneous structures, some of them, such as those of the base of the skull, are developed in the primordial cartilaginous cranium, some are portions of the visceral skeleton, and some are so-called covering

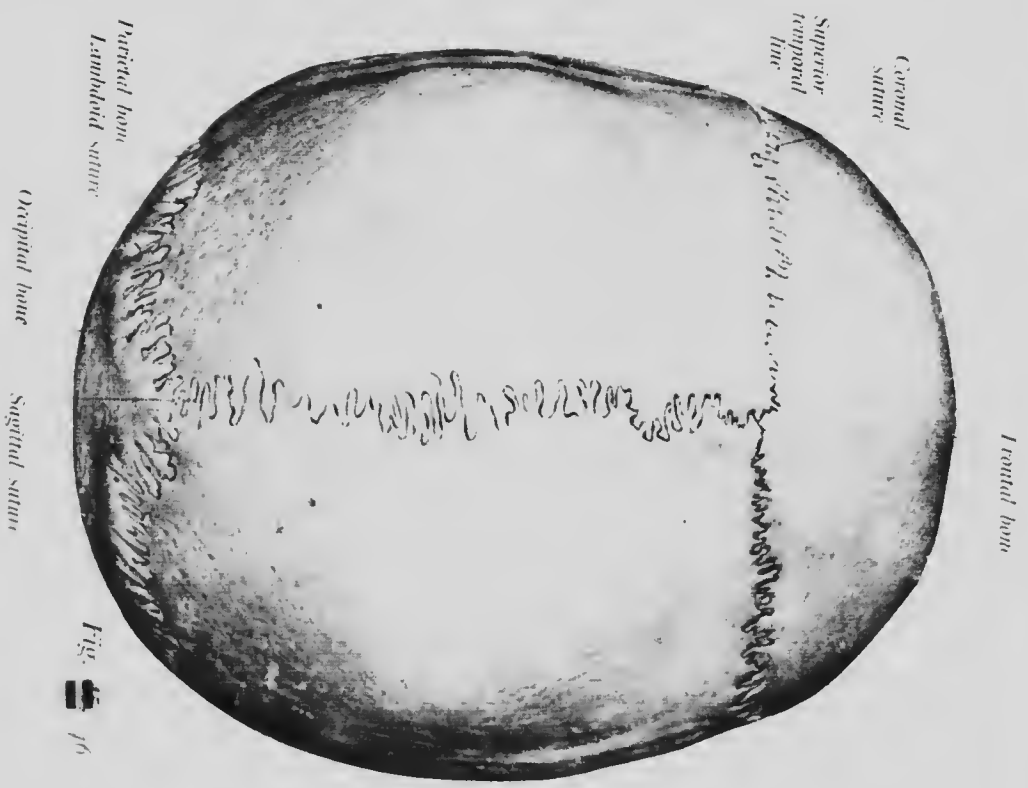


Fig. 76

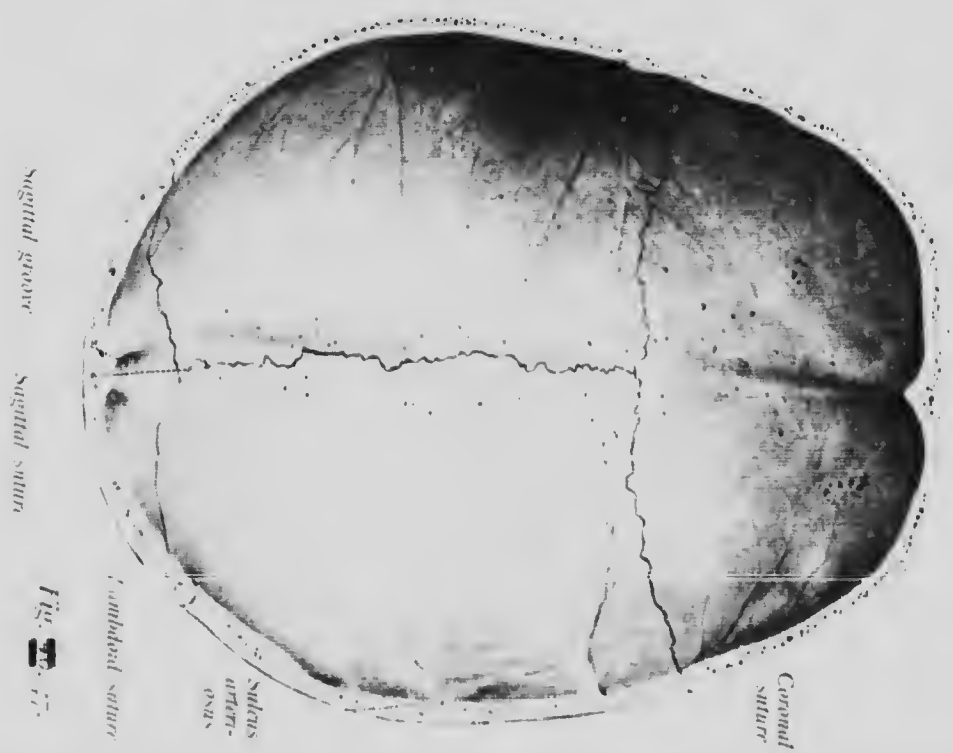


Fig. 77

anterior
transverse
median

by four
the apex
sagittal
suture,
side of
forifice,

slight
sutures,
find a
passes
of the
numbers
repres-
desig-

individual
antrum
occipital
e, and
er, the
omatic

and from
the devel-
covering



or dermal bones, which serve to close in the cranium, the upper portion of which is represented in the cartilaginous primordial skeleton. Only a part of the cranial bones are preformed in cartilage, the majority being formed by direct ossification of connective tissue. Those which are preformed in cartilage are also known as primordial bones, and they are the occipital, with the exception of the upper part of the squamous portion, the sphenoid, with the exception of the internal plate of the pterygoid process, the entire ethmoid and the inferior turbinal, and the petrous and mastoid portions of the temporal.

The cranial bones formed in membrane are the upper part of the squamous portion of the occipital, the parietals, the frontal, the squamous and tympanic portions of the temporals, the vomer, the nasals, and the lacrymals.

The only portions of the visceral cephalic skeleton which are preformed in cartilage and are to be regarded as primordial bones are the hyoid and the small auditory ossicles situated within the temporal bone. The following bones of the face are formed in membrane: the maxilla, the palate bones, the internal plates of the pterygoid processes of the sphenoid bone, the zygomatic bones, and the mandible.

THE CRANIAL BONES.

THE OCCIPITAL BONE.

The occipital bone (Figs. 48 to 51) is composed of three portions which are not sharply separated, and of these portions one is paired and two are single. They are termed the *basilar portion*, the *lateral portions*, and the *squamous portion*, and are grouped about the *foramen magnum* in such a way that the basilar portion is in front, the lateral portions are to either side, and the squamous portion is behind the foramen.

The **basilar portion** of the adult skull and the body of the sphenoid bone are united by osseous tissue (Fig. 51), but up to the time of puberty they are articulated by the *spheno-occipital synchondrosis* or *fissure* (see page 47). The lower surface of the basilar portion, which forms a part of the external surface of the base of the cranium, lies almost horizontally, but the cerebral surface passes obliquely from above downward and from before backward and forms the *clivus* (Blumenbachii). The inferior surface (Fig. 50) presents a median projection, the *pharyngeal tubercle*, for the attachment of the pharyngeal aponeurosis, and to either side are roughened surfaces for the insertions of the rectus capitis anticus minor and major muscles.

The surface of the *clivus* (Figs. 43, 44, and 51) is slightly concave and its lateral margins exhibit a groove, frequently quite shallow, the *inferior petrosal groove*, which forms with a similar groove of the temporal bone (see page 55), over the petro-occipital fissure, a channel for the inferior petrosal sinus of the dura mater.

The **lateral portions**, also termed the *condyloid portions*, extend posteriorly, and gradually become broader and thinner as they pass into the squamous portion of the bone. Their most important structures are the *condyles* (Figs. 41, 42, 48, and 50), which are situated upon their inferior surface and articulate with the first cervical vertebra. The articular surfaces of the condyles are reniform in shape and are markedly convex, particularly from before backward; they extend from the anterior margin to about opposite the middle of the foramen magnum, but only their posterior halves border directly upon this opening. Behind the condyles there is a depression, the *condyloid fossa* (Fig. 48), with the (inconstant) orifice of the *condyloid canal*, a so-called emissary foramen, and the base of the condyle is traversed from side to side by the *hypoglossal canal* (Figs. 49 and 50), through which the twelfth cranial nerve, the hypoglossal, leaves the skull.

FIG. 48.—The occipital bone seen from behind ($\frac{1}{3}$).

FIG. 49.—The occipital bone seen from in front ($\frac{1}{3}$).

FIG. 50.—The occipital bone seen from below ($\frac{1}{3}$).

FIG. 51.—The occipital and sphenoid bones seen from above ($\frac{1}{3}$). The right anterior clinoid process is fused with the middle one.

Upon the outer margins of the lateral portions of the bone, projecting toward the temporal bone, there is a prominence, the *jugular process* (Figs. 48, 49, 50, and 51), in front of which is situated a notch, the *jugular notch*, which is subdivided by a small *intrajugular process* (Figs. 50 and 51), into a small anterior and a larger posterior compartment. By apposition of the notches to corresponding notches of the temporal bone there is formed the *jugular foramen* (Figs. 43 and 44), which is divided into two compartments by a ligament extending between the corresponding intrajugular processes (see page 55).

The inner or cerebral surface of the lateral portion of the occipital exhibits a blunt protuberance, the *jugular tubercle* (Fig. 51), above and to the outer side of the internal orifice of the hypoglossal canal, which consequently passes through the lateral portion of the bone, below the jugular tubercle and above the condyle. Beside the jugular process and beginning in the jugular notch is seen the commencement of the *sigmoid groove* (see page 43), which curves over the cerebral surface of the jugular process.

The largest portion of the occipital bone is formed by the **squamous portion**, which is flat and moderately curved, and in which an internal and an external surface may be recognized. It is bounded by the occipitomastoid suture, forming the *mastoid border*, and by the lambdoid suture, forming the *lambdoid border*, and its apex is situated at the posterior extremity of the sagittal suture.

The most striking formation upon the rather markedly concave internal or cerebral surface (Fig. 49) is the *crucial eminence*, the ridges of which form four shallow fossæ, two *superior occipital fossæ* and two *inferior occipital fossæ*. The middle of the cross is formed by the *internal occipital protuberance*, while the inferior median limb, the *internal occipital crest*, passes to the posterior margin of the foramen magnum. The remaining three limbs are grooves produced by the venous sinuses of the dura mater; the two lateral ones are called the *transverse grooves* and the superior one is the posterior extremity of the *sagittal groove* (see page 44).

The external surface of the squamous portion (Fig. 48) is markedly convex in both the sagittal and transverse directions, and is divided into two surfaces, an inferior nuchal surface (*planum nuchale*), roughened for the insertion of numerous muscles, and a superior smoother triangular occipital surface (*planum occipitale*). These two surfaces are separated by the superior nuchal line, a roughened ridge for muscular attachment, which passes in a curved direction from the *external occipital protuberance* to the occipito-mastoid suture, and a short distance above the linea superior we observe the somewhat more sharply curved *linea suprema*.

The entire planum nuchale, from the external occipital protuberance to the foramen magnum, is traversed by the *external occipital crest*. From about the middle of this crest, and parallel to the linea suprema, there passes outward the *inferior nuchal line*, upon which there are fre-

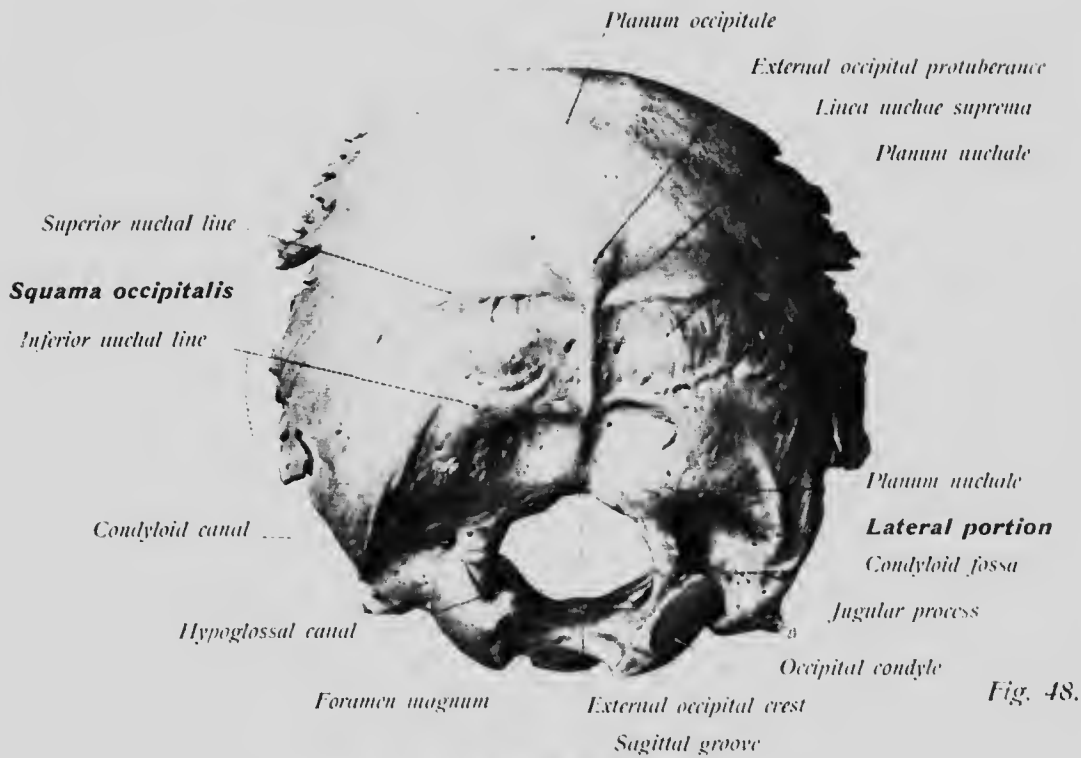


Fig. 48.

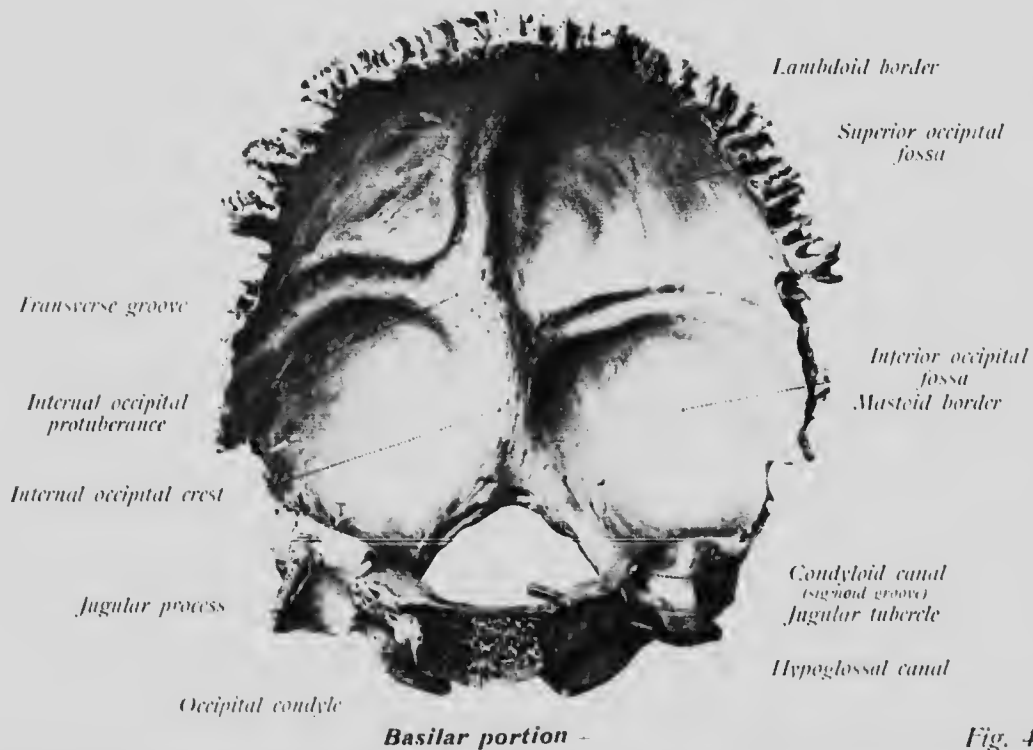


Fig. 49.



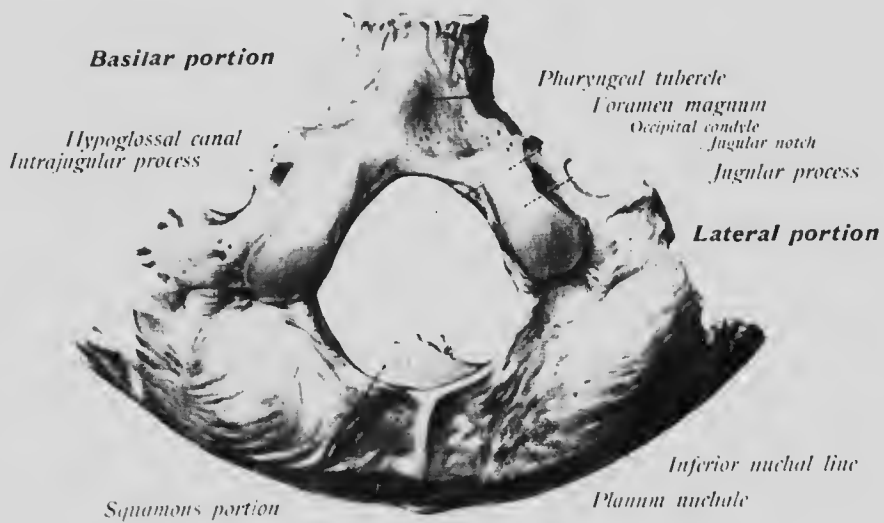


Fig. 50.

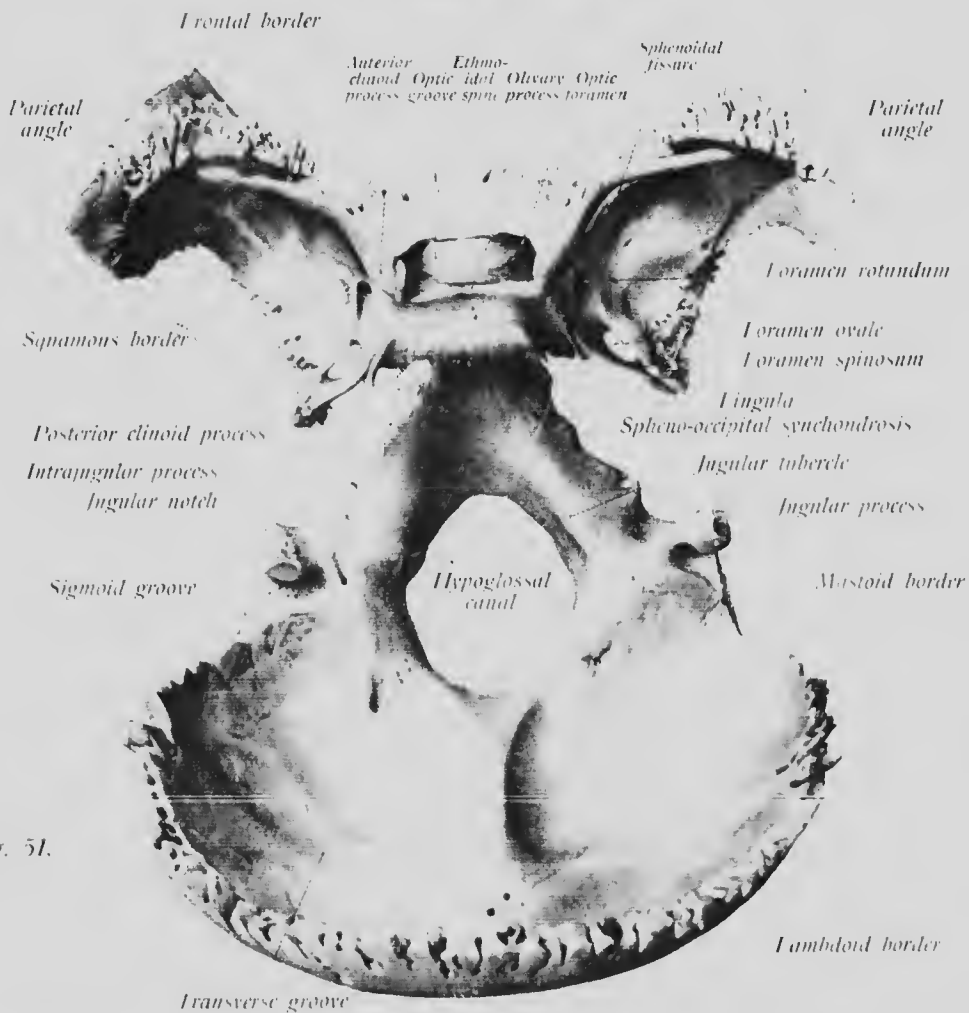



Fig. 51.



quently two particularly well-marked roughened ridges, the *crest for the rectus capitis posterior major muscle* and that for the *rectus minor*.

The relations of the occipital bone to the neighboring bones of the skull have been previously described on pages 38 and 40.

Only the basilar portion, the lateral portions, and the lower part of the squamous portion are preformed in cartilage, the upper part of the squamous portion (the *planum occipitale*) being formed in membrane. At the beginning of the fourth fetal month, four (or five) points of ossification appear, one in the basilar portion, one in each lateral portion, and one (or two) in the lower part of the squamous portion. The upper part of the squamous portion is separately formed, and is partly isolated from the remainder of the bone until after birth by a suture, the *sutura mendosa*. Sometimes the part of the squamous portion which is not preformed in cartilage remains independent, from the persistence of the *sutura mendosa*, and forms the triangular *os interparietale (os ince)*. For a long time after birth (until the end of the fourth year) the lateral portions are separated from the body and from the lower part of the squamous portion by the *anterior and posterior interoccipital synchondroses*.

THE SPHENOID BONE.

In its form the sphenoid bone (Figs. 51 to 54) somewhat resembles a winged insect. It consists of the following parts: (1) The *body*; (2) the two *greater wings* (also called the *temporal wings*); (3) the two *lesser wings* (also called the *orbital wings*); (4) the *pterygoid processes*.

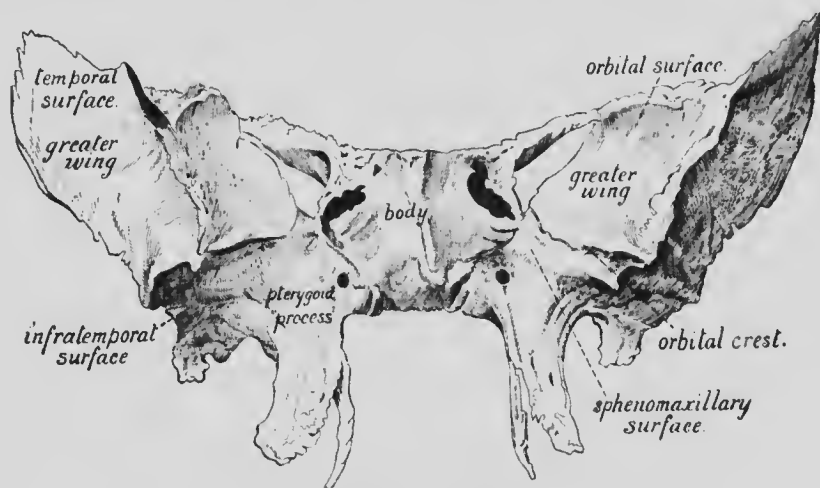


FIG. 52.—The sphenoid bone seen from in front.

In the adult skull the sphenoid is firmly united to the occipital bone, the two together forming one large bone, the *os basilare* (Fig. 51).

The **body of the sphenoid** (Fig. 52) forms the center of the bone, from which all the other portions radiate. Posteriorly it articulates with the occipital bone (*spheno-occipital synchondrosis*, see page 43), and anteriorly with the ethmoid bone. Its upper surface is formed by the *sella turcica* (Fig. 54); its lower surface forms a portion of the external surface of the base of the skull (Fig. 42) and articulates with the *ala vomeris* and the sphenoidal process of the palate bone. It contains a cavity communicating with the nasal fosse, the *sphenoidal sinus*,

FIG. 53.—The sphenoid bone seen from in front (†).

FIG. 54.—The sphenoid bone seen from behind (†).

which is completely divided into two portions by a sagittal septum which is rarely situated exactly in the median line. The two sinuses communicate with the posterior superior portion of the nasal fossæ by means of irregular openings in the anterior surface of the body of the sphenoid bone (Fig. 53). The greater portion of the almost rectangular anterior surface of the body (Figs. 52 and 53) is formed by two thin, approximately triangular bony platelets, the *sphenoidal turbinated bones* (*conchæ sphenoidales*), which, although usually united with the sphenoid, are to be regarded as portions of the ethmoid; they are frequently continuous with the ethmoid and may be represented by a number of small independent bones (*ossa Bertini*). They form the inferior margins of the apertures of the sphenoidal sinuses, and in the neighborhood of the apertures some small fossæ which close in the posterior ethmoidal cells are frequently visible.

The anterior extremity of the septum of the sinuses appears upon the anterior surface of the body of the sphenoid in the shape of a low ridge, the *sphenoidal crest* (Fig. 53). It is continued upon the lower surface of the body of the sphenoid, where it becomes more pronounced and forms the *sphenoidal rostrum*, to which is attached the ala vomeris.

The upper surface of the body (Figs. 43, 44, and 51) is the most strongly marked surface of the bone. Its most striking structure is the so-called *sella turcica* (see also page 41), which is that portion of the upper surface of the body which belongs to the middle cranial fossa, smaller portions of the body helping in the formation of the floors of the anterior and of the posterior fossæ. The portion in the anterior fossa is a plane surface in front of the sella turcica, connecting the two lesser wings, and is called the *jugum sphenoidale*; toward the adjacent lamina cribrosa of the ethmoid bone it presents a process, the *ethmoidal spine* (Fig. 51), the shape of which varies greatly in different individuals.

Behind the jugum sphenoidale at the anterior margin of the sella turcica there is a shallow groove, the *optic groove* (*sulcus chiasmatis*), so called because it contains the decussation or chiasma of the optic nerves (Fig. 51). It is continued on either side into the *optic foramen*, which leads into the orbital cavity.

Behind the optic groove the body of the sphenoid presents a flat elevation, the *olivary eminence* (*tuberculum sellæ*), the margins of which sometimes give origin to the inconstant *middle clinoid processes*, and between the eminence and the high back of the saddle, the *dorsum sellæ*, there is situated a rather deep, slightly elliptical depression, the *hypophysial fossa*, which lodges the pituitary body or *hypophysis*. On each side of this fossa there is upon the root of the greater wing of the sphenoid a shallow but rather broad groove, situated at the junction of the upper and lateral surfaces of the body of the sphenoid bone and limited externally toward the greater wing of the sphenoid by a fine bony platelet, the *lingula* (Fig. 51). This groove is called the *carotid groove* (Fig. 54), since it lodges the internal carotid artery.

The dorsum sellæ bears upon either side slightly pointed sharp corners, the *posterior clinoid processes*. Behind the dorsum sellæ a portion of the *clivus* also belongs to the body of the sphenoid

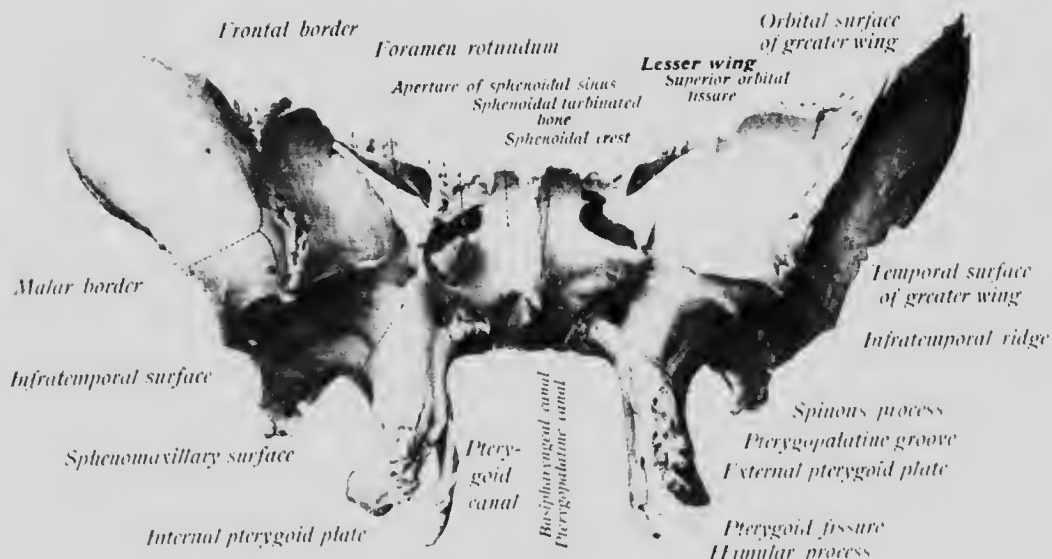


Fig. 53.

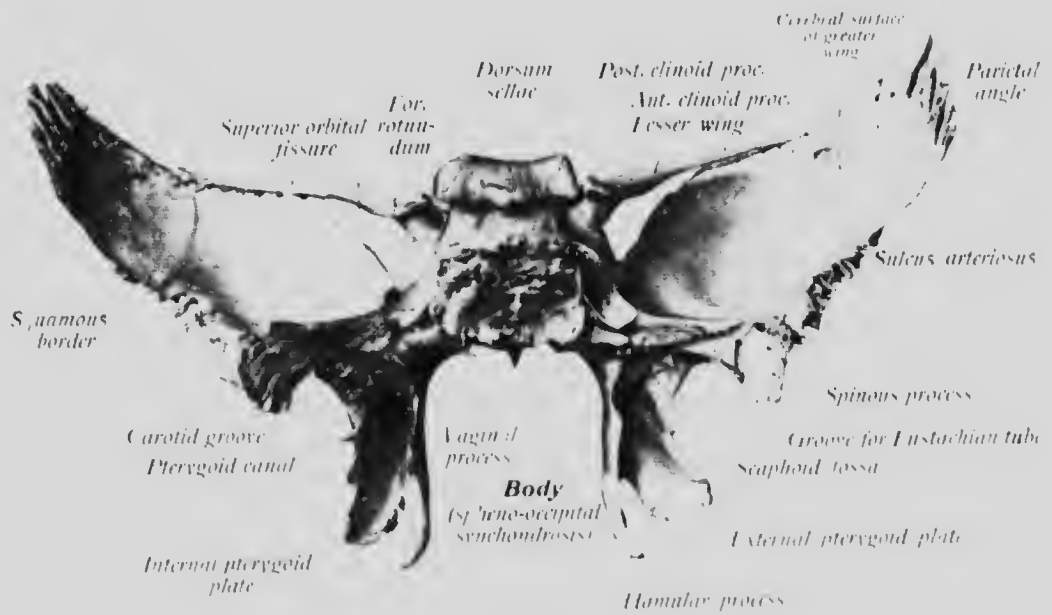


Fig. 54

bone (see also page 43), which thus aids in forming a part of the floor of the posterior cranial fossa (Fig. 45).

The posterior surface of the body of the sphenoid bone (Fig. 54) is adherent to the occipital bone. In young individuals, if a synchondrosis still exists, the surface is rough and irregular.

The greater portion of the lower surface of the body of the sphenoid, like the anterior one, forms a boundary of the nasal fossæ and bears the *sphenoidal rostrum*. On this surface there are also two small sagittal grooves or canals, the inner of which is the *basipharyngeal canal* (Fig. 53); while the outer one, above which is the *vaginal process* of the pterygoid process (Fig. 54), is the *pharyngeal canal* (Fig. 53) (see also page 51).

The lateral surfaces of the body of the sphenoid bone give origin to the two greater wings of the sphenoid, while the pterygoid processes arise from the lower surface of the body of the bone.

The **lesser** or **orbital wings** are narrow, almost horizontal, bony plates arising from the body of the sphenoid bone by two roots which surround the optic foramen (Fig. 51). Their upper surfaces form the posterior portion of the floor of the anterior cranial fossa (see page 41 and Fig. 45) and their posterior margins separate the anterior from the middle fossa. The posterior margin of each wing terminates internally in a rather sharp point, the *anterior clinoid process*, which partly overhangs the sella turcica, and the inferior surface forms the roof of the sphenoidal (superior orbital) fissure and also aids in the formation of the orbit. The lesser wings articulate anteriorly with the orbital plate of the frontal bone (*sphenofrontal suture*, see page 37), and between the lesser and the greater wings there remains a fissure, broad internally and narrowing toward its outer extremity, the *sphenoidal (superior orbital) fissure* (Figs. 38, 51, and 54). It leads into the orbit and its greater portion is closed by a membrane; it gives passage to the nerves of the ocular muscles (the oculomotor, the abducens, and the trochlear), to the first or ophthalmic division of the trigeminus, and to the superior ophthalmic vein.

The **greater** or **temporal wings** of the sphenoid arise from the lateral surfaces of the body of the sphenoid by broad roots in which are situated three openings, the *foramen rotundum*, the *foramen ovale*, and the *foramen spinosum* (Fig. 51). The foramen rotundum leads obliquely anteriorly through the bone into the sphenomaxillary fossa (*fossa pterygopalatina*), and transmits the maxillary nerve (the second division of the trigeminus). The foramen ovale traverses the bone in a vertical direction and makes its exit upon the external surface of the base of the skull (see page 39, and Figs. 41 and 42); it transmits the mandibular nerve (the third division of the trigeminus). The foramen spinosum pursues the same direction and gives passage to the middle meningeal artery.*

The greater wing, like the lesser one, is practically horizontal. It possesses three distinctly separated surfaces, the *cerebral*, the *orbital*, and the *temporal*, and there may also be recognized a *frontal border* (Fig. 51), the very rough margin directed toward the frontal bone, a *zygomatic*

* The greater wings have also been described, although not quite correctly, as arising from the body of the sphenoid by three roots, a middle broad root, situated between the foramen rotundum and ovale, an anterior narrower root between the foramen rotundum and the sphenoidal fissure, and a very narrow posterior one, between the foramen ovale and spinosum. The latter, however, can scarcely be regarded as a root.

border, in contact with the zygomatic bone, and a *squamosal border*,* directed toward the temporal bone. The most external portion of the greater wing, which is in contact with the parietal bone in the sphenoparietal suture, is known as the *parietal angle*, and its most posterior, pointed portion, which is directed toward the petrous portion of the temporal bone, is called the *spine* (Figs. 53 and 54). The cerebral surface is distinctly concave and exhibits the internal orifices of the *foramen rotundum, ovale, and spinosum* (Fig. 51), the last receiving its name on account of its location in the spine.† It also occasionally shows *digitate impressions* and *cerebral jugæ* (see pages 41 and 61), and a *sulcus arteriosus* which is continued from the temporal bone.

The almost plane, slightly concave, quadrangular *orbital surface* (Figs. 38 and 53) is the smallest of the three surfaces. It forms a portion of the outer wall of the orbit, and in this situation its *zygomatic border* articulates with the zygomatic bone by means of the *sphenozygomatic suture*. The sphenomaxillary or inferior orbital fissure separates the greater wing from the maxilla, and at the margin of this fissure, the orbital surface possesses a sharp edge, the *orbital crest*, which separates it from the *sphenomaxillary surface* (Fig. 53), a lower portion of the temporal surface. In the vicinity of the superior orbital fissure the orbital surface exhibits a bony spine of variable development which is called the *spina recti lateralis* and is the point of origin for the muscle of the same name.

The *temporal surface* (Figs. 39, 40, and 53) is by far the largest of the three surfaces of the greater wing of the sphenoid and is distinctly angulated at the level of the *infratemporal crest* (see page 39). The almost vertical portion of the temporal surface, situated above this crest, forms a portion of the *planum temporale* (see page 38), while the portion situated below the crest is divided into the more horizontal *infratemporal surface* and the triangular *sphenomaxillary surface* by a rather low ridge which is called the *sphenomaxillary ridge*. The sphenomaxillary surface (Fig. 53) looks rather anteriorly and overlaps the root of the pterygoid process, while the infratemporal surface is directed more to the side, and presents the external orifices of the foramen ovale and the foramen spinosum. It forms the posterior wall of the *pterygopalatine (sphenomaxillary) fossa* (see page 78), and contains the anterior or external orifice of the foramen rotundum. It is sharply separated from the orbital surface by the orbital crest (Fig. 53).

While the greater and lesser wings of the sphenoid are practically horizontal, the third pair of processes, the **pterygoid processes** (Figs. 53 and 54), pass almost vertically downward and are apposed (Figs. 41 and 42) to the posterior surface of the maxilla (see page 67) and to the hard palate (see page 79), forming the lateral boundaries of the posterior nares. Each pterygoid process arises from the lower surface of the body of the sphenoid by two roots, between which is the *pterygoid (Vidian) canal* (Fig. 53), which runs almost horizontally, its anterior extremity being in the pterygopalatine fossa, and its posterior one in the foramen lacerum. Below the pterygoid canal the pterygoid process divides into two lamellæ, the *internal* and the *external pterygoid plate*. The internal plate is narrower and almost vertically placed, while

* So named where it borders upon the squamous portion of the temporal bone; in the region of the sphenopetrosal fissure (see page 40) it is called the *petrosal border*.

† Occasionally the foramen spinosum is only partially limited by the sphenoid bone, i. e., it is simply a notch in the spine.

the external plate is broader and directed more externally. Between the two is situated the *pterygoid fossa*, which is narrow above, wide below, and open posteriorly, and whose anterior inferior boundary is formed by the tuberosity or pyramidal process of the palate bone, which closes the space, the *pterygoid notch*, between the two plates.

At the base of the internal plate there is a small elliptical fossa, the *scaphoid fossa* (Fig. 54), to the outer side of which, toward the spine, there is a shallow groove, in which is situated the cartilaginous portion of the Eustachian tube which connects the middle ear with the nasopharynx. At its lower end the internal plate terminates in the slender hook-like hamular process (*hamulus pterygoideus*) (Figs. 53 and 54), the groove at the base of this being called the *hamular groove* and forming a pulley for the tendon of the tensor veli palatini.

Beside the scaphoid fossa is situated a small, flat, rather triangular process called the *vaginal process* (Fig. 54), which is directed toward the sphenoidal rostrum; together with the sphenoidal process of the palate bones it aids in the formation of the *pharyngeal canal* (see page 49).

Upon the anterior surface of the pterygoid process, running downward from the anterior extremity of the pterygoid canal, there is a shallow groove, the *pterygo-palatine groove* (Fig. 54), which, with similarly named grooves upon the palate and maxillary bones, forms the *pterygo-palatine canal*, whose external orifices are the palatine foramina of the hard palate (see pages 40 and 78).

Since the sphenoid bone is almost exactly in the center of the skull and has relations with both the cranial and the facial bones, it articulates with a large number of the bones of the skull (see page 37 *et seq.*). These are the occipitals, the temporal, the parietal, the frontal, the ethmoid, the maxilla, the zygomatic, the palate, and the vomer. It also forms a portion of the anterior, middle, and posterior cranial fossæ, of the orbit, of the nasal fossæ, of the temporal fossæ, of the infratemporal fossæ, and of the sphenomaxillary fossæ.

A regular development of the sphenoid, it may be said that the entire bone is preformed in cartilage with the exception of the external plates of the pterygoid processes and the sphenoidal turbinated bones, which are developed in membrane. Ossification begins toward the end of the second fetal month. Isolated centers appear in the anterior and posterior portions of the body of the bone, so that for a time there are two sphenoid bones, as it were, situated one behind the other. The lesser wings arise from special centers, as do also the greater wings, the centers for the latter also forming the outer plates of the pterygoid processes. The lesser wings unite with the anterior center of the body of the sphenoid between the sixth and seventh fetal months, the greater wings do not unite with the posterior center until after birth, and the two halves of the body of the sphenoid do not unite until after birth, and then but slowly, so that an *intersphenoidal synchondrosis* exists for a long time.

The external plate of the pterygoid process is formed in membrane, but soon unites (in the seventh fetal month) with the external plate. The sphenoidal turbinated bones appear much later and do not unite with the body of the sphenoid until the age of puberty and at the same time the sphenoid-occipital synchondrosis commences to disappear. The sphenoidal sinuses arise during childhood, but increase considerably in extent during later life.

Variations are frequent in the sphenoid bone, such as the occurrence of middle clinoid processes (see page 48) and their fusion with the anterior or posterior clinoid processes. By ossification of the pterygo-spinous ligament (see page 44) there is not infrequently formed a *pterygo-spinous process* (*processus Cicerini*).

THE TEMPORAL BONE.

The temporal bone (Figs. 55 to 63) is situated in the lateral part of the base of the skull, and forms portions of the middle and posterior cranial fossæ. Upon either side one of the temporal bones fills in the large gap in the *os basilare* (see pages 40 and 47).

FIG. 55.—The right temporal bone seen from the outer (lateral) surface (†).

FIG. 56.—The right temporal bone seen from the cerebral surface (†).

Each temporal bone consists of four portions: (1) A *squamous portion*, (2) a *petrous portion*; (3) a *mastoid portion*; (4) a *tympanic portion*. The petrous portion is also termed the *pyramid*.

The squamous and mastoid portions are placed almost vertically, while the pyramid is practically horizontal. At the external auditory meatus, the individual portions of the temporal bone are grouped in such a manner that the smallest portion, the tympanic portion, is situated in front of and below the auditory canal, the mastoid portion is behind, the squamous portion above, and the petrous portion internally and anteriorly.

THE SQUAMOUS PORTION.

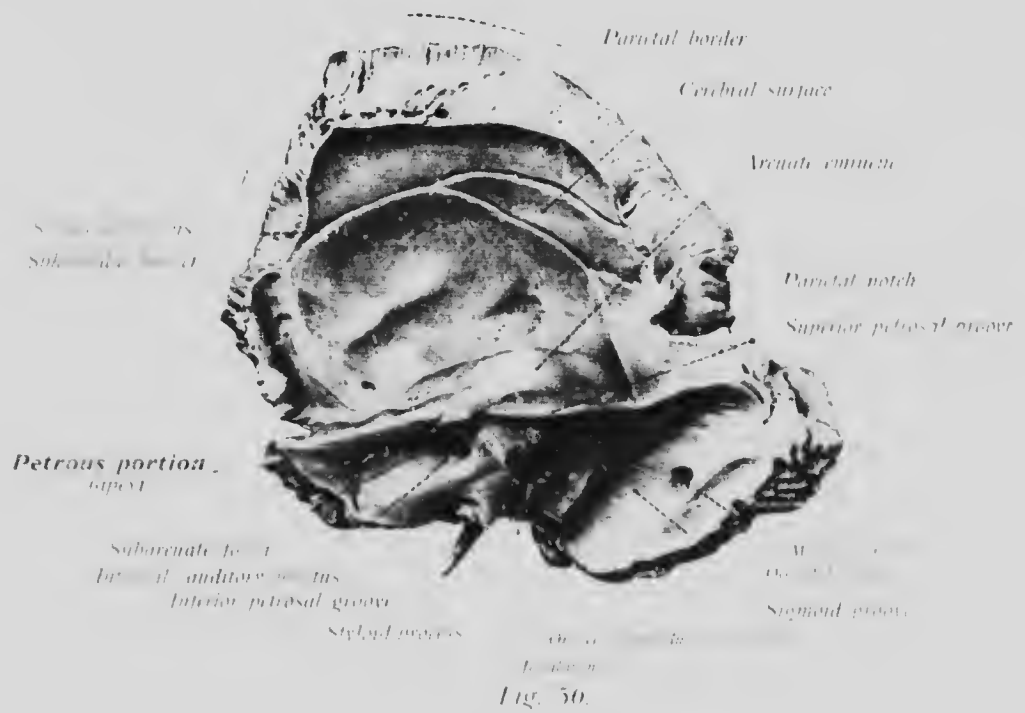
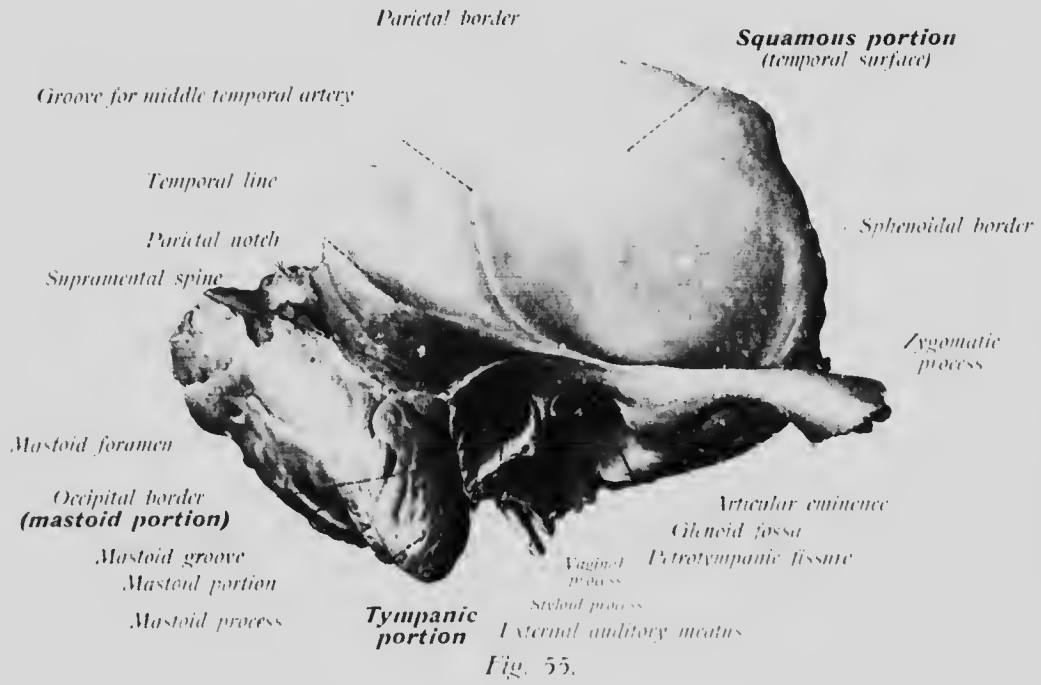
The squamous portion of the temporal bone (Figs. 55, 56, and 57) consists of an approximately semicircular vertical bony plate which is concave internally and convex externally. Anteriorly it articulates (Figs. 39 and 40) with the temporal surface of the greater wing of the sphenoid by the *sphenosquamosal suture* (*sphenoidal border*), and superiorly with the parietal bone by means of the *squamosal suture* (*parietal border*, see page 38). A deep notch, the *parietal notch*, accommodates the sphenoidal angle of the parietal bone and separates the squamous portion from the mastoid portion, which is situated inferiorly and posteriorly.

The *zygomatic process* (Fig. 55) springs from the external surface of the squamous portion of the temporal bone and aids in the formation of the zygomatic arch, by articulating with the temporal process of the zygomatic bone by means of the *zygomaticotemporal suture*. It is almost horizontal at its origin, but later it rotates through about 90 degrees, so that it assumes a vertical position and forms a bony process flattened from side to side. Its posterior prolongation above the external auditory meatus forms a *supramastoid ridge*, which posteriorly becomes continuous with the terminal portion of the inferior temporal line (see Fig. 39).

The part of the squamous portion which lies below the zygoma forms part of the external surface of the base of the skull and is consequently almost horizontally placed (Fig. 58), and borders upon the infratemporal surface of the greater wing of the sphenoid bone. It is therefore advantageous to subdivide the squamous portion of the temporal bone into a larger *vertical portion* and a smaller *horizontal portion*.

In the vertical portion there may be recognized an external *temporal surface* and an internal *cerebral surface* (the latter is absent in the horizontal portion). The temporal surface forms a part of the *planum temporale* and of the *fossa temporalis* (see Fig. 39), and is usually smooth, though its lower portion may sometimes be roughened by the origin of the temporal muscle. It presents a shallow groove for the middle temporal artery, beginning above the external auditory meatus and running upward.

At the junction of the horizontal and vertical parts is situated the roof of the external auditory meatus, the remaining walls of the auditory canal being formed by the tympanic portion, and just above the external auditory meatus, at the transition into the mastoid portion, there is frequently found a small bony spine, the *supramastoid spine* (Fig. 55).



The horizontal part (Fig. 58), situated in the base of the skull, exhibits a large fossa at the root of the zygomatic process. This is the *mandibular* or *glenoid fossa*, which accommodates the condyloid process of the mandible and consists of an articular surface and of an anterior portion, the *articular eminence*, which is also partially covered by cartilage. The two roots of the zygomatic process surround the mandibular fossa. In front of the articular eminence there remains a small portion of the inferior surface of the squamosal portion, which completes the infratemporal surface of the greater wing of the sphenoid bone, and behind the mandibular fossa lies the *petrotympanic* or *Glaserian fissure* (Figs. 55 and 58).

The margins of the squamous portion of the temporal bone (Figs. 56, 57, and 58) are extremely rough and sharp, and, in the squamous suture, they overlie the margins of the adjacent parietal bone and greater wing of the sphenoid; at the inferior extremity of the sphenosquamosal suture only does the margin of the infratemporal surface of the greater wing of the sphenoid overlap the squamous portion of the temporal.

Its internal or cerebral surface is smaller than the external one, owing to the width of the squamosal suture, and it is separated from the petrous portion, always in the new-born and usually even in the adult, by a more or less ossified suture, the *petrosquamosal fissure*. Its cerebral surface consists of only a vertical portion, which, in addition to *sulci arteriosi* for the branches of the middle meningeal artery, occasionally exhibits cerebral juga and digitate impressions.

THE MASTOID PORTION.

The mastoid portion of the temporal bone (Figs. 55 to 58) derives its name from the mastoid process, the most important structure of this portion of the temporal bone. At the parietal notch it articulates with the mastoid angle of the parietal bone (*parietomastoid suture*), and the occipital border articulates with the squamous portion of the occipital (*occipitomastoid suture*; see Fig. 42). In the temporal bone itself the mastoid portion borders upon the tympanic portion (*tympanomastoid fissure*), upon the petrous portion, and upon the squamous portion; it is separated from the latter during youth by the *squamosomastoid suture* (Figs. 59 and 60), which becomes more or less obliterated in later life. It presents a rough, markedly convex external surface, which bears the mastoid process, and an internal concave cerebral surface.

The *mastoid process* is a broad, conical, bony projection covering a considerable part of the mastoid portion, and presents upon its inner surface a deep notch, the *mastoid notch* (Fig. 58). Internal to this notch, between it and the occipitomastoid suture, there is a shallower groove for the occipital artery.

Behind the mastoid process, upon the external surface of the mastoid portion, is the *mastoid foramen* (Figs. 55 and 56), the external orifice of the mastoid emissarium, which varies in size and may be absent. It lies immediately beside, or sometimes even in, the occipitomastoid suture.

The cerebral surface of the mastoid process presents a broad groove, the *sigmoid groove* (see also Fig. 43), which usually contains the internal orifice of the mastoid emissarium (Fig. 57). In this situation the mastoid portion is directly continuous with the posterior surface of the pyramid.

The mastoid process contains numerous air spaces known as the *mastoid cells* (Figs. 61

FIG. 57.—The right temporal bone seen from the cerebral surface and from the apex of the petrous portion ($\frac{1}{3}$).

FIG. 58.—The right temporal bone seen from below ($\frac{1}{3}$).

FIG. 59.—The right temporal bone of a new-born child ($\frac{2}{3}$).

FIG. 60.—The left temporal bone of a four-year-old child ($\frac{2}{3}$).

In Figs. 59 and 60 the squamous portion is green, the petrous and mastoid portions yellow, and the tympanic portion white.

and 63), and these may become so large, particularly in later life, that they markedly attenuate the bony tissue and even expand it. They are connected with the cavity of the middle ear, the *tympanic antrum*.

The mastoid process is one of the chief points for muscular attachment which the skull possesses, and it receives the insertions of the sternocleidomastoid and of portions of the splenius capitis and of the longissimus capitis muscles. The mastoid notch gives origin to the posterior belly of the digastric muscle. Several openings may be present in the vicinity of the mastoid foramen. The depression beside the suprasmatal spine and above the mastoid process is also called the *mastoid fossa*.

THE PETROUS PORTION.

The petrous portion or pyramid of the temporal bone (Figs. 56 to 58) forms a portion of both the external and internal surfaces of the base of the skull (see Figs. 42 and 43). It has the shape of a three-sided horizontal pyramid, two of the surfaces being directed toward the cranial cavity and one externally, and the axis of the pyramid passing obliquely from behind forward and from without inward. There may consequently be distinguished internally an anterior surface and a posterior surface, and externally an inferior surface, and there is a superior, an anterior, and a posterior border. The superior border separates the two cerebral surfaces; the two remaining borders separate the cerebral surfaces from the external one.

The petrous portion in the adult is directly continuous externally with the tympanic portion, and its internal anterior surface borders upon the squamous portion (*petrosquamosal fissure*, see page 53) and upon the sphenoid bone (*sphenopetrosal fissure*). The base and a part of the posterior margin is continuous with the mastoid portion even during early fetal life, and the anterior portion of the posterior margin articulates with the lateral portion of the occipital bone (*petro-occipital fissure*). The apex of the petrous portion projects into the foramen lacerum (see Fig. 42), in the space between the sphenoid and the occipital bones.

The anterior cerebral surface forms a portion of the floor of the middle cerebral fossa, and presents a flattened projection lying at right angles to the axis of the pyramid and known as the *arcuate eminence* (Fig. 56), because it overlies the semicircular canal of the internal ear which is embedded in the petrous portion of the bone. Upon this anterior surface there is also a small slit-like orifice, the *hiatus Fallopii* (*hiatus canalis facialis*) (Fig. 57), from which the great superficial petrosal nerve passes toward the apex of the pyramid and to the foramen lacerum in a groove (Fig. 57).

External and anterior to the hiatus canalis facialis there is a second smaller opening, the *superior aperture of the tympanic canaliculus* (Fig. 57), the place of exit of the lesser superficial petrosal nerve, which also passes forward to the region of the foramen lacerum in a groove.

Squamous portion (cerebral surface)

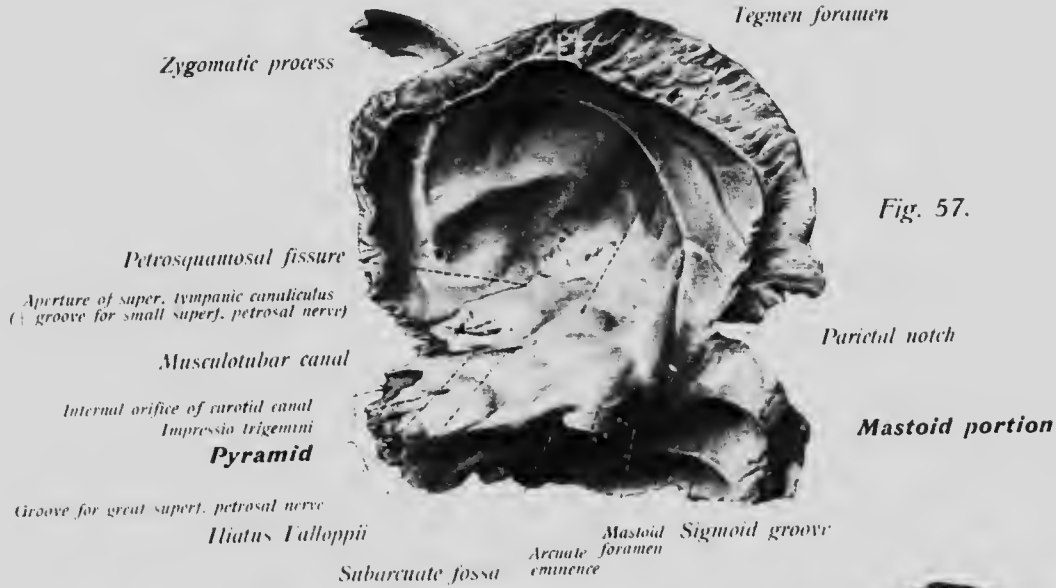

Fig. 57.

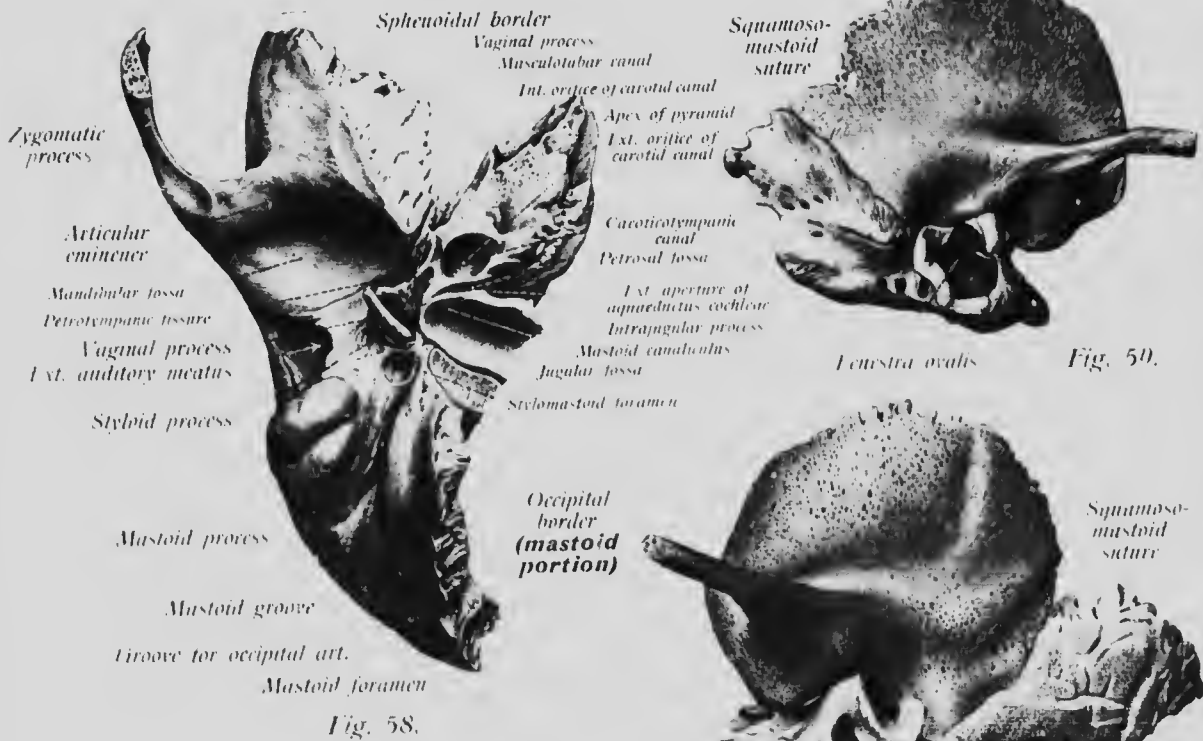


Fig. 59.

Fig. 60.



The rather thin bony plate of the petrous portion which forms the anterior surface of the pyramid between the hiatus canalis facialis and the arcuate eminence, and which extends to the petrosquamosal fissure, is the roof of the middle ear or tympanic cavity, and is called the *tegmen tympani*.

Near the apex of the petrous portion the anterior surface exhibits a depression of varying shape, usually but a slight excavation, which is known as the *trigeminal impression* (Fig. 57) and lodges the semilunar (Gasserian) ganglion of the trigeminal nerve.

The superior border of the pyramid, which separates the two cerebral surfaces from each other, shows upon its surface a shallow furrow, occasionally emphasized by pronounced elevated margins, the *superior petrosal groove*, which empties into the sigmoid groove. Like the latter, it contains a sinus of the dura mater.

The posterior cerebral surface of the petrosal portion is almost vertically placed and forms a portion of the posterior cerebral fossa. At about the middle of the pyramid, nearer the superior than the posterior border, it exhibits an approximately round opening, the *internal auditory foramen* (Fig. 56), which leads into a short canal, the *internal auditory meatus*, which lodges the facial and auditory nerves.

Above and somewhat external to this opening and immediately below the border of the petrous portion, there is a depression, the *subarcuate fossa* (Fig. 56), the concavity of which is directed toward the apex of the pyramid. Sometimes it is but slightly marked, though it is distinctly developed and very large in the infantile skull; it contains a process of the dura mater. Below and external to it, and at about the level of the orifice of the internal meatus, there is a slit like orifice, the *external aperture of the aqueductus vestibuli* (Fig. 56), which is open externally and below, and accommodates a process (the ductus endolymphaticus) of the membranous ear.* In the vicinity of the anterior portion of the posterior border there is a quite shallow groove, the *inferior petrosal groove* (Fig. 56), which, together with a similarly named groove of the occipital bone, forms a channel in the petro-occipital fissure for the inferior petrosal sinus of the dura mater (see also Fig. 43).

The posterior border of the pyramid is separated from the occipital bone (the basilar and lateral portions) by the petro-occipital fissure and the jugular foramen. It presents the *jugular notch* (Fig. 56), corresponding to the similarly named notch of the occipital bone, and also usually an *intrajugular process* (see page 46).

The anterior border is separated from the base of the greater wing of the sphenoid bone by the *sphenopetrosal fissure* and by the *foramen lacerum*; the *apex of the pyramid* is in contact with the lateral surface of the body of the sphenoid bone. At the foramen lacerum, close to the actual apex of the pyramid, there is an irregular opening, the *internal carotid foramen* (Fig. 57), which leads into the *carotid canal*, a short canal which traverses the inner half of the petrous portion of the temporal bone and lodges the internal carotid artery.

External to the internal carotid foramen is situated the entrance to a canal which passes into the middle ear beneath the tegmen tympani, the *musculotubar canal* (Fig. 57), so called because it contains both the tensor tympani muscle and the Eustachian tube (see also page 51).

* A groove runs from the external aperture of the aqueductus vestibuli to the jugular notch.

FIG. 61.—The left temporal bone divided through the axis of the petrous portion ($\frac{1}{4}$).

FIG. 62.—The right temporal bone divided in a plane passing through the external auditory meatus and nearly parallel to the axis of the petrous portion ($\frac{1}{4}$).

FIG. 63.—The right temporal bone divided in the upper half through the axis of the petrous portion and below horizontally, the wall of the canalis musculo-tubarius being partly chiseled away to show the septum ($\frac{1}{4}$).

In this situation the spine of the sphenoid insinuates itself into the angle between the anterior border of the pyramid and the cerebral surface of the squamosal portion, so that the groove for the Eustachian tube (see page 51), running upon the inferior surface of the sphenoid bone, leads into the orifice of the musculotubar canal.

The external surface of the petrous portion forms part of the external surface of the base of the skull. It presents quite a number of noteworthy structures and is the roughest and most uneven surface of the bone. At its junction with the mastoid portion there is a rounded opening, the *stylomastoid foramen* (Fig. 58), the external orifice of the *facial canal*, which traverses the temporal bone in a curve and lodges principally the facial nerve.

In front of the stylomastoid foramen is situated the *styloid process* (Figs. 55 and 58), the remains of one of the branchial arches. Sometimes it is short and thick and sometimes it is very long,* and it is usually placed in a sort of bony sheath, the *vaginal process* (Fig. 55), which is mainly in contact with the process anteriorly and belongs to the tympanic portion. The styloid process gives origin to three muscles (stylohyoideus, styloglossus, and stylopharyngeus).

To the inner side of the styloid process, toward the posterior border of the pyramid, there is a rounded or an oval depression, the *jugular fossa* (Fig. 58), which borders upon the jugular notch. It lodges the upper extremity of the internal jugular vein (*bulbus venæ jugularis superior*), and at the bottom of it a small canal, the *mastoid canaliculus* (see page 58), begins as a groove. Near the jugular fossa, toward the apex of the pyramid and close to its posterior border, is situated the small funnel-like *orifice of the aqueductus (canaliculus) cochleæ* (Fig. 58).

Behind the jugular fossa and internal to the stylomastoid foramen, the posterior border of the pyramid presents a somewhat roughened surface for articulation with the occipital bone.

In front of the jugular fossa and separated from it by a narrow ridge, there is a large, almost circular foramen, the *external carotid foramen* (Fig. 58), which leads into the carotid canal, the posterior wall of which presents a number of small foramina, the external orifices of the *carotico-tympanic canaliculi*, for the nerves of the same name.

Between the external carotid foramen, the jugular fossa, and the external orifice of the aqueductus cochleæ, there is a small and sometimes poorly marked depression, the *petrosal fossa* (Fig. 58), which contains the inferior aperture of the tympanic canaliculus, which transmits the tympanic nerve. Internal and anterior to the external carotid foramen, and toward the foramen lacerum there is a roughened surface for the origin of the levator veli palatini muscle.

* The process on the temporal bone is frequently quite short, but it may be continued as a bony spicule in the stylohyoid ligament (see page 110).

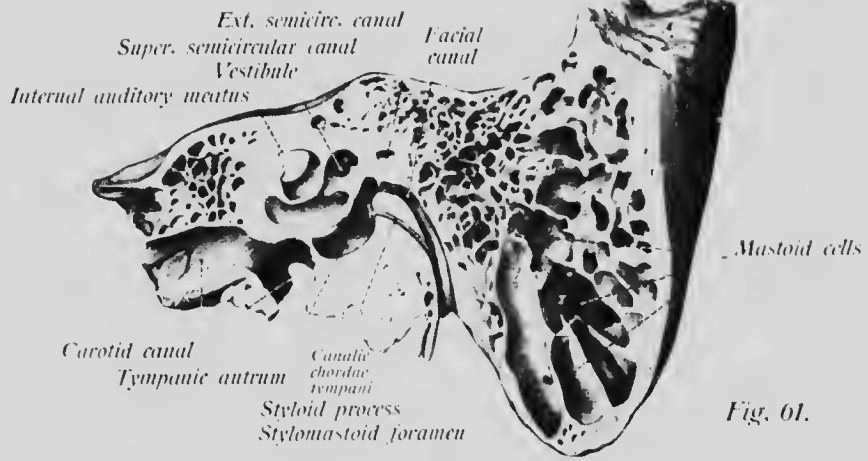


Fig. 61.

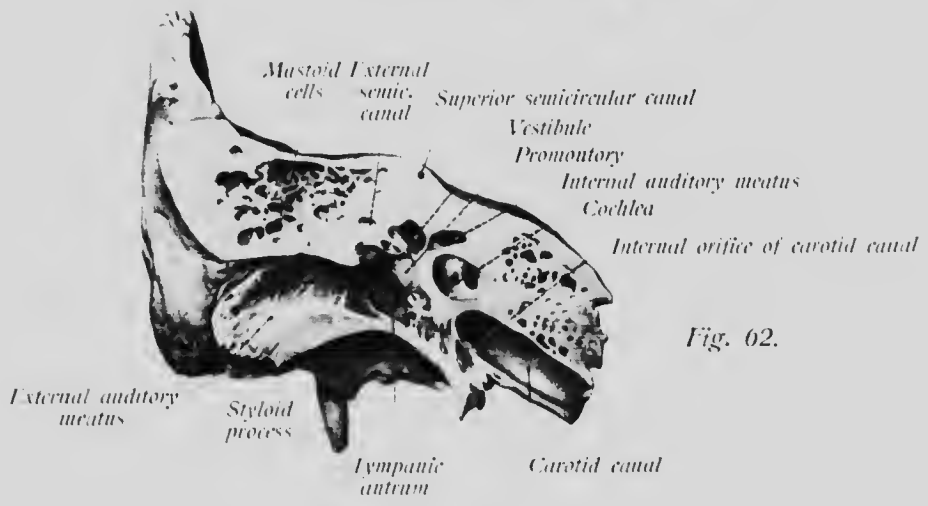


Fig. 62.

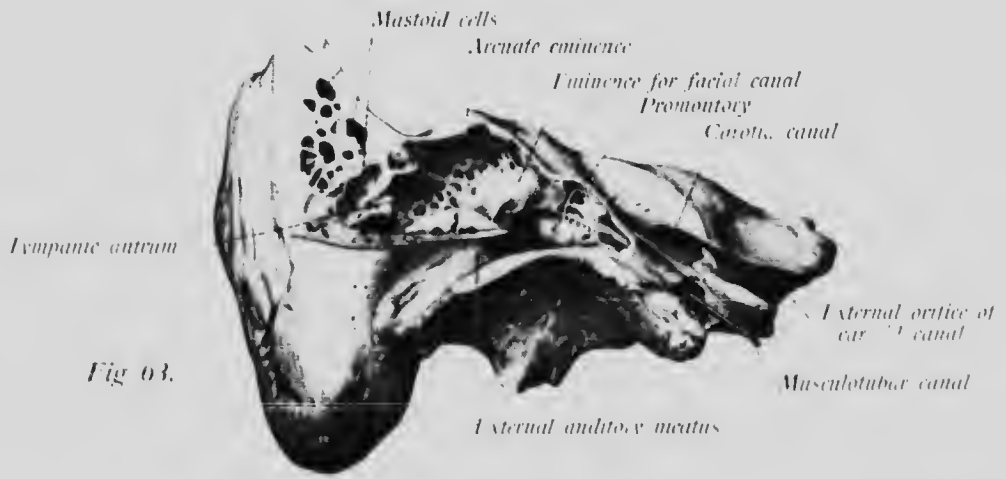


Fig. 63.



The anterior portion of the external surface of the pyramid, the greater part of which is concealed by the tympanic portion, forms the inner wall of the cavity of the middle ear.

THE TYMPANIC PORTION.

The tympanic portion (Fig. 55) is a small, slightly curved portion of the temporal bone which becomes secondarily adherent to the remaining portions and is represented in the newborn by a simple ring open above (Fig. 59). Outgrowths from this ring form the anterior, posterior, and inferior walls of the external auditory meatus, the orifice of this, and the outer wall of the tympanic cavity.*

A process of the tegmen tympani, the *inferior process*, is pushed in between the squamous and tympanic portions internally. It is bounded upon one side by the previously mentioned petrosquamosal fissure, and upon the other by a second groove, the *petrotympanic* or *Glaserian fissure*,† both of which unite to form the *tympanosquamosal fissure*. The tympanic portion is separated from the mastoid portion by the *tympanomastoid fissure*, which contains the outlet of the mastoid canaliculus. The tympanic portion also forms the *zaginal process* (see page 56).

At the inner extremity of the external auditory meatus, toward the tympanum, there is a circular groove, the *tympanic groove*, only the upper quadrant of which is wanting (*i. e.*, the portion of the groove not formed by the tympanic portion). This groove gives attachment to the tympanic membrane.

At the margins of the groove, and consequently of the tympanic portion, there are two small bony spicules, known as the *greater* and *lesser* spines, and, furthermore, in this situation there is a notch between the tympanic portion and the upper wall of the meatus which is furnished by the squamous portion: this is called the *tympanic notch*.

THE MOST IMPORTANT CANALS OF THE TEMPORAL BONE.

In the temporal bone there is a series of canals which transmit vessels or nerves, or usually vessels and nerves together. The most important of these are the following:

The *facial canal* (Fig. 61) contains, in addition to blood-vessels, the seventh cranial nerve, the facial, which gives off two branches during its course in the temporal bone. The canal may be divided into three portions, which are placed approximately at right angles to each other, so that the canal is bent upon itself in two situations. The first two portions of the canal are horizontal, the last one is vertical.

The first portion of the canal runs from the internal auditory meatus to the hiatus Fallopii, and therefore almost at right angles to the axis of the pyramid. The second portion begins at the hiatus‡ and lies almost exactly in the axis of the pyramid in the inner wall of the tympanum (*paries labyrinthica*), above the so-called *fenestra ovalis* (*fenestra vestibuli*). The canal finally bends vertically downward (at the *pyramidal eminence* of the tympanum) and terminates at the stylomastoid foramen. Just before its termination it gives off a *canaliculus chordæ tympani*, which passes obliquely upward and forward to enter the tympanum. It transmits a branch of the facial nerve known as the chorda tympani, which traverses the tympanum and leaves this cavity through the petrotympanic fissure.

* On account of their relation to the sense of hearing the remaining structures (cavities, canals, etc.) situated in the petrous portion will be considered in detail in the section upon organs of special sense.

† The petrotympanic fissure transmits the chorda tympani nerve as well as blood vessels, frequently through separate foramina.

‡ The bend of the canal in this situation is called the *geniculum of the facial canal*.

FIG. 64.—The outer surface of the right parietal bone ($\frac{1}{2}$).

FIG. 65.—The inner surface of the right parietal bone ($\frac{1}{2}$).

While the facial canal is the longest of the canals of the petrous portion, the *carotid canal* (Figs. 61 to 63) is the widest. It is also bent at a right angle. It commences at the external carotid foramen upon the external surface of the petrous portion of the temporal and passes at first almost vertically upward, in contact with the anterior wall of the tympanum; in the immediate vicinity of the *chlea* it bends at a right angle and then runs almost horizontally in the axis of the pyramid to reach its irregular and frequently incomplete superior orifice at the apex of the petrous portion. Fine canals, the *caroticotympanic canaliculi*, lead from the carotid canal into the tympanic cavity.

The *musculotubar canal* (Fig. 63) runs parallel to the carotid canal and in such immediate proximity to it that portions of both canals have a common wall. It begins at the inner side of the apex of the petrous portion of the temporal bone upon the anterior border of the pyramid, between the petrous portion and the horizontal part of the squamous portion, and runs approximately in the axis of the pyramid. An incomplete horizontal septum which proceeds from the inner and posterior wall (bordering upon the carotid canal) separates an upper smaller compartment, the semicanal for the tensor tympani, from a larger inferior one, the semicanal for the Eustachian tube; both compartments have their exits in the anterior wall of the tympanum. The canal contains the tensor tympani muscle and the Eustachian tube.

The *tympanic canaliculus*, for the nerve of the same name, proceeds from the petrosal fossa, and at first passes vertically upward into the inferior wall of the tympanum to be continued as a groove, the *groove of the promontory*, upon the inner wall of the tympanic cavity. It then leaves the tympanum as a canal passing from its upper wall to the superior aperture of the tympanic canaliculus on the anterior surface of the petrous portion, where it communicates with the cranial cavity.

The *mastoid canaliculus* begins in the jugular fossa as a groove, crosses the lower portion of the facial canal at a right angle, and terminates in the tympanomastoid fissure. It transmits the auricular branch of the pneumogastric nerve.

In addition to the air-cells of the mastoid process, the temporal bone also contains a larger cavity, the *tympanic antrum* (Fig. 63). (For a detailed description see the special sense organs.) This is in connection with the mastoid cells behind and with the musculotubar canal in front. It is not separated from the external auditory meatus by osseous tissue but only by membrane.

In the development of the temporal bone, the petrous portion and the mastoid process are developed in common from the cartilaginous auditory vesicle, and the squamous and tympanic portions are added later as supplementary bones. The styloid process has no connection whatever with the remaining portions of the temporal bone and arises from a portion of the branchial skeleton.

Commencing at the third fetal month, several centers appear in the cartilaginous auditory vesicle and subsequently unite to form a common origin for the petrous and mastoid portions. The latter is not distinctly developed even at birth; a mastoid process gradually forms, but it is not distinct until late in childhood. The first center of ossification for the squamous portion appears toward the end of the second fetal month, and the tympanic portion ossifies at about the same time as the pyramid.

In the temporal bone of the new-born (Fig. 50) the tympanic portion has the shape of a ring open above, and is known as the *annulus tympanicus*; it is at first merely attached to the remaining bones. A very distinct suture, the

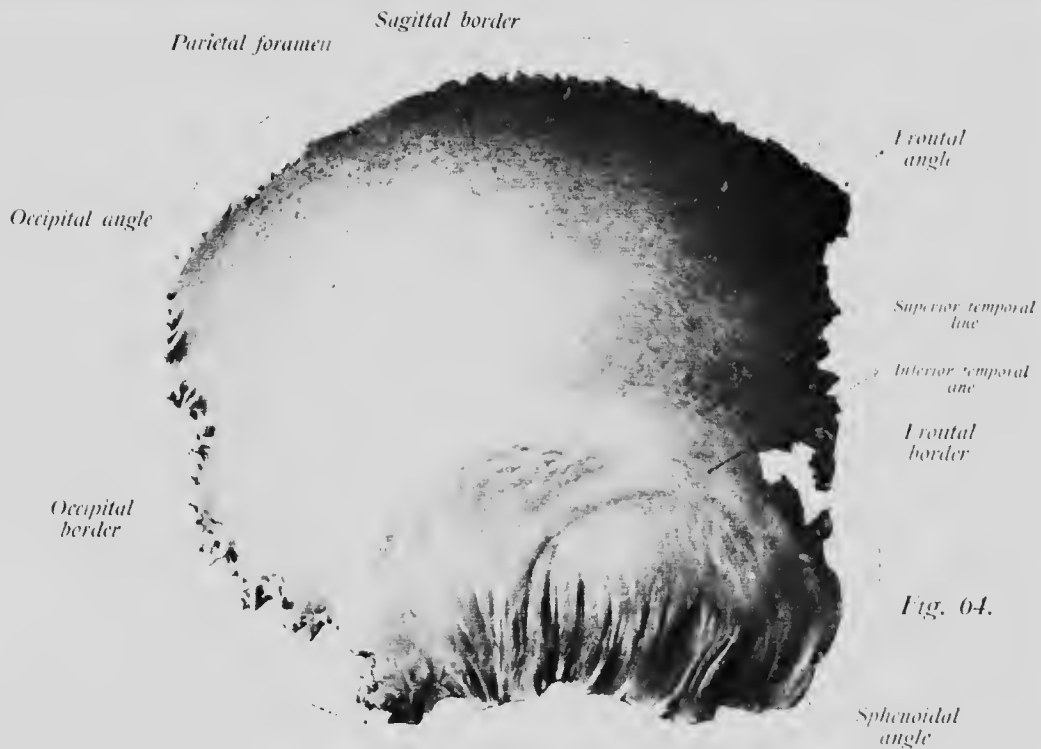

Fig. 64.

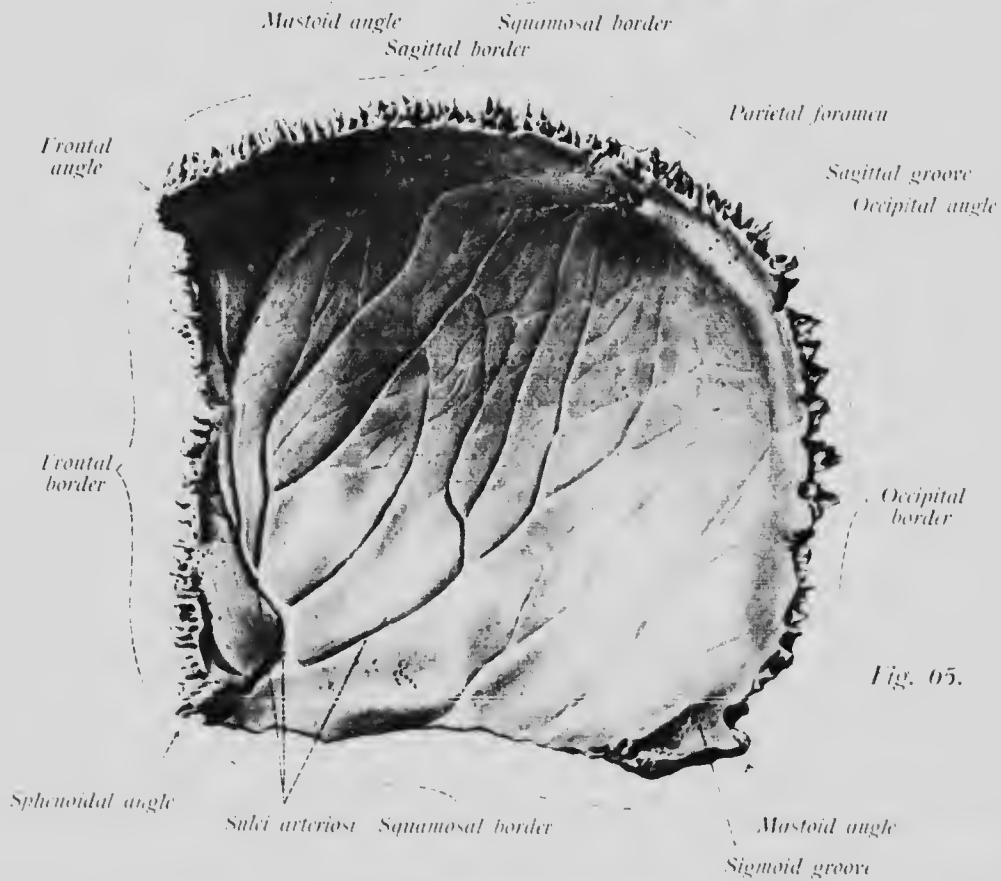



Fig. 65.



squamosomastoid suture, indications of which may be visible in adult life, separates the squamous from the mastoid portions. The bone also varies considerably from that of the adult in other respects, although all the portions are already united by osseous tissue. Especially large in the new-born is the subarcuate fossa.

During the first years of life the tympanic portion develops by the growth of the annulus tympanicus to a trough-like structure, and it is as the result of this growth that the bony meatus is formed. There nevertheless remains a constant unossified portion of the inferior wall of the meatus (Fig. 60), which usually closes in during the fifth year. The mastoid process becomes distinct at this time, but does not contain air-cells until the time of puberty.

The styloid process, arising from the second cartilaginous branchial arch, ossifies late and subsequently becomes connected with the temporal bone.

THE PARIETAL BONE.

The parietal bone (Figs. 64 and 65) is a typical flat bone which arises from the membranous cranial capsule and is not preformed in cartilage. It is one of the simplest of the cranial bones, is distinctly quadrangular in shape, and is markedly curved both in the sagittal and in the frontal direction. It presents for examination two surfaces, an external convex *parietal surface*, and an internal concave *cerebral surface*.

The four borders of the bone are named respectively the *frontal*, the *sagittal*, the *occipital*, and the *squamosal* border, and by them the bone articulates (Figs. 38 and 40) at the coronal suture with the frontal bone by its frontal border, at the sphenoparietal, squamosal, and parietomastoid sutures with the greater wings of the sphenoid and with the temporal bone by the squamosal border, and at the lambdoid suture with the occipital bone by the occipital border. In the sagittal suture, the sagittal borders of both parietal bones articulate with each other (Fig. 46). The anterior, superior, and posterior margins are markedly serrated, corresponding in character to the sutures (*sutura serrata*); the inferior margin, however, is beveled and its external surface is overlain at the squamosal suture by the margin of the temporal bone. The four angles of the bone are the *frontal angle*, the anterior superior angle, formed by the coronal and sagittal sutures; the *sphenoid angle*, the anterior inferior angle at the sphenoparietal suture; the *occipital angle*, the posterior superior angle, formed by the sagittal and lambdoid sutures; and the *mastoid angle*, the posterior inferior angle, at the parietomastoid suture, filling out the parietal notch of the temporal bone. The most acute angle is the sphenoidal.

The external or parietal surface (Fig. 64) presents at its point of greatest curvature the *parietal eminence*. Below this run the *superior and inferior temporal lines* (see also Figs. 39 and 40), the latter being much more distinct than the former. Below these lines the external surface of the parietal bone forms a portion of the *planum temporale* (see Fig. 39).

In the vicinity of the sagittal suture and near its posterior extremity is situated the *parietal foramen*, a so-called emissary foramen. Sometimes the internal and sometimes the external orifice is wanting; the former leads into the sagittal groove.

The most striking structures upon the cerebral surface (Fig. 65) are the extensive grooves for the blood-vessels, *sulci arteriosi*, of which, as a rule, there is a well-marked anterior and a less pronounced posterior one. They are for the branches of the middle meningeal artery and are accurate moulds of these vessels.* The cerebral surface also exhibits two other grooves which accommodate venous sinuses of the *dura mater* (see also page 44); the sagittal border

* Much more rarely *sulci venosi* also occur. On the other hand, the commencement of the sulcus arteriosus is not infrequently converted into a short canal by a bridge of osseous tissue (see Fig. 65).

FIG. 66.—The frontal bone seen from in front ($\frac{2}{3}$).

FIG. 67.—The frontal bone seen from behind ($\frac{1}{3}$).

presents one-half of the *sagittal groove*, while the mastoid angle contains a small portion of the *sigmoid groove* (see also Figs. 43 and 44). Digitate impressions and cerebral juga likewise occur and granular *foveolæ granulares* (*Pacchionian depressions*) are still more common.

The parietal bone develops in membrane in the third fetal month from a center of ossification situated in the parietal eminence. Even in the new-born the bony trabeculae show a distinct radiation from this point.

THE FRONTAL BONE.

The frontal bone (Figs. 66 to 69) consists of a vertical and a horizontal portion. The vertical portion is known as the *frontal portion* and the horizontal portion is composed of two *orbital plates*, and a small median *nasal portion*. At the orbital margins the horizontal and vertical portions become continuous.

The **frontal portion**, the main portion of the entire bone, articulates in the coronal suture with both parietal bones by its *parietal border* (Figs. 39 and 40) and in the sphenofrontal suture with the greater wing of the sphenoid bone. It forms the entire frontal portion of the cranial vertex and presents two surfaces for examination, an external *frontal surface* and an *internal cerebral surface*.

The *frontal surface* (Fig. 66) is markedly convex in both the sagittal and the transverse direction and presents some distance above the orbital cavities two feebly projecting flattened elevations, the *frontal eminences*. Immediately above the orbital margins and parallel to them are two slightly projecting ridges, the *superciliary arches*, the development of which varies considerably in different individuals; the flat area between these two ridges is called the *glabella*. The remainder of the external surface is smooth, although there may be a slight roughening in the median line which represents the remains of the original *frontal* or *metopic suture*.

The *supraorbital border* is situated at the junction of the vertical with the orbital plate. A portion of it is furnished by the *zygomatic process* of the frontal bone, which also forms part of the external orbital margin and, in the latter situation, articulates with the frontosphenoidal process of the zygomatic bone in the zygomaticofrontal suture (Figs. 37 and 38). The *temporal line* commences at the zygomatic process and separates the frontal surface of the frontal portion of the bone from the small temporal surface, the latter surface, almost in the sagittal plane, forming a portion of the *planum temporale* and being that part of the frontal bone which borders upon the temporal surface of the greater wing of the sphenoid bone.

Immediately above the supraorbital border there are foramina, which may be represented by notches of varying depth in the border itself. The inner one is designated as the *frontal notch* or *foramen* (Fig. 65), while the outer one is known as the *supraorbital notch* or *foramen** (Figs. 66, 68, and 69).

The inner or *cerebral surface* of the frontal portion (Fig. 67) presents a median ridge upon

* The supraorbital notch is much more frequently present as a foramen than the frontal notch; sometimes both of the notches form a single shallow groove.

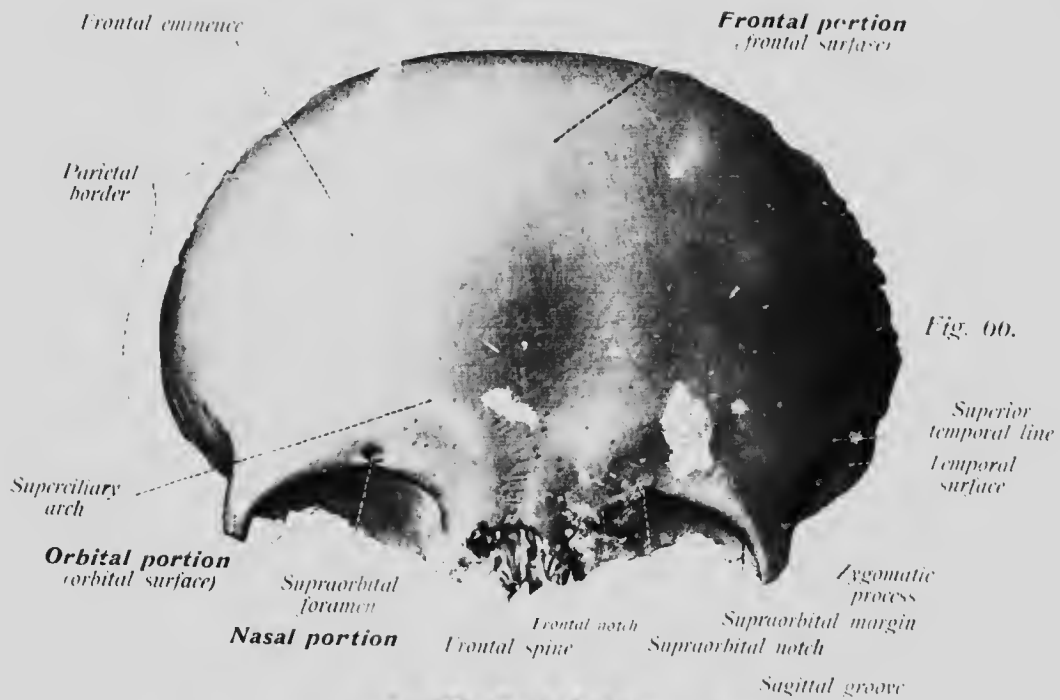


Fig. 66.

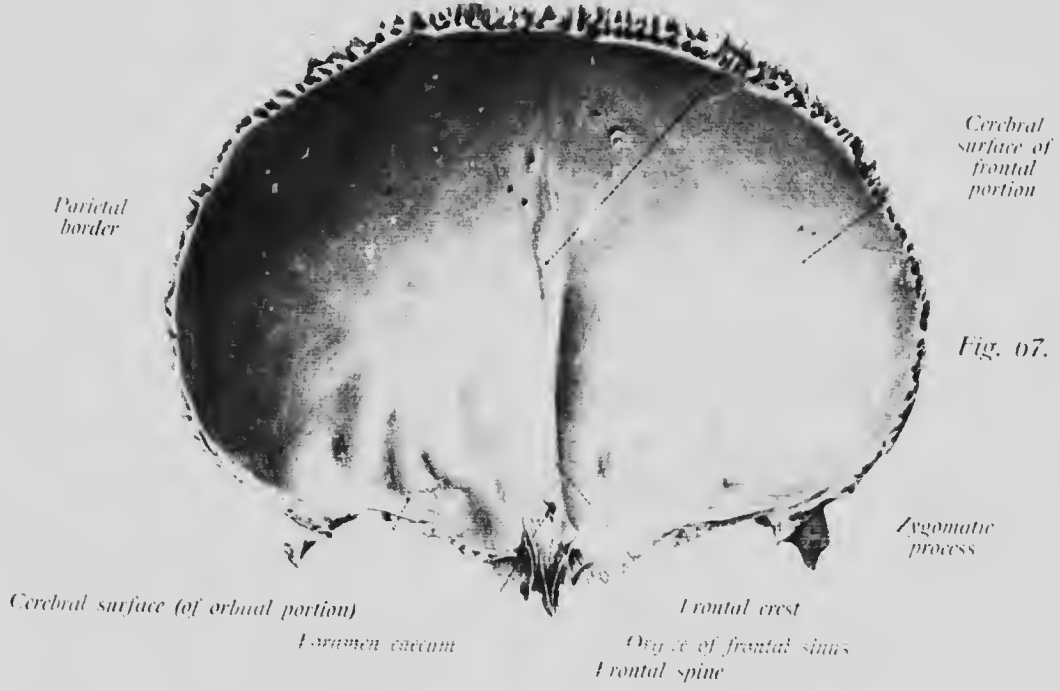

Fig. 67.

2

its lower portion, the *frontal crest*, which extends to the *foramen cæcum* (see page 41), and is continued superiorly as a groove, the commencement of the *sagittal groove* (see page 44). The cerebral juga, digitate impressions, and *sulci arteriosi* upon the cerebral surface of the orbital portion are sometimes continued upon the inner surface of the vertical plate, as there is no distinct boundary between the cerebral surfaces of the two portions of the bone. The foramen cæcum is sometimes situated entirely within the frontal bone.

The two **orbital plates** of the frontal bone are separated by a deep notch, the *ethmoidal notch* (Fig. 68), which articulates with the *cribriform plate* of the ethmoid bone. They possess two surfaces, a superior *cerebral surface*, which forms a portion of the anterior cerebral fossa, and an *orbital surface*, which constitutes a portion of the roof of the orbit. The cerebral surface (Fig. 67) is separated from the ethmoid bone by the frontoethmoidal suture (Figs. 43 and 44), and is in contact with the lesser wing of the sphenoid bone at the sphenofrontal suture. It is almost flat and exhibits quite distinct cerebral juga and digitate impressions, as well as the *sulci arteriosi* of the anterior and middle meningeal arteries.

The *orbital surface* (Figs. 68 and 69) is distinctly concave, and forms the largest part of the roof of the orbit and also a portion of its internal and external walls. In this situation it articulates (Figs. 37 and 38) with the greater wing of the sphenoid bone by the sphenofrontal suture, with the lamina papyracea of the ethmoid bone by the frontoethmoidal suture, and with the lachrymal bone by the frontolachrymal suture. The appearance of the ethmoidal notch as seen from the inferior surface of the frontal bone between the orbital surface is quite different from that which it presents from the cerebral surface. It is not limited by a simple suture, but its borders are rather broad and irregular, and are provided with small depressions, the *ethmoidal depressions*, which complete the air-cells of the ethmoid bone. In the septa between the ethmoidal cells there are two grooves or canals, an anterior and a posterior, which run respectively to the *anterior and posterior ethmoidal foramina*, situated beside or in the *frontoethmoidal suture*; they give passage to the vessels and nerves of the same name.

The portion of the orbital surface which is in the inner wall of the orbit always presents a small depression, the *trochlear depression* (Figs. 68 and 69), and sometimes a small bony spicule, the *trochlear spine*, both of which are so named on account of the fibrocartilaginous pulley of the superior oblique muscle being attached in this situation. In the outer portion of the orbital surface beneath the zygomatic process there is situated a shallow depression, which lodges the lachrymal gland.

The **nasal portion** of the frontal bone (Figs. 66 and 67) is the small median portion situated between the orbital cavities and projecting somewhat below the frontal portion. It possesses a very irregular roughened border, known as the *nasal border*, for articulation with the nasal bone and the frontal process of the maxilla, and its inferior surface is marked by a bony ridge, the *frontal spine*, which, together with the rough nasal border, articulates with the bones which form the skeleton of the nose.

The frontal bone, like many of the cranial bones, contains a cavity, the *frontal sinus* (Fig. 102), or, accurately speaking, two cavities, which are separated by a septum usually placed to one side of the median line. Like the majority of the bony sinuses they communicate with the nasal cavity, the communication in this instance being effected by the two openings (Fig. 67)

FIG. 68.—The frontal bone seen from below ($\frac{2}{3}$).

FIG. 69.—The frontal bone, the greater part of the ethmoid, and the nasal bones in place, seen from below ($\frac{2}{3}$). The frontal bone is white, the ethmoid yellow, and the nasal pink.

FIG. 70.—The ethmoid bone seen from above ($\frac{1}{2}$).

FIG. 71.—The ethmoid bone seen from the side ($\frac{1}{2}$).

FIG. 72.—The ethmoid bone together with the *conchæ sphenoidales*, which are united with it, seen from above and partly from behind ($\frac{1}{2}$).

situated between the frontal spine and the ethmoidal notch. The development of the frontal sinuses is subject to great individual variation; they are generally larger in advanced life than during youth, and they are always situated at the base of the frontal portion, especially behind the superciliary ridges, the prominence of which is actually dependent upon the size of the sinuses. They frequently also extend into the orbital plates for a varying distance, and are sometimes enormously developed and markedly distend the frontal bone in the region of the superciliary ridges.

The frontal bone is developed entirely in membrane from two completely separated portions, which grow from two centers of ossification in the frontal eminences; these centers, like those of the parietal bone, appear toward the end of the second month. Even in the new-born the two halves of the frontal bone are completely separated by the frontal suture (Fig. 105), which does not disappear until the second year of life and may sometimes be present in the adult, and is then also termed the *metopic suture*. At about the time it disappears the frontal sinuses begin to develop and they enlarge quite gradually until the time of puberty, when they increase more rapidly.

THE ETHMOID BONE.

The ethmoid bone (Figs. 70 to 73) forms the median portion of the nasal skeleton; and its *cribriform plate* aids in the formation of the floor of the anterior cerebral fossa. In the articulated skull the largest portion of the ethmoid is concealed by other bones; it is quite centrally placed and articulates with several of the cranial bones and with the majority of the facial bones.

It has, as a whole, an irregularly cubical form, and presents a median and two lateral portions. The former consists of a small horizontal plate, the *cribriform plate*, and of a larger vertical plate, which consists of a small thickened portion situated above the cribriform plate, the *crista galli* (Fig. 71), and of a larger portion, the *perpendicular plate*, situated below the cribriform plate, which aids in the formation of the bony nasal septum (Fig. 73).

If the median portion of the ethmoid bone be observed from in front or from behind, or, still better, in cross-section (Fig. 98), it will be seen to be shaped like a dagger, the handle of which is formed by the *crista galli*, the guard by the cribriform plate, and the blade by the perpendicular plate.

Attached to the lateral margins of the lamina cribrosa are the two *lateral masses*, also termed the *ethmoidal labyrinths*, which are air-containing structures with thin bony walls, and form a part of the outer walls of the nasal fosse and a part of the inner wall of the orbit.

The *crista galli* (Figs. 70, 71, and 73) is a pointed bony ridge situated in the sagittal plane; it is high in front and low behind, and gives attachment to the falx cerebri. The *cribriform plate* (Figs. 69, 70, and 72) is an approximately rectangular plate situated between the cranial

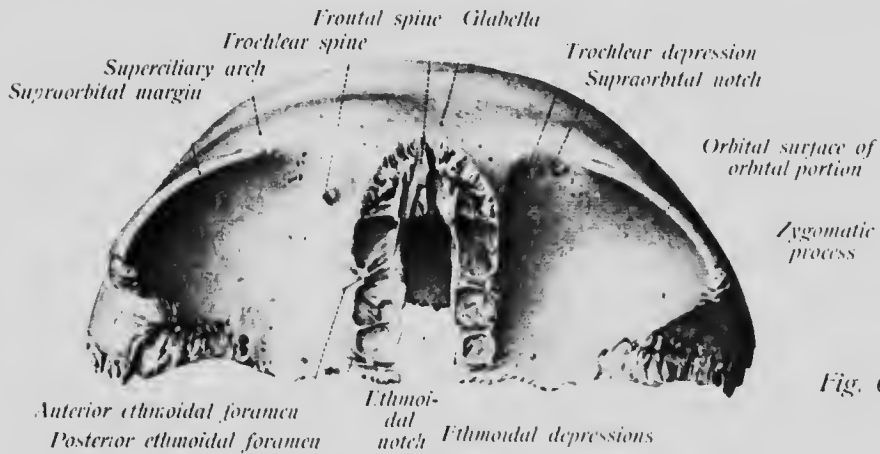


Fig. 68.

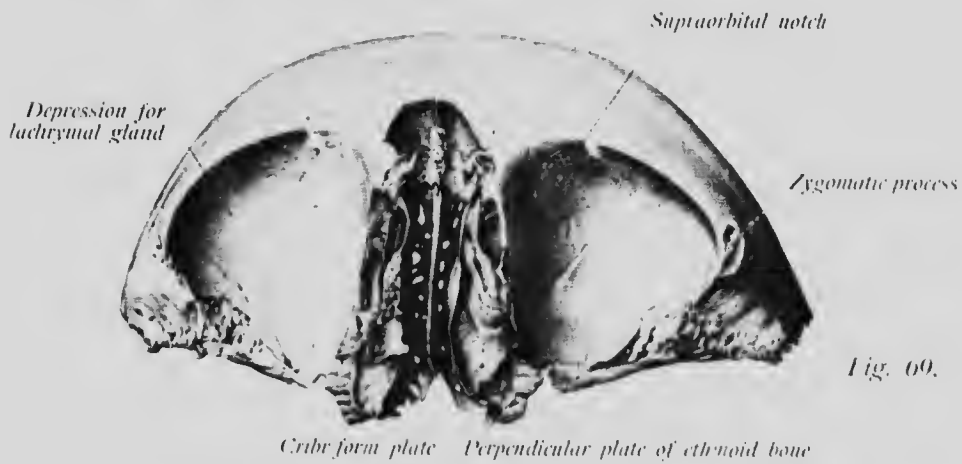


Fig. 69.

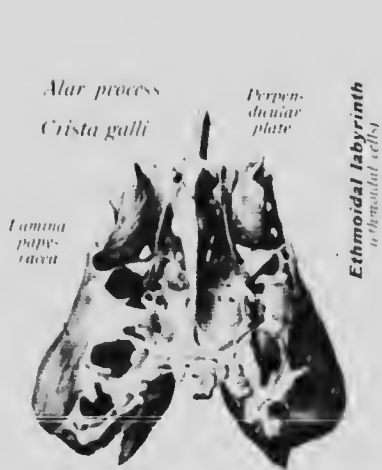

Fig. 70.

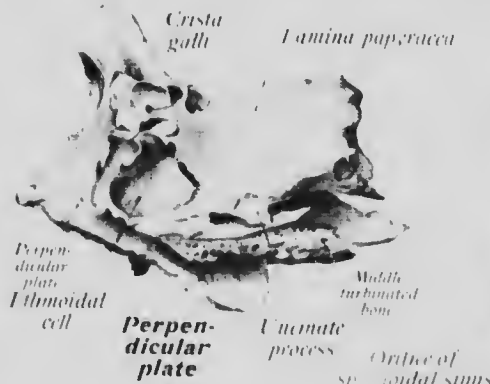


Fig. 71.



Fig. 72.

Sphenoidal turbinate bone



and nasal cavities, and it consequently forms a portion of the roof of the nasal fossæ. It possesses a number of irregularly rounded foramina, through which pass the olfactory nerves from the olfactory bulb, which rests upon the cribriform plate; the nerves for the most part continue their course downward in small bony grooves upon the nasal septum and the lateral nasal wall. The most anterior foramen, frequently incomplete, gives passage to the anterior ethmoidal vessels and nerve. In front of the crista galli, the cribriform plate sends out two small, somewhat quadrangular, bony platelets, the *alar processes* (Fig. 70), which pass toward the base of the frontal crest of the frontal bone and usually complete the foramen cæcum posteriorly (Figs. 43 and 44). The cribriform plate is situated in the ethmoidal notch of the frontal bone and articulates posteriorly with the ethmoidal spine of the sphenoid bone.

The *perpendicular plate* (Figs. 69 and 73) extends downward in the space between the two lateral masses and forms the anterior superior portion of the bony nasal septum. It is approximately pentagonal in shape. Its anterior superior border articulates with the frontal spine by the frontoethmoidal suture; its anterior inferior border is continuous with the cartilaginous nasal septum*; its inferior border articulates with the superior border of the vomer, which forms the remainder of the bony septum; its posterior border articulates with the sphenoidal crest of the body of the sphenoid bone by the sphenothmoidal suture; and its superior border is received between two ridges upon the inferior surface of the cribriform plate.

The *ethmoidal labyrinths* or *lateral masses* are paired structures. Their cavities are more or less completely subdivided by numerous fine bony platelets into the *ethmoidal cells*, which are only partially situated within the ethmoid bone and are frequently closed in by neighboring bones, particularly by the frontal.

We may consequently distinguish the ethmoidal cells proper, *i. e.*, those which are actually inclosed within the ethmoid bone by the lamina papyracea, from those which are closed in by the bones adjacent to the ethmoid (the frontal, lachrymal, sphenoidal, maxillary, and palatine cells).

The external surface of the labyrinth forms a portion of the inner wall of the orbit (Figs. 95 and 96). It is quadrilateral in form, and, on account of its extreme thinness, is known as the *lamina papyracea* (Fig. 70), although it is also known as the *os planum*. In the orbital cavity it articulates anteriorly with the lachrymal bone, inferiorly with the maxilla, posteriorly with the palate bone (the orbital surface) and superiorly with the orbital plate of the frontal bone,† the two *ethmoidal foramina* (see page 61) being situated either close to or actually in the frontoethmoidal suture (Figs. 95 and 96). The margins of the adjacent bones aid more or less in closing in the ethmoidal cells.

The internal wall of the ethmoidal labyrinth (Figs. 101 and 102) forms the upper portion of the outer nasal wall, and from it two thin rough bony plates, whose free margins are slightly rolled up, project into the nasal fossa; these are the short *superior* and the longer *middle turbinated bone* (*conchæ nasales superior et media*). The anterior extremity of the middle turbinated bone articulates with the ethmoidal crest of the frontal process of the maxilla, while

* In this situation the perpendicular plate is usually grooved for the attachment of the cartilage of the nasal septum, it is rarely placed exactly in the median line but usually deviates to one side.

† These sutures have been previously noted and they will be considered in detail upon page 79.

its posterior extremity is attached to the similarly named crest of the palate bone. Between the superior and middle turbinated bones is situated the superior meatus of the nose, which is short and developed only in the posterior portion of the nasal fossæ. Between the middle and inferior turbinated bones (the latter structure being an independent bone) is the middle meatus, in which, covered by the middle turbinated bone, there is a bulging of the ethmoidal wall, the *ethmoidal bulla*, a rudimentary turbinated bone, and another rudimentary turbinal (the os nasoturbinale of the mammalia) is the sickle-shaped *uncinate process* (Figs. 81 and 102), which is also covered by the middle turbinated bone. It articulates with a process of the inferior turbinated bone (see below) and helps to close the orifice of the maxillary sinus. Between the uncinat process and the ethmoidal bulla is a wide fissure, the *infundibulum*, which leads both into the orifice of the frontal sinus and into the ethmoidal cells; its orifice in the nasal fossa is known as the *hiatus semilunaris* (Fig. 101).

The ethmoidal cells communicate partly with one another, partly with the air-cells of the adjacent bones, and in all cases, either directly or indirectly, with the nasal fossæ.

The ethmoid bone is completely preformed in cartilage. Ossification commences late (in the fifth month of embryonic life) and proceeds from the lamina papyracea and the middle turbinated bone. In the new-born, the two labyrinths have already ossified as far as the superior turbinated bone, but they are not connected, since the cribriform and perpendicular plates do not possess ossific centers until the first year of life, when they gradually effect a bony union of the two labyrinths. The remainder of the perpendicular plate does not ossify until the fifth year.

THE INFERIOR TURBINATED BONE.

While the two upper turbinated bodies are portions of the ethmoid bone, the inferior one (*concha nasalis inferior*) (Figs. 79, 81, 82, and 98) is an independent structure and it is also the largest of the three. It is a thin roughened bony plate, the free margin of which is turned upon itself and slightly rolled up. It consists of a body and of three processes.

The narrow, leaf-shaped *body* is placed in the sagittal plane. It is convex toward the nasal septum, concave toward the lateral nasal wall, broader in front than behind, and is provided with many depressions and small foramina. The anterior portion of the lateral border articulates with the conchal crest of the maxilla (Figs. 81, 101, and 102), and the posterior portion of this border is attached to the similarly named crest of the palate bone.

The largest of the three processes is the *maxillary process* (Fig. 82), which is directed downward and outward, and closes a considerable portion of the orifice of the maxillary sinus (see Fig. 101). The *lacrimal process* (Figs. 61 and 82), passing forward and upward, articulates with the lower border of the lacrimal bone by the lacrymoconchal suture, and forms a portion of the wall of the nasal duct (*nasolacrimal canal*) (Fig. 79). The *ethmoidal process* (Figs. 81, 82, and 102) is directed upward and backward and articulates with the uncinat process of the ethmoid bone in the region of the orifice of the maxillary sinus.

The inferior turbinated bone ossifies in immediate connection with the ethmoid bone in the fifth month of embryonic life.

THE LACHRYMAL BONE.

The *lacrimal bone* (Fig. 78) is an approximately rectangular bony plate, very thin and frequently even perforated, situated in the inner wall of the orbit between the frontal process of

the maxilla and the lamina papyracea of the ethmoid bone (Figs. 95 and 96). It articulates with the nasal portion of the frontal bone above, with the inferior turbinate bone below, and extends inward as far as the nasal fossa (the sutures are considered upon page 79).

It presents an external or *orbital surface*, and an internal or *ethmoidal surface*, which is in contact with the ethmoid bone. The ethmoidal surface closes in the *lacrimal cells*, and a small portion of it aids in the formation of the outer nasal wall in the middle meatus, as it articulates with the lacrimal process of the inferior turbinate bone by the lacrymoconchal suture (Fig. 101).

The anterior portion of the orbital surface exhibits a wide groove which, together with a similar groove on the frontal process of the maxilla, forms a depression for the lacrimal sac (see Fig. 77). The posterior boundary of this depression is the *posterior lacrimal crest* which extends downward into a hook-like process (bent up anteriorly), the *hamulus lacrimalis* (Fig. 78). This is situated in the lacrimal notch between the frontal process of the maxilla and the orbital surface of the body of the same bone (see page 67). The posterior portion of the orbital surface, situated behind the lacrimal crest, is smooth.

[The lacrimal bone is formed by ossification of membrane and usually develops from a single center which appears during the third or fourth month of fetal life. Occasionally two centers appear, from one of which the hamulus develops, and more rarely a number of centers occur, in which case the bone is represented by a number of separate parts.—E.D.]

THE NASAL BONE.

The *nasal bones* (Figs. 86 and 87) are two flat, elongated, trapezoidal bones, which meet in the median line to form the bridge of the nose (Figs. 37 and 38). The internasal suture separates the short internal margins of the two bones, while the external margin of each, considerably longer, articulates with the frontal process of the maxilla by the nasomaxillary suture. The shorter and thicker superior margin is in contact with the nasal portion of the frontal bone by the nasofrontal suture; the longer and thinner inferior margin forms the upper boundary of the anterior nares (*apertura piriformis*) and gives attachment to the cartilaginous nasal skeleton.

The slightly concave inner (nasal) surface of each bone presents a groove, the *ethmoidal groove* (Fig. 87), for the anterior ethmoidal nerve, and in the neighborhood of this are one or more fine foramina, the *nasal foramina*, leading to the slightly convex external surface of the bone. Both the superior and inferior margins of the bone are usually irregularly serrated.

[Each nasal bone is developed from a single center of ossification which appears in membrane at about the third month of fetal life. At birth the length of the bones hardly exceeds their breadth.—E.D.]

THE VOMER.

The *vomer* (Figs. 73 to 75) of the adult skull is a flat single bone, approximately trapezoid in shape, which forms the inferior and posterior portion of the bony nasal septum (Fig. 73). Its upper end is thickened and spread out into two plates, the *ala* (Fig. 74), which articulate with the inferior surface of the body of the sphenoid bone in such a manner that the sphenoidal rostrum is received between them, while the vaginal processes of the pterygoid process and

FIG. 73.—The osseous nasal septum seen from the left side. The frontal, sphenoid, maxilla, and palate bones, and also the lamina cribrosa of the ethmoid and the ala vomeris, have been sawed through close to the median line. The ethmoid is yellow, the vomer (except the cut surface of the ala) pink.

FIG. 74.—The vomer seen from behind (†).

FIG. 75.—The vomer seen from the side (†).

FIG. 76.—The right maxilla seen from the inner surface (†).

FIG. 77.—The right maxilla seen from the outer surface (†).

the sphenoidal process of the palate bone (see page 70) are applied to their margins. The posterior border of the vomer forms the *septum choanarum*; the narrow anterior border articulates with the cartilaginous septum of the nose and the anterior portion of the nasal crest of the maxilla; the superior border is attached to the perpendicular plate of the ethmoid; and the inferior one is firmly fixed to the nasal crests of the maxilla and palate bone (Fig. 73).

The vomer arises during the third month of fetal life as two plates situated one on either side of the upper part of the cartilaginous septum of the nose, which subsequently disappears, so that the two plates become adherent after birth, with the exception of the ala, which remain separated throughout life.

THE MAXILLA.

The maxilla (Figs. 76, 77, and 79) is a paired bone which forms the center of the facial skeleton, all portions of which are more or less intimately connected with it. It assists in the formation of the orbit and forms a considerable portion of the nasal fossæ and of the roof of the mouth.

It consists of a *body* and of four processes, the *frontal* or *nasal process*, the *zygomatic process*, the *palatine process*, and the *alveolar process*. Of these, the alveolar process is directed downward and the frontal process upward, while the zygomatic and palate processes extend in the horizontal plane, the former externally, the latter internally.

The *body* of the maxilla is irregularly cubical, and contains a large cavity, the *maxillary sinus* (Figs. 76, 79, 97, and 98), also known as the *antrum of Highmore*. In the body there may be recognized four surfaces: the *anterior*, the *nasal*, the *orbital*, and the *infratemporal*.

The actual facial surface of the bone, the *anterior surface* (Fig. 77), is convex, and its superior border forms a portion of the infraorbital margin. Below this margin is an irregularly rounded opening, the *infraorbital foramen* (Figs. 37, 38, and 77), which gives exit to the vessels and nerves of the same name and is the termination of the infraorbital canal. Below the infraorbital foramen there is a depression, the *canine fossa*, which gives origin to the musculus caninus (levator anguli oris). The anterior border of the facial surface forms a portion of the lateral boundary of the *apertura piriformis* (anterior nares), and at the infraorbital margin the surface becomes continuous with the triangular *orbital surface*, which articulates with the lachrymal, zygomatic, and ethmoid bones, but is separated from the greater wing of the sphenoid by the inferior orbital (sphenomaxillary) fissure (Figs. 95, 96, and 97). This is a smooth surface; it assists in forming the floor of the orbit, and exhibits a gradually deepening groove, the *infraorbital groove* (Fig. 96), along which there is frequently to be observed an infraorbital suture.

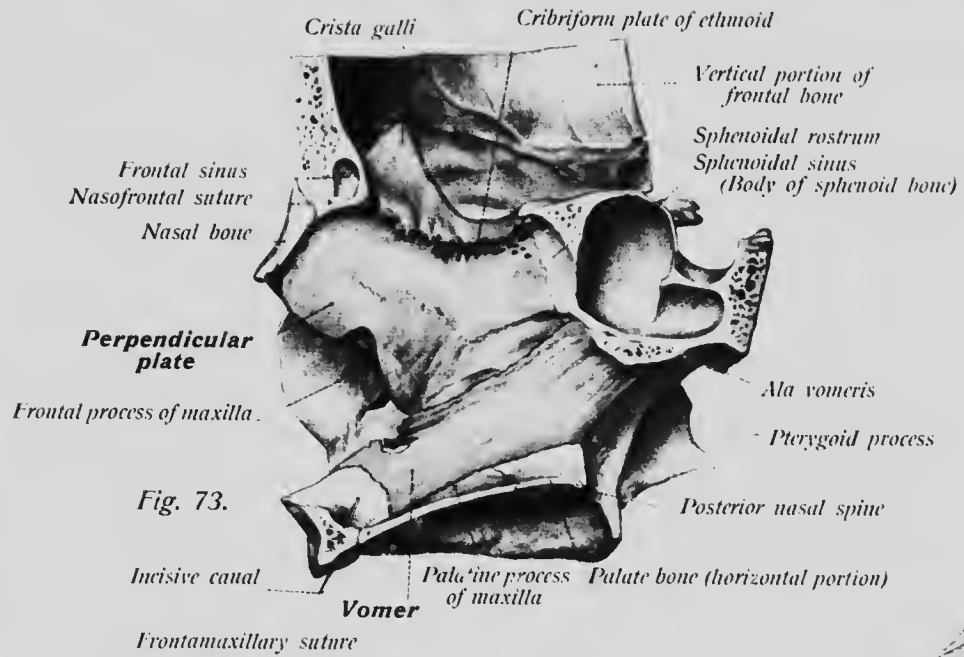


Fig. 73.

Ala vomeris



Fig. 74.

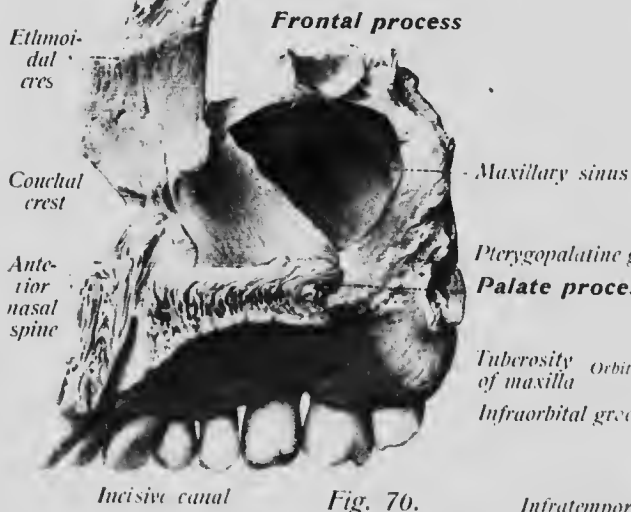


Fig. 70.

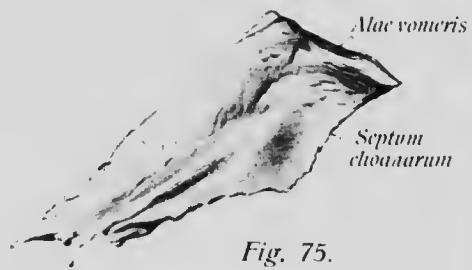

Fig. 75.

Infratemporal surface
Alveolar foramina

Zygomatic process

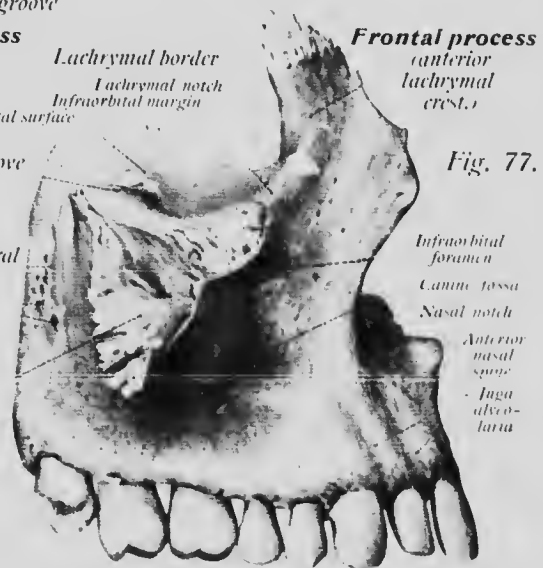


Fig. 77.



The infraorbital groove gradually leads into a canal, the *infraorbital canal*, which runs to the *infraorbital foramen*. The inner margin of the orbital surface presents a notch, the *lachrymal notch* (Fig. 77), which accommodates the hamulus of the lachrymal bone.

The *infratemporal surface* (Fig. 77) is situated behind the zygomatic process, toward the infratemporal and sphenomaxillary fossæ, and represents the posterior surface of the body of the maxilla. It bulges somewhat posteriorly, forming the *tuberosity*, and presents a *pterygopline groove* (see page 79), and also from two to four small foramina, known as the *alveolar foramina*,* which transmit the nerves and vessels of the same name. The superior internal angle articulates with the orbital process of the palate bone.

The *nasal surface* (Fig. 76) forms the lower portion of the outer wall of the nasal fossa; it exhibits a large irregular opening, the *orifice of the maxillary sinus*. Above this orifice there are usually fossæ and depressions which close in the incomplete *maxillary cells* of the ethmoid bone. Only a small part of the anterior portion of the nasal surface is exposed in the lateral nasal wall, the entire roughened posterior portion of this surface being concealed by other bones, namely the palate bone, the inferior turbinate bone, and the uncinatè process of the ethmoid (Fig. 81), which considerably diminish the size of the orifice of the maxillary sinus (see also page 69). Between the orifice of the sinus and the frontal process there is a deep groove, the *lachrymal groove* (Fig. 90), which is converted into the *nasolachrymal canal* by the lachrymal bone and the lachrymal process of the inferior turbinate bone (see page 64). The transition of the nasal surface to the frontal process is indicated by a rough ridge, the *conchal crest* (Fig. 76), for the attachment of the anterior portion of the inferior turbinate bone (*concha nasalis inferior*) (see also page 64).

The upper extremity of the **frontal process** articulates with the nasal portion of the frontal bone by the frontomaxillary suture; its inner margin is in contact with the nasal bone by the nasomaxillary suture, and its outer or lachrymal border is opposed to the lachrymal bone along the lachrymomaxillary suture (Figs. 37 and 38). It narrows as it passes upward and presents an external surface, forming the lateral portion of the bony nose, and an internal surface, directed toward the nasal cavity. This internal surface is separated from the nasal surface of the body of the bone by the *conchal crest*, and parallel to it there is a less prominent ridge, the *ethmoidal crest*, for articulation with the anterior portion of the middle concha of the ethmoid bone.

The external surface of the frontal process presents the *lachrymal groove*, which, together with the similarly named groove of the adjacent lachrymal bone, forms a depression for the accommodation of the lachrymal sac. The sharp anterior border of this fossa is called the *anterior lachrymal crest* (Figs. 77 and 95). The frontal process also forms the largest part of the lateral boundary of the apertura piriformis.

The **zygomatic process** (Fig. 77) is broad, short, and three-sided, and terminates in a rough articular surface for the body of the zygomatic bone (zygomaticomaxillary suture). The maxillary sinus extends into the base of the process.

* These lead into small canals, the *alveolar canals*, which contain the nerves and vessels for the molar teeth and terminate in the posterior alveoli, while the alveolar canals for the canine and incisor teeth proceed from the floor of the infraorbital canal and run within the thin anterior wall of the body of the maxilla.

FIG. 78.—The left lachrymal bone seen from its median surface ($\frac{1}{2}$).

FIG. 79.—The lower half of the facial portion of the skull which has been divided horizontally, seen from above ($\frac{1}{2}$).

FIG. 80.—The right maxilla and palate bone, seen from the inner surface ($\frac{1}{2}$).

FIG. 81.—The right maxilla, palate bone, inferior turbinated bone and part of the ethmoid, seen from the inner surface ($\frac{1}{2}$).

FIG. 82.—The inferior turbinated bone seen from its lateral surface ($\frac{1}{2}$).

In Figs. 79 and 81 the maxilla is colored yellow, the sphenoid green, the palate bone blue, and the ethmoid orange.

The zygomatic process forms the lower portion of the outer margin of the inferior orbital (sphenomaxillary) fissure, and is continued as a flat process, the orbital plate, upon the orbital surface of the body of the bone in such a manner that it forms the floor of the original infraorbital groove. In young subjects this orbital plate is always separated from the other bones by the *infraorbital suture*, which is also frequently observable in the adult skull.

The **alveolar process** is convex externally, concave internally, and contains eight of the sixteen upper teeth. It is directly continuous with the lower surface of the body of the bone, is separated from the frontal process by the *nasal notch* (Fig. 77), and forms the inferior and a portion of the lateral boundary of the apertura piriformis. Both alveolar processes are in contact in the median line in the intermaxillary suture, and their superior margins form the anterior extremity of the *nasal crest* and the *anterior nasal spine*. The free inferior margin of the process, the *limbus alveolaris*, contains the sockets (*alveoli*) for the roots of the teeth, and these are separated from each other by the *interalveolar septa*. The roots of the front teeth particularly cause the walls of the alveoli to project externally and in this manner produce the *juga alveolaria* (Fig. 77).

The apices of the posterior alveoli are situated immediately beneath the maxillary sinus and are separated from it only by thin layers of bone (Fig. 98), and at the summit of every alveolus is the orifice of an alveolar canal (see page 67). Posteriorly the alveolar process is directly continuous with the tuberosity, anteriorly with the palatine process.

The **palatine processes** (Figs. 79 and 100) of the two maxillæ articulate in the median line in the anterior portion of the middle palatine suture (Figs. 41 and 42) and form the largest portion of the hard palate. Each presents a slightly concave, relatively smooth nasal surface, which forms the floor of the nasal fossa, and a markedly concave, extremely rough palatine surface, which is directly continuous externally with the alveolar process. In the median line immediately behind the junction of the two alveolar processes each palatine process exhibits upon its palatine surface an *incisive notch*, and the corresponding notches of the two bones form the inferior opening of the *incisive foramen* (Fig. 100), which has two orifices into the nasal fosse, one on either side of the bony nasal septum (Fig. 78). The palatine surface (Fig. 100) also possesses rough longitudinal ridges and grooves, the *palatine spines* and *grooves*, the latter accommodating the vessels and nerves of the hard palate.

Upon the nasal surface of the palatine processes the thickened and rolled up margins of the two bones unite in the median suture to form the *nasal crest* (Fig. 79), into which is inserted the inferior margin of the vomer. To either side of the anterior extremity of this crest is situated one of the nasal orifices of the incisive canal.

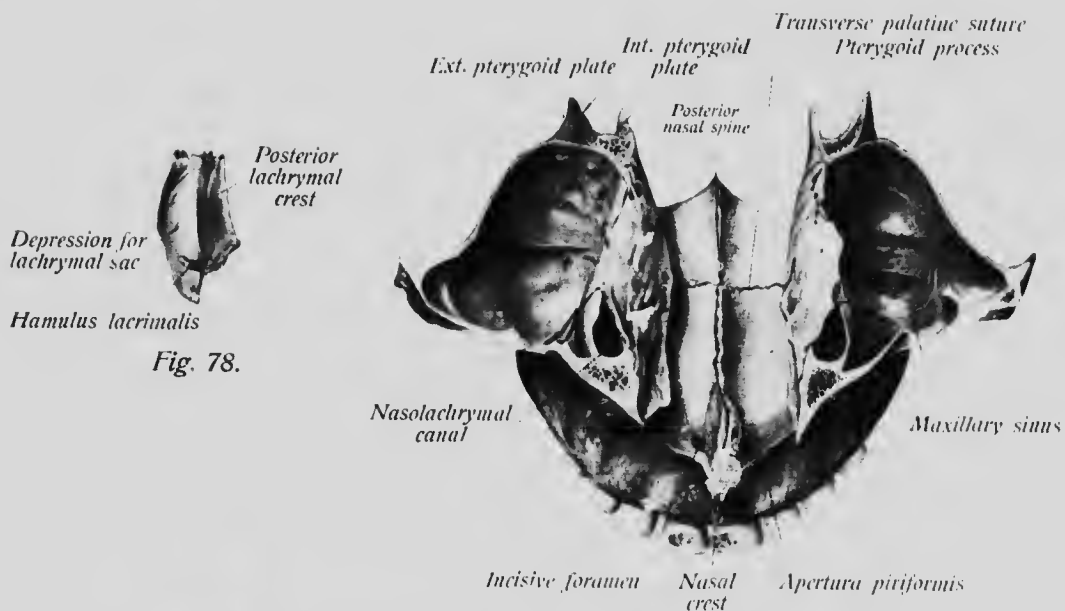


Fig. 78.

Fig. 79.

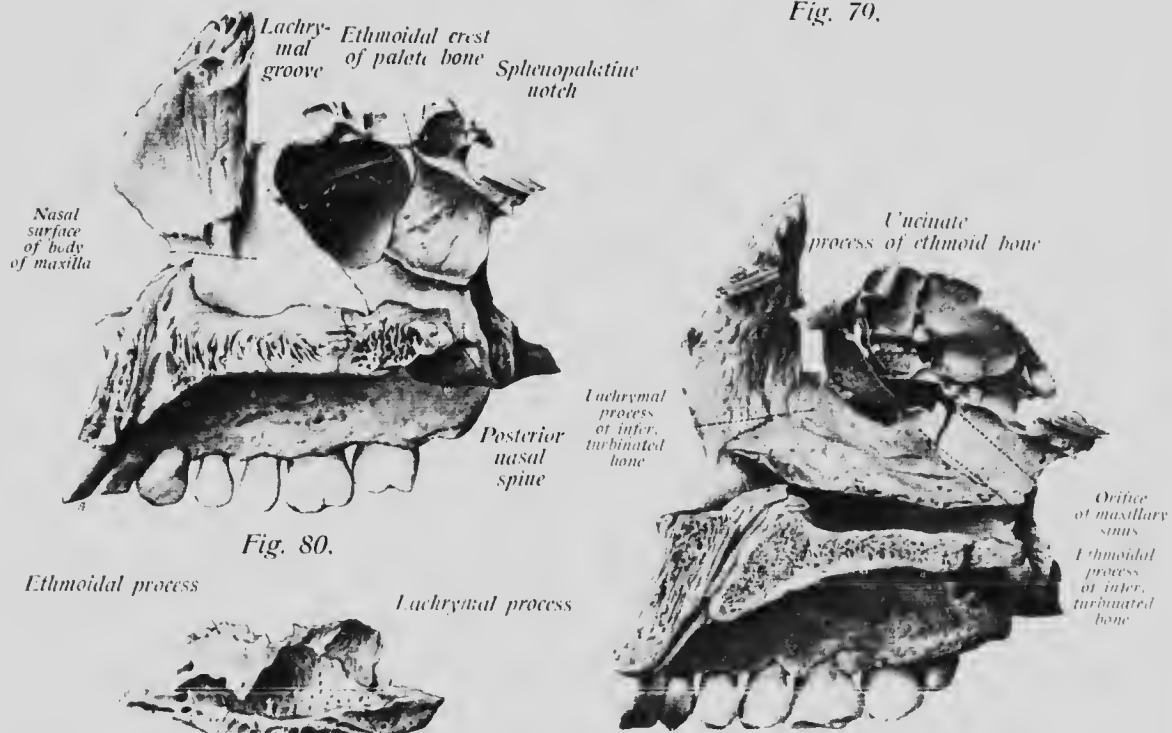



Fig. 80.

Fig. 81.

Fig. 82.



In the skull of the new-born and of the child the hard palate always shows an *incisive suture*, which is also frequently observed even in adult life (Fig. 100).

In the fetus both the incisor teeth and their alveoli are situated in a special bone, the *intermaxillary bone* or *os incisivum*, which also forms the anterior portion of the hard palate. Although the portion of the incisive suture indicating the boundary between the intermaxillary bone and the alveolar process usually disappears before birth, the incisive suture upon the hard palate is maintained for a considerably longer time.

The upper jaw is formed in membrane toward the end of the second fetal month, from four or five centers of ossification, two of which form the intermaxillary bone and remain independent longer than the others, which usually unite as early as the fourth month of fetal life. The infraorbital suture is another indication of the complex origin of the maxilla. The upper jaw of the new-born is considerably flatter than the fully developed bone, and the alveolar process is entirely wanting, first appearing with the development of the teeth and not being completely formed until a considerably later period. The upper jaw contains a maxillary sinus even during fetal life.

THE PALATE BONE.

The *palate bone* (Figs. 83 to 85) is a flat paired bone, very thin in certain places, which is applied to the posterior portion of the maxilla and also articulates with the sphenoid (body and pterygoid processes) and with the inferior turbinated bones. It consists of two rectangular bony plates placed at right angles to each other, one, the *horizontal plate*, being in the horizontal, and the other, the *perpendicular plate*, in the sagittal plane. The palate bone also possesses three processes.

The *horizontal plates* of the two palate bones form the posterior portion of the hard palate (Figs. 41, 42, and 100). They articulate with each other in the posterior portion of the middle palatine suture, and with the palatine processes of the maxilla in the transverse palatine suture. At the posterior extremity of the median suture the two palate bones together form the *posterior nasal spine* (Figs. 83 and 100), as well as the posterior portion of the *nasal crest* upon the nasal surface of the hard palate (Fig. 78), and their posterior margins form the lower boundary of the choanae (Figs. 41 and 42). The rough palatine surface of the horizontal plate (Fig. 100), like the similar surface of the palatine process of the maxilla, exhibits palatine spines and grooves, and also presents, near the postero-external angle, the *greater palatine foramen*, one of the orifices of the *pterygopalatine canal*. The nasal surface (Fig. 79), however, is smooth and distinctly concave, like the corresponding surface of the palatine process of the maxilla.

The *perpendicular plate* of the palate bone is narrower and thinner, but longer than the horizontal one. Its *maxillary surface* (Fig. 84) is applied to the rough surface of the posterior portion of the nasal surface of the maxilla and also partly lies in front of and partly closes the orifice of the maxillary sinus. Its internal or *nasal surface* (Fig. 85) forms the posterior portion of the lateral nasal wall (Figs. 101 and 102), and presents two horizontal parallel ridges, a distinct inferior one, the *conchal crest* (Fig. 85), for the attachment of the inferior turbinated bone (Figs. 101 and 102), and a less pronounced superior one, the *ethmoidal crest* (Fig. 84), for the middle turbinated bone. At the posterior border of the perpendicular plate there is a groove, the *pterygopalatine groove* (Fig. 84), which, with the similarly named grooves of the maxilla (see Fig. 76) and of the pterygoid process of the sphenoid bone (see Fig. 53), forms the *pterygopalatine canal*, whose inferior extremity is the previously mentioned *greater palatine foramen*. In its vicinity are also the orifices of several smaller lateral ramifications, the *palatine canals*, most

- FIG. 83.—The right palate bone seen from behind (†).
 FIG. 84.—The right palate bone seen from the outer surface (†).
 FIG. 85.—The right palate bone seen from the inner surface (†).
 * = surface which completes the pterygoid fossa.
 FIG. 86.—The left nasal bone seen from the outer surface (†).
 FIG. 87.—The left nasal bone seen from its inner surface (†).
 FIG. 88.—The right malar bone seen from the outer surface (†).
 FIG. 89.—The right malar bone seen from the temporal surface (†).

of which perforate the pyramidal process and end on the hard palate as the *lesser palatine foramina*.

Of the three processes of the palate bone, the *pyramidal process* or *tuberosity* passes backward from the junction of the two plates of the bone, filling in the pterygoid notch of the pterygoid processes of the sphenoid bone and completing the pterygoid fossa.

The other two processes, the *orbital* and the *sphenoidal processes*, are given off from the upper portion of the perpendicular plate above the ethmoidal crest, and are separated from one another by a deep notch, the *sphenopalatine notch* (Figs. 84 and 85). The inferior surface of the body of the sphenoid bone converts this notch into the *sphenopalatine foramen* (Fig. 102), an important communication between the pterygopalatine (sphenomaxillary) fossa and the nasal cavity, which gives passage to vessels and nerves (see page 78).

The *orbital process* (Figs. 83, 85, and 96) is the anterior and larger of the two processes, and is directed outward. Its upper surface forms the most posterior portion of the floor of the orbit, articulating with the lamina papyracea by the palatoethmoidal suture and with the orbital portion of the maxilla by the palatomaxillary suture. Its anterior surface is closely applied to the maxilla, while the internal one has an irregular boundary and articulates with the ethmoid labyrinth, where it assists in closing in some of the ethmoidal cells, the *palatine cells*. The orbital process is also in contact with the external surface of the body of the sphenoid bone by the sphenoorbital suture, and forms the posterior portion of the inner margin of the inferior orbital (sphenomaxillary) fissure.

The thin posterior *sphenoidal process* (Figs. 83, 85, and 101), directed internally, is applied to the ala vomeris, to the inferior surface of the body of the sphenoid bone, and to the sphenoidal conchæ (sphenoidal turbinated bones), and also partly closes the orifice of the sphenoidal sinus.

The palate bone is formed in membrane in the third fetal month and is already ossified at about the middle of the fetal life, but like the upper jaw it is rather short in the new-born.

The orbital surface of the orbital process is sometimes unusually large, and the width of the perpendicular plate is subject to great individual variation.

THE ZYGOMATIC BONE.

The *zygomatic* or *malar* bones (Figs. 88 and 89) are three-sided, flat, strong bones which form the prominence of the cheek. They articulate with the frontal, sphenoid, and maxillary bones (Figs. 37 and 38), and also with the temporal bone by means of the zygoma which bridges over the temporal fossa (Figs. 39 and 40) (the sutures are described upon pages 37 and 80). The small orbital plate, placed at right angles to the malar surface, assists in the formation of

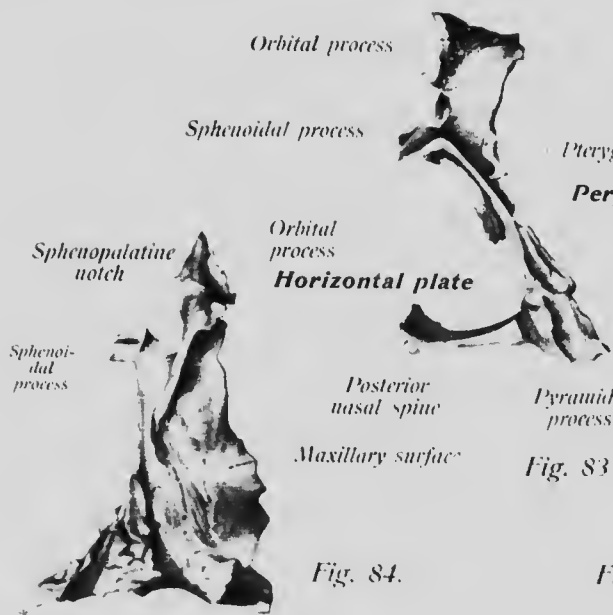


Fig. 84.

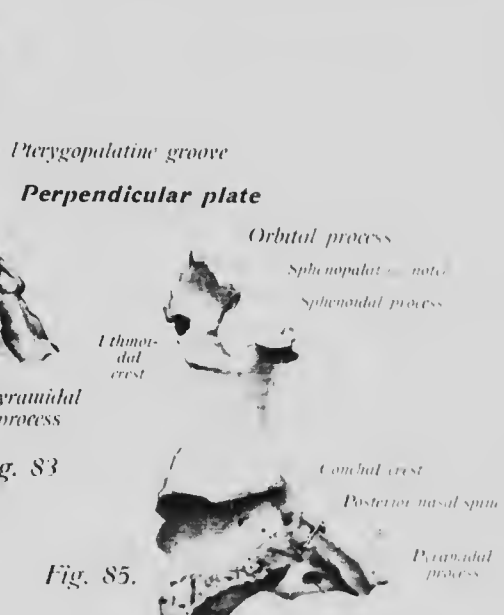


Fig. 85.

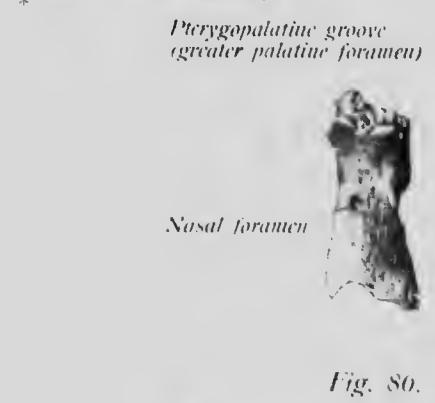


Fig. 86.



Fig. 87.

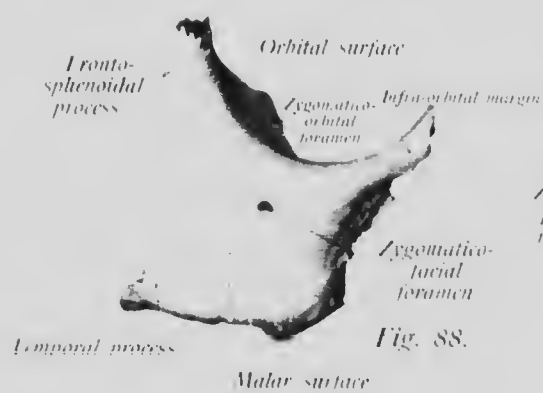



Fig. 88.

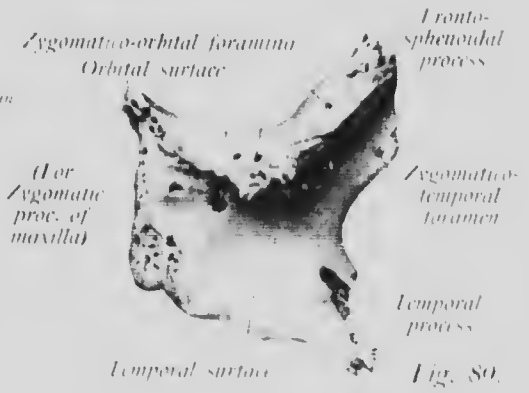

Fig. 89.



the orbit. The malar bone presents three surfaces, the *facial* or *malar surface*, the *posterior* or *temporal surface*, and the *orbital surface* formed by the upper surface of the orbital plate.

The *orbital surface* is slightly concave and its anterior border forms part of the infraorbital margin (Fig. 95). It articulates with the orbital surface of the greater wing of the sphenoid bone, is usually separated from the orbital surface of the maxilla by the *inferior orbital* (sphenomaxillary) *fissure*, and forms a portion of the floor and of the outer wall of the orbit. Upon this surface is the *zygomatico-orbital foramen* (Fig. 88), leading into a branching canal, whose external orifices are the *zygomaticotemporal* and *zygomaticofacial foramina*, although frequently these two canals are entirely independent of each other, in which case there are two zygomatico-orbital foramina (Fig. 88).

The quadrilateral *malar plate* possesses a convex malar surface and a slightly concave temporal surface. It articulates by means of its anterior rough margin with the zygomatic process of the maxilla, and in common with the orbital plate it gives off the *frontosphenoidal process* (Figs. 88 and 89), which passes upward, forming the outer margin of the orbit, and articulates with the zygomatic process of the frontal bone and the zygomatic border of the greater wing of the sphenoid bone. The *temporal process* passes posteriorly to form the zygoma by articulating with the zygomatic process of the temporal bone (Figs. 39 and 40). The sutures between the zygomatic and the adjacent bones have been previously noted (page 37), and will be reviewed in another place (page 80). The malar surface shows the *zygomaticofacial foramen* (Fig. 89); the temporal surface, the *zygomaticotemporal foramen* (Fig. 88).

The zygomatic bone is formed in membrane and commences to develop about the beginning of the third fetal month from two separate centers of ossification. In rare instances the two portions of the bone are separated even in adult life by a suture which may be seen at about the middle of the bone. Since the bone is gradually pushed outward during its development and during the growth of the individual, it happens that in one-half of the specimens the orbital surface no longer forms one of the boundaries of the inferior orbital (sphenomaxillary) fissure.

THE MANDIBLE.

The *mandible* (Figs. 90 to 93) is a single bone, and is the only bone of the skull which is connected to the remaining bones by a joint instead of by sutures. It consists of two main portions, a *body* and two *rami*. The upper end of each ramus is composed of two processes, an anterior pointed *coronoid process* and a posterior rounded *condyloid process* (Fig. 93), the two being separated by the *notch of the mandible* (*sigmoid notch*). The *body* of the mandible is an approximately paraboloid bony plate from the posterior extremities of which the rami pass vertically upward. Its inferior margin is termed the *base* of the mandible; the superior margin is the *alveolar portion*, and contains, in the adult, sixteen dental alveoli for the lower teeth, which are separated from each other by the interalveolar septa. The free margin of the alveolar process is called the *alveolar border*, and the roots of the teeth, particularly those of the front ones, expand the thin bony mass of the process and produce longitudinal ridges upon the surface of the bone, the *alveolar juga* (Fig. 90).

The middle of the external surface of the body of the mandible exhibits a rough projection, the *mental protuberance* (Fig. 90), which marks the union of the originally separate halves of the bone (Fig. 89), and to either side of this projection and toward the base of the mandible

FIG. 90.—The mandible seen from in front (†).

FIG. 91.—The mandible seen from the outer surface (†).

FIG. 92.—The mandible seen from below (†).

FIG. 93.—One-half of the mandible seen from the inner surface (†).

FIG. 94.—The hyoid bone seen from in front and above (†).

is the *mental tubercle*. Above and to the outer side of the mental tubercle is situated the *mental foramen*, giving exit to the vessels and nerve of the same name and forming the inferior opening of the *mandibular (inferior dental) canal*, which traverses the greater portion of the body of the mandible. There is also to be observed upon the outer surface of the body a smooth ridge, the *oblique line*, which passes downward from the root of the coronoid process, gradually fades away, and finally entirely disappears somewhat to the outer side of the mental foramen (Figs. 90 and 91).

The internal surface of the body of the mandible (Figs. 92 and 93) exhibits, to either side of the median line, a shallow depression which is known as the *digastric fossa*, since it received the insertion of the anterior belly of the digastric muscle, and above this there is a short, rough, irregular prominence, the *mental spine*, which is usually a paired structure and sometimes also shows a further transverse subdivision; it gives origin to the geniohyoid and geniohyoglossus muscles. To the outer side of the mental spine there is a larger shallow depression which lodges the sublingual salivary gland, and between the sublingual and digastric fossæ is the termination upon the inner surface of the body of the mandible and gives origin to the mylohyoid muscle.

A certain distance below the mylohyoid line there is a groove which commences at the *mandibular foramen* (Figs. 92 and 93) situated upon the inner surface of the ramus, and gradually disappears as it passes forward; this is the *mylohyoid groove* and contains the vessels and nerve of the same name. Below the mylohyoid line, to the outer side of the depression for the sublingual gland, and frequently difficult of recognition, there is a much shallower depression for the submaxillary gland.

Each **ramus** forms almost a right angle with the body of the bone, and is both broader and thinner than the body. It passes upward, broadens, and divides into two processes, an anterior *coronoid* and a posterior *condyloid process*, which are separated by the notch of the mandible (the sigmoid notch).

The ramus, like the body of the bone, possesses an external surface and an internal surface, a portion of the latter being directed toward the oral cavity. The external surface (Fig. 90) is roughened at the angle, forming the *masseteric tuberosity* for the insertion of the masseter muscle. There is a corresponding rough area upon the inner surface, the *pterygoid tuberosity*, for the insertion of the internal pterygoid muscle.

At about the middle of the ramus there is an opening, the *mandibular (inferior dental) foramen* (Fig. 93), the superior opening of the *mandibular (inferior dental) canal*,* which passes

* The mandibular canal is continued within the bone beyond the mental foramen almost to the median line and gives off small lateral ramifications which lead to the apices of the alveoli

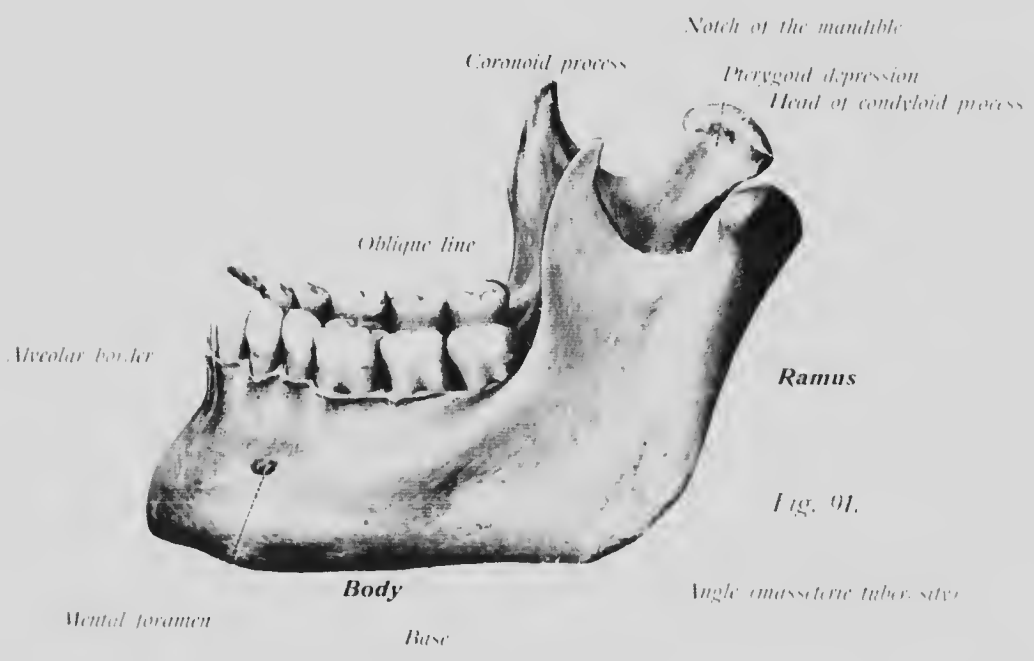
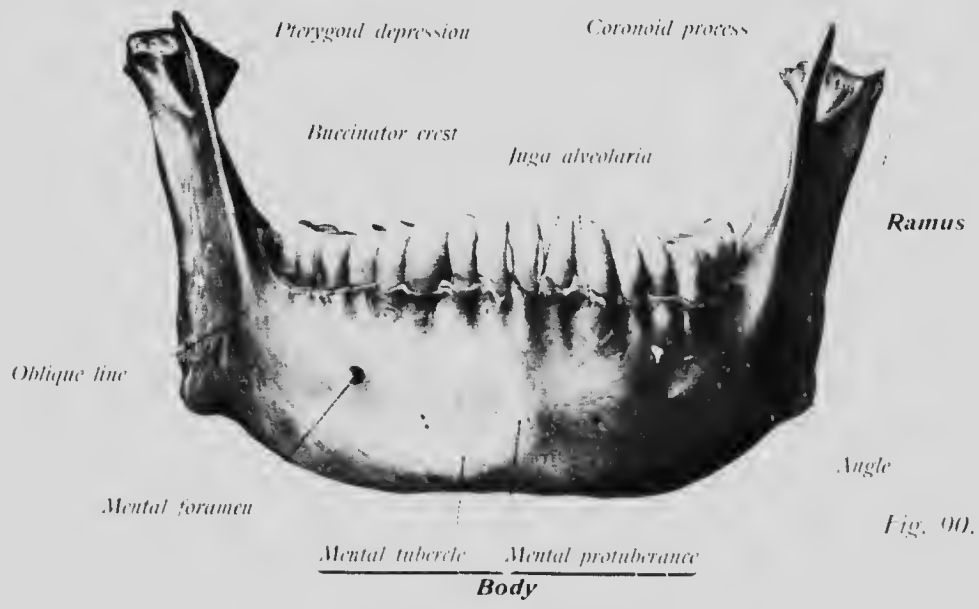




Fig. 04.

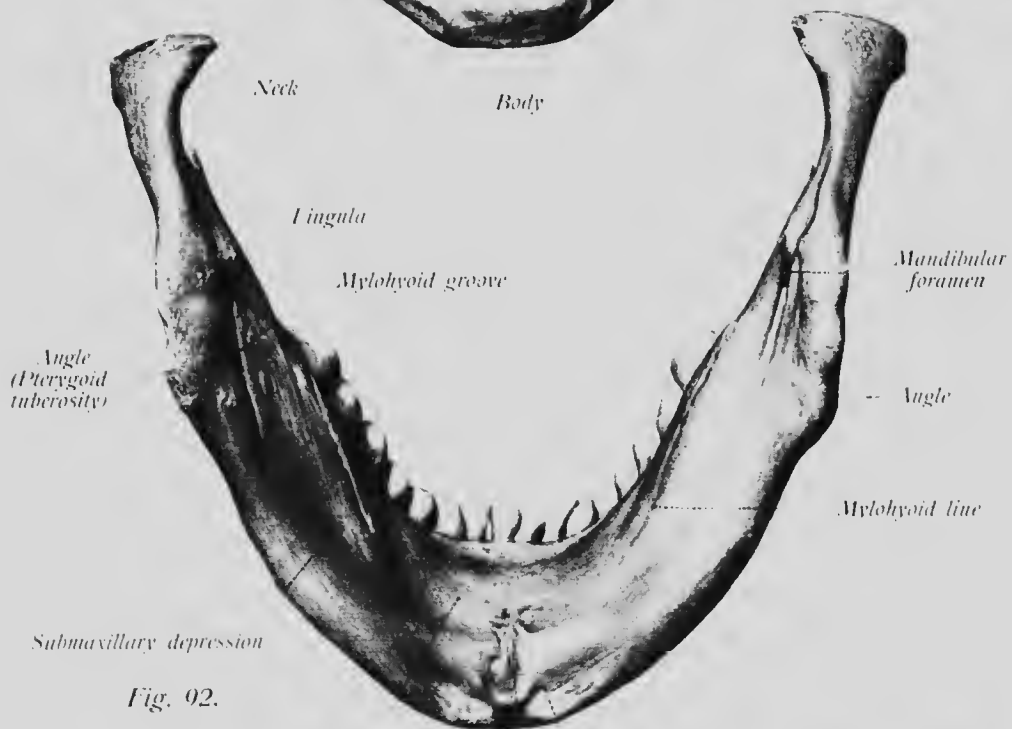



Fig. 02.


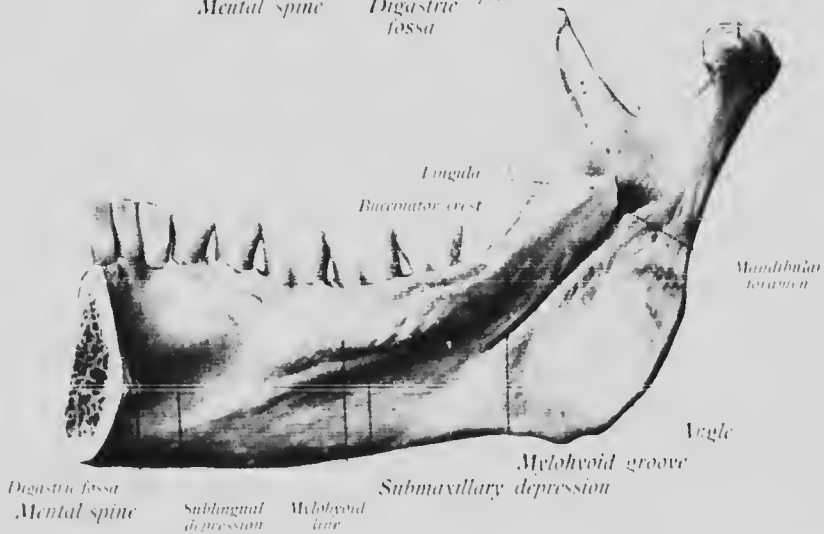


Fig. 03.





obliquely through the mandible to the mental foramen and transmits the inferior dental vessels and nerve. A thin tongue-shaped bony plate, the *lingula*, overhangs the anterior margin of the foramen.

The *coronoid process* is flattened from side to side and terminates in a more or less sharp apex which gives attachment to the temporal muscle. In the prolongation of its anterior margin runs the previously described oblique line, and passing from its base to the region of the last molar tooth is a ridge, the *buccinator crest* (Fig. 93), for the origin of the buccinator muscle.

The *condyloid process* terminates above in a condyle, whose *head* (Fig. 91) is separated from the base of the process by a constriction known as the *neck* (Fig. 92). The articular surface itself is ellipsoidal and its longitudinal axis is placed almost transversely, although directed somewhat posteriorly, so that the condyloid process, in contrast to the coronoid, is compressed from before backward. Upon the anterior surface of the neck of the condyle there is a shallow *pterygoid depression*, which receives part of the insertion of the external pterygoid muscle.

The lower jaw is formed in membrane about Meckel's cartilage, a cartilage of the visceral skeleton which marks the position of the adult mandible. The first center of ossification appears in the second fetal month upon both sides external to Meckel's cartilage; a second center appears above the first, and the two unite in such a manner that they form a groove which is open above for the reception of the teeth. Even at birth the two halves of the mandible are usually separated by a synchondrosis, and they do not unite until the first year. The condyloid process is preformed in cartilage and is developed by the direct transformation of the cartilage into bone. The lower jaw of the new-born is very low, possesses no alveolar portion, and the ramus is still but poorly developed and forms a very obtuse angle with the body.

THE HYOID BONE.

The hyoid bone (Fig. 94) is a small horseshoe-shaped structure situated in the base of the tongue; it does not articulate with the skull but is connected with it by the stylohyoid ligament.

It consists of a body, from either side of which proceed the *greater* and the *lesser cornua*. The body is slightly curved horizontally, the anterior surface being rough and slightly convex, the posterior one smooth and slightly concave. The *greater cornua* are long and thin and are connected to the body either by bony tissue or by cartilage, more rarely by fibrous connective tissue or by a joint. They pass horizontally outward from the body of the bone, and are directed backward and usually slightly upward, their ends exhibiting a bulbous thickening. The *lesser cornua* are frequently cartilaginous, and arise close to the bases of the greater ones; they are directed upward, however, and also outward and backward. They are much shorter than the greater cornua and are connected with the styloid process of the temporal bone by the stylohyoid ligament. The nature of their attachment to the hyoid bone is subject to considerable variation.

The hyoid bone is preformed in cartilage and arises chiefly from the second branchial arch (the hyoid arch), the greater cornua, however, representing the third arch. The body (two centers) and the greater cornua commence to ossify at birth, the lesser cornua at a much later period. Sometimes the lesser cornua extend far into the stylohyoid ligament (see page 116), just as the styloid process does, the two bones having a common embryonic origin.

THE ORBITAL CAVITIES.

Each orbit (Figs. 95 to 99) is a quadrilateral prismatic space having the shape of a tall horizontal pyramid, the apex of which is situated posteriorly in the region of the optic

FIG. 95.—The left orbit seen from in front ($\frac{1}{2}$).

FIG. 96.—The median wall of the left orbit, the outer wall having been removed ($\frac{1}{2}$).

FIG. 97.—The outer wall of the right orbit, the median one having been removed ($\frac{1}{2}$).

In all these figures the frontal bone is violet; the ethmoid orange; the lachrymal pink; the sphenoid green; the nasal, parietal, and zygomatic bones white; and the palate bone blue.

foramen. Its base is a quadrangle with rounded corners, and forms the entrance to the cavity (*aditus orbitæ*).

The four walls of the orbit are designated the superior, the internal, the external, and the inferior. Since there is no sharp dividing-line between the superior and internal and between the internal and inferior walls, and also since such a dividing-line is partly absent between the external and superior wall, the pyramidal orbital space possesses for the most part no sharp angles; indeed, posteriorly the pyramid has practically but three sides.

Each orbit is formed by seven bones: the frontal, the sphenoid, the ethmoid, the lachrymal, the maxilla, the zygomatic, and the palatine. The sutures between these bones are described on pages 79 and 80. The upper wall or the roof of the orbit (Fig. 95) is formed by the orbital portion of the frontal bone, and in the posterior portion also by the lesser wing of the sphenoid bone. It is horizontal, smooth, and slightly concave.

The inner wall (Fig. 97) is formed anteriorly by the lachrymal bone and posteriorly by the lamina papyracea of the ethmoid bone and by a small portion of the ala parva of the sphenoid (near the junction of the inner wall with the roof). Below the lamina papyracea, the orbital surface of the maxilla extends upward from the floor upon the inner wall, and its frontal process also forms a narrow portion of the inner wall, internal to the lachrymal bone and immediately adjacent to the internal orbital margin. The inner wall of the orbit is approximately vertical and its anterior portion exhibits the fossa for the lachrymal sac.

The floor of the orbit (Fig. 99) passes quite gradually into the inner wall, and its posterior portion is separated from the largest (posterior) portion of the outer wall by the inferior orbital (sphenomaxillary) fissure. Its greatest portion is formed by the orbital surface of the maxilla, only a small posterior portion being formed by the orbital process of the palate bone. In the anterior portion of the orbit the zygomatic bone also forms a narrow strip of the floor, but the extent to which it takes part is subject to considerable variation (see page 71). The inferior orbital wall is quite smooth and is almost exactly horizontal (slightly inclined outward, forward, and downward).

The outer wall of the orbit (Fig. 97) is the most isolated of all, since the two orbital fissures separate from it the remaining walls in the posterior portion of the orbit. The inferior orbital (sphenomaxillary) fissure separates more than half of the length of the outer wall from the floor, and one-third of its extent is separated from the roof by the superior orbital (sphenoidal) fissure. It is practically formed by two bones, the orbital surface of the greater wing of the sphenoid bone contributing the posterior portion, and the orbital surface of the zygomatic bone the anterior portion. The latter portion, however, also contains a part of the orbital portion of the frontal bone, which extends downward more or less from the roof. The outer wall of the orbit is slightly

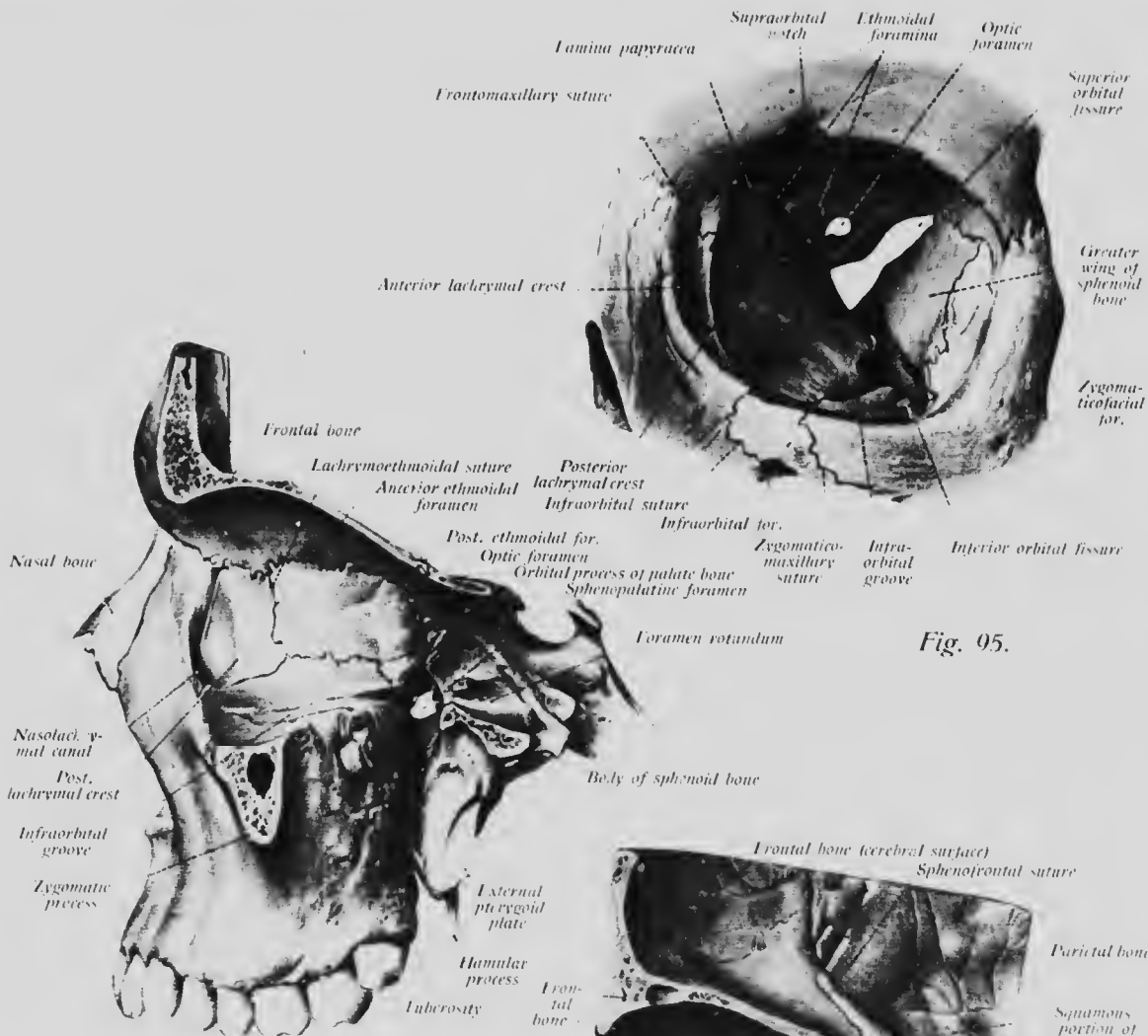


Fig. 96

Fig. 95.

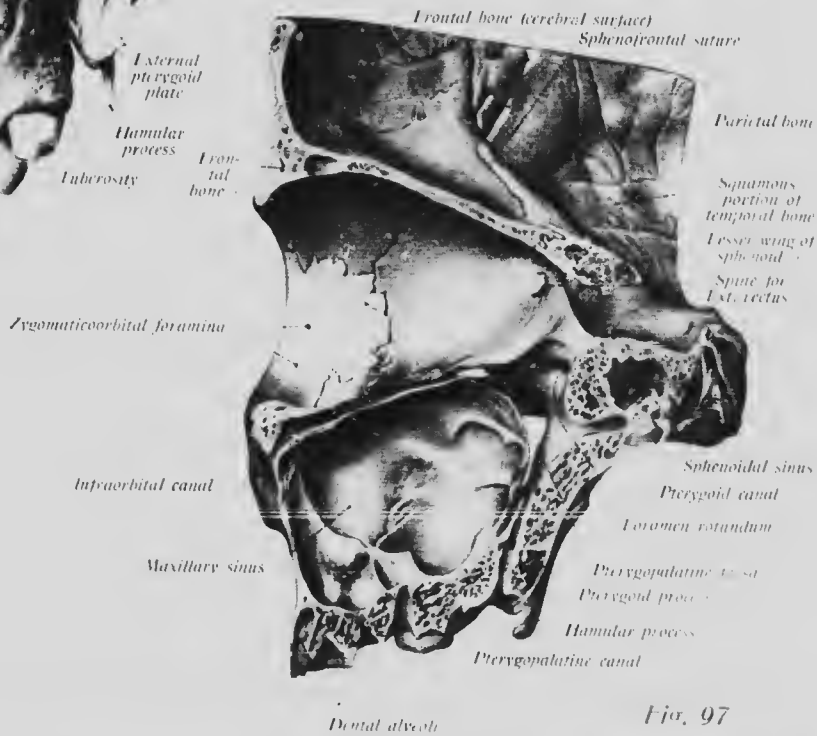


Fig. 97



concave and is not exactly vertical, but directed somewhat from above downward and from without inward.

The margins of the orbit are known as the supraorbital and the infraorbital. They are, of course, connected at their extremities by the lateral walls of the orbit.

The supraorbital margin (Fig. 96) is usually sharper than the inferior one; it is formed by the frontal bone (the vertical plate and the zygomatic process) and contains one shallow notch or two deeper ones, the *supraorbital* and *frontal notches* or *foramina* (Fig. 67), which transmit the frontal and supraorbital vessels and nerves. The frontal bone extends lower down internally than it does externally. The infraorbital margin (Fig. 99) is formed internally by the maxilla, and externally by the zygomatic bone, these bones extending internally and externally as far as the frontal bone. A portion of the internal margin (Fig. 97) is furnished by the anterior lachrymal crest of the frontal process of the maxilla, and its smoothest portion is situated above this crest. The external margin (Fig. 97) is formed by the zygomatic bone, particularly by its frontosphenoidal process.

The following foramina and fissures lead either into or from the orbit:

1. The *optic foramen* (Fig. 96), situated in the root of the lesser wing of the sphenoid bone, leads from the cranial cavity to the apex of the orbit and transmits the optic nerve and the ophthalmic artery.

2. The *superior orbital* (sphenoidal) *fissure* (Fig. 95), between the greater and lesser wing of the sphenoid, also leads from the cranial into the orbital cavity and transmits the ophthalmic, oculomotor, trochlear, and abducens nerves and the superior ophthalmic vein. This fissure separates the outer from the upper wall of the orbit. Its internal portion is wide; its external portion is narrow and closed by a membrane.

3. The *inferior orbital* (sphenomaxillary) *fissure* (Fig. 95), between the maxilla and the orbital process of the palate bone on one side and the greater wing of the sphenoid bone or the greater wing and the zygomatic bone on the other, leads from the pterygopalatine (sphenomaxillary) fossa into the orbital cavity and transmits the infraorbital vessels and nerve. It separates the outer wall from the floor of the orbit and is larger antero-externally than it is postero-internally. The external boundary of the fissure is furnished by the crista orbitalis of the greater wing of the sphenoid bone.

4. The superior opening of the *nasolachrymal* (*nasal*) *canal* (Fig. 99), in the fossa for the lachrymal sac; this canal leads from the orbital into the nasal cavity and transmits the nasolachrymal (nasal) duct.

5. The *anterior ethmoidal foramen* (Figs. 95 and 96), passing from the orbital to the cranial cavity and transmitting the anterior ethmoidal vessels and nasal nerve.

6. The *posterior ethmoidal foramen* (Figs. 95 and 96), leading into the nasal cavity and transmitting the posterior ethmoidal vessels. Both this and the preceding foramen are situated in or to one side of the frontoethmoidal suture in the inner wall of the orbit.

7. The *zygomaticoorbital foramen* or *foramina* (Fig. 97), in the outer wall of the orbit pass through the malar bone to the temporal fossa and to the face, and transmit the nerves and vessels of the same name or their branches.

8. The entrance of the *infraorbital canal* (for the vessels and nerve of the same name),

FIG. 98.—A frontal section through the anterior part of the skull, showing the orbits, the nasal fossæ, and the maxillary sinuses ($\frac{1}{3}$).

FIG. 99.—The floor of the left orbit seen from above, the roof having been removed ($\frac{1}{4}$).

FIG. 100.—The maxilla, palate bone, and lower ends of the pterygoid process of the sphenoid, seen from the oral surface (the hard palate) ($\frac{1}{4}$).

leading to the infraorbital foramen, is situated in the floor of the orbit. It commences at the inner end of the inferior orbital fissure as the infraorbital groove (Fig. 99).

9. The *frontal* and *supraorbital foramina*, situated in the supraorbital margin.

The orbit contains the following depressions or fossæ:

1. The *fossa for the lachrymal gland* (Fig. 69), on the frontal bone beneath the outer portion of the supraorbital margin.

2. The *trochlear depression* (Fig. 68), also on the frontal bone, where it passes into the inner wall of the orbit, for the attachment of the pulley of the superior oblique muscle.

3. The *fossa for the lachrymal sac* (Fig. 99), situated in the inner wall of the orbit between the anterior lachrymal crest of the frontal process of the maxilla and the posterior lachrymal crest of the lachrymal bone.

The only groove in the orbit is the *infraorbital groove* (Fig. 98), upon the orbital surface of the body of the maxilla.

There are several projections into the orbital cavity. These are the anterior and posterior lachrymal crests which form the fossa for the lachrymal sac, and a bony spine upon the greater wing of the sphenoid bone near the outer margin of the superior orbital fissure, the *spine for the external rectus muscle* (Fig. 99). The frontal bone occasionally presents a trochlear spine alongside of the trochlear depression.

The orbital walls vary greatly in their thickness. The thinnest wall is the inner one, both in the region of the lamina papyracea of the ethmoid bone and also in that of the lachrymal bone, the latter bone even being sometimes defective. The roof of the orbit not infrequently contains a portion of the frontal sinus, in which case it is hollow. The outer wall is usually the thickest.

THE NASAL CAVITY.

The bony nasal cavity (Figs. 99, 101, and 102) is subdivided into two symmetrical nasal fossæ by the nasal septum, which is frequently oblique and not exactly in the median sagittal plane. The cavity is highest just behind the anterior nares and gradually becomes lower toward the posterior nares, and nine of the bones of the skull—the nasal, frontal, ethmoid, sphenoid, maxilla, palate, inferior turbinate, lachrymal, and vomer—take part in its formation. In each nasal fossa there may be recognized a roof, a floor, an internal wall, and an external wall. The anterior opening of the two bony nasal fossæ is known as the *apertura piriformis* (anterior nares), while the posterior opening of each is the *choana*. The former (Figs. 37 and 38) is bounded by the nasal bones and by the frontal processes and bodies of the maxilla, while each choana (posterior naris) (Figs. 41 and 42) is bounded by the palate bone, the internal plate of the pterygoid process, and the body of the sphenoid bone. The roof of the nasal cavity is formed anteriorly by the two nasal bones and by the nasal portions of the frontal bones, in the middle by the

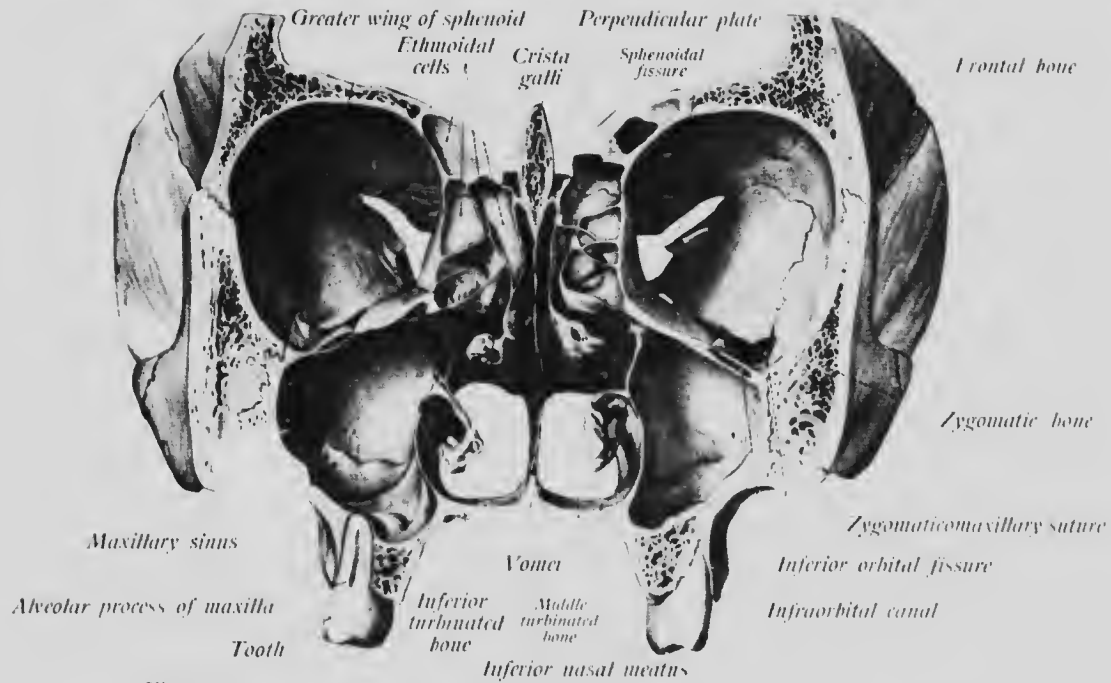


Fig. 98.

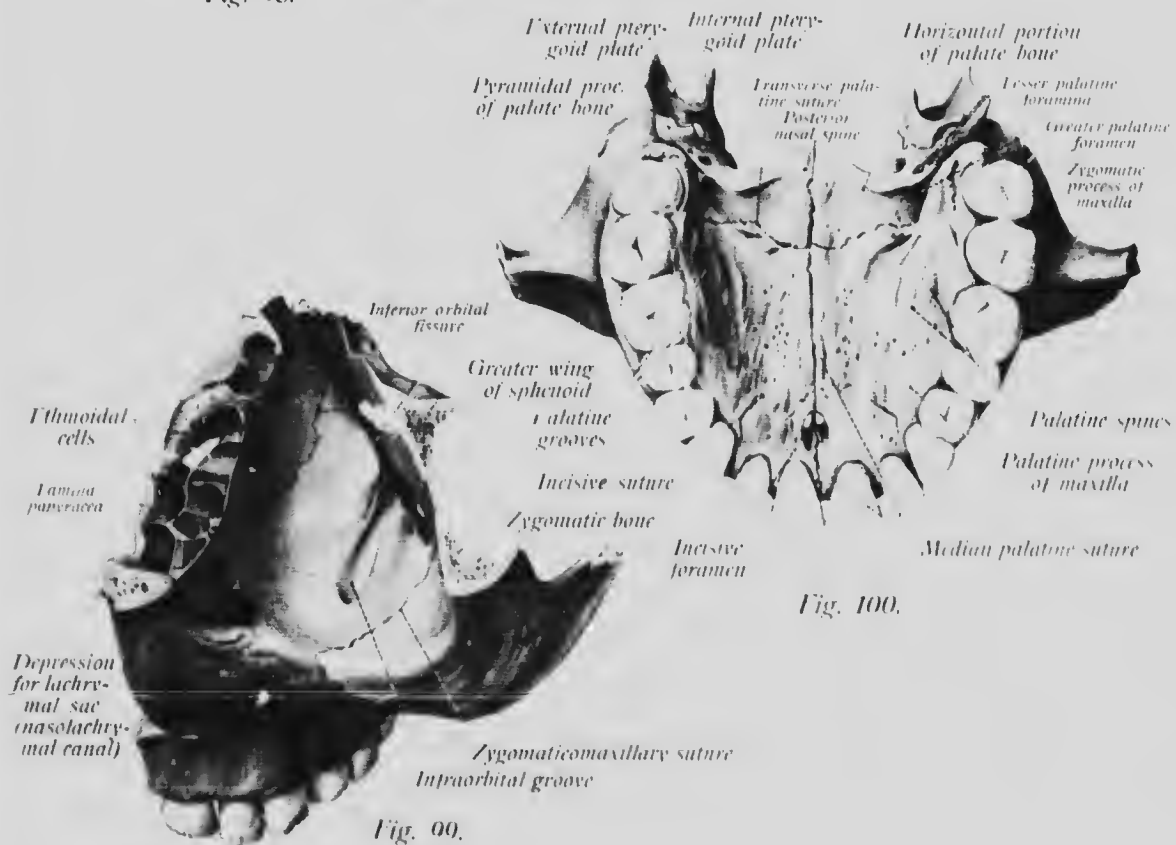


Fig. 100.

Fig. 99.

cribriform plate of the ethmoid, and posteriorly by the body of the sphenoid. It is curved so that its anterior and posterior portions also form, so to speak, an anterior and a posterior wall.

The floor of the nasal fossa (Fig. 79) is formed by the upper surface of the hard palate, composed of the palatine processes of the maxillæ and the horizontal plates of the palate bones.

The internal or median wall is smooth and of simple composition, the anterior portion being incomplete in the bony skeleton. The external wall is extremely complicated. The median wall (Fig. 72) is the *nasal septum*, the antero-superior portion of which is formed by the perpendicular plate of the ethmoid bone, the postero-inferior portion by the vomer. It is attached above to the frontal crest of the frontal bone, below to the nasal crest of the hard palate, and behind and above to the sphenoidal crest and rostrum.

The external nasal wall (Figs. 101 and 102) exhibits three peculiar foliate prominences the free margins of which are rolled up upon themselves; these are the *turbinated bones* or *concha nasales*.

The inferior of these is an independent bone, the *concha nasi inferior*. It is the largest and longest of the turbinated bones, while the superior is the smallest and shortest. The superior and middle turbinated bones are processes of the ethmoid bone.

The outer portion of each nasal fossa is divided into three canals by the three turbinated bones: the *superior meatus*, between the superior and middle turbinated bones; the *middle meatus*, between the middle and inferior turbinated bones; and the *inferior meatus*, between the inferior turbinated bone and the floor of the nasal fossa. Above the superior turbinated bone in the superior meatus is situated a cleft-like recess known as the *sphenoethmoidal recess*.

The portion of the nasal fossa situated between the inner margins of the turbinated bones and the nasal septum is termed the *common meatus of the nose*; the posterior portion situated behind the posterior extremities of the turbinated bodies is known as the *naso-pharynx* or *naso-pharyngeal meatus*.

The external nasal wall is formed by the following bones: the ethmoid (superior posterior portion); the nasal surface of the frontal process of the maxilla (superior anterior portion) and the nasal surface of the body of the bone (inferior anterior portion); the vertical plate of the palate bone (posterior inferior portion); the inferior turbinated bone (inferior middle portion); and the inner surface of the lachrymal bone (quite a small portion in the anterior part of the middle meatus).

In addition to the main nasal cavity there is a series of accessory cavities; these are the air-containing cavities of the majority of the cranial bones, particularly of the maxilla, frontal, sphenoid, and ethmoid.

There is a large number of openings leading into the nasal cavity.

(a) The foramina of the cribriform plate of the ethmoid bone in the roof of the nasal cavity, transmitting the olfactory nerves and the anterior ethmoidal vessels and nerves.

(b) The superior orifice of the incisive canal (Fig. 79), on either side of the nasal crest in the floor of the nasal cavity, which transmits the terminations of the anterior palatine vessels and nerve.

(c) The inferior orifice of the nasolachrymal canal in the inferior meatus, which contains the nasolachrymal duct.

FIG. 101.—View of the lateral wall of the right nasal fossa, the nasal septum having been removed ($\frac{2}{3}$).

FIG. 102.—View of the lateral wall of the right nasal fossa, the middle turbinated bone having been removed ($\frac{2}{3}$).

In these figures the frontal bone is violet, the lachrymal pink, the ethmoid orange, the maxilla yellow, the palatine blue, the sphenoid green, and the other bones white.

FIG. 103.—The left pterygopalatine fossa seen from the side, after the removal of the zygomatic bone ($\frac{2}{3}$). The maxilla is yellow, the palatine bone blue, the sphenoid green, and the zygomatic and temporal bones white.

(d) The *hiatus semilunaris* (Fig. 101), in the middle meatus in the region of the infundibulum, which leads to the orifice of the frontal sinus (Fig. 102) and to the openings of the anterior ethmoidal cells; the middle meatus also contains the orifice of the maxillary sinus.

(e) The openings of the middle and posterior ethmoidal cells in the superior meatus.

(f) The upper and posterior portion of the nasal cavity contains the sphenothmoidal recess, the orifice of the sphenoidal sinus (Fig. 102), the small posterior ethmoidal foramen (leading into the orbital cavity and transmitting the vessels of the same name), and the *sphenopalatine foramen* (Fig. 102), which accommodates the ganglion and vessels of the same name and communicates with the pterygopalatine (sphenomaxillary) fossa.

THE ROOF OF THE ORAL CAVITY, THE HARD PALATE.

The roof of the oral cavity (Fig. 100) is formed by the hard palate. It is a markedly concave elliptical bony plate, composed of the palatine processes of the maxillæ and of the horizontal portions and of part of the pyramidal processes or tuberosities of the palate bones. It presents in the median line the median palatine suture, upon which a bony swelling, the *torus palatinus*, is occasionally observed; it also contains the transverse palatine suture and sometimes the remains of the incisive suture. At the anterior extremity of the median suture is situated the single incisive foramen, by which the bony oral cavity communicates with both bony nasal fossæ; posteriorly in the horizontal plate of each palate bone is the greater palatine foramen, and the pyramidal process contains the lesser palatine foramina (inconstant). All these foramina are the orifices of the pterygopalatine canal.

THE PTERYGOPALATINE FOSSA.

The *pterygopalatine* or *sphenomaxillary fossa* (Fig. 103) lies between the anterior surface of the pterygoid process of the sphenoid bone, the perpendicular portion of the palatine bone, and the posterior extremity of the maxilla. It is funnel-shaped and is continued directly downward into the pterygopalatine canal, which is bounded by the same three bones. It opens out superiorly into the inferior orbital (sphenomaxillary) fissure which communicates with the orbit and externally the pterygomaxillary fissure connects the pterygopalatine with the infratemporal fossa.

Opening into the pterygopalatine fossa are the *foramen rotundum*, by which it communicates with the cranial cavity, the *pterygoid canal*, which passes horizontally backward in the root of the pterygoid process, and the *sphenopalatine foramen*, leading into the nasal cavity. The fossa contains the sphenopalatine ganglion of the maxillary nerve as well as arteries and veins.

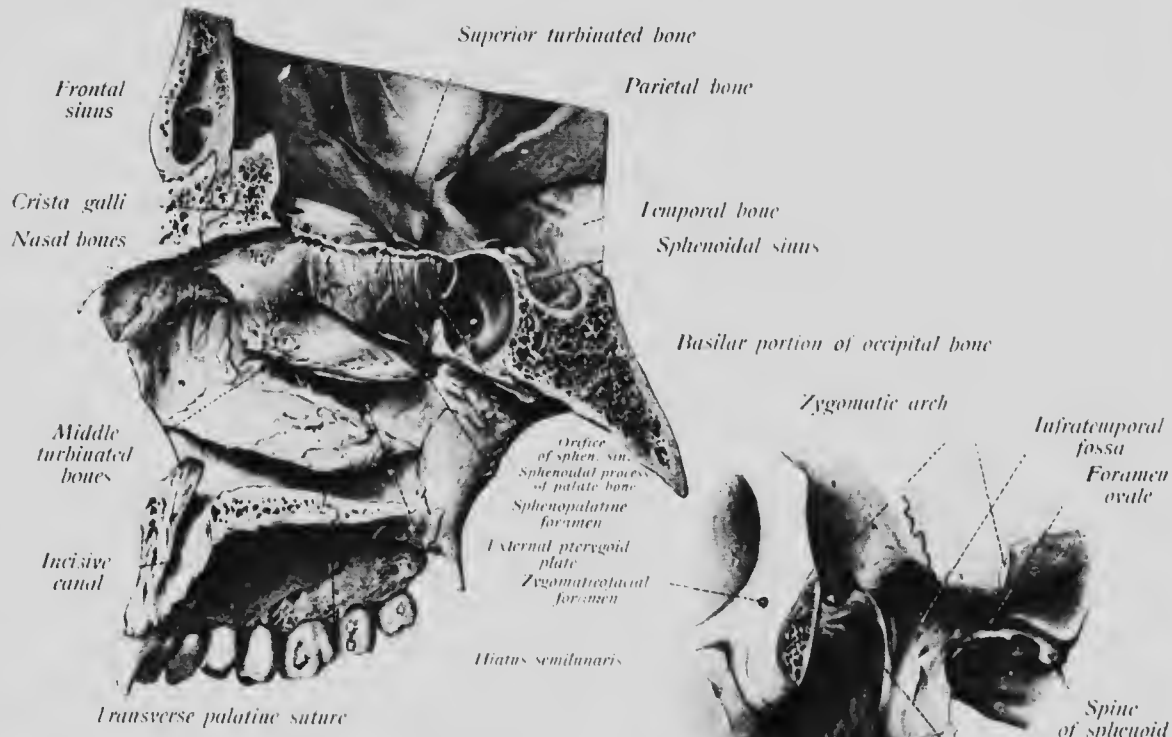


Fig. 101.

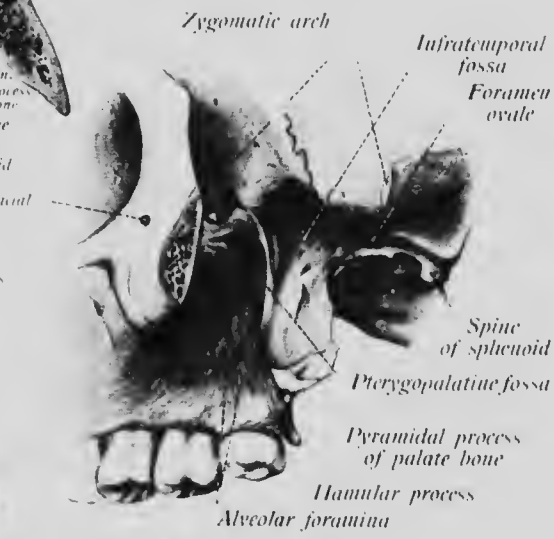


Fig. 103.

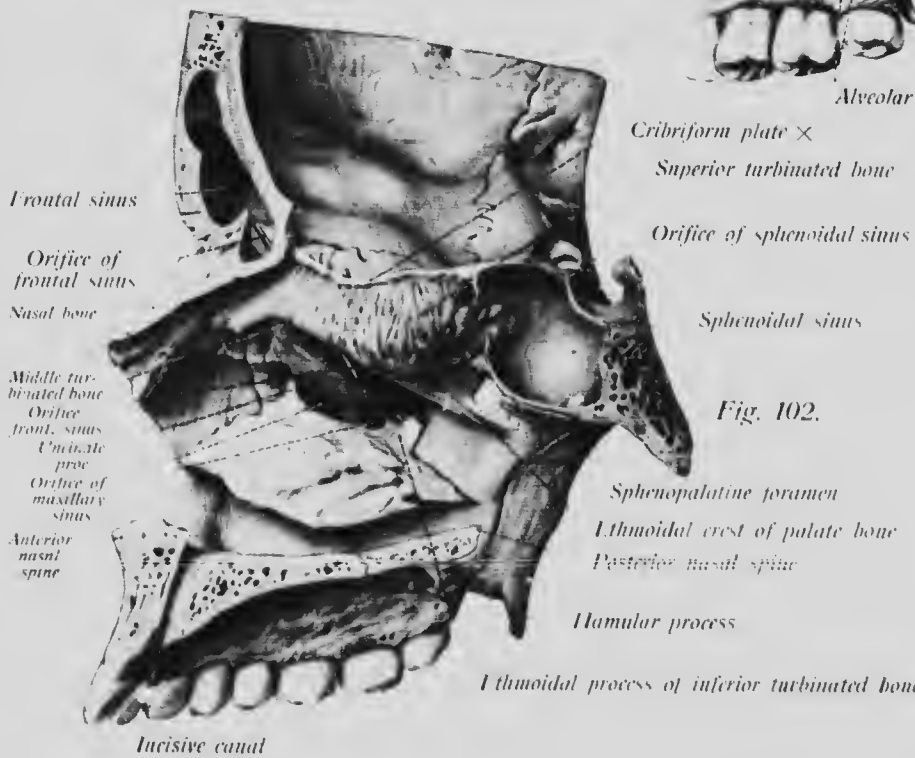



Fig. 102.



The pterygopalatine canal, proceeding from the pterygopalatine fossa, is formed by the union of the pterygopalatine grooves of the pterygoid process and of the palate bone and maxillary bone; it gives off fine canaliculi which pass to the nasal cavity, and finally subdivides into a number of canals which terminate in the palatine foramina.

THE INFRATEMPORAL FOSSA.

The *infratemporal (zygomatic) fossa* (Fig. 103) has only a partial bony boundary, and is directly continuous above with the temporal fossa at the infratemporal crest of the greater wing of the sphenoid bone.

It is situated between the infratemporal surface of the greater wing of the sphenoid bone, the infratemporal surface and tuberosity of the maxilla, and the external plate of the pterygoid process. It has no external or posterior boundary.

THE SUTURES OF THE SKULL.

The sutures of the skull are subdivided into the long sutures of the cranial vertex and the short sutures between the remaining cranial bones. The long sutures are named according to their shape, the shorter ones according to the bones which they separate. Several separate sutures are frequently grouped together and named as a single suture; for example, the fronto-ethmoidal suture.

The *coronal suture* (Figs. 37 to 40) is situated between the parietal margins of the frontal and the frontal margins of the parietal bones.

The *sagittal suture* (Figs. 45 and 46) is situated between the sagittal margins of the two parietal bones.

The *lambdoid suture* (Figs. 39, 40, 45, and 46) is situated between the occipital margins of the parietal bones and the lambdoid margin of the occipital.

The *squamosal suture* (Figs. 39 and 40) is situated between the squamous margin of the parietal bone and the parietal margin of the squamous portion of the temporal.

The *occipitomastoid suture* (Figs. 39 and 40) is situated between the occipital margin of the mastoid portion of the temporal bone and the mastoid margin of the squamous portion of the occipital. It frequently contains the mastoid foramen.

The *parietomastoid suture* (Figs. 39 and 40) is situated between the mastoid angle of the parietal bone and the parietal notch and a part of the mastoid portion of the temporal bone.

The *sphenoparietal suture* (Figs. 39 and 40) is situated between the sphenoidal angle of the parietal bone and the parietal angle of the sphenoid bone.

The *sphenofrontal suture* (Figs. 39 and 40) is situated between the frontal margins of the greater and lesser wings of the sphenoid bone and the orbital portion of the frontal bone.

The *sphenoorbital suture* is situated between the anterior margin of the external surface of the body of the sphenoid bone and the orbital process of the palate bone.

The *sphen-ethmoidal suture* is situated between the crest of the sphenoid bone and the posterior margin of the perpendicular plate of the ethmoid.

The *sphenosquamosal suture* (Figs. 39 and 40) is situated between the squamous margin of the greater wing of the sphenoid bone and the sphenoidal margin of the temporal bone.

The *frontoethmoidal suture* (Figs. 37, 38, 43, and 44) is situated between the inner margin of the orbital portion of the frontal bone (the outer margin of the ethmoidal notch) and the outer margin of the cribriform plate of the ethmoid, between the posterior margin of the nasal portion of the frontal bone and the anterior margin of the cribriform plate (*foramen cecum*), and also between the upper margin of the lamina papyracea of the ethmoid and the inner margin of the orbital portion of the frontal bone. The latter portion of the suture is in the inner wall of the orbit and frequently contains the ethmoidal foramina (Fig. 96).

The *nasofrontal suture* (Figs. 37 and 38) is situated between the nasal portion of the frontal bone and the upper margin of the nasal bone.

The *internasal suture* (Figs. 37 and 38) is situated between the inner margins of the two nasal bones.

The *frontomaxillary suture* (Figs. 37, 38, and 95) is situated between the nasal portion of the frontal bone and the frontal process of the maxilla.

The *frontolachrymal suture* (Figs. 37 and 38) is situated between the orbital portion of the frontal bone and the upper margin of the lachrymal bone.

The *zygomaticofrontal suture* (Figs. 37 to 40) is situated between the frontosphenoidal process of the zygomatic bone and the zygomatic (external angular) process of the frontal.

The *sphenozygomatic suture* (Figs. 39 and 40) is situated between the zygomatic margin of the greater wing of the sphenoid and the zygomatic bone.

The *zygomaticotemporal suture* (Figs. 39 to 42) is situated between the temporal process of the zygomatic bone and the zygomatic process of the temporal bone.

The *zygomaticomaxillary suture* (Figs. 37 and 38) is situated between the zygomatic bone and the zygomatic process of the maxilla.

The *nasomaxillary suture* (Figs. 37 and 38) is situated between the frontal process of the maxilla and the outer margin of the nasal bone.

The *ethmoideomaxillary suture* is situated at the junction of the inner wall with the floor of the orbit and separates the lower margins of the lamina papyracea of the ethmoid bone from the orbital surface of the body of the maxilla.

The *lachrymoconchal suture* is situated between the lachrymal process of the inferior turbinated bone (concha nasalis inferior) and the lachrymal bone.

The *lachrymomaxillary suture* (Figs. 39 and 40) is situated in the inner wall of the orbit between the lachrymal margin of the maxilla and the anterior (and inferior) margin of the lachrymal bone.

The *lachrymoethmoidal suture* is situated in the inner wall of the orbit between the lachrymal bone and the lamina papyracea of the ethmoid.

The *intermaxillary suture* (Figs. 37 and 38) is situated between the alveolar processes of the two maxillæ.

The *palatomaxillary suture*, in the floor of the orbit, is situated between the posterior margin of the orbital surface of the maxilla and the orbital process of the palate bone.

The *palatoethmoidal suture* is situated immediately alongside of the preceding suture

between the posterior extremity of the lamina papyracea of the ethmoid and the orbital process of the palate bone.

The *median palatine suture* (Figs. 41, 42, and 100) traverses the hard palate in the median line.

The *transverse palatine suture* (Figs. 41, 42, and 100) is situated between the palatine processes of the maxilla and the horizontal portions of the palate bones.

The following sutures are inconstant: the *infraorbital suture* (see page 66), the *incisive suture* (see page 69), the *petrosquamosal suture* (see page 54), the *squamosomastoid suture* (see page 53), the *sphenomaxillary suture* (between the pterygoid process and the body of the maxilla), the *frontal or metopic suture* (see page 60), and the *sutura mendosa* (see page 47).

The *petrooccipital* and *sphenopetrosal fissures* are filled with fibrocartilage (*petrooccipital* and *sphenopetrosal synchondroses**).

THE SKULL OF THE NEW-BORN.

The skull of the new-born (Figs. 104 to 106) differs in many respects from that of adult life (see the development of the individual bones of the skull). The vertical plate of the occipital bone still exhibits the *sutura mendosa* (Figs. 105 and 106) and is separated from the lateral portions by the *posterior intraoccipital synchondrosis*; the lateral portions are separated from the basilar portion by the *anterior intraoccipital synchondrosis*. The two halves of the body of the sphenoid are still separated by the *intersphenoidal synchondrosis* and the *sphenooccipital synchondrosis* separates the sphenoid from the occipital bone.

In the temporal bone may be observed the *tympanic annulus*, one of the most striking formations of the skull of childhood, and also the *squamosomastoid suture*, which still completely separates the squamous and the petrous (together with the mastoid) portions. The two halves of the frontal bone are separated by the *frontal suture*, and the *incisive suture* is still visible in the maxilla, that is to say, in the hard palate. The maxilla and the mandible are still quite differently shaped from the adult structures, and the latter bone exhibits a median suture. The ethmoidal labyrinths are independent of each other. But most striking is the incomplete ossification of the cranial vault. In the lines of the sutures there are more or less narrow membranous connections of the contiguous bony margins, which form large spaces particularly in those situations where several sutures come together. These spaces are known as the *fontanelles* or *fonticuli*, and six of them may be recognized, two of which are single and two double:

1. The *frontal* or *anterior fontanelle* (Fig. 105) is the largest of all and is quadrangular in shape, the short diagonal being situated in the transverse and the long diagonal in the sagittal direction. It occurs at the junction of the frontal, sagittal, and coronal sutures, between the two halves of the frontal bone and the two parietal bones.

2. The *occipital* or *posterior fontanelle* (Fig. 105) is small and triangular, and is situated at the junction of the sagittal and lambdoid sutures, between the two parietal bones and the vertical portion of the occipital bone.

* True synchondroses exist in the skull only during childhood.

FIG. 104.—Skull of a new-born child from the side (¾).

FIG. 105.—Skull of a new-born child from above (¾).

FIG. 106.—Skull of a new-born child from behind and below (¾).

3. The two *sphenoidal fontanelles* (Fig. 104) are of medium size, irregular in form, poorly defined, and situated between the parietal angles of the greater wings of the sphenoid bones and the sphenoidal angles of the parietal bones, in the location of the later-developed *sphenoparietal sutures* and the contiguous bony margins.

4. The two *mastoid fontanelles* (Fig. 106) are situated between the mastoid angles of the parietal bones and the parietal notches of the temporal bones, extending outward to the neighboring bony margins. They resemble the antero-lateral fontanelles in respect to their size, shape, and boundaries.

By the progressive ossification of the flat bones of the cranial vault, the fontanelles become closed in the first year of life, rarely later, the frontal fontanelle closing last (at the end of the first or the beginning of the second year). At the same time the coronal, sagittal, and lambdoid sutures develop, whereby small bony areas frequently remain as independent structures within the sutures, and are known as *supernumerary bones*, *Wormian bones*, or *ossa suturarum*. They are particularly common in the sagittal and lambdoid sutures, where they are sometimes present in large numbers and are occasionally of considerable size.

THE SKELETON OF THE EXTREMITIES.

The skeletons of the upper and lower extremities are more or less similar. They are composed of: (1) The girdle of the extremity, and (2) the free extremity. The shoulder girdle is composed of the scapula and the clavicle; the pelvic girdle of the two pelvic bones. The skeleton of each free extremity consists of a proximal, a middle, and a distal segment, these being represented in the upper extremity by the bone of the arm, the bones of the forearm, and the bones of the hand, and in the lower extremity by the thigh-bone, the bones of the leg, and the bones of the foot. The skeleton of the proximal segment of each extremity consists of a single bone: in the upper extremity, the *humerus*; in the lower one, the *femur*. The middle segment is formed by two bones: the *radius* and *ulna* in the forearm; the *tibia* and *fibula* in the leg. The distal segments, the hand and the foot, contain a number of bones, those of the hand being subdivided into the *carpal* bones, the *metacarpal* bones, and the *phalanges* of the fingers, and those of the foot into the *tarsal* bones, the *metatarsal* bones, and the *phalanges* of the toes.

The extremities also contain a number of sesamoid bones; they occur in the upper extremity only in the hand; in the lower extremity they are to be found both in the foot and also in the region of the knee (the knee-cap or patella).

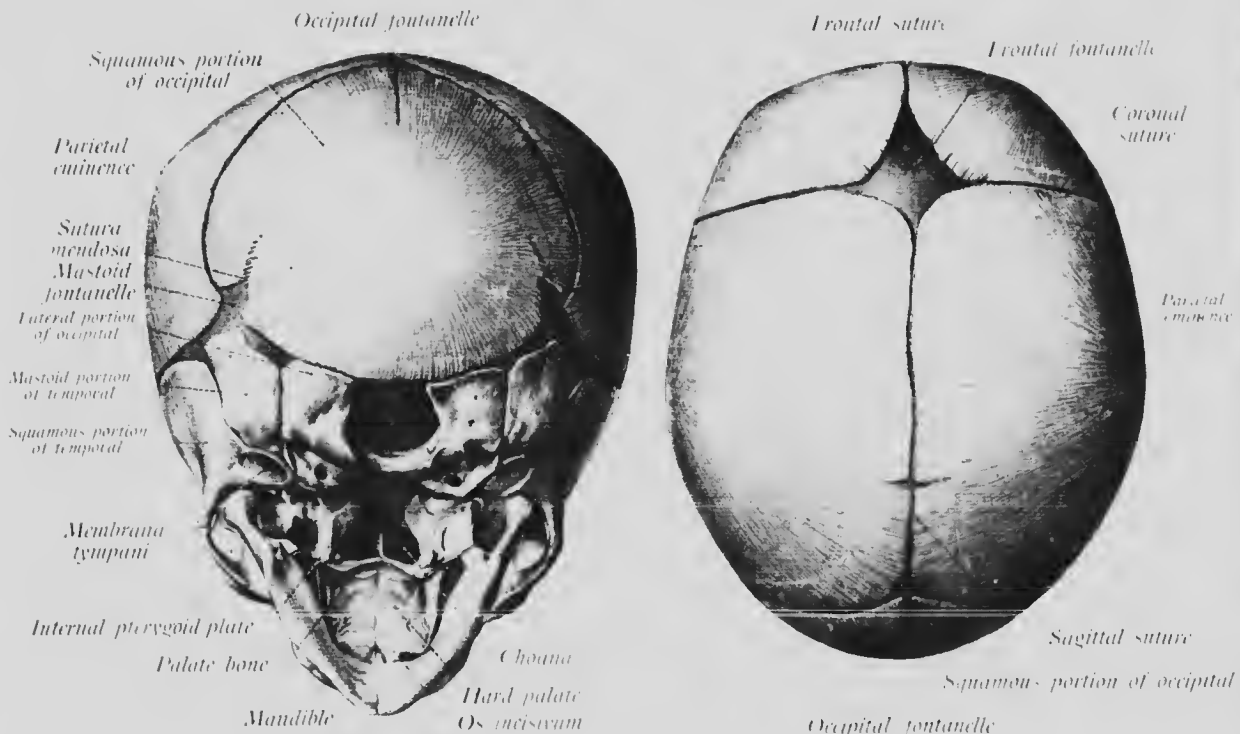
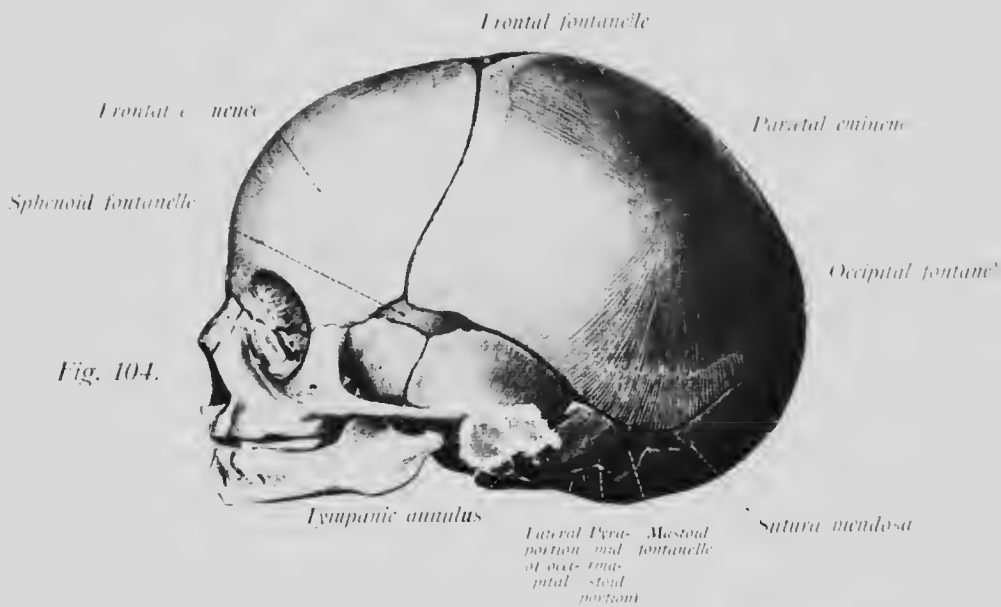


Fig. 106.

po
th
cl
sti
lat

thi
the
fac
int
ma
an
the
bo
(su
Th
ter
ter
(be
sur
jac

son
the
aris
man

rou
flatt
upp
inj
give

sent
thic

THE SKELETON OF THE UPPER EXTREMITY.

THE SHOULDER GIRDLE.

Unlike the pelvic girdle, the shoulder girdle is not completely closed, but remains open posteriorly, its posterior constituent, the *scapula*, having no direct or indirect connection with the corresponding bone of the opposite side, while the anterior skeletal portions, the *clavicles*, close the shoulder girdle anteriorly by their connection with the manubrium sterni. Both constituents of the shoulder girdle articulate with each other, and the free upper extremity articulates with the scapula.

THE SCAPULA.

The shoulder-blade or scapula (Figs. 107 to 110) is a decidedly flat bone which is very thin in places and exhibits several marked processes. It articulates only with the clavicle and the humerus; otherwise it is completely free and the surface resting against the ribs is separated from them by the intervening muscles. It is triangular in form, and there may consequently be recognized in it three sides, three angles, and two surfaces. According to the position of the scapula when the arm lies close to the side of the body, the three angles are designated as the *internal (superior) angle*, the *inferior angle*, and the *external angle*. The margins are the *internal or vertebral* (between the internal and inferior angles), the *superior* (between the internal and external angles), and the *external or axillary* (between the external and inferior angles). The anterior surface, directed toward the ribs, is termed the *costal surface*, and the posterior one the *dorsal surface*.

The *costal surface* (Fig. 109) is relatively smooth and somewhat concave, the shallow depression being termed the *subscapular fossa*, from the subscapular muscle which arises from its surface. Several rough lines, the *lineæ musculares*, commence at the vertebral margin and pass outward almost transversely across the surface.

The *dorsal surface* (Fig. 108) is rough, and is subdivided into two portions by a marked roughened ridge, the *spine*, which commences at the upper half of the vertebral margin as a flattened projection and gradually becomes more elevated as it passes outward. The small upper area is known as the *suprascapular fossa* (Fig. 107), and the larger lower one as the *infrascapular fossa*; both of these names being derived from the muscles to which the fossæ give origin.

The *vertebral border* of the scapula (also termed the *base*) is not exactly straight, but presents a slight angle at the origin of the spine. The upper and lower portions of the border are thickened; the middle portion is thin.

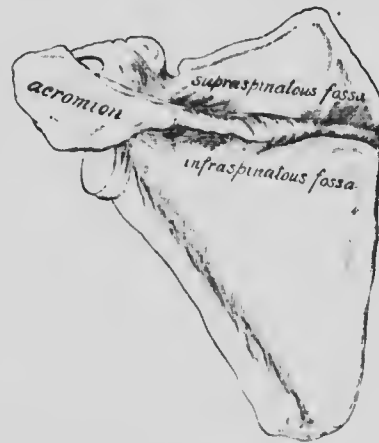

FIG. 107.—The dorsal surface of the left scapula.

FIG. 108.—The dorsal surface of the left scapula ($\frac{1}{2}$).

FIG. 109.—The costal surface of the left scapula ($\frac{1}{2}$).

FIG. 110.—The left scapula seen from the outer angle and axillary border ($\frac{1}{2}$).

FIG. 111.—The left clavicle seen from below ($\frac{1}{2}$).

FIG. 112.—The left clavicle seen from above ($\frac{1}{2}$).

This border receives the insertion of the serratus magnus muscle, which also extends outward upon the costal surface in the vicinity of the superior and inferior angles, so that the costal surface presents two shallow triangular areas for the attachment of muscles, in addition to the subscapular fossa.

The *superior border* presents a notch, the *scapular notch* (Figs. 108 and 109), which may be either deep or shallow, and to the outer side of this there projects from the superior margin a strong, curved, hook-like process, the *coracoid process* (Fig. 109). This arises by a broad base between the scapular notch and the outer angle, and is at first directed upward and somewhat forward; it then becomes narrower, makes a distinct turn, and passes forward and outward to end in a roughened apex.

The *axillary border* (Fig. 110), so called because it is directed toward the axilla, is slightly thickened and roughened, particularly toward the external angle. A furrow separates this elevated border from the anterior surface of the bone.

The *internal angle* is either a right or an obtuse angle; the *inferior one* is acute with a markedly rounded apex. At the *external angle* is situated the so-called *head* of the scapula, which presents the articular surface for the head of the humerus, the *glenoid cavity* (Fig. 110), which is smooth, slightly concave, and shaped like a pear with the apex upward.

Above the glenoid cavity is a small surface, the *supraglenoid tuberosity* (Fig. 110), which gives origin to the narrow cord-like tendon of the long head of the biceps, and below the cavity there is a larger, markedly roughened surface, the *infraglenoid tuberosity*, which gives origin to the broad strong tendon of the triceps. The head of the scapula is separated from the remainder of the bone by a slight constriction called the *neck*.

The *spine* of the scapula (Fig. 108) arises by a broad base from the dorsal surface between the supraspinatus and infraspinatus fossæ, and gradually becomes higher as it passes from the vertebral border to the neck of the bone. It passes over the neck, overhangs the glenoid cavity from above and behind, and terminates in a strong, broad, flattened process, the *acromion*. Internal to its apex, the acromion presents an elongated, flat, articular surface for the attachment of the acromial end of the clavicle.

The scapula is preformed in cartilage during fetal life. The first center of ossification appears in the third month of embryonic life in the region of the neck, but ossification proceeds so slowly that large areas are still cartilaginous in the new-born. During the first year of life an independent center appears in the coracoid process,* from which is formed the greater portion of this projection. At the age of puberty special epiphyseal centers make their appearance, in the apex and the base of the coracoid process, in the acromion (usually several centers), in the base of the scapula, in the inferior angle, in the glenoid fossa (usually somewhat later), sometimes at the margin of the spine of the scapula, and (even earlier, in the tenth year) in the external angle of the scapula in the region of the origin of the biceps tendon.

* In reptiles, birds, and the lowest mammalia the coracoid process is an independent bone.

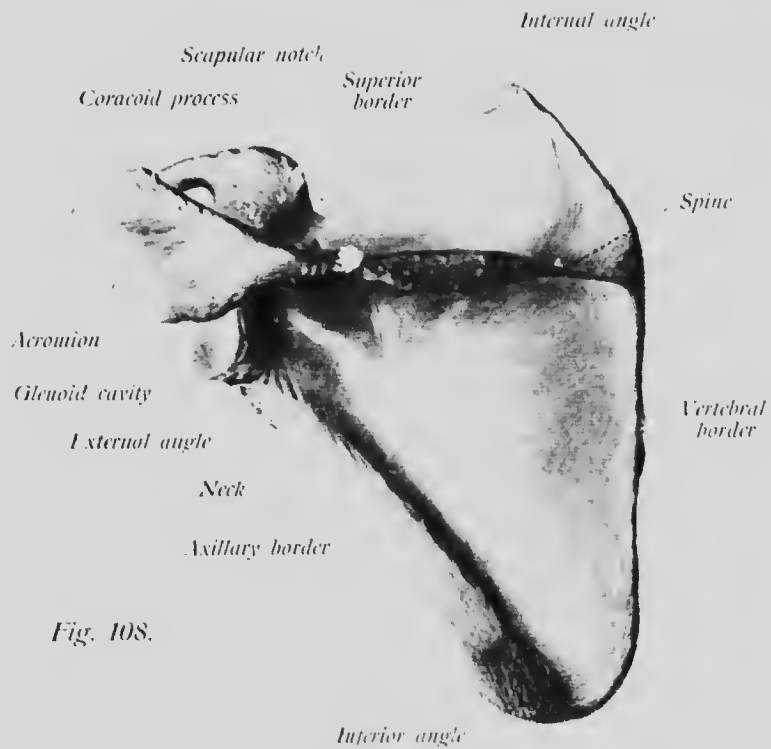


Fig. 108.

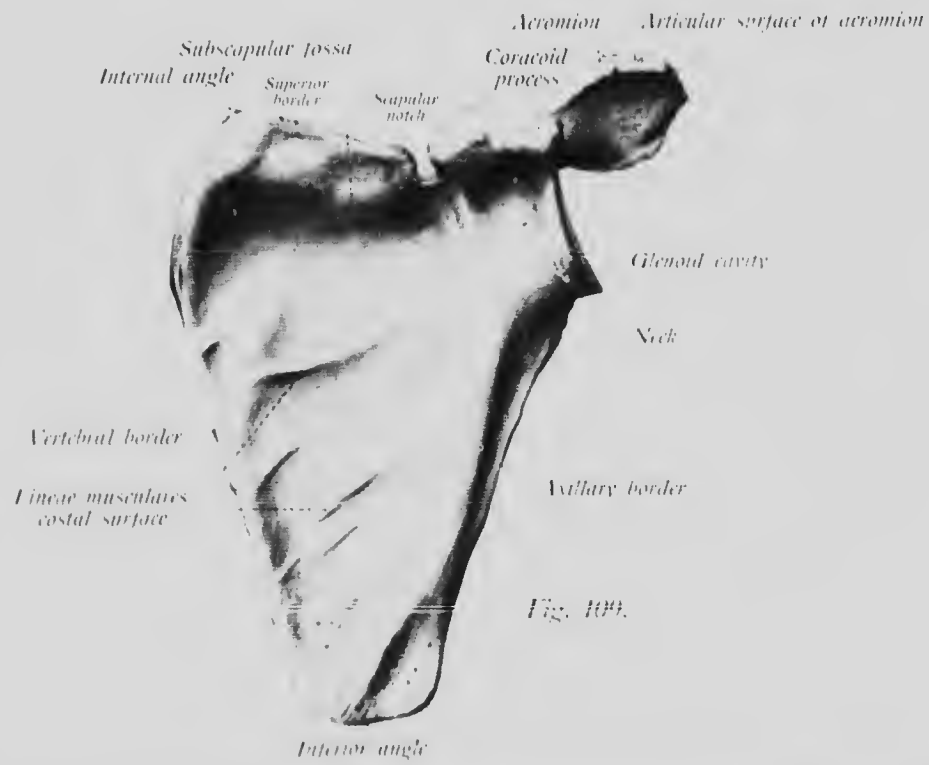


Fig. 109.

1875
1876
1877
1878
1879
1880
1881
1882
1883
1884
1885
1886
1887
1888
1889
1890
1891
1892
1893
1894
1895
1896
1897
1898
1899
1900
1901
1902
1903
1904
1905
1906
1907
1908
1909
1910
1911
1912
1913
1914
1915
1916
1917
1918
1919
1920
1921
1922
1923
1924
1925
1926
1927
1928
1929
1930
1931
1932
1933
1934
1935
1936
1937
1938
1939
1940
1941
1942
1943
1944
1945
1946
1947
1948
1949
1950
1951
1952
1953
1954
1955
1956
1957
1958
1959
1960
1961
1962
1963
1964
1965
1966
1967
1968
1969
1970
1971
1972
1973
1974
1975
1976
1977
1978
1979
1980
1981
1982
1983
1984
1985
1986
1987
1988
1989
1990
1991
1992
1993
1994
1995
1996
1997
1998
1999
2000
2001
2002
2003
2004
2005
2006
2007
2008
2009
2010
2011
2012
2013
2014
2015
2016
2017
2018
2019
2020
2021
2022
2023
2024
2025

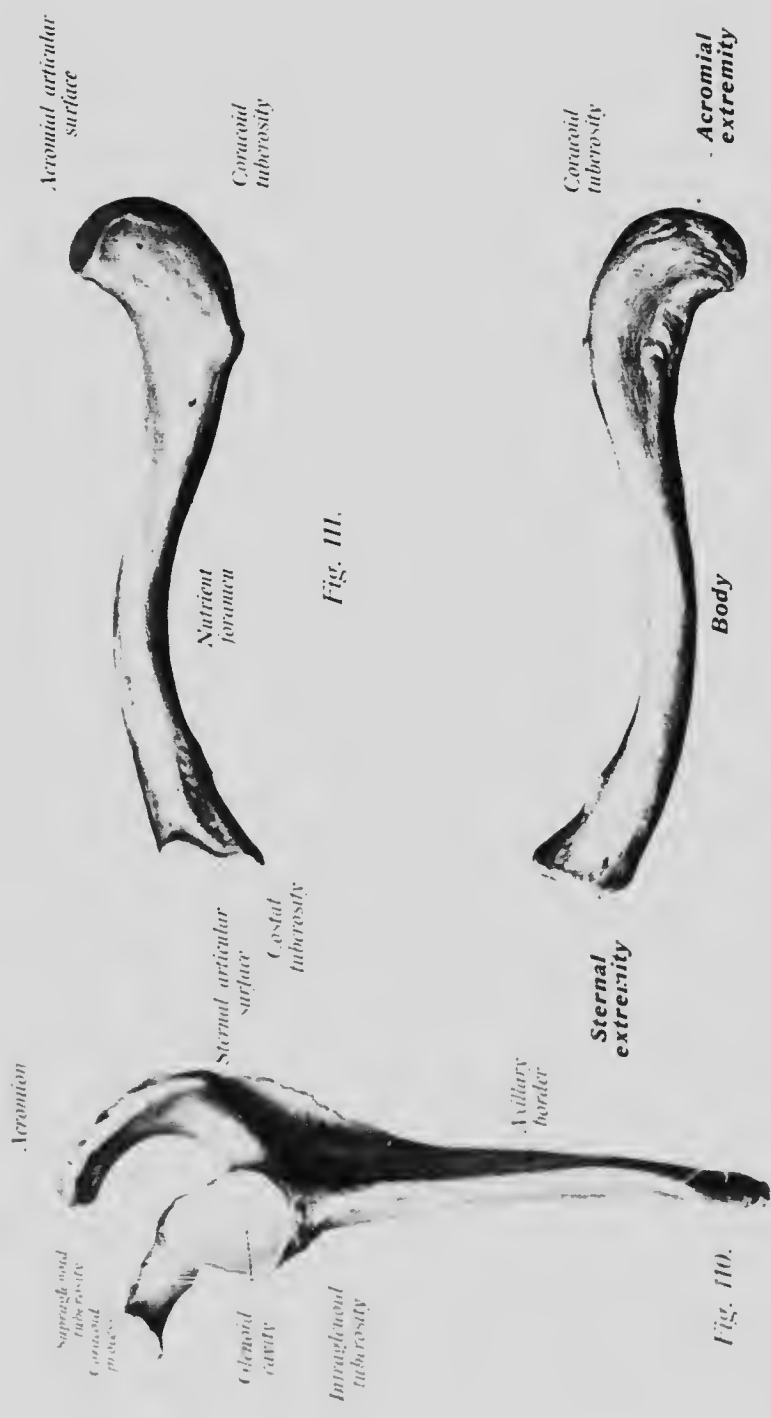


Fig. 111.

Fig. 112.

Fig. 110.



The different accessory centers fuse with the main center between the seventeenth and the twentieth or twenty-fifth years.

The scapular notch is sometimes converted into a foramen by a bridge of osseous tissue.

THE CLAVICLE.

The *clavicle* (Figs. 111 and 112) is an S-shaped tubular bone in which may be recognized a middle portion and two ends. The middle portion is termed the *body*, and the ends are named from the bones with which they articulate, the inner one being called the *sternal extremity* and the outer one the *acromial extremity*.

The *sternal end* (Fig. 112) is thick, triangular in cross-section, and convex anteriorly; the acromial end is flattened and concave anteriorly. At the inner end of the sternal extremity there is a triangular articular surface (Fig. 111), which helps to form the sternoclavicular articulation, and external to this facet a roughening upon the lower surface of the bone, the *costal tuberosity*, for the attachment of the costoclavicular (rhomboid) ligament.

The body is triangular, like the sternal end, but its edges are rounded. As a rule, there is a nutrient foramen at about the middle of the inferior surface near the anterior margin (Fig. 112).

The flattened *acromial extremity* bears upon its lower margin a roughened surface, the *coracoid tuberosity*, for the attachment of the coracoclavicular (conoid and trapezoid) ligament, and also a small smooth articular facet for connection with the acromion.

The clavicle is preformed in cartilage.* The main center of ossification appears as early as the seventh week of embryonic life, so that the clavicle is the first portion of the embryonic skeleton to ossify. Only the sternal end possesses an epiphyseal center, which is flat and does not appear until from the fifteenth to the eighteenth year.

THE SKELETON OF THE FREE UPPER EXTREMITY.

THE HUMERUS.

The *humerus* (Figs. 113 to 116) is a typical long bone. It is composed of a long middle piece, the *shaft*, and of two thickened extremities, the *superior* and *inferior* extremities.

The upper extremity bears the *head*, which is placed at an angle with the axis of the bone and is directed inward and somewhat backward. It is almost hemispherical (Fig. 115) and is separated from the shaft of the bone by a shallow constriction, the *anatomical neck*. In addition to the head, the upper or proximal extremity of the humerus presents two rough prominences—a larger one directed outward, the *greater tubercle*, and a smaller one looking inward and forward, the *lesser tubercle*, and between the two there is a deep groove, the *intertubercular* or *bicipital groove*.

The greater tubercle is composed of three facets situated one above the other for the insertions of the supraspinatus (Fig. 115, 1), infraspinatus (Fig. 115, 2), and teres minor (Fig. 115, 3) muscles; the lesser tubercle receives the insertion of the subscapular muscle. The upper portion of the intertubercular groove is lined with cartilage; the tendon of the long head of the biceps runs in the groove and is accompanied in its upper portion by a diverticulum of the capsule of the shoulder-joint.

Below the tubercles, at the junction of the upper extremity and the shaft, there is a decided

* The tissue in which the first center of ossification of the clavicle appears is not true cartilage but prochondral tissue, which subsequently gradually assumes the character of true cartilage on either side of the ossific center.

FIG. 113.—The left humerus seen from behind ($\frac{1}{2}$).

FIG. 114.—The left humerus seen from in front ($\frac{1}{2}$).

FIG. 115.—The head of the left humerus seen from above ($\frac{1}{3}$).

FIG. 116.—The lower end of the left humerus seen from below ($\frac{1}{3}$).

diminution in the thickness of the bone, forming what is called the *surgical neck*, because the humerus is easily broken in this situation.

The upper portion of the shaft of the humerus is almost cylindrical, while the lower portion is prismatic and flattened.

Passing downward from either tuberosity upon the upper portion of the shaft there is a rough ridge; one is the *greater tubercular* (bicipital) *ridge*, which gives insertion to the pectoralis major muscle, and the other the *lesser tubercular* (bicipital) *ridge*, into which the latissimus dorsi and teres major muscles are inserted. The intertubercular (bicipital) groove is continued downward between these ridges for a short distance and they form its lips (Fig. 114).


Below the greater tubercular ridge upon the outer and posterior portion of the shaft there is a large, flat, roughened surface, the *deltoid tuberosity* (Fig. 114), for the insertion of the deltoid muscle, and at about the middle of the shaft and upon its inner aspect there is a roughening, which is rarely distinct, for the insertion of the coracobrachialis muscle. Near this rough surface there is a large nutrient foramen (Fig. 114) which leads downward into the bone as the nutrient canal.

In the lower half of the shaft three surfaces, an *antero-internal*, an *antero-external*, and a *posterior*, can be recognized. The two anterior surfaces are separated from each other by a flat elevation and from the posterior one by the sharp *external* and *internal borders* of the bone (Fig. 114). The external border commences below the deltoid tuberosity and is separated from it by a shallow *groove for the radial* (musculospiral) *nerve* (Fig. 114). It is sometimes termed the musculospiral groove, and gives attachment by its margins to the outer and inner heads of the triceps muscle. It pursues a spiral course about the middle of the humerus, passing from above downward and from within outward and gradually disappearing below.

The lower portion of the shaft becomes flatter and broader, and its lateral borders run downward to terminate in two rough projections which are known as *epicondyles* (Fig. 116), the sharp outer border passing to the small *external epicondyle* and the inner one to the more prominent *internal epicondyle*. The posterior surface of the internal epicondyle presents a shallow groove for the ulnar nerve.

Below the epicondyles is situated the lower articular surface of the humerus (Fig. 116) which articulates with the bones of the forearm. This articular surface presents a separate area for each bone, a large *trochlea* with a median groove being situated internally for the ulna and a smaller hemispherical *capitulum* externally for the radius. Above the trochlea and upon the antero-internal surface at the level of the epicondyle there is a moderately deep depression, which is known as the *coronoid fossa* (Fig. 114) because it accommodates the coronoid process of the ulna when the arm is flexed, and above the capitulum, upon the lower portion of the antero-

Greater tubercle
Upper
extremity



Head

Surgical neck

Shaft

Groove for radial nerve

Posterior surface

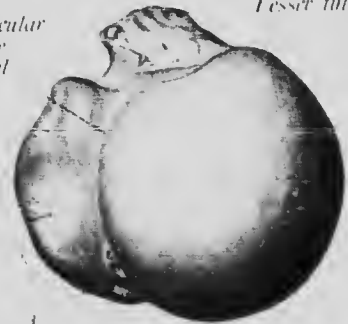Lower
extre-
mity
External
epicondyle

Trochlea

Groove for
ulnar nerve

Lesser tubercle

Intertubercular
groove
Anatomical
neck



Greater
tubercle

Head

Anatomical neck

Intertubercular groove

Greater tubercle

Lesser tubercle

Lesser tubercular ridge

Greater tubercular
ridge

Deltoid tubercle

Nutrient
foramen

Fig. 114.

Internal border

Antero-internal surface

Coronoid fossa

Internal
epicondyle

Trochlea

External
epicondyle

Head

Capitulum

External border

Antero-external
surface

Radial fossa

External
epicondyle

Capitulum

Groove for
ulnar nerve

Trochlea

Fig. 115.

Fig. 116.



external surface, is the much smaller and shallower *radial fossa* (Fig. 114) for the head of the radius. Opposite to these two fossæ upon the lower portion of the posterior surface is situated a broad deep depression, the *olecranon fossa* (Fig. 113), which accommodates the olecranon when the arm is extended.

The humerus, like most of the long bones, is developed from a center of ossification for the diaphysis or shaft and from two or more epiphyseal centers. The diaphyseal center appears in the eighth week; the epiphyses are still cartilaginous at birth. During the first year a center appears in the upper epiphysis (for the head), then follow those for the capitulum, the greater tubercle, the lesser tubercle, and finally those for the trochlea and separate centers for each epicondyle which appear between the tenth and twelfth year. Complete ossification of all parts of the bone and the disappearance of the synchondroses between the epiphyses and the diaphysis do not occur until from the twentieth to the twenty-second year.

Between the olecranon and coronoid fossæ the humerus is as thin as paper and sometimes even perforated. The epicondyles serve as points of muscular origin, the internal one giving origin to the superficial flexors and pronators of the forearm, the external one to the superficial extensors. Above the internal epicondyle the inner border of the humerus occasionally presents a second process, known as the *supracondylar process*. The inner portion of the trochlea extends lower than does the external portion, and its surface represents an almost complete cylinder, which is interrupted only by the thin bony plate between the coronoid and olecranon fossæ. The capitulum is placed somewhat anteriorly and is scarcely visible from behind:

THE ULNA.

The *ulna* (Figs. 117 to 119) is a three-sided prismatic long bone which is thick above and quite small below. It is composed of a shaft and of a superior and an inferior extremity. The strong *upper extremity* presents a *semilunar* or *greater sigmoid notch* (Figs. 117, 119, and 124), which articulates with the trochlea of the humerus and is constricted in its middle. Its anterior portion rests upon the upper surface of the *coronoid process* (Fig. 119), a broad beak-like projection directed anteriorly, and its posterior portion rests upon the anterior surface of a very strong bony process, the *olecranon*, which forms the tip of the elbow and projects quite a distance above the coronoid process. The external or radial side of the proximal extremity of the ulna presents a notch, the *radial* or *lesser sigmoid notch* (Fig. 116), for the head of the radius, and passing downward from this cavity there is a rough longitudinal ridge, the *supinator ridge* (Fig. 117). Immediately below the coronoid process is situated a broad roughened area which is directed anteriorly, and is termed the *tuberosity* (Fig. 119).

The olecranon receives the insertion of the large triceps muscle, the extensor of the forearm, and the supinator ridge gives origin to the greater portion of the supinator brevis muscle. The brachialis anticus muscle is inserted into the tuberosity and the coronoid process also gives origin to portions of several of the muscles of the forearm.

The *shaft* of the bone becomes much thinner and more rounded toward its lower extremity, so that while the bone resembles a three-sided prism in its upper portion, it becomes cylindrical in its lower fourth. In the shaft may be recognized an anterior *volar*, a posterior or *dorsal*, and an *internal* or *ulnar surface*. The *internal surface* is separated from the posterior one by the *dorsal border*, and from the anterior one by the *volar border*. The third border is sharp and is directed toward the radius; it separates the anterior from the posterior surface and is called the *interosseous ridge* (Fig. 119). The *volar surface* contains the *nutrient foramen*, from which a *nutrient canal* passes toward the elbow within the bone, but otherwise the surface exhibits no peculiarities.

FIG. 117.—The left ulna seen from the outer surface ($\frac{2}{3}$).

FIG. 118.—The left ulna seen from behind ($\frac{2}{3}$).

FIG. 119.—The left ulna seen from in front ($\frac{1}{3}$).

FIG. 121.—The left radius seen from in front ($\frac{2}{3}$).

FIG. 122.—The left radius seen from the inner side ($\frac{2}{3}$).

FIG. 123.—The left radius seen from behind ($\frac{2}{3}$).

FIG. 124.—The upper extremities of the radius and ulna seen from above and somewhat in front ($\frac{1}{3}$).

FIG. 125.—The lower extremities of the radius and ulna seen from below ($\frac{1}{3}$).

The *inferior extremity* of the bone is rounded and is also called the *capitulum*. Its radial side presents an articular surface for the radius, the *articular circumference* (Fig. 110), and a pointed process projecting beyond the capitulum, the *styloid process* (Figs. 117 to 119). The distal surface of the capitulum and the articular circumference are both covered by cartilage.

The center for the diaphysis of the ulna appears in the third fetal month; the centers for the epiphyses appear after birth, that for the lower epiphysis not being present until the sixth year. The upper epiphysis has two centers for the olecranon (only the apex of which is formed by the diaphysis) and one for the coronoid process. There is also a special center for the styloid process.

THE RADIUS.

The *radius* (Figs. 121 to 125) is the outer of the two bones of the forearm, and in comparison with the ulna, it is narrow and thin above and broad and thick below.

Its *superior extremity* (Fig. 124) is formed by the disc-like *head* of the bone, a distinct constriction below the head being designated as the *neck*, which portion of the bone is cylindrical.

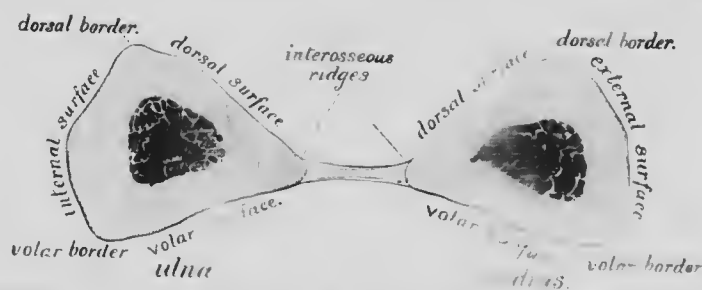


FIG. 120.—Transverse section through the middle of the forearm, to show the relative positions of the radius and ulna.

The upper surface of the head exhibits a flattened articular surface for the head of the humerus, and the upper circumference of the margin of the head is called the *articular circumference* (Fig. 124).

Below the neck the upper portion of the volar surface exhibits a prominent projection, the *tuberosity* (Figs. 121, 122, and 124), for the attachment of the *brachialis* muscle.

The shaft of the radius, like that of the ulna, is shaped like a triangular prism, and the three surfaces are arranged in a similar manner, so that *volar*, *dorsal*, and *external surfaces*, and the *volar* and *dorsal borders*, and an *interosseous ridge* may be recognized (Figs. 121 to 125). The interosseous

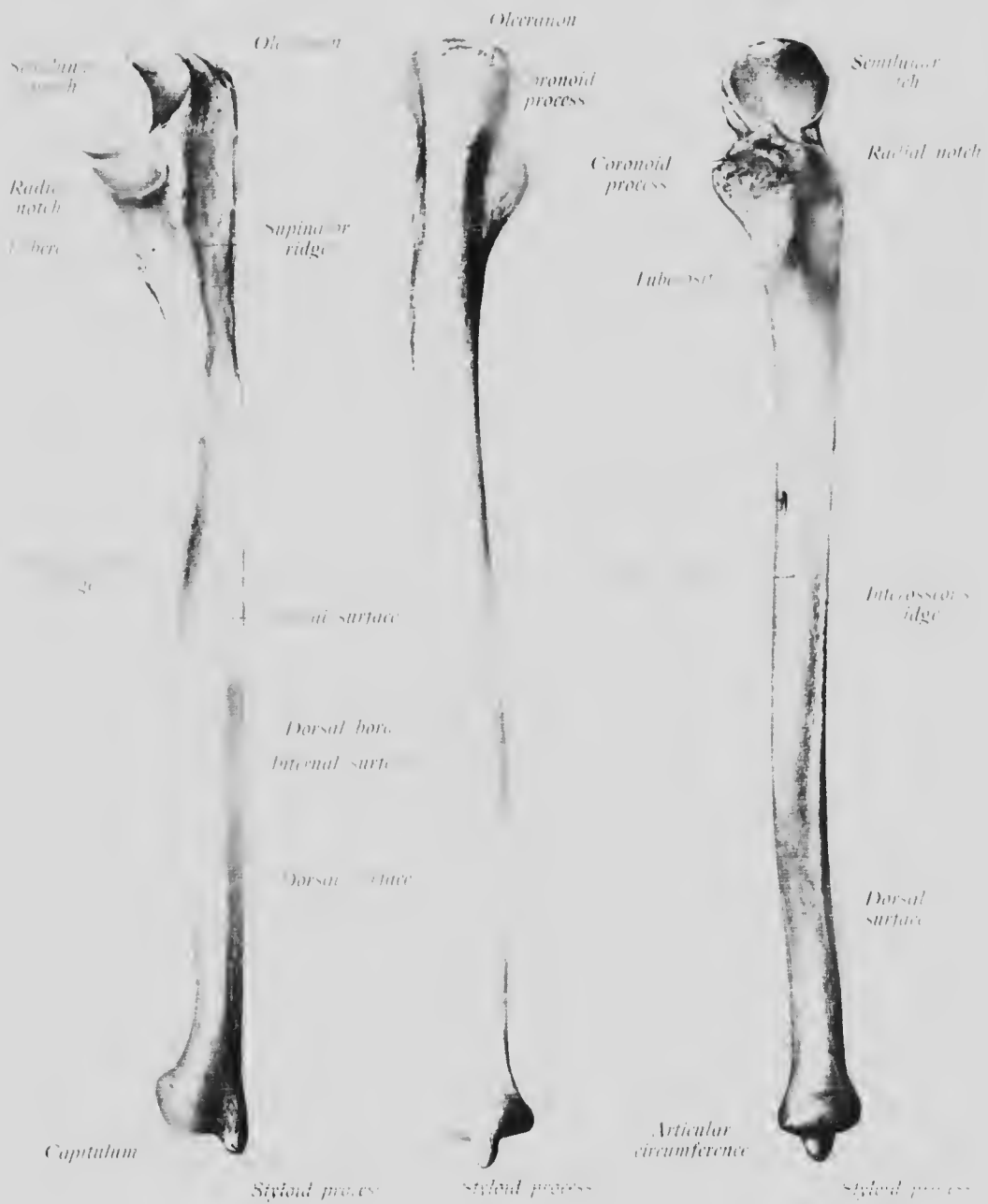


Fig. 117.

Fig. 118.

Fig. 119.

in front (}).

Its radial
 (10), and a
 (110). The
 artilage.

physes car
 is two at
 Then

in on

distin
 yndric

the
 r-

, marked
 asele,
 , and the
 jaces, and
 erosseous






Fig. 121.

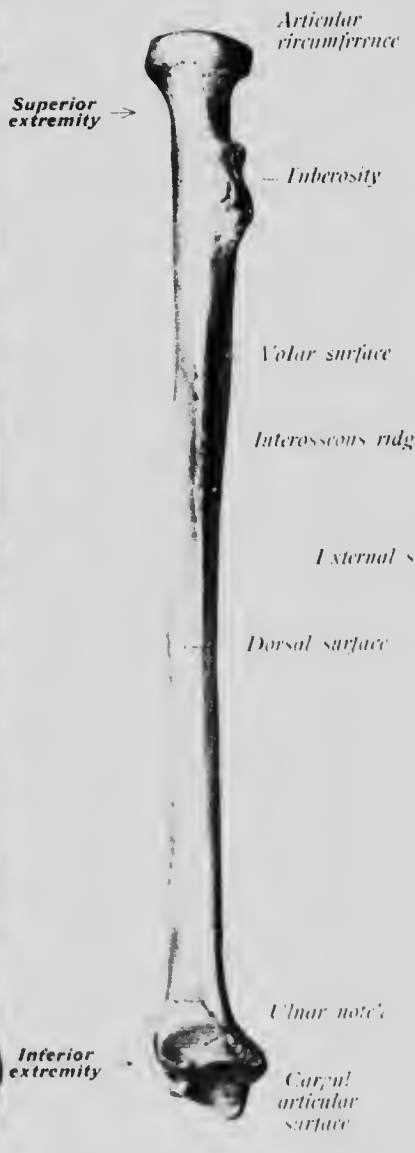


Fig. 122.




Fig. 123.

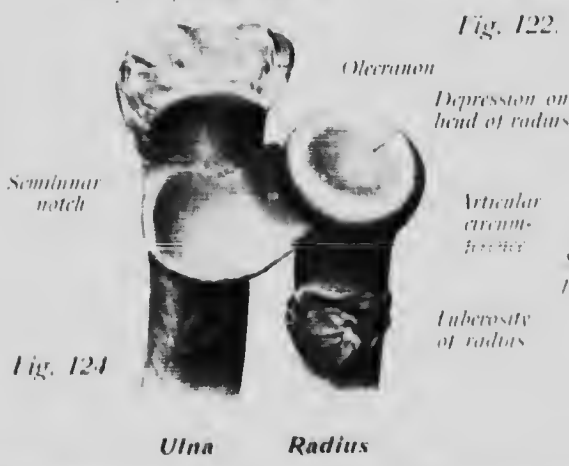


Fig. 124

Ulna Radius

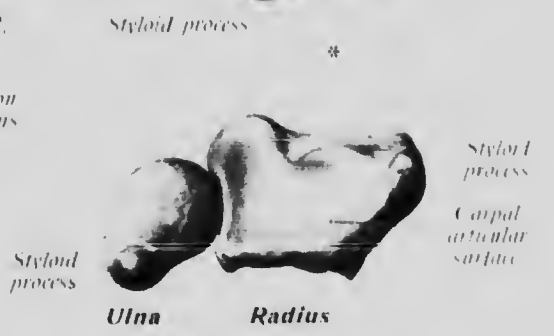



Fig. 125.



ridge is situated opposite to the similarly named ridge of the ulna, and is only the sharp margin possessed by the radius, the two remaining margins having markedly rounded edges.

The three surfaces of the radius exhibit no structure of particular note, except that the volar surface contains the nutrient foramen, the *nutrient canal*, like that of the ulna, passing in a proximal direction through the compact substance into the medullary cavity.

The broad inferior extremity (Fig. 125) is flattened, so that a volar and a dorsal surface are distinctly differentiated. The interosseous ridge terminates below in a slightly excavated surface, the *ulnar* or *sigmoid notch* (Fig. 122), which articulates with the capitulum of the ulna. Opposite to this surface, upon the radial side, the *styloid process* (Figs. 121, 123, and 125) projects beyond the bone; it is broader and less pointed than the corresponding process of the ulna.

The volar surface of the inferior extremity (Fig. 121) is smooth and slightly concave; the dorsal surface is traversed by ridges (Fig. 123*) which separate distinct grooves for the tendons of the extensor muscles of the hand and of the fingers, a particularly deep one accommodating the tendon of the extensor pollicis longus muscle.

The distal or *carpal articular surface* is directed toward the carpal bones; it is concave and usually distinctly subdivided into two facets (Fig. 124), by means of which the radius articulates with the scaphoid and semilunar bones.

The radius is somewhat shorter than the ulna and the two bones are so related that the ulna projects considerably beyond the proximal end of the radius and the radius extends beyond the distal extremity of the ulna. Both bones are curved, but in an opposite direction, so that the concavities of the two bones are directed toward each other. The ulna also exhibits a slight torsion.

In supination both bones of the forearm are parallel and the interosseous ridges are opposite one another (Fig. 120); in pronation the bones are crossed, since the inferior extremity of the radius (together with the hand) rotates about the ulna, while the head of the radius rotates in the radial notch of the ulna. In addition to their articulations with each other, the radius articulates with the humerus and the carpal bones, but the ulna articulates with the humerus only.

The development of the radius is similar to that of the ulna. The center for the diaphysis appears in the third fetal month, while the nuclei for the epiphyses do not appear until the fifth year, the upper epiphysis being developed from a single center. Accessory nuclei appear still later in the tubercle and in the styloid processes of the radius. Ossification is not complete until the twentieth year.

THE BONES OF THE HAND.

THE CARPAL BONES.

The eight bones of the *carpus* (Figs. 126 to 131) are arranged in a proximal and a distal row. Passing from the radial to the ulnar side the proximal row contains the *navicular*, or *scaphoid* bone, the *lunate* or *semilunar* bone, the *triquetral* or *cuneiform* bone, and the *pisiform* bone. Passing in the same direction, the distal row is composed of the *greater multangular* bone or *trapezium*, *lesser multangular* bone or the *trapezoid*, the *os capitatum* or *os magnum*, and the *hamate* or *unciform* bone.

The bones of the proximal row (really the first three only) are not situated in a straight line, but are curved so as to form an arch which is slightly convex proximally and markedly concave distally (Figs. 128 and 129). In the distal row the capitatum projects markedly toward the proximal row and is accommodated by its concavity.

FIG. 126.—The lower ends of the bones of the forearm, and the carpal and metacarpal bones in their natural positions, seen from the dorsal surface ($\frac{2}{3}$).

The preparation was made from a frozen hand, whereby the relative position of the bones could be perfectly determined.

FIG. 127.—The same preparation seen from the volar surface ($\frac{2}{3}$).

FIG. 128.—The bones of the left hand seen from the dorsal surface ($\frac{2}{3}$).

FIG. 129.—The same preparation seen from the volar surface ($\frac{2}{3}$).

FIG. 130.—Frozen preparation of the bones of the left hand, together with the lower ends of the radius and ulna, seen from the dorsal surface ($\frac{2}{3}$).

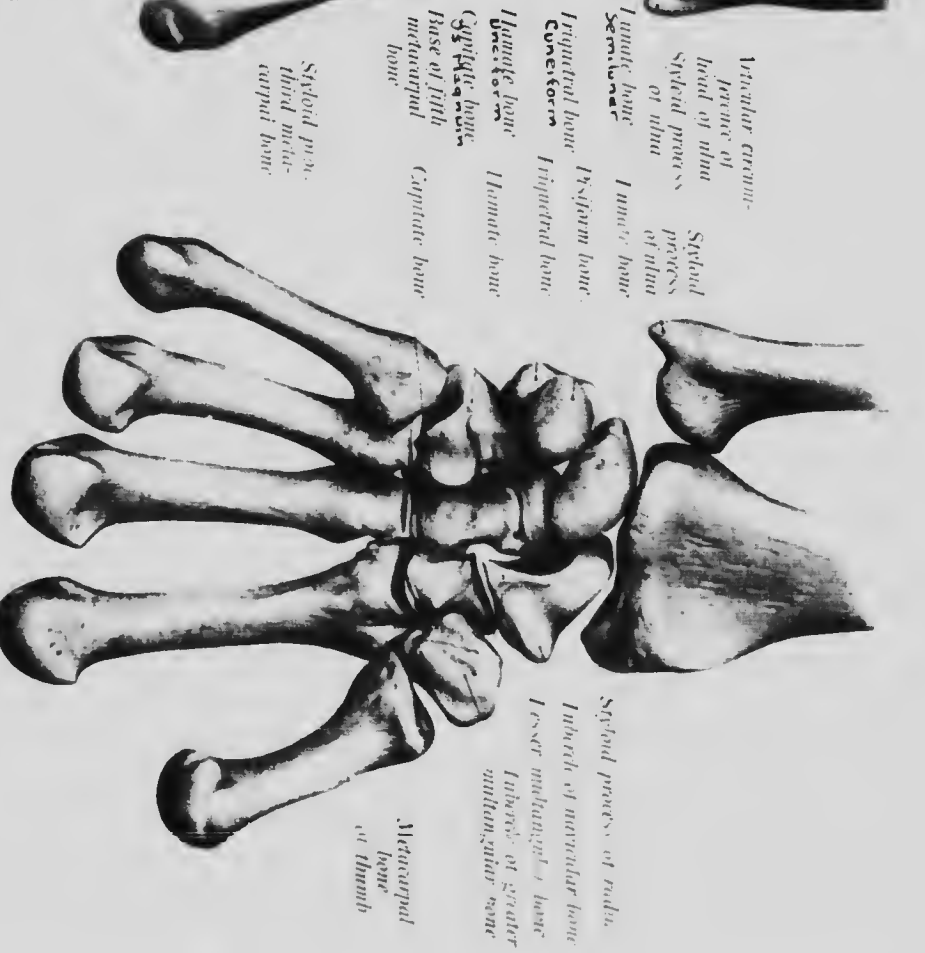
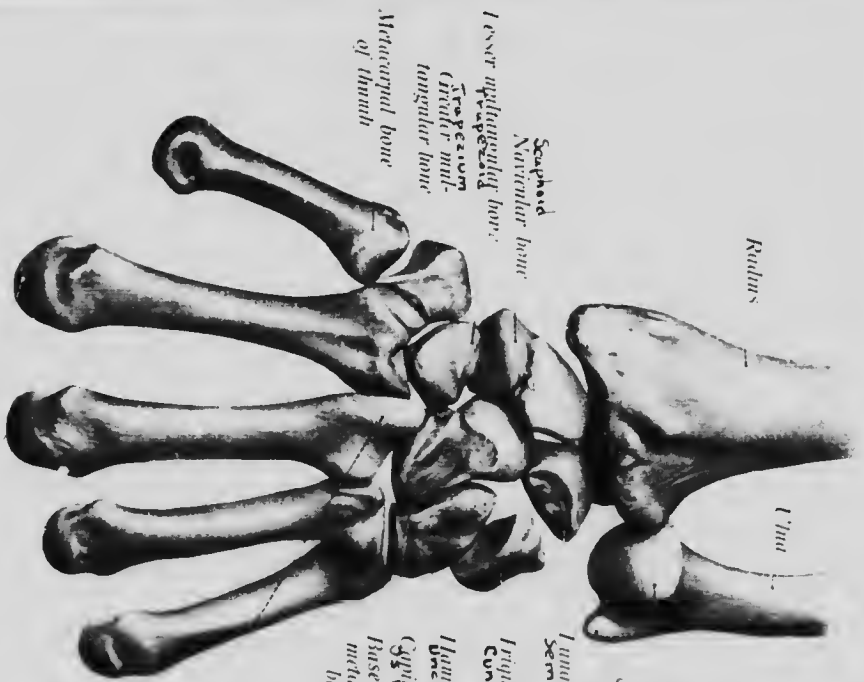
FIG. 131.—The same preparation seen from the volar surface ($\frac{2}{3}$).

All the bones are irregularly shaped and are difficult of description. The navicular (scaphoid) bone is ellipsoidal; its distal surface is excavated, and the radial border of its palmar surface is provided with a rough tubercle (Fig. 127). The lunate (semilunar) bone is shaped like a half-moon, the triquetrum (cuneiform) resembles a short three-sided pyramid, and the pisiform bone is irregularly spherical. The greater (trapezium) and lesser multangular (trapezoid) bones are irregularly cubical and the palmar surface of the former exhibits an elongated flattened elevation, the *tubercle* (Fig. 127). The capitatum or os magnum is the largest bone of the set, and its length is much greater than its breadth; its proximal end is large and forms the head of the bone, which is covered with cartilage. The hamatum (unciform) is also large and irregularly wedge-shaped, and its palmar surface is provided with a flat, slightly curved process, the *hamulus* or *unciform process* (Fig. 129).

The carpal bones do not lie in a single plane, but form an arch which is convex posteriorly and concave anteriorly. The concavity is increased by the two bony prominences which are situated upon both the radial and the ulnar sides of the palmar surface of the carpus and form the *carpal groove*. The radial carpal eminence (Figs. 127 and 131) is formed by the tubercles of the navicular and greater multangular bones; the ulnar eminence, by the pisiform bone and the hamulus of the hamatum.

The small, almost spherical pisiform bone is situated only in the palmar surface of the carpus; all of the remaining carpal bones possess a roughened dorsal and palmar surface. Both surface of the four bones situated at the radial and ulnar margins of the carpus, the navicular (scaphoid)—greater multangular (trapezium), triquetrum (cuneiform), and hamatum (unciform)—are connected by lateral, radial and ulnar surfaces but the numerous remaining surfaces (numerous on account of the irregular shapes of the bones) are smooth articular facets covered with cartilage for articulation with each other, with the radius, or with the metacarpal bones.

The pisiform bone has but a single articular facet for connection with the triquetrum (cuneiform), but all of the remaining carpal bones have several articular surfaces. The most important of these are the following: the navicular (scaphoid) and lunate (semilunar) bones each possess a convex articular surface which articulates with the distal end of the radius; the triquetrum is not connected with the ulna, however, but with an intervening disc of cartilage. Of the joints between the proximal and the distal row of the carpal bones, the most important is that between the convex surface of the head of the capitatum and the concave surfaces of the lunate and navicular bones.



Heads of metacarpal bones

Fig. 120.

Fig. 127.

Vertical text on the left edge, likely bleed-through from the reverse side of the page. The text is extremely faint and mostly illegible, but appears to contain a list of items or a table of contents.



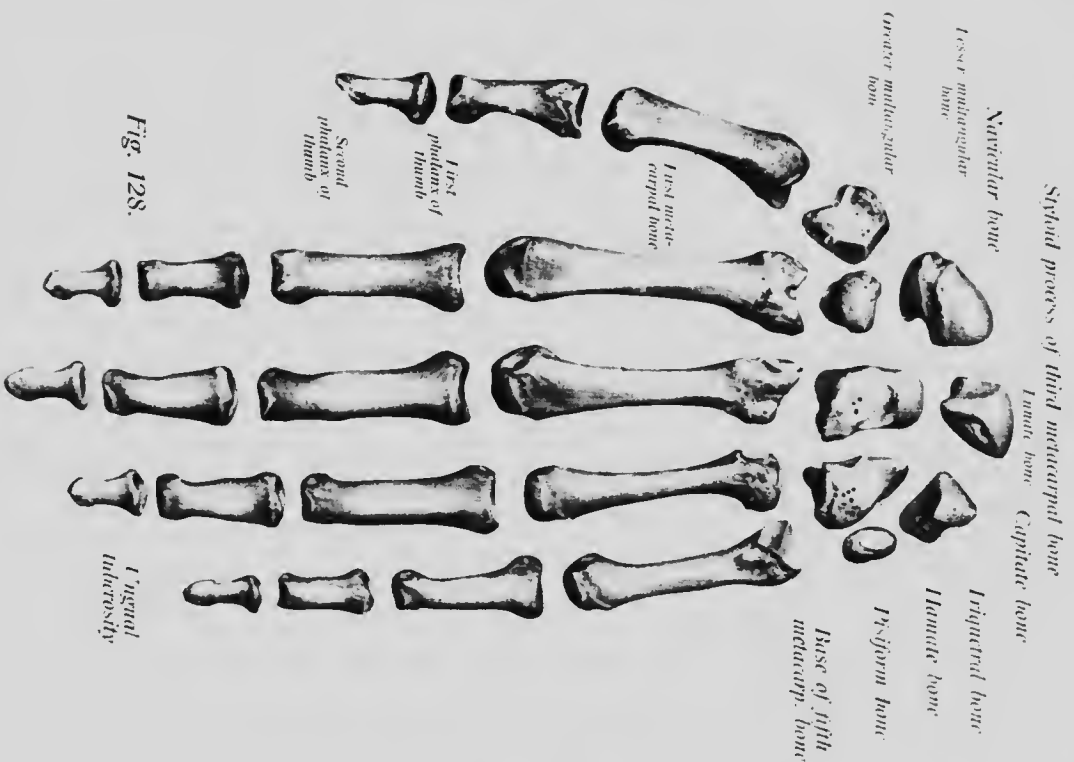


Fig. 128.

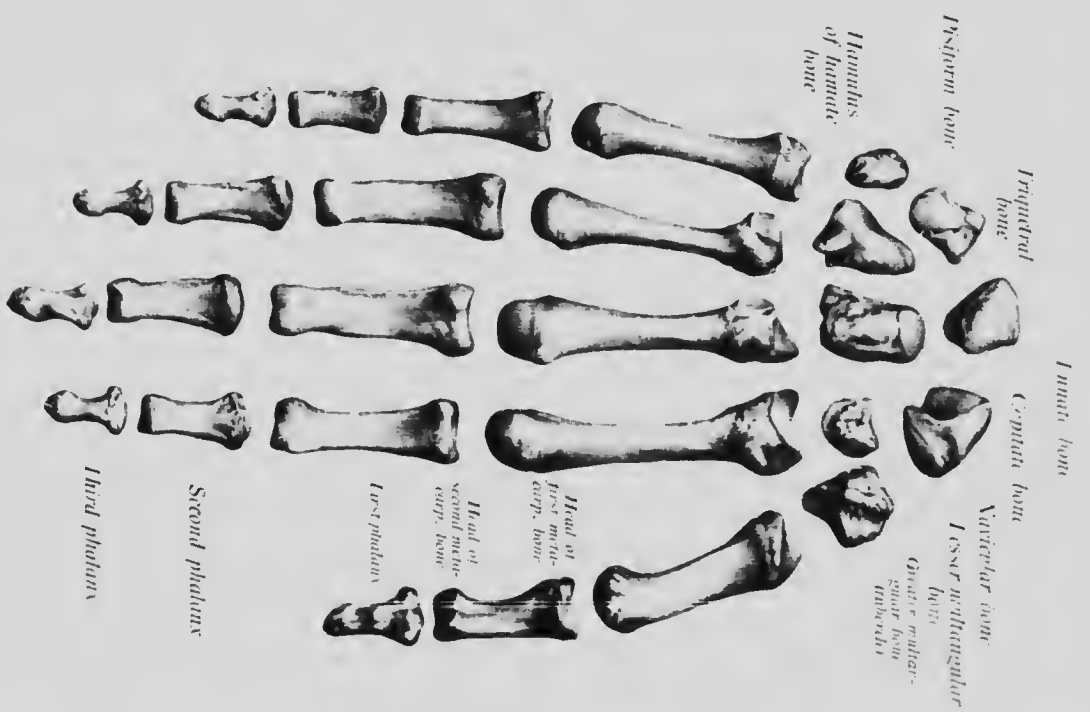


Fig. 129.

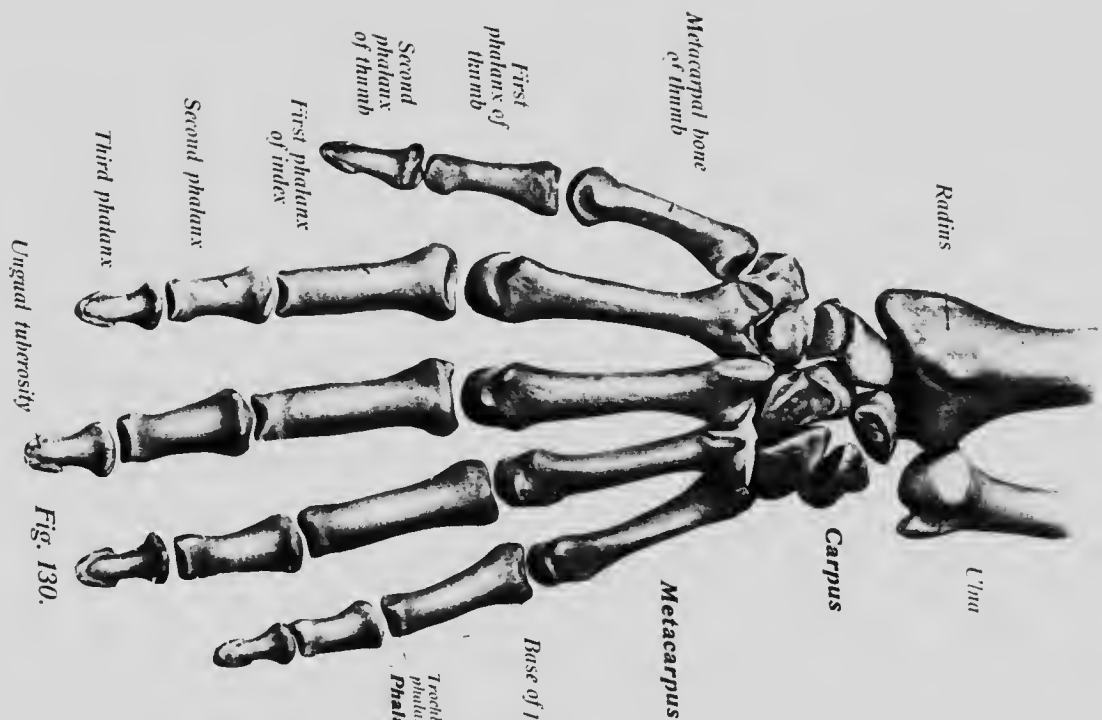


Fig. 130.

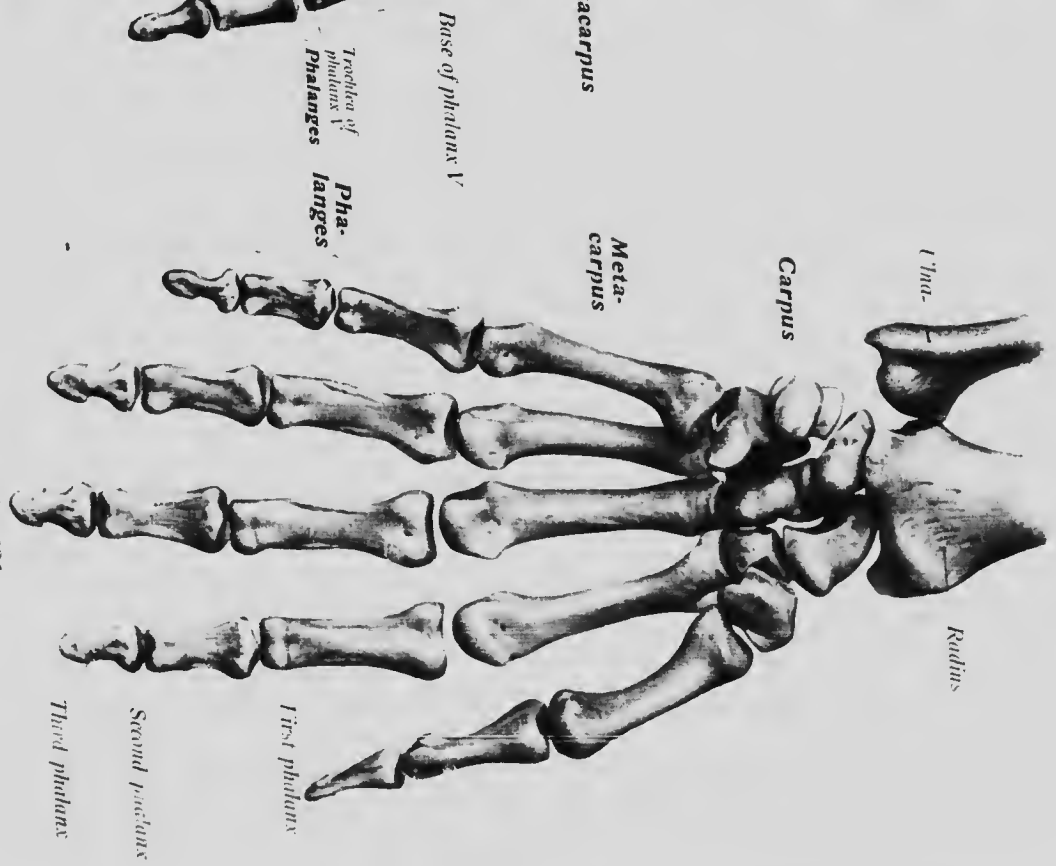



Fig. 131.



The greater multangular articulates with the first metacarpal bone by a distinctly saddle-shaped surface; the lesser multangular (trapezoid) articulates with the second, the capitatum (os magnum) with the third, and the hamatum (unciform) with the two remaining metacarpal bones (Figs. 126 and 127).

In addition to these, the following less important articular facets may be noted: on the navicular (scaphoid), for the lunatum (semilunar), capitatum (os magnum), greater (trapezium), and lesser multangular (trapezoid) bones; on the lunatum (semilunar) bone, for the navicular, capitatum (os magnum), triquetral (cuneiform), and hamate (unciform) bones; on the triquetral (cuneiform) bone, for the lunatum (semilunar) and hamatum (unciform) bones, and usually quite a small facet for the second metacarpal bone; on the lesser multangular (trapezoid) bone the articular facets include the greater portion of the surface of the bone, there being facets for the second metacarpal, the greater multangular, the capitatum, and the navicular bone; on the capitatum (os magnum), for the hamatum (unciform), lesser multangular (trapezoid), the second, the third, and the fourth metacarpal bones; and on the hamate (unciform) bone for the capitatum, triquetrum, and lunate bone.

All of the carpal bones are cartilaginous at birth, and each ossifies from a single center. In the capitatum and hamatum the center appears during the first year, in the remaining bones between the third and the ninth year, and in the pisiform not until the twelfth year or even later.

Supernumerary carpal bones are not rare. The most frequent is a *central bone*, a portion of the skeleton situated between the two rows, the appearance of which is explained by the development of the cartilaginous carpus, in which the bone is clearly represented. In the adult it is usually fused with the navicular, forming its tubercle.

THE METACARPAL BONES.

The five *metacarpal bones* (Fig. 126 to 131) are typical long bones in which may be recognized a proximal extremity or *base*, a *shaft*, and a distal extremity or *head*. The bases articulate with the distal row of carpal bones, the heads with the proximal row of the phalanges. The metacarpal bone of the thumb is the shortest, that of the index-finger the longest, and they gradually decrease in length toward the little finger.

The bases of the metacarpal bones are irregularly cubical and thicker than the shaft; that of the metacarpal bone of the thumb bears a saddle-shaped surface for articulation with the trapezium, and the remaining ones present, in addition to the articular facets for the carpal bones, lateral surfaces for articulation with each other. The base of the third metacarpal bone presents a styloid process (Fig. 128) which is directed toward the radial side.

The base of the first metacarpal bone has a single articular surface, that of the second has three, a small radial one for the greater multangular (trapezium), a large proximal one for the lesser multangular (trapezoid), and a small ulnar one for the base of the third metacarpal bone; the base of the third metacarpal presents a larger proximal facet for the capitatum (os magnum), a small radial one for the second metacarpal bone, and a small ulnar one for the fourth metacarpal bone; the base of the fourth metacarpal bone similarly possesses a proximal facet for the hamate (unciform) bone, a radial one for the third, and an ulnar one for the fifth metacarpal bone; and the base of the fifth metacarpal has a proximal facet for the hamate (unciform) bone and a radial facet for the fourth metacarpal (Figs. 127 and 129). Each of the nutrient foramina leads into a nutrient canal which pursues the same direction as those of the bones of the forearm.

The shaft of each metacarpal bone, with the exception of that of the thumb, is approximately three-sided, and possesses a *palmar* and a *dorsal border*. The palmar border becomes flat as it passes toward the base, while the dorsal border widens out into a surface as it approaches the head.

The heads of the bones are provided with spherical articular surfaces, and their sides present depressions which serve for the attachment of ligaments. Their bases (with the exception of that of the freely movable bone of the thumb) are closely approximated, but both the shafts and the heads are separated by large interspaces which are known as the *interosseous spaces* (Figs. 126 and 127). Between the heads these spaces are filled by ligamentous masses, between the shafts by muscles.

According to the statements of most authors, the metacarpal bones develop from a diaphyseal center in the middle of the bone and from an epiphyseal center in the head; only the metacarpal bone of the thumb differing in that its epiphyseal center is in the base. Occasionally the third metacarpal has a separate center for its styloid process. The epiphyseal centers do not appear until after birth, while the diaphyseal center appears very early (in the ninth week) before the centers in the radius and in the ulna.

THE BONES OF THE FINGERS.

Each finger has three bones or *phalanges*, but the thumb has but two (Figs. 128 to 131). These are designated as the proximal or first phalanx, the middle or second phalanx, and the distal, terminal, unguis or third phalanx. The thumb has no middle phalanx. The phalanges diminish in length as we pass toward the finger-tips, so that the terminal phalanges are the shortest, and the longest phalanx is the proximal one of the middle finger.

The phalanges are long bones composed of a proximal extremity or *base*, of a *shaft*, and of a distal extremity or *trochlea*. The bases of the proximal phalanges have concave hemispherical sockets for the heads of the metacarpal bones; the articular surfaces or bases of the remaining phalanges present a double concavity separated by a median elevation.

The shafts of the phalanges have sharp lateral borders, and their dorsal surfaces are convex, their palmar ones plane or slightly concave. The short bodies of the unguis phalanges terminate in a rough horseshoe-shaped expansion, the *unguis tuberosity* (Fig. 130). The distal extremities of the proximal and middle phalanges exhibit small fossæ, similar to those upon the heads of the metacarpal bones, for the attachment of ligaments, and the nutrient canals run toward the finger-tips, in an opposite direction to those of the other bones of the extremity.

The phalanges are developed like the metacarpal bone of the thumb, each phalanx being ossified from a center in the shaft and from an epiphyseal center in the proximal extremity; there are no centers for the distal ends. The proximal phalanx ossifies first (third month) and then follow the middle and the terminal phalanges.

THE SESAMOID BONES.

In addition to the bones previously described, the hand also contains a varying number of *sesamoid bones*. Two of these are constantly found at the metacarpophalangeal joint of the thumb, and occasionally others occur at the similar joints of the index and little fingers, but in the latter situation they may be replaced by fibro-cartilage. In the thumb they are usually covered with cartilage upon one side and are connected with the articulation. There is also usually a sesamoid bone at the interphalangeal joint of the thumb.

THE SKELETON OF THE HAND AS A WHOLE.

The metacarpal and phalangeal bones do not lie in one plane, but form a curved surface, convex upon the dorsum and concave in the palm; in the metacarpal region this curve may

be considerably increased or diminished by the muscles of the hand. The convexity of the dorsal surfaces reaches its highest point at the metacarpal bone of the index-finger, and from this point declines gradually toward the metacarpal bone of the little finger and abruptly toward that of the thumb. The so-called dorsal surfaces of the metacarpal bone and of the two phalanges of the thumb are directed externally and their borders, instead of their surfaces, are consequently directed toward the dorsum of the hand. The dorsal surface of the metacarpal bone of the little finger is also directed somewhat toward the ulnar side.

While the metacarpal bone of the index-finger is the longest, the phalanges of the middle finger are longer than those of the index-finger, so that the middle finger is the longest finger. The phalanges of the ring-finger are also longer than those of the index-finger.

In correspondence with the functions of the hand as a prehensile organ, the fingers are well developed and take up almost half of the entire length of the hand. The length of the carpus is about one-sixth of the entire length of the hand.

THE SKELETON OF THE LOWER EXTREMITY.

THE PELVIC GIRDLE.

The *pelvic girdle* consists of the two *innominate bones* and in contrast to the shoulder girdle, which is closed anteriorly only, it is also closed posteriorly by the articulation of the innominate bones with the sacrum. The connection of the bones of the pelvic girdle is also much firmer than that of the bones of the shoulder-girdle. Together with the sacrum, the two innominate bones form the *bony pelvis*.

THE INNOMINATE BONE.

The *innominate* or *coxal bone* (Figs. 132 to 134) is a single bone in the adult only. In the new-born and until the age of puberty (Figs. 135 and 136) it consists of three bones separated by cartilage (synchondroses)—the *ilium*, the *pubis*, and the *ischium*. All three bones are in contact in the *acetabulum* and unite at about the age of puberty to form the innominate bone. The portions of the ilium, pubis, and ischium which unite in the acetabulum are the thickest parts of their respective bones and are designated the *bodies*.

The *ilium* forms the upper portion of the innominate bone; it is the largest of the three bones and forms the upper third of the acetabulum. It consists of a *body* and of an upper portion or *ala*.

The *pubis* forms the antero-inferior portion of the innominate bone and the antero-inferior third of the acetabulum. It is separated from the ischium by a large foramen, the *obturator foramen*, except at the inferior boundary of the foramen, where it is attached to the ischium by a synchondrosis which disappears before the age of puberty. It is composed of a *body* and of two *rami*. The *superior ramus* (Fig. 134) forms the upper boundary of the obturator foramen, the *inferior ramus*, the anterior one.

The *ischium* forms the postero-inferior portion of the innominate bone, the postero-inferior third of the acetabulum, and the inferior and posterior boundary of the obturator

FIG. 132.—The right innominate bone seen from the outer surface ($\frac{1}{2}$).

FIG. 133.—The right innominate bone seen from the inner surface ($\frac{1}{2}$).

foramen. It is composed of a *body* (Fig. 134) and of two rami, a *superior* and an *inferior ramus*, which, like those of the pubic bone, form boundaries of the obturator foramen.

In the adult innominate bone the thickened and somewhat constricted portion of the bone, upon whose outer surface is the acetabulum, gives off a bony plate, the *ala of the ilium* (Fig. 134), which passes upward and presents an external convex and an internal concave surface. Below and in front of the acetabulum, the middle portion of the bone sends out a second plate, which is perforated by the obturator foramen (rami of the pubis and ischium).

The *ala of the ilium* (Fig. 137) is shaped like the horns of a buck, without the tips. In the middle it is frequently as thin as paper. Its superior margin is markedly thickened and rough and is known as the *crest of the ilium*, and upon this crest are three rough lines, produced by the attachment of the abdominal muscles. They are most distinct in the middle of the iliac crest, where it is thickest and reaches its greatest height, and are termed the *external*, the *internal*, and the *middle lips* of the crest (Figs. 132 and 134).

Anteriorly the crest of the ilium ends in a spine, the *anterior superior spine* (Figs. 132 to 134), and at the posterior extremity of the crest there is another less pronounced spine, the *posterior superior spine* (Fig. 131). Below the posterior superior spine, and separated from it by a shallow notch, is the *posterior inferior spine*, and below this the posterior margin of the innominate bone presents a deep paraboloid notch, the *great sciatic notch* (Fig. 132), whose upper boundary is formed by the posterior margin of the *ala*, and its antero-inferior one by the bodies of the ilium and ischium.

Below the anterior superior spine at the anterior border of the body of the ilium is situated the *anterior inferior spine* (Figs. 132 to 134). It is placed at a greater distance from the anterior superior spine than is the posterior inferior from the posterior superior one, and is situated immediately above the upper and anterior margin of the acetabulum.

The external surface of the *ala* of the ilium (Fig. 132) is rough and convex, and presents three rough lines which indicate the areas of origin of the gluteal muscles. These lines are designated as the *posterior or superior*, the *anterior or middle*, and the *inferior* gluteal lines. The posterior gluteal line is almost vertical and runs across the posterior portion of the *ala* of the ilium to the upper boundary of the great sciatic notch, and the small area of the ilium which it bounds gives origin to a portion of the gluteus maximus muscle and contains both posterior spines.

The long anterior line passes backward in an arched manner from the anterior superior spine; it is at first almost horizontal, then nearly vertical, and ends near the superior line at the upper margin of the great sciatic foramen. The surface of the *ala* included between it and the superior line gives origin to the gluteus medius muscle.

The inferior line is considerably shorter than the anterior one. It commences between the anterior superior and anterior inferior spines and passes backward almost horizontally above the acetabulum to the middle of the great sciatic foramen. It is but slightly curved and is apt

rior
one,
Fig.
ace.
late,

In
and
aced
iliac
the

2 to
pos-
it by
the
those
ne by

ated
erior
l im-

sents
s are
lines.
e ala
ilium
Both

erior
ne at
t and

en the
above
is apt

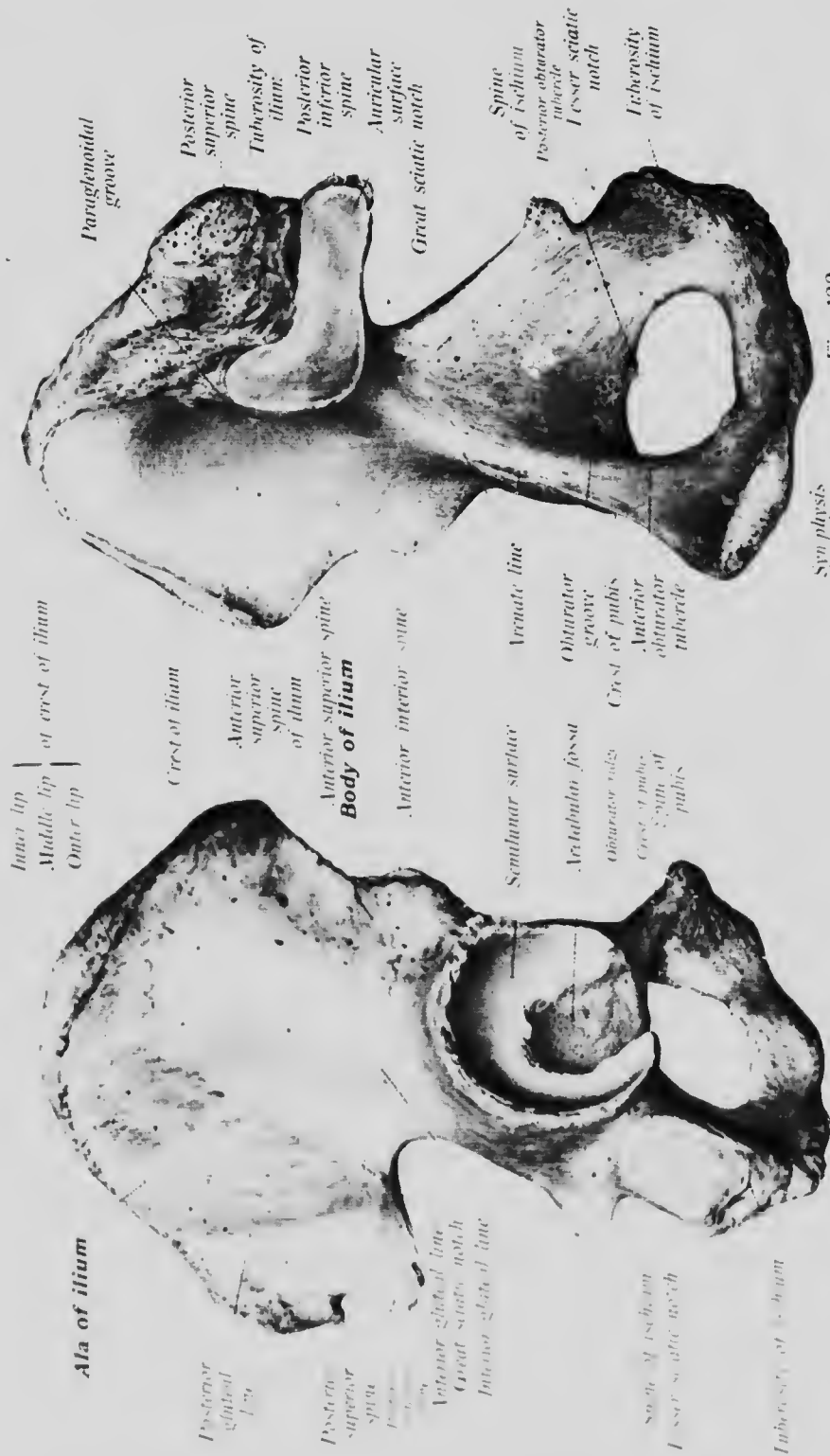



Fig. 133.

Syn physis

Fig. 132.



to be the least distinct of the three lines. The surface included between it and the anterior gluteal line gives origin to the *glutæus minimus*.

The inner surface of the *ala* (Fig. 133) is composed of two portions, of which the larger anterior one is slightly excavated and is known as the *iliac fossa*, while the posterior one is uneven and is further subdivided into two areas, an antero-inferior one, the *auricular surface* (Fig. 135), for articulation with the similarly named surface of the sacrum, and a postero-superior extremely rough one, the *tuberosity of the ilium* (Fig. 133), which corresponds with the similarly named surface of the sacrum. At the border of the auricular surface there is a distinct groove known as the *paraglenoidal groove* (Fig. 133).

The *iliac fossa*, the middle of which is frequently as thin as paper,* is separated from the remaining portions of the innominate bone (the body of the ilium, the pubis, and the ischium) by a line which is continued upon the pubis and is known as the *arcuate line* (Fig. 133). This line forms a portion of the dividing line between the true and the false pelvis, the *terminal (iliopectineal) line*, and is consequently also known as the iliac portion of the terminal line.

The *body of the ilium* forms the upper portion of the acetabulum (see page 96) and a portion of the boundary of the great sciatic notch. It is directly continuous, particularly upon its inner surface, with the *ala* of the ilium above, and in the adult with the bodies of the pubis and ischium below.

The **pubic bone** is intimately connected by its body with the ilium and with the ischium, and forms a portion of the acetabulum (see page 96). At the junction of the bodies of the pubis and ilium there is a low rounded elevation, the *iliopectineal eminence* (Fig. 135), which belongs to both bones in the adult after the ossification of the synchondrosis.

Passing downward and forward from the body of the pubic bone is the approximately three-sided *superior ramus* (Fig. 135), which is practically horizontal, and forms the upper boundary of the obturator foramen. Its anterior extremity, which also gives origin to the inferior ramus, presents an oblong surface, the *symphysis* (Fig. 133), for articulation with the bone of the opposite side, and the anterior surface is directed forward and outward, the inferior one inward and forward, and the posterior one toward the interior of the pelvis. The upper border presents a sharp edge, the *crest* of the pubis (Fig. 133), which represents the continuation of the arcuate line of the ilium and is the pubic portion of the iliopectineal line. The crest terminates anteriorly in a small projection situated about a fingerbreadth from the symphysis and known as the *tubercle* or *spine* of the pubis (Figs. 132 and 134).

At the junction of the superior ramus with the body of the pubis the posterior or pelvic surface of the bone presents a broad shallow groove, the *obturator groove* (Fig. 132), which gradually fades away as it passes inward upon the inferior surface toward the obturator foramen. The sharp ridge which forms the inner boundary of the groove is known as the *obturator ridge* (Fig. 131).

The obturator groove is usually bounded in front and below by a process directed toward the obturator foramen, the *anterior obturator tubercle* (Fig. 133), and a posterior boundary is sometimes furnished by a *posterior obturator tubercle*, which arises from the ischium and is also directed

* Sometimes there is a foramen in this situation.

FIG. 134.—The right innominate bone seen from in front ($\frac{1}{2}$).

FIG. 135.—The right innominate bone of a five- or six-year-old child seen from the inner surface ($\frac{1}{2}$). In Figs. 134 and 135 the ilium is yellow, the ischium green, and the pubis blue. Parts that are still cartilaginous are white.

FIG. 136.—The same seen from the outer surface ($\frac{1}{2}$).

toward the obturator foramen. Between these two tubercles is stretched the upper margin of the obturator membrane (see page 129).

The *inferior ramus* of the pubis is flatter and possesses but two surfaces, an *anterior* and a *posterior or pelvic surface*. It passes obliquely downward and outward from the *symphysis* and is connected with the inferior ramus of the ischium at the site of a slight constriction.

The **ischium** is shaped very much like the pubis, and in the adult its body is intimately connected with those of the ilium and pubis. It forms the antero-inferior boundary of the *great sciatic notch*, and in this situation presents a sharp triangular projection, the *spine* (Fig. 132). Below the spine is situated the *lesser sciatic notch*, which is not so deep as the greater one and is formed entirely by the ischium, its inferior boundary being furnished by the large rough *tuberosity* of the ischium (Fig. 132), which forms the main portion of the outer surface of the superior ramus. From the tuberosity, the thin flat inferior ramus passes forward and upward (Fig. 134), forming almost a right angle with the superior ramus of the ischium. Together with the inferior ramus of the pubis, it forms the lower boundary of the obturator foramen.

The **acetabulum** (Fig. 132) is formed by the bodies of the ilium, pubis, and ischium, but dividing-lines between its component portions are visible in youthful individuals only. It is a hemispherical cavity with elevated margins looking directly outward, and only the anterior inferior portion of the margin toward the obturator foramen is incomplete; this gap is known as the *acetabular or cotyloid notch*.

The floor of the acetabulum is composed of two differently shaped portions. The larger portion, the *semilunar surface* (Fig. 132), is smooth and covered with cartilage; it forms the upper and lateral portions of the cavity and extends downward to the borders of the cotyloid notch. The remaining quadrate area commences at the borders of the acetabular notch; it is rough and uneven and is known as the *acetabular fossa*.

The **obturator foramen** (Fig. 134) is a large opening, the shape of which is subject to considerable individual variation; it may be either oval or triangular, its longest diameter being transverse in some cases and vertical in others. Its borders are formed by the rami of the ischium and of the pubis, and are for the most part sharp, being flat only where the obturator groove runs into the foramen.

The innominate bone is formed from three main centers of ossification, one for the ilium, one for the ischium, and one for the pubis. The center for the ilium appears in the preformed cartilage at the beginning of the third fetal month, that for the ischium in the beginning of the fourth month, and that for the pubis in the fifth month. At birth and even during the first years of life (Figs. 135 and 136) a large portion of the innominate bone is still cartilaginous (the margins of the acetabulum, the crest of the ilium, the tuberosity of the ischium, and the spine of the ischium). In the acetabulum, a Y-shaped cartilage remains until the age of puberty, when the three portions of the bone become united by osseous tissue, the two inferior rami (of the pubis and ischium) becoming united still earlier, in the seventh or eighth year. In addition to the main centers, there appear a somewhat variable number of epiphyseal centers, of which those worthy of special mention are: one at the entire crest of the ilium, one in the tuberosity of the ischium, one in the

face (†).
 are white.
 margin of
 or and
 a physis
 mately
 of the
 e (Fig.
 greater
 e large
 surface
 d and
 . To
 amem.
 m, but
 It is
 anterior
 known
 larger
 ns the
 styloid
 h; it
 ect to
 being
 of the
 rator
 hium,
 of fetal
 at birth
 ginous
) In
 uted
 ighth
 y those
 in the

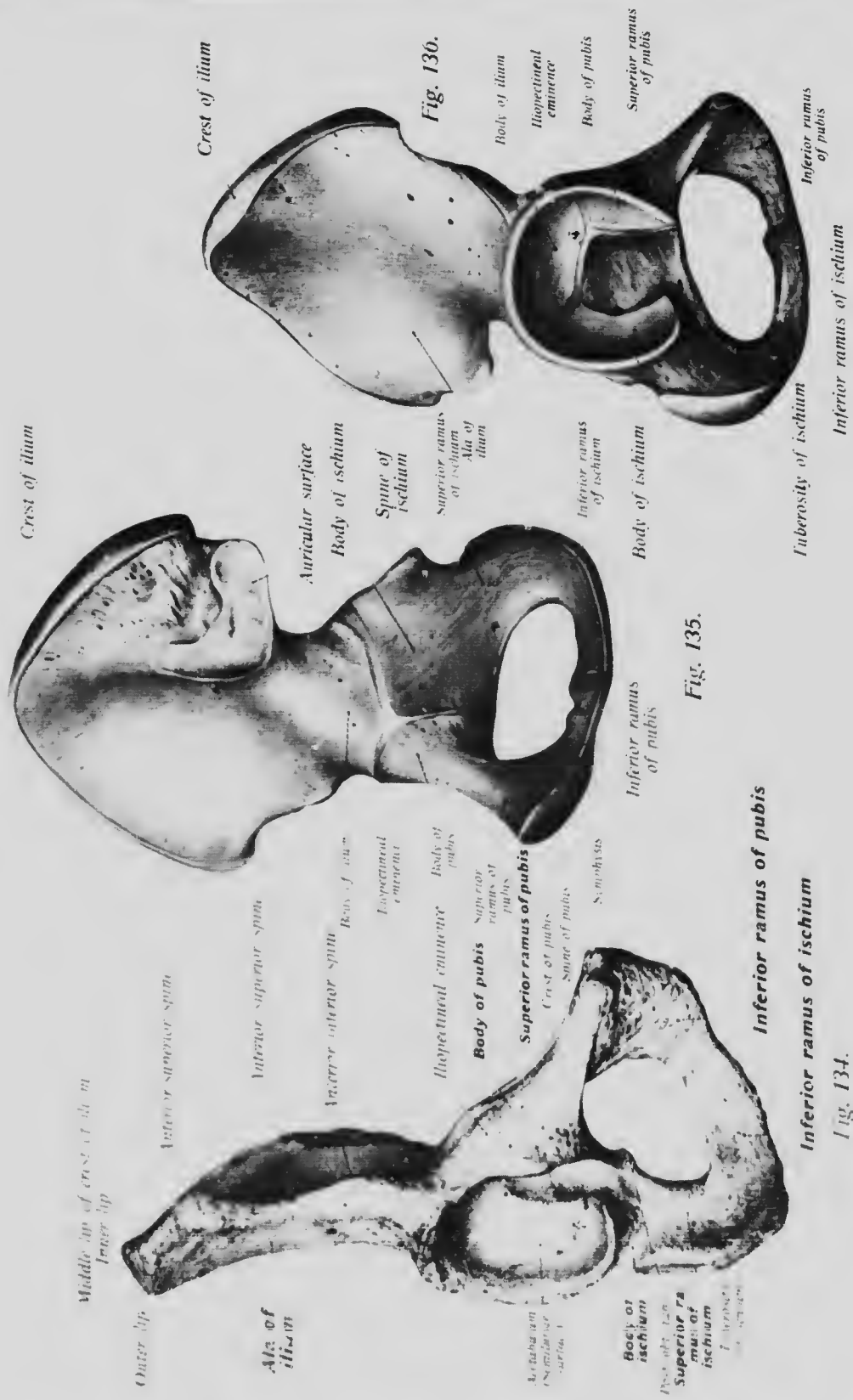


Fig. 134.

Fig. 135.

Fig. 136.

L

1. The first part of the document is a header section containing the following information:
 a. The title of the document, which is "The History of the United States".
 b. The author's name, which is "John Adams".
 c. The date of publication, which is "1780".
 d. The publisher's name, which is "The American Book Company".
 e. The location of the publisher, which is "New York, N.Y.".

The main body of the document is a detailed historical account of the United States, starting from the early 17th century and continuing through the late 18th century. It covers the following topics:

- The early colonial period, including the settlement of Jamestown and the Pilgrims in Plymouth.
- The growth of the colonies and the increasing tensions with Great Britain.
- The American Revolutionary War, from the outbreak in 1775 to the signing of the Declaration of Independence in 1776.
- The formation of the new nation and the early years of the United States government.
- The challenges faced by the young nation, including economic difficulties and the threat of foreign intervention.

The document concludes with a reflection on the early years of the United States and the challenges that lay ahead.

spine of the ischium, one in the symphysis, one in the anterior inferior spine of the ilium, and one in the spine of the pubis. Some of these do not appear until after puberty, about which time one or two epiphyseal centers also appear in the floor of the acetabulum. The epiphyses do not unite with the main portion of the bone until from the twentieth to the twenty-fifth year.

The pelvis as a whole is considered upon page 130.

THE SKELETON OF THE FREE LOWER EXTREMITY.

THE FEMUR.

The *femur* (Figs. 137 to 141) is the largest long bone of the human body, and consists of a *superior extremity*, a *shaft*, and an *inferior extremity*.

The *superior extremity* presents a *neck* (Fig. 140), which is placed at an obtuse* angle to the axis of the bone and is surmounted by the *head*. This forms more than a hemisphere, representing from two-thirds to three-fourths of a sphere, and is directed inward and upward. It is covered with cartilage with the exception of a rough and slightly depressed area somewhat below and to the inner side of the middle (Fig. 138), to which is firmly attached a peculiar ligament of the hip-joint, the *ligamentum teres*.

That portion of the bone which forms a constriction immediately below the head and which broadens externally toward the shaft is designated as the *neck* of the femur, and is shaped like an obliquely truncated cylinder, the superior border being about twice as long as the inferior one. The upper extremity of the bone, at the margin of the neck, presents two large, strong protuberances, the *trochanters* (Fig. 140), which receive the attachment of numerous muscles. The *greater trochanter* is considerably larger than the lesser one and is situated externally, forming the entire outer portion of the superior extremity of the femur. Its slightly curved apex projects above the femoral neck, and below its apex is situated the *trochanteric (digital) fossa* (Fig. 138).

The *lesser trochanter* (Fig. 140) is a short conical projection which is placed opposite to the greater trochanter upon the inner side of the upper extremity of the femur, and is directed somewhat posteriorly. It is much smaller than the great trochanter and is situated at a lower level. The two trochanters are connected upon the anterior surface of the femur by a distinctly elevated ridge which commences at the apex of the great trochanter, and is termed the *intertrochanteric ridge*. The intertrochanteric line and ridge form the posterior boundary of the neck of the femur. The greater and lesser trochanters give insertion to a large number of muscles.

The *shaft* (Figs. 137 to 139) is almost cylindrical, although toward its lower extremity it becomes broader and assumes the shape of a three-sided prism with rounded margins. Its anterior and lateral surfaces are strikingly smooth, but the posterior surface presents a rough line, the *linea aspera*, which is composed of two distinct lips, an *inner* and an *outer lip* (Fig. 137). In the middle of the femur they are closely approximated, but diverge toward both

* In the female the angle approaches a right angle.

† The intertrochanteric line does not actually run to the lesser trochanter, but passes beneath it to the inner lip of the linea aspera.

- FIG. 137.—The right femur seen from behind ($\frac{2}{3}$).
 FIG. 138.—The right femur seen from the inner surface ($\frac{2}{3}$).
 FIG. 139.—The right femur seen from in front ($\frac{2}{3}$).
 FIG. 140.—The upper end of the right femur seen from behind ($\frac{1}{2}$).
 FIG. 141.—The lower end of the right femur seen from below ($\frac{1}{2}$).
 FIG. 142.—The patella seen from in front ($\frac{1}{2}$).
 FIG. 143.—The patella seen from behind ($\frac{1}{2}$).

the upper and the lower extremity of the bone, passing toward the trochanters above and to the epicondyles below.

The outer lip of the *linea aspera* passes upward to a long broad elevation, the *gluteal tuberosity** (Fig. 140), which is usually flat but markedly roughened, and receives the greater portion of the insertion of the *glutæus maximus* muscle. The internal lip becomes less distinct as it passes upward and is continuous with the intertrochanteric line. Parallel to the upper part of the inner lip and somewhat to the outer side of it is situated a second rough line, the *pectineal line* (Fig. 140), for the insertion of the *pectineus* muscle.

Toward the lower extremity of the femur the two lips of the *linea aspera* gradually diverge and form the boundaries of an almost plane triangular area upon the posterior surface of the bone, the *popliteal surface* (Fig. 137). Upon the line, above its middle, there are usually one or more nutrient foramina which lead into canals pursuing a distinct upward (proximal) direction.

The *shaft* of the femur exhibits a distinct curvature, which is convex anteriorly (Fig. 139), and upon its anterior broad portion there may be distinguished an antero-internal, an antero-external, and a posterior surface. The *linea aspera* furnishes either the origin or the insertion for a large number of muscles.

The *inferior extremity* of the femur is very broad, and presents two convex condyles (Fig. 137), a larger *internal condyle* and a smaller *external condyle*, which are directed posteriorly and are separated from each other by the *intercondyloid fossa*, an *intercondyloid line* separating this fossa from the popliteal surface. Anteriorly (Fig. 139) the cartilaginous surfaces of both condyles are continuous with an articular surface, the *patellar surface*, which is concave from side to side and convex from above downward, so that the entire articular surface of the lower end of the femur is shaped somewhat like a horseshoe. Above the condyles upon the lateral surfaces of the lower end of the bone are situated two rough and slightly prominent processes, the epicondyles (Figs. 137, 138, and 141), which are termed the *internal epicondyle* and the *external epicondyle*. The lower portions of the lips of the *linea aspera* run downward to the epicondyles, which give origin to the *gastrocnemius* muscle.

Like most of the long bones, the femur is developed from a diaphyseal and two primary epiphyseal centers. The diaphyseal center appears as early as the seventh week of embryonic life, and while the lower epiphyseal center is usually visible at birth, the center for the head of the femur does not appear until after birth (at the end of the first year). At a later period special epiphyseal centers appear in the greater trochanter (fourth year) and in the lesser trochanter (thirteenth to fourteenth year).

Although the center for the lesser trochanter appears later than any of the other epiphyseal centers, it is the

* Sometimes the gluteal tuberosity develops into a more pronounced projection, the *third trochanter*.

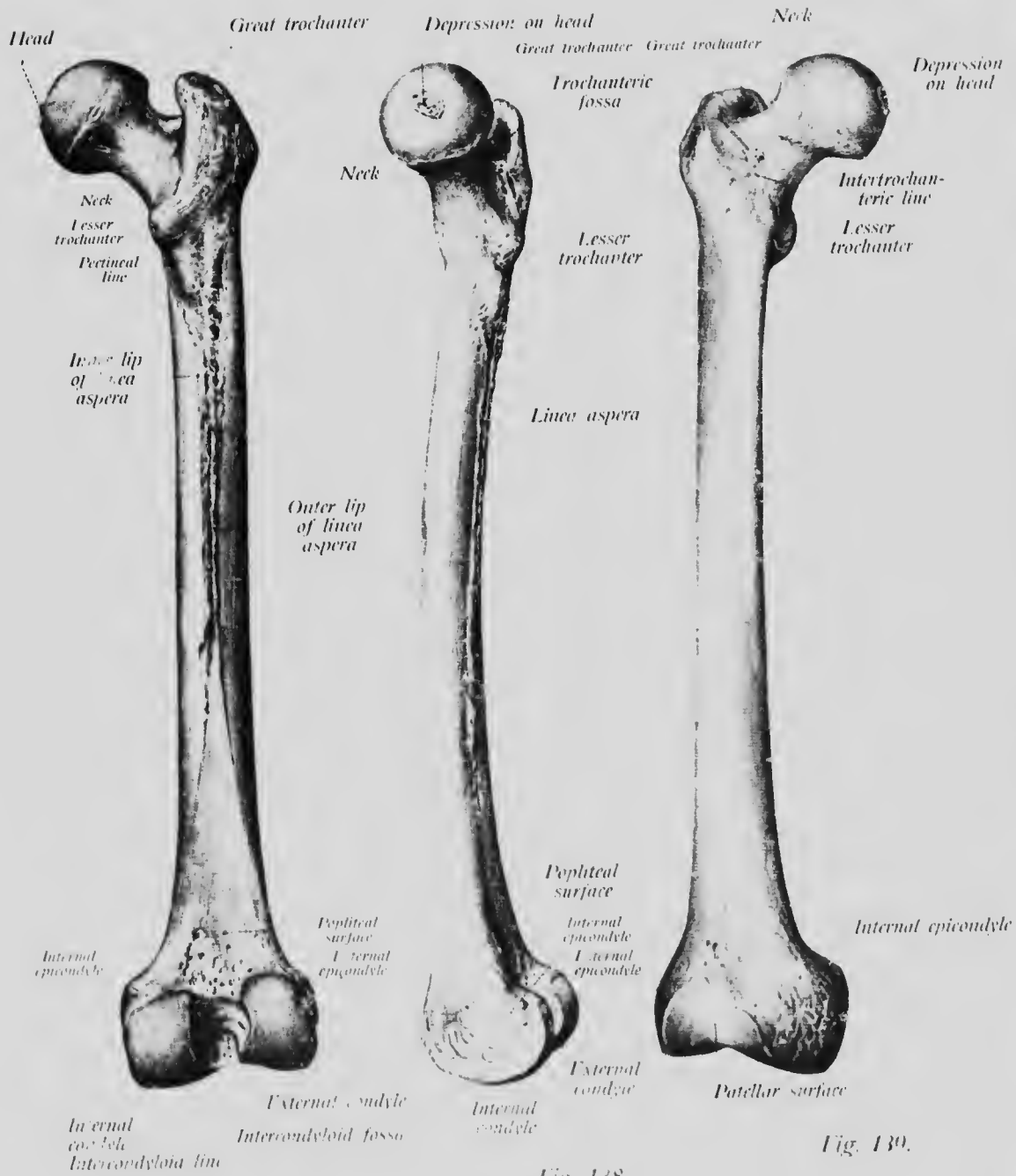


Fig. 137.

Fig. 138.

Fig. 139.



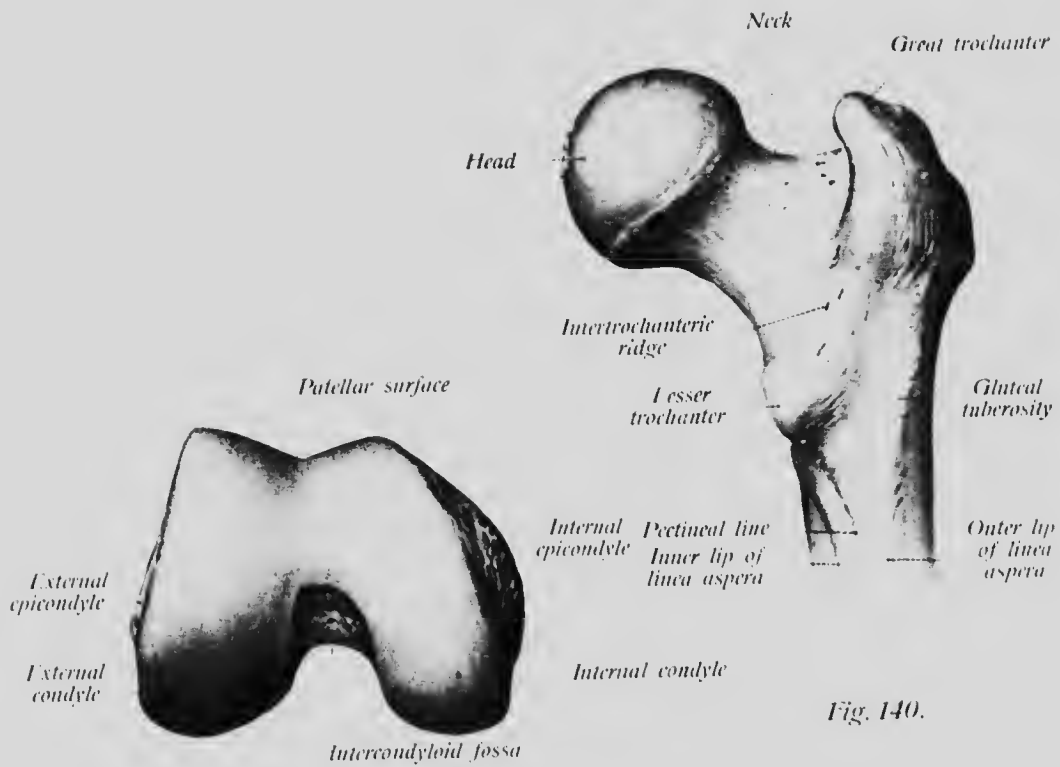


Fig. 140.

Fig. 141.




Fig. 142.

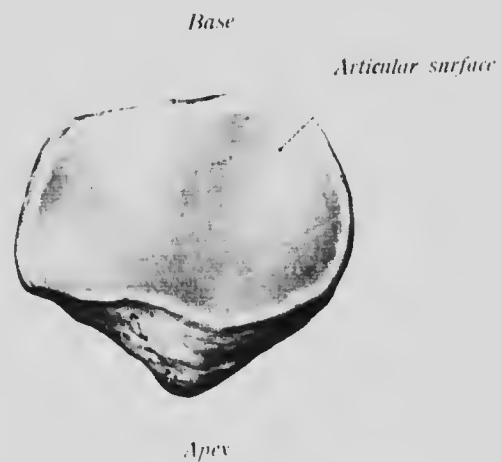



Fig. 143.





first to unite with the shaft of the femur (seventeenth year); then follows the union of the trochanter major, then that of the head of the femur, and finally (at the twentieth year) that of the lower end of the femur with the shaft of the bone.

THE PATELLA.

The *patella* (Figs. 142 and 143) is a flat, rounded, disc-like bone which is nothing more than a large sesamoid bone in the tendon of the quadriceps femoris muscle. The upper border is broad and is called the *base*, and the lower portion of the bone terminates in a point, the *apex*. The anterior surface is rough; the posterior is smooth and covered with cartilage for about two-thirds of its extent, this cartilaginous surface being apposed to the patellar surface of the femur and known as the *articular surface*. The posterior surface of the apex is not covered with cartilage and is rough like the anterior surface.

The patella is formed from a single center which does not appear until the fourth year. Ossification is not complete until after puberty.

THE TIBIA.

The *tibia* (Figs. 144 to 147 and 150 to 152) is the inner and by far the larger of the two bones of the leg. It is composed of a *superior extremity*, a *shaft*, and an *inferior extremity*.

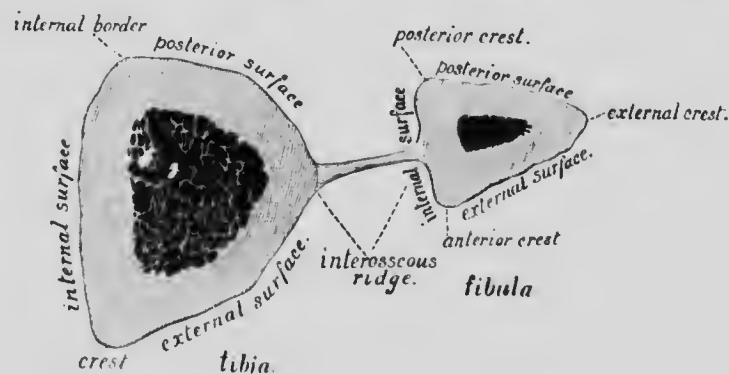


FIG. 147.—A section of the bones of the crus taken at about the middle of their length (schematized).

The *superior extremity* is the thickest portion of the bone. It presents two condyles (Fig. 151), which articulate with the lower end of the femur, and are known as the *internal* and *external condyles*. They exhibit upon their upper surfaces two rounded, triangular, slightly concave areas, the *internal* and *external superior articular surfaces*, for the femoral condyles, whose concavities (especially that of the external one) are considerably less than the convexities of the femoral condyles. These areas are separated by a median elevation, the *intercondyloid eminence* or *spinous process*, which presents two small tubercles, the *internal* and *external intercondyloid tubercles*, and in front of and behind the eminence are small shallow depressions which are known respectively as the *anterior* and *posterior intercondyloid fossae* (Fig. 151).

The articular surfaces are bounded by the almost vertical bony margin of the upper end

- FIG. 144.—The right tibia seen from in front ($\frac{2}{3}$).
 FIG. 145.—The right tibia seen from behind ($\frac{2}{3}$).
 FIG. 146.—The right tibia seen from the outer surface ($\frac{2}{3}$).
 FIG. 148.—The right fibula seen from the inner surface ($\frac{2}{3}$).
 FIG. 149.—The right fibula seen from the outer surface ($\frac{2}{3}$).
 FIG. 150.—The tibia and fibula seen from behind ($\frac{2}{3}$).
 FIG. 151.—The upper ends of the tibia and fibula seen from above ($\frac{1}{2}$).
 FIG. 152.—The lower ends of the tibia and fibula seen from below ($\frac{1}{2}$).

of the tibia, the *infraglenoidal margin* (Fig. 144), and at the lower portion of the external surface of this margin is an almost flat, elliptical, articular surface for the head of the fibula (Fig. 145), while below it, the anterior surface of the bone presents a large roughened elevation, the *tuberosity* (Fig. 144). The entire upper end of the tibia is bent slightly backward toward the shaft of the bone (Fig. 146).

The *shaft* of the tibia is of a distinctly triangular prismatic form. It is thick at its junction with the upper extremity, and as it passes downward becomes more slender, at first gradually and then rapidly (Figs. 144 to 146). It presents for examination three borders and three surfaces. The sharp anterior *crest* (Fig. 144), somewhat S-shaped and beginning at the lower margin of the tuberosity, separates the *internal* and *external surfaces*, while the equally sharp *interosseous ridge* (Figs. 145 and 146), directed toward the fibula (Fig. 147), is situated between the *external* and *posterior surfaces*. The third border of the tibia is rounded; it separates the inner and posterior surfaces and is known as the *internal border*.

The upper portion of the posterior surface of the shaft exhibits a rough line, the *popliteal or oblique line* (Fig. 145), which passes from above downward and from without inward from the articular surface for the fibula to the internal border. Below it is situated the *nutrient foramen*, which is usually very large and distinct, and leads into a canal which passes obliquely downward. The nutrient canal of the tibia consequently runs in an opposite direction to that of the femur.

The *inner surface* of the tibia, like its anterior border, is situated immediately beneath the skin and may be easily felt. The *outer surface* presents no special characteristics. Toward the lower end of the bone the borders (with the exception of the interosseous ridge) become rounded off, so that in this portion the bone is almost cylindrical.

The inferior extremity of the tibia is considerably smaller than the upper one, but it is distinctly thicker than the lower portion of the shaft. Its inferior surface (Fig. 152) presents a slightly concave articular surface for the astragalus, and upon its inner side there is a process which projects below the remainder of the bone and is known as the *internal malleolus* (Fig. 144). The external surface of this process forms an articular surface for the astragalus, and is directly continuous with the inferior articular surface of the bone. Upon the posterior surface of the internal malleolus is a broad groove (Fig. 144) for the tendon of the tibialis posterior muscle, and the outer surface of the lower end of the bone presents a notch, the *fibular notch*, for the reception of the fibula (Fig. 146), this notch not being, however, an articular surface and therefore not being covered with cartilage.

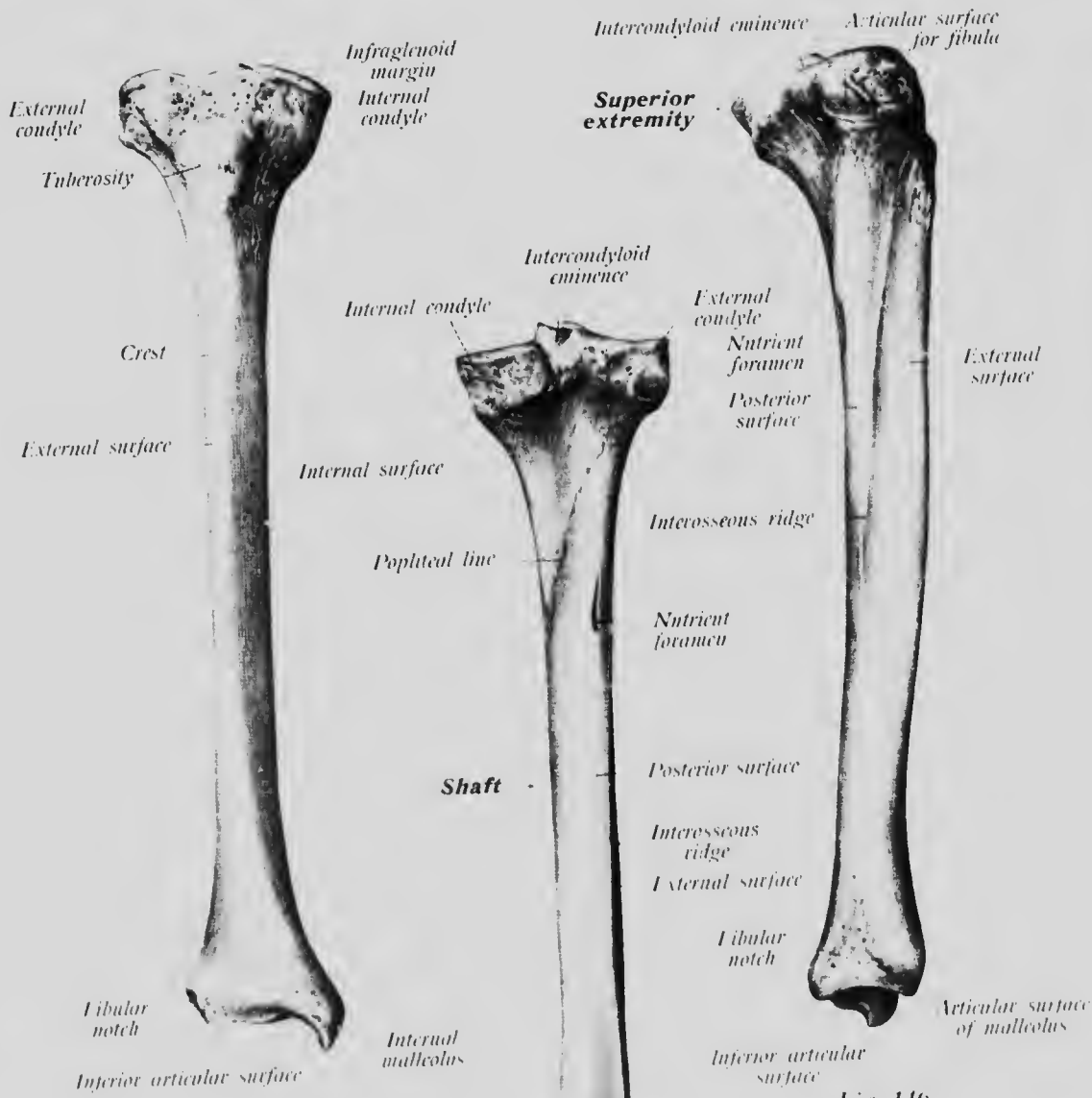


Fig. 144.

Fig. 145.



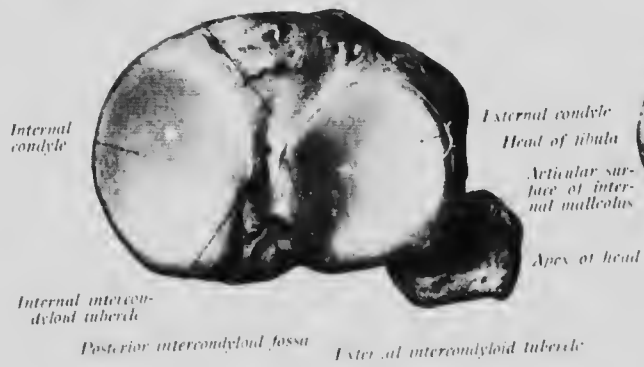

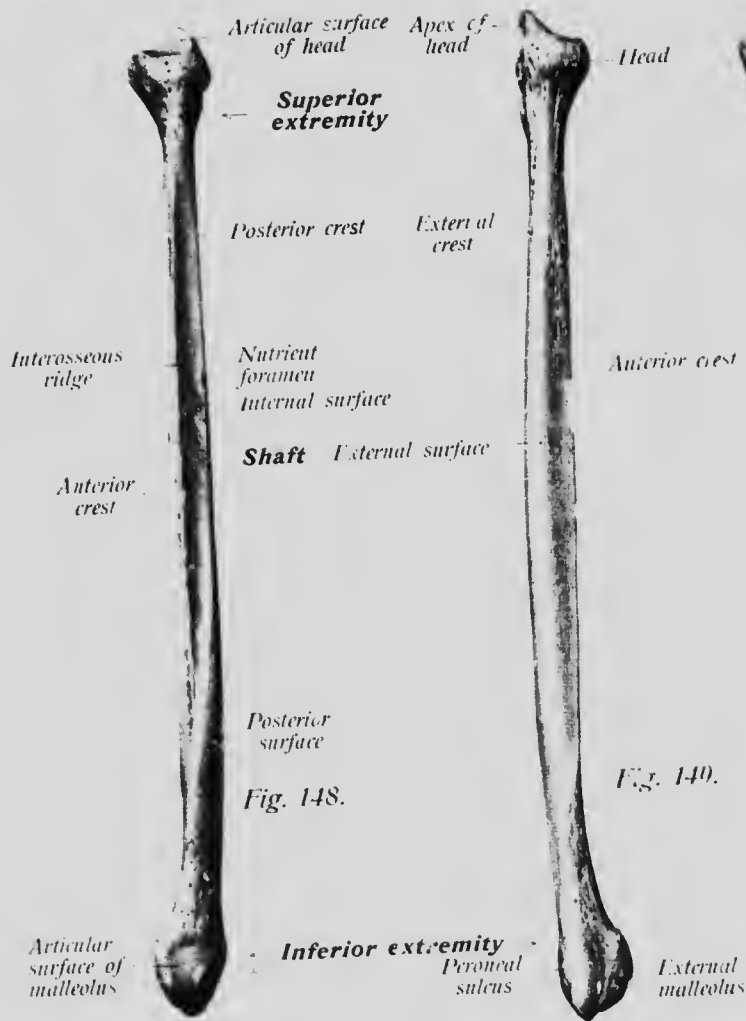


Fig. 151.

Fig. 152.

Faint, illegible text visible along the left edge of the page, likely bleed-through from the reverse side.

The diaphyseal center of the tibia appears in the seventh week of embryonic life, but usually several days later than that of the femur. The upper (proximal) epiphysis ossifies immediately before or after birth, the distal one not until the beginning of the second year. The lower epiphysis unites with the shaft in the eighteenth, the upper in the twenty-second year.

THE FIBULA.

The *fibula* (Figs. 148, 149, 151, and 152) is a slender bone, and although its upper extremity is situated lower than that of the tibia, it is but a trifle shorter than that bone, since it projects below it (Fig. 150). It is situated upon the outer side of the leg, and is composed of an *upper extremity*, a *shaft*, and a *lower extremity*. The superior extremity is formed by the *head* (Fig. 148), the inferior by the *external malleolus*. The *head* is distinctly thickened as compared with the slender shaft of the bone, and its uppermost portion, which is directed outward and somewhat backward, is known as the *apex*. It presents a small flat articular facet (Fig. 148) for articulation with the tibia.

The *shaft* of the fibula is of a distinctly triangular prismatic form, and its three surfaces are internal, external, and *posterior* (Fig. 147). The three borders are very sharp and do not pursue straight course on account of a distinct torsion of the lower end of the bone about its longitudinal axis; they are known as the *anterior*, *external*, and *internal crests*, the anterior crest separating the internal and external surfaces, the posterior crest the posterior and internal surfaces, and the external crest the posterior and external surfaces. The inner surface also presents a feebly developed border, the *interosseous ridge* (Fig. 148), so that the fibula may be said to possess four borders. The nutrient foramen is situated slightly above the middle of the posterior surface and at a lower level than that of the tibia; it leads into a canal which is directed downward.

The tibia and the fibula have, therefore, different relations than do the radius and the ulna, a surface of the fibula (internal surface) being directed toward a border of the tibia (the interosseous ridge), and the similarly named surfaces of the two bones do not lie in the same planes (Fig. 147).

The inferior extremity of the fibula is formed by the *external malleolus*, which is longer and more pointed than the internal one. Its inner aspect presents a flat articular surface (Figs. 148 and 152), which is immediately contiguous to the inferior articular surface of the tibia, and its external circumference is marked by a shallow groove for the tendons of the two peroneal muscles (Fig. 149). Alongside of the articular surface there is always a depression for the attachment of ligaments (Fig. 148, 3).

The diaphyseal center of the fibula appears somewhat later than that of the tibia (eighth week of fetal life), and the epiphyseal centers develop at a considerably later period, the inferior in the second and the superior in the third or fourth year. The inferior epiphysis unites with the shaft before the superior, as is the case in the tibia, but the union of the two occurs later than in the tibia.

THE BONES OF THE FOOT.

The skeleton of the foot (Figs. 153 to 155), like that of the hand, consists of three divisions, the *tarsus*, the *metatarsus*, and the *phalanges*.

FIG. 153.—A frozen preparation of the bones of the foot seen from the plantar surface ($\frac{2}{3}$).

FIG. 154.—The same preparation seen from the dorsal surface ($\frac{2}{3}$).

FIG. 155.—The same preparation seen from the outer side ($\frac{2}{3}$).

FIG. 156.—The right talus (astragalus) seen from below ($\frac{1}{2}$).

FIG. 157.—The right talus (astragalus) seen from above ($\frac{1}{2}$).

THE TARSAL BONES.

The *tarsus* (Figs. 153 to 155) consists of seven bones. (1) The *talus* or *astragalus*; (2) the *calcaneus*; (3) the *navicular* or *scaphoid* bone; (4) the *cuboid* bone; and (5 to 7) the *external*, *middle*, and *internal cuneiform* bones. Only in the distal portion of the tarsus, where the cuboid articulates with the three cuneiform bones, is there an indication of an arrangement in rows as in the carpus, and in further contrast to the hand, a single tarsal bone articulates with both bones of the leg, while the carpus articulates with the radius only.

THE TALUS.

The *talus* or *astragalus* (Figs. 156, 157) is a short bone, irregularly cuboid in shape, and is composed of a *body* and of a *head*, the constriction between the two being termed the *neck*.

The *body* is the thickest and most posterior portion of the bone. Its upper surface presents a cartilaginous trochlear surface, the *trochlea* (Fig. 157), with which the tibia and fibula articulate, and it possesses three surfaces, a large superior one and two smaller lateral ones. The *superior surface* is convex in the longitudinal (sagittal) axis of the bone and concave from side to side; it is broad anteriorly and narrow posteriorly. The lateral surfaces are almost flat and approximately triangular, the external one being much larger than the internal. The external surface is known as the *external malleolar surface*; it forms the outer side of the astragalus and is continued upon a strong process of the bone, the *external process* (Figs. 154 and 156), which is directed outward. The *internal surface* forms a part of the inner side of the astragalus, the remainder of which is rough, and is termed the *internal malleolar surface*. Behind the trochlea and directed backward is the *posterior process* (Fig. 157), which is notched by a broad groove for the tendon of the flexor hallucis longus.* The *lower surface* of the bone (Fig. 156) presents a distinctly concave, almost transverse, ovoid articular facet, the *posterior articular facet*, for the calcaneus, whose outer portion lies upon the lower surface of the external process, while its inner and posterior portion is upon the corresponding surface of the posterior process.

In front of this articular facet is situated a broad groove, the *sulcus tali* (Fig. 155), which is wider externally than internally and the floor of which is roughened. Together with the similar groove of the calcaneus it forms the *sinus of the tarsus*, which is filled by ligaments.

In the region of the *neck* the lower surface of the astragalus in front of the *sulcus tali* presents an oblong, slightly convex, articular facet, parallel to the posterior one, and known as the *middle articular facet* for the calcaneus, and bordering upon this, and forming a portion of the head of the talus, is a small, slightly convex elliptical *anterior articular facet* for the calcaneus (Fig. 156).

* There may consequently be distinguished upon the posterior process an *internal* and an *external tubercle*.

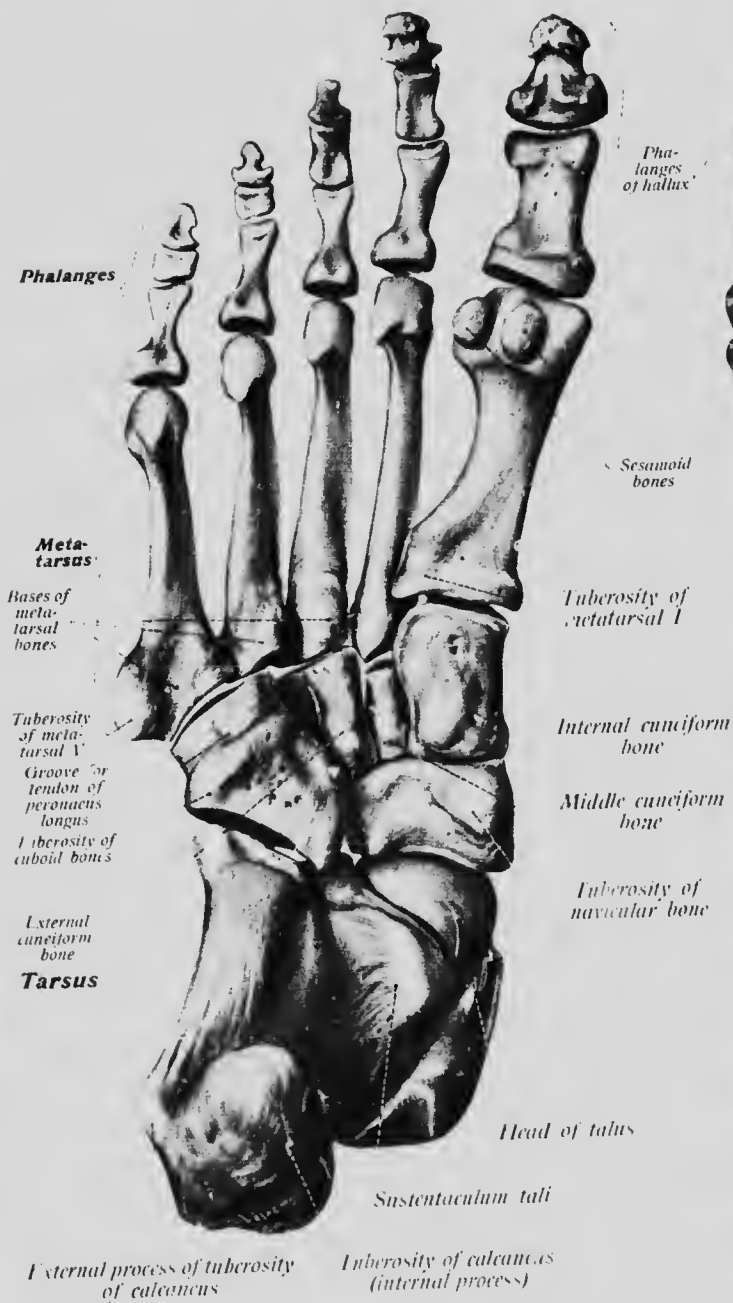

Fig. 153

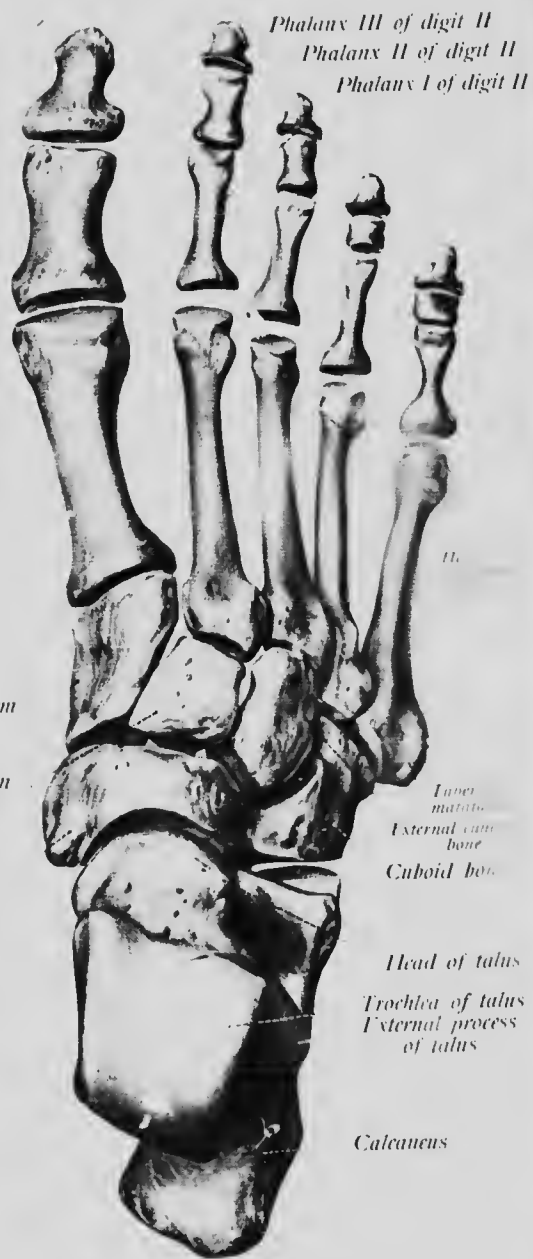

Fig. 154.

1870
1871
1872
1873
1874
1875
1876
1877
1878
1879
1880
1881
1882
1883
1884
1885
1886
1887
1888
1889
1890
1891
1892
1893
1894
1895
1896
1897
1898
1899
1900
1901
1902
1903
1904
1905
1906
1907
1908
1909
1910
1911
1912
1913
1914
1915
1916
1917
1918
1919
1920
1921
1922
1923
1924
1925
1926
1927
1928
1929
1930
1931
1932
1933
1934
1935
1936
1937
1938
1939
1940
1941
1942
1943
1944
1945
1946
1947
1948
1949
1950
1951
1952
1953
1954
1955
1956
1957
1958
1959
1960
1961
1962
1963
1964
1965
1966
1967
1968
1969
1970
1971
1972
1973
1974
1975
1976
1977
1978
1979
1980
1981
1982
1983
1984
1985
1986
1987
1988
1989
1990
1991
1992
1993
1994
1995
1996
1997
1998
1999
2000
2001
2002
2003
2004
2005
2006
2007
2008
2009
2010
2011
2012
2013
2014
2015
2016
2017
2018
2019
2020
2021
2022
2023
2024
2025

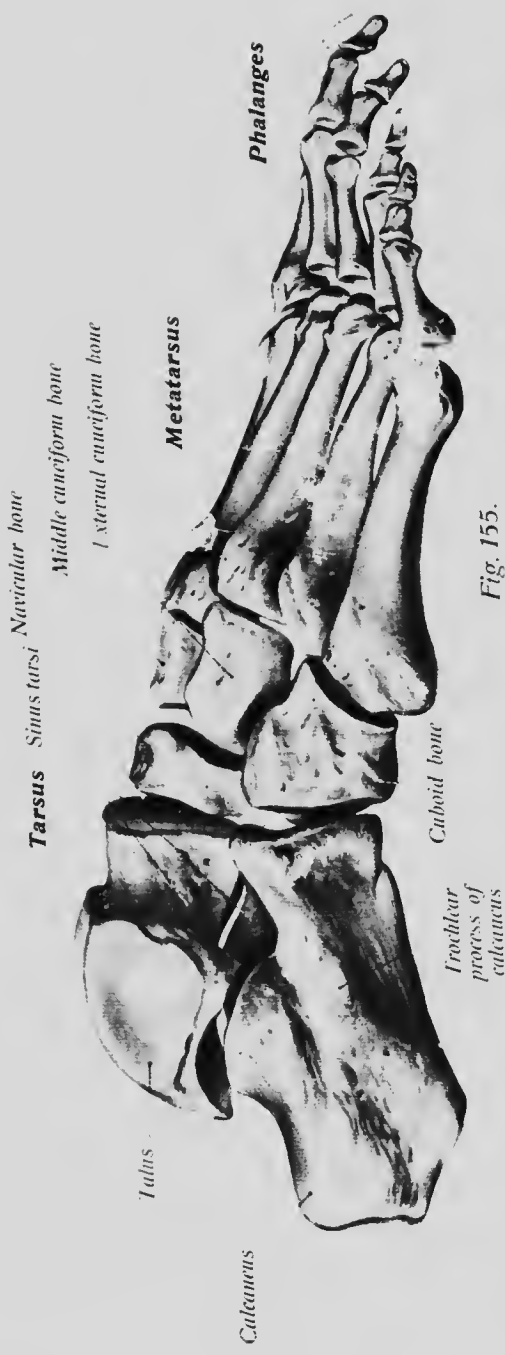

Fig. 155.



Fig. 150.

Fig. 157.



The neck is distinctly constricted only upon the upper and outer surface; upon the lower and inner aspect it is not sharply defined from either the head or the body of the bone.

The *head* of the talus (astragalus), the rounded anterior extremity of the bone, presents an ellipsoidal articular surface for articulation with the navicular bone.

The posterior process is sometimes an independent bone, and is then designated as the *os trigonum*. It represents what is usually an independent bone in the lower vertebrates.

THE CALCANEUS.

The *calcaneus* (Figs. 158 to 160) is the largest of the tarsal bones, and forms the postero-inferior portion of the tarsus. It articulates with the *talus* (*astragalus*) by means of three articular facets and with the cuboid bone, and has its longitudinal axis directed from behind forward and slightly from within outward.

The main portion of the bone is termed the *body*. The posterior thickened extremity is known as the *tuberosity* and projects posteriorly far beyond the remaining bones of the foot; its plantar surface presents two processes or tubercles, the *internal* and *external process* (Fig. 153), and in front of the tuberosity is flat and covered by the long plantar ligament (see page 141).

Upon the upper aspect of the calcaneus (Fig. 160) may be observed the three facets for articulation with the talus (astragalus); they are known as the *posterior*, *middle*, and *anterior articular facets*. The posterior is the largest and is markedly convex, the middle and anterior are slightly concave, and the anterior is the smallest. The middle facet lies upon the sustentaculum tali, and between the middle and posterior is a groove, the *sulcus calcanei*, which is wider externally than internally and, together with the sulcus tali, forms the *sinus of the tarsus*.

The markedly concave internal surface of the calcaneus (Fig. 158) presents a broad process, the *sustentaculum tali*, which projects toward the talus (astragalus) and bears the middle facet for articulation with that bone. Below it is a broad groove, the direct continuation of that upon the posterior process of the talus (astragalus), known as the *groove for the flexor hallucis longus*. A similar but shallower groove is situated upon the otherwise flat vertical external surface of the bone (Fig. 150), the *peroneal groove*, and above this there is usually a small blunt projection known as the *trochlear (peroneal) process*.

The anterior surface of the calcaneus presents a saddle-shaped facet, for articulation with the cuboid bone.

THE NAVICULAR BONE.

The *navicular* or *scaphoid* bone (Figs. 161 and 162) is situated at the inner side of the tarsus between the talus (astragalus) behind and the three cuneiform bones in front (Figs. 153 and 154). Its long axis is placed transversely to the axis of the foot, and it is convex anteriorly, markedly concave posteriorly, and distinctly convex upon its dorsal surface. Near the inner border of the plantar surface it presents a strong rounded *tuberosity*.

The concave posterior surface of the bone (Fig. 163) forms the socket for the head of the talus (astragalus); the slightly convex anterior surface (Fig. 162) exhibits three facets for the three cuneiform bones; and the external surface presents a small flat inconstant facet for the cuboid bone.

- FIG. 158.—The right calcaneus seen from the inner surface ($\frac{4}{5}$).
 FIG. 159.—The right calcaneus seen from the outer surface ($\frac{4}{5}$).
 FIG. 160.—The right calcaneus seen from above ($\frac{4}{5}$).
 FIG. 161.—The right navicular bone seen from behind ($\frac{1}{2}$).
 FIG. 162.—The right navicular bone seen from in front ($\frac{1}{2}$).
 FIG. 163.—The right cuboid bone from the inner surface ($\frac{1}{2}$).
 FIG. 164.—The right internal cuneiform bone seen from in front ($\frac{1}{2}$).
 FIG. 165.—The right middle cuneiform bone seen from behind ($\frac{1}{2}$).
 FIG. 166.—The right external cuneiform bone seen from behind ($\frac{1}{2}$).

THE CUBOID BONE.

The *cuboid* bone (Fig. 163) is situated on the outer side of the foot, in front of the anterior extremity of the calcaneus and behind the bases of the fourth and fifth metatarsal bones (Figs. 153 and 154). It is irregularly cuboid in form and its inner border is longer than the outer one. Its dorsal surface is convex, its anterior surface presents two articular facets for the bases of the fourth and fifth metatarsal bones, and its posterior surface is saddle-shaped and articulates with the calcaneus. The internal surface (Fig. 163) presents a flat articular facet for connection with the external cuneiform bone, and a small inconstant one for the navicular, and the external surface is narrow and forms a part of the outer border of the foot. The plantar surface presents a flattened tuberosity (Fig. 153), in front of which is situated a broad groove, the *peroneal groove*, which is lined with cartilage and accommodates the tendon of the peroneus longus muscle.

THE CUNEIFORM BONES.

The three cuneiform bones (Figs. 164 to 166) are situated between the navicular and the bases of the first three metatarsal bones, and, as their name indicates, are more or less wedge-shaped.

The **internal or first cuneiform bone** (Fig. 164) is by far the largest and also the longest of the three, and it has the narrow edge of its wedge directed dorsally, so that its plantar surface is much broader than the dorsal surface. Its internal surface is directly continuous with the narrow dorsal one; the anterior semilunar surface articulates with the base of the metatarsal bone of the great toe; the posterior triangular surface articulates with the navicular bone; and the external surface is in contact with the middle cuneiform and with the base of the second metatarsal bone, and exhibits articular facets for both.

The **middle or second cuneiform bone** (Fig. 165) is the smallest and the shortest of the three. The thin edge of its wedge is directed downward and is almost concealed between the external and the internal cuneiform bones; its base forms part of the dorsal surface of the foot, and its posterior surface presents a triangular articular facet for the navicular bone. The middle cuneiform also articulates with the second metatarsal, and with the external and internal cuneiform bones.

The **external or third cuneiform bone** (Fig. 166) is somewhat larger (especially in length) than the middle one. Its thin edge is likewise directed downward and its broadest surface looks

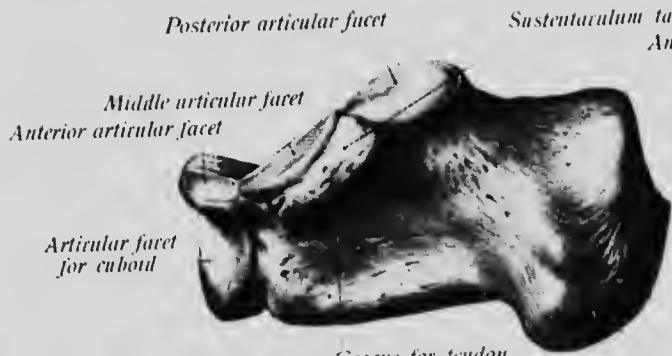

Fig. 158.

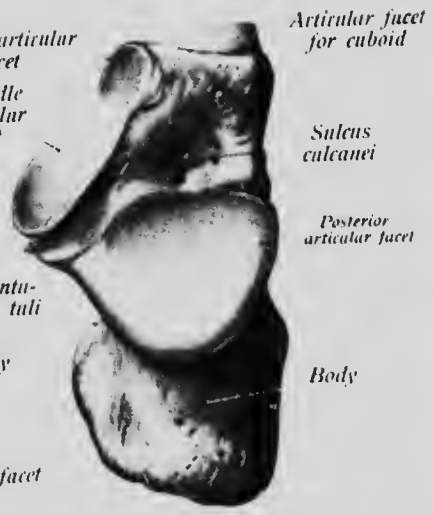

Fig. 160.

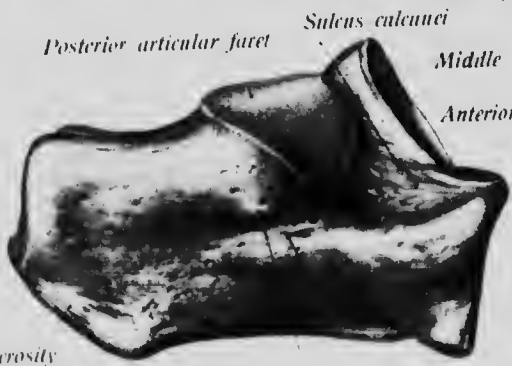


Fig. 150.



Fig. 161.




Fig. 162.

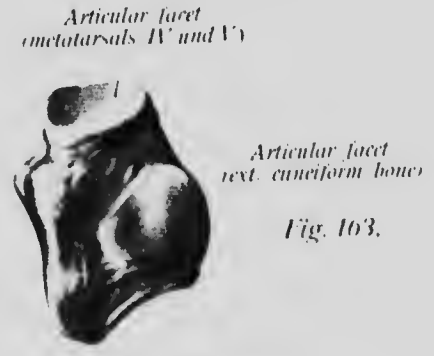

Fig. 163.

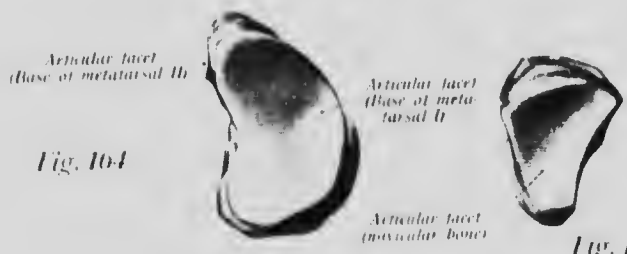

Fig. 164.

Fig. 165.





Fig. 166.



toward the dorsum of the foot. It articulates with the navicular, cuboid, and middle cuneiform, and with the second, third, and fourth metatarsal bones.

THE FIVE METATARSAL BONES.

The metatarsal bones (Figs. 153 to 155) are typical long bones, each consisting of a proximal extremity or *base*, of a *shaft*, and of a distal extremity or *head*. They articulate with the cuboid and cuneiform bones behind and with the phalanges in front, and the bases of the second to the fifth metatarsal bones also articulate with each other.

The first metatarsal bone is short and very thick; the second is the longest. The *base* of the first possesses a broad plantar projection, the *tuberosity of the first metatarsal*, which is directed outward, and that of the fifth presents a similar process, the *tuberosity of the fifth metatarsal*, which extends some distance beyond the outer border of the foot.

The bases of the metatarsal bones exhibit the following articular facets: the base of the first presents a single facet for the internal cuneiform bone; that of the second a proximal facet for the middle cuneiform, an inner facet for the internal cuneiform, and two lateral facets for the third metatarsal and the external cuneiform; that of the third an internal (frequently a double) facet for the second metatarsal, a proximal one for the external cuneiform, and an external one for the fourth metatarsal bone; the base of the fourth has a proximal facet for the cuboid, two internal facets for the third metatarsal and the external cuneiform, and an external one for the fifth metatarsal bone; and the base of the fifth metatarsal bone presents a proximal facet for the cuboid and an internal facet for the fourth metatarsal bone.

The *shafts* of the metatarsal bones, particularly those of the second to the fifth, become more slender toward their heads and exhibit a curvature, the convexity of which is directed toward the dorsum of the foot. In contrast to their quadrangular bases, they are of triangular prismatic form.

The *heads* of the second to the fifth metatarsal bones are smaller than the bases and are compressed from side to side. They present extensive articular surfaces, convex in the sagittal direction, which extend far upon the plantar surface of the head and serve for articulation with the bases of the proximal phalanges. On the lateral surfaces of the heads are depressions for the attachment of ligaments, and the plantar surface of the strong head of the first metatarsal bone presents two concave articular facets, separated by a ridge, for the two constant sesamoid bones of the great toe.

THE BONES OF THE TOES, PHALANGES.

The four lesser toes each have three phalanges, but the great toe, like the thumb, has but two (Figs. 153 to 155). The phalanges of the great toe are considerably thicker than those of the remaining four toes, and also thicker than those of the thumb, while the phalanges of the four lesser toes are considerably shorter and more slender than those of the fingers.

In other respects the phalanges of the toes are almost exactly like those of the fingers, with the exception of irregularities of development which are most noticeable in the distal phalanges of the two outer toes and are largely to be attributed to the effects of disuse. The middle phalanges of these two toes are strikingly short, usually even shorter than the terminal phalanges; and in all the toes it is only the proximal phalanges that can be said to be well developed.

As in the hand, each phalanx presents a *base* and a *trochlea*, and the distal ends of the third phalanges terminate in an *ungual tuberosity*.

THE SESAMOID BONES OF THE FOOT.

Two sesamoid bones, remarkable on account of their size, are constantly found at the metatarsophalangeal joint of the great toe (Fig. 153). Inconstant sesamoids are also found in the tendon of the peroneus longus muscle, at the interphalangeal joint of the great toe, and less frequently in the tendon of the tibialis posterior muscle.

THE SKELETON OF THE FOOT AS A WHOLE.

The skeleton of the foot (Figs. 153 and 155) differs from that of the hand not only in the number and form of the component elements of the tarsus, but also in certain peculiarities, chiefly due to the functional adaptation of the foot as a support for the erect body. While the axis of the hand is situated in the direct continuation of that of the arm and forearm, the axis of the foot is placed at almost a right angle to that of the lower extremity, and while in the hand the phalanges take up about one-half of the length of the skeleton, in the foot the tarsus alone occupies the proximal half and the metatarsus and phalanges together form the anterior half. The phalanges make up only a fifth of the entire length of the foot.

The foot shows a much more pronounced curvature than do the relatively flat and closely approximated bones of the hand, and this curvature is practically a constant one. The convexity is directed toward the dorsal, the concavity toward the plantar surface, and the deepest point of the concavity is situated at the apex of the middle cuneiform bone, the dorsal surface of the same bone likewise forming the highest point of the middle portion of the arch.

The arch of the foot is supported posteriorly by the tuberosity of the calcaneus and anteriorly by the heads of the metatarsal bones. The tarsal arch is formed exclusively by the tarsus and metatarsus and is open internally, since the inner border of the foot is much higher than the outer one, which is in contact with the ground throughout its entire length. The sinus of the tarsus (see page 102) is a striking formation which gradually becomes narrower as it passes inward and backward from the outer side of the dorsal surface. The tarsus is much narrower posteriorly than anteriorly.

The phalanges of the second to the fifth toe do not lie in one plane even during extension, but are strongly curved with the convexity upward and seem to be bent upon the heads of the metatarsal bones like claws, so that only their tips touch the ground.

The second toe is the longest and marks the longitudinal axis of the foot.

Usually the only tarsal bones possessing centers at birth are the calcaneus (sixth month) and the talus (astragalus) (seventh month); the center for the cuboid appears at about the time of birth. The external cuneiform is the first of three cuneiform bones to ossify (first year), the internal is the next (third year), and the middle one is the last, its ossification and that of the navicular bone occurring respectively in the fourth and the fourth to the fifth year. The calcaneus alone has a disc-like epiphyseal center upon its posterior surface, corresponding to the tuberosity, this appears in the tenth year and fuses with the rest of the bone at from the fifteenth to the sixteenth year.

The metatarsal bones ossify much earlier than do the tarsal bones and ossification proceeds in a manner quite similar to that of the metacarpal bones. The diaphyseal nuclei appear in the eighth to the ninth fetal week and the epiphyseal centers also are like those of the metacarpal bones, appearing in the third to the fourth year and not uniting with the diaphyseal center until after puberty.

The ossification of the phalanges of the foot also corresponds exactly to that of the phalanges of the hand. The diaphyseal centers appear in the third fetal month, the epiphyseal centers in the third to the fourth year, and the union of the epiphyses with the diaphyses, as in the metatarsal bones, occurs after puberty.

at the
and in
and less

in the
chiefly
axis of
the foot
changes
proxi-
changes

closely
convexity
point
of the

eriorly
as and
the outer
tarsus
inward
eriorly

ension,
of the

ragalus)
the first of
last, its
The cal-
appears

er quite
and the
uniting

l The
ne union

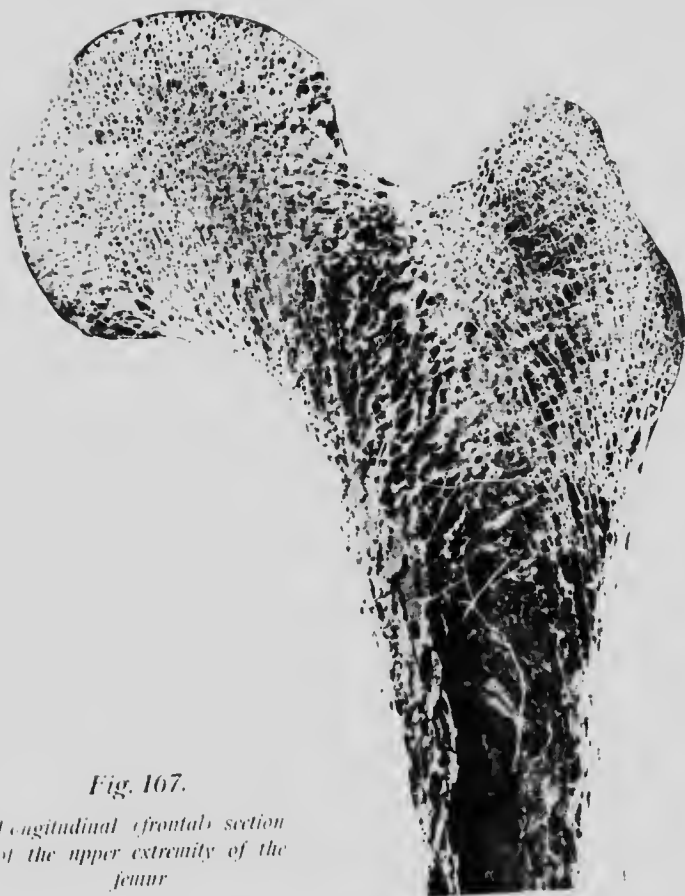

Fig. 167.
Longitudinal (frontal) section
of the upper extremity of the
femur



Longitudinal (sagittal)
section of the calcaneus

Fig. 168.



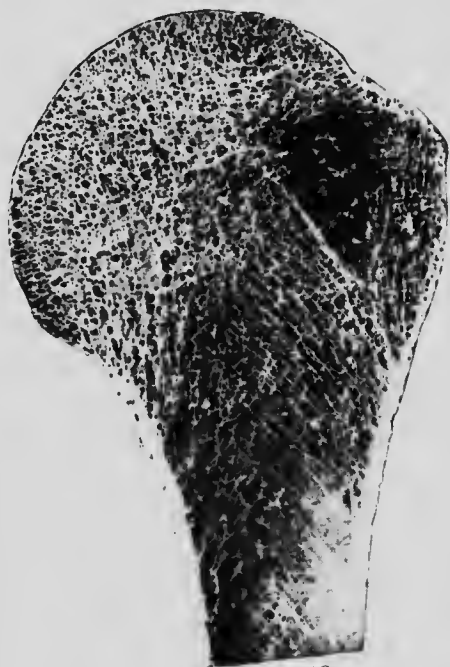

Fig. 169.

Longitudinal (frontal) section of the upper extremity of humerus.

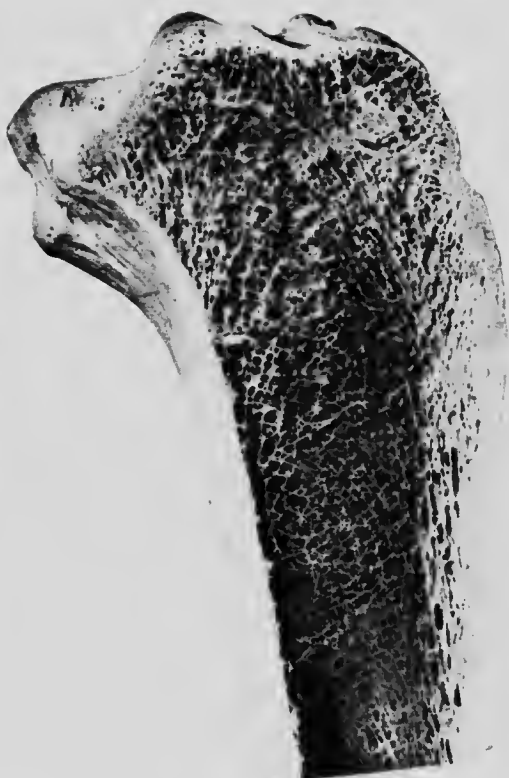

Fig. 170.

Longitudinal (sagittal) section of the upper extremity of tibia.



Fig. 171.

Sagittal section of lumbar vertebra.



SYNDESMOLOGY.

GENERAL SYNDESMOLOGY.

The bones of the body are connected with each other in one of two ways. Two neighboring bones may be connected simply by intervening ligamentous, cartilaginous, or any other form of connective tissue, this form of connection between two parts of the skeleton being called a *synarthrosis*, or the cartilaginous articular surfaces of two neighboring bones may be so approximated that the two opposed surfaces conform to each other and are separated by a space. Such a mode of connection is a *diarthrosis* or a *joint*, and is by far the more perfect mode of connection, allowing of a much more extensive range of motion between the bones.

SYNARTHROSES.

The synarthroses are classified, according to the character of the tissue connecting the ends of the bones, into *syndesmoses*, *synchondroses*, and *symphyses* (mixed synarthroses). In the syndesmoses the intervening substance is fibrous connective tissue (usually formed connective tissue, see the Sobotta-Huber Atlas and Epitome of Histology), in the synchondroses it is cartilage, and in the mixed synarthroses, cartilage and fibrous connective tissue.

Synchondroses are rare in the adult body, but are found in those situations in the undeveloped skeleton which subsequently become ossified, such as the connections between the epiphyses and diaphyses of the long bones (see page 21). An example is furnished by the attachment of the first rib to the manubrium of the sternum.

The *syndesmoses* are subdivided into two groups, *true syndesmoses* and *sutures* (see pages 79 and 80). The true syndesmoses are those in which interosseous ligaments, which may be elastic, actually connect the bones to each other, and, like the joints, they are frequently strengthened by accessory ligaments. The lower end of the fibula is firmly connected with the tibia by such a syndesmosis. In the sutures of the skull, however, the soft syndesmotic mass does not connect the bones, which are united by the sutures themselves, but rather separates them. A peculiar characteristic of the suture is the interlocking of the contiguous bony margins by means of serrated projections in the *serrate sutures*, but if one bony margin overlaps the other, like two shingles on a roof, it is spoken of as a *squamous suture*. Another subdivision of the suture is the relatively infrequent *harmonic suture*, which is the simple firm apposition of two contiguous bones, and the fixation of the teeth in the alveoli of the jaws may also be designated a variety of syndesmosis, the *gomphosis*, the syndesmotic mass in this instance being furnished by a thin layer of periosteum (see page 68).

In the mixed synarthroses or *symphyses* the tissue connecting the ends of the bones is fibrocartilage. Typical examples are furnished by the connections of the bodies of the vertebrae

by the *intervertebral fibrocartilages*, and by the connection of the two pubic bones by the *interpubic fibrocartilage*.

We occasionally find a combination of a synarthrosis (particularly the syndesmosis) with a joint, as in the connection of the sacrum with the innominate bone, or articular spaces may appear within the symphyses, and such arrangements are termed half-joints (*amphiarthroses*).

DIARTHROSES.

The *diarthroses* or *true joints* are characterized by congruent cartilaginous surfaces which are separated from each other by a capillary space, and are provided with a number of structures, the majority of which are absent in the synarthroses. These are the *articular capsules*, the accessory *ligaments*, and the *articular cartilages*. They may also be provided with special structures, such as the interarticular cartilages or *menisci*, diverticula of the synovial membrane forming *synovial bursæ*, *glenoidal lips*, joint cushions (designated by different names in the different joints), and bony locking mechanisms.

The *articular capsule* usually surrounds the cartilaginous articular surfaces of the contiguous bones so as to form a completely closed articular cavity. It consists of an external firm fibrous layer, the *fibrous layer*, and of an internal softer vascular layer, the *synovial layer* or *membrane*. The latter gives off microscopic thread-like vascular processes of irregular shape, the *synovial villi*, and occasionally it forms large structures visible to the naked eye, the *synovial folds*.

The articular cavity, usually a capillary space, is filled with a viscid fluid, the *synovia*.

The articular capsule varies in thickness; it is sometimes strengthened by accessory ligaments and sometimes interrupted, so that diverticula of the synovial membrane protrude through its openings and form synovial bursæ (see also page 143), whose cavities are consequently directly continuous with that of the articulation (communicating synovial bursæ).

Accessory ligaments form important components of the articulations, and according to function the ligaments of the body can be subdivided into the following classes: (1) *Ligaments of fixation*; *i. e.*, those ligaments which firmly unite two bones, as in the syndesmoses. (2) *Reinforcing ligaments* of the joint capsule; these are more or less adherent to the capsule itself, but sometimes appear as independent structures. (3) *Check ligaments*, *i. e.*, ligaments which are capable of limiting certain movements of the joint. (4) *Ligaments of conduction*, *i. e.*, ligaments whose function is to conduct vessels and nerves to a part of a bone. (5) Ligaments which take the place of bone. These last are found in those situations where neither fixation, nor inhibition, nor any other of the usual functions of a ligament is required; they extend between portions of the same bone or convert a notch into a foramen.

The interarticular cartilages or articular discs (termed *menisci* when of a purely fibrous character) serve to adapt mutually articular surfaces which are not completely congruent. They are attached to the inner surface of the joint capsule and extend for a varying distance between the cartilaginous ends of the bones. In the most extreme cases they divide the articular cavity into two portions, so that the articular extremity of one bone is in relation to one side of the articular disc and that of the other bone to the other side. In such a joint the articular extremities of the two bones are not in immediate contact with each other, and it is consequently possible to distinguish *unilocular* and *bilocular joints*.

In other cases the discs or menisci are perforated in the middle or they are semicircular in shape, so that the cartilaginous extremities of the bone are in contact only in the middle of the articulation. The menisci frequently serve the purpose of deepening the socket or they may act as joint cushions.

The articular margins or *glenoidal lips* are usually circular connective tissue or fibrocartilaginous structures which are situated upon the margins of the bony socket for the purpose of increasing its size.

The joint cushions, usually consisting of fatty tissue, fill out the space in many of the joints, and are for the purpose of breaking the jar of the movements of the ends of the bone.

Bony locking mechanisms limit the movement of a portion of the skeleton, the movable part striking against a bony projection.

A joint is usually composed of only two bones, in which case it is termed a *simple joint*. Sometimes, however, three or more bones concur into the formation of a joint or portions of the socket are formed of connective-tissue components (ligaments, etc.), in which case the joint is termed a *compound joint*.

The joints of the human body are classified according to the shape of their articular surfaces. These subdivisions are as follows: (1) Uniaxial joints; (2) biaxial joints; (3) polyaxial joints.

The uniaxial joints are composed of two varieties, those with a transverse axis and those with a longitudinal axis; *i. e.*, the axis of motion in the first variety is at right angles to the axis of the moving bone and in the second variety the two axes are coincident.

1. UNIAXIAL JOINTS.

(a) **With a Transverse Axis.**—The *hinge joint* or *ginglymus* belongs in this class. These joints are broad and the articular surfaces are usually not quite cylindrical, the convex surface exhibiting a median excavation and the concave socket a corresponding elevation. This conformation together with strong lateral ligaments prevents the lateral displacement of the bones, so that the axis of motion coincides with the axis of the cylindroid and is consequently horizontal. The motions permitted by a ginglymoid joint are designated as flexion and extension, and in complete extension the bones form an angle of 180 degrees. Types of the ginglymus or hinge joint are furnished by the interphalangeal joints of the fingers and toes.

The *spiral* or *cochlear joint* forms a subvariety of the hinge joint. The excavation in the cylindroid and the elevation in the socket form a portion of a spiral, and as a result of this formation, flexion is accompanied by a certain amount of lateral deviation. Examples are furnished by the ankle-joint and by a portion of the elbow joint.

(b) **With a Longitudinal Axis.**—The only joint of this character is the *pivot* or *trochoid joint*, also termed a *lateral ginglymus*. The articulating surfaces are horizontal sections of a cylinder or cone and the solid cylinder rotates upon its axis in a hollow cylindrical socket. The superior radio-ulnar articulation and the median articulation of the atlas and axis are typical examples of this form of joint.

2. BIAXIAL JOINTS.

This class of joints includes the *ellipsoidal* or *condyloid* joint and the *saddle joint*.

In the *ellipsoidal joint* the convex surface of an ellipsoid of rotation articulates with a corresponding concavity, and the two axes of motion, the lesser and the greater axis, are placed at right angles to one another, but both pass through the same bone. An example is found in the atlanto-occipital articulation.

The *saddle joint* is formed by the approximation of two saddle-shaped surfaces, *i. e.*, surfaces which are concave in one direction and convex in the other. Each surface alternately forms a head and a socket, and the two axes are at right angles to one another but are situated in different bones. The most typical saddle joint of the human body is the carpometacarpal articulation of the thumb.

In reality the motions in the ellipsoidal and saddle joints are not strictly biaxial, but may occur in any intervening axis between the two, and one of the two motions is frequently so limited that the joint practically becomes a ginglymus.

3. POLYAXIAL JOINTS.

The only polyaxial joints are those with spherical surfaces, the *spheroid joints*. These are subdivided into two varieties, the *gliding joints* or *arthrodia* and the *ball-and-socket joint* or *enarthrosis*.

In the *arthrodia* a spherical head moves in a spherical socket, but the articulating surfaces are segments of very large spheres, and may seem in some cases to be almost planes. Comparatively little motion can take place between the surfaces, and what does occur is more or less of a gliding character. Good examples of arthrodia are to be seen between the articulating processes of the vertebrae.

In the *enarthroses* the articulating surfaces are more extensive segments of smaller spheres and the capsular ligaments are roony and relaxed, so that a considerable range of motion is possible between the two bones. Typical examples of these ball-and-socket joints are to be found in the shoulder-joint and hip-joint.

SPECIAL SYNDESMOLOGY.

JOINTS AND LIGAMENTS OF THE VERTEBRAL COLUMN.

THE CONNECTIONS OF THE VERTEBRAL BODIES.

The bodies of the true vertebrae are connected by *intervertebral fibrocartilages* (Figs. 172 to 175), each of which (Fig. 174) consists of an external firm *fibrous ring* composed of concentric and interwoven bundles of connective tissue, and of a central gelatinous or *pulpy nucleus*, the latter being firmly compressed within the fibrous ring and between the adjacent vertebral surface, so that it rises above the level of a horizontal section of the disc. Among other substances it contains true cartilage and the remains of the chorda dorsalis, an embryonic structure which indicates the future position of the vertebral column and is composed of a substance resembling

cartilage. The intervertebral fibrocartilages are attached to the upper and lower surfaces of the contiguous vertebrae, which are covered with a thin layer of cartilage.

The area of the intervertebral fibrocartilages is somewhat greater than that of the vertebral surfaces between which they are situated, and they are thickest in the middle, where they rest against the slightly concave surfaces of the vertebrae. There is no fibrocartilage between the atlas and the axis; the first one is situated between the second and third cervical vertebrae and the last one between the fifth lumbar vertebra and the sacrum. There are consequently twenty-three intervertebral fibrocartilages. Like the bodies of the vertebrae, they increase both in circumference and in height from above downward; the smallest and thinnest are situated between the cervical vertebrae, the largest and thickest between the lumbar vertebrae. The lowermost discs are much thicker (about one-third) in front than behind, a condition which is particularly noticeable in the last one, which is situated at the promontory.

THE INTERVERTEBRAL ARTICULATIONS.

In addition to the mixed synarthrotic connection between the vertebral bodies, the true vertebrae also articulate with each other by means of the *intervertebral articulations*. The two superior articular processes of a vertebra articulate with the two inferior articular processes of the overlying bone (see page 23), and the cartilaginous surfaces of each joint are enclosed by an articular capsule, which is relaxed in the cervical and tense in the lower vertebral region. There are no accessory ligaments. The joints are really arthrodia, and the synarthrotic connections of the bodies and the ligaments of the arches limit their range of motion to a considerable extent.

THE LIGAMENTS OF THE VERTEBRAL COLUMN.

The ligaments of the vertebral column are composed of two groups: those which run throughout the entire length of the vertebral column; and those which regularly recur between the contiguous vertebrae. The first group consists of the *longitudinal ligaments*, of which there is an anterior and a posterior one. The *anterior longitudinal ligament* is attached to the anterior surfaces of the vertebral bodies and of the intervertebral fibrocartilages; the *posterior* one (partly) invests their posterior surfaces.

The *anterior longitudinal ligament* (Figs. 172, 180, and 185) commences at the pharyngeal tubercle upon the base of the skull as a narrow band which becomes much wider as it descends, and it terminates upon the anterior surface of the sacrum. It is intimately united to the intervertebral fibrocartilages, but is only loosely connected with the middle concave portions of the vertebral bodies. The ligament gradually disappears laterally by becoming continuous with the periosteum of the bodies of the vertebrae, and is composed of long superficial fibers and of short deep ones which pass from one vertebra to another.

The *posterior longitudinal ligament* (Figs. 173 and 177) extends along the posterior surface of the vertebral bodies as the anterior ligament does along their anterior surfaces, but it is considerably narrower than the anterior ligament. It begins as an independent ligament at the second cervical vertebra, but it is continued upward to the cranial cavity as the *tectorial membrane* (see page 115). It becomes narrower as it descends and terminates in the sacral canal. It is likewise composed of a superficial and of a deep layer.

- FIG. 172.—The anterior longitudinal ligament in the lower thoracic portion of the vertebral column, together with the costo-vertebral ligaments seen from in front ($\frac{3}{4}$).
- FIG. 173.—The posterior longitudinal ligament in the lower thoracic and upper lumbar portions of the vertebral column. The vertebral arches have been removed ($\frac{3}{4}$).
- FIG. 174.—Horizontal section through an intervertebral fibrocartilage (somewhat enlarged).
- FIG. 175.—Two thoracic vertebrae divided longitudinally in the median line and showing the ligamenta flava.
- FIG. 176.—The ligamenta flava of the thoracic vertebral arches seen from in front, the arches having been separated from the bodies. The left ribs have been disarticulated and removed; the right ones are retained in their natural position ($\frac{3}{4}$).
- FIG. 177.—The posterior longitudinal ligament and intervertebral fibrocartilages of the lumbar vertebrae, the vertebral arches having been removed ($\frac{3}{4}$).
- FIG. 178.—A longitudinal section taken at about 45 degrees to the median plane through four thoracic vertebrae to show the costo-vertebral articulations ($\frac{3}{4}$).
- FIG. 179.—The ligaments of the middle and lower thoracic vertebrae and their ribs, seen from behind ($\frac{3}{4}$).
- FIG. 180.—The ligaments of the middle and lower thoracic vertebrae and their ribs seen from the left side. The uppermost rib has been disarticulated and removed ($\frac{3}{4}$).

It widens opposite each intervertebral fibrocartilage, to which it is firmly united, but it is but loosely connected to the bodies of the vertebrae, being separated from them by venous plexuses.

In addition to the longitudinal ligaments, this group also contains a portion of the *supraspinous ligament*. It will be described subsequently, however, together with the interspinous ligaments with which it is intimately connected.

The short ligaments of the vertebral column, connecting contiguous vertebrae, are subdivided into those connecting the arches and those connecting the processes.

The ligaments between the vertebral arches, the *ligamenta flava* (Figs. 175 and 176), are strong and are composed almost entirely of elastic tissue, to which they owe their pronounced yellow color and hence their name. They extend anteriorly as far as the posterior margins of the articular capsules of the intervertebral articulations and consequently close the vertebral canal except at the situation of the intervertebral foramina. With the exception of a distinct groove in the median line, their internal surface is absolutely smooth and is directly continuous with the inner surfaces of the vertebral arches. By their elasticity they keep the posterior wall of the vertebral canal smooth during flexion of the vertebral column and they also support the backward movement of the vertebral column during extension. They commence between the second and third cervical vertebrae (sometimes between the first and second) and extend to the last lumbar vertebra, and are strongest below and weakest above.

The *intertransverse ligaments* (Figs. 179 and 180) are unimportant and inconstant ligaments connecting the transverse processes of the vertebrae; they are particularly developed in the thoracic and lumbar regions.

The *interspinous ligaments* (Fig. 175) connect the spinous processes of contiguous vertebrae and attain their greatest development in the lumbar region. They are continuous anteriorly with the ligamenta flava and posteriorly with the *supraspinous ligament* (Fig. 179) which connects the apices of the spinous processes and forms an independent ligament. The interspinous

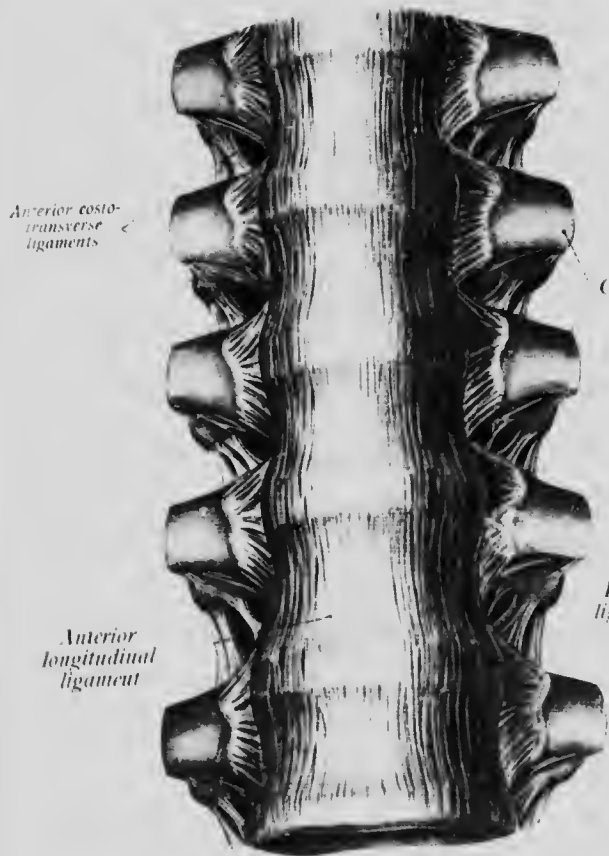


Fig. 172.

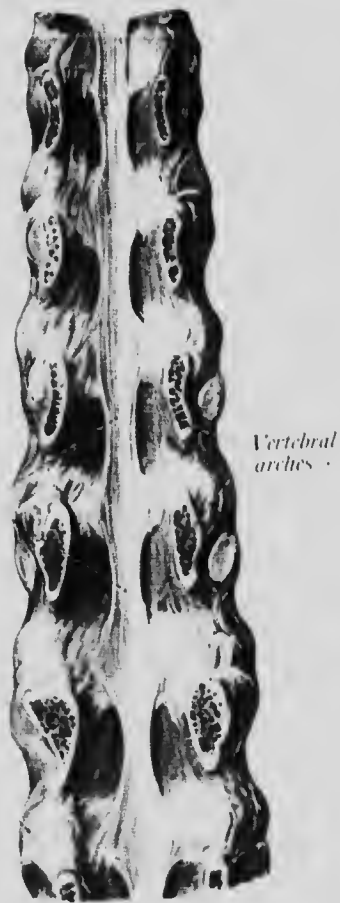

Fig. 173.




Fig. 174.

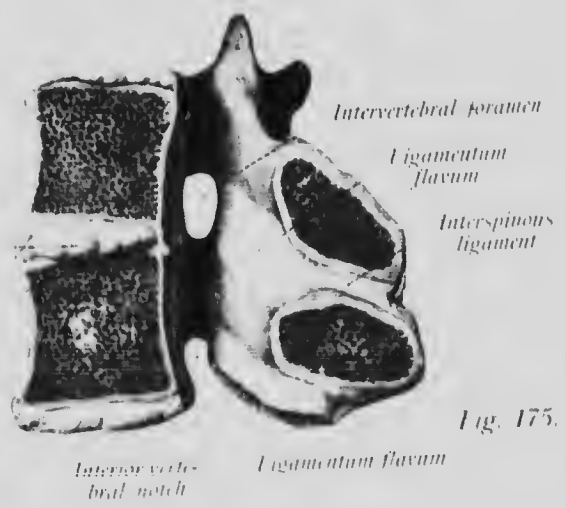


Fig. 175.



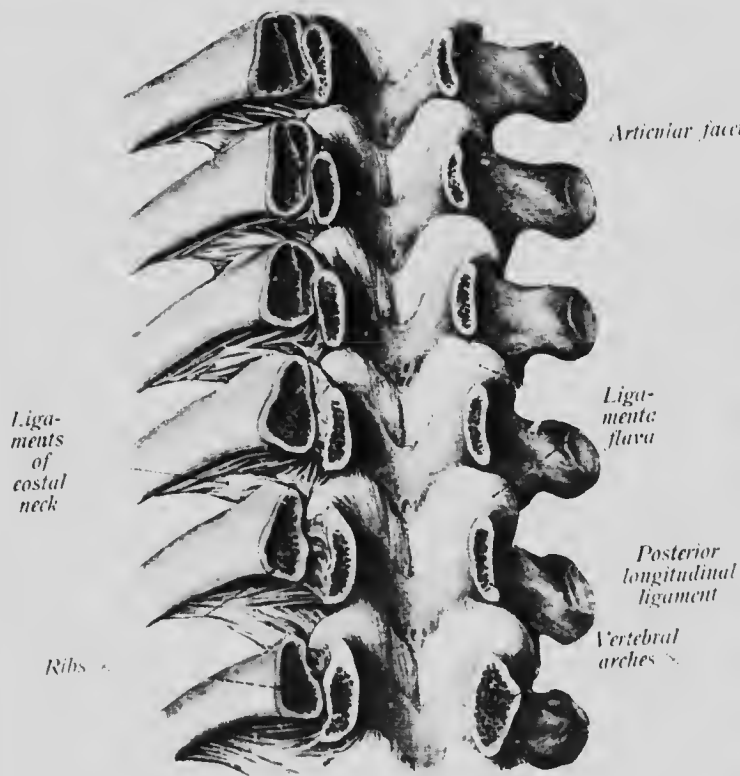
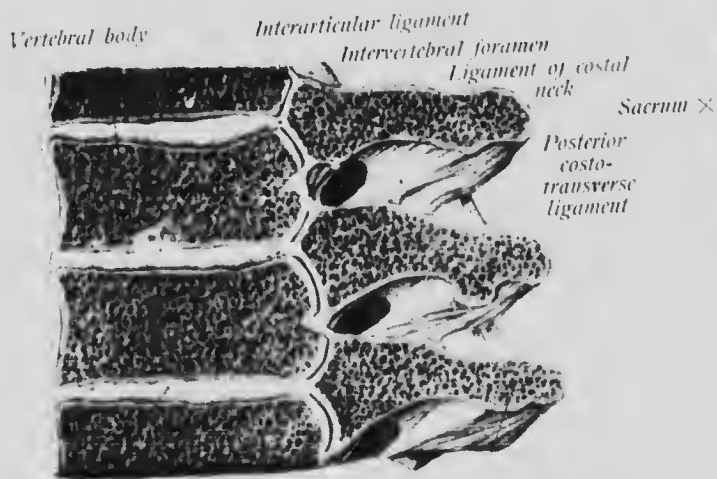


Fig. 176.

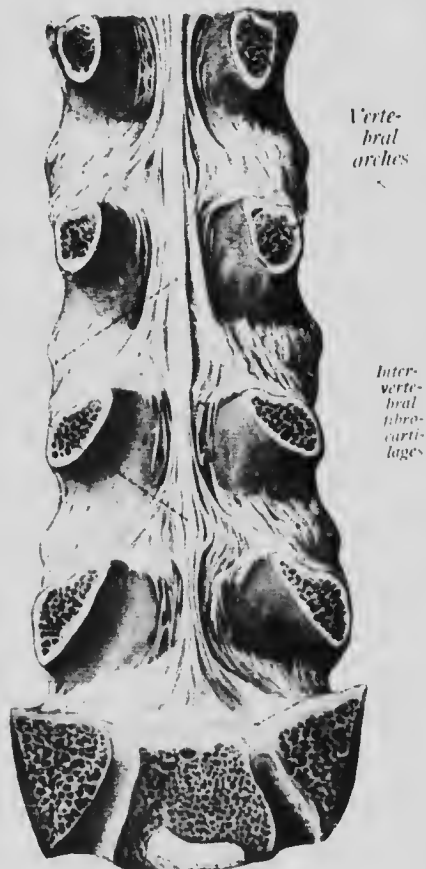

Fig. 177.



Intervertebral fibrocartilage

Head of rib

Tubercle of rib

Fig. 178.



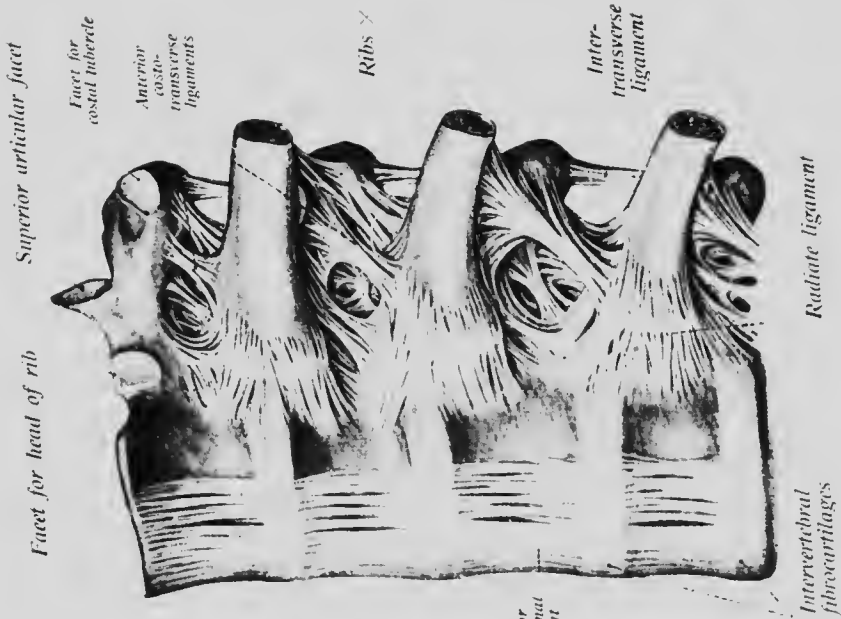


Fig. 180.

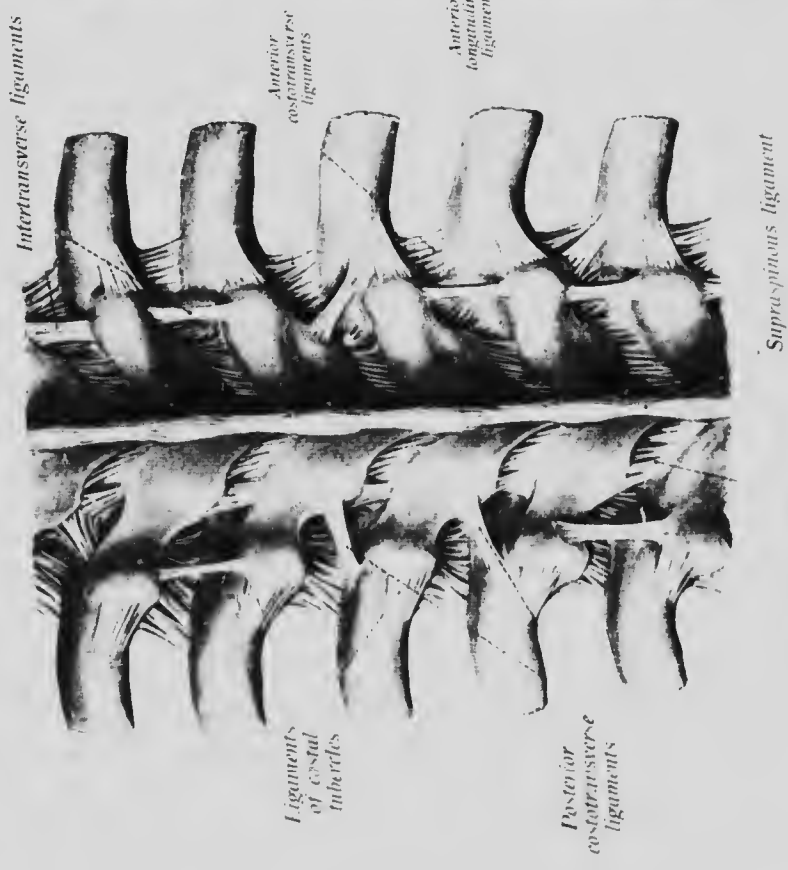


Fig. 170.



and supraspinous ligaments are found throughout the entire extent of the true vertebræ. In the cervical vertebræ they form the *ligamentum nuchæ* (Fig. 239), which is rich in elastic fibers, although relatively poorly developed in the human subject. It commences at the spinous process of the seventh cervical vertebra (vertebra prominens) and is inserted into the external occipital crest and the external occipital protuberance. It consists of a posterior vertical band which is stretched between the previously mentioned terminals and which receives oblique additions from the tips of the spinous processes of the remaining cervical vertebræ.

THE ARTICULATION OF THE SACRUM AND COCCYX.

The apex of the sacrum and the first coccygeal vertebra are connected by the *sacrococcygeal symphysis* and by a number of relatively unimportant ligaments. Upon the anterior surface of the two bones is situated the *anterior sacrococcygeal ligament* (Fig. 210), to either side are the *lateral sacrococcygeal ligaments* (Fig. 210), passing to the transverse process of the first coccygeal vertebra and thereby forming a fifth sacral foramen, and posteriorly there are the *posterior sacrococcygeal ligaments*, which are two in number, a superficial and a deep one. The *superficial posterior sacrococcygeal ligament* (Figs. 206 and 207) connects the sacral and coccygeal cornua, and closes in the greater portion of the sacral hiatus; the *deep posterior sacrococcygeal ligament* (Fig. 206) extends between the posterior surfaces of the bodies of the first coccygeal and last sacral vertebra and represents the lowermost extremity of the posterior longitudinal ligament.

The movements of the vertebral column are dependent upon the positions of the articular processes, and they are much freer in the cervical and lumbar regions than in the thoracic. Flexion and extension are most pronounced in the lumbar region, lateral curvature in the thoracic region, and while the range of motion between any two vertebræ is slight, the full range of motion of the entire vertebral column is considerable, since it represents the sum total of the motions of its individual segments.

THE ARTICULATION OF THE UPPER TWO CERVICAL VERTEBRÆ WITH EACH OTHER AND WITH THE OCCIPUT.

The Atlanto-occipital and the Atlanto-axial Articulations.—The movements of the head upon the vertebral column are made possible by a combination of joints which includes both atlanto-occipital articulations and the atlanto-axial articulation. The *atlanto-occipital articulations* function as bilaterally symmetrical joints, each of which is formed by an occipital condyle and a superior articular facet of the atlas, and from the shape of the articular surfaces is classified as an ellipsoidal joint. The capsule is rather roomy and relaxed and the joint possesses no individual accessory ligaments.

The *atlanto-axial (atlanto-epistropheic) articulation* is much more important and complicated and consists of three separate articulations. These are the two articulations between the inferior articular surface of the atlas and the superior articular surface of the axis (epistropheus) and the articulation between the anterior surface of the odontoid process and the posterior surface of the arch of the atlas. All three joints work together, their surfaces together forming an articular surface resembling a cone. The axis of rotation of the joint is vertical and corresponds to the long axis of the odontoid process.

The articulation between the odontoid process and the anterior arch of the atlas is a pivot

FIG. 181.—A frontal longitudinal section of the sternum and costal cartilages ($\frac{3}{4}$).

FIG. 182.—A portion of the occipital bone together with the atlas and axis (epistropheus) and their ligaments seen from behind. On the left side the capsule of the atlanto-axial articulation has been removed ($\frac{9}{16}$).

FIG. 183.—A portion of the occipital bone together with the upper three cervical vertebrae seen from in front. The capsular ligaments have been removed on the right side ($\frac{9}{16}$).

(trochoid) joint with incomplete articular surfaces, since the odontoid process is frequently covered with cartilage upon its anterior surface only, its posterior surface articulating with the transverse ligament of the atlas by a separate joint. Both joints have separate capsules; the posterior one is also regarded as a synovial bursa.

The paired lateral articulations are peculiar in that both of the articulating surfaces are slightly convex, so that during rest there is only a line of contact. The rotation effected by the combined joints is consequently not in one plane, but assumes a spiral character.

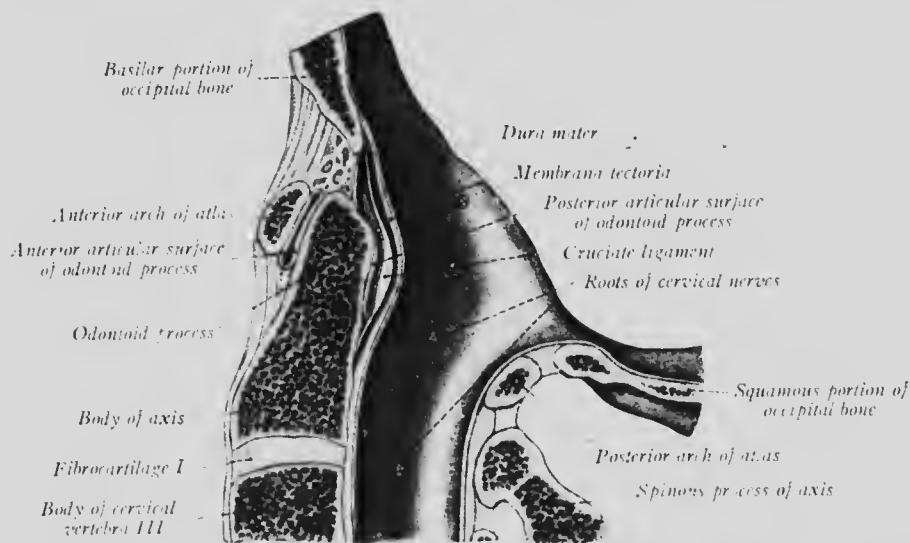


FIG. 184.—A median longitudinal section through the atlanto-axial articulation (articulatio atloepistropheica), somewhat schematized.

The capsules of the atlanto-axial joints are roomy and relaxed. The articulation is provided with a series of accessory ligaments which effect an extremely firm connection between the head and the first two vertebrae.

The *transverse ligament* of the atlas (Figs. 186 and 187) is a very strong and firm fibrocartilaginous band which is attached to the inner margins of the lateral masses of the atlas; it passes across the spinal foramen of the atlas in a curved direction, the convexity being posterior, and invests the odontoid process of the axis (*dens epistrophei*) behind. It divides the spinal foramen into two compartments, a small anterior one for the reception of the odontoid

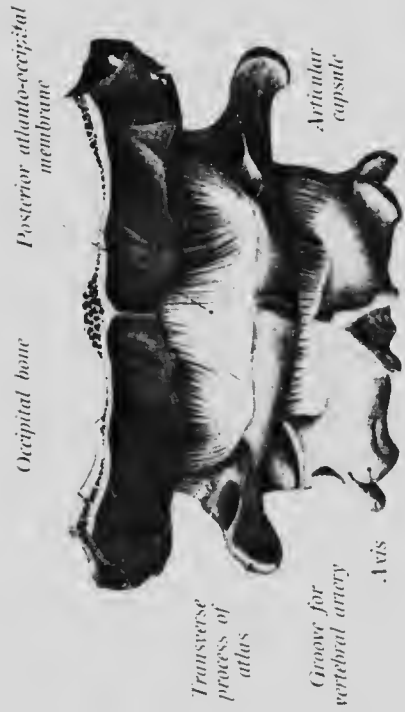

Fig. 182.

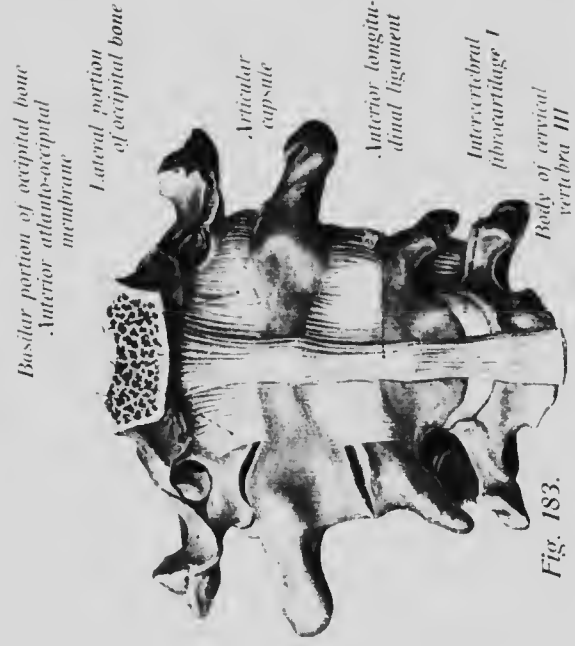


Fig. 183.

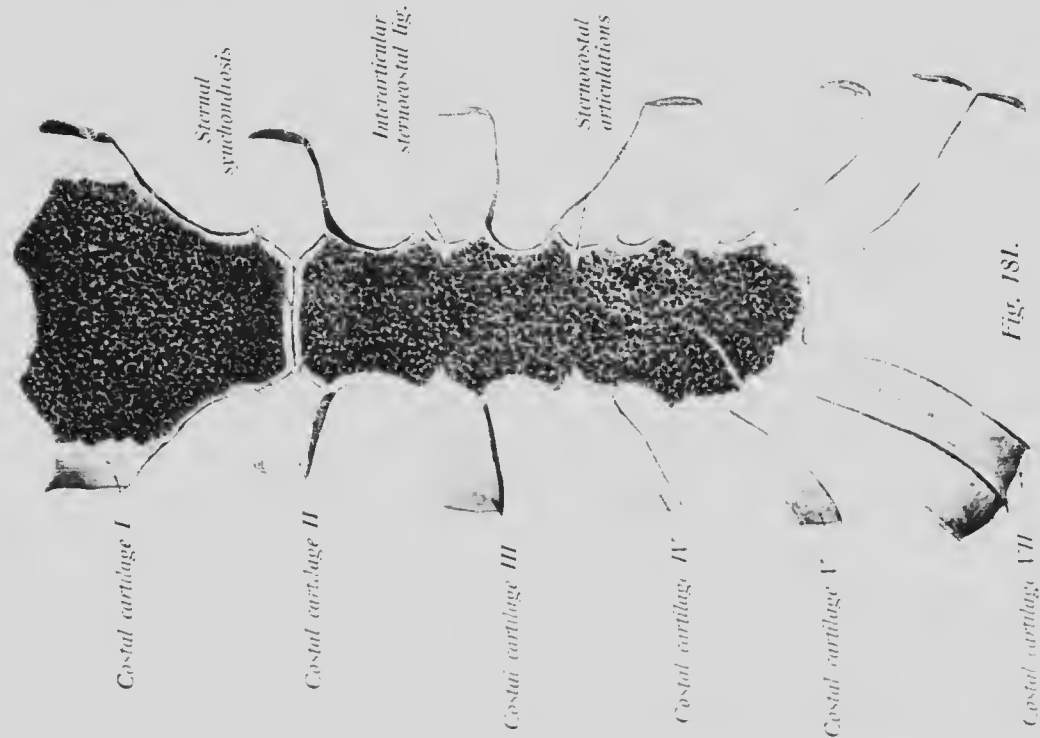


Fig. 181.



process and a larger posterior one for the spinal cord. The portion of the ligament which is in contact with the posterior surface of the odontoid process is covered with cartilage and there is (usually) an articulation in this situation.

From the middle of the transverse ligament of the atlas are given off two vertical fasciculi, one of which passes upward toward the occipital bone and the atlanto-occipital membrane, while the other passes downward and is inserted into the posterior surface of the body of the axis (epistropheus). The combination of these fasciculi with the transverse ligament forms what is known as the *cruciate ligament* (Fig. 187).

The joint possesses three other ligaments which arise from the odontoid process of the axis, a small weak middle ligament and two strong lateral ligaments. The middle ligament is known as the *apical odontoid ligament* (Fig. 188) and runs from the tip of the odontoid process to the margin of the occipital bone. It is a quite thin and insignificant structure and has scarcely any mechanical function. It contains remains of the chorda dorsalis (see page 110).

The strong ligaments extending laterally from the odontoid process are the *alar ligaments* (Fig. 188), and they pass obliquely upward toward the inner margins of the condyles of the occipital bone. They attach the odontoid process to the skull and act as check ligaments for the atlanto-axial joint. The cruciate ligament partly covers them when viewed from behind.

The ligaments arising from the odontoid process and the transverse ligament of the atlas are separated from the vertebral canal by a firm broad ligamentous mass, the *vertical membrane* (Fig. 185), which forms a smooth surface exhibiting in relief the underlying odontoid process and alar ligaments. In the skull it is continuous with the dura mater, and below it is continued into the deeper layers of the posterior longitudinal ligament. It is separated from the atlas by a plexus of veins.

A further peculiarity of the articulation of the first two cervical vertebrae with the occiput is furnished by the *atlanto-occipital (obturator) membranes*, which serve to close the broad spaces which exist between the atlas and the occiput. The *anterior atlanto-occipital (obturator) membrane* (Fig. 183) fulfils this function upon the anterior surface of the two vertebrae; it is stretched between the occipital bone and the anterior arch of the atlas and is adherent to the upper extremity of the anterior longitudinal ligament.

The *posterior atlanto-occipital (obturator) membrane* (Fig. 182) is to be regarded as representing the uppermost portion of the ligamenta flava, although it has not the elastic structure of the latter ligament, and is much thinner. It closes in the space between the occiput and the posterior arch of the atlas, leaving apertures for the passage of vessels and nerves, and is continued in the interspace between the atlas and axis, taking the place of the first ligamentum flavum.

In the atlanto-occipital articulation there is practically no movement permitted about the short sagittal axis, but the chief movement occurs about the horizontal and transverse axis and consists of the nodding movements of the head.

In the atlanto-axial articulation the actual rotation of the head occurs about a vertical axis passing through the odontoid process of the axis. The main joint acts as a pivot-joint, but the rotation is controlled by the alar ligaments and amounts to about 40 degrees only in each direction; the lateral joints allow of a spiral motion.

- FIG. 185.—The tectorial membrane seen from behind. The posterior portion of the occipital bone and the arches of the three upper cervical vertebrae have been removed, as well as the capsular ligaments of the right side ($\frac{9}{16}$).
- FIG. 186.—The atlanto-odontoid articulation. The odontoid process (*dens epistrophei*) and the anterior arch of the atlas have been cut ($\frac{9}{16}$).
- FIG. 187.—The cruciate ligament after removal of the tectorial membrane. The articular capsules have also been removed on the right side ($\frac{9}{16}$).
- FIG. 188.—The alar ligaments after removal of the cruciate ligament. The articular capsules as in the preceding figure ($\frac{9}{16}$).

THE ARTICULATIONS OF THE RIBS WITH THE VERTEBRAL COLUMN AND WITH THE STERNUM.

The posterior extremities of the ribs are connected with the thoracic vertebrae by arthroïdial joints (Figs. 172, 176, and 178 to 180); their anterior extremities (Fig. 181) articulate with the sternum or with each other by means of either arthroïdial joints or synchondroses. The anterior extremities of the two lowermost ribs are not attached to any portion of the skeleton.

The ribs are connected to the vertebrae by a double articulation. The head of each rib articulates with the bodies of two adjacent vertebrae (the exceptions are given upon page 26) and the tubercles of the ribs, with the exception of the last two (see page 27), articulate with the transverse processes.

The articulations of the heads of the ribs, with the exception of the uppermost and the two lowermost, are characterized by the fact that the intervertebral fibrocartilage between the two vertebrae forming the articular cavities is continued, as the *interarticular ligament* (Fig. 178), as far as the crest upon the head of the rib, and divides the articulation into two compartments. The weak articular capsules are reinforced by the *radiate (stellate) ligaments* (Figs. 172 and 180), which arise from the head of the rib and radiate to the lateral surfaces of the bodies of the vertebrae forming the articulation.

The *costo-transverse articulations* have capacious capsules and are characterized by possessing quite a number of reinforcing or check ligaments. The posterior surface of the capsule is reinforced by a short tense ligament, the *ligament of the costal tubercle (posterior costo-transverse ligament)* (Fig. 179), which is approximately quadrangular and composed of parallel fibers, and extends outward and slightly upward from the tip of the transverse process to the posterior surface of the neck of the articulating rib.

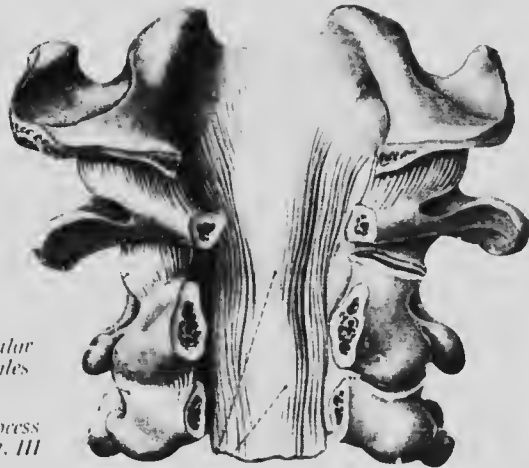
The *ligament of the neck (middle costo-transverse or interosseous ligament)* (Fig. 178) almost completely fills the space between the neck of the rib and the transverse process of the thoracic vertebra. It is horizontal and passes from the anterior surface of the transverse process of the vertebra to the posterior surface of the neck of the rib. The *costo-transverse (superior costo-transverse) ligaments* run between the posterior extremities of the ribs and the transverse processes, and each may be regarded as consisting of an *anterior* and a *posterior costo-transverse ligament*, both of which pursue a similar course from the neck of the rib to the transverse process of the overlying vertebra. The anterior ligament (Figs. 179 and 180) is tolerably strong and approximately rhomboid in shape; it passes from the lower margin of the transverse process

Occipital bone

Transverse process

Articular capsules

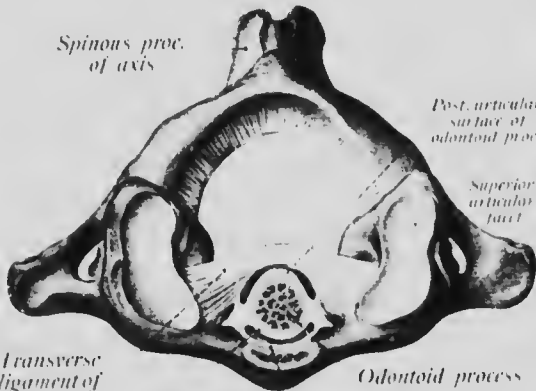
Transverse process of cervical vert. III



Membrana tectoria

Fig. 185.

Spinous proc. of axis



Transverse ligament of atlas

Ant. art. surface of odontoid proc.

Lacet for odontoid process
Fig. 186.

Post. articular surface of odontoid proc.

Superior articular facet

Odontoid process

Apical odontoid ligament
Occipital bone

Articular capsules

Fig. 188.

Odontoid process

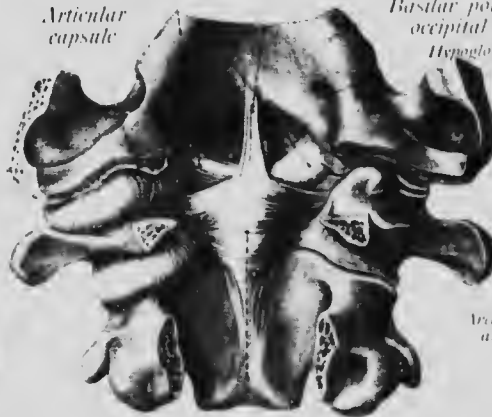Alar ligaments

Cruciate ligament (superior limb)

Articular capsule

Basilar portion of occipital bone
Hypoglossal canal

Sigmoid groove



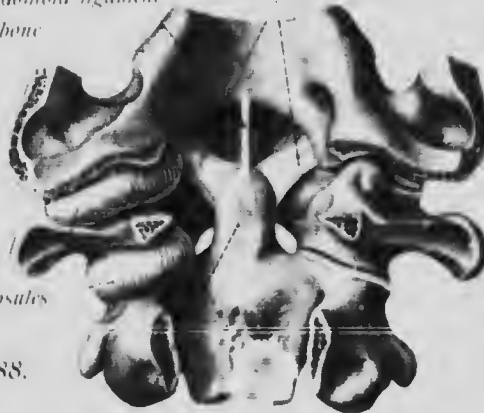Arch of atlas and axis

Body of axis

Cruciate lig.

Fig. 187.

Alar ligaments



Body of axis

1944
1945
1946
1947
1948
1949
1950
1951
1952
1953
1954
1955
1956
1957
1958
1959
1960
1961
1962
1963
1964
1965
1966
1967
1968
1969
1970
1971
1972
1973
1974
1975
1976
1977
1978
1979
1980
1981
1982
1983
1984
1985
1986
1987
1988
1989
1990
1991
1992
1993
1994
1995
1996
1997
1998
1999
2000
2001
2002
2003
2004
2005
2006
2007
2008
2009
2010
2011
2012
2013
2014
2015
2016
2017
2018
2019
2020
2021
2022
2023
2024
2025

and frequently also from the lower border of the adjacent rib to the neck of the next lower rib. The posterior ligament (Fig. 179) is much weaker than the anterior one; it is triangular in shape and runs from the base of the transverse process (or also from the articular process) to the posterior surface of the neck of the next lower rib. The two ligaments form the boundaries of an opening, the *costo-transverse foramen*, which gives passage to the intercostal branch of the spinal nerve.

The movements of the ribs upon the vertebrae are considerably limited by the surrounding check ligaments. The two joints, that of the head and that of the tubercle, act together as a combined articulation which partakes of the nature of a pivot joint, whose axis corresponds to the neck of the rib and is therefore almost transverse. The movement about this axis is such that the anterior extremities of the ribs are elevated, and the distance between their anterior extremities and the vertebral column is increased.

The costal cartilages are connected with the sternum partly by synchondroses and partly by movable joints, the *sterno-costal articulations* (Fig. 181). The first costal cartilage is always united to the sternum by a synchondrosis, but between the anterior extremities of the second to the seventh costal cartilages and the sternum, however, there are usually true joints. The second sternocostal articulation (and frequently the remaining ones) always contains an *inter-articular ligament* (Fig. 181) which passes from the synchondrosis between the manubrium and the body of the sternum, or from the outer margin of the body, to the anterior extremity of the costal cartilage and divides the joint into two compartments. This ligament is inconstant in the articulations of the third to the seventh costal cartilages with the sternal border, and when it is present it is frequently so situated that the articulation is unequally subdivided.

The anterior surfaces of the articular capsules of the sternocostal articulations are reinforced by the *radiate ligaments* (Fig. 192) which arise from the ends of the costal cartilages and spread out like fans upon the anterior surface of the sternum. The interlacing fibers of the radiate ligaments of the lower cartilages form a membrane, the *sternal membrane*, upon the anterior surface of the lower portion of the sternum, and are blended with the periosteum in this situation.

Joints, which are known as the *interchondral joints*, may also be present between the costal cartilages of the fifth to the tenth ribs (see page 33), and in the sternum itself there is a *sternal synchondrosis* (see page 34) between the manubrium and body which frequently has an articular cavity, and sometimes also a synchondrosis between the body and the xiphoid process.

The *intercostal ligaments* are really modified fasciae which will be considered in the description of the muscles (see page 169).

The actual range of motion of the costal cartilages in the sternocostal articulations is quite limited, but it is considerably increased by the elasticity of the cartilages themselves. The costo-vertebral and the costosternal articulations act simultaneously and in the same manner.

THE ARTICULATIONS AND LIGAMENTS OF THE HEAD.

The only movable joint between the bones of the head is the temporo-maxillary articulation. The remaining bones are united by sutures, the terminology of which has already been discussed

FIG. 189.—The right temporo-mandibular articulation seen from the outer side ($\frac{1}{2}$).

FIG. 190.—The right temporo-mandibular articulation seen from the inner side ($\frac{1}{2}$).

FIG. 191.—The right temporo-mandibular articulation opened by a sagittal section. The zygomatic arch has been removed ($\frac{1}{2}$).

in the section upon osteology. Considerable quantities of connective tissue are found only in the sphenopetrosal fissure, in the foramen lacerum, and in the petro-occipital fissure (*sphenopetrosal* and *petro-occipital* synchondroses).

THE TEMPOROMANDIBULAR ARTICULATION.

The temporomandibular articulation (Figs. 189 to 191) is the joint between the condyloid process of the mandible and the *mandibular fossa* of the temporal bone. It is completely subdivided into an upper and a lower portion by an oblong, biconcave *articular disc* (Fig. 191), which is adherent to the capsular ligament by its circumference. The two joints which are thus formed, namely, that between the mandible and the disc and that between the disc and the mandibular fossa, act separately.

The articular capsule of the joint (Fig. 191) is rather thin and relaxed. It embraces the mandibular fossa as far as its posterior non cartilaginous surface, the articular eminence, and the head of the condyloid process, and is inserted into the neck of the mandible. Its external surface is reinforced by a ligament passing from the zygoma to the neck of the condyloid process, the *temporomandibular (external lateral) ligament* (Fig. 189), and its fibers pass from above downward and from before backward.

In the temporomandibular articulation the socket is formed partly by the mandibular fossa and partly by the articular eminence, and over the latter an approximately congruent surface for the head of the condyle is formed by the articular disc. The two temporomandibular articulations act simultaneously.

When the mouth is opened the head of the condyle with the interarticular disc glides forward upon the articular eminence, and when the mouth is closed it slips back into the mandibular fossa. The opening and closing of the mouth are consequently attended by a sliding of the mandible (a gliding joint).

In addition to this modified form of hinge movement, the articulation possesses a second kind of motion, the lateral displacement of the mandible in reference to the skull. In this movement one condyloid head remains in the mandibular fossa while the other advances upon the articular eminence, a movement which is not possible when the mouth is opened to its greatest extent. Both the hinge and the lateral movements are combined in the act of mastication.

INDEPENDENT LIGAMENTS IN THE HEAD.

In the vicinity of the temporomaxillary articulation, but without any direct connection with the joint, are situated two ligaments, the sphenomandibular ligament (Fig. 190) and the stylomandibular ligament (Figs. 191 and 192). The *sphenomandibular ligament* arises from the under surface of the greater wing of the sphenoid bone near its spine and is inserted into the lingula of the mandible. The *stylomandibular ligament* takes origin from the styloid process, which is frequently embedded in the ligament for some distance, and passes to the inner surface of the angle of the jaw. Both ligaments are weak and resemble fasciæ, and this is particularly true of the stylomandibular ligament, which radiates directly into the fascia of the internal pterygoid muscle (buccopharyngeal fascia, see page 184).

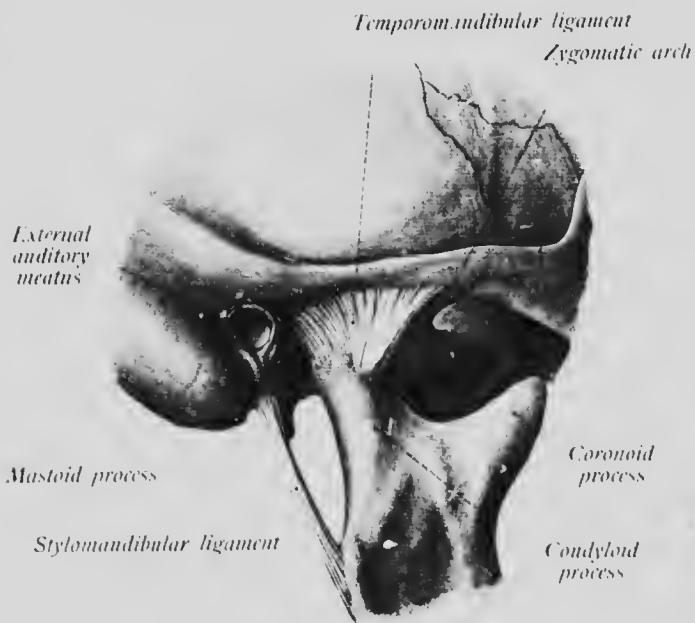


Fig. 189.

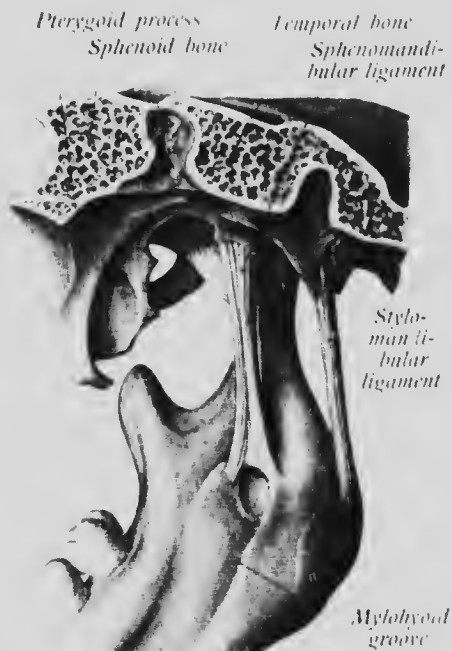

Fig. 190.

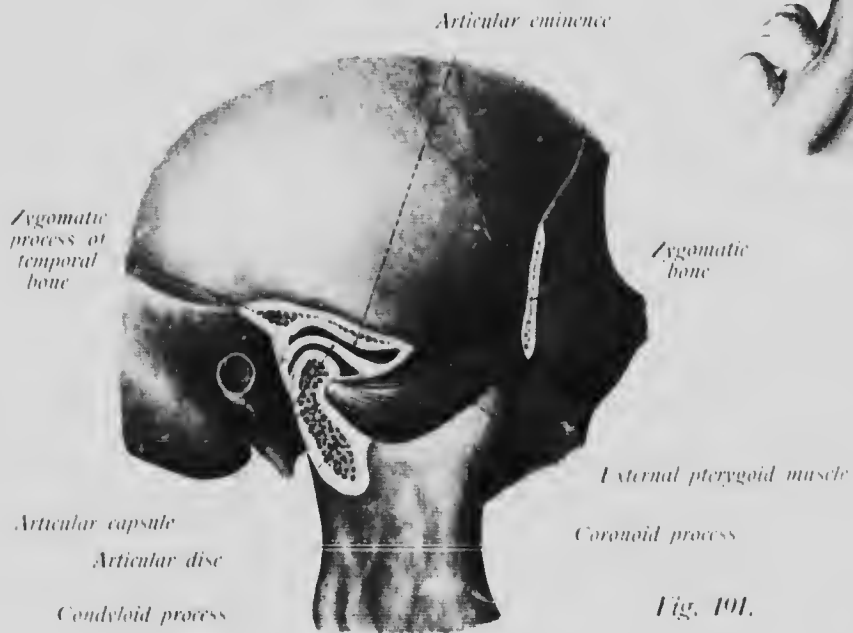


Fig. 191.

1
2
3
4
5
6
7
8
9
10
11
12
13
14
15
16
17
18
19
20
21
22
23
24
25
26
27
28
29
30
31
32
33
34
35
36
37
38
39
40
41
42
43
44
45
46
47
48
49
50
51
52
53
54
55
56
57
58
59
60
61
62
63
64
65
66
67
68
69
70
71
72
73
74
75
76
77
78
79
80
81
82
83
84
85
86
87
88
89
90
91
92
93
94
95
96
97
98
99
100
101
102
103
104
105
106
107
108
109
110
111
112
113
114
115
116
117
118
119
120
121
122
123
124
125
126
127
128
129
130
131
132
133
134
135
136
137
138
139
140
141
142
143
144
145
146
147
148
149
150
151
152
153
154
155
156
157
158
159
160
161
162
163
164
165
166
167
168
169
170
171
172
173
174
175
176
177
178
179
180
181
182
183
184
185
186
187
188
189
190
191
192
193
194
195
196
197
198
199
200
201
202
203
204
205
206
207
208
209
210
211
212
213
214
215
216
217
218
219
220
221
222
223
224
225
226
227
228
229
230
231
232
233
234
235
236
237
238
239
240
241
242
243
244
245
246
247
248
249
250
251
252
253
254
255
256
257
258
259
260
261
262
263
264
265
266
267
268
269
270
271
272
273
274
275
276
277
278
279
280
281
282
283
284
285
286
287
288
289
290
291
292
293
294
295
296
297
298
299
300
301
302
303
304
305
306
307
308
309
310
311
312
313
314
315
316
317
318
319
320
321
322
323
324
325
326
327
328
329
330
331
332
333
334
335
336
337
338
339
340
341
342
343
344
345
346
347
348
349
350
351
352
353
354
355
356
357
358
359
360
361
362
363
364
365
366
367
368
369
370
371
372
373
374
375
376
377
378
379
380
381
382
383
384
385
386
387
388
389
390
391
392
393
394
395
396
397
398
399
400
401
402
403
404
405
406
407
408
409
410
411
412
413
414
415
416
417
418
419
420
421
422
423
424
425
426
427
428
429
430
431
432
433
434
435
436
437
438
439
440
441
442
443
444
445
446
447
448
449
450
451
452
453
454
455
456
457
458
459
460
461
462
463
464
465
466
467
468
469
470
471
472
473
474
475
476
477
478
479
480
481
482
483
484
485
486
487
488
489
490
491
492
493
494
495
496
497
498
499
500
501
502
503
504
505
506
507
508
509
510
511
512
513
514
515
516
517
518
519
520
521
522
523
524
525
526
527
528
529
530
531
532
533
534
535
536
537
538
539
540
541
542
543
544
545
546
547
548
549
550
551
552
553
554
555
556
557
558
559
560
561
562
563
564
565
566
567
568
569
570
571
572
573
574
575
576
577
578
579
580
581
582
583
584
585
586
587
588
589
590
591
592
593
594
595
596
597
598
599
600
601
602
603
604
605
606
607
608
609
610
611
612
613
614
615
616
617
618
619
620
621
622
623
624
625
626
627
628
629
630
631
632
633
634
635
636
637
638
639
640
641
642
643
644
645
646
647
648
649
650
651
652
653
654
655
656
657
658
659
660
661
662
663
664
665
666
667
668
669
670
671
672
673
674
675
676
677
678
679
680
681
682
683
684
685
686
687
688
689
690
691
692
693
694
695
696
697
698
699
700
701
702
703
704
705
706
707
708
709
710
711
712
713
714
715
716
717
718
719
720
721
722
723
724
725
726
727
728
729
730
731
732
733
734
735
736
737
738
739
740
741
742
743
744
745
746
747
748
749
750
751
752
753
754
755
756
757
758
759
760
761
762
763
764
765
766
767
768
769
770
771
772
773
774
775
776
777
778
779
780
781
782
783
784
785
786
787
788
789
790
791
792
793
794
795
796
797
798
799
800
801
802
803
804
805
806
807
808
809
810
811
812
813
814
815
816
817
818
819
820
821
822
823
824
825
826
827
828
829
830
831
832
833
834
835
836
837
838
839
840
841
842
843
844
845
846
847
848
849
850
851
852
853
854
855
856
857
858
859
860
861
862
863
864
865
866
867
868
869
870
871
872
873
874
875
876
877
878
879
880
881
882
883
884
885
886
887
888
889
890
891
892
893
894
895
896
897
898
899
900
901
902
903
904
905
906
907
908
909
910
911
912
913
914
915
916
917
918
919
920
921
922
923
924
925
926
927
928
929
930
931
932
933
934
935
936
937
938
939
940
941
942
943
944
945
946
947
948
949
950
951
952
953
954
955
956
957
958
959
960
961
962
963
964
965
966
967
968
969
970
971
972
973
974
975
976
977
978
979
980
981
982
983
984
985
986
987
988
989
990
991
992
993
994
995
996
997
998
999
1000

In addition to these structures, the head possesses another independent ligament, the *pterygospinous ligament*, which passes from the spine of the sphenoid bone to the upper extremity of the outer plate of the pterygoid process. Sometimes this ligament becomes ossified, and it then forms the pterygospinous process (Civinini).

THE LIGAMENTS OF THE HYOID BONE.

The greater cornua of the hyoid are connected with the body of the bone either by movable joints or by synchondroses, or they are united by synostoses. The lesser cornua are frequently cartilaginous and are connected to the body by movable joints or by syndesmoses.

Each lesser cornu is connected to the styloid process of the temporal bone by the *stylohyoid ligament*.

A portion of the lesser cornu, or a rod of cartilage not connected with the hyoid bone, sometimes extends into the stylohyoid ligament, and in a similar manner the styloid process or a separated bony spicule may extend far into the ligament. All three portions, the lesser cornu, the stylohyoid ligament, and the styloid process, have a common origin in the second visceral arch.

THE JOINTS AND LIGAMENTS OF THE UPPER EXTREMITY.

THE STERNOCLAVICULAR ARTICULATION.

The sternoclavicular articulation (Fig. 192) is the joint between the clavicular notch and the sternal articular surface of the clavicle. The two articulating surfaces are incongruent, but they are adapted to each other by the interposition of an articular disc, which divides the articulation into two completely separated cavities, the articulation in this respect resembling the temporomandibular joint. The edges of the disc, the inner one in particular, are somewhat thickened.

The articular capsule is thin and relaxed, but, except on its inferior portion, it is reinforced upon all sides by strong ligaments. The most striking of these is the *sternoclavicular ligament*, which is adherent to the anterior surface of the capsule. The *interclavicular ligament* is a single ligament which passes across the jugular notch at the upper margin of the sternum and connects the sternal ends of both clavicles, thus reinforcing the upper portions of the capsules of both sternoclavicular articulations.

The *costoclavicular (rhomboid) ligament* is exceedingly strong, and although really an independent ligament it belongs from the functional standpoint to the sternoclavicular articulation. It extends between the cartilage of the first rib and the costal tuberosity of the clavicle, and almost completely fills the space between the sternal end of the clavicle and the first rib. Its fibers are rather short and become tense when the clavicle is but slightly abducted from the thorax.

The sternoclavicular articulation is an arthrodial joint and its range of motion would be quite considerable were it not for the reinforcing ligaments, particularly the costoclavicular ligament, which limits its motion to a marked degree. Slight motion of the clavicle is accompanied by a pronounced movement of the scapula, since the clavicle generally acts as a lever for the latter bone.

- FIG. 102.—The two sternoclavicular joints, together with the costosternal articulations of the two upper ribs, seen from in front. The right sternoclavicular joint has been opened by a sagittal section ($\frac{1}{2}$).
- FIG. 103.—The left shoulder and acromioclavicular joints seen from above and from the inner surface ($\frac{1}{4}$).
- FIG. 104.—The left shoulder-joint seen from behind, the long head of the triceps being cut and the terminal portions of the supraspinatus, infraspinatus, and teres minor muscles cut and turned outward ($\frac{1}{4}$).
- FIG. 105.—The left shoulder-joint seen from behind and above. The acromion process has been removed, and the neighboring muscles treated as in the preceding figure ($\frac{1}{4}$).
- FIG. 106.—The socket of the left shoulder-joint after removal of the articular capsule and the tendon of the biceps muscle ($\frac{1}{4}$).
- FIG. 107.—A frontal longitudinal section of the shoulder-joint, parallel to the tendon of the long head of the biceps ($\frac{1}{2}$).

THE ACROMIOCLAVICULAR ARTICULATION.

The *acromioclavicular articulation* (Figs. 103, 104, and 106) is the joint between the acromial articular surface of the clavicle and the acromial articular surface of the scapula, and it consequently forms the connection between the two components of the shoulder girdle. The articulation may contain an articular disc, but it is small and varies greatly in the degree of its development; it is frequently incomplete and often entirely absent. The upper portion of the articular capsule is the strongest, and is still further reinforced by the *acromioclavicular ligament* (Figs. 104 and 106), which connects the bones forming the articulation.

A strong ligamentous connection between the acromial end of the clavicle and the scapula is effected by the *coracoclavicular ligament* (Figs. 103 and 106), which passes from the upper surface of the base of the coracoid process to the coracoid tuberosity of the clavicle. The ligament is composed of two parts, an anterior flat quadrangular portion, known as the *trapezoid ligament*, and a posterior triangular one, broad above and narrow below, the *conoid ligament*. Between the two the subclavius muscle is inserted.

The acromioclavicular articulation has but a slight range of motion. The coracoclavicular ligament acts as a check ligament, just as the costoclavicular ligament does in the sternoclavicular articulation. The relative position of the two bones, can scarcely be changed voluntarily, but passive movements, producing a change in the angle between the two bones, etc., occur. The small, indistinctly bounded, and usually flat articular surfaces allow of a displacement of the two bones, but the direction of the movement is not determined by the shape of the articular facets.

THE LIGAMENTS OF THE SCAPULA.

There are three ligaments attached to the scapula (Figs. 103, 105, and 106) which do not belong to any of the neighboring joints. These are the *coracoacromial ligament*, the *superior transverse ligament*, and the *inferior transverse ligament*.

The *coracoacromial ligament* (Figs. 103, 104, and 106) is a flat, tense, strong ligament which connects the anterior margin of the acromion with the posterior surface of the anterior extremity of the coracoid process. It is situated immediately above the shoulder-joint.

The *superior transverse ligament* (Figs. 103 and 105) is a short, tense ligament which bridges

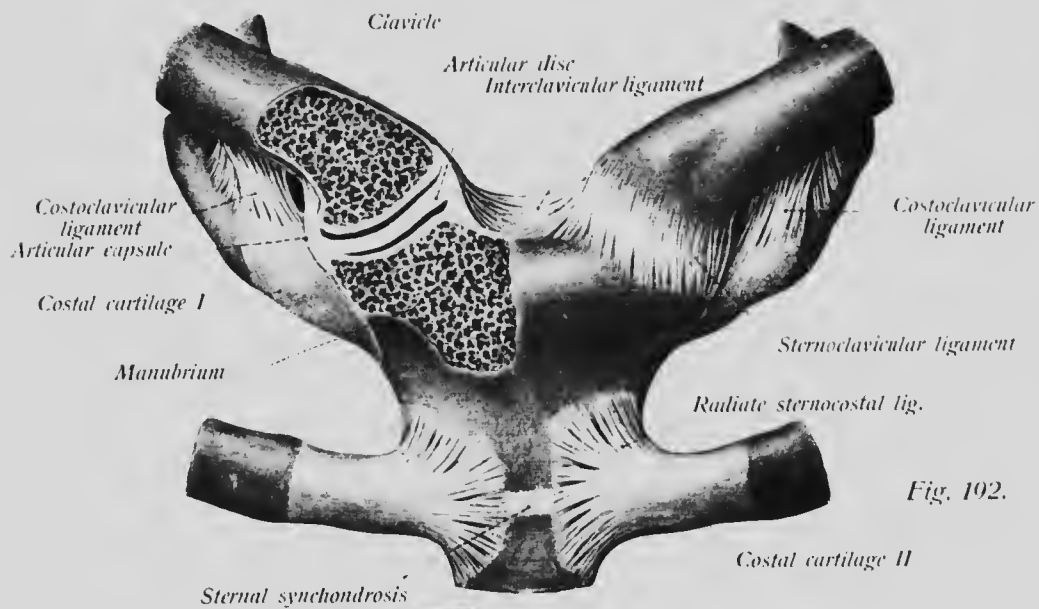


Fig. 192.

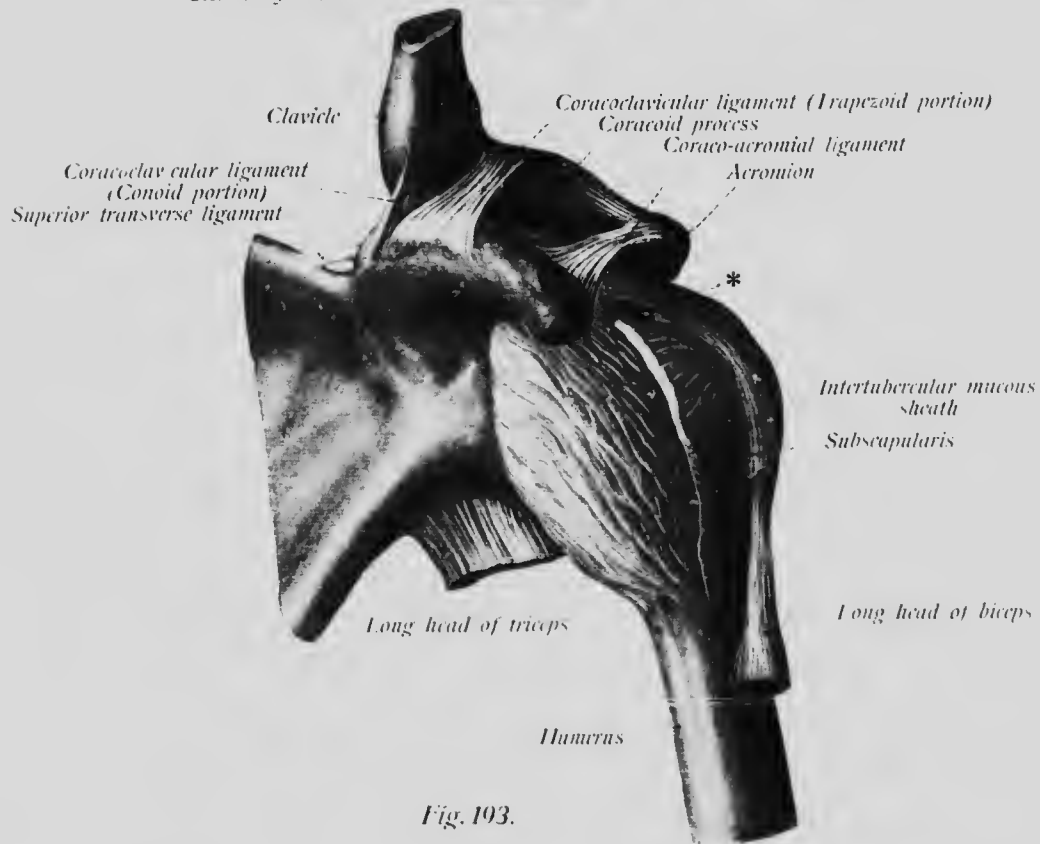



Fig. 193.



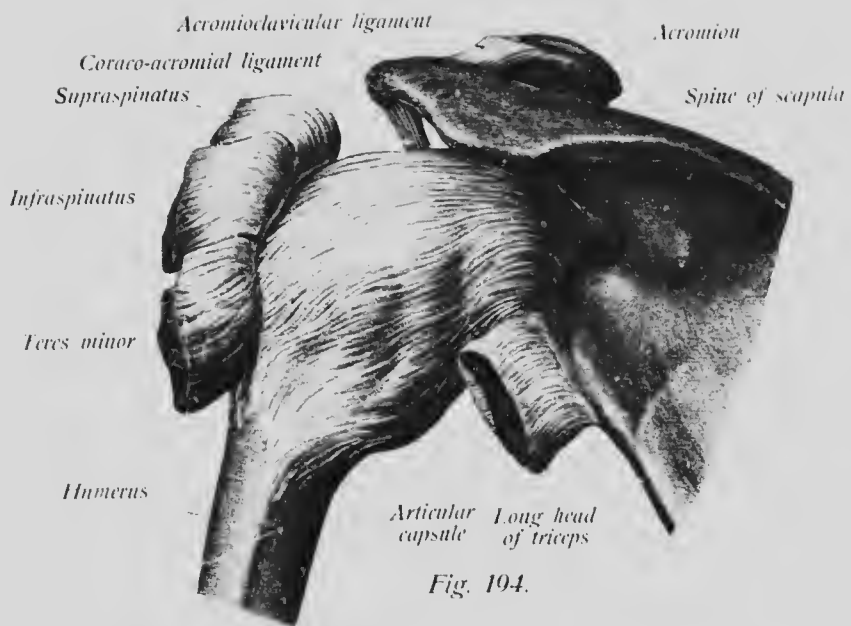


Fig. 194.

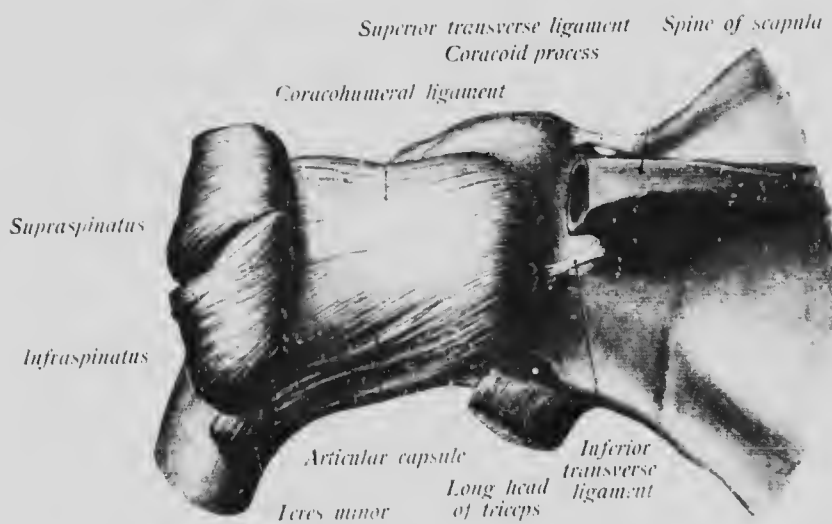
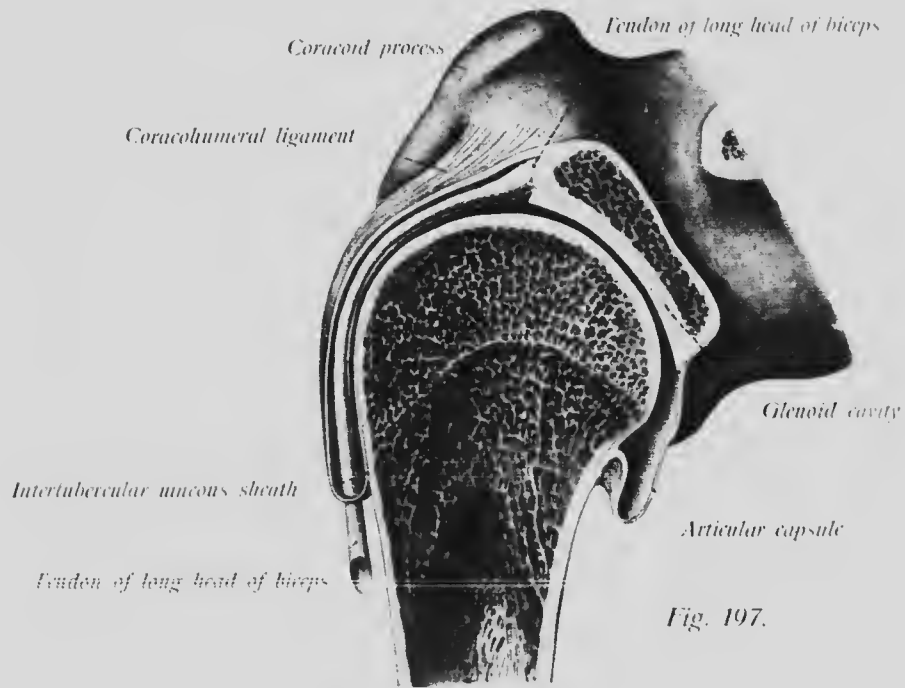
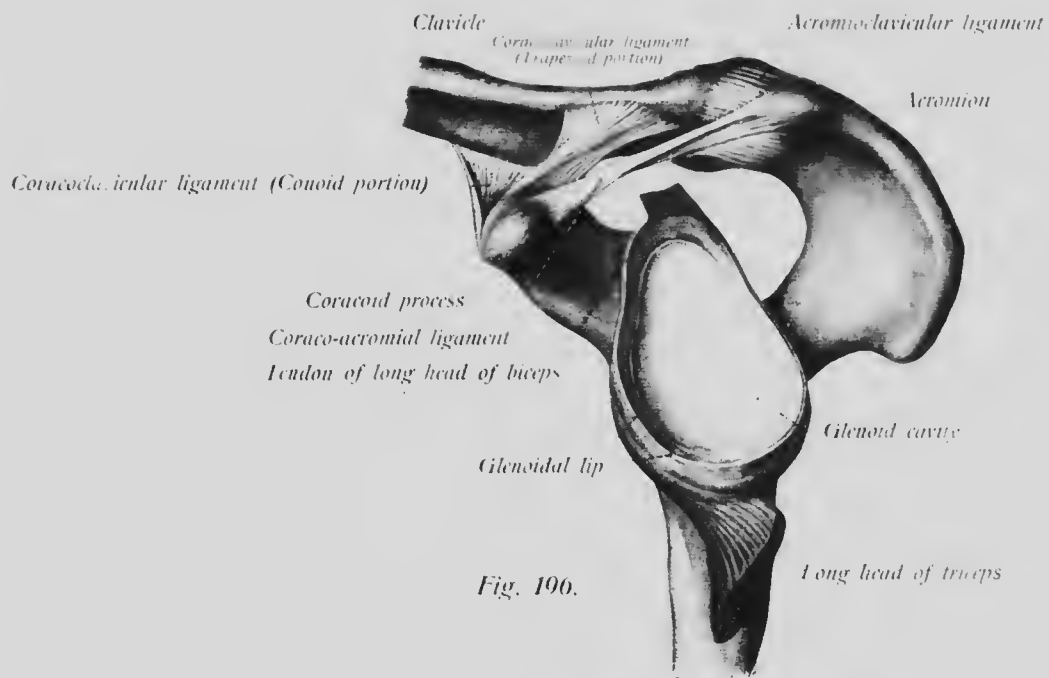


Fig. 195.





1. The first part of the document is a list of names and addresses, including:

 Mr. J. H. Smith, 123 Main St., New York, N.Y.

 Mr. A. B. Jones, 456 Elm St., Boston, Mass.

 Mr. C. D. Brown, 789 Oak St., Chicago, Ill.

 Mr. E. F. Green, 101 Pine St., Philadelphia, Pa.

 Mr. G. H. White, 202 Cedar St., St. Louis, Mo.

 Mr. I. J. Black, 303 Birch St., San Francisco, Cal.

 Mr. K. L. Gray, 404 Spruce St., Portland, Me.

 Mr. M. N. Blue, 505 Ash St., Cincinnati, Ohio.

 2. The second part of the document is a list of names and addresses, including:

 Mr. P. Q. Red, 606 Willow St., New York, N.Y.

 Mr. R. S. Yellow, 707 Maple St., Boston, Mass.

 Mr. T. U. Purple, 808 Cedar St., Chicago, Ill.

 Mr. V. W. Green, 909 Pine St., Philadelphia, Pa.

 Mr. X. Y. Blue, 1010 Spruce St., St. Louis, Mo.

 Mr. Z. A. Black, 1111 Birch St., San Francisco, Cal.

 Mr. B. C. Gray, 1212 Ash St., Portland, Me.

 Mr. D. E. White, 1313 Willow St., Cincinnati, Ohio.

 3. The third part of the document is a list of names and addresses, including:

 Mr. F. G. Red, 1414 Maple St., New York, N.Y.

 Mr. H. I. Yellow, 1515 Cedar St., Boston, Mass.

 Mr. J. K. Purple, 1616 Pine St., Chicago, Ill.

 Mr. L. M. Green, 1717 Spruce St., Philadelphia, Pa.

 Mr. N. O. Blue, 1818 Ash St., St. Louis, Mo.

 Mr. P. Q. Black, 1919 Willow St., San Francisco, Cal.

 Mr. R. S. Gray, 2020 Birch St., Portland, Me.

 Mr. T. U. White, 2121 Cedar St., Cincinnati, Ohio.

 4. The fourth part of the document is a list of names and addresses, including:

 Mr. V. W. Red, 2222 Maple St., New York, N.Y.

 Mr. X. Y. Yellow, 2323 Pine St., Boston, Mass.

 Mr. Z. A. Purple, 2424 Spruce St., Chicago, Ill.

 Mr. B. C. Green, 2525 Ash St., Philadelphia, Pa.

 Mr. D. E. Blue, 2626 Willow St., St. Louis, Mo.

 Mr. F. G. Black, 2727 Birch St., San Francisco, Cal.

 Mr. H. I. Gray, 2828 Cedar St., Portland, Me.

 Mr. J. K. White, 2929 Spruce St., Cincinnati, Ohio.

 5. The fifth part of the document is a list of names and addresses, including:

 Mr. L. M. Red, 3030 Maple St., New York, N.Y.

 Mr. N. O. Yellow, 3131 Pine St., Boston, Mass.

 Mr. P. Q. Purple, 3232 Spruce St., Chicago, Ill.

 Mr. R. S. Green, 3333 Ash St., Philadelphia, Pa.

 Mr. T. U. Blue, 3434 Willow St., St. Louis, Mo.

 Mr. V. W. Black, 3535 Birch St., San Francisco, Cal.

 Mr. X. Y. Gray, 3636 Cedar St., Portland, Me.

 Mr. Z. A. White, 3737 Spruce St., Cincinnati, Ohio.

 6. The sixth part of the document is a list of names and addresses, including:

 Mr. B. C. Red, 3838 Maple St., New York, N.Y.

 Mr. D. E. Yellow, 3939 Pine St., Boston, Mass.

 Mr. F. G. Purple, 4040 Spruce St., Chicago, Ill.

 Mr. H. I. Green, 4141 Ash St., Philadelphia, Pa.

 Mr. J. K. Blue, 4242 Willow St., St. Louis, Mo.

 Mr. L. M. Black, 4343 Birch St., San Francisco, Cal.

 Mr. N. O. Gray, 4444 Cedar St., Portland, Me.

 Mr. P. Q. White, 4545 Spruce St., Cincinnati, Ohio.

 7. The seventh part of the document is a list of names and addresses, including:

 Mr. R. S. Red, 4646 Maple St., New York, N.Y.

 Mr. T. U. Yellow, 4747 Pine St., Boston, Mass.

 Mr. V. W. Purple, 4848 Spruce St., Chicago, Ill.

 Mr. X. Y. Green, 4949 Ash St., Philadelphia, Pa.

 Mr. Z. A. Blue, 5050 Willow St., St. Louis, Mo.

 Mr. B. C. Black, 5151 Birch St., San Francisco, Cal.

 Mr. D. E. Gray, 5252 Cedar St., Portland, Me.

 Mr. F. G. White, 5353 Spruce St., Cincinnati, Ohio.

 8. The eighth part of the document is a list of names and addresses, including:

 Mr. H. I. Red, 5454 Maple St., New York, N.Y.

 Mr. J. K. Yellow, 5555 Pine St., Boston, Mass.

 Mr. L. M. Purple, 5656 Spruce St., Chicago, Ill.

 Mr. N. O. Green, 5757 Ash St., Philadelphia, Pa.

 Mr. P. Q. Blue, 5858 Willow St., St. Louis, Mo.

 Mr. R. S. Black, 5959 Birch St., San Francisco, Cal.

 Mr. T. U. Gray, 6060 Cedar St., Portland, Me.

 Mr. V. W. White, 6161 Spruce St., Cincinnati, Ohio.

 9. The ninth part of the document is a list of names and addresses, including:

 Mr. X. Y. Red, 6262 Maple St., New York, N.Y.

 Mr. Z. A. Yellow, 6363 Pine St., Boston, Mass.

 Mr. B. C. Purple, 6464 Spruce St., Chicago, Ill.

 Mr. D. E. Green, 6565 Ash St., Philadelphia, Pa.

 Mr. F. G. Blue, 6666 Willow St., St. Louis, Mo.

 Mr. H. I. Black, 6767 Birch St., San Francisco, Cal.

 Mr. J. K. Gray, 6868 Cedar St., Portland, Me.

 Mr. L. M. White, 6969 Spruce St., Cincinnati, Ohio.

 10. The tenth part of the document is a list of names and addresses, including:

 Mr. N. O. Red, 7070 Maple St., New York, N.Y.

 Mr. P. Q. Yellow, 7171 Pine St., Boston, Mass.

 Mr. R. S. Purple, 7272 Spruce St., Chicago, Ill.

 Mr. T. U. Green, 7373 Ash St., Philadelphia, Pa.

 Mr. V. W. Blue, 7474 Willow St., St. Louis, Mo.

 Mr. X. Y. Black, 7575 Birch St., San Francisco, Cal.

 Mr. Z. A. Gray, 7676 Cedar St., Portland, Me.

 Mr. B. C. White, 7777 Spruce St., Cincinnati, Ohio.

 11. The eleventh part of the document is a list of names and addresses, including:

 Mr. D. E. Red, 7878 Maple St., New York, N.Y.

 Mr. F. G. Yellow, 7979 Pine St., Boston, Mass.

 Mr. H. I. Purple, 8080 Spruce St., Chicago, Ill.

 Mr. J. K. Green, 8181 Ash St., Philadelphia, Pa.

 Mr. L. M. Blue, 8282 Willow St., St. Louis, Mo.

 Mr. N. O. Black, 8383 Birch St., San Francisco, Cal.

 Mr. P. Q. Gray, 8484 Cedar St., Portland, Me.

 Mr. R. S. White, 8585 Spruce St., Cincinnati, Ohio.

 12. The twelfth part of the document is a list of names and addresses, including:

 Mr. T. U. Red, 8686 Maple St., New York, N.Y.

 Mr. V. W. Yellow, 8787 Pine St., Boston, Mass.

 Mr. X. Y. Purple, 8888 Spruce St., Chicago, Ill.

 Mr. Z. A. Green, 8989 Ash St., Philadelphia, Pa.

 Mr. B. C. Blue, 9090 Willow St., St. Louis, Mo.

 Mr. D. E. Black, 9191 Birch St., San Francisco, Cal.

 Mr. F. G. Gray, 9292 Cedar St., Portland, Me.

 Mr. H. I. White, 9393 Spruce St., Cincinnati, Ohio.

 13. The thirteenth part of the document is a list of names and addresses, including:

 Mr. J. K. Red, 9494 Maple St., New York, N.Y.

 Mr. L. M. Yellow, 9595 Pine St., Boston, Mass.

 Mr. N. O. Purple, 9696 Spruce St., Chicago, Ill.

 Mr. P. Q. Green, 9797 Ash St., Philadelphia, Pa.

 Mr. R. S. Blue, 9898 Willow St., St. Louis, Mo.

 Mr. T. U. Black, 9999 Birch St., San Francisco, Cal.

 Mr. V. W. Gray, 10101 Cedar St., Portland, Me.

 Mr. X. Y. White, 10202 Spruce St., Cincinnati, Ohio.

over the scapular notch and converts it into a foramen. It is occasionally replaced by bone (see page 84). The suprascapular nerve passes beneath this ligament, while the transverse artery of the scapula (suprascapular artery) passes over it.

The *inferior transverse ligament* (Fig. 195) is much weaker than the superior one. It consists of delicate connective-tissue fasciculi which form a bridge beneath the base of the acromion where the supraspinous and infraspinous fossæ communicate with each other, and covers certain small branches of the blood-vessels. The ligaments of the scapula belong to that class of ligaments which take the place of bony structures.

THE SHOULDER-JOINT.

The shoulder-joint (Figs. 193 to 197) is the articulation between the glenoid cavity of the scapula and the head of the humerus. The *glenoid cavity* is relatively small and very slightly concave, but it is considerably enlarged and deepened by a markedly fibrous articular lip, the *glenoidal lip* (*glenoid ligament*) (Fig. 196), which surrounds the margin of the bony socket. In spite of this, however, the socket of the shoulder-joint is still considerably smaller than the head of the humerus, and consequently does not interfere with the free movement of the latter bone.

The articular capsule (Figs. 194 and 195) is roomy and relaxed, as must necessarily be the case in a freely movable enarthrosis. It arises from the margin of the glenoidal lip and is inserted into the anatomical neck of the humerus, and although it is in itself thin, it acquires considerable strength from its adherence to the tendons of the surrounding muscles (supraspinatus, infraspinatus, teres minor, subscapularis) and to a reinforcing ligament, the *coracohumeral ligament* (Figs. 195 and 197). This ligament arises from the outer border of the base of the coracoid process and passes, independently at first and then inseparably connected with the upper and posterior portion of the capsular ligament, to the insertion of the latter structure in the neighborhood of the two tuberosities. A somewhat weaker fasciculus strengthens the inner portion of the capsule.

A peculiarity of the shoulder-joint is that it contains, throughout its entire length, the tendon of the long head of the biceps (see page 188). This tendon, which arises from the supraglenoid tubercle and is adherent to the upper portion of the glenoidal lip, passes through the articular cavity beneath the coracohumeral ligament and leaves it at the intertubercular groove, being accompanied for a certain distance outside of the joint by a tubular prolongation of the synovial membrane, the *intertubercular mucous sheath* (Figs. 193 and 197). This portion of the intertubercular groove is lined with cartilage. At the termination of the mucous sheath the synovial membrane is closely adherent to the tendon, and it also extends beneath the tendon of the subscapularis muscle in the shape of a bursa which communicates with the articular cavity (Fig. 193). This *subscapular bursa* has a very thin wall and is situated beneath the concave anterior surface of the coracoid process, between the coracohumeral ligament and the reinforcing fibers of the internal portion of the capsule.

The shoulder-joint is the most freely movable articulation in the entire human body, and permits of movements in all directions. The chief movements are: pendulum movements in the sagittal plane, which are more extensive ante-

FIG. 198.—The left elbow-joint seen from in front (3).

FIG. 199.—The left elbow-joint seen from behind and from the radial side (3).

FIG. 200.—The bones of the left forearm with the interosseous membrane; the annular ligament has been divided (3).

riorly than posteriorly; raising and lowering of the arm in a coronal plane (abduction and adduction, the former motion not being possible beyond a horizontal plane); and rotation of the arm about its longitudinal axis. During the movements of the arm the capsular ligament is thrown into folds upon one side and made tense upon the other and in certain extreme positions it may act as a check ligament.

THE ELBOW-JOINT.

The elbow-joint is a typical compound joint, being formed by the association of the lower end of the humerus with the upper ends of the radius and ulna, and so consisting of three articulations. The trochlea of the humerus articulates with the semilunar (greater sigmoid) notch of the ulna (the *humero-ulnar articulation*), the capitulum of the humerus with the depressed surface on the head of the radius (the *humero-radial articulation*), and the radial (lesser sigmoid) notch of the ulna with the articular circumference of the radius (the *proximal radio-ulnar articulation*).

The three articulations are surrounded by a common articular capsule (Figs. 198; 199) which is roomy and relaxed, particularly in front and behind. It encloses the three articulations. The lower end of the humerus (the olecranal, coronoid, and radial fossæ), is attached to the capsule just below the tip of the olecranon, at the margin of the semilunar (greater sigmoid) notch, and at the tip of the coronoid process, and the entire head and the greater portion of the neck of the radius are situated within it. The only portions of it which are firm and tense are the lateral ligaments and the *annular ligament* which surrounds the upper end of the radius.

There may be recognized a *radial* or *external lateral ligament* and an *ulnar* or *internal lateral ligament*. The *radial lateral ligament* (Figs. 198 and 199) arises from the external epicondyle and passes as two fasciculi to the annular ligament, with which a portion of its fibers are continuous. The *ulnar lateral ligament* (Fig. 198) arises from the internal epicondyle of the humerus and passes in a radiating manner to the ulnar margin of the semilunar notch.

The *annular ligament* (Fig. 199) is a firm tense ligament which surrounds the head of the radius like a sling and forms three fourths of the circumference of the socket for the pivot joint of the proximal radio-ulnar articulation, the remaining fourth being formed by the radial (lesser sigmoid) notch of the ulna. The ligament arises from the anterior margin of the semilunar (greater sigmoid) notch and is inserted into the posterior margin of the radial notch. Below it the capsule is thin, and at the neck of the radius forms a small protrusion which is known as the *saccular recess*.

The brachialis anticus muscle passes over the anterior surface of the capsular ligament of the elbow joint (Fig. 201) and some of its fibers are inserted directly into this structure. The triceps muscle, particularly its middle head, holds a similar relation to the posterior surface of the capsule, from which the tendon of the muscle is separated by fatty tissue.

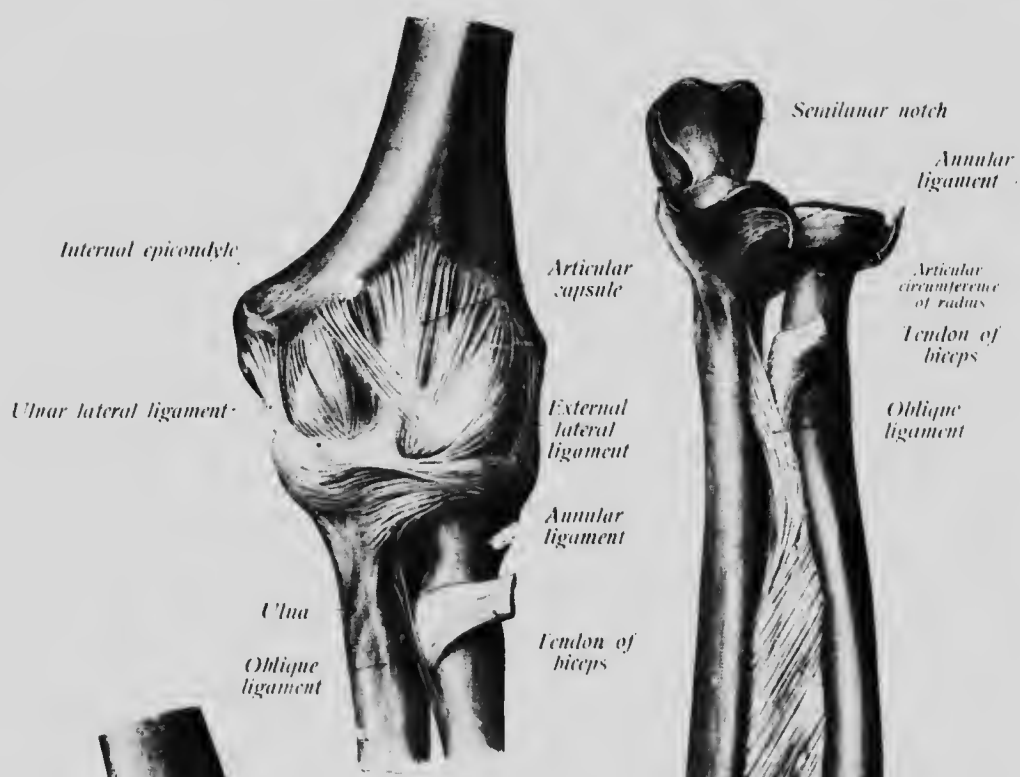


Fig. 198.



Fig. 200.

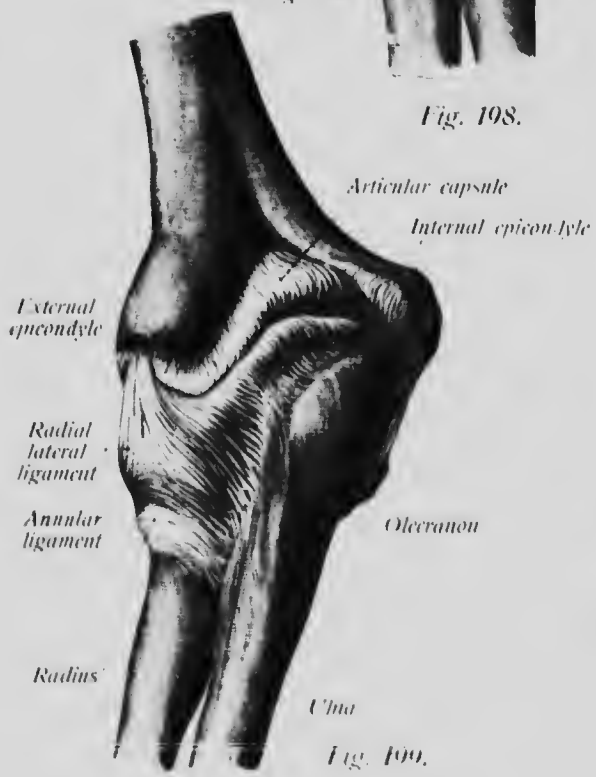

Fig. 199.

Articular capsule of distal radio-ulnar articulation

From a physiological standpoint the elbow is a combination of two joints only, since the humero-radial articulation does not function as an independent joint. These two joints are the hinge joint of the humero-ulnar articulation and the pivot joint of the proximal radio ulnar articulation.

The flexion of the forearm upon the arm is not a pure hinge motion, but rather that of a spiral joint, since the surfaces of the trochlea and the median ridge of the semilunar notch resemble that of the worm of a screw. From a practical standpoint, however, the elbow may be regarded as a ginglymus or hinge joint, whose axis of movement passes through the two epicondyles. The humero-radial articulation is not involved in this movement, since the ends of the respective bones are scarcely in contact during flexion.

The axis of the trochlea of the humerus is not placed at right angles to the axis of the humerus, but cuts it obliquely, and, consequently, when the forearm is extended the elbow forms an obtuse angle of about 140 degrees, which is open externally; while when the joint is flexed this angle becomes an acute one. When the forearm is flexed the coronoid process of the ulna rests in the coronoid fossa, and when it is strongly extended, the olecranon is received into the olecranal fossa, which is cushioned with fatty tissue.

The humero-radial articulation is only passively involved in the pivot movement of the proximal radio-ulnar joint, since the radius rotates in the socket about its long axis, and the actual pivot movement takes place in the proximal and distal radio-ulnar articulations. Both movements of the elbow-joint are completely independent.

THE DISTAL RADIO-ULNAR JOINT AND THE INTEROSSEOUS MEMBRANE.

The radius and ulna are connected by a thin *interosseous membrane* (Fig. 200) which almost completely fills the space intervening between the two bones of the forearm. It is attached to the interosseous ridges of the two bones and consists for the greater part of fibers which pass obliquely downward from the radius to the ulna. It does not, however, extend to the uppermost part of the interosseous space and possesses an opening in its lower portion for the passage of blood-vessels. It represents a membranous supplement to the bones of the forearm, and, like these structures, it gives origin to various muscles.

In addition to the connection by the interosseous membrane, the radius and ulna are held together also by the *oblique ligament* (Figs. 199 and 200), which passes obliquely from the coronoid process of the ulna to the lower margin of the tuberosity of the radius, and is directly in contact with the upper portion of the interosseous membrane.

The *distal radio ulnar joint* (Figs. 202 to 204) is the joint between the articular circumference of the capitulum of the ulna and the ulnar (sigmoid) notch of the radius, and also between the capitulum of the ulna and the articular disc which separates the head of the ulna from the triquetral (cuneiform) bone. Anatomically it is an independent joint, but it functions in association with the proximal radio-ulnar articulation.

The socket for the capitulum of the ulna (Fig. 202) is formed by the ulnar notch of the radius as well as by the articular disc; the portion of the socket formed by the radius is almost vertical, and that formed by the disc is practically horizontal, and a portion of the lateral surface as well as the inferior surface of the capitulum of the ulna consequently rests in the socket of the joint. The articular capsule is somewhat roomy and relaxed, and a prolongation of it, known as the *saccular recess*, extends upward between the bones of the forearm above the level of the articulation.

The *articular disc* is attached upon one side to the ulnar margin of the middle portion of the radius, where it insensibly merges into the cartilaginous covering of this portion of the bone;

FIG. 201.—Sagittal section of frozen preparation of the left elbow-joint ($\frac{1}{2}$).

FIG. 202.—A frozen section through the radiocarpal articulation parallel with the dorsal surface of the hand ($\frac{1}{2}$).

upon the other side it is attached to the styloid process of the ulna. In rare instances it is perforated.

The movement in the distal radio-ulnar joint is a rotation of the radius about the ulna which is simultaneously carried out in the proximal radio-ulnar articulation also. During the movement known as *pronation*, the radius is applied obliquely to the ulna, so that the two bones cross; the opposite movement, the return to the parallel position of the two bones, is called *supination*. The axis of movement of both radio-ulnar articulations passes through the heads of both bones and is consequently placed obliquely to the axes of the bones. The angle of rotation of the lower end of the radius about the ulna amounts to about 180 degrees.

THE JOINTS AND LIGAMENTS OF THE HAND.

The joints of the hand may be divided into those of the carpus and those of the fingers. Those of the carpus are: (1) The *radiocarpal* or *wrist-joint*; (2) the *intercarpal joint*; (3) the *joint of the pisiform bone*; (4) the *common carpo-metacarpal joint*; (5) the *carpo-metacarpal joint of the thumb*.

The joints of the fingers include the *metacarpo-phalangeal articulations* and *digital or inter-phalangeal articulations*.

THE JOINTS OF THE CARPUS.

The radiocarpal articulation, the articulation of the pisiform bone, and the carpo-metacarpal articulation of the thumb are usually independent joints, while the common carpo-metacarpal articulation is, as a rule, connected with the intercarpal joint.

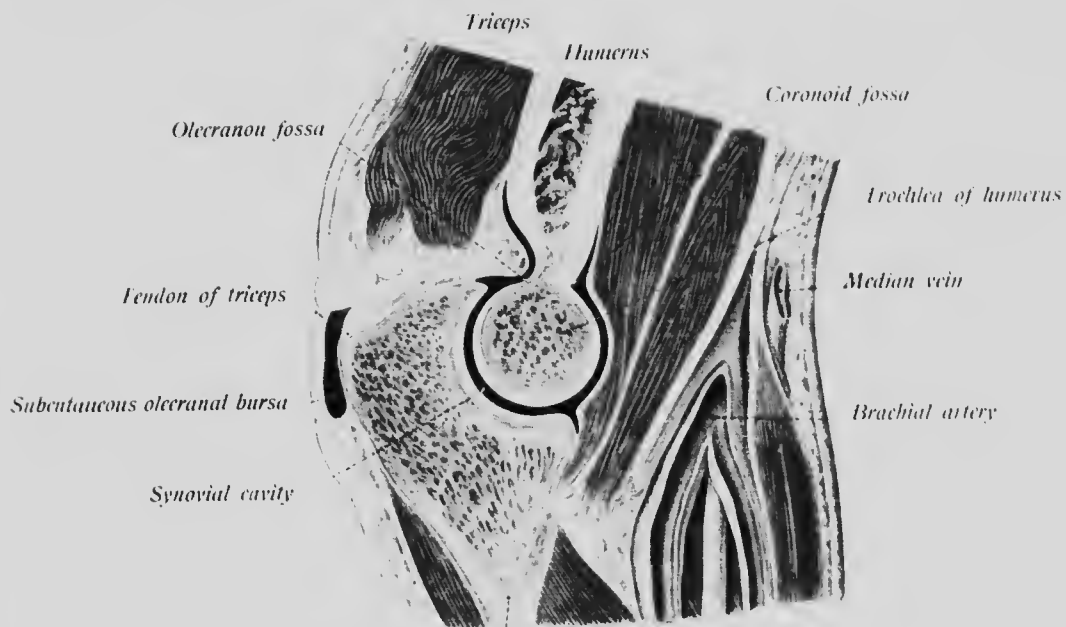
The *radiocarpal articulation* is the joint between the carpal articulating surface of the radius and the triangular articular disc interposed between the ulna and the triquetral (cuneiform) bone upon one side, and the proximal articular facets of the first row of carpal bones—navicular (scaphoid), lunatum (semilunar), and triquetrum (cuneiform)—upon the other, the navicular and lunate bones articulating with the radius and the triquetrum (cuneiform) bone with the triangular articular disc in such a manner that the radius and the disc together form a socket, while the corresponding articular facets of the three carpal bones form a condyle.

The articulation is completely separated from the intercarpal joint, but in rare instances it communicates with the articulation of the pisiform bone. It is separated from the intercarpal articulation by the short ligaments connecting the navicular, the lunate, and the triquetral (cuneiform) bones.

The articular capsule of the joint is thin, capacious, and relaxed, and embraces the cartilaginous extremities of the bones entering into the articulation.

From the shape of its articulating surfaces the radiocarpal articulation is an ellipsoidal joint. The curvature of the surfaces is greater in the sagittal than in the coronal diameter.

The *intercarpal articulation* is the joint between the two rows of carpal bones and is formed by the distal articular facets of the navicular, lunate, and triquetral (cuneiform) bones upon



Ulna
Fig. 201.

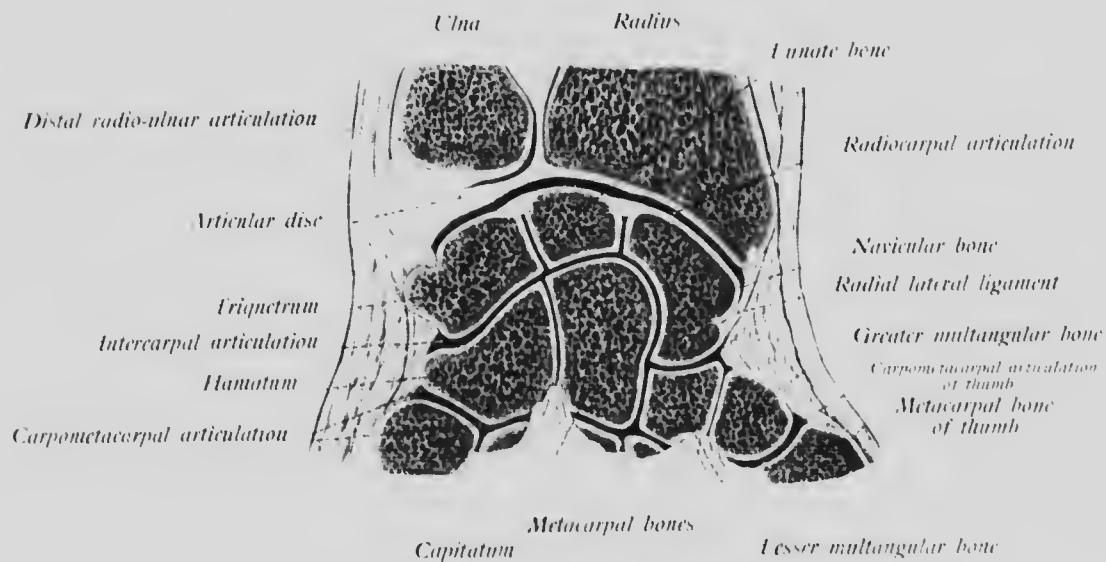


Fig. 202.

7

the one side, and by the proximal facets of the greater and lesser multangular (trapezium and trapezoid), capitate (os magnum), and hamate (unciform) bones upon the other. The first row of the carpal bones practically forms a socket for the head of the capitatum (os magnum) and the proximal portion of the hamatum (unciform), and toward the radial, and to a certain extent also the ulnar, side of the joint, the proximal row exhibits a convex and the distal row a concave surface, since the navicular bone presents a convexity toward the greater and lesser multangular (trapezium and trapezoid) bones. As a result, the line of the joint is not a simple curve, but has an irregular *S* shape (Fig. 202).

The articular cavity of the joint is very complicated, since it extends from the actual articular line both proximally and distally between the individual carpal bones of both rows. It is separated from the radiocarpal joint by the previously mentioned ligaments, and similar ligaments connect the bones of the second row and separate the intercarpal from the carpo-metacarpal articulation. The latter separation is incomplete, however, and these two articulations usually communicate between the capitatum (os magnum) and the lesser multangular (trapezoid) bone, since interosseous ligaments are usually wanting in this situation. The thin articular capsule exhibits no special peculiarities and resembles that of the radiocarpal articulation.

The *articulation of the pisiform bone* is a small unimportant joint between the contiguous surfaces of the pisiform and triquetral (unciform) bones, and is usually an independent articulation. As the pisiform bone is simply the sesamoid bone of the flexor carpi ulnaris, this joint is analogous to those situated between the sesamoid bones of the great toe and the head of the first metatarsal bone. The ligaments arising from the pisiform bone are similarly to be regarded as continuations of the tendon of the flexor carpi ulnaris; they are the *pisiform ligament* (Fig. 204), passing to the hamulus of the hamate (unciform) bone, and the *pisiform-metacarpal ligament* (Fig. 204), which passes to the base of the fifth metacarpal bone and sends prolongations to the neighboring metacarpal bones.

The *carpo-metacarpal joint* (Fig. 202) is the joint between the bases of the second to the fifth metacarpal bones and the distal articular facets of the lesser multangular (trapezoid), of a small portion of the greater multangular (trapezium) (see page 91), capitate (os magnum), and hamate (unciform) bones. The articular cavity, which is usually single, communicates, as a rule, with the intercarpal joint in the manner previously described. It is sometimes composed of two separate articulations, each of which connects two metacarpal bones.

The bones forming the carpometacarpal articulation are capable of only slight movements and the articular capsule is correspondingly tense and firm. In addition to the previously mentioned surfaces, it also embraces the lateral articular facets between the bases of the individual metacarpal bones (see page 91), and the articulation consequently includes the concealed intermetacarpal articulations. The articulation is an arthrodiium.

The *carpo-metacarpal joint of the thumb* is the joint between the saddle-shaped articular facet at the distal extremity of the greater multangular bone (trapezium) and the base of the metacarpal of the thumb. It is always an independent articulation, communicating with none of the other carpo-metacarpal joints nor with any of the carpal joints. From the shape of the articulating surfaces the articulation is a saddle joint, and although the surfaces are not completely congruent, it is the most pronounced saddle joint in the human body.

- FIG. 203.—Articulations and ligaments of the hand seen from the dorsal surface (3).
 FIG. 204.—Articulations and ligaments of the hand seen from the volar surface, the transverse carpal ligament having been removed (3).
 FIG. 205.—Articulations of the middle finger seen from the side (3).

In the movements of the hand the radiocarpal and intercarpal articulations act together as hinge joints. The four chief movements of the hand are flexion, extension, radial flexion (or, better, radial abduction), and ulnar flexion (or, better, ulnar abduction). By a combination of these movements it is possible to effect an almost complete circumduction of the hand.

The chief movements of the joints are flexion and extension. The axes of rotation of the two hinge joints are not placed at right angles to the axis of the forearm, but obliquely and intersecting each other.* During flexion of the radio-carpal articulation, the hand deviates to the radial side; during the similar movement in the intercarpal articulation the hand deviates to the ulnar side and *vice versa*. If one joint is flexed and the other extended, the movements in the axis of the extremity neutralize each other, while the lateral movements (radial and ulnar abduction, as the case may be) are more pronounced. If both joints are flexed or extended together, the lateral movements neutralize each other and the movements in the axis of the extremity (flexion or extension) are more pronounced.

The carpo-metacarpal articulations are arthrodia and are but slightly movable; this is particularly true of the carpo-metacarpal joints of the second and third fingers. They move slightly when the concavity of the hand is increased or diminished, that is to say, during hollowing or flattening of the palm, and during opposition of the little finger.

The range of motion of the carpo-metacarpal joint of the thumb is much more extensive. Like all saddle joints it is biaxial, but owing to the incongruity of the articulating surfaces, the curvatures of one of the surfaces being always more pronounced than those of the other, the movements about the two axes may be so combined that actual circumduction is possible. The chief movements of this joint are abduction (away from the index-finger), adduction (toward the index-finger), and opposition (bringing the thumb opposite to the little finger). During the latter motion the concavity of the palm is markedly increased.

THE CARPAL LIGAMENTS.

The *carpal ligaments* (Figs. 203 and 204) are composed of the ligaments between the bones of the forearm and the carpal bones and of those which connect the carpal bones with each other and with the bases of the metacarpal bones.

Of the first group, the ligaments which connect the ulna with the carpus are weak, while the radius is connected to the carpus by strong ligaments. It will be remembered that the carpal bones articulate with the radius only.

The only ligament arising from the ulna is the *ulnar lateral ligament* (Figs. 203 and 204), which passes from the styloid process of the ulna to the triquetral (cuneiform) bone. The corresponding ligament upon the radial side is the *radial lateral ligament* (Figs. 202 and 204) which passes from the styloid process of the radius to the navicular bone. The radius is connected to the carpus also by two strong ligaments which reinforce the dorsal and palmar surfaces of the capsule.

The *dorsal radiocarpal ligament* (Fig. 203) passes obliquely from the lower end of the radius to the dorsal surface of the first row of carpal bones and is attached particularly to the triquetral (cuneiform) bone. The corresponding anterior ligament, the *volar radiocarpal ligament* (Fig. 204), is longer than the dorsal one; it arises from the margin of the articular surface of the carpus and is inserted not only into the bones of the first row, but also into the capitatum (*os magnum*).

* This description of the movements of the hand has been materially modified by the more recent studies of these articulations. It must not be supposed that the two rows of carpal bones cannot move upon each other; during radial abduction the navicular bone is markedly moved toward the adjacent bones.

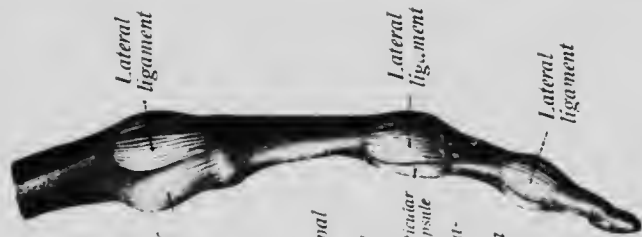

Fig. 205.

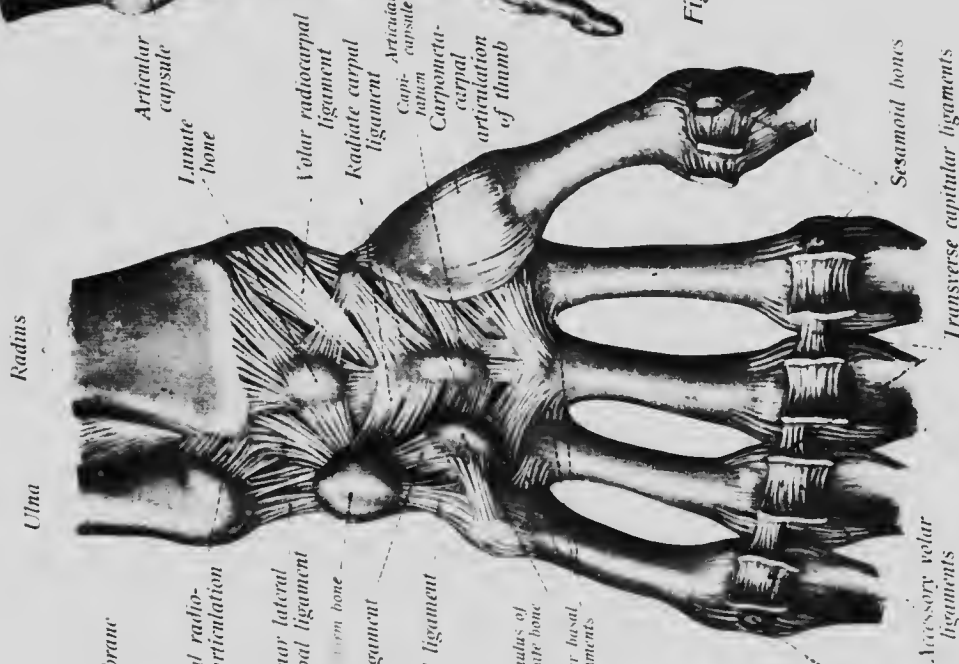


Fig. 204.

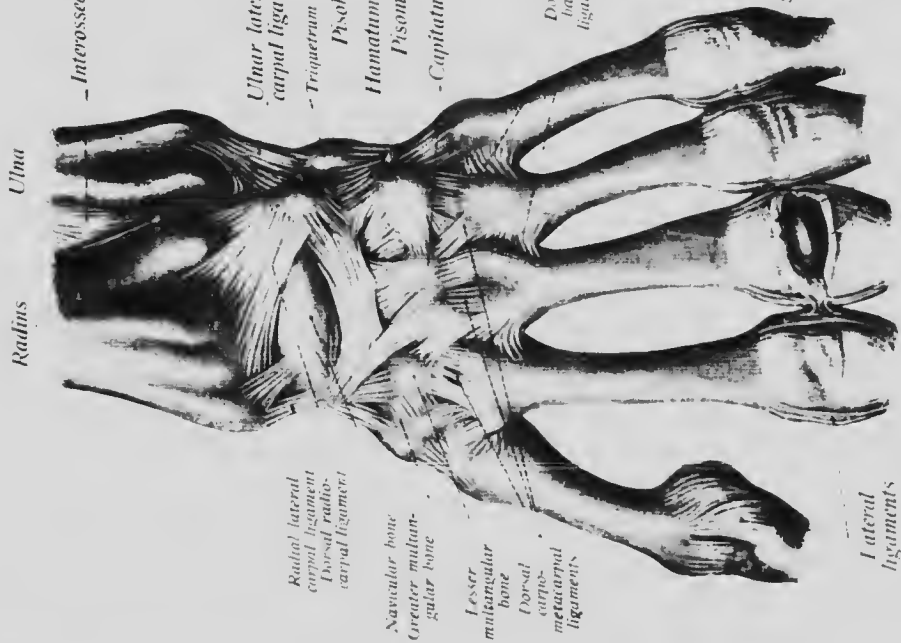


Fig. 203.

Lateral ligament

Articular capsule

Lunate bone

Volar radiocarpal ligament

Radiate ligament

Articular capsule

Capitate

Carpo-metacarpal articulation

of thumb

Lateral ligament

Lateral ligament

Radius

Ulna

Sesamoid bones

Transverse carpal ligaments

Interosseous membrane

Distal radio-ulnar articulation

Ulnar lateral carpal ligament

Triquetrum

Pyrohamate ligament

Hamatum

Pisometacarpal ligament

Capitulum

Hamulus of hamate bone

Volar basal ligaments

Dorsal basal ligaments

Sesamoid bone

Accessory velar ligaments

Ulna

Radius

Articular capsule of the metacarpophalangeal articulation III

Lateral ligaments

Radial lateral carpal ligament


Dorsal radio-carpal ligament

Navicular bone

Greater multangular bone

Lesser multangular bone

Dorsal carpo-metacarpal ligaments



The *transverse carpal (anterior annular) ligament* (Fig. 282) is a particularly strong ligament which serves to refer the tendons in place (see page 205) than an accessory ligament of the carpus. It connects the two carpal eminences, but is also attached to the radius, and converts the carpal groove into a canal.

Upon the floor of the carpal canal are found the ligaments which connect the individual carpal bones (Fig. 204); they radiate toward the head of the trapezium os magnum forming the *radiate carpal ligament*.

The remaining carpal ligaments which unite the carpal bones or connect them with the bases of the metacarpal bones are designated according to their position as the *volar carpo-metacarpal ligaments*, the *volar* and *dorsal carpo-metacarpal ligaments* * and the *volar* and *dorsal basal ligaments* (Figs. 204 and 205). The *interosseous* ligaments are situated in the interstices between the bases of the metacarpal bones.

THE FINGER JOINTS.

The *metacarpo-phalangeal articulations* (Figs. 205) are the joints between the heads of the metacarpal bones and the bases of the phalanges. Although the articulating surfaces are irregularly spherical, the movements of the joints are restricted by ligaments. The articular surfaces of the heads of the metacarpal bones become somewhat cylindrical upon the ulnar aspect of the bones so that the articular contact during extension are spherical, while during flexion they are cylindrical. The joints are consequently a mixture of ginglymoid and trochoidal types (*ginglymo-trochoidal*). The metacarpo-phalangeal joint of the thumb is an exception; it resembles the metacarpophalangeal articulations and is a true ginglymo-articulation.

The *articular capsules* (Fig. 205) are thin and somewhat relaxed, but they are reinforced in several places. The *lateral ligaments* are eccentrically inserted into the heads of the metacarpal bones, so that they become tense during flexion of the phalanges; they arise from a small depression on the lateral surfaces of the heads of the metacarpal bones. The anterior surfaces of the capsules are reinforced by the *accessory volar ligaments* (Fig. 204) which are connected with the flexor tendons (see page 205), and by the *transverse carpal ligaments* (Fig. 282) which are flat strong ligaments connecting the heads of the second and third metacarpal bones. The dorsal surfaces of the capsules are protected by the dorsal aponeuroses of the fingers (see page 205), which are intimately connected with them.

The *metacarpo-phalangeal joint of the thumb* always contains two sesamoid bones (a radial and an ulnar) (Fig. 204), which are embedded in the articular capsule; the surfaces directed toward the articulation are covered by cartilage. Sesamoid bones occasionally occur in the metacarpo-phalangeal joints of the other fingers (see also page 92).

The movements of the metacarpo-phalangeal joints of the four fingers consist of hinge movements by which the phalanges are flexed and extended. During flexion, the lateral ligaments are tense, and prevent any lateral motion. During extension, however, these ligaments become relaxed and the spherical articular surfaces are in contact, so that

* In connection with the individual ligaments of the pisiform bone there is a volar carpo-metacarpal ligament which passes from the hamulus of the hamate (unciform) bone to the base of the fifth metacarpal bone; it is the *hamato-metacarpal ligament*.

- FIG. 206.—The female pelvis with its ligaments, seen from behind ($\frac{2}{3}$).
 FIG. 207.—The female pelvis with its ligaments, seen from below ($\frac{2}{3}$).
 FIG. 208.—The male pelvis with its ligaments, seen from in front ($\frac{2}{3}$).
 FIG. 209.—The female pelvis with its ligaments, seen from in front ($\frac{2}{3}$).
 FIG. 210.—The male pelvis with its ligaments, seen from above ($\frac{2}{3}$).
 FIG. 211.—The female pelvis with its ligaments, seen from above ($\frac{2}{3}$).

while extensive rotation is impossible, the phalanges and consequently the fingers can be abducted and adducted. The metacarpo-phalangeal articulation of the thumb is a pure hinge joint.

The *digital* or *interphalangeal articulations* (Fig. 205) are the joints between the individual phalanges of the fingers, the bases forming the articular sockets and the trochlear surfaces constituting the articular heads. The articulations are pure hinge joints. Lateral ligaments (Fig. 205) at the sides of the capsules prevent any lateral motion, and the articular capsules are roomy. Volar flexion is the only movement of which these joints are capable.

THE JOINTS AND LIGAMENTS OF THE PELVIC GIRDL.

THE PELVIC LIGAMENTS, SYNARTHROSES AND DIARTHROSES.

The pelvic girdle and its ligaments form the *pelvis* (Figs. 206 to 211 and 215), which, unlike the shoulder girdle, is complete both anteriorly and posteriorly, the pubic bones being connected anteriorly by a symphysis and the pelvic girdle completed posteriorly by the sacrum, which articulates with the two iliac bones either by joints or half joints.

The *symphysis pubis* (Figs. 208 and 209) is a mixed synarthrosis connecting the symphyseal surfaces of the two pubic bones. These surfaces are covered with cartilage and the space between them is filled by a mass, consisting largely of dense connective tissue and partly of fibrocartilage, which is termed the *interpubic fibrocartilage*. This interpubic tissue is broader in front than behind and its posterior portion frequently contains a space resembling an articular cavity, so that the symphysis is converted into a half joint (amphiarthrosis).

The symphysis is reinforced by fibers which pass across its upper margin from the pubic spine of one side to that of the other; these fibers are intimately connected with the interpubic fibrocartilage and form the *superior pubic ligament* (Fig. 210). The lower margin of the symphysis is reinforced by a more independent structure, the *arcuate (inferior pubic) ligament* (Figs. 206 and 208), which is approximately triangular and rounds off the pubic angle.

The posterior connection of the pelvic girdle is a paired articulation which is termed the *sacroiliac articulation*. It occurs between the auricular surface of the sacrum and the similarly named surface of the ilium, and is an almost immovable joint, a true amphiarthrosis. The rough irregular surfaces of the two bones are scarcely adapted for reciprocal movements, and the strong ligaments surrounding the articulation further insure its immobility.

In addition to being connected by the auricular surfaces, the innominate bone and the sacrum are also held together by a strong ligament passing between the tuberosities of the two

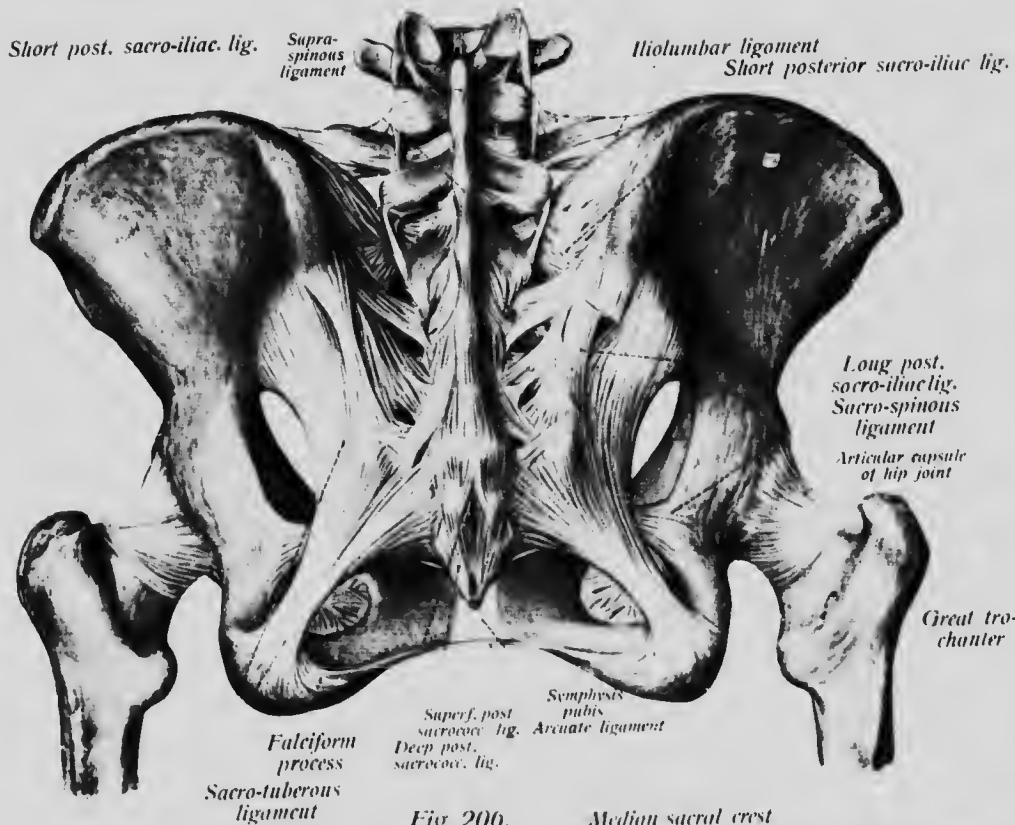
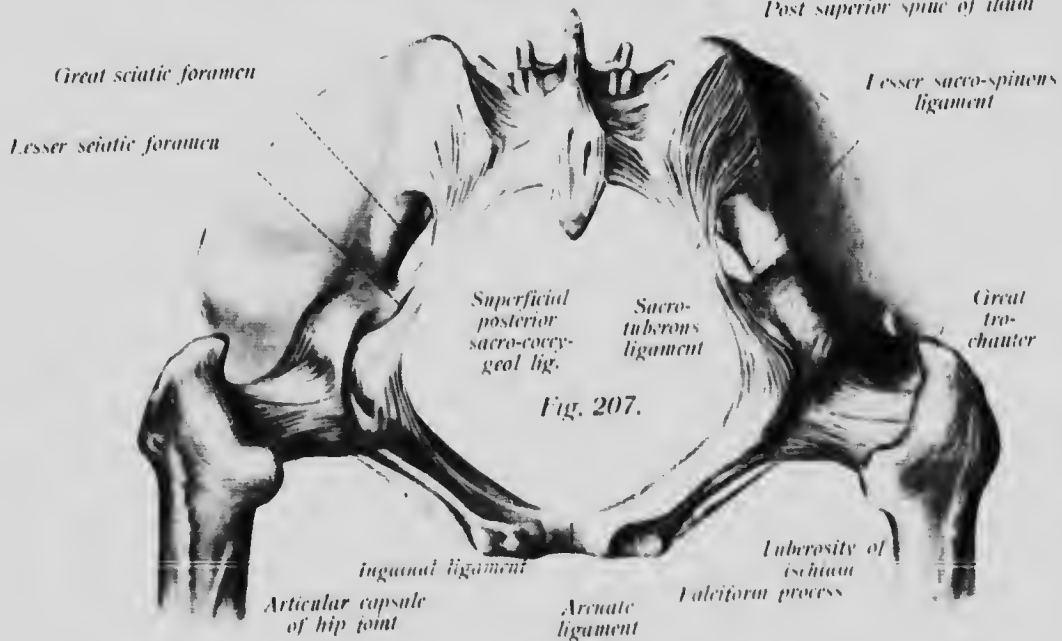

Fig. 206.

Median sacral crest

Post superior spine of ilium



1870
1871
1872
1873
1874
1875
1876
1877
1878
1879
1880
1881
1882
1883
1884
1885
1886
1887
1888
1889
1890
1891
1892
1893
1894
1895
1896
1897
1898
1899
1900
1901
1902
1903
1904
1905
1906
1907
1908
1909
1910
1911
1912
1913
1914
1915
1916
1917
1918
1919
1920
1921
1922
1923
1924
1925
1926
1927
1928
1929
1930
1931
1932
1933
1934
1935
1936
1937
1938
1939
1940
1941
1942
1943
1944
1945
1946
1947
1948
1949
1950
1951
1952
1953
1954
1955
1956
1957
1958
1959
1960
1961
1962
1963
1964
1965
1966
1967
1968
1969
1970
1971
1972
1973
1974
1975
1976
1977
1978
1979
1980
1981
1982
1983
1984
1985
1986
1987
1988
1989
1990
1991
1992
1993
1994
1995
1996
1997
1998
1999
2000
2001
2002
2003
2004
2005
2006
2007
2008
2009
2010
2011
2012
2013
2014
2015
2016
2017
2018
2019
2020
2021
2022
2023
2024
2025

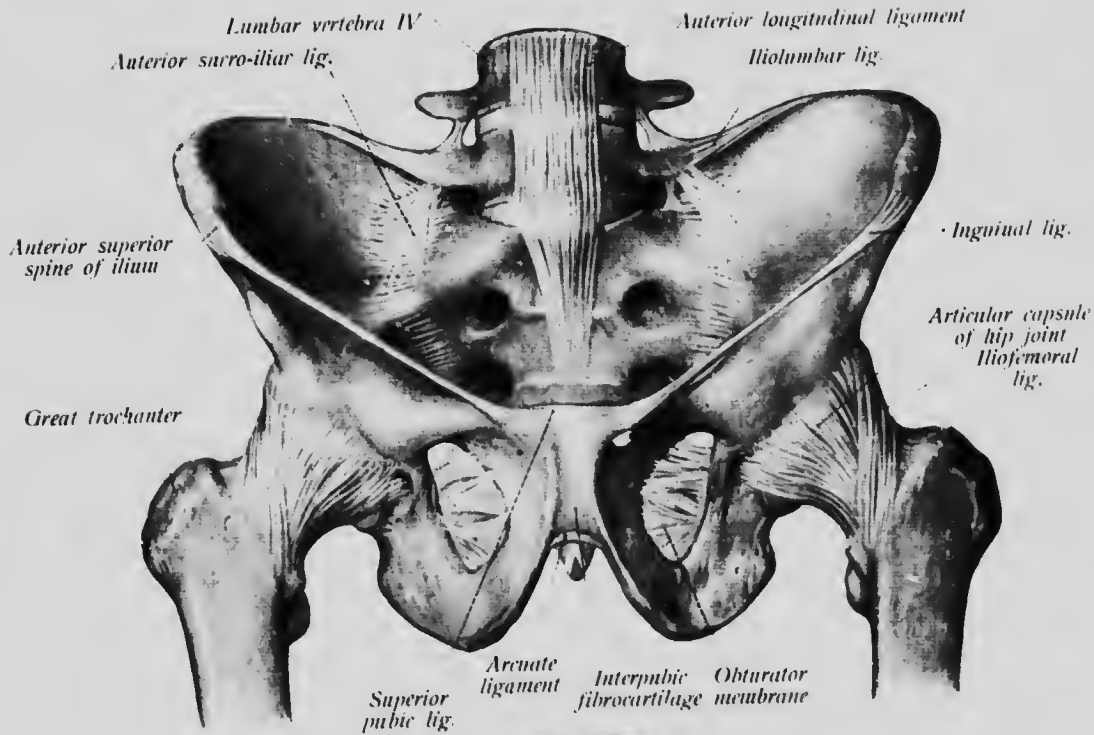


Fig. 208.

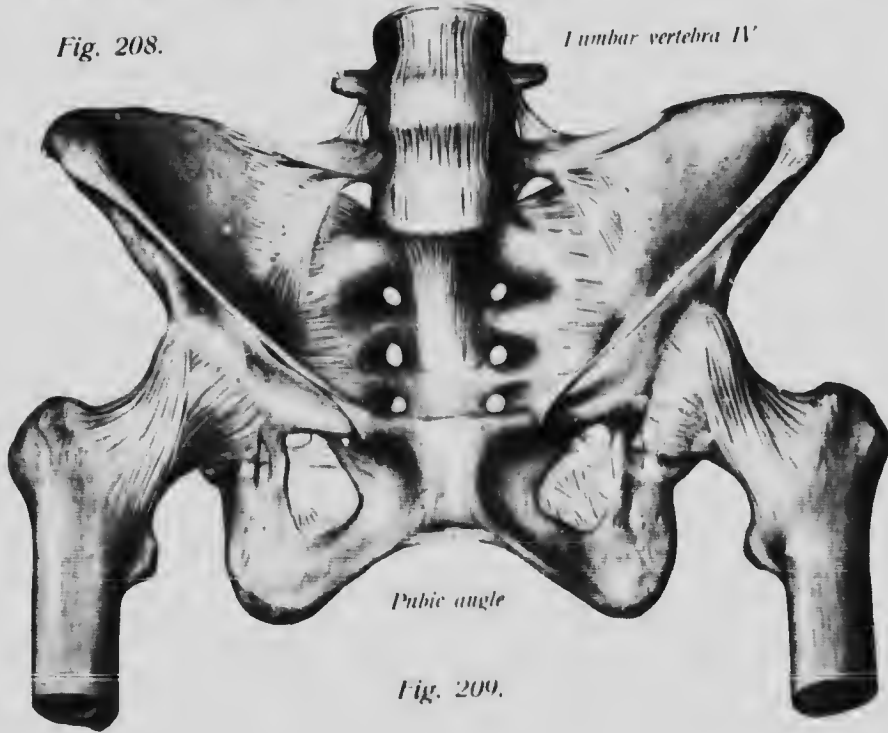


Fig. 209.

1870
1871
1872
1873
1874
1875
1876
1877
1878
1879
1880
1881
1882
1883
1884
1885
1886
1887
1888
1889
1890
1891
1892
1893
1894
1895
1896
1897
1898
1899
1900
1901
1902
1903
1904
1905
1906
1907
1908
1909
1910
1911
1912
1913
1914
1915
1916
1917
1918
1919
1920
1921
1922
1923
1924
1925
1926
1927
1928
1929
1930
1931
1932
1933
1934
1935
1936
1937
1938
1939
1940
1941
1942
1943
1944
1945
1946
1947
1948
1949
1950
1951
1952
1953
1954
1955
1956
1957
1958
1959
1960
1961
1962
1963
1964
1965
1966
1967
1968
1969
1970
1971
1972
1973
1974
1975
1976
1977
1978
1979
1980
1981
1982
1983
1984
1985
1986
1987
1988
1989
1990
1991
1992
1993
1994
1995
1996
1997
1998
1999
2000
2001
2002
2003
2004
2005
2006
2007
2008
2009
2010
2011
2012
2013
2014
2015
2016
2017
2018
2019
2020
2021
2022
2023
2024
2025

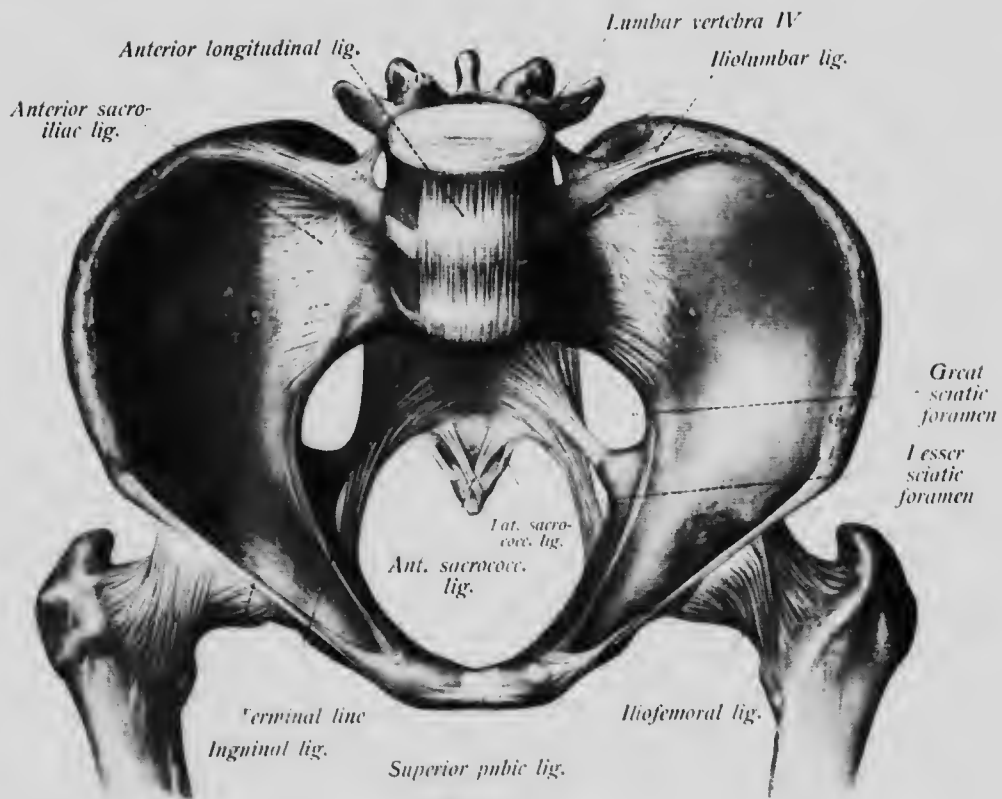


Fig. 210.

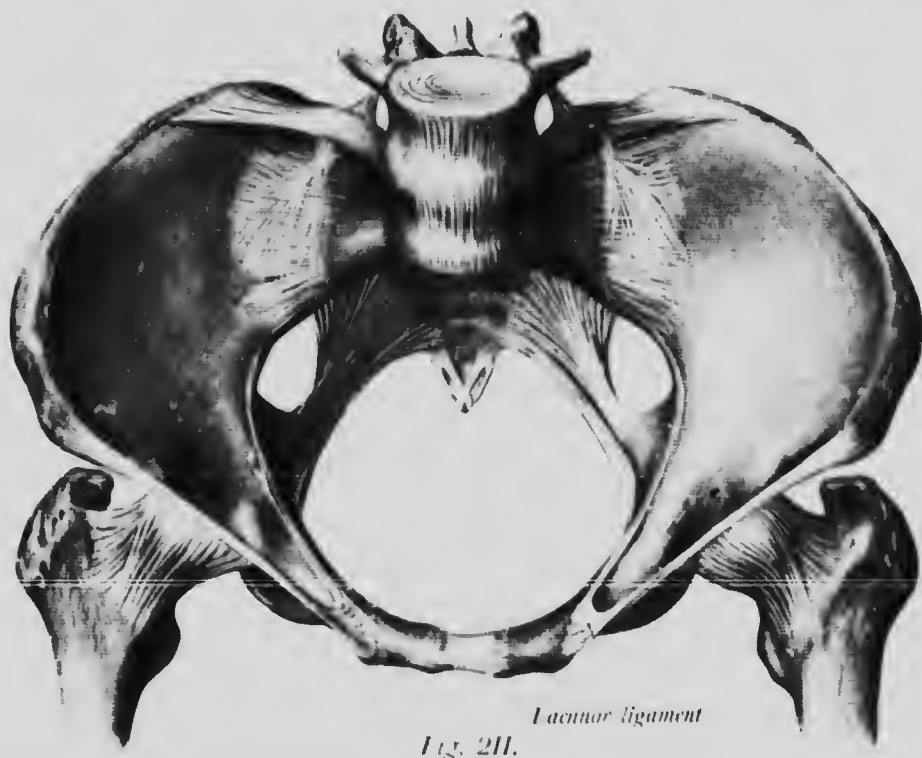



Fig. 211.



bones, the *interosseous sacroiliac ligament* (Fig. 215). Since this ligament completely fills the space between the tuberosities of the ilium and the sacrum, it may be said that these two bones are connected anteriorly by an amphiarthrosis and posteriorly by a syndesmosis, but from the physiological standpoint, the syndesmosis is the most important part of the articulation, since it firmly unites the pelvic bone to the sacrum which bears the weight of the entire trunk.

The sacrum and ilium are also connected by the following ligaments: the *anterior sacroiliac ligaments* (Figs. 208, 210, and 215), which pass as flat bands, composed of transverse, oblique, and frequently interlacing fibers, from the anterior surface of the sacrum in front of the iliosacral joint to the anterior surface of the ilium, and particularly to the linea terminalis; the *posterior sacroiliac ligaments* (Figs. 206 and 215), of which there are to be distinguished a long and a short ligament. The *short posterior sacroiliac ligament* consists of a number of fibers which pass obliquely from the lateral ridges of the sacrum to the iliac crest in the region of the posterior inferior spine. The *long posterior sacroiliac ligament* is composed of superficial longitudinal fasciculi which run from the posterior superior spine of the ilium to the lateral portion of the dorsal surface of the sacrum and intermingle in this situation with the origin of the *sacro-tuberous (great sacrosciatic) ligament*. It covers in the corresponding short ligament posteriorly.

The iliac bone is also connected to the fifth lumbar vertebra by the *iliolumbar ligament* (Figs. 206 and 208). This is a strong ligament which passes from the transverse process of the fifth lumbar vertebra to the iliac crest, and is frequently connected with the uppermost fibers of the anterior sacroiliac ligament. Through it the last lumbar vertebra and also the last intervertebral fibrocartilage are included in the pelvis, and are connected not only with the ilium but also with the sacrum.

THE INDEPENDENT LIGAMENTS OF THE PELVIS.

In addition to the ligaments which directly connect the individual parts of the pelvic girdle, there is another series of ligaments which belong to that class of ligaments which take the place of bones (see page 108). These are: (1) The *obturator membrane*; (2) the *sacro-tuberous (great sacrosciatic) ligament*; and (3) the *sacrospinous (lesser sacrosciatic) ligament*.

The *obturator membrane* (Figs. 208 and 216) is a rather thin membrane which closes in the obturator foramen with the exception of the upper portion, in which is situated the prolongation of the obturator groove, the opening, the *obturator canal* (Fig. 216), which thus forms giving passage to the obturator vessels.

The *sacro-tuberous (great sacrosciatic) ligament* (Figs. 206, 207, 210, and 211) has a broad origin from the lateral portion of the entire posterior surface of the sacrum, from the posterior portion of the iliac crest in the region of the posterior superior and inferior spines (where it is connected with the posterior sacroiliac ligaments), and from the posterior surface of the coccyx. It becomes narrower as it passes downward, but again broadens out near its insertion into the tuberosity of the ischium. It covers the sacrospinous ligament posteriorly, and the two ligaments are adherent at their intersection. The *spur-like process* (Figs. 206 and 207) is a narrow oblique continuation of the sacro-tuberous ligament, which passes along the lower margin of the ischium and pubis and gradually disappears anteriorly.

The *sacrospinous (lesser sacrosciatic) ligament* (Figs. 206, 207, 210, and 211) is more deeply situated than the sacrotuberous ligament, and arises from the lateral margins of the lower portion of the sacrum and of the upper portion of the coccyx. It rapidly becomes narrower and passes almost horizontally forward and outward, crossing the sacrotuberous ligament shortly before reaching its insertion at the tip of the spine of the ischium. Its pelvic surface covers and is adherent to the coccygeus muscle (see Splanchnology).

The sacrospinous ligament converts the greater sciatic notch into an elliptical foramen which is termed the *great sciatic (sacrosciatic) foramen*, and the two ligaments, the sacrospinous and the sacrotuberous, convert the lesser sciatic notch into a foramen, the *lesser sciatic (sacrosciatic) foramen*. This latter foramen is triangular with rounded angles and is separated from the great sciatic foramen by the sacrospinous ligament. The sacrotuberous ligament forms a portion of the outlet of the pelvis.

THE PELVIS AS A WHOLE.

The following bones enter into the formation of the pelvis: the two innominate bones, the sacrum, the coccyx, and the fifth lumbar vertebra; and its boundaries are also partly formed by the interpubic fibrocartilage, the obturator membrane, and the sacrotuberous and sacrospinous ligaments. The iliolumbar ligament forms a portion of the pelvic wall.

In the *pelvis* may be recognized the *false* or *greater pelvis*, and the *true* or *lesser pelvis*. The former forms the floor of the abdominal cavity, and is wide open above and in front and is bounded only partly by bone. Its cavity is considerably larger than that of the true pelvis, from which it is separated by the terminal (iliopectineal) line (Fig. 210). It is bounded by the ale of the ilium, by the fifth lumbar vertebra together with the promontory, and by two iliolumbar ligaments.

The *true* or *lesser pelvis* is a short canal, the greater portion of whose boundaries are bony. The anterior wall is short while the posterior one is considerably longer, and it is open above and below. The upper opening is termed the *superior aperture of the pelvis* or the *pelvic inlet* (Figs. 210 and 211), whose boundary is formed by the terminal line, by the promontory, and by the upper margin of the interpubic fibrocartilage. The terminal line is composed of a sacral, an iliac (the arcuate line), and a pubic (crest of the pubis) portion.

The actual *cavity of the pelvis* is bounded posteriorly by the concave pelvic surface of the sacrum and by the anterior surface of the coccyx; laterally by the pelvic surfaces of the bodies of the ilium, pubis, and ischium (the floor of the acetabulum), by the sacrotuberous and sacrospinous ligaments, by the rami of the pubis and ischium, and by the obturator membranes; and anteriorly by the symphysis pubis with its ligaments and by the anterior extremities of the two pubic bones.

The anterior wall of the pelvic cavity is by far the shortest, while the posterior wall is the longest. The posterior portions of the lateral walls exhibit two openings, the upper elliptical greater sciatic foramen and the lower triangular lesser sciatic foramen; the anterior portions contain the openings in the obturator membranes which form the obturator canals (see page 129). The upper more capacious portion of the pelvic cavity is designated as the *plane of pelvic expansion*, while the inferior contracted portion is known as the *plane of pelvic contraction*.

The *inferior aperture of the pelvis* or *pelvic outlet* (Fig. 207) is bounded by the lower margin of the symphysis (arcuate ligament), by the tuberosities of the ischium, by the inferior rami of the ischium and pubis, by the sacrotuberous ligaments, and by the tip and the lateral margins of the sacrum. These boundaries, unlike those of the pelvic inlet, do not lie in the same plane. The coccyx forms the lowermost point of the pelvic outlet, and next come the tuberosities of the ischia, which project downward, while the boundary curves markedly upward in the region of the sacrotuberous ligaments and particularly at the lower margin of the symphysis.

The angle which the two inferior rami of the pubis form with the symphysis is known as the *pubic angle* (Fig. 209). It is rounded off by the arcuate ligament to form the *pubic arch*.

The pelvis is not horizontal but inclined, the degree of its inclination varying in different individuals, but usually averaging about 60 degrees. The plane of the pelvic inlet consequently passes obliquely from above downward and from behind.

The pelvis exhibits, as does no other portion of the skeleton, typical sexual characteristics. This is particularly noticeable in the true pelvis. In the female the false pelvis is lower, broader, and flatter, and the alæ of the ilium usually show a less marked curvature. The true pelvis exhibits similar characteristics, and its cavity in particular is more capacious. In the male the pelvic inlet is heart-shaped (from the marked projection of the promontory), while in the female it is elliptical, and the pelvic outlet in the male is also much narrower than in the female on account of the convergence of the tuberosities of the ischia. The pubic angle in the male pelvis forms an acute angle of about 75 degrees, while in the female it forms a right or obtuse angle (90 to 100 degrees).

For a more detailed account of the pelvic diameters and of the pelvis in its relations to obstetrics the reader is referred to the text-books and atlases of topographic anatomy.

The *inguinal* or *Poupart's ligament* (Figs. 207 and 209) is not one of the actual ligaments of the pelvis, but is a portion of the aponeurosis of the external oblique muscle of the abdomen. It arises from the anterior superior spine of the ilium and is inserted into the spine of the pubis. An almost horizontal continuation of the ligament passes from its insertion to the upper margin of the horizontal ramus of the pubis, forming the *lacunar* (Gimbernat's) *ligament* (Fig. 207).

THE HIP-JOINT.

The *hip-joint* or *coxal joint* is the articulation between the acetabulum of the innominate bone and the head of the femur. The acetabular cavity is considerably deepened by a strong circular fibrocartilaginous ligament, the *glenoidal lip* (cotyloid ligament) (Fig. 216), so that the socket embraces more than half of the spherical head of the femur, and the joint consequently belongs to that group of the spheroidal articulations which is known as an *enarthrosis*.

The *glenoidal lip* (Fig. 214) of the hip-joint is triangular in cross-section and stretches across the notch of the acetabulum, converting it into a cleft-like foramen. This portion of the glenoidal lip is known as the *transverse ligament* (Fig. 214).

The acetabular fossa (Fig. 214) does not come into direct contact with the cartilaginous surface of the head of the femur and is not covered with cartilage, but by a cushion of fat and by synovial villi. From this fatty cushion, and particularly from the acetabular notch, there arises

FIG. 212.—The right hip-joint seen from in front (3).

FIG. 213.—The right hip-joint seen from behind (3).

FIG. 214.—Socket of the right hip-joint after cutting through the articular capsule and the round ligament. The head of the femur has been removed (3).

FIG. 215.—Section through the pelvis and the two hip-joints taken in a plane almost at right angles to the axis of the pelvis (3).

FIG. 216.—The right hip-joint opened through the anterior wall of the articular capsule so as to show the round ligament. The head of the femur has been drawn out of the socket and rotated outward and backward (3).

a broad characteristic ligament of the hip-joint, the *round ligament* (*ligamentum teres*) (Figs. 214 and 216), which becomes slightly narrower and is inserted into the depression on the head of the femur. This ligament is flat, and only its external portion is formed of firm connective-tissue fasciculi; in its interior nutrient vessels pass to the head of the femur. It lies in folds upon the cushion of fat in the acetabular fossa, and on account of its length and soft structure plays little part in checking the movements of the joint.

The strong *articular capsule* of the hip-joint (Figs. 212, 213, and 215) is markedly reinforced by accessory ligaments. It arises from the outer circumference of the glenoidal lip and embraces not only the head of the femur but also the greater portion of its neck. Anteriorly it is inserted into the intertrochanteric line; posteriorly it does not extend so far, and surrounds only somewhat more than the half of this portion of the neck of the femur.

The reinforcing ligaments are firmly adherent to the capsule of the hip-joint and are composed of longitudinal and of circular fibers. The latter are known as the *orbicular ligament* (*zona orbicularis*) (Fig. 215) and embrace the narrowest portion of the femoral neck; they pursue a circular course within the innermost fibrous layers of the capsular ligament and are rather intimately connected with the longitudinal ligaments. The longitudinal fasciculi receive different names according to their places of origin, and since each of the three parts of the innominate bone gives origin to one of the fasciculi, they are consequently known as the *iliofemoral*, *pubocapsular*, and *ischiocapsular ligaments*.

The *iliofemoral ligament* (Figs. 212 and 216) is the strongest of the three ligaments and is one of the thickest ligaments in the body. It arises in the region of the anterior inferior spine of the ilium, passes obliquely across the anterior surface of the articular capsule, broadening as it goes, and is inserted into the entire length of the intertrochanteric line. The *pubocapsular ligament* (Figs. 212 and 216) arises from the horizontal ramus of the pubis and passes across the inner and posterior portion of the articular capsule toward the lesser trochanter. The *ischiocapsular ligament* (Figs. 215 and 218) arises from the body of the ischium and runs in the posterior portion of the capsular ligament; the majority of its fibers pass into the *zona orbicularis*, but some of them converge upward to the great trochanter.

The thinnest places in the capsule of the hip-joint are situated in its lower portion between the pubocapsular and the ischiocapsular ligaments, and above the *zona orbicularis* between the ischiocapsular and iliofemoral ligaments. There is also a thin place in the antero-internal wall of the capsule between the iliofemoral and pubocapsular ligaments, and a communication occasion-

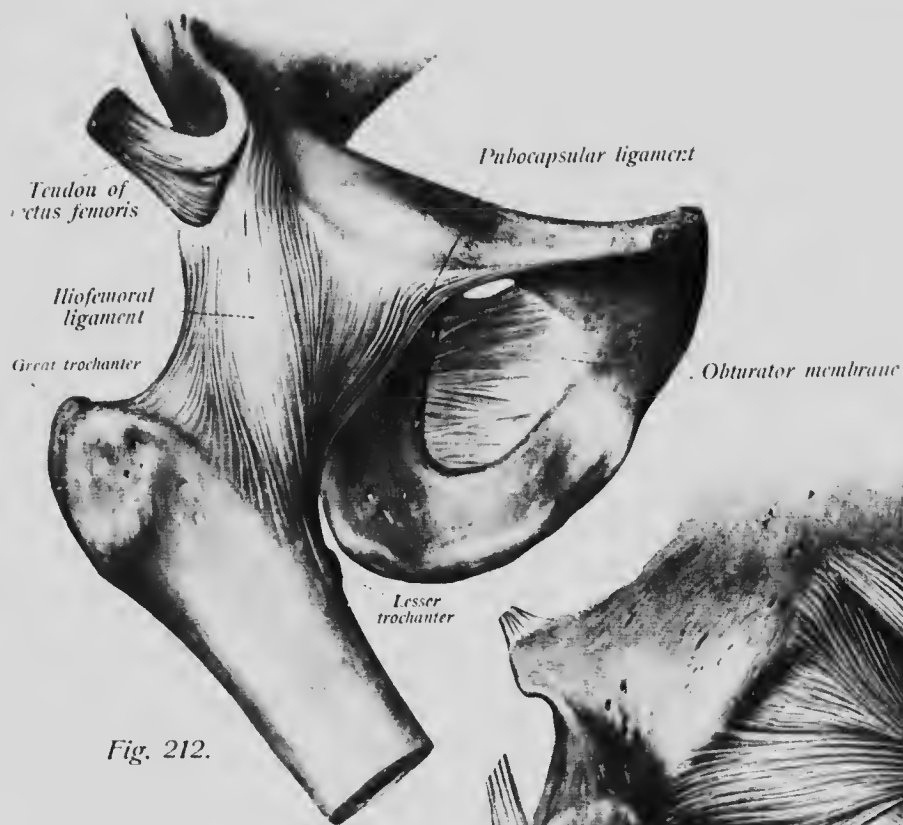


Fig. 212.

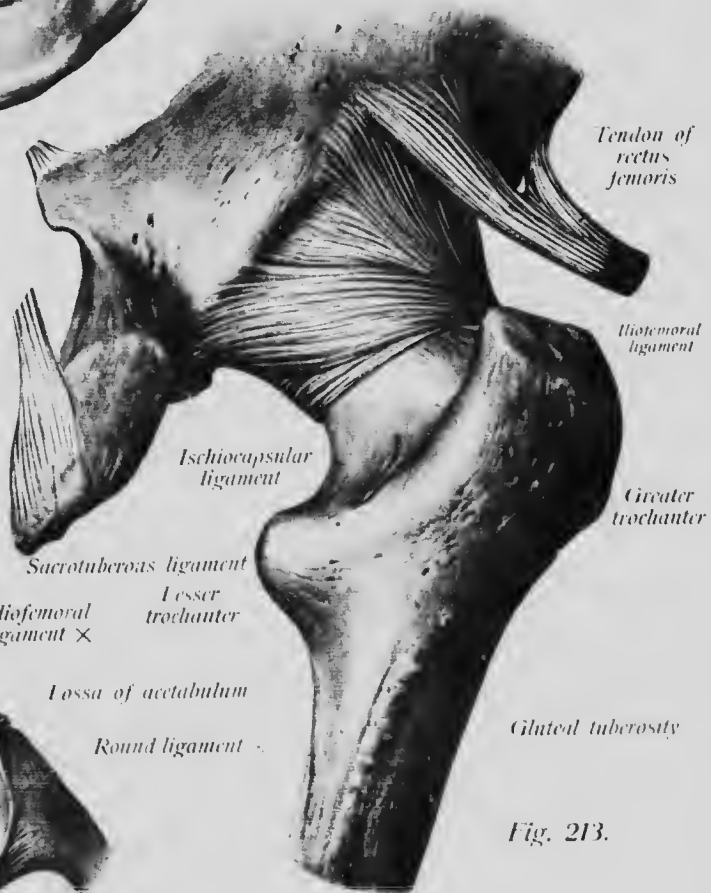


Fig. 213.

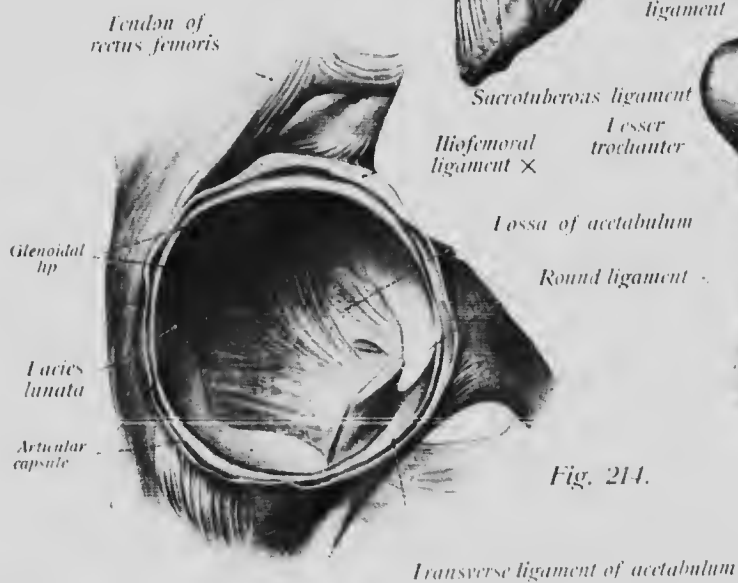


Fig. 214.

1870
1871
1872
1873
1874
1875
1876
1877
1878
1879
1880
1881
1882
1883
1884
1885
1886
1887
1888
1889
1890
1891
1892
1893
1894
1895
1896
1897
1898
1899
1900
1901
1902
1903
1904
1905
1906
1907
1908
1909
1910
1911
1912
1913
1914
1915
1916
1917
1918
1919
1920
1921
1922
1923
1924
1925
1926
1927
1928
1929
1930
1931
1932
1933
1934
1935
1936
1937
1938
1939
1940
1941
1942
1943
1944
1945
1946
1947
1948
1949
1950
1951
1952
1953
1954
1955
1956
1957
1958
1959
1960
1961
1962
1963
1964
1965
1966
1967
1968
1969
1970
1971
1972
1973
1974
1975
1976
1977
1978
1979
1980
1981
1982
1983
1984
1985
1986
1987
1988
1989
1990
1991
1992
1993
1994
1995
1996
1997
1998
1999
2000
2001
2002
2003
2004
2005
2006
2007
2008
2009
2010
2011
2012
2013
2014
2015
2016
2017
2018
2019
2020
2021
2022
2023
2024
2025

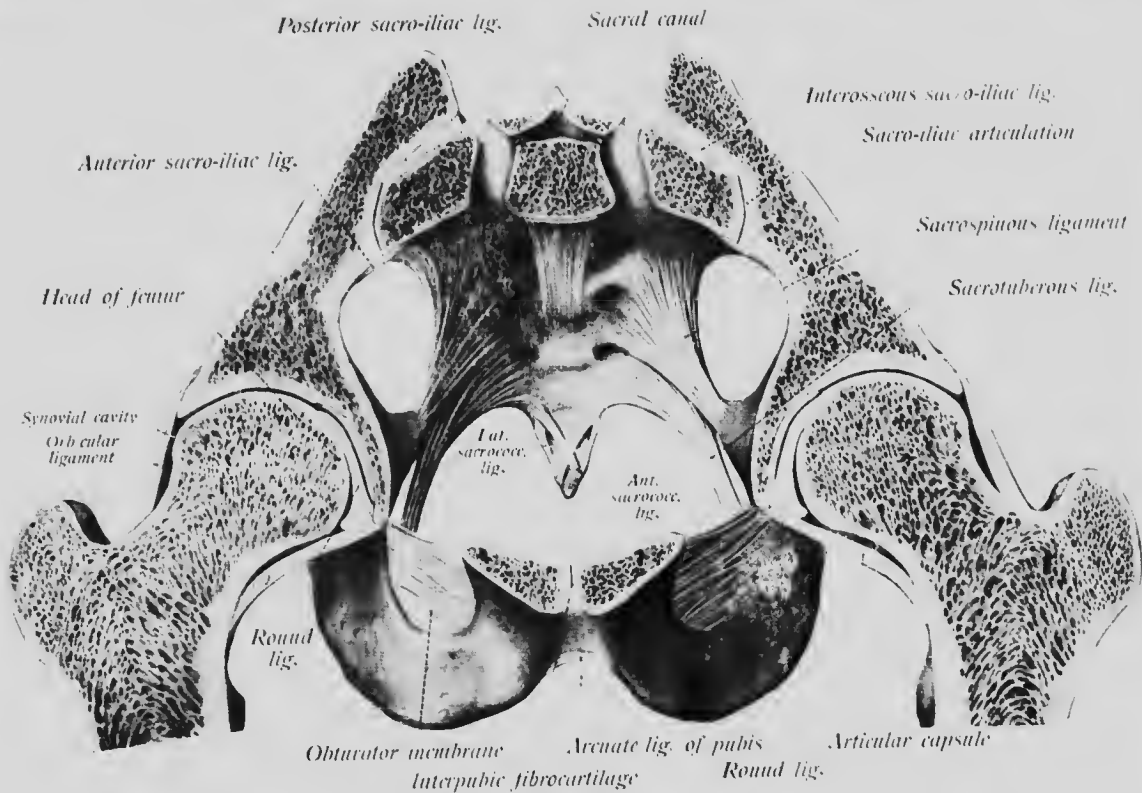


Fig. 215.

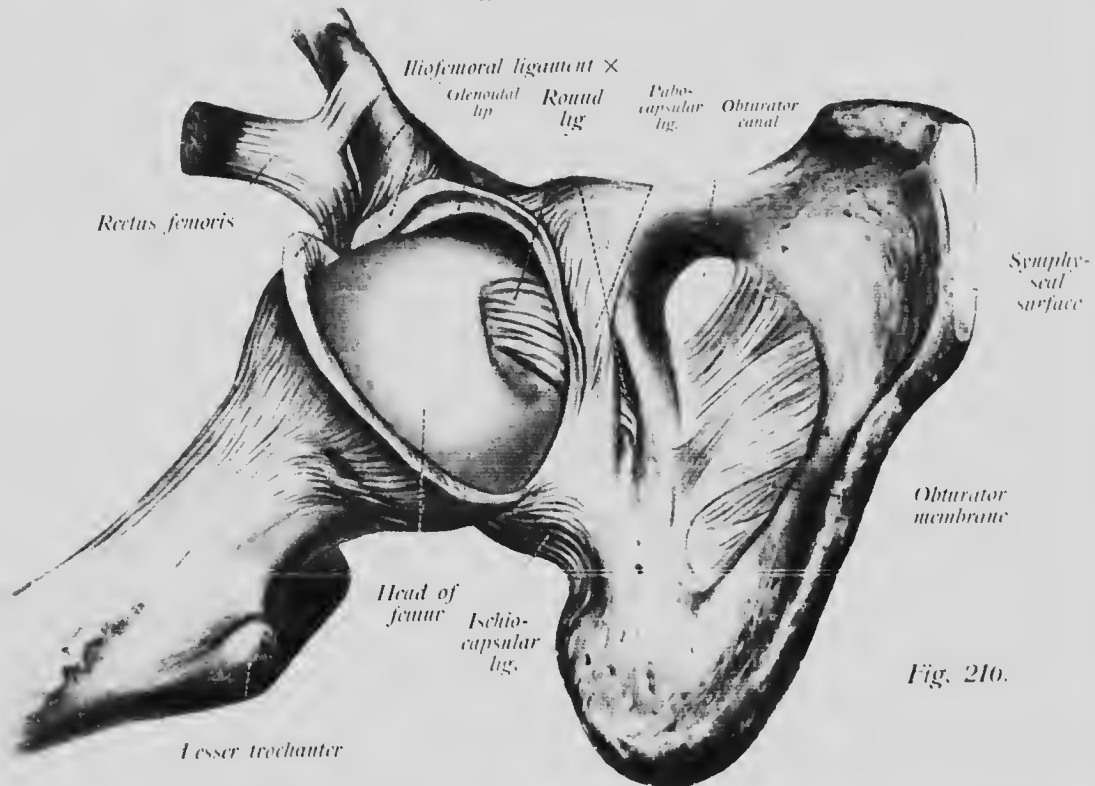


Fig. 216.



ally exists at this point between the synovial cavity of the hip and the *iliopectineal bursa* which is situated beneath the iliopsoas muscle (see page 211).

The hip-joint is a ball-and-socket joint, and although the socket embraces more than one-half of the spherical head of the femur and limits the range of motion to a slight extent, movements in all directions are possible. Since the head of the femur forms a marked angle with the axis of the bone, the axis of movement of the joint does not pass through, but forms an acute angle with, that of the femur. The chief movements of the hip-joint are abduction and adduction (separation and approximation of the lower extremities), flexion (anteriorly) and extension (dorsal flexion is impossible on account of the tension of the iliofemoral ligament), rotation, and circumduction. When the joint is half flexed (the "middle" position) all of the ligaments are relaxed. In the upright position the iliofemoral ligaments are tense and steady the pelvis upon the femora.

The round ligament has no mechanical function whatever, but acts simply as a ligament of conduction (see page 158). It is occasionally wanting in man and regularly absent in many animals, and is to be regarded as an originally extra-articular structure, probably a portion of the pectineus muscle, which has been displaced into the joint. The head of the femur is held in its socket not only by the strong capsular ligaments but also by atmospheric pressure.

THE KNEE-JOINT.

The *knee-joint* (Figs. 217 to 222) is the articulation between the condyles (and the articular surface for the patella) of the femur and the condyles of the tibia, and the posterior surface of the patella is also passively involved in the formation of the articulation. Disregarding the patella, it will be noticed that, in contrast to the elbow, only two bones are included in the articulation, as the fibula is completely excluded from it.

From the form of its articular surfaces as well as on account of the manifold character of its structures, the knee-joint is one of the most complicated articulations of the human body. The articulating surfaces are incongruent, since the concavities of the condyles of the tibia are less than the convexities of the condyles of the femur. The *femoral condyles* are separated by the deep intercondylar fossa, and their posterior portions are spherical while their anterior surfaces are cylindrical and unite in front of the intercondyloid fossa to form the articular surface for the patella (Fig. 220). Ordinarily the condyles of the femur present their cylindrical surfaces to the tibia and the articulation is consequently a hinge joint, the intercondyloid eminence of the tibia being received into the intercondyloid notch of the femur and preventing lateral displacement of the articulating surfaces. The most posterior portions of the femoral condyles, however, are spherical, and when they rest upon the condyles of the tibia, during flexion of the knee joint, they form a double arthrodial joint. From the shape of its articulating surfaces the knee joint is consequently a ginglymo arthrodial articulation.

Upon the condyle of the tibia are situated two *menisci*, which from their position are termed the *internal* and the *external meniscus* (Fig. 221). They are but loosely connected with the condyles of the tibia and are attached only to the capsular ligament and to the intercondyloid eminence, so that they may be moved upon the surfaces of the tibial condyles. Their external margins are thick, their internal margins thin, and their cross-sections are decidedly wedge-shaped.

The *internal meniscus* (the *internal semilunar cartilage*) is narrower than the external one and does not form a complete semicircle, but is a segment of a circle whose radius is larger than that of the external meniscus. The *external meniscus* (the *external semilunar cartilage*) is almost completely circular and is open only at its point of attachment to the intercondyloid eminence.

FIG. 217.—The right knee-joint in extension seen from in front (3).

FIG. 218.—The right knee-joint in extension seen from behind (3).

FIG. 219.—The right knee-joint in extension opened by two lateral incisions. The quadriceps muscle, together with the patella, has been reflected downward (3).

FIG. 220.—The right knee-joint in flexion after removal of the articular capsule and the lateral ligaments (3).

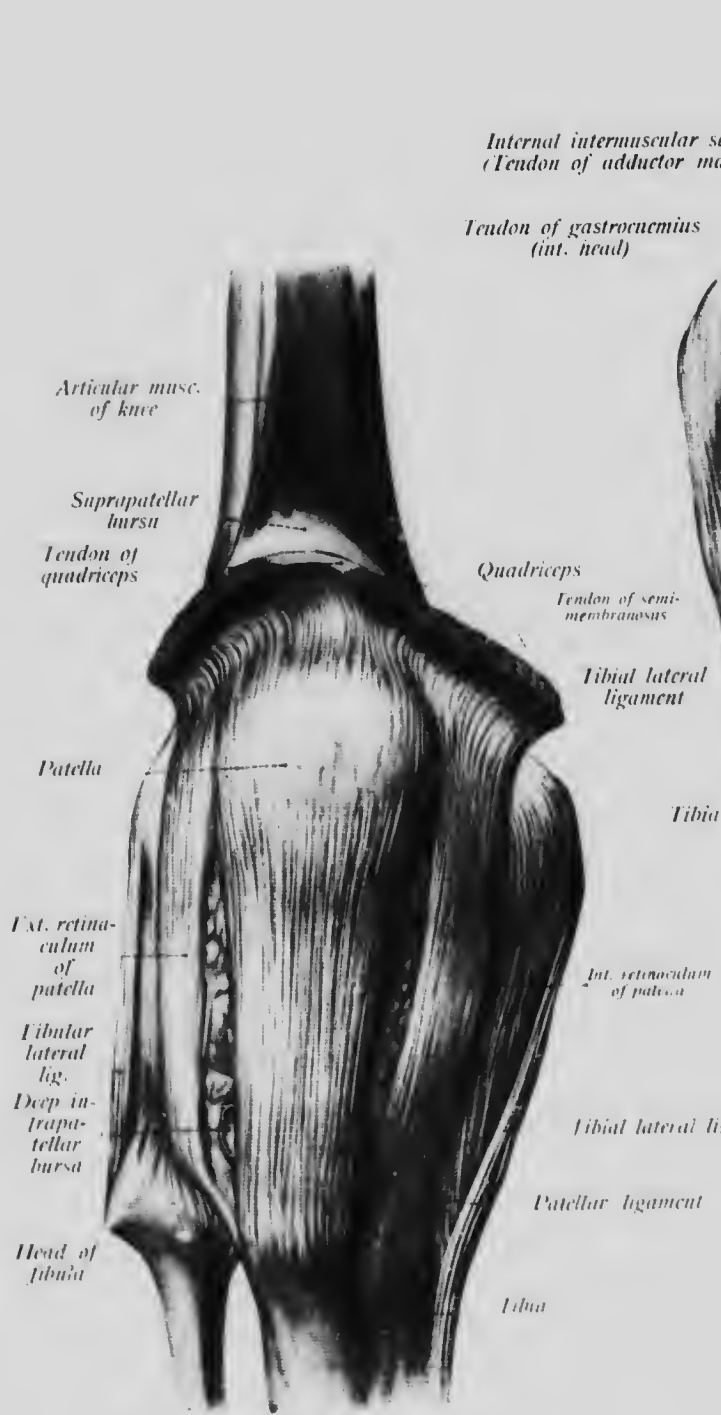
It is broader than the internal meniscus, and, as its radius is smaller, it covers the condyle of the tibia except in the situation of its relatively small median hiatus. It arises in the anterior intercondyloid fossa of the tibia and runs to the external intercondyloid tubercle, while the internal meniscus passes from the anterior margin of the articular surface of the internal condyle to the posterior intercondyloid fossa. The anterior portions of both menisci are connected by fasciculi which vary greatly in their development and are known as the *transverse ligament*, and their thick external margins are adherent to the articular capsule, the external meniscus being less intimately adherent, and hence more movable than the internal one.

In addition to the menisci, the articular cavity also contains two important accessory ligaments, the *crucial ligaments* (Figs. 220 and 221), of which there are two, an *anterior* and a *posterior*. Their anterior surfaces are provided with a synovial covering which passes as a septum through the posterior portion of the articulation, and they are strong ligaments firmly connecting the tibia with the femur. They both arise from the intercondyloid fossa of the femur and pass to the tubercles and intercondyloid fossa of the tibia. The anterior ligament has a broad origin on the inner surface of the external condyle of the femur, and, becoming narrower, it passes to the anterior intercondyloid fossa and to the anterior intercondyloid tubercle of the tibia. The posterior ligament passes from the outer surface of the internal condyle of the femur to the posterior intercondyloid fossa and to the corresponding tubercle of the tibia; it is flat at its origin but rounded at its insertion, and is usually stronger than the anterior ligament. During rest (semiflexion), the two ligaments cross in such a way that the anterior one is in front of the posterior. The latter is usually connected with the external meniscus.

With the exception of certain diverticula of the synovial membrane, which will subsequently be described, the articular capsule is attached to the margins of the cartilaginous articular surfaces. Its line of attachment upon the posterior surface of the femur is indicated by the intercondyloid line, so that the entire intercondyloid fossa is situated within the articular cavity.

The knee joint possesses a number of peculiarities: its synovial folds are more pronounced than those of any other joint in the body; its synovial membrane gives off diverticula, some of which are of large size and pass beneath the neighboring muscles; it is much strengthened by the majority of the overlying tendons; and the patella is embedded in the anterior portion of the articular capsule and forms the immediate anterior boundary of the articular cavity.

The majority of the reinforcing ligaments of the knee joint are adherent to the capsule throughout the greater portion of their extent. There are two lateral ligaments, the *fibular* and the *tibial lateral ligament*. The *tibial (internal) lateral ligament* (Figs. 217 and 218) arises from the internal epicondyle and is intimately adherent to the capsular ligament; its superficial fibers run to the



Articular musc.
of knee

Suprapatellar
bursa

Tendon of
quadriceps

Patella

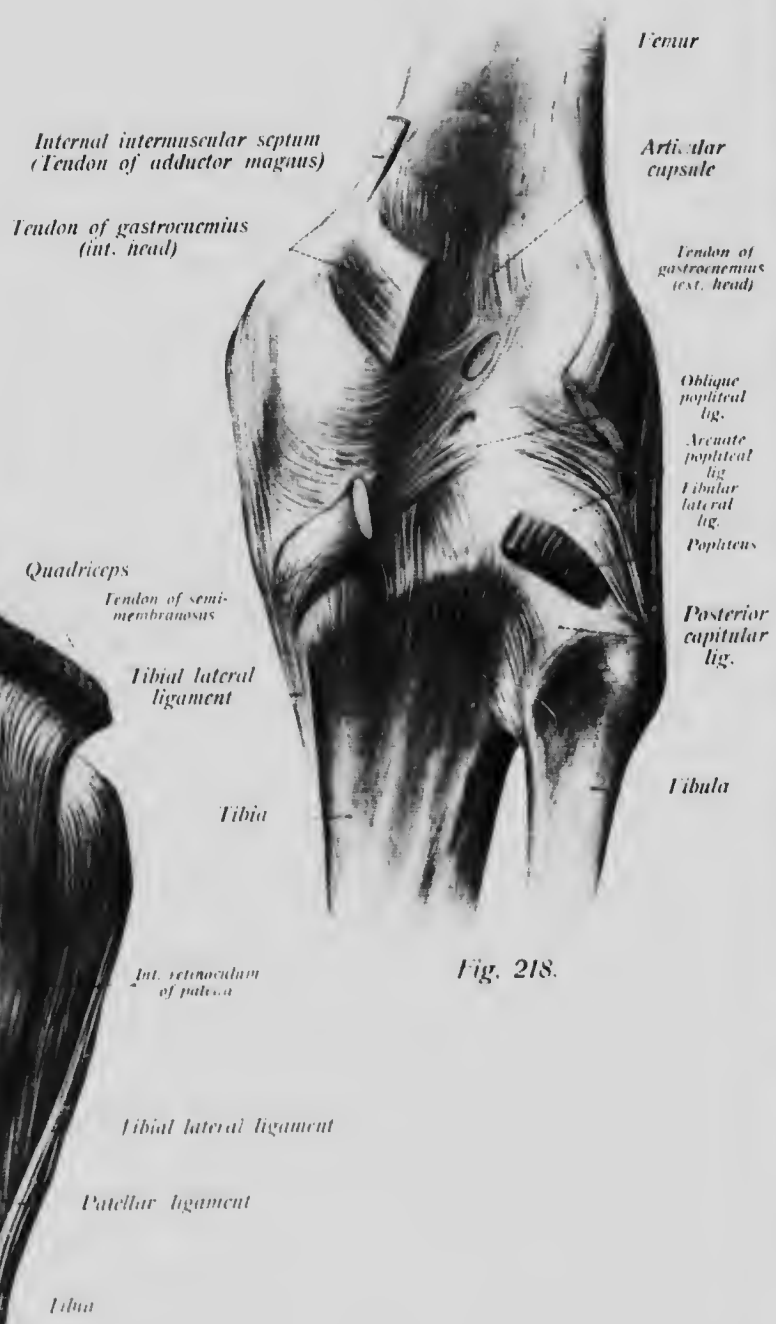Ext. retina-
culum
of
patella

Fibular
lateral
lig.

Deep in-
frapa-
tellar
bursa

Head of
fibula

Fig. 217.



Internal intermuscular septum
(Tendon of adductor magnus)

Tendon of gastrocnemius
(int. head)

Quadriceps

Tendon of semi-
membranosus

Tibial lateral
ligament

Tibia

Int. retinaculum
of patella

Fibular lateral ligament

Patellar ligament

Tibia

Femur

Articular
capsule

Tendon of
gastrocnemius
(ext. head)

Oblique
popliteal
lig.

Arcuate
popliteal
lig

Fibular
lateral
lig.

Popliteus

Posterior
capsular
lig.

Tibula

Fig. 218.



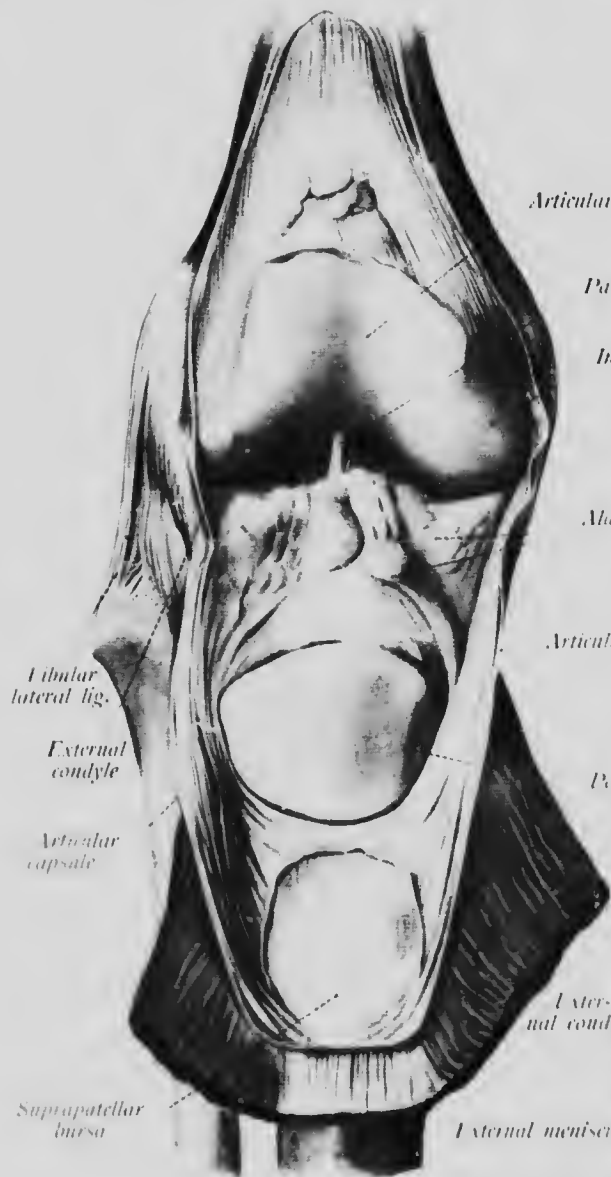

Fig. 210.

Articular surface for patella
Patellar fold of synovial membrane
Internal condyle
Muc folds
Articular capsule
Patella
Patellar surface

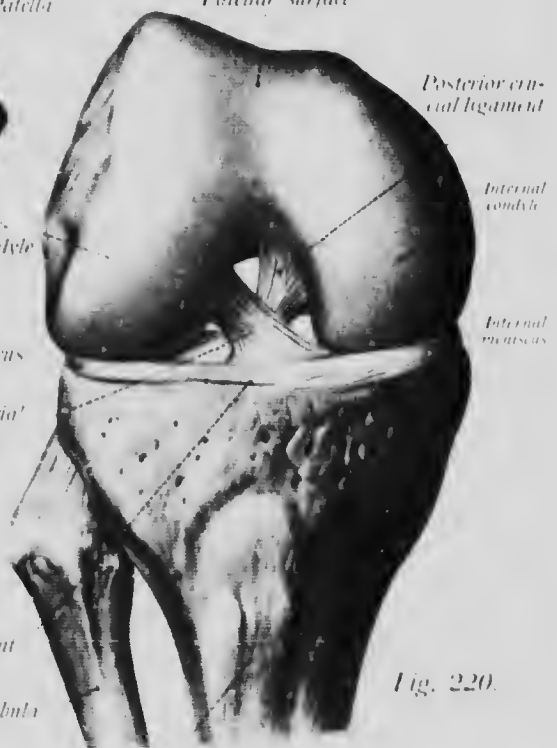

Fig. 220.

External meniscus
Anterior cruciate ligament
Anterior capsular lig.
Transverse ligament
Tibia
Tuberosity of tibia



inner margin of the condyle of the tibia, while the shorter deep fibers pursue a somewhat oblique course and pass posteriorly to be inserted into the internal meniscus and into the infraglenoidal margin of the internal condyle.

The main portion of the *fibular (external) lateral ligament* (Figs. 217, 218, and 219) is separated from the capsular ligament by fatty tissue, and consequently appears as a firm, independent, flattened cord which passes from the external condyle of the femur to the head of the fibula. A deeper and shorter portion of the ligament (the *short external lateral ligament*) is adherent to the capsule.

The posterior wall of the capsule is reinforced by two ligaments which are intimately connected with the muscles which have their insertion in the vicinity of the knee-joint. The *oblique popliteal ligament* (Fig. 218) is a continuation of the tendon of the semimembranosus muscle and runs obliquely from below upward and from within outward upon the posterior surface of the capsular ligament, in which structure it finally disappears. The *arcuate popliteal ligament* (Fig. 218) passes in a curved manner above the tendon of the popliteus muscle, the concavity of the curve being directed upward. It runs from the region of the external condyle of the femur to the posterior wall of the capsule of the knee joint, some of its fibers passing also to the head of the fibula and to the deeper fasciculi of the fibular lateral ligament, these fibers being termed the *retinaculum of the arcuate ligament*.

The anterior wall of the knee-joint is formed almost entirely by the tendon of the quadriceps cruris muscle and its continuations. The tendon of this muscle is really inserted into the base of the patella, but it is continued onward as the flat but very strong *patellar ligament* (Figs. 217 and 222) which passes from the tip of the patella to the tuberosity of the tibia. The patellar ligament, however, is independent of the knee-joint and is not adherent to the capsular ligament; it is one of the thickest ligaments of the body, and it is separated from the upper end of the tibia and from the capsular ligament by fatty tissue and by a constant bursa, the *accipitrua patellar bursa* (Fig. 222), which does not communicate with the synovial cavity. Both the patella and the actual tendon of the quadriceps, however, directly form a portion of the anterior boundary of the joint, and the anterior portion of the capsular ligament is also reinforced by lateral fibrous continuations of the quadriceps, which are known as the *internal* and *external patellar retinacula* (Fig. 217). They arise from the lateral margins of the patella, receive fibers from the vasti upon either side (see page 205), and pass downward to the lateral margins of the condyles of the tibia.

The synovial folds of the knee joint are the *alar folds* (Figs. 219 and 222) and the *patellar synovial fold* (Fig. 221). The greater portion of the alar folds consist of the fatty tissue which is situated behind the patellar ligament, and is covered by the synovial membrane; they project into the knee joint from either side of the patella. The *patellar synovial fold* is a fibrous band of variable size which usually contains a considerable quantity of fat; it arises from the anterior wall of the capsule between the two alar folds, with which it is connected, and is inserted into the intercondyloid fossa of the femur.

The largest diverticulum of the synovial membrane of the joint is the *suprapatellar bursa* (Fig. 222), which extends upward beneath the tendon of the quadriceps femoris for almost a hand's breadth. It always communicates with the synovial cavity, usually by quite a large aperture, and receives the insertion of those fibers of the quadriceps which are termed the articular

FIG. 221.—The condyles of the tibia with the two menisci and the origins of the crucial ligaments (4).

FIG. 222.—Sagittal section of the right knee-joint in extension. The section passes through the external condyle of the tibia (4).

FIG. 223.—The right tibia and fibula with their ligaments (4).

muscle of the knee (subcrureus) (see page 215). The suprapatellar bursa does not lie directly upon the anterior surface of the femur, but is separated from it by a cushion of fat.

There are two or three other considerably smaller diverticula of the synovial membrane at the posterior portion of the articulation. These are the *popliteal bursa*, beneath the tendon of the popliteus, the *semimembranous bursa*, beneath the tendon of the semimembranosus, and the *internal gastrocnemial bursa* (Fig. 304), beneath the tendon of the inner head of the gastrocnemius. The last two bursae may communicate.

There are other bursae in the neighborhood of the knee-joint which have no direct relation to the articulation. In addition to the previously mentioned deep infrapatellar bursa, these are: the *subcutaneous prepatellar bursa* (Fig. 222), a subcutaneous bursa which is constantly found in front of the patella; the *subfascial prepatellar bursa*, between the fascia and the tendon of the quadriceps; the *subtendinous prepatellar bursa*, between the quadriceps tendon and the periosteum of the patella; and the *subcutaneous infrapatellar bursa*, which is situated in front of the patellar ligament (see also page 234).

As might be supposed from the shape of the articulating surfaces, there are two kinds of motion possible in the knee-joint, a hinge motion (flexion of the leg and the return to the extended position) and a movement of rotation which is possible only when the knee is flexed. Rotation is impossible when the knee is extended, not only from the shape of the articulating surfaces (see page 135), but especially on account of the tension of the lateral ligaments, which are relaxed only during flexion of the joint. The lateral ligaments also prevent a lateral displacement of the bones during flexion of the articulation. The crucial ligaments serve mainly to hold the femur and tibia together; they are so situated that one of them is always tense in any position of the joint, the posterior ligament being tense during part of the movement of flexion and part of the movement of extension, and the anterior one during the whole of flexion. The crucial ligaments also check the movement of rotation.

The patella glides upon the surface of the femur, and has no influence upon the mechanism of the articulation. During extension of the joint it is pulled upward by muscular action and during flexion it descends toward the tibia.

The function of the meniscus is rather to form an articular cushion than to supplement and deepen the articular socket. In some positions of the joint they act both as cushions and as portions of the articular socket, in other positions they act only as cushions, and in still others they exert no influence whatever upon the mechanism of the joint. During some of the movements of the articulation they are markedly displaced or strongly compressed.

THE ARTICULATIONS OF THE TIBIA AND FIBULA.

The tibia and fibula are connected with each other in three ways: their upper extremities articulate by means of a small joint, the *tibiobular articulation*; the bodies of the bones are connected by the *interosseous membrane*; and the lower extremities are united by tense ligaments, forming the *tibiobular syndesmosis*.

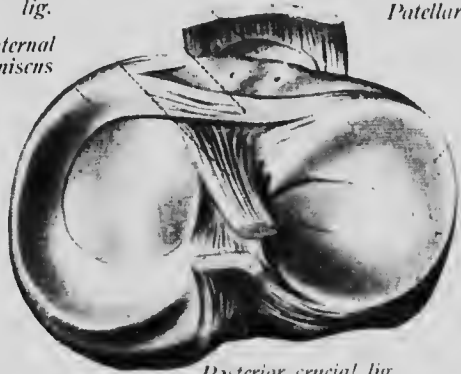
The *tibiobular articulation* (Figs. 217, 218, 220, and 223) is the joint between the fibular articular surface of the tibia and the capitular articular surface of the fibula. It is an arthrodium with almost plane articular surfaces and possesses strong accessory ligaments, which reinforce the capsule anteriorly and posteriorly and are known as the *anterior* and *posterior capitular ligaments* (Figs. 218, 220, and 223). The tense capsular ligament snugly embraces the oval articular surfaces. This articulation may occasionally communicate with the knee joint (through the popliteal bursa).

Transverse ligament
Anterior crucial
lig.

Deep infrapatellar bursa

Patellar lig.

Internal
meniscus




External ueniscus

Posterior crucial lig.

Fig. 221.

Anterior capitular ligament



of radius

Interosseous
membrane

Biceps
femoris

Gastro-
cnemius
(ext.
head)

1 sternal
co nyle
of tenor

1 sternal
meniscus

External
meniscus

Tendon of
quadriceps

Supra-
patellar
bursa

Articular
surface
of patella

Patella

Subcutaneous
prepatellar
bursa

Muc
folds

Patellar
ligament

Deep infra-
patellar bursa

Anterior h₂ of
external malleolus

Fig. 222.

Fig. 223.



The *interosseous membrane* (Fig. 223) resembles the interosseous membrane of the forearm very closely and extends between the interosseous ridges of the two bones. It consists chiefly of oblique fibers, the majority of which run downward from the tibia to the fibula, although some pursue a course at right angles to this direction. Its upper portion contains a large foramen for the passage of blood-vessels.

The *tibiofibular syndesmosis* (Figs. 223, 224, and 226) is situated between the fibular notch of the tibia, which is not covered by cartilage, and the internal surface of the external malleolus. It is formed by two ligaments, rich in elastic fibers, the *anterior* and *posterior ligaments of the external malleolus* (tibiofibular ligaments) (Figs. 225 and 226), which are situated upon the anterior and posterior surfaces of the lower end of the two bones. They pass obliquely downward from the tibia to the fibula and are made tense when the broader portion of the superior articular surface of the talus (astragalus) enters into the articular socket of the ankle-joint. The lower ends of the tibia and fibula may consequently be passively separated for a certain distance; this is, however, practically the only movement between the tibia and fibula.

THE JOINTS AND LIGAMENTS OF THE FOOT.

The joints and ligaments of the foot will be considered separately, since many of the ligaments of the foot belong to several joints.

THE JOINTS OF THE FOOT.

The joints between the talus (astragalus) and the bones of the leg and those between the individual bones of the foot may be divided into the following groups:

1. The *Articulations of the Talus (Astragalus)*, which include the *talocrural articulation* (the ankle-joint), the *talocalcaneal articulation*, the *talocalcaneo-navicular articulation*, and the *calcaneocuboïd articulation*.
2. The *Torsal Arthrodia*.
 - (a) The *intertarsal articulations* (the *cuneonavicular articulation*).
 - (b) The *tarsometatarsal joints* (the *tarsometatarsal* and *intermetatarsal articulations*).
- (3) The *Joints of the Toes* (the *metatarsophalangeal* and *digital (interphalangeal)* articulations).

The ankle joint or *talocrural articulation* (Figs. 224 and 226) is the joint between the astragalus and the two bones of the leg. The articulating surfaces are the trochlea of the talus upon the one hand, and the inferior articular surface of the tibia and the articular surfaces of the internal and external malleoli upon the other.

The articular capsule, which surrounds the cartilaginous surfaces and is inserted toward the neck of the astragalus, is thin; its anterior and especially its lateral portions are rather tense, while the posterior portion is roomy and relaxed.

From its function and in accordance with the form of the articular surfaces, the talocrural articulation is a hinge joint, the socket of which, however, is formed by two bones. As the syndesmosis connecting the tibia and the fibula does not absolutely preclude motion, the broad anterior portion of the trochlea of the talus can be accommodated by a



FIG. 224.—The ankle-joint seen from behind (3).

FIG. 225.—Horizontal frozen section through the tarsal articulations (3).

FIG. 226.—Frontal frozen section through the ankle and posterior talocalcaneal joints (3).

slight separation of the bones of the leg; and when the foot is depressed, the narrow posterior portion of the trochlea has so much room in the articular socket that slight lateral movements are possible in the axis of the fibula. The ankle-joint is consequently not a pure hinge joint, although it acts mainly as such; its movements are those of plantar and dorsal flexion.

The *talocalcaneal articulation* (Figs. 225 and 226) is the joint between the convex posterior articular surface of the calcaneus and the concave posterior calcaneal articular surface of the talus (astragalus). The articulating facets are portions of the surface of a cone, the axis of which is almost sagittal, but directed somewhat obliquely upward and forward. The articular capsule is roomy and relaxed. This articulation occasionally communicates with the ankle-joint.

The *talocalcaneo-navicular articulation* (Figs. 225 and 230) is the joint formed by the head of the (talus) astragalus, the anterior and middle articular facets of the calcaneus, the posterior articular facet of the navicular, and the navicular fibrocartilage of the plantar calcaneonavicular ligament (see page 141). The joint is a pronouncedly compound articulation, and includes an *anterior talocalcaneal* and a *talonavicular articulation*. The socket for the head of the talus (astragalus) is formed by four different cartilage-covered surfaces. The articulation is separated from the posterior calcaneo astragaloid joint by the sinus of the tarsus and its articular capsule exhibits no special peculiarities.

The *calcaneocuboid articulation* (Fig. 225) is the joint between the cuboid articular surface of the calcaneus and the posterior articular surface of the cuboid bone. The surfaces are approximately saddle-shaped. Together with the talonavicular joint, it forms the *transverse articulation of the tarsus* (Chopard's joint).

From a functional standpoint the talocalcaneo-navicular joint is composed of two portions. The first of these is the joint between the talus (astragalus) and the navicular bone, which acts together with the calcaneocuboid articulation. It is an ellipsoidal joint, while the talonavicular articulation is a saddle-joint. Although these joints are biaxial, they check each other reciprocally, so that during motion each joint loses one of its axes of movement and a common uniaxial hinge-joint results, the transverse tarsal joint. The remaining portion of the talocalcaneo-navicular joint acts together with the talocalcaneal joint, whose axis coincides with that of the transverse tarsal joint. Both joints, or rather both combinations of joints, always work together; during adduction there is also an elevation of the inner margin of the sole of the foot (supination), and during abduction there is a simultaneous elevation of the outer margin of the sole of the foot (pronation). The anatomical and physiological associations of the joints are altogether different, as is also the case at the elbow and at the inferior radio-ulnar articulation (see pages 122 and 123).

The arthrodia of the tarsus consist of a variable number of single or combined articulations, since neighboring articular cavities frequently intercommunicate, and while the number of articular facets is relatively large, the number of joints is comparatively small because the small lateral articular facets do not all form independent articulations.

The *cuneonavicular articulation* (Fig. 225) is the joint between the articular surface of the navicular bone and the posterior articular facets of the three cuneiform bones; it also extends between the opposed articular facets of the cuneiform bones and between the internal articular

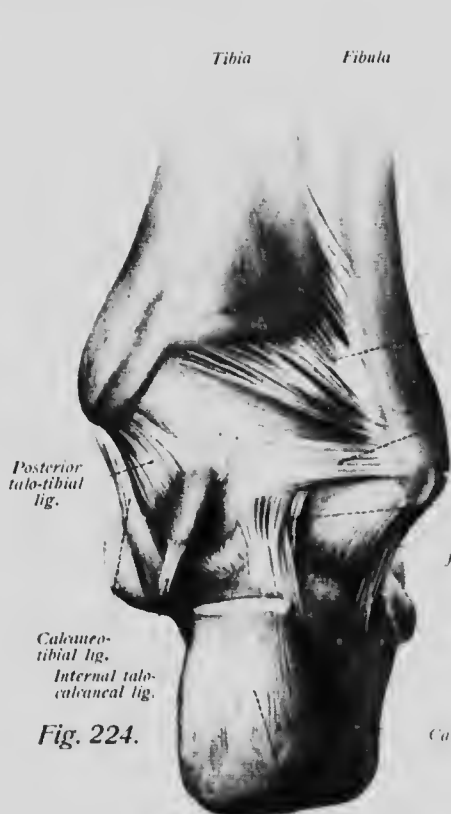

Fig. 224.

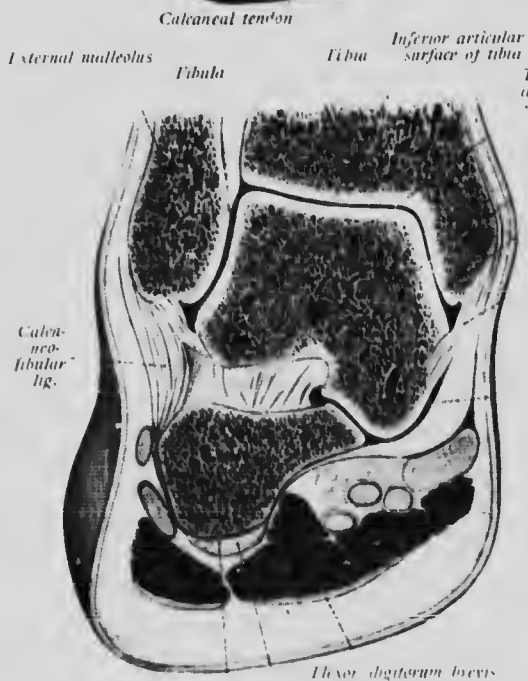


Fig. 220.

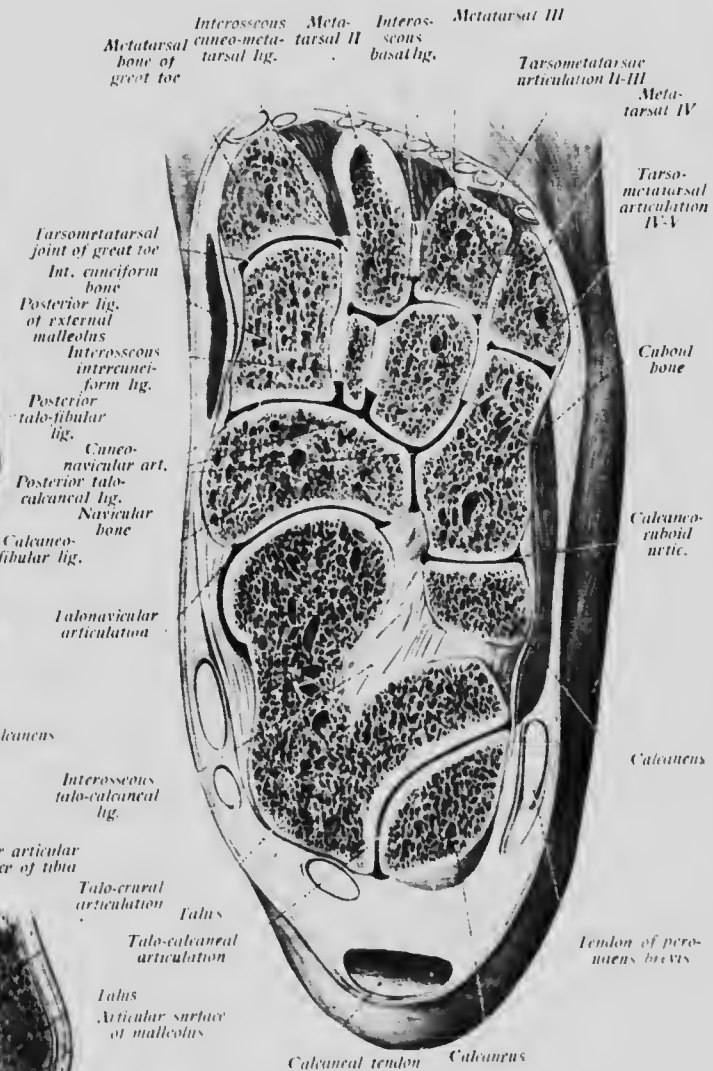


Fig. 225.

Tibia Fibula

Metatarsal bone of great toe Interosseous cuneo-metatarsal lig. Metatarsal II Interosseous busathg. Metatarsal III Tarsometatarsal articulation II-III Metatarsal IV

Tarsometatarsal joint of great toe Int. cuneiform bone Posterior lig. of external malleolus Interosseous intercuneiform lig. Posterior talo-fibular lig. Cuneo-navicular art. Posterior talo-calcaneal lig. Navicular bone Calcaneo-fibular lig. Talonavicular articulation

Tarso-metatarsal articulation IV-V

Cuboid bone

Calcaneo-cuboid artic.

Calcaneus

Calcaneus

Interosseous talo-calcaneal lig.

Calcaneal tendon

Internal malleolus

Fibula

Tibia Inferior articular surface of tibia

Talo-cranial articulation Talus

Talo-calcaneal articulation

Talus Articular surface of malleolus

Tendon of peroneus brevis

Calcaneal tendon Calcaneus

Deltoid ligament

Posterior talo-calcaneal articulation

Calcaneo-fibular lig.

Flexor digitorum brevis

Calcaneus Long plantar ligament

7

surface of the cuboid and the corresponding surfaces of the navicular and external cuneiform bones. The joint also usually communicates between the internal and middle cuneiform bones with the second tarsometatarsal joint, and is consequently a very complicated articulation.

The *tarso-metatarsal articulation* (Lisfranc's joint) (Fig. 225), together with the *inter-metatarsal articulations* (Fig. 225), form three separate joints: one connecting the metatarsal bone of the great toe with the internal cuneiform bone; one connecting the bases of the second and third metatarsal bones with each other and with the middle and external cuneiform bones; and the third connecting the fourth and fifth metatarsal bones with the cuboid bone. The line of Lisfranc's joint has its most proximal point at the inner margin of the sole of the foot and its most distal point at the base of the second metatarsal bone, so that a deep indentation is present in this situation. From this point the joint-line pursues a markedly distal direction and then makes a distinct curve toward the proximal portion of the foot.

The movements in the tarsal arthrodia are extremely slight, since numerous tense ligaments limit the range of motion very considerably. The slight movements which are possible supplement the chief movements of the foot.

The *metatarso-phalangeal* and the *digital (interphalangeal) joints* resemble the corresponding joints of the hand with slight variations. The metatarso-phalangeal joint of the great toe in particular exhibits a special mechanism, as two large sesamoid bones are embedded in the plantar surface of its capsular ligament (see page 106) and transform the articulation into a species of hinge joint. A further peculiarity is the marked dorsal extension of the articular surfaces, particularly those of the second to the fifth metatarsal bones, which permit of a hyperextension (dorsal flexion) of the toes. These articulations also resemble hinge joints more than arthrodia (ginglymoarthrodia). Ossification is frequently observed between the individual phalanges, particularly in the little toe. The accessory ligaments of these joints are similar to those of the hand (*transverse capitular* (Figs. 228 and 229), *accessory plantar*, and *lateral ligaments*).

THE LIGAMENTS OF THE TARSUS.

The ligaments of the tarsus (Figs. 224 to 230) may be subdivided into: (1) The ligaments of the ankle-joint, (2) the ligaments between the astragalus and the calcaneus, (3) the dorsal tarsal ligaments, (4) the plantar tarsal ligaments, and (5) the interosseous tarsal ligaments.

The **ligaments of the ankle-joint** (Figs. 224 and 226 to 228) connect the bones of the leg with the talus (astragalus) and the calcaneus, and pursue a more or less vertical direction. Each of the two malleoli is connected with the neighboring tarsal bones. The *deltoid ligament* (Fig. 227) arises from the internal malleolus and radiates to the talus (astragalus), the calcaneus, and the navicular bone. It is narrower at its origin, broad at its insertion, and is composed of four separate ligaments: the *anterior talo-tibial*, the *posterior talo-tibial*, the *calcaneo-tibial*, and the *tibio-navicular ligaments*.

The *anterior talo-tibial ligament* (Fig. 227) passes to the anterior extremity of the neck of the talus (astragalus) and is almost completely covered by the *calcaneo-tibial ligament* (Fig. 227) which runs to the margin of the sustentaculum tali. The *posterior talo-tibial ligament* (Figs. 224

FIG. 227.—The ligaments of the tarsus seen from the inner side (¾).

FIG. 228.—The ligaments of the foot seen from above and from the outer side (¾).

FIG. 229.—The ligaments of the foot seen from the plantar surface (¾).

FIG. 230.—The ligaments of the foot seen from the dorsal surface. The talus has been removed so as to show the participation of the navicular ligament in forming the socket of the talocalcaneo-navicular joint (¾).

and 227) goes to the posterior process of the talus, and the *tibio-navicular* (Fig. 227) has its insertion upon the dorsal surface of the navicular bone.

Ligaments pass in a similar manner from the external malleolus to the talus (astragalus) and to the calcaneus. These are known as the *anterior talo-fibular*, the *posterior talo-fibular*, and the *calcaneo-fibular ligaments*. The *anterior talo-fibular ligament* (Fig. 228) passes almost horizontally from the anterior surface of the external malleolus to the anterior margin of the trochlea of the talus; the *posterior talo-fibular* (Fig. 224) pursues a corresponding course and connects the posterior border of the external malleolus with the outer tubercle of the posterior process of the talus; and the *calcaneo-fibular ligament* (Figs. 226 and 230) passes somewhat obliquely downward and backward from the tip of the external malleolus to the outer surface of the calcaneus. Upon this ligament run the tendons of the two peroneal muscles (see page 222).

The ligamentous connections between the astragalus and the calcaneus consist of the reinforcing ligaments of the talo-calcaneal articulation and of the ligamentous mass which occupies the sinus of the tarsus, the *interosseous talo-calcaneal ligament*. The latter (Figs. 225 and 230) consists of a number of firm fibrous layers and forms a species of syndesmosis between the two bones.

The reinforcing ligaments of the posterior articulation of the two bones are known as the *internal*, *external*, *posterior*, and *anterior talo-calcaneal ligaments*. The *external* and particularly the *anterior* ligaments, which bridge over the sinus of the tarsus, are connected with the interosseous ligament. The *external ligament* (Fig. 228) passes from the outer and lower surface of the neck of the talus (astragalus) to the upper surface of the calcaneus; the *anterior ligament* connects the lower surface of the talus (astragalus) with the upper surface of the calcaneus; the *posterior ligament* connects the outer tubercle of the posterior process of the talus with the upper surface of the calcaneus; and the very narrow *internal ligament* passes from the inner tubercle of the posterior process of the talus to the sustentaculum tali.

The dorsal and plantar ligaments of the foot are practically horizontal, and are composed partly of transverse and partly of longitudinal fasciculi which connect neighboring bones and consequently reinforce the articular capsules. The plantar ligaments are considerably the stronger, and some of them connect distant portions of the tarsus, passing over one or even more bones.

The **dorsal tarsal ligaments** are those which connect the talus (astragalus) and the calcaneus with the navicular and the cuboid bones. They are the *dorsal talo-navicular ligament*, the *dorsal calcaneo-navicular ligament*, and the *bifurcate ligament*. The *bifurcate ligament* (Fig. 228) connects the antero-internal angle of the calcaneus with the dorsal surfaces of the navicular and

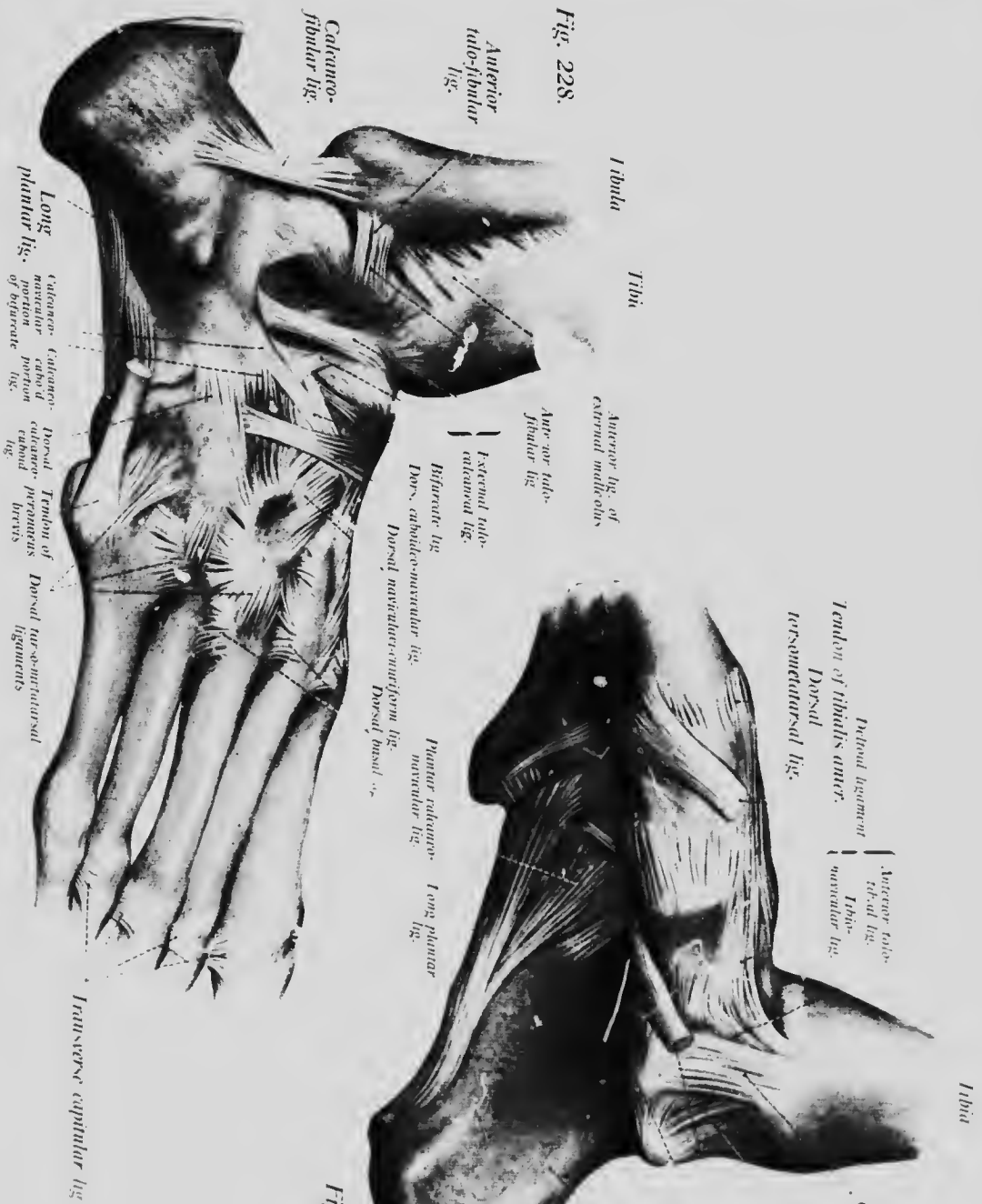


Fig. 227.

Fig. 228.



Transverse capitular ligaments

Metatarso-phalangeal articulations

Sesamoid bone

Tendon of peroneus longus

Plantar tarsometatarsal lig.

Plantar ligaments

Tendon of peroneus brevis
Groove for tendon of peroneus longus

Plantar naviculari-cuneiform ligaments

Plantar cuboideo-navicular lig.

Tendon of tibialis posterior

Dorsal inter-cuneiform ligts.

Dorsal tarso-metatarsal ligaments

Dorsal cuneocuboid lig.

Long. plantar lig.

Plantar calcaneo-navicular lig.

Dorsal naviculari-cuneiform ligts.

Dorsal calcaneo-cuboid lig.
Tendon of peroneus brevis

Fig. 229.

Articular facet of navicular bone
Navicular fibrocartilage

Middle articular facet of calcaneus
Interosseous talo-calcaneal ligament
Anterior articular facet of calcaneus
Posterior articular facet of calcaneus

Fig. 230.

1870

cuboid bones; it necessarily divides into two portions, one for each bone, known as the *calcaneo-navicular* and the *calcaneocuboid portions*.

The navicular is connected with the cuneiform bones by the three *dorsal navicular-cuneiform ligaments* (Fig. 228). The first of these is the broadest. The cuboid and navicular bones are connected by the *dorsal cuboideo-navicular ligament* (Fig. 228); the cuneiform bones are connected with each other by the *dorsal intercuneiform ligaments* (Fig. 230); and the *dorsal cuneo-cuboid ligament* (Fig. 230) runs between the external cuneiform and cuboid bones.

The connection between the bases of the metatarsal bones and the tarsal bones is effected by the *dorsal tarsometatarsal ligaments* (Figs. 228 and 230); the bases of the metatarsals are connected with each other by the four *dorsal basal ligaments* (Fig. 228).

The **plantar tarsal ligaments** maintain the normal arch of the foot. By far the largest and strongest of them is the *long plantar ligament* (Figs. 226, 227, and 229), which is, indeed, one of the strongest ligaments of the body. It arises from the entire lower surface of the calcaneus in front of the tubercles of the tuberosity, its width almost entirely covering the bone, and its strong longitudinal fasciculi are inserted into the tuberosity of the cuboid. From the main mass of the ligament there are given off superficial fasciculi which pass over the tendon-sheath of the peroneus longus situated in the cuboid groove, and extend to the bases of the outer metatarsal bones (see page 227, Fig. 312).

The second strongest ligament of the tarsus is the *plantar calcaneo-navicular ligament* (Figs. 227 and 229), whose strong fibers pass obliquely between the sustentaculum tali and the navicular bone. The dorsal surface of the ligament is covered with cartilage and contains the *navicular fibrocartilage* (Fig. 230), which forms a portion of the socket for the head of the talus (astragalus) (see page 138). Upon the dorsal surface of the foot this ligament is connected with the tibio-navicular ligament.

The *plantar calcaneocuboid ligament* is adherent to the dorsal surface of the long plantar ligament and reinforces the plantar surface of the articular capsule of the calcaneocuboid joint. The navicular and the cuneiform bones are connected by the *plantar naviculari-cuneiform ligaments* (Figs. 227 and 230); the cuboid and the navicular bones by the *plantar cuboideo-navicular ligament* (Fig. 230); the cuboid and the external cuneiform bones by the *plantar cuneo-cuboid ligament*; and the three cuneiform bones with each other by the *plantar intercuneiform ligaments*. There are also *plantar tarso-metatarsal ligaments* and three *plantar basal ligaments*, which pursue a similar course to the corresponding dorsal ligaments.

The **interosseous ligaments** are those ligaments of the foot which are situated neither upon the dorsal nor the plantar surface, but which connect contiguous surfaces of the tarsal or metatarsal bones in those situations where no articular connection exists. They really represent syndesmoses, and are found only between those bones which move upon each other but slightly, if at all. In addition to the previously mentioned interosseous talocalcaneal ligament (Figs. 229 and 230), these ligaments are the *interosseous cuneo-cuboid ligament*, the *interosseous intercuneiform ligaments*, the *interosseous cuneo-metatarsal ligaments* (particularly between the internal cuneiform and the base of the second metatarsal bone, where an interosseous basal metatarsal is wanting), and the *interosseous basal metatarsal ligaments*. The upper and lower surfaces of some of these ligaments are in direct contact with the corresponding dorsal and plantar ligaments.

MYOLOGY.

GENERAL MYOLOGY.

Myology is the study of the muscles and of their accessory structures, such as tendons, aponeuroses, fasciæ, intermuscular septa, tendon arches, pulleys, mucous bursæ, tendon-sheaths (*vagina mucosæ*), *tendon retinacula*, and sesamoid bones.

The musculature of the human body occurs in two forms which present both histological and physiological differences (see "Atlas and Epitome of Normal Histology," Sobotta-Huber). The actual skeletal muscles are composed only of striated muscular tissue.

The muscles form the fleshy portion of the body, and are contractile structures which vary considerably in size and shape. A **typical muscle** is composed of a muscular *belly*, which forms the greater portion of it, and of two ends, one of which is known as the *origin*, or *head*, and the other as the *insertion*, the origin being that end which is attached to the usually more fixed portion of the skeleton and the insertion that attached to the more freely movable portion, but the physiological relation of origin and insertion may be reversed. As a rule, both the origin and the insertion possess a tendon of varying length, which is usually considerably thinner than the muscle.

Muscles are distinguished according to their shapes. A great many, particularly those forming the mass of the extremities, are fusiform or spindle-shaped, while others are broad, thin, and flat; muscles whose length but slightly exceeds their breadth are designated short muscles. Some muscles surround orifices of the body or canals, and their fibers are circularly arranged: they are known as *orbicular muscles*, or, if they serve to close orifices, such as the mouth, for example, as *sphincters*. Those muscles in which the fasciculi pass to a tendon developed at the side of the muscle are known as pinnate or penniform muscles, and if the tendon be situated in the middle and receives muscular fasciculi from either side, the muscle is said to be bipinnate or bipenniform.

The majority of the muscles have a single head, but occasionally two, three, or four heads unite to form a muscular belly, producing a biceps, triceps, or quadriceps muscle. A muscle composed of two bellies with an intervening tendon is termed a biventer or digastric muscle.

If muscles pass only over one joint of the body (particularly in the extremities), they are known as monoarticular muscles; if they extend over two main joints in their course, they are called biarticular.

Tendons occur in connection with nearly all the muscles, and are completely absent in the sphincters only, though partly wanting in the orbicular muscles. Every muscle, however, has not a tendon at both ends, it frequently happening that only the tendon of insertion is developed, while the origin is purely muscular. The fibers of the tendons of origin or insertion are very

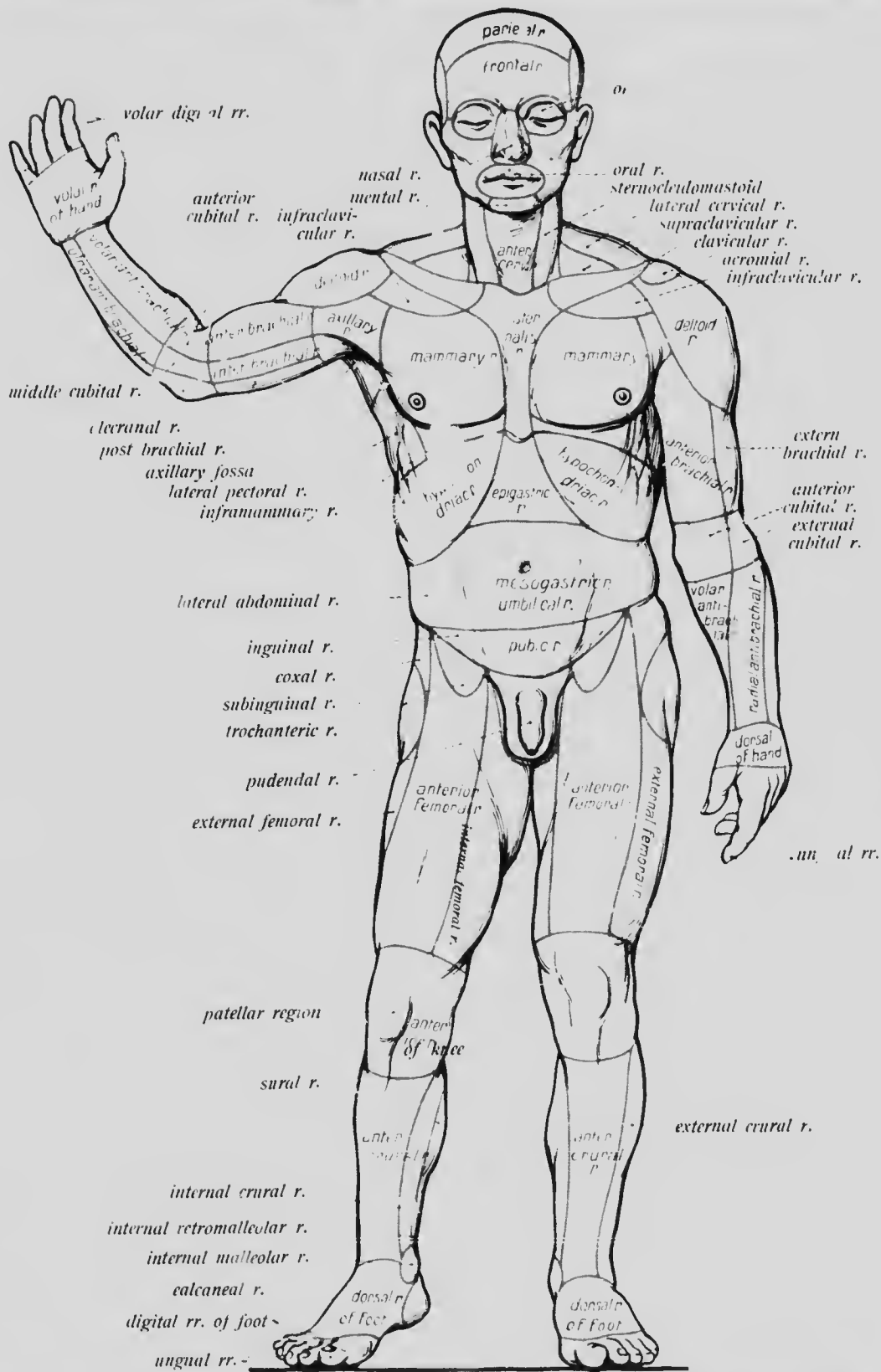


Fig. 231. Regions of the human body.



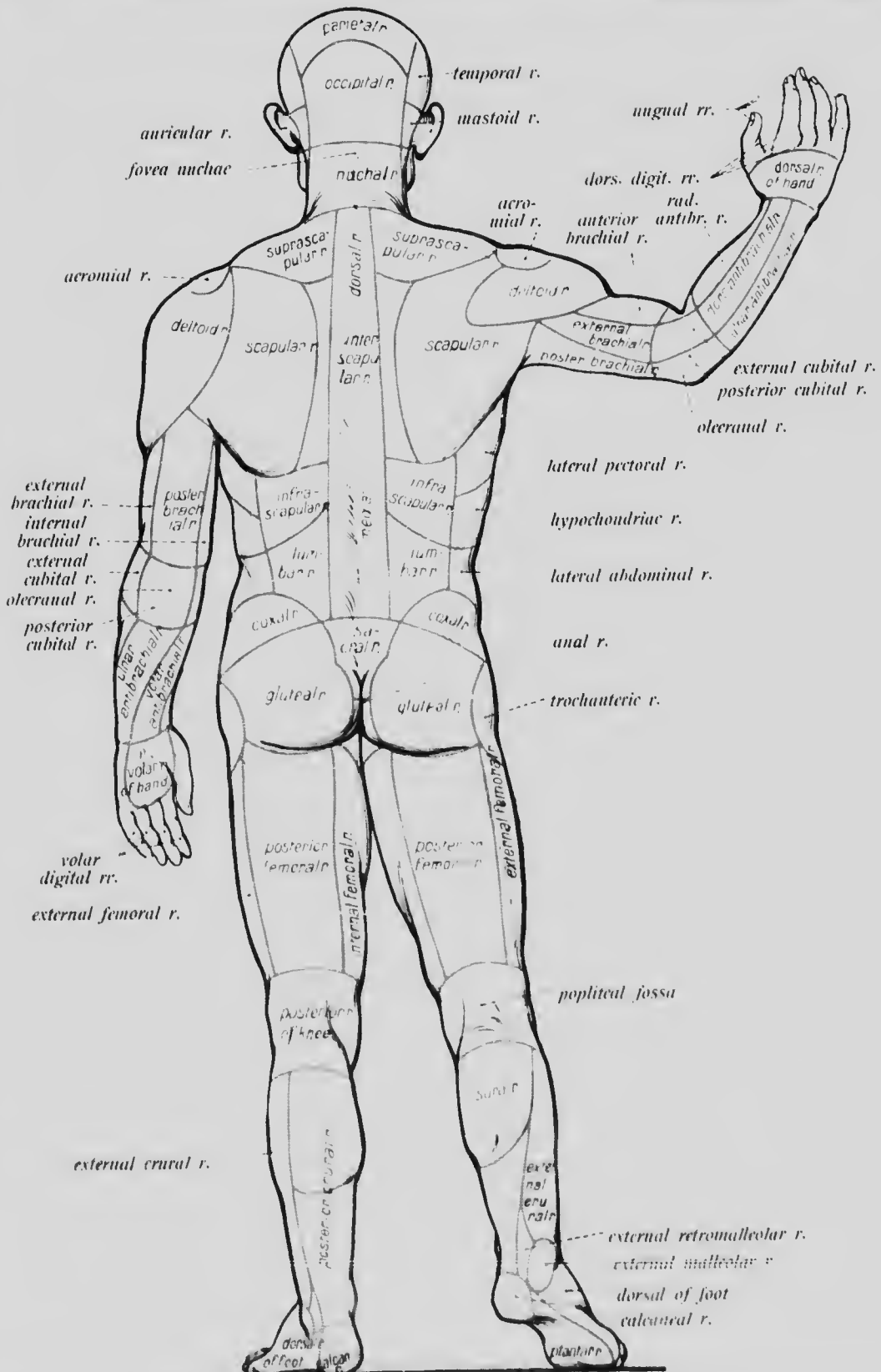


Fig. 232. Regions of the human body.

1870
1871
1872
1873
1874
1875
1876
1877
1878
1879
1880
1881
1882
1883
1884
1885
1886
1887
1888
1889
1890
1891
1892
1893
1894
1895
1896
1897
1898
1899
1900
1901
1902
1903
1904
1905
1906
1907
1908
1909
1910
1911
1912
1913
1914
1915
1916
1917
1918
1919
1920
1921
1922
1923
1924
1925
1926
1927
1928
1929
1930
1931
1932
1933
1934
1935
1936
1937
1938
1939
1940
1941
1942
1943
1944
1945
1946
1947
1948
1949
1950
1951
1952
1953
1954
1955
1956
1957
1958
1959
1960
1961
1962
1963
1964
1965
1966
1967
1968
1969
1970
1971
1972
1973
1974
1975
1976
1977
1978
1979
1980
1981
1982
1983
1984
1985
1986
1987
1988
1989
1990
1991
1992
1993
1994
1995
1996
1997
1998
1999
2000
2001
2002
2003
2004
2005
2006
2007
2008
2009
2010
2011
2012
2013
2014
2015
2016
2017
2018
2019
2020
2021
2022
2023
2024
2025

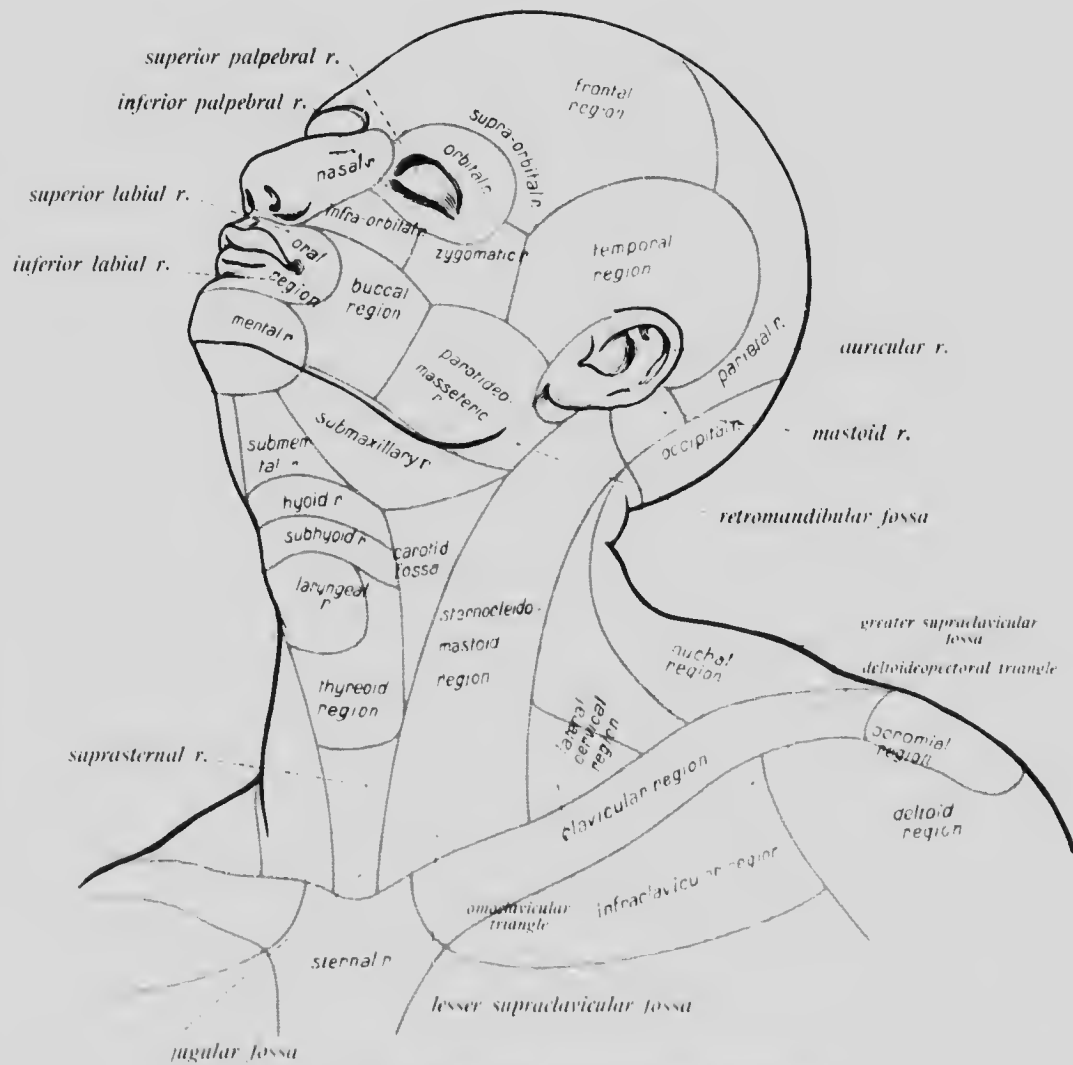


Fig. 233. Regions of the head and neck.



perineal regions.

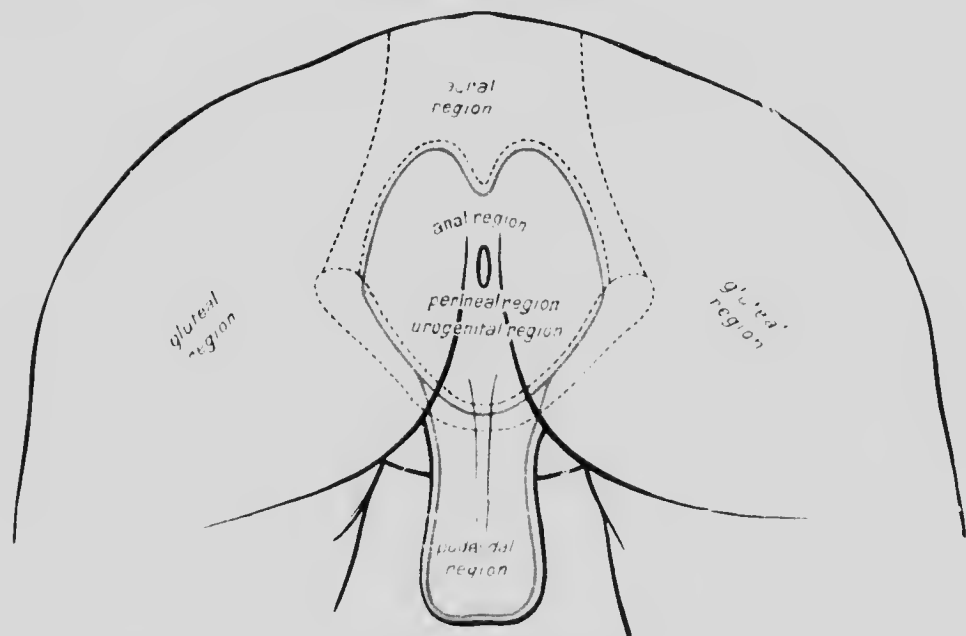


Fig. 234. Male perineum.

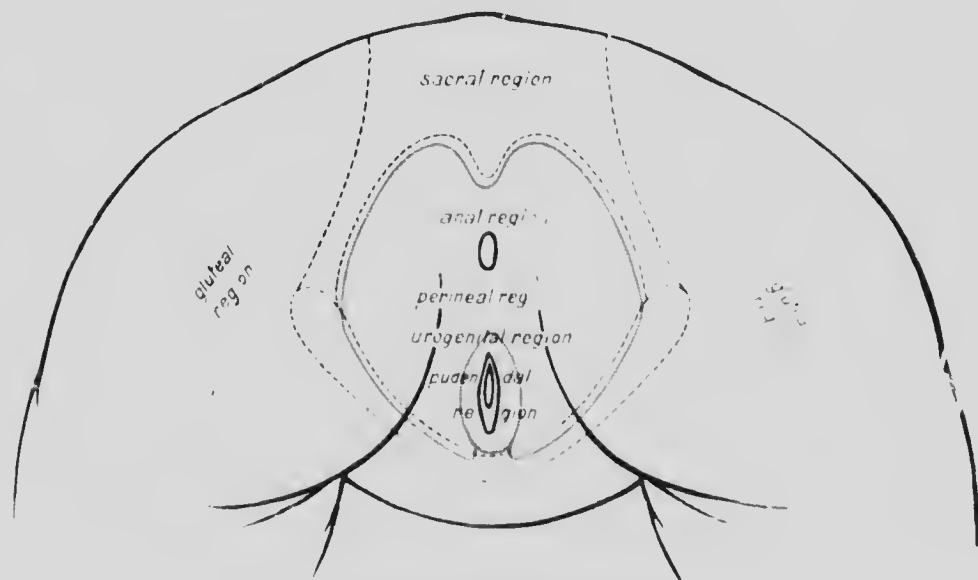



Fig. 235. Female perineum.



frequently mixed with muscular fibers, so that neither a purely muscular nor a purely tendinous origin or insertion exists.

The spindle-shaped muscles have cylindrical and frequently very long tendons, but the flat muscles usually arise by means of flattened tendons which are known as *aponeuroses*, and, in the cases of the flat muscles, may serve as fasciæ for other muscles. The round tendons also occasionally form aponeuroses in the vicinity of their insertions.

Broad tendinous plates are sometimes found upon one of the surfaces of a muscle in the middle of its course, and a muscle may possess a number of tendinous interruptions, arranged at more or less regular distances from each other; these are termed *tendinous inscriptions*.

The *fasciæ* are connective-tissue coverings which surround individual muscles or groups of muscles. They are frequently adherent to their muscles and form their aponeuroses, and are especially well developed in the extremities, where they form a common superficial sheath for all of the muscles. Some muscles do not possess fasciæ, as, for example, the muscles situated in the skin, such as the platysma and the majority of the facial muscles.

The *intermuscular septa* are intimately connected with the fasciæ, being sheet-like prolongations of those of the extremities, extending to the periosteum so as to form partitions between groups of muscles having a similar function (synergists*); they frequently also give origin to muscles.

The *tendinous arches* are ligamentous bands which bridge over vessels or nerves and protect them as they pass through a muscle; they may also pass between two neighboring bones and furnish a support for muscular origin.

Pulleys or *trochleæ* are for the purpose of giving the tendon of a muscle a different direction from that of the belly. The *tendon retinacula* operate in a similar manner, and are found chiefly in those situations where tendons run in a bony groove. They hold the tendons firmly in the channel and prevent their displacement; a similar function is served by the *vaginal ligaments* which maintain the tendon-sheaths (see below) in position.

The *mucous bursæ* are thin-walled cavities filled with a fluid similar to that of the synovia of the joints. They are found where muscles or tendons pass over bony prominences or where tendons are inserted into a bone, and serve to prevent friction between the muscles and tendons and the bone. They are frequently diverticula of the synovial membranes of the joints (see page 108).

The *tendon-sheaths* or *vagina mucosa* act in a similar manner; they surround the tendons of the muscles of the extremities (particularly in the hand and foot) for a certain distance, and protect the tendons from friction during action. They are partly protected by retinacula, and partly by *vincula*.

Sesamoid bones are mechanical accessories of the tendons in which they are usually embedded. They are not necessarily bony but are often only fibrocartilaginous, and serve the purpose of increasing the working angle of the tendons and of making it possible for the tendons to glide over the joint. The patella (see page 99) is the largest sesamoid bone of the body.

The striated musculature of the body, with few exceptions, arises from the myotomes of the mesodermic somites. The musculature of the trunk arises directly from these structures, and its segmental arrangement, corresponding to its

* Muscles having opposite functions are termed antagonists.

FIG. 236.—The superficial layer of the flat muscles of the back together with the neighboring muscles of the head, neck, abdomen, and buttock. Upon the right side the rhomboideus major and the teres major are represented covered by fascia.

origin, can usually be distinctly recognized in the deeper layers of the muscles of the back and neck. The muscles of the abdomen and of the extremities arise secondarily from the myotomes. In man the musculature of the extremities is very strongly developed and covers the entire dorsal and part of the ventral musculature of the trunk.

[In the following pages the classification adopted for the muscles is a topographical one, an arrangement which best accords with an atlas designed as an aid for the laboratory. Such a classification, however, is in many cases faulty in that it fails to present the true morphological relations of the muscles, sometimes grouping together muscles which have entirely different morphological values, and sometimes separating in different groups muscles which in reality are closely related. At the close of each section where it seems necessary there will be found a brief morphological classification of the muscles of which it treats.—ED.]

SPECIAL MYOLOGY.

THE MUSCLES OF THE TRUNK.

THE MUSCLES OF THE BACK.

The muscles of the back are arranged in layers and extend throughout the neck, the back, and the lumbar region. The muscles of the individual layers may be advantageously grouped,

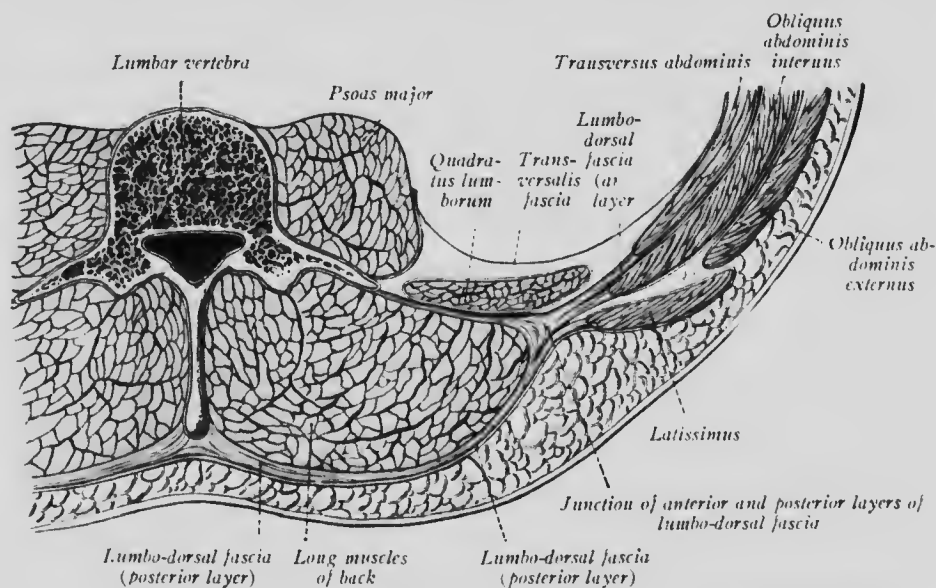


FIG. 237.—Transverse section of the posterior wall of the abdomen in the lumbar region (schematic).

according to their shape, in three subdivisions—the flat or surface muscles, the long muscles, and the short muscles. The flat muscles are still further subdivisible into several layers, some of

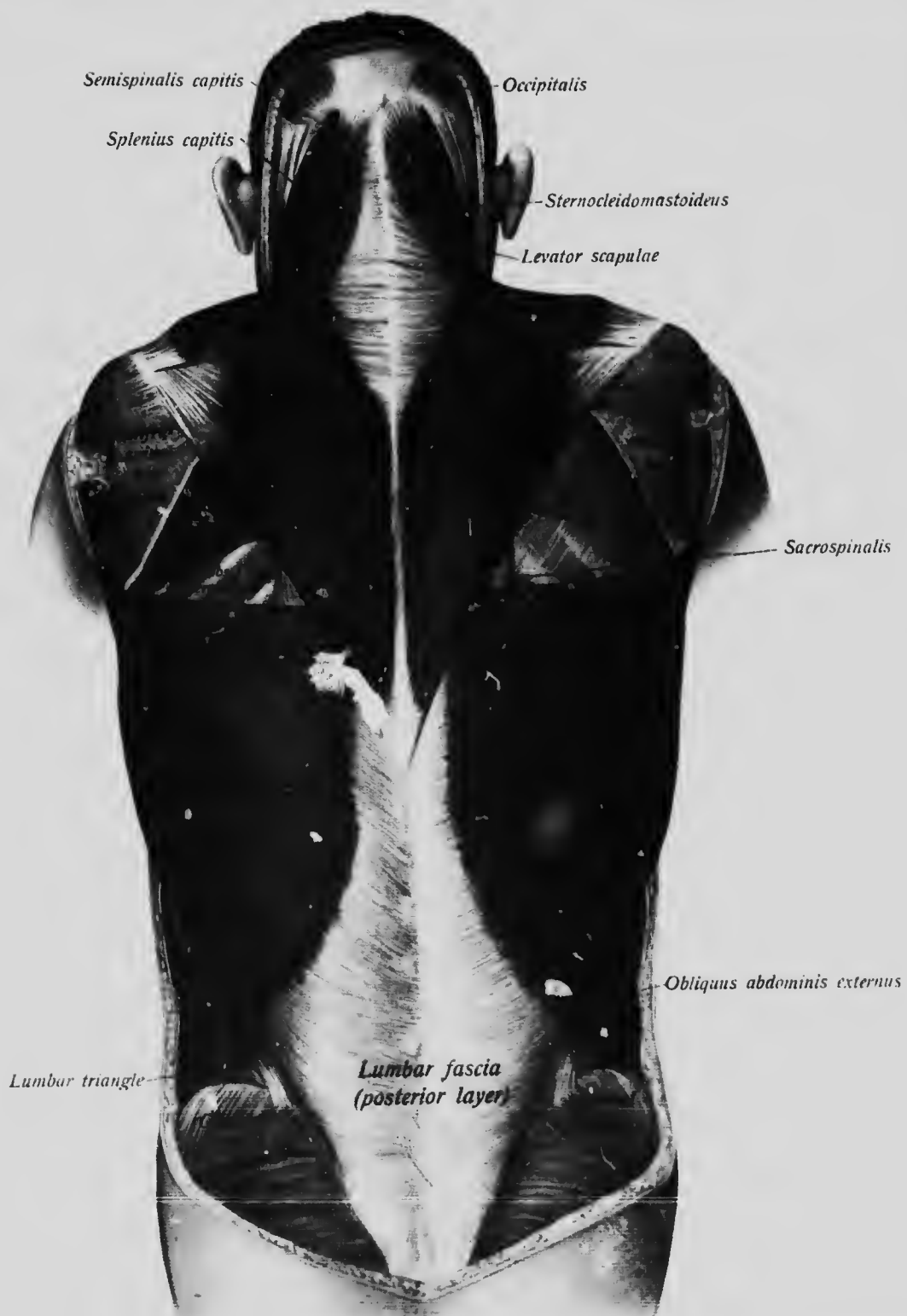

Fig. 236.

1870
1871
1872
1873
1874
1875
1876
1877
1878
1879
1880
1881
1882
1883
1884
1885
1886
1887
1888
1889
1890
1891
1892
1893
1894
1895
1896
1897
1898
1899
1900
1901
1902
1903
1904
1905
1906
1907
1908
1909
1910
1911
1912
1913
1914
1915
1916
1917
1918
1919
1920
1921
1922
1923
1924
1925
1926
1927
1928
1929
1930
1931
1932
1933
1934
1935
1936
1937
1938
1939
1940
1941
1942
1943
1944
1945
1946
1947
1948
1949
1950
1951
1952
1953
1954
1955
1956
1957
1958
1959
1960
1961
1962
1963
1964
1965
1966
1967
1968
1969
1970
1971
1972
1973
1974
1975
1976
1977
1978
1979
1980
1981
1982
1983
1984
1985
1986
1987
1988
1989
1990
1991
1992
1993
1994
1995
1996
1997
1998
1999
2000
2001
2002
2003
2004
2005
2006
2007
2008
2009
2010
2011
2012
2013
2014
2015
2016
2017
2018
2019
2020
2021
2022
2023
2024
2025

which completely conceal the others; the superior layers are inserted into the skeleton of the upper extremity and consequently are really muscles of the extremity. The long and short muscles are portions of the actual musculature of the trunk, and are situated in the groove between the spinous processes of the vertebræ and the angles of the ribs (or the costal processes of the remaining vertebræ), and many of them extend upward as far as the head. The long muscles of the back extend over a large number of vertebræ and in their superficial layers extend over the entire vertebral column; the short muscles pass from vertebra to vertebra.

The flat muscles are also designated as superficial, the long and short as deep muscles of the back.

THE FLAT MUSCLES OF THE BACK.

The flat muscles of the back (Figs. 236 and 238) are arranged in three layers which partially overlap each other. The first layer is formed by the trapezius and the latissimus dorsi, the second by the rhomboidei and the levator scapulæ, and the third by the serratus posterior superior and inferior and the splenius capitis and cervicis. The muscles of the first and second layers are inserted into the skeleton of the extremities; those of the third layer find their insertions in the skeleton of the trunk.

The First Layer.

The **trapezius or cucullaris** (Figs. 236 and 256) takes its name from the trapezium formed by the muscles of the two sides. Each muscle by itself is triangular, its longest border being situated at the vertebral column. It is flat and smooth; below, and particularly above, it is very thin, and it is situated in the nuchal, median dorsal, suprascapular, scapular, and infrascapular regions. It takes origin from the following situations: from the inner half of the superior nuchal line (extending to the linea suprema as a short thin tendon), from the external occipital protuberance, from the nuchal ligament (by a muscular origin, sometimes by a short tendon in the upper portion), and from the spinous processes and supraspinous ligaments of all of the thoracic vertebræ (more or less tendinous).

It is inserted into the upper end of the acromial third of the clavicle, into the inner margin of the acromion, and into the middle length of its upper border, and partly also into the inner portion of the lower border of the spine of the scapula.

The superior fibers of the trapezius pass from within outward and from above abruptly downward to the lateral portion of the neck (Fig. 256); the middle fibers are the shortest and pass almost horizontally outward; while the inferior fibers run from within outward and from below abruptly upward. Tendinous areas are constantly found at the origin of the trapezius from the occiput, in the region of the seventh cervical vertebra and of the spines of the upper thoracic vertebræ, and at its insertion into the inner end of the spine of the scapula; the fibers coming from the spines of the lower thoracic vertebræ are also tendinous for a certain distance, and in the region of the spines of the upper thoracic vertebræ the muscles of the two sides form a broad, well-developed, trapezoid aponeurosis.

At the occiput the trapezius joins the tendinous insertion of the sternocleidomastoid. Between the two muscles, the splenius capitis and the levator scapulæ are always partly visible, and if the upper part of the trapezius is narrow, a portion of the semispinalis capitis also appears

between it and the splenius capitis. The deltoid has its origin immediately adjacent to the insertion of the trapezius, and a small transverse muscle occasionally passes between the insertions of the trapezius and the sternocleidomastoid; it is known as the *transversus nuchæ* (Fig. 244), and usually has a tendinous origin from the tendon of one muscle and passes to the tendon of the other.

The trapezius is supplied by the accessory nerve and by the cervical plexus.

On account of the different directions taken by the fibers in different portions of the trapezius the function of the muscle is complicated, and differs according to whether all portions of the muscle contract simultaneously or individual portions contract separately. Its action also depends upon whether the scapula is fixed or movable. The upper portion of the trapezius elevates the entire shoulder girdle, the lower portion pulls the scapula downward, and the middle portion draws the scapula backward toward the vertebral column. The scapula is also drawn backward by the action of the entire muscle, since the upper and lower fasciculi neutralize each other to a certain extent and aid the middle portion of the muscle. If the shoulder-blade is fixed, the muscle turns the head; when both scapulae are fixed and the two muscles act together, the head is extended. The muscle may also fix the scapula. It usually acts together with the levator scapuli, the rhomboidei, the splenii, and the other muscles of the back.

The **latissimus dorsi** (Figs. 236, 238, 269, and 272) is a broad, thin, triangular muscle which becomes somewhat thicker toward its insertion. The upper portion of its origin is partly concealed by the trapezius, and it is situated in the median dorsal, the sacral, the lumbar, the infra-scapular, and the scapular regions. Its origin is tendinous throughout, with the exception of three or four accessory digitations which arise from the three or four lower ribs. The tendon of origin is furnished by the posterior surface of the posterior layer of the lumbodorsal fascia (see page 156), by means of which the muscle arises from the spinous processes of the lower five or six thoracic vertebrae, from the spinous processes of the lumbar vertebrae, and from the median ridge of the sacrum and the neighboring portion of the outer lip of the crest of the ilium. The superior fibers run almost horizontally; the inferior fibers ascend abruptly from within outward and from below upward, and toward the insertion the fibers converge, and terminate in a flat tendon which is adherent to that of the teres major and is inserted with it into the lesser tubercular ridge (the posterior lip of the bicipital groove) of the humerus. An almost constant bursa, the *latissimus bursa*, separates the non-adherent portions of the tendons of the latissimus dorsi and teres major.

The tendinous surface of the posterior layer of the *lumbodorsal fascia* (Figs. 238 and 240) is widest in the region of the middle and lower lumbar vertebrae, and it becomes markedly narrower as it extends upward, and to a lesser degree as it passes downward. Between the upper border of the latissimus, the lower border of the trapezius, and the vertebral border of the scapula, there is a triangular space, which is larger or smaller according to the position of the scapula and in which are visible a portion of the rhomboideus major, small portions of one or more of the middle ribs with their intercostal muscles, and a segment of the iliocostalis dorsi. Upon the neighboring dorsal surface of the scapula, the dense infraspinatus fascia covers the infraspinatus muscle, and a portion of the deltoid muscle, covered by its fascia, is also visible in this situation.

The costal serrations of the latissimus dorsi interdigitate with the inferior serrations of the obliquus abdominis externus (Fig. 247). Between the outer border of the latissimus, the posterior border of the external oblique, and the crest of the ilium there is usually a small triangle,

the *lumbar triangle* or *triangle of Petit* (Fig. 236), in which a portion of the origin of the *abdominis internus* from the anterior layer of the lumbar fascia (see page 160) is exposed. The posterior border of the *latissimus dorsi* forms a part of the posterior boundary of the *axillary fossa*, and the muscle not infrequently receives accessory fibers from the inferior angle of the scapula (the scapular digitation).

Since the *latissimus* is really one of the muscles of the extremity, it is supplied from the plexus brachialis, its nerve being the thoracodorsal (middle or long subscapular) nerve.

The *latissimus dorsi* adducts the arm, carrying it backward and rotating it inward.

The Second Layer.

The second layer of the flat muscles of the back (Fig. 238) is covered by the trapezius, with the exception of a portion of the *rhomboideus major*, which is exposed between the *latissimus* and the trapezius, and of that part of the *levator scapulae* which is situated immediately beneath the cervical fascia at the outer border of the trapezius. This layer is not represented beneath the *latissimus* which directly overlies the third layer.

The **rhomboideus major** (Fig. 238) is a flat and rather thin quadrangular muscle which arises from the spinous processes and supraspinous ligaments of the upper four thoracic vertebrae. Its fibers are distinctly parallel and pass downward to be inserted into the vertebral border of the scapula below the root of the spine. The muscle is frequently rather intimately connected with the *rhomboideus minor*, and, according to the position of the scapula, may be either quadrangular or rhomboidal in shape.

The **rhomboideus minor** (Fig. 238) resembles the major in every respect, but is much narrower. It takes origin from the spinous processes of the two lowermost cervical vertebrae and inserts into the vertebral margin of the scapula above the root of the spine. The two *rhomboidei* are separated by a cleft, which is usually quite narrow, and as a rule their origins are distinctly tendinous (aponeurotic).

The *rhomboidei* are supplied from the brachial plexus by the dorsal scapular nerve. They draw the scapula toward the vertebral column and somewhat upward.

The **levator scapulae** (Figs. 238 and 258) is the only one of the flat muscles which possesses any considerable degree of thickness. It is an elongated muscle which arises by four short tendinous digitations from the posterior tubercles of the transverse processes of the four upper cervical vertebrae, the largest digitation coming from the transverse process of the atlas. The digitations unite to form a single belly which passes outward and downward and is inserted into the superior angle of the scapula immediately alongside of the *rhomboideus minor*.

The *levator scapulae* forms a portion of the lateral cervical region and is immediately adjacent to the posterior margin of the *scalenus posterior*. Its origin is partly covered by the posterior portion of the *sternocleidomastoid*.

The *levator scapulae*, like the *rhomboidei*, is supplied by the dorsal scapular nerve. It elevates the superior angle of the scapula and consequently the entire shoulder-blade, thereby assisting the trapezius and the *rhomboidei*. When the scapula is fixed, it can incline and rotate the cervical portion of the vertebral column.

FIG. 238.—The deeper layers of the flat muscles of the back.

On the left side the trapezius and latissimus have been cut away; on the right side the rhomboidei have also been cut and reflected and the lumbodorsal fascia has been retained only where it is in relation with the origin of the serratus posterior inferior and below.

The Third Layer.

The muscles of this layer (Figs. 238 and 239) are situated partly beneath the rhomboidei and partly directly beneath the latissimus and the trapezius. The two splenii are also covered at their origins by a muscle of the same layer, the serratus posterior superior.

The **serratus posterior superior** (Fig. 238) is a flat muscle, rhomboidal in shape, which is tendinous for almost half its breadth and is wholly or almost wholly covered by the rhomboidei. It arises by an aponeurosis from the spinous processes of the two lowermost cervical and of the two uppermost thoracic vertebrae, passes outward and downward, and is inserted by four flat muscular digitations into the outer side of the angles of the second to the fifth ribs.

It is supplied by the upper (first to fourth) intercostal nerves. It draws the upper ribs upward and backward and acts as a muscle of inspiration by enlarging the thorax.

The **serratus posterior inferior** (Fig. 238) resembles the serratus posterior superior in many respects, but it is flatter and its fibers run from within outward and from below upward. It arises from the anterior surface of the posterior layer of the lumbodorsal fascia in common with the latissimus dorsi, at the level of the two lowermost thoracic and the two uppermost lumbar vertebrae; it is at first a thin and independent aponeurosis, but subsequently becomes entirely muscular, and is inserted into the lower borders of the lower four ribs by digitations which frequently vary in their development or may be wanting.

The muscle is supplied by the lower (ninth to twelfth) intercostal nerves. It draws the lower ribs backward and downward. Whether it aids inspiration or expiration is uncertain; in either case its influence upon the ribs is very slight. It may increase the tension of the lumbar fascia.

The **splenius capitis** (Figs. 238 and 239) is a strong, elongated, strap-shaped muscle, which arises by means of the nuchal ligament from the spinous processes of the lower four or five cervical and from the upper two or three thoracic vertebrae. It passes from within outward and from below upward, partly covered by the trapezius, the rhomboidei, and the serratus posterior superior, and its insertion is into the outer half of the uppermost nuchal line of the occipital bone extending as far as the mastoid process. The insertion is covered by the sternocleidomastoid.

The **splenius cervicis** (Fig. 239) is situated immediately to the outer side of the splenius capitis. It arises in immediate succession to the latter muscle from the spinous processes of the third or fourth to the fifth or sixth thoracic vertebrae, and passes obliquely outward and upward as a flat but rather slender muscle, to be inserted into the posterior tubercles of the transverse processes of the upper two or three cervical vertebrae. Its insertion is intimately connected with the origin of the levator scapulae.

The two splenii are supplied from the posterior divisions of the second to the eighth cervical nerves. When the muscles of both sides act in common, they pull the head (or the neck) backward, and when the muscles of one side act alone they turn the head (or the neck) toward the side of the contracting muscle.

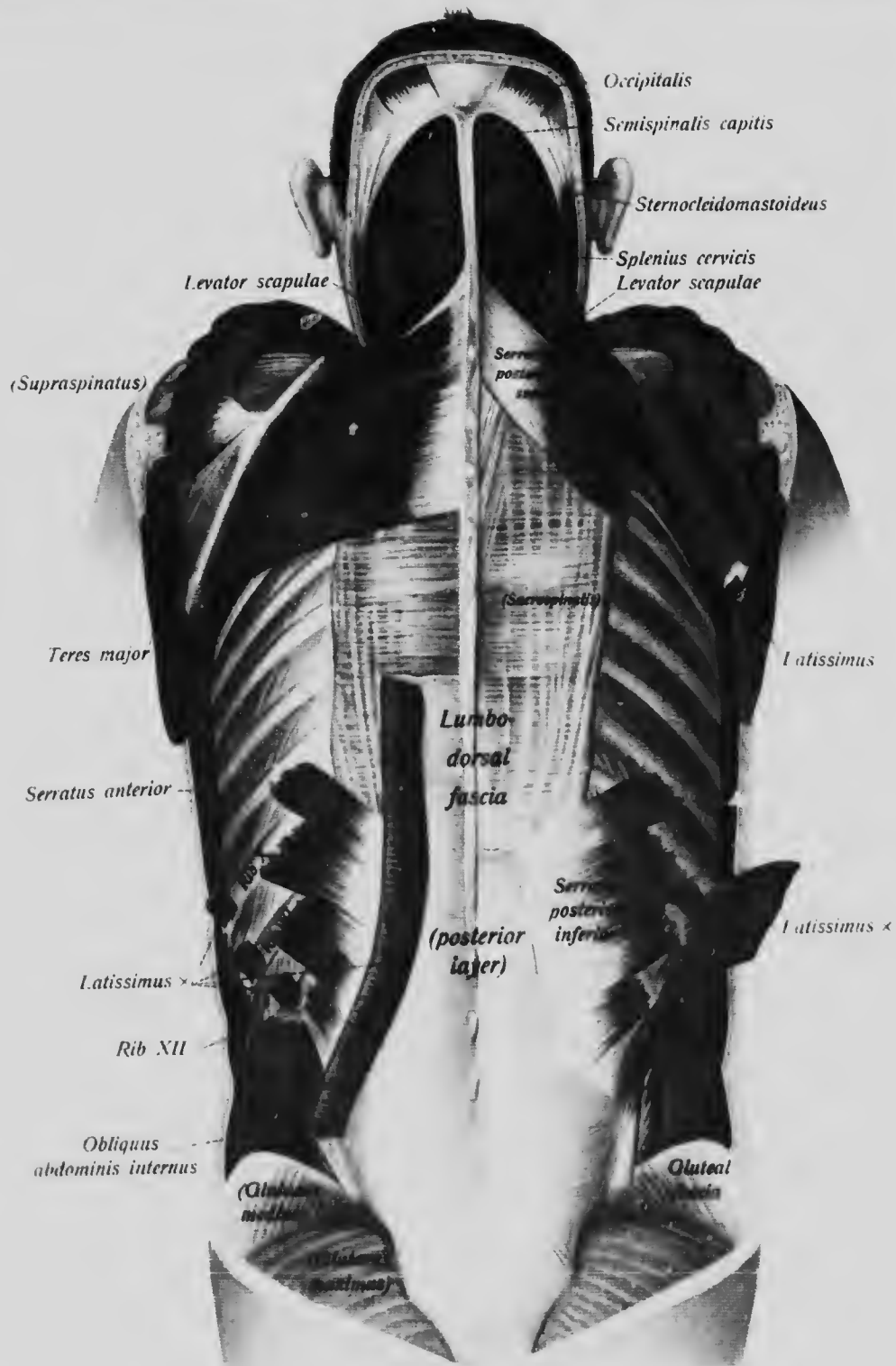

Fig. 238.

1870
1871
1872
1873
1874
1875
1876
1877
1878
1879
1880
1881
1882
1883
1884
1885
1886
1887
1888
1889
1890
1891
1892
1893
1894
1895
1896
1897
1898
1899
1900
1901
1902
1903
1904
1905
1906
1907
1908
1909
1910
1911
1912
1913
1914
1915
1916
1917
1918
1919
1920
1921
1922
1923
1924
1925
1926
1927
1928
1929
1930
1931
1932
1933
1934
1935
1936
1937
1938
1939
1940
1941
1942
1943
1944
1945
1946
1947
1948
1949
1950
1951
1952
1953
1954
1955
1956
1957
1958
1959
1960
1961
1962
1963
1964
1965
1966
1967
1968
1969
1970
1971
1972
1973
1974
1975
1976
1977
1978
1979
1980
1981
1982
1983
1984
1985
1986
1987
1988
1989
1990
1991
1992
1993
1994
1995
1996
1997
1998
1999
2000
2001
2002
2003
2004
2005
2006
2007
2008
2009
2010
2011
2012
2013
2014
2015
2016
2017
2018
2019
2020
2021
2022
2023
2024
2025

THE LONG MUSCLES OF THE BACK.

The long muscles of the back (Figs. 239 and 242) are subdivided into two layers according to the direction of their fasciculi. In the superficial layer, the *spino transversalis*, the fibers pass from the spinous processes to the transverse processes or to the ribs; in the deep layer, the *transversospinalis*, they pass from the transverse to the spinous processes. The *spinalis*, belonging to the upper layer, is the only muscle passing from spinous process to spinous process.

The First Layer. The Spino transversalis and Spinalis.

The muscles of this layer (Fig. 239) fill the vertebral groove between the spinous processes of the vertebræ and the angles of the ribs, and extend over a large area of the vertebral column, usually the entire length of the back. With the exception of a small portion which may lie directly beneath the skin, between the trapezius and the latissimus dorsi (see page 145), they are completely covered either by the flat muscles of the back or by the posterior layer of the lumbar fascia. The spinotransverse fibers form a single, large, complicated muscle, the *sacrospinalis*.

The **sacrospinalis** or *erector spinae* (Figs. 239 and 241) is a long and strong muscular mass which extends from the dorsal surface of the sacrum and the crest of the ilium to the skull. It forms a single mass only in its lower portion, dividing as it passes upward into two separate muscles, the external and weaker *iliocostalis* and the internal and stronger *longissimus dorsi*. Internal to the latter muscle and adherent to it is situated the *spinalis*, so that the superficial layer of the long muscles of the back is arranged in three longitudinal strips upon either side of the vertebral column, a strong median one, the *longissimus*, an external one, the *iliocostalis*, and an internal one the *spinalis*. Before its division the sacrospinalis is a thick powerful muscular mass, whose surface is strongly aponeurotic and which arises from the dorsal surface of the sacrum, from the spinous processes of the lumbar vertebræ, and from the crest of the ilium and is included between the two layers of the lumbar fascia (see page 150). The *iliocostalis lumborum* and the *longissimus dorsi* pass upward directly from this mass.

The **iliocostalis** (Figs. 239 and 241) is the outer portion of the sacrospinalis, and is composed of three subdivisions—the *iliocostalis lumborum*, *dorsi*, and *cervicis*.

The *iliocostalis lumborum* (Figs. 239 and 241) arises in common with the *longissimus* and inserts into the angles of the fifth to the twelfth ribs. The superior insertions are by means of long tendons, while the lower insertions are in the shape of fleshy serrations, the lowermost of which is the strongest and passes to the lower border of the twelfth rib.

The greater portion of the origin of the *iliocostalis dorsi* (Figs. 239 and 241) is covered by the *iliocostalis lumborum*. It arises by means of special accessory serrations from the inner side of the angles of the twelfth to the seventh ribs, and is inserted by thin tendons which pass to the angles of the sixth to the first ribs and to the transverse process of the last cervical vertebra.

The *iliocostalis cervicis* (Figs. 239, 240, and 241), also termed the *cervicalis ascendens*, is a slender muscle the origin of which is intimately connected with the *iliocostalis dorsi*. It comes from the upper and middle ribs in a variable manner and is inserted by narrow tendons into the transverse processes of the middle cervical vertebræ immediately alongside of the *scaleni posterior* (see page 175), with the origin of which it may be adherent.

FIG. 239.—The superficial layer of the long muscles of the back. All the flat muscles, the splenii and the iliocostalis of the left side have been removed.

The **longissimus**, the inner portion of the sacrospinalis, is composed of three subdivisions—the *longissimus dorsi*, *cervicis*, and *capitis*.

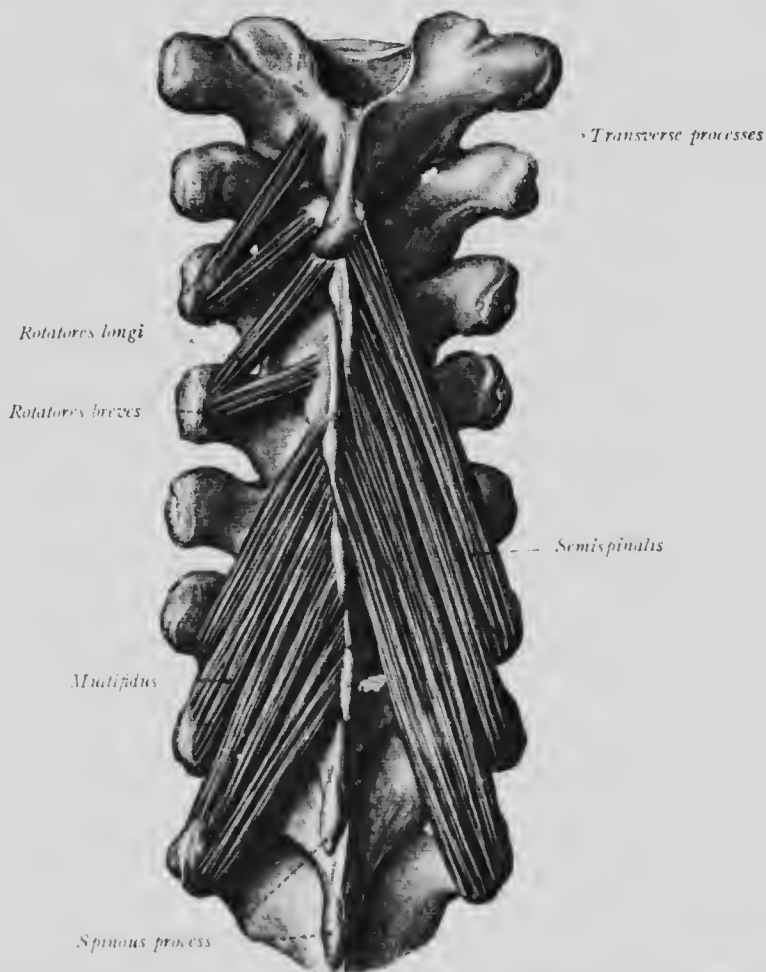
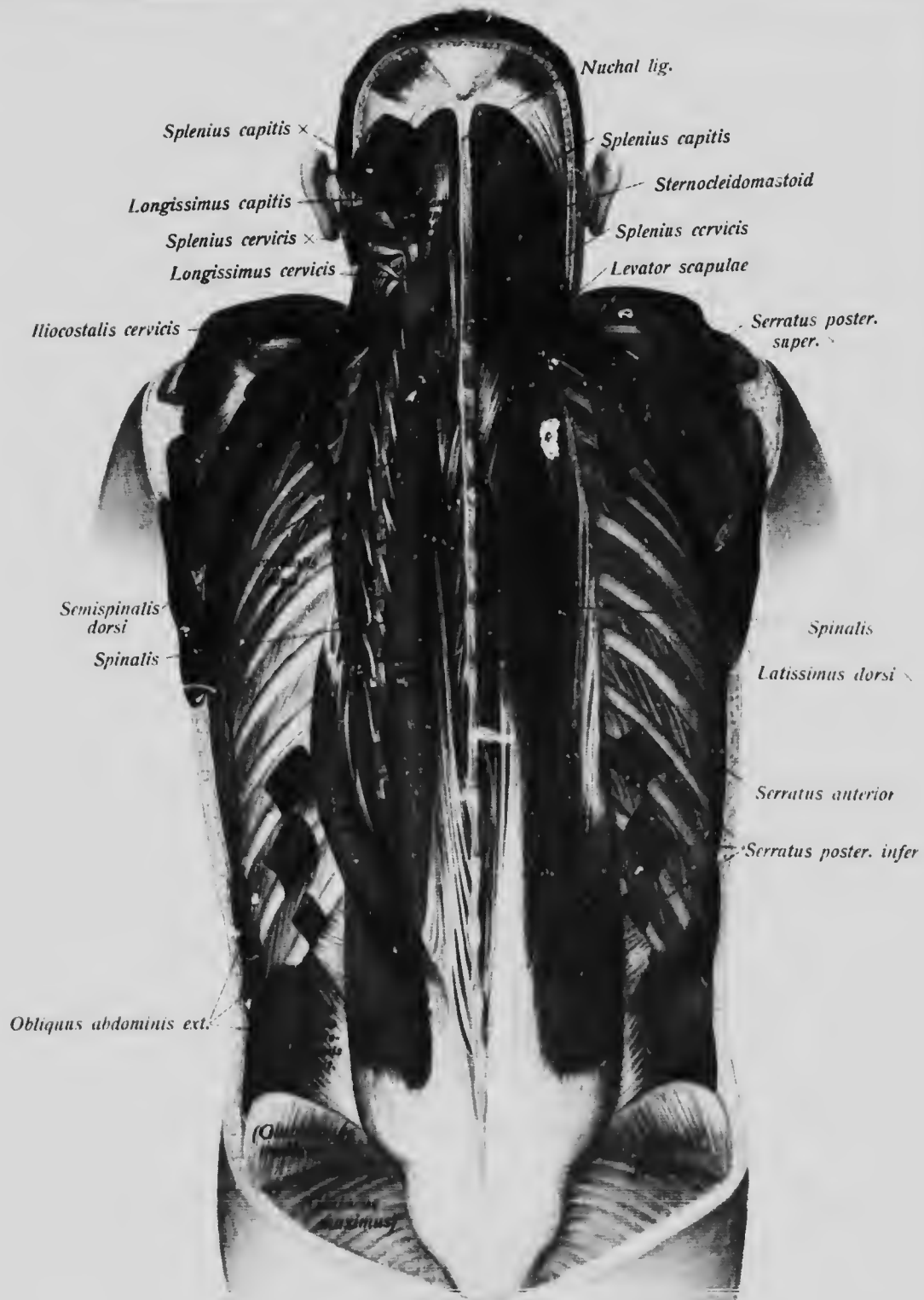


FIG. 240.—Diagram of the arrangement of the various portions of the transversospinalis (semispinalis, multifidus, rotatores).

The *longissimus dorsi* (Figs. 239 and 241), in addition to its common origin with the iliocostalis lumborum, receives accessory origins from the transverse processes of the low or thoracic vertebrae. Its insertions are arranged in an internal and in an external series, and are partly



Nuchal lig.

Splenius capitis ×

Splenius capitis

Longissimus capitis

Sternocleidomastoid

Splenius cervicis ×

Splenius cervicis

Longissimus cervicis

Levator scapulae

Iliocostalis cervicis

Serratus poster. super.

Semispinalis dorsi

Spinalis

Spinalis

Latissimus dorsi

Serratus anterior

Serratus poster. infer

Obliquus abdominis ext.

Fig. 239.



fleshy, partly tendinous, and their digitations are frequently variable. Those of the internal series are inserted into the accessory processes of the upper lumbar vertebrae and into the transverse processes of the thoracic vertebrae; those of the external series insert into the apices of the transverse processes (costal processes) of the upper lumbar vertebrae and into the ribs between the angles and the tubercles. The serrations of the internal insertions consequently pass to the transverse processes and their homologues, while those of the external series run to the ribs or homologous parts.

The *longissimus cervicis* (Figs. 239, 241, and 242), also known as the *transversalis cervicis*, is the direct continuation of the longissimus dorsi. It arises from the transverse processes of the upper thoracic vertebrae, is situated immediately internal to the iliocostalis cervicis, and is inserted by tendinous slips into the transverse processes of the upper and middle cervical vertebrae.

The *longissimus capitis** (Figs. 239, 241, and 242) is the only portion of the sacrospinalis which extends up to the head. It is situated internal to the longissimus cervicis, with the origin of which it is frequently united, and arises by separate short tendinous slips of variable extent from the transverse and articular processes of the middle and lower cervical vertebrae and from the transverse processes of the upper thoracic vertebrae. This muscle often presents a tendinous inscription, is inserted by a short tendon into the posterior margin of the mastoid process, and is completely concealed by the splenius capitis. The iliocostalis and longissimus cervicis and the longissimus capitis are situated beneath (in front of) the two splenii.

The **spinalis** (Figs. 239 and 241) is composed of the *spinalis dorsi, cervicis, and capitis*, of which the spinalis dorsi alone is an independent and constant muscle, the spinalis cervicis being inconstant and the spinalis capitis a part of the semispinalis capitis.

The *spinalis dorsi* (Figs. 239 and 241) is intimately connected with the tendinous origins of the longissimus dorsi which come from the spinous processes of the lumbar vertebrae and takes its origin partly from these bony points. It is situated alongside of the spines of the thoracic vertebrae and contains numerous tendinous fasciculi. It takes its origin from the spinous processes of the upper lumbar and of the lower thoracic vertebrae and passes to the spines of the middle and upper thoracic vertebrae, bridging over one or two of the spinous processes (usually the ninth or the ninth and tenth).

The *spinalis cervicis* (Fig. 241) is inconstant and, when present, is frequently quite rudimentary. It is a very slender muscle which arises from the spinous processes of the sixth and seventh cervical vertebrae and inserts into the spinous processes of the epistropheus (axis) and of the third cervical vertebrae.

An inconstant muscular fasciculus which arises from the spinous processes of the lower cervical and upper thoracic vertebrae is designated the *spinalis capitis*. It forms a portion of the semispinalis capitis, with which it will be described (see page 152).

The Second Layer. The Transversospinalis.

The fibers of this layer (Figs. 239 to 242), passing from the transverse to the spinous processes, represent in their arrangement a portion of the original trunk musculature which has

* This muscle has also been termed the *transversalis capitis*, the *complexus minor*, and the *tractus mastoideus*.

FIG. 241.—The deeper layers of the long muscles of the back.

On the left side the sacrospinalis has been partly removed and the semispinalis has been cut and reflected.

FIG. 242.—The cervical portion of the deeper layers of the muscles of the back, seen from the side. The trapezius and splenii have been removed.

undergone but slight changes. They are arranged in three layers, each of which is described as a special muscle, although they are not separated by fascia, but are distinguishable from each other chiefly by the length of their fasciculi. The *semispinalis*, the most superficial layer, has the longest and consequently the most slanting fibers, which bridge over from four to six spinous processes; the *multifidus*, the middle layer, has fasciculi which pass over two or three vertebral spines; and the *rotatores*, forming the deepest layer, either extend over only one spinous process (*rotatores longi*) or pass to the next succeeding vertebra (*rotatores brevis*). With the exception of the semispinalis capitis, all of the fibers of the transversospinalis end at the spinous process of the axis. The semispinalis is absent in the lumbar region, and the rotatores are situated chiefly in the thoracic region.

The **semispinalis** (Figs. 230, 241, and 242) consists of the *semispinalis dorsi*, *semispinalis cervicis*, and *semispinalis capitis*.

The *semispinalis dorsi* (Figs. 230 and 241) and *cervicis* (Fig. 241) are directly continuous without demarcation, the lowermost fibers arising from the transverse processes of the lower thoracic vertebrae, and the uppermost fasciculi terminating at the spinous process of the axis. The muscle is stronger and more fleshy in the neck than it is in the back. The fibers of the semispinalis dorsi are intermingled with numerous tendinous fasciculi and are also partly connected with the spinalis dorsi. The muscle is completely covered by the longissimus dorsi and the semispinalis capitis.

The *semispinalis capitis* (Figs. 230, 241, and 242) is a flat but rather thick muscle and is the strongest muscle of the neck. As a rule, it consists of two portions which are separated below but adherent above at their insertion—a stronger external or semispinal portion and a weaker internal or spinal portion. The semi-spinal segment, sometimes termed the *complexus*, arises by numerous short tendinous slips from the transverse processes of the third cervical to the fifth or sixth thoracic vertebrae, while the spinal segment arises from the spinous processes of the lower cervical and of the upper thoracic vertebrae (the *spinalis capitis*). This latter portion is characterized by a tendinous inscription, and hence is sometimes termed the *biventer cervicis*, and sometimes, when the *spinalis capitis* is absent, its origin extends to the transverse processes of the second to the sixth cervical vertebrae. The external portion of the muscle also usually possesses a broad tendinous inscription which is situated above the middle tendon of the biventer. Both portions of the muscle unite and pass to the nuchal surface of the occipital bone, where they insert between the superior and inferior nuchal lines.

The **multifidus** (Figs. 241 and 242) consists of the *multifidus lumborum*, *dorsi*, and *cervicis*, but these segments cannot be clearly demarcated from each other. It commences below at the posterior surface of the sacrum and terminates above at the spinous process of the epistropheus (axis). It is strongest in the lumbar region, where it lies directly beneath the longissimus; it is weakest in the thoracic region, where it is covered by the semispinalis dorsi; and in the cervical

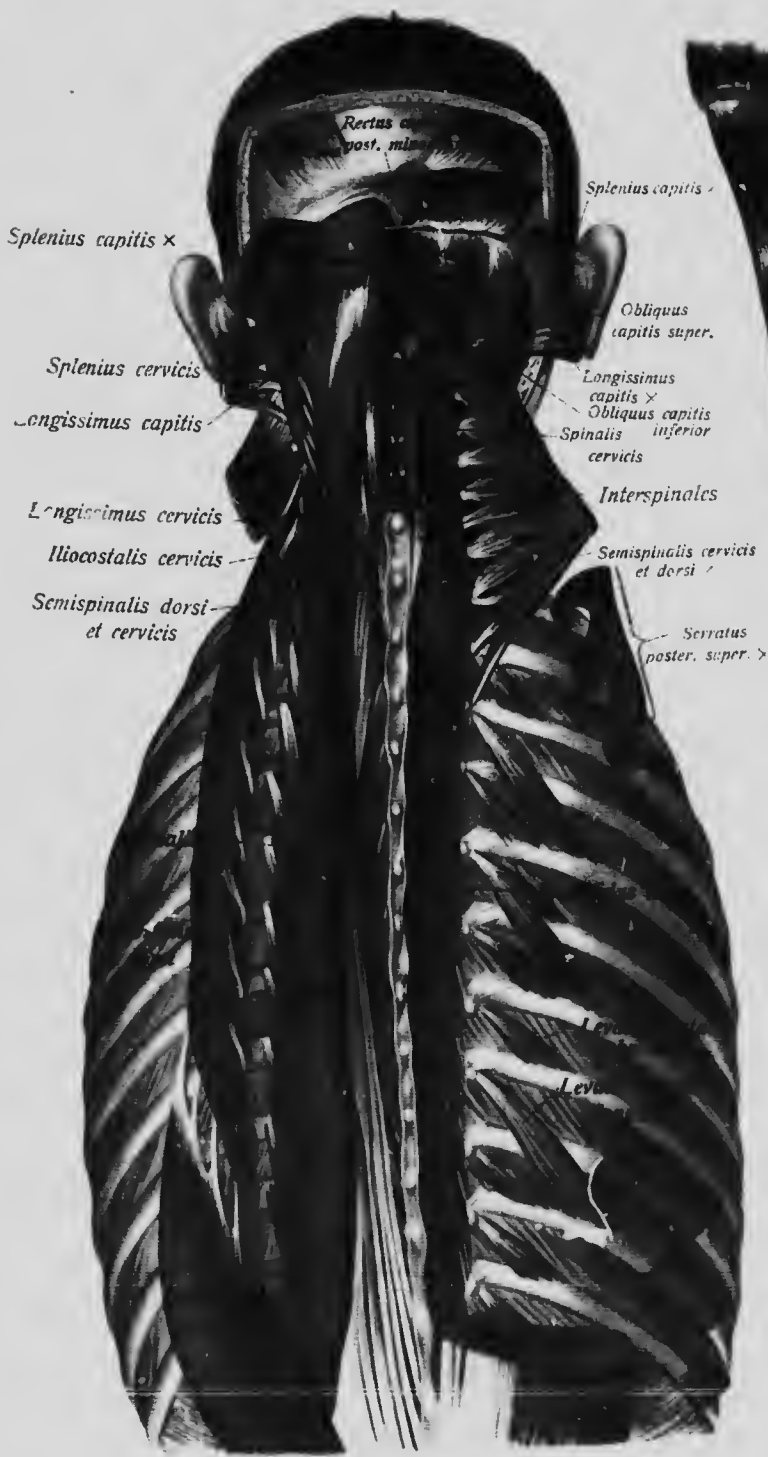

Fig. 211

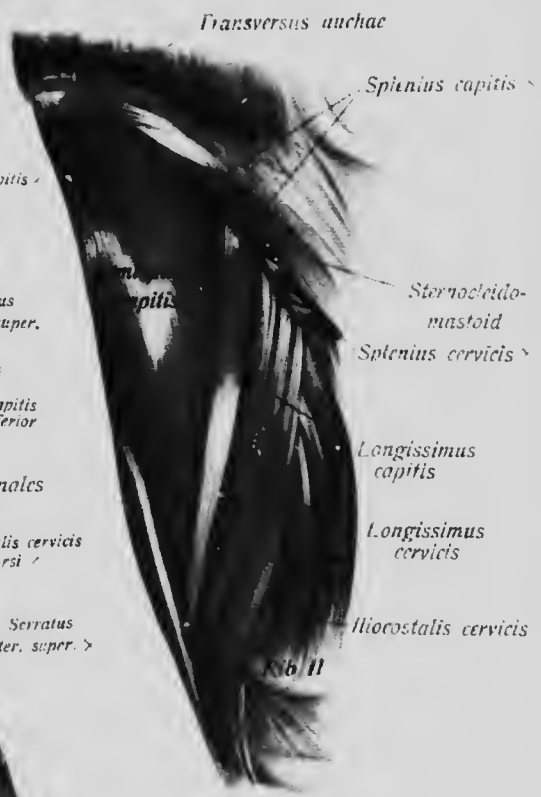

Fig. 242.

1870
1871
1872
1873
1874
1875
1876
1877
1878
1879
1880
1881
1882
1883
1884
1885
1886
1887
1888
1889
1890
1891
1892
1893
1894
1895
1896
1897
1898
1899
1900
1901
1902
1903
1904
1905
1906
1907
1908
1909
1910
1911
1912
1913
1914
1915
1916
1917
1918
1919
1920
1921
1922
1923
1924
1925
1926
1927
1928
1929
1930
1931
1932
1933
1934
1935
1936
1937
1938
1939
1940
1941
1942
1943
1944
1945
1946
1947
1948
1949
1950
1951
1952
1953
1954
1955
1956
1957
1958
1959
1960
1961
1962
1963
1964
1965
1966
1967
1968
1969
1970
1971
1972
1973
1974
1975
1976
1977
1978
1979
1980
1981
1982
1983
1984
1985
1986
1987
1988
1989
1990
1991
1992
1993
1994
1995
1996
1997
1998
1999
2000
2001
2002
2003
2004
2005
2006
2007
2008
2009
2010
2011
2012
2013
2014
2015
2016
2017
2018
2019
2020
2021
2022
2023
2024
2025

region it is partly concealed by the semispinalis cervicis, to the outer side of which it is covered by the semispinalis capitis. In the lumbar region the greater portion of its fibers arise from the accessory and mamillary processes, in the thoracic region from the transverse processes, and in the cervical region from the articular processes of the four lower cervical vertebrae. The fasciculi are intermixed with tendinous fibers and generally extend over two or three vertebrae, combining

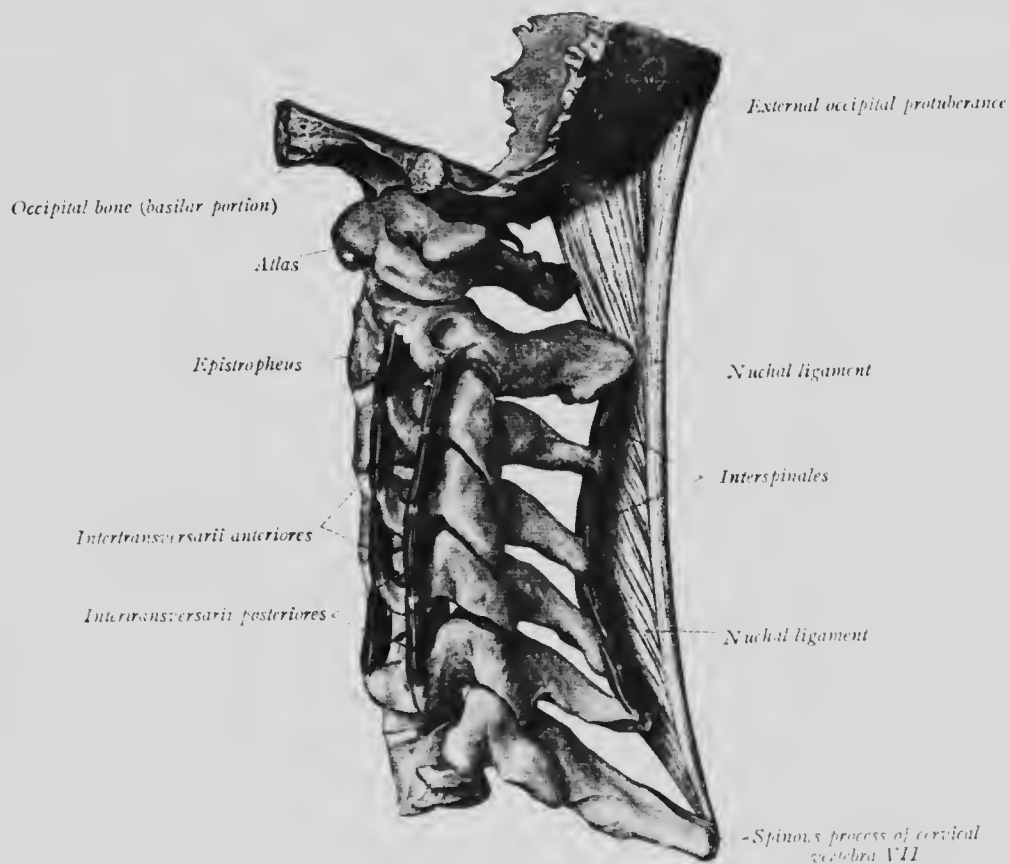


FIG. 243.—Diagram of the cervical interspinales and intertarsarii and of the nuchal ligament.

to form a single uninterrupted muscular layer, the deeper portion of which is distinguishable only with difficulty from the rotatores, part of whose fibers pass in the same direction (Fig. 240).

The **rotatores** are composed of the *rotatores longi* and *breves*. They are small, flat, and partly tendinous muscles which lie immediately upon the vertebral arches throughout the entire spinal column, but are chiefly developed in the thoracic region. The *rotatores breves* (Fig. 240) are almost horizontal and pass from the transverse process of one vertebra to the root of the spinous process of the vertebra next above; the *rotatores longi* (Fig. 240) extend over one or sometimes

two vertebrae before inserting into the roots of the spinous processes, their fibers having a course parallel to that of the multifidus.

All of the long muscles of the back are supplied by the posterior divisions of the spinal nerves (cervical, thoracic, lumbar, and sacral).

The majority of the long muscles of the back have the same functions. If the muscles of the two sides act together, they hold the trunk upright, extend the vertebral column and the head, and bend the head and vertebral column backward. During unilateral action they bend or rotate the vertebral column toward the contracting side. The strongest action upon the head is exerted by the two *semispinales capitis*; when they act together, they pull the head backward, but when they act singly they rotate the head so that the face is drawn toward the opposite side, and consequently in the opposite direction to that in which it is turned by the *splenius capitis*.

THE SHORT MUSCLES OF THE BACK.

The short muscles of the back are divided into two groups: those which are found throughout the entire flexible vertebral column and those which are situated between the axis and the

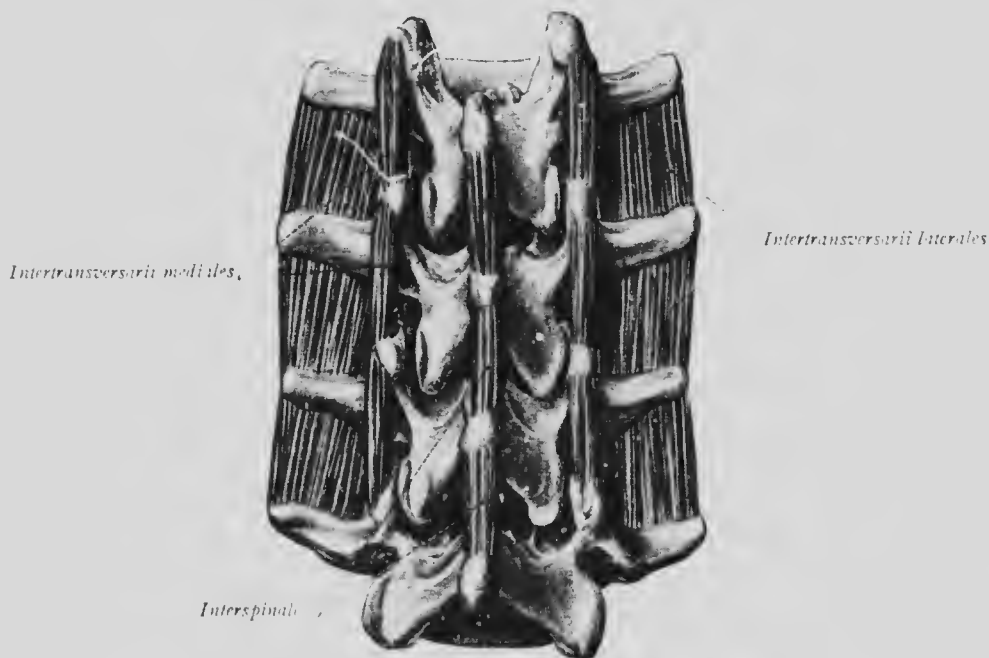


FIG. 244.—Diagram of the lumbar interspinous and intertransversarii.

atlas. The first group is composed of two further subdivisions: the *interspinales*, between the spinous processes of the vertebrae; and the *intertransversarii*, between the transverse processes. The second group is also designated as the short muscles of the neck.

The **interspinales** (Figs. 241, 243, and 244) are small muscles which are well developed only in the cervical region and may be entirely wanting throughout the thoracic vertebral column. They are connected with the interspinous ligaments and pass from the spinous process of one

vertebra to that of the next lower one, and in the bifid spinous processes of the cervical vertebrae they form paired structures. Like the majority of the muscles of the back, they do not extend beyond the spinous process of the epistropheus (axis).

The **intertransversarii** (Figs. 243 and 244) are small, short, paired muscles which connect the transverse processes of neighboring vertebrae. They are double upon both sides and are well developed both in the cervical and in the lumbar vertebral column. They may be entirely absent from the thoracic column.

In the cervical region *intertransversarii anteriores* and *posteriores* (Fig. 243), which run between the anterior and posterior tubercles of the transverse processes, are differentiated. Both muscles are about equally developed; the anterior ones are situated in the anterior cervical rather than in the nuchal region.

The intertransversarii of the lumbar region are composed of the wider and stronger *intertransversarii laterales*, running between the transverse processes, and the narrower and weaker *intertransversarii mediales*, which extend between the accessory and mammillary processes (Fig. 244).

As regards their function and innervation, the interspinales and the intertransversarii resemble the long muscle of the back.

THE SHORT MUSCLES OF THE NECK.

The short muscles of the neck (Figs. 241 and 250) are the *rectus capitis posterior major*, the *rectus capitis posterior minor*, the *rectus capitis lateralis*, the *obliquus capitis superior*, and the *obliquus capitis inferior*.

The **rectus capitis posterior major** (Fig. 241) arises by a short tendon from the spinous process of the axis, runs upward and outward, becoming much broader, and inserts into the middle portion of the inferior nuchal line of the occipital bone.

The **rectus capitis posterior minor** (Fig. 241) is considerably weaker than the major. It is a small triangular muscle which arises by a short tendon from the posterior tubercle of the atlas to the inner side of and partly beneath the rectus major. It runs to the inner third of the inferior nuchal line of the occipital bone.

The **rectus capitis lateralis** (Fig. 250) arises from the transverse process of the atlas and inserts into the jugular process of the occipital bone. It represents the uppermost intertransversarius.

The **obliquus capitis superior** (Fig. 241) also arises from the transverse process of the atlas, and runs to the outer third of the inferior nuchal line of the occipital bone, where its tendinous insertion partly covers the rectus capitis posterior major.

The **obliquus capitis inferior** (Fig. 241) is a rather strong and fleshy muscle which runs from the spinous process of the epistropheus (axis) to the transverse process of the atlas. It is thick in the middle and becomes narrower toward its origin and insertion.

The short muscles of the neck are supplied by the posterior division of the first cervical nerve (occipital nerve).

The function of the short muscles of the neck, practically consists of a rotation or extension of the head, dependent upon whether they act upon one or both sides. The rectus minor can only extend the head (nodding movement); the rectus lateralis inclines the head to one side; the obliquus inferior and the rectus major rotate the head in the same direction and are opposed by the obliquus superior.

FIG. 245.—Superficial and second layers of the abdominal and pectoral muscles seen from in front. On the right side the pectoralis major and the obliquus abdominis externus have been removed.

Between the rectus capitis posterior major and the obliquus capitis superior and inferior is situated a small triangle (the *suboccipital triangle*) in which is exposed the posterior arch of the atlas, crossed by the vertebral artery.

THE FASCIÆ OF THE BACK.

In the dorsal region there are but two fasciæ worthy of note, the *lumbodorsal fascia* and the *nuchal fascia*. The upper layer of the flat muscles of the back is covered only by the general superficial fascia.

The **lumbodorsal fascia** (Figs. 236 to 238) is composed of two layers, the strong posterior layer, which is superficially situated in the back and forms the aponeurosis of the latissimus and the serratus posterior inferior, and the anterior or deep layer, which is developed only in the lumbar region, where the long muscles of the back are included between the two layers.

The *posterior layer* (Figs. 236 and 238) covers the sacrospinalis from behind and extends above the uppermost portion of the latissimus to the inferior margin of the aponeurosis of the serratus posterior superior. Although the fascia becomes considerably thinner after it ceases to be the aponeurosis of the latissimus, it usually still contains distinct tendinous slips. In the thoracic region the posterior layer is attached laterally to the angles of the ribs, and is covered by the trapezius and by the rhomboidei.

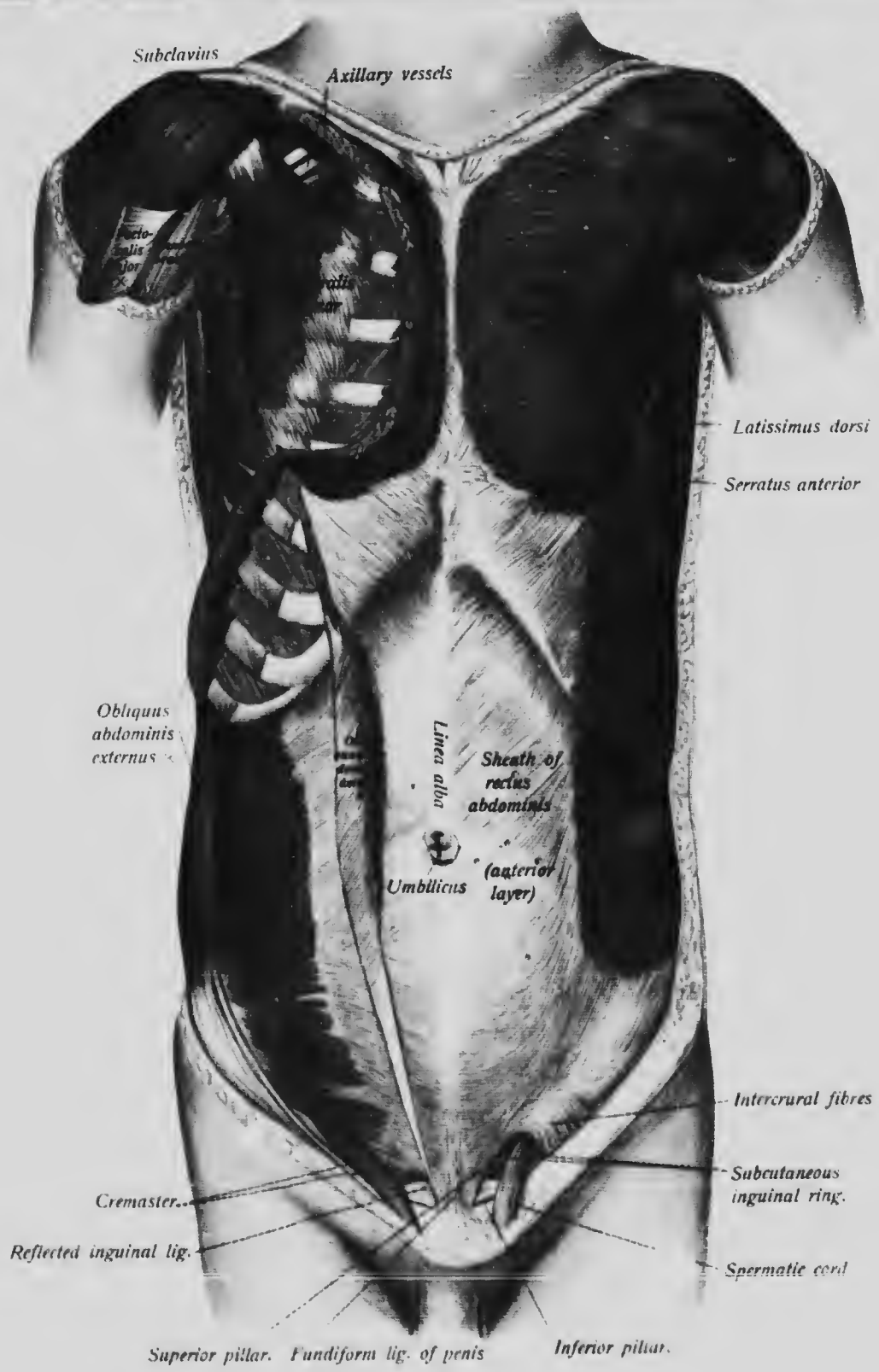
The *anterior layer* (Fig. 237) runs from the inner lip of the crest of the ilium to the twelfth rib, and is attached internally to the transverse processes of the lumbar vertebrae. Its upper margin forms a firmer tendinous band which passes from the transverse process of the first lumbar vertebra to the twelfth rib and is known as the *lumbocostal (external arcuate) ligament* (Fig. 251). The anterior layer is situated between the sacrospinalis and the quadratus lumborum, and at the outer margin of the sacrospinalis the two layers unite and give origin to several of the abdominal muscles.

The thin **nuchal fascia** is situated beneath the trapezius and also partly beneath the rhomboidei. It is continuous below with the upper portion of the lumbodorsal fascia and externally with the fascia of the neck, and the fasciæ of the two sides are connected in the median line with the nuchal ligament.

[The trunk musculature is derived from the trunk myotomes of the embryo and is clearly divisible into two portions: (1) the dorsal trunk musculature, derived from the dorsal portions of the myotome and supplied by the dorsal (posterior) branches of the spinal nerves; and (2) the ventral trunk musculature, developed from the ventral portions of the trunk myotome, and supplied by the ventral branches of the spinal nerves.

When considered from this standpoint, the muscles of the back as arranged above clearly form a somewhat heterogeneous group. The flat muscles are for the most part supplied by ventral branches of the spinal nerves or, in the case of the trapezius, by a cranial nerve, a fact which at once distinguishes them from the long and short muscles (together with the rhombi, which form the true dorsal musculature). The majority of the flat muscles are in reality muscles of the upper limb, and the trapezius is primarily part of the cranial musculature; they will be considered later in connection with the other muscles of their groups.

So far as the true dorsal musculature is concerned, comparative anatomy has shown that it is composed of two parallel groups of muscles, a lateral one, which consists of muscles primarily passing from the transverse processes to the ribs, and hence is termed the *transversocostal group*, and a more median one, whose muscles pass from the transverse to the



Subclavius

Axillary vessels

Latissimus dorsi

Serratus anterior

Obliquus abdominis externus

Linea alba

Sheath of rectus abdominis

Umbilicus

(anterior layer)

Intercostal fibres

Subcutaneous inguinal ring.

Cremaster.


Reflected inguinal lig.

Spermatic cord

Superior pillar. Fundiform lig. of penis

Inferior pillar.

Fig. 245.



spinous processes, and which has been termed the *transverso-spinal* group. The constitution of the two groups is as follows:

Transverso-costal:—*Sacrospinalis, iliocostalis, longissimus, and splenius.*

Transverso-spinal: *Spinalis, semispinalis, multifidus, rotatores, interspinales, intertransversarii posteriores, and laterales, rectus capitis posterior major, rectus capitis posterior minor, rectus capitis lateralis, obliquus capitis superior, and obliquus capitis inferior.*—[E.D.]

THE ABDOMINAL MUSCLES.

The **abdominal muscles** (Figs. 245 to 250) form the anterior, the lateral, and a portion of the posterior abdominal wall, and extend from the lower margin of the thorax to the upper margin of the pelvis. They are subdivided into the anterior abdominal, of which three are flat muscles and one a straight muscle, and the posterior abdominal, the quadratus lumborum.

THE ANTERIOR ABDOMINAL MUSCLES.

THE FLAT ABDOMINAL MUSCLES.

The flat abdominal muscles (Figs. 245 to 250) include the *obliquus externus*, the *obliquus abdominis internus*, and the *transversus abdominis*; they are arranged in three layers and form the lateral and a portion of the anterior abdominal wall. According to the direction of their fibers, the two oblique muscles may be regarded as the direct continuations of the intercostales, the *obliquus internus*, in particular, being directly continuous with the lower intercostal muscles.

The **obliquus abdominis externus** (Figs. 245 to 249) is a broad flat muscle which is aponeurotic anteriorly and markedly so in its anterior inferior portion. It is situated in the lateral pectoral, the hypochondriac, the epigastric, the mesogastric (lateral abdominal and umbilical), and the hypogastric (inguinal and pubic) regions.

It arises by eight fleshy serrations from the eight (fifth to twelfth) lower ribs, the upper five serrations interdigitating with the lower ones of the serratus anterior, the lower three with those of the latissimus dorsi. The majority of the fibers of the muscle, like those of the intercostales externi, run from above downward and from without inward; the superior fibers, however, pass somewhat horizontally, while the inferior ones approach a vertical direction.

The fibers coming from the lower ribs have an extensive fleshy insertion into the outer lip of the crest of the ilium, extending anteriorly to the anterior superior spine and posteriorly almost to the outer margin of the latissimus dorsi. The remainder of the insertion is aponeurotic and passes to the inguinal (Poupart's) ligament, the greater portion of which is formed by the tendinous fasciculi of the muscle (see page 163), and to the anterior layer of the sheath of the rectus, by means of which it is continued to the linea alba. Almost the entire anterior abdominal surface is consequently aponeurotic; especially in the lower abdominal region the muscle fibers commence quite at the side.

The *obliquus abdominis externus* is in relation superiorly with the abdominal portion of the pectoralis major, externally with the serratus anterior, postero-externally with the latissimus dorsi, with which it forms the lumbar (Petit's) triangle (see page 147), and inferiorly with the

FIG. 247.—The superficial layer of the abdominal muscles and the serratus anterior seen from the left side.

The pectoralis major and minor and the inner portion of the clavicle have been removed and the arm has been drawn backward.

iliac crest opposite to the glutæus medius. In the region of the symphysis pubis the tendinous fibers of the aponeurosis form an opening by bridging over the space between the pubic spine (the insertion of the inguinal ligament) and the upper margin of the symphysis. In this manner

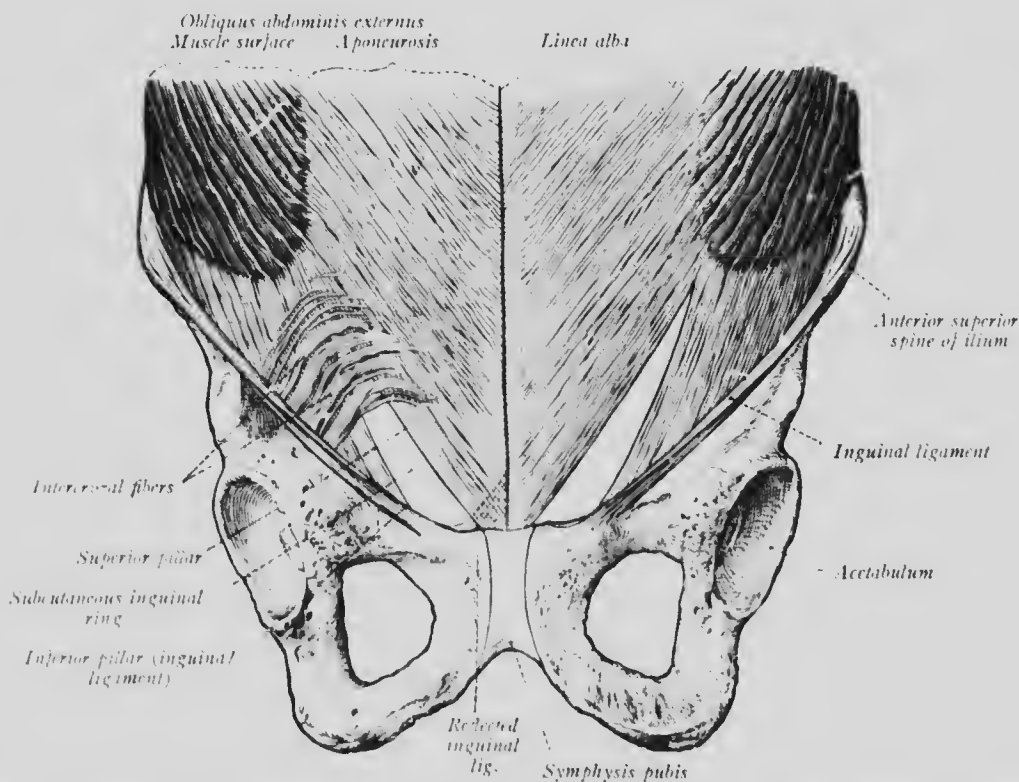


FIG. 249.—Diagram of the subcutaneous inguinal ring. On the right only a portion of the aponeurosis of the obliquus abdominis is represented.

there is formed a triangle, the outer angle of which is directed upward and outward, and which constitutes the *subcutaneous inguinal (external abdominal) ring* (Figs. 245 and 246). The margins of the ring are formed by the aponeurosis of the obliquus abdominis externus, and are known as the *superior crus* or *pillar* and the *inferior crus* or *pillar* of the ring.

The upper and outer angle of this triangular slit in the aponeurosis of the external oblique muscle is rounded off by fibers which arise from the region of the inguinal ligament and are

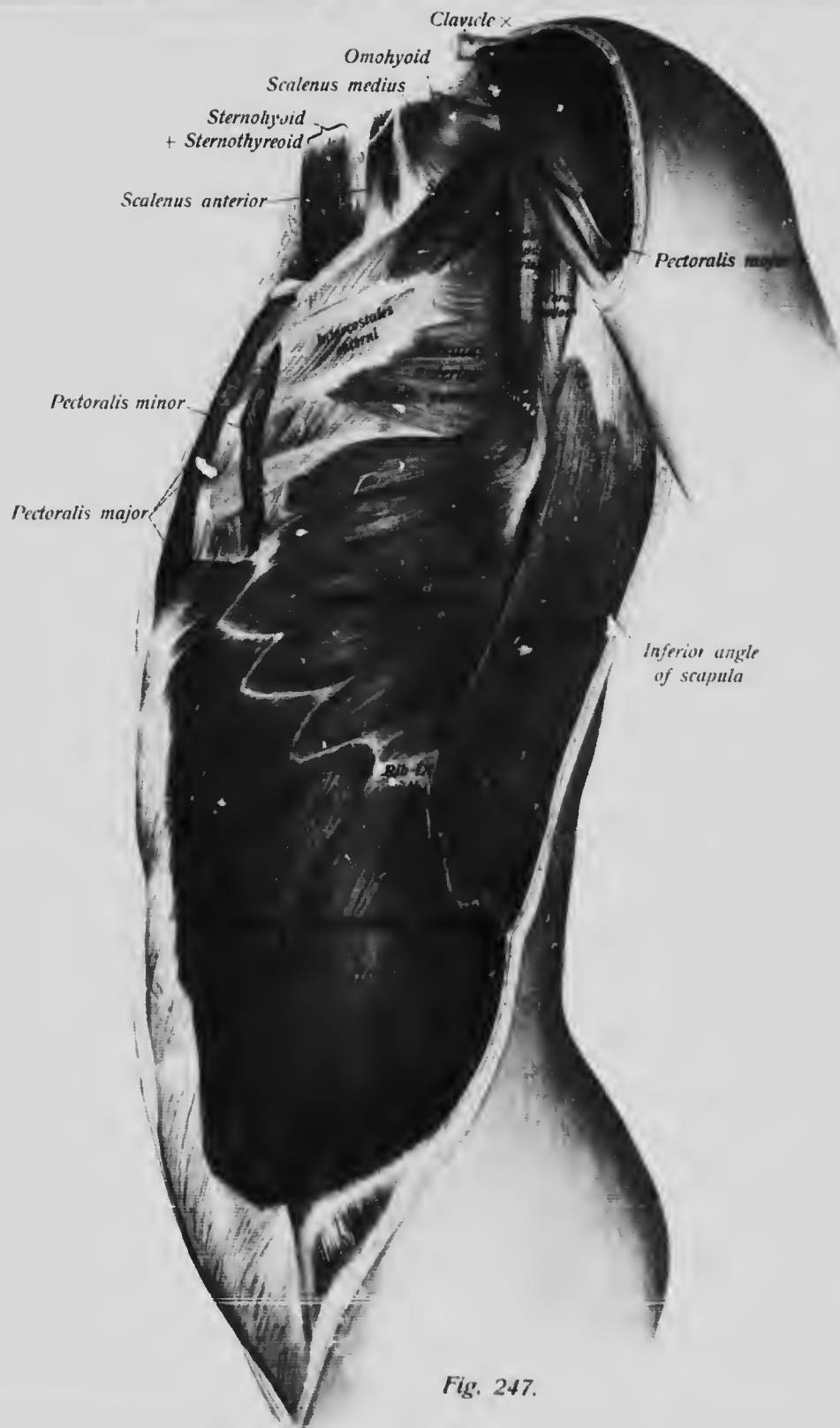


Fig. 247.

1870
1871
1872
1873
1874
1875
1876
1877
1878
1879
1880
1881
1882
1883
1884
1885
1886
1887
1888
1889
1890
1891
1892
1893
1894
1895
1896
1897
1898
1899
1900
1901
1902
1903
1904
1905
1906
1907
1908
1909
1910
1911
1912
1913
1914
1915
1916
1917
1918
1919
1920
1921
1922
1923
1924
1925
1926
1927
1928
1929
1930
1931
1932
1933
1934
1935
1936
1937
1938
1939
1940
1941
1942
1943
1944
1945
1946
1947
1948
1949
1950
1951
1952
1953
1954
1955
1956
1957
1958
1959
1960
1961
1962
1963
1964
1965
1966
1967
1968
1969
1970
1971
1972
1973
1974
1975
1976
1977
1978
1979
1980
1981
1982
1983
1984
1985
1986
1987
1988
1989
1990
1991
1992
1993
1994
1995
1996
1997
1998
1999
2000
2001
2002
2003
2004
2005
2006
2007
2008
2009
2010
2011
2012
2013
2014
2015
2016
2017
2018
2019
2020
2021
2022
2023
2024
2025

situated superficially and in front of the aponeurosis itself. They are known as the *intercrural* (*intercolumnar*) fibers or the *anterior crus* or *pillar* (Figs. 245 and 246). The inner angle is similarly rounded off by fibers of variable development which originate at the attachment of the inguinal ligament to the pubic spine and pass toward the linea alba beneath the aponeurosis. These fibers are known as the *reflected inguinal* (*triangular*) *ligament*, or sometimes as the *ligament*

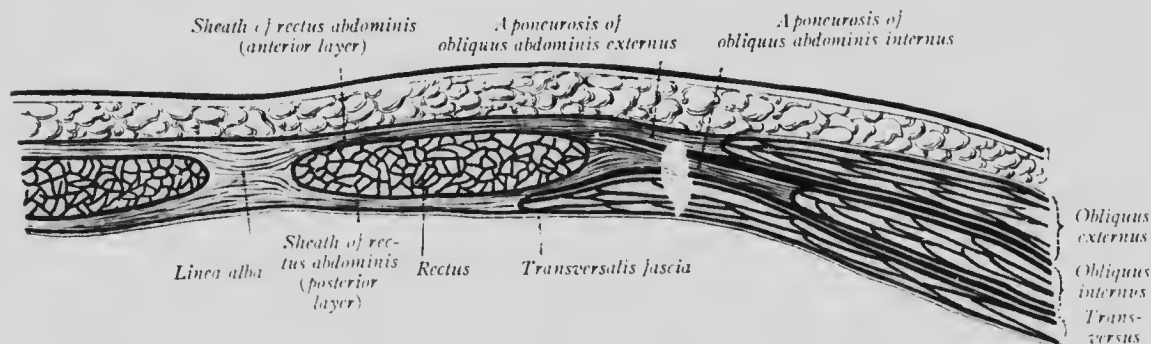


FIG. 248.—Transverse section of the anterior abdominal wall about a hand's breadth above the umbilicus (diagrammatic).

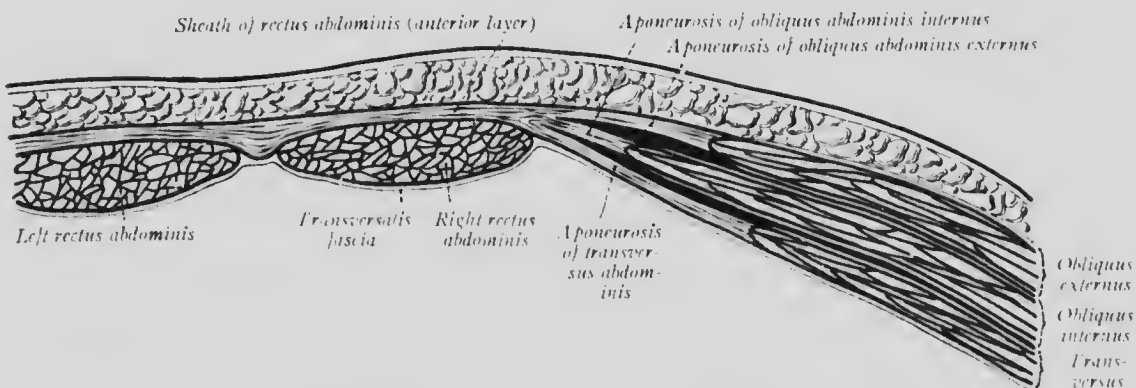


FIG. 249.—Transverse section of the anterior abdominal wall midway between the umbilicus and the symphysis pubis (diagrammatic).

of Colles or the *posterior crus* (Figs. 245 and 246). As a result of the presence of the fibers and the ligament, the ring becomes irregularly quadrangular in shape.

It is the anterior extremity of a canal, the inguinal canal, which passes obliquely through the abdominal walls, and transmits the spermatic cord in the male, and the round ligament of the uterus in the female.

(For a more detailed account of the inguinal canal the reader is referred to text-books and atlases of topographic anatomy and to the section upon splanchnology.)

FIG. 250.—The deeper layers of the abdominal muscles.

On the left side the anterior layer of the sheath of the rectus abdominis and the obliquus abdominis externus have been removed; on the right side, in addition, the rectus abdominis, the pyramidalis, and the obliquus abdominis internus. The external intercostal ligaments have been removed on the left side.

The **obliquus abdominis internus** (Figs. 245, 248 to 250), like the externus, is a decidedly flat muscle. With the exception of the small area in the lumbar triangle it is completely covered by the obliquus externus. It arises from almost the entire length of the middle lip of the crest of the ilium, extending anteriorly as far as the anterior superior spine, from the junction of the two layers of the lumbodorsal fascia (see page 156), and from the outer two-thirds of the inguinal ligament. The direction of the fibers of the upper portion of the muscle is similar to that of the intercostales interni (from without inward and from below upward); the middle fibers are less oblique, and the lower ones are horizontal, those of the lower third even passing slightly from without inward and from above downward, like those of the obliquus externus.

The posterior fibers coming from the lumbar fascia have fleshy insertions into the lower borders of the three lower ribs. The long fibers coming from the iliac crest, as well as the horizontal and descending fasciculi from the inguinal ligament, pass into the sheath of the rectus, the two layers of which are formed by the aponeurosis of the obliquus internus (Fig. 248).

The muscular portion of the obliquus internus is broader than that of the externus and consequently approaches much more closely to the sheath of the rectus in the anterior abdominal wall, especially in its lower portion (Fig. 249). A variable number of the inferior fibers of the obliquus internus accompany the spermatic cord, as the *cremaster* (Figs. 245 and 250), as far as the testicle, and consequently pass through the external abdominal ring as flat isolated fasciculi, and in the female a few fibers of the muscle are similarly continued upon the round ligament of the uterus.

The **transversus abdominis** (Figs. 248 to 250) is a flat, rather thin, and largely aponeurotic muscle which is completely covered by the obliquus internus. It arises by flat muscular serrations from the inner surface of the six lower ribs and from the cartilages of the seventh to the tenth, interdigitating with the serrations of origin of the diaphragm (see page 164). It also arises by an aponeurosis from the entire length of the junction of the two layers of the lumbodorsal fascia, from the internal lip of the crest of the ilium, and from the outer third of the inguinal ligament. The fibers pass almost transversely and are attached to the aponeurotic insertion in a curved line, the *semilunar line (line of Spigelius)* (Fig. 250), in such a manner that the uppermost fibers coming from the ribs almost approach each other in the median line, the middle ones become aponeurotic at quite a distance from this location, and the inferior fasciculi remain muscular for a somewhat greater distance. The upper two-thirds of the aponeurosis of the transversus, together with that of the internus, form the posterior layer of the sheath of the rectus (Fig. 248); the lower third together with the aponeuroses of the obliquus internus and externus, forms the anterior layer of the sheath (Fig. 249).

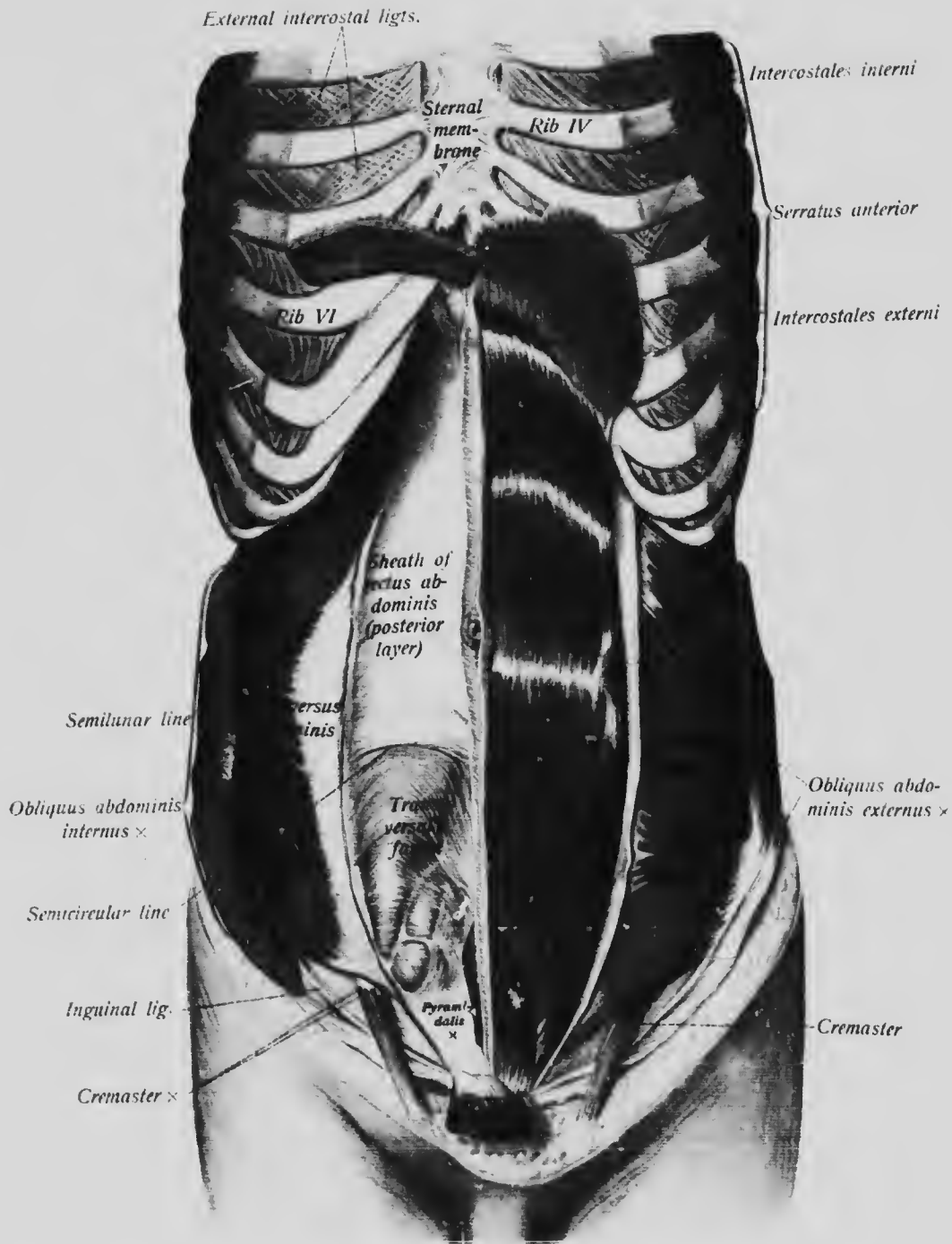


Fig. 250.

1870
1871
1872
1873
1874
1875
1876
1877
1878
1879
1880
1881
1882
1883
1884
1885
1886
1887
1888
1889
1890
1891
1892
1893
1894
1895
1896
1897
1898
1899
1900
1901
1902
1903
1904
1905
1906
1907
1908
1909
1910
1911
1912
1913
1914
1915
1916
1917
1918
1919
1920
1921
1922
1923
1924
1925
1926
1927
1928
1929
1930
1931
1932
1933
1934
1935
1936
1937
1938
1939
1940
1941
1942
1943
1944
1945
1946
1947
1948
1949
1950
1951
1952
1953
1954
1955
1956
1957
1958
1959
1960
1961
1962
1963
1964
1965
1966
1967
1968
1969
1970
1971
1972
1973
1974
1975
1976
1977
1978
1979
1980
1981
1982
1983
1984
1985
1986
1987
1988
1989
1990
1991
1992
1993
1994
1995
1996
1997
1998
1999
2000
2001
2002
2003
2004
2005
2006
2007
2008
2009
2010
2011
2012
2013
2014
2015
2016
2017
2018
2019
2020
2021
2022
2023
2024
2025

THE STRAIGHT ABDOMINAL MUSCLE, RECTUS ABDOMINIS.

The **rectus abdominis** (Figs. 248 to 250) is a flat, broad, and rather thick muscle. It arises (Fig. 250) broadly by flat muscular serrations from the cartilages of the fifth to the seventh ribs and from the xiphoid process, and its fibers pass almost vertically downward just to either side of the median line. The muscle becomes somewhat narrower as it descends and is inserted by a much narrower tendon into the upper border of the pubis between the pubic tubercle and the symphysis, a portion of the tendinous fasciculi of the muscles of the two sides interlacing in front of the pubic symphysis.

The rectus is characterized by possessing several narrow, transverse, slightly curved or dentate tendinous intersections, the *tendinous inscriptions (transverse lines)* (Fig. 250), which traverse a portion or the entire width of the muscle, but do not usually extend throughout its thickness. The number varies between three and four. The uppermost one lies immediately below the origin of the muscle in the region of the costal arch and is sometimes developed only in the inner half of the muscle; the third is situated at the level of the umbilicus or somewhat above it; and the second is about midway between the first and the third. A fourth intersection is inconstant, but, when present, is below the umbilicus and usually traverses only the outer half of the muscle. In the vicinity of the tendinous intersections the muscle is adherent to the anterior layer of its sheath.

Instead of being surrounded by fascia, the rectus is inclosed by the aponeurotic layers of its *sheath* (Figs. 245, 247 to 250), which consists of an anterior and a posterior layer. Only the anterior layer covers the muscle throughout; the posterior layer forms a sheath for only the upper two-thirds of the muscle (Figs. 248 and 249). At the junction of the middle with the lower third of the length of the muscle (or even somewhat higher) the posterior layer of the rectus sheath abruptly ceases in the shape of a slightly curved line, the *semicircular line (line of Douglas)* (Fig. 250), and below this line, the muscle is in immediate relation posteriorly with the transversalis fascia (see page 163).

The layers of the sheath are formed from the flat abdominal muscles (Figs. 248 and 249) in such a way that the aponeurosis of the obliquus internus splits into two layers in the upper two-thirds of the sheath, one of which forms the anterior layer and the other the posterior; in the lower third of the rectus, however, the aponeurosis of the obliquus internus forms only the anterior layer. The aponeurosis of the obliquus externus passes into the anterior layer; the upper two-thirds of that of the transversus goes to the posterior layer, and the lower third to the anterior layer.

At the inner margin of the rectus the two layers of the sheath unite with each other and with the corresponding layers of the opposite side to form a thick tendinous strip, the *linea alba* (Fig. 245), which extends between the xiphoid process and the sternum.

The linea alba usually possesses a special tensor muscle in the shape of the inconstant **pyramidalis** (Fig. 250). This is a triangular muscle arising broadly from the tendon of insertion of the rectus abdominis and passing obliquely inward to be inserted into the lower portion of the linea alba.

The rectus and pyramidalis, like the other muscles of the anterior abdominal wall, are innervated by branches of the lower intercostal nerves; the flat abdominal muscles also receive branches from the iliohypogastric and the ilioinguinal nerves from the lumbar plexus. The cremaster muscle is supplied by the external spermatic nerve (the genital branch of the genitocrural nerve).

When all the anterior abdominal muscles act together their function is to diminish the size of the abdominal cavity and to compress the abdominal contents, the increased intra-abdominal tension aiding in the evacuation of the contents of the intestines, of the uterus, and possibly also of the urinary bladder. With the exception of the transversus abdominis, these muscles also draw the thorax downward, the rectus directly downward, and the obliqui, when acting separately, toward the side of the contracting muscle. When the thorax is fixed, the anterior abdominal muscles and particularly the rectus, raise the pelvis.

THE POSTERIOR ABDOMINAL MUSCLE.

The **quadratus lumborum** (Figs. 251 and 254) is a flattened, rather thick, and approximately quadrilateral muscle which forms a portion of the posterior abdominal wall. It extends

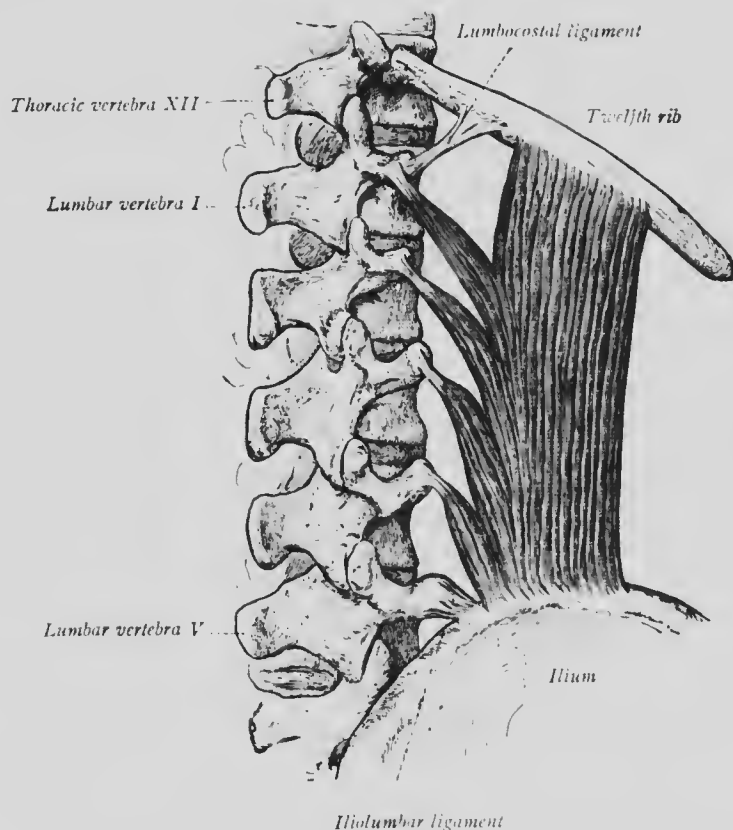


FIG. 251.—The quadratus lumborum seen from the side and somewhat from behind (diagrammatic).

between the crest of the ilium and the twelfth rib, and consists of two incompletely separated layers, a posterior and an anterior. The *posterior portion* (Fig. 251) arises by aponeurotic fibers from

the posterior part of the inner lip of the crest of the ilium and from the iliolumbar ligament and extends to the inner half of the lower border of the twelfth rib and to the transverse processes of the upper four lumbar vertebrae. The *anterior portion* of the muscle arises from the transverse processes of the lower and middle lumbar vertebrae, the fibers intimately interlacing with those of the posterior portion, and inserts into the transverse process of the first lumbar vertebra and into the inner half of the last rib.

The inner half of the quadratus lumborum is placed beneath (posterior to) the psoas major, and it is situated in front of the anterior layer of the lumbodorsal fascia, which separates it from the sacrospinalis. The lateral lumbocostal arch (external arcuate ligament) of the diaphragm bridges over the insertion of the muscle into the twelfth rib. To the outer side of the muscle there is visible the aponeurotic origin of the transversus abdominis from the lumbodorsal fascia, and at the crest of the ilium it becomes continuous on the iliacus.

The quadratus lumborum is supplied by muscular branches from the lumbar plexus. It draws the last rib downward and bends the vertebral column toward the side.

THE ABDOMINAL FASCIÆ.

The superficial layer of the flat abdominal muscles is covered only by the *general superficial fascia* (Figs. 248 and 249), which is, however, well developed in the lower portion of the abdomen in the region of the subcutaneous inguinal ring, where it forms what is known as *Scarpa's fascia*. From this situation it extends downward upon the thigh and also envelops the spermatic cord as the *cremasteric fascia*. The sheath of the rectus muscle serves as its fascia.

The inner surface of the abdominal musculature, *i. e.*, the inner surface of the transversus abdominis and the posterior surface of the posterior layer of the sheath of the rectus, is lined by the *transversalis fascia*, which also covers the anterior surface of the quadratus lumborum and is especially strong over that muscle. It is rather firmly adherent to the aponeurosis of the transversus and to the posterior layer of the sheath of the rectus; below the semicircular line it is frequently very thin and forms the only posterior covering of the rectus abdominis (see page 161 and Fig. 249). Above the symphysis, it is connected with the so-called *adminiculum linea alba* (see below), and at the inguinal (Poupart's) ligament, with the posterior surface of which it is adherent, it becomes continuous with the iliac fascia (see page 231). Superiorly the fascia gradually disappears upon the lower surface of the diaphragm.

The *linea alba* (Figs. 245 and 248) is formed by the union of the aponeuroses of the flat abdominal muscles in the median line of the abdomen. It is broader above than below the umbilicus and, at the umbilicus itself, it is adherent to the integument. At its insertion into the upper margin of the symphyseal cartilage, its posterior surface is reinforced by a triangular fibrous expansion, sometimes containing muscle fibers, which passes upward from the superior pubic ligament and is known as the *adminiculum linea alba*.

The *inguinal ligament* (*Poupart's ligament*) (Figs. 208 to 210) is also formed by the aponeuroses and fasciæ of the abdomen. It extends as a strong tendinous band from the anterior superior spine of the ilium to the spine of the pubis, some of its fibers radiating at its insertion to the inner extremity of the crest of the pubis and forming an almost horizontal triangular

FIG. 252.—The diaphragm and the muscles of the posterior abdominal wall.

The anterior abdominal wall and the abdominal viscera have been removed; the thorax has been bent backward so that the lumbar vertebrae are strongly convex forward.

ligament, the *lacunar ligament* (*Gimbernal's ligament*) (Figs. 212 and 213), which is also connected with radiating fibers of the fascia of the thigh (see page 231). The *reflected inguinal ligament* (*triangular ligament*) (Fig. 245) is also formed by radiating fibers from the inguinal ligament, which pass to the posterior surface of the anterior layer of the sheath of the rectus (see page 159). The inguinal ligament gives origin not only to the flat abdominal muscles, but it also furnishes attachment to the fascia of the abdomen and thigh (see page 231), and the deeper layers of the integument are also adherent to it.

[The ventral portions of the trunk myotomes during their development undergo a considerable amount of differentiation, forming a number of muscle groups. From each myotome a portion is cut off which comes to lie ventral to the vertebrae or ribs, forming what is termed the *hyposkeletal* group of muscles. Similarly the ventral edges of the myotomes are separated to form band-like muscles, whose fibers are directed longitudinally and which are situated immediately adjacent to the mid-ventral line. These constitute what is termed the *rectus* group. And, finally, the intervening portions of the myotomes divide tangentially into three layers, whose fibers assume an oblique or transverse direction and which constitute what is known as the *oblique* group of muscles.

The abdominal muscles are referable to these groups as follows:

Hyposkeletal: *Psoas major* and *psoas minor* (see p. 210).

Rectus: *Rectus abdominis* and *pyramidalis*.

Oblique: *Obliquus abdominis externus*, *obliquus abdominis internus*, *transversus abdominis*, and *quadratus lumborum*.

It is also probable that the *intertransversarii laterales* of the lumbar region are properly referable to the oblique group.—E.O.]

THE DIAPHRAGM.

The *diaphragm* (Fig. 252) is a single independent muscle, which, from a topographical standpoint, is best considered with the abdominal muscles. Its shape differs from that of all the other skeletal muscles, in that it is a thin and markedly dome-shaped muscle, which is stretched across the inferior aperture of the thorax in such a way that it is convex toward the thorax and concave toward the abdomen. It consists of a central tendinous portion, the *central tendon*, and of a peripheral muscular portion.

The muscular fasciculi of the diaphragm are subdivided according to their origin into three parts, which are designated the *sternal portion*, the *costal portion*, and the *lumbar portion*, and of these the lumbar portion is the strongest and the sternal portion by far the weakest. The fibers of all three portions are inserted into the margins of the central tendon.

The *sternal portion* (Figs. 252 and 253) arises from the posterior surface of the xiphoid process and consists of but a few slender fasciculi.

The *costal portion* (Figs. 252 and 253) arises by broad fleshy serrations from the inner surface of the six lower costal cartilages and from the eleventh and twelfth ribs, being also attached to the lumbocostal ligament in this situation, interdigitating with the *transversus abdominis* and with the *transversus thoracis*, following the curvature of the dome of the diaphragm and passing to the central tendon. The fibers of this portion, although weaker than those of the lumbar portion,

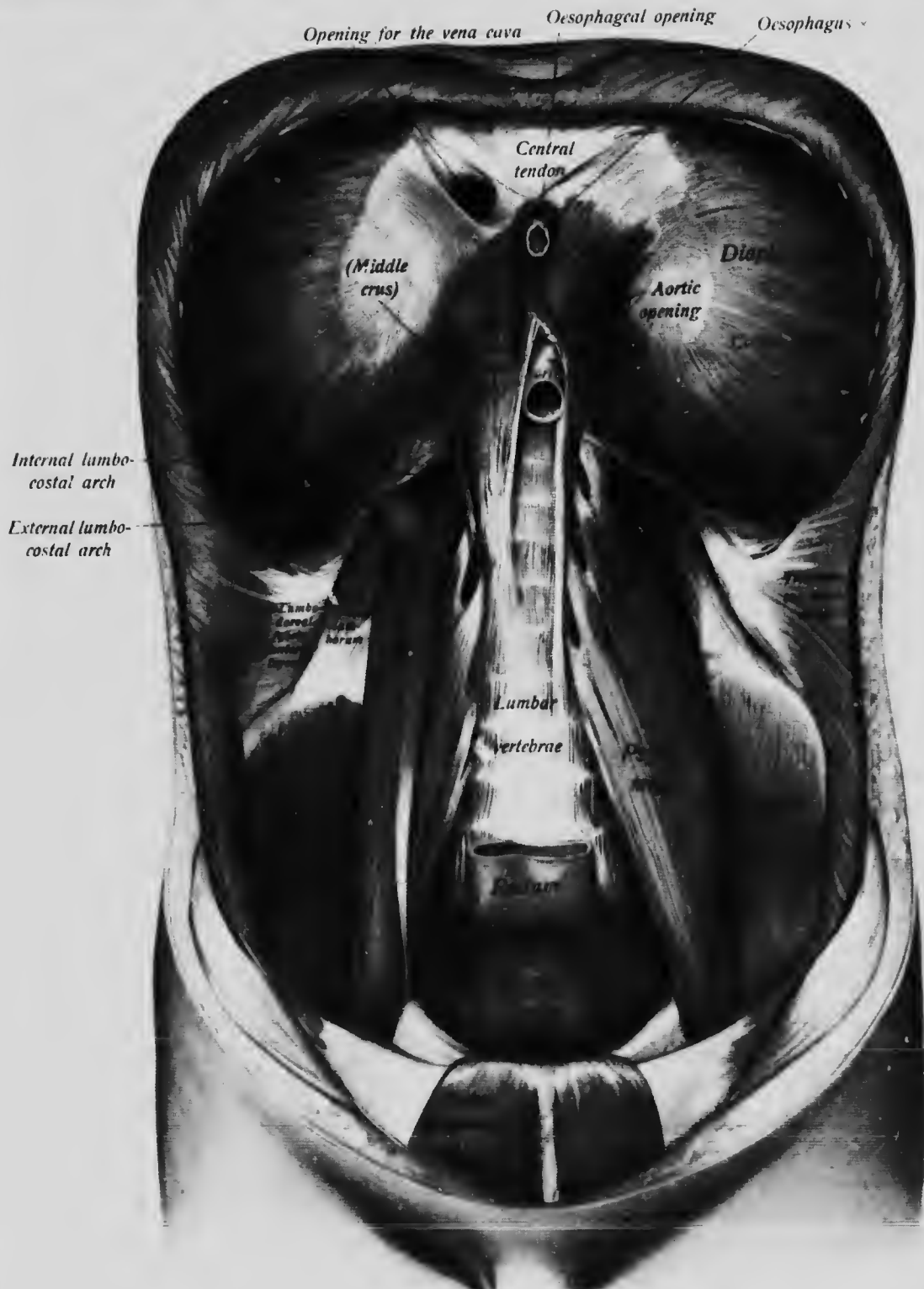


Fig. 252



cover a much larger area and form the main portion of the dome of the diaphragm. Between the individual serrations of origin there are sometimes linear intervals which contain no muscular tissue.

The greater part of the *lumbar portion* (Fig. 252) comes from the bodies of the lumbar vertebræ. Upon either side there may be distinguished three crura, or pillars, the *crus mediale*, *intermedium*, and *laterale*. The *inner crura*, sometimes termed simply the crura, are by far the strongest parts. They arise by tendinous fibers from the anterior surfaces of the third and fourth lumbar vertebræ and from the anterior longitudinal ligament and the intervertebral fibrocartilage between the two vertebræ, and their outer margins soon become muscular while the inner ones remain tendinous. They may arise at different levels on the two sides, and when this is the case, it is the right crura which is always the longer of the two. The inner tendinous margins unite at the level of the twelfth thoracic vertebra or at that of the eleventh intervertebral fibrocartilage to form a pointed arch with tendinous margins, which is converted into a short canal by the anterior surfaces of the last thoracic and the first lumbar vertebra. The opening so formed gives passage to the aorta and is consequently designated the *aortic opening* (Fig. 252).

The fibers of the entire lumbar portion, and especially those of the inner crura, pass at first almost vertically upward in front of the lumbar column, but just before their insertion into the central tendon they follow the curvature of the diaphragm, and in this situation they enclose a second opening in the diaphragm, which is elliptical, the long axis being vertically placed. The margins of the foramen are purely muscular and, as it gives passage to the esophagus, it is known as the esophageal opening. In its formation there usually occurs a decussation of the fibers of the two inner crura.

The *middle crura* are considerably weaker and more slender than the inner ones. They arise by short tendons from the lateral surfaces of the body of the second lumbar vertebra and are at first separated from the inner crura by narrow slits, but before their insertion into the central tendon they become closely approximated to the muscular tissue of these.

The *outer crura* practically arise from the two tendinous lumbocostal arches, the *internal* and *external lumbocostal arches* (*arches of Haller*). The *internal lumbocostal arch* (*internal arcuate ligament*) passes from the body of the first lumbar vertebra to the tip of the transverse process of the same bone, crossing over the psoas major, while the *external lumbocostal arch* (*external arcuate ligament*) extends from the transverse process of the first lumbar vertebra to the twelfth rib and bridges over the quadratus lumborum. The slender fibers of the lateral lumbar portion of the diaphragm arise chiefly from the internal lumbocostal arch and also from the transverse process and lateral margin of the body of the first lumbar vertebra. Only a few fibers arise from the external lumbocostal arch and these may be entirely absent; they represent the connection between the lumbar and the costal portions of the diaphragm. The fasciculi of the outer crura are considerably shorter than those of the inner and middle ones.

The *central tendon* (Fig. 252) is a fibrous layer which may be either uniform or shaped like a clover leaf* and its fasciculi undergo manifold decussations. The convex surface of the central tendon is situated anteriorly; the more marked concavity is placed posteriorly. In it there may be recognized a middle almost plane or but slightly curved portion, which is situated between the

* The clover leaf form is present when the central tendon extends toward the sternal portion.

two domes of the diaphragm, and two leaflets which are directed posteriorly. The left leaflet is the smaller and forms the left dome of the diaphragm; the right is larger and forms the right dome. At the base of the right leaflet near its posterior margin is situated a large irregular rounded opening, completely within the central tendon, which gives passage to the inferior vena cava and is designated the *opening for the vena cava (quadrilateral foramen)*.

The curvature of the diaphragm is not uniform, but there is a middle lower portion and two lateral domes which project markedly toward the thoracic cavity. The right dome is more capacious and extends to a higher level than the left; its highest point corresponds to the fourth, that of the left to the fifth intercostal space. Posteriorly the diaphragm (the lumbar portion) extends much lower than it does anteriorly. Its transverse is considerably larger than its sagittal diameter.

The diaphragm possesses a series of foramina and spaces which give passage to vessels and nerves. These are: (1) The *aortic opening*, which is only partly formed by the diaphragm; (2) the *esophageal opening*, purely muscular and formed entirely by the diaphragm; (3) the *opening for the vena cava*, situated entirely within the tendinous portion of the muscle; and (4) the slit-like spaces between the inner and middle crura and between the middle and external crura. The latter spaces give passage to the vena azygos, to the vena hemiazygos, and to the sympathetic and the splanchnic nerves, which are arranged in a variable manner. In addition to the aorta, the aortic opening also transmits the thoracic duct.

The motor nerve of the diaphragm is the phrenic nerve from the cervical plexus.

The diaphragm is the chief muscle of respiration. By the contraction of its fibers the domes of the diaphragm are drawn downward and the costal portions are drawn away from contact with the thoracic wall, so that the thoracic cavity is increased in size and the abdominal cavity is diminished.

[The diaphragm, from the developmental standpoint, belongs to the cervical musculature, the muscular tissue which it contains being derived from the fourth (and to a certain extent from the third and fifth) cervical myotomes; the entire structure lying at one period of the development in the cervical region and later migrating downward to its final position between the thorax and abdomen. Hence it is that it is supplied by the phrenic nerve, which arises from the fourth (third to fifth) cervical nerve, and elongates in proportion as the diaphragm recedes toward its final position.—ED.]

THE THORACIC MUSCLES.

The muscles of the thorax (Figs. 245, 247, 253, and 254) are composed of two main groups: (1) Those which arise from the thoracic skeleton and insert into the skeleton of the upper extremity; these are, consequently, really muscles of the extremity; and (2) the actual muscles of the thoracic wall, which are known as the intercostales.

The first group is arranged in three layers which are not exactly superimposed. The first layer is formed by the *pectoralis major*, the second by the *pectoralis minor* and the *subclavius*, and the third by the *serratus anterior*.

THE THORACIC MUSCLES OF THE UPPER EXTREMITY.

The First Layer. The Pectoralis Major.

The *pectoralis major* (Fig. 245) is a large, flat, thick muscle which is situated in the sternal, infraclavicular, mammary, axillary, and inframammary regions, its outer border forming the

anterior boundary of the axilla. The muscle is approximately triangular in shape, since its origin is very extensive and its insertion quite limited.

It arises by three more or less separated portions, which are designated as the *clavicular*, the *sternocostal*, and the *abdominal* portions. The clavicular portion comes from the sternal half of the clavicle, the sternocostal portion from the anterior surface of the manubrium and the body of the sternum, with accessory digitations from the cartilages of the second to the sixth or seventh rib, while the abdominal portion, which is by far the smallest portion of the origin of the muscle, is a flat bundle which is attached to the lower margin of the sternocostal portion and arises by an aponeurosis from the anterior layer of the sheath of the rectus abdominis.

Toward its insertion, the pectoralis major becomes considerably narrower but correspondingly thicker. Only the fibers of the clavicular portion and the upper fibers of the sternocostal portion pursue their original course, the greater number of the fibers of the sternocostal and abdominal portions passing from the anterior surface of the muscle toward the posterior surface of the tendon of insertion, so that an extensive twisting of the muscular fasciculi occurs in the outer portion of the muscle.

The tendon is inserted (Fig. 260) into the entire length of the greater tubercular (anterior bicipital) ridge of the humerus. It consists of a weaker posterior aponeurotic layer and of a stronger anterior layer which becomes tendinous immediately before its actual insertion. Both layers are adherent below; the anterior is formed by the clavicular and by the upper part of the sternocostal portion, the lower by the bulk of the sternocostal and abdominal portions.

Tendinous fasciculi from the insertion of the pectoralis major not infrequently bridge over the intertubercular (bicipital) groove and pass to the latissimus. These fibers sometimes contain muscle fibers (the *muscle of Langer*).

The two pectorales arise from the anterior surface of the sternum in such a way that an area is left in the middle of the bone, narrow above and somewhat broader below, which contains no muscular tissue and in which is exposed the sternal membrane. In this situation the sternal head of the sternocleidomastoid (Fig. 255) (see page 171) borders immediately upon the pectoralis, and at the clavicle the origin of the pectoralis is situated exactly opposite to the clavicular head of the sternocleidomastoid. The anterior margin of the deltoid usually borders immediately upon the upper convex margin of the pectoralis major, a considerable space between the two muscles, known as the *deltoideopectoral triangle*, usually existing only immediately below the clavicle, and the cephalic vein (Fig. 291) usually runs in the groove between the two muscles. At its lower margin the pectoralis major is continuous with the aponeurosis of the abdominal muscles (the sheath of the rectus), and its outer margin borders anteriorly upon the obliquus abdominis externus and posteriorly upon the serratus anterior. The tendon of insertion is situated between the deltoid upon one side and the short head of the biceps and the coracobrachialis upon the other; in this situation it is separated from the latissimus by the intertubercular (bicipital) groove.

An exceedingly inconspicuous muscle, the *sternalis*, is quite rarely found upon the pectoralis major. It may be present upon one or both sides, is elongated, tendinous at its extremities, and is usually connected with the tendon of the sternocleidomastoid and the sheath of the rectus as well as with the pectoralis major, and usually represents a dislocated portion of the latter muscle.

The pectoralis major is supplied by the anterior thoracic nerves. Together with the latissimus, it adducts the arm, and when it acts alone, it draws the arm anteriorly and toward the chest and, at the same time, rotates it internally.

The Second Layer. The Pectoralis Minor and the Subclavius.

The **pectoralis minor** (Fig. 245) is a flat triangular muscle which is completely concealed by the pectoralis major and, at its insertion, also by the deltoid. It arises by thin tendinous slips, frequently indistinctly separated, from the costochondral articulations of the second or third to the fifth ribs; it passes upward and outward and becomes markedly narrower toward its short tendinous insertion into the tip of the coracoid process.

It covers the upper portion of the serratus anterior and bridges over the axillary vessels and the brachial plexus.

The pectoralis minor, like the major, is supplied by the anterior thoracic nerves. It draws down the scapula, or, if the scapula be fixed, elevates the ribs, and it can also aid in fixing the scapula.

The **subclavius** (Figs. 245 and 260) is a small, elongated, somewhat flattened muscle which arises by a tendon from the first costal cartilage alongside of the costoclavicular ligament, and is inserted into the under surface of the acromial end of the clavicle between the two portions of the coracoclavicular ligament (see page 120). In this situation there is usually a shallow groove in the bone.

The nerve supplying the muscle is the subclavian from the brachial plexus.

The muscle, by its contraction, fixes the clavicle in the sternoclavicular joint, and when the shoulder girdle is fixed the muscle elevates the first rib.

The Third Layer. The Serratus Anterior.

The **serratus anterior** (*serratus magnus*) (Figs. 247, 250) is covered in its upper portion by both pectoral muscles; its lower portion is situated in the lateral pectoral region and, immediately below the pectoralis major, is covered only by the integument and fascia, the most inferior portion of the muscle, however, being placed beneath the anterior margin of the latissimus.

The muscle is flat throughout, irregularly quadrilateral in shape, and its middle portion is very thin; it forms a muscular plate which is adapted to the curved surface of the thorax. It arises from the first to the ninth ribs by means of individual serrations, the lower five of which are distinctly separated and interdigitate with the serrations of the origin of the obliquus externus abdominis. In the broad muscle sheet formed by the union of the serrations, three portions, distinctly differentiated by the direction of their fibers, may be recognized. The fibers of the upper and lower portions converge toward the insertion of the muscle, while those of the middle segment pass in the same direction but in a diverging manner. The upper converging portion (Fig. 258) arises as a rather strong muscular mass from the first and second ribs and from an intervening tendinous arch; it inserts into the superior angle of the scapula; the middle diverging portion is by far the thinnest and weakest part of the muscle and it arises from the second* and third ribs and diverges markedly to be inserted into the entire length of the vertebral border of the scapula; and the lower converging portion, which is the strongest part of the entire muscle, arises from the fifth to the ninth ribs and passes to the inferior angle of the scapula. The fibers of the lower portion are the longest and those of the upper portion are the shortest. The

* The second rib consequently gives origin to two serrations.

muscle is fleshy throughout, with the exception of the insertion of the middle portion, which is sometimes aponeurotic.

In order to reach the vertebral border of the scapula, the serratus anterior must pass backward for quite a distance along the thoracic wall, to which it is attached by loose connective tissue. When the muscle reaches the axillary border of the scapula it passes behind the subscapularis as far as the vertebral border of the bone and is separated from this muscle by a very loose connective tissue. Throughout its course it forms the inner wall of the axilla.

The serratus anterior is supplied by the long thoracic nerve from the brachial plexus.

When all the fibers of the muscle contract simultaneously, they fix the scapula, which is also drawn forward at the same time. The upper converging portion draws the superior scapular angle anteriorly; the lower portion pulls the inferior angle forward and downward, and in the latter case the anterior angle, together with the glenoid cavity, ascends, as in elevation of the arm above the horizontal. When the scapula is fixed by the muscles of the back (trapezius, rhomboidei, levator scapulae), the serratus can also elevate the ribs and act as an accessory muscle of respiration.

THE MUSCLES OF THE THORACIC WALLS.

The muscles of the thoracic walls are the *intercostales*, the *levatores costarum*, the *subcostales*, and the *transversus thoracis*.

The **intercostales** (Figs. 247, 250, 253, and 254) occupy the eleven intercostal spaces and are composed of two layers, an external, the *intercostales externi*, and an internal, the *intercostales interni*. The *intercostales externi* (Figs. 241, 247, 250, and 254) pass from above downward and from without inward between the borders of adjacent ribs; they are short flat muscles which frequently contain numerous tendinous fibers. They commence posteriorly in the region of the costal tubercles and extend anteriorly as far as the costochondral articulations, leaving the spaces between the costal cartilages free. In these spaces are found tendinous slips which run in the same direction as the fibers of the *intercostales externi* and extend to the margin of the sternum; they are called the *external intercostal ligaments (ligamenta coruscantia)*.

The *intercostales interni* (Figs. 250, 253, 254) run from above downward and from within outward between the borders of adjacent ribs, and they arise from the lower border of the upper rib of each intercostal space in such a manner that the costal groove is situated between the two muscular layers. They cross the *intercostales externi* at right angles and are covered by them except in the spaces between the costal cartilages. They extend anteriorly to the sternum or to the anterior extremities of the cartilages of the false ribs and end posteriorly at the costal angles. In the region of the costal cartilages they lie behind the external intercostal ligaments and those portions of them occurring in these situations are also termed the *intercartilaginei*. Between the posterior extremities of the ribs they are replaced by tendinous structures which are called the *internal intercostal ligaments*.

The *intercostales externi* are covered almost throughout their entire extent by the thoracic, abdominal, and dorsal muscles (pectoralis major and minor, serratus anterior, obliquus abdominis externus, latissimus, scapulae posteriores, rhomboidei), with the exception of a small area between the trapezius and the latissimus (Fig. 238).

The **levatores costarum** (Fig. 243), from the course of their fibers, belong to the external intercostal muscles. They are situated in the dorsal thoracic region immediately beside the deeper layers of the long muscles of the back, are covered by the sacrospinalis (particularly by the

FIG. 253.—The sternum, sternal ends of the clavicles and the ribs, with the intercostales, and the transversus thoracis, seen from behind.

FIG. 254.—The fifth to the twelfth thoracic vertebræ and the vertebral extremities of the corresponding ribs, with the intercostales and subcostales, seen from in front.
On the left side the intercostal ligaments have been removed.

iliocostalis), and are divided into the *levatores costarum breves* and *longi*. The *levatores costarum breves* (Fig. 243) arise from the transverse processes of the seventh cervical to the eleventh thoracic vertebræ and insert into the rib next below between the tubercle and the angle. The *levatores costarum longi* (Fig. 243) are found chiefly on the lower ribs and are distinguished from the breves in that they pass over one rib and insert into the second below near its costal angle. The levatores costarum become markedly broader toward their insertion and usually possess aponeuroses.

The **subcostales** (Fig. 254) are flat muscles which are not always present and vary greatly in their development. From the direction of their fibers they are to be grouped with the internal intercostal muscles, with the posterior portion of which they are continuous. They are found chiefly in the lower thoracic region and bridge over one or two ribs. They are usually partly tendinous both at their origin and at their insertion.

The **transversus thoracis** (*triangularis sterni*) (Fig. 253) is a very thin flat muscle, the greater portion of which is tendinous, which arises by a broad aponeurosis from the posterior surfaces of the body and xiphoid process of the sternum and inserts by short broad tendinous slips into the inner surfaces of the cartilages of the second or third to the sixth ribs. The muscle is constant but very variable in its development.

All the muscles of the intercostal series are supplied by the intercostal nerves which pass, together with the vasa intercostalia, between the internal and the external intercostal muscles.

The intercostal muscles are important muscles of respiration. The great majority of them are muscles of inspiration, but the transversus thoracis and the subcostales probably play some part in expiration.

THE PECTORAL FASCIA.

The *pectoral fascia* lies upon the pectoralis major and the lower portion of the serratus anterior. The *coracoclavicular fascia* (*costocoracoid membrane*) is a much more pronounced layer which is situated beneath the pectoralis major and upon the pectoralis minor, covering the subclavius and the axillary vessels. It is particularly firm where it lies upon the subclavius and inserts into the lower surface of the clavicle. Internally it is inserted into the upper costal cartilages; externally it is continuous with the axillary fascia.

[As was the case in the dorsal region, all the muscles referred to the thoracic region in the above description do not strictly belong to the thoracic musculature, but belong in part to the musculature of the upper extremity. This is true with regard to the muscles of the first three layers, only those described as the muscles of the thoracic walls being trunk muscles.

These may be classified similarly to the abdominal muscles, but owing to the presence of a sternum in the thoracic region and to the lessened mobility of the thoracic portion of the spinal column due to the presence of fully developed ribs, no representatives of either the rectus or hyposkeletal groups occur in this region. The classification is consequently as follows:




Fig. 254.



Fig. 253.

1871
1872
1873
1874
1875
1876
1877
1878
1879
1880
1881
1882
1883
1884
1885
1886
1887
1888
1889
1890
1891
1892
1893
1894
1895
1896
1897
1898
1899
1900
1901
1902
1903
1904
1905
1906
1907
1908
1909
1910
1911
1912
1913
1914
1915
1916
1917
1918
1919
1920
1921
1922
1923
1924
1925
1926
1927
1928
1929
1930
1931
1932
1933
1934
1935
1936
1937
1938
1939
1940
1941
1942
1943
1944
1945
1946
1947
1948
1949
1950
1951
1952
1953
1954
1955
1956
1957
1958
1959
1960
1961
1962
1963
1964
1965
1966
1967
1968
1969
1970
1971
1972
1973
1974
1975
1976
1977
1978
1979
1980
1981
1982
1983
1984
1985
1986
1987
1988
1989
1990
1991
1992
1993
1994
1995
1996
1997
1998
1999
2000
2001
2002
2003
2004
2005
2006
2007
2008
2009
2010
2011
2012
2013
2014
2015
2016
2017
2018
2019
2020
2021
2022
2023
2024
2025

Hyposkeletal: wanting;

Rectus: wanting;

Oblique: *Intercostales externi, intercostales interni, subcostales, transversus thoracis, and levatores costarum.*

In addition, two muscles described as belonging to the muscles of the back are probably members of the thoracic oblique group, namely, the *serratus posterior superior* and the *serratus posterior inferior*—ED.]

THE MUSCLES OF THE NECK.

The muscles of the neck (Figs. 256 to 259 and 267) include the platysma, the sternocleidomastoid, the hyoid muscles, and the deep cervical muscles. The hyoid muscles are subdivided into the suprahyoid and the infrahyoid group; the deep cervical muscles are composed of an outer group, the scaleni, and of an inner group, the prevertebral muscles.

The **platysma** (*m. subcutaneus colli*) (Figs. 260 and 267) is a thin, flat, quadrilateral muscle which is situated in the subcutaneous connective tissue in the neck, the upper portion of the chest and the lower portion of the face. It arises (Fig. 267) from the fascia over the pectoralis major and the deltoid at the level of the first or second rib, by separate fasciculi which are frequently separated by interspaces. At the level of the clavicle these fasciculi unite to form a broad, thin, compact muscular layer, which leaves uncovered the anterior cervical region but covers more or less extensively the lateral cervical, the sternocleidomastoid, the carotid, and submaxillary regions, and toward the chin the margins of the two muscles converge and meet each other in the mental region, frequently interlacing.

Some of the fibers of the platysma are attached to the lower border of the mandible, while the rest pass over the mandible and appear upon the face, gradually disappearing partly upon the parotideo-masseteric fascia, and partly by intermingling with the risorius and triangularis by which they reach the angle of the mouth.

The platysma is supplied by the cervical branch of the facial nerve. It wrinkles the skin in the cervical and upper thoracic regions and acts upon the angle of the mouth with the facial muscles. It can also increase the tension of the fascia in the facial, cervical, and thoracic regions.

The **sternocleidomastoideus** (Figs. 258, 255, 256, 260, and 262) is a strong, broad, and thick muscle which is situated in the sternocleidomastoid region. It arises by two heads, a strong, thick, tendinous, sternal head from the anterior surface of the manubrium, and a short, tendinous, clavicular head from the sternal end of the clavicle.

The sternal head passes over the sternoclavicular articulation and forms a muscular interspace of varying size, the *lesser supraclavicular fossa*, by uniting with the clavicular head. It becomes much wider as it passes upward to assist in forming the thick belly of the muscle and partly conceals the clavicular portion.

The sternocleidomastoid is inserted into the outer surface of the mastoid process of the temporal bone and into the outer half of the superior nuchal line, the anterior portion of the insertion being effected by a short, the posterior portion by a long tendon.

The muscle passes obliquely through the neck from below upward and from within outward. At its insertion it borders upon the trapezius (see page 145), with the anterior margin of which

FIG. 255.—Superficial layer of the muscles of the neck, seen from in front. On the right side the sternohyoid and anterior belly of the digastric, and the submaxillary gland have been removed.

FIG. 256.—Superficial layer of the muscles of the neck, seen from the left side.
* = External carotid artery.

it forms a triangle in which are situated the splenius capitis, the levator scapulae, the scaleni, and the inferior belly of the omohyoid. The anterior margin of the muscle borders upon the infrahyoid muscles, bounds the carotid fossa (a deep muscular interspace containing the large vessels of the neck, *i. e.*, the common carotid artery and the internal jugular vein, and the vagus nerve), and crosses over and conceals the posterior belly of the digastric and stylohyoid. The upper part of its anterior margin is also in relation with the parotid gland.

The sternocleidomastoid together with the trapezius is supplied by the accessory nerve.

When both sternocleidomastoids act together, they draw the head downward and forward; when one muscle acts alone, it turns the head obliquely so that the face looks upward and toward the opposite side.

THE HYOID MUSCLES.

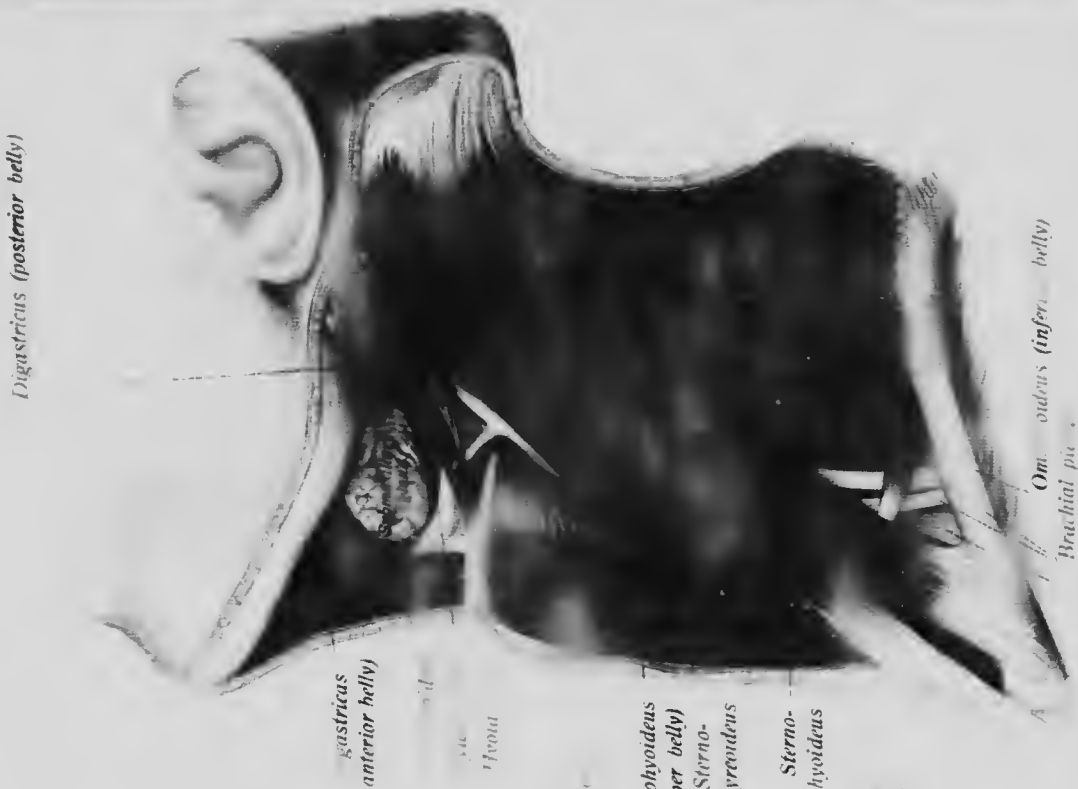
The Infrahyoid Muscles.

The infrahyoid muscles (Figs. 255, 256, and 258) are situated between the hyoid bone and the upper margin of the thorax, chiefly in the anterior cervical region. They represent a continuation of the rectus abdominis into the neck, being the remains of an original single muscular layer which is interrupted in the thoracic region. Some of these muscles, like the rectus abdominis, have retained indications of their original segmental tendinous intersections. The group includes the *sternohyoideus*, the *sternothyroideus*, the *thyrohyoideus*, and the *omohyoideus*.

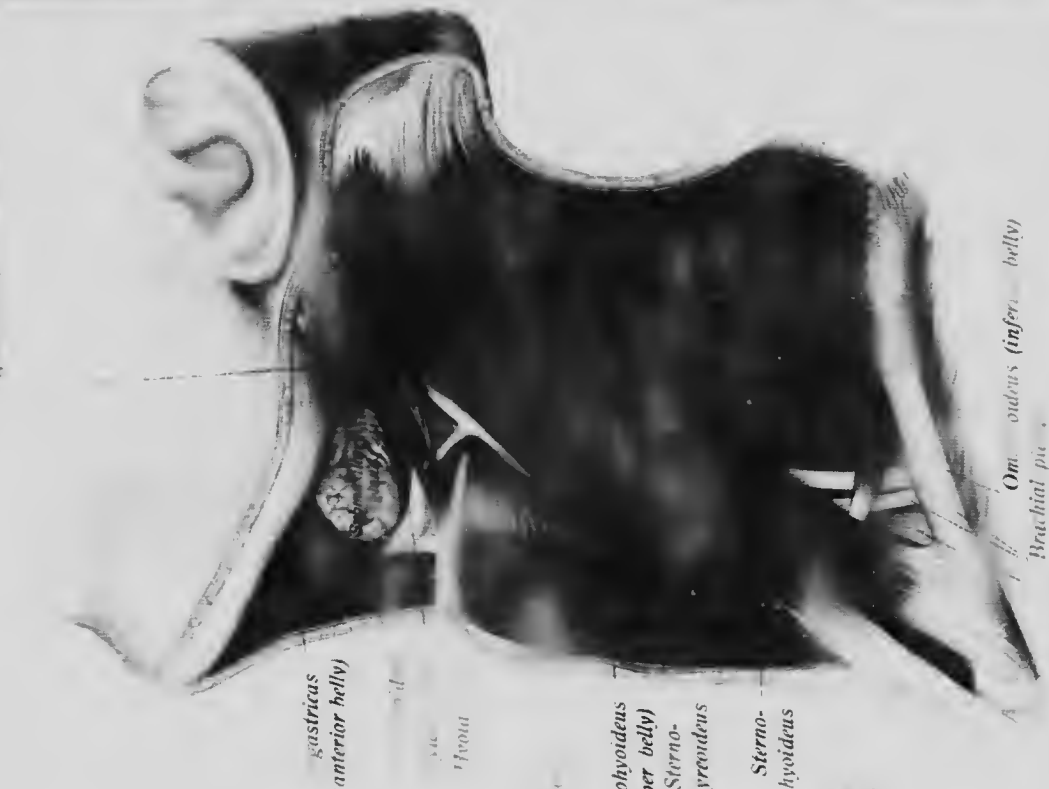The **sternohyoideus** (Figs. 253, 255, 256, and 258) is a flat, long, and narrow muscle which is situated in the suprasternal, thyroid, laryngeal, subhyoid, and submental region. It arises (Fig. 254) from the internal surface of the first costal cartilage and from the anterior surface of the manubrium and the capsule of the sternoclavicular articulation, and its lower margin is fixed by the sternal end of the clavicle and the sternum. The muscle passes upward at a slight distance from the median line, and is inserted into the anterior surface of the body of the hyoid bone. It not infrequently exhibits a tendinous intersection.

The **sternothyroideus** (Figs. 253, 255, 256, and 258) is a broad, flat muscle which arises from the same origin as the sternohyoideus, but its lower margin is attached to the thyroid gland. Its fibers pass upward and forward, and are inserted into the anterior surface of the body of the hyoid bone. The lower margin of the muscle which covers the thyroid gland, passes directly upward, so that only a narrow space is left in the median line between the two muscles of opposite sides, and is inserted into the oblique line of the thyroid cartilage. (For additional details see "Sole Anology.") The space between the two muscles is situated a portion of the larynx, the thyroideus gland, and the trachea.

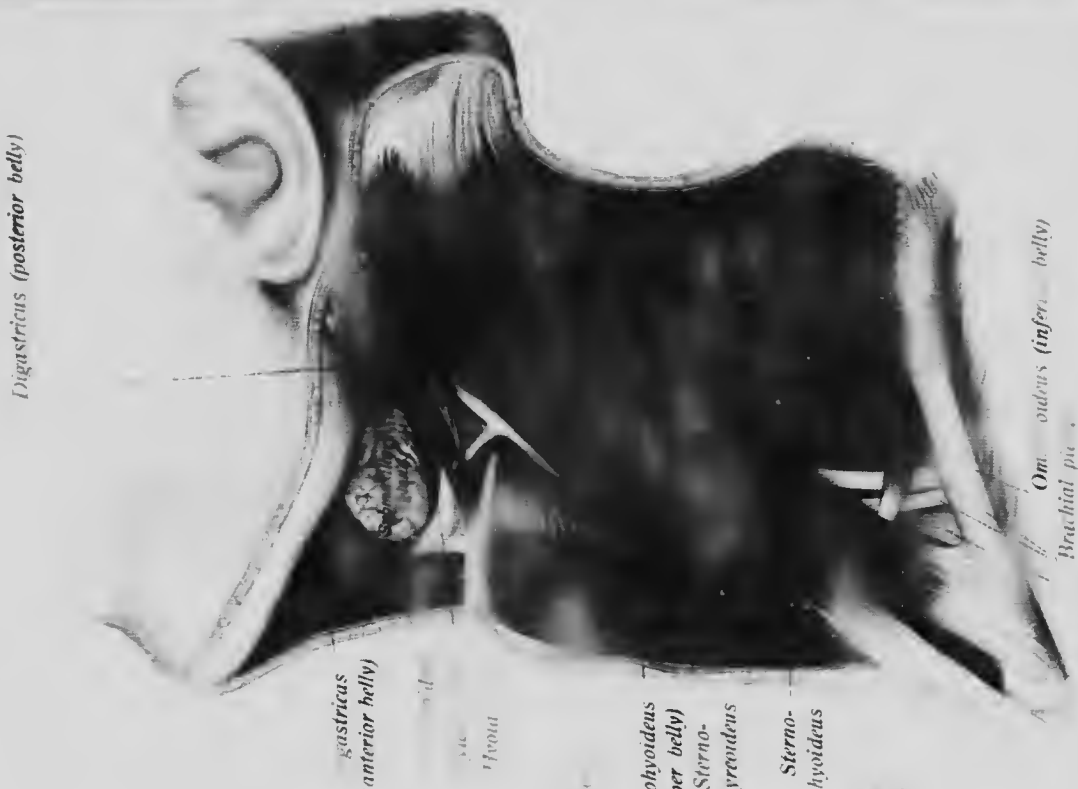
Digastricus (anterior belly)



Digastricus (posterior belly)



Tendon of digastricus



Stylohyoideus



Hydrohyoideus



Sternohyoideus



Brachial plexus



Subclavian artery



Omohyoideus (superior belly)



Sternothyroideus



Omohyoideus (inferior belly)



Brachial plexus



Scalenus anterior



Fig. 256

1870
1871
1872
1873
1874
1875
1876
1877
1878
1879
1880
1881
1882
1883
1884
1885
1886
1887
1888
1889
1890
1891
1892
1893
1894
1895
1896
1897
1898
1899
1900
1901
1902
1903
1904
1905
1906
1907
1908
1909
1910
1911
1912
1913
1914
1915
1916
1917
1918
1919
1920
1921
1922
1923
1924
1925
1926
1927
1928
1929
1930
1931
1932
1933
1934
1935
1936
1937
1938
1939
1940
1941
1942
1943
1944
1945
1946
1947
1948
1949
1950
1951
1952
1953
1954
1955
1956
1957
1958
1959
1960
1961
1962
1963
1964
1965
1966
1967
1968
1969
1970
1971
1972
1973
1974
1975
1976
1977
1978
1979
1980
1981
1982
1983
1984
1985
1986
1987
1988
1989
1990
1991
1992
1993
1994
1995
1996
1997
1998
1999
2000
2001
2002
2003
2004
2005
2006
2007
2008
2009
2010
2011
2012
2013
2014
2015
2016
2017
2018
2019
2020
2021
2022
2023
2024
2025

The **thyreoideoideus** (Figs. 255, 256, and 258) appears to be a direct continuation of the sternothyroid. It is a flat muscle, the greater portion of which is concealed by the upper belly of the omohyoid, and it passes from the oblique line of the thyroid cartilage to the hyoid bone, where it is inserted beside the sternohyoid into the lateral portion of the body and into the base of the greater cornu. A fasciculus sometimes passes from this muscle to the thyroid isthmus and is known as the *levator glandule thyroideae*.

The **omohyoides** (Figs. 255, 256, and 258) is a long, flat, narrow muscle which is composed of two distinctly separated bellies. The *inferior belly* arises from the upper border of the

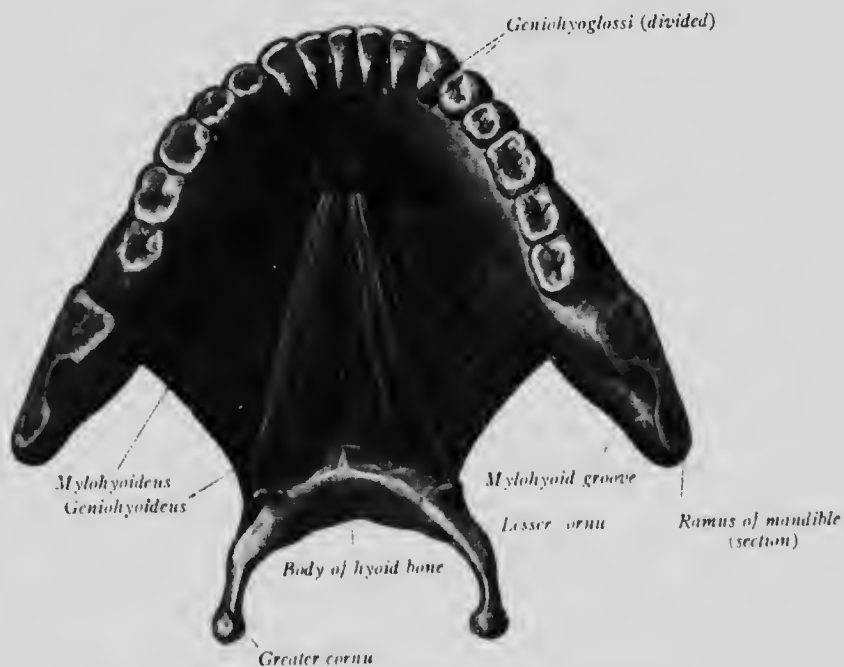


FIG. 257.—The mylohyoid and geniohyoid muscles, seen from above.

scapula between the inner angle and the notch, sometimes being also attached to the transverse ligament. It is at first covered by the trapezius and the clavicle and then becomes superficial in the greater supraclavicular fossa as it passes to the posterior margin of the sternocleidomastoideus. Beneath the latter it forms a flat intermediate tendon which is adherent to the cervical fascia and to the sheath of the great vessels of the neck. The *superior belly* commences at the intermediate tendon, appears at the anterior margin of the sternocleidomastoid, partly concealed by the sternothyroid and thyreoideoideus, and is inserted immediately alongside of the sternohyoid into the lower border of the lateral portion of the hyoid bone in front of the thyreoideoideus.

The infrahyoid muscles are supplied from the upper cervical nerves through the so-called ansa hypoglossalis. The thyreoideoideus receives a special branch from the same nerves, which accompanies the hypoglossal.

FIG. 258.—Deep layer of the muscles of the neck, seen from the left side.

The anterior belly of the digastric, the mylohyoid, the sternocleidomastoid, and the sternal end of the clavicle have been removed.

FIG. 259.—The deep muscles of the neck, seen from in front.

On the right side the longus capitis has been drawn outward.

The infrahyoid muscles depress the hyoid bone, the sternothyroid draws down the larynx, and the thyrohyoid approximates the hyoid bone to the larynx. They also act as accessory muscles of deglutition, and, by its attachment to the sheath of the great vessels, the omohyoid facilitates the return of blood through the internal jugular vein.

The Suprahyoid Muscles.

The suprahyoid muscles (Figs. 255 to 258) lie between the hyoid bone and the mandible. They are the *digastricus*, the *stylohyoideus*, the *mylohyoideus*, and the *geniohyoideus*.

The **digastricus** (*biventer mandibular*) (Figs. 255, 256, and 258) is a typical two-bellied muscle with a distinct cylindrical intermediate tendon which is attached to the hyoid bone. The two bellies form an obtuse angle, open above, in which is situated the submaxillary salivary gland. The anterior belly is a fairly thick muscle which passes from the intermediate tendon, frequently receiving a few tendinous fibers directly from the hyoid bone, to the digastric fossa of the mandible, where it is inserted by a short tendon. The *posterior belly* is longer but somewhat weaker than the anterior one. It arises from the mastoid notch of the temporal bone and passes with the *stylohyoideus* to the hyoid region, where it becomes continuous with the intermediate tendon.

The anterior belly of the digastric lies in the submental and mental regions, between the skin and the mylohyoid; the posterior belly is completely concealed at its origin by the sternocleidomastoid, and further anteriorly it separates the submaxillary region from the carotid fossa.

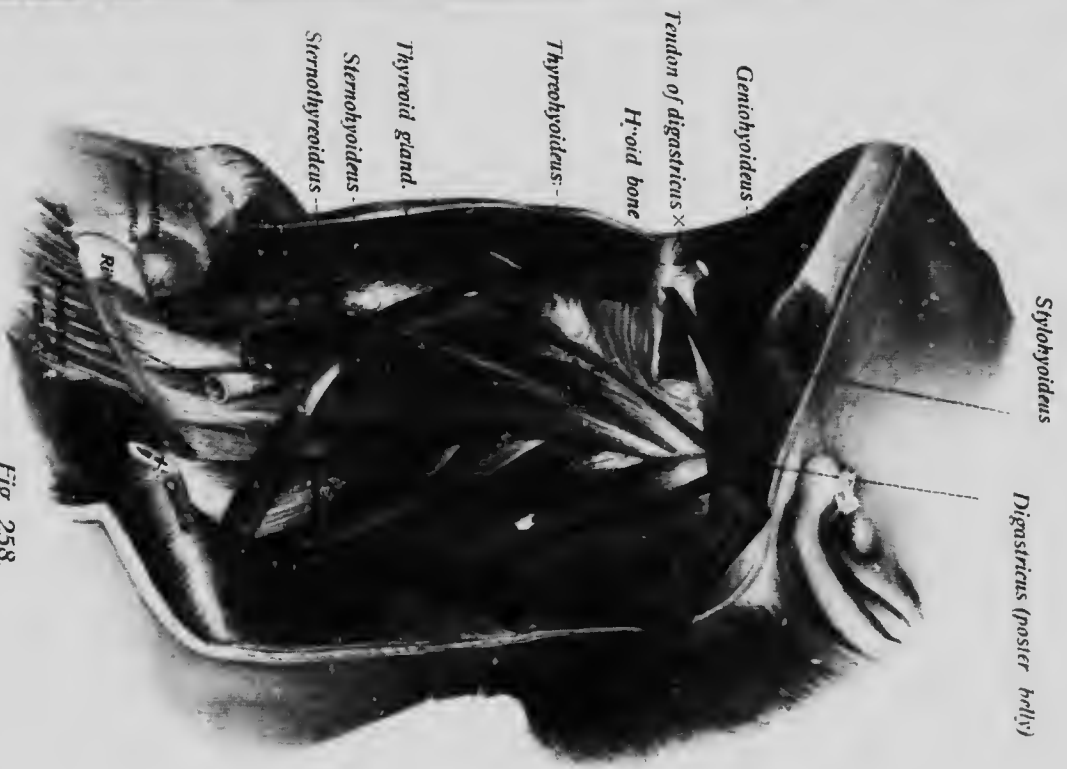
When the hyoid bone is fixed, the anterior belly depresses the lower jaw and opens the mouth; the posterior belly draws the hyoid bone backward and upward and, together with the *stylohyoid* and the infrahyoid muscles, fixes the hyoid bone. The posterior belly is supplied by the facial nerve, the anterior belly by the mylohyoid nerve from the third division of the trigemini.

The **stylohyoideus** (Figs. 255, 256, and 258) arises by a tendon from the styloid process of the temporal bone and runs to the hyoid bone as a flat rounded muscle above and almost parallel to the posterior belly of the digastric. Before its insertion into the bone it almost always divides into two slips, between which the intermediate tendon of the digastric passes. These slips have muscular attachments to the base of the greater cornu and to the posterior extremity of the body of the hyoid bone.

The action of the muscle is similar to that of the posterior belly of the digastric and it is also supplied by the facial nerve.

Between the infrahyoid muscles and the anterior border of the sternocleidomastoid there remains a deep space bounded above by the posterior belly of the digastric; this is the *carotid fossa*, and it contains the great vessels and nerve of the neck (the common carotid artery, the internal jugular vein, and the vagus nerve). The lateral wall of the pharynx forms its floor.

The **mylohyoideus** (Figs. 256 to 258 and 265) is a peculiar broad, flat muscle which is situated in the submental and submaxillary regions and is partly covered by the anterior belly of



1870
1871
1872
1873
1874
1875
1876
1877
1878
1879
1880
1881
1882
1883
1884
1885
1886
1887
1888
1889
1890
1891
1892
1893
1894
1895
1896
1897
1898
1899
1900
1901
1902
1903
1904
1905
1906
1907
1908
1909
1910
1911
1912
1913
1914
1915
1916
1917
1918
1919
1920
1921
1922
1923
1924
1925
1926
1927
1928
1929
1930
1931
1932
1933
1934
1935
1936
1937
1938
1939
1940
1941
1942
1943
1944
1945
1946
1947
1948
1949
1950
1951
1952
1953
1954
1955
1956
1957
1958
1959
1960
1961
1962
1963
1964
1965
1966
1967
1968
1969
1970
1971
1972
1973
1974
1975
1976
1977
1978
1979
1980
1981
1982
1983
1984
1985
1986
1987
1988
1989
1990
1991
1992
1993
1994
1995
1996
1997
1998
1999
2000
2001
2002
2003
2004
2005
2006
2007
2008
2009
2010
2011
2012
2013
2014
2015
2016
2017
2018
2019
2020
2021
2022
2023
2024
2025

the digastric. The two muscles of opposite sides unite in the median line in a slightly tendinous *mylohyoid raphe*, and form a muscular layer which extends across the mandibular arch and constitutes the floor of the mouth.

Each muscle arises (Fig. 257) by a short tendon from the mylohyoid line of the mandible, and the majority of the fibers run obliquely to the median raphe, some of them, however, passing to the upper border of the body of the hyoid bone.

The muscle is supplied by the mylohyoid nerve from the third division of the trigeminus. During deglutition it elevates the entire floor of the mouth, together with the tongue; the hyoid bone is also drawn upward by the fibers inserted into it, and when the hyoid bone is fixed, the muscle depresses the lower jaw, assisting the digastric.

The **geniohyoideus** (Figs. 257, 258, and 265) is a rather strong, slightly flattened muscle which is situated between the muscles of the tongue proper and the mylohyoid, the inner margins of the muscles of the two sides being in immediate contact. Each muscle has a tendinous origin from the mental spine of the mandible (Fig. 257), and becoming considerably broader as it passes backward, has a fleshy insertion into the anterior border and upper surface of the body of the hyoid bone.

The geniohyoid is supplied by fibers from the first and second cervical nerves, which accompany the hypoglossal nerve. It draws the hyoid bone forward, or, when the hyoid bone is fixed, it depresses the lower jaw. Together with the infrahyoid and the posterior suprahyoid muscles, it fixes the hyoid bone.

THE DEEP MUSCLES OF THE NECK.

The Group of the Scaleni.

The **scaleni** (Figs. 244, 247, 258, and 259) are composed of three (rarely four) muscles which pass from the transverse processes of the cervical vertebrae to the first and second ribs. Their origins are concealed by the sternocleidomastoid, but they are partly situated immediately beneath the skin in the lateral cervical region.

The **scalenus anterior** (Figs. 247, 258, and 259) is a long muscle which is almost wholly covered by the sternocleidomastoid and partly so by the inferior belly of the omohyoid. It arises by tendinous slips from the anterior tubercles of the transverse processes of the fourth to the sixth cervical vertebrae, and passes downward and forward to the first rib, becoming narrow and tendinous at its insertion into the scalene tubercle. The anterior surface of the muscle just above the insertion is provided with an aponeurosis.

The **scalenus medius** (Figs. 258 and 259) is longer and usually stronger than the anterior, with which it is closely related by its short tendons of origin. It arises from the anterior tubercles of all of the cervical vertebrae and is situated to the outer side of and partly beneath the scalenus anterior. It is inserted by a broad short tendon into the outer surface of the first rib about a fingerbreadth to the outer side of the scalenus anterior.

Between the insertions of the scalenus anterior and medius into the first rib there is a space which gives passage to the subclavian artery and to the greater part of the brachial plexus.

The **scalenus posterior** (Figs. 244 and 259) is the smallest of the scaleni, and is frequently adherent to the medius, from which it is distinguishable only by its separate insertion. It arises from the transverse processes of the fifth to the seventh cervical vertebrae, is situated between the

scalenus medius and the levator scapulae, and is inserted by a short tendon into the upper border of the second rib. Its insertion is covered by the upper digitations of the serratus anterior.

There is occasionally present a small independent muscular fasciculus situated between the scalenus anterior and medius. It is known as the *scalenus minimus*, and is inserted into the first rib and also into the dome of the pleura.

The scaleni receive their nerve-supply partly from the cervical plexus and partly (the scalenus posterior) from small special branches of the brachial plexus. They elevate the two upper ribs.

THE PREVERTEBRAL CERVICAL MUSCLES.

The muscles of the prevertebral group (Figs. 258 and 259) are situated to the inner side and above the scaleni, from which they are separated by the transverse processes of the cervical vertebrae. They are the *longus colli*, the *longus capitis*, and the *rectus capitis anterior*.

The *longus colli* (Fig. 259) is a rather thin flat muscle which is situated between the cervical viscera and the bodies of the upper thoracic and of all of the cervical vertebrae. Its upper and outer portion is covered by the longus capitis, and between the two muscles and to either side of the median line there is a space, the width of the little finger, in which may be seen the anterior longitudinal ligament of the vertebral column. The muscle has the form of a very obtuse-angled triangle, the obtuse angle being placed at the transverse process of the sixth cervical vertebra.

It is composed of three portions, each of which constitutes a side of the triangle. The *inner portion* is the longest, and extends from the body of the third thoracic vertebra to the axis. It arises by tendinous slips from the bodies of the upper thoracic and the lower cervical vertebrae, and inserts, partly by muscular and partly by tendinous tissue, into the bodies of the upper cervical vertebrae. The *upper and outer portion* arises by flat tendinous digitations from the anterior tubercles of the transverse processes of the upper cervical vertebra and is inserted into the anterior tubercle of the atlas, this portion being sometimes termed the *longus atlantis*, and also into the bodies of the underlying cervical vertebrae in common with the inner segment of the muscle. The *lower and outer portion* arises from the lateral surfaces of the bodies of the upper thoracic vertebrae and is inserted by the tendinous slips into the transverse processes of the lower cervical vertebrae.

The *longus capitis* (*rectus capitis anterior major*) (Figs. 258 and 259) is a rather broad flat muscle the upper portion of which is somewhat thickened. It lies to the outer side of the longus colli and covers its upper and outer segment, and arises by distinctly separated tendinous digitations from the anterior tubercles of the transverse processes of the third to the sixth cervical vertebrae. From these origins it passes upward and slightly inward, and is inserted into the lower surface of the basilar portion of the occipital bone. There is a distinct aponeurosis upon the anterior surface of the muscle somewhat above its middle.

The longus colli and the longus capitis are supplied by special branches of the cervical plexus. They bend the cervical vertebral column anteriorly, and, when they act unilaterally, turn the head toward the side of the contracting muscle. In the turning movement, the longus capitis and the upper and outer segment of the longus colli act together.

The **rectus capitis anterior** (*minor*) (Fig. 259) is a small muscle passing between the atlas and the occipital bone and is almost entirely concealed by the longus capitis. It arises from the base of the atlas and passes upward and inward behind the insertion of the longus capitis, to be inserted into the under surface of the basilar process of the occipital bone.

Both the function and the innervation of this muscle are intimately connected with those of the preceding ones.

THE FASCIÆ OF THE NECK.

In the neck two fasciæ may be distinguished: the *cervical fascia* and the *prevertebral fascia*. The cervical fascia is further subdivided into a superficial stronger and a deeper weaker layer.

The *superficial layer of the cervical fascia* covers the sternohyoid, the sternothyroid, the thyrohyoid, the anterior surface of the sternocleidomastoid, the inferior belly of the omohyoid, the posterior belly of the digastric, the stylohyoid, the submaxillary gland, and the carotid fossa; it is itself concealed by the platysma. This superficial layer is connected above with the parotidomasseteric fascia, and also covers in the space between the posterior border of the sternocleidomastoid and the anterior border of the trapezius.

The *deep layer of the cervical fascia* unites with the superficial layer at the anterior border of the sternocleidomastoid, so that in the middle of the neck but a single layer of fascia covers the larynx and the upper portion of the trachea. It covers the posterior surface of the sternocleidomastoid, which is consequently ensheathed between the two layers, the posterior surface of the posterior belly of the digastric and of the stylohyoid, the floor of the carotid fossa and the scaleni. It is intimately adherent to the intermediate tendon of the omohyoid and behind the manubrium of the sternum it extends downward to the first rib, while posteriorly it is continuous with the nuchal fascia.

The *prevertebral fascia* is a rather dense layer of fascia which covers the prevertebral muscles and the anterior surfaces of the cervical and of the upper thoracic vertebrae. It is separated from the cervical viscera by loose connective tissue.

[In the cervical region again the topographical relations of the muscles are far from agreeing with their developmental relations, many of the muscles described above, such as the platysma, the sternocleidomastoid, and all the suprahyoid muscles, with the exception of the geniohyoid, belonging to the cranial musculature. The true cervical muscles, *i. e.*, those derived from the cervical myotomes, may be classified as follows:

Hyposkeletal: *longus colli*, *longus capitis*, and *rectus capitis anterior*.

Rectus: *sternohyoideus*, *sternothyroideus*, *thyrohyoideus*, and *omohyoideus*.

Oblique: *scaleni* (and probably also the *intertransversarii anteriores*).

As has already been pointed out, the musculature of the diaphragm is also derived from the cervical myotomes and is probably to be regarded as a portion of the oblique group.—Ed.]

THE MUSCLES OF THE HEAD.

The muscles of the head are composed of two large and completely independent groups: (1) The cutaneous muscles of the head, *i. e.*, muscles which arise directly or indirectly from the cephalic skeleton but which are inserted into the skin of the face or scalp or are situated in the skin of the face; and (2) the muscles of mastication, which are typical skeletal muscles in every respect.

FIG. 260.—The superficial layer of the facial muscles and the neighboring muscles of the neck seen from the side and slightly from in front.

FIG. 261.—The orbicularis oculi seen from behind.

The muscle together with the integument has been removed; the lachrymal portion is represented in connection with the inner margin of the orbit.

THE MUSCLES OF THE FACE AND OF THE SCALP.

The cutaneous muscles of the face exhibit manifold peculiarities by which they are more or less differentiated from the ordinary skeletal muscles. They possess no fasciæ, they exhibit but a slight degree of independence, and many of them are so combined and their fibers interlace to such an extent that it is often purely a matter of choice whether individual fasciculi are regarded as special muscles or as the heads of a larger muscle. The arrangement of the facial muscles into sphincters or muscles of closure is also characteristic. The group includes the *epicranius* as well as the muscles of the face proper.

THE EPICRANIUS.

The **epicranius** (Figs. 260, 262, and 264) consists of a middle aponeurosis which envelops the cranium, the *galea aponeurotica*, and of muscles which arise in the frontal and occipital regions and are inserted into the galea. This is thickest in the occipital region, becomes thinner toward the forehead and particularly toward the temples, and gradually loses its aponeurotic character (especially in the temporal region). It is connected to the skin by fibrous connective-tissue fasciculi and separated from the cranial periosteum by loose areolar tissue.

The **frontalis** is a very thin, broad, and flat muscle which is intimately adherent to the skin of the eyebrows. It has a broad origin above the supraorbital margin, extends over the vertical portion of the frontal bone, and is inserted into the galea aponeurotica in the upper portion of the forehead. It has also a slender origin, which varies in size, from the bony bridge of the nose; when strongly developed, it is known as the *procerus (pyramidalis) nasi*, but it is always immediately connected with the frontalis. The two frontales are separated in the median line by a narrow area containing no muscular tissue.

The **occipitalis** is also a flat, broad, and an approximately quadrilateral muscle which arises on each side by short tendinous fibers from the highest nuchal line; it passes upward, and after a comparatively short course is inserted into the galea aponeurotica in the occipital region. The width of the muscle is much greater than its height, in contrast to the opposite condition in the frontalis.

Like all the facial muscles, the frontalis and the occipitalis are supplied by the facial nerve.

Both muscles are tensors of the galea aponeurotica. They pull the scalp forward or backward, and the frontalis wrinkles the skin of the forehead.

A portion of the *auricularis* is also related to the galea aponeurotica. This muscle presents three portions, an *auricularis anterior, superior*, and *posterior*, and like almost all the facial muscles they are subject to great individual variations in the degree of their development.

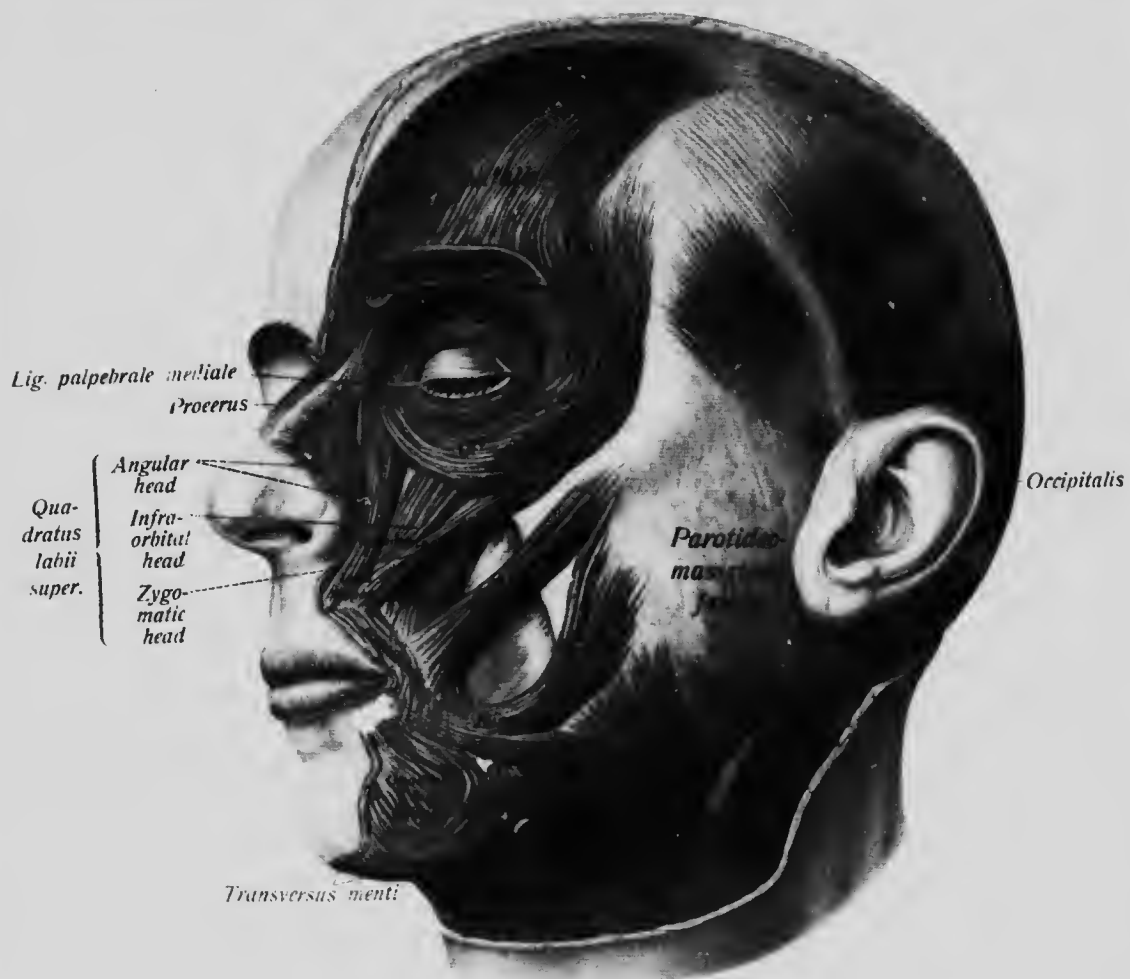


Fig. 260.

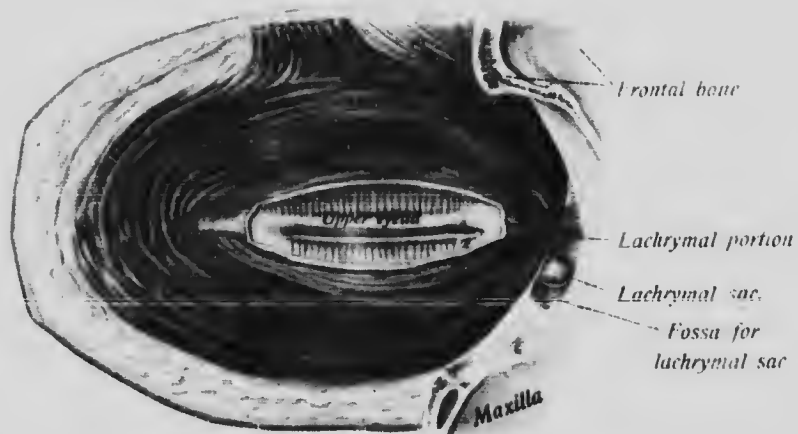

Fig. 261.

1870
1871
1872
1873
1874
1875
1876
1877
1878
1879
1880
1881
1882
1883
1884
1885
1886
1887
1888
1889
1890
1891
1892
1893
1894
1895
1896
1897
1898
1899
1900
1901
1902
1903
1904
1905
1906
1907
1908
1909
1910
1911
1912
1913
1914
1915
1916
1917
1918
1919
1920
1921
1922
1923
1924
1925
1926
1927
1928
1929
1930
1931
1932
1933
1934
1935
1936
1937
1938
1939
1940
1941
1942
1943
1944
1945
1946
1947
1948
1949
1950
1951
1952
1953
1954
1955
1956
1957
1958
1959
1960
1961
1962
1963
1964
1965
1966
1967
1968
1969
1970
1971
1972
1973
1974
1975
1976
1977
1978
1979
1980
1981
1982
1983
1984
1985
1986
1987
1988
1989
1990
1991
1992
1993
1994
1995
1996
1997
1998
1999
2000
2001
2002
2003
2004
2005
2006
2007
2008
2009
2010
2011
2012
2013
2014
2015
2016
2017
2018
2019
2020
2021
2022
2023
2024
2025

The **auricularis anterior** (*attrahens auriculæ*) (Fig. 260) has a very thin and usually quite a small origin from the superficial temporal fascia (see page 184); when well developed, the muscle extends to the frontalis. It is inserted by a short tendon into the cartilage of the auricle and into the cartilaginous external auditory meatus.

The **auricularis superior** (*attollens auriculæ*) (Fig. 260) is usually the strongest portion of the auricularis. It arises broadly from the galca aponeurotica above the temporal region and becomes markedly narrower as it descends to be inserted by a tendon into the upper margin of the root of the auricle.

The **auricularis posterior** (*retrahens auriculæ*) (Fig. 264) consists of one or more flat slender fasciculi which arise over the tendon of the sternocleidomastoid and are attached to the posterior extremity of the root of the auricle. The *transversus nuchæ* (see page 146) which is not infrequently present possibly also belongs to the auricularis posterior.

The functions of the individual portions of the auricularis are to move the auricle in the direction of the muscular fibers. The innervation is from the facial nerve.

THE PROPER MUSCLES OF THE FACE.

The remaining muscles of the face proper are composed of three groups: the *palpebral muscles*, those surrounding the orbital orifice; the *oral muscles*, those situated about the mouth; and the *nasal muscles*, those situated upon the nose.

THE PALPEBRAL MUSCLES.

The palpebral musculature forms the **orbicularis oculi** (*palpebrarum*) (Figs. 260 and 261). This is a flat muscle, situated chiefly in the orbital region, which forms a broad ring about the entrance to the orbit, and is composed of three portions, the *orbital*, the *palpebral*, and the *lacrimal portion*. Only the last portion possesses a certain degree of independence; the orbital and palpebral portions are directly continuous with each other.

The *orbital portion* forms the broader external circumference of the muscular ring, and lies upon the margin of the orbit immediately beneath the skin. Its broad fasciculi arise from the frontal process of the maxilla and the adjacent portion of the frontal bone, and pass in a wide curve about the entrance of the orbit to return almost to their starting point at the inner canthus. The muscle is connected with many of its neighbors, particularly with the frontalis, and fibers which radiate into the skin of the eyebrow constitute what is termed the *corrugator supercilii* (Figs. 262 and 264), while others which pass to the cheeks are known as the *malar portion* of the muscle.

The *palpebral portion* is the more posterior portion of the muscular ring, and is that part of the muscle which is situated within the eyelids. The fibers of the muscles of both the upper and the lower lid arise at the inner canthus from a short horizontal tendinous band, the *internal palpebral ligament*, and pass as fine fasciculi in an arched manner to the outer canthus, where they are partially interlaced and form the *external palpebral raphe*. (For a further description of the relations of the fibers in the eyelid itself, see "Atlas and Epitome of Histology," Sobotta Huber.)

The *lacrimal portion*, also known as *Horner's muscle* (Fig. 261), is a deeply situated portion of the muscle, which is connected with the palpebral portion. It arises from the posterior lachry-

FIG. 262.—The deeper layer of the facial muscles.

The quadratus labii superioris, zygomaticus, triangularis, quadratus labii inferioris, the parotideo-masseteric fascia, the parotid gland, and a portion of the superficial layer of the temporal fascia have been removed.

FIG. 263.—The oral musculature seen from behind.

The muscles, together with the integument, have been separated from the bones, and the mucous membrane covering the muscles has been removed.

mal ridge of the lachrymal bone and the fibers pass horizontally across the lachrymal sac to the margins of the lids, where they decussate and disappear in the fibers of the palpebral portion. (A more detailed description will be found in the section upon "The Eye.")

The orbicularis oculi, like all of the facial muscles, is supplied by the seventh cranial or facial nerve.

Its function is to close the palpebral fissure. The fibers of the lachrymal portion facilitate the entrance of the lachrymal secretion into the lachrymal canaliculi and also assist it onward, and those fibers which pass to the eyebrow and the forehead, wrinkle the skin in these regions.

THE ORAL MUSCLES.

The muscles of the oral region consist of the *buccinator*, of the circular fibers situated about the mouth which form the *orbicularis oris*, of the muscles of the upper lip, of the muscles of the lower lip, of muscles which are situated upon the skin, and of muscles which radiate into the angles of the mouth. The great majority of these muscles are intimately connected with each other.

The **quadratus labii superioris** (Figs. 260 and 262) is situated in the upper lip in the nasal, infraorbital, malar, buccal, and superior labial regions.

It has in general a triangular shape and arises by three heads: the *angular head* from the bony bridge of the nose in connection with the frontalis and the orbicularis oculi; the *infraorbital head*, arising broadly from the infraorbital margin and covered by the orbital portion of the orbicularis oculi; and the *zygomatic head*, a slender fasciculus from the malar surface of the zygomatic bone, which is usually adherent to the lateral radiations of the orbicularis oculi.

The *angular head* (*levator labii superioris alæque nasi*) is composed of two portions, an inner one passing to the ala of the nose (*levator alæ nasi*), and a stronger outer one which unites with the two other heads of the quadratus and passes to the musculature of the upper lip near the inner side of the angle of the mouth. The *infraorbital head* (*levator labii superioris*) is the broadest, and the somewhat inconstant *zygomatic head* (*zygomaticus minor*) the longest head of the muscle. At the insertion of the quadratus labii superioris into the upper lip its muscular fibers interlace with those of the orbicularis oris.

The **zygomaticus** (*zygomaticus major*) (Fig. 260) is an elongated, rather strong, and easily isolated muscle which is situated in the malar, buccal, and oral regions. It has an independent origin from the malar surface of the malar bone, close beside the zygomatic head of the quadratus labii superioris, and runs to the angle of the mouth, where it fuses with the orbicularis oris and the neighboring muscles.

The **risorius** or "smiling" muscle (Figs. 260 and 267) is a thin, approximately triangular muscle of variable development which is situated chiefly in the parotideo-masseteric and buccal regions. It arises from the parotideo-masseteric fascia (see page 184), sometimes extending

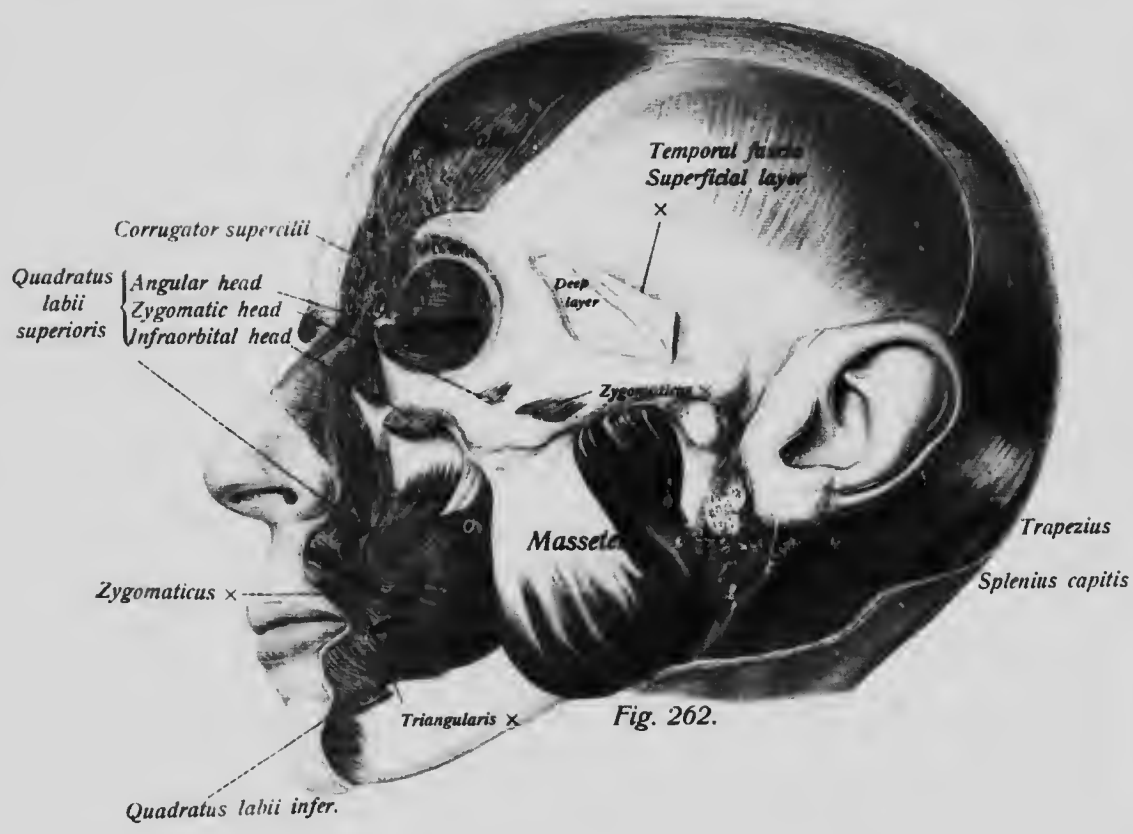


Fig. 262.

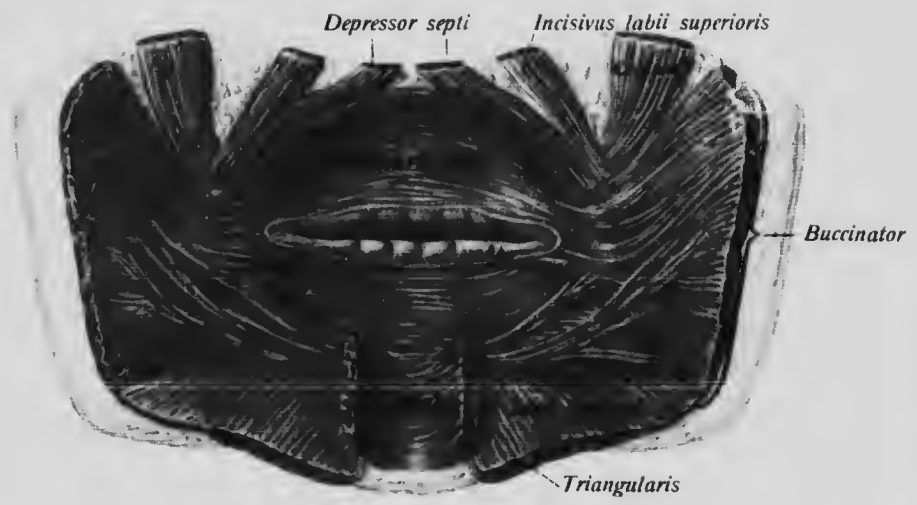


Fig. 263.

1
2
3
4
5
6
7
8
9
10
11
12
13
14
15
16
17
18
19
20
21
22
23
24
25
26
27
28
29
30
31
32
33
34
35
36
37
38
39
40
41
42
43
44
45
46
47
48
49
50
51
52
53
54
55
56
57
58
59
60
61
62
63
64
65
66
67
68
69
70
71
72
73
74
75
76
77
78
79
80
81
82
83
84
85
86
87
88
89
90
91
92
93
94
95
96
97
98
99
100
101
102
103
104
105
106
107
108
109
110
111
112
113
114
115
116
117
118
119
120
121
122
123
124
125
126
127
128
129
130
131
132
133
134
135
136
137
138
139
140
141
142
143
144
145
146
147
148
149
150
151
152
153
154
155
156
157
158
159
160
161
162
163
164
165
166
167
168
169
170
171
172
173
174
175
176
177
178
179
180
181
182
183
184
185
186
187
188
189
190
191
192
193
194
195
196
197
198
199
200
201
202
203
204
205
206
207
208
209
210
211
212
213
214
215
216
217
218
219
220
221
222
223
224
225
226
227
228
229
230
231
232
233
234
235
236
237
238
239
240
241
242
243
244
245
246
247
248
249
250
251
252
253
254
255
256
257
258
259
260
261
262
263
264
265
266
267
268
269
270
271
272
273
274
275
276
277
278
279
280
281
282
283
284
285
286
287
288
289
290
291
292
293
294
295
296
297
298
299
300
301
302
303
304
305
306
307
308
309
310
311
312
313
314
315
316
317
318
319
320
321
322
323
324
325
326
327
328
329
330
331
332
333
334
335
336
337
338
339
340
341
342
343
344
345
346
347
348
349
350
351
352
353
354
355
356
357
358
359
360
361
362
363
364
365
366
367
368
369
370
371
372
373
374
375
376
377
378
379
380
381
382
383
384
385
386
387
388
389
390
391
392
393
394
395
396
397
398
399
400
401
402
403
404
405
406
407
408
409
410
411
412
413
414
415
416
417
418
419
420
421
422
423
424
425
426
427
428
429
430
431
432
433
434
435
436
437
438
439
440
441
442
443
444
445
446
447
448
449
450
451
452
453
454
455
456
457
458
459
460
461
462
463
464
465
466
467
468
469
470
471
472
473
474
475
476
477
478
479
480
481
482
483
484
485
486
487
488
489
490
491
492
493
494
495
496
497
498
499
500
501
502
503
504
505
506
507
508
509
510
511
512
513
514
515
516
517
518
519
520
521
522
523
524
525
526
527
528
529
530
531
532
533
534
535
536
537
538
539
540
541
542
543
544
545
546
547
548
549
550
551
552
553
554
555
556
557
558
559
560
561
562
563
564
565
566
567
568
569
570
571
572
573
574
575
576
577
578
579
580
581
582
583
584
585
586
587
588
589
590
591
592
593
594
595
596
597
598
599
600
601
602
603
604
605
606
607
608
609
610
611
612
613
614
615
616
617
618
619
620
621
622
623
624
625
626
627
628
629
630
631
632
633
634
635
636
637
638
639
640
641
642
643
644
645
646
647
648
649
650
651
652
653
654
655
656
657
658
659
660
661
662
663
664
665
666
667
668
669
670
671
672
673
674
675
676
677
678
679
680
681
682
683
684
685
686
687
688
689
690
691
692
693
694
695
696
697
698
699
700
701
702
703
704
705
706
707
708
709
710
711
712
713
714
715
716
717
718
719
720
721
722
723
724
725
726
727
728
729
730
731
732
733
734
735
736
737
738
739
740
741
742
743
744
745
746
747
748
749
750
751
752
753
754
755
756
757
758
759
760
761
762
763
764
765
766
767
768
769
770
771
772
773
774
775
776
777
778
779
780
781
782
783
784
785
786
787
788
789
790
791
792
793
794
795
796
797
798
799
800
801
802
803
804
805
806
807
808
809
810
811
812
813
814
815
816
817
818
819
820
821
822
823
824
825
826
827
828
829
830
831
832
833
834
835
836
837
838
839
840
841
842
843
844
845
846
847
848
849
850
851
852
853
854
855
856
857
858
859
860
861
862
863
864
865
866
867
868
869
870
871
872
873
874
875
876
877
878
879
880
881
882
883
884
885
886
887
888
889
890
891
892
893
894
895
896
897
898
899
900
901
902
903
904
905
906
907
908
909
910
911
912
913
914
915
916
917
918
919
920
921
922
923
924
925
926
927
928
929
930
931
932
933
934
935
936
937
938
939
940
941
942
943
944
945
946
947
948
949
950
951
952
953
954
955
956
957
958
959
960
961
962
963
964
965
966
967
968
969
970
971
972
973
974
975
976
977
978
979
980
981
982
983
984
985
986
987
988
989
990
991
992
993
994
995
996
997
998
999
1000

upward as far as the zygoma and covering the radiating fibers of the platysma in this situation. The lower portion of the muscle is connected with the platysma and frequently appears to be a direct continuation of some of the individual fasciculi of the latter muscle (Fig. 267). It is inserted into the labial musculature at the angle of the mouth immediately below the zygomaticus major.

The **triangularis** (*triangularis labii inferioris* or *depressor anguli oris*) (Fig. 260) forms the superficial layer of the musculature of the lower lip. It is a flat triangular muscle, situated in the buccal, mental, and inferior labial regions, and arises broadly from the anterior extremity of the lower border of the body of the jaw. Its fibers are inserted into the labial musculature of the lower lip near the angle of the mouth, some of its superficial fasciculi passing to the opposite side in an arched manner to form a single subcutaneous muscle which is known as the *transversus menti* (Fig. 260).

The quadratus labii superioris, the zygomaticus, the risorius, and the triangularis form the superficial layer of the oral muscles and conceal the greater number of those which are now to be described.

The **caninus** (*triangularis labii superioris* or *levator anguli oris*) (Figs. 260, 262, and 264) arises from the canine fossa of the maxilla and passes into the musculature of the lip above the zygomaticus. It is a flattened elongated muscle and is almost entirely concealed by the overlying quadratus labii superioris and zygomaticus.

The **quadratus labii inferioris** (*depressor labii inferioris*) (Figs. 260, 262, and 264) is a flat quadrangular muscle, the posterior portion of which is covered by the triangularis. It arises from the anterior extremity of the lower border of the jaw and passes to the orbicularis oris in the lower lip.

The **incisivi** (*labii superioris et inferioris*) (Fig. 263) are small slender muscles which arise from the alveolar jugs of the superior and inferior lateral incisors and pass directly into the musculature of the orbicularis oris.

The **orbicularis oris** (*sphincter oris*) (Figs. 262 and 263) is the muscle which surrounds the mouth and forms the proper musculature of the lips. The fasciculi of the muscle run in quite different directions and, at the angles of the mouth and in both the upper and lower lips, are intimately connected with the fibers of both quadrati, the triangularis, the caninus, the risorius, the zygomaticus, and the buccinator, some of the fibers of these muscles passing in the same direction as the fasciculi of the orbicularis oris. In addition to the fibers which encircle the mouth, the orbicularis oris also possesses sagittal and vertical fasciculi; the latter form a small slender muscle, situated alongside of the median line of the upper lip, which is inserted into the cartilaginous nasal septum and is known as the *depressor septi (nasii)* (Fig. 263).

The **mentalis** (*levator menti* or *levator labii inferioris*) (Figs. 262 to 264) is a short muscle situated in the mental region, which arises from the lower jaw near the alveolar jugum of the median incisor. Some of the arising fibers unite with those of the muscle of the opposite side, but the greater number are inserted into the integument of the chin. The origin of both mentales is covered by the quadratus labii inferioris.

The **buccinator** (Figs. 262, 264, and 265) is a flat muscle, extending between the upper and the lower jaw, and situated immediately beneath the buccal mucous membrane. Only the

FIG. 264.—The deepest layer of the facial muscles and the temporalis.

The caninus, the zygomatic arch, a portion of the zygomatic bone with the origin of the masseter and the temporal fascia have been removed.

FIG. 265.—The two pterygoidei seen from the inner surface.

The anterior portion of the skull has been divided in the sagittal plane, and the temporal bone in an oblique plane; the tongue and soft palate have been removed.

anterior border of the muscle is superficial, passing into the orbicularis oris and the other muscles of the mouth. It is the strongest muscle in the oral region.

It arises from the buccinator ridge of the mandible, from the posterior extremity of the alveolar process of the maxilla, and from the pterygomandibular raphe. The *pterygomandibular raphe* (pterygomaxillary ligament) is embedded in the buccopharyngeal fascia (see page 184) and extends from the hamulus of the internal pterygoid plate to the posterior border of the alveolar portion of the mandible. It separates the buccinator from the constrictor pharyngis superior (see "Splanchnology"). At the angles of the mouth the fibers of the buccinator muscles are directly continuous with those of the orbicularis oris, while the posterior surfaces border immediately upon the oral mucous membrane. The anterior portion of each muscle is covered by the risorius, the triangularis, the zygomaticus, and the caninus, while the posterior portion is situated beneath the masseter (see page 183), from which it is separated by a mass of fat, the *buccal fat mass* (*Bichat's fat mass*).

The buccinator is perforated by the parotid duct, and the small buccal glands rest directly upon the muscle.

THE NASAL MUSCLES.

The muscles of the nose are much less important than those of the mouth. The feebly developed **nasalis** (Figs. 262, 264, and 266) is composed of a *transverse portion* and an *alar portion*. The *transverse portion* is a flat and very thin muscle which arises from the upper jaw and is adherent to the angular head of the quadratus labii superioris upon the bridge of the nose; it is united with its fellow of the opposite side by means of a thin aponeurosis termed the *compressorium*. The *alar portion* comes from the alveolar jugum of the upper canine tooth and goes to the cartilage of the ala of the nose; its greater portion is covered by the quadratus labii superioris, although a small portion is also concealed by the orbicularis oris. The ala of the nose also receives constantly the insertion of a portion of the angular head of the quadratus labii superioris.

All of the muscles of the face proper are supplied by the facial nerve. Their function is to produce the movements of expression, closure of the mouth, movements of the lips, and compression of the contents of the mouth (as, in blowing, the buccinator).

THE MUSCLES OF MASTICATION.

The muscles of mastication are composed of four strong separate muscles which are divided into two groups, the first group is formed by the *masseter* and the *temporalis*, the second by the two *pterygoidei*.

The **masseter** (Fig. 262) is a thick, strong, and approximately quadrilateral muscle which

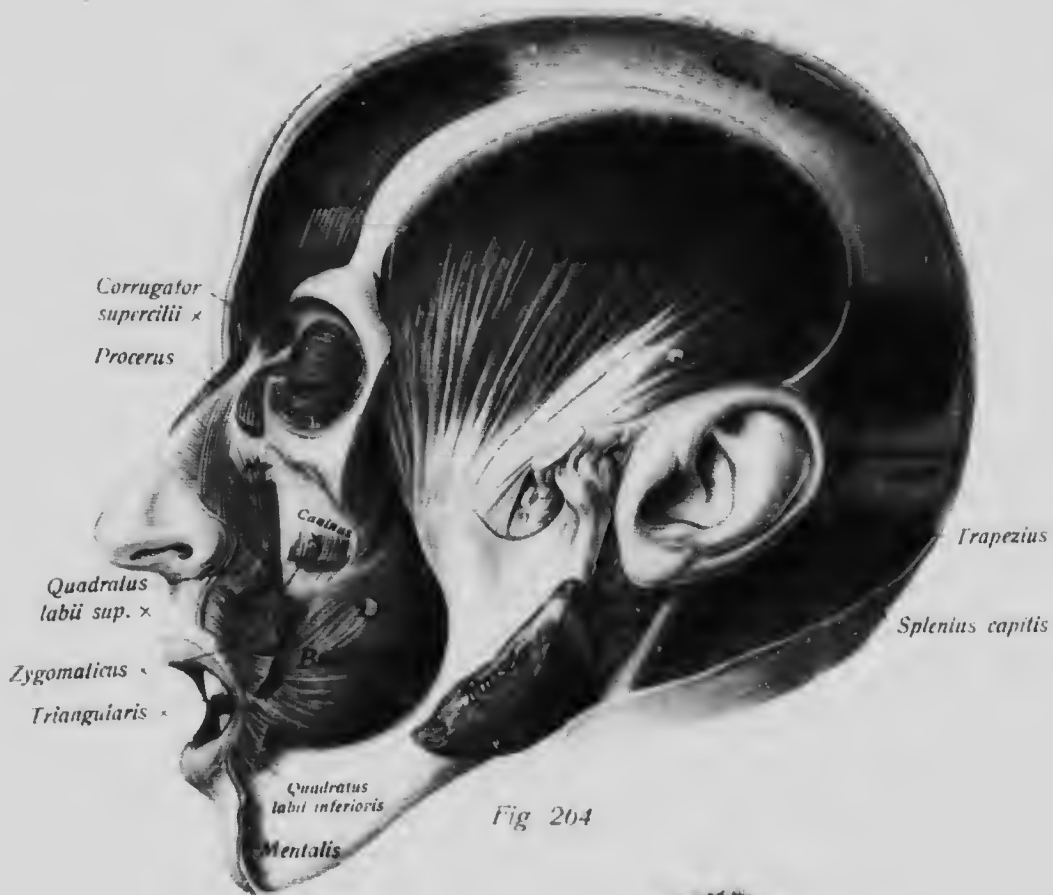

Fig 264

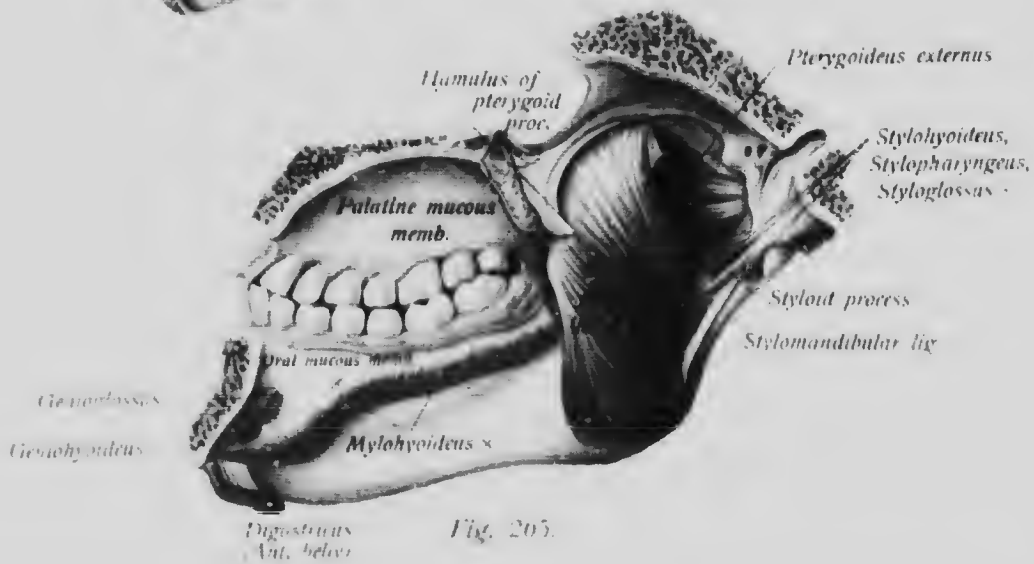


Fig. 265.



is situated chiefly in the parotideo-masseteric and partly also in the zygomatic region. Its superficial portion arises by a broad aponeurosis from the lower border of the anterior and middle thirds of the zygoma, while the deep portion takes a short muscular origin from the lower border and the inner surface of the posterior part of the zygomatic arch. Its chief insertion is into the angle of the jaw and into the adjacent portions of the body and of the ramus, the deep portion being inserted into the ramus above the superficial portion, which conceals it.

The aponeurosis covers more than half of the length of the muscle and usually penetrates its interior in the shape of individual serrations.

The masseter is covered behind by the parotid gland, whose duct passes transversely across the muscle, and in front by the parotideo-masseteric fascia. Its anterior portion is also in relation with the uppermost portion of the risorius, which is still more superficial than the parotideo-masseteric fascia, with the zygomaticus, and partly with the zygomatic head of the quadratus labii superioris. Only the lower portion of the muscle is situated immediately beneath the fascia, the aponeurosis being usually covered by a layer of fatty tissue. It covers the insertion of the temporalis and is separated from the buccinator by the *buccal fat mass* (see page 182).

The masseter is supplied by the masseteric branch of the third division of the trigeminus. It closes the mouth by bringing the lower jaw in contact with the upper.

The **temporalis** (Fig. 264) is a broad strong muscle, rather flat in its upper portion, which covers the *planum temporale* and the temporal fossa. In the temporal region it is almost subcutaneous, and takes a muscular origin from the entire surface of the *planum temporale* below the inferior temporal line, partly from the anterior portion of the temporal fossa, and also from the overlying deep layer of the temporal fascia. The wide fasciculi of the muscle converge toward the coronoid process of the mandible, and in doing so become markedly tendinous upon the outer surface. They embrace the entire apex of the process and upon its inner surface extend downward as far as the base.

The muscle is supplied by the deep temporal branches from the motor portion of the third division of the trigeminus. Its function is to close the mouth, moving, like the masseter, the lower toward the upper jaw.

The **pterygoideus externus** (Figs. 265 and 266) is a triangular, fairly strong muscle which is situated in the infratemporal fossa between the temporalis and the pterygoideus internus. It arises by two more or less distinctly separated heads: the larger and inferior from the outer surface of the outer plate of the pterygoid process, from the pyramidal process of the palatine bone, and from the tuberosity of the maxilla; the smaller and superior one from the infratemporal crest and surface of the greater wing of the sphenoid bone. The two heads unite, the muscle becomes markedly narrower, and is inserted by a short tendon into the pterygoid fossa of the head of the mandible, some fibers passing also to the articular disc of the temporomaxillary articulation.

The **pterygoideus internus** (Figs. 265 and 266) is stronger than the externus, which conceals its origin, and its fasciculi cross those of the latter muscle. It takes a partly tendinous origin from the pterygoid fossa of the sphenoid bone and passes to the inner surface of the angle

FIG. 266.—The deep layers of the facial muscles, the buccinator, and the pterygoids, seen from the side.

The lower portion of the temporalis together with the coronoid process of the mandible has been removed; the whole of the masseter is also removed and the parotid duct has been severed near its entrance into the buccinator.

FIG. 267.—The left platysma, seen from the side.

of the jaw, where it is inserted exactly opposite to the masseter. The outer surface of the muscle is usually aponeurotic.

[The pterygoideus internus is an elevator of the mandible, assisting the temporalis and masseter. The pterygoideus externus draws the condyle of the mandible and the articular disc forward upon the articular eminence; when the muscle of one side acts alone, it draws forward the mandibular condyle to which it is attached, the other one pivoting in the mandibular fossa, and the result being an apparently lateral movement of the mandible.—E.D.]

The muscles are supplied by the external and internal pterygoid nerves from the third division of the trigeminus.

THE FASCIÆ OF THE HEAD.

The *parotideo-masseteric fascia* (Fig. 260) is the layer of fascia which passes over the parotid gland and the masseter muscle. At the zygoma it is connected with the temporal fascia, at the anterior margin of the masseter with the buccopharyngeal fascia, and at the angle of the jaw with the cervical fascia.

The *temporal fascia* (Figs. 260 and 262) is the strongest fascia in the head and in its lower portion divides into two layers, the *superficial* and the *deep*, which are separated by fatty tissue. The interspace between the two layers becomes larger as they descend, the superficial layer inserting into the anterior, the deep into the posterior border of the zygoma. The upper circumference of the temporal fascia is connected with the galea aponeurotica.

The anterior portion of the *buccopharyngeal fascia* lies upon the buccinator and is connected with the parotideo-masseteric fascia; the posterior portion is stronger, more tendinous, and covers the inner surface of the pterygoideus internus. In this posterior portion are embedded the *pterygomandibular raphe* (*pterygomaxillary ligament*) and the *stylomandibular* (*stylomaxillary*) *ligament* (see page 118). In this situation the fascia forms the postero-lateral wall of the oral cavity and the lateral wall of the pharynx.

[The cranial musculature, considered from the developmental standpoint, includes several muscles in addition to those which are assigned to the head in the above description, since it is properly to be regarded as consisting of all the muscles supplied by the cranial nerve. Among these nerves there exist motor fibers of two different qualities: (1) lateral motor roots whose nuclei of origin may be regarded as occupying a position intermediate between the sensory nuclei and (2) the median motor roots, which correspond in all their essentials to the anterior roots of the spinal cord. The lateral motor roots, which occur in connection with the fifth, seventh, ninth, tenth, and eleventh cranial nerves, are distributed to the muscles associated with the embryonic branchial arches, while the median motor roots are represented by the third, fourth, sixth, seventh, eighth, ninth, and tenth cranial nerves, and supply the muscles associated with the eyelids and tongue.

In accordance with the difference of innervation, which is of great morphological importance, the cranial musculature may be divided into two groups: (1) The *myogenic* muscles, supplied by median motor roots; and (2) the *branchiomeric* muscles, supplied by lateral motor roots. The muscles belonging to the former group, as well as certain of those belonging to the latter, are described in connection with the regions to which they belong, but for the sake of completeness they will be included in the classification that follows. In the classification of the muscles of each group the individual nerve-



Fig. 267.

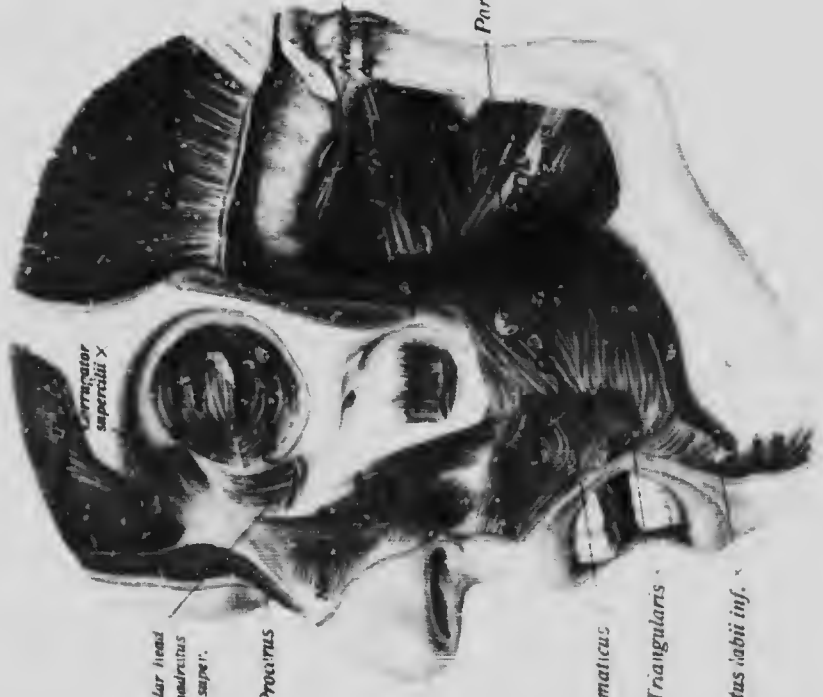

Fig. 266.

Angular head
of quadratus
labii super.


Procerus

Zygomaticus

Triangularis

Quadratus labii inf.

Parotid duct.



1. MYOMERIC MUSCLES.

- (a) The oculomotor muscles: *levator palpebræ superioris*, *rectus superior*, *rectus medialis*, *rectus inferior*, and *obliquus inferior*.
- (b) The trochlearis muscles: *obliquus superior*
- (c) The abducens muscles: *rectus lateralis*
- (d) The hypoglossus muscles: *genioglossus*, *hyoglossus*, *styloglossus*, and *lingualis*.

2. BRANCHIOMERIC MUSCLES.

- (a) The trigeminus muscles: *masseter*, *temporalis*, *pterygoideus externus*, *pterygoideus internus*, *mylohyoides*, *mentalis*, *coracobrachialis*, *tricus* (anterior belly), *tensor palati*, and *tensor tympani*.
- (b) The facialis muscles: *stylohyoideus*, *digastricus* (posterior belly), *stapedius*, *platysma*, *epicranius*, and the auricular, palpebral, oral, and nasal muscles as classified above.
- (c) The vago-accessorius muscles: *stylopharyngeus*, *levator veli palatini*, *musc. uvulae*, *palatoglossus*, *palatopharyngeus*, *constrictores pharyngis*, the laryngeal muscles, *trapezius*, and *sternocleidomastoideus*.—[E.D.]

THE MUSCLES OF THE UPPER EXTREMITY.

The muscles of the upper extremity are composed of four chief groups:

I. The **muscles of the shoulder**, *i. e.*, muscles which arise from the shoulder-girdle, pass through the region of the shoulder, and are inserted into the skeleton of the free upper extremity in the vicinity of the shoulder-joint. This group includes the *deltoides*, the *supraspinatus*, the *infraspinatus*, the *teres minor*, the *subscapularis*, and the *teres major*.

II. The **muscles of the upper arm**, *i. e.*, muscles the greater portion of which are situated in the upper arm. This group is subdivided into: (1) The muscles of the flexor surface; (2) the muscles of the extensor surface.

Group II, 1, is composed of the *biceps brachii*, the *coracobrachialis*, and the *brachialis*; group II, 2, is formed by the *triceps brachii* (and the *anconeus*).

III. The **muscles of the forearm**, *i. e.*, those of which the greater portions are situated in the forearm. According to their arrangement and position they are composed of three subdivisions: (1) the muscles of the flexor surface; (2) the muscles of the radial side; (3) the muscles of the extensor surface.

The muscles of the flexor surface are arranged in two layers. The superficial layer is formed by the *pronator teres*, the *palmaris longus*, the *flexor carpi radialis*, the *flexor digitorum sublimis*, and the *flexor carpi ulnaris*. The deep layer is composed of the *flexor digitorum profundus*, the *flexor pollicis longus*, and the *pronator quadratus*.

The radial group consists of the *brachioradialis*, the *extensor carpi radialis longus*, and the *extensor carpi radialis brevis*.

In the muscles of the extensor group the *supinator* holds a special position. The remaining muscles are composed of three subdivisions: (a) A superficial layer, formed by the *extensor digitorum communis*, the *extensor digiti V proprius*, and the *extensor carpi ulnaris*; (b) a deep oblique layer, formed by the *abductor pollicis longus* and the *extensor pollicis brevis*; (c) a deep straight layer, composed of the *extensor pollicis longus* and the *extensor indicis proprius*.

IV. The **muscles of the hand**, *i. e.*, those which extend between parts of the skeleton of the hand. These muscles are subdivided into three groups: (1) The muscles of the thenar

FIG. 268.—The muscles of the posterior surface of the left scapula and the neighboring portion of the extensor surface of the upper arm.

The deltoid has been removed with the exception of its origin and insertion; portions of the dorsal muscles inserting into the vertebral border of the scapula and also of the latissimus dorsi and pectoralis major have been retained.

FIG. 269.—The muscles of the anterior surface of the left scapula and the neighboring portion of the flexor surface of the upper arm.

Portions of the thoracic, cervical, and dorsal muscles which insert into the scapula or humerus have been retained.

eminence; (2) the muscles of the hypothenar eminence; and (3) the lumbricales (four) and the interossei (seven). The *palmaris brevis* is also situated in the hand. The muscles of the thenar group are the *abductor pollicis brevis*, the *flexor pollicis brevis*, the *opponens pollicis*, and the *adductor pollicis*; those of the hypothenar group are the *abductor digiti V brevis*, the *flexor digiti V brevis*, and the *opponens digiti V*. The interossei are composed of the *interossei dorsales* (four) and the *interossei volares* (three).

THE MUSCLES OF THE SHOULDER.

The **deltoides** (Figs. 268 and 270) is a thick, triangular, markedly curved muscle which is situated in the deltoid region. It arises, opposite to the insertion of the trapezius, by short tendons from the acromial third of the clavicle and from the border of the acromion, by a wide aponeurosis from the entire length of the spine of the scapula, and partly from the infraspinatus fascia (see page 207). Its fibers, which are grouped into coarse fasciculi separated by deep interspaces, converge toward intramuscular septa, so that the muscle rapidly diminishes in size as it passes toward its insertion, which is into the deltoid tuberosity of the humerus. The upper surface of the insertion is muscular; the lower is tendinous and is separated from the greater tubercle of the humerus by a large bursa, the *subdeltoid bursa* (Fig. 268).

The anterior border of the deltoid is practically in contact with the clavicular portion of the pectoralis major, although between the two muscles there is usually a quite narrow space, the deltoideo-pectoral triangle, which becomes broader as it approaches the clavicle and in which runs the cephalic vein. The posterior border of the muscle is in relation with the infraspinatus, the fascia of which partly covers its under surface, and the entire upper border is in contact with the trapezius. Its insertion is embraced by the origin of the brachialis.

The deltoid is supplied by the axillary (circumflex) nerve. It elevates the arm to the horizontal plane.

The **supraspinatus** (Fig. 268) is a triangular, moderately strong muscle which fills the supraspinatus fossa and is completely concealed by the insertion of the trapezius. It arises from the entire extent of the supraspinatus fossa and from the enveloping supraspinatus fascia. The markedly narrowed tendon of insertion passes beneath the acromion and the coracoacromial ligament, immediately above the articular capsule of the shoulder-joint (to which it is adherent), and is attached to the uppermost facet of the greater tubercle of the humerus.

The **infraspinatus** (Fig. 268) is also triangular, but it is stronger and broader than the supraspinatus. The outer half of the muscle is covered by the deltoid, while the inner half is

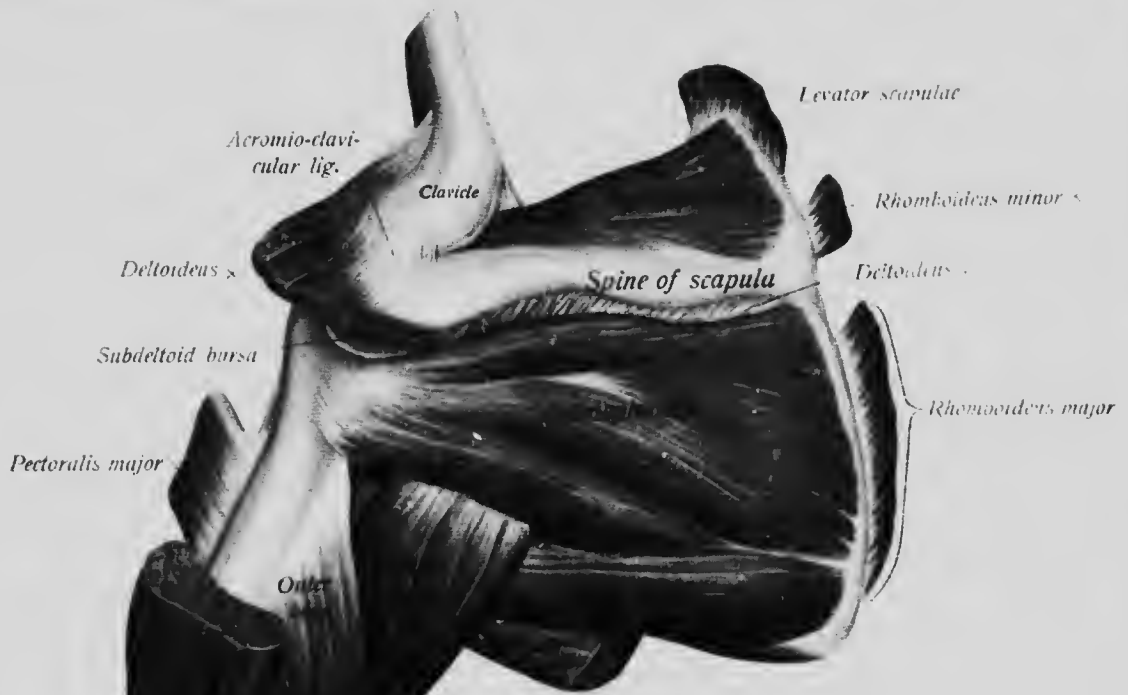


Fig. 208.

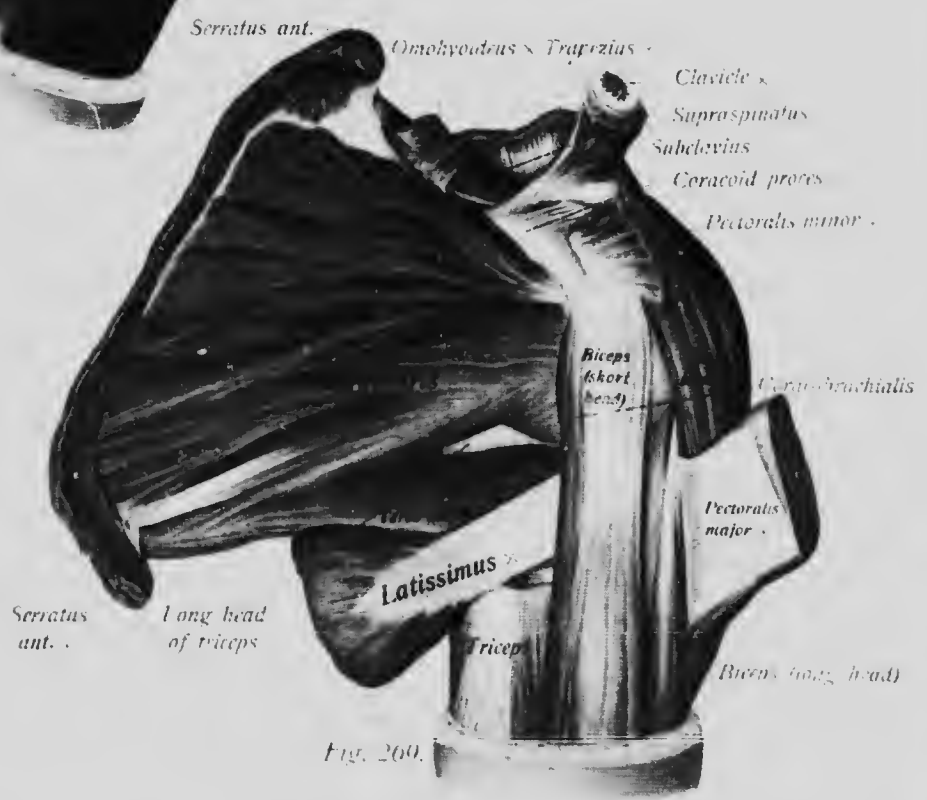


Fig. 209.





immediately beneath the skin in the scapular region (see page 146). The muscle arises from the entire surface of the infraspinatus fossa and from the markedly aponeurotic enveloping infraspinatus fascia. The fibers are practically horizontal, and as they converge toward the insertion frequently form a kind of intermediate tendon. The terminal tendon is a flat strong tendon, and, like that of the supraspinatus, is adherent to the articular capsule of the shoulder-joint; it is inserted into the middle facet of the greater tubercle of the humerus.

The supraspinatus and the infraspinatus are supplied by the suprascapular nerve. They rotate the arm outward (backward).

The **teres minor** is an elongated quadrangular muscle, situated immediately below the infraspinatus, to which it is more or less adherent. It is covered by the infraspinatus fascia, from which it takes a partial origin, and in its outer third it is also covered by the deltoideus. It arises from the lower part of the infraspinatus fossa and from the middle portion of the axillary border of the scapula. The tendon of the muscle is but slightly narrowed and is inserted into the lowermost facet of the greater tubercle, being, like the tendons of the preceding muscles, also adherent to the articular capsule of the shoulder-joint.

The teres minor is supplied by the axillary (circumflex) nerve and is an external rotator like the supraspinatus and the infraspinatus.

The **teres major** (Figs. 268 and 269) is stronger and longer than the teres minor. Its origin is covered by the latissimus, being situated between this muscle and the teres minor, and it lies along the axillary border of the scapula somewhat nearer to the dorsal surface. It arises from the dorsal surface of the lower third of the axillary border of the scapula, extending downward as far as the inferior angle, and, crossing the long head of the triceps, it terminates in a broad thick tendon which is situated in front of that of the latissimus and is inserted with it into the entire length of the lesser tubercular ridge (see page 146).

Between the teres major and minor there is a triangular aperture which is subdivided by the long head of the triceps into an inner triangular and an outer quadrangular space. The triangular space gives passage to the circumflex scapular artery, while the quadrangular space transmits the axillary nerve and the posterior circumflex artery of the humerus.

The teres major is supplied by the subscapular nerves. It is an internal rotator of the arm, assisting the latissimus.

The **subscapularis** (Fig. 260) is a broad, flat, triangular muscle which completely fills the subscapular fossa. The muscle with its fascia is in contact with the serratus anterior by its entire width, with the origin of the short head of the biceps and the coracobrachialis by its insertion, and with the teres major and the origin of the long head of the triceps by its lower border. The upper border of the muscle is adjacent to the origin of the omohyoid.

It arises from the subscapular fossa and from the muscular lines thereon. Its fasciculi converge to a number of intermuscular septa, and the strong broad tendon of insertion passes over the anterior surface of the articular capsule of the shoulder joint, to which it is firmly adherent, and is attached to the lesser tubercle of the humerus and to the neighboring portion of the lesser tubercular ridge.

FIG. 270.—The deltoid and muscles of the upper arm seen from the side.

FIG. 271.—The muscles of the upper arm seen from the side and from behind.

The part of the antibrachial fascia which covers the anconeus has been removed and the outer head of the triceps has been severed and turned aside in either direction.

FIG. 272.—The muscles of the flexor surface of the upper arm, superficial layer.
The deltoid has been removed.

FIG. 273.—The muscles of the flexor surface of the upper arm, deep layer.
The deltoid and biceps have been removed.

Immediately below the coracoid process, and on the under surface of the subscapularis near its insertion, there is a constant bursa which is a diverticulum of the synovial membrane of the shoulder-joint and is known as the *subscapular bursa* (see page 121).

The subscapularis is supplied by the subscapular nerves from the brachial plexus. It is an internal rotator of the arm.

THE MUSCLES OF THE UPPER ARM.

THE MUSCLES OF THE FLEXOR SURFACE.

Upon either side of the lower portion of the arm there is a distinct *intermuscular septum* (Figs. 270 to 273) between the muscles of the flexor and those of the extensor surface. The *internal intermuscular septum* is the stronger of the two and ends at the internal epicondyle, the external intermuscular septum is weaker and extends downward as far as the external epicondyle. These septa give origin to muscles of both groups, the external septum furnishing attachment also for the radial group.

The **biceps** (Figs. 272 and 273) is a long, large, spindle-shaped muscle which is situated immediately beneath the brachial fascia in the anterior brachial and cubital regions, and arises by two distinct heads, the long head and the short head. The long head arises from the supraglenoid tuberosity of the scapula by means of a long cylindrical tendon, which passes through the cavity of the shoulder joint (see page 121) and through the intertubercular groove, being enveloped in the latter situation by the *intertubercular mucous sheath* (Fig. 273). The tendon of the short head is short, flat, and adherent to that of the coracobrachialis; it comes from the coracoid process of the scapula.

Each head of the biceps forms a cylindrical muscular belly (the short head almost immediately after its origin) and the two bellies may remain separated for quite a distance, though in immediate contact with one another, but always unite above the elbow joint (never before reaching the middle of the arm) to form a single muscle. The widest part of this muscle is at the middle of the arm; and to either side of it a distinct groove may be recognized, the *internal* and *external bicipital grooves*. As it passes downward, the muscle becomes narrower, and in the region of the elbow joint it passes into a tendon of insertion which consists of two portions, a deep, flat, strong tendon and a thin superficial portion known as the *lacertus fibrosus* (Figs. 272, 273, 274, and 291). The latter is composed of superficial radiating fibers from the tendon

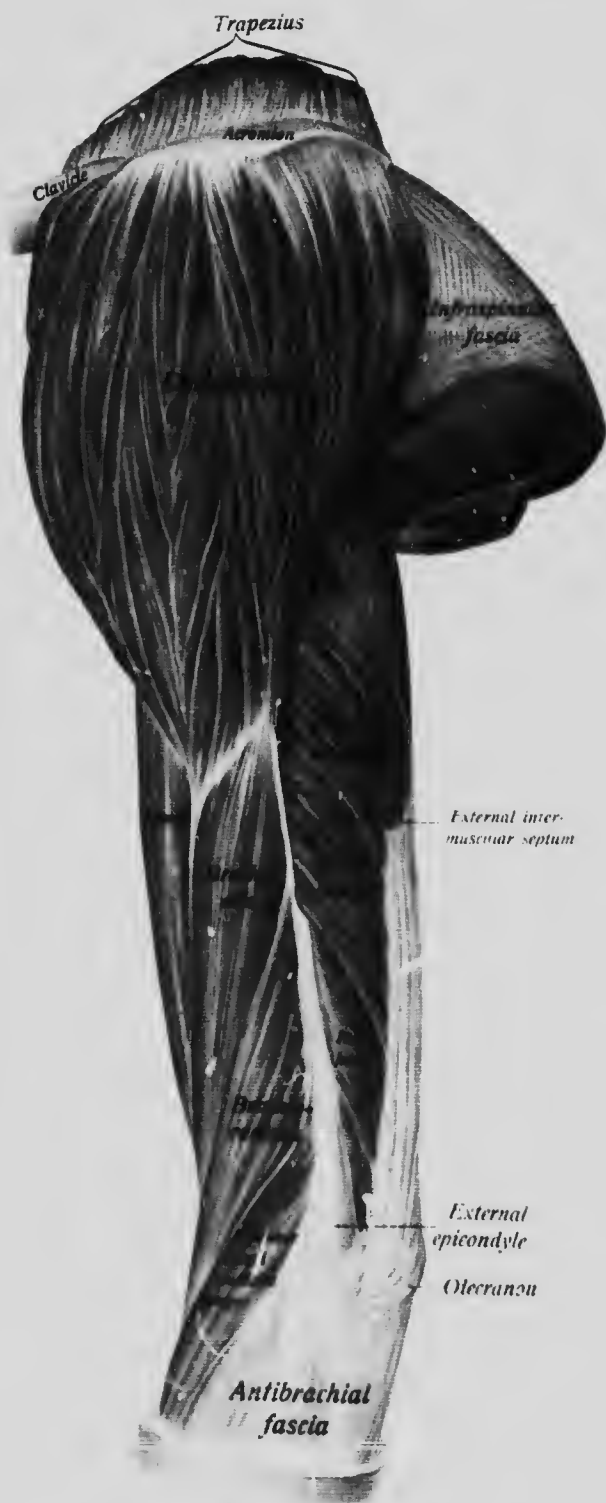

Fig. 270.

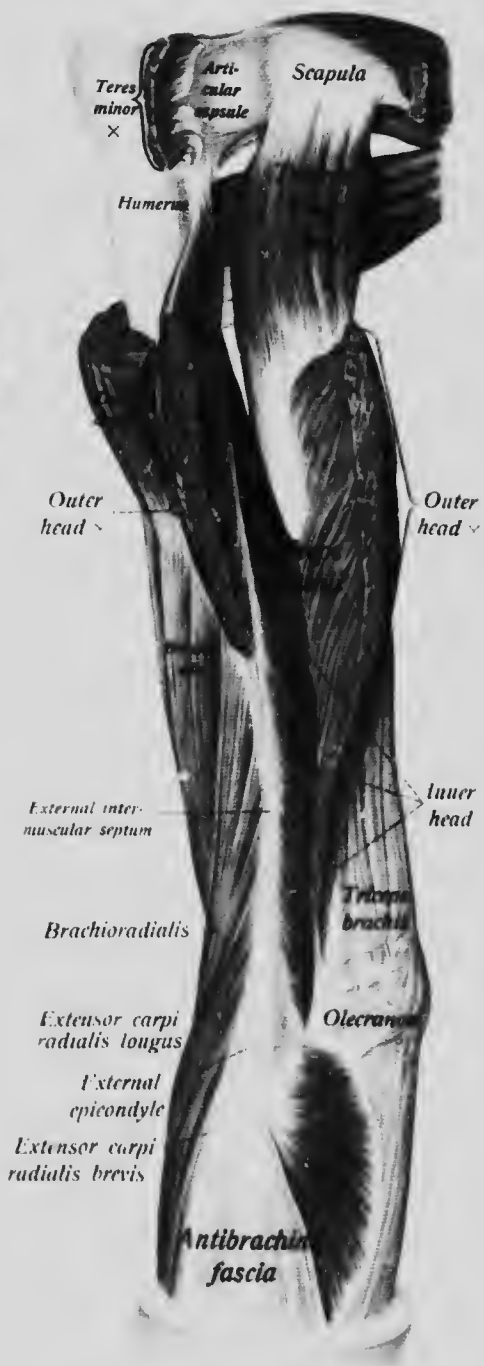


Fig. 271.



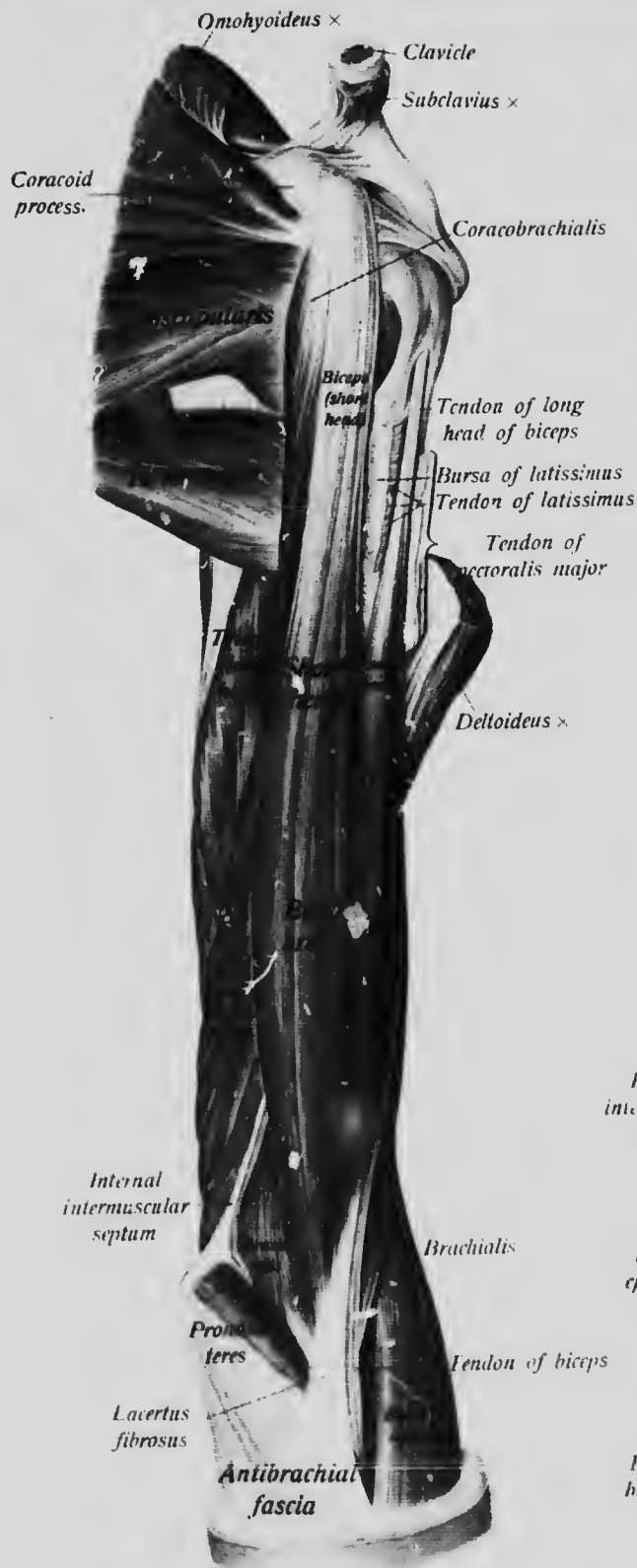



Fig. 272.



Fig. 273.



of the biceps, which pass obliquely across the antecubital fossa toward the ulnar side and fade away in the antibrachial fascia covering the superficial flexors of the forearm.

The actual tendon of the biceps muscle passes deep down between the flexor and the radial groups of muscles and inserts into the tuberosity of the radius (Figs. 273 and 275). Between the tendon of insertion and the radius there is placed a bursa, the *bicipitoradial bursa* (Fig. 273).

The biceps is supplied by the musculocutaneous nerve. It flexes the forearm, supinates the forearm (in common with the supinator brevis), and increases the tension of the antibrachial fascia. A third or accessory head of the biceps is present in rare instances; it arises from the humerus in common with the brachialis.

The **coracobrachialis** (Fig. 273) is a long and rather flat muscle, which is placed alongside of the short head of the biceps and is almost entirely concealed by this structure. Its short tendon of origin, arising from the tip of the coracoid process, is adherent to the short head of the biceps and covers the insertion of the subscapularis and the tendons of the latissimus and teres major shortly before their insertion. It is inserted into the anterior and internal surfaces of the humerus at about its middle, below the lesser tubercular ridge, and into the internal intermuscular septum. The muscle possesses a long slit which gives passage to the musculocutaneous nerve.

The coracobrachialis is supplied by the musculocutaneous nerve. It elevates the upper arm, assisting the deltoideus.

The **brachialis** (Figs. 273 to 275) is a strong, broad, rather flat, elongated muscle, almost entirely concealed by the biceps, which is situated in the lower two thirds of the flexor surface of the arm. It arises from the antero-internal surface of the humerus, somewhat above the middle of the bone and, embracing the insertion of the deltoid, takes origin also from the antero-internal and antero-external surfaces of the lower portion of the shaft of the humerus, and from the internal and external intermuscular septa, the origin from the internal intermuscular septum extending downward almost to the internal condyle. The anterior surface of the muscle is distinctly hollowed to accommodate the overlying biceps, and in the lower portion of the arm it appears to either side of that muscle. On the outer side it is in relation with the outer head of the triceps and with the brachioradialis; on the inner side, it is especially distinct and is in relation with the inner head of the triceps. It is inserted into the tuberosity of the ulna by means of a strong tendon which is especially well developed upon the anterior surface of the muscle. Its insertion is concealed by the tendon of the biceps and also by the superficial flexors of the forearm arising from the internal condyle.

The brachialis is supplied by the musculocutaneous nerve and usually also by the radial. It is a pure flexor of the forearm.

THE MUSCLES OF THE EXTENSOR SURFACE.

The **triceps** (Figs. 268 and 270 to 273) is a large elongated muscle which possesses three heads. The *long head* (*anconeus longus*) (Figs. 268 and 271 to 273) is a somewhat rounded muscle which arises by a short tendon from the infraglenoidal tuberosity of the scapula. It passes between the teres major and minor, that is to say, in front of the teres minor and behind the

teres major (see page 187), and becomes aponeurotic upon its inner surface. It is frequently connected with the latissimus dorsi by a tendinous slip.

The *outer head (anconeus lateralis)* (Figs. 270 and 271) arises from the postero-external surface of the humerus, commencing immediately below the greater tubercle, and from the upper half of the upper two-thirds of the external intermuscular septum. The origin of this outer head is fibrous above but fleshy below; its fibers run downward and inward to the common tendon of the triceps.

The *inner head (anconeus medialis)* (Figs. 271 to 273) arises more deeply than the outer one, and its fibers are shorter and extend further downward; as a rule, however, it is not as strong as the outer head. It arises from the entire length of the internal intermuscular septum, opposite to the brachialis and partly covered by the biceps, from the posterior surface of the humerus below the groove for the radial nerve, and from the external intermuscular septum as low down as the external epicondyle. The portion of it which comes from the internal intermuscular septum and which is not concealed by the biceps, lies immediately beneath the brachial fascia, as does also that portion arising from the external intermuscular septum, which is not covered by the outer head. A large part of the inner head is concealed by the outer one, and between the origins of the inner and outer heads the radial nerve runs in its groove.

The fibers of the inner and outer heads unite with those of the long head and pass into the common extensor tendon, which commences upon the posterior surface of the muscle at about the middle of the arm and is inserted chiefly into the olecranon process of the ulna. The insertion not only completely surrounds the olecranon, but also radiates to the ulna and the antibrachial fascia.

The triceps occupies the entire extensor surface of the arm between the intermuscular septa, and is consequently situated in the postero-external and postero-internal brachial regions. The relations of the long head have already been described (see page 187). The inner head is in relation with the brachialis at the internal intermuscular septum, and at the internal epicondyle its fibers are continued directly into the anconeus; the outer head, at the external intermuscular septum, is in relation successively with the brachialis, the brachioradialis, and sometimes also with the extensor carpi radialis longus.

The triceps is supplied by the radial nerve. It extends the forearm.

From a functional and topographic standpoint the triceps is associated with the **anconeus** (*anconcus quartus*) (Figs. 271, 278, and 280), which is situated in the upper part of the forearm, and is a flat triangular muscle lying beneath but not adherent to the antibrachial fascia. The lower angle of the muscle is placed between the flexor carpi ulnaris and the superficial group of extensors. It arises by a short tendon from the external epicondyle, passes over the articular capsule of the elbow-joint, to which it is adherent, and is inserted into the upper portion of the posterior surface of the ulna immediately below the olecranon. The upper fibers of the muscle are usually directly continuous with the lower portion of the inner head of the triceps.

The anconeus has a function and innervation similar to that of the triceps, and in addition it increases the tension of the articular capsule of the elbow-joint. There is frequently a small muscular fasciculus passing between the internal epicondyle and the olecranon over the ulnar nerve; it is known as the *epitrochleo-anconeus*.

THE MUSCLES OF THE FOREARM.

THE MUSCLES OF THE FLEXOR SURFACE

THE SUPERFICIAL LAYER.

The superficial layer of the flexor group (Fig. 274) consists of a muscle complex which arises by a common tendon from the internal epicondyle. All of the muscles of this group with the exception of the pronator teres pass beyond the wrist-joint and become tendinous at a varying distance above this articulation, and they occupy the ulnar side of the volar surface of the forearm. In the upper portion of the forearm they are all adherent to the antibrachial fascia, with the exception of the flexor digitorum sublimis, and conceal the insertion of the brachialis. They are separated from the radial group of muscles by a deep groove through which the tendon of the biceps passes to its insertion (see page 188), and in contrast to the muscles of the deep layer they arise chiefly in the upper arm and, with the exception of the pronator teres, consequently pass over two articulations.

The **pronator teres** (Figs. 273 and 274) is the outermost of the group, is an elongated quadrangular muscle which arises by two heads. The *humeral head* is the stronger and comes from the common tendon of origin; the *ulnar head* is more deeply placed, coming from the coronoid process of the ulna, and is frequently here joined to the tendon of the brachialis. The space between the two heads gives passage to the median nerve.

The belly of the pronator teres covers the junctions of the biceps and supinator and passes below the latter muscle to the middle of the volar surface of the radius, where it is attached to the bone by a short tendon (Fig. 280).

This muscle, like the majority of the group, is supplied by the median nerve. As indicated by its name, it pronates the forearm, and it can also assist the brachialis in flexing the elbow. If a supracondyloid process be present, it usually gives a partial origin to the muscle.

The **flexor carpi radialis** (*radialis internus*) (Fig. 274) is a spindle-shaped muscle, the distal half of which is tendinous. It is the outermost of the group passing from the radial to the ulnar side, and arises like its fellow from the common tendon and from the antibrachial fascia. In the middle of the forearm it is enclosed in a sheath which passes through a special sheath (see page 205) beneath the transverse carpal ligament in the groove of the multangulum majus to the base of the second, and sometimes to the third metacarpal bone.

The muscle is supplied by the median nerve. Together with the flexor digitorum profundus it produces velocity of flexion, when it acts with the radial extensors it causes radial flexion (radial abduction).

The **palmaris longus** (Fig. 274) is the smallest and weakest of the superficial muscles of the entire layer, and is weak, frequently absent, and tendinous. It follows the same course. Its origin is adherent to those of its neighbors and is from the common tendon and the antibrachial fascia. The long tendon becomes markedly flattened in the lower forearm and is situated immediately beneath the fascia; it passes over the transverse carpal ligament, to which it is partly adherent, and radiates into the palmar aponeurosis (see page 205).

This muscle acts chiefly as a tensor of the palmar and of the antibrachial fascia. It can also assist in flexing the forearm. It is supplied by the median nerve.

FIG. 274.—The superficial layer of the muscles of the flexor surface of the forearm together with the brachioradialis, seen from in front.

FIG. 275.—The superficial layer of the muscles of the flexor surface of the forearm after removal of the palmaris longus and the flexor carpi radialis, seen from in front and slightly from the radial side.

The brachioradialis is drawn outward to show the supinator and the insertion of the tendon of the biceps.

The **flexor digitorum sublimis** (Figs. 274 to 276) is concealed at its origin by the palmaris longus and the flexor carpi radialis, and the greater portion of its ulnar border is covered by the flexor carpi ulnaris. The main origin of the muscle, the *humeral head*, forms the deepest portion of the common tendon arising from the internal epicondyle, while the second head, the *radial head*, arises by a flat tendon from the volar surface and border of the radius below the insertion of the supinator. The two heads are connected by a tendinous arch beneath which passes the median nerve, and unite to form a broad and strong muscular belly which is usually composed of two distinct portions, a superficial and a deep. The deep portion receives the oblique fibers from the radius and soon gives off the tendons for the index and little fingers, while the tendons for the middle and ring fingers proceed from the superficial portion. The four tendons, which frequently do not become independent until near the wrist-joint, run through a synovial sheath together with the tendons of the deep flexor and pass beneath the transverse carpal ligament to the middle phalanges of the second to the fifth fingers (see page 205).

The flexor digitorum sublimis is exclusively supplied by the median nerve. It flexes the middle phalanges of the four fingers.

The **flexor carpi ulnaris** (*ulnaris internus*) (Figs. 274 and 276) is the innermost and the most posterior muscle of the group. Its posterior border is in relation with the anconeus and the superficial extensors, being separated from the latter by the dorsal border of the ulna. In addition to a *humeral head* the muscle also possesses an *ulnar head* from the anterior surface of the olecranon, the ulnar nerve passing between the two heads. An additional origin is furnished by the antibrachial fascia, which is adherent to the upper two-thirds of the ulnar border of the muscle and by means of which the muscle arises from the volar border of the ulna. The muscle is distinctly semipenniform in structure, since a tendon is formed in its inner border at the middle of the forearm, into which muscular fibers radiate almost as far down as the wrist-joint. This tendon is inserted into the pisiform bone and the insertion is thence prolonged to the metacarpus by the ligaments of the pisiform bone (see page 125).

The muscle is supplied by the ulnar nerve. When acting with the flexor carpi radialis it effects volar flexion, together with the extensor carpi ulnaris it produces ulnar flexion.

THE DEEP LAYER.

The deep layer of the muscles of the flexor surface consists of the two deep flexors of the digits and of the pronator quadratus. It is almost entirely concealed by the superficial layer.

The **flexor digitorum profundus** (Figs. 275 and 277) is a broad, strong, thick muscle which arises from the volar surface of the ulna from the coronoid process to the junction of the

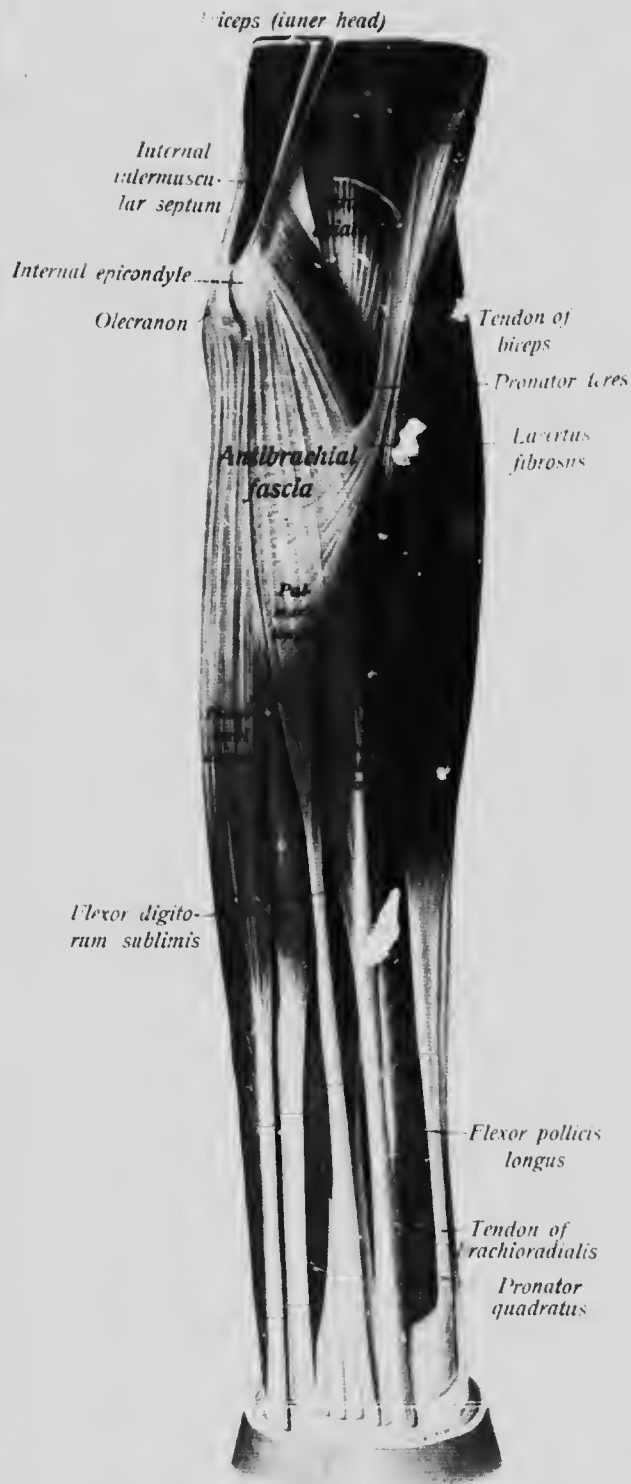

Fig. 274.

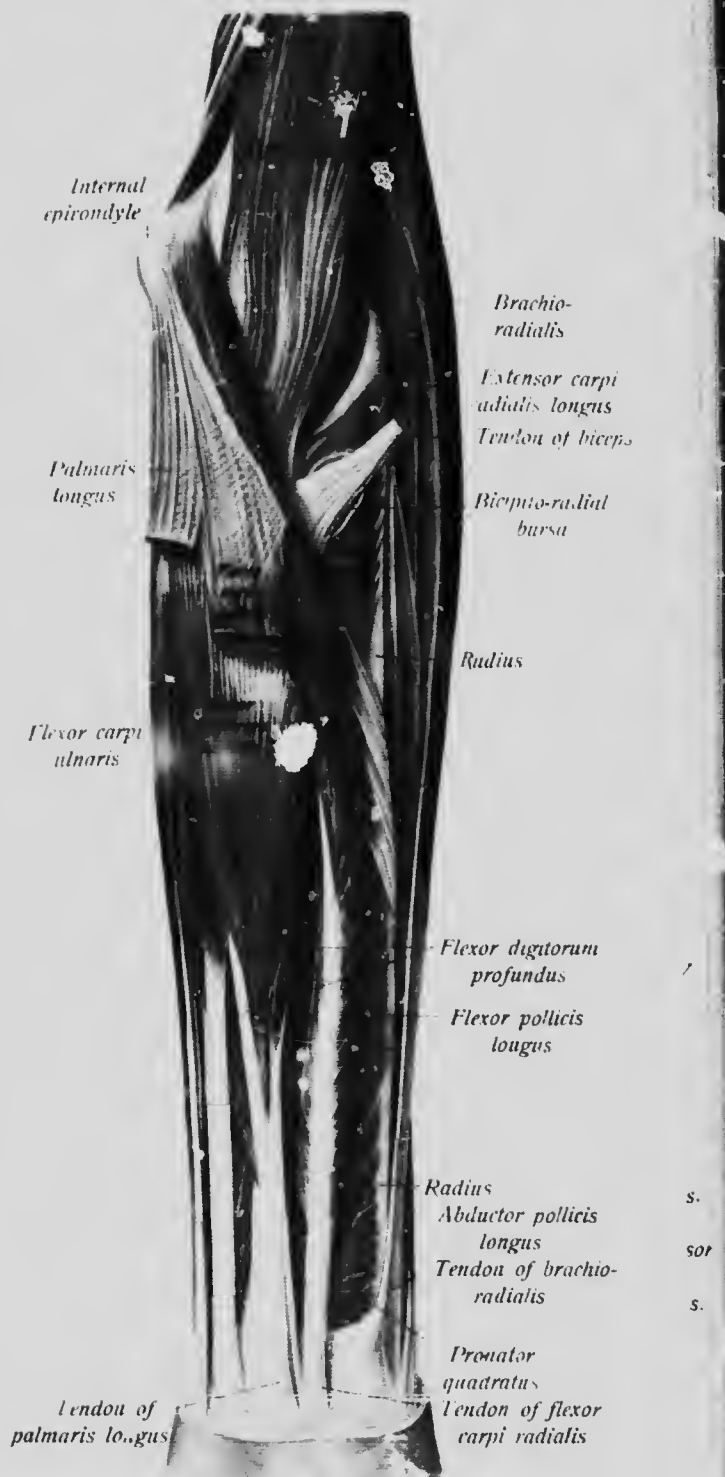


Fig. 275.

1870
1871
1872
1873
1874
1875
1876
1877
1878
1879
1880
1881
1882
1883
1884
1885
1886
1887
1888
1889
1890
1891
1892
1893
1894
1895
1896
1897
1898
1899
1900
1901
1902
1903
1904
1905
1906
1907
1908
1909
1910
1911
1912
1913
1914
1915
1916
1917
1918
1919
1920
1921
1922
1923
1924
1925
1926
1927
1928
1929
1930
1931
1932
1933
1934
1935
1936
1937
1938
1939
1940
1941
1942
1943
1944
1945
1946
1947
1948
1949
1950
1951
1952
1953
1954
1955
1956
1957
1958
1959
1960
1961
1962
1963
1964
1965
1966
1967
1968
1969
1970
1971
1972
1973
1974
1975
1976
1977
1978
1979
1980
1981
1982
1983
1984
1985
1986
1987
1988
1989
1990
1991
1992
1993
1994
1995
1996
1997
1998
1999
2000
2001
2002
2003
2004
2005
2006
2007
2008
2009
2010
2011
2012
2013
2014
2015
2016
2017
2018
2019
2020
2021
2022
2023
2024
2025

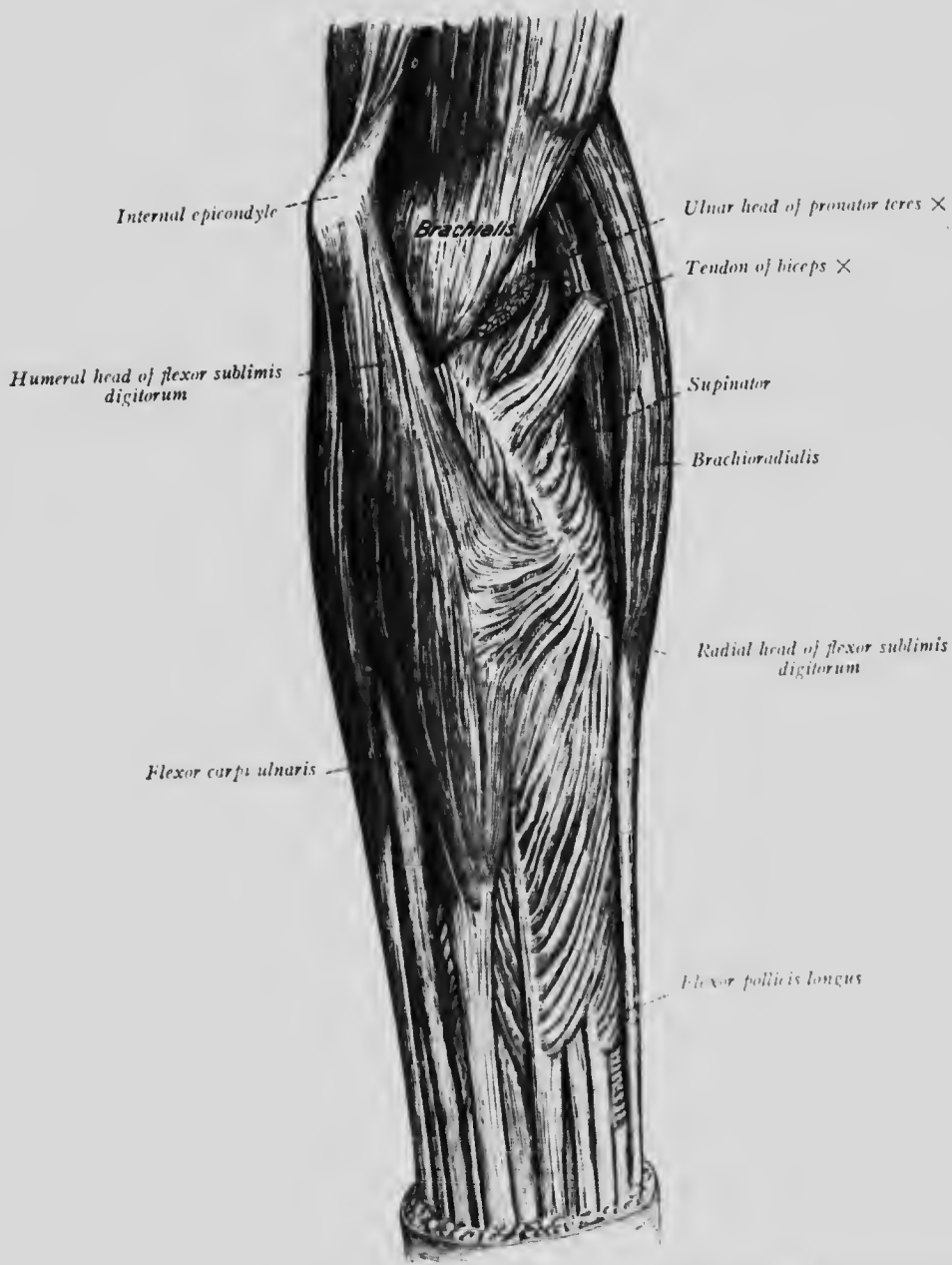


FIG. 276.—The flexor sublimis digitorum after removal of the flexor carpi radialis, the palmaris longus, and the pronator teres (somewhat diagrammatic).

FIG. 277.—The deep layer of the muscles of the flexor surface of the forearm after removal of the superficial layer, seen from in front.

FIG. 278.—The muscles of the forearm seen from the radial side.

middle and lower thirds of the bone, and from the adjacent portion of the interosseous membrane. Four parallel tendons are soon given off, the one situated nearest to the radial side coming from a separate muscular belly composed of the fibers proceeding from the interosseous membrane. These tendons run in the same synovial sheath as do those of the flexor sublimis and pass beneath the transverse carpal ligament (the anterior annular ligament) to terminate upon the ungual phalanges of the second to the fifth fingers (see page 205).

The ulnar half of the muscle is supplied by the ulnar nerve, the radial half by the median nerve. It flexes the terminal phalanges of the four fingers.

The **flexor pollicis longus** (Figs. 275 to 277) is a spindle-shaped muscle placed immediately alongside of the flexor digitorum profundus; it is penniform above and semipenniform below. It arises from the volar surface of the radius between the insertion of the supinator and the upper border of the pronator quadratus. It also usually receives a slender fasciculus, frequently aponeurotic, from the coronoid process and from the internal condyle; this origin, however, which is known as the *humeral head*, does not come directly from the bone but from the muscular mass of the superficial flexors. The muscle becomes tendinous almost immediately below its origin, the upper portion receiving the muscular fibers from either side, the lower portion from the radial side only, and the tendon runs in its own tendon-sheath beneath the transverse carpal ligament and passes between the two heads of the flexor pollicis brevis to the ungual phalanx of the thumb.

The muscle is supplied by the median nerve. It flexes the terminal phalanx of the thumb.

The **pronator quadratus** (Figs. 277 and 284) is a flat quadrilateral muscle which is concealed by all the tendons of the flexor muscles and lies upon the volar surfaces of both bones of the forearm toward their distal extremities. It arises from the volar border of the ulna and is inserted into the volar surface and border of the radius, both its origin and insertion being usually by short aponeuroses.

The muscle is supplied by the median nerve (volar interosseous nerve) and pronates the forearm.

THE RADIAL GROUP OF THE MUSCLES OF THE FOREARM.

The three muscles of the radial group are placed at the radial side of the forearm and of the lower portion of the arm in the so-called radial region, between the flexors and the extensors. The brachioradialis belongs more to the flexor surface, but the other two muscles are upon the extensor side of the forearm, and while the superficial layers of both flexor and extensor muscles are adherent to the fascia of the forearm, the extensor carpi radialis brevis is the only muscle of the radial group in which a similar relation obtains.

The **brachioradialis** (*supinator longus*) (Figs. 270, 271, and 274 to 279) is a very long flat

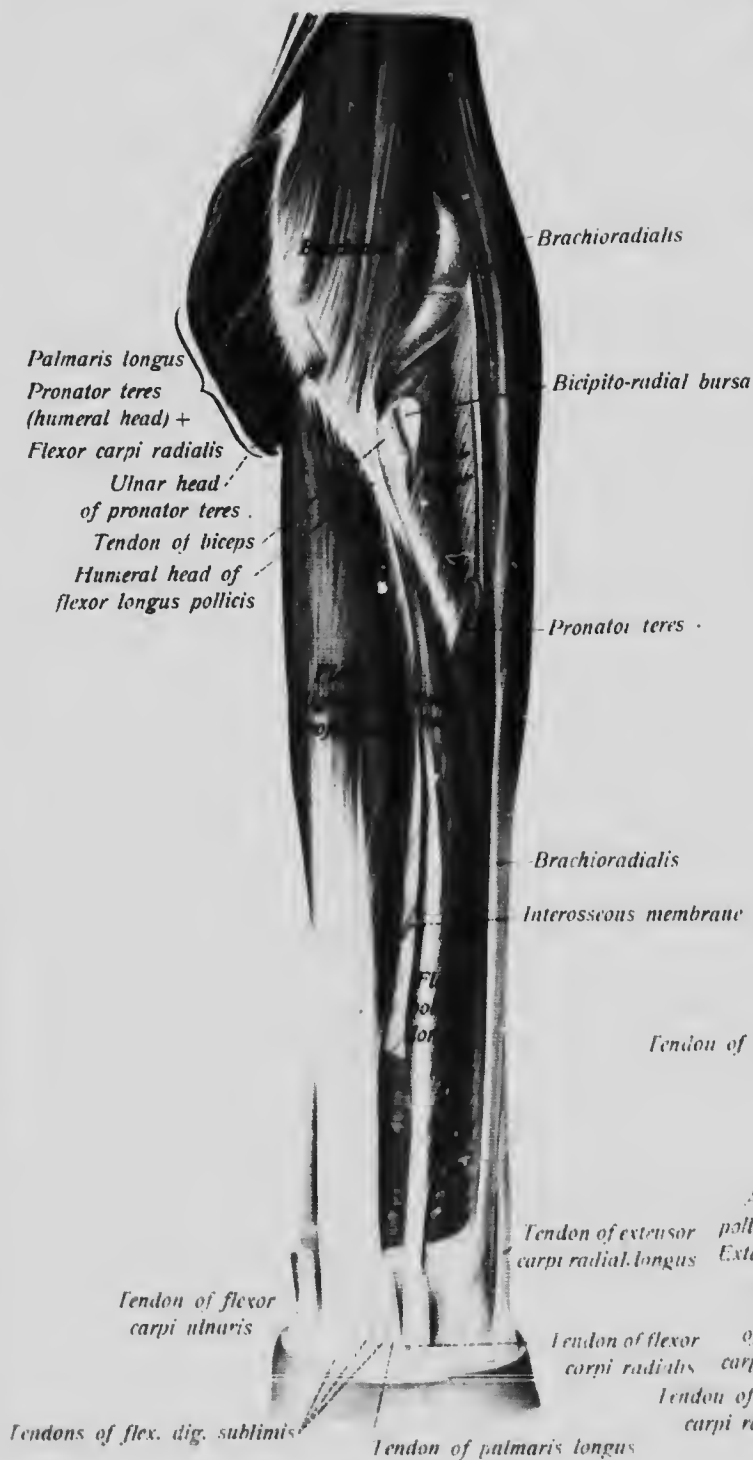


Fig. 277.



Tendon of extens. indicis propr
Fig. 278.

1871
1872
1873
1874
1875
1876
1877
1878
1879
1880
1881
1882
1883
1884
1885
1886
1887
1888
1889
1890
1891
1892
1893
1894
1895
1896
1897
1898
1899
1900
1901
1902
1903
1904
1905
1906
1907
1908
1909
1910
1911
1912
1913
1914
1915
1916
1917
1918
1919
1920
1921
1922
1923
1924
1925
1926
1927
1928
1929
1930
1931
1932
1933
1934
1935
1936
1937
1938
1939
1940
1941
1942
1943
1944
1945
1946
1947
1948
1949
1950
1951
1952
1953
1954
1955
1956
1957
1958
1959
1960
1961
1962
1963
1964
1965
1966
1967
1968
1969
1970
1971
1972
1973
1974
1975
1976
1977
1978
1979
1980
1981
1982
1983
1984
1985
1986
1987
1988
1989
1990
1991
1992
1993
1994
1995
1996
1997
1998
1999
2000
2001
2002
2003
2004
2005
2006
2007
2008
2009
2010
2011
2012
2013
2014
2015
2016
2017
2018
2019
2020
2021
2022
2023
2024
2025

muscle which is in immediate relation in the forearm with the superficial layer of the flexor surface (see page 191).

It arises from the external intermuscular septum of the upper arm, where it is in immediate relation with the outer portion of the brachialis on the one side and with the outer head (or inner head, see page 190) of the triceps on the other (Figs. 270 and 271). The origin ends some distance above the external epicondyle. In the forearm the brachioradialis becomes somewhat narrower, covers the supinator and the insertion of the pronator teres (Figs. 274 and 275), and, in the middle of the forearm, terminates in a flat tendon which runs over the insertion of the pronator quadratus to be attached to the upper end of the styloid process of the radius. The radial nerve passes between the outer portion of the brachialis and the brachioradialis.

The muscle is supplied by the radial nerve. It is practically a flexor of the forearm, and the name, supinator longus, formerly applied to it, does not correctly state its function.

The **extensor carpi radialis longus** (*radialis externus longus*) (Figs. 270, 271, and 278) is a long flat muscle resembling the brachioradialis. It arises as a direct continuation of the origin of the latter muscle, from the lower end of the external intermuscular septum of the upper arm and from the external epicondyle opposite to the lowermost portion of the inner head of the triceps (Figs. 270 and 271) (see page 190), and terminates above the middle of the forearm in a somewhat flattened tendon. It lies immediately adjacent to the brachioradialis (upon its ulnar and somewhat posteriorly), covers the volar and lateral surfaces of the radius, passes beneath the dorsal carpal ligament, and inserts into the dorsal surface of the base of the second metacarpal bone (see also page 203).

The **extensor carpi radialis brevis** (*radialis externus brevis*) (Figs. 270, 271, and 278) lies immediately beside the longus. It arises just below the latter muscle from the external epicondyle, the antibrachial fascia, and the articular capsule of the elbow joint; it covers the lateral surface of the radius and becomes tendinous somewhat below the middle of the forearm. The flattened tendon is longer than that of the longus, with which it passes beneath the dorsal carpal ligament, and is inserted into the base of the third metacarpal bone.

Both extensores carpi radiales are supplied by the radial nerve. Together with the extensor carpi ulnaris they produce dorsal flexion; and with the flexor carpi radialis they effect radial flexion (radial abduction). Their tendons are crossed in the forearm by the extensor pollicis brevis and the abductor pollicis longus, and their insertions are crossed by the tendon of the extensor pollicis longus.

THE MUSCLES OF THE EXTENSOR SURFACE.

With the exception of the supinators, the extensors are situated to the ulnar side of the radial group.

The **supinator** (*supinator brevis*) (Figs. 275 to 277 and 280) is a flat muscle which curves about the upper extremity of the radius and is in relation with many of the muscles of the forearm. Its origin is concealed by the anconeus, its middle portion by the superficial extensors, and its anterior (volar) portion by the radial group and the pronator teres. The insertion of the

FIG. 279.—The superficial layer of muscles of the extensor surface of the forearm.

FIG. 280.—The deep layer of muscles of the extensor surface of the forearm.

The superficial layer of the extensors has been removed, the cavities of the dorsal carpal ligament have been opened and the tendons of the superficial muscles removed.

muscle is in immediate relation with the insertion of the tendon of the biceps and with the bicipito-radial bursa.

It arises from the external epicondyle of the humerus, from the radial lateral and annular ligaments of the elbow-joint, and from the supinator ridge of the ulna. It is tendinous at its origin and usually exhibits a superficial aponeurosis in the middle of its course. Some of the fibers run almost horizontally and some of them obliquely forward and downward, passing to the upper, outer, and lower portion of the tuberosity of the radius and to the volar surface and border, the outer surface, the dorsal surface and border of the same bone. The fibers passing to the volar border terminate immediately above the insertion of the pronator (radii) teres.

The muscle usually consists of a superficial and of a deep portion which are not sharply differentiated, and between the two portions the deep (posterior interosseous) branch of the radial nerve passes.

The supinator is supplied by the radial nerve. As its name indicates, it supinates the forearm.

THE SUPERFICIAL LAYER OF THE EXTENSORS.

This layer consists of three muscles, adherent to each other at their origins, which are partly in common with the extensor carpi radialis brevis from the external epicondyle of the humerus and the antibrachial fascia, and they terminate in tendons which are distinctly directed toward the ulnar side and pass beneath the dorsal carpal ligament to the back of the hand. They are situated in the dorsal region of the forearm, chiefly upon the dorsal surface of the ulna (and upon the supinator above), and are in relation externally with the extensor carpi radialis brevis, internally with the anconeus and below with the flexor carpi ulnaris.

The **extensor digitorum communis** (Figs. 278, 279, and 289) is a broad, flat, strong muscle which arises from the external epicondyle of the humerus and the antibrachial fascia; it is intimately adherent to the extensor digiti V and partly to the extensor carpi radialis brevis. Somewhat below the middle of the forearm it divides into three (or four) bellies (Fig. 279) which terminate in round tendons; the ulnar one gives off tendons for both the ring and little fingers when only three bellies are present. The tendons pass beneath the dorsal carpal ligament to the back of the hand (Fig. 289), where those for the ulnar fingers are connected by slender transverse or oblique tendinous fasciculi, the *junctura tendinum*. In the fingers, these tendons form the main portion of the dorsal aponeurosis.

The **extensor digiti V proprius** (Figs. 279 and 289) is a thin slender muscle which is so closely connected with the extensor digitorum communis that it seems to be a part of it. Its slender tendon passes through a separate compartment in the dorsal carpal ligament to the dorsal aponeurosis of the little finger (Fig. 281) and is sometimes double, taking the place of the tendon of the extensor communis to the little finger, which may be poorly developed or even absent (Fig. 289).

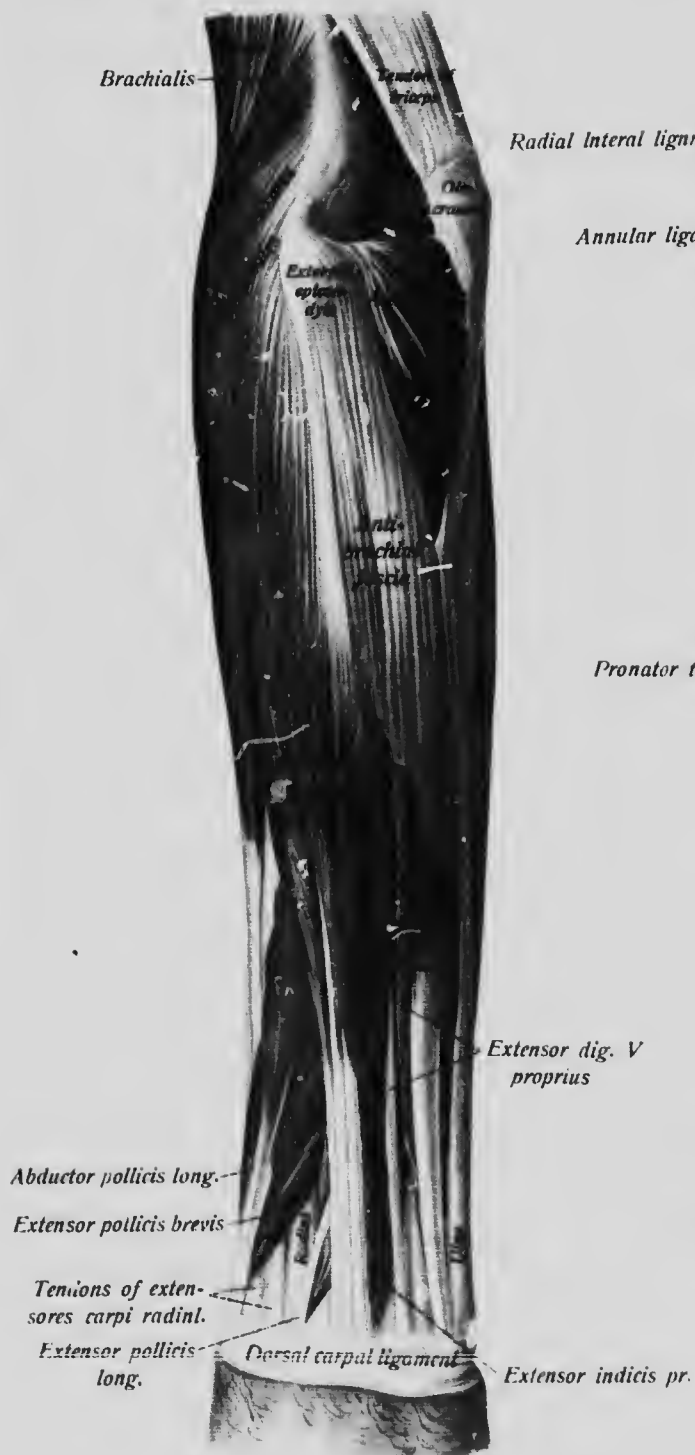
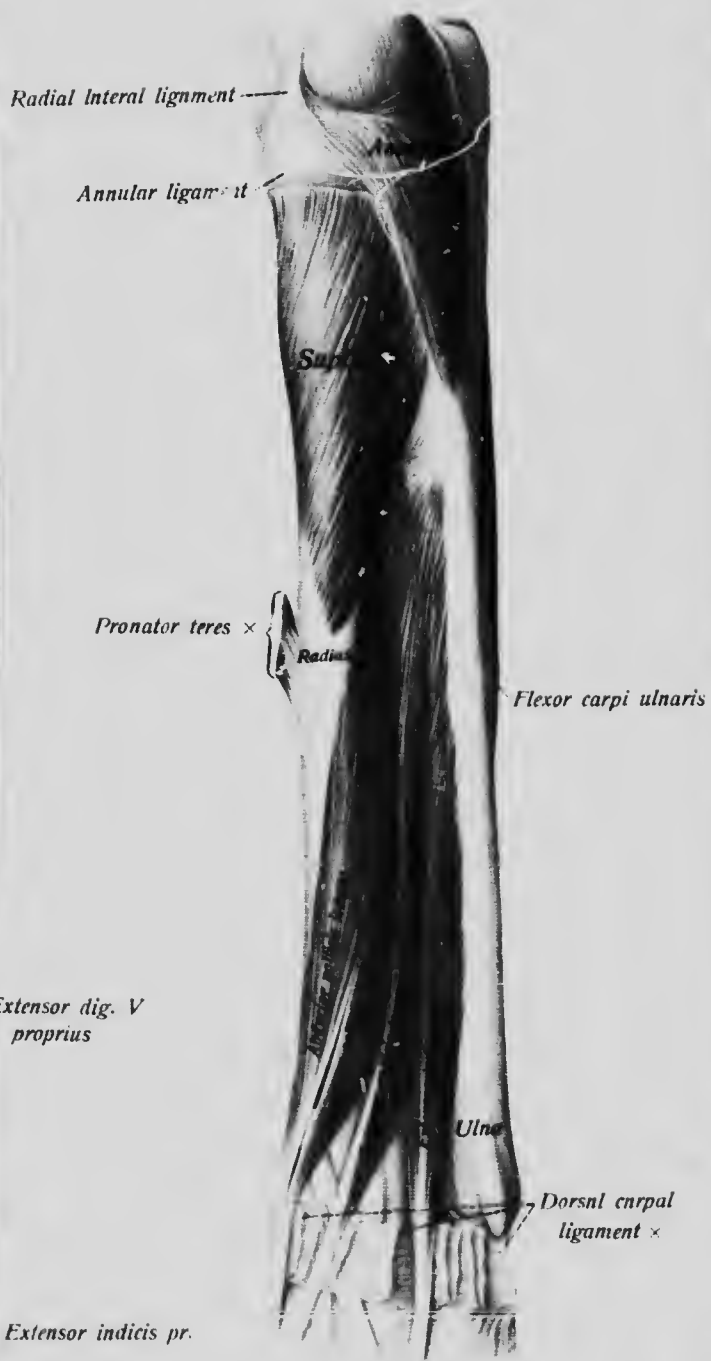


Fig. 270.



Tendon of extensoris carpi radialis brevis
Tendon of extensoris carpi radialis longi

Fig. 280.



Both muscles are supplied from the radial nerve. They extend the four ulnar fingers especially their proximal phalanges.

The **extensor carpi ulnaris** (*ulnaris externus*) (Figs. 279 and 289) arises together with the two other muscles of this group from the external epicondyle of the humerus, and also from the articular capsule of the elbow-joint and quite extensively from the antibrachial fascia, with which the muscle is adherent for almost half of its entire length. It is in relation above with the anconeus and lower down is separated from the flexor carpi ulnaris by the dorsal border of the ulna. It passes over the dorsal surface of the ulna, becomes tendinous in the lower third of the forearm, runs beneath the dorsal carpal ligament, and inserts into the base of the fifth metacarpal bone.

The extensor carpi ulnaris is supplied from the radial nerve. When acting with the extensores carpi radiales, it produces dorsal flexion, and together with the flexor carpi ulnaris it effects ulnar flexion (ulnar abduction).

THE DEEP OBLIQUE GROUP OF EXTENSORS

This layer is differentiated from the deep straight group by the fact that only the origins of the muscles comprising it are concealed by the superficial extensors. The muscles become superficial below and cross the tendons of both extensores carpi radiales in the lower third of the forearm. Like the muscles of the deep flexor group, they pass over only the wrist joint.

The **abductor pollicis longus** (*extensor ossis metacarpi pollicis*) (Figs. 279, 280, and 289), the outermost of the group, is a flat strong muscle, the origin of which is completely concealed by the superficial group of extensors. It has a long pointed origin from the dorsal surface of the ulna and also arises from the interosseous membrane and from the dorsal surface of the radius below the insertion of the supinator. In the lower third of the forearm it crosses, together with the extensor pollicis brevis, the tendons of the extensores carpi radiales at an acute angle and terminates in a tendon (or two tendons) which passes beneath the dorsal carpal ligament to be inserted chiefly into the base of the metacarpal bone of the thumb. Tendinous fibers usually radiate also to the greater multangular bone and to the abductor pollicis brevis (see page 199).

The muscle is supplied from the radial nerve. It abducts the thumb and also assists in the extension of this digit.

The **extensor pollicis brevis** (Figs. 279, 280, and 289) is situated more to the ulnar side and is by far the weakest muscle of the group. It is a slender muscle, situated immediately alongside of the abductor, and arises from the interosseous membrane and from the dorsal surface of the radius. It crosses the tendons of the extensores carpi radiales and its slender tendon passes through the same compartment as the abductor (Fig. 289) and is inserted into the dorsal aponeurosis of the first phalanx of the thumb.

It is supplied from the radial nerve. It extends and abducts the first phalanx of the thumb.

THE DEEP STRAIGHT GROUP OF EXTENSORS.

The muscles of this group lie immediately to the ulnar side of the preceding, but they are deeply placed in the forearm and are completely concealed by the superficial extensors.

The **extensor pollicis longus** (Figs. 279, 280, and 289) is stronger than the brevis. It arises from the dorsal surface of the ulna and from the interosseous membrane and forms a

FIG. 281.—Tendons and muscles (interossei dorsales) of the dorsum of the hand. The dorsal carpal ligament is retained, the rest of the dorsal fascia being removed.

FIG. 282.—The palmar aponeurosis and the palmaris brevis. The thenar and hypothenar muscles are shown covered by the fascia.

long, slender, muscular belly which passes downward to the wrist-joint beside the extensor digitorum communis. Just before reaching the wrist it terminates in a tendon which passes through a special compartment in the dorsal carpal ligament (Fig. 280), crosses* the tendons of the extensores carpi radiales immediately before their insertion, and is attached to the unguis phalanx of the thumb, being partly adherent to the tendon of the extensor pollicis brevis.

This muscle is also supplied from the radial nerve. It extends the unguis phalanx of the thumb and assists the action of the abductor.

The **extensor indicis proprius** (the *indicator*) (Figs. 279, 280, and 280) is a long slender muscle situated to the ulnar side of the extensor pollicis longus. It arises chiefly from the dorsal surface of the ulna, receiving additional fibers from the interosseous membrane, is completely concealed by the extensor digitorum communis, and passes through the dorsal carpal ligament in the same compartment with the latter muscle (Fig. 280). Just above the wrist-joint it terminates in a tendon which runs on the dorsum of the hand alongside of the tendon of the communis for the index finger and forms with this tendon the dorsal aponeurosis of that finger.

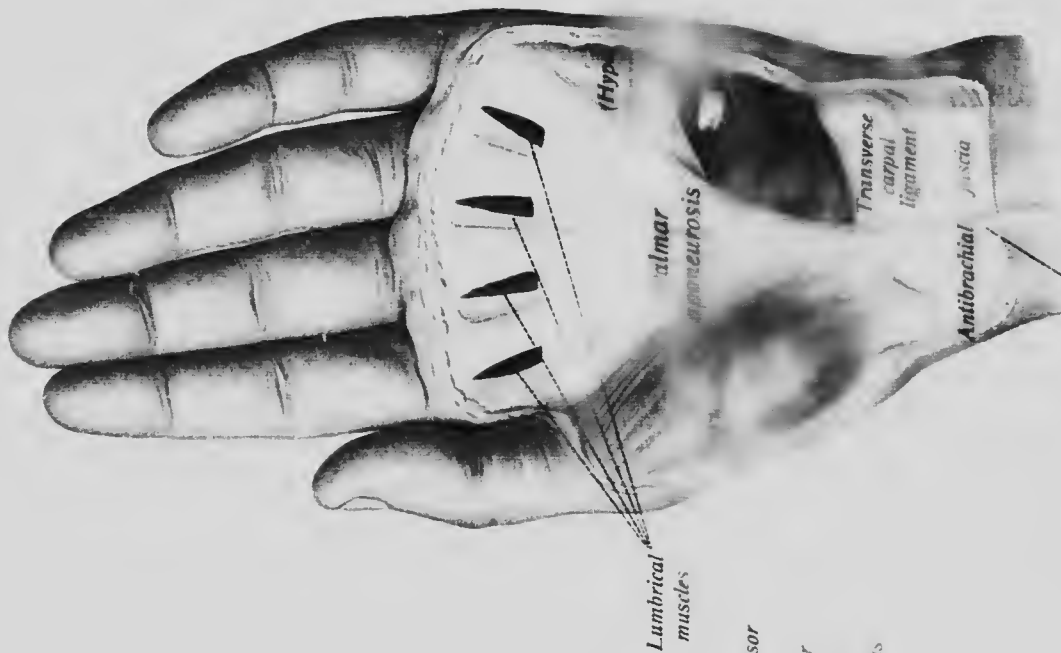It is supplied from the radial nerve. It aids in the extension of the index-finger.

THE MUSCLES OF THE HAND.

The thenar and hypothenar eminences occupy respectively the radial and ulnar borders of the hand, but the flexor tendons and lumbricales, running in the middle of the palm, are covered by a strong aponeurosis which is usually a direct radiation of the tendon of the palmaris longus (see page 193) and is known as the *palmar aponeurosis* (Fig. 284) (the palmar fascia). This aponeurosis is always connected with the transverse carpal ligament and gradually divides away upon either side into the fascia of the thenar and hypothenar eminences. It is broad at the transverse carpal ligament and becomes broader as it passes downward toward the fingers, and its longitudinal fasciculi, which gradually disappear in the integument over the bases of the proximal phalanges of the second to the fifth fingers, are united in the distal portion of the palm by transverse fasciculi, which close in the interspaces lying between the longitudinal fasciculi passing to the individual fingers. These spaces give passage to the vessels and nerves for the margins of the fingers, and beneath them are situated the lumbricales.

The ulnar margin of the denser central portion of the palmar aponeurosis and the transverse carpal ligament give origin to a muscle which passes over the muscles of the hypothenar eminence and the ulnar vessels to the integument at the ulnar border of the hand. This muscle is situated entirely within the superficial fascia of the palm, varies in its development in different individuals, and is termed the *palmaris brevis* (Fig. 282).

*This crossing occurs within the dorsal carpal ligament, so that the tendon-sheaths also cross each other (see the description of the tendon sheaths of the hand, page 203).



Tendon of palmaris longus
Fig. 282.

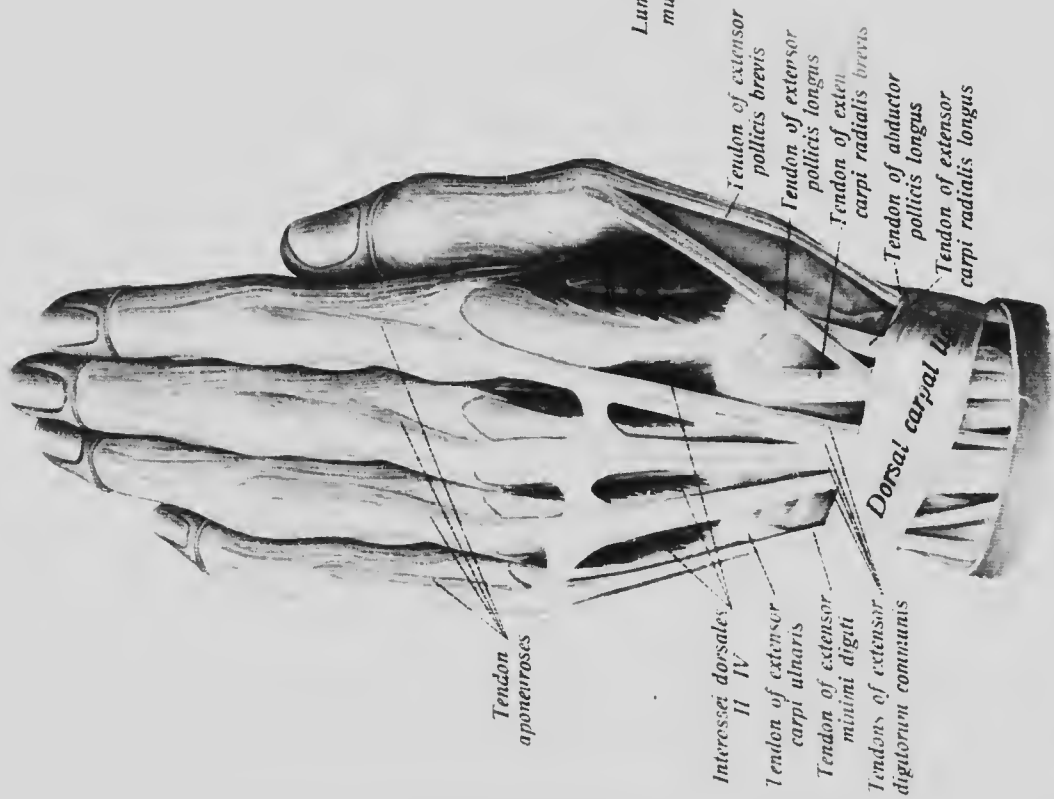



Fig. 281.



THE MUSCLES OF THE HAND.

It is supplied by the superficial volar branch of the ulnar nerve and is a tensor of the skin of the ulnar border of the hand.

THE MUSCLE OF THE THENAR EMINENCE.

The **abductor pollicis brevis** (Figs. 285 and 290) is the most superficial of the muscles of the thenar eminence. It arises by a broad short tendon from the tuberosity of the navicular bone and from the transverse carpal ligament, becomes markedly narrower toward its insertion, and is attached by means of a short tendon, containing the radial sesamoid tendon, to the base of the first phalanx of the thumb. It is usually adherent to the adjacent tendon of the abductor pollicis longus (see page 197).

It is supplied by the median nerve and abducts the thumb.

The **opponens pollicis** (Figs. 283, 284, and 290) is a rather short, moderately strong muscle, the greater portion of which is concealed by the abductor brevis. It arises from the tuberosity of the greater multangular bone (the trapezium) and from the transverse carpal ligament and inserts by oblique, partly tendinous fibers into the entire length of the radial border of the metacarpal bone of the thumb.

It is supplied by the median nerve and opposes the thumb.

The **flexor pollicis brevis** (Figs. 283 and 284) is situated on the ulnar side of the abductor and is only partly concealed by the latter muscle. It consists of a superficial or radial and a deep or ulnar head. The *superficial head* arises from the transverse carpal ligament beside and distal to the origins of the abductor and the opponens, it conceals the ulnar border of the latter muscle, becomes adherent to the ulnar or deep head, and is attached to the basal phalanx of the thumb by means of the radial sesamoid bone. The *deep head* arises from the bottom of the carpal canal, chiefly from the palmar surfaces of the lesser multangular (trapezoid) and capitate (os magnum) bones, is adherent to the oblique fibers of the abductor pollicis, and passes to the ulnar sesamoid bone and to the ulnar side of the basal phalanx of the thumb. The deeper portions of the two heads are adherent, but the superficial portions form a groove for the tendon of the flexor pollicis longus.

Both heads together flex the first phalanx of the thumb; the radial head assists opposition, the ulnar aids adduction. The radial head is supplied by the median nerve, the ulnar by the deep volar branch of the ulnar nerve.

[The description of the muscle given above follows the plan which is usual in anatomical text-books. Comparative anatomy shows very clearly, however, that the two heads are really of very different significance, the radial head being the true flexor brevis pollicis, while the ulnar head is a portion of the adductor. This is indicated in the human hand by the different nerve-supply of the two heads. (D)]

The **adductor pollicis** (Figs. 283, 284, and 290) is situated in the depths of the palm. It is covered by the palmar aponeurosis, by the tendons of the flexores digitorum, and by the lumbricales, and rests upon the interosseus volaris I (and dorsalis I). Some of its fibers, which have an oblique direction and are intimately connected with the deep head of the flexor brevis, arise at

FIG. 283.—The palmar muscles after removal of the palmar aponeurosis. The tendon-sheath of the middle finger has been split lengthwise.

FIG. 284.—The deep layer of the palmar muscles. The transverse carpal ligament and the abductores digiti V and pollicis brevis have been removed. The tendons of the long flexors have been removed from the carpal canal and, after splitting the tendon-sheaths of the fingers, have been partly removed and partly drawn aside.

the bottom of the carpal canal from the palmar surfaces of the lesser multangular (trapezoid) and capitate (os magnum) bones, but the greater number arise from the palmar surface of the shaft of the third metacarpal bone, and pass almost horizontally toward the narrow tendon of insertion which is attached to the basal phalanx of the thumb by means of the ulnar sesamoid bone.

The muscle is supplied by the ulnar nerve. It adducts the thumb, *i. e.*, approximates the thumb and index-finger.

THE MUSCLES OF THE HYPOTHENAR EMINENCE.

The **abductor digiti quinti** (Figs. 285 and 290) is the strongest and innermost muscle of the group. It arises from the pisiform bone, sometimes also from the transverse carpal ligament, and is inserted into the ulnar border of the dorsal aponeurosis of the little finger.

It is supplied by the ulnar nerve, and abducts the little finger, *i. e.*, separates the little from the ring finger.

The **flexor digiti quinti brevis** (Figs. 285 and 286) arises from the transverse carpal ligament and from the hamulus of the hamate (unciform) bone. It is a small slender muscle situated to the radial side of the abductor and may be entirely absent, or fused with the opponens. Its short tendon of insertion is attached beside that of the abductor into the basal phalanx of the little finger.

It is supplied by the ulnar nerve. It flexes the first phalanx of the little finger.

The **opponens digiti quinti** (Figs. 283, 284, and 290) arises together with the preceding muscle and runs to the ulnar border of the metacarpal bone of the little finger.

It also is supplied by the ulnar nerve and opposes the little finger.

THE INTEROSSEI AND THE LUMBRICALES.

The **interossei** completely fill the interspaces between the metacarpal bones. Those muscles situated nearer to the dorsal surface are known as the *interossei dorsales*, those nearer the palmar surface as the *interossei volares*.

The four **interossei dorsales** (Figs. 281, 285, and 286) are located in the dorsal portions of the four interosseous spaces, the largest being the interosseus dorsalis primus, which is situated between the metacarpal bones of the thumb and index finger. They arise by two heads from the opposite surfaces of the contiguous metacarpal bones and are the only muscles which are partly visible beneath the fascia upon the back of the hand. Near the heads of the metacarpal bones

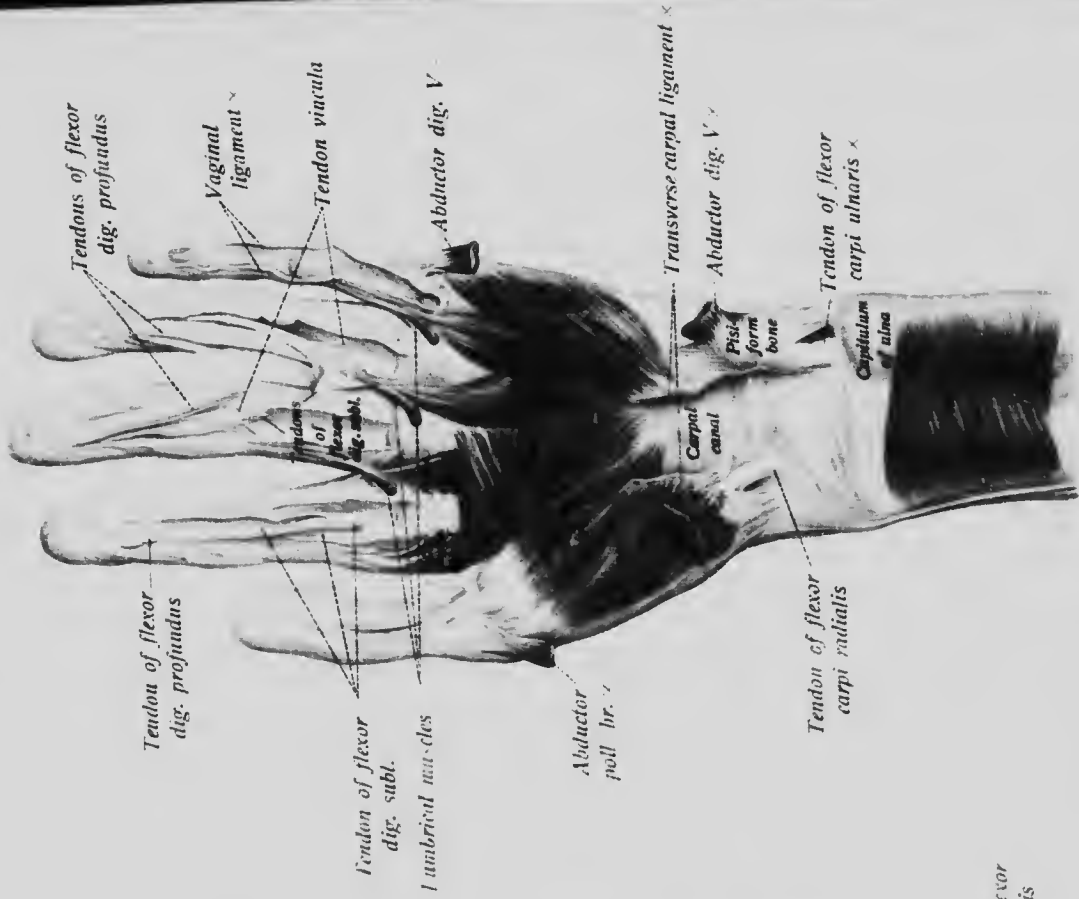


Fig. 284.

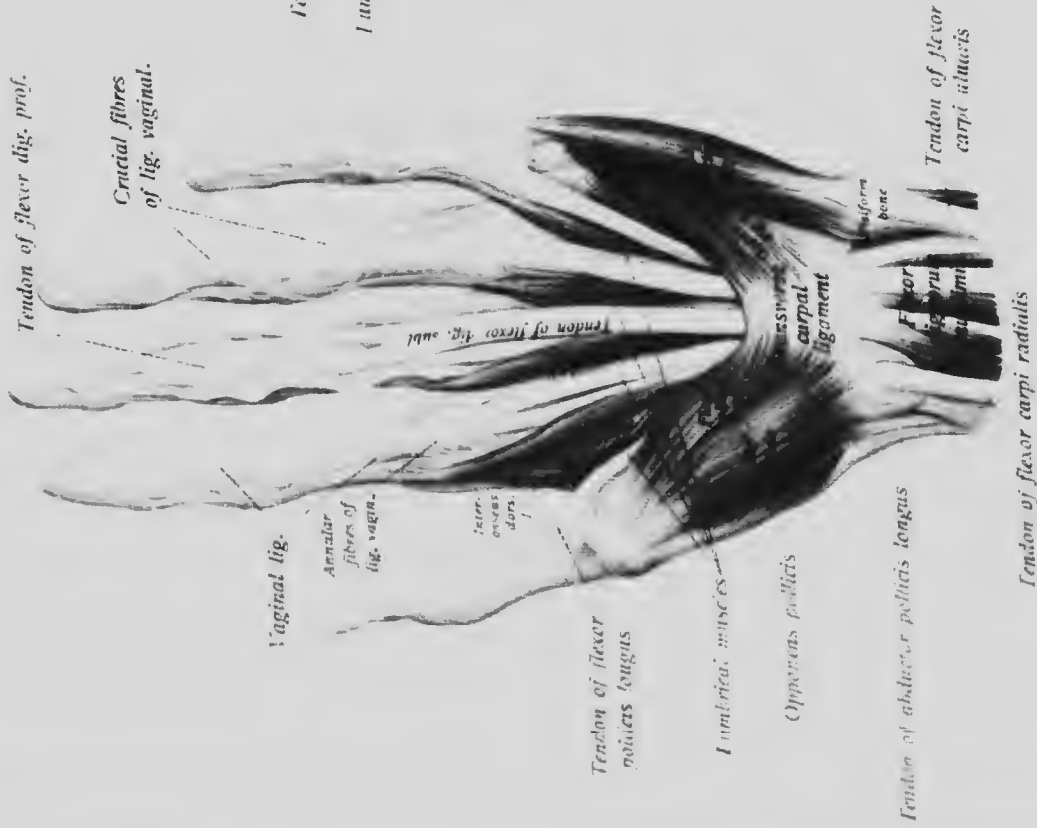



Fig. 283.



they terminate in short tendons which radiate into the dorsal aponeuroses of the basal phalanges (see page 205) (Fig. 286), the middle finger receiving the tendons of the second and third muscles, while the tendon of the first passes to the radial side of the index-finger, and that of the last to the ulnar side of the ring-finger.

The **interossei volares** (Figs. 284 and 287) are three in number and are deeply placed in

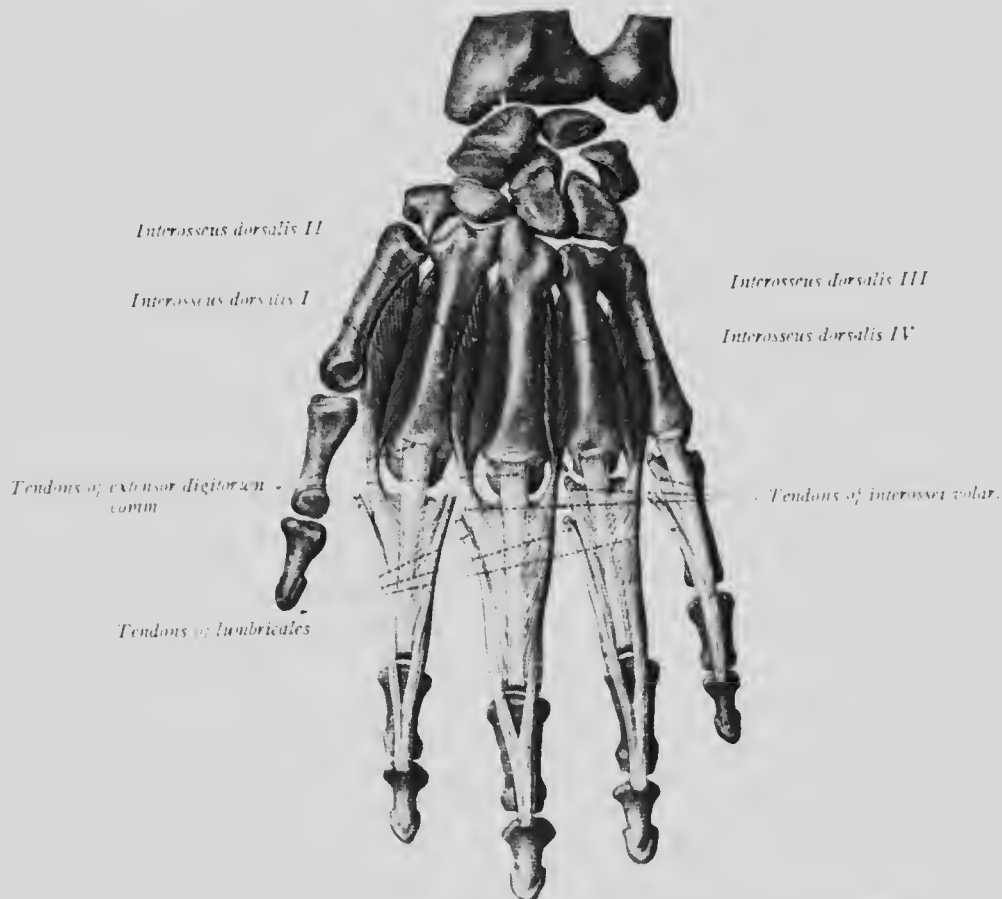


FIG. 285 — Diagram of the dorsal aponeurosis of the fingers and of the interossei dorsales.

the palm, the two ulnar muscles (the second and third) being situated beside the abductor pollicis and the first or radial one beneath the latter muscle. They arise by a single head, the first one coming from the ulnar border of the metacarpal bone of the index-finger and the second and third from the radial sides of the fourth and fifth metacarpal bones. Each muscle is inserted into the extensor tendon of the finger from the metacarpal bone of which it takes its origin. The index finger consequently receives the tendon of an interosseus dorsalis upon its radial side and

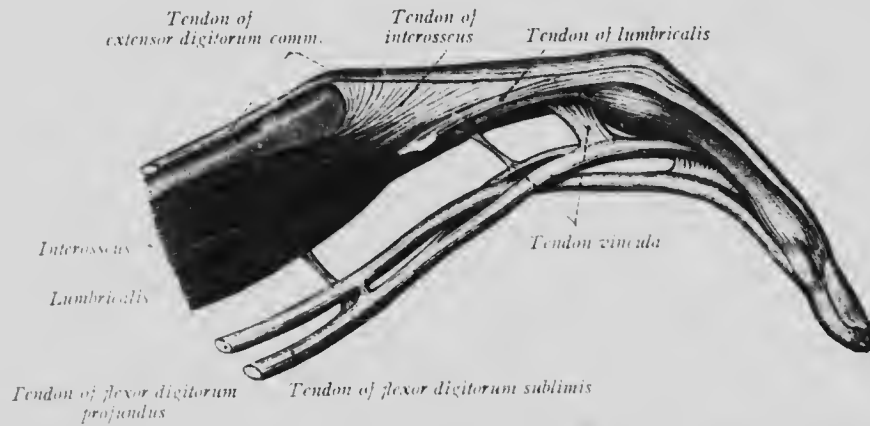


FIG. 286.—Diagram showing the relation of the tendons of the interossei and lumbricales to the dorsal aponeurosis of the fingers and the arrangement of the long flexor tendon of the fingers.

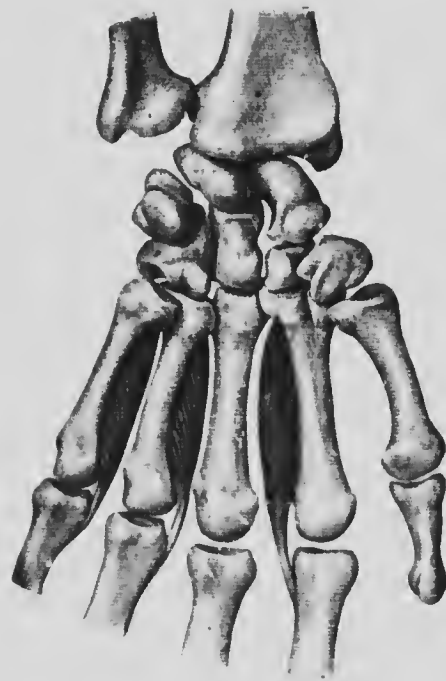


FIG. 287.—Diagram of the interossei volares.

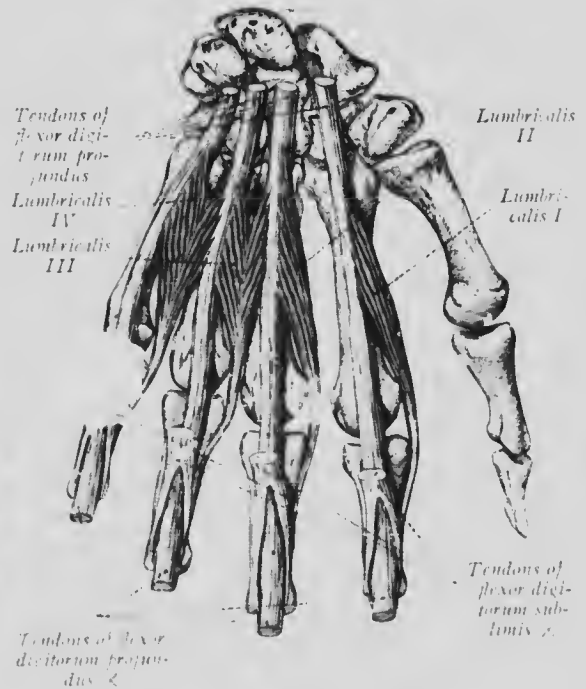


FIG. 288.—Diagram of the lumbricales.

the tendon of an interosseus volaris upon its ulnar side; the middle finger has two interossei dorsales; the ring-finger has a volar tendon upon its radial, and a dorsal tendon upon its ulnar side; and the little finger received a single tendon, that of the third interosseus volaris, upon its radial side. The interossei dorsales are posterior and the interossei volares anterior to the transverse capitular ligaments (see page 127), which consequently separate the two groups of interossei in the region of their insertions.

[As stated above, it is customary to recognize but three interossei volares. A fourth is, however, present in the form of an exceedingly slender muscle which arises from the first metacarpal and is inserted into the ulnar side of the base of the first phalanx of the thumb, along with the ulnar head of the flexor brevis pollicis, with which muscle it is frequently more or less extensively fused.—ED.]

All of the interossei are usually supplied by the ulnar nerve. They either abduct or adduct the fingers. The middle finger may be moved toward either the index-finger or ring-finger by the action of its interossei dorsales, the first interosseus dorsalis pulls the index-finger toward the thumb; the last one draws the ring finger toward the little finger. The first volaris pulls the index toward the middle finger; the second draws the ring toward the middle finger; and the third adducts the little toward the ring-finger. The interossei also resist the action of the lumbricales (see below).

The four *lumbricales* (Figs. 283, 286, 288, and 290) are long, narrow, worm-like muscles which arise deep in the palm from the four tendons of the flexor digitorum profundus. The two radial muscles arise by a single head from the radial borders of the two radial tendons, while the two ulnar muscles usually arise by two heads from the adjacent borders of the three ulnar tendons. Near the basal phalanges of the fingers they terminate in very slender tendons which are inserted, from the radial side, into the dorsal aponeuroses of the fingers in common with the interossei.

The two radial lumbricales are usually supplied by the median nerve, the two ulnar by the ulnar nerve. They flex the basal phalanges of the fingers and extend the second and third phalanges.

THE RELATIONS OF THE EXTENSOR TENDONS AND THEIR SHEATHS BENEATH THE DORSAL CARPAL LIGAMENTS.

As the tendons of the extensors of the hand and of the fingers pass over the wrist joint (Figs. 280, 283, and 289) they are enclosed in the synovial sheaths and held in the grooves upon the dorsal surfaces of the radius and ulna by a thickened portion of the antibrachial fascia, the *dorsal carpal (posterior annular) ligament*. The individual synovial sheaths are situated in different compartments of the ligament, since this structure is attached to the longitudinal ridges upon the bones and especially to those of the radius.

These compartments will be described in the order in which they are encountered in passing from the radial to the ulnar side of the wrist (Figs. 280 and 289). The tendons of the extensor pollicis brevis and abductor pollicis longus pass through a common compartment and to a certain extent are invested by a common synovial sheath. The second compartment gives passage to the tendons of the extensor carpi radialis longus and brevis, which usually possess individual synovial sheaths. The third compartment is superficially placed and is not longitudinal but oblique; it crosses the tendons and synovial sheaths of the more deeply situated second compartment at an acute angle and contains the tendon and synovial sheath of the extensor pollicis longus. Next follows the largest of all the compartments; it contains in a common sheath the

four tendons of the extensor digitorum communis and that of the extensor indicis proprius. The fifth compartment contains the slender tendon of the extensor digiti V proprius and is superficially situated. The sixth and last compartment gives passage to the tendon of the extensor carpi ulnaris.

The synovial sheaths are considerably longer than the width of the dorsal carpal ligament; those of the extensores communis, indicis, and digiti V may extend to the middle of the metacarpus.

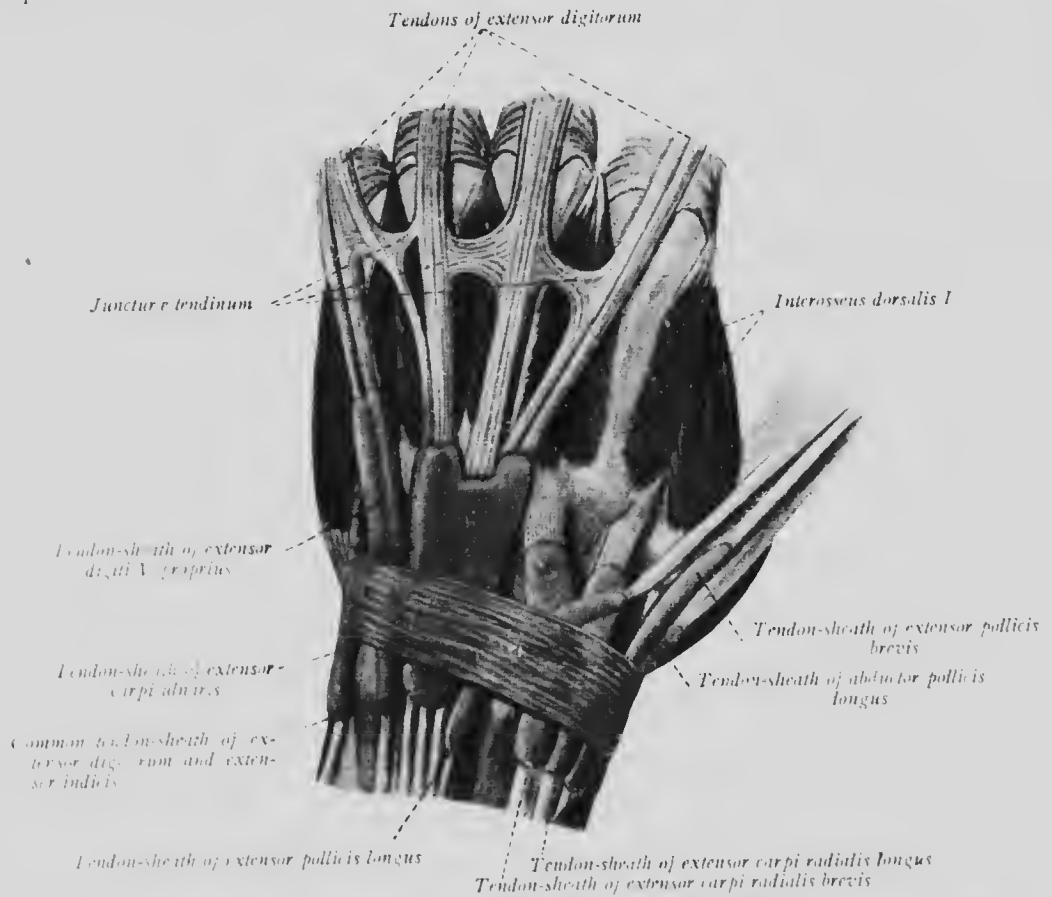


FIG. 280.—The arrangement of the tendons of the extensor muscles and tendon-sheaths beneath the dorsal carpal ligament and in the hand (somewhat schematic).

THE EXTENSOR TENDONS OF THE FINGERS.

The extensor tendons or dorsal aponeuroses of the fingers (Figs. 281, 286, and 289) are chiefly composed of the tendons of the extensores digitorum, but also receive fibers from the tendons of the interossei and lumbricales.

The tendon of the extensor or those of the two extensors* which pass to a finger, become flattened in the region of the metacarpo-phalangeal joint and divide into a strong longitudinal fasciculus, which continues onward in the same direction as the main tendon, passing to the head of the first phalanx and to the articular capsule between the first and second phalanges, and into weaker oblique fasciculi which unite with the tendons of the interossei.

These form flat expansions over the basal phalanges, which pass to the lateral margins of the extensor tendon (Fig. 286) and are also continued to the middle phalanges, uniting with the oblique fasciculi of the extensor tendon and with the tendinous expansions of the lumbricales proceeding from the radial sides of the finger. These lateral fasciculi of the dorsal aponeurosis come from both margins of the finger, unite at the capsular ligament between the second and third phalanges, and are inserted together into the base of the latter bone.

The direct continuation of the extensor tendon consequently terminates at the head of the basal phalanx.

The dorsal aponeuroses are firmly attached to the convex surfaces of the phalanges and are intimately connected with the articular capsules of the interphalangeal joints.

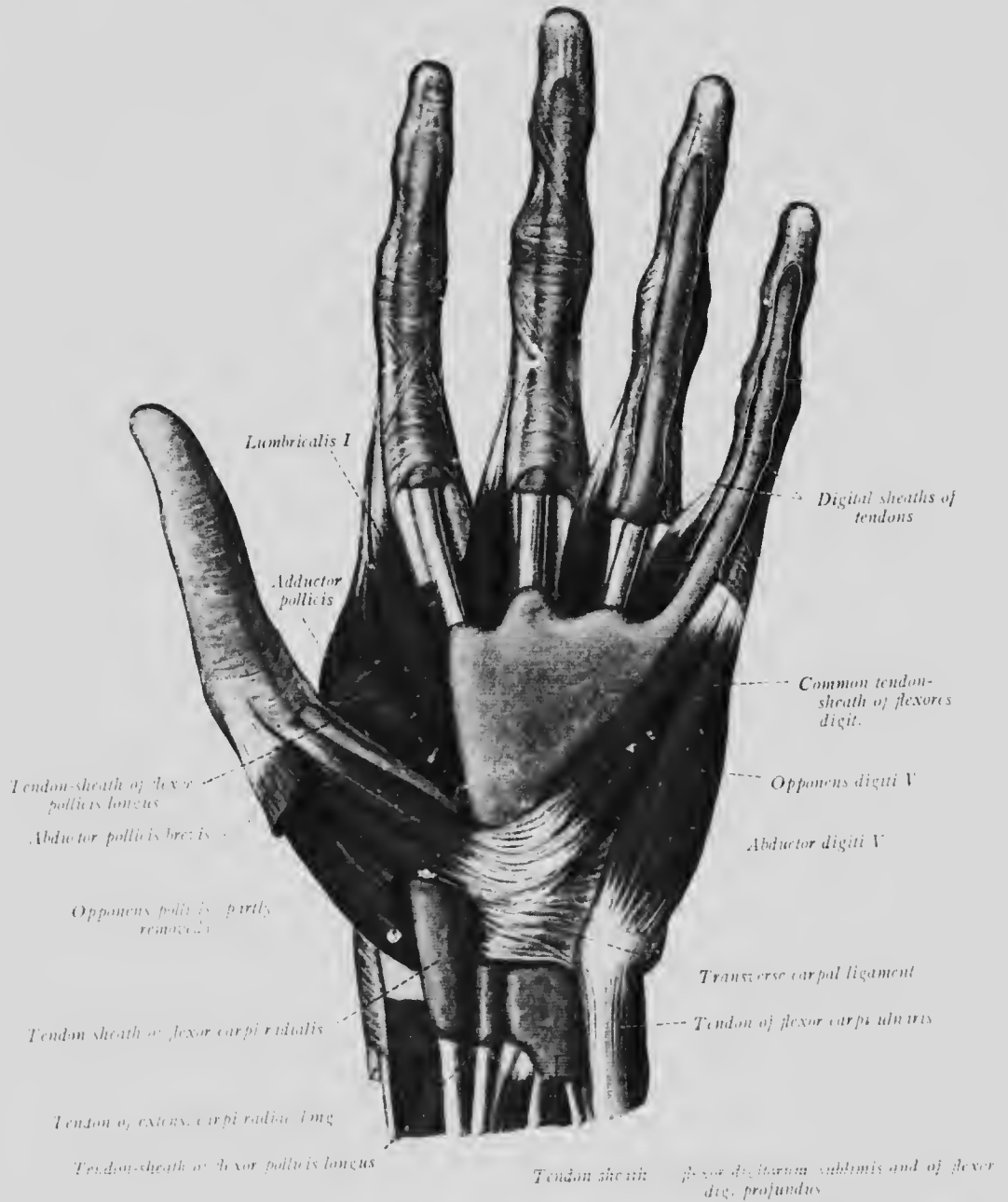
THE TENDONS AND SYNOVIAL SHEATHS OF THE FLEXOR TENDONS IN THE PALM.

Just as the extensor tendons run in synovial sheaths upon the back of the hand, so we find the tendons of the flexores digitorum, and those of the flexor pollicis longus and flexor carpi radialis surrounded by synovial sheaths and passing beneath the *transverse carpal ligament* in the carpal canal (Figs. 283, 285, and 290). The flexor carpi ulnaris has no synovial sheath. The outermost synovial sheath in the carpal canal (Fig. 282) is that of the flexor carpi radialis, which extends to near the insertion of the tendon and is almost entirely concealed by the origins of the thenar muscles. Next this sheath is the long narrow one for the flexor pollicis longus, which extends from the upper margin of the transverse carpal ligament to the terminal phalanx of the thumb. Next in order, passing toward the ulnar side, is the large sheath which contains the eight tendons of the flexor digitorum sublimis and profundus; it commences above the transverse carpal ligament and extends to about the middle of the palm. Only the synovial sheath for the tendons of the little finger is continued directly into the finger itself.

The fingers possess separate synovial sheaths (Fig. 290), commencing at the metacarpo-phalangeal joints and extending to the bases of the terminal phalanges, which are surrounded by fibrous structures known as the vaginal ligaments (Fig. 285). In the distal portion of the fingers these sheaths become thinner and are frequently interrupted, and according as to whether their fasciculi cross each other or are arranged circularly in this situation, *crucial* and *annular* ligaments may be distinguished.

Over the metacarpal bones the tendons of the flexor sublimis rest immediately upon those of the profundus within the tendon-sheaths, but at the middle of the first phalanges they divide, forming slits which give passage to the tendons of the profundus. In this situation the latter tendons become somewhat broader, exhibit an indistinct median longitudinal fissure, and are eventually attached to the bases of the ungual phalanges. The two slips of each sublimis

*The index and the little finger usually possess two tendons.



Pl. 200.—The arrangement of the tendon-sheaths, of the long flexors and of the flexor carpi radialis (somewhat diagrammatic).

tendon pass beneath that of the profundus and are attached to the lateral margins of the second phalanx, so that the tendons of the flexor sublimis are consequently perforated by those of the profundus (the *chiasma of the tendons*), the former being inserted into the middle and the latter into the terminal phalanges. The flexor tendons are indirectly connected with the basal phalanges by small ligaments, the *tendon vincula*, some of which are thread-like (filiform), while others, particularly those in the middle phalanx, are triangular. They not only connect the tendons of the sublimis and profundus to the basal phalanges, but also those of the profundus to the middle phalanges.

THE FASCIÆ OF THE UPPER EXTREMITY.

The muscular masses of the upper extremity are enveloped by a common fascia (Figs. 201 and 202) which is particularly well developed in the arm and forearm and which has received different names in different regions. At the shoulder there are recognized an *axillary*, a *supraspinatus*, an *infraspinatus*, and a *subscapular fascia*; in the arm, the *brachial fascia*, in the forearm, the *antibrachial fascia*; and in the hand, the *dorsal fascia* and the *palmar aponeurosis*.

The *axillary fascia* (Fig. 201) is a thin layer which closes in the axillary cavity. It is directly continuous below with the much stronger brachial fascia, is perforated by a number of blood vessels, and contains several strong fasciculi (sometimes muscular) which pass from the latissimus to the pectoralis.

The *supraspinatus fascia* covers the supraspinatus and is partly tendinous in character.

The *infraspinatus fascia* (Fig. 238) is a very dense tendinous fascia which covers the infraspinatus, the teres minor, and the teres major, giving partial origin to the first two muscles and also to the deltoideus, beneath which muscle it gradually disappears.

The *subscapular fascia* is thin and covers the subscapularis muscle.

The *brachial fascia* (Figs. 201 and 202) is the immediate continuation of the preceding fasciæ and is quite thin above the insertion of the deltoideus. It consists chiefly of transverse fasciculi and upon its anterior surface the relief of the biceps may be distinctly recognized, to either side of which are situated the *external* and *internal bicipital grooves*. In the lower part of the arm the fascia gives off the two *intermuscular septa* which pass to the bone between the two muscular groups of this region, the *internal intermuscular septum* extending downward to the internal epicondyle and the *external* one to the external epicondyle.

The anterior surface of the fascia exhibits orifices for the passage of cutaneous nerves and veins. (For further detail see sections upon "Neurology" and "Angiology.")

The *antibrachial fascia* (Fig. 201, 202) is directly continuous with the brachial fascia in the region of the elbow-joint and, with the exception of one region, is considerably stronger than this fascia. It is particularly dense below the region of the elbow, forming an aponeurosis which is adherent to the superficial layers of the flexor and extensor muscles (see page 101), and the *lucertus fibrosus* of the biceps tendon (see page 188) is really formed by this fascia. It is thinnest in the cubital fossa and over the brachioradialis and extensor carpi radialis longus, with which it is not adherent.

In the lower portion of the forearm the antibrachial fascia gives off deeper layers which enclose the individual muscles and tendons. Toward the wrist joint the volar and dorsal

FIG. 291.—The fascia of the left arm seen from the volar surface.
 FIG. 292.—The fascia of the left arm seen from the dorsal surface.

surfaces are reinforced by strong circular fibers, forming the *volar carpal ligament* (Fig. 291), which is situated above the wrist-joint and over the flexor tendons and is continuous by its distal margin with the transverse carpal ligament (see page 127).

The *dorsal carpal (posterior annular) ligament* (Fig. 281) is a very strong, broad, oblique fasciculus which passes from without inward and from above slightly downward. It is connected with the dorsal surface of the radius, the styloid process of the ulna, and the triquetral (cuneiform) bone, and forms the previously described compartments for the extensor tendons (see page 203).

The *dorsal fascia of the hand* commences at the distal margin of the dorsal carpal ligament. As it is very thin, the line of demarcation is much more noticeable than is the one between the ligament and the antibrachial fascia. The *palmar aponeurosis* (see page 198) is well developed and is by far the strongest of the fasciæ of the upper extremity.

THE MOST IMPORTANT BURSÆ OF THE UPPER EXTREMITY.


1. The *subacromial bursa* is situated beneath the acromion and above the insertion of the tendon of the supraspinatus.
2. The *subdeltoid bursa* (see page 186) (Fig. 268).
3. The *coracobrachial bursa* is situated at the tip of the coracoid process, where it gives origin to the coracobrachialis and to the short head of the biceps.
4. The *infraspinatus bursa*, at the insertion of the infraspinatus into the greater tubercle of the humerus.
5. The *subscapular bursa* (see page 121 and 188).
6. The *bursa of the teres major*, at the insertion of the tendon of the teres major into the greater tubercular ridge.
7. The *bursa of the latissimus dorsi*. (see page 146).
8. The *subcutaneous olecranal bursa* (Fig. 221) between the olecranon and the skin.
9. The *subcutaneous epicondylar bursæ* (*internal* and *external*), over the epicondyles of the humerus.
10. The *intra-tendinous* and *subtendinous olecranal bursa* situated respectively within and upon the insertion of the tendon of the triceps (inconstant).
11. The *bicipitoradial bursa* (see page 189) (Figs. 273 and 275).
12. The *cubital interosseous bursa*, between the upper extremities of the radius and ulna.
13. The *bursa of the extensor carpi radialis brevis*, at the base of the third metacarpal bone.
14. The *dorsal subcutaneous metacarpophalangeal bursæ*, inconstant subcutaneous bursæ upon the dorsal aspect of the joints of the same name.
15. The *dorsal subcutaneous digital bursæ*, subcutaneous bursæ upon the dorsal side of the proximal interphalangeal joints.
16. The *bursa of the flexor carpi ulnaris*, at the attachment of the flexor carpi ulnaris to the pisiform bone.

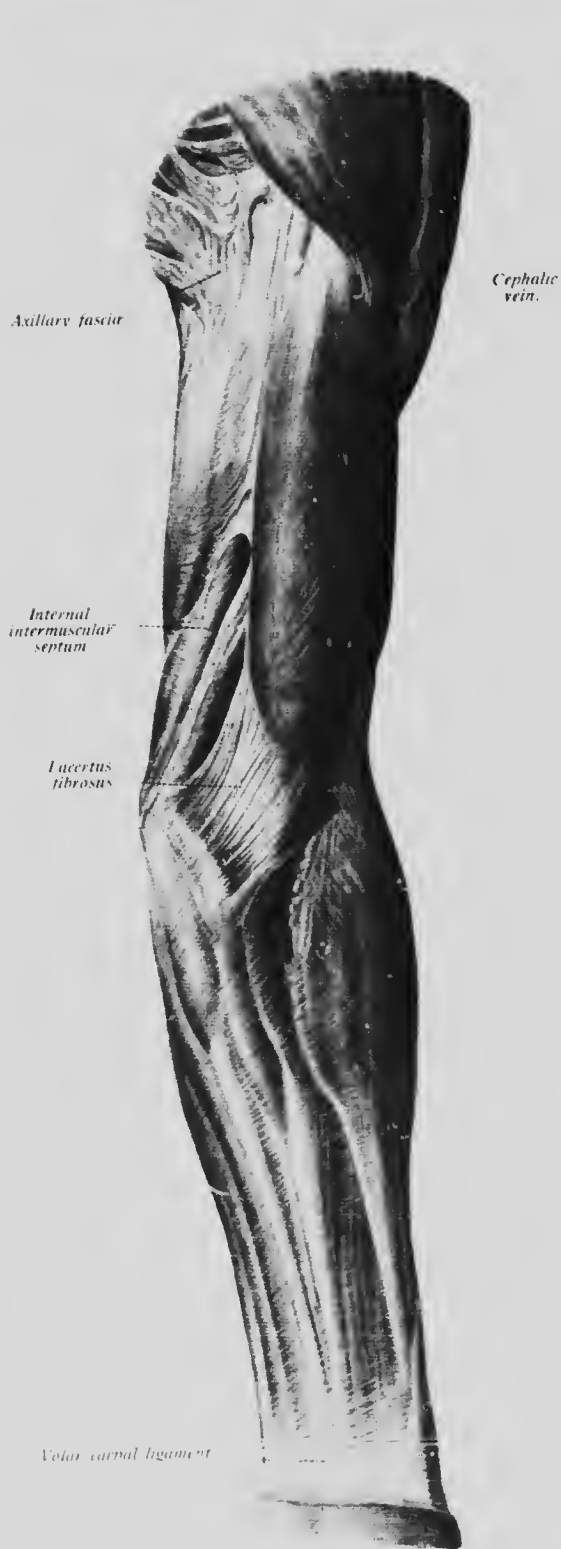

Fig. 201.

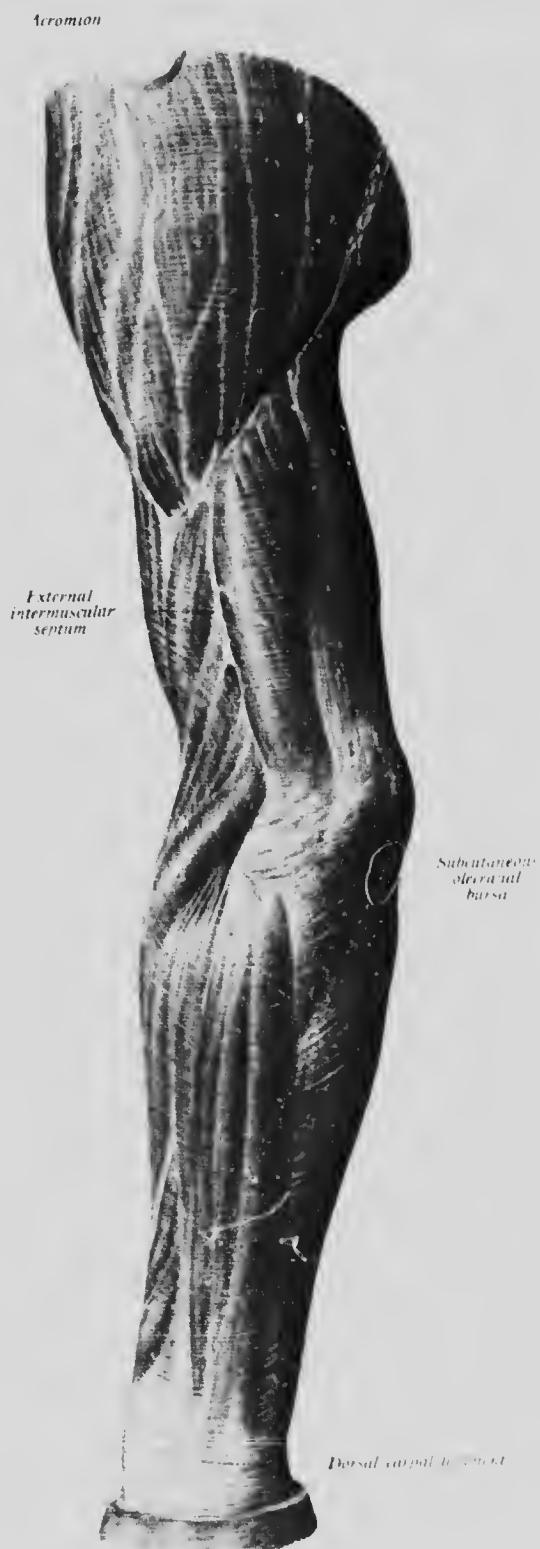

Fig. 202.



17. The bursa of the flexor carpi radialis, at the tubercle of the navicular bone.
 18. The intermetacarpophalangeal bursa, situated at the metacarpophalangeal articulations, posterior to the capitular ligaments.

[In the development of the muscles of the upper extremity, the earliest differentiation observable is a separation of the muscle sheet which lies upon the posterior or extensor surface of the limb from that which lies upon the anterior or flexor surface. In accordance with this, it is possible to recognize a group of posterior or, as they are preferably termed, post-axial muscles, and a second group of pre-axial muscles, in each of the segments of the limb, and it is noticeable that the former, in so far as they are supplied by nerves given off after the establishment of the cords of the brachial plexus, receive their innervation through the posterior cord, while the latter are supplied by derivatives of the anterior (*i. e.*, the inner and outer) cords.

The classification of the limb muscles according to the limb segments, as given above, may therefore be supplemented by dividing each set into a post-axial and a pre-axial group, thus:

I. THE MUSCLES OF THE SHOULDER (to which should be added the pectoral muscles and the superficial muscles of the back with the exception of the trapezius).

(a) Post-axial muscles: levator scapulae, rhomboideus minor, rhomboideus major, serratus anterior, deltoideus, supra-spinatus, infraspinatus, teres minor, subscapularis, teres major, and latissimus dorsi.

(b) Pre-axial muscles: pectoralis major, pectoralis minor, subclavius, and coracobrachialis.

II. THE MUSCLES OF THE UPPER ARM.

(a) Post-axial muscles: triceps, anconeus.

(b) Pre-axial muscles: biceps, brachialis.

III. THE MUSCLES OF THE FORE ARM.

(a) Post-axial muscles: brachio-radialis, extensor carpi radialis longus, extensor carpi radialis brevis, extensor digitorum communis, extensor digiti quinti proprius, extensor carpi ulnaris, supinator, abductor pollicis longus, extensor pollicis brevis, extensor pollicis longus, and extensor indicis proprius.

(b) Pre-axial muscles: pronator teres, flexor carpi radialis, palmaris longus, flexor carpi ulnaris, flexor digitorum sublimis, flexor digitorum profundus, flexor pollicis longus, and pronator quadratus.

IV. THE MUSCLES OF THE HAND.

(a) Post-axial muscles: wanting.

(b) Pre-axial muscles: palmaris brevis, abductor pollicis brevis, opponens pollicis, flexor brevis pollicis, abductor digiti quinti, opponens digiti quinti, flexor brevis digiti quinti, lumbricales, adductor pollicis, interossei volares, interossei dorsales.—ED.]

THE MUSCLES OF THE LOWER EXTREMITY.

The muscles of the lower extremity are divided into the muscles of the hip, the muscles of the thigh, the muscles of the leg, and the muscles of the foot. The muscles of the hip are again subdivided into an anterior and a posterior group, the former consisting of the *iliopsoas*, and the latter of the *gluteus maximus*, the *gluteus medius*, the *gluteus minimus*, the *piriformis*, the *obturator internus* with the *gemelli*, the *quadratus femoris*, and the *tensor fasciae latae*.

In the thigh there may be distinguished the muscles of the anterior surface, those of the inner side, and those of the posterior surface. The first two groups are separated by the *sartorius*; the muscle of the anterior surface is the *quadriceps femoris*; those of the inner side are the *pectineus*, the *adductor longus*, the *gracilis*, the *adductor magnus*, the *adductor minimus*, and the *obturator externus*; and those of the posterior surface are the *biceps femoris*, the *semitendinosus*, and the *semimembranosus*.

In the leg there may be distinguished the muscles of the posterior surface (the muscles of the calf), the muscles of the anterior surface, and the muscles of the outer side. The muscles

of the posterior surface are arranged in two layers, the superficial one being formed by the *triceps suræ* and the deep one consisting of the *popliteus*, the *tibialis posterior*, the *flexor digitorum longus*, and the *flexor hallucis longus*. The anterior group is composed of the *tibialis anterior*, the *extensor digitorum longus*, the *peronæus tertius*, and the *extensor hallucis longus*. The external group is formed by the *peronæus longus* and *brevis*.

The muscles of the foot may be divided into the muscles of the dorsum and the muscles of the sole (plantar muscles). The muscles of the dorsum are the *extensor digitorum brevis* and the *extensor hallucis brevis*. The muscles of the sole are composed of a median group, the *flexor digitorum brevis* and the *quadratus plantæ*: of a group passing to the great toe, the *abductor hallucis*, the *flexor hallucis brevis*, and the *adductor hallucis*: and of a group passing to the little toe, the *abductor digiti V*, the *flexor brevis digiti V*, and the *opponens digiti V*. The *lumbricales* and the *interossei* are also situated in the sole of the foot.

THE MUSCLES OF THE HIP.

THE INTERNAL MUSCLES OF THE HIP, THE ILIOPSOAS.

The **iliopsoas** (Figs. 252, 296, 297, 299, and 300) is composed of the *psaos major* and the *iliacus*, which are completely separated in the upper portion of their course but united at their insertion. This muscle frequently also includes a *psaos minor*.

The **psaos major** is a long, strong muscle, the greater portion of which is situated in the posterior abdominal wall. It arises from the upper and lower margins of the bodies of the twelfth thoracic to the fourth lumbar vertebrae, from the intervertebral fibrocartilages, and from the tendinous arches which pass over the concavities of the middle of the bodies of the lumbar vertebrae and the lumbar vessels. A second series of origins comes from the transverse processes of all of the lumbar vertebrae, but is concealed by the fibers proceeding from the vertebral bodies, and the nerves forming the lumbar plexus pass between the two origins of the muscle.

The muscle is flat above but becomes narrower and thicker as it passes downward and outward over the terminal line of the pelvis and beneath the inguinal ligament to unite with the iliacus.

It lies upon the lateral surfaces of the upper and middle portions of the lumbar vertebral column and its upper portion is bridged over by the internal lumbo-costal arch of the diaphragm. The outer margin of the muscle is in relation above with the quadratus lumborum, which it partly conceals, and below with the inner margin of the iliacus. The inner margins of the two *psaos major* muscles form the lateral boundaries of the pelvic inlet.

The **iliacus** is a flat, thick, strong muscle which fills the entire iliac fossa. It arises from the iliac fossa, extending upward to the crest of the ilium and forward to the anterior superior and inferior spines, and passes downward and forward behind the inguinal ligament and fuses with the *psaos major*.

The combined iliopsoas passes beneath Poupart's ligament through the muscular lacuna (see page 231) into the thigh, where it is placed between the rectus femoris and the pectineus and forms a deep fossa with the latter muscle, the *iliopectineal fossa*. It runs directly over the capsular ligament of the hip-joint, passes slightly backward, and is inserted by a short tendon into the lesser trochanter. Where the muscle runs over the iliofemoral ligament of the hip-

joint there is a bursa which not infrequently communicates with the articular cavity, the *iliopectineal bursa* (Fig. 208).

A *psoas minor* (Fig. 238) is present in somewhat more than half of all cases. It is a flat thin muscle, lying upon the psoas major and arising from the body of the last thoracic or the first lumbar vertebra and from the intervertebral disc between the two. The muscle soon passes into a flat tendon which becomes continuous with the iliac fascia covering the iliopsoas (see page 231) and is inserted with this fascia in the region of the iliopectineal eminence.

The iliopsoas is supplied from the lumbar plexus. It flexes the thigh and also rotates it slightly inward. The psoas minor is a tensor of the iliac fascia.

THE GLUTEAL MUSCLES.

The **glutæus maximus** (Figs. 203 and 204) is a large strong muscle, particularly thick* in its lower portion, and is situated in the gluteal region immediately beneath the skin. It is covered by a thin layer of fascia and by the layer of subcutaneous fat which is very well developed in this situation.

The muscle arises from the external surface of the ilium (Fig. 203) between the posterior gluteal line and the posterior portion of the iliac crest, from the posterior surface of the sacrum and coccyx (and from the posterior sacroiliac ligament in this situation), and from the sacro-tuberous ligament. Its fibers pass from above downward and from within outward. The fasciculi are unusually thick and distinctly separated from each other by penetrating septa of fascia and fat; the lower (inner) fasciculi are the longest, and this portion of the muscle is twice as thick as the upper (outer) segment.

The superficial fibers of the muscle, especially those of the upper weaker half, pass over the greater trochanter to the iliotibial band of the fascia lata (see page 232); the deeper fibers, particularly the longer inferior ones, are inserted into the gluteal tuberosity.

The inner and upper margin of the glutæus maximus is in relation with the posterior layer of the lumbodorsal fascia, where this structure gives origin to the latissimus; the antero-external portion is in relation with the glutæus medius and the gluteal fascia, which envelops the latter muscle. It runs over the tuberosity of the ischium and the origins of the flexor group of muscles (see page 218), these latter making their appearance beneath the fascia below the inner and lower

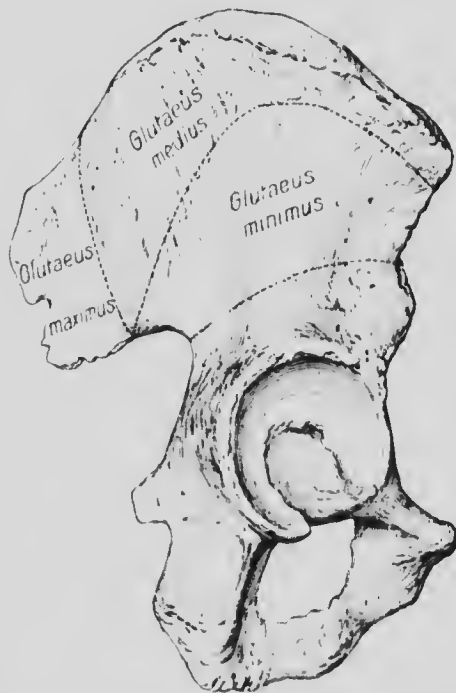


FIG. 203. The origins of the three glutei upon the dorsum of the ilium. The gluteal lines are represented by the dotted lines.

*The glutæus maximus is one of the thickest muscles in the human body.

FIG. 204.—Superficial layer of the posterior muscles of the hip.

The portion of the superficial layer of the fascia lata which covers the tensor fasciæ latae has been removed. * = position of greater trochanter.

FIG. 205.—Middle layer of the posterior muscles of the thigh.

The gluteus maximus has been divided and reflected.

margin of the gluteus maximus. The insertion conceals the tendinous origin of the vastus lateralis from the trochanter major. The tendon of insertion is separated from the great trochanter by a large bursa, the *trochanteric bursa* (Fig. 205), beneath which there is usually one or two additional bursæ, the *gluteofemoral bursa* or *bursæ* (Fig. 205). About half of the gluteus medius, the piriformis, the obturator internus and gemelli, the vastus femoris, and the adductor minimus are covered by the gluteus maximus.

The gluteus maximus is supplied by the inferior gluteal nerve. It extends the thigh and is the antagonist of the iliopsoas.

The **gluteus medius** (Figs. 203, 205) is also a strong, flat, thick muscle, part of which is concealed by the gluteus maximus, the remainder of it (Fig. 204) being situated in the upper gluteal region directly beneath the gluteal fascia, to which it is adherent. It arises from the outer surface of the ilium (Fig. 203), in the area between the anterior gluteal line, the iliac crest, and the posterior gluteal line, and from the gluteal fascia. The fibers of the muscle converge toward the greater trochanter, the posterior fasciculi being more or less independent and passing obliquely downward and outward, the middle fibers running directly downward and the anterior ones downward and inward. The short and broad tendon of insertion is attached to the outer portion of the greater trochanter (Fig. 205), extending upward as far as the tip of this process.

While the greater portion of the gluteus medius is covered by the gluteus maximus, it in turn completely conceals the gluteus minimus, and its posterior margin is usually in immediate relation with the upper margin of the piriformis. Beneath its insertion there is usually situated a bursa, the *posterior bursa of the gluteus medius* (Fig. 301).

The muscle is supplied by the superior gluteal nerve. It abducts the thigh; the larger anterior portion also acts as an internal rotator, the posterior portion (frequently characterized by a species of intermediate tendon and by a different direction of its fibers) also as an external rotator.

The **gluteus minimus** (Figs. 203, 301, and 302) is a flat, broad, fan-like muscle which lies upon the outer surface of the ala of the ilium and the postero-superior aspect of the articular capsule of the hip joint. It arises from the posterior surface of the ilium between the anterior and inferior gluteal lines (Fig. 203), and the fibers converge from all sides toward the greater trochanter. In the middle of its course the muscle develops a broad aponeurosis which passes directly into a short broad tendon. The insertion is into the tip and inner border of the great trochanter.

The gluteus minimus, like the medius, is supplied by the superior gluteal nerve. It also has a similar function (abduction).

The **piriformis** (Figs. 205, 208, and 300 to 302) is a decidedly conical muscle which is usually in immediate relation with the posterior border of the gluteus medius. Its insertion is

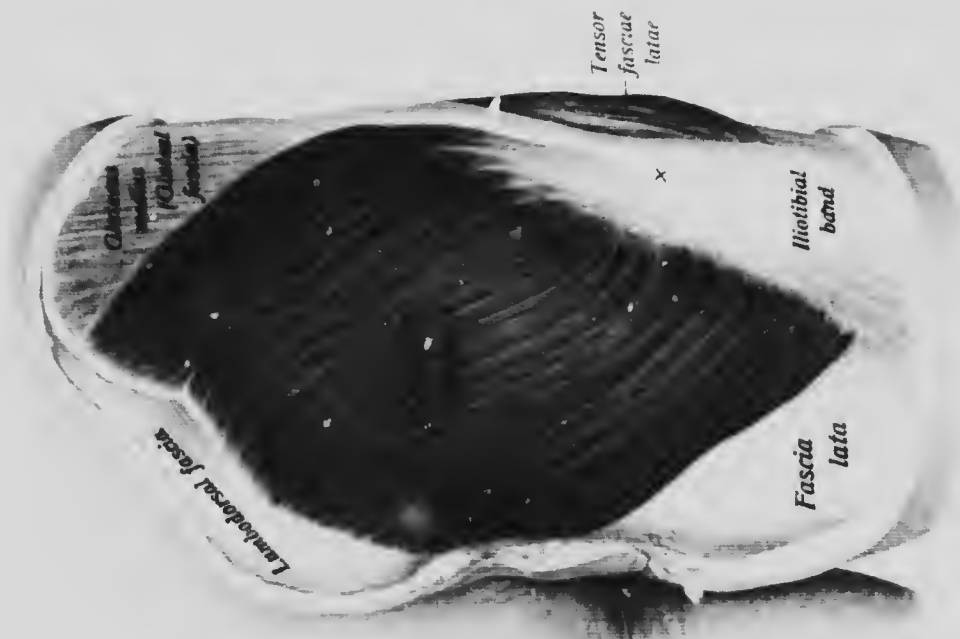


Fig. 204.

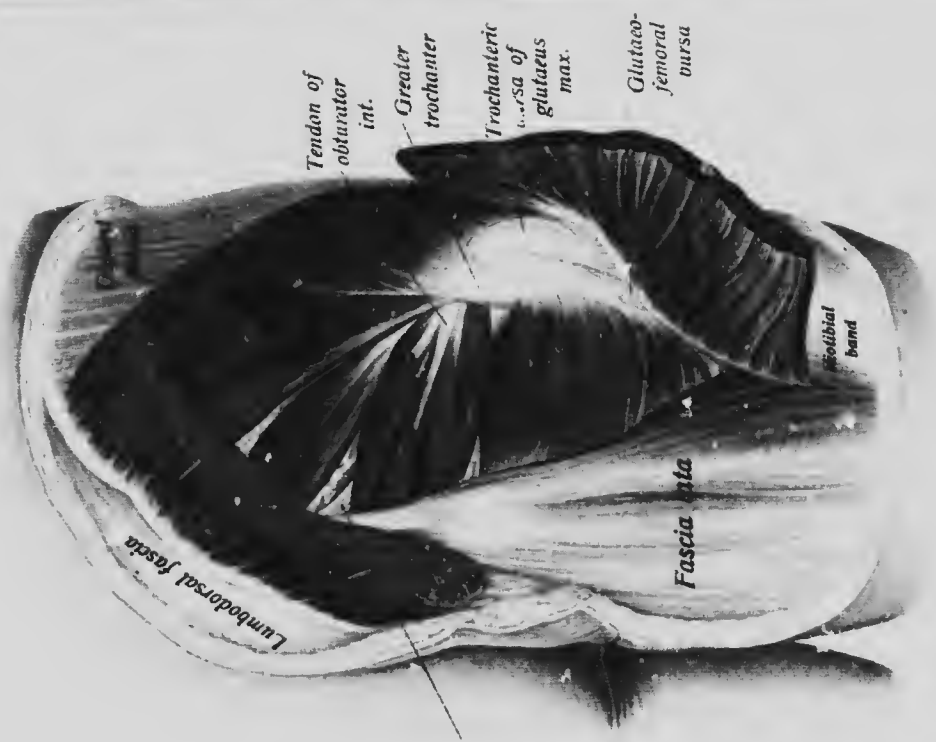


Fig. 205.



covered by the *glutæus medius* and *minimus*, the middle or main portion of the muscle is directly beneath the *glutæus maximus*, and the origin is situated within the pelvic cavity. It arises from the pelvic surface of the sacrum at the margins of the anterior sacral foramina II to IV (frequently also from between the foramina or concealing them), and from the margin of the greater sciatic notch. After leaving its flat and broad origin, the muscle becomes somewhat narrower, passes through the middle of the greater sciatic foramen, beneath the *glutæus maximus* becomes tendinous rather abruptly, and is inserted by a slender rounded tendon into the tip of the greater trochanter.

The *piriformis* does not fill the greater sciatic foramen but divides it into two compartments which transmit both vessels and nerves, the sciatic nerve being one of several structures which leave the pelvic cavity through the lower compartment.

The *piriformis* is usually supplied by direct branches from the sciatic plexus. It is an external rotator. It is sometimes perforated by a portion of the sciatic nerve.

The **obturator internus** (Figs. 295 and 300 to 302), like the *piriformis*, arises in the true pelvis, but it passes to the gluteal region through the lesser sciatic foramen. The muscle arises from the obturator membrane and the adjacent surfaces of the pubis and ischium and, to a certain extent, from the obturator fascia. It is very broad at its origin, but becomes markedly narrower as its fibers converge toward the lesser sciatic foramen, in passing through which the muscle bends at almost a right angle around the margin of the lesser sacrosciatic notch, the surface directed toward the bone being tendinous, and reaches the gluteal region, where it soon terminates in a slightly flattened tendon which passes directly to the trochanteric fossa, where it is inserted.

After passing through the lesser sciatic foramen and reaching the posterior surface of the pelvis, the muscle receives two accessory heads in the form of the slender *gemelli*. The *gemellus superior* arises from the spine of the ischium, the *gemellus inferior* from the ischial tuberosity. They are inserted into the tendon of the obturator internus almost throughout their entire length, so that they together with the tendon form a kind of penniform muscle. Where the obturator internus bends about the margin of the lesser sciatic notch there is constantly situated a bursa, the *bursa of the obturator internus*, and upon the muscle lies the thick sciatic nerve.

The obturator internus, together with the *gemelli*, is usually supplied by direct branches from the sacral plexus. Like the *piriformis*, it is an external rotator of the thigh.

The **quadratus femoris** (Figs. 295 and 301) is a flat, thick, rectangular muscle situated in front of the *glutæus maximus*. It arises from the outer border of the tuberosity of the ischium and inserts by a short tendon into the intertrochanteric ridge. The upper margin of the muscle is in immediate relation with the *gemellus inferior*, and the lower margin with the *adductor minimus*. Usually beneath the *quadratus*, or in the groove between it and the *gemellus inferior*, runs the obturator externus, upon which lies the sciatic nerve.

The quadratus femoris is supplied by the sciatic nerve. It is an external rotator of the thigh.

The **tensor fasciæ latæ** (Figs. 294 and 296) is a flat elongated muscle, narrow above and broad below, which is situated between the two layers of the fascia lata (see page 232) in the upper gluteal, trochanteric, and external femoral regions. It arises by a short and flat tendon from

FIG. 296.—The superficial layer of muscles of the anterior surface of the thigh.

FIG. 297.—The muscles of the anterior surface of the thigh after removal of the sartorius.
The inguinal ligament has also been removed.

the anterior superior iliac spine, and at the junction of the upper and middle thirds of the thigh becomes distinctly broader and is continuous with the iliotibial band (tract of Maissiat) of the outer side of the fascia lata. Anteriorly the muscle is in immediate relation with the sartorius, posteriorly with the glutæus medius, and it partly covers the vastus lateralis.

The muscle is supplied by the superior gluteal nerve and serves to increase the tension of the fascia lata.

THE MUSCLES OF THE THIGH.

THE SARTORIUS.

The **sartorius** (Fig. 296) is a very long, flat, narrow muscle running diagonally across the anterior surface of the thigh, and is the longest muscle of the body.* It arises from the anterior superior spine of the ilium in common with the tensor fasciæ latæ but in front of the latter muscle, becomes considerably broader for a short distance after its origin, passes inward and downward below the iliopsoas and upon the upper portion of the rectus femoris, covers the groove between the vastus medialis and the adductors in the middle third of the thigh (see page 217), and reaches the lower portion of the internal femoral region. In this situation it gradually becomes narrower and is twisted so that the surface which was anterior in the upper portion of the thigh now becomes internal. It then takes up a position beside the outer (anterior) margin of the gracilis and becomes tendinous as it passes over the inner aspect of the articular capsule of the knee-joint, and its flattened tendon runs above that of the gracilis to be inserted into the inner border of the tuberosity of the tibia, being separated from the bone by the sartorial bursa. The tendon of insertion forms the uppermost of the group of tendons known as the *pes anserinus* (see page 219).

The sartorius is supplied by the femoral nerve. It aids in the flexion of the thigh and the extension of the lower leg and acts as an internal rotator when the knee-joint is flexed.

THE MUSCLES OF THE ANTERIOR SURFACE.

The **quadriceps femoris** (Figs. 296 to 298, 301, and 302) consists of four different heads, the most independent of which, the *rectus femoris*, unites with the remainder only in the lower portion of its course. This head passes over two articulations, while the remaining three are intimately adherent with each other and extend over the knee-joint only.

The **rectus femoris** (Figs. 296 to 298) is a long, thick, decidedly spindle-shaped muscle, which is situated in the anterior femoral region, lying for the most part immediately beneath the deep fascia. It arises by a short, strong, bifurcated tendon (Fig. 298), one part of which comes from the anterior inferior spine of the ilium and pursues the same direction as that of the muscle

*The sartorius also possesses the longest muscular fasciculi in the body.

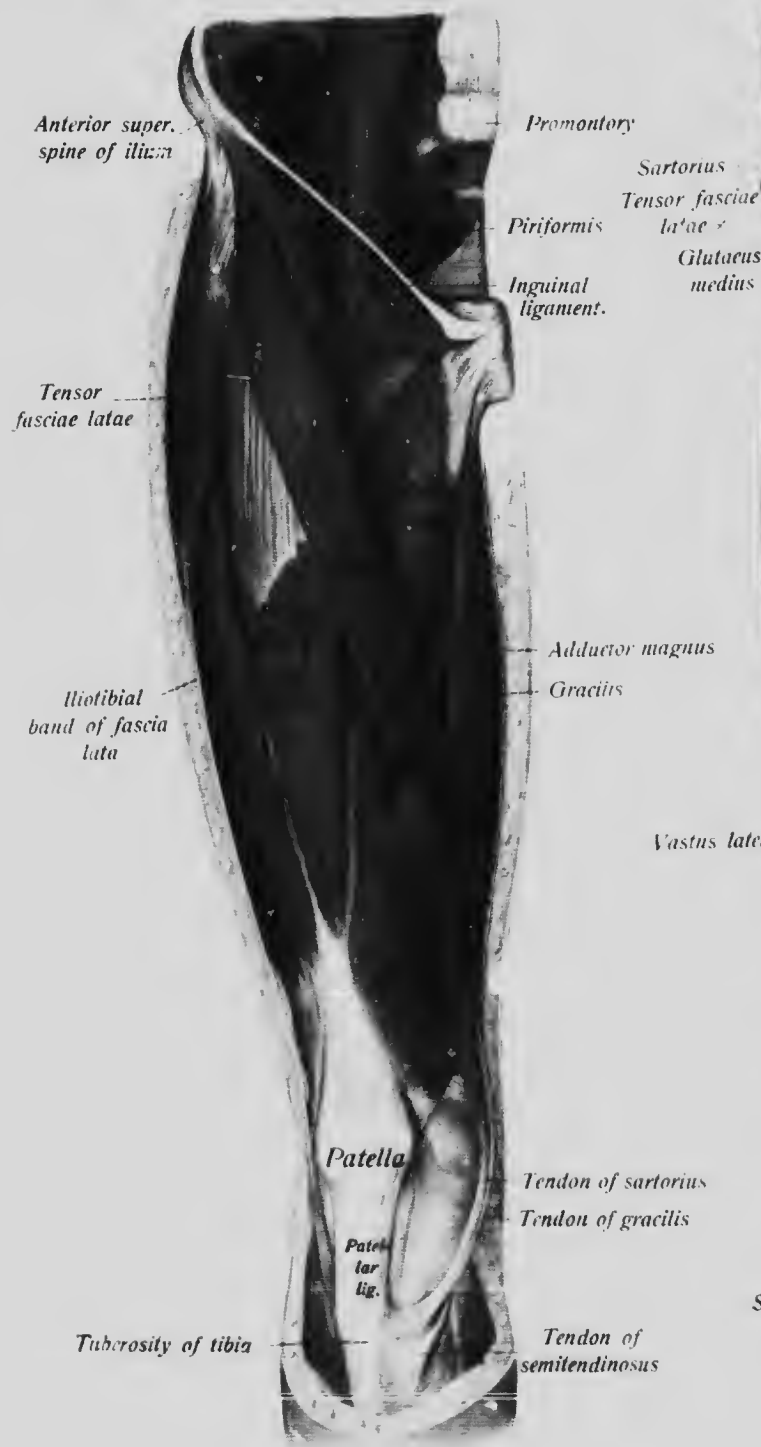


Fig. 296.

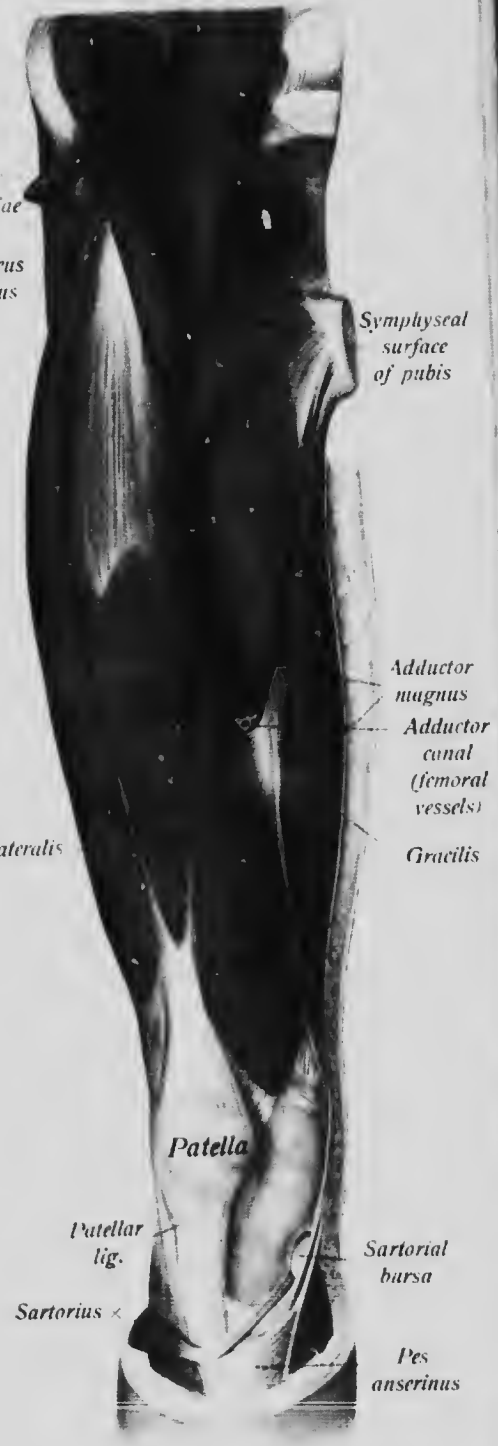

Fig. 297.

[The main body of the page is mostly blank or contains extremely faint, illegible text.]

[The left margin contains faint, illegible text, likely bleed-through from the reverse side of the page.]

itself, while the other proceeds from the upper margin of the acetabulum and joins the origin from the anterior inferior spine at a right or obtuse angle, the two together being continued downward as an aponeurosis upon the anterior surface of the muscle. The fibers of the muscle do not run longitudinally, but diverge downward and backward toward the insertion from a tendinous strip in the middle of the muscle. The flat tendon of insertion commences upon the anterior aspect of the muscular belly a few centimeters above the patella and unites with the remaining heads to pass to the upper margin of this bone.

The **vastus medialis** (*internus*) (Figs. 296 to 298) is a large, flat, thick muscle situated the anterior and internal femoral regions. Its origin is from the inner lip of the linea aspera of the femur where it is adherent to the insertions of the adductors. Its fibers run downward and forward, some of them being inserted into the upper margin of the patella with the common tendon and some of them passing independently to the inner margin of this bone. The greater portion of the muscle is situated in the lower third of the femur; its outer margin is fused with the vastus intermedius.

The **vastus lateralis** (*externus*) (Figs. 296 to 298, 301, and 302) is an unusually strong, large, flat muscle, which forms the chief bulk of the musculature of the external femoral region. It is stronger than the medialis and does not extend as far downward as this muscle, being situated chiefly in the upper and middle thirds of the thigh. It arises from the outer lip of the linea aspera as far upward as the great trochanter and to a certain extent from the outer portion of the latter prominence, and its fibers run quite obliquely from behind forward and from above downward, the direction of the upper fasciculi approaching the vertical.

The entire external surface of the muscle is covered by a broad aponeurosis; its inner margin conceals the greater portion of the vastus intermedius, with which it is inseparably connected, and it is inserted by means of the common tendon into the upper and outer margins of the patella.

The **vastus intermedius** (*crureus*) (Fig. 298) is a flat muscle, the anterior surface of which is tendinous and distinctly excavated to accommodate the overlying rectus femoris. It is the least independent of all the heads of the quadriceps, since its lateral margins are inseparably connected with the other two vasti. It arises from almost the entire length of the anterior surface of the shaft of the femur, and its fibers pass from behind downward and forward into the anterior tendinous surface of the muscle and subsequently into the common tendon of the quadriceps. The lower fasciculi of the vastus intermedius pass to the joint and are known as the *m. articularis genu* (*subcrureus*).

The common tendon of insertion of the four heads of the quadriceps arises immediately above the patella by the union of the tendon of the rectus with those of the vasti. It embraces the entire upper and the lateral margins of the patella, the latter structure simply serving as a sesamoid bone for the tendon which is continued to the tuberosity of the tibia as the patellar ligament (see page 135). The actual point of insertion of the quadriceps is consequently this roughened process of the tibia.

The quadriceps is supplied by the femoral nerve. In extending the leg it elevates the patella

FIG. 298.—The deep layer of muscles of the anterior surface of the thigh. The iliopsoas, sartorius, rectus femoris, pectineus, adductor longus, and gracilis have been removed.

FIG. 299.—The insertion of the iliopsoas and the origin of the obturator externus. The adductors have been divided and reflected; the femur has been sawed through below the trochanters, and is slightly flexed and rotated outward.

FIG. 300.—The origins of the piriformis and the obturator internus. The pelvis has been divided in the median line.

THE INTERNAL OR ADDUCTOR GROUP.

The muscles of this group arise from the pubis and ischium in such a way that they form a series of rings about the obturator foramen. The outermost ring is formed by the *obturator externus*, the middle by the *adductor brevis* and *minimus*, and the inner by the *pectineus*, the *adductor longus*, the *gracilis*, and the *adductor magnus*.

The **pectineus** (Figs. 296 and 297) is a flat, strong, quadrangular muscle situated between the iliopsoas and the adductor longus in the subinguinal and anterior femoral regions, and forming, together with the iliopsoas, the ilipectineal fossa. It arises from the crest of the pubis as far forward as the pubic tubercle, passes obliquely from above downward and from within outward, and is inserted by a short tendon into the pectineal line of the femur. The insertion is partly concealed by the iliopsoas, covers the obturator externus and the upper part of the adductor brevis, and passes over the inner surface of the articular capsule of the hip-joint.

The pectineus adducts the thigh and also assists flexion. It is supplied by the obturator and femoral nerves.

The **adductor longus** (Figs. 296 and 297) is a thick, flat, almost triangular muscle, situated between the pectineus and the gracilis. It arises by a rather narrow but short and strong tendon from the superior pubic ramus, between the origins of the pectineus and gracilis, becomes decidedly broader as it passes downward, and is inserted by a short tendon into the middle third of the inner lip of the linea aspera. The fibers of the muscle pursue a direction similar to those of the pectineus, although they run more directly downward. If the muscle is well developed its upper margin is immediately continuous with the lower margin of the pectineus, and while it is situated between the pectineus and the gracilis above, its lower portion lies upon the adductor magnus, which is exposed between the adductor longus and the gracilis. The upper portion of the adductor longus covers the adductor brevis, the lower the adductor magnus, its tendon of insertion is concealed by the sartorius and is adherent to the cagnis of the vastus medialis (see page 215), and, together with the sartorius and the inguinal ligament, the muscle forms a triangle, the *femoral triangle* (triangle of Scarpa).

The adductor longus is supplied by the obturator nerve; it adducts the thigh.

The **gracilis** (Fig. 297) is a long, thin, slender muscle, situated upon the inner aspect of the thigh. It arises by a flat tendon from the superior and inferior rami of the pubis near the symphysis, becomes somewhat broader at first, but soon narrows and, just above the knee joint, passes into a long, round, slender tendon which runs to the inner border of the tubercle of the tibia and radiates into the *pes anserinus* as the second tendon of that structure.

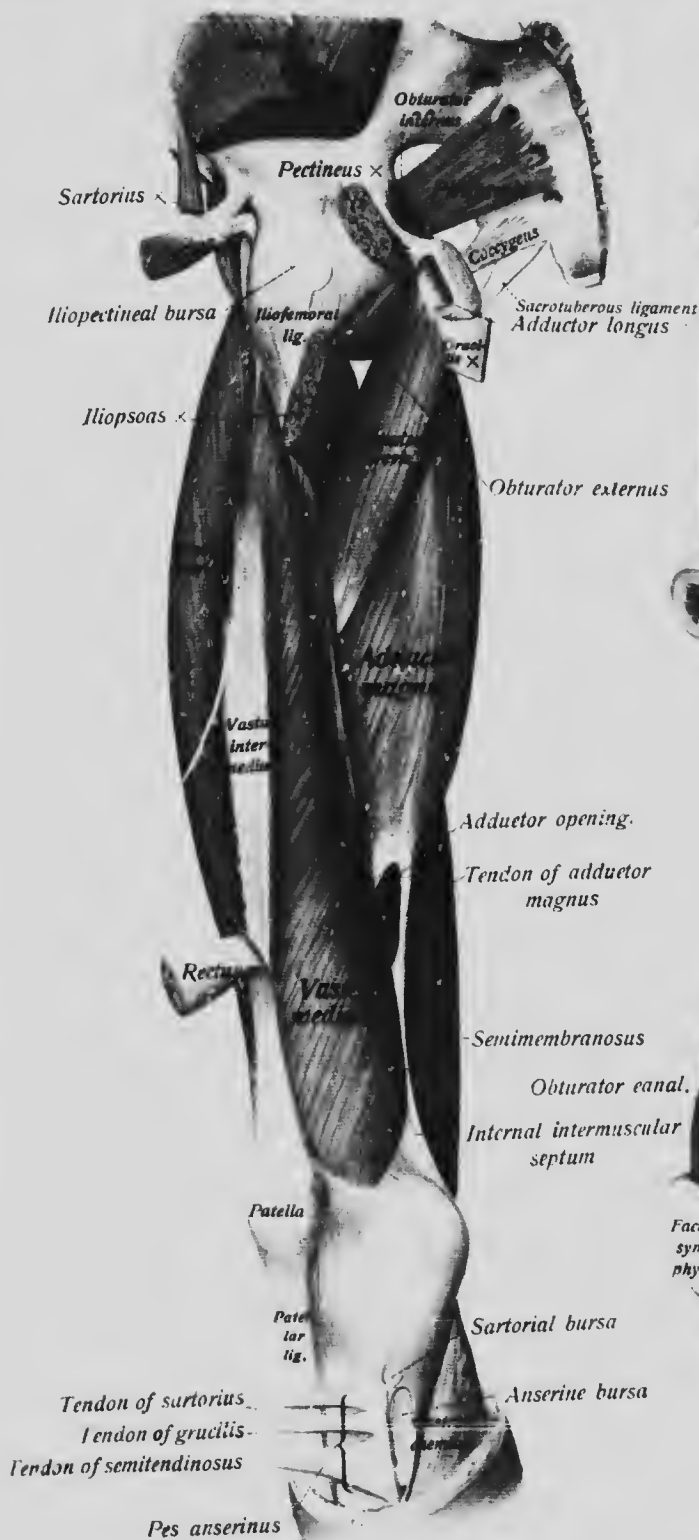


Fig. 298.

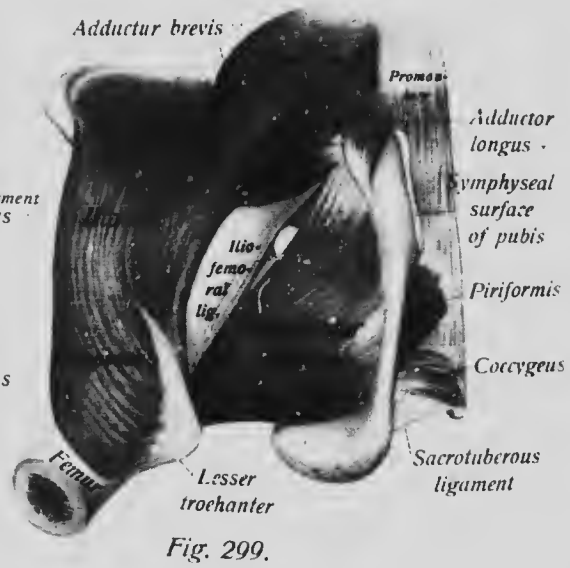


Fig. 299.

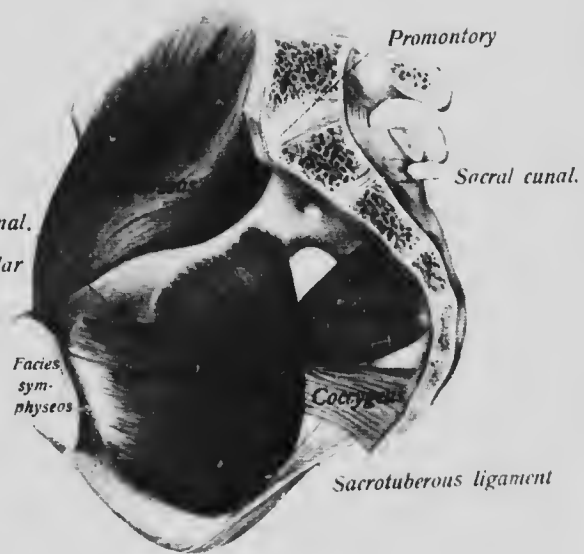


Fig. 300.



The muscle is supplied by the obturator nerve. When the knee is extended, it adducts the thigh and assists in the flexion of the knee-joint, and, when the knee is flexed, rotates the leg inward.

The **adductor brevis** (Fig. 298) is a long, broad, rather thick muscle which is situated in the middle layer of the adductors (behind the pectineus and adductor longus, but in front of the adductor magnus). It is longer than the pectineus, shorter than the adductor longus, and is usually completely concealed by these two muscles. It arises from the superior ramus of the pubis, nearer the obturator foramen than the adductor longus, and its fibers pursue a course similar to those of the latter muscle, but not so oblique, to the upper third of the inner lip of the linea aspera of the femur.

The nerve-supply and the function are those of the adductor longus.

The **adductor magnus** (Figs. 296 to 298, 301, and 302) is the strongest of the adductors. It forms the deepest layer and is situated most posteriorly, arising from the inferior pubic ramus and from the lower border of the tuberosity of the ischium. Its upper fibers pass but slightly downward, the middle are more oblique, and the lower and innermost fibers pursue in almost vertical direction: the upper and middle fibers pass behind the adductor longus and brevis to a muscular or short tendinous insertion into the upper two thirds of the inner lip of the linea aspera; the lower, almost vertical fibers, however, pass into a round slender tendon which runs to the lowest portion of the linea aspera and to the internal epicondyle of the femur. At about the lower third of the thigh this insertion contains an elongated orifice, known as the *tendinous adductor opening* (Fig. 298), which has tendinous boundaries and gives passage to the femoral vessels.

Between the tendinous origin of the vastus medialis and the short tendinous insertions of the adductor brevis, longus, and magnus, there is a deep groove which is converted into a canal, the *adductor (Hunter's) canal*, by the sartorius. It contains the femoral vessels, and the tendinous fibers of both groups of muscles are interwoven in this situation to form a fibrous vascular sheath.

While the greater portion of the anterior surface of the adductor magnus is covered by the adductor longus and brevis, its posterior surface lies upon the flexor muscles, and it is consequently situated between these two sets of muscles. The sciatic nerve lies upon its posterior surface.

The **adductor minimus** (Figs. 297, 301, 302) is a small, flat, approximately quadrangular muscle, which frequently appears to be simply the upper portion of the adductor magnus, with which it is always directly continuous. It arises from the inferior pubic ramus or from the junction of the inferior rami of the pubis and ischium, its upper fibers being almost horizontal, and running below (distal) and parallel to the quadratus femoris (covering in the uppermost fibers of the adductor magnus from behind) to be inserted into the upper end of the femur below the great trochanter and beside the gluteal tuberosity. Its lower fibers run obliquely downward and are inserted, together with those of the adductor magnus, into the upper extremity of the inner lip of the linea aspera. The sciatic nerve lies also upon the adductor minimus (see p. 215).

The adductor magnus and minimus are chiefly supplied by the obturator nerve and partly also by the sciatic nerve. Their action is similar to that of the other adductors.

The **obturator externus** (Figs. 298 and 299) belongs to the adductor group only on account

FIG. 301.—The deep layer of the posterior hip muscles and the superficial layer of the flexors of the thigh region.
The gluteus maximus and medius and the obturator internus have been removed.

FIG. 302.—The deep layer of the posterior hip muscles and the deep layer of the flexors of the thigh region.
The gluteus maximus and medius, the quadratus femoris, the long head of the biceps, and the semitendinosus have been removed.

of its position and innervation. It is situated upon the outer and lower surface of the pubis and ischium and is completely covered by the pectineus, the adductor longus, and the adductor brevis. Like the obturator internus within the pelvis, it arises from the pubis, from the ischium, and from the obturator membrane. It becomes narrower and thicker, runs over the lesser trochanter, and passes over and behind the insertion of the iliopsoas, along the neck of the femur between the gemellus inferior and quadratus femoris, largely covered by the latter muscle, to the trochanteric fossa, where it is inserted beside the obturator internus. The muscle becomes tendinous a short distance before its insertion.

The obturator externus is supplied by the obturator nerve. It acts as an external rotator.

THE POSTERIOR GROUP, THE FLEXORS.

This group consists of but three muscles, the *biceps femoris*, the *semitendinosus*, and the *semimembranosus*, which have a more or less common origin from the ischial tuberosity; as they pass toward the knee they are grouped in such a way that the biceps is external and the semitendinosus and semimembranosus internal. The three muscles lie in the posterior femoral region and their origins are concealed by the gluteus maximus.

The **biceps femoris** (Figs. 301, 302) is a large, strong muscle which is composed of a long biarticular and of a short monoarticular head and belly. The long head (Fig. 301) is a rather strong tendon which arises in intimate connection with the semitendinosus from the lower aspect of the tuberosity of the ischium. It passes downward and becomes continuous with a broad muscular belly, which at first lies behind the adductor magnus and then passes markedly outward to take up a position behind the vastus lateralis. At the lower third of the thigh it receives the second head or short head (Fig. 302), which is short and rhomboid, and arises from the lower half of the outer lip of the linea aspera.

At the junction of the two heads, or somewhat above it, the posterior surface of the long head possesses a distinct aponeurosis which is directly continuous with the tendon of insertion. The short head is muscular throughout its entire course.

The two heads unite just above the knee joint and the muscle is inserted by a tendon into the capitulum of the fibula. The inner margin of the biceps forms one of the boundaries of the popliteal fossa (see page 220).

The long head of the biceps is supplied by the tibial nerve, and the short head by the peroneal nerve.

The **semitendinosus** (Fig. 301) is muscular in its upper two thirds and tendinous in its lower third. At its origin from the tuberosity of the ischium it is completely adherent to the long



Fig. 301

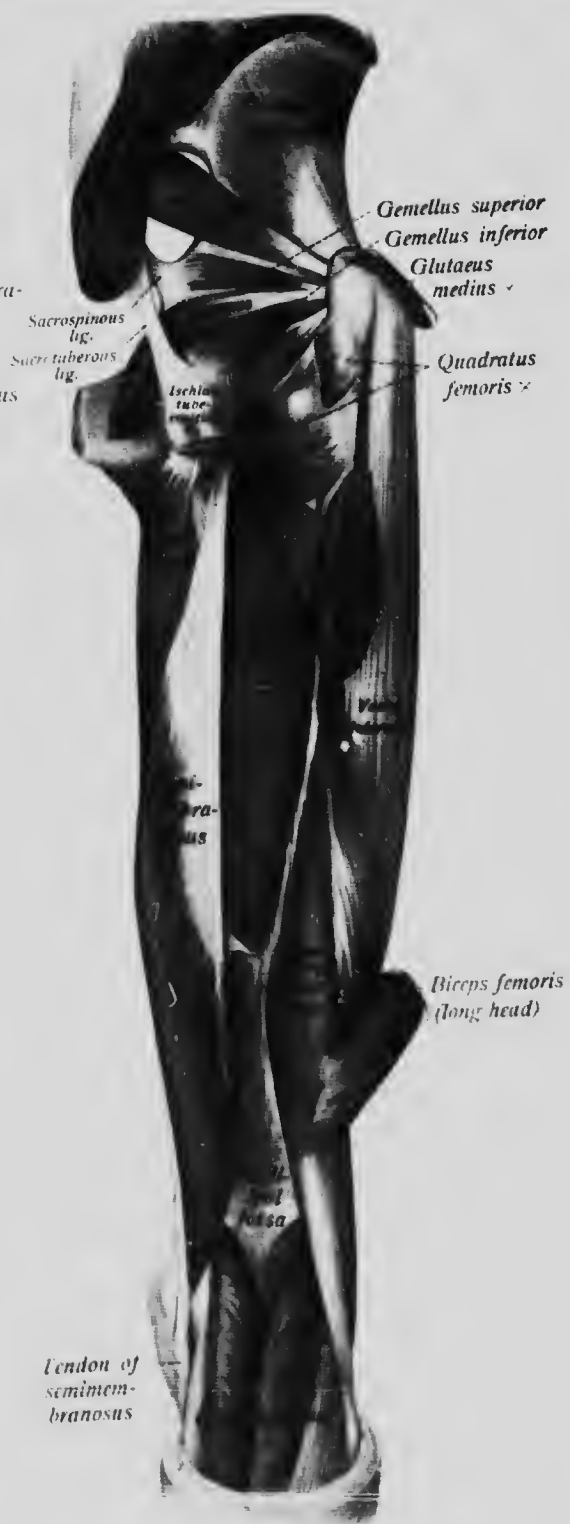

Fig. 302.

1
2

head of the biceps, although its tendon is somewhat shorter, and its muscle portion frequently exhibits a tendinous intersection. In the lower fourth of the thigh it passes into a cylindrical tendon which is inserted into the inner surface of the tubercle of the tibia and forms the lowermost tendon of the pes anserinus (Fig. 298).

The three tendinous expansions of the sartorius, gracilis, and semitendinosus forming the pes anserinus (Fig. 298) are peculiar in that they form fan-like radiations between which are situated thin membranes. The broad tendinous surface of the pes anserinus is separated from the bone by the *anserine bursa* (Fig. 298). In addition to its attachment to the tibia, the pes anserinus is also intimately connected with the crural fascia.

The semitendinosus is supplied by the tibial nerve. It flexes the leg and rotates it inward.

The **semimembranosus** (Fig. 302) is a very peculiar muscle. Its upper third or half consists of a flat membranous tendon, then follows a flat but very thick muscular belly, which finally terminates at its insertion in a flattened round tendon. The muscle arises from the tuberosity of the ischium, in front of the long head of the biceps and the semitendinosus, by a flat tendon which lies between the posterior surface of the adductor magnus and the upper portion of the semitendinosus; upon the outer side it extends downward as far as the middle of the thigh, while it is somewhat shorter upon its inner aspect. From this tendon are given off muscular fasciculi which pass from above downward and from without inward, and become continuous with a more rounded tendon situated upon the inner side of the muscle and commencing at the middle of the thigh. This tendon of insertion passes to the internal tubercle of the tibia, a small portion radiates into the oblique popliteal ligament (see page 135), and some fibers also run anteriorly to the inner margin of the tibia. Beneath the tendon of the semimembranosus there is situated a bursa which communicates with the knee-joint, the *bursa of the semimembranosus* (see page 136).

While the upper portion of the semimembranosus is situated in front of the semitendinosus and the long head of the biceps, in the lower third of the thigh, the muscle lies internal to the biceps, together with which it forms the upper boundary of the popliteal fossa (see below).

The nerve-supply and the function of the semimembranosus are similar to those of the semitendinosus, and it also acts as a tensor of the capsular ligament of the knee joint.

THE MUSCLES OF THE LEG.

THE MUSCLES OF THE POSTERIOR SURFACE. THE CALF MUSCLES.

The muscles of the posterior aspect of the leg (Figs. 303 to 305) are composed of two layers: a superficial layer formed by the *triceps suræ*, and a deeper layer, consisting of the *popliteus* above and of the *tibialis posterior*, *flexor hallucis longus*, and *flexor digitorum longus* below.

THE SUPERFICIAL LAYER, THE TRICEPS SURÆ.

The **triceps suræ** consists of a superficial biarticular and bicapital portion, the *gastrocnemius*, and of a deeper monarticular portion, the *soleus*.

The **gastrocnemius** (Fig. 303) is a flat, elongated, distinctly bicapital and very strong muscle,

FIG. 303.—The superficial muscles of the calf of the leg.

FIG. 304.—The second layer of the calf muscles. The gastrocnemius has been removed.

FIG. 305.—The deep musculature of the calf, seen from behind and from the inner side. The triceps suræ has been removed.

which is situated upon the posterior aspect of the knee and leg; its muscular belly is situated chiefly in the sural region, while its tendinous portion is located in the posterior crural region. The two heads, the *inner head* (*gastrocnemius medialis*) and the *outer head* (*gastrocnemius lateralis*), arise by tendons from the upper extremities of the epicondyles of the femur and exhibit aponeuroses upon their internal and external surfaces, extending downward almost to the middle of the muscle. Beneath the somewhat stronger inner head is situated a bursa which communicates with the interior of the knee-joint, the *inner gastrocnemial bursa* (Fig. 304) (see also page 136). Both heads of the muscle pass immediately over the posterior surface of the knee-joint forming the inferior boundary of the popliteal fossa, and below the articulation they become broader and are united in such a manner that their line of union is indicated by a median groove which extends almost to their insertion into the common tendon. Somewhat below the middle of the leg, the muscular tissue terminates rather suddenly in a broad tendon which becomes narrower and fuses with that of the soleus.

The **soleus** (Fig. 304) is a flat, very broad, and rather thick muscle, the upper portion of which is covered by the gastrocnemius, the lower portion being situated immediately beneath the deep fascia to either side of the gastrocnemius tendon. The muscle arises from the capitulum, posterior surface, and outer border of the fibula, from the popliteal line and the surface immediately below it upon the posterior surface of the tibia, and from a tendinous arch passing over the popliteal vessels between the tibia and fibula, the tendinous *arch of the soleus*. Shortly after its origin the muscle becomes broader, and exhibits upon its posterior aspect an aponeurosis which is continuous with a tendon which fuses with that of the gastrocnemius and also receives the insertions of lower lying lateral muscular fasciculi. This tendon of the triceps suræ, broad at first and becoming narrower and thicker as it passes downward, is known as the *calcaneal tendon* (*tendo Achillis*). It is the strongest tendon in the entire body and is inserted into the upper margin of the tuberosity of the calcaneus.

The triceps suræ also includes the **plantaris** (Fig. 304), a small muscle with a very short but rather strong belly and a very long slender tendon. It arises from the external epicondyle of the femur, to the inner side of and somewhat above the outer head of the gastrocnemius, which partly covers it, and the short muscular belly is directed obliquely outward and downward between the gastrocnemius and soleus. The slender tendon lies upon the inner side of the tendo Achillis, and fades away partly into this structure and partly into the deep fascia of the leg.

The triceps suræ is supplied by the tibial nerve. It produces plantar flexion of the foot. The plantaris acts as a tensor of the tendo Achillis.

THE POPLITEUS.

The **popliteus** (Figs. 304 and 305) is a flat triangular muscle which is in a class by itself. It is situated in the same layer as the soleus, with which it is directly related by its lower and outer



Fig. 303.




Fig. 304.

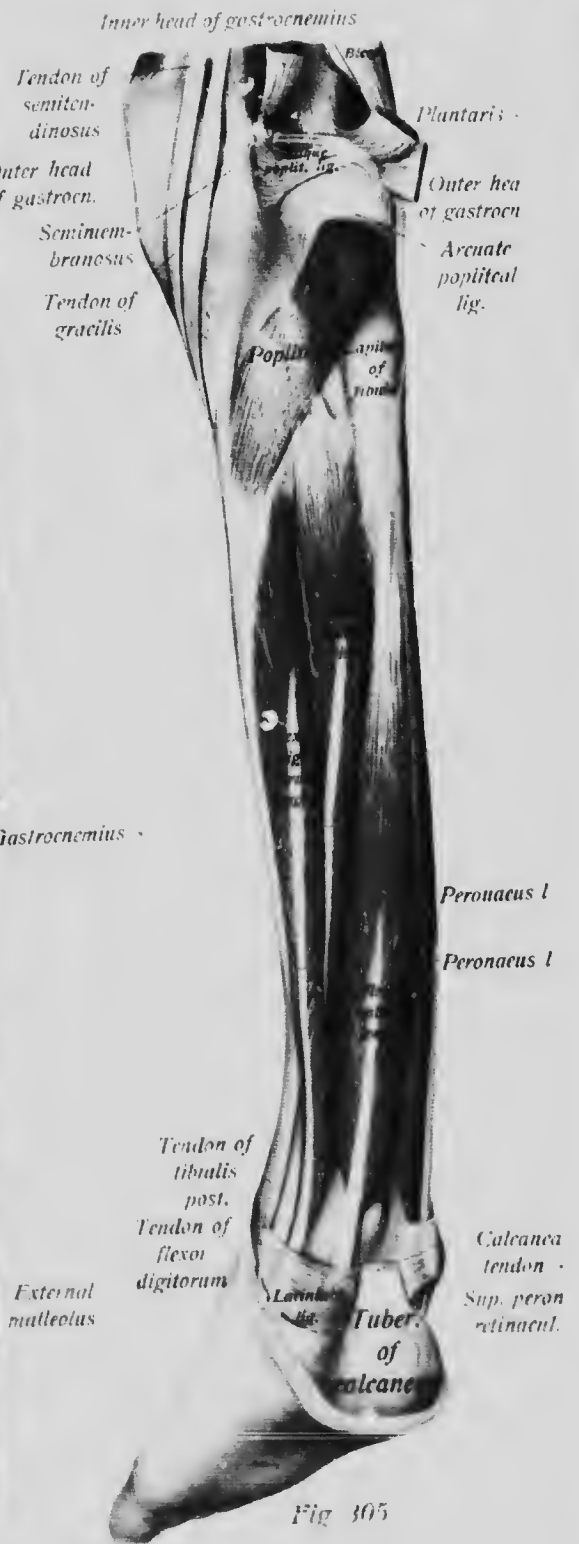



Fig. 305.



margin, and is covered by the gastrocnemius; it runs immediately over the posterior surface of the knee-joint. It arises (inserts) by a tendon from the external epicondyle of the femur and from the arcuate popliteal ligament and inserts (arises) in the triangular area above the popliteal line upon the posterior surface of the tibia. The lower portion of the muscle is covered by a fascia, aponeurotic in character, which also gives origin to muscular fibers. Beneath the tendon of origin (insertion) is situated the *popliteal bursa* (see page 136), which communicates with the knee-joint.

The popliteus is supplied by the tibial nerve. It acts as a tensor of the articular capsule of the knee-joint and helps to rotate the tibia inward (when the knee is flexed).

THE DEEP LAYER.

The muscles of this layer (Fig. 305) (the position of which has been previously described) have experienced a peculiar displacement with reference to those of the anterior group, since the tibialis posterior is pushed away from the tibia and situated in the middle, while the flexor digitorum lies against the tibia; the flexor hallucis consequently lies upon the fibula, and therefore to the outer and not to the inner side of the flexor digitorum, as might be expected. The correct relation is restored by a crossing of the muscles, that of the tibialis posterior occurring in the leg, while the tendons of the flexor hallucis and of the flexor digitorum do not cross until they reach the sole of the foot.

The **tibialis posterior** (Figs. 305 and 312) is a long, rather flat, distinctly penniform muscle (the lower portion is only semipenniform), which arises by a short tendon from the upper portion of the posterior surface of the tibia, from the interosseous membrane, and from the inner surface of the fibula beside the flexor digitorum, which frequently partly covers it. Immediately below this origin a very strong tendon appears in the middle of the muscle, verging gradually to its inner border, and passes behind the internal malleolus to the sole of the foot. The tendon is inserted chiefly into the tuberosity of the navicular bone (Fig. 312), some fasciculi being directly prolonged to the internal cuneiform and others radiating also to the remaining cuneiform bones and extending as far as the cuboid.

Above the malleolus, the tibialis posterior crosses beneath the flexor digitorum, so that its tendon assumes a position internal to that of the latter muscle. Behind the malleolus it is situated within a tendon-sheath in the *lacinate ligament* (see page 231).

The tibialis posterior is supplied by the tibial nerve. It produces plantar flexion of the foot and also elevates the inner margin of the sole (supination).

The **flexor digitorum longus** (Figs. 305 and 311) resembles the tibialis posterior in its external appearance. It is penniform above, semipenniform below, and lies at first upon the tibia and, in the lower fourth of the leg, between the tibialis posterior and the flexor hallucis, the former muscle being crossed by it at a slightly higher level. The muscle arises from the posterior surface and interosseous crest of the tibia, and its tendon, like that of the tibialis posterior, is developed upon the inner border of the muscle. This tendon is situated to the outer side of that of the tibialis posterior and runs beneath the lacinate ligament to the sole of the foot (Fig. 311), where it divides into four tendons for the outer four toes. These perforate the tendons of the flexor

FIG. 306.—The muscles of the anterior surface of the lower leg and of the dorsum of the foot. The transverse crural ligament has been removed.

FIG. 307.—The muscles of the lower leg and of the dorsum of the foot, seen from the side.

digitorum brevis and pass to the unguis phalanges. (Further details as to the relations of the tendons are given on page 231.)

The muscle is supplied by the tibial nerve and flexes the second to the fifth toes (especially the unguis phalanges).

The **flexor hallucis longus** (Figs. 305 and 311) resembles the other two muscles in this group, but it is somewhat shorter and stronger and, at the same time, distinctly penniform. It is the most external muscle of the group and preserves this relation throughout the leg. It arises by a short tendon from the posterior surface and outer border of the fibula, below the origin of the soleus, *i. e.*, from the lower two-thirds of the bone, extending downward to just above the malleolus. A thick tendon which is situated in the center of the broad muscle, commences in the middle of the leg and passes through the outer compartment of the lacinate ligament to the sole of the foot (Fig. 311), where it crosses the tendon of the flexor digitorum and runs to the unguis phalanx of the great toe and indirectly also to the other toes.

The muscle is supplied from the tibial nerve. It flexes the great toe and indirectly also the four lesser toes.

THE MUSCLES OF THE OUTER SIDE OF THE LEG, THE PERONÆI.

The posterior borders of both of these muscles are in relation with the soleus and with the deep flexor group, while their anterior margins are in relation with the muscles of the extensor group, from which they are separated in the lower third of the leg by the lower portion of the shaft of the fibula and the external malleolus. They are situated in the external crural region.

The **peronæus longus** (Figs. 306 and 307) is a very long, distinctly semipenniform muscle, which arises by indistinctly separated anterior and posterior heads. The anterior head is a short tendon from the head of the fibula, the contiguous portion of the external condyle of the tibia and the crural fascia; the posterior springs from the upper two-thirds of the outer surface and outer border of the fibula. At the junction of the middle and upper thirds of the leg, both heads pass into a slightly flattened tendon upon the anterior surface of the muscle, which broadens as it descends and passes beneath the *retinacula peronæorum* (Fig. 307) (see page 230) in the groove behind the external malleolus, to the outer side of the sole of the foot. Deep down in the sole the tendon lies in the groove of the cuboid (Figs. 311 and 312), is provided with a thick sesamoid cartilage or sesamoid bone, and passes to the tuberosity of the metatarsal bone of the great toe, some fibers being prolonged to the internal cuneiform and to the base of the second metatarsal bone.

The peronæus longus almost entirely conceals the origin of the peronæus brevis; in the lower part of the leg the latter may be seen both in front of and behind the margins of the peronæus longus or its tendon.

The peronæus longus is supplied from the peroneal nerve. It abducts the foot, assists in producing plantar flexion, and elevates the outer margin of the sole (pronation).

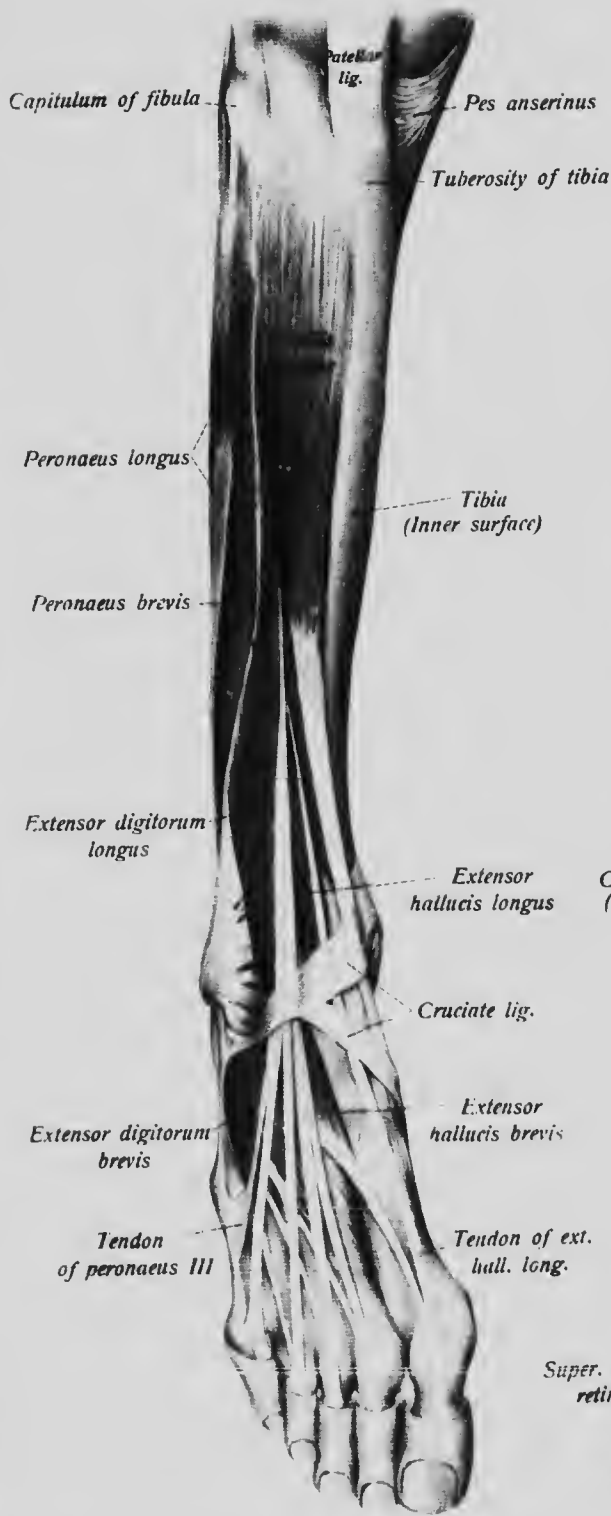



Fig. 306.



Fig. 307.



The **peronæus brevis** (Figs. 306, 308, and 315) is shorter than the longus, which it markedly resembles, and by which it is largely concealed. It arises from the outer surface and anterior border of the lower half of the fibula as far down as the upper margin of the external malleolus. The tendon commences in the middle of the upper portion of the muscle and then passes to the anterior margin in a similar manner to that of the peronæus longus; it is situated in front of the tendon of the peronæus longus, passing with it in the groove of the external malleolus and beneath the retinacula peronæorum (see page 230) to the tuberosity of the fifth metatarsal bone, which it embraces by a wide insertion (Fig. 315). Some fibers of the tendinous insertion are usually prolonged into the dorsal aponeurosis of the little toe.

The peronæus brevis is supplied also from the peroneal nerve. It abducts the foot and assists in the production of dorsal flexion and pronation.

THE ANTERIOR GROUP. THE EXTENSORS.

The outer margin of this group is in relation with the peronæi, but otherwise it is entirely isolated, since its inner margin is bounded by the inner surface of the tibia. The muscles of this group are situated in the anterior crural region.

The **tibialis anterior** (Figs. 306 and 316) is a long muscle which is broad above and narrow below. It is the strongest muscle of the group and arises from the outer surface of the tibia as far upward as the external condyle and from the interosseous membrane. The upper third of the muscle is markedly adherent to the deep fascia of the leg, and somewhat below the middle of the leg it develops a flat, broad tendon which becomes thicker and narrower as it descends. This tendon passes beneath the cruciate ligament (see page 229) to the dorsum of the foot, and upon reaching the inner margin, is inserted into the inner and plantar surfaces of the internal cuneiform bone and into the inner border of the base of the first metatarsal bone.

The muscle is supplied by the deep branch of the peroneal nerve. It effects dorsal flexion and elevation of the inner margin of the foot (supination).

The **extensor hallucis longus** (Figs. 306 and 316) is a rather weak semipenniform muscle lying to the outer side of the tibialis anterior and between it and the extensor digitorum. These two muscles, particularly the latter, conceal the greater portion of the origin of the extensor hallucis, which is from the inner surface of the lower two thirds of the fibula and from the adjacent portion of the interosseous membrane. Almost immediately after its origin, a tendon is formed which is situated in the anterior and inner portion of the muscle; it receives muscular fibers which are directed obliquely from above downward and from without inward and passes beneath the cruciate ligament to the dorsal surface of the great toe.

The muscle is supplied by the deep branch of the peroneal nerve. It extends the great toe.

The **extensor digitorum (communis) longus** (Figs. 306 and 315) is the outermost muscle of the group, and is stronger than the extensor hallucis, which it otherwise resembles. The upper portion of this muscle is narrow and arises from the upper end of the fibula between the peronæus longus and the tibialis anterior, but its greater portion arises from the anterior border of the fibula, extending downward to just above the malleolus, and from the interosseous mem-

FIG. 308.—The muscle of the dorsum of the foot. The compartments of the cruciate ligament have been opened and the tendons of the flexor digitorum longus are shown shortly before their insertions.

FIG. 309.—The plantar aponeurosis.

FIG. 310.—The superficial layer of the plantar muscles. The plantar fascia has been largely removed from the surface of the flexor digitorum brevis.

brane. The upper portion of the muscle is adherent to the origin of the tibialis anterior and to the deep fascia of the leg. The tendon is situated on the anterior margin of the muscle and receives the middle and inferior fibers, which pursue a course similar to those of the extensor hallucis. During its passage through the cruciate ligament or just above it, the tendon subdivides into four flat, rather weak tendons, which join to the dorsal aponeuroses of the second to the fifth toes.

The **peronæus tertius** (Figs. 306 and 315) seems to be a part of the extensor digitorum. It arises from those fibers of the lateral muscle which come from the lower portion of the tibia; its flat tendon runs beneath the cruciate ligament with those of the extensor digitorum, and is inserted by means of a continuous expansion into the dorsal surface of the first metatarsal bone.

The peronæus tertius, together with the peronæus secundus, assists in pronating the foot. Both muscles are supplied by the deep peroneal nerve.

THE MUSCLES OF THE FOOT.

THE MUSCLES OF THE DORSUM.

Upon the dorsal aspect of the foot, the dorsum of the foot is provided with two muscles.

The **extensor digitorum brevis** (Figs. 306, 308, and 315) is a small flat, triangular muscle which arises from the dorsal surface of the calcaneus, between the bases of the second, third, and fourth toes. It arises from the extensor digitorum longus, with which it is adherent, from the dorsal surface of the calcaneus, passes forward and inward, and in the region of the base of the first metatarsal bone becomes continuous with a flat narrow tendon which runs over the metatarsal tuberosity. In the region of the base of the first metatarsal bone, the two tendons together forming the dorsal aponeurosis of the foot.

The **extensor digitorum brevis** (Figs. 306, 308, and 315) arises together with the preceding muscle from the dorsal surface and the adjacent portion of the lateral surface of the calcaneus, and divides into three (rarely four) muscular bellies which terminate in very slender tendons to the second, third, and fourth toes, and fusing with the tendons of the extensor digitorum longus to form dorsal aponeuroses.

Both muscles upon the dorsum of the foot are supplied by the deep peroneal nerve. They extend the toes. A tendon for the little toe is rarely present.

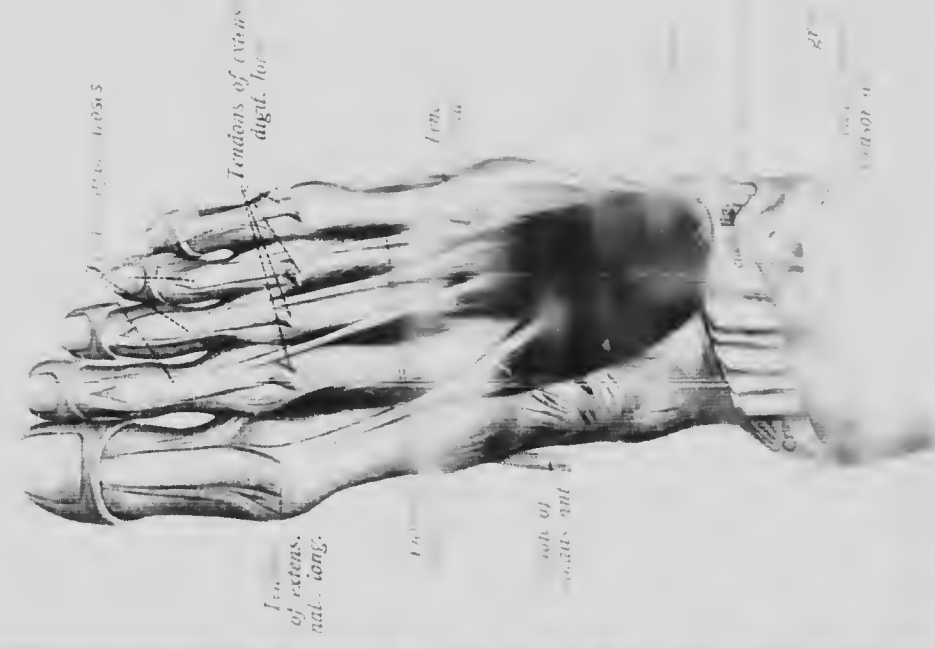

Fig. 300



Fig. 310



Fig. 300

Fig. 310



THE MUSCLES OF THE SOLE OF THE FOOT.

The muscles of the sole differ materially from those of the palm, since in addition to the groups for the great and little toes there is also a central muscular mass. This central group is formed by the flexor digitorum brevis and the quadratus plantæ, an accessory head of the flexor digitorum longus which arises in the foot. The superficial muscles of the sole are covered by the plantar aponeurosis (plantar fascia) (Fig. 309) (see page 233), with which they are partly adherent.

THE MUSCLES OF THE MIDDLE OF THE SOLE OF THE FOOT.

The **flexor digitorum brevis** (Fig. 310) is a thick elongated muscle entirely covered by the plantar fascia, and forms the *middle plantar eminence* (see page 233) (Fig. 309). It arises by a short tendon from the inner tubercle of the calcaneus and from the plantar fascia, with which the entire proximal half of the muscle is adherent. Just in front of the middle of the sole it subdivides into four bellies, terminating in four flat tendons, which behave in exactly the same manner as do those of the flexor digitorum sublimis in the hand, *i. e.*, they are perforated by the tendons of the flexor longus in the region of the proximal phalanges and are inserted chiefly into the second phalanges.

The posterior portion of the flexor digitorum brevis is in immediate relation with the two abductors (hallucis and digiti V) which form the middle and external plantar eminences (Fig. 309), and the origin of the muscle is especially adherent to the abductor hallucis. Its anterior portion covers the tendons of the flexor digitorum longus and the lumbricales and is in relation on either side with the short muscles of the great and little toes.

The muscle is supplied by the internal plantar nerve.

The **quadratus plantæ**, also termed the *flexor accessorius* and the *caro quadrata Sylvii* (Fig. 311), may be regarded as a plantar head of the flexor digitorum longus. It is situated upon the dorsal surface of the flexor brevis and is entirely covered by the latter muscle. It takes origin by means of two heads, of which the inner is usually the stronger, from the plantar surface of the calcaneus and from the long plantar ligament, and the flat and approximately quadrangular muscle inserts into the outer margin of the tendon of the flexor longus digitorum as it passes obliquely across the sole of the foot from within outward and from behind forward. The insertion occurs before the flexor digitorum longus tendon has subdivided into its four digital slips and after it has crossed the tendon of the flexor hallucis. At the crossing of these tendons they assume their proper positions (see page 222) and are always connected by anastomotic fibers. While the tendon of the flexor hallucis runs in the long axis of the toe, and consequently in the axis of traction, those of the flexor digitorum pursue an oblique course as above described and deviate from the axis of traction by about 30 degrees.

The quadratus plantæ is supplied by the external plantar nerve. It converts the oblique axis of traction of the tendons of the flexor digitorum longus into a straight one and increases the traction upon the tendons.

FIG. 311.—The middle layer of plantar muscles.

The flexor digitorum brevis, the abductor hallucis, and the abductor digiti quinti have been removed; the tendons of the digits and of the peroneus longus have been opened.

FIG. 312.—The deep layer of plantar muscles.

The tendons of the flexor digitorum longus, the flexor hallucis longus, and the quadratus plantar have been removed.

THE MUSCLES OF THE BALL OF THE GREAT TOE.

The muscles of the ball of the great toe differ from those of the thenar eminence not only in their number but also in the fact that one of them arises from the posterior extremity of the calcaneus and the other two from the anterior portion of the tarsus. The ball of the great toe consequently contains one long and two short muscles, while all four muscles of the thenar eminence are practically of the same length, on account of the shortness of the carpus.

The **abductor hallucis** (Fig. 310) is a long, triangular, penniform muscle which occupies the entire inner margin of the foot and whose origin is situated immediately alongside of that of the flexor digitorum. It forms the internal plantar eminence (Fig. 309) and arises from the inner tubercle of the calcaneus from the adjacent portion of the inner surface of that bone, from the lacinate ligament, and also from the plantar aponeurosis, which covers the muscle completely by the radiations of its middle portion. Soon after its origin, a flat strong tendon develops in the middle of the muscle, which is inserted by means of the internal sesamoid bone into the first phalanx of the great toe and into its dorsal aponeurosis. The flexor hallucis brevis is situated between the tendons of the abductor hallucis and flexor hallucis longus.

The muscle is supplied by the internal plantar nerve. Its chief function is the abduction of the great toe.*

The **flexor hallucis brevis** (Figs. 311 and 312) is much shorter than the abductor. It arises partly from the plantar surfaces of the middle and external cuneiform bones and partly from the tendinous prolongations of the long plantar ligament which form the sheath of the peroneus longus. Like the flexor pollicis brevis, the insertion of the muscle divides into two slips, between which passes the tendon of the flexor hallucis longus. The inner slip, together with the adductor hallucis, passes into the tendon of the internal sesamoid bone; the outer slip, together with the adductor hallucis, passes to the external sesamoid bone. The outer margin of the muscle is in relation with the abductor, the inner with the adductor hallucis.

The muscle flexes the great toe and is supplied partly by the internal plantar nerve and partly by the external plantar nerve.

The **adductor hallucis** (Fig. 312) is a distinctly bicapital muscle and the two heads do not unite until they almost reach the insertion. The *oblique head* is a round, strong, elongated muscle arising from the plantar surface of the external cuneiform bone, in common with and partly adherent to the flexor hallucis, from the bases of the second and third metatarsal bones,

*The marked development of most of the muscles of the great and little toes, in spite of the limited range of motion of these digits within the usual coverings of the foot, allows of the conclusion that these muscles not only move the toes, but that they play an important role in supporting the arch of the foot, especially since the abductor digiti V does not extend to the toe at all, but is inserted into the practically immovable fifth metatarsal bone.

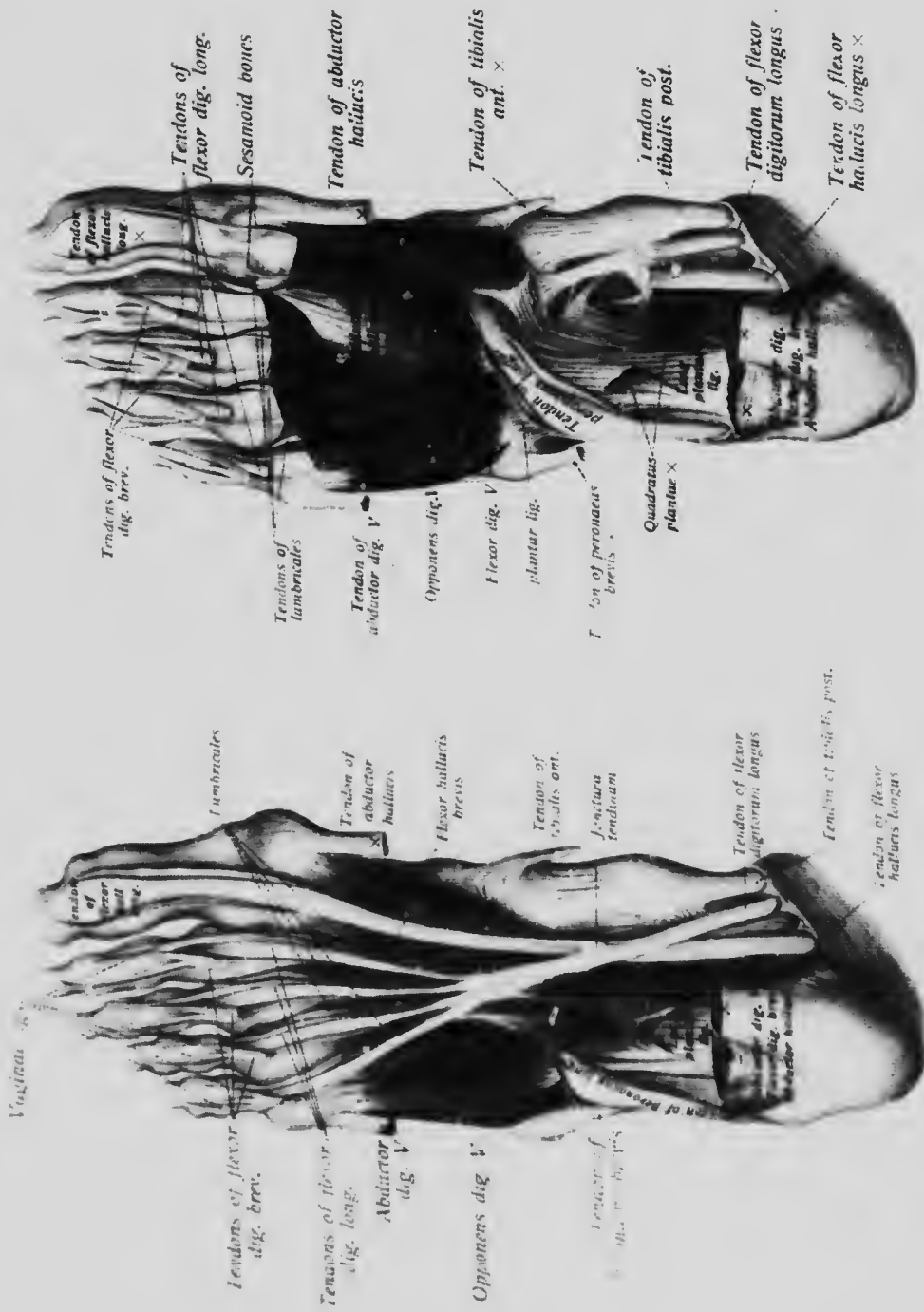


Fig. 312.

Fig. 311.

Tendon of flexor hallucis longus ×

Tendons of flexor dig. long.

Sesamoid bones

Tendon of abductor hallucis

Tendon of tibialis ant. ×

Tendon of flexor digitorum longus

Tendon of flexor hallucis longus ×

Tendons of flexor dig. brev.

Tendons of lumbricals

Tendon of abductor dig. V.

Opponens dig.

Flexor dig. V.

plantar lig.

Tendon of peroneus brevis

Quadratus plantar ×

Tendon of flexor dig. long.

Tendon of flexor hallucis longus

Lumbricals

Tendon of abductor hallucis

Flexor hallucis brevis

Tendon of tibialis ant.

Juncture tendinum

Tendon of flexor digitorum longus

Tendon of tibialis post.

Tendon of flexor hallucis longus

Tendon of flexor dig. long.

Abductor dig. V.

Opponens dig. V.

Tendon of peroneus brevis

Juncture tendinum

Tendon of flexor dig. long.

Tendon of flexor hallucis longus



and especially from the anterior extremity of the long plantar ligament (see page 141). The broad muscular belly is at first situated in the middle of the sole, covering the plantar interossei, and it then passes inward toward the external sesamoid bone of the great toe, and in this situation unites with the weaker *transverse head*. This arises by a purely muscular origin from the plantar aspect of the tarsometatarsal joints of the second to the fifth toes; it remains muscular until its insertion, while the oblique head usually exhibits an aponeurosis before reaching this point. Both heads are inserted together into the first phalanx of the great toe, the tendon of insertion containing the external sesamoid bone.

The adductor hallucis is supplied by the external plantar nerve. Its chief function is adduction of the great toe.

THE MUSCLES OF THE BALL OF THE LITTLE TOE.

The muscles of this group correspond to those of the hypothenar eminence both in number and in function, but the abductor is much longer than the other two muscles.

The **abductor digiti quinti** (Fig. 310) resembles the abductor hallucis not only in its position but in many other respects. It forms the external plantar eminence, and is thick and broad behind and narrow and tendinous in front. It arises by a short tendon from the outer tubercle of the calcaneus beside the flexor digitorum brevis, and also quite extensively from the plantar aponeurosis, which covers the greater portion of the muscle. The insertion is partly into the tuberosity of the fifth metatarsal bone and partly into the outer border of the first phalanx of the little toe. The inner margin of the abductor digiti V is in relation with the flexor digitorum brevis behind and with the flexor digiti V brevis in front.

It is supplied by the external plantar nerve. Its special function is abduction of the little toe.

The **flexor digiti quinti brevis** (Figs. 310 and 311) is a small elongated muscle which arises chiefly from the anterior portion of the long plantar ligament (see page 141) and is inserted by a short tendon into the first phalanx of the little toe. It is in relation externally with the third plantar interosseous muscle.

The **opponens digiti quinti** (Fig. 311) is smaller but somewhat broader than the flexor brevis, the two muscles having a common origin. It inserts into the outer border of the anterior portion of the fifth metatarsal bone, extending forward almost as far as the head. The muscle is almost entirely covered by the abductor digiti V.

The flexor and opponens digiti V are supplied by the external plantar nerve. Their chief functions are indicated by their names.

THE INTEROSSEI PEDIS.

There are, as in the hand, four dorsal and three plantar **interossei** (Figs. 312 to 314); the former arise by two heads, the latter by one. The difference between the hand and the foot consists in the fact that not the middle but the second toe receives the tendons of two *dorsal interossei* (the first and the second), while the third and the fourth pass from the outer side into the extensor tendons of the third and fourth toes (Fig. 313). The inner head of the first dorsal interosseous is poorly developed; it arises only from the base of the first metatarsal bone and from the ligaments of the tarsometatarsal joint, not from the shaft of the bone.

The *plantar interossei* (Fig. 314) are stronger than the dorsal. They arise from the outer borders of the three outer metatarsal bones and pass to the same borders of the corresponding toes.

The *interossei pedis* are supplied by the external plantar nerve. Their functions are the same as those of the palmar *interossei*, with certain modifications dependent upon the difference in their position (see page 203).

THE LUMBRICALES.

The *lumbricales* (Fig. 311) of the foot arise from the tendons of the flexor digitorum longus; the first lumbricalis has a single origin from the inner margin of the first tendon and the other

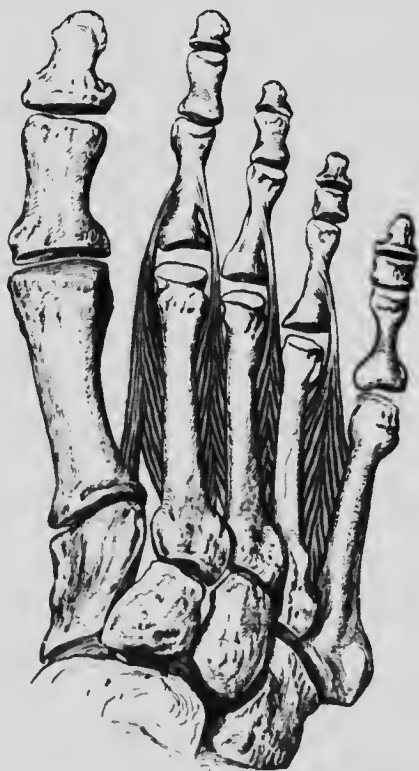

FIG. 313.—Diagram of dorsal interossei of the foot.

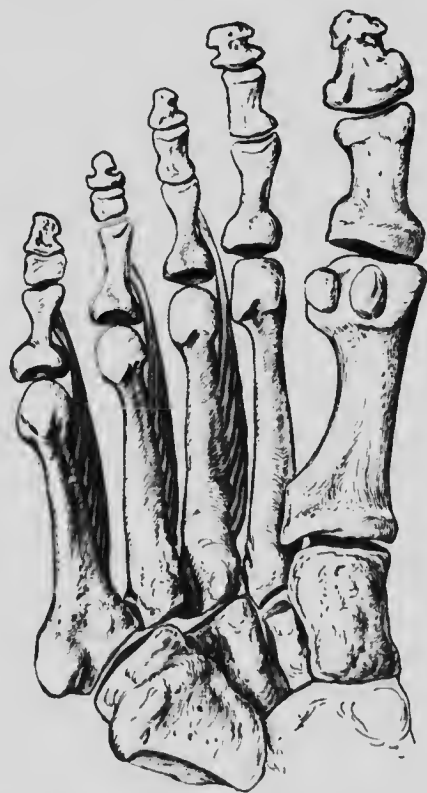


FIG. 314.—Diagram of the plantar interossei of the foot.

three have a bicapital origin. In the vicinity of the metatarsophalangeal joints, they pass from the inner side into the dorsal aponeuroses of the toes. At their insertions are usually situated small bursae, the *lumbrical bursa*.

These muscles are supplied in a variable manner partly by the external plantar nerve and partly by the internal plantar nerve. Their functions are similar to the corresponding muscles in the hand (see page 203).

THE SYNOVIAL SHEATHS OF THE FOOT.

Like the tendons of the muscles of the forearm, the muscles of the leg run in synovial sheaths as they pass into the foot. The retinacula of these synovial sheaths are formed partly by reinforcements of the deep fascia and partly by processes of the ligaments of the foot.

Upon the dorsum of the foot (Fig. 315) are situated three synovial sheaths; one for the *tibialis anterior*, one for the *extensor hallucis longus*, and a common one for the tendons of the

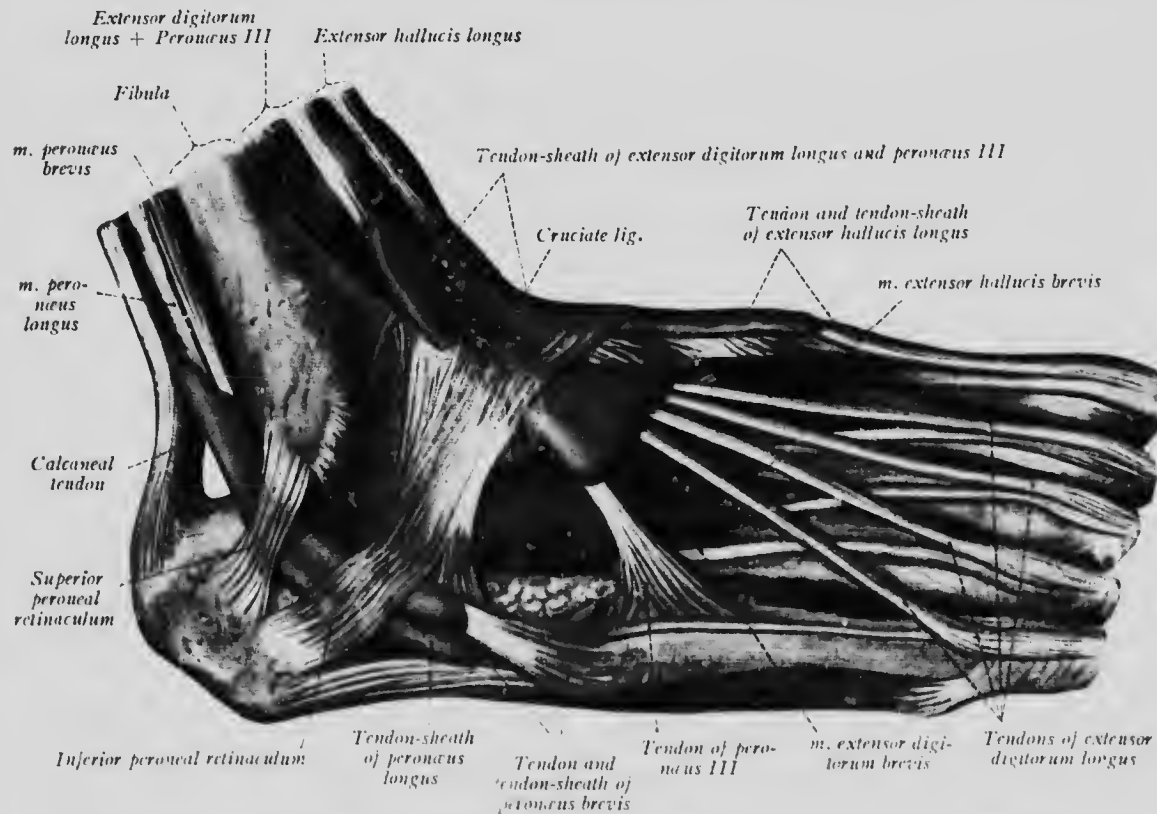


FIG. 315. —The tendon-sheaths and retinacula of dorsum and external surface of the foot (somewhat diagrammatic).

extensor digitorum longus and *peroneus tertius*. They commence in the leg and extend for a variable distance upon the dorsum of the foot. Their retinaculum is chiefly formed by a reinforcement of the dorsal fascia of the foot, the *cruciate (anterior annular) ligament*, which arises from the outer surface of the calcaneus, where it is adherent to the interosseous talocalcaneal ligament, and divides into a distal and a proximal band which form almost a right angle with each other (Fig. 306). The proximal band runs to the internal malleolus, the distal to the dorsal surfaces of the navicular and internal cuneiform bones, and when the latter band is prolonged

to the external malleolus, as sometimes occurs, the ligament presents a cruciform appearance. The outer undivided half of the ligament is connected at its origin with the inferior peroneal retinaculum and the ligament contains three compartments separated by fibrous partitions, for the three synovial sheaths.

At the outer side of the ankle-joint the two peroneal muscles (longus and brevis) have a common synovial sheath (Fig. 315), the upper and lower portions of which are usually subdivided for a short distance. This sheath is held in place by two retinacula which are frequently indistinctly separated. The *superior peroneal retinaculum* (Figs. 307 and 315) passes from

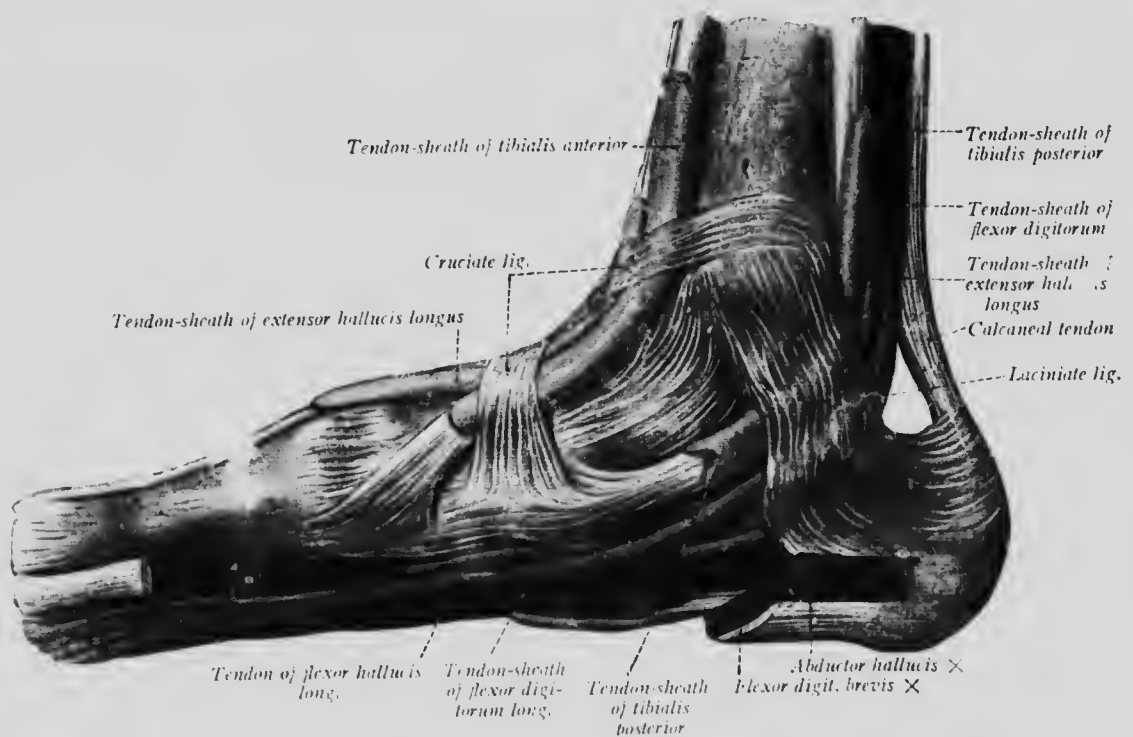


FIG. 316. - The tendon-sheaths and retinacula of the internal border of the foot (somewhat diagrammatic).

the posterior border of the internal malleolus to the upper extremity of the tuberosity of the calcaneus, and is also connected with the deep fascia of the leg. The *inferior peroneal retinaculum* (Figs. 307 and 315) extends from the outer extremity of the cruciate ligament to the outer surface of the calcaneus and its trochlear process.

At the inner side of the ankle joint (Fig. 316) there are three synovial sheaths for the tibialis posterior, the flexor digitorum longus, and the flexor hallucis longus. The sheath for the tibialis posterior is the shortest and extends only to the inner border of the foot. The two remaining sheaths are continued into the sole of the foot and extend as far as the decussation of the tendons.

These sheaths are held in place by the *laciniate (internal annular) ligament* (Figs. 305 and 316), a wide, poorly defined band which commences at the internal malleolus and passes partly to the inner and upper border of the calcaneus and partly to the plantar surface of the foot as far forward as the navicular bone. It contains three distinctly separated compartments for the three synovial sheaths.

In the sole of the foot, in addition to the continuations of the synovial sheaths of the flexor hallucis longus and digitorum longus, there is situated the special synovial *sheath of the peroneus longus*, which surrounds the tendon of this muscle in its passage across the sole within the groove of the cuboid (Figs. 311, 312, and 316) and almost to the point of its insertion.* This sheath is at first situated above (dorsal to) the flexor digitorum brevis and the tendon of the longus, and its retinaculum is furnished by a prolongation of some of the fibers of the long plantar ligament which pass beyond the cuboid to the base of the metatarsal bones (see page 141).

The flexor tendons of the toes also possess synovial sheaths which resemble those in the fingers, although they are correspondingly shorter and smaller. The longest sheath is usually that for the tendon of the flexor pollicis longus. The retinacula for these sheaths are the *vaginal ligaments*, which are analogous to the similar structures in the fingers (see page 205).

Within the synovial sheaths of the second to the fifth toes exactly the same relations obtain which we have previously observed in the fingers, since the weak tendons of the flexor digitorum brevis are perforated by the much stronger tendons of the flexor digitorum longus (see page 207).

THE FASCIÆ OF THE LOWER EXTREMITY.

The lower extremity is enveloped in a very strong fascia (Figs. 317 to 320) which is unusually thick in certain situations. In the different regions of the extremity this fascia receives corresponding names, and we consequently speak of the iliac fascia, the fascia lata, the crural fascia, the dorsal fascia of the foot, and the plantar aponeurosis.

THE ILIAC FASCIA.

The *iliac fascia* covers the anterior surface of the iliopsoas above the inguinal ligament. At the inner margin of the psoas major this fascia is continuous with the pelvic fascia; at the outer margin it passes into the thigh with the iliopsoas and joins the pectineal fascia to form the *iliopectineal fascia*, a portion of the fascia lata (see page 232). In doing this the fascia is attached to the anterior superior spine of the ilium, to the inguinal ligament, and to the iliopectineal eminence (the *iliopectineal ligament*) and divides the space beneath the inguinal ligament into two compartments, an outer compartment for the iliopsoas and the femoral nerve, the *lacuna musculorum*, and an inner one for the femoral vessels, the *lacuna vasorum*. The iliac fascia is directly continuous with the transversalis fascia (see page 163). The lacuna vasorum is rounded off and bounded internally by the lacunar (Gimbernat's) ligament (see page 164), and forms the internal femoral ring (see page 233).

THE FASCIA OF THE THIGH. FASCIA LATA.

The *fascia lata* (Figs. 317 and 318) consists of two layers which are separated only in certain situations, and its different portions vary greatly in thickness. It is composed of longitudinal

* Within this sheath the tendon of the peroneus longus develops a sesamoid bone (or cartilage).

FIG. 317.—The fascia of the thigh seen from in front.

FIG. 318.—The fascia of the thigh seen from behind.

FIG. 319.—The fascia of the lower leg seen from behind.

FIG. 320.—The fascia of the lower leg, seen from in front, and the dorsal fascia of the foot.

and transverse fasciculi which are so arranged that sometimes one set and sometimes the other preponderates, or both may occur together. In a general way the posterior portion of the fascia lata is stronger than the anterior and the external portion is decidedly thicker than the internal.

Upon the posterior surface of the thigh the very thin superficial layer of the fascia lata covers the glutæus maximus, while the deep layer passes beneath the muscle, and over that portion of the glutæus medius which is not covered by the maximus, the fascia assumes a markedly tendinous or aponeurotic character and is termed the *gluteal fascia* (Figs. 238, 240, and 241). In the *gluteal sulcus* (Fig. 318), over the lower portion of the glutæus maximus, the fascia contains numerous strong transverse fasciculi, and over the flexor muscles it is of average thickness and is composed chiefly of transverse fasciculi which are especially well marked in the popliteal region, where the superficial layer of the fascia lata covers in the popliteal space and its contents, the deep layer enveloping its muscular margins.

The strongest portion of the fascia lata is situated upon the outer side of the thigh and is known as the *iliotibial* (or *Maissiat's*) *band* (Figs. 206 and 318). This band is composed chiefly of strong tendinous longitudinal fasciculi and receives the insertion of the tensor fasciæ latæ* and of a portion of the glutæus maximus (see page 211). Its lower extremity is attached to the external tuberosity of the tibia, and beneath it is situated the vastus lateralis with its large aponeurosis. In the lower portion of the thigh the fascia lata gives off a septum upon either side, and these pass between the femoral muscles to the lips of the linea aspera, forming the *internal* and *external intermuscular septa*. Just below the inguinal ligament the fascia lata is composed of two layers. The superficial layer passes over the anterior surface of the sartorius and the great femoral vessels; the posterior goes behind the sartorius and covers in the iliopectineal fossa (see page 210) and the groove between the vastus medialis and the adductors. Over the adductor muscle the fascia is very thin and transparent. The portion of it covering the pectineus is also called the *pectineal fascia*; it unites with the lower extremity of the *iliac fascia* to form the *iliopectineal fascia* covering the floor of the iliopectineal fossa.

Immediately below the inguinal ligament the superficial layer of the fascia lata exhibits a free internal margin, the *falciform margin* (Fig. 317), which, together with the pectineal fascia, bounds a round or oval depression in the fascia lata, the *oval fossa* (saphenous opening). The inferior portion of the falciform margin, which passes almost imperceptibly into the pectineal fascia, is called the *inferior cornu*, while the superior portion, extending upward to the lacunar ligament, is termed the *superior cornu*. The opening of the oval fossa is covered by a portion of the superficial layer, the *cribriform fascia*, which contains a considerable quantity of fat and quite a number of foramina, the largest of which gives passage to the *great saphenous vein* (the internal saphenous vein). This vein comes from the foot and leg, runs upon the fascia lata, and

* The surface of the tensor fasciæ latæ is also covered by a very thin layer of the fascia lata.

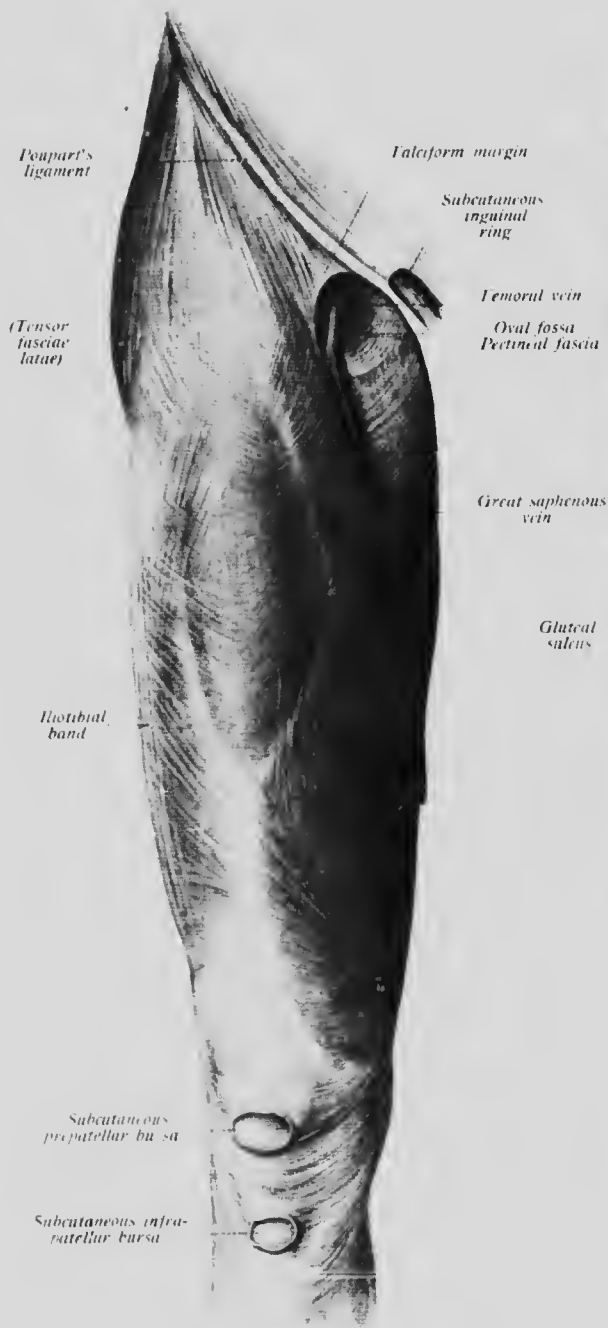


Fig. 317.

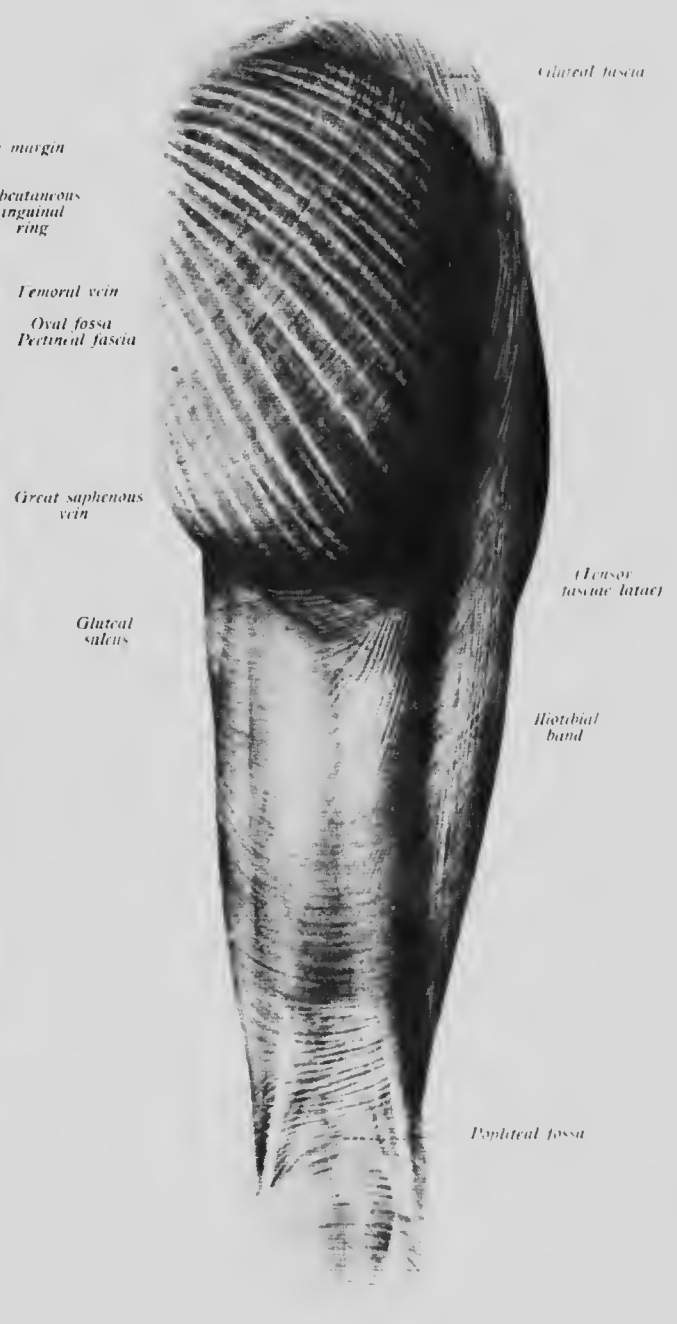


Fig. 318.

1870
1871
1872
1873
1874
1875
1876
1877
1878
1879
1880
1881
1882
1883
1884
1885
1886
1887
1888
1889
1890
1891
1892
1893
1894
1895
1896
1897
1898
1899
1900
1901
1902
1903
1904
1905
1906
1907
1908
1909
1910
1911
1912
1913
1914
1915
1916
1917
1918
1919
1920
1921
1922
1923
1924
1925
1926
1927
1928
1929
1930
1931
1932
1933
1934
1935
1936
1937
1938
1939
1940
1941
1942
1943
1944
1945
1946
1947
1948
1949
1950
1951
1952
1953
1954
1955
1956
1957
1958
1959
1960
1961
1962
1963
1964
1965
1966
1967
1968
1969
1970
1971
1972
1973
1974
1975
1976
1977
1978
1979
1980
1981
1982
1983
1984
1985
1986
1987
1988
1989
1990
1991
1992
1993
1994
1995
1996
1997
1998
1999
2000
2001
2002
2003
2004
2005
2006
2007
2008
2009
2010
2011
2012
2013
2014
2015
2016
2017
2018
2019
2020
2021
2022
2023
2024
2025




Popliteal fossa

Calcaneal tendon

*Dorsal fascia
of foot*

Fig. 319.




*Subcutaneous
bursa*

*Subcutaneous
infrapatellar bursa*

Transverse crural lig.

Cruciate ligament

Fig. 320.



empties into the femoral vein, which is situated in the region of the oval fossa. The oval fossa (the saphenous opening) is the external or subcutaneous femoral ring and the external orifice of the femoral canal. (For a more detailed description the reader is referred to the text books and atlases of topographic anatomy.)

THE FASCIA OF THE LEG, FASCIA CRURIS.

The *fascia cruris* (Figs. 319 and 320) envelops the muscles of the leg, but is wanting over the inner surface of the tibia; it is nickest anteriorly below the knee, where it is adherent to the extensors, the peronæi, and the tendons of the pes anserinus. It gives off the *anterior intermuscular septum*, which passes between the extensors and the peronæi to the anterior border of the fibula, and the *posterior intermuscular septum*, which passes between the peronæi and the flexors to the posterior border of the fibula, and its upper and inner portion is adherent to the pes anserinus (see page 219). Upon the posterior aspect of the leg it divides into a superficial and a deep layer, the former covering the triceps suræ, the latter the deep group of flexors; the triceps suræ and its tendon, the tendo Achillis, are consequently completely invested by this fascia. In addition to the previously described retinacula (see page 230) the fascia cruris is especially reinforced by the *transverse crural ligament*, which is composed of transverse fasciculi passing from the tibia to the fibula above the ankle. It is situated to the proximal side of the cruciate ligament, with which it gradually becomes continuous.

THE FASCIÆ OF THE FOOT.

While the dorsal fascia of the foot (Fig. 320) is an exceedingly thin layer, the plantar aponeurosis (Fig. 309) is the thickest portion of the entire fascia of the leg. In the middle of the sole it consists of a very thick aponeurotic layer, composed chiefly of longitudinal fasciculi with some fibers which pass obliquely toward the lateral margins of the foot. The proximal portion of the aponeurosis arises from the inner and outer tubercles of the calcaneus and is closely adherent to the long muscles of the foot which take their origins from the same bony points; it is considerably thicker than the broader distal portion. The aponeurosis together with the long muscles forms the three *plantar eminences* (*internal, middle, and external*; see pages 223 to 227). Its lateral portions are much weaker than the central portion, and the thickest part of the lateral portion is situated over the origin of the abductor digiti V. Numerous slender fasciculi pass from the entire margin of the aponeurosis to the skin, and toward the toes the aponeurosis divides into four slips, corresponding to the four outer toes, which are bound together by transverse fibers, the *transverse fasciculi*. Upon the toes the aponeurosis gradually disappears in the connective tissue layers of the skin.

Both the fascia lata and the fascia cruris, like the fasciæ of the upper extremity, give passage to vessels and nerves.

THE MOST IMPORTANT BURSÆ OF THE LOWER EXTREMITY.

1. The *subcutaneous trochanteric bursa*, the chief bursa upon the great trochanter.
2. The *trochanteric bursa of the gluteus maximus* (see page 212, Fig. 295).
3. The *gluteo-moral bursa* (see page 212, Fig. 295), inconstant.

4. The *sciatic bursa of the gluteus maximus*, between the tuberosity of the ischium and the gluteus maximus.
5. The *anterior (trochanteric) bursa of the gluteus medius*, between the tendons of the gluteus medius and maximus.
6. The *posterior (trochanteric) bursa of the gluteus medius*, between the tendons of the gluteus medius and the piriformis (see page 212).
7. The *trochanteric bursa of the gluteus minimus*, at the insertion of the muscle of the same name into the great trochanter.
8. The *piriform bursa*, at the insertion of the muscle of the same name into the great trochanter.
9. The *bursa of the obturatorius internus* (see page 213, Fig. 301).
10. The *bursa of the rectus femoris*, at the origin of the muscle of the same name from the margin of the acetabulum.
11. The *iliopectineal bursa* (see page 211, Fig. 298) occasionally communicates with the hip-joint.
12. The *subtendinous iliac bursa*, at the insertion of the iliopsoas into the lesser trochanter.
13. The *pectineal bursa*, at the insertion of the muscle of the same name.
14. The *superior bicipital bursa*, at the origin of the long head of the biceps.
15. The *inferior bicipital bursa*, between the tendon of insertion of the biceps and the long external lateral ligament of the knee-joint.
16. The *subcutaneous prepatellar bursa* (see page 136, Figs. 317 and 320).
17. The *subjascial prepatellar bursa* (see page 136).
18. The *subtendinous prepatellar bursa* (see page 136).
19. The *suprapatellar bursa* (see page 135) communicates almost always with the knee-joint.
20. The *subcutaneous infrapatellar bursa*, in front of the upper extremity of the ligamentum patellae (see page 136, Figs. 317 and 320).
21. The *deep infrapatellar bursa* (see page 135).
22. The *subcutaneous bursa of the tuberosity of the tibia*, a subcutaneous bursa over the tubercle of the tibia.
23. The *sartorial bursa* (see page 214, Fig. 298).
24. The *anserine bursa* (see page 216, Fig. 298).
25. The *popliteal bursa* (see pages 136 and 221) communicates with the knee-joint.
26. The *internal gastrocnemial bursa* (see pages 136 and 220, Fig. 303) also communicates with the knee-joint.
27. The *semimembranous bursa* (see pages 136 and 219) may communicate with the knee-joint.
28. The *subcutaneous external malleolar bursa*, subcutaneous bursa over the external malleolus.
29. The *subcutaneous internal malleolar bursa*, subcutaneous bursa over the internal malleolus.
30. The *bursa of the cruris tali*, in the interosseous ligament in the sinus tarsi between the

talocrural and talonavicular articulations, may communicate with the articular cavity of the talocalcaneonavicular articulation.

31. The *subtendinous bursa of the tibialis anterior*, at the insertion of the tendon of the tibialis anterior.

32. The *subtendinous bursa of the tibialis posterior*, at the insertion of the tendon of the tibialis posterior.

33. The *subcutaneous calcaneal bursa*, a subcutaneous bursa beneath the tuber calcanei.

34. The *bursa of the calcaneal tendon*, at the insertion of the tendo Achillis.

35. The *intermetatarsophalangeal bursa*, corresponding to the intermetacarpophalangeal bursa.

36. The *lumbrical bursa* (see page 228).

[As in the case of the upper extremity, so too in the lower a classification of the muscles of each of the groups recognized above into *post-axial* and *pre-axial* sets can be made. Owing, however, to a rotation which the lower limb undergoes during its development, an inversion of its surfaces, as compared with those of the upper limb, occurs, so that the post-axial muscles of the thigh, leg, and foot are situated on the anterior surface and the pre-axial muscles on the posterior surface. Furthermore, there is not, in the nerve plexuses of the lower limb, that definite separation of the fibers of the pre-axial and post-axial muscles into distinct cords, such as are found in the brachial plexus, but the pre-axial and post-axial fibers do not complete their separation—a rule, until they have reached the lower third of the thigh, the division of the great sciatic nerve into the tibial and peroneal nerves occurring at about that level.

Bearing these facts in mind, a morphological classification of the muscles of the lower limb may be made as follows:

I. THE MUSCLES OF THE HIP.

(a) Post-axial muscles: *gluteus maximus, gluteus medius, gluteus minimus, and tensor fasciæ latae**

(b) Pre-axial muscles: *iliacus, piriformis, obturator externus, obturator internus, gemelli, and quadratus femoris*

II. THE MUSCLES OF THE THIGH.

(a) Post-axial muscles: *sartorius, quadriceps femoris, and biceps femoris (shorter head)*†

(b) Pre-axial muscles: *pectineus, gracilis, adductor longus, adductor brevis, adductor magnus, adductor minimus, semimembranosus, semitendinosus, and biceps femoris (long head)*

III. THE MUSCLES OF THE LEG.

(a) Post-axial muscles: *extensor digitorum longus, peroneus tertius, extensor hallucis longus, tibialis anterior, peroneus longus, and peroneus brevis*

(b) Pre-axial muscles: *gastrocnemius, plantaris, soleus, popliteus, flexor digitorum longus, tibialis posterior, flexor hallucis longus, and quadratus plantæ*‡


IV. THE MUSCLES OF THE FOOT.

(a) Post-axial muscle: *extensor digitorum brevis, and extensor hallucis brevis*

(b) Pre-axial muscles: *flexor digitorum brevis, abductor hallucis, flexor brevis hallucis, abductor digiti quinti, abductor digiti quarti, lumbricales, adductor hallucis, flexor brevis digiti quinti, and interossei* [11]

* The biceps femoris really represents two muscles with a common insertion at long head, but the short head and its short head belongs primarily to the gluteal set of muscle.

† The quadratus plantæ, although situated in the foot, is nevertheless morphologically one of the muscles of the leg, being a derivative of the same muscle-mass which give rise to the flexor longus hallucis and the flexor peroneus.



INDEX

- ABDOMINAL** fasciæ, 163
 muscles, 157
 anterior, 157
 development, 164
 development, 154
 flat, 157
 development, 164
 posterior, 162
 development, 164
 straight, 161
 development, 164
 portion of pectoralis major muscle, 167
 ribs, 128
 ring, external, 158
- Abductor digiti quinti** muscle, 220, 227
 function of, 200, 227
 nerve supply of, 200, 227
 brevis muscle, 186, 210
- hallucis** muscle, 210, 226
 function of, 226
 nerve supply of, 226
- pollicis brevis** muscle, 186, 199
 function of, 199
 nerve supply of, 199
- longus** muscle, 185, 197
 function of, 197
 nerve supply of, 197
- Accessory ligaments**, 108
 of foot, 139
 plantar ligament, 139
 process, 28
 volar ligaments, 127
- Acetabular fossa**, 96
 notch, 96
- Acetabulum**, 93, 96
 development, 96
- Acromial extremity of clavicle**, 85
- Acromioclavicular articulation**, 120
 ligament, 120
- Acromion** process, 84
- Adductor brevis** muscle, 209, 216, 217
 function of, 217
 nerve supply of, 217
 canal, 217
 hallucis muscle, 210, 226
 function of, 227
 nerve supply of, 227
 longus muscle, 209, 216
 function of, 216
 nerve supply of, 216
 magnus muscle, 209, 216, 217
 function of, 217
 nerve supply of, 217
 minimus muscle, 209, 216, 217
- Adductor minimus** muscle, function of, 217
 nerve supply of, 217
 muscles of thigh, 216
 opening, tendinous, 217
 pollicis muscle, 186, 199
 function of, 200
 nerve supply of, 200
- Aditus orbitæ**, 74
- Adnunculum lineæ albiæ**, 163
- Ale of ethmoid**, 63
 of ilium, 93, 94
 surfaces of, 94, 95
 vomera, 30, 65
- Alar folds of knee**, 135
 ligaments, 115
 portion of nasalis muscle, 182
 processes, 63
- Alveolar border of mandible**, 74
 foramina, 67
 jugo, 71
 portion of mandible, 74
 process, 37
 of superior maxillary, 66, 68
- Alveoli for teeth**, 68, 71
- Amphiarthrosis**, 108
- Anatomical neck of humerus**, 85
- Anatomy**, definition, 17
 descriptive, definition, 17
 general, definition, 17
 special, definition, 17
 systematic, definition, 17
 topographic, definition, 17
- Anconæus lateralis** muscle, 199
 longus muscle, 189
 medialis muscle, 199
 muscle, 185, 199
 function of, 199
 nerve supply of, 199
 quartus muscle, 199
 function of, 199
 nerve supply of, 199
- Angiology**, definition, 17
- Angle**, external, of scapula, 84
 inferior, of scapula, 84
 intrasternal, 35
 internal, of scapula, 84
 mastoid, 34
 of Louis, 34
 of parietal bone, frontal, 59
 mastoid, 59
 occipital, 59
 sphenoidal, 59
 of ribs, 32
 of scapula, external, 84
- Angle of scapula, inferior**, 83
 internal, 83
 superior, 83, 84
 of sternum, 34
 parietal, 59
 pubic, 131
 sphenoidal, 36
 subcostal, 35
- Angular head of quadratus labii superioris** muscle, 180
- Angulus sterni**, 34
- Ankle-joint**, 137
 ligaments of, 139
- Annular ligament**, 122
 anterior, 127, 229
 internal, 231
 of palm, 205
 posterior, 203, 208
- Annulus tympanicus**, 58
- Anserine bursa**, 219
- Antagonist** muscles, 143
- Anterior abdominal muscles**, 157
 development, 164
 annular ligament, 127, 229
 arch of atlas, 25
 of vertebra, 22
 articular facet of calcaneus, 103
 c. tabes, 10
 atlantoccipital menibrane, 115
 belly of digastric muscle, 174
 capitular ligament, 136
 clinoid process, 41, 49
 condyloid canal, 40, 45
 coronoid process of mandible, 74
 costotransverse ligament, 116
 cranial fossa, 41
 crest of fibula, 101
 crucial ligament, 134
 crus of subcutaneous inguinal ring, 159
 ethmoidal foramen, 61, 75
 fontanelle, 81
 gluteal line, 94
 inferior spine of ilium, 94
 intercondyloid fossa, 99
 intermuscular septum, 233
 interocipital synchondrosis, 47
 intertransversarius muscle, 155
 intraoccipital synchondrosis, 81
 lacrimal crest, 97
 layer of lumbodorsal fascia, 159
 ligament of external malleolus, 137
 longitudinal ligament of vertebral column, 111
 muscles of leg, 223
 nares, 66, 76

- Anterior nasal spine, 37, 68
 obturator membrane, 115
 tubercle, 95
 pelvic surface, 90
 pillar of subcutaneous inguinal ring, 159
 portion of quadratus lumborum muscle, 163
 sacral foramina, 28
 sacrococcygeal ligament, 113
 sacroiliac ligament, 129
 superior spine of ilium, 94
 surface of superior maxillary, 66
 of thigh, muscles of, 214
 of ulna, 87
 talocalcaneal articulation, 138
 ligament, 140
 talofibular ligament, 140
 talotibial ligament, 129
 trochanteric bursa of gluteus medius, 234
- Anteroexternal surface of humerus, 86
 Anterointernal surface of humerus, 86
 Antibrachial fascia, 207
 Antrum of Eustachian, 66
 tympanic, 51, 58
 Aortic opening of diaphragm, 165, 166
 Apertura piriformis, 37, 65, 66, 76
 Aperture of aqueductus vestibuli, external, 55
 of pelvis, inferior, 131
 superior, 130
 of tympanic canaliculus, superior, 54
 Apex of fibula, 101
 of patella, 99
 of pyramid of temporal bone, 115
 Apical odontoid ligament, 115
 Aponeurosis, 143
 palmar, 198, 207, 208
 Apophyses, 20
 Appendicular skeleton, 22
 Aqueductus cochlear, orifice of, 56
 vestibuli, aperture of, external, 55
- Arch, costal, 33
 lumbo-costal, external, 165
 internal, 165
 of Haller, 165
 of solea, 220
 of vertebrae, 22, 33
 ligaments between, 113
 pubic, 131
 superolary, 66
 tuberosity, 133
 zygomatic, 38, 49
- Arched eminence, 54
 ligament, 128
 external, 159, 165
 internal, 165
 line, 95
 popliteal ligament, 135
- Arm, bones of, 85
 upper, extensor surface of, muscles of, 160
 flexor surface of, muscles of, 158
- Arm, upper, muscles of, 185, 188
 classification, 209
- Artery, vertebral, 25
 canal for, 26
- Arthrodia, 110
- Articular capsules, 108
 of hip-joint, 132
 of phalanges of foot, 137
 of hand, 127
 cartilages, 21, 108
 circumference of radius, 88
 of ulna, 88
 crest of sacrum, 29
 discs, 108, 118
 of elbows, 123
 eminence, of occipital bone, 40
 of temporal bone, 53
 margins, 108, 109
 processes, 20
 of sacrum, superior, 29
 of vertebrae, 23
 surfaces of calcaneus, 103
 of patella, 99
 of radius, carpal, 89
 of tibia, inferior, 100
 superior, 99
- Articularis genu muscle, 215
 subcutaneous muscle, 215
- Articulations, 107, 108
 acromioclavicular, 120
 ankle, 137
 atlantoaxial, 112, 115
 atlantocapitular, 113, 115
 atlanto-occipital, 113, 115
 ball-and-socket, 110
 biaxial, 110
 bilocular, 108
 calcaneocuboid, 137, 138
 carpometacarpal, 137, 138, 141, 142, 145
 of thumb, 124, 125
 Chopart's, 138
 cochlear, 109
 compound, 109
 condylar, 110
 costovertebral, 110
 oval, 131
 carpal, 137, 138
 digital, 128, 137, 139
 ellipsoidal, 110
 gliding, 110
 hinge, 109
 hip, 131
 humero-radial, 122
 humero-ulnar, 122
 intercarpal, 124
 intercondylar, 117
 intermetatarsal, 137, 139
 interphalangeal, 128, 137, 139
 intertarsal, 137
 intervertebral, 111
 Elfrans's, 139
 metacarpophalangeal, 127
 of thumb, 127
 metatarsophalangeal, 137, 139
 of astragalus, 137
 of atlas, 113
 of axis, 113
- Articulations of carpus, 124
 of costal cartilages, 117
 of elbow, 122
 of fibula, 136
 of fingers, 127
 of first and second cervical vertebrae, 113
 of foot, 137
 of hand, 124
 of head, 117
 of knee, 133
 of pelvic girdle, 128
 of phalanges of foot, 157
 of hand, 127
 of pisiform bone, 124, 125
 of ribs with sternum, 116, 117
 with vertebral column, 29, 116, 117
 of sacrum, 113
 of shoulder, 121
 of sternum with ribs, 116, 117
 of talus, 137
 of tibia, 136
 of toes, 137
 of upper extremity, 110
 of vertebral column, 110
 with ribs, 26, 116, 117
 of wrist, 124
 pelvic, 128
 pivot, 109
 polyaxial, 110
 radiocarpal, 124
 radioulnar, distal, 123
 proximal, 122
 sacroiliac, 128
 saddle, 110
 simple, 109
 spheroid, 110
 spiral, 109
 sternoclavicular, 110
 sternocostal, 117
 talocalcaneal, 137, 138
 talocalcaneonavicular, 137, 138
 talocrural, 137
 tarsometatarsal, 138
 tarsometatarsal, 137, 138
 tarsometatarsal, 137, 139
 trapezometatarsal, 118
 tibiofibular, 136
 transverse, of tarsus, 138
 trochlear, 109
 true, 108
 uniaxial, 109
 with longitudinal axis, 109
 with transverse axis, 109
 unilocular, 108
- Atragalus, 102. See also *Talus*
- Atlantoaxial articulations, 113, 115
- Atlantocapitular articulations, 113
- Atlantooccipital articulation, 113, 115
 membrane, 115
 anterior, 115
 posterior, 115
- Atlas, 24, 25
 articulations of, 113
 development of, 21
 lateral masses of, 25
 transverse ligament of, 114

- Atollens auriculæ muscle, 170
 Attrahens auriculæ muscle, 170
 Auditory canal, internal, 55
 foramen, internal, 55
 meatus, external, 38, 40
 internal, 43
 Auricular surface of ilium, 95
 of sacrum, 29
 Auricularis anterior muscle, 178, 179
 muscle, 178
 functions of, 179
 nerve supply of, 179
 posterior muscle, 178, 179
 superior muscle, 178, 179
 Axial skeleton, 22
 Axillary border of scapula, 84
 fascia, 207
 fossa, 147
 margin of scapula, 83
 Axis, 23, 25
 articulations of, 113
 dens of, 25
 development of, 7
 odontoid process of, 25

 Back, fascia of, 156
 muscles of, 144
 development of, 156
 flat, 145
 development, 156
 long, 149
 development, 156
 short, 154
 development, 156
 Ball of great toe, muscles of, 226
 of little toe, muscles of, 227
 Ball-and-socket joint, 110
 Basal ligaments, dorsal, 127, 141
 interosseous, 127
 metatarsal, 141
 planta, 141
 volar, 127
 Base of mandible, 71
 of metatarsal bones, 61
 of metatarsal bones, 105
 of patella, 99
 of phalange of fingers, 99
 of toes, 105
 of scapula, 83
 Basilar portion of occipital bone, 15
 Basipharyngeal canal, 49
 Basis cranii externa, 49
 Belly of muscle, 142
 Biarticular muscles, 142
 Biaxial joints, 110
 Biceps brachii muscle, 185, 188
 function of, 185
 nerve supply of, 189
 tendon of long head of, 184
 femoris muscle, 209, 218
 function of, 218
 nerve supply of, 218
 Bichat's fat mass, 182, 183
 Bicipital bursa, inferior, 234
 superior, 234
 groove, external, 188, 207
 Bicipital groove, internal, 188, 207
 of humerus, 85
 ridges, 86
 Bicipitoradial bursa, 189
 Bifurcate ligament, 140
 Bilocular joints, 108
 Bipenniform muscles, 142
 Bipinnate muscles, 142
 Biventer cervicis muscle, 152
 mandibule muscle, 174
 muscle, 142
 Bloodvessels of bones, 21
 Bone-cartilage, 20
 Bone-marrow, 21
 Bones, 19
 bloodvessels of, 21
 broad, 19
 calcineal, 20
 composition of, 20
 development of, 21
 flat, 19
 heads of, 20
 inorganic constituents of, 20
 irregular, 20
 long, 19. See also *Long bones*.
 macrated, 20
 membranous, 21, 22
 neck of, 20
 nerves of, 21
 nutrient canals of, 20
 organic constituents of, 20
 pneumatic, 19
 short, 19
 tissue of, 20
 tubular, 19
 visceral, 22
 Bony locking mechanisms, 108, 109
 pelvis, 93
 tissue, 20
 Brachial fascia, 207
 Brachialis muscle, 185, 189
 function of, 189
 nerve supply of, 186
 Brachioradialis muscle, 185, 194
 function of, 195
 nerve supply of, 195
 Branchiomeris muscles, 184, 185
 Breast bone, 23, 34. See also *Sternum*
 Broad bones, 19
 Broad fat mass, 182, 183
 Buccinator (cheek) muscle, 186, 188
 Buccopharyngeal fascia, 184
 Bulbus venæ jugularis superior, 57
 Bursæ, anserine, 210, 234
 bicipital, inferior, 234
 superior, 234
 acipitoradial, 189
 olecranon, subcutaneous, 235
 coracobrachial, 208
 cubital interosseous, 208
 digital, dorsal subcutaneous, 208
 gastrocnemial, internal, 146, 147, 234
 gluteofemoral, 212, 234
 hypocondylar, 133, 234
 infrapatellar, deep, 135
 subcutaneous, 136, 234
 Bursæ, infraspinatus, 208
 intermetatarsophalangeal, 209
 intermetatarsophalangeal, 235
 intra-tendinous olecranon, 208
 latissimus, 146
 lambrical, 228
 malleolar, subcutaneous external, 234
 internal, 234
 metacarpophalangeal, dorsal subcutaneous, 208
 mucous, 143
 of calcaneal tendon, 235
 of extensor carpi radialis brevis, 208
 of flexor carpi radialis, 209
 ulnaris, 208
 of gluteus maximus, sciatic, 234
 trochanteric, 212, 233
 medius, anterior trochanteric, 234
 posterior, 212
 trochanteric, 212, 234
 minimus, trochanteric, 234
 of latissimus dorsi, 146
 of lower extremity, 233
 of obturator internus, 213
 of obturatorius internus, 213, 234
 of rectus femoris, 234
 of semimembranosus muscle, 219
 of sinus tarsi, 234
 of teres major, 208
 of tibialis anterior sub-tendinous, 235
 posterior sub-tendinous, 235
 of tuberosity of tibia, subcutaneous, 234
 of upper extremity, 208
 olecranon, 208
 pectineal, 234
 piriform, 234
 popliteal, 136, 220, 221, 234
 prepatellar, subcutaneous, 136, 234
 sub-fascial, 136
 sub-tendinous, 136
 sartorial, 214, 234
 sciatic, of gluteus maximus, 234
 semimembranosus, 136, 219, 234
 sub-sacro-mial, 208
 subcutaneous epicondylar, 208
 olecranon, 208
 subclavoid, 186, 208
 subscapular, 121, 188
 sub-tendinous thoracic, 234
 obscure, 208
 suprapatellar, 135, 234
 synovial, 108
 communis dig. 108
 trochanteric, 212
 anterior of gluteus medius, 234
 of gluteus minimus, 234
 maximus, 212, 234
 posterior, of gluteus medius, 212, 234
 subcutaneous, 234
 Calcaneal bursa, subcutaneous, 235
 tendons, 220
 bursa of, 235

- Calcaneocuboid articulation, 137, 138
 ligament, 41
 plantar, 141
 Calcaneofibular ligament, 140
 Calcaneonavicular ligament, 141
 dorsal, 140
 plantar, 141
 Calcaneotibial ligament, 139
 Calcaneus, 102, 103
 articular surfaces of, 103
 body of, 103
 development, 106
 facets of, 103
 groove of, 103
 surfaces of, 103
 Calc muscles, 219
 Calvaria, inner aspect of, 44
 Canal, adductor, 217
 alveolar, 67
 auditory, internal, 55
 basipharyngeal, 49
 carotid, 55, 58
 external orifice of, 40
 condyloid, 40, 45
 anterior, 40, 45
 posterior, 40
 dental, inferior, 72
 facial, 56, 57
 geniculum of, 57
 for vertebral artery, 26
 vein, 26
 Hunter's, 217
 hypoglossal, 40, 45
 infraorbital, 67
 entrance of, 75
 inguinal, 159
 mandibular, 72
 musculotubular, 55, 58
 nasal, 75
 nasolachrymal, 64, 67, 75
 nutrient, of art. 87
 of bones, 20
 of radius, 89
 of temporal bone, 57
 palatine, 69
 pharyngeal, 49, 51
 pyriform, 50, 78
 pterygopalatine, 51, 69
 sacral, 29
 spinal, 31
 vertebral, 31
 vidian, 71
 Canaliculi, caroticotympanic, 55
 Canaliculus chordæ tympani, 57
 cochlear, orifice of, 56
 mastoid, 58
 tympanic, 58
 Canalis vertebralis, 31
 Canine fossa, 66
 Caninus muscle, 184
 Capitular ligament, anterior, 136
 posterior, 136
 transverse, of foot, 139
 of hand, 127
 Capitulum of humerus, 86
 of ulna, 88
 Capsules, articular, 108
 of hip joint, 132
 of phalanges of
 foot, 137
 of hand, 127
 Caro quadrata Sylvii muscle, 225
 Caroticotympanic canaliculi, 56, 58
 Carotid canal, 55, 58
 external orifice of, 40
 foramen, external, 56
 internal, 55
 fossa, 172, 174
 groove, 41, 48
 tubercle, 26
 Carpal articular surface of radius, 89
 bones, 82, 89
 articulations of, 124
 central, 91
 development, 91
 supernumerary, 9
 surfaces of, 90, 91
 eminence, radial, 90
 ulnar, 90
 groove, 90
 ligaments, 126
 dorsal, 203, 208
 extensor tendon sheaths be-
 neath, 203
 radiate, 127
 transverse, 127, 205
 volar, 208
 Carpometacarpal articulation, com-
 mon, 124, 125
 of thumb, 124, 125
 ligament, dorsal, 127
 volar, 127
 Carpus, 89
 articulations of, 124
 ligaments of, 126
 Cartilages, 21
 articular, 21, 108
 bone, 20
 costal, 33
 articulations of, 117
 interarticular, 108
 scapular, 133
 functions of, 136
 Cavities, glenoid, 84, 121
 nasal, 75
 oral, orifice of, 75
 orbital, 75
 pelvic, 13
 Cells, ethmoidal, 63, 64
 frontal, 62
 lacrimal, 63, 65
 mastoid, 58
 maxillary, 63, 67
 palatine, 63, 70
 sphenoidal, 63
 Centers of ossification, 21
 Central canal bone, or
 tendon of diaphragm, 164, 165
 Cerebral, 1
 of sphenoid bone, 20
 surfaces of frontal bone, 41, 67
 of orbital bones, 6
 of parietal bone, 39
 of sphenoid bone, 12, 19
 of temporal bone, 52
 Cervical fascia, 177
 Cervical muscles, prevertebral, 176
 ribs, 35
 vertebræ, 23. See also *Vertebra,*
 cervical.
 Cervicalis ascendens muscle, 149
 Chassaignac's tubercle, 26
 Check ligaments, 108
 Chiasma of tendons, 207
 Choane, 39, 76
 Chopart's joint, 138
 Chorda dorsalis, 110, 115
 tympani, 57
 Clavicle, 83, 85
 body of, 85
 development, 85
 extremities of, 85
 Clavicular notches, 34
 portion of pectoralis major muscle,
 167
 Clinoïd process, anterior, 41, 49
 middle, 48
 posterior, 48
 Clivus, 43, 45, 48
 Coccygeal cornua, 30
 Coccyx, 30
 development of, 31
 joints of, 113
 movements of, 113
 Cochlear joint, 109
 Collar bone, 85. See also *Clavicle.*
 Colles' ligament, 159
 Common carpometacarpal joint, 124,
 125
 meatus of nose, 77
 Communicating synovial bursa, 108
 Complexus minor muscle, 151
 muscle, 152
 Compound joints, 109
 Compressor narium, 182
 Concha nasalis inferior, 64, 67, 77
 Conchæ nasales, 77
 media, 64
 superior, 63
 sphenoidales, 48
 Conchal crest, 67, 69
 Conduction ligaments, 108
 Condyles, 20
 femoral, 98, 133
 of occipital bone, 45
 of tibia, external, 99
 internal, 99
 Condylol canal, 40, 45
 anterior, 40, 45
 posterior, 40
 fossa, 45
 joint, 40
 portions of occipital bone, 45
 processes, 200
 of mandible, 71, 73
 posterior, 72
 of skull, 38
 Conoid ligament, 126
 Coracoacromial ligament, 136
 Coracobrachial bursa, 208
 Coracobrachialis muscle, 188, 189
 function of, 189
 nerve supply of, 187
 Coracoclavicular fascia, 17

- Coracoclavicular ligament, 120
 Coracohumeral ligament, 121
 Coracoid process of scapula, 84
 tuberosity, 85
 Cornua of fascia lata, 232
 of hyoid bone, greater, 73
 lesser, 73
 Coronal suture, 36, 37, 79
 Coronoid fossa, 86
 process of cranium, 38, 72
 of mandible, 71, 73
 of ulna, 87
 Corrugator supercilii muscle, 179
 Costa, 32. See also *Ribs*.
 Costal arch, 33
 cartilages, 33
 articulations of, 117
 groove, 32
 portion of diaphragm, 164
 process, 24
 surface of scapula, 83
 tubercle, ligament of, 116
 tuberosity of clavicle, 85
 Costoclavicular ligament, 119
 Costocoracoid membrane, 170
 Costotransverse articulations, 116
 foramen, 117
 ligament, anterior, 116
 middle, 116
 posterior, 116
 superior, 116
 Cotyloid ligament, 131
 notch, 96
 Coxal bone, 93
 development, 96
 joint, 131
 Cranial bones, 44, 45
 fossæ, 41-43
 anterior, 41
 middle, 41
 posterior, 41, 43
 vault, inner aspect of, 41
 Cranium, 36. See also *Skull*.
 cerebrale, 41, 45
 viscerale, 41
 Cremaster muscle, 160
 functions of, 162
 nerve supply of, 162
 Cremasteric fascia, 163
 Crest, 20
 buccinator, 73
 conchal, 67, 69
 ethmoidal, 67, 69
 for rectus capitis posterior major
 muscle, 17
 frontal, 41, 61
 infratemporal, 39, 53
 lacrimal, anterior, 67
 posterior, 65
 nasal, 68, 69
 occipital, external, 49
 internal, 41, 49
 of fibula, 101
 of head of ribs, 32
 of ilium, 94
 lips of, 91
 of neck of rib, 32
 of pubis, 65
 Crest of sacrum, 29
 of tibia, 100
 orbital, of sphenoidal bone, 50
 sphenoidal, 48
 Cribriform fossa, 232
 plate of ethmoid bone, 41, 61, 62
 Crista, 43, 62
 Cuneiform bones, 43, 46
 common, 134
 anterior, 134
 of pedal, 298
 posterior, 134
 Cuneiform ligament, 117, 229
 of tarsometatarsal, 233
 Crura, center of diaphragm, 165
 intermetura of diaphragm, 165
 laterale of diaphragm, 165
 mediale of diaphragm, 165
 of subcutaneous inguinal ring, an-
 terior, 159
 inferior, 158
 posterior, 159
 superior, 158
 Cubital interosseous bursa, 208
 Cuboid bone of foot, 102, 104
 development, 106
 Cuboideonavicicular ligament, dorsal,
 141
 plantar, 141
 Cucullaris muscle, 145
 functions of, 146
 nerve supply of, 146
 Cuneiform bones, external, 104
 first, 104
 internal, 104
 middle, 104
 of foot, 102, 104
 development, 106
 of hand, 89, 90, 91
 second, 104
 third, 104
 ligaments, navicular, dorsal, 141
 Cuneocuboid ligament, dorsal, 141
 interosseous, 141
 plantar, 141
 Cuneometatarsal ligaments, inter-
 osseous, 141
 Cuneonavicular articulation, 137, 138
 Deltoid head of flexor pollicis brevis
 muscle, 199
 infrapatellar bursa, 135
 layer of calf muscles, 221
 of cervical fascia, 177
 of extensors of forearm, oblique,
 197
 straight, 197
 of flexor muscles of forearm, 192
 muscles of neck, 175
 posterior sacrococcygeal ligament,
 113
 temporal fascia, 184
 Deltoid ligament, 139
 tuberosity, 86
 Deltoidpectoral triangle, 167
 Deltoid muscle, 187, 186
 Deltoid muscle, function of, 186
 nerve supply of, 186
 Dens epistrophei, 25, 26, 114
 of axis, 25
 Dental canal, inferior, 72
 foramen, inferior, 72
 Depressor anguli oris muscle, 181
 labii inferioris muscle, 181
 septi nasi muscle, 181
 Descriptive anatomy, definition, 117
 Designations of positions, 17, 18
 Diameters of pelvis, 131
 Diaphragm, 164
 crura of, 165
 development, 166
 foramina of, 166
 functions of, 166
 nerve supply of, 166
 Diaphyseal center of ossification, 21
 Diaphysis, 19
 Diarthroses, 107, 108. See also *Articu-
 lations*.
 Digastric fossa, 40, 72
 muscle, 142, 174
 functions of, 171
 nerve supply of, 171
 Digital articulations, 128, 137, 139
 bursa, dorsal subcutaneous, 208
 fossa, 97
 Digitate impressions, 41
 of sphenoid bone, 50
 Diploë, 19
 Disarticulated skull, 36
 Discs, articular, 108, 118
 of elbow, 123
 Distal radioulnar articulation, 123
 Dorsal arch of vertebra, 22
 basal ligaments, 127, 141
 border of metacarpal bones, 91
 of radius, 88
 of ulna, 87
 calcaneonavicular ligament, 140
 carpal ligaments, 203, 208
 extensor tendon sheaths be-
 neath, 203
 carpometacarpal ligament, 127
 cuboideonavicicular ligament, 141
 cuneocuboid ligament, 141
 fascia of hand, 207, 208
 intercarpal ligament, 127
 interunciform ligament, 141
 interossei muscles, 227
 ligaments of foot, 140
 navicular-cuneiform ligaments, 141
 radiocarpal ligament, 126
 subcutaneous digital bursa, 208
 metacarpophalangeal bursa, 208
 surface of radius, 88
 of scapula, 83
 of ulna, 87
 talonavicular ligament, 140
 tarsal ligaments, 140
 tarometatarsal ligaments, 141
 Dorsum, muscles of, 224
 seller, 41, 48
 Douglas' line, 161
 Ductus endolymphaticus, 55

- ELBOW**, articular disc of, 123
 articulations of, 122
Elbow-joint, 122
 movements of, 123
Ellipsoidal joint, 110
Embryology, definition, 17
Eminence, arcuate, 54
 articular, of temporal bone, 40, 53
 carpal, radial, 90
 ulnar, 90
 crucial, 43, 46
 frontal, 60
 hypothenar, 198
 muscles of, 200
 iliopectineal, 95
 intercondyloid, of tibia, 90
 olivary, 41, 48
 parietal, 59
 plantar, external, 33
 internal, 233
 middle, 225, 233
 pyramidal, 57
 thenar, 198
 muscles of, 199
Enarthrosis, 110, 131
Epicondyles, 20
 of femur, external, 98
 internal, 98
 of humerus, 86
Epicranial muscle, 178
Epiphyses, 19
Epiphysal centers of ossification, 21
 line, 21
Episternal bones, 36
Epistropheus, 23, 25
Epitrochleoanconeus muscle, 190
Erector spinae muscle, 149
Esophageal opening of diaphragm,
 165, 166
Ethmoid bone, 62
 ale of, 63
 cribriform plate of, 41, 61, 62
 development of, 64
 in newborn, 64, 81
 lateral masses of, 62, 63
 perpendicular plate of, 62, 63
Ethmoidal cells, 60
 cells, 63, 64
 crest, 67, 68
 depression, 64
 foramen, 63
 anterior, 61, 75
 posterior, 61, 75
 groove, 65
 labyrinth, 62, 63
 notch, 61
 process of inferior turbinate bone,
 64
 spine, 41, 48
 surface of lachrymal bone, 65
Ethmoideomaxillary suture, 80
Eustachian tube, cartilaginous portion
 of, 51
 semicanal for, 58
Extensor carpi radialis brevis muscle,
 185, 195
 longus muscle, 185, 195
 ulnaris muscle, 185, 197
Extensor carpi ulnaris muscle, function
 of, 197
 nerve supply of, 197
digiti V proprius muscle, 185, 196
 function of, 197
 nerve supply of, 197
digitorum brevis muscle, 210, 224
 communis muscle, 185, 196
 function of, 197
 nerve supply of, 197
 longus muscle, 210, 223
 function of, 224
 nerve supply of, 224
hallucis brevis muscle, 210, 224
 function of, 224
 nerve supply of, 224
 longus muscle, 210, 223
 function of, 223
 nerve supply of, 223
indis proprius muscle, 185, 198
 function of, 198
 nerve supply of, 198
of leg, 223
ossis metacarpi pollicis muscle, 197
pollicis brevis muscle, 185, 197
 function of, 197
 nerve supply of, 197
 longus muscle, 185, 197
 function of, 198
 nerve supply of, 198
surface of forearm, muscles of, 195
 of upper arm, muscle of, 189
tendons of fingers, 204
 of hand, 203
 sheaths of, 203
External abdominal ring, 158
 angle of scapula, 83, 84
 angular process of frontal bone, 36
 aperture of aqueductus vestibuli, 55
 arcuate ligament, 150, 165
 auditory rotator, 38, 40
 bicipital groove, 188, 207
 border of humerus, 86
 carotid foramen, 50
 condyle of femur, 98
 of tibia, 90
 crest of tibia, 101
 cuneiform bones of foot, 102, 104
 epicondyles of femur, 98
 of humerus, 86
 intercondyloid tubercle of tibia, 90
 intercostal ligaments, 160
 intercostales muscles, 165
 intermuscular septa of arm, 207
 of thigh, 237
 lateral ligament of arm, 122
 of head, 115
 of knee, 135
 lumbocostal arch, 165
 malleolar bursa, subcutaneous, 234
 surface of talus, 102
 malleolus, 101
 ligaments of, anterior, 137
 posterior, 137
 margin of scapula, 83
 meniscus of knee-joint, 133
 occipital crest, 46
 protuberance of, 46
External palpebral raphe, 170
 patellar retinaculum, 135
 plantar eminence, 233
 process of calcaneus, 103
 of talus, 102
 pterygoid plate, 40, 50
 rectus muscle, spine for, 76
 semilunar cartilage, 133
 subcutaneous epicondylar bursa,
 208
 superior articular surface of tibia, 90
 surface of shaft of tibia, 100
 talocalcaneal ligament, 140
 tubercle of talus, 102
Extremities, lower, bursae of, 233
 fasciae of, 231
 free, skeleton of, 97
 muscles of, 209
 classification, 235
 skeleton of, 82, 93
 of long bones, 19
 skeleton of, 22, 82, 83
 upper, articulations of, 119
 bursae of, 208
 fasciae of, 207
 free, skeleton of, 85
 ligaments of, 119
 muscles of, 185
 development, 209
 skeleton of, 82, 83
 thoracic muscles of, 166
FACE, bones of, 41
 muscles of, 178
 functions of, 182
 nerve supply of, 182
 proper, 179
facial canal, 56, 57
 geniculum of, 57
 surface of malar bone, 71
Lacriform margin of fascia lata, 232
 process, 120
False pelvis, 130
 ribs, 33
 vertebrae, 22, 28
Fasciae, 143
 abdominal, 163
 antibrachial, 207
 axillary, 207
 brachial, 207
 lucopharyngeal, 185
 cervical, 177
 coracoclavicular, 170
 cremasteric, 163
 cruris, 233
 gluteal, 232
 iliac, 231, 232
 iliopectineal, 231, 232
 infraspinatus, 207
 lata, 231
 lumbodorsal, 146, 156
 nuchal, 156
 of back, 156
 of foot, 233
 of hand, dorsal, 207, 208
 of head, 184
 of leg, 233

- Fascia** of lower extremity, 231
of neck, 177
of thigh, 231
of upper extremity, 207
parotidomasseteric, 184
pectineal, 232
pectoral, 170
prevertebral, 177
Scarpa's, 193
subscapular, 207
superficial, general, 163
supraspinatus, 207
temporal, 184
transversalis, 193
Fasciculi, transverse, 233
Fat mass, Bichat's, 182, 183
buccal, 182, 183
Female pelvis, 131
Femoral condyles, 133
triangle, 216
Femur, 82, 97
condyles of, 98
development, 98
epicondyles of, 98
extremities of, 97, 98
head of, 97
neck of, 97
shaft of, 97, 98
surfaces of, 97, 98
trochanters of, 97
Fenestra ovalis, 57
vestibuli, 57
Fenestration of ribs, 36
Fibers of subcutaneous inguinal ring, 159
Fibrocartilage, interpubic, 108, 128
intervertebral, 108, 110
navicular, 141
Fibrous layer of articular capsule, 108
ring of intervertebral fibrocartilage, 110
Fibula, 82, 101
and tibia, relations, 101
apex, 101
articulations of, 136
borders of, 101
crests of, 101
development, 101
extremities of, 101
head of, 101
interosseous membrane of, 136, 137
shaft of, 101
surfaces of, 101
Fibular lateral ligament, 134, 135
notch, 100
Finger joints, 127
Fingers, bones of, 92
extensor tendons of, 204
movements of, 127
synovial sheaths of, 205
First cuneiform bone of foot, 104
Fissura petrotympanica, 40, 53, 57
Fissure, Glaserian, 40, 53, 57
inferior orbital, 37, 39, 66, 71, 74, 75
infundibular, 64
petrooccipital, 40, 43, 54, 81
petrosquamosal, 53, 54
Fissure, petrotympanic, 40, 53, 57
sphenoidal, 37, 42, 49, 74, 75
sphenomaxillary, 37, 39, 74, 74, 75
sphenoccipital, 45
sphenopetrosal, 39, 40, 42, 54, 55, 81
superior orbital, 37, 42, 49, 74, 75
tympanomastoid, 53, 57
tympanosquamosal, 57
Fixation ligaments, 108
Flat abdominal muscles, 157
development, 164
bones, 10
muscles of back, 145
development, 156
Flexion vertebrae, 23
Flexor accessorius muscle, 225
brevis digiti V muscle, 210
carpi radialis muscle, 185, 191
function of, 191
nerve supply of, 191
ulnaris muscle, 185, 192
function of, 192
nerve supply of, 192
digiti quinti brevis muscle, 180, 200, 227
function of, 200, 227
nerve supply, 200, 227
digitorum brevis muscle, 210, 225
nerve supply of, 225
longus muscle, 210, 210, 221
function of, 222
nerve supply of, 222
profundus muscle, 185, 192
function of, 194
nerve supply of, 194
sublimis muscle, 185, 192
function of, 192
nerve supply of, 192
hallucis brevis muscle, 210, 226
function of, 226
nerve supply of, 226
longus muscle, 210, 210, 222
function of, 222
groove for, 193
nerve supply of, 222
of thigh, 218
pollicis brevis muscle, 186, 199
function of, 199
nerve supply of, 199
longus muscle, 185, 194
function of, 194
nerve supply of, 194
surface of forearm, muscles of, 191
of upper arm, muscles of, 188
tendons of palm, 205
Floating ribs, 34
Fontanelles, 81
frontal, 81
mastoid, 82
occipital, 81
posterior, 81
sphenoidal, 82
Fonticuli, 81
Foot, articulations of, 137
bones of, 101
calcaneus of, 102, 103
Foot, cuboid bone of, 102, 104
cuneiform bones of, 102, 104
fasciae of, 233
ligaments of, 137
accessory, 139
interosseous, 141
lumbricoides muscles of, 228
metatarsal bones of, 105
muscles of, 224
classification, 235
navicular bone of, 102, 103
phalanges of, 82, 105
sesamoid bones of, 82, 106
skeleton of, 101, 106
sole of, muscles of, 225
synovial sheaths of, 229
talus of, 102
tarsal bones of, 102
vaginal ligaments of, 231
Foramina, 20
alveolar, 67
anterior sacral, 28
auditory, internal, 55
caecum, 41, 61, 80
carotid, external, 56
internal, 55
costotransverse, 117
dental, inferior, 72
ethmoidal, 63
anterior, 61, 75
posterior, 61, 75
frontal, 60, 75, 76
incisive, 30, 68
infraorbital, 37, 66, 67
intervertebral, 23, 31
jugular, 13, 43, 69
lacertum, 39, 40, 42, 43, 55
magnus, 40, 44, 45
mandibular, 72
mastoid, 40, 43, 53, 54
mental, 37, 72
nasal, 65
nutrient, 20
of bone, 30
of tibia, 100
of ulna, 87
obturator, 93, 96
of diaphragm, 166
of nasal cavity, 77
of sacrum, intervertebral, 20
of sternum, 36
of xiphoid process, 36
optic, 41, 48, 75
ovale, 39, 42, 49, 59
palatine, greater, 10, 69
lesser, 40, 70
parietal, 44, 59
quadrilateral, 106
rotundum, 42, 49, 59, 78
sacral, 28, 29
intervertebral, 29
sacrospinous, 130
sciatic, great, 130
lesser, 140
sphenopalatine, 70, 78
spinal, 23
spinous, 39, 42, 49, 59
stylomastoid, 10, 56



- Foramina, supraorbital, 60, 75, 76
 transversarium, 24
 vertebrales, 23
 zygomaticofacial, 71
 zygomaticoorbital, 71, 75
 zygomaticotemporal, 71
- Forearm, extensor surface of, muscles of, 195
 flexor surface of, muscles of, 191
 muscles of, 185, 191
 classification, 200
 radial muscles of, 194
- Forehead, bony, 36
- Fossæ, 20
 acetabular, 96
 anterior cranial, 41
 axillary, 147
 canine, 66
 carotid, 172, 174
 condyloid, 45
 coronoid, 86
 cranial, 41-43
 anterior, 41
 middle, 41
 posterior, 41, 43
 cribriform, 232
 digastric, 40, 72
 digital, 97
 for lachrymal gland, 76
 sac, 76
 glenoid, 38, 53
 hypoglossal, 48
 hypophyseal, 41
 iliac, 95
 ilipectineal, 210
 infraspinatus, of scapula, 83
 infratemporal, 79
 intercondyloid, 98
 anterior, 99
 posterior, 99
 jugular, 10, 10, 50
 mandibular, 38, 40, 53, 118
 mastoid, 54
 middle cranial, 41
 occipital, inferior, 44, 40
 superior, 46
 olecranon, 87
 oval, 232
 petrosal, 56
 posterior cranial, 41, 13
 pterygoid, 40, 51
 pterygopalatine, 49, 50, 78
 radial, 87
 scaphoid, 51
 sphenomaxillary, 40, 50, 78
 sphenoid, 55
 subscapular, 83
 supraclavicular, lesser, 171
 supraspinatus, of scapula, 83
 temporal, 38, 54
 trochanteric, 97
 zygomatic, 79
- Fovea, 20
 articularis dentis, 25
- Foveolæ granulares, 44, 60
- Free lower extremity, skeleton of, 97
- upper extremity, skeleton of, 85
- Frons, 36
- Frontal angle of parietal bone, 59
 bone, 36, 60
 borders of, 60
 cerebral surfaces of, 41
 development of, 62
 frontal portion of, 60
 in new born, 62, 81
 nasal portion of, 60, 61
 orbital plates of, 61
 surfaces of, 61
 sulci arteriosi of, 61
 surfaces of, 60
 zygomatic process of, 60
- border of parietal bone, 59
 of sphenoid bone, 49
- cells, 63
 crest, 41, 61
 eminences, 60
 fontanelle, 81
 foramen, 60, 75, 76
 notch, 60, 75
 plane, 17
 portion of frontal bone, 60
 process of maxilla, 37
 of superior maxillary, 66, 67
 sinus, 61
 development, 62
 spine, 61
 surface of frontal bone, 60
 suture, 60, 81
- Frontalis muscle, 178
 functions of, 178
 nerve supply of, 178
- Frontoethmoidal suture, 41, 61, 80
- Frontolachrymal suture, 37, 80
- Frontomaxillary suture, 37, 80
- Frontosphenoidal process, 37, 71
- Fusiform muscle, 142
- GALEA aponeurotica, 178
- Gastrocnemial bursa, inner, 220
 internal, 136, 220, 234
- Gastrocnemius lateralis muscle, 220
 medialis muscle, 220
 muscle, 219
- Gemelli muscles, 209, 213
 Gemellus inferior muscle, 213
 superior muscle, 213
- General anatomy, definition, 17
 superficial fascia, 163
- Geniculum of facial canal, 57
- Geniohyoides muscle, 174, 175
 functions of, 175
 nerve supply of, 175
- Gimbernat's ligament, 141, 163, 164, 231
- Ginglymoarthrodia, 127, 149
- Ginglymus, 109
 lateral, 109
- Girdle, pelvic, 93
 articulations of, 128
 ligaments of, 128
 shoulder, 83
- Glabella, 60
- Gladius of sternum, 34
- Gland, lacrymal, fossa for, 76
- Glaserian fissure, 40, 53, 57
- Glenoid cavity, 84, 121
 fossa, 38, 53
 ligament, 121
- Glenoidal lip, 108, 109, 121
 of hip, 131
- Gliding joints, 110
- Gluteus maximus muscle, 209, 211
 function of, 212
 nerve supply of, 212
- medius muscle, 209, 212
 function of, 212
 nerve supply of, 212
- minimus muscle, 209, 212
 function of, 212
 nerve supply of, 212
- Gluteal fascia, 232
 line, anterior, 94
 inferior, 94
 middle, 94
 posterior, 94
 superior, 94
 muscles, 211
 sulcus, 232
 tuberosity, 98
- Gluteofemoral bursa, 212, 233
- Gomphosis, 107
- Gracilis muscle, 209, 216
 function of, 217
 nerve supply of, 217
- Great sacrosacral ligament, 129
- saphenous vein, 232
- sciatic foramen, 130
 notch, 94, 96
- toe, ball of, muscles of, 226
- Greater cornua of hyoid bone, 73
- multangular bone, 80, 90
- palatine foramen, 40, 69
- pelvis, 130
 sigmoid notch of ulna, 87
- trochanter, 97
 tubercle of humerus, 85
 tubercular ridge, 86
 wings of sphenoid bone, 47, 49
- Groove, bicipital, external, 188, 207
 internal, 188, 207
 of humerus, 85
 carotid, 41, 48
 carpal, 90
 costal, 32
 ethmoidal, 65
 for flexor hallucis longus, 103
 for musculospiral nerve, 86
 for radial nerve, 86
 hamular, 51
 infraorbital, 60, 76
 intertubercular, of humerus, 85
 lachrymal, 67
 musculospiral, 86
 mylohyoid, 72
 obturator, 95
 of calcaneus, 103
 of promontory, 58
 of talus, 102
 optic, 41, 48
 palatine, 68
 paraglenoidal, 95
 peroneal, 103, 104
 petrosal, inferior, 44, 45, 55

- Groove, petrosal, superior, 43, 55
 pterygopalatine, 51, 67, 69
 pulmonary, 35
 sagittal, 44, 46, 60, 61
 sigmoid, 43, 49, 53, 60
 subclavian, 33
 transverse, 43, 46
 tympanic, 57
- HALLER'S arches, 165
- Hamate bone, 80, 90
- Hamatometacarpal ligament, 127
- Hamular groove, 51
 process, 4c, 51
- Hamulus lacrimalis, 65
 process, 90
 pterygoidcus, 40, 51
- Hand, articulations of, 124
 bones of, 80
 carpal bones of, 80
 extensor tendons of, 203
 sheaths of, 203
 ligaments of, 124
 metacarpal bones of, 91
 movements of, 126
 muscles of, 185, 198
 classification, 209
 palm of, tendons of, 205
 phalanges of, 82, 92. See also *Phalanges of hand*.
 sesamoid bones of, 82, 92. See also *Sesamoid bones of hand*.
 skeleton of, 92
- Hard palate, 39, 68, 78
 in newborn, 60
 tuberosity of, 40
- Harmonic suture, 107
- Head, articulations of, 117
 fasciæ of, 184
 ligaments of, 117
 independent, 118
 muscles of, 177
 of bones, 20
 of femur, 97
 of fibula, 101
 of humerus, 85
 of metacarpal bones, 91, 92
 of metatarsal bones, 105
 of muscle, 142
 of radius, 88
 of ribs, 32
 of scapula, 84
 of talus, 102, 103
 skeleton of, 22, 30
- Hiatus, 20
 canalis facialis, 47, 54
 Fallopii, 43, 54
 semilunaris, 64, 78
- Hinge joint, 109
- Hip, muscles of, 210
 classification, 235
 internal, 210
- Hip-joint, 131
 articular capsule of, 132
 glenoidal lip of, 131
 movements of, 122
- Horizontal plate, 17
- Horizontal plates of palate bone, 60
 portion of hard palate, 39
 of squamous portion of temporal bone, 52
- Horner's muscle, 170
- Humeral head of flexor carpi ulnaris muscle, 192
 digitorum sublimis muscle, 192
 pollicis longus muscle, 194
 of pronator teres muscle, 191
- Humeroradial articulations, 122
- Humeroulnar articulation, 122
- Humerus, 82, 85
 anatomical neck of, 85
 borders of, 86
 development, 87
 extremities of, 85
 head of, 85
 neck of, anatomical, 85
 surgical, 86
 shaft of, 85
 surfaces of, 86
 surgical neck of, 86
 tubercles of, 85
- Hunter's canal, 217
- Hyoid bone, 73
 body of, 73
 development, 73
 ligaments of, 119
 muscles, 172
- Hypoglossal canal, 40, 45
 fossa, 48
- Hypophyseal fossa, 41
- Hypophysis, 48
- Hyposkeletal muscles, 164
- Hypothenar eminence, 198
 muscles of, 200
- Iliac bursa, subtendinous, 234
 fasciæ, 231, 232
 fossa, 95
- Iliacus muscle, 210
 dorsi muscle, 149
 lumborum muscle, 149
 muscle, 149
 functions of, 154
 nerve supply of, 154
- Iliofemoral ligament, 132
- Iliolumbar ligament, 120
- Iliopectineal bursa, 133, 211, 234
 eminence, 95
 fasciæ, 231, 232
 fossa, 210
 ligament, 231
 line, 95
- Iliopsoas muscle, 200, 210
 function of, 211
 nerve supply of, 211
- Iliotibial band, 232
- Ilium, 93, 94
 ala of, 93, 94
 surfaces of, 94, 95
 body of, 95
 crest of, 94
 lips of, 94
 development, 96
- Ilium, spines of, 94
 tuberosity of, 95
- Incisive foramen, 39, 68
 muscles, 181
 notch, 68
 suture, 60, 81
- Incisor teeth in fetus, 69
- Incisura, 20
 mastoidea, 40
- Independent ligaments of head, 118
- Indicator muscle, 198
- Inferior angle of scapula, 83, 84
 aperture of pelvis, 131
 articular surfaces of tibia, 100
 belly of omohyoideus muscle, 173
 bicipital bursa, 234
 cornu of fascia lata, 232
 crus of subcutaneous inguinal ring, 158
 dental canal, 72
 foramen, 72
 extremity of femur, 97, 98
 surfaces of, 98
 of fibula, 101
 of humerus, 85
 of radius, 89
 of tibia, 99
 of ulna, 87, 88
 gluteal line, 94
 intervertebral notch, 23
 maxillary, 71. See also *Mandible*.
 meatus of nose, 77
 nuchal line, 41, 46
 occipital fossa, 41, 46
 orbital fissure, 37, 39, 66, 71, 74, 75
 peroneal retinaculum, 230
 petrosal groove, 43, 45, 55
 pillar of subcutaneous inguinal ring, 158
 process of temporal bone, 57
 pubic ligament, 128
 ramus of ischium, 94
 of pubis, 93, 96
 temporal line, 59
 thoracic aperture, 35
 transverse ligament, 121
 turbinated bone, 64, 67, 77
 development, 64
 vertebral notches, 23
- Infraglenoidal margin of tibia, 100
 tuberosity, 84
- Infrapsoas muscles, 172
 functions of, 174
 nerve supply of, 173
- Infraorbital canal, 75
 entrance of, 75
 foramen, 37, 66, 97
 groove, 66, 76
 margin, 75
 suture, 68, 81
- Infrapetalar bursa, deep, 135
 subcutaneous, 136, 234
- Infraspinatus bursa, 208
 fasciæ, 207
 fossa of scapula, 84
 muscle, 185, 186
 function of, 187
 nerve supply of, 187

- Infrasternal angle, 35
 Infratemporal crest, 39, 50
 fossa, 79
 surface of sphenoid bone, 50
 of superior maxillary, 66
 Infundibular fissure, 64
 Inguinal canal, 159
 ligament, 131, 163
 reflected, 159, 164
 ring, subcutaneous, 158
 Inner crura of diaphragm, 165
 gastrocnemial bursa, 220
 head of gastrocnemius muscle, 220
 of triceps muscle, 190
 lip of linea aspera, 97
 portion of longus colli muscle, 176
 vitreous table of flat bones, 19
 Innominate bone, 93
 development, 96
 Inscrptions, tendinous, 143
 of rectus abdominis, 161
 Insertion of muscle, 142
 Interaveolar septa, 68
 Interarticular cartilages, 108
 ligament, 116, 117
 Intercarpal articulations, 124
 ligament, dorsal, 127
 volar, 127
 Interclavicular ligaments, 169
 Intercondral joints, 117
 Interclavicular ligament, 119
 notch of manubrium, 34
 Intercolumnar fibers of subcutaneous
 inguinal ring, 159
 Intercondyloid eminence of tibia, 99
 fossa, 98
 anterior, 99
 posterior, 99
 line, 98
 tubercle, external, 99
 internal, 99
 Intercostal ligaments, 117
 external, 169
 internal, 169
 spaces, 35
 Intercostales externi muscles, 169
 interni muscles, 169
 muscles, 166, 169
 functions of, 170
 nerve supply of, 170
 Intercrural fibers of subcutaneous in-
 guinal ring, 159
 Intercuneiform ligament, dorsal, 141
 interosseous, 141
 plantar, 141
 Intermaxillary bone, 69
 suture, 37, 80
 Intermittent crus of diaphragm, 165
 Intermetatarsal bursa, 209
 Intermetatarsal articulations, 137, 139
 Intermetatarsophalangeal bursa, 235
 Intermuscular septa, 143
 anterior, of leg, 233
 external, of arm, 207
 of thigh, 232
 internal, of arm, 188, 207
 of thigh, 232
 of arm, 188, 207
 Intermuscular septa, posterior, of leg,
 233
 Internal angle of scapula, 83, 84
 Annular ligament, 231
 Arcuate ligament, 165
 Auditory canal, 55
 foramen, 55
 meatus, 43
 Bicipital groove, 188, 207
 Border of humerus, 86
 of tibia, 100
 Carotid foramen, 55
 Cerebral surface of frontal bone, 60
 Condyle of femur, 98
 of tibia, 99
 Crest of fibula, 107
 Cuneiform bones of foot, 102, 104
 Epicondyle of femur, 98
 of humerus, 86
 Gastrocnemial bursa, 136, 220, 234
 Intercondyloid tubercle of tibia, 99
 Intercostal ligaments, 169
 Intercostales muscles, 169
 Intermuscular septum of arm, 188,
 207
 of thigh, 232
 Lateral ligament of knee, 134
 of radius, 122
 Lumbocostal arch, 165
 Malleolar bursa, subcutaneous, 234
 surface of talus, 102
 Malleolus, 100
 Margin of scapula, 83
 Meniscus of knee-joint, 133
 Muscles of hip, 210
 of thigh, 216
 Occipital crest, 44, 46
 protuberance, 43, 46
 Palpebral ligament, 179
 Patellar retinaculum, 135
 Plantar eminence, 233
 Process of calcaneus, 103
 Pterygoid plate, 40, 50
 Semilunar cartilage, 133
 Subcutaneous epicondylar bursa,
 208
 Superior articular surface of tibia,
 99
 Surface of shaft of tibia, 100
 of talus, 102
 of ulna, 87
 Talocalcaneal ligament, 140
 Tubercle of talus, 102
 Internasal suture, 37, 65, 80
 Interoccipital synchondroses, 47
 Interosseal dorsales muscles, 186, 200
 functions of, 203
 nerve supply of, 203
 muscles of foot, 210, 227
 of hand, 186, 200
 Pedis muscles, 227
 dorsal, 227
 functions of, 228
 nerve supply of, 228
 plantar, 227, 228
 Volares muscles, 186, 200, 201
 function of, 203
 nerve supply of, 203
 Interosseous basal ligaments, 127
 metatarsal ligaments, 141
 bursa, cubital, 208
 cuneocuboid ligament, 141
 cuneometatarsal ligaments, 141
 intercuneiform ligament, 141
 ligaments of foot, 141
 of neck, 116
 membrane of radius and ulna, 123
 of tibia and fibula, 136, 137
 ridges of fibula, 101
 of radius, 88
 of tibia, 100
 of ulna, 87
 Sacroiliac ligament, 129
 Spaces of metacarpal bones, 92
 Talocalcaneal ligament, 140
 Interphalangeal articulations of foot,
 137, 139
 of hand, 128
 Interpubic fibrocartilage, 108, 128
 Intersphenoidal synchondrosis, 51, 81
 Interspinales muscles, 154
 functions of, 155
 nerve supply of, 155
 Interspinous ligaments, 112
 Intertarsal articulations, 137
 Intertransversarii anterior muscles,
 155
 laterales muscles, 155
 mediales muscles, 155
 muscles, 154, 155
 functions of, 155
 nerve supply of, 155
 posteriores muscles, 155
 Intertransverse ligaments of vertebral
 column, 112
 Intertrochanteric line, 97
 ridge, 97
 Intertubercular groove of humerus, 85
 mucous sheath of biceps, 121, 188
 Intervertebral discs, 30
 fibrocartilages, 108, 110
 foramen, 23, 31
 of sacrum, 29
 joints, 111
 Intrajugular process, 46, 55
 Intraoccipital synchondrosis, anterior,
 81
 posterior, 81
 Intratendinous olecranon bursa, 208
 Irregular bones, 20
 Ischiocapsular ligament, 132
 Ischium, 93, 96
 development, 96
 JAWS. See *Mandible* and *Maxilla*.
 Joint. See *Articulations*.
 cushions, 108, 109
 Jugal alveolaria, 68
 Jugular foramen, 40, 41, 43
 fossa, 40, 46, 50
 notch of manubrium, 34
 of temporal bone, 55
 process, 43, 46
 tubercles, 43, 46
 Jugum sphenoidale, 41, 48
 Juxtauræ tendinæ, 196

- KNEE-CAP**, 99. See also *Patella*.
Knee-joint, 133
 menisci of, 133
 functions of, 136
 movements, 136
 semilunar cartilages of, 133, 136
 transverse ligament of, 134
- LACERTUS fibrosus**, 188, 207
Lachrymal bone, 37, 64
 development, 65
 surfaces of, 65
 cells, 63, 65
 crest, anterior, 67
 posterior, 65
 gland, fossa for, 76
 groove, 67
 notch, 67
 portion of orbicularis oculi muscle, 179
 process of inferior turbinate, 64
 sac, fossa for, 76
Lachrymoconchal suture, 80
Lachrymoethmoidal suture, 80
Lachrymomaxillary suture, 80
Laciniate ligament, 221, 231
Lacuna musculorum, 231
 vasorum, 231
Lacunar ligament, 131, 163, 164, 231
Lambda border of occipital bone, 40
 suture, 38, 79
Lamina papyracea, 62
Langer's muscle, 167
Lateral crest of sacrum, 29
 crus of diaphragm, 165
 ginglymus, 109
 intertransversarius muscle, 155
 ligament, external, of arm, 122
 of head, 118
 of knee, 135
 fibular, 134, 135
 internal, of arm, 122
 of knee, 134
 of fingers, 127
 of foot, 139
 radial, 126
 tibial, 134
 ulnar, 126
 masses of atlas, 25
 of ethmoid, 62, 63
 of sacrum, 29
 portions of occipital bone, 40, 45
 sacrococcygeal ligaments, 113
 surface of radius, 88, 89
Latissimus bursa, 146
 dorsi muscle, 146
 functions of, 147
 nerve supply of, 147
Leg, anterior muscles of, 223
 extensors of, 223
 fasciæ of, 233
 muscles of, 219
 classification, 235
 outer muscles of, 222
 posterior muscles of, 219
Lesser cornua of hyoid bone, 73
 multangular bone, 89, 90
Lesser palatine foramen, 40, 70
 pelvis, 130
 sacrosclatic ligament, 129, 130
 sciatic foramen, 130
 notch, 96
 sigmoid notch of ulna, 87
 supraclavicular fossa, 171
 trochanter, 97
 tubercle of humerus, 85
 tubercular ridge, 86
 wings of sphenoid bone, 47, 49
Levator alæ nasi muscle, 180
 anguli oris muscle, 181
 glandulæ thyroideæ muscle, 173
 labii inferioris muscle, 181
 superioris alæque nasi muscle, 180
 muscle, 180
 menti muscle, 181
 scapulæ muscle, 147
 functions of, 147
 nerve supply of, 147
Levatores costarum breves muscles, 170
 longi muscles, 170
 muscles, 169
Ligamenta coruscantia, 169
 flava, 112
Ligaments, 108
 accessory, 108
 acromioclavicular, 120
 alar, 115
 annular, 122
 anterior, 127, 229
 internal, 231
 of palm, 205
 posterior, 203, 208
 apical odontoid, 115
 arcuate, 128
 external, 156, 165
 internal, 165
 popliteal, 135
 basal dorsal, 127, 141
 interosseous, 127
 metatarsal, interosseous, 141
 plantar, 141
 volar, 127
 bifurcate, 140
 calcaneocuboid, 141
 plantar, 141
 calcaneofibular, 140
 calcaneonavicular, 141
 dorsal, 140
 plantar, 141
 calcaneotibial, 139
 capitular, anterior, 136
 posterior, 136
 transverse, of foot, 139
 carpal, 126
 dorsal, 203, 208
 extensor tendon sheaths beneath, 203
 radiate, 127
 transverse, 127, 205
 volar, 208
 carpometacarpal, dorsal, 127
 volar, 127
 check, 125
 Colles', 159
Ligaments, conoid, 120
 coracoclavicular, 120
 coracoclavicular, 120
 coracohumeral, 121
 costoclavicular, 119
 costotransverse, anterior, 116
 middle, 116
 posterior, 116
 superior, 116
 cotyloid, 131
 crucial, 134
 anterior, 134
 of palm, 205
 posterior, 134
 cruciate, 115, 229
 crural, transverse, 233
 cuboideonavicular, dorsal, 141
 plantar, 141
 cuneocuboid, dorsal, 141
 interosseous, 141
 plantar, 141
 cuneometatarsal, interosseous, 141
 deltoid, 139
 dorsal, of foot, 140
 Gimbernat's, 131, 163, 164, 231
 glenoid, 121
 hamatometacarpal, 127
 iliofemoral, 132
 iliolumbar, 129
 iliopectineal, 231
 inguinal, 131, 163
 reflected, 159, 164
 interarticular, 110, 117
 intercarpal dorsal, 127
 volar, 127
 intercartilaginal, 169
 interclavicular, 119
 intercostal, 117
 external, 169
 internal, 169
 intercuneiform, dorsal, 141
 interosseous, 141
 plantar, 141
 interosseous, 116
 basal, 127
 metatarsal, 141
 cuneocuboid, 141
 cuneometatarsal, 141
 intercuneiform, 141
 of foot, 141
 sacroiliac, 129
 talocalcaneal, 140
 interspinous, 112
 intertransverse, of vertebral column, 112
 ischioapsular, 132
 lacinate, 221, 231
 lacunar, 131, 163, 164, 231
 lateral, external, of arm, 122
 of head, 122
 of knee, 135
 of foot, 135
 of arm, 134, 135
 internal, of head, 122
 of knee, 134
 of fingers, 127
 of foot, 139
 radial, 122, 126

- Ligaments, lateral, tibial, 134
 ulnar, 122, 126
 lumbo-costal, 156
 navicular cuneiform, dorsal, 141
 plantar, 141
 oblique, 123
 popliteal, 135
 odontoid apical, 115
 of ankle-joint, 139
 of conduction, 108
 of costal tubercle, 116
 of external malleolus, anterior, 137
 posterior, 137
 of fixation, 108
 of foot, 137
 accessory, 139
 of hand, 124
 of head, 117
 independent, 118
 of hyoid bone, 119
 of lower extremities, 128
 of neck, 116
 of pelvic girdle, 128
 of scapula, 120
 of upper extremities, 119
 of vertebral column, 111
 orbicular, 132
 palpebral, internal, 179
 patellar, 135
 pelvic, 128
 independent, 129
 pisohamate, 125
 pisometacarpal, 125
 plantar accessory, 139
 long, 141
 of foot, 140
 tarsal, 141
 popliteal, arcuate, 135
 oblique, 135
 Poupert's, 131, 163
 pterygomaxillary, 184
 pterygospinous, 119
 pubic, inferior, 128
 superior, 128
 pubocapsular, 132
 radial lateral, 122, 126
 radiate, 116, 117
 radiocarpal, dorsal, 126
 volar, 126
 reinforcing, 108
 rhomboid, 119
 round, 132, 133
 sacrocoxycal, anterior, 113
 lateral, 113
 posterior, 113
 sacroiliac, anterior, 129
 interosseous, 129
 posterior, 129
 sacrosclatic, great, 129
 lesser, 129, 130
 sacrospinous, 120, 130
 sacrotuberous, 120
 sphenomandibular, 118
 stellate, 116, 117
 sternoclavicular, 119
 stylohyoid, 119
 stylomandibular, 118, 184
 stylo-maxillary, 184
- Ligaments, supraspinous, 112
 talocalcaneal, anterior, 140
 external, 140
 internal, 140
 interosseous, 140
 posterior, 140
 talofibular, anterior, 140
 posterior, 140
 talotibial, anterior, 139
 posterior, 139
 tarsal, 139
 dorsal, 140
 tarsometatarsal, dorsal, 141
 plantar, 141
 temporomandibular, 118
 tibionavicular, 139, 140
 transverse, capitular, 127
 inferior, 121
 of atlas, 114
 of hip, 131
 of knee, 134
 superior, 120
 trapezoid, 120
 triangular, 150, 164
 ulnar, lateral, 122, 126
 vaginal, 143
 of foot, 23:
 volar, accessory, 127
 Ligamentum nuchæ, 113
 teres, 132
 Limbus alveolaris, 68
 Linea alba, 161, 163
 aspera, 97, 98
 muscularis, 83
 suprema, 46
 terminalis, 29
 Lingula, 48, 73
 Lips, glenoidal, 108, 109, 121
 of hip, 131
 of crest of ilium, 94
 Lisfranc's joint, 139
 tubercle, 32
 Little toe, ball of, muscles of, 227
 locking mechanisms, bony, 108, 109
 Long bones, 19
 diaphyses of, 19
 epiphyses of, 19
 extremities of, 19
 neck of, 20
 shaft of, 19
 head of triceps muscle, 189
 muscles of back, 149
 development, 156
 plantar ligament, 141
 posterior sacroiliac ligament, 129
 Longissimus capitis muscle, 150, 151:
 cervicis muscle, 150, 151
 dorsi muscle, 149, 150
 muscle, 149, 150
 functions of, 154
 nerve supply of, 154
 Longitudinal ligaments of vertebral column, 111
 Longus atlantis muscle, 176
 capitis muscle, 176
 functions of, 176
 nerve supply of, 176
 colli muscle, 176
 Longus colli muscle, functions of, 176
 nerve supply of, 176
 Louis' angle, 34
 Lower extremity, bursa of, 233
 fasciæ of, 231
 free, skeleton of, 97
 muscles of, 209
 classification, 235
 skeleton of, 82, 93
 jaw, 37. See also *Mandible*.
 portion of longus colli muscle, 176
 Lumbar portion of diaphragm, 164, 165
 ribs, 28, 35
 triangle, 147
 vertebrae, 27
 Lumbo-costal arch, external, 165
 internal, 165
 ligament, 156
 Lumbo-dorsal fasciæ, 146, 156
 Lumbosacral vertebra, 30, 36
 Lumbricales bursæ, 228
 muscles of foot, 210, 228
 of hand, 200, 203
 functions of, 203
 nerve supply of, 203
 Lunate bone, 89, 90
- MAISSIAT'S band, 232
 Malar bone, 36, 70. See also *Zygomatic bone*.
 portion of orbicularis oculi muscle, 179
 surface of malar bone, 71
 Male pelvis, 131
 Malleolar bursa, subcutaneous external, 234
 internal, 234
 surfaces of talus, 102
 Malleolus, external, 101
 ligaments of, anterior, 137
 posterior, 137
 internal, 100
 Mammillary process, 28
 Mandible, 37, 71
 body of, 71
 borders of, 71
 development, 73
 in new-born, 73, 81
 notch of, 71
 processes of, 71
 ramus of, 37, 71, 72
 Mandibular canal, 72
 foramen, 72
 fossa, 38, 40, 53, 118
 Manubrium of sternum, 34
 Marrow, bone, 21
 Masseter muscle, 182
 functions of, 183
 nerve supply of, 183
 Masseteric tuberosity, 72
 Mastoid angle, 48, 59
 border of occipital bone, 46
 canaliculus, 56, 58
 cells, 53
 fontanelles, 82

- Mastoid foramen**, 40, 43, 53, 54
 fossa, 54
 notch, 53, 54
 portion of temporal bone, 38, 40, 52, 53
 process, 38, 40, 53, 54
- Maxillæ**, 37, 66
 body of, 66
 development, 60
 frontal processes of, 37
 in newborn, 60, 81
 nasal processes of, 37
 processes of, 37, 66
 surfaces of, 66
- Maxillary cells**, 63, 67
 process of inferior turbinate, 64
 sinus, 66
 orifice of, 67
 surface of palate bone, 60
- Meatus acusticus externus**, 38
 auditorius externus, 40
 nasopharyngeal, 77
 of nose, 77
 common, 77
 inferior, 77
 middle, 64, 77
 superior, 64, 77
- Medial crus of diaphragm**, 165
 intertransversarius muscle, 155
- Median palatine suture**, 30, 81
 plane, 17
- Medullary cavity**, 10
- Membrane, atlantooccipital**, 115
 posterior, 115
 costocoracoid, 170
 interosseous, of radius and ulna, 125
 of tibia and fibula, 136, 137
 obturator, 115, 120
 anterior, 115
 posterior, 115
 sternal, 117
 synovial, 108
 tectorial, 111, 115
- Membranous bones**, 21, 22
- Meniscus**, 108
 of knee-joint, 133
 function of, 136
- Mental foramen**, 37, 72
 protuberance, 72
 spine, 72
 tubercle, 72
- Mentalis muscle**, 181
- Metacarpal bones**, 82, 91
 base of, 91
 borders of, 91
 development, 92
 head of, 91, 92
 shaft of, 91
 surfaces of, 91
- Metacarpophalangeal articulations**, 127
 of thumb, 127
 bursa, dorsal subcutaneous, 208
- Metacarpus**, 91
- Metatarsal bones**, 82, 105
 base of, 105
 development, 106
 head of, 105
- Metatarsal bones, shaft of**, 105
 ligaments, basal interosseous, 141
- Metatarsophalangeal articulations**, 137, 139
- Metatarsus**, 105
- Metopic suture**, 60, 62, 81
- Middle articular facet of calcaneus**, 103
 of talus, 102
 clinoid processes, 48
 costotransverse ligament, 116
 cranial fossa, 41
 crura of diaphragm, 163
 cuneiform bones of foot, 102, 104
 gluteal line, 94
 margin of nose, 6, 77
 plantar eminence, 25, 233
 turbinate bone, 163
- Monarticular muscles**, 142
- Mucous bursa**, 143
 sheath, intertubercular, 121, 188
- Multangular bone, greater**, 80, 90
 lesser, 80, 90
- Multifidus cervicis muscle**, 152
 dorsi muscle, 152
 lumborum muscle, 152
 muscle, 152
 functions of, 154
 nerve supply of, 154
- Muscles**, 142
 abdominal, 157
 antagonistic, 143
 belly of, 142
 biarticular, 142
 biceps, 142
 bipenniform, 142
 bipinnate, 142
 biventer, 142
 cervical, prevertebral, 176
 development, 143
 digastric, 142
 fusiform, 142
 gluteal, 211
 head of, 142
 hyoid, 172
 infrahyoid, 172
 insertion of, 142
 monarticular, 142
 nasal, 170, 182
 of anterior surface of thigh, 214
 of back, 144
 flat, 145
 long, 49
 short, 154
 of extensor surface of forearm, 195
 of upper arm, 189
 of face, 178
 of flexor surface of forearm, 191
 of upper arm, 188
 of foot, 224
 of forearm, 185, 191
 of hand, 185, 198
 of head, 177
 of hip, 210
 of hypothenar eminence, 200
 of leg, 210
 of lower extremity, 209
 of mastication, 182
- Muscles of neck**, 171
 of scalp, 178
 of shoulder, 185, 186
 of thenar eminence, 190
 of thigh, 214
 of thoracic walls, 160
 of trunk, 144
 of upper arm, 185, 188
 extremity, 185
 oral, 170, 180
 orbicular, 142
 origin of, 142
 alpebral, 170
 annular, 142
 pinnate, 142
 prevertebral cervical, 176
 quadriceps, 142
 short, 142
 sphincter, 142
 spindle-shaped, 142
 suprahyoid, 174
 synergistic, 143
 thoracic, 160
 triceps, 142
 typical, 142
- Musculospiral groove**, 86
 nerve, groove for, 86
- Musculotubular canal**, 55, 58
- Mylohyoid groove**, 72
 line, 72
 ridge, 175
- Mylohyoid muscle**, 174
 functions of, 175
 nerve supply of, 175
- Myology**, 142
 definition, 17
 general, 142
 special, 142
- Myomeric muscles**, 184, 185
- NARES**, anterior, 66, 76
 posterior, 39
- Nasal bones**, 37, 65
 development, 65
 in newborn, 65
 border of frontal bone, 61
 canal, 75
 cavity, 76
 foramina of, 77
 conchæ, 37
 crest, 68, 69
 foramina, 65, 77
 muscles, 170, 182
 notch, 68
 portion of frontal bone, 60, 61
 process of maxilla, 37, 66, 67
 septum, 37, 76, 77
 spine, anterior, 37, 68
 posterior, 30, 60
 surface of palate bone, 60
 of superior maxillary, 66, 67
- Nasalis muscle**, 182
- Nasofrontal suture**, 37, 65, 80
- Nasolachrymal canal**, 64, 67, 75
- Nasomaxillary suture**, 37, 65, 80
- Nasopharyngeal meatus**, 77
- Nasopharynx**, 77

- Navicular bone of foot, 102, 103
 development, 106
 of hand, 89, 90
 fibrocartilage, 141
 Naviculari-cuneiform ligaments, dorsal, 141
 plantar, 141
 Neck, fasciæ of, 177
 ligaments of, 116
 muscles of, 171
 deep, 175
 short, 155
 development, 156
 of femur, 97
 of humerus, anatomical, 85
 surgical, 86
 of long bones, 20
 of radius, 88
 of ribs, 32
 of scapula, 84
 of talus, 102, 103
 Nerves of bones, 21
 Neurology, definition, 17
 Nose, meatus of, 77
 common, 77
 inferior, 77
 middle, 64, 77
 superior, 64, 77
 Tachal fascia, 156
 l. e., inferior, 41, 46
 superior, 41, 46
 surface of occipital bone, 46
 Nutrient canal of arm, 87, 89
 of bones, 20
 of radius, 87, 89
 foramen, 20
 of tibia, 100
 of ulna, 87
- OBLIQUE** head of adductor hallucis muscle, 226
 ligament, 123
 line of mandible, 72
 of tibia, 100
 muscles, 164
 popliteal ligaments, 135
 Obliquus abdominis externus muscle, 157
 functions of, 162
 nerve supply of, 162
 internus muscle, 157, 160
 functions of, 162
 nerve supply of, 162
 capitis inferior muscle, 155
 functions of, 155
 nerve supply of, 155
 superior muscle, 155
 functions of, 155
 nerve supply of, 155
- Obturator externus muscle, 209, 216, 217
 functions of, 218
 nerve supply of, 218
 foramen, 93, 96
 groove, 95
 internus muscle, 209, 213
 functions of, 213
- Obturator internus muscle, nerve supply of, 213
 membrane, 115, 129
 anterior, 115
 posterior, 115
 ridge, 95
 tubercle, anterior, 95
 posterior, 95
 Occipital angle of parietal bone, 59
 bone, 38, 40, 45
 basilar portion of, 40, 45
 borders of, 46
 condyles of, 45
 condyloid portions of, 45
 development of, 47
 in new-born, 47, 81
 lambdoid border of, 46
 lateral portions of, 40, 45
 mastoid border of, 46
 nuchal surface of, 41, 46
 relations of, 38, 40
 squamous portion of, 38, 45, 46
 border of parietal bone, 59
 condyles, 40
 crest, external, 46
 internal, 44, 46
 fontanelle, 81
 fossa, inferior, 44, 46
 superior, 26
 protuberance, external, 41, 46
 internal, 43, 46
- Occipitalis muscle, 178
 functions of, 178
 nerve supply of, 178
- Occipitomastoid suture, 38, 40, 43, 53, 79
- Occiput, articulation of first and second vertebrae with, 113
- Odontoid ligament, apical, 115
 process, 25, 26
- Olecranal bursa, 208
- Olecranon, 87
 fossa, 87
- Olivary eminence, 41, 48
- Omoxyoideus muscle, 172, 173
- Opponens digiti quinti muscle, 200, 227
 function of, 200, 227
 nerve supply of, 200, 227
- V muscle of foot, 186, 210
 pollicis muscle, 186, 199
 function of, 199
 nerve supply of, 199
- Optic foramen, 41, 48, 75
 groove, 41, 48
- Oral cavity, roof of, 78
 muscles, 179, 180
- Orbicular ligament, 132
 muscles, 142
- Orbicularis oculi muscle, 179
 functions of, 180
 nerve supply of, 180
 oris muscle, 180, 181
- Orbit, margins of, 75
 walls of, 73, 74
 development, 76
- Orbital cavities, 37, 73
 crest of sphenoidal bone, 50
- Orbital fissure, inferior, 37, 39, 66, 71, 74, 75
 superior, 37, 42, 49, 74, 75
 plates, 61
 surfaces of, 61
 portion of orbicularis oculi muscle, 179
 process of palate bone, 70
 surface of lachrymal bone, 65
 of malar bone, 71
 of orbital plates, 61
 of sphenoid bone, 49, 50
 of superior maxillary, 66
 wings of sphenoid bone, 47, 49
- Orifice of aqueductus cochleæ, 56
 of canaliculus cochleæ, 56
 of maxillary sinus, 67
- Origin of muscle, 142
- Os basilare, 47, 51
 capitatum, 89, 90
 incæ, 47
 incisivum, 69
 interparietale, 47
 magnum, 89, 90
 nasoturbinale, 64
 planum, 63
 trigonum, 103
- Ossa Bertini, 48
 suturatum, 82
- Ossification, 21
 centers, 21
- Osteology, 19
 definition, 17
 general, 19
 special, 22
- Outer crura of diaphragm, 165
 head of gastrocnemius muscle, 220
 of triceps muscle, 190
 leg muscles, 222
 lip of linea aspera, 97, 98
 portion of longus colli muscle, 176
 vitreous table of flat bones, 19
- Outgrowths, 20
- Oval fossa, 232
- PACCHIONIAN** depressions, 44, 60
- Palate bone, 69
 development, 70
 horizontal plates of, 69
 in newborn, 70
 perpendicular plate of, 69
 processes of, 70
 surfaces of, 69
 hard, 39, 68, 78
 in newborn, 68
 tuberosity of, 40
- Palatine canals, 69
 cells, 65, 70
 foramen, greater, 40, 69
 lesser, 40, 70
 grooves, 68
 process, 39, 66, 68
 spines, 68
 suture, median, 39, 81
 transverse, 39, 81
- Palatoethmoidal suture, 80
- Palatomaxillary suture, 80

- Palm, tendons of, 205**
 flexor, 205
- Palmar aponeurosis, 198, 207, 208**
- Palmaris brevis muscle, 186, 198**
 function of, 199
 nerve supply of, 199
 longus muscle, 185, 191
 function of, 191
 nerve supply of, 191
- Palpebral ligament, internal, 179**
 muscles, 179
 portion of orbicularis oculi muscle, 179
 raphe, external, 179
- Paraglenoidal groove, 95**
- Parietal angle, 50**
 base, 36, 59
 angles of, 59
 borders of, 59
 development of, 59, 60
 in new-born, 60
 sulci of, 59
 surfaces of, 59
 border of frontal bone, 60
 of temporal bone, 52
 condylocondylar, 59
 foramen, 44, 59
 notch, 52
 surface of parietal bone, 59
- Parietomastoid suture, 38, 53, 79**
- Parotidomasseteric fascia, 184**
- Patella, 99**
 apex of, 99
 base of, 99
 development, 99
 surfaces of, 99
- Patellar ligament, 135**
 retinaculum, external, 135
 internal, 135
 surface of femur, 98
 synovial fold, 135
- Pectineal bursa, 234**
 fascia, 232
 line, 98
- Pectineus muscle, 209, 216**
 function of, 216
 nerve supply of, 216
- Pectoral fascia, 170**
- Pectoralis major muscle, 166**
 functions of, 167
 nerve supply of, 167
 minor muscle, 166, 168
 functions of, 168
 nerve supply of, 168
- Pedicles of vertebra, 23**
- Pelvic contraction, plane of, 130**
 diarthroses, 128
 expansion, plane of, 130
 girll, 93
 articulations of, 128
 ligaments of, 128
 inlet, 130
 ligaments, 128
 independent, 129
 outlet, 131
 synarthroses, 128
- Pelvis, 128, 130**
 aperture of, inferior, 131
- Pelvis, aperture of, superior, 130**
 bony, 93
 cavity of, 130
 diameters of, 131
 false, 130
 female, 131
 greater, 130
 lesser, 130
 ligaments of, 129
 male, 131
 true, 130
- Penniform muscles, 142**
- Perichondrium, 21**
- Periosteum, 21**
- Peroneus brevis muscle, 210, 223**
 functions of, 223
 nerve supply of, 223
 longus muscle, 210, 222
 function of, 222
 nerve supply of, 222
 sheath of, 231
 tertius muscle, 210, 224
 function of, 224
 nerve supply of, 224
- Peroneal groove, 103, 104**
 process, 103
 retinaculum, inferior, 230
 superior, 230
- Perpendicular plate of ethmoid bone, 62, 63**
 of palate bone, 60
- Pes anserinus, 214, 216**
- Petit's triangle, 147**
- Petoorcital fissure, 40, 43, 54, 81**
 synchondrosis, 81, 118
- Petrosal border of sphenoidal bone, 50**
 fossa, 56
 groove, inferior, 43, 45, 55
 superior, 43, 55
- Petrosquamosal fissure, 53, 54**
 suture, 81
- Petrotympenic fissure, 53, 57**
- Petrous portion of temporal bone, 40, 52, 54**
 apex of, 55
- Phalanges of foot, 82, 105**
 development, 106
 of hand, 82, 92
 articular capsules of, 127
 articulations of, 127
 borders of, 92
 development, 92
 movements of, 127
 shaft of, 92
 surfaces of, 92
 trochlea of, 92
 ungual, 92
- Pharyngeal canal, 40, 51**
 tubercle, 45
- Pillar of subcutaneous inguinal ring, 159**
 anterior, 159
 inferior, 158
 posterior, 159
 superior, 158
- Pinnate muscles, 142**
- Piriform bursa, 234**
- Piriformis muscle, 209, 212**
- Piriformis muscle, function of, 213**
 nerve supply of, 213
- Pisiform bone, 80, 90**
 articulation of, 124, 125
- Pisohamate ligament, 125**
- Pisometacarpal ligament, 125**
- Pituitary body, 48**
- Pivot joint, 100**
- Plane of pelvic contraction, 130**
 expansion, 130
- Plantar basal ligaments, 141**
 calcaneocuboid ligament, 141
 calcaneonavicular ligament, 141
 cuboideonavicular ligament, 141
 cubocuboid ligament, 141
 cuneiform, external, 233
 internal, 233
 middle, 225, 233
 intercuneiform ligaments, 141
 interossei muscles, 227, 228
 ligament, accessory, 130
 long, 141
 of foot, 140
 naviculari-cuneiform ligaments, 141
 surface, 18
 tarsal ligaments, 141
 tarsometatarsal ligaments, 141
- Plantaris muscle, 220**
- Planum nuchale, 41, 46**
 occipitale, 41, 46
 sternale, 34
 temporale, 38, 50, 52, 59, 60
- Platysma muscle, 171**
 functions of, 171
 nerve supply of, 171
- Pneumatic bones, 19**
- Polyaxial joints, 110**
- Popliteal bursa, 136, 221, 234**
 ligament, arcuate, 135
 oblique, 135
 line, 100
 space, 98
- Popliteus muscle, 210, 219, 220**
 function of, 221
 nerve supply of, 221
- Porus acusticus internus, 43**
- Positions, designations of, 17, 18**
- Postaxial muscles of lower extremity, 235**
 of upper extremity, 209
- Posterior abdominal muscle, 162**
 development, 164
 annular ligament, 203, 208
 arch of vertebra, 22
 articular facet of calcaneus, 103
 of talus, 102
 atlanto-occipital membrane, 115
 belly of digastric muscle, 171
 bursa of gluteus medius, 212
 capitular ligament, 136
 condyloid processes, 48
 condyloid canal, 40
 process of mandible, 72
 costotransverse ligament, 116
 cranial fossa, 41, 43
 crucial ligament, 134
 crus of subcutaneous inguinal ring, 159

- Posterior ethmoidal foramen**, 61, 75
 fontanelle, 81
 gluteal line, 94
 inferior spine of ilium, 94
 intercondyloid fossa, 99
 intermuscular septum, 233
 interoccipital synchondrosis, 47
 intertransversarius muscle, 155
 intraoccipital synchondrosis, 81
 lachrymal crest, 65
 layer of lumbodorsal fascia, 156
 ligament of external malleolus, 137
 longitudinal ligament of vertebral column, 111
 muscles of thigh, 218
 nares, 39
 nasal spine, 39, 69
 obturator membrane, 115
 tubercle, 95
 pelvic surface, 96
 pillar of subcutaneous inguinal ring, 159
 portion of quadratus lumborum muscle, 162
 process of talus, 102
 sacral foramina, 29
 sacrococcygeal ligaments, 113
 sacroiliac ligament, 129
 surface of fibula, 101
 of humerus, 86
 of legs, muscles of, 219
 of tibia, 100
 of ulna, 87
 of zygomatic bone, 71
 talocalcaneal ligament, 140
 talofibular ligament, 140
 talotibial ligament, 139
 trochanteric bursa of gluteus medius, 212, 234
Poupart's ligament, 131, 163
Preaxial muscles of lower extremity, 235
 of upper extremity, 209
Prepatellar bursa, subcutaneous, 136, 234
 subfascial, 136
 subtendinous, 136
Prevertebral cervical muscles, 176
 fascia, 177
Procerus nasi muscle, 178
Processes, 20
 accessory, 28
 acromion, 84
 alar, 63
 alveolar, 37, 66, 68
 articular, 20
 of vertebrae, 23
 coid, anterior, 41, 49
 middle, 48
 posterior, 48
 condyloid, 20, 38, 71, 72, 73
 coracoid, 84
 coronoid, of mandible, 38, 71, 73
 anterior, 72
 of ulna, 87
 costal, 24
 ethmoidal, of inferior turbinated, 64
 of calcaneus, 103
 of talus, 102
 falciform, 129
 frontal, of maxilla, 37, 66, 67
 frontosphenoidal, 37, 71
 hamular, 40, 51, 90
 inferior, of temporal bone, 57
 internal, of calcaneus, 103
 intrajugular, 46, 55
 jugular, 43, 46
 lachrymal, of inferior turbinated, 64
 mammillary, 28
 mastoid, 38, 40, 53, 54
 maxillary, of inferior turbinated, 64
 nasal, of maxilla, 37, 66, 67
 odontoid, 25, 26
 of sacrum, superior articular, 29
 of vertebrae, 23
 orbital, 70
 palatine, 39, 66, 68
 peroneal, 103
 posterior, of talus, 102
 pterygoid, 39, 47, 50
 pterygospinous, 51
 pyramidal, 40
 of palate bone, 70
 sphenoidal, of palate bone, 70
 spinous, of tibia, 99
 of vertebrae, 23
 styloid, of metacarpal bone, 91
 of radius, 89
 of temporal bone, 40, 56
 of ulna, 88
 supracondyloid, 87
 temporal, of ulnar bone, 71
 transverse, of vertebrae, 23
 trochlear, of calcaneus, 103
 unciform, 90
 uncinate, 64
 vaginal, of pterygoid processes, 49, 51
 of temporal bone, 56, 57
 xiphoid, 34
 foramen of, 36
 zygomatic, of frontal bone, 60
 of maxilla, 66, 67
 of temporal bone, 36, 38, 39, 52
Processus civinini, 51
 costarius, 24
 mastoides, 40
 pyramidalis, 40
Promontory, groove of, 58
 of vertebral column, 30
Pronation, 124
Pronator quadratus muscle, 185, 194
 function of, 194
 nerve supply of, 194
Psoas muscle, 185, 191
 function of, 191
 nerve supply of, 191
Protuberance, mental, 71
Proximal radioulnar articulation, 122
Psoas major muscle, 210
 minor muscle, 210, 211
Pterygoid canal, 50, 78
Pterygoid depression, 73
 fossa, 40, 51
 notch, 51
 plate, external, 40, 50
 internal, 40, 50
 process, 39, 47, 50
 tuberosity, 72
Pterygoidei muscles, 182, 183
 functions of, 184
 nerve supply of, 184
Pterygoideus externus muscle, 183
 internus muscle, 183
Pterygomandibular raphe, 182, 184
Pterygomaxillary ligament, 184
Pterygopalatine canal, 51, 69
 fossa, 50, 78
 groove, 51, 67, 69
Pterygospinous ligament, 119
 process, 51
Pubic angle, 131
 arch, 131
 ligaments, inferior, 128
 superior, 128
Pubis, 93, 95
 development, 96
 ramus of, 95, 96
Pubocapsular ligament, 132
Pulleys, 143
Pulmonary groove, 35
Pulpy nucleus of intervertebral fibrocartilage, 110
Pyramid of temporal bone, 52, 54
 apex of, 55
Pyramidal eminence, 57
 process of palate bone, 40, 70
Pyramidalis muscle, 161
 functions of, 162
 nerve supply of, 162
 nasi muscle, 178
QUADRATUS femoris muscle, 209, 213
 function of, 213
 nerve supply of, 213
labii inferioris muscle, 181
 superioris muscle, 180
lumborum muscle, 162
 functions of, 163
 nerve supply of, 163
plantae muscle, 210, 225
 function of, 225
 nerve supply of, 225
Quadriceps femoris muscle, 209, 214
 function of, 215
 nerve supply of, 215
 muscle, 142
Quadrilateral foramen, 166
RADIAL carpal eminence, 90
 fossa, 87
 head of flexor digitorum sublimis muscle, 192
 lateral ligament, 122, 126
 muscles of forearm, 104
 nerve groove for, 86
 notch of ulna, 87
Radiate carpal ligament, 127

- Radiate ligaments, 116, 117
 Radiocarpal articulations, 124
 ligament, dorsal, 126
 volar, 126
 Radioulnar articulation, distal, 123
 proximal, 122
 Radius, 82, 88
 and ulna, relations, 89
 articular circumference of, 88
 borders of, 88
 development, 89
 extremities of, 88
 head of, 88
 interosseous ridge of, 88
 neck of, 88
 nutrient canal of, 89
 shaft of, 88
 surfaces of, 88
 tuberosity of, 88
 Rax arcus vertebræ, 23
 Ramus of ischium, 94
 of mandible, 37, 71, 72
 of pubis, 93, 95, 96
 Rectus abdominis muscle, 161
 development, 164
 functions of, 162
 nerve supply of, 162
 capitis anterior major muscle, 176
 minor muscle, 177
 functions of, 177
 nerve supply of, 177
 lateralis muscle, 155
 functions of, 155
 nerve supply of, 155
 posterior major muscle, 155
 crest of, 147
 functions of, 155
 nerve supply of, 155
 minor muscle, 155
 functions of, 155
 nerve supply of, 155
 femoris muscle, 214
 muscles, 164
 external spine for, 76
 Red bone-marrow, 21
 Reflected inguinal ligament, 150, 164
 Reinforcing ligaments, 108
 Retinacula peroneorum, 222, 230
 Retinaculum of arcuate ligament, 135
 patellar, external, 135
 internal, 135
 peroneal, inferior, 230
 superior, 230
 tendon, 142, 143
 Retrahens auriculæ muscle, 179
 Rhachischisis, 36
 Rhomboid ligament, 119
 Rhomboideus major muscle, 147
 functions of, 147
 nerve supply of, 147
 minor muscles, 147
 functions of, 147
 nerve supply of, 147
 Ribs, 22, 32
 abdominal, 28
 angle of, 32
 articulations of, with sternum, 116,
 117
 Ribs, articulations of, with vertebral
 column, 26, 116, 117
 body of, 32
 bony, 32, 33
 cervical, 35
 curvature of, 33
 development of, 35
 eleventh, 33
 false, 33
 fenestration of, 36
 first, 32
 floating, 33
 head of, 32
 length of, 33
 lumbar, 28, 35
 movements of, 117
 neck of, 32
 sacral, 36
 second, 33
 surface curvature of, 33
 torsion curvature of, 33
 true, 33
 twelfth, 33
 typical, 32, 33
 Ring, abdominal, external, 158
 inguinal, subcutaneous, 158
 Ridge, bicipital, 86
 interosseous, of fibula, 101
 of radius, 88
 of tibia, 100
 of ulna, 87
 intertrochanteric, 97
 obturator, 95
 sphenomaxillary, 50
 scapinator, 87
 temporal, 38
 tubercular, greater, 86
 lesser, 86
 Risorius muscle, 180
 Roof of oral cavity, 78
 Root of vertebra, 23
 Rostrum, sphenoidal, 48, 49
 Rotary vertebra, 23
 Rotatores breves muscles, 152, 153
 longi muscles, 152, 153
 muscles, 152, 153
 functions of, 154
 nerve supply of, 154
 Round ligament, 132, 133

 SACULAR RECESS, 122, 123
 Sacral canal, 29
 cornu, 29
 foramina, 28, 29
 intervertebral, 29
 hiatus, 29, 31
 rib, 36
 tuberosity, 29
 Sacrococcygeal ligament, anterior, 113
 lateral, 113
 posterior, 113
 symphysis, 113
 Sacroiliac articulation, 128
 ligament, anterior, 129
 interosseous, 129
 posterior, 129
 Sacrosacral foramina, 130
 Sacrosacral ligament, greater, 129
 lesser, 129, 130
 Sacrospinalis muscle, 149
 functions of, 154
 nerve supply of, 154
 Sacrosphenoid ligament, 129, 130
 Sacrotuberous ligament, 129
 Sacrum, 28
 apex of, 28, 30
 base of, 28
 canal of, 29
 crests of, 29
 development of, 31
 dorsal surface of, 29
 female, 30
 foramina of, 28, 29
 intervertebral, 29
 joints of, 113
 male, 30
 movements of, 113
 pelvic surface of, 28
 processes of, superior articular, 29
 tuberosity of, 29
 upper surface of, 29
 Saddle joint, 110
 Sagittal border of parietal bone, 59
 groove, 44, 46, 60, 61
 plane, 17
 suture, 79
 Saphenous opening of fascia lata, 232
 vein, great, 232
 Sartorial bursa, 214
 Sartorius muscle, 209, 211
 function of, 214
 nerve supply of, 214
 Scapular tubercle, 32
 Scaleni muscles, 175
 functions of, 176
 nerve supply of, 176
 Scalenus anterior muscle, 175
 medius muscle, 175
 minimus muscle, 176
 posterior muscle, 175
 Scap, muscles of, 178
 Scaphoid bone of foot, 102, 103
 development, 106
 of hand, 89, 90
 fossa, 51
 Scapula, 83
 angles of, 83, 84
 base of, 83
 borders of, 83, 84
 development, 84
 head of, 84
 ligaments of, 120
 margins of, 83
 neck of, 84
 spine of, 83, 84
 surfaces of, 83
 Scapular notch, 84
 Scarpa's fascia, 103
 Sciatic bursa of gluteus maximus, 234
 foramen, great, 130
 lesser, 130
 notch, great, 94, 96
 lesser, 96
 Second cuneiform bone, 104
 Sella turcica, 41, 47, 48

- Semicanal for Eustachian tub -8
for tensor tympani, 58
- Semicircular line, 161
- Semilunar bone, 89, 90
cartilages, 133
function of, 136
line, 160
notch of ulnar, 87
surface of acetabulum, 96
- Semimembranous bursa, 136, 219, 234
muscle, 209, 218, 219
function of, 219
nerve supply of, 219
- Semispinalis capitis muscle, 151, 152
cervicis muscle, 152
dorsi muscle, 152
muscles, 152
functions of, 154
nerve supply of, 154
- Semitendinosus muscle, 209, 218
function of, 219
nerve supply of, 219
- Septum choanarum, 39, 66
intermuscular, 143
anterior, of leg, 233
external, of arm, 207
of thigh, 232
internal, of arm, 188, 207
of thigh, 232
of arm, 188, 207
of leg, 233
of thigh, 232
posterior, of leg, 233
nasal, 37, 76, 77
- Serrate suture, 107
- Serratus anterior muscle, 166, 168
functions of, 169
nerve supply of, 169
- magnus muscle, 168
functions of, 169
nerve supply of, 169
- posterior inferior muscle, 148, 171
functions of, 148
nerve supply of, 148
- superior muscle, 148, 171
functions of, 148
nerve supply of, 148
- Sesamoid bones, 143
of foot, 82, 106
of hand, 82, 92
- Sheath, intertubercular mucous, 121, 188
peroneus longus, 231
rectus abdominis, 161
synovial, of dorsal carpal ligament, 203
of fingers, 205
of flexor tendons of palm, 205
of foot, 229
- Short bones, 19
external lateral ligament of knee, 137
muscles, 142
of back, 154
development, 156
of neck, 155
development, 156
posterior sacroiliac ligament, 120
- Shoulder, articulations of, 121
- Shoulder girdle, 83
muscles of, 185, 186
classification, 209
- Shoulder-blade, 83. See also *Scapula*.
- Shoulder-joint, 121
movements of, 121
- Sigmoid groove, 43, 46, 53, 60
notch of mandible, 38, 71
of radius, 89
of ulna, greater, 87
lesser, 87
- Simple joint, 100
- Sinus, frontal, 61
development, 62
maxillary, 66
orifice of, 67
of tarsus, 102, 103
sphenoidal, 47
- Skeleton, appendicular, 22
axial, 22
divisions of, 22
of extremities, 22, 82
of foot, 101, 106
of free lower extremity, 97
upper extremity, 85
of hand, 92
of head, 22, 36
of lower extremities, 82, 93
of trunk, 22
variations in, 35
of upper extremities, 82, 83
- Skull, 36
anterior aspect of, 36
base of, external surface of, 39
internal surface of, 41
bones of, 44
developmental classification, 44
disarticulated, 36
external surface of base of, 39
inner aspect of, 44
lateral aspect of, 37
of newborn, 81
superior aspect of, 44
sutures of, 70
- Smiling muscle, 180
- Sockets for teeth, 68
- Sole of foot, muscles of, 225
- Soleus, arch of, 220
muscle, 219, 220
- Special anatomy, definition, 17
- Sphenothmoidal recess, 77
suture, 79
- Sphenofrontal suture, 37, 41, 49, 79
- Sphenoid bone, 37, 39, 47
body of, 47
borders of, 49, 50
cerebral juga of, 50
surface of, 42
development of, 51
digitate impressions of, 50
greater wing of, 42
in newborn, 51, 81
lesser wings of, 41
orbital crest of, 50
variations in, 51
wings of, greater, 47, 49
surfaces of, 49
lesser, 47, 49
- Sphenoid bone, wings of, orbital, 47, 49
temporal, 47, 49
spine of, 39
- Sphenoidal angle, 36, 59
cells, 63
crest, 48
fissure, 37, 42, 49, 74, 75
fontanelles, 82
process of palat. bone, 70
rostrum, 48, 49
sinus, 47
spine, 56
turbanated bones, 48
- Sphenomandibular ligament, 118
- Sphenomaxillary suture, 37, 39, 71, 74, 75
fossa, 49, 50, 78
ridge, 50
surface of sphenoidal bone, 50
suture, 81
- Sphenooccipital fissure, 45
synchondrosis, 41, 45, 47, 81
- Sphenoorbital suture, 79
- Sphenopalatine foramen, 70, 78
notch, 70
- Sphenoparietal suture, 37, 38, 42, 70, 82
- Sphenopetrosal fissure, 39, 40, 42, 54, 55, 81
synchondrosis, 81, 118
- Sphenosquamosal suture, 38, 39, 42, 43, 52, 80
- Sphenozygomatic suture, 37, 38, 50, 80
- Spheroid joints, 110
- Sphincter muscles, 142
oris muscle, 181
- Spiegelius' line, 160
- Spina recti lateralis, 50
- Spinal canal, 31
column, 22. See also *Vertebral column*.
- Spinalis capitis muscle, 151, 152
cervicis muscle, 151
dorsi muscle, 151
muscles, 149, 151
functions of, 154
nerve supply of, 154
- Spindle-shaped muscles, 142
- Spine, 20
anterior nasal, 37
ethmoidal, 41, 48
for external rectus muscle, 76
frontal, 61
mental, 72
nasal anterior, 68
posterior, 69
of ilium, anterior inferior, 94
superior, 94
posterior inferior, 94
of ischium, 96
of pubis, 95
of scapula, 83, 84
palatine, 68
sphenoidal, 56
supramental, 52
trochlear, 61
tympanic, greater, 57
lesser, 57

- Spinotransversalis muscle, 4
Spinous process of tibia, 99
 of vertebrae, 23
Spiral joint, 109
Splanchnology, definition, 17
Splenius capitis muscle, 148
 functions of, 148
 nerve supply of, 148
 cervicis muscle, 148
 functions of, 148
 nerve supply of, 148
Squamosal border of parietal bone, 59
 of sphenoid bone, 50
 suture, 38, 43, 52, 79
Squamosomastoid suture, 53, 59, 81
Squamous portions of occipital bone,
 38, 45, 46
 of temporal bone, 38, 49, 43, 52
 suture, 107
Stellate ligaments, 116, 117
Sternal extremity of clavicle, 85
 membrane, 117
 portion of diaphragm, 164
 synchondrosis, 117
Sternalis muscle, 167
Sternoclavicular articulation, 110
 ligament, 110
Sternocleidomastoideus muscle, 171
 functions of, 172
 nerve supply of, 172
Sternocostal articulations, 117
 portion of pectoralis major muscle,
 167
Sternohyoideus muscle, 172
Sternothyreoideus muscle, 172
Sternum, 22, 34
 angle of, 34
 articulations of ribs with, 116, 117
 body of, 34
 development of, 35
 foramen of, 39
 gladiolus of, 34
 manubrium of, 34
 notches of, 34
 xiphoid process of, 34
Straight abdominal muscle, 161
 development, 164
Stylohyoid ligament, 119
Stylohyoideus muscle, 174
 functions of, 174
 nerve supply of, 174
Styloid process of metacarpal bone, 91
 of radius, 80
 of temporal bone, 40, 50
 of ulna, 88
Stylomandibular ligament, 118, 184
Stylomastoid foramen, 40, 50
Stylomaxillary ligament, 184
Subacromial bursa, 208
Subarcuate fossa, 55
Subclavian groove, 33
Subclavius muscle, 166, 168
 functions of, 168
 nerve supply of, 168
Subcostal angle, 35
Subcostales muscles, 169, 170
Subcutaneous bursa of tuberosity of
 tibia, 234
Subcutaneous calcaneal bursa, 235
 colli muscle, 171
 digital bursa, dorsal, 208
 epicondylar bursa, 208
 external malleolar bursa, 234
 infrapatellar bursa, 136, 234
 inguinal ring, 158
 internal malleolar bursa, 234
 metacarpophalangeal bursa, dorsal,
 208
 olecranal bursa, 208
 prepatellar bursa, 136, 234
 trochanteric bursa, 234
Subdeltoid bursa, 186, 208
Subfascial prepatellar bursa, 136
Suboccipital triangle, 150
Subscapular bursa, 124, 188
 fascia, 107
 fossa, 23
Subscapularis muscle, 185
 functions of, 184
 nerve supply of, 188
Subtendinosus, 190
 tibialis ante-
 rior, 233
 posterior, 233
 bursa, 234
 anal bursa, 108
 prepatellar bursa, 136
Sulcus, 20
 arteriosus, 43, 44
 of frontal bone, 61
 of parietal bone, 59
 of sphenoid bone, 50
 of temporal bone, 53
 calcaneus, 107
 chiasmatis, 41, 48
 gluteal, 232
 nervi spinalis, 24
 tali, 102
 venosus, of parietal bone, 59
Superciliary arches, 60
Superficial fascia, general, 193
 head of flexor pollicis brevis muscle,
 199
 layer of arm muscles, 210
 of cervical fascia, 177
 of extensors of forearm, 196
 of flexor muscles of forearm, 191
 posterior sacrococcygeal ligament,
 113
 temporal fascia, 184
Superior angle of scapula, 83, 84
 aperture of pelvis, 130
 of tympanic canaliculus, 54
 articular processes of sacrum, 29
 surfaces of tibia, 99
 belly of omohyoideus muscle, 173
 bicipital bursa, 234
 border of scapula, 84
 cornu of fasciata, 232
 costotransverse ligament, 116
 crus of subcutaneous inguinal ring,
 158
 extremity of femur, 97
 of fibula, 101
 of humerus, 85
 of radius, 88
 of tibia, 99
Superior extremity of ulna, 87
 gluteal line, 94
 intervertebral notch, 23
 margin of scapula, 83
 maxillary, 66. See also *Maxilla*
 mentus of nose, 64, 77
 nuchal line, 41, 46
 occipital fossa, 46
 orbital fissure, 37, 42, 49, 74, 75
 peroneal retinaculum, 230
 petrosal groove, 43, 55
 pillar of subcutaneous inguinal ring,
 158
 pubic ligament, 128
 ramus of ischium, 94
 of pubis, 93, 95
 surface of talus, 102
 temporal line, 59
 thoracic aperture, 35
 transverse ligament, 120
 turbinate bone, 63
 vertebral notches, 23
Supernumerary bones, 82
Supination, 124
Supinator brevis muscle, 195
 longus muscle, 194
 muscle, 185, 195
 function of, 196
 nerve supply of, 196
 ridge, 87
Supraclavicular fossa, lesser, 174
Supracondylar process, 87
Supraglenoidal tuberosity, 84
Suprathyoid muscles, 174
Supramastoid ridge, 52
Supramental spine, 52
Supraorbital border of frontal bone,
 60
 foramen, 60, 75, 79
 margin, 75
 notch, 60, 75
Suprapatellar bursa, 135, 234
Supraspinatus fascia, 207
 fossa of scapula, 83
 muscle, 185, 186
 function of, 187
 nerve supply of, 187
Supraspinous ligament, 112
Surgical neck of humerus, 86
Sustentaculum tali, 103
Sutura mendosa, 47, 81
Sutura serrata, 59
Suture, 107
 coronal, 36, 37, 79
 ethmoidomaxillary, 80
 frontal, 60, 81
 frontoethmoidal, 41, 61, 81
 frontolachrymal, 37, 80
 frontomaxillary, 37, 80
 harmonic, 107
 incisive, 60, 81
 infraorbital, 68, 81
 intermaxillary, 37, 80
 internasal, 37, 65, 80
 lachrymoethmoidal, 80
 lachrymomaxillary, 80
 lambdoid, 38, 79

- Suture, median palatine, 39, 81
 mendosal, 47, 81
 metopic, 60, 62, 81
 nasofrontal, 37, 65, 80
 nasomaxillary, 37, 65, 80
 occipitomastoid, 38, 40, 43, 53, 79
 of skull, 79
 palatine, median, 39, 81
 transverse, 39, 81
 palatoethmoidal, 80
 palatomaxillary, 80
 parietomastoid, 38, 53, 79
 petrosquamosal, 81
 sagittal, 79
 serrate, 50, 107
 sphenothmoidal, 79
 sphenofrontal, 37, 41, 49, 79
 sphenomaxillary, 81
 sphenoorbital, 79
 sphenoparietal, 37, 38, 42, 79, 82
 sphenosquamosal, 38, 39, 42, 43, 52, 80
 sphenozygomatic, 37, 38, 50, 80
 squamosal, 38, 43, 52, 79, 107
 squamosomastoid, 53, 59, 81
 transverse palatine, 39, 81
 zygomaticofrontal, 39, 37, 80
 zygomaticomaxillary, 37, 39, 67, 80
 zygomaticotemporal, 38, 52, 80
- Symphysis, 107
 pubis, 95, 128
 sacrooccygeal, 113
- Synarthrosis, 107
 mixed, 107
 pelvic, 128
- Synchondrosis, 107
 epiphyseal, 21
 interoccipital, anterior, 47
 posterior, 47
 intersphenoidal, 51, 81
 intraoccipital, anterior, 81
 posterior, 81
 petrooccipital, 81, 118
 sphenoccipital, 41, 45, 47, 81
 sphenopetrosal, 81, 118
 sternal, 34, 117
- Syndesmology, 107
 definition, 17
 general, 107
 special, 110
- Syndesmosis, 107
 tibiofibular, 136, 147
 true, 107
- Synergists, 144
- Synovia, 108
- Synovial bursa, 108
 communicating, 108
 folds, 108
 patellar, 135
 layer of articular capsule, 108
 membrane, 108
 sheaths of dorsal carpal ligament, 203
 of fingers, 205
 of flexor tendons of palm, 205
 of foot, 220
 of peroneus longus, 234
 villi, 108
- Systematic anatomy, definition, 17
- TALOCALCANEAL articulation, 137, 138
 anterior, 138
 ligament, anterior, 140
 external, 140
 internal, 140
 interosseous, 140
 posterior, 140
- Talocalcaneonavicular articulation, 137, 138
- Talocrural articulation, 137
- Talofibular ligament, anterior, 140
 posterior, 140
- Talonavicular articulation, 138
 ligament, dorsal, 140
- Talotibial ligament, anterior, 139
 posterior, 139
- Talus, 102
 articular facets of, 102
 articulations of, 137
 body of, 102
 development, 106
 groove of, 102
 head of, 102, 103
 neck of, 102, 103
 surfaces of, 102
- Tarsal bones, 82, 102
 articulations of, 137, 138
 development, 106
 ligaments, 139
 dorsal, 140
 plantar, 141
- Tarsometatarsal articulations, 137, 139
 ligaments, dorsal, 141
 plantar, 141
- Tarsus, 102
 articulations of, 137, 138
 ligaments of, 139
 sinus of, 102, 103
 transverse articulation of, 138
- Tectorial membrane, 111, 115
- Teeth, alveoli for, 68, 71
 incisor, in fetus, 69
 sockets of, 68, 71
- Tegmen tympani, 55, 57
- Temporal bone, 37, 38, 51
 articular eminence of, 53
 canals of, 57
 development of, 58
 in newborn, 58, 59, 81
 inferior process of, 57
 mastoid portion of, 38, 40, 52, 53
 petrous portion of, 40, 52, 54
 apex of, 55
 pyramid of, 52, 54
 apex of, 55
 squamous portion of, 38, 49, 44, 52
 tympanic portion of, 38, 40, 52, 57
 fascia, 184
 fossa, 38
 line, 41, 60
 inferior, 59
 superior, 59
 process of zygomatic bone, 71
 ridge, 38
 surface of zygomatic bone, 71
- Temporal surface of sphenoid bone, 49, 50
 of squamous portion of temporal bone, 52
 wings of sphenoid bone, 47, 49
- Temporalis muscle, 182, 183
 functions of, 183
 nerve supply of, 183
- Temporomandibular articulation, 118
 ligament, 118
- Temporomaxillary articulation, 11
 Tendinous adductor opening, 217
 arches, 143
 inscriptions, 143
 of rectus abdominis, 161
- Tendo Achillis, 220
- Tendons, 142
 central, of diaphragm, 164, 165
 chiasma of, 207
 flexor, of palm, 205
 of fingers, extensor, 204
 of hand, extensor, 203
 of long head of biceps, 121
 of palm, 205
 retinacula, 142, 143
 vincula, 207
- Tendon-sheaths, 143
- Tensor fasciæ latæ muscle, 200, 213
 function of, 214
 nerve supply of, 214
 tympani, semicanal for, 58
- Teres major muscle, 185, 187
 function of, 187
 nerve supply of, 187
 minor muscle, 185, 187
 function of, 187
 nerve supply of, 187
- Terminal line of ilium, 95
- Thenar eminences, 198
 muscles of, 199
- Thigh, adductor muscles of, 216
 anterior surface of, muscles of, 214
 fascia of, 231
 flexors of, 218
 internal muscles of, 216
 muscles of, 214
 classification, 235
 posterior muscles of, 218
- Third (unciform) bone, 104
 trochanter, 98
- Thoracic muscles, 166
 vertebra, 26
 eleventh, 26, 27
 first, 26
 walls, muscles of, 169
- Thorax, 22, 35
 apertures of, 35
 muscles of, 166
 walls of, muscles of, 169
- Thumb, bones of, 92
 carpometacarpal joint of, 124, 125
 metacarpophalangeal articulation of, 127
- Thyrohyoidæus muscle, 172, 173
- Tibia, 82, 99
 and fibula, relations, 101
 articular surfaces of, inferior, 100
 superior, 99

- Tibia, articulations of, 136
 borders of, 100
 condyles of, 99
 crest of, 100
 development, 101
 extremities of, 99
 interosseous membrane of, 136, 137
 shaft of, 99, 100
 surfaces of inferior extremity of, 99
 of shaft of, 100
 of superior extremity of, 99
 tuberosity of, subcutaneous bursa of, 234
 Tibial lateral ligament, 134
 Tibialis anterior muscle, 210, 223
 function of, 223
 nerve supply of, 223
 posterior muscle, 210, 219, 221
 function of, 221
 nerve supply of, 221
 Tibiofibular articulation, 136
 syndesmosis, 136, 137
 Tibionavicular ligament, 139, 140
 Tissue, bony, 20
 Toes, articulations of, 137
 bones of, 105
 great, ball of, muscles of, 226
 little, ball of, muscles of, 227
 Topographic anatomy, definition, 17
 Torus palatinus, 78
 Trachelomastoid muscle, 151
 Transversalis capitis muscle, 151
 cervicis muscle, 151
 fascia, 163
 Transverse articulation of tarsus, 138
 capitular ligament of foot, 139
 of hand, 127
 carpal ligament, 127, 205
 crural ligament, 233
 fascioli, 233
 groove, 43, 46
 head of adductor hallucis muscle, 227
 ligament, inferior, 121
 of atlas, 114
 of hip, 131
 of knee, 134
 superior, 120
 lines of rectus abdominis, 161
 palatine suture, 39, 81
 plane, 17
 portion of nasalis muscle, 182
 processes of vertebrae, 23
 Transversocostal muscles, 156, 157
 Transversospinalis muscle, 149, 151, 157
 Transversus abdominis muscle, 157, 160
 functions of, 162
 nerve supply of, 162
 menti muscle, 181
 nuchae, 146, 179
 thoracis, 169, 170
 Trapezium, 89, 99
 Trapezium muscle, 145
 functions of, 149
 nerve supply of, 146
 Trapezoid, 89, 99
 Trapezoid ligament, 120
 Triangle, deltoidepectoral, 167
 femoral, 216
 lumbar, 147
 of Petit, 147
 suboccipital, 156
 Triangular ligament, 159, 164
 Triangularis labii inferioris muscle, 181
 superioris muscle, 181
 muscle, 181
 sterni muscle, 170
 Triceps brachii muscle, 142, 185, 189
 function of, 190
 heads of, 189, 190
 nerve supply of, 190
 surae muscle, 210, 219
 function of, 220
 nerve supply of, 220
 Trigeminal impression, 13, 55
 Triquetral bone, 89, 99
 Trochanteric bursa, 212
 of gluteus maximus, 233
 medius, anterior, 234
 posterior, 212, 234
 minimus, 234
 subcutaneous, 233
 fossa, 97
 Trochanters, 97
 greater, 97
 lesser, 97
 third, 98
 Trochlea, 143
 of phalanges of foot, 105
 of hand, 92
 of talus, 102
 Trochlear area of humerus, 86
 depression, 61, 79
 process of calcaneus, 103
 spine, 61
 Trochoid joint, 109
 True joints, 168
 pelvis, 130
 ribs, 33
 syndesmosis, 107
 vertebrae, 22
 Trunk, muscles of, 144
 skeleton of, 22
 variations in, 35
 Tubercle, 20
 carotid, 26
 costal, ligament of, 116
 intercondylar, external 99
 internal, 99
 jugular, 43, 46
 mental, 72
 obturator, anterior, 95
 posterior, 95
 of Chassaignac, 26
 of humerus, greater, 85
 lesser, 85
 of Lisfranc, 32
 of neck of ribs, 32
 of pubis, 95
 of talus, external, 102
 internal, 102
 of trapezium, 99
 pharyngeal, 45
 Tubercle, scalene, 32
 Tubercular ridge, greater, 86
 lesser, 86
 Tuberculum caroticum, 20
 sellae, 41, 48
 Tuberositas atlantis, 25
 Tuberosities, 20
 coracoid, 85
 costal, 85
 deltoid, 86
 gluteal, 98
 infraglenoidal, 84
 masseteric, 72
 of calcaneus, 103
 of fifth metatarsal bone, 105
 of first metatarsal bone, 105
 of hard palate, 40
 of ilium, 95
 of ischium, 96
 of maxilla, 67
 of navicular bone, 103
 of palate bone, 70
 of radius, 88
 of scaphoid bone, 103
 of tibia, 100
 subcutaneous bursa of, 234
 of ulna, 87
 pterygoid, 72
 sacral, 29
 supraglenoidal, 84
 ungual, 92, 105
 Tubular bones, 19
 Turbinate bones, 37, 77
 inferior, 64, 67, 77
 development, 64
 middle, 63
 sphenoidal, 48
 superior, 63
 Tympanic annulus, 81
 antrum, 54, 58
 canaliculus, 58
 aperture of, superior, 54
 groove, 57
 notch, 57
 portion of temporal bone, 38, 40, 52
 57
 spines, greater, 57
 lesser, 57
 Tympanomastoid fissure, 53, 57
 Tympano-quadrate fissure, 57
 Ulna, 82, 87
 and radius, relations, 89
 borders of, 87
 development, 88
 extremities of, 87, 88
 shaft of, 87
 surfaces of, 87
 Ulnar carpal eminence, 99
 head of flexor carpi ulnaris muscle, 102
 of pronator teres muscle, 101
 lateral ligament, 122, 126
 notch, 89
 Uniform bone, 89, 99
 process, 99
 Uncinate process, 64

Ungual phalanges, 92
 tuberosity, 92, 105
 Uniaxial joints, 109
 Unilocular joints, 108
 Upper arm, extensor surface of, muscles of, 189
 flexor surface of, muscles of, 188
 muscles of, 185, 188
 classification, 209
 extremity, articulations of, 119
 bursæ of, 208
 fasciæ of, 207
 free, skeleton of, 85
 ligaments of, 119
 muscles of, 185
 development, 209
 skeleton of, 82, 83
 thoracic muscles of, 166
 portion of longus colli muscle, 170
 VAGINÆ mucosæ, 147, 143
 Vaginal ligaments, 143
 of foot, 231
 process, 40, 51
 of temporal bone, 56, 57
 Vastus externus muscle, 215
 intermedius muscle, 215
 internus muscle, 215
 lateralis muscle, 215
 medialis muscle, 215
 Vein, saphenous, great, 232
 vertebral, canal for, 26
 Vena caval opening of diaphragm, 166
 Ventral arch of vertebra, 22
 Vertebrae, 22
 arches of, 22, 23
 articular processes of, 23
 bodies of, 22, 23
 connections of, 110
 caudales, 37
 cervical, 23
 characters of, 24
 first, 23, 25
 and second, articulations of, 113
 development, 31
 second, 23, 25
 development, 31

Vertebrae, cervical, seventh, 24
 third to sixth, 24
 development, 31
 false, 22, 28
 flexion, 23
 lumbar, 27
 lumbosacral, 30, 36
 pedicles of, 23
 processes of, 23
 prominens, 25
 root of, 23
 rotatory, 23
 spinous processes of, 23
 supernumerary, 35
 thoracic, 26
 first, 26
 twelfth, 26, 27
 transverse processes of, 23
 true, 22
 Vertebral arches, ligaments between, 112
 artery, 25
 canal for, 26
 border of scapula, 83
 canal, 31
 column, 22, 30
 articulation of ribs with, 116, 117, 261
 curvature of, 30
 development, 31
 intertransverse ligaments of, 112
 joints of, 110
 ligaments of, 111
 movements of, 113
 promontory of, 30
 margin of scapula, 83
 notches, 23
 vein, canal for, 26
 Vertical portion of squamous portion of temporal bone, 52
 Vidian canal, 50
 Villi, synovial, 108
 Vincula, 143
 of tendon, 207
 Visceral bones, 22
 Vitreous tables of flat bones, 19
 Volar basal ligaments, 127
 border of radius, 88
 of ulna, 87


Volar carpal ligament, 208
 carpometacarpal ligament, 127
 intercarpal ligament, 17
 ligaments, accessory, 127
 radiocarpal ligament, 126
 surface, 18
 of radius, 88
 of ulna, 87
 Vomer, 39, 65
 ala of, 65
 development, 66

WALLS of thorax, muscles of, 169
 Wings of sphenoid bone, 47, 49
 Wormian bones, 82
 Wrist-joint, 124

XIPHOID process, 34
 foramen of, 30

YELLOW bone-marrow, 21

ZONA orbicularis, 132
 Zygoma, 70
 Zygomatic arch, 38, 39, 40
 bone, 6, 70
 development, 71
 surfaces of, 71
 border of sphenoid bone, 50
 fossa, 79
 head of quadratus labii superioris muscle, 180
 process of frontal bone, 60
 of maxilla, 66, 67
 of temporal bone, 36, 38, 39, 52
 Zygomaticofacial foramen, 71
 Zygomaticofrontal suture, 36, 37, 80
 Zygomaticomaxillary suture, 37, 39, 67, 80
 Zygomaticoorbital foramen, 71, 75
 Zygomaticotemporal foramen, 71
 suture, 38, 52, 80
 Zygomaticus major muscle, 180
 minor muscle, 180
 muscles, 180





SAUNDERS' BOOKS

— on —

SURGERY

and

ANATOMY

W. B. SAUNDERS COMPANY

925 WALNUT STREET PHILADELPHIA
9, HENRIETTA STREET COVENT GARDEN, LONDON

SAUNDERS' REMARKABLE SUCCESS

WE are often asked to account for our extraordinary success. We can but point to modern business methods, carefully perfected business machinery, and unrivalled facilities for distribution of books. Every department is so organized that the greatest possible amount of work is produced with the least waste of energy. The representatives of the firm are men with life-long experience in the sale of medical books. Then, too, we must not overlook that major force in the modern business world—**advertising**. We have a special department devoted entirely to the planning, writing, and placing of advertising matter; and we might mention that the money annually spent in advertising now far exceeds the entire annual receipts of the House during its earlier years. These extraordinary facilities for disposing of large editions enable us to devote a large amount of money to the perfecting of every detail in the manufacture of books.

A Complete Catalogue of our Publications will be Sent upon Request

The prices of all books bound in sheep or half morocco have been advanced FIFTY CENTS PER VOLUME over the prices herein listed, excepting Keen's Surgery and Nothnagel's Practice

Keen's Surgery

AN UNABRIDGED TREATISE FOR THE SURGEON AND
THE GENERAL PRACTITIONER

Surgery: ITS PRINCIPLES AND PRACTICE. Written by 66 eminent specialists. Edited by W. W. KEEN, M.D., LL.D., HON. F.R.C.S., ENG. AND EDIN., Professor of the Principles of Surgery and of Clinical Surgery at the Jefferson Medical College, Philadelphia. Five large octavo volumes of about 950 pages each, containing 1500 text-illustrations and 50 colored plates. Per volume: Cloth, \$7.00 net; Half Morocco, \$8.00 net.

IN FIVE VOLUMES—1500 TEXT-CUTS AND 50 COLORED PLATES
VOLUME I—JUST READY

THE EMINENT CONTRIBUTORS

Robert Abbé, M.D.	David L. Edsall, M.D.	B. G. A. Moynihan, F.R.C.S.
J. G. Adam, M.D.	D. N. Esendrath, M.D.	J. G. Mumford, M.D.
E. Wyllys Andrews, M.D.	Wm. L. Estes, M.D.	John C. Munro, M.D.
G. E. Armstrong, M.D.	J. M. T. Finney, M.D.	John B. Murphy, M.D.
Thomas L. Bennett, M.D.	John A. Fordyce, M.D.	E. H. Nichols, M.D.
A. D. Bevan, M.D.	Chas. H. Frazier, M.D.	A. J. Ochsner, M.D.
Warren S. Bickham, M.D.	Leonard Freeman, M.D.	William Osler, M.D.
John F. Bunnie, M.D.	Frederick H. Gerrish, M.D.	Edmund Owen, F.R.C.S.
George E. Brewer, M.D.	John H. Gibbon, M.D.	Jos. Ransohoff, M.D.
J. Bland Sutton, F.R.C.S.	George Gottstein, M.D.	Brig. Gen. R. M. O'Reilly
A. T. Cabot, M.D.	Ludvig Becktoen, M.D.	Admiral P. M. Rixey,
Hampton L. Carson, Esq.	Orville Horwitz, M.D.	John B. Roberts, M.D.
E. A. Codman, M.D.	Albert Kocher, M.D.	A.W. Mayo Robson, F.R.C.S.
Wm. B. Coley, M.D.	Karl Gustav Lemander, M.D.	W. L. Rodman, M.D.
M. L. Coplin, M.D.	Bransford Lewis, M.D.	Eugene A. Smith, M.D.
George W. Cline, M.D.	R. W. Lovett, M.D.	Harmon Smith, M.D.
Harvey Cushing, M.D.	W. G. MacDonald, M.D.	Wm. G. Spiller, M.D.
J. Chalmers DaCosta, M.D.	Edward Martin, M.D.	Weller Van Hook, M.D.
John C. DaCosta, Jr., M.D.	Rudolph Matas, M.D.	J. P. Warlasse, M.D.
E. B. Dench, M.D.	Chas. A. Mayo, M.D.	F. C. Wood, M.D.
I. N. Dercum, M.D.	Wm. J. Mayo, M.D.	George Woodsey, M.D.
G. E. deSchweinitz, M.D.	Maj. Walter D. McCaw	Hugh H. Young, M.D.

Fowler's Treatise on Surgery

IN TWO VOLUMES

A Treatise on Surgery. By GEORGE R. FOWLER, M. D., Professor of Surgery (Emeritus), New York Polyclinic, Surgeon to the Methodist Episcopal (Seney) Hospital, Brooklyn; Surgeon-in-Chief to the Brooklyn Hospital. Two imperial octavo volumes of 725 pages each, containing 888 original text-illustrations and 4 colored plates. Per set: Cloth, \$15.00 net; Half Morocco, \$17.00 net.

**JUST READY
WITH 888 ORIGINAL ILLUSTRATIONS**

This entirely new work presents the science and art of surgery as it is practised to-day. The first part of the work deals with general surgery, and embraces what is usually included under the head of principles of surgery. Special attention is given to the subject of inflammation from the surgeon's point of view, due consideration being accorded the influences of traumatism and bacterial infection as the predisposing and exciting causes of this condition. Then follow sections on the injuries and diseases of separate tissues, gunshot injuries, acute wound diseases, chronic surgical infections (including syphilis), tumors, surgical operations in general, foreign bodies, and bandaging. The second part of the work is really the clinical portion, devoted to regional surgery. Herein the author especially endeavors to emphasize those injuries and surgical diseases that are of the greatest importance, not only because of their frequency, but also because of the difficulty of diagnosis and the special care demanded in their treatment. The text is elaborately illustrated with entirely new and original illustrations.

Rudolph Matas, M. D., *Professor of Surgery, Tulane University of Louisiana.*

"After a careful examination of this work I am glad to state that the completed text fully confirms the assurance I entertained. That this work would prove a text book of high order and abstruse merit. These splendid volumes fully justify the repute of their author for earnestness, thoroughness, and learning."

Howard A. Kelly

and E. HURDON on the

Vermiform Appendix

RECENTLY ISSUED—AN AUTHORITATIVE WORK

The Vermiform Appendix and Its Diseases. By HOWARD A. KELLY, M. D., Professor of Gynecology in the Johns Hopkins University, Baltimore; and E. HURDON, M. D., Assistant in Gynecology in the Johns Hopkins University, Baltimore. Handsome octavo volume of 827 pages, containing 399 superb original illustrations and 3 lithographic plates. Cloth, \$10.00 net; Half Morocco, \$11.00 net.

WITH 399 SUPERB ORIGINAL ILLUSTRATIONS

This work is one of the most magnificent medical books ever published, containing some four hundred beautiful illustrations, in the preparation of which the artists of the Johns Hopkins Hospital have spent many years. Each beautifully and accurately portrays the condition represented, and together they form a magnificent collection unequalled by those in any other work on the subject ever placed upon the market. A large amount of original work has been done for the anatomic chapter, for which over one hundred original illustrations have been made. *Appendicitis* naturally receives the fullest consideration. The pathology is not only amply and clearly described, but it is beautifully illuminated with an abundance of illustrations depicting the pathologic conditions with rare fidelity. Diagnosis and treatment, by far the most important sections to the practitioner and surgeon, are elaborately discussed and profusely illustrated. Special chapters are devoted to the peculiarities of appendicitis in children, and to the characteristics of the vermiform appendix in typhoid fever. A valuable chapter is that on the medicolegal status of appendicitis.

British Medical Journal

"It reaches the high-water mark of medical monographs, both in regard to the learning, research, and clinical reasoning of the text, and in the quality of its illustrations. These are really magnificent."

Kelly and Noble's Gynecology and Abdominal Surgery

Gynecology and Abdominal Surgery. Edited by HOWARD A. KELLY, M. D., Professor of Gynecology in Johns Hopkins University; and CHARLES P. NOBLE, M. D., Clinical Professor of Gynecology in the Woman's Medical College, Philadelphia. Two imperial octavo volumes of 900 pages each, containing 650 original illustrations, some in colors.

IN TWO VOLUMES—VOLUME I JUST READY

WITH 650 ILLUSTRATIONS BY MAX BRÖDEL AND HERMANN BECKER

In view of the intimate association of gynecology with abdominal surgery the editors have combined these two important subjects in one work. For this reason the work will be doubly valuable, for not only the gynecologist and general practitioner will find it an exhaustive treatise, but the surgeon also will find here the latest technic of the various abdominal operations. It possesses a number of valuable features not to be found in any other publication covering the same fields. It contains a chapter upon the bacteriology and one upon the pathology of gynecology, dealing fully with the scientific basis of gynecology. In no other work can this information, prepared by specialists, be found as separate chapters. There is a large chapter devoted entirely to *medical gynecology*, written especially for the physician engaged in general practice. Heretofore the general practitioner was compelled to search through an entire work in order to obtain the information desired. *Abdominal surgery* proper, as distinct from gynecology, is fully treated, embracing operations upon the stomach, upon the intestines, upon the liver and bile-ducts, upon the pancreas and spleen, upon the kidneys, ureter, bladder, and the peritoneum. Special attention has been given to *modern technic* and illustrations of the very highest order have been used to make clear the various steps of the operations. Indeed the illustrations are truly magnificent, being the work of *Mr. Max Brödel* and *Mr. Hermann Becker* of the Johns Hopkins Hospital.

Moynihan's Abdominal Operations

Abdominal Operations. By B. G. A. MOYNIHAN, M. S. (LOND.), F.R.C.S., Senior Assistant Surgeon, Leeds General Infirmary, England. Octavo, beautifully illustrated. Cloth, \$7.00 net; Half Morocco, \$8.00 net.

JUST ISSUED—NEW (2nd) EDITION

TWO LARGE EDITIONS IN ONE YEAR

It has been said of Mr. Moynihan that in describing details of operations he is at his best. The appearance of this, his latest work, therefore, will be widely welcomed by the medical profession, giving, as it does, in most clear and exact language, not only the actual *modus operandi* of the various abdominal operations, but also the preliminary technic of preparation and sterilization. Complications and sequelae and after-treatment are presented in the same clear, clean-cut manner as the operations themselves. The beautiful illustrations have been especially drawn.

Edward Martin, M. D.

Professor of Clinical Surgery, University of Pennsylvania

"It is a wonderfully good book. He has achieved complete success in illustrating, both by words and pictures, the best technique of the abdominal operations now commonly performed."

Moynihan on Gall-stones

Gall-stones and Their Surgical Treatment. By B. G. A. MOYNIHAN, M. S. (LOND.), F.R.C.S., Senior Assistant Surgeon, Leeds General Infirmary, England. Octavo of 458 pages, fully illustrated. Cloth, \$5.00 net; Half Morocco, \$6.00 net.

RECENTLY ISSUED—NEW (2d) EDITION

Mr. Moynihan, in revising his book, has made many additions to the text, so as to include the most recent advances. Especial attention has been given to a detailed description of the early symptoms in cholelithiasis, enabling a diagnosis to be made in the stage in which surgical treatment can be most safely adopted. Every phrase of gall-stone disease is dealt with, and is illustrated by a large number of clinical records. The account of the operative treatment of all the forms and complications of gall-stone disease is full and accurate. A number of the illustrations are in color.

British Medical Journal

"He expresses his views with admirable clearness, and he supports them by a large number of clinical examples, which will be much prized by those who know the difficult problems and tasks which gall-stone surgery not infrequently presents."

Scudder's Treatment of Fractures

WITH NOTES ON DISLOCATIONS

The Treatment of Fractures: with Notes on a few Common Dislocations. By CHARLES L. SCUDDER, M. D., Surgeon to the Massachusetts General Hospital, Boston. Octavo volume of 562 pages, with 736 original illustrations. Polished Buckram, \$5.00 net; Half Morocco, \$6.00 net.

**RECENTLY ISSUED NEW (5th) EDITION, ENLARGED
FIVE LARGE EDITIONS IN LESS THAN FIVE YEARS**

Five large editions of this remarkable work have been called for in less than five years. For this new fifth edition Dr. Scudder has made numerous additions throughout the text, and has added some fifty new illustrations, greatly enhancing the value of the work. The articles on Dislocations, illustrated in that practical manner which has made Dr. Scudder's work so useful, will be found extremely valuable.

Joseph D. Bryant, M.D., *Professor of the Principles and Practice of Surgery, University and Bellevue Hospital Medical College.*

"As a practical demonstration of the topic it is excellent, and as an example of bookmaking it is highly commendable."

Bickham's Operative Surgery

A Text-Book of Operative Surgery. By WARREN STONE BICKHAM, M. D., PH.D., M., Visiting Surgeon to Charity Hospital and to Touro Hospital, New Orleans. Octavo of 1000 pages, with 559 beautiful illustrations, nearly all original. Cloth, \$6.00 net; Half Morocco, \$7.00 net.

RECENTLY ISSUED, 2nd EDITION—TWO EDITIONS IN SIX MONTHS

This absolutely new work completely covers the surgical anatomy and operative technic involved in the operations of general surgery. The practicability of the work is particularly emphasized in the 559 magnificent illustrations which form a useful and striking feature.

Nicholas Senn, M. D., *Professor of Surgery, Rush Medical College.*

"A somewhat careful examination of the text and illustrations of Dr. Bickham's book on Operative Surgery has satisfied me of its merits. The book will meet with favor on the part of teachers, students, and practitioners."

Gould's Operations on the Intestines and Stomach

The Technic of Operations upon the Intestines and Stomach. By ALFRED H. GOULD, M. D., of Boston. Large octavo, with 190 original illustrations, some in colors. Cloth, \$5.00 net; Half Morocco, \$6.00 net.

JUST ISSUED

Dr. Gould's new work is the result of exhaustive experimentation, the technic of the operations described being simplified as far as possible by experiments on animals, thus leading to the development of many new features. The text is purposely concise, the technic being presented very clearly by the numerous practical illustrations, all made from actual operations done either upon the animal or the human being. As the success of gastro-intestinal surgery depends upon an accurate knowledge of the elementary steps, a thorough account of repair is included, followed by a full description of all the important stitches, knots, and instruments used in intestinal surgery.

DaCosta's Modern Surgery

Modern Surgery—GENERAL AND OPERATIVE. By JOHN CHALMERS DACOSTA, M. D., Professor of the Principles of Surgery and of Clinical Surgery in the Jefferson Medical College, Philadelphia. Octavo of 1283 pages, with 872 illustrations. Cloth, \$5.50 net; Half Morocco, \$6.50 net.

JUST ISSUED—THE NEW (5th) EDITION

For this new fifth edition the work has been entirely rewritten and reset. One hundred new practical illustrations have been added; and the work has been enlarged by the addition of two hundred pages. To keep the book of a size to handle conveniently, a thinner but high grade paper has been used. Da Costa's Surgery in this edition will more than maintain the reputation already won.

The Medical Record, New York

"The work throughout is notable for its conciseness. Redundance of language and padding have been scrupulously avoided, while at the same time it contains a sufficient amount of information to fulfil the object aimed at by its author—namely, a text book for the use of the student and the busy practitioner."

Schultze and Stewart's Topographic Anatomy

Atlas and Text-Book of Topographic and Applied Anatomy. By PROF. DR. O. SCHULTZE, of Würzburg. Edited, with additions, by GEORGE D. STEWART, M.D., Professor of Anatomy and Clinical Surgery, University and Bellevue Hospital Medical College, N. Y. Large quarto of 189 pages, with 25 colored figures on 22 colored lithographic plates, and 89 text-cuts, 60 in colors. Cloth, \$5.50 net.

RECENTLY ISSUED

It was Professor Schultze's special aim, in preparing this work, to produce a Text-Book and Atlas, not for the anatomist alone, but more particularly for the general practitioner. The value of the knowledge of topographic anatomy in bedside diagnosis is emphasized throughout the book. The many colored lithographic plates are exceptionally excellent.

Arthur Dean Bevan, M.D., *Professor of Surgery in Rush Medical College, Chicago.*

"I regard Schultze and Stewart's Topographic and Applied Anatomy as a very admirable work, for students especially, and I find the plates and the text excellent."

Sobotta and McMurrich's Human Anatomy

Atlas and Text-Book of Human Anatomy. In Three Volumes. By J. SOBOTTA, M.D., of Würzburg. Edited, with additions, by J. PLAYFAIR McMURRICH, A. M., Ph.D., Professor of Anatomy, University of Michigan, Ann Arbor. Three large quartos, each containing about 250 pages of text and over 300 illustrations, mostly in colors. Per volume: Cloth, \$6.00 net.

JUST READY

The great advantage of this over other similar works lies in the large number of magnificent lithographic plates which it contains, without question the best that have ever been produced in this field. They are accurate and beautiful reproductions of the various anatomic parts represented.

Edward Martin, M.D., *Professor of Clinical Surgery, University of Pennsylvania.*

This is a piece of bookmaking which is truly admirable, with plates and text so well chosen and so clear that the work is most useful to the practising surgeon."

Eisendrath's Surgical Diagnosis

A Text-Book of Surgical Diagnosis. By DANIEL N. EISENDRATH, M.D., Adjunct Professor of Surgery and Clinical Surgery, College of Physicians and Surgeons, Chicago. Octavo of 600 pages, with 400 entirely new and original text-illustrations and some colored plates. Cloth, \$6.50 net; Half Morocco, \$8.00 net.

JUST READY

WITH 400 ORIGINAL ILLUSTRATIONS

Of first importance in every surgical condition is a correct diagnosis, for upon this depends the treatment to be pursued; and the two—diagnosis and treatment—constitute the most practical part of practical surgery. Dr. Eisendrath takes up each disease and injury amenable to surgical treatment, and sets forth the means of correct diagnosis in a systematic and comprehensive way. Definite directions as to methods of examination are presented clearly and concisely, providing for all contingencies that might arise in any given case. The magnificent illustrations, some four hundred in number, are all entirely new and original, having been drawn directly under Dr. Eisendrath's personal supervision. They are not only excellent from an artistic standpoint, but also from a practical point of view, for each one indicates precisely how to diagnose the various conditions.

Eisendrath's Clinical Anatomy

A Text-Book of Clinical Anatomy. By DANIEL N. EISENDRATH, A. B., M. D., Adjunct Professor of Surgery and Clinical Surgery, College of Physicians and Surgeons, Chicago. Octavo of 515 pages, illustrated. Cloth, \$5.00 net; Sheep or Half Morocco, \$6.00 net.

RECENTLY ISSUED

This new anatomy discusses the subject from the clinical standpoint. A portion of each chapter is devoted to the examination of the living through palpation and marking of surface outlines of landmarks, vessels, nerves, thoracic and abdominal viscera. The illustrations are from new and original drawings and photographs.

Medical Record, New York

A special recommendation for the figures is that they are mostly original and were made for the purpose in view. "The sections of joints and trunks are those of formalized cadavers and are unimpeachable in accuracy."

International Text-Book of Surgery

SECOND EDITION, THOROUGHLY REVISED AND ENLARGED

The International Text-Book of Surgery. In two volumes. By American and British authors. Edited by J. COLLINS WARREN, M.D., LL.D., F.R.C.S. (Hon.), Professor of Surgery, Harvard Medical School; and A. PEARCE GOULD, M.S., F.R.C.S., of London, England.—Vol. I. *General and Operative Surgery.* Royal octavo, 975 pages, 461 illustrations, 9 full-page colored plates.—Vol. II. *Special or Regional Surgery.* Royal octavo, 1122 pages, 499 illustrations, and 8 full-page colored plates.

Per volume: Cloth, \$5.00 net; Half Morocco, \$6.00 net.

ADOPTED BY THE U. S. ARMY

In this new edition the entire book has been carefully revised, and special effort has been made to bring the work down to the present day. The articles on the effect upon the human body of the various kinds of bullets, and the results of surgery in the field are based on the latest reports of the surgeons in the field.

American Text-Book of Surgery

American Text-Book of Surgery. Edited by W. W. KEES, M.D., LL.D., Hon. F.R.C.S., Eng. and Lond., and J. WILLIAM WHITE, M.D., Ph.D. Octavo, 1363 pages, 551 text cuts and 30 colored and half-tone plates. Cloth, \$7.00 net; Half Morocco, \$8.00 net.

FOURTH EDITION, RECENTLY ISSUED—OVER 42,000 COPIES

In this present edition every chapter has been extensively modified, and many of them have been partially, and some entirely, rewritten. Six entirely new chapters appear: *Military Surgery, Nasal Surgery, Tropical Surgery, Examination of the Blood, Immunity, and Surgery of the Pancreas.*

Edmund Owen, F.R.C.S., *Member Royal College of Surgeons, London*

"Personally I should not mind it being called **The** Text-Book (instead of **A** Text-Book) for I know of no single volume which contains so readable and complete an account of the science and art of surgery as this does.

American Illustrated Dictionary**Just Issued
New (4th) Edition**

The American Illustrated Medical Dictionary. With tables of Arteries, Muscles, Nerves, Veins, etc.; of Bacilli, Bacteria, etc.; Eponymic Tables of Diseases, Operations, Stains, Tests, etc. By W. A. NEWMAN DORLAND, M.D. Large octavo, 840 pages. Flexible leather, \$4.50 net; with thumb index, \$5.00 net.

Howard A. Kelly, M.D., *Professor of Gynecology, Johns Hopkins University, Baltimore.*

"Dr. Dorland's dictionary is admirable. It is so well gotten up and of such convenient size. No errors have been found in my use of it."

Golebiewski and Bailey's Accident Diseases

Atlas and Epitome of Diseases Caused by Accidents. By DR. ED. GOLEBIEWSKI, of Berlin. Edited, with additions, by PEARCE BAILEY, M.D. Consulting Neurologist to St. Luke's Hospital, New York City. With 71 colored figures on 40 plates, 143 text-cuts, and 549 pages of text. Cloth, \$4.00 net. *In Saunders' Hand-Atlas Series.*

Helferich and Bloodgood on Fractures

Atlas and Epitome of Traumatic Fractures and Dislocations By PROF. DR. H. HELFERICH, of Greifswald, Prussia. Edited, with additions, by JOSEPH C. BLOODGOOD, M. D., Associate in Surgery, Johns Hopkins University, Baltimore. 216 colored figures on 64 lithographic plates, 190 text cuts, and 353 pages of text. Cloth, \$3.00 net. *In Saunders' Atlas Series.*

Sultan and Coley on Abdominal Hernias

Atlas and Epitome of Abdominal Hernias. By PR. DR. G. SULTAN, of Gottingen. Edited, with additions, by WM. B. COLEY, M. D., Clinical Lecturer and Instructor in Surgery, Columbia University, New York. 119 illustrations, 36 in colors, and 277 pages of text. Cloth, \$3.00 net. *In Saunders' Hand-Atlas Series.*

Warren's Surgical Pathology**Second
Edition**

Surgical Pathology and Therapeutics. By J. COLLINS WARREN, M.D., F.F.D., F.R.C.S. (Hon.), Professor of Surgery, Harvard Medical School. Octavo, 873 pages; 136 illustrations, 33 in colors. Cloth, \$5.00 net; Half Morocco, \$6.00 net.

Zuckerkindl and DaCosta's Surgery**Second
Edition**

Atlas and Epitome of Operative Surgery. By DR. O. ZUCKERKINDL, of Vienna. Edited, with additions, by J. CHAMBERS DACOSTA, M.D., Professor of the Principles of Surgery and Clinical Surgery, Jefferson Medical College, Phila. 40 colored plates, 278 text cuts, and 410 pages of text. Cloth, \$3.50 net. *In Saunders' Atlas Series.*

Lewis' Anatomy and Physiology for Nurses Just Issued

Anatomy and Physiology for Nurses. By LEROY LEWIS, M. D., Surgeon to and Lecturer on Anatomy and Physiology for Nurses at the Lewis Hospital, Bay City, Michigan. 12mo, 317 pages, with 146 illustrations. Cloth, \$1.75 net.

A demand for such a work as this, *treating the subjects from the nurse's point of view*, has long existed. Dr. Lewis has based the plan and scope of this work on the methods employed by him in teaching these branches, making the text unusually simple and clear.

Nurses Journal of the Pacific Coast

"It is not in any sense rudimentary, but comprehensive in its treatment of the subjects in hand."

McClellan's Art Anatomy Recently Issued

Anatomy in Its Relation to Art. By GEORGE MCCLELLAN, M. D., Professor of Anatomy, Pennsylvania Academy of the Fine Arts. Quarto volume, 9 by 12½ inches, with 338 original drawings and photographs, and 260 pages of text. Dark blue vellum, \$10.00 net; Half Russia, \$12.00 net.

Howard Pyle, in the Philadelphia Medical Journal

"The book is one of the best and the most thorough text-books of art-anatomy which it has been the writer's fortune to fall upon, and, as a text-book, it ought to make its way into the field for which it is intended."

Senn on Tumors Second Revised Edition

Pathology and Surgical Treatment of Tumors. By NICHOLAS SENN, M. D., Ph. D., LL. D., Professor of Surgery, Rush Medical College, Chicago. Handsome octavo, 718 pages, with 478 engravings, including 12 full page colored plates. Cloth, \$5.00 net; Sheep or Half Morocco, \$6.00 net.

Journal of the American Medical Association

"The most exhaustive of any recent book in English on this subject. It is well illustrated and will doubtless remain as the principal monograph on the subject for some years."

Senn Practical Surgery Based on Dr. Senn's 25 Years' Experience

Practical Surgery. A Work for the General Practitioner. By NICHOLAS SENN, M. D., Ph. D., LL. D., Professor of Surgery in Rush Medical College, Chicago. Octavo of 1133 pages, with 650 illustrations, many in colors. Cloth, \$6.00; Sheep or Half Morocco, \$7.00 net. *Sold by Subscription*

"It is of value not only as presenting comprehensively the most advanced teachings of modern surgery in the subjects which it takes up, but also as a record of the matured opinions and practice of an accomplished and experienced surgeon."—*Annals of Surgery*

Macdonald's Diagnosis and Treatment

A Clinical Text-Book of Surgical Diagnosis and Treatment. By F. W. MACDONALD, M. D. (Edn.), F.R.C.S. (Edn.), Professor Emeritus of the Practice of Surgery and of Clinical Surgery in Hamline University, Minneapolis. Octavo, 798 pages, illus. Cloth, \$5.00 net; Sheep or Half Morocco, \$6.00 net

Haynes' Anatomy

A Manual of Anatomy. By IRVING S. HAYNES, M.D., Professor of Practical Anatomy, Cornell University Medical College. Octavo, 680 pages, with 42 diagrams and 134 full-page half-tones. Cloth, \$2.50 net.

"This book is the work of a practical instructor—one who knows by experience the requirements of the average student, and is able to meet these requirements in a very satisfactory way."—*The Medical Record, New York.*

American Pocket Dictionary

Recently Issued
Fourth Revised Edition

The American Pocket Medical Dictionary. Edited by W. A. NEWMAN DORLAND, A.M., M.D., Assistant Obstetrician, Hospital of the University of Pennsylvania, etc. 566 pages. Full leather, limp, with gold edges, \$1.00 net; with patent thumb index, \$1.25 net.

"I am struck at once with admiration at the compact size and attractive exterior. I can recommend it to our students without reserve!"—JAMES W. HOLLAND, M.D., *Professor of Medical Chemistry and Toxicology, at the Jefferson Medical College, Philadelphia.*

Beck's Fractures

Fractures. By CARL BECK, M.D., Professor of Surgery, New York Post-graduate Medical School and Hospital. With an Appendix on the Practical Use of the Röntgen Rays. 335 pages, 170 illustrations. Cloth, \$3.50 net.

"The use of the rays with its technic is fully explained, and the practical points are brought out with a thoroughness that merits high praise."—*The Medical Record, New York.*

Barton and Wells' Medical Thesaurus

Recently Issued

A Thesaurus of Medical Words and Phrases. By WILFRED M. BARTON, M. D., Assistant to Professor of Materia Medica and Therapeutics, and Lecturer on Pharmacy, Georgetown University, Washington, D. C.; and WALTER A. WELLS, M. D., Demonstrator of Laryngology, Georgetown University, Washington, D. C. 12mo of 534 pages. Flexible leather, \$2.50 net; with thumb index, \$3.00 net.

Stoney's Surgical Technic

Recently Issued
New (2d) Edition

Bacteriology and Surgical Technic for Nurses. By EMMA M. A. STONEY, Superintendent at the Carney Hospital, South Boston, Mass. Revised by FREDERIC R. GRIFFITH, M. D., Surgeon, of New York. 12mo, 266 pages, illustrated. \$1.50 net.

"These subjects are treated most accurately and up to date, without the superfluous reading which is so often employed. Nurses will find this book of the greatest value."—*Practical Nurse and Hospital Review.*

Grant on Face, Mouth, and Jaws

A Text-Book of the Surgical Principles and Surgical Diseases of the Face, Mouth, and Jaws. For Dental Students. By H. HORACE GRANT, A.M., M.D., Professor of Surgery and of Clinical Surgery, Hospital College of Medicine. Octavo of 231 pages, with 68 illustrations. Cloth, \$2.50 net.

"The language of the book is simple and clear. We recommend the work to those for whom it is intended."—*Philadelphia Medical Journal.*

Preiswerk and Warren's Dentistry

Just Issued

Atlas and Epitome of Dentistry. By PROF. G. PREISWERK, of Basel. Edited, with additions, by GEORGE W. WARREN, D.D.S., Professor of Operative Dentistry, Pennsylvania College of Dental Surgery, Philadelphia. With 44 lithographic plates, 152 text cuts, and 343 pages of text. Cloth, \$3.50 net. *In Saunders' Atlas Series.*

"Nowhere in dental literature have we ever seen illustration which can begin to compare with the exquisite colored plates produced in this volume."—*Dental Review.*

Beck's Surgical Asepsis

A Manual of Surgical Asepsis. By CARL BECK, M.D. 65 pages, 65 text-illustrations and 12 full-page plates. Cloth, \$1.25 net.

"The book is well written. The data are clearly and concisely given. The facts are well arranged. It is well worth reading to the student, the physician in general practice, and the surgeon."—*Boston Medical and Surgical Journal.*

Griffith's Hand-Book of Surgery

Recently Issued

A Manual of Surgery. By FREDERIC R. GRIFFITH, M.D., Surgeon to the Bellevue Dispensary, New York City. 12mo of 579 pages, with 417 illustrations. Flexible leather, \$2.00 net.

"Well adapted to the needs of the student and to the busy practitioner for a hasty review of important points in surgery."—*American Medicine.*

Senn's Syllabus of Surgery

A Syllabus of Lectures on the Practice of Surgery. Arranged in conformity with "American Text-Book of Surgery." By NICHOLAS SENN, M.D., PH.D., LL.D., Professor of Surgery, Rush Medical College, Chicago. Cloth, \$1.50 net.

"The author has evidently spared no pains in making his Syllabus thoroughly comprehensive, and has added new matter and alluded to the most recent authors and operations. Full references are also given to all requisite details of surgical anatomy and pathology."—*British Medical Journal.*

Keen's Addresses and Other Papers

Recently Issued

Addresses and Other Papers. Delivered by WILLIAM W. KEEN, M.D., LL.D., F.R.C.S. (Hon.), Professor of the Principles of Surgery and of Clinical Surgery, Jefferson Medical College, Philadelphia. Octavo volume of 441 pages, illustrated. Cloth, \$3.75 net.

Keen on the Surgery of Typhoid

The Surgical Complications and Sequels of Typhoid Fever. By WM. W. KEEN, M.D., LL.D., F.R.C.S. (Hon.), Professor of the Principles of Surgery and of Clinical Surgery, Jefferson Medical College, Philadelphia, etc. Octavo volume of 386 pages, illustrated. Cloth, \$3.00 net.

"Every surgical incident which can occur during or after typhoid fever is amply discussed and fully illustrated by cases. . . . The book will be useful both to the surgeon and physician."—*The Practitioner, London.*

Moore's Orthopedic Surgery

A Manual of Orthopedic Surgery. By JAMES E. MOORE, M.D., Professor of Clinical Surgery, University of Minnesota, College of Medicine and Surgery. Octavo of 356 pages, handsomely illustrated. Cloth, \$2.50 net.

"The book is eminently practical. It is a safe guide in the understanding and treatment of orthopedic cases. Should be owned by every surgeon and practitioner."—*Annals of Surgery.*

Fowler's Operating Room

Just Issued

The Operating Room and the Patient. By RUSSELL S. FOWLER, M. D., Surgeon to the German Hospital, Brooklyn, New York. Octavo of 172 pages, illustrated. Cloth, \$2.00 net.

Dr. Fowler has written his book for surgeons, nurses assisting at an operation, internes, and all others whose duties bring them into the operating room. It contains explicit directions for the preparation of material, instruments needed, position of patient, etc.—all beautifully illustrated.

Nancrede's Principles of Surgery

Recently Issued
New (2d) Edition

Lectures on the Principles of Surgery. By CHAS. B. NANCREDE, M.D., LL.D., Professor of Surgery and of Clinical Surgery, University of Michigan, Ann Arbor. Octavo, 407 pages, illustrated. Cloth, \$2.50 net.

"We can strongly recommend this book to all students and those who would see something of the scientific foundation upon which the art of surgery is built."—*Quarterly Medical Journal, Sheffield, England.*

Nancrede's Essentials of Anatomy.

Recently Issued
Seventh Edition

Essentials of Anatomy, including the Anatomy of the Viscera. By CHAS. B. NANCREDE, M.D., Professor of Surgery and of Clinical Surgery, University of Michigan, Ann Arbor. Crown octavo, 388 pages; 180 cuts. With an Appendix containing over 60 illustrations of the osteology of the body. Based on *Gray's Anatomy*. Cloth, \$1.00 net. *In Saunders' Question Compend.*

"The questions have been wisely selected, and the answers accurately and concisely given."—*University Medical Magazine.*

Martin's Essentials of Surgery.

Seventh Edition
Revised

Essentials of Surgery. Containing also Venereal Diseases, Surgical Landmarks, Minor and Operative Surgery, and a complete description, with illustrations, of the Handkerchief and Roller Bandages. By EDWARD MARTIN, A.M., M.D., Professor of Clinical Surgery, University of Pennsylvania, etc. Crown octavo, 338 pages, illustrated. With an Appendix on Anti-septic Surgery, etc. Cloth, \$1.00 net. *In Saunders' Question Compend.*

"Written to assist the student, it will be of undoubted value to the practitioner, containing as it does the essence of surgical work."—*Boston Medical and Surgical Journal.*

Martin's Essentials of Minor Surgery, Bandaging, and Venereal Diseases.

Second Revised
Edition

Essentials of Minor Surgery, Bandaging, and Venereal Diseases. By EDWARD MARTIN, A.M., M.D., Professor of Clinical Surgery, University of Pennsylvania, etc. Crown octavo, 166 pages, with 78 illustrations.

Cloth, \$1.00 net. *In Saunders' Question Compend.*

"The best condensation of the subjects of which it treats yet placed before the profession."—*The Medical News, Philadelphia.*



