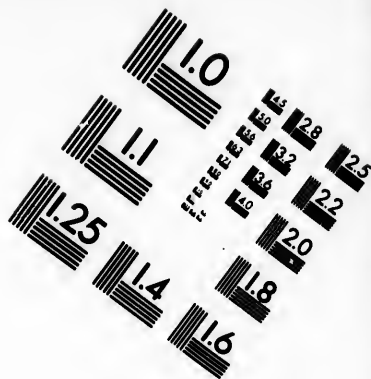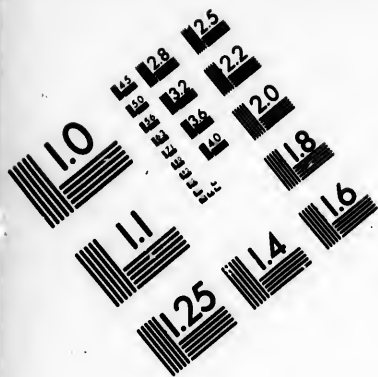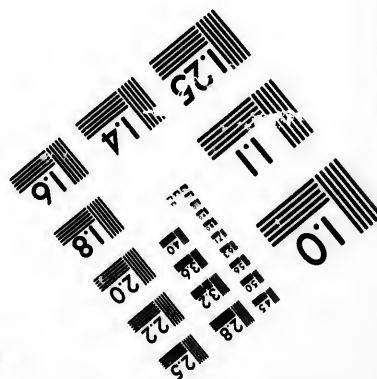

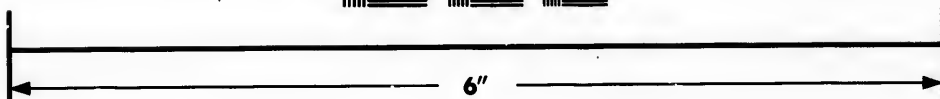



**IMAGE EVALUATION  
TEST TARGET (MT-3)**



**Photographic  
Sciences  
Corporation**

23 WEST MAIN STREET  
WEBSTER, N.Y. 14580  
(716) 872-4503

**CIHM/ICMH  
Microfiche  
Series.**

**CIHM/ICMH  
Collection de  
microfiches.**



**Canadian Institute for Historical Microreproductions / Institut canadien de microreproductions historiques**

**© 1985**

Technical and Bibliographic Notes/Notes techniques et bibliographiques

The Institute has attempted to obtain the best original copy available for filming. Features of this copy which may be bibliographically unique, which may alter any of the images in the reproduction, or which may significantly change the usual method of filming, are checked below.

L'institut a microfilmé le meilleur exemplaire qu'il lui a été possible de se procurer. Les détails de cet exemplaire qui sont peut-être uniques du point de vue bibliographique, qui peuvent modifier une image reproduite, ou qui peuvent exiger une modification dans la méthode normale de filmage sont indiqués ci-dessous.

- |  |  |
|--|--|
| <input type="checkbox"/> Coloured covers/<br>Couverture de couleur   | <input type="checkbox"/> Coloured pages/<br>Pages de couleur   |
| <input type="checkbox"/> Covers damaged/<br>Couverture endommagée  | <input type="checkbox"/> Pages damaged/<br>Pages endommagées   |
| <input type="checkbox"/> Covers restored and/or laminated/<br>Couverture restaurée et/ou pelliculée  | <input type="checkbox"/> Pages restored and/or laminated/<br>Pages restaurées et/ou pelliculées  |
| <input type="checkbox"/> Cover title missing/<br>Le titre de couverture manque   | <input checked="" type="checkbox"/> Pages discoloured, stained or foxed/<br>Pages décolorées, tachetées ou piquées   |
| <input type="checkbox"/> Coloured maps/<br>Cartes géographiques en couleur   | <input type="checkbox"/> Pages detached/<br>Pages détachées  |
| <input type="checkbox"/> Coloured ink (i.e. other than blue or black)/<br>Encre de couleur (i.e. autre que bleue ou noire)   | <input checked="" type="checkbox"/> Showthrough/<br>Transparence   |
| <input type="checkbox"/> Coloured plates and/or illustrations/<br>Planches et/ou illustrations en couleur  | <input type="checkbox"/> Quality of print varies/<br>Qualité inégale de l'impression   |
| <input checked="" type="checkbox"/> Bound with other material/<br>Relié avec d'autres documents  | <input type="checkbox"/> Includes supplementary material/<br>Comprend du matériel supplémentaire   |
| <input type="checkbox"/> Tight binding may cause shadows or distortion<br>along interior margin/<br>La reliure serrée peut causer de l'ombre ou de la<br>distorsion le long de la marge intérieure   | <input type="checkbox"/> Only edition available/<br>Seule édition disponible   |
| <input type="checkbox"/> Blank leaves added during restoration may<br>appear within the text. Whenever possible, these<br>have been omitted from filming/<br>Il se peut que certaines pages blanches ajoutées<br>lors d'une restauration apparaissent dans le texte,<br>mais, lorsque cela était possible, ces pages n'ont<br>pas été filmées. | <input type="checkbox"/> Pages wholly or partially obscured by errata<br>slips, tissues, etc., have been refilmed to<br>ensure the best possible image/<br>Les pages totalement ou partiellement<br>obscurcies par un feuillet d'errata, une pelure,<br>etc., ont été filmées à nouveau de façon à<br>obtenir la meilleure image possible. |
| <input type="checkbox"/> Additional comments:/<br>Commentaires supplémentaires:  |  |

This item is filmed at the reduction ratio checked below/  
Ce document est filmé au taux de réduction indiqué ci-dessous.

|                          |                          |                          |                                     |                          |                          |
|--------------------------|--------------------------|--------------------------|-------------------------------------|--------------------------|--------------------------|
| 10X                      | 14X                      | 18X                      | 22X                                 | 26X                      | 30X                      |
| <input type="checkbox"/> | <input type="checkbox"/> | <input type="checkbox"/> | <input checked="" type="checkbox"/> | <input type="checkbox"/> | <input type="checkbox"/> |
| 12X                      | 16X                      | 20X                      | 24X                                 | 28X                      | 32X                      |

The copy filmed here has been reproduced thanks to the generosity of:

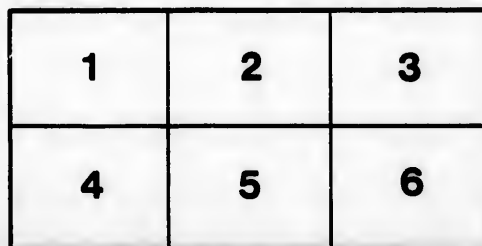
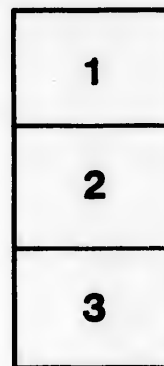
Medical Library  
McGill University  
Montreal

The images appearing here are the best quality possible considering the condition and legibility of the original copy and in keeping with the filming contract specifications.

Original copies in printed paper covers are filmed beginning with the front cover and ending on the last page with a printed or illustrated impression, or the back cover when appropriate. All other original copies are filmed beginning on the first page with a printed or illustrated impression, and ending on the last page with a printed or illustrated impression.

The last recorded frame on each microfiche shall contain the symbol  $\rightarrow$  (meaning "CONTINUED"), or the symbol  $\nabla$  (meaning "END"), whichever applies.

Maps, plates, charts, etc., may be filmed at different reduction ratios. Those too large to be entirely included in one exposure are filmed beginning in the upper left hand corner, left to right and top to bottom, as many frames as required. The following diagrams illustrate the method:



L'exemplaire filmé fut reproduit grâce à la générosité de:

Medical Library  
McGill University  
Montreal

Les images suivantes ont été reproduites avec le plus grand soin, compte tenu de la condition et de la netteté de l'exemplaire filmé, et en conformité avec les conditions du contrat de filmage.

Les exemplaires originaux dont la couverture en papier est imprimée sont filmés en commençant par le premier plat et en terminant soit par la dernière page qui comporte une empreinte d'impression ou d'illustration, soit par le second plat, selon le cas. Tous les autres exemplaires originaux sont filmés en commençant par la première page qui comporte une empreinte d'impression ou d'illustration et en terminant par la dernière page qui comporte une telle empreinte.


Un des symboles suivants apparaîtra sur la dernière image de chaque microfiche, selon le cas: le symbole  $\rightarrow$  signifie "A SUIVRE", le symbole  $\nabla$  signifie "FIN".

Les cartes, planches, tableaux, etc., peuvent être filmés à des taux de réduction différents. Lorsque le document est trop grand pour être reproduit en un seul cliché, il est filmé à partir de l'angle supérieur gauche, de gauche à droite, et de haut en bas, en prenant le nombre d'images nécessaire. Les diagrammes suivants illustrent la méthode.

errata  
to

pelure,  
n à

32X



80

## EXCISION OF THE SCAPULA FOR SARCOMA.<sup>1</sup>

BY

FRANCIS J. SHEPHERD, M.D.,

Professor of Anatomy and Lecturer on Operative Surgery, McGill University; Surgeon to the Montreal General Hospital.

The operation of excision of the scapula for disease is one of comparative rarity, so much so that I deemed it not unimportant to place on record a case in which I have lately operated. As far as I am aware no case has previously been recorded in Canadian medical literature. Langenbeck was the first to remove the entire scapula for disease in 1855; the patient was a boy aged 12. In 1856 Mr. Syme removed the whole scapula from a woman aged 70, for tumour. Since then the bone has been occasionally removed for disease, but more frequently for injury. As far as my knowledge goes the whole upper extremity has been removed more often than the scapula alone, chiefly because primary disease confined to the scapula is rare. The case related below was sent me by Dr. Wm. Ferguson, of Kingston, New Brunswick, who had made an early diagnosis of the condition.

Mrs. C., married, æt. 33, was admitted into a private ward of the Montreal General Hospital on June 25th, 1896, for an enlargement of the left scapula. She has always been strong and healthy until last winter. Whilst driving a long distance and holding a child in her arms, she felt a severe pain in her shoulder; this pain continued intermittently from that time. Two months before entering hospital she consulted Dr. Ferguson for pain in the left shoulder and also down the left arm. He at that time made a careful examination of the shoulder, but could detect nothing abnormal, so thinking the pain was rheumatic, he prescribed accordingly. A few weeks later the patient had a bronchial attack and was confined to bed, and at this time, when applying remedies to the chest, her sister discovered a lack of symmetry in the scapular regions, and Dr. Ferguson was again called and discovered a tumour below the spine of the left scapula. I saw her a week later and by that time the tumour had become well marked. It was confined to the fossa below the spine of the scapula. It was the size of a closed fist, fixed, firm, non-fluctuating, was not tender and moved with the scapula. Operation was recommended and agreed to.

*Operation, June 26th.*—After being etherized the left arm was

<sup>1</sup> Read before the Canadian Medical Association Montreal, August, 1896.

bandaged and the parts about the scapula cleansed. An incision was made from the acromion process to the superior angle of the scapula and continued down the posterior border to the inferior angle. The skin was now rapidly dissected away, and then the muscles attached to the spine and vertebral border were cut through, viz., the trapezius levator anguli scapulae and the rhomboids. Here the bleeding was free from the muscular branches of the posterior scapular artery. The scapula was now lifted up and the serratus magnus muscle severed and the vessels secured. To complete the excision of the lower end of the scapula, it was necessary to make a second horizontal incision at the base of the vertical one. The muscles attached to the superior border of the bone were now cut through, viz., infra spinatus, omohyoid and deltoid. The tip of the acromion being quite free from disease, was sawn through leaving the deltoid and trapezius muscles attached. The joint was now opened and the muscles of the axillary border (viz., teres major and minor, latissimus dorsi and long head of the triceps) detached, the end of the coracoid process was cut through with forceps, leaving the attachment of the biceps, coracobrachialis and the pectoralis minor. The long head of the biceps was cut through when the joint was opened. The scapula and the tumour was now removed. The patient lost but little blood during the operation, though there was much oozing, for which a rubber drain was introduced at the lower end of the wound. The patient made an uninterrupted recovery, the wound healing by first intention. A week after operation there was some rise of temperature and a fluctuating tumour felt; this was opened and found to be synovial fluid secreted by the joint, which when removed immediately relieved the symptoms.

In two weeks the patient was out driving and left for home well on the 16th of July, but having her left arm in a sling. Dr. Wyatt Johnston who examined the scapula, reported that the tumour was a myeloid sarcoma and confined to the infraspinous fossa.

