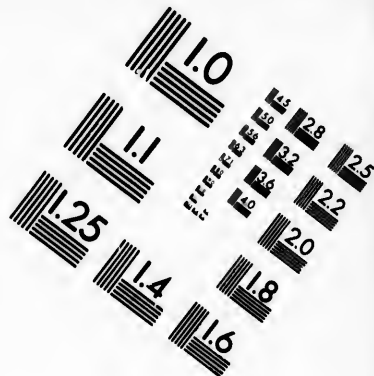
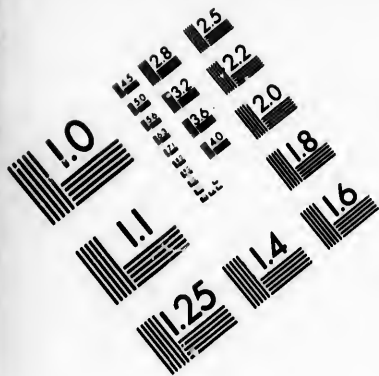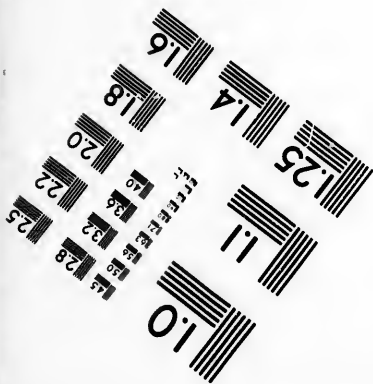
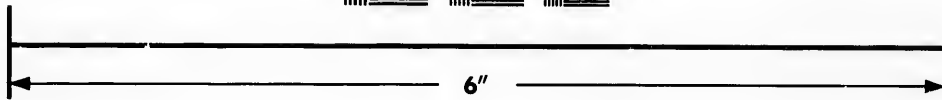



**IMAGE EVALUATION
TEST TARGET (MT-3)**



**Photographic
Sciences
Corporation**

23 WEST MAIN STREET
WEBSTER, N.Y. 14580
(716) 872-4503

128
132
22
20
8

**CIHM/ICMH
Microfiche
Series.**

**CIHM/ICMH
Collection de
microfiches.**



Canadian Institute for Historical Microreproductions / Institut canadien de microreproductions historiques

10

© 1985

Technical and Bibliographic Notes/Notes techniques et bibliographiques

The Institute has attempted to obtain the best original copy available for filming. Features of this copy which may be bibliographically unique, which may alter any of the images in the reproduction, or which may significantly change the usual method of filming, are checked below.

L'Institut a microfilmé le meilleur exemplaire qu'il lui a été possible de se procurer. Les détails de cet exemplaire qui sont peut-être uniques du point de vue bibliographique, qui peuvent modifier une image reproduite, ou qui peuvent exiger une modification dans la méthode normale de filmage sont indiqués ci-dessous.

- Coloured covers/
Couverture de couleur
- Covers damaged/
Couverture endommagée
- Covers restored and/or laminated/
Couverture restaurée et/ou pelliculée
- Cover title missing/
Le titre de couverture manque
- Coloured maps/
Cartes géographiques en couleur
- Coloured ink (i.e. other than blue or black)/
Encre de couleur (i.e. autre que bleue ou noire)
- Coloured plates and/or illustrations/
Planches et/ou illustrations en couleur
- Bound with other material/
Relié avec d'autres documents
- Tight binding may cause shadows or distortion
along interior margin/
La reliure serrée peut causer de l'ombre ou de la
distorsion le long de la marge intérieure
- Blank leaves added during restoration may
appear within the text. Whenever possible, these
have been omitted from filming/
Il se peut que certaines pages blanches ajoutées
lors d'une restauration apparaissent dans le texte,
mais, lorsque cela était possible, ces pages n'ont
pas été filmées.
- Additional comments:/
Commentaires supplémentaires:

- Coloured pages/
Pages de couleur
- Pages damaged/
Pages endommagées
- Pages restored and/or laminated/
Pages restaurées et/ou pelliculées
- Pages discoloured, stained or foxed/
Pages décolorées, tachetées ou piquées
- Pages detached/
Pages détachées
- Showthrough/
Transparence
- Quality of print varies/
Qualité inégale de l'impression
- Includes supplementary material/
Comprend du matériel supplémentaire
- Only edition available/
Seule édition disponible
- Pages wholly or partially obscured by errata
slips, tissues, etc., have been refilmed to
ensure the best possible image/
Les pages totalement ou partiellement
obscurcies par un feuillet d'errata, une pelure,
etc., ont été filmées à nouveau de façon à
obtenir la meilleure image possible.

This item is filmed at the reduction ratio checked below/
Ce document est filmé au taux de réduction indiqué ci-dessous.

10X	14X	18X	22X	26X	30X
<input type="checkbox"/>	<input type="checkbox"/>	<input type="checkbox"/>	<input checked="" type="checkbox"/>	<input type="checkbox"/>	<input type="checkbox"/>
12X	16X	20X	24X	28X	32X

The copy filmed here has been reproduced thanks to the generosity of:

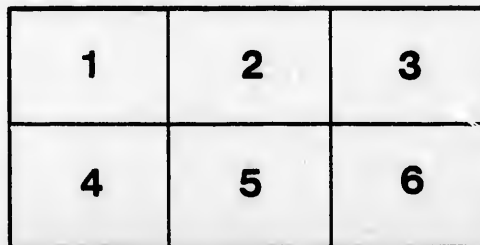
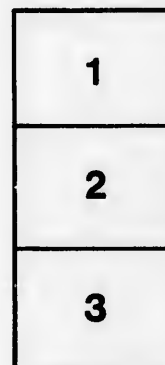
Medical Library
McGill University
Montreal

The images appearing here are the best quality possible considering the condition and legibility of the original copy and in keeping with the filming contract specifications.

Original copies in printed paper covers are filmed beginning with the front cover and ending on the last page with a printed or illustrated impression, or the back cover when appropriate. All other original copies are filmed beginning on the first page with a printed or illustrated impression, and ending on the last page with a printed or illustrated impression.

The last recorded frame on each microfiche shall contain the symbol \rightarrow (meaning "CONTINUED"), or the symbol ∇ (meaning "END"), whichever applies.

Maps, plates, charts, etc., may be filmed at different reduction ratios. Those too large to be entirely included in one exposure are filmed beginning in the upper left hand corner, left to right and top to bottom, as many frames as required. The following diagrams illustrate the method:



L'exemplaire filmé fut reproduit grâce à la générosité de:

Medical Library
McGill University
Montreal

Les images suivantes ont été reproduites avec le plus grand soin, compte tenu de la condition et de la netteté de l'exemplaire filmé, et en conformité avec les conditions du contrat de filmage.

Les exemplaires originaux dont la couverture en papier est imprimée sont filmés en commençant par le premier plat et en terminant soit par la dernière page qui comporte une empreinte d'impression ou d'illustration, soit par le second plat, selon le cas. Tous les autres exemplaires originaux sont filmés en commençant par la première page qui comporte une empreinte d'impression ou d'illustration et en terminant par la dernière page qui comporte une telle empreinte.

Un des symboles suivants apparaîtra sur la dernière image de chaque microfiche, selon le cas: le symbole \rightarrow signifie "A SUIVRE", le symbole ∇ signifie "FIN".

Les cartes, planches, tableaux, etc., peuvent être filmés à des taux de réduction différents. Lorsque le document est trop grand pour être reproduit en un seul cliché, il est filmé à partir de l'angle supérieur gauche, de gauche à droite, et de haut en bas, en prenant le nombre d'images nécessaire. Les diagrammes suivants illustrent la méthode.

SOME REMARKS
ON
PENETRATING WOUNDS OF THE EYEBALL.

BY
F. BULLER, M.D.,
PROFESSOR OF OPHTHALMOLOGY, MCGILL UNIVERSITY.

(Read before the Canadian Medical Association, at Ottawa, September, 1888.)

SOME REMARKS ON PENETRATING WOUNDS OF THE EYEBALL.

BY FRANK BULLER, M.D.,
Professor of Ophthalmology, McGill University.

(Paper read before the Canadian Medical Association, at Ottawa, September, 1888.)

Accidental penetrating wounds of the eyeball are liable to prove disastrous in three principal ways :

- (1) From the immediate destructive character of the injury.
- (2) From the consecutive inflammatory reaction.
- (3) From extension of the latter to the other eye.

With the first of these factors the ophthalmic surgeon has nothing to do, but with the second and third his responsibility may be grave in the extreme. Notwithstanding the well-known rules of procedure in the management of injuries to the eye, none but the expert can justly appreciate the difficulties and dangers that now and then require to be faced. For my own part, many years' experience have impressed me more and more with one important fact ; that is, the paramount importance of immediate attention to this class of injuries. I have no statistics to offer, but I am quite sure the lack of prompt and suitable treatment is the chief element in the disastrous results so often seen to follow comparatively unimportant injuries.

I do not propose to take up the whole subject of traumatic lesions of the eye, but will confine my remarks to penetrating wounds in what is known as the ciliary region—that is, a zone of the eyeball bounded in front by the cornea and behind by the posterior extremities of the ciliary processes. The breadth of this

zone is about five or six millimetres. It has been called the dangerous region, from the belief that wounds of this part were particularly liable to be followed by sympathetic ophthalmia. With certain reservations the designation may be accepted, inasmuch as the vast majority of sympathetic ophthalmias are associated with cyclitic trouble in the exciting eye. On the other hand, it is undoubtedly true that wounds in this region are often not followed by any serious consequences, even when left to the *vis medicatrix natura*. I have seen extensive ruptures of the eyeball from excessive violence in this region recover with fairly good vision, without any surgical interference whatever. Such a favorable result, however, can only be regarded as exceptional. On the other hand, comparatively trivial injuries in this locality are not infrequently followed by loss of vision in one or both eyes. If the injury has involved the lens to the extent of causing traumatic cataract, there is always considerable risk of disastrous complications. Under these circumstances, a more or less protracted irido-cyclitis, with all its attendant dangers, may be unavoidable.

Clean cut wounds, either with or without traumatic cataract, are, as a rule, much more amenable to treatment than are lacerations or injuries inflicted with blunt objects which tear and bruise the part injured; here, in addition to the unfavorable nature of the wound itself, the whole eyeball is more likely to have suffered greater violence, besides which, septic or irritating substances are more likely to lodge in the wound or inside the eyeball when the penetrating wound has been effected in this way. This observation affords a natural indication in the management of all wounds in the ciliary region.

Whenever such a wound, whether clean cut or lacerated, is allowed to heal with any portion of the uveal structures entangled in the scleral aperture, there is a serious risk of consecutive irido-cyclitis and of sympathetic ophthalmia. It is for this reason that immediate attention, if possible, within a few hours after the injury, is almost indispensable to success. Every ophthalmic surgeon of any considerable experience has seen many cases of sympathetic ophthalmia which could have been prevented by proper attention to the original lesion.

I believe all authorities on injuries of the eye agree in advising the restoration or removal of a prolapsed iris when this structure is found entangled in the wound ; any prolapse of the ciliary body, they say, should be cut off. As far as it goes, this advice is sound enough, though too often in practice sadly neglected ; but in regard to entanglement of portions of the ciliary body, the recommendation is, in my opinion, much too vague. I hold that the edges of the wound should be completely freed of uvea throughout its extent ; this can often only be accomplished by separating the edges of the wound, and with fine scissors and forceps clearing away all the uvea from its inner surface so that the bare and clean sclerotic can be brought into accurate coaptation with one or more fine sutures. This is a procedure I have repeatedly carried out, and always with the most satisfactory results, but to be effectual, it should be done early, within twenty-four hours of the injury. The usual antiseptic precautions are, of course, observed prior to and during the operation, and, indeed, for two or three days after. The wound by this time will have healed, and the continued use of antiseptics is then hardly necessary.

In stitching the sclerotic, I sometimes pass the needle through its whole thickness, but it answers just as well to go less deeply ; in any case, a fine and exceedingly sharp needle should be used. The so-called Hagadorn's needle is the best. The silk sutures may be of the finest. I always use No. 1 for this purpose. After the operation of cleaning and uniting the scleral wound in this way there is apt to be a pretty sharp inflammatory reaction ; but this can be controlled by iced compresses soaked in a weak solution of perchloride and changed frequently. This treatment should be commenced as soon after the operation as the eye begins to become painful, and should be continued until all reaction has ceased : three or four days will usually suffice. Atropine instillations and the internal use of antipyrin are accessory measures of some value.

Some ten years ago I reported a case of complete recovery after an extensive wound involving cornea, iris, sclerotic and ciliary body. Figure 1 represents the position and extent of

the wound inflicted by the bursting of a soda-water bottle. There was a clean cut through the inner edge of the cornea, thence upwards and backwards through the ciliary region. There was

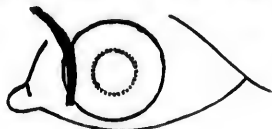


FIGURE 1.

no injury of the lens, but some vitreous had escaped, and both iris and corresponding portion of the ciliary body were prolapsed and engaged in the wound. These being thoroughly cleared away, two stitches were inserted, one at the sclero-corneal juncture, the other about four millimetres further back. These secured good coaptation of the scleral edges. A perfect recovery ensued, and the eye maintained a normal appearance, with the exception of the large iridectomy inwards. Vision being nearly perfect when an acquired myopic astigmatism was corrected with a suitable concave cylinder glass.

Two other cases of quite recent occurrence are also good illustrations of the same class of injury. Figure 2 is that of an

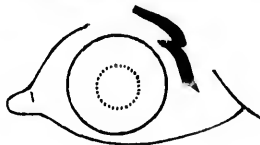

FIGURE 2.

eye which I treated a few weeks ago for a long wound across the upper and outer part of the ciliary region, likewise a bottle accident. There was a long jagged wound through the upper eyelid, and a similar wound in the sclerotic, more than half an inch in length. Much of the vitreous had escaped. The anterior chamber was filled with blood, and the eye had a collapsed appearance. Owing to the lateness of the hour repair of the wound was delayed until the following day. One stitch sufficed to unite the scleral edges sufficiently closely. For about a week there was pretty severe reaction, which finally yielded to the antiphlogistic measures already mentioned, and at the end of

two weeks the eye presented a normal appearance, with the exception of a little congestion at the seat of injury. Only a narrow blue line marking the course of the wound. Vision improving rapidly as the blood in the vitreous chamber becomes absorbed.

Figure 3 is that of an eye penetrated by a sharp-pointed

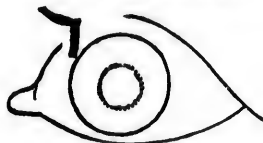

FIGURE 3.

fragment of glass two weeks ago. There was a clean-cut triangular wound in the ciliary region, much vitreous had escaped, and a great deal of blood was effused in the eye, so that there was only quantitative perception of light. Iris and lens were strongly retracted. The patient was destitute of self-control, and an anæsthetic had to be administered in order to repair the wound as already described. One stitch at the apex of the triangle sufficed to bring the clean scleral edges into perfect coaptation. The reaction was quite severe for two days, but the constant application of iced compresses allayed all undue inflammatory symptoms in three or four days. Now the external appearance of the eye is perfectly normal. There is no trace of irritation, and the vision is improving so much that fingers can be counted with the wounded eye at two feet distance.

Quite small, clean cut wounds in the anterior part of the eye are only likely to be serious when complicated with traumatic cataract, if at, or very close to the corneal margin, there may be an entanglement of iris, which must be dealt with on the principles already quoted, either replacement or removal; when situated further back, such small wounds are best managed by non-interference.

Lacerated and punctured wounds inflicted by large or blunt-pointed objects should be treated on the same principles as incised wounds, and an endeavor made to coapt clean scleral surfaces. To accomplish this, a certain amount of trimming of the

scleral wound may be necessary, even at the expense sometimes of enlarging the aperture somewhat ; but when every possible precaution has been taken with this class of wounds, most of them will go wrong in one of two ways—either an acute suppurative panophthalmitis will speedily extinguish the flickering ray of hope, or an equally unfortunate termination will occur through the slower but more insidious and dangerous ravages of a chronic iridocyclitis, leaving a shrunken and sensitive eyeball, with a choice between sympathetic ophthalmia or some preventive operation which at best may leave a maimed and sightless eyeball.

