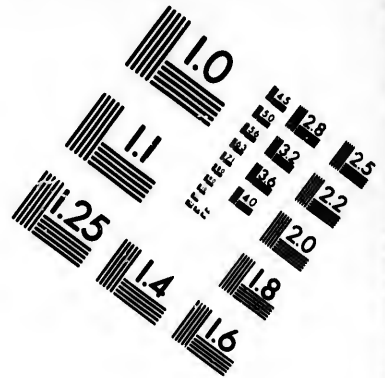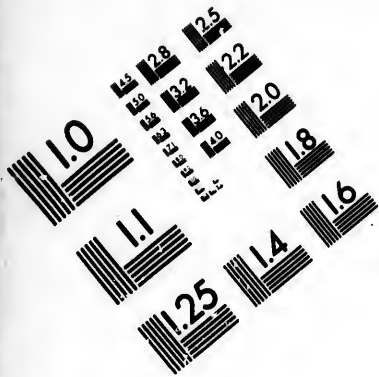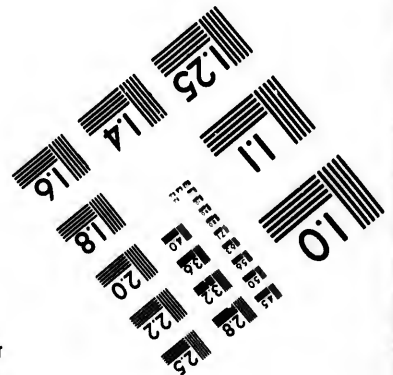
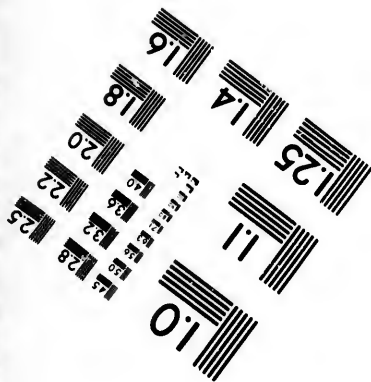




**IMAGE EVALUATION  
TEST TARGET (MT-3)**



**Photographic  
Sciences  
Corporation**

23 WEST MAIN STREET  
WEBSTER, N.Y. 14580  
(716) 872-4503

**CIHM/ICMH  
Microfiche  
Series.**

**CIHM/ICMH  
Collection de  
microfiches.**



**Canadian Institute for Historical Microreproductions / Institut canadien de microreproductions historiques**

**© 1985**

Technical and Bibliographic Notes/Notes techniques et bibliographiques

The Institute has attempted to obtain the best original copy available for filming. Features of this copy which may be bibliographically unique, which may alter any of the images in the reproduction, or which may significantly change the usual method of filming, are checked below.

L'institut a microfilmé le meilleur exemplaire qu'il lui a été possible de se procurer. Les détails de cet exemplaire qui sont peut-être uniques du point de vue bibliographique, qui peuvent modifier une image reproduite, ou qui peuvent exiger une modification dans la méthode normale de filmage sont indiqués ci-dessous.

- Coloured covers/  
Couverture de couleur
- Covers damaged/  
Couverture endommagée
- Covers restored and/or laminated/  
Couverture restaurée et/ou pelliculée
- Cover title missing/  
Le titre de couverture manque
- Coloured maps/  
Cartes géographiques en couleur
- Coloured ink (i.e. other than blue or black)/  
Encre de couleur (i.e. autre que bleue ou noire)
- Coloured plates and/or illustrations/  
Planches et/ou illustrations en couleur
- Bound with other material/  
Relié avec d'autres documents
- Tight binding may cause shadows or distortion along interior margin/  
La reliure serrée peut causer de l'ombre ou de la distorsion le long de la marge intérieure
- Blank leaves added during restoration may appear within the text. Whenever possible, these have been omitted from filming/  
Il se peut que certaines pages blanches ajoutées lors d'une restauration apparaissent dans le texte, mais, lorsque cela était possible, ces pages n'ont pas été filmées.
- Additional comments:/  
Commentaires supplémentaires:

- Coloured pages/  
Pages de couleur
- Pages damaged/  
Pages endommagées
- Pages restored and/or laminated/  
Pages restaurées et/ou pelliculées
- Pages discoloured, stained or foxed/  
Pages décolorées, tachetées ou piquées
- Pages detached/  
Pages détachées
- Show-through/  
Transparence
- Quality of print varies/  
Qualité inégale de l'impression
- Includes supplementary material/  
Comprend du matériel supplémentaire
- Only edition available/  
Seule édition disponible
- Pages wholly or partially obscured by errata slips, tissues, etc., have been refilmed to ensure the best possible image/  
Les pages totalement ou partiellement obscurcies par un feuillet d'errata, une pelure, etc., ont été filmées à nouveau de façon à obtenir la meilleure image possible.

This item is filmed at the reduction ratio checked below/  
Ce document est filmé au taux de réduction indiqué ci-dessous.

10X	14X	18X	22X	26X	30X
<input type="checkbox"/>	<input type="checkbox"/>	<input type="checkbox"/>	<input checked="" type="checkbox"/>	<input type="checkbox"/>	<input type="checkbox"/>
12X	16X	20X	24X	28X	32X

The copy filmed here has been reproduced thanks to the generosity of:

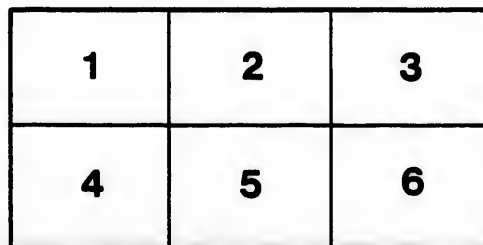
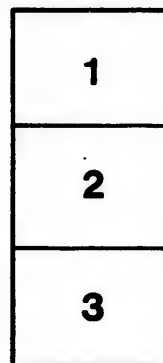
Medical Library  
McGill University  
Montreal

The images appearing here are the best quality possible considering the condition and legibility of the original copy and in keeping with the filming contract specifications.

Original copies in printed paper covers are filmed beginning with the front cover and ending on the last page with a printed or illustrated impression, or the back cover when appropriate. All other original copies are filmed beginning on the first page with a printed or illustrated impression, and ending on the last page with a printed or illustrated impression.

The last recorded frame on each microfiche shall contain the symbol  $\rightarrow$  (meaning "CONTINUED"), or the symbol  $\nabla$  (meaning "END"), whichever applies.

Maps, plates, charts, etc., may be filmed at different reduction ratios. Those too large to be entirely included in one exposure are filmed beginning in the upper left hand corner, left to right and top to bottom, as many frames as required. The following diagrams illustrate the method:



L'exemplaire filmé fut reproduit grâce à la générosité de:

Medical Library  
McGill University  
Montreal

Les images suivantes ont été reproduites avec le plus grand soin, compte tenu de la condition et de la netteté de l'exemplaire filmé, et en conformité avec les conditions du contrat de filmage.

Les exemplaires originaux dont la couverture en papier est imprimée sont filmés en commençant par le premier plat et en terminant soit par la dernière page qui comporte une empreinte d'impression ou d'illustration, soit par le second plat, selon le cas. Tous les autres exemplaires originaux sont filmés en commençant par la première page qui comporte une empreinte d'impression ou d'illustration et en terminant par la dernière page qui comporte une telle empreinte.

Un des symboles suivants apparaîtra sur la dernière image de chaque microfiche, selon le cas: le symbole  $\rightarrow$  signifie "A SUIVRE", le symbole  $\nabla$  signifie "FIN".

Les cartes, planches, tableaux, etc., peuvent être filmés à des taux de réduction différents. Lorsque le document est trop grand pour être reproduit en un seul cliché, il est filmé à partir de l'angle supérieur gauche, de gauche à droite, et de haut en bas, en prenant le nombre d'images nécessaire. Les diagrammes suivants illustrent la méthode.

Shepherd, F. J.

617.23

A CASE OF SARCOMA OF THE ARM INVOLVING THE SKIN—AM-  
PUTATION—RECURRENCE IN THE STUMP A YEAR LATER,<sup>1</sup>

BY

FRANCIS J. SHEPHERD, M. D.,

Surgeon to the Montreal General Hospital.

**T**HE following case is of interest, chiefly on account of the difficulty of diagnosis and the rather unusual course of the affection which in a comparatively early stage rapidly involved the lymphatic trunks of the arm, and the glands in the axilla. The microscopic characters of the affection are also somewhat unusual, and are fully described separately by Dr. Wyatt Johnston, who kindly examined the various specimens for me.

*Case.*—C. A. B., machinist, aet, 35, married, entered my service at the Montreal General Hospital on May 28, 1890, complaining of an ulcerated left forearm.

Patient lives in the country and has always been very healthy. There is absolutely no history of syphilis. Has been married two years, and his wife had a miscarriage in 1888, and a healthy child now living born in 1889; never, that he knows of, had any injury to the arm.

*History.*—About the middle of December 1888, he first noticed three small nodules about the size of peas beneath the skin, covering the back part of the middle third of the left ulna. These nodules were painless, and moved freely beneath the

<sup>1</sup>Read before the meeting of the American Dermatological Association, Washington, September 5, 1891.

skin. They gradually increased in size, and became adherent to the skin; soon the skin became red and inflamed, and finally in August, 1889 (eight months after the commencement of the disease), they ulcerated. The ulcers were poulticed freely, but this treatment seemed only to hasten the rapidity with which they deepened and enlarged, and now, for the first time, they became very painful, the pain being especially severe at night. The three sores thus formed, soon became one large irregular ulcer with sharp edges, and sloughy base. The discharge was never great and was of rather a watery consistency. Later on other lumps appeared in the neighborhood, which also became attached to the skin, and breaking down subsequently resulted in small ulcers.

*Condition on entering Hospital.*—The patient is a well nourished man, having a healthy appearance and with a good appetite. He says he has not lost flesh lately. Heart, lungs, kidneys, etc., are found to be perfectly healthy. On examining the left forearm, three large ulcers are seen on the middle third of its extensor surface. The largest is the size of a 25 cent piece. They are deep, purulent with sharp indurated edges and irregular in shape; the bases are sloughy and have rather a honeycomb appearance. The surrounding skin is red, swollen and eczematous. Near the elbow are several smaller ulcers and between the two sets of ulcers are a number of small shot-like nodules quite moveable beneath the skin. In addition to this, on the inner side of the biceps from the bend of the elbow to the axilla, can be felt a chain of nodules, large and small, which feel very much like buckshot under the skin. They seem to follow the course of blood vessels. They are painless, and are covered by perfectly healthy skin. The arm is comparatively useless, the hand being swollen and oedematous, and the extensor muscles paretic, this causes the characteristic wrist drop. A portion of one of the growths was excised and submitted to Dr. Wyatt Johnston, pathologist to the hospital, who pronounced the case to be probably one of spindle celled sarcoma, but he should like specimens for further examinations. However, it was decided to try antisyphilitic treatment, and the patient was put upon gr. xx pot. iod. three times a day, largely diluted, at the same time black wash was applied to the ulcers, the dose of iodide was increased to one drachm three times a day, and there was for a time marked improvement, but later this improvement ceased, and the patient's condition remained much the same as it was previous to treatment. The

pain returning and the ulcers, which at one time, showed a tendency to heal, increasing slowly in size. The iodide treatment was continued for a month, and had the effect of disordering the patient's digestion. Dr. Johnston, wishing to have specimens for further examination, I placed the patient under ether and excised some of the deeper nodules which extended up the inner side of the biceps, these I found to follow the course of the lymphatic trunks and to be intimately associated with the veins, and they were, in consequence, difficult to excise. In appearance these lumps or growths were grayish in color, irregular and beady in outline and not encapsuled. On sections they were firm and the cut surface showed numerous opaque white spots, the size of pin heads with translucent tissue between. The wound caused by this small operation healed by first intention, and from these facts this part of the arm was much less painful. The specimens thus removed were examined almost immediately by Dr. Johnston, who gave a more positive opinion that the case was one of spindle cell sarcoma, and advised removal of the arm.

The patient went home to settle his affairs and returned a month later, the 24th of July, and the reporter notes "that several new nodules have appeared about the elbow and up the inner side of the arm, also, that the first three ulcers on the forearm have coalesced forming one huge ulcer, with irregular, deeply excavated but firm edges and a sloughy face discharging a watery fluid."

The pain was so great that amputation of the arm at the shoulder joint was readily consented to. The operation was performed on the 26th of July, 1890. After removal of the arm it was seen that the axilla was filled with enlarged and infiltrated glands of the same character as the nodules removed from above the elbow, and that the affected glands reached even above the clavicle. They were all carefully dissected away, and this took time as they closely embraced the axillary vessels. The posterior flat was also studded with small nodules of the same character and a considerable portion of it had to be removed.

In two weeks the patient returned home with the wound completely healed by first intention, and feeling much pleased with the result of the operation, as it had entirely relieved the severe pain previously complained of.

I heard from him occasionally and the report was that he had rapidly gained flesh and was feeling perfectly well. How-

ever, by the beginning of May, 1891, about ten months after the operation. the stump became acutely painful, he could not sleep, and had recourse to opiates, he soon lost appetite and flesh and came again to the hospital in the middle of June, 1891, looking ill and miserable. Upon examining the stump I found that there was fulness in it which was not natural, and in cutting down in it I came on a large mass of new growth which did not involve the skin, but extended up into the axilla. I excised this very freely, and closed the wound, which healed in a few days. The pain was relieved, though not removed by this operation, but he returned home much better. He re-entered hospital on July 1st, saying that the pain had returned and was worse than ever, and that I must do something for him. At the previous operation I had removed the enlarged nerve ends of the brachial plexus, but now I determined to dissect the plexus above the clavicle. This was done the next day, an inch from each cord being excised. I dissected freely, but could find no trace of the new growth above the clavicle, the glands not being involved. This operation completely relieved the pain. He returned home in a week feeling very well. I have since heard from him, and he says, with the exception of slight pain occasionally felt in the armpit, he was very comfortable.

*Dr. Wyatt Johnston's Report on the Character of the Tumors.*

— On May 31, 1890, examined a portion of growth from arm of C. A. B. Sections made after hardening in absolute alcohol show epidermis normal, cutis thick and dense; immediately beneath the cutis are a large number of flattened cells, resembling those seen in a large spindle-celled sarcoma, and arranged in loose clumps apparently within the subcutaneous lymph spaces. No lepra or tubercle bacilli. On June 27, 1890, examined an elliptical piece of skin, removed, with nodule attached, from the inner side of arm below elbow. It contained a small reddish papule the size of a split pea and situated deeply. In addition to the skin a large mass of infiltrated tissue was examined. On lightly scraping this a whitish juice was readily obtained, and was found to be composed of fatty detritus and large flattened cells of very variable outline. The diameter of these cells ranged from 0.015 to 0.050 m.m. Many of these cells were pear or anvil shaped, with a long tapering pole. Ovoid forms were very common; they lie close together, without any intervening inter-cellular substance. A small proportion were flattened and thin with folded edges. The nuclei were usually multiple, and a few of the cells showed highly refract-



ing hyaline bodies beside the nuclei (plasmosomata), but there was no appearance of parasitic plasmodia or bacteria. Cultures in glycerine agar remained sterile. The sections which were made after fixation in various fluids (absolute alcohol, diluted alcohol, Müller's fluid, 1 per cent. sublimate and Fleming's solution) showed the arrangement of the cells to be somewhat different to what had been anticipated from the appearance of the cells in the juice obtained from scraping the cut surface; now a delicate inter-cellular substance seemed to lie between each cell, and the appearance of the cells themselves in section suggest endothelium rather than epithelium. The nuclei were large and rich in chromatin, and mitotic figures were frequent, the diaster form being most common. The growth appeared to arise in the cutis and to be unconnected with the epidermis or rete; it did not appear to proceed from the sebaceous glands, or from the sweat glands when it was seen in the earliest stages in the very small nodules, but the lymphatics seem to be the structures earliest involved. After amputation of the arm some portions of skin and gland tissue from the axilla were examined. Sections made through the skin showed to the naked eye a diffuse thickening. Under the microscope the epidermis is not thicker than normal and the fibrous tissue in the cutis is not increased, but a very considerable overgrowth of the several glands exists, together with a much less marked overgrowth of the sebaceous glands. This overgrowth, though extensive and ill defined at the borders, has more the appearance of adenoma than cancer and contrasts sharply with the tumor mass lying immediately beneath it. These tumor masses have precisely the same appearance as those first examined, and consist of large closely-set cells, flattened or of irregular spindle shape, and extremely rich in chromatin. A few dilated thin walled vessels are seen and also some minute hemorrhages. In the deeper parts of the sub-cutaneous tissue a number of enlarged lymph glands are seen, which show areas of spindle cell infiltration.

From a secondary operation performed in June, 1891, portions of infiltrated tissue were obtained which show the cutis and sub-cutis to be infiltrated by cells similar in appearance and arrangement to those seen in previous examinations. The spindle cell infiltration has involved the scar of the amputation wound. The tumor above described is certainly a rare one and presents many features of interest. From an anatomical point of view the most interesting fact is the co-existence of tubular adenoma in the sweat glands, distinct from the sarcoma. The

structure of the tumor itself is also anomalous, at some spots resembling carcinoma in the nature and arrangement of its cells.

The early involvement of the lymphatics in this case made it one of unusual interest. Though the future prospects in the case are not bright, still the man by the amputation has gained at least a year if not more of comparative comfort. In his *Archives of Surgery*, Vol. II, p. 123, Mr. J. Hutchinson relates a case of a sarcomatous eruption imitating syphilis in which there was very general involvement of the lymphatic glands. In this case the nodules showed no tendency to ulcerate. Melanotic sarcoma, it is well known, has a tendency to spread by the lymphatics.

*P. S.* — *Oct. 24, 1891.* — Since reading the above paper I have heard from the patient, who says that an ulcerating growth, has appeared on the right cheek and is growing rapidly.

