

**CIHM/ICMH
Microfiche
Series.**

**CIHM/ICMH
Collection de
microfiches.**



Canadian Institute for Historical Microreproductions / Institut canadien de microreproductions historiques

© 1985

Technical and Bibliographic Notes/Notes techniques et bibliographiques

The Institute has attempted to obtain the best original copy available for filming. Features of this copy which may be bibliographically unique, which may alter any of the images in the reproduction, or which may significantly change the usual method of filming, are checked below.

L'Institut a microfilmé le meilleur exemplaire qu'il lui a été possible de se procurer. Les détails de cet exemplaire qui sont peut-être uniques du point de vue bibliographique, qui peuvent modifier une image reproduite, ou qui peuvent exiger une modification dans la méthode normale de filmage sont indiqués ci-dessous.

- | | |
|---|---|
| <input type="checkbox"/> Coloured covers/
Couverture de couleur | <input type="checkbox"/> Coloured pages/
Pages de couleur |
| <input type="checkbox"/> Covers damaged/
Couverture endommagée | <input type="checkbox"/> Pages damaged/
Pages endommagées |
| <input type="checkbox"/> Covers restored and/or laminated/
Couverture restaurée et/ou pelliculée | <input type="checkbox"/> Pages restored and/or laminated/
Pages restaurées et/ou pelliculées |
| <input type="checkbox"/> Cover title missing/
Le titre de couverture manque | <input checked="" type="checkbox"/> Pages discoloured, stained or foxed/
Pages décolorées, tachetées ou piquées |
| <input type="checkbox"/> Coloured maps/
Cartes géographiques en couleur | <input type="checkbox"/> Pages detached/
Pages détachées |
| <input type="checkbox"/> Coloured ink (i.e. other than blue or black)/
Encre de couleur (i.e. autre que bleue ou noire) | <input checked="" type="checkbox"/> Showthrough/
Transparence |
| <input type="checkbox"/> Coloured plates and/or illustrations/
Planches et/ou illustrations en couleur | <input type="checkbox"/> Quality of print varies/
Qualité inégale de l'impression |
| <input type="checkbox"/> Bound with other material/
Relié avec d'autres documents | <input type="checkbox"/> Includes supplementary material/
Comprend du matériel supplémentaire |
| <input type="checkbox"/> Tight binding may cause shadows or distortion along interior margin/
La reliure serrée peut causer de l'ombre ou de la distorsion le long de la marge intérieure | <input type="checkbox"/> Only edition available/
Seule édition disponible |
| <input type="checkbox"/> Blank leaves added during restoration may appear within the text. Whenever possible, these have been omitted from filming/
Il se peut que certaines pages blanches ajoutées lors d'une restauration apparaissent dans le texte, mais, lorsque cela était possible, ces pages n'ont pas été filmées. | <input type="checkbox"/> Pages wholly or partially obscured by errata slips, tissues, etc., have been refilmed to ensure the best possible image/
Les pages totalement ou partiellement obscurcies par un feuillet d'errata, une pelure, etc., ont été filmées à nouveau de façon à obtenir la meilleure image possible. |
| <input type="checkbox"/> Additional comments:
Commentaires supplémentaires: | |

This item is filmed at the reduction ratio checked below/
Ce document est filmé au taux de réduction indiqué ci-dessous.

10X	14X	18X	22X	26X	30X
<input type="checkbox"/>	<input type="checkbox"/>	<input type="checkbox"/>	<input checked="" type="checkbox"/>	<input type="checkbox"/>	<input type="checkbox"/>
12X	16X	20X	24X	28X	32X

The copy filmed here has been reproduced thanks to the generosity of:

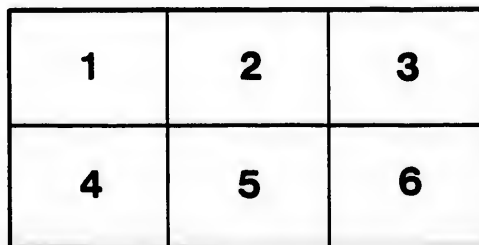
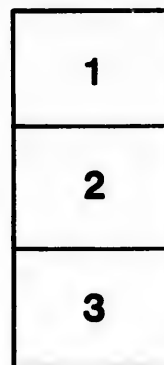
Medical Library
McGill University
Montreal

The images appearing here are the best quality possible considering the condition and legibility of the original copy and in keeping with the filming contract specifications.

Original copies in printed paper covers are filmed beginning with the front cover and ending on the last page with a printed or illustrated impression, or the back cover when appropriate. All other original copies are filmed beginning on the first page with a printed or illustrated impression, and ending on the last page with a printed or illustrated impression.

The last recorded frame on each microfiche shall contain the symbol \rightarrow (meaning "CONTINUED"), or the symbol ∇ (meaning "END"), whichever applies.

Maps, plates, charts, etc., may be filmed at different reduction ratios. Those too large to be entirely included in one exposure are filmed beginning in the upper left hand corner, left to right and top to bottom, as many frames as required. The following diagrams illustrate the method:



L'exemplaire filmé fut reproduit grâce à la générosité de:

Medical Library
McGill University
Montreal

Les images suivantes ont été reproduites avec le plus grand soin, compte tenu de la condition et de la netteté de l'exemplaire filmé, et en conformité avec les conditions du contrat de filmage.

Les exemplaires originaux dont la couverture en papier est imprimée sont filmés en commençant par le premier plat et en terminant soit par la dernière page qui comporte une empreinte d'impression ou d'illustration, soit par le second plat, selon le cas. Tous les autres exemplaires originaux sont filmés en commençant par la première page qui comporte une empreinte d'impression ou d'illustration et en terminant par la dernière page qui comporte une telle empreinte.

Un des symboles suivants apparaîtra sur la dernière image de chaque microfiche, selon le cas: le symbole \rightarrow signifie "A SUIVRE", le symbole ∇ signifie "FIN".

Les cartes, planches, tableaux, etc., peuvent être filmés à des taux de réduction différents. Lorsque le document est trop grand pour être reproduit en un seul cliché, il est filmé à partir de l'angle supérieur gauche, de gauche à droite, et de haut en bas, en prenant le nombre d'images nécessaire. Les diagrammes suivants illustrent la méthode.

etails
s du
odifier
une
mage

rrata
to

pelure,
n à



32X

ho lu


Adami, J. G.

**NOTES ON THE LUNGS OF ONE OF KOCH'S EARLIEST
TUBERCULIN PATIENTS.**

BY

J. G. ADAMI, M.A., M.D.,
Professor of Pathology McGill University, Montreal.

Reprinted from the Montreal Medical Journal, September, 1895.



NOTES ON THE LUNGS OF ONE OF KOCH'S EARLIEST TUBERCULIN PATIENTS.*

By J. G. ADAMI, M.A., M.D., (Cantab.) M.R.C.S., Eng.,
Professor of Pathology McGill University, Montreal.

The lungs in the case about to be recorded possess a certain amount of interest, inasmuch as according to the history given by the patient, a highly intelligent man, thirty-three years old, he was one of the first to undergo treatment under Professor Koch in Berlin.

The patient, A. Rickstrom, was born in Finland and was in good health until 1890, when he suffered from hæmoptysis, followed by a cough, night sweats and progressive emaciation. He was admitted under Koch at the Victoria Hospital in Berlin and there continued for fifty-two weeks undergoing periodic inoculations with tuberculin. Under this treatment his appetite improved, he began to gain flesh, and the night sweats passed away. He returned to Finland, and his health appeared to be restored. In June, 1893, he came to Canada and was employed as a skilled mechanic in the engineering laboratory at McGill University. He remained apparently in perfect health until January of this year, when the cough returned, and all the old symptoms—night sweats, loss of flesh and bodily weakness. On March 20th there was an hæmoptysis, about half a gallon of blood being lost; on the 23rd and 24th there were two severe hæmorrhages. From this time until April 18th, he being now a patient under Dr. Stewart at the Royal Victoria Hospital, there was constant slight expectoration of blood with but little cough. On this last date severe hæmorrhages recurred, in all about a quart of blood being lost. Following upon this there was rapid loss of power, and the patient died ten days later.

At the autopsy it was noticeable that there was no indication of tuberculosis other than in the lungs, save for some quite recent and minute ulcers in the jejunum and ileum. The lungs, however, presented very characteristic tubercular changes. There were firm adhesions at both apices—so firm that on the left side the knife had to be employed to separate them. Both apices showed old tuberculosis in the shape of well-encapsuled caseous masses and small contracted cavities with dense envelopes and smooth but uneven internal aspect. In addition, the upper two-thirds of the uppermost lobe of the right lung and the upper half of the upper lobe of the left lung were greatly consolidated, contracted and presenting very well-marked

* Read before the Montreal Medico-Chirurgical Society, June 28th, 1895.

interstitial fibroid change. Here evidently in both apices were to be seen the results of treatment in 1890-91—abundant signs of arrest of the tubercular process. It was, however, clear that the process had only been arrested—for the rest of the lung tissue was the seat of numerous rather large miliary tubercles, which from their distribution were broncho-pneumonic—distributed along the course of sundry bronchi. Injecting the pulmonary arteries with water led to the escape of the fluid through one of the main bronchi of the upper lobe of the left lung. Following this up a long cavity was entered into containing a globular laminated clot over what was the seat of rupture of the artery. Some difficulty was experienced in finding the actual lesion, the artery filled with thrombus escaping detection for some little time.

Bringing all these facts together it would seem most probable that the second attack of advancing tuberculosis was not a second infection, or infection anew, but originated in the old arrested foci of the disease, where the process lighting up again in the walls of one of the old incompletely contracted cavities had been followed by dissemination of the virus throughout the air passages, and had prepared the way for rupture of arteries passing along the walls of the cavity.

The recent tubercles were most numerous in the neighbourhood of the old tubercular disturbance. It was interesting to note that upon microscopical examination they were found to be surrounded with very little pneumonic disturbance; they were not of the rapidly advancing type, but on the contrary were in general fibroid, with distinct caseous centres and large outer zones of developing fibrous tissue. This would indicate one of two conditions—either the bacilli causing the lesions were relatively attenuated, or the reaction on the part of the tissues was relatively considerable. We should be prepared to accept the latter alternative if, as is not impossible, the beneficial effects of long-continued tuberculin infection last for a considerable period, but I know of no case in which this has been demonstrated for periods longer than a few months. It should here be added that the microscopical appearances of sections of the lungs were in harmony with the clinical history and with the general results of the autopsy. The pectoral and other muscles were fairly well-developed and of good colour; there was a fair amount of subcutaneous fat.

But perhaps the most interesting feature of the specimen was the evidence it gave of the extent of pulmonary tuberculosis capable of being arrested by Koch's treatment. Both apices had clearly been the seat of extensive tuberculous change. There was extensive tubercular pleurisy, much caseation, and the development of numerous (five or six) cavities in the two apices. The treatment that the patient had undergone during his year's stay in the Berlin hospital had succeeded in bringing the lesion to a standstill during four years.

