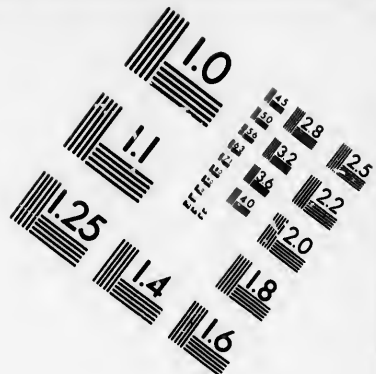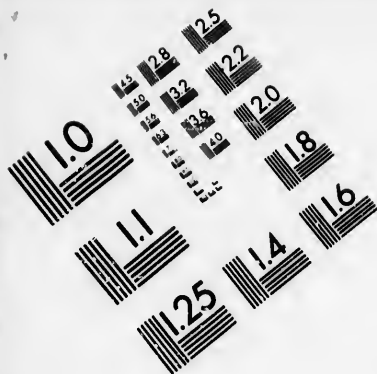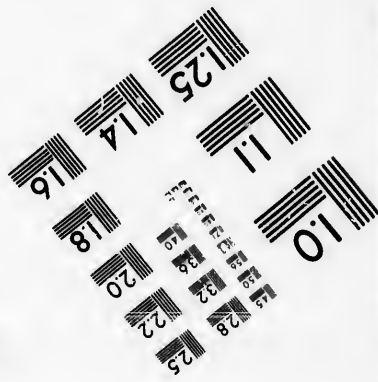
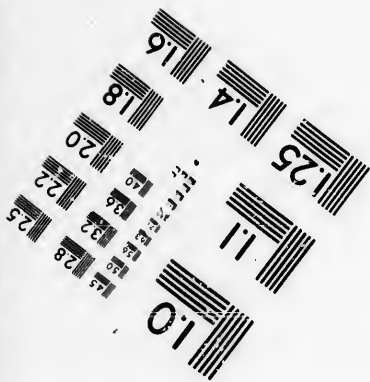
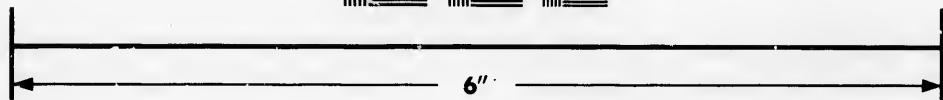




**IMAGE EVALUATION
TEST TARGET (MT-3)**



**Photographic
Sciences
Corporation**

20 WEST MAIN STREET
WEBSTER, N.Y. 14580
(716) 872-4503



**CIHM/ICMH
Microfiche
Series.**

**CIHM/ICMH
Collection de
microfiches.**



Canadian Institute for Historical Microreproductions / Institut canadien de microreproductions historiques



© 1986

Technical and Bibliographic Notes/Notes techniques et bibliographiques

The Institute has attempted to obtain the best original copy available for filming. Features of this copy which may be bibliographically unique, which may alter any of the images in the reproduction, or which may significantly change the usual method of filming, are checked below.

L'Institut a microfilmé le meilleur exemplaire qu'il lui a été possible de se procurer. Les détails de cet exemplaire qui sont peut-être uniques du point de vue bibliographique, qui peuvent modifier une image reproduite, ou qui peuvent exiger une modification dans la méthode normale de filmage sont indiqués ci-dessous.

- | | |
|--|--|
| <input checked="" type="checkbox"/> Coloured covers/
Couverture de couleur | <input type="checkbox"/> Coloured pages/
Pages de couleur |
| <input type="checkbox"/> Covers damaged/
Couverture endommagée | <input type="checkbox"/> Pages damaged/
Pages endommagées |
| <input type="checkbox"/> Covers restored and/or laminated/
Couverture restaurée et/ou pelliculée | <input type="checkbox"/> Pages restored and/or laminated/
Pages restaurées et/ou pelliculées |
| <input type="checkbox"/> Cover title missing/
Le titre de couverture manque | <input checked="" type="checkbox"/> Pages discoloured, stained or foxed/
Pages décolorées, tachetées ou piquées |
| <input type="checkbox"/> Coloured maps/
Cartes géographiques en couleur | <input type="checkbox"/> Pages detached/
Pages détachées |
| <input type="checkbox"/> Coloured ink (i.e. other than blue or black)/
Encre de couleur (i.e. autre que bleue ou noire) | <input checked="" type="checkbox"/> Showthrough/
Transparence |
| <input type="checkbox"/> Coloured plates and/or illustrations/
Planches et/ou illustrations en couleur | <input type="checkbox"/> Quality of print varies/
Qualité inégale de l'impression |
| <input type="checkbox"/> Bound with other material/
Relié avec d'autres documents | <input type="checkbox"/> Includes supplementary material/
Comprend du matériel supplémentaire |
| <input type="checkbox"/> Tight binding may cause shadows or distortion
along interior margin/
La reliure serrée peut causer de l'ombre ou de la
distorsion le long de la marge intérieure | <input type="checkbox"/> Only edition available/
Seule édition disponible |
| <input type="checkbox"/> Blank leaves added during restoration may
appear within the text. Whenever possible, these
have been omitted from filming/
Il se peut que certaines pages blanches ajoutées
lors d'une restauration apparaissent dans le texte,
mais, lorsque cela était possible, ces pages n'ont
pas été filmées. | <input type="checkbox"/> Pages wholly or partially obscured by errata
slips, tissues, etc., have been refilmed to
ensure the best possible image/
Les pages totalement ou partiellement
obscurcies par un feuillet d'errata, une pelure,
etc., ont été filmées à nouveau de façon à
obtenir la meilleure image possible. |
| <input type="checkbox"/> Additional comments:/
Commentaires supplémentaires: | |

This item is filmed at the reduction ratio checked below/
Ce document est filmé au taux de réduction indiqué ci-dessous.

10X	14X	18X	22X	26X	30X
<input type="checkbox"/>	<input type="checkbox"/>	<input type="checkbox"/>	<input type="checkbox"/>	<input checked="" type="checkbox"/>	<input type="checkbox"/>
12X	16X	20X	24X	28X	32X

The copy filmed here has been reproduced thanks to the generosity of:


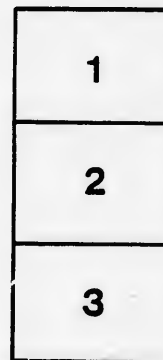
Medical Library
McGill University
Montreal

The images appearing here are the best quality possible considering the condition and legibility of the original copy and in keeping with the filming contract specifications.

Original copies in printed paper covers are filmed beginning with the front cover and ending on the last page with a printed or illustrated impression, or the back cover when appropriate. All other original copies are filmed beginning on the first page with a printed or illustrated impression, and ending on the last page with a printed or illustrated impression.

The last recorded frame on each microfiche shall contain the symbol \rightarrow (meaning "CONTINUED"), or the symbol ∇ (meaning "END"), whichever applies.

Maps, plates, charts, etc., may be filmed at different reduction ratios. Those too large to be entirely included in one exposure are filmed beginning in the upper left hand corner, left to right and top to bottom, as many frames as required. The following diagrams illustrate the method:



L'exemplaire filmé fut reproduit grâce à la générosité de:

Medical Library
McGill University
Montreal

Les images suivantes ont été reproduites avec le plus grand soin, compte tenu de la condition et de la netteté de l'exemplaire filmé, et en conformité avec les conditions du contrat de filmage.

Les exemplaires originaux dont la couverture en papier est imprimée sont filmés en commençant par le premier plat et en terminant soit par la dernière page qui comporte une empreinte d'impression ou d'illustration, soit par le second plat, selon le cas. Tous les autres exemplaires originaux sont filmés en commençant par la première page qui comporte une empreinte d'impression ou d'illustration et en terminant par la dernière page qui comporte une telle empreinte.

Un des symboles suivants apparaîtra sur la dernière image de chaque microfiche, selon le cas: le symbole \rightarrow signifie "A SUIVRE", le symbole ∇ signifie "FIN".

Les cartes, planches, tableaux, etc., peuvent être filmés à des taux de réduction différents. Lorsque le document est trop grand pour être reproduit en un seul cliché, il est filmé à partir de l'angle supérieur gauche, de gauche à droite, et de haut en bas, en prenant le nombre d'images nécessaire. Les diagrammes suivants illustrent la méthode.

rrata
to

pelure,
n à

Byers. W.G.M.
Buller. F.

Buller, Frank
+
Byers, W.G.M.

Qu

1900

QUARTERLY REPORT OF THE EYE AND EAR CLINIC OF THE
ROYAL VICTORIA HOSPITAL, MONTREAL.


BY

FRANK BULLER, M.D.,
Surgeon to the Department,

AND

W. GORDON M. BYERS, M.D.,
Assistant-Oculist and Auriat.

Reprinted from the Montreal Medical Journal, March, 1900.



THE STATE OF TEXAS,
COUNTY OF [illegible]

[illegible]

[illegible]

Dr. J. S. Lewis OCT 23 '31

QUARTERLY REPORT OF THE EYE AND EAR CLINIC OF
THE ROYAL VICTORIA HOSPITAL, MONTREAL.

BY

FRANK BULLER, M.D.,
Surgeon to the Department,

AND

W. GORDON M. BYERS, M.D.,
Assistant-Oculist and Aurist.

A Case of Acquired, Double-sided Lenticonus Posterior.

Removal of the Lens of one Eye by McKeown's Method—Recovery of Normal Vision.

Lenticonus, the condition in which the curvature of the lens is abnormally increased, is one of the rarest affections in eye surgery. In a recent article Pergens¹ was only able to gather 15 cases from the literature to add to his own which occurred in a buphthalmic globe. The affection occurs as a congenital or acquired condition, and may affect one or both eyes. In nearly every instance the increased convexity was confined to the posterior surface of the lens, and in several cases was associated with posterior polar cataract. In four cases the presence of divergent strabismus denoted the exclusion of the affected eye from binocular vision.

The following case is especially interesting because of its being the first instance in which operative treatment was adopted for the cure of the condition. The ease with which the lens was removed by McKeown's procedure, and the brilliant result obtained from the operation more than justify the adoption of this method in the management of all similar cases. The case is as follows:—

Mrs. G., at. 60, entered the Royal Victoria Hospital, Sept. 29th, 1899. She complained of gradual loss of vision during the past four or five years, previous to which time her sight had been excellent in every respect. Two years ago she consulted a local optician and procured a pair of glasses (strong minus lenses), which helped her a little for a short time. The patient could assign no cause for the loss of vision. A short time before the onset of the ocular condition she had had an attack of quinsy, but of late her general health had been good.

Patient was an elderly, well nourished woman. Examination of urine negative.

¹ Pergens's—"Buphthalmus with Lenticonus Posterior," Archives of Ophthalmology, Vol. XXVIII., p. 620.

OCT 23 '01

Dr. D. S. Lewis

Lids, conjunctiva, and lachrymal apparatus of both sides normal; the corneæ were clear and bright and both showed a normal curvature with the ophthalmometer, *i.e.* $\frac{1}{2}^\circ$ of astigmatism, according to the rule.

On first throwing light into the eyes the impression was that one had to do with a case of conical cornea, but further examination with the ophthalmometer, a mirror for parallax movement, and the direct method, showed that the case was one of double-sided lenticonus posterior. There appeared to be both by the direct and indirect methods a more or less rounded opacity near the posterior pole of each lens. In certain positions, however, one got practically clear but reduced images of the retinal vessels and fundi through the centres of the lenses showing that the opacity was due more to the irregular refraction of light than to definite changes in the lens substance itself.

At the same time with the direct method one could see there was slight but definite loss of transparency in the lens near its posterior capsule. The condition was more marked on the right than on the left side. At all times there were the optical phenomena of squirming and wriggling of the vessels.

The left fundus was absolutely normal. Along the inferior nasal branch of the right retinal artery and some millimeters from the optic disc was a large, irregular patch of golden-yellow colour the exact nature of which could not be made out. In one place a retinal vein was slightly hidden from view in its substance, but it was too dull and too far from the optic disc to be medullated nerve fibres; it was certainly not an atrophic condition, and apparently not an exudate.

There were a moderate number of opacities in each eye in the anterior part of the vitreous which moved rather quickly; Tu. in both.

Without mydriatic, R.V. = $\frac{6}{60}$, L.V., $\frac{1}{60}$, not improved.

With mydriatic, R.V. = $\frac{6}{60}$; $0^\circ - 0.5 - 0.5 = \frac{6}{24}$. L.V. = $\frac{6}{60} - 0.5 = \frac{6}{24}$.

Though the periphery of the lens was less myopic than the centre, the exact difference was not absolutely determined. The correction under mydriasis may be taken roughly as the measurement of the marginal error.

October 4th, 1899: Right preliminary iridectomy, cocain.

November 1st, 1899: Right extraction, cocain. Capsule was first freed from the lens by the injection underneath it of a physiological salt solution as recommended by McKeown of Belfast.² After the entrance of the saline solution there was no red reflex from the fundus, the lens having become totally opaque. A free incision having been made in the capsule the lens was now expressed with ease, the small

² McKeown—"A Treatise on Unripe Cataract." H. K. Lewis, London.

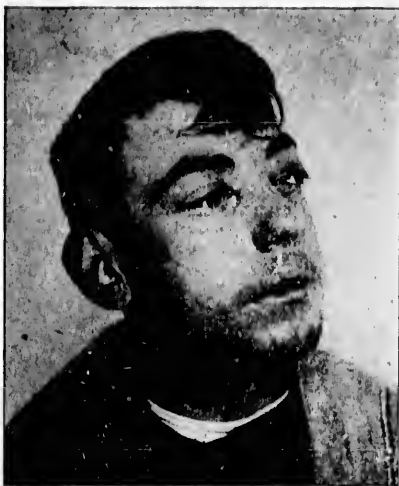

FIGURE I.



FIGURE II.

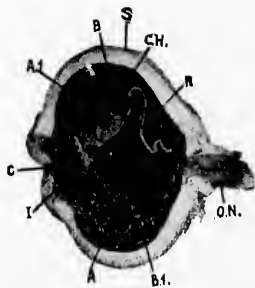


FIGURE III. S., sclerotic; Ch., choroid; R., retina; A, A1., sub-choroidal space; B, B1., sub-retinal space; O. N., optic nerve. Iris (I.) attached to posterior surface of cornea at C.

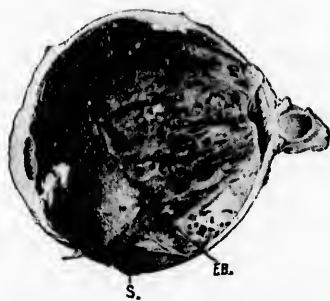



FIGURE IV. Foreign body (F.B.) held in position by bands of connective tissue; S., margin of equatorial staphyloma.



amount of lens substance remaining being afterwards washed out with the salt solution.

December 7th, 1899 : A thin capsule which had formed over the pupillary area was needled, and on January 11th, a day or so before the patient was discharged from the hospital, the following note was made of her condition :—

Right eye quiet ; angles of the coloboma in position ; thin capsule all over the pupillary area ; small but central aperture. A few opacities in the anterior part of the vitreous ; fundus as before ; Tn.

Right eye, $90^\circ \pm 0.0$; $0^\circ \pm 1.5$. R. V. = $0/60$; $0^\circ + 1 + 10.0 = \frac{1}{2}$; $0^\circ + 1 + 14.0$ Jæger 1.

Left eye as before.

A Case of Exophthalmos from Empyæma of the Frontal Sinus and Ethmoidal Cells—Operation—Recovery.

The frequency with which eye-surgeons are called upon to deal with disease of the frontal sinus and ethmoidal cells is explained by the close proximity of these structures to the orbit. Tumours generally originating within the accessory cavities of the nose find the way of least resistance towards the orbit, and the orbital structures themselves are of such a nature as to be readily affected by inflammation spreading from the neighbouring sinuses. The following report is in general typical of what occurs when secretion is pent up in the frontal sinus and ethmoidal cells. The sudden onset is to be explained both by a probable lack of careful observation on the part of the patient, and by the onset of an acute orbital cellulitis secondary to the chronic empyæmic condition. An interesting point is the failure of the transillumination to give accurate information. Although the left frontal sinus was filled with pus the light intensity was the same on both sides, while on the other hand the left antrum which was distinctly darker than the right was absolutely free from secretion.

The patient, a butcher, *at. 19*, came to the out-patient department, December 19, 1899, with a history of painful bulging of the eye extending over 15 days. The protrusion was said to have come on suddenly (during the night) and the patient stated that the proptosis had not increased since the time of its first recognition. Weakness, loss of appetite and chilly sensations were the constitutional accompaniments of the local condition.

Present Condition : See photograph. Noticeable pallor and obvious weakness, general appearance that of a very sick man ; tongue furred, bowels confined ; temperature 102° .

Left eye exhibits an exophthalmos of 15 mm ; bulging forward and slightly upward ; the upper half of the cornea covered by the lid which

is reddened but not swollen. Slight degree of marginal blepharitis and moderate injection of the conjunctival vessels with watery discharge; slight tumefaction of the conjunctiva towards the inner angle; pupil the same size as the right, normal in all its reactions.

Fulness of the veins of the left side is the only ophthalmoscopic change present. Left vision equals $\frac{1}{2}$.

Some tenderness and indefinite fulness over the anterior part of the inner wall of the orbit. Tension of globe —1.

All movements of the left eye are very markedly impaired, though the excursion outwards is slightly better than in the other directions.

The right eye is normal in every respect, vision equals $\frac{1}{2}$.

Examination of the nose reveals a small amount of pus in the middle meatus, and on the posterior extremity of the middle turbinate of the affected side. Transillumination shows no difference in the transparency of the two frontal sinuses; the left antrum of Highmore is distinctly darker than that of the right side.

Operation, Dec. 14th, 1899: A transverse incision was made over the inner end of the left frontal sinus and the median extremity of this joined by another vertical cut at right angles. Skin and periosteum dissected back. The withdrawal of the trephine after its entrance into the frontal sinus was followed by the welling out of a considerable amount of muco-purulent matter. The anterior wall of the sinus was now laid freely open with bone forceps and the cavity carefully cleaned. The ethmoidal cells, transformed in great part into a soft pulpy material which oozed freely, were removed, as far as possible, by careful scraping. An opening into the nose was then made in the usual way and a drainage tube inserted.

Contrary to what was expected, the antrum of Highmore of the left side, though freely exposed, was found to be free from secretion. The difference noted in the illumination seemed to have been caused by an unusual thickness of the bony wall of this side.

The operation was followed by a gradual abatement of all symptoms. On the eighth day the temperature reached normal and remained so, the protosis slightly diminished, and the movements of the eye became perfect in all directions. Drainage was maintained for some time to guard against the recurrence of the condition.

When last seen, March 4th, the exophthalmos present was barely perceptible. Vision was normal, and the movements of the globe perfect in all directions. The general condition of the patient was excellent.

A Peculiar Case of Injury to the External Auditory Canal.

P. S., a healthy looking boy from the country *æt.* 10, was sent to the Hospital Dec. 29th, 1899.

A month previous to admission he fell from a load of hay head first to the ground. Immediately after the accident he complained of pain in the left ear which continued with much suffering for about a week when the ear began to discharge a purulent fluid with some relief of the pain. The discharge has persisted ever since.

On admission the external meatus was found occluded by a fleshy mass resembling an ordinary soft polypus and was discharging freely a thin yellowish pus. There was in addition to this a little swelling of the tissues below the ear and considerable tenderness on pressure in the same locality. The house-surgeon was directed to snare off as much of the polypoid growth as he could reach and keep the ear thoroughly clear with boric acid syringing. This was done and the cleansing treatment continued until Jan. 7th, when an examination showed the condition to be about the same as when first admitted.

It was then decided to administer an anæsthetic and make a thorough exploration of the auditory canal. This at once revealed a firm substance occluding the canal. On grasping this mass with forceps some shreds of woody fibre were brought away and the mass, though distinctly movable, was firmly imbedded and evidently extended downwards into the swollen and tender region below the ear. With a little manipulation the mass was grasped by the forceps and drawn out. It proved to be the woody stem of some weed or shrub which had penetrated the outer end of the floor of the auditory canal from above downwards and lodged in the tissues of the neck below the ear.

After its removal the auditory canal and the track of the foreign body were thoroughly syringed with solution of hydrarg. perchlor, and lightly packed with iodoform gauze. This was removed after two or three days and the subsequent treatment consisted in keeping the ear clean. Ten days later the wound was entirely healed and the ear found in a normal condition; only a small reddened scar marked the point of entrance of the foreign body in the floor of the meatus.

The accompanying Figure (11.) shows the actual size and character of the foreign body, (4.6 mm. long by .5 mm. thick), the somewhat pointed extremity of which was smooth and clean whilst the part occluding the meatus was torn and ragged, having evidently been broken off from a longer stem in the fall. The consequences to the ear itself would have been much more serious had the missile penetrated the drum membrane as usually happens in injuries of this kind.

Systematic Examination of Excised Eyeballs.

(From the Pathological Laboratory of the Royal Victoria Hospital.)

Case I: Atrophia Bulbi, following Perforating Wound of the Cornea.

J. K., æt. 3, was brought to the hospital in Dec., '98; the child's right eye was visibly shrunken and though quiet when first seen, there

was marked filling of the perieorneal and conjunctival vessels after the usual slight examination. A large cicatrix, situated about the middle of the cornea, extended from the outer almost to the inner corneo-scleral margin. The central parts of the iris were drawn forward and firmly attached to the posterior surface of the corneal scar (anterior synchia). The anterior chamber, was deeper on the temporal than on the nasal side; V. equals no p l; T.— 1.

The parents stated that the eye had been injured in the August previous, but that there had been practically no pain in the organ.

Examination: Measurements of the globe, 18 mm. antero-posteriorly, 22mm. transverse. Nothing of interest apart from what is noted above.

Section (Fig. III) in the vertical meridian after hardening in formalin, and freezing in the usual manner, shows a central corneal scar in transverse section, and the anterior surface of the cornea somewhat depressed at this point, giving the whole structure an epsilon-like appearance. The pupil seems to be entirely closed by a purse-like contraction, and the whole central area of the iris is drawn forwards and attached to the convexity on the posterior surface of the cornea. The anterior chamber is thus divided into two almost equal compartments. The lens is very much shrunken; a small portion remaining is in close contact with the posterior surface of the iris. On each side from the corneo-scleral margin to well beyond the equator of the globe, the ciliary body and choroid are extensively detached from the sclerotic. The space thus formed is filled by a clear firm exudate which is seen by the aid of the lens to be traversed by fine stretched fibrils of the lamina fusca and lamina suprachoroidea. To the inner side of the choroid the retina is extensively detached and thrown into numerous folds. The subretinal space is likewise filled with an exudate similar to that in the sub-choroidal space.

The sclerotic coat gradually increases in thickness from about the orra serrata to the entrance of the optic nerve on each side of which it measures between 3 and 4 mm.

Microscopically, sections taken below the level of the corneal cicatrix make clear a few points in connection with the globe. The exudate between the sclerotic and choroid on the one hand and the choroid and retina on the other is entirely free from cellular elements. The choroidal vessels where this structure adheres to the sclerotic are moderately dilated but elsewhere, in the detached areas, the vessels are not to be seen.

The bundles of the sclerotic generally show a lack of compactness and towards the posterior pole, corresponding to the enlargement, observed macroscopically, this condition is especially noticeable.

Remarks : The condition of the globe described above is one which is seen with comparative frequency after penetrating wounds of the cornea. In the collection at the Royal Ophthalmic Hospital, London, there are numerous specimens showing similar changes. This form of atrophy, however, is not to be confused, though it frequently is, with the atrophía bulbi following upon a plastic iridocyclitis. Here the changes are more of a trophic or mechanical nature and the first link in the chain is in all probability the shrinking of the vitreous following upon an escape of its substance through a perforation or rupture of the hyaloid membrane. The absence of the normal support of the retina leads to detachment of that structure and the vacuum thus created brings about in turn a separation of the choroid. The order of detachment of the retina and choroid might, however, be reversed, and in this instance the anterior synechia may have also played a part.

*Case II: Perforating Wound of Cornea—Traumatic Cataract—
Uveo-Retinitis—Secondary Glaucoma—Ciliary and Posterior
Staphyloma—Calcareous Degeneration of the Cornea.*

About 30 years previously the patient, a male *æt.* 50, had accidentally run a needle into the right eye, which was painful and irritable for 10 or 12 weeks. The organ was perfectly quiet until three weeks before coming to the hospital when it became inflamed and painful for a second time. V. equals no P.L.; Tn; other conditions as below:—

Microscopical Examination : The eye measures 27 mm. in the antero-posterior by 25 mm. in the transverse meridian. The cornea is opaque and carries in its middle half a transverse calcareous band. At its upper and inner margin is situated a small, rounded, dark-colored bulging, measuring about 4 mm. in the transverse by 3 mm. in the antero-posterior direction, which bulges outwards 2 mm. beyond the normal curvature of the sclerotic.

Section : At the upper surface of the globe the sclerotic is very much thinned and bulges outwards beyond the surface of the globe to the extent above mentioned. The point of greatest protuberance occurs just at the site of the ciliary body, which is greatly atrophied and stretched to form a thin, perforated, lining-membrane along the inner surface of the staphyloma. The iris is firmly adherent about its pupillary margin to the anterior surface of the lens, which is reduced to a thin atrophic disc, 0.5 to 1 mm. in thickness.

On either side of the central adhesion, the most typical condition of *iris bombé* is present, while both angles of the anterior chamber are completely blocked by the iris which is closely adherent to the posterior surface of the cornea for some distance inwards towards the centre.

A rounded ridge marks the line of separation between the staphyloma and the upper part of the posterior chamber.

The choroid and retina show evidence of long-standing inflammation leading to atrophy and pigmentary disturbances especially along the posterior margins of the ciliary processes. There is deep cupping of the optic disc.

Microscopical Examination: The calcareous degeneration noted macroscopically is seen as isolated, rounded bodies or aggregated masses of a yellowish color. These are situated for the most part in the anterior layers of the cornea, immediately beneath Bowman's membrane, but occasionally they break through this structure and are seen imbedded in the corneal epithelium.

Under the microscope the anterior boundary of the bulging corresponds, as nearly as possible, to the corneo-scleral junction. The wall of the staphyloma is composed of a few strands of greatly attenuated sclerotic mixed with pigment cells, which also form a more or less connected layer on its inner surface. The conjunctiva is continued backwards over the anterior three-fourths of the prominence and between the two structures is a rich plexus of dilated vessels.

The lens corresponds roughly to a dumb-bell in shape. At either end a clear band of lens-matter in the periphery surrounds a central area of amorphous debris, while the central part connecting these two portions is filled up by newly-formed, fibrous connective-tissue, presumably derived from the iris on account of the relatively large number of pigment cells imbedded in its substance. Further confirmation is also found in the fact that the capsule of the lens is everywhere intact except about the middle of its anterior surface.

The iris where applied to the posterior surface of the cornea is reduced to a thin layer of pigment and on the other hard Descemet's membrane is noticeably diminished in thickness where the cornea and iris are in contact with one another. At the point on either side where the iris leaves the cornea the posterior elastic lamina becomes increased in breadth and the endothelial cells can be followed both along its posterior surface and the front of the iris for some distance.

The choroid is reduced to a comparatively thin band of tissue, free for the most part, from blood vessels. While the pigment proper of this coat has almost entirely disappeared; the retinal pigment cells are seen in the usual situation. The thickness of this layer varies however; in some places it is very much thinned or wanting, in others broader than the average.

The entire appearance of the retina is altered. This structure now consists of a meshwork of fibrillæ in which are imbedded rounded or

oval cells of moderate size and staining property, evidently the nuclei of the cells from which the processes originate.

Case III: Foreign Body in the Globe—Traumatic Cataract—Chronic Uveo-Retinitis—Secondary Glaucoma—Equatorial Staphyloma.

The patient, a blacksmith, æt. 77, had been struck in the eye with a piece of metal 25 years previously. He was operated upon shortly after the accident but never regained the sight of that side and the eye had been subject to severe attacks of pain from time to time.

Macroscopical: The eye measures 25 mm. antero posteriorly, by 27 mm. transversely. The cornea is small and opaque, and the anterior chamber, which is shallow, contains a yellowish exudate in the periphery above and below. A slight bulging occurs in the equatorial region upwards (equatorial staphyloma). Tension x 2.

Section: (Fig. IV). The cornea appears to be of normal thickness but the anterior chamber is shallow and blocked at each angle by the periphery of the iris. Breaks in the continuity of the tissue of this structure occur here and there from atrophy, while along its posterior surface it adheres to the lens, which is greatly reduced in size, irregular and cataractous. The ciliary processes are greatly atrophied and flattened and the choroid and retina throughout their whole extent show extensive atrophic changes with numerous spots of accumulated pigment. There is no cupping of the optic disc. At the equator of the globe above there is marked thinning of the sclerotic, which bulges slightly at this point. Close to the margin of the staphyloma on the inner surface of the globe lies a small dark foreign body of steel or iron firmly retained in position by strong bands of white organized tissue, which extend outwards from the sides of the choroid along the posterior extremities of the ciliary process.

Microscopical: The epithelial layer is present only as an irregular fringe, in many places the cells being entirely absent. A comparatively large number of clear spaces occur between the bundles of the *substantia propria* of the cornea, and attached to the sides of these are seen, not infrequently, one or more fixed corneal cells. Now and again a wandering leucocyte is found lying free in the spaces.

The ciliary processes and ciliary bodies are greatly flattened and atrophied, and the angle of the anterior chamber of both sides is blocked for a considerable distance by the periphery of the iris, which is firmly adherent to the posterior surface of the cornea. The anterior chamber is much diminished in size. The shape of the iris is such that it forms a roughly-triangular structure, one side of which is applied to Descemet's membrane, another forms the rounded posterior boundary

of the anterior chamber, and a third and largest extends from the inner apex (where it meets the same structure of the opposite side through a thin bridge of iris-tissue) to the ciliary body. These areas show a most intense small-round-cell infiltration.

The shape of the lens is roughly the same as in Specimen II. On either side is a rounded, cataractous mass the centre of which has undergone extensive calcareous degeneration. Between the two stretches an irregular band of newly-formed fibrous connective-tissue, which seems here, also, to have been derived from the iris on account of the presence of numerous pigment cells. The lens has been dislocated in the direction of the staphyloma, described below, and on this side, somewhat internally to the ciliary body, its capsule is in immediate contact with Descemet's membrane, the iris having, at this point, undergone complete atrophy from pressure.

The staphyloma consists of thinned and stretched sclerotic, in the outer layers of which pigment cells are also found; its inner surface is lined towards the periphery by the atrophied choroid, and more towards the centre by a single layer of flattened cells, though in the very middle of the concavity all these structures are wanting. The retina bridges over the base of the staphyloma, and the angles of the subretinal space, thus formed, are occupied by a reticulated tissue-mass in which are imbedded numerous pigment granules and round mononuclear cells.

The choroid and retina elsewhere present the characteristics of an atrophic, plastic choroido-retinitis. The latter structure generally is converted into a mesh-work of fine fibrillar cells with rounded or oval nuclei; only in the vicinity of the optic disc of each side can traces of the nuclear layers still be made out. The vessels show very typically the usual thickening of the walls, and concomitant narrowing or obliteration of their lumina. Where the retina crosses the base of the staphyloma and also in front of the optic disc is seen in its substance a considerable number of large clear cavities of more or less rounded shape, but entirely free from exudate of any kind. The choroid is reduced to a thin atrophic seam and its pigment generally is mostly seen along its anterior margin, now and again shoving into the retina as isolated irregular clumps. As a whole the thickness of the pigment layer between the choroid and retina tends to vary greatly in some places being much more developed than in others. To the inner side of the anterior end of the staphyloma, and in front of the retina at the optic disc, is seen an irregular, wavy, nucleated mass of newly formed fibrous tissue. In the former situation it represents part of the bands which held the foreign body in position.

