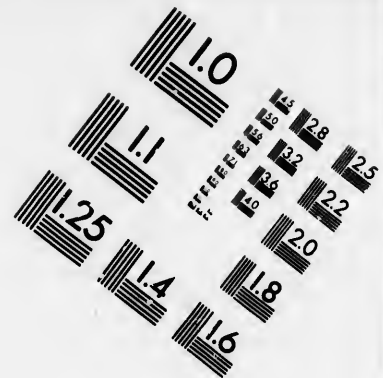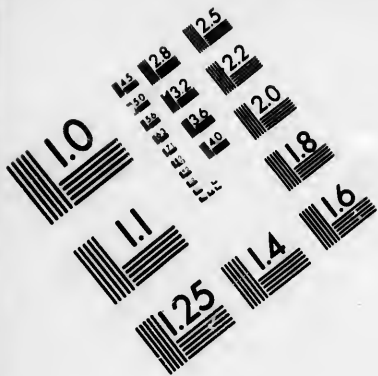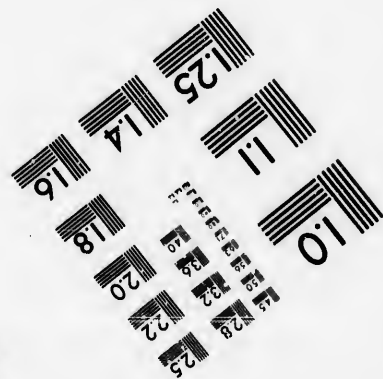




### IMAGE EVALUATION TEST TARGET (MT-3)



Photographic  
Sciences  
Corporation

23 WEST MAIN STREET  
WEBSTER, N.Y. 14580  
(716) 872-4503

**CIHM/ICMH  
Microfiche  
Series.**

**CIHM/ICMH  
Collection de  
microfiches.**



**Canadian Institute for Historical Microreproductions / Institut canadien de microreproductions historiques**

**© 1986**

Technical and Bibliographic Notes/Notes techniques et bibliographiques

The Institute has attempted to obtain the best original copy available for filming. Features of this copy which may be bibliographically unique, which may alter any of the images in the reproduction, or which may significantly change the usual method of filming, are checked below.

L'Institut a microfilmé le meilleur exemplaire qu'il lui a été possible de se procurer. Les détails de cet exemplaire qui sont peut-être uniques du point de vue bibliographique, qui peuvent modifier une image reproduite, ou qui peuvent exiger une modification dans la méthode normale de filmage sont indiqués ci-dessous.

- |   |   |
|---|---|
| <input type="checkbox"/> Coloured covers/<br>Couverture de couleur  | <input type="checkbox"/> Coloured pages/<br>Pages de couleur  |
| <input type="checkbox"/> Covers damaged/<br>Couverture endommagée   | <input type="checkbox"/> Pages damaged/<br>Pages endommagées  |
| <input type="checkbox"/> Covers restored and/or laminated/<br>Couverture restaurée et/ou pelliculée   | <input type="checkbox"/> Pages restored and/or laminated/<br>Pages restaurées et/ou pelliculées   |
| <input type="checkbox"/> Cover title missing/<br>Le titre de couverture manque  | <input checked="" type="checkbox"/> Pages discoloured, stained or foxed/<br>Pages décolorées, tachetées ou piquées  |
| <input type="checkbox"/> Coloured maps/<br>Cartes géographiques en couleur  | <input type="checkbox"/> Pages detached/<br>Pages détachées   |
| <input type="checkbox"/> Coloured ink (i.e. other than blue or black)/<br>Encre de couleur (i.e. autre que bleue ou noire)  | <input checked="" type="checkbox"/> Showthrough/<br>Transparence  |
| <input type="checkbox"/> Coloured plates and/or illustrations/<br>Planches et/ou illustrations en couleur   | <input type="checkbox"/> Quality of print varies/<br>Qualité inégale de l'impression  |
| <input type="checkbox"/> Bound with other material/<br>Relié avec d'autres documents  | <input type="checkbox"/> Includes supplementary material/<br>Comprend du matériel supplémentaire  |
| <input type="checkbox"/> Tight binding may cause shadows or distortion along interior margin/<br>La reliure serrée peut causer de l'ombre ou de la distortion le long de la marge intérieure  | <input type="checkbox"/> Only edition available/<br>Seule édition disponible  |
| <input type="checkbox"/> Blank leaves added during restoration may appear within the text. Whenever possible, these have been omitted from filming/<br>Il se peut que certaines pages blanches ajoutées lors d'une restauration apparaissent dans le texte, mais, lorsque cela était possible, ces pages n'ont pas été filmées. | <input type="checkbox"/> Pages wholly or partially obscured by errata slips, tissues, etc., have been refilmed to ensure the best possible image/<br>Les pages totalement ou partiellement obscurcies par un feuillet d'errata, une pelure, etc., ont été filmées à nouveau de façon à obtenir la meilleure image possible. |
| <input checked="" type="checkbox"/> Additional comments:<br>Commentaires supplémentaires:   | Pagination as follows : [51] - 56 p.  |

This item is filmed at the reduction ratio checked below/  
Ce document est filmé au taux de réduction indiqué ci-dessous.

10X	14X	18X	22X	26X	30X
<input type="checkbox"/>	<input type="checkbox"/>	<input type="checkbox"/>	<input checked="" type="checkbox"/>	<input type="checkbox"/>	<input type="checkbox"/>
12X	16X	20X	24X	28X	32X

The copy filmed here has been reproduced thanks to the generosity of:

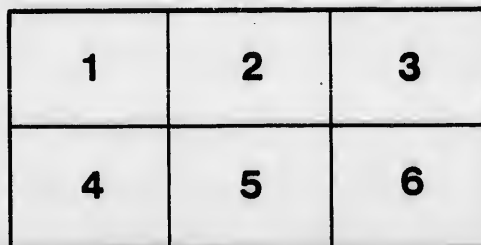
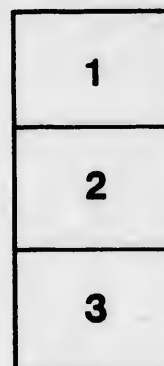

Medical Library  
McGill University  
Montreal

The images appearing here are the best quality possible considering the condition and legibility of the original copy and in keeping with the filming contract specifications.

Original copies in printed paper covers are filmed beginning with the front cover and ending on the last page with a printed or illustrated impression, or the back cover when appropriate. All other original copies are filmed beginning on the first page with a printed or illustrated impression, and ending on the last page with a printed or illustrated impression.

The last recorded frame on each microfiche shall contain the symbol  $\rightarrow$  (meaning "CONTINUED"), or the symbol  $\nabla$  (meaning "END"), whichever applies.

Maps, plates, charts, etc., may be filmed at different reduction ratios. Those too large to be entirely included in one exposure are filmed beginning in the upper left hand corner, left to right and top to bottom, as many frames as required. The following diagrams illustrate the method:



L'exemplaire filmé fut reproduit grâce à la générosité de:

Medical Library  
McGill University  
Montreal

Les images suivantes ont été reproduites avec le plus grand soin, compte tenu de la condition et de la netteté de l'exemplaire filmé, et en conformité avec les conditions du contrat de filmage.

Les exemplaires originaux dont la couverture en papier est imprimée sont filmés en commençant par le premier plat et en terminant soit par la dernière page qui comporte une empreinte d'impression ou d'illustration, soit par le second plat, selon le cas. Tous les autres exemplaires originaux sont filmés en commençant par la première page qui comporte une empreinte d'impression ou d'illustration et en terminant par la dernière page qui comporte une telle empreinte.

Un des symboles suivants apparaîtra sur la dernière image de chaque microfiche, selon le cas: le symbole  $\rightarrow$  signifie "A SUIVRE", le symbole  $\nabla$  signifie "FIN".

Les cartes, planches, tableaux, etc., peuvent être filmés à des taux de réduction différents. Lorsque le document est trop grand pour être reproduit en un seul cliché, il est filmé à partir de l'angle supérieur gauche, de gauche à droite, et de haut en bas, en prenant le nombre d'images nécessaire. Les diagrammes suivants illustrent la méthode.

etails  
s du  
odifier  
une  
image

errata  
to

pelure,  
on à

32X

Pun

Armstrong, GE

## Surgery.

### Puncture and Incision of the Pericardium.

DELORME ET MIGNON. "Sur la ponction et l'incision du pericarde."  
—*Revue de Chirurgie*, Décembre, 1895.

[Commenced in the April Number.]

There are four methods of approaching the pericardium :

1. By trephining the sternum.
2. By passing close beneath the inferior border of the thoracic cage beneath the seventh costal cartilage, starting from the xiphoid appendix.
3. By puncture through an intercostal space.
4. By resecting one or two of the costal cartilages.


Trephining the sternum was advised by Riolan in 1648. The suggestion was accepted by Laennec, Bayer and by Skielderup. It was only done once on the living by Malle. In this way he removed 300 grammes of serous liquid. The relief was instant, but the patient ultimately succumbed to tuberculosis of the intestines and lungs.

Soft and superficial, the sternum is easily trephined. There is no danger of wounding the internal mammary arteries, but there is danger of the bone becoming infected and suppurating, and also danger of the fluid escaping into the cellular tissue of the mediastinum and there setting up inflammatory action. Another danger difficult to avoid is the wounding of the right pleura.

Epigastric incision as a method of approaching the pericardium was suggested to D. Larrey by observing a penetrating wound in a soldier, in which the instrument entered between the xiphoid and seventh costal cartilages passing through the pericardium from below upwards.

The operation is easy of performance, and the left terminal branch of the internal mammary artery can be secured without any special difficulty. But if the abdomen is distended the diaphragm may be pushed up so far as to be in danger of being wounded, and then again there is the danger of wounding the left pleura.

Puncture of the pericardium, since the attempt of Schub in 1840, has been often performed. An ordinary trocar has been used in the majority of cases, sometimes an aspirator needle and sometimes direct puncture with a scalpel.



As to the point of puncture, operators have been guided either by the anatomy of the region or by the clinical signs. The pericardium lies beneath the 2nd, 3rd, 4th and 5th intercostal spaces. It extends a few centimetres to the right of the right border of the sternum, and it has been suggested to puncture it to the right of the sternum.

The internal mammary artery passes 2 or 3 millimetres from the border of the sternum in children and 10 to 15 millimetres in adults. In the fourth interspace there is danger of wounding the heart if the puncture is deep.

Aran, without regard to anatomical points and only bent on avoiding the wounding of the heart, chose the points where silence and absence of bruits were the most complete.

The early operators used a hydrocele trocar, but the needle of an aspirator is now generally used and is to be recommended. After discussing the method of Baizeau and Dieulafoy the authors advise the following:

Along the left border of the sternum, that is, about 15 millimetres from the median line, an incision is made through the skin, beginning a finger's breadth below the lower border of the 7th costal cartilage, passing upwards across the 6th and 5th intercostal spaces. This incision is 4 centimetres in length. In the 6th interspace by preference, if the space will admit the needle, otherwise in the 5th interspace, very exceptionally in the lower internal angle of the 4th interspace, a No. 2 needle of Dieulafoy is slowly inserted in apposition to the left border of the sternum. When the needle has entered to the level of the posterior surface of the sternum, or for a distance of 8 mm, the handle is very much depressed and the point of the needle is carried upwards parallel with the posterior surface of the sternum. When the point of the needle has been forced upwards 1 or 2 centimetres the handle is raised and the point carried forward until fluid appears in the tube. After evacuation the incision is sutured. By this method the internal mammary artery and left pleura are avoided and the risks of wounding the heart are reduced to a minimum.

It is very important that the pleura be not wounded. If the pericardial effusion is serous, probably little harm would result, but if sanguinolent or purulent the result might be disastrous. Even by the method recommended by the authors one is not absolutely certain to avoid the pleura. They found in testing the question that in 32 cadavers, where the puncture was made in the 5th interspace, the pleura was wounded 12 times, and when made in the 6th interspace 6 times. When punctured in the 4th or 3rd interspace the pleura was pierced in nearly every instance. The lung is in less danger as it is generally pushed aside by the effusion. Occasionally the heart has

been wounded, especially when adherent to the anterior wall of the pericardium. This is not necessary fatal if a small needle be used.

Incision of the pericardium is performed after resecting portions of the 5th and 6th intercostal cartilages. The following is recommended and by this method the authors claim that the pleura and internal mammary arteries are not endangered; the pericardium is opened at a dependent part, and in case of pericardial adhesion, there is no danger of wounding the heart.

1. A vertical incision is carried one centimetre to the left of the left border of the sternum from the inferior border of the 7th costal cartilage to the upper border of the 4th. From the extremities of this incision two transverse incisions, each 2 centimetres long, are carried horizontally to the left.

2. The skin, cellular tissue and the attachments of the pectoralis major are elevated and the cartilages laid bare.

3. The 5th costal cartilage is separated from the border of the sternum and the soft parts detached from the borders and under surface and then forcibly elevated, pressure being made upon it 4 centimetres from the edge of the sternum, so that the cartilage is fractured at this point instead of at its junction with the rib. The 6th cartilage is treated in the same manner.

4. The perichondrium is then incised vertically and removed, when the triangularis sterni is exposed with the internal mammary vessels lying upon it.

5. A director is then passed along the border of the sternum, and with the finger the pleura is separated from the pericardium and pushed to the left with the triangularis sterni muscle and the internal mammary vessels.

6. The opaque white pericardium being now exposed, is pinched up and incised; a director is inserted into the opening and with a pair of scissors the opening is enlarged.

If found necessary the 4th cartilage can also be removed.

Since the introduction of antiseptic methods, incision of the pericardium is coming more into favour, as in this way one is certain of not wounding the pleura, mammary vessels, lung or heart, and the fluid can be removed with certainty, as well as fibrinous clots, and medicated solutions can be used if thought advisable.

As these patients often take chloroform or ether badly, it is suggested that it is often advisable to puncture or aspirate first, perhaps with the aid of a local anaesthetic, the more complicated operation of incision being reserved until the heart has recovered itself at least partially.

In the recumbent position there is less danger of syncope and the operator can work to greater advantage.

*Geo. E. Armstrong.*

### Method of Operating in Appendicitis.

WHITE. "Should the appendix be removed in every case of appendicular abscess."—*Annals of Surgery*, June, 1896.

MCBURNEY. "Transactions of the section on general surgery of the College of Physicians of Philadelphia."—*Ibid.*

The writer, after mentioning several points which still admit of legitimate differences of opinion, discusses this question at considerable length. In the cases where the operation is undertaken early, that is before the third or fourth day, there is rarely any doubt about the propriety of removing the appendix, but when we come to the later cases, where a strong wall of adhesions has been formed about the abscess, the case is not so clear.

Some surgeons would remove the appendix in every case, fearing either a return of the disease or a fæcal fistula. The views of a number of surgeons are quoted, and all are strongly of the opinion that in certain cases it is not well to disturb things too much, but to be content with draining the abscess cavity, cleansing and packing it with iodoform gauze, rather than run the risk of infecting the general peritoneum by more radical methods. The writer sums up as follows: "Every medical man knows of the inflammatory obliteration of mucous channels, of the retrograde metamorphosis and disappearance of infected sloughs, or of their fibroid transformation into cicatricial tissue; of the shutting in of abscess cavities with infected walls, and of the coincident death of the bacteria therein as the supply of pabulum is cut off; of the spontaneous healing of fæcal fistulæ. On the other hand, most surgeons of to-day have knowledge of cases in which patients with almost purely local symptoms, in excellent general condition and with distinctly circumscribed abscess, have died of general peritonitis within forty-eight hours after the removal of a deeply-imbedded and adherent appendix."

In the discussion which this paper evoked Dr. McBurney mentioned two classes of abscesses which may be met with as a result of suppuration about the appendix. In one the pus has already approached the anterior abdominal wall and the abscess can be evacuated without opening the general peritoneal cavity. If, in such a case, the appendix forms an integral portion of the barrier which protects the peri-



toneum, no manipulation should be practised. The other form of abscess admits of different treatment. Here the pus and appendix are surrounded by coils of intestine, and the whole mass lies back in the abdomen away from the anterior abdominal wall. Here one must open the general peritoneal cavity as a first step. It is then possible, with gauze or sponges, to isolate the infected area until the mass is unravelled, the appendix removed and the parts cleansed. Every case of suppurative appendicitis is ready for operation as soon as a diagnosis can be made, and the speaker did not agree with Treeves that very few cases required operation before the fifth day. "It is much better to carefully and deliberately approach the abscess than to wait for the abscess to come to the point."

In the course of his paper Dr. White gives the following rules for operation as being such that few, if any, surgeons will dissent from them: "Immediate operation is indicated whenever the onset of a case of appendicitis is marked by both suddenness and severity; whenever, during even a mild attack, the symptoms at the end of twenty-four hours are unrelieved or are growing worse; whenever, in cases seen later, a firm, slowly-forming, well-defined mass is to be felt in the right iliac fossa; whenever at any time a sudden increase in the acuteness of the pain and a rapid diffusion of tenderness occur; whenever there is good reason for believing the appendix infection to be tubercular in character; whenever attacks of any type have been numerous, or are increasing in either number or gravity, or have unfitted the patient for work or activity, or have caused local symptoms which are permanent and persistent or have at any time put the patient's life in great danger." *Robt. C. Kirkpatrick.*

#### **Puncture and Incision of the Pericardium.**

DELORME ET MIGNON. "Sur la ponction et l'incision du péricarde"  
—*Revue de Chirurgie*, 10 Janvier, 1896.

(Commenced in the April Number.)

In their final article, Delorme and Mignon discuss the results of puncture and incision of the pericardium.

They have collected 102 cases; of these 61 are reported to have died, 36 to have been cured, and in two instances the results are not given by the operators.

They contend, and rightly, that these figures do not truly represent the benefits that may be derived from puncture and incision, as in many of these cases the operation was performed as a last resort, the patient really dying from lesions developed before the operation was

performed. They urge that if it can be shown that puncture and incision of the pericardium are sometimes followed by cure and always by amelioration of the symptoms, that they have gained their cause. They report one case where death was undoubtedly caused by the operation. The trocar had been forced through the left 4th interspace, close to the sternum. The operator withdrew two ounces of blood; five minutes afterwards the patient died from hæmorrhage into the pericardium. The autopsy showed that the trocar had penetrated the right ventricle of the heart on the middle of its anterior surface.

In a few instances a fluid, sero-sanguinolent at the time of operation, became purulent afterwards. This may have been due to dirty instruments and imperfect technique.

Many of the unfortunate results are avoidable.

Patients bear the operation well.

Of 100 cases, 82 were punctures and 18 incisions. Of the 82 punctures 54 died and 28 recovered, a mortality of 65 p.c. Of the 18 incisions 7 died and 11 recovered, or a mortality of 38 p.c.

These figures speak strongly in favour of incision as compared with puncture.

These articles are of great value and are well illustrated, and they lead one to think that there is a legitimate field here for the surgeon to step in and do useful work.

*Geo. E. Armstrong.*

