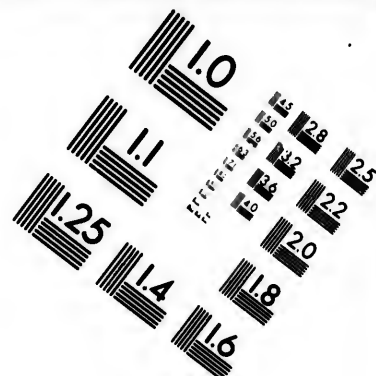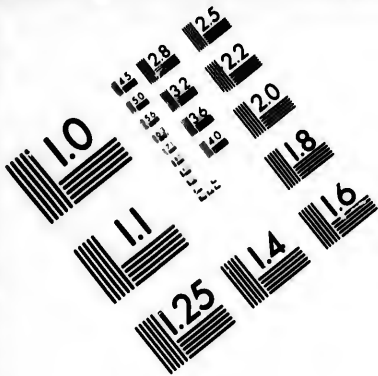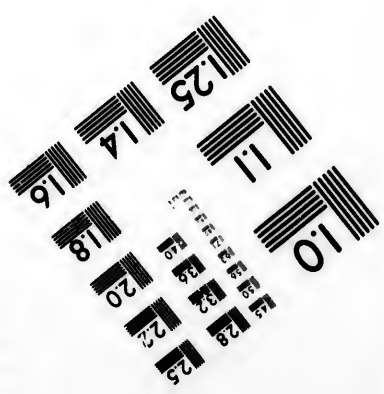





**IMAGE EVALUATION
TEST TARGET (MT-3)**



**Photographic
Sciences
Corporation**

23 WEST MAIN STREET
WEBSTER, N.Y. 14580
(716) 872-4503

2.5
2.2
2.0

**CIHM/ICMH
Microfiche
Series.**

**CIHM/ICMH
Collection de
microfiches.**

01



Canadian Institute for Historical Microreproductions

Institut canadien de microreproductions historiques

1980

Technical and Bibliographic Notes/Notes techniques et bibliographiques

The Institute has attempted to obtain the best original copy available for filming. Features of this copy which may be bibliographically unique, which may alter any of the images in the reproduction, or which may significantly change the usual method of filming, are checked below.

L'Institut a microfilmé le meilleur exemplaire qu'il lui a été possible de se procurer. Les détails de cet exemplaire qui sont peut-être uniques du point de vue bibliographique, qui peuvent modifier une image reproduite, ou qui peuvent exiger une modification dans la méthode normale de filmage sont indiqués ci-dessous.

- Coloured covers/
Couverture de couleur
- Covers damaged/
Couverture endommagée
- Covers restored and/or laminated/
Couverture restaurée et/ou pelliculée
- Cover title missing/
Le titre de couverture manque
- Coloured maps/
Cartes géographiques en couleur
- Coloured ink (i.e. other than blue or black)/
Encre de couleur (i.e. autre que bleue ou noire)
- Coloured plates and/or illustrations/
Planches et/ou illustrations en couleur
- Bound with other material/
Relié avec d'autres documents
- Tight binding may cause shadows or distortion
along interior margin/
La reliure serrée peut causer de l'ombre ou de la
distortion le long de la marge intérieure
- Blank leaves added during restoration may
appear within the text. Whenever possible, these
have been omitted from filming/
Il se peut que certaines pages blanches ajoutées
lors d'une restauration apparaissent dans le texte,
mais, lorsque cela était possible, ces pages n'ont
pas été filmées.
- Additional comments:/
Commentaires supplémentaires:

- Coloured pages/
Pages de couleur
- Pages damaged/
Pages endommagées
- Pages restored and/or laminated/
Pages restaurées et/ou pelliculées
- Pages discoloured, stained or foxed/
Pages décolorées, tachetées ou piquées
- Pages detached/
Pages détachées
- Showthrough/
Transparence
- Quality of print varies/
Qualité inégale de l'impression
- Includes supplementary material/
Comprend du matériel supplémentaire
- Only edition available/
Seule édition disponible
- Pages wholly or partially obscured by errata
slips, tissues, etc., have been refilmed to
ensure the best possible image/
Les pages totalement ou partiellement
obscurcies par un feuillet d'errata, une pelure,
etc., ont été filmées à nouveau de façon à
obtenir la meilleure image possible.

This item is filmed at the reduction ratio checked below/
Ce document est filmé au taux de réduction indiqué ci-dessous.

10X	14X	18X	22X	26X	30X
<input type="checkbox"/>	<input type="checkbox"/>	<input type="checkbox"/>	<input checked="" type="checkbox"/>	<input type="checkbox"/>	<input type="checkbox"/>
12X	16X	20X	24X	28X	32X

The copy filmed here has been reproduced thanks to the generosity of:


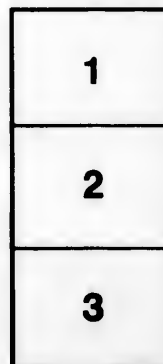
National Library of Canada

The images appearing here are the best quality possible considering the condition and legibility of the original copy and in keeping with the filming contract specifications.

Original copies in printed paper covers are filmed beginning with the front cover and ending on the last page with a printed or illustrated impression, or the back cover when appropriate. All other original copies are filmed beginning on the first page with a printed or illustrated impression, and ending on the last page with a printed or illustrated impression.

The last recorded frame on each microfiche shall contain the symbol \rightarrow (meaning "CONTINUED"), or the symbol ∇ (meaning "END"), whichever applies.

Maps, plates, charts, etc., may be filmed at different reduction ratios. Those too large to be entirely included in one exposure are filmed beginning in the upper left hand corner, left to right and top to bottom, as many frames as required. The following diagrams illustrate the method:



L'exemplaire filmé fut reproduit grâce à la générosité de:


Bibliothèque nationale du Canada

Les images suivantes ont été reproduites avec le plus grand soin, compte tenu de la condition et de la netteté de l'exemplaire filmé, et en conformité avec les conditions du contrat de filmage.

Les exemplaires originaux dont la couverture en papier est imprimée sont filmés en commençant par le premier plat et en terminant soit par la dernière page qui comporte une empreinte d'impression ou d'illustration, soit par le second plat, selon le cas. Tous les autres exemplaires originaux sont filmés en commençant par la première page qui comporte une empreinte d'impression ou d'illustration et en terminant par la dernière page qui comporte une telle empreinte.

Un des symboles suivants apparaîtra sur la dernière image de chaque microfiche, selon le cas: le symbole \rightarrow signifie "A SUIVRE", le symbole ∇ signifie "FIN".

Les cartes, planches, tableaux, etc., peuvent être filmés à des taux de réduction différents. Lorsque le document est trop grand pour être reproduit en un seul cliché, il est filmé à partir de l'angle supérieur gauche, de gauche à droite, et de haut en bas, en prenant le nombre d'images nécessaire. Les diagrammes suivants illustrent la méthode.



POST-MORTEM EXAMINATIONS

METHODS AND TECHNIQUE

—BY—

JOHN CAVEN, B.A., M.D., (Toronto)

L.R.C.P., (London)

Professor of Pathology, University of Toronto Medical Faculty.

ILLUSTRATED

J. A. CARVETH & CO.,


Toronto, Canada.


170300

RB 57

C 34

Entered according to Act of Parliament of Canada,
in the year one thousand nine hundred, by J. A.
CARVETH, at the Department of Agriculture, Ottawa.





CONTENTS.

CHAPTER I.

EQUIPMENT AND PREPARATION

	PAGE
Instruments, Bacteriological Outfit, Hands and Wounds, Handling the Knife	5

CHAPTER II.

THE BODY

Care of the Body, Opening, Closing, Replacing the Skull Cap, Cleaning up.	9
---	---

CHAPTER III.

RECORDS

Making Records, Keeping Records, Form of Record	12
---	----

CHAPTER IV.

INTRODUCTION TO THE EXAMINATION—INSPECTION AND SECTION DEFINED

Order of Examination of Viscera	14
---	----

CHAPTER V.

TECHNIQUE OF EXAMINATION

Head, Abdomen and Thorax, Organs of the Abdomen, Removal of the Pelvic Viscera en masse, Spinal Column, Skeleton	17
--	----

CHAPTER VI.

CRIMINAL POISONING

Preparations for Examinations, Points of Technique	32
--	----

CHAPTER VII.

EXAMINATION OF THE NEW BORN

Infanticide, Period of Development of the Fœtus, Proof of Breathing, Cause of Death	34
---	----

CHAPTER VIII.

PRESERVATION AND PREPARATION OF TISSUES


Preservatives and their Application, Preparation of Materials for Microscopic Examination, Method of Rapid Examination	37
--	----

CHAPTER IX.

WEIGHTS AND MEASUREMENTS OF ORGANS	40
--	----

ILLUSTRATIONS.

PLATE.	PAGE.
I. FASTENING ON OF SKULL-CAP BY MEANS OF A BANDAGE	6
II. SECTIONING THE BRAIN; OPENING INTO LEFT LATERAL VENTRICLE	12
III. LINES OF VERTICAL SECTION FOR BRAIN	18
IV. OPENING THE HEART—RIGHT SIDE	20
V. OPENING THE HEART—LEFT SIDE	22
VI. LINES SHOWING METHOD OF SECTIONING LUNGS—FIRST INCISIONS	26



Technique of Post-Mortem Examinations

Post-mortem examinations are made for two different purposes, viz.:—For ascertaining facts from a scientific standpoint, and secondly, for discovery from legal reasons. The operations of the examination will vary more or less according to the object in view. Before considering the technique of the operations there are some general points relating to preparation for the work which it will be useful to take up.

EQUIPMENT, INSTRUMENTS, ETC.—Although a very useful post-mortem examination can be made with but few and simple instruments, a good and complete outfit is of course desirable when it can be obtained. The following list contains such an outfit as should be found in hospital mortuaries, where examinations are habitually performed for scientific purposes:

Knives—Scalpels, three sizes; cartilage knife; brain knife.

Scissors—Bowel scissors; straight, probe pointed; curved on flat, blunt point.

Saws—Large amputation; small butcher or finger.

Forceps—Dissecting, several pairs.

Costotome—Rib shears.

Rachitome—Double saw or double curved chisels.

Chisels—Large for opening head; set of smaller ones for bone work; set of gouges.

Probes—Long and short, flexible.

Director—Grooved.

Mallet—Or hammer; rawhide mallet preferable.

Head-rest—Or holder.

Steel Tape—English and French systems.

Calipers.

Glass Graduate—One litre; also one of 250 cc. subdivided.

Catheters—Set, web.

Hook—For raising skull cap.

Brad-awl.

Needles—Large, veterinary.

Copper Wire—Light.

Double Carpet Tacks.

Heavy Linen Thread and narrow tape.

Sponges.


When found possible, apparatus of some kind for weighing organs as taken from the body should be within reach. Fluids, too, ought to be quantitatively estimated as a routine process. A large glass syringe will often be found useful for the removal of fluids from cavities when dipping out by means of a cup or graduate is not feasible. If the syringe be graduated and have a piece of rubber tubing for a tip, so much the better. The use of sponges is not advised. In some cases the measurements of organs must be taken.

BACTERIOLOGICAL OUTFIT—All post-mortem examinations should involve more or less bacteriological work. Even in out-of-door work there is but little difficulty in manipulating the necessary apparatus; certainly no post-mortem room should be without it. The following simple equipment will be found ample:

1. *Test Tubes* with media; at least beef broth and agar.
2. *Spirit Lamp* or Bunsen burner.
3. *Platinum Wire Inoculators* mounted in glass rods.
4. *Dressing Forceps.*
5. *Scalpels*—Two.
6. *Scissors.*
7. *Small Copper Plate* on handle (specimen lifter or spatula will do.)
8. *Empty, Plugged and Sterilized Test Tubes.*
9. *Capillary Glass Tubes* three inches long.
10. *Cover Slips.*

The object of the above equipment is, of course, that one should be able to make directly from the body when opened, cultures from such fluids and tissues as may seem necessary.

HANDLING THE KNIFE—In post-mortem examinations the largest knife suitable to the work in hand will be found the best. The tendency amongst beginners is to work with too little freedom, making small, weak cuts, and thus not only wasting time but leaving organs and tissues in poor condition for naked eye examination. Firm, sweeping cuts with a large knife—sharp of course—nearly always give the fairest, smoothest surfaces for inspection. One author says that one clean, sweeping cut in the wrong direction is better than many small, undecided cuts in the right direction. This can be seen to perfection in the case of liver or kidney; in




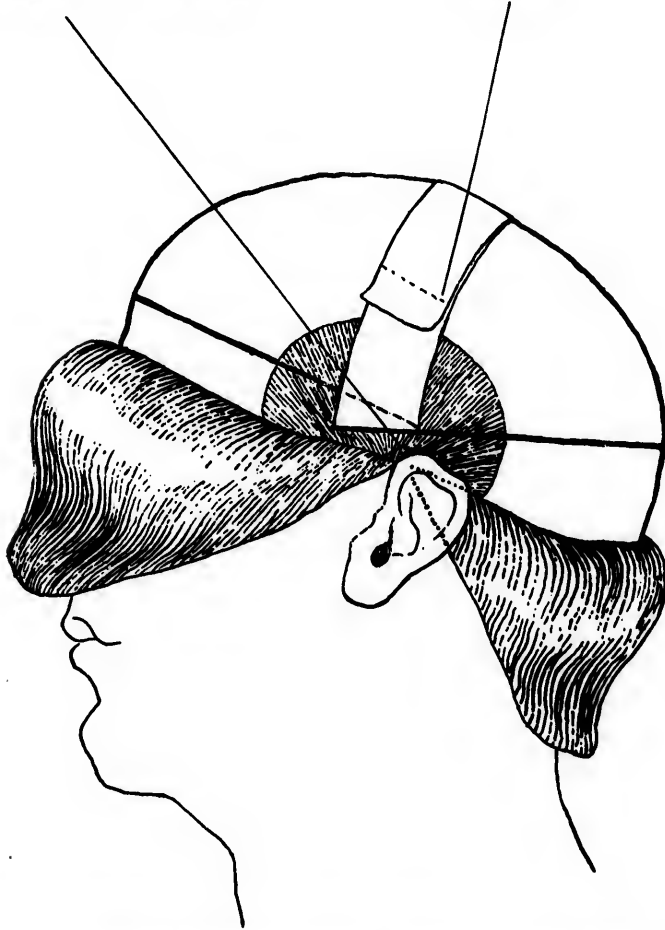



PLATE I.

Posterior saw-cut continued forward.

Bandages.



FASTENING ON OF SKULL-CAP BY MEANS OF A BANDAGE



both a smooth surface is necessary, not the "staircase" appearance resulting from timorous cutting. In order to work well with the knife the handle should be taken freely into the palm of the hand, as one would grasp a sword hilt, not as a pen holder would be used, and the belly of the knife should be made to do the cutting, not the point. In fact, in selecting knives one should see to it that the blades of the larger ones are made with a prominent, curving belly, the cutting edge ending somewhat abruptly in a point which is in a straight line with the back. The larger the knife, up to certain limits, the more easily can it be handled. Work requiring fine dissection should not be undertaken at the post-mortem, but set aside for leisure.


HANDS AND WOUNDS—When possible the operator at a post-mortem examination should wear rubber gloves. The best kind of glove is that known as the "Veterinary," which is made very thin and of pure rubber, fitting closely to the hand and not interfering a great deal with the sense of touch. A thicker glove is more commonly chosen on account of its cheapness, but with it almost nothing can be ascertained by touch. Any difficulty in drawing on of the gloves may be overcome by dusting the hand with some dry powder, e.g., violet powder. An objection to any form of glove lies in the fact of its becoming very slippery when soiled with blood. Rubber gloves may be worn for a long time if washed free of oil or grease after using. If any fat be left on them they rot quickly: soap and warm water will readily free them of grease. When gloves are not available, some operators protect the hands by coating them with vaseline or oil of some kind. It is a good plan to examine the hands carefully before entering on an autopsy in order to determine whether any cuts or abrasions exist. These may be present but not visible, but if the hands be exposed to the fumes of ammonia for a few seconds, the resulting nipping will locate them. In septic cases some such precaution is always advisable. When breaks in the skin are discovered, they should be disinfected with strong tincture of iodine or carbolic acid, and then covered up with collodion or rubber plaster, even though gloves are to be used.

Of all forms of post-mortem wounds a puncture with needle or knife point is the most dangerous; in many instances it is practically a stab inoculation into a good medium. In order to treat such a wound properly, it should at once be enlarged by a clean knife point until there is no difficulty in reaching the very bottom of it by disinfectants. Throwing a ligature of some kind around the finger above the wound and causing free bleeding in this way

is a useful measure. Sucking the wound—often resorted to—may be useful so far as the wounded member is concerned, but may lead to infection of the lips or tongue. Inoculation not seldom takes place through hair follicles, and although the results commonly remain localized, in the form of large pimples or boils, they may be sufficiently painful and disabling. It is chiefly in cases of peritonitis with large, purulent exudations, that this form of infection is seen. It is best avoided by washing the hands and arms, from time to time, in running water. *It is a good rule to wash the hands frequently in making examinations, no matter what the disease under investigation may be.*

If infection does occur, as proven by appearances some hours after exposure, the best immediate treatment is excision of the inoculated area.





THE BODY.

CARE OF BODY—In making post-mortem examinations the greatest possible care ought to be taken not to disfigure the body, but to leave it in such condition that friends may not be shocked by its appearance. In private work this is of very special importance. Naturally many people are greatly adverse to such procedure and ordinary decency should lead investigators to do everything possible to avoid giving pain; moreover, one slip in this respect will almost certainly prevent future opportunities of examination for the individual who makes it. A reputation for carelessness in such matters travels. Occasionally it is necessary to examine a body under trying conditions; for example, it may be prepared for burial and confined, or the room in which it lies may not be a fit one. In such cases every precaution possible must be taken to prevent soiling of clothing, coffin trimmings, carpets, etc. A good supply of old newspapers will be found very useful. They may be tucked in so as to protect the trimmings if the examination be made in the coffin, or they may be placed upon the floor. Dispose of them by rolling up and burning. Remember always to work with windows open when possible and always to leave them open after the examination. The odor of a dead body which has been opened will rapidly permeate a whole house, therefore isolate the room by closing doors of communication. If an examination is to be made in a private dwelling everything necessary to be used should, if possible, be taken in his kit by the examiner. This is to save the friends. In this connection remember that the less noise made the better; especially subdue the noise of hammer, chisel and saw, if so situated that friends may hear and be distressed. A chisel may be protected by a folded towel. Water or oil may be poured on the blade of a saw. Cleaning up after a post-mortem ought not to be left to the friends. Any debris that cannot be disposed of within the body or thrown into a closet should be taken away from the house and everything around the body left as found.


OPENING THE BODY—To open the thorax and abdomen stand on the right side of the body, and with a large knife make an incision from the supra-sternal notch to the symphysis pubis, in the midline, passing to the left of the umbilicus. This incision should go down to the sternum in the thorax and to the muscle in the abdomen. Commonly, one is not allowed to open higher than the


top of the sternum, but when possible should begin just below the symphysis of the lower maxilla. It is difficult, though possible, to remove the organs of the neck and mouth without opening it in front.

Opening Abdomen—Next make a small opening completely through the belly wall just over the pit of the stomach; insert the first two fingers of the left hand into the opening, pull well forward and place blade of knife between fingers; open the belly down to the pubis. Cut across the recti abdominis muscles about the middle, not damaging the skin; reflect the skin and muscles from the thoracic wall, exposing the inner third of the clavicles above and carrying the reflection well down to the axillary line below. The reflection of the skin must be so done as that all costo-chondral junctions are well exposed. Some operators make a cross cut in the skin of the abdomen in order that everything may be well exposed; this is quite unnecessary except in special instances, and merely gives extra work in sewing up. To free the recti muscles from their attachments to the pubic bones may be of use at times.

CLOSING BODY—When a body is about to be sewn up after examination all fluids should be removed from the cavities. Decomposition is accelerated by the escape of fluids into the cavities and tissues. If the sewing be properly done there should be no leakage even though fluids be left. Commence sewing from the lower end of the abdominal incision by passing a thread through from side to side at the very extremity of the cut and tying it firmly. Then sew upwards, thrusting the needle through the skin only—not including fat—taking in about one-quarter of an inch from the cut edge, first one side then on the other, at intervals of about three-quarters of an inch. If the needle be held in the right hand and the thread drawn tight with the left a perfectly watertight seam will be made. The stitch is the same used as in sewing the covers on a baseball or lawn-tennis ball. When the sternum has been completely removed it should be fixed in position by a couple of stitches through intercostal muscles or costal cartilages. In some cases it may be desirable to cover up the skin-stitching; this is best done by means of a strip of rubber plaster heated before application. When organs have been removed from a body it may be thought better to introduce something to take their place in order to preserve its shape; sawdust answers well when it can be used; cotton wadding, newspapers, old rags, etc., will all answer a good purpose.

REPLACING SKULL CAP—The skull cap should be replaced with the greatest possible precision, otherwise signs of the examination will be visible in the shape of more or less deformity of the





brow. The simplest method of retaining the cap in position is by drawing a couple of stitches—interrupted—through the temporal fascia and muscle on either side and tying firmly. The best plan, however, involves drilling small holes, with an awl, in both cap and skull base, at a short distance from the cut edges and wiring together with copper wire, or driving in double carpet tacks. The tacks are to be preferred; should the holes be made too far apart it may be necessary to spread the tack points, which is easily done by forcing a knife handle between them. Three such tacks—one on each side and one behind—are sufficient. Do not attempt to insert the one behind exactly in the midline, since there the skull is thickest. Another method of fixation, which is useful sometimes, can be applied when the skull cap is removed by two cuts of the saw, which meet at an angle in the temporal region. If the cut from the rear be continued forward in the temporal region past the angle of meeting with that from the front, a bandage may be slipped into this across the base and then drawn taut, and pinned or sewed over the top of the replaced cap. (See plate No. 1). The chief point in replacing the cap is to make sure that it fits closely and snugly in front, leaving no ridge. If the scalp has been stretched, as it often is in raising, it improves the appearance of the brow to fit a layer or two of paper closely to the bone, and, after smoothing it down, draw the scalp over it. It may be well to note here that plaster of Paris can often be used to good effect in places where otherwise deformities must result from removal of pieces of bone. It should be mixed tolerably thick, and salt may be added to bring about rapid setting.

CLEANING UP—After the examination all exposed parts of the body (face and hands especially) must be carefully inspected to see that absolutely no blood is left upon them. It will rub off dry generally; if water be necessary cold only should be used. In washing his hands after a post-mortem the operator should use cold water only; warm water intensifies any odor which may cling to them. A soft soap, or better still, ethereal fluid soap is the best cleanser. The odor often clings to the hands even after prolonged washing; rubbing them with powdered mustard after thoroughly drying will remove it for a time. The process may have to be repeated. A solution of permanganate of potassium quickly removes odor, but also requires to be made use of a number of times. If carbolic acid be used the odor will only be made worse by combination with the disinfectant.

N.B.—The evaporation of a few drops of formaldehyde diluted with water upon an iron shovel or saucepan in a closed room will at once destroy any odor.

RECORDS.


RECORDS—In making records of post-mortem examinations it is of prime importance to remember that the records should be of *facts*, not *opinions*. What the examiner sees, feels, smells, etc., must constitute the record, not what he infers from appearances; thus it is proper to say that the mucous membrane of the stomach is “thickened, rugose, of slaty color,” etc., etc., but not that the mucous membrane of the stomach “presents the signs of chronic inflammation.” Notes should be dictated and taken down as the examination proceeds; when possible they should be written with ink, and with so much care as will preclude any question arising later as to what was meant by the examiner. It is usual to re-write the notes so that a fair copy may be kept, especially in case of an inquest, but the original report ought to be such that in case of necessity it may be used for any purpose, formal or otherwise.

The value of notes will vary, not only with completeness, but with the way in which framed. Conciseness is to be aimed at, but brevity must not be mistaken for conciseness. The recorder must remember that in medico-legal cases it is useless to attempt to supply omissions from memory when in the witness box. Every fact to be made use of must be found in the report. If a proper system of examination be followed, nothing of importance will be passed over. It is best to have a certain number of routine observations which one will always make in regard to the different organs, the noting of which will ensure accuracy up to a certain point, and render every examination of *some* value.

FORM FOR RECORD OF A POST-MORTEM EXAMINATION.—

When the record is made for use in a legal inquiry or Court it is customary to begin with a statement of the qualification of the individual deposing to make the deposition in the case in question, and of the fact that he has made a post-mortem examination thus: “I, A.B., am a duly qualified and registered medical practitioner of the Province of Ontario. I have this day made a post-mortem examination of the body of A. Y., at L—, and report as follows” :—

Then follows the report, which is divided into two main parts, viz, —Inspection and Section. Reports of this kind vary in extent




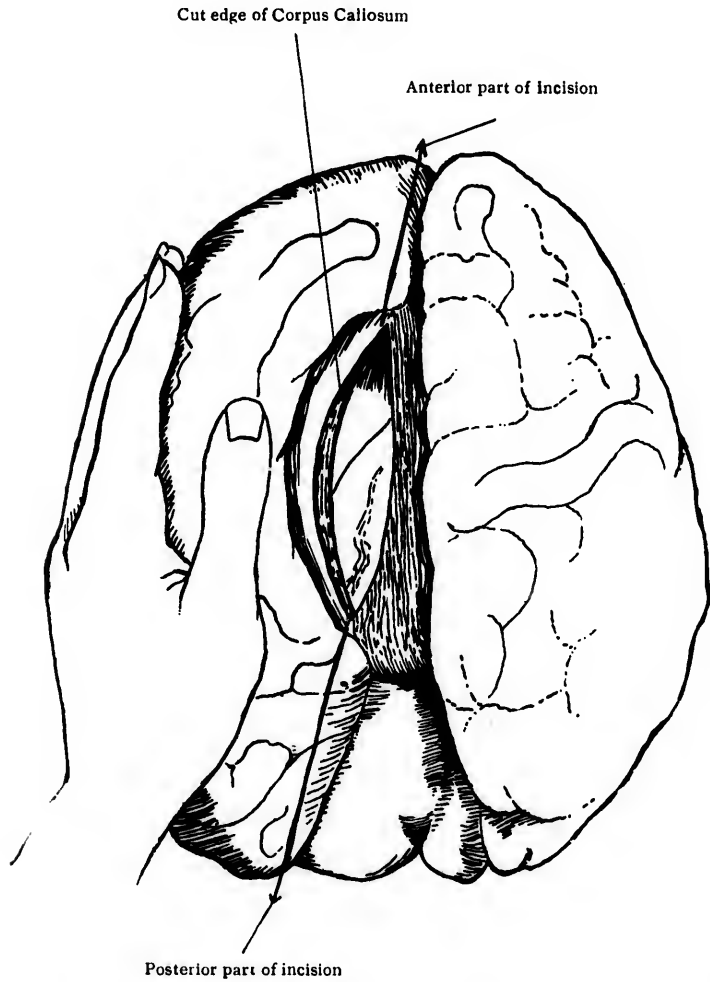



PLATE II.



SECTIONING THE BRAIN ; OPENING INTO LEFT LATERAL VENTRICLE



and in the amount of detail entered into in different cases. The endeavor should be to render the whole thing as short and as simple as is consistent with a sufficient record. Technical terms should be avoided when possible and explained when necessary to a correct understanding of the situation by the laity. In some instances a complete scientific record may be necessary even for the purpose of a legal investigation, but these will be relatively few.

The underneath report may be taken as an example of what is commonly sufficient :

“ Inspection shows the body of a white man of apparently about 45 years of age. The body is fairly well nourished and well developed. Rigor mortis and post-mortem staining are well marked. External orifices are all right and there are no signs of violence visible externally.

“ Section shows that the internal organs, excepting the kidneys and blood vascular system, are in a fairly healthy condition.

“ The kidneys show marked fibrosis and contraction. There is general vascular sclerosis with marked hypertrophy of the heart.

“ Death was due to the condition of the kidneys and blood vascular system and therefore to natural causes.”

In cases in which an individual has died of some injury such as a knife stab or bullet wound, the description of the wounds causing death must be complete and accurate, the examination forming itself, so to speak, around this description.

In an investigation for scientific purposes the chief point to be observed is that the examination be complete. Every organ and tissue *ought* to be examined, and if any are omitted it should be only because it is impossible to make the examination under the circumstances or because it is evident that nothing can be gained therefrom.

INTRODUCTION TO THE EXAMINATION—INSPECTION AND SECTION DEFINED

A post-mortem examination naturally falls under two chief heads, viz :—*Inspection* and *Section*.

By Inspection is meant that examination which is made chiefly by eyesight and without employing instruments. It concerns itself with what can be seen and felt, without opening into the body. In certain cases it will involve also more or less complete investigation of the surroundings of a body. If a body be found lying for examination in a hospital morgue, naturally no special attention is given to environment ; but if it be found lying in a ditch by the roadside, then the medical examiner must inspect surroundings and the relation of the body to them as carefully as he examines the body itself. Commonly such work is done by police and the body removed to more fitting quarters for the medical examination, but sometimes not.

By Section is meant the opening into the body by means of instruments and the examination of organs and tissues thereby made possible. In carrying out such investigations it will be found necessary to follow a certain routine, which will be indicated by two considerations :

1st. Convenience in carrying on the examination.


2nd. Preservation of existing relations so that deviations and abnormalities may be readily detected.


Several methods of post-mortem examinations have been devised—notable amongst these being the procedure of *Virchow*. The following order does not profess to be original nor to follow *exactly* any of the forms already published.

Inspection—In order to inspect a body properly it must be entirely stripped of clothing. If necessary the clothing itself should be carefully examined as removed, stains, tears and damages of any kind being noted and relationship of such to damage in the tissues of the body carefully looked for. Examine from head to foot, noting peculiarities and abnormalities.

Inspect :—

- (a) Skin and appendages—noting, *e.g.*, post-mortem staining.
- (b) Muscular system—noting, *e.g.*, rigor mortis.





(c) External orifices—noting, *e.g.*, discharges from vagina and ear.

(d) Eyes—noting, *e.g.*, condition of pupils.

(e) Bony skeleton, as far as it can be examined by manipulation.

(f) Whole body for evidence of external signs of violence.

N.B.—As the question of identification sometimes comes up, special attention may be called for towards such features and peculiarities as will aid in determining identity, *e.g.*, scars, tattooing, moles, etc.

Inspection being completed, section comes next. Before entering upon detail we tabulate shortly the steps of the section, indicating by letters of alphabet the order to be adhered to in taking out and examining the organs. Circumstances beyond control may prevent our following *exactly* the order indicated, but it will prove a general guide.

1.—Head and Brain to be examined first, handling in such a fashion as to avoid depleting the rest of the body of blood.

2.—Thorax and Abdomen: On reflecting skin from thorax open it and abdomen at same time.

Thorax—

(a) Mammary gland.

(b) Anterior Mediastinum.

(c) Diaphragm—as to height.

(d) Pleuræ.

(e) Pericardium.

(f) Heart.

(g) Lungs: including organs of neck and mouth

Abdomen—

(a) Omentum.

(b) Peritoneum.

(c) Spleen.

(d) L. Kidney and ureter.

(e) R. Kidney and ureter.

(f) Supra-renal capsules.

(g) Bladder, prostate and urethra in male.

Bladder, urethra in female.

(h) Uterus and vagina in female.

(i) Testicles and vasa deferentia or ovaries and tubes.

(j) Appendix vermiformis.

(k) Small intestine up to duodenum.

(l) Large intestine.

- (m) Connection between liver, pancreas and duodenum.
- (n) Diaphragm.
- (o) Stomach and oesophagus.
- (p) Duodenum.
- (q) Pancreas and duct.
- (r) Liver, gall bladder.
- (s) Aorta.
- (t) Mesentery.
- (u) Large veins ; any vessels necessary.
- (v) Thoracic duct ; lymphatic system generally.
- (w) Spinal cord.
- (x) Muscles.
- (y) Skeleton.

In case it be necessary to examine certain of the more delicate and difficult-to-handle structures, as, for example, parts of the sympathetic nervous system, special care must, of course, be given to the handling and removal of the organs generally, so that the parts sought may not be damaged, and may be removed with least difficulty.

The following are the chief points to which attention must be directed in making a report, so far as it relates to the viscera of the body : —

- 1 Position—normal, misplaced or displaced.
- 2 Size—three measurements, length, breadth and thickness.
- 3 Weight—both English and French systems.
- 4 Shape.
- 5 Color.
- 6 Blood—estimating amount.
- 7 Appearance of cut surface—how organ cuts.
- 8 Contents (if hollow).
- 9 Adhesions to surroundings.
- 10 Signs of traumatism.
- 11 Signs of disease.

In describing contents of hollow viscera or cavities note :—


- (a) Quantity.
- (b) Characters—color, consistency, odour, feel (rubbing some between thumb and finger tips), adhesiveness (in relation to wall of cavity), reaction.

te
he
en
he
st

be
he

ss.

me
all



TECHNIQUE OF SECTION

HEAD

Properly the head ought to be examined first, in order that a correct estimate of the amount of blood in its vessels may be made. If the chest be opened first, the body lying in the usual position, the blood will be largely drained away from the head.

Scalp—Part the hair from ear to ear over the vertex; incise the scalp, following the line of parting of hair and cutting clean to the bone, the extremities of the incision falling just behind the upper and anterior point of junction of ear and scalp; reflect the scalp forward as far as the supra-orbital ridge and backward to the occipital protuberance, using the knife for dissection, *not dragging upon the scalp*. The scalp can be readily stripped off by dragging, but will then be found so much stretched as to render difficult replacing it without marked deformity. Examine the scalp, incising it from the inside when necessary.

Skullcap—Run the knife around the skull, cutting the pericranium, temporal fascia and muscle clean through to bone; the incision may run straight around the cap or may be dropped downwards in each temporal region so that the anterior and posterior sections meet at an angle of from 60 to 75 degrees in the temporal region. The latter is the better way, although if a holder is to be applied to the skull to keep it steady, the former cut must be employed (see Plate No. 1). The saw is then applied and the outer table of the skull cut through, the inner being left for chisel and mallet. N.B.—*The chisel and mallet must not be employed where fracture of the skull is suspected.*

The skullcap having been completely severed by saw, chisel and mallet, is best removed by inserting the hook provided for the purpose under the anterior cut edge and pulling firmly. If adhesions between the dura mater and the bone prevent ready removal, these may be worked free by the handle of a scalpel or by a chisel. In the case of infants and children it is often necessary to incise the dura all the way around at the edge of the bone and remove cap and dura together. This ought not to be necessary in adults. If no hook is to be had then the cap must be pried off by chisel or other appropriate tool. In the case of young children it is often

possible to dispense with the last inch or two of the saw cut around the cap, the parietals dislocating readily from the tip of the occipital bone and leaving the cap attached by a hinge of pericranium behind. This renders the replacing of the cap much more easy.

Dura Mater—This membrane must now be incised throughout its entire circumference on a level with the cut edge of the skull. It is best done with a probe-pointed, slightly curved bistoury. Care should be taken not to lacerate brain substance. Then the cut dura being turned up from both sides to the mid-line, it must be freed from the crista galli in front, and drawn firmly backwards out of the longitudinal fissure. It can then be freed behind if necessary.

Brain—In removing the brain from the skull the left hand should be used as a support to prevent tearing of nerve structure, the necessary manipulation of instruments being made by the right. Inserting the tips of the fingers of the right hand over the frontal lobes, draw them gently backward till the optic chiasm comes plainly into view; the olfactory bulbs come readily with the brain and require no special handling. Cut the optic nerves as close to the skull base as possible, and then sever the internal carotid. Still draw gently backwards upon the brain until its own weight be found sufficient to carry it back, and now support it as required; sever the nerves on both sides close to the bone (the fourth is usually torn away), free the dura from its attachment along the tentorium border of the petrous part of the temporal bone, carrying the edge of the knife outwards and backwards and avoiding wounding of the cerebellum; this must be done upon both sides, carrying the cut backwards as far as possible, and calls for the use of a small and very sharp scalpel; let the brain now hang back far enough to put the cord and vertebral vessels upon the stretch; cut all nerves still attached; thrust a long, thin, narrow-bladed knife into the spinal canal and cut through the cord as low down as possible; turn the edge of the knife outwards on one side, severing the vertebral vessels, and then change over and repeat the operation on the other side. The brain will now fall out into the hands by its own weight, leaving the dura mater attached to the skull base behind.

Section of Brain—If within the examiner's power to do so he should harden the brain *en masse* before cutting, making use of Müller's Fluid or a formaldehyde solution. This, of course, takes some time to accomplish, but the results are most satisfactory. The whole organ can be sliced into a series of parallel sections as


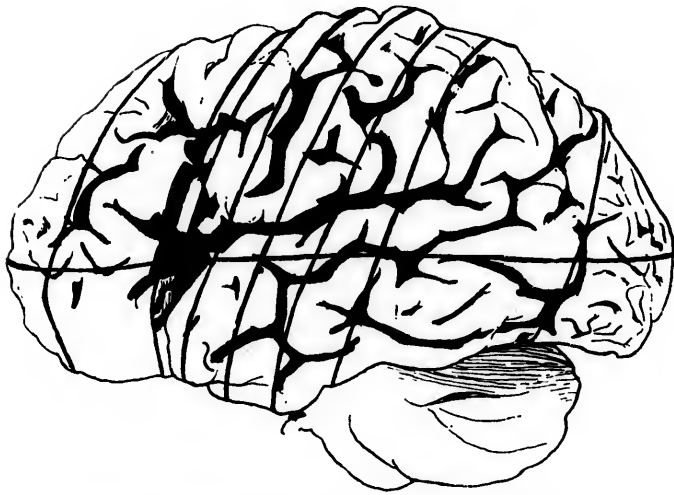


PLATE III.



LINES OF VERTICAL SECTION FOR BRAIN. (BLACKBURN)

thin as
ening i
Vircho

15

into th
be sus
gently
in wat

20

a shar
and p
gently
the ba

30

callos

40

the op
ing u
callos
left la
blade
left h
of an
being
later
contr
ventr
incis
extre
left l
cula
matt
trich
incis
whit
hem
be r
turn
seri
from

plat

thin as desirable and lesions studied in continuity. Where hardening is out of the question and the brain must be sliced at once, Virchow's method is recommended.

1st—Examine the base, following the mid-cerebral arteries out into the fissures of sylvius; if hemorrhage from miliary aneurism be suspected the fine arteries from the perforated spaces should be gently drawn out of the brain substance and examined by floating in water.

2nd—Examine the leptomeninges over the whole surface; with a sharp knife incise the membranes from front to back an inch from and parallel to the longitudinal fissures; raise the membranes gently from the convolutions, working from the incision towards the base, inspecting for thickening, discoloration, adhesion, etc.

3rd—Open the longitudinal fissure and inspect the corpus callosum.

4th—The brain resting upon its base with the occiput towards the operator, open the longitudinal fissure with the left hand, drawing upon the left hemisphere sufficiently to expose the corpus callosum without tearing it, then with a long-bladed knife open the left lateral ventricle from above with one long clean incision. The blade of the knife should be entered into the inner surface of the left hemisphere at an acute angle and one-half to three-quarters of an inch above the upper surface of the corpus callosum,* the cut being made downwards and outwards from before, back, until the lateral ventricle is opened. (See plate No. 2). The knife must be controlled to prevent damage to the structures in the floor of the ventricle. When the roof of the ventricle has been opened, the incision must be deepened anteriorly and posteriorly towards the extremities of the anterior and posterior cornua. Then allow the left hemisphere to fall outwards by its weight and expose the ventricular cavity. Next make an incision from before, back, in the white matter just outside of and parallel with the outer limit of the ventricle; again allow the hemisphere to fall outwards and make another incision parallel with the last, but farther out and higher up in the white substance. Repeat these incisions till all the interior of the hemisphere is exposed. The cortex being left uncut the mass can be reformed by a rolling up movement from the outside. Then turning the brain so that the front is next the operator, a similar series of incisions is made in the right hemisphere—the cutting being from behind forward. The corpus callosum is now severed, a knife

*Some make this cut in the substance of the corpus callosum, as shown in plate No. 2.

blade being passed through the foramen of Monroe and made to cut upwards and forwards. Next turn back the corpus callosum and fornix, exposing the velum interpositum. Reflect the velum, examine the third and fifth ventricles and make a series of parallel side to side incisions through the floor of the lateral ventricles, thus sectioning the corpora striata and optic thalami. The sections ought not to be thicker than one-eighth of an inch. Next cut through the right posterior pillar of the fornix and turn it with the velum interpositum and corpus callosum over to the left side. Then open into and examine the fourth ventricle making an incision vertically through the centre of the vermes of the cerebellum. The falling away of the cerebellar hemispheres opens up the ventricles. The cerebellum may now be examined by a cut running out into the central branch of the arbor vitæ on each side from the fourth ventricle. Secondary cuts radiating from the central one will complete the section.


The medulla, pons, crura and corpora quadri-gemina remain to be sectioned. This is done by a series of parallel cuts made close to one another and passing through the parts from the basal surface upwards, after the hemispheres have been restored to form by rolling up as before directed.

If the brain is to be sliced from vertex to base the cuts must be made parallel to one another, beginning in the frontal region and progressing backwards. The method recommended by Blackburn is shown in Plate No. 3, and the operator is referred to it. This method can be usefully followed only when the organ has been properly hardened.

Pituitary Body—This structure is so completely shut in by bone that its attachment to brain usually gives way and leaves it enclosed in the sella turcica, from which it must be removed, by itself, using bone forceps to free it if necessary. The infundibulum remains attached to the base of the brain.

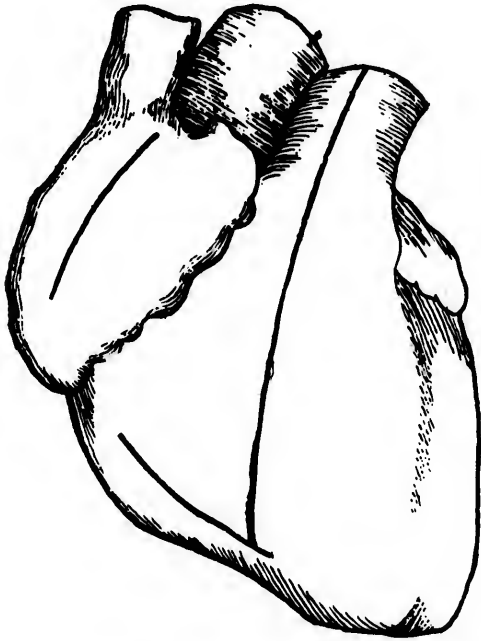Base of Skull and Venous Sinuses—Any investigations of the bones of the base of the skull which may be desired can now be made, the dura mater being stripped off as found necessary and the bones operated upon by saw or chisel, or both. The blood sinuses should be slit with scissors.

Ear—The ear may be examined after opening into the petrous temporal by means of chisel and hammer. It will be found more satisfactory to remove the entire petrous bone by sawing it out after reflecting the skin with the external ear and examine carefully at leisure.






PLATE IV.



OPENING THE HEART—RIGHT SIDE

Incisions indicated by dark lines

Eye—To get at the eye remove the orbital plate of the frontal and expose the ball from behind. The posterior part of the eyeball may be removed—keeping behind the ciliary region—by a pair of scissors, and the retina examined. Deformity is prevented by stuffing the front part of the eye with cotton wadding. If the wadding be soaked with a 1% solution of formaldehyde the cornea will keep its form and have no tendency to collapse.

Face—The face must be examined in such a fashion as to leave the least deformity. The skin is removed, after carrying the scalp incision behind the ear to the angle of the jaw, with the utmost care, in order that no damage be done it which would appear in the face. Parts of the facial bones can be removed as found necessary, and the cavities left filled with plaster of Paris, which is then moulded as nearly as possible to the form of the bone removed. It is better not to attempt such examinations, however, without special permission. Growths lying in the soft tissues of the face may be opened into from within the mouth or from behind after lifting the skin of the face. Every effort must be made to avoid damaging the appearance of the face.

Nose—Cut out the ethmoid bone to inspect the frontal sinuses and upper nasal passages. By cutting up beneath the upper lip in such a fashion as to free the alæ nasi subcutaneously and then cutting through the cartilaginous septum, the soft parts can be turned upwards and the lower passages examined from in front.

ABDOMEN AND THORAX

The abdominal cavity being now opened,* inspection of its contents follows and notes are taken of such abnormalities as are apparent without disturbing relationships of organs.

Opening Thorax—If there be any suspicion of pneumo-thorax dissect the skin from the ribs deeply towards the spine on the suspected side; fill the pocket so made with water and then thrust a scalpel blade between the ribs into the chest; if air or gas be present it will bubble up through the water. The scalpel must be so handled as to avoid doing damage to any of the thoracic viscera.

The opening of the thorax is begun by disarticulating clavicles from sternum; enter the blade of a small scalpel into the joint, edge downwards, *i.e.*, towards the feet of the body, and cut down and out; then cut through the cartilages of the ribs close to the costo-chondral junction in such fashion that none of the organs within the chest may be damaged by the knife. If the rule of


*See page 9; paragraph on opening the body.

sticking close to the costo-chondral junction be followed out a sufficiently large opening to admit of free inspection and manipulation will be made. Should the costal cartilages be calcified or ossified the costotome will be required to cut them. A saw will answer very well if no costotome be available. The separation of the sternum in this way will be complete and the whole front must now be lifted out. Breaking across the sternum near the top in order to save disarticulation from the clavicle is often resorted to, but is extremely bad practice and should not be done. Many in removing the sternum limit themselves as nearly as possible to the sternal borders and thus have a small opening into the chest, through which the inspection and manipulation of thoracic organs is carried out with no little difficulty. There is absolutely nothing gained by this; the resulting deformity is not seen in either case and certain points of importance, in pathological relations, for instance, are very liable to be overlooked in the latter.

Pleurae—Inspection of thoracic contents in situ follows. Feel for pleuritic adhesions by passing a hand in around the chest wall. It will be found useful to have an assistant fold the skin freed from the same side, over the cut edges of the rib cartilages so that the backs of the examiner's hands may escape scraping and abrasion. Infection has not seldom been effected through wounds made in this way. Estimate fluid if present in the pleural sacs. Note position of heart and its relations to lungs and mediastinum.

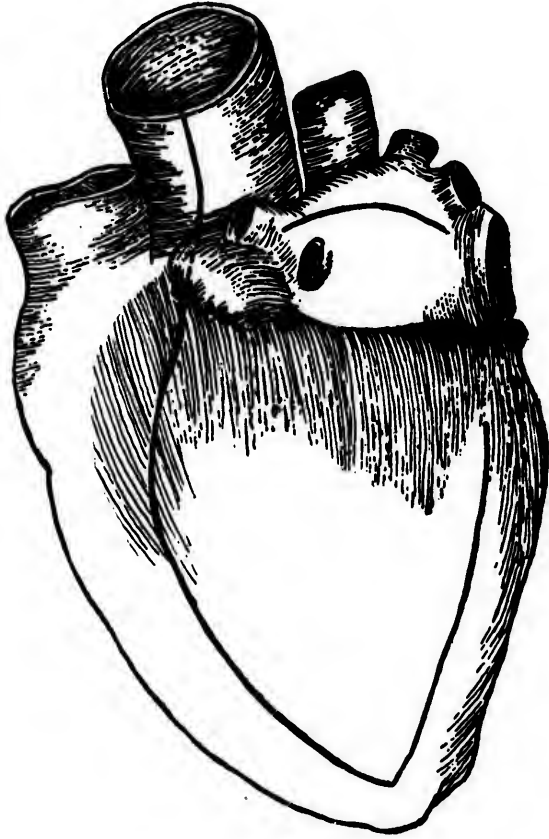Pericardium—Pericardium; pinch it up in the centre and cut a small opening with scalpel or scissors; from this central opening cut straight upwards, down to the left and down to the right, making a 'leech bite' opening. Each cut should be about two inches long. Inspect sac throughout, noting adhesions, fluid, etc.

Heart—Heart may be opened in the body, after undergoing careful external examination, or may be removed before opening. If the valves are to be submitted to a water test for competency, of course the organ must be removed intact. It is probably better in any case to remove before opening. In order to remove, grasp the heart by the apex with the left hand and, lifting strongly out of its sac directly away from the body, cut all attachments as close to the parietal pericardium as possible, beginning with the vessels below. The cavities should now be cleaned of blood, fluid or clotted, and the water test applied. To apply this test a long tapering, small calibre tap is required, the nozzle of which can be passed through auricles into ventricle. All outlets but that in use are closed, e.g. by means of pressure forceps; water is then allowed to run in till the ventricle walls are judged to be sufficiently tense;






PLATE V.



OPENING THE HEART—LEFT SIDE
Incisions indicated by dark lines


the tap nozzle being then rapidly withdrawn, if the valves, mitrals or tricuspids, are competent, the ventricle under test should retain the water. In case of the aortics and pulmonaries the part of the aorta or pulmonary artery remaining attached to the heart is filled with water and if the column be sufficiently heavy and the valves quite healthy they will be forced into position and carry the column of water. If the coronary vessels be nicked the water will escape in spite of a healthy valve. On the whole, the water test for valvular competency is not of great value. The opening of the heart after its removal from the body is easier than while it lies in the pericardium. The incisions to be made are as follows:—


First, open the right auricle by a straight cut in its long axis and about midway between top and bottom. (See Plate No. 4)

Second, open the right ventricle by two incisions: (a) a cut in the anterior wall of the right ventricle parallel and one-half inch internal to its right border, running from just below the auriculo-ventricular ring to the apex and extending completely through the heart wall: (b) a cut at an acute angle to the last, made with the bowel scissors; the scissors are to be thrust into the incision (a) just above the papillary muscle of the tricuspid valve which springs from the anterior wall of the ventricle, and made to cut upwards out through the pulmonary artery. A triangular flap is thus left, the lifting of which exposes the inner surface of the right ventricle, together with the tricuspid valve and pulmonary valve. To open the left side of the heart make incisions in the auricle and ventricle similar to those in the right side, that in the left ventricle, however, lying parallel to and half an inch from the *left* border instead of the *right* border, and the scissors cutting from the apex out through the aorta. In cutting through the aorta the pulmonary artery must be pulled away with the left hand so that the scissors may pass behind it and not damage it. Thus we have mitral and aortic valves together with inside of left ventricle fully exposed. (See Plate No. 5).

A rough test of valvular openness can be made in case of tricuspids and mitrals, by thrusting the index and second fingers of the left hand through the opening made into the auricle, and so into the valve, where they are separated from one another widely; the index finger of the right hand is then inserted through the ventricular incision, and if things are right, there should be room for it to lie in the valve between the two fingers from the left hand; this proves approximately that no stenosis exists. To complete the heart examination, inspect the auricular chambers, noting especially the foramen ovale, inspect endocardium and myocardium and examine coronary arteries.

Lungs—Having already, during inspection, examined the pleurae for fluid and adhesions, remove the lungs separately by drawing them out of the chest, taking the root between the middle and ring fingers of the left hand and then cutting through it between fingers and vertebral column. Take the left lung firstly, then the right. *Split both lungs from apex to base, down at the most prominent line behind.* (See Plate No. 6). The following description by Fowler cannot be improved upon: "According to the recommendations of Virchow, the sections should always be in the same lines, the first exposing the largest possible surface, and all others in the same lobe parallel with it; the organ after the examination presenting an appearance similar to the leaves of a book. To examine the left lung, place it on the table with the root downwards and the *base* towards you. If there be no interlobar adhesions, or only such as can be easily broken down, holding the blade parallel with the table, make a section through the upper lobe at the level of half the depth of the interlobar sulcus, commencing just below the apex and extending thence along the posterior border and the sulcus. The section must stop before the part is entirely severed. This 'leaf' should then be turned over, and the whole of the upper lobe will be displayed. The first section through the lower lobe is made along the prominence of the posterior border, through the base, and then towards the sulcus again, stopping before the part is completely separated. If the interlobar adhesions cannot be separated without injury to the lung, a single long section should be made from apex to base along the posterior border, and carried through the lung towards its anterior margin. To examine the right lung, place it on the table with the root downwards and the *apex* towards you. Any easily separable interlobar adhesions having been dealt with as already directed, the point of the blade is inserted at the lower and anterior extremity of the upper lobe, and an incision is made at the level previously mentioned, upwards and outwards towards its apex and anterior margin. The middle lobe is separately incised from below upwards. The incision in the lower lobe, starting from the anterior margin of the base, is continued through this part and along the prominent posterior border, stopping short of the sulcus, so that the section may not be complete. If the interlobar adhesions cannot be easily broken down, a single section is made as in the left lung, but from base to apex instead of *vice versa*." Open up bronchi and blood vessels with probe-pointed scissors, and make a further series of incisions in each lung, the cuts radiating from the root in the direction of the bron-





chi. Examine carefully the lymph glands at the root of the lung. *When suspicion of pulmonary embolism or thrombus exists the pulmonary artery must be opened between heart and lungs before these are removed from the body.* A pair of small, sharp-pointed scissors is the best instrument. Split the pulmonary artery just where it leaves the right ventricle, the slit extending as far as possible in the direction of the vessel. If the heart be removed previously, the search for thrombus will almost certainly be vain. If it be considered necessary the trachea and larynx may now be removed and opened for examination. They may be removed after incision of the skin from the upper end of the sternum to the chin, or, where this is not permitted, by working subcutaneously, a rather difficult task.

ORGANS OF THE ABDOMEN

Omentum—Note the quantity of fat, also adhesions or other abnormalities and their results, if any, upon other organs.

Spleen—Remove the spleen by drawing it forward from under the ribs with the left hand and cutting its vessels and attachments with the right hand. To examine it make a series of parallel cross sections.

Kidneys—The removal of the kidneys, which to many appears to present difficulties, is very easily effected if their location in the body be remembered. Remove the left kidney first, proceeding as follows: Draw the descending colon towards the midline of the body with the left hand and then cut freely through the peritoneum outside of the colon and in the flank. The incision should be parallel to the descending colon and six inches in length. Next insert the right hand into the retro-peritoneal area through the incision so made, and directing it upward seize the kidney and drag it out through the incision. The renal blood vessels will permit the organ to be brought out but a short distance; they must then be cut through, care being taken not to damage the ureter. The ureter is now freed from its surroundings down as far as the pelvic brim. If it be found sound then cut it across and free the kidney; if it be thought better to take kidney, ureter and bladder out together, free the ureter down to its entrance into the bladder wall (see p. 29.) The further examination of the kidney is made by splitting it from convexity to hilum in its long axis, performing this operation with one stroke of the knife in order to leave a good surface for inspection. The incision into the kidney ought to be so exactly median in position as that calyces and pelvis are also exposed by the same cut.


In taking out the right kidney the very same steps are gone through as in case of the left, reversing the operations. The ascending colon is carried into the midline, and the peritoneum opened just outside of it, etc. So much of the ureter as remains attached to the kidney should be slit open with probe-pointed scissors. When the kidney has been slit open the adhesiveness of its capsule to it should be tested by lifting it from the cut edge with thumb nail and index finger tip and peeling it back. Sometimes when there is a great amount of fat packed into the areolar tissue, embedding the kidney, the capsule proper peels off very readily and remains behind in the fat. In removing the kidney one must always be prepared for the discovery of peri-renal trouble—abscess, for instance, which will complicate matters considerably. Not *too* fast is a good motto if everything is to be discovered and made clear.

Supra-renals—The supra-renal capsules break down with great rapidity after death, and their removal, except as debris, is often impossible. It is best to attempt to bring them with the kidneys. A very little care will render this possible; that on the right side is more difficult to free, without destroying it, than that on the left, being so frequently firmly attached to the under surface of the liver.

Bladder—The bladder must be opened by a perpendicular cut of the knife from the outside in, and as long in extent as its condition of dilatation or contraction at the time will permit of. In the male, after inspection of the mucosa, the prostate is to be examined by palpation, as likewise the urethral orifice. Where the pelvic viscera have been removed *en masse*, of course each organ can be gone into separately and somewhat more completely; after examination of the prostate by palpation, the bladder may be loosened up in front, just behind the symphysis pubis and the urethra cut across in front of the prostate, which can then be dragged up and incised for examination.

Penis and Urethra—By dissection, beginning at the lower end of the abdominal incision, together with manipulation, the penis with urethra may be drawn out of the skin covering it, cutting being necessary only where the mucosa of the prepuce is attached around the glands. The urethra is then laid open, the floor being cut, and examined. The body of the penis can now be restored to its skin sheath and held in position by a stitch.

Testicles—The testicles can readily be brought into view for examination by drawing upwards upon the cords, at the same time




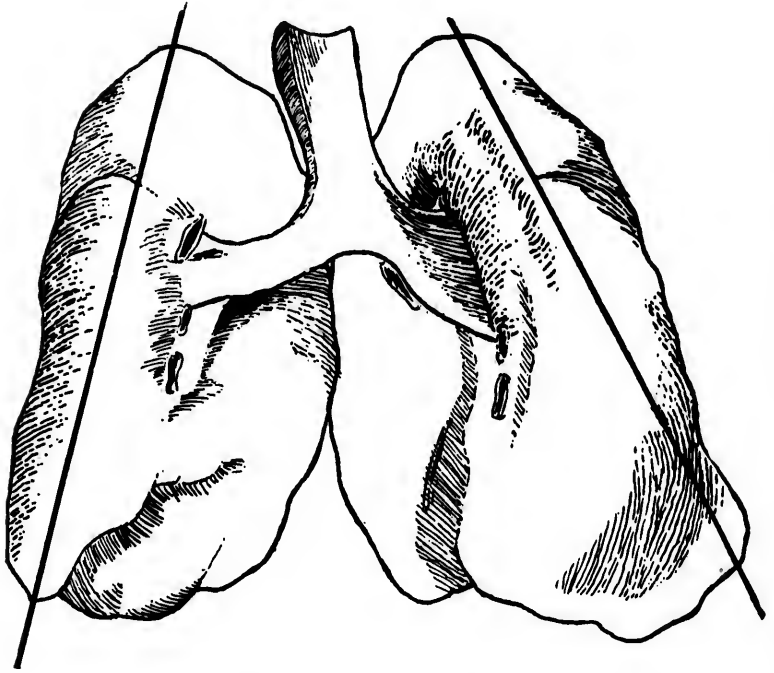


PLATE VI.



FIGURES SHOWING METHOD OF SECTIONING LUNGS—FIRST INCISIONS

passing a finger into the scrotum from above and freeing the glands from retaining attachments. Incision is then practised, slicing the gland in its long axis.

Ovaries—In the female the ovaries may be examined either independently or after the pelvic viscera have been removed *en masse*. In either case there is no difficulty, the splitting of them with a knife being a simple procedure.

Fallopian Tube—The tubes are examined by laying them open with a fine probe-pointed pair of scissors when possible; otherwise it may be necessary to split the tube with a sharp knife. A cross section is often quite as instructive as a longitudinal.

Intestines—Begin at the caecum, examining first the appendix vermiformis to determine its exact position and relations. Then cut through the mesentery four or five inches from the ilio-caecal valve; tie a ligature round the ilium and cut through the small gut between the ligature and valve. The presence of the valve does away with the need of a second ligature. Strip the small intestine from the mesentery, drawing with the left hand upon the cut extremity of the ilium and see-sawing with a large, sharp-bladed knife, across the gut at the attachment of the mesentery. Inspect the mesenteric glands as the stripping goes on. When the duodenum is reached, tie the gut and cut off. Open the small intestine from end to end with the bowel scissors; simply thrusting the round-ended blade into the gut, and drawing the gut towards the operator against the angle of the partially opened blades will split the tube rapidly. To examine the bowel it is then drawn on the flat through between the index and middle fingers of the left hand, water falling on it from a tap during the operation. Examine next the large gut.

Large Intestine—Free it with the knife, beginning at the caecum and working round to the sigmoid flexure. If the intestine has not already been tied off and cut through, then do so now, leaving the rectum behind. Clean out with a stream of water from the tap and open the bowel from end to end.

Measure the appendix vermiformis, open and inspect it.

Bile Ducts—The next step involves examination of the ducts from liver and pancreas and the portal vessels. Make an opening on the front of the duodenum and then with probe-pointed scissors incise it up and down for a sufficient distance to expose the bile papilla. Then, having washed out the mucus and other intestinal contents, make pressure upon the ductus communis, beginning as far up towards the liver as possible and working down

towards the intestine. If no obstruction be present bile should flow freely from the papilla. Using the bile papilla as a guide, cut into the ductus communis choledochus, lay it open as far as possible and also the cystic duct. A very slight dissection now exposes the portal vein, which should be laid open as far as possible. The bile ducts and portal vein may now be cut across. Dissect out the duodenum, taking the pancreas with it; tie and cut across the duodenum just below the pylorus. Complete examination of duodenum and pancreas, opening pancreatic duct.

Liver—To remove the liver, cut down the diaphragm on both sides so that the gland may be lifted up and turned over towards the right side, then free entirely and complete the examination outside of the body by making a series of parallel cuts from behind forwards. Let these cuts pass completely through the organ.


Gall Bladder—Dissect the gall bladder off the liver and open from the fundus towards the cystic duct. Open up with scissors what remains of the duct.

Stomach—The removal of the stomach is now undertaken by clipping all remaining attachments below the diaphragm, freeing the œsophagus from the diaphragm and from the aorta, and finally cutting through the œsophagus at the highest point possible. Open the œsophagus with bowel scissors and continue the cut through the cardiac orifice and along the *greater* curvature of the stomach to expose its mucosa. Never cut along the lesser curve of the stomach unless for some very special reason.

In some cases it may be necessary to closely inspect the veins of the lower end of the œsophagus and of the stomach. In cirrhosis of the liver, for example, great varicosity of these veins may occur, and the patient die from hemorrhage due to perforation of some of them. It is well to remember that although of very considerable calibre and easily seen when injected, when empty they collapse completely and the damage may be found with considerable difficulty.

Aorta—Remove the aorta down to the bifurcation, lay it open along the front. If necessary open the iliac arteries in situ.

Organs of the Neck and Mouth—The common practice is to remove the trachea, larynx, thyroid, upper part of œsophagus, pharynx and tonsils, tongue and soft palate together. When it is allowable to open the skin of the neck up to the chin the difficulty of removing these organs is not great. After the skin incision dissect up the trachea and œsophagus from below, taking the thyroid lobes and working up behind the larynx and pharynx as



far as possible. Then enter the blade of the knife through the floor of the mouth just back of the point of the chin and cut backwards close to the lower jaw first on one side, then the other. The tongue can now be drawn out of the mouth, an incision made across the soft palate in front of the uvula, and a few strokes more will free all structures desired and permit of their being lifted out. When it is impossible to open the skin of the neck and those organs must be removed, considerable patience and care is necessary to avoid wounding the hands, since the greater part of the work must be done in the dark.

REMOVAL OF PELVIC VISCERA EN MASSE

When possible to make a complete examination it is best to remove the pelvic viscera *en masse*. After the kidneys have been freed, though still attached to bladder by ureters, ligate the upper part of the rectum, using two tapes an inch and a half apart and cut it through between the tapes. Then spread the legs and make an elliptical incision through the skin surrounding vulva and anus in a female, surrounding anus if in a male. These incisions should extend through skin deeply into fat. Then free the organs as much as possible from within the pelvis, cutting close to its bony walls; finally in the male, drawing upwards on the rectum, pass the knife down alongside the anus and run it around, following the skin incision already made; then the penis being already freed from its skin sheath as described (p. 26), cut the suspensory ligament and drawing the organ into the pelvis beneath the pubic arch, free the bladder and lift everything out. In the female the same procedure is carried out by freeing the pelvic organs as much as possible from within the pelvis, and then passing the knife underneath the pubic arch and following around in the skin incision which surrounds vulva and anus. Some remove a small wedge of bone from the symphysis pubis in order to obtain greater freedom in using the knife. When the organs have been removed lay them on a tray or board for further examination. In the case of the male, open the bladder and rectum with blunt scissors and wash them out. In the case of the female split up the urethra and then bladder and inspect; then open the vagina, using scissors and splitting the anterior wall; next with knife or scissors split the uterus from os to fundus in midline of anterior surface and from the upper end of this first incision carry one up into each cornu. Open the bowel from behind with bowel scissors. The ovaries and tubes are then examined, splitting the former in their long axis with a knife and opening the latter with fine probe-pointed scissors if possible, if not, incising them with a knife.

Examine the broad ligaments.

SPINAL COLUMN

The spinal column is to be examined by inspection after clearing it of interfering structures. When necessary complete the examination by removing parts suspected or known to have undergone morbid changes. The saw and large chisel will be found most useful in this work.

Spinal Membrane and Cord—These structures may be exposed in two ways, viz., either by removing the bodies of the vertebræ from the front after cleaning out the viscera, or by removing the vertebral arches from behind.


Opening spinal canal from in front: To accomplish this operation a pair of specially formed chisels are requisite. A wedged-shaped piece of the vertebral bodies is sawn out in front in the lumbar region, and the points of the chisels being introduced one on each side, they are driven upwards with blows of the mallet until the canal is laid open by removal of the bodies. The cord is then taken out with membranes intact, the nerve roots and vessels being cut through with a sharp knife close to the wall of the canal. The dura mater is slit longitudinally on the posterior surface and the cord examined by a series of parallel cross sections made at right angles to its long axis, and from $\frac{1}{8}$ to $\frac{1}{2}$ inch apart. These must be made with a very sharp knife, the cord being slightly on the stretch, in order to leave a proper surface for examination.

Opening the spinal canal from behind: Most operators will find it easier to enter the spinal canal from the dorsal surface of the body than from the ventral. There are two ways of exposing the vertebral arches, viz.: either by making an incision over the spines of the vertebræ from base of skull to sacrum and cleaning away the muscle on each side to the requisite depth, or by making a flap of the skin by incising three inches to the right side of the spinal ridge. The latter method is the better and will be described.

N.B.—When removing the cord this way it is better, for obvious reasons, to do so before any work has been done on the front of the body.

1st—Make a skin incision across the column at right angles to it, as high up at the base of the neck as necessary. This incision should reach three inches on each side of the vertebral column. Make a second similar incision across the base of the column, low enough to allow of the cauda equina being taken out.

2nd—Join the right extremities of these two cuts with a third parallel to the column and three inches from it.



3rd—Reflect all the tissues down to the bone as far over as the cross incisions reach on the left side of the column.

4th—With saw and bone forceps (costotome works well) open the bony arches of the column and expose the dura mater.

5th—Remove the cord in the dura and treat as before described.

Nerves—The individual nerves of the body, if to be examined, must be carefully dissected out from anatomical knowledge. It is always important in handling nerve tissue to avoid putting any great strain or pressure upon it.

SKELETON

Examination of Bony Skeleton—At times it may be necessary to examine the skeleton as a whole, or certain bones separately. No special directions are required for guidance in this work. All incisions for removal of bones must be made so as to deface the body as little as possible, *e.g.* incise the soft tissues in the posterior surface of a limb rather than the anterior. Opening up of medullary cavities may be done with a saw or chisel and mallet. A good plan is to begin operations with the saw and continue with the chisel. When a bone is removed it is often found advisable to replace it with something else. A piece of a broom handle makes a good substitute for a femur or humerus, etc., etc.

Vertebrae are readily examined by saw or chisel from within the body.


CRIMINAL POISONING


In cases where death is suspected to be due to criminal poisoning certain special precautions must be undertaken, to ensure detection of the poison, if possible. The routine of the examination does not necessarily differ from that of any other case, except in connection with the saving of certain of the viscera, nor is it in itself necessarily of great value, except in so far as it permits of the obtaining possession of the organs and visceral contents, the analysis of which may prove or disprove the presence of poison. The appearances found at the time of examination may or may not be useful as corroborative evidence, but to decide *absolutely* that poison was present and the cause of death, in the absence of proper chemical analysis by an expert, would be a dangerous and a wrong thing to do. It follows, of course, that there are some cases in which the proof of poisoning can never be had from the body, since we know that certain poisons cannot be found by analysis.

Some few poisons leave traces of their operation, which are fairly characteristic, in the mouth and downwards through the digestive tract. Carbolic acid may be specified as an example. It will be proper then in all suspected cases to examine specially for such traces, beginning from the lips. The sense of smell may be of great use also in detection of certain poisons, as for example prussic acid.

It will be readily seen that the examiner must take special precautions in such cases so that he may be able to say that there was no possibility of any tampering with the organs of the body, without his knowledge, during the time they were in his possession, *i.e.*, from the time the body came under his hands until all necessary parts were handed over to the analyst.

Before undertaking examination in cases where poisoning is suspected, the examiner must prepare a number of jars or bottles in which to carry away material from the body for analysis. Large sized fruit jars or "sealers" or "gem jars" are recommended as most generally useful; the sizes holding three pints or two quarts are large enough; smaller sizes may be obtained if desired. The jars should be purchased new and cleaned out under the personal super-





vision of the examiner ; one should *never* take old bottles, nor even new ones the cleaning of which has not been personally overlooked.

Removal of Viscera —The abdomen should be opened first. In removing hollow viscera, ligatures must be used in such a fashion as to prevent either escape of contents or entrance of foreign matter from without ; the stomach, for instance, must be taken out unopened, both œsophagus and duodenum being ligated before removal. As the organs are removed they should be transferred at once to the bottles provided, each organ or part of an organ occupying a separate bottle, the bottles closed, sealed and labelled. The reason for separating organs by placing each in its own bottle lies in the fact, that where two or more are kept lying in contact for some time, absorption by one from another occurs. Thus, if the stomach and kidney were placed in the same jar, the kidney containing arsenic, the stomach none, by the time the organs came into the hands of the analyst the stomach would probably contain arsenic.

The label on each bottle should tell what organ or tissues it contains, where and when taken and by whom. The jars ought to be sealed and delivered to the analyst by the examiner personally, they not having left his possession meantime.

No preservative fluid should be put into the jars if it can be avoided, but if such has been necessary then an accurate statement of the formula must be written upon the label.

The organs usually examined in supposed poisoning cases are stomach and intestines with contents, liver and kidneys ; certain fluids—blood, inflammatory exudates, urine, amniotic fluid, cerebrospinal fluid—may give information at times. Other organs and tissues will be preserved as found necessary.*

Embalming and Criminal Poisoning — One of the important questions that may arise in connection with the investigation of a suspected poisoning case is, as to whether or not the body has been embalmed after death, before a post-mortem examination has been made, and, if so, by what materials. More than once a failure of justice has happened through doubts arising because the embalming process has been carried out, or because it has been impossible to determine whether it has been carried out or not. Up till the present time nearly all embalming fluids have contained more or less arsenic ; at present an attempt is being made to introduce fluids whose ingredients will give rise to none of the difficulty spoken of above.

*Some advise opening hollow viscera and bottling contents, so that the organs may be examined in recent condition.

EXAMINATION OF THE NEWBORN INFANT

In the examination of the body of a newborn infant there are three chief points to be settled, viz. :—

A.—At what period of development was the child born ?

B.—Did it breathe ?

C.—What caused its death ?

A.—The answer to the first question of the three is of importance since it determines the viability of the child, whether or not it could have been born alive and whether or not it could have lived to become adult. Investigation of the following points, which will be carried out chiefly by external inspection, will enable us to answer.

1. What are the measurements of the foetus ? (length, etc.)
2. What is its weight ? (If it has been so situated as to lose water—*e.g.*, by preservation in alcohol—this must be taken into account.)
3. Are the limbs formed ?
4. Are the fingers and toes outlined ?
5. Are fingers and toes separated ? Are the nails indicated or developed ?
6. Are the ribs visible as such ?
7. Are head and neck distinct, apart from the body ?
8. Is sex differentiated ? Are the sexual organs formed ?
9. Is the intestine completely within the body cavity or is there still a part of it in the cord ?
10. Are the eyes, ears and mouth formed ?
11. Is there hair on the head or body ?
12. Does the umbilical cord show a spiral twist or not ?
13. Are the testes descended—if a male—and if not, is the cause some abnormal condition or merely lack of development ?
14. Is there vermix caseosa on the skin ?
15. What centres of ossification, if any, are present ?

Whilst it is not necessary to consider *all* of these questions in order to determine viability, it has been thought well to make the list such as may be useful in determining the age of any foetus.

B.—Although it seems to have been proved that “ a child may be born alive and be destroyed before it has breathed ” (v. Taylor's Jurisprudence, 12th edition, p. 576), yet it is also certain that there are “ no sure medical signs by which a child that has *not* breathed

are

port-
not
ived
will
s to


c.)
lose
into

ated

?
or is

s the
t ?

ns in
e the
s.
l may
ylor's
there
athed



can be proved to have been living when it was maltreated" (Op. cit., p. 576). Hence the importance of the lung examination in the newborn.

There are a number of different points to be taken into consideration in determining whether air has been inspired into the lungs or not. The color of the lung substance, for example, is to be looked to—the light greyish red of inflated lung being in marked contrast with the livid purple of the foetal condition. Then crepitation on handling is a sign of value as indicating the presence of air in the lung. Of all tests, however, the most important is that known as the Hydrostatic Test, which depends upon the fact that lung which has been inflated with air will not sink in water.

In the foetus the lung is normally in a condition of airlessness, which, when found persistent in the born child, is known as *atelectasis*. In this condition the organ sinks in water. It must not be supposed, however, that the fact of lung sinking in water is proof complete of atelectasis or foetal airlessness, since there are certain other conditions which bring about the same result. *Anything* which causes airlessness will cause it to sink. In this connection we have to take into account specially, collapse, consolidation, and the results of prolonged hypostatic congestion with oedema.

By collapse we understand that the lung has been inflated with air; that further inspection is prevented and that the air already present is absorbed and the vesicular walls fall in.

By consolidation we understand the filling of air vesicles by foreign matter such as an inflammatory exudate or blood.

In prolonged hypostatic congestion with oedema the air vesicles become filled with fluid and free cells to such an extent as to exclude air.

In all of the above conditions lung will sink in water and we are compelled in examination to determine which is present. It is worth noting that in true atelectasis alone it is possible to inflate the lung artificially without much trouble.

There is still another point that must not be forgotten in applying the Hydrostatic Test, namely, that lung may not sink in water on account of the presence of some gas or gases derived from decomposition, especially with putrefaction. Commonly, the state of matters as a whole will enable the examiner to determine whether floating be due to decomposition or not, but in certain instances he will be unable to decide satisfactorily to himself.


The application of the Hydrostatic Test is simple enough. After tying the trachea, lungs and heart are taken out together

and placed in a vessel of water. If the individual has breathed the mass will float. Some lay stress upon the taking of the heart with the lung, but as a matter of fact it is of no consequence whether it be taken or left.

After testing the whole lung mass at once each should be tried separately, then each lung should be divided into a number of parts and these tested; finally an effort should be made, by means of pressure, to expel the air from very small pieces of lung substance. If respiration has been carried on completely it will be found impossible to so far expel the air from even a small portion of lung substance as to cause it to sink in water.

he
th
er

ed
rts
of
ce.
nd
ng



PRESERVATION OF TISSUES

In relatively few post-mortem examinations which are not made in connection with scientific institutions is it found necessary to examine microscopically tissues and organs obtained. Commonly the purposes of the examiner are served by a naked eye inspection; yet from time to time it is found advisable to go farther. In such cases the question of preservation of material to be examined is a matter of importance. Fortunately it is not often necessary to have recourse to elaborate and costly methods. We propose to give here a few such formulæ as may be of value to the general practitioner who finds himself called upon to make post-mortem examination without special preparation or equipment. We shall also describe a quick method of cutting and preparing sections of tissues for microscopic examination; a method which will permit of diagnosis being completed with the post-mortem examination. However, while describing the method of slide preparation, we would hesitate to recommend those, who of necessity, have little opportunity for work with the microscope, to rely upon their own judgment as to minute changes, particularly if the case be a medico-legal one.

Fixing and Hardening—The sooner after death that a post-mortem can be held the better will be the results so far as fixing of the elements is concerned. The general practice, however, is to defer examination to such a time that we need not expect to be able to demonstrate nuclear changes no matter what reagents are employed. Very useful results, however, are attained with carefully hardened tissues, even when examination has not been had till many hours after death. Select a piece at junction of normal and abnormal, then the smaller the piece, the greater the amount of fluid, and the oftener the changing, the better are the results.

The following fluids are within the reach of everyone and offer no difficulties in application :—

Alcohol,
Müller's Fluid : bichromate of potash,
Formaldehyde.

1—*Alcohol*—Can be used for any kind of tissue; the only fluid worth trying with tissues taken from a body which has lain a long time before examination. It may be used in two ways :—

(a) Tissue is dropped into alcohol of full strength, and after a week or ten days changed into 85% alcohol and kept there.

(b) Tissue is put into alcohol 1 + water 2 for twenty-four hours; changed into alcohol 2 + water 1 for twenty-four hours; changed into alcohol 95% and kept there, or better finally into alcohol 85%. There is less shrinkage and loss of blood by the latter method.

2—Müller's Fluid: Composed of bichromate of potash $2\frac{1}{2}$ pts., sulphate of soda 1 pt., water 100 pts. by weight; applicable to all kinds of tissue; especially useful when blood is to be retained in the tissue or presence of fat determined. The chief objection to its use lies in the fact that it penetrates tissue very slowly, taking weeks where the others take days and hours; counter-balancing this, however, is the fact that material can hardly go wrong in it provided the fluid be used in large quantities; lying in it for an unlimited length of time is no detriment to the tissue if too much evaporation be prevented. A heavy growth of fungus, even upon the surface of the jar, will do no harm to the contents and help prevent evaporation. The following method of using Müller's fluid is recommended:—Immerse material for twenty-four hours; change and immerse for forty-eight hours; change again at end of forty-eight hours and then once a week until the fluid remains clear, *i.e.*, throws down no deposit. When treatment with Müller is complete remove tissues to running water, where they must remain till the water comes away clear and free from all stain. The tissue may now be preserved in alcohol 70 to 95%, or at once sectioned for microscopic work.

3—Formaldehyde: This is usually supplied retail in a 40% watery solution known as formalin. One of the chief advantages of formaldehyde is the rapidity with which it operates upon tissues immersed in it. It may be made use of in solutions of 5 to 20 parts formalin in 95 to 80 parts of 70% alcohol.

A RAPID METHOD OF MAKING SECTIONS FOR MICROSCOPIC EXAMINATION.

A rapid method of preparing specimens of tissue for microscopic examination has been devised by T. S. Cullen, of Baltimore, the steps of which are here given. This method has the special virtue of furnishing slides which are permanent in character and quite good enough for any purpose of diagnosis.

1. Tissue is taken direct from the operating or post-mortem room and sections cut on a freezing microtome—either ether or carbon dioxide being used as freezing agent.

2. Sections are next placed in a five per cent. (5%) watery solution of formalin for from three (3) to five (5) minutes.

our
ars;
nto
the

ts.,
all
l in
to
king
cing
n it
an
uch
pon
help
fluid
ange
rty-
i.e.,
plete
the
may
d for


40%
ages
sues
o 20

DPIC

micro-
more,
pecial
r and

ortem
er or

atery



3. Sections are then placed in fifty per cent. alcohol (50%) for three (3) minutes and then
4. Transferred to absolute alcohol for one (1) minute.
5. Staining and mounting are now carried out as follows :—
 - (a) Stain in haematoxylin for two (2) minutes.
 - (b) Decolorize as necessary in acidulated alcohol.
 - (c) Wash in water.
 - (d) Stain in eosin; a drop or two of a two per cent. (2%) solution added to ninety-five per cent. (95%) alcohol.
 - (e) Complete dehydration in absolute alcohol.
 - (f) Clarify with clove oil.
 - (g) Mount in Canada balsam.

The whole of the above process can be gone through in fifteen minutes from receipt of fresh tissue.

In case it be considered desirable to retain the blood within the vessels of tissue under investigation, then two hours (2 hrs.) treatment of it with a ten per cent. (10%) watery solution of formalin previous to sectioning is advised. In case this be done, however, the elements will not be found so distinctly stained as in the previous process.

WEIGHT AND MEASUREMENT OF ORGANS

Bladder, urinary; average capacity, moderately filled, one pint; will contain much more if distended.

Cerebellum; weight about 5 ounces.

Cerebrum; weight, male, max. 64 ozs. = 1810 grms.

min. 34 " = 1060 "

female, max. 56 " = 1585 "

min. 31 " = 880 "

In majority of males it runs from 46—53 ozs.

" " females " " 40—47 "

In the male it averages 4 to 5 ozs. heavier than in the female, *i.e.*, about 9%.

Intestines; small, averages 22 feet long in adult; 9 feet 5 inches in newborn; duodenum 12 inches; of the remainder, the jejunum makes $\frac{2}{3}$, ileum $\frac{1}{3}$; large intestines average 5 feet 6 inches.

Appendix vermiformis averages 3.85 inches in adult.

Kidneys; weight, R. $4\frac{3}{4}$ ozs.; L. $5\frac{1}{10}$ ozs. = R. 140 grms.; L., 150 grms.

Liver; average weight in male 50—60 ozs. } = 1200—2000 grms.
" " female 40—50 " }

Lungs; average weight, R. 22 ozs.; L. 20 ozs.

Pancreas; average weight $2\frac{1}{4}$ — $3\frac{1}{2}$ ozs. = 65—102 grms.
min. $1\frac{1}{2}$ oz.; max. 6 ozs.

Prostate Gland; weight $4\frac{1}{2}$ — $4\frac{3}{4}$ drachms = 20.5 grms.

Measurements—transverse $1\frac{1}{2}$ inches = 36 mm.

Vertical $1\frac{1}{4}$ " = 30 "

Antero-posterior $\frac{3}{4}$ " = 18 "

Spinal Cord; length about 18 inches = 45 mm. in adult.

Spleen; varies greatly in weight in health; averages about 6 ozs. = grms. 170.

Thyroid Gland; weight slightly over 1 oz. = 30—40 grms.

Measurements—2 inches = 50 min. long.

$1\frac{1}{4}$ " = 30 " broad.

$\frac{3}{4}$ " = 15 " thick.

Isthmus $\frac{1}{2}$ " = 12 " wide.

$\frac{1}{4}$ — $\frac{3}{4}$ " = " deep.

Heart: weight averages 10—13 ozs., for both males and females.

Measurements—L. vent. wall $\frac{1}{4}$ inch to $\frac{1}{2}$ inch.

R. " " $\frac{1}{4}$ " all over.

Stomach: capacity varies greatly; in adult $\frac{2}{3}$ of a pint to $1\frac{1}{2}$ pints.

Uterus: adult = $1\frac{1}{10}$ ozs.— $1\frac{1}{2}$ ozs. = 33—41 grms.; thickness of wall, 1—2 cms.

Kidney Cortex: $\frac{1}{2}$ —1 cm.

NS

one pint;

female,

5 inches
jejunum

ms.; L.,

o grms.

about 6

s.

emales.

$\frac{1}{2}$ pints.

ness of

