

**CIHM  
Microfiche  
Series  
(Monographs)**

**ICMH  
Collection de  
microfiches  
(monographies)**



**Canadian Institute for Historical Microreproductions / Institut canadien de microreproductions historiques**

**© 1996**

## Technical and Bibliographic Notes / Notes technique et bibliographiques

The Institute has attempted to obtain the best original copy available for filming. Features of this copy which may be bibliographically unique, which may alter any of the images in the reproduction, or which may significantly change the usual method of filming are checked below.

- Coloured covers / Couverture de couleur
- Covers damaged / Couverture endommagée
- Covers restored and/or laminated / Couverture restaurée et/ou pelliculée
- Cover title missing / Le titre de couverture manque
- Coloured maps / Cartes géographiques en couleur
- Coloured ink (i.e. other than blue or black) / Encre de couleur (i.e. autre que bleue ou noire)
- Coloured plates and/or illustrations / Planches et/ou illustrations en couleur
- Bound with other material / Relié avec d'autres documents
- Only edition available / Seule édition disponible
- Tight binding may cause shadows or distortion along interior margin / La reliure serrée peut causer de l'ombre ou de la distorsion le long de la marge intérieure.
- Blank leaves added during restorations may appear within the text. Whenever possible, these have been omitted from filming / Il se peut que certaines pages blanches ajoutées lors d'une restauration apparaissent dans le texte, mais, lorsque cela était possible, ces pages n'ont pas été filmées.
- Additional comments / Commentaires supplémentaires:

L'Institut a microfilmé le meilleur exemplaire qu'il lui a été possible de se procurer. Les détails de cet exemplaire qui sont peut-être uniques du point de vue bibliographique, qui peuvent modifier une image reproduite, ou qui peuvent exiger une modifications dans la méthode normale de filmage sont indiqués ci-dessous.

- Coloured pages / Pages de couleur
- Pages damaged / Pages endommagées
- Pages restored and/or laminated / Pages restaurées et/ou pelliculées
- Pages discoloured, stained or foxed / Pages décolorées, tachetées ou piquées
- Pages detached / Pages détachées
- Showthrough / Transparence
- Quality of print varies / Qualité inégale de l'impression
- Includes supplementary material / Comprend du matériel supplémentaire
- Pages wholly or partially obscured by errata slips, tissues, etc., have been refilmed to ensure the best possible image / Les pages totalement ou partiellement obscurcies par un feuillet d'errata, une pelure, etc., ont été filmées à nouveau de façon à obtenir la meilleure image possible.
- Opposing pages with varying colouration or discolourations are filmed twice to ensure the best possible image / Les pages s'opposant ayant des colorations variables ou des décolorations sont filmées deux fois afin d'obtenir la meilleure image possible.

This item is filmed at the reduction ratio checked below /  
Ce document est filmé au taux de réduction indiqué ci-dessous.

10x	14x	18x	22x	26x	30x
				✓	
12x	16x	20x	24x	28x	32x

The copy filmed here has been reproduced thanks to the generosity of:

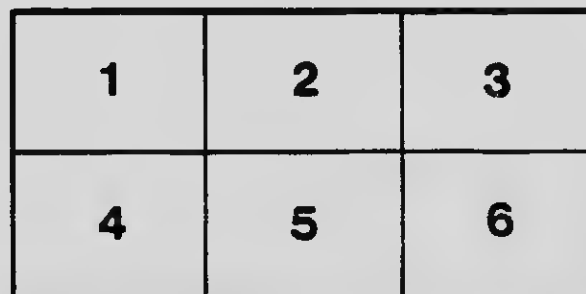
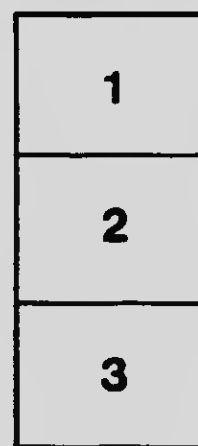
Oster Library,  
McGill University,  
Montreal

The images appearing here are the best quality possible considering the condition and legibility of the original copy and in keeping with the filming contract specifications.

Original copies in printed paper covers are filmed beginning with the front cover and ending on the last page with a printed or illustrated impression, or the back cover when appropriate. All other original copies are filmed beginning on the first page with a printed or illustrated impression, and ending on the last page with a printed or illustrated impression.

The last recorded frame on each microfiche sheet contains the symbol  $\rightarrow$  (meaning "CONTINUED"), or the symbol  $\nabla$  (meaning "END"), whichever applies.

Maps, plates, charts, etc., may be filmed at different reduction ratios. Those too large to be entirely included in one exposure are filmed beginning in the upper left hand corner, left to right and top to bottom, as many frames as required. The following diagrams illustrate the method:



L'exemplaire filmé fut reproduit grâce à la générosité de:

Oster Library,  
McGill University,  
Montreal

Les images suivantes ont été reproduites avec le plus grand soin, compte tenu de la condition et de la netteté de l'exemplaire filmé, et en conformité avec les conditions du contrat de filmage.

Les exemplaires originaux dont la couverture en papier est imprimée sont filmés en commençant par le premier plat et en terminant soit par la dernière page qui comporte une empreinte d'impression ou d'illustration, soit par le second plat, selon le cas. Tous les autres exemplaires originaux sont filmés en commençant par la première page qui comporte une empreinte d'impression ou d'illustration et en terminant par la dernière page qui comporte une telle empreinte.

Un des symboles suivants apparaîtra sur la dernière image de chaque microfiche, selon le cas: le symbole  $\rightarrow$  signifie "A SUIVRE", le symbole  $\nabla$  signifie "FIN".

Les cartes, planches, tableaux, etc., peuvent être filmés à des taux de réduction différents. Lorsque le document est trop grand pour être reproduit en un seul cliché, il est filmé à partir de l'angle supérieur gauche, de gauche à droite, et de haut en bas, en prenant le nombre d'images nécessaire. Les diagrammes suivants illustrent la méthode.

MICROCOPY RESOLUTION TEST CHART

(ANSI and ISO TEST CHART No. 2)



1.0

4.5

5.0

5.6

6.3

7.1

8.0

9.0

10

2.8

2.5

3.2

2.2

3.6

2.0

4.0

1.8



1.1



1.25



1.4



1.6



APPLIED IMAGE Inc

1653 East Main Street  
Rochester, New York 14609 USA  
(716) 482 - 0300 - Phone  
(716) 288 - 5989 - Fax

30

*Reprinted from the Transactions of the Montreal Medico-Chirurgical Society for November 16th, 1917, published in the Canadian Medical Association Journal, March, 1918.*

**PATHOLOGICAL SPECIMENS:** Series by Dr. Maude E. Abbott, who remarked as follows:

The specimens I am about to demonstrate were presented to the McGill Medical Museum by a recent graduate, Dr. Alton Goldhloom, now of the Boston Floating Hospital, to whose initiative and enthusiasm we are much indebted for a most valuable collection, unsurpassed both in brilliancy of colour preservation and in pathological interest. The collection consists of the intestines from a series of cases of acute enteritis in children, and also the lungs from two cases of exceptional interest of pulmonary disease in infants.

The microscopic appearances in these two last named specimens, which I now show on the epidiascope, form an interesting comparative study of the histological changes in syphilis and tuberculosis respectively. In the syphilitic slide the inflammatory reaction is of a markedly productive character with the formation of a vascularized granulation tissue which progresses from the blood vessels, very rich in plasma cells and other polynuclear elements, with few giant cells and relatively little caseation. In the tuberculous lung, on the other hand, we see an acute necrosing process, large caseating areas destitute of blood vessels containing both epitheloid and giant cells, and surrounded by a zone of lymphocytic invasion and a deeply congested periphery. Spirochaetes are seen stained by the Levaditi method in the syphilitic lung and no tubercle bacilli, but the latter are present in great numbers in the slide of caseous pneumonia, stained by carbol-fuchsin.

The series of acute enteritis is of interest, both in the types of disease represented, which include acute catarrhal, ulcerative and membranous forms, and also from the clinical standpoint in regard to the development of acidosis, which Dr. Goldhloom tells me is being investigated there in all cases of infantile diarrhoea by the estimation of the CO<sub>2</sub> tension of the alveolar air and the alkaline reserve of the plasma by the Mariott apparatus. He writes: "The study of the respiratory changes in diarrhoeal cases is most fascinating. There are two types, it seems, of acidosis; one which

is caused by the ketone bodies, the result of the starvation and the inability of the inflamed bowel to utilize carbohydrate,—this is seen mainly in the so-called infection cases.  $\text{CO}_2$  in these cases may be quite low, but seldom below 22 or 25 mm. There is another condition, however, not infectious but fermental, characterized by a profuse watery diarrhœa with marked desiccation, where much more severe grades of acidosis are seen, with  $\text{CO}_2$  tension as low as 15 or 20 mm., needing soda intravenously, and often very fatal. This is frankly not due to ketone bodies formation, for they will be found in the urine only in very small amounts, and there will be no acetone odour to the breath. This type of acidosis is due to the fact that owing to an excessive loss of fluid by the bowel, the kidneys attempt to conserve this by diminished excretion with the result that the acid products of metabolism are retained. It is more severe and more deadly in our experience than the other type. Frequently the diarrhœal condition becomes a secondary consideration for the time being, the necessity of neutralizing the diminished alkalinity of the blood being so very urgent. We have therefore found the estimation of the  $\text{CO}_2$  tension of inestimable value, and easily and quickly carried out at the bedside even on the youngest infant."

The exact details of the seven specimens, which are mounted and put on exhibition by Mr. Judah here, are as follows:

1. *Congenital syphilis of lungs of infant with multiple gummata and so-called white (syphilitic) pneumonia. Spirochaetes in tissues by Levaditi method. Tubercle bacilli absent.*

The right lung is somewhat larger than the left and is diffusely mottled with dark red areas scattered over a surface of paler fleshy tint, the whole diffusely consolidated except in a small portion along its upper border, which is airless. Its central part is occupied by one large and several smaller caseous gummata, the largest of which presents a central cavity surrounded by a thick caseating wall and extends from the upper into the middle lobe through the pleural surfaces of the two lobes which are firmly adherent to each other at this point by extension of the gummatous inflammatory tissues.

The left lung presents one large gumma with central cavitation in its upper lobe and is air-containing in about two-thirds of its extent. Its lower lobe is of a fleshy feel and pale pinkish colour and is quite airless and solid, presenting the gross appearance of the young granulation tissue characteristic of syphilitic pneumonia.

From a male infant aged six weeks, a typical congenital luetic

with ruffles, fissures about the anus, pinched finger nails. Shotty adenopathy, palpable spleen and liver 3 cm. below the intercostal border, superficial ulcers in buttocks. Full term. Breast fed. Clear history of luetic infection in father thirteen years previously. Admitted to hospital with diarrhea and complaint of failure to gain weight and grow. The infant never coughed, probably owing to extreme weakness, and physical examination of chest was negative, so that no pulmonary lesion was suspected. Failed to rally and wasted away in a week. Wassermann reaction was positive and von Pirquet negative.

Microscopical examination showed the lung largely obliterated by a cellular granulation tissue, rich in plasma cells and other polyblasts, partly vascularized, interchanging with areas of fibroplastic and mature fibrous tissue, especially well developed around and progressing from blood vessels. Small tuherele-like, mostly fibroid, nodules are also numerous. Caseation is generally absent, although tendency to necrosis and some actual necrosis of tissue is to be noted. In earlier places distinct cellular fibrous interalveolar thickening occurs. The whole sufficiently characteristic of the syphilitic process to enable the diagnosis to be made. (Entry No. 6062.)

2. *Acute disseminated caseous tuberculosis of lungs of infant with acute tuberculous pleurisy and extensive caseation in mediastinal and peribronchial lymphatic glands, and extension through lymphatics to pleura and outer surface of pericardium. Anomalous lobulation.*

Both lungs with the trachea, bronchi, pericardial sac, and mediastinal glands attached, carefully dissected to show the mediastinal structures. The heart has been removed and the interior of the pericardial sac exposed. The left lung has but one lobe and the right a very rudimentary division.

A large mass of densely caseating and enlarged glands, most of which are discrete from each other, are grouped about the arch of the aorta just above the pericardium and encircling the anterior surface and right side of the trachea and its bifurcation. Seen from the front these glands form a continuous chain of coronal shape running from the root of the right to that of the left lung, being larger and more numerous on the left side where the outer surface of the pericardium is seen to be involved, and a series of delicate lymphatics run from the lower glands of the chain to the pleural surface over the hilum of the lungs. The pleura in this neighbourhood and also over the diaphragmatic surface and over

the whole right lung is the seat of an extensive yellowish exudate and numerous caseating tubercles. The posterior aspect of the specimen shows the mass of caseating glands seen from the front dipping down at the back of the hilum of the right lung, and a portion of the right parietal pleura completely covered with a tuberculous inflammatory exudate. The apex of this lung is transformed into a dense caseous mass the size of a walnut and there is extension downwards of the process by lobular foci of caseous broncho-pneumonia and an acute fibrinous pleurisy.

From a male infant aged fifteen months. History of failure to gain and loss of weight for past seven months. Cough during past three or four months, loss of appetite and listless. Dulness in right interscapular region and breath sounds increased over this area and inconstant fine crackling râles heard. Lumbar puncture showed increased pressure, 150 cells and tubercle bacilli. Cerebro-spinal signs came on after the child had been ten days in hospital.

The post-mortem showed the lungs as above, also tuberculous meningitis, miliary tuberculosis of liver and spleen and kidney, but none of mesenteric lymph nodes or peritoneum. Horseshoe kidney. Both lungs were left attached to the mediastinum in order to show the relationship of tuberculous peritoneal lymph nodes to the main tuberculous process. Note the advanced lesion at the apex of the right lung which was noted as somewhat unusual in a child of this age. (Entry No. 6262.)

3. *Horseshoe kidney and spleen of anomalous shape, the seat of acute miliary tuberculosis.* (From the preceding case.)

4. *Small intestine. Death from acute intestinal indigestion of infancy, with acute intoxication.*

A piece of jejunum showing marked injection of follicles which project from the mucosa as bright red areas.

From an exclusively breast fed infant with an acute attack of diarrhoea, no pus or blood. No vomiting. Physician's examination negative. Diarrhoea very watery. Child did not rally. Diagnosis—acute intestinal indigestion. Parenchymatous degeneration of kidneys; fatty infiltration of liver. (Entry No. 6261.)

5. *Acute ulcerative ileo-colitis of infancy.* (Infectious diarrhoea, bacillary dysentery.)

The colon, appendix, and portion of ileum, showing a dematous mucous membrane, intense injection of mucosa with pin-point areas of denuded endothelium diffusely scattered through large and small intestine. Ulcers are not of follicular type, but are

rather in  
Some app  
others a  
pseudo m

From  
before ad  
ment. p  
about on  
deal of te  
tous dege

6. Ac

A sm  
fect abov  
of the dy  
to the rec

7. A

most fata

A po  
a young c

The  
ileum sho  
thickening  
membrane  
lower par  
above the  
in its imm

Histo

stools. C  
Convulsion  
death. Sp  
per day w

At po  
large howe  
and was th  
pus and ly  
and fatty i

Discu

Dr. Abbot  
clear exhibit  
cussion is  
and thanks



rather irregular areas where the endothelium has been eroded. Some appear as chinks and streaks or triangular cuts in the mucosa, others as shallow punched-out, pin-head sized cavities. No pseudo membrane has been formed.

From a female infant aged nine months. Onset one week before admission, diarrhoea with pus and blood, eight to nine movements per day. Prostrated. Markedly desiccated. Survived about one week after admission. Extremely toxic. Had a great deal of tenesmus. No clinical evidence of acidosis. Parenchymatous degeneration of kidneys. (Entry No. 6263.)

6. *Acute ulcerative ileo-colitis in infancy.*

A small piece of jejunum from the preceding case about four feet above the ileo-cæcal valve to show the abrupt commencement of the dysenteric lesion, which was continuous from that point down to the rectum as shown in specimen No. 5. (Entry No. 6263.)

7. *Acute membranous ileo-colitis of infancy* (probably the most fatal form of infantile diarrhoea known).

A portion of ileum, cæcum, colon and a piece of sigmoid from a young child; mounted in three strips.

The whole of the large bowel and the greater portion of the ileum shows an active inflammatory process with congestion and thickening in the mucosa, which is the seat of the patchy adherent membrane. These changes are most marked in the cæcum and lower part of colon and sigmoid. The ileum for about 12 cm. above the ileo-cæcal valve is relatively free from disease, the area in its immediate neighbourhood is intensely involved.

History of severe diarrhoea six days. Pus and blood in stools. CO<sub>2</sub> tension alveolar air 30 mm., white blood cells, 20,000. Convulsions on admission which continued intermittently until death. Spinal tap negative. Stools between eight and thirteen per day with blood and pus.

At post mortem the process was seen to be most marked in the large bowel which was œdematous with patches of active congestion and was throughout the seat of a putrid inflammation, covered with pus and lymph exudate. Parenchymatous degeneration of kidneys and fatty infiltration of liver. (Entry No. 6259.)

Discussion: Dr. F. M. Fry: I am sure we all wish to thank Dr. Abbott and Dr. Goldbloom for giving us such a wonderfully clear exhibition of diseases in infants. I do not see that any discussion is necessary but I would like to express our gratification and thanks for the privilege of seeing such an excellent series.



