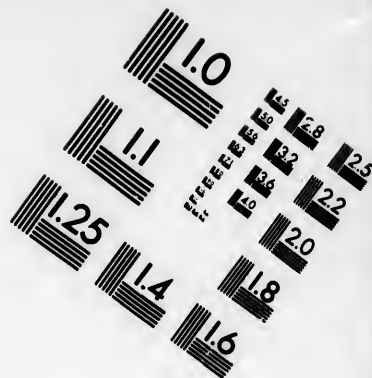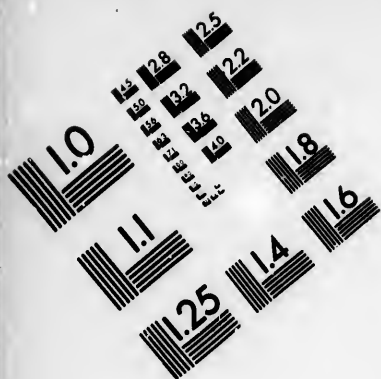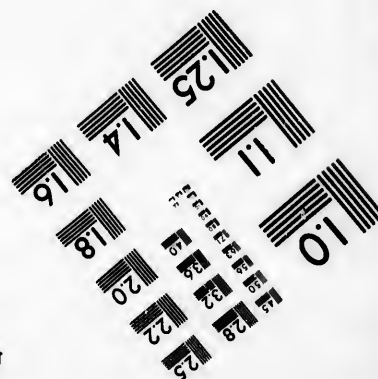
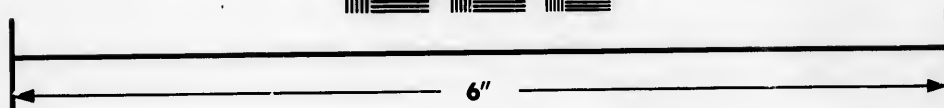



# IMAGE EVALUATION TEST TARGET (MT-3)



Photographic  
Sciences  
Corporation

23 WEST MAIN STREET  
WEBSTER, N.Y. 14580  
(716) 872-4503

**CIHM/ICMH  
Microfiche  
Series.**

**CIHM/ICMH  
Collection de  
microfiches.**



**Canadian Institute for Historical Microreproductions / Institut canadien de microreproductions historiques**

**© 1985**

# Technical and Bibliographic Notes/Notes techniques et bibliographiques

The Institute has attempted to obtain the best original copy available for filming. Features of this copy which may be bibliographically unique, which may alter any of the images in the reproduction, or which may significantly change the usual method of filming, are checked below.

- ☐ Coloured covers/  
Couverture de couleur
- ☐ Covers damaged/  
Couverture endommagée
- ☐ Covers restored and/or laminated/  
Couverture restaurée et/ou pelliculée
- ☐ Cover title missing/  
Le titre de couverture manque
- ☐ Coloured maps/  
Cartes géographiques en couleur
- ☐ Coloured ink (i.e. other than blue or black)/  
Encre de couleur (i.e. autre que bleue ou noire)
- ☐ Coloured plates and/or illustrations/  
Planches et/ou illustrations en couleur
- ☐ Bound with other material/  
Relié avec d'autres documents
- ☐ Tight binding may cause shadows or distortion along interior margin/  
La reliure serrée peut causer de l'ombre ou de la distorsion le long de la marge intérieure
- ☐ Blank leaves added during restoration may appear within the text. Whenever possible, these have been omitted from filming/  
Il se peut que certaines pages blanches ajoutées lors d'une restauration apparaissent dans le texte, mais, lorsque cela était possible, ces pages n'ont pas été filmées.
- ☐ Additional comments:/  
Commentaires supplémentaires:

L'Institut a microfilmé le meilleur exemplaire qu'il lui a été possible de se procurer. Les détails de cet exemplaire qui sont peut-être uniques du point de vue bibliographique, qui peuvent modifier une image reproduite, ou qui peuvent exiger une modification dans la méthode normale de filmage sont indiqués ci-dessous.

- ☐ Coloured pages/  
Pages de couleur
- ☐ Pages damaged/  
Pages endommagées
- ☐ Pages restored and/or laminated/  
Pages restaurées et/ou pelliculées
- ☒ Pages discoloured, stained or foxed/  
Pages décolorées, tachetées ou piquées
- ☐ Pages detached/  
Pages détachées
- ☒ Showthrough/  
Transparence
- ☐ Quality of print varies/  
Qualité inégale de l'impression
- ☐ Includes supplementary material/  
Comprend du matériel supplémentaire
- ☐ Only edition available/  
Seule édition disponible
- ☐ Pages wholly or partially obscured by errata slips, tissues, etc., have been refilmed to ensure the best possible image/  
Les pages totalement ou partiellement obscurcies par un feuillet d'errata, une pelure, etc., ont été filmées à nouveau de façon à obtenir la meilleure image possible.

This item is filmed at the reduction ratio checked below/  
Ce document est filmé au taux de réduction indiqué ci-dessous.

10X	12X	14X	16X	18X	20X	22X	24X	26X	28X	30X	32X
					✓						

The copy filmed here has been reproduced thanks to the generosity of:

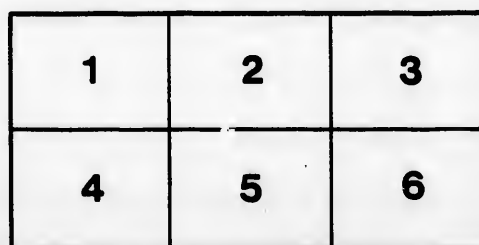
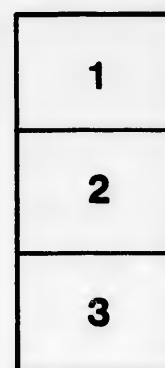

Medical Library  
McGill University  
Montreal

The images appearing here are the best quality possible considering the condition and legibility of the original copy and in keeping with the filming contract specifications.

Original copies in printed paper covers are filmed beginning with the front cover and ending on the last page with a printed or illustrated impression, or the back cover when appropriate. All other original copies are filmed beginning on the first page with a printed or illustrated impression, and ending on the last page with a printed or illustrated impression.

The last recorded frame on each microfiche shall contain the symbol ➡ (meaning "CONTINUED"), or the symbol ▼ (meaning "END"), whichever applies.

Maps, plates, charts, etc., may be filmed at different reduction ratios. Those too large to be entirely included in one exposure are filmed beginning in the upper left hand corner, left to right and top to bottom, as many frames as required. The following diagrams illustrate the method:



L'exemplaire filmé fut reproduit grâce à la générosité de:

Medical Library  
McGill University  
Montreal

Les images suivantes ont été reproduites avec le plus grand soin, compte tenu de la condition et de la netteté de l'exemplaire filmé, et en conformité avec les conditions du contrat de filmage.

Les exemplaires originaux dont la couverture en papier est imprimée sont filmés en commençant par le premier plat et en terminant soit par la dernière page qui comporte une empreinte d'impression ou d'illustration, soit par le second plat, selon le cas. Tous les autres exemplaires originaux sont filmés en commençant par la première page qui comporte une empreinte d'impression ou d'illustration et en terminant par la dernière page qui comporte une telle empreinte.

Un des symboles suivants apparaîtra sur la dernière image de chaque microfiche, selon le cas: le symbole ➡ signifie "A SUIVRE", le symbole ▼ signifie "FIN".

Les cartes, planches, tableaux, etc., peuvent être filmés à des taux de réduction différents. Lorsque le document est trop grand pour être reproduit en un seul cliché, il est filmé à partir de l'angle supérieur gauche, de gauche à droite, et de haut en bas, en prenant le nombre d'images nécessaire. Les diagrammes suivants illustrent la méthode.

tails  
du  
odifier  
une  
image

trata  
o

pelure.  
à

32X

Ce/

Hingston, Wm. H.

RE-PRINTED FROM THE "CANADA MEDICAL & SURGICAL JOURNAL."  
MARCH, 1884.

## CERTAIN FORMS OF CLUB FOOT.

By WM. H. HINGSTON, M.D., L.R.C.S., EDIN.,  
Professor of Clinical Surgery, Montreal School of Medicine; Surgeon  
to Hotel Dieu.

(Read before the Medico-Chirurgical Society of Montreal, Jan. 25, 1884.)

It is precisely one hundred years since, as Adams says, the treatment of club foot was limited to mechanical appliances, when Thilenius proposed the division of the tendo-Achillis by an open wound; sixty-eight years since the division of the same tendon subcutaneously was performed—if Delpech's operation deserves to be so designated; and fifty-three years since Stromeyer improved upon the operation of Delpech by puncture and subcutaneous division. The modification of the operation of Thilenius, so far, concerned the manner of dealing with the tendo-Achillis, for to that tendon alone was imputed all the blame of the deformity, until comparatively recently, when other structures—tendinous, muscular, ligamentous, bony—have received attention. I intend here to speak only of that inveterate form of club foot; not of that simple form with which all are familiar, and which the nurse's, and, later, the mother's hand alone may remedy; nor of that other form which mechanical appliances may easily correct; nor of the milder form which tenotomy alone will cure; nor of a still severer form in which tenotomy of certain tendons, aided by mechanical appliances, suffices to remedy; but of that still severer form in which division of all the tendons and fascia commonly, or exceptionally at fault, followed by the use of the best mechanical contrivances, are powerless to remedy. One such case I exhibited to you last year, in the person of Emelie, aged 15

years, upon whom I had operated in the early part of 1881 for exaggerated talipes equino-varus. It may be in the recollection of some of you, that, when I showed to this Society the young girl in question upon whom I had performed the operation which had been introduced to the profession by Dr. Phelps, of Chateaugay, N.Y., based on the principle enunciated by Dr. Post, of New York, in dealing with wry neck, I mentioned that I had already, with the tenotome, divided, without much amelioration of the deformity, all the muscles usually at fault in this affection. There remained, to undo the excessive arch and shortening and doubling-in of the foot, excision of a portion of the tarsal bones; but the additional shortening of the foot that would result, not to speak of the considerable risk to limb and life of opening into the inter-tarsal articulations, made me disinclined to resort to it. You saw the result of the operation in a completely straightened foot, without any diminution, but with increase of its length, and with but temporary impairment of its strength. The operation, so far as the members of this Society knew, was a novel one, and one not without the apparent qualifications of rashness.

I shall give short notes of a second, third and fourth, and two photographs of the last.

J. McG., æt. 19 years, the subject of exaggerated talipes equino-varus, entered the Hotel Dieu on 12th February, 1883. He had been born with the deformity, but, as years rolled on, the deformity had become greater. The heel was drawn up; the foot very strongly inverted, and bent inward upon itself. The patient walked on the outside of his foot; and the usual cutaneous and tarsal thickness existed there. I could not undo, in the slightest, this exaggerated deformity. I divided subcutaneously the plantar fascia, tibialis posticus, and anticus, and the flexor pollicis and long flexor digitorum, and, lastly, *as is usual with me*, the tendo-Achillis. With the exception of bringing down the heel somewhat, the deformity, notwithstanding considerable force, was not relieved—the excessive arch remaining as before. I then adopted free open incision; swept the knife across the sole of the foot, dividing tissue after tissue till the bones were

reached. The excessive arch was then in great measure, but not completely, remedied. Across the ball of the foot a padded splint was applied, and on this, adhesive plaster to which were attached cords which led over pulleys, and a weight of 12 lbs. was suspended. With the exception of looking after the foot-piece, and sliding it nearer to, or farther from, the open wound, no surveillance was needed. The dressing consisted of vaseline for the first two days, and afterwards carbolic lotion or red wash, as suppuration was more or less abundant. When the patient left the hospital, on 30th April, his foot was quite straight and supported his weight comfortably. I have since learned that the foot is in every respect like the other.

CASE III.—Is that of a boy, J. D., aged 10 years, who entered the Hotel Dieu under my care on 15th October, 1883, for double congenital talipes equino-varus. The deformity in both feet, but chiefly in the left, was excessive, and no amount of force, even under chloroform, could diminish it. Subcutaneous division of the supposed faulty tendons of the left foot was performed, and in the order named in previous case; but, apart from giving greater freedom to the heel on the division of the tendo-Achillis, the rigidity and deformity remained. I then used the scalpel very freely to the sole of the foot, dividing all the tissues down to the bone, and gradually unfolded the excessive arch. This added most markedly to the length of the foot—the cut edges at their centre gaping apart to the extent of nearly two inches. I had difficulty in keeping up extension. The boy was a mischievous fellow, difficult to control. Pulleys were ineffectual, as they were tampered with either by himself or some other patient. But what was found to restrain him effectually was a quickly-setting plaster-Paris splint, with a fenestra opposite to the incision. Through this the gaping wound was filled with tow soaked in Peruvian Balsam and renewed once a day. Granulation went on with surprising rapidity to the end. (I may here say, by way of parenthesis, that Peruvian Balsam, used in this way, is, without exception, the best application with which I am acquainted, and fully merits the favor in which it is held by Sayre and others.)

CASE IV.—This subject was the same as the preceding, the foot this time being the right one. As the deformity was not so great as in the left I hoped, by free subcutaneous division, to remedy it in great measure; but the relief obtained by tenotomy was so inconsiderable that I proceeded at once to treat it as I had treated the left. The order of division was as in preceding



(Before the operation.)



case, with this difference, that structures already divided subcutaneously required no further attention by the open wound. The great difficulty in the treatment of the second foot, as in the first, was to keep up proper extension. Every additional day in the hospital added to the boy's cunning and to his desire to display it, regardless of consequences, to the admiring



*(After the operation.)*

patients around him. During my absence of a couple of days from the city the boy manipulated things as he wished ; and on my return, finding the old state of things partially restored, I put him again under chloroform and forcibly extended the foot. This forcible tearing open of a partially healed wound, I may add, was followed by more suffering than was the original operation.

In talipes equino-varus, however exaggerated the degree, there is, there can be, no contraction of either the abductor or of the short flexor of the little toe. The plantar fascia is almost always at fault, and its division remedies to some extent the deformity. The division of the flexor brevis muscle still further relieves the tension ; the separation of the flexor longus digitorum still further ; division of the tendon of the flexor longus pollicis still more markedly ; and that of the flexor accessorius still further. The lumbricales, as they are on the phalangeal side of the incision, escape division—while division of the tendon of the tibialis posticus completes in a satisfactory manner the relief of the deformity, unless, as in Case I., the long calcaneo-cuboid ligament, a much longer ligament than its name implies, be also partially severed. The hemorrhage is not what might *a priori* be expected. The internal plantar artery, 'tis true, is divided ; but the external plantar, much larger than the internal, escapes division, if the knife be not needlessly carried beyond, or in front of, the base of the fifth metatarsal bone. Leaving the large external plantar untouched, its numerous distributing branches suffice to keep the muscles, and the digits and their appendages, abundantly supplied with blood. In no case was the temperature of the foot on the distal side of the incision lowered, and granulations sprang up as abundantly on that as on the central side. The internal plantar nerve is divided early in the operation ; and, if the incision be carried too far back, the external plantar suffers also ; but this would be unwarrantable. Respect for the arteries prevents our carrying the incision too far forward ; and respect for the nerve too far backward.

A question will now obviously suggest itself: Why not divide all these muscular structures subcutaneously? And in the answer to which lies the gist of the whole question: the skin itself is largely at fault, and must be divided; and the division of the artery necessitates an open wound. In Case II. every muscle and tendon were divided down to the bone, but the relief was not what I expected till the unfolding process had gone on for several days after division. In the third and fourth cases (those of the young boy) I was disheartened at the imp's devices with the aid of other patients in the ward to relieve his foot of restraint. The weight and pulley were not equal to him.

The quickly-setting plaster, to which a little salt had been added, applied under strong extension, suited admirably in one foot; and in the other a simple and inexpensive device, suggested to me by Dr. Phelps, and which I now show to you, was used with satisfaction. Most of you are familiar with the method of applying adhesive plaster around the foot, and along the outer side of the leg; but in this plan the plaster so applied is divided between its two attachments on foot and leg, and two pieces of thick wire, like telegraph wire, and made into hooks or two buckles, are attached, and these are drawn together with strings and tightened as the plaster loosens. This device is a simple, inexpensive and efficient one, and is much better than the single piece of adhesive plaster which, when it slips, becomes useless.

What is 1st, the position of the operation; and what are, 2nd, the limits of its application? It is a most useful one, and one which, compared with excision of a wedge-shaped portion of the scaphoid—an operation which hitherto has not met with any considerable favor—is simple, safe, and requires no dexterity whatever in its performance.

What are the limits of its application? These appear to me clearly defined: 1st. Eliminate all cases in which, by hand or by mechanical appliances, or by both, deformity can be relieved. 2nd. Eliminate all cases which can be relieved by tenotomy. 3rd. Eliminate all cases where these, or any of these methods, or all combined, may suffice; for in all those

cases would the operation by open division be un-warrantable.

But in those cases of exaggerated club foot, as these now submitted, with excessive arching and shortening, and more especially with narrowing and rolling in of the foot upon itself, *which cannot be relieved by the usual methods*, operation by open division offers important advantages.

