

**CIHM
Microfiche
Series
(Monographs)**

**ICMH
Collection de
microfiches
(monographies)**



Canadian Institute for Historical Microreproductions / Institut canadien de microreproductions historiques

© 1996

Technical and Bibliographic Notes / Notes technique et bibliographiques

The Institute has attempted to obtain the best original copy available for filming. Features of this copy which may be bibliographically unique, which may alter any of the images in the reproduction, or which may significantly change the usual method of filming are checked below.

- Coloured covers / Couverture de couleur
- Covers damaged / Couverture endommagée
- Covers restored and/or laminated / Couverture restaurée et/ou pelliculée
- Cover title missing / Le titre de couverture manque
- Coloured maps / Cartes géographiques en couleur
- Coloured ink (i.e. other than blue or black) / Encre de couleur (i.e. autre que bleue ou noire)
- Coloured plates end/or illustrations / Planches et/ou illustrations en couleur
- Bound with other material / Relié avec d'autres documents
- Only edition available / Seule édition disponible
- Tight binding may cause shadows or distortion along interior margin / La reliure serrée peut causer de l'ombre ou de la distorsion le long de la marge intérieure.
- Blank leaves added during restorations may appear within the text. Whenever possible, these have been omitted from filming / Il se peut que certaines pages blanches ajoutées lors d'une restauration apparaissent dans le texte, mais, lorsque cela était possible, ces pages n'ont pas été filmées.
- Additional comments / Commentaires supplémentaires:

L'Institut a microfilmé le meilleur exemplaire qu'il lui a été possible de se procurer. Les détails de cet exemplaire qui sont peut-être uniques du point de vue bibliographique, qui peuvent modifier une image reproduite, ou qui peuvent exiger une modifications dans la méthode normale de filmage sont indiqués ci-dessous.

- Coloured pages / Pages de couleur
- Pages damaged / Pages endommagées
- Pages restored end/or laminated / Pages restaurées et/ou pelliculées
- Pages discoloured, stained or foxed / Pages décolorées, tachetées ou piquées
- Pages detached / Pages détachées
- Showthrough / Transparence
- Quality of print varies / Qualité inégale de l'impression
- Includes supplementary material / Comprend du matériel supplémentaire
- Pages wholly or partially obscured by errata slips, tissues, etc., have been refilmed to ensure the best possible image / Les pages totalement ou partiellement obscurcies par un feuillet d'errata, une pelure, etc., ont été filmées à nouveau de façon à obtenir la meilleure image possible.
- Opposing pages with varying colouration or discolourations are filmed twice to ensure the best possible image / Les pages s'opposant ayant des colorations variables ou des décolorations sont filmées deux fois afin d'obtenir le meilleur image possible.

This item is filmed at the reduction ratio checked below /
Ce document est filmé au taux de réduction indiqué ci-dessous.

	10X		14X		18X		22X		26X		30X
	12X		16X		20X		24X		28X		32X

The copy filmed here has been reproduced thanks to the generosity of:

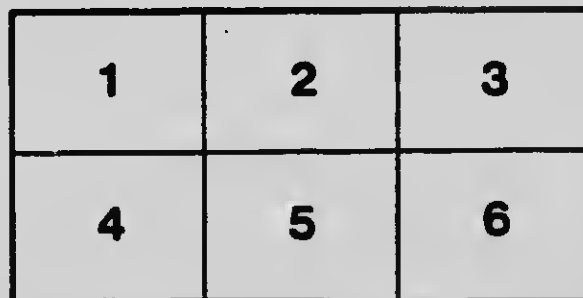
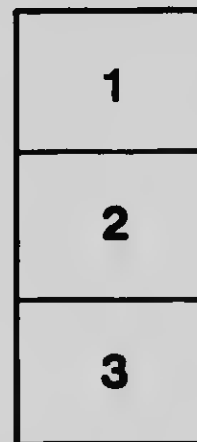
D.B. Weldon Library
University of Western Ontario

The images appearing here are the best quality possible considering the condition and legibility of the original copy and in keeping with the filming contract specifications.

Original copies in printed paper covers are filmed beginning with the front cover and ending on the last page with a printed or illustrated impression, or the back cover when appropriate. All other original copies are filmed beginning on the first page with a printed or illustrated impression, and ending on the last page with a printed or illustrated impression.

The last recorded frame on each microfiche shell contains the symbol \rightarrow (meaning "CONTINUED"), or the symbol ∇ (meaning "END"), whichever applies.

Maps, plates, charts, etc., may be filmed at different reduction ratios. Those too large to be entirely included in one exposure are filmed beginning in the upper left hand corner, left to right and top to bottom, as many frames as required. The following diagrams illustrate the method:



L'exemplaire filmé fut reproduit grâce à la générosité de:

D.B. Weldon Library
University of Western Ontario

Les images suivantes ont été reproduites avec le plus grand soin, compte tenu de la condition et de la netteté de l'exemplaire filmé, et en conformité avec les conditions du contrat de filmage.

Les exemplaires originaux dont la couverture en papier est imprimée sont filmés en commençant par le premier plat et en terminant soit par la dernière page qui comporte une empreinte d'impression ou d'illustration, soit par le second plat, selon le cas. Tous les autres exemplaires originaux sont filmés en commençant par la première page qui comporte une empreinte d'impression ou d'illustration et en terminant par la dernière page qui comporte une telle empreinte.

Un des symboles suivants apparaît sur la dernière image de chaque microfiche, selon le cas: le symbole \rightarrow signifie "A SUIVRE", le symbole ∇ signifie "FIN".

Les cartes, planches, tableaux, etc., peuvent être filmés à des taux de réduction différents. Lorsque le document est trop grand pour être reproduit en un seul cliché, il est filmé à partir de l'angle supérieur gauche, de gauche à droite, et de haut en bas, en prenant le nombre d'images nécessaire. Les diagrammes suivants illustrent la méthode.

CONSTITUTIONAL HISTORY OF THE UNITED STATES

BY CHARLES A. BEAN

THE UNIVERSITY OF CHICAGO PRESS

THE UNIVERSITY OF CHICAGO
FOUNDED BY JOHN D. ROCKEFELLER

THE DECENNIAL PUBLICATIONS

A DESCRIPTION OF THE BRAINS AND SPINAL CORDS OF
TWO BROTHERS DEAD OF HEREDITARY ATAXIA

CASES XVIII AND XX OF THE SERIES IN THE FAMILY DESCRIBED BY DR.
SANGER BROWN. WITH A CLINICAL INTRODUCTION
BY DR. SANGER BROWN

BY

LEWELLYS F. BARKER

PROFESSOR AND HEAD OF THE DEPARTMENT OF ANATOMY

PRINTED FROM VOLUME X

CHICAGO
THE UNIVERSITY OF CHICAGO PRESS
1903

Copyright 1903
BY THE UNIVERSITY OF CHICAGO

PRINTED SEPTEMBER 1, 1905

5307

A DESCRIPTION OF THE BRAINS AND SPINAL CORDS OF
TWO BROTHERS DEAD OF HEREDITARY ATAXIA

CASES XVII AND XX OF THE SERIES IN THE FAMILY DESCRIBED BY DR.
SANGER BROWN. WITH A CLINICAL INTRODUCTION
BY DR. SANGER BROWN

LEWELLYS F. BARKER

THE valuable material which forms the basis of this study was presented (for investigation) by Dr. Sanger Brown, of Chicago, to Dr. William H. Welch, Professor of Pathology in Johns Hopkins University, who kindly turned it over to me. I wish to express my thanks to both these gentlemen for the opportunity they have given me of studying the pathological changes in a disease so rarely met with.

The description of the anatomical findings will be preceded by a Clinical Introduction by Dr. Sanger Brown.

CLINICAL INTRODUCTION BY DR. SANGER BROWN

As an introduction to Dr. Lewellys Barker's Anatomical Report, and for the purpose of facilitating correct deductions therefrom, as well as for the convenience of those interested who either have not read or do not now distinctly remember my clinical report of the series first published in 1892 in *Brain* and in the *North American Practitioner*, I shall undertake to supply some data intended to give a general idea of the characteristic clinical features, together with a reproduction of my original genealogical chart (see next page) showing the hereditary relation of the disease, and the age at which it first made its appearance in the individuals affected. Finally I shall furnish a more particular history of the cases supplying the material for Dr. Barker's report.

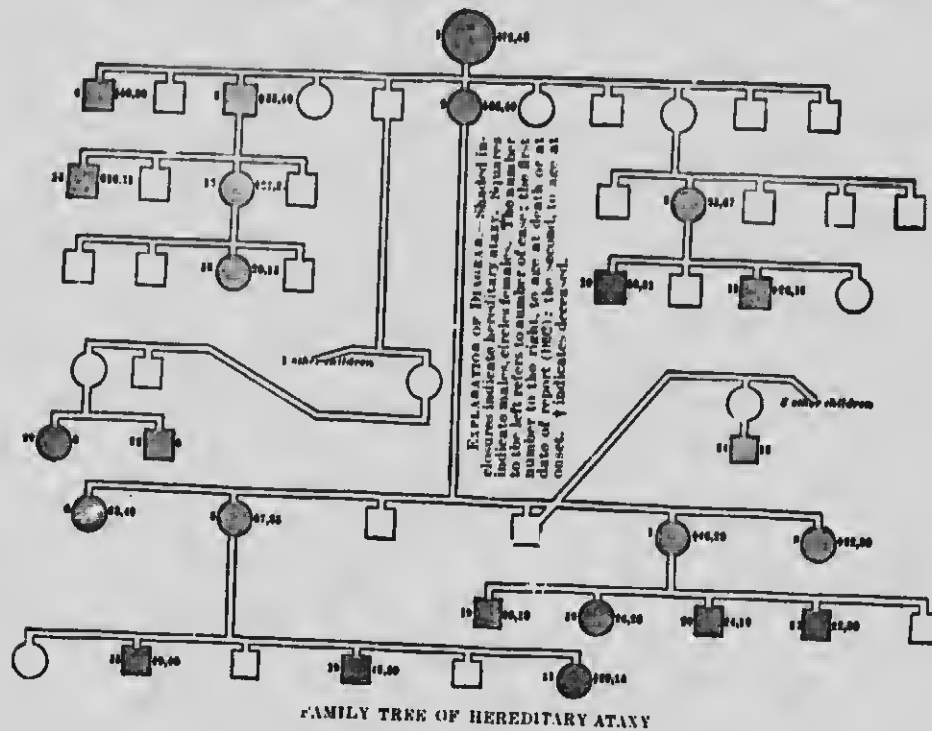
From a careful survey of all the cases comprised in the series, I presented in my original paper a general summary, which I here quote:

"Taking these cases alone for a text, and assuming them to be cases of hereditary ataxia, the following diagnostic criteria might be fairly deduced:

"Hereditary ataxy is a disease which may be traced through several—at least four—generations, increasing in extent and intensity as it descends, tending to occur earlier in life and to advance more rapidly. It usually attacks several members of the same family. It occurs most frequently between the ages of sixteen and thirty-five, but it may begin as early as eleven and as late as forty-five. It shows no marked preference for sex, but it descends through females four times as frequently as through males. Atavism rarely occurs. The influence of an exciting cause can rarely be

4 DESCRIPTION OF BRAIN AND SPINAL CORD IN HEREDITARY ATAXIA

demonstrated, but in some instances a fall or injury has appeared to determine the onset; and any cause like child-bearing or lactation, which very much depresses the vital forces, may produce a rapid advance of all the symptoms. There is always considerable inco-ordination of all the voluntary muscles, and a sluggishness of the movements which they produce, when the disease is well established. This is usually noticed first in the muscles of the legs, but in a few months or years extends to the



arms, face, eyes, head, and organs of speech. Sometimes it occurs first in the upper extremities, and sometimes in the organs of speech.

"The ataxy is often extreme, and the gait devious, the patient deviating several feet on either side of the intended line of progression before he loses the power of walking. The ataxy is not markedly increased by closing the eyes. The sense of posture is perfect.

"Some weakness of the muscles of the legs, without atrophy, is frequently an advanced symptom, and occasionally [in the late stages] there is permanent spastic contraction of the legs. In developed cases there are usually extensive choreiform movements of the head, and often of the arms, accompanying all voluntary move-

ments. These irregular movements occur in the hands, legs, or head whenever it is attempted to maintain either of these parts in a fixed position by a voluntary muscular effort. Movement ceases during sleep. The pulse-rate may be increased to 112 in advanced cases or may be normal.¹

"There is usually some degree of atatic ptosis, with over-contraction of the levator on looking upward. In rare cases there may be temporary diplopia, in the early stages due to weakness of the external [lateral] rectus. There is no nystagmus of any kind.

"Atrophy of the optic nerve is a constant and early symptom, and usually progresses slowly with the other symptoms. Rarely it begins earlier in one eye than the other.

"The response of the Iris to light and accommodation is sluggish and diminishes with the advance of the optic-nerve atrophy; when this latter is complete, as may happen in advanced cases, there may be complete internal and external ophthalmoplegia.

"There is always marked disturbance of the articulation, probably due to incoordination of the musculæ concerned, for weakness cannot be demonstrated. In some cases there is a troublesome tendency to strangulation in swallowing liquids, due to their going into the larynx, but otherwise swallowing is in no way difficult.

"Occasionally the sphincters are slightly, but positively, affected, this symptom appearing only in those cases where spontaneous pains in the legs coexist, having some of the characteristics of those occurring in locomotor ataxy. Excepting the spontaneous pains already mentioned, there is no disturbance of sensibility. There are no vaso-motor or trophic symptoms, but there is a marked tendency to emaciation; there is no hypertrophy or valvular lesion of the heart.

"The knee-jerk is always exaggerated, and there is frequently ankle-clonus, and the cutaneous reflexes are also always exaggerated, but to a less degree. The exaggeration of the reflexes is an early symptom, and they often decline considerably when the disease is far advanced.

"There is never paralytic club-foot, nor any other deformity excepting rarely permanent spastic contractions of the legs in advanced cases. In none of these cases have the patients ever suffered from rheumatism, so far as I can learn.

"I wish to repeat that the above summary of the symptomatology of hereditary ataxy is only intended to apply to this particular series of cases; and I have only presented it in this way so that it might be the more easily compared with other series."

I shall now quote from my original paper the clinical notes of the cases upon which Dr. Barker's anatomical report is founded, indicating any omissions or additions by asterisks and brackets respectively. As Case XVIII was the one which first presented itself, the notes may appear somewhat unnecessarily full and circumstantial. In

¹I am inclined to attribute the pulse-rate noted by Dr. Bridge to emotional disturbance, because I have made

repeated examinations in the six cases under my care and found it only subject to normal variations.

6 DESCRIPTION OF BRAIN AND SPINAL CORD IN HEREDITARY ATAXIA

extenuation I beg to state that when the observations were made I felt I was, perhaps, exploring a new territory and naturally wished to establish the clinical landmarks as firmly as possible. To this end, with the kind co-operation of the family physician, Dr. R. L. James, I presented (happily) the two identical cases now under discussion in person before the Neurological Section of the American Medical Association at the 1892 meeting, in Detroit, where they were seen by some of the best-known representative neurologists of this country and by Dr. James Taylor, of London.

CLINICAL NOTES OF CASE XVIII, MADE IN MAY, 1891

A business man, thirty, single, of temperate habits, good family history, except that his mother became ataxic at about thirty-three, the disease progressing steadily until she died of tubercular diarrhoea at forty-eight. The patient was active and vigorous in every way until attacked by his present disease, being rather among the foremost in all athletic sports and school work. His attention was first attracted to this disease while he was working with a surveying party in Texas, and then it was noticed by others before he himself noticed it. At that time he was twenty years old, and the ataxy was manifested by a staggering gait, which was so marked that his chief thought him intoxicated; but now he recollects that at least two years before this, or when he was eighteen years old, the draughtsmen in the office where he worked complained that he rendered their desks or drawing boards so unsteady when he leaned against them that they could not well go on with their work; and he further distinctly remembers that on a certain occasion at about this time, when in company with other young men in the country, he was quite unable to read the large letters of an advertisement at a considerable distance, though each of his companions could read them with comparative ease. He feels confident that this comparative visual defect had not always existed.

I should say here that this patient has a good English education, and that his intellectual capacity is above the average, so that, notwithstanding his affliction, he would at the present time be justly regarded as a well-informed man. He feels quite certain, too—and in this he is corroborated by his older relatives who have had an opportunity of observing him closely—that at the age of fourteen, when his voice underwent the change incident to puberty, there appeared a gradually increasing defect in utterance; his speech was slower and his syllables less definite and distinct than formerly. The ataxy has always been much more pronounced if he was fatigued, and he now remembers that at the age of eighteen he could not walk in a straight line when very tired.

There has been some progressive loss of power in the legs from the first, but this has been insignificant throughout in comparison with the ataxy. As already stated, the ataxy was first noticed in the legs and has progressed more rapidly in them than in other situations. But it has been distinct in the arms from a very early period.

* * * * *
At no time has there been any pain or any other disturbance of sensation; neither has there been any muscular wasting, cramp, or trophic manifestations. The sphincters have not been affected, and the patient thinks sexual power has not been more impaired than can be attributed to the general decline in bodily weight and strength, which has gradually supervened in the past six years, the weight having fallen from 136 to 112 pounds in that period.

I should have stated that a tendency to choke [strangle] while eating has all along been a troublesome symptom.

* * * * *
For several years past vision has progressively failed, so that he could best read in a dim light.

THE PRESENT CONDITION

Patient is considerably emaciated, though he eats fairly and sleeps well. He is of medium size and well formed. The sensibility is normal; the knee-jerk is greatly exaggerated and equal on both sides; there is a slight ankle-clonus; the skin reflexes appear in the main normal, but the cremasteric and abdominal are not strongly pronounced. There is marked ataxia in nearly all voluntary movements; so that the patient can walk only when supported by an attendant, and can stand only when leaning against some solid support. Closure of the eyes does not materially increase his difficulty. The gait is such as would usually be described as cerebellar; the patient leans rather backward against his attendant and sways from side to side and all the time has an uncomfortable sense of insecurity, as if his head must fall backward to the ground. He experiences a distinct loss of power in the legs, which he thinks is even greater than could be accounted for by his general decline in bodily vigor, but the muscles are firm and well developed. All the voluntary muscular movements are slowly performed, and of this the patient is quite conscious. He cannot reach out his hand suddenly to seize any given object. The hand moves slowly and deviates several inches in various directions from the direct line that would normally be taken in such an effort. This tardiness of movement is readily noticed when the patient raises his eyes; on being addressed, or in winking, the eyelids will rise so slowly as to be suggestive of temporary ptosis, but in the end they are raised too high, so that the sclerotic is often so much exposed as to display an expression usually associated with some intense emotion, when in fact the patient is suffering from no emotional disturbance whatever. Though ataxy in the muscles that move the tongue would be difficult of conclusive demonstration, because the normal movements could hardly be definitely described (and the same might be said of the muscles that move the lips), yet a careful observer would see at a glance that the movement of both tongue and lips (especially the former in this case, because a full beard is worn) were far wider in range than usual. There is no difficulty in swallowing, excepting the tendency to choke already noticed, which might be explained by ataxy and tardiness of the muscles concerned, because no extraordinary effort has to be made, and there is no tendency for liquids to pass out through the nose.

There is a marked inco-ordination of the various muscles of facial expression, which is easily observed when the changes are going on incident to the discussion of an absorbing topic, the action being more marked now in this group of muscles and now in that, so that people casually meeting the patient frequently get the impression that there is some mental defect.

There is no spontaneous movement during sleep or waking repose, but a comparatively slight voluntary movement gives rise to very extensive and peculiar movements in muscles far removed from those required for the execution of the act. For instance, when the patient puts out his hand to take a book from a table beside which he may be sitting, the whole upper part of the body goes through a series of irregular movements highly suggestive of chorea. This is particularly the case with the head, which is somewhat inclined forward, moved from side to side, and the chin is protruded; and there is often an unassociated movement of the other hand. In none of these movements is there ever anything approaching a jerk.

OCULIST'S REPORT.²

Patient states that for ten years past he has suffered from some gradual impairment of vision and has had double vision at times, of not more than a few days' duration, but not for

²This case and five others of the series were thoroughly examined by Dr. W. F. Montgomery, Professor of Ophthalmology in the Woman's Medical College, whose reports I herewith append. And two of the less advanced cases (XIX

and XX) were minutely examined by Dr. Casey Wood, Professor of Ophthalmology in the Post-Graduate Medical School in this city.

8 DESCRIPTION OF BRAIN AND SPINAL CORD IN HEREDITARY ATAXIA

several years past. Examination shows marked ptosis when the patient is at rest, but by an effort he can raise the lids, showing sclerotic above the cornea when the eyes are directed in a horizontal plane. There is perfect co-ordination of the ocular muscles except to extreme right, where there is slight lagging of the external [lateral] rectus—not enough, however, for the production of diplopia; the lids and conjunctivæ are normal.

The pupils respond to light but very slowly; and the same is true of accommodation. Dilatation also occurs slowly on stimulation of the skin of the neck.

Vision is 20/200 in either eye. Snellen No. 5 can be read, though with difficulty, at eight inches in an ordinary light; much more easily in a dim light.

The ophthalmoscope shows a decided blanching of the optic discs and lessening of the caliber of the arteries, with slight but distinct atrophic changes in the retina.

There are only slight peripheral limitations of the field, and almost complete color-blindness, red only being distinguished with any degree of certainty.

[Articulation was very much affected, and in view of this fact I am greatly surprised that I did not call attention to it more explicitly in my original publication. By exercising much care and deliberation the patient was easily understood, but even then the labials were often indistinct; with less attention the articulation became somewhat confluent, with considerable elision in polysyllables. Forced utterance was conspicuous, owing, obviously, to inco-ordination between the muscles concerned in respiration, articulation, and phonation respectively.]

All the above-described symptoms advanced now more rapidly, now more slowly, up to the time of death, which occurred from simple exhaustion, emaciation having become extreme, and no intercurrent disease having been discovered either by ante- or post-mortem examination. For several days prior to death, the patient was unable to utter a sound or move a limb; the only evidence he gave that he heard what was said to him having been afforded by a slight movement of the brows.

For the last three years he had been unable to see well enough to read, but up to the end he could distinguish outlines of large figures under favoring conditions of light. The articulation had gradually failed, so that for a number of months it had been little more than a succession of grunts, intelligible only to his nurses, and vocal efforts almost invariably provoked paroxysms of coughing with distressing signs of strangulation. For fully a year before the end, and while he still had sufficient strength, he was unable to use table utensils in eating, and though he could support his weight on his legs, he could make no progress in walking on account of the extreme ataxia, even when assisted, and for more than a year had ceased making the attempt.

CLINICAL NOTES OF CASE XX,³ BROTHER OF CASE XVIII. MADE IN JUNE, 1891

Business man, twenty-four, single, well developed, cheerful disposition, and correct habits. General health always good. Did well in his studies at school and excelled in athletic sports. The ataxia appeared without exciting cause at the age of eighteen. The unsteadiness of gait and some uncertainty in use of the hands and difficulty of articulation came on together, and not until two years later was any visual defect realized. He has carried a cane for the last few months, but can walk fairly well without one, though deviating considerably from a straight line. He thinks his strength is in no way impaired, for only a few weeks ago he rode a successful tandem race with a brother who is not affected.

³Inasmuch as death occurred in this case in a comparatively early stage of the disease, both from my notes and from memory I have expanded and elaborated somewhat the record as first published. At that time it only appeared

necessary to identify the case so as to warrant its incorporation into the series. Now it is a question of correlating the anatomical findings with the symptoms.

EXAMINATION

The knee-jerks are markedly exaggerated and all other reflexes active. There is well-marked ataxia in all four extremities. All usual movements, however, can be performed, though with evidently increased deliberation and attention. When in repose the facial muscles are considerably relaxed, giving the patient a heavy and stolid expression, which is often quite at variance with the prevailing state of mind. But during conversation the expression is similar to that already noted in the preceding case.

OCULIST'S REPORT

There is marked static ptosis, greater in the left eye, with inco-ordinate overaction of the levator. All movements of the ocular muscles and all pupillary reflexes are sluggish. All are present, however, and in no event can nystagmus be produced. Vision is 20/80 in each eye, and Snellen No. 3 is read well enough at ten inches. Patient reads much better in a dim light. The average expert would pronounce the fundus normal, without knowing anything of the condition of vision. The color-sense is not much affected, and there is some peripheral limitation of the field of vision. All the negations mentioned in connection with the preceding case might be repeated in reference to this one.

The disease had progressed steadily and evenly, but not very rapidly, up to within fourteen months prior to death, which occurred in 1897, when symptoms of pulmonary tuberculosis made their appearance and advanced to a fatal termination. Apart from the weakness incident to the intercurrent disease, the patient was able to walk without assistance, feed and dress himself, read ordinary print, and easily make himself understood in conversation, up to the end. The knee-jerks were much more markedly exaggerated and ataxy of all voluntary movements were more pronounced than when the case was first reported. There was at no time any mental defect, diplopia, disorder of general sensation of the special senses, except vision, or the sphincters, nor was there any muscular atrophy or trophic changes.

If intercurrent disease had not intervened, it appears to me reasonable to assume that in a few years this case would have advanced to a condition of utter helplessness.

Incidentally Case XIX died from simple exhaustion within the present year, all the symptoms originally enumerated having greatly advanced and no new ones having been added.

A son of Case XVI has well-marked symptoms of the disease, which first appeared at the age of eighteen, five years before I examined him last year.

Many thanks are due Dr. R. L. James, of Blue Island, Ill.; the family of both patients, for reporting to me their condition from time to time, and for assisting at the autopsy in Case XVIII; and to Dr. C. L. Minor, of Asheville, N. C., for holding the autopsy in Case XX.

THE ANATOMICAL FINDINGS

The brain and cord of Case XVIII were hardened in Müller's fluid and sent in this from Chicago to Baltimore, where this study was begun. The tissues from Case XX were removed by Dr. Charles L. Minor; the mass of the brain and cord was hardened in formalin, but special pieces of tissue were prepared in a series of fixing reagents, at my suggestion. I wish here to express my sincere thanks to Dr. Minor for the care and fidelity with which he followed out all the details of these suggestions.

10 DESCRIPTION OF BRAIN AND SPINAL CORD IN HEREDITARY ATAXIA

The tissues of these cases represent material so rarely available that it has seemed to me desirable to put on record a rather full account of the general morphology of the specimens, so that other investigators, dealing with similar cases and wishing to compare them with these, may find in this article a sufficiently detailed description. For this reason a description, which might otherwise have seemed unnecessarily prolix, will be justified.

DESCRIPTION OF MORE ADVANCED CASE (CASE XVIII OF SANGER BROWN'S SERIES)

CEREBRUM OF CASE XVIII

HEMISPHERIUM DEXTRUM

(Figs. 3, 6, 7, 11)

FISSURA SYLVII.—Distance from ramus anterior horizontalis to ramus posterior ascendens, 5.5 cm. The ramus anterior horizontalis is 2 cm. long, reaching to within 0.8 cm. of the sulcus frontalis inferior. The ramus anterior ascendens is rudimentary in reality, though at first sight it would appear to be well marked. On close examination it is seen that what appears to be it is a sulcus which anastomoses above with the sulcus frontalis inferior, and superficially below with the fissure of Sylvius, though it does not cut through the opercular margin. The real ramus ascendens is situated just behind this and is scarcely visible from the surface. It makes a small incisure only between the pars opercularis and the pars triangularis of the gyrus frontalis inferior.

The fissure of Sylvius bifurcates behind into a ramus posterior ascendens 2.8 cm. long and a ramus posterior descendens 1.2 cm. long. A sulcus subcentralis posterior makes a superficial anastomosis with the fissura Sylvii behind, as does a sulcus subcentralis anterior in front of the central gyrus.

SULCUS CENTRALIS [ROLANDI].—The medial extremity stops 0.8 cm. short of the medial margin of the hemisphere, 1 cm. in front of the incisura sulci cinguli. The lateral extremity terminates in an obliquely placed basal piece 1.5 cm. long which runs parallel to the sulcus subcentralis anterior. In its upper part the sulcus is superficially connected with the pars medialis of the sulcus postcentralis. Otherwise it forms no anastomoses.

Relative length	7 cm.
Absolute length	8.4 cm.
Inclination of furrow with fissura longitudinalis cerebri	72°

Neither genu is well marked.

SULCUS PRÆCENTRALIS.—This is distinctly divided into a pars inferior, a pars superior, and a pars medialis.

Pars inferior.—This forms almost a semicircle with concavity backward. The lower extremity cuts deeply into the pars opercularis of the gyrus frontalis inferior, about midway between the sulcus diagonalis and the sulcus subcentralis anterior, ending 1 cm. from the fissura Sylvii. The upper extremity curves backward into the gyrus centralis anterior, just below the gyrus which connects the gyrus centralis anterior with the gyrus frontalis medius. A deep ramus anterior passes forward and upward into the gyrus frontalis medius. The pars inferior communicates superficially about its middle with the sulcus frontalis inferior, though a deep annectant gyrus separates the two sulci in the depth.

Pars superior.—Its lateral extremity begins in a short sagittal piece, placed just above the gyrus connecting the gyrus centralis anterior with the gyrus frontalis medius. The sulcus

extends transversally medialward for 3.2 cm., when it is interrupted by an annectant gyrus extending between the gyrus frontalis superior and the gyrus centralis anterior. At the junction of its upper and middle thirds this pars superior anastomoses with the sulcus frontalis superior in front.

Pars medialis.—A transverse sulcus, 2 cm. long, situated a little anterior to the upper part of the pars superior and parallel to it. It gives off a ramus sagittalis posterior, 2 cm. long, which cuts deep into the gyrus centralis anterior, reaching to within 0.7 cm. of the sulcus centralis. No part of the sulcus præcentralis reaches the medial margin of the hemisphere.

SULCUS FRONTALIS INFERIOR.—It begins behind in the pars inferior of the sulcus præcentralis, to extend forward for a distance of 2.4 cm., to be interrupted there by a superficial annectant gyrus extending from the pars triangularis of the gyrus frontalis inferior to the gyrus frontalis medius. It anastomoses below with the sulcus in the posterior part of the pars triangularis (false anterior ascending ramus of the Sylvian fissure). At its termination behind the annectant gyrus mentioned, it turns upward to anastomose with one of the segments of the sulcus frontalis medius. In front of the annectant gyrus is a transversal sulcus 2 cm. long, the lower part of which bisects the pars triangularis. This is probably to be regarded as the sulcus radiatus of Eberstaller. Running sagittally forward from its middle and curving around the gyrus between it and the upper extremity of the ramus horizontalis of the Sylvian fissure is a sulcus which ends in front in another obliquely placed transversal sulcus, which is to be regarded as the lateral segment of the sulcus frontomarginalis of Wernicke.

SULCUS FRONTALIS SUPERIOR.—It begins behind in the pars superior, 2.8 cm. from the medial margin of the hemisphere. It passes forward for 3.3 cm., where it is crossed almost at right angles by a transversal sulcus connected with the complex of the sulcus frontalis medius. The sulcus here makes a slight jog lateradward and is continued for 2 cm. farther forward, when it turns sharply medialward to end 1.4 cm. from the medial margin of the hemisphere. In front of it, between it and the medial limb of the sulcus frontomarginalis, are two more or less transversally placed compensatory sulci. At the point where it turns medialward, the sulcus frontalis superior anastomoses with a transversal sulcus which is one segment of the sulcus frontalis medius.

SULCUS FRONTALIS MEDIUS.—Instead of the typical sagittal sulcus, so frequently met with, this hemisphere shows two transversally placed sulci, a sulcus transversus frontalis posterior and a sulcus transversus frontalis anterior such as Tenchini and Mingazzini describe. The former anastomoses above with the sulcus frontalis superior and ends below close to the sulcus frontalis inferior; the latter anastomoses above with the sulcus frontalis superior, sends a short anterior sagittal ramus into one of the compensatory sulci in front of the sulcus frontalis superior, and lateralward bifurcates. The superior limb of bifurcation runs backward behind the gyrus frontalis medio-inferior to anastomose with the sulcus frontalis inferior, the anterior limb terminating in the gyrus frontalis medius.

SULCUS CINGULI.—It is of the "continuous" type, there being no subdivision into pars anterior, pars intermedius, and pars posterior. It begins in front below the genu corporis callosi, the gyrus fornicatus intervening, but it does not reach as far as the "carrefour" of Broca. It runs more or less parallel to the corpus callosum, and leaves everywhere between it and that structure a broad gyrus cinguli. Behind the lobulus paracentralis it curves upward to the margin of the hemisphere and cuts into the facies convexa for a distance of 1.2 cm. It gives off two deep radial rami into the medial surface of the gyrus frontalis superior; one, a little behind the level of the sulcus frontomarginalis, reaches the medial margin of the hemisphere and extends for a few mm. upon the facies convexa; the other, 1.5 cm. in front of the level of the pars superior of the sulcus præcentralis, just reaches the medial margin of the hemisphere.

12 DESCRIPTION OF BRAIN AND SPINAL CORD IN HEREDITARY ATAXIA

SULCUS OLFACTORIUS.—It is situated entirely upon the orbital surface and presents no unusual features.

SULCI ORBITALES.—The ramus lateralis and ramus intermedius are two long, deep furrows running nearly parallel to each other throughout almost the entire extent of the orbital surface. The sulcus orbitalis transversus is interrupted by them behind. In front of their anterior extremities is a curved transversal compensatory sulcus situated just at the margin of the orbital surface. The ramus medialis is but feebly developed. The medial part of the sulcus orbitalis transversus is deep.

ACCESSORY SULCI OF LOBUS FRONTALIS:

1. *Sulcus diagonalis operculi.*—1.8 cm. long; situated in the pars opercularis of the gyrus frontalis inferior. It forms no anastomoses.

2. *Sulcus fronto-marginalis of Weierstrass.*—It is entirely separated from segments of the sulcus frontalis medius, and is represented by a Y-shaped sulcus complex, the stem of the Y being directed backward into the gyrus frontalis medius. The medial limb of the Y runs almost transversally toward the medial margin of the hemisphere, and near it undergoes tripartite subdivision. The lateral limb of the Y passes sagittally forward and also divides into three parts, the middle branch cutting into the orbital surface. The most lateral segment of the sulcus has been described along with the sulcus frontalis inferior of the sulcus radiatus.

3. *Sulcus frontalis medialis.*—This sulcus has two well-marked sagittal segments. The more posterior, 1.7 cm. long, ends anteriorly in a transversal piece 1.5 cm. long. The more anterior segment is 2 cm. in length, and gives off a short medial and a short lateral ramus. In front of it, between it and the sulcus transversus frontalis anterior of the sulcus frontalis medius, is a short compensatory transversal sulcus. The ramus posterior of the pars medialis of the sulcus precentralis is almost in a line with the sagittal segment of the sulcus frontalis medius.

4. *Sulcus rostralis.*—A deep, well-marked sulcus running for some distance parallel to the anterior part of the sulcus cinguli. It then turns forward and runs to the medial margin of the hemisphere, to anastomose there with one of the branches of the tripartite subdivisions of the medial segment of the sulcus fronto-marginalis. There is no sulcus rostralis inferior. Between the two radiating arms of the sulcus cinguli is a long, deep, sagittal sulcus on the medial surface of the gyrus frontalis superior. It gives off a number of short rami into the substance of the gyrus.

SULCUS PARACENTRALIS.—About the middle of the lobus paracentralis a vertical ramus from the sulcus cinguli cuts into the substance for a distance of 1.5 cm. In front of this there is a J-shaped depression and behind it a V-shaped depression in the surface.

SULCUS INTERPARIETALIS:

1. *Sulcus postcentralis.*—This sulcus is divided into three segments: (a) a pars inferior, (b) a pars intermedius, (c) a pars superior.

The *pars inferior* is an oblique segment 2.5 cm. long, cutting into the gyrus supramarginalis above, and slightly into the gyrus centralis posterior below. Near its lower extremity it anastomoses with the well-marked sulcus subcentralis posterior of Marchand.

The *pars intermedius* 3.3 cm. long, runs almost parallel to the sulcus centralis. It is limited below by a gyrus connecting the gyrus supramarginalis with the gyrus centralis posterior. Above, it cuts into the gyrus centralis posterior, and a little above its middle it anastomoses with, or gives rise to, the sulcus interparietalis proprius.

The *pars superior* is curved somewhat like the letter S. Its medial extremity is situated behind the incisura sulci cinguli and reaches to within 0.7 cm. of the margin of the hemisphere. The sulcus is markedly convex forward about its middle. Just below this convexity, a short

sagittal sulcus, cutting across the gyrus centralis posterior, connects the pars superior with the upper part of the sulcus centralis.

2. *Sulcus interparietalis proprius*.— It begins a little above the middle of the pars Intermedius of the sulcus postcentralis, and extends in a curve backward and medialward to terminate 0.5 cm. in front of the anterior limb of the U formed by the sulcus paroccipitalis. At the junction of its middle and posterior thirds it gives off a ramus medialis which extends to the margin of the hemisphere, and makes an anastomosis with one of the sulci in the præcuneus. This ramus medialis gives off a short sagittal branch which passes forward and accounts for the marked anterior convexity of the middle of the pars superior of the sulcus postcentralis. Below the sulcus interparietalis proprius anastomoses with the sulcus Intermedius primus of Jensen and also gives off (a) a ramus which runs into the gyrus supramarginalis to end blindly in that gyrus, and (b) a ramus which extends into the gyrus angularis, passes through it running almost parallel to the sulcus Intermedius primus, to anastomose with the sulcus temporalis superior.

3. *Sulcus paroccipitalis of Wilder*.— It is entirely separated from the rest of the sulcus interparietalis and forms the usual U around the portion of the fissura parietooccipitalis which cuts into the facies convexa. The medial extremity of the anterior limb of the U reaches to within 0.5 m. of the margin of the hemisphere. From the latter extremity of this limb a ramus sagittalis anterior is given off, which runs forward for 1.3 cm., "overlapping the posterior extremity of the sulcus interparietalis proprius." The posterior limb of the U bifurcates as it approaches the margin of the hemisphere. It forms no anastomosis with the sulcus occipitalis transversus.

SULCUS PARIETALIS SUPERIOR.— This sulcus runs nearly transversally on the facies convexa, being situated between the anterior limb of the U of the sulcus paroccipitalis behind and the ramus medialis of the sulcus interparietalis proprius in front. Its lateral extremity is curved a little forward. Medialward it runs to the margin of the hemisphere and anastomoses with sulci on the surface of the præcuneus.

SULCUS SUPAPARIETALIS.— This sulcus is represented by two segments. The anterior segment anastomoses in front with the sulcus cinguli and behind turns up and anastomoses with a vertical sulcus præcuneal. The posterior segment is shallow and irregular. It is limited behind by a gyrus which connects the posterior part of the præcuneus with the gyrus cinguli.

SULCI PRÆCUNEI.— The præcuneus presents three sulci— one anterior vertical sulcus and two antero-posterior sulci. The anterior vertical sulcus anastomoses below with the anterior segment of the sulcus subparietalis; it runs backward and upward to the margin of the hemisphere to form a superficial anastomosis with the ramus medialis of the sulcus interparietalis proprius. The two antero-posterior sulci divide the part of the præcuneus behind the vertical sulcus into three parallel gyri. The uppermost antero-posterior sulcus anastomoses at its anterior extremity with the sulcus parietalis superior which is continued upon the medial surface of the hemisphere.

FISSURA PARIETOOCIPITALIS.— Distance from medial margin of hemisphere to anastomosis with fissura calcarina, 3 cm.; extent upon facies convexa, 2.2 cm. On the medial surface near its upper part it anastomoses with the upper antero-posterior surface of the præcuneus. This corresponds to an anastomosis with a sulcus on the superficies posterior lobi parietalis of the brother's brain. This brain has been hardened in Müller's fluid, and the fissura cannot be opened so as to permit of the examination of the posterior surface of the parietal lobe.

FISSURA CALCARINA:

Length of truncus	3.5 cm.
Length of fissura propria	3.3 cm.

14 DESCRIPTION OF BRAIN AND SPINAL CORD IN HEREDITARY ATAXIA

It anastomoses behind with a sulcus which passes downward, cutting off a portion which otherwise would be a part of the gyrus lingualis between it and the *polus occipitalis*.

SULCUS OCCIPITALIS TRANSVERSUS.—Above, it begins 4 mm. behind the posterior limb of the sulcus paroccipitalis, but is completely separated from it. It passes transversally downward and a little backward to anastomose with a sulcus running at right angles to it.

SULCI OCCIPITALEA SUPERIORES.—The surface is marked by slight depressions: there are no definite sulci.

SULCI OCCIPITALEA LATERALES.—There is one lateral sulcus, running from a point just above the *polus occipitalis* forward and downward to the inferior surface of the hemisphere, there to form the postero-lateral limb of the H-shaped sulcus complex. Behind the lower part of the sulcus occipitalis transversus a short sulcus runs backward and downward (almost at right angles to the course of the sulcus occipitalis transversus).

SULCUS TEMPORALIS SUPERIOR.—It begins in front and a little below the *polus temporalis* and runs backward. The gyrus temporalis superior is very narrow, averaging less than 1 cm. in thickness. The sulcus curves downward in its posterior part, owing to the ramus posterior descendens of the Sylvian fissure. Behind this region it again runs backward for a distance of 2 cm. and then turns sharply upward, curves a little forward and ends by anastomosing above with the sulcus interparietalis. In this part of its course, the sulcus runs almost parallel to the sulcus intermedialis primus of Jensen, and between the two is a transversally placed gyrus, cut off from the anterior portion of the gyrus angularis.

SULCUS TEMPORALIS MEDIUS.—The brain has been a long time in Müller's fluid and has become brittle. Portions of the surface in the region of the sulcus temporalis medius have been broken off, and the details with regard to this sulcus are obscured. It appears to run sagittally backward for a distance of about 6 cm. and then to be interrupted. The sulci in the lobulus parietalis inferior are well preserved, as are those in the posterior portion of the temporal lobe. The arrangement is peculiar. Behind the terminal part of the sulcus temporalis superior and below the sulcus interparietalis and in front of the sulcus occipitalis transversus is a large, more or less triangular area of brain surface. Within it is a Y-shaped sulcus complex, the stem of the Y (below) corresponding in all probability to a segment of the sulcus temporalis medius (Eberstaller), *i. e.*, to Wernicke's sulcus occipitalis anterior. The anterior limb of the Y corresponds to the continuation of the stem and represents the sulcus about the extremity of which the gyrus angularis winds. The posterior limb of the Y is the sulcus about which the lobulus parietalis posterior inferior is situated. Cutting into the middle of the area from above is a short descending ramus from the sulcus paroccipitalis. This appears to be the representative of Eberstaller's sulcus intermedialis secundus, as it separates the gyrus angularis in front from the lobulus parietalis posterior inferior behind.

SULCUS TEMPORALIS INFERIOR.—It begins in front 2.4 cm. behind the *polus temporalis*, is a shallow sulcus, and is interrupted by a gyrus which connects the gyrus temporalis inferior with the gyrus fusiformis. Behind, a segment runs on the inferior surface for a distance of 4 cm.; opposite, about the middle of this segment, is the incisura formerly called the incisura præoccipitalis. It leads into an H-shaped sulcus complex in the lower part of the temporal lobe. The posterior superior limb of this complex passes upward and anastomoses with a sagittal sulcus which runs forward from the lower end of the sulcus occipitalis transversus to cut deep into the gyrus temporalis medius.

FISSURA COLLATERALIS.—It begins close behind the fissura rhinea, which is here only a shallow incisure and does not communicate with it. Its greatest convexity medialward corresponds to the insertion of the tip of the gyrus lingualis into the gyrus hippocampi. Around its posterior extremity an annectant gyrus passes from the gyrus lingualis to the gyrus fusiformis.

The gyrus lingualis is irregularly grooved by three sulci. The largest begins near the angle of junction of the fissura calcarina with its truncus and runs downward and backward, and then lateralward, to form the posterior inferior limb of the H-shaped sulcus complex referred to at the posterior part of the temporal lobe. Passing out of this sulcus, and at right angles to it, are two shallow sulci which anastomose in front with the posterior part of the fissura collateralis.

HEMISPHERIUM SINISTRUM

(Figs. 4, 5, 6, 9, 10)

FISSURA CEREBRI LATERALIS (SYLVII).—The ramus anterior ascendens and the ramus anterior horizontalis come off from the main fissure by a common stem 1.4 mm. long. This stem bifurcates, and the ramus posterior horizontalis proper is 1.3 mm. long. The ramus anterior ascendens is 1.6 mm. long. The pars triangularis of the gyrus frontalis inferior is thus diminutive. This appears to be in part due to the very marked development of the sulcus diagonalis which cuts very deep into the pars opercularis and the lower part of the latter is driven deep into the fossa Sylvii.

SULCUS CENTRALIS.—The lateral extremity anastomoses with a very well marked sulcus subcentralis anterior. The latter is 2 cm. long and makes a superficial anastomosis below with the fissure of Sylvius.

Cutting into the operculum from in front in a direction at right angles to the sulcus subcentralis anterior is a little sulcus which does not appear to have been hitherto described. It is situated just below the insertion of the root of the gyrus frontalis inferior into the gyrus centralis anterior.

The sulcus centralis presents about its middle a knee projecting forward, due to an incisure into the gyrus centralis posterior from the sulcus postcentralis.

A second small knee, due to a similar cause, is seen 1.5 cm. from the medial margin of the hemisphere. The medial extremity of the sulcus reaches just to the medial margin of the hemisphere and does not pass over upon the facies medialis.

Inclination of sulcus centralis to fissura longitudinalis cerebri	70°
Relative length	7.7 cm.
Absolute length	9.7 cm.

Other than that with the sulcus subcentralis anterior, the sulcus centralis forms no anastomoses.

SULCUS PRÆCENTRALIS.—This presents for examination three portions: a pars inferior, a pars superior, and a pars medialis.

1. *Pars inferior.*—This forms an X-shaped complex, the anterior superior limb of the X being the ramus anterior of Eberstaller, the posterior inferior limb a ramus posterior passing beneath the insertion of the root of the gyrus frontalis medius into the gyrus centralis anterior. The other two limbs of the X represent the main direction of the sulcus. The latter is 4 cm. long, the ramus anterior 2 cm. long, and the ramus posterior 1.3 cm. long. The pars inferior anastomoses near its lower part with the sulcus frontalis inferior.

2. *Pars superior.*—It is 2.8 cm. long and "overlaps" the upper part of the pars inferior in the greater part of its extent, being situated behind it and separated from it by a superficial gyrus, a part of the gyrus frontalis medius. Near its upper or medial extremity it gives origin to the sulcus frontalis superior which passes forward at right angles to it. Its medial extremity is separated from the pars medialis by an annectant gyrus which connects the gyrus frontalis superior with the gyrus centralis anterior.

3. *Pars medialis.*—It consists of an obliquely placed H-shaped sulcus complex, situated between the medial extremity of the pars superior and the medial margin of the hemisphere.

16 DESCRIPTION OF BRAIN AND SPINAL CORD IN HEREDITARY ATAXIA

The cross-bar of the H is the continuation of the general direction of the sulcus præcentralis. The medial extremity of the posterior side-bar of the H just reaches the medial margin of the hemisphere.

SULCUS FRONTALIS INFERIOR.—This begins behind in the pars inferior of the sulcus præcentralis and passes forward between the gyrus frontalis medius and the gyrus frontalis inferior. About the middle of the pars opercularis it anastomoses with a very pronounced sulcus diagonalis operculi. Beyond this point the sulcus curves upward and forward to end in the gyrus frontalis medius. Running out of it near its extremity is a sulcus which winds around the gyrus projecting upward owing to the ramus anterior horizontalis of the fissura Sylvii. This sulcus passes downward and forward to terminate in a transversal sulcus—the lateral limb of the sulcus frontomarginalis (*fm₁*). In the gyrus frontalis medius, opposite the ramus anterior horizontalis of the Sylvian fissure, is a short, slightly curved transversal sulcus which probably represents the sulcus radiatus of Eberstaller on this side.

SULCUS FRONTALIS SUPERIOR.—It begins near the upper part of the pars superior of the sulcus præcentralis, 3.2 cm. from the medial margin of the hemisphere; it passes forward and undergoes a jog, where it is crossed by a deep transversal sulcus of the gyrus frontalis superior. It is then continued forward and medialward to within 1 cm. of the medial margin, when it suddenly curves around lateralward to terminate very close to the sulcus frontalis medius, but without actually anastomosing with the latter. This deflection of the extremity is apparently due to a deep incisure into the facies convexa from the medial margin just in front of it.

SULCUS FRONTALIS MEDIUS.—This is divided into two segments. The more posterior is situated in the gyrus frontalis medius, in front of the ramus anterior of the pars inferior of the sulcus præcentralis. It is 3 cm. long and runs obliquely from behind and below, forward and upward. It gives off two incisures into the brain tissue in front of it.

The anterior segment is separated from the posterior segment by a gyrus connecting the pars medialis of the gyrus frontalis medius with the pars lateralis. It begins behind in a curved transversal basal piece and extends sagittally forward for a distance of 1.5 cm. when it bifurcates to form the middle and medial segments of the sulcus fronto-marginalis (*fm₂*, *fm₁*).

SULCUS CINGULI.—It begins 0.8 cm. behind the carrefour of Broca. It is nowhere interrupted. Behind it ends in an unusual way, reaching the margin of the hemisphere at a point 2.3 cm. behind the sulcus centralis. It does not pass for more than 2 mm. upon the facies convexa. Intercalated between this incisure sulci cinguli and the sulcus centralis is the pars superior of the sulcus postcentralis. The sulcus cinguli in its course gives off a number of radiating sulci which pass toward the margin of the hemisphere and into the substance of the gyrus frontalis superior.

SULCUS OLFACTORIUS.—This is situated entirely on the orbital surface and presents no peculiarities.

SULCI ORBITALES.—These are very irregular. The sulcus orbitalis transversus of Weisbach is represented in its medial half by short, obliquely placed segments, entirely separated from one another. In its lateral half it is continued deep and extends almost to the Sylvian margin of the orbital operculum.

The ramus lateralis and ramus intermedius go out from the sulcus orbitalis transversus at the same point. The ramus medialis is short and is independent of the sulcus orbitalis transversus.

ACCESSORY SULCI OF THE LOBUS FRONTALIS:

1. *Sulcus diagonalis operculi.*—This is very deep, and its lateral extremity together with the lower part of the whole pars opercularis of the gyrus frontalis inferior tends to be sunk into the depth of the fossa Sylvii, and to be partially hidden from view by the overlapping lobus temporalis. The sulcus anastomoses above with the sulcus frontalis inferior.

2. *Sulcus radiatus*.—*Vite supra*.

3. *Sulcus frontomarginalis* (*Wernicke*).—It consists of three segments—medial, middle, and lateral—of which the last named is independent of the other two. This lateral segment (*fm₃*) forms the basal terminal piece of the sulcus which behind is continuous with the sulcus frontalis inferior. The medial (*fm₁*) and middle (*fm₂*) segments represent the limbs of bifurcation of the sulcus frontalis medialis. The medial segment reaches to the medial margin of the hemisphere, and the middle segment extends to within 0.7 of the lateral isolated segment.

4. *Sulcus frontalis medialis*.—There are no sagittal segments whatever to the sulcus. Instead, there are five obliquely transversal segments.

5. *Sulcus rostralis*.—This is well developed. It begins behind in Broca's curve-four and follows a course nearly parallel to the margin of the hemisphere, terminating above at the medial margin, 4 mm. behind the medial limb of the sulcus frontomarginalis.

Below the frontal pole another sulcus, representing in all probability the sulcus frontalis inferior, begins, extending for 2 cm., upon the medial surface of the hemisphere, then turns upon the facies orbitalis and runs obliquely forward and lateralward, to end in the anterior part of that surface.

SULCUS PARACENTRALIS.—The lobulus paracentralis presents a U-shaped sulcus. The base of the U and its anterior limb are deep; the posterior limb of the U is very shallow.

SULCUS INTERPARIETALIS:

1. *Sulcus postcentralis*.—This consists of three segments—inferior, middle, and superior. The inferior segment is only 1.5 cm. long, and about its middle anastomoses with the sulcus retrocentralis transversus of Eberstaller, behind it.

The middle portion is 1 cm. long and anastomoses near its upper part with the sulcus interparietalis proprius. One and a half cm. above its lower end it gives off a ramus sagittalis anterior which cuts deep into the gyrus centralis posterior, and causes a knee in the sulcus centralis.

The superior or medial segment begins 2 cm. from the medial margin of the hemisphere and extends to the margin between the sulcus centralis and the incisura sulci cinguli. Its lateral extremity curves forward into the gyrus centralis posterior. About its middle it gives off a ramus posterior which acts as a compensatory sulcus for the incisura sulci cinguli on the facies convexa.

2. *Sulcus interparietalis proprius*.—It begins in the upper part of the middle portion of the sulcus postcentralis, and follows a tortuous course backward and medialward. Behind it forms a superficial anastomosis with the U described by the sulcus paroccipitalis. About midway in its course it gives off a ramus caudalis which runs medialward and forward toward the medial part of the sulcus postcentralis. The sulcus intermedius primus of Jensen passes lateralward from it between the gyrus supramarginalis and the gyrus angularis.

3. *Sulcus paroccipitalis*.—This sulcus forms the usual U about the fissura parietooccipitalis of the facies convexa. The anterior limb of the U reaches the medial margin of the hemisphere; the posterior limb of the U does not. The posterior limb of the U, together with a sulcus running lateralward from its junction with the foot of the U, makes the sulcus occipitalis transversus.

SULCUS PARIETALIS SUPERIOR.—It anastomoses at the medial margin of the hemisphere with the sulcus præcunei.

SULCUS SUBPARIETALIS.—This sulcus is separated from the sulcus cinguli in front by a gyrus 1.4 cm. wide connecting the præcuneus with the gyrus cinguli. It curves backward and downward but is separated behind from the fissura calcarina by a gyrus which connects the præcuneus with the gyrus cinguli.

18 DESCRIPTION OF BRAIN AND SPINAL CORD IN HEREDITARY ATAXIA

SOLCI PRÆCUNEI.—A vertical sulcus præcuneus anastomoses at the medial margin with the sulcus parietalis superior. It extends downward upon the medial surface to within 0.8 cm. of the sulcus subparietalis. Turning around its lower extremity between it and the sulcus subparietalis is a gyrus arcuatus. This gyrus is bounded in front and behind by two vertical sulci præcuneus which anastomose below with the sulcus subparietalis and extend to within about 1 cm. of the medial margin of the hemisphere.

FISSURA PARIETOCIPITALIS.—Distance from medial margin of hemisphere to anastomosis with fissura calcarina, 3.8 cm. Near the medial margin the fissura undergoes tripartite subdivision, one branch passing forward and running along the medial margin of the præcuneus (corresponding to the sulcus on the posterior surface of the parietal lobe of the brother's brain), a second limb cutting backward for 0.5 cm. into the facies convexa (on the anterior surface of the occipital lobe), and the third limb passing transversally upon the facies convexa. There is thus left a pyramidal depression at the margin of the hemisphere at the junction of the occipital and parietal lobes where no brain substance exists.

FISSURA CALCARINA:

Length of truncus	3.2 cm.
Length of fissura propria	3.7 cm.

At a point 1.2 cm. from the margin of the hemisphere the fissura undergoes tripartite subdivision, the upper limb passing into the cuneus, the lower into the gyrus lingualis, and the middle (the continuation of the fissura propria) passing to the medial margin to anastomose there with a sulcus occipitalis lateralis.

SULCI OCCIPITALES SUPERIORES.—Behind the sulcus occipitalis transversus, and medialward from it is a transversal sulcus, short but deep, which reaches as far as the margin of the hemisphere. A second superior sulcus appears as a "commissure" sulcus posterior to the lateral extremity of the sulcus occipitalis transversus.

SULCI OCCIPITALES LATERALES.—There are three shallow occipital sulci on the lateral surface of the occipital lobe.

SULCUS TEMPORALIS SUPERIOR.—It is interrupted opposite the sulcus subcentralis anterior by a gyrus temporellus medio-superior and farther back by a second similar gyrus. The gyrus temporellus superior is narrow, being 0.8 to 1 cm. in width.

SULCUS TEMPORALIS MEDIUS.—The brain has been injured on this side, so that no satisfactory description of this sulcus is possible.

SULCUS TEMPORALIS INFERIOR.—It begins in front near the polus temporalis and passes backward, superficially interrupted, to reach the junction of the inferior with the lateral surface at the so-called incisura præoccipitalis. It then turns upward and backward upon the facies convexa; a superficial sulcus connects the sulcus temporalis medius with the sulcus temporalis inferior in this region.

FISSURA COLLATERALIS.—It begins in front, behind the fissura rhinea, and passes backward, being markedly convex medially. It terminates behind at the junction of the inferior with the convex surface of the hemisphere, about 2 cm. behind the point where the sulcus temporalis inferior passes to the convex surface. The gyrus lingualis presents no typical sagittal sulcus, but instead is irregularly subdivided by two sulci which run across the gyrus at right angles to its longest diameter.

THE CEREBELLUM (CASE XVIII)

(Figs. 1, 2, 25)

This organ looks normal in size and shape. It was divided into sagittal slabs, and sections from each of these were stained by Weigert's method. A sagittal section in the median plane is

illustrated in Fig. 25. The drawing was kindly made for me by my associate, Dr. D. G. Revell. The lingula cerebelli is not well preserved and is schematically illustrated.

The lobulus centralis, though well developed, is not very long in its vertical diameter. It does not enter into the formation of the *facies superior cerebelli*. There are seven *Randwülste* on its anterior surface and five on its posterior surface.

The monticulus, subdivided into culmen and declive, is well developed. As in the brain of the brother, the lobus intermedius (between the lobulus centralis and the first part of the culmen) is unusually well developed. Compare Figs. 25 and 26, with Stilling's Fig. 122. From the vertical limb of the arbor vitæ there are eight offshoots, corresponding to Stilling's C¹ to C⁸ (Stilling's *erste bis achte Wände*), while from the horizontal limb of the arbor vitæ come off the projections corresponding to Stilling's C⁹ to C¹⁶ (Stilling's *vierte bis sechste Wände*). There would seem to be no marked alteration in the number and character of the *Randwülste* on the different *Wände*, though perhaps the depressions between them are rather shallower than normal. The deep slit between the culmen and the declive is continuous lateralward with the sulcus which separates the *pars anterior* from the *pars posterior* of the lobulus quadrangularis. The folium vermis comes off from a terminal offshoot of the horizontal portion of the arbor vitæ, in relation to the lowermost portion of the declive.

The tuber vermis, well developed, is arranged around one principal stem of the arbor vitæ, which bifurcates into two main subdivisions.

The pyramis, as is usual, has a single stem of arbor vitæ which bifurcates near the periphery of the vermis inferior.

The uvula is large and well developed; it seems macroscopically quite normal.

The nodulus is perhaps relatively a little small, but otherwise presents normal appearances.

The hemispheres are well developed; the individual parts show the normal characteristic macroscopic arrangement.

MICROSCOPICAL EXAMINATION OF CASE XVIII

All the tissue was hardened in Müller's fluid, and the microscopical examination has therefore been practically limited to the study of Weigert preparations, and carmine specimens.

MEDULLA SPINALIS

PARS LUMBALIS (Fig. 44):

DIMENSIONS

Antero-posterior diameter	0.7 cm.
Transverse diameter	0.94 cm.

Radices anteriores et posteriores.—These are small and contain fewer fibers than normal. The connective tissue of the endoneurium is increased in amount. In the anterior roots a very large proportion of the fibers are small. The number of large fibers appears to be diminished.

Pia mater.—This is thickened, as in the other case, measuring as much as 0.159 mm. in thickness in places.

Subpial layer of neuroglia or so-called "glial sheath."

Maximum thickness opposite anterior horn	0.045 mm.
Maximum thickness opposite funiculus lateralis	0.2 mm.
Average thickness over funiculus posterior near medial line	0.061 mm.
Average thickness over funiculus posterior near entrance of posterior root	0.063 mm.
Maximum thickness over Lissauer's fasciculus	0.133 mm.

Sections stained with Weigert's myelin sheath stain and with iron hæmatoxylin stain.—The tissue does not stain satisfactorily, owing to imperfect hardening. There is no difficulty, however, in coming to a decision as to the state of the various fasciculi.

The different fasciculi of the funiculi anteriores and of the funiculi laterales present no areas of degeneration. The only alterations noticeable in these preparations are met with in the funiculi posteriores. Here there is tolerably symmetrical degeneration of both funiculi. The lightening corresponds in general to the area designated by Flechsig as the "middle root zone." The degeneration is most marked in the middle of the dorsal funiculus at a level drawn through the substantia gelatinosa of the two sides. It extends dorsalward, but leaves Flechsig's dorsal root zone unaffected, the latter sending a triangular process in between the degenerated area and the posterior median septum on each side. Ventralward the degeneration extends almost to the substantia grisea, but the white matter of the dorsal funiculi nearest the gray matter (corresponding to Flechsig's ventral root zone) is less affected. Though the number of fibers is greatly diminished in the lightened areas, the degeneration is only partial. Nowhere have all the fibers disappeared. The lightening is due to the disappearance of a portion of the medullated fibers and to a corresponding increase in the neuroglia. The distribution of the lesion is well shown in Fig. 44.

The gray matter, as a whole, looks less voluminous than normal; the substantia gelatinosa is less deep than in healthy specimens. A section at the level of T XII was kindly measured by Professor H. H. Donaldson, who found the area of the white matter 9.375 cu.² and the area of the gray matter 2.186 cu.², the ratio being 1:4.3.

Sections stained with Van Gieson's preparations and with uranium carmine.—The excessive connective tissue in the anterior and posterior roots and in the pia mater is collagenous, white, fibrous tissue staining intensely in acid fuchsin. In the degenerated area in the funiculus posterior the neuroglia is seen to be diffusely increased and stained of a pink or rose-red color, single yellow myelin sheaths or small groups of myelin sheaths standing out sharply on account of their isolation. There is a tendency to the formation of stripes of neuroglia, radiating dorso-medialward from the dorso-medial surface of the substantia grisea of the cornua posteriores. The blood-vessels are larger in these glia bands, and many of them have unusually distinct fibrous tissue coats which stain in acid fuchsin. The fibers which remain undegenerated in the area in which the neuroglia is increased vary in size. I got the impression, however, that the finer fibers of the area have suffered more than the coarser fibers from the disease-process.

The anterior horn cells appear to be reduced somewhat in number. The methods employed do not permit of any satisfactory description of the internal morphology of these cells. The central canal is obliterated, its place being taken by an irregular aggregation of proliferated ependymal cells.

PARS THORACALIS (UPPER PART) (Fig. 43).—The cord has been injured somewhat on removal, but the effects of the injury can be easily distinguished, so that there is no doubt as to the actual changes in the tissues.

MEASUREMENTS

Antero-posterior diameter	6 mm.
Transverse diameter	7.5 mm.

The pia mater is thickened as in the lumbar region. The subpial neuroglia layer is in general delicate in the pars thoracalis.

Sections stained with Weigert's myelin sheath stain or with iron hæmatoxylin.—The anterior and posterior roots are small and the connective tissue is exaggerated in them, though not so markedly as in the roots of the lumbar nerves.

There are no degenerated areas visible in the funiculi anteriores.

The funiculi laterales present marked alterations. On each side the direct cerebellar tract of Flechsig is almost completely degenerated. Only here and there can a fiber of large caliber be made out in the area corresponding to this fasciculus. A good many fine fibers are visible in that portion of the area immediately adjacent to the main part of the pyramidal tract, but these are doubtless themselves fibers of the pyramidal tract which are normally mixed in with the fibers of the direct cerebellar tract. This marked area of degeneration of the direct cerebellar tract is situated as always in the dorso-lateral portion of the funiculus. The ventro-lateral region of the funiculus shows no distinct area of lightening, though the large fibers of that region seem to be less numerous than normal. It is therefore probable that the ventro-lateral cerebellar tract of Gowers has suffered some, though the chief lesion in the funiculi laterales is undoubtedly an extensive degeneration of the dorso-lateral direct cerebellar tract of Flechsig.

The pyramidal tract is not degenerated, nor can I make out any alteration in the fasciculus lateralis proprius.

In the funiculi posteriores there are some partial degenerations tolerably definitely localizable. The partial degeneration assumes approximately the shape of the letter W. The lateral limbs of the W correspond to regions in the funiculi cuneati of the two sides; the medial limbs, to the regions in the fasciculi graciles of the two sides. The degeneration is fairly symmetrical. That in the fasciculus cuneatus of each side occupies a rather broad strip corresponding to about one-third of the width of the fasciculus at its broadest part (opposite the substantia gelatinosa). Dorsalward the strip becomes narrower and ceases at some little distance from the dorsal periphery. Ventralward the degenerated area in the fasciculus cuneatus approaches the median line and fuses with that of the fasciculus gracilis. Though this degeneration passes far ventralward, almost to the substantia grisea, it does not quite reach the latter. Flechsig's ventral root zone remains almost entirely undegenerated. A strip of some breadth intervenes lateralward from the degenerated area between it and the substantia grisea of the dorsal horn.

In the fasciculus gracilis the degenerated strip is narrow; rather fusiform, and more medially than laterally situated. The strip is widest and the degeneration in it most intense about midway between the dorsal periphery and the ventral extremity of the fasciculus. The degenerated area does not extend dorsalward as far as the posterior surface, but growing gradually less distinct, terminates at some distance from this. Ventralward the strip fuses laterally on each side with the degenerated strip in the fasciculus cuneatus.

It will be noticed that the description of this degeneration corresponds very closely in a negative way to Trepinski's description in a positive way of his third foetal system in the thoracic portion of the cord. (Cf. Fig. 290, p. 434, of my book on *The Nervous System*.) It also reminds one forcibly of Flechsig's description of the degeneration in a case of incipient tabes in the upper portion of the thoracic cord, described by him in the *Neurologisches Centralblatt* for 1890.

Lissauer's fasciculi are intact on both sides.

These specimens reveal further important alterations in the white fibers which enter the gray matter of the cord. Thus, while Waldeyer's nucleus of the dorsal horn still stains black and is rich in fine medullated fibers, the nucleus dorsalis on each side is almost entirely devoid of them. There is a marked contrast between the nucleus dorsalis of this case and that of the case to be subsequently described, where many of the fine medullated fibers of Clark's nucleus are still retained. The substantia gelatinosa is still crossed with many radiating bands of fine black fibers, and medullated fibers pass forward toward the anterior horns of gray matter.

Sections stained with van Gieson's method and with Schmaus's uranium carmine.—Specimens stained by these methods demonstrate very beautifully the proliferation of the neuroglia in the areas of partial degeneration in the dorsal funiculi. In the place of the fibers which

have degenerated there are dense masses of rose-pink staining neuroglia. The increase in the neuroglia is much more marked in the fasciculus cuneatus than in the fasciculus gracilis. Here, too, as in the pars lumbalis, there is a tendency to the arrangement of the neuroglia in coarse strands radiating out from the dorsal horns of gray matter. In the areas in which the neuroglia is increased, the blood-vessels are larger and have thicker walls than normal. I get the impression that in the areas of partial degeneration the small fibers have suffered more than the fibers of larger caliber.

The appearance of the degenerated area in the lateral funiculus corresponding to the direct cerebellar tract is very different from that of the partial degeneration of the dorsal funiculi. While in the latter case one is impressed with the proliferation of the glia, and the compression of the fibers, in the former it is the great loss of fibers and the spaces formerly occupied by them which strikes one, rather than the increase in the glia. There has probably been an increase in the glia substance in the region of the direct cerebellar tract, but it is not in the form of solid masses as in the dorsal funiculi, but instead forms a coarse, much perforated network. It looks as though the fibers had simply been dissolved out, and that the glia and endoneurial framework normally present had been swollen or slightly exaggerated in amount. Undoubtedly the process involving the glia here is a wholly different one from that which affects the glia in the dorsal funiculi.

The cells in the nucleus dorsalis have almost entirely disappeared. Here and there a single cell can be made out, probably corresponding to the isolated large fibers still preserved in the direct cerebellar tract.

PARS CERVICALIS (INTUMESCENTIA) (Fig. 42):

DIMENSIONS	
Antero-posterior diameter	6.5 mm.
Transverse diameter	11.0 mm.

Sections stained with Weigert's myelin sheath stain or with iron hæmatoxylin.—I can make out no alterations in the funiculi anteriores. In the funiculi laterales the dorso-lateral areas (direct cerebellar tract) are very extensively degenerated on both sides, though a few more large fibers are preserved on one side than on the other. The ventro-lateral areas (region of Gowers's tracts) do not contain so many large fibers as normally, but there is no marked lightening of this region.

In the funiculi posteriores there are extensive areas of partial degeneration, giving rise to moderate lightening in the ventral half of the fasciculus gracilis and in the ventral and middle portions of the fasciculus cuneatus. The dorsal third of the fasciculus gracilis is entirely free from the degeneration process, and the periphery of the fasciculus cuneatus is involved. Ventralward the area of degeneration of the fasciculus gracilis fuses with that of the fasciculus cuneatus. Close to the posterior commissure and gray matter of the dorsal horn the fibers are better preserved. The degeneration is only partial in the lightened areas and is, perhaps, most intense in the middle of Burdach's and in the ventral third of Goll's fasciculus. The anterior and posterior white commissures present no noticeable alterations.

Sections stained with van Gieson's method and with Schmaus's uranium carmine.—The decrease of white fibers of the nerve roots, especially in the radices anteriores, is distinctly visible. There are fewer nerve cells in the anterior horns than normal. The proliferation of glia in the degenerated areas in the funiculi posteriores is pronounced. The region of the direct cerebellar tract in the funiculi laterales stains red and the tissue is not dense; one sees there a much perforated network with only a few medullated fibers retained.

MEDULLA OBLONGATA AND PONS VAROLI.—The small size of the medulla oblongata and pons

is evident macroscopically. The length of the pons in the ventral middle line is 2.2 cm., transverse distance between nervi trigemini of two sides 3 cm., maximal thickness 2.5 cm. The depression between the pyramis and the oliva is more marked than usual. The lower part of the medulla has been injured on removal of the brain, so that the nucleus funiculi cuneati and the nucleus funiculi gracilis cannot be examined except in their upper parts; there, however, they are smaller than normal; the bulk of the upper part of the nucleus funiculi cuneati is certainly diminished. There is slight thinning of fibers in the stratum interolivare lemnisci and also higher up in the lemniscus medialis. The pyramids are well developed and stain normally. The nuclei arcuati are small. The layer of gray matter of the nucleus olivaris inferior looks thinner than normal and the number of cells present in it somewhat reduced. The fibræ olivo-cerebellares are less prominent than normal, as are also the fibræ arcuatae externæ. The corpus restiforme is rather smaller than normal, and shows a thinning of fibers with network-like increase of neuroglia. The nuclei nervi hypoglossi are smaller than normal, and contain correspondingly fewer cells. The nucleus on one side contains fewer cells than that on the other. The tractus solitarii are present, and show no recognizable alterations. The tractus spinalis nervi trigemini looks normal. The lateral region of the formatio reticularis and the nuclei laterales are much less developed than in normal specimens, and the notch dorsal to the olive is deepened as in Menzel's case. The mass of substantia gelatinosa medial to the tractus spinalis nervi trigemini is small.

In the pons the diminution in size is general, but the various structures appear to be fairly evenly developed in relation to one another. The fasciculi longitudinales pontis and fibræ transversæ pontis look normal and the great nuclei pontis are relatively well represented. The masses of gray matter in the pars dorsalis pontis are not markedly altered in appearance.

THE CEREBELLUM

1. SAGITTAL SECTION IN MEDIAN PLANE (Fig. 25):

a) *The arbor vitæ.*

(1) *Main vertical limb.*—This medullary stem receives as usual the bands of medullated fibers (laminæ medullares) from the first three *Wände* of the monticulus and part of those from the fourth *Wand*. Part of the fiber bands enter the main vertical limb from in front, part from behind. The main vertical limb descends to form with the horizontal limb the fiber-mass of Stilling's corpus trapezoidem.

(2) *Horizontal limb.*—This medullary stem receives as usual the vertical laminæ medullares, corresponding to Stilling's fifth and sixth *Wände* and most of the white fibers from Stilling's fourth *Wand*. It runs forward to enter the corpus trapezoideum from behind. Below it receives the *Markäste* from tuber, pyramis and uvula.

(3) *Stilling's corpus trapezoideum.*—In the median plane this is of minimum dimensions. Its configuration and contents, however, correspond to Stilling's descriptions of the normal cerebellum. It receives directly or indirectly the laminæ medullares from all the subdivisions of the vermis superior and inferior.

b) *The great anterior decussation-commissure.*—This includes the fibers passing from the left lateral half of the vermis into the right half and *vice versa* at the base of the lingula and of the lobulus centralis, and throughout the whole extent of the main vertical limb of the arbor vitæ. It is Stilling's "*grosse vordere Kreuzungs-Commissur*."

c) *The posterior decussation-commissure.*—This includes the fibers which run transversely from one side of the worm to the other at the posterior end of the horizontal limb of the arbor vitæ, immediately after entrance of the *Markäste* of the declive, folium and tuber.

d) *The nucleus of the roof (nucleus fastigii).*—This nucleus, Stilling's *Lachkern*, is in

24 DESCRIPTION OF BRAIN AND SPINAL CORD IN HEREDITARY ATAXIA

its normal position in the lower half of the trapezoid mass of white matter behind the lingula and the lobulus centralis. Its dimensions are those ordinarily met.

2. SAGITTAL SECTION 1 CM. LATERAL FROM SAGITTAL MEDIAN PLANE.—The section passes through the ala lobuli centralis, the lobulus quadrangularis, the lobulus semilunaris superior, the lobulus inferior, the lobulus biventer and the flocculus. The appearance corresponds closely to B. Stilling's Vol. II (atlas), Plate VIII*b*, Figs. 65 und 66.

The transverse, vertical and obliquely cut fibers in the central white substance correspond in numbers and position to normal descriptions.

The dentate nucleus (*nucleus dentatus*) (Stilling's *corpus dentatum s. ciliare cerebelli*) in its more medial part is seen in the section. No trace (except one minute island of cells) of the nucleus globosus or of the nucleus emboliformis is present as the section passes just lateralward from these gray masses. In this section the ellipse formed by the cut section of the dentate nucleus is open in the middle below, and also in its anterior superior region. The typical tortuous appearance of the section of the nucleus is present; this is due to the *Zacken* and *Gegenzacken* of Stilling. The greatest length of the nucleus dentatus in the sagittal direction is 18 mm. The cell-bodies in the gray matter of the nucleus dentatus as seen in sections at this level are reduced to almost one-quarter the normal number. Within the nucleus dentatus is a mass of nerve-fibers for the most part cut obliquely. But instead of the compact, solid masses of medullated fibers usually seen, the fibers are somewhat thinned and under the loop the Weigert preparation shows lightening; the lightening is tolerably general, though it is most pronounced perhaps at the upper part and the posterior part of the intranuclear fiber-mass. In this fiber-mass are ten or twelve sections through large blood-vessels visible to the naked eye; these vessels are surrounded by large clear spaces.

The *fibræ semicirculares cerebelli*, or Stilling's *halbzirkelförmige Faserzüge*, lying in that part of the central white matter of the cerebellum which is situated between the upper margin of the nucleus dentatus and the bases of the various *Wände* of the lobulus quadrangularis show no alteration that can be made out in the Weigert sagittal section at this place. Between the *fibræ semicirculares* and the bases of the *Wände* of the lobulus quadrangularis the *quirlanden-förmige Fasern* of Stilling are present and at the bases of the *Wände* themselves the bundles of fibers cut in cross-section, so characteristic of the normal cerebellum, are to be seen in what appear to be normal numbers.

In this central white matter (*corpus medullare*) beneath the base of the lamina medullaris of the posterior part of the lobulus quadrangularis, there is a slightly lightened area in the Weigert section; the lightening may be due to a slight thinning of the fibers in this area.

The white matter of the flocculus is well developed and stains normally, as do the laminae medullares of the other portions of the inferior surface of the hemisphaerium cerebelli. The section passes through a part of the corpus rostriforme. A histological study of the substantia corticalis in sagittal sections at this plane reveals no striking alterations. The molecular layer, layer of ganglion cells, and granular layer show normal relative development.

DESCRIPTION OF THE LESS ADVANCED CASE (CASE XX)

CEREBRUM

HEMISPHERIUM DEXTERUM

(Figs. 12, 14, 16, 17, and 18)

FISSURA CEREBRI LATERALIS [STLVII]:

Truncus.—The *polus temporalis* does not cover more than the middle half of the *pars orbitalis* of the *gyrus frontalis inferior*; it fails to reach anteriorly as far as the *sulcus orbitalis transversus* by a distance of 0.5 cm.

Fissura propria.—The angle formed with the longest antero-posterior diameter is 13° . The linear distance from the junction with the ramus anterior horizontalis to the junction with the ramus posterior ascendens is 6.2 cm. The ramus posterior ascendens goes off at an angle of 71° and is 2.0 cm. in length. The ramus posterior descendens is 1 cm. in length.

Ramus anterior horizontalis and ramus anterior ascendens.—These arise by a common stem, the horizontal ramus cutting deep into the gyrus frontalis inferior and reaching to within 0.7 cm. of the sulcus frontalis inferior. It is very prominent on the lateral surface of the cerebrum. The ascending anterior ramus is only 0.5 cm. long. It passes upward and backward from the common stem. It is inconspicuous on the lateral surface, especially in comparison with the sulcus diagonalis operculi.

SULCUS CENTRALIS [ROLANDI].—The medial extremity extends beyond the junction of the convex and medial surfaces of the hemisphere, encroaching for a few millimeters upon the medial surface. The genu superior is more marked than the genu inferior. The sulcus turns backward into the paracentral lobule and stands in the typical relation to the extremity of the sulcus cinguli (cf. Eberstaller). The lateral extremity of the sulcus is situated 1.5 cm. from the fissure of Sylvius. Between it and the fissure of Sylvius is intercalated an oblique sulcus (the course of which is almost perpendicular to that of the lower third of the sulcus centralis). It is 2.3 cm. in length and is bifurcated at its lower extremity. This is evidently a special case of Eberstaller's *ctr.-Furche* (Retzius's "sulcus subcentralis anterior").

No anastomoses with other sulci.

Relative length	7.8 cm.
Absolute length	10.0 cm.

Inclination of sulcus with fissura longitudinalis cerebri, measured on a line drawn from the point where the sulcus cuts the medial margin to the lower extremity of the sulcus, 66° .

LINEAR DISTANCE OF THE MEDIAL END OF THE SULCUS

From the frontal pole	120 mm.
From the occipital pole	95 mm.

that is, as 56:44.

LINEAR DISTANCE OF LATERAL END

From frontal pole	89 mm.
From occipital pole	112 mm.

SULCUS PRÆCENTRALIS:

1. *Pars inferior (sulcus præcentralis inferior of Eberstaller)*.—The pars inferior is superficially continuous with the pars superior, though the two segments are distinctly separated from one another by a gyrus in the depth. The lower extremity of the pars inferior reaches to within 0.9 cm. of the margin of the Sylvian fissure, making a deep incisure in the interval between the sulcus subcentralis anterior and the sulcus diagonalis. The pars inferior about its middle forms a deep anastomosis with the posterior extremity of the sulcus frontalis inferior. At first sight there would seem to be no ramus anterior of Eberstaller (ramus horizontalis of Cunningham) on this side, but on closer examination and comparison with the opposite hemisphere it is seen that in reality such a ramus exists. It is, however, completely separated from the main sulcus by an annectant gyrus extending between the lateral and medial roots of the gyrus frontalis medius.

2. *Pars superior (sulcus præcentralis superior of Eberstaller)*.—This pars is a transversally placed foot-piece to the sulcus frontalis superior with which it forms a deep anastomosis. Its lateral extremity extends backward into the gyrus centralis anterior, posterior from the medial extremity of the pars inferior and reaches within 0.5 cm. of the sulcus centralis. The

superficial anastomosis of the pars superior with the pars inferior is situated 1 cm. above and in front of this lateral extremity. The medial extremity of the pars superior fails (by 0.5 cm.) to reach the medial border of the hemisphere, apparently owing to the very marked development there of a sulcus which is probably to be identified with the sulcus præcentralis medialis of Eberstaller. The latter sends two rami forward, one behind, the other in front of, the medial extremity of the sulcus præcentralis superior. The more posterior and lateral ramus is separated from the medial extremity of the sulcus præcentralis superior by a narrow gyrus, only 0.4 mm. in thickness. Passing backward from about the middle of the sulcus præcentralis superior, and cutting deep into the substance of the gyrus centralis anterior for a distance of 1.5 cm. is a well-marked branch (ramus sagittalis posterior of Retzius). This is in almost a direct line with the sulcus frontalis superior, and is probably to be recognized as a part of the latter sulcus, instead of as a part of the sulcus præcentralis. The sulcus complex formed by the sulcus præcentralis superior and the sulcus frontalis superior is an unusually good example of the "cruciform type" which has frequently been described.

3. *Pars medialis (sulcus præcentralis medialis of Eberstaller)*.—This commences on the medial surface in about the middle of the paracentral lobule as a ramus,⁴ which begins 0.7 cm. above the sulcus ciuguli and extends vertically upward for a distance of 1.3 cm., then turns at an angle of 108° forward and slightly medialward for a distance of 1.4 cm., where it bifurcates on the medial margin of the hemisphere to form two slightly curved terminal prongs. One of these runs forward along the edge of the hemisphere for a distance of 1.1 cm.; the other, lateralward for the same distance, to terminate in the gyrus centralis anterior close behind the medial portion of the sulcus præcentralis superior (*vide supra*).

SULCUS FRONTALIS INFERIOR.—This sulcus is completely interrupted by a superficial anastomosis of the pars triangularis of the gyrus frontalis inferior with the gyrus frontalis medius. This gyrus evidently corresponds to Eberstaller's *vordere Tiefenwindung*. The posterior part of the sulcus anastomoses behind with the pars inferior of the gyrus præcentralis, extends, tortuous, 1.7 cm. forward and somewhat lateralward, and terminates in a transversal sulcus which cuts above into the gyrus frontalis medius to within 0.4 cm. of the sulcus frontalis medius, and below into the pars triangularis to within 0.8 cm. of the ramus anterior horizontalis of the Sylvian fissure.

The anterior part of the sulcus frontalis inferior begins as an oblique slit, 1.7 cm. long and directed from behind and lateralward (in the pars triangularis) upward and medialward into the gyrus frontalis medius. From a little above the middle of this oblique piece, the main sulcus runs forward for a distance of 1 cm. and there gives off a short medial ramus which cuts into the gyrus frontalis medius; it then turns abruptly (angle of 85°) lateralward, to end in the middle of a sagittally placed terminal sulcus, 1.5 cm. in length. The latter is situated almost exactly on the border of the orbital surface. The anterior extremity of this terminal piece lies 0.7 cm. in front of the lateral extremity of the sulcus frontalis marginalis. It seems probable that we have here to deal with a fusion of the anterior portion of the sulcus frontalis inferior with the sulcus radiatus of Eberstaller.

SULCUS FRONTALIS SUPERIOR.—The anastomosis of this sulcus with the pars superior of the sulcus præcentralis has already been noted. This occurs at a point 2 cm. distant from the medial margin of the hemisphere. The sulcus is continued back into the gyrus centralis anterior. I agree with Eberstaller that this prolongation (called by Retzius the ramus sagittalis posterior of the sulcus præcentralis) belongs in reality to the sulcus frontalis superior.

The main sulcus follows a tortuous course forward and medialward and terminates in front about 2.5 cm. from the margin of the hemisphere. At about the junction of its posterior

⁴ This ramus may represent a sulcus paracentralis proprius.

and middle thirds it gives off a ramus which cuts lateralward and slightly backward deep into the gyrus frontalis medius. Between this ramus and the sulcus centralis is an isolated gyrus which, at first sight, might be thought to belong to the gyrus frontalis superior, but which must be regarded as a part of the medial portion of the gyrus frontalis medius. The sulcus frontalis superior is nowhere interrupted by annectant gyri, nor does it form anastomoses other than that with the sulcus præcentralis.

SULCUS FRONTALIS MEDIUS.—This is a pronounced sagittal sulcus, almost completely dividing the gyrus frontalis medius into two halves, and so establishing the "four-convolutions" type of the frontal lobe in this hemisphere. It begins behind close to the inferior portion of the sulcus præcentralis, as a shallow piece which may, in reality, represent a detached ramus anterior of the inferior præcentral sulcus. One and five-tenths cm. in front of its posterior extremity it is crossed by a transversal sulcus 1.5 cm. long; then becoming very deep, it extends 1.5 cm. farther forward and bifurcates into a medial ramus 1 cm. long and a lateral (more sagittal) ramus which extends for a distance of 2 cm. and is then interrupted in the depth by an annectant gyrus connecting the pars medialis with the pars lateralis of the gyrus frontalis medius. In front of this gyrus in the depth, the sulcus makes a deep cut backward and medialward into the pars lateralis of the gyrus frontalis medius, while farther onward it bifurcates to form the two limbs of the sulcus frontomarginalis of Wernicke.

SULCUS CINGULI.—This sulcus belongs to Eberstaller's "continuous type."

The pars anterior begins under the front part of the genu corporis callosi, passes forward, then upward, and later backward. It is very shallow in all parts of its course and runs unusually close to the corpus callosum, making a very narrow gyrus fornicatus in front. At its posterior extremity it curves up into the medial surface of the gyrus frontalis superior, to terminate 0.7 cm. from the margin of the hemisphere.

The main course of the pars anterior is, however, continued backward as the pars intermedius, the latter being much more widely separated from the corpus callosum than is the pars anterior. Behind, the pars intermedius becomes somewhat irregular and goes over into the pars posterior. The ascending portion of the latter undergoes a Y-shaped bifurcation (*Y-förmig gegabelt*). The anterior limb of the Y passes up to the medial margin of the hemisphere and terminates a few millimeters behind the medial extremity of the sulcus centralis. The posterior limb of the Y terminates in the præcuneus without reaching the margin of the hemisphere.

SULCUS OLFACTOIVS.—Deep; begins 1 cm. from the medial margin, behind. Bifurcates at posterior extremity. No anastomoses. Length, 4.4 cm. Passes forward and medialward. Reaches medial margin and extends 0.7 cm. upon medial surface.

SULCUS ORBITALIS.—This is of the H type.

The sulcus orbitalis transversus, ramus lateralis, ramus medialis, and ramus intermedius are all present. The ramus intermedius forms a superficial anastomosis with the ramus lateralis. Running backward from the sulcus orbitalis transversus into the gyrus frontalis inferior is a sagittal ramus. Its course is nearly parallel to that of the medial extremity of the sulcus orbitalis transversus.

ACCESSORY SULCI OF THE LOBE FRONTALIS:

1. *Sulcus diagonalis operculi.*—Very deep; typical direction; extends 2.4 cm. on lateral surface and 1 cm. on inferior surface of pars opercularis. No anastomoses.

2. *Sulcus radiatus.*—Cannot be distinctly made out. If present at all, it belongs to the sulcus-complex, composed of that part of the sulcus frontalis inferior which lies along the front part of the base of the pars triangularis and anastomoses farther forward with the lateral segment of the sulcus frontomarginalis of Wernicke.

3. *Sulcus frontomarginalis of Wernicke.*—The lateral portion (f_{m_1}) anastomoses with

the anterior extremity of the *gyrus frontalis inferior*; the middle portion (*f_m*) is 1.8 cm. long, is entirely in the *facies convexa* and is the lateral limb of bifurcation of the anterior extremity of the *sulcus frontalis medius*, but the posterior of the two is evidently the continuation of the *sulcus frontalis medialis*, the anterior being partially separated by a deep annectant *gyrus*.

4. *Sulcus frontalis medialis and other accessory sulci of the gyrus frontalis superior.*—The *gyrus frontalis superior* is divided into two distinct gyri by a well-developed *sulcus frontalis medialis* (medial frontal sulcus of Cunningham), a deep sagittal sulcus, 4 cm. in length. There are no accessory transversal sulci. The marked development of the *sulcus frontalis medialis* gives rise to that rare appearance known as the "five-convolution" type of frontal brain.

5. *Sulcus rostralis.*—Very deep and well marked. A far more conspicuous sulcus than the *pars anterior* of the *sulcus cinguli*. It begins in the lower part of the *sulcus rostralis transversus* and, following a course almost perpendicular to the *sulcus cinguli*, terminates in the *gyrus frontalis superior* at a point vertically above the anterior extremity of the *corpus callosum*. A number of radially directed furrows run out from it into the *gyrus frontalis superior* toward the margin of the hemisphere.

6. *Sulcus rostralis inferior.*—Well developed; 3.5 cm. long; deep and continuous. Ebner's says of this sulcus: "Gut ausgebildet flüchtet sie sich nur an sogenannten windungs-, beinahe furchenreichen Gehirnen."

7. *Sulcus olfactorius transversus.*—Shallow; entirely on medial surface of hemisphere. Anastomoses with the *sulcus rostralis inferior*.

8. *Sulcus paracentralis.*—*Cf.* description of *sulcus praecentralis medialis*.

SULCUS INTERPARIETALIS:

1. *Sulcus postcentralis.*—This sulcus is continuous and does not anastomose with the *sulcus interparietalis proprius*. Its lateral extremity anastomoses with the *sulcus subcentralis posterior* of Marchand. Its medial extremity turns backward and ends 1 cm. from the medial margin of the hemisphere. The sulcus is deep throughout, there being no annectant gyri in the depth.

2. *Sulcus interparietalis proprius.*—This begins in an X-shaped sulcus-complex. The lateral posterior limb of the X, which cuts across the *gyrus angularis*, is separated from the rest of the complex by an annectant *gyrus* in the depth. The medial posterior limb of the X corresponds to the main course of the sulcus separating the *lobulus parietalis superior* from the *lobulus parietalis inferior*. The medial anterior limb of the X measures 2 cm. in length, the lateral 1.5 cm. The medial posterior limb (main sulcus) passes backward and slightly medialward for 2 cm., where it bifurcates. The medial limb of bifurcation cuts into the *lobulus parietalis superior*, the other limb communicating superficially with the posterior part of the *sulcus interparietalis* (the so-called *paroccipital sulcus* of Wilder).

3. *Sulcus paroccipitalis* of Wilder.—This forms a U around the *fissura parietooccipitalis* of the *facies convexa*. Its anterior extremity begins 3 cm. from the margin of the hemisphere, 0.7 cm. in front of the *fissura parietooccipitalis*. Its posterior extremity is 1.3 cm. from the margin of the hemisphere where it appears to anastomose with the *sulcus occipitalis transversus*, but on examination it is found to be separated from it by an interrupting *gyrus* which reaches almost to the surface.

SULCUS PARIETALIS SUPERIOR.—The sulcus appears as a direct transversal continuation of the *sulcus praecuneus* upon the *facies convexa*. After an extent of 1.5 cm. it ends in a sagittal cross-piece 1 cm. long. It does not anastomose with the *sulcus postcentralis* or with the *sulcus interparietalis*.

SULCUS SUBPARIETALIS AND SULCUS PRAECUNEUS.—The former forms a superficial anastomosis with the *pars posterior* of the *sulcus cinguli*, passes backward for 2.5 cm., and bifurcates into a posterior and an inferior terminal ramus. A little behind its middle it anastomoses with the *sulcus praecuneus*.

FISSURA PARIETOOCIPITALIS.—Distance from medial margin of hemisphere to point of junction with the truncus of the calcarinus fissure, 3.8cm. The fissure extends 1.5cm. on the facies convexa and then bifurcates into two short superficial terminal rami. On opening up the fissure from the medial surface, the superficies posterior lobi parietalis comes into view. A typical gyrus cuneus of Ecker exists. Near the medial border of the surface a deep tortuous sulcus passes upward and about 1cm. from the medial margin of the hemisphere reaches the facies medialis; it then turns sagittally forward through the præcuneus for a distance of 2cm. and then turns vertically upward 1cm. behind the sulcus præcuneus to terminate near the medial margin of the hemisphere.

The portion of the superficies posterior lateral from the sulcus just described is marked near the bottom of the fissura parietooccipitalis by a transverse sulcus above which is a V-shaped sulcus. The lateral limb of this V corresponds to the anterior limb of bifurcation of the fissura parietooccipitalis as seen from the facies convexa. There thus arises a diminutive lobulus parietooccipitalis in the sense of Retzius at the lower end of the fissure. It comes, however, in the domain of the gyrus arcuatus posterior of the lobulus parietalis.

FISSURA CALCARINA.—Length of truncus, 1.8cm. The fissure extends 3.8cm. beyond the truncus, terminating behind 0.5cm. from the margin of the hemisphere, where it undergoes a slight bifurcation.

SULCUS OCCIPITALIS TRANSVERSUS.—It begins 0.5cm. behind the fissura parietooccipitalis and 1cm. from the medial margin of the hemisphere. Its lateral extremity anastomoses with the sulcus occipitalis lateralis, giving rise to a stellate sulcus-complex at the junction of the occipital and temporal lobes.

SULCI OCCIPITALES SUPERIORES.—There is only one such sulcus. It is situated behind the sulcus occipitalis transversus. Slightly curved, it runs parallel to it from below upward to the margin of the hemisphere, and then turns and runs on the medial surface of the lobus occipitalis, delimiting a peripheral gyrus of the cuneus. Parallel to it, and separating the apical from the middle part of the cuneus on the medial surface, is a second short sulcus.

SULCI OCCIPITALES LATERALES.—Opposite the polus occipitalis and running parallel to the margin of the hemisphere at a distance of 1cm. from it, is a sulcus 3cm. long. Only the medial one-fourth of this is above the level of the fissura calcarina of the medial surface. The rest is opposite the gyrus lingualis. Anastomosing with this sulcus near its upper (medial) extremity is a sulcus 3.3cm. long. At the junction of its medial and anterior thirds it forms a superficial anastomosis with the sulcus occipitalis transversus, though a deep occipito-parietal anastomosis prevents fusion in the depth.

SULCI TEMPORALES TRANSVERSI.—The sulcus temporalis transversus tertius and the sulcus temporalis transversus primus are well marked, but as the gyrus temporalis transversus primus and the gyrus temporalis transversus secundus are fused, the sulcus temporalis transversus secundus is absent. Opposite the area of fusion there is a sulcus on the external surface of the gyrus temporalis superior which passes downward on the inferior surface of the gyrus and subdivides this as far as the bottom of the sulcus temporalis superior.

SULCUS TEMPORALIS SUPERIOR.—The sulcus is very deep and presents transverse gyri on both its walls. Its anterior extremity stops short of the frontal pole. It is not bifurcated, nor is there any transversal sulcus in front of it. At the point where the sulcus turns upward behind, it is interrupted by a superficial anastomosing gyrus temporalis medio-superior. Behind this the sulcus passes upward and a little backward into the gyrus angularis to within 1cm. of the sulcus interparietalis. The sulcus intermedius primus between the gyrus angularis and the gyrus supramarginalis makes a superficial anastomosis below with the anterior part of the sulcus temporalis superior. The anterior portion of the gyrus angularis is cut across by a sulcus

which anastomoses above with the sulcus interparietalis, below with the sulcus temporalis superior. An oblique sulcus, parallel to the ramus posterior ascendens and the ramus posterior descendens of the fissure of Sylvius, divides the gyrus supramarginalis into a medial and a lateral half. This sulcus anastomoses behind with the sulcus intermedius primus of Jensen.

SULCUS TEMPORALIS MEDIUS.—It begins in a slight bifurcation 1 cm. behind the *polus temporalis* and extends backward 3.8 cm., where it is interrupted by a superficial annectant gyrus temporalis medio-inferior. Behind this gyrus it begins again in a basal cross-piece nearly 3 cm. long, which cuts almost through the gyrus temporalis superior; less deeply into the gyrus temporalis medius. It then passes backward to the notch on the margin of the hemisphere formerly called the *incisura præoccipitalis*, and turns upward and backward for a distance of 4 cm., terminating in an H-shaped sulcus complex in the gyrus parietalis inferior posterior. Between its posterior extremity and the posterior extremity of the sulcus frontalis superior, passing down from the sulcus interparietalis between the gyrus angularis and the gyrus parietalis posterior inferior, is a well-marked sulcus intermedius secundus.

SULCUS TEMPORALIS INFERIOR.—The main portion of this sulcus begins about 2 cm. below and behind the *polus temporalis* and passes in a curved direction (concavity medialward) backward, to end in a cross-piece 2 cm. long. In front of it, between it and the anterior extremity of the lobe temporalis, is a curved transversal "compensatory" sulcus, 1.5 cm. long. Running forward to the margin of the poles from near the middle of this is a sagittal ramus 0.8 cm. in length. Behind, the sulcus is represented by a short furrow passing backward for less than 0.2 cm. behind the medial extremity of the so-called *incisura præoccipitalis*. The gyrus between this and the sulcus occipitalis lateralis is accordingly assumed to be the continuation backward of the gyrus temporalis inferior.

A transverse sulcus connects the fissura rhinea with the sulcus temporalis inferior and separates the incurved extremity of the gyrus temporalis inferior (in front) from the anterior extremity of the gyrus fusiformis (behind).

FISSURA COLLATERALIS.—Its anterior extremity is separated from the fissura rhinea by a broad gyrus rhiuencephalo-fusiformis. The sulcus is deep and overhung by the gyrus fusiformis. It passes backward in a marked curve with convexity medialward. It anastomoses behind with the sulcus sagittalis gyri lingualis which bisects the gyrus lingualis. The inferior margin of the gyrus lingualis is delimited by part of an H-shaped sulcus complex. The anterior superior limb of this H runs forward into the gyrus fusiformis and subdivides its posterior portion into two sagittal gyri. The more medial of these connects with the inferior portion of the gyrus lingualis, thus forming a gyrus fusiformo-lingualis. Lateralward from the H-shaped sulcus complex the gyrus lingualis is connected with the gyrus temporalis inferior by a gyrus temporo-lingualis. The fissura colliata, which is separated from the truncus of the fissura calcarina by a broad gyrus rhiuencephalo-lingualis.

SULCI INSELE.—The sulcus centralis insulæ of Guldberg divides the insula into lobulus insulæ anterior and the lobulus insulæ posterior. The gyrus centralis posterior primus, gyrus centralis posterior secundus of the posterior lobulus are fused into a single mass, showing three short superficial sulci on the surface. The lobulus anterior insulæ is divided into four radiating gyri by means of three rather shallow sulci.

HEMISPHERIUM SINISTRUM

(Figs. 13, 15, 16, 17 and 19)

FISSURA CEREBRI LATERALIS [SYLVII];

Truncus.—The *polus temporalis* does not project beyond the pars orbitalis of the gyrus frontalis inferior, except at its posterior border; the extremity of the *polus* is more than 1 cm. distant from the sulcus transversus.

Fissura propria.—This forms an angle of 13° with the longest antero-posterior diameter of the hemisphere. The distance from the ramus anterior horizontalis to the ramus posterior ascendens is 7.2 cm. The ramus posterior ascendens goes off at an angle of 68° and is 1.8 cm. long. The ramus posterior descendens measures 1.6 cm. in length. There appears to be only one anterior sulcus, the ramus anterior ascendens, but on close examination a rudimentary ramus anterior horizontalis indicating the limits of the pars triangularis can be made out, cutting only a few mm. into the cerebral substance.

SULCUS CENTRALIS (ROLANDI).—The medial extremity fails to reach by 0.5 cm. the junction of the *facies convexa* with the *facies medialis*, notwithstanding the fact that the sulcus cinguli cuts into the *facies convexa* for a distance of 1.2 cm. The lateral extremity is continuous with the sulcus subcentralis anterior, though there is a low annectant gyrus in the depth separating the two. The anterior subcentral sulcus appears to connect the sulcus centralis with the Sylvian fissure, but on pulling aside the margin of the latter it is seen that the subcentral sulcus terminates in the substance of the inferior surface of the operculum. The genu inferior and the genu superior are both well marked.

Relative length of sulcus centralis	6.7 cm.
Absolute length of sulcus centralis	8.6 cm.
Inclination (measured according to Eberstaller) ^a	63°
Distance in a straight line of the medial end of the sulcus from the frontal pole	114 mm.
Ditto from the occipital pole	83 mm.
Distance in a straight line of the lateral end from the frontal pole	93 mm.
Ditto from the occipital pole	112 mm.

SULCUS PRÆCENTRALIS:

1. *Pars inferior (sulcus præcentralis inferior of Eberstaller)*.—This is only superficially connected with the pars superior, an annectant gyrus passing from the medial portion of the base of the gyrus frontalis medius to the gyrus centralis anterior, being depressed below the surface by a shallow sulcus only. The lateral extremity of the sulcus is 0.8 mm. from the margin of the Sylvian fissure, there being no separating sulcus diagonalis on this side. The medial extremity passes in front of the lateral extremity of the pars superior. There is a typical anterior sagittal ramus (ramus horizontalis of Cunningham) passing forward and a little medialward into the substance of the gyrus frontalis medius and terminating in a transversal sulcus 0.8 mm. long. The lateral portion of the foot of the gyrus frontalis medius is connected with the foot of the gyrus frontalis inferior by an annectant gyrus 0.4 cm. in thickness. The latter prevents the anastomosis of the sulcus frontalis inferior with the sulcus præcentralis inferior. The posterior extremity of the sulcus frontalis inferior almost bisects the angle formed by the sulcus præcentralis inferior with its ramus sagittalis inferior.

2. *Pars superior (sulcus præcentralis superior of Eberstaller)*.—This is an irregular sulcus, 3 cm. in length. Its lateral extremity has a shallow sagittal base 1 cm. in length. Its medial extremity passes medialward and a little forward, and, shortly before terminating, bends sharply backward into the gyrus centralis anterior to, and 1 cm. from, the medial margin of the hemisphere. The sulcus frontalis superior is continuous with the medial extremity of this sulcus. One and one-half cm. lateralward from this anastomosis a ramus sagittalis posterior passes backward into the gyrus centralis anterior, causing a deflection of that gyrus and giving rise to a knee in the sulcus centralis.

3. *Pars medialis (sulcus præcentralis medialis of Eberstaller)*.—This is represented by a short sulcus in the gyrus centralis anterior between the medial extremity of the pars superior

^a The deformation of the hemisphere in hardening makes this measurement of doubtful value.

of the sulcus præcentralis and the sulcus centralis. Its medial extremity begins 2 mm. from the medial margin. The sulcus has a transversal limb extending directly lateralward for a distance of 1.5 cm. It then turns at a right angle and runs sagittally backward for 1 cm. to terminate within 0.4 cm. of the pars superior.

SULCUS FRONTALIS INFERIOR.—The sulcus is continuous superficially. It is prevented from uniting with the pars inferior of the sulcus præcentralis by a superficial annectant gyrus extending between the pars opercularis of the gyrus frontalis inferior, and the lateral portion of the foot of the gyrus frontalis medius. It begins behind, close to the angle formed by the pars superior of the sulcus præcentralis with its ramus sagittalis anterior, passes forward and a little lateralward for a distance of 3.5 cm., and ends in the middle of an obliquely transverse terminal sulcus 3 cm. long. The medial limb of this terminal cross-piece cuts into the gyrus frontalis medius to within 0.7 cm. of the sulcus frontalis medius, while the lateral limb cuts into the pars trigularis to within 0.5 cm. of the rudimentary ramus ascendens horizontalis of the fissure of Sylvius. Cutting into the gyrus frontalis medialis from about the middle of the sagittal portion of the sulcus frontalis inferior is a short medially-directed ramus. Eberstaller's *rordere Tiefenwindung* is distinctly visible in the depth in front of the latter.

SULCUS FRONTALIS SUPERIOR.—The sulcus anastomoses behind with the upper part of the pars superior of the sulcus præcentralis, though they are partially separated by a deep annectant gyrus. The sulcus at its posterior extremity is only 1.5 cm. from the medial margin of the hemisphere. It is not prolonged behind the sulcus præcentralis into the gyrus centralis anterior. It passes forward and a little lateralward (instead of, as usual, medialward) and forms in front a superficial anastomosis with the sulcus frontalis medius, an annectant gyrus making the communication a very shallow one. The sulcus is not interrupted. It presents incisures into the gyrus frontalis superior above and the gyrus frontalis medius below. In front of the anastomosis with the sulcus frontalis medius is a short isolated obliquely sagittal sulcus, and in front of this again a transversal sulcus 2.5 cm. long on the facies convexa, and extending for 1 cm. upon the facies medialis. These two isolated sulci, although behind the sulcus frontomarginalis, may, perhaps, be regarded as interrupted segments of the anterior extremity of the sulcus frontalis superior.

SULCUS FRONTALIS MEDIUS.—The sulcus on this side is very irregular. One cm. in front of the anterior termination of the ramus anterior of the inferior portion of the sulcus præcentralis is a transversal sulcus 3 cm. long, shallow, and unconnected with other sulci. One and one-half cm. further forward the sulcus frontalis medius proper begins as a transversal basal piece. The medial extremity of this forms a superficial anastomosis with the sulcus frontalis superior. Passing forward from the middle of this basal sulcus a sagittal sulcus extends 1.5 cm. forward, and then bifurcates into the two limbs of the sulcus frontomarginalis of Wernicke.

SULCUS CINGULI.—It consists of two pieces, the pars posterior and the pars intermedius being continuous, the pars anterior being separated from the rest of the sulcus. The pars anterior begins in its usual position between the genu corporis callosi and extends forward and then upward, cutting through the medial surface of the frontal lobe to reach the margin of the hemisphere about 4 cm. behind the frontal lobe. The pars intermedius commences about 1 cm. in front of the anterior extremity of the corpus callosum and in the plane of the superior surface of that structure. It curves backward approximately parallel to the corpus callosum and, becoming continuous with the deep pars posterior, passes up behind the lobulus paracentralis to the margin of the hemisphere, and even extends for a distance of 1.3 cm. upon the convex surface.

SULCUS OLFACTORIUS.—One cm. deep, 4.4 cm. long. It passes forward and slightly medialward, but fails to reach the medial margin by 0.4 cm. No anastomoses.

SULCUS ORBITALIS.—It is much more irregular than on the right side. The sulcus orbitalis transversus is marked and anastomoses with the ramus lateralis and ramus intermedius. The ramus medialis is shallow and does not communicate with the sulcus orbitalis transversus, nor with the ramus intermedius.

ACCESSORY SULCI OF THE LOBUS FRONTALIS:

1. *Sulcus diagonalis operculi.*—Absent on this side, or possibly represented by the lower part of the sulcus præcentralis inferior.
2. *Sulcus radiatus.*—Not represented, though some might look upon the transversal termination of the sulcus frontalis inferior as representing the sulcus radiatus.
3. *Sulcus frontomarginalis (Wernicke).*—The lateral segment (fm_1) is absent. The middle and medial segments (fm_2 , fm_3) are present and appear as limbs of bifurcation of the anterior extremity of the sulcus frontalis medius. The medial limb is directly continuous in the depth with the sulcus frontalis medius, but the middle portion is partially separated by a deep annectant gyrus. In front of fm_2 , fm_3 is a transverse sulcus situated exactly on the orbital margin. It may be regarded as a doubling of fm_2 .
4. *Sulcus frontalis medialis and other accessory sulci of the gyrus frontalis superior.*—There is no continuous sagittal sulcus on this side. In the posterior part of the gyrus frontalis superior is an oblique curve. Farther forward are two transversal curves cutting almost entirely across the gyrus. Still more anteriorly is an oblique curve 2.5 cm. long, passing from behind and near the medial margin forward and lateralward. About half-way between this and the medial limb of the sulcus frontomarginalis is a transversal sulcus extending 2.5 cm. upon the facies convexa and 1 cm. upon the facies medialis. The medial surface of the gyrus frontalis superior, aside from the sulcirostrales, is unusually deeply and multiply fissured.
5. *Sulcus rostralis.*—Deep and well marked; begins below the knee of the corpus callosum, runs parallel to the pars anterior of the sulcus cinguli, and terminates in a Y-shaped bifurcation. The posterior limb of the Y anastomoses with a short ramus given off by the pars anterior sulci cinguli near its extremity.
6. *Sulcus rostralis inferior.*—Three cm. long; deep; well marked.
7. *Sulcus olfactorius transversus.*—Well developed; 1.5 cm. long; situated entirely on the facies orbitalis.

SULCUS PARACENTRALIS.—Above the pars posterior of the sulcus cinguli is a sulcus 3.5 cm. long dividing the lobulus paracentralis into an upper and lower portion. At the anterior extremity of this sulcus a vertical ramus passes up to the margin of the hemisphere and extends for a distance of 0.4 mm. upon the facies convexa. The posterior extremity of the sulcus paracentralis is bifurcated.

SULCUS INTERPARIETALIS:

1. *Sulcus postcentralis.*—The sulcus is subdivided into a shorter superior and a longer inferior portion. The pars superior begins on the medial margin of the hemisphere, curves lateralward and then forward around the incisura sulci cinguli, and terminates close to the sulcus centralis. The pars inferior is an obliquely transversal sulcus, 2.5 cm. long, bifurcated at both extremities. It forms no anastomoses. It is separated from the pars superior by a gyrus which connects the gyrus centralis posterior with the lobulus parietalis superior. It is separated from a deep sulcus subcentralis posterior by a gyrus which connects the gyrus centralis posterior with the lobulus parietalis inferior.
2. *Sulcus interparietalis proprius.*—It begins 0.7 cm. behind the sulcus postcentralis inferior, being separated from it by a gyrus connecting the lobulus parietalis superior with the lobulus parietalis inferior. It passes obliquely backward and medialward to anastomose with

the sulcus paroccipitalis behind, and with the sulcus parietalis superior medially. In the depth it is partly separated from each by annectant gyri.

3. *Sulcus paroccipitalis of Wilder*.—The sulcus forms a U embracing the portion of the fissura parietooccipitalis which cuts into the facies convexa. The posterior limb of the U, after giving off a short lateral ramus, passes medialward and backward almost to the edge of the hemisphere. It does not anastomose with the sulcus occipitalis transversus.

SULCUS PARIETALIS SUPERIOR.—An S-shaped sulcus on the facies convexa situated between the pars superior of the sulcus præcentralis in front and the fissura parietooccipitalis behind. Its medial extremity begins at the medial margin of the hemisphere just in front of the sulcus præcuneus, being separated from the latter by an annectant gyrus. Its lateral extremity forms a superficial anastomosis with the sulcus interparietalis proprius. There is a shallow, short oblique groove in the cortex between the sulcus præcentralis superior and the sulcus parietalis superior (in the gyrus arcuatus medius), and a second shallow groove between the sulcus parietalis superior and the fissura parietooccipitalis (in the gyrus arcuatus posterior).

SULCUS SUBPARIETALIS.—Its anterior extremity is separated from the sulcus cinguli by a gyrus connecting the gyrus fornicatus with the præcuneus. Its posterior extremity is separated from the truncus of the fissura calcarina by a gyrus 1 cm. broad connecting the posterior inferior angle of the præcuneus with the gyrus cinguli.

SULCUS PRÆCUNEUS.—A deep sulcus, running upward and backward from the middle of the sulcus subparietalis, bisects the præcuneus; its upper extremity terminates on the medial margin of the hemisphere just behind the beginning of the sulcus parietalis superior. The anterior and posterior halves of the præcuneus are in turn bisected by irregular vertical sulci which anastomose below with the sulcus subparietalis, terminating above in the substance of the præcuneus short of the margin of the hemisphere. The anterior vertical ramus is bifurcated at its upper extremity.

FISSURA PARIETOOCIPITALIS.—Distance from the medial margin of the hemisphere to point of junction with the truncus fissure calcarinae, 4 cm. The fissure extends 1.7 cm. upon the facies convexa and ends without bifurcation. A typical gyrus cunei of Ecker exists. The superficies posterior lobi parietalis is very simple. There is a marked gyrus cuneo-præcuneus at about the junction of the lower and middle thirds. Above this the surface is concave and slightly irregular. There is no lobulus parietooccipitalis.

FISSURA CALCARINA.—Length of truncus, 1.9 cm. Length of fissura propria, 3.8 cm. The fissura is separated from the fissura parietooccipitalis in the depth by an annectant gyrus which extends from the cuneus to the gyrus cinguli. The fissura propria follows a sinuous course to the margin of the hemisphere and extends for a distance of 1.2 cm. upon the facies convexa. A sulcus sagittalis inferior cunei (Retzius) passes through the lower part of the cuneus running approximately parallel to the fissura calcarina. It extends also for a distance of 1.1 cm. upon the facies convexa.

SULCUS OCCIPITALIS TRANSVERSUS.—This is a deep sulcus, entirely separated above from the end of the sulcus paroccipitalis by an annectant parietooccipital gyrus 0.6 cm. broad. The course of the sulcus is sinuous. It is very convex forward below its middle. Length, 4 cm. It ends below about 1 cm. above the lower margin of the facies convexa. It forms the two posterior limbs of an X-shaped sulcus complex situated at the posterior extremity of the lobus parietalis.

SULCI OCCIPITALES SUPERIORES.—There is only one such sulcus. It is 2 cm. long, begins 0.5 cm. below the posterior curve of the sulcus paroccipitalis, runs nearly parallel to the upper part of the sulcus occipitalis transversus, and terminates 0.4 cm. above the uppermost sulcus occipitalis lateralis. About its middle it gives off a posterior ramus less than 0.5 cm. long.

SULCI OCCIPITALES LATERALES.—Of these there are two connected by a cross-piece and giving rise to an H-shaped sulcus complex. The upper of these begins 0.6 behind the sulcus occipitalis transversus, and ends behind near the margin of the hemisphere about midway between the sulcus sagittalis cunei and the fissura calcarina. The lower one ends behind below the fissura calcarina on the facies convexa, close to the *polus occipitalis*.

SULCI TEMPORALES TRANSVERSI OF HESCHL.—The sulcus temporalis transversus tertius separates the *gyrus temporalis transversus secundus* from the *gyrus temporalis transversus tertius*; it is a deep, well-marked groove which reaches the free surface of the *gyrus temporalis superior* and cuts through it into the sulcus temporalis superior, just in front of a well-marked superficial *gyrus temporalis medio-superior secundus* which exists on this side. The sulcus temporalis transversus secundus is marked only in its posterior part. The sulcus temporalis transversus primus is a very shallow groove separating the *gyrus temporalis transversus primus* from the insular portion of the surface.

SULCUS TEMPORALIS SUPERIOR.—It begins behind the *polus temporalis*, an obliquely placed "compensatory" sulcus intervening. One cm. behind its anterior extremity a sulcus goes off from it backward and downward to the sulcus temporalis medius. The sulcus temporalis superior is continued backward to about the junction of its anterior and middle thirds, where it is interrupted by a superficial *gyrus temporalis medio-superior secundus*. Behind this *gyrus* the sulcus begins again in the middle of a long curved transversal sulcus, the extremities of which cut into the *gyrus temporalis superior* and the *gyrus temporalis medius* respectively. The sulcus itself passes backward, curves around the projection of the *gyrus temporalis superior*, caused by the *ramus posterior descendens* of the Sylvian fissure, and then turns upward to end 0.6 cm. from the sulcus interparietalis, midway between the sulcus intermedius primus and the sulcus intermedius secundus of Jeusen. At the point where the sulcus temporalis superior turns upward it anastomoses freely with the sulcus which runs backward into the lobulus parietalis posterior inferior and communicates behind with the anterior superior limb of the X-shaped sulcus complex mentioned in connection with the sulcus occipitalis transversus.

SULCUS TEMPORALIS MEDIUS.—It is manifoldly interrupted. It begins as a curved obliquely placed sulcus 2 cm. long, situated in front of the anterior extremity of the sulcus temporalis inferior, the segment looking like a "compensatory" sulcus for the latter. A little farther back is a shallow curved sulcus, 1.5 cm. long, connected with the oblique sulcus which anastomoses with the anterior portion of the sulcus temporalis superior. Farther back are two long, curved depressions, both of which cut deep into the *gyrus temporalis medius*, the anterior one cutting deep into the *gyrus temporalis inferior*. The posterior extremity of the more posterior of the two anastomoses with the transversal sulcus, which, in turn, forms a superior superficial anastomosis with the sulcus temporalis inferior. A broad *gyrus temporalis medio-inferior* now interrupts the sulcus, which begins again behind it as an obliquely transversal furrow from the middle of which the sagittal sulcus passes backward and then curves upward and backward to run toward the lobulus parietalis posterior inferior. The sulcus just above this, terminating in the lobulus parietalis posterior inferior, may be considered, if desired, as the most posterior segment of this sulcus temporalis medius.

SULCUS TEMPORALIS INFERIOR.—It begins 2 cm. behind the *polus temporalis* and runs backward for 5.5 cm. It is then interrupted by a *gyrus* connecting the *gyrus temporalis inferior* with the *gyrus fusiformis*. Behind this annectant *gyrus*, a sagittal continuation of the sulcus forms the cross-piece of an H-shaped sulcus complex, the side bars of the H being transversal sulci which pass down from the sulcus temporalis medius, across the *gyrus temporalis inferior* into the *gyrus fusiformis*. Another annectant *gyrus* between the *gyrus temporalis inferior* and the *gyrus fusiformis* again interrupts the sulcus. Behind this the continuation of the sulcus forms

the top piece to a π -shaped terminal sulcus complex. Between its posterior extremity and the lower extremity of the sulcus occipitalis transversus a third gyrus connects the gyrus temporalis inferior with the gyrus fusiformis.

FISSURA COLLATERALIS.—This is shallower than on the right side, is separated in front from the gyrus hippocampi by a long, narrow gyrus which runs from the incurved polus temporalis to the middle of the gyrus hippocampi. Behind, it ends near the posterior extremity of the hemisphere, in an obliquely transversal cross-piece, the medial limb of which goes between the two vertical pieces of the π -shaped sulcus complex at the posterior extremity of the sulcus temporalis inferior. The gyrus lingualis is subdivided by a sagittal sulcus which anastomoses in front with the fissura collateralis below the annectant gyrus rhinencephalo-lingualis.

SULCI INSULAE.—Guldberg's central sulcus of the island separates the posterior lobe with its two gyri from the anterior lobe with its four gyri.

THE CEREBELLUM

(Figs. 21, 22, 23, 24, and 25)

The cerebellum looks a little small. It has, however, been distorted in the hardening process. The actual measurements are as follows:

Length (anteroposterior), in the middle	4.1 cm.
Right side (maximal)	6.7 cm.
Left side (maximal)	6.8 cm.
Greatest transverse diameter	9.2 cm.
Greatest height or thickness	4.2 cm.

The distortion has flattened the vertical and increased the anteroposterior diameter. The incisura cerebelli posterior is deep.

Vermis.—The lingula cerebelli has been torn in separating the cerebellum from the rest of the brain stem. It is well developed, is not atrophic or rudimentary, and is a lingula simplex, not duplex. The vincula lingulae cerebelli are symmetrical and not separated from the lingula by notches. The two sides of the posterior free surface of the lingula are symmetrical. The anterior surface is firmly fused posteriorly with the velum medullare anterius.

Lobulus centralis.—This is well developed. It lies almost entirely on the anterior free surface of the cerebellum, but its most superior portion is visible from the facies superior and thus enters to a slight extent into the formation of this surface. On its anterior surface eight *Randwülste* are present, separated from one another by depressions. These *Randwülste* run in general parallel to one another and vary only slightly in thickness. The upper three *Randwülste* are marked off from the ala lobuli centralis on each side by deep indentations; below these three, however, the junction is grooved, but there is no incisure. The delimitation is more sharply marked off on the left than on the right side.

The posterior surface of the lobulus centralis is slightly concave. It presents seven *Randwülste* of approximately equal width. There are no incisures between the *Randwülste* of the central lobule and its alae.

The apex of the central lobule is rather blunt.

The dimensions of the lobulus centralis are as follows:

A. Of facies anterior:

1. From above downward (apex to base)—in the middle 17 mm.
(Stilling's normal measurements vary between 10 and 20 mm.)
2. From right to left—

Above	9 mm.
(Stilling's normal, 4-10 mm.)	
Middle	9.5 mm.
(Stilling's normal, 6-10 mm.)	

B. Thickness:

Just beneath apex	2 mm.
In the middle	5 mm.
At the base	4 mm.

The *ala lobuli centralis* present on both sides the typical double concavity on the anterior free surface corresponding to the *brachium conjunctivum* and the *brachium pontis*. The anterior free surface of each *ala* is subdivided by sulci into numerous *Randwülste* more markedly than in most of Stilling's cases: the configuration is somewhat different on the two sides. The right *ala* presents seven *Randwülste*, the longest being the fifth, which measures 15 mm.; the upper two are the shortest. The sulci do not extend all the way to the posterolateral margin. There is no fusion with the *brachium conjunctivum*, the two being separated by the *pia mater*. The left *ala* also presents seven *Randwülste*. There is a tendency to a radial arrangement of the sulci from a center situated near the lateral apex. An area which is not subdivided exists near this apex. The posterior free surface of the *ala* presents well-marked *Randwülste* and sulci; on the left side this surface is fused with the *lobus intermedius*. The dimensions of the anterior surface of the *ala lobuli centralis* are as follows:

From above downward:

a) Next the lobulus centralis, right side	12 mm.
left side	11 mm.
(Stilling's average, 11-12 mm.)	
b) In the middle, right side	10 mm.
left side	10 mm.
(Stilling's average, 7-8 mm.)	
c) Behind middle of brachium pontis, right side	7 mm.
left side	10 mm.
(Stilling's average, 4-5 mm.)	

Width:

a) Upper margin, right side	18 mm.
left side	22 mm.
(Stilling's average, 16-22 mm.)	
b) Lower margin, right side	16 mm.
left side	18 mm.
(Stilling's average, 14-20 mm.)	

In general, then, it may be stated that the lobulus centralis and its *ala* are well developed and the asymmetry is within normal limits.

Monticulus.—The monticulus on examination is found to be developed in both culmen and declive. There is a high lobus intermedius between the lobulus centralis and the first portion of the culmen. Its apex does not, however, reach the surface of the vermis superior. The general configuration of the culmen, when distortion has been discounted, corresponds very closely to that depicted in Stilling's Fig. 122. The declive is also typical, though the sagittal section (Fig. 26) has, in this region, deviated somewhat from the median plane, so that the posterior part of the section passes through the edge of the hemisphere and not through the posterior part of the worm.

Other parts of vermis.—The tuber, pyramis, nvula, and nodulus of the vermis inferior are present in the gross specimen in normal arrangement.

Hemisphaeria cerebelli.—The hemispheres show no marked microscopic alterations.

Lobulus quadrangularis.—Counts of the *Randwülste* give the following results:

Upper surface:

Right side—

1. Near vermis	21
	(Stilling's normal, 17-19)
2. Near pons	14
	(Stilling's normal, 12-14)
3. In middle, between vermis and pons	20
	(Stilling's normal, 22-26)

Left side—

1. Near vermis	14
	(Stilling.)
2. Near pons	15
3. In middle, between vermis and pons	23

The six walls (*Wände*) correspond to the six *Wände* of the *Monticulus*. The first wall is doubled on the left side; the second, on the right side. The fourth wall is but slightly developed, being represented by a projection in the depth, between the third and fifth walls.

The dimensions of the *lobulus quadrangularis* are as follows on the upper surface:

1. In sagittal direction next to <i>monticulus</i> , left	4.3 cm.
right	4.6 cm.
	(Stilling, 33-40 mm.)
Next to <i>brachium pootis</i> , left	2.3 cm.
right	2.4 cm.
	(Stilling, 18-20 mm.)
2. In transversal direction on anterior margin, left	2.0 cm.
right	2.4 cm.
	(Stilling, 23-35 mm.)
Posterior margin, left	5.8 cm.
right	5.7 cm.
	(Stilling, 65-72 mm.)

Lobulus semilunaris superior.— On the right side the number of *Randwülste* on the surface near the *incisura cerebelli posterior* is five; on the left side, seven. On the right side, on the surface in the middle, there are thirteen *Randwülste*; on the left side, fourteen.

The maximal sagittal measurement of the upper surface on the right side is 1.2 cm.; on the left side, 1.8 cm. The curved measurement transversally along the posterior margin is on the right side 7.5 cm.; on the left side, 6.5 cm.

Lobulus semilunaris inferior:

Number of <i>Randwülste</i> near vermis, right	8
left	10
“ “ “ lateral margin, right	4
left	3
“ “ “ in middle, right	8
left	9
Maximal sagittal measurement, right	1.7 cm.
left	2.2 cm.
Maximal length of posterior margin, right	7.4 cm.
left	7.0 cm.

40 DESCRIPTION OF BRAIN AND SPINAL CORD IN HEREDITARY ATAXIA

The anterior and posterior roots of the spinal nerves show no alteration, except possibly a slight increase in the endoneurium.

The pia mater is a little thickened.

Thickness of pia over funiculus lateralis	- . . .	0.078 to 0.155 mm.
Thickness of pia over funiculus posterior	- . . .	0.048 to 0.081 mm.
Thickness of pia over funiculus anterior	- . . .	0.037 to 0.087 mm.

The subplal layer of neuroglia (*Glia-tulle* of the Germans) is much thicker in the lumbar region than normal. The average thickness over the funiculus anterior is 0.18 mm. There are two triangular indentations in the anterior part of the cord where this glial layer measures 0.261 mm. and 0.243 mm. in depth.

Thickness of subplal layer of glia over fasciculus Lissaueri	- . . .	0.152 mm.
Thickness of subplal layer of glia over funiculus posterior (lateral part)	- . . .	0.017 mm.
Thickness of subplal layer of glia over funiculus posterior (near median septum)	- . . .	0.004 mm.

Study of sections stained with Weigert's myelin sheath stain or with iron hematoxylin stain of chromicized tissues.—The fasciculi stain, on the whole, normally. There are no degenerated areas. An exception is to be made for the middle root zone (Flechsig) of the funiculus posterior, which is lighter than the rest of the funiculus, and the glia is more abundant than normal in this lightened area. In view of the fact that the nucleus dorsalis and the direct cerebellar tract higher up are degenerated, it is interesting to note that it is this middle root zone of Flechsig in the lumbar cord which contains those posterior root fibers which run in to end in the gray matter of the nucleus dorsalis at a higher level. Aside from the alteration in this middle root zone, the dorsal funiculi show no change. Lissauer's fasciculus is well developed. The pyramidal tracts and fasciculi proprii of the funiculus lateralis look normal. No alteration can be made out in the funiculus anterior. The fine medullated fibers (terminals and collaterals) which pass through the substantia gelatinosa appear normal in number and distribution. The anterior and posterior white commissures show no change.

Sections stained by Nissl's method, in thionin, and in toluidin blue.—The anterior horn cells are present in nearly normal number, though they may be slightly reduced. No change in size, shape, or distribution is discoverable. The internal morphology of these cells appears to be quite normal. The nuclei are centrally placed, and the nucleoli stain intensely. The stichochrome arrangement of the tigroid masses is well preserved in the dendrites and also in the perikaryons. Abundant masses of lipochrome can be seen in many of the anterior horn cells.

PARS THORACALIS.—The cord has been a little flattened on removal. The dimensions are:

Anterior posterior diameter	- . . .	0.5 mm.
Transverse diameter	- . . .	0.9 mm.
Average diameter in the two directions	- . . .	0.7 mm.

Professor Donaldson's measurements of a cross-section show an area of white matter of 6.955 sq. cm. and an area of gray matter of 0.673 sq. cm. This is a ratio of 1:13,⁶ which is clearly abnormal.

The anterior and posterior roots of the spinal nerves show no changes.

The subplal layer of neuroglia measures as follows:

⁶Cf. Donaldson, H. H. and D. G. Davis. A description of chart showing the areas of the cross-sections of the human spinal cord at the center of each spinal nerve. *J. Comp. Neurol.*, Granville, Vol. XIII (1903), pp. 18-39.

Thickness over funiculus lateralis (direct cerebellar tract)	. . .	0.35 mm.
Thickness over funiculus anterior	. . .	0.26 mm.
Thickness over funiculus posterior (funiculus cuneatus)	. . .	0.35 mm.
Thickness over funiculus posterior (funiculus gracilis)	. . .	0.22 mm.

Sections stained with Weigert's myelin sheath stain or with iron hæmatoxylin after chromicizing. (Fig. 45.)

Funiculus anterior.—Nothing abnormal discernible.

Funiculus lateralis.—The fasciculus spinocerebellaris dorsolateralis (direct cerebellar tract) is almost entirely degenerated. Throughout the whole thoracic portion of the spinal cord a narrow stripe, situated on the dorsolateral surface of the cord, corresponding to the position of this tract, is almost devoid of medullated fibers, its place being represented only by glia. This area of degeneration does not extend farther forward, in the middle and lower portion of the thoracic cord at any rate, than a point opposite the columna intermediolateralis of the substantia grisea. It extends backward for a variable distance and usually does not reach as far behind as Lissauer's fasciculus. The internal margin of the degenerated stripe is irregular, corresponding to the admixture of the direct cerebellar tract with adjacent fiber systems (pyramidal tract). The external margin of the degenerated stripe is the periphery of the cord. Scattered medullated fibers still exist in the degenerated area. These vary in diameter from 5 to 15 microns, the majority being large fibers (the average diameter of the fibers of the direct cerebellar tract is about 8μ).

The maximum depth of the degenerated area measured from the surface of the cord inward is on one side 0.915 mm. and on the other 0.560 mm. The degenerated area begins, as a rule, 1 mm. anterior to Lissauer's funiculus, and extends ventralward for a distance of 2.5 mm. The area is comma-shaped, the head of the comma being directed ventralward and the tail dorsalward.

The fasciculus spinocerebellaris ventrolateralis (Gowersi) shows no recognizable alterations, at least in the middle and lower thoracic cord. The fasciculi cerebrospinales laterales look normal, as do the fasciculi laterales proprii.

Funiculus posterior.—A light strip near the medial septum on each side, ventrally continuous with a much less lightened and very diffuse area in the lateral portion of the fasciculus cuneatus on each side, is visible. The glia is slightly increased in amount in this area. The areas correspond to the distribution of the third system of fibers (foetus 35 cm. long) of Trepinski's developmental studies—that is, to precisely the same system of fibers as that to which belong the fibers of the middle root zone of the lumbar portion of the spinal cord. Otherwise the funiculi posteriores show no alterations.

Sections stained by Nissl's method, in thionin, and in toluidin blue.—Sections were taken from ten different levels of the pars thoracalis. The whole cord is flattened anteroposteriorly, possibly owing to slight injury on removal. With this flattening there is marked displacement of the posterior horns to the side. The anterior horn cells are present in normal numbers, are of the usual size, and present the typical stichochromo arrangement of their tigroid masses.

The cells of the columna intermediolateralis are a striking feature of the sections throughout the pars thoracalis, and they are present in normal numbers, are elliptical usually in shape, and measure from 7μ to 38μ in the long diameter and from 5μ to 18μ in the short diameter (Ziehen gives as the normal 12 to 15μ in the long, and 5 to 15μ in the short, axis). The tigroid substance in these cells is very variable. The masses are irregular in size, shape, and distribution. In many of the cells the tigroid masses are arranged at the periphery, the center of the cell being pale or staining diffusely blue. The nuclei of some of these cells are situated at one pole or one edge of the cell; they may have a crescentic shape and look shrunken.

The cells of the column posterior include (1) the cells of the nucleus dorsalis (Clarke's column), (2) the cells of the substantia gelatinosa Rolandi, (3) the cells of the zonal layer (*cellules limitantes*), and (4) the cells of the column posterior propria (Waldeyer's nucleus of the dorsal horn).

Of these, the cells of Clarke's column interest us most, for they have almost entirely disappeared throughout the whole length of the nucleus. In many sections not a single cell is visible; where any cells are left at all, the number does not exceed from one to three in a section (Fig. 35). The few cells remaining present no characteristic alterations when compared with the normal cells of control preparations. The tigroid masses are irregular in size and distribution; occasionally they are peripherally disposed. The nuclei may be eccentrically placed, and the nucleoli stain intensely.

An examination of the so-called Gierke's cells of the substantia gelatinosa has been made. On comparison with control preparations, they appear to be normal.

The marginal cells of the zonal layer are normal in number and appearance. I cannot detect any alteration in the triangular cells of Waldeyer's nucleus of the dorsal horn.

PARS CERVICALIS AND TRANSITION INTO MEDULLA:

Sections stained by Weigert's method, and with iron hæmatoxylin.—The degenerated area still corresponds to the situation of the direct cerebellar tract. The area is larger than in the thoracic portion of the cord, and begins nearer the dorsal horn. In sections through the junction of the spinal cord with the medulla oblongata the degenerated area is exquisitely marked out. It is approximately triangular in shape, the apex of the triangle being on the surface, behind, opposite the dorsal horn, the base in front. The two sides of the triangle are formed by the periphery of the cord and the lateral surface of the lateral pyramidal tract respectively. On one side of the cord a large bundle of pyramidal tract fibers plunges directly through the degenerated area, just after decussation; these fibers are surrounded on all sides by the pale yellow glia of that part of the cord from which fibers of the direct cerebellar tract have almost entirely disappeared (*vide* Fig. 41). The distance from the apex to the base of the triangle is 2.128 mm.; the width of the base is 0.598 mm. A few scattered healthy fibers remain in the degenerated area, as was the case in the sections through the pars thoracalis. These are chiefly fibers of very large caliber. The subpial neuroglia layer over the degenerated area measures 0.113 mm. in thickness.

There is slight diffuse lightening of the area extending for 1 to 1.5 mm. in front of the main triangle of degeneration, and with the high power it is seen that the nerve fibers do not stand so closely together here as they do normally. Either a few fibers of the direct cerebellar tract have been present in this area, or we have to deal with a slight loss of fibers in the ventral spino-cerebellar tract of Gowers.

In the dorsal funiculi there is a long, narrow, slightly lightened strip close to the medial margin of the fasciculus gracilis, and a still more diffuse, slightly lightened area near the lateral middle portion of the fasciculus cuneatus. There has been an actual loss of fibers from these areas.

The fasciculi cerebrospinales contain no lightened areas in the cross-sections. This is true, also, of the various fasciculi proprii. Helweg's path is not distinguishable by any color differences from the surrounding white matter.

Sections stained by Nissl's method, with thionin, and with toluidin blue.—The cells of the ventral horns are present in normal number and distribution. The tigroid substance is abundant, and a large number of these cells are richly provided with masses of lipochrome. No alteration in any of the nerve-cells in this portion of the nervous system is discernible.

MEDULLA OBLONGATA

(Figs. 29, 30, 40, and 41)

LEVEL OF DISTAL PORTION (ABOVE DECUSSATIO PYRAMIDUM AND AT THE LOWER PART OF THE DECUSSATIO LEMNISCORUM, CENTRAL CANAL STILL CLOSED):

Sections stained with Weigert's myelin sheath stain or with iron hamatoxylin.—There is a triangular area of degeneration in the position of the direct cerebellar tract which is situated, at this level, just ventrolateral from the laterally deflected dorsal horn on each side. The apex of the triangle is directed medialward; the base, somewhat curved, corresponds to the periphery of the medulla. Between the apex of the triangle and the most ventral portion of the substantia gelatinosa, an area, 0.25 mm. in breadth, of undegenerated, rather fine fibers, intervenes. On the very periphery of the medulla, the area of degeneration is bounded by some medullated fibræ arcuatae externae.

The funiculi posteriores are normal in appearance, as are the pyramids and the bundles in the regions of the medulla other than that of the direct cerebellar tract. The spinal tract of the trigeminal nerve looks normal.

LEVEL OF NUCLEI NERVI HYPOGLOSSI AND NUCLEUS ALAE CINERÆ:

Sections stained by Weigert's method.—The pyramids and stratum interolivare lemniscæ are normal on each side. The fibræ arcuatae internæ and fibræ arcuatae externæ appear normal. The tractus spinalis n. trigemini and the fasciculus solitarius are well developed and unaltered. The degenerated area corresponding to the direct cerebellar tract has disappeared at this level, apparently having turned into the corpus restiforme. The latter structure, however, appears to be evenly dark and the position of the degenerated fibers is not ascertainable. The root fibers of the nervus hypoglossus look normal. The fibræ olivocerebellares show no obvious change. No extensive alterations have been made out in the various masses of gray matter at this level—nucleus nervi hypoglossi, nucleus alae cineræ, nucleus olivaris inferior, nuclei olivares accessorii, nucleus funiculi cuneati, and nuclei arenati. The number of cells in the gray matter of the olive is probably smaller than normal; indeed, the size of all the structures seems somewhat diminished (cf. Fig. 33).

LEVEL OF PROXIMAL EXTREMITY OF THE MEDULLA OBLONGATA AT REGION OF ENTRANCE OF N. ACUSTICUS:

Sections stained by Weigert's preparations.—No alterations are visible in the vestibular nerve or its nuclei.

PONS VAROLII

LEVEL OF BRACHIUM CONJUNCTIVUM AND VELUM MEDULLARE ANTERIUS:

The brachium conjunctivum is smaller in volume than normal; the fibers are a little thinned; the average caliber of the fibers is small; the glia is rather more abundant than normal. The fasciculus longitudinalis medialis, though rather small in volume, in transverse section stains normally. There is no degeneration of the lemniscus lateralis. The fasciculus tegmenti centralis (*centrale Haubenbahn*) is of normal size and stains well. The longitudinal fasciculi and the transverse fibers of the pons stain normally. The gray matter of the formatio reticularis in the pars dorsalis pontis and that of the nuclei pontis in the pars ventralis appear to be normal in amount and distribution.

CEREBELLUM

WEIGERT PREPARATIONS

STUDY OF SAGITTAL SECTIONS THROUGH CEREBELLUM:

1. *Sagittal sections near median plane of vermis* (Fig. 26).

a) *Corpus medullare.*—The laminae medullares look normal in Weigert preparations. In

44 DESCRIPTION OF BRAIN AND SPINAL CORD IN HEREDITARY ATAXIA

the corpus trapezoidum and the main vertical limb of the arbor vitae the transversely running fibers of the great anterior decussation are to be seen.

b) *Substantia corticalis*.—Except that the verula is on the whole somewhat smaller than in the brother's brain, the appearances are very much the same. The molecular layer is separated from the granular layer by the layer of ganglion cells. The latter are very irregularly distributed, but this is true of the normal cerebellum.

c) *Nucleus fastigii*.—The area for this nucleus is present in its normal position, but the study of a number of sections shows an apparent diminution in the number of nerve-cells present in it. The nerve-cells found are smaller than normal. Glia cells are abundant. The medullated fibers extending through the brachium conjunctivum between the region of Deiter's nucleus in the medulla and the region of the nucleus of the roof are a prominent feature of the sections; they are present in apparently normal numbers.

2. *Sagittal section about 6½ mm. or 7 mm. lateral from the median plane*.—The section passes through the nucleus globosus and the nucleus emboliformis and through the medial portion of the hemisphaerium cerebelli, thus cutting, above, the lobulus quadrangularis and the lobulus semilunaris superior, and, below, the lobulus semilunaris inferior, the lobulus gracilis, the pyramis, and the tonsilla.

a) *Substantia corticalis*.—No alterations are discernible.

b) *Nucleus emboliformis*.—In this section this nucleus is spindle-shaped, the maximum length of the spindle being 8 mm., its maximum dorsoventral diameter, 2½ mm.; above it are three minute islands of gray matter, which belong to the most medial part of the nucleus dentatus, while below and behind it is the mushroom-like head of the nucleus globosus. Beneath it and in front of it are the fibers of the brachium conjunctivum. The section evidently passes through only the more lateral and posterior part of the nucleus emboliformis. Large numbers of large ganglion cells are present.

c) *Nucleus globosus*.—This section passes through the posterior head of the mushroom-like nucleus and through the posterior part of its stem.

Greatest vertical diameter in sections = 2 mm.
Greatest sagittal diameter in sections = 5¼ mm.

Owing to the flattening of the cerebellum as a whole in the hardening process, it is probable that the vertical diameter is here very small owing to an increase in the transverse diameter. The nucleus globosus is separated from the under surface of the nucleus emboliformis by a well-preserved narrow band of medullated fibers. Numbers of ganglion cells are present in the nucleus.

d) *Nucleus dentatus*.—Only three small islands of ganglion cells are present; these are obviously cross-sections through the most medial projections of the dentate nucleus.

e) *Corpus medullare*.—The laminae medullares of the different cortical areas are well developed and fuse with the central white substance. The transversely and obliquely cut fibers corresponding to the anterior and posterior decussation-commissures look normal. The fibers of the brachium conjunctivum (*Stilling's processus cerebelli ad corpora quadrigemina*) look a little thinner and the blood-vessels in it are dilated.

3. *Sagittal section through hemisphaerium cerebelli about 14 mm. lateral from sagittal median plane of vermis*.—The section passes through the lobus quadrangularis, lobulus semilunaris superior, lobulus semilunaris inferior, lobulus gracilis, lobus biventer, and the flocculus, the lateral part of the nucleus dentatus, the fibræ semicirculares cerebelli, and the central part of the brachium pontis.

The nucleus dentatus is here growing small in size and is much convoluted. The cells in its gray matter are more numerous than in the nucleus dentatus of the brother, but less

numerous than in a normal control. Each cell contains a mass of yellowish green pigment (in toluidin blue preparations) which is probably identical with the lipochrome of anterior horn cells. I can make out no decided alterations in the corpus medullare at this plane.

4. *Sagittal sections through hemisphaerium cerebelli lateral from the nucleus dentatus.*—The corpus medullare gradually grows smaller in volume, the fibræ semicirculares less distinct as in normal preparations. No alterations other than the general diminution in volume are discernible.

STUDY OF FRONTAL SECTIONS THROUGH CEREBELLUM:

1. *Frontal section a few millimetres in front of apex of culmen.*—This section passes in front of all the gray nuclei of the cerebellum and shows, besides the cortical portions of the vermis and hemisphaerium, the great central mass of white matter just as it is going over into the brachium pontis. No areas of degeneration are visible.

2. *Frontal section near apex of culmen.*—The section has passed a little obliquely lateralward and backward, having caught the jagged edge of the latero-inferior portion of the anterior extremity of the nucleus dentatus. The mass of fibers corresponding to the area of the brachium conjunctivum looks thin and lightened in Weigert preparations, though it is crossed by obliquely cut strands of deeply staining fibers of large caliber. The latter accumulate near the nucleus fastigii. The latter is not well developed, and relatively few cells are to be found in it.

3. *Frontal section about 6 mm. behind highest point of culmen.*—The origin of this section is easily recognizable by the horseshoe shape presented by frontal sections of the nucleus emboliformis in this plane. Below it is a cross-section of the nucleus globosus, here represented by a large, rather triangular mass with two small gray masses lateral from it and one small gray mass just medial from it. All these lie in the hilus of the nucleus dentati. The only representative of the nucleus fastigii is a minute mass of gray matter near the median plane of the vermis.

The white matter within the nucleus dentatus looks pale in Weigert preparations, and the blood-vessels are dilated. This pallor is not so marked, however, as in the brain of the brother. The great anterior decussation-commissure is well developed and stains lateously in the Weigert preparations.

4. *Frontal section through the declivity and posterior extremity of the nucleus dentatus.*—Sections through this level show the most posterior portions of the nucleus dentatus imbedded in the corpus medullare. Sections through the nucleus dentatus when compared with sections from the normal cerebellum reveal a smaller number of nerve-cells.

NISSL PREPARATIONS

Sections were made from the cortex of the vermis and of the cerebellar hemispheres. No striking differences in appearance in the sections from the two sources could be made out, except that the Purkinje cells in the hemisphere look smaller than in the vermis. (Cf. Figs. 28 and 29.)

The *molecular layer* measures from 0.326 mm. to 0.363 mm. in thickness. It is thicker near the bases than at the summits of the folia.

The *granular layer* measures 0.4 mm. in thickness at its thickest part. It is, however, very variable in depth and near the bottom of the interlamellar sulcus may be as thin as 0.1 mm. These measurements are smaller than those given as normal by Poirier et Charpy, according to whom the molecular and granular layers are of equal thickness, each measuring 0.5 mm. in depth. Von Kölliker, however, gives as the normal thickness of the molecular layer in human beings the measurements 0.15–0.40 mm.; he does not make any statement regarding the thickness of the granular layer.

The Purkinje cells are of normal size in the vermis, but rather small in the hemisphere; they present cell bodies rich in stainable substance of Nissl, large, pale nuclei, and large, deeply

staining nucleoli. The question, "Are the Purkinje cells present in normal numbers?" is a difficult one to answer. They often lie very close together in the single row in which they are arranged, but wide gaps between Purkinje cells are very frequently met with (*vide* Fig. 29). These gaps may be as wide as 0.6 mm. Stilling's statement with regard to the distances between the individual Purkinje cells is as follows:

Die grossen Nervenzellen liegen nämlich, in mehr oder minder regelmässiger Weise, in mehr oder minder grossen Strecken von einander entfernt, und lassen also einen Zwischenraum, meist je von $1/50''$, zwischen sich; oft stehen sie auch gedrängter in einer und derselben Ebene, nur durch eine Entfernung je von $1/150''$ getrennt; nicht selten berühren sich sogar mehrere unmittelbar. In manchen Ebenen sind sie dagegen wieder auffallend weit, bis zu $1/12''$, von einander entfernt. Da man in seinen Abschnitten doch meist nur Theile der einzelnen grossen Nervenzellen (nutzlos) zu Gesicht bekommt, so übersieht man gewiss oft genug Fragmente dieser Nervenzellen, und wo eine auffallend lange Strecke ohne grosse Nervenzellen erscheint, lagen vielleicht dennoch einige, die durch die Präparation unkenntlich wurden. Immerhin aber treten in den, zwischen den einzelnen grossen Nervenzellen befindlichen, grösseren oder kleineren Zwischenräumen dennoch die einzelnen Elemente der Zellen- und Körnerschicht in unmittelbare Berührung resp. Verbindung, d. h. an zahllosen Stellen.

If he had dealt with thinner sections, he would doubtless have met with instances of greater intervals, but, even allowing for the difference in thickness of sections, it would seem not unlikely that there is in the case here described an actual diminution in the total number of Purkinje cells as compared with Stilling's findings. On comparison with control preparations, however, I am not convinced that the number of Purkinje cells is below normal. In Fig. 27 has been reproduced a section of the hemisphere of the cerebellum of a physician dead of myasthenia gravis, in which disease there is presumably no diminution in the number of Purkinje cells. The interspaces between cells are seen to be very large.

In Krohn's case of atrophy of the cerebellum, met with in an ataxic cat, studied in Donaldson's laboratory, there was extensive atrophy of the cerebellum as a whole, with marked diminution in thickness, particularly of the molecular layer. In places the Purkinje cells had disappeared entirely, leaving open, empty spaces in their places, and the Purkinje cells in general were markedly shrunken. There seemed to be but little alteration in the granular layer or in the white medullary substance.

CEREBRAL CORTEX:

Gyrus centralis anterior.—The gray matter is 2 mm. thick on the surface, 2.5 to 3 mm. thick on the walls of the sulci. The plexiform layer measures 0.319 mm. in thickness. The various layers of pyramidal cells are present in Nissl preparations. I can make out no definite alterations in them.

Gyrus cuneus (near fissura calcarina), Nissl preparations.—The plexiform layer measures 0.156 mm. in depth. It contains a very few scattered nuclei, the majority being small and round and looking like ordinary glia nuclei. A few polygonal and spindle-shaped nuclei are, however, also present in this layer. The layer of small pyramidal cells and the layer of medium-sized pyramidal cells together measure 0.438 mm. in depth. The layer of large stellate cells is 0.133 mm. deep; that of the small stellate cells, 0.292 mm.; and that of the small pyramidal cells, with ascending axones, 0.119 mm. deep. The giant pyramidal cells are widely removed from one another and their cell-bodies and nuclei look normal. The layer of pyramidal cells with curved, ascending axones measures 0.199 mm. in depth and the layer of spindle-shaped cells, 0.20. The total thickness of the gray matter here is 1.6 mm. in its thinnest part.

* W. O. KROHN, "Atrophy of Cerebellum in Cat," *Journal of Nervous and Mental Diseases*, New York (October, 1892).

RÉSUMÉ OF MORBID ANATOMY

The brains and cords of both cases are relatively small, the cords, medulla, and pons in each case looking smaller in proportion than the cerebrum.

The cerebral cortex in both cases is well fissured; indeed, if there be abnormality, it is on the side of over-fissuration rather than on that of under-fissuration. The form of the various sulci and gyri is fully described in the protocols, and a study of these reveals no deviations from the normal type which can be regarded as standing in relation to the disease from which the family suffered. The cerebral topography is, however, interesting, aside from the pathology of the case, in that it presents an opportunity for comparing the similarities and differences in the brain-surfaces of two brothers.

The cerebellum, though a little small in each case, is very typical in macroscopic configuration. The cerebellar peduncles (superior, middle, and inferior) are all relatively small; the diminution in size is not marked, however.

The spinal cord looks a little smaller than normal in each case, that of Case XVIII looking smaller than that of Case XX; and this is in accord with the actual measurements. Measurements made by Professor Donaldson show an abnormal ratio between the area of white matter and the area of gray matter in the cross-sections.

The microscopic study in both cases reveals marked degeneration in the gray and white matter of the spinal cord, medulla oblongata, and cerebellum. The degeneration is considerably more advanced in Case XVIII than in Case XX, though the difference is in degree rather than in kind. The degeneration involves in both cases chiefly nerve-cells and nerve-fibers of centripetal paths, including one system of exogenous fibers of the posterior funiculus (apparently corresponding to the third fetal system of Trepinski), the dorsal nucleus of Clarke, the direct cerebellar tract of Flechsig in the lateral funiculus and its continuation in the restiform body. In these structures the degeneration is very extensive; in addition there has been some involvement of the dentate nucleus of the cerebellum and the brachium conjunctivum, and probably also of the inferior olivary nucleus of the medulla oblongata; in the more advanced case there may be a slight diminution in the number of the anterior horn cells, and of the fibers of the nerve-roots.

Corresponding to the degeneration in the white fibers of the spinal cord, there has been an increase in the glia tissue—an increase which is relatively more pronounced in the dorsal funiculus than in the area of the lateral funiculus corresponding to the direct cerebellar tract.

Only one case from this family has been previously studied histologically, but that one, fortunately, by Dr. Alois Meyer,¹ who found no circumscribed cerebellar lesion, but made out a marked diminution in the number of cells in Clarke's nucleus, a degeneration of the direct cerebellar tract, and an elective degeneration of the posterior funiculus, especially marked in the pars cervicalis, where it involved the medial

¹ A. MEYER, "The Morbid Anatomy of a Case of Hereditary Ataxia," *Brain*, London, Vol. XX (1897), pp. 276-88.

part of the fasciculus gracilis, and to a less extent the posterior part of this fasciculus and the most medial part of the fasciculus cuneatus.

In general, then, the lesions in the three cases thus far studied are nearly identical as regards the neurones involved, though there are differences in the extent of the process quite in accord with the differences in clinical symptoms as the cases were more or less advanced. Dr. Meyer interprets the degeneration in the posterior funiculus as a degeneration of the collaterals which connect the lower levels with the higher (cerebral and cerebellar) apparatus, comparable to the degeneration of the lateral pyramidal tracts of the lower segments of the cord where the basilar part of the cerebral peduncle and the pyramids of the medulla show no degeneration. I am inclined to look upon the degeneration in the posterior funiculus rather as systemic; *i. e.*, as involving certain only of the stem-fibers and collaterals of the intramedullary continuation of the posterior roots, namely, those corresponding to one period of medullation in the embryo. Recent studies make it appear probable (1) that the medullation of the fibers of the posterior roots corresponds more or less closely to the medullation of their intrafunicular continuations, and (2) that the fibers of the posterior funiculi which terminate in the nucleus dorsalis are terminals of the main ascending limb of bifurcation rather than collaterals. In the near future the writer hopes, in another paper, to enter into a rather full discussion of the relation of the lesions found in these cases to the clinical symptoms presented by the patients during life, a discussion which necessarily involves some consideration of the whole question of co-ordination. The discussion of the relations of the disease to Friedreich's ataxia and similar maladies, and of the validity of Marie's classification of hereditary cerebellar ataxia is also deferred. It will be of especial interest to contrast the Haud family studied clinically by Klippel and Durante and anatomically by Thomas and Roux with the cases described above. In the French family the lesion involved chiefly the ventrolateral cerebellar fasciculus of Gowers'; Meyer's studies and my own show that, in the American family described by Sanger Brown, the dorsolateral cerebellar tract is the one which degenerates. The present report together with that of Dr. Adolf Meyer, makes it very clear that the morbid anatomy of the affected members of the family described by Dr. Sanger Brown presents very constant features; we now know with certainty the neurone-systems principally involved in the individuals who are affected, though we are as yet entirely ignorant as to why just these neurone-systems should be picked out.

LEGENDS FOR FIGURES (PLATES XXVIII-XXXIX)

- FIG. 1.—Case XVIII. Cerebellum. Facies superior.
 FIG. 2.—Case XVIII. Cerebellum and rhombencephalon. Facies inferior.
 FIG. 3.—Case XVIII. Cerebrum. Hemisphaerium dextrum, polus frontalis.
 FIG. 4.—Case XVIII. Cerebrum. Hemisphaerium sinistrum, polus frontalis.
 FIG. 5.—Case XVIII. Cerebrum. Hemisphaerium sinistrum, polus occipitalis.
 FIG. 6.—Case XVIII. Cerebrum. Hemisphaerium dextrum, polus occipitalis.

* P. MARIE, "Sur l'hérédité ataxique cérébelleuse," *Semaine méd.*, Paris, Vol. XIII (1893), pp. 444-7.

- FIG. 7.—Case XVIII. Cerebrum. Hemisphaerium dextrum, facies convexa.
 FIG. 8.—Case XVIII. Cerebrum. Hemisphaerium sinistrum, facies convexa.
 FIG. 9.—Case XVIII. Cerebrum. Hemisphaerium sinistrum, facies inferior.
 FIG. 10.—Case XVIII. Cerebrum. Hemisphaerium sinistrum, facies superior.
 FIG. 11.—Case XVIII. Cerebrum. Hemisphaerium dextrum, facies superior.
 FIG. 12.—Case XX. Cerebrum. Hemisphaerium dextrum, facies convexa.
 FIG. 13.—Case XX. Cerebrum. Hemisphaerium sinistrum, facies convexa.
 FIG. 14.—Case XX. Cerebrum. Hemisphaerium dextrum, facies medialis.
 FIG. 15.—Case XX. Cerebrum. Hemisphaerium sinistrum, facies medialis.
 FIG. 16.—Case XX. Cerebrum. Facies superior.
 FIG. 17.—Case XX. Basia cerebri.
 FIG. 18.—Case XX. Cerebrum. Hemisphaerium dextrum, polus frontalis.
 FIG. 19.—Case XX. Cerebrum. Hemisphaerium sinistrum, polus frontalis.
 FIG. 20.—Case XX. Rhombencephalon and cerebellum. Ventral view.
 FIG. 21.—Case XX. Cerebellum. Facies superior. Left half.
 FIG. 22.—Case XX. Cerebellum. Facies superior. Right half.
 FIG. 23.—Case XX. Cerebellum. Facies inferior. Right half.
 FIG. 24.—Case XX. Cerebellum. Facies inferior. Left half.
 FIG. 25.—Case XVIII. Cerebellum. Sagittal section. Near median plane of vermis.
 FIG. 26.—Case XX. Cerebellum. Sagittal section. A little lateral from median plane of vermis in front, but passing somewhat obliquely so as to cut through most medial part of the hemisphere behind.
 FIG. 27.—Section through the cerebellar hemisphere of a man dead of myasthenia gravis; supposedly normal distribution of Purkinje cells.
 FIG. 28.—Section through cerebellar hemisphere of Case XX; same magnification as in Fig. 27.
 FIG. 29.—Section through vermis superior of Case XX; same magnification as in Fig. 27.
 FIG. 30.—Section through a portion of the nucleus dentatus cerebelli of a presumably normal case.
 FIG. 31.—Section through the nucleus dentatus cerebelli of Case XX, showing diminution in number of cell-bodies. The diminution is more pronounced in this section than in many other sections, but there are numerous places where the cells are as few as here represented.
 FIG. 32.—Section through a portion of the nucleus olivaris inferior, showing the number of cells in a presumably normal case.
 FIG. 33.—Section through a portion of the nucleus olivaris inferior of Case XX. The section is thinner than that of Fig. 32, so that the decrease in the number of cells is not so great as might at first sight appear. There is moderate diminution, however, throughout.
 FIG. 34.—Section through the nucleus dorsalis [Clarkii] of the lower thoracic cord from a case of myasthenia gravis. Number of cells presumably normal.
 FIG. 35.—Section through the nucleus dorsalis [Clarkii] of the lower thoracic cord of Case XX, showing remarkable loss of cell-bodies.
 FIG. 36.—Section through colliculus inferior, and pars basilaris pontis of Case XX. Weigert preparation.
 FIG. 37.—Section through pons at level of brachium pontis, Case XX. Weigert preparation. The brachium conjunctivum shows some thinning of its fibers under the microscope, though this is not brought out in the illustration.
 FIG. 38.—Section through the upper part of the medulla oblongata, Case XX.

FIG. 39.—Section through the medulla oblongata at the level of the lower part of the nucleus olivaris inferior, Case XX.

FIG. 40.—Section through the medulla oblongata at the upper part of the decussatio lemniscorum and nucleus olivaris accessorius, Case XX.

FIG. 41.—Section through the lower part of the medulla oblongata at the level of the decussatio pyramidum, Case XX. The degeneration of the direct cerebellar tracts is well shown. The degenerated area on one side contains islands of medullated fibers, probably displaced fibers of the lateral pyramidal tract.

FIG. 42.—Section through the cervical enlargement of the spinal cord of Case XVIII.

FIG. 43.—Section through the spinal cord of Case XVIII. Pars thoracalis.

FIG. 44.—Section through the spinal cord of Case XVIII. Intumescentia lumbalis.

Level of T xii.

FIG. 45.—Section through the spinal cord of Case XX. Pars thoracalis.

FIG. 46.—Section through the spinal cord of Case XX. Intumescentia lumbalis. Level of L iii.

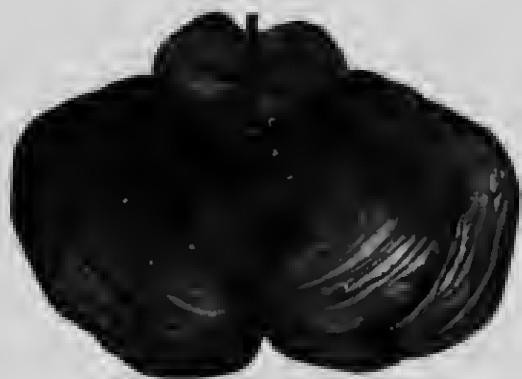

FIG. 1



FIG. 2



FIG. 3

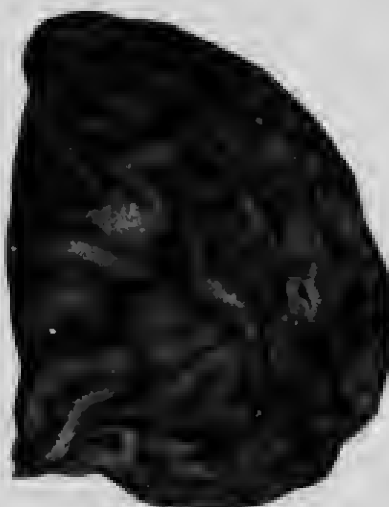

FIG. 4

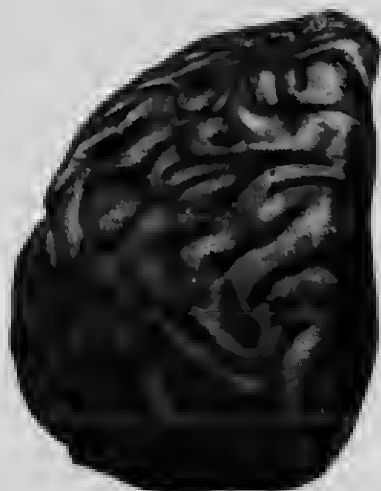

FIG. 5

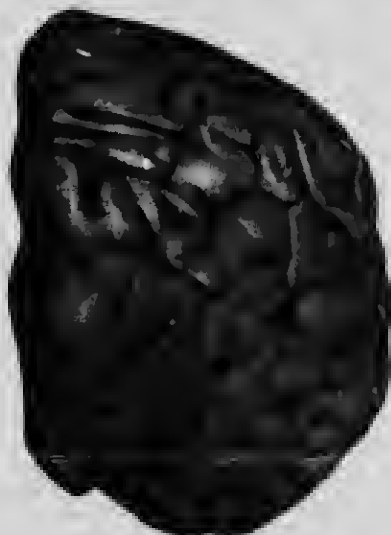

FIG. 6

[The page contains extremely faint and illegible text, likely bleed-through from the reverse side of the document. The text is too light to be transcribed accurately.]

111

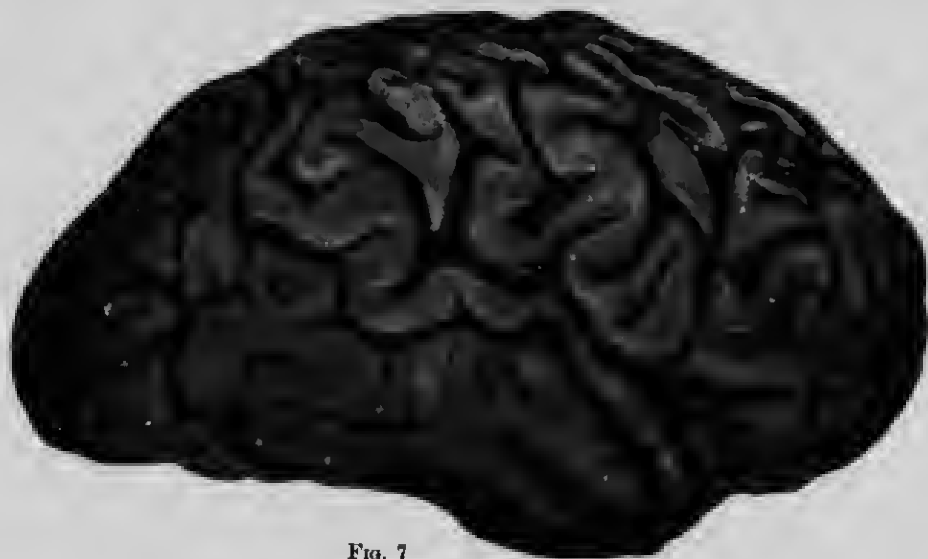


FIG. 7

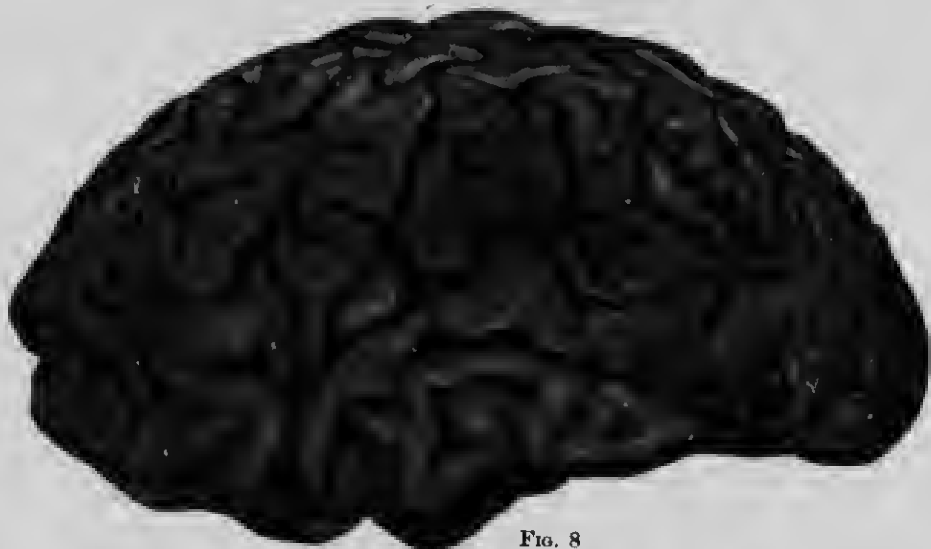

FIG. 8

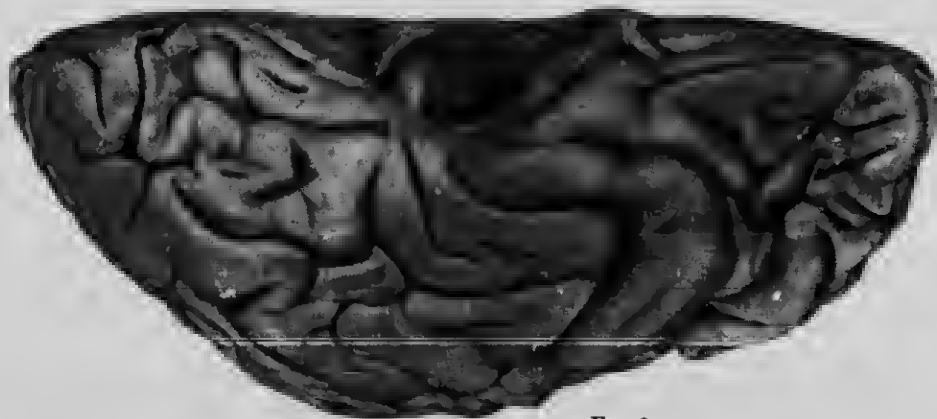

FIG. 9

4

11
12



FIG. 10

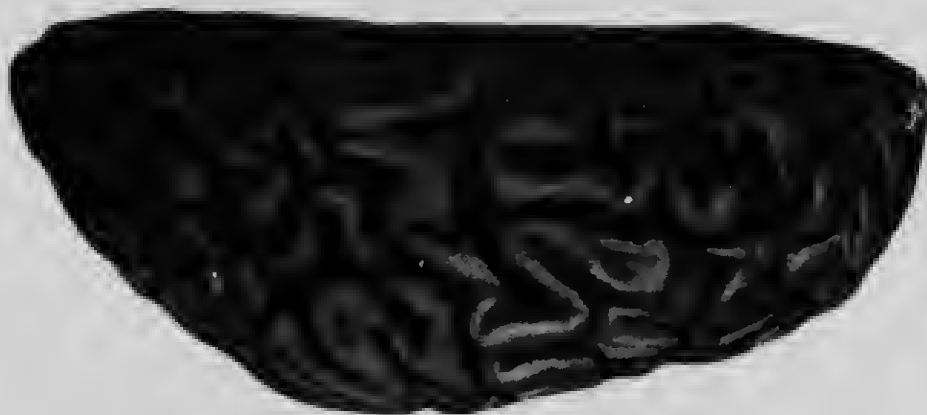

FIG. 11

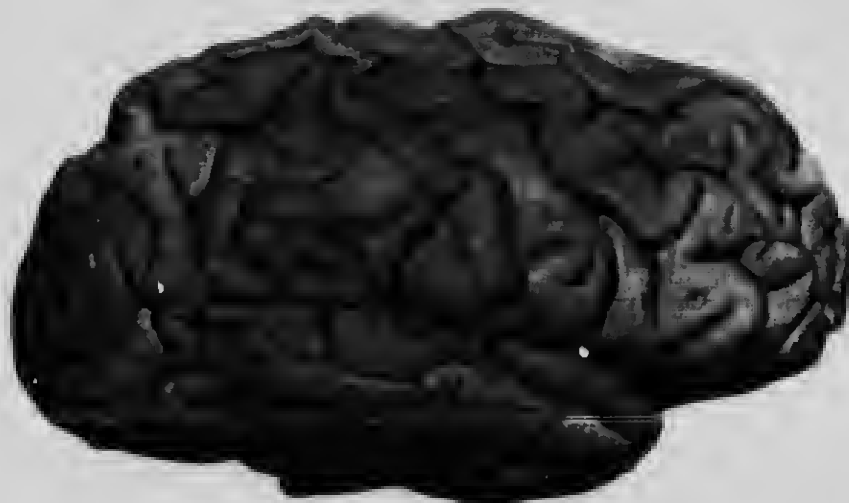

FIG. 12



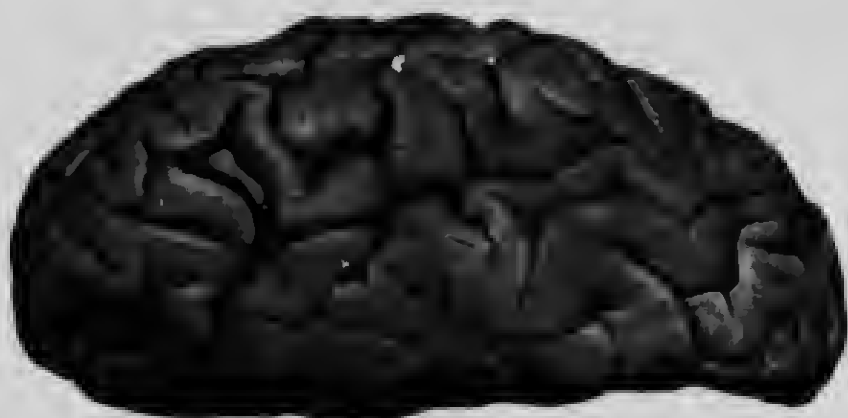


FIG. 13

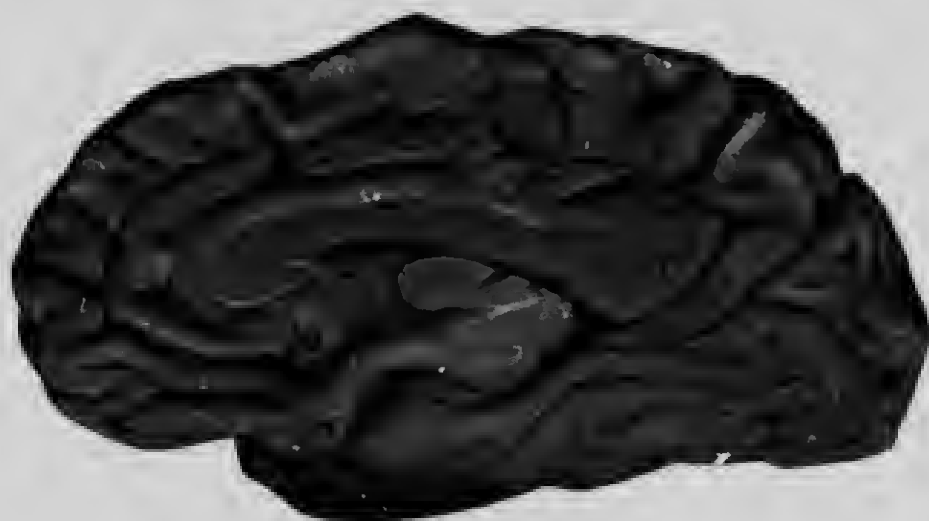

FIG. 14

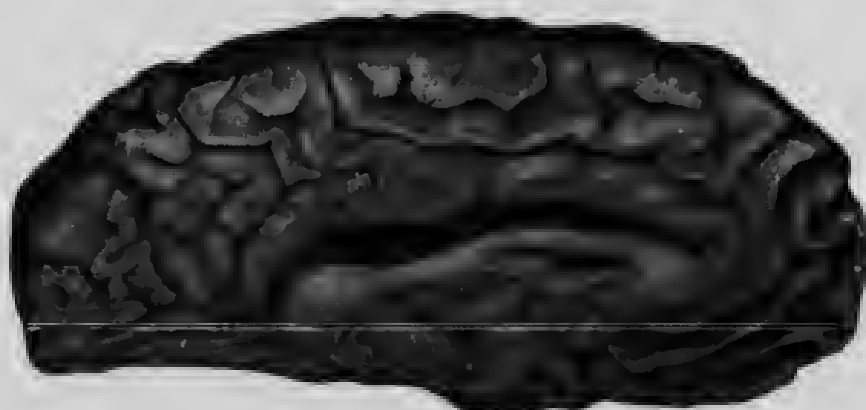


FIG. 15






FIG. 16



FIG. 17



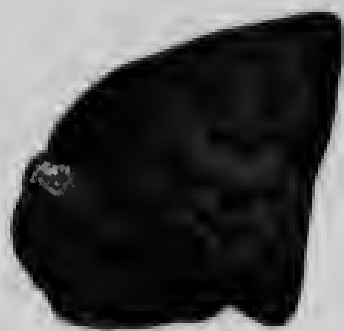


FIG. 18




FIG. 19



FIG. 20

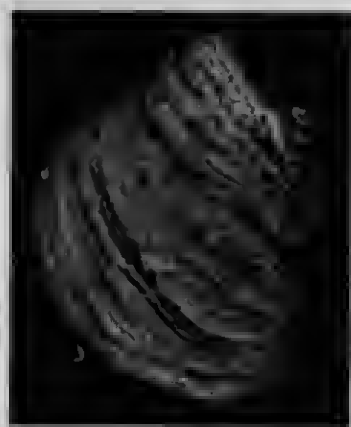

FIG. 21



FIG. 22

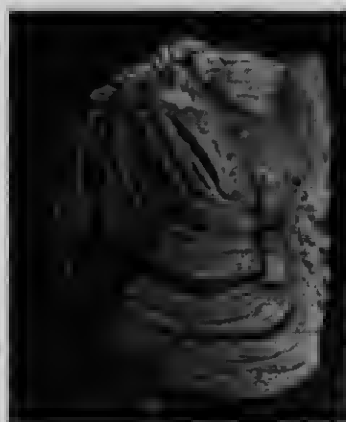


FIG. 23

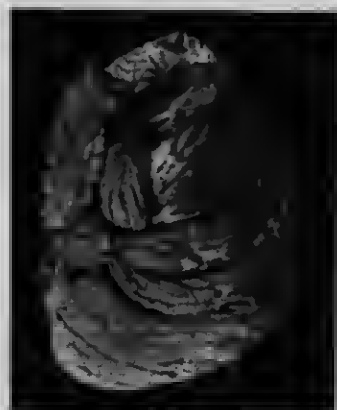

FIG. 24



FIG. 25

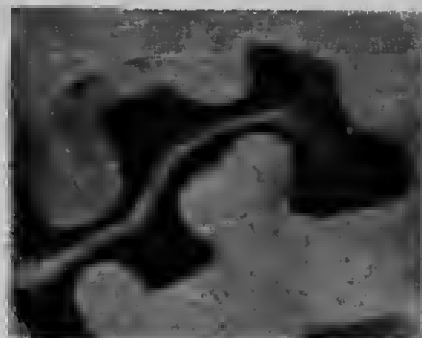

FIG. 27

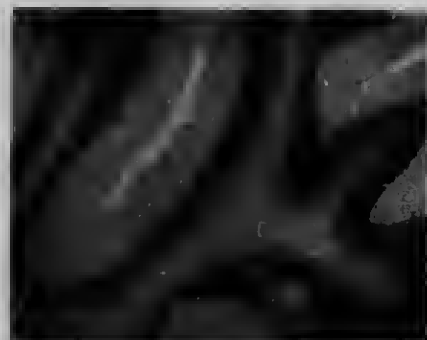


FIG. 28



FIG. 29

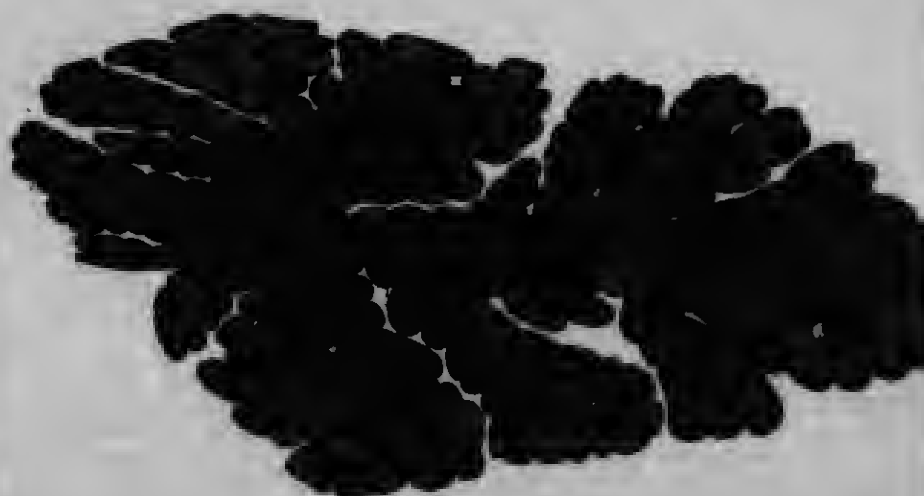


FIG. 26






FIG. 30



FIG. 31




FIG. 32



FIG. 33



FIG. 34



FIG. 35






FIG. 36




FIG. 37



FIG. 38



FIG. 39

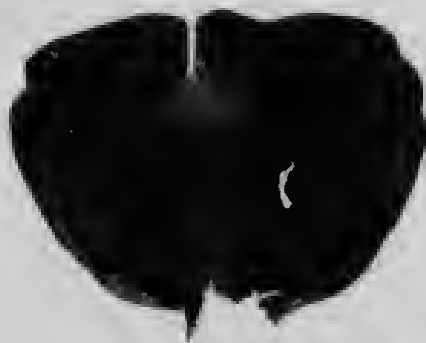


FIG. 40

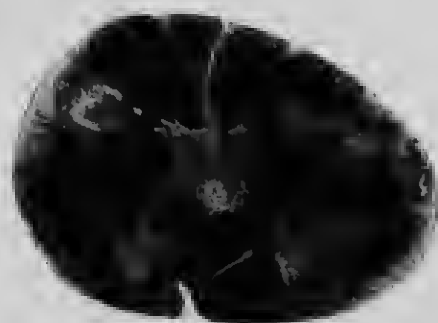


FIG. 41







FIG. 42

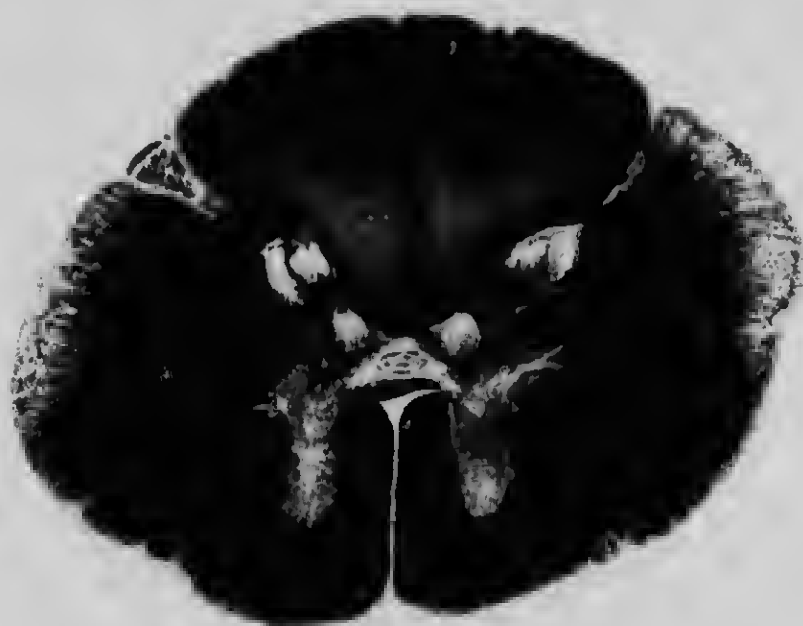

FIG. 43

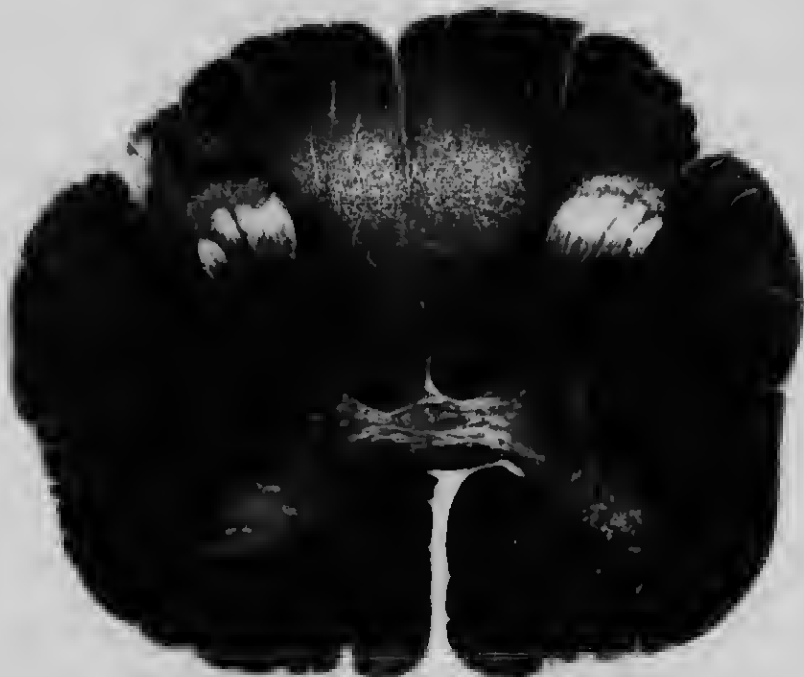

FIG. 44



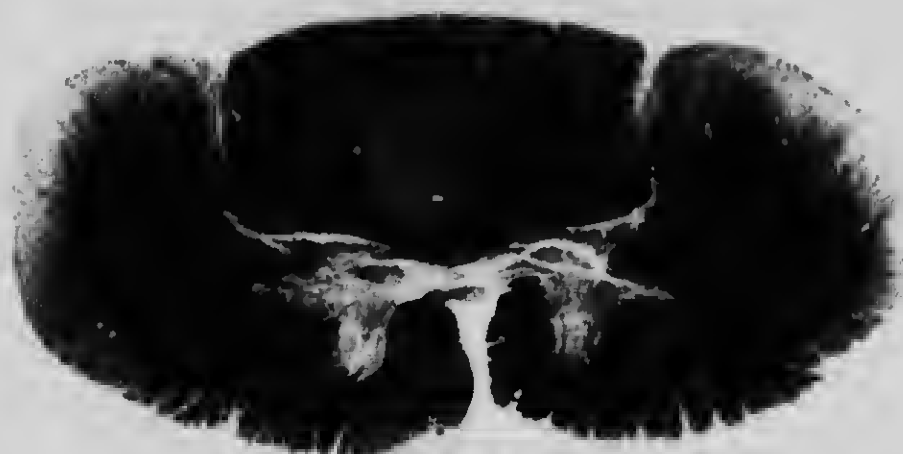


FIG. 45

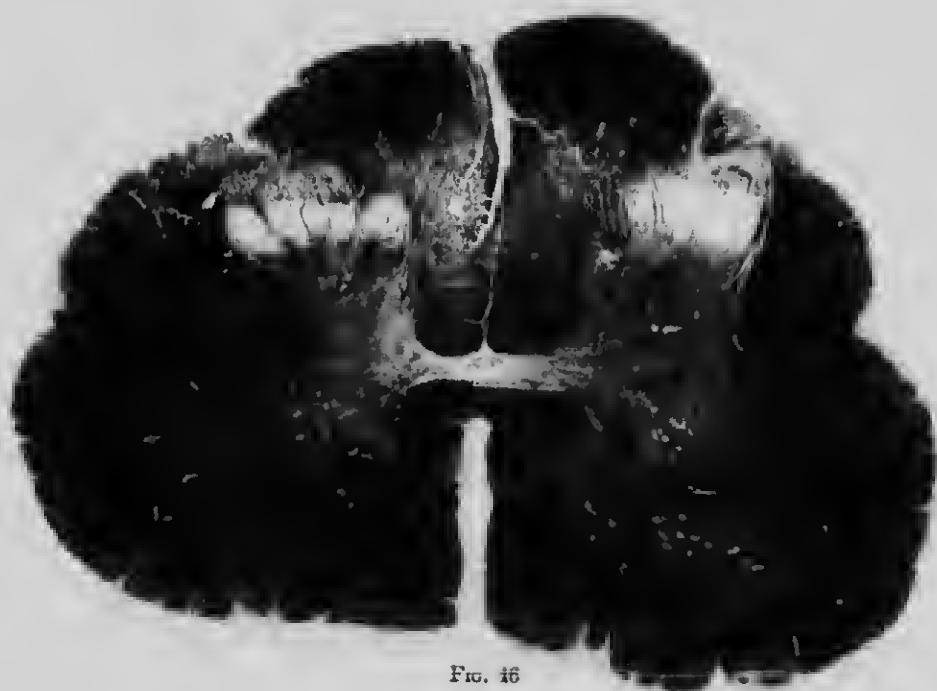

FIG. 46



The first part of the document discusses the importance of maintaining accurate records of all transactions. It emphasizes that every entry, no matter how small, should be recorded to ensure the integrity of the financial statements. The second part of the document provides a detailed breakdown of the company's revenue and expenses for the period. It includes a table showing the following data:

Category	Amount
Revenue	\$1,200,000
Cost of Goods Sold	\$750,000
Gross Profit	\$450,000
Operating Expenses	\$300,000
Operating Income	\$150,000
Interest Expense	\$20,000
Income Tax Expense	\$30,000
Net Income	\$100,000

The final part of the document concludes with a summary of the company's financial performance and a statement of the preparer's responsibility. It states that the information presented is true and correct to the best of the preparer's knowledge and belief.