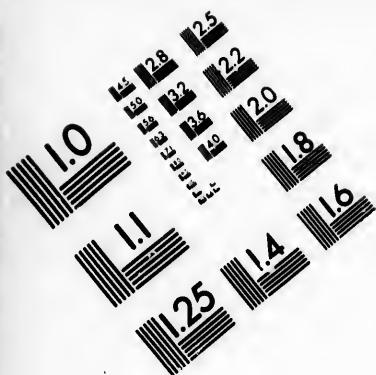





**IMAGE EVALUATION
TEST TARGET (MT-3)**



**Photographic
Sciences
Corporation**

23 WEST MAIN STREET
WEBSTER, N.Y. 14580
(716) 872-4503

28
25
22
20
18

**CIHM/ICMH
Microfiche
Series.**

**CIHM/ICMH
Collection de
microfiches.**



Canadian Institute for Historical Microreproductions / Institut canadien de microreproductions historiques

11
10
01

© 1985

Technical and Bibliographic Notes/Notes techniques et bibliographiques

The Institute has attempted to obtain the best original copy available for filming. Features of this copy which may be bibliographically unique, which may alter any of the images in the reproduction, or which may significantly change the usual method of filming, are checked below.

L'Institut a microfilmé le meilleur exemplaire qu'il lui a été possible de se procurer. Les détails de cet exemplaire qui sont peut-être uniques du point de vue bibliographique, qui peuvent modifier une image reproduite, ou qui peuvent exiger une modification dans la méthode normale de filmage sont indiqués ci-dessous.

- Coloured covers/
Couverture de couleur
- Covers damaged/
Couverture endommagée
- Covers restored and/or laminated/
Couverture restaurée et/ou pelliculée
- Cover title missing/
Le titre de couverture manque
- Coloured maps/
Cartes géographiques en couleur
- Coloured ink (i.e. other than blue or black)/
Encre de couleur (i.e. autre que bleue ou noire)
- Coloured plates and/or illustrations/
Planches et/ou illustrations en couleur
- Bound with other material/
Relié avec d'autres documents
- Tight binding may cause shadows or distortion along interior margin/
La reliure serrée peut causer de l'ombre ou de la distortion le long de la marge intérieure
- Blank leaves added during restoration may appear within the text. Whenever possible, these have been omitted from filming/
Il se peut que certaines pages blanches ajoutées lors d'une restauration apparaissent dans le texte, mais, lorsque cela était possible, ces pages n'ont pas été filmées.
- Additional comments:/
Commentaires supplémentaires:

- Coloured pages/
Pages de couleur
- Pages damaged/
Pages endommagées
- Pages restored and/or laminated/
Pages restaurées et/ou pelliculées
- Pages discoloured, stained or foxed/
Pages décolorées, tachetées ou piquées
- Pages detached/
Pages détachées
- Showthrough/
Transparence
- Quality of print varies/
Qualité inégale de l'impression
- Includes supplementary material/
Comprend du matériel supplémentaire
- Only edition available/
Seule édition disponible
- Pages wholly or partially obscured by errata slips, tissues, etc., have been refilmed to ensure the best possible image/
Les pages totalement ou partiellement obscurcies par un feuillet d'errata, une pelure, etc., ont été filmées à nouveau de façon à obtenir la meilleure image possible.

This item is filmed at the reduction ratio checked below/
Ce document est filmé au taux de réduction indiqué ci-dessous.

10X	14X	18X	22X	26X	30X
<input type="checkbox"/>	<input type="checkbox"/>	<input type="checkbox"/>	<input checked="" type="checkbox"/>	<input type="checkbox"/>	<input type="checkbox"/>
12X	16X	20X	24X	28X	32X

The copy filmed here has been reproduced thanks to the generosity of:

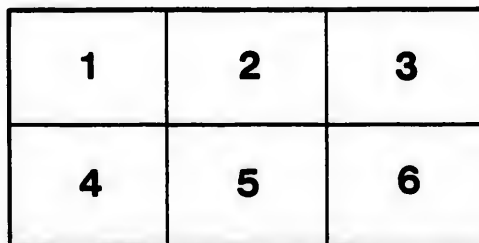
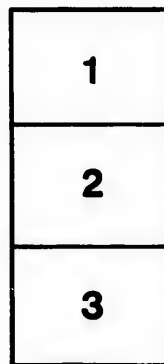
Medical Library
McGill University
Montreal

The images appearing here are the best quality possible considering the condition and legibility of the original copy and in keeping with the filming contract specifications.

Original copies in printed paper covers are filmed beginning with the front cover and ending on the last page with a printed or illustrated impression, or the back cover when appropriate. All other original copies are filmed beginning on the first page with a printed or illustrated impression, and ending on the last page with a printed or illustrated impression.

The last recorded frame on each microfiche shall contain the symbol \rightarrow (meaning "CONTINUED"), or the symbol ∇ (meaning "END"), whichever applies.

Maps, plates, charts, etc., may be filmed at different reduction ratios. Those too large to be entirely included in one exposure are filmed beginning in the upper left hand corner, left to right and top to bottom, as many frames as required. The following diagrams illustrate the method:



L'exemplaire filmé fut reproduit grâce à la générosité de:

Medical Library
McGill University
Montreal

Les images suivantes ont été reproduites avec le plus grand soin, compte tenu de la condition et de la netteté de l'exemplaire filmé, et en conformité avec les conditions du contrat de filmage.

Les exemplaires originaux dont la couverture en papier est imprimée sont filmés en commençant par le premier plat et en terminant soit par la dernière page qui comporte une empreinte d'impression ou d'illustration, soit par le second plat, selon le cas. Tous les autres exemplaires originaux sont filmés en commençant par la première page qui comporte une empreinte d'impression ou d'illustration et en terminant par la dernière page qui comporte une telle empreinte.

Un des symboles suivants apparaîtra sur la dernière image de chaque microfiche, selon le cas: le symbole \rightarrow signifie "A SUIVRE", le symbole ∇ signifie "FIN".

Les cartes, planches, tableaux, etc., peuvent être filmés à des taux de réduction différents. Lorsque le document est trop grand pour être reproduit en un seul cliché, il est filmé à partir de l'angle supérieur gauche, de gauche à droite, et de haut en bas, en prenant le nombre d'images nécessaire. Les diagrammes suivants illustrent la méthode.

rrrata
to

pelure.
n à

A CASE OF PRIMARY CANCER OF THE LIVER.¹

By C. F. MARTIN, B.A., M.D.

Demonstrator of Pathology, McGill University; Assistant Physician, Royal Victoria Hospital.

and

W. F. HAMILTON, M.D.,

Assistant Demonstrator of Medicine, McGill University; Assistant Physician, Royal Victoria Hospital.

The exceptional occurrence of a primary cancer of the liver with secondary involvement of the stomach may render the present case of some interest. While, however, we do not regard the condition as undoubtedly of hepatic origin, there seem nevertheless to be many points in favour of this view, while the growths found in the stomach and elsewhere seem to have been secondary.

The clinical notes on the case may be briefly summarized as follows: N. McL., aged 60 years, presented himself for treatment at the Royal Victoria Hospital complaining of weakness, diarrhœa and pain in the abdomen, chiefly localized in the region of the liver and stomach.

He had been failing in health for six months, and during the last four months he was unable to work. The pain complained of, as well as the abdominal swelling, had troubled him for about three months.

His history gave no evidence of gastric disease, further than recurring attacks of gastritis, following on excess in alcohol, to which he had been addicted for many years.

His condition was that of one extremely emaciated and feeble, with rough, dry skin. The abdomen was distended. There was ascites and some diarrhœa. Examination in the region of the liver showed that organ enlarged. Its margin was felt about 2½ inches below the normal margin in the mammary line. It was hard and through the thin abdominal wall its surface was felt to be uneven. There was no jaundice.

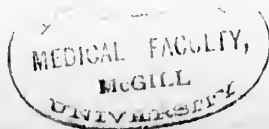
No tumour was palpable in the stomach, abdomen, testicles nor rectum.

Œdema of lower extremities developed and the pulmonary signs indicated œdema of the lungs.

The patient died of asthenia after a few days sojourn in the hospital.

The *autopsy*, performed 8 hours after death, gave the following results in brief:

¹ Read before the Montreal Medico-Chirurgical Society, February 21, 1895.



ing no sign of protuberance or adhesion. No nodules existed in the immediate vicinity in the wall, but 10 cm. from it were five or six firm, slightly elevated masses, apparently submucous, the largest measuring $1\frac{1}{2}$ cm. in diameter.

The remaining portion of the alimentary tract was free from disease.

Thoracic cavity—In the lungs, beyond bilateral pleural adhesions, some slight hydrothorax and hypostatic pneumonia, there was but little worthy of note.

The *heart* showed milk spots upon its surface; its muscle was brownish in colour, the papillary muscles somewhat hypertrophied and fibroid. The coronary vessels atheromatous, as was also the first part of the aorta.

The organs of the neck presented merely the usual pathological conditions coincident with old age.

The brain—Dura adherent and somewhat thickened, the convolutions small; the basal vessels markedly atheromatous.

Microscopic examination of various portions of the liver neoplasms confirmed the macroscopic diagnosis. The epithelial cells were very large, of irregular shape and polygonal in outline. In some of the small secondary nodules the cells were seen in the portal vessels, but there was nowhere any indication of a true glandular type of growth.

The stomach growth presented superficial necrosis of the gland structure, great thickening and infiltration of epithelial cells in the submucosa and a very small fibrous stroma. The cells in some places filled blood vessels, in others lymph spaces.

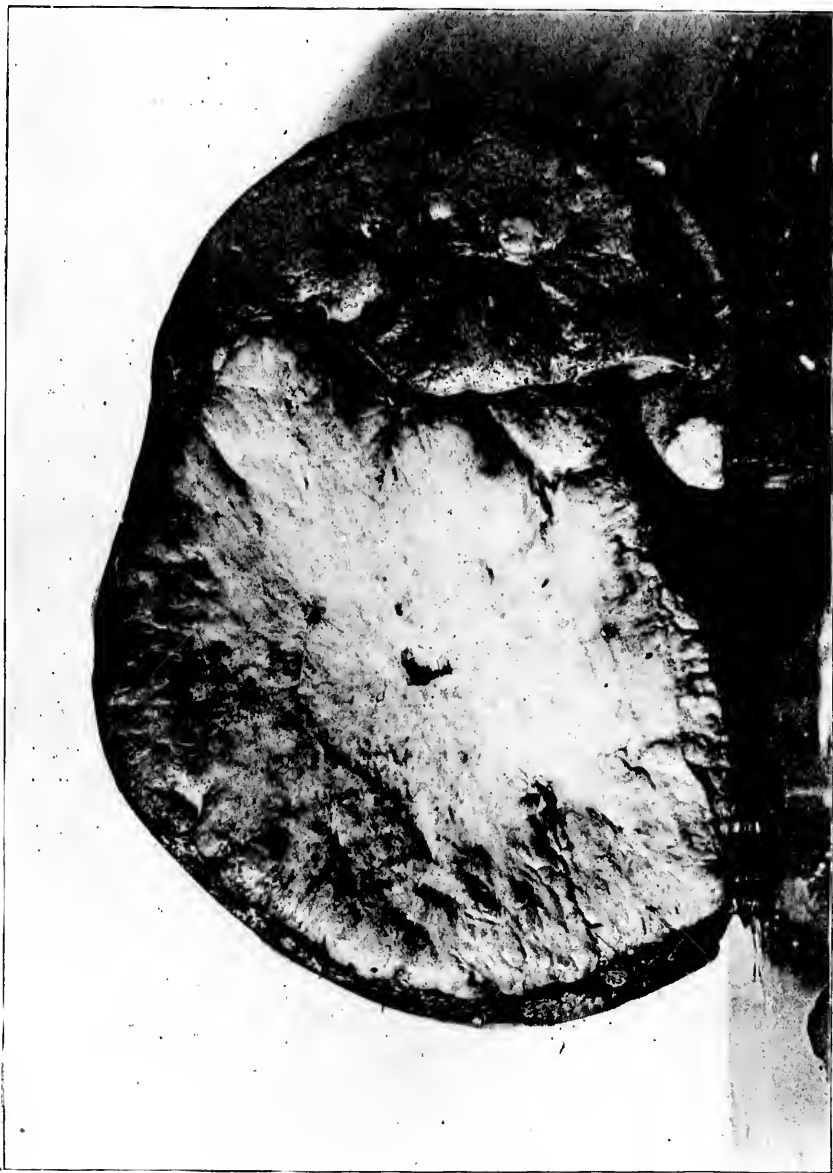No other new evidence was adduced from an examination of the remaining organs.

Conclusions—The conditions then found present a neoplasm in the stomach of small size, well circumscribed and circular in outline, with but little evidence of erosion and ulceration, while microscopically the constituent elements are chiefly cellular, with an inappreciable amount of fibroid change—that is to say, a growth apparently of very recent date. In the liver, on the other hand, the cancerous tumour is of enormous size, of markedly dense consistence from fibroid change, and on minute examination is seen to be made up of fibrillated masses out of all proportion to the insignificant amount of cellular growth—in other words, a neoplasm of long duration.


In endeavouring to make a pathological diagnosis as to the primary seat of the disease, the general appearances, though of great use as a guide, would not in themselves be sufficient as evidence, for it is everywhere recognized that growths in the stomach may for a long time remain small and apparently quiescent, while the secondary foci grow to enormous proportions; yet one would expect in such cases that there would be evidence either of chronic ulceration or of fibroid change, but neither of these conditions is manifest in the present instance.

Again the neoplasm in the stomach is circular, slightly elevated, regular in outline and well circumscribed, thus corresponding in general characteristics to the description given by Grawitz among the rare cases of secondary cancer of the stomach formed by metastases.

Should insistence be laid on this organ as the primary seat of the neoplasm one could surely render cautiously in future a diagnosis of primary cancer of the liver when the original focus can for so long a



PRIMARY CANCER OF LIVER (TAKEN FROM A SECTION THROUGH THE CENTRE OF THE WHOLE ORGAN).
[PHOTOGRAPHED BY MR. D. PATRICK.]



Anatomical diagnosis—Primary cancer of liver; secondary cancer of stomach, periportal glands, pancreas, vena cava; chronic gastritis; chronic interstitial nephritis; hypertrophy of prostate and chronic cystitis; arterial sclerosis.

Necropsy (performed eight hours after death)—The body was that of a large-sized, much emaciated old man, presenting the usual signs of death; the abdomen markedly distended, the legs very oedematous.

Abdominal cavity—Panniculus adiposus and muscles much wasted. About 200 cc. of turbid brownish-red fluid free in the cavity. The visible intestines normal. The *omentum* presented atrophic fat. The *liver* descended in the mammary line 7 cm. below the costal margin. Apart from slight perisplenitis the *spleen* was normal.

The *suprarenals* had pale centres. The *kidneys* were firm, their capsules adherent, the surface dotted over with cysts and of a deep red colour, the cortex narrowed and presenting much evidence of interstitial new growth.

The *bladder* wall was much thickened and the organ dilated; there were numerous small diverticuli, but no signs of calculi. The *prostate* showed moderate hypertrophy of the lateral lobes. The *testicles* were small and soft.

Liver—Weight 4340 grms. The common duct at the duodenal orifice showed some slight swelling of the mucosa, while above it the canal was markedly dilated. The cystic duct was normal. On the upper surface of the liver there were some loose adhesions to the diaphragm. The organ itself was much enlarged, the surface reddened and dotted over with varying sized nodules of a yellowish or reddish-yellow colour, the largest being 5 cm. in diameter. For the most part they were soft, some almost semi-fluid, their surfaces regular and their outline more or less well defined. The usual cyanotic atrophy surrounded the most of them.

The organ was of firm consistence, and on incision it showed that almost the *entire parenchyma of the right lobe* was replaced by one large, firm, rounded mass of whitish colour, more reddish-yellow towards the periphery. The mass was 18 cm. in diameter, more or less regularly spherical on section, and was covered at no place by more than 2 cm. of liver tissue. Incision at various levels showed that the mass was almost everywhere of equal consistence, that it radiated from a central point where a small cyst existed and around which the tissue was dense. The periphery, on the other hand, was softer and presented a few hæmorrhages and some bile pigment. The surrounding liver cells were pressed into concentric layers, and even here presented secondary nodules of infiltration. In the left lobe were a number of smaller nodules similar in character to those described previously.

The *gall-bladder* was flattened, pushed to one side and contained a small quantity of dark green viscid bile. The cystic duct was free and there were no evidences here of neoplasm.

The periportal glands were much enlarged, softened and irregular in outline, their centres broken down.

The *vena cava* as it passed through the liver showed on its inner surface three small areas where the neoplasm, extending through the vessel coats, protruded into the lumen, thus giving rise to parietal thrombi. The Portal vein was free.

The *mesenteric glands* and thoracic duct were free from disease.

The *pancreas* small, soft, without evidences of cancerous infiltration; in the immediate vicinity of the tail was an enlarged cancerous gland in size equal to a walnut.

The *stomach* was distended with gas and contained about 50 cc. of greenish semi-fluid material in which various tests showed the absence of free hydrochloric acid.

The mucosa was thickened and reddened in patches. Along the lesser curvature and situated on the posterior wall 4 cm. from the cardiac opening was a round, elevated, well circumscribed nodule 3 cm. in diameter.

The mass was only moderately firm and on section showed but little density of structure. The serosa was only involved from within, the external surface present-

time retain characters incident only to the very early conditions of growth, for it might well be argued that on the same basis such growths in the stomach might remain still smaller, even invisible to the unaided eye, while the secondary foci grow to enormous extent. Considering, on the other hand, that the disease originated in the liver, we have in favour of the view the evident duration of the growth as seen from its size and minute characters.

From the enormous variations in type of cancer cells it is not always possible to differentiate the original seat by microscopic examination, and our present case would come under such a category.

There are three chief modes whereby secondary cancers of the stomach may arise, firstly, by direct extension from neighbouring organs, such as the pancreas, liver, glands and œsophagus, or by the newly formed lymphatics in adhesions between these organs; secondly, by implantation from the œsophagus, such as might occur from an ulcerating carcinoma of the tongue. In these cases, which are rare, the cancer cells drop down, or are carried down into the stomach, and becoming fixed in their new situation they proliferate and form secondary tumours. It is in the same way, too, that secondary peritoneal cancers are so frequently formed in Douglas' pouch by the gravitation of the malignant cells from the serous coats of the stomach or the liver. Thirdly, secondary cancers of the stomach may form by hæmatogenous metastases; these last are extremely rare and have been put on record by Grawitz. In such cases the tumours are well circumscribed, circular and regular in outline.

In addition should be mentioned the possibility of cancer cells travelling against the stream of the circulation, thus moving along the portal vein and mesenteric vessels and lymphatics, and thus setting up a secondary growth in the stomach, just as occurs in involvement of the left supra clavicular glands when cancer cells travel along the course of the thoracic duct.

