


**CIHM
Microfiche
Series
(Monographs)**

**ICMH
Collection de
microfiches
(monographies)**



Canadian Institute for Historical Microreproductions / Institut canadien de microreproductions historiques

© 1999

Technical and Bibliographic Notes / Notes techniques et bibliographiques

The Institute has attempted to obtain the best original copy available for filming. Features of this copy which may be bibliographically unique, which may alter any of the images in the reproduction, or which may significantly change the usual method of filming are checked below.

- Coloured covers / Couverture de couleur
- Covers damaged / Couverture endommagée
- Covers restored and/or laminated / Couverture restaurée et/ou pelliculée
- Cover title missing / Le titre de couverture manque
- Coloured maps / Cartes géographiques en couleur
- Coloured ink (i.e. other than blue or black) / Encre de couleur (i.e. autre que bleue ou noire)
- Coloured plates and/or illustrations / Planches et/ou illustrations en couleur
- Bound with other material / Relié avec d'autres documents
- Only edition available / Seule édition disponible
- Tight binding may cause shadows or distortion along interior margin / La reliure serrée peut causer de l'ombre ou de la distorsion le long de la marge intérieure.
- Blank leaves added during restorations may appear within the text. Whenever possible, these have been omitted from filming / Il se peut que certaines pages blanches ajoutées lors d'une restauration apparaissent dans le texte, mais, lorsque cela était possible, ces pages n'ont pas été filmées.
- Additional comments / Commentaires supplémentaires:

L'Institut a microfilmé le meilleur exemplaire qu'il lui a été possible de se procurer. Les détails de cet exemplaire qui sont peut-être uniques du point de vue bibliographique, qui peuvent modifier une image reproduite, ou qui peuvent exiger une modification dans la méthode normale de filmage sont indiqués ci-dessous.

- Coloured pages / Pages de couleur
- Pages damaged / Pages endommagées
- Pages restored and/or laminated / Pages restaurées et/ou pelliculées
- Pages discoloured, stained or foxed / Pages décolorées, tachetées ou piquées
- Pages detached / Pages détachées
- Showthrough / Transparence
- Quality of print varies / Qualité inégale de l'impression
- Includes supplementary material / Comprend du matériel supplémentaire
- Pages wholly or partially obscured by errata slips, tissues, etc., have been refilmed to ensure the best possible image / Les pages totalement ou partiellement obscurcies par un feuillet d'errata, une pelure, etc., ont été filmées à nouveau de façon à obtenir la meilleure image possible.
- Opposing pages with varying colouration or discolourations are filmed twice to ensure the best possible image / Les pages s'opposant ayant des colorations variables ou des décolorations sont filmées deux fois afin d'obtenir la meilleure image possible.

This item is filmed at the reduction ratio checked below / Ce document est filmé au taux de réduction indiqué ci-dessous.

10x	14x	18x	22x	26x	30x
<input type="checkbox"/>	<input type="checkbox"/>	<input type="checkbox"/>	<input checked="" type="checkbox"/>	<input type="checkbox"/>	<input type="checkbox"/>
12x	16x	20x	24x	28x	32x

The copy filmed here has been reproduced thanks to the generosity of:

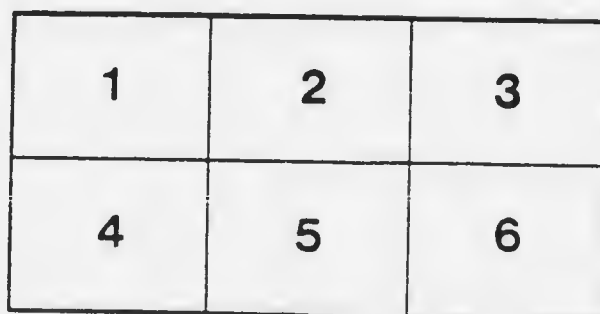

McGill University
Health Sciences Library
Montreal

The images appearing here are the best quality possible considering the condition and legibility of the original copy and in keeping with the filming contract specifications.

Original copies in printed paper covers are filmed beginning with the front cover and ending on the last page with a printed or illustrated impression, or the back cover when appropriate. All other original copies are filmed beginning on the first page with a printed or illustrated impression, and ending on the last page with a printed or illustrated impression.

The last recorded frame on each microfiche shall contain the symbol \rightarrow (meaning "CONTINUED"), or the symbol ∇ (meaning "END"), whichever applies.

Maps, plates, charts, etc., may be filmed at different reduction ratios. Those too large to be entirely included in one exposure are filmed beginning in the upper left hand corner, left to right and top to bottom, as many frames as required. The following diagrams illustrate the method:



L'exemplaire filmé fut reproduit grâce à la générosité de:

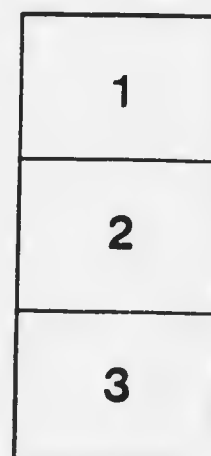
McGill University
Health Sciences Library
Montreal

Les images suivantes ont été reproduites avec le plus grand soin, compte tenu de la condition et de la netteté de l'exemplaire filmé, et en conformité avec les conditions du contrat de filmage.

Les exemplaires originaux dont la couverture en papier est imprimée sont filmés en commençant par le premier plat et en terminant soit par la dernière page qui comporte une empreinte d'impression ou d'illustration, soit par le second plat, selon le cas. Tous les autres exemplaires originaux sont filmés en commençant par la première page qui comporte une empreinte d'impression ou d'illustration et en terminant par la dernière page qui comporte une telle empreinte.



Un des symboles suivants apparaîtra sur la dernière image de chaque microfiche, selon le cas: le symbole \rightarrow signifie "A SUIVRE", le symbole ∇ signifie "FIN".

Les cartes, planches, tableaux, etc., peuvent être filmés à des taux de réduction différents. Lorsque le document est trop grand pour être reproduit en un seul cliché, il est filmé à partir de l'angle supérieur gauche, de gauche à droite, et de haut en bas, en prenant le nombre d'images nécessaire. Les diagrammes suivants illustrent la méthode.



MICROCOPY RESOLUTION TEST CHART

(ANSI and ISO TEST CHART No. 2)




APPLIED IMAGE Inc

1653 East Main Street
Rochester, New York 14609 USA
(716) 482-0300 - Phone
(716) 288-5989 - Fax



DISEASES OF THE EYE



217.7
P268ul.2

DISEASES OF THE EYE

A MANUAL FOR STUDENTS AND
PRACTITIONERS

BY

J. HERBERT PARSONS. D.Sc., M.B., B.S.,
F.R.C.S.

OPHTHALMIC SURGEON, UNIVERSITY COLLEGE HOSPITAL; SURGEON, ROYAL
LONDON (MOORFIELDS) OPHTHALMIC HOSPITAL; LATE OPHTHALMIC
SURGEON, HOSPITAL FOR SICK CHILDREN, GREAT ORMOND STREET.

SECOND EDITION

THE MACMILLAN COMPANY
OF CANADA, LIMITED
TORONTO

1912

MEDICAL LIBRARY — MCGILL UNIVERSITY

Printed in Great Britain.

PREFACE TO THE SECOND EDITION

THE text has been revised throughout in this edition and several new sections added. Some of the illustrations of the first edition have been transferred to plates, and some new illustrations have been introduced into the text.

My indebtedness for numerous illustrations is in most cases acknowledged in the text. I have to thank Mr. Nettleship and Mr. Holmes Spicer for the use of blocks from Nettleship's "Diseases of the Eye." I am indebted for the original drawings to Mr. Nettleship for Plate III., Fig. 2; the figures on Plates IV., V., and VI; Plate VIII., Fig. 2; Plate IX., Fig. 2; Plate X., Figs. 1 and 2; Plate XI., Fig. 1; Plate XII., Fig. 2; Plate XIII., Fig. 1; and for Figs. 172, 176, 177; to Mr. Lister for Plate VIII., Fig. 1; Plate XI., Fig. 2; Plate XIII., Fig. 2, and for Figs. 191, 194; to Mr. Lawford for Plate XIV., Fig. 2, and for Fig. 192; and to Mr. Percy Flemming for Plate XIV., Fig. 1.

Those who, having studied this manual, wish to pursue the subject more deeply should read Fuchs's "Textbook of Ophthalmology." They will find Ophthalmic Optics

PREFACE.

more fully treated in my "Elementary Ophthalmic Optics" (J. & A. Churchill), Pathology in my "Pathology of the Eye" (4 vols., Hodder & Stoughton), Treatment in Hanke's "Treatment of Diseases of the Eye," translated by G. Coats and myself (Hodder & Stoughton).

J. HERBERT PARSONS.

QUEEN ANNE STREET, W.,
January, 1912.

CONTENTS

SECTION I.

ANATOMY AND PHYSIOLOGY.

CHAP.	PAGE
I. ANATOMY	1
II. PHYSIOLOGY	18
III. ELEMENTARY OPTICS	25
IV. ELEMENTARY PHYSIOLOGICAL OPTICS	41
V. THE NEUROLOGY OF VISION	83

SECTION II.

THE EXAMINATION OF THE EYE.

VI. EXTERNAL EXAMINATION	91
VII. OPHTHALMOSCOPIC EXAMINATION	111
VIII. THE FUNDUS OCULI	145
IX. FUNCTIONAL EXAMINATION	154

SECTION III.

DISEASES OF THE EYE.

X. DISEASES OF THE CONJUNCTIVA	171
XI. DISEASES OF THE CORNEA	222
XII. DISEASES OF THE SCLEROTI	277
XIII. DISEASES OF THE IRIS AND CILIARY BODY	282
XIV. GLAUCOMA	306
XV. THE LENS	329
XVI. DISEASES OF THE VITREOUS	351
XVII. DISEASES OF THE CHOROID AND RETINA	357
XVIII. DISEASES OF THE OPTIC NERVE	401
XIX. INTRA-OCULAR TUMOURS	413
XX. SYMPTOMATIC DISTURBANCES OF VISION	422
XXI. INJURIES TO THE EYE, PANOPHTHALMITIS, AND SYMPATHETIC OPHTHALMIA	431
XXII. OPERATIONS UPON THE EYEBALL	463

SECTION IV.

ERRORS OF REFRACTION.

CHAP.	PAGE
XXIII. RETINOSCOPY	496
XXIV. ERRORS OF REFRACTION	506
XXV. ANOMALIES OF ACCOMMODATION	528

SECTION V.

DISORDERS OF MOTILITY OF THE EYE.

XXVI. ANATOMY AND PHYSIOLOGY OF THE EXTRINSIC OCULAR MUSCLES	531
XXVII. PARALYTIC AND KINETIC STRABISMUS. NYSTAGMUS .	543
XXVIII. CONCOMITANT STRABISMUS. HETEROPIORIA . . .	558

SECTION VI.

DISEASES OF THE ADNEXA OF THE EYE.

XXIX. DISEASES OF THE LIDS	587
XXX. DISEASES OF THE LACRYMAL APPARATUS	621
XXXI. DISEASES OF THE ORBIT	638

APPENDICES.

APPENDIX.

I. PRELIMINARY INVESTIGATION OF THE PATIENT . . .	655
II. THERAPEUTIC NOTES	658
III. REQUIREMENTS OF CANDIDATES FOR ADMISSION INTO THE PUBLIC SERVICES	664

INDEX	673
-----------------	-----

DISEASES OF THE EYE.

SECTION I.

ANATOMY AND PHYSIOLOGY.

CHAPTER I.

ANATOMY.

THE sensory nerves of the body are provided with end organs, by means of which they receive specific physical stimuli and transform them into nerve impulses. The nerves of the special senses are no exceptions to the rule, and the eye is the highly differentiated and complex end organ of the sense of sight.

The wall of the globe is composed of a dense, elastic supporting membrane (Fig. 1). The anterior part of the membrane is transparent—the cornea; the remainder is opaque—the sclerotic. The anterior part of the sclerotic is covered by mucous membrane—the conjunctiva—which is reflected from its surface on to the lids.

The *cornea* consists of three layers: the epithelium, the substantia propria, and Descemet's membrane. The epithelium, which is stratified, may be regarded as the continuation of the conjunctiva over the cornea proper. It lies upon a homogeneous lamina of the substantia

DISEASES OF THE EYE.

propria, called Bowman's membrane. The substantia propria may be regarded as the continuation forwards of the sclerotic. Descemet's membrane is a thin elastic membrane, covered on its posterior surface by endothelium: it may be regarded as the continuation forwards of

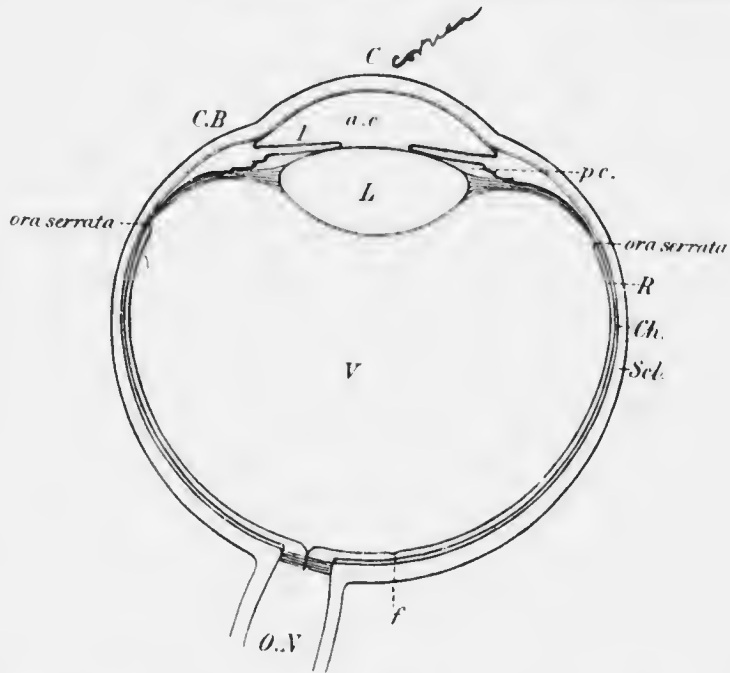


FIG. 1.—Diagrammatic horizontal section of the eye. C, cornea; a.c., anterior chamber; I, iris; C.B., ciliary body; p.c., posterior chamber; L, lens; V, vitreous; R, retina; Ch., choroid; Sch., sclerotic; f, fovea centralis; O.N., optic nerve.

the uveal tract. We shall see that the relationship of the three layers is of some pathological importance, for when as is often the case the cornea suffers secondarily to some conjunctival complaint the epithelium and superficial layers are most likely to be affected: similarly, in diseases of the sclerotic the substantia propria suffers most, and in diseases of the uveal tract the endothelium, Descemet's membrane,

and the adjoining posterior layers of the substantia propria.

The cornea is set into the sclerotic like a watch glass, *i.e.*, the sclerotic overlaps the cornea all round the periphery. The cornea is very richly supplied with nerve-fibres derived from the trigeminal. It has no blood vessels with the exception of minute festoons, about 1 mm. broad, at the periphery: the cornea is therefore dependent for its nourishment upon diffusion of lymph, which is supplied from the conjunctival vessels.

Lining the sclerotic are two membranes: an outer, highly vascular, concerned chiefly in the nutrition of the eye, and comprising the greater part of the uveal tract; and an inner, nervous, the true visual nerve ending, concerned in the reception and transformation of light stimuli, and called the retina.

The uveal tract consists of three parts, of which the two posterior, the choroid and ciliary body, line the sclerotic, whilst the anterior forms a free circular diaphragm, the iris. The plane of the iris is approximately coronal: the aperture of the diaphragm is the pupil. Situated behind the iris and in contact with the pupillary margin is the crystalline lens.

The anterior chamber is a space filled with lymph, the aqueous humour; it is bounded in front by the cornea, behind by the iris and the part of the anterior surface of the lens which is exposed in the pupil. Since the sclerotic overlaps the cornea at the periphery it enters into the boundaries of the anterior chamber at the part which is known as the angle of the anterior chamber (Fig. 2). In the inner layers of the sclerotic at this part there is a network of venous spaces which is called the canal of Schlemm. At the periphery, just anterior to the canal of Schlemm, Descemet's membrane splits up into fibrillæ, which are continuous with a meshwork of fibres stretching

between the sclerotic and the iris, and known as the *ligamentum pectinatum iridis*. These fibres are covered by endothelium, which is continuous with that lining the cornea and also with that covering the iris. The spaces in the network of the *ligamentum pectinatum iridis* are called

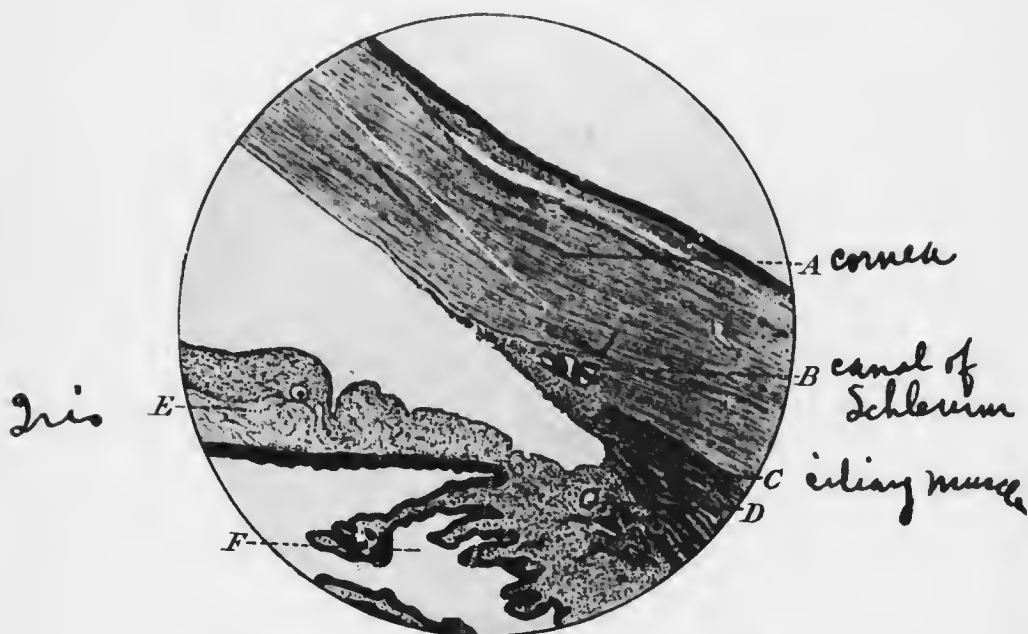


FIG. 2. — Angle of the anterior chamber. A, cornea; B, canal of Schlemm, which appears as several small spaces in the sclerotic just outside the *ligamentum pectinatum iridis*: it thus consists of irregular anastomosing venous channels which are cut across in the section; C, ciliary muscle; D, *circulus arteriosus iridis major*; E, iris; F, ciliary processes.

the spaces of Fontana: they are much better developed in lower mammals than in man. The tissue separating the *ligamentum pectinatum* from the canal of Schlemm is somewhat denser, and there is no free communication between the anterior chamber and the venous plexus, a thin membrane, covered on each surface by endothelium,

being interposed. We shall see that a thorough knowledge of the anatomy of angle of the anterior chamber is essential to the proper understanding of several pathological problems, especially that of glaucoma.

The anterior chamber is about 2.5 mm. deep in the centre in the normal adult: it is shallower in very young children and also in old people.

The uveal tract, as already mentioned, consists of the iris, the ciliary body, and the choroid, from before backwards.

The iris is composed of a pigmented stroma, consisting of branched connective tissue cells and containing a rich supply of blood vessels which run in a radial direction. The stroma is covered on its posterior surface by two layers of pigmented epithelium, which properly belong to the retina and are therefore called the *pars iridica retinae*, or *pars retinalis iridis*. The anterior layer consists of flattened cells, which are very firmly attached to the stroma, the posterior of cubical cells, not so firmly attached to the anterior layer. Near the pupillary margin and concentric with it is a bundle of unstriated muscle fibres, *the sphincter iridis*. There is also a set of cells, elongated in the radial direction, which acts as a *dilatator iridis*.

The anterior surface of the iris is covered with a single layer of endothelium, except at some minute depressions or crypts which are found most at the ciliary border. Here the lymph spaces between the stroma cells communicate directly with the anterior chamber: this is probably a device for ensuring rapid transference of lymph from the iris to the anterior chamber and *vice versa*, so as to facilitate quick movements of the pupil in response to variations in the intensity of the light falling upon the eye. The iris is thinnest at its

attachment to the ciliary body, so that if torn it tends to give way here.

The iris is richly supplied by sensory nerve fibres derived from the trigeminal, a fact which it is important to remember, since touching or cutting the iris, especially if it is inflamed, is intensely painful. The sphincter iridis is supplied by motor nerve fibres derived from the oculomotor nerve, whilst the motor fibres of the

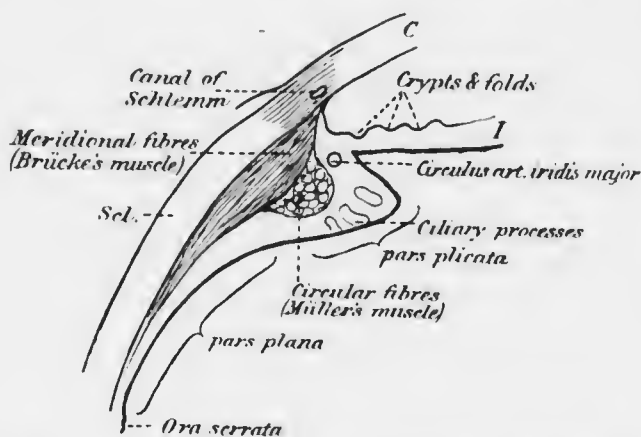


FIG. 3.—Diagrammatic meridional section of the ciliary body.
Note that the sclerotic overlaps the cornea, as shown by the shading.

dilatator iridis are derived from the cervical sympathetic nerve.

The *ciliary body* in antero-posterior section is shaped roughly like an isosceles triangle, with the base forwards. The iris is attached to about the middle of the base, so that a small portion of the ciliary body enters into the posterior boundary of the anterior chamber at the angle (Fig. 3). The chief mass of the ciliary body is composed of unstriated muscle fibres, the *ciliary muscle*. This consists of two parts, an outer, in contact with the sclerotic, consisting of antero-posterior or meridional

fibres, and an inner, consisting of fibres running at right angles to the former, and therefore arranged in a circle concentric with the base of the iris. The meridional fibres can be traced far back, well into the choroid, whereas the circular fibres are confined to the anterior part.

If an eye is cut in half in an antero-posterior direction and the inner surface of the ciliary body is inspected, it will be noticed that the anterior part has a number of folds upon it, whilst the posterior part is smooth. The anterior part is, therefore, called the *pars plicata*, the posterior, the *pars plana*. If the plications are counted with the naked eye or under slight magnification, it will be found that there are about seventy in the whole circumference. If microscopical sections are examined, innumerable smaller plications and processes, *the ciliary processes*, will be seen upon the *pars plicata*. These contain no part of the ciliary muscle, but consist essentially of tufts of blood vessels, not unlike the glomeruli of the kidney. They are covered upon the inner surface by two layers of epithelium, which belong properly to the retina, and are hence called the *pars ciliaris retinæ*. As in the *pars iridica retinæ*, the outer layer, corresponding with the anterior in the iris, consists of flattened cells, the inner of cubical cells, but unlike what obtains in the iris, they are not both pigmented, but only the outer layer.

The ciliary body extends backwards as far as the *ora serrata*, at which point the retina proper begins abruptly; the transition from ciliary body to choroid, on the other hand, is gradual, though this line is conveniently accepted as the limit of the two structures. The *ora serrata* is slightly more anterior on the nasal than on the temporal side.

The ciliary body is richly supplied with sensory nerve

fibres derived from the trigeminal, so that great pain results from injury or acute inflammation. The ciliary muscle is supplied with motor fibres from the oculomotor nerve.

The choroid is an extremely vascular membrane in contact everywhere with the sclerotic, though not firmly adherent to it, so that there is a potential space between

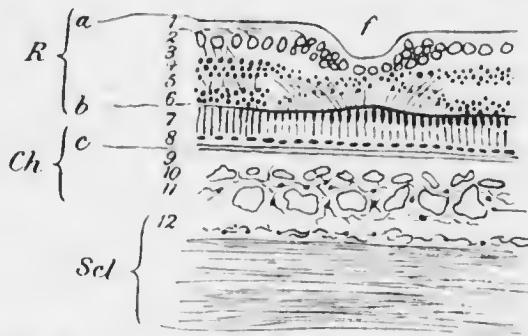


FIG. 4.—Diagrammatic section of retina, choroid, and sclerotic at posterior pole of the eye. R, retina, with *f*, fovea centralis; *a*, internal limiting membrane; 1, nerve fibre layer; 2, ganglion cell layer; 3, internal reticular layer; 4, internal nuclear layer; 5, external reticular layer; 6, external limiting membrane; 7, rods and cones; 8, retinal pigment epithelium. Ch, choroid; *c*, membrana vitrea or membrane of Bruch; 9, choriocapillaris; 10, layer of medium-sized vessels or Sattler's layer; 11, layer of large vessels or Haller's layer. Scl, sclerotic, with 12, lamina fusca on its inner surface.

the membrane of Bruch there is a capillary plexus, the *choriocapillaris*. Following upon this is the layer of medium sized vessels, whilst most external are the large vessels. The vessels are held together by a stroma consisting of branched pigmented connective tissue cells. It is easy to remember that the capillaries are innermost, because one of the chief functions of the choroid is to nourish the outer layers of the retina.

the two structures, which acts as a lymph space (Fig. 4). On the inner side, the choroid is covered by a thin elastic membrane, the *lamina vitrea*, or *membrane of Bruch*.

The blood vessels of the choroid increase in size from within outwards, so that immediately beneath

The choroid is supplied with sensory nerve fibres from the trigeminal.

The *retina* proper corresponds in extent with the choroid, which it lines. As already mentioned, however, and as shown by embryological research, it is continued forwards as a double layer of epithelium as far as the edge of the pupil. If the two layers of epithelium are traced backwards, the anterior layer in the iris is found to be continuous with the outer layer in the ciliary body, and this again is continued into the hexagonal pigment epithelium, which covers the membrane of Bruch. Similarly, the posterior layer in the iris, although pigmented, passes into the inner unpigmented layer of the ciliary body, and this suddenly changes at the ora serrata into the highly complex retina proper.

The retina proper consists of a number of layers. Most external, in contact with the pigment epithelium, is a neural epithelium, the rods and cones (Fig. 4). Following this, in order from without inwards, are the outer nuclear, the outer reticular, the inner nuclear, the inner reticular, the ganglion cell, and the nerve fibre layers. These special nervous constituents are bound together by neuroglia, the better developed vertical strands being called the fibres of Müller. The interlacement of neuroglial fibrils on the outer side form a sort of membrane which acts as a basement membrane for the rods and cones, the outer limiting membrane. Similarly on the inner side the bases of Müller's fibres spread out and form an inner limiting membrane upon the inner surface of the nerve fibre layer. Here the retina is in contact with the vitreous, which also has an extremely delicate bounding membrane, the hyaloid membrane: this is regarded by some as identical with the inner limiting membrane of the retina.

At the optic disc the fibres of the nerve fibre layer

pass into the optic nerve, the other layers of the retina stopping short abruptly at the edge of the porus opticus.

At the posterior pole of the eye, which is situated about 3 mm. to the temporal side of the optic disc, a specially differentiated spot is found in the retina of higher mammals (man and monkeys), the *fovea centralis*, or yellow spot. As its name implies, it is a depression or pit, and here only cones are present in the neuro-epithelial layer and the other layers are almost completely absent.

The fovea is the most sensitive part of the retina, and it is surrounded

by a small area, the macula, which, though not so sensitive, is more so than other parts of the retina. It is here that the nuclear layers become gradually thinned out, whilst on the other hand parts of the reticular layers are

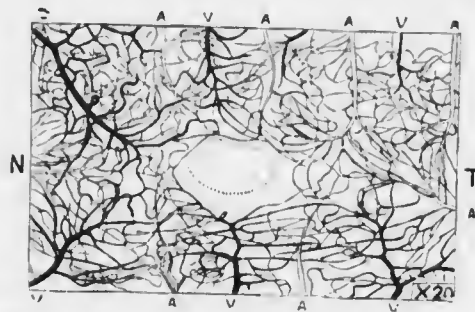


FIG. 5. Blood vessels in the macular region of the human retina. (Nettleship.) The central gap corresponds with the fovea centralis. N, nasal side; T, temporal side; A, arteries; V, veins. The meshes are much smaller than at the periphery of the retina.

specially in evidence: the ganglion cells too, instead of consisting of a single row of cells, are heaped up into several layers. There are no blood vessels in the retina at the macula, so that its nourishment here is entirely dependent upon the choroid (Fig. 5): by way of compensation the meshes of the capillary network of the choriocapillaris are particularly small here.

The so-called *optic nerve* is really a lobe of the brain, and therefore belongs properly to the central nervous system. Embryological and morphological investigations show that the bipolar cells of the retina, the nuclei of

which are in the inner nuclear layer, probably correspond with the cells in the dorsal root ganglion of an ordinary sensory nerve (neurons of the first order). Similarly, the ganglion cells correspond morphologically with the cells of the nucleus gracilis, or nucleus cuneatus (neurons of the second order). Hence the part of the visual nervous mechanism which corresponds with an ordinary peripheral sensory nerve is a microscopic cell and its processes situated within the retina itself. All the remainder is really part of the central nervous system, and we shall see that it responds to pathological processes more like the central than the peripheral nervous system.

The *porus opticus* is the aperture in the sclerotic through which the optic nerve passes. It varies much in shape in different cases, but in all it is traversed by a transverse network of connective tissue fibres containing much elastic tissue, the *lamina cribrosa*. The fibres of the nerve fibre layer of the retina pass through the meshes of the *lamina cribrosa*, and on the posterior side they suddenly become surrounded by medullary sheaths. These nerve fibres, which comprise the greater number of the nerve fibres in the so-called optic nerve, are the axis cylinder processes of the ganglion cells of the retina. They are therefore afferent or centripetal fibres, but the optic nerve also contains a few efferent or centrifugal fibres.

The *lens* is a biconvex mass of peculiarly differentiated epithelium. It will be remembered that it is developed from an invagination of the epidermal epiblast of the *fœtus*, so that what was originally the surface of the epithelium comes to lie in the centre of the lens, the peripheral cells corresponding with the basal cells of the epidermis. Just as the epidermis grows by the proliferation of the basal cells, the old superficial cells being cast off, so the lens grows by the proliferation of the peripheral cells. The old cells, however, cannot be cast

off, but become massed together in the centre or nucleus: moreover the newly formed cells elongate into fibres, the lens fibres, which have a rather complicated arrangement. Without going into details, it is important to bear in mind that the nucleus of the lens consists of the oldest cells and the periphery or cortex of the youngest. Further, it must be pointed out that at an early stage the productive basal cells become limited to a single row of cubical cells covering the anterior surface. The mass of epithelium which constitutes the lens is surrounded by a hyaline membrane, the lens capsule, which is thicker over the anterior than over the posterior surface: it is a cuticular deposit secreted by the epithelial cells.

The lens in fetal life is almost spherical: it gradually becomes flattened so as to assume the biconvex shape. It is held in place by the suspensory ligament or zonule of Zinn. This is not a complete membrane, but consists of bundles of fibrils which pass from the surface of the ciliary body to the capsule. The flattening of the lens is due to these fibrils becoming more and more stretched as the eye grows. The fibrils pass in various directions and the various bundles often cross one another. Thus the most posterior arise from the pars plana of the ciliary body almost as far back as the ora serrata: these lie in contact for a considerable distance with the ciliary body and then curve towards the equator of the lens to be inserted into the capsule: most are inserted slightly anterior to the equator. A second group of bundles spring from the summits and sides of the ciliary processes, *i.e.*, far forwards, and pass backwards to be inserted into the lens capsule, slightly posterior to the equator. A third group pass from the summits of the processes almost directly inwards to be inserted at the equator.

It will be noticed that there is a somewhat triangular

space between the back of the iris and the anterior surface of the lens, having its apex at the point where the pupillary margin comes in contact with the lens; it is bounded on the outer side by the ciliary body. This is the *posterior chamber*: it contains lymph of the same nature as the aqueous.

Behind the lens is the large vitreous chamber, containing the *vitreous humour*. It is a jelly-like material, intersected by delicate fibrils with a few cells and wandering leucocytes. It is bounded by the excessively delicate hyaloid membrane, but it is doubtful whether this is present at the anterior part where the vitreous is in contact with the lens.

THE BLOOD SUPPLY OF THE EYE.

The arrangement of the blood vessels which supply the eye is peculiar and is of great importance in considering pathological conditions.

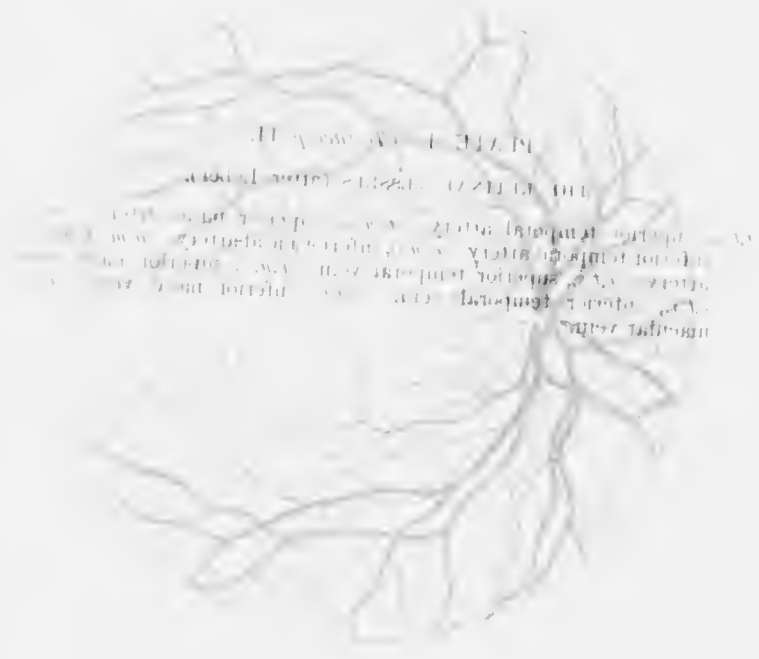
The arteries of the eye in man are all derived from the ophthalmic artery, which is a branch of the internal carotid. The ophthalmic artery has very few and insignificant anastomoses, so that on the arterial side the ocular circulation is an offshoot of the intracranial circulation. This is not the case to so marked a degree of the venous outflow of the eye. Whilst in man most of the blood passes to the cavernous sinus by way of the ophthalmic veins, yet it must be remembered that these anastomose freely in the orbit, the superior ophthalmic vein communicating with the angular vein at the root of the nose, and the inferior ophthalmic vein with the pterygoid plexus. Hence too great stress must not be laid upon the circulation in the retina as a guide to the condition of the intracranial circulation, as has been done in the past.

The retina is supplied by the central artery, which

enters the nerve on its lower surface, 15—20 mm. behind the globe. The central artery divides on or slightly below the surface of the disc into the main retinal trunks, which will be considered in detail later (Plate I.). The retinal arteries are end-arteries and have no anastomoses at the ora serrata. The only place where the retinal system anastomoses with any other is in the neighbourhood of the lamina cribrosa. The veins of the retina do not accurately follow the course of the arteries, but they behave similarly at the disc, uniting on or slightly below the surface of the disc to form the central vein of the retina, which accurately follows the course of the corresponding artery.

The uveal tract is supplied by the ciliary arteries, which are divided into three groups—the short posterior, the long posterior, and the anterior (Plate II.; Fig. 6). The short posterior ciliary arteries, about twenty in number, pierce the sclerotic in a ring around the optic nerve, running perpendicularly through the sclera, to which fine branches are given off. The long posterior ciliary arteries, two in number, pierce the sclerotic slightly farther away from the nerve, in the horizontal meridian, one on the nasal, the other on the temporal side. They traverse the sclerotic very obliquely, running in it for a distance of 4 mm. The anterior ciliary arteries are derived from the muscular branches of the ophthalmic artery to the four recti. They pierce the sclerotic near the limbus or corneo-scleral margin, giving off twigs to this region, to the conjunctiva and sclerotic.

The ciliary veins also form three groups—the short posterior ciliary, the *venae vorticosae*, and the anterior ciliary. The short posterior ciliary veins are unimportant; they do not receive any blood from the choroid, but only from the sclerotic. The *venae vorticosae* are the most important, consisting usually of four large trunks which



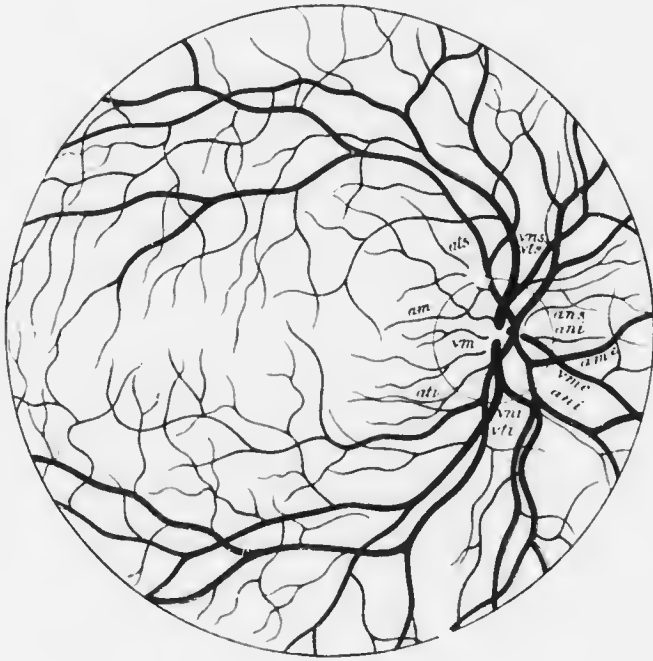
PLANTAE
A. ...
...
...
...
...

PLATE I. (To face p. 11.)

THE RETINAL VESSELS (after Leber).

a.t.s., superior temporal artery. *a.n.s.*, superior nasal artery. *a.t.i.*, inferior temporal artery. *a.n.i.*, inferior nasal artery. *a.m.*, macular artery. *v.t.s.*, superior temporal vein. *v.n.s.*, superior nasal vein. *v.t.i.*, inferior temporal vein. *v.n.i.*, inferior nasal vein. *v.m.*, macular vein.

PLATE I.





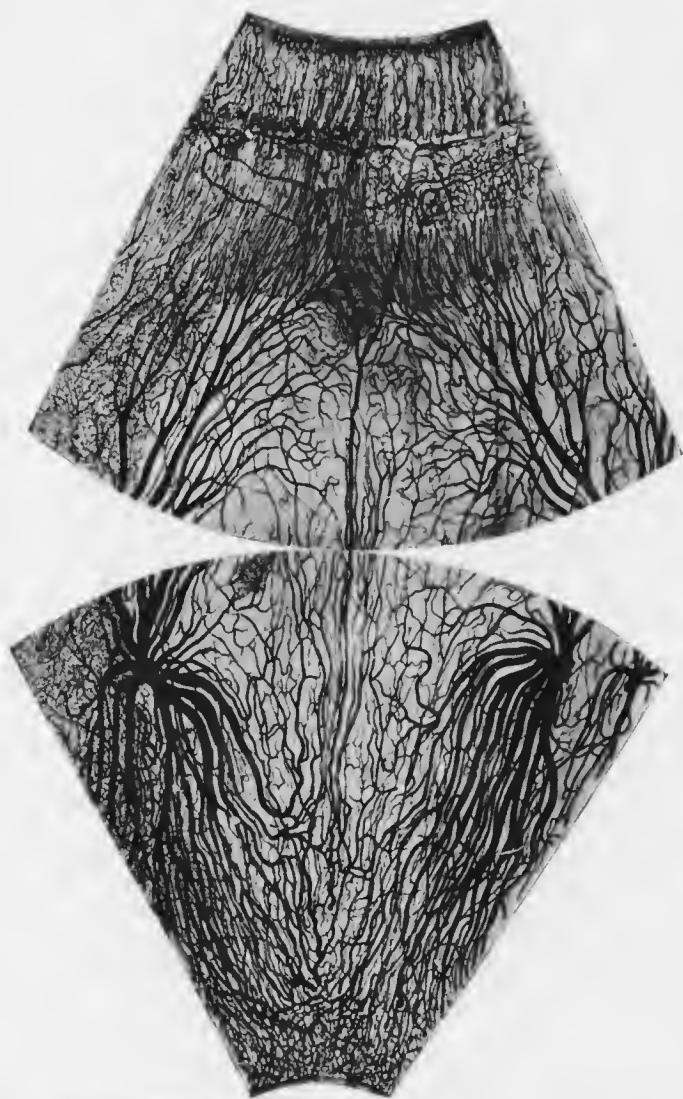


FIG. 6.—Blood vessels of the human uveal tract, injected, from the optic disc to the edge of the iris. (After Leber.) Arteries, black; veins, paler. Running up the centre is a long posterior ciliary artery. Two vorticosae veins and their tributaries are seen. The capillaries are only partially filled in.

open into the ophthalmic vein. They enter the sclerotic rather behind the equator of the globe, two above and two

below: they pass very obliquely through the sclera. The anterior ciliary veins are smaller than the corresponding arteries, since they receive blood only from the outer part of the ciliary muscle.

Of these ciliary vessels the short posterior ciliary arteries supply the whole of the choroid, being reinforced anteriorly by anastomosis with recurrent branches from the ciliary body. The ciliary body and iris are supplied by the long posterior and anterior ciliary arteries. The blood from the whole of the uveal tract, with the exception of the ciliary muscle, normally leaves the eye by the *venae vorticosæ* only.

The two long posterior ciliary arteries pass forwards between the choroid and the sclerotic, without dividing, as far as the posterior part of the ciliary body. Here each divides into two branches (Fig. 6): they run forwards in the ciliary muscle, and at its anterior part bend round in a circular direction, anastomosing with each other and thus forming the *circulus arteriosus iridis major*. This is situated in the ciliary body at the base of the iris: from it the ciliary processes and iris are supplied. Other branches from the major arterial circle run radially through the iris, dividing dendritically and ending in loops at the pupillary margin. A circular anastomosis takes place a little outside the pupillary margin, the *circulus arteriosus iridis minor*.

The tributaries of the vorticosæ veins, which receive the whole of the blood from the choroid, are arranged radially, the radii being bent, so as to give a whorled appearance—hence their name. The veins of the iris are collected into radial bundles which pass backwards through the ciliary body, receiving tributaries from the ciliary processes. Thus reinforced, they form an immense number of veins running backwards parallel to each other through the smooth part of the ciliary body. After

PLATE II. (Yonah's 18.)

THE GLIARY SYSTEM OF VERTEBRATES (after Leber).

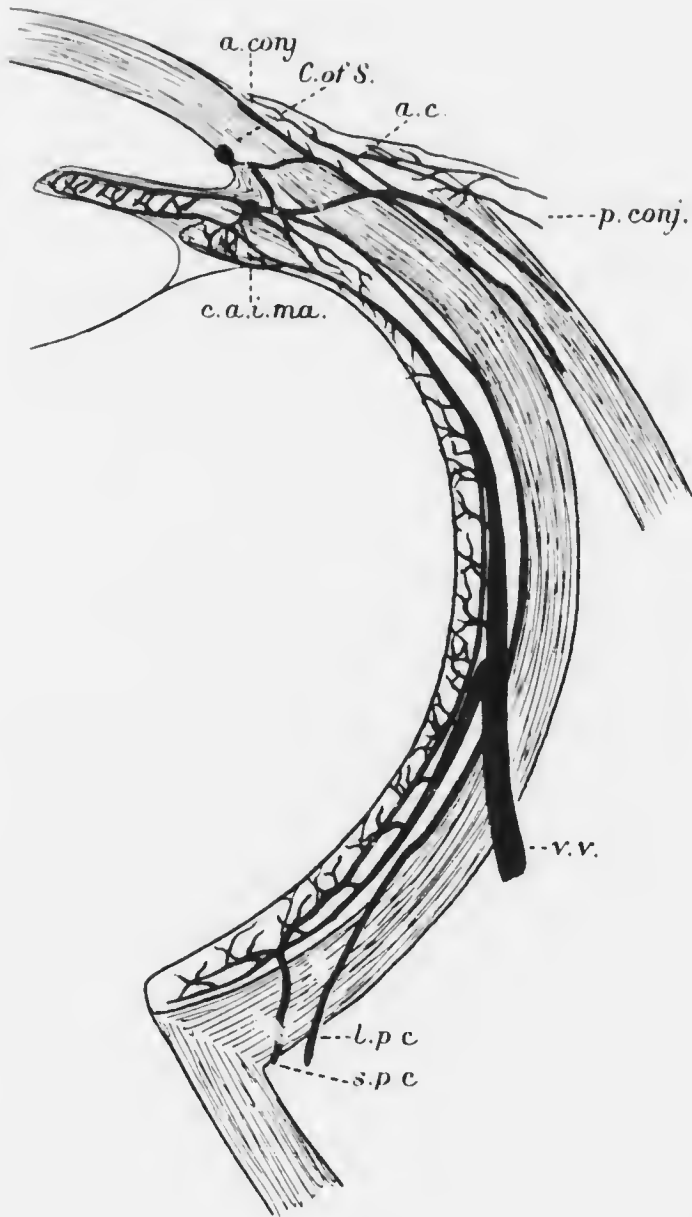
1. short posterior ciliary arteries. 2. long posterior ciliary artery.
3. anterior ciliary vessels. 4. canal of Schlemm. 5. 6. 7. 8. 9. 10. 11. 12. 13. 14. 15. 16. 17. 18. 19. 20. 21. 22. 23. 24. 25. 26. 27. 28. 29. 30. 31. 32. 33. 34. 35. 36. 37. 38. 39. 40. 41. 42. 43. 44. 45. 46. 47. 48. 49. 50. 51. 52. 53. 54. 55. 56. 57. 58. 59. 60. 61. 62. 63. 64. 65. 66. 67. 68. 69. 70. 71. 72. 73. 74. 75. 76. 77. 78. 79. 80. 81. 82. 83. 84. 85. 86. 87. 88. 89. 90. 91. 92. 93. 94. 95. 96. 97. 98. 99. 100. 101. 102. 103. 104. 105. 106. 107. 108. 109. 110. 111. 112. 113. 114. 115. 116. 117. 118. 119. 120. 121. 122. 123. 124. 125. 126. 127. 128. 129. 130. 131. 132. 133. 134. 135. 136. 137. 138. 139. 140. 141. 142. 143. 144. 145. 146. 147. 148. 149. 150. 151. 152. 153. 154. 155. 156. 157. 158. 159. 160. 161. 162. 163. 164. 165. 166. 167. 168. 169. 170. 171. 172. 173. 174. 175. 176. 177. 178. 179. 180. 181. 182. 183. 184. 185. 186. 187. 188. 189. 190. 191. 192. 193. 194. 195. 196. 197. 198. 199. 200. 201. 202. 203. 204. 205. 206. 207. 208. 209. 210. 211. 212. 213. 214. 215. 216. 217. 218. 219. 220. 221. 222. 223. 224. 225. 226. 227. 228. 229. 230. 231. 232. 233. 234. 235. 236. 237. 238. 239. 240. 241. 242. 243. 244. 245. 246. 247. 248. 249. 250. 251. 252. 253. 254. 255. 256. 257. 258. 259. 260. 261. 262. 263. 264. 265. 266. 267. 268. 269. 270. 271. 272. 273. 274. 275. 276. 277. 278. 279. 280. 281. 282. 283. 284. 285. 286. 287. 288. 289. 290. 291. 292. 293. 294. 295. 296. 297. 298. 299. 300. 301. 302. 303. 304. 305. 306. 307. 308. 309. 310. 311. 312. 313. 314. 315. 316. 317. 318. 319. 320. 321. 322. 323. 324. 325. 326. 327. 328. 329. 330. 331. 332. 333. 334. 335. 336. 337. 338. 339. 340. 341. 342. 343. 344. 345. 346. 347. 348. 349. 350. 351. 352. 353. 354. 355. 356. 357. 358. 359. 360. 361. 362. 363. 364. 365. 366. 367. 368. 369. 370. 371. 372. 373. 374. 375. 376. 377. 378. 379. 380. 381. 382. 383. 384. 385. 386. 387. 388. 389. 390. 391. 392. 393. 394. 395. 396. 397. 398. 399. 400. 401. 402. 403. 404. 405. 406. 407. 408. 409. 410. 411. 412. 413. 414. 415. 416. 417. 418. 419. 420. 421. 422. 423. 424. 425. 426. 427. 428. 429. 430. 431. 432. 433. 434. 435. 436. 437. 438. 439. 440. 441. 442. 443. 444. 445. 446. 447. 448. 449. 450. 451. 452. 453. 454. 455. 456. 457. 458. 459. 460. 461. 462. 463. 464. 465. 466. 467. 468. 469. 470. 471. 472. 473. 474. 475. 476. 477. 478. 479. 480. 481. 482. 483. 484. 485. 486. 487. 488. 489. 490. 491. 492. 493. 494. 495. 496. 497. 498. 499. 500. 501. 502. 503. 504. 505. 506. 507. 508. 509. 510. 511. 512. 513. 514. 515. 516. 517. 518. 519. 520. 521. 522. 523. 524. 525. 526. 527. 528. 529. 530. 531. 532. 533. 534. 535. 536. 537. 538. 539. 540. 541. 542. 543. 544. 545. 546. 547. 548. 549. 550. 551. 552. 553. 554. 555. 556. 557. 558. 559. 560. 561. 562. 563. 564. 565. 566. 567. 568. 569. 570. 571. 572. 573. 574. 575. 576. 577. 578. 579. 580. 581. 582. 583. 584. 585. 586. 587. 588. 589. 590. 591. 592. 593. 594. 595. 596. 597. 598. 599. 600. 601. 602. 603. 604. 605. 606. 607. 608. 609. 610. 611. 612. 613. 614. 615. 616. 617. 618. 619. 620. 621. 622. 623. 624. 625. 626. 627. 628. 629. 630. 631. 632. 633. 634. 635. 636. 637. 638. 639. 640. 641. 642. 643. 644. 645. 646. 647. 648. 649. 650. 651. 652. 653. 654. 655. 656. 657. 658. 659. 660. 661. 662. 663. 664. 665. 666. 667. 668. 669. 670. 671. 672. 673. 674. 675. 676. 677. 678. 679. 680. 681. 682. 683. 684. 685. 686. 687. 688. 689. 690. 691. 692. 693. 694. 695. 696. 697. 698. 699. 700. 701. 702. 703. 704. 705. 706. 707. 708. 709. 710. 711. 712. 713. 714. 715. 716. 717. 718. 719. 720. 721. 722. 723. 724. 725. 726. 727. 728. 729. 730. 731. 732. 733. 734. 735. 736. 737. 738. 739. 740. 741. 742. 743. 744. 745. 746. 747. 748. 749. 750. 751. 752. 753. 754. 755. 756. 757. 758. 759. 760. 761. 762. 763. 764. 765. 766. 767. 768. 769. 770. 771. 772. 773. 774. 775. 776. 777. 778. 779. 780. 781. 782. 783. 784. 785. 786. 787. 788. 789. 790. 791. 792. 793. 794. 795. 796. 797. 798. 799. 800. 801. 802. 803. 804. 805. 806. 807. 808. 809. 810. 811. 812. 813. 814. 815. 816. 817. 818. 819. 820. 821. 822. 823. 824. 825. 826. 827. 828. 829. 830. 831. 832. 833. 834. 835. 836. 837. 838. 839. 840. 841. 842. 843. 844. 845. 846. 847. 848. 849. 850. 851. 852. 853. 854. 855. 856. 857. 858. 859. 860. 861. 862. 863. 864. 865. 866. 867. 868. 869. 870. 871. 872. 873. 874. 875. 876. 877. 878. 879. 880. 881. 882. 883. 884. 885. 886. 887. 888. 889. 890. 891. 892. 893. 894. 895. 896. 897. 898. 899. 900. 901. 902. 903. 904. 905. 906. 907. 908. 909. 910. 911. 912. 913. 914. 915. 916. 917. 918. 919. 920. 921. 922. 923. 924. 925. 926. 927. 928. 929. 930. 931. 932. 933. 934. 935. 936. 937. 938. 939. 940. 941. 942. 943. 944. 945. 946. 947. 948. 949. 950. 951. 952. 953. 954. 955. 956. 957. 958. 959. 960. 961. 962. 963. 964. 965. 966. 967. 968. 969. 970. 971. 972. 973. 974. 975. 976. 977. 978. 979. 980. 981. 982. 983. 984. 985. 986. 987. 988. 989. 990. 991. 992. 993. 994. 995. 996. 997. 998. 999. 1000.

PLATE II. (To face p. 16.)

THE CILIARY SYSTEM OF VESSELS (after Leber).

s.p.c., short posterior ciliary arteries. *l.p.c.*, long posterior ciliary artery.
a.c., anterior ciliary vessels. *C. of S.*, canal of Schlemm. *c.a.i.m.a.*,
circulus arteriosus iridis major. *v.v.*, venæ vorticosæ. *a.conj.*,
anterior conjunctival vessels. *p.conj.*, posterior conjunctival
vessels.

PLATE II.





reaching the choroid they converge to form the large anterior tributaries of the vorticosse veins. The veins from the outer part of the ciliary muscle on the other hand pass forwards and unite with others to form a plexus, part of which is the so-called canal of Schlemm. These vessels drain into the anterior ciliary veins. The marginal loops of the cornea and the conjunctival vessels are branches of the anterior ciliary (Plate II.).

CHAPTER II.

PHYSIOLOGY.

In order that the eye may satisfactorily perform its duties as an organ of vision it is essential that a sharp image of objects in the outer world shall be formed upon the retina, which is effected by means of a series of curved surfaces, and the curvature of these surfaces and their relative positions to each other must be kept constant. For this purpose it is necessary that the walls of the globe should be kept stretched.

If a small cannula connected with a narrow-bored mercury manometer is pushed into the anterior chamber or into the vitreous of an animal it will be found that the mercury in the manometer will rise about 25 or 30 mm. (Fig. 7). In other words, the contents of the eyeball, which are for the most part fluid, exert a pressure upon the inner side of the walls which is about 25 mm. of mercury greater than the atmospheric pressure which falls upon the outside of the walls; the walls are thus kept well stretched.

This pressure inside the eye is called the intraocular pressure, or the *tension*, of the eye. (These terms are used indiscriminately, though it is not quite accurate to do so.) In order that the tension of the eye may be kept up, work must be done by the organism, and a moment's consideration will make it evident that the source of energy must be the blood pressure. This conjecture has been proved conclusively true by experiments on animals, in which it is

found that the intraocular pressure follows passively every change in the general blood pressure (Fig. 8).

It is obvious that it must be the fluid constituent of the contents of the globe which keeps up the internal pressure. This fluid fills the anterior and posterior chamber and permeates the vitreous. It is comparable to the lymph which bathes the tissues in other parts of the body, and it is indeed the lymph of the eye. In other parts of the body the chief function of the lymph is to carry food material to the tissue cells, and to carry away the effete products of the cell metabolism. It has a further function of keeping up the normal tissue tension. Both of these functions attain an unusual degree of importance in the case of the eye. We have already seen the necessity for keep-




FIG. 7.—Diagram of manometer placed in communication with anterior chamber, showing that the normal intraocular pressure is about 25 mm. of mercury.

ing up the normal tension of the eye. As regards the nourishment of the cells, our review of the anatomy of the eye has shown that there are large areas, notably the whole of the lens and the vitreous, which possess no blood supply. They are dependent entirely for their nutrition upon the lymph.

If water were to be forced into an impermeable elastic bag, the internal pressure might be kept indefinitely above the pressure upon the outside of the bag. Such an arrangement for keeping up the intraocular pressure would be unsatisfactory owing to the function of the lymph in nutrition. The stagnant fluid would soon lose all its food material, which would be used up, and it would become

loaded with the excreted products of the cells, which would have a very deleterious effect upon them. Hence it



FIG. 8.—Tracing of right carotid blood pressure, intraocular pressure from canula in anterior chamber of left eye of a dog, which was fully under the influence of morphia, A.C.E. mixture, and curare. Stimulation of the vasomotor centre, showing that the intraocular pressure follows passively all the changes in the general blood pressure as produced by Traube-Hering curves and constriction of the arterioles of the splanchnic area.

is essential that the lymph shall be constantly renewed. This occurs in the eye. The lymph is continually being

renewed, but at the same time it is equally rapidly being removed, and thus the amount present is kept constant.

It has been shown that in other parts of the body lymph is formed by filtration out of the capillaries: the amount poured out and its chemical composition are dependent upon the difference in pressure on the two sides of the filtering membrane, *i.e.*, the capillary wall. On the one side there is the relatively high intracapillary pressure, on the other the low tissue tension. Exactly the same is found to be the case in the eye. Here the intracapillary pressure is higher than in other parts of the body, but the extracapillary pressure is also higher than usual, being as much as 25 mm. of mercury, *i.e.*, the intraocular pressure. The difference between the two pressures is, however, less in the eye than elsewhere. Consequently we may expect to find on the one hand that the amount of lymph produced in a given time is small, and on the other hand that its chemical composition will differ materially from that of lymph elsewhere. Both these conjectures have been substantiated. The rate of production is so slow that it probably takes nearly an hour for the aqueous in the anterior chamber to be renewed. The chemical composition of the aqueous is consistent with the view that filtration is going on at a small difference of pressures, for under these circumstances we shall expect very little of the large-moleculed proteids of the blood to be able to get through the capillary wall. As a matter of fact the aqueous contains excessively little proteid (0.045 per cent.). In spite of the fact that the conditions of the production of aqueous are consistent with the view that it is a simple process of filtration, it is more generally spoken of as a secretion.

We have already noticed the resemblance of the ciliary processes to the glomeruli of the kidney. It is always

dangerous to deduce physiological function from anatomical structure alone, but in the case of the ciliary body experiment and clinical and pathological observation alike confirm the conjecture that the processes are the chief if not the only site of the production of the aqueous in the human eye. If the iris and ciliary body are removed, as can be done in the rabbit without immediate destruction of the eye, no more aqueous is formed and the eye rapidly becomes soft and shrinks. That the effect is not due to the absence of the iris is shown by the fact that the iris is sometimes almost completely absent as a congenital defect, yet the aqueous is normally secreted. We may therefore conclude that the aqueous is "secreted" by the ciliary processes.

The greater part of the lymph thus produced passes into the posterior chamber. Thence it passes forwards through the pupil into the anterior chamber, the free communication between the two chambers being facilitated by the perpetual movements of the iris. A small quantity—not more than one-fiftieth part—of the aqueous secreted by the ciliary body passes backwards into the vitreous, which it nourishes. Situated in the vitreous, running directly forwards from the optic disc almost as far as the posterior pole of the lens, is a small tubular lymph space, the canal of Cloquet. It is the lymph space which originally surrounded the fetal hyaloid artery; it persists after the latter disappears. The lymph of the vitreous finds its way into this space, which communicates with the perivascular lymph spaces surrounding the central vessels of the retina. By this route the lymph passes out of the eye through the optic nerve into the vaginal space. Only a very small proportion of the lymph produced by the ciliary processes, as mentioned—probably not a fiftieth part—finds its exit from the eye here. What becomes of the remainder? We have already said that it passes

forwards into the anterior chamber. It was at one time thought that it transuded through the cornea and escaped into the conjunctival sac. This is not so: it is now known that it filters away through the angle of the anterior chamber into the venous plexus which is called the canal of Schlemm. Having passed into the canal of Schlemm the effete lymph is carried away by the anterior ciliary veins.

It might be expected that so vascular a tissue as the choroid is concerned in the production of lymph. It is probable, however, that it produces only sufficient to nourish its own tissues and the outer layers of the retina. The retinal capillaries extend no deeper into the retina than the outer reticular layer; consequently the rods and cones and the pigment epithelium are dependent upon the choroid for their nutrition. The choroidal lymph passes out of the eye chiefly by way of perivascular lymph spaces around the vorticose veins, a small quantity passing into the subchoroidal space and so into the lymph sheaths of the posterior ciliary vessels. The retinal lymph passes away by perivascular lymph sheaths through the optic nerve into the vaginal space. The retina and choroid, then, only produce a sufficiency of lymph for their own requirements, and have nothing to do with sustaining the intraocular tension.

Similarly it might be thought that the vascular iris provided some of the aqueous. It is not easy to disprove this hypothesis, but it is easy to show that the iris is to some extent concerned in absorption, and it is highly improbable that the same structure carries on such opposite functions.

It has already been stated that sharp images of external objects must be formed upon the retina if the latter are to be seen clearly. Before considering how this is effected it will be advisable to refresh the reader's memory upon the

elementary principles of optics. I would seriously impress upon the student that success in the diagnosis, and hence in the treatment, of diseases of the eye is impossible if such elementary principles of optics as are set forth here are not thoroughly mastered.

CHAPTER III.

ELEMENTARY OPTICS.

It is a familiar fact that a candle flame emits light in all directions. The light is transmitted in straight lines, so that we may imagine the light coming from the candle as consisting of an immense number of straight lines, all intersecting in some part of the flame. If we consider a minute point in the flame, then all the straight lines which cross in this point may be said to diverge from it. Each of these hypothetical straight lines is called a ray.

Now, every point on such a ray represents, or is the image of, the point of light from which it springs. This is shown very clearly by a simple experiment carried out in a dark room. Make a pin-hole in a piece of cardboard (Fig. 9, A), and hold the cardboard in front of the candle (C) at a little distance from it.

Beyond the cardboard hold up a white screen (B), so that the cardboard is between the screen and the candle. A dim image (D) of the flame will be thrown upon the screen, and it will be noticed that it is upside down, *i.e.*, an inverted image of the flame is formed. This is due to the fact that the cardboard cuts off all the rays of light from the candle except such as can pass through the hole. The only rays from the top of the flame which can pass through the hole are those which are caught upon the lower part of the

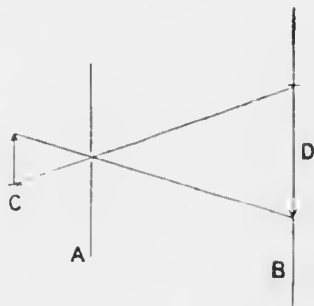


FIG. 9.

screen. They represent the top of the flame; hence they reproduce its shape accurately. The image is very dim because only a few rays of light can pass through the small hole. Now make another hole a little distance away from the first. Another inverted image of the flame is seen. If a dozen holes are made, a dozen images appear. If two holes are very close together the images will overlap. If a large hole is made, so many images overlap that all resemblance to the original flame is lost, and part of the screen becomes uniformly illuminated. If we take

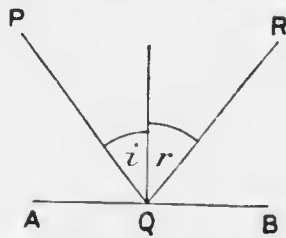


FIG. 10.—The ray from P which strikes the mirror AB at Q is reflected to R, so that PQ and QR are in the same plane, viz., that of the paper, and the angle of incidence, i , is equal to the angle of reflection, r .

away the cardboard altogether the whole screen becomes illuminated, and we now know that this is because we have an infinite number of images of the flame all overlapping each other.

Light travels with different velocities in different media. If the velocity is less in one medium than another the first medium is said to be optically denser than the second.

When light, travelling in one medium, meets another medium it breaks up into two parts: part is *reflected* back into the first medium; part is *refracted* into the second medium. If the second medium is opaque none of the light is refracted.

REFLECTION.

Let us now consider what happens to a ray of light when, travelling in one medium, it is reflected from the surface of a denser medium. We have already said that its direction is altered. Before it meets the surface it is called an incident ray; after it leaves the surface it is

called the reflected ray. If a line is drawn at right angles to the surface at the point where the incident ray meets it, it is found to be an invariable rule that the incident ray makes the same angle with this line, which is called the normal, that the reflected ray makes with it. Put in formal language, this law of reflection is that *for all surfaces the angle of incidence is equal to the angle of reflection, and is in the same plane with it* (Fig. 10).

Plane Mirrors.—Let us apply this rule to an ordinary flat mirror (Fig. 11). If P is a luminous point in front of the mirror AB, the ray PQ will be reflected towards R, and the ray PS towards T; *i.e.*, the reflected rays QR and ST appear to come from *p*, a point as far behind the mirror as P is in front of it. As the rays QR and ST have to be produced backwards in order that they may meet, no real

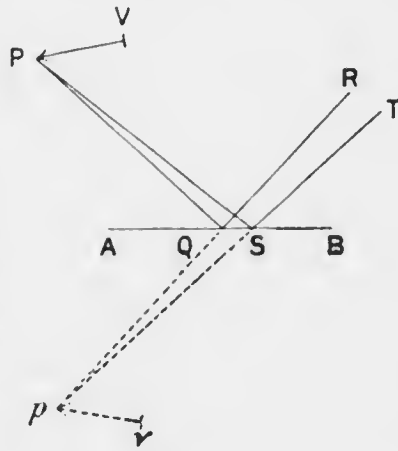


FIG. 11.

image is formed, and such an image is called a virtual image. Note that the rays reflected from a plane mirror are divergent. The same reasoning holds good for every point on the object PV, its image being *pv* as far behind the mirror as the object is in front of it: moreover, the size of the image is equal to that of the object.

Concave Mirrors.—Here the normal to the surface is the radius of the sphere. If AH (Fig. 12) is part of the section of a concave mirror and PB is an object, K being the centre of the sphere, then the line HKB is called the axis, and H the apex of the mirror. The ray PK through

the centre of the sphere will obviously be reflected along itself, so that the image of P must be on PK . The ray PA , parallel to the axis, will meet PK in p . Hence p is the image of P . Now it is found that all rays parallel to the axis and not very far removed from it cut the axis in the same point, F , and this point bisects the line HK . This point is called the principal focus of the mirror. If the object PB were removed a very great distance away from the mirror, all the rays which fell upon a small portion of the mirror near H would diverge so little from each other that they would all be practically parallel to BH , and the image of PB would be extremely small and

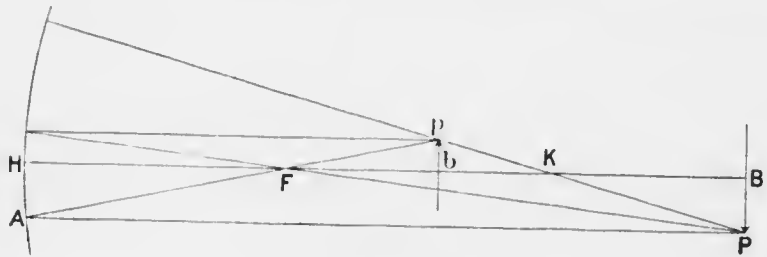


FIG. 12.

situated at F . In each of these cases the image is an inverted one of the object.

It is an axiom of optics that the direction of the rays is reversible. Hence, if pb were an object, it would have its image at PB , and if there were an object at F , all the rays from it reflected by the mirror would be parallel to the axis, and the image would be infinitely large and situated at infinity.

What would happen if the object were situated between F and H ? In that case (Fig. 13) the rays would diverge after reflection as if they came from an object behind the mirror, much as they do with a plane mirror. The image would therefore be a virtual one, situated behind

the mirror: it would be erect and larger than the object.

The important fact to remember with regard to

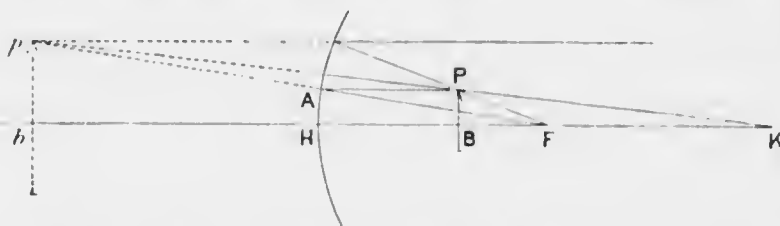


FIG. 13.—The ray from P parallel to the axis is reflected through F , the principal focus. The ray FP is reflected parallel to the axis. The ray KP is normal to the surface, and is therefore reflected on itself. Any two of these rays will give the situation of p , the image of P .

concave mirrors is that if the object is farther away from the mirror than its focal distance, *i.e.*, than half its radius of curvature, the image is a real inverted one situated also in front of the mirror. This is the condition

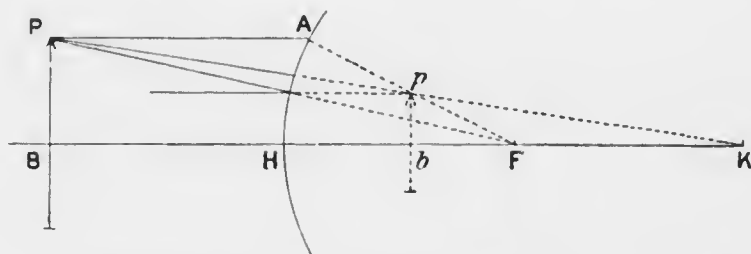


FIG. 14.—Reflection by a convex mirror. The description of Fig. 13 applies equally to this case.

which is almost always present in the ordinary use of ophthalmic instruments.

Convex Mirrors.—We are not accustomed to use convex mirrors in ophthalmic instruments, but it is necessary to know what happens with them since the cornea acts as a convex mirror. Here, as will be seen from Fig. 14, the image is always virtual, erect, and smaller than the

object. As with the concave mirror, if the object is a long way off, the image will be situated at the principal focus, *i.e.*, at a distance equal to half the radius of curvature behind the mirror.

REFRACTION.

We have now to consider what happens to the refracted ray when the incident ray, travelling in one medium, *e.g.*, air, meets an optically denser medium, *e.g.*, glass. We have already said that the light will now travel more slowly. It follows

directly from this fact that it will be deflected towards the normal to the surface, and it will be more deviated the greater the difference in optical density between the two media. If the density of air is taken as unity, then the ratio of its density to that of the second medium is called the

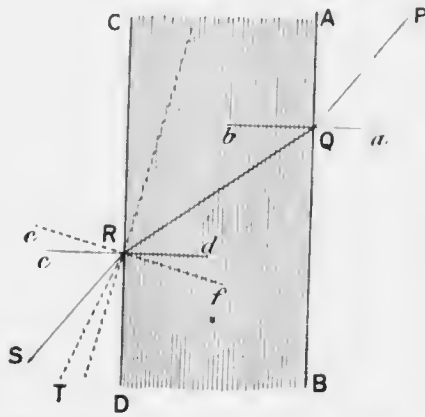


FIG. 15. Refraction by a plane lamina.

index of refraction of the medium.

Plane Lamina.—Let us see what happens when an incident ray, such as PQ (Fig. 15), meets the surface of a plate of glass with parallel sides. It will be deflected towards the normal, *ab*. When the ray passes out of the glass on the other side, it will obviously be deflected away from the new normal, *cd*, just as much as PQ was deflected towards it. Hence the emergent ray RS will be parallel to the incident ray PQ. If the plate of glass is very thin, RS will be practically continuous with PQ.

Prisms.—If we imagine one side (CD) of the plate in the last figure to revolve round R, we shall be able to understand the nature of refraction by a prism. QR will now make a larger angle with the new normal $c'f$ than it did with the old one cd . Consequently the angle of refraction will also be larger, *i.e.*, the new direction of the emergent ray will be RT. In other words, the ray is deviated towards the base of the prism.

The ray PQRS in Fig. 16 is said to pass symmetrically through the prism. Under these circumstances, if the prism is made of crown glass, the deviation of the ray is approximately equal to half the refracting angle of the prism, a .

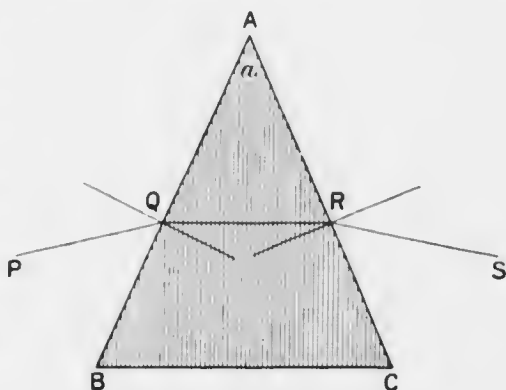


FIG. 16.—Refraction by a prism.

We are accustomed to project objects along the direction of the rays of light as they enter the

eye, and in doing so we ignore the effect of refraction since it enters relatively little into our everyday experience. If, therefore, we look at a candle P through a prism, as in Fig. 17, the light will appear to come from p . Objects, then, seen through a prism, appear displaced towards the apex of the prism.

Lenses.—Ordinary lenses are pieces of glass with spherical surfaces. The line passing through the centres of curvature of the surfaces is called the axis of the lens. Fig. 18 shows the chief varieties of lenses, *viz.*, (1) bi-convex, (2) biconcave, (3) plano-convex, (4) plano-concave,

(5) convexo-concave or meniscus: these names require no further explanation.

The effect of a biconvex lens upon rays of light meeting it, is very similar to what would occur if it were replaced by two prisms set base to base (Fig. 19).

If the incident rays are parallel to the axis they will be refracted in such a manner that they all cross the axis in a single point upon the other side of the lens. This point is called the principal focus of the lens, and its distance from the lens is called the focal distance or length of

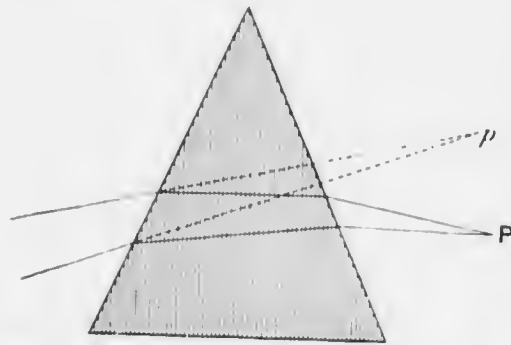


FIG. 17. Displacement of objects seen through a prism. The object P appears to be situated at *p*.

the lens. When the lens has the same medium, *e.g.*, air, on each side of it, the two principal foci, one on each side of the lens, are situated at equal distances from it. For thin glass lenses of low power the focal distance is

equal to the radius of curvature of the two surfaces when these are equally curved. If there is an object a very long distance away from the lens, the rays which come from it are practically parallel. Hence in this case an image of the object will be formed by the lens at its principal focus; it will be inverted and very small. If the object is gradually brought nearer and nearer to the lens (Fig. 20) the image will recede farther and farther from it; from being very small it will grow larger and larger, until, when the object is at the principal focus, the image will have receded to infinity, and it will be infinitely large, *i.e.*, all the rays

coming from the object at the principal focus are parallel to the axis and to each other after refraction. If the object is brought still closer to the lens than its focal distance (Fig. 21) it will be found that its image is a

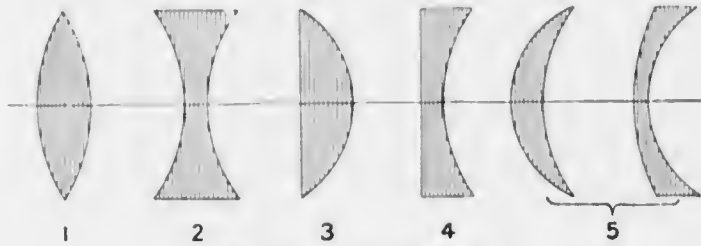


FIG. 18.—Types of lenses.

virtual one behind the object, and that it is erect and larger than the object. The positions of the object and image bear a constant relationship to each other and are called conjugate foci.

There is a point in the middle of a biconvex lens which

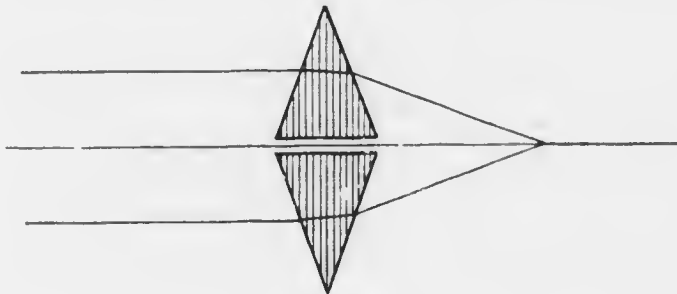


FIG. 19.

is called its optical centre. With thin lenses any ray which passes through this point is practically not deviated at all. It is easy to understand why this is so. If PQRS (Fig. 22) is such a ray and tangents are drawn to the two surfaces at the points Q and R, these two tangents will be

parallel to each other. Consequently, the lens acts for such a ray exactly as if it were a plate with parallel sides, and we have already seen that in such a case the emergent

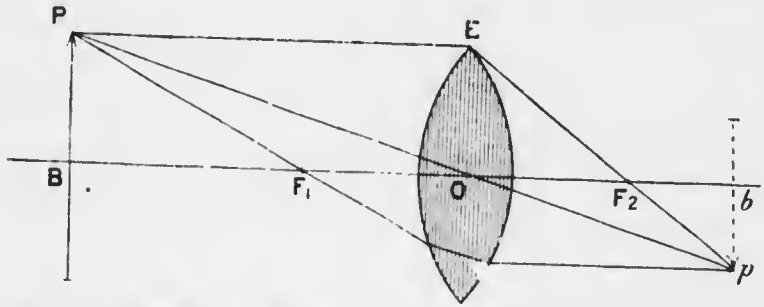


FIG. 20.—The ray PE, parallel to the axis, is refracted through the second principal focus F_2 . The ray PF_1 , through the first principal focus, is refracted parallel to the axis. The ray PO, through the optical centre of the lens, is not deflected. Any two of these rays gives the situation of p , the image of P .

ray is parallel to its original direction. If the lens is very thin the refracted ray will be practically continuous with the incident ray.

If we know these facts, viz., that rays passing through

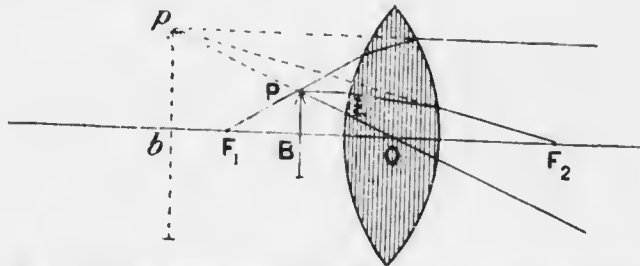


FIG. 21.—The description of Fig. 20 applies equally to this figure.

the optical centre are not deviated, and that rays passing through the principal focus are parallel to the axis after refraction, we can easily construct the image of an object in any given position. Thus, in Fig. 20, if PB is an

object, the ray PO through the optical centre O will not be deviated; the ray PE parallel to the axis will pass through the second principal focus F_2 ; and the ray PF_1 through the first principal focus will be parallel to the axis after refraction. Hence pb must be the image of PB .

The effect of a biconcave lens upon rays of light meeting it is very similar to what would occur if it were replaced by two prisms set apex to apex (Fig. 23).

Here, if the incident rays are parallel to the axis they will be divergent after refraction, and the amount of divergence of the individual rays will be such that if they are produced backwards they will all cross the axis in a single point upon the same side of the lens that they came from. This and the corresponding point on the other side of the lens are called the principal foci. The

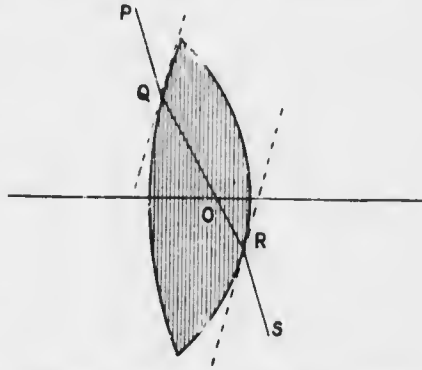


FIG. 22.—Properties of the optical centre of a lens.

biconcave lens also has an optical centre, situated upon the axis within it and having the same properties as in the case of the convex lens. The image of any object formed by a concave lens can be constructed in exactly the same manner as for a convex lens (Fig. 24). It will be found that in every position of the object the image is always virtual, erect and smaller than the object.

Plano-convex and plano-concave lenses act like biconvex and biconcave respectively, but in them the optical centre is on the curved surface at the point where the axis cuts it. Menisci act as convex or concave lenses according as the convex or the concave surface has the

greater curvature. In them the optical centre is outside the lens.

It will have been noticed that the refractive power of a lens varies inversely as the focal distance, *i.e.*, a lens with

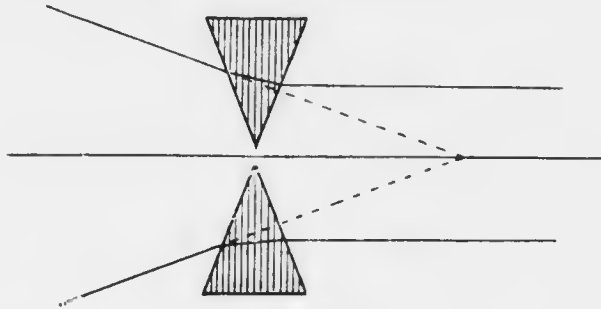


FIG. 23.

a short focal distance will bend the rays more than one with a longer focal distance. It is necessary to have some system of numbering lenses so as to indicate their refractive

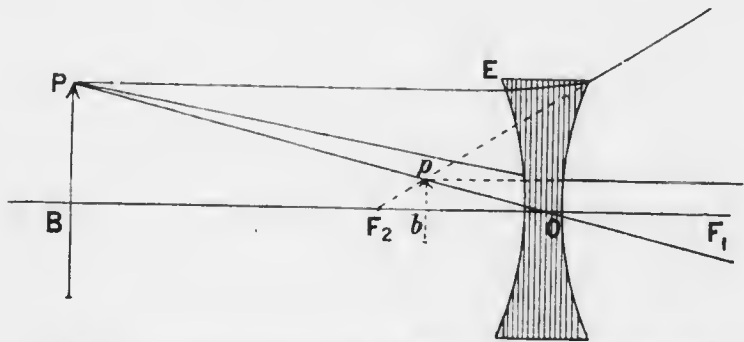


FIG. 21.—The description of Fig. 20 applies equally to this figure.

power. The most convenient system for ophthalmic purposes is that which takes a lens with a focal distance of 1 metre as a standard. Such a lens is said to have a refractive power of 1 *dioptré*. A lens with a focal length of half a metre will be twice as strong as one whose focal

length is 1 metre: the refractive power of such a lens is therefore 2 dioptries. Similarly, a 3 D (3 dioptry) lens has a focal length of one-third of a metre, or 33 cm.; a 4 D lens, 25 cm.; and so on. It is important to remember that in this system the standard is a metre, not a centimetre or a millimetre; otherwise confusion may arise.

Lenses were formerly numbered according to their focal lengths measured in inches. Since the inch has a different value in different places, the method is unsatisfactory. Prescriptions for spectacles are, however, sometimes met with in this notation. They are easily transformed into the dioptric system by remembering that there are 40 inches (roughly, or 36 Paris inches) in 1 metre. Therefore a 40 inch lens = 1 D; a 20 inch lens = 2 D; a 4 inch lens = $\frac{40}{4} = 10$ D; and so on: a lens of focal length = 4 Paris inches = $\frac{36}{4} = 9$ D.

Convex lenses are indicated by a plus sign (+), concave by a minus (-) sign before the number.

Cylindrical lenses are also used in ophthalmology; their nature and use will be considered at a later stage.

The accompanying diagram (Fig. 25) indicates the usual arrangement of lenses, &c., in the trial case.

We often wish to find out whether a lens is convex or concave, and what its refractive power is. There are several ways of doing this, but the simplest is with the assistance of the trial case. Hold a convex lens up near the eye and look at distant objects through it; then move the lens a little from side to side: the distant objects will seem to move in the opposite direction to that in which the lens is moved. If we repeat the process with a concave lens the objects seem to move in the same direction as the lens. The reason is to be found in the fact that a convex

Duplicate Sets of Convex Spheres from + 0.25 D to + 2.0 D	Duplicate Sets of Convex Cylinders from + 0.25 D to + 7 D	Duplicate Sets of Concave Cylinders from - 0.25 D to - 7 D	Duplicate Sets of Concave Spheres from - 0.25 D to - 20 D
+ 2 + 1.75 + 1.5 + 1.25 + 1.0 + 0.75 + 0.5 + 0.25	etc. + 0.75 + 0.5 + 0.25	etc. - 0.75 - 0.5 - 0.25	
etc.			etc.
	Prisms.		
	Coloured Glasses, &c.		
+ 2 + 1.75 + 1.5 + 1.25 + 1.0 + 0.75 + 0.5 + 0.25			+ 2 + 1.75 + 1.5 + 1.25 + 1.0 + 0.75 + 0.5 + 0.25

FIG. 25.—Diagram of the arrangement of lenses, &c., in a trial case.

lens forms an inverted, whilst a concave forms an erect image. If we place two lenses of opposite sign but equal curvature in contact with one another the combination will make a plate with parallel sides: such a plate, as we know, does not practically deflect the rays of light at all. Hence we can determine the strength of a lens by exactly neutralising it with a lens of the opposite sign out of the trial case. Let us take a concrete example, a particular lens which we wish to determine. We hold it up and find that distant objects seem to move in the opposite direction to the lens. We know that it is a convex lens. We then put a weak concave lens in contact with it and repeat the process. We find that

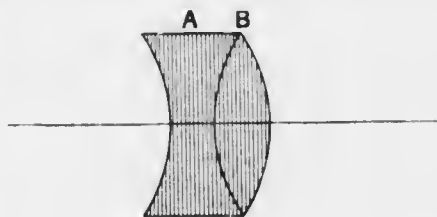


FIG. 26.

with a -2 D lens objects still seem to move in the opposite direction, though not so much. With a -3 D lens there is only a trace of movement, and with a -3.5 D lens there is no movement at all. We conclude that the original lens was $+3.5$ D. In performing this test it is important to have the two lenses as closely in contact as possible, and also to have their centres in contact. If the centre of one lens is higher than that of the other they will obviously not counteract each other exactly. If they are not in contact the result will be either too high or too low.

When the lenses are in contact the refractive power of the combination (D) is equal to the algebraical sum of the refractive powers of the two lenses (d_1, d_2): i.e., $D = d_1 + d_2$, or $\frac{1}{F} = \frac{1}{f_1} + \frac{1}{f_2}$ where F, f_1, f_2 , are the respective focal distances (Fig. 26).

Suppose, however, that two convex lenses are separated by a distance c (Fig. 27). The lens A will make parallel rays converge

towards a , but after a distance c they meet the lens B; hence the convergence of the rays is not expressed by $\frac{1}{f_1}$, but by $\frac{1}{f_1 - c}$. Therefore the combined effect of the lenses, D , or $\frac{1}{F}$, is now equal to

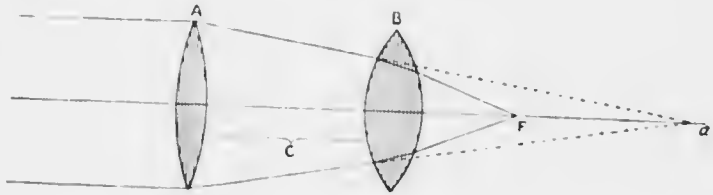
$$\frac{1}{f_1 - c} + \frac{1}{f_2}$$


FIG. 27.

If the second lens (B) is a concave one (Fig. 28) its effect will be one of divergence, so that it must have a negative sign, and D will now be equal to $\frac{1}{f_1 - c} - \frac{1}{f_2}$.

Examples: (1) $f_1 = 333$ mm.; $f_2 = 250$ mm.; $c = 133$ mm.

$$\text{Then } \frac{1}{F} = \frac{1}{333 - 133} + \frac{1}{250} = \frac{1}{111}$$

That is, the combination of a + 3 D lens with a + 4 D, separated

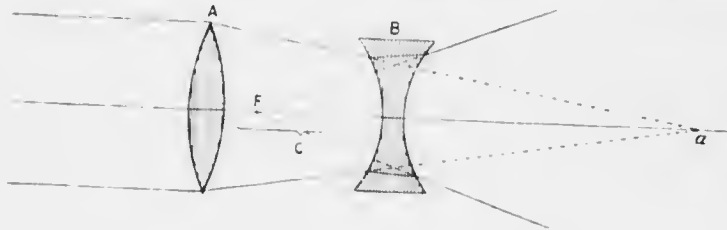


FIG. 28.

by a distance of 133 mm., will be that of a + 9 D lens, instead of + 7 D if they had been in contact.

(2) $f_1 = 333$ mm.; $f_2 = -83$ mm.; $c = 133$ mm.

$$\text{Then } \frac{1}{F} = \frac{1}{333 - 133} - \frac{1}{83} = \frac{1}{142}$$

That is, the combination of a + 3 D lens with a - 12 D, separated by a distance of 133 mm., will be that of a - 7 D lens, instead of - 9 D if they had been in contact.

CHAPTER IV.

ELEMENTARY PHYSIOLOGICAL OPTICS.

THE eye as an optical instrument very much resembles an ordinary photographic camera. The latter consists of a dark chamber with an aperture in front containing a strong convex lens, and with a movable back behind. The effect of the lens is exactly like that shown in Fig. 20. PB will represent the object to be photographed; the movable back is adjusted so that it occupies the position of pb , in which case a sharp image of the object will be thrown upon the ground glass which forms the back. The ground glass is then replaced by a sensitive plate, and the photograph is taken.

In the eye the retina corresponds with the sensitive plate. Instead of having only one lens in the front aperture, represented by the crystalline lens, there is also a curved plate with parallel sides, the cornea, which acts very much like another lens. The object of this more complicated arrangement is to shorten the focal distance of the system, so that the eye may be shorter and more compact.

From this analogy we see that the eye, from the optical point of view, acts like a strong convex lens. We have already stated that when a lens has the same medium on each side of it the anterior and the posterior focal distances are equal to one another. This is not the case in the eye. Here the medium in front is air, whilst behind the lens there is the vitreous, which has a higher refractive index, rather more than that of water. Hence the anterior and posterior principal focal distances are not

equal, the anterior being about 13 mm. in front of the cornea, and the posterior about 23 mm. behind it.

The cornea has about the same optical density or refractive index as the aqueous, which is also equal to that of the vitreous. The anterior surface of the cornea may be regarded as nearly spherical, the radius of curvature being 8 mm. The centres of curvature of the cornea and the two surfaces of the lens are all on the same straight line, which is called the *optic axis*. When a ray of light meets the cornea (Fig. 29) the ray will be

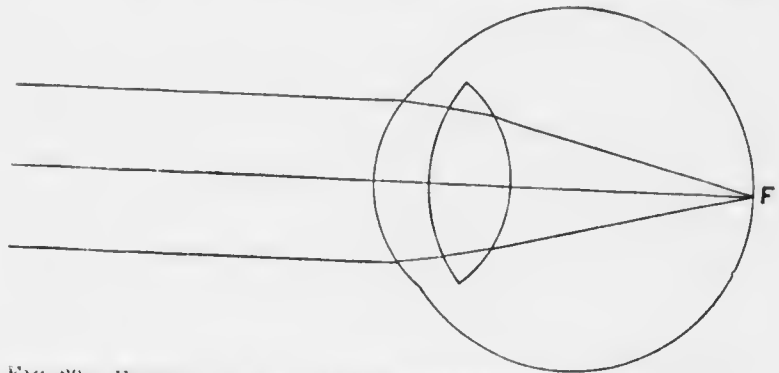


FIG. 29.—Emmetropic eye. Parallel rays are brought to a focus on the retina.

deflected towards the normal, *i.e.*, towards the radius drawn through the point of incidence. It will pass through the layers of the cornea in the new direction, and will also continue in the same direction through the aqueous, for, as we have said, the refractive index of the aqueous is the same as that of the cornea. When the ray meets the lens, which has a greater refractive index than the aqueous, it will again be deflected in the same sense, *i.e.*, towards the axis, upon which the cornea and lens are centred.

We have seen that in the case of a lens, and the same is true of any homocentric optical system, parallel rays

meet at the principal focus. Hence, if parallel rays fall upon the cornea, they will be brought to a focus 23 mm. behind it. Now, the rays which are emitted by a luminous body are divergent. If, however, the object is a long distance away, the individual rays in any small bundle will diverge so little from each other that they may be regarded as practically parallel. This is the case with the small bundles of rays which are able to enter the pupil of the eye. Hence, as in the case of a convex lens (*vide* p. 32), the image formed by the eye of these distant objects will be situated at the principal focus, *i.e.*, 23 mm.

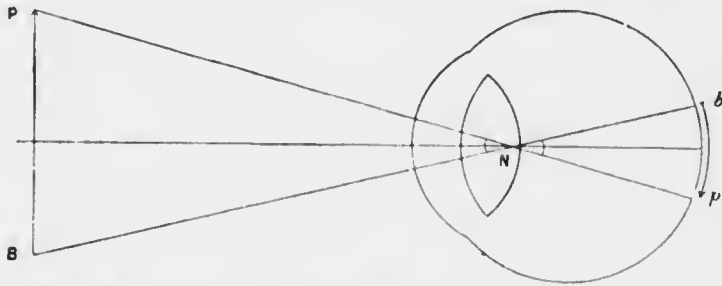


FIG. 30.—Nodal point of the eye, visual angle, and relative sizes of object and retinal image.

behind the cornea. But that is exactly the distance of the retina from the cornea in the normal eye. Hence we see that the normal eye in its condition of rest is so constituted that distant objects form their images upon the retina (Fig. 29).

The optic axis, produced backwards to meet the retina, cuts it almost exactly at the fovea centralis. Hence, any distant object on the prolongation forwards of the optic axis will have its image at the fovea, which is the best spot for distinct vision.

We notice that, just as with a convex lens, the image is inverted. It is re-inverted psychologically in the brain.

It is easy to find the size of the retinal image which any external object will form since the eye possesses an optical centre, which, however, is usually called the *nodal point* (N), quite similar to the optical centre of the lens. In the eye this point is situated upon the optic axis near the back of the lens. As in the case of lenses any ray which passes through this point will not be deflected. If, therefore, there is an object PB (Fig. 30) in front of the eye, the size of its retinal image pb is found by joining the extremities of the object and the nodal point and producing these lines until they meet the

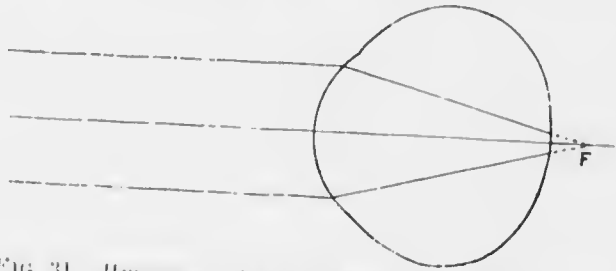


FIG. 31.—Hypermetropic eye. Parallel rays tend towards a focus behind the retina.

retina. The lines will enclose an angle, PNB , which is called the *visual angle*; in other words, the angle subtended by the object at the nodal point is called the visual angle. It is of course equal to the angle pNb , which is subtended by the retinal image at the nodal point.

In some eyes the retina is not situated in exactly the right place for the images of distant objects to be clearly focussed upon it. It may be too far forward (Fig. 31), or too far back (Fig. 32); in the former case they are said to be hypermetropic, in the latter myopic. If we consider the effect upon parallel rays we shall see that in the hypermetropic eye they have not had space to come to a

foci, whereas in the myopic eye they have not only come to a focus, but have commenced to diverge. In each case a blurred image will be formed upon the retina, and vision will be impaired. Such conditions are called errors of refraction or *ametropia* ($\acute{\alpha}$, privative, $\mu\acute{\epsilon}\tau\rho\omicron\nu$, measure; not according to measure). In contradistinction to hypermetropia and myopia the normal condition is called emmetropia.

It has already been stated that in optics the direction of the rays is reversible. Let us imagine a minute point on the retina to be luminous. It will give out rays

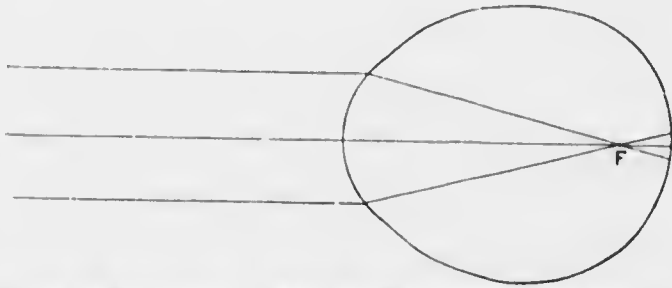


FIG. 32.—Myopic eye. Parallel rays are brought to a focus in front of the retina.

which will diverge in all directions. Some of these rays will meet the lens and cornea and pass out of the eye. Now, in the emmetropic eye, those rays which get through the pupil will have to submit to exactly the same optical deviations as the parallel rays falling upon the cornea did when they passed into the eye and came to a focus on the retina. Hence, on the principle of the reversibility of the rays, the rays coming from a point on the retina will be parallel to each other when they leave the eye (Fig. 29).

Suppose, however, that the eye is hypermetropic owing to being too short (Fig. 33). The rays coming from a point on the retina will not have had space to

diverge so much from the axis as the corresponding rays of the emmetropic eye before they fall upon the back of the lens. (Compare the effect of placing an object closer to a convex lens than its principal focus (Fig. 21).) The lens and aqueous and cornea will therefore cause them to converge less than in the emmetropic eye. They will therefore still be divergent when they leave the eye, though of course not so divergent as when they were passing through the vitreous. In fact, their direction will be the same as if they came from a point behind the eye. The nearer the retina is to the lens, the more divergent they will be,

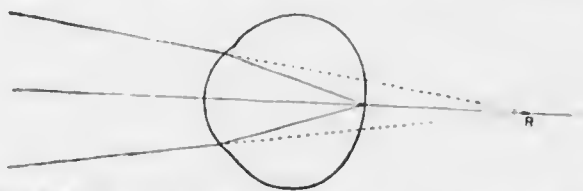


FIG. 33.—Hypermetropic eye. Rays from a point on the retina are divergent when they emerge from the eye, as if they came from the point, R, behind the eye.

and the nearer to the back of the eye will be the point from which they seem to come. This virtual point (R) behind the eye is called the *remote or far point* of the eye. The point on the retina and this point behind the eye are really conjugate foci (Fig. 33).

Suppose now that the eye is myopic owing to being too long (Fig. 34). The rays coming from a point on the retina will have become more divergent from the axis than the corresponding rays of the emmetropic, and still more divergent than those of the hypermetropic eye before they fall on the back of the lens. (Compare the effect of placing an object farther away from a convex lens than its principal focus (Fig. 20).) The refractive media in front will therefore cause them to converge more than in the emmetropic eye. They will hence be convergent when

they leave the eye, and will cross in a point (R) somewhere in front of the eye (Fig. 34). The farther the retina is from the lens, *i.e.*, the higher the degree of myopia, the more convergent they will be, and the nearer to the front

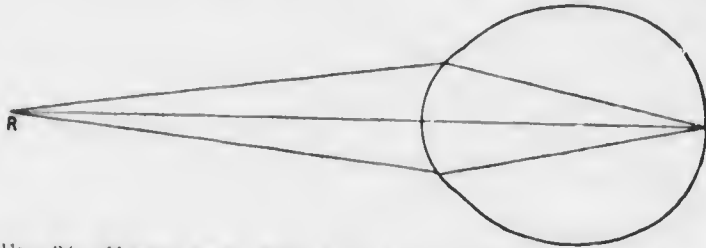

FIG. 34.—Myopic eye. Rays from a point on the retina are convergent when they emerge from the eye, so that they cross at a real point, R, in front of the eye.

of the eye will be the point where they cross. This point is again the conjugate focus to the point on the retina, but in this case it is a real point. It is also called the remote or far point of the eye.

Where then is the far point of the emmetropic eye?

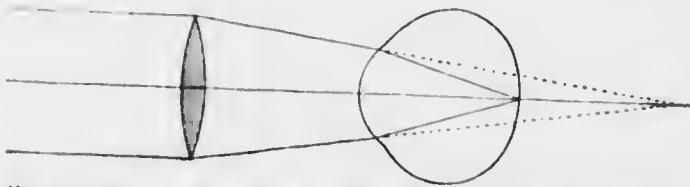

FIG. 35.—Hypermetropic eye. Parallel incident rays brought to a focus on the retina by means of a suitable convex lens.

We have seen that in each of the other conditions it is where the rays emitted from a point on the retina meet after emerging from the eye. In the emmetropic eye the emergent rays are parallel to each other. But parallel rays meet at infinity; therefore the far point of the emmetropic eye is at infinity.

It is obvious that, in hypermetropia, if we give the rays the requisite amount of convergence before they

enter the eye they will be brought to a focus upon the retina. We can do this by placing a convex lens in front of the eye (Fig. 35). This is what is done by means of spectacles. The refractive or convergent power of a convex lens is the reciprocal of its focal distance. Hence in hypermetropia of 1 D, a convex lens of 1 D or 1 metre focal distance placed in contact with the cornea will direct parallel rays towards a point 1 metre behind the eye, *i.e.*, to the far point of the eye. Such a lens acting in combination with the refractive force of the eye would bring the rays to a focus on the retina. But lenses cannot be worn in contact with the cornea. If the lens is placed 20 mm. in front of the cornea its

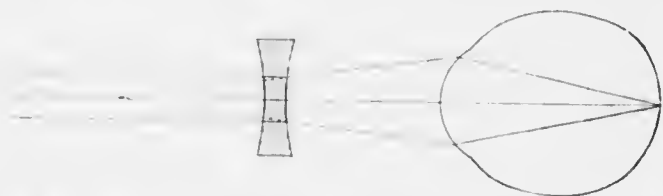


FIG. 36.—Myopic eye. Parallel incident rays brought to a focus on the retina by means of a suitable concave lens.

focal length will have to be 1,020 mm. instead of 1,000 mm. (*vide* p. 40), but this small difference is negligible, and we are accustomed to measure errors of refraction by the strength of the lens which is required when it is placed in the ordinary position of a spectacle lens (Fig. 35).

Similarly in myopia, if we give the rays the requisite amount of divergence before they enter the eye they will be brought to a focus upon the retina. We do this by placing a concave lens in front of the eye (Fig. 36). Here we should want a -1 D lens in contact with the cornea to correct a myopia of 1 D, *i.e.*, an eye whose far point is 1 metre in front of the eye. Since the glass has to be worn about 20 mm. in front of the eye it

will have to be rather stronger, *i.e.*, it will have to be of a focal distance of 980 mm. instead of 1,000 mm.

There is an advantage in having the correcting glass in ametropia in the position of the anterior focus of the eye, because under these conditions the size of the retinal image is exactly the same as if the eye were emmetropic (Figs. 37, 39). The anterior focus is about 13 mm. in front of the eye, and this is so close that the lashes are apt to rub against the glasses, soiling them and causing discomfort. Hence spectacles are usually placed slightly farther away. We have already discovered one effect of this, *viz.*, that the convex glass in hypermetropia has to be rather weaker, and that the concave glass in myopia has to be slightly stronger. It also has an effect upon the size of the retinal image, making it larger in hypermetropia and smaller in myopia (Figs. 38, 40). The increase in size in hypermetropia is advantageous, but the diminution in myopia is a disadvantage, especially in very high degrees. Consequently in the latter the glasses ought to be made to fit as closely to the eyes as possible, the eyelashes being cut short if necessary.

We have seen that in every case the far point and a point on the retina are conjugate foci. Hence an object situated at the far point of any eye will have a sharp image upon the retina (Fig. 34). This may be made clearer perhaps if we consider the myopic eye from another point of view. We have seen that the rays from a point on the retina meet in front of the eye at the far point. We may again use the principle of reversibility of rays. If there is a luminous point at the far point, the rays emitted from it which enter the eye will meet on the retina; in other words, the image of an object at the far point will be upon the retina.

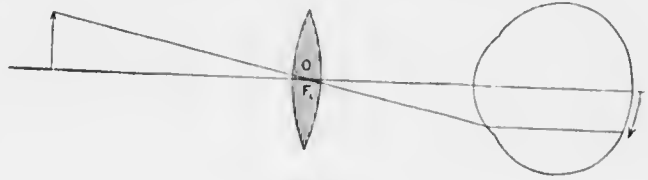


Fig. 37.

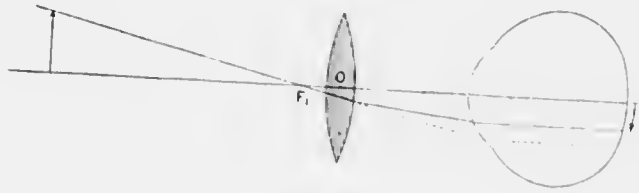


Fig. 38.

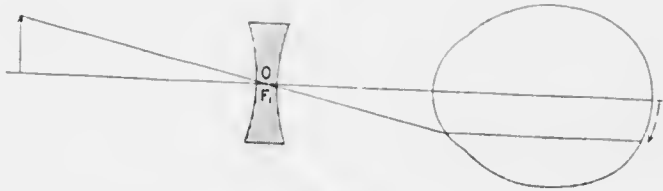


Fig. 39.

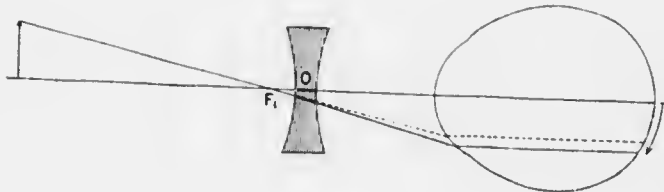


Fig. 40.

FIGS. 37-40.— Effect of correcting lenses upon the size of the retinal image. In Figs. 37, 39, where the optical centre of the lens, *O*, coincides with the anterior focal point of the eye, *F*₁, the size of the retinal image is the same as in emmetropia. When the lens is closer to the eye than the anterior focal distance of the eye the size of the retinal image is diminished (convex lens, Fig. 38) or increased (concave lens, Fig. 40)

From these considerations we learn how it is that a patient with myopia cannot see clearly things which are a long distance away, whereas he can see things which are near. In common parlance, he is "short-sighted." He can see things at a distance better if he screws up his eyes. This is because he thus makes a narrow slit to look through, and this slit acts like the hole in the cardboard before a candle (*vide* p. 25). The term myopia originated in this peculiarity (*μύω*, to shut; *ὄψ*, the eye or countenance).

The patient with hypermetropia, on the other hand, can see neither distant nor near objects clearly with his eyes at rest, since the far point is virtual, and it is impossible to place an object at its situation. We shall see later that he is better off than the myope by virtue of accommodation.

We have already seen that the emmetrope sees only distant objects clearly with his eyes at rest, since the rays from such distant objects are nearly parallel. For practical purposes objects more than 6 metres (20 feet) away from the eye form clear images upon the retina.

The condition of an eye, whether emmetropic, hypermetropic, or myopic, is called its refraction, or more accurately its static refraction, since the term applies to the eye at rest.

We have hitherto considered only such errors of refraction as are due to axial shortening or lengthening of the eye (*axial ametropia*). It is not difficult to understand that ametropia might be due to other causes. Thus, myopia might be due to the refractive power of the eye being too strong: in this case parallel rays would be brought to a focus in front of the retina even if this were in its normal position. Increase or decrease in the refractive power of the eye might be due to two

causes. It might be due to alteration in the refractive indices of the media, or to alteration in the curvatures of the refractive surfaces: ametropia due to these causes is called *index* or *curvature ametropia* respectively. Both are much less common than axial ametropia. Index ametropia is very rare, though we shall have a physiological example of it later (*vide* p. 62).

Curvature ametropia has a special importance, not

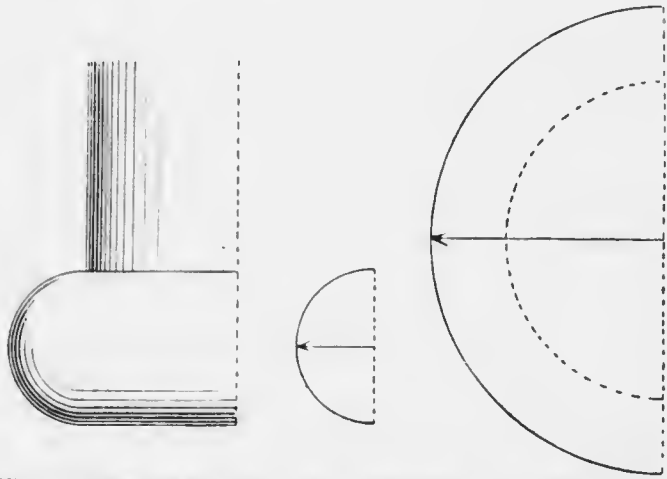


Fig. 41.—Base of an Ionic column, showing torus. The small section to the right shows the radius of curvature in the vertical direction, the large section that in the horizontal.

because it gives rise to simple hypermetropia or myopia, but because it is the cause of another very troublesome error of refraction, called *astigmatism*. In most eyes, even if they are ametropic, the areas of the refractive surfaces uncovered by the pupil and used in vision are very nearly spherical. Sometimes, however, they are not. In most of these cases it is the cornea which is at fault, and the error is generally of such a nature that this surface is flatter from side to side than it is from above downwards. Even in these cases the curvatures

in the vertical and horizontal meridians are both spherical, but the radius of curvature of the horizontal meridian is longer than that of the vertical. Perhaps the pressure of the lids on the globe tends to squeeze it above and below. A familiar example of such a surface, which is said to have a *toric* curvature, is seen at the base of an ordinary Ionic column (Fig. 41). Here the centre of curvature of the horizontal section is the same as that of the column, whilst the centre of curvature of the vertical section is in a line with the surface of the upper

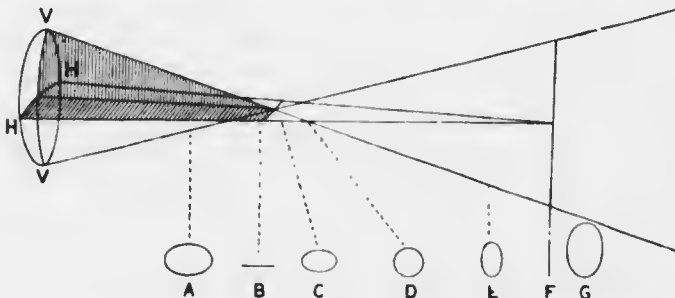


FIG. 42.—Sturm's conoid. V V, vertical meridian of refracting surface, more curved than H H, the horizontal meridian. A, B, C, D, E, F, G, sections of conoid. From B to F is the focal interval of Sturm. D shows the circle of least diffusion.

part of the column. It is obvious that any other section of this surface than the vertical or horizontal will not be spherical but elliptical.

What will be the effect of such a toric cornea upon the refraction of the eye? Clearly the more curved meridian will have more refractive or convergent power than the less curved: hence if parallel rays fall upon the surface the vertical rays will come to a focus sooner than the horizontal. The rays after refraction will be perfectly symmetrical when referred to the vertical and horizontal planes. They will have two foci. The whole bundle of rays is called Sturm's conoid, and

the distance between the two foci is called the focal interval of Sturm. It is difficult to represent this conoid on a plane surface (Fig. 42), but we can see what sections of the bundle or pencil of rays would look like at different distances from the refractive surface (Fig. 42, A—G).

At A the section will be a horizontal oval or oblate ellipse, because the vertical rays are converging more rapidly than the horizontal. At B the vertical rays have come to a focus, whilst the horizontal are still converging: the section will be a horizontal straight line. At C, D, and E the vertical rays are diverging and the horizontal are still converging. At one place in this focal interval there will be a spot (D) where the vertical rays have diverged from the axis exactly as much as the horizontal rays have converged towards it. Here the section is a circle, which is called the *circle of least diffusion*. At F the horizontal rays come to focus whilst the vertical are diverging: the section will be a vertical straight line. Beyond this point, as at G, both sets of rays are diverging and the section will always be a vertical oval or prolate ellipse.

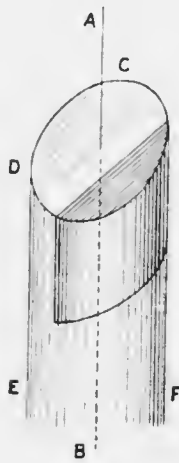


FIG. 43.

What will happen if the retina is situated at either of these points of section? In the first place it is obvious that the retinal image will always be blurred, and it is because the rays never come to a focus in a single point that the condition is called astigmatism (α , privative, $\sigma\tau\acute{\iota}\gamma\mu\alpha$, a point). If the retina cuts the conoid at A, where none of the rays have come to a focus, every meridian will be in the same condition, though in

different degree, as in the axial hypermetropic eye: this condition is therefore called *compound hypermetropic astigmatism*. If the retina is at B the vertical meridian will be in the condition of an emmetropic eye, whilst the horizontal will still be in the condition of a hypermetropic one: this condition is called *simple hypermetropic astigmatism*. At C, D, and E the vertical meridian will be in the condition of a myopic, and the horizontal still in that of a hypermetropic eye: this is called *mixed astigmatism*. At F the vertical meridian is still myopic, whilst the horizontal is in the same condition as in an emmetropic eye: this is *simple myopic astigmatism*. Beyond F, as at G, both meridians are in the condition of an axial myope, the rays having crossed in the vitreous: this is *compound myopic astigmatism*. All these positions of the retina are met with in actual practice, though probably there is often a combination of axial and curvature defects.

It will be readily seen that such a condition cannot be corrected by means of any spherical lens. We must obtain some means of affecting one set of rays more than the other. This means is found in cylindrical lenses.

Suppose CDEF is a cylinder of glass (Fig. 43): AB is called the axis of the cylinder. If a slice is cut off the cylinder by a plane parallel to the axis, it would form a cylindrical lens. Fig. 44 gives representations of a convex and a concave cylinder. The direction *ab* is called the axis of the cylinder, since it is parallel to the axis of the original cylinder from which the slice may be supposed to have been taken. It is important here to

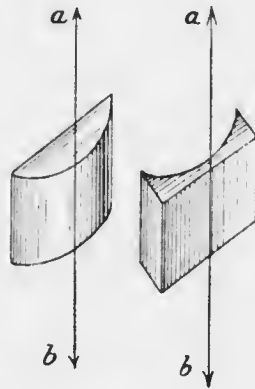


Fig. 44.

warn the student not to confuse the axis of a spherical and the axis of a cylindrical lens, as they are totally different things. The axis of a cylinder has just been

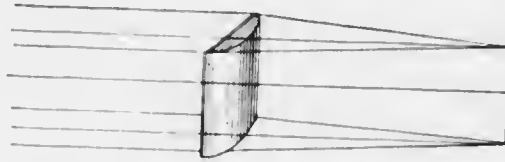


FIG. 45.—Refraction of parallel rays through a plano-convex cylinder.

described: the axis of a spherical lens is the line joining the centres of curvature of the two surfaces.

How will a cylindrical lens affect parallel rays falling upon its surface? In the direction of its axis it is simply a plane lamina with parallel sides, so that it will have no effect upon the rays. In the direction at right angles to its axis it is spherical on one side and plane on the other: it will therefore act exactly like a plano-convex or a plano-concave lens, *i.e.*, it will make the rays either converge or diverge. If a convex cylinder is held between a point of light and a screen, a position can be found for the screen such that a sharp bright line is thrown upon it (Fig. 46): this is the focal line of the cylinder.

It is to be noted that the line is in the direction of the




FIG. 46.—Refraction of divergent rays from a point of light through a plano-convex cylinder.

axis of the cylinder. If another convex cylinder of the same strength were held

with its axis at right angles to the first, it would obviously form a focal line perpendicular to the first focal line. If the two cylinders are put in contact with their axes at right angles, all the rays after refraction must pass through both lines. The only place where they can

go through both lines is where the lines intersect. Hence we see that two cylindrical lenses of equal strength, placed in contact with their axes at right angles, act exactly like a convex spherical lens of the same strength as either of the cylinders.

When the cornea has its directions of greatest and least curvature at right angles to one another, the condition is called *regular astigmatism*. In the commonest form, as we have said, the vertical meridian is the more curved, the horizontal the less: this condition is generally called regular astigmatism "according to the

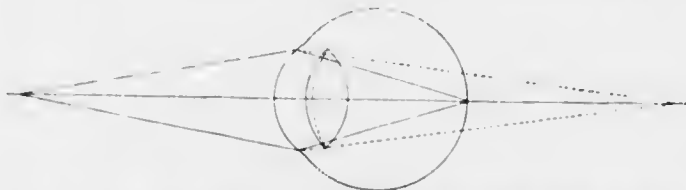


FIG. 47. Effect of accommodation. The dotted lines show the curvature of the anterior surface of the lens and the course of rays with the eye at rest (static refraction). The solid lines show the curvature of the anterior surface of the lens and the course of rays with active accommodation (dynamic refraction).

rule." Sometimes the reverse is found: this is said to be "against the rule." Not infrequently the axes are oblique. Often after ulceration, &c., the surface of the cornea is irregular. This causes the rays of light to be refracted irregularly, so that there is no symmetry at all about them and different groups form foci in various positions. This is called *irregular astigmatism*: it cannot be corrected, and can only occasionally be improved by glasses.

Accommodation.—We have to consider now how it is that a person with normal sight can not only see distant objects, but also near ones. If an object is situated near the eye, *e.g.*, at ordinary reading distance—about 22 cm. or 9 inches—the divergence of the rays which it emits cannot be neglected. Since the converging

power of the refractive media of the emmetropic eye is only strong enough to make parallel rays come to a focus on the retina, it is obvious that divergent rays falling upon the cornea will not nearly have come to a focus (Fig. 47). They will indeed be made convergent, but only to such a degree that they would meet somewhere behind the retina. Now if we can make the converging power of the eye stronger, a point may be reached when it is just strong enough to bring them to a focus on the retina. This is what is done by accommodation, and the manner in which the converging power of the eye is increased is by making the crystalline lens stronger.

We have seen that the refractive power of a convex lens depends upon its refractive index and upon the curvature of its surfaces. In accommodation, it is the latter which undergoes change. The curvature of the surfaces of the lens at rest in the eye is approximately spherical, and the radius of curvature of the anterior surface is 10 mm., whilst that of the posterior surface is 6 mm. In accommodation, the curvature of the posterior surface remains almost the same, but the anterior surface changes so that in strong accommodation its radius of curvature becomes 6 mm. The eye under these conditions, which are called its dynamic refraction, has a much increased converging effect upon the incident rays.

The mechanism by which this change in the curvature of the lens is brought about is as follows (Fig. 48). The lens substance is plastic, so that it tends to conform accurately to the shape of its capsule. As has been described (p. 12), the capsule is anchored to the ciliary body by the suspensory ligament. In the condition of rest, the fibres of the suspensory ligament are stretched. In the ciliary body is the ciliary muscle, which takes its origin from its anterior attachment to the sclerotic at

the angle of the anterior chamber. When the muscle contracts, it pulls the posterior part of the ciliary body and the anterior part of the choroid forwards slightly. The effect upon the suspensory ligament is to slacken it, and with it the lens capsule. The posterior surface of the lens is fixed by the support of the jelly-like vitreous, so that the slackening of the capsule makes itself most felt in the anterior part, which becomes bowed forwards.

The generally accepted theory here described is that of von Helmholtz. According to Tscherning the ciliary muscle tightens the suspensory ligament, so that the peripheral parts of the anterior surface of the lens are flattened and the central or pupillary area is increased in curvature.

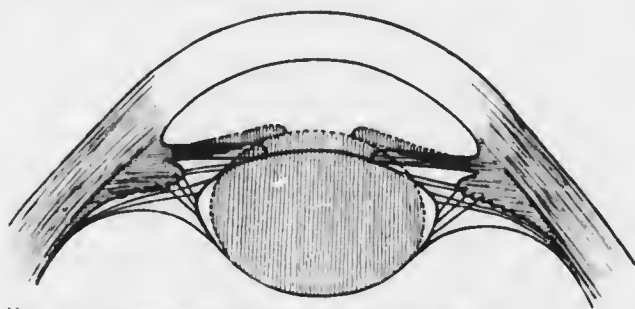


FIG. 48.—Diagram of Helmholtz' theory of accommodation.

Our control over the ciliary muscle, though involuntary, is very delicate, so that all distances up to quite close to the eye can be accurately focussed. The nearest point at which small objects can be clearly distinguished is called the *near point*, or *punctum proximum*. It is most accurately determined by gradually bringing a fine thread closer to the eye until it is found impossible to see it perfectly clearly. In practice it is sufficient to use very fine print and to determine the point at which it first becomes impossible to read it. The distance can be measured by a centimetre or inch tape held close beside the eye. For ordinary clinical purposes it is usually sufficient to judge the distance. At this point accommodation is exerted to

its maximum, the lens capsule is as slack as it is possible to make it, and an object could only be seen clearly at a nearer point by placing a convex lens in front of the eye.

It has been shown that the far point of the eye varies according to its static refraction, *i.e.*, according to whether it is emmetropic, hypermetropic, or myopic. The near point also varies with the static refraction, but it also varies with the age of the patient, the reason being that the lens becomes less plastic as age advances. We have stated that the lens is a mass of epithelium of which the central part is the oldest (*vide* p. 12). As the lens gets older the central cells become tougher and more compressed, thus forming a relatively hard nucleus. The nucleus is less plastic than the younger cortex, and as age advances more and more of the fibres become converted into nucleus. Consequently the lens tends less and less to respond to changes in tension of the capsule. Thus, a child of ten, the earliest age at which it is possible to obtain satisfactory measurements, is able to see a small object clearly when it is only 7 cm., or less than 3 inches, from the eye. A person of thirty years of age cannot see clearly at less than 14 cm., or about 5½ inches from the eye.

Now, we have pointed out that the refractive power of a lens in dioptries is the reciprocal of its focal distance measured in metres (*vide* p. 36). The same method is applied to measure the static and dynamic refractive powers of the eye. Thus, the static refractive power of a myopic eye whose far point is 1 metre in front of the eye is said to be 1 dioptré; this is usually expressed by saying that the eye has 1 D of myopia. Similarly, if a hypermetropic eye has its far point half a metre behind the eye it is said to have 2 D of hypermetropia. By this method the emmetropic eye, which has its far point at

infinity, has no refractive power when it is at rest, since $\frac{1}{\infty} = 0$.

Applying the same method to the dynamic refractive power, the child of ten, whose near point is 7 cm. from his eye, has a refractive power of $\frac{100}{7} = 14$ D, and a man of thirty whose near point is 14 cm. from his eye has a refractive power of $\frac{100}{14} = 7$ D.

By this means we can obtain a general rule for indicating the amount or *amplitude of accommodation*, not only of emmetropic but also of hypermetropic or myopic eyes. This is given by the formula $A = P - R$, which states that the amplitude of accommodation is equal to the refractive power of the eye when fully accommodated (*i.e.*, the reciprocal of the distance of the near point in metres), less the refractive power of the eye at rest (*i.e.*, the reciprocal of the distance of the far point in metres).

A few examples will make this clearer. Thus, the emmetropic child of ten has an amplitude of accommodation of $\frac{100}{7} - \frac{1}{\infty} = 14 - 0 = 14$ D. What is the amplitude of accommodation of an emmetrope whose near point is 12.5 cm. from his eye? Here $A = \frac{1000}{125} - \frac{1}{\infty} = 8$ D. From statistics which have been collected we can deduce that this man was about twenty-six years old (*vide* p. 64). Now let us take a case of myopia, *e.g.*, a myope of 2 D whose near point is 8 cm. in front of his eye. His amplitude of accommodation will be $A = \frac{100}{8} - 2 = 10.5$ D. What is the amplitude of accommodation of a hypermetrope of 3 D whose near point is 12.5 cm. from his eye? Here the far point is behind the eye and distances

measured in this direction must have the opposite sign to those measured in front of the eye. Hence $A = \frac{1000}{125} - (-3) = 8 + 3 = 11 \text{ D.}$

The numbers given by these calculations for the amplitude of accommodation give the strength of the convex lens which would have to be placed in contact with the cornea in order that the near point might be brought to the required distance without using the accommodation. Several interesting facts come to light from the calculations. Thus a hypermetrope of 3 D has to exert 11 D of accommodation in order that he may see clearly at 12.5 cm., whilst an emmetrope has to exert only 8 D of accommodation to bring about the same result. We see, then, that the hypermetrope has to exert an amount of accommodation equivalent to the amount of his hypermetropia in order to focus parallel rays upon his retina, *i.e.*, he has to use this amount of accommodation in order to see distance objects clearly. Again, in the case of the myope of 2 D, his far point is half a metre, or 50 cm., from his eye; he can see clearly at that distance without accommodating, but he has to exert 10.5 D of accommodation in order that he may see clearly at 8 cm. from his eye. This patient, then, has to exert nearly as much accommodation to alter his points of clear vision from 50 cm., to 8 cm., *i.e.*, through 42 cm., that a hypermetrope of 3 D has to employ in order to move his point of distinct vision from infinity up to 12.5 cm.

The effect of age upon the static and dynamic refraction is given in Fig. 50, which is the result of a large number of statistics and gives the average results. From this table we see that even the far point alters in advanced age. After about fifty the eye tends to become hypermetropic, so that at eighty it has about 2.5 D of

hypermetropia. This has nothing to do with accommodation, and hence nothing to do with loss of plasticity in the lens. It is, however, due to changes going on in the lens, viz., an alteration in its refractive index so that it has a weaker converging power.

The refractive indices of the successive layers of the lens increase from the periphery towards the nucleus. The effect is twofold: it tends to correct aberration by increasing the convergence of the central rays, and the total refractive index of the whole lens is increased, being greater than the refractive index of the nucleus. For it may be looked upon as a central bi-convex lens encapsuled in two menisci (Fig. 49). The menisci act as concave lenses because the curvature of the nucleus is greater than that of the periphery of the lens. Hence they tend to counteract the effect of the central lens, but not so much as if their refractive index was the same. In old age the index of the peripheral layers increases, so that the total refractive index of the lens becomes less, and the eye becomes hypermetropic.

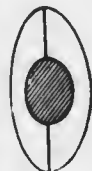

FIG. 49.

If we turn our attention to the curve of the near point we see that the amplitude of accommodation gradually diminishes throughout life. Now, we are accustomed to hold books for reading or work for sewing, &c., at about 10 inches, or 25 cm., from the eyes. In order to be able to see clearly at 25 cm. from the eye we have to exert $\frac{100}{25} = 4$ D of accommodation. If we look at the table we shall see that an emmetrope has only 4 D of accommodation left at about forty-one years of age. He will still be able to see clearly at 25 cm., but not closer. If he is about forty-six he will only have 3 D of accommodation left. He will not now be able to see clearly at 25 cm., but he will have to hold his book farther off, viz., at $\frac{100}{3} = 33$ cm. If he is still older he will have to hold the book yet farther off, and he will probably have to use very large

print or he will not see clearly at all. This is the condition which is called *presbyopia* (*πρέσβυς*, old).

It will be seen that a patient never requires more than + 4 D to correct his presbyopia only, since that is the amount of accommodation required to place the far point of the resting emmetropic eye at reading distance. A

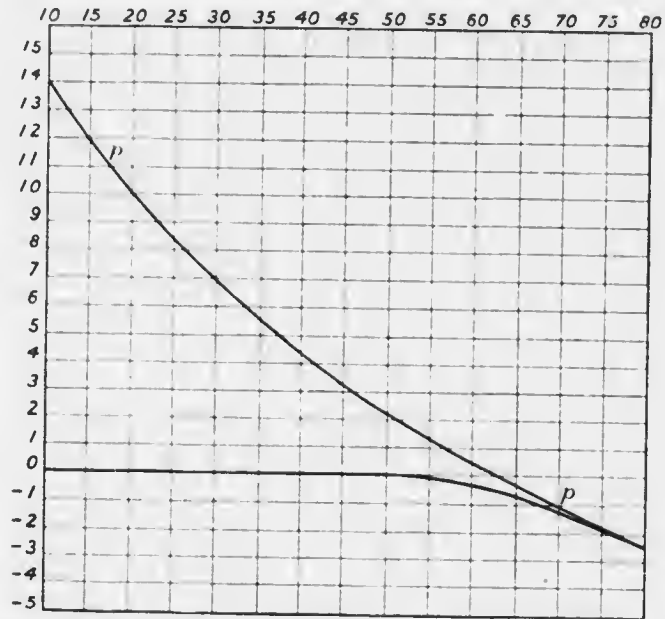


FIG. 50. Chart of static and maximum dynamic refraction at various ages. (Donders.) Abscissae, ages; ordinates, accommodation in dioptres.

convenient rule to remember is that a presbyope requires + 1 D for every five years after forty; *i.e.*, at forty-five, + 1 D; at fifty, + 2 D; at fifty-five, + 3 D; at sixty and later, + 4 D. The rule errs in giving rather too liberal a correction; a slightly smaller correction is often more comfortable.

It is a common error amongst students to think that presbyopia is a condition which commences at about forty-five years of age in emmetropes, and earlier in hyper-

metres. Of course this is not so: the condition which has been increasing throughout life first becomes troublesome when the near point of the eye has receded so far that it is beyond comfortable reading distance.

There are two other phenomena which occur with accommodation, one affecting the iris, the other the direction of the eyes. In order that we may see a near object we must look at it; hence in order that we may see it at the same time with both eyes they must each turn inwards or converge. The amount of convergence, like the amount of accommodation, depends upon the distance of the object. It is therefore easy to understand that there is a near relationship between accommodation and convergence. We shall have more to say upon this subject when we consider the various forms of squint.

When we accommodate for a near object the pupil becomes smaller, or contracts. Experiment has shown that this movement of the iris is associated with the accompanying act of convergence rather than with accommodation *per se*. It is not easy to explain the object of contraction of the pupil on convergence; it is probably of the nature of an associated movement, or, as I have termed it, *synkinesis* (σύν, with, κίνησις, movement).

It is not uncommon for the refraction of the two eyes to be different: this condition is called *anisometropia* (ἀ, privative; ἴσος, equal; μέτρον, measure). It might be anticipated that this could be corrected to some degree or entirely by unequal accommodation in the two eyes. Thus, if one were emmetropic and the other hypermetropic both eyes would be able to distinguish distant objects clearly if the hypermetropic one alone accommodated the requisite amount to correct its hypermetropia. It has been conclusively proved, however, that this does not occur. When these cases are not corrected by the proper glasses clear vision is wholly unobtainable.

Although astigmatism is chiefly due to faulty curvature of the cornea, in some cases there is also lenticular astigmatism. This is not generally due to unequal curvature of the surfaces, but to slight tilting of the lens, so that the incident rays fall upon it obliquely. If we look through a tilted glass lens at printed matter we shall see that the letters become distorted and elongated in one direction; this is a form of astigmatism. The astigmatism of the crystalline lens is generally of such a nature that it tends to counteract the corneal astigmatism, though sometimes it adds to the effect. As in anisometropia, it might be

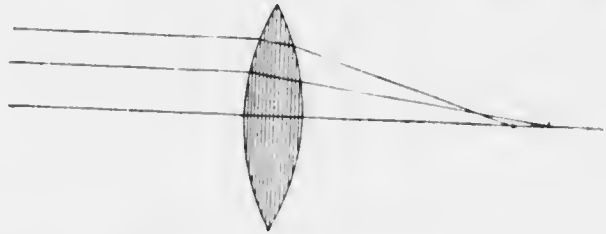


FIG. 51.—Spherical aberration.

thought that astigmatism could be corrected by accommodation. If, for instance, the ciliary muscle acted only at the sides and not at all above or below, the anterior surface of the lens would become more curved in the horizontal than in the vertical meridian. This would counteract the effect of the ordinary form of corneal astigmatism. It has been proved, however, that this also does not occur. When the ciliary muscle acts, it acts equally all round the circle; and when one ciliary muscle acts, the one in the opposite eye acts simultaneously and equally under ordinary conditions.

THE PUPILS.

The iris acts like the diaphragm of any ordinary optical system, such as a photographic camera or a microscope.

In discussing the effects of spherical mirrors in reflecting, and of spherical surfaces in refracting the rays of light, we said that in each case they were all brought to a focus in a single point. This is really only an approximation, which is sufficiently accurate for rays close to the axis. In a convex spherical lens, for instance, parallel rays near the axis meet at the principal focus (*vide* p. 32). The rays farther away from the axis, however, are refracted too much, so that they cut the axis nearer the lens than the principal focus (Fig. 51). This causes a blurring of the edges of the image, which is said to be due to *spherical aberration*. The diaphragm cuts off these peripheral rays, and thus prevents the blurring. In the eye the surfaces are not even spherical near the periphery, and are often not so in the centre, so that much more aberration is liable to occur. The iris reduces the effects of the evil to a minimum.

There is also another form of aberration due to the imperfect refraction at spherical surfaces. White light is made up of all the colours of the spectrum. The component rays are refracted differently, the violet most, the red least. Hence there is a tendency for the white light to be split up into its components, in which case the image will have a coloured edge. This phenomenon is called *chromatic aberration*.

When light enters the eye and falls upon the retina the pupil contracts. We have already seen that the pupils also contract when the optic axes converge in accommodation. On the other hand they dilate if the skin of any part of the body is pinched or any sensory nerve is stimulated to the extent of causing pain. These responses to stimuli of various kinds are very rapid and delicate, and are easily observed. When they are altered by disease the changes which occur afford very valuable information as to the condition of the nerve tracts involved. The tracts are

rather complicated, but it is essential that they should be understood.

Under normal conditions, with equal illumination—a point too frequently neglected—the pupils are equal on the two sides. It is very rare to meet with unequal pupils in a normal person; such cases do apparently occur, but every possible pathological cause must be eliminated before we admit that the condition is an idiosyncrasy.

On the other hand, the size of the pupils varies much in different people under the same conditions of illumination, &c. In old people it is smaller than in the young, sometimes to so great an extent that the pupils are almost “pin-point.” They are often smaller in hypermetropes, and larger in myopes, than in emmetropes; they are said to be smaller in blue eyes than in brown. The causes of these differences are conjectural, and need not detain us. The two facts of prime importance have been mentioned, viz., that there are two reflexes, that to light and that to sensory stimulation, which act in opposite directions. The normal size of the pupil may be looked upon as essentially the resultant of these two forces.

The motor innervation of the pupil is as follows (Fig. 52). The sphincter pupillæ is innervated by the third cranial nerve. The pupil-constrictor fibres start in the anterior part of the third nucleus in the floor of the aqueduct of Sylvius. They pass out of the mid-brain and run in the main trunk of the third nerve as far as the orbit. Here the fibres pass into the branch which supplies the inferior oblique muscle, leaving it by the short root of the ciliary ganglion. From the ciliary ganglion they pass by the short ciliary nerves to the eye, piercing the sclerotic around the optic nerve, being here in company with the short ciliary arteries (*vide* p. 14). The nerve fibres pass forwards in the choroid and ciliary body to the iris.

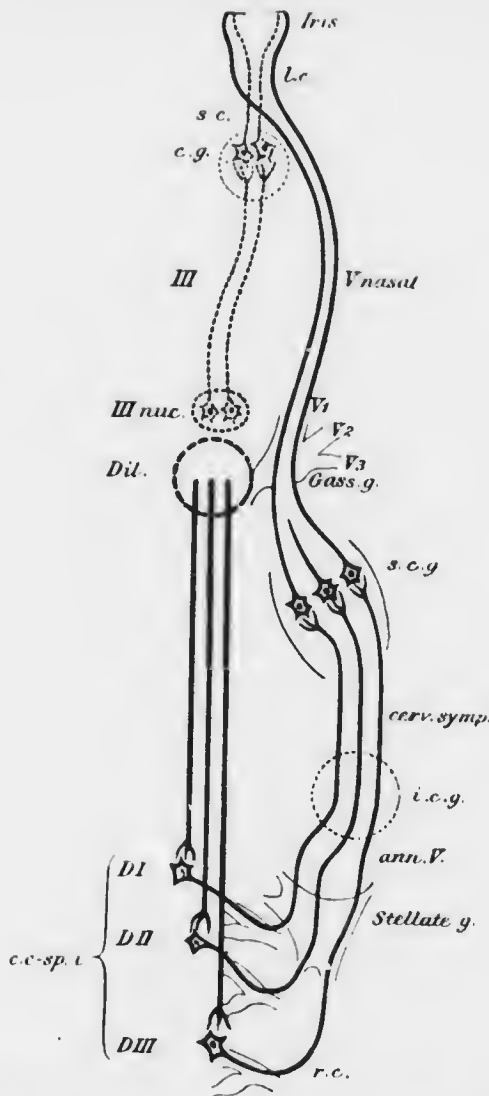


FIG. 52.— Diagram of the efferent pupillary paths. Dotted lines, pupillo-constrictor: *III nuc.*, nucleus of third nerve; *c.g.*, ciliary ganglion; *s.c.*, short ciliary nerves. Solid lines, pupillo-dilator: *Dil.*, hypothetical dilator centre in the medulla; *c.c-sp.t.*, Budge's centrum cilio-spinalis inferius; *DI*, *DI I*, *DI II I*, first, second, and third dorsal nerves (see text); *r.c.*, ramus communicans; *Stellate g.*, stellate ganglion; *ann.V.*, annulus of Vieussens; *i.c.g.*, inferior cervical ganglion; *cerv. symp.*, cervical sympathetic; *s.c.g.*, superior cervical ganglion; *Gass. g.*, Gasserian ganglion; *V1*, *V2*, *V3*, first, second, and third divisions of the fifth nerve; *V nasal*, nasal branch of the ophthalmic (first) division of the fifth nerve; *l.c.*, long ciliary nerves.

The dilatator pupillæ is supplied by the cervical sympathetic nerve. The dilatator tract probably commences in the mid-brain not far from the constrictor tract. It

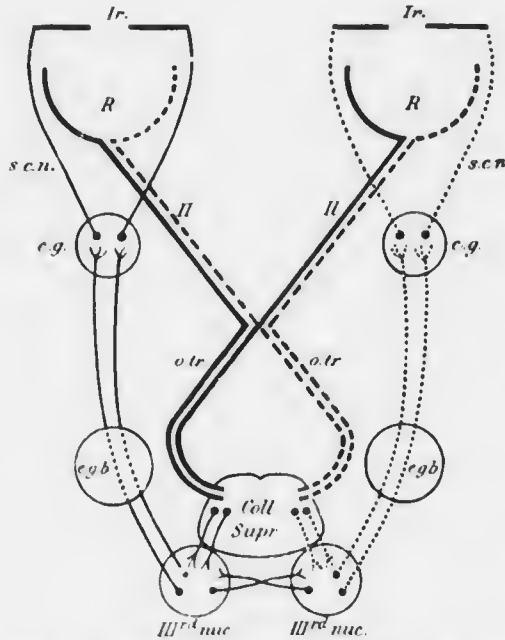


FIG. 53.—Diagram of the afferent and efferent pupillary paths for light stimuli. Afferent paths from left sides of retinae, thick solid lines; afferent paths from right sides of retinae, thick dotted lines; efferent paths of left eye, thin solid lines; efferent paths of right eye, thin dotted lines. *Ir.*, iris; *R*, retina; *II*, optic nerve; *otr*, optic tract; *Coll. Supr.*, colliculus superior or anterior corpus quadrigeminum; *IIIrd nuc.*, nucleus of third nerve; *egb*, external geniculate body; *c.g.*, ciliary ganglion; *s.c.n.*, short ciliary nerves.

passes downwards through the medulla oblongata into the lateral columns of the cord. The fibres leave the cord by the ventral roots of the first three dorsal and probably the last two cervical nerves, enter the rami communicantes, and run to the first thoracic or stellate ganglion.

From here they pass by the anterior limb of the annulus of Vienssens into the cervical sympathetic. In this nerve they run up the neck

to the superior cervical ganglion, whence they pass with the carotid plexus into the skull. They run over the anterior part of the Gasserian ganglion and pass into the first or ophthalmic division of the fifth nerve, following the nasal branch, which they leave finally to enter the

long ciliary nerves, thus avoiding the ciliary ganglion. The long ciliary nerves enter the eye on each side of the optic nerve, accompanying the long ciliary arteries. Like them, they run forwards between the choroid and sclerotic, enter the ciliary body and thus reach the iris.

These complicated paths will be seen at a glance in the accompanying diagrams.

We have now to consider the nervous mechanism of the reflexes. The light reflex is carried out entirely through the constrictor centre, so we may put the dilatator tract aside for the moment. The afferent fibres are contained in the optic nerve, arising from all parts of the retina (Fig. 53). It is unknown whether they belong to the large or the small fibres of the optic nerve. It is certain that they undergo partial decussation in the chiasma, like the visual fibres, and that they enter the optic tracts. It is also certain that, unlike the visual fibres, they do not enter the lateral geniculate body, but leave the tract to pass by an unknown path to the third nucleus.

The constrictor centre possesses "tone," *i.e.*, it is perpetually sending out impulses which keep the pupil slightly contracted. If light falls upon the retina of one eye its pupil constricts—*the direct reaction to light*; but the pupil of the opposite eye also contracts simultaneously—*the consensual reaction to light*. This consensual reaction should always be tested since it gives useful information which cannot be obtained from the direct reaction. Thus, if there is a block on one optic nerve so that there is no direct reaction to light, but the consensual reaction from light thrown upon the other eye is unimpaired, we know that the block, whatever it may be, does not affect the efferent constrictor tract, *i.e.*, the trunk of the third nerve, the branch to the inferior oblique, and the short ciliary nerves are intact. The consensual reaction is probably carried out by means of

fibres which unite the two constrictor centres in the third nucleus.

That the afferent pupil-constrictor fibres undergo partial decussation in the optic chiasma is proved by Wernicke's *hemianopic pupil reaction*. This reaction is pathognomonic of disease of one optic tract. It will be seen from Fig. 53 that such a lesion will cut off the afferent impulses from corresponding halves of each retina, *i.e.*, from the temporal half of one and the nasal half of the other. If light is thrown upon these parts of the retina the pupils do not contract, but if it is thrown on the other halves of the retina the pupils respond.

The sensory reflex is more complicated than the light reflex, for both the dilatator and the constrictor centres play a part in its production under normal conditions. It has been shown that sensory stimulation causes first a rapid dilatation of the pupil due to augmentation of the dilatator tone through the cervical sympathetic, and then a second dilatation, rapid in onset but slow in disappearance, due to inhibition of the constrictor tone. There are other reflexes and synkineses, *e.g.*, emotional, which need not detain us.

Minute examination of the pupil when the intensity of the light entering the eye is altered, shows that the pupil contracts and then oscillates rapidly, finally settling down into a condition of contraction which is slightly less than the summit of the first wave. In its sudden response, the pupil as it were oversteps the mark, oversteps it again in the opposite direction, and so on. Two different types of exaggeration of this oscillation are met with under abnormal conditions. One is the condition in which the oscillations are very large and easily seen, and which are to a large extent independent of the light falling upon the eye. This is called *hippus*; its origin is obscure, but it undoubtedly depends upon the rhythmic

activity of the nervous centres, and is not a peripheral phenomenon. More important is the lack of sustained contraction under the continued influence of light. Here the pupil contracts sluggishly when the intensity of the light is increased, but whilst the light is still kept constant it slowly dilates, often with superposed sluggish oscillations. This is a pathological phenomenon dependent upon diminished conductivity in the afferent path of the light reflex, *i.e.*, usually in the optic nerve (*see* Retrobulbar Neuritis).


Drugs are so frequently employed in ophthalmic practice for the purpose of dilating or constricting the pupils or paralysing the accommodation, that it is important to know exactly how they act. Pupil-dilating drugs are called mydriatics; pupil-constricting, miotics; drugs which paralyse the ciliary muscle, cycloplegics. All drugs which dilate the pupil also paralyse the accommodation in greater or less degree; many attempts have been made to discover a drug which will effect the former purpose without the latter, but without success. Similarly, all miotics stimulate the ciliary muscle to contract, so that the eye assumes a condition of partial or complete accommodation.

The vexed question whether these drugs act upon the respective muscle fibres or upon the nerve endings contained in them need not be discussed here. The strongest mydriatic which we possess is *atropin*; it paralyses the sphincter iridis and ciliary muscle completely, and is said also to stimulate the dilatator iridis. It has so potent an action that it abolishes the tone of the ciliary muscle. Thus, an emmetropic eye placed fully under the influence of atropin becomes hypermetropic to the extent of about 1 D; this must be taken into account in correcting errors of refraction. Atropin solution (*e.g.*, 1 per cent.) instilled into the conjunctival sac is absorbed through the cornea



MICROCOPY RESOLUTION TEST CHART

(ANSI and ISO TEST CHART No. 2)



APPLIED IMAGE Inc

1653 East Main Street
Rochester, New York 14609 USA
(716) 482-0300 - Phone
(716) 288-5989 - Fax

into the anterior chamber, where it acts locally upon the intrinsic muscles. It takes a considerable time to cause complete paralysis, hence it is usual to order it for use at home three times a day for at least three days. The effects do not pass off for about ten days. One drop of 0·5 per cent. atropin sulphate solution causes wide dilatation of the pupil in thirty to forty minutes, and complete paralysis of accommodation in about two hours; the effects do not pass off entirely till from three to seven days. Duboisin, hyoscin, and daturin act similarly to atropin.

Homatropin acts more quickly than atropin, and the effects pass off more quickly. Its full effect is obtained by an oily solution (in *Ol. Ricini*, 1 per cent.) in three-quarters of an hour, especially if combined with cocaine (2 per cent.), which acts chiefly by increasing the permeability of the cornea. The effects pass off completely in forty-eight hours, or much more quickly if a drop of eserine (1 per cent.) is instilled. The mixture of homatropin and cocaine, which is commonly employed for estimating refraction, does not paralyse the intrinsic muscles so fully as atropin, the tone of the ciliary muscle not being abolished so thoroughly. Homatropin alone probably acts upon the iris through the sphincter only.

Cocaine, besides its anæsthetic effect through the endings of the fifth nerve in the cornea, iris, &c., also stimulates the sympathetic nerve endings in the dilatator iridis. It does not paralyse the sphincter, so that the dilatation of the pupil is only moderate, and the pupil continues to react to light even after prolonged application. Cocaine is a useful drug in confirming the diagnosis of paralysis of the sympathetic nerve: if this nerve is paralysed cocaine fails to dilate the pupil. The effect is not due to degeneration of the nerve endings, as I have found that cocaine fails to act very soon after section of the sympathetic in the neck in animals.

Eserin or physostigmin, the most powerful miotic we possess, acts by stimulating the third nerve endings in the sphincter and in the ciliary muscle. It is therefore an antagonist of atropin, but it is unable to overcome the dilatation produced by atropin. On the other hand, eserin readily overcomes the dilatation produced by homatropin and cocain. These facts are of very great importance and must be carefully borne in mind. Comparably with cocain eserin fails to produce constriction of the pupil after section of the third nerve.

Eserin, unlike the common mydriatics, causes some smarting and injection of the ciliary vessels when instilled into the conjunctival sac. What is more unpleasant is the "dragging" sensation in the eye which patients complain of when it is acting. It may be so irritating as to cause vomiting, but this only occurs in very sensitive persons or when the drug is pushed. Owing to these symptoms it should not be instilled more frequently nor in stronger doses than requisite to ensure the desired result. A 0.5 per cent. solution or one considerably weaker is often adequate.

Eserin begins to contract the pupil and cause spasm of accommodation in about five minutes; its maximum effect is reached in twenty to forty-five minutes. The effect on accommodation lasts only an hour or two, that on the pupil two to three days.

Pilocarpin acts similarly to eserin, but is less potent.

In irritative miosis, due to stimulation of the third nerve, light, accommodation, and eserin will cause greater constriction, atropin dilatation. In paralytic miosis, due to paralysis of the sympathetic, light, accommodation, and eserin will cause constriction, atropin little or no dilatation.

In spastic mydriasis light, accommodation and eserin will cause constriction. In paralytic mydriasis there is

no reaction to light or accommodation, and eserin acts very feebly.

VISUAL PERCEPTIONS.

When light falls upon the retina it acts as a stimulus to a sensory nerve ending. As contact of the skin with a foreign substance causes the sensation of touch, so stimulation of the retina causes visual perceptions. The changes which go on as the result of a suitable stimulus in an ordinary tactile end organ, the physiological impulses in the afferent sensory nerves, and the psychological interpretation of these impulses in the brain which we call tactile sensation, are all relatively simple. In the visual nervous mechanism they are much more complex and highly differentiated.

We may first very briefly consider the changes which occur in the end organ itself. Light falling upon the retina causes at least four effects. (1) The pigment in the hexagonal cells of the retinal epithelium migrates from the bodies of the cells into the processes which lie between the rods and cones. (2) The cones become shorter. Both these effects are slow; both give more response to the violet end of the spectrum than to the red end; both are consensual as well as direct—light on one retina causes the effect on both, though the other be kept in darkness. (3) The visual purple, a substance which is found only in the rods, is bleached, so that a sort of photograph or optogram of the luminous object is formed. (4) Changes of electrical potential are set up in the retina.

We are more concerned, however, with the sensations which result from stimulation of the retina with light. These are of three kinds, which are called the Light Sense, the Colour Sense, and the Sense of Form. Each of these may become disordered, so we must examine what they really mean.

The *Light Sense* is the faculty of the retina which permits us to perceive light, not only as such, but in its gradations of intensity. By utilising shadows cast by the retinal blood vessels upon the rods and cones it can be proved that the neuro-epithelium is the actual sentient layer of the retina. It is in this layer that the clear image of objects in the outer world are focused. The rays stimulate the rods and cones and give us the sensation of light.

If the light which is falling upon the retina is gradually reduced in intensity there comes a point when it is no longer perceived: this is called the *light minimum*. It varies very greatly according to the amount of light which has been falling upon the retina before the observation is made. We are all aware that if we go from bright sunshine into a dimly lit room we cannot perceive the objects in the room until some time has elapsed: the eyes have to become "adapted" to the amount of illumination. Hence observations on the light minimum are only comparable one with the other when the eye is in the condition of dark adaptation. Since this involves keeping light from the eye for at least twenty to thirty minutes the investigation is tedious, and perhaps this is the chief reason why it is much neglected clinically.

Having ascertained the light minimum, if the light is gradually increased in intensity there are points at which we can clearly distinguish a difference in the amount of illumination. We can do this best if we have two illuminated areas of equal size to compare, as is done in special instruments for the purpose, called photometers. We can then find out how much brighter one area must be in order that we may distinguish a difference in illumination. This is called the *light difference*. It is found to vary with the amount of illumination—the greater the amount of illumination the greater will have to be the difference in

order that we may be conscious of any difference at all. Indeed, light difference follows a well-known law which is valid for all sensory impressions.

Neither of these functions of the light sense are much used in ophthalmology. There is no doubt that the light minimum is increased in diseases which impair the percipient elements, viz., the rods and cones (see *Retinitis pigmentosa*). It is said that disease of the conducting

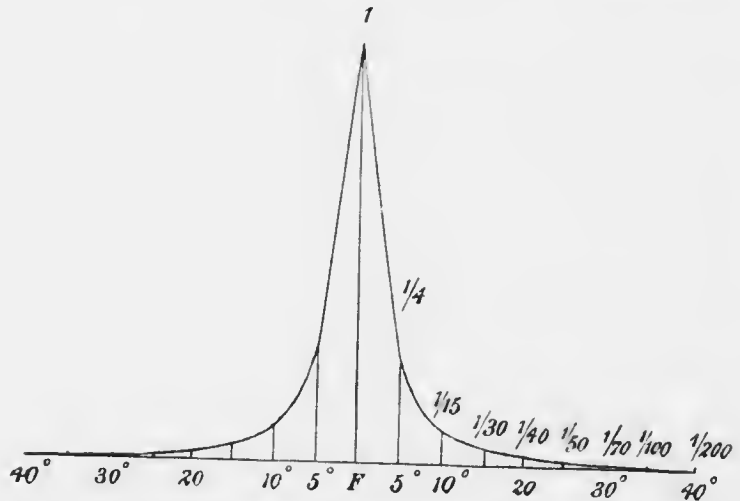


FIG. 54. Acuity of form sense in different parts of the retina. (Dor.)
F. fovea centralis. Abscissa, degrees towards the periphery of the retina; ordinates, relative acuity, that at the fovea being unity.

elements, the nerve fibres, causes increase in the light difference.

The rods appear to be much more sensitive to low illumination than the cones, so that in the dusk we see with our rods. Nocturnal animals, like the bat, have few or no cones.

The *Form Sense*, which is next in importance, is the faculty of the retina which enables us to perceive the shape of objects in the outer world. Here the cones

play the greatest part, and where they are most massed together and most highly differentiated, viz., at the macula, there the form sense is most acute. It falls off very rapidly towards the periphery, as is shown in Fig. 54, and it is noticeable that the curve agrees fairly well with the diminution in the number of cones. We are accustomed to speak of acuity in distinguishing the shapes of objects as *acuity of vision*, and we mean by that the greatest acuity which it is possible to obtain. The acuity of vision, therefore, applies to central vision, or the vision of objects whose images are formed at the fovea and its immediate neighbourhood, the macula lutea.

In determining the acuity of vision, we utilise the visual angle (*vide* p. 44). We naturally choose as our basis the *minimum visual angle*, i.e., the angle which two luminous points must subtend at the nodal point of the eye in order that they may be perceived as separate and distinct. Now, in order that we may get separate impressions from two points close together on the retina it is necessary that two cones shall be stimulated, and that there shall be a cone between these two which is not stimulated. If we know the diameter of a cone we can calculate the minimum angle which must be subtended at the nodal point in order that these requirements may be fulfilled. This angle, as we have already seen, is equal to the angle subtended on the other side of the nodal point by the two luminous points. As a matter of fact these calculations agree fairly well with the results of observations. It might be thought that the observation was a very easy one, but there are several complications. It is found that there is a certain amount of spread of the stimulus from one cone to surrounding ones, due chiefly to natural irregular astigmatism of the refractive media, especially the lens. This causes bright objects on a dark background to appear a little larger than they really are :

the phenomenon is called irradiation. It is not altogether a disadvantage, for it helps us very much in seeing actual points of intense light, like the stars, millions of miles away. In clinical work it would be a disadvantage to have an unduly high standard of visual acuity, because nearly everybody would be abnormal according to the standard. It is found that a minimum visual angle of 1 minute ($1'$) or one-sixtieth of a degree gives a very good average, and it is upon this basis that test types are constructed (*vide* p. 156).

The *Colour Sense* is that faculty of the retina whereby we are enabled to distinguish different colours and different colour tones. The exact investigation of the colour sense is one of great complexity, for the different colours of the spectrum differ in luminosity, so that this disturbing factor has to be added to those dependent upon the physiological condition of the retina, *e.g.*, its state of adaptation, and so on.

If three colours sufficiently far apart on the spectrum are chosen, all the other colours can be formed by their combination in suitable proportions, and white light can also be formed in the same manner. There are reasons for choosing red, green and blue for these "primary" colours. Now, we know that physiological impulses are in some sense a reflex or image of the physical stimuli which give rise to them, *e.g.*, sound waves cause physiological impulses, which are perceived as sound, and so on. If, therefore, we imagine three slightly different kinds of impulse set up by the stimulation of the retina by red, green and blue light respectively, their combinations in suitable proportions would enable us to perceive the whole gamut of the spectrum, including white light. This is the basis of the Young-Helmholtz theory of colour vision. According to Hering's theory, chemical changes in three different types of "visual substance" situated in the retina

cause the sensations of colour (including white and black). The three substances are white-black, red-green, and blue-yellow. If anabolic or building-up changes (Assimilation) are set up in these substances, the sensations of white, red and blue are caused respectively. If katabolic or breaking-down changes (Dissimilation) are set up, black, green and yellow result.

Perhaps no subject affords a better field for conjectures than the theory of colour vision. It is sufficient here for us to emphasise the importance of the three primary colours, upon which stress is laid by the Young-Helmholtz theory, and the intimate relations which exist between red and green, blue and yellow, and white and black, which is the foundation of the Hering theory. It is necessary to realise so much because the colour sense is defective in a fairly large proportion of people. This congenital abnormality is called *colour blindness (q.v.)*. In it the importance of the three primary colours and the intimate relation of the pairs of colours are forcibly brought out.

The three types of visual perception are not confined to the minute area of central or macular vision. All are present in greater or less degree in more peripheral parts of the retina. In disease the earliest and most delicate traces of failing function are often to be found in the peripheral parts, central vision remaining perfectly normal. Hence the great importance of knowing the normal limits of the light perceptive and the colour perceptive areas of the retina.

The *field of vision* is the projection of these percipient areas of the retina on the outer world. When we stand upon the sea shore and look at or "fix" a ship on the horizon it forms a retinal image at the fovea. We are accustomed, then, to consider that any object in the outer world which forms the image at the fovea is situated somewhere upon the *line of vision*, i.e., the line passing

through the fovea and the nodal point of the eye. The foveal image is "projected" outwards along this line. Whilst still fixing the ship we are conscious of seeing, less clearly, innumerable objects for miles around. From our knowledge of the refractive mechanism of the eye we know that these objects must form their retinal images upon peripheral parts of the retina. Regarded from the side of the eye the image upon any point of the peripheral part of the retina is "projected" outwards along the line joining the point with the nodal point. The field of vision, then, is the projection outwards of all the points upon the retina which can give rise to visual perceptions. We will postpone the consideration of its properties to a later stage (*vide* p. 165).

CHAPTER V.

THE NEUROLOGY OF VISION.

In the preceding chapter we have considered the process of vision up to the point at which the retinal

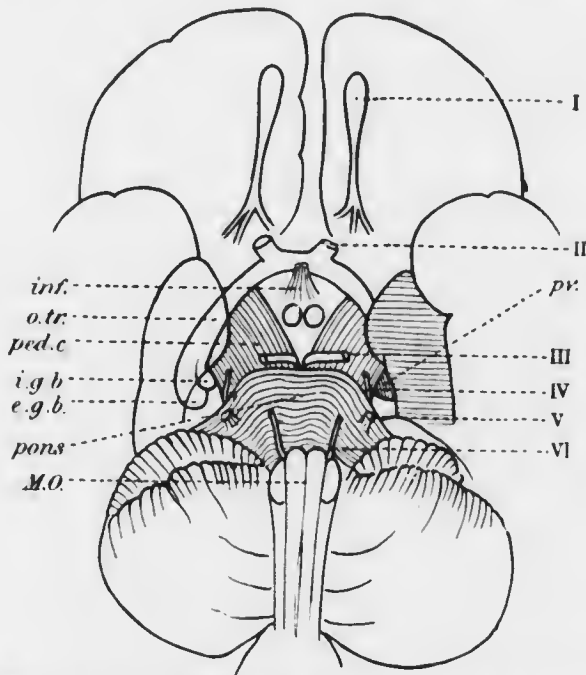


FIG. 55.—Diagram of the base of the brain, showing superficial origin of the I, II, III, IV, V, and VI cranial nerves: *inf.*, infundibulum; *o.tr.*, optic tract; *ped.c.*, cerebral peduncle; *i.g.b.*, internal geniculate body; *e.g.b.*, external geniculate body; *pv.*, pulvinar of optic thalamus; *M.O.*, medulla oblongata.

receptive elements, the rods and cones, have become stimulated. As with other sensory nerves, stimulation

of the end organ causes the development of nervous impulses which travel up the afferent tracts of the central nervous system to the brain. The comparison of the afferent tracts of common sensation with those of vision throws so much light upon the latter that it is worthy of a moment's consideration.

The sensory impulse of common sensation, *e.g.*, in the leg, is carried by a nerve fibre along the sensory nerve and the dorsal spinal root to the cord: it travels up in the posterior columns of the cord to the nucleus gracilis or the nucleus cuneatus as the case may be (Fig. 56). The whole of this course is along the processes of a single cell or neuron, which has been called the neuron of the first order. The impulse is taken up in the nucleus gracilis or cuneatus by a second cell, and is carried along the nucleo-thalamic tract or mesial fillet to the opposite optic thalamus; other fibres, especially those derived from the nucleus cuneatus, pass to the superior colliculus or corpus quadrigeminum. The cells in the nuclei gracilis and cuneatus are the neurons of the second order. A third cell, the neuron of the third order, situated in the thalamus or colliculus, carries on the impulse to the cortex cerebri. Here the nervous impulse is transformed into a psychic impulse, a change which is not and probably never can be understood.

Let us compare with this the visual afferent tracts (Fig. 57). The end organ is the neural epithelium of rods and cones. The first true conducting nerve cell or neuron of the first order is the bipolar cell of the inner nuclear layer with its axon in the inner reticular layer. This microscopic cell corresponds morphologically with a dorsal root ganglion cell and its long processes stretching in some cases from the tip of the toe to the top of the spinal cord. The neurons of the second order are the ganglion cells in the retina whose processes pass into the nerve fibre layer

and along the optic nerve to one of three terminations: most (80 per cent.) end in the lateral or external

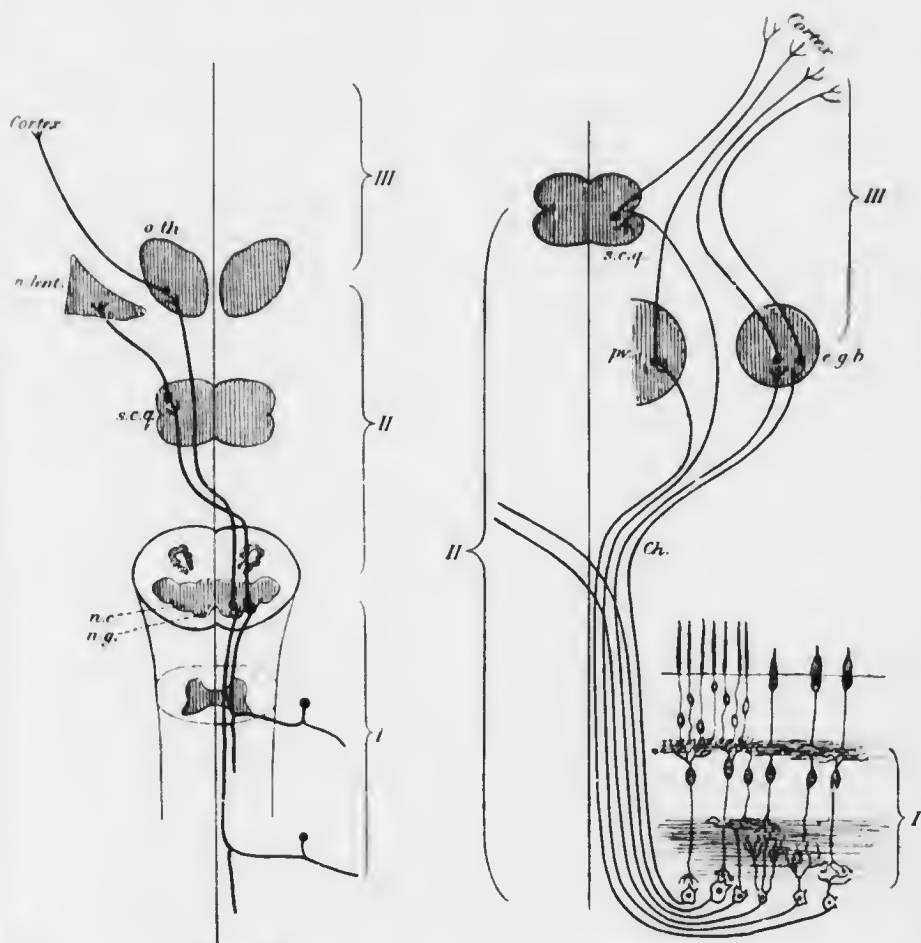


FIG. 56.

FIG. 57.

FIGS. 56 and 57.—Fig. 56 represents a diagram of the neurons of the most direct path of common sensation. Fig. 57 represents the neurons of the afferent visual path. I, II, III, neurons of the first, second, and third orders respectively; *n.c.*, nucleus cuneatus; *n.g.*, nucleus gracilis; *s.c.q.*, superior corpus quadrigeminum; *n.lent.*, nucleus lenticularis; *o.th.*, optic thalamus. I in Fig. 57, rod and cone bipolars in the retina. *Ch.*, chiasma; *e.g.b.*, external geniculate body; *pr.*, pulvina of optic thalamus.

geniculate body, others pass to the optic thalamus, and a few go to the superior colliculus. At these three sites a new cell, the neuron of the third order, takes up the transmission of the impulse, travelling by way of the

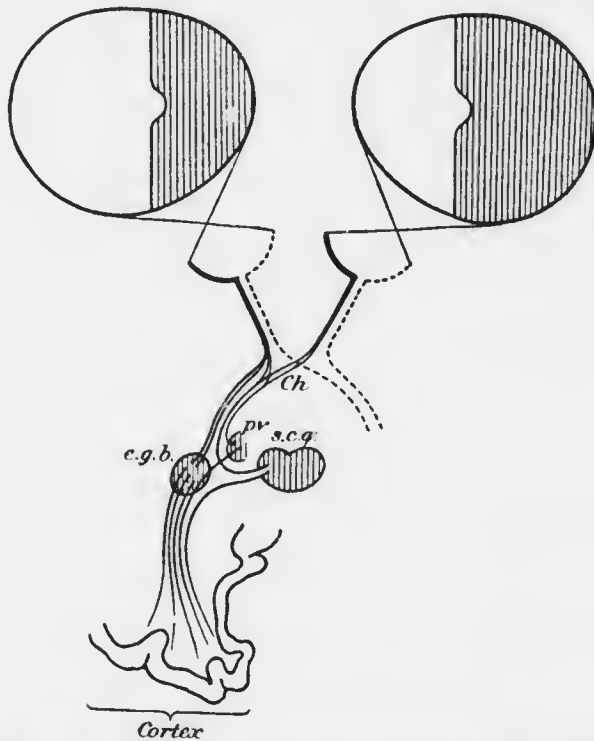


FIG. 58.—Diagram of the afferent visual paths from the retina, with the corresponding fields of vision. (After von Monakow.) *Ch.*, chiasma; *pv.*, pulvinar of optic thalamus; *e.g.b.*, external geniculate body; *s.c.g.*, superior corpus quadrigeminum.

optic radiations of Gratiolet to the cortex of the occipital lobe, which is the so-called *visual centre*.

We see, then, the morphological identity of the two systems, in spite of the great anatomical differences which specialisation has brought about. We may emphasise again the fact that the peripheral optic nerve

proper is a bipolar cell in the inner nuclear and inner reticular layers of the retina, whilst the so-called optic nerve is a part of the central nervous system homologous with the posterior columns of the spinal cord.

We must now investigate more minutely the individual parts of the visual system. The results which are about to be described are derived from three sources—embryo-

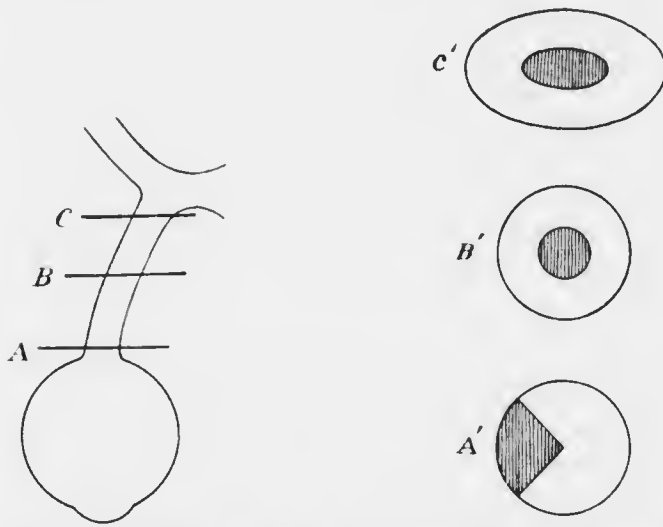


FIG. 59.—Distribution of the papillo-macular fibres in the optic nerve. The shaded areas in A', B', C', represent the papillo-macular bundle in sections corresponding with A, B, and C.

logy, experiments upon animals, and clinical observation as controlled by post-mortem findings.

Let us first trace the fibres from the various parts of the retina (Fig. 58). In general it may be said that the fibres from peripheral parts enter the middle of the nerve, whilst the fibres from parts near the nerve enter the peripheral parts of the nerve: they probably maintain this relative position as far back as the chiasma. There is however one disturbing factor, viz., the fibres from the

macular region. This part is specially well supplied. The fibres pass into the outer part of the nerve, where they are spread over an area which is triangular in section, with the apex towards the centre of the nerve (Fig. 59). These *papillo-macular fibres* soon become more centrally situated, so that in the posterior part of the nerve they are all in the centre. Tracing them still farther backwards some decussate in the chiasma, whilst others enter the optic tract of the same side. They spread out widely in the two tracts and in the lateral geniculate bodies. The axons of their corresponding neurons of the third order are also widely distributed in the optic radiations and end in the lips of the calcarine fissure of the occipital lobe, probably along its whole length. We see then that each macular region is represented in each occipital lobe, so that no lesion confined to one occipital lobe will abolish central vision in either retina.

The fibres from peripheral regions of the retina, on the other hand, form two distinct groups, corresponding with the temporal and nasal halves of the retina. The limitation is very exact, as if a vertical line divided the retina into two halves at the level of the fovea; since the foveal fibres have a different distribution the line makes a little curve round it so as to avoid it (Fig. 58). The fibres from the temporal half of the retina enter the chiasma but do not decussate; they pass into the optic tract of the same side. Thence they run to the lateral geniculate body, and a few to the thalamus and superior colliculus. The fibres from the nasal half of the retina enter the chiasma, decussate, and pass into the optic tract of the opposite side, having a similar distribution on the other side. The corresponding neurons of the third order pass by the optic radiations to the corresponding occipital lobes. We see, therefore, that a

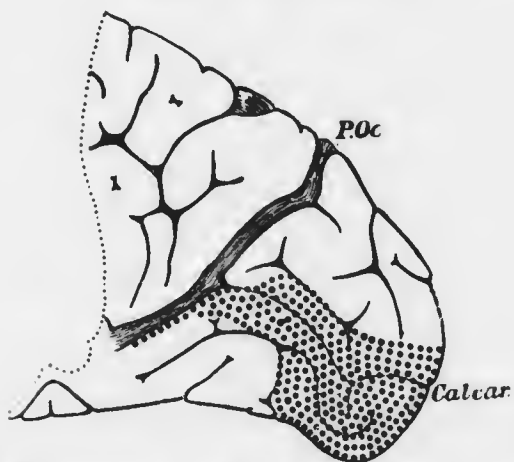
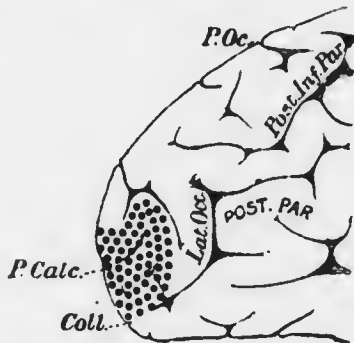
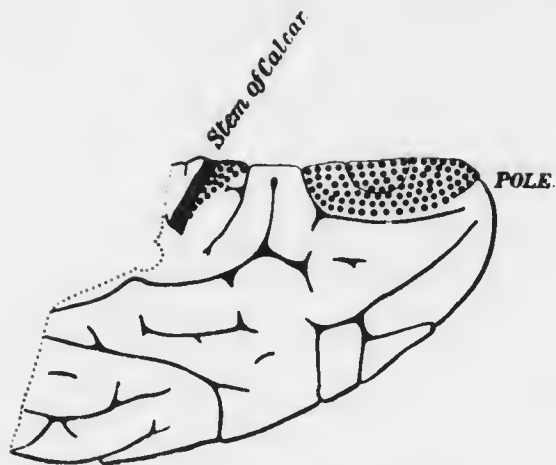


FIG. 60. Visuo-sensory area of a healthy man of fifty-five. (J. S. Bolton.) *P.Oc.*, parieto-occipital fissure; *Calcar.*, calcarine fissure; *Coll.*, collateral fissure.

lesion of one occipital lobe or optic tract will cause blindness of the temporal half of the retina on the same side and of the nasal half of the retina on the opposite side. Projecting this outwards such a lesion will cause loss of vision in the opposite half of the binocular field of vision, a condition which is known as *hemianopia* (hemionopia, hemianopsia). We may recall the fact that the afferent pupil-constrictor fibres have a similar semi-decussation in the chiasma.

The visual fibres in the optic radiations maintain a posterior position in common with the sensory fibres from the rest of the body, being thus situated behind the motor fibres in the internal capsule. They are close to the posterior cornu of the lateral ventricle, so that they are liable to pressure here when the ventricle is distended.

The occipital cortex in and about the calcarine fissure differs from the cortex elsewhere in the possession of a white line, the line of Gemari, interpolated in the grey matter. This area, which is the primary visual or visuo-sensory area (Fig. 60), is the cortical projection of the corresponding halves of both retinae. In this projection the part above the calcarine fissure represents the upper corresponding quadrants, the part below the lower corresponding quadrants of both retinae.

It may be mentioned that there are efferent fibres in the optic nerves. They are axons of cells in the lateral geniculate body. Their function is unknown, but they are probably concerned in the movements of the pigment epithelium and of the cones; possibly also in the chemical changes in the visual purple.

SECTION II.

THE EXAMINATION OF THE EYE.

CHAPTER VI.

EXTERNAL EXAMINATION.

OPHTHALMIC patients may be roughly divided into two groups: those who present manifest objective signs of disease, and those who, presenting no outward and visible signs, have abnormal subjective symptoms. The division is convenient both in theory and in practice. The second group, in all but "functional" cases, have latent objective signs which it is our duty to discover. In the first group the manifest signs may mask even more serious conditions which it is our duty to bring to light. Not infrequently we are confronted with obscure cases which demand the most careful systematic examination in order that nothing may be overlooked. Though it is not always possible, or even necessary, to go through the lengthy routine of an exhaustive systematic examination, yet the details of such a routine must be firmly engrafted in our minds, ready for instant application, if we wish to avoid mistakes in diagnosis.

We shall first describe the methods of examination of the parts which can be observed with the unaided eye, though we shall often ensure accuracy by artificial assistance. Next, we shall describe the methods which must

he employed to examine the deeper parts of the eye. Finally, we shall map out a routine of systematic examination.

In the patients who belong to our first group we shall at once be confronted with visible signs of disease. We shall not consider in this place gross signs such as marked protrusion or proptosis, great deviations of the optic axes from the normal parallelism, and so on. These will be more conveniently investigated in their special relations. We shall confine ourselves to conditions affecting the globe itself.

The Conjunctiva.—In the normal position of the lids only that part of the bulbar conjunctiva which is exposed in the palpebral aperture, together with parts of the intermarginal strip along the edges of the lids, is visible. In order thoroughly to investigate the whole conjunctival sac it is necessary to expose the palpebral conjunctiva and the fornices.

The lower fornix is easily exposed by drawing down the lower lid whilst the patient looks towards the ceiling.

The upper palpebral conjunctiva is exposed by everting the upper lid.

Eversion of the upper lid requires some practice. (1) The best, and often the easiest, method is as follows: Stand facing the patient. Place the right index finger horizontally along the patient's left upper lid whilst he looks towards his feet. Draw the skin of the lid outwards: this causes the inner part of the edge of the lid to come forwards, whilst at the same time the pressure of the finger affords a fixed point around which the lid can revolve in a vertical direction. Insinuate the right thumb under the projecting edge of the lid, and roll the lid upwards towards the index finger. The right lid is everted in the same manner, using the left hand.

This method is very easy when the eyes are prominent,

and it causes a minimum of discomfort to the patient. When the eyes are deeply set in the orbit, as is often the case in old people whose orbital fat has become to a great extent absorbed, more pressure is needed and a little pain is caused. In such cases the following method may be adopted; the tyro will generally find it easier:

(2) Place a probe or thin pencil horizontally along the skin of the upper lid at the level of the upper border of the tarsus, the patient looking towards his feet.

Seize the eyelashes between the left index and thumb, and draw the lid away from the globe, using the probe as a fixed point. Rotate the lid in a vertical direction round the probe, which is then withdrawn.

In many cases we wish to evert the upper lid when standing behind the patient, who may be lying on a couch. In this case the following is the best method:

(3) Place the left index finger vertically upon the lid whilst the patient is looking towards his feet. Seize the lashes with the right index and thumb, and rotate the lid around the tip of the left index.

In babies a special arrangement of the patient facilitates thorough examination of the conjunctival sac and eye:

(4) The surgeon sits facing a nurse, who holds the child on her lap. The baby's head is placed between the surgeon's knees; its body is on the nurse's lap. She holds the child's hands against its body, thus keeping them out of the way, and at the same time steadying the child. If, as is often the case, there is blepharospasm, eversion of the lids is extremely easy; indeed, it becomes troublesome when we wish to examine the cornea. Here the spasm of the orbicularis fixes the lids against the globe, and the slightest attempt to draw the lids apart causes both to become everted. When this does not occur, method (3) must be adopted.

Having everted the upper lid we can examine the palpebral conjunctiva, but we are still unable to see the upper fornix. This can usually be effected in adults by the following manœuvre: (1) With the lid still everted by the first method it is fixed in that position by the left thumb placed upon its margin at about the middle. The right thumb or finger is placed in the middle of the lower lid. Firm, steady pressure is then made through the lower lid upon the globe in a direction straight backwards, as if to push the globe into the orbit. In the meantime firm pressure is also exerted backwards upon the upper lid with the left thumb. The fornix will generally start forwards suddenly, but only if the patient keeps looking well down towards his feet all the time.

This method, though unpleasant, is not painful. The only other method of exploring the upper fornix is more effectual, but also painful. The eye should therefore be well cocained.

(2) The upper lid is everted in the usual manner. A retractor is then inserted under the everted lid into the fornix. The margin of the lid being fixed as in (1), the lid is everted a second time, so that the fornix is fully exposed. Sometimes it is necessary to grasp the everted lid with forceps and thus evert it a second time.

By these manœuvres the conjunctival sac can be thoroughly explored. Special attention must be paid to the favourite sites for foreign bodies and manifestations of disease, *e.g.*, foreign bodies often lodge on the palpebral conjunctiva about 2 mm. from the margin at about the middle of the lid; trachoma follicles are most marked in the upper fornix; scarring from old trachoma is most marked in the palpebral conjunctiva, &c. Adhesions between palpebral and ocular conjunctiva and obliteration of either fornix cannot fail to be noticed. Inflammatory conditions can be thoroughly examined: accurate diagnosis often depends upon minute

investigation. Patches of granulation tissue which bleed easily may mark the site of embedded foreign bodies, or, if on the palpebral conjunctiva, the site of a chalazion.

The ocular conjunctiva can be almost completely examined without everting the lids if the eye is moved up and down whilst the lids are kept apart. The redness which is observed in irritative and inflammatory conditions varies in its distribution and nature according to the

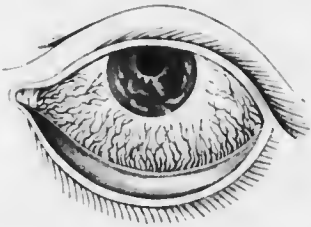


FIG. 61.—Conjunctival congestion — engorgement of the posterior conjunctival arteries and veins. (After Guthrie.)

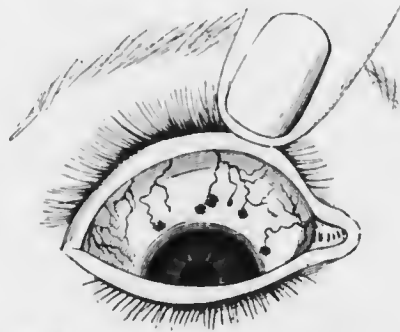


FIG. 62.—Congestion of the perforating branches of the anterior ciliary arteries. (Dalrymple.) The dusky spots at the seats of perforation are often seen in dark-complexioned persons.

cause. Here we must remember the groups of vessels with which we have to deal (*vide* p. 14). Three groups may be distinguished, though most of them are too small to be recognised in health: (1) the proper vessels of the conjunctiva or posterior conjunctival vessels (Plate II.); (2) the anterior conjunctival vessels, which supply the area adjacent to the limbus or corneal margin and send minute loops into the edge of the cornea itself (*vide* p. 17; Fig. 61); (3) the anterior ciliary vessels, lying in the subconjunctival or episcleral tissue. In the last group the perforating branches of the arteries are seen in health as

several comparatively large tortuous vessels which suddenly cease about 2 to 4 mm. from the corneal margin. They have very numerous small episcleral branches which are invisible in health, but when dilated form a pink zone of fine, straight, very closely set vessels around the cornea. The corresponding perforating veins are very small, but more numerous than the arteries; their episcleral branches form a closely-meshed network.

Congestion of the individual groups of vessels affords important evidence as to the seat of the mischief. The



FIG. 63. — Ciliary congestion — engorgement of episcleral twigs of the anterior ciliary arteries. (After Dalrymple.)



FIG. 64. — Congestion of the anterior ciliary veins, episcleral venous plexus. (After Dalrymple.)

conjunctival vessels can be distinguished from the anterior ciliary by the following points: (1) they are a brighter brick-red, the ciliary vessels being seen through the conjunctiva, which imparts a purple tinge; (2) if the conjunctiva is moved to and fro over the sclerotic by the finger placed on the lower lid the conjunctival vessels also move whilst the ciliary remain stationary; (3) the individual vessels and the network they form can be seen in the conjunctival system, whereas the ciliary form for the most part a diffuse reddish violet blush in which the separate vessels are indistinguishable; (4) if the blood is pressed out of the vessels the ciliary fill up at once on

removing the pressure, since they anastomose very freely, whilst the conjunctival fill slowly.

In general, congestion of the conjunctival vessels, leaving a relatively white zone around the cornea, accompanied by mucous or muco-purulent secretion, is indicative of conjunctivitis. If there is much irritation and so-called photophobia, with some blepharospasm and very watery—lacrimal—secretion, we suspect the presence of a foreign body on the cornea or under the lid, so that it rubs against the cornea: the condition may be due to misplaced lashes (*trichiasis*). Phlyctenular ophthalmia may produce a similar picture. In such a case there is also usually congestion of the anterior conjunctival vessels. Careful examination shows that the vessels in the circumcorneal zone are bright red, and that the corneal loops are also dilated and visible. Any irritation of the cornea—ulcers, abrasions, &c.—causes this conjunctival congestion of the circumcorneal zone and corneal vessels. Though conjunctival they do not move with the membrane. A definite leash of dilated vessels confined to the conjunctiva or encroaching upon the cornea is usually indicative of phlyctenular disease.

Pink circumcorneal congestion is also met with in inflammation of the iris. Here the anterior ciliary vessels are also involved.

Circumcorneal congestion of a peculiar lilac tint, more deeply seated and often patchy, is associated with cyclitis and deep scleritis. This is the condition which is known as ciliary congestion par excellence.

Dusky congestion at the limbus, composed of a fine reticulum—the episcleral venous plexus—often points to glaucoma, but may accompany other diseases, especially in old people.

These conditions run into one another very frequently, so that they then cease to have special diagnostic importance.

Lacrymal Apparatus.—Conjunctival congestion of one eye only, or signs of irritation such as watering, should lead us to suspect the efficiency of the lacrymal apparatus. Simple epiphora or flow of tears on to the cheek may be due to blocking of one or both puncta or to their malposition, or to blockage elsewhere in the canaliculi or nasal duct. Displacement of the lower canthum may be easily overlooked. The puncta are *not* visible normally without slightly everting the lids. Displacement is often very slight, due to slackness of the lid causing a little rolling out or ectropion, especially in old people. In spasm of the orbicularis the lid may be rolled in too much (entropion); this may also cause epiphora. Sometimes with more conjunctival inflammation, but often without, there is distension and chronic inflammation of the lacrymal sac. In all such cases we carefully observe the exact position of the puncta, whether they are in apposition to the bulbar conjunctiva as they should be, and also whether there is any regurgitation from the lacrymal sac when it is pressed upon. The lacrymal sac is situated in the lacrymal fossa between the inner canthus and the nose: the fundus extends slightly above the level of the inner palpebral ligament, which is on a line with the canthus. Pressure inwards and backwards in this position will press upon the sac. If there is any obstruction to the flow of the contents into the nose by the nasal duct, as is usually the case when the sac is inflamed, the contents will generally regurgitate into the conjunctival sac by way of the canaliculi, and will be seen pouring from the puncta. We note whether the contents are tears, mucus, or muco-pus.

Without describing special methods of ascertaining if the lacrymal passages are patent (Chap. XXX.), a simple test may be mentioned. A drop of fluorescein solution is placed in the conjunctival sac and the patient is told

to blow his nose. If the passages are free, the handkerchief will be stained with the solution.

The Sclerotic.—Inspection of the sclerotic around the cornea may reveal raised nodules of episcleritis with their localised areas of vascular congestion (*vide* p. 277). Deep scleritis may be shown by dusky ciliary congestion and opacification of the deeper layers of the cornea at the periphery (sclerosing keratitis, *vide* p. 280).

Definite blue coloration of the circumcorneal sclerotic, except in young children, is pathological. It is most frequently due to ciliary staphyloma, a giving way of the sclera owing to inherent weakness (injury, scleritis, &c.) or to increased intraocular pressure (glaucoma). Discoloration may be due to pigmentation. Slight duski-ness around the spots where the anterior ciliary vessels perforate is not uncommon in people with dark complexions. Otherwise pigmentation in this neighbourhood, either in the conjunctiva or sclerotic, should be regarded with suspicion as indicative of melanotic sarcoma. Definite nodules of deeply pigmented tissue in the situation of the perforating vessels is very significant of sarcoma of the ciliary body.

If there is bulging of the sclerotic an attempt should be made to transilluminate it in the dark room. If it is a true ectasia (staphyloma) light will pass through into the eye. The light should be concentrated upon the spot by a strong lens (*vide* p. 101).

The abrupt or very gradual curvature of the sclerotic as it passes back from the cornea may indicate high hypermetropia or myopia respectively.

The Cornea.—A little experience will enable us to recognise at a glance if the cornea is smaller than usual. A small cornea with a shallow anterior chamber is very suggestive of glaucoma.

The cornea should be bright and transparent. We

first examine its surface. Any loss of substance, such as an abrasion, may easily be overlooked without special care. The condition of irritation and lachrymation will often put us on the track, but these features may be so slight as to pass unnoticed. The following methods should be adopted :

(1) Place the patient facing the window. Stand in front and direct the patient to follow the index finger, which is held horizontal and moved slowly up and down. The finger is then held vertical and moved from side to side. Whilst these manœuvres are being carried out the image of the window or corneal reflex, as it is called, is carefully watched. If the surface of the cornea is normal there will be no distortion of the reflex as it passes over it. If there is an abrasion the image will be distorted here, and will be less clearly defined. This method should always be resorted to first, as it is good practice in observation and needs no artificial aid which may not be available under some circumstances.

(2) If the first method gives uncertain results or fails, instil a drop of fluorescein solution (2 per cent.). This is best done by telling the patient to look towards his feet; the conjunctiva above the cornea is then lightly touched with the tip of a glass rod which has been dipped in the solution. A pad of cotton wool is immediately placed upon the closed lids so as to mop up the excess and the tears which tend to flow over the face. If this detail is not attended to the face becomes stained unnecessarily. It is a good plan to wash out the excess of fluorescein with a drop of cocaine solution, but it is not essential. Any spot on the surface of the cornea which is denuded of epithelium will appear green.

A bundle of dilated conjunctival vessels near the limbus will often mark the site of a foreign body upon the cornea.

Opacities of the cornea may be so faint that they require very minute investigation, and the same is true of the details—depth, &c.—of gross opacities. We can study them best by focal or oblique illumination.

Focal or oblique illumination is carried out as follows

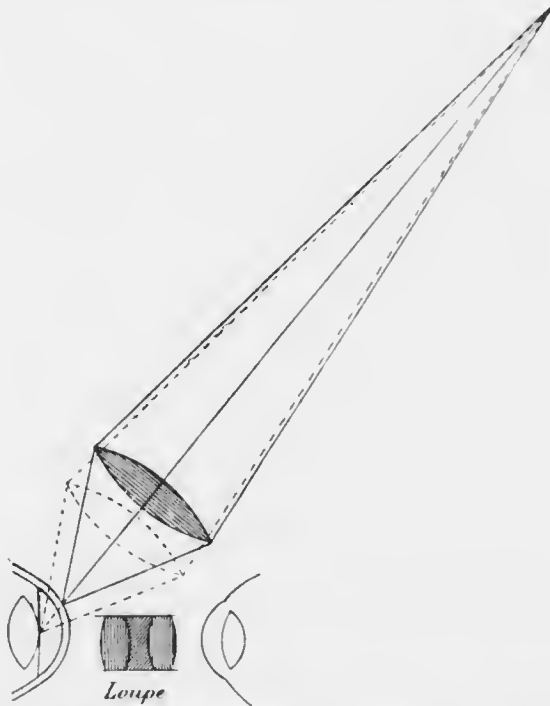


FIG. 65.—Focal or oblique illumination. The diagram shows how the focus of the light may be altered by slightly shifting the position of the concentrating lens.

(Fig. 65): the patient is placed, preferably in the dark room, with a light about two feet in front but slightly to one side. The light is concentrated upon the cornea by a strong convex lens (the large lens in the ophthalmoscope case). The rays of light are brought to a focus by the lens. The cornea or other superficial structures

can thus be examined under the intense light of the converging rays. The position of the minute image of the light formed by the lens can be moved over the surface of the cornea by slight lateral movements of the lens without altering the position of the light. Similarly the light may be focused upon the iris or crystalline lens by moving the lens slightly nearer to the eye.

Having thus brilliantly illuminated the part of the cornea which we wish to investigate, we may magnify the spot by looking through a very strong convex lens or corneal loupe held in the other hand. The management of the two lenses requires a little practice, but is easily mastered. A few words of explanation about the corneal loupe will help us to employ it to best advantage.

When we magnify a small object with a strong convex lens we place it within the focal distance of the lens and view it through the lens. We know that under these conditions the lens forms an enlarged image upon the same side as the object, but farther away (*vide* p. 34, Fig. 21). In order that we may see the image to best advantage we must see as much of it as possible, and we must see it under the largest possible visual angle. The first requisite demands that the observer's eye shall be as close to the lens as possible. The second requisite depends upon the relative distances of the object and the eye from the lens: in practice these are found by slight movements of the lens.

In employing focal illumination, then, first focus the light upon the required spot. Then place the corneal loupe near the spot and look through it. Slowly advance the loupe towards the cornea until the spot comes into focus. Then get the eye as close to the loupe as possible. In this manner we shall see all there is to be seen.

By moving the light and the loupe slowly over the whole surface of the cornea we can thoroughly explore it.

By advancing the convex lens we can illuminate successively the back of the cornea, the iris and anterior part of the lens, and finally the deeper parts of the lens. By simultaneously advancing the position of the lense towards the cornea we can successively bring these structures into accurate focus and examine them under considerable magnification. We cannot get beyond the back of the lens with a high power loupe, as it works at too short a focal distance. Moreover, in order to examine the deeper parts of the lens we must have the light almost in front of the patient, otherwise they will not be illuminated.

Focal illumination without the assistance of a loupe or a dark room is often of great advantage through the good illumination which it affords. One soon gets into the habit of concentrating the light from the window upon the eye with the convex lens with a view to improving the optical conditions.

The cornea is often affected secondarily to the conjunctiva, as in phlyctenular ophthalmia. In such conditions the eye is most irritable and resistant to examination in bright light. The slightest attempt to separate the lids is accompanied by violent blepharospasm, especially in children. Yet it is in such cases that it is of the greatest importance to know and watch the condition of the cornea. For aught we know it may be ulcerated, and may even be upon the point of becoming perforated. Any roughness, or even an amount of pressure which is quite justifiable in other cases, may suffice to cause the perforation which it should be



FIG. 66. — Bent wire lid retractor.

our chief effort to avoid. In such a case the lids must be separated by retractors. We may use simple bent wire retractors (Fig. 66) or Desmarres' retractor (Fig. 67). In babies the position recommended in method (4), p. 93, is employed: older children are placed upon a couch. The retractors are inserted gently into the palpebral aperture, first the upper, then the lower, the curved ends being insinuated between the lids and the globe. Traction is then made upon the retractors, not only in opposite directions up and down, but also away from the globe, so that the lids are lifted off the globe at the same time that they are separated. In these cases the globe tends to roll forcibly upwards when light falls upon it, which makes it very difficult to see the cornea even with the use of retractors. The difficulty may be overcome by pressing the end of the lower retractor well into the lower fornix, which drags the eye downwards by pulling on the ocular conjunctiva.



FIG. 67. —
Desmarres'
lid retractor.

When we have satisfied ourselves that there is little or no fear of perforation we may dispense with retractors. It has been pointed out that in children an attempt to separate the lids when there is much blepharospasm is usually followed by eversion of both lids, the cornea still remaining hidden. The way to overcome this difficulty is to place the two thumbs close to the edges of the lids and to press gently but firmly upon the globe as the lids are drawn apart. In this manner they are separated without becoming everted, but we must be extremely careful not to exert undue pressure and not to touch the cornea with the thumb nails.

In many diseases new vessels are formed in the cornea.

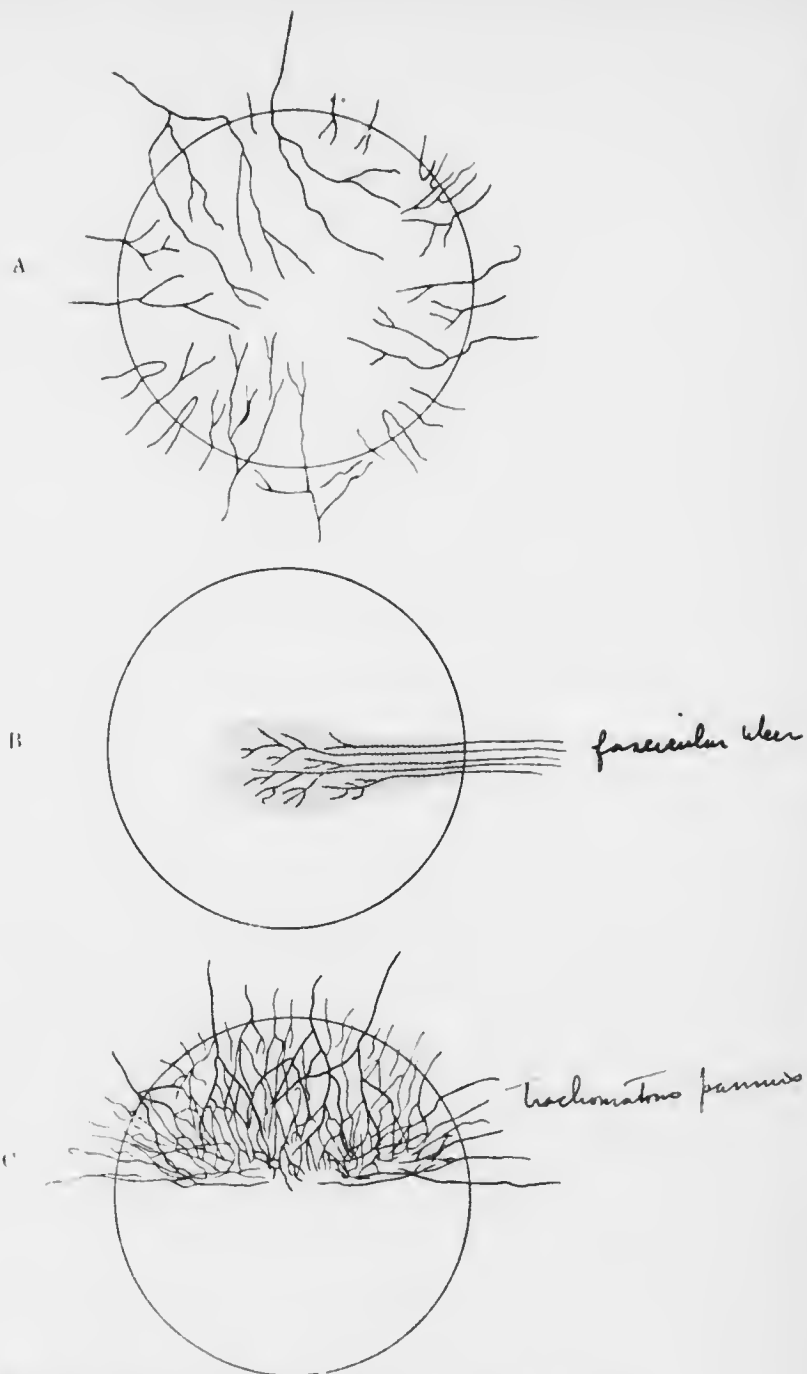


FIG. 68.—Diagrams of superficial corneal vessels. A, general vascularisation; B, a single leash of vessels, as in fascicular ulcer (*vide* p. 250); C, localised vascularisation, as in trachomatous pannus (*vide* p. 203).

An exact knowledge of their position, whether superficial or deep, and of their distribution, whether localised, general, peripheral, above, and so on, will often settle a disputed point in diagnosis.

Superficial vessels (Fig. 68) in the cornea are distinguished from deep (Fig. 69) by the following features: (1) superficial vessels can be traced over the limbus into the conjunctiva, whilst deep ones seem to come to an abrupt end at the limbus; (2) superficial vessels are bright

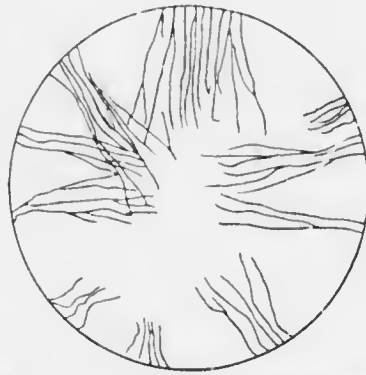


FIG. 69. Diagram of deep corneal vessels, as in interstitial keratitis (*vide* p. 261).

red and well defined, whilst deep ones are ill defined, greyish red, or cause only a diffuse reddish blush; (3) superficial vessels branch in an arborescent fashion, dichotomously, whilst deep ones run more or less parallel to each other in a general radial direction, and branch at very acute angles, like a besom; (4) superficial vessels may raise the epithelium over

them so that the surface of the cornea is uneven, whilst with deep ones the cornea, though hazy, is smooth.

The Anterior Chamber.—The anterior chamber is shallow in extreme youth and in old age; at other periods of life it is about 2.5 mm. deep normally. It must be remembered that we estimate the depth of the anterior chamber by the position of the iris, and that we view the iris through the cornea, which is a strongly refracting convex surface. The effect of this is to magnify the iris and pupil, and to make it appear farther forwards than it really is. The same applies to anything in

the anterior chamber, *e.g.*, the point of a knife in operations.

Good binocular vision enables us to estimate the depth of the anterior chamber when we are looking at it from in front. The observation should be confirmed by taking a profile view.

The anterior chamber is abnormally shallow in glaucoma. It is often abnormally deep in irido-cyclitis. It is frequently unequal in depth in different parts. For example, it may be deeper at the periphery than in the centre in irido-cyclitis; on the other hand, when the iris is bowed forwards (*iris bombé*) it is funnel-shaped, the centre being deep, the periphery very shallow.

After considering the depth, attention must be paid to the contents. In some wounds and ulcers of the cornea, and rarely without them, there is pus in the anterior chamber. It forms a layer at the bottom, the surface of the pus being level (*hypopyon*). A similar layer of blood may occur after contusions or spontaneously (*hyphæma*). The aqueous may be hazy, a condition not always easy to distinguish from haziness of the cornea. Such cases lead us to examine very carefully the back of the cornea with the loupe under focal illumination to see if there are any precipitates ("*keratitis punctata*") upon it, or we may see flocculent specks in the aqueous. All these conditions are of great diagnostic and prognostic importance.

The Iris.—We pay attention first to the *colour* of the iris and the clearness of its pattern. The two irides or parts of the same iris may be of different colour, both conditions being known as *heterochromia iridis*. Dark brown spots in the iris, not raised above the surface, are common. Care must be taken to distinguish them from small tumours of the same colour or white (*sarcoma*, *tubercle*, *gumma*). "*Muddiness*" of the iris is the

expression used for indistinctness of the pattern, caused by inflammatory exudates. A muddy iris, with small irregular pupil and sluggish reaction to light, is indicative of iritis.

The *position* of the iris must be noted, especially the plane in which it lies (*vide* pp. 291, 301, 311). Special attention should be paid to any adhesions (synecchia) anterior—to the cornea, or posterior—to the lens capsule. *Tremulousness* of the iris (iridodonesis) is seen when the eyes are moved rapidly if the iris is not properly supported by the lens, *e.g.*, in absence, shrinkage, or dislocation of the lens, slackness of the suspensory ligament, &c. It is best seen in a dark room with oblique illumination.

The Pupils.—A point which should be examined at an early stage in every routine examination of the eyes is the condition of the pupils. This is the more important since the routine examination frequently demands the use of a mydriatic, and if the pupils have not previously been noted it may be necessary to require the attendance of the patient on another occasion when the effect of the mydriatic has passed off.

The examination of the pupils requires careful attention to details if trustworthy results are to be obtained. It is best carried out as follows :

Place the patient facing the light, which should not be too bright : see that the two pupils are equally illuminated. Note the size, shape and contour of each pupil. Cover both eyes with the palms of the hands, preferably without touching the face. Tell the patient to look straight at you. Remove one hand and watch the pupil. Replace this hand and remove the other, watching the other pupil. Note down and compare the results (*direct reaction to light*). Remove one hand so that this eye is exposed to light (it should be shaded from intense light). Watch this pupil as the hand is removed from the other eye. Repeat the

process whilst watching the other pupil (*consensual reaction to light*).

Now tell the patient to look quite across the room, as far off as possible. Suddenly hold up the index finger vertically at about six inches from the patient's nose, and tell the patient to look at it. Watch the pupils while he accommodates for the finger (*reaction to accommodation*).

When the reaction to light is feeble and the pupils are already small, it is difficult to be certain of the results in bright diffuse daylight, the corneal reflexes adding to the difficulty. In such cases the patient should be taken into the dark room and the light concentrated upon one pupil by focal illumination. By a slight lateral movement of the convex lens (*vide p. 101*) the focus of light can be moved on or off the pupil, the pupillary movements being watched the while. If there is no movement under these conditions we may conclude that the reaction to light is absent.

It is better not to use the ophthalmoscope mirror in this procedure, as the patient is very likely to look at it, and a reaction to accommodation may be mistaken for one to light. Note very carefully if the constriction of the pupil to light is well maintained (*vide p. 407*).

The same method will elicit the *hemianopic pupil reaction* (Wernicke) in the rare cases (lesion of one optic tract) in which it is present. To test for it, the light is placed in front, but rather to one side of the patient. The light is focused with the lens upon the opposite side of the retina, and the pupil watched. The light is then moved to the other side and is now focused on the other side of the retina. If the reaction is present the pupil will react briskly when one half of the retina is illuminated, but very slightly or not at all when the other half is illuminated. It usually reacts slightly even in the latter case, owing to the impossibility of preventing diffusion of

light on to the sensitive half of the retina, and for this reason the test is rarely unequivocal.

When the pupils are small to start with (spinal miosis), do not react to light, but react to accommodation, the condition is known as the Argyll Robertson pupil. It occurs especially in para-syphilitic disease, most commonly and in its most characteristic form in tabes, and frequently in general paralysis of the insane; but it is also found in other syphilitic diseases of the central nervous system.

If the above directions are carried out we shall have reliable information as to the shape and relative size of the pupils and their reactions. A few of the commoner conditions may be enumerated here.

Very large pupils will suggest that a mydriatic has been used. It is not uncommon for it to have been used inadvertently. We not infrequently see a patient with the right pupil widely dilated complaining of dimness of vision. Inquiry will often elicit the fact that he has been using a liniment for rheumatism. The explanation is that the liniment contained belladonna, and that after using it with his right hand he rubbed his right eye with the soiled fingers. Often patients use ointment or drops prescribed for other patients. We must always be on our guard against such traps. These pupils are usually quite immobile, and the patient complains of dimness of vision, especially in near work.

The pupil is also large and immobile in complete atrophy of the optic nerve: this may be due to absolute glaucoma. In acute glaucoma it is usually large, immobile, and oval with the long axis vertical; the condition is generally unilateral. If only one eye is blind from disease of the optic nerve this pupil is rather larger than its fellow as a rule, but the consensual reaction to light on the sound eye is much increased, granted of course that the third nerve is intact. Dilatation of the pupils with

retained mobility is found sometimes in myopia and in conditions of impaired nerve tone, *e.g.*, anemia; it is also found in cases of disseminated sclerosis with optic atrophy, which rarely if ever leads to complete loss of sight in this disease. Dilatation as a reflex to painful impressions has already been mentioned. Unilateral dilatation may result from irritation of the cervical sympathetic in the presence of glands in the neck, pneumonia, phthisis, chronic pleurisy, thoracic aneurism, &c., but it is rare from this cause: it may also be due to syringomyelia, acute anterior poliomyelitis and meningitis affecting the lower cervical and upper dorsal part of the spinal cord and to pressure on the sympathetic fibres leaving the cord in the lower cervical and upper dorsal ventral roots. Temporary dilatation of one pupil is not very uncommon. Unilateral dilatation with immobility may result from a blow on the eye (Chap. XXI.).

The pupils are small in babies and in old people. When the pupils are small, as under the influence of bright light, the relation to the centre of the cornea can be best seen: the centre of the pupil is usually a little to the nasal side of the centre of the cornea. Small pupils are rarely perfectly round. A small immobile pupil should make us suspect old iritis with posterior synechiæ, and should lead to investigation with a mydriatic—homatropin for diagnostic purposes—to see if the pupil dilates regularly. Bilateral small immobile pupils make us suspect disease of the central nervous system (*e.g.*, pontine hæmorrhage); further examination may show that the immobility is confined to reaction to light (*vide* p. 110). A small sluggish pupil, with muddiness of the iris, is associated with iritis, which may be primary or secondary to corneal trouble.

Very small immobile pupils suggest the use of drugs, either locally, *e.g.*, eserin, or through the general system, *e.g.*, morphia.

The chief causes of inequality of the pupils have already been mentioned incidentally. As indicative of central nervous disease it is found in general paralysis.

We must note carefully the nature of the contraction when the pupil reacts to light, and especially if the constriction is well maintained (*vide* p. 407).

The Lens.—The lens cannot be thoroughly examined without the assistance of the ophthalmoscope. By inspection, aided if necessary by focal illumination, we note any opacities in the pupillary area. The pupil may be blocked with iritic exudates (inflammatory pupillary membrane, blocked pupil).

Opacities in the lens itself are seen by oblique illumination as grey, white or yellowish patches. According to their distribution and nature we diagnose the various forms of cataract, but our observations must always be confirmed and controlled by ophthalmoscopic examination. The following example will show how easily one may be led astray. When the light is concentrated by focal illumination upon the pupil of a young person's eye the lens substance seems almost perfectly clear; at most we see a faint bluish haze. If we examine the lens of an old person in the same manner the haze is much more pronounced; the lens substance in fact looks slightly milky. We might conclude that the patient has cataract. Examination with the ophthalmoscope will, however, show a perfectly clear red reflex. The explanation is that the lens substance becomes more optically dense, *i.e.*, the refractive index increases, as the person grows older (*vide* p. 62). Now the higher the refractive index of a substance the greater will be the reflection from its surface. The milkiess which we see is due to rays of light which are reflected from the lens and enter our eyes. The more rays reflected the more will the lens appear milky.

If, however, the white appearance is very pronounced,

and especially if it is strictly localised to certain parts of the lens substance, we may safely diagnose cataract. A spot in the centre of the pupil, looking as if it were on the surface of the lens, may be a pupillary exudate or an anterior polar cataract. Triangular spokes of opacity with their apices towards the centre are indicative of senile cataract. A very white appearance over the whole pupillary area suggests a total cataract; if it is yellow and the iris is tremulous we suspect a shrunken calcareous lens.

The Tension.—Last in the external examination, but by no means of least importance, we test the tension of the eye. It is done in the same manner as testing for fluctuation in other parts of the body.

Stand facing the patient, who is told to keep looking towards his feet. Place the index fingers of both hands side by side upon the upper lid, steadying them by the other fingers lightly applied to the brow. Keep one finger quite still, pressing upon the globe through the lid. Now attempt gently to indent the globe with the other finger, pressing directly downwards, concentrating the attention meanwhile on the impression which is conveyed to the stationary finger. Repeat the process on the other eye.

The student should practise this manœuvre on a number of healthy eyes. He will thus obtain a mental estimate of what is to be considered normal tension— T_n . In absolute glaucoma the eye is usually stony hard: this condition is generally indicated by the convention $T + 3$, a misuse of numbers, but one in common use. The gradations of increased tension from T_n to $T + 3$ are usually indicated by the conventions T full ($T +$), $T + 1$, $T + 2$. Similarly the gradations of diminished tension are represented by T minus ($T -$), $T - 1$, $T - 2$, $T - 3$.

CHAPTER VII.

OPHTHALMOSCOPIC EXAMINATION.

The internal parts of the eye beyond the lens cannot be seen without the assistance of the ophthalmoscope. A little consideration of the optical conditions of the eye will show the reason.

Under ordinary circumstances the pupil looks black, and no red reflex, much less a clear image, is obtained from



FIG. 70.

the fundus. If, as in Fig. 70, there is a source of light, *L*, in front of the eye, and the eye is focused upon it or accommodated for it, the light and a spot upon the retina are conjugate foci: *i.e.*, the image of the spot of light is a spot on the retina. Reversing the direction of the rays, all rays from the illuminated spot of the retina are brought to a focus at the source of light. Therefore no rays will enter an observing eye unless it is situated actually at the source of light. The problem solved by von Helmholtz when he discovered the ophthalmoscope (1851) was practically that of making the observing eye at the same time the source of illumination of the observed fundus.

If the eye is not focused for the source of light the conditions are different, and some slight luminosity of the pupil may be seen. This is one cause of luminosity

in the pupils of the hypermetropic eyes of young children and most carnivora. Extreme hypermetropia is also the cause of the so-called anaurotic cat's eye, which is due to detachment of the retina, glioma of the retina, &c. In these cases the retina is pushed forwards and the fundus at this spot becomes highly hypermetropic, the reflex from the pupil being often the first symptom noticed. The same principle applies to the reflex from the eye after the lens has been removed by extraction of cataract.

In hypermetropia the conjugate focus of the source of light, L , is a point, l , behind the retina (Fig. 71). Hence

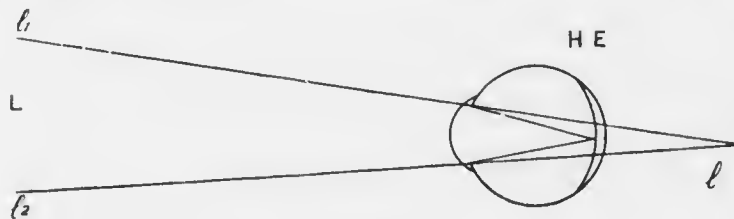


FIG. 71.

the emergent rays from the illuminated area of the fundus are divergent, as if coming from l . Therefore an observing eye situated anywhere within the area $l_1 l_2$ of the cone of emergent rays will catch some of them, and the pupil of the observed eye will appear feebly illuminated. Under these circumstances it is not necessary for the observing eye to occupy the exact position of the source of light, but only a spot in its immediate neighbourhood. On the same principle, the extremely hypermetropic retina in glioma retinae, &c., can be seen well by focal illumination.

In high myopia the emergent rays are strongly convergent, and become divergent after coming to a focus at the remote point (Fig. 34). Beyond this point

some of the divergent rays may enter an observing eye suitably situated and the observed pupil appears illuminated.

The luminosity of albinos' eyes is due to light entering the eye, not only through the pupil, but also through the iris and sclerotic. That this is the true explanation is shown by the fact the pupil looks black if it is observed through a small hole in an opaque screen. A small

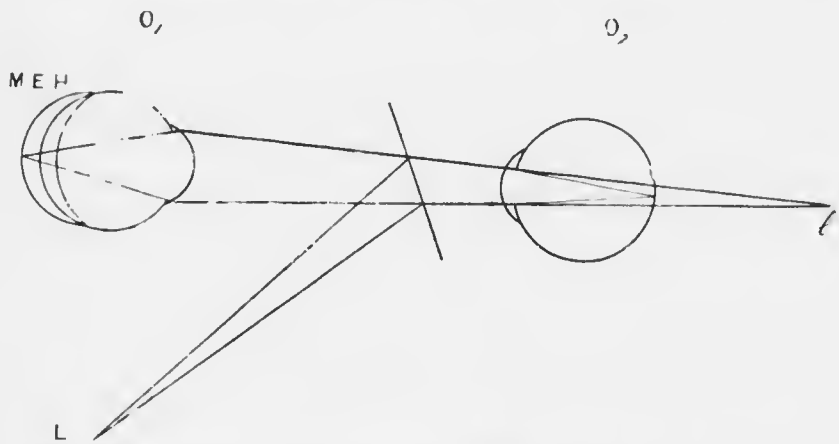


FIG. 72.—Diagram of von Helmholtz' ophthalmoscope. O_1 , observed eye; O_2 , observer's eye; L , source of light; I , image of L formed by the plane mirror—immediate source of light; $M E H$, relative positions of retina in myopia, emmetropia, and hypermetropia respectively, showing the relative sizes of the areas of retina illuminated in each case.

amount of light passes through the sclerotic in the normal eye.

It will help us to understand the principles of the ophthalmoscope if we say a few words about its historical development. The original ophthalmoscope of von Helmholtz was merely a plane plate of glass (Fig. 72). A source of light was placed beside the observed eye and the glass plate obliquely in front of it, so that a portion of the light was reflected from the surface of the

plate into the eye. On looking through the transparent plate an observer could now receive some of the rays from the fundus into his own eye, and thus obtain an image of the illuminated fundus. Since but a small proportion of the light received upon the plate is reflected at its surface the illumination is feeble. Nevertheless, the principle is worth bearing in mind as a ready means of getting a view of a fundus in the absence of a more satisfactory ophthalmoscope. Moreover, an error of refraction in the observed eye may be obviated by using the corresponding spectacle glass of the patient as the ophthalmoscopic mirror.

Von Helmholtz next increased the amount of light reflected by superposing three plane plates. The back of the glass was next converted into a more powerful mirror by silvering it, leaving a small portion unsilvered or leaving a hole in the mirror, through which the observer might look. The illumination was still feeble, since the rays reflected by a plane mirror are divergent (*vide* p. 27). Ruete therefore (1852) introduced the perforated concave mirror which still holds the field. The final modification was the addition of a battery of small lenses of various strengths, which might be brought into position behind the aperture. The multitudinous forms of "refraction ophthalmoscopes" are merely various mechanical contrivances for doing this most conveniently.*

There are two chief methods of ophthalmoscopic examination, the direct method (*v.* Helmholtz, 1851) and the indirect method (Ruete, 1852). The ophthalmoscope

The student is advised to procure a good ophthalmoscope at the outset of his clinical work in the medical wards. The cheaper forms are not only waste of money, but are a perpetual source of annoyance. The modification of Couper's ophthalmoscope, generally known as Morton's, is most strongly recommended.

is provided with two mirrors, one a small one, slightly tilted, for the direct method, the other a large one, not tilted, for the indirect method. Both are concave, the former with a focal distance of 30 cm., the latter of 10 cm. It is an advantage to have also two plane mirrors corresponding with these; with such a four-mirror ophthalmoscope the surgeon is fully equipped for every detail of ophthalmoscopy and retinoscopy.

The importance of system in his methods is so often impressed upon the student that he is liable to underrate it through sheer reiteration. It will perhaps suffice to say here that in using the ophthalmoscope he will inevitably come to grief unless he pursues his examination on a well ordered plan. The order of examination should be as follows:

- (1) Preliminary examination with the mirror alone at a distance of about 1 metre from the patient;
- (2) Examination with the mirror alone at a distance of about 20 cm. (reading distance) from the patient; this is sometimes called the distant direct method;
- (3) Examination by the indirect method;
- (4) Examination by the direct method.

The following facts will impress upon the student the reasonableness of this procedure. By (1) we obtain knowledge of the nature of the refraction of the eye under examination; this will prevent many little difficulties when we come to closer quarters. By (2) we see any gross changes, especially opacities in the refractive media; these may be made at once evident by this method, whereas they may be very puzzling if first observed by (3) or (4). In addition, we shall see the details of any very hypermetropic part of the fundus, such as a detached retina or glioma of the retina; these also are by no means difficult to miss by (3) and (4). By (3) we get a general view of the fundus—the largest

possible area under moderate magnification; it is exactly comparable to microscopic examination with a low power. By (4) we examine details under a higher magnification; it is exactly comparable to microscopic examination with a high power.

The student should commence by taking a patient whose pupils have been dilated with atropin, *e.g.*, a boy of twelve or fourteen who has come for the correction of his refraction. The atropin will have had the additional advantage of having paralysed the patient's accommodation. The observer should know his own refraction.

The patient is taken into the dark room and seated beside the light. The light is placed to the side which is to be examined, but well behind the level of the patient's face; the eye should be as much as possible in darkness. The observer sits facing the patient, about a metre from him. He reflects the light from the large ophthalmoscope mirror into the eye, meanwhile looking through the sight-hole. This requires a little practice, but is quickly mastered. When the light falls on the eye he notices a red reflex from the pupil. There ought to be no black spots in the pupillary area, but either a uniform red reflex or obscure details of the fundus.

The observer now stands up and approaches the patient until his eye, still with the large mirror, is about 9 inches from the eye under observation. He can now see the cornea and iris clearly, and can confirm any points which he has made out previously by the external examination.

He then sits down again at about a metre from the patient. Still keeping the light upon the eye with the large mirror, with his left hand he holds the large convex lens, which he will find in the ophthalmoscope case, close

in front of the eye. He will be wise not to hold the lens absolutely vertical, but to tilt it a very little. He will probably see only the magnified iris through the lens. He now watches the red reflex from the pupil, and slowly withdraws the lens from the eye towards himself. At a certain point he will see an inverted image of the fundus quite clearly. The indirect method requires also some practice, but the amount required may be much diminished and much greater accuracy attained if the optical conditions under which the examination is made are thoroughly understood. These will be explained immediately.

Having obtained a good general view of the fundus, the observer again approaches the patient. He now uses the small tilted mirror of the ophthalmoscope. The mirror is tilted so that it faces towards the light. Looking through the sight-hole he first gets the light upon the eye; this is best effected from a short distance away. When the light is well on the pupil and the observer can see the red reflex he approaches slowly nearer and nearer, watching that the light does not leave the pupil, until his brow is almost or quite touching the patient's brow. If now both the patient and the observer are emmetropic, the inexperienced observer will probably see the details of the fundus only indistinctly. He should then turn up with his index finger applied to the milled disc on the back of the ophthalmoscope successively stronger concave glasses (usually marked with white numerals). He will then probably see the fundus quite clearly. The image is erect, *i.e.*, the opposite of that by the indirect method. Here again practice is needed, and a knowledge of the optical conditions is quite essential.

We will now consider the chief features which are to be learnt in each stage of the examination, and how they are to be learnt.

1. Preliminary Examination with the Mirror at 1 metre.—We will suppose that the observer is emmetropic, or that his refraction has been corrected, and that the accommodation of the observed eye is at rest or paralysed. In examining the right eye the patient is told to look at the observer's right little finger which is held up: this is easily done whilst holding the ophthalmoscope. In examining the left eye the patient is told to look at the observer's left ear. In this manner the optic disc, which lies a little to the nasal side of the posterior pole of the eye, is brought into the observer's line of vision. When the optic disc is opposite the pupil we shall notice from a distance of 1 metre that the red reflex becomes much paler or even whitish.

If the eye is highly hypermetropic or myopic we shall see some details of the fundus, *e.g.*, a few vessels running across the reflex. The explanation is easy from what we have already learnt.

Consider first the hypermetropic eye. If we think of two spots on the retina, say at opposite edges of the disc, the rays reflected from these points will form two bundles of divergent rays when they leave the eye, just as if they came from the corresponding virtual remote points behind the eye (Fig. 73). The greater the distance from the eye, the greater will be the area over which these divergent rays will spread, so that at 1 metre some of the peripheral rays of each pencil will enter the observer's eye. By a slight effort of accommodation the observer will be able to bring these divergent rays to a focus on his retina, so that he will obtain a clear image of each point, and necessarily also of the intervening region. It is exactly as if the eye were taken away and the two points were situated at the remote points. Hence the image will be erect.

If the observer now shifts a little to one side, the

observed eye remaining stationary, more rays will enter his eye from the neighbourhood of the opposite point, and less from the neighbourhood of the point on the same side as that to which his movement is directed. Although the points remain stationary, more of the fundus on the opposite side and less of the fundus on the same side will be seen. Hence the points will seem to move in the same direction as his own movement. The observer mentally regards the very sharp outline of the pupil as a fixed object of comparison, and as more of the fundus on the opposite side comes into view, whilst a




FIG. 73. Examination with the mirror at 1 metre. O_1 , observed eye, which is hypermetropic; O_2 , observer's eye, emmetropic, but accommodated for the divergent rays from O_1 .

corresponding amount on the same side disappears, this is mentally interpreted as a movement of the image in the same direction.

If, therefore, when the light is reflected into the eye at a metre distance we see vessels in the pupillary reflex, and if they appear to move in the same direction when the head is moved slightly to one side, we conclude that the eye is hypermetropic.

Consider now the myopic eye (Fig. 74). Here the emitted rays from the two points will be strongly convergent in each case, and a real inverted image of the points and intervening area will be formed at the remote

point of the eye, *i.e.*, between the observer and the observed eye. The rays will diverge from this image, and the effect will be exactly the same as if there were an actual inverted object in this position. If the myopia is sufficiently high, the image will be beyond the observer's near point, so that he will be able to accommodate for it. If he moves to one side he will see more of the observed fundus on the same side and correspondingly less on the

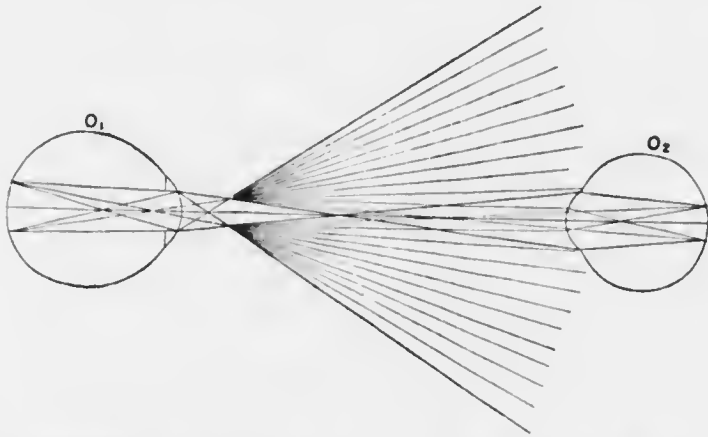


FIG. 74. Examination with the mirror at 1 metre. O_1 , observed eye, which is highly myopic; O_2 , observer's eye, emmetropic, but accommodated for the divergent rays from the far point of O_1 .

opposite side, so that the fundus will appear to have moved in the opposite direction.

If, therefore, when the light is reflected into the eye at a metre distance we see vessels in the pupillary reflex, and if they appear to move in the opposite direction when the head is moved slightly to one side, we conclude that the eye is myopic.

What will happen in emmetropia (Fig. 75) or low myopia, for the effect will be similar? Here the rays passing out of the eye from the two points will be parallel

or very slightly convergent, and their direction will be that of their axes, which is the continuation of the lines joining the points with the nodal point of the eye. As these axes constantly diverge from one another, the observer at a distance of 1 metre cannot receive portions of both pencils of rays upon his own pupil, consequently he cannot obtain a clear image of the whole intermediate region between the spots. He may get a clear image from two spots very close together, but only if his accommodation is almost completely suspended, so that nearly parallel rays are brought to a focus upon his retina.




FIG. 75. Examination with the mirror at 1 metre. O_1 , observed eye, which is emmetropic; O_2 , observer's eye: none of the rays from the widely distant points on the fundus of O_1 enter O_2 . If the points are close together the rays of the two bundles will be nearly parallel, and would form a clear image on the retina of O_2 if the accommodation of O_2 were almost completely in abeyance.

The same reasoning applies to low hypermetropia, for here the remote point of the eye is so far behind the retina that the rays diverge very little when they leave the eye, so that they are almost parallel.

If, therefore, when the light is reflected into the eye at a distance of a metre we see only a red reflex in the pupil, without any details, we conclude that the eye is either emmetropic or has only a low degree of ametropia.

A still simpler means of discovering the condition of the refraction is as follows. Still throwing the light into the eye with the large concave mirror we tilt it gently in various directions. We shall see a shadow move across the pupil; if the shadow is very dark there is considerable

error of refraction. If it moves in the opposite direction to that in which we move the (concave) mirror the eye is hypermetropic; if in the same direction it is myopic. This method is used for correcting refraction, and we shall consider it in detail later (*see* Retinoscopy).

II. Preliminary Examination with the Mirror at the convenient distance for near vision (22 cm.).—At this distance the observer will be most suitably situated for distinct unaided vision, and he will be able to examine the superficial parts of the eye more accurately. If he is presbyopic he will naturally have to correct his presbyopia, and he may have to do so if he is strongly hypermetropic. If he is very myopic he will have to approach closer.

The advantages of a preliminary examination in this manner are (1) the recognition of opacities in the refractive media; (2) the recognition of a detached retina or other substance not far behind the lens; (3) the confirmation of the results found by the external examination.

(1) *The diagnosis of opacities in the refractive media.*—If the eye is normal there will be a red reflex from the pupil. If there is any opaque body in the course of the rays reflected from the fundus it will stop these rays and will therefore appear black. The whole field may be black, as when the lens is entirely opaque, or when the vitreous is filled with blood. In the latter case oblique illumination will show the red blood behind the transparent lens: the blood looks red in this case because of the light reflected from its surface.

Opacities vary in shape, size, and position. We are particularly concerned to discover their position, as this frequently gives the key to their nature.

The first point to determine is whether the opacity is movable. This is done by telling the patient to move his eye in different directions—towards the ceiling, towards

the floor, to the right, to the left—and then to look straight forward. A floating opacity will then continue to move after the eye is brought to rest. It must therefore be either in the aqueous or vitreous. In the former position it can be seen and diagnosed by other methods. If it is in the vitreous and is freely movable we also learn that the vitreous is fluid, which is not its normal consistency. If the opacity moves only with the eye it may be in the cornea, lens, or vitreous, which, under these circumstances, will have its usual viscous consistency.

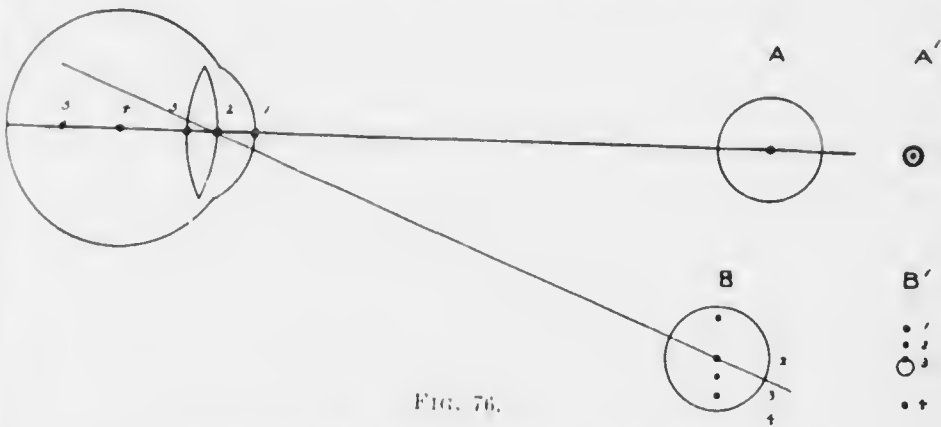
The next point is to determine its exact position. This is effected in the preliminary examination with the mirror alone by *parallaxic displacement*.

In Fig. 76, if 4 is the centre of rotation of the eye, and if there are opacities at 1, 2, 3, 4, 5, then, when the eye is rotated a small amount, the opacities, 1, 2 and 3, in front of the centre of rotation will move in the direction of rotation, and 5, behind the centre, will move in the opposite direction, whilst 4, at the centre, will not move. It is obvious that the amount of movement will be greater the farther the opacity is from the centre of rotation. Now, we have no means of defining the centre of rotation by ophthalmoscopic examination, but all the movements will be referred to the edge of the pupil for comparison (*vide* p. 122). If the observer is situated at A, all the opacities will appear as a single spot in the centre of the pupillary reflex. If he shifts his position to B, or if the eye is rotated a corresponding amount in the opposite direction, the opacity 2 will remain in the centre of the pupil, whilst 1 will move towards one edge of the pupil, and 3, 4 and 5 towards the opposite edge, 5 being lost entirely behind the iris.

Hence we deduce the rule that if the eye is moved slightly in a given direction, opacities in the pupillary

plane will appear stationary: those in front of that plane will move in the same direction, and those behind will appear to move in the opposite direction, the amplitude of apparent movement being a rough indication of their distance from the pupillary plane.

There is another guide which we may make use of, viz., the corneal reflex. This is the image of the mirror formed by the cornea. With the ordinary concave mirror it is a virtual image (*vide* p. 29) situated about 4 mm. behind the anterior surface, *i.e.*, a short distance behind the



anterior surface of the lens (behind 2 in Fig. 76). The centre of curvature of the cornea is situated 8 mm. behind its anterior surface, *i.e.*, less than 1 mm. behind 3 (Fig. 76). The corneal reflex will always cover this latter spot, the centre of curvature of the cornea, no matter what the position of the eye. Hence an opacity situated here will always be covered by the corneal reflex: opacities in front of the centre of curvature move in the same sense with regard to the reflex as the eye moves; and opacities behind it move in the opposite direction to the movement of the eye. Therefore, in Fig. 76, in the first position of the eye, the opacities 1, 2, 3, 4, 5, will all appear in the

centre of the corneal reflex (A'): in the second position they will appear as in B' : so that an opacity at the posterior pole of the lens will scarcely leave the edge of the reflex, whereas an anterior polar opacity will move much farther from it.

One peculiar apparent opacity is seen by the mirror alone, and this method affords the surest means of discovering the defect. This is the edge of a dislocated lens, or the notch in the edge of the lens in congenital coloboma of the lens. When the edge of the lens crosses the pupillary area it is seen as an intensely black crescent, sharply defined peripherally but merging centrally into the clear red reflex. The reason of this appearance is that the whole of the light which falls upon the extreme edge of the lens is totally reflected; none of it leaves the eye, so that none can enter the observer's eye.

We not infrequently meet with very fine opacities, especially in the vitreous. If we use a concave mirror and a bright light we shall probably fail to see them, the reason being that these very delicate opacities are partially transparent, so that if the light is very bright some passes through them and contrast is reduced. Contrast is further reduced by reflection of light from their surfaces. They are, as it were, drowned in light. In order that we may be sure of not missing fine opacities the best method to adopt is to use a plane mirror. The rays reflected from a plane mirror are divergent (*vide* p. 27): hence less light enters the eye. If we have no plane mirror available the light should be reduced, but this is not so satisfactory. We may increase our chances of seeing the specks if we place a convex lens behind the mirror, which will have the effect of magnifying them (Fig. 21).

(2) *The recognition of detached retina, &c.*—A detached retina is situated much in front of its normal position:

it is therefore in the position of the fundus of a very hypermetropic eye. When light is thrown in from a mirror at reading distance light will probably be reflected from the surface in such a way that some rays will enter the observer's eye. A difference of reflex in different directions is noticed, red in some, grey or black in others. More minute investigation will reveal a whitish or greyish uneven surface upon which there are almost black wavy lines; these are the retinal vessels. Particular stress is laid upon this point, because the appearances of a detached retina by the indirect and direct methods may be very puzzling to the beginner. If the precaution is always taken of using the mirror alone first little difficulty is likely to arise.

Besides a detached retina we shall also be able to see anything else in a similar position, *e.g.*, a tumour pushing the retina forwards, or a tumour of the retina itself (glioma), and so on.

None of these will be seen unless they are pushed forwards very considerably; hence we must not asseverate the absence of a detached retina, &c., if we fail to see it by this method.

(3) *Confirmation of the results found by the external examination.*—We are able by this method not only to confirm the results previously arrived at by external examination, but also to supplement them by important subsidiary information. Thus we are able to map out the limits of opacities in the lens much more accurately, since they now appear black on a red background, and as has already been shown we can determine their exact position with much greater precision.

We may have noticed a black spot in the iris in a case with the history of a foreign body having gone into the eye. It is probable that the foreign body has passed

through the iris, and that the black spot is a hole. The examination with the mirror often at once settles the question, for if there is a hole we shall be able to find some position in which a red reflex can be seen through the hole. The absence of a red reflex does not prove the absence of a hole, for the lens may be opaque behind the hole.

The following is a somewhat similar example. We have noticed a black patch at the ciliary margin of the iris, convex in outline towards the pupillary margin. It may be a melanotic sarcoma of the ciliary body growing forwards and implicating the iris: or it may be a separation of the iris from its ciliary attachment (iridodialysis). In the latter case it will be possible to obtain a reflex through it by the mirror, whereas in the former it will be opaque.

We have said that by this method opacities in the refractive media appear black. Superficial opacities, however, such as those in the cornea and near the anterior surface of the lens, can be seen in their natural colours by approaching still nearer to the eye. Under these conditions more light is reflected from the surface of the opacities and some of it enters the observer's eye. It will be objected rightly that now we shall be within our near distance and consequently shall not be able to see anything clearly. This is true, but it can be obviated by assisting our accommodation by putting up gradually stronger convex glasses behind the ophthalmoscope mirror as we approach the eye. This has the additional advantage of magnifying the opacity. If we approach very close to the eye and place a + 20 D lens behind the mirror we shall see the opacities highly magnified. This glass will be acting very much like an ordinary magnifying glass, so we shall have to focus it in much the same manner. We therefore start a little distance from

the cornea and watch carefully as we get nearer and nearer: there will come a point when the opacity is very clearly defined.

Suppose now that under the same circumstances, with the $+20$ D lens in the position for seeing the cornea, we wish to examine an opacity near the surface of the lens it can be done in two ways. We may continue to approach still nearer until it comes into focus; or we can use a weaker lens, retaining our original position.

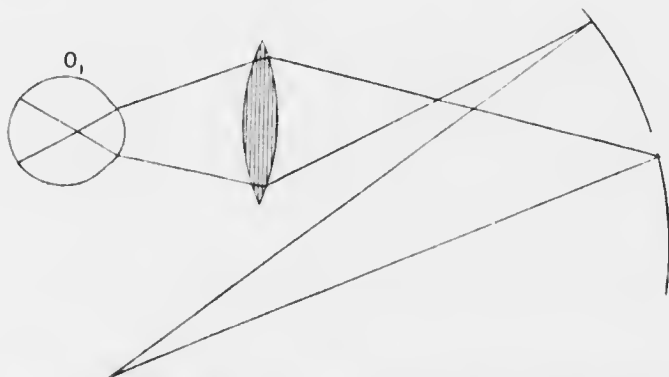


FIG. 77.—Indirect method. Illumination of the fundus, showing the course of rays from the source of light to the mirror, through the lens, and through the eye: also the area of the field of illumination.

The weaker lens is most easily produced by moving up stronger and stronger concave lenses in front of the $+20$, until the opacity is accurately focused. This is made possible in most ophthalmoscopes by having a $+20$ D lens set in a disc which lies behind the sight-hole: the lens can be turned into position when required, and does not interfere with the use of the other lenses at the same time. The opacity in the lens will of course not be quite so highly magnified by the second as by the first method.

III. **The Indirect Method.**—The indirect method of examination with the ophthalmoscope consists essentially in making the eye, whatever be its refraction, highly myopic by placing a strong convex lens in front of it (Figs. 77—79). The effect of this will be to form a real inverted image of the fundus between the observer and the convex lens, as will be easily understood from the accompanying diagrams. If the eye is already myopic the convergent rays which come from any point on its

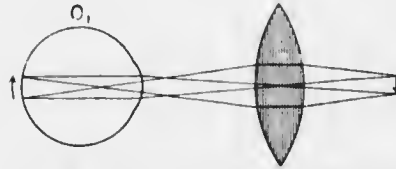


FIG. 78. Indirect method. Emergent rays from the fundus, showing the formation of the image. In the figure the lens is situated at the anterior focal plane of the eye; the rays which are parallel inside the eye, therefore, pass through the optical centre of the lens. The rays which pass through the nodal point of the eye are rendered convergent by the lens. The points where these two systems of rays cross gives the position of the image, which is seen to be inverted.

fundus will be made still more convergent by the lens, and the inverted image which is always formed in myopia will be brought close to the lens.

If the eye is emmetropic the parallel rays emitted will be made strongly convergent, and where they cross the inverted image will be formed.

If the eye is hypermetropic the rays will still be made convergent, for the lens used is so

strong that the divergence in hypermetropia is never strong enough to prevent it.

It will be seen that with the same lens the inverted image is formed at different distances beyond it according to the refraction of the eye. If the lens is kept at a constant distance from the eye, *e.g.*, its own focal distance, the emmetropic image will be formed at the focal distance of the lens beyond it: the myopic will be nearer to the lens, the hypermetropic further from it (Fig. 79).

In all cases the image is magnified, the amount of

magnification depending upon the retraction of the eye, the strength of the lens, and its distance from the eye. With a + 13 D the fundus of an emmetropic eye is magnified about five times.

One of the greatest difficulties in using the indirect method is the group of reflexes formed by the eye and the surfaces of the lens. We have seen that the cornea forms a reflex of the mirror when it is used alone. This reflex, when seen through the convex lens, is magnified, so that it may cover the pupil and prevent anything

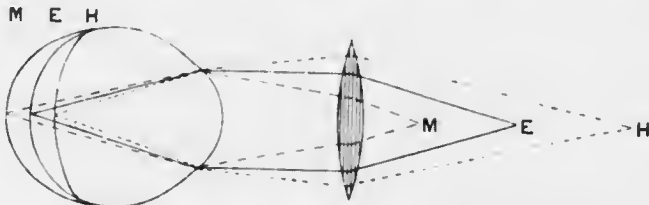


FIG. 79.—Indirect method. Position of the image according to the refraction of the eye. In this figure the lens is situated at its own focal distance from the cornea. In emmetropia the parallel emergent rays, therefore, cross at the principal focus of the lens, E. In myopia the convergent emergent rays cross nearer to the lens than its principal focus, viz., at M; in hypermetropia the divergent emergent rays cross farther from the lens than its principal focus, viz., at H.

behind being seen. But the surface of the lens towards the observer acts like another convex mirror, and forms another reflex situated behind the lens. Similarly the surface of the lens near the patient acts like a concave mirror and forms a reflex on the observer's side of the lens. These reflexes are very troublesome, but they may be got out of the way by a little manoeuvring. It has been said that the two lens reflexes, which are the most troublesome, are images of the mirror formed on opposite sides of the lens. If we tilt the lens a little it will be found that these reflexes move in opposite directions, and we can look quite comfortably between

them. We must be careful not to tilt the lens more than is necessary, because if we look obliquely through a tilted lens objects appear distorted: in fact we produce one type of astigmatism. The distorted image of the disc produced in this manner may be attributed to astigmatism in the eye, when none is really present.

Another difficulty which the beginner usually experiences is due to him getting too close to the patient. If he understands the position of the image which he is looking for, as described above, he will discover why he can see no sharp image when he is too close to the patient. Most people using the indirect method think that they are looking at the pupil. As a matter of fact, when the fundus is seen clearly, they are not accommodating for the pupil, but for the real image of the fundus, which is in the air somewhere between the lens and the observer. Now we can only see an object clearly with the unaided eye if it is at a convenient distance away. Consequently, if the observer gets so close to the patient that he is less than the distance of his near point from the aerial image he cannot see it clearly.

If we like to do so we can get over this difficulty and still remain closer to the patient. In order to do so, the observer must help his accommodation by putting up a convex lens in front of his eye. If we put up a +1 D or +2 D behind the ophthalmoscope mirror, we shall not only see the image clearly at a shorter range, but we shall also magnify it, an additional advantage.

As regards the position of the convex lens before the patient's eye, there is a considerable range over which we can see the fundus quite well, but some positions are better than others. In practice we find the best position by putting the lens close to the eye to start with, steadying it by the little finger applied to the patient's

brow, and gradually bringing it farther away from the eye until the best position is obtained.

Theoretically, from the point of view of the maximum field of fundus seen, the best place for the lens is its own focal distance from the patient's pupil. But this is the very worst place from the point of view of the corneal reflex. The latter is situated at about the level of the iris (4 mm. behind the cornea, *vide* p. 127). If the convex lens is at its focal distance from it, the rays from this image will be made parallel by the lens, *i.e.*, the reflex will fill the whole area of the lens, and we shall see nothing else. Hence the best position for practical purposes is either nearer to or farther from the eye than this position. We shall see later that a convenient distance is when the lens is at its focal distance from the anterior focus of the eye. Here, slight tilting of the lens, besides shifting the lens reflexes out of the way, will also move the corneal reflex and the image of the fundus in opposite directions, and so get the corneal reflex out of the way.

We can tell by the indirect method whether the eye is emmetropic or ametropic by observing the effect of shifting the lens on the size of the image of the fundus. We use the disc as the best guide, getting it into the field by telling the patient to look in the appropriate direction, *i.e.*, towards the raised right little finger when examining the right eye, towards the left ear when examining the left.

Place the lens close to the eye and gradually bring it farther away. If the image of the disc does not alter in size the eye is emmetropic; if it gets smaller the eye is hypermetropic; if it gets larger the eye is myopic.

If we understand why this is so, we shall be able to remember what happens in each case. Imagine two points, *a* and *b*, upon the fundus, *e.g.*, upon opposite edges of the disc (Fig. 86). If they

are illuminated, one of the many divergent rays emitted by each must be parallel to the axis. These two rays, when they pass out of the eye, will cross at the anterior focus of the eye, whatever its refraction may be, as long as the error is one of undue length or shortness (*axial ametropia*). They will cross at the anterior focus because they are parallel to each other before refraction. Now, suppose that the convex lens used in the indirect method is situated at its focal distance from the anterior focus of the eye. These two rays, after they have crossed, will meet the convex lens, and since they come from the focus of the lens they will be parallel to each other after refraction. As we have already seen (p. 133), under such circumstances the image of the fundus is formed in emmetropia at the focal distance of the convex lens (F') from it (E): in myopia the image will be nearer the lens (M), in hypermetropia farther away (H). The two rays which we have been considering

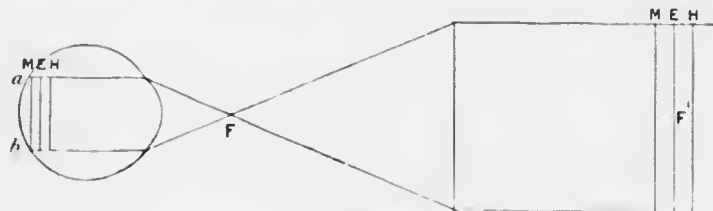


FIG. 80.

must represent the images of the two points on the fundus. Hence the distance between them after refraction by the eye and by the lens will give the size of the image of the portion of fundus between a and b . We see therefore that when the lens is at its own focal distance from the anterior focus of the eye the magnification of the image is the same in emmetropia, in axial myopia, and in axial hypermetropia.

If the lens is nearer the eye than the above distance (Fig. 81) the rays under consideration will diverge after refraction by the convex lens. Hence, if the lens is less than its own focal distance from the anterior focus of the eye, the magnification is greatest in axial hypermetropia, least in axial myopia, and intermediate in emmetropia. Conversely, if the lens is farther from the eye, the rays under consideration will be convergent after refraction by it. Hence, if the lens is more than its own focal distance from the anterior focus of the eye, the magnification will be greatest in axial myopia, least in axial hypermetropia, and intermediate in emmetropia.

In *curvature ametropia*, such as we meet with in astigmatism, the results are not quite the same, but they are easily deduced if we remember that there are now two anterior foci to the eye, one for each meridian. There are also two nodal points. When the lens is at its focal distance from the cornea the magnification is the same in emmetropia and any ametropia of curvature. Under these circumstances the disc appears circular. If the lens is nearer the eye the image is elliptical, with its long axis in the less refractive meridian, *i.e.*, generally horizontal. If the lens is farther from the eye the long axis is in the more refractive meridian, *i.e.*, generally vertical. As mentioned before, it is essential that the lens should be held almost vertical, as any inclination makes it itself astigmatic.

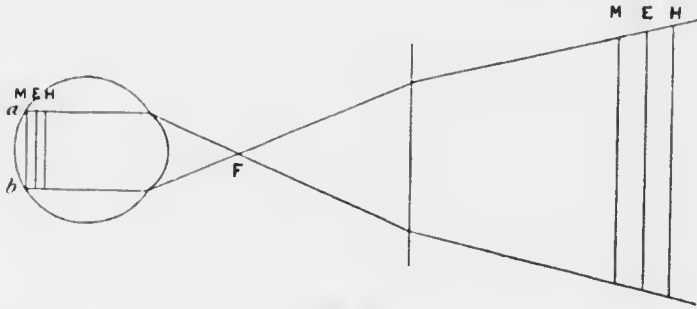


FIG. 81.

If the disc is really oval, as in high myopia, the axis of the ellipse will of course remain unaltered.

Ametropia of index of refraction occurs in old age. Aphakia, the condition when the lens has been removed, may be considered an extreme form of index ametropia. Here the position of the nodal point remains invariable, and if the convex lens is at its focal distance from this point the image is the same size in emmetropia and ametropia of index of refraction. If the lens is moved closer to the eye the image increases in hypermetropia and diminishes in myopia, whilst it remains the same in emmetropia. Since the image is formed at a considerable distance beyond the focus of the lens in the high hypermetropia of aphakia it is convenient to use a stronger lens, *e.g.*, +18 D.

Differences of level of two points near each other on the fundus are made very evident by parallactic displacement

in the indirect method. Thus, in Fig. 82, if there are two spots, *a* and *b*, at different levels in the fundus, *e.g.*, on the edge of the disc and at the bottom of a glaucoma cup, when the lens is shifted slightly so that its optical centre moves from o_1 to o_2 , the images of *a* and *b* will move from a_1 to a_2 , and b_1 to b_2 . It is of historical interest that this displacement was at one time wrongly interpreted, so that a glaucomatous cupping of the disc was diagnosed as a swelling.

IV. The Direct Method.—In the direct method the observer approaches as close as possible to the patient's

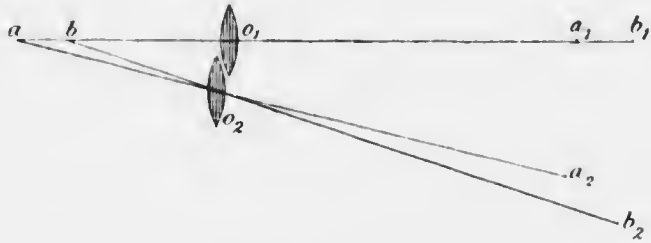


FIG. 82. Indirect method. Parallax displacement.

eye (Fig. 83). If the eye is hypermetropic the emergent rays will be divergent, as if coming from the virtual remote point behind the eye. Owing to the short distance between the eyes a large pencil will fall upon the observer's pupil, and may be brought to a focus upon his retina if he makes a suitable effort of accommodation. If he is presbyopic, or if his accommodation is relaxed, he will only obtain a clear image by placing a convex lens behind the sight-hole of the mirror (Fig. 84, H).

If the observed eye is emmetropic the emergent rays will be parallel, and consequently can only form a clear image upon the observer's retina if his accommodation is absolutely relaxed (Fig. 84, E)—unless, indeed, he

counteracts the amount of his accommodation by a corresponding concave lens in front of his eye (*vide* p. 140).

If the observed eye is myopic the emitted rays are convergent. If the myopia is moderate the real image of the fundus at the far point of the eye will be behind the observer's head, *i.e.*, he will catch the convergent rays before they have come to a focus. These convergent rays, entering his emmetropic eye, are brought to a focus in his vitreous; hence he cannot possibly obtain

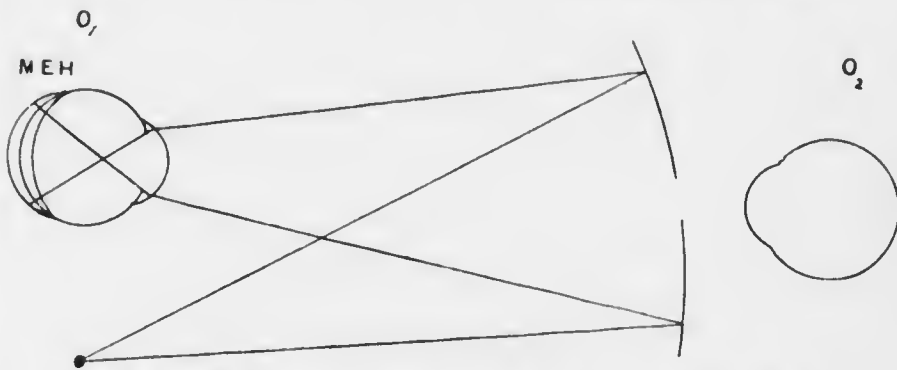


FIG. 83.—Direct method. Illumination of the fundus, showing the course of rays from the source of light to the mirror and through the eye; also the area of the field of illumination. Compare with Fig. 77.

a clear image unless he counteracts the convergence by an equivalent concave lens behind the mirror (Fig. 84, M). If the observed eye is very highly myopic its punctum remotum will be situated somewhere in the space between the eye itself and the observer's retina, and it may be in such a position that it is impossible to obtain a clear image with any correction. For example, the remote point may be just behind the sight-hole of the mirror. Here it is too close to be accommodated for, and no correcting glass situated at the same position will have any effect upon the rays, for they will nearly all pass through the

optical centre of the lens. The practical outcome of this discussion is to get as close to the eye as possible.

Much stress is generally laid upon the necessity and the difficulty of relaxing one's accommodation in examination by the direct method. It is difficult to relax the

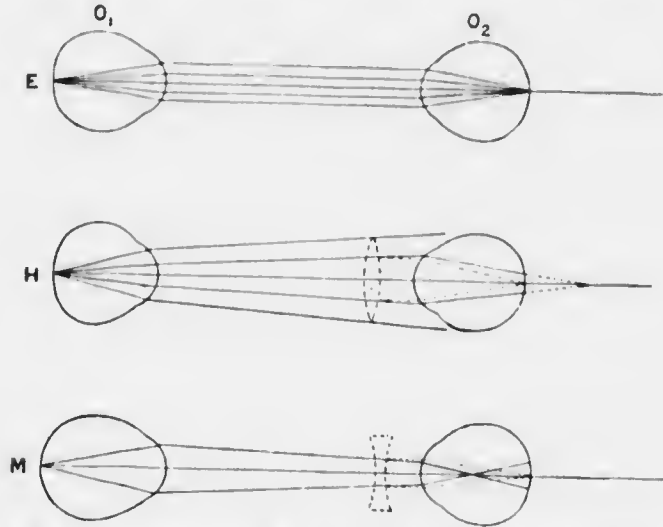


FIG. 81.—Direct method. Emergent rays from the fundus of the observed eye, O_1 , showing the formation of the retinal image on the retina of the observer's eye, O_2 . In emmetropia, E, the emergent parallel rays are brought to a focus on the retina of O_2 if the accommodation of this eye is absolutely at rest. In hypermetropia, H, the emergent divergent rays are brought to a focus on the retina of O_2 , either by means of accommodation or by placing a convex lens in front of O_2 . In myopia, M, the emergent convergent rays can only be brought to a focus on the retina of O_2 by placing a concave lens in front of O_2 .

accommodation entirely when the eye is apparently close to the object looked at. The observer should try to think that he is looking at a very distant object, but even then, as soon as he directs his attention to details of the picture, he is almost certain to accommodate. It is best for the beginner not to worry himself about this point: if he cannot see an emmetropic fundus clearly let him put up

minus lenses until he does. After he has acquired facility in seeing anything at all it will be soon enough for him to grapple with this difficulty.

The image by the direct method is always erect. Thus, in hypermetropia it is exactly as if the observer were looking at an actual object situated at the remote point of the eye, *i.e.*, some distance behind the eye. In myopia the converging rays are caught before they cross; they are made suitably less convergent by the correcting lens behind the mirror, so that again an erect image is seen. In emmetropia the emergent rays are parallel and are, therefore, also caught before they cross—at infinity; hence, again, an erect image is seen.

The image is always magnified, and it is magnified more than by the indirect method. In emmetropia the fundus is seen magnified about fifteen times. In hypermetropia it is magnified less, and in myopia more than in emmetropia.

The field of ophthalmoscopic vision by the direct method, *i.e.*, the area of the fundus which can be seen, varies with the distance of the observer from the eye and with the refraction of the eye. It increases as the eye is approached—another reason for getting as close to the eye as possible. It is greatest in hypermetropia, least in myopia, and intermediate in emmetropia. Thus, we see the largest area, least magnified, in hypermetropia, and we see the least area, most magnified, in myopia.

In astigmatism the magnification is greatest in the more myopic meridian, and least in the more hypermetropic. In the usual form of astigmatism the image of the disc is an ellipse with the long axis vertical—the opposite of the usual image by the indirect method, with the lens near the eye (*vide* p. 137). It is obvious that there can be no clear image of the whole field by the direct method in astigmatism. *Only lines perpendicular*

to the meridian which is corrected are seen clearly. Lines in any meridian other than the two principal ones cannot be seen clearly by any spherical correcting glass, but only by a cylindrical lens or combination of a spherical and a cylindrical.

From what has been said it is obvious that the correcting lens behind the sight-hole of the mirror also represents the spectacle glass which will be required to correct the refraction if it is placed in the same position. This, of course, is only true if the observer is emmetropic, or has his refraction corrected, and if his accommodation is quite at rest. Since it is difficult to relax the accommodation completely, this method of determining any error of refraction should only be used as a rough estimate, unless the observer is an expert. Some surgeons attain great skill in measuring the refraction by the direct method. They can even correct astigmatism. In this case they correct one meridian first, which gives the line, correcting the meridian at right angles to it; the process is then repeated in the other meridian.

If there is a difference in level between two points on the fundus, *e.g.*, the edge of the disc and the bottom of a glaucoma cup, it is made manifest by the direct method also by parallax displacement. If we focus the edge of the disc and then move slightly to one side the edge of the disc will appear to move over the bottom of the cup, *i.e.*, it moves in the opposite direction. An object farther forward, therefore, moves in the opposite direction to the movement of the observer's head.

The difference in level can be accurately measured. In the example given, the bottom of the disc will be relatively myopic to the edge, since it is farther away from the back of the lens. If the eye is emmetropic and the edge of the disc can be seen clearly without the assistance of any correcting lens we shall require a concave

lens to see the vessels at the bottom of the cup clearly. It can be proved that if the correcting lens is at the anterior focus of the eye a difference of 3 D is equivalent to 1 mm. difference of level. We must get as close as possible to the eye when measuring differences of level, because only then are the conditions of accuracy fulfilled. If, with the observer's accommodation at rest, he sees the edge of the disc clearly with no correcting lens, but requires - 3 D to see the bottom clearly, he knows that the bottom is 1 mm. behind the edge. He will of course see the bottom clearly with a higher concave lens if he counteracts the excess by accommodating: hence he must be careful to choose the lowest minus lens.

Similarly projections forwards can be measured. Here the observer chooses the highest convex lens with which he can see some well-defined point on the top of the eminence. The same rule that 3 D is equivalent to 1 mm. holds good. Suppose, for example, that he is measuring the swelling of the disc in a case of optic neuritis. He first finds the highest convex glass with which he can see clearly a retinal vessel a little distance away from the disc. He then finds the highest convex glass with which he can see a vessel or a small hæmorrhage as near the top of the swollen disc as he can judge. The difference between the two lenses will give the height of the swelling.

It will be seen that the difficulty of relaxing the accommodation enters into this estimation. The student need not, however, be dismayed. Very fairly accurate results can be obtained without relaxing the accommodation, for if he is accommodating the same amount when he measures the top of the swelling that he is when he measures the level of the surrounding fundus the difference between the two observations will be the same as if he was not accommodating at all. He can ensure this fairly well by always choosing the highest convex lens; it is safest

to choose the lens which just makes the object looked at appear a little blurred. Of course the eye may be myopic: if for "convex lens" in the above description "relatively convex lens" be substituted— -1 D being relatively convex to -4 D —the principle is the same.

An object in the vitreous, *e.g.*, a large opacity, is in the same condition as the fundus of a hypermetropic eye. If the eye is emmetropic, so that the fundus is visible without any correcting lens, the opacity can be examined either by accommodating for it or by putting up convex lenses until it is clearly focused. If it is close behind the lens accommodation will have to be assisted by a convex lens in any case, unless the observer withdraws further from the eye. It will be seen, therefore, that by putting up convex lenses from 0 to $+20\text{ D}$ we can thoroughly explore the emmetropic eye from the fundus to the surface of the cornea.

Examined in this manner the appearance of opacities in the vitreous or lens will vary with the amount of light stopped by them, *i.e.*, by their density, and with the amount of light reflected from their surfaces. If they are very dense they will appear black against the background of the red reflex. If they are semi-transparent they will appear red or whitish according to the relative amounts of light transmitted from the fundus and reflected from the surface. A detached retina may therefore look red or white, according to its degree of transparency. If much light is reflected from the surface details may be seen upon it; otherwise it appears uniformly black.

CHAPTER VIII.

THE FUNDUS OCULI.

WHEN the fundus is observed by the indirect method it is seen to be of a bright red colour. This is due chiefly to the blood circulating in the choroid. In people of dark complexion no choroidal blood vessels are seen on account of the retinal pigment epithelium, which, whilst dense enough to blur any details, is not sufficiently dense to prevent the colour of the blood manifesting itself.

The Optic Disc.—The first object to be sought is the optic disc or papilla (Plate III., Fig. 1). As already mentioned, it is done by making the patient look slightly towards the nasal side. The reflex then suddenly changes from bright red to white, and if the optical conditions are properly arranged in accordance with the directions given in the last chapter the disc will be clearly seen.

The disc is pale pink in colour, the tint showing considerable variations within the limits of normality. It is nearly circular, but seldom perfectly so; it is about 1.5 mm. in diameter, but of course is seen magnified. The oval appearance due to astigmatism must be borne in mind (*vide* p. 141). The edges are usually quite sharp, but sometimes a little irregular. Not uncommonly, especially in old people, there is a narrow white ring around the pink disc, *the scleral ring*; this is due to the choroid and the pigment epithelium of the retina not extending quite up to the margin of the disc so that the sclerotic is seen through the retina. Sometimes there is a ring of black pigment around the margin of the disc, due to the retinal

pigment epithelium being heaped up here. More commonly parts of the circumference have black patches, but they are not continuous. These features are of no importance from the pathological point of view.

The disc itself is seldom uniformly pink. The central part is usually paler and may be quite white, and this lighter area may extend nearly to the temporal edge of the disc; it rarely extends quite to the edge. The temporal side is therefore normally paler than the nasal. The central vessels emerge from the middle of this white area, and careful examination with the direct method will show that the area is a funnel-shaped depression, *the physiological cup*. This cup varies very much in different eyes. When it is very deep the central part may be seen to be speckled with grey spots: these are the meshes of the lamina cribrosa through which the nerve fibres are passing. Sometimes there is scarcely any physiological cup: the disc is then more uniformly pink, and the central vessels may have already divided before they come to the surface. The true nature of the physiological cup is best understood by comparing the ophthalmoscopic picture with a microscopic section vertically through the nerve head.

The colour of the disc is due to the white fibres of the lamina cribrosa seen through the vascularised nerve fibres. Where the nerve fibres are thinnest, *i.e.*, in the cup, the white lamina shines through brightest. The grey spots in the lamina, when they are seen are due to the non-medullated nerve fibres reflecting less light than the white connective tissue fibres.

The Retinal Vessels.—The retinal vessels are derived from the central artery and vein, which usually divide into two branches at or near the surface of the disc. These branches are above and below, and form a superior and an inferior trunk (Plate I.). Each trunk usually divides into



PLATE III. (To face p. 146.)

THE NORMAL FUNDUS.

- Fig. 1.—Appearance of a typical disc, macula, and vessels; slightly marked physiological cup, showing a typical lamina cribrosa.
- Fig. 2. A "reticulated" fundus showing appearances due to excessive choroidal pigmentation or defective pigment in the retina epithelium.



PLATE III. (To face p. 146.)

THE NORMAL FUNDUS.

- Fig. 1.—Appearance of a typical disc, macula, and vessels; slightly marked physiological cup, showing stippling of lamina cribrosa.
- Fig. 2.—A "tigroid" fundus, showing appearances due to excessive choroidal pigmentation or defective pigment in the retinal epithelium.

PLATE III

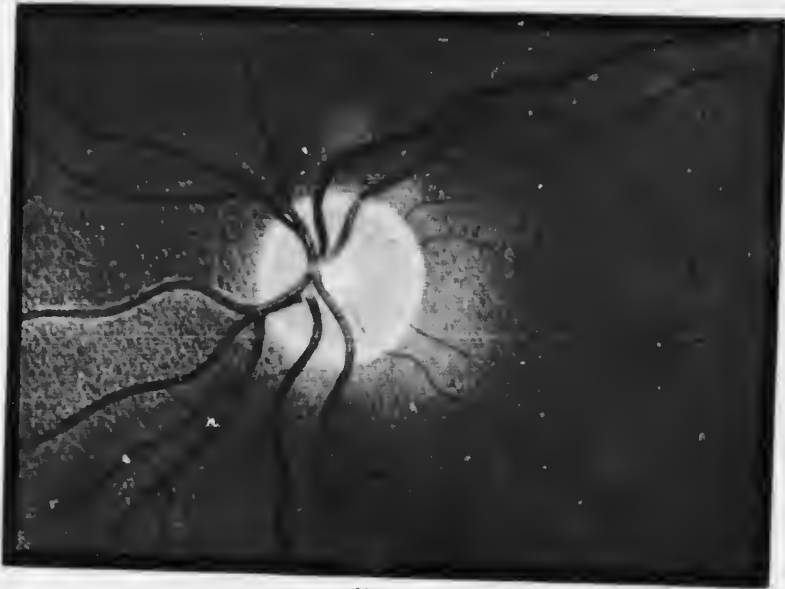


FIG. 1




FIG. 2.

two, one of which sweeps up or down towards the temporal side, the other sweeping up or down towards the nasal side. These branches are called the superior and inferior temporal and nasal arteries and veins. They divide dichotomously into innumerable branches.

The arteries are distinguished from the veins in being lighter red and narrower. The veins have a purplish tint and are often more convoluted; less frequently the arteries are tortuous. What is actually seen is the blood column, not the actual vessel wall, which is transparent. Each, but especially the arteries, may have a bright silvery streak running longitudinally down the centre, due to reflection of light from the convex cylindrical surface.

The mode of branching of the vessels is subject to great variation, though it is derived from the fundamental type described. The variations are generally of no practical importance. The primary division of the superior and inferior trunks usually takes place on or very near the disc. The nasal branches run much more radially than the temporal, which make a very decided sweep to avoid the macula.

The Macula lutea is situated about 3 mm. or 2 disc-diameters (2 p.d.) to the temporal side of the edge of the disc, and is a little below the level of the horizontal diameter. It is very difficult to see without a mydriatic, for the bright light on this most sensitive spot causes maximal constriction of the pupil: the corneal reflex then usually obliterates all view. It may generally be seen by using very dim illumination.

The macula varies in appearance according to illumination, refraction, complexion, &c. In general, it is a small circular area of a deeper red than the surrounding fundus, sometimes looking almost black. There is nearly always a *foveal reflex*, due to reflection of light from the walls of the foveal depression. This is most frequently seen as a

silvery ring of light, hiding everything behind it: it may be circular or oval, according to the incidence of the light and the refraction of the eye. Often there is an intensely bright spot at or close to the fovea, also due to reflection. The deeper red of the macula is due to the thinness of the retina, so that the specially vascular choriocapillaris of this region is seen more clearly: shadows thrown by the edges of the foveal depression may contribute a share to the deepening of the colour.

The macular region is supplied by twigs from the superior and inferior temporal arteries, and by small branches coming straight from the disc. There are no retinal blood vessels actually at the fovea (Fig. 5), and none can be seen ophthalmoscopically for a little distance around. Occasionally there are small arteries (cilio-retinal) derived from the ciliary system. They start near the edge of the disc, run inwards, and then bend sharply outwards towards the macula (Fig. 85).

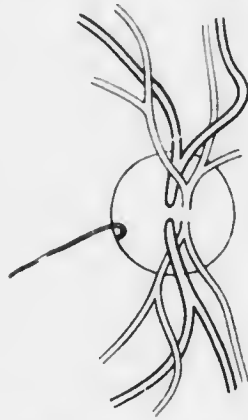


FIG. 85.—A cilio-retinal artery.

The General Fundus.—The appearance of the general fundus varies enormously within healthy limits. It is especially determined by the complexion of the patient, which may be taken as an index of pigmentation in different parts of the body. In people who are neither very dark nor very light the spaces between the retinal vessels show a uniform redness occasionally with a very delicate punctate stippling, especially towards the periphery. In albinos the choroidal vessels are seen clearly, the spaces between them being white, due to the sclerotic shining through. In very dark people the fundus is a

darker red, and indications of the choroidal vessels are often seen as indefinite brighter red streaks. Sometimes the pigment between the choroidal vessels is particularly dense, or the pigment is deficient in the retinal pigment epithelium, whilst the choroid is deeply pigmented: the choroidal vessels are then seen separated by deeply pigmented polygonal areas (*tigroid* or *tessellated fundus*) (Plate III., Fig. 2).

There is no difficulty in distinguishing the choroidal from the retinal vessels when both are visible (Cf. Plate X., Fig. 2). The former are broader and ribbon-like, without any central reflex streak: they anastomose freely, unlike the retinal vessels, which do not anastomose at all. Moreover in certain parts, their anatomical distribution is very characteristic (*vide* p. 14).

All the details of the fundus will be seen much better by the direct method, unless the eye is very myopic, when the magnification is so great and the area seen is so small that it is difficult to find any given spot.

Under normal conditions no pulsation can be seen in the retinal arteries. The retinal veins may, however, often be seen to pulsate at or near the edge of the disc, or indeed wherever they take a very sharp bend. This is usually due to transmitted pressure. The blood pressure is lowest in the veins near the disc, and there is a certain amount of obstruction to the flow of blood as the vessels pass through the narrow neck at the lamina cribrosa. With each arterial pulsation the intraocular pressure is suddenly raised slightly, so that the pressure on the outside of the walls of the veins is increased. This causes a sudden increased obstruction to the outflow of blood from the eye: the wall of the vein becomes slightly compressed, recovering itself during the arterial diastole. Hence pulsation is observed, and it will be seen best where the intravenous pressure is least, *viz.*, nearest the heart, *i.e.*,

at the disc, and where there is any additional obstruction, viz., near the lamina cribrosa and at any sharp bend. The venous pulsation can be increased or made manifest if absent by slight pressure on the globe, which has the effect of increasing the intraocular pressure. This normal venous pulse is seen without artificial aid from pressure on the globe in 70 to 80 per cent. of people. It will be noticed that it is diastolic: it has therefore been called the *negative venous pulse*.

Two other forms of venous pulse occur in pathological conditions.

The *positive venous pulse* is presystolic, continuing into the systolic phase: it is due to tricuspid regurgitation, and is permitted by the normal insufficiency or absence of valves in the jugular veins. The *transmitted centripetal venous pulse* is an accentuation of the normal tendency of the pulse wave to progress through the capillaries into the veins, owing to the intraocular tension. It is due to venous congestion, with or without increased vis a tergo.

Arterial pulsation is always pathological. The blood pressure in the ophthalmic artery is only a few mm. Hg. below that of the carotid in animals. Considering the differences of blood supply it would be unwise to apply the result directly to man, but there is no doubt that the pressure in the central artery is far above the intraocular pressure. It would not be surprising, therefore, if the pulse wave were transmitted and could be seen. There are two reasons which militate against this: (1) the intraocular pressure damps the pulsation, and the increase in pressure which accompanies each pulsation is spread over the whole volume of the contents of the globe, and is transmitted to the plastic sclerotic; (2) such pulsations as survive this damping effect are too slight to be observed in such small vessels by ordinary ophthalmoscopic examination.

Two types of arterial pulsation occur pathologically: (1) a true pulse wave, accompanied by locomotion of the vessels; (2) an intermittent flow of blood, or pressure pulse. In the latter the arteries fill only with the heart beats, being empty between them; it is only visible on the disc, and may be produced in a normal eye by external pressure upon the globe by a finger applied to the lid. This type of pulsation is a pure pressure phenomenon, and is caused by any considerable increase of intraocular tension with normal or lowered blood pressure, *e.g.*, in glaucoma, or by any considerable diminution of blood pressure with normal intraocular pressure, *e.g.*, in syncope, orbital tumours, &c. The true arterial pulse occurs in cases of aortic regurgitation or aneurysm, in exophthalmic goitre, &c.: it is not confined to the disc. It is equally a pressure phenomenon, but the differences of pressure are smaller.

Capillary pulsation is seen only in aortic regurgitation as a systolic reddening and diastolic paling of the disc.

The order of examination of the details of the fundus should be systematic. Applying the indirect method we obtain a general view. The patient is instructed to fix the gaze in such a direction that the disc is brought into view. It will occupy about the centre of the field, and a considerable area around will be visible. Any gross abnormality is detected at once. The shape and colour of the disc, the arrangement of the vessels, the colour of the choroidal reflex (its uniformity or tessellation), gross abnormalities (white or pigmented spots, &c.), are readily noted. The patient is then directed to look up to the ceiling, to the right, to the left, and down to the ground; in the latter position the lid is gently raised by a finger of the hand which is holding the large lens, as otherwise it will cover the pupillary area. In this manner the periphery of the fundus is brought into view. Even when the central parts of the fundus are uniformly tinted the periphery often displays traces of the choroidal vessels, associated with greater pigmentary stippling or a diminution of pigment. Only minute investigation with the direct method can show whether this is normal

or pathological. The characteristic type and distribution of the pigmentation of retinitis pigmentosa is best demonstrated in this manner.

Having thus obtained a good general idea the systematic examination is repeated by the direct method, paying special attention to points which the indirect method has left uncertain. The details of the disc—physiological or pathological cupping, blurring of the edges or swelling, abnormalities of the edges in the form of crescents and so on—are inspected. Attention is then turned to the vessels. Abnormalities in arrangement or distribution, the presence of cilio-retinal vessels, &c., are noted. The details of the individual vessels—their relative size, irregularity of contour or varicosity, visibility of the walls as shown by the presence of white lines along the edges, abnormalities of the reflex streak, &c.—are investigated. The vessels are traced towards the periphery and the smaller vessels inspected. Changes often occur near the vessels, such as small hæmorrhages, white spots of exudate, &c.; these are carefully looked for.

Next, the macula is examined: this should never be omitted. It may be brought into view by telling the patient to look into the light: with unintelligent patients it is best to say nothing, but fix the temporal edge of the disc and pass horizontally outwards for a distance of about two papilla diameters (a convenient unit in ophthalmoscopic topography), when the macula will be found. If the patient is not under a mydriatic or the pupil movements are not abolished by disease (optic atrophy, &c.) the light should be lowered so that the constriction of the pupil may be reduced to a minimum. The corneal reflex is always troublesome, but has to be dodged. Any abnormality at or near the macula is of the utmost importance. Black or white spots are often very difficult to distinguish from shadows or reflexes: if

either can be made out by any means (*e.g.*, the use of a concave lens) to have a definite sharp contour, and if they do not seem to shift in the slightest degree when a minute movement is made with the mirror, it may be concluded that they are pathological entities.

Finally, the periphery of the fundus is investigated. It is important to know how far out we can see by the direct method. It can be shown theoretically and proved practically that the fundus can usually be seen only a short distance beyond the equator of the eye. There is therefore a zone behind the ora serrata which is invisible. The periphery, even in an emmetropic eye, is usually best seen with a low convex lens, owing to the obliquity of the axis of the rays as they pass through the crystalline lens.

CHAPTER IX.

FUNCTIONAL EXAMINATION.

In the second great group (*vide* p. 91) of ophthalmic patients there are no manifest objective signs of disease and we are dependent at the outset upon the subjective symptoms of which the patient complains. In these cases, after a rapid, but careful, external examination to eliminate any objective sign which may have escaped observation it is usually most convenient to proceed at once to the functional or subjective examination. Whether this produces evidence of abnormality or not, it is imperative to proceed then to the systematic internal examination with the ophthalmoscope.

On the other hand, in the first group of ophthalmic patients, in spite of external signs of disease which may suffice to account for the symptoms, it is the surgeon's duty to eliminate as far as possible all other evidence of abnormality. Ophthalmoscopic examination may be impossible at the first visit, and subjective functional testing may be so vitiated by the obvious disease as to afford no useful information. In such cases functional and internal examination should be postponed until a future visit, but in no case should it be entirely omitted. It should be borne in mind that, rightly or wrongly, the surgeon is liable to be held responsible for the discovery of any disorder of the eye which manifests itself at or about the time of his examination.

The functional examination of the eye proper consists in testing the acuity of the forms of visual perception

which have been already mentioned: viz., the light sense, the colour sense, and the sense of form. They are usually tested in the reverse order. Each eye must be tested separately throughout. In the preliminary examination it is sufficient to test first the acuity of central vision for distant and for near points, then roughly the field of vision, and finally the reactions of the pupils, afterwards proceeding forthwith to the ophthalmoscopic examination. It may then be necessary to revise the rough test of the field of vision by taking it with greater precision, to supplement the tests with white light by those with coloured objects, both in the central and peripheral parts of the field, and to estimate, more or less accurately, the light minimum and the light difference. In the routine examination it is well to test roughly the condition of the extrinsic muscles

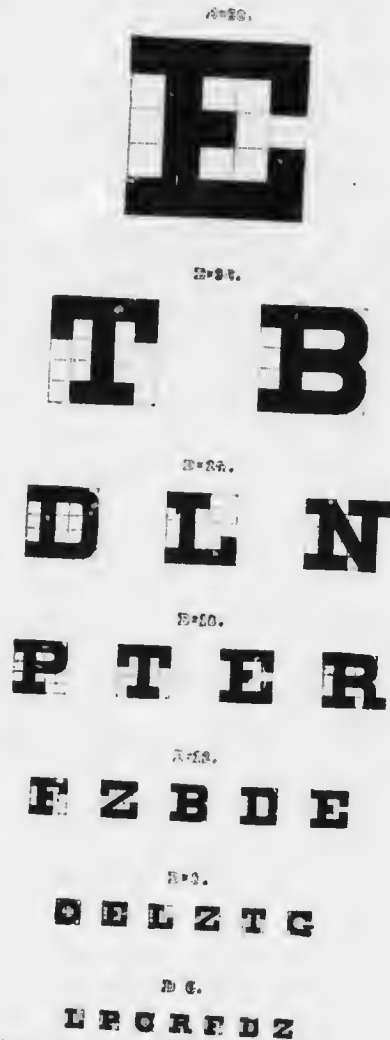


FIG. 86. — Snellen's Distant Test Types (reduced). The lines, from above downwards, should be read at 60 metres, 36 metres, 24 metres, 18 metres, 12 metres, 9 metres, and 6 metres respectively, i.e. at these distances the letters subtend a visual angle of 5'.

before proceeding to the ophthalmoscopic examination (Section V.).

The Acuity of Vision.—The acuity of distant central vision is now almost invariably tested by means of Snellen's Test Types (Fig. 86). These are constructed upon the fundamental principle that the average minimum visual angle is 1 minute.

The types consist of a series of letters diminishing in size. The breadth of the lines of which the letters are composed is such that the edges subtend an angle of 1 minute at the nodal point of the eye. Each letter is of such a shape that it can be placed in a square, the sides of which are five times the breadth of the constituent




FIG. 87.

lines (Fig. 86). Hence the whole letter will subtend an angle of 5 minutes at the nodal point of the eye (Fig. 87).

In order that these conditions may be fulfilled it is obvious that such a letter to be used as a test a long distance from the eye must be larger, and the constituent lines must be broader than in the case of a letter to be used near the eye. In Snellen's types the largest letter will subtend 5 minutes at the nodal point if it is 60 metres from the eye. Those in the second line will subtend 5 minutes if they are 36 metres from the eye; those of the consecutive lines 24 metres, 18 metres, 12 metres, 9 metres, and 6 metres. Sometimes smaller letters corresponding to 5 metres, 4 metres, 3.5 metres are used.

A person with average acuity of vision ought therefore to be able to read the top letter at 60 metres, the second line at 36 metres, the third at 24 metres, and so on. Now, it would be very inconvenient to have to alter the distance between the patient and the letters to this large extent. A numerical convention which gives a fair comparative estimate of the value of different acuities of vision has therefore been adopted.

The patient is kept at a fixed distance from the types. This distance should never be less than 5 metres, or preferably 6 metres. At such a distance the divergence of the rays in the small bundle which enters the pupil is so slight that it can be neglected, the rays being considered parallel. If the distance were 3 metres, for example, an appreciable amount of accommodation would have to be exerted by an emmetropic eye in order to bring the rays to a focus upon the retina: hence the estimate of distant vision would be fallacious.

A normal patient 6 metres from the types ought to be able to read every letter from the top to the end of the 6 metre line; many people can read more in a good light. Suppose the patient can only read the 18 metre line. His distant vision is obviously defective. The numerical convention which is used to record this is a fraction in which the numerator is the distance at which he is from the types, and the denominator is the distance at which a person with normal vision ought to be able to read the last line which he succeeds in reading. The patient under consideration will therefore have his distant vision recorded thus: $V = \frac{6}{18}$. The normal patient's vision

will be $V = \frac{6}{6}$.

These fractions give an indication that the normal patient's vision is unity, whilst the other patient's is

one-third as good. The fraction should not be reduced in this manner, because it is only an accurate numerical estimate under special conditions. It should be used merely as a convention, just as numbers are used to indicate variations in tension, though this is far less defensible. If the fraction is reduced much valuable information is lost. In its original form it indicates the actual types used and the actual distance away from the types; it therefore eliminates doubt as to the accuracy of the application of the test.

If the patient cannot read the largest letter he is told to walk slowly towards the types. At a certain distance he may be able to see the top letter. He should then be moved back a little, since he may not have understood exactly where to look. In this manner the farthest point at which he can distinguish the top letter is determined. If this is 3 metres, the vision is recorded thus— $V = 3/60$. Perhaps he is unable to see the top letter even close to it. In that case he is asked to count the extended fingers of the surgeon's hand, held up at about 1 metre against a dark background: the distance is varied to obtain about the maximum. This is recorded thus— $V = \text{fingers at 1 metre}$. If he cannot count fingers he is told to look at the light, either artificial or the window: the surgeon's hand is then moved between the eye and the light. If he can distinguish the movements of the hand it is recorded as $V = \text{hand movements}$. If he is unable to distinguish hand movements he is taken into the dark room and the light is alternately switched on and off, or light is concentrated on his eye with a convex lens or with the ophthalmoscope mirror, and he is asked to say when the light is on the eye and when it is off. If he succeeds in doing this, $V = \text{p. l. (perception of light)}$. If he fails to see the light at all the vision is recorded a $V = \text{no p. l.}$

It does not follow that a patient who reads 6/6 is emmetropic: he cannot be myopic unless he is screwing up his eyes, and in any case he cannot be very myopic. He may, however, be hypermetropic, for by an effort of accommodation he can bring the practically parallel rays emitted by the letters to a focus on his retina. We wish, then, to find out if he is accommodating. It is done by finding out the highest convex lens, placed before his eye in a testing spectacle frame, with which he can still read 6/6.

Directly a convex lens is placed before the eye in a patient who has good accommodative power it tends to make objects look blurred. Hence it is best to start with a convex lens which will quite definitely blur the types, and then gradually counteract it by placing concave lenses of increasing strength in contact with it. A + 4 D lens is put in front of the eye. Probably the patient now reads only a few lines. With the + 4 D still in position a - 0.5 D is put in front of it; the patient perhaps reads another line. The - 0.5 D is replaced by a - 1 D; he still fails to read 6/6. The - 1 D is replaced by - 1.5 D; we will suppose that he now reads 6/6. This proves that he has average normal vision with a + 2.5 D lens. With the assistance, therefore, of a 2.5 D convex lens he can relax his accommodation the corresponding amount. It by no means follows that this represents the total amount of his hypermetropia. As has already been pointed out (*vide* p. 62), the younger the person the greater the capacity to accommodate. Young people, therefore, have great facility in accommodating. If they are hypermetropic this fund has been drawn upon for a long period, so that a condition of partial contraction of the ciliary muscle becomes normal to them. Sometimes even there is excessive contraction of the muscle, so that they become artificially myopic,

a condition which is called "spasm of accommodation": it is probably diagnosed more often than it occurs.

The younger the patient, therefore, the easier it will be for him to accommodate, and the more difficult to relax his accommodation completely. That part which he can relax when convex lenses are used as described above is called his *manifest hypermetropia* (Hm.). The part which he is unable to relax, which can only be determined by paralysing the ciliary muscle, is called his *latent hypermetropia* (Hl.). The sum of the manifest and latent hypermetropia is called the *total hypermetropia*. In extreme youth nearly all the hypermetropia is latent: the lens is so resilient that it is impossible to prevent it responding to the slightest stimulus. As the lens becomes less plastic more and more of the hypermetropia becomes manifest, until, finally, when accommodation disappears entirely, all the hypermetropia is manifest. The older the patient, therefore, the nearer the manifest hypermetropia represents the total amount.

The vision of the patient in the above example is usually recorded thus: $V = \frac{6}{6}$, Hm. + 2.5.

With intelligent patients who do their best to read as many letters as possible without continual encouragement from the surgeon, the manifest hypermetropia is obtained with less trouble by simply putting up convex lenses of gradually increasing strength until the last line which was read with the unaided eye becomes blurred.

An older patient than the one considered in the previous example will very likely read more with a convex glass than without it. Thus a patient of fifty-five may perhaps read only 6/12, whilst with a + 2 D he reads 6/6. This man has a manifest hypermetropia of 2 D. Since he is fifty-five years of age he has only 1 D of accommodation left (*vide p. 63*). When he reads with the unaided eye

he uses up this 1 D in getting as far as 6/12; he is unable to accommodate any more, so the lower letters are too blurred to read. He may manage to read 6/6 with the assistance of a + 1 D, since this, with the remnant of his accommodation, will fully correct his hypermetropia. On seeking the highest convex glass we find he can read 6/6 as well or better with + 2 D. This, therefore, represents his manifest hypermetropia. Such

$$\text{a case is recorded—} V = \frac{6}{12}, \text{Hm. } + 2 = \frac{6}{6}$$

Apart from counteracting a convex lens as described above the student should never use concave lenses in testing the distant vision, unless the patient is under a mydriatic. An emmetrope or even a hypermetrope, if neither is presbyopic, will read 6/6 quite well with weak concave lenses in front of the eye; he simply accommodates the amount which is requisite to counteract the lens. Hence, unless the patient is under the influence of a mydriatic, we learn nothing from the procedure; it is therefore redundant.

Having tested the distant vision and determined the amount, if any, of the manifest hypermetropia, the near vision should next be tested. For this purpose test types for near vision are used (Fig. 88). Snellen's are constructed on exactly the same principle as the distant ones, and are therefore most scientifically accurate. For actual reading, however, people can often read types which are smaller than Snellen's smallest if the lines forming the letters are a little broader. This is chiefly due to the fact that an idea of the shape of letters will often permit them to be accurately guessed when they are not clearly visible. This is, indeed, an objection to the use of letters as test objects at all. Jaeger's near test types, which are very frequently used, are simply the ordinary printers' founts of type, from the smallest

J. 1 (Sn. 0.5).

50 cm.

As she spoke, Moses came slowly on foot, and cowering under the deal box which he had strapt round his shoulders like a pellar. "Welcome, welcome, Moses! well, my boy, what have you brought us from the fair?—I have brought you myself," cried Moses, with a sly look, and resting the box on the dresser. "Ay, Moses," cried my wife, "that so

J. 2 (Sn. 0.6).

60 cm.

five shillings and twopence is no bad days work. Come, let us have it then."—"I have brought back no money," cried Moses again. "I have hid it all out in a bargain, and here it is," pulling out a bundle from his breast: "here they are; a gross of green spectacles, with silver rims and

J. 4 (Sn. 0.8).

80 cm.

mother," cried the boy, "why won't you listen to reason? I had them a dead bargain, or I should not have brought them. The silver rims alone will sell for double the money."—"A fig for the silver rims," cried my wife, in a passion: "I dare

J. 6 (Sn. 1).

1 m.

the rims, for they are not worth sixpence; for I perceive they are only copper varnished over."—"What!" cried my wife, "not silver! the rims not silver?"—"No," cried I, "no more silver

J. 8 (Sn. 1.25).

1.25 m.

with copper rims and shagreen cases? A murrain take such trumpery! The blockhead has been imposed upon, and should have known his company better."—"There,

J. 10 (Sn. 1.5).

1.5 m.

the idiot!" returned she, "to bring me such stuff: if I had them I would throw them in the fire."—"There again you are wrong, my dear," cried I;

J. 12 (Sn. 1.75).

1.75 m.

By this time the unfortunate Moses was undeceived. He now saw that he had

J. 14 (Sn. 2.25).

2.25 m.

asked the circumstances of his deception. He sold the horse, it

FIG. 88.—TEST-TYPES FOR NEAR VISION.

Jaeger Test-Types, with approximate Snellen equivalents, and the most remote distances at which each should be read with average normal vision.

upwards (nonpareil, minion, &c.). They are sufficiently accurate for practical purposes.

The patient is told to hold the test card. The position where he holds it of his own accord will often impart useful information. If he is old and holds it a long distance away, he is most likely to be an emmetropic or hypermetropic presbyope. If he holds it closer than the ordinary reading distance and reads the smallest type fluently, he is probably myopic, whatever his age may be.

Take first the example of an emmetrope. We find that he reads 6/6, that he has no manifest hypermetropia, and that he reads Jaeger 1, holding it of his own accord at ordinary reading distance (22 cm. or 9"). This is recorded— $V = 6/6$, no Hm., J. 1. If no distance is stated in recording the near vision it is understood to be the normal distance.

Take now a patient who reads only 6/60, has no manifest hypermetropia, but reads Jaeger 1 fluently, only, however, when the card is held much closer than normal to the eye. In this case the distance at which the card is held should be guessed or measured. Let us suppose that it is about 5 inches. This is recorded— $V = 6/60$, no Hm., J. 1 at 5".

Take now a patient of fifty-five who reads 6/6, and has no manifest hypermetropia. We give him the near types, and he holds the card a long distance off, but even so cannot read Jaeger 1. In this case it is waste of time to discover exactly which type he can read, and to measure the distance at which he can read it. We know that as he is fifty-five he has only 1 D of accommodation remaining (*vide* p. 63). What we wish to know is whether he can read Jaeger 1 at ordinary reading distance if we correct his presbyopic defect. We therefore at once put up a +3 D lens before the eye, tell him to hold the types closer, and ask him if he can read the smallest. He will probably



MICROCOPY RESOLUTION TEST CHART

(ANSI and ISO TEST CHART No. 2)



APPLIED IMAGE Inc

1653 East Main Street 14609 USA
Rochester, New York
(716) 482 - 0300 - Phone
(716) 288 - 5989 - Fax

do so easily. This is recorded thus— $V = 6/6$, no Hm., $\bar{c}. + 3 = J. 1$.

Finally, take a patient of fifty who reads 6/12, but with $+ 2 D$ 6/6. He will hold the near types a long distance away as in the last example; if we investigate the question he will not be able to read nearly as well even a long distance away as the last patient. He has only 2 D of his accommodation remaining, but he also has 2 D of hypermetropia. We cannot therefore expect him to read Jaeger 1 at ordinary reading distance unless we not only correct his presbyopia but also his hypermetropia. We therefore at once put up a $+ 4 D$, and find that he reads Jaeger 1 at ordinary distance quite well. This is recorded thus— $V = 6/12$, Hm. $+ 2 = 6/6$, $\bar{c}. + 4 = J. 1$.

The ordinary rule of presbyopic loss of accommodation, viz., 1 D for each five years after forty, is rather a liberal allowance, and we often find that patients are more comfortable with slightly less (*vide* p. 64). In no case should more be ordered.

An indication of the *range of accommodation* is given by the knowledge of the manifest hypermetropia, combined with the ability to read the small types at ordinary reading distance. Strictly, the accommodation should be more carefully tested in each case, but it is often neglected.

The method adopted to find the near point of the eye has already been mentioned (*vide* p. 59). For practical purposes it is sufficient to use the smallest Jaeger or Snellen near type and approach it nearer and nearer to the eye until it can no longer be read. The last point at which it can be read gives the near point. The distance of the near point from the eye is then measured with a tape. This distance is transformed, if necessary, into millimetres (25 mm. = 1 inch), and the range of accommodation is deduced from the formula $A = P - R$ (*vide*

p. 61). Of course, the full range of accommodation in a hypermetrope cannot be accurately arrived at unless the total hypermetropia is known; this may require the use of a mydriatic. Practically, however, we are chiefly concerned in discovering paralysis or paresis of accommodation, such as may occur after diphtheria or previous use of a mydriatic. In these cases the knowledge of the distance of the near point is sufficient.

The next step—one which is far too often neglected—is in every case to test the *pupil reactions* and record them. If the visual tests have shown deficiency it may be necessary to use a mydriatic, in which case it will be impossible to test the pupil reactions at a later stage of the same visit; hence the importance of recording them at once.

We should also test the field of vision roughly.

The Field of Vision.—There are several methods of testing the field of vision.

(1) A rough, but very useful, method which should be applied in every case, at any rate if there is the slightest suspicion of defect, is as follows:—

The surgeon stands facing the patient at a distance of 18 inches to 2 feet. The patient covers his left eye with the palm of his hand. He is told to look straight into the surgeon's left eye. The surgeon closes his right eye. He then moves his hand in from the periphery towards the common line of vision of the patient's right and his own left eye, keeping his hand in the plane half-way between the patient and himself. Directly he sees it himself the patient ought to say that he also sees it. The movements of the hand are repeated in various parts of the field—above, below, to the right, to the left, and so on.

This method is extremely simple, rapidly applied, and an excellent test. It will be seen that the surgeon tests

the range of the patient's field by that of his own, which may be considered normal; moreover, he is continually watching the patient's eye, so that he can at once observe any deflection from the point of fixation.

The gross defects in the field which are most likely to escape recognition are homonymous and bitemporal hemianopia, the latter usually due to acromegaly or tumour of the pituitary body (Chap. XX.). They may be roughly tested for by telling the patient to look straight at the surgeon, situated as before, both eyes being open. The surgeon holds up both hands, one in each temporal field, and the patient is told to touch the surgeon's hand. If he asks "Which one?" he has not bitemporal hemianopia, since he sees both hands. If he promptly points to one hand he should be asked if he sees the other; if he does not, he probably has homonymous hemianopia.

If any defect is indicated by these methods or is suspected from other features of the case it must be accurately mapped out and recorded with the perimeter.

(2) *The Perimeter.*—The perimeter consists essentially of an arc, marked on the back in degrees of a circle, capable of being revolved round a pivot which the patient fixes with the eye under examination (Fig. 89). The chart, which has concentric circles marked upon it, corresponding with the degrees on the arc, is under the surgeon's control at the back of the perimeter. In self-registering perimeters, which are almost invariably used, the readings are recorded by perforations with a sharp point.

The details of taking a perimetric chart can only be taught by actual demonstration. It will suffice to emphasise here the chief procedures to be followed in order that accuracy may be attained.

The patient is seated with his back to the light. His chin rests upon the chin-rest; the face is vertical and not

tilted to one side; one eye is covered. The other eye, situated at the centre of the arc, fixes the white dot around which the arc revolves.

The field should first be taken with a white object




FIG. 89.—McHardy's perimeter.

10 mm. in diameter. At least eight meridians must be investigated, preferably sixteen. If the field is very small a 5 mm. square should be substituted, and the process repeated. In each meridian the object should be carried quite up to the fixation point, as there may be areas inside the limits of the field which are blind (*absolute scotomata*).

These should be mapped out with the same accuracy as the extreme limits of the field. If the scotomata are small the limits may be determined with an intelligent patient best with a very small object, *e.g.*, 2 mm. square.

Having mapped out the field for white the process




FIG. 90. Perimeter chart of right eye (Landolt). T, temporal side; N, nasal side; W, for white object; B, for blue; R, for red; G, for green.

should be repeated with similar, but coloured, objects. Red or green should be used first, then blue or yellow: if the red and green are complementary, *i.e.*, if the tints when combined would produce white, their fields will be found to be identical; the same applies to the blue and yellow. Special care must be taken to investigate the central part of the field for red and green, since conditions are not uncommon, *e.g.*, tobacco amblyopia, in which these

colours are not recognised by central vision (*relative scotomata*).

The extent of the normal field, with a 10 mm. square, under good illumination, is shown in the accompanying chart (Fig. 90). The peculiar shape is largely due to the interference caused by the nose and the brows. It is seen that the field for white extends upwards 45° , outwards rather more than 90° , downwards 70° , and inwards 60° .

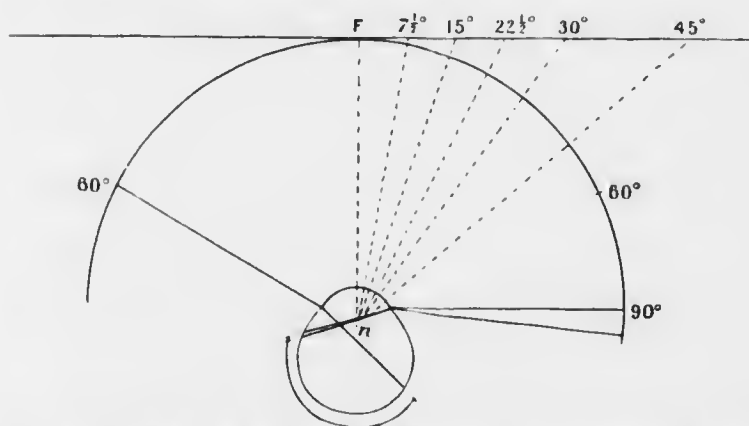


FIG. 91.—Diagram of the right eye, showing the relationship of the retina to the degrees of the perimetric arc, and the relative value of the latter when projected on a tangent scale. *n*, nodal point. *F*, point of fixation.

The field for blue and yellow is roughly 10° less in each direction, that for red and green another 10° less.

Even the ordinary perimetric observation is a relatively rough test and purely subjective. It must always be regarded with suspicion in dull or neurotic patients. The maximum field is obtained from objects which subtend a visual angle of $\frac{1}{2}^\circ$: the ordinary 10 mm. object at the distance used—30 cm.—corresponds with a visual angle of 2° .

(3) For more accurate investigation of details another method must be employed, but it is applicable only to

the central area. It consists in placing the patient 2 metres from the centre of a large black screen (2 metres or more broad). The patient fixes a spot in the centre of the screen and smaller circular discs of ivory, 1 mm. to 10 mm. in diameter, attached to a long black rod are brought in from the periphery on a level with the screen. At this distance a 3 mm. object subtends a visual angle of about 5 minutes. It will be noticed that, the angles being projected on to a flat surface, tangents are recorded, not angles themselves as with the arc. Hence only a small area can be investigated, and the distortion must be taken into account. Some points of diagnostic importance which cannot be elicited by the perimeter can be brought out by this method.

If the charts of the two eyes are superposed there will be a large central area which is common to both eyes: this is the *field of binocular vision*.

The Light Sense may be roughly tested by means of Bjerrum's test types, which consist of Snellen's test types printed grey on a grey background of different intensity.

SECTION III.

DISEASES OF THE EYE.

CHAPTER X.

DISEASES OF THE CONJUNCTIVA.

THE conjunctiva shows very considerable variations in appearance at different ages and in people who follow various employments. The peculiarities of colour, vascularity, laxity, &c., which are consistent with health can be learnt only by repeated observation.

It is necessary for a scientific appreciation of pathological conditions to be cognisant of the normal structure of a part. The conjunctiva is divided into two portions, palpebral and bulbar; the folds uniting these parts are the fornices. The palpebral conjunctiva is said to commence at the anterior margin of the edge of the lid, but from this point to the posterior margin of the edge (the intermarginal strip) and for about 2 mm. beyond (to the sulcus subtarsalis) there is a transitional zone covered with stratified epithelium and partaking of the characters of both skin and conjunctiva (Chap. XXIX.). There are two layers of epithelium over the palpebral conjunctiva: from the fornices to the limbus the epithelium becomes gradually thicker, forming eventually again a stratified epithelium. Below the epithelium is an adenoid layer, consisting of loose connective tissue containing mononuclear lymphocytes: below this a fibrous layer, much

denser and passing insensibly into the underlying tissues—lid or sclerotic. The palpebral conjunctiva is firmly adherent to the tarsus, whilst the bulbar portion is freely movable over the sclerotic except close to the cornea.

Bacteriology. — The conjunctival sac is practically never free from organisms. Most are non-pathogenic, but some of these are morphologically identical with pathogenic organisms. Diplococci indistinguishable from pneumococci are found; they may be innocuous to animals or prove themselves true pneumococci. It may be stated at once that the pneumococcus is one of the most dangerous organisms in the pathology of the eye. Another bacterium, the so-called xerosis bacillus, is morphologically identical with the diphtheria bacillus; it can only be distinguished by skilled examination of cultures. Staphylococci are found; they are relatively innocuous in the absence of other organisms, but play an important part in mixed infections. Streptococci, *Bac. coli*, &c., are pathogenic, but rare. Other pathogenic organisms — gonococci, Koch - Weeks' bacilli, diplobacilli—will be discussed later.

INFLAMMATION OF THE CONJUNCTIVA.

Conjunctivitis. — Inflammation of the conjunctiva manifests itself in many grades and many types. It is always accompanied by hyperemia and by increased secretion. The hyperemia varies in degree and in distribution: the secretion varies in nature and amount.

Hyperemia may be transitory, or recurrent and chronic. The former is caused by temporary irritation, as by a foreign body in the conjunctival sac (which includes the surface of the cornea): in such a case the increased secretion is almost wholly a reflex secretion of tears.

Recurrent or chronic congestion may be caused by the conditions of life—dusty, ill-ventilated rooms, exposure to strong light, &c. It is often due to conditions remote from the conjunctiva itself. Very frequently it is a reflex irritation due to errors of refraction: in such cases the edges of the lids may participate. Other causes are found in errors of metabolism—gout, over-eating and drinking, and so on.

Simple hyperæmia of the type described causes a sense of discomfort, often described as tightness, grittiness, inability to keep the eyes open, tiredness, &c. Bright light is resented, but there is seldom true photophobia. The conjunctiva often looks quite normal until the lower fornix is exposed, when it will be seen that the parts in contact are congested and sticky. The discomfort frequently comes on only in the evening or after near work. In the gouty cases there may be œdema—*chemosis*.

Chemosis affects the most loosely attached parts of the conjunctiva, *i.e.*, principally the bulbar conjunctiva and fornices. The mucous membrane becomes swollen and gelatinous in appearance. The swollen membrane forms a wall around the cornea, which it may overhang in severe cases. The palpebral conjunctiva is little affected, but the tissues of the lid are often also œdematous, so that the lids are swollen and the upper hangs down over the lower.

Whenever watering of the eyes is complained of, and whenever only one eye is congested or shows signs of conjunctivitis, the lacrymal passages must be investigated. Pressure with the finger backwards and inwards over the lacrymal sac may cause regurgitation of fluid—tears, mucus, or pus—showing that the outflow into the nose is obstructed. If no regurgitation can be detected, the position of the lower punctum must be noted. It ought to be invisible until the lid is slightly everted.

The *treatment* of simple hyperemia consists primarily in the removal of the cause. Defective conditions of life must be ameliorated if possible. The irritation of strong light must be removed, or modified by the use of dark glasses. They should be chosen of the type which cuts off the actinic rays of the spectrum, *i.e.*, neutral tint ("smoked"), not blue.

Errors of refraction must be corrected. It should be remembered that the error may be artificial, through the use of wrong spectacles. The amount and conditions of near work should be specifically stated.

Defects of the lacrymal apparatus must be treated (Chap. XXX.). If no defect is noted, local treatment of the hyperemia is ordered for a time; but if the condition does not improve, the patency of the lacrymal passages must be demonstrated by syringing. The beginner must be careful, however, that he does not do harm rather than good.

Errors of metabolism must be treated on general medical principles. Such causes are easily overlooked; hence they should be specially borne in mind.

Local treatment consists in bathing the eyes frequently with hot boric lotion, with or without a mild astringent, *e.g.*, zinc sulphate, gr. i. or ii. to $\bar{3}$ i. A drop of a mixture of equal parts of tincture of opium and distilled water, night and morning, will be found soothing. Hazeline, 20 η to $\bar{3}$ i., is sometimes useful, but varies in its effect in different people. Cocain must be used with diffidence: its effects are transitory, and it has a deleterious action upon the corneal epithelium, but in quite weak doses often affords much comfort.

In cases where temporary alleviation—usually of the disfiguring signs—is insistently desired, a drop of adrenalin solution (1 in 1000) instilled into the eye will remove the discomfort and reduce the redness of

the conjunctiva. The effect is, however, very transitory, but it will often earn gratitude. It is especially useful after the removal of a foreign body from the cornea.

The *nature of the secretion* in conjunctivitis is of diagnostic importance. It may be watery, mucous, mucopurulent, or purulent, and the disease is often classified accordingly. Most forms of acute conjunctivitis are due to bacterial agency. Unfortunately, each pathogenic organism does not produce a specific clinical picture. It is therefore wise in the meantime to retain the old clinical terminology.

Watery secretion is usually due to reflex secretion of tears. The other types of secretion show some relation to the bacterial cause, and must be distinguished on account of the information they convey as to the probable severity of the condition and the indication they provide for special measures of treatment.

The chief forms of conjunctivitis may be divided into two groups: acute, and sub-acute or chronic. Acute conjunctivitis may be classified as simple acute (including mucopurulent), purulent, membranous, and phlyctenular. Sub-acute or chronic conjunctivitis includes simple chronic conjunctivitis, angular conjunctivitis, follicular conjunctivitis, trachoma, tubercle, and syphilis.

Simple Acute Conjunctivitis (*Syn.—Catarrhal Conjunctivitis*).—The condition described as hyperæmia of the conjunctive passes imperceptibly into a condition characterised by greater and more general hyperæmia and a thicker mucous discharge which gums the lids together. The lids are usually described as being stuck together in the mornings, because the condition is most noticed after they have been closed for a considerable period. The causes, symptoms, and treatment are the same as in simple hyperæmia.

Various more intense forms of simple acute conjunctivitis are met with: they are probably all of bacterial origin, the organisms differing in different cases.

The commonest form is **Muco-purulent Conjunctivitis**. Here, as the name implies, the secretion is muco-purulent; it is more profuse than in the simpler forms. As in most cases of conjunctivitis the disease is contagious, being transmitted directly by the discharge and possibly by the air of ill-ventilated rooms, though this method is

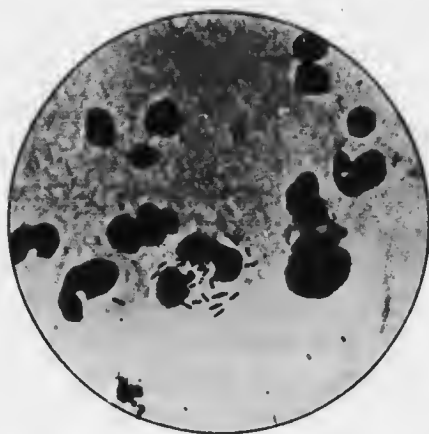


FIG. 92. Koch-Weeks' bacilli ($\times 1000$).

doubtful, since most of the organisms are non-sporing and are easily destroyed by drying. The whole conjunctiva is a fiery red ("pink eye"); all the conjunctival vessels are congested, except the circum-corneal zone in the milder cases (*vide* p. 95). Flakes of muco-pus are seen in the fornices, and often between and upon the margins of the lids. If the discharge is allowed to dry the lashes become matted together by dirty yellow crusts. These may be easily mistaken for the condition found in blepharitis, but if the crusts are bathed off the underlying lid margins will be found healthy. Flakes of mucus passing across the cornea often gives rise to coloured haloes, owing to their prismatic action. These "haloes" must be carefully distinguished from those met with in glaucoma (*q.v.*).

The discharge is at first mucous, but gradually becomes

more purulent. Beginners are liable to mistake mucopurulent for true purulent conjunctivitis. In the former, the more purulent masses are found among the lashes and at the inner canthus, whilst the fornices and bulbar conjunctiva show only flakes of translucent or yellowish secretion. In the latter, crusts of inspissated pus may be seen among the lashes and at the canthi, but when the lids are separated fluid pus wells out.

The disease reaches its height in three or four days: if untreated it is liable to pass into a less intense, chronic condition. Complications are rare, but abrasions of the cornea are liable to become infected and to give rise to ulcers. Occasionally marginal ulcers form—in debilitated or old people, or as the result of improper treatment.

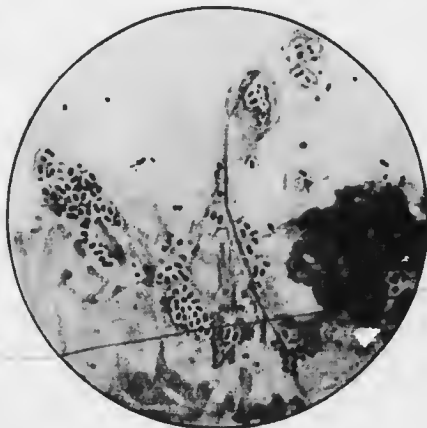


FIG. 93.—Pneumococci ($\times 1000$).

Muco-purulent conjunctivitis frequently complicates phlyctenular conjunctivitis.

Pathology.—Muco-purulent conjunctivitis is frequently caused by the Koch-Weeks' bacillus (Fig. 92). This is a very slender rod, varying much in length. It stains badly with the ordinary basic dyes, *e.g.*, Löffler's methylene blue; it is decolourised by Gram. Groups of bacilli found in much degenerated, "skeletonised" pus cells are very characteristic.

The organism is rapidly destroyed by drying. It has been known to give rise to very definite epidemics. In England the cases are usually sporadic, though moderate

transmission is common. An attack confers immunity for some time.

The Koch-Weeks' bacillus is by no means the only cause of muco-purulent conjunctivitis. Diplococci which are indistinguishable from pneumococci (Fig. 93) also cause it, probably more frequently in England. Pneumococic conjunctivitis, though not definitely separable from the other acute forms clinically, shows distinct tendencies which should be borne in mind, the more so since the pneumococcus is the cause of hypopyon ulcer (*q.v.*). There is usually more œdema (chemosis), small

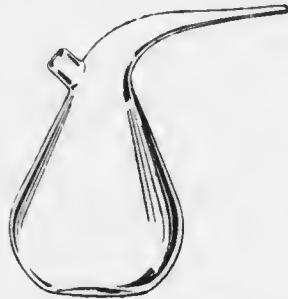

FIG. 94. Umline.

ecchymoses are common, and a membranous film may form—“pseudo-membranous conjunctivitis.” It is commonest in northern countries and in the cold weather, and is more often found in children than adults. It ends with a crisis, like pneumococic infection of the lungs, after which the organism rapidly disappears from the secretion.

The muco-purulent conjunctivitis associated with phlyctenular conjunctivitis is usually due to staphylococcus aureus, which may also set up conjunctivitis in cases of blepharitis and eczema or impetigo of the skin. This organism also sometimes causes a muco-purulent discharge after cataract extraction and other operations.

Other organisms have been found, but their ætiological relationship to the disease is not proved.

Treatment.—The best treatment for muco-purulent conjunctivitis is the frequent washing out of the conjunctival sac with lotio hydrargyri perchloridis (1 in 5000) (called hereafter sublimate lotion). It should be warmed and diluted by the addition of a little boiling water. The

lotion must not be simply applied to the lids. It is well for the surgeon himself or a competent nurse to wash out the conjunctival sac the first time. For this purpose an "undine" (Fig. 94) is the most convenient reservoir. The lids are everted and the lotion is poured from a little height over the whole surface, every crevice being irrigated as thoroughly as possible. The nozzle of the undine should not be allowed to touch any part of the eye. The patient may be directed to use the ordinary eye-bath for the application of eye lotions. If a child, the parents should be instructed to hold the lids apart, the child lying upon its back. A pad of cotton wool, dripping with the lotion, which may be warmed, is then held over the eye and the lotion squeezed out: the process is repeated until all discharge has been washed away. The lotion may be warmed by placing the bottle in hot water, but the addition of an equal part of hot water suffices: eye lotions act chiefly by washing out deleterious material, since they cannot be used sufficiently strong to act as efficient antiseptics. For this reason boric acid lotion is probably nearly as efficacious.

Boric acid ointment or sterile vaseline is smeared along the lids at bed-time, or, in children, as often as they are put to sleep: it prevents the lids from sticking together—a two-fold benefit, that of obviating pain on opening them, and that of preventing discharge from being retained.

The eyes should never be bandaged, as it prevents the free exit of the secretion. If there is any photophobia a shade or dark goggles should be worn. The patient should spend as much time out of doors as possible.

If this treatment is properly carried out, the patient will be well in a few days. Even if only partially successful there will then be less discharge.

If the case is not progressing as rapidly as could be

desired, or the attendants are not reliable, and if the discharge is subsiding, it is wise to paint the lids once with silver nitrate solution (gr. x. to $\frac{3}{4}$ i.). This is the strength which should always be used for painting lids. Stronger solutions act too vigorously as caustics, and if a caustic effect is desired, it can be obtained with greater precision by other means. Weaker solutions are precipitated by the chlorides in the lacrymal secretion, so that they are practically useless.

The following is the best method of painting lids. A glass rod is used, tapering at each end (Fig. 95). The finger should be passed over the ends each time before use to make sure that they are not chipped. The end is dipped in lotion to damp it. A *very thin* wisp of cotton



FIG. 95.—Glass rod.

wool is then tightly wound round the end, starting where it begins to taper: this fixes the wool. The end of the wisp is left loose, so that it may absorb the solution. The other end of the rod is armed in the same manner.

The patient, if a child, is placed upon its back. The lids are everted; the wool, dipped in the silver solution, is applied freely to the conjunctival sac, the cornea being protected as much as possible. It is quite unnecessary to neutralise the excess of nitrate with salt solution, as is often taught. The excess may be mopped up with a pad of dry absorbent wool. If, as is usually the case, the other eye is affected, the other end of the rod is used in the same manner. In the absence of a glass rod the best implement is an ordinary wooden match, used in the same way. The match can be thrown away after use. The glass rod must be sterilised by boiling. A camel's hair brush should not be used: it cannot be kept aseptic.

A single painting with silver nitrate will often produce an excellent result. It is good as a prophylactic if discharge is inadvertently introduced into a normal eye. Other preparations of silver—protargol (20 per cent.), argyrol (25 per cent.), &c.—are not so efficacious, but they have the advantage of being less painful.

The conjunctiva generally returns to a perfectly normal condition. If the case has been neglected and chronic inflammatory signs persist, astringents should be used as for chronic conjunctivitis (*q.v.*).

Purulent Con-
conjunctivitis (*Syn.*—*Acute Blepharorrhoea*, *Gonorrhoeal Conjunctivitis*) is a much more serious condition. It occurs in two forms — as ophthalmia neonatorum in babies, and as gonorrhoeal conjunctivitis in the adult. Certainly the former, and probably the latter, is not invariably gonorrhoeal.

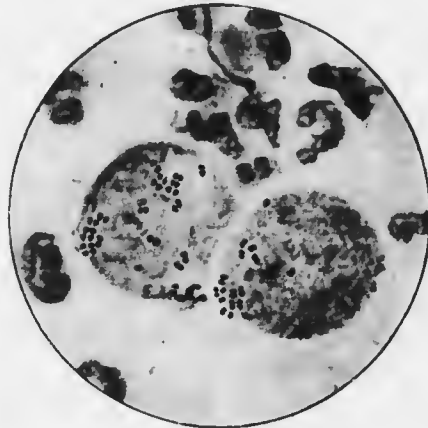


FIG. 96.—Gonococci ($\times 1000$).

Gonorrhoeal Conjunctivitis (*Syn.*—*Acute Blepharorrhoea of Adults, &c.*).—Gonorrhoeal conjunctivitis is even more serious in the adult than in babies; fortunately, considering the prevalence of gonorrhoea, it is comparatively rare. Whilst generally due to the gonococcus it is important from the medico-legal point of view to remember that the same features may be found with streptococci, diphtheria, and probably mixed infections. The gonococcus is a bean-shaped diplococcus, staining readily, decolourised by Gram, and found within both leucocytes

and epithelial cells (Fig. 96). The micrococcus catarhalis and the meningococcus, both Gram-negative, are sometimes found in the conjunctival sac. They may be distinguished from the gonococcus by the ease with which cultures are obtained and by agglutination tests.

The disease is due to direct infection from the genitals. Males suffer most, the right eye before the left in a right-handed person. There is more swelling of the lids and conjunctiva than in children, copious purulent discharge, more tendency to involvement of the cornea, and marked constitutional disturbance—rise of temperature, and so on, but especially very marked depression of spirits. The greater danger to the cornea is due to the chemosis, which produces blood and lymph stasis and facilitates the retention of secretion.

The incubation period is a few hours to three days. The upper lid becomes enormously swollen and tense, overhanging the lower, and edged with pus. Eversion, which is difficult, shows that the palpebral conjunctiva is deep red and velvety: rarely there is a membrane. Occasionally the discharge is sanious rather than purulent, especially in streptococcal cases. There is great pain: the preauricular gland is enlarged and tender, and may suppurate.

After two or three weeks the purulent discharge diminishes, but subacute conjunctivitis persists for several weeks longer. The gonococcus is still present—a point of great importance, both as regards contagion and treatment.

The most important point in diagnosis is the coincidence of urethritis. The most important point in prognosis is the condition of the other eye.

Corneal complications are the rule, and constitute the causes of blindness. There may be diffuse haziness of the whole cornea, with grey or yellow spots near the centre. Ulcers may occur at any part, and are due to necrosis of the epithelium through direct invasion by the organisms.

Marginal ulceration, which may extend completely round the cornea, is due to retention of pus in the angle formed by the chemotic conjunctiva. When ulceration has commenced it progresses rapidly and deeply, since the tissues are bereft of their first line of defence—the epithelium. Perforation is therefore common, with all its attendant dangers (*vide* p. 228). Ulceration commencing late in the history is not so dangerous.

The greatest care should be taken to prevent injury to the cornea during the manipulation necessary for diagnosis and treatment. Abrasions are easily produced by the finger nails, and even by the rough use of wool swabs. Such abrasions rapidly become dangerous ulcers.

Treatment must be directed first to protection of the other eye. This is at once sealed up with a Buller's shield, which consists of a watch-glass stuck in a frame of adhesive



FIG. 97.—Buller's shield.

plaster, or better, rubber (Fig. 97). The rubber is hermetically sealed down to the face and nose except at the lower outer angle, where a small piece of tubing is inserted under the edge. If this means of ventilation is not adopted the glass becomes hazy and the eye cannot be properly observed: moreover, the irritation to the eye is greater. Special attention should be directed to fixing the shield near the nose, *i.e.*, on the side of the source of infection. Patients should be told to sleep lying on the same side as the affected eye.

If the second eye should show signs of infection it must

be treated, but every utensil or dressing which is applied to the eye must belong to a totally different set from that used for the worse eye, otherwise it may be inoculated rather than treated. The less affected eye must always be dressed first.

If pus from a gonorrhoeal conjunctivitis spurts into the surgeon's eye, the conjunctival sac should be freely irrigated with sublimate lotion and the lids painted once with silver nitrate (*vide* p. 180). The eye should be carefully watched, but no further drastic treatment applied unless conjunctivitis supervenes. The accident is due to carelessness, for every attendant on a gonorrhoeal case should wear protective goggles.

If the disease is fully established and there is abundant purulent discharge, the eye must be irrigated every two hours during the day and every four hours during the night with warm boric or weak sublimate lotion (1 in 8000). Iced wet dressings are applied in the intervals, but are to be bandaged on quite loosely, so as to avoid retention of discharge. The patient is kept in bed, and if intelligent, can bathe his lids in iced lotion in the intervals. Iced applications afford much relief to the patient, though hot ones are probably more efficacious.

Most reliance must be placed on applications of silver nitrate, but they must be used with discretion. When not contraindicated the conjunctiva of the everted lids should be well painted with silver nitrate, gr. x. to ξ i., not oftener than once a day. Special care must be taken to avoid injury (*vide* p. 103). This treatment is contraindicated in the very early stage before free discharge has set in, and also in later stages if there is much bony swelling with comparatively little discharge. Under these conditions the stasis is so great that reaction is inefficient: the caustic, in fact, induces the necrosis which it should be our endeavour to avoid. In such cases hot applications and

leeches should be relied upon. The latter are applied over the temporal region near the outer canthus. If the lids are very tight the outer canthus should be split (canthoplasty). The ends of strong blunt-pointed scissors are inserted between the lids into the angle under the outer canthus, which is then divided by a single snip in a horizontal direction. This has the good effect of bleeding the patient slightly, and also of giving free exit to discharge.

Scarification of the chemosed conjunctiva has been recommended and may be done. The removal of the ring of conjunctiva which overhangs the cornea is good, but demands cocaine, which has a bad effect on the corneal epithelium. Mercury, by inunction or small doses of calomel, is said to diminish the chemosis.

It is of great importance to attend to the general health. The bowels must be kept freely open. The strength must be reinforced by every available means—good food, tonics, alcohol if necessary. An occasional sleeping draught and the use of sedatives must be ordered according to general principles. Every effort must be made to combat the depression from which these patients suffer.

In the final stage of the disease silver nitrate should be used at increasing intervals for a week or fortnight after the purulent discharge has ceased. Astringent lotions are then employed (*vide* p. 197).

Corneal complications require very active treatment (*vide* pp. 231, *sqq.*).

Ophthalmia neonatorum is a preventable disease occurring in new-born children as the result of carelessness at the time of birth; it is responsible for a large proportion (10 per cent., Fuchs) of all blind people. It is due to infection by vaginal or faecal matter, or from dirty rags used to clean the eyes. Purulent discharge is usually noticed on the third day; when it occurs later it is

generally due to post-partum infection. Both eyes are usually affected. The conjunctiva is intensely inflamed, bright red, swollen, and pouring out thick, yellow pus. Marked chemosis is a distinguishing feature from severe muco-purulent conjunctivitis.

There is great risk of corneal ulceration in ophthalmia neonatorum, especially, as is usually the case, when it is due to the gonococcus, which has the power of invading intact epithelium. Often the cornea is already ulcerated, and not infrequently perforated, when the child comes under observation. Ulceration usually occurs over an oval area just below the centre of the cornea, corresponding with the position of the lid margins when the eyes are closed and consequently rotated upwards somewhat. More rarely marginal ulcers are formed as in the gonorrhœal conjunctivitis of adults.

Metastatic arthritis occurs rarely, as in gonorrhœal urethritis.

The baby's eyes must be examined as described in method (4), p. 93. The surgeon must wear protective goggles lest pus spurt into his eyes when the child's lids are separated.

Pathology.—Probably 60—70 per cent. of cases are due to the gonococcus; the *Bac. coli* is responsible for some of the remainder, probably through faecal infection, streptococci for others. Streptococcal conjunctivitis is even more virulent than gonococcal, the cornea being in imminent danger. A film should be taken from every case.

Treatment.—The disease is preventable; *prophylactic* treatment is therefore of prime importance. The newborn baby's closed lids should be thoroughly cleansed and dried. The lids are then separated, and a drop of silver nitrate solution, gr. x. to $\frac{3}{4}$ i., instilled into each eye (Credé's method). The eyes must be carefully watched during the first week.

If the disease is established the eyes must be irrigated

every two hours with sublimate lotion, and the lids painted once daily with silver nitrate. The surgeon must wear protective goggles. The slightest sign of corneal haziness is an indication for the use of atropin, 0.5 per cent. (*vide* p. 231). The use of antigonococcic serum has been advocated.

Membranous Conjunctivitis (*Syn.*—*Diphtheritic Conjunctivitis*).—As in inflammation of the throat the surface may become covered by a fibrinous membrane, so the same may occur in the conjunctiva; and just as the milder clinical varieties in the former were distinguished as croupous from the severer or diphtheritic, so also with conjunctivitis. It has been placed beyond dispute, however, that mild cases may be diphtheritic, and severe non-diphtheritic; hence it is best to speak simply of membranous conjunctivitis until a bacteriological examination has placed the matter beyond dispute. A variety of organisms other than the diphtheria bacillus, *e.g.*, pneumococcus, streptococcus, can produce a membrane, especially in weakly children, *e.g.*, after measles; these cases are sometimes called pseudo-membranous. They cannot be distinguished clinically with certainty.

Membranous conjunctivitis occurs chiefly in children, and shows all degrees of severity; it may be as virulent as the worst cases of gonorrhœal ophthalmia. It is uncommon in England, but it is of the utmost importance that it should be recognised when seen, not only on account of the grave danger to the eye but also from the risks of contagion.

In mild cases there is some swelling of the lids and a muco-purulent or sanious discharge. On everting the lids the palpebral conjunctiva is seen to be covered with a white membrane, which peels off readily without much bleeding.

In severe cases the lids are more brawny: the conjunctiva

is permeated with semi-solid exudates, which impair the mobility, compress the vessels, prevent the formation of a free discharge, and tend to necrosis both of the conjunctiva and cornea. Here the membrane separates much less readily, the underlying surface bleeding unless it is too infiltrated and solid. The membrane may be patchy or cover the whole palpebral conjunctiva, often beginning at the edge of the lid. It is seldom found on the ocular conjunctiva. The preauricular gland may be enlarged and may suppurate. The temperature is raised, unless the patient is in a moribund condition. Albumin is frequently present in the urine.

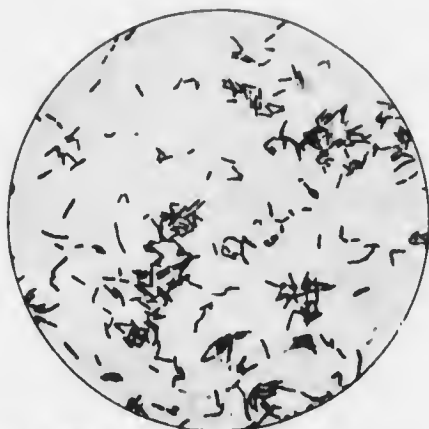

FIG. 98.—Diphtheria bacilli ($\times 1000$).

For six to ten days there is great peril to the cornea. Then the sloughs begin to separate and the discharge becomes more profuse. In a few days the conjunctiva assumes a red and

succulent appearance. There is danger now of adhesions forming between the palpebral and bulbar parts of the conjunctiva (symblepharon).

Post-diphtheritic paralysis, even of accommodation, is rare.

Cases of less severe but more chronic membranous conjunctivitis are occasionally met with. In them the membrane is cast off, but occurs again and again. The pathology of these cases is not understood.

Pathology.—Competent bacteriologists have shown that there is little or no relationship between the severity of

the local condition and the presence or absence of the Klebs-Löffler bacillus (Fig. 98). Only series of cases in which positive results have followed inoculation into animals are absolutely trustworthy, owing to the difficulty of distinguishing the diphtheria from the xerosis bacillus, with which it is morphologically identical.

Other cases may be due to the action of heat, caustics, severe atropin irritation, herpes iris, and other non-bacterial causes. Other bacteria which occasionally form membranes are streptococcus, Koch-Weeks' bacillus, gonococcus, pneumococcus, &c.

It is quite rare to obtain evidence of primary diphtheria of the throat, though the disease may have been derived from a case of faucial diphtheria, and extension to the nose and throat by way of the lacrymal sac and nasal duct occurs. The genitalia should be examined for diphtheria or leucorrhœic discharge.

Treatment.—Every case should be treated as diphtherial unless good negative evidence is afforded by filus and serum cultures. In mild cases isolation need not be strict until the bacteriological report is obtained on the second day.

The treatment is essentially that of purulent ophthalmia, with one important exception, viz., that painting with nitrate of silver is not to be resorted to. Further, canthoplasty is not to be done, since both these procedures increase the area from which toxins may be absorbed.

Local treatment consists of hot irrigations and bathings as for purulent ophthalmia (*q.v.*). One drop of atropin should be instilled at the commencement of treatment. Quinine lotion, gr. iii. to \bar{z} i., with a minimum of acid to dissolve the salt, has been recommended.

The most important general treatment is the administration of antitoxin as in faucial diphtheria. Since the

antitoxin is innocuous it should be used at once in every doubtful case. I have obtained benefit by local instillations of antitoxin, which is a rational procedure but seems to have been neglected. Special attention should be paid to the nutrition, and tonics are indicated.

Corneal complications must be suitably treated (*vide* p. 231).

Phlyctenular Conjunctivitis (*Syn.—Eczematous Conjunctivitis*).—In phlyctenular conjunctivitis (Plate IV., Fig. 1) one or more small, round, grey or yellow nodules, slightly raised above the surface, are seen on the bulbar conjunctiva, generally at or near the limbus; they rarely occur on the palpebral conjunctiva. The disease is very frequently complicated with muco-purulent conjunctivitis, in which case the whole conjunctiva is intensely reddened. In pure phlyctenular conjunctivitis the congestion of the vessels is limited to the area around the phlyctens.

The disease is most frequent in children from five or six to ten or twelve years of age, but not very young children; it is rarely seen in adults. The children often have enlarged lymphatic glands in the neck, &c., or other signs of tubercle; on the other hand every sign of tubercle may not infrequently be lacking: the children, however, are seldom robust. The first attack often follows an exanthem, especially measles. Rhinitis and adenoids are frequently present; signs of congenital syphilis may be found.

Phlyctens, as the name suggests (*φλύκταινα*, a bleb), at first much resemble blebs: it is doubtful, however, whether there is a true vesicular stage. They may be so small as to be seen with difficulty, but they usually measure about 1 mm. in diameter, occasionally reaching a diameter of 3 mm. or 4 mm. The larger ones are yellow, and have been described as pustules. In the later stages the epithelium over the surface is often destroyed, small ulcers being formed. When this occurs on the conjunctiva proper

ery
ons
to
to
de
n-
W.,
es,
ar
ly
ry
is,
d.
ne
ix
i;
d
;
e-
m
,
y
,
;
o
e
r
e
e
s
r



Fig. 1

FIG. 1. The eye of a human being, showing the position of the lens and the iris.



Fig. 2

PLATE IV. (*To face p. 190.*)

Fig. 1. -Phlyctenular conjunctivitis, showing two phlyctens on the conjunctiva and one on the cornea.

Fig. 2. Follicular conjunctivitis.

PLATE IV.





*Follicles
conjunctivae*

FIG. 1



*Follicles
conjunctivae*

FIG. 2



Vertical text or markings along the left edge of the page, possibly bleed-through from the reverse side or a scanning artifact. The text is extremely faint and difficult to read, but appears to be organized in a list-like structure with some bolded or larger text at the top of the column.

it is of little moment, since healing takes place rapidly without the formation of a scar. When it occurs on the cornea, as is very frequently the case, it is much more serious (*vide* p. 249).

Very frequently the skin of the lids and cheeks shows an eczematous condition, and eczema will be found not uncommon, if searched for, in other parts of the body. This fact has led the condition to be regarded by some as an ocular manifestation of eczema. The disease has indeed been regarded as an exanthem. It is probable that in most cases the eczema of the lids and face is secondary to the continual irritation of the skin induced by the overflow of tears and the rubbing of the wet surface with the hands.

Pathology throws some light on the disorder, though it by no means settles the causation. A simple phlycten shows in section a triangular area of intense infiltration, the apex of the triangle being towards the deeper layers. The sub-epithelial adenoid layer normally contains a few mononuclear lymphocytes, but in the phlycten they are very numerous and closely packed together. The epithelium is intact, and it is doubtful if a vesicular stage has ever been observed.

If there is a considerable amount of conjunctivitis of the muco-purulent type, not only are lymphocytes present but there are also many polymorphonuclear leucocytes, both in the sub-epithelial tissues and amongst the epithelial cells. In such cases the epithelium is quickly destroyed.

If a bacteriological examination is made, many of the organisms of muco-purulent conjunctivitis may be found. In the pure phlyctenular cases only staphylococci are found in abundance. Now staphylococci are not so common as might be expected in the normal conjunctival sac; it has, therefore, been concluded that the disease is due to staphylococcic infection. If staphylococci are rubbed into a healthy or excoriated conjunctiva a transitory redness

occurs and rapidly passes off. Phlyctens have never been produced in this manner. The nearest approach to the artificial production of phlyctens has been by injecting cultures of tubercle bacilli, in which the organisms have been killed, into the veins of rabbits. It is doubtful if the infiltrates were real phlyctens in these experiments, but it is certain that the administration of tuberculin has not infrequently been followed by an attack of phlyctenular conjunctivitis in the human subject.

We are now in a position to judge more accurately what probably occurs in phlyctenular ophthalmia. It is not improbable that the true cause of the outbreak is a toxæmia, the toxins—probably tuberculous—not being very potent, but sufficient if the patient is already in a weakened condition. The irritation of the eye leads the child to rub it vigorously. The lacrymation and rubbing cause an eczematous condition of the skin, in which the staphylococci normally present flourish and increase. These are rubbed into the eye, increasing the irritation, without being primarily responsible for the disease. Other organisms are also rubbed in if they happen to be present; they find a suitable nidus in the debilitated conjunctiva, and an acute muco-purulent conjunctivitis is superposed upon the phlyctenular disease.

Simple phlyctenular conjunctivitis is attended with few symptoms. There is some discomfort and irritation associated with reflex lacrymation. If there is no muco-purulent complication and if the cornea is not involved there is little or no photophobia.

Complications, however, are the rule, partly because the behaviour of the child conduces to them, partly because the favourite situation for the phlyctens is near the cornea. Here they are often astride the limbus. It has already been mentioned that the epithelium of the cornea is closely associated anatomically and developmentally with the

conjunctiva. It is not surprising therefore that there is a great tendency for the superficial layers of the cornea to suffer when the conjunctiva is disordered, and this is seen par excellence in phlyctenular ophthalmia. The special corneal complications will be considered later (*vide* p. 249). In all such cases lachrymation is increased, muco-purulent discharge is often present, and photophobia is intense.

The term photophobia ($\phi\acute{\omega}\varsigma$, light; $\phi\acute{o}\beta\omicron\varsigma$, fear; dread of light) is a misnomer. It is the term applied to the blepharospasm which is set up by the conjunctival, or more probably corneal, irritation, and which becomes greatly increased on the slightest attempt to separate the lids, especially if the attempt is made in bright light. This blepharospasm is not abolished in the dark; it is abolished by thorough application of cocain, though this is difficult to effect. It must be concluded therefore that it is a reflex due to afferent impulses travelling along the fifth nerve, not along the optic nerve. It has been said that light acts as the stimulus to the fifth nerve endings in the cornea. This conjecture must be regarded as a survival of the old fallacy. There is no evidence to prove—though it is not disproved—that light can stimulate the fifth nerve endings. It is far more probable that “photophobia” is due to a vicious circle of such a nature that movement of the lid over a spot denuded of epithelium, where the nerve endings are laid bare, causes reflex contraction of the orbicularis; this increases the irritation, increasing in turn the blepharospasm.

Photophobia is more intense when the phlyctens are near the cornea, than when at a distance. It varies rather with their number than their size, and is extreme if they are so numerous as to form a ring round the cornea.

Temporary blindness has been observed occasionally in children after long-continued blepharospasm. It passes off in two or three weeks and is probably functional, induced

primarily by the desire not to see and facilitated by the effect of prolonged pressure upon the globe by the tightly closed lids.

Severe blepharospasm makes the greatest care in the first examination imperative. The condition of the cornea is in all cases and at all costs to be placed beyond doubt. It facilitates investigation if the lids are gently separated and a drop of 2 per cent. cocain instilled. The child is left for 5 to 10 minutes and the eyes are then examined with all the precautions described above (p. 103).

Phlyctenular conjunctivitis shows a very marked tendency to recur at intervals during the age period which is specially concerned. These recurrences usually take place when some intercurrent malady or defective condition in the patient's surroundings leads to lowering of vitality.

Treatment.—Simple phlyctenular conjunctivitis is usually readily amenable to treatment, which must be local and general.

Local treatment consists in bathing the eyes frequently with hot boric or sublimate lotion: yellow oxide of mercury ointment, gr. iv. to viii. to ζ i., is used, a piece the size of a hemp seed being placed within the lids three times a day: the eye is gently massaged by a finger placed upon the upper lid, moving the lid upon the globe.

Ointments are best applied on a glass rod. The child is placed upon its back on a couch and an assistant holds the arms against the body, keeping the legs still by pressure with the elbows. The surgeon separates the lids with two fingers of *or.* hand and places the end of the glass rod carrying the ointment between the separated lids. Keeping the rod in position the lids are allowed to close upon its end, and it is then withdrawn by carrying it outwards towards the temple. The other end of the rod and the surgeon's other hand are used for the other eye.

If there is any corneal complication, or evidence of its imminence, atropin, gr. iv. to $\frac{5}{8}$ i., is combined with the yellow ointment.

Very frequently the soddening of the skin with tears and the wrinkling of the skin through blepharospasm cause excoriations (rhagade) at the outer canthus. They much increase the blepharospasm and should always be looked for and treated. They are very troublesome unless attacked by cauterisation. They should be touched with the sharp point of the solid silver nitrate or the mitigated silver stick.

An efficient substitute for the yellow oxide which has fallen into undeserved disuse is finely powdered calomel, dusted into the eye, best from a camel's hair brush, which is not allowed to touch the eye. It often produces a remarkable improvement in intractable cases, but it must not be employed if iodides are being given internally; under these circumstances the unstable and extremely irritating mercurous iodide is formed in the conjunctival sac.

The photophobia is best treated, when severe, in the following manner. The child's face should be plunged in cold water and the mouth and nose kept under water until he struggles for breath: this is repeated three or four times—daily if necessary. The treatment is useless if not carried out ruthlessly, but no other method is so efficacious. It is not uncommon for a single application to render further treatment of the photophobia unnecessary.

The eyes are not to be bandaged unless corneal ulceration is so severe as to assume the preponderant rôle. A shade, covering both eyes and extending well over the temples, should be ordered. Smoked glasses may be substituted, but they should not be tightly fitting goggles, which will become soiled with the discharge and are cleaned with difficulty.

General treatment is never to be neglected, otherwise recurrence is inevitable. Fresh air is the best tonic, and the children should be kept out of doors as much as possible: the windows of living and sleeping rooms must be kept open. Cold or sea-baths are useful. Good food, with a plentiful supply of fresh vegetables, is indicated. A calomel purge should initiate the general régime.

Cod liver oil and maltine are given in the cool weather and throughout the year if well tolerated. Phosphates and iodide of iron form substitutes or supplementary tonics.

General régime must be continued for a prolonged period in order to prevent recurrence, and in any case, phlyctenular ophthalmia should be regarded as a sign of debility which requires attention.

Simple Chronic Conjunctivitis occurs as a continuation of simple acute conjunctivitis, sometimes in spite of orthodox treatment, especially in the "gouty" type of patient. It is frequent when the cause of irritation is continuous—smoke, dust, heat, bad air, late hours, abuse of alcohol, and so on. A very common cause is the chronic reflex irritation induced by errors of refraction, overuse of the eyes in bright electric light, &c. Permanent irritation from concretions (*vide* p. 213) in the palpebral conjunctiva, misplaced lashes, dacryocystitis, chronic rhinitis, &c., must be remembered and as far as possible eliminated. It is often necessary to make a thorough and systematic investigation of the local and general conditions before the cause can be found. The disease is too frequently regarded as trivial, but it is a source of great discomfort to the patient, who is duly grateful for permanent relief.

Burning and grittiness are complained of, especially in the evening, when the eyes often become red. Difficulty in keeping the eyes open is a common symptom. The lids may or may not be stuck together on waking.

The discharge is slight, most frequently subnormal, so that the edges of the lids feel hot and dry.

The eyes may look quite normal on first examination. When the lower lid is pulled down the posterior conjunctival vessels are seen to be congested, and the surface of the mucous membrane is sticky. The palpebral conjunctiva, upper and lower, may be congested, with velvety papilliform roughness. Occasionally it is succulent and fleshy.

Treatment consists in eliminating the cause and restoring the conjunctiva to its normal condition. Errors of refraction are perhaps most likely to be forgotten; they should be sought out as a matter of routine. When heat is a prominent aetiological factor, *e.g.*, in cooks, spectrum blue glasses may be ordered, since they cut off the heat rays to a large extent. The treatment of the special local conditions mentioned above will be discussed in their proper place.

Local treatment consists essentially in diminishing congestion and restoring the conjunctiva to its normal suppleness and secretory activity. It must be remembered that the condition is largely one of lack of tone, due to defective response to prolonged irritation. A stimulating treatment is therefore indicated, and is supplied by astringent applications, which not only act by relieving the congestion, but also promote a more healthy lymph flow and glandular secretion.

In mild cases weak astringent lotions suffice, *e.g.*, boric lotion with zinc sulphate, gr. ii. to $\frac{3}{4}$ i., alum lotion, gr. iv. to $\frac{3}{4}$ i., &c. They should be used two or three times a day, not immediately before going to bed. Adrenalin has a transient effect in diminishing redness and itching. Boric acid ointment or sterile vaseline should be applied to the margins of the lids at bed-time.

In severer cases a preliminary painting with silver nitrate

solution is indicated, repeated once or twice a week if necessary. Silver preparations should not be ordered for application at home, since prolonged use may lead to staining of the conjunctiva (argyrosis).

Atropin, which is always resorted to by the inexperienced in intractable diseases of the eye, does much more harm than good. It causes great inconvenience from paralysis of accommodation, and has little effect upon the conjunctiva, such as it has being deleterious. Apart from this, it is extremely dangerous in elderly patients, who are specially liable to chronic conjunctivitis. In them, more than in others, there is grave danger that atropin may induce an acute attack of glaucoma, a disaster which it is impossible to overrate.

In the more severe cases of chronic conjunctivitis there is often an abnormal amount of secretion from the Meibomian glands. It should be squeezed out of the glands by pressure on the lid with the thumb against a glass rod laid upon the conjunctival surface.

Angular Conjunctivitis (*Syn.—Diphlocaillary Conjunctivitis*) is one of the few forms in which a specific organism causes a typical clinical picture. In it the reddening of the conjunctiva is limited almost exclusively to the intermarginal strip, especially at the inner and outer canthi, and to the bulbar conjunctiva in the same neighbourhood. Besides the conjunctivitis there is also excoriation of the skin at the inner and outer angles, which may be very slight, a mere scurfiness, but is nearly always present. After a few cases have been seen the typical picture is very easy to recognise, but the condition is not always typical. There is discomfort, with slight muco-purulent discharge; blinking is often complained of. If untreated the condition becomes chronic and may give rise to definite blepharitis. Clear, shallow corneal ulcers may occur, but are rare.

Pathology.—The disease is due to the Morax-Axenfeld diplobacillus (Fig. 99). The bacilli consist of pairs of large, thick rods, placed end to end. They stain well with basic stains, are decolourised by Gram, and are easily recognised in films. There is an incubation period of four days.

Treatment.—Diplobacillary conjunctivitis responds readily to zinc salts. These may be applied in the form of boric lotion with zinc sulphate, gr. ii. to $\frac{3}{4}$ i., or as drops, preferably the former. Boric ointment is applied to the lids at night.

Follicular Conjunctivitis occurs frequently in children and young adults, both eyes being affected. It is characterised by the formation of small round or oval translucent bodies, 1 mm. or 2 mm. in diameter,




FIG. 99.—Diplobacilli ($\times 1000$).

in the lower fornix (Plate IV., Fig. 2); they are less commonly seen in the upper fornix, never on the plica semilunaris or bulbar conjunctiva. They are raised above the surface, are often arranged in parallel rows, and consist of localised aggregations of lymphocytes—follicles, sometimes wrongly termed granulations—in the sub-epithelial adenoid layer.

Microscopically follicles are indistinguishable from the solitary lymph patches in the intestine, and often also from the follicles of trachoma (*q.v.*). They do not occur in the normal conjunctiva in man. The conjunctiva is not reddened or swollen. They persist for an indefinite

time, causing few symptoms, and disappear without leaving any trace, such as scarring (cf. Trachoma).

Follicular conjunctivitis is usually due to overcrowding, living in badly ventilated rooms, especially schoolrooms, and so on. Isolated follicles may occur in the outer part of the lower fornix in any chronic conjunctivitis of long standing. They may be due to overuse of atropin or eserin (*vide* p. 210). The children are seldom robust, and adenoid vegetations in the throat, which are of a similar nature, are often present. The disease is probably not contagious, and never develops into trachoma, as has been held by some good observers.

Treatment—Follicular conjunctivitis seldom requires local treatment. A weak astringent lotion may be ordered, and yellow oxide of mercury introduced within the lids once or twice a day. If the follicles are very large painting with silver nitrate solution will do good. Atropin, if in use, should be stopped or replaced by an equivalent (*vide* p. 210).

Special attention should be directed to the refraction, and any errors corrected.

The general health and surroundings must be investigated and put upon a sound basis.

Trachoma (*Syn.*—*Granular Conjunctivitis*) is a much more serious form of folliculosis, which is responsible for the blinding of enormous numbers of people in places where it is endemic. Both eyes are almost always affected. It may be stated at once that in England it is a rare disease except where large numbers of Irish or aliens are herded together.

In making a diagnosis the relative frequency of various forms of disease should always be borne in mind. It is a truism, but it is often disregarded, that an unusual type of case is less likely to be a rare disease than an unfamiliar manifestation of a common one. A better class child with

follicles in the conjunctiva is most unlikely to be a case of trachoma, whereas, if the child goes to a board school in the east end of London, where there are large numbers of trachomatous aliens, the distinction of follicular conjunctivitis from trachoma becomes a matter of great difficulty.

The changes met with in the conjunctiva in trachoma are of two types, which are often present simultaneously. The *papillary* type is not specially characteristic; it is usually a more definite form of the papillary enlargement and congestion which is met with in other severe forms of conjunctivitis. The conjunctiva covering the upper tarsus is most affected, and appears red and velvety. This condition may pass into one with more uniform jelly-like thickening. Only in the comparatively infrequent cases in which no follicles can be seen will the true disease pass wholly unsuspected.

The *follicular* type (Fig. 100) manifests itself in the presence of follicles in the conjunctiva. When small they cannot be distinguished from the follicles of follicular conjunctivitis, and microscopical examination shows that they are fundamentally identical. They often, however, assume a size and appearance which is seldom or never seen in follicular conjunctivitis, but they differ most in having a characteristic distribution. The large follicles may be 5 mm. or 6 mm. in diameter. They are translucent, and look like grains of boiled sago ("sago grains").

The follicles usually commence in the lower fornix, but in most cases they quickly appear in the upper also. Unlike what obtains in follicular conjunctivitis they are not limited to the fornices. They often form a row along the upper margin of the upper tarsus, whence they invade the palpebral conjunctiva, appearing upon the tarsal surface, though they are less numerous in this situation.

They are common about the caruncle, and may be seen on the plica semilunaris. They are very rare on the bulbar conjunctiva, but when seen here they are pathognomonic of trachoma.

The disease is very chronic and leads to much irritation, photophobia, lachrymation, &c., with some mucopurulent discharge. In certain districts abroad trachoma is endemic, and a very acute form is observed. It is very doubtful if true acute trachoma is ever seen in England: what usually passes for it is of quite different origin. It is due to the lowering of resistance of the trachomatous conjunctiva, whereby it becomes specially liable to inter-

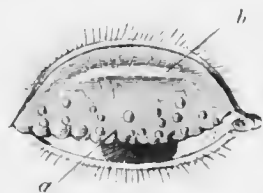


FIG. 100. — Trachoma. (Nettleship.) *a*, trachoma follicles; *b*, scar in typical position, parallel with the edge of the lid.

current attacks of other forms of acute conjunctivitis. This is facilitated by the irritation, which leads to rubbing of the eyes, so that contamination is readily brought about. The so-called acute trachoma met with in England is therefore chronic trachoma upon which an acute mucopurulent or purulent conjunctivitis has been engrafted.

Trachoma is an extremely contagious disease. Pathological anatomy reveals nothing characteristic, for it is doubtful if the recently discovered "trachoma bodies" are truly pathognomonic: there is lymphocytic infiltration of the whole of the adenoid layer of the parts of the conjunctiva affected. Special aggregations of lymphocytes, without a definite capsule, form follicles which are generally indistinguishable from those of follicular conjunctivitis. In late stages and large follicles the stroma and cells tend to become hyaline and gelatinous: sometimes the surface becomes broken and the contents are extruded into the conjunctival sac. In other cases a

fibrous capsule forms around the follicles, which thus become isolated: more and more fibrous tissue is laid down, giving rise to cicatricial bands such as are never formed in follicular conjunctivitis, and are very characteristic.

Bacteriology has failed to elucidate the pathology of the disease. Various specific organisms have been described, but all have failed to resist criticism.

Trachoma is endemic in many parts of the world, *e.g.*, Russia, Poland, East Prussia, parts of Austria-Hungary, Egypt, &c. It shows a predilection for certain races, *e.g.*, Irish, Jews, but it is not a racial disease; the predilection depends upon the mode of life of the individuals. Extended observation militates against the view that any race is exempt.

The disease flourishes amongst people who are crowded together in unhealthy rooms—in armies, navies, asylums, workhouse schools, &c.—wherever the lower classes are herded together. Children and debilitated adults are most susceptible, but the robust are not exempt. It is commoner in low-lying, damp districts.

The disease is spread by transference of conjunctival secretion by means of fingers, towels, &c. The presence of much discharge, whether of true trachomatous origin or due to intercurrent conjunctivitis, increases the liability of contagion. On the other hand, scrupulous cleanliness suffices to prevent the extension of the disease to healthy subjects.

Complications.—Whilst trachoma very rarely affects the bulbar conjunctiva it not infrequently attacks the cornea.

Trachomatous pannus is a lymphoid infiltration, with vascularisation, of the margin of the cornea, usually limited to the upper half (Figs. 101, 67 C), but tending to spread towards the centre and to involve the whole cornea. The upper part of the margin of the cornea becomes

cloudy, and minute superficial vessels, springing from the corneal loops, grow inwards towards the centre. The haziness and vascularisation increase until the upper half of the cornea is affected. The vessels are all superficial (*vide* p. 106), and microscopic examination has shown that they lie at first between Bowman's membrane and the epithelium. They carry in with them a small amount of granulation tissue. In later stages Bowman's membrane disappears and the superficial layers of the substantia propria become involved.

In progressive pannus the vessels are mostly parallel to each other and directed vertically downwards, anastomosing little. They extend to a level which forms a horizontal line, and beyond this line there is a narrow strip of infiltration and haze. In regressive pannus, on the other hand, the vessels extend a short distance beyond the area which is infiltrated and hazy: this difference is useful in estimating the results of treatment.

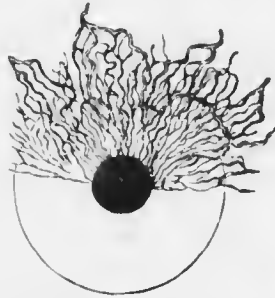


FIG. 101. — Trachomatous-pannus. (Nettleship.)

In more severe cases the vascularisation is not limited to the upper part, but superficial vessels grow in from all sides and the whole cornea becomes vascularised and opaque.

Pannus is not due to the rough upper lid rubbing upon the cornea. This is doubtless a predisposing factor, but in many conditions in which the lids are rough from some other cause pannus does not occur. It is not due to continuity, since the bulbar conjunctiva from the limbus to the fornix is unaffected. It is induced by contiguity, probably by direct infection, and this part of the cornea is most affected because it is covered by the lid both day and night.

It may resolve completely, leaving the cornea quite clear, but only in cases treated early, when the vessels have not yet destroyed Bowman's membrane. In other cases a permanent opacity results. Occasionally the corneal substance becomes weakened so that the cornea bulges under normal intraocular pressure and ectasia follows (keratectasia).

Corneal Ulcers are commonest at the advancing edge of the pannus. They are shallow, little infiltrated, and very irritable, causing much lachrymation and photophobia. Indolent central ulcers may form, or there may be ulcers in any part of the cornea, but especially over the pannous area.

Sequela.—Apart from the results of pannus and corneal ulceration the most malign effects of trachoma are caused by distortions of the lids. A peculiar drooping of the upper lids is very characteristic (*trachomatous ptosis*). It gives a sleepy appearance to the patient. There is always some scarring (Fig. 100), and when this is extensive the shape and position of the lids, especially the upper, are altered. Through the great swelling of the conjunctiva they may be turned outwards (ectropion), and through the later contraction of the scar tissue they may be turned inwards (entropion), causing the lashes to rub against the cornea (trichiasis), &c. (See Chap. XXIX.)

Treatment.—If there is much discharge the case must first be treated with a view to diminishing it and reducing congestion. The lids should be painted once daily with silver nitrate solution; sublimate lotion should be thoroughly used three or more times a day, and boric ointment applied to the edges of the lids at bed-time.

In a few days the conjunctivitis will be much less, and an attempt must be made to get rid of the follicles. In relatively slight cases this is best affected by scouring the conjunctiva with a smooth crystal of copper sulphate. The crystal is fixed in a wooden holder and is pointed at the end.

The lids are everted, and the point of the copper stick is pushed well up into the upper fornix and moved from one side to the other, the lid being lifted away from the globe by the stick during the manœuvre so as to avoid touching the cornea. The stick is then rubbed firmly over the whole of the palpebral conjunctiva.

The application of the copper stick is very painful, especially during the first few applications. Cocain may be previously instilled, but it does not prevent the intense smarting. It is important to start with the upper fornix, since this is most affected and most difficult to reach: if it is not done first blepharospasm and the struggles of the patient will make it impossible afterwards. It is useless to apply copper too gently: it must be firmly rubbed into the conjunctiva. Some of the sulphate dissolves in the tears, and should be mopped up with a pad of dry wool, since it is very irritating to the cornea. Pannus is no contraindication to the use of the copper stick, but quite the reverse: copper sulphate applied to the lids is the best treatment for pannus. The pannus itself is not treated directly at all. On the other hand, corneal ulceration of any kind or degree is an absolute contraindication: in these cases, even if pannus is present, reliance must be placed on silver nitrate until the ulcers are healed. Unfortunately silver has little specific influence over the trachomatous process, whereas that of copper is undoubted.

The copper stick must be applied once daily, otherwise the case is certain to run on indefinitely. Sublimate lotion is ordered for home use as before.

In most cases of trachoma the treatment advised will suffice to bring about that condition of amelioration which is usually described as cure. Relapses are common, occurring sooner or later, according to the length and assiduity of treatment. I am doubtful myself whether trachoma is ever really cured by the methods adopted.

In severer cases more drastic remedies must be employed. Probably the best of the stronger applications is a concentrated solution of perchloride of mercury in glycerine. It has been used as strong as 4 per cent.; under these circumstances it acts as a caustic. It is painted on the fornix and everted lids. This treatment is almost unbearably painful, and is followed by intense reaction, the conjunctiva and lids becoming enormously swollen. The pain lasts for several hours, gradually diminishing in intensity. Ice, or lint wrung out in iced water, should be applied to the lids immediately after the application. There is no doubt that much benefit is derived from the treatment.

When the follicles are numerous and very prominent the treatment is shortened by attacking them mechanically. It may be done by various forms of scarification or expression. In performing any operation upon trachomatous patients protective goggles must be worn by the surgeon and the immediate attendants.

The conjunctiva is first thoroughly cocaine'd. Scarification may be performed with the finger nails—an objectionable practice—or by a knife or sharp needle.

In *expression* one of the many forms of expressor is used—*e.g.*, Graddy's forceps (Fig. 102), Knapp's roller forceps (Fig. 103). The upper lid is everted, and one limb of the forceps is pushed up into the fornix, the other being laid upon the palpebral conjunctiva. The two limbs are



FIG. 102.—Graddy's forceps.


then pressed together with moderate force and are drawn in a horizontal direction from one end of the fold to the other. The fold of the fornix should in this manner be thoroughly mangled, and all the follicles squeezed out. Some recommend the immediate application of sublimate solution (1 in 2000), but it is best simply to apply cold compresses, since there is always considerable reaction.

If the follicles in the upper fornix are very large and closely packed it is well to commence treatment by excising the fornix. There is always a redundancy of tissue here, and no evil results ensue. The upper lid is everted doubly (*vide* p. 94) so as to expose the retrotarsal fold completely. A silk suture is then passed through the fold at each end. By dragging on the sutures the whole fold is drawn out. It is then excised with scissors.

Pannus requires no special treatment, but corneal ulcers must be treated on general principles (*vide* p. 231).

Hygienic treatment must be carried out so far as practicable. The influx of aliens into the east end of London has made trachoma a serious menace to our own population. The exclusion of trachomatous aliens is urgently demanded. The isolation of trachomatous school children is being carried out by the Metropolitan Asylums Board.

Tubercle of the Conjunctiva is rare: it nearly always produces ulceration. Conjunctival ulceration should always suggest either the presence of an imbedded foreign body or a tuberculous or syphilitic lesion.



FULL SIZE
FIG. 103.
Knapp's roller
forceps.

Tubercle occurs in several forms: (1) small miliary ulcers usually on the palpebral conjunctiva; (2) granules on the palpebral conjunctiva resembling trachoma follicles (Fig. 104); (3) gelatinous cockscomb like excrescences on the fornices; (4) polypoid pedunculated outgrowths. The conjunctiva may be affected by extension of lupus from the face.

The preauricular gland is often enlarged and may suppurate. The disease is chronic, and the ulcers are indolent. The patients are usually young, and often free from clinical signs of tuberculous disease elsewhere in the body. There is very little doubt that the lesion may be the primary seat of tubercle, the bacilli being inoculated into minute abrasions, which are probably always present in the conjunctiva, caused by dust. There is little pain or irritation unless the ulceration is extensive.

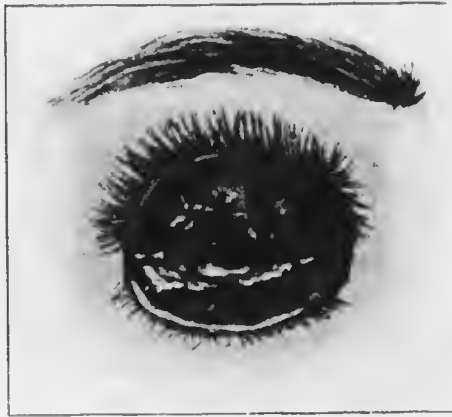

FIG. 104. — Tubercle of the conjunctiva (After Eyre.)

It is not improbable that the second type is frequently mistaken for trachoma, and it is possible that it is cured by the treatment founded on the wrong diagnosis.

Pathology. — Scrapings may show tubercle bacilli. Sections show typical giant-cell systems. In doubtful cases inoculation experiments should be made.

Treatment. — The disease should be eradicated, more especially as being often the primary focus. The affected

conjunctiva should be excised, or if this is not feasible, thoroughly scraped and cauterised.

Injections of the latest form of tuberculin have given encouraging results, and subconjunctival injections of 2 per cent. guaiacol cacodylate may be employed.

Extension to the globe is probably rare. If prolonged treatment fails and the disease spreads it may be necessary to excise the eye.

Syphilis rarely manifests itself in the conjunctiva. Ulceration of the palpebral or still more of the bulbar conjunctiva is always suggestive of the condition. (*See* Chap. XXIX.)

Some Rarer Forms of Conjunctival Inflammation.—One or two rarer forms of inflammation of the conjunctiva demand passing notice since they may be mistaken for those already described.

Conjunctivitis caused by Drugs (Atropin Irritation, &c.).—Some people are particularly susceptible to atropin, and more rarely to eserin and other drugs, locally applied to the conjunctiva. The lids become swollen, tense, and red, in fact erysipelatous. Examination of the conjunctiva will often show follicles, and even rarely a membrane. The cause is obscure: sometimes the condition seems to be due to a special solution or brand of the drug, owing to some impurity. Workers with crysophanic acid suffer from conjunctival irritation, and prolonged internal administration of arsenic causes the same effect. The dust of teak wood is particularly irritating to the conjunctiva.

Treatment.—In atropin irritation the drug should be avoided. If a mydriatic is imperative, some other should be substituted, *e.g.*, duboisin sulphate, 0·5 per cent.; scopolamin hydrobromide, 0·25 per cent. to 0·5 per cent., or hyosein, 0·5 per cent., may be used, but toxic symptoms sometimes occur. It is said that atropin may be continued

if it is scrupulously kept away from the skin by covering the lids with glycerine or ointment up to the margins.

The conjunctiva soon recovers after cessation of the cause, but astringent lotions accelerate the cure.

Spring Catarrh (*Syn.—Vernal Catarrh*).—This is a recurrent conjunctivitis occurring with the onset of hot weather, and therefore rather a summer than a spring complaint. It is found in young people, usually boys, associated with the usual symptoms of mild conjunctivitis.

Burning, itching, some photophobia, and lachrymation are the chief symptoms. Both eyes are affected. In the cooler months the condition subsides and gives no trouble, but recurs with the return of heat.

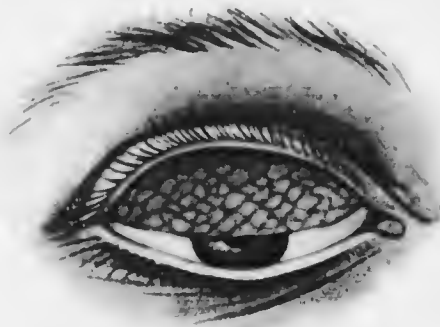

FIG. 105.—The palpebral form of spring catarrh.

The disease is met with amongst all classes, is sporadic, and non-contagious. It has been attributed on insufficient grounds to the action of the actinic rays of the spectrum.

Two types of objective signs are met with: (1) the palpebral form; (2) the bulbar form; both may be combined, but this is relatively rare. The palpebral form is easily recognised if typical. On everting the upper lid the palpebral conjunctiva is seen to be hypertrophied and mapped out into polygonal raised areas, not unlike cobblestones (Fig. 105). The colour is bluish white, like milk, and this appearance is seen also over the lower palpebral conjunctiva.

The flat-topped nodules are hard, and consist chiefly of dense fibrous tissue, but the epithelium over them is thickened, giving rise to the milky hue. In vertical section they resemble circinnvallate papillae. Eosinophile leucocytes are present in them in great numbers and may be found in the secretion.

The palpebral form cannot be mistaken if typical, but it may resemble trachoma. The type of patient, the milky hue, the freedom of the fornix from implication, and the characteristic recurrence in hot weather will usually prevent mistake.

The bulbar form is less characteristic. In it there is a wall of thickening at the limbus, more gelatinous in appearance, and also milky. It may be mistaken for phlyctenular conjunctivitis.

In both forms the lesions persist during the cold months, though they are less marked.

Serious complications never supervene, and the ultimate prognosis is good.

Treatment is purely symptomatic. Tinted glasses should be worn. The irritation is best relieved by very weak acetic acid, gr. i. to ʒ vi. Adrenalin gives temporary relief. Gentle massage with the upper lid after application of yellow oxide of mercury ointment or 1—2 per cent. guaiacol ointment is beneficial. Astringents are harmful; boroglyceride has been recommended, with arsenic internally. Excision of the nodules, sometimes advised, seems to be useless.

Ophthalmia nodosa is a nodular conjunctivitis which may be mistaken for tubercle—pseudo-tuberculous disease of the conjunctiva. It is due to the irritation of the hairs of certain caterpillars, and therefore always commences in the late summer months. Small semitranslucent, reddish, or yellowish grey nodules are formed in the conjunctiva and sometimes in the iris. On microscopical examination

hairs surrounded by giant cells and lymphocytes are found.

Treatment.—The nodules in the conjunctiva should be excised. Otherwise the condition is treated on general principles.

Electric Light Ophthalmia (Photophthalmia).—The ultraviolet rays of the electric light, especially of the arc lamp, may cause extreme burning pain, lachrymation, photophobia, blepharospasm, and swelling of the palpebral conjunctiva and retrotarsal folds, coming on a few hours later.

Treatment.—Cold compresses, dark glasses, and astringent lotions.

Snow Blindness.—The cause and symptoms of snow blindness are the same as of electric light ophthalmia. Smoked or orange tinted (not blue) glasses should be used as a prophylactic measure. The treatment is the same as for electric light ophthalmia.

DEGENERATIVE CHANGES IN THE CONJUNCTIVA.

Concretions (*Syn.*—"Lithiasis").—Concretions occur as minute hard yellow spots in the palpebral conjunctiva. They are due to the accumulation of epithelial cells and inspissated mucus in depressions which are called Henle's glands. They never become calcareous, so the term is a misnomer, but they are so hard that when they project from the surface they scratch the cornea and give the sensation of a foreign body in the eye. They are common in elderly people. There is no reason to attribute them to gout, but uric acid deposits have been observed in the palpebral conjunctiva of gouty patients. Concretions should be removed with a sharp needle.

Pinguecula is a triangular patch on the conjunctiva, found usually in elderly people, especially those exposed to

dust, wind, and so on. It occurs in the direction of the palpebral aperture, the apex of the triangle being away from the cornea. It affects the nasal side first, then the temporal. It is yellow in colour and looks like fat, whence the name (*pinguis*, fat). It is not due to fat, but to an excessive development of yellow elastic fibrous tissue. It is particularly conspicuous when the eye is inflamed, since the pinguicula remains relatively free from congestion: mistakes in diagnosis may then occur. It requires no

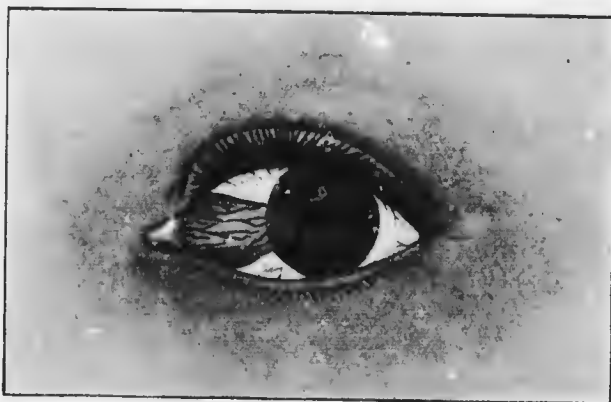

FIG. 106. Pterygium.

treatment, but may be removed if the disfigurement is great.

Pterygium (*πτερυξ*, a wing).—This is a peculiar encroachment of the conjunctiva on the cornea (Fig. 106). It is triangular in shape, and when single is always upon the nasal side; when double the temporal one has developed later. It is derived from pinguicula. It must be carefully distinguished from *pseudo-ptyerygium*, which is due to the tip of a fold of chemotic conjunctiva becoming adherent to an ulcer within the corneal margin. It may occur at any part of the cornea. The conjunctiva then forms a bridge over the limbus, and a fine probe can always

be passed beneath it, which is not possible with a true pterygium.

The apex of the pterygium is usually blunt; there is no ulcer in the cornea beyond it, as formerly described, but there are often small opacities. In the early stage the pterygium is thick and vascular; it advances over the cornea and may reach the pupillary area and interfere with vision. When it ceases to grow it becomes thin and pale, but never disappears.

The true pterygium is a single layer of conjunctiva, adherent in its whole length to the sclerotic and cornea, though only loosely, except at the apex. The area of adhesion is always smaller than its breadth, so that there are folds at the upper and lower borders.

Pterygium is not due to a fold of conjunctiva being dragged across the cornea by a progressive ulcer as was once taught. It is probably due to malnutrition of the cornea, resulting from the pinguecula. Granulation tissue grows in and invaginates the epithelium, destroying Bowman's membrane. When it ceases to progress dense fibrous tissue is formed.

Treatment.—Pterygium is best left alone unless it is progressing rapidly towards the pupillary area, or is very disfiguring. The latter reason is not of much weight, since it cannot be removed without leaving a scar.

The apex of the pterygium may be destroyed with the actual cautery. Removal is effected by seizing the neck, near the corneal margin, with fixation forceps, raising it, and shaving or dissecting the apex from the cornea. Care must be taken not to go too deep. The pterygium is freed from the sclerotic for about half the distance towards the canthus. Two converging incisions with scissors separate the apex and greater part of the body. The conjunctiva is then freed from the sclerotic above and below so as to admit of the two edges being sutured together.

Pterygium sometimes recurs after removal. This may be only apparent, owing to vascularisation of the denuded area. If it actually re-forms and extends towards the pupillary area, it must again be removed.

SYMPTOMATIC CONDITIONS.

Subconjunctival Ecchymosis, due to the rupture of small vessels, frequently occurs. It may be the result of direct injury, or, more commonly, occur spontaneously. Very minute ecchymoses, or possibly thromboses, are seen in severe conjunctivitis, especially pneumococic. Larger ones accompany severe straining, especially in old people, *e.g.*, on lifting heavy weights, vomiting, &c. In these circumstances they indicate a weakness of the vessel walls, and should be regarded as a danger signal. Other signs of arterio-sclerosis should be sought in the fundus oculi and elsewhere, and, if found, warning of the possibility of cerebral hæmorrhage given, with appropriate instructions for its avoidance. Very frequently no such signs can be discovered, and the condition, though unsightly, is trivial. Subconjunctival ecchymoses are not infrequently seen in children with whooping cough: they need arouse no anxiety.

More serious are the large subconjunctival ecchymoses which sometimes follow blows or falls on the head. They may then be due to extravasation of blood along the floor of the orbit, the result of a fractured base.

The importance of subconjunctival hæmorrhage is always symptomatic, since the eye itself is never endangered.

Treatment.—The blood becomes absorbed in from one to three weeks without treatment. Boric lotion is usually ordered as a placebo. Dionin may be used to accelerate absorption in young patients, but should not be employed in elderly subjects with arteriosclerosis.

Xerosis (*Syn.*—*Xerophthalmia*) (*Ξηρός*, dry) is a dry, lustreless condition of the conjunctiva which occurs in two groups of cases: (1) as a sequel of local ocular affection: (2) associated with general disease.

The first type is a cicatricial degeneration of the conjunctiva—(a) following trachoma, burns, pemphigus, diphtheria, &c., commencing in isolated spots, ultimately involving the whole conjunctiva and cornea; (b) following exposure, due to ectropion or proptosis, whereby the eye is not properly covered by the lids. As the result of the rare affection of the conjunctiva with pemphigus the cicatricial contraction of the conjunctiva may be extreme and progressive, a sort of keloid condition being induced (*essential shrinking of the conjunctiva*): the lids may then be quite adherent to the globe, the cornea being opaque like skin.

In the other group of cases xerosis occurs in a mild form, found in children, usually boys, accompanied by night blindness (Chap. XX.), and characterised by small triangular white patches on the outer and inner sides of the cornea, covered by a material resembling dried foam, which is not wetted by the tears. The cases usually occur during the summer months, and the children are not conspicuously ill-nourished. A similar mild form, also associated with night blindness, is met with in adults in some countries, *e.g.*, India, but seldom if ever in England. A severe form is found in marasmic children, associated with keratomalacia (*vide* p. 253) and necrosis of the cornea.

Pathology.—The chief changes are in the epithelium, which becomes epidermoid, *i.e.*, exactly like that of skin, with granular and horny layers. The foamy spots are due to horny epithelium, which becomes cast off into the conjunctival sac and accumulates in the lower fornix. Owing to this change the epithelium ceases to secrete mucus. It becomes dry: a certain amount of vicarious

activity is set up in the Meibomian glands (Chap. XXIX.), which cover the surface with their fatty secretion. The watery tears then fail to moisten the conjunctiva. The so-called xerosis bacilli, which are pseudo-diphtheria bacilli, grow profusely under these conditions, but they have no causal relationship and are of no importance.

It is to be noted that xerosis has nothing to do with any failure of function on the part of the lacrymal apparatus. The conjunctiva can be quite efficiently moistened by its own secretions alone. If the lacrymal gland is extirpated xerosis does not follow. If on the other hand the secretory activity of the membrane itself is impaired xerosis follows, in spite of normal or increased lacrymal secretion.

Treatment.—Xerosis is a symptom, and its treatment must therefore be purely symptomatic. Local treatment consists in relieving the dryness with boric acid ointment, olive oil, milk, weak alkaline solutions, &c. : smoked glasses should be worn.

In the marasmic cases restoration of normal nutrition is the all-important aim, though the patients have often gone too far.

CYSTS AND TUMOURS.

The only common **cysts** found in the conjunctiva are due to dilatation of lymph spaces. When small these often form rows of little cysts on the bulbar conjunctiva (*lymphangiectasis*). Occasionally single, though multilocular, cysts occur (*lymphangioma*). Larger retention cysts of Krause's accessory lacrymal glands occur in the upper fornix (Chap. XXIX.). Subconjunctival cysticercus and hydatid are rare in England. Non-parasitic cysts require simple removal of the anterior walls.

Tumours of the conjunctiva have all a tendency to be

polypoid, owing to the perpetual movements of the globe and lids.

Papillomata occur at the inner canthus and in the fornices. In the latter position they may be mistaken for the cockscomb type of tubercle, but the individual leaflets may be separated by a probe. They should be snipped off.

Simple Granulomata, generally polypoid, often grow from tenotomy wounds or the sites of foreign bodies. They consist of ordinary exuberant granulation tissue. They



FIG. 107.—Dermoid of the conjunctiva, in a somewhat unusual situation. Note the hairs.

are common in empty sockets after excision, and at the site of chalazions which have been insufficiently scraped (Chap. XXIX.). They should be removed by scissors.

Fibromata, also generally polypoid, occur in sockets. They may be soft or hard, and require simple removal.

Nevi or *congenital moles* are not uncommon. They are white gelatinous or pigmented nodules situated by preference at the limbus or near the plica semilunaris. They have the same structure as in the skin—groups, often alveolar, of “nevus cells” in close connection with the epithelium. They are congenital and tend to grow at

puberty, rarely becoming malignant. They should be excised.

Dermoids are lenticular yellow tumours, usually astride the corneal margin, most commonly at the outer side (Fig. 107). Not infrequently there is a notch in the upper lid corresponding with the position of the tumour. They consist of skin in an abnormal situation, with epidermoid epithelium, hairs, sebaceous glands, &c. They

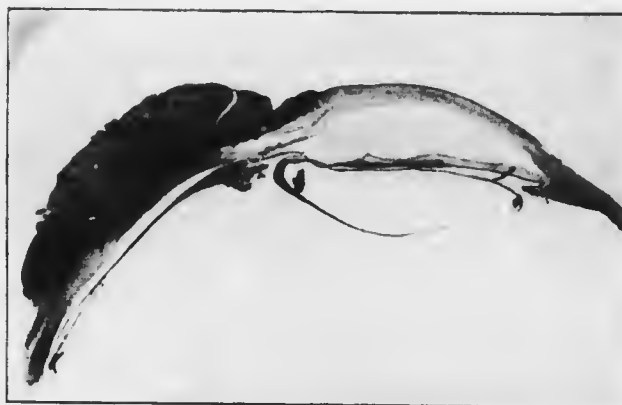


FIG. 108.- Epithelioma of the conjunctiva, from a section ($\times 6$).

are congenital and tend to grow at puberty. They should be removed.

Dermo-lipomata or *fibro-fatty tumours* are congenital tumours found at the outer canthus in babies. They consist of fibrous tissue and fat, sometimes with dermoid tissue on the surface. They are not encapsuled. The main mass should be removed, but it will be found that the fat is continuous with that of the orbit: care must be taken not to injure the extrinsic muscles.

Sarcoma is rare. It occurs at the limbus, is usually pigmented, and most of the patients have been old. Sarcomata spread over the surface of the globe, but rarely penetrate it. Recurrence and metastasis occur as

elsewhere in the body. They may be alveolar—derived from naevi—or round or spindle celled. They must be removed as freely as possible and examined microscopically. On the slightest sign of recurrence the eye must be excised, and if recurrence again takes place the orbit must be exenterated.

Epithelioma occurs par excellence where one kind of epithelium passes into another, hence in the eye chiefly at the limbus (Fig. 108), and at the edges of the lids. Papillomata in old people often take on malignant proliferation. Like sarcomata, epitheliomata spread over the surface and into the fornices, rarely penetrating the globe. They have the characteristic structure. The treatment is the same as for sarcoma: it is well in both cases to cauterise the base with the actual cautery after the first removal.

CHAPTER XI.

DISEASES OF THE CORNEA.

The special importance of diseases of the cornea depends upon the fact that they often leave permanent opacities which seriously lower the visual acuity, whilst the complications which not infrequently attend them may lead to the loss of the eye.

INFLAMMATION OF THE CORNEA (KERATITIS).

Inflammation of the cornea may be purulent or non-purulent. An immense amount of research has been devoted to inflammation of the cornea from the earliest investigations of Bowman (1849) onwards, and much of our knowledge of inflammation in general is derived from these researches.

Purulent Keratitis, Ulceration of the Cornea.—Purulent keratitis is nearly always exogenous, *i.e.*, it is due to pyogenic organisms which invade the cornea from without. The first line of defence is the epithelium. It has been pointed out that the only organisms which are known to be able to attack normal epithelium are the gonococcus and the diphtheria bacillus; but many other bacteria are capable of producing ulceration, notably the pneumococcus.

When we remember the exposed position of the cornea it is not surprising that minute abrasions are extremely common. They are probably of everyday occurrence, but other factors have also to be reckoned with. Pathogenic organisms of high virulence are not always present

in the conjunctival sac, and if they are, as is often the case, the resistance of the normal tissues has to be taken into account. It is too often forgotten that normal tissues with a healthy blood supply and lymph flow are well armed against any but the most virulent invaders. Even with these prolonged contact is usually necessary.

Apart from actual abrasions many causes of diminished resistance of the epithelium are met with. Such are drying, as in xerosis, necrosis due to deficient nutrition, as in keratomalacia, desquamation as the result of œdema or neuro-paralytic keratitis. If cocaine is instilled too freely, especially if the lids are not kept closed in the intervals, the epithelium becomes dull and is finally thrown off. Hence this drug is to be used with caution and only under supervision; it should seldom if ever be given in lotions for use at home.

Malnutrition affects not only the epithelium but also the whole cornea. In badly nourished cornea ulceration is apt to be deep, leading to early perforation, and also extensive, resulting in widespread necrosis. Such septic ulcers, due to the attack of ordinary pyogenic organisms, occur after injuries in asthenic conditions in keratomalacia, lagophthalmia, &c. Corneal ulcers are much commoner in the lower orders, doubtless owing to the defective resistance of the tissues and the more frequent exposure to injury.

In the commonest form of suppurative keratitis—the corneal ulcer—there is localised necrosis in the most anterior layers of the cornea. The sequestrum is partly disintegrated and cast off into the conjunctival sac, and partly adheres to the surface of the ulcer. Usually the epithelium is destroyed and cast off over an area considerably larger than the ulcer itself, and the same applies to Bowman's membrane. The epithelium, however, rapidly advances towards the ulcer, grows over its edge, and even over the slough or pus which forms the floor.

The ulcer is usually saucer-shaped, and the walls project above the normal surface of the cornea (Fig. 109), owing to the imbibition of fluid by the corneal lamellæ, which causes them to swell. The spaces between the lamellæ are packed with leucocytes for some distance around the ulcer, appearing as a grey zone of infiltration. This is the progressive stage.

A line of demarcation forms as in necrosis elsewhere in the body. The toxins are most concentrated near the centre where there are most organisms. A wall of polymorphonuclear leucocytes forms a second line of defence. At a certain distance the tissues are protected:




FIG. 109. Vertical section of a corneal ulcer, showing infiltration of the substantia propria.

here the leucocytes are not paralysed or killed by toxins, but exert their digestive functions, macerating and dissolving the necrotic tissues. When the dead material has been thrown off the ulcer is somewhat larger, but the cloudiness has disappeared, the floor and edges are smooth and transparent, and the regressive stage is reached.

Meanwhile vascularisation has been going on (Plate V., Fig. 1). Minute superficial vessels grow in from the limbus near the ulcer. They supply the pabulum to restore the loss of substance. Sometimes they are so exuberant as to overstep the limits of utility, *e.g.*, in fascicular ulcer (*vide* p. 250).

When the ulcer has become vascularised, everything is prepared for cictrisation, which is carried out exactly

et
to
h
re
r,
ne

in
ne
of
of
l:



PLATE V. (No. 521)

1 - 1 - 2 - 1 - 1
1 - 1 - 2 - 1 - 1



as,
nd
ad
he
th

s,
us
he
to
er

is
ly

521/0

PLATE V. (To face p. 221.)

Fig. 1.—Nebula, with recent vascular ulcer.

Fig. 2.—Phlyctenular pannus.

PLATE V.



FIG. 1.

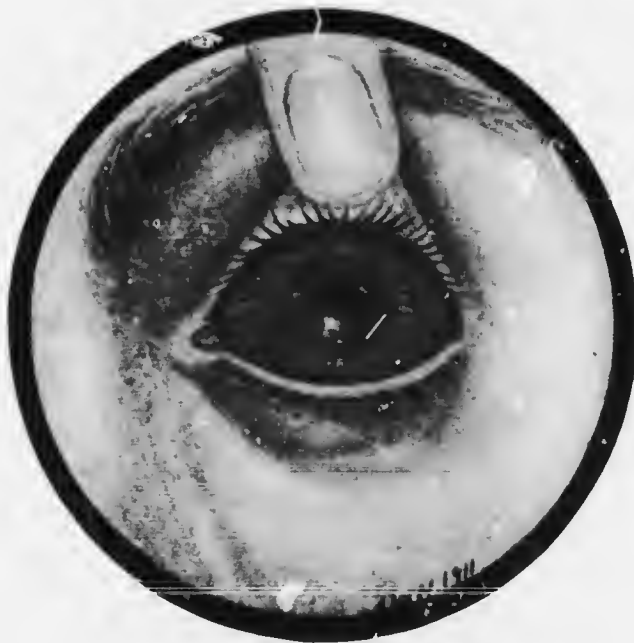

FIG. 2.

as in other connective tissues. The fixed connective tissue cells, here the corneal corpuscles, divide and form masses of nucleated spindle-shaped cells, over which the epithelium grows and is lifted to its normal level. The nuclei and vessels gradually disappear, and a mass of fibrous tissue is formed. The fibres are not arranged regularly like the normal lamellæ, so that they refract the light in various directions: the scar is, therefore, more or less opaque according to its thickness. If it is very large and dense some of the larger vessels persist permanently; the smaller ones disappear. Bowman's membrane is never regenerated, and if it has been destroyed, as is the case in all but very superficial abrasions, some degree of permanent opacity remains.

During the progressive stage there is lachrymation, photophobia, and pain, owing to the exposure of the fibrils of the ophthalmic division of the fifth nerve. Some of the toxins elaborated by the bacteria diffuse through the cornea into the anterior chamber, just as atropin does when instilled into the conjunctival sac. Here they exert an irritative effect upon the vessels of the iris and ciliary body, so that hyperæmia of the iris, with or without definite ciliary injection, occurs. The irritation may be so great that leucocytosis takes place, and polymorphonuclear leucocytes are poured out by the vessels of the iris and ciliary processes. They pass into the aqueous and gravitate to the bottom of the anterior chamber, where they form an *hypopyon* (Fig. 125).

There are several important facts about hypopyon which must be borne in mind. The pus cells do not come from the cornea, as was once thought. This is proved by the following facts: (1) Descemet's membrane is impermeable to leucocytes, though fluids readily pass through it; (2) the cells sometimes contain pigment granules, obviously derived from the uveal tract; (3) it

the ulcer has not perforated the hypopyon is sterile. The last fact is of the greatest importance, both theoretically and practically. It shows that the leucocytosis is due to toxins, not to actual invasion of bacteria, which, indeed, are as incapable of passing through the intact Descemet's membrane as are leucocytes. It accounts for the ease and rapidity with which hypopyon is often absorbed: it may develop in an hour or two, rapidly disappear, and as readily reappear. Such hypopyons are very fluid, always moving to the lowest part of the anterior chamber if the position of the patient's head is changed. The fact that the hypopyon is sterile has great practical importance—it is unnecessary to remove the pus, as is the rule in all other parts of the body; if the ulcerative process can be stopped the hypopyon will be absorbed.

The hypopyon may be so small that it is scarcely visible, being hidden behind the rim of sclera which overlaps the cornea. It may reach half way up the iris, having a flat upper surface in accordance with the laws of gravity. It may fill the anterior chamber, wholly obscuring the iris. The larger hypopyons are usually less fluid, owing to the formation of a fibrinous network which imprisons the leucocytes in its meshes. Such hypopyons are much less readily absorbed, and it may be necessary or advisable to evacuate them.

The scar tissue which replaces the destroyed portions of the cornea usually fills in the gap exactly, so that the surface is level. If it is thin the resulting opacity is slight and is called a *nebula* (Plate V., Fig. 1); if rather more dense it is sometimes called a *macula*; if very dense and white it is called a *leucoma*. A thin, diffuse nebula covering the pupillary area interferes more with vision than a strictly localised dense leucoma, so long as the latter does not block the whole pupillary area. The reason is that the leucoma stops all the light which falls upon it

nebula
macula
leucoma

(Fig. 110), whereas the nebula refracts it irregularly, allowing many of the rays to fall upon the retina, where they blur the image formed by the regularly refracted rays. An opacity does not necessarily prevent the light from being focused upon the retina immediately behind it. Thus, a central opacity of the cornea will not prevent the focusing of an object upon the macular region, for the rays passing through the clear peripheral parts of the cornea will be refracted towards the macula, only those rays being cut off which are incident to the corneal surface at the opaque region. There is thus a loss of brightness rather than of

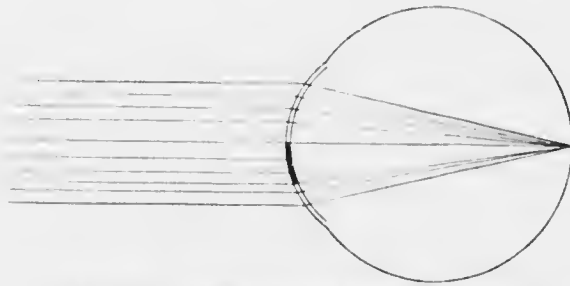


FIG. 110.—Optical effect of a corneal opacity.

definition, though definition will also be impaired by the superposition of a diffuse entoptic image of the opacity upon the clear image of the external object.

When Bowman's membrane has been destroyed the opacity is permanent, but even then it tends to clear more or less. The younger the patient the more clearing may be anticipated. The deeper the cicatrix the less it clears; perforating wounds remain permanently opaque. This fact is well illustrated by the punctures made by discission needles in needling cataract: they remain as grey spots in the cornea throughout life.

Extremely thin cicatrices may be almost or quite transparent. In them there is often deficient scar tissue formed

so that the surface is flattened or even indented. Such corneal *facets* can only be seen by carefully examining the corneal reflex (*vide* p. 100), but they cause considerable defect of visual acuity.

From the same cause—deficiency of scar tissue—the cornea may be markedly thinner at the site of the ulcer than elsewhere. The scar may then bulge above the surface, owing to ineffectual resistance to the normal intraocular pressure. As the cicatrix becomes consolidated the bulging may disappear, or it may remain permanently as an *ectatic cicatrix* (keratectasia from ulcer).

Some ulcers, especially those due to the pneumococcus and septic organisms, extend rapidly in depth. There is then grave danger of perforation. The whole thickness of the cornea except Descemet's membrane and a few corneal lamellæ may be destroyed. Descemet's membrane, like other elastic membranes, offers great resistance to inflammatory processes. It is, however, unable alone to support the intraocular pressure: it therefore becomes protruded through the ulcer, appearing upon the surface as a transparent vesicle, which is called a *keratocoele*. This may persist, surrounded by a white cicatricial ring, or it may eventually rupture.

Perforation and its effects.—When an ulcer perforates the aqueous suddenly escapes and the intraocular pressure sinks to zero, *i.e.*, to the atmospheric pressure. The iris and lens are driven forwards into contact with the back of the cornea.

The effect of perforation upon the nutrition of the cornea is good: owing to the diminution of intraocular pressure the diffusion of lymph through the cornea is facilitated. Ulceration usually ceases, pain is alleviated, and cicatrization proceeds rapidly. The complications which attend perforation are however of extreme danger to sight and

even to the preservation of the eye. These complications vary according to the position and size of the perforation.

Usually the perforation takes place opposite some part of the iris, which therefore lines the aperture when the aqueous escapes. The iris becomes gummed down to the opening by lymph, which gradually organises, and an *anterior synechia* is formed. The blocking of the perforation with iris allows the anterior chamber to be re-formed, fresh aqueous being rapidly secreted.

The aqueous often escapes very quickly owing to some sudden exertion on the part of the patient, *e.g.*, coughing, sneezing, straining at stool, or spasm of the orbicularis. Any such sudden exertion causes a rise in general blood pressure, which at once manifests itself by a rise in intra-ocular tension. The weak floor of the ulcer is unable to support the sudden strain and gives way. In such a case, especially if the perforation is large, a portion of the iris is carried not only into the opening but through it, and a *prolapse of iris* is produced. The prolapse may not include the pupillary margin, in which case it is hemispherical: or the pupillary margin may also prolapse, a tag of iris lying free upon the cornea. In either case the colour of the iris soon becomes obscured by the deposition of grey or yellow lymph upon the surface. In large prolapses the stroma becomes thinned and the black retinal pigment epithelium is thrown into relief.

Sometimes the whole cornea sloughs, with the exception of a narrow rim at the margin, and *total prolapse of iris* occurs. The pupil usually becomes blocked with exudate, and a false cornea is formed, consisting of iris covered by lymph.

If the perforation takes place very suddenly the suspensory ligament of the lens is much stretched. It may rupture partially, causing tilting or dislocation of the lens,

or wholly, so that the lens may be expelled through the perforation.

If prolapse of iris has occurred cicatrisation may still progress. The lymph which covers the prolapse or pseudo-cornea becomes organised, and forms a thin layer of connective tissue over which the conjunctival or corneal epithelium rapidly grows. The contraction of

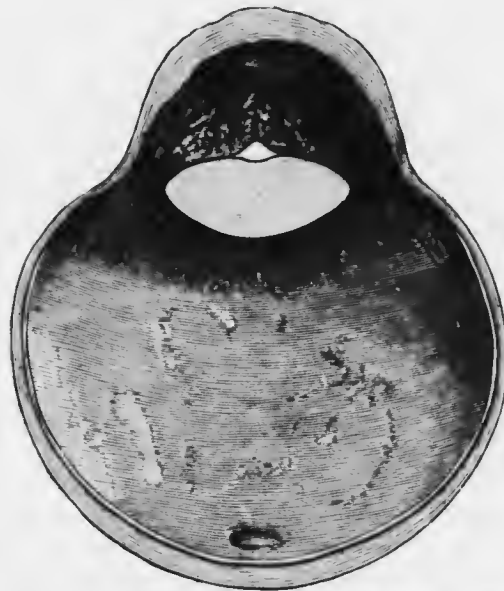


FIG. 111.—Anterior staphyloma, showing also an anterior capsular (pyramidal) cataract. (R. L. O. H. Museum.)

the bands of fibrous tissue tend to flatten the protruding prolapse or pseudo-cornea. It rarely, however, becomes quite flat; more commonly the iris and cicatricial tissue are too weak to support the restored intraocular pressure, which is often increased, owing to the advance in position of the iris (*vide* p. 307).

The cicatrix tends therefore to become ectatic, and such an ectatic cicatrix in which the iris is incarcerated is called an *anterior staphyloma* (Fig. 111). If the prolapse of iris is partial the resulting staphyloma will be partial; if total, a total staphyloma will ensue. The bands of scar tissue on the staphyloma vary in breadth and thickness, producing a lobulated surface, hence the name (*σταφυλή*, a bunch of grapes).

If the perforation happens to be opposite the pupil it cannot be covered with iris. The pupil often becomes adherent to the margin, and the aperture becomes filled with exudate. The anterior chamber is then re-formed very slowly: the lens remains long in contact with the ulcer, and permanent opacity may occur in it—*anterior capsular cataract* (Fig. 111). As the anterior chamber re-forms the exudate filling the opening is submitted to strain. It frequently ruptures, especially if the patient is restless. This process may be repeated again and again, so that the opening may become permanent—*corneal fistula*.

The sudden reduction of intraocular pressure when the perforation occurs removes support from all the intraocular blood vessels. They become dilated and may rupture, *intraocular hæmorrhage* taking place. The retinal vessels may rupture, causing vitreous hæmorrhage, or the choroidal, causing subretinal or subchoroidal hæmorrhage. It may be so profuse that the contents of the globe are extruded with the outflowing blood: indeed in very rare cases the hæmorrhage may endanger life, for it is most likely to occur in old people with atheromatous vessels.

Finally, the organisms which have caused the ulceration of the cornea may gain access to the interior of the eye as the result of perforation, the vitreous acting as an excellent culture medium. *Purulent irido-cyclitis* or even *panophthalmitis* may thus be set up, a result especially prone to occur in gonorrhœal ophthalmia and in hypopyon ulcer (*q.v.*).

Treatment of Uncomplicated Ulcers.—Cleanliness, heat, rest, and protection are the fundamental principles of the treatment of corneal ulcers. Surgical cleanliness is the principle which should regulate the use of lotions; heat is employed to prevent stasis and encourage repair; local rest is attained by the use of atropin; rest and protection

from deleterious external agencies are aimed at in the use of bandages.

The ordinary treatment of a simple uncomplicated ulcer is as follows. The conjunctival sac is washed out carefully three or more times a day with a considerable quantity of a mild antiseptic lotion, which should be used as hot as can be borne comfortably (*vide* p. 178). It acts principally by washing away secretions and necrotic material, which carry with them many of the organisms and their toxins. It is impossible to apply antiseptics sufficiently strong to kill the organisms, hence it is of little importance whether weak sublimate lotion (1 in 8000) or simple boric lotion be used.

After each irrigation a drop of 1 per cent. atropin solution or a small lump of 1 per cent. atropin ointment is introduced between the lids.

A protective bandage is then applied. It consists of a pad of sterile gauze tissue, or a layer of cyanide gauze covered by a pad of cotton wool, kept in place by a bandage, firmly but not tightly applied. A simple tie bandage suffices. This is of sufficient length to pass round the head and tie behind. It passes obliquely above the sound eye, over the ulcerated eye, and under the ear of the side of the affected eye, where the bandage is given a single turn; the ends are tied just above the occipital protuberance.

This treatment suffices for mild cases.

In more severe cases hot fomentations should be applied in the intervals between bathing with lotion, which should be done more frequently—every three or four hours. The compresses should be made of large round pads of plain or boric lint, on one surface of which gutta-percha tissue is sewn. The compresses are placed in a cloth and immersed in boiling water: by keeping the ends of the cloth out of the water and turning them in opposite directions the excess of the water is wrung out without scalding the fingers. The compress is applied as hot as can be borne.

It is at once covered with a large pad of hot cotton wool, and bandaged into position.

Atropin has a twofold function in the treatment of corneal ulcers. In the first place it keeps the eye at rest by paralyzing the intrinsic muscles, both the sphincter iridis and ciliary muscle. In the second place it prevents most of the dangerous results of iritis (*vide* p. 282). Corneal ulcers are always accompanied by more or less iridic and ciliary hyperæmia, and actual inflammation often occurs.

Eserin has been recommended instead of atropin in the treatment of some ulcers. It has been held that prolapse is less likely to occur when a peripheral ulcer perforates if the pupil is contracted. This is a fallacy. Even with complete dilatation under atropin the pupil at once contracts when the aqueous escapes. The objections to eserin are that it prevents rest by keeping the sphincter iridis and ciliary muscle in a state of tonic contraction, that it irritates the iris and tends to increase iritis, with consequently greater risk of the formation of posterior synechiæ, and that it causes discomfort or even pain in the eye. It is never to be used for a simple ulcer, though it may have beneficial effects in special chronic types (*vide* p. 252).

Any contributory cause for ulceration must of course receive attention. Prominent among such causes are conjunctival conditions and general malnutrition. Thus, the ulcers associated with trachomatous pannus will not heal if the lids are neglected (*vide* p. 205).

In purulent conjunctivitis and trachoma the lids should be painted with silver nitrate, even during the progressive stage. The copper stick must not be used in trachoma, owing to the irritative effect upon the cornea. The presence of much conjunctival discharge is a contraindication to the use of a bandage; the benefit derived from it is more than counteracted by the retention of secretions (*vide* p. 179). It must be replaced by a shade.

To restrain children from touching their bandages a straight splint may be applied to the front of the arm, reaching a little beyond the elbow, thus preventing flexion.

In debilitated adults or old people and marasmic children the building up of the constitution by good food, fresh air, and tonics is often more important than the treatment of the local condition.

When cicatrisation is complete and all irritative signs have passed off an attempt must be made to render the scar as transparent as possible. The results are usually disappointing, but cicatrices clear considerably in young patients, and in many others a gratifying improvement may be noticed in the course of months or years. Stimulating treatment is indicated, beginning with weak irritants and passing cautiously to stronger. Insufflations of finely powdered calomel may be used first. If it is well borne dilute yellow oxide of mercury ointment is employed. A small lump of the ointment, gr. iv. to $\frac{5}{8}$ i., is placed in the conjunctival sac and rubbed in gently by rotatory movements of the upper lid by means of the finger. The massage with the lid should be employed three times a day for periods of 5 to 10 minutes. If it is not resented stronger ointment, up to gr. xvi. to $\frac{5}{8}$ i., is used. As the eye becomes accustomed to one form of irritation it is well to change the drug from time to time. Iodine, 5 to 10 per cent., may be added to the ointment, or used in 10 to 15 per cent. solution. On application, especially for the first few times, it causes great œdema of the conjunctiva and a burning sensation. The surgeon should make the first application, as the patient is often alarmed at its severity. The stimulation of the blood and lymph flow induced by this drug is undoubtedly beneficial.

In very intractable cases the same effect may be produced by subconjunctival injections of 2 to 10 per cent.

sodium chloride solution. Ten to fifteen minims of sterile solution are injected under the bulbar conjunctiva as far as possible behind the upper part of the limbus. The pain, which may be severe, is diminished by the addition of 2 per cent. cocain, or 0.1 per cent. acain to the solution. The injections should not be repeated more than once a week.

Old, degenerated, often calcareous cicatrices are best left alone, since they are liable to break down and form





FIG. 112. Lang's speculum. This form is preferable to the ordinary type, as it keeps the lashes out of the field of operation.

very dangerous ulcers, owing to the lack of resistance in the scar tissue.

If a small dense leucoma covers the pupillary area vision may be much improved by an optical iridectomy (Chap. XXII.).

Some improvement in appearance may be obtained by tattooing dense leucomata. It is only suitable for firm smooth scars in perfectly quiet eyes, and is even then not without danger. Indian ink is tattooed into the scar with a grooved needle, under cocain, and with thorough antiseptic precautions. The eye must not be held with fixation forceps since the punctures

in the conjunctiva will be tattooed: smooth forceps must be used. More justifiable is the tattooing of small central nebulae; it has the effect of cutting off



FULL SIZE
FIG. 113.

FULL SIZE
FIG. 114.

FIG. 113.—Ordinary fixation forceps. FIG. 114.—Claw fixation forceps. The latter should be used only when a particularly firm grip of the episcleral tissue is desired, *e.g.*, in operating upon an unsteady patient under cocaine.

the irregularly refracted rays, so that vision is improved (*vide p. 227*).

Treatment of Complicated Ulcers.—If perforation is imminent special means must be adopted to prevent it. The patient should be confined to bed, and laxatives given.

It has already been pointed out that perforation improves the nutrition of the cornea. Perforation may sometimes be anticipated with advantage by *paracentesis*. By this procedure the aqueous is evacuated slowly, and the more dangerous results of perforation may be avoided. Another indication for paracentesis is extreme pain.

Paracentesis may be performed through the floor of the ulcer or just inside the periphery of the cornea. When the aqueous has escaped and the inflamed iris comes in contact with the cornea the most acute pain is felt. If, therefore, the patient is very nervous, a general anæsthetic should be used, but it is to be avoided if possible on account of the straining and vomiting which may attend its administration. Whenever possible the eye is thoroughly cocainized by instilling one drop of a 2 per cent. solution every five minutes for a quarter of an hour, the lids being closed during the intervals.

The patient lies upon his back upon the operating table. The conjunctival sac is washed out with warm boric lotion or saline. The speculum (*Fig. 112*) is inserted, and the eye is fixed with fixation forceps (*Figs. 113, 114*) by taking up a fold of conjunctiva at a convenient




FIG. 115. FIG. 116.

Broad needles.

spot close to the corneal margin. The points of the forceps should be pressed well into the conjunctiva so as to include the episcleral tissue, otherwise they are liable to tear the conjunctiva if much traction is exerted, as by an involuntary movement of the patient. The incision is made with a broad needle (Figs. 115, 116), preferably one bent on the flat, or a keratome (Fig. 117), or a paracentesis needle (Fig. 118).



FIG. 117.
Keratome.



FIG. 118.
Desmarres'
paracente-
sis needle.



FIG. 119.—
Spatula.

If the floor of the ulcer is to be incised the point is inserted here so that the blade makes an angle of about 45° with the cornea. Directly it is pushed through the floor the plane of the blade is altered so that it lies against the back of the cornea; if this is not done there is imminent danger of wounding the lens. The instrument is


pushed on until the incision is sufficiently long. It is then very slowly withdrawn, so that the aqueous may flow off very gradually. If the aqueous escapes suddenly the lens may be wounded, intraocular hæmorrhage may occur, or the iris may prolapse. If the last misfortune occur the prolapse must be excised (*vide* p. 240). If the operation is performed well, probably little aqueous will escape. The spatula (Fig. 119) is then applied to the edge of the wound which is nearer to the corneal margin, and this lip

is gently depressed. The aqueous then escapes slowly and with a minimum disturbance to the eye. The aqueous can be evacuated on the following day by simply opening the wound with the spatula and depressing the lip.

If the incision is made near the periphery of the cornea it should be 1 to 2 mm. inside the lower margin, especially if there is an hypopyon present. The keratome is then entered in the plane of the iris, and its direction changed as before as soon as the point is seen to be inside the anterior chamber.

In deep ulcers, such as are liable to perforate, the removal of necrotic material may be hastened by scraping the floor with a spatula, or the ulcer may be cauterised (*vide* p. 246). If the actual cautery is used it may be made deliberately to perforate the centre of the floor of the ulcer, so that the aqueous may escape and better conditions of nutrition be set up. This procedure can only be recommended in special cases.

Another procedure is to scrape the floor of the ulcer and then to cover it with a flap of conjunctiva. The conjunctiva is separated from the limbus near the ulcer. A second incision is made with scissors parallel to the first, so that a strip of conjunctiva rather wider than the breadth of the ulcer is separated from the globe but



FULL SIZE
FIG. 120.

FULL SIZE
FIG. 121.

Iris forceps, straight and bent.

remains attached at the two ends. This is then shifted on to the cornea so as to cover the ulcer. The wound in the bulbar conjunctiva may be closed by a stitch. The lids are then carefully lifted over the strip, so as not to displace it, and the eye is bandaged.



FIG. 122. De W. ker's scissors. The blades should be blunt-pointed for iridectomy, one sharp-pointed for iridotomy.

If perforation has occurred the treatment depends upon its size and situation. If it is small or in the pupillary area prolapse of iris is not to be feared. Rest in bed, atropin, and a firmly applied bandage suffice: all forced expiration—blowing the nose, coughing, &c.—must be avoided. A sneeze can often be inhibited by firm pressure with the finger upon the middle of the upper lip close to the nose. If a small perforation is over the iris adhesion to the cornea usually occurs. It may become detached when the anterior chamber re-forms, or may be drawn out into a fine thread. No special treatment is required.

If prolapse of iris has occurred it must be excised. No attempt should be made to replace the prolapse in these cases because the iris has become soiled with pus and replacement may result in infection of the interior of the eye and panophthalmitis.

Iridectomy of prolapsed iris is performed as follows. Instruments required: speculum, fixation forceps,

two pairs of iris forceps (Figs. 120, 121), de Wecker's scissors (Fig. 122), iris repositor (Fig. 123).

If the patient is a child or highly excitable, a general anæsthetic is used, otherwise cocain suffice (*vide* p. 237). The conjunctival sac is washed out (*vide* p. 178). The speculum is inserted, and the eye fixed with fixation forceps held in the left hand. The iris repositor is passed into the wound between the iris and the cornea, with a view to freeing any adhesion. The longer the prolapse has existed the firmer will be the adhesion of the iris to the cornea. It may be impossible to free it, and in this case effectual iridectomy cannot be performed. Having freed the iris as much as possible the fixation forceps are handed over to an assistant. The prolapse is seized with iris forceps held in the right hand, as close to the cornea as possible, and drawn well out from the wound. The second pair of iris forceps, held in the left hand, is then applied again as near the cornea as possible, and the iris drawn still further out. (Capsule forceps (Fig. 124) are very good for this purpose.) De Wecker's scissors are then taken in the right hand, and the iris is cut off close to the cornea. If the operation has been successfully performed the stump of iris retracts into the anterior chamber and is quite free from the wound. Atropin is instilled, and a pad and bandage applied.

It is to be noted here that the iris is extremely ductile; it can be dragged out much farther than might be expected, and it must be dragged out as far as possible in order that the incision may be through clean iris tissue, all the soiled part being removed. Some operators prefer



FIG. 123.—Iris repositor, made of silver: it can be bent to any required angle.

to retain the fixation forceps in the left hand throughout, drawing out the iris with iris forceps in the right hand. In this case the assistant cuts off the prolapse. The method has the advantage that any sudden movement of the eye may be counteracted or followed by co-ordinated movements of the two hands of the same individual. Such sudden jerks have been known to drag the whole iris out of the wound, since it tears away at the thinnest part, viz., near the ciliary border. In ordinary cases the greatest danger is that of wounding the lens. A conjunctival flap may be used after excision of the prolapse (*vide* p. 239).

Iridectomy of prolapsed iris is only possible within the first few days, before adhesion has become firm. It is not to be performed after this has occurred, nor in the case of very large prolapses.

In very large prolapses there is much bulging and the base is often constricted. Every attempt should then be directed to obtaining a flat cicatrix. In addition to rest in bed and the means already advised a pressure bandage must be applied for a prolonged period. A pressure bandage differs from an ordinary protective bandage only in that the space around the eye is packed carefully with cotton wool to the level of the nose and that considerable pressure is exerted in applying the bandage.

Keratocoele is treated first by rest and a pressure bandage. If this fails the vesicle may be punctured, and the case treated like a perforated ulcer.

Fistula of the cornea is treated first like a perforated ulcer. If this treatment fails the edges of the fistula must



FULL SIZE
FIG. 124.
Couper's capsule forceps.

be cauterised with the actual cautery. In order that this may be done there must be some trace of an anterior chamber, otherwise the lens will be injured.

Hypopyon Ulcer.—When an eye is injured so that an abrasion of the cornea is produced there is grave danger of infection from virulent pyogenic organisms. The probabilities of this occurrence depend upon the presence of such organisms and upon the amount of resistance which the tissues possess. Of all the organisms which are capable of producing deep ulceration by far the most dangerous, because the most widely spread, is the pneumococcus. It is not infrequently present in the normal conjunctival sac, but it is particularly likely to be present if there is any inflammation of the lacrimal sac (dacryocystitis). The presence of dacryocystitis is therefore a standing menace to the eye. The pneumococcus, more than any other organism, tends to give rise to hypopyon, but other pyogenic organisms may also produce this result.

The substance which produces the injury may carry the infecting agent. The commonest causes are scratches with the finger nail, leaves or branches, grains of corn, and minute foreign bodies, especially stone.

Unless the organism be very virulent some lack of resistance on the part of the tissues must be predicated. Hence hypopyon ulcers are much commonest in adults, especially alcoholic people, and in the lower rather than the upper classes. The debilitating effects of hot weather are noticeable. Hypopyon ulcers also occur during or after acute infectious diseases, such as measles, scarlet fever, small-pox, and so on. In small-pox it is not a variolous pustule upon the cornea, but it differs from the typical hypopyon ulcer.

Hypopyon ulcers vary in type according to the infective agent and the age of the patient. In about 70—80 per cent. of all cases in adults the cause is the pneumococcus,

and the ulcer is then of a very characteristic type, and has been called *ulcus serpens* from its tendency to travel over the cornea in a serpiginous fashion.

The typical *ulcus serpens* is a greivish-white or yellowish disc near the centre of the cornea (Plate VI., Fig. 1). The opacity is greater at the edges than at the centre and is particularly well marked in one special direction. A cloudy grey area, made up of fine lines, surrounds the disc, but is also more marked in the same direction. The whole of the cornea may be lustreless or hazy. There is violent iritis, and the aqueous is cloudy or there may be a definite hypopyon. The lids are slightly œdematous and there is conjunctival and ciliary congestion. The subjective symptoms at the early stage are pain in the eye and brow, and a variable amount of photophobia.

The ulcer increases in size and depth. On the side of the densest infiltration, which often looks like a yellow crescent, the tissues break down and the ulcer spreads; on the other side it may be undergoing simultaneous cicatrisation. In this manner it travels forwards. Meanwhile the hypopyon has become more evident, but it may vary in size from hour to hour (*vide* p. 226).

If left to pursue its natural course the hypopyon will increase and become fibrinous, the ulcer will perforate, usually forming a large opening through which the iris prolapses. The whole cornea, except the narrow rim nourished by the corneal loops (Plate II.) may necrose, and panophthalmitis destroy the eye. In other cases an extremely dense cicatrix in which the iris is incarcerated (*adherent leucoma*) destroys sight. This may be flat or cœtatic (anterior staphyloma). Sometimes the iris is bound down to the lens before perforation occurs. In such cases there are posterior synechiae, which may be annular or total (*vide* p. 287), and the pupil may be blocked by exudates which organise into fibrous tissue (occlusion of the pupil).

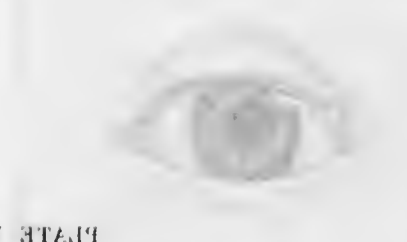
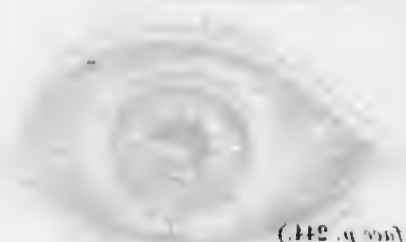
PLATE VI. (Vol. No. 244.)

- Fig. 1.—Ulcer serpens with crescentic infiltrated advancing border above. There was no hypopyon when the figure was drawn. (From a drawing by Dr. S. H. Hershman.)
- Fig. 2.—Iritis with irregular pupil and ring synchia causing bulging forwards of the iris ("iris bombe").
- Fig. 3.—Persistent pupillary membrane. Note the origin of the strands from the position of the minor arterial circle.
- Fig. 4.—Persistent pupillary membrane. The strands are adherent to the lens capsule, which has finely granular pigment upon its surface.

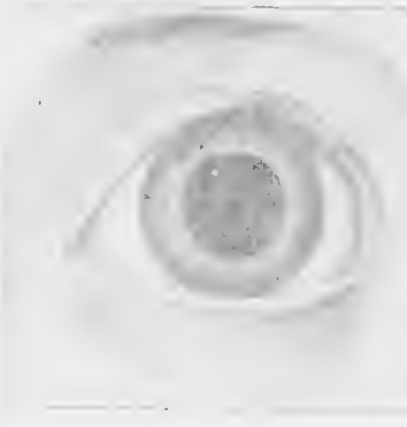


PLATE VI. (To face p. 244.)

- Fig. 1.—Ulcer serpens, with crescentic infiltrated advancing border above. There was no hypopyon when the figure was drawn. (From a drawing by Dr. S. H. Habershon).
- Fig. 2.—Iritis, with irregular pupil and ring synechia, causing bulging forwards of the iris ("iris bombé").
- Fig. 3.—Persistent pupillary membrane. Note the origin of the strands from the position of the minor arterial circle.
- Fig. 4.—Persistent pupillary membrane. The strands are adherent to the lens capsule, which has finely granular pigment upon its surface.

PLATE VI.

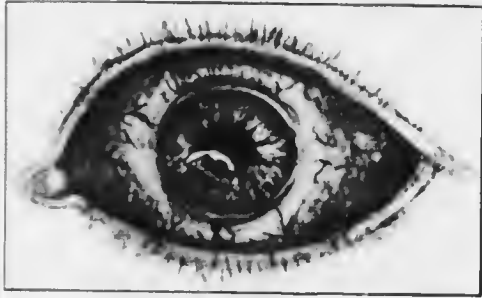

FIG. 1.

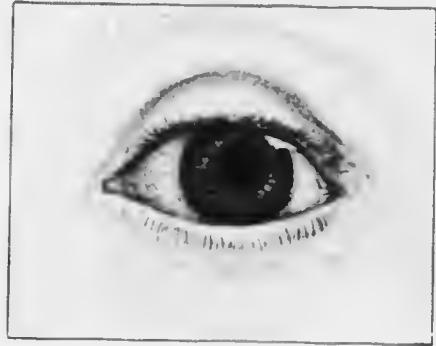

FIG. 2.

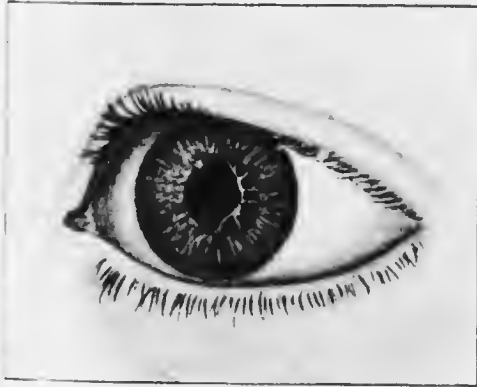

FIG. 3.

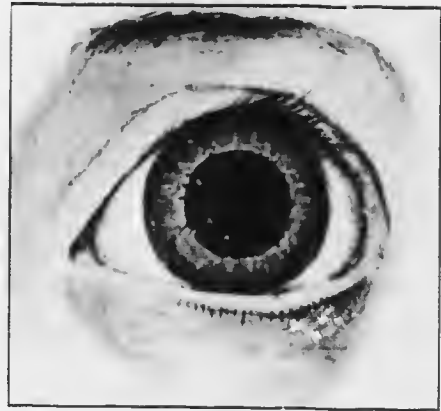


FIG. 4.

Though hypopyon ulcer occurs sometimes in children it never assumes the typical form of an *ulcus serpens*. In them and in some cases in adults the serpiginous character of the ulcer is not apparent, but it is distinguished by its great tendency to extend in depth, so that perforation readily occurs. On the whole, such ulcers have a milder course than the *ulcus serpens*, and this is especially the case in children. It is doubtless due partly to the fact that less virulent organisms are at work, especially

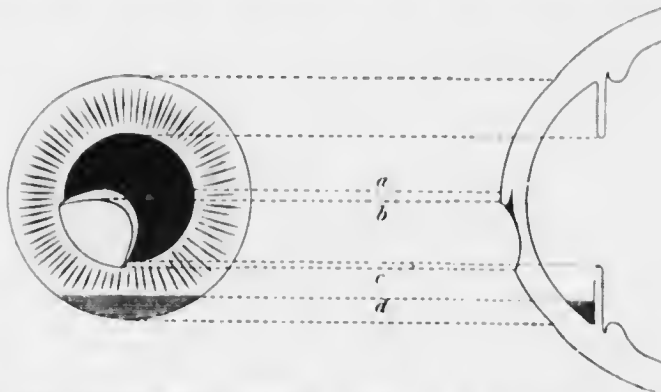


FIG. 125. Diagram of hypopyon ulcer. *a b*, advancing infiltrated border; *b c*, ulcerated surface; *d*, upper level of hypopyon.

applicable to adult cases, and partly to greater resistance of the tissues, especially applicable to children.

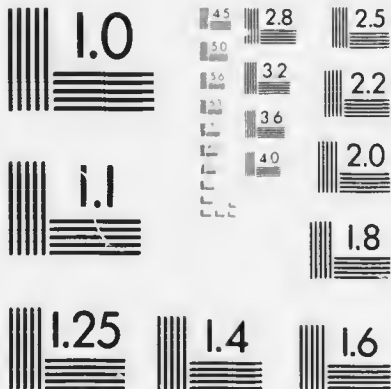
Pathology.—The *ulcus serpens* is due to the pneumococcus, either alone or mixed with other organisms. There is no doubt that the essential features are caused by the pneumococcus alone. A variety of organisms—staphylococci, streptococci, gonococci, &c.—have been found in atypical hypopyon ulcers.

Anatomically, the *ulcus serpens* shows at first a depressed surface covered with slough (Fig. 125). The corneal lamellæ around and below the ulcer are separated by masses of polymorphonuclear leucocytes.



MICROCOPY RESOLUTION TEST CHART

(ANSI and ISO TEST CHART No. 2)



APPLIED IMAGE Inc

1653 East Main Street
Rochester, New York 14609 USA
(716) 482-0300 - Phone
(716) 298-5989 - Fax

In the progressive stage the infiltration is chiefly limited to an area, wedge-shaped in section, corresponding with the yellow crescent. In other parts the edges are clean, and may be covered with epithelium. Often there is infiltration just anterior to Descemet's membrane at a spot exactly opposite the floor of the ulcer, whilst the intervening lamellae are normal. This fact accounts to some extent for the great tendency to perforation, since the inflammatory process is going on as it were from both surfaces of the cornea.

The hypopyon consists of polymorphonuclear leucocytes massed together in the lower angle. In the later stages they are enmeshed in a network of fibrin. It has been

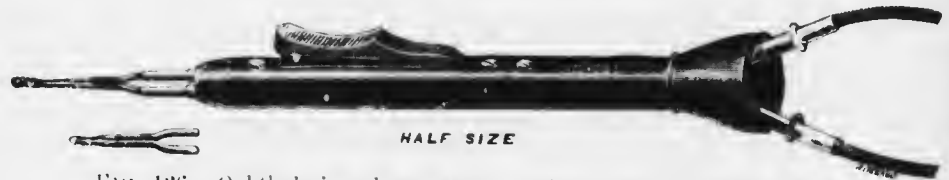

FIG. 126. Ophthalmic galvano-cautery, which may be worked off the main with a transformer, or off a portable accumulator.

pointed out that the leucocytes are derived from the iris and ciliary processes (*vide* p. 225).

Treatment.—In all cases of hypopyon ulcer in adults treatment must be initiated at once and must be energetic. The first stage is cauterisation of the ulcer. If it is performed skilfully it does no harm and may save the eye.

Cauterisation may be performed with pure carbolic acid or with the actual cautery, the most convenient form of the latter being the galvano-cautery (Fig. 126). In my opinion the latter method, which requires more skill possesses no advantages and has some disadvantages. Apart from the dangers attending the use of the actual cautery, carbolic acid has the advantage of penetrating a little more deeply than it is actually applied, thus extending

its antiseptic properties more widely: it acts both as a caustic and an antiseptic. No harm is done even if the acid spreads over the normal cornea. Although the parts touched become at once quite white the normal tissues rapidly recover without detriment. The acid must not, however, touch the conjunctiva, otherwise very acute conjunctivitis is set up and adhesion between the lids and globe may occur.

Pure carbolic acid is applied as follows. The patient is seated or lying upon a couch. The ulcer is first stained with fluorescein (2 per cent.), in order that its limits may be more clearly defined. The conjunctival sac is thoroughly cocained (*vide* p. 237). The surgeon stands behind or at the head. With his left hand he separates the lids as in removing a foreign body, steadying the globe at the same time. The ulcer is scraped with a spatula and together with the surrounding cornea is dried with the point of a piece of blotting paper. A wooden match, somewhat pointed, is dipped into the carbolic acid. Care is taken that the wood is thoroughly wet, but has no drop of acid hanging to it which may run over the cornea. The ulcer is then touched over the whole of its surface with the point of the match. If there is sufficient carbolic acid on the match the spot touched becomes white. Special care is taken thoroughly to cauterise the advancing edge of an *ulcus serpens*, *i.e.*, the part marked by a yellow crescent.

Cauterisation with carbolic acid may be repeated two or three times at intervals of one or two days if the ulcer still progresses. If this treatment, combined with the use in the intervals of mild antiseptic lotions, atropin, and hot compresses, as for less severe ulcers, does not check the progress, yet more drastic measures must be resorted to.

Of these the most important is *paracentesis*. It may be performed as already described, but in the case of hypopyon

ulcers what is called *Saemisch's section* offers some advantages. It consists in completely dividing the ulcer from one side to the other, the ends of the incision being in healthy corneal tissue. It must be remembered that if the operation is performed under cocaine the most excruciating pain is felt when the iris comes into contact with the cornea. For this reason it is best to use a general anæsthetic.

Saemisch's Section.--Instruments required: speculum, fixation forceps, Graefe knife (Fig. 127), smooth iris forceps; in case the iris should prolapse, the following should also be at hand: two pairs of iris forceps, de Wecker's scissors, iris repositor.



FULL SIZE
FIG. 127.—
Narrow
Graefe
knife.

After cocainizing or anæsthetising, the eye is washed out and the speculum is inserted. The eye is fixed with fixation forceps in the usual manner (*vide* p. 237). The point of the Graefe knife is inserted in healthy cornea just outside the edge of the ulcer, preferably at the advancing part where the yellow crescent is densest. The edge of the knife is directed forwards, so that if the lens advances before the section is complete it will touch the back of the knife and not be wounded. The knife is passed across the anterior chamber until the point is seen beyond the opposite edge of the ulcer. The counter-puncture is made in healthy cornea here, and the knife is pushed on so as to cut out. The aqueous pours out, and carries with it much of the hypopyon. Atropin is instilled, and the eye bandaged.

If the ulcer is very large it is impossible to make the puncture and counter-puncture in healthy cornea. In these cases, too, the knife usually cuts out as it is in the

act of passing across the ulcer. If the hypopyon is very fibrinous it may be necessary to pull the coagulum out with the smooth iris forceps.

This procedure improves the conditions of nutrition of the cornea and evacuates the hypopyon. It is not to be advocated in mild or in the early stage of severe cases, but as a last resource it may prove beneficial.

Mycotic Hypopyon Ulcer.—A rare form of hypopyon ulcer due to a fungus, the *aspergillus fumigatus*, is occasionally met with. In it the slough is dry in appearance, and is surrounded by a yellow line of demarcation, which gradually deepens into a gutter. As the name implies there is an hypopyon. Treatment is the same as for other hypopyon ulcers.

Phlyctenular Keratitis.—It has already been pointed out that phlyctens are commonly found seated upon the limbus. They may also occur within the corneal margin. The fact must be emphasised that the disease is essentially conjunctival, and when the cornea is affected it is the conjunctival element of the cornea, viz., the epithelium and the superficial layers immediately underlying it, which suffers. Phlyctenular keratitis does not necessarily result in ulceration, so that in these cases it is incorrect to classify it as a purulent keratitis, but it is convenient to consider the corneal manifestations of the disease under this heading because the complications and their treatment are similar to those of corneal ulcers in general.

Corneal phlyctens are localised infiltrations of exactly the same nature as conjunctival phlyctens. They cause more pain and reflex blepharospasm (photophobia) than do the conjunctival ones, symptoms which are worst in the morning. They may become absorbed without destruction of the overlying epithelium: in this case they cause no permanent opacity. The tendency for the epithelium to be destroyed or rubbed off is very great (cf. p. 190), and

the denuded surface easily becomes infected. In this manner a small superficial ulcer is formed.

The corneal phlycten is a grey nodule, slightly raised above the surface. If the epithelium breaks down and an ulcer is formed the surface becomes covered with polymorphonuclear leucocytes and looks yellow. The subsequent course depends probably upon the nature of the infection and the condition of nutrition of the patient. It may deepen rapidly and even perforate, though this is comparatively uncommon.

A very characteristic form of phlyctenular ulcer is the *fascicular ulcer* (Figs. 68 B, 128). This is a serpiginous ulcer which steadily creeps over the cornea, usually towards the centre, advancing slowly for weeks. It is supplied by a leash of vessels which lie in a shallow gutter and follow the advance of the ulcer. The ulcer starts near the limbus and heals on the peripheral side, whilst the central margin remains grey and infiltrated. As long as this infiltrated crescent is seen the ulcer is progressing. It always remains superficial and never perforates. When healing finally takes place the vessels gradually disappear, but the whole of the track of the ulcer remains as a permanent opacity, densest, however, where the ulcer stops.

The severest cases of phlyctenular keratitis are accompanied by a diffuse deep-lying infiltration. The large greyish area is dotted over with minute spots. The deep infiltration may disappear entirely, or it may become yellow and break down, forming a large ulcer.

Sometimes the phlyctens are so closely packed at the




FIG. 128. — Fascicular ulcer, travelling inwards towards the centre of the cornea. (Nettleship.)

limbus that they become confluent and may even surround the cornea. If they break down and form a *ring ulcer* an extremely dangerous condition is set up. The nutrition of the whole cornea is endangered, and even if total necrosis does not occur an extensive perforating ulcer may be formed at the margin.

More commonly, however, a continuous infiltration of the limbus leads to the development of superficial vessels at the periphery of the cornea, a condition which is called *phlyctenular pannus* (pannus eczematosus or serophulosus) (Plate V., Fig. 2). Unlike trachomatous pannus (*q.r.*) it shows no special predilection for the upper part of the cornea. It is thin and not very vascular, and usually undergoes complete resolution, though the course is generally very tedious. It is accompanied by intense blepharospasm.

Treatment of phlyctenular keratitis is the same as that of phlyctenular conjunctivitis (*q.r.*) until ulceration has occurred. In these cases atropin is to be combined with the yellow oxide of mercury ointment. If the latter causes much irritation, or if the ulcer is at all deep, simple atropin ointment should be substituted. The yellow ointment is particularly beneficial in fascicular ulcers, but may fail to stop their progress. The crescentic infiltrate should then be cauterised with pure carbolic acid or the actual cautery, or the vessels may be destroyed with the actual cautery. Pure carbolic does not destroy vessels efficiently, and whenever this is desired the actual cautery must be used. These extreme measures are seldom required in phlyctenular keratitis. If a fascicular ulcer has already reached the centre of the cornea and lies over the pupillary area it is not a bad plan to allow it to progress still farther, because the opacity left by the track of vessels is less dense than that left at the final site of ulceration.

Ring ulcer must be treated by hot compresses, atropin, and a pressure bandage.

Deep ulcers and the scars left by phlyctenular keratitis must be treated on general principles (*vide* p. 232).

Marginal Ulcer.—Apart from the ring ulcers of phlyctenular keratitis ulcers not infrequently occur in this situation in old people, especially in the gouty. They are shallow and little infiltrated, often multiple. Sometimes they heal rapidly, but as rapidly recur, so that the process drags on indefinitely, to the detriment of the patient's health. Frequently the ulcers become vascularised, and the vessels persist. More serious rare forms of deep marginal ulceration also occur in old people, and a very serious form of superficial marginal ulcer is also met with (*vide* p. 258). Marginal ulcers are often accompanied by severe neuralgic pains in the face and head.

Treatment.—The recurrent marginal ulcers of gouty people are best treated by painting the ulcer with weak silver nitrate solution, gr. v. to $\frac{3}{4}$ i. They often heal up quickly after this application, combined with weak antiseptic lotions. Recurrence, however, can only be prevented, and that with difficulty, by constitutional treatment, which includes the special diets and drugs for gout, as well as fresh air and moderate exercise. The eyes should be protected with smoked glasses. If this treatment fails, and and the ulcers are vascular, destruction of the vessels with the actual cautery is most likely to succeed. Sometimes eserine does good in these cases.

Central Ulcer.—Symmetrical central ulcers of an extremely indolent type are not infrequently met with in badly nourished children. They probably occur here because this part of the cornea is furthest from the nourishing vessels. They are quite superficial, show little infiltration and no vascularisation; they form shallow round pits or facets about 2 mm. in diameter. There is little or no reaction, either in the form of lacrymation or photophobia. They do not spread either superficially or in

depth, nor do they show any tendency to heal. When they finally heal they often leave permanent clear facets, showing the absence of a proper supply of pabulum during the cicatricial stage. They appear to have nothing in common with phlyctenular keratitis except that both conditions are indications of defective nutrition. They are not uncommonly associated with trachoma.

They sometimes occur outside the centre of the cornea, and may perforate, allowing a knuckle of iris to prolapse. This prolapse should not be cut off, owing to the relatively large gap in the cornea, and the defective powers of repair in the debilitated patient.

Treatment must be directed especially to improving the general nutrition. A few weeks in a convalescent home in the country will effect more than any local treatment. Atropin and boric lotion are used locally. Trachoma, if present, must be suitably treated.

Keratomalacia is a rare disease in England, affecting badly nourished children. The conjunctiva becomes dry and shows xerotic spots (*vide* p. 217). The cornea becomes dull and insensitive; the haze increases and yellow infiltrates form. Finally the whole cornea necroses and may seem to melt away within a few hours. In the rare cases in which the children are old enough to exhibit the symptom the disease commences with night blindness; they are able to see much better in the daytime than in the dusk. The children are usually extremely ill and very frequently die. Owing to their apathetic condition they do not close the lids, so that the cornea is continually exposed.

Treatment must be directed to the general health and environment. The lids should be kept closed under moist warm compresses. The nutrition of the cornea is sometimes benefited by the use of eserin.

Atheromatous Ulcers occur in old dense leucomata,

especially such as have undergone degenerative changes resulting in the formation of hyaline fibrous tissue and calcareous deposits. Such scars have little vitality and the deposits act as foreign bodies. They readily succumb to infection, the epithelium being badly nourished. When ulceration once commences it proceeds rapidly and deeply, with little or no effort at repair. Perforation takes place, and is often followed by panophthalmitis.

Treatment.—The eye is frequently blind and disfiguring. In such cases it is well to excise it at once, thus relieving the patient of much unnecessary misery. If it is worth saving the condition must be treated on general principles.

Keratitis o lagophthalmo occurs in eyes insufficiently covered by the lids. The epithelium of the exposed cornea becomes desiccated and the substantia propria hazy. Owing to the drying the epithelium is cast off, and the cornea falls a prey to infective organisms.

The condition is due to any cause which may produce lagophthalmia, *e.g.*, extreme proptosis as in exophthalmic goitre or orbital tumour, paralysis of the orbicularis, and so on. The absence of reflex blinking is an important factor, as well as defective closure of the lids during sleep. Patients extremely ill from any disease are liable to this form of keratitis.

Treatment consists in keeping the cornea well covered. In mild cases it is sufficient to bandage the eyes at night. If possible the cause of the exposure must be removed. In the meantime it may be necessary to keep the lids closed with plaster and a bandage, or partially to sew them together (*vide* p. 256).

Neuroparalytic Keratitis occurs in some cases in which the fifth nerve is paralysed. It does not occur in all cases; thus, if the Gasserian ganglion is removed for trigeminal neuralgia with proper precautions only a small proportion of the cases get neuroparalytic keratitis. The disease has

been known since the time of Magendie, and was attributed to special trophic impulses conducted by the nerve. This theory was combated, and the view advanced that the condition depended upon the loss of sensation in the eye. As a result, reflex blinking was more or less abolished, minute foreign bodies were not felt and therefore not removed, abrasions were unnoticed and untended, so that ulceration was readily induced and pathogenic organisms had free play. Neither of these theories satisfactorily accounts for the facts. It will be seen that the disease of the cornea usually has a very characteristic nature, quite different from the ulceration of neglected injuries. It is probable that in some manner not fully understood the disease is due to irritative changes in or about the degenerating nerve, and that mere section or paralysis of the nerve is unable to produce the disease in the absence of such irritative conditions.

The characteristic feature of neuroparalytic keratitis is the desquamation of the corneal epithelium. The surface of the cornea becomes dull, and the epithelium is thrown off, first at the centre, then over the whole surface except a narrow rim at the periphery. The whole of the epithelium may peel off intact. The substantia propria then becomes cloudy and finally yellow, breaking down into a large ulcer, which is usually accompanied by hypopyon. There is no pain, owing to the anaesthesia, but ciliary injection is marked. A large perforation occurs if the case is not speedily treated. In any case the resulting leucoma is generally so large as to destroy useful vision. Relapses are the rule, the healed scar quickly breaking down again, and the whole process being repeated.

After complete removal of the Gasserian ganglion sensation is never regained.

Treatment.—The ordinary treatment of corneal ulcer should be tried as a preliminary, special care being devoted to the protection of the eye with a bandage.

Improvement is often marked, but directly the bandage is relinquished the ulceration starts anew. In these cases it is best to suture the lids together, and to keep them sutured for a long period, only separating them when the conditions of the weather—warmth, absence of high winds, and so on, are favourable. It is usually insufficient to narrow the palpebral aperture by lateral or median tarsorrhaphy, *i.e.*, suturing the lids at the canthi

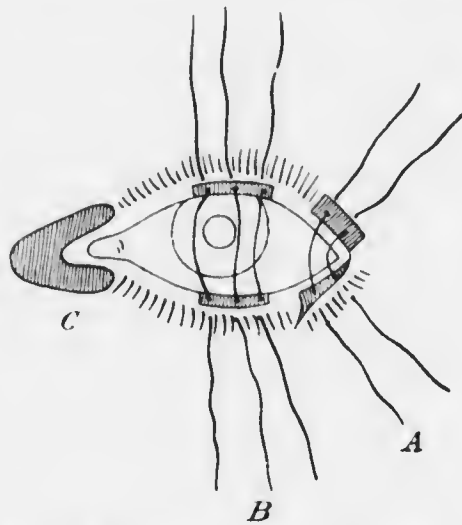


FIG. 129. — Tarsorrhaphy. A, lateral, by Fuchs's method; B, central; C, median.

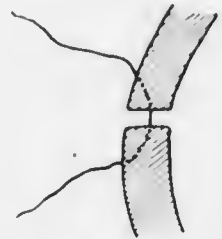


FIG. 130. — Insertion of stitches in central tarsorrhaphy.

(Fig. 129). Too great an area of cornea is left exposed. It is best to suture them for 8—10 mm. in the middle (central tarsorrhaphy).

No anæsthetic is necessary, since sensation is lost in the conjunctiva and lids. The mucous membrane is dissected up from the margin of the lower lid just posterior to the lashes over a rectangular area about 8—10 mm. long in the middle of the lid. The edge of the upper lid is similarly treated at the corresponding

position. Two or three sutures are then passed through the skin so that they come out at the posterior edge of the bare surface (Fig. 130), not on the posterior surface of the lid where they would rub against the cornea. After being similarly carried through the skin of the other lid they are tied, and the freshened surfaces are brought into contact. In a few days, if the stitches have not torn out, the lids will be firmly adherent.

In the worst cases the eye is useless, and tends to become a source of perpetual trouble. It is then best to excise it, which may be done without any anæsthetic.

Dendritic Ulcer is the result of herpes febrilis, more rarely of herpes ophthalmicus. The vesicular stage is rarely seen, the epithelial wall of the vesicle being quickly broken. Minute shallow clear facets, like abrasions, are found in the first stage. They may be easily overlooked. They generally cause much pain, lacrymation and blepharospasm. They may spread in all directions, coalescing with others and forming a large shallow ulcer with crenated edges. More often gray striæ extend in one or more directions, increase in length, and send out lateral branches, which are generally knobbed at the ends (Fig. 131). In this manner a dendritic figure, not unlike a liver-wort, is formed. The surface over the infiltrates breaks down, and an extremely irritating and chronic type of ulcer is produced. It is often associated with frontal neuralgia. Such an ulcer may persist in spite of treatment for weeks or months, sending out fresh branches but never extending in depth.

Treatment.—The ulcer should be carefully cauterised

D.E.



FIG. 131. Dendritic ulcer, somewhat diagrammatic.

with pure carbolic acid. Absolute alcohol has been recommended for the purpose in these cases, but causes much pain after the cocain has ceased to act. If carbolic fails to stop the progress the actual cautery should be used. Atropin, &c., and a pad and bandage are used, but in many cases it is advisable simply to use smoked glasses and get the patient out in the fresh air as much as possible. The general health must not be neglected, especially as the patient often becomes very depressed.

Chronic Serpiginous Ulcer (*Syn.*—*Rodent Ulcer*, *Mooren's Ulcer*).—This is a rare superficial marginal ulcer, usually occurring in elderly people, and spreading, if not checked, over the whole cornea. It undermines the epithelium and superficial lamellæ at the advancing border, forming an overhanging edge, which is very characteristic. The base becomes quickly vascularised. It never perforates, but goes on with intermissions for months, until eventually a thin nebula is formed over the whole cornea, and sight is much diminished. Both corneæ are affected, but not always simultaneously.

Treatment.—No treatment is of any avail except the actual cautery, and that not invariably. The overhanging edge should be cut off with scissors, and then the whole surface of the ulcer, and especially the margin, should be well cauterised.

Non-suppurative Keratitis.—This occurs in two types, superficial and deep. The superficial forms include some purely symptomatic conditions, such as pannus. Some of them, such as herpes, may lead to the formation of ulcers and pass into the purulent type. The deep forms never suppurate.

Herpes Corneæ.—Herpes of the cornea occurs most commonly in herpes febrilis, more rarely in herpes ophthalmicus.

In herpes febrilis vesicles form upon the cornea quite

similar in nature to those which may be present, but are not always so, upon the lips or angle of the nose. The patients are usually suffering from some febrile condition, *e.g.*, influenza, pneumonia, &c., but it may be so trivial as to escape observation. The vesicles are scarcely the size of a pin's head and are often arranged in rows or groups. They quickly rupture, forming abrasions which heal rapidly, leaving no opacity. In severe cases,

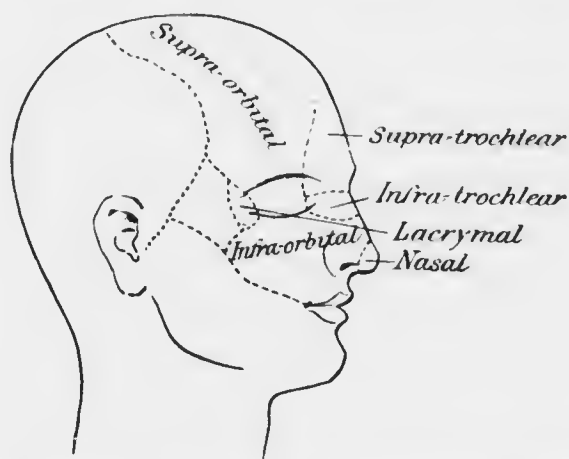


FIG. 132.—Distribution of the branches of the ophthalmic division of the fifth nerve on the face.

however, ulcers are formed (*vide* p. 257). The acute stage is accompanied by great irritation, lachrymation, and blepharospasm. The ocular affection is usually unilateral and on the same side of the face as vesicles on the lips, &c. The cornea is generally not anæsthetic except at the spots attacked.

In herpes ophthalmicus one or more of the branches of the ophthalmic division of the fifth nerve (Fig. 132) is marked out by rows of vesicles or the scars left by them, exactly as in herpes zoster in other parts of the body. Corneal vesicles are rare, but when they occur are exactly like

those of the febrile form, and behave in the same manner. More commonly there is a diffuse deep infiltration of the cornea, associated with iridocyclitis (*q.v.*). The cornea is usually insensitive. This is tested by touching it with a wisp of cotton wool, and comparing with the opposite eye. The slightest touch is followed by reflex closure of the lids



FIG. 133.— Herpes ophthalmicus.

if the cornea is sensitive. The intraocular tension is not infrequently somewhat diminished in the early stage. The disease is due to lesions in the Gasserian ganglion of the same type as those found in the posterior root ganglia in herpes zoster. Patients often give the history of an attack of "erysipelas," but the typical distribution of the scars removes any difficulty in diagnosis.

Herpes corneae may be mistaken for phlyctenular

keratitis. The former occurs usually in adults, the latter in children. The clear vesicles differ in appearance from the grey infiltrations of phlyctenular keratitis. After the vesicles have burst, the shape and the total absence of vascularisation are distinguishing features.

Treatment.—The eyes should be protected with a bandage. When the vesicles have ruptured, atropin and warm compresses give most relief. It is sometimes necessary to use cocain when the pain is acute, though it has a bad effect upon the epithelium. Oily applications—ol. ricini—are sometimes grateful. Prolonged ulceration must be treated as recommended under dendritic ulcer (*vide* p. 257). The general health must be attended to; quinine, valerian, salicylic preparations, *e.g.*, salicylates, aspirin, &c., are useful.

Superficial Punctate Keratitis is a rare condition allied to herpes febrilis, but no vesicles are formed. It commences as an acute conjunctivitis. At this stage, or after it has passed off, rows of superficial grey dots are seen scattered over the cornea, least at the periphery. They remain unchanged for months, but gradually disappear. The disease affects one or both eyes in young people, usually with some febrile affection.

Treatment as for herpes.

Interstitial Keratitis (*Syn.*—*Parenchymatous Keratitis*) is a deep keratitis usually affecting children between the ages of five and fifteen, the subjects of congenital syphilis. It is commoner in girls than boys.

After slight irritative symptoms, with some ciliary congestion, one or more hazy patches appear in the cornea, near the margin or towards the centre (Plate VII., Fig. 1). If they are near the margin they push forwards towards the centre; if at the centre, others appear and fuse, until finally the whole cornea looks lustreless and dull. Minute examination shows that the patches are in the deep layers

and are made up of denser spots and fine streaks. In two to four weeks the whole cornea is hazy with a steamy surface, giving a general appearance like that of ground glass. Denser spots can always be seen in the general mist. In the severest cases the whole cornea becomes quite opaque, so that the iris is hidden; as a rule the iris can be seen dimly.

Meanwhile vascularisation has occurred. It is of the deep type (*vide* p. 106), consisting of radial bundles of brush-like vessels. The larger marginal plaques may be very vascular; as they are covered by a layer of hazy cornea their bright scarlet is toned down to a dull reddish pink ("salmon patches"). The separate vessels can only be seen by magnification. The small salmon patches are often crescentic; when larger they are sector-shaped. The opacity extends a little beyond the vessels, which seem to push the opacity in front of them. In the acme of the condition the vessels run in radial bundles almost, but seldom quite, to the centre of the cornea. There is often a moderate degree of superficial vascularisation, greater in some cases than in others, but never extending far over the cornea. The conjunctiva may be heaped up like an epaulette at the limbus, so that some slight resemblance to phlyctenular keratitis may be seen. Indeed, it is probable that these patients are both syphilitic and "strumous."

After the disease has reached its acme it commences to subside. The cornea clears from the margin towards the centre, which may long remain hazy, though it too finally clears, except in the worst cases. As the cloudiness disappears the vessels become obliterated, but though they cease to carry blood they remain permanently as fine opaque lines; they can be demonstrated only by magnification either with oblique illumination or more definitely by the direct method (*vide* p. 144). The characteristic radial course and distribution affords permanent proof of



PLATE VII. (To face p. 282.)
Fig. 1.—Interstitial keratitis showing general infiltration of the cornea with vasculization at the periphery, especially above ("salmon patch").
Fig. 2.—Iritis.



Fig. 1.--Interstitial keratitis, showing general infiltration of the cornea with vascularisation at the periphery, especially above ("salmon patch").

Fig. 2.--Episcleritis.

PLATE VII



FIG. 1



FIG. 2.

previous occurrence of interstitial keratitis, and is important evidence of congenital syphilis.

At the height of the disease vision may be reduced to finger-counting or hand movements, and there is much lachrymation and reflex blepharospasm. Very mild cases are met with in which the patches of cloudiness are thin, scarcely vascularised at all, and clear up quickly. In the marginal type the opacity may be limited to a sector.

The surface never becomes ulcerated. It is frequently stippled, steamy, and slightly uneven, and this condition may persist. In the worst cases the cornea may be enormously thickened and gelatinous in appearance. The impression given is that the cornea is very cecatic, and that the eye is in a hopeless condition; it will probably clear up well with useful vision. In no case must an eye be removed on account of interstitial keratitis.

Interstitial keratitis is almost invariably symmetrical, though an interval of three or more weeks usually intervenes before the onset in the second eye. Rarely the interval is several months or even years. Delayed interstitial keratitis, *i.e.*, in patients over thirty, occasionally occurs and is more liable to be unilateral; it is also often very severe. Interstitial keratitis in acquired syphilis is rare, and is also generally unilateral; several cases have been reported in which the primary lesion has been on the lids or face, and the keratitis has been limited to the same side.

Pathology.—The rare cases of interstitial keratitis which have been examined anatomically show that the infiltration of the cornea is almost entirely limited to the deeper layers lying immediately anterior to Descemet's membrane (Fig. 134).

It has been pointed out that corneal conditions which are secondary to conjunctivitis are superficial. Similarly deep keratitis is secondary to disease of the uveal tract.

Thus, in tubercle of the iris (*q.v.*) it is not uncommon in the late stages to meet with an interstitial keratitis fundamentally the same as in congenital syphilis. Further, anatomical investigation has shown that in the latter form the uveal tract is profoundly affected. Thus, it is the rule for a considerable degree of iritis to be present. Sometimes there is severe cyclitis, as shown by the presence of precipitates ("keratitis punctata,"




FIG. 131.—Section of interstitial keratitis, showing infiltration confined to the deeper layers of the substantia propria ($\times 60$). *E.*, epithelium; *B.m.*, Bowman's membrane; *S.p.*, substantia propria; *D.m.*, Descemet's membrane with endothelium.

vide p. 301) on the back of the cornea. Not infrequently there is choroiditis. If the pupil of the unaffected eye is dilated and the periphery of the fundus carefully examined, patches of anterior choroiditis will not uncommonly be found. All these facts support the view that the disease is fundamentally a uveitis, and that the keratitis is secondary, *i.e.*, merely symptomatic. Clinically it masks the uveitis, which is thus liable to be overlooked, and hence the disease is called a keratitis. It is very important to realise the true pathology, since treatment must be

directed to avoiding the deleterious results of iridocyclitis rather than those of keratitis.

Etiology.—It has already been stated that nearly all cases which are not obviously secondary to tubercle of the iris, &c.—and these are rare—are due to congenital syphilis. Owing to the importance of diagnosing this



FIG. 135.



FIG. 136.



FIG. 137.



FIG. 138.



FIG. 139.



FIG. 140.

FIGS. 135 TO 140.—Hutchinson's teeth. (Nettleship.)

complaint in doubtful cases the principal signs may be enumerated.

(1) General features. Prominence of frontal eminences, flatness of the bridge of the nose, breadth of face, stupidity or undue precocity, deafness.

(2) Hutchinson's teeth (Figs. 135—140). There is nothing characteristic in the first dentition. In the permanent teeth only two, the upper central incisors, are

to be relied upon, but the other incisors and first molars are often deformed. The characteristic change in the central upper incisors appears to depend upon defective formation of the central lobe (Figs. 136, 139—140). Soon after eruption this lobe wears away, leaving a vertical notch at the centre of the cutting edge (Fig. 135). If the cause has acted so intensely as to prevent the development of the central lobe, there is, instead of a notch, a narrowing and thinning of the cutting edge as compared with the crown, and this according to its degree produces a resemblance to a screwdriver or peg (Figs. 137, 138). The teeth are too small in every dimension, so that the incisors are separated from one another by considerable spaces. In extreme cases all the incisors are peggy and much dwarfed. The changes are usually symmetrical, but Fig. 139 shows one tooth typically deformed and the other normal.

(3) Linear cicatrices, relics of former rhagades, are met with at the angles of the mouth. Cicatrices on the hard or soft palate or elsewhere in the mouth point to antecedent syphilitic ulcerations.

(4) Shotty, painless lymphatic glands are felt in the neck, especially in the posterior triangle.

(5) Hard periosteal nodules, best found upon the shins, and chronic synovitis of the joints, especially the knee joints, may be present.

Evidence of acquired syphilis may be sought in the parents.

Treatment.—It is usual to order antisyphilitic remedies, but it is doubtful if they have any influence over the course of the disease. Mercury inunctions, or powders or pills of mercury combined with chalk and ipecacuanha, or perchloride of mercury may be given. Iodide is best administered in children in the form of syrup of iodide of iron, and may be combined with syrup of phosphates

as a tonic. Cod liver oil or maltine may be used when there is a tuberculous element about the condition, and in all cases general hygienic regime must be instituted.

Local treatment consists in guarding against the evil effect of the uveitis which is an invariable accompaniment of the disease. Atropin is ordered as a routine measure, with the double purpose of keeping the ciliary body and iris at rest and preventing the formation of posterior synechiæ. There is often great difficulty in getting the




FIG. 141. Arcus senilis.

pupil to dilate, probably owing to defective penetration of the drug through the diseased and vascularised cornea. Smoked glasses are ordered.

In later stages the means used for clearing corneal cicatrices (*vide* p. 234), depending essentially upon improving the lymph flow through the cornea, are also indicated for the opacities of interstitial keratitis. Prolonged use of yellow oxide of mercury ointment, combined with atropin in the earlier stages, is commonly made.

Other forms of deep keratitis, *e.g.*, the central deep keratitis of adults, senile marginal deep keratitis, sclerosing keratitis (*vide* p. 280) occur. Like interstitial keratitis they are probably all secondary.

DEGENERATIVE CHANGES IN THE CORNEA.

Arcus senilis is a fatty degeneration of the cornea met with in old people (Fig. 141). It commences as a crescentic grey line concentric with the upper and lower margin of the cornea. The extremities of the crescents finally meet, and an opaque line, thicker above and below, is formed completely round the cornea. It is characterised by being separated from the margin by a narrow line of comparatively clear cornea. It is sharply defined on the

peripheral side, fading off on the central. It is never more than about 1 mm. broad, and is of no importance, either from the point of view of vision or of the vitality of the cornea.




FIG. 142. Band-shaped opacity of the cornea, from an eye with iridocyclitis.

Arcus juvenilis is exactly similar to arcus senilis, but is a rare condition found in children. Even arcus

senilis may develop at a comparatively early age, but the juvenile condition is probably congenital. It is of no importance. The characteristic diagnostic feature of both these opacities is the presence of a line of clear cornea between them and the limbus. This is occasionally found in old sclerosing keratitis, but in this case the opacity is usually localised to some one part of the cornea and extends farther towards the centre.

Band-shaped Opacity (*Syn.*—*Transverse Calcareous Film, Zonular Opacity*).—This is a common condition in old, blind, shrunken eyes. It is due to defective nutrition

and exposure. It lies entirely in the interpalpebral area, commencing at the inner and outer sides, and progressing until it forms a continuous band across the cornea (Fig. 142). Near the corneal loops, just inside the limbus, the cornea is generally relatively clear. The condition is due to hyaline degeneration of the superficial parts of the substantia propria, followed by the deposition of calcareous salts.

As a rare condition it is found in otherwise healthy eyes.

Treatment.—In the rare form last mentioned, improvement of vision may be obtained by scraping off the opacity, which is usually calcareous and quite superficial. In the common form the eye is blind, and nothing remains but to remove it if it is painful or unsightly.

Other Degenerative Changes are frequently met with in old leucomata, anterior staphylomata, and so on. They consist of hyaline degeneration, calcification, &c. Such scars are liable to a serious form of ulceration (*vide* p. 253).

Rare degenerative conditions are nodular and reticular opacities, &c. Little is known about them, but they occur as a familial disease.

ECTATIC CONDITIONS.

It has already been stated that ectatic conditions of the cornea may result from inflammation, viz., keratectasia (*vide* p. 228), and anterior staphyloma (*vide* p. 230). Two forms of ectasia of non-inflammatory origin are known, viz., keratoconus and keratoglobus.

Anterior Staphyloma is a protuberant cicatrix arising from a prolapse of the iris; it may be partial or total (Fig. 111). It may follow a perforating wound, but is usually due to perforation of an ulcer, especially such as

is caused by ophthalmia neonatorum. The primary protrusion occurs at the moment of prolapse. Cicatrisation follows, and in the case of small prolapse may lead to flattening of the scar. In other cases of small, and in all cases of large prolapse the contraction of the scar tissue is insufficient to bring this about, and the soft cicatrix yields to the normal intraocular pressure. Generally the prolapse of the iris leads to blocking of the angle of the anterior chamber, the intraocular tension rises, and the cicatrix yields still more, or if it was previously flat, secondary protrusion takes place.

Partial staphylomata are usually conical, rarely hemispherical; they usually extend to the margin on one side. Total staphylomata are usually hemispherical, rarely conical. There is invariably a rim of cornea around the pseudo-cornea, this rim being well nourished by the peripheral blood vessels and never necrosing through ulceration. The thickness of the staphyloma varies very greatly in different cases, and often in different parts of the same staphyloma. In the latter bands of cicatricial tissue develop, whilst the intermediate parts project; in this manner a racemose staphyloma is produced.

The pseudo-cornea is formed by organisation of the exudates on the surface of the prolapsed iris. It consists of fibrous tissue covered by epithelium, and lined by rarefied iris pigment epithelium. The epithelium on the anterior surface is often very thick and epidermoid; the fibrous tissue often undergoes degeneration. The anterior chamber is obliterated in total staphyloma, whilst the posterior chamber is enormously enlarged, and filled with yellow albuminous fluid.

The sight is always diminished, and in total staphyloma is reduced to perception of light or total blindness. The eye may project between the lids, so that a xerotic

condition is set up and atheromatous ulcers may form. Ectropion of the lids may occur mechanically. The tension is raised, either as the cause of the protrusion, or as a result of the blockage of the angle of the anterior chamber (Chap. XIV.). This may lead to pain. The staphyloma may be so thin that rupture occurs on the least injury, and may be several times repeated.

Treatment.—Total anterior staphyloma is best treated by excision of the eye, with or without the insertion of a glass globe in Tenon's capsule. Patients will often prefer to keep the eye if it is painless and not too disfiguring.

Various methods of ablation, in which the anterior part of the eye is removed and the contents scooped out, have been devised as an alternative for excision. They give a movable stump on which to set an artificial eye, but they are open to the objection that they are not entirely free from the danger of causing sympathetic ophthalmia (*q.v.*).

Treatment of partial staphyloma is directed to obtaining flattening of the cicatrix, preventing or relieving increased intraocular tension, and improving sight. The attempts which should be made at the early stage have already been described (*vide p. 242*). Iridectomy is sometimes advisable with a view to improving vision and preventing or curing glaucoma (*q.v.*). It cannot be performed at the site of the staphyloma, since there is no anterior chamber here, but must be done over the clearest part of the cornea.

Keratoclasia differs from anterior staphyloma in that the iris takes no part in it. Its causation and prevention have already been discussed (*vide p. 228*). When it is fully developed treatment is useless.

Keratoconus (*Syn.—Conical Cornea*) is probably due to a congenital weakness of the cornea, though often it

only manifests itself after puberty. The cornea is thin and weak near the centre, and gradually bulges forwards more and more; the apex is always slightly below the centre. It is at first perfectly transparent, and vision is impaired through the protrusion and alteration in curvature. If advanced the conical shape is easily recognised in profile. In the less advanced cases diminution in the size of the corneal reflex over the centre is the chief guide. With the ophthalmoscope mirror at a distance of 1 metre a ring of shadow concentric with the margin is seen on the red reflex, altering its position on moving the mirror. It is due to a zone through which few rays pass into the observer's eye owing to the emergent rays on the central side being convergent whilst those on the peripheral side are divergent.

The patient becomes myopic, but the error of refraction cannot be satisfactorily corrected with glasses owing to the hyperbolic nature of the curvature. The condition is almost invariably bilateral, though frequently more advanced on one side than the other. It may be extremely slight and very slowly progressive, or the reverse. In the later stages the apex may become opaque, but ulceration, rupture, increase of tension and so on do not occur.

Treatment.—Various methods have been adopted to stop the process. Miotics are probably useless. The best treatment is cauterisation of the apex with the actual cautery. The cauterisation at the extreme apex must be deep, and perforation here has been advocated. The latter procedure is not without danger to the eye. Some operators remove a small wedge-shaped slice from the thickness of the cornea at the apex. It is more difficult to perform and does not give better results on the whole than the cautery. The scarring from cauterisation is much less than might be anticipated, but it may be advisable to do an optical iridectomy if vision is still very bad.

Keratoglobus is the hemispherical protrusion of the whole cornea which is met with in infantile glaucoma (*q.v.*).

SYMPTOMATIC CONDITIONS.

There are many pathological conditions of the cornea which are merely evidence of disease in other parts of the eye or of extension of disease. Some are often described as true diseases of the cornea, notably as forms of "keratitis." This involves a wrong principle and a misuse of terms which can only lead to confusion. Since it is of great importance to distinguish these conditions from primary affections of the cornea, both from the points of view of diagnosis and treatment, it will be well to review the more common here.

In **glaucoma** there is nearly always uniform diffuse bluish haze of the whole cornea. It is due to alterations in the refractive conditions of the corneal elements, brought about by the increased intraocular pressure, and not to any gross pathological change. If the condition persists the cornea becomes hazy throughout, and this haziness, unlike the former, does not immediately disappear when the intraocular tension is relieved. Here there is definite œdema, due to the impediment which prolonged tension causes to the diffusion of lymph. It manifests itself first in the epithelium, which becomes steamy and stippled. Sections show that this is due to accumulation of fluid in and between the cells, especially the basal cells (Fig. 143). Fluid also accumulates between the lamellæ and around the nerve fibres. If the œdema lasts for a very long period, as in eyes blinded with absolute glaucoma, the epithelium may be raised into vesicles or bullæ (*vesicular or bullous "keratitis"*). The evidence of prolonged tension makes it easy as a rule to distinguish

this condition from herpetic vesicular keratitis; moreover the vesicles or bullae have firmer epithelial walls and show less tendency to burst.

Nearly allied to bullous "keratitis" is the formation of epithelial threads, which adhere to the cornea by one end, whilst the other, which is often club-shaped, hangs down free. This is commonly called *filamentary "keratitis."* It occurs in the same conditions, *i.e.*, usually associated with




FIG. 113.—Edema of the cornea and vesicular "keratitis," from a glaucomatous eye ($\times 60$).

glaucoma, but it may be seen rarely without any apparent cause in cases of the herpetic type.

Keratic recipitates, usually badly termed "keratitis punctata" or "k.p." in England, are often deposited upon the back of the cornea in cyclitis and iridocyclitis. The greatest care must be taken not to overlook them, since they may be almost the only objective sign of serious disease. They may be on the back of a clear cornea or the deeper layers may be infiltrated as a result of the

iridocyclitis; thus, they are not uncommon in interstitial keratitis. Their appearance and nature will be described in discussing their cause (*vide* p. 300).

Opacities of the cornea are often secondary or symptomatic. Such are the grey or white, usually tongue-shaped marginal opacities which follow scleritis. Owing to their resemblance to the sclerotic they are called *sclerosing "keratitis"* (*vide* p. 280).

Congenital opacities of various kinds are sometimes met with. Many are not truly congenital, but are due to injury received at birth.

Striate opacity occurs in various forms. The commonest form is that seen after operations upon the globe in which a peripheral section has been made, as in cataract extraction. Here, when the section is above, delicate grey lines run down vertically from the wound and may pass completely across the cornea (Fig. 144). They can be seen clearly only by magnification. They disappear spontaneously as the wound heals. They are due to slight folding of the cornea, whereby Descemet's membrane and the adjacent lamellæ become wrinkled. Radial striæ are seen around wounds or ulcers; they are partly referable to the same cause, partly to distension of the interlamellar spaces by œdema. The fine hatching which is seen around ulcers and sometimes after tight bandaging are to be referred to similar causes.




FIG. 144. — Striate opacity of the cornea, following section of the cornea above for extraction of cataract.

Opacities of the cornea may be due to improper treatment. One of the commonest is due to *deposits of lead salts* upon an abrasion or ulcer. An insoluble, densely opaque white film is precipitated and adheres very firmly. The spot is sharply defined and looks like white paint.

Probably the deposit is always thrown off eventually, but a very long time may elapse. An attempt should be made to scrape it off, but it is wisest never to use lead lotions at all in the treatment of any affections of the eye. They can always be replaced by equally efficient substitutes.

Pigmentation of the cornea may also occur from improper treatment. Prolonged use of silver nitrate as a paint or in the form of drops is followed by dark brown staining of the conjunctiva and slight staining of the cornea. The condition is called *argyrosis*, and in the conjunctiva is found to be due to impregnation of the elastic fibres with metallic silver; in the cornea Descemet's membrane is stained. It is permanent; hence silver solutions, including profargol, argyrol, &c., should never be ordered as drops or for use at home, at any rate without stringent injunctions.

Blood in the cornea is rare. It may occur as a bright red spot quite superficially at the margin or as a greenish or rusty stain over the whole surface. In the latter case it is derived from blood in the anterior chamber, associated with high tension—a relatively infrequent combination. The stain is due to minute rod-shaped granules of derivatives of hæmaglobin in the lamellæ. It clears very slowly from the margin, and in this stage resembles extraordinarily the appearance of the lens when it is dislocated into the anterior chamber.

Tumours of the cornea, so-called, are probably always secondary extensions, most commonly from the conjunctiva, the limbus being a favourite situation for these growths (*vide* p. 218).

CHAPTER XII.

DISEASES OF THE SCLEROTIC.

REDNESS of the white of the eye is caused by a variety of conditions. The commonest is conjunctivitis; the next common some inflammation of the anterior part of the uveal tract, viz., the iris and ciliary body. Some of the distinctive characteristics of the redness in conjunctival and ciliary inflammation have already been pointed out (*vide* p. 96). Redness of the white of the eye may also be caused by inflammation of the sclerotic, and it is a frequent error amongst beginners to ascribe the other forms to this disease. It must therefore be borne in mind that episcleritis and scleritis are relatively uncommon.

INFLAMMATION OF THE SCLEROTIC.

Two forms of inflammation of the sclerotic are described, superficial or episcleritis, and deep or scleritis. They might equally well be considered mild and severe forms of the same disease, but the distinction is convenient clinically since they usually differ in the course they take.

Episcleritis is an inflammatory affection of the deep subconjunctival connective tissues, including the superficial scleral lamellæ. A circumscribed nodule, which may be as large as a lentil, appears usually two or three millimetres from the limbus (Plate VII., Fig. 2). It is hard, immovable, and very tender, the conjunctiva moving freely over it. It is traversed by the deeper episcleral vessels, and therefore looks violet, not bright red. It is extremely chronic, never ulcerates, and may be entirely absorbed.

but more frequently leaves a slate-coloured scar behind, to which the conjunctiva is adherent. The cornea and nasal tract rarely participate in the inflammation.

There may be little or no pain, but usually there is a feeling of discomfort and tenderness on pressure, and severe "neuralgia" is often complained of. The nodule becomes gradually absorbed in the course of days, or, more frequently, weeks, but during the process of absorption, or soon after, fresh nodules of the same type arise. In this manner the disease may drag on for months. Both eyes are frequently affected. In the worst cases the disease extends into the deeper parts of the sclerotic, and thus passes almost imperceptibly into scleritis.

Anatomically dense lymphocytic infiltration of the subconjunctival and episcleral tissues is found.

Rheumatism and gout are commonly indicted as the chief causes of episcleritis. A history of acute rheumatism is rarely obtained; more commonly there has been well marked "muscular rheumatism." Tuberculous or syphilitic patients seem predisposed, and almost invariably there is some cause of general debility. It is commonest in elderly people (cf. Scleritis), and in women.

Treatment.—General treatment is of more avail than local. Even in cases in which no history of rheumatism can be elicited, salicylic preparations—salicylates, salicin, aspirin—seem to do good, and should be tried. If they fail resort should be had to iodides.

The most useful local treatment is massage by the finger applied to the upper lid. A simple boric ointment may be used or a weak yellow oxide of mercury ointment, but strong stimulants can rarely be borne. In the more severe cases warm compresses, atropin, and leeches to the temple should be employed. In the worst cases the constant current, scarification or superficial cauterisation are indicated. Every effort must be made

to build up the constitution, and success often depends upon these measures.

Scleritis is rarer than *episcleritis*. There are usually nodules, or a single nodule, but the area affected is much less circumscribed. The swelling is at first dark red or bluish, later it becomes pale violet and semitransparent, like porcelain. It may extend entirely round the cornea, forming a very serious condition known as *annular scleritis*. *Scleritis* differs from *episcleritis* in that the cornea and nveal tract are involved, some iritis, but more cyclitis and anterior choroiditis being present. There is no ulceration, but much absorption, so that the sclerotic is thinned, a dark purple cicatrix being formed, which is often too weak to withstand the intraocular pressure, so that cecasia follows (*ciliary staphyloma*). In many cases of diffuse deep *scleritis* hard whitish nodules develop in the inflamed zone. They are the size of a pin's head and lie beneath the conjunctiva, all at about the same distance from the corneal margin: they disappear without disintegrating.

Anatomically *scleritis* is the same as *episcleritis*, but extends deeper: there is dense lymphocytic infiltration of the sclera, the lamellæ being separated by cords of cells.

Both eyes are usually affected. Young adults are the most common subjects (cf. *Episcleritis*), and women more often than men. The causes are obscure, but of the same type as in *episcleritis*.

Scleritis is most serious on account of its sequelæ and complications. Uveitis of some kind is probably an invariable accompaniment. It is uncertain whether it may be a result or a cause of the *scleritis*; most probably it is neither, but both are due to a common cause. This cause is probably the absorption of toxins from some septic focus. It is often difficult or impossible to find the focus, but special attention should be directed to the nasal

sinuses and generative organs, the latter especially in women. In other cases the alimentary canal is probably at fault, and many of the drugs which have been found beneficial probably act chiefly by disinfecting the intestinal tract. In some cases the disease is undoubtedly tuberculous and in others syphilitic. Ciliary staphyloma leads to distortion of the globe, and vision is impaired by it and by the many deleterious effects of the uveitis. Secondary glaucoma usually follows.

Apart from these complications scleritis nearly always extends to the cornea, causing *sclerosing keratitis* (Fig. 145). An opacity develops at the margin of the cornea near the



FIG. 145.—Sclerosing keratitis.
(Nettleship.)

scleritic nodule. It is approximately triangular or tongue-shaped, the rounded apex being towards the centre of the cornea. Similar opacities may develop farther from the margin and even at the centre. The opacities are grey or greyish yellow, becoming denser until they exactly resemble the sclerotic—hence the name. There is little or no vascularisation, and ulceration never occurs. Some clearing from the centre towards the periphery, as well as near the marginal corneal loops, occurs, but the densest parts usually persist as bluish clouds. The whole margin of the cornea may become opaque like the sclerotic, but the pupillary area almost invariably escapes.

Treatment is the same as for episcleritis. When tubercle is suspected injections of tuberculin should be employed. Dionin and subconjunctival injections of saline, &c., have been recommended.

Ulceration of the sclerotic is always secondary, either from without or from within. Extension from the

conjunctiva is almost always due to tuberculous ulceration, rarely syphilitic. Extension from within is almost always from the iris or ciliary body and is usually tuberculous in the case of the iris, syphilitic in that of the ciliary body. Ulceration of malignant growths which have perforated the sclerotic also occurs—sarcoma of the iris or ciliary body, glioma of the retina. All these conditions are rare.

CHAPTER XIII.

DISEASES OF THE IRIS AND CILIARY BODY.

The uncount term *uveitis* has the merit of emphasising an important fact, viz., the close relationship which exists between the anatomically distinct parts of the uveal tract. It draws attention to the frequency with which inflammatory processes involve the tract as a whole, and are not strictly limited to a single part. This feature is particularly well exemplified in inflammation of the iris and ciliary body. Probably iritis never occurs without some cyclitis, nor, a fortiori, cyclitis without some iritis. The disease is called iritis or cyclitis according as the iris or ciliary body appears clinically to be the more affected. The same disposition is also seen with regard to the choroid, though in less degree. General uveitis is most common in the more chronic types of inflammation, but it is probable that the ciliary body is often involved in many cases which we are accustomed to regard as pure choroiditis.

For convenience of description it is best to consider diseases of the various parts of the uveal tract separately, but the anatomical, physiological, and pathological continuity of the parts can be scarcely too forcibly insisted upon.

INFLAMMATION OF THE IRIS AND CILIARY BODY.

Iritis. In order that iritis and the special dangers which attend it may be thoroughly understood, it is necessary to remember the anatomical arrangements of

the iris and the pathological changes which occur in it. The iris is practically a diaphragm of blood vessels and unstriped muscle fibres held together by a very loose, spongy stroma. In its perpetual movements the pupillary margin slides to and fro upon the lens capsule. The more the pupil is constricted the more of the posterior surface of the iris is in contact with the lens capsule ; when fully dilated the iris probably does not touch the lens at all.

Inflammation of the iris is fundamentally the same process as occurs in other connective tissues: it consists in dilatation of the blood vessels, impairment of the capillary walls, exudation of a highly albuminous lymph into the tissue spaces, and leuco- or lympho-cytosis. Owing to the extreme vascularity of the iris and the peculiar distribution of the vessels, and to the looseness of the stroma, these generic features of inflammation produce special results. Thus, simple hyperæmia tends to cause the pupil to contract mechanically, on account of the radial disposition of the vessels. This is to some extent physiological, but is greatly increased under pathological conditions. The extreme vascularity and the looseness of the tissues causes an unusually large amount of exudation on the one hand and of swelling on the other. Owing to the greater albuminous content of the fluid its viscosity is increased so that it escapes into the anterior chamber and out of the anterior chamber by way of the filtration angle (*vide* p. 23) with greater difficulty. The iris, from being a partially wrung-out flat sponge becomes a sponge full of sticky fluid. Hence its freedom of movement is greatly impaired, and the normal reactions become very sluggish or completely abolished. The fluid, too, contains deleterious substances which act as irritants: the nerve endings are stimulated so that the muscle fibres contract. In any case in which the

sphincter and dilatator fibres are equally and uniformly stimulated the sphincter overcomes the dilatator, so that constriction of the pupil follows.

It is easy now to understand the chief signs of iritis. The pupil is constricted, partly owing to hyperæmia, partly to irritation; the edge of the pupil is markedly irregular. The reactions of the pupil are sluggish, partly owing to the same causes which induce constriction, partly to what may be termed water-logging. The latter condition causes an alteration in the appearance of the iris. The delicate iris pattern, instead of being clear and sharply defined, becomes blurred and indistinct ("muddy" iris). The colour undergoes considerable change, varying according to the condition of normal pigmentation. In fair people with little pigmentation, the blue iris becomes bluish or yellowish green; brown irides show less difference, but become greyish or yellowish brown. In any case comparison of the colour of the two irides will usually reveal some light difference, for iritis is generally unilateral during the acute attack.

As a result of the change in colour and blurring of the iris pattern, the hyperæmia of the iris itself is not very obvious, but it manifests itself in circumcorneal ciliary congestion (*vide* p. 96). This is most marked if the ciliary body is seriously involved, but the conjunctival vessels are also frequently moderately engorged, so that care is necessary in distinguishing the condition from conjunctivitis. The secondary nature of the conjunctival congestion is shown by the relatively slight discharge: what discharge there is is chiefly lacrymal, never mucopurulent in the absence of actual conjunctivitis as a complication.

The iris is richly supplied with sensory nerves from the ophthalmic division of the fifth nerve. It is not surprising, therefore, that pain is a prominent symptom

of acute iritis. It is not confined to the eye, though severe neuralgic pain is felt here, but is also referred to other branches of the first division of the fifth nerve, especially to the brow and parts supplied by the supraorbital and trochlear branches, but also to the cheeks and malar bone, and sometimes to the nose and teeth. It is worst at night.

The albuminous exudates escape slowly into the anterior chamber and mix with the normal aqueous. If the ciliary body is much involved the aqueous itself is abnormally albuminous. The aqueous often contains leucocytes and minute flakes of coagulated proteid, seldom fibrinous networks except in severe cases. It therefore becomes hazy, further interfering with a clear view of the iris and easily mistaken for haziness of the cornea, which is usually not involved. In very intense cases, especially of traumatic iritis with septic infection, large numbers of polymorphonuclear leucocytes are poured out; these sink to the bottom of the anterior chamber and form an hypopyon. Hypopyon is rare in simple iritis without perforation of the globe. Hyphema, or blood in the anterior chamber, may also occur, but is rare in simple iritis.

The abnormal condition of the aqueous impairs the nutrition of the endothelium which covers the back of the cornea. The cells become sticky and may desquamate in places. The exudates tend to stick to the more affected spots, forming *keratic precipitates* ("keratitis punctata"). These are seldom present in simple iritis, but form a prominent feature of cyclitis, varying roughly with the amount of cyclitis present.

The more albuminous the aqueous the more viscous it becomes. This viscous fluid filters out of the anterior chamber by the filtration angle with difficulty. Hence there is a tendency for the fluid to be retained, so that the intraocular tension rises. The rise is minimal and of

no serious import in cases of simple iritis—in fact, it is scarcely appreciable by clinical methods. If, however, the ciliary body is much involved the albuminous constituents of the aqueous are very markedly increased, and rise of tension may be so great as to endanger the sight, requiring special attention.

The exudates which are poured out by the iris and ciliary body are naturally most concentrated in their immediate neighbourhood. They cover the surface of the iris as a thin film and spread into, and often completely over, the pupillary area. In this manner the pupil may become "blocked" with exudates, a condition which very

seriously impairs the sight of the eye. Moreover, the exudates tend to stick the iris down to the lens capsule, so that it becomes immovably fixed.

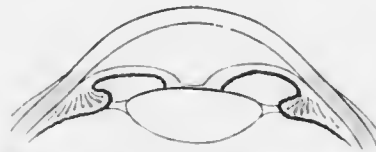

FIG. 146. Diagram of seclusion and occlusion of the pupil, with bowing forwards of the iris ("iris bombe"). (Nettleship.)

If the patient is seen in the early stages and atropin is instilled the pupil dilates,

though not so readily as a normal pupil, on account of the water-logging of the iris. By continuous treatment the iris may be freed from the lens capsule and the pupil becomes completely dilated and circular.

The exudates, however, show a great tendency to become quickly organised. This is particularly seen in most cases of iritis, less frequently in cyclitis; when it is a very marked feature of the case the inflammation is often described as *plastic*. If the exudates which bind the iris to the lens capsule have not been already broken down they become converted into fibrous bands which atropin is wholly unable to rupture. Such firm adhesions of the pupillary margin to the lens capsule are called *posterior synechiæ* (*συνέχεια*, to hold together). When they are

present a mydriatic causes only the intervening portions of the circle of the pupil to dilate and the pupil assumes a festooned appearance (Plate VII., Fig. 2; Fig. 150). Even in the absence of a mydriatic minute inspection will generally show irregularities of the pupillary margin due to the synechia. Such an irregular pupil is a sign of present or past iritis. For diagnostic purposes homatropin should be instilled and the result confirmed by the appearance of the dilated pupil. Owing to the contraction of organising exudates upon the surface of the iris the retinal pigment epithelium may be pulled outwards over the pupillary margin. Patches of pigment are then seen in this situation (ectropion of the nveal pigment).

In very severe cases of plastic iritis, or after recurrent attacks, the whole circle of the pupillary margin may become tied down to the lens capsule. The condition is called *annular* or *ring synechia* or *seclusio pupillae* (Figs. 146, 149); it is one of great danger to the eye (*vide p. 308*). In similar cases, especially if the case has been neglected and the pupil not well dilated by atropin at an early stage, the exudates in the pupillary area may also organise. A film of opaque fibrous tissue then fills the pupil; this condition is called blocked pupil, or *occlusio pupillae* (Figs. 146, 149). If there had been much cyclitis the posterior chamber (Fig. 1) also becomes filled with exudates which may organise. They then tie down the whole of the back of the iris to the lens capsule; this condition is called *total posterior synechia* (Fig. 147). It leads to retraction of the peripheral part of the iris, so that the anterior chamber becomes abnormally deep at the periphery, sometimes much deeper than in the centre.

Iritis is most frequently mistaken either for conjunctivitis or for acute glaucoma. The points which distinguish it from conjunctivitis will be gathered from what has already been described. The error of mistaking iritis for

glaucoma is the most serious which can be made, more particularly because the treatment of the two conditions is diametrically opposed. Dilatation of the pupil with atropin, which is urgently necessary in iritis, is the worst possible treatment of glaucoma (q.v.). At the cost of

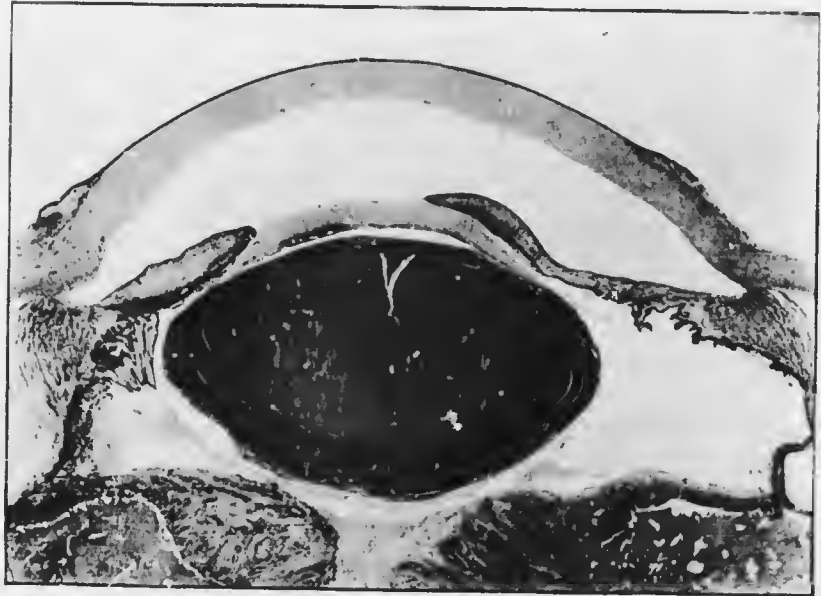


FIG. 147. Total posterior synechia ($\times 7$), from a case of plastic iridocyclitis commencing to cause phthisis bulbi. The iris is completely adherent to the lens capsule, and the periphery is retracted. There is a delicate inflammatory pupillary membrane (occlusio pupillae). There is also an anterior capsular cataract, due to the inflammation: it contains calcareous deposits, as shown by the patch of dark staining. The ciliary body is degenerated and detached from the sclerotic at the posterior part. The retina is completely detached and folded behind the lens.

some repetition, the distinguishing features will be given here.

(1) In iritis the pupil is smaller than normal and irregular; in glaucoma it is larger and oval, usually with the long axis vertical.

(2) In iritis the intraocular tension is scarcely appreciably

raised unless much cyclitis is present; in glaucoma it is always appreciably raised, and is often very high.

These are the two chief objective signs. Cases occasionally arise which are doubtful even to the most experienced. A useful and harmless procedure which will almost invariably settle the question is the following: A drop of 2 per cent. homatropin (*not* atropin) solution is instilled. As the pupil dilates, in iritis the irregularities are emphasised and synechiæ are almost always revealed; the tension is not appreciably affected by the mydriatic; in glaucoma the pupil probably dilates slowly but quite evenly, retaining its roundness; the tension is appreciably increased by the mydriatic. As soon as glaucoma is definitely diagnosed by this test eserine (1 per cent.) must be immediately instilled and repeated at intervals (*vide* p. 326). Atropin is never to be used for diagnostic purposes since eserine is incapable of counteracting its mydriatic effect, and if the case is found to be one of glaucoma immediate iridectomy would be imperative.

(3) The subjective symptoms differ in the two diseases. Vision is usually more impaired in glaucoma than in iritis. In acute glaucoma the onset of the pain is sudden, and it is so severe that it is frequently accompanied by vomiting.

It will be advisable again to enumerate the chief symptoms and signs of iritis. The subjective symptoms are: pain, of a neuralgic character, referred not only to the eye but also to the supra-orbital region; dimness of vision, due to cloudiness of the aqueous, exudates in the pupillary area, &c. The objective signs are: constriction and irregularity of the pupil, unless a mydriatic has already been instilled, in which case the irregularity is emphasised by the presence of the posterior synechiæ. If the mydriatic is instilled early these synechiæ may break down so that the pupil again becomes quite round; in

such cases spots of lymph or pigment upon the anterior capsule of the lens often leave permanent marks of old synechia, and form most valuable evidence of previous iritis (Fig. 148). It has already been pointed out (p. 5) that the posterior layer of the retinal pigment epithelium on the back of the iris is less firmly attached to the iris than the anterior. When a synechia breaks down some of the posterior layer often tears away and remains attached to the lens capsule: these pigmented spots never disappear entirely. Discoloration or muddiness of the iris, whereby the iris pattern is masked: hyperemia, manifesting itself chiefly as circumcorneal ciliary congestion; exudations, manifesting themselves either as more or less cloudiness of the aqueous or as solid deposits in the pupillary area and upon the iris: these are conspicuous signs of inflammation of the iris.



FIG. 148. Spots of pigment on the lens capsule, left by posterior synechia which have broken down. (Nettleship.)

The course of iritis varies with its intensity. Even the slightest acute cases take three or more weeks before inflammation entirely subsides. The best sign is the prompt action of atropin, for in the worst cases it has little or no effect. Improvement is shown by good dilatation, diminution of injection and pain. In the chronic cases the ciliary body is almost always more seriously involved; the condition is one of irido-cyclitis. The inflammatory signs are less, but diminution of vision is progressive, and the disease not infrequently lasts for years.

One of the most characteristic features of iritis and cyclitis is the great tendency to relapse. It depends, not upon the synechia, as was once taught, but upon the constitutional cause of the disease. Each fresh attack runs a similar, though usually less severe, course, often leaving fresh traces and increased impairment of vision.

Complete resolution may occur in slight cases treated early and suitably. The exudates become absorbed, the synechiæ break down, leaving only such slight traces that vision may be perfect. Comparatively slight cases may, however, leave very serious results if they are improperly treated, and in severe cases these are the rule. Most of the evil results are attributable to neglect of or impossibility of early dilatation of the pupil, which causes permanence of the posterior synechiæ. If these are few, no special injury or impairment of sight follows, but future attacks are more likely to result in an increased number or in ring synechia.

Ring synechia, or *seclusio pupillæ*, is one of the worst sequels of the disease, since, if unrelieved, it inevitably leads to secondary glaucoma and destruction of sight. Owing to the complete shutting off of the pupil the aqueous which is secreted by the ciliary body (*vide* p. 21) is unable to pass forwards into the anterior chamber, the iris being a non-permeable membrane. It therefore collects behind the iris, which becomes bowed forwards like a sail, a condition which is called *iris bombé* (Fig. 149). Regarded from in front, the anterior chamber is seen to be funnel-shaped, deepest in the centre and shallowest at the periphery. The filtration angle is obliterated by the adhesion of the iris to the cornea and sclera at the periphery (peripheral anterior synechia). Hence the fluid is retained within the eye and the intraocular tension rises (*vide* p. 308).

Organisation of the exudates in the pupillary area leads to the formation of an inflammatory pupillary membrane or *occlusio pupillæ*. This interferes directly with the transmission of light rays and is often associated with ring synechia, with or without total posterior synechia (*vide* p. 287). In such cases there is generally plastic cyclitis and the eye is irretrievably affected.

Repeated attacks of iritis lead to atrophy of the iris, which becomes dirty grey, like felt or blotting paper. Red streaks often mark the site of permanently dilated vessels, usually of new formation and therefore not necessarily radial in direction. The pupillary margin is thin and frayed: the reactions are diminished.

Varieties of Iritis.—The varieties of iritis are usually



FIG. 149. Iris bombé, with very broad peripheral anterior synechia, annular posterior synechia (seclusio pupillæ), and inflammatory pupillary membrane (occlusio pupillæ). There is also an anterior capsular cataract.

divided into primary and secondary, the latter being those which are due to extension of inflammation from some other part of the eye, usually the cornea. The primary iritides are due to some general dyscrasia, though it is not always possible to determine its exact nature (so-called idiopathic iritis). The most undoubted cause is certainly syphilis; other causes are gonorrhœa, tubercle,

and diabetes; alleged causes are gout, "rheumatism," acute exanthemata, &c. Finally, iritis is usually an important element of sympathetic ophthalmia (*q.v.*).

Syphilitic Iritis manifests itself in two forms. Syphilis is the commonest cause of simple plastic iritis, which occurs in the secondary stage, soon after the skin eruptions, usually within the first year after infection. There may be nothing characteristic about this form of iritis, or nodules may occur upon the iris (*vide infra*). Syphilitic iritis does not usually recur, thus differing from the "rheumatic" form. Simple plastic iritis also occurs in congenital syphilis, usually as an accompaniment of interstitial keratitis (*q.v.*). It also occurs in very young babies with congenital syphilis, without any corneal complication, but usually with large nodules or gummata on the iris. This is not common, but is probably the only cause of iritis in very young children apart from direct injury. It is sometimes seen so soon after birth that it almost certainly in these cases commences as an intrauterine inflammation.

The iris also becomes inflamed in some cases of acquired syphilis late in the secondary or very rarely during the tertiary stage. These cases are characterised by the formation of yellowish red nodules near the pupillary and ciliary borders of the iris, but not in the intermediate region. The nodules are usually multiple and vary in size from that of a pin's head upwards (Fig. 151). It has been customary to consider these nodules either condylomata or gummata, according to the stage of the complaint. There

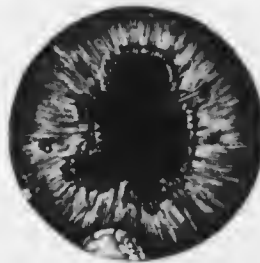

FIG. 150. Plastic iritis with nodules in the angle of the anterior chamber. (Nettleship, from a drawing by Holmes Spicer). The patient was not syphilitic.

is no good ground, either clinical or pathological, for the distinction, and the term *gummatous iritis* may be used for all these cases. There is generally much exudation in gummatous iritis, and broad synechiæ are formed. The nodules are liable to be mistaken for tubercle (*q.v.*) or sarcoma (*q.v.*): the absence of iritis and the presence of only a single nodule usually distinguishes the latter condition. Gummatous iritis may rarely extend to the corneo-sclera at the angle of the anterior chamber and lead to perforation of the globe.



FIG. 151.—Nodules occurring in the secondary stage of syphilis, situated at the pupillary border of the iris. (Nettleship, from a drawing by W. G. Laws.)

Gonorrhœal Iritis is probably more common than is generally supposed. It occurs especially in those cases which have gonorrhœal "rheumatism," and seldom supervenes until after one attack of arthritis, usually in the knees. It exhibits no special signs: it tends to recur, often during the onset of a gleet or arthritic attack. There is little doubt that it is a metastatic infection. Another, more characteristic form may occur

during the acute attack. The exudates into the anterior chamber then have a peculiar gelatinous appearance.

"*Rheumatic Iritis*."—In patients with iritis, in whom no specific or gonorrhœal taint can be discovered, a history of rheumatic pains in the muscles and joints can often be elicited. Iritis seldom accompanies an attack of acute rheumatism, and only rarely can a history of such an attack be obtained. The patients are often gouty or have rheumatoid arthritis. What the pathological relationship of the iritis is to these complaints must remain a matter of conjecture until their ætiology is placed beyond dispute. The iritis in these cases is usually a plastic iritis

of moderate severity. It shows a very marked tendency to recur, and the recurrence seems to bear a direct relationship to the recurrent attacks of pain or arthritis.

Diabetic Iritis is rare: it is probably a gouty iritis occurring in a diabetic subject. It shows a marked liability to the formation of new or enlarged vessels in the iris, with the formation of plastic exudates and occasionally an hypopyon. On the whole it runs a favourable course.

Tuberculous Iritis occurs in a miliary and a conglomerate or solitary form. In the former there is usually a yellowish white nodule surrounded by numerous smaller satellites: there is the same tendency as in gummatous iritis for the nodules to be near the pupillary or ciliary margins. In conglomerate tubercle there is a yellowish white tumour, though smaller satellites may be present. The nodules contain giant cells. There is usually less general iritis than in the gummatous form, but there is almost always some. The condition may be mistaken for gummatous iritis or for sarcoma. The absence of specific history, a negative Wassermann reaction, the failure of antisyphilitic treatment, and the age of the patients—children or young adults—are distinguishing features from gummatous iritis. The presence of satellites, the usual, but not invariable, absence of visible vessels upon the surface of the nodules, the age of the patient, and the presence of iritis distinguish it from sarcoma. The diagnosis may be extremely difficult, but the great rarity of sarcoma of the iris should be borne in mind (*vide* pp. 200—201). Simple iritis is said to be sometimes tuberculous: this form is excessively rare.

In conglomerate tubercle of the iris the corneo-sclera at the angle of the anterior chamber almost invariably becomes ultimately eroded and involved. The wall of the globe is thus weakened and eventually gives way. The tuberculous

mass then grows rapidly through the perforation, and a large portion of the iris may become prolapsed. In this manner the eye is inevitably lost.

Sympathetic Iritis.—See Sympathetic Ophthalmia, Chap. XXI.

"Serous" Iritis.—See p. 299.

Secondary Iritis: Purulent Iritis.—See Chap. XXI.

Treatment.—Dilatation of the pupil with atropin and hot applications are the essentials of local treatment. Atropin acts in three ways: (1) by keeping the iris and ciliary body at rest; (2) by diminishing hyperemia; (3) by breaking down posterior synechia and preventing the formation of fresh ones. It may be used in the form of drops of a 1 per cent. solution or as an ointment of the same strength. I prefer the ointment for the following reasons: (1) its action is more continuous; (2) it is easier to apply, since it usually works into the eye even if only rubbed along the lashes; (3) it is less likely to cause symptoms of poisoning, which are not uncommon with the drops in children. Symptoms of poisoning—dryness of the throat, flushing of the face, delirium, &c.—are due to the excess of solution—often considerable in unskilful hands—passing down the nasal duct into the nose and throat. The dose administered in this manner is never lethal.

Atropin should be pushed in the early stages, best by frequency of application rather than increased strength. Every four hours is usually sufficient. When the pupil is well dilated, two or three times a day suffices. If atropin irritation ensues, hyoscin, scopolamin, or duboisin should be substituted.

Hot applications are extremely grateful to the patient, diminishing the pain, and are of therapeutic service in encouraging a more vigorous blood and lymph flow. Hot fomentations and bathings may be used, but dry heat applied to the surface of the closed lids has the same

effect. It may be effected by means of a Japanese muff-warmer, which is bandaged over a pad of wool, previously well heated and applied to the eye. By this means the heat is considerable and continuous, with a minimum of trouble and discomfort.

In very severe cases, or when the pupil does not readily respond to atropin, depletion of blood from the temple should be resorted to. The best method is by two or three leeches applied a short distance outside the external canthus. They should not be too far from the eye, nor too near, for in the latter case much œdema of the lids may follow. Heurteloup's artificial leech may be used, but is not so efficacious.

If the pain is very intense a hypodermic injection of morphia may be given. Aspirin is very useful in relieving pain.

General treatment should be commenced by a smart saline purge, and the bowels must be kept freely open throughout the acute stage.

In other respects the general treatment depends upon the cause. In syphilitic iritis the patient is rapidly got under the influence of mercury, best by inunctions. This is most effectual in the cases occurring during the secondary stage, but should also be used in the gummatus form. Here it is supplemented by iodides. The infantile form of acute syphilitic iritis responds rapidly to mercury, but neither drug is very efficacious in the congenital type, and in this, as well as in the later stages of the other forms, general tonic treatment is indicated.

In other forms of iritis, where a rheumatic taint is suspected or where no satisfactory cause can be found, it is usual to order salicylic preparations, and they appear to do good, not only in these, but also in gonorrhœal and diabetic iritis.

In the convalescent stage smoked glasses are ordered—

for both eyes, especially on account of the consensual reaction to light.

Tuberculous iritis is treated by the same local applications as other forms. The usual constitutional treatment must be pushed. Improvement and even complete resolution have been recorded from the use of tuberculin injections.

Some authors consider that tuberculous iritis is generally the primary manifestation of the disease in the body. They therefore advocate the removal of the eye as soon as the diagnosis is made, in order that the danger of extension of the disease to other parts of the body may be minimised. If perforation of the globe has taken place and the eye is irretrievably lost immediate excision should be urged, but in other cases ordinary treatment, supplemented by tuberculin, should be persisted in.

Treatment of Sequelæ and Complications.—For the treatment of coincident cyclitis see p. 302.

Firm posterior synechie can sometimes be broken down by placing a small particle of solid atropin in the conjunctival sac. Care must be taken to prevent the dissolved atropin from passing down the nasal duct by pressure with the finger upon the lacrymal sac by the patient himself, but the surgeon must see that the pressure is rightly applied and kept up.

Annular synechia demands an iridectomy in all cases in order to restore communication between the anterior and posterior chambers, and thus avoid the supervention of secondary glaucoma (*vide* p. 308). No operative procedure of this kind must be undertaken during an acute or even the slightest attack of iritis if it can be possibly avoided, since the traumatic iritis set up will frustrate the object of the operation by filling the coloboma with exudates, and may even cause the loss of the eye. It is best, if possible, to forestall a ring synechia by performing the iridectomy

before the adhesion extends round the whole circle. This can often be done, because operable ring synechia, *i.e.*, ring synechia without total synechia, is frequently the result of recurrent attacks of quiet or almost painless iritis, during each of which more of the circle is involved. The iridectomy is performed during a quiescent interval.

Total posterior synechia can seldom be operated upon with success. Iridectomy is seldom possible, and the only procedure which can be adopted is extraction of the lens by a specially devised operation. Iridectomy or iridotomy may be possible if the lens is shrunken.

Cyclitis has already been referred to incidentally. The exudates from the ciliary body pass into the anterior chamber directly from that part which forms a boundary of the chamber (Fig. 2), and by passing forwards through the pupil. When they organise in the plastic form they not only cause total posterior synechia, but also surround the lens and extend throughout the vitreous. Behind the lens they form a transverse membrane or cyclitic membrane. Strands of fibrous tissue are formed in the vitreous. They become anchored to the retina in various places, and by their subsequent contraction often lead to detachment of the retina. The exudates which organise upon the surface of the ciliary body cause the destruction of the ciliary processes, which results in abolishing or seriously diminishing the secretion of aqueous. Hence the intra-ocular tension becomes lowered and the eye is quite soft to the touch. The walls of the globe fall in, and the eye becomes shrunken—*phthisis bulbi* ($\phi\theta\acute{\iota}\omega$, to waste) (Fig. 152). After this has occurred degenerative changes supervene, and the choroid becomes converted after months or years into bone.

Chronic Irido-cyclitis (*Syns.*—*Simple Cyclitis*, “*Serous Iritis*”).—This is an extremely insidious and chronic

disease, characterised by diminution of vision with slightly marked physical signs. In severe cases there is ciliary congestion, tenderness on pressure over the ciliary region, deep anterior chamber, precipitates ("keratitis punctata") on the back of the cornea, and dust-like opacities in the vitreous. The tension is usually slightly raised in the earlier stages, lowered in the later. There may be œdema of the upper lid and neuralgic pain in the eye and brow.

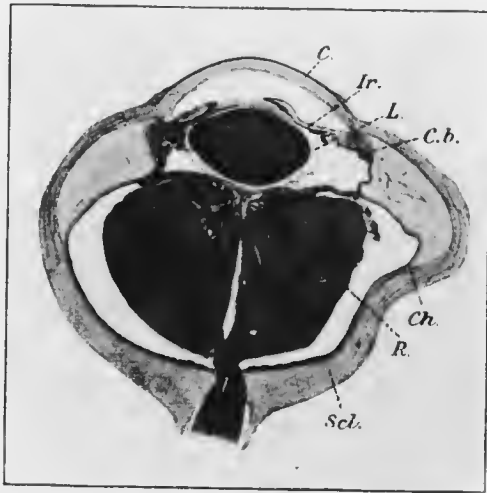


FIG. 152.—Phthisis bulbi, due to irido-eyelitis ($\times 3$). *C.*, cornea; *Ir.*, iris; *L.*, lens; *C.b.*, ciliary body; *Ch.*, choroid; *R.*, retina, detached and folded up behind lens, separated from choroid by albuminous coagulum; *Scl.*, sclerotic.

There is sometimes myopia, owing to irritation of the ciliary muscle.

The *keratic precipitates* ("k.p.") (Fig. 153) consist of leucocytes which are deposited from the aqueous upon the back of the cornea and stick there. They may contain pigment granules, showing their origin from the uveal tract (pigmented k.p.). In the most characteristic form they are scattered over a triangular area of the lower part of the cornea, the smaller spots being above, the larger below

(Fig. 153). This arrangement is due to gravitation of the particles towards the bottom of the anterior chamber, combined with the perpetual movements of the eye, which are mostly in the horizontal direction. The typical arrangement is often but not always observed. More commonly a few isolated spots are seen scattered irregularly over the lower part of the cornea. They require great care in examination for their discovery (*vide* p. 101), and their importance cannot be over-estimated. The smaller spots frequently coalesce, forming small plaques, which gradually become more translucent ("mutton-fat k.p."). Similar spots are rarely seen upon the anterior capsule of the lens, but the leucocytes do not readily stick here owing to the smooth surface, devoid of endothelium.

The vitreous opacities are of the same nature, viz., wandering leucocytes, but many are also probably minute particles of albuminous exudate. Their mobility in the vitreous shows that the consistency of this substance has undergone change, sometimes amounting to complete fluidity, and is due to defective nutrition.

The depth of the anterior chamber is an important sign, not easily explained. It is undoubtedly connected with the deficient filtration of the albuminous aqueous through the angle, which also accounts for the rise in tension. The peripheral part of the anterior chamber is often particularly deep, even deeper than the central: this is however more marked in the later stages of plastic cyclitis, when it is due to mechanical retraction of the iris from organisation of exudates in the posterior chamber.

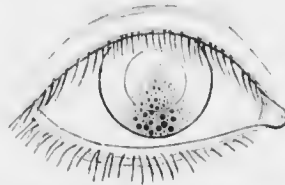


FIG. 153.—Typical arrangement of spots on the back of the cornea in "keratitis punctata" (k.p.). (Nettleship, from a sketch by Dr. Herringham.)

In the slightest and most insidious cases of irido-cyclitis the symptoms and physical signs are minimal. Considerable diminution of vision without obvious cause should always excite apprehension, and the cornea should be most carefully explored by oblique illumination with magnification by the loupe, as well as by the direct method with a strong convex lens. A few spots of k.p. are decisive proof of cyclitis, and may be the sole physical sign. Change in the colour of the iris, due to atrophy, is an important sign, since it may at once attract attention.

Chronic irido-cyclitis occurs under similar conditions to simple iritis. Syphilis may be the cause. It is probably always due to some form of toxæmia or bacterial metastasis, and a careful search should be made for a septic focus in some part of the body. It is most frequently found in the mouth—pyorrhœic alveolaris—in the nose and accessory nasal sinuses, or, especially in women, in the genital tract. Very often no such source of toxins can be demonstrated, but the patients are usually of a debilitated type. There is often constipation, and it is not improbable that the intestinal tract is a frequent source of the toxins.

The disease is generally very chronic and liable to exacerbations with gradual and insidious formation of posterior synechiæ. Vision is greatly diminished during the more acute stage, but recovers considerably in the intervals, but each recurrent attack leaves more and more permanent defect. The eye may finally become soft and tender, and enter into the condition of phthisis bulbi, but this usually occurs only after many years in simple cases of irido-cyclitis. Less serious cases, however, not uncommonly occur, especially when the septic focus, *e.g.*, pyorrhœa alveolaris, is discovered and is amenable to radical treatment.

Treatment of irido-cyclitis is essentially the same as that

of iritis, but special attention must be directed to any septic foci which may be found and to the general health. The cases often drag on indefinitely, with occasional exacerbations. During the more acute phases energetic treatment with atropin, hot bathings or the mull-warmer, and if necessary blisters or leeches, is indicated. The patient should be kept in bed and submitted to mercurial inunctions or baths, which often do good in cases in which there is no specific history. Diaphoresis by vapour baths and hypodermic injections of pilocarpin may be tried in intractable cases, which form the majority.

If the intraocular tension is raised seriously, so that there is danger to the sight of the eye from this cause, it must be relieved by paracentesis (*vide* p. 237). It usually has only a transitory effect, and may require to be repeated every two or three days. It is theoretically unsatisfactory, since the comparatively sudden reduction of the intraocular pressure to zero causes dilatation of the ciliary vessels and allows the passage of a lymph which is even more albuminous than that which has been let out. It should therefore not be resorted to unless imperatively indicated. On the other hand the final result is often very satisfactory, probably because the rapid flow of lymph flushes out the secretory channels and carries away endothelial and epithelial débris and stagnant toxins.

During the intervals between exacerbations the pupils should be kept moderately dilated with weak (0.5 per cent.) atropin. The patient should have plenty of fresh air, good diet, and tonics.

If the eye becomes useless, shrunken, and painful it may be necessary to excise it.

Plastic Irido-cyclitis.—The pathology of this condition has already been described incidentally. In it the signs of irido-cyclitis in general are increased. The cyclitic membrane behind the lens may be seen with the

ophthalmoscope or even by oblique illumination. In young children the condition forms one type of pseudo-glioma (Chap. XIX.). In the later stages the degenerative changes in the ciliary body prevent it from fulfilling its functions of supplying the eye with lymph and nutriment. The vitreous suffers first, and later the lens, which becomes opaque. Finally the eye shrinks (phthisis bulbi).

Treatment is the same as for chronic irido-cyclitis. The blind, shrunken globe is often painful and a continual source of annoyance to the patient. It should, under these circumstances, be excised.

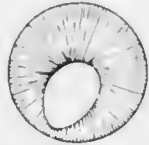


FIG. 154.— Congenital coloboma of the iris.

Purulent Irido-cyclitis.— See Chap. XXI.

Sympathetic Irido-cyclitis.— See Chap. XXI.

CONGENITAL ABNORMALITIES OF THE IRIS.

One iris may have a different colour from the other, or parts of the same iris may differ in colour. Both conditions are known as *heterochromia iridis*.

The pupil is normally slightly to the inner side of the centre of the cornea. In some cases it is considerably displaced, usually also to the nasal side—*corectopia* (*κόρη*, pupil, *ἐκ*, out of, *τόπος*, place). Rarely there are other holes in the iris besides the pupil—*polycoria*.

The iris may be apparently absent—*aniridia* or *irid-remia*. Anatomical investigation has shown that there is always a narrow rim persistent at the ciliary border, but it is hidden from view during life by the sclerotic. On examination the ciliary processes and the suspensory ligament of the lens can be seen. Aniridia is usually bilateral. There is a tendency for secondary glaucoma to develop in these eyes.

There may be a gap in the iris, usually pear-shaped or like a gothic arch, continuous with the pupil and extending towards, but not always as far as, the ciliary border. It is called a *congenital coloboma* (κολόβωμα, mutilation) of the iris (Fig. 154). It is usually downwards or down and slightly in, corresponding with the position of the fetal, so-called choroidal cleft: such a coloboma is called typical. Colobomata are found in other directions, and are then called atypical. Typical coloboma of the iris is often associated with typical coloboma of the choroid (*q.v.*). It is one of the commonest congenital malformations of the eye.

Persistent Pupillary Membrane is due to persistence of part of the anterior vascular sheath of the lens, a fetal structure which normally disappears shortly before birth. Fine threads stretch across the pupil, or may be anchored down to the lens capsule (Plate VI., Figs. 3, 4). They are distinguished from post-inflammatory synechiae in always coming from the anterior surface of the iris just outside the pupillary margin, *i.e.*, from the position of the corona or circulus iridis minor. Such tags are of frequent occurrence and are of no pathological importance. They are commonest in young children and probably undergo further absorption as age advances.

CHAPTER XIV.

GLAUCOMA.

GLAUCOMA is a symptomatic condition, not a disease *sui generis*. The characteristic symptom, or rather physical sign, is increased intraocular pressure. It will be clear from the description of the mechanism whereby the normal intraocular pressure is maintained (*vide* p. 18) that increase may be due either to (1) increased production of lymph associated with normal or diminished outflow, or to (2) diminished outflow associated with normal or increased inflow. Though the factors which bring about increased production of aqueous cannot be eliminated, yet it may be taken as certain that pathological increase of tension is almost invariably due to defective outflow.

Two great classes of cases in which the tension is pathologically increased can be distinguished, viz., (1) those in which the tension is only moderately increased, in which the anterior chamber is deep, and in which there are more or less definite signs of inflammation of the ciliary body (Chap. XIII.); and (2) those in which all grades of increased tension are met with, in which the anterior chamber is shallow, and in which, though there may be very evident signs of congestion and irritation, any definite signs of ciliary inflammation are either absent or secondary in onset. It is well to keep these two groups quite separate, since their pathogenesis is different and the differences in clinical course and treatment are marked. The term glaucoma should be limited to the second group.

True glaucoma may be conveniently divided into two



PLATE VII (A. J. 1900)

Fig. 1. Buccinator muscle ("Fuchs's colonnades"). Note the deep
 the deep water is normally kept in this position.
 Fig. 2. Buccinator muscle in situ. A and B show the
 buccinator muscle. Note the junction of the muscle with
 the buccinator muscle and the position of the buccinator
 muscle.




PLATE VIII

PLATE VIII (To face p. 306.)

- Fig. 1. Inferior crescent ("Fuchs's coloboma"). Note the distortion of the disc, which is unusually well marked in this case.
- Fig. 2. Cupped disc in glaucoma. R. and L. discs from a case of primary glaucoma. Note the bending of the vessels in the R. eye, the scleral rings, and the exposure of the lamina cribrosa.

PLATE VIII




FIG. 1



FIG. 2

forms, primary and secondary. Primary glaucoma, acute and chronic, has been called idiopathic, since it comes on without any apparent fundamental cause. Since the pathology of secondary glaucoma has been fairly well elucidated and throws some light upon that of primary, the former will be considered first.

Secondary Glaucoma.—We have seen that the increased tension of irido-cyclitis is due to defective filtration of the aqueous at the angle of the anterior chamber owing to the viscous nature of the fluid. Secondary glaucoma is almost invariably due to mechanical obstruction at the same spot. Usually the obstruction takes the form of adhesion of the iris to the back of the corneo-sclera. This peripheral anterior synechia causes the obliteration of the network of the ligamentum pectinatum iridis, and prevents the fluid from gaining access to the canal of Schlemm. It is therefore imprisoned within the eye and the intraocular pressure rises. In order that this may occur it is necessary that the angle should be obliterated over a considerable part of its circumference, but there is a great tendency in most cases for the cause which has produced partial peripheral anterior synechia eventually to complete the circuit. In some cases in which secondary glaucoma supervenes there is no actual synechia, but the meshes of the ligamentum pectinatum are choked with leucocytes, pigment granules, fibrin, &c., so that filtration is inefficient.

Though peripheral anterior synechia is undoubtedly the immediate cause of secondary glaucoma, it is itself produced by a variety of conditions, most of which are various forms of anterior or posterior synechia.

When an anterior synechia is formed the plane of the iris is advanced, so that the angle of the anterior chamber on this side is made more acute than normal. The cause which led to the formation of the synechia also causes iritis, usually of the traumatic type. Traumatic iritis is

merely a plastic iritis due to injury. In it much exudation is poured out, possessing great tendency to organise. It collects in the diminished angle and becomes transformed into fibrous tissue, which welds the iris and corneo-sclera together, thus producing a peripheral anterior synechia, which may be strictly localised, so that no secondary glaucoma supervenes. Such eyes however are liable to fresh attacks of iritis, often of an insidious character. Each attack is followed by further occlusion of the angle, until finally the amount remaining open is insufficient to carry out efficient filtration and the tension rises.

The chief causes of secondary glaucoma are the following.

(1) *Perforation of the cornea with anterior synechia*.—The perforation may be an operation wound, *e.g.*, extraction of cataract, for a peripheral section through the corneo-scleral margin or actually in the sclerotic near the margin has a similar effect to a wound in the cornea. The synechia need not necessarily be of iris, but after cataract extraction is often one of the lens capsule, which has the same effect of advancing the contiguous parts of the iris and obliterating the angle. Secondary glaucoma after operations may also be due to other causes.

(2) *Annular posterior synechia* (*vide* p. 287).—This acts by interposing an impermeable barrier between the posterior and anterior chambers. The lymph secreted by the ciliary body is thus prevented from passing forwards into the anterior chamber. The iris becomes bowed forwards—*bombé*—and the periphery becomes apposed to the corneo-sclera, where it later becomes adherent. The aqueous is thus unable to escape from the eye and the tension rises. If the condition is not relieved by operation secondary glaucoma causes blindness. The prolonged high tension then causes degeneration of the ciliary processes, which ceases to produce so much fluid, so that finally the tension may be normal or even sub-normal, and the eye may shrink. The

condition is relieved by iridectomy, or if this is impossible, by iridotomy, communication between the posterior and anterior chambers being thus restored.

(3) *Wound of the lens.*—When the lens is wounded it swells (*vide* p. 447), and pushes the iris forwards into contact with the corneo-sclera. Mere apposition is sufficient to produce permanent secondary glaucoma, which should at once be relieved by operation (*vide* p. 448). If it is not performed the iris becomes adherent to the corneo-sclera and the glaucoma becomes permanent, although the lens may be eventually absorbed.

(4) *Dislocation of the lens.*—This may be complete through the pupil into the anterior chamber. It then blocks the angle, especially if the iris is firmly contracted against its posterior surface. Partial lateral dislocation of the lens causes it to push forwards the iris on the side towards which it is dislocated. Since the circle of the equator of the lens is not much smaller than that of the angle a considerable portion of the latter is blocked, and secondary glaucoma supervenes.

(5) *Intraocular tumour.*—The mechanism whereby this produces secondary glaucoma will be described later (*vide* p. 415).

(6) *Intraocular hæmorrhage.*—Severe intra-vitreous or sub-choroidal hæmorrhage forces forwards the vitreous and lens, so that the iris is pushed into contact with the cornea. It also acts by filling the eye with highly albuminous fluid which filters with difficulty. If the vessel which has ruptured is large the tension may be raised to that of blood pressure.

A special type of glaucoma is sometimes met with after retinal hæmorrhage, which may be due to some unknown cause or to thrombosis of the central vein (*q.v.*). It is probably caused by mixture of the lymph with albuminous fluids. Such cases are sometimes grouped together under

the designation *hemorrhagic glaucoma*, a term which is however best avoided. They may be indistinguishable from primary glaucoma if not seen until the media are too opaque for ophthalmoscopic examination. Iridectomy is likely to be accompanied by severe hemorrhage, and is therefore contraindicated.

Primary Glaucoma.—The cause of primary glaucoma is unknown. The most probable theory is that of Priestley Smith, who attributes the preponderant rôle to the lens. It has already been pointed out (*vide* p. 11) that the lens continues to grow throughout life. The space between the equator of the lens and the ciliary processes, the circumferential space, will therefore become smaller as the patient becomes older. If the eye is small the space may become so diminished that slight congestion of the ciliary processes may bring them in contact with the lens. The effect will be to prevent the fluid which is secreted by the ciliary body from passing forwards through the pupil. The lens will therefore be forced forwards, and will push the iris in front of it, making the anterior chamber very shallow, and bringing the periphery of the iris in contact with the corneo-sclera. In this manner the filtration angle will be occluded and glaucoma will supervene. If the condition persists an acute attack of glaucoma is caused. If the occlusion of the angle is not complete a subacute attack is caused, and the spontaneous diminution of the congestion of the ciliary body may relieve the condition. The onset of fresh congestion leads to another attack, and thus chronic glaucoma is brought about. It will be seen from what follows that the facts fit in very well with this theory.

Primary glaucoma is essentially a disease of late adult or advanced life. It is commonest in women, who are more liable to venous congestion in various parts of the body. Hypermetropic eyes are more susceptible than those with normal or myopic refraction: in fact, primary glaucoma is

rare in myopic eyes. This has been shown to be due not to the hypermetropia *per se*, but to the smallness of the eyes. In order that an eye may be hypermetropic it is not necessary for it to be small, but as a matter of fact hypermetropic eyes usually are small. It has been found that the size of the cornea is a good criterion of the size of the ring formed by the ciliary processes, *i.e.*, of the

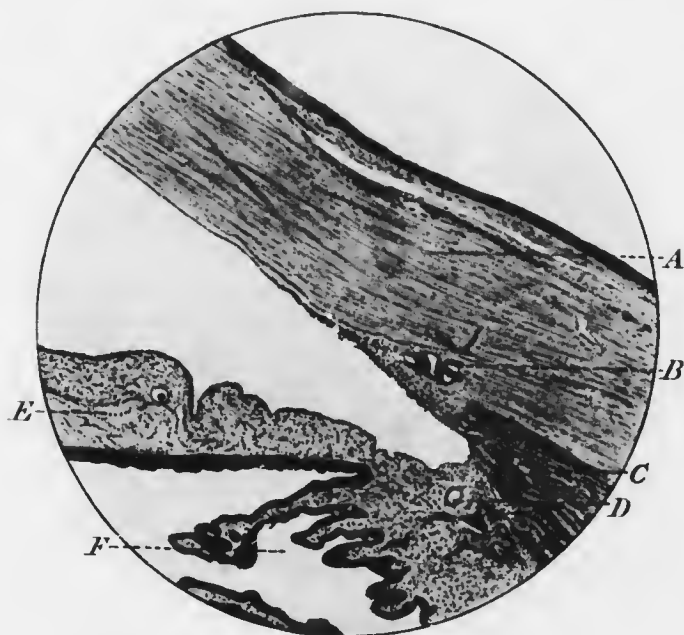


FIG. 155.—Normal angle of anterior chamber.

circumferential space. The size of the lens varies little in different eyes of patients of the same age. It follows, therefore, that an eye with a small cornea will probably have a small circumferential space, and will be very liable to glaucoma.

As age advances the anterior chamber becomes shallower. If the cornea is small this will have the effect of diminishing the size of the angle of the anterior chamber. Filtration

is carried out less easily when the meshes of the ligamentum pectinatum iridis are crowded together than when they are widely separated. In these eyes a very slight further diminution of the angle may bring on an attack of glaucoma. Thus, the mere dilatation of the pupil with a mydriatic, by folding up the iris so that it is crowded into the angle, may suffice to occlude it entirely:

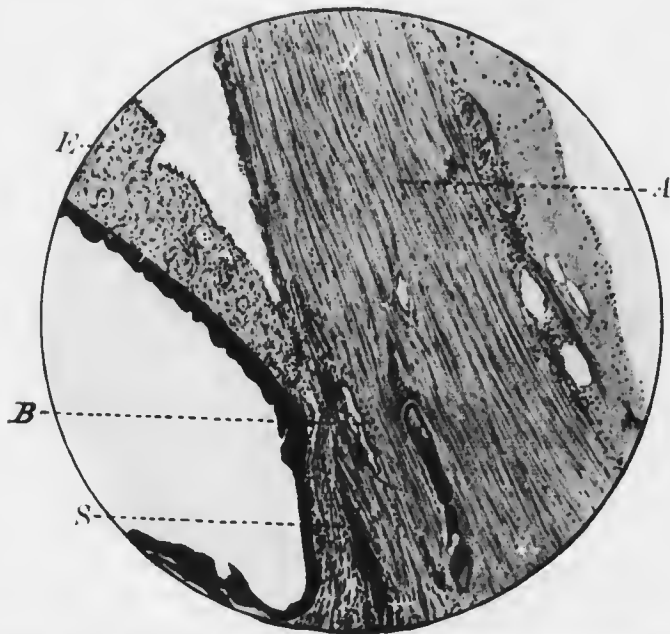


FIG. 156.—Peripheral anterior synechia (S), causing blockage of the filtration angle. A, cornea; B, canal of Schlemm; I, iris.

hence the extreme danger of instilling a mydriatic into the eyes of elderly people, especially if they are hypermetropic or have small corneæ and shallow anterior chambers.

Since both eyes usually have a similar structure, glaucoma is likely to be bilateral, but one eye is often affected before the other.

The anatomical effects of pathological increased intra-ocular pressure are as follows. The already shallow

anterior chamber is made still more shallow. In an early acute attack the periphery of the iris is merely apposed to the corneo-sclera. In the later stages and in chronic glaucoma of some standing it is firmly adherent. The longer the condition has lasted the firmer is the union. The iris is first bound down by organised exudate; later, the iris stroma atrophies and the inner wall of Schlemm's canal, which may be almost obliterated, is covered only by degenerated retinal pigment epithelium. Anterior to this a "false" angle is formed where the iris leaves the cornea; no filtration can take place either through the peripheral anterior synechia or through the false angle.

The part of the eye which suffers earliest and most from the increased pressure is the head of the optic nerve. The lamina cribrosa, which is more resistant than the nerve tissue, is less resistant than the sclerotic. Hence it becomes pushed backwards, the nerve fibres being depressed also. The first manifestation of the effects of pressure is a bowing backwards of the connective tissue which forms the lamina cribrosa, so that it becomes concave anteriorly instead of passing straight across the porus opticus. This effect continually increases, until the lamina cribrosa is displaced backwards as a whole. Meanwhile the nerve fibres have been pressed together, so that the papilla becomes flat or depressed. The pressure causes the nerve fibres to atrophy, so that finally the lamina cribrosa is exposed upon the surface. In the final stage a deep cup is formed, generally having overhanging edges.

Pulsation of the arteries at the edge of the disc is often seen in glaucoma. Whilst venous pulsation is of little importance spontaneous arterial pulsation is always pathological (*vide* p. 150). It is not always spontaneous in glaucoma if the tension is not very high, but even then it is induced by very slight pressure of the finger through the lid. The arterial pulsation is due to the increased

pressure upon the walls of the vessels, so that the intravascular pressure is only able to force blood through at the height of the cardiac systole.

Other parts of the eye show less change. The pressure causes degeneration of the nerve fibre layer of the retina. The choroid becomes degenerated and thinned, only the larger vessels remaining. The ciliary body becomes degenerated in the last stages, after which the tension may cease to be raised owing to defective secretion of lymph.

The physiological effects of pathological increased intraocular pressure are manifold. Pain is complained of, due to stretching of the sensory nerves of the eye. The



FIG. 157.—A, diagram of meridional section of normal disc; B, diagram of meridional section of glaucomatous cupped disc. Note the displacement backwards of the lamina cribrosa.

The patient sees coloured haloes round lights; these are due to alteration in the refractive conditions of the corneal lamellæ. The pupil becomes slightly dilated and immobile, owing probably to œdema and pressure on the ciliary nerves as they run through the choroid. Rapid diminution in the amplitude of accommodation may be a prominent feature, so that there is an apparent increase in presbyopia. It is attributable to pressure on the ciliary nerves and on the ciliary muscle. Diminution of vision is due to cloudiness of the media, retardation of the blood flow, and pressure on the nerve fibres in the retina and optic papilla. Cloudiness of the media affects the cornea principally, and is due in the early stages to altered refractive conditions, in the later to œdema. Pressure on the nerve fibres first affects the temporal side of the retina, and therefore the

nasal side of the field. Later, the field becomes contracted in all directions, and central vision is depressed. Finally, vision is abolished, owing to total atrophy of all the fibres.

Acute Glaucoma.—In even the most acute cases of glaucoma careful inquiry will often elicit prodromal symptoms. Transient attacks of obscuration of vision, as if a cloud were in front of the eye, have occurred. Bright

lights have appeared to be surrounded by rainbow haloes. A feeling of discomfort in the eye and neuralgic headache accompany these symptoms. Such attacks become more frequent, come on especially at night and after excitement or worry. It is noticed that stronger glasses are required for near work. This condition may extend over months or years.

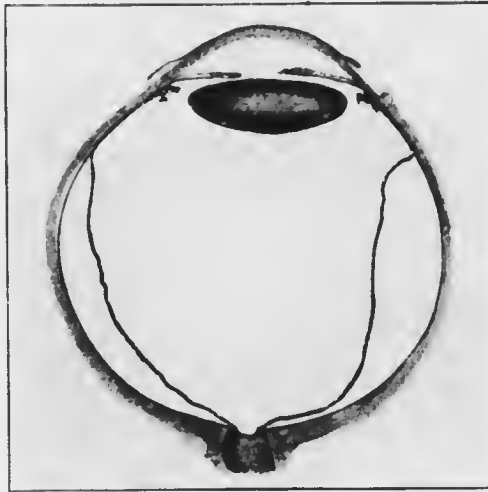


FIG. 158. Horizontal meridional section of a glaucomatous eye.

If the patient is examined whilst the symptoms are present it will be found that there is a slight haziness of the cornea, so that it looks bluish, like glass that has been breathed upon—hence the term glaucoma (*γλαυκός*, sea green). If the field of vision is taken between the attacks some slight contraction of the nasal field will be found, but central vision may be perfect.

The acute attack sets in suddenly. It may be due to

some condition inducing venous congestion, *e.g.*, constipation, menstruation, over-feeding, alcohol, &c., or to worry, fatigue, a recent illness, or to the instillation of a mydriatic. Intense pain is felt in the eye and over the distribution of the fifth nerve. The pain is frequently so bad that it causes vomiting, and the attack is liable to be mistaken for a severe "bilious attack." The temperature may be raised. The vision rapidly diminishes, so that in a few hours only hand movements can be recognised.

Objective examination shows some oedema of the lids and conjunctiva; the latter is intensely congested and looks dusky red, owing to the dilatation of the veins. Ciliary congestion is marked. The cornea is cloudy and insensitive to the touch. The anterior chamber is very shallow. The iris is discoloured, the pupil moderately dilated and oval, generally with the long axis vertical. The reactions to light and accommodation are abolished. Ophthalmoscopic examination is impossible owing to the cloudiness of the cornea. The tension of the eye is considerably raised.

There is no true inflammation in the early stages, so that the term inflammatory glaucoma, frequently used, is inadvisable; it should be replaced by *congestive glaucoma*.

If the condition is not relieved by operation, the amount of permanent diminution of vision depends upon the severity and duration of the acute attack. Total abolition of vision may result. More frequently improvement occurs, ushered in by diminution of pain. Considerable lowering of the visual acuity, and, still more, contraction of the field follows every acute attack. All grades, indeed, may be met with, from the mild prodromal attacks to the severest, with complete blindness. The tension remains permanently slightly elevated. Some congestion and irritability persists. The pupil reacts sluggishly, and the iris shows signs of atrophy, usually first in one or more

sectors. Ophthalmoscopic examination now becomes possible. Cupping of the optic disc may or may not be found, according to the duration of the raised tension before and after the acute attack. A single acute attack is not followed by cupping immediately, for this demands more or less prolonged high tension.

In every disease of one eye the other should be thoroughly examined. In acute glaucoma it may be found that chronic glaucoma has existed long unobserved in the other eye, and well marked cupping of the disc may be present. The same causes which induced the acute attack in one eye may rapidly induce a similar attack in the other. The pain and worry associated with preparations for operation and so on increase the danger. This eye should therefore be carefully watched, and prophylactic measures adopted. It is usually sufficient to instil a drop of 1 per cent. solution of eserine in the sound eye every day so as to keep the pupil contracted.

It is of the utmost importance that pathological cupping of the disc should always be recognised when present (Plate VIII., Fig. 2). It differs in ophthalmoscopic appearance from a deep physiological cup, with which it is most likely to be confounded, in that the excavation reaches to the edges of the disc and the sides are steep, not shelving. The retinal vessels have the appearance of being broken off at the margin of the disc. If they are accurately focused here their continuations upon the floor of the cup are slightly out of focus and look broader and paler. When the edges overhang, as is often the case, the course of the vessels as they climb the sides of the cup is hidden. By the indirect method slight lateral movement of the large lens causes a distinct parallax (*vide* p. 138), which is more marked the deeper the cup. By the direct method the difference in level between the vessels at the edge and on the floor can be measured (*vide* p. 142).

There is always some atrophy of the optic nerve when the disc is cupped by the glaucomatous process: it is therefore not surprising that there may be great difficulty in distinguishing a shallow glaucoma cup from the slight depression which follows simple atrophy of the nerve without increase of tension (*vide* p. 409). If the cup is deep and total it is certain to be glaucomatous. In shallow glaucomatous cups the disc has a pink colour, whereas the atrophic cup is white. In many early cases all the conditions have to be weighed carefully before it is possible to come to a definite conclusion; the field of vision usually affords the most important criterion, the contraction being chiefly nasal in early glaucoma, concentric in optic atrophy.

The final stage of the untreated disease is *absolute glaucoma*. The eye is completely blind. The anterior ciliary veins are dilated, and a reddish blue zone surrounds the cornea. The cornea is clear, but insensitive; it may have vesicles (bullous keratitis) or filaments (filamentary keratitis) upon it. The anterior chamber is very shallow. The iris is dilated, atrophic, and may have a broad zone of pigment around the pupil (ectropion of the uveal pigment). The pupil is grey or greenish, instead of jet black. The optic disc is deeply cupped. The tension is high; usually the eyeball is as hard as stone.

Such an eye is generally painful, with temporary exacerbations, though patients often prefer to bear the pain rather than submit to excision. If it is still retained degenerative changes occur. The more important are due to giving way of the sclerotic before the continued high intraocular pressure. In this manner scleral staphylomata are produced. They may be in the neighbourhood of the ciliary body—ciliary staphylomata, or at the equator—equatorial staphylomata.

Anatomical investigation shows that *ciliary staphylomata*

are of two kinds. In one, the region where the iris is adherent to the corneo-sclera gives way (Fig. 159). These are called *intercalary staphylomata* (Fig. 160). In them the iris projects into the anterior chamber from an attachment at the anterior margin of the staphyloma, whilst the ciliary body, little altered, forms the posterior margin. The other form is the true *ciliary staphyloma* (Fig. 161). In them the region of the ciliary body itself gives way, so that it becomes spread out over the inner surface of the ectasia. In many cases both parts becomes ectatic.

Clinically it is impossible to distinguish between these forms.

Equatorial staphylomata can only be seen clinically when the eye is turned well to one side and the lids separated. The thinning and bulging of the sclerotic occurs principally at the spots which are weakened by the perforation of the vortex veins and are unsupported by the recti muscles. Such globes may become enormous, with walls as thin as paper. There is considerable danger of rupture from slight injury.

Sooner or later the tension becomes normal or diminished in eyes with absolute glaucoma. This may be due either to stretching of the walls as already explained, or to

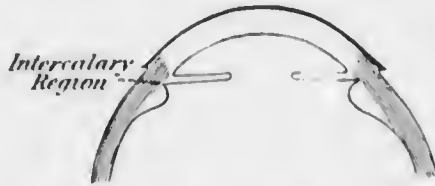


FIG. 159.—Diagram showing intercalary region.

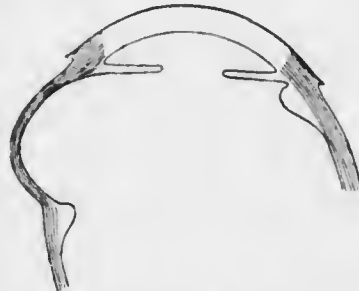


FIG. 160.—Diagram showing intercalary staphyloma.

degeneration of the ciliary body, whereby its secretory functions are diminished or abolished. Usually both factors play a part, varying according to the particular case. Such an eye may even shrink, but more commonly ulceration of the cornea occurs, owing to the defective resistance of the degenerated tissues. Hypopyon ulcer, panophthalmitis, phthisis bulbi then form the sequence of events.

Diagnosis.—Acute glaucoma is more likely to be mistaken for iritis than any other disease. The differential diagnosis has already been discussed (p. 288).

Treatment.—Acute glaucoma demands immediate energetic treatment. It is imperative that the tension shall be reduced as soon as possible. Theoretically this is best and most permanently effected by immediate iridectomy, and in most cases other measures fail. In any case they should not be dilly-dallied with too long. The moment is, however, an unfavourable

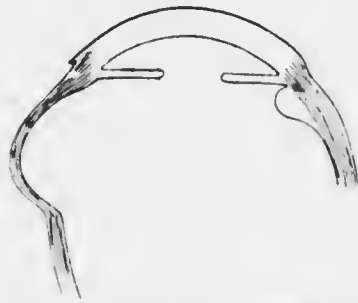


FIG. 161. —Diagram showing true ciliary staphyloma.

one for operation. The conjunctiva is chemosed, the anterior chamber is extremely shallow, there is no time for exhaustive preparations, and a general anæsthetic will be necessary owing to the impermeability of the stretched cornea to cocain.

It is, therefore, permissible to try other remedies for a short time first. Eserin (1 per cent.) should be instilled every five minutes for the first half hour, one drop being placed in the other eye at the commencement: the eserine drops are then continued every half hour until the tension falls or operation is decided upon. Meanwhile the eye is continually bathed with water as hot as can be borne.

This generally relieves some of the pain. If after an hour or two there is no sign of improvement, as indicated by distinct diminution of tension and good constriction of the pupil, iridectomy must be at once performed. Posterior sclerotomy may be employed as a temporary measure for the relief of tension whilst preparations for the iridectomy are being made (*vide* Chap. XXII.).

Even if the results are satisfactory iridectomy must be performed as soon as the eye is quiet. There is, indeed, one objection to non-operative treatment, even when successful, and to posterior sclerotomy, viz., that the patient may refuse the radical operation when the acute stage has passed off. In cases in which this is to be feared, it is advisable in the patient's interest to perform the operation at once.

Chronic Glaucoma, sometimes called simple glaucoma, is fundamentally the same disease as acute primary glaucoma; every grade of severity is met with, but the more chronic forms are so insidious that special attention must be directed towards their discovery.

The patient usually complains of transient attacks of obscuration of sight, and of gradually diminishing acuity of vision; but in some cases there may be no history of haloes and the diminution of vision is continuous and very insidious.

The eyes may appear perfectly normal at the first examination, though sometimes the anterior ciliary veins are congested, and the pupil is somewhat dilated and sluggish. An abnormally small cornea should draw attention to the possibility of glaucoma, and hypermetropia increases the probability. The tension may be quite normal, and is found to be elevated only during an attack of cloudy vision. Hence it may be necessary to examine the patient frequently and at various times in the day, especially during such attacks.

Subjective examination will often reveal no diminution

of central vision. Hence it is of the utmost importance to take a careful chart of the field of vision, when some contraction of the nasal field is almost certain to be found (Fig. 162).

Ophthalmoscopic examination will often show some cupping of the disc; frequently it is far advanced, though the symptoms have been so slight as to have passed almost

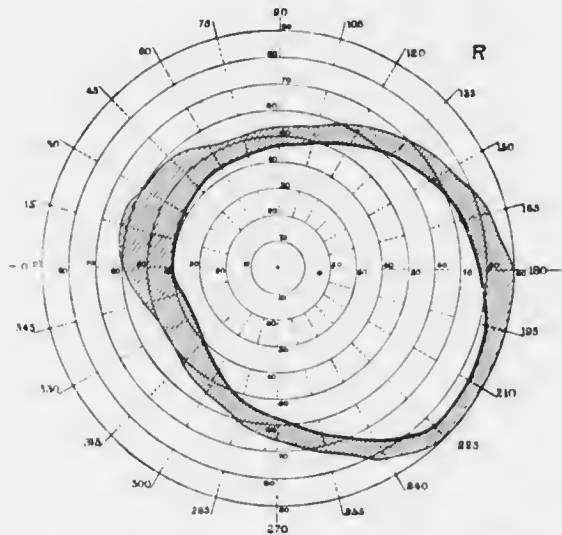


FIG. 162.—Field of vision in commencing glaucoma, showing contraction of nasal side.

noticed. The field in these cases will be found to be much damaged.

Primary glaucoma invariably attacks both eyes sooner or later; usually one is considerably more advanced than the other. The chronic form sometimes occurs in young people, and seems to attack men almost as frequently as women. It also occasionally occurs in myopic eyes.

Diagnosis.—Chronic glaucoma has frequently been mistaken for cataract or optic atrophy. Cases occur in which

the gradual loss of vision is attributed to cataract, and the patient is told that nothing can be done until the cataract is ripe for operation. Vision is thus irretrievably lost. As a rule diagnosis is very easy. The haze of the pupil is bluish, diffuse and uniform, unlike the usual appearance in cataract. The pupil may be slightly dilated and generally reacts less to the stimulation of light. Examination with the ophthalmoscopic mirror in most cases renders the diagnosis certain by showing a uniform red reflex and the absence of opacities in the lens.

Doubt as to the presence of glaucoma may arise in cases with senile striæ in the lens. In patients predisposed to glaucoma the swelling of the lens which occurs in the early stages of cataract (*vide infra*) may lead to increase of the intraocular tension. The disc is not usually cupped in these cases, but there is generally more failure of vision than is accounted for by the lenticular opacity, and the field of vision may show contraction on the nasal side; the reaction of the pupil to light may be sluggish. In such cases it is advisable to do a preliminary iridectomy, which should be of the glaucoma type with a large and peripheral coloboma.

Cupping of the disc in glaucoma is accompanied by atrophy of the nerve fibres, and it may be difficult to distinguish this atrophy from optic atrophy due to other causes, especially those giving rise to what is known as "primary" optic atrophy. The latter condition shows some depression of the surface of the disc which is usually too slight to be actually measured by the ophthalmoscope, but is demonstrated by the bending of the vessels as they pass over the edge of the disc. The depression is greater in most cases of chronic glaucoma. In cases which give rise to difficulty in diagnosis little aid is afforded by the tension of the eye, which may be normal or inappreciably raised at the time of examination. Reliance must be

placed upon the history of the case, the condition of the cornea and anterior chamber, and the record of the field vision. The latter shows concentric constriction in primary optic atrophy, more marked contraction of the nasal side in glaucoma. Accurate mapping out of the blind spot and the central region of the field on a large scale by placing the patient 2 metres distant from a black screen and using a small white test object (a disc 3 mm. in diameter) affords confirmatory evidence. In glaucoma there is an area of relative defect in the field which can always be traced in direct continuity with the blind spot, which is not the case in optic atrophy.

Treatment.—Iridectomy should be performed as soon as the condition is definitely diagnosed, the chief criterion in doubtful cases being the condition of the field of vision. If there is contraction of the nasal side iridectomy should be performed at once, even if central vision is quite normal.

The prognosis of iridectomy in chronic glaucoma is not nearly so good as in the acute form, owing to the fact that the periphery of the iris is often firmly adherent to the corneo-sclera before the condition is diagnosed. Hence special endeavour must be made to open up the occluded angle. It is not sufficient to make the section at the corneo-scleral margin, since when the iris is torn away it is almost certain to tear at the false angle, and little or no good results. The section is made as peripheral as is consistent with safety to the ciliary body, *i.e.*, 2 mm. behind the corneo-scleral margin, with the object of carrying the incision through the adherent part of the iris, though it must be confessed that this object is probably seldom if ever attained. The piece of iris removed should be about one-fifth of the entire circumference.

In the more chronic cases of long standing this procedure sometimes succeeds in spite of impossibility of restoring the normal method of filtration. It effects this by establishing

a *filtering scar*, *i.e.*, the new scar is composed of spongy tissue, through the interstices of which the intraocular fluid is able to make its way into the subconjunctival tissue, where it is absorbed. Such a scar is usually formed only if there is some impediment to proper cicatrisation, such as is caused by incarceration of the iris in the wound. The causes which lead to the formation of a filtering scar have their own dangers to the eye, and no satisfactory means of ensuring a safe scar of this nature are known. It is seldom justifiable deliberately to cause incarceration of the iris, for it does not always succeed in producing a filtering scar and is attended with serious dangers. Attempts have been made to ensure a filtering cicatrix by snipping off a small piece of the anterior lip of the wound (Lagrange's operation), making a small scleral flap (Herbert's operation), trephining, and so on. These methods are on their trial, but encouraging results have been obtained.

In very advanced cases the field of vision may be found reduced almost to the fixation point. Experience teaches that in these cases iridectomy may not only do no good, but may result in the sudden complete loss of all vision. After explaining this risk to the patient it is still advisable in most cases to perform the operation, because this unfortunate result is rare, and in any case the eye is likely to become painful unless the tension is relieved.

Since glaucoma always occurs in the other eye sooner or later the question of a prophylactic iridectomy in this eye arises. Since the operation is attended by some danger, both immediate and remote, *e.g.*, the possibility of sympathetic ophthalmia, and since the advent of glaucoma may be long delayed, it is inadmissible to perform iridectomy until some slight contraction of the nasal field can be demonstrated. The greatest care must be taken to warn the patient of the danger of the disease attacking the

other eye, and of the earliest symptoms. He should be examined thoroughly and the field of vision taken every three months, and he should be instructed at once to consult the surgeon if any signs of the disease occur. He should also be warned against putting drops, lotions, or ointment of any kind into his eyes without the advice of an ophthalmic surgeon.

When one eye has been almost or quite lost at the time of the first visit it becomes a serious question whether the better eye should not be operated upon rather than the worse. Many such difficulties arise in the treatment of glaucoma, and can only be decided by the conditions of the individual case.

If iridectomy has been done in a case of chronic glaucoma and has failed, anterior sclerotomy or one of the more modern operations for the formation of a filtering scar should be performed.

It has been stated that iridectomy is unconditionally indicated when chronic glaucoma is definitely diagnosed. Cases arise in which it is impossible to be certain that the disease is present, and others in which operation is refused. In such cases the pupils should be kept contracted by miotics. Eserin or pilocarpin often succeed in reducing the tension of chronic glaucoma and postponing the evil day when useful vision is lost. *They never cure chronic glaucoma.* Hence they must be adopted only as a temporary means of alleviation or as useful adjuncts. If the tension is definitely raised and operation is refused, 1 per cent. eserin should be ordered three times a day until the tension is normal. If the tension is not definitely raised the pupils should be kept moderately constricted with 0.5 per cent. or 0.25 per cent. eserin once or twice a day for a prolonged period. The stronger solutions cause considerable conjunctival and ciliary irritation if used constantly.

Infantile Glaucoma (*Syns.—Buphthalmia, Hydrophthalmia*).—Glaucoma in rare cases attacks children, when it assumes a quite different clinical appearance. It arises from congenital blockage of the angle of the anterior chamber, due either to a congenital defect whereby the root of the iris does not become normally separated from the corneo-sclera or becomes adherent to it through intra-uterine or infantile inflammation. The fundamental condition is therefore the same as in glaucoma in adults, viz., defective filtration of lymph from the eye. The reason why it assumes so different a clinical picture is dependent entirely upon the greater plasticity and extensibility of the walls of the young eye. Instead of offering an insuperable resistance to increased internal pressure the sclerotic gives way more or less uniformly, so that the globe becomes very large.

The thinned sclerotic of the ciliary region is bluish in colour, owing to the uveal pigment showing through. The intercalary region, or junction of the cornea and sclerotic also gives way, so that the cornea is forced forwards and assumes a globular shape (*keratoglobus*). The anterior chamber is therefore extremely deep (Fig. 163). The lens does not participate in the general enlargement; owing to the expansion of the ciliary region the suspensory ligament is stretched so that the lens is flattened and displaced slightly backwards. This removes some support to the

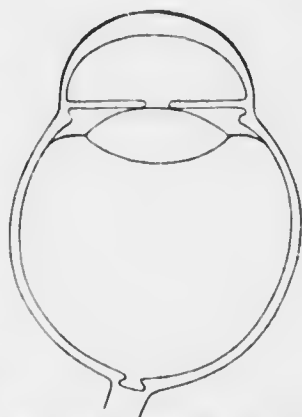


FIG. 163.—Diagram of eye with infantile glaucoma (*buphthalmia*). Note the stretching of the corneo-sclera at the periphery, the flattening and displacement backwards of the lens, the cupping of the disc, and the general enlargement of the globe.

iris, which becomes tremulous (iridodonesis). The optic disc is deeply cupped if the condition has lasted long.

The intraocular tension is raised, but often scarcely appreciably as determined by clinical methods owing to the expansion of the globe. This fact for a long period prevented the true pathology of the disease from being recognised.

As a result of the expansion the eyes are usually myopic, though less than might be anticipated from their length. This is due to the flattening of the lens and its displacement backwards, as well as to some flattening of the cornea, all of which factors tend to counteract the axial myopia.

Treatment is very unsatisfactory. Iridectomy and sclerotomy have been employed with success, but more frequently with failure. Miotics are useless.

CHAPTER XV.

THE LENS.

THE lens is composed entirely of epithelium, which is surrounded by a cuticular envelope or capsule. It is, therefore, subject only to degenerative changes, and is incapable of becoming inflamed. Degenerative changes in the lens invariably result in loss of transparency in the parts affected. This condition of partial or complete opacification is called *cataract*.

The degenerative changes commence by the accumulation of fluid between the lens fibres, so that spindle-shaped spaces are formed. They, in the first instance, cause opacity merely by the irregular refraction which they induce. Later, the fluid contains albuminous deposits which are actually opaque: they form globular masses, called Morgagnian globules. At a later stage the fibres break down into rounded masses which are indistinguishable from the Morgagnian globules.

Cataracts are classified according to the position and extent of the opacity or opacities in the lens, and it is found that the situation and distribution correspond with various combinations of clinical conditions—age, general disease, &c. In some cataracts the opacities spread and fuse until the whole lens becomes opaque: such are called progressive cataracts: in others they remain stationary. Senile cataract, which is the commonest form of all, is a progressive cataract.

Senile Cataract.—This, as its name implies, rarely occurs in persons under fifty years of age.

In the *incipient* senile cataract radial spokes or sectors of opacity are seen, with clear areas between them (Figs. 164—5). They are difficult to see in daylight or by oblique illumination (*vide* p. 112), and cataract should not



FIG. 164—Senile cataract. 1, section, showing opacities in the cortex; 2, appearance by reflected light—dark striae on a red background; 3, appearance by oblique illumination—grey striae on a dark background. (Nettleship.)

be diagnosed without confirmation with the ophthalmoscope. With the undilated pupil only the ends of the spokes are seen, but when the pupil is dilated with cocaine

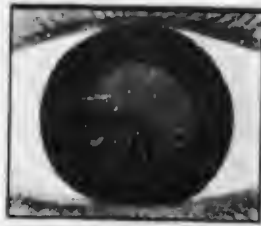


FIG. 165.—Commencing senile cataract. The striae confined to the lower part of the lens, a very common mode of commencement.

or homatropin (*never* with atropin, *vide* p. 312), the linear opacities are often found to be the apices of sectors, with their bases towards the periphery. Careful examination with oblique illumination and the ophthalmoscope will show that the opacities are in the superficial parts or cortex of the lens, some in front of the nucleus, others behind. They start from the region of the equator and

extend towards the axis of the eye, more and more spokes and sectors developing as time goes on.

Seen by oblique illumination the opacities are grey; seen with the ophthalmoscopic mirror at reading distance they appear black against a red background.

This typical arrangement of the opacities is subject to variations. Often there are punctate opacities between the

sectors. Sometimes a diffuse opacity forms in the layers surrounding the nucleus, or they may appear simultaneously here and at the equator, or they may be scattered irregularly throughout the cortex. At the very earliest stage the opacities shift with the incidence of the light, showing that they are merely differences of refractive index (*vide supra*).

In the progressive stage the lens contains more water than normal, and this is associated with swelling of the fibres. When the opacity has become considerable the swelling causes an appreciable *intumescence* of the whole lens, shown by the increasing shallowness of the anterior chamber.

The nucleus undergoes little change and does not become opaque, but eventually the whole of the cortex is cataractous. The cataract is then said to be ripe or *mature*. The whole of the pupillary area may appear to be opaque before the cataract is mature, since the most superficial layers of the cortex are the last to degenerate. As long as there is any clear lens substance between the pupillary margin of the iris and the opacity the iris throws a shadow upon the grey opacity when light is cast upon the eye from one side (Fig. 166, A). When the cortex is completely opaque the pupillary margin lies almost in contact with the opacity, separated only by the capsule; the iris then throws no shadow, and the cataract is known to be mature (Fig. 166 B). This is an important guide to the most favourable time for operation.


At this stage it will be found that the anterior chamber has regained its normal depth. The watery fluid has been absorbed from the lens, which has again returned to its normal volume.

If the process is allowed to go on uninterrupted the stage of *hypermaturation* sets in. The cortex is then completely disintegrated and transformed into a pultaceous mass.



MICROCOPY RESOLUTION TEST CHART

(ANSI and ISO TEST CHART No. 2)



APPLIED IMAGE Inc

1653 East Main Street
Rochester, New York 14609 USA
(716) 487-3300 - Phone
(716) 283-5989 - Fax

Usually the loss of water continues so that the lens becomes more and more inspissated and shrunken. The lens is then flat and yellow, often with cretaceous deposits and bright specks due to crystals of cholesterol. The anterior capsule becomes thickened by proliferation of the anterior cubica

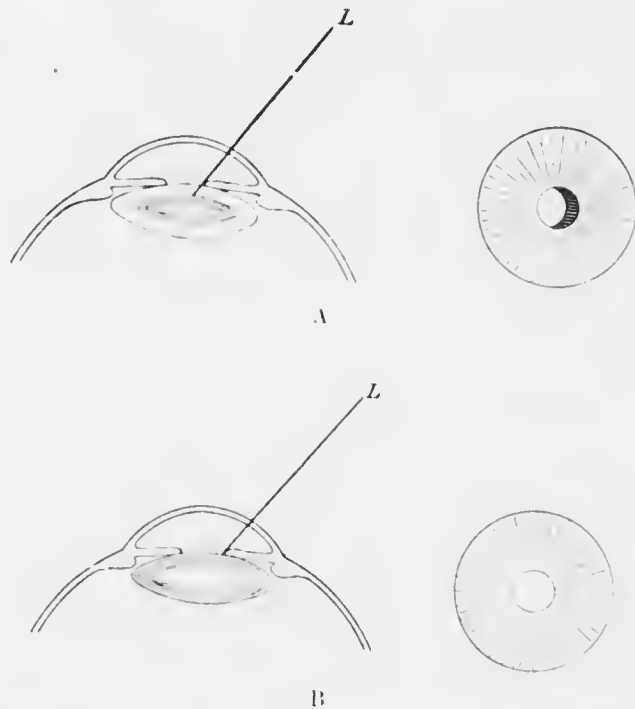


FIG. 166. — A, shadow of iris by oblique illumination in immature cataract; B, absence of shadow in mature cataract.

cells, so that a dense white capsular cataract is formed at the anterior pole in the pupillary area. Owing to shrinkage the lens and iris become tremulous, the anterior chamber being much deepened. Degeneration of the suspensory ligament may lead to luxation of the lens.

Sometimes the absorption of water ceases at the stage of maturity. The cortex then becomes quite fluid, and

the nucleus sinks to the bottom of the capsule. The liquefied cortex is milky, the nucleus appearing as a brown shading, limited above by a semicircular line. The nucleus alters its position with changes in position of the head. Such a cataract is called a *Morgagnian cataract* (Fig. 167).

In rare cases the sclerosis of the lens fibres which causes the development of the nucleus extends beyond the usual limits, so that the whole of the lens becomes converted into nucleus. Such a lens is hard, dark brown, and semi-transparent. The pupil looks black, the brownish colour being revealed only by oblique illumination. The condition is called *black cataract*, though strictly speaking it is not a true cataract.

The mode of treatment of cataract depends largely upon the amount of central sclerosis, *i.e.*, upon the size of the nucleus. Up to about thirty years of age the nuclear fibres are still fairly soft, and capable of becoming absorbed if the aqueous gains access to them. After this age absorption is very slow and incomplete, and if cataract occurs the nucleus must be removed from the eye. The size of the nucleus then determines the size of the incision which is necessary. The cases in which the nucleus is very small are called *soft cataracts*, since they consist chiefly of soft cortical matter. In most patients over fifty the nucleus is large, and these cataracts are called *hard cataracts*, although the lens is by no means hard throughout. This only occurs in black cataract, in which the nucleus reaches its maximum size, *viz.*, that of the whole lens. Such cataracts require a very large section for their removal.

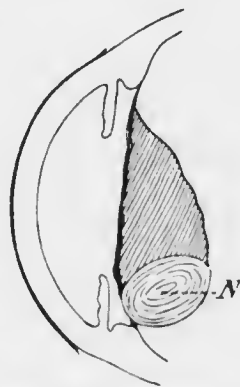


FIG. 167.—Diagram of Morgagnian cataract. N, nucleus of lens.

Symptoms.—The appearance of black spots in front of the eyes is usually the first symptom complained of. They differ from the ordinary *museae volitantes* occasionally complained of in normal eyes, and much exaggerated in cyclitis, &c., in that they are stationary, retaining their relative position in the field of vision in different positions of the eye. Uniocular polyopia, another symptom, is the doubling, trebling, &c., of the objects seen with the eye. It is due to the irregular refraction of the degenerating lens, so that several images are formed of each object. It is often worst on looking at bright lights, and is therefore noticed most in the evening.

As the opacity extends and becomes denser, the acuity of central vision suffers, especially when there is much central opacity. In the latter cases vision is often better in a dull light, owing to the dilatation of the pupil. In most cases of senile cataract the pupillary region suffers latest, so that a bright light is grateful to the patient, both on account of the better illumination and also because the rays which pass through the irregularly refracting peripheral parts of the lens are cut off, but the patients seldom like to face the light.

Eventually the central area becomes affected and vision steadily diminishes until only quantitative perception of light remains. In many cases of mature senile cataract fingers can still be counted at a few feet, or at least hand movements discerned. In all cases light should be perceived readily and the direction of incidence accurately indicated. The detection of the *projection of light* is of the utmost importance, as it affords important evidence as to the probabilities of a good result from operation. It is tested as follows. The opposite eye is covered securely by the palm of the patient's hand. Light is then reflected from the ophthalmoscopic mirror into the cataractous eye from various directions, the patient looking straight forwards

He is told to point with his other hand in the direction from which the light seems to come. He ought to do this readily and accurately. If he does not, we suspect some disease of the retina, *e.g.*, patches of retino-choroidal atrophy, &c., and a less favourable prognosis is given. Relatively poor projection is not an absolute contra-indication to operation, and each case must be determined on its merits.

It will be seen that cases of advanced cataract in which the fundus cannot be satisfactorily explored by the ophthalmoscope at the first visit, and in which projection is relatively bad, offer considerable difficulties in deciding the treatment to be adopted. It is therefore of the greatest importance that every case of incipient cataract should be most carefully explored and exhaustive notes of the ophthalmoscopic condition taken, so that at a later stage, when the fundus can no longer be observed, its previous condition is already on record. Every case of incipient cataract should therefore have the pupil dilated with homatropin so that a thorough examination of the eye may be recorded. A drop of 1 per cent. eserine must invariably be instilled before the patient leaves, otherwise there is danger that an attack of glaucoma may be induced by the administration of the mydriatic. The field of vision should also be taken at this stage.

The rate of development of senile cataract varies greatly, sometimes occupying many years, or, indeed, the cataract may never reach maturity. The progress is usually more rapid in very old people. Very rapid maturation in younger patients usually indicates some complication, *e.g.*, cyclitis, diabetes, &c. The forms with fine radial lines are slower than those with cloudy opacities. It is best to examine every case at stated intervals, a careful drawing of the opacities being recorded at each visit. The length of the intervals must be determined by the individual case.

Treatment.—No treatment by drugs, &c., has any effect upon the progress of uncomplicated senile cataract.

In *incipient cataract* the condition of the patient may be much ameliorated during the tedious process of maturation. A low degree of myopia (1 D to 4 D) may develop during this stage; it is due to increase in the index of refraction of the nucleus of the lens. If found it should be corrected. Tinted glasses may be found beneficial, the tint varying with the circumstances of the case. Amber tinted glasses are most generally useful. They cause an extraordinary increase of definition even in normal persons, a phenomenon due to psychic causes. Blue glasses, which allow the chemically active ultra-violet rays to pass, are not contraindicated in this case, since the cutting off of the more luminous rays is restful. These or smoked glasses are indicated, especially when there is a considerable degree of central opacity, since the pupils are kept slightly dilated. This effect may be obtained with greater certainty by instilling a very weak mydriatic. Atropin, $\frac{1}{16}$ to $\frac{1}{8}$ gr. to $\bar{3}$ i., one drop every other day, may be ordered, if homatropin is found not to raise the tension. The slightest sign of glaucoma, *e.g.*, high hypermetropia, small cornea, very shallow anterior chamber, &c., contraindicates this treatment, and it is wise to observe the tension carefully during the treatment in all cases. Sometimes weak atropin causes more blurring, in which case it must be abandoned.

There is no reason to restrict the use of the eyes in incipient uncomplicated senile cataract, but the patient may be much assisted by instructions as to the arrangement of illumination and so on. If the pupillary area is free brilliant illumination will be found best; if the opacities are largely central, a dull light beside and slightly behind the patient's head will give the best result.

In mature cataract the lens must be extracted. Before

deciding to operate, attention must be paid to details other than those connected with vision, previously described. Most important amongst these is the state of the conjunctival sac. If there is the slightest conjunctivitis, and above all, if there is dacryocystitis, a course of preliminary treatment is necessary. Old people frequently suffer from chronic conjunctivitis induced by senile ectropion, &c. It is best treated by relieving the cause as far as possible, and the use of astringent lotions. An occasional painting with silver nitrate is the most potent means which we possess of removing infective organisms from the conjunctival sac in these cases, since they are carried away mechanically with the desquamated epithelium, &c. Often the process is long and tedious, and doubt as to the safety of operating still persists. In such cases a bacteriological examination should be made, and if pathogenic organisms are found, especially virulent pneumococci, operation must still be postponed.

The presence of a mucocele is an absolute contraindication to operation. It must be cured (Chap. XXX.), or the lacrymal sac must be excised, or the canaliculi must be temporarily obliterated. The latter may be effected by tying a ligature round each canaliculus or by cauterising each punctum with the actual cautery. The best treatment is usually excision of the sac.

In every case the eye to be operated upon should be tied up with a pad and bandage the night before operation. The surgeon must examine the pad himself, and if there is any discharge upon it, or if the lids are gummed together with inspissated secretion, the operation must be postponed.

The treatment of *unilateral* and of *immature cataract* offers some difficulty. When the cataract is mature in one eye whilst the other retains good vision little advantage is gained by operating upon the cataract. The

difference in refraction between the two eyes after operation will be so great that it will be impossible for the patient to see well if the refraction is corrected, and if uncorrected the large blurred images formed by the eye may be a positive disadvantage. The sole advantage which is gained is an increase of the field of vision on the affected side. This may be a matter of great importance, as in people who work amidst machinery or have to go about where there is much traffic: in these exceptional cases extraction is indicated. There is also the slight advantage that the eye is prepared for the time when vision fails in the less affected eye, but this may be long delayed. These slight advantages do not as a rule justify operation, which, it must be remembered, is attended with some, if usually trivial, danger, not only to the eye operated upon, but also to the other eye (*vide* p. 456). On the other hand, the cataract must not be allowed to progress to too advanced a condition of hypermaturity. Operation is then more difficult and more dangerous. The case should be watched, and if signs of thickening of the capsule, calcareous deposits, &c., appear, extraction should be performed even though the vision in the other eye is still good.

Cases of immature cataract with loss of useful vision require even more skill in the determination of the best time for operation. The difficulties and dangers of extraction are undoubtedly increased by operating whilst there is still a large amount of clear soft cortex. It is difficult to remove from the eye, tends to the production of iritis and other complications, and leads to the formation of dense secondary cataract (*vide* p. 345). Immaturity, however, is not an absolute bar to operation: extraction under these circumstances may be followed by perfect results. It must be remembered that the patients are old, and, if not operated upon, are doomed to practical blindness, which in the lower classes entails the loss of

all wage-earning capacity. Operation will probably be attended by at least the recovery of useful vision, whereby the conditions of existence are much ameliorated. It is not necessary, therefore, to wait indefinitely for complete maturity if useful vision has already been lost.

Some surgeons temporise in these cases, performing a preliminary iridectomy, on the grounds that the operation accelerates the ripening of the cataract. It certainly occurs in rare cases, but is by no means constant. Preliminary iridectomy has the advantage of facilitating the subsequent extraction, but has the considerable disadvantage of subjecting the patient to the discomforts and dangers of two operations instead of one. It may be



FIG. 168.—Lamellar cataract. 1, 2, 3, as in Fig. 164. (Nettleship.)

employed in complicated cases in which it is desired to test the reaction of the eye to operative interference, for it is a less severe operation than extraction, and will afford indications as to the advisability of further procedures. It is also to be advocated in cases with much diffuse opacity, often more concentrated in the central part of the posterior cortex, for in them the diminution in visual acuity is very marked, maturation is indefinitely delayed, and the complications produced by a large amount of sticky cortex are much to be feared.

Cataracts of Congenital or Infantile Origin.—These are almost always partial and stationary. The commonest forms are lamellar and anterior capsular; less common are the various forms of congenital cataract, mostly of lamellar type, sometimes central or total.

Lamellar Cataract (*Syns.* — *Zonular, Perinuclear Cataract*). This usually occurs so early in infancy that it is doubtful if it is not congenital. Although there is no



FIG. 169. Lamellar cataract

true nucleus at this early age the central parts of the lens are conveniently termed the nucleus. The opacity in lamellar cataract is situated in the layers surrounding this central core, which itself usually contains punctate opacities; the superficial cortex is quite clear

(Figs. 168—170). When the pupil is dilated a grey discoid opacity is seen, surrounded by a perfectly transparent marginal area. The diameter of the disc varies, that of the

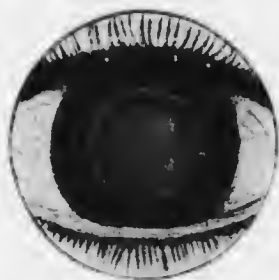


FIG. 170.—Lamellar cataract with very slight opacity. V = $\frac{1}{12}$.

clear peripheral area varying inversely. With the mirror the disc appears black and sharply defined at the outer edge, diminishing in density towards the centre; the peripheral area shows a normal red reflex.

Along the outer edge spokes of opacity, resembling the handles of a steering wheel, often extend slightly into the clear area (Fig. 169). They are called

riders, and are due to spindle-shaped opacities between the lens fibres in layers a short distance outside the main opacity. Occasionally two concentric rings of opacity are seen. The cataract is usually stationary, but cases occur in which total opacity gradually develops. Both

eyes are almost always affected, though not always to the same degree.

The opacity is always sufficiently large to fill the area of the undilated pupil. The diminution of vision is therefore entirely dependent upon the density. The patients are usually said to be "near-sighted," because they hold objects close to the eyes in order to obtain larger retinal images.

There is no doubt that lamellar cataract is due to a period of malnutrition at some stage of late intra-uterine or early infantile life. This is shown especially by the almost invariable accompaniment of defective enamel in certain of the permanent teeth. The hypoplasia differs essentially from the condition of the teeth in congenital syphilis. The teeth have an eroded appearance, with transverse lines across them, the incisors and canines being most affected (Fig. 171).



FIG. 171.—Hypoplasia of teeth.

The cause of the malnutrition is probably to be found in errors of feeding and possibly exanthemata. There is some reason to think that rickets is a cause, and congenital syphilis has been indicted, but on insufficient grounds. A history of convulsions is extremely common.

Treatment depends upon the density and the diameter of the opacity. In cases with dense opacity and very poor vision with undilated pupils the treatment depends upon the diameter of the opacity. If it is small with a wide area of clear cortex, and if distant vision is much improved when the pupil is dilated and the refraction corrected so far as possible, an optical iridectomy should be performed. These cases are, unfortunately, quite uncommon. Usually the opacity is large, and it is then necessary to remove the lens, which has the grave disadvantage that it abolishes accommodation. Since the patients are almost always seen when quite young, the central core of the lens does not

yet form a hard nucleus. Non-sclerosed lens fibres become absorbed if the aqueous gains access to them. Hence lamellar cataract can be treated by discission or needling, whereby an aperture is made in the anterior capsule through which the aqueous enters. This is the ordinary treatment of lamellar cataract, but it should not be employed unless the vision is seriously impaired or the other methods of treatment are impossible. As all varieties of density are met with the advisability of needling in cases with fair vision has to be considered. The decision of this question depends upon whether vision with corrected refraction and retained accommodation is to be preferred to probably improved vision after operation without accommodation. I



FIG. 172. Anterior capsular cataract. (Nettleship.)

am of the opinion that vision of 6/12, or even 6/18, with retained accommodation, is more valuable than a problematic 6/9, or even 6/6 without accommodation, but

with the necessity of wearing constantly very strong convex glasses. I do not therefore operate in such cases.

Anterior Capsular Cataract (*Syn.*—*Anterior Polar Cataract*).—This form of cataract is commonly known as anterior polar. It is best to reserve this term for any cataract at or near the anterior pole of the lens, since there are two forms of anterior polar cataract, viz., anterior capsular and anterior cortical. Similarly the term posterior polar should be used in the same manner, though there is more ambiguity here. There are two forms of opacity which are known as posterior polar cataract. The posterior cortical cataract is the commonest form of complicated cataract (*vide* p. 347) (Fig. 176). The other posterior polar "cataract" is not a cataract at all, since it

is due to persistence of part of the posterior vascular sheath of the lens, and is therefore situated upon the posterior surface of the lens, *i.e.*, it is not a true lenticular opacity (Fig. 178).

Anterior capsular cataract is due to proliferation of the cubical cells which line the anterior capsule (Fig. 173), and is usually limited in uncomplicated cases to a small area in the centre of the pupil (Fig. 172). The stimulus to proliferation is caused by contact with the normal or inflamed cornea. Contact of the lens with the normal cornea only causes opacity in the lens if it occurs at an early age. This is indeed fortunate, for if it were not so

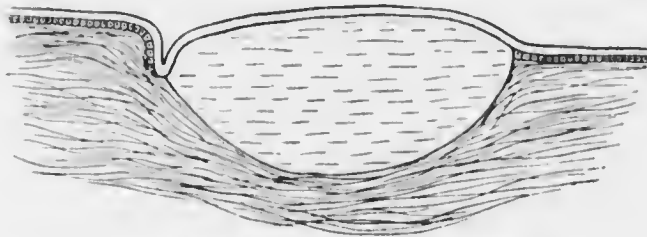


FIG. 173.—Diagram of section of anterior capsular cataract.

most intraocular operations, *e.g.*, iridectomy, would be impossible. In very young children it is probable that a very short time of contact is all that is necessary. The older the patient the longer is the time required. Contact with an inflamed cornea is more liable to produce an anterior capsular cataract than with the normal cornea. In most cases it is due to perforation of a corneal ulcer, more rarely to a perforating wound.

Anterior capsular cataract is sometimes congenital, when it is also probably due to contact with the cornea, possibly without actual perforation. In these cases it is almost always bilateral, whereas the acquired form is generally unilateral.

When an ulcer perforates the aqueous escapes and the

lens and iris are driven forwards into contact with the back of the cornea. If the perforation becomes blocked with iris the anterior chamber re-forms, the length of time of contact between the lens and cornea varying in different cases. If it is short, no harm may be done to the lens, unless the patient is very young. If it is more prolonged an anterior capsular cataract is formed and the lens adheres more or less to the wound. When the anterior chamber re-forms the lens usually separates completely from the cornea: less frequently the adhesion stretches out into a fine filament, which may persist or break. Occasionally the adhesion is so firm that the lens is permanently anchored to the cornea: the eye is usually lost by panophthalmitis or secondary glaucoma in these cases.

The dragging upon the adhesion when the anterior chamber is re-formed may cause a conical protrusion of the cataract—*pyramidal cataract* (Figs. 111, 172).

The deleterious effects of contact may affect the underlying cortical fibres, so that an anterior cortical cataract may occur with a capsular one. In the absence of cortical degeneration the opacity is so small and sharply defined that vision is little impaired, and no treatment is required.

Congenital Cataract manifests itself in a variety of different forms. As already stated, anterior capsular and typical lamellar cataracts may be congenital. Many other forms are nearly allied to the lamellar type. To this category belong the following:—

Central or nuclear cataract, a small spherical opacity in the centre of the lens, surrounded by clear cortex.

Fusiform cataract, also called spindle-shaped, axial, or coralliform, an antero-posterior spindle-shaped opacity, sometimes with offshoots giving an appearance much resembling coral: this form shows a great tendency to occur in families.

In other congenital cataracts minute points of opacity

are seen scattered throughout the lens, or limited to parts—*punctate cataract*. Many varieties of this type occur.

Most of these congenital cataracts are stationary. They may be associated with other congenital stigmata, such as nystagmus, congenital colobomata, &c. They may require no treatment, or optical iridectomy or discission may be indicated (*vide* p. 341). It is wise to wait until puberty in cases apparently suitable for optical iridectomy, the pupils being kept dilated with atropin in the meantime, since some are not stationary but gradually progress to the formation of total cataract.

Total cataract may be congenital or the result of progressive partial congenital cataract. The lens may be shrunken and much degenerated, and there are often other congenital defects in the fundus, &c. These cases should be treated by discission, but the prognosis given must be very guarded. Sometimes needling reveals persistence of the posterior vascular sheath of the lens, with or without persistence of the hyaloid artery. In such cases violent attempts to remove the opacity by needling will result in the loss of the eye.

Secondary Cataract (*Syn.* — *After-cataract*) is the opacity which persists or follows after the extraction or discission of the lens. In both these operations the posterior and part of the anterior capsule remain *in situ*. If only the posterior capsule remains in the pupillary area the corrected vision will probably be good, though it may be much impaired by wrinkling of the capsule and the consequent irregular refraction. In many cases, especially when the cataract is not quite mature, some soft, clear cortex sticks to the capsule. This becomes partially absorbed by the action of the aqueous, but it often becomes shut off from the aqueous by adhesion of the remains of the anterior capsule to the posterior capsule.

In such cases the cubical cells which line the anterior capsule also persist : they continue to fulfil their function of forming new lens fibres, though those formed under the abnormal conditions are abortive and opaque (Fig. 174). If these remnants lie in the pupillary area a dense membrane is formed through which the rays of light penetrate with difficulty, so that vision is very imperfect. If the previous operation has been followed by iritis, exudates also adhere to the lens remnants and organise, thus contributing a fibrous membrane in addition.

Secondary cataract is demonstrated either by oblique

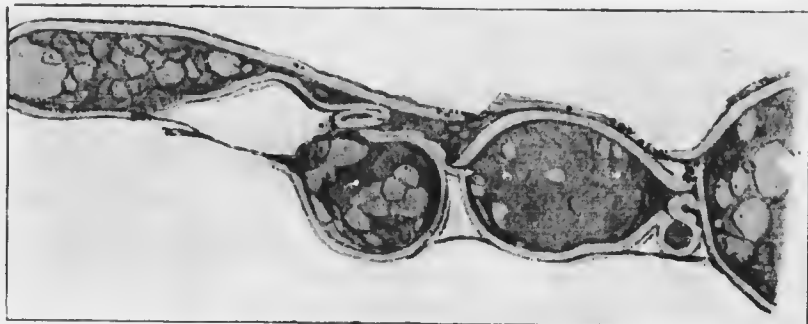

FIG. 174.—Secondary cataract from a section by Treacher Collins.

illumination or by the ophthalmoscope. If fine, it may be difficult to see, forming a grey film by the former method, a cobweb-like haze by the latter. The denser membranes are easily recognised. They vary in density, showing coarse opaque bands separated by more transparent areas.

Treatment.—Secondary cataract requires needling (*vide* p. 472).

Complicated Cataracts (*Syn.*—*Secondary cataracts*) are those forms which result from malnutrition of the lens, due to disease of other parts of the eye or of the general system. The lens is nourished by lymph which is supplied by the ciliary body. If, owing to disease of the ciliary

body or to lymph secreted from abnormal blood, the nutrition of the lens suffers, opacities are formed. They usually commence in the centre of the posterior part of the cortex, and are therefore at first *posterior cortical cataracts* (often called posterior polar) (*vide* p. 342) (Figs. 175—6). The opacity seldom remains confined to this situation: it progresses, affecting first the periphery of the anterior cortex close to the nucleus, finally involving the whole cortex. In many cases the opacities are fine and dust-like, and are scattered throughout the cortex from the commencement, increasing in number and density as time goes on.

The total cataract formed in this manner is usually soft



FIG. 175. —Posterior cortical cataract. 1, 2, 3, as in Fig. 164. (Nettleship.)

and uniform in appearance. In still later stages the watery constituents become absorbed, the capsule becomes thickened, the whole lens shrinks, giving rise to tremulousness of the iris, and other degenerative changes—calcification, &c.—ensue.

Complicated cataracts occur in advanced cases of cyclitis, in absolute glaucoma, in choroido-retinitis—disseminated choroiditis, “retinitis” pigmentosa, &c.—in high myopia, in detachment of the retina, &c.: they also occur in suppurative inflammation of the cornea, especially that produced by *ulcus serpens*. The opacity in the posterior cortex, which is generally stellate in shape, is seen in its most characteristic form in “retinitis” pigmentosa, in which disease also its slow progress can be easily watched. The vision is already much diminished before complicated cataract makes its appearance. This fact is of the utmost

importance from the prognostic point of view, since, even if the cataract is successfully removed, the progressive diminution in vision due to changes in the fundus is not thereby influenced. In every doubtful case not only must the central and peripheral vision be carefully investigated, but an exhaustive search must be made for precipitates upon the back of the cornea.

Treatment must be directed in the first case to the cause of the complication. This is often tedious and unsatisfactory, but must be persevered in as long as useful vision persists. If then the perception and projection of light




FIG. 176. Posterior cortical cataract (posterior polar cataract), seen by reflected light.

appear to be fairly good, and the cataract is of a nature suitable for operation, it should be removed by discission or extraction, according to the age of the patient. Many cases are not suitable for operation, mostly on account of the very defective vision and projection of light. Even in these if there is a possibility of success, operation may be undertaken after warning the patient of the doubtful issue,

for the loss of such an eye weighs little against a possibility of improved vision. It is wise in these cases to do a preliminary iridectomy (*vide* p. 339).

Diabetic Cataract should be regarded as a form of complicated cataract. Cataract in diabetic persons is by no means always diabetic in the proper sense of the term. Senile cataract of the usual type, following the usual course, often occurs, and should be treated in the ordinary manner, though in the early stages the general disease must invariably receive every attention, both in the matter of diet and drugs. True diabetic cataract is comparatively rare. It is always bilateral. Dusty opacities appear throughout the

cortex and rapidly increase until total cataract supervenes. A uniform milky opacity of rapid onset should always suggest the possibility of diabetes, though of course the urine should be tested as a matter of routine in all cases of cataract.

Diabetic cataract, though usually occurring in patients with a large percentage of sugar in the urine, is not due to the mere presence of sugar in the aqueous, for it is never sufficiently concentrated to cause cataract *per se*. The cause is unknown, but is probably some deleterious agent in the lymph secreted by the ciliary body.

Treatment.—It is imperative in all cases of true diabetic cataract to treat the general condition before adopting operative measures. It is rare for the opacity to clear up under such treatment; but since cases do occur, and since operations upon the eyes of diabetic patients have special dangers of their own, this chance should always be afforded.

If general treatment is unsuccessful the cataract must be extracted. In spite of the special difficulties attending the operation the results are often quite satisfactory, though a guarded prognosis should be given. Contrary to what might be anticipated, the wound usually heals well. The special dangers are local and general. Of the former, the tendency to severe iritis and to hæmorrhage are the most important. The necessary manipulation of the iris is likely to set up traumatic iritis of a peculiarly violent type.

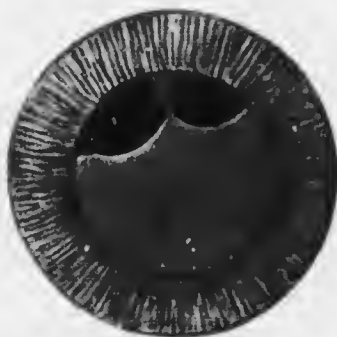


FIG. 177.—Coloboma of the lens (Marcus Gunn). The direction of the coloboma, upwards, is somewhat unusual. Note the defective development of the suspensory ligament of the lens.

Iridectomy in the course of the operation may be attended with much hemorrhage, which not only obscures the view of the field of operation, but may endanger the eye: violent intra-vitreous or subchoroidal hemorrhage may destroy the eye at the time of operation. Diabetic cataract is the one form of cataract in which simple extraction, *i.e.*, extraction without iridectomy, is definitely indicated. The chief danger affecting the general system in these cases is the risk of the sudden onset of diabetic coma. It is comparatively slight, and must be guarded against as far as possible by a suitable course of anti-diabetic treatment before operating.

Traumatic Cataract.—See p. 447.

Persistence of the Posterior Vascular Sheath (*Syn.*—*Posterior Polar Cataract*).—See p. 355.

CONGENITAL ABNORMALITIES OF THE LENS.

Besides the various forms of *congenital cataract* (*vide* p. 344), abnormalities in the shape and position of the lens occur.

Coloboma of the lens is the condition in which there is a defect in the inferior margin, usually notch-shaped; less frequently it occurs in some other part of the margin (Fig. 177).

Ectopia lentis or congenital dislocation is a subluxation of the lens, usually upwards or up and in, and bilateral. The condition is often hereditary. The lens is small, but the edge is generally invisible until the pupil is dilated. The usual signs of subluxation (*vide* p. 439) are then seen.

CHAPTER XVI.

DISEASES OF THE VITREOUS.

THE vitreous humour is an inert, jelly-like structure which subserves optical functions. It possesses no blood vessels in post-natal life, and is incapable of becoming inflamed: the old term "hyalitis" rests upon misconception, and should be avoided. We have, therefore, to deal only with symptomatic conditions.

Opacities.—Black specks, floating before the eyes, are seen by normal persons under favourable conditions. These *museæ volitantes* are opacities of various kinds, viewed entoptically, *i.e.*, they throw a shadow upon the sentient elements of the retina, thus appearing as dark spots in the field of vision. Any relatively intransparent bodies situated anterior to the rods and cones are therefore able to produce *museæ*. To this category belong the corpuscles circulating in the retinal blood vessels: if it were not for the fact that the retina is normally adapted for red light the entoptic images of the circulating corpuscles would be a serious impediment to clear vision. Other *museæ* are due to minute specks in the vitreous, so small and so slightly intransparent that they cannot be seen objectively by the ophthalmoscope.

Under abnormal conditions *museæ* may be so increased as to interfere with vision and to become visible by the ophthalmoscope. They then indicate some disease of the uveal tract, particularly of the ciliary body: they are found in cyclitis, retino-choroiditis, myopia, &c. In their slightest manifestation they are dust-like opacities, which may

permeate the whole vitreous or be limited to the anterior part. When very fine a plane mirror and magnification by a convex lens are necessary in order to distinguish them (*vide* p. 128). They are due to minute albuminous coagula and aggregations of leucocytes, the former derived from the ciliary body and choroid, the latter only from the ciliary body and possibly the retina. In the more severe cases flakes and threads are seen, and the entoptic images may be so sharply defined that an intelligent patient is able to draw them accurately. The larger opacities are often found after hæmorrhage into the vitreous. They almost invariably float about, showing that the vitreous is fluid (*vide infra*), though they may be more or less anchored to the retina.

In some cases membranes can be seen stretching in various directions through the vitreous, especially transversely behind the lens. They are due to vitreous hæmorrhage or to cyclitis, but in the latter case the membranes which are formed in greatest abundance are generally invisible owing to opacities in the lens.

Very frequently in the slighter cases no objective signs of disease can be made out in the fundus: the foci are either too fine to be appreciated or are anterior to the field of ophthalmoscopic vision, *i.e.*, in the anterior part of the choroid or in the ciliary body.

The prognosis depends upon the cause. It is characteristic of vitreous hæmorrhage that absorption usually takes place without organisation, owing to the absence of fibroblasts in the vitreous. When organisation occurs, as in so-called retinitis proliferans (*q.v.*), it is most marked near the disc, from which membranes and strands stretch forwards. This is due to the presence of mesoblastic tissue, containing potential fibroblasts, around the central vessels. Even then organisation rarely occurs in the absence of some general dyscrasia, *e.g.*, syphilis,

nephritis, &c. In all other cases, therefore, the prognosis is good, bearing always in mind the tendency to recurrent hæmorrhage. There is one form of severe vitreous hæmorrhage which occurs in apparently healthy young adults: it is probably due to a blood condition associated with defective coagulability. It has a great tendency to attack both eyes in succession and to recur, so that though absorption may be complete in the early attacks permanent damage or complete loss of sight may ultimately follow.

Treatment is that of the cause. In most cases it is extremely tedious, being that of iridocyclitis (*vide* p. 302). In cases of recurrent hæmorrhage attempts may be made to increase the coagulability of the blood by the administration of calcium salts, the treatment being controlled by repeated estimations of the coagulation time.

Slight cases of *muscæ volitantes*, without objective signs, require no direct treatment. Patients should be advised to ignore the spots as much as possible, as they are often only visible when attention is specially directed to them. Any error of refraction should be corrected, and special indications as to the amount and conditions of near work should be given. In many cases the patients suffer from gastro-intestinal disorders, which should be suitably treated.

Fluidity of the Vitreous (*Syn.*—*Synchisis*, *συχχέω*, to pour together, disturb) is due to absorption of the fibrils and degeneration of the jelly-like tissue, caused by the digestive action of leucocytes and their secretions. It is therefore a common feature in the cases in which opacities are present, and is due to the same causes. It cannot be diagnosed with certainty in the absence of opacities, and is indicated by their free movements when the eye is rapidly moved. Fluidity of the vitreous may in some cases be simply a senile degeneration.

The degeneration of the vitreous which leads to fluidity

often causes the deposition of crystals of cholesterol, which sink to the bottom of the vitreous chamber, but are stirred up by movements of the eye. They then appear as a very beautiful shower of golden rain—*synchisis scintillans*. There may be relatively little interference with vision.

Fluidity of the vitreous requires no treatment in itself, but it is a serious complication if any intraocular operation is contemplated. In such eyes the suspensory ligament of the lens is often weak, so that prolapse of the vitreous, dislocation of the lens, and so on, may occur. Even when the vitreous pours out under these circumstances useful vision may yet be retained, the vitreous being replaced by lymph.

Blood in the Vitreous.—Hæmorrhage into the vitreous has already been referred to (*vide* p. 352). It may result from arteriosclerosis or inflammation of the retina, from contusions or wounds of the eye, or without apparent cause (*vide* p. 353). Small hæmorrhages are seen ophthalmoscopically and can be accurately watched, though the surrounding vitreous always contains exudates, unless the blood is subhyaloid (*vide* p. 381). Larger hæmorrhages, filling the vitreous with blood, are suspected when no reflex can be obtained on throwing in light with the mirror. It may then be possible to see a red mass behind the lens by oblique illumination.

Pus in the Vitreous.—This is found only in panophthalmitis, which is almost invariably due to a perforating wound or ulcer, though cases of metastatic inflammation of the retina and choroid also occur and lead to a similar result (*vide* p. 364). The reflex with the ophthalmoscopic mirror is poor or absent. Oblique illumination shows a yellow mass behind the lens. The eye is always intensely inflamed, and little difficulty is usually experienced in arriving at a correct diagnosis. The *treatment* in cases of exogenous infection is that of panophthalmitis due to

performing injury (*vide* p. 456). In the rare cases of endogenous infection it is that of the primary cause.

Persistent Hyaloid Artery.—The hyaloid artery, which in fetal life nourishes the vitreous and supplies blood to the posterior vascular sheath of the lens, usually disappears completely before birth. A remnant, stretching forwards from its origin on the disc, is normal in oxen. Similar remnants are not very rare in man: they appear as a strand projecting from the disc into the vitreous.




FIG. 178.—Opacity due to persistence of part of the posterior vascular sheath of the lens, often called posterior polar cataract. Note that the opacity is usually more circumscribed than in posterior cortical cataract. (Fig. 176.)

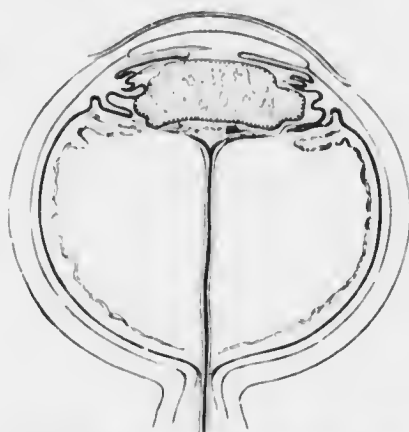


FIG. 179.—Diagram of persistent hyaloid artery, with persistence of the posterior vascular sheath of the lens. (Treacher Collins.)

There may be membranes veiling the disc from view in such cases. In other cases only the anterior part of the hyaloid artery persists, appearing as a circular spot on the back of the lens, often inaccurately termed a posterior polar cataract (Fig. 178). More or less of the posterior vascular sheath may persist in such cases, giving rise to a larger central opacity on the back of the lens. The hyaloid artery may persist in its entirety with more or less of the vascular sheath (Fig. 179). It may contain blood, and blood vessels may be seen upon the back of

the lens: it is then liable to be mistaken for a glioma of the retina, and constitutes one form of pseudoglioma.

The appearance of the posterior part of the hyaloid artery, when persistent, is very characteristic. A filmy, greyish cord, sometimes containing blood, passes forwards from the disc towards the lens. It undergoes serpentine writhings when the eye is moved.

When the hyaloid artery is persistent there is often defective or atypical development of the vitreous, part of which resembles fibrous tissue in structure. Every stage may be met with, from that interfering little or not at all with vision to complete opacity, usually with mal-development of the whole eye—microphthalmia.

Foreign Bodies in the Vitreous.—See p. 441.

Parasites in the Vitreous.—*Cysticercus* is excessively rarely found in the vitreous in England, though it is less uncommon in some other countries. The actual parasite may be seen ophthalmoscopically as a pearly translucent mass with peristaltic movements. The treatment—removal—is very difficult.

CHAPTER XVII.

DISEASES OF THE CHOROID AND RETINA.

It has already been pointed out that different parts of the uveal tract rarely suffer alone. This intimate connection is most marked in the anterior parts, and clinically the evidence of cyclitis when the choroid is inflamed is slight, though not entirely wanting. The outer layers of the retina are dependent for their nutrition upon the choroid, so that when the latter suffers the former is always involved secondarily. Primary affections of the retina occur without involvement of the choroid: primary affections of the choroid invariably involve the retina secondarily in greater or less degree.

This profound relationship between the retina and choroid, so indisputably manifested clinically, renders it advisable to consider their diseases in close connection with each other. It will be found that some diseases commonly designated as "retinitis" are in reality secondary to a primary choroiditis, whilst others also included under the same term are not inflammatory, as is suggested by the word. It is well, therefore, to bear in mind that "retinitis" is used in a broad sense. The same ambiguity is noticed in the use of the term "choroiditis," which frequently designates a purely degenerative condition, without any evidence of inflammation.

PRIMARY AFFECTIONS OF THE CHOROID.

Inflammation affecting the choroid primarily—*choroiditis*—occurs in two forms, exudative and suppurative.

The former appears in the form of isolated foci of inflammation scattered over certain areas of the fundus, and is conveniently classified according to the position of the areas involved. The latter spreads over the whole choroid and retina, and the primary seat may be in the retina: it leads ultimately to panophthalmitis.

Exudative choroiditis is generally syphilitic in origin, and affects chiefly either the posterior part of the fundus—disseminated choroiditis—or the anterior part—anterior choroiditis.

Disseminated Choroiditis may be taken as a type of the disease (Plate IX., Fig. 1). The recent foci are seen ophthalmoscopically as yellowish, clearly defined spots: when near a retinal vessel they lie at a deeper level than the vessel. They are due to infiltration of the choroid, the exudates hiding the choroidal vessels which cause the normal red reflex. In the early stages the elastic membrane of Bruch is intact: under these circumstances only fluid exudates can pass through it, but these suffice to make the overlying retina cloudy and grey. The exudates not only pass into, but also through the retina, so that punctate or diffuse opacities are seen in the vitreous. When the vitreous haze is excessive the ciliary body is also probably involved. In later stages the membrane of Bruch may be absorbed, though it offers considerable resistance in common with all elastic membranes. When this has occurred leucocytes are enabled to pass through into the retina and vitreous.

Owing to the fibroblastic activity of the choroidal stroma the exudates become organised, so that a small white mass of fibrous tissue is formed, which destroys the normal structures of the choroid and retina and fuses the two membranes firmly together. The colour of the spots therefore gradually changes to white, partly due to the fibrous tissue deposited, partly to thinning and atrophy,

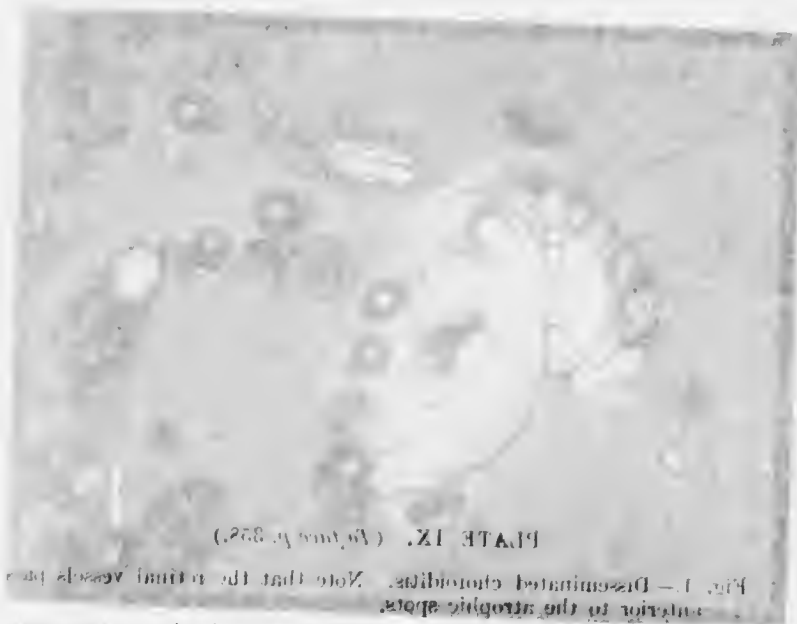


PLATE IX. (Woods No. 252.)

FIG. 1.—Disseminated choroiditis. Note that the normal vessels are replaced by the atrophic spots.
 FIG. 2.—Bilateral choroid (H. eye, number 1010), due to the same disease as in Fig. 1. Note the atrophic spots.



The following figures illustrate the changes in the fundus of the eye in the various stages of the disease. The first figure shows the fundus in the early stage of the disease, and the second figure shows the fundus in the late stage of the disease. The third figure shows the fundus in the late stage of the disease, and the fourth figure shows the fundus in the late stage of the disease.

PLATE IX. (To face p. 358.)

- Fig. 1.—Disseminated choroiditis. Note that the retinal vessels pass anterior to the atrophic spots.
- Fig. 2.—Ruptured choroid (R. eye, indirect method), due to blow with a fist eighteen months previously.

The following figures illustrate the changes in the fundus of the eye in the various stages of the disease. The first figure shows the fundus in the early stage of the disease, and the second figure shows the fundus in the late stage of the disease. The third figure shows the fundus in the late stage of the disease, and the fourth figure shows the fundus in the late stage of the disease.

PLATE IX.



FIG. 1.

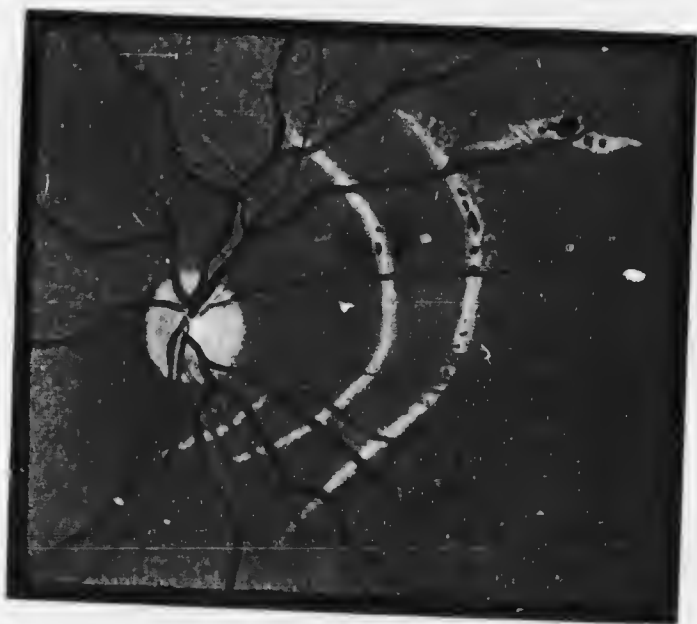

FIG. 2.



whereby the white reflex from the sclerotic is permitted to shine through (Fig. 180).

The pigment of the retinal pigment epithelium is extremely resistant, even though the cells which contain it be destroyed. It tends to become heaped up into masses, partly intra-, partly extra-cellular: moreover the pigment cells are stimulated to proliferate. Isolated masses of black pigment are thus formed in the white areas, but more particularly at the edges, so that in the atrophic stage white spots surrounded by a black zone of pigment are seen (Fig. 181). The process has then reached its natural termination, and these spots remain permanently almost unaltered.

Meanwhile fresh foci arise and pass through the same stages, until finally the whole fundus may be covered with

atrophic spots. In the milder cases only a few spots are formed and the exudates in the vitreous become reabsorbed. In the more severe the spots are very numerous, the vitreous opacities increase, and finally the nutrition of the lens suffers and a complicated cataract (*q.v.*) results.

The symptoms in the early stages are principally the defects of vision due to the retinal lesions and to cloudiness of the vitreous. The spots are slightly raised, so that the

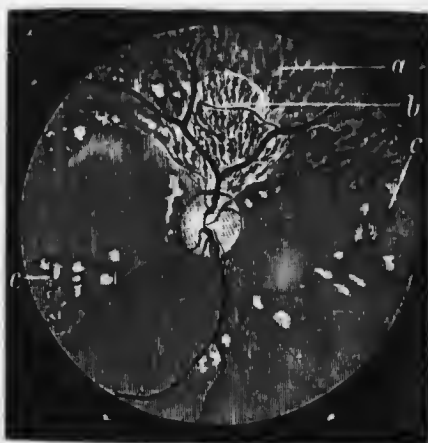


FIG. 180. — Atrophy after syphilitic choroiditis. (Nettleship, after Hutchinson.) *a*, atrophy of pigment epithelium; *b*, atrophy of epithelium and choriocapillaris, exposing the large choroidal vessels; *c*, spots of complete atrophy, many with pigment accumulation.

contour of the retina is altered. This causes distortion of the images, giving rise to similar appearance of distortion of the objects seen—metamorphosia: thus straight lines appear to be bent in various directions. Frequently objects appear smaller than they are—micropsia: sometimes larger—macropsia: these results are probably due to



FIG. 181.—Section of a patch of disseminated choroiditis, showing the fusion of the degenerated retina (*R*) and choroid (*Ch*) ($\times 60$). Note the heaping up of the retinal pigment epithelium (*P*) at the edges of the adhesion. *Scl.*, sclerotic.

separation or crowding together respectively of the rods and cones. Subjective symptoms of light—photopsiæ—occur, such as flashes of light, due to retinal irritability.

In the later stages the affected spots are incapable of giving rise to visual impulses, so that positive insular scotomata exist in the field of vision. Their relative importance depends upon their situation. Peripheral

scotomata may pass unnoticed, but central scotoma destroys direct vision. Peripheral vision still permits the patient to get about well, but all fine work is impossible.

The disease is chronic, organisation of the exudates taking several weeks. The occurrence of fresh spots may extend the acute stage over months, and the ultimate defects are permanent.

As already mentioned the disease is usually due to syphilis, generally acquired, sometimes congenital, but in many cases the cause is obscure, anaemia and disorders of nutrition being assigned. The changes produced by myopia cause similar signs and symptoms; they are not inflammatory, but degenerative from the commencement (Chap. XXIV.).

Treatment is primarily that of the aetiological factor—syphilis or such cause as can be discovered. Iodide of potassium may assist absorption in all cases, and should be administered. The general régime advised for cyclitis (*q.v.*) is suitable in these cases. Marked irritative symptoms indicate the use of dark glasses, the abandonment of all near work, and sometimes the application of leeches.

Anterior Choroiditis is also usually syphilitic, and manifests itself in the same form as disseminated, but is confined to the peripheral parts of the fundus. On this account it is frequently discovered only by the ophthalmoscope. Similar changes are also sometimes found in high myopia. Simple pigmentary changes at the periphery occur in old people as a senile degeneration.

The periphery of the fundus is often peppered over with minute spots of pigment in congenital syphilis; this is possibly a purely retinal affection. It can only be distinguished by degree from a similar pigmentation which may be a mere idiosyncrasy.

Central Choroiditis occurs in disseminated choroiditis, and in certain rare forms. In Förster's areolar central choroiditis the spots are said to behave in exactly the opposite manner to those of disseminated; they are first black, then enlarge, becoming white in the centre, and finally quite white. The disease extends outwards, the peripheral spots being always the most recent.

Diffuse Choroiditis is characterised in the early acute stage by one or more plaques of yellowish white or grey areas, shading off at the edges into normal fundus. The patches spread and coalesce so that the greater part of the fundus may be finally involved. The exudates gradually organise, leaving white areas in which the larger choroidal vessels persist, as a characteristic band-like network. The retinal pigment becomes heaped up into dense black, irregular spots, variously grouped. The retinal vessels course over the patches little changed in appearance. The coalesced areas leave islands and spaces of normal fundus between them when organisation is complete. Fresh exudates occur simultaneously with the organisation of older ones, and sometimes the edge of a patch appears to creep over the fundus like the advance of a myxomycetes.

Some of these cases are syphilitic, some tuberculous (*q.v.*). In others the cause cannot be traced, but probably many are due to metastatic bacterial invasion (*vide infra*, Metastatic Endophthalmitis).

Purulent Choroiditis.—See p. 454.

Tubercle of the Choroid occurs in acute or miliary and chronic forms. Miliary tubercles are found in the late stages of acute miliary tuberculosis, especially tuberculous meningitis. Ophthalmoscopically they appear as round, pale yellow spots, most frequently observed in the neighbourhood of the disc, though any part of the choroid

may be attacked. Generally only three or four spots are seen, but as many as sixty or seventy have been found. They vary in size from pin-point specks to 1 or 2 mm. in diameter. They usually project slightly, so as to raise the retina, but the inner surface is often quite flat, whilst the outer surface projects into the sclera. They afford most important diagnostic evidence of tubercle in cases of meningitis and obscure general



FIG. 182. Section of miliary tubercle of the choroid ($\times 60$), from a child with hip disease who died of meningitis. Note the giant cells and the small round cells at the periphery.

disease. Microscopically they consist of typical giant-cell systems, containing a variable number of tubercle bacilli (Fig. 182).

Chronic tubercle of the choroid may occur as a diffuse inflammation affecting large areas or the whole choroid and characterised by the extensive development of granulation tissue, or, more rarely, as a solitary or conglomerate mass, simulating sarcoma. In the former case the choroid becomes replaced by granulation tissue containing giant cells, which spreads until it involves the

retina and finally fills the posterior part of the globe. The sclerotic becomes eroded: perforation takes place, usually near the anterior part of the eye, a fungating mass appearing under the conjunctiva. The chronic forms of tubercle of the choroid may nearly simulate glioma of the retina (*q.v.*), constituting one form of pseudo-glioma (*q.v.*).

They are commoner in children than in adults, but in all cases certainty as to their tuberculous nature can rarely be obtained clinically. Similar ophthalmoscopic appearances are met with resulting from metastatic choroiditis (*q.v.*), and from changes following localised hæmorrhage into the deep layers of the retina (so-called "massive exudation" in the retina). Von Pirquet's test may afford help in the diagnosis.

Treatment.—No local treatment is indicated in miliary tubercle of the choroid. The patient quickly succumbs to the general disease. In diffuse and conglomerate tubercle treatment with tuberculin should be instituted in the early stages, but if the eye is extensively involved it is best to enucleate it, and thus remove a dangerous focus from which the organism may be disseminated into the system.

Metastatic Endophthalmitis. Endogenous bacterial infection of the eye manifests itself in various ways. Most commonly the uveal tract is affected, either as a whole (metastatic uveitis) or in its individual parts, as for example in gonorrhœal iritis. The milder forms of iridocyclitis (*q.v.*) and uveitis are probably due to toxins circulating in the blood-stream, and derived from bacterial foci in other parts of the body, *e.g.*, the mouth, the generative apparatus, especially in women, the intestinal tract and so on. It is certain, however, from anatomical examination that actual bacterial embolism occurs, and in these cases two facts stand out prominently. First, various organisms show a special selectivity for the various structures of the

eye. Thus the tubercle bacillus never attacks the retina primarily, though this structure is often involved secondarily in tuberculous disease of the choroid. Secondly, except in the case of extremely virulent organisms such as the streptococcus the inflammation set up by endogenous infection is usually less severe than when the organism is introduced directly into the eye from without. Thus if the eye is infected with pneumococci by a perforating wound an exogenous panophthalmitis (*q.v.*) is likely to be set up, leading to the complete destruction of the organ. So much is this the case that saprophytic organisms, such as the bacillus subtilis, which are non-pathogenic in other parts of the body, often cause panophthalmitis. If, however, an organism such as the pneumococcus invades the eye by way of the blood-stream, though an intense inflammation results it tends to subside more rapidly than in the exogenous cases. Probably the organism becomes attenuated in the blood-stream and tissues through the controlling effect of specific anti-bodies. In this manner virulent bacteria may set up endophthalmitis of every grade of severity. In the days when puerperal fever was prevalent, intense metastatic panophthalmitis, often attacking both eyes, was not uncommon. It was characterised by the appearance of an hypopyon and the rapid development of a yellow pupillary reflex due to pus in the vitreous. An intense metastatic uveitis, involving iris, ciliary body and choroid, and due to bacterial invasion was set up. Such cases progressed exactly like ordinary exogenous panophthalmitis (*q.v.*).

They are now seldom seen, but cases of metastatic bacterial invasion often of obscure origin still occur in which the early stages of uveitis with hypopyon is present. Ophthalmoscopically the media are hazy, so that the yellow œdematous retina is only dimly seen. Under treatment the condition gradually subsides, not infrequently with the restoration of useful vision. In the more severe

cases, such as occur in children, and are probably often due to the diplococcus intracellularis of Weichselbaum there is an exuberant development of new fibrous tissue of cyclitic origin. These cases are not easily distinguished clinically from glioma, and form the largest group of so-called pseudo-

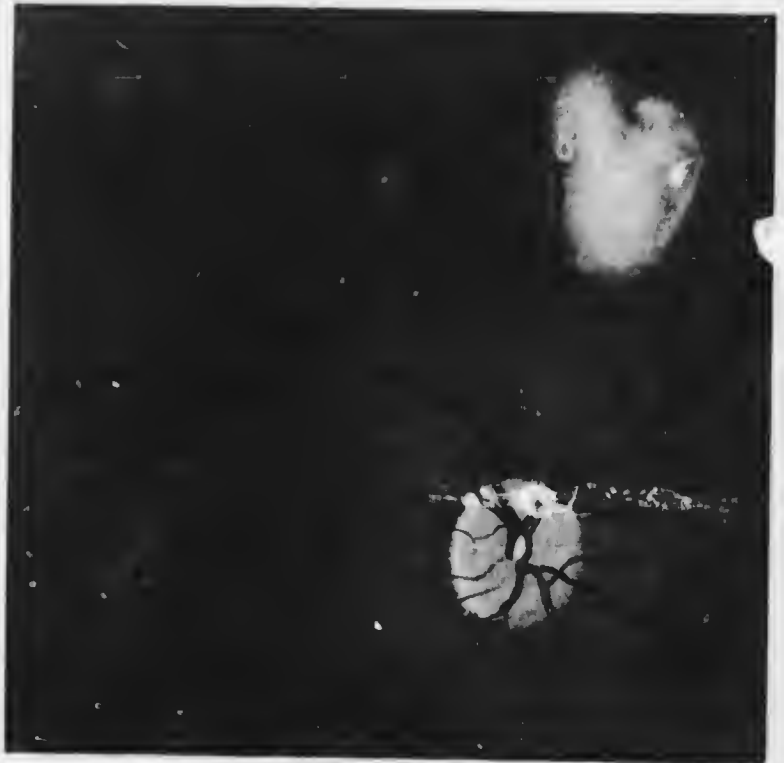


FIG. 183. Metastatic choroiditis.

glioma (*q.v.*). In the milder cases there is less development of cyclitic fibrous tissue in the vitreous and less scarring of the retina, but whitish atrophic spots and areas accompanied by pigment disturbance persist as evidence of the previous inflammation. Yet milder cases give rise to ophthalmoscopic appearances which may be

mistaken for diffuse or conglomerate tuberculous disease of the choroid (*q.v.*) (Fig. 183), or thrombosis of a branch of the central vein of the retina. In some cases the optic papilla has been the chief local focus, and an appearance of intense papillitis with much exudation extending into the neighbouring retina is seen. Some of the cases have been associated with firmicidiosis, and there is little doubt that they are due to metastatic infection with staphylococci. Others have been proved to be due to the pneumococcus, *diplococcus intracellularis* of Weichselbaum, &c. Other obscure cases of retinitis with white spots or oval areas, usually near the disc, with or without hæmorrhages, are probably due to the same cause.

The *treatment* depends upon the severity of the attack, and the possibility of determining the primary focus and the specific organism. In the worst cases the patient should remain in bed, and the purgatives and drugs for the relief of pain should be administered. Hot applications should be made and atropin instilled. If the eye becomes full of pus it should be enucleated or eviscerated according to the principles which govern the treatment of panophthalmitis of exogenous origin (*q.v.*).

In the milder cases purgatives and general tonic treatment are indicated. Atropin should be instilled to keep the eye at rest, and dark glasses worn. Counter-irritation with leeches or blisters to the temple may be indicated. If the primary source of infection can be discovered it must be treated radically. If the organism can be isolated vaccine treatment is indicated, and in the more obscure cases treatment with a polyvalent vaccine may be of some avail.

Degenerative Changes may be post-inflammatory or primary. The former, culminating in localised spots of complete atrophy, have already been considered. Generalised atrophy, more or less complete, is found in

the later stages of glaucoma. The loss of nourishment to the retina causes atrophy of the outer layers and of the nerve fibre layer in these cases. Degenerative changes in the choroid often cause migration of pigment from the pigment epithelium into the more superficial parts of the retina. The pigment tends to become deposited in the perivascular lymph spaces, so that the retinal vessels may be mapped out here and there by pigment. More noticeable ophthalmoscopically are jet-black branched spots of pigment, resembling bone cor-puscles, and standing out in sharp relief. This condition is seen in its most typical form in "retinitis" pigmentosa, which is in reality due to primary choroidal atrophy. An almost identical picture, though usually without the characteristic distribution of the pigmented spots, may result from choroidal atrophy due to other causes, *e.g.*, syphilis. This migration of pigment into the retina is shown to be due to interference with the choroidal circulation by the fact that it occurs after division of the short ciliary vessels in rabbits.

Primary choroidal degeneration may be localised or general: the best example of the latter is so-called retinitis pigmentosa, which will therefore be considered here.

Localised choroidal atrophy, apart from the post-inflammatory forms, is usually either central or circum-papillary.

Central Choroiditis, or more properly *central choroidal atrophy*, is most commonly the result of myopia (*q.v.*), syphilis, contusion (Chap. XXI), or old age.

Senile central choroidal atrophy assumes two chief forms. In *central guttate choroiditis* (Tay's choroiditis) there are numerous minute yellowish white spots in the macular region (Plate X., Fig. 1). They may increase in numbers, but otherwise they remain stationary. Some slight pigmentation may occur, and the discs are rather pale. The



PLATE Z (Vol. p. 382)

Fig. 1 - Central portion choroidal decussation (Fig. 2 choroidal) from a woman, set II, without failure of sight.
Fig. 2 - Central portion choroidal decussation, from a woman, set II, age 41. Note the exposure of the choroidal vessels, the walls of which are thickened by perivascular changes.

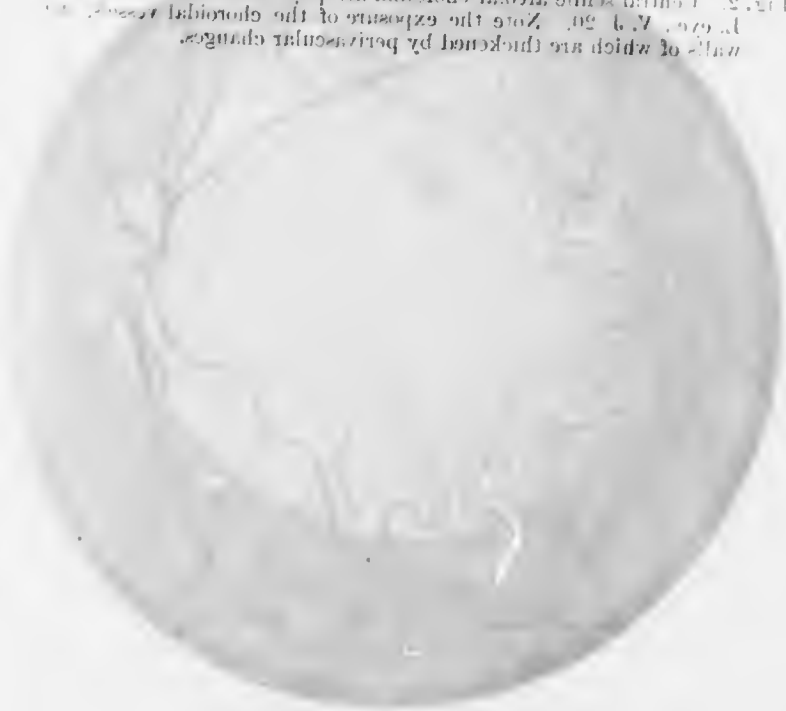

PLATE X. (*To face p. 368.*)

Fig. 1.—Central guttate choroidal deposits ("Tay's choroiditis"), from a woman, æt. 41, without failure of sight.

Fig. 2.—Central senile areolar choroidal atrophy, from a woman, æt. 60, L. eye; V. J. 20. Note the exposure of the choroidal vessels, the walls of which are thickened by perivascular changes.

PLATE X.

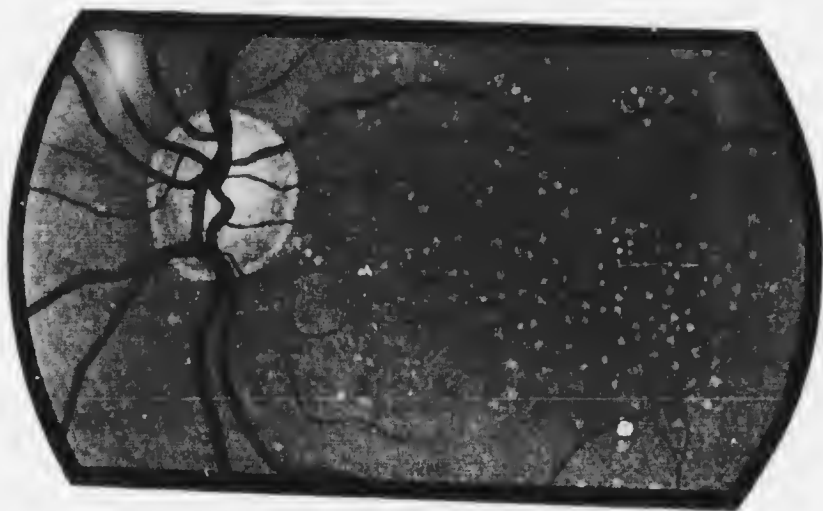


FIG. 1.

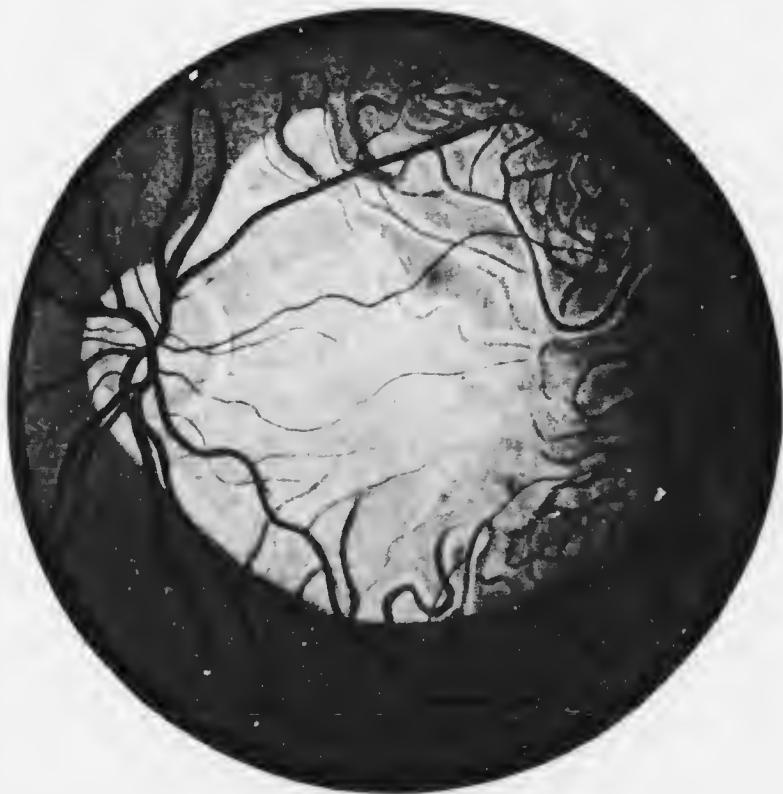


FIG. 2.

condition is bilateral, and may be mistaken for albuminuric retinitis (*q.v.*). It is due to peculiar hyaline excrescences on the surface of the choroid, commonly known as *colloid bodies* (Fig. 184). They are of the same nature as Bruch's membrane, and like it are secreted by the pigmented epithelial cells.

Central areolar choroidal atrophy—to be carefully distinguished from Förster's areolar choroiditis (*vide p. 362*)—appears as a large circular or oval patch of degeneration in the macular region through which the choroidal vessels




FIG. 184.—Section of "colloid bodies," seated upon the membrane of Bruch. They are undergoing calcification, as shown by the deeper staining in the inner parts. They are covered with stretched pigment epithelial cells.

are visible, owing to atrophy of the retinal pigment epithelium (Plate X., Fig. 2). As a result of atrophy of the choroid the sclerotic shines through and the patch is white, though traversed by choroidal vessels. Only the larger choroidal vessels are seen, the smaller ones having disappeared, and even the large ones appear smaller than usual owing to endovascular degeneration of the walls. There is an absolute central scotoma. The condition is to be feared in cases of cataract in which perception of light seems defective; hence the great importance of investigating the fundus thoroughly in cases of immature cataract. It is possible that this form of central choroidal atrophy is due to extravasation of exudates.

Besides these conditions minute changes limited to the area at and immediately around the fovea centralis occur not infrequently in old people and lead to grave disturbance or abolition of central vision. It is generally necessary to dilate the pupil with cocain or homatropin in order that they may be seen, care being taken to instil eserin when the examination is finished (*vide* p. 312). When central vision is very poor in an elderly patient and no cause can be found to account for the defect such as cataract, glaucoma, &c., pathological changes will probably be found at the macula. In the early stage the fovea is surrounded by a ring of very fine pigment spots. The stippling is more sharply defined on the foveal side which usually has a circular or crenated edge; it diminishes rapidly peripherally, where the fundus becomes normal. The fovea gradually becomes paler in colour and the stippling denser, the change being associated with rapidly increasing failure of vision, until eventually the small central scotoma becomes absolute.

Circumpapillary Choroidal Atrophy is found in myopia (*q.v.*) and in late stages of glaucoma.

"**Retinitis pigmentosa**" is an extremely chronic, progressive degeneration of the choroid, commencing in childhood and often resulting in blindness in middle or advanced life. The choriocapillaris suffers first, so that the nutrition of the outer layers of the retina fails early. The degeneration commences in a zone near the equator of the eye, and gradually spreads both anteriorly and posteriorly. The macular region is not affected until very late in the disease. The condition is bilateral. The peculiar site of origin has been attributed to the relatively weak choroidal circulation in this zone, which is the meeting place of the short ciliary and the recurrent ciliary arteries (*vide* p. 16).

The symptoms of the disease are very characteristic.

the most prominent being defective vision in the dusk (night blindness). Vision under low illumination is carried on essentially by the rods, and night blindness is a sign of defective nutrition of these structures, which, from their situation, suffer first in disease of the choroid.

Examination of the vision may show perfect central

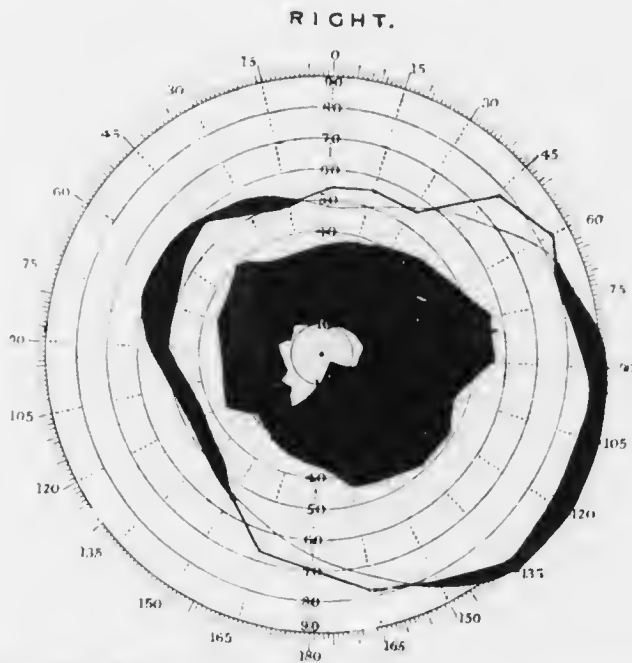


FIG. 185.—Ring scotoma, from a case of retinitis pigmentosa.

visual acuity. Investigation of the field of vision, seldom satisfactory in children, but more reliable in young adults, shows concentric contraction of the fields. In early cases a partial or complete annular or ring scotoma is found (Fig. 185). As the case progresses the field becomes continually slowly smaller, until at last it is reduced to a small area round the fixation point. Central vision may even now be normal, but the patients are quite incapacitated for

getting about, for they are in much the same condition as a person looking down two long cylinders—they see only the thing they are actually looking at and nothing around. They therefore grope about helplessly. Loss of central vision does not usually occur until fifty or sixty, but vision may be lost earlier through cataractous changes occurring in the lens.

Ophthalmoscopic examination shows also a very characteristic picture (Plate XI.). In the zone affected the retina is studded with small jet-black spots, resembling bone corpuscles or spiders. They are found especially along the course of the vessels (*vide* p. 368). As the pigment from the retinal pigment epithelium migrates into the superficial layers the epithelium itself becomes decolourised, so that the choroidal vessels are now visible, and the fundus appears tessellated. The pigment spots which lie near the retinal vessels are seen to be anterior to them, so that they hide the course of the vessels. There is no question, therefore, as to their exact position in the retina itself. In this respect they differ from the pigment around spots of choroidal atrophy (*vide* p. 359), in which the retinal vessels can be traced over the spots.

In the earliest stages it can be proved that it is a zone of the retina which is affected and not the most anterior part, for normal retina may be seen at the peripheral limits of the ophthalmoscopic field. In the later stages this area diminishes *pari passu* with extension of the disease towards the centre.

As the pigmentation increases and the retina becomes more and more atrophic the ganglion cells are destroyed, thus leading to degeneration of their axis cylinders, viz., the fibres in the nerve fibre layer of the retina and the fibres in the optic nerve. Optic atrophy, therefore, sets in and gradually increases. The disc exhibits the characteristics of primary optic atrophy (*vide* p. 409).



PLATE XI. (To face p. 375.)

retinal fragments. Note the bean-shaped shape of the
retinal fragments. (Owing to the migration of pigment from the
retinal fragments into the choroidal vessels beneath the retina, the
retinal fragments are stained and the well-marked aggregation of pigment
is retinal pigment. Note the small size of the retinal
fragments, especially in the center, and the color of the mass which
is rather more yellow and waxy-looking.

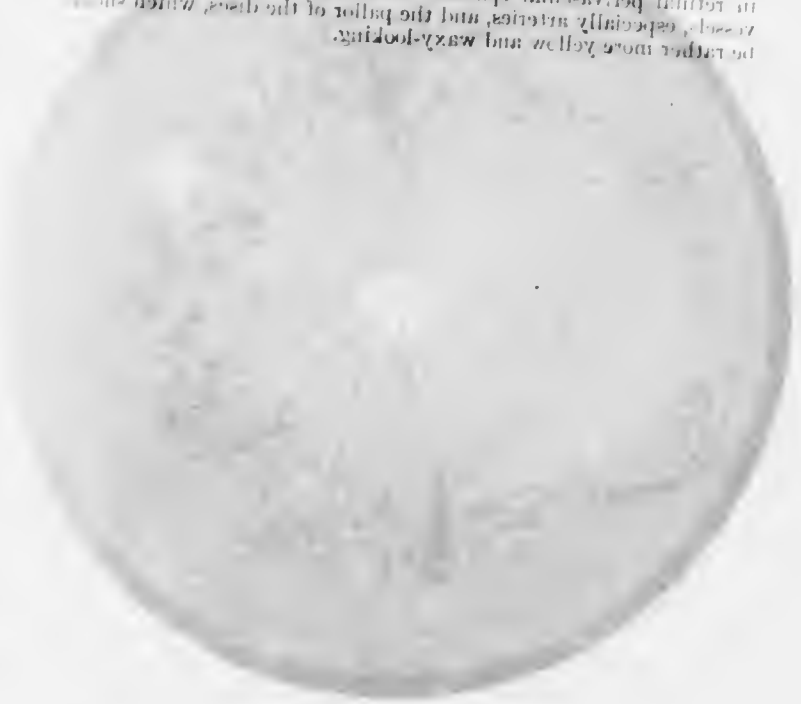

PLATE XI. (*To face p. 372.*)

"Retinitis" pigmentosa. Note the bone-corpusele shaped spots of retinal pigmentation. Owing to the migration of pigment from the retinal epithelium the choroidal vessels become visible. Fig. 2 shows the zomular distribution and the well-marked aggregation of pigment in retinal perivascular spaces. Note the small size of the retinal vessels, especially arteries, and the pallor of the discs, which should be rather more yellow and waxy-looking.

PLATE XI.



FIG. 1.

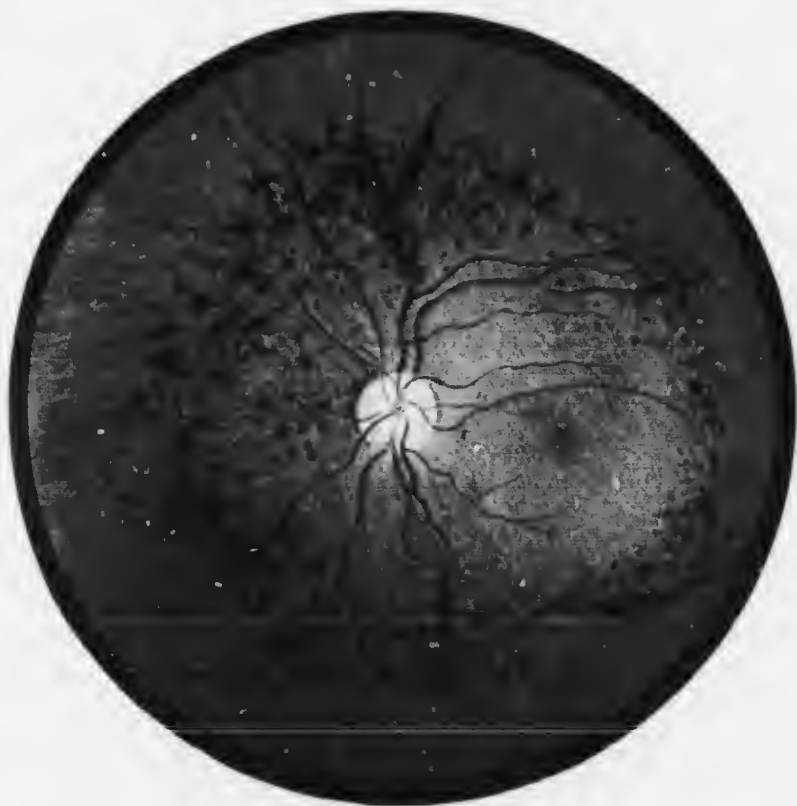

FIG. 2.

but is not quite typical of this condition. The disc is pale, but seldom more than yellowish white; there is no excess of fibrous tissue, but the vessels are very small and thread-like.

In the later stages the nutrition of the lens suffers. The complicated cataract which is formed is a very typical form of progressive posterior cortical cataract, going on to complete opacification of the cortex.

The cause of retinitis pigmentosa is unknown. Several members of the same family are often affected, and consanguinity of the parents is not infrequent. Other members of the family are found not infrequently to suffer from insanity, epilepsy, or other signs of mental debility. The patients are sometimes deaf or deaf and dumb, and evidences of cerebral disease or of congenital anomalies in the eyes or other parts of the body may be present. Congenital syphilis may produce similar results, though these cases are seldom quite typical (*vide* p. 368).

Treatment is eminently unsatisfactory, since nothing appears to have a decided influence upon the course of the disease. Strychnine by the mouth or by hypodermic injection should be employed, and the constant current has been advocated.

Retinitis pigmentosa sine pigmento is a variety of the disease with the same symptoms, but without visible pigmentation of the retina. It is progressive and leads to optic atrophy, therein differing from *congenital night blindness*, which is a rare hereditary disease without ophthalmoscopic signs, remaining stationary throughout life.

Allied to these conditions is *retinitis punctata albescens*, in which, with similar symptoms, the retina shows hundreds of small white dots distributed fairly uniformly over the whole fundus.

Sarcoma of the Choroid.—See p. 414.

PRIMARY AFFECTIONS OF THE RETINA.

Primary Retinitis, in its most severe manifestations, is almost always the result of some general disease, and should, therefore, be properly regarded as a symptomatic disease. It is probable that slight inflammation of the retina may be caused by overuse or misuse of the eyes, but though some of the symptoms may be ascribed to it, ophthalmoscopic signs are wanting or so little marked as to be ambiguous.

Retinitis in general gives rise to the following symptoms and signs, only some of which need be present in individual cases. There is usually some change in visual acuity. Rarely it is increased in the early stages; more commonly it is diminished throughout. There may be concentric diminution of the field of vision, or scotomata may be present corresponding with the areas specially affected. There may be metamorphopsia, micropsia, or macropsia (*vide* p. 360). The light sense is diminished, and photophobia may be present. Pain is almost invariably absent, though discomfort may be complained of.

The ophthalmoscopic signs may be diffuse or localised. There may be general oedema, manifesting itself as a faint, diffuse haze, obscuring details, so that the normal bright red appearance is replaced by a paler cloudiness, often with definite white streaks, especially along the course of the vessels; or there may be circumscribed areas of exudation. The latter appear as white spots, discrete or confluent, or yellowish plaques, varying in size. They are not pigmented and the edges are ill-defined, so that there is little danger of mistaking them for patches of choroidal atrophy. The blood vessels usually show marked changes. The veins are distended, often irregular, darker than normal, and tortuous; the arteries are less altered, but the finer branches are also tortuous. Hemorrhages are common, though they are not

in themselves evidence of primary retinitis. When occurring in the superficial layers they are flame-shaped, with feathery edges, situated particularly along the course of the vessels; when in the deeper layers they are round, with better defined contours.

The optic nerve, being in anatomical and physiological continuity with the retina, often suffers with it; when this occurs to a marked extent the condition is called *neuro-retinitis*. The margin of the disc is then obscured and often shows a radial striation. The disc is red, and may be measurably swollen, though seldom, if ever, so much as in the condition known as choked disc.

Retinal atrophy, which follows severe retinitis, is shown by permanent whitish or yellow opacity, with diminution in the size of the vessels, which are often bordered by white lines. The optic disc may show all the signs of advanced atrophy (*vide* p. 410).

It has already been pointed out that retinitis is most frequently the symptom of an internal disease. It is therefore usually bilateral. The diseases most commonly causing the condition are syphilis, vascular disease, albuminuria, diabetes, and leucæmia.

The *treatment* of retinitis consists in giving the eyes complete rest and in combating the general disease which is the cause. All near work is forbidden and the eyes are protected with smoked glasses, or even confinement in a darkened room. Whether due to syphilis or not mercury and iodides are given with a view to aiding the reabsorption of exudates and restoring the transparency of the vitreous, if this is affected. Mercury is contra-indicated in renal retinitis. These means are supplemented by purgatives, diaphoretics, and tonics.

The blood vessels of the retina are peculiarly subject to disease in retinitis, partly as a factor in the inflammation, but more prominently as a concomitant of general disturbance

or disease. It will be well, therefore, to discuss the commoner forms of vascular disease of the retina before passing on to describe the chief types of retinitis in greater detail.

Vascular Disorders of the Retina.

Anæmia may be part of general anæmia or due to local causes. It may be sudden or slow in onset. Sudden anæmia is seen in embolism of the central artery of the retina (*q.v.*) and in quinque amblyopia (*q.v.*). Ophthalmoscopically there is great attenuation of the retinal vessels and the optic disc is pale. Anæmia of slow onset is seen in atrophy of the retina from any cause, such as previous retinitis, and in disease of the vessel walls as part of a general vasculitis. In both cases the vessels are attenuated, and sometimes in the former and commonly in the latter the walls become thickened and visible as white lines bordering the red blood stream: eventually the vessels may be transformed into white strands or may even disappear.

Embolism of the Central Artery of the Retina causes sudden and complete retinal anæmia. The eye, usually the left, becomes suddenly quite blind. Examination of the fundus reveals a very typical picture (Plate XII., Fig. 1). The larger arteries are reduced to threads, the smaller ones are invisible. The veins are little altered except on the disc, where they are contracted. Within a few hours the retina loses its transparency, becoming opaque milky-white, especially in the neighbourhood of the disc and macula. Owing to the opacity of the retina the outlines of the disc, which is abnormally pale, are obscured. At the fovea centralis, where the retina is extremely thin, the red reflex from the choroid is visible. It appears as a round "cherry-red" spot, presenting a strong contrast to the cloudy white background. The peculiar tint of the



PLATE XII. (Page 370.)

Fig. 1. Fundus of the central artery of the retina. Note the position of the retina at the posterior pole and the "ghost" spot in the macula. The vessels are reduced in size, subsequently the optic papilla atrophied, and the vessels still smaller.

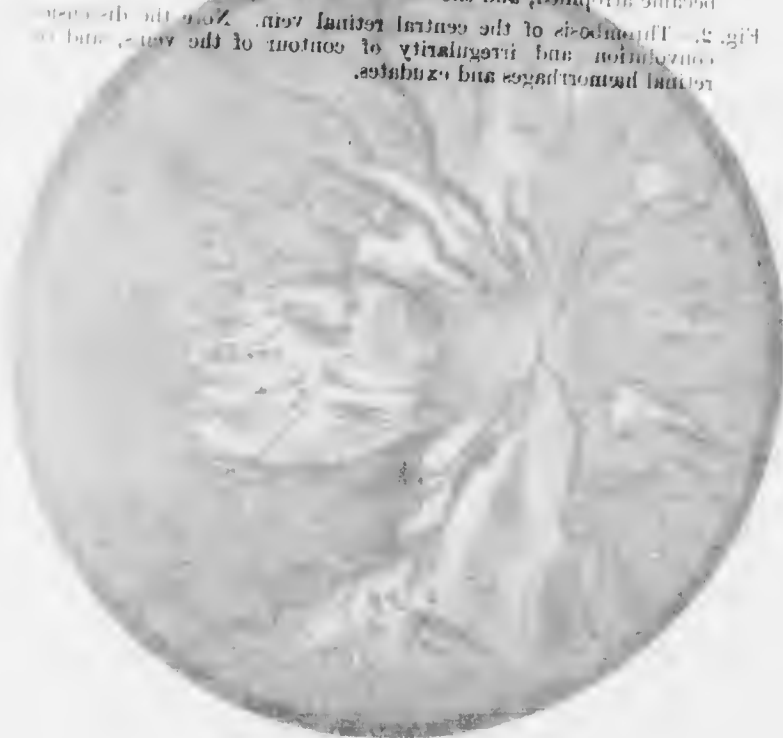

Fig. 2. Fundus of the central retinal vein. Note the dilatation and irregularity of contour of the vessels and the retinal hemorrhages and exudates.

Fig. 1. Embolism of the central artery of the retina. Note the edema of the retina at the posterior pole and the "cherry-red" spot at the macula. The vessels are reduced in size. Subsequently the disc became atrophied, and the vessels still smaller.

Fig. 2.- Thrombosis of the central retinal vein. Note the distension, convolution, and irregularity of contour of the veins, and the retinal hemorrhages and exudates.

PLATE VII

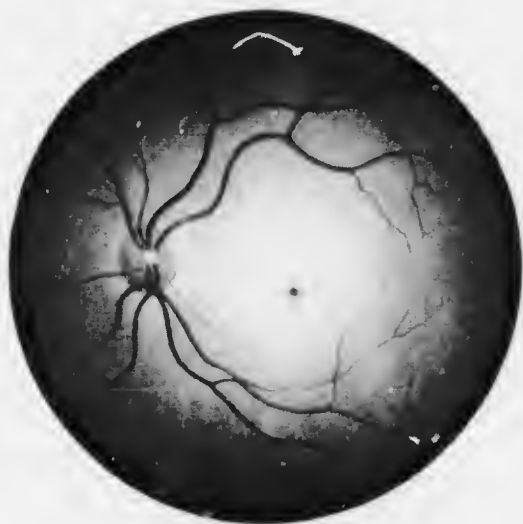


FIG. 1.



FIG. 2.

spot is due to this contrast. In the majority of cases there is no hæmorrhage here, as was once thought, though hæmorrhages here and in the immediate neighbourhood do occur rarely. The contrast sometimes brings into relief minute blood vessels near the macula which are otherwise invisible.

Sometimes the obstruction to the blood flow is not complete, or the flow may be partially restored in the course of a few days. Another peculiar phenomenon may be observed or may be induced by gentle pressure upon the globe. In some of the vessels, usually veins, the column of blood is broken up into red beads separated by clear interspaces. The beads move in a jerky fashion through the vessels, sometimes in the normal direction of blood flow, sometimes in the opposite direction. If the veins are easily emptied of blood or arterial pulsation is produced by slight pressure on the eye-ball it is evidence of incomplete blockage.

The retinal œdema or possibly coagulation necrosis takes several weeks to clear up. The membrane regains its transparency, but is completely atrophic. The vessels are contracted or reduced to white threads. The disc is atrophic. If there have been hæmorrhages spots of degeneration replace them, and cholesterol crystals and pigmented spots may be seen in the papillo-macular region.

In some cases a certain degree of central vision persists in spite of apparent complete occlusion of the central artery. It is due to the presence of cilio-retinal arteries (*vide* p. 148) which, when present, always supply the macular region, and naturally escape occlusion. The remainder of the field of vision is lost.

In other cases the embolus is arrested in a branch of the central artery. The area supplied by this branch is then affected alone. In the early stages the corresponding scotoma is usually somewhat indefinite, but later it settles down to a permanent sector-shaped defect.

When perception of light is lost the pupil is large and the direct reaction to light fails. In some cases faint perception of light may be regained in the temporal region of the field: it is possibly due to partial establishment of collateral circulation. The intraocular tension is normal, as might be anticipated.

Embolism of the central artery, like cerebral embolism,

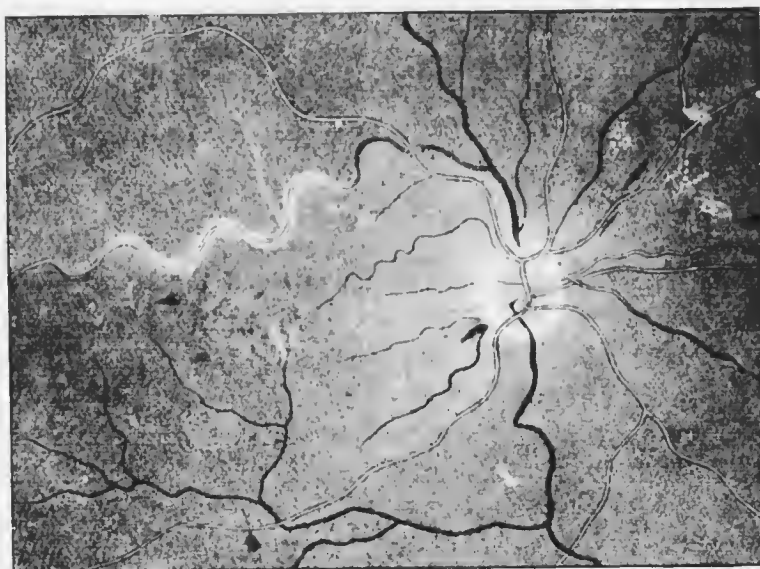


FIG. 186. "Silver-wire" arteries, degeneration of the walls of a vein, and white spots of degeneration.

occurs with mitral stenosis, especially if there has been fresh endocarditis. This factor is, however, very frequently absent, and it is probable that most cases are really due to thrombosis. There has been endarteritis, due to general arteriosclerosis from nephritis, &c., and the already narrowed lumen of the vessels has become suddenly occluded. The onset may be less rapid in such cases and preceded by premonitory symptoms, such as obscuration of vision, &c. Other cases render it probable that the

condition may be due simply to spasm of the walls of the artery, a theory which accounts for some remarkable cures.

The condition has been observed at ages varying from fifteen to eighty. Rare cases of simultaneous bilateral blocking of the central arteries have been recorded.

Treatment is seldom of any avail, but attempts should

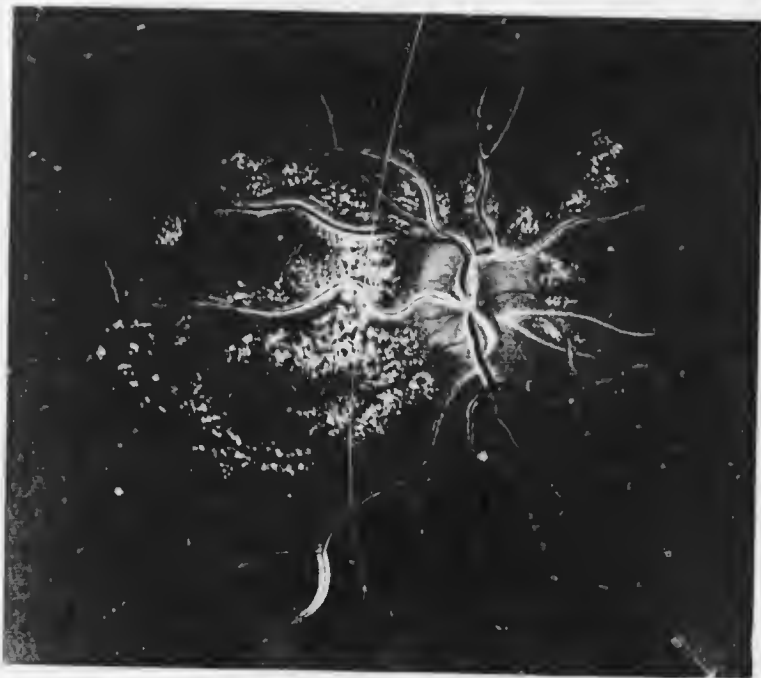


FIG. 187. Perivascular changes in the retinal vessels.

be made to drive the obstruction on into a less important branch if the case is seen early. Inhalation of amyl nitrite, massage of the globe, and paracentesis of the cornea have been employed for this purpose; such measures must be adopted without delay.

Degenerative Changes in the Retinal Vessels, apart from their interest as a local manifestation of disease, are of the utmost importance in general prognosis. They

may be the first evidence of arteriosclerosis, pointing to the danger of cerebral hemorrhage, and indicating lines of treatment which may prolong life. Undue tortuosity of the vessels is of no significance unless accompanied by other abnormalities, such as irregularity in the size and breadth of the arteries, so that they present a beaded appearance. Minute military aneurysms are seen in rare

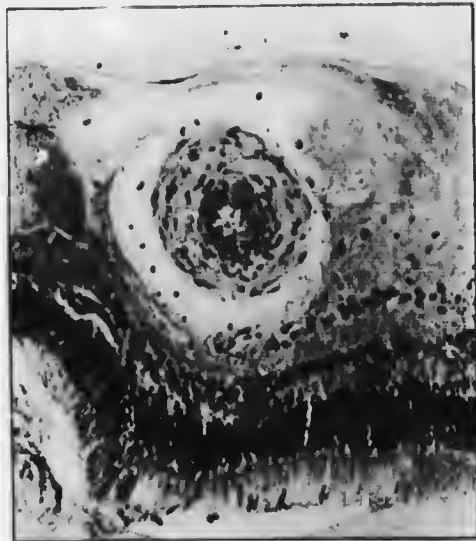


FIG. 188. Retinal vein with enormously thickened wall and narrow lumen. (Coats.) The perivascular lymph space is dilated.

cases. The normal light reflex from the vessel walls is often unusually bright and broad, especially in vessels at some distance from the disc ("silver-wire" arteries) (Fig. 186). Under normal conditions it is possible to see a vein through an artery at a point of crossing; in arteriosclerosis the artery loses its translucency so that the vein is obscured. Moreover, the artery exerts an abnormal pressure on the veins so that the blood flow is obstructed; the vein seems therefore to stop at the crossing and is

more distended on the distal side than on the side towards the disc. The veins may also exhibit a beaded appearance, with alternate constrictions and dilatations. More pronounced changes make the walls of the vessels visible, so that the blood column, often narrowed, is bounded by white lines, the thickened fibrous walls (Fig. 188): this may affect both arteries and veins, usually only individual vessels, in a portion of their course (Figs. 186, 187).

The changes indicated lead to increased permeability of the walls, and increased internal pressure, due to general disease, supplements this defect, and causes undue extravasation of lymph, and even hæmorrhage. Edema of the retina thus arises, manifesting itself as a greyish opacity around the disc, or in spots along the course of the vessels. Hæmorrhages occur as linear striated extravasations along the vessels, or as round spots scattered over the fundus.

Hyperæmia may be arterial or venous. Arterial hyperæmia, characterised by fulness and tortuosity of the arteries, accompanies not only inflammation of the retina, but also inflammation of neighbouring structures, especially the uveal tract. Venous hyperæmia, characterised by dilatation and great tortuosity of the veins, is the result of impeded return of blood to the heart. It may be due to general venous congestion, seen in its most extreme form in congenital malformation of the heart, or to local causes. The latter most commonly affect the veins in the *porus opticus*, as is seen in moderate degree in glaucoma and optic neuritis, and in extreme form in thrombosis of the central vein of the retina. Increased intraorbital pressure, as from a tumour, may also impede the exit of blood from the eye.

Hæmorrhages from the retinal vessels may be pre-retinal or intra-retinal. *Pre-retinal or subhyaloid hæmorrhages* are extravasations of blood between the retina and

the hyaloid membrane of the vitreous. They always occur in the neighbourhood of the macula, and are usually large. They are round at first, but quickly become hemispherical, the upper margin being straight; this is due to the effect of gravity (Plate XIII., Fig. 1). Occasionally two such hemorrhages may be seen in the same eye. They are generally absorbed without causing permanent injury, but may recur. Intra-retinal hemorrhages, as already mentioned, are striate or flame-shaped when situated in the nerve fibre layer, rounded or irregular when in the deeper layers or between the retina and choroid. Intra-retinal hemorrhages are absorbed very slowly, gradually becoming white, rarely pigmented.

Retinal hemorrhages are due to many causes. Most frequently the vessel walls are weakened by general disease, which may be a vascular degeneration due to age or to altered composition of the blood, as in pernicious anemia, leucemia, scurvy, purpura, sepsis, albuminuria, diabetes, phosphorus poisoning, &c. Any of the causes leading to retinal hyperemia may give rise, secondarily, to hemorrhages. Traumatism is another cause, and is often responsible for very extensive extravasations of blood, which may burst through into the vitreous. To this category belong the post-operative hemorrhages. When the globe is opened in performing cataract extraction, or, still more, iridectomy for glaucoma, the normal or raised intraocular tension is suddenly reduced to zero. The intraocular vessels then dilate, and great strain is thrown upon their walls. If these are diseased, there is much danger of their rupturing. Considering the age and condition of these patients, it is surprising that hemorrhage is not more frequent.

Venous Thrombosis may affect the central vein of the retina (Plate XII., Fig. 2) or one of its branches (Fig. 189). In the former case the obstruction is always just behind



PLATE XII (No. 382)

The 1-2-3-4-5-6-7-8-9-10-11-12-13-14-15-16-17-18-19-20-21-22-23-24-25-26-27-28-29-30 hours after probable time of onset
 Four months later the patient was referred to psychiatric hospital
 his right

Fig. 2. - Diagrams illustrating showing the origin of the new
 neurons from the laminar stratum or from the base
 bands stretch forward into the stratum, a feature which cannot
 be traced in a drawing.



The subhyaloid haemorrhage is the commonest form of haemorrhage in the eye. It is usually caused by a rupture of the vessels of the choroid or retina. It is usually seen in the form of a dark, opaque, or semi-transparent, mass in the anterior chamber of the eye. It is usually seen in the form of a dark, opaque, or semi-transparent, mass in the anterior chamber of the eye. It is usually seen in the form of a dark, opaque, or semi-transparent, mass in the anterior chamber of the eye.

PLATE XIII. (To face p. 382.)

- Fig. 1.—Subhyaloid haemorrhage, 96 hours after probable time of onset. Four months later the patient was reported to have quite recovered his sight.
- Fig. 2.—"Retinitis proliferans," showing the origin of the new-formed fibrous tissue in the favourite situation at or near the disc. The bands stretch forwards into the vitreous, a feature which cannot be adequately represented in a drawing.

The subhyaloid haemorrhage is the commonest form of haemorrhage in the eye. It is usually caused by a rupture of the vessels of the choroid or retina. It is usually seen in the form of a dark, opaque, or semi-transparent, mass in the anterior chamber of the eye. It is usually seen in the form of a dark, opaque, or semi-transparent, mass in the anterior chamber of the eye.

The subhyaloid haemorrhage is the commonest form of haemorrhage in the eye. It is usually caused by a rupture of the vessels of the choroid or retina. It is usually seen in the form of a dark, opaque, or semi-transparent, mass in the anterior chamber of the eye. It is usually seen in the form of a dark, opaque, or semi-transparent, mass in the anterior chamber of the eye.

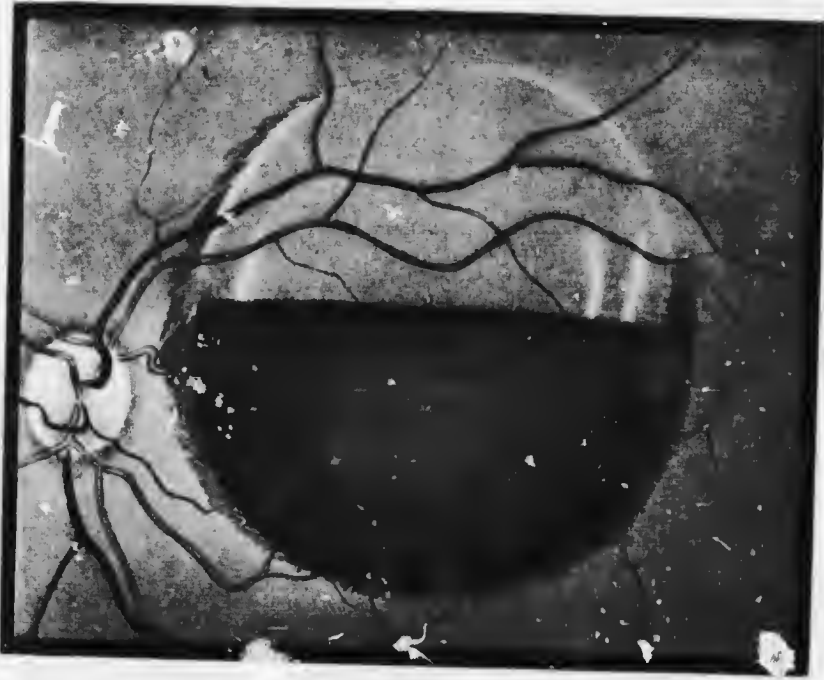


FIG. 1

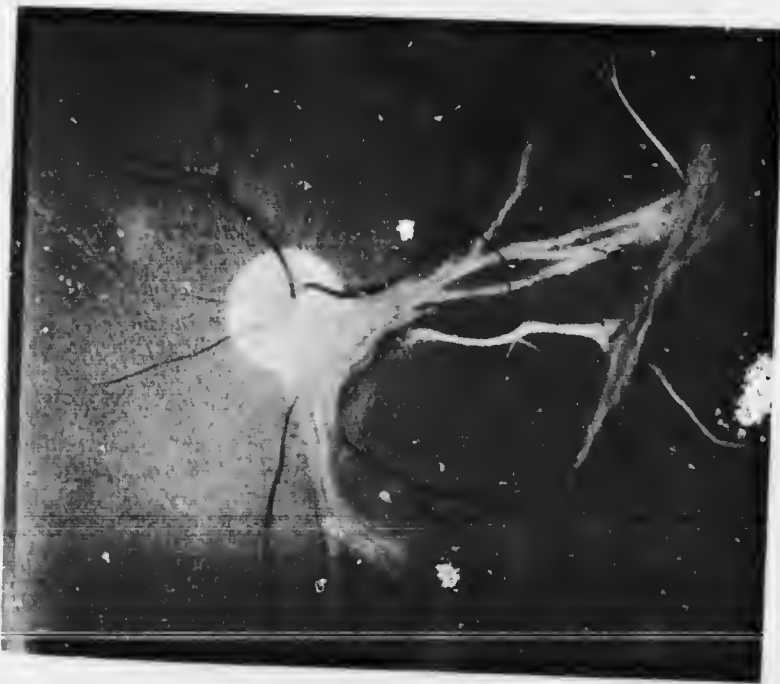

FIG. 2

the lamina cribrosa. All the veins of the retina become enormously engorged with blood, and extremely tortuous. Blood escapes at innumerable spots, so that the retina is

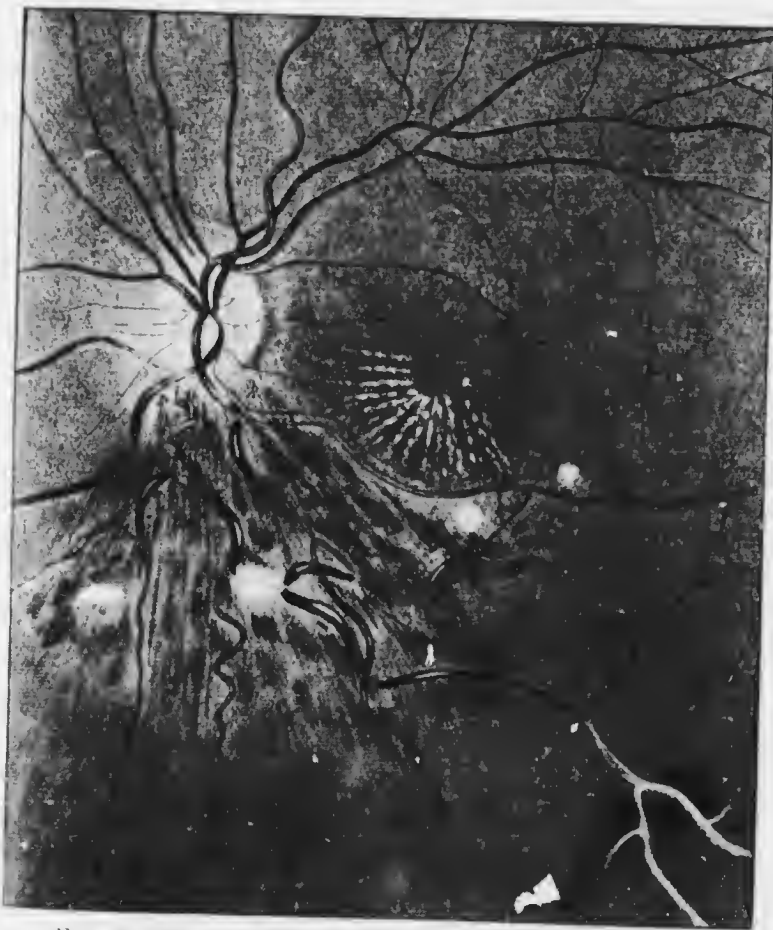

FIG. 189.—Thrombosis of a branch of the central retinal vein.

covered with hemorrhages. Sight is much impaired, and recurrent extravasations finally destroy it entirely. When a single branch is blocked the edema and hemorrhages are limited to the area supplied by the vein. The affected retina becomes atrophic, and secondary glaucoma ensues

in a considerable number of the cases, probably owing to the increased albuminous constituents of the intraocular lymph.

The patients are usually elderly, with cardiac or vascular disease, often induced by nephritis. Thrombosis may, however, be due to local causes, such as orbital cellulitis, following facial erysipelas, &c.

Special Forms of Retinitis.

Syphilitic Retinitis.—Syphilis is one of the commonest causes of retinitis, but it is usually a secondary retinitis, accompanying disease of the choroid (Chap. XVII.). It however occurs as a primary retinitis also, and in this form syphilitic endarteritis is a prominent sign. There are opacities in the vitreous, especially in the posterior part; the retina is cloudy, particularly in the neighbourhood of the disc, which may be hyperæmic. White spots may be seen in the macular region, and yellowish or white spots, often bounded by pigment, at the periphery of the fundus. The vessels may be degenerated (*vide* p. 379), with whitish exudations along their course; hæmorrhages are rare.

Every transition is seen to a condition much resembling choroido-retinitis pigmentosa (*vide* p. 370), but seldom showing such a characteristic distribution of the pigment.

The subjective symptoms are defective central vision, night blindness, irregular and concentric contraction of the field, with or without central, paracentral, or ring scotomata, and metamorphopsia.

In most cases the amount of organisation which takes place at the sites of the inflammatory deposits of syphilitic retinitis is very small, but in some cases there is a well-marked tendency to the formation of new blood vessels. These may not be limited to the retina itself, but may

extend into the vitreous, forming convoluted coils. They are held together by a minimum of delicate connective tissue (cf. *Retinitis proliferans*).

In acquired syphilis the disease usually occurs one to two years after infection: usually both eyes are involved, but not with simultaneous onset. As a rare manifestation the macular area is alone affected, showing a grey or yellow deposit, or numerous small yellow spots and dots of pigment. This form shows a great tendency to relapse.

Retinitis is not uncommon in congenital syphilis. Such patients often show a dusty or peppery, discrete pigmentation of the retina at the periphery, associated with a tigroid condition of the fundus in this situation. It is only distinguishable from what is often seen as a normal condition by the greater aggregation of the pigment. In more definite forms there are yellowish-red and black spots at the periphery (anterior retinitis), a condition often seen in interstitial keratitis (*vide* p. 264), or larger grey or white patches may be seen, or the condition observed in the acquired form may be fully developed.

Albuminuric Neuro-retinitis, in its most typical form, presents an ophthalmoscopic picture which is almost pathognomonic, being simulated only in some cases of intracranial tumour (Plate XIV.). In addition to the general signs of retinitis—haziness of the retina and disc, hyperæmia and hæmorrhages—the distinguishing feature is the presence of brilliant white spots and patches in the retina. The earlier deposits are cloudy, with soft edges; the later brighter, more sharply defined and punctate. The disc is surrounded by large white patches or by a continuous "snow-bank." Around the macula are smaller dots or round patches, also silvery white. Radiating from the fovea are spokes of white dots or fine lines, forming a star-shaped figure, which is extremely characteristic. The fovea itself escapes, and the star is often incomplete in

some direction. The vessels generally show very definite degenerative changes (*vide* p. 379).

Albuminuric retinitis by no means always displays the typical picture. Often there is a neuro-retinitis which exhibits no characteristic features specially associated with nephritis. In these cases there is moderate swelling of the disc—seldom so much as in the choked disc of intracranial disease—more or less widespread œdema and hæmorrhages. Irregularly scattered bright white spots and patches may

be present or wanting. *The urine should be examined in every case of retinitis.*



FIG. 190. Albuminuric retinitis.
Masses of fibrinous exudate in the retina.

The white spots of albuminuric retinitis are chiefly composed of exudates, which are often fibrinous (Fig. 190). They are situated particularly in the inner layers, but may be present in all the layers. There is some leucocytic infiltration, and peculiar swollen nucleated structures—cytoid bodies—are found in the nerve fibre

layer: they are probably varicose nerve fibres. The exudates and necrotic retinal elements undergo fatty degeneration. The peculiar arrangement of the spots in the macula is attributed to the radial disposition of Müller's fibres, but it is probable that when the œdema is considerable there may be actual radial folds in the retina, within which the exudates accumulate. The changes in the blood vessels are those common to vasculitis in other small vessels, consisting of endo- and peri-vasculitis and hyaline degeneration of the walls.

Albuminuric retinitis may occur in all forms of nephritis.



PLATE XIV. (To face p. 888.)

Aluminuric neuro-retinitis. Note the papillitis and macular star-shaped figure, especially marked in Fig. 1, and the masses of white exudate in the retina. The patient from whom Fig. 2 was taken, a man, aged 21, died three months after the drawing was made.



PLATE XIV. (To face p. 386.)

Albuminuric neuro-retinitis. Note the papillitis and macular star-shaped figure, specially marked in Fig. 1, and the masses of white exudate in the retina. The patient from whom Fig. 2 was taken, a man, æt. 21, died three months after the drawing was made.

PLATE XIV.

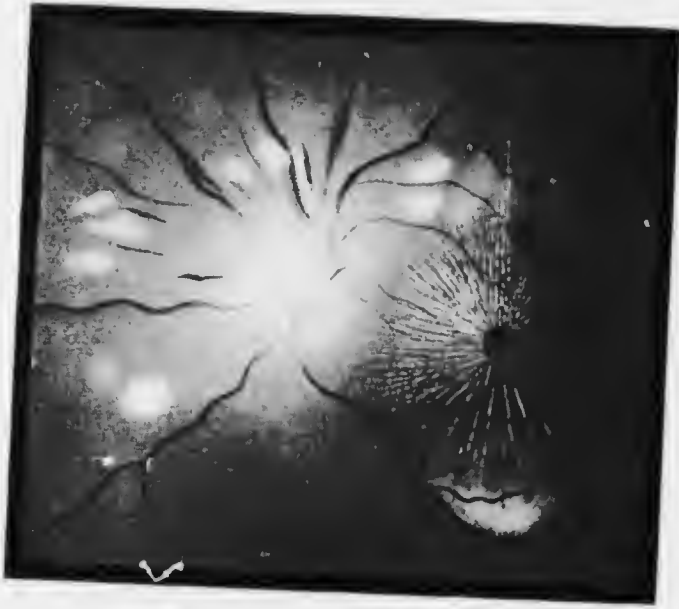

FIG. 1



FIG. 2

-shaped
exudate
a man.



including scarlatinal and puerperal nephritis, but in by far the greatest number of cases the disease is chronic interstitial nephritis. The last-mentioned fact accounts for the small quantity or even total absence of albumin in the urine in some cases. Though the degree of retinitis bears no fixed relationship to the nature or severity of the renal mischief, yet in all cases its presence is of grave significance. The retinal changes may be the first evidence of renal disease, hence the extreme importance of their discovery, which is accentuated by the fact that the majority of hospital patients die in from six months to two years. This rule does not apply to the scarlatinal and puerperal cases. In the latter the prognosis is worse the earlier the onset of the retinitis, but fortunately it usually commences in the later months of pregnancy. The artificial induction of abortion is indicated, and usually has a prompt beneficial effect.

Diminution of visual acuity is commonly the only symptom complained of, and, as mentioned, may lead to the discovery of the renal disease. Generally the history of severe headaches can be elicited. The condition is almost always bilateral.

It is important to note that transient blindness may occur in the course of nephritis, especially associated with uræmia. In these cases the retina shows no abnormality, or at most changes which may occur independently of the disease. This *uræmic amaurosis* is distinguished in being sudden total blindness, whereas the defective vision of albuminuric neuro-retinitis is slower in onset and never complete. Sight usually returns in one or two days. Such attacks may occur in scarlatinal and puerperal nephritis. They are accompanied by the other symptoms of uræmia, viz., headache, vomiting, convulsions and coma.

The *treatment* of these conditions is purely constitutional.

Diabetic Retinitis.—Retinitis is a relatively rare complication of diabetes and occurs in the late stages; it is not improbable that it is frequently missed owing to the peripheral position of the lesions, opacities of the lens, &c. It is bilateral. Irregularly scattered small, bright, white spots in the macular region are the commonest manifestation. The stellate arrangement is usually absent, but it must be remembered that albuminuria is a frequent concomitant of the late stages of diabetes, and all the characteristics of albuminuric retinitis may occur. The white spots may coalesce into larger plaques with crenated edges, which indicate their mode of formation. Punctate hæmorrhages are freely scattered over the fundus. The optic disc is generally normal, as well as the remainder of the retina.

The prognosis depends upon the severity of the constitutional condition, and the treatment is that of diabetes.

Hæmorrhagic Retinitis is a term loosely applied to those forms of retinitis accompanied by hæmorrhages, for hæmorrhages may occur, as has already been seen, in the absence of all signs of inflammation of the retina.

Leucæmic Retinitis.—When retinitis occurs in the course of leucæmia the ophthalmoscopic appearances are characteristic. The retinal vessels are greatly distended, and the blood within them is much paler than normal. The whole fundus is pale and of a yellowish tint. Very typical are white spots and patches surrounded by a red rim; they consist of leucocytes surrounded by red corpuscles. These are present only rarely. In some cases the ordinary picture of hæmorrhagic retinitis is seen. In every doubtful case the blood should be examined.

“Retinitis Proliferans.”—When hæmorrhage occurs into the vitreous the blood clot is usually almost completely absorbed. This is probably due to the absence of fibroblasts in the vitreous and their scantiness in the

retina, for the retinal connective tissue consists of neuroglia, an epiblastic structure which probably takes no part in fibrous tissue formation. The only mesoblastic tissue in the retina is that forming and surrounding the retinal blood vessels. In some cases, however, blood clot may organise, giving rise to masses of fibrous tissue in the vitreous, vascularised by newly formed blood vessels derived from the retinal system (Plate XIII., Fig. 2). This condition is known as "retinitis proliferans." The tissue is most commonly situated near the disc and the vessels spring from this neighbourhood, probably owing to the fact that there is more mesoblastic tissue here than in other parts of the fundus.

There seems to be some special factor necessary to stimulate organisation, and it is found in some general diathesis. In nearly all these cases there is either a history of syphilis or the patient is suffering from nephritis, diabetes, or some other form of toxæmia.

Vision is generally greatly impaired and often lost. No treatment is of much avail, but hypodermic injections of fibrolysin may be tried, combined with constitutional régime.

Retinitis Circinata.—Retinal hæmorrhage may give rise to yet another condition in rare cases. In retinitis circinata there is a girdle of bright white spots around the macula. The diameter of the girdle, which is usually an imperfect circle or ellipse, or horse-shoe shaped, is generally considerably greater than a papilla diameter.

Purulent Retinitis.—This is most commonly due to a septic perforating wound, being then a precursor of panophthalmitis (*vide* p. 454). Rarely it is a metastatic condition, occurring in pyæmia, and probably starting in a septic embolus. In the early stages there is severe retinitis with hæmorrhages. Suppuration rapidly follows, involving the vitreous, so that a yellow reflex is obtained.

The condition often passes into panophthalmitis, but less commonly than in cases of exogenous infection. Pyogenic organisms are attenuated in the blood stream and tissues, so that the process may subside with the restoration of useful vision (*vide* p. 364).

Retinitis from Bright Light, which might be termed *photo-retinitis*, occurs after exposure of the unprotected eyes to bright sunlight, as in looking at an eclipse of the sun with unprotected eyes ("eclipse blindness"), or the electric light, as in the intense flash of the short-circuiting of a strong current. The relative parts played by the visible rays of the spectrum and the chemically active ultra-violet rays is not fully understood, but much protection is afforded against the deleterious action of the latter by the cornea and lens, which have the property of absorbing many of these rays (*cf.* p. 213).

The symptoms are persistence of the after-image, passing on later into a positive scotoma, and metamorphopsia. Ophthalmoscopically there may be no signs at first, or a white spot is seen at the fovea with a red ring round it. Later there are usually deposits of pigment around the fovea. Prognosis must be guarded, since, though improvement often occurs, some defect usually remains and the positive scotoma may persist permanently.

The *treatment* is that of retinitis in general. Smoked glasses should be used, or ruby-coloured glasses, *i.e.*, such as cut off the ultra-violet rays.

Toxic Amblyopia.—Tobacco, alcohol, quinine, filix mas, carbon disulphide, and other poisons sometimes produce defective vision, which is then known as toxic amblyopia. It is usually described as a form of retro-bulbar neuritis (*q.v.*), but experimental and pathological evidence tends to show that the condition is primarily retinal.

Tobacco amblyopia results from the excessive use of

tobacco, either by smoking or chewing. Smokers of shag and tobacco mixtures suffer most. In nearly all cases there is also over-indulgence in alcohol. It is known that alcohol alone may produce toxic amblyopia, and cases in which tobacco caused the disease in total abstainers from alcohol have been published. In most cases the patients are already in a debilitated condition.

The patient complains of increasing fogginess of vision, which is usually least marked in the evening and in a dull light. Central vision is greatly diminished. The field of vision is found to be full, but there is a central colour scotoma for red and green. This is usually small, but in rare cases may extend to the limits of the red field, or even be absolute. Both eyes are affected. Ophthalmoscopically there may be congestive haze of the edges of the optic disc followed by undue pallor of the temporal side of the disc.

The course is chronic, and the prognosis is good if the toxic agents are discontinued absolutely. Very rarely optic atrophy may result, but it is doubtful if these are uncomplicated cases.

The disease is probably due to poisoning of the ganglion cells of the retina. In experimental cases, and in one case examined in man, the cells showed vacuolation and breaking up of the Nissl granules. This leads to degeneration of the nerve fibres, demonstrable only after they have obtained their medullary sheaths, *i.e.*, behind the lamina cribrosa. The degeneration is found to be limited to the papillo-macular bundle (*vide* p. 87). The ganglion cells of the fovea and macular region are the most highly differentiated and are liable to suffer first and most severely in any toxic condition. The degeneration is therefore a wedge-shaped area on the temporal side of the nerve immediately behind the globe, but becomes a circular central area more posteriorly (Fig. 59).

This degeneration was discovered early in the history of the disease, and combined with the clinical similarity to undoubted cases of retrobulbar neuritis led to the conclusion that it was the primary seat of the disease.

The amblyopia produced by carbon disulphide, nitrobenzol, diabetes, wood spirit, iodoform, lead, arsenic, &c., resembles that of tobacco.

Treatment consists in total abstinence from tobacco and alcohol. It should be combined with tonic treatment, especially the administration of strychnine. Iodide of potassium may be given, and copious draughts of water, combined with exercise, have been recommended.

Quinine amblyopia differs in some striking characteristics from tobacco amblyopia. Here total blindness (amaurosis) follows the use of the drug, even in such small doses as 12 grains in susceptible persons. The pupils are dilated and immobile. Deafness and tinnitus aurium are present. Ophthalmoscopically the retinal vessels are extremely contracted and the disc is very pale. In less marked cases or at a later stage the fields of vision are much contracted. The fields gradually widen out, but do not regain their normal limits. Central vision may be completely restored. The discs may remain pale for years or become normal. Occasionally blindness is permanent and optic atrophy ensues.

Treatment consists in discontinuing the drug, administering amyl nitrite or nitro-glycerine, supplemented by strychnine and digitalis.

Detachment of the Retina (*Syns.*—*Ablatio retinae, Amotio retinae*).—The retina may become separated from the choroid by being pulled up from within or pushed up from without. The simplest example of the former mode is in the late stages of plastic cyclitis when the strands of connective tissue which become attached to the retina contract during the process of organisation. The simplest

example of the second mode is separation by means of a choroidal hemorrhage, such as may occur from a blow or disease of the vessels.

Clinically detachment of the retina is observed most commonly in three conditions, viz., after a blow, in high myopia, and in sarcoma of the choroid; to these must be added a not inconsiderable number of cases in which no cause can be assigned. The exact mechanism of detachment in these cases is by no means completely understood; indeed, detachment of the retina is still one of the difficult problems of pathology.

The patient usually complains that there is a cloud in front of one eye, so that parts of objects, usually the upper or lower parts, are not seen. In other words, there is a positive scotoma, as is confirmed by making a chart of the field of vision. As a rule central vision is intact at first, but all detachments of the retina tend in time to be complete; when the macular region becomes affected central vision is lost, and when the detachment is total perception of light is lost. The first symptom observed sometimes is transient flashes of light (*photopsiæ*), due to slight movements which irritate the neuro-epithelium. They should always be regarded with serious attention, but not infrequently occur, especially in myopic eyes, without being followed by detachment.

A small detachment causes much less definite signs. Some obscuration of vision is noticed, but the diagnosis can only be arrived at by careful examination of the fundus and of the field of vision. In sarcoma of the choroid the detachment may be very small and in any position, thus differing from the other forms, in which it is generally larger, though often shallow, and confined to the lower part of the fundus. Sarcoma of the choroid may start in the neighbourhood of the macula, and in this case central vision is early affected, as shown by

distortion of objects (metamorphopsia, micropsia, &c.) or a relative scotoma for colours.

Externally the eye looks normal; the anterior chamber may be deep and the tension diminished, though rarely much in the early stage. In cases due to sarcoma of the choroid the tension is always raised in the later stages and the anterior chamber is shallow; occasionally the tension is raised early in these cases.

It is by no means difficult to miss diagnosing a detachment of the retina even when it is large, especially if it is also shallow. The symptoms may be indefinite, for the

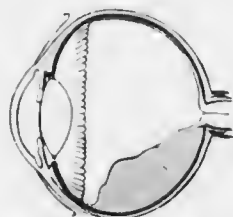


FIG. 191. — Diagrammatic sagittal section of eye with partial simple detachment of the retina. (Nettleship.)

retina may obtain sufficient nourishment from the fluid which underlies it to retain its functions only partially impaired for a considerable period. Failure in diagnosis is almost always due to the omission of a proper routine examination of the eye. The observer often employs the direct method, possibly after a casual examination by the indirect, without previously examining with the mirror alone. A shallow detach-

ment will then appear little altered from the normal fundus. It is true that it is more hypermetropic, but the observer does not realise that he is exercising rather more accommodation in looking at it than at the rest of the fundus. Now, if the eye is examined with the mirror alone at ordinary reading distance, although perhaps no details of the retina are seen—and they will only be seen if the retina bulges far away from the choroid—yet some difference in the nature of the reflex as the eye is turned in various directions will at once arrest attention.

Further examination by the direct method will then show

the following changes (Plate XV.). The detached portion of retina has a different tint from the normal fundus. In the most typical condition it is quite white or grey, with folds which show a bright sheen at the summits and appear greenish grey in the depressions. During slight movements of the eye the folds show oscillations. The retinal vessels are seen coursing over the surface. They naturally follow all the curves of the folds. Very striking is their abnormal colour. Owing to the fact that they are separated from the choroid, which is responsible for the red reflex of the normal fundus, they are under much the same conditions as an ordinary vitreous opacity, *i.e.*, they cut off the light reflected from the choroid. They therefore look much darker than usual, and may be almost black. They show no central light streak and appear smaller than normal.

If now this portion of the fundus is observed with the highest convex glass with which it can be seen plainly it will be found that the rest of the fundus is out of focus; this proves that it is displaced forwards and must therefore be detached from the choroid.

In the early stages, and sometimes for a long period in shallow detachments, the colour differs little from the normal red reflex. Such cases are much less easy to diagnose, and may give rise to great difficulty, especially if the apparent detachment is far forwards, for the periphery even of the emmetropic eye is usually seen best with a low convex glass.

When the detachment is very extensive great balloon-like folds may be seen, and these will probably cut off all view of the disc. At the edges of the detachment a considerable degree of pigmentary disturbance may be seen. White spots of exudation, hæmorrhages, &c., may be seen on the surface of the detached retina. Not infrequently a hole is visible, through which the bright

red choroid can be seen. It has been said that there is a hole in every detached retina, but it is not always visible ophthalmoscopically.

In total detachment the retina is umbrella-shaped, remaining attached at the disc and at the ora serrata. Still later it becomes bunched up behind the lens, the part attached to the disc being pulled out into a straight cord. In these cases the disturbance to nutrition of the eye leads to the development of a complicated cataract (*q.v.*), so that ophthalmoscopic examination becomes impossible.

The description given applies especially to so-called *simple* detachment, *i.e.*, detachment not due to sarcoma of the choroid. The difference may be slight, but accurate diagnosis is of the utmost importance, since the life of the patient may depend upon it. The chief diagnostic features are given in treating of sarcoma of the choroid, and should be very carefully studied (*vide* p. 414).

The space between the retina and choroid is filled with a highly albuminous fluid secreted by the choroid (Figs. 191, 152, 147).

The prognosis in simple detachment is unfavourable. Even if replacement occurs spontaneously or as the result of treatment relapses commonly happen, and total blindness results. Detachment in a myopic eye should be an indication for extreme care of the other, which may be regarded as predisposed to the same accident.

Treatment.—In spite of the futility of treatment in the majority of cases it should be systematically applied and perseveringly carried out in all cases which come under observation at an early stage, *i.e.*, before the retina has become so degenerated as to have lost all excitability to light. The treatment is excessively tedious, and is absolutely useless unless minute directions are given and observed.

Of the many modes which have been advocated the

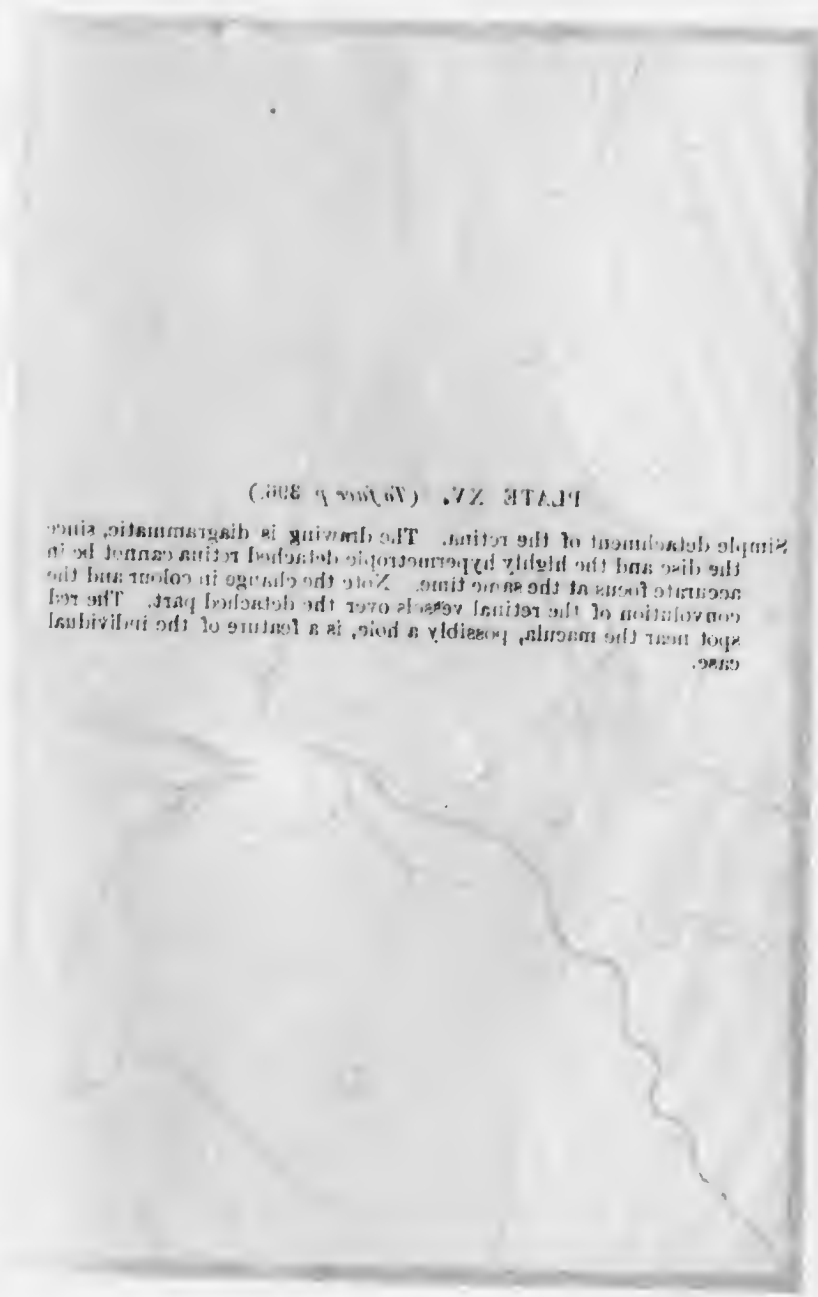


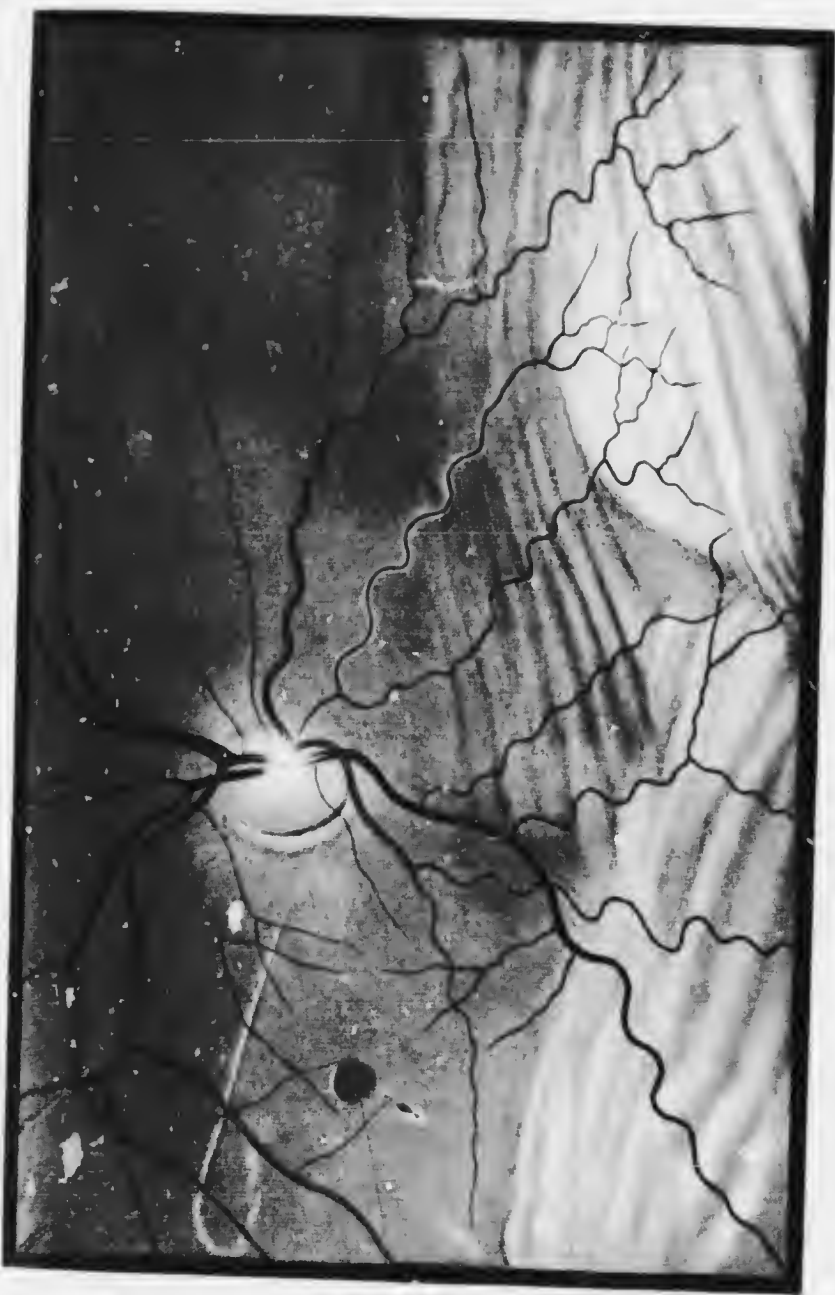PLATE XV. (Facing p. 308.)

Simple detachment of the retina. The drawing is diagrammatic since the disc and the highly hypermetropic detached retina cannot be in accurate focus at the same time. Note the change in colour and the convolution of the retinal vessels over the detached part. The red spot near the macula, possibly a hole, is a feature of the individual case.

PLATE XV. (*To face p. 396.*)

Simple detachment of the retina. The drawing is diagrammatic, since the disc and the highly hypermetropic detached retina cannot be in accurate focus at the same time. Note the change in colour and the convolution of the retinal vessels over the detached part. The red spot near the macula, possibly a hole, is a feature of the individual case.

PLATE VI.



nce
in
the
red
ual

following is probably the best. The patient is put to bed and must lie in the supine position without moving more than is absolutely necessary for several weeks. The head should be placed between sandbags. The patient must not be allowed to get up for micturition or defaecation. Atropin is instilled, and the eye is lightly but firmly bandaged, the space between the nose and cheek being filled with cotton wool. A thorough course of pilocarpin injections is given—every day for a week, repeated after a week's interval, and so on. Mercury is administered either by inunction or by the mouth. Iodides are given.



Operative procedures may be adopted. Of these the best are subconjunctival injections of 10 per cent. salt solution once or twice a week. Acon, 0·1 per cent., may be added to the saline to relieve pain. Not more than 5 minims should be injected at first, as far away from the limbus as possible at the upper part of the globe. The eye should of course be previously cocained.

Probably more efficacious is *scleral puncture*. This is effected as follows. The eye is cocained and washed out (*vide p. 237*). A speculum is inserted, and the patient is told to look as far as possible in the direction away from the detachment, *i.e.*, if the detachment is downwards he looks well up. The eye is fixed in this position with fixation forceps, held by an assistant. The surgeon takes the conjunctiva far back with another pair of fixation forceps and pulls it well forwards. He then introduces a Graefe cataract knife straight into the globe at a point corresponding with what he considers the site of greatest detachment, usually near the equator. The back of the knife is directed forwards. The knife is pushed in until it perforates the choroid *and* the retina, *i.e.*, for 10 or 12 mm. It is then rotated so that the face of the blade is at right angles to its former position and is withdrawn. In this manner a somewhat valvular wound is made. As the knife is



MICROCOPY RESOLUTION TEST CHART

(ANSI and ISO TEST CHART No. 2)



APPLIED IMAGE Inc

1653 East Main Street 14609 USA
Rochester, New York
(716) 482 - 0300 - Phone
(716) 288 - 5989 - Fax

withdrawn the subretinal fluid escapes. The fixation forceps are then removed; the conjunctiva, which has been pulled forwards, retracts and covers the wound. Atropin is instilled and a bandage applied.

Scleral puncture is probably useless unless the retina is pierced, thus establishing a communication between the subretinal space and the vitreous, and so aiding the reabsorption of the subretinal fluid. The retina may become anchored at the site of the wound.

Glioma of the Retina.—See p. 418.

CONGENITAL ABNORMALITIES OF THE CHOROID AND RETINA.

Coloboma of the Choroid and Retina is a congenital malformation in which the choroid and retina are more or less badly developed over a certain area, usually the lower part (typical coloboma). The typical coloboma is due to defective closure of the fetal, so-called choroidal, cleft. Ophthalmoscopically there is a glistening white area, usually with patches of pigment at the edges. There is often also coloboma of the iris (*q.v.*), and the eye may be small (microphthalmia). The condition is often bilateral, and is frequently hereditary. The patch is oval or comet-shaped, with the rounded apex towards the disc, which may be included or not. A few vessels are seen over the surface, some retinal, others derived from the choroid at the edges, but most derived from the posterior ciliaries directly. The surface is often depressed irregularly (ectatic coloboma). The central vision is generally bad, and there is a scotoma in the field corresponding more or less accurately with the coloboma, though this usually contains some retinal elements near the edges.

Similar patches, often symmetrical in the two eyes, occur in other situations (atypical coloboma), notably at the

macula (central or macular coloboma). It is probable that some of these are due to intra-uterine inflammation.

Albinism is the defective development of pigment in the eye. There is no pigment in the eye at all, nor indeed in the whole body, in total albinism, so that the iris looks pink, and the patients suffer much from dazzling. Partial albinism is commoner, and the absence of pigment is then limited to the choroid and retina, the irides being blue. With the ophthalmoscope the retinal and choroidal vessels are seen with great clearness, separated by glistening white

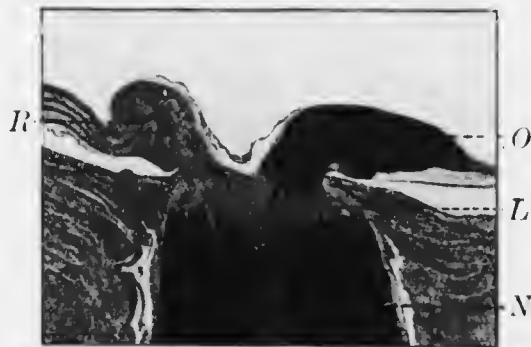

FIG. 192.—Opaque nerve fibres (*O*), stained by the Weigert-Pal method. *R*, retina. *L*, lamina cribrosa. *N*, optic nerve.

spaces where the sclerotic shines through. There may be pigment in the macular regions, which may therefore look normal. Nystagnus, photophobia, and defective vision—partly due to myopia, or less frequently, hypermetropia—are generally present. There may be strabismus, usually convergent. The condition is hereditary.

Treatment consists in correction of the refraction by glasses which should be tinted.

Opaque Nerve Fibres.—The medullary sheaths of the fibres of the optic nerve cease normally at the lamina cribrosa. Occasionally patches of fibres regain these sheaths after they have passed through the lamina cribrosa

(Fig. 192). They appear ophthalmoscopically as white patches, the peripheral edges of which are striated. Usually the patches are continuous with the disc; occasionally they are isolated, but rarely far from the disc. When present the blind spot is enlarged, or a scotoma corresponds with the position of the patch. It is important to be able to diagnose them, since they may be easily mistaken for exudates, *e.g.*, albuminuric retinitis. They not infrequently occur in both eyes. They are not strictly speaking congenital, for myelination of the optic nerve progresses from the brain towards the periphery, and is not completed until shortly after birth.

CHAPTER XVIII.

DISEASES OF THE OPTIC NERVE.

The optic nerve may be attacked by inflammation at any part of its course. The head of the nerve within the globe is frequently affected alone, and this condition is often called optic neuritis. When the nerve is affected behind the eye the condition is called retro-bulbar or retro-ocular neuritis.

Hyperæmia of the Optic Disc is a condition which can rarely be diagnosed with certainty. Perfectly normal discs of different individuals show variations in colouring, and slight differences of illumination alter the appearances. There is no doubt that hyperæmia occurs as a precursor of optic neuritis, and in some of these cases it is possible to distinguish greater redness of the disc in one eye than in its fellow under the same conditions of examination.

Papillitis (*Intraocular Optic Neuritis*) and Papilloedema.—Papillitis occurs in two groups of cases which should be carefully distinguished, viz., as part of a neuro-retinitis (*vide* p. 375, 385), and as a result of intracranial disease. The pathology of the two conditions is totally different, though the ophthalmoscopic features may be almost or quite identical. These general features will be considered first, the differences being discussed afterwards.

It has already been pointed out that the colour of the disc is a fallacious criterion of abnormality. Attention should be directed especially to the edges, which will always be found blurred in papillitis, usually first on the temporal side, later in the whole circumference. The blood

vessels are altered, the arteries being small, the veins distended. In the early stages the disc is usually redder than normal. In the later stages the blurring of the edges is much greater, and the disc looks larger than usual. Exudates cover the vessels in places, and the veins are enormously distended and very tortuous. The papilla is paler than normal and may be white: it shows radial streaks, and small hæmorrhages are generally present upon it and the surrounding retina. The disc is now quite definitely and measurably swollen (*vide* p. 143).

In the optic neuritis of neuro-retinitis the swelling of the disc is usually moderate—2 or 3 D—shelving off gradually into the surrounding retina, which shows the signs of retinitis (*vide* p. 375). The disc is redder than normal, owing to dilatation of the capillaries, but the distension and tortuosity of the veins is moderate. The “optic neuritis” of intracranial disease may in some cases be a true descending neuritis, and will then show the condition just described, except that there is little or no retinitis. More commonly, however, the condition is one of intense œdema with no true inflammation, and this gives rise to papillœdema or “choked disc” (Plate XVI., Fig. 1). Here there is enormous swelling—up to 8 or 10 D—usually delimited much more definitely from the surrounding retina, which shows little change. The veins are enormously distended and very tortuous; the vessels are hidden in places by white exudates. There are frequently hæmorrhages on the swollen papilla. In many cases it is impossible to distinguish ophthalmoscopically between the two forms. The swelling may be unusually great in neuro-retinitis, and the appearances due to intracranial disease may be almost identical with the neuro-retinitis of renal disease, including the star figure at the macula, particularly in children.

The symptoms of papillitis may be extremely vague.



PLATE VII (Anatomical)

Fig. 1. The illustration of a "choked disc" of intervertebral disc. The swelling of the disc is shown by the location of the white substance, the venous congestion and the hemorrhage. The changes in the fundus (under method) are shown. The venous congestion and the swelling of the disc are shown in the anterior part of the posterior body of the vertebra and the posterior part of the anterior body. The posterior part of the anterior body is shown in the anterior part of the posterior body. The anterior part of the posterior body is shown in the posterior part of the anterior body. The posterior part of the anterior body is shown in the anterior part of the posterior body. The anterior part of the posterior body is shown in the posterior part of the anterior body.



PLATE XVI. (To face p. 102.)

- Fig. 1.—Papilloedema or “choked disc” of intracranial disease. Note the swelling of the disc, as shown by the bending of the vessels, the white exudates, the venous congestion and the hemorrhages.
- Fig. 2.—Myopic changes in the fundus (indirect method). Note the myopic crescent and the visibility of the choroidal vessels, due to the stretching of the posterior pole of the eye and the consequent thinning of the retinal pigment layer. The pigmentation and appearance of splits at the macula and the spots of choroidal atrophy are such as occur in severe cases of high myopia.

PLATE XVI.



FIG. 1.



FIG. 2.



Central vision may be quite normal, in which case the pupils will also be normal in size and reactions. It is very important to remember this fact, which emphasises the necessity of examining the fundus in all cases of headache, &c. Even in this stage there may be some concentric contraction of the field of vision. Transient attacks of blurred vision, lasting for a few minutes up to an hour or so, are not uncommon in the early stages of papillœdema. Later central vision is reduced, even to complete blindness. The pupils will then be large and immobile. In less severe cases or in the intermediate stage central vision is defective, the field is markedly reduced concentrically, and relative scotomata—first to green and red—or absolute scotomata may be present. There may be hemianopia or other defects in the field dependent upon the nature of intracranial mischief.

Both in neuro-retinitis and in intracranial disease the condition is generally bilateral, though not necessarily equal on the two sides. The relative amount of swelling may be of localising value in the case of intracranial disease; in frontal tumours and middle ear disease the swelling is usually greater on the side of the lesion. Unilateral papillœdema, with or without "secondary" optic atrophy on the other side, suggests a tumour of the opposite olfactory lobe or orbital surface of the frontal lobe or of the pituitary body (*vide* p. 406).

The course is chronic, the prognosis bad. Occasionally, especially in syphilis, the disease subsides under treatment and good vision is preserved. The same applies to cases due to intracranial pressure if the pressure is relieved early. Generally the nerve fibres are destroyed, post-neuritic atrophy (*q.v.*) follows, and the patient becomes blind.

Diagnosis is easy in severe cases; it may be very difficult in slight cases. Here the colour of the disc is no sure guide unless there is undoubted difference between the two eyes.

Attention should be directed to the edges of the disc; if these can be seen clearly defined with any lens there is no neuritis, but it does not follow that there is neuritis if they appear blurred. Astigmatism causes apparent blurring of the disc margin and there is a condition known as pseudo-



FIG. 193.—Pseudo-neuritis.

neuritis, seen particularly in hypermetropic eyes and due largely to a peculiar reflex, nearly simulating slight neuritis (Fig. 193). In such cases attention must next be directed to the amount of swelling. In the absence of other indubitable signs such as exudates or hæmorrhages papillitis should not be diagnosed unless at least 2 D of swelling can

be demonstrated. In some cases it is necessary to keep the patient under careful observation for a considerable period before certainty can be arrived at.

Etiology.—The chief causes of papillitis are those of neuro-retinitis (*q.v.*) and intracranial disease. The latter is the most frequent cause, especially intracranial tumour, at least 80 per cent. of these cases giving rise to the condition. Any intracranial tumour in any position, with the exception of the medulla oblongata, may cause papilloedema, the highest percentage being found with tumours of the mid-brain, parieto-occipital region, and cerebellum. Meningitis is the next commonest cause, especially tuberculous meningitis—basal meningitis relatively rarely. Other intracranial causes are abscess, thrombosis of the cavernous sinus, aneurysm, hydrocephalus (rarely), &c.

Toxæmia accounts for most of the other cases. Syphilis may act in this manner or as an intracranial gumma; it is a frequent cause. Papillitis may be due to any of the acute febrile diseases, but only in exceptional cases, and to acute anemia from sudden loss of blood. Malformation of the cranium, *e.g.*, oxycephaly, intra-orbital tumours and inflammations—caries, periostitis, &c.—and tumours of the optic nerve act directly upon the nerve.

Pathology.—In neuro-retinitis there is true inflammation of the nerve, but even then œdema plays a prominent part owing to the obstruction to the outflow of venous blood at the site of the lamina cribrosa (*vide p. 149*). Most cases of “choked disc” are at first caused by simple œdema, without inflammation; in the later stages there may be some inflammatory reaction—infiltration with leucocytes, &c.—due to the irritation of the necrosed tissues. In a minority of cases due to intracranial disease, especially meningitis, there may be a descending neuritis, with true inflammation of the nerve.

The mechanism whereby œdema is induced by intra-

cranial disease has been the subject of much dispute and is still an unsolved problem. There is no doubt that one of the most important factors is increased intracranial pressure. This is proved by the fact that the œdema almost invariably subsides, even though the intracranial disease continues, if the pressure is relieved by freely opening the skull. If communication is cut off from one intravaginal space by pressure of a tumour of the pituitary body or olfactory region papilloedema does not occur on this side, but the optic nerve passes into a condition of partial or complete "secondary" atrophy (*vide* p. 410). The mode of action of increased intracranial pressure is unknown. The following theories have been advanced: (1) impediment to the return of lymph along the intravaginal space of the nerve; (2) impediment to the return of venous blood—this is improbable owing to the free anastomosis in the orbit (*vide* p. 13); (3) arterial anæmia, leading to altered conditions of osmosis at the nerve-head.

The *treatment* of optic neuritis is essentially that of the underlying cause. Local treatment is of no avail, but all sources of irritation, such as bright light, &c., should be guarded against. Intracranial pressure should be relieved before vision is lost, even if the cause is a tumour which cannot be completely extirpated.

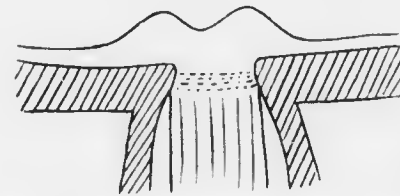


FIG. 194. Diagrammatic meridional section of optic disc in papillitis.

Retrolbulbar Neuritis.—The intra-orbital portion of the optic nerve may become inflamed as the result of extension from the surrounding tissues. Retrolbulbar neuritis is usually divided into an acute, so-called symptomatic form, and a chronic, idiopathic form. The latter is the condition

which we have described as toxic amblyopia and have attributed to a primary retinal lesion.

Acute retrobulbar neuritis is usually unilateral. The patient complains of defective vision, and sometimes of pain on moving the eye. The pain is increased by pressure upon the globe, and neuralgia and headache may be present. Ophthalmoscopic examination will probably reveal a quite normal fundus. It is therefore very easy to overlook the true condition and to attribute the symptoms to hysteria. Careful methodical examination will minimise this danger. Diagnosis at this stage will depend upon thorough investigation of the pupil reactions and of the field of vision. The patient should be asked if he ever squinted (*vide* p. 426).

At first glance the pupil reactions will be apparently normal, both directly and consensually to light, as well as to accommodation. More minute inspection will show, however, that though the pupil of the affected eye reacts to light the contraction is not maintained under the bright illumination, *i.e.*, instead of remaining contracted the pupil slowly dilates whilst the light is still kept upon the eye. This phenomenon, if it can be placed beyond dispute, is of the utmost diagnostic significance.

The field of vision shows a central scotoma, which may be relative for colours or absolute. It is not always quite central, but may be paracentral or sectorial or in the form of a ring around the fixation point. There is usually some peripheral loss of the field and there may be complete blindness.

In the later stages or more severe cases there are usually ophthalmoscopic changes. These are distension of the veins, with diminished calibre of the arteries, or actual papillitis, moderate in degree. With or without these preliminary changes atrophy of the optic disc may ensue. In every case in which the inflammation in the nerve

behind the globe is so great as to lead to destruction of the nerve fibres in this situation the degeneration extends not only towards the brain but also towards the eye. In the milder cases pallor of the disc is limited to the temporal side, corresponding with degeneration of the papillo-macular fibres. It has already been noted that the ganglion cells at the macula are more liable to be affected by deleterious agents than those in other parts of the retina. The same fact applies to their axis cylinder processes, contained in the papillo-macular bundle, wherever in their course the noxious agent acts. This accounts for the clinical similarity between true retrobulbar neuritis and toxic amblyopia.

The causes of acute retrobulbar neuritis are local and general. Amongst the former periostitis and transmission of inflammation from the ethmoidal and sphenoidal sinuses may be mentioned; hence attention should be directed to any nasal complication. Hemorrhage into the optic nerve sheath or orbit and fracture of the base of the skull, involving the optic foramen, may produce a similar clinical picture. Amongst general diseases which cause retrobulbar neuritis insular sclerosis is one of the most important. Other alleged causes are rheumatism, chills, infectious diseases, &c. The prognosis depends upon the cause and the possibility of combating it. In multiple sclerosis the affection of the nerve rarely leads to complete blindness.

Treatment consists in attacking the cause. The eyes must be protected from bright light, and kept at rest by atropin and abandonment of near work. When the cause is obscure, mercury, iodides, diaphoresis, and tonics may be used.

Optic Atrophy is the term usually applied to the condition of the disc when the optic nerve is degenerated. It has been pointed out that injury to the nerve fibres in any part of their course leads to degeneration not only on the

proximal (cerebral) side—as might be anticipated for afferent fibres—but also on the distal (ocular) side (*vide* p. 407). Optic atrophy follows extensive disease of the retina from destruction of the ganglion cells, *e.g.*, in “retinitis” pigmentosa; it also follows destruction of the nerve in the orbit, as in rupture of the nerve at the optic foramen in fracture of the base of the skull, severe retrobulbar neuritis, &c. The break in continuity of the fibres may be at the disc itself, such as results from the strangulation of the papillitis of neuro-retinitis or papilloedema. These cases are distinguished as *post-neuritic atrophy*, owing to special features which they often exhibit. Besides these causes there is a well-defined group of cases in which optic atrophy occurs without previous evidence of severe local inflammation, but associated with general disease, usually of the central nervous system, or without discoverable disease. Such cases are described as *primary atrophy*.

The essential ophthalmoscopic features of optic atrophy in general are alteration in the colour of the disc and changes in the blood vessels. The disc is always pale, but may show varieties of tint specially associated with various types of atrophy. The pallor affects the whole disc and must be carefully distinguished from the white centre, often encroaching upon the temporal side, due to physiological cupping. The change in the vessels is always on the side of contraction, but may be absent.

In primary (grey, tabetic, spinal) atrophy the disc is grey or white, sometimes with a greenish or bluish tint (Plate XVII., Fig. 1). The stippling of the lamina cribrosa is seen; the edges are sharply defined, and the surrounding retina looks normal. Owing to the absorption of the nerve fibres there is slight cupping (atrophic

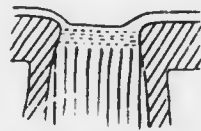

FIG. 195.—Diagrammatic meridional section of the optic disc in atrophic cupping. Note that the lamina cribrosa is not displaced (*cf.* Fig. 157).

cupping) (Fig. 195), which must be carefully distinguished from glaucomatous cupping. It is shallow and saucer-shaped, as shown by the slight bending of the vessels, but is scarcely measurable with the ophthalmoscope. There is no retraction of the lamina cribrosa. The vessels are normal or only slightly contracted. Both eyes are generally affected.

In the "secondary" atrophy of retrobulbar mischief the condition nearly resembles primary atrophy, but there is greater pallor, and the vessels are more likely to be contracted. In the "consecutive" atrophy of retinal and choroidal disease, as typically represented by the late stages of "retinitis pigmentosa, the disc has a yellowish waxy appearance, the edges are less sharply defined, and the vessels are very markedly contracted, sometimes to almost complete disappearance.

Post-neuritic atrophy may be indistinguishable from the other forms ophthalmoscopically. More commonly it can be diagnosed with considerable probability by characteristic signs (Plate XVII., Fig. 2). These depend upon the fact that the absorption of the exudates leads to a certain amount of reactionary organisation, with the formation of a variable quantity of fibrous tissue upon the disc. This tissue obscures the lamina cribrosa and fills in the atrophic cup. It extends over the edges, which are thus indefinite, and along the vessels as a thickening of the perivascular sheaths. Further, it throttles the vessels, so that they become markedly contracted. Owing to previous neuro-retinitis the surrounding retina often shows permanent changes, chiefly manifested by pigmentary disturbance. When such changes are well marked previous papillitis may be hypothesized with extreme probability, but in their absence the conclusion that there has not been papillitis is not justifiable. The amount of reactionary organisation varies greatly in different cases, and the tissue laid down is

shed
ceer-
ut is
re is
are
are

the
re is
con-
and
late
wish
and
s to

from
only
by
pend
eads
the
n the
ls in
are
f the
s, so
rious
rma-
ance.
may
their
tis is
ation
wn is



PLATE ZLII (V. 10)

OLD ALBERT

PLATE ZLII (V. 10)

OLD ALBERT

PLATE ZLII (V. 10)

OLD ALBERT



PLATE XVII. (*7th face p. 410.*)

OPTIC ATROPHY.

Fig. 1. — Primary optic atrophy. Note the pallor and sharply cut margin of the disc, the exposure of the lamina cribrosa, and the absence of circumpapillary retinal changes

Fig. 2. — Postpapillitic atrophy. Note the pallor and blurring of the edges of the disc, the filling in of the atrophic cup with fibrous tissue so that the lamina cribrosa is not seen, the disturbance of the retina in the immediate neighbourhood of the disc, and the thread-like arteries.

PLATE XVII.



FIG. 1.

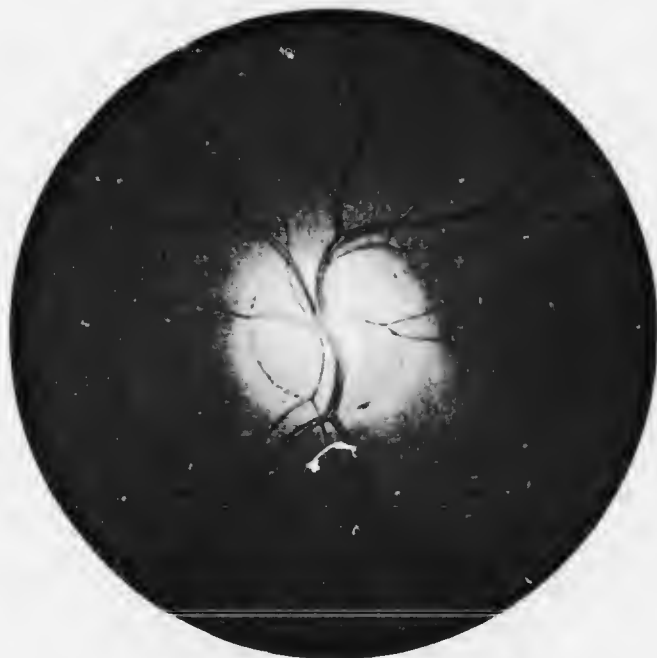

FIG. 2.

in the course of time gradually reabsorbed to some extent.

In total optic atrophy the pupils are dilated and immobile to light and the patient is blind. When unilateral the consensual reaction to light is exaggerated. In partial optic atrophy central vision is depressed and there is concentric contraction of the field, with or without scotomata, relative or absolute, according to the cause. In primary atrophy the disease is usually slowly progressive, ending after months or years in complete blindness. It is important to note that no deduction as to the amount of vision can be made from the ophthalmoscopic appearances. The presence of all the signs of atrophy is not inconsistent with a certain, sometimes considerable, amount of vision.

The chief cause of primary optic atrophy is tabes. It may be the first sign, and the other symptoms and signs may be long delayed. The patient should be carefully investigated for a history of syphilis, the presence of Argyll-Robertson pupils, the absence of knee-jerks, the presence of anesthesia, inco-ordination, and soon. Both eyes are affected, but often in unequal degree. The disease advances slowly but surely to complete blindness—progressive optic atrophy par excellence. A similar condition may be due to general paralysis and insular sclerosis, less commonly to other forms of central nervous disease: in insular sclerosis the course of the disease is usually different—variations or repeated acute attacks, seldom causing blindness. Excessive hæmorrhage, menstrual defects, cold, arterio-sclerosis, &c., have been ascribed as causes in doubtful cases. Primary optic neuritis is occasionally hereditary.

“Secondary” atrophy is caused by compression of the optic nerves, chiasma, or tracts by tumours, aneurysm, distension of the lateral ventricles (hydrocephalus), &c. It

may follow rupture of the optic nerve at the foramen, section of the nerve, compression by blood clot, &c., without previous neuritis.

Treatment is that of the cause. For the lesion of the nerve itself mercury, iodides, strychnine, nitroglycerine, the constant current, &c., may be used, but seldom have any effect.

Tumours of the Optic Nerve.—See Chap. XXXI.

CONGENITAL ABNORMALITIES OF THE OPTIC DISC.

Coloboma of the Optic Disc.—This occurs in two forms, one of which is common, the other rare. The common form is due to incomplete closure of the choroidal fissure, and manifests itself as an *inferior crescent*, much resembling the myopic crescent (*q.v.*), but situated at the lower edge of the disc (Plate VIII., Fig. 1). It is a crescent, whiter than the disc itself, situated at the lower border. It occurs most commonly in hypermetropic and astigmatic eyes, which are often found to have slightly defective vision though the error of refraction is corrected.

In what is commonly known as *coloboma of the disc* (or nerve sheath) there is greater failure of the fetal fissure to close. The disc then looks very large and the vessels have a very abnormal distribution, appearing only above or irregularly round the edges. The apparent disc is really the sclerotic and inner surface of the sheath of the nerve, the nerve itself being usually spread out as a pink horizontal linear band at the upper part. The floor of the coloboma is white and measurably depressed, often quite cecatic. The eye usually has defective vision.

CHAPTER XIX.

INTRA-OCULAR TUMOURS.

INTRA-OCULAR tumours are rare, but of supreme importance, since they are usually malignant and endanger the life of the patient.

Tumours of the Iris. Sarcoma of the iris is extremely rare. It is not uncommon to see irides with dark brown spots (melanomata), due to congenital aggregations of retinal pigment epithelium. As a rule these are benign, but occasionally they take on malignant proliferation. Any increase of size must be watched with suspicion. True sarcoma, composed of pigmented or unpigmented spindle-shaped or round cells, occurs as an isolated nodule. It grows rapidly, and if left attacks the corneo-sclera and perforates the globe. It gives rise to metastases from which the patient dies.

Although it is the only new growth of importance met with in the iris, it may be diagnosed from gumma or tubercle only with difficulty. The chief points of difference are the absence of inflammation as shown by synechia, &c., the absence of satellites, the frequency of pigmentation, and the rapid increase in size.

Treatment.—The growth should be watched for a short time and if found to increase in size should be removed by iridectomy if this is feasible. The specimen is subjected to expert microscopic investigation. If the growth is malignant and has not been completely removed or shows signs of recurrence the eye must be excised at once.

Sarcoma of the Choroid is not so rare as sarcoma of the iris. The growth arises from malignant proliferation of the stroma cells of the outer layers. It forms at first a lens-shaped mass, raising the retina over it. By the process of growth increased tension is thrown upon the elastic membrane of Bruch, which finally ruptures. The cells then proliferate through the opening and form a globular "head" in the subretinal space, separated from

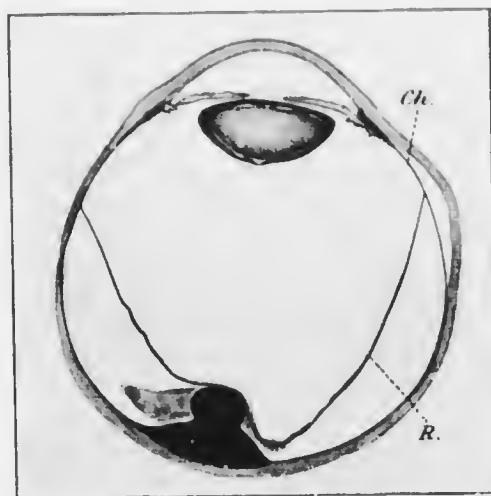


FIG. 196. Section of sarcoma of the choroid ($\times 9$), showing the typical mushroom shape. *Ch.*, pars plana of ciliary body, continuous posteriorly with the choroid, behind *R.* retina.

the mass in the choroid by a narrow "neck" (Fig. 196). The retina remains in contact with the tumour at the summit of the head, but is detached from the choroid at the sides, the intervening space being filled with albuminous fluid. The growth may be in any situation, and the fluid may sink down to the lowest part of the eye, forming there a "simple" detachment isolated from that over the tumour. As the tumour progresses the retina is more and more detached, until no part remains *in situ*. The nutrition of the lens then suffers, so that it becomes opaque.

The tumour may fill the globe before perforating the sclerotic, or this may occur relatively early along the perivascular spaces of the vortex veins or ciliary vessels. The orbital tissues then become infiltrated. The lymphatic glands are not affected, but metastases occur in the liver and elsewhere.

The growth is usually pigmented—melanotic sarcoma, rarely unpigmented—leucosarcoma. The cells are spindle-shaped or round. They may be arranged in columns (cylindroma) or around blood vessels (angio-sarcoma), and are then probably endotheliomata.

The course of sarcoma of the choroid is commonly divided into four stages: (1) the quiescent stage; (2) the glaucomatous stage; (3) the stage of extra-ocular extension; (4) the stage of metastasis. This is probably the typical chronological order of events, but secondary glaucoma may arise at a very early stage or be delayed until after extra-ocular extension has taken place, and there is evidence to show that metastases may occur at an early stage.

The cause of the glaucoma is obscure: in most cases it is due to the lens and iris being forced forwards, so that the angle of the anterior chamber becomes blocked. In other cases, particularly those of early onset, obstruction to the venous outflow from the eye is the probable explanation, the tumour being in some instances so situated as to press upon a vortex vein.

Sarcoma of the choroid usually occurs in adults between forty and sixty. It is always primary, single, and unilateral. The patient may come under observation in the early stage when there is only detachment of the retina. The earliest cases to seek advice are those in which the tumour is near the macula, since vision is then most strikingly affected. In other cases the tumour has usually attained a considerable size, and the patient may apply for treatment for relief of the pain of glaucoma.

It is of the utmost importance that the cause of the detachment of the retina should be diagnosed in these cases. We have already seen that "simple" detachment of the retina is most frequently found in myopic eyes or after a blow, though many cases are apparently "idiopathic." In simple detachment the lower part of the retina is usually affected, though not always. There is therefore presumptive evidence—of only slight weight—that a detachment in the upper part is due to a tumour of the choroid. In detachments of considerable size the tension of the eye is normal or subnormal in the absence of a growth; if the tension is raised quite definitely a growth may be diagnosed almost with certainty. A simple detachment shows numerous, more or less parallel, folds, and undulations can be seen to travel over the surface when the eye moves. The detachment at the summit of a tumour is usually rounded and fixed, though in the surrounding parts it may show all the signs of a "simple" detachment. Patches of pigment upon the rounded part support the diagnosis of a tumour, but pigment disturbance, more particularly at the periphery, is not uncommon in simple detachment. Rarely a system of blood vessels having an entirely different mode of distribution to the retinal vessels can be made out between the latter vessels. This is the most positive evidence of growth, but it is only occasionally seen. A very small, round detachment in the macular region or upper part of the globe is almost certain to be due to a tumour of the choroid. If the detachment is sufficiently anterior transillumination with a specially devised lamp will afford assistance in diagnosis, a simple detachment being transparent, a choroidal growth opaque.

Diagnosis may be extremely difficult if the patient is first seen when glaucoma has already supervened. Dependence must then be placed largely upon the history. Defective vision may have been noticed, but

the premonitory haloes of glaucoma have been absent, and vision has gone from bad to worse without remissions. One eye only is involved. The other may be perfectly normal, or at least not of the glaucomatous type with small cornea and so on, and the field of vision in this eye will show no contraction on the nasal side. The affected eye will probably have no perception of light, so that if any doubt remains it should be excised.

Treatment.—The eye should be excised as soon as possible after arriving at the diagnosis. Although sarcoma of the choroid rarely travels down the nerve it is wise to cut it as long as may be. If the growth has already burst through the globe the orbit should be exenterated.

Prognosis is fair if the tumour is small and entirely intraocular, but even in these cases metastasis may have occurred. The disease is invariably fatal, usually within five years, if not eradicated by operation.

Sarcoma of the Ciliary Body is fundamentally of the same nature and gives rise to the same symptoms as sarcoma of the choroid, the differences being only those dependent upon the anatomical disposition of the parts. Thus, the retina being here more adherent to the underlying uvea, and being reduced to a double layer of epithelial cells, is not detached. When the growth has spread to the choroid the retina proper becomes detached. The tumour may attain considerable size before it causes symptoms, which are then referable to displacement or distortion of the lens and interference with the ciliary muscle. The ciliary circulation is impeded, and conspicuous dilatation of one or two anterior perforating ciliary vessels should always arouse suspicion. The growth may invade the angle of the anterior chamber. It then has the appearance of an iridodialysis, a dark crescent showing at the root of the iris. That it is not an iridodialysis is shown by the fact that no reflex can be obtained through it on

illuminating with the ophthalmoscopic mirror and from the absence of history of a blow. In the case of a leucosarcoma the crescent may be yellowish, but vessels will usually be visible upon the surface, and these render the diagnosis easy. The growth may be visible by oblique illumination with a widely dilated pupil.

Sarcoma of the ciliary body is less common than that of the choroid. The treatment and prognosis are the same.

Secondary Carcinoma of the Choroid occurs sometimes in late stages of scirrhus of the breast, rarely in cancer of other organs. There is obscuration of vision, and ophthalmoscopic examination reveals a widespread shallow detachment of the retina. The disease is nearly always bilateral, and as it is usually only one of many metastatic deposits and the patient is generally in the last stages of general carcinomatosis no special treatment is indicated.

Glioma of the Retina is a malignant disease confined to infants. It is probably always congenital, though it may remain quiescent or pass unnoticed until the fifth or sixth year or even later. The disease is rare; the second eye is affected, independently and not by metastasis, in about one-fourth of the cases, but frequently the growth cannot be recognised even on careful examination until after months or even years. Several children of the same family are sometimes affected.

The child is brought to the surgeon on account of a peculiar yellow reflex from the pupil, sometimes called "amaurotic cat's eye." If left untreated glioma runs through the same stages as sarcoma of the choroid, viz., (1) the quiescent stage; (2) the glaucomatous stage; (3) the stage of extra-ocular extension; (4) the stage of metastasis. The second stage results in enlargement of the globe, with apparent or real exophthalmos. Pain is severe during this stage, but is relieved when the tumour

bursts through the sclerotic. Perforation often occurs at the limbus, and is followed by rapidly fungating growth. Metastasis first occurs in the preauricular and neighbouring glands, later in the cranial and other bones. Direct extension by continuity to the optic nerve (which is early affected) and brain is commoner, and metastases in other

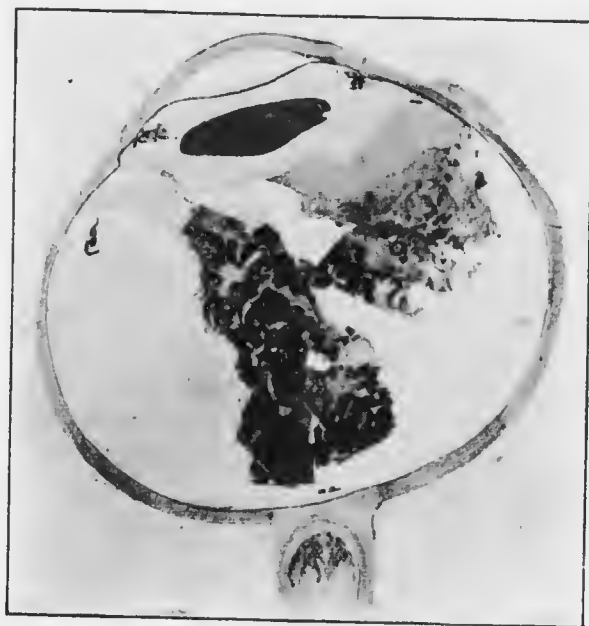

FIG. 197.—Section of glioma of the retina ($\times 3$). Note the rings of deeply stained cells surrounding blood vessels; also the infiltration of the anterior part of the optic nerve.

organs, usually the liver, are relatively rare (cf. sarcoma of the choroid). In most cases the first stage lasts from six months to a year.

Glioma is a malignant growth of the retina composed chiefly of small round cells with large nuclei, characteristically arranged around blood vessels, and showing great tendency to degenerative changes (Fig. 197). It is a disease sui generis, and bears no resemblance to glioma of the

brain, from which it must be carefully distinguished. It probably originates in fetal, undifferentiated retinal cells: when the other eye is affected it is a separate focus, and not an extension via the chiasma. It is invariably multiple (cf. sarcoma of the choroid). When seen very early, as for example in the second eye, a larger mass is seen surrounded by numerous punctate satellites. Microscopically minute deposits are seen scattered in various situations throughout the globe. It may grow principally outwards, separating the retina from the choroid—glioma exophytum, or inwards towards the vitreous—glioma endophytum. There is no fundamental distinction, but the ophthalmoscopic appearances differ in the two types. In the former the condition resembles a mere detachment of the retina; in the latter polypoid masses may be seen projecting into the vitreous. Hemorrhages upon the surface are not uncommon, especially in glioma endophytum.

Several conditions occurring in children may give rise to similar signs, and cause great difficulty in diagnosis. These have been grouped together under the term *pseudoglioma*. The chief are (1) inflammatory deposits in the vitreous, with or without detachment of the retina; (2) tubercle of the choroid, especially the confluent type; (3) congenital defects, due to persistence of part of the fibrovascular sheath at the back of the lens. The first group are due to a quiet form of cyclitis, which may have passed unnoticed or may have caused slight redness of the eyeball with inflammatory deposits in the anterior chamber; these, however, are usually soon absorbed. A history of fits, unconsciousness, attacks of screaming, ear disease, one of the acute specific fevers, syphilis, &c., may be obtained. Iritis, or the results of iritis or iridocyclitis, *e.g.*, posterior synechie, retraction of the base of the iris, and so on, are often present.

In all cases atropin should be instilled and both eyes

should be thoroughly examined ophthalmoscopically, under chloroform if necessary. The tension may then be satisfactorily tested, and may afford useful information which cannot be obtained without an anæsthetic. Raised tension is in favour of glioma, lowered of pseudoglioma. Even when every precaution is taken there is a considerable group of cases in which it is absolutely impossible to be certain of the diagnosis. Considering that the life of the patient is at stake and that the eye is in any case useless as an organ of sight, these cases should be treated as glioma.

Treatment.—The treatment of glioma is excision of the eye at the earliest possible moment. The optic nerve should be cut long, and the cut end invariably submitted to microscopical examination. If there is any doubt of extension of the disease to the conjunctiva or orbital tissues exenteration of the orbit is imperative. In cases where the diagnosis is doubtful the eye should be removed, for in inflammatory pseudoglioma the eye is destined to shrink and become unsightly. In no case should both eyes be removed at the same operation, but if one is proved by microscopical examination to be gliomatous and the other contains a similar growth, the second eye should also be excised if consent of the parents can be obtained.

The prognosis of glioma, if untreated, is absolutely bad, the patient invariably dying. The prognosis is fair if the eye is removed before extra-ocular extension has occurred. In the absence of disease of the second eye the patient may be regarded as out of danger if there is no recurrence in the orbit within three years, but the remaining eye should be carefully examined under atropin at frequent intervals for a much longer period. There are several cases on record of cure after removal of both eyes for glioma retine.

CHAPTER XX.

SYMPTOMATIC DISTURBANCES OF VISION.

APART from the disturbances of vision which have been already considered and have their origin in the eye itself, there are others dependent upon lesions in the visual nervous tracts. They not infrequently closely simulate the disorders due to peripheral causes, or, being early evidence of disease, lead the patient to consult an ophthalmic surgeon. There are also visual defects the cause and seat of which are imperfectly elucidated: though some are probably peripheral in origin it will be convenient to consider them here.

Hemianopia (*Syns.*—*Hemianopsia*, *Hemiopia*).—Hemianopia denotes loss of half of the field of vision. The commonest clinical form is so-called *homonymous hemianopia*, in which the right or left half of the binocular field of vision is lost, owing to loss of the temporal half of one field and the nasal half of the other. The condition may be due to a lesion situated in any part of the visual tracts from the occipital lobe to the chiasma. A focus of disease in this area causes loss of vision of the corresponding halves of each retina (hence the designation homonymous), *i.e.*, loss of the opposite halves of the visual fields. Since the afferent pupillary fibres part company with the visual fibres before the latter enter the so-called primary optic centres—external geniculate body, pulvinar, and superior colliculus (*vide* p. 85)—a means of diagnosis of the seat of the lesion, whether in the optic tract or above that level, is provided. If the lesion is

SYMPTOMATIC DISTURBANCES OF VISION. 423

above the primary centres the pupil reactions are normal; if it is in the optic tract Wernicke's hemianopic pupil reaction should be present (*vide pp. 72, 109*). It must be

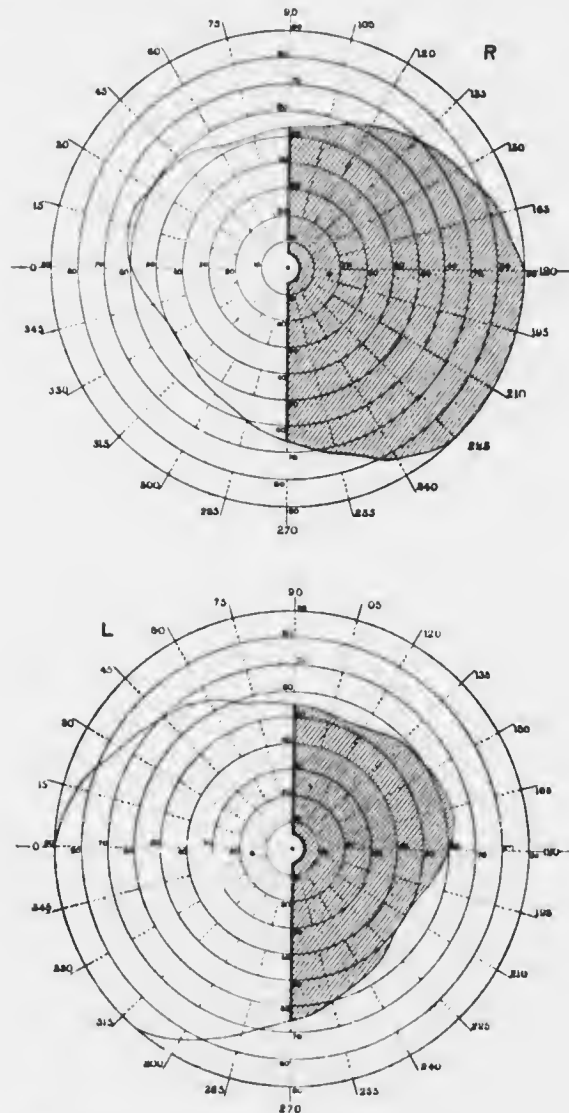


FIG. 198.—Charts of fields of vision in homonymous hemianopia.

remembered, however, that this reaction is always difficult to elicit, and with the methods usually employed is seldom conclusive unless definitely present. The majority of cases of hemianopia are due to lesions above the primary centres, usually in the occipital lobe or optic radiations. The exact site must be determined by collateral symptoms, caused by involvement of neighbouring structures, *e.g.*, word-blindness (probably angular gyrus), hemianæsthesia, with or without hemiplegia (internal capsule), &c.

In most cases of hemianopia the fixation point of each eye escapes (Fig. 198). This is probably due to two causes—widespread representation of the foveal region in the occipital lobe of the same side, owing to spread of the fibres of the papillo-macular bundle and of the corresponding neurons of the third order; and bilateral representation of each foveal region in each occipital lobe. Occasionally the fixation point is engulfed. Rare cases of double hemianopia have been reported; vision is then not necessarily entirely lost, since the fixation point may escape.

Rare cases of homonymous *quadrant hemianopia* have also been reported, in which corresponding quadrants of each field—the upper or lower half of one temporal, and the upper or lower half of the other nasal—have been lost. These are generally caused by cortical or sub-cortical partial lesions of one occipital lobe, destruction of the part above the calcarine fissure leading to loss of the lower quadrants, and *vice versa*.

Bitemporal hemianopia is usually caused by disease of the pituitary body, which then presses upon the chiasma, so that the fibres going to the nasal halves of each retina are destroyed (Fig. 199). The condition is common in the advanced stages of acromegaly. The delimitation of the blind areas in the two fields is usually less accurate in these cases, and as they progress the loss in one eye may be more rapid than that in the other, so that finally one eye may

become completely blind whilst the other retains a portion of the field. Wernicke's reaction should be present.

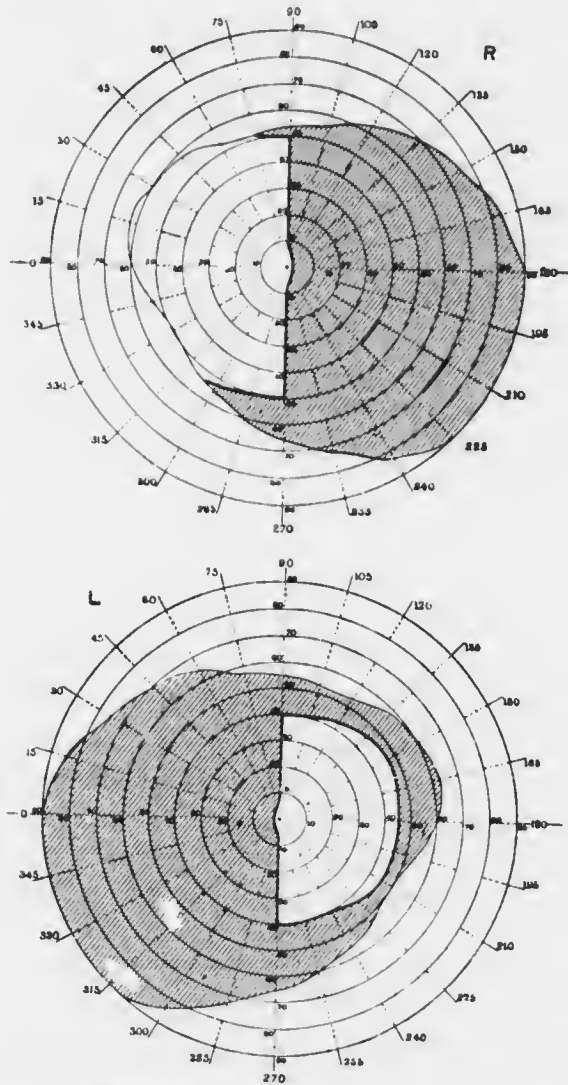


FIG. 199.—Charts of fields of vision in bitemporal hemianopia.

In the early stages of tumour of the pituitary body the pressure is usually greater on one side than the other.

The first sign is that of unilateral retro-bulbar neuritis, with relative central scotoma. This is followed by progressive "secondary" atrophy, often accompanied by papilloedema on the opposite side (*vide* p. 403).

Binasal hemianopia is one of the greatest rarities, if, indeed, it can be said to occur at all in typical form. It necessitates two lesions, one on each side of the chiasma, destroying the fibres to the temporal halves of each retina whilst leaving the nasal fibres intact.

Cases have been described in which there has been loss of half of one field and general blurring or amblyopia of the whole of the other. In some of these cases a lesion has been found post mortem involving one occipital lobe and extending into the angular gyms. *Heteronymous amblyopia* has therefore been ascribed to lesion of the angular gyms. It is probable that this is merely a survival of the erroneous idea that the cortical representation of vision is in the angular gyms. It is probable that this gyms has to do with visual conceptions, *i.e.*, mental visual impressions of a higher order than the perceptions represented in the occipital cortex.

Amblyopia (*ἀμβλῦσις*, blimt) and **Amaurosis** (*ἀμαυρόσις*, dark) are the terms used for partial and complete loss of sight respectively in one or both eyes. They are not used of all cases of partial or complete blindness, but have become restricted to certain forms of a more or less indefinite character devoid of ophthalmoscopic or other marked objective signs.

Unilateral amblyopia is usually either *congenital* (*vide* p. 563) or from psychological suppression of the retinal image — *amblyopia ex anopsiâ* (*vide* p. 563) : these varieties are discussed elsewhere. Unilateral amblyopia may be due to high refractive errors in the eye. It is then not a true amblyopia, since correction with suitable glasses in early life cures the condition if sufficient perseverance is exercised.

In older people glasses often fail : this may be attributed either to the development of a true amblyopia from disuse or, more probably, to defective receptivity of the higher centres. Unilateral amblyopia is also a symptom of retrobulbar neuritis (*q.v.*).

Bilateral amblyopia is found in the various forms of toxic amblyopia (*q.v.*). Bilateral amaurosis occurs in uræmia (*vide p. 387*) and in meningitis. Both amblyopia and amaurosis occur in hysteria.

Hysterical amblyopia, as might be expected, exhibits protean manifestations. It may be unilateral, but is more commonly bilateral. There is usually concentric contraction of the fields, with or without colour defects. A spiral field is very characteristic, *i.e.*, the field continually diminishes whilst it is being taken, so that it may be finally limited to the fixation point. The patients, however, get about perfectly well unaided, an impossibility in cases of genuine highly contracted fields (*vide p. 372*). The condition is sometimes called anaesthesia of the retina, an undesirable designation. Sometimes there are irritative symptoms—blepharospasm, blinking, lachrymation, &c.—hyperaesthesia of the retina. The pupillary reactions are perfect, affording an invaluable objective diagnostic sign. The prognosis in hysterical amblyopia is good, though treatment is usually tedious. The chief difficulty consists in eliminating organic disease, such as retrobulbar neuritis, injury, embolism of the central artery of the retina, sympathetic ophthalmia, and so on.

Night-blindness occurs *par excellence* in retinitis pigmentosa (*q.v.*) and in xerophthalmiâ (*q.v.*). It is also found in endemic form, especially after exposure to bright sunlight in hot countries, *e.g.*, amongst soldiers and sailors. The patients are usually overwrought as by long marching, or debilitated as by scurvy, fasting in Lent, &c. The condition generally improves rapidly if the eyes are

protected and the nutrition attended to; cod-liver oil is specially indicated. The affection is purely local, due to abnormal retinal fatigue, as is shown by the fact that covering one eye with a bandage during the day has been found to restore sight enough for the ensuing night's watch on board ship, the unprotected eye remaining as bad as ever.

Day-blindness occurs in some cases of congenital amblyopia. It also occurs in all cases of reflex blepharospasm.

Coloured Vision is sometimes complained of, and red is the colour usually noticed. *Erythropsia* occurs particularly after cataract extraction if the eyes are exposed to bright light and are over-strained. It is met with also in snow blindness. Red vision is sometimes complained of by neurotic hypermetropic children. Chromatopsia also occurs in some cases during the resolution of optic neuritis when the ensuing atrophy is not complete.

Metamorphopsia; Micropsia; Macropsia or Megalopsia; Photopsiæ (*vide* pp. 360, 374).

Muscæ volitantes (*vide* p. 351).

Colour Blindness or Achromatopsia may be congenital or acquired. Acquired colour blindness, partial as in cases with relative scotomata, or complete as in disease of the optic nerve, has been referred to incidentally in treating of the various disorders of the eye in which it occurs. It may also be a symptom of disease of the central nervous system, especially perhaps the lowest parts of the occipital cortex.

Congenital colour blindness is seldom discovered except when specially tested, since the patients compensate for their defect by attention to shade and texture, combined with experience. It occurs in 3 to 4 per cent. of males, but is rare in females (0.4 per cent.). It is of grave importance in certain occupations, *e.g.*, railway signalmen, engine drivers, and sailors. Total congenital colour blindness is almost unknown. The commonest form is red-

green blindness, yellow-blue blindness being rare. Many red-green cases are partial, only the feebler tints being confused. Such varieties of dyschromatopsia are not easily distinguished from the imperfect discrimination of tints by normal people. The fundamental axiom in colour testing is that no importance should be attached to the naming of colours. Many normal people are very ignorant of colour names, and many colour-blind people attain considerable proficiency in naming colours accurately, being guided by collateral evidence of shade, texture, and so on.

Many tests for congenital colour blindness have been devised. The only really satisfactory method is by means of the spectrum. *Holmgren's wools* are used by the Board of Trade, &c., and are sufficiently good. Test I. consists in presenting to the candidate a pale green sample and telling him to select from the heap of wools all those which seem to correspond in colour. If he is colour blind he will probably select several of the "confusion colours"—greys, buffs, straw colour, &c.—as well as greens. He is next given a rose colour (II.): if he matches this with blues or violets he is red-blind; if with greys or greens he is green-blind. He is then given a bright red skein (III.): if he is red-blind he will choose dark greens and browns, if green-blind pale greens and browns.

Sir William Alney has recommended the addition of two other tests. IV. is a purple skein: if the candidate is colour blind he will probably select any shade of blue or green, also pinks and greys. V. is a yellow skein: the colour-blind candidate will probably select greenish yellows, light yellow-greens, fawns and pinks (Plate XIX.). Probably all red-blind people are also green-blind. In blue-blindness purples, reds and orange are confused in test II.

Malingering. Cases occasionally occur of men who hope to gain some advantage by pretending to be blind. It is rare for complete blindness to be assumed, and such cases

can only be detected by constant watching of the person's behaviour. When one eye is said to be blind in spite of absence of sufficient objective evidence to account for the condition, the demonstration of malingering resolves itself into a contest of wits between the surgeon and the individual. Many tests have been devised, and several should be employed in each case.

(1) A low concave or convex glass (O. 25 D) is placed before the "blind" eye, and a high convex (+10 D) before the "good" eye, and the examinee is told to read the distant types. If he succeeds malingering is proved.

(2) A prism is placed base downwards before the "good" eye and the examinee is told to look at a candle. If he admits to seeing two candles malingering is proved.

(3) The surgeon stands behind the patient and covers the "blind" eye with his hand, at the same time holding a prism of 10 degrees base down before the "good" eye in such a manner that the edge of the prism passes horizontally across the centre of the pupil. Monocular diplopia results. The surgeon then simultaneously removes his hand from the "blind" eye and shifts the prism upwards so that the whole pupil is covered by it. If the examinee still admits to seeing two candles malingering is proved.

(4) Whilst the examinee looks at a candle a prism of 10 degrees is placed outwards before the "blind" eye. If the eye moves inwards in order to eliminate diplopia it is not blind.

(5) Snellen's coloured types may be employed. The letters are printed in green and red. If a red glass is placed before the "good" eye and the patient reads all the letters the other eye is not blind, for the eye looking through the red glass can only see the red letters. Care must be taken in this test that the red glass cuts off all the rays from the green letters as tested by the surgeon's own vision.

CHAPTER XXI.

INJURIES TO THE EYE, PANOPHTHALMITIS, AND SYMPATHETIC OPHTHALMIA.

The eye is protected from direct injury by the lids and the projecting margins of the orbit. Nevertheless, it is not exempt from foreign bodies, the action of caustics, contusions by blunt and wounds by sharp instruments.

FOREIGN BODIES, BURNS, &c.

Foreign Bodies, which are usually small—particles of coal dust, emery, steel, &c.—may pitch upon the conjunctiva or upon the cornea. In the former case they cause sudden discomfort and reflex blinking. The foreign body sticks to the palpebral conjunctiva and is liable to be dragged across the cornea, which it excoriates. It may get floated by tears towards the inner canthus, and so into the nasal duct. Very frequently it becomes lodged at about the middle of the upper sulcus subtarsalis (*vide* p. 587), where it is most likely to irritate the cornea, or in the upper fornix. It may occasionally become imbedded in the bulbar conjunctiva.

Particles of steel and emery are very liable to fly straight on to the cornea and penetrate into the epithelium or substantia propria. Larger particles of steel, or less commonly stone, glass, &c., may perforate the globe (*vide* p. 443). When situated in the cornea they cause great pain and irritation. If left in this situation they expose the cornea to the dangers of infection by organisms in the conjunctival sac and ulceration. This may lead to a small superficial

slough being cast off, carrying the foreign body with it. The small ulcer thus formed may heal, but if virulent organisms are present, a spreading ulcer, with or without hypopyon, may develop.

It is not always easy to discover a foreign body upon the cornea. A leash of dilated blood vessels at some spot near the limbus may direct attention to its position. In case of doubt the eye should be cocained and the cornea thoroughly examined under oblique illumination with a loupe. The use of fluorescein will sometimes, but not always, reveal the position.

Treatment.—Foreign bodies must be removed as soon as possible, and as far as possible with antiseptic precautions. If situated in the lower fornix they are easily removed with a clean handkerchief after everting the lower lid. If not found in this position the upper lid should be everted (*vide* p. 92); the particle will generally be found in its favourite situation, and can be removed in the same manner or by passing the finger over the surface. If it is still invisible the upper fornix should be brought into view (*vide* p. 94) and the particle removed. In case of difficulty, previous application of cocain will materially assist.

If the foreign body is imbedded in the bulbar conjunctiva it should be picked out by a needle after application of cocain. If a discission needle is not at hand a darning needle may be used; it should be passed through a flame first, so as to sterilise it. This little operation is performed in the same manner as removal of foreign bodies from the cornea (*vide infra*). It may be necessary to snip off the small piece of conjunctiva containing the foreign body with scissors.

Removal of foreign bodies from the cornea is effected as follows: The eye is cocained and the patient seated in a chair. The surgeon stands behind the patient and holds the lids apart with the first and second fingers of his left

hand, pressing slightly backwards so as to steady the globe. An assistant focuses the light upon the cornea, the patient being told to look in the direction which affords the best view of the particle. A sterilised spud (Fig. 200) is used to remove it. Only if this fails after repeated efforts should a needle be resorted to. It may be a dissection needle, or in default of that a damping needle (*vide supra*). The greatest care should be exercised not to scrape up the epithelium more than is absolutely necessary. Emery and steel particles cause a little ring of brown stain around them, which should be scraped off; if it is not done the patient is likely to return, under the impression that the foreign body has not been removed. If there is any sign of ulceration and *the patient is young, with normal tension*, a drop of 1 per cent. atropin should be instilled, warning being given that the sight will be misty for a few days. If the patient is over forty or has any signs indicative of the possibility of glaucoma arising (*vide p. 311*), atropin should be avoided and the eye should be examined daily for a time. In every case the eye is kept bandaged for a day, and boric lotion is ordered. If ulceration occurs it is treated in the usual manner (*vide p. 231*). Special attention should be given to particles of stone, which show a greater tendency than steel, &c., to cause ulceration, probably because steel particles are often hot, and therefore sterile, when they enter the eye.

Occasionally sharp steel and other particles penetrate deeply into the cornea, without, however, perforating.

D.E.



FIG. 200.—
Spud for
removing
foreign
bodies
from the
cornea.

The efforts made to remove them may push them still deeper or even into the anterior chamber. When such an accident is feared, special precautions must be adopted. If the particle is steel and a large magnet, *e.g.*, Haab's or Volkman's, is available, this method should be tried (*vide* p. 452). It will generally fail, the particle being so small that an insufficient number of lines of force pass through it. In these cases or when the particle is non-magnetisable a broad needle should be passed into the anterior chamber and pressed against the back of the cornea whilst the foreign body is being removed with a needle. If the foreign body escapes into the anterior chamber it must be removed by other methods (*vide* p. 451).

Burns and Injuries by Caustics.—Burns by hot water or steam, hot ashes, exploding powder, molten metal, &c., and injuries by caustics, such as lime, strong acids and alkalis, &c., endanger the eye chiefly in two ways, *viz.*, by injuring the cornea, and by producing symblepharon. Strong ammonia is particularly harmful, hydrochloric acid (spirits of salt) much less so. Immediately after the accident there is intense conjunctivitis, and in this stage it is difficult to be certain of the extent of the injury. Prognosis should therefore be guarded, care being taken to impress upon the patient the gravity of the injury and the necessity for constant supervision. In the worst cases the cornea is dull or opaque. In the succeeding days an eschar forms and is thrown off. This is followed by granulation of the injured conjunctiva and frequently by ulceration of the cornea. The corneal condition must be treated like a corneal ulcer (*vide* p. 231). In bad lime burns, &c., the whole cornea may be destroyed, perforation takes place, and the eye shrinks. In less severe cases a dense leucoma forms, porcelain-like in lime burns, and sight is lost. The chief danger derived from the condition of the conjunctiva is that of adhesion of the lid to the globe. It is most likely to

occur with the lower lid, the caustic acting principally upon the lower fornix, which is obliterated by organisation of the granulation tissue. The symblepharon thus produced impedes the movements of the globe and may even interfere with its nutrition. Every precaution must be adopted to prevent its occurrence.

Treatment.—In the earliest stages of injury by caustics the excess of deleterious material must be removed. Acids may be neutralised by dilute alkalis (lotio sodii bicarbonatis, 3 per cent.) and alkalis by weak acids (lotio acidi borici) or milk. Particles of lime must be perseveringly picked out with forceps, after previous application of cocain. A few drops of ol. ricini may be instilled.

To prevent symblepharon a glass rod is well coated with vaseline or boric acid ointment, or if the cornea is involved atropin ointment, and the point is swept round the upper and lower fornices, so that they are well packed with ointment. In severe cases cold compresses should be applied, and the patient put to bed.

In the succeeding days, if symblepharon still threatens, the treatment with ointment and the glass rod is repeated once or more times daily according to the severity of the case. A strip of tin-foil, gold-beaters' skin, guttaperecha tissue, or linen, smeared with ointment, may be inserted into the fornix and kept in place by a bandage. If symblepharon occurs it must be suitably treated (*vide* p. 610), but prevention in this case is very much easier than cure.

CONTUSIONS BY BLUNT INSTRUMENTS.

Injuries by blunt instruments vary in severity from a simple corneal abrasion to rupture of the globe. There is no part of the eye which may not be so injured by

contusion as seriously to diminish vision. Moreover, in some cases the changes are progressive, so that *in all cases a very guarded prognosis should be given*. The various conditions which may follow contusion will be briefly enumerated.

Cornea.—A simple *abrasion* may be caused. It is recognised by distortion of the corneal reflex and by the use of fluorescein (*vide* p. 100). It may become infected and give rise to a corneal ulcer. In the simple cases the use of a lotion, *e.g.*, boric acid, boric ointment to prevent the lids from sticking together, and a pad and bandage for a few days suffices. Ulceration must be treated suitably (*vide* p. 231).

Deep opacity may be found, usually in the form of delicate grey striae interlacing in different directions. They are due to accumulation of lymph in the interlamellar spaces; occasionally to wrinkling of Descemet's membrane (*vide* p. 275). They generally clear up without leaving a permanent opacity.

Rupture of the cornea is very rare. Descemet's membrane may be ruptured alone. In complete rupture an attempt may be made to save the eye by suture.

Sclerotic.—*Rupture of the globe* is generally due to it being suddenly and violently forced against the orbital walls. The force is usually applied from the direction down and out, where the eyeball is least protected by the orbital margin: the eye is forced into contact with the pulley of the superior oblique muscle. The sclerotic gives way up and in at its weakest part, *viz.*, in the neighbourhood of the canal of Schlemm. The wound is oblique, being farther forwards internally than externally, where it appears more or less concentric with the corneal margin and about 3 mm. behind it. The conjunctiva is often intact, but there are always severe injuries to other parts of the eye. The iris is generally prolapsed or torn away (iridodialysis) or

retracted. The lens may be expelled from the eye or escape under the conjunctiva (subconjunctival dislocation of the lens) or be forced back into the vitreous, making the anterior chamber deep. The anterior chamber contains blood (hyphæma) and there may be hæmorrhage into the vitreous. Detachment of the retina occurs, with or without subretinal or subchoroidal hæmorrhage. The eye usually shrinks and is lost.

Treatment.—In severe cases nothing remains but to excise the collapsed globe. In less severe cases, without extrusion of the contents of the globe, atropin may be instilled, cold compresses applied, and the patient kept in bed. Sometimes good results follow suture of the rupture. If the rupture involves the periphery of the cornea the iris alone may be prolapsed. It is then a good plan to insert the sutures in the sclerotic without tying them, before excising the prolapse; they are then tied.

In subconjunctival dislocation of the lens it would seem a natural procedure to open the conjunctiva and let out the lens. This is, however, absolutely contraindicated in the early stage. It must be remembered that there is an opening directly into the vitreous, and that such a procedure will almost inevitably involve escape of vitreous, and possibly panophthalmitis. Atropin should be instilled and cold compresses applied. The lens will gradually become absorbed, but no harm will accrue if the remnants are removed after the scleral rupture has healed.

Iris.—Most injuries to the iris caused by contusion are due to sudden incurving of the cornea, whereby the aqueous is forced back against the iris and lens.

Traumatic mydriasis may follow a contusion. The pupil is large and immobile, and usually remains moderately dilated permanently. It is due probably to paralysis of the motor nerve fibres, though there are minute ruptures in the pupillary margin. *Radiating lacerations* of the iris

sometimes extending to the ciliary margin, are rare (Fig. 201). *Iridodialysis* is commoner (Fig. 202). The iris is torn away from its ciliary attachment for a variable distance. On inspection a black biconvex area is seen at the periphery, and the pupillary edge bulges slightly inwards. With the ophthalmoscopic mirror a reflex can be obtained through the peripheral gap, and the fibres of suspensory ligament and edge of the lens may be visible. Unocular diplopia may be produced by this injury. In *traumatic aniridia* or *iridocentesis* the iris is completely torn

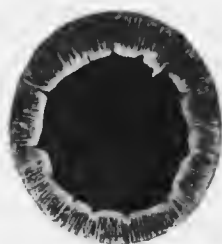

FIG. 201. Lacerations of the pupillary margin of the iris and dislocation of the lens, following a blow. (From a drawing by Holmes Spicer.)

away from its ciliary attachment, contracts into a minute ball, and sinks to the bottom of the anterior chamber, where it may be impossible to see it. Rarely the same appearance is caused by *total inversion* of the iris, the whole iris being doubled back into the ciliary region out of sight. More commonly inversion is partial, so that the appearance of a coloboma (*q.v.*) is obtained. In all these cases there is usually hyphaema, and other injuries, such as partial dislocation of the lens and so on, may be present.

The *treatment* consists in rest and the application of cold compresses. Atropin should be instilled in iridodialysis, but not in ruptures of the iris.

Ciliary Body.—Contusions may cause diminution in the amplitude or loss of accommodation, owing to paralysis of the ciliary muscle. The ciliary body may be involved in rupture of the globe (rupture, prolapse, &c.), and plastic cyclitis may be induced.

Lens.—Subconjunctival *dislocation* of the lens has already been described. The same mechanism which produces the various injuries of the iris may cause the

lens to be forced back into the vitreous. The suspensory ligament is then ruptured. The rupture may be complete or partial. When complete the lens may sink to the bottom of the vitreous chamber, where it may be visible as a yellowish mass; occasionally it remains clear and cannot be seen. Partial rupture of the suspensory ligament occurs with subluxation of the lens, which may be displaced laterally with or without some degree of rotation. This leads to irregularity in the depth of the anterior chamber, which is deeper in the part unsupported by the lens. With the pupil dilated the edge of the lens may be seen, as a grey convex line by oblique illumination, but more readily and unmistakably as a black line with the ophthalmoscopic mirror (*vide* p. 128). The want of support to the iris causes tremulousness (iridodonesis) on the slightest movement of the eye, a tremulousness which is limited to the unsupported part.

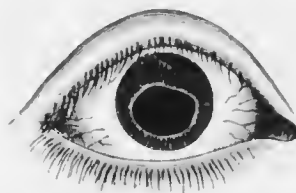


FIG. 202.—Iridodialysis following a blow. (Nettleship.)

Blows upon the eye less directly from before backwards occasionally cause dislocation of the lens into the anterior chamber. It rarely occurs with a lens of normal size, but not infrequently by quite trivial injury when the lens is shrunken. The clear lens in the anterior chamber is not always easily recognised, but it does not long remain clear, and diagnosis is then easy. It is more globular than normal owing to its freedom from the restraint of the suspensory ligament. When still clear it looks like a globule of oil in the anterior chamber. With oblique illumination it has a golden rim, due to total reflection of the light; this is the exact opposite of the total reflection when the edge of the lens is seen with the mirror, the light being then totally reflected back into

the eye. The lens in the anterior chamber causes spasm of the sphincter iridis, which may occur at the moment when it is passing through the pupil. Intense iridocyclitis is then set up. In most cases of dislocation forwards the lens is shrunken, and the suspensory ligament has become partially absorbed; dislocation into the anterior chamber may occur in these cases spontaneously, without any contusion. Unless the lens is very small, extreme irritation is set up by its presence in the anterior chamber, and the eye is lost if it is allowed to remain.

Dislocation of the lens always causes considerable disturbance of vision. In partial rupture of the suspensory ligament there is astigmatism which is enormously increased by tilting of the lens. The slackening of the suspensory ligament causes increased curvature and myopia, which may be more than compensated by backward displacement. In total dislocation into the vitreous the effect is that of the old cataract operation of couching; the pupillary area is aphakic, the refraction is highly hypermetropic, requiring cataract glasses for its correction.

If the lens is displaced so much laterally that the edge crosses the pupil unioocular diplopia is present. Through the aphakic area of the pupil the eye is highly hypermetropic, through the phakic portion it may be myopic, in addition to which the periphery of the lens acts as a prism. Ophthalmoscopic examination under these conditions shows two images of the disc by the indirect method, differing considerably in size. By the direct method the fundus may be observed through the phakic or through the aphakic portion of the pupil, different lenses being required to correct the refraction in the two cases.

Subluxation of the lens may occur as a congenital condition (ectopia lentis) (*vide* p. 350).

Besides the immediate consequences of dislocation of the lens, very serious remote effects may follow. In subluxation the lens is very liable to become opaque, owing to malnutrition. The pressure of the edge of the lens on the back of the iris and on the ciliary body often sets up severe iridocyclitis, which may lead to the loss of the eye, and even endanger the other by sympathetic ophthalmia (*q.v.*). Secondary glaucoma is a very frequent sequel (*vide* p. 309).

Treatment.—In the absence of irritation vision may be improved in total luxation into the vitreous and in subluxation by suitable glasses. In the latter case it is usually impossible to correct the astigmatism, but sometimes the aphakic part of the pupil can be used. If iridocyclitis or secondary glaucoma is present the lens should be extracted if it is possible. It is imperative when the lens is in the anterior chamber. In all cases it is unusually difficult. If it is impossible an iridectomy may improve matters, but more usually fails. If the eye is blind and painful it should be excised. For the treatment of subconjunctival dislocation see p. 437.

Besides dislocation of the lens, *concuSSION cataract* occasionally follows a contusion. In most of these cases the capsule is ruptured, though the site of rupture, usually behind the equator, cannot be seen clinically. The lens gradually becomes opaque as in traumatic cataract after needling or perforating wound. More or less absorption takes place, but it may be permanently incomplete. The condition should be treated in the same manner as traumatic cataract.

Vitreous.—Haemorrhage into the vitreous is the commonest effect produced in it by contusion. The vitreous chamber may be filled with blood. In this case no reflex will be obtained with the ophthalmoscopic mirror. With oblique illumination a dull red hue may be seen, especially

if the pupil is dilated. The blood may become almost completely absorbed, but cloudy opacities remain. In rare cases "retinitis" proliferans follows from organisation of the clot (*vide* p. 388).

Liquefaction of the vitreous and opacities in it may follow a blow owing to uveitis and defective nutrition, and without hæmorrhage.

Choroid.—*Rupture of the choroid* occurs as the result of contusion. Immediately after the injury the view is obscured by extravasation of blood. When it has become absorbed the rupture, usually not far from the disc and concentric with it, is seen as a curved white streak over which the retinal vessels pass (Plate IX., Fig. 2). The retina may also be ruptured, but this is exceptional. The edges of the streak are pigmented in the later stages; in the earlier, remnants of blood may be seen. The white appearance is due to the sclerotic shining through. The rupture is generally to the outer side of the disc, and there are often two or three of different sizes, more or less concentric with each other.

A contusion may cause choroidal hæmorrhage, which may be small, shown later by patches of choroido-retinal atrophy, or large, sub-retinal or sub-choroidal. The latter can seldom be seen ophthalmoscopically, but are part of more extensive mischief.

Retina.—It has already been pointed out that *detachment of the retina (q.v.)* is often due to contusion. *Rupture of the retina* with rupture of the choroid is rare. *Hæmorrhages* into the retina occur: they are usually small, but large hæmorrhages into the vitreous (*vide supra*) are in part derived from retinal vessels.

Comotio retinae is a frequent result of blows upon the eye. Instead of the normal bright red colour the retina shows a milk-white cloudiness, usually near the papilla and posterior pole and over a considerable area. It is

probably due to oedema. It disappears after some days, and vision may be restored to normal.

Serious changes are apt to occur at the macula, and are easily overlooked immediately after the accident, or it may be impossible to obtain a good view. A "hole" may occur at the macula. It appears as a small circular deep red patch, just as if a hole had been punched out. It is doubtful if it is a true hole. In other cases the macula looks deeper in colour than normal, and in the course of time it becomes pigmented. The spots of pigment are very fine, mostly aggregated near the fovea, with a few further afield. This *pigmentation* is the sign of serious defect in central vision, which has a tendency to increase progressively.

PERFORATING INJURIES.

Perforating injuries may be caused by sharp instruments or by foreign bodies.

A wound with a sharp instrument may penetrate the cornea, the corneo-scleral junction, or the sclerotic; it may pass in for a variable distance, wounding the iris, lens, &c., or pass through the eye.

Wounds of the conjunctiva are common. They heal readily, but the process may be hastened, and the resulting adhesion to the sclerotic lessened by introducing one or more sutures. Polypoid masses of granulation tissue sometimes form on the surface; they should be snipped off with scissors after application of cocaine.

Wounds of the cornea may be linear or lacerated. The margins swell up and become cloudy through imbibition of fluid. If small and limited to the centre they heal well unless they become infected. A permanent dense opacity is left, and the contraction of the organising scar tissue causes irregular astigmatism. If the wound

becomes infected it must be treated like a perforating ulcer. The danger is greatly increased (1) if the wound is large, especially if it extends into the sclerotic, or (2) if the lens is also wounded. In the former case prolapse of the iris is almost certain to occur. It must be excised (*vide* p. 240), care being taken that the iris is quite free. If in a few days it is found that there is an anterior synechia this should be divided as soon as the wound is sufficiently healed to permit of the necessary procedures without re-opening it. If it is not done the traction on the iris will keep up irritation in the eye, as shown by ciliary injection, &c., and such eyes are liable to cause sympathetic ophthalmia.

Wound of the lens increases the gravity of the case enormously. The lens swells and keeps the iris in contact with the cornea, so that re-formation of the anterior chamber is much delayed. If at length it re-forms the aqueous becomes filled with swollen lens fibres, which also irritate the iris. Infection, which is one of the greatest dangers of all perforating wounds, is particularly likely to occur in these cases. The excision of any prolapsed iris in such a manner as to free it completely from the wound is extremely difficult. The subsequent prolonged contact of the iris with the cornea facilitates the formation of broad anterior synechiæ which it may be found impossible to divide. Ciliary injection is kept up, and sympathetic ophthalmia is very liable to supervene if the eye is retained too long.

Wounds of the corneo-sclera are commonly held to be particularly liable to set up sympathetic ophthalmia (*q.v.*). In them the ciliary body is injured directly, and may be prolapsed. There is the usual danger of infection, and if it occurs panophthalmitis is certain to follow on account of the ready communication with the vitreous. If this does not happen ciliary irritation is

kept up. There can be no question that the sterility of the instrument which caused the accident is of the utmost importance, quite apart from actual suppurative infection. It is uncommon for a wound with a sterile instrument to cause sympathetic inflammation, though it cannot be positively denied that such cases may occur. If the lens is wounded the chances of saving the eye are greatly diminished.

Treatment.—If the injury is strictly limited, and has been caused by an instrument which is probably sterile, an attempt should be made to save the eye. If the iris or ciliary body, or both, are prolapsed, they must be excised. Some vitreous will inevitably be lost during the operation. The following procedure may be adopted: A general anæsthetic is given, unless specially contra-indicated. The conjunctival sac is washed out with a large quantity of perchloride lotion. A speculum is inserted; it may be kept from pressing on the globe by an assistant. The wound is thoroughly inspected, the opening in the conjunctiva being enlarged if necessary. Fine silk sutures are then inserted in the sclerotic, but are not tied, great care being exercised not to press unduly upon the eye. The prolapsed iris and ciliary body are then excised as in the operation for simple prolapsed iris (*vide* p. 240). The scleral sutures are then tied. Finally the conjunctiva is sutured over the wound. Atropin is instilled, the eye bandaged lightly, and the patient put to bed.

If the eye does not quiet down in the course of a week or ten days, as shown by diminution of ciliary injection and cessation of photophobia and lachrymation, it should be excised. In the interval the cornea is examined most carefully each day by oblique illumination with the loupe for precipitates ("k.p."). If they are seen the eye should be excised. Similar care is devoted to the discovery of

"k.p." in the opposite eye, and if they should be found there excision of the injured eye is still more imperative at the earliest possible moment. If the eye quiets down quickly and there is no evidence of iridocyclitis in either eye the case will probably do well, but it should be kept under observation for a very prolonged period (*vide* p. 456).

If there is much prolapse of vitreous as well as of iris and ciliary body, or if the lens is wounded, there is little probability of saving the eye. If it is almost certain that useful vision will be lost the risks of sympathetic should not be run, but the eye should be promptly excised.

Wounds of the sclerotic are not always easily recognised. The eye may have been wounded through the lid. The bruising and laceration of the lid may make examination of the eye difficult. The lid should be raised from the globe and drawn back with a Desmarres' retractor, under an anæsthetic if necessary. Even when the eye is examined the effusion of blood under the conjunctiva may render the diagnosis uncertain, still more the question of perforation. When perforation has occurred, there is reduction in the intra-ocular tension. If the perforation is near the cornea, the anterior chamber is shallow or obliterated. If the wound is large, prolapse of some of the contents of the globe occurs. The uvea—iris, ciliary body, or choroid—are most easily recognised on account of their pigmentation. Very often the gelatinous vitreous can be seen hanging out of the wound. Hyphæna and vitreous hæmorrhage may be present with or without perforation.

Treatment.—If the injury is so severe that there is no likelihood of recovery of useful vision, the eye should be excised at once. If there is a chance of useful vision, or if permission to excise is withheld, the sclerotic may be sutured after excision of prolapsed vitreous, &c.

Such eyes usually shrink, unless indeed panophthalmitis ensues.

Wounds of the lens cause traumatic cataract. Usually the anterior capsule is wounded; when the posterior capsule is torn, the lymph in the vitreous acts in the same manner as the aqueous. A few hours after the injury the lens becomes cloudy in the vicinity of the wound owing to the action of the aqueous upon the fibres, causing them to swell. They protrude through the opening in the capsule as flocculent grey masses, some of which become free and sink to the bottom of the anterior chamber. Sometimes the whole chamber is full of white flocculi, and the lens nucleus may escape entire. The masses are gradually dissolved by the aqueous, and pass out with it through the angle of the chamber. In this manner, in young patients, the whole lens, with the exception of the capsule, may be absorbed. Usually absorption ceases earlier through closure of the capsular wound. The enclosed lens fibres become opaque, and discission is necessary to cause their complete absorption; in adults, with a hard nucleus, extraction may be necessary (*vide* p. 472). The smaller the wound in the capsule, the sooner it is likely to close. In rare cases, with very small, though it may be deep, wounds, the opacity may remain limited to the site of injury.

A certain amount of inflammatory reaction with ciliary injection is always set up, which may be excessive, even in the absence of infection. It will then be found that the intraocular tension is raised. The swelling of the lens forces the periphery of the iris against the cornea and secondary glaucoma supervenes. This tendency is increased by the difficulty with which the highly-albuminous aqueous escapes from the eye, especially if the wound in the capsule is large and much of the lens substance has escaped into the anterior chamber. If the secondary glaucoma is not

relieved, the sight will be lost by destruction of the optic nerve. The aqueous and swollen lens substance must therefore be let out by a curette evacuation (*vide* p. 476).

Traumatic cataract is deliberately induced in the operation of discission.

In the absence of secondary glaucoma, the condition is treated by rest in bed, atropin, and a bandage. It is of the utmost importance that the pupil shall be kept well dilated. If it is not, adhesions will form between the iris and the lens capsule. The tendency to iritis is increased, a ring synechia may form, leading to a more serious form of secondary glaucoma, and in any case a subsequent needling will be made more difficult and dangerous. *Sterile* atropin ointment, 1 per cent., should be used three or four times daily. If the pupil does not dilate satisfactorily, hot bathings should be given every four hours, and in the case of adults leeches may be applied.

Perforating wounds with retention of foreign bodies have special features and dangers. Eyes containing foreign bodies are particularly liable to set up sympathetic ophthalmia. In cases of perforating wound, the question often arises whether a foreign body has been retained within the eye. The foreign bodies most likely to penetrate the eye and be retained are minute chips of steel, stone, and particles of glass, less frequently spicules of wood. In chipping stone with an iron chisel, it is usually a chip of the chisel and not of the stone which enters the eye.

The foreign body may pass through the cornea or the sclerotic. The wound of entry may be extremely minute. The patient may even be unaware that a foreign body has penetrated the eye. If it has passed through the cornea, the minute wound or scar can always be found

by careful examination with oblique illumination and a loupe. It may escape detection in the sclerotic.

The foreign body may be retained in the anterior chamber. Here it may fall to the bottom of the chamber, and if very small be hidden by the sclerotic. It is generally, however, caught in the iris, and can be recognised with a loupe. A piece of glass in the anterior chamber is exceptionally difficult to see, on account of its refractive index differing so little from that of the surrounding media.

The foreign body may pass into or through the lens, either by way of the iris or of the pupil. In each case a traumatic cataract is produced, which undergoes the usual changes (*vide* p. 447). If the particle has passed through the iris there will be a hole in this structure. If the case is seen very early or very late, the hole looks black by oblique illumination, but shows a red reflex when illuminated by the ophthalmoscopic mirror. In the intermediate stage the cataractous lens behind the hole prevents a red reflex from being seen. A hole in the iris is of the utmost diagnostic significance, since it occurs only as the result of perforation by a foreign body. It is possible for a foreign body to pass through the iris and through the circumferential space without wounding the lens. The foreign body may be visible in the lens, either before or after dilatation of the pupil.

The foreign body may be retained in the vitreous; in this case the changes set up cause liquefaction of the vitreous sooner or later, and the particle sinks to the bottom of the chamber. More commonly it passes through the vitreous and lodges in the retina or choroid, or it may pass quite through the globe into the orbit. If the particle is small, the lens clear, and there has been little hæmorrhage, the body may be seen ophthalmoscopically in the vitreous or retina. The track through

the vitreous looks like a grey line. The foreign body, generally black, and often with a metallic lustre, is surrounded by white exudate and red blood clot. If the particle has been long *in situ* it may become more or less encapsuled, a small white area of fibrous tissue being seen with dense masses of black pigment in and around it.

If there is any doubt as to the presence of a foreign body in the eye, a skiagram must be taken. If the substance is one which gives a good shadow, *e.g.*, steel, lead (shots), &c., its position can be accurately localised by suitable apparatus. Glass which contains much lead may give a good shadow, so that the diagnosis is facilitated in these difficult cases. The foreign body may be proved to be outside the globe, in which case anxiety as to the occurrence of sympathetic ophthalmia is set at rest.

The prognosis is always bad. It is least bad if the foreign body is in the anterior chamber and the lens is not wounded. The eye may be saved if it is in the lens, especially in young people, whose lenses are capable of becoming completely absorbed. Very rarely a foreign body is retained in the vitreous or retina for a long period without destroying sight. This is particularly rare in the case of particles of iron, for the metal undergoes chemical changes and the tissues of the eye become stained with rust (*siderosis bulbi*). The reddish brown colour of the iris is then very characteristic; red spots under the anterior capsule of the lens, arranged in radial fashion and seen when the pupil is dilated, are pathognomonic. It must be constantly borne in mind that eyes containing foreign bodies are liable at any time to set up sympathetic ophthalmia.

Treatment.—It is a rule that the foreign body should be removed. There are rare exceptions to this rule, more

particularly if (1) the foreign body was probably sterile; (2) little damage has been done to vision; and (3) the process of removal will almost inevitably destroy sight. These conditions are most often fulfilled in the case of minute foreign bodies in the retina.

Magnetisable foreign bodies are more easily removed than others, since the small or the large electro-magnet can be brought to bear upon them.

A chip of steel free in the anterior chamber is removed by making an incision with a keratome or broad needle at

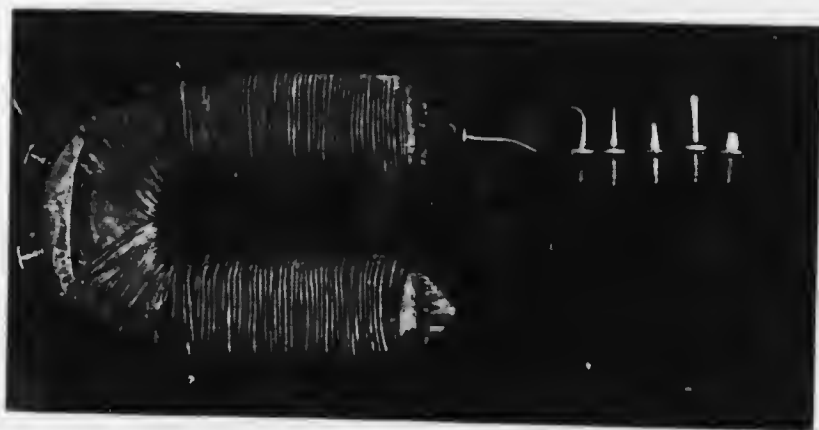


FIG. 203. Small magnet, with poles of various shapes.

the periphery of the cornea and introducing the pole of the small electro-magnet (Fig. 203) just within the wound. All the preparations for dealing with a prolapse of iris must be made (*vide* p. 240).

A foreign body on the iris may sometimes be removed with iris forceps through a similar incision. If it is entangled in the iris tissue, the iris must be drawn out of the wound and the part containing the foreign body excised with de Wecker's scissors, as in the operation for iridectomy (*vide* p. 463).

If the foreign body is in the lens, a few days should be

allowed to elapse for the aqueous to act upon the lens fibres. A curette evacuation (*vide* p. 476) is then performed and the foreign body will probably be evacuated with the lens matter, or it may be removed by forceps, or if magnetisable, by the small magnet. In a young subject it may be advisable to increase the opening in the capsule by discission a few days before doing a curette evacuation. In these cases a subsequent needling will often be required to obtain a clear opening in the pupillary area of the capsule. It should be done in exactly the same manner as after discission for lamellar cataract. If the patient's other eye is normal he will not be able to wear the correcting glass for the aphakic eye, but his field of vision will be increased on this side. A more cogent reason for operating is found in the fact that it is easier to obtain a clear opening at this period than after months or years, when the capsule will have become thickened and very difficult to divide. In elderly patients it may be necessary to extract the lens by the operation for senile extraction (*vide* p. 477), but the large amount of soft lens matter will increase the dangers of the operation.

If the foreign body is in the vitreous or retina it is practically impossible to remove it without very seriously damaging the eye unless it is magnetisable. The treatment then lies between leaving it alone and watching the case, or excising the eye on account of the damage done or the danger of sympathetic.

If the substance is iron it may be possible to remove it with the large magnet (Haab's or Volkman's). This will be facilitated by knowing its position, either by direct observation or by skiagraphy: some hint may be obtained from the position of the wound of entry and the probable direction in which the foreign body was travelling.

The patient is seated in front of the magnet if Haab's instrument is used (Fig. 204), or lies on his back if

Volkmann's is employed. The eye is brought close to the magnet, the cornea touching the pole. This is important, since if there is a large piece of iron in the eye and the cornea is not in contact with the pole, the whole eye may be drawn forward out of the socket when the current is turned on. Moreover, the direction of the core of the



FIG. 204.—Haab's giant magnet.

magnet should coincide as nearly as possible with the direction of entry of the foreign body. The current is then turned on: some pain is usually felt when a piece of steel is present within the eye. If the operation is successful the foreign body comes forward into the anterior chamber. It may be necessary to turn the current on and off several times before this happens. If the particle is small and deeply imbedded the operation is likely to fail: hence it should be

performed as soon as possible after the injury, before the chip has become firmly encapsuled or imbedded in exudates. The foreign body often passes round the lens, not through it. It may be seen hulging the iris forwards. The current should then be turned off and the eye adjusted so that the particle will be drawn towards the pupil. When it has fallen into the anterior chamber it should be removed with the small magnet in the manner already described.

In some cases when the foreign body has been accurately localised and the large magnet has failed to bring it forward it can be removed by the small magnet introduced through a scleral incision made as nearly as possible over the site.

The immediate effects of extraction of foreign bodies with the large magnet is often good, but irreparable damage is often done to the eye. The tracks through the vitreous often become filled with fibrous tissue. As this organises and contracts, the retina is pulled up, and total detachment destroys vision. Or more severe iridocyclitis may be set up and the eye shrinks.

PANOPHTHALMITIS.

Panophthalmitis is generally caused by infected wounds, whether accidental or the result of operations, and ulcers. Less frequently it is metastatic, accompanying pyæmia and puerperal fever, meningitis, and orbital cellulitis (*vide* p. 364). In the exogenous form the vitreous is usually first affected: organisms grow in it as in a culture medium, and purulent retinitis, cyclitis, and choroiditis are set up (Fig. 205). In the endogenous forms there may be a septic embolism of a retinal artery or the choroid may be first affected. In this group it may be bilateral.

In both forms there is rise of temperature, headache, drowsiness, and sometimes vomiting. In the exogenous forms the edges of the wound become yellow and necrotic,

hypopyon appears, there is great chemosis, with intense ciliary and conjunctival congestion, and the lids are swollen and red. There is severe pain in the eye, due at first to iritis, later to increased tension. The vitreous becomes purulent, as shown by a yellow reflex by oblique illumination. The anterior chamber soon becomes full of pus, and



FIG. 205.—Section of the retina and choroid in panophthalmitis ($\times 60$), following a perforating wound.

the cornea cloudy and yellow. There may be exophthalmos and limitation of movement of the globe. In the metastatic cases rapid failure of vision, a yellow reflex, and hypopyon are found in the early stages.

If the case is left to take its course the pus bursts through, usually just behind the limbus. The pain subsides, and after prolonged suppuration the eyeball shrinks.

The prognosis is bad, the eye being almost invariably lost. The condition is not likely to set up sympathetic ophthalmia.

Treatment.—In the early stages after operation wounds an attempt must be made to stay the process. The edges of the wound are cauterised with pure carbolic acid or the actual cautery. The anterior chamber may be washed out with hydrogen peroxide solution, and iodoform introduced. Hot fomentations and leeches are applied, and atropin instilled.

As soon as it is evident that the eye cannot be saved it should be excised. This should not be left too long, and great care should be taken that no undue pressure is put upon the eye. If pus escapes there is danger of purulent meningitis being set up, the patient's life being thereby endangered. On this account many surgeons refuse to excise these eyes. They open the eye freely by a crucial incision and wait until all signs of suppuration have disappeared before excising the shrunken remnants of the globe.

If pus escapes during excision of an eye with panophthalmitis, the globe should be opened freely and the contents scooped out. The interior of the sclerotic is then swabbed out with perchloride lotion (1 in 2,000) and the conjunctival sac irrigated with a large quantity of weaker lotion (1 in 5,000). The sclerotic may then be excised at once, the risk of meningitis being small, or excision may be postponed.

SYMPATHETIC OPHTHALMIA.

Sympathetic ophthalmia is the much dreaded condition in which serious inflammation attacks the sound eye after injury of the other eye. In recent years sympathetic ophthalmia has become a rare disease, in spite of the fact that ophthalmic surgery has become more conservative.

This gratifying fact is due to increased skill in the treatment of perforating wounds, particularly in the application of antiseptic principles. A perforating wound, especially if a foreign body is retained within the eye, is, however, a source of great anxiety to the most experienced surgeon.

Sympathetic ophthalmia almost always results from a perforating wound, especially such as is caused by a foreign body which remains within the eye. Wounds in the ciliary region—the so-called “dangerous zone”—involving the ciliary body and leading to its incarceration in the scar, have always been considered specially dangerous: it is doubtful if, *per se*, they are more dangerous than others. If suppuration supervenes sympathetic ophthalmia is very unlikely to follow; hence perforating ulcers very rarely cause it. It is also extremely rare without perforation, if indeed it ever occurs under these circumstances.

Children are particularly susceptible, but it occurs at any age. It usually begins four to eight weeks after the injury to the first eye (the exciting eye) has taken place, rarely earlier, but the onset may be delayed for many months or even years—it is said as many as 40 years.

There is always iridocyclitis in the exciting eye. Usually it is a plastic iridocyclitis which has been set up by injury and has not subsided in the course of three or four weeks. Instead of quieting down the ciliary injection remains, there is lachrymation and the eye is tender: special attention should be directed to the presence or absence of precipitates (“k.p.”) on the back of the cornea. In the rarer cases of delayed sympathetic ophthalmia the exciting eye has passed into a quiescent state. It may have shrunken completely. The onset of sympathetic ophthalmia in the second eye is then often ushered in by return of irritation—ciliary injection, tenderness, &c.—in the shrunken globe. The exciting eye, whilst showing evident traces of old iridocyclitis, may yet possess useful vision.

Sympathetic ophthalmia—the disease in the second or sympathising eye—is almost always a plastic iridocyclitis. In rare cases it manifests itself as a neuro-retinitis or choroiditis. In cases which the surgeon knows to be liable to the condition the first sign may be the presence of precipitates ("k.p.") on the back of the cornea, noticed at this early stage because they have been dreaded and carefully watched for. In other cases the patient first seeks advice for defective vision or inflammation in the uninjured eye (sympathetic irritation).

Prodromal symptoms are sensitiveness to light and transient indistinctness of objects. The latter is due to weakness of accommodation; objects become blurred when doing fine work, but after an interval of rest vision improves. On examination at this stage there may be lachrymation, slight ciliary injection, tenderness of the eyeball, as shown by the patient shrinking from an attempt at examination, precipitates on the back of the cornea, and vitreous opacities. The prodromal symptoms may occur in intermittent attacks, spread over a considerable period.

When fully developed all the signs and symptoms of iridocyclitis (*q.v.*) are present, varying in degree according to the severity of the case. The prognosis as to vision is always doubtful, but if there is much deposition of plastic exudates in the pupillary area it becomes extremely grave. Cases showing little exudation ("serous iritis"), but a deep anterior chamber and "k.p.," have a more favourable prognosis, but they may at any moment develop into the severe plastic type. Tension, difficult to determine on account of tenderness, is moderately raised in the early stages. It may then pass into the condition of lowered tension with gradual shrinking of the globe: or the iridocyclitis may subside, the eye quieting down and retaining fair vision. In the worst cases a ring synechia forms and

secondary glaucoma supervenes (*vide* p. 308), or both oclusio and seclusio pupillæ or total posterior synechia (*vide* p. 299) occur and the eye shrinks. Sympathetic ophthalmia sometimes takes two or more years to run its course.

The *pathology* of sympathetic ophthalmia is unknown. The evidence which has accumulated in modern times tends to show that it is an infective disease. It is least liable to occur in otherwise likely cases if the wound or the retained foreign body is sterile. On the other hand, it very rarely occurs if actual suppuration has taken place in the exciting eye; possibly this may be due to some specific organism being destroyed by the superabundant growth of pyogenic organisms. It is more likely to occur from retention of shot, a chip of stone, glass, china, &c., than from that of a particle of hot steel, probably because the latter is sterile.

Sterility of an ocular wound is usually judged by a satisfactory course of healing and the absence of suppuration. It is by no means certain that all such wounds are, strictly speaking, sterile. The resistance of the patient's tissues has to be taken into account. With the same precautions a cataract wound may heal readily in a healthy man, but only after prolonged subacute iridocyclitis in a weakly patient. In many of these cases there are reasons for delayed cicatrisation, such as incarceration of the iris, synechia of lens capsule, &c., but the exact mode in which they act is a matter of conjecture.

Various theories have been brought forward to explain the occurrence of inflammation in the sympathising eye. It has been suggested that severe inflammation in one eye produces a tendency to ciliary irritation in the other eye by some occult means connected with their anatomical and physiological symmetry: there is no evidence to support this conjecture. More probable, *à priori*, is the view that

infection travels along the optic nerve *via* the chiasma. On this theory one would anticipate neuro-retinitis in the sympathising eye as the most frequent manifestation of the disease, but it is extremely rare. The experiments supporting this theory fail to substantiate it. The most probable theory is that there is a specific organism, which has as yet escaped observation, possibly because it is so small as to be ultra-visible by the microscope, but one which causes general infection through the blood stream. Possibly it is a protozoön which is not stained by any of the methods at present devised: evidence derived from examination of the blood has recently been brought forward in favour of this view. It may be conjectured that the organism is harmless to other organs of the body, and that it finds a suitable nidus only in the other eye, and even then only under favourable circumstances. This theory explains best the facts of both ordinary and anomalous cases. When sympathetic ophthalmia supervenes after the injured eye has long been shrunken it may be conjectured that the organism has lain quiescent and encapsuled. The fact that in such cases the shrunken eye is again injured or becomes spontaneously irritable and inflamed shortly before the outbreak of inflammation in the other eye lends colour to this view. Cases in which the injured eye is excised and sympathetic ophthalmia is said to supervene many years afterwards are best explained as ordinary iridocyclitis—a by no means rare disease—occurring quite independently of the injury.

The *treatment* of sympathetic ophthalmia is one of the most difficult problems in ophthalmology, and often demands the exercise of great judgment.

It is, in the first place, prophylactic. In every case of perforating wound, with or without the retention of a foreign body, the question of excision of the eye on account of danger to its fellow arises. It may be assumed

as an axiom that sympathetic ophthalmia never occurs after the excision of an injured eye unless it has already commenced at the time of operation. Hence, early excision is a positive safeguard against the disease. The injury to the eye may, however, be otherwise trivial, so that restoration of good sight may be possible. The rule should be to excise any eye which is so injured that it is improbable that useful vision will be regained. In cases where this is doubtful expectant treatment may be adopted for a time. If the eye quiets down quickly it is unlikely to set up sympathetic. What, then, are the chief causes which keep up irritation? The most important are entanglement of the iris or ciliary body or lens capsule in the wound, and the presence of a retained foreign body. Every effort must therefore be made to free the iris or ciliary body from the wound by excision of any prolapse, followed, if necessary, by division of anterior synechia. Upon the success of these efforts the retention of the eye may depend. If they fail, which is most likely to be the case if the lens is also wounded, ciliary injection is certain to continue.

During this expectant period the most careful watch is kept for "k.p." If the eye continues irritable, with ciliary injection, photophobia, and lachrymation, and above all if "k.p." appears, the eye should be excised. It is seldom wise to wait longer than a fortnight unless there are undoubted signs of amelioration. The slightest sign of ciliary irritation or "k.p." in the other eye indicates the necessity for immediate excision of the injured eye. Care must be taken not to confuse a simple conjunctivitis with ciliary irritation.

Even more difficult to decide is the treatment in those cases in which sympathetic ophthalmia has already supervened. If the case is seen early, shortly after the onset of inflammation in the sympathising eye, and if the injured

or exciting eye has no useful vision, this useless eye should be excised at once. There is no question that the excision of the exciting eye has a good effect upon the process in the sympathising eye if performed early. At a later stage there is no evidence to show that it exerts any influence at all.

The chief difficulty arises when the exciting eye has useful vision and the inflammation in the sympathising eye is severe. If this is the condition soon after the injury it may be wise to excise the injured eye. If, however, a considerable time has elapsed since the injury, excision of the exciting eye is likely to have little or no influence upon the process. Moreover, in the end the injured eye may have better vision than the sympathising one, for if the iridocyclitis is severe the sympathising eye may be lost in spite of all efforts. Under these conditions, therefore the injured eye should be retained.

The treatment of the sympathetic iridocyclitis is that of iridocyclitis in general (*vide* p. 302). In addition to atropin, hot bathings, rest in a dark room, leeches, &c., the patient should be brought rapidly and thoroughly under the influence of mercury. Mercurial inunctions should be pushed, so that salivation occurs within a week, and the patient should then be kept on the border line of mercurialisation for a considerable period. On the theory that the disease is a protozoal infection the intravenous injection of "606" (Salvarsan) has been advocated: the results have been encouraging. In later stages pilocarpin injections and the administration of iodides may assist in the absorption of exudates, and lead to improvement of vision. Perseverance in these measures, aided by general tonic treatment, is of the utmost importance.

CHAPTER XXII.

OPERATIONS UPON THE EYEBALL.

OPERATIONS UPON THE CORNEA.

Paracentesis for hypopyon ulcer has already been described (*vide* p. 237). Paracentesis for cyclitis is performed in identically the same manner as in the second method there described.

OPERATIONS UPON THE IRIS.

Iridectomy, which consists in the excision of a portion of the iris, is performed for the following conditions:— (1) Prolapsed iris; (2) corneal or lenticular opacities (optical iridectomy); (3) glaucoma; (4) as a preliminary or as part of cataract extraction; (5) threatening ring synechia; (6) ectatic corneal cicatrices; (7) foreign bodies in or small cysts or tumours of the iris.

Iridectomy for prolapsed iris has already been described (*vide* p. 240).

Optical iridectomy is indicated in some cases of localised opacities of the cornea or lens, very rarely for occlusion of the pupil or subluxation of the lens. In all cases there must be proof or good reason to believe that the light percipient structures are capable of performing their functions. If the patient is old enough to have the vision tested it should show improvement when the pupil is dilated by a mydriatic. The opacities must be localised, and in the case of lenticular opacities there must be good reason to assume that they are stationary.

An optical iridectomy should be as narrow as possible, in order to avoid dazzling and to obtain an approximation to stenopæic vision (vision through a narrow slit, *vide* p. 25). It should not extend to the ciliary border. The site of election is down and in (Fig. 206), but in the case of corneal opacities the clearest region of the cornea must be chosen, unless this happens to be above, in which case the coloboma would be covered by the lid and useless for vision.

Instruments required :—Speculum, two pairs of fixation forceps, bent keratome, iris forceps, de Wecker's scissors, iris repositor. General anaesthesia is only necessary in very young or neurotic patients.

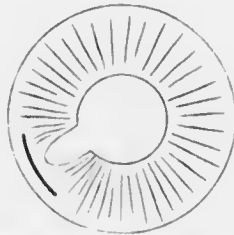


FIG. 206.—Diagram of wound and coloboma in optical iridectomy at the site of election.

The keratome is inserted at or just inside the apparent corneo-scleral margin, the blade being kept parallel to the plane of the iris. It is pushed on until the incision is sufficiently long. The handle is then depressed, so that the blade lies against the back of the cornea: the danger of pricking the lens with the point is thus reduced to a minimum. The keratome is then slowly withdrawn. The iris forceps are inserted closed, then opened very slightly and the iris seized just outside the pupillary margin. The iris is drawn out of the wound and a portion excised with de Wecker's scissors. A slit-like coloboma is made by holding the scissors so that the blades are in the direction of a radius of the iris (Fig. 208). The iris is freed from the wound, unless already free, by the repositor. Sterile atropin ointment is introduced into the conjunctival sac, and the eye is bandaged.

Iridectomy for glaucoma has for its object the opening up of a sufficiency of the angle of the anterior chamber to

permit of efficient filtration of lymph. It is essential, therefore, that the coloboma shall extend to the ciliary attachment of the iris, and that it shall be broad at the periphery. It has already been pointed out that when the iris is torn away the fracture occurs at the thinnest part, viz., at the ciliary attachment. This will generally happen in iridectomy for acute glaucoma, if the attack is the first or early in the history of the disease. In chronic glaucoma,




FIG. 207. Lawford's speculum for the left eye.

however—and the same applies to an acute exacerbation occurring in the course of chronic or subacute glaucoma—the periphery of the iris is firmly adherent to the corneo-sclera. When the iris is torn away the fracture will be at the false angle, and filtration of lymph will not be facilitated. The rules usually given as guidance to the correct performance of iridectomy for glaucoma are that the section shall be peripheral and the coloboma wide. From the above remarks it will be seen that a very peripheral section is not very important in true acute glaucoma, but that it has usually been thought of importance in chronic glaucoma.

In acute glaucoma and in acute exacerbations of the chronic form a general anæsthetic is required, chiefly because the high tension prevents sufficient absorption of

cocain to render the cornea—much less the iris—anaesthetic, partly also because the patient's self-control has been shattered by pain and anxiety. In chronic glaucoma, if the tension is not very high, local anaesthesia may suffice.

Instruments required: speculum (Fig. 207), two pairs of fixation forceps, narrow Graefe cataract knife, iris forceps, de Wecker's scissors, iris repositor. Lawford's speculum is preferable to Lang's for iridectomy upwards, cataract extraction, &c., as it interferes less with the field of operation.

The surgeon stands above the patient, using his right hand to make the section for the right eye, the left hand for the left eye. After the lids have received a final cleansing with ether soap, &c., and the conjunctival sac has been douched with boric lotion or saline, the speculum is inserted. The fixation forceps are held in the left hand, the knife in the right, care being taken that the back of the knife is away from the surgeon.



FIG. 208.—Diagram of wound and coloboma in glaucoma iridectomy.

(It is an extremely awkward accident to introduce the knife with the back upwards). The eye is fixed close to the limbus below, or down and in for the right eye, down and out for the left; if the latter, care must be taken not to rotate the globe. The knife is held with its plane parallel to the plane of the iris. The point is introduced at least 1 mm.—in chronic glaucoma 2 mm.—behind the apparent corneo-scleral margin. It is inserted at the point corresponding with seven minutes to twelve on a clock face (Fig. 208). As soon as the point is in the anterior chamber it will look much brighter than the part in the corneo-sclera; if this is not noticeable it is probable that the knife is badly directed

and is burrowing in the cornea. It is passed steadily onwards across the anterior chamber to a spot corresponding with seven minutes past twelve on the dial of a clock, where the counter-puncture is made. In glaucoma, especially acute glaucoma, the anterior chamber is very shallow, so that it may be very difficult to pass the knife across without catching in the iris and wounding the lens, a most disastrous accident. The deepest part of the chamber is at the periphery, and it will usually be found easiest to coax the point of the knife round the periphery, gently pushing the iris away with the hack.

As soon as the counter-puncture is made the knife is pushed on until 5 or 6 mm. are exposed. Cutting out is performed by a series of small sawing movements, little pressure upwards being required with the very sharp knife. It is very necessary to use these sawing movements properly, as the sharpest knife fails to cut if it is simply pressed hard against a surface.

In this manner the section through the corneo-sclera is kept at a uniform distance of 1 or 2 mm. behind the apparent corneo-scleral margin. Some conjunctival flap has already been cut at the sides, but the middle of the knife blade is still under the conjunctiva. The edge of the knife is then directed forwards and the conjunctiva cut through by one or two sawing movements.

During these manœuvres care must be taken that the points of the fixation forceps are not pressing into the globe, which is very likely to occur owing to the attention being concentrated upon the section. It may lead to subluxation or complete extrusion of the lens.

The eye is now fixed with fixation forceps, just below the cornea, by an assistant, who also draws the eye downwards. This requires a little skill. If the eye is simply pulled down the wound will gape. It should be rather pushed down and back by the points of the fixation

forceps. The surgeon takes the iris forceps in his left hand and de Wecker's scissors in his right. With a sterile swab the assistant turns down the conjunctival flap so that it lies over the cornea, unless this has been done previously with the back of the knife after completion of the section. The points of the closed forceps are then inserted in the wound and carried to a point half-way between the pupillary and ciliary margins of the iris at a point slightly to the right of the vertical meridian of the cornea. The forceps are opened slightly, and the iris gripped. The iris is pulled out and cut to the right side of the forceps. This stroke makes the right limb of the coloboma. The iris is then drawn across towards the left. By this movement it is torn from its attachment for the whole width of the section. It is then drawn a little back towards the right, so that it may not be jammed into the left angle of the incision. The freed part is then cut off by a second snip of the scissors. This stroke makes the left limb of the coloboma.

The iris repositor is then taken by the surgeon, the eye still being fixed as before. The tip of the repositor is introduced into the wound and insinuated between the cornea and the iris on one side. By a radially directed movement the iris is smoothed out towards the centre of the pupil, so that if the edge of the coloboma is caught in the angle of the wound it will be freed. The same manoeuvre is repeated on the other side of the wound. This part of the operation is very important, and may be very difficult. Only when the edge of the pupil is in its natural position and looks circular but for the small defect in the upper part is the surgeon convinced that the pillars of the coloboma are free from entanglement in the wound. The conjunctival flap is then turned back over the wound with the iris repositor, care being taken that it is not folded upon itself. The assistant removes the fixation

forceps. Any blood clot is carefully removed with forceps or a swab. The surgeon lifts the speculum away from the eye, at the same time seizing the upper lashes in the middle of the lid. Removing the speculum, he lifts the upper lid over the wound in such a manner as to prevent the lid from displacing the conjunctival flap.

Both eyes are bandaged. The unoperated eye may be uncovered after two days.

The chief complications which may arise during the operation are hemorrhage into the anterior chamber (not



FIG. 209.

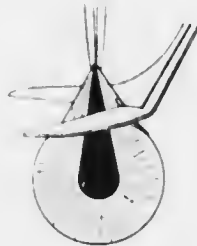

FIG. 210.

FIG. 209, iridectomy with blades of De Wecker's scissors held radially; FIG. 210, with blades held at right angles to the previous position. The former method results in a narrower coloboma, such as is preferable in optical iridectomy and in extraction of senile cataract with iridectomy.

usually serious, but inconvenient); wound of the lens (often not discovered until opacity develops); severe intra-ocular hemorrhage, leading sometimes to extrusion of the lens, vitreous, and even retina.

It may be mentioned that some surgeons use a keratome in this operation. Some also cut off the iris with one snip of the scissors, the blades being directed at right angles to the direction of the forceps (Fig. 210). It is difficult to imagine how this can produce an absolutely peripheral coloboma.

The after-treatment consists in complete rest in bed.

The eye is dressed once daily; neither mydriatic nor miotic is instilled unless complications supervene.

The chief complications arising after the operation are extrusion of the lens (due to too large a section), injury to




FIG. 211. Drawing up of the iris after extraction of cataract with incarceration of the pillars of the coloboma.

to the eye by the patient (usually during sleep) (*vide* p. 434), severe intraocular hemorrhage, &c. Delay in re-formation of the anterior chamber for several days may happen; though undesirable, it may lead to no ill effects. The wound may hudge, with or without prolapse of iris or incarceration of the angles of the coloboma in the wound. A cystoid cicatrix may result, not altogether undesirable from the point of view of filtration in chronic glaucoma, but liable to arouse iridocyclitis or permit infection and panophthalmitis. Bulging of the wound may be due to partial subluxation of the lens, which may necessitate extraction under grave technical difficulties. Wound of

the lens during the operation leads to traumatic cataract, also demanding extraction.

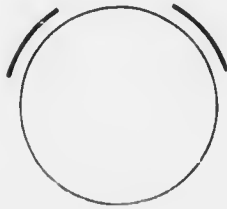


FIG. 212. Diagram of wounds in anterior sclerotomy.

has been drawn up to the wound of a faulty cataract extraction with incarceration of the pillars of the coloboma (Fig. 211). It may be a necessary preliminary to iridectomy in cases of bombe iris. It is performed with a Graefe knife or with de Wecker's scissors. The operation is too technical to be described in detail here. The results are often unsatisfactory.

OPERATIONS UPON THE SCLEROTIC.

Sclerotomy.—*Anterior Sclerotomy* is performed by some surgeons instead of iridectomy for certain cases of glaucoma. It is more frequently indicated after iridectomy has been performed and has failed permanently to relieve the increased tension. It may also be done in hupththal-

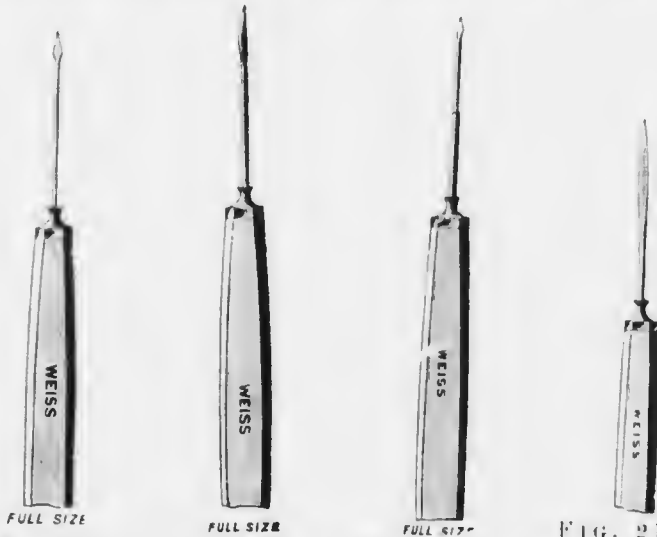


FIG. 213.—
Beer's discis-
sion needle,
with lance-
shaped point.

FIG. 214.—
Discission
needle with
sickle-shaped
edge.

FIG. 215.—
Bowman's
discission
needle with
stop.

FIG. 216.—
Saunders's
discission
needle, with
long cutting
edge.

mia. The section is commenced in exactly the same manner as in iridectomy for glaucoma, though if an iridectomy has already been done it may be advisable to choose some other part of the corneal limbus. The counter-puncture is made in the same manner, but instead of cutting completely out a bridge of sclera is left (Fig. 212). If the iris presents in either wound it is replaced with the repositor; no part of the iris is excised.

The object of the operation is to open up the filtration

angle. The section must therefore be as peripheral as is consistent with the safety of the ciliary body.

Posterior Sclerotomy is employed by some surgeons as a preliminary to iridectomy for glaucoma. It is especially indicated as a temporary measure for relieving pressure while preparations are being made for the iridectomy. It has the advantage of causing the anterior chamber to become deeper, so that the subsequent operation is facilitated. Posterior sclerotomy is also indicated in cases of early detachment of the retina, the site of operation being chosen according to the situation of the detachment. In this case it is essential that the retina shall be perforated. The operation is sometimes used for extraction of a foreign body in the vitreous with the small magnet (*vide* p. 454).

The operation as performed for detachment of the retina has already been described (*vide* p. 397).

OPERATIONS UPON THE LENS.

Discission or **Needling** of the intact lens should rarely be performed after fifteen years of age; it may be employed up to thirty or even thirty-five, but the nucleus of the lens is then likely to give trouble. It is indicated in most cases of dense lamellar cataract, some cases of congenital cataract, and some cases of high myopia. Discission is used at any age for the division of dense secondary cataract (after-cataract).

Needling of the soft lens in young patients usually requires a general anæsthetic, though it is quite painless under cocain. The pupil must be fully dilated with atropin.

Instruments required: speculum (Fig. 207), fixation forceps, cataract needle (Figs. 213—216). I prefer a needle with a fairly long cutting edge. If the lenticular opacity is

scarcely visible in diffuse daylight, it is best to perform the operation in a darkened room with oblique illumination. The surgeon stands above the patient. The conjunctival sac having been douched and the speculum inserted, the eye is fixed down and in (right eye) with fixation forceps held in the left hand. The needle is introduced just outside the limbus (Fig. 217), *i.e.*, through the conjunctiva and sclero-cornea, in a plane parallel to that of the iris, at a point just above the horizontal meridian of the cornea. It is carried through the anterior chamber until the point reaches the lower part of the pupil. The handle is then slightly raised, so that the point just perforates the lens capsule. The handle is then moved so that it and the point move through arcs of circles which have their centre at the spot where the shaft is engaged in the corneo-sclera. Having thus made a curved, more or less vertical incision in the capsule, a second incision is

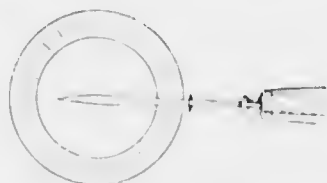


FIG. 217. Diagram of discission with one needle.

This is done by very slightly withdrawing the needle so as to disengage it. It is then passed farther on towards the left side of the pupil. The handle is again slightly raised, and at the same time rotated, so that the cutting edge is brought in contact with the capsule. As the needle is slowly withdrawn a straight incision is made in it in a horizontal direction. When this is sufficiently large the handle is depressed. The handle is rotated so that the plain of the blade faces upwards, and the needle is quickly withdrawn from the eye. By withdrawing it quickly no aqueous should be lost. If much aqueous is lost anterior synechia may result. Sterile atropin ointment is introduced into the conjunctival sac, and both eyes are bandaged.

The most important point about after-treatment is keeping the pupil well dilated, which is done by atropin ointment three or four times a day. There is always some ciliary reaction. The amount of swelling of the lens fibres depends upon the size of the incisions in the capsule, but also varies with different lenses. The reaction is often very slight in cases of true congenital cataract; in these cases the iris scarcely responds at all to atropin. If it is particularly desired to avoid the necessity of a subsequent



FIG. 218.—
Ziegler's knife.

curette evacuation the incisions should be quite small in the first operation. If it is intended to perform a curette evacuation (*vide* p. 476) the incisions may be as large as possible, and the needle may even be introduced moderately deeply into the lens and the fibres broken up. In these cases, and occasionally when it is not anticipated, there is great swelling of the lens; the anterior chamber becomes filled with flocculent masses; there is intense ciliary injection accompanied by raised tension and pain. The tension sometimes subsides in a few hours with leeching, but if not must be relieved at once, or the sight will be seriously damaged by secondary glaucoma. A curette evacuation is then done (*vide* p. 476). In cases in which no curette evacuation is performed a second and third needling will usually be necessary before a clear opening is obtained. Intervals of several weeks or even months may elapse until the absorption set up by the previous operation is complete. The final needling will be of the type of a discission for secondary cataract.

Discission of Secondary Cataract (after-cataract) is performed in exactly the same manner as discission of the soft lens if the after-cataract is not too dense to be divided

by a single needle. Some surgeons advise needling every case of senile extraction as soon as the eye has quieted down, *i.e.*, in a fortnight or three weeks: the capsule is then soft and easily divided. If there has been iritis or irido-cyclitis needling is contraindicated until all signs of inflammation have passed off: hence a careful search for "k.p." must be made in every case.

If the capsule is dense and thickened a Ziegler's knife may be used (Fig. 218), or two needles may be employed. By the latter method no undue strain is thrown upon the ciliary body, and the membrane is prevented from tearing away from the ciliary body instead of being torn in the centre.

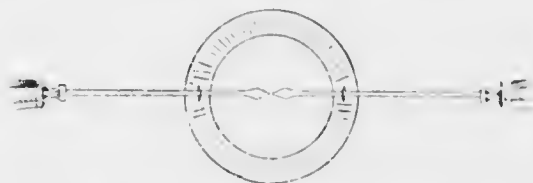


FIG. 219.—Diagram of discission with two needles. The needles have been inserted, but not yet rotated.

The same instruments are required together with an extra needle. The needles may be "stop" needles, though this should not be necessary. The eye is fixed by an assistant. The needles are introduced with the flat surfaces upwards through the cornea at opposite sides of it in the horizontal meridian, 3 or 4 mm. internal to the apparent margin (Fig. 219). They are then rotated through a right angle, so that the cutting edges are applied to the membrane. They are passed through the centre of the membrane close to each other. The handles are then simultaneously raised, so that each needle rotates around the spot on the shaft which is engaged in the cornea. In this manner the points are drawn apart, and the membrane is cut. A further attempt may be made to tear it in the direction at right

angles. The needles are rotated so that the flat surfaces are again upwards, and are withdrawn quickly so that aqueous may not be lost. Atropin is instilled, and the eye is bandaged. There is seldom much reaction, unless the previous operation has been faulty; in such cases the additional irritation may precipitate an attack of sympathetic ophthalmia.

It may be mentioned that needling operations are by no means so simple as they appear in the hands of an experienced operator. Every movement of the needle must be made round the spot where the shaft penetrates the globe.

Curette Evacuation or **Linear Extraction** is the operation whereby after discission, whether accidental (traumatic cataract) or intentional, the softened lens matter is let out of the anterior chamber.

Instruments required: speculum (Fig. 207), fixation forceps, bent keratome, curette (Fig. 221), iris repositor. Local anaesthesia suffices, except in the case of children or unruly patients.

The pupil must be fully dilated with atropin. The position of the section is of little importance; some surgeons place it above, where it is under the upper lid, others below. The surgeon stands accordingly either above or at the side of the patient.

The conjunctival sac having been douched and the speculum inserted, the eye is fixed with fixation forceps. The keratome is passed through the cornea, 1 mm. internal to the apparent margin (cf. wound in Fig. 206), with the blade parallel to the plane of the iris. It is pushed on until the incision is about 5 mm. long. The point may be dipped so as to pass into the lens without disadvantage, and the incision may be increased as the keratome is being slowly withdrawn by extending each angle, using the two edges of the keratome like knives. The tip of the curette

is then gently insinuated just within the edges of the wound, not quite into the anterior chamber. Slight pressure is exerted upon the peripheral lip, and the soft lens matter travels along the groove of the curette. No attempt should be made to remove the whole of the lens matter, on account of danger of rupture of the suspensory ligament and escape of vitreous. The remnants of lens matter will be absorbed. There is no probability of the iris prolapsing or becoming incarcerated in the wound if it is properly dilated, but the repositor should be at hand in case this accident occur. Sterilised atropin ointment is inserted, and both eyes are bandaged.

Usually the ciliary irritation is greatly benefited by the operation. The greatest care must be exercised as to surgical cleanliness, for most of the accidents from infection in treating soft cataract occur, not from needling, but from curette evacuation. Anterior synechia of iris or capsule, iridocyclitis, or sympathetic ophthalmia may occur, but are happily rare.

Some surgeons extract soft cataracts by the linear method without previous dissection. This mode of treatment is not advocated.

Extraction of senile cataract and of lenses containing a hard nucleus may be performed with or without iridectomy. The latter method should only be adopted in rare cases. The iridectomy is performed by some surgeons six weeks or more before extraction. I advise this method only in cases of immature cataract (*vide* p. 339), and in cases where it is necessary to operate, though there is some doubt as to the sterility of the conjunctiva, &c., in spite of thorough preliminary treatment. Infection is likely to be more under control after iridectomy than after extraction, and the behaviour of the eye in the first operation is a guide to its probable behaviour after extraction.

In every case of cataract, before operating the condition

of the patient's conjunctiva and lacrymal apparatus is thoroughly investigated. If there is any regurgitation of tears, mucus, or pus on pressure over the lacrymal sac, the condition must be cured (*vide* p. 629) before operation. If there is any conjunctivitis, it must be treated and cured.



FULL SIZE

FIG. 220.—Graefe cataract knife. A slightly broader knife is used in cataract extraction than in glaucoma iridectomy; it has the advantage of being less resilient. The knives used for glaucoma iridectomy are generally re-ground cataract knives.



FULL SIZE

FIG. 221.—Cystotome (Moorfields' pattern) and curette. (These should *not* be at the two ends of the same instrument.)

as shown by the absence of pathogenic organisms on bacteriological examination. Some of these cases are very troublesome (*vide supra*); in case of doubt, the patency of the nasal duct should be demonstrated by syringing.

The usual preparation of the patient—bath, purgative, and so on—is made as for any major operation. The lids

are cleansed with ether soap on the previous night. A clean pad is placed on the eye, and a bandage is applied. This is kept on until the patient is brought to the operating room. The pad is then removed and submitted to the inspection of the surgeon. If there is any muco-purulent or purulent discharge on the pad, the operation must be postponed, and the cause investigated and removed.

Cataract Extraction with Iridectomy ("Combined Extraction.") — Local anesthesia suffices, unless the patient has lack of self-control. Sterile 2 per cent. solution of cocaine is instilled into the eye three times at intervals of five minutes, the eyelids being kept closed between the applications of the drops. At the last instillation a drop is also instilled into the other eye. This is necessary, since, if fluid happens to drop off the instruments into this eye during the operation, the patient is liable to squeeze the lids together reflexly, unless the eye is cocained: moreover it helps the patient to keep both eyes open, diminishing the risk of winking. The surgeon stands above the patient, making the section



FIG. 222.—Maunoir's angular iris scissors.

with his right hand on the right eye, and with his left hand on the left eye. (Some surgeons stand below and at the side for the left eye, and cut away from themselves, using the right hand).

Instruments required: speculum (Fig. 207), two pairs of fixation forceps, Graefe cataract knife (Fig. 220), bent iris forceps, de Wecker's scissors, cystotome (Fig. 221), curette (Fig. 221), iris reposer, [probe-pointed bent scissors (Mannoir's) (Fig. 222), lens spoon (Fig. 223)]. The instruments in brackets are not required for uncomplicated extraction, but must always be ready.

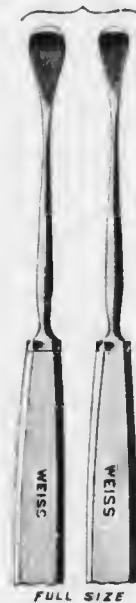

FIG. 223.
Critchett's
lens spoon.

The following description applies to operation upon the right eye.

The conjunctival sac having been douched and the speculum inserted, the patient is told to look towards his feet, and the eye is fixed with fixation forceps applied just outside the limbus directly downwards or down and in below the horizontal meridian of the cornea. The point of the Graefe knife is inserted in the apparent corneo-scleral margin at a point corresponding with ten or twelve minutes to twelve on the dial of a clock (Fig. 224). It is passed across the anterior chamber to the corresponding spot on the opposite side, ten or twelve minutes past twelve respectively. The knife is made to cut out in exactly the same manner as in iridectomy for glaucoma (*q.v.*), but following the corneo-scleral margin. A conjunctival flap should be made as in that operation, but it will be narrower at the sides, since the section is further forwards. It may be made slightly broader above by carrying the conjunctival incision a little upwards after the corneo-sclera has been divided before turning the knife to cut directly forwards.

The fixation forceps are then removed. If the patient is unsteady, they are handed over to an assistant, who applies them below the cornea and maintains fixation. If the patient is submissive, he is simply told to keep looking towards his feet all the time. He is warned that he may feel a little pain during the next stage, but that he must keep still, or the operation may be unsuccessful.

The iris forceps are taken in the left hand and the de Wecker's scissors in the right (irrespective of the eye which is being operated upon). The conjunctival flap is turned down over the cornea by means of a swab. The



FIG. 224. — Diagram of wound in extraction of senile cataract.

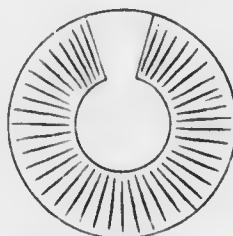


FIG. 225. — Diagram of coloboma in cataract extraction with iridectomy.

closed points of the forceps are inserted at the centre of the wound and passed straight downwards to just above the pupillary margin of the iris. The blades are opened slightly, and the iris seized and drawn out of the wound. The piece of iris grasped is cut off with one snip of the de Wecker's scissors, the blades of which are held radially to the iris, *i.e.*, with the points directed upwards (Fig. 209).

The iris reposer is now taken and the iris replaced as in the operation for iridectomy (*q.v.*). Particular care is taken to free it from the angles of the wound, usually an easy task at this stage owing to the support afforded by the lens and the smoothness of the surface of the capsule.

The patient still looking towards his feet, the cystotome

is introduced with the cutting edge directed towards the left and slightly upwards. It is passed on until the point is near the lowest part of the pupillary margin. The cutting edge is then directed backwards, the handle is slightly raised, and the lens capsule is incised vertically as the instrument is slowly withdrawn.

The cystotome is then taken in the left hand, and the curette in the right. The back of the curette is placed horizontally upon the lower part of the cornea (from about twenty minutes to twelve to about twenty minutes past twelve). Gentle but firm pressure is made upon the cornea in a direction backwards and slightly upwards. This causes the nucleus of the lens to be tilted so that the upper edge appears presenting in the wound. The lens nucleus is coaxed out of the wound by repeating the pressure with the curette, but more and more in an upward direction. Meanwhile the lens may be gently helped out by the cystotome in the left hand. As soon as the diameter of the nucleus has passed through the wound, pressure upon the cornea is immediately relaxed. The nucleus is directed down over the cornea into the curette.

If there is much clear soft lens matter, this is coaxed out of the wound by gently repeating the stroking movements with the curette on the cornea. Too much pressure must not be exerted. Any soft matter protruding from the wound is removed with the curette.

The iris repositor is now again used to free the iris from the angles of the wound. If the iris has been carefully replaced after the iridectomy, as recommended above, little trouble will probably be experienced at this stage. If this step has been omitted it is likely that the nucleus may have jammed the iris into the angles of the wound during its expulsion and there may be great difficulty in freeing it. In addition, the repositor is swept over the whole line of the wound, so as to push back into the anterior chamber

any tags of capsule which may be presenting. These are so transparent as to be invisible, and it is extremely important that they should not become incarcerated in the wound.

The conjunctival flap is then turned back into its natural position by the repositor, care being taken that it is not doubled up.

The removal of the speculum and closure of the lids are carried out as in iridectomy (*q.v.*). Both eyes are bandaged, and the patient is put to bed without altering his recumbent posture. It is a good plan to operate with the patient upon a suitable bed, so that it is unnecessary to move him.





Remarks upon the operation.—The size of the section depends upon the probable size of the nucleus of the lens. It must be remembered that the cortex is soft and broken up; the width of the incision must be as large or slightly larger than the diameter of the nucleus. In black cataract the whole lens is sclerosed, so that a very large section must be made; in these cases it should involve half the circumference of the cornea. More harm is done by bruising the edges of the wound than by having a wound which is unnecessarily large. If the nucleus does not come forward through the wound with moderate pressure of the curette it is probably because the section is too small. The wound should then be enlarged with the probe-pointed bent scissors (Fig. 222). The probe-point of one blade is inserted between the iris and cornea at one angle of the wound, which is then extended by a single snip. The same manœuvre may be repeated at the other angle.

The iris is more easily cut off by holding the de Wecker's scissors at right angles to the direction of the forceps, *i.e.*, horizontally (Fig. 210). This makes a larger coloboma, which is unnecessary and has some disadvantages.



MICROCOPY RESOLUTION TEST CHART

(ANSI and ISO TEST CHART No. 2)



APPLIED IMAGE Inc

1653 East Main Street 14609 USA
Rochester, New York
(716) 482 - 0300 - Phone
(716) 288 - 5989 - Fax

Hæmorrhage may occur into the anterior chamber. The blood is derived from the conjunctival flap or from an



FIG. 226. Diagram of Moorfields' cataract bandage. The semicircular opening is for the bridge of the nose. The upper and lower tapes are passed above and below the ears. The long single tapes pass behind the head and are brought forward and tied over a pad of wool placed at the upper part of the bandage over the forehead.

hyperæmic iris. An attempt may be made to drive it out of the wound by stroking the cornea upwards with a spatula, but too much time should not be devoted to this endeavour. If it fails the capsulotomy must be done with great care to avoid catching the iris.

The capsule is divided in all sorts of different directions by different operators. Probably the most satisfactory is a circumferential incision just inside and parallel with the wound. It is less easy to do

than the method recommended. The other methods have no advantage. Some surgeons remove the anterior capsule by capsule forceps (Fig. 124), which has very decided advantages, but has also its own special dangers.

The dressings should consist of two large round pads of sterilised gauze covered

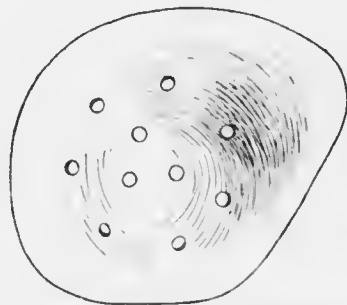


FIG. 227.—"Cartella" shield for right eye.

by similar pads of sterilised cotton wool. They are kept in position firmly, but without undue pressure, by a cataract bandage. Of the many types of the latter the Moorfields' pattern (Fig. 226) is probably the best. With aged or

unruly patients a wire or "cartella" shield (Fig. 227) should be placed over the dressing.

The most serious accident which may occur during extraction is prolapse of vitreous at an early stage. It may be due to inherent weakness of the suspensory ligament, which gives way whilst the section is being made or the iridectomy done. More commonly it is due to undue pressure on the eye by the fixation forceps. In concentrating all their attention on the section beginners often allow the left hand to dig the fixation forceps into the globe. Special attention must therefore be devoted to the avoidance of this mistake, which has also the lesser disadvantage of forcing out the aqueous and allowing the iris to float up in front of the knife. Should this occur the iris will be cut and pain caused, often leading the patient to flinch. The section must be completed, however, in the usual manner. Escape of vitreous may also be due to pressure with the curette in the attempt to expel the lens. The necessity of such great pressure is probably owing to the wound being too small or to the capsulotomy having been inefficiently performed. The former contingency has already been dealt with. The latter is overcome by more careful repetition of the capsulotomy. If pressure with the curette causes the vitreous to appear without any sign of the engagement of the edge of the lens in the wound resort must be made at once to scoop extraction. Hence the importance of having the spoon always in readiness in every case of extraction. The spoon is passed directly backwards into the vitreous so as to make certain that it passes behind the lens. It is then rotated forwards so that the lens is caught between the spoon and the back of the cornea. The lens is kept pressed up against the cornea and is removed by a rapid further rotation of the spoon. Some vitreous is certain to be lost, but it is imperative that the lens should be delivered,

or the eye will almost inevitably be lost. The eye is dressed at once in these cases without any endeavour being made to replace the iris, as any such manœuvre is likely to lead to further loss of vitreous. In spontaneous rupture of the suspensory ligament and in other cases badly managed the lens may sink back into the vitreous. In such cases it is usually futile to attempt to remove it. The eye should be dressed at once, and if the lens floats up into the pupillary area at a later date a further attempt may be made to remove it.

Prolapse of the vitreous after delivery of the lens is less serious, though it increases the tendency to cyclitis, with opacities in the media, and may be followed by detachment of the retina.

After-treatment.—The patient lies quietly upon his back. He is directed to avoid all straining. A sneeze may be inhibited by pressure with the finger on the upper lip close to the septum of the nose. All patients should have their hands loosely tied to the bed at night, so that they are unable to touch the eyes. Many eyes are lost from neglect of this precaution, for patients often knock or rub their eyes when they are half asleep.

The food must be fluid during the first few days; no aperient is given for three or four days.

On the day following the operation the bandage is removed, the lids are bathed with warm boric lotion, gently separated, and a drop of sterile 1 per cent. atropin solution instilled. The wound may be inspected, but should not be disturbed more than is absolutely necessary.

On the second day it is examined more thoroughly. The pupil should be round and well dilated. Another drop of atropin is instilled. If the pupil is not well dilated on the third day there is probably some trace of iritis, and the atropin should be instilled more frequently,

and it may be advisable to resort to hot bathings. In most cases there is no iritis, and after a transient ciliary injection the eye quiets down, so that it is almost free from injection in a week or ten days.

On the fourth or fifth day the unoperated eye may be left unbandaged. If both eyes are kept bandaged too long old people often become delirious. On the slightest sign of wandering in speech the unoperated eye should be uncovered at once.

It is wise to keep healthy patients in bed for a week. Most cataract patients, however, are old, and extremely liable to hypostatic congestion of the lungs. Such patients should be propped up in bed on the third or fourth day, and allowed to sit up out of bed soon after. A light dressing is kept on for ten days or a fortnight; afterwards smoked glasses are worn until cataract glasses can be ordered, *i.e.*, in about six weeks. It is very important that smoked glasses should be worn continually, otherwise the patient is quite likely to develop red vision or erythroptasia.

Cataract Extraction without Iridectomy ("Simple Extraction").—Many surgeons advocate extraction of cataract without iridectomy in suitable cases, but opinion differs much as to the criteria of suitability for this operation. It is performed in the same manner as the combined operation, except that the iridectomy is omitted. The lens is delivered through the pupil.

Comparing the two operations, it may be succinctly stated that the chief advantages of *simple extraction* are: Simplicity of the operation, including especially minimum of mutilation, of instruments required, and of instruments introduced into the interior of the eye; optical advantages of a round pupil—minimal dazzling, best visual acuity, and best field; cosmetic advantage of a round pupil; ease of reposition of the iris; minimal danger of incarceration of capsule in the wound; infrequency of prolapse of

vitreous ; greater protection of deeper parts of the eye from infection ; absence of pain and bleeding from cutting the iris. Of these it may be remarked that the optical advantages are not overwhelmingly manifest. The cosmetic effect is rarely of sufficient importance to outweigh the risks, though occasionally it is a justifiable argument, as in the case of an unsightly unilateral cataract in a young woman, or in a man in whom it forms a bar to obtaining employment. It is doubtful whether prolapse of vitreous is more frequent in combined than in simple extraction. Bleeding from the iris is only very exceptionally of any importance ; when there is much bleeding in cataract extraction the blood is derived from the conjunctival flap or from a too peripheral section. The chief disadvantages of simple extraction are : risks of prolapse of the iris ; less efficient treatment of the anterior capsule ; greater difficulty in removal of soft lens matter ; greater danger of ring synechia and secondary glaucoma if iritis should occur.

The chief advantages of *combined extraction* are : greater ease in expression of the nucleus ; greater ease in removal of soft lens matter ; increased facility in dealing with the anterior capsule, and therefore diminished necessity for subsequent discission ; diminished risk of prolapse of the iris ; diminished risk of secondary glaucoma. The chief disadvantages are : greater complexity of the operation, including especially need of more instruments and of the introduction of more instruments into the eye, and greater duration of the operation ; optical and cosmetic disadvantages ; greater danger of incarceration of iris and capsule in the wound ; greater danger of post-operative glaucoma ; pain and bleeding from the iris.

The frequency of prolapse of the iris and the dangers resulting therefrom are such serious risks that no surgeon should perform simple extraction until he has obtained

exhaustive experience of the combined operation. If there is any difficulty in replacing the iris after a simple extraction, or if the pupil, when the iris is reposed, is not quite circular, an iridectomy should be done at once. Prolapse is liable to occur within the first twenty-four hours of the operation. If it is not treated by an immediate iridectomy a very serious condition will result. The incarcerated iris will fail to withstand the intraocular pressure and a "cystoid cicatrix" will be formed. Visual acuity will be diminished by excessive astigmatism and the eye exposed to grave danger from iridocyclitis, and even panophthalmitis or sympathetic ophthalmia.

Many of the disadvantages of both operations, including the danger of prolapse of iris, are obviated by a modification in which after simple extraction has been performed a small button-hole is made in the periphery of the iris. After the lens has been extracted, as in simple extraction, the periphery of the iris is gently drawn out of the wound by iris forceps and the smallest possible fold is snipped off with de Wecker's scissors. The aperture in the iris is peripheral, so that it is almost entirely hidden by the sclerotic, and in any case is completely covered by the upper lid, while at the same time sufficient drainage from the posterior into the anterior chamber is provided for. Prolapse of iris is less likely to occur than in simple extraction, and it is quite unlikely that the capsule will be left entangled in the wound, a decided drawback to extraction with the ordinary form of iridectomy.

The chief complications arising after cataract extraction are striate "keratitis," incarceration of the iris in the angles of the wound, prolapse of the iris, iritis, iridocyclitis, sympathetic ophthalmia, secondary glaucoma, intraocular hemorrhage, infection of the wound, panophthalmitis, &c. These subjects are referred to under their respective headings.

EXCISION OF THE EYEBALL.

A general anæsthetic is required. The operation can be performed almost painlessly under eucain, novocain, or cocain, and this method is sometimes advisable in old people with diseased arteries, or in patients with heart disease.

Instruments required: speculum, two pairs of fixation forceps, tenotomy scissors (Fig. 228), strabismus hook (Fig. 229), blunt-pointed scissors—straight or curved on the flat (Fig. 230).

The surgeon stands above the patient.

The conjunctival sac having been douched and the speculum inserted, the surgeon seizes the conjunctiva just outside the limbus at the highest part of the cornea. The conjunctiva is incised here with the tenotomy scissors. The point of one blade of the scissors is passed under the conjunctiva and pushed on as far as possible round the cornea.




FIG. 228.—Tenotomy scissors.

By carrying the point out under the looser bulbar conjunctiva it may be taken a third of the distance round the circumference; the edge is then brought close up to the

limbus before the conjunctiva is divided. Still fixing the eye in the same position the manoeuvre is repeated on the other side of the cornea. Finally, the portion below the cornea is divided. The conjunctiva should be divided completely round the cornea, and close to it in three or four cuts.

The peripheral edge of the cut conjunctiva is then taken up by the forceps, and the bulbar conjunctiva is separated from the globe as far back as the equator in all directions by a series of small snips, the blades of the scissors being kept flat in close contact with the eyeball. In this manner the capsule of Tenon is simultaneously opened.

The tenotomy hook is then taken in the left hand, the scissors being retained in the right. The recti muscles are taken up one by one and divided close to the globe. It is well to begin with the superior rectus, since it is the most difficult to get at, especially if the other recti have been previously divided. The obliques are found by passing the hook farther back and carrying it round close to the globe.

The speculum is then taken and held widely open and pressed back into the orbit. If the muscles have been properly divided the globe springs forwards between the blades of the speculum. The other pair of scissors is now taken in the right hand. The globe is seized with the fingers of the left hand. The points of the closed scissors are passed into the orbit—to the outer side of the eye on the right side, to the inner on the left. The optic nerve is felt for with the closed scissors: it is easily recognised. The scissors are withdrawn a short distance, opened, and the blades pushed down, one on each side of the nerve, which



FIG. 229. Strabismus hook, flat Moorfields' pattern.

is then divided. The sensation of dividing the nerve is unmistakable. The eyeball can then be freely drawn

forwards. There are probably some remnants of the obliques still attached to the globe. These are divided close to the eye. The bleeding is profuse for a moment, but may be controlled by a little pressure with a pad of cotton wool. The edges of the conjunctiva are then pulled together with the fixation forceps, the lids are closed, and the dressing is applied. The latter should consist of a small spherical pad of cotton wool, then a round flat pad of sterilised or cyanide gauze, then a thick round pad of sterilised wool. The bandage is applied with firm pressure. The patient is kept in bed for one or two days.

If the globe is perforated and collapsed excision is more difficult. The eyeball should be held forward with large strong vulsellum forceps. In children also excision is difficult. The orbit is small in proportion to the



FIG. 230. Excision scissors.

size of the globe. Here the manœuvre with the speculum to dislocate the ball forwards is often unsuccessful, and strong

pressure may burst the eye. It is best levered out with the points of the excision scissor.

It is very easy to cut the sclera instead of the nerve, especially with curved excision scissors. I always prefer straight scissors; indeed, straight instruments should always be used in preference to curved whenever it is possible, because it is much easier to judge the position of the point. Straight scissors are particularly indicated when the nerve has to be cut long, as in excision for glioma retinae and sarcoma of the choroid. Special precautions must be taken in excision for panophthalmitis (*vide* p. 456).

Evisceration of the eyeball is recommended only in some cases of panophthalmitis (*q.v.*). Some surgeons use it in anterior staphyloma and other conditions. Although the stump affords a good foundation for an artificial eye, the operation is not to be recommended in these cases; it has been followed by sympathetic ophthalmia.

Evisceration with insertion of an artificial vitreous—*Mules's operation*—is even more objectionable on theoretical grounds, but is still performed by many surgeons. In this operation a glass sphere is inserted inside the sclerotic, which is stitched over it. The globe must be much smaller than the normal vitreous chamber. There is very severe chemosis and pain after the operation, and the glass globe may be extruded. Sympathetic ophthalmia has followed this procedure.

Excision, with the introduction of a glass globe in Tenon's capsule, is much less objectionable than Mules's operation. In carefully selected cases it is a good method, and affords admirable support to an artificial eye. The eye is much more movable than after simple excision, so that the simulation of a red eye is more exact. Care must be taken during the excision to keep close to the eyeball and to injure Tenon's capsule as little as possible. The recti

muscles are drawn together over the small glass globe by a buried purse-string suture. The conjunctiva is sutured by a superficial purse-string suture. There is some inflammatory reaction, with chemosis, but much less than after Mules's operation, and little or no pain. If the operation has not been well performed, the globe may slip into the orbit, becoming loose, usually beneath the lower lid. If this occurs it must be removed and the case treated as an ordinary excision.

An *artificial eye* should not be worn less than six weeks after excision. A small eye is first worn for an hour or two a day until the conjunctiva becomes used to the foreign body. Eight or nine weeks after the operation a full sized eye may be worn. It is taken out at night, carefully washed, and kept in water. If it becomes in the slightest degree rough at the edges it must be discarded at once. This usually occurs from chemical action of the secretion upon the enamel in about a year, so that in any case a new eye should be obtained every year. Various types of artificial eye are made. Snellen's "reform" eye gives a better cosmetic effect after the ordinary excision than the old shell, which may be used when there is good support, as after insertion of a globe in Tenon's capsule. The methods of insertion and removal of the artificial eye should be learnt by every surgeon by seeing it done.

Contracted Socket is the result of a faulty excision, cellulitis in the orbital tissues, or the continued wearing of a rough artificial eye. The first two causes lead to the formation of dense cicatricial bands across the socket, rendering the wearing of a prothesis impossible. The last cause usually results in obliteration of the lower fornix, so that the eye cannot be kept in place.

Contracted sockets are difficult to remedy. It is easy to divide the bands and make a new groove to hold the eye in position, but unless the wounds become covered with

epithelium the edges heal together and no improvement is produced. It is therefore necessary to perform some plastic operation, whereby the wounds made are covered with an epithelial graft or skin flap. Grafting the wound with a Tiersch graft, mucous membrane from the mouth of the frog, or mucous membrane from the lip may suffice. In other cases larger skin flaps are necessary. Each case must be dealt with according to the exact conditions.

SECTION IV.

ERRORS OF REFRACTION AND ANOMALIES OF ACCOMMODATION.

CHAPTER XXIII.

RETINOSCOPY.

(Before reading this section the student should revise his knowledge of the optical conditions of the eye and the methods of testing visual acuity by again reading Chapters III., IV., VII., and IX.)

It has been already pointed out that the condition of the refraction of an eye can be estimated in various manners. The systematic examination of the visual acuity will in most cases *indicate* the absence or the nature of any error of refraction. The examination with the mirror at a distance of 1 metre also indicates the refractive condition by the visibility of retinal vessels and the direction of parallax displacement: as will be shown below, this method may be made to give very accurate estimation of the exact refraction. The indirect method also indicates the refractive condition by the apparent change in size of the disc when the large lens is moved away from the eye. By the direct method the condition of the refraction can be accurately measured if the surgeon has acquired the ability completely to relax his accommodation.

Retinoscopy, or, more correctly, *skiascopy* or the *shadow test*, is the most accurate means at our disposal of estimating the condition of the refraction objectively. It depends upon the fact, first pointed out by Bowman, that when light is reflected from a mirror into the eye the direction in which the light travels across the pupil varies with the condition of refraction of the eye. If the light is thrown into a myopic eye from a concave mirror at a distance of 1 metre the light, or what is easier to observe,

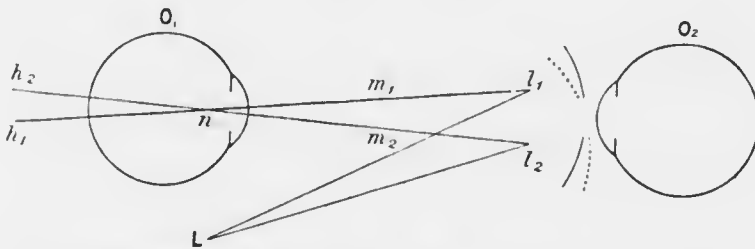


FIG. 231.—Diagram of retinoscopy with a concave mirror. O_1 the observed eye; O_2 , the observer's eye. The image of the source of light L is formed at l_1 (the immediate source of light) by the mirror. If O_1 is hypermetropic a virtual image of l_1 is formed on the line $l_1 n$, passing through the nodal point n , as at h_1 . If O_1 is myopic a real inverted image is formed as at m_1 . If the mirror is tilted downwards, as shown by the dotted line, l_1 moves to l_2 , h_1 to h_2 , and m_1 to m_2 . This shows that the shadow moves in opposite directions in hypermetropia and myopia.

the shadow, moves across the pupil when the mirror is slowly tilted in the same direction as that in which the mirror is moved (Fig. 231). If a plain mirror is used, the other conditions remaining the same, the shadow will be seen to move in the opposite direction to the movement of the mirror. If the eye is hypermetropic the direction in which the shadow moves is the opposite of that with the myopic eye. If the eye is emmetropic or has only a very low degree of myopia no shadow will be visible; the pupil will be either completely illuminated or completely dark.

The light seen in the pupil is the blurred image of the illuminated area of the fundus as seen by the observer when he accommodates for the observed pupil. The shadow is merely the image of the edge of the illuminated area.

Imagine a point of light in front of an eye, the pupil being dilated and the accommodation paralysed by atropin (Fig. 232). The divergent rays which enter the eye are made convergent by the refractive media, so that a circular area of the fundus, varying in size according to the refraction of the eye, is illuminated. If the point of light moves upwards, the light on the retina will move downwards.

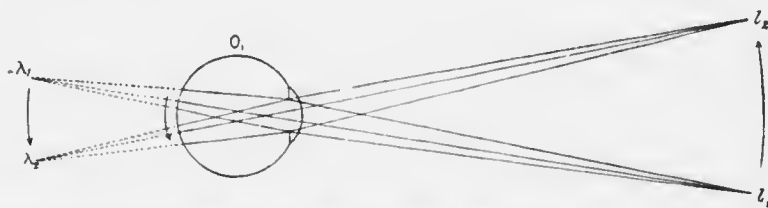


FIG. 232. Showing the course of incident rays and field of illumination of the fundus in hypermetropia. L_1 forms a virtual image at λ_1 , L_2 at λ_2 . The field of illumination is determined by the pupil of O_1 .

Now consider the rays of light which are reflected from the illuminated area. In the hypermetropic eye they will be divergent, as if they came from a point behind the eye. This far point, corresponding with the illuminated area, will move in the same direction, *i.e.*, downwards. Now imagine an observer, placed in front of the eye to look towards a point of light situated at the position of the far point, but to accommodate for the position of the observed pupil. He will see a circle of light with a blurred margin, not a point, because he is not accommodating accurately for the far point. When the illumination on the retina moves down the circle of light which the observer sees will appear to move down also (Fig. 232).

Again, consider the rays of light reflected from the illuminated area on the fundus of a highly myopic eye. They will be convergent and will cross at a real point in front of the eye. This far point, corresponding with the illuminated area, will move upwards when the illuminated area moves downwards. An observer placed in front of the eye and farther from it than the far point, if he looks towards the far point but accommodates for the observed pupil, will see a circle of light with a blurred margin. When the illumination on the retina moves down the circle of light which the observer sees will move up, *i.e.*, in the opposite direction to the

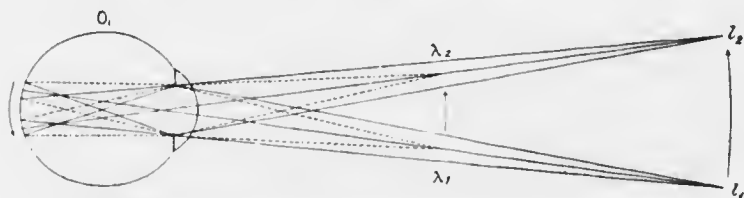


FIG. 233.—Showing the course of incident rays in myopia.

movement in the case of the hypermetropic eye (Fig. 233).

Now suppose that the observer's eye is one metre in front of the observed eye, and that the latter has 1 D of myopia. In this case the far point of the observed eye will be at the situation of the observer's eye, say at the level of his pupil (Fig. 234). In this case a very slight movement of the light on the observed fundus will throw the image at the far point off the observer's eye altogether. In other words, the observed pupil will appear to be completely bright or completely dark.

If, again, the observed eye is emmetropic, its far point will be at infinity. We may regard it as being infinitely far behind the observed eye. Here again there will be scarcely any shadow, though in reality there is a very faint

shadow moving in the same direction as for the hypermetropic eye.

The above is a simple explanation of the theory of retinoscopy. The question of the type of mirror is an entirely subsidiary one. It merely has to do with the direction of movement of the immediate source of light, *i.e.*, the point of light in front of the eye which has been considered above. The image of a real light behind the patient's head, formed by a concave mirror, is situated in front of the mirror. If the mirror is tilted up, the image moves up. The image of a real light behind the patient's head, formed by a plane mirror, is situated as far behind



FIG. 234.—Showing the course of the emergent rays at the point of reversal. So long as λ_1 is in the pupillary area of O_2 , the pupil of O_1 appears uniformly illuminated, and there is no shadow. Directly λ_1 passes to λ_2 the whole of the light is cut off, so that the pupil of O_1 becomes completely dark.

the mirror as the light is in front of it. When the mirror is tilted up, the image moves down.

Hence under the actual conditions of retinoscopy with a plane mirror, when the mirror is tilted to the right the immediate source of light moves to the left, and—

(a) In the hypermetropic eye, the circle of light on the fundus moves to the right, and the shadow seen in the pupil moves to the right ;

(b) In the myopic eye (above—1 D) the circle of light on the fundus moves to the right, and the shadow seen in the pupil moves to the left ;

(c) In the myopic eye of —1 D there is no shadow ;

(d) In emmetropia and myopia of less than —1 D there is a very faint shadow moving to the right.

Stated as a mere guide to practice, with the plane mirror the shadow moves in the same direction as the mirror in hypermetropia and in the opposite direction in myopia above one dioptré; in myopia of one dioptré there is no shadow, and in emmetropia and myopia of less than one dioptré there is a very faint shadow moving in the same direction as the mirror.

In actual retinoscopy the whole of the image of the illuminated area of fundus cannot be seen at once; the shadow is part of the circumference. In high degrees of ametropia the shadow has a distinctly curved border, it is very dark, and it moves very slowly (Fig. 235). In low degrees of ametropia the border of the shadow looks straight; it is faint, and it moves very rapidly.




FIG. 235.

The movement of the shadow, being a purely optical phenomenon, is of course independent of the cause of the ametropia. Consequently in astigmatism, if one axis is hypermetropic and the other myopic (mixed astigmatism) the shadow moves in opposite directions in the two meridians. Often the periphery of the cornea is flatter than the centre; correction of the refraction of the central part, which is the more important, will then differ from that of the peripheral part. These variations produce very puzzling shadows in many cases.

Retinoscopy is applied to the estimation of refraction by placing correcting lenses in front of the eye and noticing the effect upon the shadow. When the shadow has completely disappeared we know that the eye has been made myopic 1 D if the surgeon is at one metre from the patient.

Retinoscopy is conducted in a dark room. The light is

placed behind and above the patient's head. The surgeon sits at one metre from the patient. The patient wears a trial frame; the eye not under observation is covered by a screen. A mydriatic should be used by all but skilled observers, and is necessary to them in many cases. A plane mirror should be used. The patient looks at the observer's forehead.

The light is reflected into the eye, and the mirror is slowly tilted from one side to the other. The direction in which the shadow moves is noted. The horizontal meridian should be observed first, then the vertical. If the shadow appears to swirl round, not moving in the same meridian as the mirror, the eye is astigmatic, and the mirror is not moving in a direction which corresponds with either axis. A direction of movement can then be found in which the shadow will move either directly with or against the mirror; this is one of the principal axes of the astigmatism. The other axis is at right angles (regular astigmatism).

If the shadow moves with the mirror a low convex glass is put in the frame in front of the eye. If the shadow still moves in the same direction a stronger convex glass is used, and so on until no shadow can be seen. A still stronger convex glass is placed in the frame. The shadow now probably moves against the mirror. We now know that the refraction has been over-corrected. The point at which there is absolutely no shadow—the point of reversal—is somewhere between the last two lenses, and we know that at that point the refraction of the eye *plus* the lens is equivalent to one dioptré of myopia. If, for example, the shadow can still be seen to move with the mirror with + 4 D lens in the frame, and moves against it with + 5 D, we shall not be far wrong in considering that the point of reversal is + 4.5 D. A + 4.5 lens would therefore make the eye one dioptré myopic. The actual refraction is

therefore $+ 3.5$ D. If there is no astigmatism the patient ought to be able to read 6/6 with this lens. If he is under atropin a further correction must be made before glasses are ordered. Atropin not only paralyses the ciliary muscle, but also inhibits the physiological tone of the muscle. This is found by experience to be equivalent to about 1 D of accommodation. Hence the glass which should be ordered to correct the distant vision after the mydriatic has passed off is $+ 2.5$ D.

Similarly for spherical myopia. Supposing $- 4$ D eliminates the shadow against the mirror and $- 4.5$ D gives a distinct shadow with the mirror, we know that $- 4.25$ D will leave the eye with still $- 1$ D. Hence the refraction under atropin is $- 5.25$ D. The correction for atropin gives $- 6.25$ D as the lens which corrects distant vision without a mydriatic. The tone of the ciliary muscle is often less in myopia than in hypermetropia: since myopia should be under- rather than over-corrected, it is wiser to order very little more than the atropin correction, *e.g.*, 5.5 D in the above example.

In astigmatism each principal meridian is corrected separately. When one meridian is approximately corrected the shadow assumes the shape of a band. The edge of the band is parallel to the axis of the corrected meridian. Even if the light is not moved in a direction accurately at right angles to this meridian the shadow still seems to move in the same direction. This is due to an optical illusion. If a straight edge, *AB*, is placed obliquely

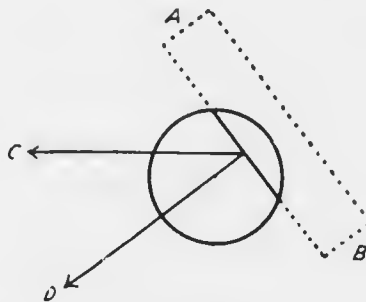


FIG. 236.

behind a circular hole in a card and is then moved horizontally in the direction of the arrow C, it will appear to be moving in the direction of the arrow D at right angles to its own edge. The shadow is most sharply defined if the mirror is moved at right angles to its edge, *i.e.*, at right angles to the corrected meridian.

The results are usually recorded thus (Fig. 237), the directions of the lines indicating the directions of the axes:—

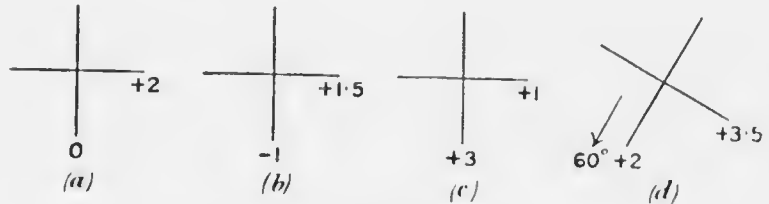


FIG. 237.

The numbers should represent what the surgeon believes to be the refraction of the eye under the mydriatic, not numbers to which further modifications have to be made, *e.g.*, the actual lenses used. In the examples given (*a*) is a case of regular simple hypermetropic astigmatism according to the rule; (*b*) regular mixed astigmatism according to the rule; (*c*) regular compound hypermetropic astigmatism against the rule; (*d*) regular compound hypermetropic astigmatism with oblique axes. The exact direction of the axis in astigmatism is usually determined by subjective trial. In children it may be found by placing the requisite cylinder in the trial frame and rotating it until no shadow can be observed in any direction. In the examples given the correcting lenses required would be (*a*) + 2 D cylinder, axis vertical; (*b*) - 1 D sphere combined with + 2.5 D cylinder, axis vertical, or + 1.5 D sph. \ominus - 2.5 D cyl., axis horizontal; (*c*) + 1 D sph. \ominus + 2 D cyl., axis horizontal, or + 3 D sph. \ominus - 2 D cyl., axis vertical; (*d*) + 2 D

sph. \ominus + 1.5 D cyl., axis 60° down and in, or down and out, according as it represents the left or the right eye.

The shadows in regular astigmatism are not always easy to correct, owing chiefly to differences in curvature of different parts of the cornea. Usually the periphery of the cornea is flatter than the centre. The centre of the pupillary area will then be corrected by a different lens from the periphery, especially with the dilated pupil. From this cause various conflicting shadows may be seen, the commonest being the so-called "scissors" shadows, where two shadows appear to meet each other and cross as the light is moved in a given direction (Fig. 238). In conical cornea a triangular shadow with its apex at the apex of the cone, *i.e.*, usually slightly below the centre of the cornea, appears to swirl round its apex as the mirror is moved.




FIG. 238.

In irregular astigmatism the shadows move in various directions in different parts of the pupillary area; they cannot be accurately corrected by spherical or cylindrical lenses, but some improvement of vision may be obtained.

In conclusion, a word of warning must be given. The correction of a given refraction by retinoscopy may be extremely easy or extremely difficult. A vast number of refractions should have been carefully corrected and confirmed by subjective tests before a surgeon should consider himself justified in ordering glasses without supervision from an expert.

CHAPTER XXIV.

ERRORS OF REFRACTION.

Myopia, or "short sight," is that dioptric condition of the eye in which, with the accommodation at rest, incident parallel rays come to a focus anterior to the light-sensitive layer of the retina. Myopia may be due theoretically to any of the following conditions:—*A.* Abnormal length of the eye—*axial myopia*. *B.* Abnormal curvature of the refracting surfaces—*curvature myopia*: (*a*) too strong curvature of the cornea; (*b*) too strong curvature of one or both surfaces of the lens. *C.* Abnormal refractive index of the media—*index myopia*: (*a*) too high index of the cornea or aqueous; (*b*) too high total index of the lens, due to (*a*) too high index of the nucleus; (*β*) too low index of the cortex; (*γ*) both these causes; (*c*) too low index of the vitreous. *D.* Abnormal position of the lens, *i.e.*, displacement forwards. *E.* A combination of the above abnormalities.

There is no question that increased length of the eye is the most important factor in the high degrees. It is not improbable that the other factors are of more importance than is commonly thought in the lower degrees. This view is supported by the fact that, as shown by actual measurement, the radius of curvature of the normal cornea may vary from 7 to 8.5 mm. Curvature myopia occurs commonly as a factor in astigmatism, but is rare as a cause of spherical myopia, and is then associated with disease of the cornea—conical cornea. Index myopia is seldom seen clinically, but it accounts for myopia as a premonitory

symptom of senile cataract, when it is due to increased refractive index of the nucleus of the lens; it also accounts for myopia in some cases of diabetes, with or without cataractous changes in the lens.

The increase in length of the eye affects the posterior pole and the surrounding area; the part of the eye anterior to the equator may be absolutely normal (Fig. 239). In

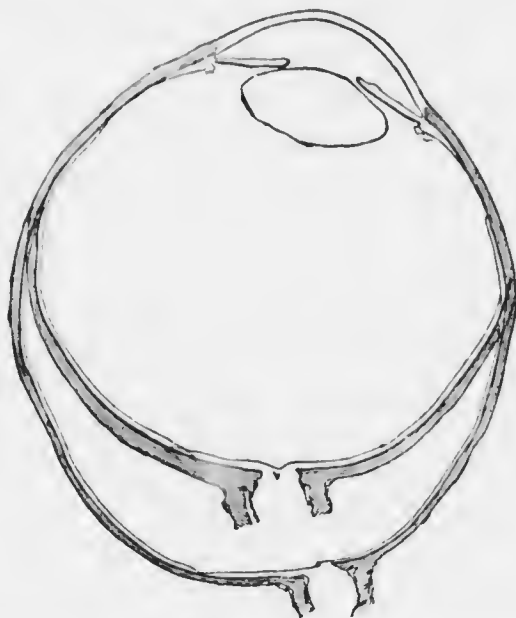

FIG. 239. Horizontal sections of emmetropic and myopic eyes from the same patient superposed, showing the identity of the pre-equatorial regions. (Heine.)

most cases the myopia is of low degree, *i.e.*, up to 5 or 6 D (simple myopia). Less commonly the error reaches a considerable degree in childhood or early youth and increases steadily up to twenty-five or more, finally amounting to 15 to 25 D or more (progressive myopia). It is impossible, clinically or pathologically, to draw a distinct line of demarcation between the two forms.

In low myopia the only symptom may be indistinct

distant vision. In other cases and in high myopia there is often, in addition, discomfort after near work, due largely to disproportion between the efforts of accommodation and convergence (*vide* p. 539). The eyes are unduly sensitive to light. Black spots are seen floating before them, and sometimes flashes of light are noticed: the latter may occur irrespective of any tendency to detachment of the retina (*vide* p. 393). In very high myopia the eyes are prominent, the pupils are large, and the anterior chamber appears deeper than normal, probably only owing to the dilatation of the pupil. There may be an apparent convergent squint, due to a large negative angle γ (*vide* p. 559). A true divergent strabismus may be found, either concomitant or affecting only one eye. Vision may be very poor, even with correction; scotomata may be present, both central and peripheral.

Ophthalmoscopically, in low myopia there may be a quite normal fundus; the optical defect will of course be noticed, especially on examination by the direct method. In the majority of cases of moderate myopia there is a "myopic crescent" (Plate XVI., Fig. 2). This is a white crescent at the temporal border of the disc; very rarely it is nasal. In higher degrees of myopia it may extend to the upper and lower borders, or a complete ring may be formed round the disc. The crescent is occasionally absent even in cases of high myopia.

The bulging at the posterior pole in high myopia is called a posterior staphyloma. It is distinguishable clinically only by its optical and pathological effects. The term should not be used as a synonym for myopic crescent as is often done. Optically posterior staphyloma causes the high error of refraction, and the edges may be actually visible by the indirect method owing to the presence of a crescentic shadow two or three disc diameters to the nasal side of the disc and concentric with

it and to the change in course of the retinal vessels (staphyloma posticum verum). Pathologically, posterior staphyloma causes degenerative changes in the choroid and overlying retina: these are commonly described as "myopic choroiditis," but this term should be abandoned since the condition is non-inflammatory and should be called myopic choroido-retinal atrophy. The changes are generally limited to the posterior pole and the surrounding

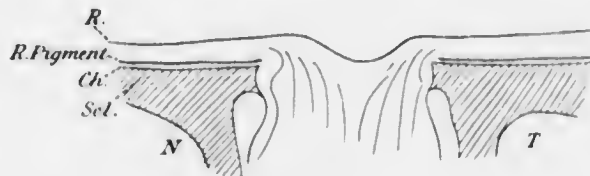


FIG. 240.

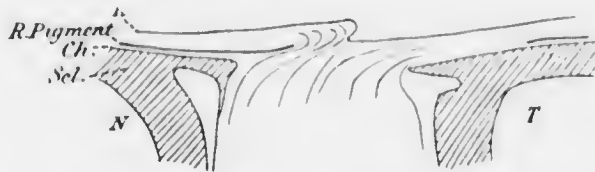


FIG. 241.

FIG. 240. Diagrammatic horizontal section of normal disc.
 FIG. 241. Diagrammatic horizontal section of myopic disc.
N, nasal side; *T*, temporal side; *R. Pigment*, retinal pigment epithelium; *R*, retina; *Ch.*, choroid; *Scl.*, sclerotic. (Modified from Heine.)

area (Plate XVI., Fig. 2). Small yellowish, white, or pigmented spots, and not infrequently white branched lines, usually horizontal, are found at and around the macula. The spots coalesce, forming irregular areas which may extend to the disc. Patches of choroidal atrophy are common near the disc: they may fuse with each other and with the myopic crescent so as to form a ring round the disc. Small foci occasionally occur at the periphery. Hemorrhages in the macular region are

generally described in high myopia. I believe them to be rare: the appearance of small hæmorrhages is very nearly simulated, but the spots undergo no change for an indefinite time: they are probably due to bunches of dilated capillaries, usually choroidal, rendered visible by rarefaction of the retinal pigment layer. The retinal pigment epithelium often uses much of its pigment in high myopia, so that the fundus is tigroid, and the choroidal vessels are well seen: this condition is not inconsistent with good vision.

Black specks in front of the eyes are often complained of in myopia. Dusty vitreous opacities may be visible with the ophthalmoscope (*vide* p. 128), or in high myopia large floating streamers. The normal *muscæ volitantes* are seen more plainly by myopic than by other eyes, probably because the entoptic image is generally larger.

A rare, but serious, change in the fundus is a small circular claret-coloured or black spot at the fovea. It may appear quite suddenly, being accompanied by great diminution of central visual acuity: it is probably due to intrachoroidal hæmorrhage or thrombosis.

Detachment of the retina is liable to occur spontaneously in high myopia (*vide* p. 393).

Ætiology.—Myopia is rare in the new-born, the percentage of cases increasing rapidly during the first two decades, remaining constant afterwards at 10 to 15 per cent., as compared with 30 per cent. for emmetropia and 50 to 55 per cent. for hypermetropia (Fig. 242). As regards sex there is no doubt that the higher grades are commoner in women than in men. High myopia is as common amongst peasants as amongst the educated classes who do more near work. It is doubtful if near work is a cause of myopia, a view which has been held since the time of Kepler. There is, however, no doubt that it has a deleterious influence upon the disease. This has been

attributed by Donders to (a) pressure of the extrinsic muscles upon the globe in strong convergence; (b) increased intraocular pressure from vascular congestion, due to the position of the head; (c) congestion of the fundus, leading to softening of the tissues. Accommodation has long been indicted as a cause of myopia. Many facts are against this view, *e.g.*, (a) accommodation occurs much more forcibly in hypermetropia; (b) it does not increase the intraocular pressure; (c) it does not affect the choroid farther back than the equator, and does not affect the sclerotic at all.

The mechanism whereby convergence influences the

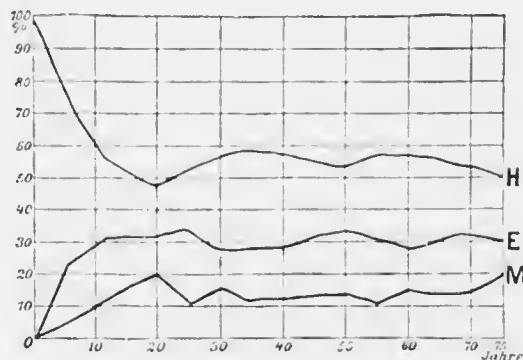


FIG. 242. — Age incidence of ametropia. (Herrnhaiser.) Ordinates, percentages; abscissa, ages.

production of myopia is the subject of many theories, *e.g.*, pressure on the vortices veins, increased intraocular tension and so on.

Neither accommodation nor convergence alone suffices to explain the genesis of myopia. There must be some individual predisposition which provides any such accessory causes with advantageous conditions. There is probably a congenital weakness of the sclerotic. Other theories invoke shortness of the optic nerve (certainly false), special conformation of the skull leading to increased interpupillary distance or alteration in the

position of the pulley of the superior oblique, &c. The view that moderate and high myopia are essentially distinct diseases, due to different causes, is probably untrue.

The cause of the myopic crescent has given rise to much discussion. It is probably congenital in origin, allied to other congenital crescents (*vide* p. 412), but there is no doubt that it may become altered by the conditions obtaining in the myopic eye. Anatomically there is considerable distortion of the papilla in myopia. It has been attributed to dragging, produced by the development of the posterior staphyloma—whether caused thus or not, it is an influential factor. Some authors ascribe the crescent to this cause (distraction crescent). In well marked cases the head of the nerve is pulled over to the temporal side. The retina, including the pigment epithelium, is pulled slightly over the nasal edge of the disc (supertraction crescent). On the temporal side the pigment epithelium stops short at a variable distance from the disc and the choroid is atrophic here (Fig. 241). This part appears ophthalmoscopically as the crescent.

The fact that the crescent may be absent in high myopia and is often present in low militates against the view that it is caused entirely by traction. It is not due to accommodation for the same reasons that myopia is not caused by this factor.

As regards *prognosis*, low or moderate degrees of myopia (up to 5 or 6 D), unless occurring in young children, have a good prognosis. They are not likely to progress, and in some of the conditions of civilised life they may even be an advantage to the individual. The same condition in a child, before the age of schooling, is of grave prognosis, because it is almost certain to progress, so that in a few years there may be 10 or 15 D of myopia, accompanied by serious fundus changes and defects of vision. The prognosis in high degrees of myopia is always grave. It

must be judged by the acuity of vision after correction and the condition of the fundus. In all cases there is some danger of retinal detachment occurring.

Treatment consists in wearing suitable correcting glasses and attention to the hygiene of the eyes. Each case must be considered on its merits.

As regards the ordering of glasses in myopia every surgeon agrees that *myopia must never be over-corrected*. Opinions differ as to details. In low myopia, up to 5 or 6 D (young children excepted), no harm is done by ordering the full distant correction for constant use, but if it is done the patient must be warned not to hold near work closer than ordinary reading distance. Many surgeons order glasses weaker by 2 or 3 D for near work. This has the effect of making the patients artificially presbyopic, *i.e.*, if they hold the work at reading distance they exert 2 or 3 D less accommodation than an emmetropic person would do, or than they themselves would do if wearing full correction. Many patients are more comfortable for near work with the weaker glasses; others derive no benefit. There is no doubt that the principle is derived from the fallacy that accommodation, *per se*, has a deleterious effect upon myopia. But there are some inherent objections to the weaker glasses. The patients often bring their work closer than reading distance. As far as accommodation is concerned this matters less with the weak glasses than with the strong, but mere accommodation is of little importance. It is convergence which is the important factor. In order to read at reading distance there must be some convergence. If the artificial presbyopic correction is given no stimulation to converge is supplied by the act of accommodation, so that in order that physiological requirements may be satisfied the visual axes should be parallel. This can only be effected by combining the glasses with prisms, bases in (*vide* p. 541). If the work is held too near

still more convergence is required, and the arguments apply still more strongly.

In general, in low myopia, the full correction may be ordered for constant use, with minute instructions as to near work; in the event of any discomfort being experienced, weaker glasses should be ordered for near work, especially if much reading and sewing, &c., is engaged in.

In high myopia it is wise always slightly to under-correct even for distance, and the same or still weaker glasses may be ordered for near work. In the highest grades the patient often sees best with glasses which are decidedly weaker than the full correction; he should be allowed to choose the ones he prefers. One reason is that the strong glasses very markedly diminish the size of the retinal images and make them very bright and clear. The retinal images are diminished because the glasses have to be worn further from the eye than the anterior focal plane (*vide* p. 49); glasses for high myopia should therefore be made to fit as close to the eyes as possible. The very bright, clear images are uncomfortable because the retina is unduly irritable, probably owing to the fact that it has become accustomed to large indistinct diffusion images. Moreover much artificial astigmatism, and therefore distortion of the image, is produced by looking obliquely through strong glasses: it is found to be most disconcerting to those who begin the use of glasses or have them much strengthened late in life. Very short-sighted people get into the habit of turning the head rather than the eyes to avoid looking obliquely through the glasses. Some high myopes can find their way about much better without any glasses.

In very high myopia the requisite amount of convergence for near work may be impossible. Reading and other near work then becomes purely unioocular. Generally one eye is better than the other, and this eye is always used. The

effort to maintain convergence under impossible conditions is soon given up, which results eventually in the disused eye becoming divergent. There are other factors which tend to cause divergent strabismus in myopia (*vide* p. 574).

As regards hygienic measures in myopia, especially in the young, near work, apart from being held in the proper position, must be restricted. It is particularly important that it should not be done too continuously. More work can be done, with less harm to the eyes, by the interpolation of frequent short intervals of rest. It is best to give precise instructions as to the amount and distribution of near work. The illumination must be good, but not too bright, and it should come from behind and beside the patient's head. If the light is bad there is a strong tendency to bring the book or work closer to the eyes in order to enlarge the retinal image. Reading in bed and stooping over near work must be forbidden.

If the eyes are irritable, or the myopia is progressing, complete rest is imperative. Atropin should be instilled once a day for a prolonged period, tonics, especially iron and arsenic, should be given, and a change of air to the country, with plenty of healthy exercise, is desirable.

Operative treatment for high myopia.—If an eye has axial myopia of 24 D, its length will be about 31 mm. If the crystalline lens of such an eye is removed, parallel rays will be focused upon the retina without the intervention of any correcting lens, and the retinal images of distant objects will be larger than those of the emmetropic eye. Hence the extraction of the lens has been strongly advocated in high myopia. In completely successful cases the improvement is enormous. The operation is, however, attended with grave dangers. The eye with high myopia is a diseased eye, which withstands operative measures badly. The vitreous is likely to be fluid and to contain opacities. The retina and choroid are probably diseased, and the

tendency to detachment of the retina is increased by operation. No dogmatic rules can yet be given for the operation. I am guided by the following principles. (1) Only young patients should be operated upon; (2) the operation should be discission without subsequent curette evacuation unless it becomes imperative on account of tension; (3) there must be at least 15 D of myopia; (4) the fundus must be fairly healthy; (5) one eye only must be operated upon. The operation might be performed under less favourable circumstances if vision was so bad as to be useless, but such cases are rare.

Hypermetropia (*Syn.—Hyperopia*) or “far sight” is that dioptric condition of the eye in which, with the accommodation at rest, incident parallel rays come to a focus posterior to the light-sensitive layer of the retina. Hypermetropia may be due theoretically to any of the following conditions:—*A.* Abnormal shortness of the eye—*axial hypermetropia*. *B.* Abnormal curvature of the refracting surfaces—*curvature hypermetropia*: (*a*) too slight curvature of the cornea; (*b*) too slight curvature of one or both surfaces of the lens. *C.* Abnormal refractive index of the media—*index hypermetropia*: (*a*) too low index of the cornea or aqueous; (*b*) too low total index of the lens, due to (*a*) too low index of the nucleus, (*β*) too high index of the cortex, (*γ*) both these causes; (*c*) too high index of the vitreous. *D.* Abnormal position of the lens, *i.e.*, displacement backwards. *E.* Absence of the lens—*aphakia*. *F.* A combination of the above abnormalities.

As in myopia, the chief factor in clinical hypermetropia is abnormality in the length of the eye; in this case the eye is too short. It must be remembered that a small eye, though too short, is not necessarily hypermetropic, since there may be uniform diminution of all the parts. This is, perhaps, most easily understood if a diagram such as Fig. 29 is considered; if such a diagram is uniformly diminished,

e.g., by photography, the parallel rays will still come to a focus on the retina. As a matter of fact hypermetropic eyes are almost invariably also smaller than normal, a fact which is of great pathological importance (*vide* p. 310).

Curvature hypermetropia occurs commonly as a factor in astigmatism; it is almost unknown as a cause of spherical hypermetropia. Index hypermetropia accounts for the hypermetropia of old age (*vide* p. 62), and is to be attributed to increased refractive index of the cortex of the lens.

Hypermetropia rarely exceeds 6—7 D, which is equivalent to a shortening of the optic axis of 2 mm. Individual cases of much higher degrees, without other anomaly, such as coloboma or microphthalmia, have been recorded—up to 24 D.

In the young the condition may cause no symptoms. When symptoms are present or arise, they are chiefly referable to the abnormal amount of accommodation which these eyes are subjected to, and to the lack of consonance between accommodation and convergence (*vide* p. 539). As has been pointed out, the healthy youth has an ample reserve of accommodation, and if he happens to be hypermetropic he accommodates for distant and near objects without being conscious of the act. If he is weakly or does much near work the perpetual overaction of the ciliary muscle is likely to produce symptoms; the condition is often called accommodative asthenopia or "eye-strain." The symptoms are noticed chiefly after reading, sewing, &c., especially in the evening by artificial illumination. The eyes ache and burn; they may feel dry, so that blinking movements are more frequent than usual, or there may be lachrymation. The conjunctiva and edges of the lids become red, and actual blepharitis may be caused. If near work is persisted in, headache, usually frontal, comes on. Typical migraine may occur.

In young children hypermetropia is a predisposing cause of convergent strabismus (*q.v.*). In all cases latent convergence is often found in hypermetropes, though other forms of heterophoria may occur (*vide p. 575*). The presence of heterophoria increases the tendency to headache, &c.

In older patients no symptoms may be caused until the power of accommodation has diminished to the extent that the far point is beyond the range of comfortable reading distance. Near work has to be held farther off than usual in order to be seen clearly. The greater the degree of hypermetropia the sooner will this symptom arise. In other words, apparent presbyopia commences at an earlier age than usual. It must be carefully borne in mind that hypermetropia predisposes to glaucoma (*q.v.*) in elderly people.

Ophthalmoscopically the fundus may exhibit no abnormality. A bright reflex, suggesting the appearance of watered silk, is commoner in hypermetropic than in emmetropic or myopic eyes. The inferior crescent is also more common in these eyes than in others, as also abnormal tortuosity of the retinal vessels. In some cases optic neuritis is nearly simulated—pseudo-papillitis (*vide p. 404*).

Anatomically the eye is shorter than normal in hypermetropia: it is also usually smaller. The changes are not confined to the post-equatorial segment as in myopia. The diameter of the cornea is often reduced, and regular astigmatism is common. The anterior chamber is shallower than normal, owing partly to the normal size of the lens (*vide p. 310*). Little weight should be attached to the old observation that the circular fibres of the ciliary muscle are hypertrophied, the meridional atrophied, in hypermetropia. No anatomical abnormalities are found in the retina, choroid or optic nerve.

The new-born are almost invariably hypermetropic (mean 2.5 D). In the first decades of life the hyper-

metropia curve falls rapidly, remaining at about 50 per cent. after the twentieth year (Fig. 242). Hypermetropia shows no predilection for either sex. It is a well known fact that savages are usually hypermetropic. The higher mammals, especially the carnivora, are hypermetropic.

Treatment consists in prescribing the correcting glasses. Unless there are definite symptoms there is no reason for insisting upon the use of glasses in the young or middle-age¹. In elderly people the hypermetropia must be corrected for near work: the ordinary presbyopic correction must be added to the hypermetropic correction, but care should be taken that these cases are rather under- than over-corrected (*vide* p. 528).

In young children the requisite correction is estimated under atropin, confirmed if possible by subjective tests. The correction, allowing for the effect of atropin upon the tone of the ciliary muscle (*vide* p. 503), is ordered for constant use or only for near work according to the severity of the symptoms. If the degree of hypermetropia is high the use of the glasses may be commenced while the child is still under the influence of atropin. In older patients with high hypermetropia it is often unwise to order the full correction at once. The ciliary muscle has been over-worked so long that complete relaxation does not occur immediately. If the full correction is ordered the eye, with its contracted ciliary muscle, *plus* the glass, is made myopic: the patient cannot see clearly at a distance, and is liable to discard the spectacles. In these cases rather more than the amount of manifest hypermetropia should be ordered. The patient is told to return in three or six months, when stronger glasses are ordered, and so on until the full correction can be borne with comfort.

Astigmatism is that condition of refraction in which a point of light cannot be made to produce a punctate image upon the retina by any spherical correcting lens.

The varieties of regular astigmatism have been already enumerated (*vide* p. 54).

Regular astigmatism, the only form which permits of optical correction, invariably produces greater or less defect in visual acuity. It is particularly liable to cause the worst forms of asthenopia or "eye-strain": the asthenopia in these cases is only in part accommodative. It is often worse in the lower degrees of astigmatism than in the higher. This is probably due to the eye endeavouring so to accommodate as to produce a circle of least diffusion (*vide* p. 53) upon the retina. Aching of the eyes, severe headaches, and typical migraine are complained of: the eyes quickly become fatigued with reading, and the letters are described as "running together."

Regular astigmatism is usually a congenital defect, due in most part to difference in curvature of the cornea in different meridians. It must be remembered that frequently the cornea is not alone at fault. Corneal astigmatism may be increased or partially corrected by lenticular astigmatism: hence the methods for correcting astigmatism, such as the ophthalmometer, &c., which are wholly dependent upon estimation of the corneal defect, are quite untrustworthy except in aphakia.

Regular astigmatism may be traumatic, following a wound, usually surgical, in the corneo-scleral margin. The contraction of the scar causes flattening of the cornea in the meridian at right angles to the wound. The astigmatism due to this cause continues to alter for many weeks after the injury, so that glasses should not be ordered for at least six weeks.

Treatment—In all cases in which astigmatism causes asthenopic symptoms the full correction should be ordered for constant use, *i.e.*, both for distant and near vision. If there is a high degree of hypermetropia or myopia, associated with a low degree of astigmatism, the effect of the cylinder

upon distant vision should be tested. If it produces no appreciable improvement simple spherical glasses should be tried first. It should be remembered that glasses placed before the eyes only correct the refraction accurately when the visual axis passes through the optical centre of the lens. When the eyes are directed to one side the lenses also act as prisms, and further, the lenses are tilted relatively to the eyes so that an astigmatic effect is produced. In the case of high spherical lenses the astigmatic effect is considerable, and may easily counteract or double the effect produced by a weak cylinder combined with the sphere. Hence weak cylinders are seldom of much use when combined with high spheres.

In low astigmatic errors the instruction as to the use of glasses depends upon the amount of asthenopia. The relief of the discomfort experienced may not be worth the trouble of wearing glasses constantly. In these cases they should be ordered for near work only, and if this fails to eliminate the symptoms the advice should be given to wear them constantly.

Aphakia is the condition of the eye when the crystalline lens has been removed. The eye is extremely hypermetropic if it was emmetropic or had only a low grade of ametropia before removal of the lens. The hypermetropia, as estimated by the correcting lens required when worn in the usual position, is about 10 or 11 D if the eye was previously emmetropic.

Accommodation is, of course, lost. The anterior chamber is deep, the iris tremulous, and there is often a coloboma of the iris upwards. In cases of doubt as to the absence of the lens the Purkinje-Sanson reflexes from the lens surfaces should be sought.

With the ophthalmoscope opacities will probably be found in the pupillary area, consisting chiefly of remnants of the lens capsule. They should be examined by oblique

illumination, by the mirror, and by the direct method. If they are dense, discission is indicated before attempting to correct the refraction; if they are slight, the advisability of needling depends upon the amount of vision obtained with correction.

In addition to the hypermetropia, there is always some astigmatism in those cases in which a corneal or corneo-scleral section has been made. If the section is in the upper part of the cornea, the astigmatism is against the rule; *i.e.*, the cornea is flattened in the vertical meridian. The astigmatism usually amounts to 2 or 3 D.

Treatment.—The refractive error is determined by retinoscopy and by subjective tests. The ophthalmometer may afford help in these cases. Great patience is often necessary, for the patients do not readily accommodate themselves to the new optical conditions. A 10 or 11 D convex lens combined with a +2 or +3 D cylinder, axis horizontal, is about the correction usually required for distance. The sphere must be stronger by 4 D for near work. The correcting glasses should not be ordered earlier than six weeks after the operation, both on account of the necessity of resting the eye and because the astigmatism changes rapidly during the first few weeks.

If one eye only has been operated upon, the other being cataractous, reversible spectacle frames may be ordered. In them the bridge is horizontal, so that when the distant glass is being used the near glass is in front of the eye which has not been operated upon, and *vice versa*.

Anisometropia is the condition in which the refraction of the two eyes shows a considerable difference. A slight difference is very common. The condition may cause asthenopic symptoms. All varieties and degrees of anisometropia occur. In the lower grades there is usually binocular vision, though it is imperfect. In the higher grades it is impossible without correction. Vision

is then unioocular, and there is some danger of the eye which is not used becoming divergent. If one eye is nearly emmetropic and the other myopic, the former may in some cases be used for distant, the latter for near, vision.

Treatment.—Correction of anisometropia offers many difficulties. It has already been mentioned that if correcting glasses are placed at the anterior focal plane of the eye, the retinal images are the same size as the emmetropic retinal image. In practice the glasses are farther from the eyes. Consequently with convex glasses the retinal image is enlarged, with concave diminished. In high grades of anisometropia, therefore, there will be a considerable difference in the size of the retinal images of the two eyes. Patients find it difficult or impossible to fuse these sharp but diverse images. Moreover on looking obliquely through the glasses the prismatic effect and the distortion are different in the two eyes, enhancing the discomfort. No universal rules can be given for the glasses which should be ordered. The following suggestions will generally be found to work well:—

If the difference between the two eyes is less than 4 D, the full correction should be ordered for constant use: they should be perseveringly worn for at least six weeks. If still they cannot be borne, it will probably be necessary to correct only the less ametropic eye for distance.

In patients of less than twelve years of age the full correction should also be ordered for constant use, even if the difference is greater than 4 D. The more ametropic eye should be exercised alone, as in cases of concomitant strabismus (*vide* p. 571). Very often the treatment will fail, but it should be tried in the interests of binocular vision. It is almost certain to fail in older patients.

When the 1.st correction cannot be worn constantly, both eyes can often be made to work together in comfort

for near work by making each eye artificially presbyopic to the extent of half the difference between the two eyes. For example, suppose one eye is emmetropic and the other has 3 D of myopia, the patient will be most comfortable with $+1.5$ D in front of the emmetropic, and -1.5 D in front of the myopic eye for near work.

THE CORRECTION OF ERRORS OF REFRACTION.

The correction of errors of refraction has been already briefly sketched. It will be well, however, to outline the method to be adopted in systematically examining for and correcting these errors, and to indicate the requirements which should be satisfied by spectacles.

If the patient is less than fifteen years of age, —

(1) Test the distant and near vision, if the child knows his letters :

(2) Test the pupil reactions :

(3) Test the muscular balance by the screen test (*vide* p. 560) :

(4) Examine the fundi with the ophthalmoscope.

Then order ungu. atropini, 1 per cent., to be inserted with a glass rod, three times a day for at least three days.

At the next visit—

(1) Determine the error of refraction by retinoscopy :

(2) Thoroughly examine the fundus with the ophthalmoscope :

(3) Confirm the retinoscopy by subjective tests, if the child knows his letters :

(4) Order the correction according to the principles enunciated in the paragraphs devoted to the respective types of refractive error.

If the patient is between fifteen and twenty-five years of age, the same procedure should be adopted, but in

many cases the prolonged action of atropin so seriously interferes with the patient's employment that it may be replaced by homatropin.

If the patient is between twenty-five and forty,—

(1) Test the distant vision, the manifest hypermetropia, and the near vision :

(2) Test the pupil reactions and the range of accommodation :

(3) Thoroughly examine the eyes with oblique illumination and by the ophthalmoscope.

If it is concluded that the defect is simply due to error of refraction, the further procedure depends upon the results of the subjective testing:—

(1) If the vision is 6/6 and J 1, with a low degree of manifest hypermetropia and few asthenopic symptoms, glasses may be ordered according to the amount of manifest hypermetropia (*vide* p. 519).

(2) If the vision is less than 6/6, no Hm, but J 1 is read fluently when the type is held closer to the eyes than normal, the patient has probably simple myopia. In general homatropin should be instilled, and the glasses ordered according to the retinoscopy and subjective tests under the mydriatic. The expert may feel justified in ordering glasses without using a mydriatic, judging by the subjective tests and his ophthalmoscopic examination, confirmed by retinoscopy without a mydriatic.

(3) If the vision is less than 6/6, and 6/6 cannot be read with any spherical glass, or if some letters only of 6/6 can be read—letters with oblique lines, *e.g.*, Z, being missed in that line and even in the other lines—the patient is probably astigmatic. Homatropin must be instilled, and the refraction corrected by retinoscopy.

If the patient is over forty, the examination will be exactly as for one between twenty-five and forty, except

that presbyopia must be taken into account, and greater care must be exercised in instilling a mydriatic. Presbyopia affects the distant vision in hypermetropes in such a manner that although 6/6 may not be read with the unaided eye, it may be possible with a convex lens. Its effect upon near vision is discussed elsewhere. It is of little use to test the near vision of a presbyope without the glass which is necessary to correct the presbyopia, since no useful knowledge is obtained. If the vision cannot be improved up to 6/6 with a spherical lens, the patient is probably astigmatic, or has some disease of the eye, *e.g.*, incipient cataract. If ophthalmoscopic examination indicates merely the presence of astigmatism, homatropin (*never atropin*) should be instilled, but *in every case in which this is done one drop of eserin, 0.5 per cent., is instilled into the eye before the patient leaves.* After estimating the error of refraction by retinoscopy it is advisable to see the patient again after the effects of homatropin have passed off before ordering glasses for near vision.

Spectacles.—In children spectacles with large round or "round oval" "eyes" should be ordered, otherwise the child may look over them.

In adults with astigmatism spectacles or rigid pince-nez must be ordered, never "folders." The latter are never to be recommended, and are absolutely contra-indicated in astigmatism.

It is very important that all glasses fit accurately. In distant glasses the lenses must be centred so that the centres are exactly opposite the centres of the pupils when the visual axes are parallel. Near glasses are decentred slightly inwards, and the lenses are tilted so that the surfaces form an angle of 15° with the plane of the face.

Various forms of bifocal glasses are sometimes used. In

them the upper part contains the distant correction, the lower part the near. If recommended, patients should be warned that they may experience some difficulty in going downstairs and so on, since objects on the ground will appear blurred when looking through the glasses.

If tinted glasses are desirable, *e.g.*, in high myopia, albinism, &c., the correcting lenses may be tinted.

CHAPTER XXV.

ANOMALIES OF ACCOMMODATION.

Presbyopia has been already explained (*vide* p. 62). It is a physiological condition and therefore not properly included amongst anomalies of accommodation. It is convenient, however, to discuss its clinical treatment here, since it is so nearly allied to the correction of errors of refraction.

It has been shown that no convex lens of greater strength than 4 D should be ordered to correct presbyopia in the absence of hypermetropia; further, that the rule that a presbyope requires +1 D for every five years after forty errs on the side of being a somewhat liberal allowance. Rather less, and never more, should be ordered. Some people, especially if they have hypermetropia, and therefore still stronger glasses for near work, have discomfort with their proper presbyopic correction. It is usually due to the absence of any stimulus, derived from the accommodative effort, to converge (*vide* p. 539). Theoretically the visual axes should be parallel when the presbyopic correction is used. Convergence, however, is necessary in order that both eyes may see the near object. It may be eliminated by combining prisms, bases in, with the correcting glasses.

In many occupations, *e.g.*, bootmaking, carpentering, and so on, the work is held at a greater distance than ordinary reading distance. The correction for work must then be ordered according to the distance, a weaker glass being required for a distance greater than 22 cm.

Myopes of course may require no glass for near work. Their presbyopic correction is estimated by the algebraic sum of their myopia and presbyopia.

Paralysis of Accommodation, or *cycloplegia*, occurs in disease as well as from the direct action of drugs (cycloplegics) such as atropin and homatropin. Unilateral cycloplegia is generally due to drugs, contusion (*vide* p. 438), or to paralysis of the third nerve. Bilateral paresis, less commonly paralysis, is most frequent after diphtheria, but may occur after debilitating illness, influenza, syphilis, diabetes, cerebral disease, &c. Paresis of accommodation occurs as a premonitory symptom of glaucoma.

In complete paralysis the sphincter pupillæ is also generally paralysed, so that the pupil is widely dilated. In paresis the pupil may be scarcely at all affected, especially after diphtheria, but in this disease the reverse of the Argyll-Robertson pupil may be met with, viz., loss of reaction to accommodation with retained reaction to light. The symptoms depend upon the condition of the refraction. If the patient is myopic, the defect may pass quite unnoticed; if he is emmetropic, near vision will be alone affected; if he is hypermetropic, both distant and near vision will be affected, but particularly the latter. In paresis it may be possible to diagnose the condition only by carefully measuring the range of accommodation.

The prognosis is good in cases due to drugs or diphtheria. In traumatic cases the condition may be permanent.

Treatment is that of the cause. Post-diphtheritic cases should be treated with tonics, especially strychnine. Whenever the condition is bilateral near work can be carried on by using suitable convex glasses, as in the correction of presbyopia. As a rule, however, the eyes should be kept at rest so that it is inadvisable to order glasses. Miotics

are sometimes used, but they may do harm and seldom do good. The constant current may be tried.

Spasm of Accommodation.—It has already been mentioned that the ciliary muscle has physiological tone, which is abrogated by atropin, and is equivalent to about one dioptré. In some cases it is found that atropin produces a much greater effect. This can only be due to spasm of the ciliary muscle. It is found only in young patients, and, contrary to what might be expected, more often in myopes than in hypermetropes. In any case an actual or relative myopia is produced. Spasm of accommodation is produced artificially by the installation of miotics.

In spontaneous spasm of accommodation there is nearly always some error of refraction. The eyes have usually been subjected to too much near work under unfavourable circumstances. The condition should not be diagnosed unless proved to be present by the use of atropin.

Treatment consists in the use of atropin for several weeks. The amount of near work must be limited and carried out under good conditions, the error of refraction being carefully corrected.

SECTION V.

DISORDERS OF MOTILITY OF THE EYE.

CHAPTER XXVI.

ANATOMY AND PHYSIOLOGY OF THE EXTRINSIC OCULAR
MUSCLES.

The internal rectus is inserted into the sclerotic about 5.5 mm. to the nasal side of the corneo-scleral margin, the inferior rectus 6.5 mm. below, the external rectus 7 mm. to

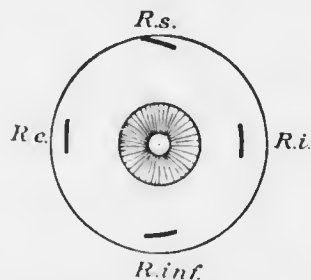


FIG. 243.—Lines of insertion of the recti muscles of right eye seen from in front.

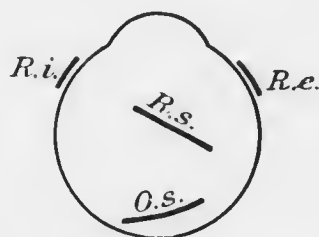


FIG. 244.—Lines of insertion of the oblique muscles and of the external and internal recti of right eye, seen from above.

the temporal side, and the superior rectus 7.5 mm. above (Fig. 243). The tendons are about 10 mm. broad. The origin of these muscles around the optic foramen is much to the nasal side of the posterior pole of the eye. It has been proved that when the extrinsic muscles act they turn the eye around a spot which is called the centre of rotation

(Fig. 245). This spot is situated about 13.5 mm. behind the centre of the cornea. It lies in the same horizontal plane as the lateral recti. Consequently when the internal or external rectus acts it rotates the eye horizontally inwards or outwards respectively around a vertical axis

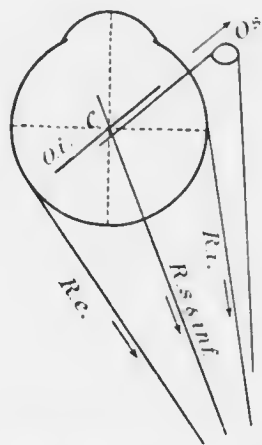


FIG. 245.—Diagram of the lines of action of the extrinsic muscles of left eye. (After Fick.) *C*, centre of rotation. The arrows show the directions of action of the muscles. *R.e.*, external rectus; *R.i.*, internal rectus; *R.s.* & *inf.*, superior and inferior recti; *O.s.*, superior oblique; *O.i.*, inferior oblique.

through the centre of rotation without any rotation about the horizontal axis. When, however, the superior rectus acts, it not only pulls the eye upwards, but also inwards, whilst there is some rotation of the cornea, so that the vertical meridian assumes a direction from above down and out (torsion). Similarly when the inferior rectus acts the eye is pulled down and in, the vertical meridian of the cornea being deviated so that it lies from above down and in (Fig. 246).

The oblique muscles are inserted into the sclerotic behind the level of the centre of rotation (Fig. 244). Their direction of action is from behind forwards and inwards. Hence the superior oblique pulls the eye downwards and outwards, the inferior oblique upwards and outwards. The mechanism is so arranged that when the superior rectus and inferior oblique act simultaneously the eye moves directly upwards; *i.e.*, the upward movement caused by each muscle is summated, whilst the inward movement and corneal rotation of the superior rectus are exactly compensated by the outward movement and contrary corneal torsion of the inferior oblique.

Similarly when the inferior rectus and superior oblique act simultaneously the eye moves directly downwards.

Every movement of the eyeball is a synkinesis (*vide* p. 65). In adversion not only does the internal rectus act, but also the superior and inferior recti, and it has been shown that the antagonistic muscles are not merely relaxed, but are actively inhibited. In abversion the external rectus and both obliques are in action. In elevation the superior rectus acts consonantly with the inferior oblique. In depression the inferior rectus acts with the superior

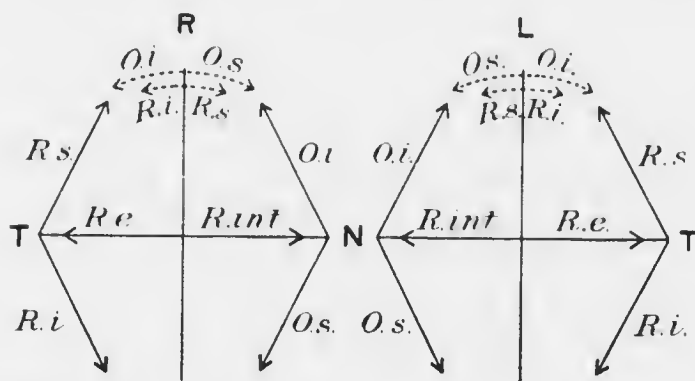


FIG. 246. Diagram of the lines of action of the extrinsic muscles upon the cornea. (Elschnig.) R, right eye; L, left eye; T, temporal sides; N, nasal sides. The dotted lines show the torsional effects.

oblique. The movements already described are all around three primary axes—vertical (movements in and out), coronal (movements up and down), and sagittal (torsion)—which pass through the centre of rotation. Still more complicated are the movements about secondary axes, *i.e.*, axes passing through the centre of rotation in some other direction, such as movements up and in, up and out, down and in, down and out.

Not only is there unioocular synkinesis: under normal circumstances there is always also binocular synkinesis.

Adversion of one eye is accompanied by abversion of the other eye—conjugate deviation; elevation or depression of one eye is always accompanied by elevation or depression respectively of the other eye. The only exception to this rule is the bilateral adversion of the eyes in convergence. Elevation of both eyes is accompanied by slight abversion

(divergence), depression by slight adversion (convergence).

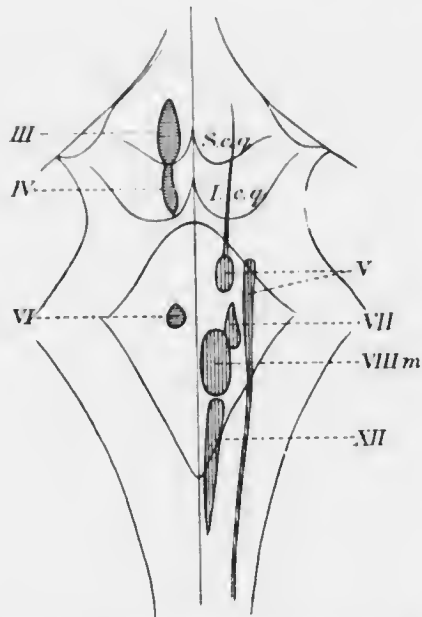


FIG. 247.—Diagram of the positions of the nuclei of the third, fourth, and sixth nerves, seen from above. *S.c.g.*, superior corpus quadrigeminum; *I.c.g.*, inferior corpus quadrigeminum.

The oculomotor, or third cranial nerve, supplies all the extrinsic muscles except the external rectus and superior oblique; it also supplies the sphincter iridis and ciliary muscle. The superior oblique is supplied by the fourth nerve, and the external rectus by the sixth nerve. A thorough knowledge of the arrangement of the nuclei of the cranial nerves in the mid-brain and medulla, and of

the course and relations of the nerves to their destinations, is requisite for accurate diagnosis of the seat of the lesion in cases in which they are involved.

The third and fourth nuclei form a large continuous mass of nerve cells situated near the middle line in the floor of the aqueduct of Sylvius beneath the corpora quadrigemina or colliculi (Figs. 247—9). The cells nearest

the middle line towards the anterior part of the third nucleus are smaller than the others; they, with the cells of the opposite side, form an unpaired nucleus with two divergent horn-like processes in front (the Edinger-Westphal nuclei) (Fig. 251), which probably supplies fibres to the ciliary muscle (accommodation) and sphincter iridis (constriction of the pupil). It is probable that in the great large-celled lateral nucleus the levator palpebræ is represented most anteriorly, then from before backwards elevation of the eye, adversion, and depression, whilst abversion is relegated to the sixth nucleus, much farther back in the medulla (Fig. 251). There is little decussation of the fibres from the third nuclei of the two sides in the anterior part, but a considerable amount in the posterior part.

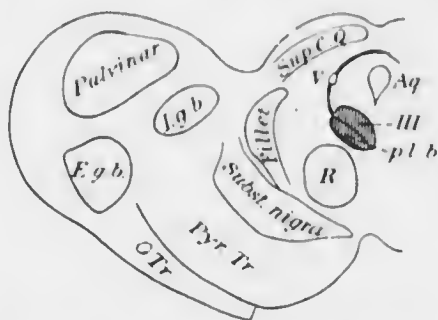


FIG. 248. Diagram of transverse section of the mesencephalon at the level of the third nucleus (level of 3, Fig. 253). *Supr. c.q.*, superior corpus quadrigeminum; *R.*, red nucleus; *I.g.b.*, internal geniculate body; *E.g.b.*, external geniculate body; *O.Tr.*, optic tract.

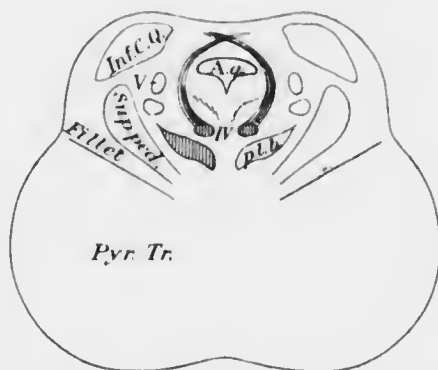


FIG. 249.—Diagram of transverse section of the mesencephalon at the level of the fourth nucleus (level of 2, Fig. 253). *Aq.*, aqueduct of Sylvius; *Inf. c.q.*, inferior corpus quadrigeminum; *p.l.b.*, posterior longitudinal bundle; *Supr. ped.*, superior peduncle of the cerebellum; *Pyr. Tr.*, pyramidal tract.

The sixth nucleus is in the immediate vicinity of the facial (seventh) nucleus (Figs. 247, 250), the fibres from which make a large bend around the sixth nucleus (Fig. 252). Hence vascular and other lesions of the sixth nucleus are very liable to be accompanied by facial paralysis.

A large and important tract of nerve fibres, derived in part from the anterior columns of the spinal cord, lies below and close to the third, fourth and sixth nuclei. This is the posterior longitudinal bundle (Figs. 248—50, 253).

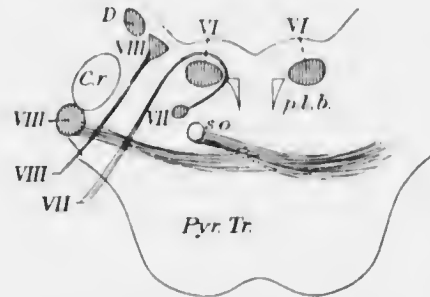


FIG. 250. Diagram of transverse section of the pons at the level of the sixth nucleus (level of 1, Fig. 253). *p.l.b.*, posterior longitudinal bundle; *D*, Deiter's nucleus; *s.o.*, superior olive; *Cr.*, restiform body; *Pyr. Tr.*, pyramidal tract.

Fibres pass between it and the nuclei under consideration: they probably have important functions in the co-ordination of movements and equilibration, which are so intimately related with vision. Amongst these fibres are also some which link up the sixth nucleus of one side

with the third nucleus of the other (Fig. 253): these are concerned in conjugate deviation of the eyes to one or other side. Hence when one sixth nucleus is destroyed the patient is unable to turn his eyes to the same side, though the power of convergence is unimpaired. Nuclear sixth nerve paralysis therefore causes loss of conjugate deviation of the eyes to the same side and is very likely to be associated with facial paralysis on the same side, whereas peripheral sixth nerve paralysis causes only loss of power of movement of the same eye to the same side.

The student should revise his knowledge of the

anatomical relations of these and the neighbouring cranial nerves in their course from the nuclei to their respective terminations.

Orientation.—Orientation of objects in space depends upon their relation to the nodal point of the eye, *i.e.*, the position of an object is determined by the line passing through the object and the nodal point, the spot where this line cuts the retina being the position of the retinal

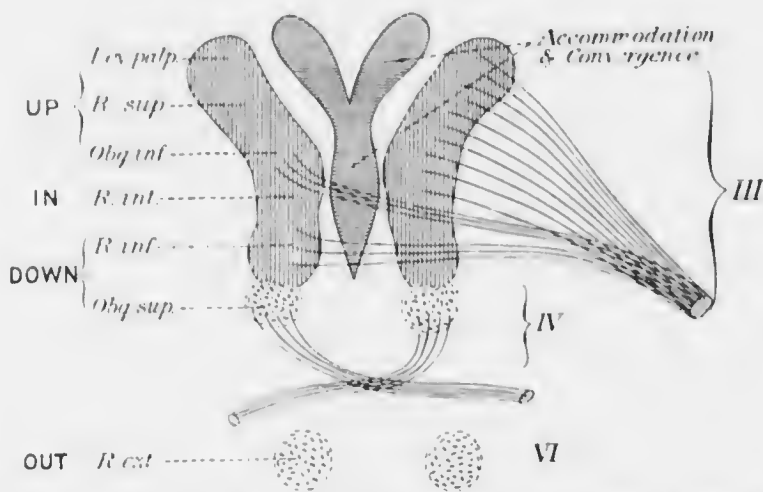


FIG. 251.—Diagram of the probable position of the nuclei of origin of the fibres to the ocular muscles in the third, fourth and sixth nuclei.

image of the object. Conversely an object is said to be *projected* along the line joining the retinal image with the nodal point. Objective orientation determines the relative positions of objects to each other. Subjective orientation, or the exact relation of the situations of objects to ourselves, is much more complex, depending upon an accurate knowledge of the position of the body and of the eyes in the body, derived largely from the muscular sense.

Corresponding Points.—When a distant object is

looked at the visual axes are practically parallel: the object forms an image upon each fovea centralis. An object to one side of the object looked at forms its retinal images upon the temporal side of one retina and upon the nasal side of the other: these are called corresponding points. Points on the two retinæ which are not corresponding points in this sense of the term are called *disparate points*.

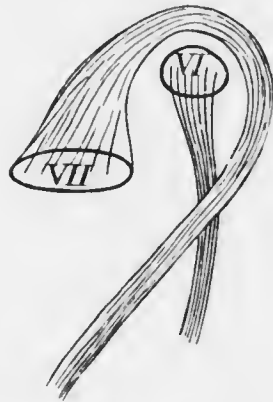


FIG. 252. Diagram of the sixth nucleus and its relation to the nucleus and the emerging fibres of the seventh nerve. The relations cannot be accurately depicted in one plane.

If an object forms its retinal images upon disparate points it will be seen double (binocular diplopia). If the disparity is slight there is a great tendency to move the eyes so that the images may be fused. It will be noticed that the two foveæ are corresponding points.

When a near object is looked at the eyes converge the requisite amount to bring the two retinal images of the object upon the two yellow spots.

Binocular Vision.—When the eyes are normal the individual sees clearly with both eyes the object looked at. The retinal images of the two eyes are not, however, identical. This is obvious when it is remembered that there is a considerable distance between the two eyes. If the object is a solid body, *e.g.*, a cube, the right eye sees a little more of the right side of the object, and *vice versa*. The two images are fused psychologically, and it is this fusion of the slightly diverse images, combined with other facts derived from experience, which enables the person to appreciate the solidity of objects. The estimation of the relative distance of objects in or near the line

of vision is still more complex. It probably depends upon the fact that the images of objects farther or nearer than the object fixed are situated at disparate points on the retinae. A more distant object will produce heteronymous diplopia, a nearer homonymous diplopia, as can be shown by experiment. The diplopia is suppressed in actual vision, but it produces a psychological impression which is translated into appreciation of distance. It will suffice if it is well understood that accuracy of stereoscopic and topical vision depends upon good sight with both eyes simultaneously.

Convergence and Accommodation.

—When a distant object is observed by an emmetropic person the visual axes are parallel and no effort of accommodation is made. If a near object is observed the eyes converge upon it and an effort of accommodation corresponding with the distance of the object is made. There are various

methods of recording the amount of convergence. One very convenient method employs the *metre angle* as a unit. Suppose an object to be situated in the median line between the two eyes at a distance of one metre from them. Then the angle which the line joining the object with the centre of rotation of either eye makes with the median line is called one metre angle (Fig. 254). With an interpupillary distance of 60 mm. this angle is about 2° . If the object is two

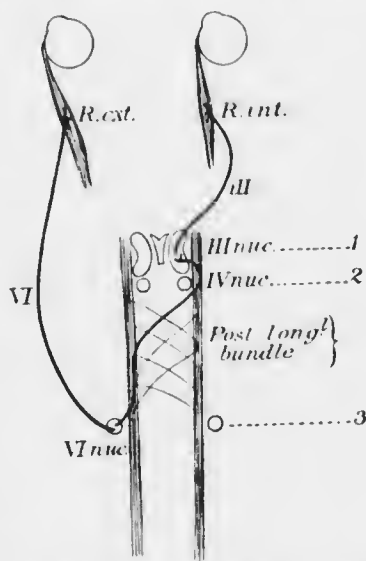


FIG. 253.—Diagram of the course of the fibres from the sixth nucleus which are concerned in conjugate deviation of the eyes. 1, 2, 3, lines of section of Figs. 248—250.

metres away the angle is approximately half as great, or $\frac{1}{2}$ m.a. If the object is 50 c.m. away the angle will be 2 m.a. Now, the amount of accommodation which an emmetropic eye exercises in order to see clearly an object 1 m. away is 1 D, 2 m. away 0.5 D, 50 cm. away 2 D, &c.

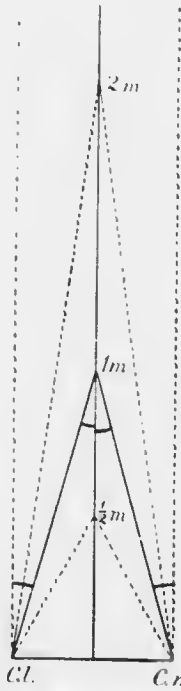


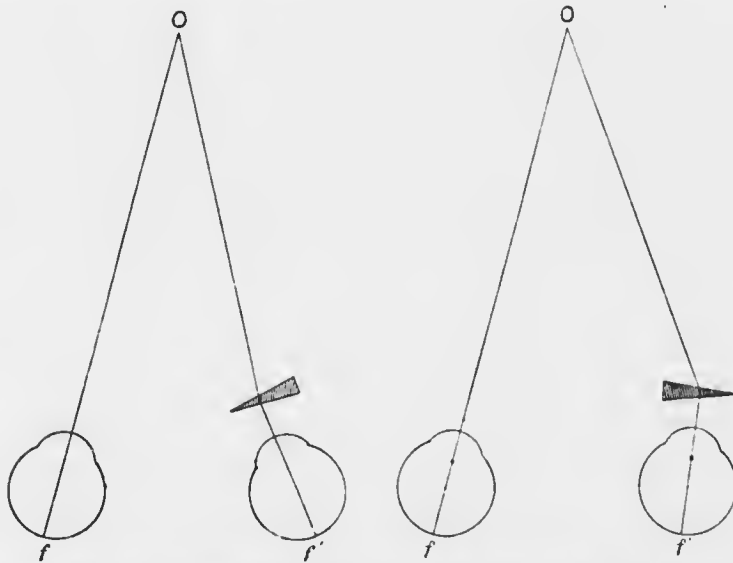
FIG. 254.—Diagram of the metre angle.
Cr., *Cl.*, centres of rotation of the right and left eyes.

Hence with an emmetropic person the amount of convergence, reckoned in metre angles, is the same as the amount of accommodation, reckoned in dioptres.

The amount of convergence can also be measured by prisms. If an object one metre distant is looked at through a prism with the base directed outwards placed before one eye, *e.g.*, the right, it may still be seen as a single object (Fig. 255). Now in order that the object may form its image upon the fovea of this eye it is necessary that the eye should be turned inwards an amount corresponding with the angle of deviation of the prism. This method, besides affording a method of recording amounts of convergence, also shows that the relationship between convergence and accommodation is somewhat elastic. In the experiment described, although the amount of accommodation exercised remains the same, the amount of convergence is altered. Indeed, if the

relationship were quite unalterable a hypermetropic person would invariably have diplopia, for his accommodation is always in excess of the corresponding value of the amount of convergence exerted by an emmetrope. Moreover, the power to converge would gradually be lost *pari passu* with loss of accommodation in advancing age.

If in the experiment described above the prism is held before the right eye with its base inwards it will still be found possible to see the object single (Fig. 256). Further, a distant object is still seen single under the same conditions if the prism has only a small angle of deviation. This can only be accomplished by active divergence of the eyes to an amount corresponding with the angle of deviation



FIGS. 255—256.—Diagrams of the action of adducting and abducting prisms. O, object of fixation: f , f' , left and right foveae centrales.

of the prism. The power of divergence, which may therefore be considered to be negative convergence, is much less than the power of convergence. Just as the difference in the amount of accommodation between the far point and the near point is called the amplitude of accommodation, so the difference in convergence between the far point and the near point is called the *amplitude of convergence*. Whereas, however, negative accommodation, *i.e.*, ability to see a point beyond infinity, or in less mathematical terms,

so to flatten the lens that a myope could see clearly without glasses, is impossible, negative convergence, as has been seen, is possible within small limits. The amplitude of convergence therefore consists of a negative portion and a positive portion. The former is measured by the strongest prism, base inwards, which can be borne without producing diplopia in distant vision. The latter is measured by the strongest prism, base outwards, which can be borne without producing diplopia in the nearest possible vision.

The convergence synkinesis is so co-ordinated that the energy exerted is accurately divided between the two internal recti. Hence it is found that the effect is the same in the above experiments whether the prism is placed before only one eye, or a prism of half the strength is placed before each eye.

CHAPTER XXVII.

PARALYTIC AND KINETIC STRABISMUS. NYSTAGMUS.

Strabismus (*στρέφειν*, to turn) or *squint* is a generic term applied to all those conditions in which the visual axes assume a position relative to each other different from that required by the physiological conditions. Strabismus may be provisionally divided into two great groups: (1) those due to known cause; (2) those due to unknown cause. To the first group belong (*a*) those due to paresis or paralysis of one or more of the extrinsic muscles—*paralytic strabismus*; (*b*) those due to irregular activity or over-activity of individual muscles or groups of muscles—a sub-group which I propose to designate *kinetic strabismus*. To the second group belong (*a*) those cases which are characterised by the fact that the visual axes, though abnormally directed, retain their relative position in all movements of the eyes; they are therefore termed *concomitant* or *comitant strabismus*. Another sub-group of the second class is (*b*) cases in which there is *latent strabismus* or *heterophoria*.

PARALYTIC STRABISMUS.

Signs and Symptoms.—(1) *Limitation of Movement.*—In paralysis of an ocular muscle the ability to turn the eye in the direction of the normal action of the muscle is diminished or lost. In slight paresis the defect in mobility may be so slight as to escape observation without special tests. In all positions in which the

affected muscle is not brought actively into play the visual axes assume their normal relationship.

Limitation of movement is tested roughly by fixing the patient's head and telling him to follow the movements of the surgeon's finger. The finger should be held vertical in testing horizontal movements, horizontal

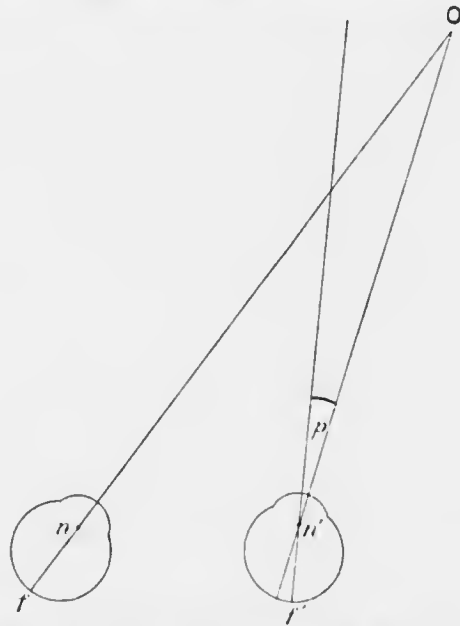


FIG. 257. Diagram of primary deviation in paresis of the right external rectus. p , angle of primary deviation; n , n' , left and right nodal points.

in testing vertical movements. An accurate record of the movements of each eye can be obtained by taking the field of fixation. The patient is seated at the perimeter as for recording the field of vision. With the head fixed and the other eye screened the patient looks as far as possible along the arc of the perimeter, test types being moved in from the periphery until he is just able to read them. The normal field of fixation is about 50° downwards and 45° in all other directions.

When the eyes are turned in the direction of the normal action of the paralysed muscle the affected eye remains stationary. It deviates therefore relatively to the other eye; this position is called the *primary deviation* (Fig. 257). The angle of deviation is the angle which the line joining the object observed with the nodal point makes with the visual line.

If the sound eye is covered by a screen, and an attempt is made to fix an object so situated that the paralysed muscle is brought into play, it will be found that the eye behind the screen deviates more than the primary deviation of the paralysed eye. For example, if the right external rectus is paralysed and the left eye is covered, then on attempting to fix an object situated to the right with the right eye the left eye will deviate very much to the right, so much in fact that its line of vision is well to the right of the object fixed. Hence, if the screen is removed suddenly the left eye will spring back to the left so as to take up fixation. This deviation of the sound eye is called the *secondary deviation* (Fig. 258). The reason why the secondary deviation is greater than the primary is that in conjugate deviation of the eyes the nervous energy is equally distributed between the muscles of the two eyes. Now the effort to take up fixation with the paralysed or paresed eye is much greater than normal. Consequently the sound eye behind the screen moves through a greater distance than normal, *i.e.*, through a distance corresponding with the excessive effort exerted. This feature is of great importance because when well marked it distinguishes paralytic squint from the concomitant type in which the secondary deviation is equal to the primary.

(2) *Diplopia*.—The chief complaint of patients with paralysis of an extrinsic muscle is often that they see double. Diplopia occurs only over that part of the field of fixation towards which the affected muscle or muscles

move the eye. If both eyes are functional and one deviates, *i.e.*, if the visual axes are not parallel in looking at a distant object, or if the amount of convergence is not accurately adapted to the position of the object in near vision, *binocular diplopia* results. When the deviation is

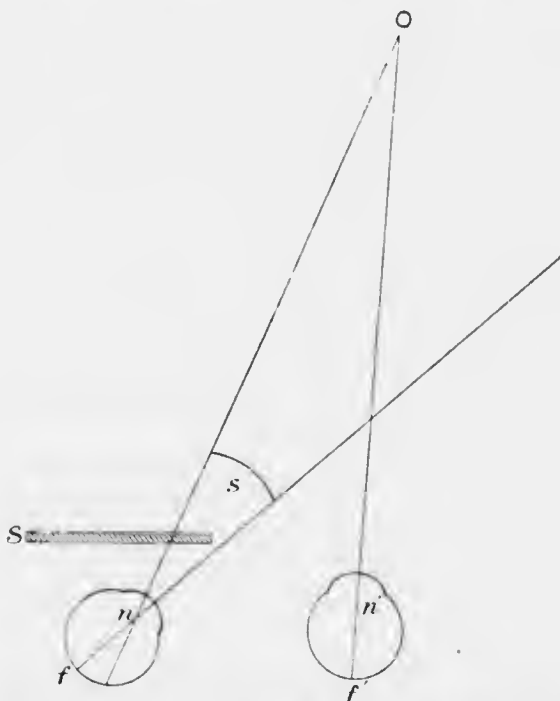


FIG. 258.—Diagram of secondary deviation in paresis of the right external rectus. *S*, screen in front of left eye; *s*, angle of secondary deviation.

due to paralysis of one or more extrinsic muscles, the eye on the sound side fixes the object accurately, whilst the other eye deviates. Suppose the right eye fixes accurately whilst the left deviates inwards, a bright, sharply defined foveal image is seen with the right eye. The image formed by the object on the left retina, falling as it does upon the line joining the nodal point with the object, lies

to the nasal side of the retina. The patient being unconscious of the malposition of his eye orients the object subjectively as if the eye were straight. He knows from experience that objects which form their images upon the nasal side of the retina are situated to the temporal side. He therefore projects the object with this eye to left of its actual position.

This is called *homonymous diplopia*, because the object as seen by the right eye is, to the right of the object as seen by the left eye (Fig. 259).

If the left eye deviates outwards, *heteronymous* or *crossed diplopia* results, because the object as seen with the right eye lies apparently to the left of the object as seen by the left eye (Fig. 260).

In binocular diplopia the image seen by the squinting eye (false or apparent image) is less distinct than that seen by the fixing eye (true image) because only in

the latter case does the image fall upon the fovea centralis. The angular displacement of the false image is equal to the angle of deviation of the eye.

(3) *False Orientation*.—It will be seen from what has already been said that false orientation is a necessary accompaniment of binocular diplopia. Suppose that a patient whose right external rectus is paralysed shuts his left eye and attempts to fix an object situated towards the

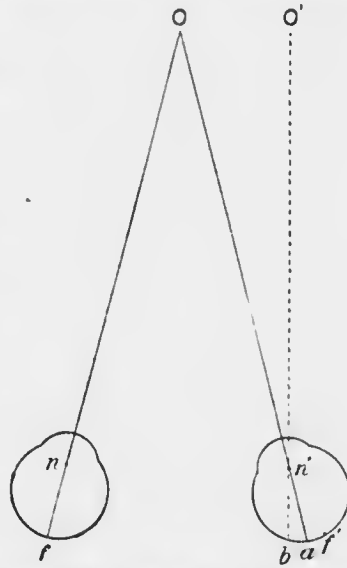


FIG. 259.—Diagram of homonymous diplopia. *f, f'*, left and right foveae; *n, n'*, left and right nodal points. The image of *O* formed at *a* is projected as if *a* were the fovea, *i.e.* to *O'*.

right. Let him now quickly strike at the object with his extended index finger. The finger will pass considerably to the right of the object. This is called *false projection*. It depends upon exactly the same principle as the increase of the secondary deviation. The object is projected according to the amount of nervous energy exerted; as this is greater than that exerted under normal circum-

stances, the object is projected too far in the direction of action of the paralysed muscle. It is essential that the finger should be directed at the object quickly, otherwise the error is noticed and compensated for. For example, if under the same circumstances the patient is told to walk towards an object situated at some distance to the right, he first steps too far to the right, then recognises his mistake and corrects it. In old paralyses the patient may learn by experience

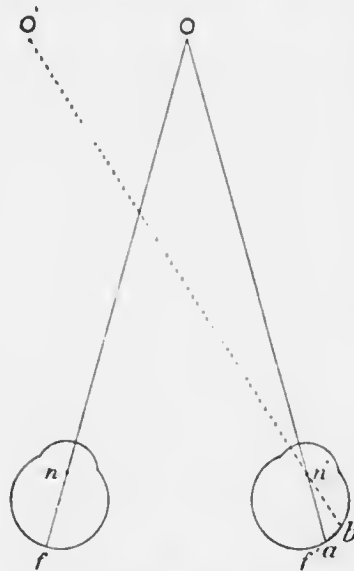


FIG. 260.—Diagram of heteronymous (crossed) diplopia.

completely to compensate for the deficiency.

(4) *Position of the Head*.—The patient holds his head so that his face is turned in the direction of action of the paralysed muscle. For example, in paralysis of the right external rectus the patient keeps his head turned to the right. The object of this manoeuvre is to abolish the diplopia and its attendant unpleasant consequences as much as possible. In complex paralysis the position of the head is still such as to relieve the diplopia to

the maximum extent, the position being adopted unconsciously.

(5) *Vertigo, &c.*—Vertigo, leading to nausea, and even vomiting, is due partly to diplopia, partly to false projection. It occurs chiefly when the paralysed muscle is called upon to exert itself. When the gaze is turned from the region of correct to that of false localisation, objects appear to move with increasing velocity in the direction in which the eye is moving. The unpleasant symptoms are counteracted partially by altering the position of the head, or completely by shutting or covering the affected eye.

In paralyzes of long standing, false orientation gradually ceases (*vide supra*). Diplopia also tends to disappear or become less troublesome; the patient learns to ignore the impressions derived from the affected eye. Contracture of the antagonists of the paralysed muscle gradually sets in, which has the effect of increasing the primary deviation. Since the retinal image is thus thrown further to the periphery, where the sensitiveness is less (*vide p. 78*), its suppression is facilitated.

Investigation of a Case of Ocular Paralysis.—The patient usually seeks advice on account of diplopia. In some cases the nature of the case is obvious immediately from the strabismus or from the manner in which the head is held. In most cases these features are too slight to decide the diagnosis.

(1) The first procedure should be to cover one eye in order to determine whether the diplopia is unocular or binocular.

(2) Having decided that the diplopia is binocular the patient should fix the surgeon's finger and the field of fixation of each eye should be carefully investigated (*vide p. 544*). In cases of complete paralysis of one or more muscles it may be possible to make an accurate diagnosis from the observation of the defective movements

combined with investigation of the exact positions of the images of the finger in different areas of the field of binocular fixation. In cases of paresis the differentiation of the images is too obscure to permit of the solution of the problem by this means.

(3) In such cases the diplopia must be investigated by more delicate tests. The patient is taken into a dark room. A red glass is placed before one eye in order to distinguish its image. A lighted candle is then moved about

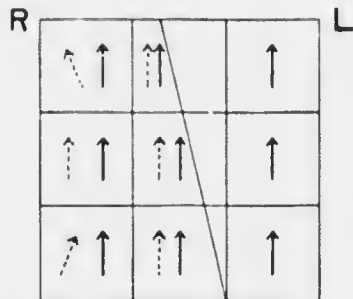


FIG. 261. Diplopia chart for the right external rectus. The oblique line through the chart shows the limit of the fields of single vision and of diplopia. The dotted arrows show the positions of the false image in different parts of the field of diplopia.

in the field of binocular fixation at a distance of at least four feet from the patient, the patient's head being kept stationary. The positions of the images are accurately recorded upon a chart with nine squares marked upon it (Fig. 261). The examination may be carried out by the surgeon turning the patient's head in various directions whilst the candle is kept stationary. The following data are derived from this examination:—

- (a) The areas of single vision and of diplopia ;
- (b) The distance between the two images in the areas of diplopia ;
- (c) Whether the images are on the same level or not ;
- (d) Whether one image is inclined or both are erect ;
- (e) Whether the diplopia is homonymous or crossed.

These data, if concordant, are sufficient to diagnose the paralysis. The false image is determined by the direction in which the images are most separated from each other. This is the direction of the normal action of the paralysed

muscle. The false image can often be recognised by being the fainter of the two or by being tilted; by covering one eye it can be shown to which eye this image belongs.

It must be remembered that these tests are purely subjective. In many cases the patients are stupid or their intelligence is obscured by intracranial disease; or contracture of the antagonistic muscles may have set in. Consequently the answers are not infrequently discordant, and accurate diagnosis may be extremely difficult or impossible.

The nature of the diplopia and the position of the

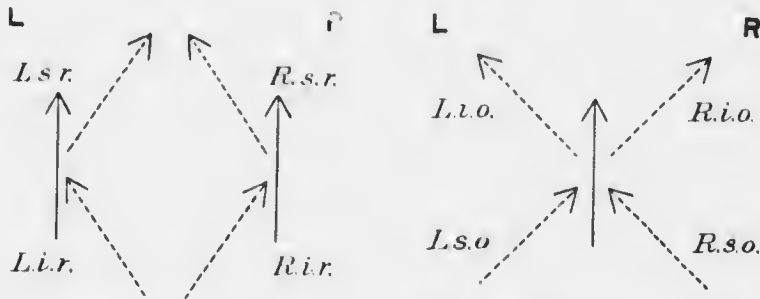


FIG. 262.—Werner's mnemonic for diplopia in paralyzes of extrinsic ocular muscles. The dotted arrow shows the relationship of the false image to the true for each extrinsic muscle.

images in each of the nine areas of the field of fixation should be worked out by the student for paralysis of each individual muscle. In performing this exercise he should rely upon his knowledge of the anatomy of the muscles and their consequent action in each position of the eye. Considerable ingenuity has been used to devise mnemonics for determining the position of the false image. One of the most satisfactory is shown in the accompanying diagrams (Fig. 262), but the student is even more liable to forget the mnemonic than his anatomy of the muscles.

Varieties of Ocular Paralysis.—If one muscle alone is affected it is generally the external rectus or the superior oblique, since each of these is supplied by an independent nerve.

Affection of several muscles simultaneously is usually due to paralysis of the third nerve. All the extrinsic and intrinsic muscles of one or both eyes may be paralysed—*ophthalmoplegia totalis*. If only the extrinsic muscles are affected the condition is called *ophthalmoplegia externa*; if only the intrinsic (sphincter pupillæ and ciliary muscle) *ophthalmoplegia interna*.

Conjugate paralysis is the term applied to abolition of certain synergies. Thus ability to look up, to the right or left, or down may be lost. Inability to converge may also occur. Such defects might be conveniently termed *symparalyses*.

Paralysis of the External Rectus.—There is limitation of movement outwards, and the face is turned towards the paralysed side. Diplopia occurs on looking to the paralysed side. It is homonymous; the images are on the same level, and erect, becoming more separated on looking more towards the paralysed side. The false image is slightly tilted on looking up or down as well as towards the paralysed side.

Paralysis of the Superior Oblique.—There is limitation of movement downwards and towards the paralysed side; the face is turned downwards and towards the *sound* side. Diplopia occurs on looking down (Fig. 263). It is homonymous; the false image is lower and its upper end is tilted towards the true image. The distance between the images and the inclination of the false image increase on looking down and towards the paralysed side. The patient has great difficulty in going downstairs, and vertigo is usually a particularly prominent symptom.

PARALYTIC AND KINETIC STRABISMUS. 553

Paralysis of the Third Nerve.—In complete paralysis of the third nerve there is ptosis, which prevents diplopia. On raising the lid with the finger the eye is seen to be deflected outwards and somewhat downwards, owing to the tone of the two unparalysed muscles. The pupil is semi-dilated and immobile, and accommodation is paralysed. There is a slight degree of proptosis, owing to loss of tone of the paralysed muscles. There is limitation of movement upwards and inwards, to a less degree downwards. With the lid raised there is diplopia, which is crossed, the false image being higher, with its upper end tilted towards the paralysed side.

Paralysis of the third nerve is often incomplete, and individual muscles may occasionally be affected alone.

Etiology.—Paralysis of ocular muscles may result from a lesion situated in any part of the nerve tracts from the cerebral cortex to the muscles. The site may therefore be intracranial or intraorbital. Cortical lesions usually cause loss of synergic movements, *e.g.*, conjugate deviation, but simple ptosis may be due to such a lesion. The diagnosis of nuclear and peripheral lesions depends largely upon knowledge of the anatomical relations of the nuclei and nerves. It is beyond the scope of this work to treat the subject exhaustively here. It may be mentioned that paralysis of the external rectus, sometimes bilateral, is common in babies. It may be due to the use of forceps during delivery, the sixth nerve being most exposed to pressure, or to maldevelopment of the nucleus. In the

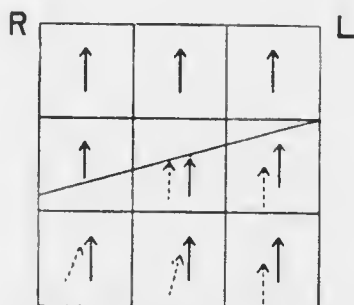


FIG. 263.—Diplopia chart for the right superior oblique.

latter case there is loss of conjugate deviation to the same side (*vide* p. 536), and the seventh nerve is normal. In acquired sixth nuclear paralysis in adults the seventh nerve is usually implicated (*vide* p. 536). In congenital paralysis of the external rectus contracture of the antagonists does not occur. Other nuclei may be maldeveloped, or they may be picked out by the lesions of syphilis, tabes, or disseminated sclerosis.

Ophthalmoplegia may be due to syphilis, tabes, poliomyelitis superior, or in rare cases to other causes. It may be congenital. As a progressive condition, associated with ptosis, it occurs as a sign of myasthenia gravis.

Other intracranial ocular paralyses are caused by affections of the blood vessels—haemorrhage, embolism, thrombosis, &c., or external pressure—tumours, blood clots, periostitis, &c.

Ocular paralyses may also be due to diphtheria, diabetes and other toxic conditions, injury, &c.

The prognosis varies with the cause. Ocular paralyses are so often early signs of grave nervous disease that the prognosis should always be guarded. Those due to peripheral disease, dependent upon syphilis or "rheumatism," may speedily recover. Long-standing cases rarely recover.

Treatment.—Syphilitic cases should be treated by mercury and increasing doses of iodides, and this treatment should be applied to all doubtful cases. Salvarsan ("606") should be tried in intractable cases. Some cases improve on salicylates, or colchicum and iodides. Diaphoresis may be used. The constant current is chiefly useful in keeping up the metabolism of the muscles until innervation is re-established. It probably has little therapeutic influence upon the paralysed nerve.

Occasionally symptomatic treatment affords relief to the patient. The diplopia may sometimes be relieved

by suitable prisms, but this treatment is rarely of much use owing to the variation in the amount of the deviation in different positions of the eyes. Occasionally good is done by exercising the weak muscle with strong prisms (*vide* p. 580). In old cases an operation may be indicated, usually tenotomy of the antagonist with advancement of the paralysed muscle, thus putting the affected muscle under better mechanical conditions. It is only suitable for paretic, not paralytic, cases, and should never be adopted until all other means have failed. It is therefore seldom indicated.

If diplopia is very troublesome and cannot be relieved by the means suggested, spectacles should be ordered with a ground glass in front of the affected eye.

KINETIC STRABISMUS.

Aberrant forms of strabismus occur as the result of irritative intracranial lesions, and are due, not to paralysis, but to irregular action or over-action of certain muscles, caused by unequal stimulation of the nerve centres or nerves. Such squints are common in meningitis and lesions of the mid-brain or cerebellum, such as tumours (glioma, tubercle, gnumma, &c.). The occurrence of the squint only during epileptiform fits or its irregularity of type may render the diagnosis from paralytic squint easy, especially when there are other prominent symptoms of cerebral irritation. In other cases, especially in the early stages of the disease, the diagnosis from paralytic or concomitant squint may be extremely difficult.

NYSTAGMUS.

Nystagmus (*νυστάζειν*, to nod) is the term applied to rapid oscillatory movements of the eyes, independent of the normal movements, which are not affected. The oscillations are involuntary, though in rare cases normal persons

can imitate them. They are usually lateral, but vertical, rotatory, and mixed rotatory and lateral or vertical nystagmus are not uncommon. The condition is almost always bilateral, though the movements may be much more marked in one eye than the other. In such cases it may be necessary to examine the eye very carefully with the ophthalmoscope (corneal reflex, retinal vessels, &c.) before the presence of nystagmus can be demonstrated. Unilateral nystagmus does occur, but it is probable that many of the cases described are really bilateral.

Nystagmoid jerks, *i.e.*, larger rhythmic jerking movements, most pronounced at the extreme limits of the normal movements of the eyes, should be distinguished from true nystagmus. They are not uncommon in normal people under certain conditions—fatigue, railway travelling, &c. The fundamental cause is probably quite different from that of true nystagmus, though both may occur together.

Nystagmus may be congenital or early infantile, or it may be acquired. These two groups of cases should also be carefully distinguished on account of their different pathological foundation. Congenital and early infantile nystagmus, *i.e.*, nystagmus dating from birth or within a few weeks of birth, occurs in congenitally malformed eyes, in albinism, and in eyes with congenital or early developed opacities of the media, *e.g.*, leucoma or anterior polar cataract due to ophthalmia neonatorum. The cause in these cases is inability to develop normal fixation. Fixation is developed during the first few weeks of life, the eyes being moved aimlessly and independently before it is acquired. Any cause seriously diminishing the acuity of macular vision occurring at this period is liable to give rise to nystagmus; if the eye is blind, nystagmus is not developed. In some congenital cases it is impossible to discover such a cause. In a few such cases ancestors or relations have been albinos.

Nystagmus may be acquired in infancy after the period at which fixation is developed. This form occurs in spasmus nutans, in which it is associated with nodding movements of the head. The nodding of the head may be antero-posterior (affirmation), lateral (negation), or rotatory. The whole symptom-complex disappears in time—one of the few cases in which nystagmus disappears spontaneously. The nystagmus may disappear in one eye before the other: such cases may be mistaken for true unilateral nystagmus.

Nystagmus in adults occurs in disseminated sclerosis, disease of the cerebellum and of the semicircular canals (*e.g.*, occasionally on syringing the ears). Some of these cases show analogy with hippus (*vide p. 72*), and like it are probably dependent upon the rhythmic activity of nerve centres. Nystagmus may also occur in adults as an "occupation neurosis," the commonest form being miner's nystagmus. This has been regarded as a myopathy, due to continued strain in unnatural situations, *e.g.*, continually looking obliquely upwards. The explanation is not completely satisfactory.

In congenital and early infantile nystagmus the patient is wholly unconscious of the movements, since objects do not appear to move. Vision is usually defective in spite of correction of errors of refraction which generally accompany the defect. In some cases of acquired nystagmus in adults objects appear to move.

The prognosis is good in spasmus nutans and in miner's nystagmus if the occupation is changed, though recovery is slow. In all other cases it is bad, though it tends to diminish with advancing years. Treatment is therefore palliative, consisting in correction of refraction, wearing smoked glasses in albinism, and treating any disease which may be present.

CHAPTER XXVIII.

CONCOMITANT STRABISMUS. HETEROPHORIA.

CONCOMITANT STRABISMUS.

In concomitant strabismus the visual axes, though abnormally directed, retain their abnormal relation to each other

in all movements of the eyes. It differs therefore in this respect from paralytic strabismus, in which the relationship of the visual axes to each other changes with every movement of the eyes in the direction of action of the paralysed muscle or in the resultant direction of action of the paralysed muscles when more than one is affected. The secondary deviation in concomitant squint is equal to the primary deviation, a fact which demonstrates the absence of paralysis (Figs. 264—5).

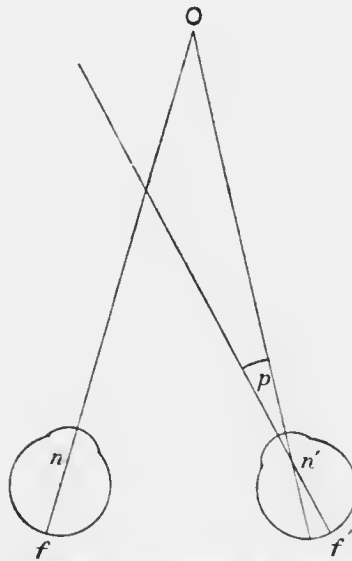


FIG. 264. — Diagram of primary deviation in concomitant convergent strabismus.

The deviation of the visual axes may be convergent or divergent, the former being the more common.

In every case in which the direction of the visual axes is aberrant paralytic strabismus must first be eliminated by testing the movements of the eyes in all directions with the finger. If they are found to be

normal and there is no complaint of diplopia it may be concluded that there is no paralysis. It does not follow that there is concomitant squint. The convergence or divergence of the axes may be only apparent. A marked appearance of convergent squint is sometimes seen in myopic eyes, of divergent squint in hypermetropic eyes. It will be observed later that true concomitant convergent squint is most commonly associated with hypermetropia, divergent with myopia, *i.e.*, the opposite of apparent strabismus.

Apparent strabismus is due to the fact that the visual axis of the eye is very rarely coincident with the optic axis (Fig. 266). The optic axis, *i.e.*, the axis upon which the cornea and lens are centred, passes through the centre of rotation of the eye and approximately through the centre of the pupil. The visual axis passes through the nodal point and the fovea centralis, thus crossing the optic axis and making a small angle with it. This angle is very nearly equal to an angle which is called the angle gamma γ ; it is commonly spoken of clinically as the angle γ . In the emmetropic eye the angle γ is said to be positive, *i.e.*, the optic axis cuts the retina internal to the fovea centralis. In hypermetropic eyes the angle γ is also positive but greater than in emmetropia. In myopia the

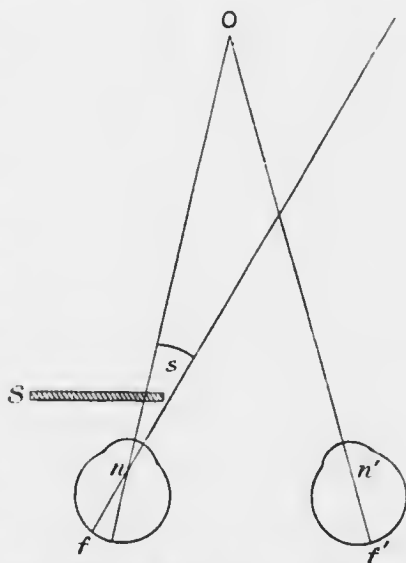


FIG. 265.—Diagram of secondary deviation in concomitant convergent strabismus.

angle γ is absent or negative, *i.e.*, the visual axis and the optic axis coincide or the latter cuts the retina external to the fovea centralis.




FIG. 266.—Apparent strabismus. *a b*, optic axis upon which the refractive surfaces are centred; *f*, fovea centralis; *n*, nodal point; *c*, centre of rotation; *O*, point of fixation; *O c*, line of vision; *O n f*, line of vision; *O c b*, angle γ . It is practically equal to *O n b*, which can be measured. In actual practice the guide to *a b* is taken from the centre of the pupil; *a b* does not usually pass accurately through the centre of the pupil, so that the result is always only approximate. The angle γ is to the nasal side in hypermetropia and emmetropia.

Now, neither of these lines can be seen, and the direction of the line of vision is judged by the position of the pupil. Hence the greater the size of a positive angle γ the more the eye will appear to look outwards. If the angle γ is negative the eye will appear to look inwards. Therefore in high hypermetropia there will be an apparent divergent squint, in high myopia an apparent convergent squint. The latter is the more striking because the emmetropic eye usually has a positive angle γ of 5° , thus producing an apparent divergence of 10° , which, however, we are accustomed to regard as the normal position of the eyes.

Having decided that the case is not one of paralytic strabismus, it is necessary next to show that it is real, not merely apparent. This is easily done as follows: The patient is told to fix the surgeon's index finger, which is held up at least two feet from the eyes. If it is held closer, as is too often done, normal convergence will vitiate the result. The

surgeon's left hand or a screen is held in front of the

patient's right eye; the left eye will now be accurately fixing the finger. The screen is then moved so as to cover the left eye, fixation being now taken up by the right eye. If the right eye moves inwards or outwards at the moment when it takes up fixation there is a true squint; if it remains absolutely motionless the squint is apparent only.

Having now eliminated both paralytic and apparent strabismus, it is almost certain that the case is one of true concomitant squint (see, however, p. 574). In concomitant squint one eye maintains fixation while the other is averted or abverted. If in the test just described the fixing eye is covered by the screen, the deviating eye generally moves outwards or inwards through an angle equivalent to the angle of the deviation in order to take up fixation. At the same time the eye behind the screen moves inwards or outwards through exactly the same angle (secondary deviation). If now the screen is removed it will generally be found that fixation immediately reverts to the first eye. Such a case is usually termed one of *unilateral strabismus*. In some cases fixation is still retained by the second eye. If it is so retained for a considerable period, *e.g.*, whilst the patient blinks several times, the squint is said to be *alternating*. Inquiry will then generally elicit the fact that the patient sometimes squints with one eye, sometimes with the other; indeed, this may be noticed whilst watching the patient. Occasionally patients with alternating strabismus can fix with either eye voluntarily, but usually they are unconscious which eye is fixing. Concomitant squint may be *constant*, or occur only at intervals—*periodic*.

It has been mentioned that when the fixing eye is covered with the screen the deviating eye usually moves so as to take up fixation. In unilateral squints of long-standing this eye may remain motionless and can only

be moved into the primary position by moving the finger, a condition which is called *eccentric fixation* (*vide* p. 564). Since it only occurs with marked deviation of long standing there is generally no difficulty in distinguishing it from apparent squint.

In performing the preliminary test to eliminate paralytic strabismus it will often be found that in true concomitant squint with considerable deviation the eyes do not move as much as usual in the direction opposite to that of the deviation. Thus, in convergent squint it may be very difficult to get the eyes to move outwards as much as normal, so that the margin of the cornea lies under the external canthus. Similarly in divergent squint it may be very difficult to get the eyes to move inwards as much as normal, so that the margin of the cornea is well covered by the internal canthus. This defective movement is commonly attributed to "insufficiency" of the external or internal recti respectively. In convergent strabismus it is probably due, not to any defect in the external rectus or its innervation, but to the fact that, fixation being dependent upon one eye, there is little stimulus to outward movement as soon as the point of fixation has passed beyond the field of fixation of this eye, *i.e.*, as soon as the nose cuts off vision of the finger. In many such cases the eye will move out completely if the finger is moved rapidly. In divergent strabismus defective inward movement is sometimes due to mechanical causes, *viz.*, the size of the myopic eye (*vide* p. 574).

It has already been mentioned that in concomitant strabismus there is no diplopia. It may be present in the earliest stages, but is invariably absent in the later. This is due to psychological suppression of the image of the squinting eye. In most cases suppression is aided by actual defect, usually ametropia, in this eye, but it is not

the complete explanation, since suppression of the image of the squinting eye is also the rule in alternating squint, in which both eyes are frequently quite normal or have the same degree of ametropia. Suppression is doubtless aided in all cases by the peripheral situation of the image in the squinting eye, but there is no doubt that the seat of suppression is really in the brain; that is, in the interpretation of the stimuli reaching the brain from the eyes those derived from the squinting eye are deliberately neglected. The ability to exclude the impulses derived from the squinting eye is an important point in attempting to arrive at the rationale of concomitant strabismus. It follows from this fact that people with convergent squint have only unocular vision, or, at most, very imperfect binocular vision.

Except in alternating strabismus the vision of the squinting eye is nearly always very defective, which is partly due in most cases to errors of refraction. In convergent strabismus the eyes are nearly always hypermetropic, with or without astigmatism, and often the squinting eye has greater ametropia. There can be little doubt that some such inherent defect may determine which eye will deviate, though it is probably never the fundamental cause of the squint.

In some cases the vision in the squinting eye is defective beyond any explanation derived from objective defects—ametropia, &c. In some such cases there is reason to believe that the defective vision dates from birth—*congenital amblyopia*. In all unilateral squints of long standing, very defective vision in the squinting eye is the rule. It is commonly attributed to the prolonged suppression of the images derived from this eye, and is hence called *amblyopia ex anopsia*. This explanation is not altogether satisfactory, since cases are well known in which vision has long been excluded by congenital cataract.

yet is quite good after successful operation. The vision in the amblyopic eye is often reduced to 6/60, and may be reduced to counting fingers. Cases of recovery of sight after loss of the fixing eye have been recorded, but unfortunately this result certainly does not invariably follow. The visual acuity may be greater in the false position than when the retinal image falls upon the fovea (eccentric fixation with "false macula"). All power of fixation may be lost by the amblyopic eye.

It has already been mentioned that the gross movements of the eyes are nearly or quite perfect in concomitant strabismus. This applies equally to dynamic convergence and accommodation. The eyes start in an abnormal position, and normal movements are superposed. Thus, in fixing a near object, the normal amount of dynamic convergence is superposed upon the abnormal static convergence or divergence.

Concomitant strabismus always commences in childhood, generally in infancy. It must, however, be carefully distinguished from the squinting which normally occurs during the first few weeks of life, before fixation is developed (*vide* p. 556); this is not concomitant. Many important factors in the aetiology of concomitant strabismus are known, and a proper appreciation of them is essential to rational treatment. No theory of the fundamental causation which has yet been advanced satisfactorily explains the condition.

Attention was early drawn by Donders to the common association of convergent strabismus with hypermetropia. He explained the relationship by the fact of the normal association of convergence and accommodation (*vide* p. 539). Hypermetropes have to exercise an effort of accommodation to see distant objects, still more to see near objects. The effort of accommodation is associated in the normal person with a corresponding effort of

convergence. If this rule be supposed to hold good for hypermetropes, the strong accommodation may be regarded as inciting an effort of convergence which is excessive for the actual point of fixation. The hypermetrope is therefore in a dilemma. He must either converge accurately for the object, in which case he will not accommodate sufficiently to see it clearly: or he must accommodate accurately for it, in which case he will converge too much. This will cause homonymous diplopia, unless he is able to suppress the image of one eye, which is exactly what the patient with convergent strabismus does.

Regarding divergence as negative convergence, the association of divergent strabismus with myopia is explained by the same theory.

There is no question that this factor is one of great importance, as is shown by the cure of some cases of squint by suitable correcting glasses. It is not, however, the fundamental cause of squint, for if it were, (1) all uncorrected hypermetropes would have to squint; (2) there would be ametropia in all cases of concomitant strabismus. The latter corollary is found to be false, for convergent strabismus, other than apparent strabismus, is occasionally found to be associated with myopia, and in alternating strabismus there is often little or no ametropia.

In spite of these facts the great importance of the association between accommodation and fixation must be strongly insisted upon. Convergent strabismus most frequently develops between the ages of two and six, *i.e.*, just at the period when the fixation of near objects throws a strain upon accommodation. It is often periodic at this stage, and noticed only when near objects are looked at. Moreover, there is an undoubted tendency for the deviation in all cases of convergent strabismus to

diminish with age, *i.e.*, with the diminution of accommodation. The relative infrequency of convergent squint in adults, compared with its frequency in children, cannot be explained solely by the fact that many cases undergo successful treatment. It may be remarked that the amblyopia persists in the formerly squinting eye; hence in every case in which satisfactory objective evidence of the cause of defective vision in one eye cannot be discovered, the patient should be asked if he ever squinted.

As already mentioned, greater ametropia in one eye, opacities in the refracting media, intraocular disease, and so on, are never the fundamental cause of strabismus, though they may determine the particular eye which loses fixation. This is especially the case when concomitant squint is preceded by latent squint (*q.v.*). It is easy to understand that when there is disturbance of muscular equilibrium which can only be overcome by special effort, any slight defect in one eye may determine the development of a manifest squint.

The application of Donders's theory to divergent strabismus associated with myopia has been mentioned. Here, since near objects are seen with little or no accommodation, the impulse to convergence is too weak. Since infants are rarely myopic, this form of divergent squint does not develop in early childhood. There are other factors besides deficient accommodation which tend to produce divergence in myopia. One is the mechanical conditions of the myopic eyeball, which, being abnormally large and long, adapts itself to the axis of the orbit. Further, the internal recti act under mechanical disadvantage from the same cause. Moreover, in very high myopia the far point of the eye is so close to it that it is impossible for convergence to be effectual—it becomes impossible to see the object with both eyes at the same

time. The better eye is then used and the other is allowed to take up the position of rest, which is usually one of divergence. Such a strabismus may remain periodic for near work only for many years; in other cases it becomes constant.

Spontaneous cure rarely if ever occurs in divergent strabismus, which tends to increase with age.

Concomitant strabismus has proved a fertile field for conjecture. There are several points bearing upon the subject which are obscure, such as the development of fixation and of binocular vision, the occurrence of congenital amblyopia, and of amblyopia ex anopsiâ, and so on. Many theories relating to these points have been stated and re-stated so frequently that they are accepted as facts. In reality, many are not susceptible of demonstration, and none have been proved. The theorist on strabismus accepts the "facts" which fit his theory, and rejects the remainder.

The prevailing theory at the present time is that strabismus is due to defect of the fusion faculty, or the capacity of combining psychologically the impressions derived from the two eyes. Some authors go so far as to hypotheate a "fusion centre" in the brain. No one will deny that the fusion of the images derived from the two eyes in binocular vision is an act in consciousness, and that it has a physical basis. This physical basis is a set of accurately co-ordinated nerve impulses. Binocular vision, then, depends upon the accuracy of co-ordination of these impulses, and this is a function of the nerve-complex as a whole, not of any particular "centre." It is indeed possible that the strabismus is caused by inco-ordination

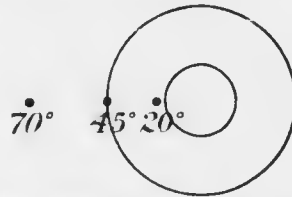


FIG. 267.- Diagram of the position of the corneal reflex as a guide to the angle of the squint.

of the afferent impulses upon which binocular vision depends, though this advances the true aetiology of the disease but little. It is just as probable that the inco-

ordination or deficiency of the afferent impulses is a result of the strabismus, which is itself due to some other cause; or both may be due to a common cause.

In every case of concomitant strabismus the angle of the deviation should be measured, so that the effects of treatment may be accurately observed. A rough indication of the angle of the squint can be obtained from the position of the corneal reflex when light is thrown into the eye with the ophthalmoscopic mirror (Fig. 267). The light is thrown in from a distance of about two feet, and the patient is told to look at the mirror; an infant does this reflexly. In the

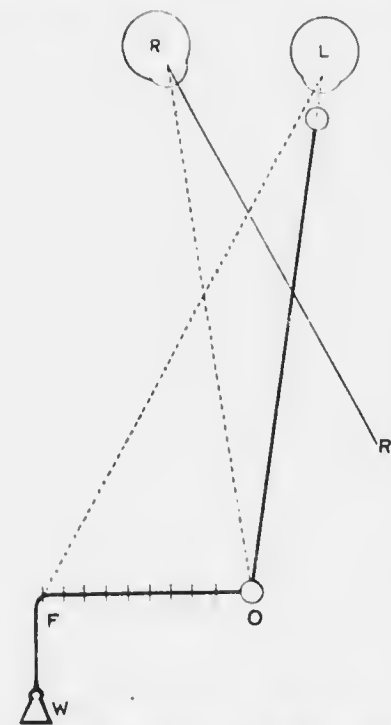

FIG. 268. Diagram of Priestley Smith's tape for measuring the angle of squint. R, right eye with internal squint; L, left eye; O, ophthalmoscope; O F, graduated tape; F, fixation point (observer's finger); W, weight. The angle measured is $\angle O L F$, which is equal to $\angle O R R'$, the angle of the squint.

fixing eye the corneal reflex will be in the centre of the pupil, or slightly to the inner side if there is a large angle γ , to the outer side if there is a negative angle γ . The light is then turned on to the squinting eye. If the reflex is about half-way between the centre of the

pupil and the corneal margin, there is a deviation of about 20° ; if it is at the corneal margin, about 45° . This test is only a rough one.

The best test in children is with Priestley Smith's tape (Fig. 268). It consists of a tape 1 metre or 60 cm. long, with a ring at each end. To one ring a second tape is attached, having a tangent scale upon it. The graduations are, of course, different, according to the length of the first tape. At the other end of the tangent tape is a small weight. The measurement is carried out in the dark room. The free ring is held by the patient or an assistant on the cheek immediately below the fixing eye. The surgeon passes one finger of the hand, which also holds his ophthalmoscope, through the other ring, and keeps the tape taut. With his disengaged hand he holds the tangent tape at right angles to the distance tape, at the same time holding up the index finger as an object of fixation. The light from the ophthalmoscope is thrown into the squinting eye, and the patient is told to look at the fixation finger. This is moved along the tangent tape until the corneal reflex is in the centre of the pupil. The angle of the squint is then read off on the tape. The direction in which the tangent tape is held, whether to the surgeon's right or left, depends, of course, upon the side of the squinting eye and the nature of the squint, whether convergent or divergent. This test is by far the best for small children of any yet devised.

The angle of deviation can also be measured with the perimeter (Fig. 269). The squinting eye is placed at the centre of the arc, and the patient fixes an object *six metres away*, situated slightly over the position of the ordinary fixation spot of the perimeter. The arc of the perimeter is turned to the horizontal position on the side towards which the squinting eye is directed. The surgeon passes a candle flame along the arc until the corneal reflex is in

the centre of the cornea of the squinting eye. He then reads off the angle of the squint on the arc. If extreme accuracy is desired, the angle γ should be measured and allowed for. It is done by covering the sound eye and making the patient fix the fixation spot of the perimeter with the squinting eye. The candle flame is again carried along the arc until the corneal reflex is again in the centre of the cornea. The angle γ is read off on the arc. The method is not suitable for children, and can only be

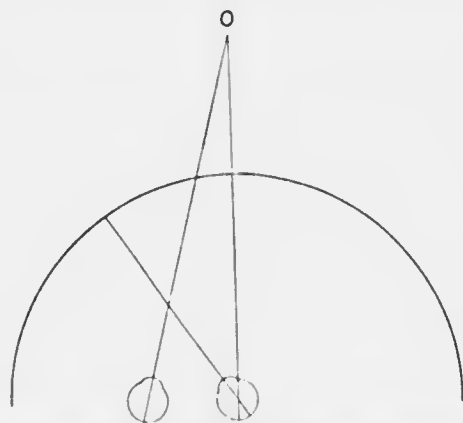


FIG. 269. Measurement of the angle of squint by the perimeter.

employed with intelligent adults. One objection to it is the tendency to fix the ordinary fixation spot of the perimeter instead of a distant spot in the same line of vision. If this mistake is made errors arise, more particularly because the amount of dynamic

convergence exerted in these cases is not always the same as with normal eyes.

The angle of deviation can also be conveniently measured on a tangent scale set against the wall, the corneal reflex of a candle flame being again used as a guide.

Treatment.—The routine treatment of a case of concomitant convergent strabismus in a child is as follows :—

(1) Record the distant vision of each eye if the child is not too young, the angle of the deviation, &c. Order ung. atropini, 1 per cent., three times a day for at least

four days. At the end of this period estimate the error of refraction by retinoscopy and confirm the result subjectively if possible; reliance should be placed on the retinoscopy rather than on subjective tests. Again measure the angle of the squint, which is likely to be less under atropin than without a mydriatic. Order the full correction for constant use. A smaller correction for the effect of atropin should be made than in hypermetropia without squint. If the error is considerable I usually subtract only 0.5 D for atropin instead of 1 D; if the error is small I order the full atropin correction to start with. Great care must be taken to correct all astigmatism, especially in the squinting eye. The patient is told to return in a month.

If the child is less than two years old I do not order glasses except in rare cases. Some surgeons order them in all cases. I prefer to eliminate accommodation by keeping both eyes under the influence of atropin; the 1 per cent. ointment need be instilled only once a day. The child should be examined at regular intervals until it is considered advisable to order glasses.

(2) After the glasses have been used constantly for a month the child is again examined. The vision is tested and the angle of the squint again measured. The treatment now depends upon the condition of the vision in the squinting eye. If, as is usually the case, this eye is amblyopic, an effort should be made to improve the vision in it by continual exercise. In order that this eye may be used the other must be prevented from seeing, or at any rate from seeing clearly. It may be done by placing a pad of cotton wool under the glass in front of the fixing eye for a certain period, *e.g.*, $\frac{1}{2}$ —1 hour, three or four times a day. This method is liable to be neglected or carried out inefficiently. A better method is to order the instillation of atropin *into the fixing eye only*, once a day. This eye

will then generally be used only for distant vision, the squinting eye being used for seeing near objects. The child is examined at intervals of a month or two, and any improvement in vision in the squinting eye, as well as any change in the angle of deviation, carefully recorded. The treatment requires watching, as in some cases the deviation becomes transferred to the atropised eye, and the vision in this eye may deteriorate.

(3) The further treatment depends upon the size of the angle of deviation, the condition of vision in the squinting eye, and a variety of other factors which differ in each case. If there is any evidence of some degree of binocular vision it may be advisable to attempt to cultivate it by *orthoptic treatment*. This consists essentially in specially devised stereoscopic exercises. It is excessively tedious and seldom successful. It has, however, one overwhelming argument in its favour, viz., that when successful it cures the squint. The cure is complete, *i.e.*, the patient is placed in the same condition as a normal person; his eyes are straight and he has binocular vision. No other treatment can be said to cure the disorder. The eyes can be put straight, but this cures only the deviation; the other elements of the disorder remain unaffected. Unfortunately orthoptic treatment succeeds only in very favourable cases, and then only after prolonged and very persevering efforts. In the majority of cases it is useless to attempt it, and in all cases it is useless unless carried out systematically and thoroughly. For the details of the treatment monographs on the subject must be consulted.

Orthoptic treatment may demand operative procedure at this stage or even earlier. If orthoptic treatment is considered hopeless or has been abandoned the further treatment consists in continuance of that described under (1) and (2), but the question of the advisability of operative interference has now to be considered.

(4) *Operation.*—Surgeons differ so much in the principles which influence them in advising operation and in the nature of the operation employed that it will be best to describe the treatment which I adopt myself.

If the deviation is 10° or less tenotomy of the internal rectus of the squinting eye should be performed, under a general anæsthetic if necessary. This will cure the deviation or reduce it to a negligible quantity.

If the deviation is more than 10° , advancement of the external rectus of the squinting eye, usually with tenotomy of the internal rectus of the same eye, will be necessary. This operation should be performed under a general anæsthetic only in very rare cases—indeed only in cases in which orthoptic treatment is indicated. The operation should therefore be postponed until the child is old enough to be operated upon under cocaine. The age varies with the individual: some quite young children, *e.g.*, under ten, submit well if judiciously managed. The operation is quite painless, except when tension is put upon the muscle. It is almost impossible to avoid slight tension during certain stages, but it need only be momentary. The objection to operating under a general anæsthetic is that the position of the eyes varies so much in different stages of anæsthesia that it gives no criterion of the final position after the anæsthetic has passed off. Very good results can, however, be obtained by an experienced operator if he keeps firmly in mind the amount of the deviation and ignores the position actually present under the anæsthetic.

The treatment of alternating concomitant convergent squint without appreciable error of refraction is purely cosmetic. These patients have no binocular vision, and it is useless to attempt to develop it unless the case is seen when the patient is very young, or immediately after

the squint has been first noticed. Usually there is considerable deviation, so that an advancement operation is required. It should be postponed until a perfect result can be guaranteed, *i.e.*, until the operation can be performed with local anaesthesia.

The treatment of concomitant divergent strabismus is similar to that of the convergent type. The refraction must be first carefully corrected, and it is advisable to order a full correction for constant use unless the myopia is very high. Tenotomy of the external rectus is seldom indicated in these cases because the benefit derived is too slight; an external tenotomy will not correct much more than 5° deviation. Advancement of the internal rectus should be left in most cases until it can be performed under cocaine. No operation is advisable in very high grades of myopia, since the size of the eye may render success mechanically impossible (*vide infra*).

In divergent strabismus over-correction is indicated, for these eyes show a great tendency to revert to their former position. In convergent strabismus the deviation should be fully corrected only in adults on account of the tendency of the deviation to diminish *pari passu* with the loss of accommodation (*vide p. 566*). Moreover, slight convergence is less unsightly than divergence.

Divergent Strabismus other than Concomitant and Paralytic.—There are cases of divergent squint which are not paralytic, nor are they strictly concomitant. Some are very nearly allied to the true myopic divergent squint and may arise from it, *e.g.*, the divergence of the worse eye after binocular fixation has been completely abandoned. Similarly the mechanical divergence of extreme myopia is neither concomitant nor paralytic.

Another form of divergence, allied to the unilateral divergence in unequal myopia, is met with occasionally in

any form of anisometropia in which the difference in refraction between the two eyes is great. In these cases, which are seldom susceptible of full correction (*vide* p. 523), one eye only is used for fixation. It is not surprising, therefore, that the unused eye assumes a position of rest, which is usually one of divergence. It is more surprising that relatively few such cases of anisometropia develop a manifest squint. When a squint is developed the patient not infrequently complains of diplopia, which is the more trying the less the divergence. These cases are difficult to treat. Prolonged use of the fullest possible correction, aided by stereoscopic exercises, should be tried first. If it fails tenotomy of the external rectus of the diverging eye may effect a cure in slight deviations. In other cases an advancement is indicated; in such cases extreme delicacy of manipulation is required. Operation undertaken for cosmetic reasons may sometimes induce or increase diplopia by approximating the true and false images; it is usually permanent in these cases and exceedingly distressing.

An eye may diverge as the result of over-effect from an internal tenotomy. Such cases were at one time not uncommon, owing to an attempt being made to obtain a greater effect than can be reasonably expected from the operation. This is only attainable by liberating the muscle very freely from Tenon's capsule; it is then prone to slip back so that it fails to become re-attached to the globe. The squint therefore resembles completely a paralytic squint. The muscle will usually be found imbedded in the tissues lying under the caruncle. When the attempt is made to move the eye inwards the caruncle is seen to be actively retracted. An advancement operation should be performed, but perfect movement is seldom regained.

Finally, a blind eye diverges sooner or later.

LATENT STRABISMUS OR HETEROPHORIA.

It is found in some apparently normal persons that in the screen test (*vide* p. 560), when the screen is removed from before one eye, that eye moves slightly inwards or outwards to regain binocular fixation; if the screen is placed in front of the other eye and then removed, this eye also moves slightly inwards or outwards respectively to regain fixation. When both eyes are fixing there is no deviation. Such a squint is called a latent squint, or in opposition to the normal condition of orthophoria, heterophoria. If the latent squint is one of convergence the condition is called esophoria, of divergence exophoria. Sometimes one eye is higher than the other; this condition is usually called hyperphoria; as a matter of fact it is impossible in these cases to be sure whether there is absolute hyperphoria of one eye or hypophoria of the other, the condition being relative only.

It must be concluded that when the eyes are screened they take up a position of rest, the extrinsic muscles exercising merely their normal tone. In cases of latent squint the position of rest is not orthophoria, with the visual axes parallel, but heterophoria, with some deviation of the axes. During normal vision the requirements of binocular vision demand a suitable readjustment of the visual axes, which can be brought about only by tonic contraction of certain muscles—in esophoria of both external recti, in exophoria of both internal recti. This involves a perpetual strain, which often manifests itself as asthenopia. As might be expected the deviation is liable to become manifest in conditions of bodily fatigue. Some periodic squints are due to this cause, and the periodicity may be very rhythmic. Thus a child may squint in the evening when he is tired; after a good night's rest the squint has disappeared, and may not return until the

second or third day, the sequence being accurately repeated. Often latent squints give no trouble until school time arrives or adult life is reached. Here the demands of near vision increase the strain. No symptoms arise perhaps until after reading or writing for an hour or two. Then "the letters seem to run together." This is due to relaxation of the overstrained muscles; the eyes momentarily assume the position of rest, and diplopia, which is not realised as actual double vision, causes blurring of the print. With an effort the blurring is overcome, but eventually this becomes impossible, headache supervenes, and the work has to be abandoned.

Analysis of the cases shows that slight eso- and exo-phoria are quite common and give rise to little or no trouble, which is not difficult to understand when it is remembered that overaction of both internal recti is physiological in ordinary convergence on near objects.

These muscles are therefore accustomed to act together and little strain is felt. The same is true in less degree of the external recti. Only when the deviation is great— 5° — 10° or more—is asthenopia frequently present. Very slight degrees of *hyperphoria*, however, almost invariably cause extreme discomfort, for in these cases overaction of muscles which are not accustomed to work together is necessary in order to keep the visual axes in the same plane. For instance, in the primary position of the eyes there must be overaction of one superior rectus and inferior oblique, combined with overaction of the other inferior rectus and superior oblique,

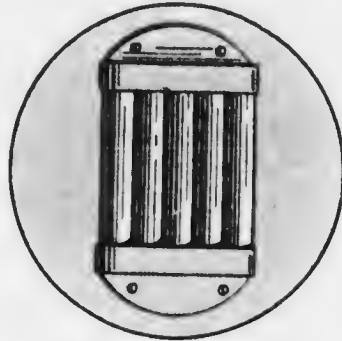





FIG. 270.—Maddox rod.



MICROCOPY RESOLUTION TEST CHART

(ANSI and ISO TEST CHART No. 2)



APPLIED IMAGE Inc

1653 East Main Street
Rochester, New York 14609 USA
(716) 482-0300 - Phone
(716) 288-5989 - Fax

and the readjustment in other positions of the eyes must be very complex.

It may be impossible to discover slight degrees of heterophoria by the screen test. More delicate tests have therefore been devised. All depend upon disassociating the two eyes. The simplest method is that of so altering the appearance of the retinal image in one eye that it affords no stimulus to fusion with the image of the other eye.

The patient is placed six metres from a candle or bright spot of light in a dark room. A Maddox rod (Fig. 270), which consists of four or five cylinders of red glass side by side in a brass disc, is placed in the trial frame before one eye. The spot of light seen through the red cylinders appears as a long red line. If the cylinders are placed with their axes horizontal the red line will be vertical. If there is orthophoria the bright spot will appear to be in the centre of the vertical red line; if there is eso- or exophoria the red line will be to one side of the spot. The angle of the deviation is measured by the strength of the prism which it is necessary to place in front of the Maddox rod in order to bring the red line and the spot together. The nature of the deviation is indicated by the position of the base of the prism, whether out or in.

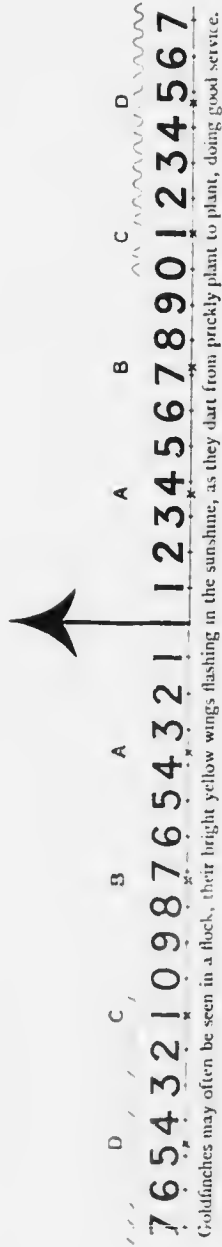The Maddox rod is then turned round so that the cylinders are vertical; the red line will now be horizontal. If there is no hyperphoria the line will pass through the bright spot. If there is hyperphoria the red line will be below or above the spot according as the relative hyperphoria is in the eye, with the rod in front of it or in the other. The amount of deviation is measured by the strength of the prism required to correct it.

The deviation in latent squint is often different in near vision from that in distant, so that both must be tested. The deviation in near vision is tested by means of a

PLATE XVIII. (To face p. 578.)

Maddox's scale to measure latent insufficiency or excess of convergence at the distance of 25 cm. with a prism of 12° (*i.e.* 6° deviation or 6° d) base upwards before the R. eye. The figure to which the lowest arrow points indicates in degrees the amount of latent convergence (black letters) or divergence (red letters) which may be present. The figures under the waved line are teens (ten, twelve, thirteen, &c.) and the capital letters, A, B, C, D, represent metre angles for an interocular distance of 64 mm.: if the lower arrow point to black A there is 1 metre angle (1 m.a. or 1 M) of convergence, if to black B, 2 m.a., &c. The printed matter under the numbers is introduced to ensure accurate accommodation for the distance (25 cm.).

PLATE XVIII



Goldfinches may often be seen in a flock, their bright yellow wings flashing in the sunshine, as they dart from pricketly plant to plant, doing good service.

special card (Plate XVIII). A strong prism—about 12° —is placed base down or up before one eye. In orthophoria the arrows are exactly in the same vertical line. In eso- or exo-phoria the lower arrow points to a number in the upper scale. This number gives the angle of deviation, which may be confirmed by counteracting the deviation with a prism base in or out before one eye.

Besides the actual measurement of the deviation in latent strabismus the strength of the muscles involved should also be tested by forcing them to a maximum effort against prisms. With the patient seated six metres from a candle the highest prism, base down, before the right eye, still permitting of single vision, gives the range of superduction of that eye. Subduction and adduction can be measured in the same manner. Adduction gives less concordant results. The normal limits of super- and subduction are 1.5° to 2.5° ; of abduction 4° to 5° .

Allied to these defects, though not strictly speaking a latent squint, is insufficiency or weakness of convergence. It will be revealed by the ordinary tests of motor balance. If there is more exophoria or less esophoria in near vision than in distant there is insufficiency of convergence. The defect causes asthenopia in near work.

Treatment.—The lower degrees of esophoria, and to a less extent of exophoria, cause no symptoms and need no special treatment. Slight exophoria often causes symptoms in young adults much engaged in near work. It is relieved by suitable prisms, bases in; if the general health improves, or the amount of near work is diminished the prisms can be dispensed with later. Hyperphoria is most likely to cause asthenopic symptoms. It is corrected by ordering suitable prisms to be combined with the glasses which correct any refractive error. If the spherical error is sufficiently great the prismatic effect may be obtained by decentring the lenses. The total prismatic

error should be divided equally between the two eyes in ordering the correction. Thus, if there is hyperphoria of 3° as measured by a 3° prism, base down before the left eye, a prism of $1\frac{1}{2}^\circ$ is ordered before each eye, base up for the right, base down for the left. When this treatment does not succeed, and the deviation is considerable, tenotomy of the superior rectus may be necessary, but such cases are rare, and operative interference should not be lightly undertaken, for it is apt to be disappointing.

The rational treatment of large degrees of eso- or exophoria consists in exercising the weak muscles against prisms. This is usually only temporarily beneficial, but the muscles can be kept in good order by repeating the exercises at intervals. The asthenopia can be relieved by ordering prisms to correct the defect, *i.e.*, prisms with their bases directed in the opposite sense to those used for exercise. This should be avoided except in such cases as those already mentioned, since it generally tends to increase the defect, so that stronger prisms have to be ordered from time to time. In severe cases operative interference—tenotomy—may be indicated.

Insufficiency of convergence may be treated by prism exercises. The following simple exercise is often sufficient without having recourse to prisms. Any error of refraction is corrected with glasses which are ordered to be used constantly. While reading the patient gradually brings the book nearer and nearer, until the print becomes blurred. He then slowly moves the book back to ordinary reading distance. The process is repeated. At about every tenth line the patient looks into the distance, so as to relax his accommodation and convergence. Two or three pages should be read in this manner three or four times a day for several weeks. The course is repeated as often as necessary.

If convergence training fails prisms, base in, must be

ordered with the reading glasses. Care must be taken not to over-correct presbyopia (*vide* p. 528).

OPERATIONS ON THE EXTRINSIC MUSCLES.

Tenotomy.—Instruments required : speculum, fixation forceps, strabismus hook, tenotomy scissors. I prefer a flat tenotomy hook (Moorfields' pattern) to the ordinary hook with a bulbous end. Local anaesthesia suffices in all but very young patients : a few drops of adrenalin (1 in 1,000) may be instilled with advantage. I usually stand above the patient's head in all operations on the extrinsic muscles.

The conjunctival sac having been donched, and the speculum inserted, the conjunctiva is seized over the muscle and a vertical incision, 8—9 mm. long, is made with scissors. It must be remembered that the internal rectus is inserted nearest, the external farther, from the corneal margin (*vide* p. 531). The tissue underlying the conjunctiva at the lower border of the muscle is then seized with the forceps and incised, care being taken to hold the scissors so that they are tangential to the globe. If this is properly done Tenon's capsule is opened. The hook is now taken in the right hand, which still retains the scissors, and the point is introduced into the opening in Tenon's capsule. It is passed backwards, then upwards between the muscle and the sclerotic. In this manoeuvre the point of the hook must be kept firmly against the globe. The point of the hook appears at



FULL SIZE
FIG. 271. —Prince's
forceps.

the upper border of the muscle. It is freed from any conjunctival or sub-conjunctival tissue which may cover it. The



FIG. 272. — Silcock's needle holder.

hook is drawn forwards until it lies close under the insertion of the muscle, but undue traction must not be exerted, as it causes severe pain. The hook is transferred to the left hand. The point of one blade of the scissors is introduced along the hook below the tendon, and the muscle is divided between the hook and the sclerotic. The hook should be introduced again and moved about in such a manner that any attachments which remain may be caught up and divided.

A pad and bandage are worn for two days, the eye being freely irrigated with boric acid lotion.

With the exception of a small puncture in the conjunctiva the whole operation can be performed sub-conjunctivally by an expert. This method has the advantage of preventing so much retraction of the caruncle in tenotomising the internal rectus as usually follows tenotomy by the open method. It is less easy and slightly more dangerous. The retraction of the caruncle in the open method can be counteracted by inserting a conjunctival suture (silk, No. 0), which however has the disadvantage that it must be removed in a few days.

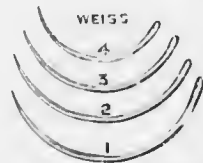


FIG. 273. — Curved needles for advancement. Size No. 2 should be used.

No attempt should ever be made to obtain a greater effect from tenotomy of the internal rectus than 10° , of the external rectus 5° . If a greater effect

is desired an advancement of the opponent must be performed.

Advancement.—Instruments required: speculum, fixation forceps, tenotomy scissors, strabismus hook, Prince's advancement forceps (Fig. 271), needle holder (Fig. 272), curved needles (No. 2) (Fig. 273). Prince's advancement forceps have one smooth blade and one armed with sharp spikes which pass through holes in the smooth blade when the blades are locked. These forceps are usually made

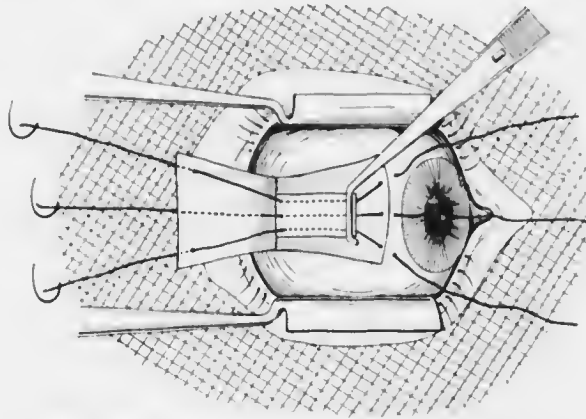


FIG. 271. Diagram of advancement operation.

in right and left pairs. There is no necessity for this: it need simply be remembered that the smooth blade must be passed below the muscle. The best needle holder is the one figured: it has narrow jaws, so that the sharply-curved needles are not broken by their pressure.

Apart from exceptional circumstances (*vide* p. 573), advancement should always be performed under local anaesthesia. A few drops of adrenalin (1 in 1,000) should be instilled just before commencing the operation.

The conjunctival sac having been douched, a mask of sterile gauze is placed over the face (Fig. 274). A hole is

cut in it, opposite the eye to be operated upon. The speculum is then inserted. The patient is told to look in the required direction, *e.g.*, in operating upon the right external rectus towards the left. A vertical incision is made in the conjunctiva over the insertion of the muscle, as in tenotomy. A rectangular flap of conjunctiva is then dissected up, parallel horizontal incisions being made from the ends of the vertical incision. Tenon's capsule is then incised at the lower border of the muscle and the hook introduced as in tenotomy. The point of the hook is freed from subconjunctival tissue in the same manner. The smooth blade of Prince's forceps is passed along the hook, which is then removed. The forceps are closed, and locked by the spring catch. They are handed over to the care of the assistant. The patient is then told to look in the opposite direction, the eye being kept steady by the assistant with the advancement forceps. The internal rectus is then tenotomised.

The external rectus is now tenotomised by cutting with the scissors between the Prince's forceps and the sclerotic. The muscle is thoroughly freed from the sclerotic and held vertical by the assistant, without undue tension.

The next stage consists in inserting the stitches (silk, No. 1). If the right external rectus is being advanced the stitches are passed from the muscle towards the cornea; if the left, in the reverse direction. We will suppose for the sake of description that the left external rectus is being operated upon. The needle is grasped by the holder about half-way between the eye and the middle of the bend. It is passed into the episcleral tissue about 3 mm. from the corneo-scleral margin. It must be directed almost perpendicularly to the globe at first, so that a firm scleral grip is obtained. This is the most important and most difficult step in the operation. The needle is brought out about 1 mm. from its point of

entry. In doing so pressure must be exerted in the direction of the curve of the needle; if the pressure is exerted in the direction of a chord of the arc of the circle of curvature of the needle the latter will inevitably break. The middle stitch is inserted first, *i.e.*, the needle is introduced in the prolongation of the horizontal meridian of the cornea. Having obtained a firm anterior hold the needle is again grasped by the holder, this time nearer its eye. The muscle is held vertical and placed somewhat on the stretch. The needle is inserted on the posterior surface, as far back as possible. It is passed through the muscle and conjunctiva and the thread is drawn through.

The other two stitches are inserted in the same manner, one above, the other below the first. Instead of bringing them through the muscle and conjunctiva as before they should be passed through the muscle first, then through the anterior corners of the conjunctival flap. The sutures are kept carefully arranged in order over the gauze mask, which prevents them coming in contact with the face.

The sutures having been inserted the advancement forceps are removed by cutting through the muscle close behind them; care must be taken not to cut the sutures. The middle stitch should be tied first. A double turn is taken in the first stage of the knotting. Absolute parallelism in the visual axes is obtained as follows. A light is placed on the ceiling immediately above the patient's face. The gauze mask is slit through so that both eyes can fix the light. When the axes are parallel the corneal reflex of the light should be in the centre of each pupil. I usually tie the sutures with an ordinary surgical knot, but if desired they may be tied in bows, so that further adjustment may be made during the first few days after the operation. The ends of the stitches must be cut short so that they do not touch the cornea.

Both eyes should be bandaged for three days or longer. The stitches are removed under cocain in a week or ten days. A slightly astringent lotion may be used until the conjunctival injection has disappeared. Occasionally a knob of granulation tissue appears in the wound; this should be snipped off. The correcting spectacles must be used as soon as both eyes are uncovered.

The chief difficulty in performing advancement, as already pointed out, is getting a firm anterior hold for the sutures. It is a common opinion that the stitches tear out through the muscle. Consequently a great variety of fancy stitches have been devised for obtaining a firm posterior hold. I am convinced that this rarely happens, for the muscle is surrounded by quite dense connective tissue which prevents tearing out. When an advancement fails it is because a firm grip on the sclerotic has not been obtained. It is useless to pass the needle through conjunctiva only; it must penetrate well into the episcleral, and even scleral, tissue. There is of course some danger of perforating the globe, and disastrous results have been known to arise from this cause; they are fortunately very rare.

SECTION VI.

DISEASES OF THE ADNEXA OF THE EYE.

CHAPTER XXIX.

DISEASES OF THE LIDS.

Anatomy.—The lids are covered anteriorly by skin and posteriorly by mucous membrane—conjunctiva tarsi; they end in a free edge about 3 mm. broad—margo inter-

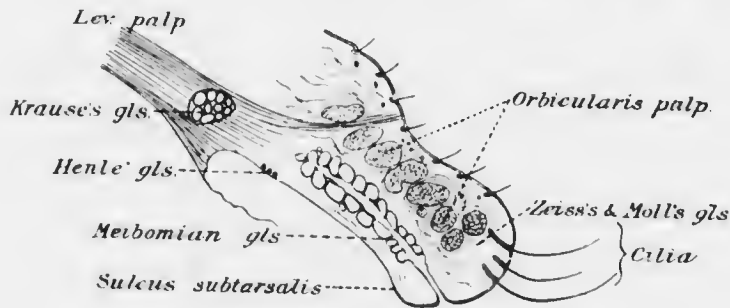


FIG. 275. —Diagram of sagittal section of upper lid.

marginalis. The substance of the lids consists of muscles, glands, blood vessels, and nerves, all bound together by connective tissue, which is particularly dense at the posterior part, where it forms a stiff plate—the tarsus (Fig. 275).

The skin of the lids differs from that of the rest of the

body merely in its thinness, its loose attachment, and the absence of fat in its corium. It is covered with fine downy hairs, which are provided with small sebaceous glands, and there are also small sweat glands. At the anterior border the hairs are specially differentiated to form a protection to the eyeball. The cilia or eyelashes are strong, short, curved hairs, arranged in two or more closely set rows. Their sebaceous follicles, like the cilia themselves, are specially differentiated, and are called *Zeiss's glands*. Apart from being larger, they are identical with other sebaceous glands. The sweat glands near the edge are also unusually large and are known as *Moll's glands*. They are situated immediately behind the hair

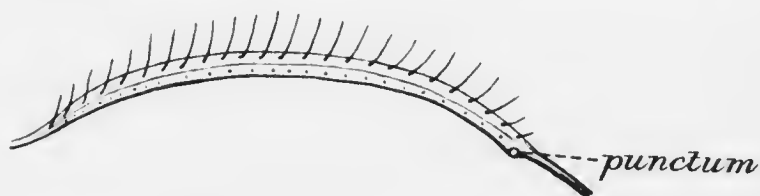


FIG. 276. Diagram of intermarginal strip.

follicles, and their ducts open into the ducts of *Zeiss's glands* or into the hair follicles, not direct on to the surface of the skin as elsewhere.

The margin or free edge of the lid is the part between the anterior and posterior borders—the intermarginal strip or *margo intermarginalis* (Fig. 276). It is covered with stratified epithelium, which forms a transition between the skin and the conjunctiva proper. The anterior border is rounded, the posterior, which lies in contact with the globe, is sharp. The capillarity induced by this sharp angle of contact is of importance in the proper moistening of the surface of the eye. Immediately anterior to the posterior border is a single row of minute orifices, just visible to the naked eye. These are the orifices of the

ducts of the Meibomian glands. Between this row of puncta and the anterior border is a fine grey line, which is important in operations in which the lid is split, as it indicates the position of the loose fibrous tissue between the orbicularis palpebrarum and the tarsus.

The tarsus consists of dense fibrous tissue; it contains no cartilage cells, so that the term tarsal cartilage is only justified in so far as it defines the consistence of the plate. Imbedded in the tarsus are some enormously developed sebaceous glands, the *Meibomian glands*. They consist of nearly straight tubes, directed vertically, each opening by a single duct on the margin of the lid. The tubes are closed at the upper end, and have numerous small caecal appendages projecting from the sides, filled with fatty glandular epithelium. The glands number from twenty to thirty, being rather fewer in the lower than in the upper lid.

The large bundles of the orbicularis palpebrarum occupy the space between the tarsus and the skin. The main central band of the levator palpebrae superioris is inserted into the upper border of the tarsus; an anterior slip passes between the bundles of the orbicularis to be inserted into the skin of the middle of the lid; a posterior slip is inserted into the conjunctiva at the fornix. The inferior rectus and oblique muscles send fibrous strands forwards into the lower lid to be attached to the tarsus and palpebral ligament.

Besides these striped muscles there is a layer of unstriped muscle in each lid. These constitute the superior and inferior tarsal muscles of Müller. The fibres of the upper arise amongst the striped fibres of the levator, pass down behind it, and are inserted into the upper border of the tarsus. The inferior lies below the inferior rectus and is inserted into the lower tarsus.

The arteries of the upper lid form two main arches,

superior and inferior, the former lying between the upper border of the tarsus and the orbicularis, the latter in a similar position just above the hair follicles. In the lower lid there is usually only one arch near the free edge. There are two venous plexuses in each lid: a post-tarsal passing into the ophthalmic veins, and a pre-tarsal opening into subcutaneous veins.

The sensory nerve supply is derived from the trigeminal. The third nerve supplies the levator palpebræ, the seventh the orbicularis, and the sympathetic Müller's muscles.

INFLAMMATION OF THE LIDS.

Almost any of the inflammatory conditions which affect the *skin* in general may attack the lids. Erysipelas is dangerous in that it may spread to the orbit, leading to cellulitis and atrophy of the optic nerve, or meningitis. Herpes ophthalmicus is often mistaken for erysipelas: its unilaterality, strict localisation to the course of branches of the ophthalmic nerve, and the characteristic formation of vesicles should prevent this mistake: permanent scarring remains after the attack. Eczema of the lids is common, especially associated with phlyctenular conjunctivitis (*q.v.*) in children. Abscesses, boils, anthrax pustule, and ulcers of various kinds may affect the skin of the lids. **O**edema of the lids may be inflammatory or passive. It is often associated with chemosis of the conjunctiva in severe conjunctivitis. Great oedema is often caused by bites of parasites, gnats, &c. In unilateral oedema the condition of the lacrymal sac and nasal duct should be investigated; it is often due to lacrymal abscess. In all cases of oedema the condition of the eyeball must be determined, with the assistance of Desmarres' retractors if necessary. **O**edema of the lids may be caused by serious purulent inflammation of the globe (panophthalmitis), of Tenon's capsule, by

phlegmon of the orbit or thrombosis of the cavernous sinus. Passive œdema may be due to nephritis, heart disease, &c., or it may be angioneurotic.

Blepharitis is a chronic inflammation of the margins of the lids. It may manifest itself as a simple hyperæmia, differing from that caused by weeping, exposure to tobacco smoke, and so on, in being more persistent. The causes and treatment are the same as for the more severe forms of blepharitis. True blepharitis occurs in two forms. In *squamous blepharitis* small white scales, like dandruff, accumulate amongst the lashes; the latter fall out readily, but are replaced without distortion. If the scales are removed the underlying surface is found to be hyperæmic, but not ulcerated. The condition is probably a seborrhœa.

In *ulcerative blepharitis* yellow crusts glue the lashes together: on removing them small ulcers, which bleed easily, are seen around the bases of the lashes. The lashes fall out or are easily pulled out, and often are not replaced, or grow in a distorted form, owing to injury to the follicles. Blepharitis causes redness of the edges of the lids, itching, soreness, lachrymation, and "photophobia."

The sequelæ of the ulcerative form are serious. If not treated energetically and with perseverance the disease is extremely chronic, causing or being accompanied by chronic conjunctivitis. Care must be taken to distinguish true blepharitis from matting together of the lids by conjunctival discharge: in the latter case removal of the crusts reveals quite normal lid margins. The ulceration is liable to extend deeply, so that the hair follicles are destroyed. Only a few small, scattered, distorted cilia are then found (*madarosis*).

When the ulcers heal the cicatricial tissue contracts. Neighbouring hair follicles are drawn out of place and a false direction is given to the remaining cilia, so that they may rub against the cornea (*trichiasis*). Or the

development of cicatricial tissue may be extreme, so that the edge of the lid becomes hypertrophied and droops in consequence of its weight (*tylosis*).

The lower lid is particularly liable to be displaced by prolonged ulcerative blepharitis. The contraction of the scar tissue drags the conjunctiva over the margin; the posterior lip of the intermarginal strip, instead of being acute-angled, becomes rounded, so that its capillarity is impaired. Tears then tend to run over (*epiphora*), a condition which is accentuated if the punctum becomes everted, so that it ceases to lie in accurate contact with the bulbar conjunctiva (*vide* p. 624). The continual wetting of the skin with tears leads to eczema, which is followed by contraction. The condition is made worse by perpetually wiping the eyes, so that eventually *ectropion* is developed. This causes still more epiphora, a vicious circle being set up.

The causes of blepharitis are multitudinous. The patients are usually debilitated, from living under poor hygienic conditions, or from disease, *e.g.*, anaemia, tubercle, syphilis, &c. The condition may follow chronic conjunctivitis, or be induced by the same causes, especially smoky atmosphere, heat (stokers, cooks), late hours, &c. It is undoubtedly often associated with uncorrected errors of refraction, especially hypermetropia and astigmatism, which probably act by inducing reflex hyperaemia. Occasionally parasites cause blepharitis, *e.g.*, blepharitis acarina, due to *demodex folliculorum*, and phthiriasis palpebrarum, due to the *pediculus pubis*, very rarely to *pediculus capitis*. In the latter condition the cilia are covered with black nits, an appearance being produced which is easily recognised when once seen.

Treatment.—The local treatment of blepharitis must be energetic in the ulcerative form. The crusts must first

be removed. This is effected most easily by soap and water, followed by thorough bathing with hot borax or bicarbonate of soda lotion, 3 per cent. The application softens the deposits, so that they can be picked or rubbed off with a pledget of cotton wool. When the crusts have been entirely removed the surface is covered with an ointment of yellow oxide of mercury, ammoniated mercury, or ichthyol (10 per cent.), which is well rubbed in for at least five minutes. These procedures should be repeated three times a day. In most cases, if the treatment is carried out properly there is a speedy cure. Unfortunately the treatment is seldom satisfactorily carried out. It is useless merely to smear ointment on the surface of the crusts. It must be applied to the inflamed tissues and rubbed well into the hair follicles.

In more severe cases, or when the above treatment is improperly done, protargol, 15 to 20 per cent., should be rubbed into the margins of the lids with a stumpy camel's hair brush until a lather is formed; this usually takes five minutes. Or the surface may be thoroughly cleaned with bicarbonate lotion and silver nitrate, 2 per cent., painted on. All loose lashes should be pulled out with epilation forceps.

Attention must be directed to the hygienic surroundings, and to the general health. Errors of refraction must be corrected.

Syphilis.—A primary sore is occasionally found on the lid margins, commencing in the conjunctiva. If situated near the outer canthus the pre-auricular gland is enlarged, if near the inner canthus the submaxillary, in accordance with the distribution of the lymphatic vessels. If recognised before the glands are affected it should be excised or destroyed by radium. At a later stage calomel ointment should be rubbed in.

Gummata occur in the lids sometimes, and tertiary syphilis may cause enormous thickening of the tarsus (syphilitic tarsitis).

Vaccinia.—The margin of the lid is occasionally inoculated from the recently vaccinated arm of a baby. Often the inoculated margin in turn inoculates the opposing margin of the other lid. Usually the pustule is at the outer canthus, and the pre-auricular gland is swollen and painful. The history generally serves to elucidate the case.



FIG. 277.—Hordeolum.

INFLAMMATION OF THE GLANDS OF THE LIDS.

Hordeolum or **stye** is a suppurative inflammation of one of Zeiss's glands (Fig. 277). In the early stages the gland becomes swollen, hard and painful, and usually the whole edge of the lid is oedematous. An abscess forms which generally points near the base of one of the cilia.

The pain is often considerable until the pus is evacuated. Styes often occur in crops, or may alternate with boils on the neck, carbuncles, or acne. Like these conditions, the disease shows deficient resistance of the body

to the invasion of staphylococci. It is commonest in young adults, but may occur at all ages, especially in debilitated persons. Not infrequently it will be found that faulty drains account for the defective health.

Treatment.—Hot compresses should be used in the early stages. When the abscess points it may often be evacuated by pulling out the corresponding cilium; but this is usually effected more satisfactorily by an incision with a small knife. It should be remembered that such an incision is exceptionally painful. The pus should be thoroughly squeezed out and a hot compress applied.

If crops of styes occur the general health must receive attention. When associated with boils, &c., the urine should be tested for sugar, especially in adults. Inquiry should be made as to the condition of the drains.

The opsonic index of the blood against staphylococci may be tested. It will usually be found to be abnormally low, and in these cases great improvement has followed the use of a staphylococcic vaccine.

Constipation must be counteracted, and tonics are useful, especially iron in some form.

Hordeolum internum is comparatively rare. It is a suppurative inflammation of a Meibomian gland of exactly the same type as the hordeolum externum or stye. It is often called a suppurating chalazion, and some may be due to secondary infection of a chalazion. The inflammatory symptoms are more violent than in external stye, for the gland is larger and is imbedded in dense fibrous tissue. The pus appears as a yellow spot shining through the conjunctiva when the lid is everted. It may burst through the duct or through the conjunctiva, very rarely through the skin.

Treatment is the same as for external stye, except that the incision should be made exactly as for a chalazion (*vide infra*).

Chalazion (*Syns.*—*Tarsal Cyst*, *Meibomian Cyst*) is a chronic inflammatory affection of a Meibomian gland. The gland tissue becomes replaced by granulation tissue containing giant cells; the disease is not caused by the tubercle bacillus. The gland becomes swollen, increasing in size very gradually and without inflammatory symptoms. Patients usually seek advice on account of the disfigurement (Fig. 278). The smaller chalazia are difficult to see, but are readily appreciated by passing the finger over the skin. If the lid is everted the conjunctiva is red or




FIG. 278.—Chalazion.

purple over the nodule, in later stages, often grey, or rarely, if infection has occurred (*vide* hordeolum internum), yellow. The grey appearance is due to alteration in the granulation tissue. This is not very vascular at any stage, but in the later stages the vessels retrogress, the nourishment of the tissue fails and it becomes converted into a jelly-like mass. Only under such conditions is the term "cyst" really applicable. Complete spontaneous resolution very rarely occurs. The contents may be extruded through the conjunctiva, and in these cases a fungating mass of granulation tissue often sprouts

through the opening, keeping up conjunctival discharge and irritation.

Chalazia are often multiple or occur in crops. They are commoner in adults than in children.

Treatment.—Quite small chalazia may be left alone; it is very difficult to evacuate them satisfactorily by the ordinary method. Larger chalazia must be incised and thoroughly scraped. The conjunctival sac is well cocainized with 2 per cent. solution. The lid is then everted and the site of the chalazion carefully examined. At the point of greatest discoloration a few crystals (not many) of solid cocain are placed upon the surface and allowed to dissolve. A vertical incision is then made with a sharp scalpel or Beer's knife (Fig. 279). Any semifluid contents which may be present escape. A small sharp spoon (Fig. 280) is then inserted into the orifice and the walls of the cavity are thoroughly scraped. The bleeding soon stops, and no dressing is usually necessary. A simple boric acid lotion is ordered for a few days.

The patient should be warned that the swelling will remain for awhile. This is due to the resistant walls, formed by the fibrous tissue of the tarsus; the cavity is kept dilated and becomes filled with blood. Sometimes, especially if the scraping has not been sufficient, granulation tissue sprouts

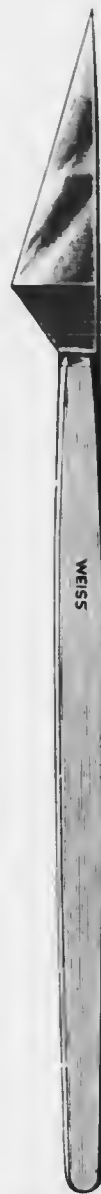

FIG. 279. — Beer's knife (devised for cataract extraction; now only used for lid operations).

from the wound. This must be snipped off with scissors, curved on the flat, after application of cocain; the cavity should be again scraped out.

Very hard chalazia are occasionally met with, particularly near the canthi; it is possible that some of these are true adenomata of the glands. They may require excision, since it may be impossible to scrape them out efficiently.



FIG. 280. Sharp spoon.

ANOMALIES OF POSITION OF THE LIDS.

Trichiasis (*τριχία*, *τρίχος*, a hair) is the condition of distortion of the cilia, so that they are directed backwards and rub against the cornea (*vide* p. 599). A few only of the lashes may be affected or the condition may be due to entropion, involving the whole margin of the lid. It may also be caused by congenital distichiasis (*vide* p. 606).

The symptoms are those of a foreign body continually present in the eye—irritation, pain, conjunctival congestion, reflex blepharospasm, lachrymation. Superficial opacities and vascularisation of the cornea are produced; recurrent ulcers of the cornea are not infrequently due to this cause.

Any condition causing entropion (*q.v.*) will cause trichiasis, trachoma and spastic entropion being among the most common. Other causes are blepharitis, and the scars resulting from injuries, burns, operations, diphtheria, &c.

Treatment.—Isolated misdirected cilia may be removed by epilation, which must, however, be repeated every few weeks. A better mode of treatment is to destroy the

hair follicle by electrolysis. The flat positive pole is applied to the temple; the negative, a fine steel needle, is introduced into the hair follicle; a current of two milliamperes is used. The negative pole is determined by placing the terminals in saline, when bubbles of hydrogen are given off by it. The strength of current can be gauged by the rate of evolution of gas. It should be remembered that electrolysis is extremely painful and tedious; the pain may be diminished by injecting cocain into the margin of the lid. If the current is of the proper strength, the bubbles evolved at the site of puncture cause the formation of a slight foam.

If many cilia are displaced, operative procedures must be resorted to. Since they are nearly allied to those performed for entropion, which is generally present, they will be described later (*vide p. 602*).

Entropion (*ἐν, in, τρέπειν, to turn*), rolling in of the lid, occurs in two forms, spastic and cicatricial. The symptoms are those of the trichiasis (*q.v.*) which is induced.

Spastic entropion is due to spasm of the orbicularis. Strong contraction of the circularly arranged fibres tends not only to approximate the lid margins, but also to turn



FIG. 281.—Griffith's ring forceps: useful for holding the lid everted in incising chalazia. The ring is on the conjunctival surface and surrounds the chalazion.

them inwards or outwards, according to the mechanical support afforded by the globe and orbital contents. If the support is insufficient, entropion is produced. This is well seen when the eyeball has been removed, but it also occurs when the globe is deeply set owing to absence of orbital fat, &c., especially if the skin of the lids is also redundant. These conditions are found *par excellence* in old people, who are therefore very liable to spastic entropion. It is also caused by tight bandaging, and is favoured by narrowness of the palpebral aperture (blepharophimosis). Spastic entropion is almost invariably restricted to the lower lid.

Cicatricial entropion is caused by cicatricial contraction of the palpebral conjunctiva; in the worst forms, found in trachoma, the tarsal plate is also bent and distorted, sometimes by atrophic, sometimes by hyperplastic changes. It is an exaggeration of the effect produced by the various causes of trichiasis (*q.v.*).

Treatment of Spastic Entropion.—If due to bandaging, the condition is often cured by simply leaving off the bandage. Wearing an artificial eye relieves the symptoms when the eyeball has been removed. In the spastic entropion of old people temporary relief may be obtained by placing a roll of lint or plaster horizontally just above the margin of the orbit, and bandaging it firmly in position; or the lid may be slightly everted by painting collodion on the skin or by pulling it out with a strip of adhesive plaster.

Permanent relief can be obtained only by operation. The simplest method is the removal of a strip of skin and muscle. Cocain, eucain or novocain is first injected subcutaneously. An oval area of skin, with the long axis horizontal and varying in width according to the amount of entropion and of superfluous skin, is marked out with a scalpel or Beer's knife just below the site of greatest displacement.

The upper incision must be close to the margin of the lid (Fig. 282). The piece of skin is dissected off. The underlying fibres of the orbicularis are then dissected off with forceps and knife, until the tarsus is exposed. It is usually unnecessary to insert sutures. The operation may be done with one snip of scissors and without cocaine, if a fold of skin is taken up with T-shaped forceps (Fig. 283). This method is not so satisfactory.

In cases of spastic entropion with much blepharospasm, canthoplasty is sometimes indicated. It consists in



FIG. 282.—Diagram of skin and muscle operation.


widening the palpebral aperture by dividing the outer canthus. The lids are separated with the fingers in such a manner as to put the canthus on the stretch. One blade of strong blunt-pointed scissors is introduced as far as possible into the conjunctival sac behind the commissure. The entire thickness, including skin and conjunctiva, is divided horizontally by a single cut. If only a temporary effect is required, no sutures are inserted. If it is desired permanently to enlarge the palpebral aperture, the conjunctiva is sutured to the skin. Temporary canthoplasty is sometimes indicated in other conditions than

spastic entropion, *e.g.*, in simple severe blepharospasm, such

as occurs in phlyctenular conjunctivitis, in acute purulent conjunctivitis with much swelling of the lids, and in removal of an enlarged eyeball or an orbital tumour.

Treatment of Cicatricial Entropion.—A very large number of plastic operations have been devised for the relief of cicatricial entropion: only the more simple will be described here. The principles governing the various operations are: (1) altering the direction of the lashes, (2) transplanting the lashes, (3) straightening the distorted tarsus. Subcutaneous injection of cocaine or a general anæsthetic is indicated; the former method does not obviate all pain, especially if the tarsus is cut.

The simplest procedure is some modification of Burrow's operation. The lid is everted over the end of a metal lid spatula (Fig. 284). A horizontal incision through the conjunctiva and passing completely through the



FULL SIZE

FIG. 283. T-shaped forceps.

tarsal plate, but not through the skin, is made along the whole length of the lid in the sulcus subtarsalis, *i.e.*, about

2–3 mm. above the posterior border of the intermarginal strip (Fig. 285). Care must be taken not to wound the punctum or canaliculus. The outer end of the strip may then be divided by a vertical incision through the free edge of the lid, including the whole thickness. In this manner the edge of the lid is left attached only by skin, and when cicatrization has occurred the edge is turned slightly outwards, so that the lashes are directed away from the eye. Relapses are not uncommon, however, and the operation may have to be repeated. It is probably better to keep the edge of the lid everted during the process of healing by means of a spindle-shaped pad of oiled silk (Fig. 286). The pad is kept in position by sutures suitably applied.

In the Jaesche-Arlt operation the zone of hair follicles is transplanted to a slightly higher position. The lid is split from the outer canthus to just outside the punctum along the grey line (*vide* p. 589) between the lashes and the orifices of the Meibomian glands. During this procedure the globe is protected by the spatula inserted between it and the lid, or held by a lid clamp (Figs. 287, 288). The incision extends between the tarsus and the orbicularis for a depth of 3–4 mm., so that the zone containing the hair follicles is thoroughly loosened (Fig. 289). An elliptical piece of skin is then removed from the lid. The lower incision extends through the skin down to the tarsus at a distance of 3–4 mm. from the edge of the lid and parallel with it for its whole length. The middle part of the




FIG. 284. — Lid spatula, which should be made of metal.

upper incision is 6—8 mm. from the edge of the lid. The elliptical piece of skin thus marked out is removed, without taking any orbicularis. The two skin incisions are then sutured. In this manner the zone of lashes is transplanted to a higher level. The gaping wound in the intermarginal strip may be filled in with skin from that excised, or by a Tiersch graft or a graft of mucous membrane; this tends to prevent the follicles from being drawn down again when the wound cicatrises. Care should be taken not to produce ectropion by removing too much skin.

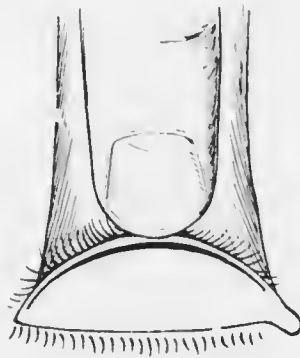


FIG. 285.—Diagram of modified Burow's operation for entropion.

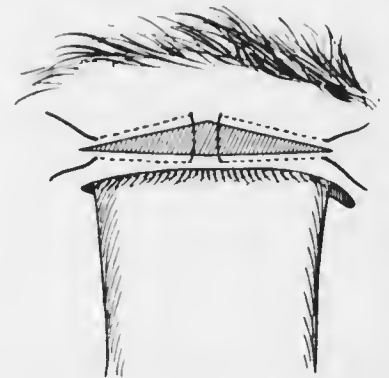


FIG. 286.—Diagram of modified Burow's operation for entropion.

Ectropion, rolling out of the lid, occurs in several forms, the chief being spastic, cicatricial, senile, and paralytic. The symptoms are due to the epiphora induced and to the chronic conjunctivitis caused by exposure. In severe cases the cornea may suffer from imperfect closure of the lids.

Spastic ectropion results from blepharospasm when the lids are well supported by the globe and when they are short, firm, and without redundant skin. It is therefore seen in children and young patients, and is readily induced by phlyctenular conjunctivitis (*vide* p. 190).

Mechanical ectropion is caused by extreme proptosis or thickening of the conjunctiva, such as occurs after purulent conjunctivitis and trachoma. In the latter disease the



FIG. 287. — Desmarest's entropion forceps for right eye.



FIG. 288. — Wilde's entropion forceps.

tarsus is often distorted. Upper and lower lids are frequently affected simultaneously.

Cicatricial ectropion results from destruction of the skin by injury, burns, ulcers, gangrene, operations, &c. Caries of the orbital bones is a common cause in children. Chronic

conjunctivitis and blepharitis also cause cicatricial ectropion, which is increased by the wetting of the skin with tears and the eczema thereby induced.

Senile ectropion is found only in the lower lid, and is due to relaxation of the tissues and degeneration of the orbicular muscle fibres. The condition is increased by the conjunctivitis and epiphora which are set up.

Paralytic ectropion results from the laxity of the lids induced by paralysis of the orbicularis. Only the lower

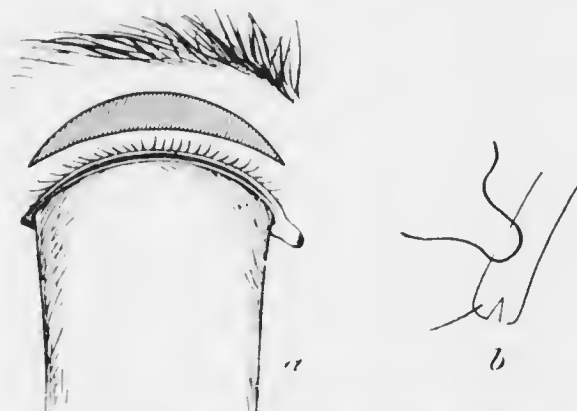

FIG. 289. Diagram of Jaesche-Alt operation for entropion.

lid is affected, the upper being kept in contact with the globe by its own weight.

Treatment.—Non-operative treatment is chiefly serviceable in spastic ectropion. Here a well-fitting bandage, unless contra-indicated by other factors, will often cure the displacement. A bandage should also be applied in ectropion paralyticum, but the condition is cured only by restoration of the innervation. The slighter degrees of senile ectropion are also amenable to non-operative treatment, though it may be advisable to slit the canaliculus in order to cure epiphora. The patient should be instructed not to pull the lid down when wiping the eye.

A large variety of operations has been devised for ectropion: only the simpler procedures will be described.

Suellen's sutures are indicated in some cases of spastic and senile ectropion. In this operation two loops of thread, inserted at the junction of the middle with the inner and outer thirds of the lid, through the ectropionised conjunctiva, are made to hold the fornix in its proper position (Fig. 290). A silk thread is armed with a needle at each end. One needle is passed in at one of the two spots indicated at the level of the top of the tarsus, *i.e.*, in the position where the fornix ought to be. The



FIG. 290.—Diagram of Suellen's sutures for ectropion.

needle is passed vertically downwards under the skin and brought out just below the level of the orbital margin. The other needle is inserted similarly 2 or 3 mm. to one side of the first, and is carried down parallel with it. The second suture is inserted in exactly the same manner at the junction of the middle with the other third of the lid. The sutures are then tied over pieces of rubber tubing laid vertically, the ectropionised fornix being thus drawn down into its normal position. The sutures may be tightened from day to day so as to cause the formation of cicatricial bands along their tracks: this was more effectual in the days when antiseptic precautions were not observed. The effect is seldom permanent.

In paralytic ectropion lateral tarsorrhaphy may be indicated. In this operation the palpebral aperture is shortened by uniting the lids at the outer canthus. The edges of the upper and lower lids are freshened for the requisite distance, the lashes being excised. The lids are then sutured together as in central tarsorrhaphy (*vide* p. 256).

In many cases of ectropion, especially senile, the lower lid is stretched and elongated. The ectropion may then



FIG. 291. Dimmer's modification of Kulmt's operation for ectropion.

be cured by shortening the lid. A wedge-shaped piece of the lid, including the whole thickness, is excised at the outer canthus. The edges of the skin wound are then sutured together, and similarly the edges of the conjunctival wound.

A more elegant method of shortening the lid is Dimmer's modification of Kulmt's operation (Fig. 291). A triangular piece of conjunctiva and tarsus is excised, the apex of the triangle being towards the fornix. The lid is then split along the grey line from the triangle to the outer canthus. A triangular area of skin is removed at the outer canthus and

the skin is slid outwards so that the gap in the tarsal plate is closed, the requisite length of the margin of the lid at the outer canthus being denuded of cilia.

In the slighter cases of cicatricial ectropion the V—Y operation of Wharton Jones is indicated (Fig. 292). A V-shaped incision, with the apex away from the lid margin, is made through the skin, the limbs of the V enclosing the cicatrix. The skin is freed from the underlying tissues and is also well undermined at the edges. The margins of the incisions are sutured in such a manner that a



FIG. 292. Diagram of V—Y operation for ectropion.

Y-shaped cicatrix results: the edge of the lid is thus raised to its normal position.

More extensive cicatricial displacement requires some form of blepharoplastic operation, flaps of skin being taken from the cheek or temporal region, or Tiersch grafts employed. Each such case must be treated on its own merits and will often exercise the ingenuity of the surgeon.

Symphlepharon (*σύν*, with, together, *βλέφαρον*, eyelid) is the condition of adhesion of the lid to the globe

D.E.

(Fig. 293). Any cause which produces raw surfaces upon two opposed spots of the palpebral and bulbar conjunctiva will lead to adhesion if the spots are allowed to remain in contact during the process of healing. Such causes are burns from heat or caustics, ulcers, diphtheria, operations, &c. Bands of fibrous tissue are thus formed, stretching between the lid and the globe, involving the cornea if this has also been injured. The bands may be narrow, but are more frequently broad, and may extend into the fornix so that the lid is completely adherent to the eyeball

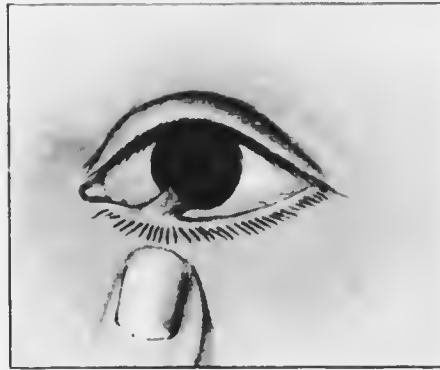


FIG. 293. Symblepharon.

over a considerable area (symblepharon posterius). Bands limited to the anterior parts and not involving the fornix are called symblepharon anterius. Total symblepharon, in which the lids are completely adherent to the globe, is rare.

Pronounced adhesions cause impairment of mobility of the eye, so that diplopia may be complained of. The adhesion may be so intimate that it is impossible to close the lids efficiently, lagophthalmia, with its baneful consequences, resulting. There is often much disfigurement.

Treatment.—The prevention of symblepharon is of the utmost importance (*vide* p. 435). When it is already established operation is necessary. Symblepharon anterius is usually easily remedied by dividing the bands and preventing re-formation of adhesions in the manner already described. When the bands are broad, and especially if there is symblepharon posterius, the separation of the lid

from the globe is difficult. There is no guide to the limitations of sclerotic and tarsus, and great care has to be exercised lest the globe be punctured. The prevention of re-formation of adhesions is much more difficult, and is successful only if the raw surfaces are covered with epithelial grafts. These may be either conjunctival or skin flaps, Tiersch grafts, or grafts of rabbit's or frog's mucous membrane.

Ankyloblepharon (*ἀγκύλη*, a thong, *βλέφαρον*, eyelid) is adhesion of the margins of the two lids. It may be either a congenital condition or due to burns, &c. It may be partial or complete, and is often combined with symblepharon. The treatment depends upon the amount of symblepharon. If it is very extensive operation may be contra-indicated. In other cases the lids are separated and kept apart during the healing process. If the adhesion extends to the angle of the lids the latter must be covered with an epithelial graft, otherwise the condition will recur.

Blepharophimosis (*βλέφαρον*, eyelid, *φιμός*, a wuzzle) is the condition in which the palpebral fissure appears to be contracted at the outer canthus. It is really unusual, but the outer angle is obscured by a vertical fold of skin. The latter is due to eczematous contraction of the skin following prolonged epiphora and blepharospasm. Mere narrowing of the palpebral aperture is often called blepharophimosis, and may be a congenital condition: it is really a form of ankyloblepharon.

The condition may require no treatment, disappearing spontaneously after the inflammation has subsided. In other cases canthoplasty is indicated.

Lagophthalmia (*λαγός*, a hare) is the condition of incomplete closure of the palpebral aperture when the eyes are shut. It may be due to narrowing of the lids from cicatrization or congenital deformity, ectropion,

paralysis of the orbicularis, proptosis due to exophthalmic goitre, orbital tumour, &c., or to laxity of the tissues and absence of reflex blinking in people who are extremely ill or moribund. Owing to exposure the cornea becomes epidermoid (xerosis corneae) or keratitis sets in. The treatment is that of keratitis e lagophthalmo (*q.v.*).

Ptosis (*πίπτειν*, to fall) is the term given to drooping of the upper lid, due to paralysis or defective development of the levator palpebrae superioris. Ptosis may also be caused by thickening and increased weight of the lid (*l.c.* p. 592). The condition may be unilateral or bilateral, partial or complete. In the higher degrees the lid hangs down, covering the pupil more or less completely, interfering with vision. An attempt is made to counteract the effect by overaction of the frontalis and by throwing back the head, the eyes being pulled downwards by the inferior recti. A very characteristic attitude is thus adopted. Forced contraction of the frontalis causes the eyebrows to be raised and throws the skin of the forehead into wrinkles. Partial ptosis may be masked by this means, but becomes manifest if the patient is asked to look up while the eyebrows are fixed by firm pressure with the fingers against the bone.

Ptosis may be congenital or acquired. The congenital form is usually, but not invariably, bilateral, and is due in most cases to defective development of the muscles. Some cases have been proved to be caused by maldevelopment of the third meelens. The condition is not infrequently hereditary. There is nearly always defect in the upward movement of the eyes, due partly to absence of the posterior insertion of the levator into the fornix (*vide* p. 589), partly to coincident maldevelopment or defective innervation of the superior rectus. It may be pointed out here that defective upward movement of the eyes is

the commonest congenital defect of bilaterally associated extrinsic muscles.

Acquired ptosis is usually unilateral. It may be part of the symptom-complex of paresis or paralysis of the whole of the third nerve, or may be due to paresis or paralysis of the branch supplying the levator. Isolated ptosis without other signs of oculomotor paralysis may result from disease of upper level centres (cerebral ptosis). Acquired ptosis may also be due to direct injury of the muscle or its nerve supply, as by wounds, fractures, &c. Mechanical ptosis is due to deformity and increased weight of the lid brought about by trachoma, tumours, &c.; it also occurs from lack of support in phthisis bulbi, anophthalmia, &c. Bilateral ptosis may occur in the acquired form, notably as part of the syndrome of myasthenia gravis.

The amount of ptosis sometimes alters with the position of the globe, attaining its highest pitch in abduction of the eye, its least in adduction or attempted adduction. Occasionally in both the congenital and acquired forms the lid rises when the jaw is moved, as in mastication, though it remains immobile when an attempt is made to look upwards. This is an example of synergism or associated movement.

Treatment.—In cases of paralysis of the third nerve treatment must be directed to removal of the cause. The fact that this nerve is so frequently affected in syphilis must be borne in mind; these cases respond to treatment better than others. In cases of incurable paralysis and in congenital and mechanical ptosis the deformity can be removed only by operation. In complete paralysis of the third nerve operation is usually contraindicated on account of the abduction of the eye. If the lid is raised in these cases the diplopia becomes manifest; simultaneous advancement of the internal rectus may diminish the

diplopia and the deformity, but is unsatisfactory and unlikely to give a permanent result.

Operations for ptosis ameliorate the condition but seldom give permanent results. In slight cases excision of an elliptical area of skin, with or without excision of the underlying fibres of the orbicularis, improves the appearance temporarily.

Of the many operations which have been devised for the more severe cases Hess's operation is the best (Fig. 294).

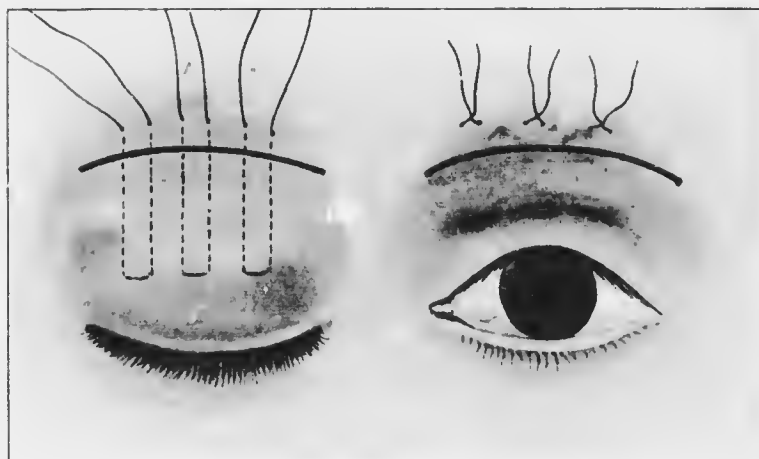


FIG. 294.—Diagram of Hess's operation for ptosis.

It may be performed under local anaesthesia by subcutaneous injections of cocain, eucain or novocain, but a general anaesthetic is better if not contraindicated. The eyebrow is shaved. An incision is made in the line of the eyebrow for 2.5 cm. The skin of the lid is then undermined through this incision so that it is completely separated from the orbicularis and tarsus over its whole area. Three silk sutures are then inserted. Each suture is armed with two half-curved needles. The first needle is inserted a little to one side of the middle line of the lid at a point

5 or 6 mm. from the margin of the lid. It is passed upwards through the orbicularis, anterior to the tarsus, and is brought out through the frontalis about 4 or 5 mm. *above* the incision in the eyebrow. The other needle on the same suture is inserted a little to the other side of the middle line of the lid at the same distance from the lid margin and is carried up parallel to the first and brought out in the same manner. The other two sutures are inserted in exactly the same manner on each side of the first. On pulling the sutures upwards the skin of the lid is thrown into a fold which corresponds with the normal fold at the upper margin of the orbit. In this manner the lid is raised the requisite amount: care must be taken that it is not raised too much, otherwise lagophthalmia will result. The effect produced at the time of operation should be slightly in excess of the desired permanent effect. The incision in the eyebrow is sutured, and then the lid sutures are tied round small pieces of rubber tubing, applied vertically to the forehead. The sutures may be tightened or loosened, if necessary, during the first few days. They are removed after ten days or a fortnight.

INJURIES OF THE LIDS.

Injuries of the most various kinds—contusions, wounds, burns, &c.—are very common. They must be treated upon general principles, but special attention must be directed to three points—(1) wounds of the skin of the lids, (2) injury of the bones of the orbit, (3) injury of the eyeball.

Wounds in the direction of the fibres of the orbicularis gape little and heal without conspicuous scarring; hence surgical wounds should be made in this direction as far as possible. Vertical wounds gape, cause disfiguring cicatrices, and often lead to ectropion, or other distortion,

especially if there is adhesion to the subjacent bone. The worst wounds are such as sever the lid vertically in its whole thickness. If they do not unite by first intention a notch (traumatic coloboma) is left in the lid margin, and disfigurement, lagophthalmia, and epiphora result. Vertical wounds severing the canaliculus require special care.

Injury to the bones of the orbit may affect the orbital margin or deeper parts. Fractures involving the margin may be diagnosed by careful palpation—unevenness, crepitation, &c. Fractures of the walls of the orbit often manifest themselves by *emphysema*. It is due to communication of the subcutaneous tissues with the nasal air sinuses, air being forced into the tissues on blowing the nose, sneezing, straining, or coughing. There is great swelling, with a peculiar soft crepitation on palpation. Fracture of the orbital bones may be followed by retraction of the globe (traumatic enophthalmos), or may be part of a more serious fracture of the base of the skull. In the latter event the optic foramen is often involved, causing laceration or compression of the optic nerve (*vide* p. 412).

Injuries involving the globe require special care both in diagnosis and treatment. In every case of injury of the lids the eyeball must be very carefully examined. Palpation will usually demonstrate considerable reduction of intraocular pressure if the eye is injured; it indicates rupture of the globe. Inspection may be difficult on account of excessive swelling and ecchymosis. In such cases the eye must be examined at all costs, the lids being separated by Desmarres' retractors, under an anæsthetic if necessary.

Contusions are often more alarming in appearance than in reality. There is great swelling and ecchymosis both in the lids and conjunctiva. In all cases a guarded prognosis should be given, for it may be impossible to

determine the full extent of the injury to the orbit (*vide* p. 645), or the eye (*vide* p. 435).

Treatment.—Simple contusions with ecchymosis require only cold compresses: a simple boric lotion is ordered for cleansing the conjunctival sac, and boric ointment to prevent the lids from sticking together.

Emphysema should be treated with a pressure bandage, and all straining, blowing of the nose, and so on, must be avoided.

Wounds must be thoroughly cleansed with an antiseptic lotion and brought together by sutures. In wounds involving the canaliculus the inner end must be searched for, and the canaliculus slit up (*vide* p. 625). If this is not done before cicatrization has occurred epiphora will follow, and it will be extremely difficult to obtain an entry into the canaliculus in order to slit it up. Lacerated wounds are likely to leave ugly scars and deformity of the lids: these must be treated by plastic operation (*vide* p. 63), &c.). If suppuration occurs the abscess must be opened and treated on general surgical principles.

TUMOURS OF THE LIDS.

Benign tumours include xanthelasma, molluscum, warts, naevus, angioma, and other tumours common to the skin and cutaneous glands.

Xanthelasma (*ξανθός*, yellow, *πλασμα*, a plate) or xanthoma is a slightly raised yellow plaque, most commonly found in the upper and lower lids near the inner canthus, and often symmetrical in the two lids and in the two eyes. The plaques are most common in elderly women. They grow slowly, and only require treatment on account of the disfigurement produced. They may be removed after subcutaneous injection of cocaine or its equivalent.

Molluscum contagiosum is a small white umbilicated tumour, generally multiple. A substance resembling sebum can be squeezed out of it. Each tumour should be squeezed out after incision and the interior touched with solid silver nitrate stick.

Nævus or mole, usually pigmented, may occur on the lids, generally affecting the margin and involving both skin and conjunctiva. Sometimes two are symmetrically situated on the lids of the same eye, indicating their origin at a time when the lids were still united. The microscopical appearance is characteristic, consisting of "nævus cells," often arranged in an alveolar manner. The growths may take on malignant proliferation.

Hæmangioma, often also called nævus, occurs in two forms—telangiectasis and cavernous hæmangioma. The former are bright red or port-wine coloured spots composed of dilated capillaries. The latter consist of dilated and anastomosing venous spaces lying in the subcutaneous tissue having all the characteristics of erectile tissue: they are not infrequently strictly localised as if partially encapsuled. They appear bluish when seen through the skin and form a swelling which increases in size on crying, lowering the head, &c. Cavernous hæmangiomata are rarely seen in adults, partly due to the fact that they are generally treated in early life, but possibly due to spontaneous atrophy and thickening of the skin.

Telangiectases may be excised if small. If larger they may be cauterised with the galvano-cautery: only a small area should be attacked at a sitting, the operation being repeated. Electrolysis or carbonic acid snow may also be used. Cavernous hæmangiomata may be excised, preferably from the conjunctival surface, if small. If larger they may be treated by electrolysis. It is a good plan to use electrolysis for a time until the tumour is consolidated with fibrous tissue, and then to excise the mass.

Lymphangioma occurs rarely in the lids.

Malignant Tumours include carcinomata and sarcomata, the former being much the more common. Epitheliomata show a preference for spots where the character of the epithelium changes; they therefore commence generally at the edges of the lids. The patients are elderly, the preauricular gland may be enlarged, or if the growth is near the inner canthus, the submaxillary lymphatic glands. Any of the glands of the lid may in rare instances undergo carcinomatous proliferation. The commonest malignant epithelial growth is the so-called rodent ulcer, which shows a predilection for the inner canthus. It is unnecessary to describe its characteristic features here.

Sarcoma is rare; it may be round or spindle-celled, pigmented or non-pigmented. The malignant growths springing from nevi are usually called sarcomata.

Treatment. — Epithelioma and sarcoma must be thoroughly extirpated at all costs, even if it involves excision of the globe or exenteration of the orbit. Rodent ulcer, if small, should be excised. If larger it is wise to treat it with radium for a time. Considerable improvement, and even cure, has been reported as the result of this treatment, but it is wise always to excise the remnants.

CONGENITAL ABNORMALITIES OF THE LIDS.

Symblepharon, ankyloblepharon, ectropion, entropion and trichiasis occur occasionally as congenital malformations. Ptosis is a fairly common congenital defect.

Distichiasis (*δύς*, double, *στίχος*, a row) is a rare condition in which there are two complete rows of cilia, often in all four lids. The posterior row replaces the Meibomian glands: it causes trouble by rubbing against the cornea.

Coloboma of the lid is a notch in the edge of the lid. The gap is usually situated to the inner side of the middle line, generally affecting the upper lid. Two or more defects may occur in the same lid. Sometimes a bridge of skin links the coloboma to the globe, or there is a dermoid astride the limbus at the site of the coloboma. There are often other congenital defects of the eye or other parts of the body, *e.g.*, coloboma of the iris, accessory auricles, &c. Some cases are due to incomplete closure of the fœtal facial cleft, others probably to pressure of amniotic bands. Occasionally there is a notch at the outer part of the lower lid, associated with maldevelopment of the malar bone.

Cryptophthalmia (*κρυπτός*, hidden) is a very rare condition in which there is total ankylo- and symblepharon, associated with abnormality of the eye and often of the orbit. The skin passes continuously from the brow over the eye to the cheek.

Microblepharon is the condition in which the lids are abnormally small. They may be absent—*ablepharon*. These conditions usually occur only in cases of microphthalmia, or congenitally small eyes.

Epicanthus is a semilunar fold of skin, situated at and sometimes covering the inner canthus. It is usually bilateral, the eyes are far apart, and the bridge of the nose is flat. It may disappear as the nose develops. It is normal in Mongolian races.

Elephantiasis neuromatodes or **plexiform neuroma** may affect the lids and orbit. In all cases the temporal region is also affected. The hypertrophied nerves may be felt through the skin. The nerve fibres are little changed, the hyperplasia affecting the endo- and perineurium. In several cases the ciliary nerves have been found affected, both outside and inside the globe, and in some cases the eye has been buphthalmic.

CHAPTER XXX.

DISEASES OF THE LACRYMAL APPARATUS.

Anatomy and Physiology. The lacrymal apparatus consists of the lacrymal glands and the lacrymal passages.

The *lacrymal glands* of each eye consist of the superior or orbital gland, the inferior or palpebral gland, and the accessory lacrymal glands or Krause's glands. All are serous acinous glands, scarcely distinguishable, microscopically, from serous salivary glands, with which they are morphologically identical. The superior gland, about the size of a small almond, is situated in the lacrymal fossa at the outer part of the orbital plate of the frontal bone. Ten or twelve *lacrymal ducts* pass from it to open upon the surface of the conjunctiva at the outer part of the upper fornix. The inferior gland consists of only one or two lobules situated upon the course of the ducts of the superior portion. It can be seen when the eye looks down and in after the upper lid has been everted. The accessory or Krause's glands are microscopic acini, lying below the surface between the fornix and the edge of the tarsus. There are about forty-two in the upper, six to eight in the lower, fornix. The ducts of numerous acini unite to form a larger duct which opens on to the fornix.

The lacrymal passages consist of the *puncta lacrymalia*, the *canaliculi*, the *lacrymal sac*, and the *nasal duct* (Fig. 295). The *puncta lacrymalia* lie near the posterior border of the free margin of the lid about 6 mm. from

the inner canthus. Each lid has one punctum and one canaliculus. The punctum is situated upon a slight elevation, larger in elderly people, the papilla lacrymalis. As already mentioned, this is visible under normal circumstances only when the lid is slightly everted (*vide* p. 98). The *canaliculus* passes from the punctum to the lacrymal sac. It is first directed vertically for about 1 to 2 mm., then horizontally for 6 to 7 mm. The canaliculi usually open separately through the outer wall

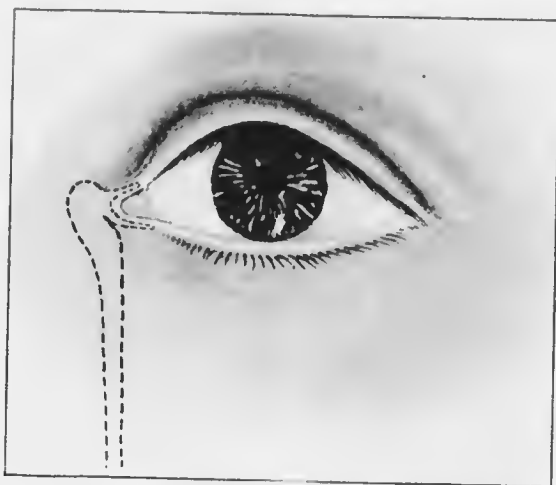


FIG. 295.—Diagram of lacrimal apparatus.

of the lacrymal sac. The *lacrymal sac* lies in the lacrymal fossa formed by the lacrymal bone. When distended it is about 15 mm. long vertically, and 5 to 6 mm. wide. The fundus extends slightly above the level of the inner tarsal ligament. The sac is surrounded by fibres of the orbicularis. The lower end narrows as it opens into the nasal duct. The *nasal duct*, varying much in size (12 to 24 mm. long, 3 to 6 mm. in diameter) passes downwards and slightly outwards and backwards, bounded by the superior maxilla and inferior turbinate,

DISEASES OF LACRYMAL APPARATUS. 623

to open at the anterior part of the outer wall of the inferior meatus of the nose. The line of the duct is given by a point just outside the inner canthus and the groove between the ala of the nose and the cheek. The upper end of the nasal duct is the narrowest part. The canaliculi are lined by stratified epithelium, the lacrymal sac and nasal duct by columnar epithelium, lying upon a corium which contains a venous plexus. The mucous lining forms an imperfect valve at the orifice into the nose.

The *lacrymal secretion* is a slightly alkaline fluid containing sodium chloride as its chief constituent. The ordinary amount secreted is just sufficient to moisten the eyeball, and is lost by evaporation. Only under reflex irritation, psychical or peripheral, is an excess secreted, and this is forced into the lacrymal sac and through the nasal duct into the nose during the act of winking, when the fibres of the orbicularis contract around the sac. It must be remembered that xerosis or dryness of the conjunctiva does not result from extirpation of the superior and inferior lacrymal glands, the moistening of the conjunctiva by Krause's glands and its own mucous cells being sufficient to prevent it. *Per contra*, epiphora does not result from extirpation of the lacrymal sac, except in the presence of psychical or peripheral stimuli to increased secretion. It is possible that the tears have some slight antiseptic properties.

DISEASES OF THE LACRYMAL GLAND.

Diseases of the lacrymal gland are rare. *Dacryo-adenitis* occurs occasionally, usually going on to suppuration. Tubercle also occurs here. A permanent *fistula* may result from rupture of an abscess in the gland. Spontaneous and traumatic *dislocation* of the gland have been described, a swelling being formed under the outer part of the upper lid.

Dacryops is a cystic swelling in the upper fornix, due to retention of secretion owing to blockage of one of the lacrymal ducts. It can only be distinguished from retention cysts of Krause's glands by its position.

Tumours of the lacrymal gland show a very marked resemblance to those of the parotid. Mixed tumours, in reality endotheliomata, containing cartilage, myxomatous material, &c., are the commonest form. Carcinomata and sarcomata are very rare.

All conditions which cause swelling of the gland may lead to impairment of movement of the eye. The globe is pushed downwards and inwards: movement outwards, and especially outwards and upwards, is limited. There may be some proptosis.

The rare diseases mentioned above must be treated on general principles.

DISEASES OF THE LACRYMAL PASSAGES.

Eversion of the lower punctum occurs from laxity of the lids in old age, from chronic conjunctivitis, blepharitis, and any cause leading to ectropion (*q.v.*). It causes epiphora, which in turn aggravates the condition (*vide* p. 604).

Treatment.—In slight cases, especially in old people, the eversion may be sufficiently counteracted by making a small scar in the fornix just behind and below the position of the punctum. This is best done with the actual cautery, a fairly deep gutter being made. As the cicatricial tissue contracts the punctum is pulled inwards towards the eye.

If this procedure fails the canaliculus should be slit up or a radical operation for ectropion performed. In the former case the greatest care must be exercised that the canaliculus is slit on its posterior wall, so that the open duct will lie against the globe. It is not necessary, nor

advisable, in these cases to slit the canaliculus completely into the sac, but it must be incised so far as is necessary to bring the slit part in contact with the eye.

Slitting the lower canaliculus is performed as follows. Instruments required: Nettleship's dilator (Fig. 296), canaliculus knife. The best form of canaliculus knife is the modification of Weber's in which the probe point is straight, not curved forwards as in the original instrument (Fig. 297). The eye should be cocained, though this will not eliminate all pain. The surgeon stands behind the patient. In operating upon the right side he everts the lower lid with his left thumb. With the right hand he inserts the point of Nettleship's dilator into the punctum, passing it directly downwards as far as it will go easily then rotating it outwards and pushing it inwards along the canaliculus. In this manner the punctum is dilated. The knife is then taken and the probe point is passed into the punctum in the same manner, first downwards, then inwards. The back of the knife is directed forwards and slightly downwards. In this manner, as the knife is pushed inwards, the posterior wall of the canaliculus is incised. In bad cases of eversion or when it is desired to slit the canaliculus completely into the sac it is necessary to rotate the handle of the knife upwards and towards the nose as soon as the probe point is stopped by the lacrymal bone. While this manœuvre

D.E.



FIG. 296.—Nettleship's canaliculus dilator.



FIG. 297.
Tweedy's
canaliculus
knife.



FIG. 298.
Stilling's
canaliculus
knife.

is being performed the lid is kept stretched outwards, so that the wall of the duct is kept taut against the edge of the knife. Care must be taken that the edge of the knife, which is directed towards the globe, does not injure the eye, though there is little danger of such an accident. A Stilling's knife (Fig. 298) is useful for completing the incision into the sac.

A probe should be passed along the incised canaliculus on the day following the operation, and occasionally on succeeding days, so as to prevent closure of the incision.

Under no circumstance should the canaliculus be slit up unless it is absolutely necessary. It should never be slit up *more* than is absolutely necessary.

Occlusion of the puncta may be congenital, which is extremely rare, or cicatricial. Epiphora is caused. These cases are very difficult to treat. An endeavour should be made to slit up the occluded punctum—not the whole canaliculus. On inspection no trace of the punctum may be visible, but it is rare that some evidence of its presence cannot be seen on minute examination of the normal site with a loupe. The point of the dilator is inserted at this site, and may succeed in opening up the punctum sufficiently to admit the probe point of the canaliculus knife. There is usually no difficulty in knowing when the knife is in the duct, as it passes on in the proper direction quite easily. If this method fails to permit an entrance the canaliculus

may be cut across vertically. When bleeding has stopped the inner cut end is examined with a loupe, and the probe point of the knife is inserted into it. If this also fails, and the upper punctum is patent, an attempt may be made to pass a small curved probe by the upper punctum into the sac and out into the lower canaliculus. This procedure requires an anæsthetic.

Occlusion of the canaliculus may be due to a scar (*vide* p. 616) or to a foreign body. Of the latter an eyelash is the commonest, less frequent a "concretion." An eyelash usually projects somewhat from the punctum, and is easily removed with forceps. Concretions are masses of the mycelium of a fungus, usually a streptothrix. They are removed by dilating the canaliculus and injecting 10 per cent. protargol.

Congenital anomalies of the puncta and canaliculi are occasionally met with. The puncta may be absent or constricted; there may be two puncta in a lid, generally opening into the same canaliculus. Sometimes a groove is found instead of a canaliculus.

Dacryocystitis or inflammation of the lacrymal sac is not uncommon, especially among the lower classes. It is generally chronic. There is epiphora, aggravated by exposure to wind, &c. Usually there is swelling at the site of the sac. Often the caruncle and neighbouring parts of the conjunctiva are inflamed. On pressure over the sac fluid regurgitates through the puncta, or more rarely passes down into the nose. The fluid may be tears, mucus, or muco-pus; the swelling is often called a *mucocele*. Bacteriological examination of the fluid demonstrates the presence of an extraordinary number of bacteria—staphylococci, pneumococci, streptococci, &c. Of these the pneumococcus is very frequently present in virulent form. This fact is of supreme importance, since it explains the frequency with which hypopyon ulcer arises in these cases,

and the danger of panophthalmitis if any intraocular operation is undertaken. Dacryocystitis is a constant menace to the eye, since minute abrasions of the cornea are of almost daily occurrence, and such an abrasion is liable at any moment to become infected and give rise to an hypopyon ulcer.

Chronic dacryocystitis is commonly attributed to the effects of stricture of the nasal duct. It is by no means certain that the stricture is primary in all these cases; it is not unlikely that it sometimes results from the inflammation of the sac or from the treatment applied to remedy the dacryocystitis. It might be anticipated that the infection was frequently derived from the nose in cases of eczema, &c., but investigation tends to negative this conjecture. There are, however, many undoubted cases in which intractable dacryocystitis has been cured by treatment of a coincident nasal inflammation. Obstruction to the lower end of the nasal duct may be caused by the pressure of nasal polypi, an hypertrophied inferior turbinate bone, extreme deviation of the septum, and so on.

Untreated chronic dacryocystitis never undergoes spontaneous resolution. The condition tends to progress, the walls of the sac ultimately become atonic, the contents never being evacuated except by external pressure. In any case an acute inflammation may arise, a lacrymal abscess being formed. This sequel may be caused by treatment, an abrasion of the epithelial lining leading to infection of the pericystic tissues.

The patients are usually elderly, and such as are exposed to dirt in the course of their daily occupations. Want of personal cleanliness is probably an important factor. Dacryocystitis may, however, occur in the newborn. In these cases it is generally due to adhesion of the epithelial lining, or to imperfect canalisation of the epithelial cord in which the nasal duct is formed. The

careful passage of a small probe *once* will cure these cases. Occasionally dacryocystitis in babies is extremely intractable: I am of the opinion that most of these cases are tuberculous or syphilitic, usually originating in caries of the surrounding bones.

Tubercle of the lacrymal sac also occurs in adults as a rare form of dacryocystitis.

Treatment. — In the new-born a simple boric lotion should be ordered, and minute directions should be given for expressing the contents of the sac, which should be done very frequently. Many cases will be cured by this treatment. If it fails after a fortnight, an anæsthetic should be given and a small probe passed down the nasal duct, the greatest care being exercised to avoid injuring the walls of the duct. It is unnecessary to slit up the canaliculus. The punctum and canaliculus are dilated with a Nettleship's dilator. A small probe (No. 1 or 2) is inserted vertically downwards into the canaliculus, then passed gently but firmly inwards until the point is felt against the lacrymal bone. The probe is then rotated upwards and towards the middle line, and pushed down the nasal duct until it touches the floor of the nose. It should be remembered that the duct is short in the new-born. The force required is quite slight if rightly applied in the line of the duct (*vide* p. 622). Since much harm may be done by bad probing these cases should be treated by an expert.



FIG. 299.—Couper's lacrymal probes.

In adults the conjunctival sac should be cocainized. The punctum is dilated and the sac syringed out with a lacrymal syringe. I prefer the glass syringes of Læer (Fig. 300). A moderately fine straight nozzle should be used. The point is inserted into the canaliculus; it need not pass into the sac. Two or three syringefuls of boric lotion are passed. Probably the whole of the fluid will regurgitate through the upper canaliculus. The operation should be repeated every day for a fortnight or longer. In the majority of cases the fluid will pass freely down into the nose in a few days. When this occurs the syringing should be repeated at constantly increasing intervals. A great number of previously untreated cases can be cured in this manner. The patient should be told to squeeze out the contents of the sac frequently in the intervals between syringing.



FULL SIZE

FIG. 300.—Læer's syringe, with nozzle, for syringing the lacrymal passages.

The rationale of this treatment depends upon the fact that the walls of the sac and upper part of the duct are inflamed. The swollen mucous membrane prevents the fluid in the sac from passing into the nose. The treatment reduces the swelling and restores the communication. If it is unsuccessful after trial for a week or fortnight

protargol (10 to 20 per cent.) should be used for syringing occasionally instead of boric lotion.

If syringing fails the condition of the nasal fossæ should be thoroughly investigated by an expert, and any

pathological condition likely to cause inflammation or obstruction of the nasal duct treated.

If no cause is discovered in the nose it is best to excise the lacrymal sac. This radical operation, properly performed, completely removes the disease, with a minimum of inconvenience to the patient.

Many surgeons, perhaps the majority, treat chronic dacryocystitis by probing. The canaliculus is slit up and probes of increasing calibre are passed down the nasal duct into the nose (Fig. 299). The objections to this method of treatment are—(1) it is impossible to probe the swollen and inflamed duct without injuring the walls; (2) such

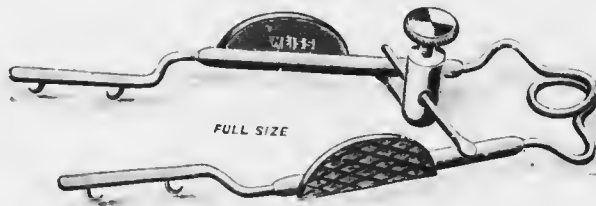


FIG. 301.—Miller's retractor.

injury may lead to infection of the surrounding tissues and an acute cellulitis; (3) in any case healing of the abrasions is accompanied by the formation of connective tissue, which contracts when it organises and leads to fibrous stricture instead of obstruction by swollen mucous membrane; (4) probing is always painful, and when once begun has to be continued for a prolonged period; (5) most cases are alleviated only temporarily, fresh courses of probing being required at intervals. Protargol should never be injected immediately after slitting up the canaliculus or probing. If an abrasion of the mucous membrane has been caused the protargol may be injected into the subcutaneous tissues and violent cellulitis follows. Orbital cellulitis and atrophy of the optic nerve have been

known to result from neglect of this rule. These facts are proof of the injury done to the mucous membrane by probing.

Some surgeons introduce styles into the nasal duct in order to keep it patent. After obtaining a passage with probes a lead or silver style is passed into the duct, the upper end being bent outwards so that it lies upon the lid or cheek, thus preventing the style from being lost. This treatment has all the objections which have been adduced against probing. Occasionally it is useful in intractable cases in young children, in whom it is difficult to extirpate the lacrymal sac efficiently. Even in such cases it is better to extirpate the sac as well as possible and pack the cavity with antiseptic gauze, so that the wound heals from the bottom.

Excision of the lacrymal sac is performed as follows. Instruments required: small scalpel, dissecting forceps, toothed (fixation) forceps, retractors (preferably Müller's (Fig. 301)), small blunt-pointed (tenotomy) scissors, blunt dissector and small sharp spoon (Fig. 302).

The operation can be performed with local anæsthesia; the best solution to employ is novocain (1 per cent.) and suprarenin (0.00125 per cent.), of which up to two drachms may be injected around sac. The lids are held stretched outwards by a finger applied near the outer canthus. This throws the internal palpebral ligament into prominence. A curved incision



FIG. 302. Lang's dissector and scoop.

is made, commencing just above the ligament and extending downwards and slightly outwards to the inferior margin of the orbit and for a short distance along it (Figs. 303—304).

The incision should be only 3—4 mm. internal to the inner canthus, otherwise there is danger of wounding the angular vein or its larger branches. The internal palpebral

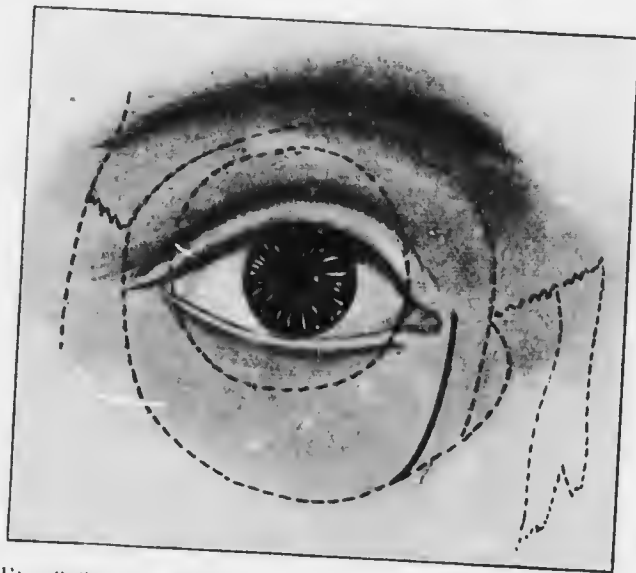


FIG. 303.—Incision for excision of the lacrymal sac. The broken lines indicate the bones and orbital margin; also the limits of the conjunctival sac.

ligament should be severed and the sac opened, but the incision should not be so deep in its inferior part. Müller's retractors are then inserted, and any hæmorrhage is stopped by firm pressure with a small swab dipped in adrenalin (1 in 1000). The mucous membrane can now be seen protruding from the opening made in the sac. It is seized on the inner side with fixation forceps and separated from the surrounding tissues by the blunt dissector. After the inner wall has been freed the fundus

and outer wall are similarly treated. The sac is then pulled forwards and freed behind. Finally the sac is pulled well up, so as to drag out as much of the mucous lining of the nasal duct as possible, and is removed by a snip of the scissors, applied as close as possible to the bone. The wound is carefully inspected to see that all of the mucous tissue is excised. The upper part of the nasal duct

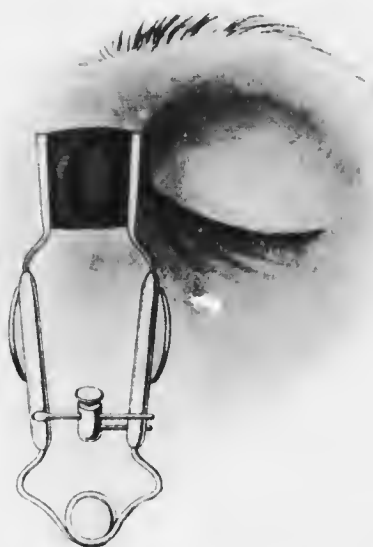

FIG. 301.—Excision of the lacrymal sac. Müller's retractor in situ.

is then thoroughly scraped out with the sharp spoon. The wound is completely sutured. A small spherical pad is applied, and over this an ordinary pressure pad and bandage. The wound generally heals by first intention; it should not be pressed with the finger to see if there is any regurgitation during the first few days, as it is easily reopened.

Difficulty is experienced in excising contracted sacs. It

may then be found that the incision has not opened the sac, which is firmly adherent to the surrounding tissues. The best guide to the position of the sac in these cases is the crest of the lacrymal bone, which can be easily felt with the finger-nail. The sac must then be separated from the bone on the inner side by scalpel or scissors. The fundus, outer wall, and posterior attachment are successively dissected free. There is usually much more hæmorrhage when this method has to be adopted. It is best controlled by firm pressure with small swabs soaked in adrenalin.

There is no objection to removing both lacrymal sacs at the same operation if there is bilateral mucocœle. When the operation is satisfactorily performed there is no regurgitation on pressure over the scar. If after a week or two there is still some regurgitation, part of the mucous membrane has been left behind, and the operation must be repeated. Usually it is the fundus of the sac which has been left. This lies above the palpebral ligament; hence the advisability of dividing the ligament in order that a good view may be obtained. Not the slightest evil results from this procedure. Sometimes regurgitation is due to leaving the mucous membrane of the upper part of the nasal duct; it will not occur if the duct is well curetted.

In all cases of cataract in which there is a mucocœle the lacrymal sac should be excised as a preliminary to extraction. Only some weeks after this operation, when there is no trace of regurgitation, is it permissible to proceed with the extraction. A more difficult problem is the presence of a mucocœle in a case of acute glaucoma. Here immediate iridectomy is indicated and admits of no delay. In these cases the sac must be completely isolated from the conjunctival sac. This is best effected by passing a ligature round each canaliculus and tying it firmly.

Some surgeons cauterise the punctum, thus sealing it up with a cicatrix. Either procedure may be followed by the development of a lacrymal abscess, but in the meantime the iridectomy wound has probably healed, and in any case the pus is evacuated through the skin and not into the conjunctival sac.

Lacrymal Abscess may be due to acute dacryocystitis or to suppuration starting in the pericystic tissues. The skin over the sac becomes red and swollen. The redness and swelling rapidly extend to the lower lid and upper part of the cheek, so that the condition may be easily mistaken for erysipelas. There is severe pain, and often some fever. The abscess usually points below and to the outer side of the sac owing to gravitation of the pus to margin of the orbit. If it opens spontaneously pus continues to be discharged for some time and a permanent fistula is likely to result.

Treatment.—If seen at the commencement of the process an attempt should be made to prevent the abscess pointing on the face by freely slitting up the lower canaliculus well into the sac. Hot fomentations are then applied frequently.

If the abscess is fully developed it should be freely opened at the site where it is pointing. The pus is squeezed out and the cavity is thoroughly plugged with cyanide gauze. A hot fomentation is applied and repeated frequently. The plugging is repeated daily, so that the cavity granulates from the bottom. If the discharge continues for a long period the cavity should be well enretted and again plugged. Usually the epithelial lining of the sac is destroyed by the purulent inflammation, the sac is permanently destroyed, and the cure is complete. In other cases some of the mucous membrane escapes destruction, and a fistula may follow. It may sometimes be closed by cauterising the edges with the

galvano-cantery, but it is better to reopen the sac along a director introduced through the fistula and extirpate the remnants.

Stricture of the Nasal Duct has already been referred to incidentally. It is probable that most intractable fibrous strictures are caused by probing, though it cannot be asseverated that they may not arise spontaneously as the result of destruction of the epithelium by extension of inflammation from the nose or lacrymal sac. Occasionally bony strictures occur, usually caused by caries.

Treatment.—The usual treatment of stricture of the nasal duct is dilatation with probes. The objections to this treatment have been mentioned. I advocate excision of the lacrymal sac in these cases.

CHAPTER XXXI.

DISEASES OF THE ORBIT.

It is unnecessary to describe the anatomy of the orbit and its contents here. The student is recommended to revise his knowledge of the subject, paying special attention to the relations of the nasal cavities and their accessory sinuses, and to the communications with the interior of the cranial cavity by way of the optic foramen and sphenoidal fissure. The intimate adhesion of the dural sheath of the optic nerve to the walls of the optic foramen is of great pathological importance, and the relations of the intraorbital to the intracranial circulation must be thoroughly appreciated. The eye is slung in position in the orbit by fascia, one sheet of which, Tenon's capsule, forms a socket in which the globe moves. This, with the sclerotic, forms a lymphatic space, lined completely with endothelium. The extrinsic muscles of the eye do not perforate this capsule, but invaginate it, the fascia being reflected from their surfaces.

The normal position of the eye is such that a straight-edge applied vertically to the middle of the upper and lower margins of the orbit just touches the closed lids over the apex of the cornea. There are individual variations which are of no pathological importance when symmetrical; in all cases of doubt the two sides should be compared.

Abnormal protrusion of the globe is called *exophthalmos* (more accurately, *exophthalmia*) or *proptosis*. It is much

commoner than abnormal retraction or *enophthalmos*. The former condition is due to many causes, amongst which increase in the orbital contents and loss of tone of the extrinsic ocular muscles are the most important. Enophthalmos is generally due to severe injury in which the orbital bones are fractured, or to orbital cellulitis with mechanical retraction by fibrous tissue. Slight degrees of exophthalmos or enophthalmos are best diagnosed by the test with a straight-edge. Accurate estimates of the amount can be obtained only by special mechanical devices (exophthalmometers). A convenient test is the following:—The patient is seated, the surgeon standing behind him. The surgeon holds the patient's head in such a manner that he looks straight down the nose. He then rotates the head backwards until he can just see the apex of one cornea. If he can see more of the other cornea, that eye is relatively proptosed.

ORBITAL INFLAMMATION.

Periostitis is not uncommon, particularly affecting the margin. It is most often due to injuries, extension of inflammation from neighbouring parts, tubercle or syphilis. Tuberculous periostitis is most frequent in children, syphilitic in adults: in the former, caries of the bone results; the latter is gummatous. In traumatic cases the margin is naturally most affected, but a traumatic element is often an exciting cause in the other cases, so that in them also the margin most frequently suffers.

When situated at the margin, the inflamed part is swollen and tender: the swelling is intimately connected with the bone, so that it cannot be moved over it. Syphilitic cases usually respond well to treatment. The other types generally go on to suppuration. An abscess is formed, and when it discharges or is opened rough

bone can be felt with a probe. In tuberculous cases particularly a fistula may result, the edges of the aperture being bound down to the bone, so that a depressed cicatrix is formed. The fistula remains open until all the necrosed bone is extruded. The cicatrization may lead to displacement of the lid—ectropion, lagophthalmia and so on.

Periostitis of the deeper parts of the orbit causes less definite signs. There is more pain of a deep-seated character. There may be proptosis with deviation in the direction of the eye. Often the true nature of the disease is only discovered by an exploratory operation, or by the evacuation of pus. The case may present all the features of orbital cellulitis (*q.v.*). If the roof of the orbit is involved, the pus may discharge into the cranial cavity, life being endangered by meningitis or cerebral abscess.

Treatment is determined by the aetiological factor. In syphilitic cases, mercury and iodide of potassium are pushed rapidly. In traumatic cases, if suppuration supervenes, the abscess is opened, hot fomentations being applied previously if necessary. In tuberculous cases an incision should be made early and any carious bone removed, care being taken not to encroach upon the cranial cavity.

In deep-seated periostitis an exploratory operation may be necessary, and should not be too long delayed. An incision is made through the skin at the margin of the orbit, the knife being passed cautiously deep into the orbit along the wall. The site of the incision is determined by the signs present. Sinus forceps are passed down the track of the wound and opened. The greatest care should be exercised to avoid unnecessary damage to the orbital contents, and this is best accomplished by keeping closely to the bony walls. Special care must be taken not to injure the pulley of the superior oblique.

If pus is found, a small drainage tube or a long strip of cyanide gauze is inserted. In periostitis of the inner wall, the bone may be extensively diseased. Severe operations, involving the opening of the frontal or ethmoid sinuses, may be essential, with or without drainage through the nose. These cases often do remarkably well. They are usually tuberculous, and occur most frequently in children. Exploration of the orbit in children is much more difficult than in adults. The eye is relatively much larger in comparison with the size of the orbit, so that there is very little room between the globe and the orbital wall. In some cases it may be advisable to perform Krönlein's operation (*vide* p. 650).

Orbital Cellulitis is purulent inflammation of the cellular tissue of the orbit. It is due to deep injuries, especially those with retained foreign body, or septic operations, *e.g.*, enucleation of the eyeball; extension of inflammation from neighbouring parts, especially the nasal sinuses and teeth; facial erysipelas; metastasis in pyæmia, meningitis, infective fevers, &c.

There is great swelling of the lids, with chemosis. The eye is proptosed, and its mobility impaired. Pain is severe, increased by movement of the eye or pressure upon it. Fever is present, and cerebral symptoms may arise. Vision may not be affected, or it may be reduced owing to retrobulbar neuritis. An abscess is formed which usually points somewhere in the skin of the lids near the orbital margin, or it may empty into the fornix conjunctivæ. Panophthalmitis may supervene. There is grave danger of extension to the meninges and brain, leading to a fatal issue from purulent meningitis or cerebral abscess. Thrombosis of the cavernous sinus (*q.v.*) may result from orbital cellulitis, and is always difficult to diagnose from it.

Treatment.—Hot fomentations are applied, but must

D.E.

not be relied upon too long. An early incision as in orbital periostitis (*q.v.*) is imperative. Even if pus is not reached, the tension is relieved and a track is prepared for its evacuation. Several incisions along the walls of the orbit are indicated, if there is no sufficient guide to the position of the focus. If the source of infection is obscure, the nose and other likely seats must be investigated, and the primary focus treated.

Thrombosis of the Cavernous Sinus may be due to extension of thrombosis from the intraorbital veins. It presents almost the same symptoms and signs as orbital cellulitis. If in addition there is œdema in the mastoid region behind the ear the diagnosis is certain, for this is due to thrombosis of the emissary vein of Santorini, which communicates with the cavernous sinus through the transverse sinus. A further point of diagnostic importance is transference of the symptoms to the opposite eye, which is the rule in thrombosis of the cavernous sinus, whereas bilateral orbital cellulitis is excessively rare. The first sign is paralysis of the opposite external rectus. It must be remembered, however, that thrombosis of the sinus may be a complication of cellulitis.

It is commonly stated that the retinal veins are greatly engorged, but it is certainly not true in many cases. There is severe supraorbital pain, owing to implication of the branches of the ophthalmic division of the fifth nerve, and the motor ocular nerves are paresed or paralysed.

Thrombosis of the cavernous sinus is usually due to caries of the petrous bone or to metastasis—pyæmia, erysipelas, &c. The patient invariably has severe cerebral symptoms and dies.

Tenonitis is inflammation of Tenon's capsule. It may be serous or purulent. There is exophthalmos straight forwards, with limitation of movement of the globe

and pain on attempted movement. There may be some œdema of the lids, and chemosis. It may occur in severe iridocyclitis, and is constant in panophthalmitis. It may also follow tenotomy, &c. Simple serous Tenonitis is rare, and has been attributed to influenza, gout, rheumatism, &c.

Treatment consists in the application of hot fomentations, and the evacuation of pus, if it forms. When it occurs as part of panophthalmitis, &c., it requires no special treatment.

DISTENSION OF THE ACCESSORY SINUSES OF THE NOSE.

The accessory sinuses of the nose—the frontal, ethmoidal and sphenoidal sinuses, and the antrum of the superior maxilla—are separated from the orbit only by thin plates of bone. The orifices which form the communication between these cavities and the nose are liable to become occluded by catarrh, polypi, &c. The normal sero-mucous discharge is thus unable to drain into the nose. The cavities become distended with fluid, and owing to the presence of pyogenic organisms pus may be formed. The treatment of the conditions thus set up cannot be considered part of the functions of the ophthalmic surgeon, but he must be prepared to diagnose them since they not infrequently appear for the first time in the ophthalmic clinic. This is particularly the case in distension of the frontal, ethmoidal and sphenoidal sinuses. Of these the frontal sinus suffers most often.

Distension or empyema of the frontal sinus causes bulging at the upper and inner part of the orbit (Fig. 305). There may be some proptosis and displacement of the eyeball downwards and outwards, but these features are more marked when the ethmoidal sinus is involved.

There is considerable pain and tenderness, with severe headache. There is often discharge from the nostril of the same side, or manifest disease of the nasal cavities. Owing to erosion of the walls of the sinus the fluid may extend under the periosteum, causing bulging into the posterior part of the orbit. It may escape into the opposite sinus and through the infundibulum of that side :

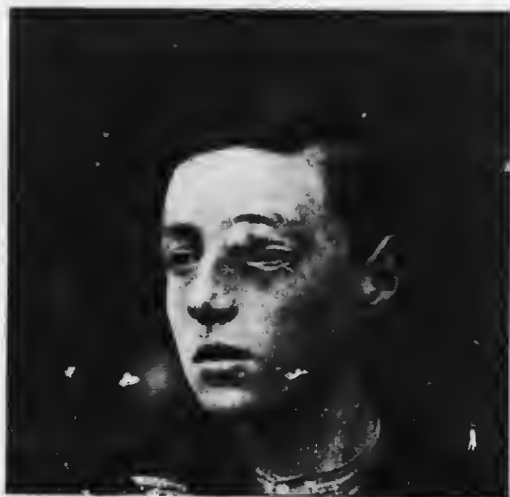

FIG. 305.—Distension of the frontal sinus.

or it may rupture into the orbit, through the skin, forming a sinus, or even into the cranial cavity. Orbital cellulitis may be set up in this manner.

Treatment of distended frontal sinus consists *i.* providing free discharge of the contents through the nose. In most cases a radical cure is effected only by laying open the sinus, scraping away completely the diseased mucous membrane, and passing a drain down into the nose. The disease is tedious to treat and much disfigurement may follow.

Distension of the ethmoidal cells by polypi, new growths or inflammatory products may also cause bulging into the orbit and displacement of the globe. Diplopia, chemosis,

venous engorgement and ptosis may be caused. Ethmoiditis is usually associated with nasal discharge. It may give rise to orbital cellulitis, or in less severe cases to retrobulbar neuritis. The latter is probably more commonly associated with inflammation and distension of the sphenoidal cells, which lie in close proximity to the optic nerve, being sometimes separated from it by a very thin lamina of bone. In doubtful cases help may be afforded by a skiagram. It has already been mentioned that the accessory sinuses of the nose are not infrequently the foci from which toxins are disseminated, leading to iridocyclitis and other metastatic septic processes in the eye (*vide* pp. 302, 364).

INJURIES OF THE ORBIT.

Injuries to the soft parts usually arise from penetration of a foreign body, which may be retained. The lids and eyeball are frequently implicated. The signs depend upon the particular structures injured. In most cases there is considerable hemorrhage: as the blood does not find a ready exit exophthalmos may result. Extravasation of blood under the conjunctiva and into the lids is common. Paralysis of extrinsic muscles may be due to direct injury or to injury of the motor nerves. The optic nerve may be severed or retrobulbar neuritis may ensue: in either case atrophy, involving the optic disc, follows (*vide* p. 408). The eyeball may be perforated or contused (*vide* p. 435) or dislocated *en masse*. Dislocation forwards between the lids occurs most often when the blow is directed from the outer side, where the orbital margin affords least protection. Insane patients sometimes enucleate their eyes by gonging them out with their fingers. Sight is not necessarily lost after dislocation forwards. Retained foreign bodies are extremely liable to set up suppuration and orbital cellulitis (*q.v.*).

Injuries to the bone most commonly affect the margin of the orbit. Fractures in this locality are easy to diagnose from the unevenness of the margin, sensitiveness to pressure, and sometimes crepitation. Emphysema (*q.v.*) may occur. The soft parts may be injured by splinters of fractured bones. Deep fractures may be caused by penetrating wounds or by severe contusions, falls, &c. Fracture of the base of the skull may involve one or both optic foramina, in which case the optic nerve is often severed, lacerated, or compressed by clot. Blindness without ophthalmoscopic signs may be caused in this manner; atrophy of the disc follows in three to six weeks (*vide* p. 408).

Treatment.—If there is a wound it must be cleansed, and, if necessary, probed. The treatment of a retained foreign body depends upon its situation and the probability of suppuration occurring. If the foreign body cannot be extracted with ease a skiagram should be taken. If the position is such that very serious manipulation would be requisite for removal, and if there is evidence that the substance is aseptic, expectant treatment may be adopted. If suppuration occur the foreign body must be removed and the case treated as one of orbital cellulitis (*q.v.*).

TUMOURS OF THE ORBIT.

Orbital tumours are rare. Benign growths include dermoid cyst, dermo-lipoma (*vide* p. 220), angioma, osteoma (Fig. 306), plexiform neuroma (*vide* p. 620), meningo-encephalocele. Of these, dermoid cysts appear as swellings under the lid, usually at the upper and outer angle; they contain sebaceous material derived from sebaceous glands in the walls, which are lined with epithelium and possess hair follicles. Clinically they may

be mistaken for meningo-encephalocèles, which usually occur at the upper and inner angle, where there are most sutures between bones. In the latter—(1) the tumour is immovably attached to the bones; (2) the hole in the bone may be palpable; (3) pulsation, synchronous with respiration and the pulse and increasing on straining, can be seen; (4) pressure may cause diminution in size due to fluid being pressed back into the cranium; (5) exploratory puncture produces clear fluid with the characteristics of cerebro-spinal fluid. Osteomata start usually from the frontal bone (Fig. 306); they are intensely hard and often large, producing great displacement of the globe.

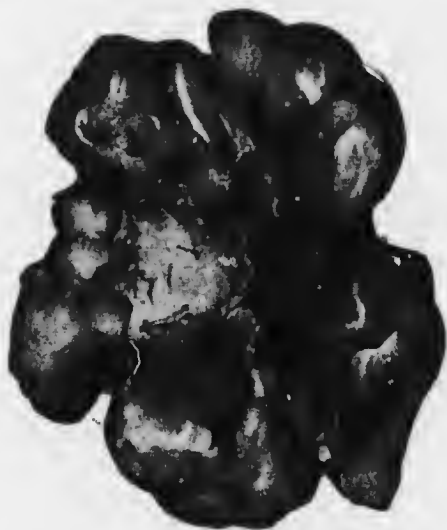

FIG. 306.—Orbital osteoma (Tweedy).

Malignant tumours of the orbit are usually sarcomata, though carcinoma derived from the lacrymal gland (*vide* p. 624) or by extension from the nasal mucous membrane also occurs. All types of sarcoma, including endothelioma, may occur. The small round celled growths include cases of lymphoma, leukaemic tumours, chloroma, &c.

Primary tumours of the optic nerve manifest themselves clinically as orbital tumours. They are rare, and are found on anatomical examination to consist of two groups—intra- and extra-dural. Of these the former are more numerous (Fig. 307). They rarely spring from the

true nervous tissue (gliomata, resembling cerebral glioma, not retinal glioma), but usually originate in the connective tissue septa derived from the pia mater and from the arachnoid sheath. They often contain tissue of mucoid type, and are hence described as myxo-sarcoma, &c. Probably most are endotheliomata which have undergone degenerative changes. Extradural tumours spring from

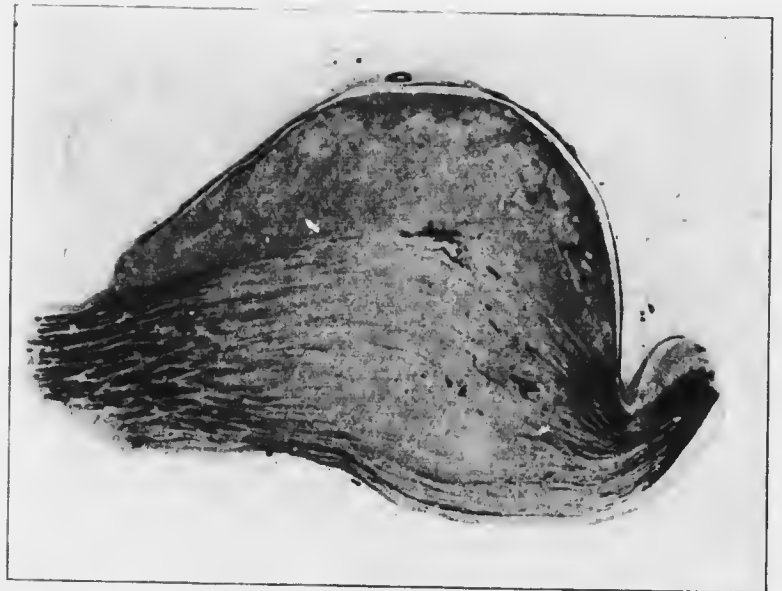

FIG. 307.—Intradural tumour of the optic nerve (Mayou). Longitudinal section, section stained by Weigert-Pal, to show distribution of the nerve fibres.

the dural sheath and are also probably endotheliomata (Fig. 308). All these optic nerve tumours are most common in children and are locally malignant, but show little or no tendency to metastasis. They may kill the patient by intracranial extension.

Most orbital tumours cause proptosis, which is very rarely straight forwards except in the case of optic nerve tumours. This is an important diagnostic feature. The

mobility of the eyeball is impaired in the direction towards the position of the tumour. Papillitis may be present, especially with optic nerve tumours. Optic atrophy from pressure on the nerve is common in the other forms. The tumour may be palpable by the finger pushed back between the globe and the orbital wall. The lymphatic glands are seldom affected.

Careful examination of neighbouring parts—nose, antrum, mouth (especially the nasopharynx, and line of the teeth)—must be made to determine whether the invasion of the orbit is secondary or whether the growth is primarily orbital.

Treatment.—An exploratory operation and removal of a portion of the growth for microscopic examination may be a necessary preliminary to radical treatment. It may be feasible to remove dermoid cysts and some other benign tumours without injury to the globe, though its mobility is likely to be impaired in extensive operations. As already mentioned, many malignant orbital growths show little tendency to metastasis, so that their treatment may be more conservative than is usual in other parts of the body. Thus it is possible in some cases of optic nerve tumour to remove the growth whilst retaining the eyeball. It can be effected

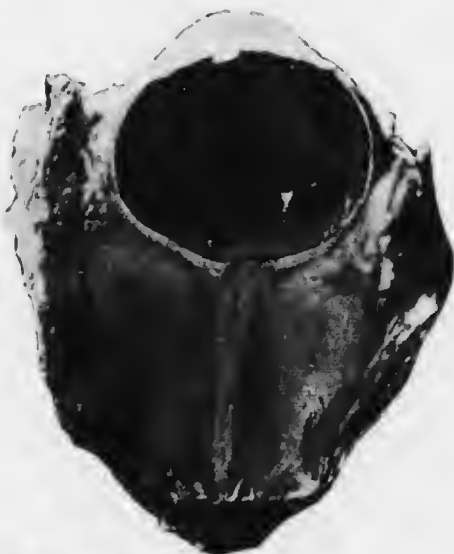

FIG. 308.—Extradural tumour of the optic nerve ($\times 1.4$).

by *Krönlein's operation*, which is also of great utility as an exploratory procedure in some cases. In it a semilunar incision is made vertically just outside the outer canthus, the convexity being directed forwards. The bone is chiselled through at the upper and lower outer angles of the orbit, and bone, muscle and skin are reflected backwards in one flap. The posterior part of the orbit is thus exposed in a manner which is impossible by any other method. The greatest care must be exercised that infection does not occur, since the spongy bone is laid open, and there is also danger of meningitis.

In the case of more malignant types of tumour their complete removal is imperative at all costs, and the eye, which may be quite normal, may have to be sacrificed. In these cases, as well as in recurrence or in orbital extension of malignant intraocular growths (glioma of the retina, sarcoma of the uveal tract), it may be necessary to remove the whole contents of the orbit.

In *eversion of the orbit* the lids may be retained if they are not implicated in the growth, but the free margins, carrying the cilia, should always be removed. If it is not done the lashes are troublesome when the lids become retracted into the orbit, as invariably follows. If the lids are removed the incision is carried through the skin at the margin of the orbit in its whole circumference. The orbital contents are separated from the walls by a periosteal elevator, so that they remain attached only at the apex of the orbit. The pedicle is then severed with strong scissors, hæmorrhage being controlled by pressure. The orbit is packed with gauze and firm pressure is kept up. At a later stage it may be advisable to apply Tiersch grafts to the walls, since the lids and conjunctiva never afford sufficient epithelial covering, and the extension of the epithelium over so large a surface is a tedious process.

SPECIAL FORMS OF EXOPHTHALMOS.

Exophthalmic Goitre (*Syns.—Graves's or Basedow's Disease*) is one of the commonest causes of exophthalmos (Fig. 309). The symptom complex includes, besides proptosis, enlargement of the thyroid gland, tachycardia and unsteady tremors. The proptosis is almost always bilateral and may be extreme, leading to lagophthalmia and its deleterious consequences (*vide* p. 254). There is



FIG. 309 — Exophthalmic goitre.

a peculiar stare, with retraction of the upper eyelid, so that there is an unnatural degree of separation between the margin of the two lids (Dalrymple's sign). Normally, when vision is directed downwards, the upper lid moves concordantly with it. In this disease the upper lid follows tardily or not at all (von Graefe's sign): this symptom is not always present and may occur in other forms of exophthalmos. There is diminished frequency of winking and imperfect closure of the lids during the

act (Stellwag's sign). There may be imperfect power of convergence (Möbius' sign), and often the skin of the eyelids shows pigmentation. Ophthalmoscopically veins and arteries may be somewhat distended, but specific signs are absent. One or more of the cardinal symptoms may be absent. The cause of the disease is unknown. The most probable theory attributes it to overproduction or other disorder of thyroid secretion, but it has also been attributed to disease of the cervical sympathetic ganglia, of the central nervous system, &c.

It is necessary for the ophthalmic surgeon to be able to recognise the disease. Further details of its usual course and treatment must be sought in medical textbooks.


Pulsating Exophthalmos is generally due to arterio-venous aneurysm, the communication taking place between the internal carotid artery and the cavernous sinus. The eyeball is protruded and the blood vessels of the conjunctiva and lids are dilated. They can be seen, or more easily felt, to pulsate synchronously with the arterial pulse. The patient complains of continual rumbling, as of a waterfall, and this can be heard on auscultation over the eye or orbit by the surgeon. The proptosis is diminished by steady pressure on the globe, and may be diminished or abrogated by pressure on the common carotid artery of the same side, or sometimes only by pressure on the carotid of the opposite side. Ophthalmoscopically the veins of the retina are greatly distended: there may be papillitis with defective vision, which may amount to complete blindness. There is often considerable pain from stretching of the branches of the fifth nerve.

The cause of the arterio-venous aneurysm is usually a severe blow or fall upon the head, but probably in all cases the walls of the artery are already degenerated

It may occur from syphilitic or other arteriosclerosis, without discoverable traumatism. The exophthalmos in rare cases subsides spontaneously. More commonly it increases, and may end in hæmorrhage or death from cerebral causes.

Treatment.—Continuous pressure applied to the carotid artery which stops the pulsation usually fails to effect a cure. Ligature of this carotid has been more successful, but recurrence of pulsation not infrequently occurs.

Intermittent Exophthalmos occasionally occurs, generally when the head is depressed, enophthalmos not infrequently being present in the erect position. The proptosis is increased by pressure on the corresponding jugular vein. It is ascribed to varicosity of the orbital veins.



APPENDIX I.

PRELIMINARY INVESTIGATION OF THE PATIENT.

The faculty of scientific observation can only be fostered by methodical investigation. The student is recommended to study each patient according to the following scheme:—

- (1) **General condition of the patient.**
- (2) **Position of the head.**—Characteristic in paralyzes of extraocular muscles (*vide* p. 548).
- (3) **Face.**—Note asymmetry, facial paralysis, affections of the skin, *e.g.*, herpes ophthalmicus, &c.
- (4) **Position of the Eyebrows.**—Vicarious action of the frontalis in ptosis (*vide* p. 612), &c.
- (5) **Orbits.**—Exophthalmos, enophthalmos, &c.
- (6) **Eyeballs.**—(a) Position and direction—strabismus.
(b) Movements (*vide* p. 543).
(c) Size and shape—microphthalmia, glaucoma (*vide* p. 311); myopia (*vide* p. 506), buphthalmia (*vide* p. 327), staphyloma, &c.
- (7) **Lids.**—(a) Position—ptosis, ectropion, entropion, &c.
(b) Palpebral aperture—ptosis, exophthalmos, &c.
(c) Movements—ptosis, exophthalmic goitre, &c.
(d) Margins—blepharitis, tumours, &c.
(e) Lashes—trichiasis, distichiasis, &c.
(f) Glands—hordeolum, chalazion, &c.
(g) Puncta lacrymalia—eversion, occlusion, &c.
(h) Lacrymal sac—swelling, regurgitation, &c.

- (8) **Conjunctiva.**—(a) Ocular—congestion (conjunctival and ciliary), secretion, phlyctenules, growths, wounds, &c.
 (b) Palpebral—congestion, granulations, scars, concretions, ulcers, &c.
 (c) Plica semilunaris—displacement in pterygium, growths, &c.
 (d) Caruncle—inflammation, granulations, growths, &c.
- (9) **Cornea.**—(a) Size—glaucoma, buphthalmia, &c.
 (b) Curvature—conical, buphthalmia, anterior staphyloma, abrasions (*vide* p. 100), &c.
 (c) Surface—corneal reflex, abrasions, ulcers, foreign bodies, &c.
 (d) Transparency—ulcers, nebulae, keratitis (superficial and deep vascularisation, *vide* p. 106), “k.p.,” striate opacity, &c.
- (10) **Sclerotic.**—(a) Curvature and colour—myopia, staphyloma, episcleritis, &c.
 (b) Vessels—ciliary injection, episcleritis, scleritis, &c.
- (11) **Anterior chamber.**—(a) Depth—(a) shallow—perforating wound, glaucoma, dislocation of lens, &c.; (β) deep—buphthalmia, irido-cyclitis, dislocation of lens, &c.; (γ) irregular—iris bombé, dislocation of lens, &c.
 (b) Contents—cloudy aqueous, hypopyon, hyphæma, foreign bodies, dislocated lens, &c.
- (12) **Iris.**—(a) Colour—muddy in iritis, heterochromia (congenital and in irido-cyclitis), atrophy, ectropion of uvea, melanomata, &c.
 (b) Position, especially plane of surface—iris bombé, retraction in irido-cyclitis, pseudo-glioma, &c.

- (13) **Pupils.**—(a) Relative size (*vide* p. 110).
(b) Reaction to light—direct, consensual, maintenance of constriction (*vide* p. 108).
(c) Reaction on convergence.
(d) *Synechiæ*—anterior and posterior.
- (14) **Intraocular tension.**—Increased in glaucoma, irido-cyclitis; diminished in irido-cyclitis, perforation or rupture of the globe, &c.
- (15) **Central vision** (*vide* p. 156).
- (16) **Lens.**—By oblique illumination and the ophthalmoscope.
- (17) **Vitreous.**—Opacities, fluidity, foreign bodies, hæmorrhage, “retinitis proliferans,” persistent hyaloid artery, &c.
- (18) **Fundus.**—(a) Optic disc—blurring of the edges, swelling, cupping, colour, crescents, &c.
(b) Retinal vessels—size, contour, tortuosity, &c.
(c) General view—retinitis, choroiditis, &c.
(d) Periphery.
(e) Macula.
- (19) **Field of vision.**

APPENDIX II.

THERAPEUTIC NOTES.

(The Strengths of lotions, &c., are given in percentages :
1 per cent. = gr. \bar{v} . to \bar{z} i. (approximately)).

LIDS.

Lotions.—3 per cent. Sodium bicarbonate,
3 per cent. Borax.

These are used for dissolving the crusts in blepharitis. They may be used in conjunction with 1 to 2 per cent. salicylic acid, 1 to 2 per cent. resorein, liquor carbonis detergens (℞ i.—iv. to \bar{z} i.), &c.

Pigments.—10 per cent. silver nitrate,
1 per cent. Picric acid,
1 per cent. Salicylic acid.

These are used for ulcerative blepharitis; the excess should be removed with cotton wool.

Ointments.—2 per cent. Ammoniated mercury,
3 per cent. Yellow oxide of mercury.

These are well rubbed into the lashes for five minutes three times a day after removing the crusts in ulcerative blepharitis. Alternative preparations are 1 per cent. salicylic acid, 3 per cent. airol, 2 per cent. resorein, 3 per cent. ichthyol, &c.

Hypodermic Injections for Local Anaesthesia.—

1 to 2 per cent. Novocain,
1 per cent. Stovain,
1 per cent. Mypin.

These drugs are less toxic than cocain. They may be combined with advantage with a haemostatic, adrenalin or suprarenin (0.0025 per cent.).

CONJUNCTIVA.

Lotions.—3 per cent. Boric acid.

1 in 5000 Perchloride of mercury.

These are used as cleansing lotions in acute conjunctivitis, and have slight antiseptic properties; they should be mixed with an equal quantity of hot water as a rule.

2 per cent. Borax.

This, combined with dilute hydrocyanic acid (1 per cent.), relieves irritation in mild conjunctivitis.

1 per cent. Alum.

1 per cent. Zinc sulphate or chloride.

These are astringent lotions used in chronic conjunctivitis. Zinc lotion is specially indicated in angular conjunctivitis (*g.c.*). Alternative preparations are 1 per cent. tannin, $\frac{1}{4}$ per cent. copper sulphate, 3 to 6 per cent. sodium sozoiodol, $\frac{1}{2}$ per cent. zinc sulphocarbolate, &c.

1 per cent. Quinine hydrochloride or sulphate.

This is recommended for membranous conjunctivitis. The least possible amount of dilute sulphuric acid should be used to dissolve the salt if the sulphate is used.

Pigments.—2 per cent. Silver nitrate.

This is used in acute conjunctivitis. Alternative preparations are 10 to 40 per cent. argyrol, 10 to 40 per cent. protargol, 5 to 10 per cent. argentamin, &c.; these are probably not so effectual.

2 to $\frac{4}{5}$ per cent. Perchloride of mercury in glycerin and water.

This is occasionally used in trachoma: it must not be allowed to touch the cornea. Lead compresses should be applied immediately after the application is made.

Drops.—The astringent lotions may be used in the form of drops. Silver nitrate should not be ordered in this form on account of the staining which may occur from prolonged use.

2 per cent. Cocain hydrochloride.

This is used for producing local anaesthesia. Conjunctival and corneal anaesthesia is complete after instilling four drops at intervals of five minutes. During the intervals the eyes should be kept closed on account

of the desiccating action on the corneal epithelium. In intraocular operations one drop should be instilled into the opposite eye (*vide* p. 179).

2 per cent. β -Eucain hydrochloride.

2 per cent. Alypin.

These may be used instead of cocain. They do not dilate the pupil and are less toxic than cocain, but they cause considerable smarting.

10 to 15 per cent. Dionin.

This causes intense oedema of the conjunctiva; after prolonged use the reaction is slight or absent. The patient complains of a burning sensation, which quickly disappears. The first application should be made by the surgeon. The drug stimulates the lymph flow, and has therefore been recommended in a large variety of cases, *e.g.*, corneal nebulae, seleritis, irido-cyclitis, &c. It must be used with caution.

Subconjunctival Injections.—These have been recommended for the same reason as dionin, and their value, if any, is still unproved. Many solutions have been used. Sterile 2 to 10 per cent. salt solution is the best; the others probably possess no advantage, and are in some cases liable to cause necrosis. The injection is made with a hypodermic needle under the bulbar conjunctiva as far back as possible above the globe. There is considerable reaction and pain. Not more than 5 to 10 minims should be injected every other day.

Ointments.—Vaseline.

15 per cent. Boric acid ointment.

These are used to prevent the lids from sticking together and thus causing retention of secretion.

1 to 3 per cent. Yellow oxide of mercury.

This is used as a stimulant and antiseptic in phlyctenular and chronic conjunctivitis.

CORNEA.

Lotions.—The same collyria as for conjunctival conditions are used as cleansing and antiseptic measures. The astringent collyria are seldom indicated.

Pigments.—1 per cent. Silver nitrate.

This is indicated in some cases of marginal ulceration (*vide* p. 252).

Pure carbolic acid.

This is used as a cauterising agent in hypopyon ulcer (*vide* p. 246).

Drops.—These are the ordinary mydriatics and cycloplegics, and in rare cases miotics (*vide infra*).

Dionin or subconjunctival injection is sometimes used with a view to clearing corneal nebulae. 2 per cent. fluorescein in 3 per cent. bicarbonate of sodium solution is used for staining ulcers and abrasions for diagnostic purposes.

Ointments.—These are the same as for conjunctival conditions.

2 to 5 per cent. iodoform, xeroform, or airof ointment may be used in corneal ulceration. Dionin (5 to 10 per cent.) and mydriatics may be prescribed in ointment form. 1 to 5 per cent. yellow oxide of mercury ointment is used in gradually increasing strength to aid in the clearing of nebulae and the opacity of interstitial keratitis: it may be combined with dionin.

MYDRIATICS AND CYCLOPLEGICS; MIOTICS.

Mydriatics and Cycloplegics (*vide p. 73*).— $\frac{1}{2}$ to 1 per cent. Atropin sulphate. $\frac{1}{4}$ to $\frac{1}{2}$ per cent. Hyoscin or Scopolamin hydrobromide. $\frac{1}{4}$ to $\frac{1}{2}$ per cent. Duboisin sulphate. $\frac{1}{2}$ to 1 per cent. Daturin sulphate.

These are used as drops or ointment in corneal ulcers, iritis, iridocyclitis, &c. Atropin is used generally, the others being employed as substitutes when atropin causes irritation. Hyoscin occasionally causes delirium and should be watched.

1 per cent. Homatropin hydrobromide, with or without
2 per cent. cocain hydrochloride.

1 to 2 per cent. Euphthalmin hydrochloride.

These are used for investigation of refraction and for ophthalmoscopic examination: also for the diagnosis of synechiæ (*vide p. 289*) and occasionally for the diagnosis of increased tension (*vide p. 285*). For refraction solutions of the same strength of the bases in castor oil are more certain in their action.

2 per cent. Cocain hydrochloride.

This is used occasionally in old people as a mydriatic for ophthalmoscopic purposes, being less likely to raise the tension, the effect being readily counteracted by miotics.

Miotics (*vide p. 74*).— $\frac{1}{2}$ to 1 per cent. Pilocarpin hydrochloride. $\frac{1}{4}$ to 1 per cent. Eserin or Physostigmin

sulphate or salicylate, with or without 1 per cent. cocain hydrochloride.

These are used in glaucoma (*q.v.*), and occasionally in other cases (*vide* p. 252). The effect of cocain is to assist the absorption of the other drug.

VASO-CONSTRICTORS.

1 in 1000 adrenalin hydrochloride or suprenin may be added with advantage to the cocain solution in performing tenotomy, advancement, &c. It is used alone in excision of the lacrymal sac, and occasionally in conjunctivitis (*vide* pp. 197, 212). It may be combined with $\frac{1}{2}$ per cent. chlorotone.

THE TREATMENT OF SYPHILITIC AFFECTIONS.

In cases of suspected syphilitic disease of the eye the possibility of demonstrating the presence of the spirochæta should be borne in mind. More generally useful is the application of Wassermann's test, for which the aid of a bacteriologist is advisable. No anti-syphilitic remedies should be used until the test has been applied. When the lesion is probably syphilitic the patient should be brought rapidly under the influence of mercury. For this purpose inunctions, intramuscular injections, or intravenous injections may be used, supplemented if necessary by administration by the mouth. Inunction is generally employed, and for this purpose the oleate of mercury is preferable to the ordinary mercury ointment. Intramuscular and intravenous injections require special technique. Intravenous injection of salvarsan ("606") is sometimes remarkably successful, especially in the acute stage of syphilitic manifestations. When the acute ocular condition is subsiding a course of treatment at Aix-la-Chapelle may be recommended when feasible. Some recent substitutes for the ordinary iodides are sajodin or iologiline tablets (1 to 3, *i.e.*, 7 to 15 gr. three times a day), iodipin (30 gr. of 25 per cent. = about 10 gr. of potassium iodide), &c.

SERUM AND VACCINE TREATMENT.

In diphtheritic conjunctivitis antitoxic serum must be used. The indications for other sera and vaccines in the domain of ophthalmology are much less precise. Thus Römer has introduced an anti-pneumococic serum for the treatment of hypopyon ulcer, but the results obtained have been disappointing. Antigonococic serum has been advocated in ophthalmic neonatorum and gonorrhœal ophthalmia. In desperate cases of septic infection of the eye after perforating wound, accidental or operative, a polyvalent serum may be employed, or if possible a vaccine made from a culture taken from the eye; oral administration of antidiphtheritic serum has been recommended in these cases. The vaccine treatment of tuberculosis is much used. Many

obscure pathological conditions in the eye suggest the possibility of a tuberculous origin. Diagnosis may be facilitated in some, probably a minority of cases by the application of von Pirquet's cutaneous test. Wolff-Eisner and Calmette's conjunctival reaction should not be used. Occasionally, as in conjunctival tuberculosis, it is possible to place the diagnosis beyond doubt by inoculation experiments on animals; the incubation period, however, is lengthy (20 to 30 days). Tuberculin treatment is best carried out by a bacteriologist who has familiarised himself with the technique.

CARE OF INSTRUMENTS.

Ophthalmic instruments should be kept in an air-tight glass cabinet, or when not constantly in use in velvet-lined cases.

All instruments should be sterilised before use by boiling in 3 per cent. sodium carbonate solution (*not* bicarbonate), made with *distilled* water. This procedure does not impair the cutting edges, but knives and scissors should not be boiled more than three to five minutes; this is amply sufficient if the surfaces are bright and free from tarnish, as they ought to be. If distilled water cannot be obtained the cutting instruments should be well soaked in pure carbolic acid before being transferred to the dish.

The instruments may be removed from the steriliser *immediately* before operating and used dry. More commonly they are immersed in fluid in a dish. The fluid should be 3 per cent. sodium carbonate which has been boiled. *In no case must borie lotion be used*, since it tarnishes the steel.

APPENDIX III.

REQUIREMENTS OF CANDIDATES FOR ADMISSION INTO THE PUBLIC SERVICES.

COMMISSIONS IN THE ARMY.

The Regulations regarding the Examination of Eyesight are as follows:—

Squint, or any morbid condition of the eyes or of the lids of either eye liable to the risk of aggravation or recurrence, will cause the rejection of the candidate.

The examination for determining the acuteness of vision includes two tests: one for distant, the other for near vision. The Army Test Types will be used for the test for distant vision, without glasses, except where otherwise stated below, at a distance of 20 feet; and Snellen's Optotypi for the test for near vision, without glasses, at any distance selected by the candidate. Each eye will be examined separately, and the lids must be kept wide open during the test. The candidate must be able to read the tests without hesitation in ordinary daylight.

A candidate possessing acuteness of vision, according to one of the standards herein laid down, will not be rejected on account of an error of refraction, provided that the error of refraction, in the following cases, does not exceed the limits mentioned, viz.: (a) in the case of *myopia*, that the error of refraction does not exceed 2.5 D; (b) that any correction for *astigmatism* does not exceed 2.5 D; and, in the case of myopic astigmatism, that the total error of refraction does not exceed 2.5 D.

Subject to the foregoing conditions, the standards of the minimum acuteness of vision with which a candidate will be accepted are as follows:—

Standard I.

<i>Right eye.</i>		<i>Left eye.</i>
Distant vision. V = 6/6.		V = 6/6.
Near vision. Reads 9, 6.		Reads 9, 6.

APPENDIX III.

665

Standard II.

<p style="text-align: center;"><i>Better eye.</i></p> <p>Distant vision.—V = 6/6.</p> <p>Near vision.— Reads 0, 6.</p>	<p style="text-align: center;"><i>Worse eye.</i></p> <p>V, without glasses, = not below 6/60; and after correction with glasses, = not below 6/24.</p> <p>Reads 1.</p>
--	--

Standard III.

<p style="text-align: center;"><i>Better eye.</i></p> <p>Distant vision, V, without glasses, = not below 6/24; and after correction with glasses, = not below 6/6.</p> <p>Near vision. = Reads 0, 8.</p>	<p style="text-align: center;"><i>Worse eye.</i></p> <p>V, without glasses, = not below 6/24; and after correction with glasses, = not below 6/12.</p> <p>Reads 1.</p>
--	--

In Standard III, the standard for the test for distant vision, without glasses, for officers of the Special Reserve, will be not below 6/36.

Inability to distinguish the principal colours will not be regarded as a cause for rejection, but the fact will be noted in the report, and the candidate will be informed.

The degree of acuteness of vision of all candidates for commissions (including preliminary examinations) will be entered in their reports in the following manner:—

Sufficient	{	Right eye V =	Reads.....
		Left eye V =	Reads.....
Defective	{	Right eye V =	Reads.....
		Left eye V =	Reads.....

No relaxation of the standard of vision will ever be allowed.

COMMISSIONS IN THE ROYAL NAVY.

Blindness or defective vision, imperfect perception of colours, fistula lachrymalis, or any chronic disease of the eyes or eyelids renders the Candidate unfit. Candidates for Naval Cadetships must possess full normal vision as determined by Snellen's tests, each eye being separately examined. For Candidates for other branches of the Royal Navy full normal vision is not required, but any defect of vision must be due to errors of refraction which can be corrected to normal by glasses, and vision without glasses must in any case be not less than $\frac{6}{60}$ with each eye, and the Candidate must also be able to read D = 0. 6 of Snellen's test types.

Recruits for the Navy and Royal Marines.

To determine the acuity of vision, Snellen's letter types are to be used, and care is to be taken that the proper distances are carefully marked off, either on the floor or the wall of the room. Should the room not be sufficiently long for the 6 metre card to be used, the 5 metre card may be substituted, and both these cards are to be supplied, as well as the proper size of types for testing near vision.

The colour sense is to be determined by means of Hedmgren's wool test, and care is to be taken that when the wools become dull from use they are renewed.

Note. For distant vision, D = 6/6 is considered normal; for near vision, ability to read H 06 at any distance chosen by the candidate.

For candidates for the Seaman Class (including Boys and Youths), Marines (excluding Marine Bandsmen), Armourer ratings, Engine Room Artificers, Electricians and Boy Artificers, full normal vision is required.

In candidates for other Artisan ratings and for Stokers the vision must be 6/8.

For all other ratings, including Writers, Ship's Stewards Assistants, Ship's Cooks, Sick Berth Staff, Boy Writers, Ship's Stewards Boys and Officer's Stewards and Cooks, the vision must not be less than 6/12.

For all ratings except Writers, Ship's Cook ratings and Officer's servants, the colour sense must be normal.

Defects of vision must only be due to errors of refraction, and must be capable of correction to 6/6 Snellen by means of glasses, and the candidate must be able to read D = 06 without the aid of glasses.

Marine Bandsmen, Sick Berth Staff, Writers, Ship's Steward ratings, Ship's Cook ratings and Officers' Servants are allowed to wear glasses.

APPOINTMENTS UNDER THE GOVERNMENT OF INDIA.

The Ecclesiastical, Education, Geological Survey, Agricultural, Indian Finance, Customs, Civil Veterinary, and other Departments not specially provided for in the following pages.

1. A candidate may be admitted into the Civil Services of the Government of India if ametropic in one or both eyes, provided that, with correcting lenses, the acuteness of vision be not less than $\frac{2}{3}$ in one eye and $\frac{2}{3}$ in the other; there being no morbid changes in the fundus of either eye.

2. Cases of myopia, however, with a posterior staphyloma, may be admitted into the service, provided the ametropia in either eye does not exceed 2.5 D, and no active morbid changes of choroid or retina be present.

3. A candidate who has a defect of vision arising from nebula of the cornea is disqualified if the sight of either eye be less than $\frac{2}{12}$; and in such a case the acuteness of vision in the better eye must equal $\frac{2}{3}$, with or without glasses.

4. Squint or any morbid condition, subject to the risk of aggravation or recurrence, in either eye, may cause the rejection of a candidate. The existence of imperfection of colour sense will be noted on the candidate's papers.

*The Departments of Forest, Surrey, Telegraph, Factories,
and for various Artificers.**

1. If myopia in one or both eyes exists, a candidate may be passed, provided the ametropia does not exceed 2.5 D, and if with correcting glasses, not exceeding 2.5 D, the acuteness of vision in one eye equals $\frac{6}{6}$ and in the other $\frac{6}{6}$, there being normal range of accommodation with the glasses.

2. Myopic astigmatism does not disqualify a candidate for service, provided the lens or the combined spherical and cylindrical lenses required to correct the error of refraction do not exceed - 2.5 D; the acuteness of vision in one eye, when corrected, being equal to $\frac{6}{6}$, and in the other eye $\frac{6}{6}$, together with normal range of accommodation with the correcting glasses, there being no evidence of progressive disease in the choroid or retina.

3. A candidate having total hypermetropia not exceeding 1 D is not disqualified, provided the sight in one eye (when under the influence of atropin) equals $\frac{6}{6}$ and in the other eye equals $\frac{6}{6}$, with + 1 D or any lower power.

4. Hypermetropic astigmatism does not disqualify a candidate for the service, provided the lens or combined lenses required to cover the error of refraction do not exceed 1 D, and that the sight of one eye equals $\frac{6}{6}$ and of the other $\frac{6}{6}$, with or without such lens or lenses.

5. A candidate having a defect of vision arising from nebula of the cornea is disqualified if the sight of one eye is less than $\frac{6}{12}$. In such a case the better eye must be emmetropic. Defects of vision arising from pathological or other changes in the deeper structures of either eye, which are not referred to in the above rules, may exclude a candidate for admission into the service.

6. Squint or any morbid condition, subject to the risk of aggravation or recurrence, in either eye, may cause the rejection of a candidate. The existence of imperfection of colour sense will be noted on the candidate's papers.

*Public Works Department and Superior Establishments,
Railway Department.*

1. If myopia in one or both eyes exists, a candidate may be passed, provided the ametropia does not exceed 3.5 D, and if, with correcting glasses not exceeding 3.5 D, the acuteness of vision in one eye equals $\frac{6}{6}$ and in the other $\frac{6}{6}$, there being normal range of accommodation with the glasses.


2. Myopic astigmatism does not disqualify a candidate, provided the lens, or the combined spherical and cylindrical lenses, required to correct the error of refraction, does not exceed 3.5 D; the acuteness of vision in

* Artificers engaged in map and plan drawing may be considered separately, and this standard relaxed if it appears to be desirable.



4-CROCOPY RESOLUTION TEST CHART

(ANSI and ISO TEST CHART No. 2)



APPLIED IMAGE Inc

1653 East Main Street
Rochester, New York 14609 USA
(716) 482-0300 - Phone
(716) 288-5989 - Fax

one eye, when corrected, being equal to $\frac{6}{8}$ and in the other $\frac{6}{8}$, together with normal range of accommodation with the correcting glasses, there being no evidence of progressive disease in the choroid or retina.

3. A candidate having total hypermetropia not exceeding 4 D is not disqualified, provided the sight in one eye (when under the influence of accommodation) equals $\frac{6}{8}$, and in the other eye equals $\frac{6}{8}$, with + 1 D glasses, or any lower power.

4. Hypermetropic astigmatism does not disqualify, provided the lens or combined lenses required to cover the error of refraction do not exceed 4 D, and that the sight of one eye equals $\frac{6}{8}$ and the other $\frac{6}{8}$, with or without such lens or lenses.

5. A candidate having a defect of vision arising from nebula of the cornea is disqualified if the sight of that eye be less than $\frac{6}{12}$. In such a case the better eye must be emmetropic. Defects of vision arising from pathological or other changes in the deeper structures of either eye, which are not referred to in these rules, may exclude a candidate.

6. Squint or any morbid condition, subject to the risk of aggravation or recurrence, in either eye, may cause the rejection of a candidate. Any imperfection of the colour sense is a disqualification for appointment to the Engineering Branch of the Railway Department, or as Assistant Superintendent in the Traffic Department. In all other cases a note as to any imperfection of colour sense will be made on the candidate's papers.

The Indian Medical Service and the Police Department.

1. Squint, or any morbid condition of the eyes or of the lids of either eye liable to the risk of aggravation or recurrence, will cause the rejection of the candidate.

2. The examination for determining the acuteness of vision includes two tests: one for distant the other for near vision. The Army Test Types will be used for the test for distant vision, without glasses, except where otherwise stated below, at a distance of 20 feet; and Snellen's Optotypi for the test for near vision, without glasses, at any distance selected by the candidate. Each eye will be examined separately, and the lids must be kept wide open during the test. The candidate must be able to read the tests without hesitation in ordinary daylight.

3. A candidate possessing acuteness of vision, according to one of the standards herein laid down, will not be rejected on account of an error of refraction, provided that the error of refraction, in the following cases, does not exceed the limits mentioned, viz.: (a) in the case of *myopia*, that the error of refraction does not exceed 2.5 D; (b) that any correction for *astigmatism* does not exceed 2.5 D; and, in the case of myopic astigmatism, that the total error of refraction does not exceed 2.5 D.

4. Subject to the foregoing conditions, the standards of the minimum acuteness of vision with which a candidate will be accepted are as follows:—

*Standard I.**Right eye.*

Distant vision.— $V = 6/6$.
Near vision.—Reads 0, 6.

Left eye.

$V = 6/6$.
Reads 0, 6.

*Standard II.**Better eye.*

Distant vision.— $V = 6/6$.

Near vision.—Reads 0, 6.

Worse eye.

V , without glasses, = not below $6/60$; and after correction with glasses, = not below $6/24$.

Reads 1.

*Standard III.**Better eye.*

Distant vision.— V , without glasses, = not below $6/24$; and after correction with glasses, = not below $6/6$.

Near vision.—Reads 0, 8.

Worse eye.

V , without glasses, = not below $6/24$; and after correction with glasses, = not below $6/12$.

Reads 1.

N.B.—In all other respects candidates for these two branches of the service must come up to the standard of physical requirements laid down for candidates for commissions in the army.

The Indian Pilot Service, and Candidates for appointments as Guards, Engine-drivers, Signalmen, and Pointsmen on Railways.

1. A candidate is disqualified unless both eyes are emmetropic, his acuteness of vision and range of accommodation being perfect.
2. A candidate is disqualified by any imperfection of his colour sense.
3. Strabismus, or any defective action of the exterior muscles of the eyeball, disqualifies a candidate for these branches of service.

The Indian Marine Service, including Engineers and Firemen.

1. A candidate is disqualified if he have an error of refraction in one or both eyes which is not neutralised by a concave or by a convex 1 D lens, or some lower power.
2. A candidate is disqualified by any imperfection of his colour sense.
3. Strabismus, or any defective action of the exterior muscles of the eyeball, disqualifies a candidate for this branch of service.

Special Duty.

Candidates for special duty under Government must possess such an amount of acuteness of vision as will, without hindrance, enable them to

perform the work of their office for the period their appointment may last. In all cases of imperfection of colour sense a note will be made on the candidate's papers.

PILOT SERVICE.

Regulations for the Medical Examination of Candidates for Pilots' Licenses.

All candidates for the Pilotage Service are examined by the Corporation's Medical Officer, both as to their Physical Fitness and as to their Acuteness of Vision and Colour Perception.

1. Form Vision. A candidate must have no defect of sight, he must be able to read without glasses $\frac{5}{6}$ by each eye separately at the required distance, and the near type at the distance for which it is marked.

2. Squint, or any defective action of the eye muscles or any disease of the eye disqualifies.

3. A candidate is disqualified by *any* imperfection of his colour sense.

4. A candidate must be also otherwise physically fit for the duties of a Pilot.

METHOD OF EXAMINATION.

A candidate is first examined as to his form vision:—

He is placed at a distance of 6 metres from a set of Snellen's Test Type Cards, arranged on a revolving box so that different cards can be exposed when required, a good light is thrown on the card; the candidate wears a trial frame and the vision of the left eye is shut off by placing a plain disc in the trial frame in front of the left eye. The distant vision of the right eye is then ascertained by the candidate reading with both eyes open the letters of one of the Type Cards. The plain disc is then put in front of the right eye and the vision of the left eye ascertained by his reading the letters of another Test Type card.

If the candidate fails to read $\frac{5}{6}$ with each eye separately, the cause of the defect is ascertained, and unless it is due to some temporary derangement of vision he is rejected.

Having read $\frac{5}{6}$ with each eye separately, the near vision is next examined by causing him to read with each eye separately the near type at the distance for which it is marked.

The candidate is next examined as to his colour vision by means of Holmgren's wools, and the method of conducting this part of the examination is the same as that laid down in the Board of Trade regulations relating to the examination of Masters and Mates, 1904 (*vide infra*).

The candidate is next given the colour ignorance test. The room is made quite dark and the candidate is placed at 6 metres distance from an illuminated ophthalmic lamp with a metal chimney and bull's-eye condenser, before which sheets of red, green and white glass are passed and he is required to name the colours.

MASTERS AND MATES OF THE MERCANTILE MARINE.

(The sight tests are three in number: (1) Form test; (2) Colour vision test; (3) Colour ignorance test. Lengthy instructions are provided as to the requirements and methods of examination. These should be studied by any candidate. Form vision is tested by Snellen's types or by dots for those who cannot read. Candidates may use both eyes or either eye, but must not use glasses of any kind. If the candidate at 16 feet from the test can read correctly three of the five letters in the fifth line from the top, or four in either of the two lines below, he may be considered to have passed the test.

These tests are at present under the consideration of a Departmental Committee of the Board of Trade and are likely to be modified at an early date.)

INDEX.

(The principal references are printed in heavy type.)

- ABERRATION**, chromatic, 67
spherical, 67
- Ablatio retinae**, 392
- Ablepharon**, 620
- Abrasion of cornea**, 436
- Abscess, lacrymal**, 636
- Accessory sinuses of the nose**, 643
- Accommodation**, 57
and convergence,
539, 564
anomalies of, 496,
528
paralysis of, 529
spasm of, 530
- Achromatopsia**, 81, **428**
- Acuity of vision**, 78, 156
- Adaptation, retinal**, 77
- Adnexa, diseases of**, 587
- Adrenalin**, 174, 197, 583, 632, 662
- Advancement operation**, 555, 573,
583
- Albinism**, 116, 148, **399, 556**
- Albuminurie neuro-retinitis**, 385
- Alypin**, 660
- Amaurosis**, 426
uræmic, 388, 427
- "**Amaurotic cat's eye**," 115
- Amblyopia**, **426**
congenital, 426, 563
ex anopsia, 426, 563
heteronymous, 426
hysterical, 427
quinine, 392
toxic, 390
- Ametropia**, **45, 496, 511**
axial, 51, 136, 566, 516
curvature, 52, 137, 506,
516, 519
index, 52, 62, 137, 506,
516, 521
- Amotio retinae**, 392
- Amplitude of accommodation**, 61,
164
convergence, 541
- Anæmia of optic disc**, 409
- D. E.**
- Anæmia of retina**, 376
- Anæsthesia, local**, 658
- Anatomy of extrinsic muscles**, 531
eye, 1
lacrymal apparatus,
621
lids, 587
- Angioma of lids**, 646
- Angle γ** , 560
metre, 539
visual, 44, 79, 156
- Angular conjunctivitis**, 198
- Aniridia, congenital**, 304
traumatic, 438
- Anisometropia**, 65, **522**
- Ankyloblepharon**, 611, 619
- Anterior chamber, anatomy of**, 3
examination of,
106
- Aphakia**, 501, **521**
- Aqueous humour**, 3
secretion of, 21
- Arcus juvenilis**, 268
senilis, 268
- Argyll-Robertson pupil**, 110, 529
- Argyrosis**, 198
- Artificial eye**, 494
- Aspergillus fumigatus**, 249
- Asthenopia**, 517, 520, 576
- Astigmatism**, **52, 519**
irregular, 57
lenticular, 66
regular, 57
- Astringent lotions**, 659
- Atropin**, **74, 233, 296, 661**
irritation, 210
- BACILLUS coli**, 186
diphtheria, 188
Koch-Weeks', 177, 189
Morax-Axenfeld, 199
tubercle, 192, 209, 295,
363
xerosis, 189, 217
- Bacteriology of choroid**, 364, 454

- Bacteriology of ciliary body, 302, 454
 conjunctiva, 172
 cornea, 222, 213
 iris, 294
 mucocele, 627
 retina, 361, 454
 sympathetic ophthalmia, 460
- Band-shaped opacity, 268
- Basedow's disease, 651
- Beer's knife, 597
- Binocular diplopia, **545**, 550
 vision, 538
- Bjerrum's test types, 170
- Benmorrhœa, 181
- Blepharitis, 591
- Blepharophimosis, 611
- Blepharospasm, 193, 428
- Blood in the cornea, 276
 supply of eye, 13
- Bowman's membrane of, 8
- Bruch, membrane of, 8
- Buller's shield, 183
- Buphthalmia, 327
- Burns, 131
- Burrow's operation, 602
- CANALICULUS, 622, 627
 slitting of, 625
- Canal of Cloquet, 22
 Schlemm, 3, 17, 23
- Canthoplasty, 601
- Carbolic acid, application of, 247
- Carcinoma of choroid, 418
 lacrimal gland, 624, 617
 lid, 619
- "Cartella" shield, 481
- Cataract, **329**
 after-, 345, 471
 anterior capsular, 231 **342**
 cortical, 342
 polar, 342
 axial, 341
 black, 333
 central, 341
 complicated, 346
 concussion, 441
 congenital, 344
 coralliform, 314
 diabetic, 348
 extraction, combined, 479
 extraction without iridectomy, 487
- Cataract, hard, 333
 infantile, 339
 incipient, 336
 lamellar, 339
 mature, 336
 Morgagnian, 333
 nuclear, 341
 perinuclear, 310
 posterior cortical, 312, **347**
 polar, 342, **347**, 355
 punctate, 315
 pyramidal, 311
 secondary, 345
 dissection of, 474
 senile, 329
 soft, 333
 total, 331, 315, 347
 traumatic, 441, **448**
 unilateral, 337
 zonular, 340
- Cauties, burns and injuries by, 434
- Cauterisation of cornea, 246
- Cautery, galvano-, 216
- Cavernous angioma, 618
 sinus thrombosis, 642
- Cellulitis, orbital, 641
- Central artery of retina, 14
- Chalazion, 596
- Chemosis, 173
- "Choked disc," 402
- Cholesterin, 332, 354
- Choriocapillaris, 8
- Choroid, anatomy of, 8
 diseases of, 357
 injuries of, 442
 sarcoma of, 414, 418
 tubercle of, 363
- Choroiditis, **357**
 anterior, 361
 central, 362, 368
 areolar, 364
 diffuse, 362
 guttate, 364
 circumpapillary, 370
 disseminated, 358
 Förster's areolar, 362
 metastatic, 365
 myopic, 506
 purulent, 454
 syphilitic, atrophy
 after, 359
 Tay's, 368

- Chromatopsia, 128
 Ciliary arteries, 11
 body, anatomy of, 6
 diseases of, 282
 injuries of, 438, 444
 sarcoma of, 417
 congestion, 96
 veins, 14
 Cilio-retinal vessels, 118
 Circle of least diffusion, 51
 Circulus arteriosus iridis major
 and minor, 16
 Cloquet, canal of, 22
 Cocain, 74, 174, 659, 661
 Coccus, gono-, 181, 186, 189, 245
 pneumo-, 177, 189, 242, 627
 staphylo-, 191, 215, 595, 627
 strepto-, 182, 186, 189, 215,
 627
 "Colloid bodies," 369
 Coloboma of choroid and retina, 398
 iris, 304
 lens, 349
 lid, 620
 optic disc, 412
 Colour blindness, 81, **428**
 Coloured vision, 428
 Colour sense, 80
 Comotio retinae, 412
 Concomitant strabismus, 558
 Concretions, 233
 Congenital abnormalities of—
 choroid, 398
 colour blindness, 428
 iris, 304
 lens, 350
 lids, 619
 nasal duct, 628
 optic nerve, 412
 pupilla, 627
 retina, 398
 Conical cornea, 271
 Conjugate deviation, 534, 536, 549
 Conjunctiva, anatomy of, 171
 bacteriology of, 172
 diseases of, 171
 examination of, 92
 hyperemia of, 95, 172
 secretion of, 175
 syphilis of, 210
 tubercle of, 208
 wounds of, 443
 Conjunctivitis, **172**
 angular, 198
 catarrhal, 175
 Conjunctivitis, diphtheritic, 187
 diplobacillary, 198
 due to drugs, 210
 eczematous, 190
 follicular, 199
 gonorrhœal, 181
 granular, 200
 membranous, 178,
 187
 muco-purulent, 176
 phlyctenular, 190
 purulent, 181
 simple acute, 175
 simple chronic, 196
 Contusion of eye, 436
 lids, 616
 Convergence, 65, 531
 amplitude of, 541
 and accommodation,
 539, 561
 insufficiency of, 580
 Copper sulphate, 206
 Corectopia, 301
 Cornea, anatomy of, 1
 blood in, 276
 diseases of, 222
 examination of, 99, 130
 in glaucoma, 273, 311
 injuries of, 436
 operations upon, 463
 pigmentation of, 276
 symptomatic conditions,
 273
 tumours of, 276
 vessels in, 196
 Corneal loupe, 102
 Corresponding points, 537
 Couper's probes, 629
 Crêde's method, 186
 Crescent, inferior, 412
 myopic, 508
 Cryptophthalmia, 620
 Crypts of iris, 5
 Cup, glaucomatous, 313, 322
 physiological, 146
 Curette, 478
 evacuation, 476
 Cyclitis, **299**
 chronic, 300
 plastic, 303
 purulent, 231, 454
 simple, 300
 sympathetic, 457
 Cycloplegia, 529
 glaucomatous, 314

- Cycloplegia, sympathetic, 157
traumatic, 438
- Cycloplegics, 73, 661
- Cystotome, 478
- Cysts, Meibomian, 596
of conjunctiva, 218
orbit, 161
tarsal, 596
- DACRYOADENITIS, 623**
- Dacryocystitis, 627
- Dacryops, 624
- Dalrymple's sign, 651
- Daturin, 74, 661
- Day blindness, 428
- Degenerative changes in—
choroid, 366
conjunctiva, 214
cornea, 268
lens, 329
retina, 357
retinal vessels, 379
vitreous, 351
- Dermoid cyst, 646
of conjunctiva, 220
- Dermo-lipoma, 220
- Descemet's membrane, 1
- Desmarres' entropion forceps, 605
retractor, 104, 590
- Diabetes, 295, 348, 388, 595
- Dilator iridis, 5
- Dimmer's operation for ectropion, 608
- Dionin, 216, 234, 660
- Diopre, 36
- Diplobacillary conjunctivitis, 198
- Diplopia, binocular, 545, 547, 550
chart, 550, 553
uniocular, 333, 440
- Discission, 472
- Dislocation of lacrymal gland, 623
lens, 309, 332, 437,
438
- Disparate points, 538
- Distichiasis, 619
- Divergent strabismus, 574
- Duboisin, 74, 661
- Dyselutromatopsia, 429
- ECCHYMOSIS, subconjunctival, 216**
- Ectasia of cornea, 228, 230, 269
sclerotic, 318, 508
- Ectopia lentis, 350
- Ectropion, 599, 604, 619
of uveal pigment, 318
- Eczematous conjunctivitis, 490
keratitis, 249
- Electric light ophthalmia, 213
- Electrolysis, 599
- Elephantiasis neuromatodes, 620
- Embolism of central artery, 376
- Emmetropia, 43, 507
- Emphysema of lids, 617
- Empyema of frontal sinus, 643
- Enophthalmos, 639
- Entropion, 599, 601, 619
cicatricial, 602
- Epicanthus, 620
- Epiphora, 592, 617, 624
- Episcleritis, 277
- Epithelioma of conjunctiva, 221
lid, 619
- Errors of refraction, 45, 496
correction of,
524
- Erysipelas of the lids, 590
- Erythroptia, 428.
- Eserin, 75, 233, 252, 320, 661
- Esophoria, 579
- Essential shrinking of conjunctiva,
217
- Ethmoiditis, 645
- Eucain, 660
- Euphthalmia, 661
- Eversion of punctum, 624
upper lid, 92
- Evisceration of eyeball, 493
- Examination, external, 91
functional, 154
ophthalmoscopic, 114
preliminary, 655
- Examination of anterior chamber,
106
conjunctiva, 92
cornea, 99
foruix, 94
intraocular ten-
sion, 113
iris, 107
lacrymal appara-
tus, 98
lens, 112
pupils, 108
sclerotic, 99
- Excision of eyeball, 490
lacrymal sac, 632
scissors, 492
- Exenteration of orbit, 650
- Exophoria, 579
- Exophthalmic goitre, 651

- Exophthalmometers, 639
 Exophthalmos, 638, 651
 intermittent, 653
 pulsating, 652
 Expression, 207
 Extraction, linear, 476
 of senile cataract, 477
 FACETS of cornea, 228, 252
 Far point, 46
 Fascicular ulcer, 250
 Fibro-fatty tumour, 220
 Fibroma of conjunctiva, 219
 Field of vision, binocular, 170, 422
 in glaucoma, 322
 unioocular, 81, 165, 422
 Field, ophthalmoscopic, 141
 Filtering scar, 325
 Fistula, corneal, 231
 lacrymal, 623, 637
 Fixation, development of, 557, 564
 eccentric, 562, 564
 Fluorescein, 98, 100, 132
 Focal illumination, 101
 Follicular conjunctivitis, 199
 Fontana, spaces of, 4
 Forceps, capsule, 242
 entropion, 605
 fixation, 236
 Graddy's, 207
 Griffith's, 599
 iris, 239
 Knapp's roller, 208
 Prince's, 581
 T-shaped, 602
 Foreign bodies, 430
 intraocular, 448
 Form sense, 78
 Förster's areolar choroiditis, 362
 capsule forceps, 212
 Fovea centralis, 10, 147, 152
 Frontal sinus, 643
 Functional examination, 154
 Fundus, 657
 oculi, 145
 albino, 148, **399**
 tessellated, 149
 "Fusion centre," 567
 GLANDS, Krause's, 587, 621
 lacrymal, 621
 Meibomian, 589, 594
 Moll's, 588
 of lids, inflammation, 594
 Zeiss's, 594
 Glass rod, 180
 Glaucoma, **306**
 absolute, 318
 acute, 315
 chronic, 321
 congestive, 316
 haemorrhagic, 310
 infantile, 327
 iridectomy for, 464
 primary, 310, 322
 secondary, 307, 441
 Glioma of optic nerve, 648
 retina, 418
 Globe, injuries involving the, 616
 Gonorrhœal conjunctivitis, 181
 Graddy's forceps, 207
 Graefe knife, 248, 478
 Graefe's sign, 651
 Granuloma of conjunctiva, 219
 Graves's disease, 651
 Griffith's forceps, 599
 HAAB'S giant magnet, 453
 Hæmangioma, 618
 Hæmorrhage, intraocular, 231, 309
 441
 retinal, 381
 Hemianopia, 90, **422**
 Hemianopic pupil reaction, 71, 109
 423
 Hering's theory, 80
 Herpes corneæ, 258
 Hess's operation, 614
 Heterochromia iridis, 107, 304
 Heterophoria, 558, 576
 Hippias, 72
 Hole in retina, 443
 Holmgren's wools, 429
 Homatropin, **73**, 661
 Hordeolum, 594
 Hutchinson's teeth, **265**
 Hyaloid artery, persistent, 355
 membrane, 13
 Hydrophthalmia, 327
 Hyoscine, 74, 661
 Hyperæmia of conjunctiva, 172
 optic disc, 401
 retina, 381
 Hypermetropia, 44, 160, 428, 468, **516**
 Hyperphoria, 577
 Hyphæma, 285, 446
 Hypophoria, 576
 Hypoplasia of teeth, 341
 Hypopyon, **225**, 246, 249, 285
 ulcer, **243**, 249

- INCISION of lacrymal sac, 633
 Inflammation of the iris and ciliary
 body, 282
 lids, 590
 sclerotic, 277
 Injuries caused by burns, 434
 perforating, 143
 to the cornea, 136
 eye, **431**, 616
 iris, 437
 lids, 615
 orbit, 616, 645
 Instruments, care of, 663
 Intraocular pressure, 18, 113, 285,
 306
 Iridectomy, 320, **463**, 470
 for glaucoma, 321, 461
 of prolapsed iris, 210
 optical, 163
 Iridemia, congenital, 301
 traumatic, 438
 Iridocyclitis. See CYCLITIS.
 Iridodialysis, 130, **438**
 Iridodonesis, 108, 113, 328, 332, 439
 Iridotomy, 470
 Iris, abnormalities of, 301
 anatomy of, 5
 atrophy of, 292
 bombé, 286, 291, 308
 diseases of, 282
 examination of, 107, 129
 injuries of, 437
 operations on, 463
 tumours of, 413
 Iritis, **282**
 diabetic, 295
 gonorrhoeal, 294
 gummatous, 294
 plastic, 293
 purulent, 454
 "rheumatic," 294
 "serous," 299
 sympathetic, 457
 syphilitic, 293
 tubercular, 295, 298

 JAEGER'S test types, 161
 Jaesche-Arlt operation, 603

 KERATECTASIA, 271
 from ulcer, 228
 Keratic precipitates ("k.p."), 274,
 286, 300
 Keratitis, **222**
 bullous, 274, 318
 e lagophthalmia, 254
 filamentary, 274, 318
 interstitial, 261
 mycotic, 249
 neuroparalytic, 254
 non-suppurative, 258
 parenchymatous, 261
 phyctenular, 249
 punctata ("k.p."), 274,
 285, 301
 purulent (*see also* Ulcer),
 222
 rare forms of, 267
 superficial punctate, 261
 vesicular, 259, 273, 318
 Keratocoele, 228
 Keratoconus, 271
 Keratoglobus, 273, 327
 Keratomalacia, 217, 253
 Keratome, 238
 Kinetic strabismus, 555
 Knapp's roller forceps, 207
 Knife, Beer's, 597
 Graefe, 248, 478
 lance, 238
 Stilling's, 626
 Tweedy's, 626
 Weber's, 625
 Koch-Weeks' bacillus, 177, 189
 "K.p.," 274, 286, 301
 Krause's glands, 589, 621
 Krönlein's operation, 650

 LACRYMAL abscess, 636
 apparatus -
 anatomy of, 621
 diseases of, 623
 examination of, 98
 secretion, 623
 Lagophthalmia, 254, **611**
 Lamellar cataract, 310
 Lamina cribrosa, 11, 116, 313, 409
 vitrea, 8
 Lang's dissector, 632
 Lawford's speculum, 465
 Lead deposits, 275
 Lens, anatomy of, 11
 diseases of (*see also* Cata-
 ract), 329
 dislocation of, 229, 319, 332,
 350, 437, **438**
 examination of, 112, 128,
 131
 injuries of, 438, 444, 447

- Lens, operations on, 472
 spoon (Critchett's), 480
 Lenses, 31
 cylindrical, 55
 measurement of, 37
 Leucoma, 226
 adherens, 244
 Levator palpebrae, 590
 Lids, anatomy of, 587
 anomalies of position of, 598,
 619
 coloboma of, 620
 diseases of, 590
 inflammation of glands of, 594
 injuries of, 615
 tumours of, 617
 Ligamentum pectinatum iridis, 4
 Light sense, 77
 Lime burn, 434
 Line of fixation, 560
 vision, 81, 559
 Lithiasis, 213
 Loupe, corneal, 402
 Lucer's syringe, 630
 Lymph of eye, 3
 secretion of, 21
 Lymphangioma of conjunctiva, 248
 lids, 619
- MACROPSIA**, 360, 392
 Macula lutea, 10, 147, 452
 of cornea, 226
 Madarosis, 591
 Maddox rod, 577
 scale, 577
 Magnet, Haab's, 453
 small, 451
 Volkmann's, 453
 Malingering, 429
 Margo intermarginalis, 587
 Mannoir's scissors, 479
 Megalopsia, 360, 374
 Meibomian glands, 589, 595
 Membranous conjunctivitis, 478,
 187
 Meningo-encephalocele, 646
 Meniscus, 32
 Mercury in syphilitic iritis, 297
 Metamorphopsia, 360, 374
 Metastatic endophthalmitis, 364
 Metre angle, 510
 Microblepharon, 620
 Microphthalmia, 356, 398, 620
- Micropsia, 360, 374
 Miodes, 73, 661
 Mirrors, 27
 Möbins' sign, 652
 Mole, congenital, 249, 618
 Moll's glands, 588
 Molluscum contagiosum, 618
 Mooren's ulcer, 257
 Moorfield's bandage, 484
 cystotome, 478
 tenotomy hook, 491
 Morax-Axenfeld diplopia, 199
 Morgagnian cataract, 333
 globules, 329
 Mucocele, 627
 Mules operation, 493
 Müller, fibres of, 9
 Müller's muscles, 589
 Müller's retractor, 634
 Muscae volitantes, 334, 351, 510
 Muscles, extrinsic, 534
 intrinsic, 5
 Müller's, 589
 operations on, 581
 Mydriasis, traumatic, 436
 Mydriatics, 73, 664
 Myopia, 44, 506
 rays in, 499
 spherical, 503
- NEVUS** of conjunctiva, 219
 lid, 618
 Nasal duct, 622
 stricture of, 637
 sinuses, 643
 Near point, 59, 164
 Nebula, 226
 Needle holder, 582
 Needles, 582
 broad, 237
 discission, 471
 paracentesis, 238
 Needling, 472
 Nephritis, 386
 Nerve, optic, anatomy of, 10, 83
 diseases of, 401
 tumours of, 648
 Nerves, motor, 68, 534
 Nettleship's dilator, 625
 Neuritis, optic, 375, 385, 401, 460,
 635
 retrobulbar, 496
 Neurology of vision, 83
 Neuroma, plexiform, 626

- Neuroparalytic keratitis, 254
 Neuro-retinitis, 375, **385**, 403
 Night blindness, 217, 253, 371, **427**
 Nodal point, 41, 559
 Nystagmus, 292, **543**, 555
- OBLIQUE** illumination 101
 Occlusion of canaliculus, 627
 punctum, 626
 Oclusio pupillae, 287, 292
 Ocular paralysis, 552
 Oedema of lids, 590
 Opacities, congenital, 275
 diagnosis of, 125, 144
 of cornea, 226, 268, 275
 lens, 329
 vitreous, 334, **351**, 510
 Opaque nerve fibres, 399
 Operations on the extrinsic
 muscles, 581
 eyeball, 463
 Ophthalmia, catarrhal, 175
 gonorrhoeal, 181
 neonatorum, 185
 nodosa, 212
 phlyctenular, 190
 sympathetic, 456
 Ophthalmoplegia, 554
 Ophthalmoscope, 116
 Ophthalmoscopic examination, **114**
 by direct method, 138
 distant direct method, 125
 indirect method, 132
 Optic atrophy, 408
 axis, 42, 559
 disc, 145
 coloboma of, 412
 iridectomy, 463
 nerve, anatomy of, 10, 83
 diseases of, 401
 tumours of, 648
 neuritis, 375, 385, **401**, 406,
 461, 649
 Optical centre, 33, 44
 Optics, 25
 physiological, 41
 Ora serrata, 7
 Orbicularis palpebrarum, 589
 Orbit, diseases of, 638
 injuries to, 616, 645
 tumours of, 646
 Orbital cellulitis, 641
 Orientation, 537
 false, 517
 Orthophoria, 576
 Orthoptic treatment, 572
 Osteoma, 647
- PANNUS**, phlyctenular, 251
 trachomatous, 203
 Panophthalmitis, 231, **365**, **454**, 590,
 641
 Papillitis, 373, 385, **401**, 460, 649
 Papilloma of conjunctiva, 219
 Papillo-macular fibres, **88**, 391, 407
 Paracentesis, **237**, 247, 303
 Parallaxic displacement, 126, 137,
 142
 Paralysis, ocular, 549, 552
 Pemphigus, 217
 Perimeter, 166
 Periostitis, 639
 Phlyctenular conjunctivitis, 190
 keratitis, 249
 Photophobia, 193, 591
 Photophthalmia, 213
 Photopsia, 360, 393
 Photoretinitis, 390
 Phthiriasis palpebrarum, 592
 Phthisis bulbi, 300
 Physiological enp, 146
 Physiology of extrinsic muscles,
 531
 eye, 18
 lacrymal appa-
 ratus, 621
 lids, 587
 Physostigmin, **75**, 661
 Pigment on lens capsule, 290
 Pigmentation of the cornea, 276
 Pilocarpin, **75**, 661
 Pinguecula, 213
 Plane lamina, 30
 mirror, 27
 Plastic iritis, 287
 Plexiform neuroma, 620
 Pneumococci, 172, 178, 243, 365,
 454, 627
 Point, far, 46
 near, 59
 nodal, 43
 Points, corresponding, 537
 disparate, 538
 Polycoria, 304
 Polyopia, 334
 Porus opticus, 11
 Posterior chamber, 13
 longitudinal bundle, 536
 Precipitates, keratic ("k.p."), 274,
 286, 301

- Pre-retinal hæmorrhage, 381
 Presbyopia, 61, **528**
 Priestley Smith's tape, 568
 theory of glaucoma, 310
 Prisms, 31
 use of, 511, 579
 Probes, lacrymal, 629
 Projection of light, 331
 objects, 537
 false, 548
 Prolapse of ciliary body, 444
 iris, 229, 240, 444, 487
 vitreous, 445, 485
 Proptosis, 639, 648
 Pseudoglioma, 420
 Pseudononitis, 404
 Pseudopterygium, 214
 Pterygium, 214
 Ptosis, 539, **612**, 619
 trachomatous, 205, 612
 Pulsating exophthalmos, 652
 Pulsation of retinal vessels, 149, 313
 Puncta lacrymalia, 621
 occlusion of, 626
 Punctum proximum, 59, 164
 remotum, 46
 Pupillary membrane, inflammatory,
 287, 292
 persistent, 305
 Pupil reactions, 71, 108
 Pupils, 66, 657
 examination of, 108
 innervation of, 68
 QUININE amblyopia, 392
 lotion, 189, 659
 RADIUM, 619
 Range of accommodation, 61, 164
 convergence, 541
 Reflection, 26
 Refraction, 30
 dynamic, 60
 errors of, 496
 correction of, 521
 static, 43, 60
 Refractive index, 30
 of cornea, 42
 of lens, 63
 Repositor, iris, 241
 Retina, adaptation of, 77
 anatomy of, 9
 detachment of, 128, **392**, 442
 diseases of, 357
 Retina, examination of, 128
 glioma of, 118
 injuries of, 442
 operations on, 397
 primary affections of, 374
 vascular disorders of, 376
 vessels, of 146
 Retinal vessels, perivascular
 changes in, 379
 Retinitis, 357, **374**, 508
 albuminuric, 385
 circinata, 389
 diabetic, 388
 from bright light, 390
 hæmorrhagic, 388
 leucæmic, 388
 pigmentosa, 369
 pigmentosa sine pig-
 mento, 370
 primary, 374
 proliferans, 388
 punctata albescens, 373
 purulent, 389, 364, **454**
 syphilitic, 384
 Retinoscopy, 496
 Retractors, Desmarres', 104
 Müller's, 631
 wire, 103
 Retrobulbar neuritis, 406
 Rodent ulcer of cornea, 257
 lid, 619
 Rupture of choroid, 442
 cornea, 436
 iris, 437
 retina, 442
 sclerotic, 436
 SAEMISCH'S section, 248
 "Salmon patches," 262
 Salvarsan ("606") in sympathetic
 ophthalmia, 462
 Salvarsan in syphilis, 554
 Sarcoma of choroid, 414
 ciliary body, 417
 conjunctiva, 220
 iris, 413
 lid, 619
 orbital, 646
 Schlemm, canal of, 3, 17, 23
 Scissors, de Wecker's, 240
 excision, 492
 Maunoir's, 479
 tenotomy, 490
 Scleral puncture, 397
 ring, 145

- Scleritis, 279
 Sclerosing keratitis, 280
 Sclerotic, diseases of, 277
 examination of, 99
 injuries of, 436, 446
 operations on, 397, 471
 Sclerotomy, anterior, 471
 posterior, 372
 Scopolamin, 661
 Scotoma, 167, 169, 369, 371, 377,
 391, 407
 absolute, 167
 central, 369, 391, 407
 relative, 169
 ring, 371
 sector-shaped, 377
 Screen test, 560
 Seclisio pupillæ, 287, 291, 308
 Serum treatment, 662
 Shadow test, 496
 Siderosis bulbi, 450
 Silcock's needle holder, 582
 Silver nitrate, application of, 180
 salts, 180, 184, 186, 205, 252,
 630, 659
 wire arteries, 378
 Skiascopy, 497
 Snellen's sutures, 607
 test types, 156, 430
 Snow blindness, 213
 Socket, contracted, 494
 Spasmus mitans, 556
 Spatula, 238
 lid, 600, 603
 Spectacles, 49, 526
 Speculum, 235
 Lawford's, 465
 Sphincter iridis, 5
 Spoon, Critchett's, 480
 Volkmann's, 598
 Spring catarrh, 211
 Spud, 433
 Squint. *See* Strabismus
 Staphylococci, 172, 178, 191, 245
 Staphyloma, anterior, 230, **269**
 ciliary, 279, **318, 320**
 equatorial, 319
 intercalary, 319
 posterior, 508
 Stellwag's sign, 652
 Stilling's knife, 626
 Strabismus, **542**
 alternating, 561
 apparent, 559
 concomitant, 559
 convergent, 558
 divergent, 558, 574
 hook, 491
 kinetic, 555
 latent, 576
 paralytic, 543
 periodic, 561, 576
 unilateral, 561
 Streptococci, 172, 186, 187, 189, 245
 Striate opacity, 275
 Sturm's conoid, 53
 focal interval, 54
 Stye, 594
 Styles, lacrymal, 632
 Subconjunctival injection, 234, 397
 Subhyaloid hæmorrhage, 381
 Sulcus subtarsalis, 171, 587
 Suspensory ligament, 12
 Sutures, Snellen's, 607
 Symblepharon, 435, **609, 619**
 Symparalysis, 552
 Sympathetic ophthalmia, 456
 paralysis of cervical,
 77
 Symptomatic conditions of—
 conjunctiva, 216
 cornea, 273
 disturbances of vision, 422
 Synchisis, 353
 scintillans, 354
 Synechia, annular, 287, 291, 308
 anterior, 228, 308, 444
 peripheral anterior, 291,
 307, 312
 posterior, 244, 287, 290
 ring, 287, 291, 308
 total posterior, 288, 290
 Synkinesis, 65, 533
 Syphilis of conjunctiva, 210
 cornea, 261
 lids, 593
 Syphilitic cases, treatment of, 554,
 662
 iritis, 293
 retinitis, 384
 Syringe, lacrymal, 630

 TARSAL cyst, 596
 Tarsorrhaphy, **256, 608**
 Tattooing, 235
 Tay's choroiditis, 368
 Tears, 623
 Telangiectasis of lids, 618
 Tenonitis, 642
 Tenon's capsule, 642

- Tenotomy, 555, 581, **573**
 scissors, 490
- Tension, intraocular, 18, 113, 285,
306, 657
- Test types, 156, 161, 170
- Therapeutic notes, 658
- Thrombosis of cavernous sinns, 641
 central artery, 382
 vein, 309, **382**
- Tiersch graft, 604
- Tigroid fundus, 149
- Tobacco amblyopia, 390
- Torsion, 532
- Torns, 53
- Toxic amblyopia, 390
- Trachoma, **200**, 598, 605, 613
- Transillumination, 99, 416
- Transverse calcareous film, 268
- Tremulous iris, 108, 113, 327, 332
- Trichiasis, 591, **598**, 619
- Tubercle of choroid, 362
 conjunctiva, 192, 209
 iris, 295
 lacrimal gland, 623
- Tumours, intraocular, 309, **413**
 of choroid, 414
 ciliary body, 417
 conjunctiva, 218
 cornea, 276
 iris, 413
 lacrimal gland, 624
 lids, 617
 optic nerve, 647
 orbit, 646
 retina, 418
- Tweedy's knife, 626
- Tylosis, 592
- ULCERATION of sclerotic, 281
- Ulcerative blepharitis, 59
- Uleer of conjunctiva, 208
 cornea, **222**
 atheromatous, 253
 central, 252
 chronic serpiginous,
 253
 dendritic, 257
 fascicular, 250
 herpetic, 258
 hypopyon, 243
 marginal, 252
 Mooren's, 257
 mycotic, 249
 perforating, 228
 ring, 251
- Uleer of cornea, "rodent," 258
 serpiginous, 243
 trachomatous,
 205, 253
 lids, rodent, 619
- Uleus serpens, 244
- Ultra-violet rays, 213, 390
- Undine, 178
- Uremic amaurosis, 587, 427
- Uveal tract, 3, 5
- VACCINE treatment, 662
- Vaccinia, 594
- Vaso-constrictors, 662
- Vene vorticosæ, 14
- Vernal catarrh, 211
- Vertigo, 549
- Vessels, choroidal, 14
 ciliary, 14
 conjunctival, 14, 95
 corneal, 17, 106
 episcleral, 14, 95
 retinal, 13, 375
- Vision, central, 657
 symptomatic disturbances
 of, 422
- Visual acuity, 78, 155
 angle, 44, 79, 156
 axis, 81, 559
 centre, 86
 perceptions, 76
 purple, 76
- Vitreous, anatomy of, 13
 blood in the, 354
 diseases of, **351**
 examination of, 125, 144
 fluidity of, 353
 foreign body in, 441
 opacities, 334, **351**, 510
 parasites in the, 356
 prolapse of, 446
 pus in the, 354
- Volkman's magnet, 452
 spoon, 598
- V—Y operation, 609
- WEBER'S knife, 625
- de Wecker's scissors, 240
- Werner's mnemonic for diplopia, 551
- Wernicke's pupil reaction, 71, 109,
 423
- Wharton Jones's operation, 609
- Wilde's entropion forceps, 605
- Wire retractor, 103

Wound of conjunctiva, 443
 cornea, 443
 corneo-sclera, 444
 lens, 309, 444, 447
 lids, 645
 perforating, 448
 sclerotic, 446

XANTHELASMA, 617
 Xanthoma, 617
 Xerophthalmia, 217

Xerosis, 217
 bacillus, 189, 247
 YELLOW spot, 10, 147, 152
 Young-Helmholtz theory, 80
 ZEIGLER'S knife, 474
 Zeiss's glands, 588, 594
 Zinc salts, 174, 197, 499
 Zinn, zonule of, 12
 Zonular cataract, 339
 opacity of cornea, 268

THE END.

PLATE . XIX.

HOLMGREN'S WOOLS FOR COLOUR BLINDNESS

Samples of the Test Wools are shown, and in the cases of the first three tests examples of mistakes made by colour blind persons. "Red-blind" and "green-blind" are so called according to the terminology of the Young-Helmholtz theory: they are better termed "protanopes" and "deutanopes" respectively. The examples are from actual cases, but it is not to be inferred that any given colour-blind person will make all these mistakes.

25772

WW 100 P268d 1912 Medical
Parsons, John Herbert,
Diseases of the eye
~~617.7/P268d.2~~ 71962103


25772

617.7

P268d.2 Diseases of the eye

AUTHOR


TITLE




McGill
University
Libraries
Medical Library

TEST I.

RED BLIND.



GREEN BLIND.



TEST II.

RED BLIND.



GREEN BLIND.



TEST III.

RED BLIND.



GREEN BLIND.



TEST IV.

TEST V.

