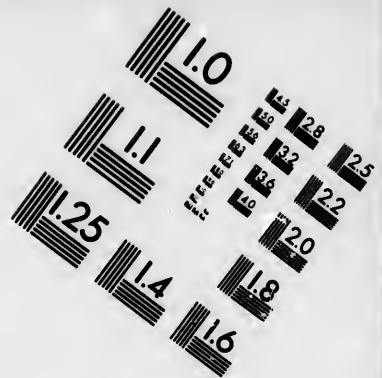
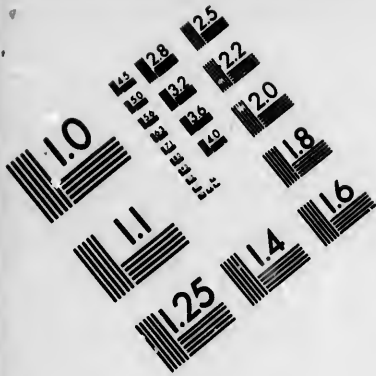




**IMAGE EVALUATION
TEST TARGET (MT-3)**



**Photographic
Sciences
Corporation**

23 WEST MAIN STREET
WEBSTER, N.Y. 14580
(716) 872-4503

28
25
22
20
18

**CIHM/ICMH
Microfiche
Series.**

**CIHM/ICMH
Collection de
microfiches.**



Canadian Institute for Historical Microreproductions / Institut canadien de microreproductions historiques

10
01

© 1986

Technical and Bibliographic Notes/Notes techniques et bibliographiques

The Institute has attempted to obtain the best original copy available for filming. Features of this copy which may be bibliographically unique, which may alter any of the images in the reproduction, or which may significantly change the usual method of filming, are checked below.

L'Institut a microfilmé le meilleur exemplaire qu'il lui a été possible de se procurer. Les détails de cet exemplaire qui sont peut-être uniques du point de vue bibliographique, qui peuvent modifier une image reproduite, ou qui peuvent exiger une modification dans la méthode normale de filmage sont indiqués ci-dessous.

- Coloured covers/
Couverture de couleur
- Covers damaged/
Couverture endommagée
- Covers restored and/or laminated/
Couverture restaurée et/ou pelliculée
- Cover title missing/
Le titre de couverture manque
- Coloured maps/
Cartes géographiques en couleur
- Coloured ink (i.e. other than blue or black)/
Encre de couleur (i.e. autre que bleue ou noire)
- Coloured plates and/or illustrations/
Planches et/ou illustrations en couleur
- Bound with other material/
Relié avec d'autres documents
- Tight binding may cause shadows or distortion along interior margin/
La reliure serrée peut causer de l'ombre ou de la distorsion le long de la marge intérieure
- Blank leaves added during restoration may appear within the text. Whenever possible, these have been omitted from filming/
Il se peut que certaines pages blanches ajoutées lors d'une restauration apparaissent dans le texte, mais, lorsque cela était possible, ces pages n'ont pas été filmées.
- Additional comments:
Commentaires supplémentaires:

Pagination as follows : [178] - 194 p.

- Coloured pages/
Pages de couleur
- Pages damaged/
Pages endommagées
- Pages restored and/or laminated/
Pages restaurées et/ou pelliculées
- Pages discoloured, stained or foxed/
Pages décolorées, tachetées ou piquées
- Pages detached/
Pages détachées
- Showthrough/
Transparence
- Quality of print varies/
Qualité inégale de l'impression
- Includes supplementary material/
Comprend du matériel supplémentaire
- Only edition available/
Seule édition disponible
- Pages wholly or partially obscured by errata slips, tissues, etc., have been refilmed to ensure the best possible image/
Les pages totalement ou partiellement obscurcies par un feuillet d'errata, une pelure, etc., ont été filmées à nouveau de façon à obtenir la meilleure image possible.

This item is filmed at the reduction ratio checked below/
Ce document est filmé au taux de réduction indiqué ci-dessous.

10X	12X	14X	16X	18X	20X	22X	24X	26X	28X	30X	32X
						/					

The copy filmed here has been reproduced thanks to the generosity of:


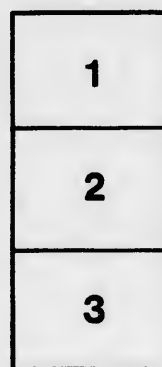

Medical Library
McGill University
Montreal

The images appearing here are the best quality possible considering the condition and legibility of the original copy and in keeping with the filming contract specifications.

Original copies in printed paper covers are filmed beginning with the front cover and ending on the last page with a printed or illustrated impression, or the back cover when appropriate. All other original copies are filmed beginning on the first page with a printed or illustrated impression, and ending on the last page with a printed or illustrated impression.

The last recorded frame on each microfiche sheet contains the symbol \rightarrow (meaning "CONTINUED"), or the symbol ∇ (meaning "END"), whichever applies.

Maps, plates, charts, etc., may be filmed at different reduction ratios. Those too large to be entirely included in one exposure are filmed beginning in the upper left hand corner, left to right and top to bottom, as many frames as required. The following diagrams illustrate the method:



L'exemplaire filmé fut reproduit grâce à la générosité de:

Medical Library
McGill University
Montreal

Les images suivantes ont été reproduites avec le plus grand soin, compte tenu de la condition et de la netteté de l'exemplaire filmé, et en conformité avec les conditions du contrat de filmage.

Les exemplaires originaux dont la couverture en papier est imprimée sont filmés en commençant par le premier plat et en terminent soit par la dernière page qui comporte une empreinte d'impression ou d'illustration, soit par le second plat, selon le cas. Tous les autres exemplaires originaux sont filmés en commençant par la première page qui comporte une empreinte d'impression ou d'illustration et en terminent par la dernière page qui comporte une telle empreinte.

Un des symboles suivants apparaîtra sur la dernière image de chaque microfiche, selon le cas: le symbole \rightarrow signifie "A SUIVRE", le symbole ∇ signifie "FIN".

Les cartes, planches, tableaux, etc., peuvent être filmés à des taux de réduction différents. Lorsque le document est trop grand pour être reproduit en un seul cliché, il est filmé à partir de l'angle supérieur gauche, de gauche à droite, et de haut en bas, en prenant le nombre d'images nécessaire. Les diagrammes suivants illustrent la méthode.

Th

A

Profe

[R]

77

With the Compliments of
DR. CASEY A. WOOD,
109 E. Adams St.,
CHICAGO.

The Relations of Optic Nerve Atrophy to General Medicine.

A CLINICAL LECTURE DELIVERED BEFORE THE CLASS OF THE POST-
GRADUATE MEDICAL SCHOOL, MARCH 24, 1897.

By CASEY A. WOOD, M.D.,

Professor of Ophthalmology in the Chicago Post-Graduate Medical School; Fellow
of the Chicago Academy of Medicine. Illustrated with stereopticon views.

[REPRINTED FROM INTERNATIONAL CLINICS, VOL. II., SEVENTH SERIES.]

(1897)



The Relations of Optic Nerve Atrophy to General Medicine.

A CLINICAL LECTURE DELIVERED BEFORE THE CLASS OF THE POST-
GRADUATE MEDICAL SCHOOL, MARCH 24, 1897.

By CASEY A. WOOD, M.D.,

Professor of Ophthalmology in the Chicago Post-Graduate Medical School; Fellow
of the Chicago Academy of Medicine. Illustrated with stereopticon views.

[REPRINTED FROM INTERNATIONAL CLINICS, VOL. II., SEVENTH SERIES.]

THE RELATIONS OF OPTIC NERVE ATROPHY TO GENERAL MEDICINE.

A CLINICAL LECTURE DELIVERED BEFORE THE CLASS OF THE POST-GRADUATE
MEDICAL SCHOOL, MARCH 24, 1897.

BY CASEY A. WOOD, M.D.,

Professor of Ophthalmology in the Chicago Post-Graduate Medical School; Fellow
of the Chicago Academy of Medicine. Illustrated with stereopticon views.

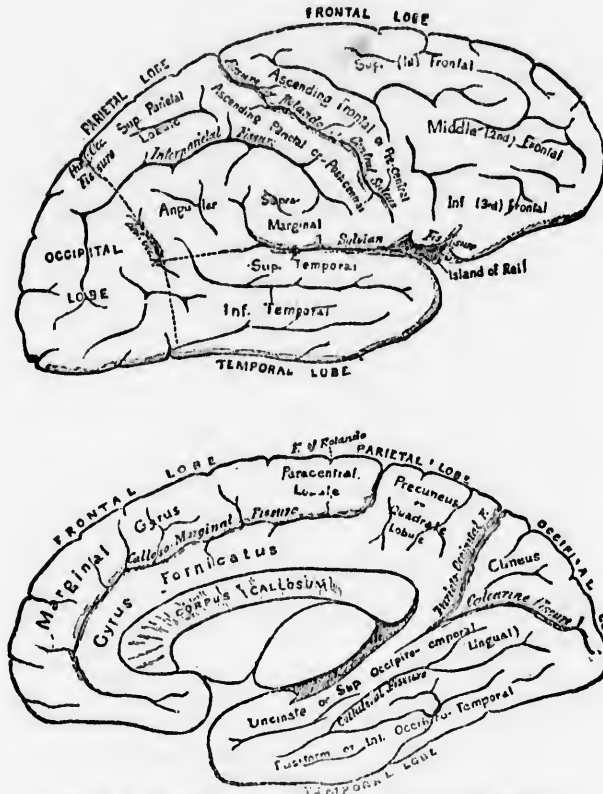
LADIES AND GENTLEMEN,—It will, of course, be impossible for me to present this matter to you fully in the course of an evening lecture, as the ground to be covered is entirely too large, but I would like, first of all, to draw your attention to the anatomy of the parts involved in the diseased processes I have to discuss.

I believe that some of the differences of opinion presented by our modern anatomists and physiologists arise from minute variations in the tissue-distributions of individuals. Many gross anomalies of structure we are familiar with. Thus, we know there is sometimes an absence of the optic commissure, and that sections of the optic nerve itself are congenitally defective, as seen in certain eyes examined both *ante* and *post mortem*. We may postulate an absence of certain (as yet undefined) fibres in congenital color-blindness, and may even feel certain that in those individuals whose visual memories are defective there exists a corresponding deficiency of connecting links between the visual and intellectual centres. But, apart from these considerations, the distribution of the fibres and tissues that compose the central organs that take part in the visual act is not necessarily invariable. These are probably disposed in different fashion within the crania of individuals. Bearing these facts in mind, let us very briefly trace the optic nerve from the visual cortical centre to its distribution within the eyeball.

As commonly taught, the cortical centre is situated about the calcarine fissure in the posterior part of the occipital lobe. This locality was proved to be its true situation in at least one case reported by Hen-

schen. A man having a well-marked left homonymous hemianopsia was found, post mortem, with a cortical softening extending seven millimetres from the posterior end of and along both sides of the right

Figs. 1 and 2.



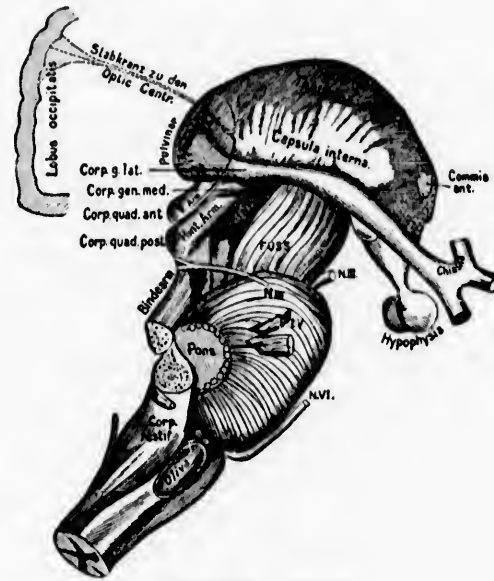
The calcarine fissure in the occipital lobe and its related areas.

calcarine fissure, a few millimetres on the ensens, downward on the lingual lobe, and forward into the hippocampal lobe. Previous experiences enabled Henschen to exclude the latter as belonging to the visual area. It is now pretty well established that the upper lip of the fissure presides over the upper quadrants of the retina, while the lower lip dominates the lower quadrants, but the area governing the macular region is not yet satisfactorily determined.

From this point the optic radiations dip under the angular gyrus around the posterior horn of the lateral ventricle and are supplied to the internal capsule, thalamus opticus, pulvinar, and external geniculate

body. They then curve around the crura cerebri and become the optic tracts and chiasma.

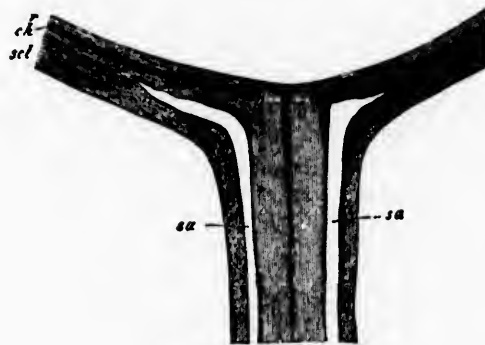
FIG. 3.



Optic nerve connections.

As they enter the eyeball it is noticeable that their outer (dural) covering is obtained from the dura mater and is practically continuous

FIG. 4.

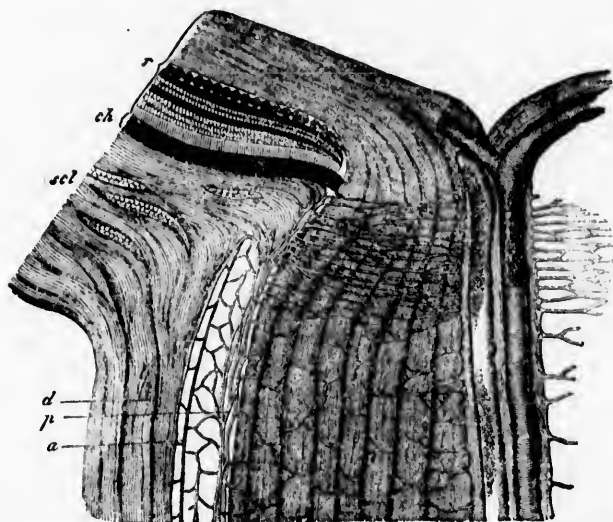


Optic nerve; horizontal section.

with the sclera and orbital periosteum. They also have an internal sheath, derived from the pia mater, which sends numerous septa or trabeculae (800, according to Krause) into the nerve-substance. This

pial covering also surrounds the nerve within the skull. Between these is an important lymph-space lined with endothelium and continuous with the arachnoid cavity. Indeed, the latter space can be infected through this canal from its bulbar ending. The swollen condition of the tissues of and about the nerve-head, commonly known as "choked disk," is the result of distention of this important canal, and many other pathological processes occur within it. It is well to remember that sixty-five per cent. of cases of choked disk are associated with tumors involving the base of the brain, and that of the other thirty-five per cent. cerebral abscess, meningitis, acute otitis media, and typhoid fever follow as causes in the order given. It is probable that this swollen condition of the papilla is not always due to mere distention of the lymph-space, but that the septic character of the effusion (de Wecker) has much to do with it.

FIG. 5.



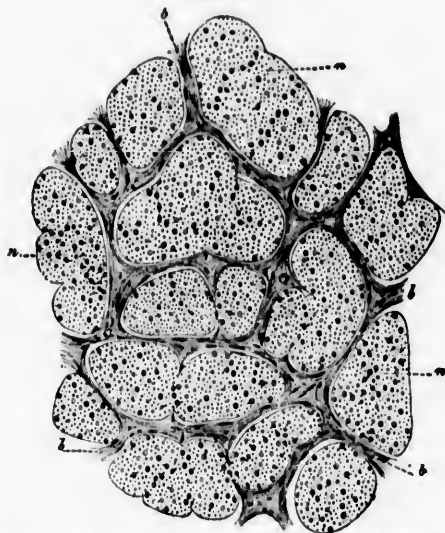
Enlarged view of a horizontal section of the optic nerve entrance into the eyeball.

The central artery and vein enter the nerve-substance about eight millimetres behind the eyeball. The trabeculae or connective-tissue framework of the optic nerve is of considerable importance because it is that structure which, as in diseases like cirrhosis of the liver, kid-

† Most of the cuts used in this lecture are taken from the Græfe-Saemisch Handbuch der ges. Augenheilkunde and the de Wecker-Landolt Traité Complet d'Ophthalmologie.

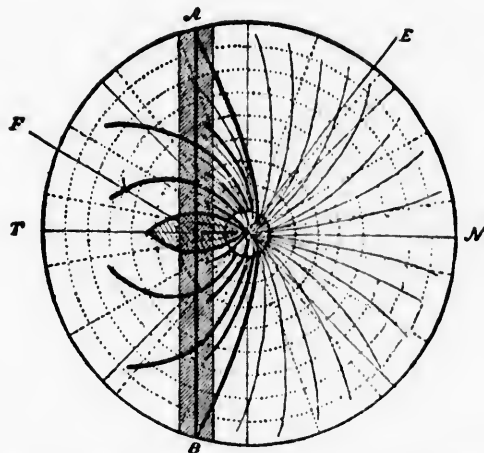
neys, and lungs, is chiefly involved in the amblyopia of tobacco-alcohol retrobulbar neuritis and many other pathological alterations.

FIG. 6.



Vertical section of the optic nerve, showing the nerve-bundles and their relation to the connective-tissue framework.

FIG. 7.



Showing the distribution of the optic fibres in the right retina; *F*, fovea centralis. (Kries.)

It has been carefully estimated that there are five millions of nerve-fibres in the optic, and that at least one-fourth of them is supplied to the macula.

To obtain a proper conception of the ramifications of the optic connections it must be remembered that the commissures of Gudden and Meynert connect the cortical centres directly, that optic fibres are supplied to the cerebellum and pons, and even follow one of the routes of the trigeminus to the posterior columns of the cord and send branches to the nuclei of the third nerve in the aqueduct of Sylvius. This last fact explains how we obtain the classic symptom-complex known as the Argyll-Robertson pupil, and how we often have paralysis of the extrinsic ocular muscles and optic nerve atrophy as common signs of the so-called locomotor ataxia.

These preliminary remarks enable me to introduce the table of Uhthoff, giving the most frequent causes of atrophy of the optic nerve:

	Men.	Women.
Spinal cord	59	55
Brain	41	23
Simple progressive	22	16
After neuritis optica	17	13
Sudden embolism of arteries	8	3
Disease and accident in orbit	8	3
Dementia paralytica	7	6
Loss of blood	4	0
Alcohol and tobacco	4	4
Lead-poisoning	2	2
Hereditary	3	2
Injury	3	2
Epilepsy	2	2
Nephritis	1	0
Railway spine	1	1
Congenital with hydrophthalmia	1	0
	183	132—72 per ct.
		51—28 per ct.

Remembering the spinal cord connections, we can easily understand how lesions of that organ may affect, first of all, the optic radiations that connect it with the cerebral bodies, and thence, by a descending process, how the degeneration may reach the opticus itself. I have also spoken of tabes dorsalis as a cause of optic nerve atrophy. Other forms of sclerosis may act in the same way.

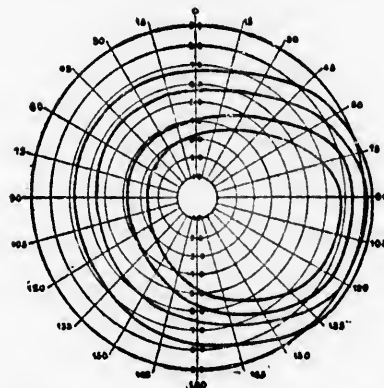
The brain-changes associated with atrophy are chiefly syphilitic. In one hundred examples of these Uhthoff found that fifty per cent. presented eye-signs. Of these there were hemianopsia in 17, concentric narrowing of the field of vision in 5, sector-like field in 4, central defect but good periphery in 4, enlargement of the blind-spot in 7. Autopsies discovered syphilitic basilar meningitis in 15, intracranial gumma in 67, *arachnitis gummosa* in 1, other specific lesions in 10.

Apart from these specific changes, well-established cases of optic nerve atrophy are facial erysipelas, fevers, hemorrhages of all kinds, persistent anaemia, the various forms of Bright's disease, diabetes, embolism and thrombosis of the arterial supply, hysteria, typhoid, measles and scarlatina, toxic agents, menstrual disturbances, arterio-sclerosis, and *la grippe*.

Quite a large percentage of atrophic changes must be placed in the "unknown" column. The optic nerve is the victim of many and varied morbid influences whose exact character is as yet ill defined. Many a person, apparently healthy, has become blind as a result of a progressive disease of the optic nerve when it has been impossible, even with the aid of a post-mortem examination, to discover any reason why the atrophy should have set in.

The microscopical changes in the nerve itself vary somewhat in the different forms of atrophy. The fibres supplied to the periphery of the retina are those that usually suffer first, and the evidence of this early change is best supplied by the perimeter.

FIG. 8.



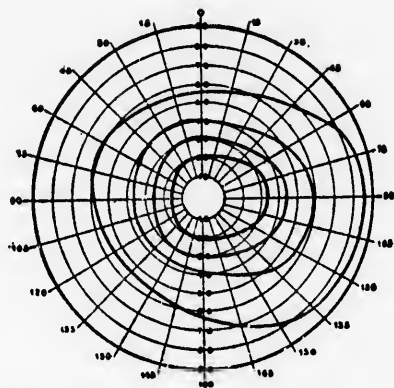
The limits (from without inward) of the normal fields of vision—white, blue, red, and green—of a right eye.

This is an instrument that should be more generally used than it is, especially by the general practitioner, for whom, to my mind, it is particularly adapted. I would strongly advise those of you who desire to have a valuable aid in the diagnosis of optic nerve atrophy—particularly if you are not expert in the use of the ophthalmoscope—to invest in a good perimeter, so that you may map out the field of vision, for white as well as for colors, in all cases where you suspect lesions, central or peripheral, of the optic nerve.

I shall have occasion to project pictures of a number of defective

fields upon the screen, and you will readily understand the diagnostic value they possess. A supreme advantage that the perimeter exhibits for the busy practitioner is that it requires no particular skill in its employment. It is a purely mechanical device, and almost any one, after a few lessons, may learn how to use it. Indeed, it is mainly for the purpose of insisting upon the great value of the perimeter and of an examination of the visual fields as an aid to diagnosis in general practice that this lecture has been prepared.

FIG. 9.



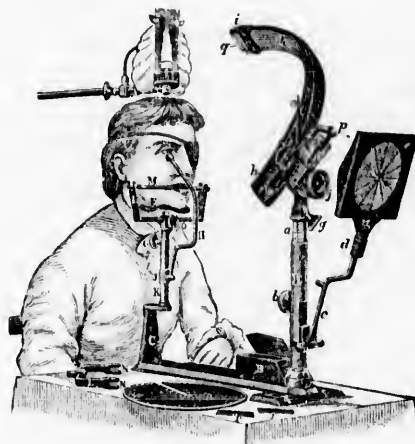
The perimeter chart of a visual field for the same colors, showing the contractions often seen in atrophy of the optic nerve.

There are numerous good perimeters, obtainable from any optician. I happen to prefer McHardy's, and now show his instrument, as well as a chart of the normal field of vision, for small white and colored objects.

The histology of optic nerve atrophy may be summed up by saying that the true nervous tissue is either absolutely destroyed (by being converted into fatty granules or myeloid corpuscles), while the trabeculae either undergo atrophic changes, or, as in the cirrhotic forms referred to, only a few axis-cylinders actually disappear, but the function of many of them is seriously interfered with in consequence of pressure exerted upon them by this interstitial framework when hypertrophied by disease. In true atrophy all the nervous tissues are reduced in size and number, the calibre of the opticus actually decreases in size, and the blood-vessels disappear. In the interstitial or cirrhotic form the nerve-fibres are squeezed together by the thickened trabeculae, but the increase in the number or size of the trabecular nuclei, fibres, and blood-vessels neutralizes this partial atrophy of the conducting

media so that the opticus in chronic interstitial neuritis (seen in tobacco intoxication, for example) presents about the same external appearance as the normal nerve. In true atrophy the intra-vaginal lymph-space,

FIG. 10.



Method of mapping out the field of vision.

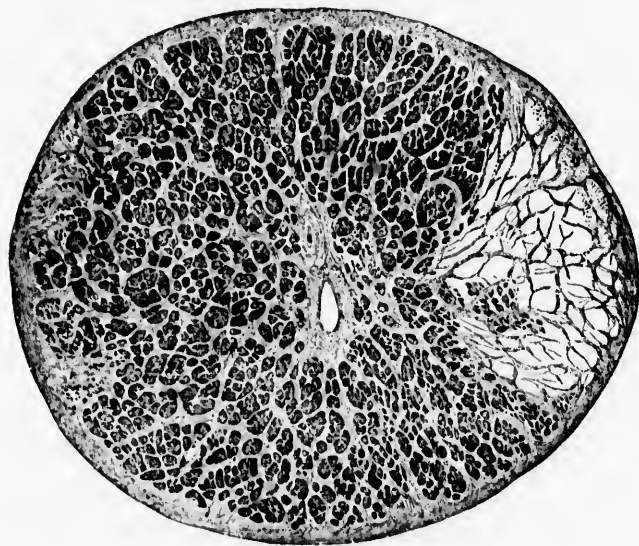
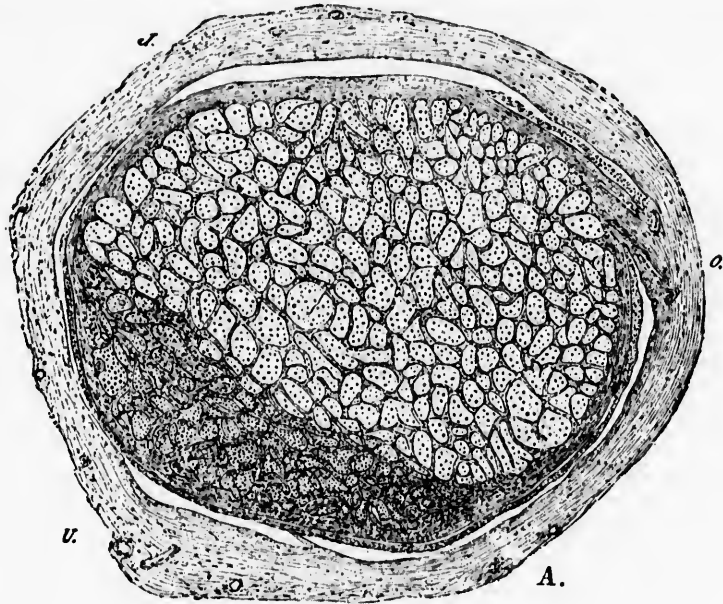
just shown, often enlarges through shrinkage of the mass of the nerve and can be very readily traced into the arachnoid spaces.

Sometimes only a portion of the nerve is affected, while the remainder continues to be sound and well nourished for years. This is a common experience, and is reflected in the perimeter charts. Again, one may have scattered nerve-bundles that have suffered (as in tobacco and alcohol amblyopia) partial or total atrophy, and these, too, will be detected by a careful examination of the visual field.

The *ophthalmoscope* is, perhaps, the most efficient agent we possess for the detection of those changes in the optic nerve that show themselves in the nerve-head and retina, but it not infrequently happens that the papilla, retinal vessels, and the retina itself appear with the mirror to be absolutely normal. Sooner or later, however, the organic lesions in the opticus fibres, as well as occasionally those changes beginning in the visual centres, show themselves within the eyeball. The nerve-head becomes paler, the vascular supply diminishes, and the vessels decrease in size. The papilla loses its semi-transparent, rosy appearance, becomes blurred in outline, and presents, from time to time, every shade of color from dirty red to bluish white. The lamina cribrosa may be seen more plainly than in the normal condition of the

nerve, chiefly because the superimposed nerve-elements have wasted away.

Figs. 11 and 12.



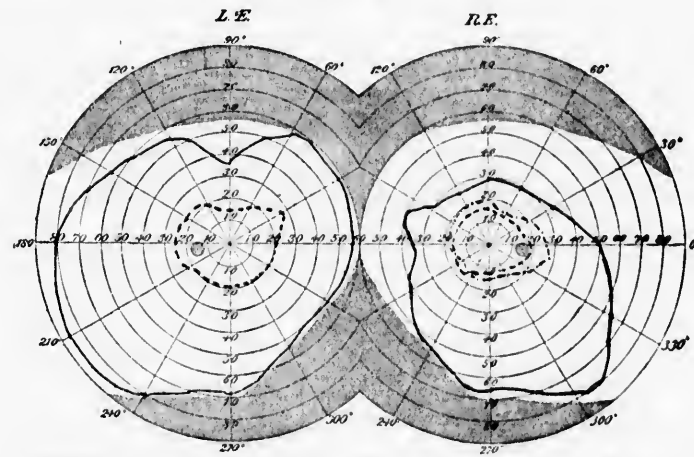
Cross sections of partly atrophied nerves.

The purely subjective symptoms of optic atrophy are of little value in the diagnosis of this disease, although misty and imperfect central vision (not improved by glasses), night-blindness, and inability to see at the side or in any part of the field should make one suspect this disease. The patient affected by most forms of optic atrophy will not be able to read Bjerrum's test-types (gray or gray-brown letters on paper of the same hue but lighter tint) as well as he does the ordinary black letters on white paper. He may have a fairly good field for white, but the color areas will be decidedly diminished.

I do not know of any more effective method of impressing upon your minds this brief sketch of optic atrophy in its relation to general diseases than to read you a few illustrative histories.

CASE I.—Miss W., aged fifty years. Her health had always been good until an attack of *la grippe* two years ago. She first noticed a short time ago that she could not read distinctly. Attempts to do any kind of near work bring on fronto-vertical headaches, accompanied by attacks of dizziness. She feels "shaky" all the time. No eye-treatment has ever helped her. There are no fundus changes. V. R. = $\frac{20}{40}$ + and Jaeger VI.; V. L. = $\frac{20}{40}$ and words of Jaeger II. This is her visual field.

FIG. 13.

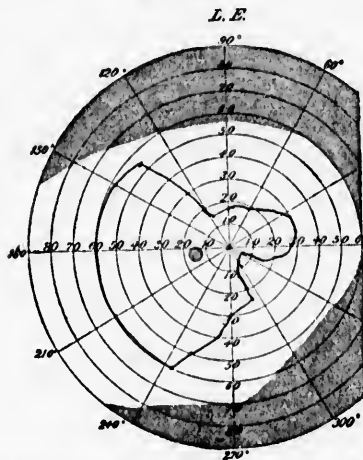


Optic nerve atrophy following *la grippe*. White —, red - - - - , green

CASE II.—J. K., aged forty-six years, had specific disease in 1880-81. No sign of tabes or other spinal or cerebral affection. In 1882 he noticed spots before his right eye. The sight then began to be impaired, getting worse during the next two or three years. Four years afterwards there were total failure of near vision, occasional ocular

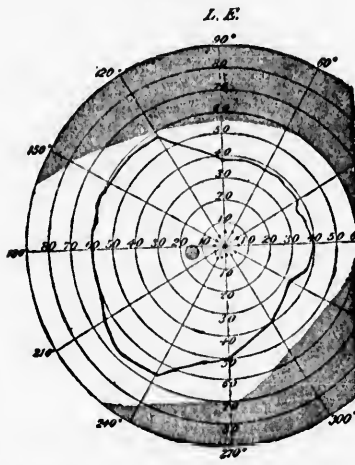
pains, "foggy" sight, color-blindness, and night-blindness. Vision in the left eye is now reduced to $\frac{1}{40}$ and Jaeger XVI. V. R. finger-counting at 10 feet, eccentrically. The field has become much improved under large doses of potassic iodide and strychnine given hypodermically. (Figs. 14, 15, and 16.)

FIG. 14.



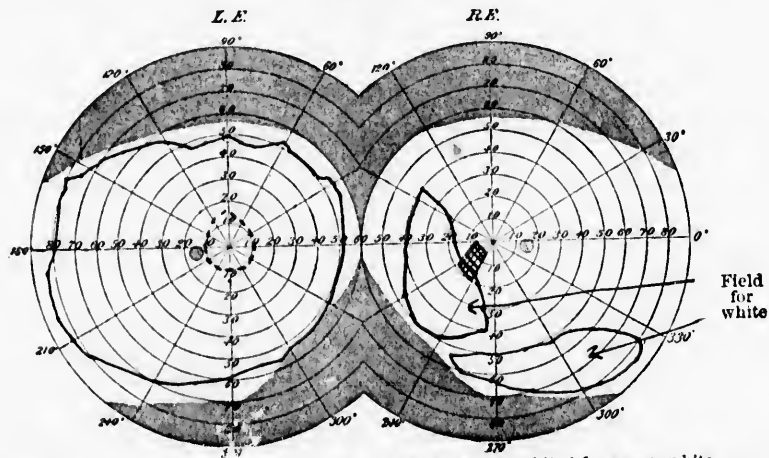
Field for white, colors doubtful. V. = fingers at three feet, no Jaeger. September 23.

FIG. 15.



Field for white —, red, color-blind for green. October 15.

FIG. 16.

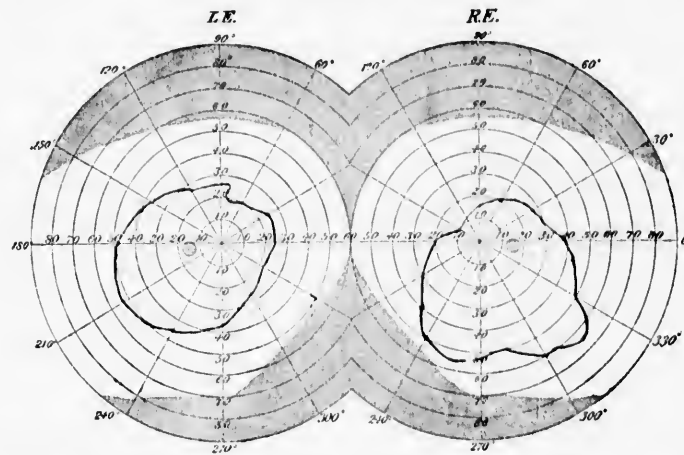


Atrophia nervi optici a luctu. V. L. = $\frac{1}{16}$, Jaeger XVI.; color-blind for green, white —, red, V. R. = fingers eccentrically; color-perception lost, no field for green or red. December 1.

CASE III.—J. C. L., fifty years of age, referred to me by Dr. Richard Dewey, who had made the diagnosis of senile dementia.

There is a history of gradual failure of vision for several years past. The patient's vision is $\frac{2}{3}$ in each eye and words of Jaeger II. can be

FIG. 17.

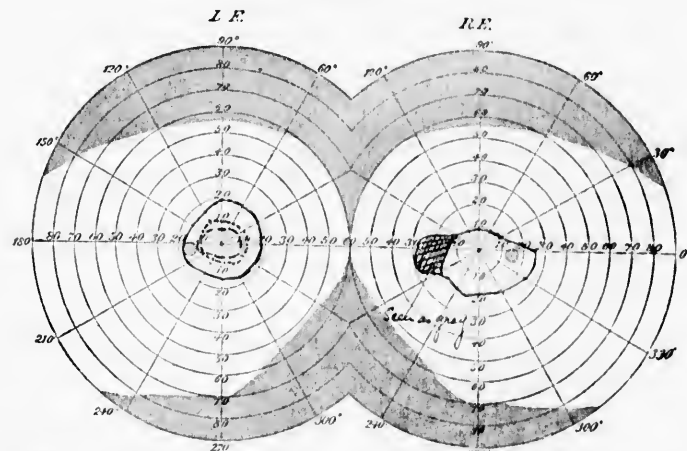


Optic nerve atrophy in a case of senile dementia. $V. = \frac{1}{3}$, both eyes. Doubtful perception of green and red.

distinguished by the aid of glasses. The stereopticon will tell the story of the visual and color fields.

CASE IV.—Girl, aged ten years. Three years ago had a severe

FIG. 18.



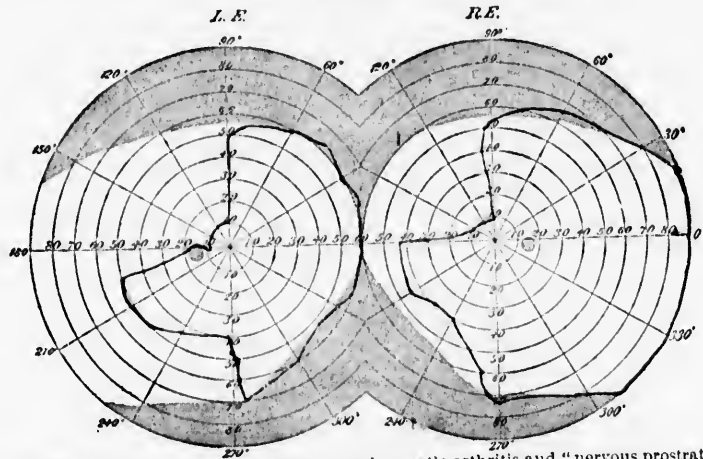
Optic nerve atrophy following severe attack of scarlatina. $V. = \frac{2}{3}$, both eyes. White —, green - - - - - , red

attack of scarlatina. There was no middle ear or renal complication, but some time afterwards she complained of headache on using her

eyes. She returned to school, but was obliged to desist from study on account of blurring of the letters and confusion of the print. She also began to hold her book close to her eyes. No other cause than the scarlet fever can be assigned for the optic nerve disease, whose principal sign is the defective field of vision.

CASE V.—A. M., aged twenty-nine years. Vision perfectly good until eight months before I saw him. Following a severe attack of rheumatic fever, complicated with much headache and "nervous prostration" (meningitis?), the patient noticed that he *could not see anything on the left side with the left eye*. There is no luetic history or symptom of tabes. The pupil contracts to strong light all over the field. Central vision is normal, and there are no fundus changes.

FIG. 19.

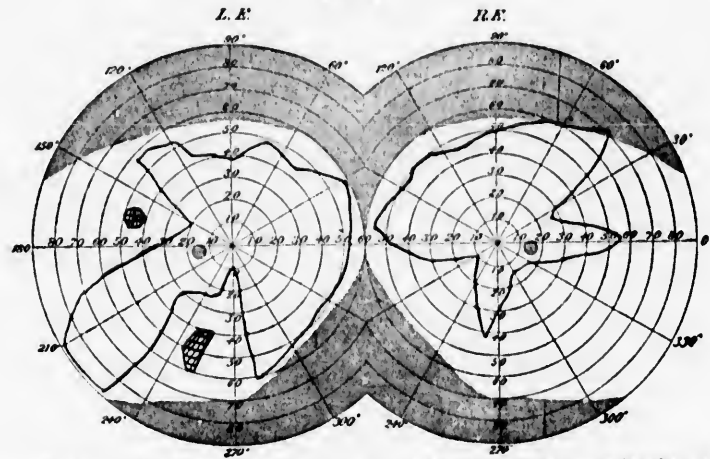


Optic nerve atrophy (hemianopsia) after acute rheumatic arthritis and "nervous prostration."
V. = $\frac{1}{2}$, both eyes. Less on right hemisphere.

CASE VI.—Man, forty-six years of age. Had syphilis at twenty-five. There are no marked ocular symptoms. Central vision is good, but his color-field, as well as his color-sense, is defective. He has all the signs of locomotor ataxia in its early stage. Miosis, Argyll-Robertson pupil, no patellar-tendon reflex, girdle and lightning leg-pains, gastric crises, doubtful Romberg symptom (although he experiences some trouble in walking in the dark), irritable temper, etc. There are no special fundus changes. About the time that he had his rectum stretched by an "official" surgeon, there occurred one of those pauses in the disease-process so characteristic of tabes and so encouraging to those ignorant pathologists who, from time to time, discover cures of this disease. I show a picture of his visual field. (Fig. 20.)

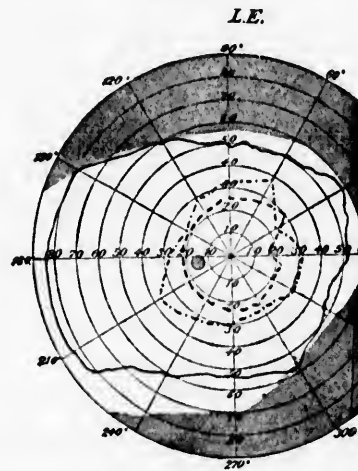
CASE VII.—D. S., aged forty-six. Doubtful history of lues in early manhood. No ocular symptoms except misty vision, not cleared up by any glass. He can, however, read words of Jaeger I. His

FIG. 20.



Optic nerve atrophy in a case of tabes. V. = $\frac{3}{8}$, both eyes. Field for white, isolated spots seen as gray.

FIG. 21.

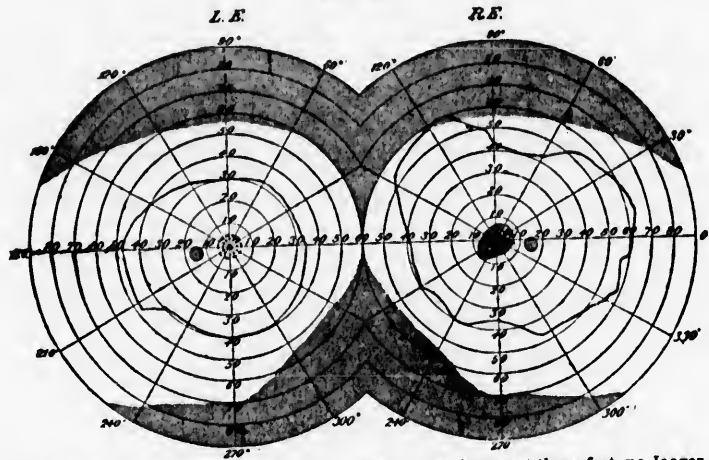


Beginning atrophy of optic nerve in tabes dorsalis. V = $\frac{3}{8}$. White —, green, red

eyes are easily fatigued, and he suffers from frontal headaches. Well-marked symptoms of posterior myelitis. The left disk is decidedly paler than the right. V. L. = $\frac{3}{8}$. Patient smokes to excess. This is his left field. (Fig. 21.)

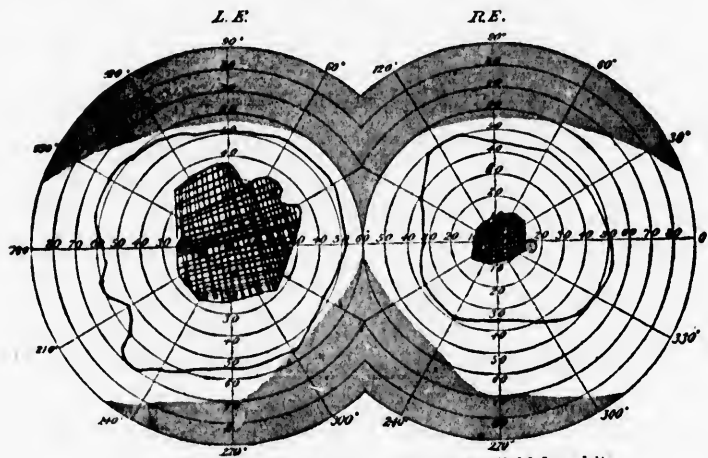
CASE VIII.—F. H., aged eighteen years. Always has had fair health, except a chronic otitis media of several years' standing. He was not suffering from this disease at the time he was attacked by blindness in his right eye, which set in suddenly in the beginning of June. Some days before, he had ridden an unusually long distance

FIG. 22.



Neuritis optica, early stage, both eyes. V. L. — 13; V. R. = fingers at three feet, no Jaeger, color scotoma at centre and white seen as gray or green. White —, red - - - -, green July 29.

FIG. 23.



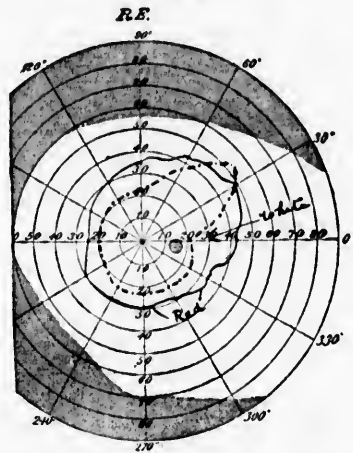
Optic nerve atrophy following optic neuritis. Field for white.

on his bicycle, which had then broken down. He was consequently obliged to tramp for many miles with the disabled machine and reached his destination entirely exhausted. This experience was re-

peated the next day, on his home-journey, from which he did not recover for over a week. I saw him four weeks afterwards; there was a well-developed neuritis optica in both eyes. Peripheral vision was affected on the left side, both central and peripheral in the right eye. Now both papillæ are pale, woolly, and present indistinct outlines, and all signs of the acute process have disappeared. The fields of vision present these pictures. (Figs. 22 and 23.)

CASE IX.—A. R., young lady, aged seventeen years, had delicate health, but did not complain of her eyes until a month before I saw her. She then noticed that she could not see well in the distance or read ordinary print with her right eye. There are no fundus

FIG. 24.



Field for red larger than that for white: white - - - - -, red ——. V. = 28, Jaeger VI.

changes. Patient is distinctly hysterical: has attacks of weeping without apparent cause, pharyngeal anæsthesia, lump in her throat, etc. Has spasm of accommodation in the right eye, but no monocular polyopia. I wish you would especially notice that *her field for red is larger than that for white*, one of the most pronounced of the ocular stigmata of hysteria.

97

INTERNATIONAL CLINICS.

Seventh Series. A Quarterly Collection of Clinical Lectures on Medicine, Neurology, Pediatrics, Surgery, Genito-Urinary Surgery and Venereal Diseases, Gynecology and Obstetrics, Ophthalmology, Laryngology, Pharyngology, Rhinology and Otology, and Dermatology. By Professors and Lecturers in the Leading Medical Colleges of the United States, Great Britain, and Canada.

EDITED BY

JUDSON DALAND, M.D.,
Philadelphia, Pa.

J. MITCHELL BRUCE, M.D., F.R.C.P.,
London, England.

DAVID W. FINLAY, M.D., F.R.C.P.,
Aberdeen, Scotland.

Illustrated. Price per volume: Cloth, \$2.75; Half Leather, \$3.00. Each volume contains about 350 pages, octavo, is printed from large, clear type on good paper, and is neatly bound in Cloth and Half Leather. A copious index is contained in each volume; and Volume IV. of each series contains in addition a general index of the four volumes for the year. *Seventh Series* commences April, 1897.

BY SUBSCRIPTION ONLY.

"This work, as the title sets forth, is a collection of the best and most practical clinical lectures delivered in the leading medical colleges of the United States, Great Britain, and Canada. These lectures, after having been reported by competent medical stenographers, are arranged by the editors in a form best suited for the purposes of this work, and afterwards they are returned to the professors and lecturers for their *personal revision*. The reader is thus given the final thoughts and most advanced practical ideas of our ablest professional teachers. These handsome and well-printed volumes, which are issued with great regularity every quarter, contain a vast amount of instructive and readable matter. The range of subjects is as wide as that of medicine itself, and the lectures upon them are gathered from the clinical schools on both sides of the Atlantic. The publication of such a repertory of bedside experience cannot fail to exercise a marked influence on thought and practice, whilst the fact that a venture of this magnitude should have attained its seventh year of existence demonstrates that its volumes have obtained a recognized and sure place in periodical medical literature. Each volume contains some fifty or sixty lectures, and commentaries upon cases of disease; a certain number of the forms are elaborated into general disquisitions, but the majority are purely clinical—that is, they are based upon cases under observation at the time of the delivery of the lecture. In our opinion, this is the only right form into which a clinical lecture should be cast. It does not and ought not to aim at being an exhaustive survey of the topic with which it deals, such a review should be reserved for the monograph or thesis; but it should bring out in clear detail the clinical facts attaching to the patient and deduct therefrom the lessons they convey."—*London Lancet*.



