IMAGE EVALUATION
TEST TARGET (MT-3)

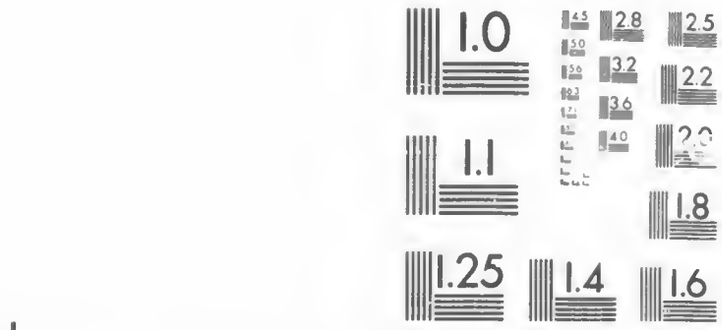

Photographic Sciences Corporation

23 WEST MAIN STREET
WEBSTER, N.Y. 14580
(716) 872-4503

CIHM/ICMH
Microfiche
Series.

CIHM/ICMH
Collection de
microfiches.

Canadian Institute for Historical Microreproductions / Institut canadien de microreproductions historiques

© 1987

Technical and Bibliographic Notes/Notes techniques et bibliographiques

The Institute has attempted to obtain the best original copy available for filming. Features of this copy which may be bibliographically unique, which may alter any of the images in the reproduction, or which may significantly change the usual method of filming, are checked below.

L'Institut a microfilmé le meilleur exemplaire qu'il lui a été possible de se procurer. Les détails de cet exemplaire qui sont peut-être uniques du point de vue bibliographique, qui peuvent modifier une image reproduite, ou qui peuvent exiger une modification dans la méthode normale de filmage sont indiqués ci-dessous.

- [x] Coloured covers/ Couverture de couleur
- [ ] Covers damaged/ Couverture endommagée
- [ ] Covers restored and/or laminated/ Couverture restaurée et/ou pelliculée
- [ ] Cover title missing/ Le titre de couverture manque
- [ ] Coloured maps/ Cartes géographiques en couleur
- [ ] Coloured ink (i.e. other than blue or black)/ Encre de couleur (i.e. autre que bleue ou noire)
- [ ] Coloured plates and/or illustrations/ Planches et/ou illustrations en couleur
- [ ] Bound with other material/ Relié avec d'autres documents
- [ ] Tight binding may cause shadows or distortion along interior margin/ La reliure serrée peut causer de l'ombre ou de la distorsion le long de la marge intérieure
- [ ] Blank leaves added during restoration may appear within the text. Whenever possible, these have been omitted from filming/ Il se peut que certaines pages blanches ajoutées lors d'une restauration apparaissent dans le texte, mais, lorsque cela était possible, ces pages n'ont pas été filmées.
- [x] Additional comments:/ Commentaires supplémentaires·

- [ ] Coloured pages/ Pages de couleur
- [ ] Pages damaged/ Pages endommagées
- [ ] Pages restored and/or laminated/ Pages restaurées et/ou pelliculées
- [x] Pages discoloured, stained or foxed/ Pages décolorées, tachetées ou piquées
- [ ] Pages detached/ Pages détachées
- [x] Showthrough/ Transparence
- [ ] Quality of print varies/ Qualité inégale de l'impression
- [ ] Includes supplementary material/ Comprend du matériel supplémentaire
- [ ] Only edition available/ Seule édition disponible
- [ ] Pages wholly or partially obscured by errata slips, tissues, etc., have been refilmed to ensure the best possible image/ Les pages totalement ou partiellement obscurcies par un feuillet d'errata, une pelure, etc., ont été filmées à nouveau de facon à obtenir la meilleure image possible.

PAGINATION AS FOLLOWS:

[439]-466pp., ILLUS.

This item is filmed at the reduction ratio checked below/
Ce document est filmé au taux de réduction indiqué ci-dessous.

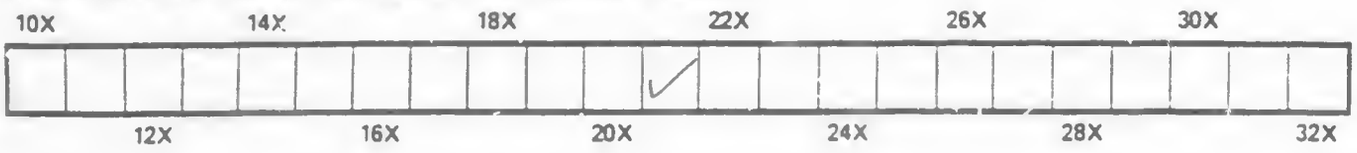

The copy filmed here has been reproduced thanks to the generosity of:

Archives of Ontario
Toronto

The images appearing here are the best quality possible considering the condition and legibility of the original copy and in keeping with the filming contract specifications.

Original copies in printed paper covers are filmed beginning with the front cover and ending on the last page with a printed or illustrated impression, or the back cover when appropriate. All other original copies are filmed beginning on the first page with a printed or illustrated impression, and ending on the last page with a printed or illustrated impression.

The last recorded frame on each microfiche shall contain the symbol ⟶ (meaning "CONTINUED"), or the symbol ∇ (meaning "END"), whichever applies.

Maps, plates, charts, etc., may be filmed at different reduction ratios. Those too large to be entirely included in one exposure are filmed beginning in the upper left hand corner, left to right and top to bottom, as many frames as required. The following diagrams illustrate the method:



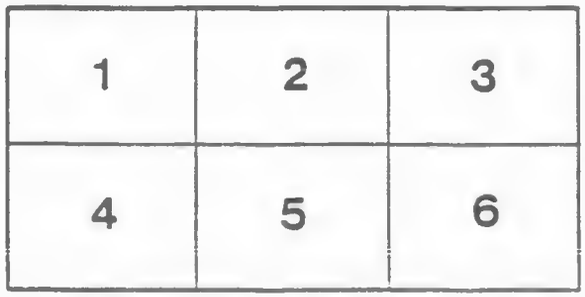

L'exemplaire filmé fut reproduit grâce à la générosité de:

Archives of Ontario
Toronto

Les images suivantes ont été reproduites avec le plus grand soin, compte tenu de la condition et de la netteté de l'exemplaire filmé, et en conformité avec les conditions du contrat de filmage.

Les exemplaires originaux dont la couverture en papier est imprimée sont filmés en commençant par le premier plat et en terminant soit par la dernière page qui comporte une empreinte d'impression ou d'illustration, soit par le second plat, selon le cas. Tous les autres exemplaires originaux sont filmés en commençant par la première page qui comporte une empreinte d'impression ou d'illustration et en terminant par la dernière page qui comporte une telle empreinte.

Un des symboles suivants apparaîtra sur la dernière image de chaque microfiche, selon le cas: le symbole ⟶ signifie "A SUIVRE", le symbole ∇ signifie "FIN".

Les cartes, planches, tableaux, etc., peuvent être filmés à des taux de réduction différents. Lorsque le document est trop grand pour être reproduit en un seul cliché, il est filmé à partir de l'angle supérieur gauche, de gauche à droite, et de haut en bas, en prenant le nombre d'images nécessaire. Les diagrammes suivants illustrent la méthode.

1887 ? -3

38

REPRINTED FROM

THE QUARTERLY JOURNAL OF MICROSCOPICAL SCIENCE.

The Termination of Nerves in the Liver.

By

A. B. Macallum, B.A.,
Fellow of University College, Toronto, Canada.

With Plate XXXIII, figs. 1 to 6.

After the completion of my studies on the termination of nerves in the cutaneous epithelium of the tadpole, I began investigations on the distribution and arrangement of nerves in other organs, and have now arrived at what I consider important results, more especially in the case of liver. That of man was first employed at the outset of the investigation, but I soon perceived that on account of the small size of the cells here I would have to resort to some other Vertebrate for control purposes; not that the liver of man does not yield definite results, but that these might always be open to doubt if taken alone. Fortunately at that time there were a number of Necturi in the Laboratory Aquarium, and to these I resorted, on the advice of Professor Wright, obtaining from them my most valuable preparations of the liver. The hepatic cells in these are from two to four times in diameter those in man. It is obvious, therefore, that for ascertaining the relations of nerves to the hepatic cells the liver of Necturus (=Menobranchus) is the most favorable that can be at the disposal of any histologist.

I made preparations also from the livers of the dog, rabbit, and frog, which turned out to be of but indifferent value, and recognising that the narrower the field of investigation is the more could attention be bestowed on the necessary details of technical manipulation and of observation, I devoted nearly the whole of my time to winning successful results from the livers

of man and Necturus. There is besides another justification for narrowing the range of the work as I have done, namely, that one of the highest and one of the lowest Vertebrate types are embraced in the investigation. I do not wish to be understood as believing that the results which I here advance are typical of every Vertebrate liver. Indeed, the following pages show a not very close agreement of results from the two types, and it would be hazardous to say which presents the form of nerve termination which has the most general occurrence in other Vertebrate livers.

I may be allowed to insist on one point about which the vaguest opinions are allowed to pass currently as correct: the hepatic cell and nerve-tissue are in close connection, not merely by contact, but by actual union.

The literature on this subject, what little there is, is full of contradictions or negative statements. Pflüger, the first observer in this line, came to definite conclusions, it is true, but although experimental physiology has partially confirmed his view, taken as a whole and not in detail, yet the workers since that time who have published descriptions of their researches on the nerves of the liver have found no such connection between these and the hepatic cells as he describes, or, in fact, none at all. The reason for these contradictory results partly is that in nearly every case the researches were based on the Mammalian liver, the cellular constituents of which are too small to admit of definitely deciding so difficult a question.

I proceed now to give a résumé of the literature on the subject, coupled with a description of the methods employed in each case. A reference to these methods is necessary in order that I may briefly outline their advantages and disadvantages.

Pflüger[1] used osmic acid to determine the course of the nerves. He found them rarely single, often in bundles, each single fibre dividing frequently and anastomosing, and finally penetrating the membrane of the liver-cells in order to terminate in the latter. The fibres retain their myeline investment up to the point of penetrating the cell. The fibres in the

[1] 'Archiv für die ges. Physiologie,' ii, 1869, also 1871.

interior of the cell terminate in a series of fine fibrils with regularly placed granules or swellings along the course of each.

Hering[1] found a rich supply of nerve-fibres entering the portal canal and branching with the vessels running in Glisson's capsule. Only a few were medullated, the finest bundles containing only non-medullated fibrils. Hering was unable to trace any nerves into the hepatic lobules.

Nesterowsky[2] injected the vessels of the cat and dog with coloured glue, and left sections of the organ so treated in a $\frac{1}{4}$ per cent. solution of gold chloride for twenty to twenty-five minutes, after which he put them in a weak solution of glycerine acidified with acetic acid, till they took a violet colour, which usually happened in five to fifteen days. In some cases he added a little of a solution of ammonium sulphide in order to bring out the nerves more prominently. He found branches of the portal vein surrounded by a plexus of coarse and fine nerve-fibres. Out of the coarser plexus arise fine anastomosing fibres, forming loops; they enter the lobules and closely twine about the blood-capillaries. Nesterowsky never observed even a connection between these nerve-fibres and the hepatic cells. He could not determine whether the nerves were medullated or not, although he thought he saw in one case examples of the former.

Kupffer[3] followed Nesterowsky's methods, and came to the conclusion that the fibres considered by the latter as nerves are simply those of connective tissue. He treated sections of the liver obtained by means of a Valentine knife with weak chromic acid solution (0·05 per cent.) and then left them for several days in a 0·01 per cent. solution of gold chloride, when they attained a red or violet colour. By means of this method he demonstrated the so-called "stellate cells," and at the same time found that the tissues immediately about the central vein of the lobule acquired a violet tint, a fact which indicated, he first thought, the presence of nerve-fibres, but he afterwards

[1] 'Strieker's Handbuch,' p. 452, Leipzig, 1871.

[2] "Ueber die Nerven der Leber," 'Virchow's Archiv,' Bd. 63, p. 412, 1875.

[3] "Ueber Sternzellen der Leber," 'Arch. für Mikr. Anat.,' Bd. xii, p. 353.

considered the structures in question to belong to connective tissue, since they acted towards a solution of nickel oxide in ammonia like the latter, and as he found the same sort of fibrils directly entering the lobules from the hepatic serosa.

Kolatschewsky[1] used two methods. In one, fine sections of the liver were pencilled out and treated for ten to twenty minutes with $\frac{1}{4}$—$\frac{1}{8}$ per cent. solution of gold chloride; these, put in water acidified with acetic acid, were left there for one or two weeks exposed to the light until they became coloured rose violet. According to the other method, sections of liver hardened with $\frac{1}{10}$—$\frac{1}{15}$ per cent. solution of ammonium bichromate were pencilled out and placed in a solution of the double chloride of gold and sodium of the strength recommended by Gerlach. The reduction is accomplished as in the first method. By these methods he found deeply coloured fibres running in the interlobular spaces and entwining ultimately about the capillaries of the lobules. Some of the fibrils end in the nuclei on the capillary walls. The fibres branch, enter into the depth of the lobules, and form there plexuses of fibrils running parallel to and around the vascular channels. The smaller the capillaries the narrower are the meshes of the plexus. Kolatschewsky was not certain that these fibres are nerves, and he never saw their connection with the hepatic cells, if such occurred. His results agree in the main with those of Nesterowsky.

Holbrook[2] made sections of the fresh liver when it was frozen, which he left in a $\frac{1}{2}$ per cent. solution of gold chloride for thirty to forty minutes. The reduction of the gold was accomplished with formic acid. In some cases he hardened the tissue first of all with chromic acid, and then used the foregoing method. He found the nerves in the portal canal provided with a large number of nuclei and occurring usually in bundles of from three to five fibres, which enter the lobules and branch at acute angles along the capillary channels. The finest nerve-fibrillæ

[1] "Beiträge zur Histologie der Leber," 'Arch. für Mikr. Anat.,' Bd. xiii, p. 415.

[2] "The Termination of Nerves in the Liver," 'Proceedings American Society of Microscopists,' p. 95, 1882.

are found running around the capillaries between these and the hepatic cells. They touch, pass between, but do not enter the latter as Pflüger maintains. Holbrook asserts that the fibrils are connected with the cement substance or protoplasmic bridges between the cells, and thereby with the outer portion of the cell reticulum. He also corroborates the results of Nesterowsky's researches.

Methods.

To demonstrate nerve-structures in the liver of Necturus the method employed was as follows: Pieces of the liver were hardened for a week or more in Erlicki's fluid, or for several days in a $\frac{1}{6}$—$\frac{1}{3}$ per cent. solution of chromic acid. After the hardening was sufficiently completed in alcohol, sections of the frozen tissue were made with a Cathcart microtome. These, when the gum was carefully removed, were put in a weak solution of formic acid (5 per cent.) for an hour, transferred to a 1 per cent. solution of gold chloride for about twenty minutes, then washed in distilled water, and the gold afterwards reduced in the dark with a 10 per cent. solution of formic acid. About thirty hours sufficed for this reduction when the temperature of the room was 20° C. The sections then had a deep red colour, but sometimes the tinge was violet. The chromatine of the nuclei of the hepatic cells took a deep blue violet tint, the caryoplasma light violet, while the cytoplasma came out very distinct as a meshwork with a pink or light carmine colour. The nerve-fibres appeared deep violet, but the connective tissue of the interlobular spaces attained a light red, sometimes a deep red colour.

When chromic acid was used as a hardening reagent the addition of any organic acid at the same time, such as acetic acid more especially, seemed to me to have the effect of robbing the nerve-fibres of their selective capacity for gold, while it increased the effect of the latter on the remaining constituents of the liver.

I do not know whether chromic acid or Erlicki's fluid offers in the method described more advantages. If there is any advantage at all it is to be obtained from the former reagent,

as with it one is apt to get beautiful preparations of the liver in which the gall-capillaries, gall-ducts, blood-capillaries, the nerves, and the elements of the hepatic cells and their nuclei are demonstrated in a way that I have found equalled by no other method of manipulation. The value of chromic acid and gold chloride in this respect I shall refer to again in a subsequent paper.

Sections of the liver of Necturus are not of any value when they are of less than 0·020 m. in thickness, that being less than half the average diameter of the hepatic cell.

In the case of the human liver chromic acid was the only reagent used in hardening. The sections were made with the paraffin method, and were subsequently treated in the manner already outlined. I found that uniformly thick or uniformly thin sections did not answer well, for in these either but short pieces of nerve-fibres or fibrils could be seen, or else they were obscured by the thickness of the section. I managed to obtain sections about half an inch square, which had a thickness at one edge two to three times greater than at the opposite one, so that the thickness decreased gradually from one edge to the other. With these sections I was able to see and follow a fibre in its full extent, together with its divisions or branchlets, and thereby gained all the advantages of a thick and a thin section, with the faults of neither so far as tracing the nerves is concerned.

The success of the preparations of the human liver was the exception and not the rule. About 10 per cent. or at most 20 per cent. of them only were valuable for all the purposes for which I made them. Sections from the same piece of liver, when treated under exactly like conditions but in different dishes, proved to be not equally successful, some being indifferent or worthless. Why this is I do not know. In the case of a very strong colouring with the gold so much as to obscure the structure, I used a ½ per cent. solution of potassic cyanide as recommended by Cybulsky.[1] By putting the over-stained section in this solution the proper depth of colour is obtained

[1] 'Zeit. für wiss. Zool.,' Bd. 39, S. 657.

by the solution of the excess of the fixed gold, this process of course being carefully watched. In this reagent one finds an additional advantage; the nerve-fibres are the last to part with the violet colour, thus being distinguished from connective-tissue fibres. It, however, does not always operate in the latter way satisfactorily.

The sections of the human liver received from the gold a dull violet or a dull red tint, while in other preparations a blue violet tint was found. In two cases I obtained preparations which to the eye appeared almost colourless, but which on examination demonstrated the nerve-fibres very distinctly.

All the sections were cleared in oil of cloves, and mounted in balsam.

In the study of the ultimate terminations of the nerves I have used the Leitz $\frac{1}{12}$ inch homogeneous immersion with special illumination. In the human liver, more especially, it was impossible to do anything with a less efficient objective. In the Necturus liver it was quite easy, however, to see the required structures with a system 7 of Leitz, but I have endeavoured in every case to verify my observations with the higher power objective.

The value of gold chloride as a reagent for differentiating nerves is not admitted by all histologists. It has been urged also that the elements it selects in a fresh tissue and those it differentiates in a tissue hardened by a reagent such as chromic acid are not necessarily the same structures. This objection has a great deal of force, especially in view of the fact that gold chloride gives a violet tint to connective tissue which has been first hardened with chromic acid; the corium of Necturus and the connective tissue around arteries are cases in point. Moreover, the tendency of a hardened tissue is to reduce equally the gold so as to give to all the tissue elements a violet colour. Yet with all its faults the method of hardening with chromic acid and the subsequent treatment with gold chloride has many advantages over other micro-chemical and staining reagents, and so far as the demonstration by it of nerve-structures are concerned no greater suspicion should be attached to results

obtained with it than to those of other histo-chemical reagents. Gold chloride employed in any way is not an infallible test for nerve-structures, for these have in the end to be determined by their intrinsic form and arrangement, by their origin and termination, or either separately. The violet colour given by gold chloride to fibres otherwise undemonstrable is therefore of accessory value only.

It is not known definitely to what organic compound is due the capacity of nerve-fibres for fixing in themselves gold chloride. R. Gscheidlen,[1] after a series of experiments, came to the conclusion that the reduction is caused by a fatty substance. He treated pieces of the ischiadic nerve of a frog with ether, alcohol, and water respectively, and found that the extract obtained with ether reduces gold in a few hours, while that obtained with alcohol took longer to do the same, the aqueous extract, on the other hand, a very long time. As 90 per cent. of the solid extract obtained with ether is fatty in its nature Gscheidlen drew the inference that a constituent of this fat reduces the gold. I do not think that this explanation will suffice, for nearly all the fat of such an extract must come from the myeline investment of the fibres, and we find that no reduction usually occurs in the medulla. Fol[2] points out that the violet colour may have another explanation than a mere reduction of the gold, and calls attention to the fact demonstrated by Lindet that this reagent forms double salts with phosphorus compounds, especially the chlorides, which give aqueous solutions of a violet colour. Whether gold chloride undergoes reduction or enters into a more complicated condition it is outside the province of the histologist to determine. It is possible, however, without transgressing limits, to consider some aspects of this question and to suggest some points which may help in the solution It seems to me that the substance which favours the production of a violet colour with gold chloride is diffused through all forms of tissue, and that it is found in a concentrated condition in nerve-tissue only. If a section of

[1] 'Arch. für Mikr. Anat.,' Bd. xiv, p. 225.

[2] 'Lehrbuch der Vergleichenden Microscopischen Anatomie,' p. 175.

liver be treated with gold chloride, and the process of colouration be watched, it will be found that the first tinge which the nerve-fibres take is red, and afterwards they show all stages transitional between that colour and violet, while the other systems of tissue slowly pass through the same order of colours to the violet tint. The nuclear chromatine is an exception, being, like nerve-tissue, quick to attain a violet tint. Occasionally other structures act like nerve-fibres towards gold, and among these may be mentioned certain paranuclear bodies in the cutaneous epithelium of Necturus which are first coloured red, then rose violet, and finally deep violet. This appears to show that the substance which fixes the gold in a violet form is not confined to nerves, but is diffused to a small degree in other tissue elements.

The finest nerve-fibrils being hardly thicker or less delicate than the trabeculæ of the cytoplasma, it is wrong to suppose that a reagent which does not specially preserve and fix the latter will do this for the former. It is in this respect that I find the reason for the failure of Nesterowsky, Kolatschewsky, and others to resolve the finer nerve terminations, seeing that the reagents they used for hardening the tissue do not render the cytoplasma distinct and firm, and with it the finer nerve-fibrils. Ammonium bichromate is not a suitable reagent for this purpose, neither is the weak solution of chromic acid such as Kupffer used. The same objection can be urged against the method of freezing the fresh liver in order to obtain sections. The method of gold colouration must not be allowed to injure the cytoplasma. The test which I always exacted of the method employed was the distinct demonstration of the cell reticulum; that being in a good state of preservation, it was only a question of the number of trials with gold chloride in order to get the desired demonstration of the termination of the finest fibrils. I think also that the clearing up of fresh tissue with formic or acetic acid previous to steeping in gold chloride is apt to destroy both the cytoplasma and the finest nerve-fibrils. It is on this ground that I advocate the use of chromic acid to fix these before subjecting them to the action

of gold chloride, and to the subsequent treatment with formic or acetic acids. Osmic acid, although useful in the case of medullated nerve-fibres, is of no value for demonstrating the finest non-medullated fibrils.

Here a few words are necessary concerning the structure of the cytoplasma. In figs. 3, 4, 5, 6 it is represented as a network with thickened nodal points. It must be admitted that it does not always appear in such a regular arrangement. The meshes are often much larger and round as if occupied by fat droplets. Often also the trabeculæ thin out toward the periphery of the cell, so as to be nearly indistinguishable. The specimens of Necturus from which these preparations were made were caught early in March, 1885, and consequently there was but a small amount of fat in the hepatic cells. The appearance presented in the figures is a normal one, for chromic acid material with hematoxylin or aniline dyes show a similar arrangement. Flemming[1] believes in the arrangement of the cytoplasma in threads throughout the cell, but doubts if these form a network such as Klein[2] describes. Structures, however, like those drawn in figs. 5 and 6, leave hardly any doubt as to the occurrence of a reticulum.

The Nerves of the Human Liver.

In sections of the liver treated successfully with gold chloride the tissues immediately about the interlobular and central veins take a rose-violet or blue-violet colour. These strongly coloured fields, observed with a low-power objective, seem to consist wholly of violet-coloured fibres, but when more highly magnified the latter, which are commonly arranged in bundles, are seen to constitute but a small part of the interlobular tissue, or of that about the central vein, there being between the bundles a quantity of connective tissue coloured light violet or red. The thickest fibres are of about 0·0035 mm. in diameter. Each bundle is composed of a varying number of fibres, and is

[1] 'Zellsubstanz, Kern, und Zelltheilung,' Leipzig, 1882, p. 28.

[2] "Observations on the Structure of Cells and Nuclei," this Journal, vol. xviii.

usually separated from its neighbour by a narrow interspace less in diameter than that of the bundle. The fibres when seen in transverse section are round, and possess nuclei which are closely applied, sometimes at definite intervals. The fibres are wavy in their course, and are clear and homogeneous. They branch frequently, the branches being of diminished size, round, and lacking the nuclei of the larger trunks. They appear in no way to be related to or derived from connective-tissue corpuscles, they do not anastomose with one another, and they nearly always have a parallel direction, decreasing in size as they pass into the smaller divisions of the interlobular canal, where their arrangement in bundles is not so common.

The violet colour of the fibres render them remarkably distinct in contrast with the rose-violet connective tissue in which they lie scattered. Sometimes, however, the connective tissue is not coloured at all, but comes out as a granulo-fibrillar appearance which is apt to be overlooked in the presence of the deeply coloured fibres. In these cases the bundles are separated by the granulo-fibrillar substances which penetrates much less prominently between the individual fibres.

Where connective tissue and nerve-fibres are coloured alike, it is useful to differentiate between the two with the aid of a weak solution of potassic cyanide. The section being placed on the slide a drop or two of this reagent is added to it and the decolouration watched with a moderately high power. When the interlobular tissue is deprived of its colour to the degree required the section is mounted in the usual way. Under the high power one now finds only a portion of the interlobular tissue retains its violet tint, and this portion is composed of the fibres above referred to. This does not necessarily show that the fibres so revealed are nerve-fibres, or definitely distinguish them from those of connective tissue. It, however, seems to agree with the experience of Cybulsky, that in tissue stained with gold chloride, and subsequently treated with potassic cyanide, the nerve-fibres retain their colour longest.

I have never seen the connection of these fibres with medullated nerves, having never found the latter in the liver, but the normal or abnormal occurrence of which in the interlobular canals I do not doubt. Medullated nerve-fibres are sometimes found in unusual places. For example, Cybulsky found a medullated nerve-fibre penetrating the cutaneous epithelium, and I also have seen the same thing in a preparation of epithelioma. One may be inclined to believe, therefore, that medullated nerve-fibres can and do occur in the liver. It is to be remembered too that gold chloride is not a good reagent for demonstrating the myeline investment of nerves, the occurrence of which may escape the eye in preparations obtained with the one method.

It is quite true, as Kupffer asserts, that in gold preparations violet-coloured tissue passes at places in from the serous covering of the liver between the hepatic cylinders. I gather from his statements that he supposes that no nerves can reach the hepatic tissue in this way. Such a supposition is groundless, seeing that the serosa and the interlobular tissue are of one and the same origin, and one is as likely as the other to contain nerve-fibres. Where in my preparations the serosa was coloured violet throughout I added a drop of the solution of potassic cyanide, and found in consequence the same to be true here which I have described for the interlobular canals, namely, the presence of the two types of tissue—nerve and connective, the latter, however, very largely predominating.

There are at times interspersed between the bundles of large, violet-coloured fibres, fibrils in which the violet colour is not so distinct, and is more readily removable with potassic cyanide than that of the large fibres, but less so than that of connective tissue. I am doubtful of the significance of these, but they apparently answer to the smaller nerve-fibres of Nesterowsky. I have had no means of determining their connection with the larger fibres.

Around the central vein of a lobule both the connective and the nerve-tissue are in small quantity. The nerve-tissue is

found absent frequently in otherwise successful preparations, and the fibres usually are not more than half a dozen, each separated from the other by a considerable interval of space.

For tracing the nerve-fibres further to their termination it is necessary to resort to the special sections which I have referred to, namely, those which decrease in thickness from one edge to the opposite one. In a section of this sort, if the thick edge includes a longitudinal view of one of the interlobular canals, every facility is thereby afforded for following these fibres. A uniformly thin section is not of much value for this purpose, as in it the fibres can be followed but a short distance, on the average equal to the combined diameter of four or five cells, and the connection of the smaller with the larger fibres is difficult to make out. Part of a section prepared in the manner described is drawn in fig. 1, which represents the border of a hepatic lobule. At such a point are found medium-sized fibres coloured deep violet, always with a clearly defined border, quite different in this respect from connective-tissue fibres. One sees them arise from the large deep violet fibres of the interlobular canals, often as a direct continuation, without branching until after they enter the lobule. They are not numerous, there being usually two of them to each capillary channel, and they run between the capillary wall and the hepatic cells. They are easily distinguished with a low power objective. At first view they appear to form a network of anastomosing fibres, but a further examination shows that the branches of these fibres cross rather than join each other. Fibres of such a diameter are never found outside the capillary channels, that is, they do not penetrate between the liver-cells. These fibres belong to what I have denominated the coarse intralobular plexus. They possess no nuclei and branch at acute angles, the resulting branches being either quite as large as the original trunks or much finer. The large ones may be considered as belonging to the plexus just mentioned. The finer may be resolved into two classes: a perivascular plexus or network and an intercellular one. The perivascular network can be best seen when one looks from above into a capillary channel cut

longitudinally. The meshes of this network are irregular and greater or less in area than that of a hepatic cell, and the fibrils are very fine, without varicose swellings, and with a violet tint appearing quite distinct against the duller tint of the background formed by the hepatic cells. This perivascular plexus is in direct continuation with the fibres of the coarse interlobular plexus, and is therefore of a nervous nature. Whether it belongs to the walls of the capillary channels or to the hepatic cells bordering on these, or to both, I do not know. Sometimes it appears to belong to one, sometimes to the other. I cannot even say whether it is distinct from the intercellular network. The latter, also, is formed of fine fibrils, which are commonly seen unconnected with each other, but which in good preparations show anastomoses enclosing a varying area and extending between the hepatic cells. The finest of these fibrils possess varicosities regularly arranged and observable only with homogeneous immersion lenses such as a $\frac{1}{12}$ inch.

All my efforts to find a further resolution of the fibrils of the perivascular plexus availed nothing in the result. They might, as Kolatschewsky found in one or two cases, terminate in the nuclei of the capillary wall, but as to this I can bring no observations either for a negati or for an affirmative view, since in my preparations the capillary walls and their nuclei, unstained by gold chloride, appeared under high magnifying power as a hyaline refracting membrane. The perivascular plexus may, as I have already pointed out, serve as origin to the intercellular plexus.

From the fibrils of the intercellular network excessively minute twigs are given off which terminate each in a delicate bead in the interior of the hepatic cells near the nucleus. In a section such as that given in fig. 1 one often suspects such intracellular terminations, but the use of homogeneous immersion objectives does not demonstrate them satisfactorily, and only a careful search of very thin sections gave in five or six cases results not at all doubtful. I found, indeed, in some specimens excessively fine fibrils of a violet colour passing from the capillary side of the hepatic cell to the

neighbourhood of the nucleus and there end with the characteristic bead-like swelling; but I could not prove to my own satisfaction that they were other than prominently coloured trabeculæ of the cell reticulum. A view of a specimen such as I have represented in fig. 2 lends itself easily to interpretation. Here a fine nerve-fibril running along the side of the hepatic cylinder gives a fine twig to each cell which reaches the vicinity of the nucleus. Sometimes a twig divides after it enters the cell, the divisions running to opposite sides of the nucleus. The terminal points of all the intracellular twigs are delicate beads. I was always compelled to believe that such twigs are really within the cell when I found their terminal beads to be on the same level as the nucleus in an optical view of the latter. It is, of course, impossible in the greater number of cases to say whether the fibrils which give rise to these intracellular twigs belong to the perivascular or to the intercellular network. In fig. 2 one finds great difficulty in determining to which network the nerve-fibril belongs, but in several cases the demonstration of the intercellular origin was quite distinct, and this has led me to conclude that only the intercellular fibrils give off intracellular twigs.

The Nerves of the Liver in Necturus.

The hepatic cells in Necturus measure 0·042—0·05 mm., and consequently in a given area of a thin section the number of cells is less correspondingly than in the human liver. From this one would expect to find a less rich supply of nerve-fibres, and results bear out this opinion. The nerve-fibres in the interlobular canals are few in number, and each has a diameter much narrower than that of the larger ones of the human liver; their course is straighter till they enter the lobules, where they pass along the capillary channels to their termination. The small quantity of connective tissue in the interlobular canals usually takes a deep violet stain and then appears homogeneous and structureless. In such a case I have not found it necessary to remove the excess of the stain, for the nerve-fibres are clearly outlined against the connective tissue. Apart from the larger

interlobular canals the connective tissue also is not demonstrated by the gold, so that one finds no difficulty in tracing a nerve-fibre for a long distance, providing it lies in the plane of the section.

Nuclei were rarely observed on the largest fibres, and whether these belonged to the sheath of the fibre or to nerve-corpuscles it was impossible to determine. The division of the fibres in the interlobular canals is not common, but branching occurs more frequently in the capillaries of the lobules. Here they give rise to fibrils of two sorts; those which form the perivascular plexus surrounding the capillary walls, and those which, few in number, apparently course between the hepatic cells. I am unable to say whether there is any morphological or physiological difference between these kinds of fibres. I am inclined, however, to think they are one and the same, for they terminate in the majority of observed cases in a like way. The intercellular fibrils arise from fibres which serve as origins to the perivascular plexus; this also supports the conclusion already stated as to their physiological value. In a thin section the intercellular fibrils are the most commonly visible. I have applied the term intercellular to them because, although they do not always run between the cells, they unquestionably lie outside the capillary channels for the greater part of their course. I have followed them in some cases for a distance equal to the combined diameters of over twenty of the cells and have found them to accommodate themselves but very little to the windings and tortuous course of the capillaries. In thin sections, where the fragment of one cell is seen to lie over that of another, one of the fibrils in question has been again and again observed to pass between their contiguous walls. Part of their course is in the capillary channel, i.e. between the wall of the blood-capillary and the adjacent liver-cells.

The meshes of the perivascular plexus vary much in size and form, being usually less than the area covered by a hepatic cell and of an irregular quadrangular or triangular shape. The fibrils which form them are wavy in their course and apparently anastomose completely with one another. Now and then only

a longitudinal section of a capillary contains a view of this plexus in all its relations, on the one hand with the hepatic cells, and on the other with the capillary wall. The latter appears closely embraced by the network which always in well-preserved specimens, borders the hepatic cells. In this respect one has great difficulty, as in the human liver, in deciding to which the network belongs physiologically, if to the capillary wall or to the cells; the terminations of this network show that it belongs to the latter. Is it to be supposed, however, that nerves are not distributed to the capillaries themselves?

It was of course much easier to determine how the long intercellular fibrils terminate than to do the same thing for the fibrils of the perivascular plexus. My first conclusion, after some observation, was that both terminate in a like manner, but I soon perceived that it was rarely possible in thin sections to decide whether a fibril which runs in the capillary channel and gives off intracellular twigs belongs to the intercellular class or to perivascular network. Both class of fibrils are equally delicate. The intercellular ones I found again and again to terminate within the hepatic cells. I had therefore to guard against confusing the two sets of fibrils as to their terminations. One of the several cases where an absolute decision was possible is drawn in fig. 3. Here fibrils of the network are seen to give off twigs which penetrate the adjoining hepatic cells, while on the opposite edge of the capillary channel a fibril, apparently belonging to the intercellular order, terminates in a like way.

The intercellular fibrils branch at certain intervals, each branch running at sharp angles with the main trunk. I believe several times to have detected a network of these branchlets. In such a case these intercellular fibrils would correspond to those of the intercellular network in the human liver. I must, however, leave this point in abeyance. If this network is usually present obstacles to its demonstration are certainly to be found in the deep tinting which the cell reticulum acquires from the gold method. The perivascular network, on the other hand, is not obscured, for the capillary walls over against which

it is usually seen are uncoloured, or nearly so. The fibrils of the intercellular order are generally so delicate that it is difficult to arrest the removal of the colour of the overlying or underlying cells with potassic cyanide at a point where the distinctness of the fibrils is retained. I had therefore no success in trying to determine definitely the common occurrence of an intercellular network.

The simple intracellular nerve-twigs always terminate in the neighbourhood of the nucleus, either singly or after branching, each terminal point being a delicate bead. The unbranched twig may end on the side of the nucleus facing the point where the twig penetrates the cell, or after curving around the nucleus on the opposite or on one of the lateral sides. When a twig branches two or more of the branchlets may terminate in the positions mentioned. In many cases it is possible to trace a twig for a certain distance after it enters the cell, but not to determine how it ends, this being usually due to the deep colour which the nucleus and the dense cytoplasma immediately about it take from the gold. On the other hand, the cytoplasma may acquire such a deep stain relatively that the determination of the presence of intracellular nerve-twigs is almost impossible. Frequently also these have but a pink or red tint while the fibrils from which they arise are deep violet.

All the forms of intracellular nerve terminations to be found in the liver of Necturus are not so simple as that just described. A form which I have several times met with having the intracellular twig branching dendritically is represented in fig. 4. A complicated mode of ending, a very common one in good preparations, appears to belong to the perivascular network. I am inclined, from reasons which I shall state further on, to regard it as a general one for the hepatic cells of Necturus. Fig. 5 shows how widely it differs from the other modes. Here a branch from the perivascular network penetrates a cell and becomes continuous with the cell reticulum in such a way as to leave the impression at first that this reticulum belongs to the nerve-twig rather than to the cell itself, this

opinion being at the same time strengthened by the fact that the cell network is coloured deep violet. The trabeculæ of the reticulum in such cases as this are very much more slender than they are as ordinarily demonstrated, but an exception is to be made of cases like that in the figure, where the trabeculæ become thickened along two or more lines so as to give the intracellular nerve-twig the appearance of a branching which extends toward the nucleus. In fig. 6, however, the reticulum is formed of trabeculæ nearly as coarse as that usually observed in the cell.

The demonstration of the simple intracellular termination occurring in the same cell with the more complicated form is apparently not possible. The former, if such is present when the other mode of termination is demonstrated, must necessarily be obscured by deep violet colour of the cell reticulum; if this depth of tint be lacking it is possible to see the simpler terminations. Both forms are often demonstrated in the same section, and therefore one cannot consider that the method of hardening previous to treatment with gold chloride may account for the presence of the one or the other on the ground of their being artificially produced.

It is probable that every hepatic cell in Necturus presents both forms of termination; otherwise we ought to conclude that there are two kinds of specifically different glandular cells in the liver according to the doctrine of the physiological homodynamy of nerves. The simpler form of termination may be regarded as the same as that found in the cutaneous epithelium of the tadpole,[1] while the more complicated mode is apparently the glandular one. At present it is useless to discuss further the specific function of these, but I hope in a future paper on nerve terminations to treat more fully this aspect of the question.

General.

In the liver of Necturus there is a mode of nerve termination which I have been unable to demonstrate in the human

[1] This Journal, November, 1885, p. 53.

liver. In this mode the nerve fibril fuses or is continuous with the reticulum, but the fibril first penetrates the cell in order to accomplish this fusion, and in this way differs from the method of termination described by Holbrook by which the fibrils are connected with the intercellular bridges or cement substance. I thought at times to see with oil immersion objectives such a fusion of the nerve-fibrils with the cell reticulum in the human liver, but it was in every case impossible to obtain demonstrations as definite as those yielded by the liver of Necturus.

This method of termination resembles to a certain extent that described by Pflüger; the resemblance would be a more complete one were the cell reticulum regarded as of nervous origin, and then the words of that observer would be applicable here also: "Man könnte demgemäss sagen, dass die Leberzelle eine Kernhaltige Anschwellung eines Nerven sei." The points of difference between the method here described and that of Pflüger's are, however, too many to permit the supposition that they are one and the same but viewed according to different modes of preparation. When one compares the observations of Nesterowsky, Kolatschewsky, and Holbrook on the extreme fineness of the nerve-fibrils so far as they could trace them, the termination of medullated nerves on the hepatic cells appears exceedingly improbable except in pathological cases.

With regard to the methods of technique employed by the other observers several objections may be urged; these I have already put forward. The methods are no doubt useful in demonstrating the course but not the termination of the nerves. It must be thoroughly understood that the nerve terminations in the interior of liver-cells are as delicate, as easily injured, and as difficult of demonstration as the finer cell structure. If this point is admitted I do not apprehend that a confirmation of the description of the nerve terminations here given will be a tardy one. Of course there are reagents which preserve well the cell structure but which do not fix it in such a way as to permit the selective capacity of gold chloride full play, and one must then endeavour to find such reagents as will give with gold chloride the best results. I have found these in Erlicki's

fluid and chromic acid, but it is possible that by varying the methods of the fixation of the gold some other reagent for hardening will give better results than I have obtained.

In conclusion, I may state that I have demonstrated these terminations to several competent observers, and among these I may mention Professor Ramsay Wright and Professor Osler. To the former I owe my thanks for his having gone over and verified every point here advanced and for the advice of which I availed myself at various times during the research.

EXPLANATION OF PLATE XXXIII, figs. 1 to 6,

Illustrating Mr. A. B. Macallum's Paper on "The Termination of Nerves in the Liver."

All the figures are representations, as exact as possible, of the structures drawn.

Fig. 1.—A section of the edge of a lobule of the human liver to show the course of the nerve-fibres. The clear spaces represent transverse and longitudinal sections of the radial capillaries where they are continuous with the interlobular capillaries. *a*. The coarse intralobular plexus. *b*. The perivascular plexus. *c*. The intercellular fibrils. *h*. The hepatic cells. The capillary walls are indistinguishable. Some of the larger nerve-fibres appear at places to run over the liver-cells, but at these points they actually follow the capillary pathways. Leitz, Oc. 3 and Obj. 7. The outlines of the cells, nuclei, and fibres were drawn with camera.

Fig. 2.—Two cells of the human liver, showing the termination of nerve-fibrils in their interior. Leitz, Oc. 3, and oil immersion $\frac{1}{12}$ inch.

Fig. 3.—Shows the simple intracellular termination of nerves in the liver-cells of Necturus. *a*. A larger nerve-fibre. *b*. An intercellular fibril, with *c*, the perivascular plexus arising from a common fibre. Erlicki's fluid, gold chloride, formic acid. Leitz, Oc. 3 and System 7.

Fig. 4.—Shows the dendritic branching of a nerve-fibril in the interior of a single hepatic cell of Necturus. Erlicki's fluid, gold chloride, formic acid. Leitz, Oc. 3 and System 7. The branching of the fibril in the interior of the cell was drawn with hom. imm. $\frac{1}{12}$ inch.

Fig. 5.—Two hepatic cells of Necturus with nerve-fibrils of the perivascular plexus; a fibril from the latter enters each of the cells and becomes continuous with the cell reticulum. Erlicki's fluid, gold chloride, formic acid. Drawn to the scale of Leitz, Oc. 3, and System 7; but the course of the fibrils outlined as seen under hom. imm. $\frac{1}{12}$ inch.

Fig. 6.—A single hepatic cell of Necturus, showing the relations of nerve-fibrils and the cell reticulum. The optical plane is above the nucleus and near the upper surface of the cell. The nerve-fibril passes over the upper surface of the cell, and gives off a branch which divides into twigs to penetrate the cell and fuse with its reticulum. Erlecki's fluid, gold chloride, formic acid. Leitz, Oc. 3, and oil imm. $\frac{1}{12}$ inch.

On the Nuclei of the Striated Muscle-Fibre in Necturus (Menobranchus) lateralis.

By

A. B. Macallum, B.A.,
Fellow of University College, Toronto, Canada.

With Plate XXXIII, figs. A and B.

While examining, several months ago, some preparations made for the purpose of demonstrating the mode of nerve termination in the striated muscle-fibre of Necturus, I found many of the isolated nuclei to possess on their surface furrows and striations hitherto undescribed, and which, I now believe, are of importance in determining the structure of the contractile element of muscle-substance. A careful study of these nuclei has further revealed other peculiarities which point to a conclusion as to the origin of the contractile element, the muscle reticulum. In view of this, I give a detailed description of the appearances presented by the nuclei, and refer them to their supposed causes.

The best preparations were obtained with gold chloride and formic acid. This method is valuable for two reasons, the nuclei are completely isolated after a stay of thirty to forty hours in the acid, and the furrows on their surface take a deep violet tint, while the remaining portion of the nuclear membrane is coloured light, or rose violet. The isolation of the nuclei from the muscle-substance prevents any confusion which might be caused by the striation of the muscle-fibre were one to examine them in situ. It is to be noted that the muscle-fibre in

Necturus macerates and disintegrates very easily in solutions of formic acid.

The long diameter of the nuclei, the largest and the smallest, measures 0·037—0·053 mm., and the transverse diameter 0·010—0·025 mm. The form of the nucleus varies somewhat, the oval being the most common; oblong and quadrate ones were occasionally observed. The membranes of old nuclei have apparently the capacity for attracting the reduced gold. In what might be considered as young nuclei, the membrane is not furrowed or but slightly so, and the chromatine is usually quite distinct, arranged in short, variously looped pieces along the long axis of the nucleus, or in the form of minute nodules (nucleoli) in different positions in the nuclear cavity (fig. A, 1 and 24). The reticulum of achromatine, or, better, caryoplasma, with the meaning attributed to that term by Carnoy, is very delicate with very narrow meshes in the nuclei just referred to. A very large number of the nuclei observed lacked chromatine while their caryoplasma was more prominent and its meshes larger. In a few, a further modification of the reticulum, to be described below, was observed.

In view of Nicolaides'[1] work on the division of nuclei in the frog's muscle, I made a careful search for like cases of division in Necturus, but the result was disappointing. Out of many hundred nuclei which I examined I found but one case of division, and that from the heart-muscle (fig. A, 11). Flemming[2] observed indirect division of the muscle nuclei in larval but not in adult Amphibia. My failure to find in Necturus what was observed by Nicolaides in the frog could not have been due to the reagent, gold chloride, for I found negative results when a mixture of chromic and acetic acids, or of these and osmic acid, was employed.

Nine out of ten of the old nuclei, i. e. those in which there remains no trace of chromatine, have markings and furrowings on their surface. Sometimes, as in fig. A, 2, a series of parallel

[1] "Ueber die Karyokinetische Erscheinungen der Muskelkörper," 'Arch. für Anat. und Phys., Phys. Abth., 1883, p. 441.

[2] 'Zellsubstanz Kern- und Zelltheilung,' Leipzig, 1882, p. 337.

furrows occupy one part of the surface of the membrane, the remainder of which is possessed of a series running in a contrary direction. They may be arranged parallel to the length of the fibre, or, as in 8, perpendicular to the long axis of the nucleus, or, as in 7 and 9, oblique to the same. Often one finds a combination of the two last mentioned modes of arrangement as represented in 10. Cases were observed in which a furrow, followed a part of the way around the nucleus, was found to divide at an acute angle, the branches completing the rest of the nuclear circumference. If the nucleus is flattened it is usual for the furrows to be confined to one surface. In 7 and 9 the number of these is respectively three and two, and in 8 they are very numerous. The depths of the furrows vary with their breadth, the latter being estimated by the breadth of the violet line of reduced gold. The depth in some nuclei is such that when one takes an optical section of them the nuclear cavity is almost divided into a series of separate compartments (25). The distance of the furrows from each other is subject also to considerable variation (10, 12, 15).

The cause of these furrows is in all probability the pressure exercised by the trabeculæ of the muscular reticulum described by Melland,[1] the transverse trabeculæ giving rise to the transverse furrows, the longitudinal ones to the furrows running parallel to the long axis of the nucleus.

Here in passing I may refer to my own observations on this muscular reticulum. These were made on specimens obtained with gold chloride from the rabbit, frog, Necturus, crayfish, and grasshopper, and as a result I accept in full the views of Melland. In my preparations of the muscle-fibre obtained from the rabbit and Necturus this reticulum is in all its aspects splendidly demonstrated. Carnoy[2] apparently holds the same view as to the cause of the striation of the muscle-fibre in Hydrophilus piceus, for he describes it as due to a re-arrangement of the reticulum of the cell (cytoplasma of that

[1] "A Simplified View of the Histology of the Striped Muscle-fibre," this Journal, July, 1885, p. 371.

[2] 'La Biologie Cellulaire,' Paris, 1884, pp. 192 and 193, fig. 38.

author) in longitudinal and transverse trabeculæ, the myosine arising from that part of the cellular contents enclosed in the meshes of the primitive reticulum of the cell.

It is not too great an inference to draw that this reticulum is the true contractile element, while the myosine shifts and accommodates itself to the conditions of the latter. In support of this I refer to fig. A, 6 and 13, in which one sees that the furrowing takes the shape and arrangement of the meshes of the reticulum.

Why the furrowing on the surface of some nuclei is longitudinal only, on others transverse, I cannot with certainty say. Of one thing I am sure: where one series of parallel furrows alone is visible, these are in by far the greater number of cases transverse to the long axis of the nucleus. The greater part of the muscle-fibre used in my preparations was in the uncontracted condition, and it is in this condition that the muscles are for the greater part of life. Following out the theory as to muscular contraction, given in the last paragraph, it is to be supposed that during rest the transverse trabeculæ of the muscle reticulum are contracted, but lengthened during contraction of the fibre, the conditions with regard to the longitudinal trabeculæ being in the reversed order. As now the contraction or shortening of the transverse trabeculæ must occur during the greater part of the life of the muscle, or during its resting periods, it is obvious that transverse furrows should be seen on the nucleus oftener and more prominent than longitudinal ones or than both combined. In this way we may explain away part of the difficulty of accounting for the occurrence of one or other series only of furrows.

E. Weber[1] found that the nuclei of the frog's muscle are provided with longitudinal striæ, which he thought due to the pressure exercised by the muscular fibrillæ. I endeavoured for the sake of comparing them with the nuclei in Necturus to isolate, after the manner already described, the nuclei of the frog's muscle, but I met with a very indifferent success. In

[1] "Note sur les noyaux des muscles striés chez la grenouille adulte," 'Archives de Physiologie,' 1874, p. 489.

the case of the few isolated, however, I could make out a certain amount of transverse striation of the membrane.

Further, as to the transverse furrows being often at acute angles with one another, an explanation for this may be found in the facts now to be described.

A few nuclei presented other appearances than those mentioned (fig. A, 9, 15, 16, 18, 19). Here the form of a oblong-meshed reticulum like that of the muscle-fibre was observed and considered by me at first to be caused by an impression produced by the latter on the surface of the nuclear membrane. I found, however, in cases where it could admit of no doubt, that the reticulum was not on, but within the nucleus. In other words, there is in the interior of some nuclei a reticulum like in every respect to that found in the muscle-substance. In these cases no chromatine or caryoplasma could be observed.

On the other hand, I observed a few nuclei in which the caryoplasma was approximately square meshed (fig. A, 23). The quadrangular form of the meshes is exhibited oftener and better in the nuclei from the heart muscle (fig. A, 20, 21). This form of the reticulum appears to be one of the stages transitional between the reticulum of the young nucleus and that referred to in the last paragraph.

In view of these facts it is safe to infer, as Carnoy and Melland have done, that the muscle reticulum is simply the modified cytoplasma, the caryoplasma being derived from the latter.[1]

Nuclei with such a modified caryoplasma as represented in fig. A, 20 and 21, must be capable of movement, or contraction and extension. This movement has been observed in the nuclei of vegetable cells by Hanstein,[2] and in the nuclei of white blood-corpuscles of Necturus by Gage,[3] and is amœboid in character. But the possession of a square-meshed reticulum implies extension and contraction in definite directions—the nucleus con-

[1] See Carnoy, op. cit., p. 250.

[2] 'Bot. Zeit.,' 1872, p. 22.

[3] 'Science,' Jan. 8th, 1886.

tracts with the muscle-fibre and extends with it again, yet not passively.

The possession of an irregularly meshed reticulum by the nucleus would imply on the part of the latter movements, if any at all, of an amœboid character. It is possible that this is just what occurred in the nuclei represented in fig. A, 10, 12, and 17, an unequal extension or contraction of all parts of the nucleus, resulting in a misplacement of the furrows and in their irregularity.

Nicolaides suggests that all muscle nuclei take a more than passive share in muscular contraction.

Some nuclei have part of their surface completely free from furrows (fig. A, 5). I think this is due to the fact that the whole of the nuclear body is not surrounded by the muscle-substance, a part of it lying between the latter and the sarcolemma.

EXPLANATION OF PLATE XXXIII, figs. A and B.

Illustrating Mr. Macallum's Paper on the "Nuclei of the Muscle-fibre in Necturus lateralis."

FIG. A, 1—25.—Nuclei of striated muscle-fibre of Necturus lateralis, 11, 20, 21, 22, representing some from the heart muscle. Mode of preparation: gold chloride, formic acid.

FIG. B.—A part of a striated muscle-fibre with its nuclei, from Necturus. Gold chloride, formic acid.

(Note.—In drawing these figures, Leitz obj. 7, and oc. 1 or 3 were employed.)

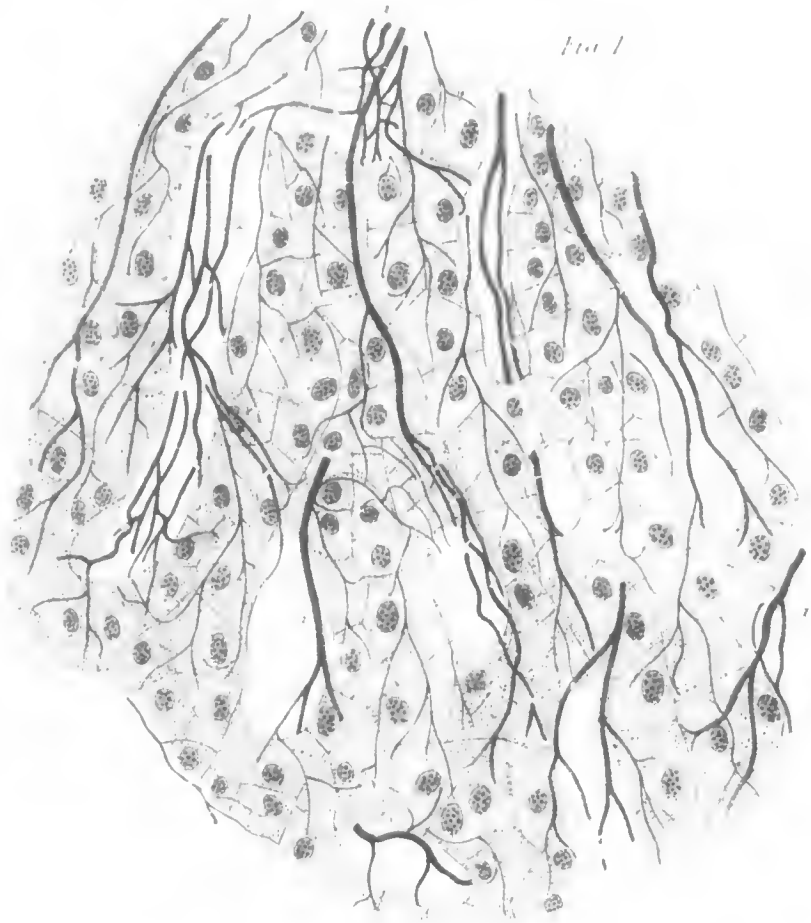

Fig A

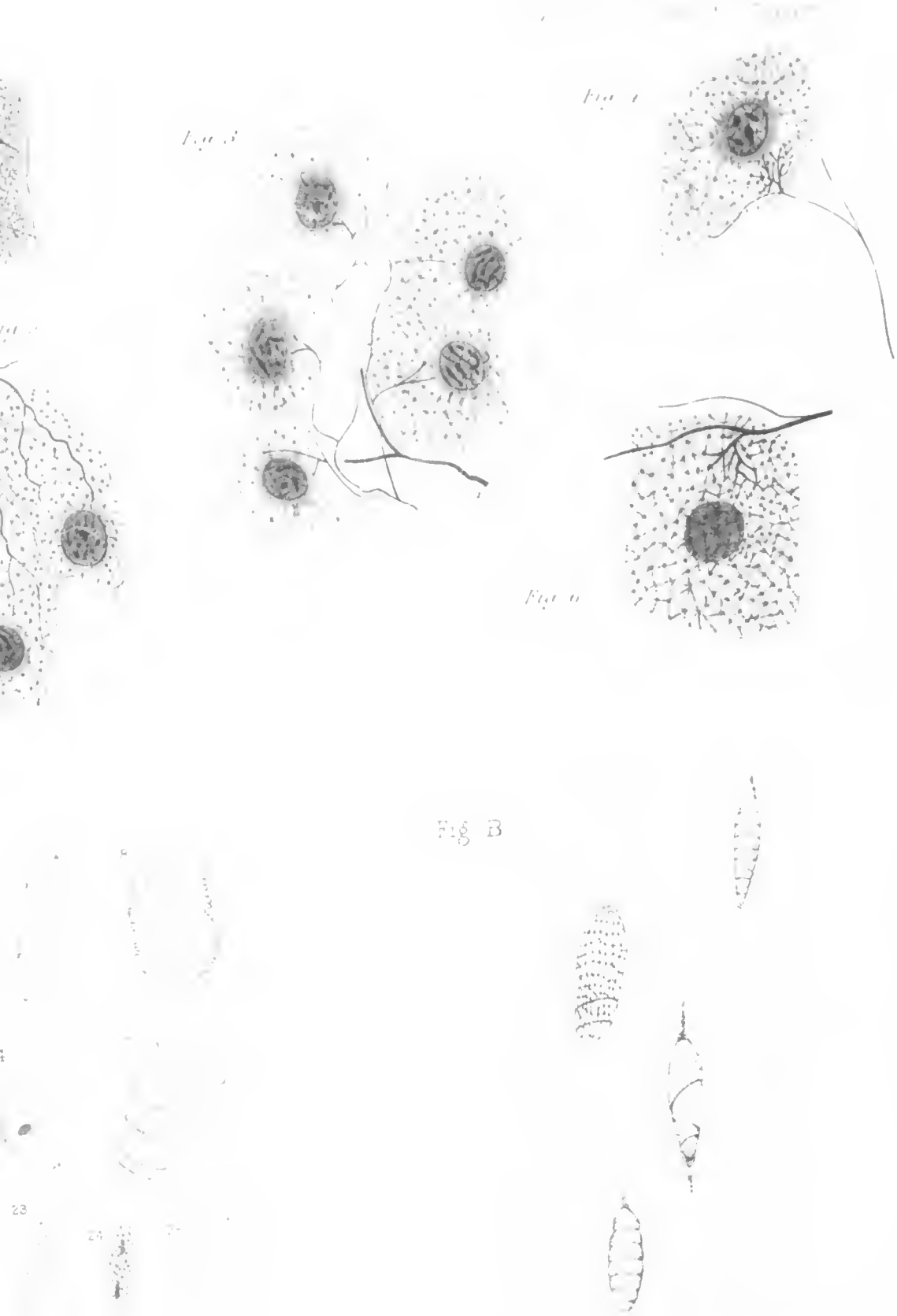

Fig B