

**CIHM
Microfiche
Series
(Monographs)**

**ICMH
Collection de
microfiches
(monographies)**



Canadian Institute for Historical Microreproductions / Institut canadien de microreproductions historiques

© 1998

The copy filmed here has been reproduced thanks to the generosity of:

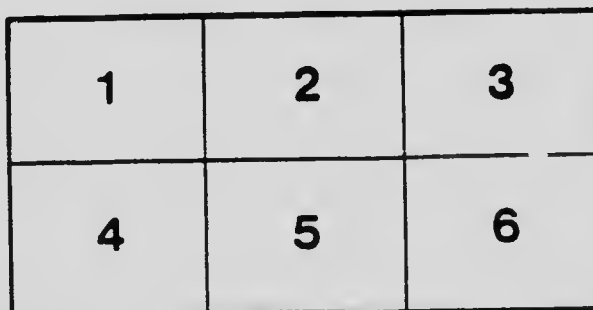
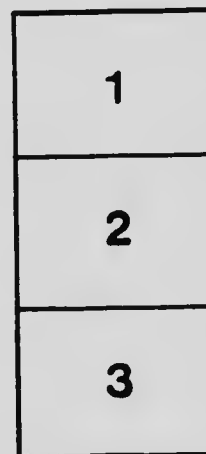
McGill University
Health Sciences Library
Montreal

The images appearing here are the best quality possible considering the condition and legibility of the original copy and in keeping with the filming contract specifications.

Original copies in printed paper covers are filmed beginning with the front cover and ending on the last page with a printed or illustrated impression, or the back cover when appropriate. All other original copies are filmed beginning on the first page with a printed or illustrated impression, and ending on the last page with a printed or illustrated impression.

The last recorded frame on each microfiche shall contain the symbol \rightarrow (meaning "CONTINUED"), or the symbol ∇ (meaning "END"), whichever applies.

Maps, plates, charts, etc., may be filmed at different reduction ratios. Those too large to be entirely included in one exposure are filmed beginning in the upper left hand corner, left to right and top to bottom, as many frames as required. The following diagrams illustrate the method:



L'exemplaire filmé fut reproduit grâce à la générosité de:

McGill University
Health Sciences Library
Montreal

Les images suivantes ont été reproduites avec le plus grand soin, compte tenu de la condition et de la netteté de l'exemplaire filmé, et en conformité avec les conditions du contrat de filmage.

Les exemplaires originaux dont la couverture en papier est imprimée sont filmés en commençant par le premier plat et en terminant soit par la dernière page qui comporte une empreinte d'impression ou d'illustration, soit par le second plat, selon le cas. Tous les autres exemplaires originaux sont filmés en commençant par la première page qui comporte une empreinte d'impression ou d'illustration et en terminent par la dernière page qui comporte une telle empreinte.

Un des symboles suivants apparaît sur la dernière image de chaque microfiche, selon le cas: le symbole \rightarrow signifie "A SUIVRE", le symbole ∇ signifie "FIN".

Les cartes, planches, tableaux, etc., peuvent être filmés à des taux de réduction différents. Lorsque le document est trop grand pour être reproduit en un seul cliché, il est filmé à partir de l'angle supérieur gauche, de gauche à droite, et de haut en bas, en prenant le nombre d'images nécessaire. Les diagrammes suivants illustrent la méthode.

McGill University Libraries

WU 900 0783 1917

Surgical therapeutics and operative tech



3 000 298 836 P

SURGICAL THERAPEUTICS
AND
OPERATIVE TECHNIQUE



SURGICAL THERAPEUTICS
AND
OPERATIVE TECHNIQUE

BY
E. DOYEN

ENGLISH EDITION

PREPARED BY THE AUTHOR IN COLLABORATION WITH

H. SPENCER-BROWNE, M.B. CANTAB., ETC.

ÉLÈVE DE L'INSTITUT PASTEUR ; PHYSICIAN ; ET CHEF DE CLINIQUE DE L'INSTITUT DOYEN

VOL. I.

TORONTO
THE MACMILLAN COMPANY OF CANADA, LTD.

1917

All rights reserved

Printed in England

TRANSLATOR'S PREFACE

THE English edition of Doyen's treatise on operative surgery is taken from the French edition, which comprises five volumes. It has been considered more convenient to present the English edition in three volumes, although none of the French text has been omitted.

Doyen's great work has had a wide success in French-speaking countries. The originality of the author's work, and the general interest shown by the innumerable visitors to his great institute in Paris, led to a general desire for an English edition of his textbook. This was in course of preparation when the war broke out.

I was requested by Dr. Doyen in 1916 to complete the work of translation, and to undertake the heavy responsibility of preparing these volumes for the press.

On carefully examining the work, a certain proportion of which had already been translated by Dr. John Knott of Dublin, I found that portions of the first two volumes were no longer in accordance with the present methods as practised at the Institute Doyen, and a long association with the author as assistant and *chef de clinique* decided me to persuade the author to recast part of his introduction, also to rewrite the important chapters relating to the surgery of bloodvessels and nerves, and the transfusion of blood.

The treatment of accessible cancers by *electro-coagulation* has also undergone considerable modification since its original introduction, and the whole article had to be rewritten. It became evident that an entirely new edition of the work was necessary. This was completed shortly before the author's sudden and lamented death.

The English edition, therefore, is *not* a translation of the existing French edition, but is taken from the material from which the second French edition will be compiled, and contains the latest developments in war surgery and surgical treatment in general.

The first volume contains much introductory matter. The author's

historical introduction will be found to be of great interest, and the chapters which follow, which describe the minutiae of his technique, will, I anticipate, be eagerly consulted. A description of his instruments follows. It will be interesting to bear in mind that this many-sided genius was a first-class mechanic, and, like certain surgeons of old, forged and turned himself many of the instruments which he invented. His therapeutic innovations are also described, and a brief account is given of his antineoplastic vaccine.

Doyen's studies in cancer alone obtained for him a world-wide reputation, and it is probable that his method of destroying cancer cells by means of electro-coagulation, by submitting accessible cancers to the action of high-frequency currents of low tension, will be largely applied in future. This new method has given most encouraging results, and certainly merits a closer study and a wider application than has been accorded to it in the past.

The task of translating a work of this description into English is fraught with great difficulties. The fear of misrepresentation dogs the path of every translator, and it is a wellnigh hopeless task to translate this author's originality of thought and phrase from the French. I would like to take this opportunity of expressing my appreciation of Dr. Doyen's patience and kind encouragement, and to thank my colleagues at the Institute for their assistance and advice.

H. SPENCER-BROWNE.

29, RUE PIERRE CHARRON,
PARIS,
March, 1917.

CONTENTS OF VOL. I

INTRODUCTION

	PAGE
STATE OF SURGICAL PRACTICE AT BEGINNING OF TWENTIETH CENTURY -	1
SURGICAL TECHNIQUES - - - - -	12
DUTIES AND RIGHTS OF THE SURGEON - - - - -	28

PART I

GENERAL SURGICAL TECHNIQUE

THE AUTHOR'S SURGICAL HOME - - - - -	34
HEMOSTASIS - - - - -	74
THE SLICING PROCESS - - - - -	103
SOME NEW FORMS OF HEMOSTATIC FORCEPS - - - - -	106
ÉCRASEMENT AND HEMOSTASIS - - - - -	123
INSTRUMENTS AND APPARATUS - - - - -	167
OPERATIONS :	
GENERAL TREATMENT OF PATIENT BEFORE, DURING, AND SUBSEQUENT, TO OPERATION - - - - -	212
NECESSITY FOR OPERATING RAPIDLY AND WELL - - - - -	256
TREATMENT OF THE WOUND OF OPERATION - - - - -	269
INFECTIOUS DISEASES IN THEIR RELATION TO SURGERY - - - - -	280
GENERAL CARE OF THE PATIENT AFTER OPERATION † - - - - -	295
GENERAL OPERATIVE TECHNIQUE - - - - -	298
SECTION AND DIVISION OF SOFT PARTS AND OF BONES - SUTURES - - - - -	335
SURGERY OF THE BLOODVESSELS :	
VASCULAR SUTURE - - - - -	359
VASCULAR TRANSPLANTATION - - - - -	363
TRANSFUSION OF BLOOD - - - - -	367

	PAGE
SURGERY OF THE NERVES - - - - -	378
AUTOPLASTIC OPERATION - - - - -	388
TREATMENT OF FISTULE - - - - -	416
DIVISION OF TISSUES IN ORDER TO REACH DEEP-SEATED REGIONS WITHOUT HEMORRHAGE - - - - -	427
METHODICAL TORSION COMBINED WITH INSTANTANEOUS CRUSHING AND TREATMENT OF PEDICLES - - - - -	430
LIGATURE OF VASCULAR PEDICLES - - - - -	433
DESTRUCTION OF PATHOLOGICAL TISSUES BY HEAT - - - - -	435
LOCAL TREATMENT OF ACCESSIBLE CANCERS BY ELECTRO-COAGULATION - - - - -	439
EVOLUTION OF THE PRINCIPAL VARIETIES OF CANCER - - - - -	453
ELECTRO-COAGULATION OF MALIGNANT TUMOURS - - - - -	456

PART II

REGIONAL SURGERY

OPERATIONS ON THE HEAD

HAIRY SCALP AND PERICRANIUM - - - - -	503
BENIGN TUMOURS - - - - -	510
MALIGNANT TUMOURS - - - - -	519
GENERAL OPERATIVE TECHNIQUE OF OPERATIONS ON THE CRANIUM - - - - -	522
CRANIECTOMY - - - - -	545
INFLAMMATORY LESIONS - - - - -	568
TUMOURS OF THE BRAIN - - - - -	583
RESECTION OF THE GASSERIAN GANGLION - - - - -	587
AUDITORY APPARATUS:	
EXPLORATION OF THE EAR - - - - -	603
TUMOURS - - - - -	609
EXTERNAL AUDITORY CANAL - - - - -	610
TYMPANIC MEMBRANE AND TYMPANUM - - - - -	614
MASTOID APOPHYSIS AND PETRO'S PYRAMID - - - - -	615
OPERATIONS ON THE VISUAL APPARATUS - - - - -	640
SUPERCILIARY REGION - - - - -	645
THE EYELIDS - - - - -	647
DISEASES OF THE EXCRETORY LACHRYMAL PASSAGES - - - - -	669
OPERATIONS ON THE CONJUNCTIVA - - - - -	674

CONTENTS

ix
PAGE

OPERATIONS ON THE VISUAL APPARATUS (<i>continued</i>):	
OPERATIONS ON THE BULBAR INSERTIONS OF THE MOTOR MUSCLES OF THE EYEBALL	676
CORNEA AND ANTERIOR CHAMBER	680
OPERATIONS ON THE IRIS	684
OPERATIONS ON THE SCLEROTIC	687
OPERATIONS ON THE CRYSTALLINE LENS	689
OPERATIONS ON THE EYEBALL	695
AFFECTIONS OF THE ORBIT	698
OPERATIONS ON THE LACHRYMAL GLANDS	704
RESECTION OF THE BRANCHES AND OF THE TRUNK OF THE OPHTHAL- MIC NERVE	706
RESECTION OF THE SUPERIOR MAXILLARY NERVE AND OF MECKEL'S GANGLION	710
OPERATIONS ON THE OLFACTORY APPARATUS:	
EXPLORATORY PROCEDURES	713
SPECIAL THERAPEUSIS	716
AFFECTIONS OF THE NOSE AND NOSTRILS	717
AFFECTIONS OF THE NASAL FOSSE	732
OPERATIONS ON THE SINUSES OF THE FACE:	
FRONTAL SINUS	738
ETHMOIDAL CELLS	742
SPHENOIDAL SINUS	742
MAXILLARY SINUS	743

PART I
GENERAL SURGICAL TECHNIQUE



SURGICAL THERAPEUTICS

AND

OPERATIVE TECHNIQUE

INTRODUCTION

The State of Surgical Practice at the Beginning of the Twentieth Century.

THE birth of antiseptic surgery dates from the second half of the nineteenth century, and it has outrun, in less than four decades, the hopes of its original promoters. The discovery will surely remain one of the most precious heirlooms transmitted by that era. Surgical *science*, properly so called, may be said to have come in with antiseptics; it matured with the expansion of bacteriology, and reached adult stability with the discovery of the Röntgen rays and other means of accurate exploration. I hope to demonstrate in the sequence of the pages of this treatise that it must also be recognized as an *art*; and that the name of *Surgeon* is merited only by one who is at the same time a profound and accomplished clinician and a prudent and skilful operator.

The surgical progress attained of recent years may be attributed chiefly to the adaptation to operative technique of recent discoveries in the exact sciences, especially in mechanics. For the past fifteen years I have continuously cultivated this adaptation in the case of every one of the capital operations of surgery. On these I have brought to bear all the fruit of long and laborious years of anatomical, histological, and bacteriological study, as well as of mechanical and mathematical experiment and research, in the practice of every individual surgical operation. Thus the reader will find in the present work the garnered harvesting of the surgical practice of a quarter of a century, tested by and filtered through my mind. The general methods described have long been studied; the details of each individual operation have been selected with care; the instruments, from the operation-table down to the smallest forceps, are all and each of well-tested type; most of them have been made, too, from original designs of my own, and under my own instructions. Thus I venture to express the hope that the present treatise will prove a reliable guide to surgeons of the present generation who wish to abandon time-worn errors, and profit by the latest results of surgical research and operative technique; and also present a reliable picture to the

coming generation of the full extent of our present conquests. The cinematographic films will recall my methods of practice, and enable the future reader to estimate the degree of advancement subsequently attained. And I here venture to suggest that a new discovery still less expected than that of Lister will be requisite to produce the next revolution in the art of surgery.

It is true that the pre-antiseptic surgery of fifty years ago would have displayed a degree of dexterity in such operations as amputation of the thigh which can hardly be surpassed to-day. On the other hand, the technique of hysterectomy—both abdominal and vaginal—of craniectomy, of gastro-enterostomy, and of intestinal resection, has (as I hope to prove in this treatise) reached a degree of perfection which can hardly be conceived, improved, and the simplicity of procedure would seem to promise a long period of survival. The same suggestion may be applied to the instruments. Those originally constructed according to primary mechanical principles, such as Heister's gag, and the tonsillotome and lithotrites of Charrière and Collin, have never been superseded; and the subpubic retractor with interfemoral fixation, for use in laparotomy performed on an inclined plane, the retractors for vaginal hysterectomy, the elastic compression forceps, and the instruments for osteal surgery, and that of other parts of the body, which have been devised by the author, and are figured in the pages of the present work, have been constructed with a degree of precision which gives him some hopeful grounds for believing that any future alteration in the structure of any of them must inevitably prove to be retrogressive.

I am, of course, aware that such views, with the prominence given to my own work in the present treatise, tend to make the reader suggest that this is too personal. But I have designedly adopted this position in the full belief that a writer can fully describe and explain only that which he has himself done; also on account of the fact that I am but carrying out the task which I imposed upon myself as far back as 1887—of renovating the surgical armamentarium, and creating a new and precise technique. Such aim is, of course, much too personal not to suffer if complicated by the admission of anything not either absolutely my own or thoroughly tested by me before adoption. And the encouragement which I have received from so many eminent foreign confrères, who have done me the honour of carrying out my operations, and of adopting my technique, and the sympathetic interest in my work which has been expressed by such men as Roux, Snéguireff, Kocher, Mickulicz, Simpson, Reverdin, Sklifassowski, Keen, MacCormac, Czerny, Virchow, and von Bergmann give me reason to hope that they, at least, will approve of my freedom of expression.

Importance of Renovation of the Surgical Armamentarium.

Renewal of the instrumentation of the surgeon's arsenal was the first essential step towards renovation of the operative technique. And I may add that anti-sepsis would have proved but a sterile discovery had not the perfection realized in the technique of the capital operations so soon con-

tributed to the extension of its domain. Then the desirable transformation of the surgeon's arsenal can be effected only by utilization of the progressive discoveries of the exact sciences, and especially of mechanics. Most surgical instruments used in the past generations were prepared by mechanics at the suggestion of surgeons who themselves were not experts in mechanical science; and who were, accordingly, obliged to depend on the skill of the instrument-maker, who had no direct knowledge of the requirements of his handiwork. Thus many instruments bear the names of surgeons, instead of those of the instrument-makers who really deserved the credit, having received but very incomplete instructions for their designs. The deficiencies of existing surgical instruments struck me at the onset of my student's curriculum in 1877 with special force, as for years I had been in the habit of using the tools of the cabinet-maker and the turner.

The first "cold" chisels which can be described as well formed and convenient to handle are those designed by MacEwen for the operation of osteotomy. They were designed with consummate skill, and the type became definitive. At the same period, M. Collin produced the Farabœuf's forceps with double articulation, which transformed the whole entery of operative surgery. I have carefully studied all types of instruments with the view of adopting those really suitable to surgical needs, and modifying or wholly reconstructing others. In this pursuit everything has been done in accordance with the theory and practice of scientific mechanics. Every model has been constructed with the view of attaining the most complete simplicity. The leverage of the arms of an instrument, and the temper of the steel of which they are made, have received equal attention from my instrument-maker and myself.

Among the types which demanded the most elaborate scrutiny in their preparation I may mention the *érasoir* and the instruments used in the surgery of the skeleton, which cost the labour of a good many weeks. And in some other departments I have found it necessary to expend much time and thought outside the domain of pure surgery: in the preparation of mechanical apparatus, as well as in the transmission of electric power along flexible conductors for the working of saws and drills. Many of those instruments have been counterfeited, often so clumsily as to lead to danger in application—for instance, the elastic intestinal clamp which, badly copied, has crushed the coats of the intestine; whereas that constructed by M. Collin secures coprostasis without production of the slightest anatomical lesion. Nevertheless, I advise young surgeons to invent no new instruments before mastering the manipulation of those already in existence. The arsenal of the surgeon should be as simple as its demands make possible; its contents are already very complex indeed.

Method in Surgery.

Superiority of the Anatomical Method. The adoption of a *method* is absolutely necessary in surgical practice, and this *method* must be carried out in every operative procedure. Method consists in the observation of

general laws, and surgical technique should be subordinated to such laws. My method, which is that expounded in the present work, is characterized by a single quality: it is the *anatomical* method. The principle which governs it is rapid dissection of the attachments of a tumour, and removal of the same from the organism, without disproportionate preoccupation with regard to its own structure, but with the minutest care in preserving the surrounding healthy tissues which are destined to carry out the process of repair. The neoplasm is extirpated while making an *anatomical preparation* of the seat of its growth.

The reader may here contrast the technique of my practice in thyroidectomy or hysterectomy with that of former methods, in which the operator proceeded to follow the outlines of the tumour when exposed, at the risk of not passing widely enough beyond its limits when dealing with cancer. He circumscribed it with ligatures or hæmostatic forceps, following the margin of the neoplasm as his sole guide; a great deal of blood was lost, and the tumour was detached with much difficulty. In the method of progressive ligatures — that of Billroth and his school — most of those were applied to quite minute vessels, and the field of operation became greatly encumbered by a host of those foreign bodies. When the application of forceps — the method of Péan — is preferred, the wound may be crowded with as many as fifty or sixty of these instruments; and most of these must be replaced with ligatures in order to avoid secondary hæmorrhage, which is so likely to prove unmanageable. But whether the method of progressive ligation or that of preventive forceipressure be adopted, the patient loses much blood during the isolation of the tumour from the venules and capillaries to which neither forceps nor ligature can be applied. The field of operation is exposed all the time to the germs of infection, and without power of resistance, contused and devitalized by the pressure of ligatures, and of the jaws of forceps. Thus it is left in a condition quite unfavourable to cicatrization. Such modes of procedure are as trying to the spectators as to the operator; much blood is inevitably lost, and the surgeon's resources become so far overtaxed that he sometimes forgets the topography of the locality in which he is wandering. Thus it is that sometimes neither operator nor assistants notice when the superior laryngeal nerve is being tied during the course of a thyroidectomy, or the ureter in extirpating a tumour of the broad ligament.

From the beginning I had always been impressed with this abuse of forceps and ligature in a field where no considerable vessel existed. When I began to operate for myself, in 1885, I soon convinced myself that the great vascularity of certain solid tumours of the abdomen was almost exclusively venous, and quite beyond proportion to the local arterial development, which had remained almost normal. I then practised rapid isolation of those tumours from their anatomical attachments without attending to the venous channels, while limiting the process of hæmostasis to the afferent arteries. The method proved successful; a retroperitoneal tumour of 30 kilogrammes in weight was removed in the course of a few minutes, by subserous decortication and without immediate application of a single ligature. The extensive cavity was then filled with a packing of sterilized napkins, and I was obliged

to tie not more than three or four arteries, and eight or ten veins, of appreciable calibre. The *method* was discovered; I had now but to apply it throughout the whole domain of surgery.

Thus the general technique of the operation is now always the same; whether it be the extirpation of a neoplasm, or the ablation of an organ such as the kidney; or the removal of a goitre, a tuberculous gland, or a retroperitoneal tumour. The accessible pole of the tumour is exposed; the growth is then rapidly isolated from its cellular capsule, so as to permit the passage of the fingers or hand, according to its size, around it; and thus detach it from whatever important organs and neuro-vascular trunks with which it may be in contact. Forceps traction may, of course, help to facilitate the process in suitable cases.

Consider the removal of a large glandular mass from the carotid region. The operation proceeds slowly till I have found somewhere on its periphery preferably above or below—an areolar interval along which the index finger can be passed under the growth. The deep surface can then be felt, and I am able to decide whether complete extirpation is possible and if the growth can be isolated from the subjacent vasculo-nervous structures. In the course of this procedure my fingers have never wounded an important vessel. The middle finger can readily follow the index, and by curving both in crotchet shape, the tumour can be raised without difficulty, so that by four or five snips of the scissors it can be detached without a jet of blood or injury of a single nerve trunk.

Such operations can be similarly conducted in all cases. When dealing with a goitre, I begin by careful ligation of all superficial veins which were necessarily divided before exposure of the tumour. When the field of operation has thus been exposed, a moment suffices to sweep the index finger around the growth, and to detach it from the investing capsule; then to pass to the deep surface, while the index and medius of the other hand function as a retractor of the upper lip of the cutaneous incision; and the fingers of the same hand, which have passed beneath the sternum, dislocate the growth through the external wound. The pedicle is then isolated, and each section of the same is ligated outside the wound, thus without any risk of involving the superior laryngeal nerve. A single movement of my *céraseur* detaches a small segment of the gland structure from the morbid mass, and the same is left in the wound to secure prophylaxis of myxœdema. The tumour by itself causes me little anxiety; my care is all directed to the locality of its growth and the important organs in contact therewith, which must be respected in the process of removal. The same general method of procedure is adopted in a case of hysterectomy. The abdomen is laid open, in the Trendelenburg position; the pouch of Douglas is exposed; and inflamed tubes or posterior fibromata, if present, are removed. The vagina is perforated on a long, curved forceps. If the upper border of the broad ligament entangles the growth, it is divided between two pairs of forceps. The cervix is then grasped with my crotchet with sliding catch, and detached, first from the vagina, then from the bladder. The uterine arteries are clamped, if bleeding; and the

6 SURGICAL THERAPEUTICS AND OPERATIVE TECHNIQUE

uterus is detached by turning from right to left, towards the operator. The blood of a fibroma re-enters the general circulation through the veins of the broad ligaments as the uterus is drawn upwards, so that at the close of the operation, after ligation of the uterine and ovarian arteries, the patient will have lost less blood than the subject of a supracervical hysterectomy in which preventive hamostasis has been carried out by the application of an elastic ligature to the uterine pedicle. And, as the operation has been no other than a dissection of the broad ligaments, with the conservation of the peritoneum essential to closure of the pelvic cavity, the process of repair can be carried out to completion; and the pelvic region reconstituted in the anatomical conditions most favourable to restoration of health.

As a final example, let us take a case of cancer of the breast with slight growth of the axillary glands. The mamma is circumscribed by two curved incisions, the upper lip of the wound is raised with the aid of a clawed forceps, and the subcutaneous areolar tissue is divided, outside the margin of the gland, down to the aponeurosis of the great pectoral muscle. The mamma is then detached from this muscle as far as the outer border of the latter; the margin of the pectoralis minor is exposed; and, through an incision in the deep fascia of the axilla, the costal wall is reached, as well as the latissimus dorsi muscle, of which the deep surface is then dissected down to its free margin. Thus the operation consists of a complete anatomical dissection of the axillary space; the contents of which are completely evacuated, first from the front and interior, then from behind and below. The whole mass, which includes in its entirety the mammary gland itself, and the lymphatic vessels and glands of the axillary fossa, without omission of the posterior group (so often forgotten) which lies between the costal wall and the deep surface of the latissimus dorsi muscle, now remains but its superior attachment, on the plane of the vasculo-nervous bundle, from which I detach it after applying the necessary ligatures. The lymphatics of the axilla, with the corresponding lymphatic glands, and the surrounding fat in which they are embedded, are thus removed *en masse*; without the necessity of taking special thought for either their number or precise locality. The area occupied by the mammary gland, and that of the entire axillary fossa are completely evacuated by anatomical dissection. The technique adopted is the same whether the cancerous growth be large or small, whether the axillary glands engaged be many or few, the history being made, in every case, to follow the outer limits of the axillary space, as I consider that too much tissue is never removed in any such procedure. The operation, in every instance, is an anatomical preparation of the external pectoral region and the axillary fossa. I think far less of the tumour itself than of its anatomical relations. When the dissection has reached a certain stage, the detached neoplasm falls away into my hand.

Thus I propose to substitute a more rational and effective method for the preventive hamostasis of forceps and ligature, which was combined with slow dissection of the morbid growth; my method consisting of rapid exposure of the attachments of the tumour and its immediate enucleation

by dissection of the region in which it is implanted, hæmostasis being limited to the afferent vessels and, in general, to those of a certain importance from which bleeding has commenced. My sole and constant preoccupation is with the anatomy of the field of operation, whether modified or not by the development of the neoplasm. My fingers have by this time been educated to discover the anatomical modifications which are due to pathological influence; tactile sensibility, when thoroughly educated, can be relied on to recognize at first touch the tissues and organs that must be respected, to discover the pedunculation of tumours, and to explore the outlines of areolar interstices, while deciding whether the margins of the same are healthy or pathological. Thus, after extirpation of the tumour, the field of operation should resemble a careful dissection of the region.

It has been alleged that I neglect hæmostasis to secure a rapid and brilliant operation. This criticism cannot be justified. I compress and tie every important vessel divided, and no surgeon takes more care to practise hæmostasis in connection with small vessels when it is really essential to do so; as, for example, in peritoneal operations. But one of the results of my method is that fewer vessels are wounded than if I resorted to the older forms of procedure. It is because each of my operations is a precise and methodical dissection of the region involved, and that nothing is left to chance, that they are almost bloodless, and that I require to do but little in the way of hæmostasis. Assuredly a scientific and logically reasoned technique curtails the time-period of capital operations, and nobody can henceforth dispute the fact that surgical success depends upon technical perfection.

The Necessity for Method in Operation.—I have pointed out the importance for the surgeon of following a definite *general method* in all operations. This, which, as adopted in my own practice, I have called the *anatomical method*, consists, not of following the outlines of the new growth, as was formerly done, but of defining the important organs which surround it, and making a genuine *anatomical preparation of the region in which it has developed*. I now wish to show how necessary it is to operate methodically. No operation can be reliably completed without provision and preparation, even down to the smallest details. This double necessity of adopting a surgical method and of applying it in operations can be most convincingly demonstrated by the cinematograph. In examining on the screen the course of one of my operations—craniectomy, hysterectomy, or resection of the knee-joint—the observer can see that the field of action is entered freely and without hesitation, and that the various stages of the procedure succeed one another without either precipitation or interruption. The movements are all precise and premeditated, the operation is carried out with the same care as in making an anatomical preparation, and the observer can follow it out through the course of every one of its details. The procedure occupies less time than would be guessed from the general impression made, simply because the operator has made no gestures or any superfluous movement of any kind; not because he has made haste. In order that this result be realized, many conditions must be fulfilled. The

diagnosis must be established beforehand, and with precision. Both operator and assistant must present the essential qualifications of surgery— manual dexterity, presence of mind, and physical energy— for it must be remembered that many operations elicit the display of a muscular prowess far above the average. Then the operating theatre must be thoroughly arranged and furnished in every detail, from the windows which admit the light, and the operating-tables, and those on which the instruments and accessories are arranged, down to the condition of the instruments themselves; of the arrangement of the dressings, drainage tubes, compresses, and bandages; even down to the reliability of the needle's eye and of the silk thread with which it is armed. Everything is so arranged as to contribute to promotion of the end in view, to facilitate and simplify the operation, and to complete the work in hand with the minimum expenditure of time and of effort, mental and physical. The cinematograph shows the necessity for turning the operation table sometimes fully 180 degrees around its axis, and how the patient must be sometimes suddenly inclined forwards through an angle of 15 to 20 degrees— or be turned backwards and downwards, through an angle of 45 degrees, into the Trendelenburg position. The arrangement of all the necessities— tables, instruments, antiseptics, washing-basins, etc.— should be adapted to the same objects; nothing should be beyond immediate reach, and no crowding should embarrass the operator's freedom of movement. The reader need hardly be reminded how the crowding of tables and assistants, or imperfect arrangement and incomplete preparation of instruments, can confuse and embarrass the most skilful operator at a critical moment. And I must here express my gratitude to the cinematograph for having demonstrated to myself more clearly than all previous experience had ever succeeded in doing, how false movements can be avoided, and invaluable time saved in the conduct of operations. When the proceedings have to be registered by the cinematograph, the assistants are thoroughly trained beforehand; every ligature has been cut to the proper length, and placed on a special tray in its assigned position. All the instruments to be used are told off for sterilization in a dry stove, a method which causes far less deterioration than does that of boiling. And when the operation is about to commence, they should be arranged by the surgeon himself on a sterilized napkin in a definite order—the same for each operation, and each item is verified a second time. My technique is uniform along every one of its main lines; and, in order to anticipate accidents, a full set of the same instruments is arranged on the same table, and in the same order. The surgeon who has to call out for a forgotten instrument in the midst of a capital operation may well be compared to the hunter who finds, when in presence of his "big game," that he has forgotten his cartridge-belt! And, in fulfilment of a duty to the memory of my great predecessors in this field, I must recall the fact that the earliest drafting of such schematic arrangement of instruments for each of the principal operations is to be found in the treatise of Dionis (1782), whose lectures in the Jardin du Roi first gave orderly precision to the mechanical details of surgical procedure.

**Parallelism of the Evolution of Surgical Asepsis and the Progress
of Public Hygiene.**

We may readily admit that while the discovery of antiseptics proved the starting point for the improvement of public hygiene, the subsequent progress of the latter may be credited with the advancement of surgical practice. Briefly stated, operations are now more successful because both surgeons and patients wash more frequently and carefully; we can affirm that antiseptics would prove useless without cleanliness—that is to say, asepsis. Surgical progress has been a direct consequence of the discovery of the application of antiseptic methods, without which visceral surgery could never have emerged to light. But antiseptics did not do everything. The true precursors of Lister were the pioneer ovariectomists, whose success was wholly due to the fact that they operated with an attention to cleanliness which was then unknown to general surgical practice. A century ago cleanliness was utterly neglected in surgical operations, as the mass of the people were ignorant of the most elementary rules of personal hygiene. Most dwellings were insanitary, children wallowed in dirt, and the use of warm water, even in the toilet of the wealthy, was scorned as a useless refinement. Physicians and surgeons bathed no more frequently than did their patients, to whom they transmitted the germs of disease on their hands and under their finger-nails. The mortality of parturient women corresponded then to that of the subjects of capital operations in the public hospitals, thanks solely to inoculation by the physician and the midwife.*

In those days at the Hôtel Dieu, Rheims (1877-1880), the instruments, very imperfectly cleaned after the previous operation, were brought forth dusty and rusty, and strewn without order on the battered and untidy metallic trays; and the surgeon cultivated the long index-finger nail, with which he picked off the crusts and scabs of wounds and of cutaneous eruptions, while he barely washed his finger-end (if even so much) after digital examination of a case of syphilis; and the Professor of Obstetrics conducted the midwifery pupils from the bedside to the mortuary, to assist in the post-mortem examination of the cases of puerperal fever. When the result of an operation was most unfavourable, the patient died of a *diathesis*; for instance, an attack of *hyperacute rheumatism*, the manifestation of a *dormant diathesis* which had been *awakened by a traumatism*, was credited with the destruction of life. Errors of quality so gross were fostered by the teaching of physicians, who were surgeons only in name and privilege of function; and who prejudiced the progress and reputation of French surgery so far and so long as to give good grounds for the severe comment of Billroth: that it followed German surgery "with slow and limping footsteps."

We now recognize the fact that in disinfecting the epidermis it is not enough to dip the hands in an antiseptic solution; immersion must be preceded by a series of washings with soap and warm water. *The surgeons*

* Our surgeons even then included many accomplished clinicians, but it must be admitted that they did not know how to wash their hands.

10 SURGICAL THERAPEUTICS AND OPERATIVE TECHNIQUE

of the transition period proved refractory to antiseptics, because they had been brought up in a period in which personal cleanliness was generally neglected. Public hygiene is deeply indebted to the discovery of Lister, who first opened up the pathway to progress by making a rational and practical use of the discoveries of Pasteur. The adoption of antiseptics in surgery was followed by the microbicidal use of the same substances at the toilet-table and in the prophylaxis of infectious disease. As usual, antiseptics soon raised an army of detractors: they opposed it with asepsis, and declared that the application of antiseptics was irritating, and even dangerous. But asepsis is no other than cleanliness, carried out to the stage of extermination of pathogenic germs. It cannot be separated from antiseptics, for it cannot be realized on the surface of the body, or on instruments and dressings, but with the aid of antiseptic agents— that is to say, of chemical and physical disinfectants. The principal step of advance upon the primitive technique of antiseptics that has been secured by the vulgarization of the aseptic method has been the substitution, in all suitable cases, of heat, dry or moist, for the application of chemical substances; and the consequent suppression, so far as possible, of the use of chemical antiseptics; which are always irritating, and sometimes toxic, in quality. The tissues of the human body, while healthy, are free from microbes. Thus the peritoneum, in an ordinary case of ovariectomy, is quite aseptic; and accordingly it is judicious to avoid irritating it by contact with chemical antiseptics. Experience has proved that the use of instruments and ligatures rendered aseptic by dry heat gives better results than their immersion in the formerly consecrated 5 per cent. solution of carbolic acid. Repeated soapings with aid of water as hot as can be borne, secure the best disinfection of the skin; and prepare it for the final ablution with an antiseptic fluid; which, by itself, would not have sufficed to purify the epidermis.

We must here remark, in passing, that the popularization of antiseptics in surgery and obstetrics has greatly influenced the care of the person among all ranks of society. Most educated people would now feel disagreeably surprised, when visited by a surgeon, if he did not wash his hands carefully in soap and warm water before using his sublimate solution, and repeat the same process scrupulously after examination of his patient. So that, far from depreciating the value of the work of Lister, we have shown that as a result of his great discovery asepsis has taken its place among our daily habits; and that the personal cleanliness which has of late years penetrated to rustic life, developed and became popularized *pari passu* with the culture of antiseptics, general and special.

Asepsis is not Everything in Surgery—Importance of Operative Technique.

—We now know that both antiseptics and asepsis have become necessary to surgical practice; the logical result of our previous statements in this regard is that there should be no antagonism—without antiseptics modern surgery could not exist. Both contribute to the security without which the operator would be impotent; nevertheless, modern surgical progress should not be attributed to them alone. The discovery of antiseptics would have remained relatively sterile if surgeons, encouraged by the success of the new method,

had not revolutionized operative technique. Their study is that of the ABC of surgical practice, while the practice is comprehensible to all who will but study it. It is the *rudè-mecum* not only of the surgeon, but of his assistants, of his patients, and, in fact, of all those who approach him. But the practice of antisepsis will not, by itself, make a surgeon; and, while admitting at the outset that every medical practitioner should be initiated in the rigorous practice of antisepsis, we conclude that the best results must necessarily be attained by the most skilful surgeon, the master of the most perfect technique. On this account, the author begins the present work by describing in every detail the practice of antisepsis and asepsis; and then proceeds to indicate, in connection with each individual operation, the technique which places the patient in the best conditions for rapid and uncomplicated recovery. It is the excellence of technique that distinguishes the surgical artist from the mere manipulator.

INTRODUCTION TO "SURGICAL TECHNICS" *

1. Pasteur and Lister.

THE teaching of surgery includes (1) the study of the various affections which require operative treatment; and (2) a description of all operations indicated; inclusive of antisepsis, instrumentation, the care of the patient before and after operation, etc. The former of these divisions constitutes *surgical pathology*; the latter, *surgical technique*, or the practice of the art of surgery. The increasing output of textbooks dealing with external pathology contrasts so strongly with the poverty of works dealing with surgical operations, that the author of the present work has it a desire to fill the vacancy; and he ventures to express the hope that this treatise will be found to summarize the knowledge indispensable to the skilled practice of surgery.

Surgical Technics.—My "Technique Chirurgicale" includes the whole sum of the knowledge which is indispensable for the practice of surgery. This work is the complement of Farabeuf's "Précis de Manuel Opératoire," which has not yet been surpassed. Farabeuf's work is, in fact, to use the expression of the master himself, *a treatise of professional manual instruction destined for the education of the hand*. He voluntarily limited himself "to description of the regular operations which should be taught and repeated on the cadaver before being attempted on the living body." Passionately devoted to anatomy, he had never practised surgery; and "did not wish to discuss special operations, because he had had no experience of them."

Special operations deserve to be submitted in their turn to a well-defined technique—one perfect enough to require but some modifications of detail in particular cases. Ligations and amputations which have hitherto been regarded as "regular operations"—are they not submitted to very similar modifications of technique when practised on the living? We operate on the cadaver in order to acquire manual dexterity; we should operate on the living body only when we possess the degree of manual dexterity which should be required of every surgeon. Accordingly this work is intended not for the student, but for the practitioner; and the operations which are included cannot be tried on the cadaver to any useful purpose. "We repeat on the cadaver," said Chassaignac, "the ligation of an artery or an amputation; we do not repeat an operation for strangulated hernia, or the ablation of a tumour." For the same reason we cannot usefully perform a vaginal hysterectomy or a craniectomy on a subject in the lecture theatre. Verify the relations of the normal uterus with the bladder and ureters before attempting your first hysterectomy, if

* Masson and Co., Edition 1897.

you feel the necessity for doing so. But with what useful purpose can we remove a uterus from the cadaver, that will give us any of either the visual or tactile sensations which we must subsequently experience in the living body? Begin with an easy case, and you will avoid wasting your time, and soiling your hands to no purpose. Do you wish to familiarize yourself with the manipulation of my instruments for osteal surgery? It is useless to try a craniectomy on the cadaver, where you would form no idea of either the vascularity of the subcutaneous tissue, or of the slight adherence of the pericranium to the bone.

He who attempts these operations should previously possess a certain experience of general surgery. It will then suffice to practise the special manipulation of burrs, of saws, and of mortising instruments; a small piece of dried bone will be enough for this purpose. Macerate a human skull, with a few femurs and tibiae, for two hours in a 2 per cent. solution of formic aldehyde (concentrated formol of 40 per cent., 2 parts; water, 98 parts); then fix in a vice the bone you wish to attack; and you have collected, at a very small expense, all the material necessary for study in your operation theatre. I will go even further; the practice of operative procedures on the cadaver is insufficient for the attainment of expert operation on the living body, even in case of the so-called "regular operations." The "surgery of the dead" is necessary for the practice of the hand, and to acquire the ready use of instruments; but he who possesses only the practice of the lecture theatre runs a great risk of not being able to perform a simple amputation suitably when he has become a practitioner. In the living body, it is not enough to amputate the limb; it is necessary to know the conditions required to obtain a cure. In recent years we have constantly heard: "The operation was quite successful, but the patient is dead." An operation should be regarded as successful only when followed by cure.

The practice of operations on the living is above all subordinated to clinical considerations. Amputate the thigh above the middle for a white swelling of the knee, and you can adopt the procedure chosen by Farabouf, that of amputating with a large anterior and small posterior flap. Follow in every point the excellent description of the master. Drain the wound and suture the skin. If you practise antisepsis, you will have an immediate remission in eight days, and a perfect stump is formed. Adopt the same procedure in a case of traumatic gangrene with evolution of gas, or one of grave streptococic infection; the stump, thus inconsiderately sutured, becomes infected, and the patient succumbs. Circular amputation, with rigorous resection of all morbid tissues and application of moist antiseptic tamponing, is undoubtedly the treatment to be chosen in such cases, and is the only one which is followed almost certainly by cure, even in diabetic and albuminuric subjects.

Accordingly, I will avoid the description in this treatise of those operations of the amphitheatre which are but seldom practised on the living body. I will devote myself more fully to the technique of ligation and other operations which are carried out, when we have become accustomed to blood,

on the living in the same way as on the cadaver (ligature of lingual, carotid, external iliac arteries, etc.); the practitioner who is broken in to the study of operative manipulation can follow from point to point, for the sake of good leadership, the descriptions given by Farabouf. On the other hand, I will point out the clinical particulars which should guide the surgeon to adopt, and prefer, in special cases a technique which is quite different, even in "regular operations," and which, in the cadaver, would seem to be unsuitable.

This book will be divided into two parts. The first will comprehend all that relates to the practice of surgery, as looked on from a general point of view; the second, a description of the special operations. From these latter I have eliminated methodically all exceptional procedures which are applicable to particular cases only. My operative technique is a general one, precise and unvarying; so that each type of operation suits all individual cases, with some simple modifications of detail.

2. The Necessity for Operating Rapidly and Well.

REVOLUTION AND REJUVENESCENCE OF SURGERY RESULTING FROM THE DISCOVERY OF ANTISEPSIS — THE NECESSITY FOR ADOPTING SIMPLE AND PRECISE OPERATIVE PROCEDURE.

The actual practice of surgery carries with it the rigid observance of antiseptic, and the laws of antiseptic are absolute. In keeping with these conditions, the author of the present volume will describe with the same rigorous precision all the types of operative procedure which, by their alliance with antiseptic, may in each case be regarded as a complete and indivisible unit. The immortal discoveries of Pasteur and the priceless achievement of Lister in the application of the same are familiar to the eyes and ears of the whole civilized world and have inseparably associated the names of two of the greatest benefactors of humanity. The former, after exploding the last defences of the doctrine of spontaneous generation (which still finds a very occasional champion), demonstrated by his memorable experiments the microbial origin of furuncle and that of gangrenous septicemia, and discovered the true cause of infection of open wounds, that obscure and murderous enemy which had previously eluded the healers of all the ages. Lister then studied the possibilities and practical means of removing the same from the field of operation, and in time succeeded in dictating to the surgeons of the civilized world the laws which should govern the practice of antiseptic.

Renovation of Surgical Practice by the Introduction of Antiseptics.—The general acceptance of Listerism meant the rejuvenescence of surgery. The pioneer ovariologists, as yet few in number, practised an imperfect asepsis, as if instinctively and without any knowledge of scientific rules and conditions, and were accordingly disconcerted by failures then inexplicable. The majority of all cases of operation, including even the minor ones, ended fatally; even that on an ingrowing toe-nail might lead to a fatal attack of

septicæmia or erysipelas as readily as would one of the major amputations. One of my former colleagues of the intern department was circumcised by a prosector of the Faculty of Medicine, who was in daily practice of manipulating dead bodies—and at the present day does so as professor—with the result that he died of fulminating septicæmia. Such occurrences were frequent in our metropolis some twenty-five years ago, and were still more disastrous in the provinces where, in keeping with the existing hospital routine, infection manifested itself in its most virulent types—*gangrenous septicæmia, hospital gangrene, tetanus, erysipelas, puerperal poisoning*. Those were the days in which the operating theatre of the Hôtel Dieu at Rheims was known as “La Barberie,” from the old custom of cutting off the hair and beard of those who died in the hospital; it fulfilled varied functions even in 1880. The male and female barber were on duty every day, and served the externs with *café au lait*. The latter prepared the poultices, administered the douches in the female wards, and performed a number of other necessary duties. Monsieur le Barbier carried out corresponding duties in the male wards, assisted at the autopsies, prepared compresses and bandages, and the waxed threads which served for ligatures of arteries, of the same quality as those employed in the post-mortem room, which was but a step from the door of the operation theatre. The latter fact enabled the hospital administration to employ a single official for the service of both compartments. It should be added, however, that a good many cases of capital operations recovered after liberal tamponing of the wound with charpie, dusted with equal parts of the respective powders of charcoal, quinine, and alum, which gave specially good results; and the amputation stumps covered with this astringent and with Guerin’s wadding dressing cicatrized, after copious suppuration, in four to five weeks.

Progress of Visceral Surgery.—At that epoch the doctrine of antiseptics was still very much opposed in France; even in Paris Listerism was strictly practised by three surgeons only: L. Championnière, Terrier, and Périer. It was then confined to ovariectomy. The field of its life-saving application, then limited to ovariectomy, has now extended to solid tumours of the pelvic cavity, and includes the most varied types of radical operation on the liver, spleen, stomach, intestine, kidney, pancreas, and lung. Casarian section, which was formerly practised only on the moribund or directly after death, has become so safe that some women have successively given several infants to the world in this way. The cranium can be fearlessly opened, and a whole cerebral lobe explored, within less than ten minutes. The surgery of the limbs has progressed in like measure: conservative resections, osteotomies, and osteal sutures have taken the place of amputations; goitres are extirpated without risk; hernia is no longer an almost incurable condition; the suturing of tendons, of nerves, and (more recently) of veins and arteries, is the present heritage of many laborious and successful experiments; and reports of sensational cures are continuously streaming in from all the great communities of civilization.

The Conquests of Anæsthesia and Antiseptics were followed by a Regrettable Reaction against the Brilliant Methods and the Manual Dexterity of the Older Surgeons.—All conquests have their shaded aspects, and the victory of Lister proved to be no exception to the rule. The unquestionable benefits of antiseptics made people neglect or forget the brilliant qualities of its pioneers. Thus young licentiates, hungering for the reputation of great operators, believed that Listerism was everything in practice. Anatomical and clinical attainments soon began to be depreciated, as very second rate accomplishments. The pupil came to regard the slow dissection carried out by his master, with the respective aids of anæsthesia and antiseptics, as the perfection of surgical achievement. Thus some months' assistance at the operations of a well-known surgeon, and the purchase of a glittering cabinet of instruments—often as useless as varied—started the surgeon on his career of activity. He was very soon looking out for an ovarian cyst or a salpingitis!

Objections to Over-Specialization.—It is a painful fact that many young surgeons, who are incapable of forming a resolution to abandon the pleasures of large cities and secure the esteem of a country clientele, assume the role of *specialists*, and immediately proceed to undertake the gravest operations. They should wait for their experience; it requires but little knowledge to perform a surgical operation. It was well known that celebrated ovariologists developed from a few years' clinical assistancy with an established expert. They had but hazy notions of anatomy and of medicine. But they could incise the abdominal wall of a female patient with a fair proportion of mechanical skill. And their efforts were often rewarded by the discovery of an ovarian cyst or a uterine fibroma, although it was sometimes a pregnant uterus, or more rarely a tumour of the liver, kidney, or spleen. A tolerable percentage of recoveries was obtained, or at least published. Thus developed the laparotomy specialists of some of the great communities, and thus did they pass from ovarian tumours to those of other organs, and from the abdomen of the female to that of the male.

At the present date we have two great divisions of peritoneal surgery. One of these is occupied by the *gynecologists*, who devote themselves to the genital organs of the female; the other is claimed by the *surgeons*, who add to the general surgery of the body that of operative interference with the abdominal viscera of the female other than the uterus and its adnexæ. The differentiation is decidedly regrettable; the really skilful surgeons must always form a very small group, and the operator who excels in pylorotomy and in operations on the liver or kidney must necessarily possess superior skill in operation on the uterus or ovary, to that attained by those who limit their procedures to the gynecological group. It should be definitely recognized that over-specialization has of recent years become a genuine source of public danger, many practitioners having no other object in the adoption of a specialty than that of securing an easier existence with better remuneration. The evil would be fairly tolerable if the unskilled gynecologists limited their activities to minor operations. But such prudent reserve is not one of their accomplishments. Then such special procedures as enrettage, colporrhaphy,

and perineorrhaphy represent in very many cases the useless employment of hours; the result is merely accessory. Gynæcological cicatrices are always well secreted, and the female patients who leave unskilful hands very much worse than before are usually among the most discreet. Antisepsis is notably difficult to practise in cases of the minor operations, such as those above referred to; and the "conservative gynæcology" which is practised unnecessarily in thousands of cases, often increases the sufferings of the patient and leads to the final mutilation of hysterectomy, which would have surely been avoided by the adoption of a judicious and rational therapeutics. The multiplicity of operations is one of the evils of the present day, of a period in which all the large communities are over supplied with specialists—of the development of a thousand laparotomists where but two or three could be found in the early days of antisepsis. The incredible vogue of *curetage* among females, which the unscrupulous specialist adroitly recommends as an urgent and delicate surgical procedure, is one of the warning examples; another is the diagnosis of, and operation for, appendicitis, preferably in the male, performed without reasonable indications. Such abuses of the privileges afforded by the licence to practise a noble and philanthropic profession should surely be exposed and condemned; they bring discredit on the name and the practice of surgery; they go a long way towards neutralizing the value of the inestimable gifts conveyed to suffering humanity by the discovery of anesthesia and of antisepsis; and they account for the fact, which is now seldom discussed in public, that the actual mortality of operations in the present day is really quite considerable. The fact must be recognized that there are surgeons practising among us who take very little thought for human life, especially in hospital practice, and that the majority of failures and fatal results are due to want of scruple or want of skill, or of both, on the part of the operator.

Surgery should ever remain an Art: all Surgeons should be true Artists.

Surgery is one of the noblest of arts; too many of its practitioners have made it a trade. Its operations were at the beginning of the past century, the appanage of a few, and surgeons regarded the accomplishments and reputation of being a brilliant operator as the highest attainable honour. They knew how to amputate injured limbs on the battlefield without the aid of anesthesia or of antisepsis, and often with brilliant results. Rapidly conducted operation has fallen quite into abeyance since the time of Maisonneuve; it would surely be well to resuscitate it, and combine it with our present antisepsis.

Hæmorrhage in Peritoneal Surgery.—The dread of hæmorrhage which preoccupied the early ovariologists is easily accounted for. In their day peritoneal hæmorrhage was a fatal occurrence. Those pioneers who instinctively practised asepsis succeeded because they operated with great caution; they cauterized the small vessels, and controlled any escape of intestinal coils by holding back with warm napkins. They avoided intra-peritoneal manipulation as far as possible, and adhesions were regarded as a grave complication. The pedicle, securely ligatured, was fixed at the

lower angle of the wound, and the abdomen was closed with the aid of metallic sutures. No ligature, or other foreign body, was left in the serous cavity. The tremulous hesitation of that period, instead of leading to simple and effective methods, gradually increased, and surgeons came to display a degree of caution of almost despairing tone and quality. The fear of hæmorrhage was so exaggerated that fifteen or twenty minutes were often devoted to hæmostatic methods among the arterioles and venules of the subcutaneous tissue. The same slow circumspicion attended the opening of the serous cavity, the puncture and evacuation of the cyst, the extraction of the sac, the ligature of the pedicle, and the closing of the abdominal cavity.

Spencer Wells and Kœberle operated with Greater Simplicity than their Followers.—Spencer Wells and Kœberle operated with greater rapidity and dexterity than did their imitators, who abused the practice of hæmostasis. They usually employed for ovariectomy but ten hæmostatic forceps and ten sponges. These were carefully counted, both before and after the operation. Their imitators, growing more and more forgetful of the brilliant and rapid methods taught them in relation to general surgery before the introduction of antiseptics, complicated to an extravagant degree the instrumental apparatus of laparotomy, and went on increasing the application of hæmostatic forceps till they actually reached the number of sixty in a single case, as we learn from Péan's observations.

Inconveniences of Esmarch's Bandage.—Esmarch's bandage was adopted for application in the surgery of the limbs. Amputations were thus carried out in a clear field of view; but on removal of the compression, the dozens of arterioles which had been paralyzed for the moment by the energetic constriction, spouted their crimson fluid like so many miniature fountains. The whole surface of the stump oozed blood, and despite the application of several dozens of forceps, followed by as many ligatures, the amount of the hæmorrhage was often quite considerable—300 to 400 grammes, or so. Petit's mode of compression was followed by none of those reactionary inconveniences; it was brought to bear on the principal artery of the limb only. Thus the use of Esmarch's bandage notably increased the time spent in large operations; when the band had been removed and hæmostasis was established, the suturing of the skin wound and the drainage still required fifteen to twenty minutes. Thus, an amputation of the thigh lasted, even in the hands of a skilled operator, up to forty or fifty minutes; while, in case of a surgical novice, an hour to an hour and a half was always required.

Overattention to Preventive Hæmostasis, which was more logically practised in the Ancient Period of its Original Application.—The practice of preventive hæmostasis extends of necessity to the whole domain of surgery. Some operators tied the vessel beforehand, and then divided it on the distal side of the ligature; or, when there were very vascular adhesions, between two ligatures. Others applied hæmostatic forceps, and tied all the vessels at the close of the operation. Others, again, divided the individual vessels between a forceps and a ligature, the latter being

placed on the cardiac side. The idea of leaving forceps in position for twenty-four to forty-eight hours after operation was suggested by a good many surgeons in case of very deep wounds and in lardaceous or very friable conditions of the perivascular tissues, which rendered the application of ligatures almost impossible.* But surgeons came in time to compress every tissue methodically, even when no considerable vessel was present, and the surgeons of highest repute adopted that laborious form of procedure. Nevertheless, despite the use of this cumbersome hæmostatic apparatus, troublesome hæmorrhage, primary or secondary, had sometimes to be dealt with. This fact led to increased circumspection, which, combined with forgetfulness of elementary anatomical facts, produced the imaginary discovery of large vessels in positions where such had never been previously described.

The Surgeons of Former Ages used a Simpler Technique and had less Fear of Hæmorrhage than those of the Schools of Billroth and Péan.—In reading the works of the surgeons who followed Ambroise Paré and copied his methods, we are struck by the simplicity and efficiency of their technique. Thus Dionis (*Cours au Jardin du Roi*, 1707), in describing perineal section, barely refers to the fact that there may be some escape of blood, and gives no directions for the arrest of hæmorrhage during the operation. The dressing consisted of a procedure of antiseptic plugging (*tamponnement antiseptique*) with pellets of charpie, covered with astringent powder or balsamic ointment; the patient was then placed in bed on several folds of sheeting, which protected the mattress from the blood or urine which must escape during the first few days. In operation for strangulated hernia he ligatured and resected the omentum. In castration he ligatured the spermatic cord *en masse*.

In amputation of the breast, says Dionis, "if there be too copious an escape of blood, we place a button of vitriol on the mouth of each bleeding artery. When there is no serious hæmorrhage, we cover the wound with pledgets covered with astringent powders. When the mammary artery yields too much blood, we apply a ligature" (p. 274, Fig. 18, N. O). Dionis repeatedly figures the ring-handled forceps, with the ligature placed in position around its jaws, ready to be pushed on to the vessel. "For removal of nasal polypi we take a large curved needle of lead or brass wire, and eye it with a large wax thread, in the middle of which we make a slip-knot that we adjust on the end of a raven's-beak forceps as if about to ligature the end of a vessel" (p. 574, Fig. 37, A, B).

Apropos of amputation, Dionis teaches (p. 744) that ligature of vessels should be carried out in one of two ways: "The first by seizing the end of the artery with a raven's-beak forceps, or with a smaller forceps which is furnished with a ring to close its blades, known as the *valet à patin* [arterial compressor], then slipping over the instrument and on to the artery the ligature prepared

* We shall find afterwards that numerous types of compression forceps existed in the eighteenth century, and even special instruments for direct forcipressure, which were to be left in position, notably in dealing with the intercostal or meningeal arteries or the sinuses of the dura mater.

and knotted, which we secure with a double knot. . . . We then pass the ligature with the help of a needle through the body of the vessel, and tie it again so as to make sure its fixation" (p. 732, Fig. 47, *X, O, P, Q, R*).

This is the knot which I have used for very vascular pedicles since 1888, without having then known the remarkable description of Dionis. I will name it, in honour of the memory of the French master, *Dionis's knot*. The second method is the following: "The legs being separated, we undo at once the ligature which is placed below the knee, and take up a raven's beak forceps (*X*) or the little forceps (*O*), which is furnished with a ring for closing the blades while holding the vessel. On each of the forceps is a knotted ligature ready to tie the vessel, and at each end of each ligature a needle. . . . We tell the assistant who holds the tourniquet to relax it a little, so that the jetting of blood may let us see the position of the vessel. . . . Having seized the vessel, we give the instrument to an assistant to hold (it is then a forceps *à arrêt*) while we apply the ligature."

Thus in every considerable procedure Dionis was a faithful disciple of Ambroise Paré, whose rehabilitation of the surgical ligature (1562-1564) encouraged operators in prompt amputation, which had previously been dreaded, even in gangrene, from fear of inability to arrest the hemorrhage by the orthodox use of styptics, caustics, boiling oil, and the red-hot iron.

The Slicing Process Is, and should Permanently Continue to be, an Exceptional Procedure.—The sectional method of removal *per vaginam* was judiciously applied (Amussat, 1849; Atlee, 1853) in dealing with uterine polypi or interstitial fibromata which were too large for removal in a single mass through the vulvar orifice. The practice became so popular that Péan and other surgeons adopted it in the case of tumours most easily accessible, which would in former days have been removed *en masse*.

Exaggerated Prolongation of Peritoneal Operations. The duration of even simple operations, which anaesthesia and antisepsis had tended to make excessive for mere amputations of the limbs, was prolonged in abdominal operations, such as hysterectomy and pylorectomy, even up to periods of five or six hours. Thus the vulgarization of peritoneal surgery proved to be a source of reaction against the simple and rapid procedures which were formerly held in honour. And thus too the methods of hesitation and tardiness, which are so peculiarly suitable to the great majority who aspire to become surgeons without the appropriate natural gifts and aptitudes, came to be disseminated as widely as, and even more widely than, anti-sepsis itself; and were soon adopted throughout the world.

Operative Dexterity of Surgeons of the Pre-antiseptic Period, and especially of Maisonneuve. If we were asked whether the conquest of antisepsis and the invasion of the peritoneum necessarily carried with them such overthrow of the methods of the earlier surgical practice, the answer would be an assured negative. But there should have been, as unfortunately there was not, in existence thirty years ago an authoritative leader of the old school of surgery—a Maisonneuve, for example—still sufficiently young and enthusiastic to place himself at the head of the Listerian revolution

and take care that during its advance the leaders should conserve what was really valuable in the older methods. A great exemplar is the noblest stimulus to the efforts of the young surgeon; and when we come to deal with operations on the bones of the face, I hope to dwell insistently on the methods of Maisonneuve, of whom my father, Dr. O. Doyen (Professor of Anatomy in the École de Médecine of Reims, who had been his pupil) used to say to me: "*Nobody operates now as he did.*" He depicted to me the master's extirpation of a superior maxilla, isolated by three strokes of a chisel, of which the handle was quite a cubit in length, and then extracted like an enormous molar tooth, at the end of a forceps. His aphoristic advice to the admiring class of pupils then followed: "Do not be frightened at the blood; when the bone drops, the hemorrhage stops." He never paid any apparent attention to the hemorrhage till the principal stage of the operation had been concluded. And his use of hemostasis comprehended but the indispensable. He amputated in the same way; it was only for a very short time that he practised removal of the limb with a *serre-nœud*, after breaking the bone between two blocks with a powerful stroke of a mallet.

The most Brilliant Operators in the Past were discouraged by the Appalling Mortality among their Patients.—The exceptional capabilities of Maisonneuve were inevitably in frequent collision with such unconquerable obstacles as septiciemia in all its forms—erysipelas, tetanus, purulent infection, gangrene with evolution of gas, hospital gangrene. Despite the brilliant success which he owed to his extreme dexterity, Maisonneuve was discouraged by the appalling mortality of bloody operations, and towards the end of his career did not dare to employ any other agent than caustics. And we see him finally disappear from active life at a time when, if he had been born thirty years later, he would have been able to give free play to his innate qualities by adopting the method of antiseptis.

Necessity of preserving the Operative Dexterity of the Surgeons of Former Times in Alliance with Antiseptis.—I had retained only the operative prowess of Maisonneuve, forgetting his sometimes extravagant tentative procedures, such as amputation of the thigh with the *serre-nœud*, and ablation of the breast with Chamquin's paste; when, in October, 1880, I came to attend the extern practice of the Paris hospitals. Thirsting to see and desirous to learn, I passed through the principal surgical services. I sought in vain for those brilliant and daring operations, that swift and sure surgical practice which had been represented to me. Received as intern in December, 1881, I had the good fortune to be admitted into the service of Dr. J. Champonnière, who initiated me into the methods of Lister. It was at that epoch that he performed his first operations on genu valgum and for the radical cure of hernia. The interesting séances of laparotomy, at which J. Champonnière, Terrier, and Périer mutually assisted one another, took place once a week.

In the same year (1882) I made my first researches on the bacteria of suppuration; then on osteomyelitis, and on the inoculation of osseous and articular tuberculosis on animals. It seemed to me useful to account as soon as possible to myself for the progress of surgery abroad

Status of Abdominal Surgery in France in 1883—Superiority of the German Surgeons. Gastro-intestinal surgery was in fact nearly unknown in France, where the mortality of ovariectomy and of hysterectomy, which were still practised with a wholly special environment, and as extraordinary operations, continued to be considerable. The school of Billroth was the only one in Europe which enjoyed a reputation justly required. I left for Germany and Austria, and visited, in 1883, the respective clinics of Czerny at Heidelberg, and of Maas at Würzburg, where I made the acquaintance of Hoffa, now so universally known for his remarkable work in connection with congenital dislocation of the hip, and in orthopaedics; finally I reached the service of Billroth in Vienna. The organization of the German clinics was admirable; Lister's method had been adopted from the time of its appearance, as an absolute and unquestionable verity, and with a tone of nearly military authority.

On my arrival at Heidelberg, I found evidence of progress. I was astonished by the method and precision with which Czerny habitually performed operations that were almost unknown in France. Perfect antisepsis and sure and well-defined methods of operative manipulation assured brilliant success to that master. I assisted at operations previously unknown to me, among which were resection of the great curvature of the stomach, and laparotomy for peritoneal tuberculosis—both of these were followed by cure. The pathological specimens were immediately studied in a laboratory attached to the operation theatre.

Critique of the Operative Technique of the German School—Exaggeration of Number of Assistants—Excessive Duration of Operation. The scientific superiority of the German surgeons at that period could not be disputed. It was their operative technique only which seemed to me to require modification, despite its apparent perfection. The excessive duration of the procedures, the number of assistants who passed the instruments and the sponges, the slowness with which sutures and ligatures were applied—in a word, all that characterized the methodic precision of German surgery wearied me in regard to the patient. Why not operate with greater speed? It seemed to me easy to do it as well, while doing it more simply and quickly. Those long séances produced on me the well-known impression of too slow a melody. I would have liked to "accelerate the movement." I had to seek elsewhere for that surgical dexterity which seemed to me to be a factor that could be so advantageously allied with those characteristics of the method of the German surgeons which I admired so much.

The Teaching of Operative Surgery by Farabœuf at the École Pratique of the Faculté de Médecine of Paris. The first course of operative surgery with Farabœuf at which I had the opportunity of assisting, a short time after my return from Vienna, at the École Pratique of the Faculté de Médecine of Paris, gave me for the first time the illusion—less the flow of blood—of a surgical séance among the most dexterous masters of thirty or forty years before, such as I had pictured it to myself.

The most brilliant of Operators on the Cadaver appear shorn of their Dexterity when operating on the Living Body, from the Fact that they are too much preoccupied by the Fear of Hæmorrhage.—Filled with admiration for the rapidity and dexterity with which Farabeuf carried out the regular operations on the cadaver, which he has also so well figured and described, I asked myself why they do not operate on the living body in the same way. Why that abysmal difference between the respective procedures of the *École Pratique de Médecine* opératoire and the operating theatre? Why is it that simplicity characterizes the former, while in the hospital, in presence of its immense apparatus, we so very generally observe hesitating movements and laborious interventions, almost as painfully wearisome to the spectator as to the operating surgeon? The answer is: The principal and constant preoccupation of all concerned is the fear of blood, in presence of which is found to disappear even the personal aptitude of those operators who most justly deserve their high reputation. It is on this account that many surgeons, who operate most brilliantly on the cadaver, lose all their confidence when incising the palpitating flesh; and thus prove themselves quite mediocre, if not almost incompetent, in the operating theatre.

Necessity for the Future Surgeon of a Mastery of Medical Clinics, of Pathological Anatomy, and of Bacteriology.—My personal experience has well proved to me the indispensable value of a laborious study of each of those fundamental domains of scientific medicine. And I embrace the present opportunity of expressing my gratitude for the inestimable benefits for which I feel that I must ever remain indebted to my great teachers. A tour in Germany gave me the opportunity of profiting by the instructions of my latest masters—Labbé, Bonilly, and afterwards Gayon; whose operative course I attended before becoming his intern assistant. In medicine I had the advantage of being the extern pupil of Bernutz, an eminent gynecologist of brilliant and perceptive genius; after which I became an intern pupil of Lancereaux, an assiduous worker in the bacteriological laboratory which then had just recently been established by Cornil; and in which Babes taught me the new methods of R. Koch. I there devoted my special attention to clinical and anatomical study of the visceral affections which tended to encroach further every day on the surgical domain and its practice. My leisure hours were consecrated to experimental research on the etiology of septicæmic diseases, for I had conceived the idea that an intimate knowledge of these would prove the most reliable guarantee for my future success in operative treatment.

Antisepsis is the ABC of the Surgeon—Manual Dexterity is the Sole Characteristic of the Operator.—Having obtained my degree and returned to my native city in 1885, my special ambition was to combine with the method of the Germans the manual dexterity which I had compelled myself to acquire in the practical school of my teacher, Farabeuf. Having then a free hand, I applied hundreds of ligatures, both at the *Hôtel Dieu* and the *École de Médecine* of Rheims, where I was made chief of the Anatomical Department. This gave me the opportunity of removing, with the watch before me, digits and metacarpals, arms, legs and thighs, in my

ardent ambition to acquire on the dead body a degree of dexterity sufficient to enable me to operate with the same confidence on the living. And I now maintain that it is only by long courses of such operations that the future surgeon can become capable of surmounting the difficulties of practice, and attain to such familiarity with the structure of the living body, that he needs no hesitation in selecting the point at which he can introduce his bistoury, even in the most dangerous areas of the human body. My father continuously impressed upon me the insufficiency of the operative methods then current in Paris, and held up the brilliant practice of Maisonneuve as the great ideal. "Learn to operate, as he did, without assistants; place your knives within reach, take up each instrument in its turn with your own hand— even down to the very last ligature. A good surgeon should never depend on those who surround him; it is thus that you can attain the desired end of operating *citò, tutò, et jucundè*." And it was thus that one who was an observant scientist proved, although not himself a practising surgeon, to be one of my very best professional masters; by training me in physical exercise, with culture of precision and address, in early life; and afterwards by sage and judicious guidance of my natural aspirations.

I soon came to eliminate the use of Esmarch's bandage in amputations, reserving it for minute dissections of parts of the limbs, operations on cases of osteomyelitis and articular resections, in which it is of the last importance to be able to follow to their extreme limits such lesions as would be obscured by the presence of the slightest oozing of blood, while it would be impossible to apply a ligature to its source. In such cases, the elastic band is removed only after completion of the suturing process and application of a compressive dressing. On the other hand, the employment of Esmarch's bandage in amputation produces a definite complication of the hæmostasis, inasmuch as under the veil of a wholly delusive security it necessitates the application of twenty to twenty-five ligatures instead of four or five, owing to the pressure-paralysis of the coats of the small vessels, which also leads to the loss of a much more considerable quantity of blood than need have occurred without its use. And it is *by suppression of every unnecessary appliance and superfluous manœuvre* that I have been able to perfect very many details of surgical technique.

Simplification of Operative Procedure is an Essential of Surgical Success— Abuse of Preventive Hæmostasis prolongs and complicates Surgical Operation.—My aphorism is: Operate with simplicity and you operate with celerity. A vaginal hysterectomy conducted with the aid of proper forceps can be terminated in less than two minutes, and pylorotomy combined with gastro-enterostomy is completed by my latest method in from forty-five to fifty minutes. My early communications on the methods of rapid operation were neglected by the Societies to which they were presented. It was in Brussels, at the first International Congress of Gynæcology (September, 1892), that I made the first attack on the abuses of preventive hæmostasis. I then demonstrated the fact that the best means of avoiding loss of blood is by rapid operation, and applying neither forceps nor ligature

except to vessels of considerable calibre. I there pointed out the inconveniences of the abuse of hæmostatic forceps, and indicated the occurrence of very serious hæmorrhage in the hands of the most convinced partisans of preventive forceipressure. And, finally, I protested against the indefinite duration of operations—up to two, three, or even four, hours, when in a simple vaginal hysterectomy thirty, forty, and even as many as over fifty forceps of large dimensions, and mostly of useless application, were left between the unhappy patient's thighs; while my operations, which were conducted much more rapidly, required only the application of two to four. I had already completed my vaginal hysterectomies in— for difficult cases—twenty or thirty minutes; and in simple, uncomplicated cases, four or five minutes, from the first to the last application of the scissors.

Rapid Ablation of Tumours is the Only Means of avoiding Serious Loss of Blood.—I have, in adapting my own method of vaginal ablation of the uterus without preventive hæmostasis, to the operation of abdominal hysterectomy, demonstrated the fact that large uterine fibromata may be removed by laparotomy, including the cervix and body of the organ, and in a few moments; without the use of elastic ligature, without preventive forceipressure of the broad ligaments, and without loss to the patient of so much blood as takes place in any of the other ordinary methods which are apparently less dreaded by operators.

The net result of my statistics goes to prove that rapid operations give results infinitely more favourable than did those formerly in vogue. Those most interested wished for confirmation of the exactitude of my assertions. In agreement with this object I have received many surgical visitors from all civilized countries. I have performed hundreds of operations in their presence, and demonstrated to them the validity of my claims to originality of procedure and superiority of results. And I can now claim that my crusade against hesitating and retrograde surgical methods have found an echo of favourable response. After the usual preliminary stage of silence and of disapproval, the critics have come to acknowledge the value of a new surgical method, which is characterized by simplicity and precision in manipulation, and the rejection of every instrument and manœuvre not absolutely indispensable. To this I have given the distinctive appellation of "The Anatomical Method."

The advantages of this method now require no further demonstration. It may have at first seemed quite unnecessary to complete in five or six minutes such an operation as a vaginal hysterectomy or a radical cure of hernia. But criticism should surely be disarmed by the successful application of such procedure to the surgery of the stomach and to resection of the intestine, with the result of reducing the time-limit to a third or a fourth of the habitual duration. Then the superiority of the rapid procedure is still more evident in the extensive craniectomies which I have been practising during the past seven or eight years, in which the immediate hæmorrhage is often startling; and in the ablation of large naso-pharyngeal polypi, for which I proposed to the Académie de Médecine more than six years ago

a new method of extirpation through the natural passages. Of course, the success of such procedures depends very largely on the dexterity of the operator. The slightest error of manipulation, the smallest delay, may lead to a fatal result. On the other hand, in presence of the results obtained, the advantages of the rapid method cannot be contested; while the security of slow procedure is but apparent.

For the Patient, Time Is Life.—The field of surgical intervention is continuously widening its borders, and new operations are daily being introduced, more laborious, and more delicate in their requirements. Thus it has come to pass that dexterity has reconquered the domain which it should never have lost. "Time is money," is the watchword of English business men. For us surgeons, "Time is life." And the fact should be recognized that anesthesia and antisepsis must lose their inestimable value in surgical practice, if manual dexterity be allowed to disappear with septicæmia.

No One can possibly become a Surgeon who does not possess the Requisite Innate Qualities.—In order to become a surgeon it by no means suffices to say, "I will be a surgeon," and then proceed to follow the prescribed course of the curriculum. One may be a good anatomist, and perform operations on the cadaver, and even on the lower animals, with the object of becoming familiar with the sight of blood and obtaining "cures." Those operations on dead human bodies and living animals can never make a surgeon of the individual who is not possessed of the essential primordial innate qualities. The surgeon should be an artist, and not a manipulator.

It has been objected to my procedures that they are dangerous, and beyond the reach of the majority of operators. I should be sorry if it were otherwise. It is high time that the fact should be recognized that anyone cannot improvise himself a surgeon; and that it does not suffice, in order to constitute an operator, to be able to manipulate some dozens of hæmostatic forceps more or less adroitly. This folly of forceps-pressure has done surgery a very great wrong, by encouraging hundreds of practitioners, who are utterly unprovided with the essential qualities, to undertake operations that they are incapable of carrying out skilfully. Consider, for example, the operation of hysterectomy by slicing, as recommended by Péan. What improvised gynæcologist has not tried that operation at least once? Having grasped the cervix, the operator divides the mucous membrane all around, and detaches: behind, the rectum; in front, all he can. With a forceps on the right and another on the left, guarding the uterine arteries, the cervix is resected. The cervical stump is then isolated to a stage a little higher, when something more is cut off; and this process is repeated till the maladroit operator arrives at the dimly irrational stage—divides the ureter, perforates the bladder, or wounds the intestine—and then, weary and bewildered, abandons after two or three hours the unfinished operation, leaving some two or three dozen forceps in the vagina. The reader may contrast that procedure with my method of anterior median hemisection. The operation is terminated in ten, fifteen, or twenty minutes, even in specially difficult cases; while it merely requires from the operator the

temperament and dexterity of a true surgeon. And the same observation applies to abdominal hysterectomy, extirpation of goitre, ablation of large naso-pharyngeal polypi, and, more particularly, to temporary hemi-cranioectomy; the operative manipulation of each of which I have definitely determined in such a way as to make it still more evident that surgery continues to be the appanage of a few only.

French Surgery should be made to reconquer its Former Leading Position.

—Maisonneuve and his contemporaries, in demanding from surgical posterity fulfilment of the "*cito, tuto, et jucunde*" rule, were inevitably ignorant of the essential item of the second term of their defective trilogism. They operated *quickly* and *well*. They were unable to operate *safely* because unacquainted with antiseptics. But we surely should retain the brilliant features which did distinguish their surgical work. The substitution of ligature for cautery by Ambroise Paré, and the invention of hemostatic forceps for continuous pressure; the application by Percy of the same principle to definitive hemostasis, which he realized by leaving in the wound his own forceps *à pivot*; Amussat's device of vaginal enucleation, *en masse* or by slices, of large interstitial uterine fibromata—all represent so many brilliant conceptions, of which we can never ignore the origin without actual injustice. Those inventors surely deserved the possession of antiseptics. And far from leaving their discoveries, and those of other surgeons of olden time, in a voluntary and undeserved oblivion, I hope to give them all their well-merited prominence in the present treatise, instead of allowing venerable methods and instruments to be still regarded as recent inventions.

It is somewhat curious to find at the onset of one's research that methods and instruments, now regarded as new, were in use more than half a century ago. For instance, before knowing Amussat's works (1840-1887), I thought I had devised a procedure wholly new, but really almost identical with his—rotation and tilting forward of the tumour, with or without slicing. I have found the so-called Hagedorn's needles figured in old books written long before his time. Other surgeons had the idea of bending their needles at the middle to an angle of 90 degrees, and having them flattened in one half, so as to be more easily grasped by the fingers or with the ordinary needle-holder (Knaur and Bienaise); I have myself had needles made which were almost identical, and in such a way as to retain a hold of the thread. Heister's gag, so ingenious in its mechanism, long remained the most perfect and the most powerful of the many made to separate the dental arches. An instrument very similar to my *érigne à glissière* for abdominal hysterectomy had been devised by Ricord for amygdalotomy. The most varied designs of instruments for opening the cranium are to be found—trephines, circular saws, perforators, etc. The old surgeons had brilliant ideas, and their penetrating imaginations made them foresee nearly all that has been realized in recent years. Thus they anticipated so many recent inventions, and it is our duty to profit by all recent advances; the progress of physics and mechanics combining with the immense advantages of antiseptics to enable us to devise, after data of mathematical precision, the most perfect types of instruments and the most suitable ways of employing them. At

the same time, an apparatus too complicated in its variety of instruments is a source of inconvenience to the surgeon, as it is likely to cause confusion. In this treatise, I purpose to select and describe what should be done in each given case; and reject what I consider bad, or defective, or useless, with the same decisive conviction that made Ambroise Paré renounce the cruel treatment with boiling oil and fire, which was meant to *caruify wounds*.

The hesitating surgery, too, which came in with anæsthesia and antiseptics, and especially characterized the abuse of hamostasis and slicing, thoroughly deserved the severe judgment pronounced by Paré on his predecessors:

"I would advise the young surgeon to abandon such wretched practices; to avoid saying any more, 'I have read it in one of the old masters, I have seen it done by one of my old fathers and masters, from whose practice I must not deviate.' This I grant you, if you understand by your good masters the books above referred to. But if you wish to remain with your masters, so as to have licence for doing wrong, and wishing to persevere in the same for ever, you will have to account to God himself, and not to your father and good practical masters who treated men so cruelly."*

Precise determination of the operative indications, rigorous practice of antiseptics, perfection of the operation itself, and the consecutive care—such are the demands which may justly be formulated by everyone who comes to claim from a surgeon the succour of his art. There is but one good method for each operation, and that is to perform it well and simply. All other methods should be rejected, just as we throw aside our used surgical dressings. And here I cannot refrain from giving expression to the inspiring hope that the spirit of the immortal Lister, who enjoyed the unspeakable satisfaction of assisting at the final and universal triumph of the antiseptics which he promulgated, approved of this my humble but earnest effort to complete the renovation of surgery, and bestow on our noble profession an operative treatise worthy of his great conception.

3. The Duties and Rights of the Surgeon.

Primum non Nocere.

Above all things avoid mischievous interference. How many of the surgeon's duties are conveyed in these three words, "Do no injury." The patient asks for cure; the surgeon should before all else be on his guard against every imprudent and hazardous operation.

The practice of surgery has been transformed during the past thirty years. Amputation has been almost discontinued. But, on the other hand, *visceral surgery* has encroached so much on medical practice that the circle of the affections which exclude justifiable operative procedure continues to narrow every day. This wondrous extension of surgery has involved the direct consequence of vastly increasing the moral responsibility of the operator.

* Œuvres, "Combustions et Gangrene," ch. xxxv.; in *Dict. Sc. Méd.*, art. A. Paré, p. 128.

The surgeon of to-day should possess, in addition to *manual dexterity*, a profound clinical education. Formerly the physician called in the surgeon to perform whatever operation he considered requisite under the circumstances. The physician in every instance made the diagnosis and decided the opportunity for intervention. The surgeon was an obedient instrument, whose function was limited to doing as he was bid. The rôle of the surgeon of to-day is a very different one indeed. In proportion to the multiplication of operative indications in respect to cases which formerly were exclusively reserved for medical therapeutics has grown the necessity for the surgeon to accustom himself to undertake the diagnosis of those internal lesions which he hardly ever came into contact with under the old régime. And their experience has developed all the more fruitfully, inasmuch as they are oftenest called on to verify, *histrory in hand*, the results of their own exploration. Accordingly it is for the surgeon of to-day to decide, in the last resort, the right time for operative intervention.

Every Medical Affection may, in one of its Phases, demand the Assistance of the Surgeon.—The words *external* and *internal* can now no longer serve to mark off pathology into two distinct divisions. A large proportion of internal maladies ordinarily fall to the care of the physician; to that of the surgeon, only in well-pronounced cases. Take biliary lithiasis, for example; so long as the affection follows a normal course, the medicinal treatment is the only one indicated. If a grave complication arise, the eventuality of an operation comes to be discussed. The physician is obliged to call in a competent surgeon, and enlighten him in regard to the early phases of the disease. It is for the surgeon then to determine the operative indications, and to act at the most suitable moment; under the guidance of his conscience, and with the assistance of his aptitude. But the united partnership of physician and surgeon can profit the patient only when each is satisfied by fulfilling, without surpassing, his own allotted function. Here are some examples of the many constantly occurring:

A woman, aged thirty-seven, who had been treated for eight years in Austria for pyelonephritis—at first left, afterward bilateral—came to me for examination. The right kidney was enlarged and painful. On the left side, in the intervals of the acute crises, in which the kidney became in its turn enlarged and tender, the chief seat of pain was towards the end of the ureter. Examination of the bladder proved negative. Catheterism of the ureters was impracticable; the sound encountered an obstacle which it would be dangerous to attempt to force. The patient, nervous and enfeebled, did not wish to submit to narcosis except when operation became necessary. After simple palpation, and use of the evidence afforded by the rational indications, I arrived at a diagnosis of right calculous pyelitis and left inferior calculous ureteritis. This diagnosis was conveyed, with the arguments on which it was based, to the physicians in charge of the case. These formally opposed every surgical intervention, and decided that there was no sign of lithiasis present, either renal or ureteral. The patient, whose sufferings went on increasing at two foci—the right renal region and the pelvic extremity of the left ureter—accepted the suggestion of operation,

in opposition to both those contradictory advices. A renal section was made, and a calculus extracted from the pelvis of the right side. Catheterism of the corresponding ureter from above pushed into the bladder other calculi which had been perceived by vaginal and intravesical palpation. Abdomino-vaginal palpation revealed besides the presence of a large ureteral calculus on the left side, not far from the bladder. Bilateral uretero-vaginal section was carried out at once. The two ureters being exposed through the anterior end *de sac*, I extracted from the left a large cylindro-spherical stone thicker than the thumb, and of 83 millimetres in length; then, from the right, a calculus of the diameter of a little finger. The recovery was apyretic. The lumbar and vaginal wounds were allowed to close spontaneously. This woman, who was almost moribund when my services were sought, had not been able to leave her bed for many months. Five weeks after the operation she was able to walk and to take a carriage drive. She returned to her family soon after. Can a surgeon be blamed in such cases for acting on his own responsibility in opposition to the advice of a number of his confrères? How many patients owe their recovery to the energy and tenacity of an enlightened operator, who is certain as regards diagnosis and confident in his own means and in the methods of their application?

Another very similar case supports the same view, in presence of corresponding conditions:

A young man suffered from necrosis of the ascending ramus of the left lower maxilla, the result of a phlegmon of great size, which had supervened on the infliction of a serious wound. The sequestrum was extracted, and some slight aphasia supervened a few days after the operation. On the following day agraphia appeared, then some muscular spasms on the right side of the face. There was no elevation of temperature. The patient did not seem to suffer much; he was able to sit up, and complained only of slight cephalalgia. I arrived, by a process of elimination, at the diagnosis of a suppurative intracranial lesion. A temporary craniectomy was performed four days after the onset of aphasia, and an abscess, containing more than 10 grammes of pus, was found at the foot of the second frontal convolution.

The general condition of this patient, apart from the existence of slight aphasia, seemed so satisfactory when I undertook the responsibility of that serious operation as to make the decision appear almost extravagant. The affection of speech did not seem to suggest hasty intervention. Nevertheless, the extent and situation of the abscess threatened sudden death by rupture into the cavity of the lateral ventricle. Four days after the operation the aphasia began to disappear, then the agraphia. Recovery took place without a single complication.

In other cases of doubtful diagnosis, I have made out for myself, by percussion and auscultation, the presence of hydatid cysts in the lung or pelvic cavity, of purulent interlobar effusions, and of pulmonary cavities, which have in turn been operated on with success. On the other hand, I have sometimes been obliged to decline all intervention, and to demonstrate the fact of having to deal with an inoperable medical affection, such as alcoholic

cirrhosis with ascites, or cancer of the pancreas; and not with a surgical case at all. The surgeon who is trained to the practice of visceral surgery has, of course, the inestimable advantage over the physician of verifying, in the course of each operation, the data furnished by the examination of the patient. The initial lesions of salpingitis, of appendicitis, the rôle of spasm of the pylorus in gastric pathology, etc., have all been surgical discoveries; and would have continued to elude the observation of clinicians in the absence of direct demonstration in the course of precocious operations.

Thus it is that whoever wishes and possesses the requisite qualities to become a surgeon, should train himself betimes in the diagnosis of visceral affections, with the view to subsequent attainment of the authority requisite for the imposition, when necessary, of his own point of view. The art of surgery is personal. Every surgeon who is truly worthy of the name should have a due consciousness of his own sagacity and of his aptitudes. He should know how to judge what he is really able to perform and what he is capable of undertaking. He may then be allowed to free himself from tutelage, and strengthen his faculties in the present for the future production of new and original work; when he may confidently calculate upon an immediate success.

PART I

GENERAL SURGICAL TECHNIQUE

Difficulties of the rigorous practice of antiseptics. The Doyen *Institut Chirurgical*—
Antiseptics and asepsis in surgery. History of haemostasis and of slicing. Practice
of écrasement and of haemostasis. Operation. Care of the patient before, during,
and after surgical intervention.

Difficulties of the Rigorous Practice of Antiseptics.

THE rigorous practice of antiseptics is indeed far from being within the reach of all. The most dangerous of all operators are really those who believe that they are operating antiseptically, while doing so by half only.

Infection is the Principal Cause of Death after Operations.—"Every solution of the continuity of the epidermis is an open door to infection." was the teaching of Velpeau some years before the discovery of antiseptics by Lister. This aphorism, now apparently so superannuated, has been too much forgotten by young surgeons. When we meet with a fatal case of operation, the usual cause of death even now is, despite the general practice of antiseptics, the infection of the field of operation—an accident which is facilitated by the lowering of vital resistance, which at length is inevitably produced in feeble and cachectic subjects, more especially in the cancerous. We cannot too strongly insist on the fact that many surgeons commit the gross error of believing themselves *a priori* aseptic, and then seeking for other causes of their want of success than direct infection of the field of operation. Such pretention to infallibility in the matter of antiseptics is as ridiculous as it is dangerous. Even in cases where complications break out at a distance from the field of operation—bronchitis, pneumonia, phlebitis, etc., it is really rare that their occurrence is not a direct result of the intervention. Infection is, indeed, capable of investing itself with slow and insidious forms—less rapidly fatal, of course, but still quite as gravely serious as peritonitis or hyperacute septicæmia. Thus it is that, whenever even the slightest complication arises, we should suspect ourselves of having committed an operative error; and refer to such, rather than elsewhere, the origin of the accidents which call for special treatment.

If the patient succumbs, investigate with scrupulous care all the probable causes of death, and interrogate your memory of the subject, in every minor detail. On the other hand, a procedure may have been adopted which was too grave in proportion to the vital resistance of the patient, and was not brought rapidly enough to a close; or, indeed, the infective process may

have been the sole cause. But, in most cases, these two factors are united. For myself, for many years, and in various hospital services, I have controlled the causes of death after operation by bringing to bear upon my researches an earnestly scientific spirit, and the adoption of a most rigorous bacteriological control. I have studied, along parallel lines, the absolute values of the various antiseptic applications and the methods of sterilization usually employed. My readers will see that my experience has led me to suppress all such antiseptic material as has been found useless. My methods of disinfection are sure, my dressings appropriate and simple. I now proceed to describe all of them in detail.

irurgical -
Practice
re, during,

within the
nose who
half only.

“Every
infection.”

antiseptics
been too
al case of
I practice
which is
inevitably
cancerous.
omit the
eking for
e field of
psis is as
break out
phlebitis.
ult of the
slow and
ly serious
even the
ring con-
the origin

probable
ery minor
which was
and was
ocess may

CHAPTER I

THE AUTHOR'S SURGICAL HOME

As operations can be carried out with reasonable hope of success only under the conditions afforded by buildings specially constructed for the purpose, and furnished with all essential antiseptic materials, it is not unsuitable to open this treatise with a description of the author's *Institut Chirurgical* before proceeding to deal with the operative technique which is there adopted.

This Institute is unique in its class, inasmuch as it includes all requisites for general and special surgery, applicable to disease of every kind and patients of all classes; as well as perfectly equipped laboratories for research in the departments of histology, bacteriology, and serotherapy. The essential difference between this and similar establishments is that the arrangements are such that the patient is induced to feel that he is not in a clinical institution. The comforts of home are provided while in receipt of every professional care which the case demands. The structure opening on the Rue Piccini is set apart for the wealthier class of patients, and also contains M. Doyen's consulting room. That on the Rue Duret is devoted to extern patients and intern treatment of the humbler classes. Full facility of communication with the several floors is secured by electric lifts and other modern appliances. The heating is provided for by five ovens containing vapour at low pressure, beside which are fixed two thermo-siphons for applying hot water.

The new patients on arrival are examined by the *chef de clinique* and distributed to the special departments. Chemical and bacteriological analyses are conducted at once, a radioscopic examination is made, and the patients are told off for extern treatment, or for reception within the Institute. The new arrivals are examined by M. Doyen from 10 a.m. till noon, and from 2 to 3 p.m. The first-class bedrooms are luxuriously fitted up; the framework of each bed is of copper; and the furniture of wood lacquered to a pure white; every room is furnished with double doors for the purpose of damping sound. The whole Institute is fitted up with electric lights, and each patient has within reach an electric bell and a switch.

Arrangements for Extern Consultation.

The arrangements for this service are among the most interesting features of the Institute. There is a central service for examination of the patients who present themselves for consultation, and their distribution to

the special services. Those patients after re-examination are sent on to the bureau of entries, where a more rigid scrutiny is carried out, or they are inscribed on the list of applicants for extern treatment. The service of extern consultation is specially carried on between the hours of 9 and 10 a.m., and from 2 to 4 p.m. This department includes ten special cabinets, which are respectively devoted to: (1) General medicine; (2) general surgery; (3) gynecology and obstetrics; (4) urinary affections; (5) diseases of the stomach, liver, and intestines; (6) diseases of the eye; (7) diseases of the ear, nose, and larynx; (8) diseases of the mouth and teeth; (9) diseases of children; (10) orthopedic surgery. To this series of consultation-rooms are attached the following services: (a) Orthopædic and plaster apparatus,



FIG. 1. OPERATION THEATRE: VIEW TAKEN FROM THE ENTRANCE DOOR.

(b) chemical and bacteriological analyses; (c) radiography and photography; (d) electricity and phototherapy; (e) massage, gymnastics, and hydrotherapy; (f) serotherapy; (g) operations and dressings.

Department of Orthopædics and Mechano-therapeutics.

This service is furnished with the most recent and most complete apparatus for rational gymnastics and mechanical therapeutics, and is completed by workshops for taking casts and for the construction of orthopedic apparatus. These are arranged according to novel indications, which have been determined or verified by the author of this work. The organization of this service is the more important, as the use of new apparatus enables him to restore without operation the integral functions of a large proportion of the limbs which would formerly have had their

osseous and articular lesions treated by resection, and other procedures productive of permanent deformity. A special apartment contains apparatus for douching, massage, and electrification. The accompanying illustrations will enable the reader to compare and contrast the respective provisions made for the comforts of the sick chamber, and the efficiency of the physical and gymnastic aids to treatment.

Department of Dispensary and Emergency Cases.

Extern dispensary and emergency work is provided for continuously night and day by the staff of clinical assistants who attend to all urgent calls from the resident patients, as well as to those of injury when applying for




FIG. 14. AUTHOR'S OPERATION TABLE (MODÈLE MARQUE) IN FIXED POSITION
LEG-SUPPORTS AND HEAD-REST HORIZONTAL.

admission. The importance of this provision is proved by the fact that a case was recently admitted of fracture of the thigh in a child, who had been refused admission to the Hôpital Beaujon, and then paraded through several pharmacies and police-barracks.

The operating theatre is completely antiseptized after each operation, and the instruments employed are immediately washed, and then sterilized in a dry-oven. Accordingly, when an urgent case is brought in, such as one of peritonitis resulting on perforation of the appendix or the rupture of an extra-uterine gestation, or a wound produced by a knife or revolver bullet, surgical intervention can be secured within less than half an hour after the arrival of the patient. Such service is the more reliably secured inasmuch as the author's private apartments are in direct communication



FIG. 2. AUTHOR'S OPERATION TABLE, WITH LEG SUPPORTS ARRANGED RECTANGULARLY.



FIG. 3. AUTHOR'S OPERATION TABLE, INCLINED FORWARDS FOR EVACUATION OF PERITONEAL FLUIDS.

38 SURGICAL THERAPEUTICS AND OPERATIVE TECHNIQUE

with the clinique, and connected by telephone with each of the floors. The attendance in the extern and emergency services is rendered doubly sure, while the immediate security of the resident patients is provided for to a degree which cannot be claimed in the case of any other institution.

Department for Admission of Patients, and General Supervision.

The organization of the clinique for intern patients was completely reformed from April 1, 1903. Admission and general supervision are con-

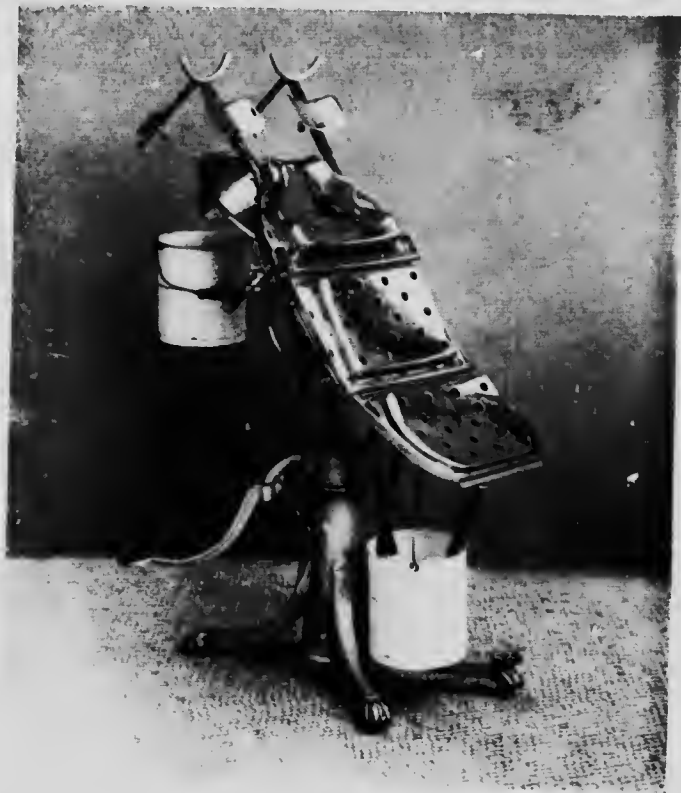

FIG. 4. AUTHOR'S OPERATION TABLE, IN THE TRENDLENBURG POSITION.

trolled by a staff of perfect competence. "Tips" and *pomboires* to officials are forbidden; the most scrupulous care is taken in the dieting of patients; and in the cleanliness of the bed linen and the furniture, and in disinfection of the bedrooms.

Operating Department.

Apartment for Chloroformization. The chamber for narcosis is situated directly opposite the operating theatre. It also functions as a magazine

for dressings, and has two beds mounted on rollers for transport of patients. General anaesthesia is carried out exclusively by ethyl chloride, administered by aid of a mask set in metallic mountings. The author has had constructed tubes of 3 c.c. capacity, hermetically sealed for retention of *kélène* (anaesthetic ethyl chloride). The lumen is wide enough for emptying in a few seconds. When used, the end is held vertically over the mask, and broken off so that the contents are deposited on the compress. In most cases a single 3 c.c. tube suffices, a second, or even more, is sometimes



FIG. 5. AUTHOR'S OPERATION-TABLE.

The Trendelenburg position is modified by elevation of the shoulders.

found necessary. The mask is applied directly to the face, and the patient rarely resists or requires to have the hands held. After twenty to thirty seconds the patient's replies become unintelligible, and a compress folded in funnel shape is substituted: into the apex of which 15 to 20 c.c. of pure chloroform has been dropped. The anaesthesia of the chloroform succeeds without interruption to that produced by the ethyl chloride. Highly neurotic and alcoholic subjects display then some excitement analagous to that of pure chloroform anaesthesia, but never with the same degree of violence.

40 SURGICAL THERAPEUTICS AND OPERATIVE TECHNIQUE

This method has been employed by me for many years, and without a single mishap. In the case of very feeble patients, however, ether can be substituted for the chloroform; and it may be dropped on the mask used for the ethyl chloride. The anaesthesia with ethyl chloride may be maintained by this agent alone up to twenty to thirty minutes, 10 c.c. of kélène being used every two or three minutes.

The patients are conveyed on roller aseptic beds, which are so made as to be readily transformed into stretchers. They can be received, with



FIG. 6. AUTHOR'S OPERATION-TABLE.

Leg-supports in form of ampoule, arranged for operations on the perineum and vagina.

two persons (anaesthetist and attendant), in the lifts which convey the patients. Thus the timid patients can be anaesthetized in their own rooms, and conveyed to the operation theatre in a few seconds.

Pharmacy and Apartment for Instruments. The apartment which combines the functions of arsenal for instruments and pharmacy, is, in addition, utilized for the process of anaesthesia. The instruments are arranged in

large glass cases, and the pharmacy is furnished with all the medicaments requisite for cases of urgency.

Operation Theatre and Sterilizing Chamber.—The chief operation theatre, in which all the capital operations are performed, is divided into two by a metallic barrier, that maintains an interval of space between the medical men present and the surgeon with his assistants. On the left of the balustrade is the entrance-door for visitors; on the right, that which



FIG. 7. AUTHOR'S OPERATION-TABLE.

The leg-supports are inclined for adaptation to elevated position of shoulders.

admits the surgeon with his assistants and the patient. A door on the right leads to the sterilizing chamber; and above it is a clock furnished with a movable hand, which indicates the time of commencing the operation. The other essential factors of antiseptic and electric lighting and communication are also provided for by the apparatus conveniently arranged near the drying-stove. The daylight is admitted on one side only, and at an angle of about 45 degrees; and the assistants are arranged on the steps on that side. The whole interior is painted of a neutral greyish-blue tint, which

gives the minimum of reflection. In this way the illumination is best concentrated on the field of operation. Powerful auxiliary lighting is also provided for, when considered requisite, by efficient portable and frontal electric lamps and reflectors, the light of which can be instantly focussed on the field of operation.

Special Apparatus of the Operation Theatre.

1. **Operation-Tables.**—The furniture and instruments call for special description. There are two operation-tables, of which one is a fixed structure,



FIG. 8. AUTHOR'S OPERATION-TABLE.

Leg-supports arranged rectangularly. An accessory table adjusted for operation on forearm.

while the other is dismountable and transportable. The fixed one (modèle Mathieu) was constructed according to my directions. It is mounted on a hydraulic support, which permits an elevation of 45 centimetres (the height may thus be made to vary from 70 centimetres to 1.15 metres). The width is 45 centimetres, and there are three movable segments of 33 centimetres each in length, making a total of about a metre. Its transverse axis of inclination is placed opposite the sacro-vertebral angle, which corresponds to the centre of gravity of the body. Three rackwork supports enable the operator to place the patient in any necessary posture. The escape of fluid is provided for in every one of the positions; a detachable funnel, from which an enamelled bucket is suspended, receives all discharges. Each of the three segments of the table is provided with a receptacle for the corresponding segment of the human body: the cervical, dorsal, and lumbo-sacral



FIG. 9.—AUTHOR'S OPERATION-TABLE.

One leg-support in horizontal position. An accessory table adjusted for operation on leg of that side.



FIG. 10.—AUTHOR'S OPERATION-TABLE.

Head-rest arranged for operation in Rose's position. The bicipital and pelvic supports are raised, for adaptation of the patient's body to the requirements of the procedure.

44 SURGICAL THERAPEUTICS AND OPERATIVE TECHNIQUE

regions are thus so thoroughly adapted that the body is supported by its own weight when in the Trendelenburg position.

Some of the advantages of special positions may be mentioned here. In the position of dorsal decubitus the pelvis is to some extent dislocated forwards; this increases the projection of the promontory, and, in case of a female, places the vaginal axis in the horizontal plane. This position is specially suitable to the performance of vaginal hysterectomy. For convenience of perineal section, or in operation on hemorrhoids, the second section of the table can be raised 10 to 15 degrees (Figs. 1x and 3). For



FIG. 11.—AUTHOR'S TRANSPORTABLE OPERATION-TABLE.
Dismantled.

operations on the kidney, the patient should be placed in the position of lateral decubitus, and the rotary mechanism may then be utilized to render the affected side more prominent.

A second rectangular section, 50×30 centimetres, should be annexed to the operation-table: it may be utilized in the performance of conservative operations on the upper or lower limb. The table should not be used in amputations of the upper extremity. For those of the lower limb the leg-support should be removed from the side at which the limb is to be operated on, while the limb to be conserved is fixed to that of the opposite side. A double articulated head-rest, furnished with automatic catches, supports the head in all the various necessary positions. A final advantage in the use of this table is the employment of a very simple mechanism for raising the patient's body from the horizontal plane through a height of 12 to 15 centimetres; this

enables us to cleanse the back from blood-stains, etc., and to change the linen. This may be done by raising the horizontal support on which the patient's shoulders rest; when the thorax has been elevated through a height of 15 to 18 centimetres, the automatic stop comes into play. The lumbar region is raised by a subjacent rackwork, which acts on the median support. The various positions are illustrated by Figs. 1A to 10; and we can say with confidence that it is the most complete and most convenient operation-table that has yet been constructed.

The profile view is given in Fig. 1A; the three sections are all in the horizontal position. At each end of the table is suspended a bucket which receives




FIG. 12.—AUTHOR'S TRANSPORTABLE OPERATION-TABLE.
Showing the various segments and the mountings of the legs.
Detached pieces shown.

the fluids. The lever that raises the bed is clearly seen on the left of the central median support; this lever is worked by the foot. To lower the table, we bring towards the lever by pressing with the hand-ladle the foot, seen in Fig. 6, above and to the left of the vertical column, which is attached by a small chain to the large lever. Rotation of the axis of this ladle raises a valve, which allows the oil in the interior of the pump to descend to the subjacent recipient. Another ladle, which is placed lower down, near the middle and to the right of the median column, serves for fixation in the central column of a vertical cylinder, which supports the whole hydraulic mechanism. This arrangement enables us to turn the operation-table on its axis, by moving the handle through half a revolution. Thus, for example, we can very readily convert the horizontal position during an operation into

a Trendelenburg position. Inclination of the operation-table, either forwards, to promote evacuation of ovarian cysts, or backwards, to attain the Trendelenburg position, is adjusted by the action of the lower rackwork to which is attached the winch shown in Fig. 6.

Fig. 13 shows the arrangement for fixation of the head. When we fix the winch on the central rackwork which controls the support destined for elevation of the lumbar region, the patient is placed in the position for nephrectomy. If the support for the shoulders is then elevated, as shown in Fig. 10, the patient is raised by the combined action of the two supports to a plane 12 or 15 centimetres above the metallic table. This manoeuvre enables us to wash and sponge the lower aspect of the body, and apply dry dressings. As already indicated, I have attached to my operation-table a




FIG. 13. —ARTHUR'S TRANSPORTABLE OPERATION-TABLE.
Horizontal position, and rectangular arrangement of leg-supports.

rectangular table with a median channel for the escape of fluids, which can be arranged at a variable height (Figs. 8 and 9). This is used in operations on the limbs other than amputations. The leg-supports are fixed in such a way that they can be removed by simply drawing them forward, whatever be the position. Fig. 10 represents the head-rest lowered into the Rose position. In that figure the support for the shoulders is raised in such a way as to permit, for example, the easier application of a dressing around the head after craniectomy.

Fig. 4 represents the operation-table arranged in the Trendelenburg position for vesical section or abdominal hysterectomy; it is furnished with leg-supports adjusted rectangularly for the pendent legs. Fig. 9 shows the same table in a modified Trendelenburg position: the dorsal segment of the

table has been raised to an inclination of about 20° by the help of the rack-work attached thereto.

For operations on the perineum, I have had leg supports constructed in the form of antennae (Figs. 6 and 7), on which the limbs are fixed in a position of semiflexion on the abdomen. It will be found in practice how many advantages these *antennae* present over the older forms of supports used for the legs: in perineal section, in operations for vesico-vaginal fistula, in ablation of hemorrhoids, and in vaginal hysterectomy. It is often advantageous to diminish the degree of depression of the body by elevating



FIG. 14. AUTHOR'S TRANSPORTABLE OPERATION-TABLE.
With forward inclination.

the shoulders with the help of the rackwork which raises the median segment of the table, and then turning the latter backwards through an angle of 15° or 20° .

AUTHOR'S TRANSPORTABLE TABLE.—The transportable table which I have had constructed by M. Collin is much simpler in structure and lighter in weight than the table with a fixed support made by Mathien, while presenting nearly the same advantages. This table consists of a folding leg with rackwork for elevating and lowering the table—properly so called—and its accessories: different forms of leg-supports, winch-handle, etc. The various pieces are shown in Fig. 15 as they appear when unpacked from the chest after transport. When setting up the Collin table, we have only to draw back from the central portion of the foot the terminal arcs

which support the weight of the patient, as shown in Figs. 12 to 17. Those arcs are fixed to the central stem of the foot by four cross tie-pieces, which are shown in Fig. 11. The table, properly so called, is then placed on the supporting pads, taking care to press down and fix in the corresponding notch the rackwork which is intended for rotation of its plane forwards, or backwards into the Trendelenburg position.



FIG. 15. AUTHOR'S TRANSPORTABLE OPERATION-TABLE.
The Trendelenburg position: leg-supports adjusted rectangularly.

The different forms of leg supports—those bent at a right angle, which are the most frequently employed (Figs. 13 to 15), the rectilinear (Fig. 17), or the antennae form (Fig. 16) are then fixed, the latter, with the help of two special pieces in two longitudinal grooved frames, each of which turns round on an axis nearly corresponding to that of the coxo-femoral articulation of the patient. Abduction and adduction are obtained by pressing from behind on two corresponding buttons. The length of the rectilinear or rectangular leg supports is modified by pressure from without

inwards—in relation to the antero-posterior axis of the table—on a small lateral lever. This pressure disengages a projecting knob, which is arranged



FIG. 16. AUTHOR'S TRANSPORTABLE OPERATION-TABLE.

Elevated for perineal operation and that of vaginal hysterectomy.

so as to penetrate one of the orifices recognizable in Figs. 13 to 15, on the lateral aspect of the leg-supports.

Fig. 12 shows the foot of the table arranged in position, while in front are the various leg-supports and the winch-handle; on the right is the table

properly so called, composed of two segments—a dorso-pelvic and an articulated head-rest; finally, to the left is the perforated plaque of the dorso-pelvic segment, which is pierced with orifices for the escape of fluids. Fig. 13 shows this table arranged for current operations—for example, one on the mammary gland or ovary. The legs are fixed in the pendent posture, which facilitates the movements of the assistants around the patient. The leg-supports must be adjusted with the length necessary so that the buttocks rest exactly at the pelvic border of the table. In this way we can, if necessary, immediately change the horizontal into the Trendelenburg position. When we wish to evacuate the contents of an ovarian cyst or a collection of ascitic fluid, the table is inclined forwards, as represented in Fig. 14. If it



FIG. 17. AUTHOR'S TRANSPORTABLE OPERATION-TABLE.
Rose's position; leg-supports adjusted horizontally.

is necessary to alter the original position into that of Trendelenburg, we first raise the table 20 or 30 centimetres by turning the winch-handle attached to the lower axle (Fig. 13). We then rotate table and patient through an angle of 180° so that the head is on the side of the glazed recess of the operation theatre, and then turn them backwards and downwards to an inclination which may vary from 15° to 45° (Fig. 15). Fig. 16 represents the table raised to its greatest elevation, and with the antennae leg-supports adjusted for vaginal hysterectomy. Fig. 17 shows it in the horizontal position, and furnished with the rectilinear leg-supports as required for placing the patient in the Rose position. The dismantling of the table

is as easy as possible, and it can be packed in a case of 95 centimetres in length, 70 in width and 35 in depth.

2. Tables for Instr —The tables for instruments are of white marble, and are two in number. The ends of the sides are protected by a parapet, which protects the sterilized instruments from contact with visitors' garments. A central orifice for drainage facilitates frequent washing (Fig. 18).

3. Aseptic Support for Tubes Intended for the Toilet of the Field of Operation.—The support intended for the tubes which convey towards the opera-



FIG. 18. TABLE FOR INSTRUMENTS.

tion table the antiseptic fluids necessary to secure sterility of the region before commencing to operate is fully represented in the subsequent figures (see Operation).

4. Wheeled Carrier for Dressings.—My wheeled carrier for dressings measures 1 metre in length by 35 centimetres in width. It is made of sheet iron, painted and varnished, and bears a double reservoir, for cold and hot water; also three receptacles which contain respectively: phenol solution of 2 per cent., sublimate solution of 1 per cent., and sterilized water. The necessary aids to washing, injection, spraying, douching, and drainage are all present—on the shelves and in the drawers; also such indispensable instruments as seissors, razor, forceps, drainage-tubes, sounds, sterilized compresses, etc.

5. Stools of Various Heights.—These stools of various heights, which are prepared by M. Stillo of Copenhagen, are represented in Fig. 20.

6. Heating of the Operation Theatre.—The temperature is kept at 23° C. (73.4° F.) in the winter and 24° to 25° C. (75.2° to 77° F.) in summer. With

the aid of duplex canalization, the radiators communicate with the steam generator in winter, and in summer with the thermo-siphon of the hot-water service—both of which function all the year round.

7. Heating of Linens.—For heating the linen, copper trays are used, furnished with double walls, the interspace of which is filled with boiling water; the temperature of this can be maintained during the night by a low gas-jet.

The Sterilizing Chamber.

The sterilizing chamber, which is attached to the operation theatre contains, in addition to the burners attached to the dry gas stove, the doors




FIG. 19. AUTHOR'S WHEELED CARRIAGE FOR DRESSINGS.

of which open into the theatre, two 100-litre boilers for the water used in ablutions, and for preparation of the phenol and sublimate solutions. There are two of the larger Lequeux's autoclaves, each of which hold six trays for compresses, on three shelves, or the same number of trays of water, or two large trays of 30 centimetres in diameter for linen tablecloths and blouses, and, finally, a table with a gas furnace, and sterilizer provided with boiling water for instruments which may be wanted by the operator and have not been

sterilized in the dry stove at 160° C. (320° F.) There are also a number of receptacles for compresses, instruments, etc.

A special system of canalization enables us to aseptinize the air of the theatre by a vapour jet coming from the autoclaves. Another system of tin tubes, which will afterwards be described in complete detail, is connected with a series of vacuum tubes. This canalization provides for the filling, with phenol solution of 2 per cent. and sublimate solution of 0.1 per cent. (by simply manœuvring some stopcocks), of the sterilized reservoirs which are placed on a higher level. These are so arranged as to transmit the respective fluids to the operation theatre, and at the requisite temperature from vessels placed at the height necessary for utilization of the force of gravity. I will return later to the study of this apparatus.



FIG. 20.—STOOLS ADJUSTED TO VARIOUS REQUISITE HEIGHTS.

Accessory Operation Theatres.

There are also two accessory operation theatres in my clinique: one is destined for use in connection with the service for extern consultation; the other is connected with the general service for operations, and is reserved for ophthalmic operations.

Procedures adopted for Disinfection—Asepsis and Antisepsis.

I. DISINFECTION WITH VAPOUR OF FORMIC ALDEHYDE.

Disinfection of Bedrooms, Bedding, and Other Objects of a Certain Volume.

—Disinfection of bedrooms, bedding, clothing, etc., is carried out with the vapour of formic aldehyde.

2. STERILIZATION WITH DRY HEAT.

Instruments, glass drainage-tubes, etc., which can bear dry heat of the requisite temperature, are placed in the dry-stove for half an hour, at a temperature of 160°C . (320°F .).

Dry-Stove—Sterilization of Instruments.—The dry-stove for sterilization of instruments is fixed in the wall of the operation theatre. It was constructed as a vapour stove by M. Lequeux according to my instructions, and includes two stories, the lower of which is used for the sterilization of instruments, and the upper for drying compresses and the sterilization of cotton, linen blouses, cloths, and tablecloths (Figs. 25 to 30). This compart-




FIG. 24. ACHARD'S DRY STOVE FOR STERILIZATION: THE SMALL MODEL.

ment can also be used for warming linens. The stove is heated by a double corona of Bunsen burners; in this way the temperature can be raised to 160°C . (320°F .) in about 30 minutes.

The course of the superheated gas in the small model of the stove is indicated in Figs. 23 and 24. The gases enter at *O*, and pass downwards and backwards at the sides, then along the upper wall of compartment I, and unite at the single orifice *a* of the complete partition *AA*—an orifice situated, as shown in Fig. 24, close to the anterior wall of the stove. They then pass back along the sides and posterior wall of the stove towards the chimney, *z*, by which they escape to the outside. In this way we have assured as completely as is possible the utilization and evacuation of the products of combustion of the Bunsen burners.

The compartment for instruments is completely closed. That for heating linens has a chimney for evaporation. The metallic door is furnished with a thermometer, which registers up to 200°C . (392°F .). In the large model it is necessary, when a uniform temperature is required throughout the whole of

the compartment for instruments, to light the entire series of gas-jets—above and below—and to place a thermometer in both the upper and the lower compartment.

An electric heating apparatus can be fitted to each of these stoves. The thermometers project through two orifices in the door of the stove, so that



FIG. 22.—AUTHOR'S DRY-STOVE FOR STERILIZATION: THE LARGE MODEL.

Heated by gas or electricity.

the temperature can be read off *in situ*. They should be watched by the person who is in charge of the process of sterilization. The various cotton and linen requisites can be sterilized in the upper compartment, which is lined with isolating partitions of pasteboard.

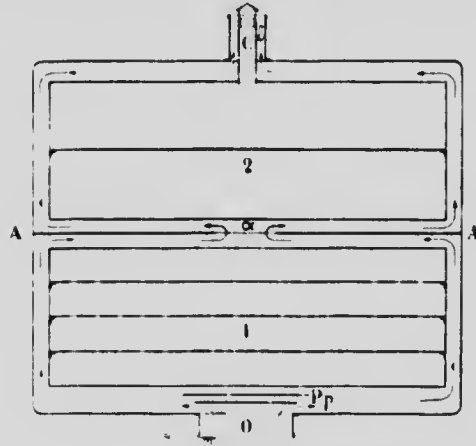


FIG. 23.

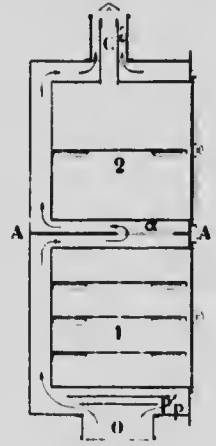


FIG. 24.

These figures represent respectively a frontal and a profile diagrammatic section of the author's small disinfector stove, showing the course of the heated gas.

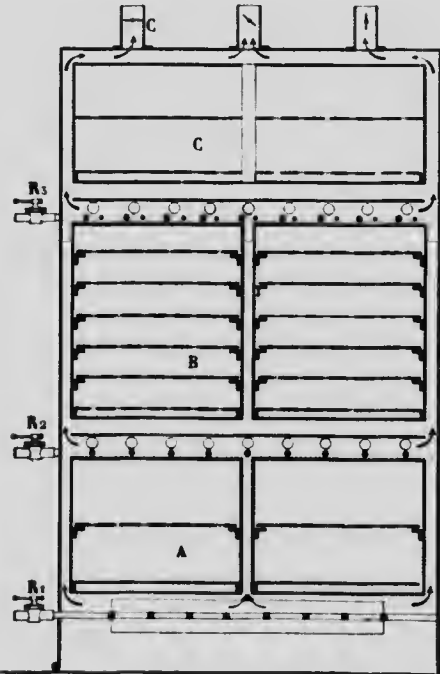


FIG. 25.—DIAGRAMMATIC SECTION OF AUTHOR'S LARGE STOVE.

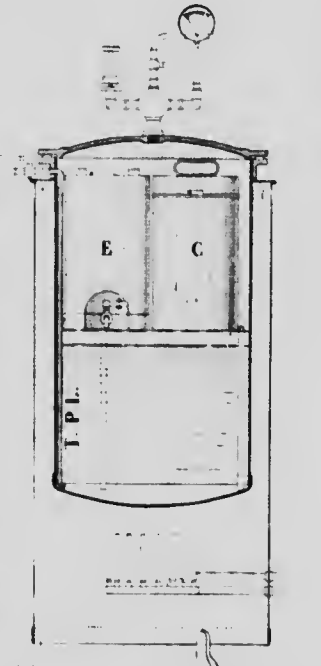


FIG. 26.—DIAGRAMMATIC SECTION OF VAPOUR STOVE.

Cases for Instruments.—The instruments are wrapped up in pinned napkins or enclosed in large metallic cases in which they are heated (Fig. 22). The dimensions of the stove are such as to permit the simultaneous sterilization of all the instruments required for ten or twelve successive major operations: laparotomies, vaginal hysterectomies, craniectomies, etc. The metallic cases are superposed in their respective compartments in such a way that the assistant can instantly take from its place that which contains the instruments required for the operation to be next performed. The dry stove being placed in the operation theatre, the sterilized instruments are within reach of the operator, and ready for use at any required moment. When about to be employed, they are arranged on sterilized napkins.



FIGS. 27 AND 28.—CASES FOR COMPRESSES AND FOR WATER, OF 16 CENTIMETRES EACH.

3. STERILIZATION BY VAPOUR UNDER HIGH PRESSURE.

Vapour Stove—Sterilization of Dressings and Compress-Sponges, Artificial Serum, etc.—The dressings, covers, and vestments used in the course of operations are sterilized by vapour under pressure at 134°C . (273.2°F .), and then dried in the upper compartment of the hot-vapour stove at 140°C . (284°F .). The vapour stove, constructed by M. Lequeux after my instructions, is of cylindrical form, and measures internally 34 centimetres in diameter and 60 centimetres in depth. A copper disc pierced with holes is placed at a level of 8 centimetres from the bottom, so that a small quantity of water always remains below the packets of compresses without moistening them. The lid is furnished with a manometer, a valve with a recoil screw and a pipe with stopcock; also with a suspensory apparatus and attached counterpoise. On the left side of the stove is a plunger tube, which descends internally to the bottom of the cylinder (Fig. 26). The stove thus con-

structured provides for the simultaneous sterilization of six packets of compresses. Those packets are enclosed in boxes of pure nickel, which are furnished with a revolving cover, providing for the opening and closing of three orifices arranged for admission of the vapour. They are superposed in threes, and the cover is so adjusted that the three orifices for the admission of vapour are left open. Between the uppermost compresses and the cover is placed a leaf of waterproof tissue, which prevents the entrance of dust when the stove is opened.

It is well to pour a few drops of carbolic solution on the bottom of each compartment before introducing the compresses. By so doing sterilization is assured, for the vapour therefrom produced always attains the temperature



FIG. 29. CASE FOR COMPRESSES OF 32 C.C. IN DIAMETER.

of the vapour of the stove. The autoclave, furnished with the necessary quantity of water, should be brought to a pressure of 2 kilogrammes, and a temperature of 134°C . (273.2°F). The manometer should register for three-quarters of an hour a pressure of over 1 kilo and over 120° (248°F), in order to secure completion of the sterilization. This result is readily obtained with the aid of the double corona of gas burners, the larger zone of which is extinguished when the maximum figure of 134° (273.2°F) has been attained.

I have over and over again satisfied myself that the sterilization of anthrax spores, of *Bacillus subtilis*, etc., was complete at the centre of the packages of compresses. When the heating of the stove has been commenced, it is well to leave the escapement open till the vapour begins to pass through; it should

then be closed till the manometer has fallen to 0° C. (32° F.). When the sterilization has been fully completed, it is opened very gently; the excess of vapour is allowed to escape, and we thus avoid having to deal with moist compresses. As soon as the sizzling has ceased, the lid is raised, and the packets of compresses are lifted out, one by one. They should be closed only after an interval of one or two hours, by pressing at the hinge with the rotatory movement necessary to close the orifices which had been left open during the process of sterilization. The compresses are then nearly dry; if required after



FIG. 30.—SUPPORT FOR CASE OF 32 C.C., FURNISHED WITH A PEDAL.

some days, the desiccation is completed in the upper compartment of the hot-air stove which is used for the sterilization of instruments. The cloths, table-covers, and large pieces of dressings are sterilized in similar metallic cases, but of 32 c.c. in diameter (Fig. 29). These are placed in the operation theatre on a special support (Figs. 30 and 31), which provides for the raising of the lid by means of a pedal.

ISOTONIC SALINE OR RINGER'S SOLUTION.

The vapour stove is similarly employed in the preparation of sterilized water. With this view it is provided with a second floor of copper, at a level

60 SURGICAL THERAPEUTICS AND OPERATIVE TECHNIQUE

of 30 c.c. above the first (Fig. 26). We are thus enabled to fill the lower compartment with water, and sterilize—simultaneously with this water—three packets of compresses. I utilize this arrangement for sterilization of the water used in diluting the 5 per cent. mother solution of phenol. The transit of the sterilized water will be described later on.

The sterilized water, which is used either for cleansing of the hands or for lavage of the peritoneum during operation, is heated simultaneously with



FIG. 31. THE 32 C.C. CASE ON ITS SUPPORTING STAND, FURNISHED WITH PEDAL.

Opening of the same by pressure of the foot on the pedal.

the packets of compresses, in cylindrical receptacles of nickel of corresponding dimensions; and furnished with a tap at the lower part, which enables us to use it indifferently for lavage of the peritoneum and for injections, subcutaneous, and even intravenous. This water has always chloride of sodium added, in the proportion of 0.7 per cent. The screw stopper of those receptacles is taken out during sterilization, and replaced as soon as the stove has been opened; the water thus sterilized can be preserved for some time without danger of contamination.

When transporting these vessels, the lower stopcock is tied with a silk thread so as to prevent accidental opening. We are thus enabled to carry out at a distance, and without fear of infection, an urgent peritoneal lavage with sterilized serum which had been treated some time previously by plunging the receptacle into boiling water. In the same stoves an artificial serum is prepared, in flasks of 1,000 grammes, containing the normal proportion of 0.7 per cent. chloride of sodium. This serum, sterilized at 134° (273.2° F.), can be injected subcutaneously in doses of 100 to 500 grammes, two or three times a day, and in serious cases even in greater quantity. Such injections are powerfully stimulating to feeble and depressed patients. Ringer's solution is now employed for preference, the formula being the following: Sodium chloride, 8; potassium chloride, 0.075; calcium chloride, 0.07; bicarbonate of soda, 0.075; distilled water, 1,000.



FIG. 32. —VESSEL OF 20 LITRES CAPACITY, FOR ANTISEPTIC SOLUTIONS.

4. STERILIZATION OF SILK.

Silk is sterilized in absolute alcohol, with which it is treated by immersion for half an hour at a temperature of 120° C. (248° F.).

ANTISEPTIC SOLUTIONS.

As already observed, the range of antiseptic solutions employed in my clinique is very limited. Those employed are the following:

(1) **Sublimate Solution of 0.2 per Cent.**—This is prepared by simply filling an enamelled vessel of 20 litres capacity with boiling water (Fig. 32), to which is added 40 grammes of bichloride of mercury in fine powder. This solution is employed in disinfection of the skin before washing with ether.

(2) **Phenic and Boric Solution of 2 per Cent.**—This is prepared in similar receptacles, in which 100 grammes of phenol and 400 grammes of sodium borate have been placed before filling with boiling water. This solution, which prevents rust, is used for boiling instruments that have not been sterilized in the dry-stove. It is also employed in washing certain open wounds.

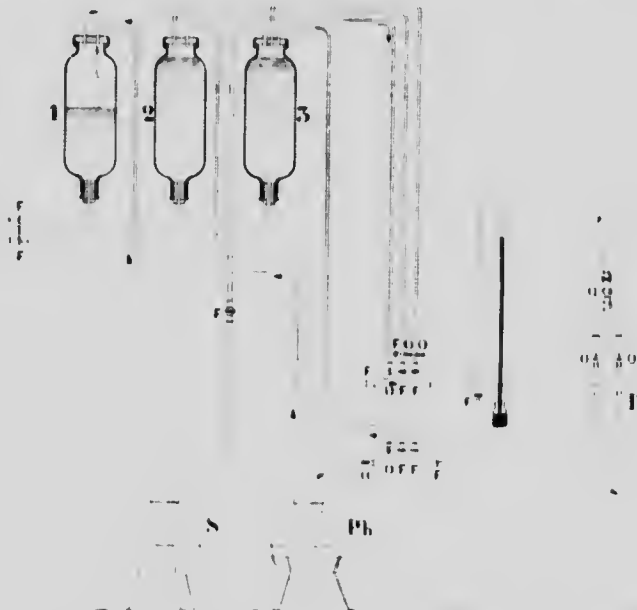


FIG. 33. MANIPULATION OF ALVERGNIAT'S TUBES.

The mercurial column of the manometer stands at 60 cms. The phenic solution of the receptacle *Ph* is aspirated into the receptacle 1, which alone communicates with the aspiration apparatus, *FOFF*, and the series of tubes. Bottle 3 has attached a special conduit, formed of glass tubes, covered with india-rubber, for aspiration of the sublimate solution into the vessel *S*. The stopcocks for recumbence of air, which are placed horizontally above the apparatus *FOFF*, on the vertical aspiration tubes of the 3 receptacles, are: the first (*E*) closed, the others (*O*) each open; so that the contents of bottles 2 and 3 can be directed towards the operation theatre during the filling of bottle 1. *E*, stopcock closed; *O* open.

(3) **Formol Solution of 2 per Cent.**—This serves for abluition of the skin and in the preparation of a saponaceous mixture which is used for disinfection of the field of operation.

(4) **Oxygenated Water.**—This is diluted at the moment of applying the dressings, by adding 3 or 4 parts of water to 12 volumes.

(5) **Labarraque's Fluid.***—This fluid, which is a special preparation of the *Maison Frère*, made by saturation of a solution of carbonate of sodium properly titrated with chlorine gas, is diluted in the same way—to 5 per cent., 10 per cent., even to 20 per cent.—at the moment of requisition, for the lavage of wounds or for other local applications. The *Codex* formula with calcium chloride can also be employed.

(6) **Ether at 65° C. (149 F.).** This is one of the most active and least expensive of the antiseptic fluids at our disposition for solution of the fatty compounds of the epidermis of the hands and of the field of operation.

Installation of Vessels for Filling with the Help of the Vacuum-Tubes of Alvergniat.—The

solution of sublimate at 0.2 per cent., and that of phenol at 2 per cent., which are destined for use in the operation theatre, are aspirated, with the aid of a battery of vacuum tubes, into large glass bottles of 20 litres capacity. To each of these is attached—(1) A tin tube for aspiration of air, grafted on the series of Alvergniat's tubes; (2) a second tube for the introduction of liquid; (3) a tube for the evacuation of the same liquid. These latter tubes are of crystal and attached to the reservoir of bichloride of mercury. The tin tubes for the rarefaction of air are furnished (Fig. 33 *FOO*) with small horizontal stopcocks for the entrance of atmospheric air when required, and are in communication by the interposition of three vertical stopcocks with a common apparatus (*FOFF*), to which are attached a manometric apparatus and another stopcock provided for the admission of air. The common apparatus communicates with the aspiration tube of a series of three Alvergniat's tubes. This disposition provides for the formation of a vacuum in a single one of the three receptacles, or in two, or in all three, simultaneously. The stopcocks provided for the entrance of air permit the evacuation of the liquid of any one of the three receptacles, in the direction of the operation theatre, while the others are being filled. They should be fitted with cotton filters, so as to anticipate every accident. The external air is not permitted to reach the receptacles but by a long ascending tube rectangularly bent—that is to say, under all the conditions requisite to complete purification. Each of the three receptacles—1, 2, and 3—communicates at its superior extremity by

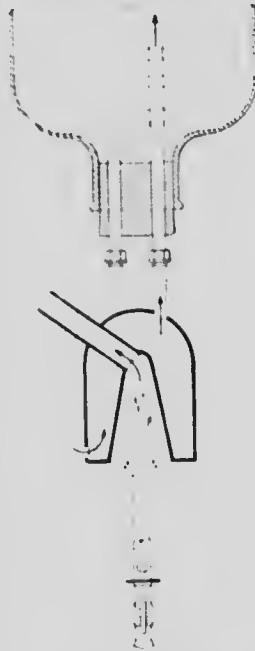


FIG. 34. THERMO-SIPHON FOR HEATING STERILE SOLUTIONS.

The central arrow indicates the tunnel for escape of the gases of combustion. The arrows indicate the circulation of the fluid in the thermo-siphon.

* Prix de l'Académie des Sciences, 20 Janvier, 1825.

a tin tube furnished with a controlling stopcock, with a cylinder of larger diameter (*DOFFF*), which ends on the right in a tube that communicates with the vapour stove. This apparatus being furnished at its left extremity with a second stopcock, *O*, we are able, by either opening the stopcock which establishes communication with the stove or sterilized water, or adapting to the other extremity of the apparatus a tube of india rubber dipping into a vessel of phenol solution, to fill, whenever required, one of the receptacles above with either the 2 per cent. phenol solution or sterilized water. Bottles 1 and 2 are usually filled with 2 per cent. phenol solution sterilized at tepid heat a little before the time of operation. The vertical tubing connected with the bottle containing the sublimate solution is covered with a tube of india rubber, and ends below with a stopcock of crystal. This tubing serves in the filling of the bottle with the bichloride of mercury solution prepared beforehand in the enamelled sheet-iron 20-litre reservoir figured above.

The system of canalization which serves for the conveyance of the fluids to the operation theatre is of tin tubing for the phenol solution, and of crystal covered with india-rubber for the sublimate. When the solutions have been carefully prepared, no precipitate is deposited in the glass bottles, and they may not require cleansing for several months, or even for several years. When the long 10-litre glass vessels are used, such as represented in Fig. 33, a thermo-siphon of the form shown in Fig. 34 may be adapted to the lower mouthpiece. The addition of this apparatus enables the operator to bring the fluids to a temperature of 50° C. (122° F.) or 55° C. (131° F.) in the course of thirty minutes. This thermo-siphon, which is made of nickel plated copper, cannot be used in the heating of the sublimate solution. It is better to prepare the latter in winter at a strength of 1 in 500, and to add subsequently an equal volume of sterilized hot water. The simplicity and perfect reliability of the whole apparatus can readily be realized by a single inspection of its working.

When the canalization system and the receptacles have been disinfected with warm 5 per cent. phenol solution, any internal contamination is impossible; the tubes, both of glass and of tin, are never brought in contact with any other matters than the sterilized water or antiseptic solutions, all of which are prepared with boiling water.

The following is a list of the antiseptic materials prepared in the laboratory for sterilization:

- Solution of phenol and borate of sodium, 2 per cent.
- Sublimate solution, 0.2 per cent.
- Sterilized saline isotonic and Ringer's solution.
- Sterilized compresses.
- Sterilized vestments, table-covers, napkins.
- Sterilized silk and Florence hair sutures.

5. DISINFECTION OF THE SKIN.

The hands of the surgeon and of his assistants, and the whole field of operation, are cleansed eight or ten times in succession by washing in warm

water with formed soap. The nails are cleansed after the fourth or fifth ablution. Another washing is then carried out, in sublimate solution, and a final one with ether. I have never employed iodine, either in the form of tincture, or in solution in water. I consider it of no practical value. The hands are now powdered with sterilized talc, and covered with sterilized gloves of india-rubber. The field of operation, having been rendered thoroughly aseptic, is surrounded with sterilized compresses.

6. ASEPSIS AND ANTISEPSIS DURING OPERATIONS.

The field of operation is usually aseptic, and it is only necessary in order to obtain good reunion, not to infect it. All instruments, threads and other material employed in the operation, are used in a dry state. These are all placed on sterilized napkins or nickel trays. The surgeon should have at hand dry compresses of sublimate solution, of 0.2 per cent., and on the table for the instrument, a tray filled with saline isotonic water, into which he can plunge almost any instrument stained with blood or soiled with pus. If the field of operation remains in a perfectly aseptic state, it is desirable to carry out no further lavage. It should merely be sponged with dry compresses. In case of the occurrence of an eruption of pus or other septic liquid, uterine incisions, or other tamponing operation, even when such accident had been anticipated, if it has taken place over a sufficiently thick layer of sterilized gauze or dry compresses, it is desirable, before closing the wound, to carry out a partial lavage, limited to the areas where there is a possibility of contamination. Such partial lavage is made with warm artificial serum (saline solution of 7 per cent.) or Ringer's solution. Three successive lavages effectively remove pus and even faecal matter from a healthy and glistening peritoneum. Tamponing can be carried out, when considered necessary, with the precaution of closing the serous cavity over the tampon with a continuous suture of fine silk.

But while a partial and rapid lavage of a healthy peritoneum may be useful, the lavages on large scale of an infected peritoneum are proportionally dangerous, as they accentuate the accidental evils by disseminating infection, and precipitate the evolution of grave symptoms. The capital consideration to be borne in mind is that the more we avoid the use of *all fluids whatever* in the course of operations, the more easily is asepsis realized.

7. ASEPSIS AND ANTISEPSIS AFTER OPERATIONS.

The dressings, which are prepared with the greatest simplicity possible, with compresses and sterilized cotton, are distributed among the assistants, according to the conditions of asepsis or infection of the wounds. The assistants who dress the *open wounds* do not touch the aseptic dressings and do not assist in operations. All the dressings are made by assistants wearing india-rubber gloves.

(1) **Aseptic Dressings.**—These are made with sterilized compresses and sterilized cotton; they are covered with an impermeable gutta-percha shield, in case of drainage or the existence of a sero-sanguinolent oozing. The

dressing should be removed when it has imbibed the fluid discharges from the wound. In certain cases, when a partial union only has been attempted — with antiseptic tamponing, for example, in the arrest of an oozing hæmorrhage — the compress may be removed after an interval of from twelve to forty-eight hours, and the skin again sutured with clips.

LAPAROTOMIES. The best dressing consists of a covering of the line of suture with protéol, over which is placed a narrow aseptic compress, retained in position by a piece of adhesive plaster. The line of union is then protected from pressure and dragging during movements of vomiting by circular bandaging of the body.

(2) **Dressing of Open Wounds.** The dressing of open wounds and of those treated by tamponing requires very special precautions. Except on the occurrence of special indications, such dressings should not be changed during the first four or five days, with the exception of external and absorbent pieces. The tampon should not be disturbed for four or five days, if all goes well. *Primum non nocet.* If, after the opening of an infected peritoneum and the employment of deep tamponing, the local and general conditions continue to improve, do nothing: *why disturb the course of nature?* The tampon should not be disturbed during the first four or five days except when indications occur which point to purulent retention beneath it which rarely happens when the tamponing has been combined with drainage with glass tubes. If the tampon becomes displaced, it can be restored to its position, less tightly fixed. If the compress is very adherent it can be lifted off by moistening with dilute oxygenated water (4 in 3 or 4 in 5). The compress swells, the adhesive matter dissolves, and the dressing can be detached without pain.

When the first tampon has been removed, it should be cautiously replaced, with the preliminary precaution of not throwing an antiseptic injection into the cavity. Such inappropriate injection, under the nominal pretext of antiseptics, might detach protective adhesions and lead to the development of grave accidents or infection. No deep injection or lavage should be practised before the sixth, eighth, or even tenth day. It is also necessary that a graduated syringe should be employed for the first injection, and that the exit of all injected fluid be assured. When there remains but the *in-fac-*
er-und, this is covered with sterilized gutta-percha leaf, so as to avoid irritation by contact of the compress sponges, which would adhere to its surface. We can then decide whether it is necessary to revivify the edges of the wound so as to secure secondary union.

S. PROTÉOL, A NEW ANTISEPTIC POWDER.

The antiseptic powder which is exclusively employed in my clinique is *protéol*, a new antiseptic chemical combination of albumin and formaldehyde, discovered by the author of this work. This is a white powder, of low specific gravity, it does not irritate the tissues, and possesses an antiseptic power which is easily demonstrable. For this purpose take three test tubes, each of about 15 centimetres in height; fill the lower third of

each with a neutral or slightly alkaline culture broth; add then an equal volume (say 1 c.c.) of protéol to the first, of iodoform to the second, and of salol to the third; agitate, and set to rest. Then inoculate each of the three with an equal quantity of a mixed culture of the most virulent and most resistant bacteria: streptococci, staphylococci, *Bacterium coli*, saprophytic bacilli, *Bacillus subtilis*, etc. — or simply with a small quantity of fecal liquid. After an interval of 12 to 24 hours, tubes 2 and 3, respectively containing iodoform and salol, will be found to furnish an abundant culture; while tube 1, which contains protéol, alone remains sterile. And let it be remembered that tube 2 contains a weight of iodoform nearly four times that of the protéol in tube 1, the density of the former compound being nearly four times that of the latter. This experiment, which can be repeated by every inquirer, is surely conclusive.

9. USES OF PROTÉOL.

Protéol is used in all cases in which iodoform, salol, and other surgical powders have been employed. One of the first results that I obtained was the cicatrization in an aged female, obese and cardiac, of a circular ulcer of the leg, of 15 c.c. in height and with a sanious and fetid discharge, for which she sought amputation. The surface was powdered with protéol, without other disinfection and without scraping; it was then covered with strips of gutta-percha tissue and an absorbent dressing. Cicatrization had commenced at the end of eight days, and was completed without further incident. This compound is specially utilized in our clinique for protection of the line of union after abdominal operations — particularly in those grave cases in which it had been the practice to cover the abdomen with icebags. The line of suture is covered with an abundant layer of protéol powder, over which is placed a sterilized compress which is retained, when the wound is aseptic, by a band of oxide of zinc plaster, when a copious oozing is anticipated (as in suppurative appendicitis), by a large gutta-percha leaf. A large piece of gummed talietas covering is then applied, the margins of which are folded on four or five elongated ice bladders wrapped in absorbent cotton. Five of these are required to cover the abdomen from the pubis to the intramammary regions.

Protéol is sufficiently antiseptic to prevent infection of the line of sutures, or of the wound when tamponed and open, in case the water escaping from the ice bladders should come to reach that position.

Advantages of a Perfect Antiseptic Installation.

The whole organization here described is practically indispensable to the securing of regular and constant operative success. Nothing should be left to chance, and sterilization of everything that touches the patient should be carried out with absolute precision and regularity. The use of heat, dry or moist, enables us to obtain this result if suitable apparatus are employed, the manipulation of which should be familiar to every intelligent hospital assistant. The organization of my operation theatre has been carried out in such a way as to enable me to perform all the most complicated capital

operations with the aid of a single assistant, who also fulfils the function of anaesthetist. Many of my confrères have seen me perform as many as eight, ten, twelve, and even fourteen operations during a single séance—from 6 or 8 a.m. to 4 p.m. In a single morning I have had as many as five operations on the stomach (pylorectomy and gastro-enterostomy); I have frequently performed three, four, or five laparotomies and as many vaginal hysterectomies, followed by one or two operations on the osseous system (craniectomy, articular resection, osteotomy). On one day alone—and by pure coincidence—I performed nine total hysterectomies, of which two were abdominal. And I have never observed in the course of any of those prolonged operative séances that the patients last operated on lost in any way when compared with the earlier ones, either in way of infection or of operative manipulation. Indeed, it has quite frequently happened to me to be called on to perform a craniectomy, or ablation of a cataract, at the close of one of my operative surgical matinées, and it has in every case been carried out with all the desirable manual dexterity.

My operations are classified in the respective orders of gravity and of asepsis: Ovariectomy, abdominal hysterectomy, craniectomy, aseptic pleurotomy, radical cure of hernia, osteotomy, operations on the liver, stomach, or intestine; then vaginal hysterectomies in the following order—fibronia, simple salpingitis, carcinoma, pelvic suppuration; and, in the last place, operations in cases of osteomyelitis, tuberculous arthritis, resection of either maxilla, cancer of the rectum, fistula of the anus, etc.

My practice of antiseptics is also so rigorous that I have often been able, in the same operative séance and without production of the smallest consecutive accident, to make extensive openings in the peritoneum or meninges of patients, after having operated, for example, on a case in which the presence of pus could not have been anticipated. Accordingly, I can affirm that a patient who was not infected before operation should always remain aseptic when the organization of the operation theatre and the antiseptic precautions are maintained at the proper standard. When we have to deal with patients already infected to a grave extent, or those who had previously been suffering from extensive suppuration, visceral cancer, infective pyelonephritis, etc., a successful result is, of course, not so definitely controllable by the surgeon. In presence of a human organism exhausted and debilitated by chronic septicæmia, the surgeon may find himself quite powerless in the effort to obtain a cure. Success in these cases depends largely on the vital resistance of the patient who is operated on; and when this vital resistance has been very seriously sapped, it may be difficult or wholly impossible to restore it. The use of my new immunizing preparation, *mycolysine*, for this purpose will be explained in a subsequent chapter.

ATTACHED SERVICES.

Laboratories for photography, simple and stereoscopic. Laboratories for cinematography and microscopic photography. Apparatus for radioecopy and radiography. Laboratories for chemistry, histology, bacteriology, and for serotherapy. Museum and consultation-rooms. The cinematograph and teaching of surgery.

Laboratories for Photography, Simple and Stereoscopic.

Photographs, both simple and stereoscopic, are taken either in the principal operation theatre, or in a large glass studio which is situated on the sixth floor. They are for the purpose of representing cases of pathological interest, or the principal stages of certain operations. The importance of this photographic service may be fairly estimated by the reader from the illustrations of the present work, which represent eight years of assiduous toil. The taking of a large number of photographs with the ordi-

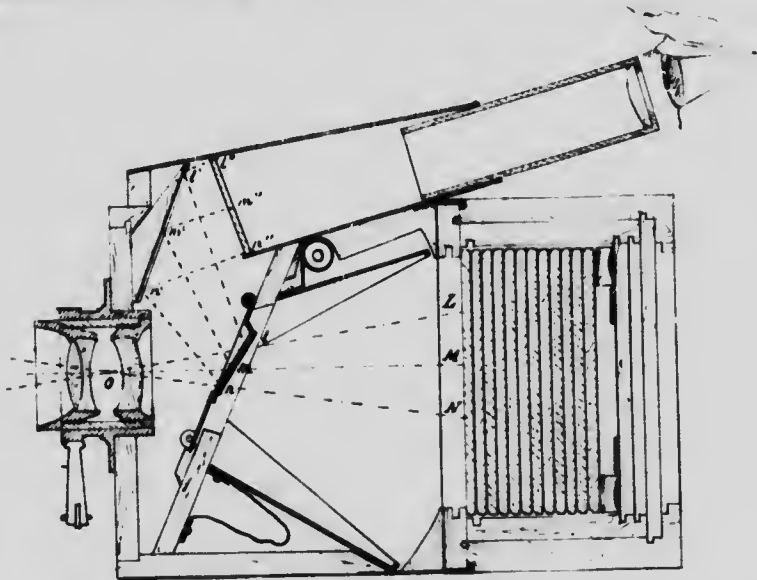


FIG. 35. SECTION OF DUPED'S PHOTOGRAPHIC APPARATUS.

O, m, m', m'', the course of the luminous rays; twice reflected by the mirrors, *m* and *m'*, and finally passing to the formation of the image on the polished glass of the plate, *L, M, N*. When the obturator mirror, *l, m, n*, is removed, the luminous rays are transmitted directly, and impress the sensitive plate at *L, M, N*.

inary apparatus in the course of surgical operations represents, of course, the expenditure of considerable time if we wish to obtain sufficiently large and clearly defined impressions. In order to obviate many inconveniences, I have devised a portable apparatus, which combines the advantages of the instantaneous apparatus most generally used, and in which the focussing is but approximate, with a possibility of controlling the clearness of the image to a degree of absolute perfection—on an unpolished glass plate, and without displacing the roll of film, or the carriage for replacing the plates.

This result I obtained by interposing, between the objective and the obturator of the plate provided for extra-rapid instantaneous exposure, an oblique obturator furnished with a small plain mirror, *m* (Fig 35). When

the shutter is closed, this mirror receives the luminous rays passing from the objective, *O*, and directs them, by reflexion at *l, m, n*, towards a second reflector placed above the objective, *O*, towards *l', m', n'*, and from this second reflecting surface they pass to a polished glass placed above the dark chamber, at *l'', m'', n''*, where an inverted image is produced, equalling in size and identical in physical qualities with the image, *L, M, N*, which comes to impress the sensitive surface at the moment of elevation of the obturator glass, *l, m, n*. With this apparatus we can obtain at will time-exposures and instantaneous ones varying from $\frac{1}{2}$ to $\frac{1}{10000}$ second.

We can take both of pathological cases and of operations, either stereoscopic pictures, which have the advantage of reproducing the natural relief; or proofs of dimensions of 13 by 18 centimetres, which can be published without enlargement; or instantaneous autochromes of the format 18 by 24 centimetres. Such proofs are the best means of fixing the principal stages of each operation. They also form valuable documents for the execution of designs with the pen; these latter may bring into evidence certain details which are not very clearly visible on the photographic proofs.

Laboratory of Cinematography.

But the *cinematograph* is the apparatus *par excellence* for the teaching of operative technique. This marvellous instrument enables us, indeed, to register, on durable films, the whole serial details of operations, precisely as they have been practised, and to reproduce them subsequently *ad infinitum* in all the teaching centres, and before thousands of spectators. It was in June, 1898, that I obtained my first cinematographic photographs of operations, representing a craniectomy and a total hysterectomy. Those films were exhibited in that year at the meeting of the British Medical Association in Edinburgh.

The apparatus, furnished with negatives and projectors, which serve for registration and preparation of cinematographic films, are of my invention; those apparatus give perfect fixation. They have recently been perfected so far as to permit the carrying out of cinematography in the natural colours.

Laboratory of Microscopic Photography.

The laboratory of microscopic photography, which is furnished with Zeiss's most recent apparatus, also serves for the development of the negatives in radiography. A laboratory is also annexed, which, being situated near the operation theatre, enables the assistants to develop the negatives while arranging and focussing the microscopic preparations that we wish to reproduce.

Radioscopy and Radiography.

It is necessary to have an installation for radioscopy and radiography at a short distance from the operation theatre. I use the new rotatory transformer of Gault. It is now easy to recognize clearly on the screen the presence of a bullet in parts of the brain which but a few years ago,

were regarded as wholly inaccessible. The chest, abdomen, and pelvis may be explored, with the result of distinguishing the outlines of large renal calculi and the condition of the coxo-femoral articulations. Antero-posterior and lateral photography of the cranial cavity are obtainable in a fraction of a second.

The applications of radioscopy and radiography to medical science are now multiplying from day to day: the search for opaque foreign bodies with the help of the X rays; study of osseous lesions (osteitis, luxation, pseudarthrosis); examination of thoracic aneurysms; of pleural effusions; of calculi of the kidney and of the ureter, etc.; exploration of the œsophagus and of the stomach after ingestion of subnitrate of bismuth, or after the introduction into the œsophagus of a sound formed of an india rubber tube filled with mercury. The X-ray theatre is near the operation theatre, so as to provide for the ready practice of radioscopic examination during the actual course of the operation—for example, following on the screen the extraction of a deeply seated foreign body with the aid of a suitable forceps.

RADIOGRAPHIC SERVICE.

The installation consists of a revolving Gaiffe commutator, a Dr. Belot's radiological table, and a radiophoscope, or closet, for the examination of the *éclipsés*.

The Revolving Commutator. This is supplied with an alternating current of 25 kilowatts (110 volts, 220 ampères). The high tension apparatus is contained in an oaken chest. It includes the commutator, which is rotated by a synchronizing motor, and the transformer. The commutator consists of four arms, which are connected at the desired moment with four sectors, in which terminate, on one side, the transformer, on the other, the terminals of a Crake's ampèremeter. Thus, of the two alternating waves, one is transmitted directly, while the other, or inverse wave, is returned in the opposite direction. No inverse wave is produced in the circuit of the ampulla. The motor is a synchronizing motor, with four poles of 15 kilowatts. The transformer is of a special type, and is remarkable for perfect transmission and isolation, without escape at the closed magnetic circuit; it possesses two primaries, and can receive a supply of 110 volts (200 ampères) on the sector, per fraction of a second. Its consumption under the action of 110 volts, is about an ampère per milliampère. The secondary produces, with a tube of medium hardness, about 150 milliampères. The effective difference of potential in traversing a hard tube is about 120,000 volts. Under those conditions all the radiographic pictures can be taken instantaneously, from $\frac{1}{100}$ second. The apparatus is mounted on a thick, steadying india rubber cushion—a marble panel holds the interrupters, an opaline panel holds the high-tension exits, the milliampèremeter, and the spintrometer; while a screen, opaque to the X rays, bears the handles for regulation and control, and, at the same time, effectively protects the operator.

2. The Radiological Table. This permits, by the mobility of the tube in all directions, a perfect centralization and the taking of radiographic

pictures with the maximum degree of precision. The installation, which is one of the most powerful of known apparatus, permits the realization, under exceptional conditions, of the objects of radioscopy and radiotherapy.

SERVICE OF D'ARSONVALIZATION.

The installation consists of the d'Arsonval-Gaiffe apparatus for interrupted currents (1906 model), and of the large auto-conduction cage of Professor d'Arsonval.

1. D'Arsonval-Gaiffe Apparatus. This is fed with an alternating current of 110 volts, and includes transformer, condensers, and sparker. The transformer, with its insulation in a metallic box (type II— the recent model produced by the Maison Gaiffe), permits, thanks to the high degree of insulation obtained, suppression of the safeguarding condensers and electrolytic resistances of the original model. The condensers and sparker are of the usual type. The chalk of the silent sparker has been advantageously replaced with vegetable oil.

2. Auto-Conduction Cage for d'Arsonvallization (Lowering of Arterial Tension). The cage consists of twenty spirals of 1 inch diameter. It is furnished with Professor Dommer's induction measurer for direct calculation of F.M.P. (practical medical unit) the value of the electro motive power of the oscillating magnetic current produced by the great solenoid for d'Arsonvallization. Normally, the primary voltmeter indicates about 110 volts, the ampèremeter 15 ampères, and the F.M.P. meter oscillates between 0.6 and 1 F.M.P. Thus the cage furnishes a maximum. Two small solenoids, of 0.85 millimetre diameter, and ten and six spirals respectively, complete the installation, and serve for local applications. From the same apparatus branches off Oudin's resonator, for the various applications of high frequency and high tension currents. This treatment is applied, before operation, to patients with high arterial tension to prevent the danger of cerebral hæmorrhage after anaesthesia, and secondary hæmorrhages, such as after operations on the tongue, uterus, rectum, etc.

Laboratory for Chemistry and Histology.

These laboratories are under my personal direction. Chemical researches and analyses are there carried out daily, also histological examination of all pathological specimens. The histological laboratory possesses a remarkable collection of microscopic sections, which are for the most part associated with the history of neoplasms. The laboratory of microscopic photography has already been described.

Laboratory of Bacteriology and of Serotherapy.

The laboratory of bacteriology and serotherapy, in which are carried out, under my control, all the microbial researches necessitated by daily operations, is furnished with the most highly finished apparatus. The department which deals with toxins, microbial vaccines, and serotherapy,

comprises a wholly specialized organization, and is submitted to the most rigorous control. It is in this laboratory that my immunizing preparations were discovered—antineoplastic vaccine, for the treatment of cancer; mycolysine, for the preventive and curative treatment of infectious diseases; and phymalose, for the treatment of tuberculosis.

The antineoplastic vaccine, which was discovered in January, 1901, is prepared from toxins and the cells of *Micrococcus neoformans*—the microbe of cancer.

Mycolysine is an immunizing preparation extracted from selected yeasts. It owes its therapeutic properties to a highly assimilable nitrogenous substance, which is an energetic stimulant to phagocytosis.

Phymalose is a combination of mycolysine and tuberculin; this preparation is a specific against the bacillus of Koch.

The mode of employment of each of these preparations will be subsequently described.

Museum.

The museum contains a great number of rare specimens— notably the whole series derived from the experiments which I carried out with firearms of small calibre from 1888 to 1895; a varied series of foreign bodies; calculi

biliary, renal, ureteral, and vesical; sections of fibromatous uteri; and finally, a remarkable series of autochrome photographs.

The Author's Institut Chirurgial includes all Appropriate Services, Technical and Scientific.—The short description which I have placed before the reader shows, I believe, that the *Institut Chirurgial* is a unique specimen of its kind, and one in which the scientific department yields to none in the organization of its technical services, and of everything that relates to practical surgery, properly so called. To unite in a single great institution all the services of general and special surgery which can possibly contribute to the improvement and cure of interesting cases; to annex to an unrivalled service of operations every new mode of treatment which may possibly cure, without operation, those cases in which loss of blood can be possibly avoided; to realize the attainment of a duplex internal organization, which provides for the treatment of nearly a hundred resident patients, while separating completely patients of the first class, which are provided with a special entrance, from those of the second and third class; to enable the latter to profit by all the advantages which are everywhere else reserved for rich patients only; to create a scientific installation, which suffices to give all patients every possible guarantee; and to publish every succeeding year discoveries of the highest interest in the respective domains of chemistry, histology, bacteriology, and serotherapy—such is the task which has been chosen, and is now, I trust, fully realized in the author's Institute.

CHAPTER II

HÆMOSTASIS AND SLICING

HÆMOSTASIS.

Importance of Hæmostasis in Surgical Practice.

DEATH from hæmorrhage was necessarily one of the phenomena which first made a special impression on the mind of primitive man. The ancient warriors knew, when one of their fellows was struck down with a javelin, that he would succumb when the weapon was extracted from the wound; the escape of blood exhausted the remaining strength of the moribund. Medical affections, which were then ill-defined, gave free scope to empiricism. The frequency of combat at close quarters, where victors and vanquished had their bodies studded with deeply penetrating wounds, compelled the surgeons of ancient times to study the best methods of dressing the same. One of the first indications was to secure hæmostasis. Amputations did not take a place in current practice till the Middle Ages, when the use of more formidable weapons of war increased the destructive injuries of lacerations and osseous fractures on the higher scale. The art of healing had by that time progressed in corresponding degree, and surgeons became bolder in their dispute with death for the rescue of the wounded who had formerly been left to the resources of Nature.

The practice of amputation drew the attention of surgeons more particularly to hæmostasis. In the olden times of great hand to hand battles, immediate hæmorrhage was one of the principal factors in the resulting mortality. The surgeon was seldom called on to practice hæmostasis on the larger vessels. The wounded who lost very much blood died on the spot, and the surgical expert had to give attention to those only who survived for some hours or some days. Before the time of A. Paré, the surgeon hesitated to remove a limb, even in a case of gangrene, for the operator feared the inability to arrest the flow of blood. Thus surgery, which was disdained by physicians, was reduced to empirical practice of a coarse type.

Wounds inflicted by firearms were then regarded as poisoned; they were burned with canteries and with boiling oil. The flow of blood which followed the amputation of a limb was combated with the aids of the red hot iron and styptics.

Ligature of bloodvessels had already been known to Hippocrates, to Celsus, to Galen, and to Paulus Ægineta; but they had no confidence in its utility, and it is to Paré that the honour belongs of having adopted it as the best means of hæmostasis in the practice of amputation. "Having

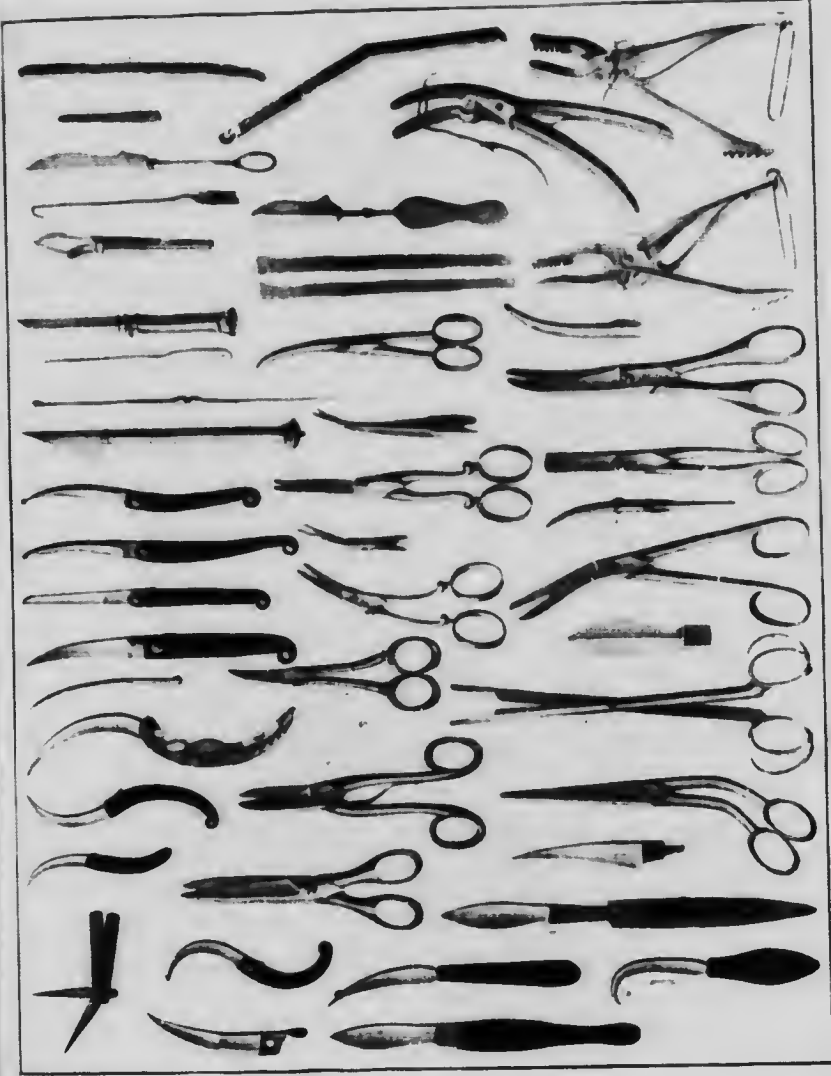


FIG. 36. PLATE 4 of SERRI'S ATLAS.

Below, on the right side, are seen three haemostatic forceps used by Bonn's and Hildbrand's.

many times employed this method of closure of veins and arteries in recent wounds from which hemorrhage took place. I thought I might as well do the same in case of amputation of a limb" (A. Paré, chap. XXXV). A Paré had made for him, for the purpose of grasping the arteries on the surface of an amputation stump, various types of forceps, which remained fixed on the vessel by the action of a spring. He, like a true apostle, imposed his method on his co-temporaries. Forcepressure had come into existence. Surgeons who adopted the practice of ligation of vessels nearly all made use of forceps, most of which were furnished with a spring, or a sliding ring, which held them in position. The mediate ligation was also used, by grasping the vessel and adjacent tissues with a tenaculum, and tying them above that instrument. As we shall see afterwards, Dionis tied vessels, after grasping with a forceps, with a thread eyed on a needle which was afterwards made to pass through the vessel and fix the ligature with a second knot, so that it could not slip. He tied and resected the omentum in operation for strangulated hernia complicated with an irreducible epiplocele. In castration he tied the spermatic cord *en masse*. In amputation of the breast he tied the mammary artery when it "gave too much blood." Ordinarily the hemorrhage was arrested by application of a button of vitriol to the small arteries, followed by an astringent dressing. Hemostasis of the great vessels of the limbs did not become an object of many researches until surgeons found themselves dealing with the hemorrhages of operations. They long contented themselves, in minor amputations, with the mere division of the limb. Even so lately as 1822, Heister figured amputation of the great toe by a single stroke with a mallet and chisel; but an arm or thigh could not be removed in this way. Hemorrhage from the large arteries necessarily engaged the attention of surgeons who undertook those major operations, and in this way special compressors came to be invented for each region, with the object of realizing preventive hemostasis by pressure on the principal artery of the limb.

When the amputation was finished, the principal vessels were each grasped with a "Patin's valet," or with one of the various types of forceps—spring, cross-action, ringed, rackwork—of which Serzig has represented the principal models in his valuable atlas (1838). A ligature was then placed on the vessel. There were also other instruments of more complex form. Columbat used forceps with eyed antennae, for the purpose of applying the ligature at some distance. The promoters of the procedure of ligation had in view the special object of avoiding the tortures of cauterization and application of boiling oil, which had been almost exclusively employed in the time of Ambroise Paré. But the employment of "Patin's valet" and other types of forceps, the furrowed jaws of which were infected with the most virulent forms of toxic agents, and of soiled ligatures which acted as septic foreign bodies, produced disastrous results; and inoculated with an incurable septicæmia the unfortunates who had been temporarily saved from death by amputation. Thus it was that the cry of humanity which was raised by Ambroise Paré led to the sacrifice of myriads of human lives, through conferring on the victims the relatively small privilege of escaping




FIG. 37. Plate 13 of SMITH'S Atlas.
Numerous varieties of hemostatic forceps of Heister, Brandt, Pate, Joubert, Scudder, Gullenreich, Trautmann, Manni Sobla, Schmecker, Percy, Bell, etc.



the tortures of fire after exposure to those of steel, and thereby removing the one great safeguard against infection.

The practice of ligation came to prevail, by degrees. The instruments of hemostasis multiplied. For hemostasis of those arteries which were specially difficult to ligature (intercostal, meningeal, etc.) compresses were devised which were left in position for two or three days (Lotter's plate, Graec's compressor, etc.). Percy applied permanent forepressure in hemostasis of the arteries of the limbs, which he grasped with forceps furnished with a rotary plate and recoil spring. His object was suppression of the ligation, the inconveniences and dangers of which had been proved, while the cause of these remained still unknown. Among them we would specially indicate that of secondary hemorrhage, which occurred at the time of the separation of the ligature when the clot was not sufficiently adherent. Suppuration retarded the normal process of obliterative endarteritis.

Surgeons had then come to recognize, too, that the *mediate* ligation of arteries was a faulty practice, that is to say, the inclusion in the ligation of tissues other than the vascular tunics. They adopted in preference that of *immediate* ligation, or placing the thread on the vessel when isolated and denuded of its cellular sheath. The artery retracted with the ligature and furnished less risk of secondary hemorrhage than when the sphacelus and elimination of the investing tissues were provoked by application of the ligature *en masse*. The immediate ligation also secured much more effectively than the mediate, or *en masse*, the division and retraction of the internal and middle tunics above the seat of strangulation of the external coat of the artery, which was in direct contact with the thread. The forceps then served hardly any other purpose than that of prehension.

The instruments which were left in position in those cases in which ligatures could not be applied (Lotter's plate, Graec's compressors, etc.) and also Percy's forceps, were difficult of application. They acted simply by producing juxtaposition of the walls of the vessel, and were bound to be insufficient to secure the division and retraction of the internal and middle tunics, the sole guarantees of rapid fixation of the obturator coagulum. Those apparatuses for hemostasis were of exceptional application. They produced occlusion of the artery by the same mechanism as simple compression, which was then fully appreciated after bleeding from the jugular vein or temporal artery.

The earliest methodic researches on the process of obliteration of arteries were those of Mannoir and of Amussat on chewing and torsion. Amussat sought, by the use of his *forceps à ligature* to procure adhesion of the clot at a number of points at which the instrument had determined the rupture of the internal coats. The researches of Mannoir on the chewing of vessels had a similar object: of fixing the clot and preventing the secondary hemorrhages which then so frequently occurred at the moment of separation of the twisted or tied extremity of the vessel, which had become necrosed as the result of a pyogenic process. Amussat and Mannoir recognized, in the course of their experiments, that the curling up of the middle and internal coats of the artery, which was much more effectively realized by torsion

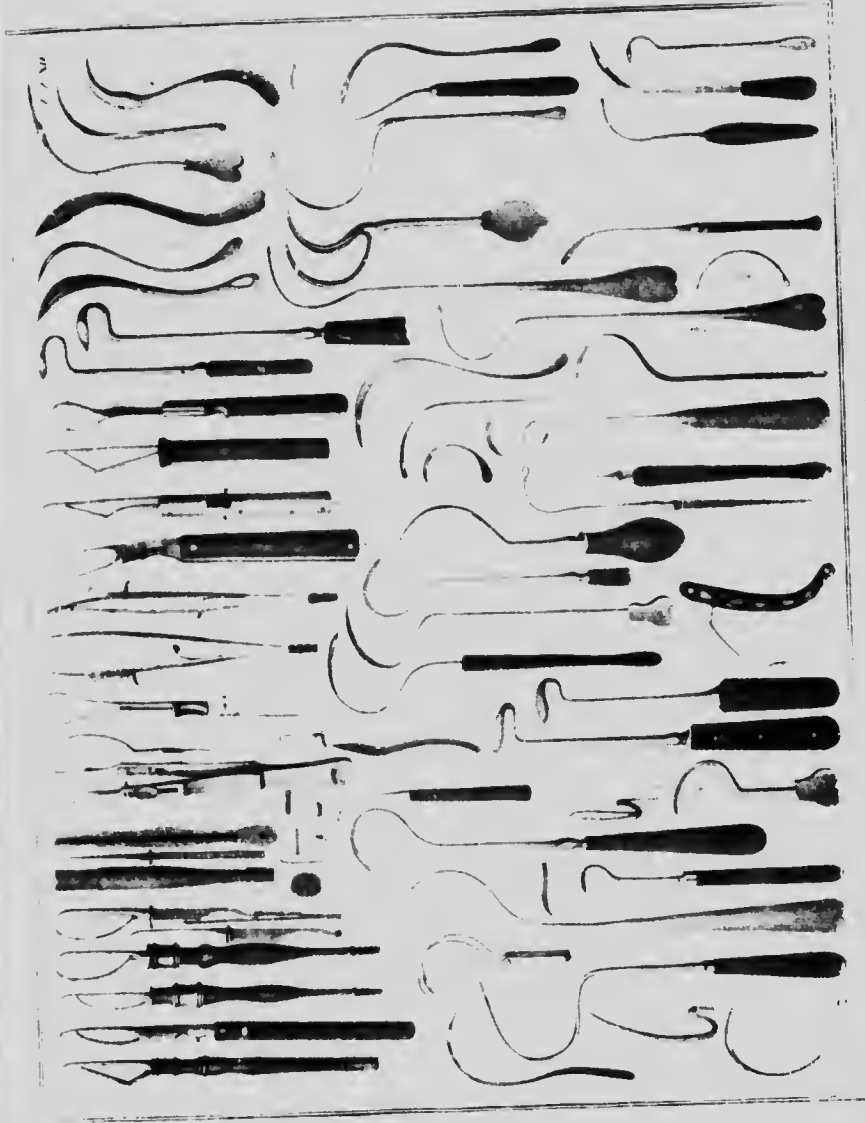


FIG. 38. PLATE II OF STARR'S ATLAS.
 Various models of instruments and forceps furnished with eyed antennae, and needles, simple and double,
 for the passage of ligatures.

than by the application of a simple immediate ligature, was the essential condition of reliable hæmostasis.

To Chassaignac belongs the honour of having first utilized *force* in the realization of hæmostasis. He demonstrated the possibility of cutting through all the soft tissues of the body, of whatever resistance, by the use of a powerful instrument; when the manual effort was multiplied, in the first model by a cogwheel, and in the final one by a double lever, furnished with a catch. The chain of Chassaignac's *écraseur*, such as I have seen him use, differed from the chain-saw formerly employed only by the fact that it was not dentated. Chassaignac thus realized the section of arteries and veins of a certain calibre without the occurrence of hæmorrhage. Hæmostasis was secured by the drawing out of the external coat of the vessel, after laceration of the more friable internal and middle tunics. It is the same result as that which follows the application—not direct, but indirect—or brute force when a limb is torn off, especially an arm. The axillary vessels, when torn by violent traction, yield no considerable flow of blood.

Chassaignac and Maisonneuve tore through the vessels by enclosing them in a metallic loop, which gradually shortened; they had the double object of suppression of hæmorrhage and occlusion of the vessels, especially the veins, which were supposed to absorb septic fluids from the wound. The habitual employment of hæmostatic forceps—sliding-catch forceps, ringed forceps of Spencer Wells, of Kœberle, of Charrière, which were adopted by Péan and Vernemil—and of ligatures became possible only after the discovery of infective germs and introduction of vigorous processes of disinfection with dry heat or vapour under pressure.

The two great concurrent schools of operative technique towards the end of the nineteenth century were that of Billroth, in Vienna, and that of Péan, in Paris. The school of Billroth practised hæmostasis with appropriately fitted needles, and tied vascular pedicles with numerous threads of silk or catgut. The school of Péan placed forceps on the smaller pedicles, and applied the ligatures after ablation of the tumour. Péan soon came to observe that in many operations—in amputation of the breast, for example—it was unnecessary to tie the arterioles to which forceps had been applied for a certain time. He then made bold so far as to leave the rack-work forceps in position for a period of twenty-four to forty-eight hours, in case of the larger arteries; then on pedicles of a certain importance, such as the broad ligaments in a case of vaginal hysterectomy. The *servant* of Cintrat was long used by Kœberle and by Péan, who had also employed the fixed clamp after ovariectomy, in the procedure of supravaginal hysterectomy. Péan, indeed, so far abused the employment of fixed forceps as to proceed, in carrying out amputations of the tongue, to the barbarous practice of fixing two strong curved forceps behind the neoplasm, and removing the projecting mass by a series of snips of the scissors. The unfortunate patient was obliged to retain those forceps as a torturing gag for a period of twenty-four to forty-eight hours. The compressed portion of the tissues became gangrenous, the tongue swelled to an enormous size, and in the majority of cases recurrence of the growth took place before the




FIG. 39. PLATE 16 OF SEHRIG'S ATLAS.
 Ambrosia's torsion forceps, Colambat's forceps with eyed antennae, forceps, etc.

samous and fœtid wound had completely cicatrized. All those inconveniences resulted from the fact that Péan, while observing the hæmostatic effect of prolonged pressure of arteries, had not sufficiently studied the anatomical conditions of hæmostasis. The fixed forceps served the purpose well when used for the mammary and facial arteries, which were secured in an isolated condition; but when he grasped the whole thickness of the tongue with a curved forceps, he fell into the same error as the surgeons of former ages had done when they practised mediate ligature.

Maisonneuve and his contemporaries carried out their operations with sounder logic and greater simplicity; they nipped and tied only those arteries which yielded a considerable jet of blood. They had no anesthetics, a fact which induced them to operate rapidly; one of the results was that there was very little blood lost. Preventive hæmostasis, whether effected by ligature or forceps, such as practised since the time of Billroth, Péan, and their respective schools, had the disadvantage of greatly prolonging the time accorded to operation, without effectively avoiding a considerable loss of blood. Thus I have seen Martin lose more than 800 grammes of blood in the course of an abdominal hysterectomy, in spite of the fact that he had applied fully as many as forty ligatures with remarkable dexterity. Péan, who applied twenty, thirty, and even as many as fifty forceps in a vaginal hysterectomy, often lost much blood in the course of an operation—which lasted one or two hours, sometimes even up to four hours—while he still failed to secure himself against the occurrence of secondary hæmorrhage with the aid of that cumbrous and complicated hæmostatic apparatus, which was powerless in dealing with the principal vessels. The fixed forceps method of Péan was merely a generalization of the old chewing procedure of *machures*, which was studied by Mannoir in 1820. The first types of hæmostatic forceps, which were the genetic successors of the old "dressing-forceps" of Charrière, and which the instrument-makers have since produced on a still more delicate model, were wholly insufficient for their intended purpose: they could secure hæmostasis only in the case of very slender arterioles and in tissues which permitted agglutination under slight pressure. In contrast with those, my forceps are of great power—capable of producing between their jaws a compressive force of 1,000 to 2,000 kilogrammes. Muscles, mucous membranes, adipose tissues, nerve fibres, internal and middle coats of vessels—especially of arteries of a certain calibre—disappear under this enormous pressure, which also agglutinates the fibro-cellular strata which are alone capable of resisting it. Chassaignac's instrument was insufficient in its application, precisely because it did not effect a real crushing of the tissues, but a *linear section* by strangulation; my forceps, on the contrary, act in crushing the tissues over a certain surface—a width of 6 to 8 millimetres—without section of any. My method not having been sufficiently comprehended by certain colleagues, who, to apply Broca's appreciation of the "imitators" of Chassaignac, succeeded "only in deteriorating, and not in perfecting," and thus risked a compromising of success, I shall here proceed to describe it with all its desirable developments. With this object, it is indispensable, in order to enable the reader to judge this important question with a full knowledge of

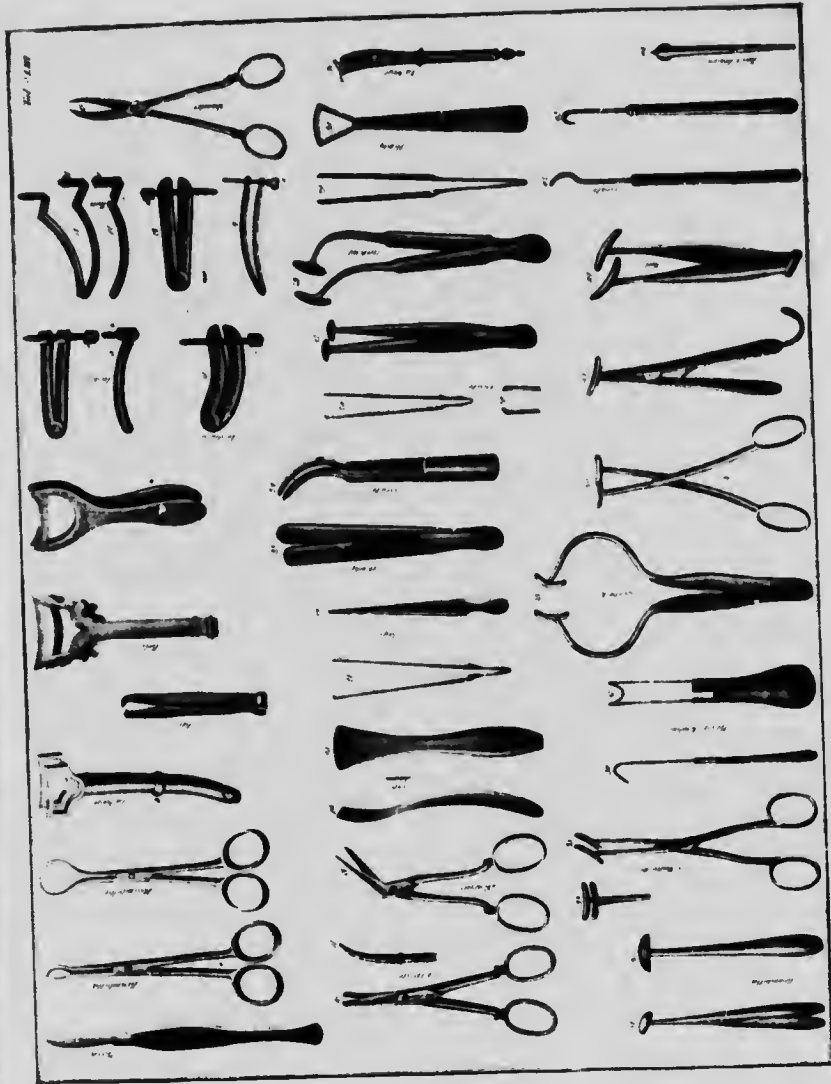


FIG. 40. PLATE 43 OF SEELIG'S ATLAS.
 Various models of forceps: T-shaped, ring-handled, with compressing screws, etc.

the data, to make a rapid preliminary study of the different methods and the numerous instruments which have successively preceded the method of extemporaneous crushing, and then to pass in review the various models of forceps and of *écraseurs* that we possess in the present day.

History of Hæmostasis.

Earliest Types of Hæmostatic Forceps.—In most operations with cutting instruments, the loss of a certain quantity of blood is, of course, inevitable. This loss of blood was formerly limited as far as possible, especially in case of the limbs, by the preliminary application of a compressing cord, and later by that of Petit's tourniquet. For the head, neck, and trunk, various compressors were employed. Almost every one of those consisted of a metallic arc or ring, which provided the point of support and presented, at the level of the wounded vessel, a compressing screw furnished with a terminal pad. Such were the tourniquet for the jugular vein (Fig. 41), Nélaton's apparatus for compression of the carotid (this apparatus was also used in treatment of torticollis*), etc. The ligature, which was known to Hippocrates,† Celsus,‡ Galen,§ Paulus Ægineta, Alphonse Ferri,¶ was employed in the treatment of open wounds long before the time of Ambroise Paré. This was oftenest applied with a needle and loop of thread which constricted the wounded vessel with the adjacent tissues; but no confidence was placed in the procedure when dealing with large arteries: gunshot and amputation wounds were sealed by the application of chemical caustics, of boiling oil, or of the red-hot iron. To A. Paré belonged the merit of demonstrating the fact that the employment of those cruel methods of "burning and carnifying wounds" was but a barbarous and unnecessary practice, and far inferior in efficiency to that of ligature.

Origin of the Hæmostatic Forceps.—A. Paré had constructed, for ligation of vessels at the surface of amputation stumps, forceps of various forms, mostly adapted to fixed pressure. He seized with one of his forceps, or "crow's beaks"—genuine instruments of forceipressure—veins and arteries simultaneously, with a little of the surrounding tissues, and tied all up together with a double thread. The introduction, by Paré, of ligation of vessels after amputation dates back to the middle of the sixteenth century. His procedure, which the master imposed on his contemporaries in true apostolic fashion, was very soon generally adopted. Thus, Dionis described, in 1707, in his *Cours d'Opérations, fait au Jardin Royal*, the ligation of vessels carried out with the aid of a continuous-pressure forceps: "We grasp the extremity of the artery with a 'crow's beak,' or small forceps furnished with a compressing ring, known as the *palette à patin* (ancient pres-

* *Characæ's "Catalogue,"* 1855, p. 65.

† Hippocrates "Opera," Fraencl., 1621, lib. vi., sect. 7.

‡ Celsi, l. viii., "De re medica," Lipsiæ, 1666.

§ Galeni, "Methodus medendi," Basiliæ, 1542, lib. v., c. 3.

¶ Æginete, P., "Medici insignis opus divinum," 1532, lib. iv., p. 53.

• Altonsi Ferri, "De scelopet. vulnere," etc., Lond., 1553; *vide "De chir. scripturas optima . . . unum editi . . . in unum conjuncti volumen,"* Tiguri, 1555.

sure forceps): then, sliding over the instrument and on to the artery a thread prepared and knotted, we tighten and secure it with a double knot. In order that this should not be pushed off over the end of the vessel by the continuous pulsation of the blood, there should be an eyed needle attached to one of the ends of the thread, which is passed through the body of the vessel, after which the ligature is made fast with some knots." We shall see afterwards that ligature of very vascular pedicles was carried out in similar fashion; and it is surely interesting to find in the text of Dionis an exact description of the knot to which I pinned my faith some years ago as the one that appeared to be the best yet devised.

The greater number of the forceps employed by A. Paré and his imitators were, as we may judge from the illustrations above given, adapted to

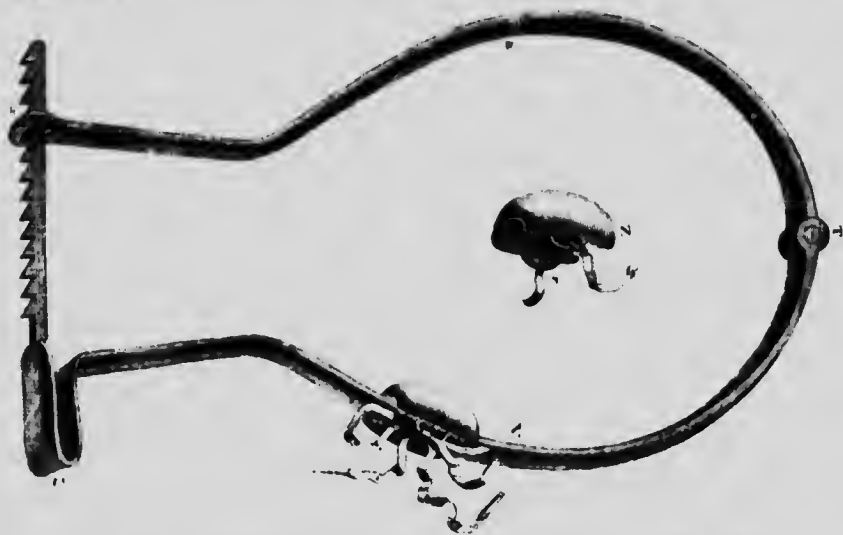

FIG. 41. COMPRESS USED IN BLEEDING FROM THE JUGULAR VEIN.*

continuous pressure. They were kept closed by various forms of mechanism—rack, ring with catch, spring action, lateral or terminal screw bolts, etc. "Those forceps for arrest of hæmorrhage, were chiefly employed when the surgeon, having no assistance, was obliged to apply the ligature by himself." To illustrate those descriptions, I have here given, from J. J. Perret (*L'Art du Coutelier*, 1771) and Scerrig (*Armamentarium Chirurgicum*, 1838), figures of the early hæmostatic forceps, which were in use till about sixty years ago. The "valet à patin" described by J. J. Perret (Fig. 42) was formed of two similar arms united by a hinge, and furnished with a spring which kept the jaws always closed; the opposed surfaces of the jaws were indented, the teeth adjusting themselves to one another. This instrument served to hold one vessel while the ligature was being applied

* J. J. Perret, Pl. 128, Fig. 9, p. 390.

to another. *It is,*" says Perret, "*the auxiliary instrument in amputation.*" We cannot ask for a designation more lucid or more demonstrative. This roughly primitive instrument approximately realized the object which is attained at present by the most highly perfected hæmostatic forceps; it arrested the flow of blood, and permitted the subsequent application of ligature.

The "valet à patin" of J. J. Perret is really a hæmostatic forceps constructed for continuous pressure. Scerig figures a great number of instruments constructed for forcipressure. Those represented in Fig. 36, which, with the other four plates taken from Scerig's Atlas, are among the most interesting of his work and those attributed to Hildanus and to Dionis (Figs. 39, 40, 41), differ from J. J. Perret's "valet à patin" in having their blades crossed, so that the spring keeps the jaws separate when not in use. Hildanus's forceps (39 and 41), when placed in position by the hand, is fixed with a ring of elongated oval outline situated at the end of one of the branches, which catches, when the surgeon requires, on the rackwork arranged at the end of the other blade. The first forceps with crossed blades and spring, and furnished with



FIG. 42.

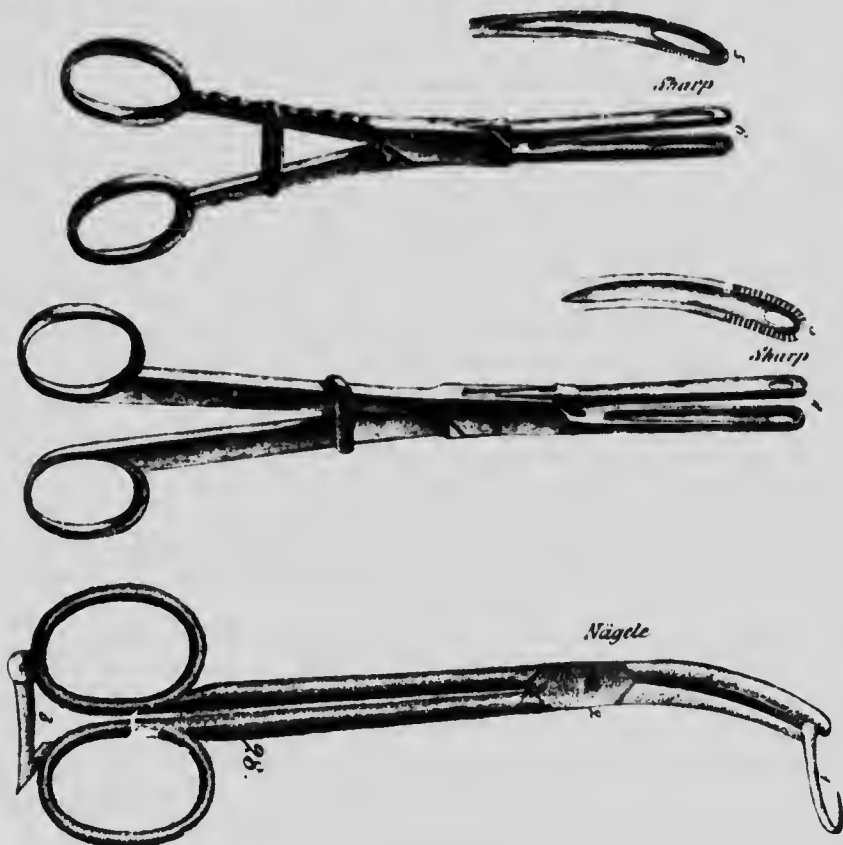
a ring for graduated tightening of the jaws in proportion to its removal from the crossing, appears to be that of Dionis (14), who also described, as we have seen, the mode of fixation of the "valet à patin."

Ring-handled Hæmostatic Forceps with Fixation Apparatus.—Heister had the merit of placing rings at the ends of those instruments of hæmostasis—in imitation of the scissors and forceps already employed in dressings. Heister's model (Fig. 49, 20, Pl. 37) is a genuine specimen of hæmostatic forceps with a ring and catch. The jaws are dentated, and the external border is cut obliquely for easier sliding passage of the ligature. An oval ring, which is placed at the level of the articulation when the jaws are opened, serves for fixation of the instrument when the vessel is grasped between them. Such mode of fixation was also used for other varieties of forceps, as the illustrations reproduced from Scerig's Atlas fully show.

Forceps with Bolt.—Finally, some other surgeons—Percy (Fig. 49, 25), Bell (*ibid.*, 26), Brunningshansen (28), De Graefe (30), Schnetter (32), Savigny (35)—preferred the older forms of spring dressing forceps, which they furnished with various forms of sliding catches, as shown in Fig. 51. Unger (39), Meyer (40), Fricke (Fig. 51, 33 to 37), devised the type of forceps furnished with a bolt which is still used by some foreign surgeons. The button which controls the sliding bolt serves at the same time to pass

on the ligature, and was placed at the extremity of the forceps (Colombat, Figs. 12 and 13, Pl. 16). The same object—that of passing on the ligature beyond the instrument—is evident in the aspect of Brambilla's forceps (Fig. 49, 10), and of that of Guillemeau (16), of Garengot (17), and of Heister (20).

Tenaculums and Forceps à Glissière furnished with Eyed Antennæ.—With the same object, tenaculums were constructed which were furnished



Figs. 43, 44, 45.


with a sliding catch, such as those of Weinhold (Fig. 49, 55) and of Bogoslovsky (56), of Paland (Fig. 50, 1 to 4), of De Graefe (8 to 10), of Bloemer (11); also forceps with a bolt catch, which had also true antennæ—Paland (5), Foerster (5, 6, 7), etc.

Needles for Sutures and for Ligatures—1. **NEEDLES CURVED ON THE FLAT.**—The same plate also shows needles furnished with handles, quite comparable to the form now used for deep sutures, which were devised by Louis

(Fig. 50, 20), Goulard (26, 32, 33, 34), and Savigny (30, 51, 55). Needles of simple form, straight and curved, were used for application of mediate ligatures, as recommended by Dionis (*vide supra*), and to assure fixity of the thread by transfixion of the vessel just below, and the use of a second knot.

2. NEEDLES INCURVED ON THE BORDER.—Boyer (Fig. 40, 2, 3, 4), Garangeot and Deschamps used, both for ligatures and sutures, needles very similar to those now attributed to Hagedorn.

3. NEEDLES CURVED ON THE FLAT IN THEIR POSTERIOR HALF, AND ON THE BORDER TOWARDS THE POINT.—Scrig also figures needles incurved along the borders in the portion adjacent to the point, and on the flat in their posterior moiety: such as are now attributed to Bienaise and to Knaur. These models present a certain degree of resemblance to those with triangular eyelet for continued suture, constructed for the author by M. Collin.



FIGS. 40, 47, 48, 49.

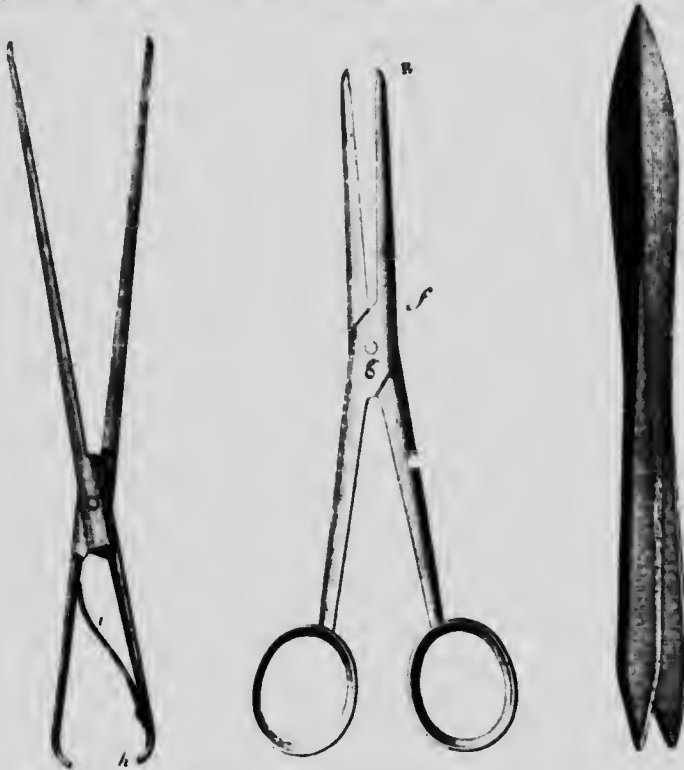Importance of Forcpressure in the Pre-antiseptic Period—1. PREVENTIVE HEMOSTASIS: THE CORD AND THE TOURNIQUET.—We have already seen that the cord and tourniquet were but accessories to hæmorrhage, and the various types of forceps already figured bear witness to the importance attached by surgeons of former ages to the use of direct forcpressure.

2. USE OF ARTERY FORCEPS IN DEFINITIVE HEMOSTASIS.—The use of the tourniquet was an adjuvant in operations on the limbs, and provided that, "when the compression was well established, the tying or twisting of the principal artery should not be carried out till the operation was finished."*

3. USE OF PROGRESSIVE HEMOSTASIS DURING THE COURSE OF OPERATION.—This practice was not exclusive; for example, hæmorrhage was carried out at the level of the section on division of the various vessels, in cases in which application of the tourniquet was impracticable. Such practice was specially recommended in operations on strangulated hernia, in which the slightest sanguineous oozing made recognition of the sac more difficult.

* Lister, "*Précis de Médecine Opératoire*," 1848, p. 52.

4. RAPID EXCISECTION OF VERY VASCULAR TUMOURS WHEN PREVENTIVE HEMOSTASIS WAS IMPRACTICABLE.—There were cases in which the more daring procedure seemed preferable, and the surgeon extirpated the tumour, as I now recommend, without preoccupation with hemostasis. "If rapid operation be desirable," says Lisfranc,* "and if the blood interferes but little with the surgeon's movements, we should not attend to the hemorrhage till the affected part has been removed." This practice seemed the safer in certain difficult cases, and was successfully applied to rapid extirpation



FIGS. 50, 51, 52.—DRESSING FORCEPS FIGURED BY J. J. PERREI.

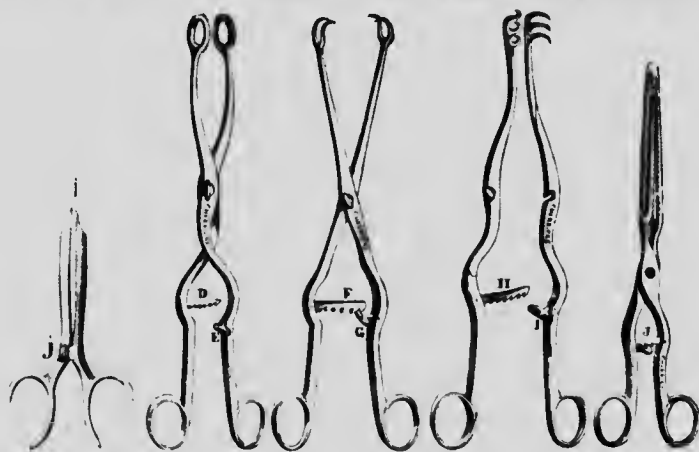
of enormous neoplasms from which timid operators had recoiled. J. L. Petit in a case in which ablation of an enormous tumour threatened dangerous hemorrhage, collected a number of his confrères and got them to compress the vessels with their fingers as soon as divided. The tumour was rapidly removed, and without grave loss of blood. The procedures of hemostasis were then regarded by the most dexterous surgeons as, in some exceptional operations, more dangerous than rapid enucleation. Thus, Petit had long before me applied in his practice the axiom that the best means of avoiding

* Bérard et Denouvillers, "*Compendium de Chir. prat.*," 1840, t. i., liv. i., p. 72.

serious loss of blood was to operate rapidly, and disregard preventive application of forceps or ligature. Use of the fingers and of compresses sufficed during the procedure. If the extirpation of a tumour be rapidly completed, the immediate hæmorrhage is insignificant. Definitive hæmostasis is afterwards carried out at leisure.

Multiplication of the Forms of Hæmostatic Forceps.—The varieties of form of hæmostatic forceps multiplied, and ended in the almost general adoption, about 1860, of the bolt (so-called "torsion") forceps, which, by means of a special grooving of its jaws, was made to function also as a needle-holder.

Use of Ring-Handled Forceps in the Eighteenth Century as Dressing Forceps and for Removal of Splinters; and of the Same Instruments, with Addition of a Catch, as Hæmostatic Forceps (Heister).—Ring-handled forceps,



FIGS. 53, 54, 55, 56, 57. CHARRIÈRE'S FORCEPS À CRÉMAILLÈRE.

which were made on the scissors model in the eighteenth century, were originally intended "for ring-handled dressings, or extraction of small pieces of bone or fragments of soft tissues from the bottom of wounds." The form of the drainage forceps used by Lister is precisely that of J. J. Perret's dressing forceps (Fig. 53). The latter dwells in his book on the advantages of the new articulated instrument, which was held "with the thumb in one ring, and the middle or index finger in the other," and the superiority of this mode of prehension over that of the older forms (with spring or elastic branches), which were similar to dissecting forceps in structure and application. We have seen that Heister first used ring-handled forceps, with the addition of a spring which held the jaws open and a sliding ring that closed them, in the prehension and ligature of vessels. The forceps thus devised by Heister is the more remarkable as its extremity is so formed as to help to slide the ligature beyond it, and thus carry the loop directly on to the vessel which it grasps (Fig. 49, 20).

Abandonment of the Ring-Handled and Cross-Bladed Hæmostatic Forceps in Favour of the Forceps with Sliding Catch.—No one can now tell why the ring-handled forceps passed for a time into almost complete oblivion. The forceps *à verrou*, which was also known as "torsion forceps" and "needle-holder forceps," was the hæmostatic instrument favoured by Maissonneuve; and it remained in general use till the adoption by Spencer Wells and Kæberle of new models of ring-handled and rackwork forceps, which are much more convenient in abdominal surgery.

Application of Rackwork Catch to the Ring-Handled Forceps.—The application of a rackwork locking apparatus to ring-handled and cross-action forceps is, as we have seen, of very old date (Hildanus). About 1855 Charrière conceived the idea of making this arrangement optional, and adopted a hinged rack which could be fixed or left free at the will of the surgeon (Figs. 53, 54, 55, 56, 57). The dentate catch could be attached to all pressure instruments which articulated either by two opposed or crossed branches.** At that date Charrière constructed the form of rack that is

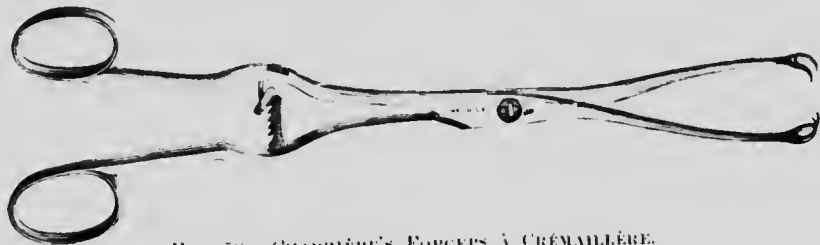

FIG. 58. CHARRIÈRE'S FORCEPS À CRÉMAILLÈRE.

most generally used at present—that furnished with lateral teeth† (Fig. 53, j), which he afterwards came to prefer to that in which the catch consisted of a projecting pin that passed into one of a series of adjacent orifices (Figs. 59, 62).‡

Charrière's *presse-artère* and forceps *à verrou* had the jaws so constructed as to enable them to function for the grasping and holding of vessels, and also as needle-holders and pin-holders (Figs. 60 and 61). The forceps with annular jaws and dentate catch represented in Fig. 54 was at last generally adopted, and replaced by degrees the forceps with sliding bolt, which was less facile of manipulation. The most varied forms were constructed, and those in use at the beginning of the century were reproduced with sensible modifications—forceps with curved jaws, oval jaws, T-shaped, clawed, etc. Those which seem to me most eligible will be indicated at the conclusion of this chapter.

The Various Hæmostatic Processes adopted since the Abandonment of the Actual Cautery and the "Button of Vitriol."—The accidents produced by separation of ligatures elicited various methods of obtaining hæmostasis without leaving foreign bodies in permanent position in the wounds. If

* Charrière's "Catalogue," 1855, pp. 58, 59, and Fig. 91.

† *Ibid.*, 1862, pp. 14, 99, 192.

‡ *Ibid.*

we except the cauterizations, to which A. Paré did full justice, in regard to the great vessels at least—the use of heat continuing to be the most effective method of arresting capillary oozings—the most interesting procedures employed for hæmostasis of the great vessels *without ligature* are: (1) torsion, (2) crushing, (3) linear écrasement, (4) application of fixed forceps.

1. TORSION.—Torsion, which was recognized by Galen and formally regulated by Amussat, succeeds when the coats of the artery are healthy, and the curling up of the internal and middle coats has been satisfactorily achieved. Tillaud has demonstrated secure obliteration of the femoral

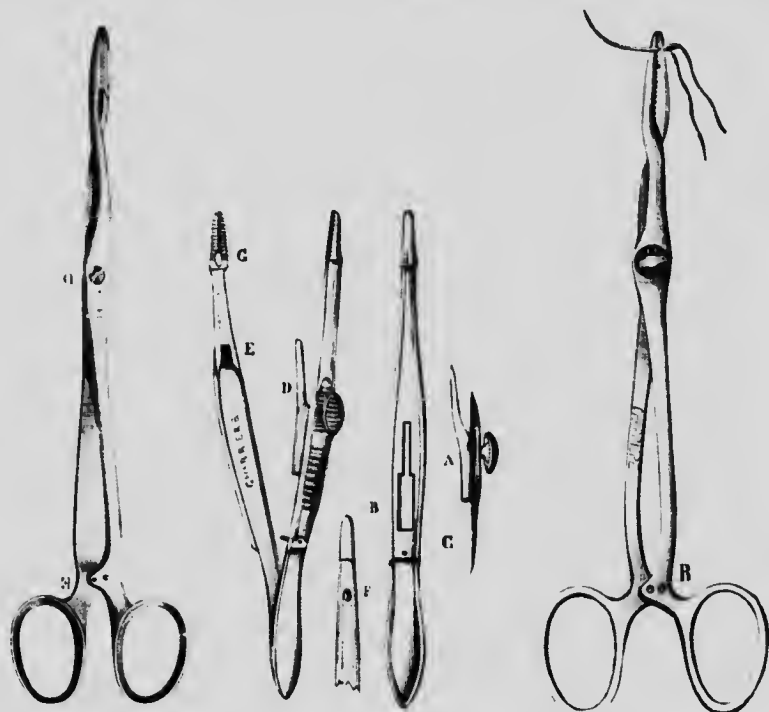


FIG. 59. —CHARRIÈRE'S
FORCEPS A ARRET.

FIGS. 60 AND 61.
FORCEPS A VERROU.

FIG. 62. CHARRIÈRE'S
NEEDLE-HOLDER FORCEPS.

artery by simple torsion. But, since antisepsis established the innocuity of ligatures, it has usually been reserved for the small arterioles which have been temporarily compressed, and that do not seem to require deligation. When torsion is ineffectual, a ligature of fine silk is applied. In few words, deligation is the simplest and surest method of hæmostasis in case of vessels of some size. The ligature should be applied *immediately* to the coats of the vessels, excluding all other tissues as completely as possible.

2. CRUSHING.—The procedure of crushing was devised by Mannoir to replace that of torsion. He tried in 1820 to obliterate arteries by using a

special forceps, constructed so as to rupture the inner coats only. He wished to realize in this way the hemostasis as previously obtained by the temporary ligatures which had sometimes been successfully applied. The crushings conserved the external coat only; they severed and folded back the internal and middle tunics. They were repeated a certain number of times on a



FIG. 63. RICORD'S TONSILLAR FORCEPS.

small portion of the trunk. Amussat repeated experiments of this kind without securing hemostasis. He then formed the idea of combining this procedure with ligature, and by so doing obtained excellent results. For the purpose he had constructed a small forceps *à baguettes*, which was intended to lacerate the inner coats throughout their whole thickness, without



FIG. 64. STRÉBY'S T-SHAPED FORCEPS.

tearing the external. This crushing of the artery was carried out above the seat of ligature. It produced perfect adhesion of the clot in the interior of the vessel so treated, and prevented all danger of secondary hemorrhage on separation of the ligature. Those tentative procedures of Mamoir and Amussat were perfectly justified in practice. It is, indeed, by their crushing



FIG. 65. MAISSONNEUVE'S SERRE-NEUF.

effects that definitive hemostasis is obtained in the case of arterioles momentarily seized between the jaws of any of the hemostatic forceps. The failure of the procedure is attributable only to the imperfection of the instruments which they used. I took up once more, in 1886, this experimental study of hemostasis. The results will be detailed in a subsequent chapter.

3. LINEAR CRUSHING (ÉCRASEMENT).—The linear crushing process (écrasement) devised by Chassaignac had long before been realized by the various forms of *serre-nœud* (see Figs. 65 and 66). Chassaignac's *écraseur* differs from the *serre-nœud* of Graefe and that of Maissonneuve in the sub-



FIG. 66. —CINTRAT'S SERRE-NŒUD.

stitution of a chain of movable links for a metallic thread. Chassaignac's instrument was remarkable for the perfection of the hæmostasis secured by its employment in the hands of those who knew how to manipulate it with all the requisite dexterity and patience. I have already referred, in



FIG. 67. —CHASSAIGNAC'S ÉCRASEUR: SMALLER FORM.

connection with the name of Maissonneuve, to the abuse that has² been made of those instruments, which were used even for amputation of the breast and of the thigh. Again, Verneil, in 1885, amputated the tongue with the *écraseur*, in case of cancer. The chain usually slipped, in spite of





FIG. 68. —CHASSAIGNAC'S ÉCRASEUR: LARGER FORM.

the steel pegs which were arranged to retain it in position. Thus the operation was incomplete, so that recurrence took place immediately—or, rather, the disease continued; without leaving the wound, in its cancerous state an opportunity of cicatrizing.

The object of the employment of the *serre-nœud* and of the *écraseur* was



FIGS. 69 AND 70. — BELLOCQ'S TOURNIQUET (J. J. Perret, Pl. 128).




FIG. 71. — BELLOCQ'S TOURNIQUET (Seelig, Pl. 15).



FIG. 72. ASSALINI'S CONVEX PRESSURE FORCEPS (Seelig, Pl. 15).

to anticipate the threatened invasion of septicæmia, by closure of the blood vessels. Those instruments are now almost forgotten. The *serre-nœud* remained a long time in favour for supravaginal amputation of the uterus. Hegar substituted for it an elastic thread, which was abandoned in its turn. Had it not been decided that constriction with a steel or a red-hot platinum wire was one of the most effective methods of dealing with mucous polypi of the nasal fossæ, the *serre-nœud* would have disappeared completely, even from the arsenal of the specialists.



FIG. 73. LOTTIER'S COMPRESSOR
(J. J. Perret, Pl. 128).

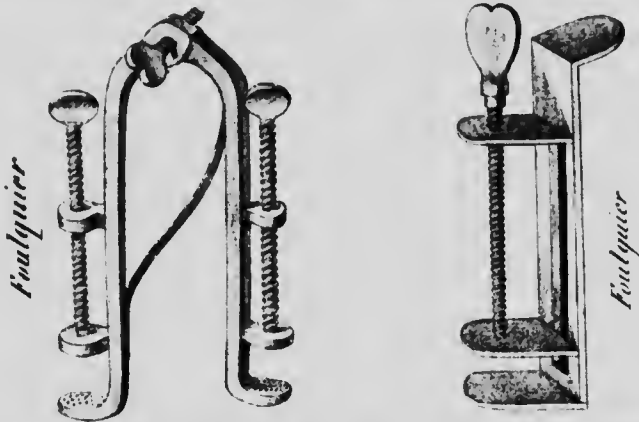


FIG. 74. LOTTIER'S COMPRESSOR
(Seelig, Pl. 15).

4. FIXED APPLICATION OF FORCEPS AND OTHER INSTRUMENTS OF HEMOSTASIS. *Application of Fixed Forceps in Wounds of Operation.*—The idea of leaving forceps for a certain period fixed on open vessels, for the purpose of securing definitive hemostasis, dates back to Percy—that is to say, to the end of the eighteenth century. Having previously tried to substitute small leaden rings for ligatures in the sealing of vessels, and which he closed by pressure with the *rabot à patin*, he had a hemostatic forceps with sliding catch-bolt constructed, of which the disc-shaped jaws were mounted on a pivot. This arrangement enabled the surgeon, after seizing the vessel and fixing the forceps in position, to turn back the blades at the surface of the

wound. Percy's procedure found little favour in those cases in which a ligature was applicable.

Instruments for Hemostasis, intended to be left in Position in those Cases in which Forcepressure was Inapplicable.—Direct and continued pressure



FIGS. 75 AND 76. FOULQUIER'S TOURNIQUET, DOUBLE AND SINGLE (Seezig, Pl. 80).

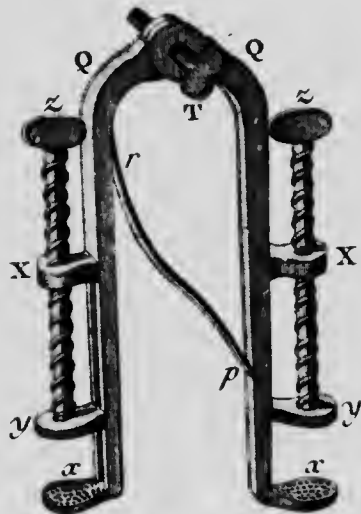


FIG. 77. FOULQUIER'S TOURNIQUET (Petret, p. 135).

on the injured vessel appeared, indeed, to be the sole reliable means of arresting hæmorrhages from vessels which could neither be readily seized nor tied; such as the intercostals in pleurotomy, and the meningeal arteries and sinuses of the dura mater in trepanning. The apparatus intended

for arrest of hemorrhage from those vessels have been described and figured by Perret and Seerig. They are: for the intercostal artery, Belloeq's tourniquet and Lotteri's plate; for the meningeal arteries and sinuses, Foulquier's tourniquet, and the corresponding instruments of Huebenthal of Ferg, and of Græfe.

(1) Belloeq's tourniquet (Perret, p. 388, Pl. 128, Figs. 1 and 2; Seerig, Pl. 25, Figs. 93-95) consists of two plates and a lever supported by a hinged rod. This latter opened, as shown in Fig. 79, so as to facilitate introduction of the plate *B*, which was covered with leather or tuffetas, into the pleural cavity. Pressure was effected with the aid of the screws *q* and *m*.



FIG. 78.



FIG. 79.




FIG. 80.



FIG. 81.

COMPRESSOR FOR THE MENINGEAL ARTERY, AND FOR THE SUPERIOR LONGITUDINAL SINUS.

(2) Lotteri's plate (Perret, Pl. 128, Figs. 7 and 8; Seerig, Pl. 15, Fig. 15, *a* and *b*), much more simple in construction, was a narrow fenestrated plate, curved in the form of a lever, of which the shorter arm, covered with leather or tuffetas, was introduced beneath the wounded artery, and the longer arm was then fixed with a bandage on the surface of the chest. Hemostasis was secured by direct pressure on the vessel at *P* (Figs. 73 and 74).

Foulquier's tourniquet (Perret, p. 412, and Pl. 135, Fig. 21; Seerig, Pl. 80, Fig. 25) consisted of two compressors, moved by a recoil screw *Q*, *Q'*, and joined by a hinge, *T*. The branches *x*, *x'* were introduced into the cranium, beneath the dura mater, and secured hemostasis in proportion to

the rigidity of pressure with which the mobile plates *y, y* were applied to the integuments by the action of the screws *z, z* (Figs. 75-77).

The compressors devised by Huebenthal and by Ferg (Figs. 78 and 79) are fairly comparable to the simple form of Foulquier's compressor (Seerig, Pl. 80). Graefe's compressor (Figs. 80 and 81) differs from the preceding in the fact of utilizing a triple series of supporting points on the cranial surface (Seerig, Pl. 80). This compressor is an arrangement of recoil screws and resisting supports, in form of a tripod (Perret, Pl. 34, Fig. 15; Seerig, Pl. 80, Figs. 19, 21, 28, 96), which were made to elevate the fragments in cases of fracture of the skull produced by direct violence.

Finally, Thierry utilized preventive and definitive hemostasis in gynaecology by constructing a special clamp for strangulation of the pedicle in removal of pedunculated uterine polypi (Fig. 82).

The Use of Artery Forceps and Ligatures was dangerous before the Discovery of Antisepsis.—Surgeons of the pre-antiseptic period had a full stock of instruments for hemostasis. They had forceps and other apparatus for

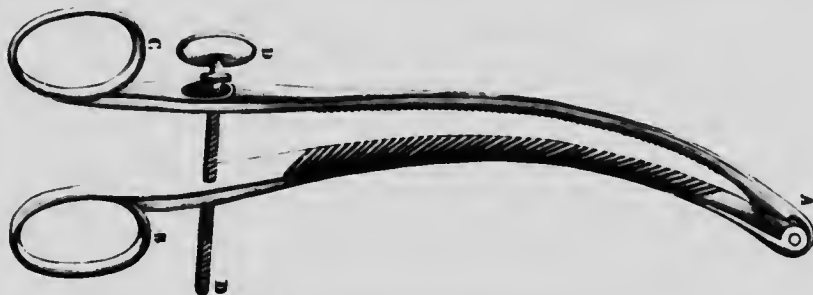


FIG. 82. THIERRY'S CLAMPING FORCEPS.

preventive forcipressure, temporary or definitive. If the use of artery forceps and ligature was of very limited range, it was merely because of their ignorance of antisepsis; the jaws of their forceps were unclean, and their ligatures infected. Thus forcipressure and ligation gave but deplorable results. The general diffusion of a knowledge of antisepsis even alone permitted their innocuous application. Absolute disinfection of both forceps and ligature is, of course, indispensable to the securing of satisfactory hemostasis.

5. ABUSE OF THE EMPLOYMENT OF HEMOSTATIC FORCEPS AND OF THE PURSUIT OF PREVENTIVE HEMOSTASIS.—The different methods of hemostasis, *preventive and progressive*, have been familiar, then, for many years.

(1) *Preventive hemostasis* was practised as digital compression; by the application of a cord, tourniquet or ligature; or of continuous pressure with forceps.

(2) *Progressive hemostasis*, which consisted in obliteration of the lumen of every bleeding vessel, was at first realized by cauterization, then by direct compression, and, more particularly, by application of the ligature and by forcipressure.

What are the relative values of those different methods ?

Preventive hæmostasis, which was judiciously reserved by the older surgeons for operations on the limbs, became generalized by the use of Esmarch's bandage; and has now extended, thanks to the elastic ligature and the clamping forceps, to general abdominal surgery. Some surgeons came to be so far terrorized by the fear of blood that they did not dare to cut anything without previous application of a hæmostatic forceps or a ligature on the cardiac side (Péan). Esmarch's bandage seemed invaluable in amputations. Thanks to its elastic preventive compression, no more blood was to be lost in operations. Much more, the precious liquid was pressed backwards towards the heart in the application of the band, and the operation was carried out in unstained tissues. Preventive hæmostasis was applied to ovariectomy; vascular adhesions were divided between ligatures, and extreme precautions were adopted for hæmostasis of the pedicle (clamp, *surc-noud*, etc.). Freund contributed to this method when he endeavoured to adopt *total abdominal hysterectomy* in removal of the cancerous uterus. The renovators of *vaginal hysterectomy*, Czerny and Martin, applied to this operation the same principle of preventive hæmostasis, and extirpated the uterus by a corresponding procedure. They detached it from within a serial chain of ligatures, which were placed, from below upwards, on the broad ligaments, with the aid of a strong curved needle. This was the procedure of Recamier, and when applicable, it is far superior to that of preventive forciquessure, which was substituted for it by Péan. The forceps, which were placed on the lower section of the broad ligaments in Péan's procedure, encumbered the field of operation, and made the detachment of the fundus and adnexæ tedious and troublesome.

Péan came, indeed, to adopt, contrary to all logical reasoning, the preventive use of forceps even in the positions of readiest access. He amputated the tongue no longer with the *érascur*, but beyond two powerful curved and clawed forceps, which were left *in situ* for twenty-four hours—a barbarous practice which merits the severe judgment of Ambroise Paré on the hæmostatic methods of his predecessors. The practice of leaving forceps fixed on the tongue was an instance of surgical aberration. If escape of blood was so very much to be dreaded, why did he not keep to the *érascur*? The instrument produced an extemporaneous hæmostasis while it imposed a torturing mouthpiece on the patient for one or two days and exposed him, after removal of the forceps, to the incidence of septicæmic complications. To have seen a few of the patients operated on by Péan in whom the open mouth allowed a ready inspection of the dark and fetid lingual stump, was enough to make one condemn his deplorable methods. Amputate the tongue in accordance with my practice, without adoption of preventive hæmostasis, and with a cutting instrument—preferably with scissors—and you will have to compress or tie only four or five small arteries. Then stitch the wound with Florentine hair sutures, and cicatrization by first intention will follow.

What a terrifying phantom some surgeons have been able to make of

arteries inferior in calibre even to the radial! The large veins which furrow the abdominal neoplasms have frightened the laparotomists still more, who thus displayed an ignorant ingenuity in creating a chimerical danger of hæmorrhage, without even daring to verify, even in a single instance, the grounds for their foolish fears. It is for such reasons and by such practices that they have used, and abused, the elastic ligature and the hæmostatic forceps—even so far as to employ them in places in which anatomy knows of no artery worthy of a special description.

6. ADVANTAGES OF THE RAPID ENUCLEATION OF TUMOURS WITHOUT ADOPTION OF PREVENTIVE HÆMOSTASIS.—The wonderful apparatus formerly used had always left me so sceptical that, when thrown on my own resources, one of my first researches was devoted to ascertaining whether blood was really so much to be feared. This was in 1886. I was called on to remove two tumours of the recto-vaginal pouch. The first was severed with the aid of the galvanic loop, according to Labbé's method, three or four arteries of some size had to be seized and tied. No other vessel of appreciable dimensions appeared to have been opened. Next day but one, having determined to decide the question of preventive hæmostasis once and for all, I grasped the neoplasm between the index and middle fingers introduced into the rectum, and the thumb in the vagina. Three or four snips with the scissors then removed it in a few moments. Two or three ligatures were applied, and the wound was stitched with Florentine hair suture. The perineum and recto-vaginal pouch had been resected to within a short distance of the neck of the uterus. In eight days the healing was complete. The wound of the first patient still continued to suppurate, and a plastic operation was ultimately found necessary. Those two facts were demonstrative: hæmorrhage was not so much to be dreaded. This principle being once established, I have adopted the method based thereon to all surgical practice.

It was then said that my method of procedure was dangerous and difficult. It is nothing of the kind. The critics, who were advocates of a bad cause, have had their just proportion of success with men of progress. Preventive forcipressure is a blind and useless practice. The abuse of hæmostatic forceps and of ligatures *en masse*, which conuse the tissues over a large area and require the absorption or shrinkage of voluminous pedicles, are obstacles to sure and rapid healing. My method, on the other hand, is simple and rational. It is, in fact, exclusively based on a knowledge of anatomy, normal and pathological. Its constituent elements are: rapid attack on the tumour, enucleation *en masse*, hæmostasis where bleeding occurs, and reunion of the wound. Far be it from me to leave anything to chance; the hæmostasis must be perfect. But in most cases I secure it only after ablation of the tumour, by seizing and tying the vessels individually. Such hæmostasis is much more satisfactory than that of preventive ligation *en masse*. Separate ligation of arteries—has it not been recognized, since the time of Desault, as much preferable to mediate ligation in the surgery of the limbs?

The type of rapid operation is realized in my procedure of total abdominal

hysterectomy. The uterus having been removed, the bleeding arteries, usually four, the uterine and utero-ovarian of each side, are, in case of the former, seized and tied; of the latter, ligatured directly, below the ovary and Fallopian tube. If there be any hemorrhagic oozing, a pad is placed at the line of the posterior vaginal-peritoneal fold, and the peritoneum is closed. Far from producing a greater loss of blood than the other forms of procedure, the hemorrhage is less in quantity. In fact, while raising the uterus, as the patient lies in the Trendelenburg position, the blood of the tumour flows back towards the broad ligaments through the great veins by which it is furrowed, and it becomes *coagulable*. It is easy to decide the advantage of this method of hysterectomy, without preventive hæmorrhage; over the supravaginal, for example, with use of the elastic ligature in which the tumour, gorged with blood, allows 150 to 200, or even 300 grammes of the precious fluid to escape on division of the pedicle.

Accordingly, I can justly claim the credit of having taught my confrères that "*the best means of avoiding the loss of blood is to suppress all preventive hæmorrhage as far as possible.*" I say "as far as possible," for the very principle of my method being to operate at the same time securely and simply. I employ preventive hæmorrhage in case of necessity, but as an exceptional manoeuvre. When there is a band or adhesion of very obvious vascularity, I tie or compress it before section. In all other cases, I proceed to the hæmorrhage only after ablation of the neoplasm. For example, in resection of the intestine, after having closed the upper and lower openings according to my usual practice, I crush the mesentery with my lever forceps, and tie it in the furrow made by the *écraseur*. Thus a few silk ligatures suffice for the hæmorrhage; the ligature is then folded beneath a serous suture. The mesentery, which is so much dreaded by those surgeons who make of it, by ligature *en masse*, a voluminous stump dangerous to the patient, is then found to be so well mated on each of its aspects—serous to serous—that it is impossible to have any doubt at the close of the operation of the extent of the intestinal segment that has been resected.

In cases of goitre I usually operate without preliminary hæmorrhage of the thyroid arteries. Some open superficial veins must bleed. They are quickly secured with the aid of forceps and silk thread, and the operation is continued without interruption. When the tumour has been drawn out, I divide its attachments from the left side with scissors, and I press a packet of compresses down into the wound. The mass is rapidly separated from the trachea, then liberated from its attachments on the right side and completely detached. A small healthy portion of the thyroid gland is separated by my *écraseur* and left in the wound. If a disquieting jet of blood occurs, I apply a forceps. Four to six ligatures usually suffice. Thus the whole operation is usually completed in ten to fifteen minutes, from the first touch of the bistoury to the final dressing, whether the goitre be of the parenchymatous or exophthalmic type.

It is the large veins which should be feared most when left open after division. The sinuses of the dura mater, for instance, may allow so large a quantity of blood to escape in a few minutes that the blanched encephalon

wobbles in its cranial enclosure, while the smaller escape of cerebro-spinal fluid aggravates the condition, which is usually, indeed, desperate in such cases. Accordingly, too great care cannot be exercised in avoiding venous hemorrhage in cranial operations. In the same way wounds of the arteries are less to be dreaded in extra-isceral surgery than those of the large veins. It has often occurred to me to demonstrate to some of my confrères when I was about to divide the carotid or femoral artery. The artery being exposed to the view of all present, I severed it at a single stroke; a crimson jet struck the wall; a forceps, and the flow of blood stopped! If we make the experiment of catching in a vessel placed before a divided artery the quantity of blood expelled by a single cardiac systole, we are astonished on observing the smallness of its quantity—10, 20, or, at the very utmost, 30 grammes' weight will be found to represent the product.

When an artery which is difficult of access happens to be wounded accidentally at the bottom of an uneven wound, direct digital compression is resorted to provisionally. Such happens in wounds of the vertebral artery during resection of the cervical vertebrae. I have never advocated the silly pretence of eliminating hæmorrhage; I have merely wished to *simplify the process, and reduce it to what is really useful and indispensable*. I recommend digital compression in amputation of the limbs. I reserve the elastic bandage for resections and removal of portions of bone where the field of operation can be clearly defined only where quite bloodless; but I apply the dressings in such cases before removal of the elastic compression. In case of the large arteries, forcipressure or ligation before section is indifferently adopted. When removal of a tumour cannot be effected very rapidly, and if the flow of blood is considerable, I divide the artery between a ligature placed on the cardiac side and a forceps on that next the tumour. Thus it is that in abdominal hysterectomy the application of forceps is useless when the tumour can be easily lifted out of the abdominal cavity; while it is indispensable when the adherent uterus cannot be extracted from the pelvis without previous division of the bi-ligamentous muscular band which prevents its elevation above the pubis. But such exceptions occur in well-defined cases, and serve but to corroborate the claims of my general method. For is not the surgeon's object the cure of the patient? *Every operation should be carried out rapidly and simply, but under the express condition that the smallest details, and especially the definitive hæmorrhage, be securely and perfectly carried out.*

THE SLICING PROCESS.

To the history of preventive hæmorrhage is attached that of *slicing*, which was made a definite method of procedure by Péan in the removal of nearly all tumours. I now propose to demonstrate that *slicing*, just as preventive hæmorrhage, is but an exceptional procedure, which should be resorted to only in special cases; otherwise producing unnecessary complications in the ablation of tumours which might have been rapidly removed in a single mass.

Introduction of Slicing by Amussat in 1840.—The slicing process in surgery corresponds to cephalotripsy and embryotomy in obstetrics. The removal in slices of tumours difficult of access dates back to Amussat, who, in 1840, had the temerity to try vaginal ablation of interstitial uterine fibromata of considerable size. The abuse afterwards made of this procedure by Péan, both in gynaecology and general surgery, and his irrational application of it to tumours broadly accessible and easy of enucleation in a single mass, have induced me to study the operations of Amussat, and to abstract the history of that interesting question.

Amussat's first operation dates from June 11, 1840. In a case of interstitial fibroma of the uterus, he conceived the idea of attacking the tumour through the vaginal canal after free section of the cervix, and extracting it by a series of manœuvres designed beforehand, but to be modified to suit the indications arising in the course of the procedure. The technique of his operation was very remarkable, and denoted a presence of mind and firmness quite surprising for the period. I now proceed to describe Amussat's method, according to the text of his two "Memoirs," published respectively in 1840* and 1842.†

He placed the patient in the position for perineal section, examined the tumour, incised the cervix and then the uterine tissue which covered the fibroma, and grasped the latter with Museux's forceps. He then freed the field of operation as far as possible, and detached the tumour gradually with his fingers from its uterine connections. When it was not too large to be extracted in a single mass, he adopted a special manœuvre, which consisted of combining direct traction on the most prominent point, or pole, of the neoplasm with indirect traction by seizing it on one of its meridians as nearly as possible to the equator. The tumour turned, swayed a little, and approached the vulva. The swaying, or "rotation," of the tumour, according to Amussat, "may be practised in four directions. Of these the anterior is best. This manœuvre shortens the operation, and prevents retroversion of the uterus. If the tumour be too bulky for extraction in a single mass through the vulva, I decide," he adds, "after having thought of crunching or carving, to remove it, as we do vesical calculi, with the aid of the principle of lithotripsy—by dividing it incompletely into two equal parts. We conceive that in making traction on one of these parts only we may succeed in extracting the entire mass, *but opened up, and by winding it, so to speak.*"

In order to secure ready access to the tumour, Amussat adopted "*incisions in the cervix,*" and made them "*with caution, so as not to wound the uterine arteries, the peritoneal fold, or the bladder itself.*" If, despite the manœuvre of anterior swaying and rotation of the tumour, which he describes so well, "*inversion of the fundus uteri*" took place during extraction of the tumour, "*the fibroma was detached from its uterine capsule often in very small sections while taking care to avoid perforation; and the inversion of the fundus of the*"

* *Revue Médicale*, August, 1840.

† "Mémoire sur l'anatomie pathologique des tumeurs fibreuses de l'utérus et sur la possibilité d'extraire ces tumeurs lorsqu'elles sont contenues dans les parois de cet organe," Paris, 1842.

organ was reduced. As subsequent treatment, Amussat recommends "continuous irrigation of the vagina, thoroughly carried out." The first interstitial fibromata of the uterus successfully removed by Amussat weighed from 338 to 440 grammes. Their volume, he said, was that of an ostrich egg.

This description of the earliest slicing operations for uterine interstitial fibromata is a very remarkable one. I here reproduce its most characteristic features with all the more interest from the fact that I had myself conceived a very similar procedure, and, of my own initiative, carried it out, from 1887 to 1892, in my operations of hysterectomy, and afterwards of vaginal hysterotomy. This procedure consisted of division of the anterior lip of the cervix; and following this, when the mass was too voluminous, by *graded slicing*, and *enucleation* of the tumour.

The practice of Amussat was very ingenious: He removed interstitial fibromata without either incision or slicing when traction, indirect and tangential to the meridian of the mass, was found sufficient to secure its oscillation and extraction; while he reserved *incision and division of the tumour* for cases in which *the removal of the single mass was impossible*. Thus he had recognized at that date the inferiority of *direct traction* at the seat of the accessible pole of the tumour, and of central segmentation "such as was practised on vesical calculi"; and adopted the rule of acting no longer on the centre of tumour, but on its periphery, and whenever possible in a tangential direction. Is not this the principle which now governs our procedures in vaginal hysterectomy, even down to the minutest details?

Thus, as his contemporaries limited hamostasis to the actually indispensable, Amussat, in devising the slicing process, knew how to determine the rules of his earliest operations; and indicated, as most to be recommended, those best suited to execution of the maximum amount of work with the minimum expenditure of time and physical effort.

The *method of central conoid enucleation* of uterine tumours was thus judged by Amussat, in 1840, as I have myself estimated its merits, and was recognized by that remarkable operator *as far inferior to manipulation applied to the periphery of the tumour*, of which the effect is to detach it from its uterine capsule by rotation, oscillation, and as if by evacuation. Amussat preferred, when possible, removal of the tumour in a single mass, without even incising it. He reserved incision and development of an opened tumour for those cases in which this supplementary procedure was found to be indispensable. He had the great merit, by discovery of the slicing process, of considering this preliminary as an exceptional procedure, and of limiting its application to those cases in which the narrowness of the field of operation did not permit the transit of a tumour of great diameter. This conception of slicing by Amussat represents, in its exactitude one of the most valiant conquests of French surgery. *The slicing process is, like that of preventive hamostasis, an exceptional manœuvre in surgery*—a procedure as valuable, when really indicated, as it proves deplorable when not actually indispensable. When the field of operation is narrow—it simplifies and accelerates the operation by rendering it more secure and increasing the chances of the patient's safety. The methodical and generalized application

of the same to surgery is, on the other hand, an objectionable and defective practice, which aggravates the dangers, and at the same time prolongs the carrying out of operations which could be completed much more simply and rapidly by the method of immediate enucleation.

SOME NEW FORMS OF HEMOSTATIC FORCEPS.

Short-Jawed Forceps—Forceps Clamp for Progressive Pressure.—The instrumental provision against hæmostasis is probably still far from being finally completed. The first ring-handled hæmostatic forceps that were employed by Péan were, as already indicated, but slightly reduced models of the dressing forceps and *forceps à arrêt* used by Charrière. Those ring-handled forceps were simple apparatus for prehension, in which a lever of the first order was substituted for one of the third; and, with the addition of certain facilities for manipulation, formed the chief improvements on the old forceps with sliding catch. Substitution, in the stronger forms of the instrument, of elongated jaws for the elliptical ones of the original type, far from increasing their power, rendered the instrument the less efficacious, as the elasticity of the branches did not permit the application of more than a limited force at the level of the rings; while the rigidity of the jaws produced an appreciable divergence of their extremities when an object of some thickness was grasped near their junction. This type of construction had been adopted, *without exception*, in all hæmostatic forceps with elongated jaws to be met with at the beginning of 1887.

If we grasp with one of those instruments, straight or curved—say Péan's, Ferrier's, or Richelot's forceps—and along the whole length of the jaw, a handkerchief folded so as to present a thickness of 6 to 8 millimetres, the further we tighten the ratchet the less constricting force is exercised on the interposed tissue. The extremities come at last even to diverge a little, and the corresponding portion of the handkerchief becomes free while that next the articulation becomes more and more vigorously crushed. This feature appeared to me so evident in 1887 that, being impressed by the grave inconveniences of those instruments in forepressure of large vascular pedicles, such as the uterine ligaments, I had special forceps constructed for me by M. Collin. These were made after a new principle—that the elasticity should no longer be located in the arms, but at the level of their jaws, which received for that purpose a concave form, and were made of steel of less hardened temper. The advantages of this new type are very evidently shown by Figs. 84 and 85, which represent three forceps: Péan's long forceps, of date prior to 1887; Richelot's forceps, as used for application to the broad ligament in March, 1887; and the author's forceps with elastic jaws, each closed on a small cylinder of wood—at first partially (Fig. 84), and then as tightly as possible (Fig. 85). In each of the plates it will be observed that my forceps is the only one that retains the extremities of its jaws in

contact. On the other hand, those of Péan's and Richelot's forceps diverge in proportion as the enclosed cylinder of wood becomes more energetically compressed. Thus it was that in the vaginal hysterectomies carried out according to Richelot's technique, there was exposure to the danger of grave

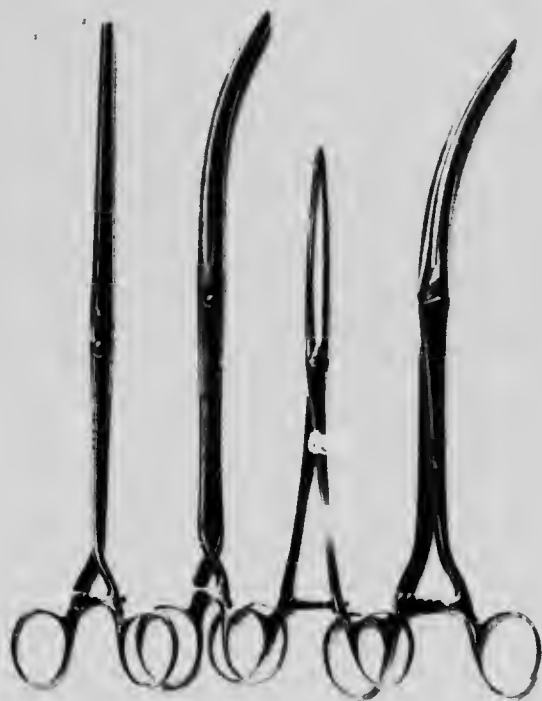


FIG. 83. FORCEPS, STRAIGHT AND CURVED ON THE FLAT.

1 and 2, Old forms, with rigid jaws. 2 is Richelot's original forceps, with rigid jaws.
3 The author's models, with elastic jaws. 4 is Richelot's actual model, as modified by Collin, and made with elastic jaws (Doyen's design).

hemorrhage from the fact that the upper border of the broad ligament escaped compression and bled into the peritoneum.

Forceps with Elastic Jaws.—The author's larger forceps for the broad ligament, with elastic jaws and serrated throughout their whole length, was constructed at the end of February, 1887, and presented on March 9 to the Société de Chirurgie of Paris. A smaller model was constructed at

the time for application to pedicles of less thickness. The importance of this absolutely original modification of the previous construction of the older forms of the long forceps for compression of pedicles, of which the rigid jaws were in contact along their whole length, was so evident that

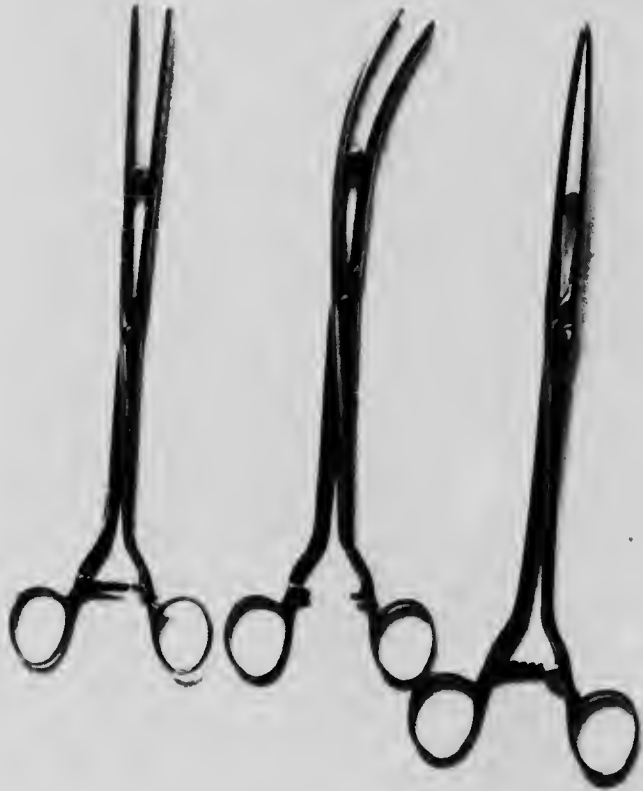


FIG. 84.
OLD FORM, WITH RIGID JAWS. RICHELIEU'S FORCEPS; OLD FORM, WITH RIGID JAWS. AUTHOR'S FORCEPS, WITH ELASTIC JAWS (1887).

The forceps are each closed, without force, on pieces of wood of the same diameter.

the latter have found themselves replaced in every instrument maker's since that epoch by the type with elastic jaws. Accordingly, it is but just that I should claim the discovery of this new type.

In using this new forceps, the extremities of the jaws, when once brought into contact, never release the tissues which they have seized. The special temper of the jaws has been determined by experiment so as

to provide for forcible strangulation at the middle portion, by exercising sufficient pressure on the rings, of a minimum thickness of vascular tissues (2 to 3 millimetres) (see Fig. 85, 4). The advantages of these forceps with long elastic jaws induced me, some years later, to apply the same principle

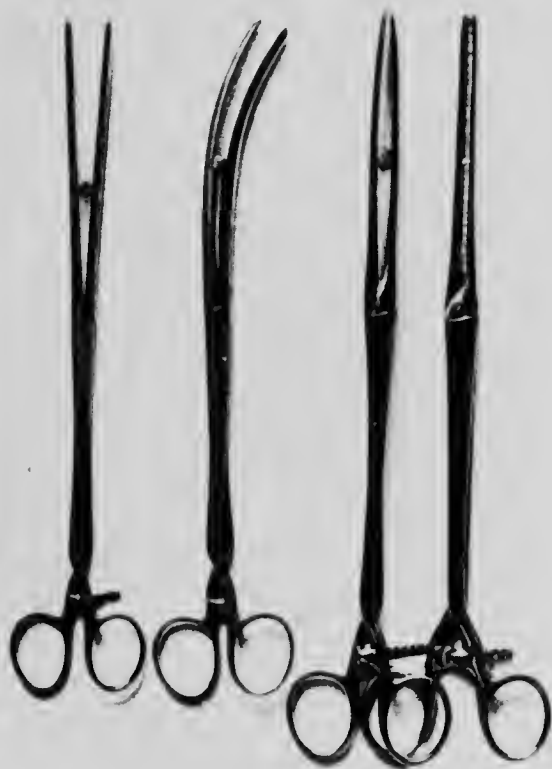


FIG. 85.

The rack is closely locked in each of the forceps. The extremities of each of the first pair diverge, while those of the third remain less widely separate than the intermediate part. The fourth forceps is the author's, the same as the third, closed tightly on a piece of cloth. We see that the construction is uniform along the entire length of the jaws.

to the construction of another long forceps curved at the border, but much more flexible, for the provisional closure of the stomach or intestine, in course of a pylorotomy or enterotomy (Fig. 92).

The new gastrectomy forceps, which have jaws so elastic as to grasp the finger without causing pain, present advantages in this operation such

110 SURGICAL THERAPEUTICS AND OPERATIVE TECHNIQUE

as we had anticipated. They permit provisional occlusion of the lumen of the intestine, without injury of the mucous membrane, or even arrest of the movement of the blood in arteries of a certain calibre.

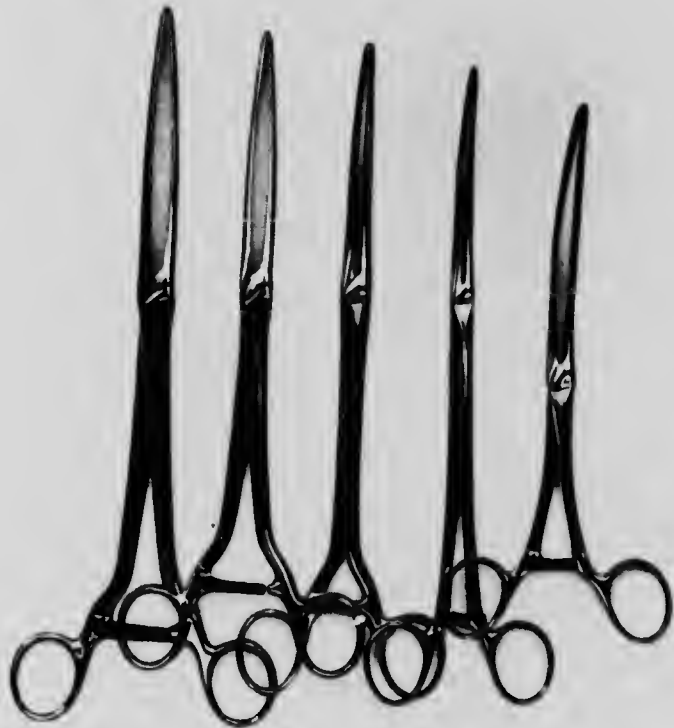

FIG. 86. —AUTHOR'S FORCEPS WITH ELASTIC JAWS.

1 and 2, Large and small forceps for the broad ligaments. 3 and 4, Curved forceps, large and small types. 5, Coprostatic forceps used in pylorotomy, gastro-enterostomy, and enterectomy.

Other forceps, still more slender in form, were constructed for the lips, with the double object of subduing pain and facilitating the removal of cancerous growths of small size by the employment of local anaesthesia with cocaine.

Hæmostatic Forceps with Elongated Jaws.—At the same date (1887) I abandoned the first Charrière type of hæmostatic forceps which Péan wanted to attribute to himself, and of which the jaws crossed when applied to tissues of some thickness. The principal use that I made of those forceps was, indeed, that of fixing the parietal peritoneum and the compresses that prevented escape of the intestines during the operation of laparotomy. And those instruments were detestable, even for that use. I have adopted



FIG. 87. COLLIN'S ORDINARY MODEL FORCEPS, WITH RIGID JAWS.



FIG. 88.—RICHELET'S FORCEPS WITH RIGID JAWS, FOR APPLICATION TO THE BROAD LIGAMENT.



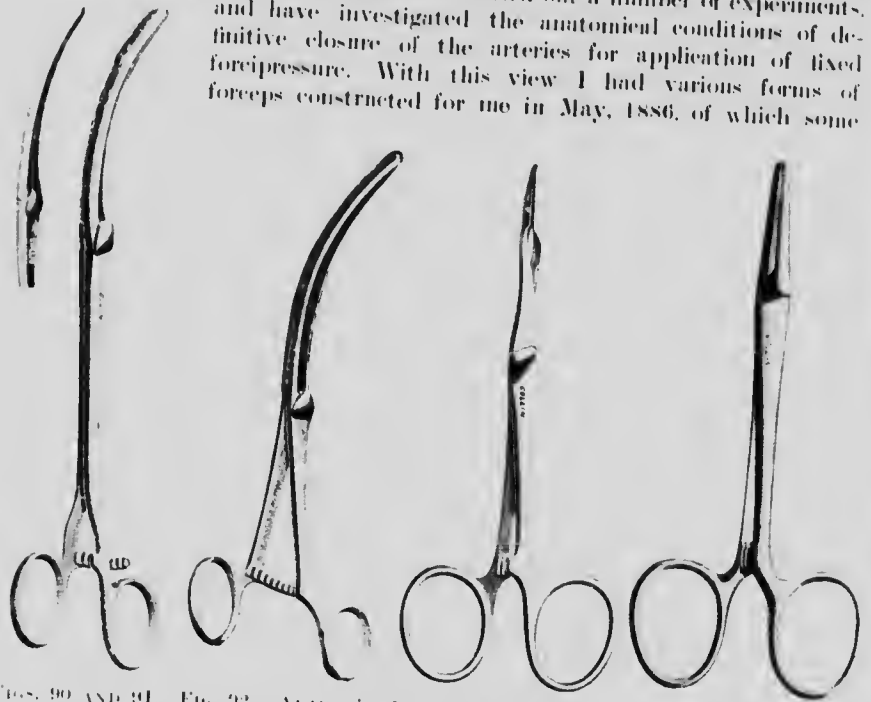
FIG. 89.—AUTHOR'S FORCEPS, WITH ELASTIC AND SERRATED JAWS, FOR THE BROAD LIGAMENT.

the model of Kæberle's forceps with elongated jaws, which was constructed by M. Collin according to the indications of M. J. Champoumière (Fig. 94).

Clawed and Ringed Forceps.—I have had constructed at the same time, for the prehension of tissues prone to slide between the teeth of the forceps already described, a forceps furnished with nine oblique claws, a rack, and ring-handles (Fig. 190): which serves equally, in certain cases, for approximation of the lips of the skin-wound at the moment of suturing. The jaws

of this forceps differ completely from those of the mouse-tooth forceps of Kocher, with which it has been erroneously confounded.

Attempt to secure Definitive Hæmostasis with the aid of a Lever Forceps, furnished with a To-and-Fro Movement of one of the Jaws in the Longitudinal Direction. These forceps did not, however, satisfy me in the attainment of hæmostasis, properly so called. I carried out a number of experiments, and have investigated the anatomical conditions of definitive closure of the arteries for application of fixed forepressure. With this view I had various forms of forceps constructed for me in May, 1886, of which some



FIGS. 90 AND 91. ALTHOFF'S CURVED FORCEPS WITH ELASTIC JAWS; LARGE AND SMALL FORM.

FIG. 92. ALTHOFF'S FORCEPS WITH ELASTIC JAWS, FOR COEPRESSION IN OPERATIONS ON THE STOMACH AND INTESTINES.

FIG. 93. HEMOSTATIC FORCEPS WITH ELLIPTICAL JAWS (KNOWN AS PEAN'S), WITH COLLIN'S ARTICULATION.

The jaws are those of the old dressing forceps (see Fig. 89).

FIG. 94. KERR'S AND CHAMPONNIÈRE'S HEMOSTATIC FORCEPS WITH ELONGATED JAWS.

were designed to multiply the pressure of the hand by special leverage, while others presented, on the opposed surfaces of the jaws, a longitudinal groove running along a plate worked by a powerful lever (Figs. 101 and 102). This grooved forceps permits me, when the rack has been fixed, to reduce the nipped structures to a minimum thickness by a series of to-and-fro movements. At the same time the degree of crushing of the tissues did not seem sufficiently considerable.

Artery Forceps with Short Jaws. It was then that I designed my actual type of artery forceps with short jaws, which realized that result far more effectively. The artery seized with the jaws of this instrument is so

thoroughly crushed that its external coat alone remains. The middle tunic is curled back, as after torsion. This result is very similar to that aimed at by Mannoir and Annussat in their own chewing method already referred to. Those operators formed a just idea of the object to be attained, but they failed in their efforts to reach it from want of a sufficiently intimate knowledge of the laws of mechanics. I have thus produced a current model of

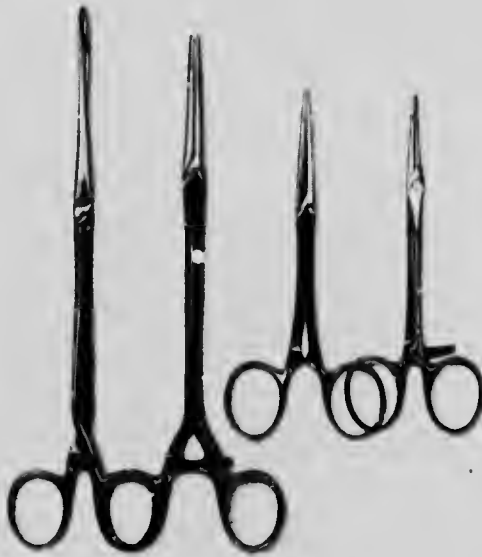

FIG. 95.—FORCEPS, CLAWED AND RINGED.

1, Collin's forceps, known as the "bullet extractors," and clawed forceps; they may be used with mucous membranes. 2, Sigmond's mouse-tooth forceps. 3, Kocher's mouse-tooth forceps. 4, Author's forceps with nine oblique claws (see Figs. 96, 97, 98, 99, and 100); a great improvement on Kocher's forceps 3.

hemostatic forceps, of which the leverage is 7×1 (Fig. 105), or 8×1 (Figs. 106 and 107); while those previously in use had a multiplying power only of; in the ordinary form (Figs. 93 and 94), 1.5 to 2; and in the most powerful, 3 to 3.5. The weaker form of my new forceps (Fig. 105) is furnished with grooved jaws (Fig. 104, 1), and serves also as holder for small curved needles. The powerful model (Fig. 106) bears, at the extremities of the jaws (Figs. 97, 5; and 104, 3), claws in the shape of a mouse's teeth, for the grasping of peripheral vessels. Clawed forceps should never be used for

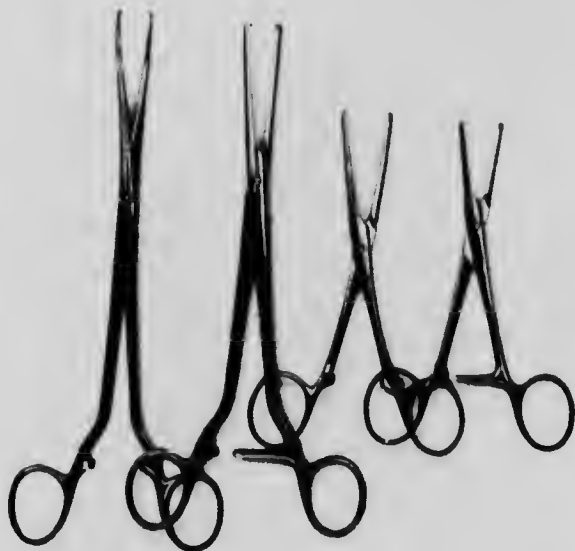

FIG. 96. THE SAME FORCEPS, OPENED.

1, Collin's forceps for bullet extraction. 2, Segond's mouse-tooth forceps. 3, Kocher's mouse-tooth forceps. 4, Author's forceps with nine oblique claws.



FIG. 97. SERIES OF DIFFERENT TYPES OF CLAWED AND RING-HANDLED FORCEPS.

1, Collin's so-called "bullet-extractor" forceps. 2, Segond's mouse-tooth forceps. 3, Kocher's mouse-tooth forceps. 4, Author's oblique claw forceps. 5, Author's short-jawed forceps. 6, Author's tongue forceps.



FIG. 98.—SECOND'S MOUSE-TOOTH FORCEPS.

These two forceps with only three teeth do not fix well.



FIG. 99. KOCHER'S MOUSE-TOOTH FORCEPS.

(See Figs. 95, 96, and 97.)



FIGS. 100A AND 100B. — AUTHOR'S FORCEPS WITH NINE OBLIQUE FLAWS WHICH FIX WITH CERTAINTY.



FIG. 101. HEMOSTATIC FORCEPS, WITH SLIDING JAWS, CONTROLLED BY A LEVER, USED FOR THE COMPRESSION OF VESSELS BY A TO-AND-FRO MOVEMENT.

prehension of the great arteries or veins, especially the great venous collecting trunks, which the claws would lacerate in irremediable fashion.

Forceps for the Great Veins. I have had constructed for ligation of all the great venous trunks and their principal tributaries, near their junction therewith, the same type of forceps; with flattened jaws, grooved quadrilaterally on the opposed faces, and without claws (Figs. 107 and 104, 2). Those forceps exclusively intended for veins are gilt, in order to prevent confusion with the clawed forceps, which are more frequently used.

The jaws of all those three types of forceps are also formed, at the distal end, in such a way as to guide the ligature directly on to the tissues grasped. The blades have very great power of compression, and each has a rack




FIG. 102. THE SAME FORCEPS, DISASSEMBLED, SO AS TO DISPLAY THE DIFFERENT PARTS OF STRUCTURE.

furnished with a number of teeth. They apply, when simply closed by the thumb and index-finger, a pressure at least four times as great as that of any of the older models. If we then approximate the rings with the pressure of the whole hand, the muscular force in case of a man of average strength being 60 to 65 kilogrammes, the pressure attained at the end of the jaws will be about 100 kilogrammes. We thus obtain even in arteries of a very moderate calibre a folding back of the middle tunica, and a constriction of the external so complete as to render ligation unnecessary in many operations.

The instrument should be left on the vessel for some minutes. The employment of those powerful forceps realizes, scientifically and regularly, haemostasis by temporary forcipressure—a result which had previously been always imperfect on account of the insufficiency of the instruments employed.

Crushing of Great Vascular Pedicles. The remarkable results which I attained at once by the method of immediate crushing, in operations on the head, neck, trunk, and limbs, led me to apply the same principle in abdominal surgery. But there was a material obstacle. The jaws of forceps intended for compression of large ovarian pedicles or uterine ligaments could not be less than 8 centimetres in length, so that, to attain a multiplication of 3×1 , the arms of the forceps would require to be 72 centimetres in length, which was far too much. Accordingly, I devised a new construction for use in these operations.

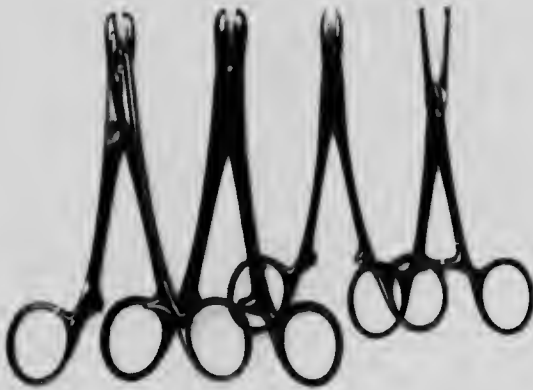

FIG. 101. AUTHOR'S HEMOSTATIC FORCEPS, WITH SHORT JAWS.

1. Clawed artery forceps.
2. Forceps without claws, for the large veins.
3. Forceps with grooved jaws, to act as needle holders.
4. Author's forceps with oblique claws, for holding the skin or mucous-membranes; equally applicable for hemostasis.

Author's Écraseur—FORCEPS-CLAMP WITH PROGRESSIVE PRESSURE.—

This new instrument, which is a forceps with progressive power of compression, multiplies the effort applied at the position of the rings from two to twenty times, and thus permits reduction of the broadest pedicles to the thickness of a leaf of paper.

This multiplication of the effort made by the hand is produced by the action of a lateral lever so arranged as to act only at the required moment. While the terminal ring remains attached to the corresponding blade of the forceps (Figs. 110 and 113), the instrument is manipulated as an ordinary forceps. When applied, for instance, to the pedicle of an ovarian cyst, the blades are closed, and then fixed in that position with the help of a

terminal rack. The multiplying power thus realized is 2×1 . We can then, by pushing the crochets that hold it, detach the ring which terminates the movable lever, and remove it from the corresponding blade. The notch of the nut then liberates at the same moment the crochets of the traction piece attached to the other blade, and the force exercised on the rings from that moment is multiplied, in proportion to their approximation, by a figure which ranges from 2 to 20. The arms and the tenons of this forceps require an exceptional resisting power; for, as shown in Figs. 103, 113, and 114, the force applied at the extremity of the jaws may amount to 600, 800, or even 2,000 kilogrammes; thus the leverage is so powerful that,



FIG. 104. JAWS OF DIFFERENT TYPES OF FORCEPS.

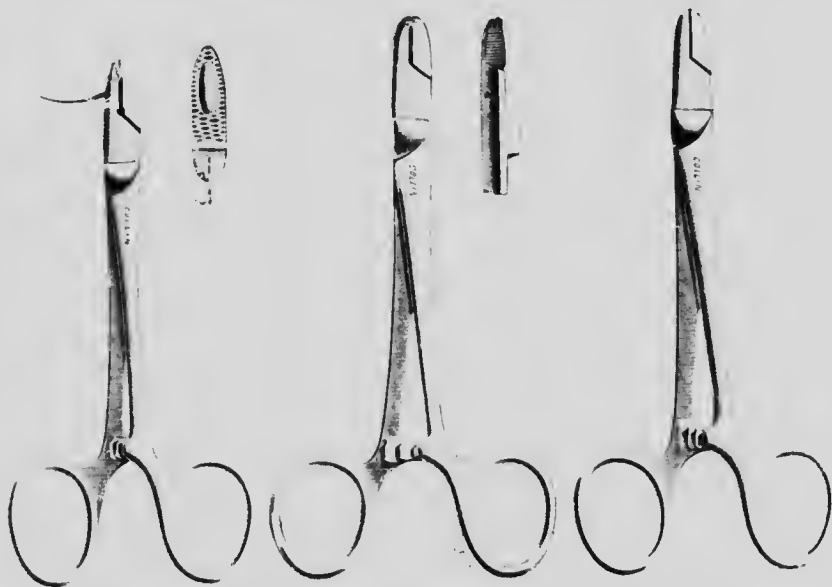
1. Author's hemostatic forceps, with hollow jaws (see Fig. 103, 3).
2. Author's hemostatic forceps for the great veins (see Fig. 103, 2).
3. Author's hemostatic forceps, clawed type (see Fig. 103, 1).
4. Author's hemostatic forceps with oblique claws (see Fig. 103, 4).
5. Author's hemostatic forceps for the tongue (see Fig. 97, 6).
6. Author's hemostatic needle holder forceps with eccentric plate.

adhesions which are reduced immediately to the thickness of their peritoneal leaflets. Most arteries are immediately obliterated. In peritoneal surgery we do not advise the division without tying of pedicles crushed in this way, as secondary hemorrhage might occur in cases in which the immediate haemostasis seemed quite satisfactory. When the instrument has been removed, the compressed structure is found reduced to so slender a thickness, that it is easy to secure definitive haemostasis with the simple aid of a very thin silk ligature. This crushing of the perivascular tissues is accordingly very advantageous, as the fine silk threads are never irritating, while ligatures of a greater thickness often produce small inflammatory or purulent foci in the tissues. We also avoid in this way leaving large omental or ligamentary pedicles—veritable foreign bodies which could be absorbed but slowly, while subject to infection all the time.

if we seize a very resisting object, such as a piece of hard wood or metal, between its jaws, the instrument would break under the mere pressure of the hand. Something must always yield when pressure is employed, so that when this instrument is made with flat jaws, it should be applied only to bodies capable of being crushed. When we want to adapt the same principle to section of bones or of metallic bodies (steel wire, etc.), it suffices to replace the flat opposed surfaces of the jaws with chisel or scissors edges.

This new forceps enables me to crush at once all such structures as the broad ligaments, pedicles of ovarian cysts, and omental and other

The use of this forceps with progressive pressure, a veritable clamp of a power previously unapplied, is accordingly one of the most effective procedures whenever it is necessary to tie *en masse* a vascular pedicle of a certain importance, and of which the constriction would require ligatures of considerable thickness. In vaginal hysterectomy crushing of the broad ligaments is specially advantageous, as forceps or ligatures were necessarily employed to secure definitive hamostasis. This reduction to a minimum thickness, by a new instrument, of those tissues which must afterwards be tied or compressed, unquestionably insures a far more rapid elimination of the necrosed structures after vaginal hysterectomy. The adipose, muscular, and



FIGS. 105A AND 105B. — FIGS. 106A AND 106B. — FIG. 107. AUTHOR'S
 AUTHOR'S HEMOSTATIC FORCEPS WITH HOLLOW AND SHORT JAWS, USED AS NEEDLE-HOLDER. AUTHOR'S POWERFUL HEMOSTATIC FORCEPS WITH CLAWED AND SHORT JAWS FOR ARTERIES. POWERFUL HEMOSTATIC FORCEPS WITHOUT CLAWS FOR LATERAL LIGATURE OF LARGE VEINS.

elastic tissues of the broad ligaments, as well as the vessels, are pressed and folded back above and below the jaws of the forceps, between which there remain but some serous leaflets and the cellular tunics of the arteries and veins. The nerve bundles are completely severed. This instrument should, however, be applied only when the pedicle has a flexible and resistant fibro-cellular envelope. We then avoid all danger of secondary hamorrhage or septic accidents produced by the presence of copious gangrenous debris at the fundus of the vagina.

These new forceps are, accordingly, no longer mere apparatus for the grasping of vessels, like the older types of hamostatic forceps—which

120 SURGICAL THERAPEUTICS AND OPERATIVE TECHNIQUE

produced hæmostasis but occasionally, and then in a defective manner—but veritable apparatus of forcipressure, designed and constructed from precise mechanical and experimental data.*

ÉCRASEUR: SMALLER FORM.—A smaller model of the écraseur (Fig. 109), which is worked with one hand, has been constructed for instant crushing of pedicles of moderate resistance.



FIG. 108. AUTHOR'S ÉCRASEUR (FORCEPS WITH PROGRESSIVE PRESSURE): LARGE MODEL.

RINGED FORCEPS.—It is necessary to have two forms of forceps, furnished with annular jaws and rackwork. One of these (Fig. 119, 2; and Fig. 120) has symmetrical elliptic rings for prehension of the lips of incised wounds, of neoplastic glands, and of ovaries; the other is furnished with eccentric rings (Figs. 119, 1; and 121), and is employed, while guided by the finger, in grasping deep-seated glands, the ovaries in the operation of vaginal hysterectomy, etc.



FIG. 109. AUTHOR'S ÉCRASEUR: SMALL MODEL.

Choice of the Best Forms of Hæmostatic Forceps.—I use twelve varieties of hæmostatic forceps (see Fig. 122):

1. A forceps of 11 centimetres in length, with hollowed jaws and a multiplying power of 7, which functions also as needle-holder, and can be used for compresses (Fig. 105).

* The whole of the above paragraph is found in the communication "Technique Chirurgicale," which was presented to the Congress held at Moscow in August, 1897; as well as my forceps-clamp for progressive pressure. This date should be noted by those surgeons who would still vainly discuss the priority of the method of instantaneous crushing.

2. A stronger forceps, with mouse-tooth claws, of 12 centimetres in length, and with a multiplying power of 8; intended for immediate hæmostasis of arteries of moderate calibre, or subsequent application of ligatures; 10 of these strong forceps are usually sufficient (Fig. 106).



FIG. 106. AUTHOR'S ÉCRASEUR: FIRST MODEL.

The blades, which were too slender, bent when the pressure of the hand was applied.

3. The same form—gift and without claws, for the lateral ligation of veins (Fig. 107).

4. Forceps with oblique claws and rack, used for grasping tissues, and to facilitate apposition and suturing of the skin (Figs. 100*a* and 100*b*).




FIG. 111. AUTHOR'S ÉCRASEUR: FIRST MODEL.

Showing the hook of the nut fixed in the notch of the movable piece borne by the other blade of the instrument.

5. Forceps with curved elastic jaws, of 27 centimetres in length, which serve for hæmostasis in case of small pedicles and deep-seated arteries; also at the toilet of the peritonæum (Figs. 90 and 91).

122 SURGICAL THERAPEUTICS AND OPERATIVE TECHNIQUE

6. Forceps with curved and elastic jaws, for temporary haemostasis of the peritoneum; also used for provisional closure of the stomach and intestine (Fig. 92).

7 and 8. Two forms of ring jawed forceps; one with elliptical, the other with eccentric, terminal rings; used for haemostasis of the deep arteries as well as for grasping small tumours of the ovaries and Fallopian tubes (Figs. 120 and 121).

9. The large form of forceps; for application to the broad ligament in vaginal hysterectomy. The same forceps, modelled in medium size, also known as the "reinforcement forceps."




FIG. 112. ALMOND'S ÉCRASEUR: SECOND MODEL.

One of the jaws was too weak and was broken in the first trial of the instrument, by the mere pressure of the hand on the multiplying lever. The instrument has been taken to pieces, so as to show the various constituent parts in detail. Above is the female limb; below, the movable ring, ending in a nut which carries a small vertical cratchet. To the right of this piece is the catch destined to be fixed on the male blade, which is placed at the bottom of the figure. This catch has a notch on which the tooth that is placed at the end of the nut of the movable ring is latched, and which transmits the power of the multiplying lever to the male blade.

10. The forceps clamp with progressive pressure, or écraseur (the large model).

11. My new écraseur with bent screw nut (see later reference).

12. The écraseur, small model.

ÉCRASEMENT AND HEMOSTASIS.

Author's Method of Instantaneous Ecrasement.—The description of the two last instruments leads me to discuss, in connection with general haemostasis, a new method that I presented in 1897 to the Congress at Moscow, which provides for instantaneous reduction of most of the large vascular pedicles to a very slight thickness. This extemporaneous crushing, as I practise it, differs essentially from the temporary application, practised by Péan, of his original fixed forceps to arteries of small calibre. This method actually demands the application of a series of new instruments, and of types previously unknown, which I have had constructed for the purpose of realizing a power of compression varying between 100 and 2,000 kilos. My short-jawed forceps, and both my models of *écraseur*, of which the original types were presented to the Congress held at



FIG. 113. AUTHOR'S ÉCRASEUR: LARGE MODEL.

The instrument is prepared for application.

Moscow in 1897, have been constructed, after previous careful calculation, in such a way as to realize with minimum expenditure of effort all the force required for thorough crushing of the tissues. I pointed out, when demonstrating the use of those instruments at Moscow, that it was not necessary to regard instantaneous crushing as a method of haemostasis, and that the slight curling up of the middle coat produced by the compression of my instruments was not sufficient to secure the haemostasis of arteries of a certain calibre, and *a fortiori*, not enough to produce haemostasis of the corresponding veins. On the other hand, the crushing produced by my short-jawed forceps (with multiplying power of 3, and constriction of 400 to 500 kilos) closes the lingual or facial arteries admirably, when these are not affected with atheroma. Nevertheless, it would be imprudent to detach the extremity of the crushed vessel, after removal of the forceps, by friction

124 SURGICAL THERAPEUTICS AND OPERATIVE TECHNIQUE

with a compress. The experiment can readily be made in the removal of a testicle. Crush the cord by application of my large écraseur for three minutes, and remove the instrument, the compressed portion is now found



FIG. 114. ACLAND'S ÉCRASEUR: LARGE MODEL.

The instrument had just before been detached from a pedicle. The movable rack-work is fixed. The lever is armed, and the tooth of the nut is locked in the notch of the movable piece which is destined to transmit the power of the lever.



FIG. 115. ACLAND'S ÉCRASEUR: SMALLER MODEL.

The rings are fixed by the rack, which must be rotated on its axis in order to free them.

reduced to the thickness of a visiting card, impressed and dried in such a way as to present a horny consistence to the scissors. Cut through it; no blood escapes. But if you rub and break it down with a compress at the upper

end, blood will be seen to appear. Thus, *simple* crushing is not a sufficiently secure method of obtaining hemostasis.

I have also observed that when fixed forceps are applied after crushing



FIG. 116. ALLIOR'S ÉCRASEUR: SMALLER MODEL.

The instrument, which is worked with one hand, is opened for the seizure of a pedicle.



FIG. 117. ALLIOR'S ÉCRASEUR: SMALLER MODEL.

The instrument has been disarticulated for the purpose of showing the constituent pieces in detail.

of the broad ligaments, it is necessary to leave them in position for thirty-six to forty-eight hours if we want to be quite sure of seeing no blood

appear on removal. The special advantage of crushing is to diminish considerably the thickness of the tissues which have to be pinched up and tied. Another demonstrative experiment can be made on resection of the omentum, the vessels of which have very thin walls and are almost devoid of fibro-cellular support. Crush the omentum, leave the *écraseur* in position for

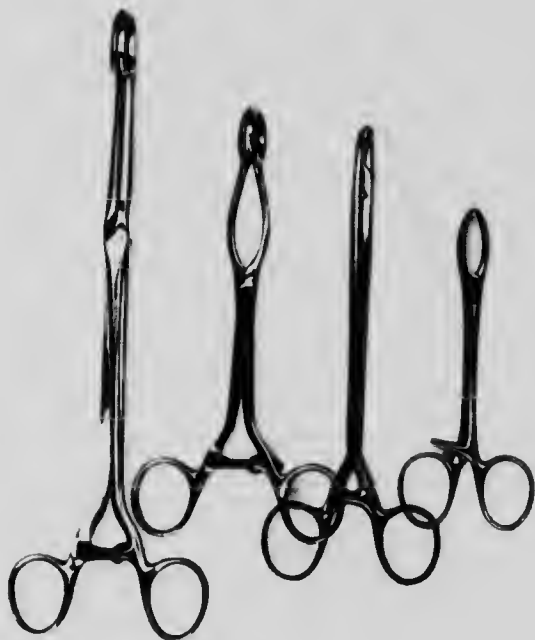

FIG. 118.

1. Author's long forceps, with eccentric rings.
2. Collin's forceps, with oval rings.
3. Author's needle-holder, with eccentric plate.
4. Author's tongue forceps.

three to four minutes, and then cut along the furrow which it has made, as far as possible from the upper margin; blood will flow. Now crush, some centimetres higher up, moderating the pressure of the *écraseur* so as to press out the adipose tissue beyond its jaws, and without laceration of the vessels by brute force, and a deep furrow will be obtained in which

the application of a fine ligature will suffice to secure hemostasis. I had made all these experiments before proposing my new method to the Congress held

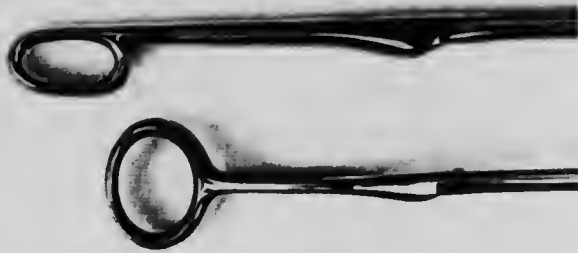

FIG. 119. EXTREMITIES OF FORCEPS 1 AND 2 OF LAST FIG.

at Moscow. I have since generalized the investigation by applying it to the surgery of the stomach, intestines, and biliary passages; and also in removal of goitre, nephrectomy, etc.



FIG. 120. COLLIN'S FORCEPS WITH OVAL RINGS, FOR GRASPING THE OVARIES AND FALLOPIAN TUBES IN HYSTERECTOMY (see Figs. 118 and 119, 2).



FIG. 121. AUTHOR'S LONG FORCEPS WITH ECCENTRIC RINGS, FOR TRACTION ON THE ADNEXA DURING VAGINAL HYSTERECTOMY.

This forceps may also be used as a hemostatic forceps in abdominal operations (see Figs. 118, 1; and 119, 1).

The procedure of extemporaneous *écrasement* is meant for the reduction of voluminous pedicles to a very small thickness, and is thus but incidentally a method of hemostasis; for the very vascular pedicles ought to

be tied in the furrow made by the *écraseur*. Surgeons who took up the study of my method in 1897 and afterwards, and who have not been prejudiced regarding hemostatic methods, have now passed over all the errors of appreciation by which I was myself retarded in 1896. Some have, indeed, sought, and quite uselessly, to oppose my forceps for progressive pressure which presents the best mechanical solution of the problem, by having heavy and clumsy forms of spring catch forceps constructed, of the cephalo-tribe type, or with an independent lever combined, which I had myself designed and rejected, after recognition of their defects, in 1896 and 1897.

Thus, instantaneous crushing is a suitable method of hemostasis only for small vessels and in well-selected cases.

Importance of Extemporaneous Écrasement in the Realization of Hæmostasis.—The procedure of crushing, the results of which in ovariectomy and hysterectomy I communicated to the Moscow Congress, and which I have since generalized by application to nearly all the major operations (thyroidectomy, nephrectomy, resection of the omentum, surgery of the stomach and intestine, etc.), presents, as regards hemostasis, a certain analogy to Chassaignac's method. My forceps, with the major multiplying power, differs completely indeed in action from the *écraseur* and the *serre-nœud*, inasmuch as it crushes the tissues over a surface of some extent, while Chassaignac's "linear *écraseur*" and Maisonneuve's *serre-nœud* act but along a very narrow line. Those instruments, nevertheless, realize the object of hemostasis in a manner almost identical.

Chassaignac presented his first model of the *écraseur* to the Société de Chirurgie, August 28, 1850. He described his instrumental method as "an articulated metallic ligature." He had, in fact, replaced the metallic thread of the *serre-nœud*, which he had found unsatisfactory, by a linked chain. This chain rolled on a pulley furnished with a catch. He presented the final model of his *écraseur* to the Society on September 20, 1854. It presented an oscillating lever, which drew the chain by an alternating to-and-fro movement (Figs. 67 and 68). The memoir published by Chassaignac on his method in 1855 bore the title, "De l'Écrasement Linéaire." The *écraseur* was adopted by nearly all surgeons, and the term "écrasement" prevailed, not only in France, but in foreign countries, over all other denominations; and even over certain neologisms, such as *sarcotripsy* and *histotripsy*. I manipulated the *écraseur* in the early years of my medical studies, and I admired its power and its mechanism. The hand acts on the chain through a powerful lever, and the constriction of the pedicle increases as the ring narrows. The middle and intercal tunics of arteries, muscular tissues—smooth and striated—adipose tissues, and nerve tissues rapidly yield. Mucous membranes are very readily divided. The skin resists a long time. Its cut margin is frayed and serrated, and immediate union becomes impossible. The advocates of linear *écrasement* recommend its division with a bistoury before applying the chain. Tendons and aponeuroses are well divided only by a bevelled chain. Chassaignac himself usually completed their division with scissors.

With regard to hemostasis, the *écraseur* gave fairly satisfactory results

when dealing with arteries of a certain calibre; but its action was not uniform, and surgeons who used it much have all found, even in cases where no dangerous secondary hemorrhage took place, a very appreciable capillary oozing at the close of the operation. Chassaignac himself noted in 1845 the occurrence of serious hemorrhage after his first amputation of the tongue. He had advanced the chain by a single turn every two hours, and the operation had lasted twenty-four hours.* Many other surgeons were obliged either to tie the stump *en masse*, or to tie separately the arteries which yielded too much blood. Arteries of a certain calibre are olditerated only when the vessel is healthy, and invested with a fibrocellular sheath susceptible of compression, and of narrowing down with agglutination before rupture. The linear éraseur is inferior to the *serre-nœud* in the production of hemostasis in vessels of very small calibre. In case of large arteries, it proves less efficacious than torsion, which folds back the internal and middle tunics to a greater distance. The galvanic loop itself, slowly tightened at a red heat, does not possess absolute hemostatic powers, and gives a dry section only when the pedicle encloses no large arteries. Thus, the early ovariotomists, who had only non-sterilized threads for ligatures, were faced by the alternative of a resection of the pedicle after the mere use of the actual cautery (applied on the surface, and as ignipuncture in the lumen, of the vessels) or leaving it exposed externally, tied with a metallic loop. Separation took place in two or three weeks, and the wound closed by secondary union.

External treatment of the pedicle was long used in abdominal amputation of the uterus. The cervical stump, transfixed with two steel needles, was strangled in the metallic loop of a *serre-nœud*, which was fixed by some twisting movements. They then began to apply an elastic ligature in the groove formed by the *serre-nœud* or the éraseur. To supersede the constriction of the pedicle by those instruments, I had made for me in 1889 a clamp formed of two crossed branches, articulated, and made to approach one another by the action of a recoil spring. Below this clamp I placed a strong silk ligature, in the furrow which it had made. The chief point, indeed, in abdominal surgery was not to risk internal hemorrhage; and neither the éraseur, nor the *serre-nœud*, nor the galvanic loop, gave the surgeon any certitude of a perfect hemostasis. Thus the clamps which were successively employed were very imperfect instruments and of insufficient powers. They were traced on the lines of the forceps of Paré and of Dionis, or rather more on those of Hildanus's rackwork forceps (Fig. 36). The original forms of the hemostatic forceps of Spencer Wells, of Kæsterle, and of Péan, were but little superior to the *forceps à verrou* of Maisonneuve. The form known as Péan's forceps, which was but a modification of Charrière's dressing forceps and *forceps à arrêt*, was found to be the most defective; for the jaws crossed when they were forcibly applied to tissues of a certain thickness.

The very various forms of forceps that were constructed at that epoch presented, each and all of them, a triple inconvenience: the jaws were very weak, the blades too elastic, and the multiplying power insufficient (1, $1\frac{1}{2}$, 2, 3, $3\frac{1}{2}$). The constriction of the jaws was limited by the elasticity of the

* A. Boursier, "Diet. Enc. des Sc. Méd.," p. 466.

blades. These forceps were but instruments of prehension, and effected the crushing of vessels only after a prolonged interval. So they had to be left in position for twelve or twenty-four hours to procure hæmostasis of even small arteries, and thirty-six to forty-eight hours in case of pedicles of a certain size. Péan had himself so far recognized the insufficiency of his forceps that he furnished the jaws of some with pointed projections, which, after fixing the tissues, passed through them into corresponding orifices of the opposed surface. The action of those forceps when left in position on the tongue, for example, was even more barbarous and cruel than that of the *crasseur*.

The methodic study of hæmostasis during the course of many operations proved to me, even from the first years of my surgical practice (1886-87): (1) that the vessels capable of producing a really dangerous hæmorrhage were much less numerous than was supposed; (2) that the flow of blood, which at first was fairly abundant, stopped almost immediately after the tumour had been completely detached, and the wound carefully plugged. In fact, the hæmorrhage produced during operation on the tumour is almost wholly venous or capillary, and those vessels produce no more when the field of operation has been thoroughly freed and compressed for some moments. Only arteries of a certain calibre and large veins, especially those of the neck, should be immediately seized and tied. The habit had been adopted, after the example of Péan, of compressing the orifices of small vessels during operation, and withdrawing the forceps at the moment of suturing. I perceived that this practice was far from being reliable, and that if we placed forceps only on vessels of a certain calibre during operation, these frequently bled, either immediately after removal of the forceps, or some time afterwards. Still more, secondary hæmorrhages were not exceptional in cases in which the forceps had been left in position even from twelve to forty-eight hours.

I have selected as ordinary hæmostatic forceps those with straight jaws, which do not cross, and blades almost rigid (Fig. 94). Then, in 1887, I had my forceps with grooved elastic jaws constructed for use in vaginal hysterectomy, and with flat pedicles of a certain importance (Fig. 89). The grooving was designed for the better fixation of the interposed tissues, and to secure a triple obliteration of the arteries, as a result of the folding back of the middle and internal tunics both above and below the forceps, and at the level of the groove. This forceps crushed the broad ligaments much more thoroughly than did the previous forms of the instrument, and seemed a rapid elimination of interposed tissues, which were found reduced after forty-eight hours to a thin cellular lamina. The pressure brought to bear between the jaws did not, however, exceed 100 kilogrammes, and a study of the action of the different forms of forceps on easily accessible pedicles, such as ovarian, proved to me that those instruments were far too feeble. They reduced the interposed tissues to the thickness of cellular leaflets, but by degrees, and by the effect of the elasticity of the blades, which is called into play with maximum power when the rack has been fixed at its deepest catch by the pressure of the hand. The jaws of these forceps crush the

tissues slowly and progressively, after the manner of the elastic ligature. When we grasp non-resisting tissues, such as the cellulo-adipose structures, with the same instrument, the crushing is immediate, but the hæmostasis is imperfect by reason of the want of plasticity of such tissue. I tried a renovation of the use of Chassaignac's linear *écraseur* or Maisonneuve's *serre-nœud* in dealing with large pedicles, as they were easily asepticized in the dry stove at 100° (320° F.). The manipulation of these instruments was much too slow; the chain or the metallic thread did not retain the desired position. I was unable to realize the object of the application of the power of the linear *écraseur* on the instant, in securing the folding back of the internal and middle arterial tunics far enough to produce hæmostasis. Those experiences induced me to have different types of forceps made for me in 1806, of which the most characteristic are the following: (1) Forceps with short jaws, blades nearly rigid, and great multiplying power (1 - 8). (2) Forceps with sliding arm—a small model, analogous to the *forceps à ressort* (with sliding catch), and with one fixed jaw striated transversely, and the other similarly striated on the opposed face, and having a longitudinal to-and-fro movement produced by a lateral button; and a large model for the broad ligaments. The sliding arm of this large model (represented in Figs. 101 and 102) is moved by a lever of the second order, which multiplies the pressure of the hand by four. The small forceps gave mediocre results for arteries of moderate calibre. The large one, which was gradually closed while I manipulated the sliding limb, reduced the broad ligaments to a very slight thickness after vaginal hysterectomy; but if I divided them directly after, the vessels bled, and I was obliged to apply fixed forceps or ligatures. Study of the action of my sliding forceps on the fresh pedicles showed me, in fact, that the arteries were reduced to their external coat, but that the inner tunics, crushed and detached by the rotation of the vessel on its axis, did not form a sufficiently reliable *bouchon* (plug).

On the other hand, the action of my short-jawed forceps, with its great multiplying power, was highly satisfactory. Placed on an artery of the calibre of the facial, and retained for four or five minutes, it reduces it to a cellular figurate lamella, almost dehydrated, and secures its permanent obliteration. The smaller veins, by reason of the marked difference of the anatomical structure of their coats, are much less effectively obliterated by these forceps than are the arteries of medium calibre. The arterioles which permeate the friable tissues, and whose coats are rather thin, behave like the small veins. But veins with a thick muscular tunic, like some of those of the leg, behave like the facial artery, and do not bleed after removal of the forceps. On the other hand, anastomosing arteries may prove the sources of secondary hæmorrhage, so that it is prudent to tie them. As a general principle of practice, then, I apply my crushing forceps only to vessels of some size, and do not remove them without ligation, except in the ordinary operations in which the great serous membranes are not engaged. But they arrest hæmorrhage from the middle meningeal artery and its branches admirably; also certain hæmorrhages from the arterioles of bone,

132 SURGICAL THERAPEUTICS AND OPERATIVE TECHNIQUE

where I crush these with the investing osseous tissue. In the general practice of surgery their use is excellent. Since 1896 I have employed no ligatures in the current operations, except in those cases in which the vessel bled after removal of the forceps. Since the construction of my forceps with large multiplying power, I have only in exceptional cases tied the facial, epigastric, or internal mammary artery; and nearly all arteries of similar calibre are as surely occluded by a powerful constriction there-

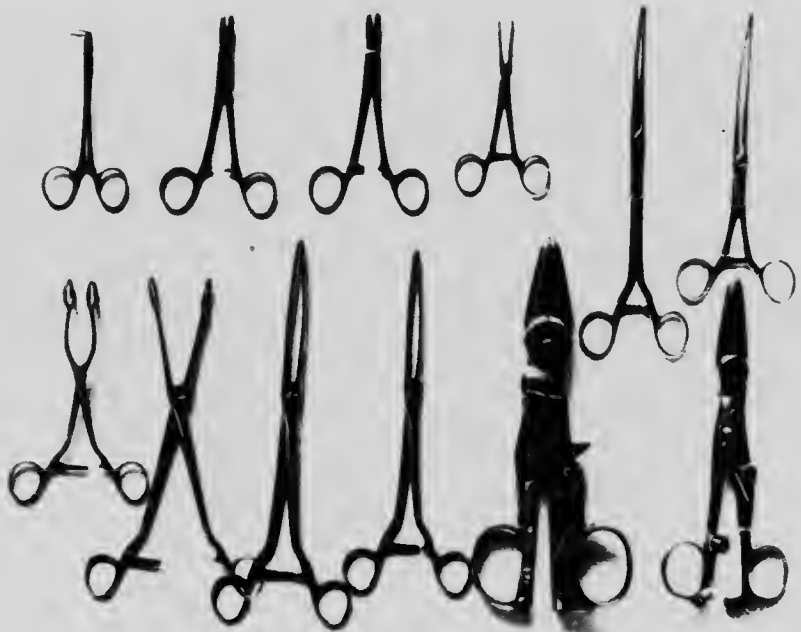


FIG. 122. MODELS OF THE FORCEPS MOST USED TO SECURE OR TO AID IN HEMOSTASIS.

1. Forceps with short excavated jaws (see Fig. 105).
2. Forceps with short jaws, with claws (see Fig. 106).
3. Forceps with short jaws, for large veins (see Fig. 107).
4. Forceps with oblique claws and rings (see Fig. 100).
5. Forceps of 27 centimetres with curved jaws (see Fig. 90).
6. Forceps for stomach and intestine (see Fig. 92).
7. Forceps with oval rings (see Fig. 120).
8. Long forceps with eccentric rings (see Fig. 121).
9. Forceps with elastic jaws: large model (see Fig. 89).
10. Forceps with elastic jaws: small model (see Fig. 86, 2).
11. Écraseur: large model (see Fig. 108).
12. Écraseur: small model (see Fig. 100).

with, lasting for three to four minutes, as by the methodic practice of torsion. If the vessel happens to bleed, either at the moment of removal of the forceps or a few moments later, I apply a ligature.

Should I apply this method to peritoneal surgery? I studied in 1896 and 1897, and before the publication of my "Technique Chirurgicale," in

which I wished to give the concluding and precise results of my method, the action of my short-jawed forceps on the uterine arteries in total abdominal hysterectomy. Like the facial, those arteries were completely occluded by a pressure of four to five minutes. But it has happened that, at the close of the operation, when, for example, making the toilet of the vagina or some moments after, one of the arteries treated by simple crushing began to bleed. This small accident, which presented no feature of gravity, inasmuch as the peritoneum was closed above the vessel, has obliged me in

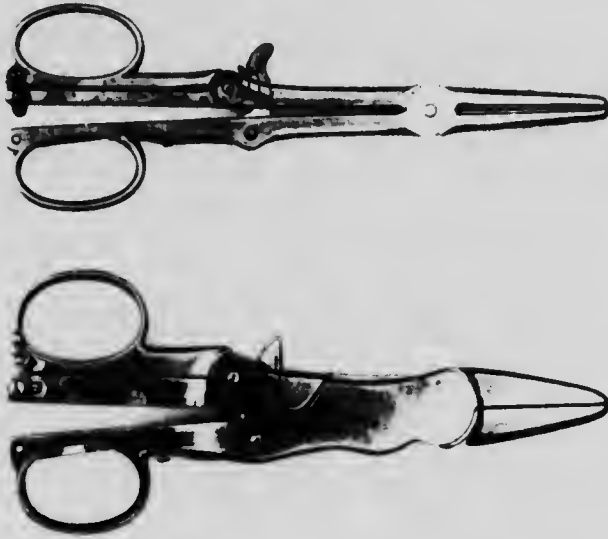


FIG. 123. AUTHOR'S ÉCRASEUR: ORIGINAL AND FINAL MODELS.

The catch of the made branch has been pushed beyond the tooth of the nut of the lever. The instrument, held in the right hand, is prepared for placing on the pedicle. In Figs. 123-127 the outline of the nut, with its projecting tooth, as well as that of the catch, on which the tooth is meant to fit in an appropriate notch, is traced in black so as to enable the reader to understand the working of the instrument.

two or three cases to apply a forceps to the bleeding artery at the fundus of the vagina, or even to compress it directly for ten to twelve hours, while leaving an open speculum in the canal. Then why should we wish to avoid the four or six ligatures which at most are required in my method of abdominal hysterectomy, since the operation is more secure by their use, and as a ligature is necessary in closing the peritoneal opening, whether the arteries of the field of operation are tied or not?

When the question was decided as regarded total abdominal hysterectomy, in which but few arteries have to be tied, the collateral one arose of

134 SURGICAL THERAPEUTICS AND OPERATIVE TECHNIQUE

the application of my method to vaginal hysterectomy, and to the large pedicles of certain ovarian cysts, for which ligation, whether *en masse* or in series, presents its inconveniences. Here I studied successively the hemostatic action of air at 300° or 400° (572°, 752° F.), Mayor's hammer, vapour by Sniegireff's method, desiccation by dry heat, the galvanic loop enclosed in one of the jaws of a special forceps (which appeared to me to offer one of the best solutions of the problem); but none of these methods of hemo-



FIG. 124. ALTHOFF'S CERASER: ORIGINAL AND FINAL MODELS.

The instrument held in the right hand is open, and ready for placing on the pedicle. The first model of the *ceraser* is produced in Figs. 123-127, side by side with the definitive one, so that the details of the functioning of the unit and catch may be distinguished, which are not fixed in Figs. 123-124.

stasis having given me results as satisfactory as those of my short-jawed forceps, I was led to construct an instrument capable of crushing instantaneously the largest and most resisting pedicles. My short-jawed forceps had a multiplying power of eight, and gave, for an effort of the hand representing 70 kilogrammes, a constricting force of 500 kilogrammes at the extremities of the jaws, and 1,120 kilogrammes at the middle. For crushing the broad ligaments, which require jaws of 0.08 metre in length, with the

same force, an instrument of 72 centimetres would be necessary, which would be quite worthy of a mechanic's workshop.

My previous experience of abdominal surgery led me to construct a forceps of still greater power, and with dimensions below 30 centimetres. I first thought of furnishing my instrument with a recoil spring and screw *à volant*, as in the cephalotribe and clamp which I had previously employed for large uterine pedicles (*vide supra*), but such did not favour rapid manipulation. It was therefore necessary to find something better; so I studied the question, and at the end of 1896 brought an exact model in pasteboard

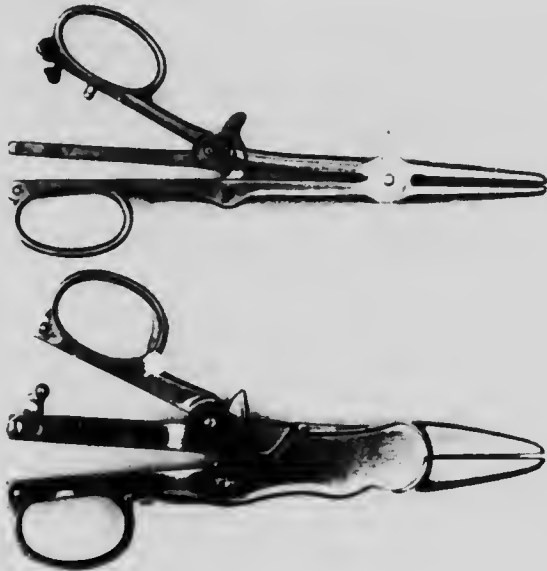


FIG. 125. AUTHOR'S ÉCRASEUR: PRIMARY AND FINAL MODELS

The pedicle is seized and grasped as tightly as possible. The female blade (that with the movable ring) is closed with the left hand. The small terminal crotchet is then pushed by the right thumb and the movable ring, disengaged, is withdrawn from the female blade till the crotchet of the nut comes to be fixed in the notch of the tenon of the other blade.

to M. Collin of the forceps clamp with lever which I have since employed in nearly all my operations. This first model proved to be too weak. One of the jaws of the second model broke when it was barely finished. I then produced at last the final model which, made with articulations with rounded angles and with arms of considerable power, cuts through a normal uterus with the mere pressure of the hand.

This instrument, which has realized a novel application of the laws of mechanics, is a lever with double action. So long as the tooth at the end

136 SURGICAL THERAPEUTICS AND OPERATIVE TECHNIQUE

of the nut of the mobile ring is not in contact with the notch of the tenon of the male branch, and the ring of the multiplying lever continues fixed to the female branch by the crotchet at its extremity, the instrument works as does an ordinary forceps. When the pedicle is seized, the terminal crotchet is pushed by the thumb of the right hand, and the mobile ring is withdrawn from the female blade till the crotchet of the nut comes to be fixed in the notch of the tenon of the male blade. To the primary multiplying power of the forceps, which is twofold, is then added the effect obtained by bringing into action the lever of the first order formed by the mobile ring, acting by its toothed nut on the median tenon of the male blade

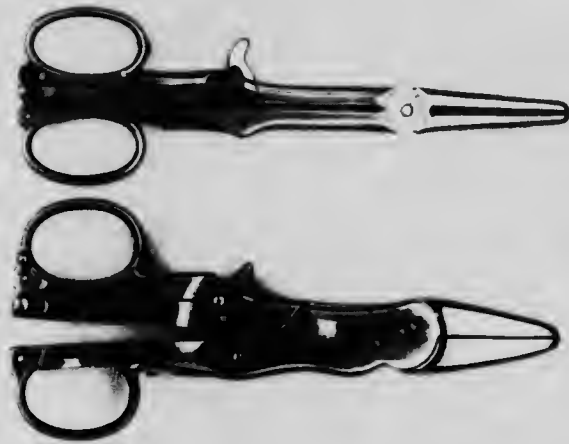


FIG. 126. AUTHOR'S ÉCRASEUR: PRIMARY AND FINAL MODELS.

The two rings are approximated by pressure of both hands joined till the movable ring comes in contact with the right portion of the female blade. The small terminal crotchet is then pushed by the index-finger, left free for the purpose, and fixes the movable ring. The forceps is thus completely closed, and may be left in position for one or two minutes.

—a lever of which the multiplying power is 10. The result of this is, that by approximating the ring handles of the instrument with both hands, we obtain at the extremity of the jaws a multiplication of 2×10 , and at their middle portion one of 2×20 . The force realized by the combined pressure of both hands being about 100 kilogrammes, that attained at the end of the jaws of the instrument is about 2,000 kilogrammes, and at the middle about 4,000 kilogrammes. When the mobile ring has been pressed into contact with the female branch, the tissues grasped between the jaws of the forceps are reduced, if the instrument is properly worked, to the thickness of a leaf of paper.

When we want to secure definitive hemostasis of the broad ligaments,

we must close the forceps and fix the movable ring in contact with the female blade, with the help of the little crotchet at the end, which it is only necessary to push back with the index-finger. The crushing then attains its maximum degree: the interposed tissues lose even their water of constitution, and present a horny appearance. When the object is merely to secure the crushing without subsequent use of the ligature, we cut off below the forceps; then detach the crotchet which fixes the movable ring, and push the tenon of the male blade so as to free the tooth of the nut already described. It then suffices to fix again, with the crotchet of the female blade, the movable ring in contact with it, and separate the jaws of the instrument, to enable us to detach the forceps, as in case of an ordinary ring handled one.

In crushing the pedicles which I intend to tie afterwards, I content myself with strong binmanual pressure on the two rings of the forceps, after having fixed the tooth of the nut in the notch of the corresponding tenon, and without the momentary fixation of the mobile ring in contact with the female blade by means of the terminal crotchet. The action of the instrument can be moderated with the hand, according to the sensations felt during the progressive laceration of the tissues. When the crushing has been completed, nothing more than a thin fibro-cellular lamella remains between the jaws, and this is almost dried when the instrument has been left one or two minutes in position.

The manipulation of this forceps is extremely simple. Its power is considerable, and it is remarkable that the crushing of large pedicles is effected almost without being perceived, so rapid is the process. I applied this instrument before the Moscow Congress in various peritoneal operations, especially in ovariectomy and vaginal hysterectomy. My object was to suppress the application of either fixed forceps or ligatures, as I had already succeeded in doing in case of the facial and corresponding arteries, by the use of my short-jawed forceps. I have established the conditions so that, after a compression of thirty to sixty seconds, we can in certain cases tear or cut the lower segment of the broad ligament in the first stage of vaginal hysterectomy without the smallest escape of blood. At the close of the operation I applied my instrument above the adnexa. I noticed that it was imprudent to cut the pedicle at that point without application of a ligature, or at least a small fixed forceps, as the peritoneal wound ascended very high in the pelvic cavity after detachment of the uterus. I also follow a definite rule, since my early abdominal operations, never to leave clotted surfaces free in the peritoneal cavity. I had noticed in my early operations that, in spite of crushing, the line of the ligamentary detachment, which became more extended after the toilet of the wound with the help of sterilized compresses, often yielded a certain quantity of blood at that moment, so that I have often been obliged to apply ligatures or fixed forceps to the utero-ovarian vessels before placing the gauze tampon in position. In fact, I apply the tampon only when the hemostasis has been perfected, and no trace of blood appears in the depth of the wound.

In studying the effect of my écraseur on long pedicles of ovarian cysts,

138 SURGICAL THERAPEUTICS AND OPERATIVE TECHNIQUE

I found that the hamostasis of the large veins was insufficient, and that it was dangerous to replace these pedicles without secure ligation. Those trials were so conclusive that I considered it to be my duty to point out the results to my readers in my original edition, and warn them against accidents of which I would otherwise have assumed the responsibility, inasmuch as I had dwelt on the general uselessness of ligation after the application of my short-jawed forceps: "I do not advise, in peritoneal surgery, cutting of the pedicles thus crushed without previous ligation, as a secondary hemorrhage may occur in cases in which the hamostasis

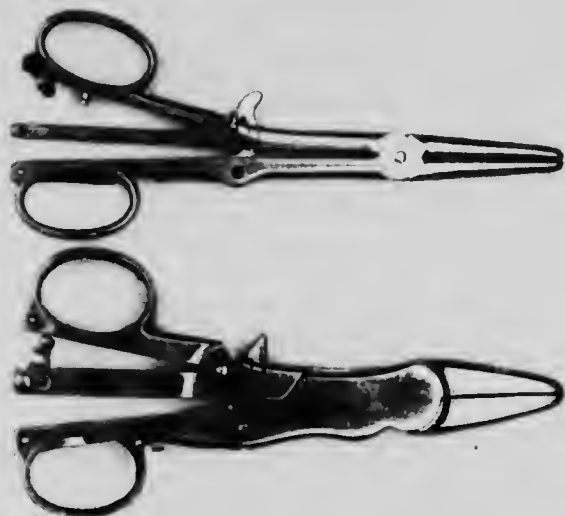


FIG. 127. ALLDOR'S ÉRASEUR: ORIGINAL AND FINAL MODELS.

The two rings of the *éraseur* are then grasped as tightly as possible between the hands, and the left index finger pushes the small terminal cratchet. The movable ring is thus set free, and separated by action of the right thumb. Pushing forward the catch of the male blade then suffices to disengage the cratchet from the notch in which it is fixed. The movable ring is then permitted to fall back on the blade of the forceps, and is fixed by pushing back the small corresponding cratchet. The forceps is then manipulated as an ordinary forceps, and is found in the position shown in Fig. 123.

had at first seemed to be satisfactory." This statement absolutely proves, of course, that if I had noticed hemorrhages after simple crushing with my lever forceps, it was because I had cut the broad ligaments after crushing, without application of either fixed forceps or ligatures.

If, on the other hand, we wish to leave the adnexa, and cut between them and the uterus, it is not even necessary to crush the broad ligament with a powerful clamp in a position in which there are no important vessels, inasmuch as the section is practised within the utero-ovarian arterial

areole. We then leave the adnexa in the abdominal cavity. At the Moscow Congress, where, after my three preliminary séances of operations—and a long communication on my procedure in hysterectomy—I insisted very specially on the employment of my lever forceps-clamp, which I there presented as a new instrument, and explained all these points. The following is a brief summary of that portion of my communication:

"Within the past few weeks it has become possible, with the help of the instrument which I have the honour to present to this Congress, to amputate the uterus without ligature or forcipressure of any vessel. Formerly Terrillon had perceived that the uterus could be, as it were, torn from the broad ligaments without appreciable escape of blood. Some American surgeons extirpated the uterus by scraping away its tissues with a kind of rasp, and without either pressure or ligation of the broad ligaments. This procedure is but a realization of the well-known hæmostasis of a limb torn off by violence, or the linear *écrasement* of Chassaignac. My instrument, which may be designated as a *casotrite* forceps, acts in a much better way. While the *écraseur* compressed the arteries on a narrow line only, my forceps ruptures the internal and middle tunics, and compresses the two leaflets of the external coat, as I have had the honour of demonstrating to those of the members of the Congress who assisted at my operations at Dr. Modlinski's clinique, and in Dr. Warneck's hospital service; and this is effected in such a way that hæmostasis is secured for arteries of the calibre of the uterine. It then sufficed for detachment of the whole inferior segment of the uterus to fix my forceps in position for about a minute as high as possible on each side of the neck, and then to cut between its jaws and the uterus. Nothing bled. The whole organ, with the adnexa, is then drawn to the vulva. With another application of the instrument I crush the upper border of each broad ligament, and if I use forcipressure or ligation, it is rather for the purpose of fixation at the bottom of the vaginal wound—whether by leaving small forceps fixed in position, or by closing the peritoneum by suturing *en masse*—than with the object of securing hæmostasis properly so called. This procedure prevents the pedicles, which have been drawn into the vagina in the course of the operation, from returning too far into the abdominal cavity."

Since the date of the Moscow Congress I have applied the crushing process, by forceps clamp with lever, in thyroidectomy, in nephrectomy (in which my method reduces the pedicles to mere cellular leaflets), and then in gastro-intestinal surgery.* By very gradual advances the use of my *écraseur* became generalized, and my method now conquers new adepts every day. I have even been copied, and with small enough success besides; so that I can recommend some of my colleagues to meditate on this appreciation by Broca of the "imitators" of Chassaignac: "He alone created the method of linear *écrasement*; he has popularized it, and conducted it to maturity. . . . Everything that they have since attempted in way of modification of his method has led to deterioration only, and not to perfecting." Now, my method presents no similarity whatever to that

* Cong. Fr. de Chir., October, 1897.

of Chassaignac, except in the power of the instruments. His object and mine were entirely different. Chassaignac's principal aim was the division of the tissues; the chain of the *écraseur* replaced the cutting instrument, and produced but a very imperfect hæmostasis. My forceps are not instruments of exeresis; they were not made for the division of tissues, but for the simplification of hæmostasis by leaving only fibro-cellular tissues remaining in the pedicle. Very often the grasping of the cellular tissues of the vessels, and the folding back of the internal and middle tunics, suffice to effect their closure; but in places where secondary hæmorrhage would be formidable (thyroidectomy, nephrectomy, castration, peritoneal operations) I place, as an additional measure of security, a fine silk ligature in the furrow made by the jaws of the forceps. The period of operation is thus considerably curtailed, as I apply but three or four ligatures where fifteen or twenty had formerly been necessary. The hæmostasis is also much more secure, as the vessels are already almost completely obliterated by the folding back of the internal and middle coats, so that the ligature is brought to bear on the external coat only. This method is very advantageous in all operations in which division of large pedicles is necessary—notably in case of the omentum. The adoption of crushing in the surgery of the gastro-intestinal tube offers the same advantages. Here the very friable tissues—mesenteric fat, muscular and mucous strata—are ruptured, and slip upwards and downwards from the jaws of the forceps; so that nothing remains in their grasp but the serous membrane and the cellular coat of vessels of some appreciable calibre. Thus the ligature *en masse* which is applied in the course of the groove made by the forceps secures simultaneously temporary occlusion of the lumen of the intestine and hæmostasis.

The numerous applications which this method has received in a relatively short time, and the excellence of the results obtained, combine to place my new instruments of hæmostasis, especially my *écraseur*, in the first rank of the recent conquests of the surgeon's arsenal. Chassaignac's *écraseur* and Maisonneuve's *serre-nœud* were destined for division only of tissues; it is for this reason that they were defective. The intern assistant of the institution passed the night in arresting the secondary hæmorrhages. Their application to supracervical hysterectomy was, however, excellent, inasmuch as no more was demanded from those instruments than they were there capable of effecting. They did not divide; they strangled. My instrument is an excellent one, because I demand from it only that which it is capable of realizing—the reduction of large pedicles to their cellular-fibrous skeletons and the definitive hæmostasis of arterioles only.

Mode of Action of the Linear *Écraseur*, of the "Serre-Nœud," and of the Galvanic Loop.—It may be useful to return for a few moments to the subject of Chassaignac's *écrasement*, in order to show the reader that, in spite of the similarity of the substantive term, my method of instantaneous crushing is by no means derived from Chassaignac's procedure, which was first applied by its author nearly sixty years ago. I have already referred to his first memoir, published in 1855, with the title, "De l'*Écrasement Linéaire*," and the survival of this term over such coinages as *surco-*

tripsie, histotripsie, etc. The first instrument substituted by Chassaignac for the unsatisfactory *serre-nœud* was in the form of an articulated chain, in place of the metallic thread, provided with an alternating to-and-fro movement. The original type did not present this alternating motion; its chain was rolled on a cylinder furnished with a catch. The final model was presented to the Société de Chirurgie on September 20, 1854. This instrument, with its double catch, was superior as a hæmostatic agent to the *serre-nœud* of Maisonneuve. Those two instruments acted in a somewhat similar way—by slowly bringing the tissues grasped into a narrow tunnel, in which they were divided after gradual elongation. The cellulo-fibrous tissues were the last to give way. But the jointed links of the chain of the *écraseur*, with their alternate movements to right and left (Chassaignac tightened by a notch every half-minute), compressed the tissues more effectively than did the metallic thread of the *serre-nœud*, which had not that to-and-fro movement. Thus the *écraseur* gave more constant results in hæmostasis in case of arteries of a certain calibre. Surgeons who have used this instrument often know, nevertheless, that its action is not always uniform. The operation should be conducted very slowly, especially towards the close. At the beginning the *écraseur* produces a simple constriction of the tissues; then it pediculizes the mass. The chain traces a deep furrow in the process of its to-and-fro movement, which shortens the active loop by some millimetres every time. The pressure increases with the narrowing of the ring, and the tissues give way more or less quickly according to their resisting power; those first to yield are the inner and middle coats of the arteries, the muscular tissues—smooth and striated—and the adipose tissue. The mucous membranes are also divided with facility. The skin resists long, and makes a jagged wound, which cannot heal by immediate union. The partisans of this procedure advised previous division with the bistoury. Tendons and aponeuroses required a bevelled chain for final division. The large arteries, surrounded with loose cellulo-fibrous tissues, are closed nearly as in torsion—by the folding back of the internal and middle tunics, and by the yielding of the outer before final rupture. The folding-up of the inner coats is, however, less complete than after torsion, which may be practised on the free end of the vessel.

Many secondary hæmorrhages have been observed after the methodical use of the *écraseur*. Chassaignac himself reported a grave case of this kind after amputation of the tongue. Great care had been used; the chain was advanced by a notch every two hours, and the operation was completed only at the end of twenty-four hours.* Legouest and Pasturel, Boyron and Demarquay, Nott, Campbell, etc., reported similar cases. The galvanic loop, which was in great favour in Paris some fifteen years ago, divided only certain tissues without hæmorrhage. It prevents that from small vessels better than the *écraseur*, but it cuts arteries of some calibre without obliterating the lumen. Even torsion, which folds back the two inner arterial tunics for a distance of many millimetres—is not it, too, in-

* *Arch. Med.*, 1855.

sufficient in some cases! The results of all those methods of hæmostasis depend very much on the nature of the tissues. The *écraseur* completely obliterates arteries of a certain calibre—only when the vessel is healthy and surrounded by tissues susceptible of compression and agglutination before the section has been completed. Obliteration of the larger arteries remains more than problematical, in spite of the crumpling and folding back of the inner and middle coats. This fact has been demonstrated experimentally on the carotid of the ox.

Both Chassaignac and Maisonneuve specially deceived themselves in thinking that their procedures obliterated the orifices of the veins, and thereby prevented "resorption of pus." The walls of the veins were little suited to this method of closure, which takes effect only in arteries of small calibre, and furnished with a thick and resistant cellular sheath. Those inconveniences of linear crushing were but too evident. I have seen Chassaignac's *écraseur* used in Rheims by my former masters—Galliet, Decès, and Gentilhomme; at Paris by Verneuil and by Després. The *serré-noud* of Maisonneuve, as modified by Cudrat (the *serré-noud* with movable head) was then frequently used by Péan in abdominal hysterectomy. The surgeons who applied to ovariectomy, and then to hysterectomy, the process of strangulation of the pedicle by aid of the *écraseur* or the *serré-noud*, always contented themselves with reducing the volume of the pedicle, and in a way preparing it by such energetic constriction for the final division. The metallic ligature was left in position, and the pedicle fixed outside the abdomen. Separation took place in two or three weeks, and the wound closed by secondary union.

I had made, in 1889, in order to be able to suppress the employment of the *serré-noud* or elastic ligature in supra-cervical hysterectomy, a clamp furnished with a recoil spring, which could be left in position. I habitually substituted a strong silken ligature on removal. The separation of the pedicle, when the constriction had been sufficient, was as soon effected as with the *serré-noud* or elastic ligature. All those methods, which are at the same time complicated and imperfect, should soon give place to a simpler and more rational technique.

The Author's Instantaneous Écrasement differs absolutely from Chassaignac's Linear Crushing.—The term *écrasement* was employed *unsuitably* enough by Chassaignac, in 1855, to designate his method of section of tissues by the action of an articulated chain. He obliterated the vessels by *dragging*, and not by crushing; and the chain of the linear *écraseur* was incapable, despite the slowness of the operation, of securely obliterating arteries of any considerable calibre, when instead of being surrounded by fibro-cellular tissues capable of sustaining a drag, the vessels were embedded in friable tissues without any cohesion. Chassaignac simply perfected Maisonneuve's method. His instrument, thanks to the mode of action of its articulated chain—by the alternating to-and-fro movement of the double catch—like the working of a real saw, was able to divide tissues too resistant for the metallic loop of Maisonneuve's *serré-noud*. Chassaignac's *linear* *écraseur* divided the tissues or strangled them on a surface of 2 1/2

3 millimetres only in width. Thus *écrasement*, when *linear*, confounds itself with *section*.

Accordingly, there is no real analogy between the mode of action of *Chassaignac's instrument* and the effects realized in the use of my various forms of *écraseur*, which do *not cut*—these instruments acting in reducing the thickness of the interposed tissues by a very considerable pressure—and agglutination, over a width of 6 to 10 millimetres, of the leaflets of cellulofibrous tissue which alone remain between their jaws. Adipose, muscular, and elastic tissues are found completely crushed between the jaws of the



FIG. 128.

1, 2, 3, Forceps with great multiplying power. 4, 5, Écraseurs: small and large models, instrument; and the cellulofibrous lamella, which alone are susceptible of bearing this pressure of 500 to 2,000 kilogrammes, without laceration, are agglutinated in a few moments to a stratum of the thickness of from $\frac{1}{4}$ to $\frac{1}{2}$ millimetre. This organic stratum, when sufficiently dehydrated, takes on in a few minutes a hard and almost horny consistence.

Present State of the Method of Instantaneous Écrasement. The procedure which I presented to the International Congress at Moscow in 1897 has not been appreciably modified since that date. The method consists of the reduction, in some seconds, with the aid of powerful instruments, of the

144 SURGICAL THERAPEUTICS AND OPERATIVE TECHNIQUE

tissues in which we want to secure haemostasis to the thickness of a thin card, or even to that of a leaf of paper. The instrument expels from between its jaws the friable and unresisting tissues, allowing but the cellulo-fibrous structures to remain, and especially the external coat of arteries of some size. The instruments used for this procedure are— (1) Three types of very powerful ringed forceps, the first of which (Figs. 128 and 129, 1) has a multiplying lever of 7 units for the arterioles and venules. This forceps can be used as a needle-holder for the fine needles. The other two, still more powerful, have a multiplying power of 8 units. The jaws are so

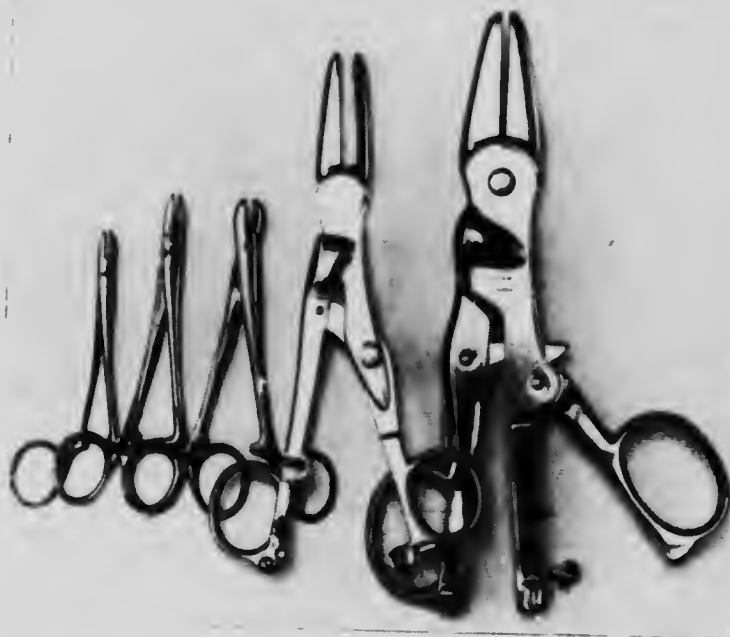

FIG. 129.

1, 2, 3, Forceps with great multiplying power. 4, 5, Escraseurs: small and large models. The forceps and escraseurs are all open.

constructed at the ends as to slide the ligature over the vessel. This sliding of the ligature may be facilitated by giving the forceps three or four brusque half rotations on its axis while the assistant tightens the first knot. The forceps is then removed, and the assistant completes the fastening of the first knot and makes the second, taking care to bring it directly up to the first knot without dragging on the thread. There are two forms of this short-jawed forceps—the first, which I have had gilt, for the purpose of ready recognition, is used for lateral ligation of the veins (Figs. 128 and 129, 2); the second is used in ligation of the deep arteries (internal maxi-

lary, uterine, etc.) (Figs. 128 and 129, 3). The latter form bears at the extremities claws which are intended for firm prehension of the vessel, it is that most frequently used, and it serves in all those cases in which the ligature is not applied to a great vascular trunk or in its immediate neighbourhood. We use exclusively, wherever there is danger of laceration of the vessels, the first type of forceps with short jaws—so valuable more especially in lateral ligation of the large vessels, such as the axillary and internal jugular, and in ligation of the collateral channels which have been divided at some millimetres from the principal trunk.

Those forceps with great multiplying powers crush the tissues in such a way that when the instrument is removed after two or three minutes the crushed portion is reduced to a cellulo-fibrous lamella, impressed with the striations of the jaws, and actually transparent. This cellulo-fibrous lamella may present a horny consistence if the tissues are sufficiently resistant. The internal coats of the arteries of moderate calibre are folded back above the level of the jaws of the forceps, and hæmostasis is assured. The coats of the venules are closed up by the pressure to which they have been subjected.

It is not, however, necessary to believe that the employment of these instruments can wholly supersede the use of ligatures. Hæmostasis depends on—(1) Folding up of the internal and middle coat of the arteries; (2) compression of the cellulo-fibrous tissues that have been agglutinated by the constricting force of the instrument, which in these models amounts to 400 kilogrammes at least, between the hands of a person of average strength. It is easy to test their hæmostatic power in the course of a morning's operations.

Apply one of these forceps to the arterioles and venules of the subpubic region, for example; then, some minutes later, in another operation, on the facial artery. The hæmostasis of the facial artery will be perfected in five or six minutes, while at the close of fifteen to twenty minutes' of compression the subpubic venules and arterioles bleed on removal of the forceps. Those arterioles have, in fact, almost no middle coat as compared with the facial; and the subpubic venules are surrounded with only a cellulo-adipose tissue devoid of resistance, and which does not undergo agglutination under the pressure of the instrument. In practice I usually tie the facial artery as a measure of security. The crushing process succeeds where torsion does. It is simpler than torsion, for it requires only the placing of the instrument and leaving it in position for some minutes; *but in no case* would I advise attempting hæmostasis without ligature in operations where there was risk of secondary hæmorrhage.

I had concluded this study of the instantaneous crushing of small vessels when I applied myself, in 1896, to study the means of securing hæmostasis without ligature in the broad ligaments and the great vascular pedicles. Simple écrasement not seeming to me to be quite secure, I tried successively attrition of vessels with various types of *forceps à glissière*, and then compression combined with heat. With this object I had various instruments constructed—notably a forceps in which one of the jaws, isolated by a

non-conducting substance, could be heated either with a platinum wire connected with a source of electricity or by some other method. The results of those trials did not satisfy me. Agglutination of the cellulo-fibrous tissues was less satisfactory than that produced by my large power forceps. Those experiments have since been repeated by other surgeons, notably in America and in Belgium.

My double-lever *écraseur* was in course of construction, and M. Collin had given me a trial of the first model. The double lever gave a multiplication of 20 units, representing a compressive force of 2,000 kilogrammes from one of 100 kilogrammes applied by the two hands combined. This instrument reduced the spermatic cord, the broad ligaments, and the pedicles of ovarian cysts, to the thickness of a delicate card; and such pedicles could, after the lapse of five or six minutes, be divided without risk of immediate hæmorrhage. The first essays were very satisfactory. Soon I observed, in an atheromatous old woman, a hæmatoma of the broad ligament produced by secondary hæmorrhage from the uterine artery. That hæmatoma suppurated and necessitated the adoption of vaginal drainage. The process of crushing without ligation was finally judged!

My first *écraseur* had a longitudinal furrow along the inner aspect of the jaws, which was meant to leave a small plug in the mouth of the arteriole, formed by the middle and inner tunics in the midst of the zone of agglutination. This was suppressed in the final model.

I abandoned the method of crushing without ligation the more readily as the instrument required to remain in place tightly closed, to give an appearance of security, during an interval three or four times longer than was required for the application of a ligature. *Loss of time, want of security*—such were the arguments which decided me to reject the instantaneous crushing, as a general method of hæmostasis, and to combine the action of the new instruments and the ligature. The process was displayed, as already mentioned, at the Congress of Moscow. *Instantaneous *écrasement**, as I said and demonstrated on that occasion, should not be regarded as a methodic procedure of hæmostasis; for, if application of the *écraseur* suffices in cases of pedicles of cellulo-fibrous structure, it proves unreliable in many other cases; atheromatous arteries are severed on account of the friability of the middle coat, veins cannot well be obliterated but when surrounded by tissues sufficiently resistant to undergo agglutination between the jaws of forceps, and thus compensate for the insufficiency of their own coats. Thus we see in laparotomy, on forcible crushing of the omentum, that arterioles and venules are completely torn; and this rupture specially occurs when there is superabundance of adipose tissue. Close the *écraseur* completely, leave it five minutes in position, divide below the jaws, remove the instrument—you have immediate hæmorrhage.

The most conclusive experiment can be made without danger in the operation of castration. Crush the spermatic cord with the large *écraseur*, maintain the compression for five minutes, then divide the spermatic cord at the lower border of the crushed surface. The cord is found reduced to a lamella of $\frac{1}{4}$ millimetre in thickness, and so thoroughly dehydrated that



FIG. 130. APPENDICITIS.

Crushing of the mesentery of the appendix with the small cerasaur, which is worked with one hand like an ordinary forceps.

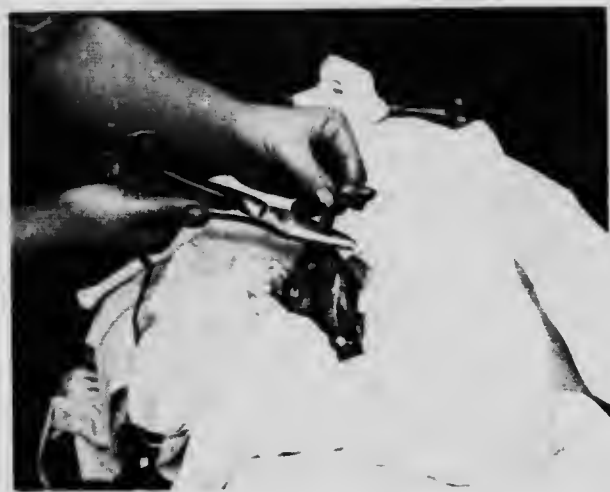

FIG. 131. APPENDICITIS.

Crushing the appendix with the small cerasaur. The ligature will be placed in the furrow made by the instrument.

it presents a horny consistence to the touch. But tease out the tissues thus agglutinated by rolling between the fingers or rubbing with a sterilized compress. They readily yield, and blood appears. This experience proves that the adoption of crushing without ligation would be a grave error in laparotomy, as the efforts of vomiting would by degrees separate the agglutinated tissue and the cellular tunic of the bloodvessels by producing within the lumen an increase of pressure calculated to provoke secondary hemorrhage.

All those particulars had been studied and finally determined by an experience of more than one year in my clinics at Reims and at Paris, before the Congress of 1897. Since that date I have generalized the practice of instantaneous crushing in nearly every department of operative procedure—nephrectomy, thyroidectomy, all the great abdominal operations—particularly those on the stomach, intestine, and gall-bladder—hemostasis of the umbilical cord, etc. The most remarkable results are assuredly those gained by application of the new method in resection of the pylorus and of the intestine. In these it is not a matter of securing hemostasis, but simply of rupturing the mucous and muscular coats of the digestive tube while preserving their serous investment. When we know how to manipulate the instrument, the walls of the stomach and intestine are reduced in some seconds to their simple serous tunic, and ligation *en masse* then suffices to obliterate the lumen. The stump is cauterized, and excluded from the peritoneum by a double purse string ligature. The effect closure of the stomach or intestine in three or four minutes, while fifteen to twenty were spent in the previous procedures. The upper and lower ends being thus obliterated, we re-establish the permeability of the canal by a lateral entero-anastomosis, which requires twelve to fifteen minutes. Thus there is a total expenditure of twenty to twenty-five minutes for a resection of the intestine, and of forty five minutes for a pylorotomy combined with a gastro-enterostomy. In case of extensive resection of the intestine, when we have to divide the mesentery for a considerable distance, the procedure of instantaneous crushing eliminates the complicated period of application of chain sutures, those voluminous and multiplex ligatures being replaced by the formation of three or four minute stumps, tied separately with fine silk threads. The *cérascur* expels the mesenteric fat, while respecting the peritoneum and the external tunic of the vessels. The result is that a very fine silk thread suffices to secure the hemostasis of a huge pedicle, on which eight or ten ligatures would formerly have been placed in a linked chain.

Thus the procedure of instantaneous crushing is not a mode of hemostasis, and should not be regarded as such. Accordingly, it would be inaccurate to apply the name of "angiotribe" or "vasotribe" to instruments of which one of the principal uses is the crushing of the muscular and mucous coats of the digestive tube, in which the question of realization of hemostasis does not present itself at all. The method should not be regarded as sufficient for hemostasis except in operations without gravity, where we have to deal with arteries of moderate calibre, with a thick and resistant external coat, and a middle one of the most pronounced elastic type. In all

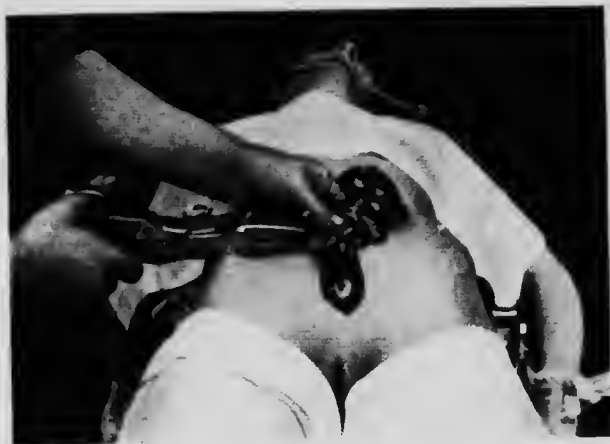

FIG. 132. —MANIPULATION OF THE LARGE ÉCRASEUR.
The instrument, manipulated as an ordinary forceps, is being placed on an adnexial pedicle.

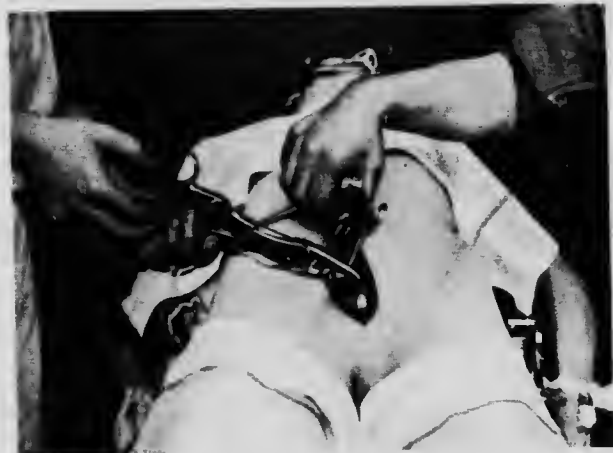

FIG. 133.
The forceps has been closed, as in case of an ordinary forceps. The multiplying lever is disengaged by pushing with the right thumb the crotchet which held it fixed to the female blade.

grave operations, without exception, this instantaneous crushing should be made to serve only for diminution of the volume of vascular pedicles, and *it is necessary to combine it with the ligature*. This mixed method is a step in advance of the former procedures of hæmostasis, since, thanks to the rapid crushing, which requires but a few seconds, the ligatures are often reduced to a very small number, and may be made of very fine silk thread. This lodges in the groove formed by the instrument, and the prominent exuberance of the tissues left above it on section of the pedicle assures the fixation.

Reduction of the number of ligatures and of the volume of the ligated pedicles; reduction of the diameter of the silk threads, which are thus now readily encysted; notable diminution of the duration of operations—such are the advantages of the method of combined *instantaneous crushing with ligature*. These results can be obtained only with good instruments and a sound technique. In case of arteries of medium calibre, we must employ the forceps with great multiplying power shown in Figs. 128 and 129 (1, 2, 3). Those forceps, left in position for some minutes, secure hæmostasis of the small arterioles, as Péan's forceps formerly did; but the effect is more secure by agglutinating the cellular coats of the vessels, while the inner ones are curled up within the lumen, as in torsion, while the hæmostatic forceps used by Péan, of which the multiplication was seldom more than two units, were too weak to procure the expected result. The ringed hæmostatic forceps (Figs. 128 and 129 1, 2, 3) have a multiplication of 7 to 8 units, and the effort made by the hand produces between their jaws a pressure of 100 to 1000 kilogrammes. The small form of the *cérasseur* (Figs. 128 and 129 4) multiplies twelve to fifteen times, according to the angle of divergence of the blades, the pressure applied at the level of the rings. This instrument has the advantage of being suited for manipulation with one hand. The large form (Figs. 128 and 129 5) which requires the use of both hands, gives a multiplication of 20 units, and realizes for a pressure of 100 kilogrammes at the rings a compressive force of 2,000 kilogrammes at the extremities of the jaws, and one of 4000 at the median position. This instrument can be manipulated so rapidly and with so great precision that the surgeon perceives in his palm the intensity of the effect realized and can limit this to even a constrictive force of 20 to 30 kilogrammes. It is, of course, evident that a certain amount of practice and a great delicacy of hand are requisite for realization in five or six seconds with an instrument of such power a compression made to vary between that of 10 and 2,000 kilogrammes. Therein precisely lies the quality of my *cérasseur*, and my method would assuredly have been more rapidly adopted if certain colleagues had not preferred resigning themselves to the repeated construction of similar instruments, instead of accepting what I placed before them after methodical study and rational experimentation. Thus it is that *cérasseurs* have been constructed which were by no means suitable for the required purpose. Stomachs and intestines have been torn up, bad results attained in cases corresponding to those in which I secured excellent ones, and my method unfavourably criticized, because the critics had neither been able

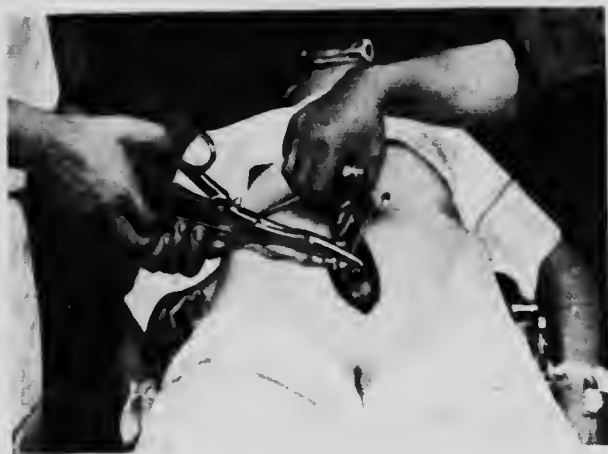

FIG. 134.

The lever, formed by the mobile ring of the female blade, is separated by the action of the thumb, till the tooth which terminates the small arm becomes engaged in the notch of the catch which is hinged on the median part of the male blade of the cerasaur.

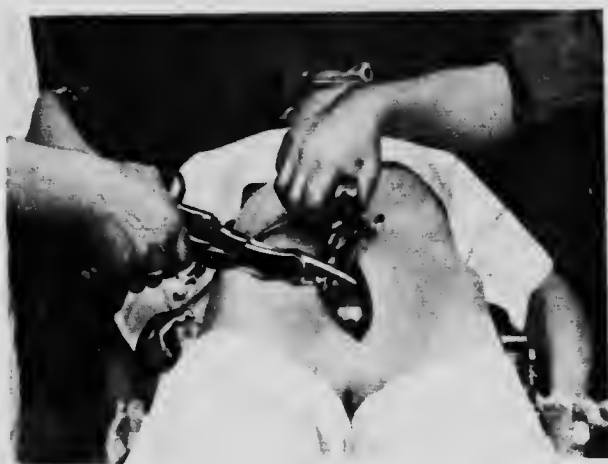

FIG. 135.

The rings are compressed with the full force of both hands. The cerasaur works like an ordinary forceps, with a multiplication of 2 units; and as the secondary lever gives a multiplication of 10 units, the multiplication of effort realized in approximation of the two rings, when the tooth of the nut of the lever is caught in the notch of the catch of the female blade, is exactly 20 units.

to understand or apply it. But the question is now decided. The method which I demonstrated in 1897 has now become a general one, applicable to nearly all the major operations, and destined to reduce to minimum thickness such pedicles as require ligation. The instruments which I had constructed for the purpose can secure hæmostasis in vessels of small calibre and with resistant cellular tunic when left in position for some minutes. And the great pedicles should be tied after being crushed with sufficient precaution to avoid inconsiderate laceration if they happen to be somewhat friable. And the process of instantaneous crushing is that to be chosen in operations on the digestive canal (resection of the pylorus and removal of intestinal neoplasms). This procedure, *combined or not with ligation*, is applicable, as already stated, to most major operations. It has the special advantage, too, of abridging their duration considerably, and it also diminishes the risks by reducing to a minimum the volume and the number of both the pedicles to be tied and the ligatures absorbed or encysted.

Application of the Method of Instantaneous Écrasement.

1. HÆMOSTASIS OF THE SMALL VESSELS. The application of Forceps 1, 2, and 3 (Figs. 128 and 129) for some minutes assures definitive hæmostasis of arterioles of elastic type and of small vessels surrounded by connective tissue of a certain resistance. But if the vessel bleeds when the forceps has been removed, we tie it with a fine silk thread. Forceps 1 (Figs. 128 and 129) serves for hæmostasis of the arteries of the dura mater; and, in lateral ligation of the veins, for prehension and ligation of the collateral veins near the principal trunk. Forceps 3 (Figs. 128 and 129), which is the strongest, is clawed for prehension of the deep vessels. It should be used only on vessels of medium calibre, and at a sufficient distance from the great arterial and venous trunks for avoidance of the risk of laceration. This is the instrument of selection in current hæmostasis. The lever gives a multiplication of 7 to 8 units, as contrasted with that of the older ringed forceps of Charrière and of Péan, which gave a multiplication of but $1\frac{1}{2}$ to 2.

2. INSTANTANEOUS CRUSHING OF PEDICLES. The smaller *écraseur* (Figs. 128 and 129, 4), which is worked with one hand, suffices in resection of the mesentery, in operation for appendicitis, and, indeed, whenever the pedicle to be crushed is small and of little resistance. It also suffices for crushing of the small intestine, and its ligation *en masse*. The large *écraseur* (Figs. 128 and 129, 5) should always be used when the pedicle is strong and resistant. It is employed every day in my operation theatre, both in general surgery, as in thyroidectomy and nephrectomy, and in abdominal operations, such as resection of the stomach and intestine, ovariectomy, and hysterectomy (abdominal and vaginal). As already stated, it reduces the volume of a pedicle to the possible minimum. The ligature is carefully placed in the furrow which it forms.

Hæmostasis of Vessels of Varied Calibre. *The efficacy of torsion and of simple compression depends on the proportion between the thickness of the walls of the arteries and the calibre of the enclosed vessel; and, secondarily, on the*

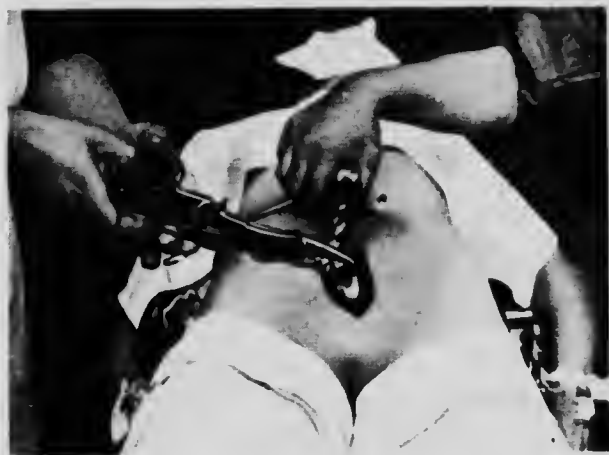

FIG. 136.

The ring of the multiplying lever, which had been momentarily fixed when fully closed by pushing back the little lateral crotchet, is again disengaged by the action of the right thumb, which acts on the same bolt in the opposite direction.

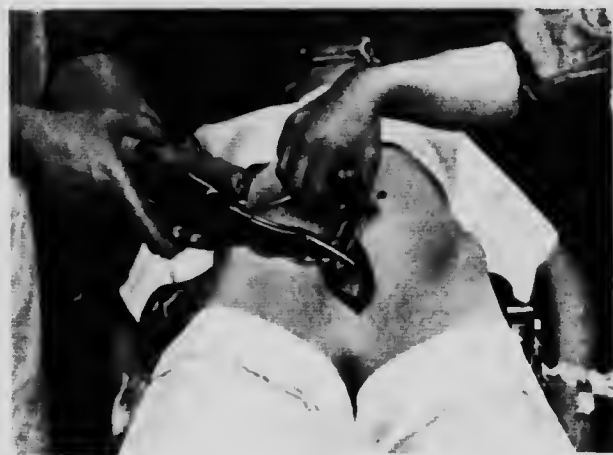

FIG. 137.

The movable ring is raised, and the catch of the male blade is moved with the left thumb so as to disengage the multiplying tooth of the short arm of the lever.

nature of the surrounding tissues. Arterial haemostasis depends, before all things, on the proportion between the thickness of the middle tunica and the calibre of the vessel. Thus, the experimental data of the haemostasis carried out on small animals, and even on dogs, are valueless when we would apply the results to surgery. The aorta of a dog is often of smaller calibre than the femoral or axillary artery of a man. The femoral artery of the dog is obliterated very easily. When we add to those anatomical conditions of haemostasis the extreme plasticity of the plasma of the blood in that animal, we cannot help being astonished at the fact that surgeons have drawn conclusions from their experiments on the dog which are used to decide their practice on the human being.

The facial artery, of which the calibre is pretty constant, is the largest of which the obliteration can be considered secure after crushing with a forceps of the type shown in Fig. 106, and it is necessary in its case that the tunics should be perfectly healthy. If the vessel does not bleed during the suturing of the skin, the closure is satisfactory. In fact, when the plug formed by the folding back of the internal and middle tunics towards the heart is insufficient, the intravascular pressure does not fail to detach it, and blood appears. Two or three successive applications of the forceps then prove insufficient, and the blood still flows, which indicates the application of a ligature. When an artery is susceptible of obliteration, it is closed at once. Nevertheless, it is prudent to leave the forceps in position for some minutes, so as to secure intimate adhesion of the two layers of the cellular tissue, which are thus united in the form of a thin and nearly desiccated lamella.

The experiments on dogs and such small animals are valueless on account of the facts that their largest arteries are too small, and the ratio of the thickness of their walls to the diameter of the lumen (taking into account the measurement of the former at each side of the latter) approaches 1 to 1 (unity pretty nearly), while in case of the human aorta it is about 1 to 3. The structure of the periarterial tissues must also be dealt with. Their plasticity and cohesion under the effects of crushing may compensate for the insufficiency of the vascular walls. Thus, the crushing of the branches of the middle meningeal artery in the thickness of the dura mater with a forceps of great multiplying power secures haemostasis; while, on the other hand, before the vessel becomes embedded in the dura mater, a ligature, or even plugging of the foramen rotundum, is necessary for the purpose. The arterioles of the omentum and, in general, all those embedded in celluloadipose tissues, should be tied with a fine silk thread, even after the fixed application of a strong forceps for some minutes, because the pressure of the forceps acts on the walls of the vessel only, and those of the arteries of the omentum and of celluloadipose tissues generally are very thin and friable.

Crushing of Isolated Vessels. The sole application of the short jawed forceps to arteries of medium and small calibre may be regarded as a valuable means of haemostasis for superficial vessels and others of slight importance. Such are the vessels which Péan taught us to close by temporary applica-

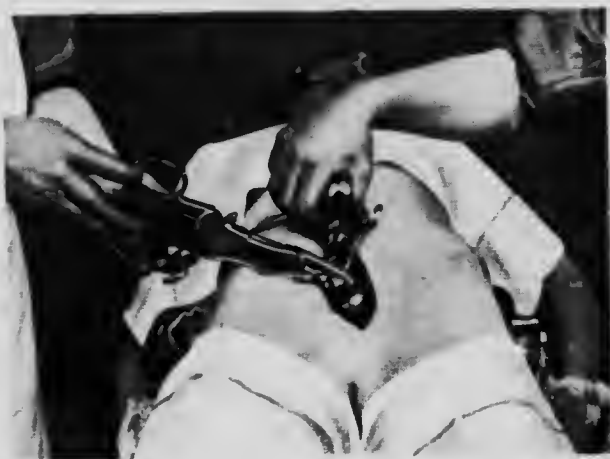

FIG. 138.

The movable ring is here represented taken back and set free, while the right index-finger fixes it anew to the female blade by pushing the foot backwards. The craseur is then manipulated like an ordinary forceps. The surgeon separates the blade with one hand, and disengages the pedicle which has just been submitted to instantaneous crushing. There remains but the application of a fine silk ligature.

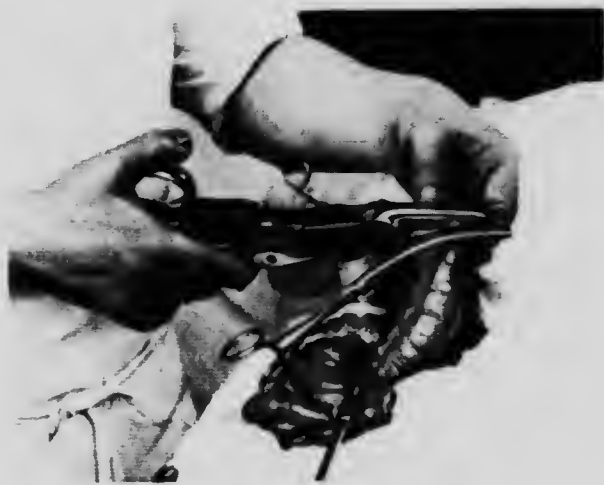

FIG. 139. RESECTION OF COLON.

Crushing of the ascending colon between two Doyen's coprostatic forceps with elastic blades.

tion of his oval-jawed forceps, which sufficed for the purpose, in spite of their weakness and ill construction. For larger vessels, and especially in peritoneal operations, I formally recommend the ligature. The best thread is of dressed silk. The crushing process permits the use of much finer threads than those formerly used. Let us now compare the treatment of the different vessels.

In practice, the vessels which are opened in course of operations may be ranged in ten categories: (1) Capillaries which habitually cease to bleed after some minutes of compression; (2) arterioles and venules of less than 1 millimetre in diameter; (3) those of 1 to 3 millimetres in diameter; (4) arteries of calibre greater than that of the radial and facial; carotid, subclavian and both internal and external iliac arteries; (5) the principal arterial trunks (aorta, introminata, common iliacs); (6) peripheral veins of medium diameter, inclusive of those of the broad ligaments; (7) the great venous trunks (from external iliacs and axillaries to the great visceral collecting trunks); (8) the sinuses of the dura mater and the middle meningeal arteries; (9) the arteries and veins of the pia mater and of the cerebral substance; (10) the intracerebral arteries and sinuses.

HÆMOSTASIS OF CAPILLARIES.—Hæmorrhage which is exclusively capillary rarely presents any danger. If the oozing resists some minutes of pressure with dry sterilized compresses, or those soaked in sterilized solution of artificial serum at 60° C. (140° F.), it is very probable that the bleeding surface presents some small arterial or venous orifices. Temporary plugging with dry sterilized compresses is the procedure usually adopted against capillary hæmorrhages. In some cases these must be left for twenty-four hours, even up to forty-eight hours, under a compressive dressing. Temporary suture of the skin over this dressing may be useful in difficult cases. If the hæmorrhage has been considerable and prolonged, the wound is drained and sutured on removal of the plug. On the surface of the intestine, of the stomach, mesentery, and certain viscera, capillary hæmorrhages may be arrested by application of the actual cautery (galvano cautery, or Paquelin's thermo cautery).

The same result may be attained by application, when practicable, of a purse-string suture, embracing the bleeding point, or a long suture with very fine silk applied with an intestinal suture needle. The cautery is applicable only when the tissues are indurated and friable. The procedures just mentioned should be adopted in preference whenever the tissues have sufficient pliability.

I tried in 1886, for hæmostasis of those small vessels, as well as those of visceral wounds (liver, kidney, spleen), the use of a jet of superheated air obtained by enclosing the knife of Paquelin's thermo-cautery in a hollow cannula pierced at the end. I applied in some cases Gaiñe's apparatus and method, which projects air at a temperature of 600° C. (1112° F.). But the results were not satisfactory.

2. HÆMOSTASIS OF THE ARTERIOLES AND VENULES OF LESS THAN 1 MILLIMETRE IN DIAMETER. The flow from those small vessels usually ceases by itself, especially if pressure be maintained on the bleeding surface with a sterilized compress. If the arterial jet is of some dimensions

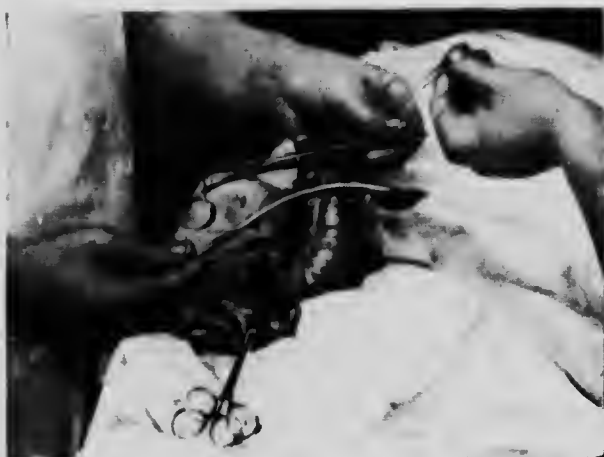

FIG. 140. RESECTION OF CECUM.

Ligature *en masse* of the ascending colon in the groove made by the jaws of the retractor.



FIG. 141. RESECTION OF CECUM.

Section of ascending colon, preparatory to ligature *en masse*.

the vessel may be pinched up with a short-jawed forceps. This instrument (with a multiplying power of 7) crushes small vessels, and secures hemostasis in some minutes. Some arterioles and venules of the subcutaneous or visceral fat may be securely obliterated by this brief crushing process. When we have to deal with subperitoneal vessels, they should be pinched up, again, and tied with a fine silk thread.

Forceps with superheated jaws, prepared by contact with a point of the thermocautery, or combination with a galvanic loop, of which I studied the functions and effects of application in 1886, have not given me any results superior to those of simple compression with my short-jawed forceps. Hemostasis of some venules with thin walls, and not sustained by cellular tissue, is often more difficult than that of arterioles of the same calibre, of which the occlusion is secured by instantaneous crushing, which causes folding back of the middle and internal times.

3. ARTERIES OF 1 TO 3 MILLIMETERS IN CALIBRE, AND THE CORRESPONDING VEINS.—Those arteries, among which we class the uterine and the uterovaginal, lingual, facial, internal maxillary, middle meningeal, etc., may usually be thoroughly ligated by application of a strong short-jawed forceps for four to five minutes. That which I usually employ for the uterine, internal maxillary, and, in general, in those regions where the artery can be crushed without the necessity of including the neighbouring tissues, is a short-jawed forceps furnished with claws, and of which the multiplying power is 8 (Fig. 106). This gives at the extremity, for a force of 50 kilogrammes applied at the rings, a compressive power of 400 kilogrammes. In the case of arteries of considerable calibre I cannot, however, recommend temporary crushing for a very short time except in regions in which secondary hemorrhage would not be actually dangerous, and in vigorous subjects whose arteries are healthy and elastic. In cases where there is the least risk, and in all cases of peritoneal surgery, uterine, for example, it is necessary to place a silk ligature beyond the jaws of the forceps.

Application of Deep-Scaled Ligatures.—The jaws of my artery forceps have been so constructed as to make the ligature slide naturally, in proportion as it is tightened, over the extremity of the instrument. The ligature is passed around the forceps, the first knot is pushed beyond the end by giving the instrument three or four rapid semi-rotations. These help to disengage the ligature, and we then tighten it while guiding each of the lateral halves on the extremity of an index finger. When the first knot has been secured, the assistant removes the forceps gently while the surgeon completes the closure. He then makes the second knot, and (preferably) a third, which is very easy to do with a little practice. To make a direct knot it suffices to change the ends of the ligature from one hand to the other. The second knot should be fully tightened by a single movement with the aid of both index fingers, while avoiding any pull on the loops and loosening of the first knot. Such is the only technique which secures the effective placing of deep ligatures: (1) Complete tightening of the first knot after removal of the forceps; (2) securing the second knot by a single movement.



FIG. 142. RESECTION OF CECUM.
Application of suture to intestinal stump outside the peritoneum.

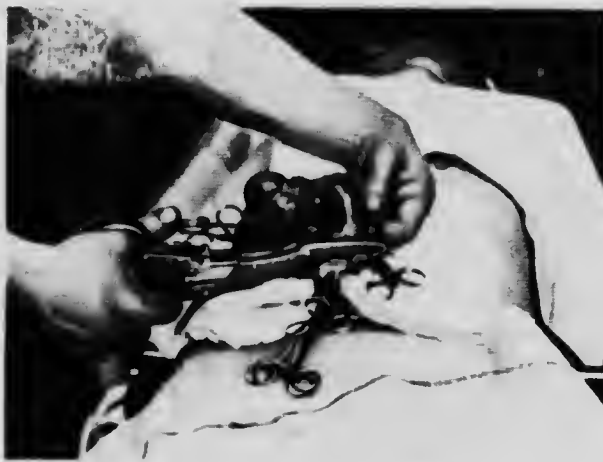

FIG. 143. RESECTION OF CECUM.
Crushing of terminal portion of small intestine.

Fixed Forceps.—When the induration or the friability of the tissues make ligature impracticable, a forceps should be duly placed and left in fixed position. In the case of small arteries this is removed at the end of twenty-four to thirty-six hours. In that of such arteries as the uterine and internal maxillary it is better to leave it for forty-eight hours. In most cases the satellite veins are tied with the artery. The facial vein should be tied by itself, and, like the facial artery, at both ends. Such should be the practice, too, in dealing with the arteries and veins of the wrist and hand.

4. HEMOSTASIS OF ARTERIES OF GREATER CALIBRE THAN THE RADIAL AND FACIAL, INCLUDING THE CAROTID, SUBCLAVIAN, AND INTERNAL AND EXTERNAL ILIACS. — While torsion has been employed with success for hæmo-

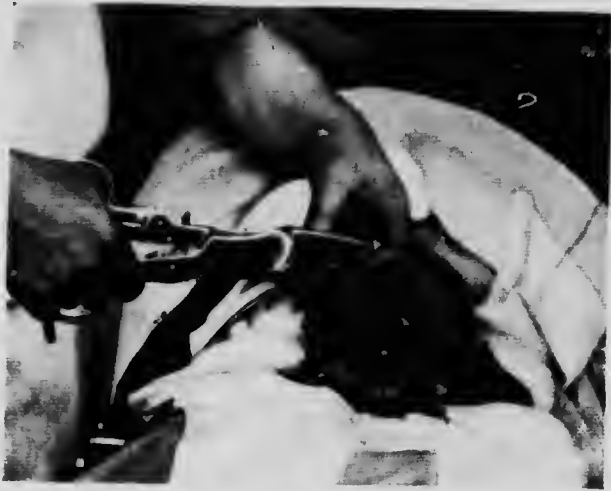

FIG. 144. PYLORIC TOMY FOR CANCER.
Crushing of the duodenum.

stasis of the brachial and femoral arteries, ligature alone is advisable in case of the arteries of which the calibre is much greater in contrast to what we find in arteries of smaller diameter than the radial than double the combined thickness of their internal and middle coats.

Torsion was an acceptable procedure in those days in which ligatures were themselves one of the means of infecting the field of operation. The practice of antisepsis placed the ligature in a secure surgical position as closely as possible to the vessel without intervention of the investing soft parts. Arteries may be tied up with their satellite veins. Single satellite veins of large size should be tied separately (popliteal, femoral, axillary). The vessel is seized with a strong arterial forceps, and the ligature is placed above it. The use of clawed forceps should be proscribed in case of the great trunks, veins, and arteries. I employ a silk ligature of medium thick-

ness. The finer forms of silk are encysted more easily. For the great arteries, such as the carotid, iliac, etc., it is prudent to double the ligature.

5. HEMOSTASIS OF THE PRINCIPAL ARTERIAL TRUNKS.—Ligature of the innominate, common iliac, and (as recently performed in America by Keen) the abdominal aorta are exceptional cases. Such experiments have hitherto given but temporary results.

Arterial Suture.—On the other hand, we obtain excellent results by suturing the arterial wound with curved needles adapted to arteriorrhaphy, of great tenuity, and armed with silk of No. 1,000. For this procedure I have had a special needle-holder forceps made.

6. HEMOSTASIS OF THE PERIPHERAL VEINS OF MEDIUM CALIBRE, INCLUSIVE OF THOSE OF THE BROAD LIGAMENTS.—Hemostasis of the superficial veins of the neck and of the subcutaneous ones of the limbs is indispensable for the prevention of those insidious secondary hemorrhages which occur by venous reflux—for example, after vomiting—in cases in which the field of operation had been absolutely dry at the time of suturing. Those veins are tied with fine silk. In application of the ligature, the short-jawed forceps is used; especially the strong one, which is furnished with claws.

Ligature of veins of medium calibre is indispensable in abdominal surgery—in the mesentery and in the broad ligaments—where the most minute venous orifice should be sought for and carefully obliterated. For the smaller veins, and especially those of the mesentery and on the vaginoperitoneal fold, the purse-string suture may prove preferable to the ligature. If there be any necessity for leaving a forceps fixed in position, it should be allowed to remain for forty eight hours.

7. HEMOSTASIS OF THE VENOUS COLLECTING TRUNKS.—As a general rule, wounding of the principal veins of the limbs is more serious than that of the corresponding arteries at the same level, for the collateral circulation is in the majority of such cases insufficient to secure the return of the venous blood towards the heart. Accordingly, we must act with great caution when removing a neoplasm adherent to the great venous trunks, of which a large wound might prove irremediable. Among the collective veins of the second order, the internal jugular alone can be ligatured without inconvenience, for the return of blood is easily carried on through the lateral sinus and the vein of the opposite side. I have frequently removed the internal jugular vein when adhering intimately, through a great part of its length, to a mass of tubercular glands. The two ends were tied with silk, or, indeed, with catgut. Wound of the internal jugular vein is, accordingly, much less grave than that of one of the other collective veins of the same calibre. It is easy to avoid the fulminating accidents of aspiration of air into the veins, which are far more exceptional than was formerly believed. It is nearly always possible to avoid making a large wound in the wall of a collective venous trunk—for example, by leaving behind the mass of pathological tissue which is immediately adherent to the external coat of the vessel. The tearing of an afferent vein at the seat of its terminal implantation is a more frequent accident. Those small wounds of the great veins are treated by *lateral ligature*, which gives excellent results in such cases.

The first care of the surgeon at the moment when blood appears is to make compression with the finger or with a sterilized compress. He then subsequently determines, by relaxing the direct compression, the point of issue of the blood, and the form and extent of the venous wound. We next deal with the question of the placing of the ligature. The great point here is to avoid enlargement of the opening in the vessel by trying to grasp it with unsuitable forceps. The form of instrument best suited to lateral ligature of veins is the forceps with short jaws, finely scored on the inner surfaces, and without terminal claws (Fig. 107), which I had constructed for my own use in 1897. When the edges of the opening are hard to grasp, the prehension may be facilitated by catching the vessel lightly with another forceps at a little distance above and below the orifice, so as to form a longitudinal fold. The short-jawed forceps is then used in such a way as to include in its grasp about 2 millimetres of the wall beyond the margins of the opening, and the ligature is then applied. It is important that it should be tightened by the first movement. The first knot is carefully made, and the forceps is removed at the moment of approximate completion of the closure so as to allow the index-fingers, which guide the respective heads of the ligature, to complete the closure. The second knot is then applied at once, taking care not to draw on the first. Both index-fingers can be used, so as to bring the second knot up to the first by a single movement, and without loosening the latter. A certain amount of practice is of course necessary for the skilful application of these ligatures, and we cannot advise young surgeons too much regarding the exercise of the same. It is rare indeed, when a first ligature has dropped off, not to find that the venous orifice had not been enlarged, and made more difficult to close.

Suture of Veins.—In case of venous wounds of extent too considerable for application of the lateral ligature, lateral suture of the wounded vessel must be adopted. Such suture is readily made, in case of the great venous trunks, with very fine round needles armed with the silk ordinarily used for intestinal suture; but it is still better to employ the extremely fine needles used in arteriorrhaphy. Two fine overlapping seams are arranged. During the process of suturing, the venous trunk should be compressed by an assistant both above and below the orifice.

I have many times recently had to suture both ends of the axillary vein, which had been torn throughout nearly its whole circumference, and with successful results. The sutures were applied at separate points, and then reinforced by suture of the investing fibrocellular sheath.

8. HEMOSTASIS OF THE SINUSES OF THE DURA MATER AND BRANCHES OF THE MIDDLE MENINGEAL ARTERY. Wounds of the sinuses of the dura mater are far from being irremediable, for obliteration of any one of them is without influence on the intracranial circulation. The hæmorrhage is usually arrested by plugging of the lumen of the sinus with a mass of aseptic gauze. It is in this way that we habitually treat those wounds of the lateral sinus which occur during erosion of the mastoid apophysis. Surgeons of the past century had invented, especially for the superior longitudinal sinus or branches of the middle meningeal artery, small compressors

furnished with a recoil spring, of which the inflected portion was introduced beneath the dura mater, while the external blade rested on the hairy scalp. Approximation of the two metallic blades compresses the vessel after the manner of action of my hemostatic forceps (Figs. 78 and 79). Those compressors were very useful when the old operation of trepanning with the crowned trepan was used. I have had constructed for my own practice a compressor which is applicable to any point on the cranial vault (Fig. 145). Now, when the use of the gouge-forceps permits us to enlarge an osseous breach in a few moments, it is always easy to expose the dura mater all around the wound in the sinns, and to close the latter with a double ligature passed through its wall with a needle above and below the opening. In a case of large wound of the lateral sinns I closed the orifice with the left index-finger until I had exposed the dura mater all around the perforation. Having succeeded in arresting the bleeding with the aid of the gouge-forceps and the application of two forceps, one above the wound and the other below, I then left the forceps in position for three days, taking care to prevent their displacement by the firm application of a voluminous dressing. When the wound of the sinns was small, I have sometimes closed it by fixing the dura mater to the skin by a narrow seam of three or four points of suture.

The middle meningeal artery and its branches are easily tied with a silk ligature passed beneath the vessel with a curved needle. It is necessary to take care in passing the needle not to wound the vessels of the pia mater. Often, indeed, we have found sufficient, in case of branches of the middle meningeal artery, the application for three or four minutes of a forceps with short jaws, of the type recommended in lateral ligation of the veins (Fig. 107). The trunk of the middle meningeal may be obliterated in the parietal stage of its course, where it lies in a complete osseous canal, by crushing the wall of the canal with one of these forceps; or at the level of the foramen rotundum by crushing the artery with the extremity of a strong grooved sound. We can also embed in the foramen rotundum a small pointed fragment of bone detached from the margin of the breach in the cranial wall.

9. HEMOSTASIS OF THE CEREBRAL VESSELS. — Hemostasis of the arteries and veins that groove the brain substance is practised in resection of the epileptogenic cortical centres and in the removal of cerebral tumours. The friability of the walls of those vessels and of the tissues which support them most frequently contra indicate their prehension with a hemostatic forceps; which must be manipulated, when its employment is essential, with a very light hand. The best procedure is to pass a loop of fine silk under the vessel at the suitable point with a round needle, and adjust the ligature at a short distance from the place at which the vessel is, or is about to be, divided. Hemostasis of the afferent veins of the superior longitudinal sinns, which tear under pressure of the finger in exploration of the brain along the falx cerebri, is usually established at the close of a few minutes



FIG. 145.
DOYEN'S COMPRESSOR FOR THE PERIPHERAL SINUSES OF THE DURA MATER IN THE OPERATION OF TEMPORARY CRANIOTOMY.

by collapse of those vessels and coagulation of the blood. If not, the margin of a sterilized compress can be introduced beneath the dura mater.

10. HÆMOSTASIS OF THE ARTERIES AND VEINS OF THE OSSEOUS TISSUES.—Bones contain, in certain localities, arteries and veins of some size. The walls of those vessels are always very thin, and their relations with the surrounding eburnated tissues do not permit the practice of ligature. Hæmostasis is accordingly obtained by crushing or folding of the investing osseous tissue or by plugging. I have never had occasion to employ wax. Compresses used in plugging should be pressed, even piled on, with force in the osseous cavity, and tightly bound down with a compressive dressing. In dealing with a pericranial hæmorrhage—for example, from a large opening in the sinuses of the diploe in the adult—the compresses used may be bound down

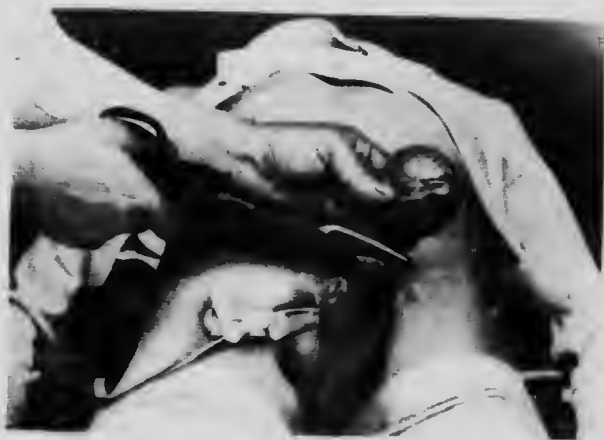

FIG. 116. CRUSHING OF THE SPERMATIC CORD.

on the subjacent osseous vault with an elastic band, which is left in position for forty-eight hours. In some cases we can use the compressor represented in Fig. 115.

Crushing of Vascular Pedicles. Whether we have to deal with the spermatic cord, the pedicle of a goitre, a nephrectomy, or an omental resection, the manipulation of the crasaur is the same. The pedicle is seized and fixed between the jaws of a long curved forceps, the convexity of which looks towards the point at which the crasaur is to be applied. The instrument is then applied like an ordinary forceps, and closed sufficiently to permit locking of the lever. The movable ring at the end of the lever, which should be placed uppermost, and towards the thumb of the right hand, is now freed by pushing the small bolt already described, and separated by the thumb. When the crotchet of the nut of the small arm of the lever is fixed in the notch of the movable piece, the two ring-handles are forcibly approximated. The terminal bolt of the female blade is closed if we wish to prolong the action of the forceps for a certain time. In

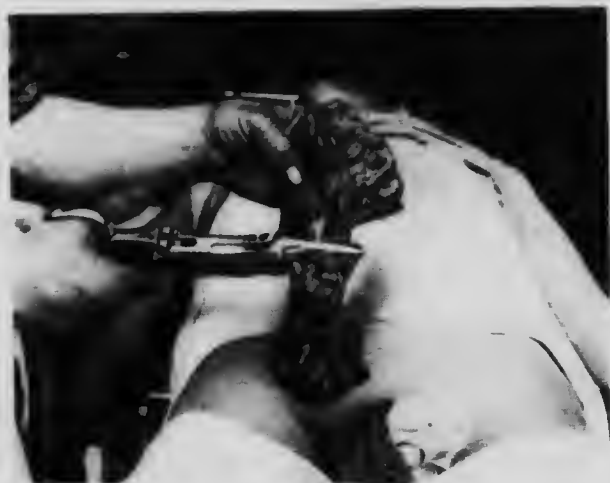

FIG. 147. CRUSHING OF A LARGE ADHERENT PEDICLE OF AN OMENTAL HERNIA.

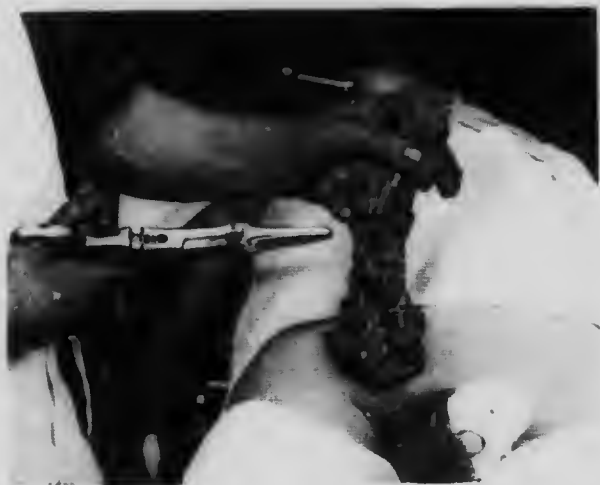

FIG. 148. PEDICLE PRODUCED BY THE ECRASTER, WHICH HAS BEEN HELD IN POSITION, TIGHTLY CLOSED, FOR TWO MINUTES.

dealing with the omentum—and, in general, with friable tissues—we must avoid sudden closure of the ring-handles, and close tightening. The precise advantage of my *écraseur* is that it allows the operator to estimate admirably with the palm of the hand the manner in which the tissues are yielding between its jaws. Being an instrument at the same time delicate and powerful, we can obtain from it the most varied effects if we only learn how to manipulate it with intelligence, and as each particular case requires.

A confrère has blamed my method of ligature *en masse* of the stomach, after application of the *écraseur*, with having led in one of his cases to the disastrous result of rupture of the stomach; but he neglected to indicate in his critical observation the fact that he had not used my *écraseur*, but one of its worst imitations, and that he had closed the instrument abruptly and

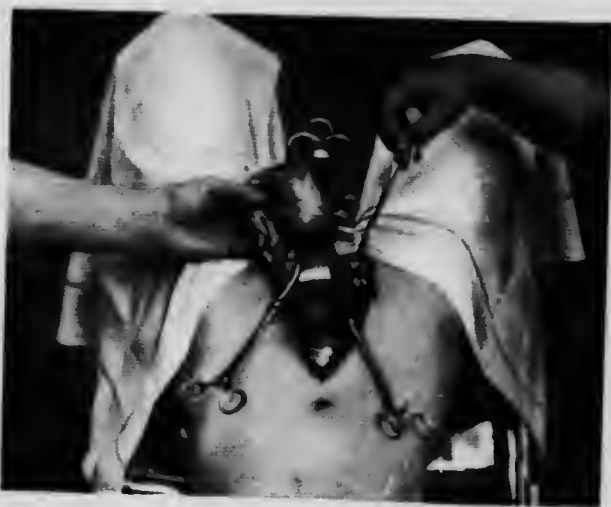


FIG. 149. TORSION OF AN ADRENAL FEAT PEDICLE, FOR FACILITATION OF CRUSHING AND LIGATURE.

completely, without even foreseeing that he should not treat the coats of the stomach like the broad ligament. This application of immediate crushing in the surgery of the stomach, intestine, and biliary passages, has, indeed, been one of the natural consequences of my experience in reduction of large vascular pedicles. The *écraseur* presses away from between its jaws the muscular and mucous strata, and allows the fibrocellular tissues alone to remain. On these the ligature is then applied. In like manner, in case of the great vascular pedicles, it eliminates from the furrow which it makes all the muscular, elastic, and adipose tissues, and leaves but the fibrocellular stratum which surrounds the vessels and the cellular walls of the latter. The process of rapid crushing enables us to realize for all great pedicles, on which enormous chain ligatures were formerly applied, ligatures which were defective because they were "mediate"—the application

of the direct or "immediate" ligature of the vessels, which has evermore been recognized as the best. I shall examine, in connection with each of the special operations, the mode of application of the *cérasseur* suitable to each case.

Methodic Torsion of Flat Pedicles, to facilitate Crushing and Ligature.—

From the time of my vaginal hysterectomies in 1887, I had the idea of placing fixed forceps from above downwards on the broad ligaments, which were thus twisted on their axes. I soon generalized this practice, with the object of facilitating forcipressure or ligature of all flat vascular pedicles. I make the pedicle, still attached to the tumour, undergo a *semi-rotation*, or *complete rotation*, on its axis. I compress it with a curved forceps. In most cases I also crush it immediately above; then I place the ligature in conditions peculiarly favourable, as the thread is no longer exposed to any effort of trying to restore the primitively flattened pedicle to a cylindrical form, such cylindrical outline having been restored by the torsion.

INSTRUMENTS AND APPARATUS.

(Constructed according to the Designs of the Author.)

I must here make the prefatory remark that many of my instruments and numerous details of my operative technique have been reproduced in other works without any indication of their origin. The reader will,



FIG. 150. AUTHOR'S TONGUE FORCEPS.

I trust, do those indiscreet procedures the justice of remembering that all the instruments which bear my name were new at the time of their appearance, and that the figures reproduced in other books, without indication of their origin, have been borrowed, either from my publications or from the various editions of Collin's catalogue. In my *Technique* will be found all the indications necessary to determine what is mine and what I have borrowed from my predecessors.

Tongue Forceps. This forceps is constructed so as to hold the tongue without wounding it. It may also be used as an artery forceps in ligature of deep-seated arterioles. The jaws bear three claws in the form of a mouse's teeth.

Gag for Use during Extraction of Teeth, either Incisor or Molar. This gag, which is manipulated like an artery forceps, is so constructed that it remains firmly fixed in position so long as the rackwork is locked. There are two forms—one for the incisors (Fig. 151), the other for the molars (Fig. 152). These instruments are used in all operations on the bucco-pharyngeal cavity.

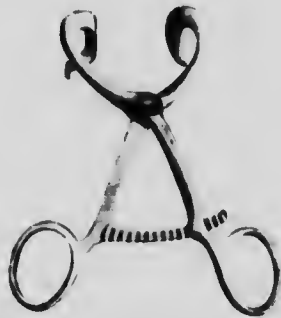

FIG. 151.—AUTHOR'S GAG, WITH RINGS AND RACKWORK: MEDIAN (INCISOR) TYPE.




FIG. 152.—AUTHOR'S GAG, WITH RINGS AND RACKWORK: LATERAL (MOLAR) TYPE.

Gag with Sliding Catch. This gag is mounted on a sliding plate, which is freed at the required moment by pressing a lateral catch (Fig. 153).

Retractor of the Labial Commissures. This instrument is composed of two valves, which are introduced at the labial commissures, each to be fixed to the corresponding portion of the other by means of a chain of little



FIG. 153.—AUTHOR'S GAG WITH SLIDING CATCH.

balls of which the extremity is fixed in an appropriate notch. If it is necessary to remove the dental arches at the same time, we introduce the separator of molars represented in Fig. 155 from the side on which the crenated valve has been placed (as indicated in Fig. 152). It will be noticed that this retractor of the labial commissures has been constructed on the lines of my subpubic retractor (shown in Figs. 233 and 234). The non-



FIG. 144. AUTHOR'S REFRACTOR FOR THE LABIAL COMMISSURES.



FIG. 155. AUTHOR'S REFRACTOR FOR THE LABIAL COMMISSURES, WITH APPLICATION OF THE BING-HANDLED REFRACTOR FOR MOLARS (FIG. 152).



FIG. 156. AUTHOR'S REFRACTOR FOR THE LABIAL COMMISSURES, WITH APPLICATION OF THE GAG WITH SLIDING CATCH.

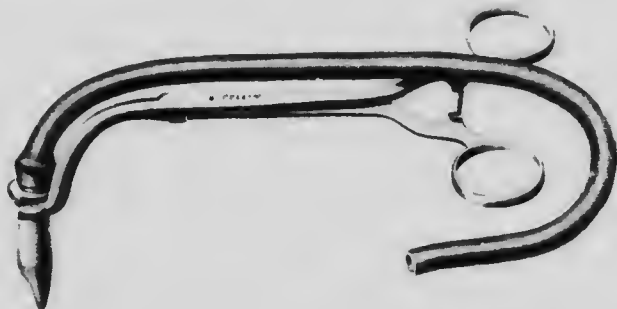


FIG. 157. LARYNGEAL CANNULA AND CANNULA HOLDER FORCEPS FOR TURBAGE OF THE LARYNX AND DIRECT ANESTHESIA DURING OPERATIONS ON THE BECCAL CAVITY AND THE PHARYNX.

erated valve may also be applied alone; it is retained in position by hooking the ball-chain on the corresponding notch of the molar gag (Fig. 152).

Apparatus for Tubage of the Pharynx during Operations on the Face.

This apparatus is formed of a ferrule of oval contour, which is introduced behind, at the base of the tongue, and is connected for the purpose of chloroform anaesthesia with a Trendelenburg funnel. This apparatus passes easily into the pharynx on account of the rigidity of the metallic tube at the end. It is enough to carry it behind the base of the tongue and



FIG. 158. ARRANGEMENT NECESSARY FOR OPERATION UNDER THORACIC HYPERPRESSURE.

press it downwards for a few centimetres. The notch, which is placed on the anterior aspect of the pharyngeal section, should be located exactly at the level of the orifice of the larynx. The pharynx is plugged with a mass of gauze at the level of the base of the tongue.

Apparatus for Tubage of the Larynx and Direct Anæsthesia. This apparatus enables us to avoid the entrance of blood into the air passages and to conduct the process of direct anaesthesia during operations on the buccal cavity and the pharynx.

Apparatus for Thoracic Hyperpressure and for Artificial Respiration. I will here describe in succession:

1. The apparatus for hyperpressure, to be used in operations on the pleural cavity.
2. The hermetic mask and pharyngeal tubes.
3. The bellows for artificial respiration.



FIG. 159. ACCIORD'S APPARATUS FOR HYPERPRESSURE.

The hermetic mask will be noticed.

1. APPARATUS FOR HYPERPRESSURE. —This apparatus consists of a receptacle for compressed oxygen, *O*, furnished with a stopper, and ending in a cylinder, to which are attached an india rubber balloon of 5 litres capacity,



and a manometer. From this the oxygen is distributed to the lungs, either pure or mingled with anæsthetic vapour. This procedure is effected by the action of a rotatory distributor, which forces the oxygen to traverse a space filled with those vapours when the handle is pressed. Suitable valves prevent the reflux of vitiated gases escaping from the lungs. To the tubulature which passes into the lungs is attached a vertical tube, which plunges into a receptacle filled with water, that can be displaced vertically. We thus obtain the hyperpressure, calculated in centimetres, by varying the plunge of the safety tube. Between the distributor *D* and the valve *S* is placed a lateral stopcock and another is placed near the receptacle *F*. Between the latter and the plunger tube is interposed a stopcock, which is closed when we want to use the bellows for artificial respiration.

2. HERMETIC MASK AND PHARYNGEAL TUBES.—The hermetic communication of the tubulature of the receptacle *F* with the lungs is secured

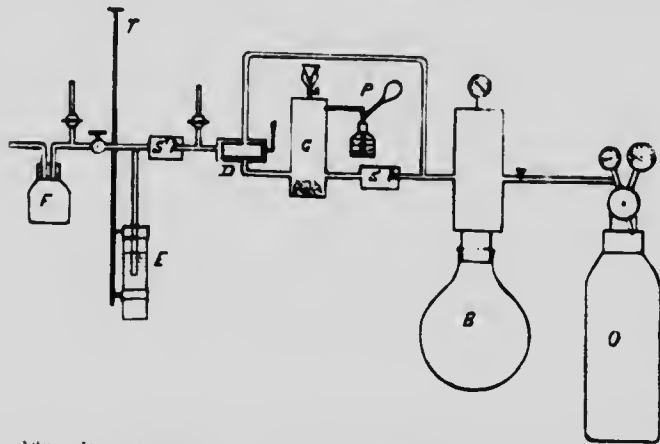


FIG. 160. DIAGRAMMATIC SKETCH OF DOYEN'S APPARATUS FOR THORACIC HYPERPRESSURE.

by an india-rubber mask, furnished with an elastic tube opposite the level of the mouth, and ending on each side in four very strong india-rubber bands, which are made to cross at the back of the head, and then tied—one pair on the forehead, and the other on the chin. The coaptation of the apparatus is secured by pneumatic pads. Two orbital openings provide for estimation of the corneal reflexes. In order to avoid obstruction of the glottis with the base of the tongue during the anæsthesia, tubage of the pharynx is effected with an angular tube, furnished with a pharyngeal limb, which is previously fixed to the india-rubber tubulature of the mask. This apparatus for pharyngeal tubage is easily introduced if we separate the jaws with a Doyen's gag, and draw the tongue forcibly forwards with a silk thread. We can plug the upper part of the pharynx with a compress above the tubage apparatus, so as to prevent the entrance of saliva. The pharyngeal tube is connected to the tubulature of the receptacle *F* by a

thick-walled india-rubber tube of 12 to 15 millimetres calibre. A truncated, conical bucco-nasal mask can also be used, which should be adjusted for the adaptation of pharyngeal tubes.

3. **BELLOWS WITH DOUBLE ACTION, FOR ARTIFICIAL RESPIRATION AND FOR INSUFFLATION OF THE LUNGS.**—The bellows consists of a parallelepipedon of wood, open at both ends, in the interior of which a partition, *C*,

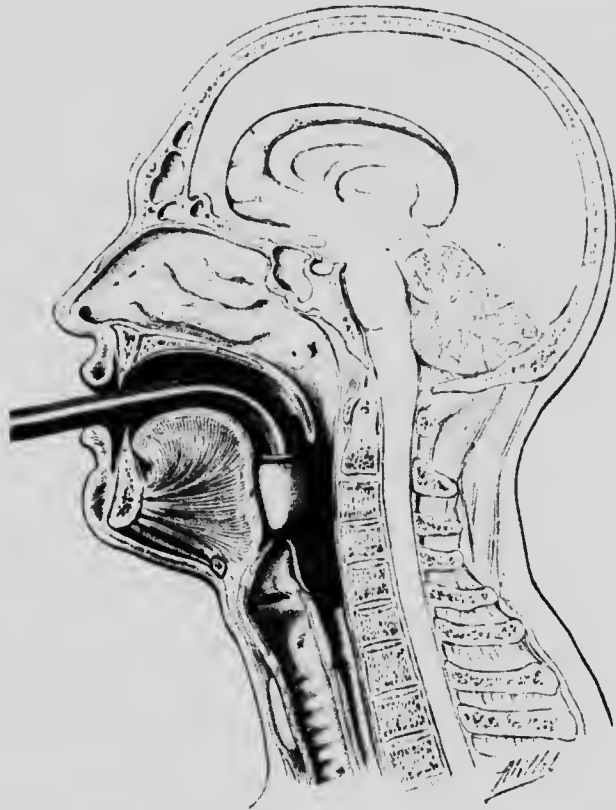


FIG. 161.—DIAGRAMMATIC SKETCH SHOWING HOW THE PHARYNGEAL TUBE, WHILE SHUTTING OFF THE PHARYNX COMPLETELY, PERMITS THE PATIENT TO BREATHE FREELY AT THE SAME TIME.

is moved by a handle, *P*, while between this partition and the upper and lower walls are disposed four pumping apparatus. Those pumps are furnished with valves which open—in the two bellows of the left side, from below upwards; and in the two of the right side, from above downwards. Thanks to this arrangement, by holding in one hand the handle attached to the lower wall of the box, and in the other the handle fixed to the movable panel, we can, by a to-and-fro movement, alternately fill and empty

174 SURGICAL THERAPEUTICS AND OPERATIVE TECHNIQUE

the two upper bellows, while emptying and filling the two lower ones. By separating the two handles, we aspire the vitiated air of the lung into the lower bellows of the left side; at the same time the pure air which had been aspirated during the preceding course into the upper bellows of the right



FIG. 162. — AUTHOR'S HERMETIC MASK.



FIG. 163. — AUTHOR'S BELLOWS FOR ARTIFICIAL RESPIRATION: FIRST STAGE.
This movement permits aspiration of the vitiated air.

side is driven into the lower one of the same side, and the vitiated air which during the same time had been driven from the left lower bellows into the upper one of the same side, is expelled externally. The separation of the handles having been carried out to the full, they are then approximated.

The pure air from the right lower bellows is thus pressed into the lung, while a corresponding quantity of pure air is aspirated into the upper bellows of the same side, to be used in the next pulmonary insufflation. The vitiated air which has just been aspirated into the left lower bellows passes into the upper one of the same side, whence it will be expelled externally by the next separation of the handles. The respiratory capacity can be varied at will—that is to say, the capacity of the bellows—by graduating the separation of the two handles.

This bellows can thus be used to maintain artificial respiration in physiological experiments, or for artificial respiration in the newly born foetus, or in case of asphyxia, by making the right upper tubulature communicate with a reservoir of oxygen.



FIG. 164. AUTHOR'S BELLOWS FOR ARTIFICIAL RESPIRATION: SECOND STAGE.
Oxygen or atmospheric air is blown into the lungs.

Combination of Function of Anæsthetic Apparatus with Facultative Hyper-pressure.—With this apparatus anæsthesia can be produced without hyper-pressure. It is enough to place the respiratory apparatus in direct communication with the receptacle *F*, with or without tubage of the pharynx, through the medium of a mask or a cornet hermetically applied to the face. The patient, when the distributor is at rest, inhales pure air, and rejects the vitiated outwards through the tube *E*, which should dip 2 or 3 centimetres under water. When the assistant to whom the process of narcosis has been entrusted wishes to administer anæsthetic vapour, he requires but to turn the handle of the distributor so far as to half or completely open the orifice of admission for the vapour contained in the receptacle *C*. Hyper-pressure is realized by elevating the tube *T* so that the tube for expiration is plunged to the requisite depth. This depth can be regulated during the operation so as to herniate the lung externally, or to retract it, according to the desire of the operator.

This apparatus secures the rejection of the vitiated air coming from the lung, as well under hyperpressure as under normal pressure.

Artificial Respiration, with or without Anaesthesia.—When the respiratory rhythm becomes weakened, it suffices to close the stopcock of the principal tubulure situated between the receptacle *F* and the valve *S*, and adapt the pulmonary tubulature of Doyen's bellows to the lateral one near the receptacle *F*, while we adapt the opposite tubulature to the lateral one which

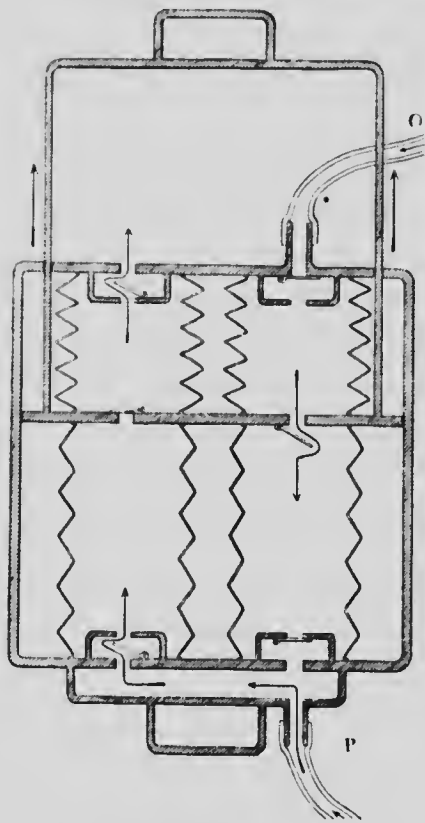


FIG. 165A.—DIAGRAM INDICATING THE PLAY OF THE VALVES DURING ASPIRATION OF VITIATED AIR.

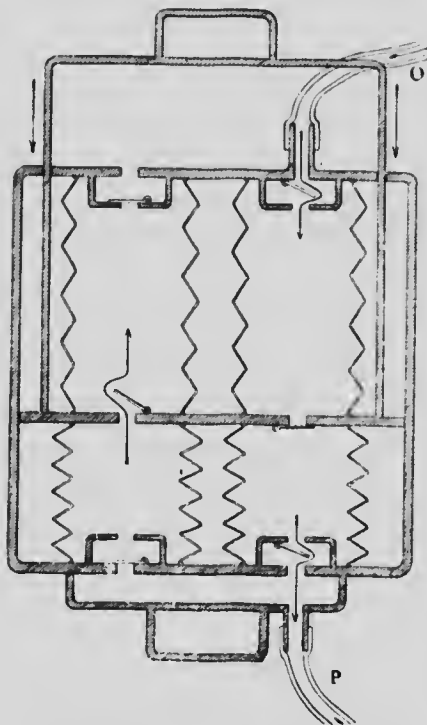


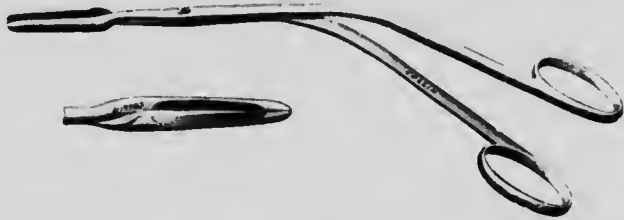
FIG. 165B.—DIAGRAM INDICATING THE PLAY OF THE VALVES DURING INSUFFLATION OF OXYGEN.

is placed between the distributor *D* and the valve *S*. The stopcocks of those lateral tubulatures are opened; it then suffices to manipulate the bellows in accordance with the normal respiratory rhythm to re-establish haemostasis. The anaesthesia can be kept up by manipulating the distributor *D*, as described above.

This bellows for artificial respiration is particularly useful when we

have to deal with a case of prolonged syncope; we can then use it alone by adapting it to the pharyngeal tube and making its tubulure *O* communicate with a reservoir of pure oxygen.

Gouge Forceps for Polypi of the Nasal Fossæ, and for Hypertrophy of the Inferior Turbinated Bone.—The use of these gouge forceps for extir-



FIGS. 166 AND 167. —AUTHOR'S GOUGE FORCEPS FOR POLYPI OF THE NASAL FOSSÆ. Hollowing out of the jaw, seen from below. This forceps is made in different models.

pation of polypi of the nasal fossæ and for abrasion of the inferior turbinated bone is very simple, and allows us to reach the most remote parts of the naso-pharyngeal space much more satisfactorily than with the *scire-naud*. Figs. 167 to 171 represent the jaws of different types of these forceps, of the actual size. The current form for ablation of mucous polypi is that shown



FIG. 168. SMALL FORM, FOR POLYPI OF THE MIDDLE MEATUS.



FIG. 169. MEDIUM SIZE, FOR DEEP-SEATED POLYPI.

in Fig. 166. This forceps can also be used for extraction of foreign bodies from the nasal fossæ. That shown in Fig. 170 has been specially constructed for operations on the superior meatus. That of Fig. 171 is used to extirpate by a single movement the whole exuberant border of the inferior turbinated bone—both mucous membrane and subjacent osseous support.



FIG. 170. SPECIAL FORM, FOR THE SUPERIOR MEATUS.




FIG. 171. LARGE FORM, FOR ABRASION OF THE FREE BORDER OF THE INFERIOR TURBINATED BONE.

Gouge Forceps for Adenoid Vegetations of the Pharynx.—This forceps, the curve of which has been calculated as that of the average mean of the naso-pharynx, enables us to extirpate adenoid vegetations by a single movement. They are made in three sizes. The jaws represented are of the actual size in Figs. 173, 174, and 175.

Forceps for Compression in Hæmorrhage from the Tonsils.—This instrument is made in two sizes—for children and for adults. One of the blades takes its point of support on the cutaneous surface of the cervical region;



FIG. 172. GOUGE FORCEPS FOR ADENOID VEGETATIONS OF THE PHARYNX.
There are three models.

the other is applied on the bleeding-point within the pharynx. The outer blade may also be utilized in the arrest of hæmorrhage from the internal jugular vein by direct compression.



FIG. 173.—GOUGE FORCEPS FOR ADENOID VEGETATIONS OF THE PHARYNX: LARGE MODEL.



FIG. 174.—GOUGE FORCEPS FOR ADENOID VEGETATIONS OF THE PHARYNX: MEDIUM MODEL.



FIG. 175.—GOUGE FORCEPS FOR ADENOID VEGETATIONS OF THE PHARYNX: SMALL MODEL.

Compressor for Hæmorrhages from the Carotid Region.—This compressor is applied after the fashion of the old-time bandage after bleeding from the external jugular vein (see Fig. 41). It secures hæmostasis by indirect com-




FIG. 176. COMPRESSION FORCEPS FOR HEMORRHAGE FROM THE TONSIL.
The smaller blade is introduced into the buccal cavity.

pression with a sterilized compress in cases in which the friability of the degenerate tissues is such as to preclude the application of either forceps or ligature (Fig. 177).

Raspatories for the Immediate Extirpation of Naso-Pharyngeal Polypi.—These raspatories, of which the curve has been calculated with the utmost care, enable us to detach the most voluminous naso-pharyngeal polypi from



FIG. 177.

This compressor is opened by unwinding the screw near the hinge. The two pads are placed at the appropriate points, and the apparatus is applied. The fixation is made doubly sure by tightening of the posterior screw, and, in front, by catching of the ball-chain in an appropriate notch.



FIG. 178.—AUTHOR'S OBLIQUE RASPATORY FOR OPERATION ON NASO-PHARYNGEAL POLYPI.



FIG. 179.—AUTHOR'S ANGULAR RASPATORY FOR OPERATION ON NASO-PHARYNGEAL POLYPI.

the basilar process in a few seconds—the ablation of which had previously been regarded as one of the most difficult of surgical operations. There are two models of this instrument.




FIG. 180.—AUTHOR'S BISTOURIES FOR OPERATIONS ON FISTULÆ.

These are five in number: two are bent at a right angle (1), (2); one with a rounded extremity (A), the other with a pointed extremity (B); one has a rounded blade, short, and slightly recurved (3).

Bistouries for Operation on Fistulæ.—These instruments are so produced as to suit the procedure of vivification by unlining, which is the one that I exclusively employ.

Hook-Jawed Forceps for Continuous Pressure.—This instrument is a forceps constructed for continuous pressure, of which the extremities are

slightly curved, and furnished with four very strong claws. It thus responds to the following indications:

1. Prehension and retraction of the lips of the wound of operation.
2. Fixation of sterilized napkins around the circumference of the wound.
3. Fixation of peritoneal compresses in laparotomy.



FIG. 181.—HOOK-JAWED FORCEPS FOR CONTINUOUS PRESSURE.

The ring at the extremity of the mitted blades provides for its use as a retractor.

When fixed on peritoneal compresses, this forceps never relaxes its hold. Accordingly, its use prevents all danger of straying of the compresses, and leaving them forgotten in the abdominal cavity.



FIG. 182.—AUTHOR'S DISSECTING FORCEPS, WITH OBLIQUE CLAWS.

Forceps with Nine Oblique Claws for Dissection, Straight and Curved.—

These forceps are furnished with oblique claws for the prehension of tissues; they are stronger and longer than the older forms. This type differs completely, both in the form and disposition of the claws, from the older varieties, which are known as "mouse-teeth."



FIG. 183.—AUTHOR'S DISSECTING FORCEPS, SHOWING THE OBLIQUITY OF THE CLAWS.



FIG. 184.—AUTHOR'S DISSECTING FORCEPS WITH CURVED CLAWS FOR STAPHYLOTRIPHY.

Ringed Forceps with Oblique Claws.—These forceps are intended for use in prehension of tissues and in suturing of the skin. They differ absolutely from Kocher's and Segond's forceps with "mice teeth" (see Figs. 93 and 99).

Needle-Holder Forceps with Short Jaws.—These forceps have the jaws excavated so as to enable them to function both as hæmostatic forceps and needle-holder for small needles.

Short-Jawed Forceps for the Large Veins.—These hæmostatic forceps, of which the inner surfaces of the jaws are scored in small quadrangles, are so constructed as to make the ligature slide on to the vessel; they are used in lateral ligation of the great veins, and in terminal ligation of vessels



FIG. 185.—AUTHOR'S FORCEPS, WITH RINGS AND NINE OBLIQUE CLAWS.



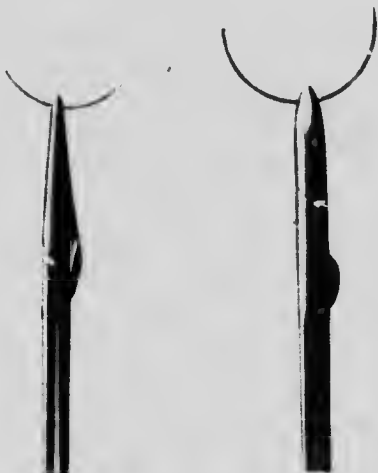
FIG. 186.—AUTHOR'S FORCEPS, SHOWING THE NUMBER OF THE CLAWS AND THEIR OBLIQUITY.



FIG. 187.—AUTHOR'S HEMOSTATIC FORCEPS, WITH SHORT AND EXCAVATED JAWS, WHICH PERMIT ITS USE AS A NEEDLE-HOLDER.



FIG. 188.—INNER SURFACE OF ONE OF THE JAWS OF THIS FORCEPS.



FIGS. 189 AND 190. PHOTOGRAPHS OF DOYEN'S NEW SPECIAL NEEDLE-HOLDER FORCEPS, FOR THE EXTREMELY FINE NEEDLES USED IN ARTERIOGRAPHY.

That on the right is used for intestinal sutures.

divided near the principal trunk. This form of the instrument is gilt, so that it will be impossible to confound it with the following.

Forceps with Jaws Short and Clawed.—These forceps, which are furnished with powerful claws, are suited to the operation of ligation of all vessels of medium and small calibre, and are so constructed as to facilitate the application of deep-seated ligatures, as in case of the uterine or internal maxillary artery.



FIG. 191.—AUTHOR'S SHORT-JAWED CLAWLESS FORCEPS, WITH FINELY QUADRILOBED INNER SURFACES OF JAWS, USED IN LATERAL LIGATION OF LARGE VEINS.

Forceps with Elastic Jaws.—In February, 1887, I designed forceps with elastic jaws for the purpose of supplying the insufficiency displayed by the long-jawed forceps of Péan, of Terrier, and of Richelot; in all of which the rigid jaws allowed the thick tissues, which we endeavoured to compress, to escape at the extremity. I had a first type constructed which was designed for the broad ligament, and of which the jaws, slightly concave,



FIG. 192.—AUTHOR'S FORCEPS WITH SHORT AND CLAWED JAWS, FOR ARTERIES.

meet first at the extremities, and approach one another in the intermediate part only as we tighten the rackwork. These forceps, the jaws of which are grooved longitudinally, have been almost universally adopted. This novel construction, devised by me, of forceps with long jaws which meet at the extremities before contact at the intermediate part, has been since applied to the old type of forceps used by Terrier and by Richelot.

of which the primitive form is now definitely abandoned. There are five forms of these instruments.

1. **FORCEPS FOR THE BROAD LIGAMENT; LARGE MODEL.**—This forceps, constructed in 1887 for the definitive forcipressure of the broad ligaments



FIG. 193.—FORCEPS WITH ELASTIC JAWS, GROOVED IN THEIR WHOLE LENGTH, FOR APPLICATION TO THE BROAD LIGAMENTS AFTER VAGINAL HYSTERECTOMY.

in the operation of vaginal hysterectomy, is very powerful; the jaws are grooved along their whole length. The length of the whole instrument is 27 centimetres.

2. **FORCEPS FOR THE BROAD LIGAMENT; SMALL MODEL.**—This forceps is 25 centimetres in length, and a little less powerful than the preceding.



FIGS. 194 AND 195.—FORCEPS OF 22 CENTIMETRES, WITH ELASTIC JAWS, INCISED AT THE BORDERS. THE SAME, WITH SLENDER JAWS.



FIG. 196.—FORCEPS FOR FIXATION ON THE PEDICLES IN VAGINAL HYSTERECTOMY.

These special forceps can be placed, instead of the long forceps with elastic jaws, on the pedicles in vaginal hysterectomy after application of the ligature. They may be removed at the end of twenty-four to forty-eight hours. The ligatures, which are left in place, secure the hæmorrhage.

It is intended for application either above or below the other, so as to supply the auxiliary pressure if one of the jaws of the larger instrument happens to break.

184 SURGICAL THERAPEUTICS AND OPERATIVE TECHNIQUE

3. CURVED FORCEPS 25 CENTIMETRES IN LENGTH, WITH SLENDER JAWS (Fig. 195).—This forceps serves for the prehension of small pedicles and the exploration and sweeping out of the uterine cavity.

4. FORCEPS 25 CENTIMETRES IN LENGTH, WITH JAWS CURVED THROUGHOUT.—This forceps is used in the prehension and ligation of pedicles. The *écraseur* is applied above the forceps, and the ligature falls spontaneously into the groove made by that instrument.



FIG. 197. LARGE CURVED FORCEPS 38 CENTIMETRES IN LENGTH.



FIG. 198.—AUTHOR'S FORCEPS WITH ELASTIC AND VERY SUPPLE JAWS, USED FOR TEMPORARY CLOSURE OF THE STOMACH OR INTESTINE.



FIG. 199. THE SAME FORCEPS WITH ELASTIC AND VERY SUPPLE JAWS OPENED, SHOWING THE PARALLELISM OF THE BLADES WHEN SEPARATED BY TISSUES OF A CERTAIN THICKNESS.

5. LARGE CURVED FORCEPS FOR USE IN CONDUCTING THE TOILET OF THE PERITONEUM.—This forceps, 38 centimetres in length, is used in the toilet of the peritoneum. It is very useful in carrying out the toilet of the peritoneum with sterilized compresses. In the operation of total abdominal hysterectomy it is introduced through the vagina, for the purpose of drawing down from the abdominal cavity into the vaginal canal the large compress which serves for tamponing.

6. CURVED FORCEPS WITH ELASTIC JAWS, FOR APPLICATION TO THE STOMACH AND INTESTINES.—This instrument, with its long elastic jaws, is intended for temporary obliteration of the lumen of the stomach or intestine, and the securing of coprostasis.

Short Curved Forceps for Passing Ligatures in the Operation of Deligation of Arteries.—This forceps, with slender jaws very much curved, is used in passing the ligature beneath the vessel in deligation of the large



FIG. 200. AUTHOR'S FORCEPS FOR THE LIGATURE OF DEEPLY PLACED ARTERIES. This instrument differs from that represented in Fig. 195 only by the curvature of its jaws.

arteries, such as the external carotid and the hypogastric. When the forceps is closed, without fixation of the rackwork, the jaws should be in contact along their whole length.

Forceps with Eccentric Rings.—This instrument enables us to seize organs not readily accessible—for example, the adnexæ in vaginal hyste-



FIGS. 201A AND 201B. AUTHOR'S FORCEPS WITH ECCENTRIC RINGS. The forceps being shown obliquely, the form of a single ring is figured.

rectomy—by sliding the instrument over the index-finger from the side opposed to the ring. This forceps is very useful for the ligature of deeply placed arteries of medium calibre (uterine, etc.).

Écraseur (Large Form).—This instrument, of which the power is immense, was constructed for the purpose of crushing large pedicles, after a series of experiments carried out in 1896. The large form, which multiplies twenty times the power applied by the hand, was presented at the International Congress at Moscow in 1897. This écraseur, of which the manipulation is very rapid, enables us to bring to bear in some seconds a pressure of 2,000 to 4,000 kilogrammes on the pedicle which it grasps.

As the pedicle usually encloses vessels of some importance, it is necessary to place a firm ligature of silk or catgut in the groove made by the écraseur (Fig. 202).

Écraseur (Smaller Form).—A reduced form of this écraseur has been constructed, for application to small pedicles, in operation for appendicitis, etc. It is worked with one hand (Fig. 203).

Author's New Écraseur.—This instrument is more powerful than the double-lever form, and has jaws of 8 centimetres in length. It possesses extraordinary power, thanks to the mode of approximating the rings, which is effected with the action of a male screw adjusted to an interrupted



FIG. 202. —AUTHOR'S ÉCRASEUR: LARGE FORM



FIG. 203. AUTHOR'S ÉCRASEUR: SMALL FORM.

female thread. This mechanism is identical with that of Collin's lithotrites. In the position represented in Fig. 204, the forceps opens and closes like an ordinary one. When we have grasped the pedicle, it suffices to bring back the movable piece which closes the female screw, to enable us to crush the pedicle by turning the male screw with the oval ring at the end (Fig. 204).

Author's New Forceps for Pediculization.—This new instrument has been constructed for the purpose of converting flat pedicles into cylindrical. The successive transformations of the pedicle, after imprisonment between the jaws of the forceps, are shown in the three figures next following, being proportional to the approximation of the blades of the instrument.

Ligature-Holding Forceps, used in Castration of Horses.—One of the most interesting applications of the process of instantaneous crushing has been its adoption in the castration of horses. In this operation it is useful to fix



FIG. 204. AUTHOR'S NEW ÉCRASEUR.

the cord immediately above the testicle with a special forceps, which serves to limit the action of the écraseur. After application of the ligature, the cord is divided below it (Fig. 207).

Needles with Triangular Eyelet.—These are curved needles, made in all sizes. They have an eye of triangular outline, so disposed that the thread is fixed by the movement of traction. They are used for suture of the deep strata of the abdominal wall (Fig. 208).



FIG. 205. AUTHOR'S NEW FORCEPS FOR PEDICELIZATION.

Needle-Holder with Eccentric Plate.—This needle-holder has its jaws terminated each by an eccentric plate, which enables the operator to grasp needles curved in any direction. This disposition permits the placing of sutures in localities in which formerly only the metallic thread and the mounted needle could be employed. There are two forms of this instrument: (1) One is made with rings, and manipulated like a haemostatic forceps (Fig. 209). (2) The other has an automatic locking apparatus, and is worked with the whole hand (Fig. 210).



1.



2.



3.

FIG. 206.

1. The blades have begun to close. 2. The blades are half closed. 3. The forceps is completely closed.



FIG. 207.—AUTHOR'S LIGATURE-HOLDER FORCEPS, FOR CASTRATION OF HORSES BY THE METHOD OF INSTANTANEOUS CRUSHING.

Near the lower ring is seen a fork, intended for momentary fixation of the two heads of the catgut ligature.



FIG. 208. AUTHOR'S NEEDLES WITH TRIANGULAR EYELET FOR CATCHING THE THREAD.

They are made of two curvatures—a slight, and a semicircular one.




FIG. 209.—AUTHOR'S NEEDLE-HOLDER, WITH ECCENTRIC JAWS AND RINGED HANDLES.





FIG. 210.—AUTHOR'S NEEDLE-HOLDER, WITH ECCENTRIC JAWS AND AUTOMATIC DETACHMENT.

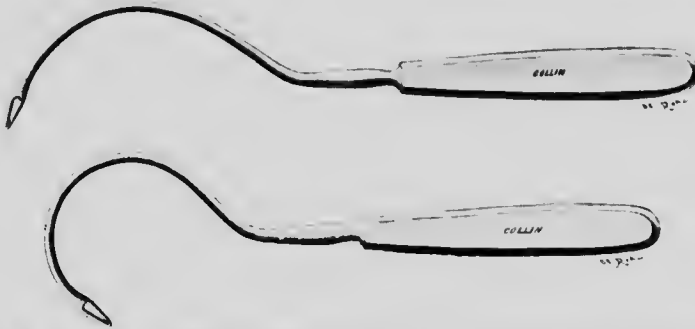Needle-Holder with Automatic Lock, for Intestinal Suture.—The ordinary form of the ring-handled needle-holder for intestinal needles is no other than the forceps with short hollow jaws which are represented in Figs. 187



FIG. 211.—AUTHOR'S NEEDLE-HOLDER FOR GASTRO-INTESTINAL SUTURE, WITH SHORT HOLLOWED JAWS AND AUTOMATIC LOCK.



FIGS. 212-215. AUTHOR'S CURVED SUTURE NEEDLES, WITH HANDLES.



FIGS. 216 AND 217. —AUTHOR'S BLUNT NEEDLES, WITH HANDLES AND RACKET-SHAPED EYE, DESIGNED FOR RETENTION OF THE LIGATURE.

This needle is made in two forms—with a medium curve (Fig. 216), and a more pronounced curve (Fig. 217).

and 188. The form with automatic lock has the same hollowed jaws, and differs from the first only in being manipulated with the whole hand, instead of being worked like a hæmostatic forceps.

Curved Suture Needles with Handles.—These needles are made with three different degrees of curvature, for suture of the skin and for deep sutures. They are bevelled only at the extremity, and on the convex side; they are very easy of manipulation. They are specially suitable for deep peritoneal purse-string sutures, and aponeurotic and cutaneous interrupted sutures (Figs. 212-219).

Blunt Needles with Handles for Ligatures.—These needles are used for deep ligatures, and for ligation of the broad ligaments in vaginal hysterectomy (Figs. 216 and 217).

Automatic Clip-Holder Forceps.—This forceps, which should be manipulated in the vertical position, is furnished with a series of hooks of special

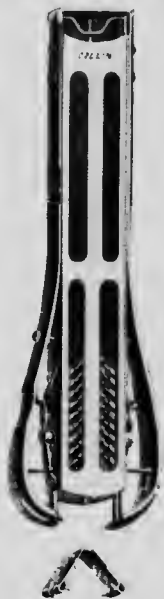


FIG. 218. ALTHOR'S AUTO-MATIC CLIP-HOLDER FORCEPS.



FIG. 219. ALTHOR'S HOOKED ANASTOMOTIC EYELET: MALE SEGMENT.



FIG. 220. ALTHOR'S HOOKED ANASTOMOTIC EYELET: FEMALE SEGMENT.

form, and very long, adapted to promote reunion of the skin of the abdominal walls after laparotomy (Fig. 218). The instrument is held like a dissecting forceps. Every time that the forceps is fully closed and the blades diverge, another clip falls between the lower notches, and is ready to be placed in position.

Hooked Eyelet for Gastro-Enterostomy and Entero-Anastomosis.— This instrument consists of a male segment (Fig. 219), which is introduced into the upper opening of the intestine or into the stomach, and a female segment (Fig. 220), which is introduced into the lower orifice. Each of those pieces should be conveyed by a special forceps. At the moment of introduction of the male segment within the female, to which it becomes fixed by a

double spring, the surrounding series of hooks perforate the duplicated gastro-intestinal wall and secure the complete contact. This anastomotic eyelet is so constructed that it invariably passes into the lower segment—the side on which the female segment should be placed. This instrument is only employed in rare cases, where its use is simple and easy. As a rule suture is preferable.

Enterotomy Forceps for Gastro-Enterostomy and Entero-Anastomosis, furnished with a Sliding Rod with Cutting Edge.—This forceps is formed of




FIG. 221. —AUTHOR'S ENTEROTOMY FORCEPS, WITH SLIDE FURNISHED WITH CUTTING BLADE.

two thick and furrowed branches, in one of which slides a small triangular blade. When the first two planes of sero-serous suture have been completed, the two blades are introduced—one into the stomach, and the other into the intestine—through two small orifices made with the thermo-cautery. They are pressed in to a depth of 25 to 30 millimetres, and the forceps is fully tightened. The anastomotic buttonhole is now made by a continued



FIGS. 222A AND 222B. —AUTHOR'S SPECULUM WITH UNILATERAL ARTICULATION.

In Fig. 222 is seen the olive at the base of the screw which serves to keep the instrument open; it is closed down tightly. To separate the valves the olive is unscrewed by some turns, and the screw drops with its winged nuts, as shown in Fig. 222A. It then suffices to approximate the two rings of the instrument (Fig. 222B) to separate the two valves.

to-and-fro movement of the triangular blade, which is then removed by being drawn towards the operator; the first anterior sero-serous plane is now finished. The rack is then unlocked, and the forceps removed; the deep circular plane is completed by adjusting, after application of the last points of suture, the terminal margin of the first sero-serous anterior plane to that of the last sero-serous posterior plane. The elastic forceps used to secure coprostasis is then removed, and the superficial sero-serous plane is completed.

Speculum for Uterine Dressings, and for Hæmostasis of the Uterine Arteries.—This speculum is specially constructed for vaginal dressings after hysterectomy, and for arrest of secondary hæmorrhage of the uterine arteries



FIG. 223.—CLAWED FORCEPS WITH OVAL RINGS, FOR TEMPORARY CLOSURE OF THE ANUS DURING VAGINAL HYSTERECTOMY.

The valves are long and straight, so as to expose a wider field. The articulation is unilateral, so that the instrument may be withdrawn while leaving a forceps in position at the depth exposed. When used, the olive at the




FIG. 224. AUTHOR'S RETRACTORS FOR VAGINAL HYSTERECTOMY: FORM OF 0.015 METRE IN WIDTH.

- No. 1. Length of valve: 0.06 metre.
- No. 2. Length of valve: 0.09 metre.
- No. 3. Length of valve: 0.12 metre.

FIG. 225. AUTHOR'S RETRACTORS FOR VAGINAL HYSTERECTOMY: FORM OF 0.06 METRE IN WIDTH.

- No. 4. Length of valve: 0.06 metre.
- No. 5. Length of valve: 0.09 metre.
- No. 6. Length of valve: 0.12 metre.

base of the opening screw should be tightly screwed up. The two valves may then be opened to the utmost without risk of detachment. When we want to disarticulate the speculum, the olive above mentioned is unscrewed by a few turns; the recoil spring is then reversed, and it suffices to open the valves to the maximum distance to enable us to separate one from the other.

The dimensions and shape of the valves may be modified at will. In case of serious uterine hemorrhage without notable increase of volume of the organ, this speculum enables us to arrest the bleeding by the procedure which I indicated long ago: closing the cervix by application of one or two clawed forceps partially closed. After vaginal hysterectomy, this forceps may be used in placing the pads or glass drains, or to arrest by direct compression a secondary or lingering hemorrhage from a uterine artery.

Anal Forceps for Use in Vaginal Hysterectomy.—This forceps consists



FIG. 226.—AUTHOR'S OBLIQUE RETRACTOR FOR RESECTION OF THE GASSERIAN GANGLION, AND FOR VAGINAL HYSTERECTOMY.

of two oval rings furnished with claws, mounted on sliding apparatus, which is fixed at the moment of grasping the anal orifice. The rack is set free by the action of a lateral lever.

Retractors for Use in Vaginal Hysterectomy—1. RETRACTORS WITH ANGULAR BEND OF 90 DEGREES.—These retractors are six in number, arranged in two series of different widths; they are specially constructed for vaginal hysterectomy.



FIG. 227.—CUTTING TUBES FOR ENUCLEATION OF UTERINE FIBROMATA.

The series includes four tubes, of which the respective diameters are 13, 18, 23 and 27 millimetres.

The valves are of three different lengths. These retractors are also used in laparotomy and in many other operations.

2. OBLIQUE RETRACTOR.—This retractor, which is of small size, is very useful in finding an open vessel at the base of the broad ligament during the operation of vaginal hysterectomy. It is also used in many other operations, especially in that of extirpation of the Gasserian ganglion.

Cutting Tubes for Enucleation of Uterine Fibro-Myomata.—These cutting tubes, which have been made, according to the author's instructions, for the enucleation of uterine fibromyomata, are no other than an adaptation

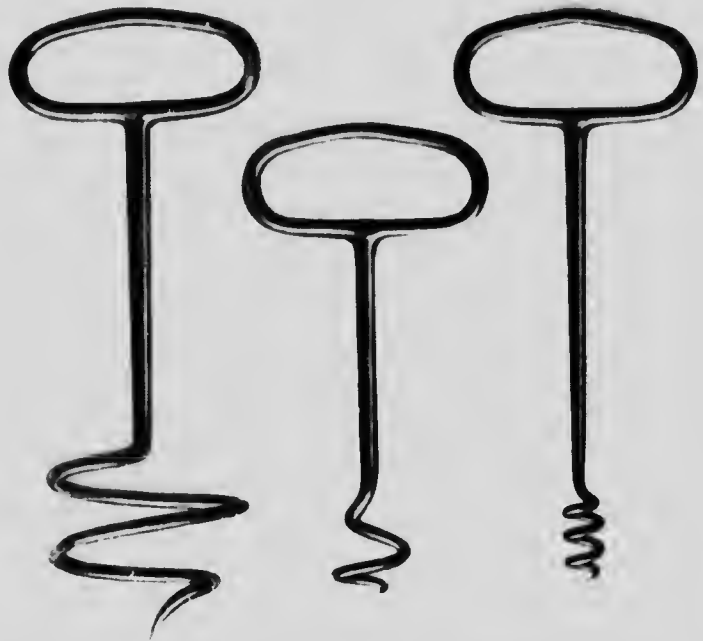
to surgery of the tubes used in the laboratory. Their use has considerably simplified the vaginal enucleation of voluminous fibromata.

Gouge Forceps for Enucleation of Interstitial Fibromyomata and Extraction of Placental Debris. These forceps are so constructed as to provide



FIG. 228. GOUGE FORCEPS FOR ENUCLEATION OF INTERSTITIAL FIBROMYOMATA, AND EXTRACTION OF PLACENTAL DEBRIS.

There is a series of three, of which the respective measurements of the jaws are 35 × 17, 30 × 13, and 17 × 8 millimetres.



FIGS. 229, 230, 231. AUTHOR'S HELICOID HOOKS: LARGE, MEDIUM, AND SMALL FORMS (Reduced scale - 3 : 5.)

for the rapid extirpation of accessible fibromata. They are also used in the procedure of slicing myomatous uterine tumours, and in the extraction of hydatidiform moles and placental debris. In this last procedure the

author's forceps, which does not wound the uterus, is far superior to the curette, which is erroneously appreciated, and of which the use is often followed by exacerbation of the septic symptoms (p. 228).

Author's Helicoid Hook.—These helicoid hooks serve for the grasping and removal of tumours in vaginal and abdominal hysterectomy. There are two forms—a large and a small (Figs. 229, 230, and 231).

Author's Hook, with Sliding Catch.—This instrument is used for prehension of the cervix in the operation of abdominal hysterectomy (Fig. 232).



FIG. 232. ACTON'S HOOK WITH SLIDING CATCH.

Suprapubic Retractor; also arranged for Interfemoral Fixation. This retractor is formed of a large valve that can be held in the hand, but which it is preferable to fix by means of a sliding pressure-screw, constructed in V-form so as to furnish interfemoral support. This supra-pubic retractor with automatic fixation eliminates an assistant in abdominal hysterectomy (Figs. 233 and 234).



FIG. 233. ACTON'S SCAPHOID RETRACTOR, WITH INTERFEMORAL FIXATION.

Glass Drainage-Tubes for Aseptic Drainage of the Peritoneum.—I have had prepared for aseptic drainage of the peritoneum special glass drains, at the extremity of each of which a small aseptic india-rubber bag can be fixed so as to receive the liquids from the field of operation. These drains are of two lengths (Fig. 235).

Instruments for Exploration of the Ureter from Above Downwards, and for Extraction of Calculi from that Tube.—Doyen's exploring-tube and calculus forceps for the ureter, which can be made to pass from the pelvis down into the bladder, are constructed of a malleable metal, so that they can be bent and curved according to the requirements of every individual case (Figs. 236 and 237).

Annular Pincers for Tumours and for Vesical Calculi.—These new pincers are constructed in three dimensions, so as to enable the operator to extract



FIG. 234.—AUTHOR'S SUPRAPUBIC RETRACTOR WITH INTERFEMORAL FIXATION, AND ANALOGOUS RETRACTOR FOR UMBILICAL COMMISSURE OF ABDOMINAL WOUND IN THE TRENDELENBERG POSITION.

A leaden counterpoise serves to fix the umbilical retractor.

tumours and calculi of very various sizes. They can be employed concurrently with the uterine gouge forceps in the extraction of interstitial fibromyomata (Fig. 238).

Shears for Ingrowing Nails.—There are two forms of these instruments—one for the inner side, the other for the outer. The jaws are so constructed as to reach the unguis margin up to the digito-dorsal fold (Figs. 239 and 240).



FIG. 235. AUTHOR'S GLASS DRAINAGE-TUBE, WITH OLIVE FOR FIXATION OF AN INDIA-RUBBER BAG.

The upper extremity has two blunt prominences, which are destined to prevent obturation of the lumen of the drain by intestinal loops.



FIG. 236. —AUTHOR'S MALLEABLE EXPLORING-TUBE FOR THE URETER.

A long olivary sound can be introduced into this tube, which passes from above downwards into the bladder.



FIG. 237. —FORCEPS FOR REMOVAL OF CALCULI FROM THE URETER FROM ABOVE DOWNWARDS.

The jaws of this forceps can rotate on the axis of the instrument, which is malleable, and can be curved at will.



FIG. 238. —AUTHOR'S ANNCULAR CLAWED PINCERS FOR THE EXTRACTION OF VESICAL CALCULI AND PREHENSION OF TUMOURS OF A CERTAIN RESISTANCE.

There are three forms of these pincers. The respective diameters of the rings are 20, 30, and 40 millimetres.

Gouges with Concave Cutting Edge, for Subcutaneous Exostoses of the Bones of the Nasal Fossæ.—I have had three forms of these gouges made, of various curves. The exostosis is detached subcutaneously, after intro-

200 SURGICAL THERAPEUTICS AND OPERATIVE TECHNIQUE

duction of the gonge between the bone and its tegumentary covering, through a small incision made with a bistoury on the inside of the nostril.



FIGS. 239 AND 240.—AUTHOR'S SHEARS FOR INGROWING NAILS. One is for the left ungual margin, the other for the right.

Raspatory for Resection of the Ribs.—This raspatory has been constructed so as to enable the operator to isolate ribs from their periosteum for a certain distance by a simple to-and-fro movement, and without risk of perforating the pleura (Fig. 241).




FIG. 241. AUTHOR'S GOUGE WITH CONCAVE CUTTING EDGE, BEVELLED AT THE EXPENSE OF ITS CONVEX SURFACE, FOR RESECTION OF EXOSTOSES OF THE BONES OF THE NASAL FOSSA.



FIG. 242. AUTHOR'S RASPATORY FOR COSTAL RESECTION.

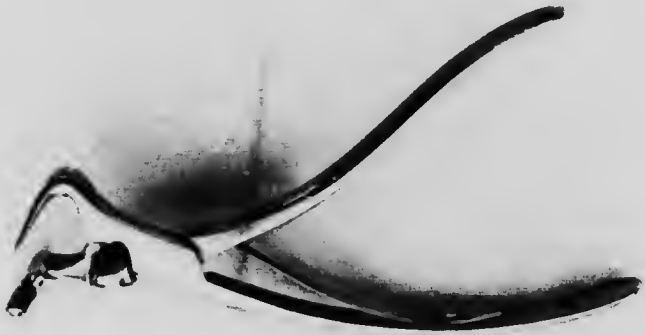


FIG. 243. AUTHOR'S COSTOTOME RASPATORY.

Author's Costotome Raspatory.—The author has combined the curved rugine of Fig. 242 with a cutting forceps, in order to perform the isolation of the rib and its section with the same instrument.

Author's Rachitome.—This instrument differs from the preceding in the arrangement of the blunt edge, which is introduced beneath the vertebral laminae. The horizontal arm is straight, whilst that of the costotome is strongly curved.

Cutting Cylindro-Spherical Tubes for the Formation of a New Cotyloid Cavity.—Operation for congenital luxation of the hip-joint has hitherto had its main desideratum in the impossibility of hollowing out a new cotyloid cavity at the desired situation and in the appropriate form. The cutting tubes which I have had constructed for me for that purpose are terminated by four triangular teeth, which are incurved so as to suggest the outlines of a hemispherical cap. The straight border of each of those teeth has a cutting edge, and is turned slightly outwards, so that the instrument, when



FIG. 244. AUTHOR'S RACHITOME.

placed in the position in which the cotyloid cavity is to be formed, can penetrate the spongy bone by the mere manual effort, and form a cavity of absolutely regular form. The osseous particles are retained in the tube, and none of them remain in the wound. These cylindro-spherical cutting-tubes are indispensable for reduction of congenital dislocation of the hip-joint (Fig. 246).

Apparatus for the Bloody Operation for Reduction of Congenital Dislocation of the Hip-Joint.—This apparatus consists of a plate pierced with a number of orifices, on which the body is fixed between four or six wooden pins and a series of metallic pieces, which are supported by a vertical column on which the symphysis pubis is fixed. On top of this vertical column is a sliding piece arranged in the horizontal transverse position, of which the extremity bears another placed in the horizontal antero-posterior position and furnished with a screw-thread and a strong nut. This piece bears at the other extremity the vertical spoon, which is meant to lower the head of the femur

or the trochanter. The vertical column being movable on its axis, and the other three pieces being adjustable by simple gliding movements, this



FIG. 245. AUTHOR'S GOUGE FORCEPS.
Very powerful and furnished with ring handles.



FIG. 246.—CYLINDRO-SPHERICAL CUTTING-TUBES, FOR THE HOLLOWING OUT OF A NEW COTYLOID CAVITY IN THE OS INNOMINATUM.

They are made of six different diameters, varying from 20 to 45 millimetres.




FIG. 247.—APPARATUS FOR THE BLOODY OPERATION FOR CONGENITAL LUXATION OF THE HIP-JOINT.

apparatus suits all ages, and, thanks to the power of the recoil screw, it can reduce all cases, without exception, of congenital dislocation of the hip-joint (Fig. 247).



FIG. 248. —DETACHABLE SHAFTS FOR USE IN THE ADJUSTMENT OF PLASTER APPARATUS ENVELOPING THE TRUNK, PELVIS, AND LOWER LIMBS.

Clamp with Screw for Retention of Compound Diaphysary Fractures.—
In certain cases of combined compound fractures, especially of the femur,

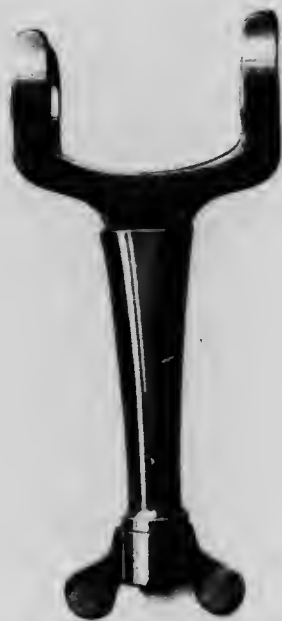

FIG. 249. CLAMP WITH SCREW FOR RETENTION OF COMPOUND DIAPHYSARY FRACTURES.

osseous suture with Arbuthnot Lane's screws (very successful when the osseous structures are solid), may not be possible. Cases occur where repair

commences with new friable callus; 6 or 7 centimetres of overlapping may occur. These cases I reduce by means of pulleys, and hold the fragments end to end by clamping each extremity close to the line of fracture in the rings of a special clamp represented in Figs. 249 and 250.



FIG. 250. THE SAME, SHOWING THE TWO PIECES FOR RETENTION, EACH ENDING IN A HALF-TURN OF A SCREW, THE TUBES IN FORM OF A TRUNCATED CONE, AND THE FEMALE SCREW.

Detachable Transom for the Adjustment of Plaster Apparatus.—These shafts are intended to facilitate the application of plaster apparatus, in which they remain enclosed till solidification has taken place. We have then but to loosen the four screws of the tie-pieces, and remove in succession the various constituent pieces of the transom (Fig. 248).

Author's Special Instruments for Craniectomy and Boring of Bones.

Operations on the cranium and boring of bones were as late as 1894 carried out with an instrumentation and technique so very defective that the simplest operations involved exceptional danger and expenditure of

time. The substitution of the instrumentation of Wagner for the antiquated trepan in temporary craniectomy had, while improving the operation, rendered the realization still more laborious and difficult. My instrumentation consists of a twofold series: (1) A number of instruments intended for manipulation with the hand; (2) a mechanical instrumentation to be worked by an electric motor.

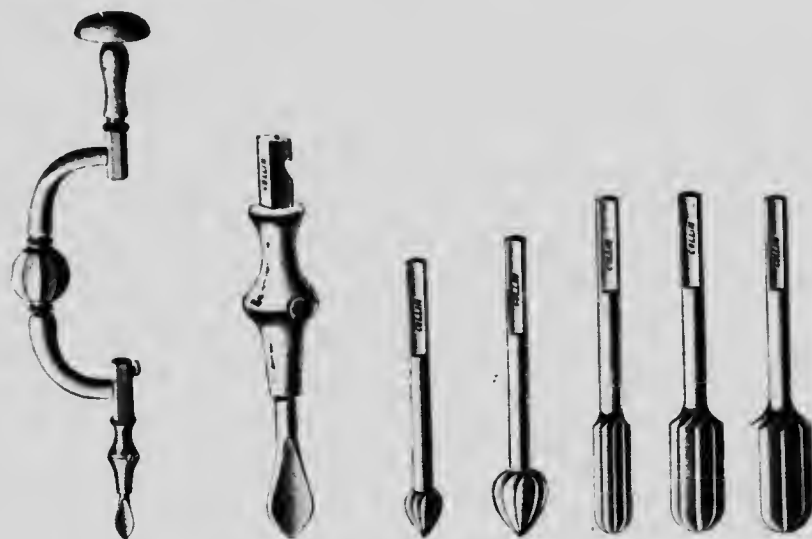


FIG. 251.—TREPAN WITH CATCH AND HOLDER WITH FLAT PIN.

FIG. 252.—H O L D E R WITH SCREW AND FLAT PIN.

FIGS. 253 AND 254.—CONICAL BURRS OF 8 AND 12 MILLIMETRES.

FIGS. 255.—CYLINDRO-SPHERICAL BURRS OF 8, 12, AND 16 MILLIMETRES IN DIAMETER.

1. MANUAL INSTRUMENTATION.—For evacuation of the mastoid apophysis or of one of the short bones, the bone is first attacked with a trepan furnished with a catch and a conical extremity, and then with a cylindrospherical burr of special shape, and 16 millimetres in diameter. This in evacuation of the mastoid apophysis enables us to reach the antrum and wall of the lateral sinus in about a minute, and without any danger of wounding the latter.

In craniectomy a number of orifices are commenced with the conical extremity, and then continued down to the dura mater, with a cylindrospherical burr of 12 millimetres in diameter. For craniectomy, surgeons who are not as yet very experienced in the use of this instrumentation can employ, for their first operations, a flat pin, guarded by means of shoulders, followed by a burr, protected by a crown, which is adjustable in the manner of the old trepans (Figs. 296 and 297). The dura mater is then detached from the inner surface of the cranium between these orifices, either with the grooved sound with large curvature and beak, represented in Fig. 277.

or with the special decollator shown in Fig. 260. The thickness of the cranium is then measured with the instrument represented in Fig. 261. The

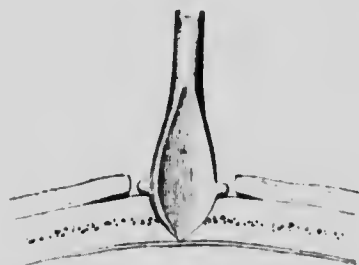


FIG. 256.—FLAT PIN FOR CRANIECTOMY, WITH SAFETY SHOULDERS.

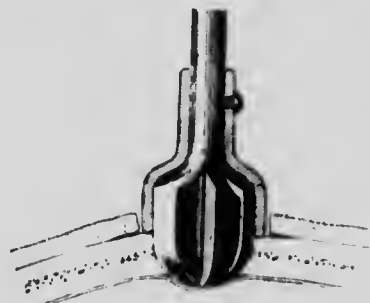


FIG. 257.—CYLIANDRO-SPHERICAL BURR, WITH ADJUSTABLE CROWN.

openings which correspond to the horseshoe-shaped incision of the integuments are then united two by two, by a sawing operation, effected with a



FIG. 258.—SUPPLEMENTARY STEM USED FOR ELONGATION, IN EVACUATION OF THE FRONTAL, ETHMOIDAL, AND SPHENOIDAL SINUSES.

special curvise instrument, regulated in such a manner as not to reach the dura mater (Fig. 262). The inner table is then divided where necessary



FIG. 259.—AUTHOR'S GROOVED AND BEAKED SOUND FOR DETACHMENT OF THE DURA MATER FROM THE CRANIAL VAULT.

with a special craniectomy forceps which removes the fragments (Fig. 264); it is then broken through where still intact with a mallet and chisel, furnished



FIG. 260. AUTHOR'S NEW DECOLLATOR OF DURA MATER.

with a protecting digit and a blunt angle (Fig. 265), which prevents any escape into the depths of the wound. The base of the fragment which is to form the hinge at the line of the vascular bridge preserved for the nutrition of the

osseous shutter, is fissured with the same mallet and chisel. By the use of this instrumentation we can cut out and mobilize a cranial shutter larger than the palm of the hand in less than ten minutes. The operation allows us to expose the meninges and brain extensively, and thus facilitates in an



FIG. 261.—MEASURER OF THE THICKNESS OF THE CRANIUM.



FIG. 262.—SLIDING SAW FOR THE CRANIUM.



FIG. 263.—CONVEX SLIDING SAW FOR LONG BONES AND VERTEBRAL LAMINAE.



FIG. 264.—CRANIECTOMY FORCEPS, WHICH CUTS AND REMOVES FRAGMENTS.



FIG. 265.—CRANIECTOMY CHISEL, WITH BLUNT ANGLE AND PROTECTIVE DIGIT.




FIG. 266.—NARROW GOUGE FOR OCCIPITAL CRANIECTOMY.

unprecedented way the exploration of cerebral abscesses, intracranial tumours, and epileptogenic centres. When the procedure has been concluded, the osteo-cutaneous flap is returned to its place, the skin is then sutured, and at the end of some weeks the cranial vault is as resistant as before.

2. **ELECTRIC INSTRUMENTATION.**—The mechanical instrumentation requires a motor of 50 to 60 kilogrammetres power, revolving at a rate of 2,500 turns per minute. The insufficiency of the electric motors previously in use, and the impossibility of procuring a flexible conductor of sufficient power, induced me to study a new type of flexible conductor based on the anatomical form of the shoulder-joint, or *enarthrosis*, which satisfies all the required conditions of mobility and of resistance.




FIG. 267.—ARTHRO'S CABLE FOR FLEXIBLE TRANSMISSION, FOR OPERATIONS ON BONES BY MEANS OF ELECTRIC INSTRUMENTATION.

Author's Flexible Transmitting Cable.—My flexible transmitting cable, which was mentioned above in connection with the electric instrumentation of the surgery of bones, deserves a special description. This flexible conductor is formed of a series of hollow cylindrical pieces of tempered steel, each end of which presents three teeth, separated by notches of somewhat greater width, in which are lodged the corresponding teeth of the adjacent

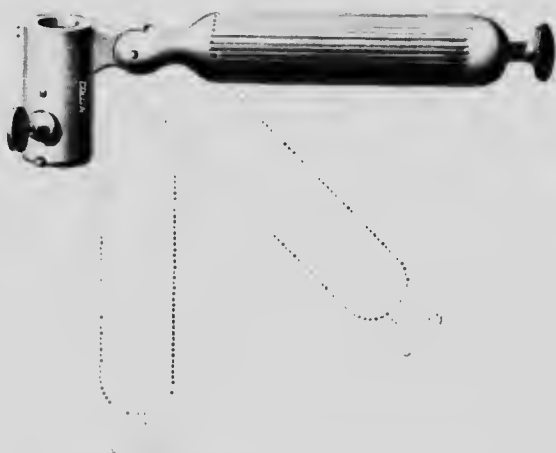


FIG. 268.—HANDLE WITH VARIABLE INCLINATION.

piece. The junction of those constituent elements in variable number enables us to construct flexible transmitting cables of a conducting power which had not been previously attained, and which give a rotatory velocity of over 3,000 turns per minute.

Handle with Variable Inclination.—At the free extremity of this flexible conductor, is adjusted a handle with variable inclination, which is fixed at an angle of 90 degrees for the movement of gouges and saws of small

diameter, so that the holder and the instrument in action are kept by the two hands in two perpendicular directions. This artifice gives the surgeon all the required security and stability, and protects the patient against any dangerous slipping.



FIG. 26. —SPHERICAL BURR OF 12 MILLIMETRES IN DIAMETER. (ACTUAL SIZE.)



FIG. 27. —SPHERICAL BURR OF 12 MILLIMETRES IN DIAMETER, MOUNTED ON A HOLDER.



FIG. 271. —SAW OF 35 MILLIMETRES IN DIAMETER.



FIG. 272. SAW OF 35 MILLIMETRES IN DIAMETER, FURNISHED WITH A PLATE WHICH LIMITS THE DEPTH OF ITS PENETRATION.




FIG. 273. MORTICING INSTRUMENTS, CONICAL AND BLUNT, ONE MOUNTED ON A HOLDER.

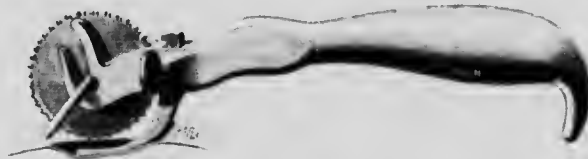


FIG. 274. SAW OF 45 MILLIMETRES IN DIAMETER, WITH ALTERNATING TEETH AND HANDLE FURNISHED WITH A SLIDING PLATE WHICH DETACHES AND PROTECTS THE DURA MATER.



FIG. 275. —THIN-BLADED SHEARS FOR CLIPPING THE EDGES OF THE CALVARIAL PLATES RAISED IN CRANIECTOMY (RIGHT AND LEFT.)




FIG. 276. —GRADUATED COMPASS.



FIG. 276B. COMPRESSOR FOR HEMORRHAGE FROM PERI-CRANIAL SINUSES.

I have studied the means of performing the section of the trigeminal nerve between the Gasserian ganglion and the protuberance. This section




FIG. 277. NEW INSTRUMENTS FOR CRANIECTOMY.

From above downwards: 3 circular saws of 5 centimetres diameter, furnished with protective discs which permit penetration of the blade to a depth of 4 millimetres in case of the first, 6 millimetres for the second, and 8 millimetres for the third. A straight decollator of the dura mater; a spiral spring; a similar spiral mounted on a straight decollator to increase the retraction of the dura mater. Two curved decollators, each furnished with an elastic spiral.

The whole thickness of the cranium can be cut through in one movement with a fine saw, with protecting disc, provided that the dura be retracted to a safe distance. This is obtained by surrounding with a metallic spiral the earlier model of the author's decollator.



FIG. 278. DETACHMENT OF THE DURA MATER WITH THE AUTHOR'S NEW DECOLLATOR BETWEEN TWO CRANIAL OPENINGS MADE WITH THE BURR.



FIG. 279. — A MORE EXTENSIVE DETACHMENT OF THE DURA MATER, WITH THE SAME DECOLLATOR FURNISHED WITH A STEEL SPIRAL.

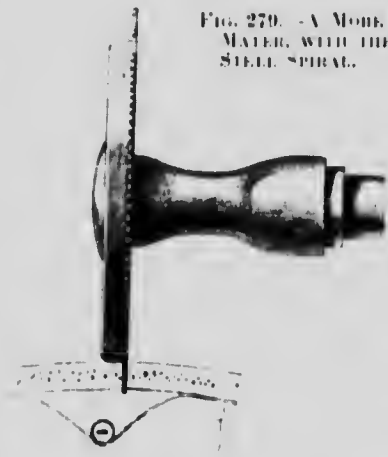

FIG. 280. DIVISION OF THE WHOLE THICKNESS OF THE CRANIUM WITH A DISC-SAW WITH PROTECTED DISCS PARALLEL TO THE DECOLLATOR, WHICH IS FURNISHED WITH A STEEL SPIRAL.

It will be seen that the dura mater has been deeply pressed back.




FIG. 281. INSTRUMENTS FOR RETRO-GASSERIAN NEURECTOMY, WITH INTRACRANIAL ENDOSCOPY.

From below upwards: Cylindrical spherical burr of 20 millimetres. Valve for protection of the cerebellum, furnished with a tube for aspiration. Speculum furnished with aspiration tube, for intracranial endoscopy. Author's neurotome.

can be performed with the aid of intracranial endoscopy, through an orifice 20 millimetres in diameter, cut through the occipital at the level of the asterion. In Fig. 281 is shown the instruments necessary for this operation.

Operating Tables.

The author's operating tables, with hydraulic fixation, and transportable, have already been described.

CHAPTER III

OPERATIONS

THE GENERAL TREATMENT OF THE PATIENT BEFORE, DURING, AND SUBSEQUENT TO SURGICAL INTERVENTION

Operations of Urgency, and Operations of Opportunity or Regulated Operations.

SOMETIMES we have to perform operations of *urgency*—they are few at the present day—and at other times at an opportune date, and after more or less prolonged observation of the pathological conditions. These latter are also known as "regulated operations," because they are carried out according to a known and fully determined technique; while the operations of urgency often demand an abnormal and exceptional technique from the very reason of the suddenness of the accidents which necessitate their performance, or the urgency of the resulting traumatism.

I. OPERATIONS OF URGENCY.

Among operations of urgency we classify—

(1) *Operations necessitated by traumatism*: Complicated fractures, injuries produced by crushing, gunshot wounds, etc.

(2) *Operations necessitated by certain pathological conditions of rapid evolution*: Internal strangulation, perforation of the stomach or duodenum, hyperacute suppurative appendicitis or salpingitis, meningeal hemorrhage.

(1) **Operations necessitated by Traumatism.**—In cases of traumatism we forbid immediate amputations, which aggravate the shock produced by the accident, and are nearly always followed by rapid death in collapse. I have had a very large experience of grave traumatisms, crushing of limbs by heavy vehicles, crushing of the pelvis, of the thorax, multiple fractures. Many of those have been observed in railway accidents. My rule is unvarying: If the wound bleeds it is plugged, and everything necessary to hemostasis is carried out at once; an elastic band suffices in case of one of the limbs. The injured person is generally insensible for some hours. It is then nearly impossible to recognize whether there are internal lesions, such as rupture of the liver, spleen, or kidneys, bruising of the intestine,

etc. On the other hand, blood-stained expectoration may reveal a simple fracture of the ribs without any deep-seated pulmonary lesion.

The patient should be placed at once in a very warm bed, and, if still unconscious, be made to swallow through an œsophageal tube, or even through a No. 16 or No. 18 catheter introduced through the nostril, some tea, rum, or grog. The only contra-indication to this procedure is the probability of a rupture of the digestive tube in cases of contusion of the abdomen. Artificial serum should be injected at once, the face and chest flapped with a moist napkin, and rapid percussion strokes made over the cardiac region. The injured person should then be placed with the head lower than the feet, so as to make sure that the brain receives a copious supply of blood. We are thus very often able to snatch wounded persons from the grasp of death who had barely a single breath of life left.

In cases of exceptionally grave traumatic shock we must occupy ourselves continuously with the injured person without a single moment's inactivity. Artificial respiration should be maintained for half an hour, or even still longer. When there has been copious hæmorrhage, the application of elastic bandages to the limbs is a valuable adjuvant. It is necessary to stimulate what vital activity remains by every available means. I have seen wounded persons, already reanimated, whose respiration slowed down as soon as they seemed calm and ready to go to sleep. We should keep them awake and give no truce till the heart and respiration have fully regained a satisfactory rhythm. If the patient survives for twenty-four hours and escapes the initial collapse, recovery is usually secured. We must then proceed to a minute examination of the lesions present, and apply appropriate local treatment to each. Contused wounds of the extremities are preferably treated by continuous irrigation. Necessary amputations are carried out at the chosen time—after the second day and under chloroform.

Examination of the first urine passed after an injury should never be omitted; it may contain blood (laceration of kidney, etc.). The presence of sugar and of albumin must be taken into account in formulating the prognosis. The injured patient should be closely watched, especially when there has been an abdominal contusion, for the symptoms of perforation may not appear till after the lapse of some days, when the crushed portion of the intestinal wall has begun to slough. In cases of contused wounds of the extremities *preventive injections of mycolysin and of anti-tetanic serum* should be administered, especially when the injured parts are soiled with earth or dust.

(2) **Operations necessitated by Pathological Conditions of Rapid Evolution.**

—The operations necessitated by certain affections which run a rapid course, such as perforation of the intestine or gall bladder, abscess of the brain, internal strangulation, etc., are as urgent as post-traumatic interventions, sometimes even more so; but the operative indication is much less evident and less precise. Accordingly the surgeon, on whom in such cases the life of the patient directly depends, should possess in the highest degree the requisite professional qualifications: *reliability in diagnosis, presence of mind, manual dexterity*. After a few hours' temporizing, intervention may

be too late. In all cases of urgent surgery the prognosis, which is always grave, should be decided with the greatest care before operation, full account being taken of the patient's age, state of the heart, of the lungs, of the liver, of the kidneys, and of the results of previous affections, biliary lithiasis, cancer of the stomach or intestine, etc., such affections always contributing to aggravate the effects of the traumatism or infectious state which necessitates surgical intervention.

2. OPERATIONS OF OPPORTUNITY, OR ARRANGED OPERATIONS.

When intervention is not a matter of absolute urgency, the surgeon should choose *the most favourable moment*, and secure, without a single omission all the best conditions for attaining success. The greatest number of operations are thus practised at *the most opportune moment* after a more or less prolonged period of observation of the pathological condition, and according to a well-arranged technique. The diagnosis of the affection which calls for the operation must be established with care. The surgeon's examination should involve the whole organism—the state of the heart, lungs, liver, kidneys, and other viscera; the examination may then be regarded as complete.

The urine is analyzed. Note is made of the quantity passed in twenty-four hours, of the amount of urea, of the presence of bile, sugar, or albumin. The presence of a small quantity of glucose or of albumin does not constitute a formal contra-indication. For have we not successfully practised under conditions of urgency, such as after crushing of a limb or in cases of strangulated hernia, bloody operations on diabetic and albuminuric patients who had not been subjected to a preliminary rigorous régime? The discovery of the presence of sugar or albumin at the time of the accident calls for a more rigid antiseptic, and the immediate adoption of a methodical internal treatment. The dosage of albumin is determined by the method of Esbach, and that of glucose by the Yvon diabetometer. When such patients are found to recover, there is all the more reason for surgical intervention in cases in which the diagnosis of such affections had been previously established. For after decision of future operation the surgeon has time to submit the patient to an appropriate preliminary régime. Thus we calculate on results as successful when we operate for vesical calculi and cataracts in diabetic patients, after having previously taken care to reduce the glycosuria to the lowest attainable limit. I have obtained almost unhopèd-for successes in operations for ovarian cysts and enormous uterine fibromata in patients affected with diabetes or albuminuria. Albuminuria may possibly be, too, merely a complication of the disease which necessitates operation, as in certain cases of uterine fibromata. In such instances the albuminuria disappears after the operation.

Whether a preliminary course of medical treatment has been thought suitable or not, the patient should take absolute rest for some days before the operation. A saline purge should then be administered, for which I prescribe 30 or 40 grammes of sulphate of magnesium dissolved in a small quantity of water, with addition of a little citron-juice. The solution is

chilled in the refrigerator, and swallowed at a gulp; the patient then drinks a glass of Vichy water immediately after, and this is followed by a cup of light broth.

As a general rule my patients are kept in the Clinique forty-eight hours before operation. They are purged on the first day; on the second they receive an appropriate diet. In cases of interstitial fibromata even two or three purgations in the week preceding operation are hardly sufficient; there are still large broken-up faecal masses, hard and gritty, found on ablation of the tumour. On the other hand, the administration, after previous purging on the eve of the operation, of from six to ten pills, each containing a centigramme of extract of opium, is useful in resection of the sigmoid flexure of the colon or of the rectum.

Injections of artificial serum (sterilized saline solution, 7 per 1,000) should be repeated for a number of days in case of feeble and anæmic patients to the amount of 500 to 1,000 grammes daily. Such injections raise the arterial tension and increase the patient's vital resistance. In case of infective lesion a number of preventive injections of mycolysine are administered, of 20 c.c. each.

MATERIALS REQUISITE IN URGENT SURGERY.

The term "urgent surgery" has generally been misunderstood. The operations generally known as *urgent* derive that character of urgency from quite special conditions, such as the sudden occurrence of a grave traumatism or of a hyperacute infection. This character of urgency, which relegates them to a separate class, indicates at the same time that the technique of these operations, which are usually necessitated by accidents or by affections which run a hyperacute course, cannot be subordinated to rules as precise as those applicable to operations that may be carried out after a certain delay, and which are determined either by the progress of the affection or the convenience of patient or surgeon.

Urgent surgery includes all cases in which intervention cannot be postponed beyond a very short time without danger of death. Immediate operation is demanded when every delay carries with it rapid aggravation of the prognosis. Thus urgent surgery includes: (1) Operations necessitated by grave traumatism, fractures of the skull, penetrating wounds of the abdomen, etc.; (2) operations demanded by pathological conditions which run a hyperacute course, cerebral abscess, perforative peritonitis, urinary infiltration, etc.; (3) operations which have become urgent on account of some error of diagnosis or by exaggerated postponement: empyema, torsion of the pedicle of an ovarian tumour, renal insufficiency symptomatic of lithiasis necessitating nephrectomy, all belong to this category. The affections which range themselves in these three categories, and which may demand operations "of urgency," have not—if we except violent hæmorrhages which demand instant application of direct compression—an evolution so rapid that the surgeon is not able to choose the time and place for operation which promise the fairest chances of success. It is, accordingly,

erroneous to believe that under pretext of immediate danger the operation should be carried out by the first comer, and in conditions incompatible with the laws of asepsis. Even the great hemorrhages do not usually prove exceptions to this rule, for if the gravity of the case is compatible with recovery, it rarely happens that the vital forces cannot be preserved, with the aids of intelligent care and direct compression, till the arrival of an experienced surgeon furnished with all necessary materials. The main object should be to perform the operation—especially in cases of laparotomy—under conditions which make sure that it will not prove more certainly fatal to the patient than temporization.

Let us suppose a penetrating wound of the abdomen. Except in cases where fulminating hemorrhage results, we have always a respite of some hours. Keep the wounded person at perfect rest, bring him under the influence of morphine, cover the abdomen with ice bladders, and you secure an interval of five to ten hours before the inflammatory complications pass beyond artificial control. In a case of latent contusion of the abdomen intervention has every chance of success if carried out before the time of the first appearance of biliary vomiting. The immediate search for a projectile within the cranium is less urgent still, especially if it has penetrated deeply. It is better to restore the strength of the patient first, and merely remove accessible débris, and apply an anti-septic dressing after arrest of hemorrhage, if such exist; for the immediate indication is to prevent imminent fatal developments, much rather than to proceed to a difficult operation which might aggravate the state of the patient. The projectile can be reached after an interval of some days, but if tolerance has been established, and the position of the intruding body can be reached only with difficulty, the patient should be kept under observation, and every surgical intervention adjourned *simul die*. The surgeon who would operate in a case of penetrating wound of the abdomen, and open the cavity without having all essential anti-septic materials at hand, would be guilty of a most reprehensible act, and would risk the death of a patient who might recover if operated on with all rigorous precautions a few hours later. We should, accordingly, condemn all hasty intervention; which necessarily is, as such, detrimental to the interest of the patient.

On the other hand, such affections as empyema and infective osteomyelitis, which do not usually fall under the heading of urgent surgery, may come to call for immediate operation when the unfavourable surroundings of the patient have led to such aggravation of the symptoms as to threaten with syncope or fulminating septicæmia. I have been called in to a case of purulent pleurisy in a young man who was a personal friend. He seemed to be in the last moments of the final agony, as I was warned at the foot of the staircase. However, I rushed upstairs with my bag of instruments, incised the skin with a single stroke, and opened the pleura with blunt scissors through the exposed intercostal space. The patient remained cyanosed and subdelirious till evening; he then gradually recovered, and in time regained his wonted vigour. After the operation I learned that a confrère of the most distinguished status had been carrying out experiments on mice while the pro-

gressive suffocation increased from hour to hour, with the pus which he had extracted by exploratory puncture, with the hope of finding the pneumococcus. This was surely pushing the love of the laboratory too far: it would have been better for the patient to have a puncture made in order to relieve the impending suffocation, even if the radical operation for the empyema were to be postponed for some days after. The best way for the clinician to arrive at a sane decision is, accordingly, to regard the interest of the patient in the first place, and always conform to the device, *Primum non nocere*: while remembering that want of decision and undue temporization may be more injurious than premature intervention, when this is adopted by a good operator.

The technique of operations "of urgency" does not, accordingly, in many cases differ from the technique of "arranged" operations. In the case of empyema referred to above, I operated as I do in all cases of empyema only with greater precipitation: the skin was incised rapidly, and I opened the intercostal space, following my usual practice, by *direct ion* with blunt scissors. The absolute urgency of the case did not lead me to deviate for even a moment from my habitual technique, which presents the simultaneous advantages of being more rapid than division of the successive layers of the muscular wall with a bistoury, and never leading to a wound of an intercostal artery. In dealing with the separate regions of the body, I shall indicate the cases of urgent surgery that may arise in connection therewith and point out the best methods of procedure: both in first care of the wounded and in regard to operative procedure. In discussing the grave cases, I shall give prominence to the clinical features that enable us to decide the question of necessity for operation and to choose the most favourable time for performance.

Urgent surgery includes all cases in which the life of the patient is in immediate danger. It is in the presence of grave situations that the true qualities of the surgeon stand revealed, and that he who possesses the highest diagnostic powers and is master of the most perfect technique stands out superior to all others. The various instruments and apparatus required in cases of urgent surgery—that is to say, in cases in which operation cannot be deferred till the patient has been conveyed to a surgical institution—will now be described. Although these operations should be strictly limited to what is necessitated by the original accidents, they demand the use of a certain number of instruments and apparatus which must be made to conform with all the rules of asepsis. Some examples will illustrate these statements: If a depressed fracture of the skull, the surgeon must elevate and remove the sunken fragments, then disinfect and plug the wound. In case of appendicitis, the intervention of urgency (and at patient's home) should, in case of a purulent cyst, be limited to free incision and evacuation of the latter, which should then be plugged. If in the former case the surgeon were to raise a large osseous flap, or in the latter to open the peritoneum which had previously escaped infection, he would expose his patient to useless risk. But in dealing with an appendicular perforation without adhesions, or a penetrating wound of the abdomen the

intervention should be complete and thorough, while also as simple and rapid as possible.

Every medical man should know enough of antiseptics to be able to apply it practically with the first confrère who comes, if the necessity happens to arise. The slightest hesitation would be culpable in a desperate case, such as perforative peritonitis or a penetrating wound of the abdomen. I could instance many cases in which the country practitioner, although hesitant at first, tried laparotomy and saved his patient. It suffices to be so far prudent as to avoid any irremediable blunder. In case of a knife stab or gunshot wound of the abdomen, a small antiseptic incision, treated by plugging, suffices for the evacuation of a deep abscess, and for verification of the diagnosis of a penetrating wound, complicated or not with hemorrhage. The incision can then be enlarged, the vessels tied, the intestine sutured, and the peritoneum sponged out. The precept which should evermore guide the practitioner is, *Primum non nocere*; and what is more dangerous in such cases than temporizing? Do as you would be done by, and you fulfil your duty; you will have the consciousness of having done all for your patient, and nothing too much. The medical man should be at the same time a sage and a man of action.

The instruments required for operations of urgency are as follows:

1. Tongue forceps.
2. Heister's gag.
3. Author's gag.
4. Tray of bistouries.
5. Two pairs of strong scissors.
6. Two forceps, dissecting and clawed.
7. Five Kœberlé's hæmostatic forceps.
8. Five forceps, ring-handled and with oblique claws.
9. Two forceps with oval rings.
10. Five artery forceps, with short jaws and claws.
11. Two short jawed forceps for veins.
12. Five hæmostatic forceps with short jaws, and needle holder.
13. Four curved forceps of 27 centimetres.
14. Four forceps with elastic jaws for the intestine.
15. Écraseur, small form.
16. Four selected retractors.
17. Three selected curettes.
18. Fifty clips and a clip-forceps.
19. Needle holder forceps, with eccentric plate and ring handles.
20. Twelve intestinal needles, and twelve selected needles with cutting edge.
21. Two needles, with handles and different curves.
22. Trepan, with catch, perforator, and two cylindro-spherical burrs of 12 and 16 millimetres.
23. A sound of metallic silver, curved and grooved.
24. Cursive saw.




FIG. 282. INSTRUMENTS REQUIRED IN URGENT CASES OF SURGICAL PRACTICE.

25. Chisel, with bevelled edge
26. Gonge forceps.
27. Craniectomy forceps.
28. Costal raspatory.
29. Chisel, with protective digit.
30. Four chisels and gongs for evacuation of osseous débris
31. Mallet

An amputation case should also be at hand.




FIG. 283. INSTRUMENTS REQUIRED IN URGENT CASES OF SURGICAL PRACTICE.

The following accessories must be added:

32. Three numbers of silk (Nos. 1, 2, and 5), in sterilized flasks.
33. A flask of Florentine hairs sterilized.
34. One metre of india-rubber drainage-tubes, non-perforated and assorted.
35. Four flasks containing each 20 grammes of phenol, dissolved in 20 grammes of alcohol at 90° C. (194° F.).
36. Four flasks containing each 20 grammes of sodium borate.
37. Flask of sublimate pastilles, each containing 2 grammes.
38. Thermo-cautère.
39. Apparatus for injection of artificial serum, and two flasks, each containing 500 grammes of sterilized saline serum (7 per 1,000).
40. Syringe of 5 c.c. for aspiration puncture, also a morphine syringe.
41. Morphine solution, 1 per 100 in cherry-laurel water, with 1 per 1,000 of atropine sulphate.
42. Solution of benzoate of caffeine of 0.1 per c.c.
43. Flask containing 1 gramme of cocaine hydrochlorate.
44. Five tubes of pure ethyl chloride of 10 c.c. each.
45. Two flasks of chloroform of 100 grammes each.
46. A flask of ether.
47. Two packages of cotton of 250 grammes each.
48. One piece of 0.50 m. square of impermeable taffetas.
49. Ten bandages of gauze and linen.
50. One bandage for the body and for the thighs.
51. Ten safety-pins.
52. Two tablecloths.
53. Two blouses of sterilized silk enveloped in sterilized napkins.
54. Two cases of sterilized compresses.
55. One packet of sterilized napkins.
56. Elastic band, which may be used as an Esmarch's bandage.

All these articles may be carried in a handbag. The silk and Florentine hair are carried in an instrument-case, with the glass and india rubber drainage-tubes. The instruments after use should be washed with tepid water, then carefully wiped and dried. They are disinfected before use; in the absence of a dry-stove, by boiling for five minutes in a 2 per cent phenol and borate solution.

The confrère in whose clientèle the operation is performed should supply—

1. Two jugs of boiling water.
2. Two jugs of cold boiled water.
3. An enamelled saucepan of 25 to 30 centimetres in diameter, in which the instruments are boiled.
4. Two dozen freshly bleached napkins.
5. Six handkerchiefs.

6. Two larger cloths.
7. A table—this may be merely an elongated dining-table—fixed on two trestles.
8. Boards, saw, and nails—in a case in which it may be necessary to construct a bench inclined at an angle of 45 degrees, to be used as an inclined plane for the Trendelenburg position.
9. A table with four basins—two for washing the hands, and two for the sublimate solution.
10. Soaps, hand-brushes, razor.

On his part the surgeon should bring, in metal cases, the instruments and accessories catalogued above (Nos. 1 to 56). All instruments should have been already sterilized with dry heat in the metal cases so as to avoid the necessity of boiling before operation. The compresses should have been sterilized in the oven, enclosed in a metal case, and thoroughly dried.

When operation has been decided on, we set to boil in the saucepan for the instruments 2 or 3 litres of previously boiled water, to which have been added 20 grammes per litre each of phenol and of sodium borate. The instruments are placed therein if not previously sterilized by dry heat, taking care to open the scissors and hamostatic forceps; also, if there be room enough, the drainage tubes, silk, and Florentine-hair threads.

A sublimate solution of 1 per 1,000 is prepared by placing the requisite number of pastilles of bichloride of mercury in a porcelain jar washed with boiling water; these are instantly dissolved in a small quantity of boiling water, and cold boiled water is then added in quantity sufficient to bring the solution to a temperature of 41° to 45° C. (104° to 113° F.).

During this time our assisting medical practitioner washes the patient and shaves and disinfects the field of operation with warm water and soap, alcohol and ether, sublimate solution, and then with a 2 per cent. phenol solution. For the eyes boric water is used, or saline solution of 0.7 to 1 per cent. If there are no sterilized napkins four or five suitable serviettes are boiled, on which the instruments and sutures are then placed. We can dip six or eight serviettes in a sublimate solution, and after wringing out place them in a disinfected basin in a solution of sublimate in boiling water. In like manner we disinfect the basins of sublimate solution made ready for the operator and his assistant. The napkins or serviettes are used to enclose the field of operation.

It will be noticed that I do not recommend flaming. This method of disinfection is far inferior to the use of boiling phenol solution. Pass a bistoury, scissors, or steel cannula through the flame of a spirit lamp; you either fail to disinfect or you burn the point or edge. If you ignite a small quantity of spirit in a basin, the flame does not disinfect the parts that remain damp, and of which the temperature cannot reach higher than that of boiling alcohol—that is to say, 80° C. (176° F.). The slightest washing with boiling water, and, above all, with boiling phenol water, disinfects far better the

various vessels, bottles, and basins; as immersion in boiling phenol solution sterilizes in a few minutes, without causing any deterioration, bistouries and other instruments which have previously been washed, wiped, and dried. The use of boiling phenol and boric watery solutions is specially indicated in the disinfection of syringes for hypodermic injection, and that of steel cannulas. The syringe is filled with water, and its function tested. It is then filled with the solution and boiled for five to ten minutes, with its cannula and glass for holding the liquid to be injected. The boiling phenol solution is then replaced by cold boiled water.

The hands of the surgeon and of his assistant are washed six or eight times with hot soap suds, then wiped carefully after cleansing of the nails, and again washed with the *cream of proteol soap*; then soaked for two minutes in sublimate solution, next in ether, and now plunged once more in sublimate solution. They are then dried, powdered with sterilized talc, and sterilized india-rubber gloves are put on. Half an hour suffices for examination of the patient and preparation for operation, which is accordingly finished within from an hour to an hour and a half after the arrival of the surgeon.

I have noted that if we have neither sterilized compresses nor stove, we must be content with the use of plugs of cotton as sponges, boiled in phenol water of 2 per cent.; and then passed through boiling water, in case of an operation in which the phenol would be too irritating for use. But it must be repeated that when the peritoneum is to be opened, the use of compresses sterilized in the oven is indispensable. Everything necessary to the operation should be prepared by the surgeon himself, who must forbid everyone to touch his instruments or vessels; he should place them all on a special table with his own hands, and then cover them with sterilized napkins. He is sure of antisepsis when he has disinfected his hands before proceeding to the preparation of the various instruments and apparatus required in the operation; he is sure of the sterilization of the instruments and auxiliaries which he himself has lifted out of the boiling solution with a long forceps—if not previously duly disinfected—and placed on a table covered with a sterilized serviette. The sublimate basins which are used during the operation should be within reach of the surgeon and of his assistant; as well as a can for emptying into, when the fluid has to be changed. It is prudent for him to fill and empty the sublimate basins with his own hands. In this way he avoids the dipping in of the soiled fingers of some over-zealous individual.

I have been often obliged in farm-houses in summer, when there were swarms of flies, to boil phenol water in large basins in the apartment where the operation was to be performed. The phenol vapours chased the flies, which are very dangerous to a sepsis of the operating field, where they are persistently trying to alight.

By following the indications thus outlined, excellent results can be obtained in operations of urgency, if we adhere to the following rules: (1) In an ill-suited medium it is necessary to abstain from every complicated intervention—that is to say, we should strictly confine ourselves to the procedure which is absolutely demanded by the state of the patient; and

(2) the surgeon should rely on himself alone to prepare all the materials for the operation, so as to make quite sure of preserving asepsis. The great object is to save the patient, and to this end a rapid plugging is often more effective than the most skilful suturing. If the patient survive a second intervention may successfully carry out, with deliberation and in perfect safety, the promotion of a secondary union, or the closing of a fistula. In operations of urgency more than in any other case, let well alone.

CASE OF INSTRUMENTS FOR AID IN URGENT SURGERY.

I have had prepared by M. Collin, on the demand of His Royal Highness the Prince of Monaco, an oblique of instruments, containing all that is necessary for cases of urgency. It encloses a printed notice with the most emphatic instructions for the first care of the injured. It contains the following:

A. Cloths and Dressings.

1. Three blouses of sterilized linen enveloped in a sterilized serviette.
2. Three aprons of sterilized linen, enveloped in a sterilized serviette.
3. Ten serviettes of sterilized linen, enveloped in a sterilized serviette.
4. Two cases of sterilized compresses.
5. Two packets of absorbent cotton, compressed and sterilized.
6. One piece of impermeable silk, of 0.5 metre square.
7. Six linen bandages, 0.06 metre wide by 10 metres long.
8. Six bandages of turlatan, of 0.12 — 10 metres.
9. Four bandages of turlatan, unseamed, and dusted with plaster in metal boxes.
10. One piece of turlatan, with seamed border, of 0.8 — 3 metres.
11. A metal box containing 2 kilogrammes of plaster for casts.
12. Six metal splints.
13. Ten of the author's compressed dressings.
14. An injector of india rubber sterilizable by boiling, which can be use for injection of artificial serum.
15. Two long and strong platinum cannule for injections of artificial serum, sterilized and enclosed in a metal case.
16. An injector of enamelled sheet iron with 2 metres of india rubber tubing, stop cock, and cannula of hardened india rubber.
17. Two uniform basins.
18. Two basins of enamelled sheet iron.



FIG. 284. AID CASE OF SURGICAL INSTRUMENTS.
Nos. 1 to 19, pp. 228 and 231.




FIG. 285.—AID-CASE OF SURGICAL INSTRUMENTS.

Nos. 20 to 40, p. 231.

B. Anæsthesia, Pharmacy, and Accessories.

19. Two compresses folded and pinned in conical shape, for general anæsthesia.
20. Five tubes of 10 grammes each of Kélène.
21. Two flasks of 100 grammes of chloroform.
22. One flask of 100 grammes of ether.
23. Two flasks of 500 grammes of sterilized artificial serum (saline solution of 0.7 per cent.).
24. Five ampullæ of sterilized solution of morphine hydrochlorate of 1 per cent.
25. Five ampullæ containing each 0.1 gramme of caffeine benzoate in sterilized solution.
26. One flask containing 1 gramme of crystallized cocaine hydrochlorate.
27. One flask of pastilles of compressed bichloride of mercury of 2 grammes each.
28. One flask containing 20 grammes of camphorated oil.
29. Two flasks of Roux and Nocard's antitetanic serum.
30. Two flasks of mycolysine prepared for injection, containing 20 c.c. each.
31. Two flasks of mycolysine prepared for injection, containing 50 c.c. each.

A case containing:

32. One sterilizable syringe, of 100 c.c., with two conical cannulæ.
33. One sterilizable syringe, of 10 c.c., with two platinum needles.
34. One sterilizable syringe, of 2 c.c., with two platinum needles.
35. One sterilizable syringe, of 1 c.c., with two platinum needles.
36. Six flasks of sterilized silk: Nos. 1, 2, and 5.
37. One metre of sterilized india-rubber drains, non-perforated, and sorted of the several diameters of 4, 8, and 12 millimetres.
38. One thermo-cautery.
39. One india-rubber bandage of 0.1 x 10 metres.
40. Three india-rubber sounds for the bladder; Nos. 12, 16, and 18.
41. Three olivary sounds for the bladder; Nos. 6, 10, and 18.
42. Two œsophageal sounds, of 8 and 12 millimetres in diameter, respectively.

43. One de Graefe panier for foreign bodies in the oesophagus.
44. One flask of cream of proteol soap.
45. Two hand-brushes.
46. One razor.
47. One nail-brush.
48. One frontal mirror.
49. One laryngeal mirror.
50. One forceps for reduction of phalangeal dislocations.

C. Surgical Instrumentation.

An operation case containing:

1. A tongue forceps.
2. Heister's gag.
3. Author's ringed gag.
4. Three Krishaber's tracheotomy tubes for children and adults.
5. One divaricator of the commissure.
6. One divaricator of the molars.
7. One case of six bistouries.
8. Four pairs of blunt scissors.
9. Two author's dissecting forceps, and forceps with oblique claws.
10. Five Koberlé's hemostatic forceps.
11. Five author's forceps with rings, and forceps with oblique claws.
12. Five author's hemostatic forceps and needle-holders with short and hollowed jaws, and two of his special needle-holder forceps for arteriorrhaphy.
13. Two forceps with oval rings.
14. Two author's blunt needles with handles and racket-shaped eyes for deep ligatures.
15. Five author's hemostatic forceps with short and clawed jaws.
16. Two author's hemostatic forceps for veins with short jaws and gilt.
17. Two author's forceps with eccentric rings.
18. Four author's forceps with elastic jaws for stomach and intestine.

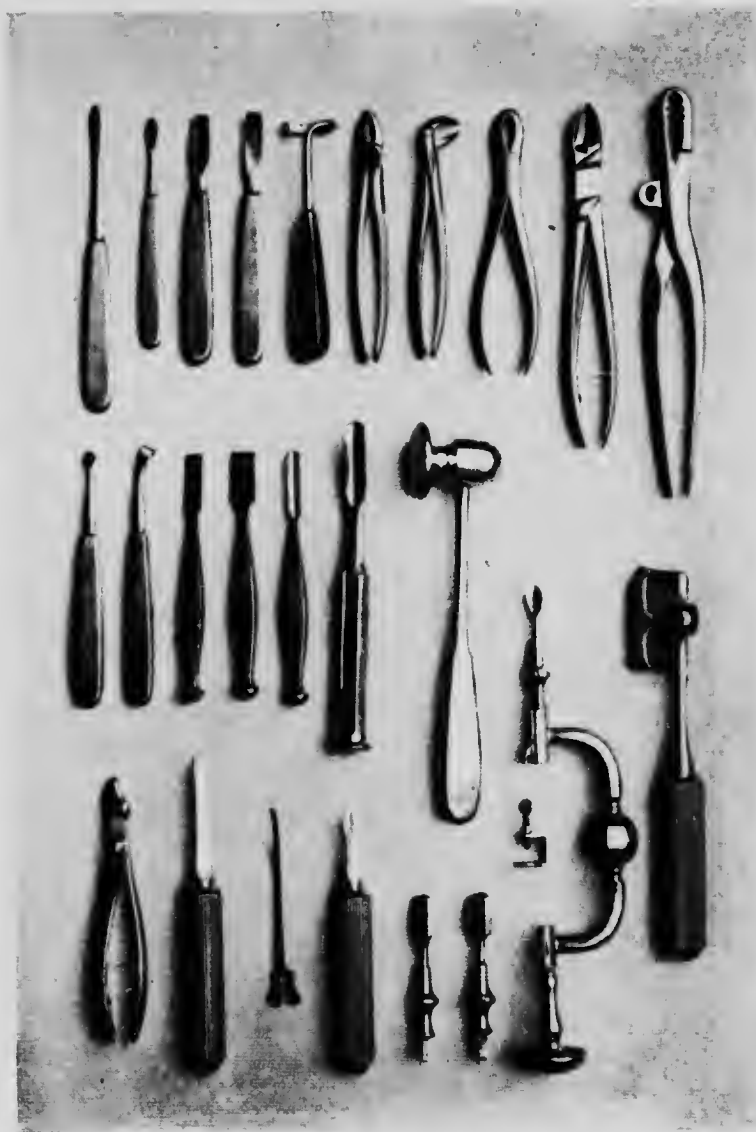

FIG. 286. - AID CASE OF SURGICAL INSTRUMENTS.
Nos. 41 to 61, pp. 231 and 232.

19. Five forceps curved at the edges, of 27 centimetres in length, one having slender jaws.
20. Author's éraseur, smaller type.
21. Four assorted retractors.
22. Four assorted curettes, of which one is uterine.

A case for sutures containing:

23. One needle-holder with eccentric plate and rings.
24. Twelve assorted angular needles and twelve round needles for intestinal suture; also twelve extra fine round needles for arteriorrhaphy.
25. Two author's needles with handles of different curves.
26. Fifty Michel's clips.
27. Two forceps for holding clips.
28. Two clawed forceps for the cervix uteri.
29. Two gouge forceps for the uterus, small and medium sized.
30. Author's speculum with unilateral articulation.
31. A rhinoscope.
32. An otoscope.
33. Forceps for removal of foreign bodies from the larynx.
34. Author's forceps for removal of foreign bodies from the nasal fosse.
35. Forceps for removal of foreign bodies from the external auditory canal.
36. Three stilettes, simple and hooked.
37. Two selected trocars.
38. Two forceps for extraction of bullets.
39. A vesical explorer.
40. Two urethral sounds of large curvature; Nos. 18 and 22.

A case for surgery of bones and craniectomy, containing:

41. Spatula.
42. Small cutting raspatory.
43. Straight raspatory.
44. Curved raspatory.
45. Author's costal raspatory.
46. One key for incisor teeth, one key for molars.
47. Author's gouge forceps.

48. Cutting forceps.
49. Farabeuf's lever.
50. Two fenestrated curettes for bones.
51. Two straight chisels.
52. Two gauges.
53. Mallet.
54. Forceps for removal of fragments in craniectomy.
55. Chisel with blunt angle for craniectomy.
56. Curved grooved sound for craniectomy.
57. Turn-screw.
58. Two cylindro-spherical burs of 12 and 16 millimetres diameter respectively, mounted on holders furnished with adjusting screws.
59. Compressor for use in hemorrhage from the sinuses of the dura mater.
60. Trepan with regulating catch and perforating drill mounted on a holder with adjusting screw.
61. Curvise saw for craniectomy.

An amputation case containing:

62. Knife of 25 centimetres.
63. Knife of 20 centimetres.
64. Knife of 15 centimetres.
65. Short knife for resection.
66. Phalangeal knife.
67. Interosseous knife.
68. Lisfranc's knife.
69. Straight raspatory.
70. Curve raspatory.
71. Small saw with movable back.
72. Large amputation saw.

All pieces of cloth and articles of dressing are sterilized in the saucepan, and afterwards dried while sterilizing the instrument cases with a dry heat of 160° C. (320° F.). The chest containing all those materials should be sealed so as to be prepared for all events. This aid-case contains the following:

General Instructions for Treatment of Cases of Grave Hæmorrhage or Apparent Death.

Immediate Care of the Wounded while Awaiting the arrival of the Medical Man. The injured person should be laid on the back in the horizontal position. It should be immediately ascertained (1) if he breathes; (2) if there is an escape of blood anywhere.

If in a state of syncope, and there has been no flow of blood; the eyelids should be separated, and the cornea touched with the pulp of the index-finger. If the pupil be dilated and the cornea insensible, the precordial region is rapidly exposed and the ear applied thereto, so as to ascertain if the heart is still beating. Such determination should be completed in a few moments.

When all signs of apparent death are present, the dental arches are separated with the help of Heister's gag (they are held separate with the ringed forceps gag), the tongue is seized with the tongue forceps, and rhythmic traction is maintained (one traction movement every three seconds). Traction is made with moderate force, and alternately relaxed. At the same time some lateral pressure movements are applied to the sides of the thorax; the operator listening, at the moment of relaxation, so as to ascertain whether air has passed in with the familiar tracheal bruit. If no air appears to penetrate, the throat is sponged with one or two compresses or handkerchiefs conveniently folded, which are pressed back with the fingers as far as the epiglottis. Artificial respiration is maintained either by *using the arms* or by *rhythmic lateral pressure* applied to the sides of the thorax.

ARTIFICIAL RESPIRATION.—The patient should be placed lying on a narrow table, and a person should hold the feet. The assistant who makes the rhythmic tractions on the tongue should be on the table, kneeling between the legs of the patient, and the person who conducts the artificial respiration standing on one side of the patient's head.

Artificial Respiration by Abduction and Extension of the Arms. To conduct artificial respiration with the help of the arms, the elbows of the patient should be grasped with the whole hand; each elbow of the patient with the opposite hand of the operator (see pp. 241 and 242).

First Movement.—Press the elbows of the patient against the chest, so as to provoke expiration.

Second Movement.—Raise them vertically, then lower them outwards and backwards in the direction of a line from the epigastric fossa to the shoulder-joint. Each time that the arm is drawn backwards we should hear the passage of air into the trachea. It is often necessary to continue the rhythmic tractions of the tongue and movements of artificial respiration for half an hour—and even, in rare cases, up to two and even three hours—to recall to life persons who have been in a state of syncope (there are examples on record of restoration of the drowned to life after three hours of effort). Artificial respiration should be conducted without violence and without brusque shaking of the patient.

Artificial Respiration by Direct Pressure on the Thorax.—In some cases it is advantageous to alternate the artificial respiration carried out with the help of the arms, and that by rhythmic pressure on the lateral aspects of the thorax. We recognize, by the respiratory bruits, which of the two forms of procedure is proving itself the more efficacious (see pp. 243 and 244).

Dr. Brückner's Automatic Apparatus for Artificial Respiration in Case of Syncope.—Dr. Brückner's automatic apparatus is the most effective one for use when we want to produce thoracic movements automatically in a case of syncope, and to re-establish hæmotosis at the same time. It is composed of a series of bellows controlled by a reservoir of oxygen under pressure. The oxygen is supplied, under a pressure of 2 kilos, at a rate of 7 litres per minute, by a Giffard ejector, which causes the draught of a column of air of six times the volume under a pressure of some grammes.

The apparatus is arranged for use in a theatre for surgical operations. A portable apparatus, enclosed in a box, is also made for use at the stations for aid to resuscitation of the drowned. If respiration suddenly ceases in the case of a patient during operation, the mask is instantly applied over the bucco-nasal orifices, taking care to draw out the tongue with the help of a forceps passed under the mask, or with a silk thread passed through the tongue with a curved needle.

It suffices to turn the stop-cock in the requisite direction to send the gas into the lung. The artificial respiration has then commenced. When the lungs have been filled with gas, the pressure within the canalization system displaces a flap, and aspiration is established. A suitable mechanical arrangement replaces the flap in its original position when the aspiration has concluded, and insufflation recommences. As soon as the respiratory movements have been re-established, the stop-cock is turned so as to place the apparatus in relation with the reservoir of india-rubber, and with the metallic mask which is annexed to it.

Procedure to be adopted in Cases of Hæmorrhage.—If there be a considerable flow of blood, the indication is to precipitate yourself on the wound and bury the fingers in it, sometimes even the wrist, for some hæmorrhages end life in two or three minutes. In such cases the bleeding must be arrested by direct pressure. We then apply, in case of a limb, an elastic ligature near the source (middle of thigh or arm); and, if the patient be in a state of syncope, endeavour to reanimate him by acting in the way above described. If the hæmorrhage be slight, we expose and disinfect the wound, and arrest the bleeding as rapidly as possible; either by direct compression or by application of an elastic ligature to the base of the limb.

INTERNAL HÆMORRHAGE.—Progressive blanching of the face and lips, with weakening of the pulse—which becomes rapid and thready, even when the person has regained consciousness—are the signs of internal hæmorrhage. The sole resource in such cases is immediate operation, which should always be carried out by an experienced surgeon. The cure of such a case cannot be secured without ligature of the wounded vessel.

INJECTION OF ARTIFICIAL SERUM.—In cases of urgency, when the patient has lost a great quantity of blood, it suffices for preparing an injection of arti-

ficial serum. This can be accomplished anywhere by boiling for ten minutes 1 litre of filtered water to which 10 grammes of sodium chloride has been added; and also boil the can, the syringe, india-rubber tube, and platinum cannula, which can also be passed through a spirit flame. The injection is made subcutaneously on the outer side of the thigh. Wash the skin with soap solution, then with ether, pass the platinum cannula obliquely through the skin, and adapt to that cannula, using a ligature if necessary, the india-rubber tube leading from the can filled with the boiled saline solution of 1 per cent., cooled to a temperature of about 38° to 40° C. (100.4° to 104° F.). Contact with the liquid should produce no unpleasant sensation of heat.

INJECTIONS OF ETHER AND OF CAFFEINE.—We may also inject deeply into the muscles of the buttock of the opposite side—*never subcutaneously*, for fear of producing an eschar slow to heal—1 or 2 c.c. of ether, and at another point 0.2 of caffeine benzoate.

INJECTION OF CAMPHORATED OIL.—Injections of camphorated oil, 1 or 2 c.c. each, may be employed concurrently with the preceding.

Examination of the Wounded.—Examination of the injured person is made at once if he has not lost consciousness. He is extended in the horizontal position. We ascertain whether there is a wound or a fracture. Wounded areas are exposed by cutting the garments. If there be no wound, we locate the fracture or fractures if such exist. When there is a wound, the hemorrhage should be at once arrested if serious.

Transport of the Injured.—The injured should always be conveyed in the horizontal position. We can improvise a stretcher by rolling the margins of a rug around two broomsticks. The broken limb may be provisionally immobilized—the upper by Mayor's sling, the lower between splints rolled in absorbent wadding.

Examination of the Injured—Preliminary Precautions.—Each of the wounds or injuries must be carefully examined. The persons who have arrived before the patient should prepare boiling water, of which a certain portion should be cooled. The hands are washed with the warm water and soap. Two or three basins, some bowls, and two plates of enamelled sheet-iron must be boiled in water. Two or three litres of sublimate solution (2 per 1,000) must be prepared by dissolving in the necessary quantity of tepid water two 1-gramme pastilles of sublimate to each litre.

The arrival of the surgeon should be awaited for the operation properly so called; the persons attending should confine their efforts to dealing with the primary accidents and the arrest of hemorrhage, as already indicated, and in assuring as far as possible asepsis of the traumatic area.

Disinfection of the Wound.—Pass the hands, already washed in warm water and soap, through the 2 per 1,000 sublimate solution. The wound is exposed and moistened with the sublimate solution, with a sterilized compress or pad of absorbent wadding. This pad is held in position, and another person washes the area surrounding the wound with soap and hot water. If a jet of superficial blood appears, a forceps is fixed in position, or a tampon alone

may be used. The tampon may be kept in place with a curved piece of wood, secured in position by the outer bandage of the dressing. This artifice is useful at the margin of the thorax, also in wounds of the abdomen and inguinal region.

Internal Medication.—When the injured person has recovered consciousness, restoratives should be administered: tea, rum, hot wine, etc., except where there is probable wound of the digestive canal; for example, in deep wounds of the neck, and generally in all cases of grave contusion and penetrating wound of the abdomen.

Examination of the Urine. The first urine passed after injury should be preserved for this purpose. It may contain blood.

Surgical Intervention. When surgical intervention is necessary, it should be carried out by a surgeon. Anæsthesia should be commenced with pure ethyl chloride with kéléne, by pouring 10 c.c. at a time on the bottom of the mask. After about thirty seconds it should be continued with chloroform (10 grammes at first, in a compress folded in conical form). The aid case contains all instruments necessary in the performance of the principal operations of urgency. The indispensable pieces of dressing are there also included. The above instructions suffice for urgent cases. I now proceed to describe the preliminaries of the major operations as these are carried out in my clinique.

The Final Preparations for Operations in General.

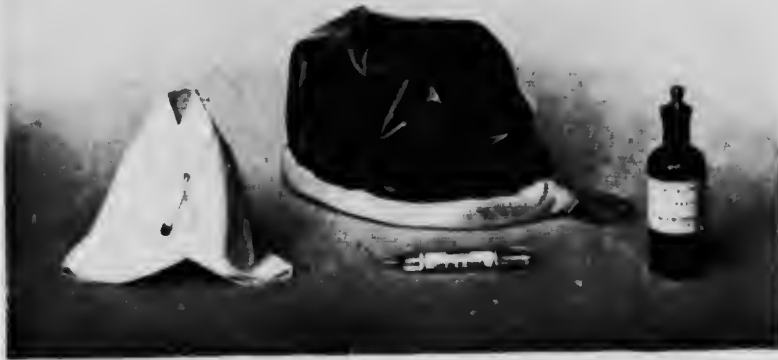Toilet of the Field of Operation. The field of operation should be shaved before intervention, then washed over and over again in a large bath with cream of proteol soap. The only exception that I make to this rule is in cases of vaginal hysterectomy in certain patients. The vulva is shaved only under chloroform. The mucous lining of the natural cavities are disinfected as completely as possible by anti-septic lavages. Labarraque's fluid diluted with 10 volumes of water is used for the mouth or rectum, sublimate solution of 2 per 1,000 for the vagina.

Local Anæsthesia. For operations in which local anæsthesia suffices I employ ethyl chloride, and when this is not forthcoming, a mixture of pounded ice and salt, or cocaine.

LOCAL ANÆSTHESIA WITH ETHYL CHLORIDE. The vapour of ethyl chloride ignites on contact with the thermo-cautére. Accordingly, if this instrument is used after anæsthesia with ethyl chloride, it will be necessary to pass beforehand over the frozen region a compress of absorbent gauze, which absorbs the last traces of the inflammable compound.

LOCAL ANÆSTHESIA WITH COCAINE. In case of a mucous membrane, cocaine is applied on the surface. Small flat pads of cotton soaked in a 1 in 10 or 1 in 20 solution of cocaine hydrochlorate are kept in contact with the surface to be incised or cauterized for about three minutes. For the skin I use interstitial injection of solution of cocaine hydrochlorate, of 1 in 50 or 1 in 200. The cocaine solutions should be freshly prepared. The

injections must be made, at first superficially, in the lymphatic network of the true skin, then in the subcutaneous cellular tissue. The first insertion of the needle is always made at a point anesthetized by ethyl chloride. For extraction of teeth I inject $\frac{1}{2}$ to $\frac{1}{4}$ c.c. of a cocaine solution of 1 in 20; first outside, then inside, the teeth which are to be removed. On the palate the lymphatic network of the mucous membrane can be seen filling and growing colourless. When the gum is too thin, the injection can be made in the gingivo-buccal or gingivo-labial fold; it there produces a small oedematous bulla near the carious tooth, which diffuses itself in two or three minutes. At the digital extremities—for instance, in operation for ingrowing toe nail—an excellent adjuvant to the interstitial injection of cocaine is the previous application of an india rubber ligature, formed by a simple drainage tube, of which the ends are fixed between the jaws of



FIGS. 288 AND 289. CHLOROFORM CONE. ETHER MASK. TUBE OF KELLIN. FLASK OF CHLOROFORM WITH DROP STOPPER.

a haemostatic forceps. This elastic constriction permits the realization of perfect local anaesthesia. We even spare the patient the slight discomfort of a hypodermic injection by taking care to render the skin insensible with ethyl chloride at the seat of the preliminary puncture. It is equally useful, when we want to obtain perfect cocaine anaesthesia in the arm or thigh, to circumscribe the region to be operated on by the turns of an elastic bandage. A series of cocaine injections can then be made, of a solution of 1 in 100 or 1 in 200. The local arrest of the circulation prolongs the local action of this anaesthetic on the nerve endings. I do not recommend interstitial injections of cocaine in the thickness of the nasal mucous membrane, where the application of a tampon soaked in cocaine solution suffices for the required purpose. This mucous membrane is, in fact, endowed with a circulation—both of blood and lymph—so active that the inter-

stitial injection of a certain quantity of cocaine solution over the septum or turbinated bones exposes to danger of sudden and sometimes very alarming phenomena of intoxication.

General Anæsthesia. In case of major operations general anæsthesia is preferable to local. The anæsthesia is always commenced when I have the fluid at hand, with kélène or pure ethyl chloride. I now proceed to describe: (1) General anæsthesia with ethyl chloride, followed or not by administration of chloroform or ether; (2) anæsthesia with chloroform; (3) anæsthesia with ether.



FIG. 299. DR. FAVÉ'S MASK (COLLIN) FOR GENERAL ANÆSTHESIA WITH PURE ETHYL CHLORIDE (KÉLÈNE).

Anæsthesia with ethyl chloride, if the operation is to last long, should be continued with chloroform or with ether; preferably with chloroform. Chloroform boils at 60° C. (140° F.), ether at 33° C. (91.4° F.). One result of those physical qualities is that chloroform does not chill the respiratory mucous membrane so much as ether does, and that accordingly, as is admitted by even the most ardent partisans of ether, it exposes patients who are prone to bronchitis far less than the latter anæsthetic does to post-operative pulmonary complications. The vapour of chloroform also

presents the advantage of not being inflammable. I use rectified chloroform in flasks of 100 grammes each, with drop stopper.

ANÆSTHESIA WITH PURE ETHYL CHLORIDE OR KÉLÈNE.—We empty into a little ether mask, or, which is simpler, into a chloroform cone, a tube of 3 c.c. of kélène, or two tubes—that is to say, 6 c.c.—of kélène, if the patient be very nervous or a probable subject of alcoholism. The mask is then immediately placed on the face. As a rule, anaesthesia is thus produced in twenty to thirty seconds, and without any violence on the part of the patient. As soon as the patient has ceased to answer questions, the anaesthesia is continued, usually with chloroform, which is poured into the conical compress; or, very exceptionally, with ether. Dr. Camus's mask for administration of ethyl chloride may be used in the same way. With its aid the pure ethyl chloride anaesthesia may be maintained for twenty or even thirty minutes. For this purpose it suffices to empty a tube of 3 c.c. of kélène into the reservoir of the apparatus every two or three minutes.

ANÆSTHESIA WITH CHLOROFORM.—If ethyl chloride be not available, we can obtain complete anaesthesia with chloroform very rapidly by the following procedure: We first pour into the compress, folded and pinned in conical form, 2 or 3 grammes of chloroform, and the cone is brought to within a few centimetres of the mouth. When the first movement of repulsion has passed off, the cone is applied on the face. Some patients then cease to breathe. This arrest of respiration is nothing else than an instinctive defence of the organism against the chloroform. The cone should then be at once withdrawn, to be reapplied only after four or five deep and regular inspirations have been again obtained. If cyanosis appears in the period of excitement, or if the patient presents intense tonic spasm, as we see in alcoholics, we again remove the cone, and await the return of respiratory movements. When the period of muscular relaxation has arrived, we allow an assistant to continue the narcosis.

Chloroform does not appear to me to be dangerous when employed in experienced hands. Nevertheless, anaesthesia should not be attempted with it in large doses and by process of suffocation, as often practised in case of young children. Pinching the nostrils is useless. If we take care to bring the chloroform gently towards the patient's mouth, and encourage him while avoiding the use of force, the respiration becomes regular, and after a moment or two we can pour 4 or 5 grammes of chloroform at once into the conical mask. In this way muscular relaxation can be secured in a few minutes. During the course of the operation I give very little chloroform. In case of feeble patients I introduce through the nostril the tube of a balloon of oxygen, after the excellent practice of Dr. J. Champomière. In all the major operations, and those which last a considerable time, I recommend the use of the tongue forceps (Fig. 294). When the patient seems to awake and begins to move, the chloroform is immediately administered in a large dose (3 to 10 grammes dropped into the cone at once). Relaxation is thus obtained in a few moments, and the operation is continued. Chloroform accidents are usually due to the fact that the anaesthetist

240 SURGICAL THERAPEUTICS AND OPERATIVE TECHNIQUE

administers it mechanically, and concerns himself too much with the details of the operation. The person to whom the grave duty of narcosis is entrusted should never have any other care. The more prolonged the surgical procedure, the weaker the patient, and the more dangerous must be the slightest inadvertence on the part of the anesthetist. In addition to the




FIG. 291.—HEISTER'S GAG AFTER STEURIG.



FIG. 292.—HEISTER'S GAG, COLLIN'S MODIFICATION.



FIG. 293.—AUTHOR'S GAG WITH RINGS AND RACK, FOR SEPARATION OF INCISOR TEETH.



FIG. 294.—AUTHOR'S TONGUE FORCEPS.

oxygen balloon he should always have within reach for urgent cases a quantity of tepid artificial serum, and Dr. Brücke's automatic respiratory apparatus. In case of feeble patients it is prudent to inject during the operation 300 to 1,000 grammes of artificial serum at a temperature of 38° C. (100° F.).

Every Case of Narcosis is Liable to Some Sudden Reverse.—If the patient becomes cyanotic, the tongue must be drawn out and the lower jaw raised, after taking care to wipe out with a compress any mucosities which obstruct the pharynx. For dealing with rigidity of the jaws, the powerful Heister gag (Figs. 291 and 292) should always be in readiness. The anaesthetist habitually separates the teeth at the beginning of the narcosis with my ringed gag (Fig. 293), and applies the tongue forceps (Fig. 294). When the respiration is feeble, he should hold his ear very close to the patient's mouth, so as to hear the breath-sounds. Holding the pulse is absolutely useless, the anaesthetist or any person being always able to ascertain its

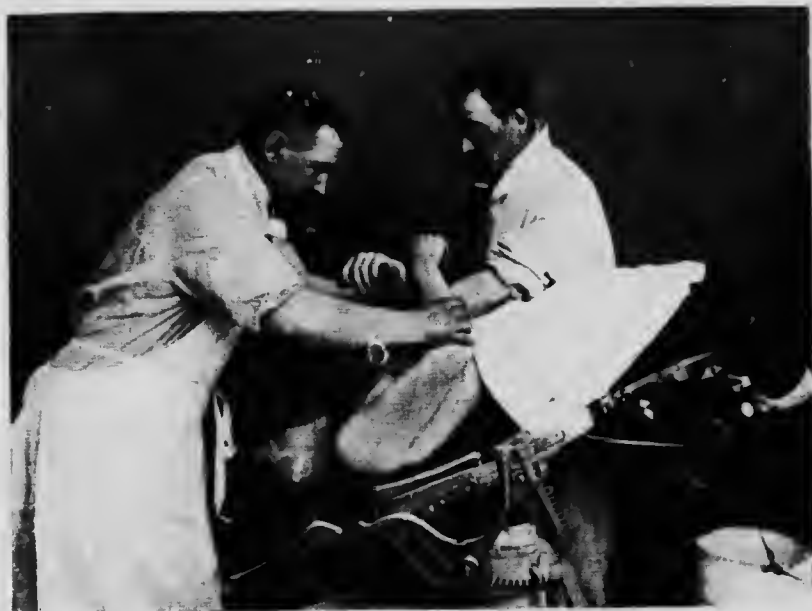

FIG. 295.—COMPRESSION OF THE THORAX WITH THE PATIENT'S ELBOWS.

state when necessary. When small and compressible, it is well to inject artificial serum. Attention to the respiratory rhythm is of far greater importance than supervision of the pulse; for, apart from the exceptionally grave and usually irremediable cases of cardiac syncope, the pulse ceases to beat in simple chloroform intoxication, only some time after the definite arrest of respiration. Accordingly the person who pays attention to the pulse alone would lose a precious interval at a critical period, when recourse should be had to artificial respiration without an instant's delay.

ANÆSTHESIA WITH ETHER.—Anæsthesia with ether is obtained by means of a suitable apparatus. When ether anæsthesia has been very

much prolonged, the patient is frequently cyanotic, and presents a less satisfactory general aspect than in case of chloroform anesthesia.

ARTIFICIAL RESPIRATION.—If respiration ceases, the rhythm must be re-established at once. The tongue is drawn forward, the pharynx sponged. If we possess it, we can apply Dr. Brücker's automatic apparatus for artificial respiration. It gives results superior to those of any of the other methods. If this apparatus is not at hand, recourse must be had to one of the following procedures:

1. *Procedure by Abduction and Extension of the Arms.*—One of the most effective modes of procedure is that by alternate compression and expan-

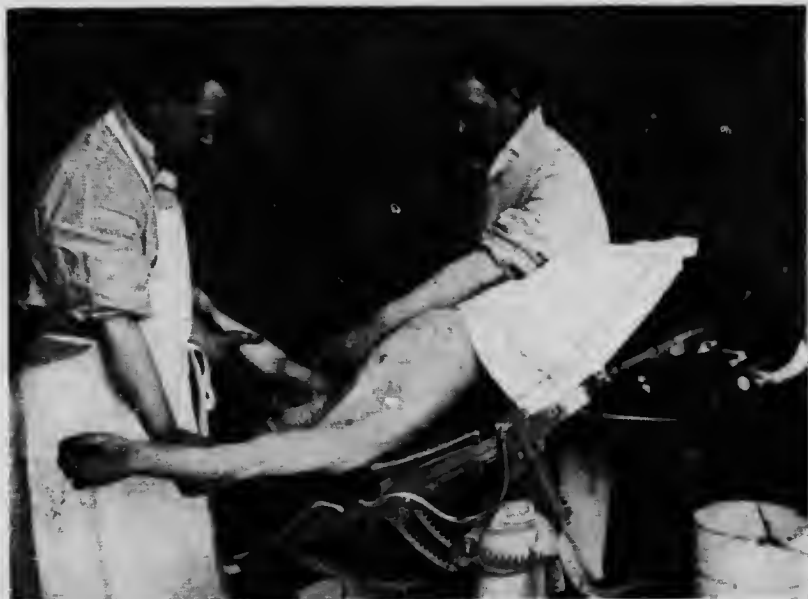

FIG. 296. EXTENSION OF THE THORAX BY DRAWING THE ARMS DOWNWARDS AND BACKWARDS.

sion of the thoracic cage by abduction and extension of the arms. It is carried out in the following way:

Respiration has just ceased; the patient is instantly detached and placed with the head inclined downwards, so as to restore the blood to the brain; an oxygen tube is introduced into the nostril, and the tongue drawn slightly outside the mouth. If the case is one of laparotomy, the field of operation is covered with aseptic compresses, and the abdominal wound is provisionally closed with the aid of three or four clawed forceps applied to the lips of the incision. The elbows of the patient are firmly grasped by the surgeon, who is placed at the side of the head of the former, and pressed firmly against the thorax; then they are drawn forcibly down-

wards and backwards (Figs. 295 and 296). If air penetrates readily into the thorax, he need continue the procedure only till the return of spontaneous respiratory movements.

2. *Procedure by Rhythmic Pressure of the Thorax.*—In some cases the movements of the arm produce no appreciable inspiratory bruit: it is then necessary to ascertain whether there is any mechanical obstruction. The surgeon makes two or three successive strong lateral pressures on the thorax, and listens for the entrance of air by the trachea. If there be no inspiratory bruit, the pharynx should be immediately cleared of mucosities. Those rhythmic lateral pressures on the thorax are made with the two hands.

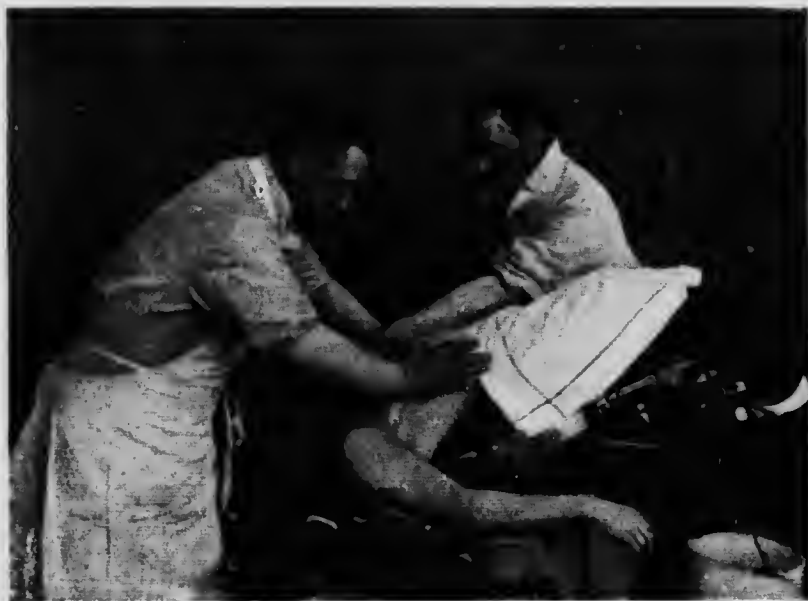

FIG. 297.—COMPRESSION OF THE THORAX WITH THE SURGEON'S HANDS.

without violence. They are often very useful when the previous movements of abduction of the arms do not produce free entrance of air. When the alternate pressure and relaxation of the thoracic cage (Figs. 297 and 298) elicit a distinct respiratory bruit every time, thus proving that the trachea is free, the artificial respiration is continued by the abduction and extension of the patient's arms. This procedure is the most efficacious, and merits a detailed description:

The surgeon, who stands on one side of the patient's head, grasps both his forearms close to the elbows, brings them to the lateral aspect of the thorax which he now compresses for an instant, then extends them downwards and backwards in the axis of the largest fascioli of the great pectoral

muscle; and in the respective vertical planes passing through the umbilicus and the corresponding axilla. Absolute silence should be observed. At each downward and backward movement of the arms an inspiratory bruit is heard. A moment of repose is then given, and an assistant applies his ear over the heart. In most cases he perceives contractile movements, sometimes feeble and far between. Some rapid percussion movements applied to the cardiac region, also application of Mayor's hammer, or of napkins dipped in very hot water are excellent adjuncts. But artificial respiration is the supreme remedy. As soon as the blood becomes charged with oxygen, the feeble circulatory process is re-animated, and the vital reflex

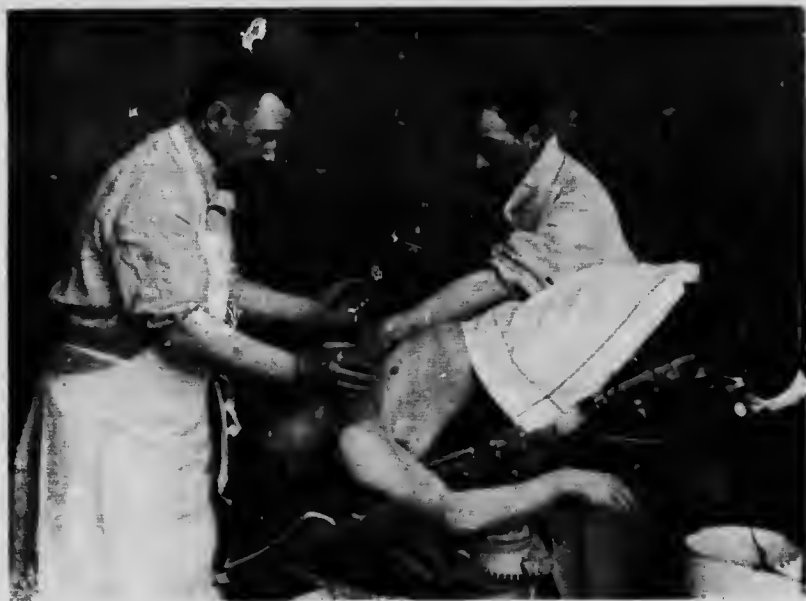

FIG. 298. SPONTANEOUS EXPANSION OF THE THORAX.

soon becomes definitely re-established. Abrupt compression of the thorax with the elbows determines a certain degree of expiration. Extension of the arms downwards and backwards, in the direction of the median fibres of the great pectoral muscle, produces the most extended inspiratory movement that can be realized. An assistant kneeling between the legs of the patient practices at the same time rhythmic tractions of the tongue, at the rate of 20 to 25 per minute. The movements of artificial respiration are abandoned only after the normal respiratory rhythm has been unmistakably established.

Absolutely forbid in every class of case the *exclusive* practice of rhythmic tractions of the tongue, which is far inferior in ease of the adult to the methods of procedure which I have just described. And even in the new-

born it is necessary to employ the same manœuvres which will be rendered still more efficacious by direct laryngeal insufflation.

Laryngeal insufflation is carried out in case of the new-born either with a special tube or with a simple gum-elastic catheter, which, at that age, is easily introduced into the trachea.

In cases of apparent death by chloroform the danger is so imminent that the smallest of possibly useful manœuvres cannot be omitted without exposure to accusation of the most culpable negligence: *Obliquely declining position; artificial respiration; rhythmic traction of the tongue; inhalation of oxygen; Mayor's hammer; electrification and rapid percussion of the precordial region; injection of artificial serum; and, if great loss of blood has occurred, application of elastic bandages on each of the lower limbs.* In this struggle against death the surgeon should put to the proof all the energy and all the perseverance requisite in an almost desperate position.

Happily, all these cases are not very grave; and, when chloroform intoxication is but slight, some movements of artificial respiration suffice for reanimation. Among the most disquieting signs, and most surely indicative of approaching death, are the dull and glassy aspect of the cornea and dilatation of the pupils. The patients, who are in a state of apparent death, are, however, almost without exception capable of reanimation. If the movements of the heart are imperceptible, while the pulmonary circulation is still free, artificial respiration, aided by the manœuvres above indicated, and which in grave cases are its indispensable complement, can save the patient. We should never despair. Ten, fifteen, twenty, or thirty minutes of continual effort, sometimes even a good deal more, may be necessary to elicit external manifestations of life. Pulmonary embolism and primary cardiac syncope are the only irremediable accidents. We should not give up our efforts to restore life till all the signs of death have existed for at least ten to fifteen minutes—complete dilatation of the pupils, unpolished and ground-glass aspect of the cornea, cyanosis or complete discoloration of the extremities, in cases of hæmorrhage fall of the rectal temperature below 36° C. (96.8° F.); and, as the final test of complete arrest of the circulation, exposure and division of the radial artery. And, to summarize, all grave accidents of narcosis are extremely rare when we use perfectly pure chloroform mingled with a small quantity of absolute alcohol; and *when the anæsthetist is both attentive and experienced.*

The anæsthetic properties of alcohol, so remarkable in the rabbit and guinea-pig, as I demonstrated in 1885 in the course of my researches on experimental cholera,* are completely compatible for conjunction with those of chloroform, while they at the same time oppose the depressing action of the latter on the nerve centres. Narcosis, like every other delicate procedure, exacts from anyone accepting its responsibility prolonged experience and sustained attention. Administration of chloroform, especially in the first few minutes, should be entrusted only to a practitioner fully broken in to all the accidents of the opening stage, in course of which even the

* Doyen, "Recherches anatomiques et expérimentales sur le choléra épidémique." *Archives de Physiologie* (1885); also Thèse de Doctorat.

slightest inadvertence may prove fatal. Also, preliminary anaesthesia with ethyl chloride appears to me to be very much superior in results to the immediate anaesthesia with chloroform or pure ether.

Preventive Tracheotomy.

Trendelenburg's Laryngeal Cannula. Trendelenburg suggested, for facilitation of extirpation of the larynx, the performing of a preliminary preventive tracheotomy, and placing a curved cannula of large calibre in the trachea provided with an annular india rubber receptacle in communication with an insufflating funnel. The cannula is introduced into the trachea, the elastic receptacle is filled with air, and its circumference is applied exactly to the internal surface of the mucous membrane. It thus prevents, if functioning perfectly, any escape of blood into the respiratory passages (Fig. 299). The narcosis is commenced before the preliminary operation of tracheotomy. It is carried out from a distance after the placing of the cannula, this latter being connected by an india rubber tube with a funnel pierced laterally

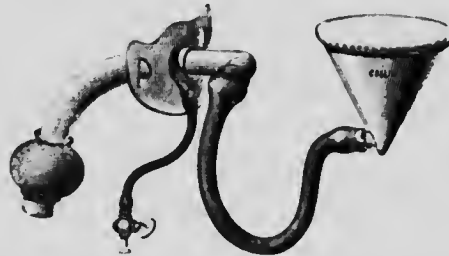


FIG. 299. TRENDLENBURG'S APPARATUS FOR DIELD ANAESTHESIA AFTER TRACHEOTOMY.

with small orifices for the entrance of air. It is only for complete extirpation of the larynx that Trendelenburg's cannula is indispensable. Chloroform insensibility being difficult to maintain during operations on the buccal cavity, some surgeons have not hesitated in grave cases to practise tracheotomy, and maintain the narcosis with the aid of Trendelenburg's cannula. This practice involves a serious complication, and it seems to us that it should be rejected as presenting more inconveniences than real advantages. Its place may be supplied by tubage of the larynx or pharynx.

Tubage of the Larynx and of the Pharynx I. TUBAGE OF THE LARYNX.

The tubage of the larynx, which I carry out with special aluminium cannulae (Fig. 300) permits the practice of anaesthesia with Trendelenburg's funnel. A regulated narcosis is thus obtained, and the operation can be completed with maximum celerity without interruption by the ceaseless menaces of the patient's awakening or obstruction of the trachea by bleeding.

These cannulae, of which there are forms of four different diameters, have been made of aluminium, so as to prevent their being drawn out of the larynx by their own weight when the patient is in Rose's declining posi-

tion, which is the most convenient for most operations on the buccal cavity. They are easily introduced by guiding along the index-finger with the tube-holding forceps made by M. Collin (Fig. 300). The dental arcades are held apart by a gag, and the tongues drawn out to facilitate access to the laryngeal vestibule. When the epiglottis can be exposed to view by means of a tongue depressor, the cannula can be introduced without being guided along

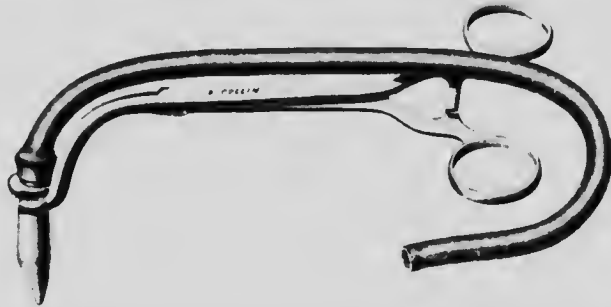


FIG. 300. LARYNGEAL CANNULA AND CANNULA HOLDER FORCEPS, FOR TRACHEA OF THE LARYNX AND DIRECT ANESTHESIA IN OPERATIONS ON THE BUCCAL CAVITY AND PHARYNX.

Trendelenburg's funnel is adapted to the extremity of the india-rubber tube.

the index-finger. Direct introduction of the cannula with the aid of the tongue depressor is very easy when the patient is sitting up, and not under the influence of an anesthetic. Under chloroform, it is better to keep the dental arches separated with a gag, to draw out the tongue, and to guide the cannula along the left index-finger.



FIG. 301. APPARATUS FOR TRACHEA OF THE PHARYNX AND DIRECT ANESTHESIA IN OPERATIONS ON THE FACE.

Trendelenburg's funnel is adapted to the extremity of the india-rubber tube.
(See Figs. 161 and 308.)

Trendelenburg's funnel attached to the extremity of an india rubber tube permits the continuance of the chloroformization by dropping some chloroform from time to time on the flannel which covers it. When the operation is finished, the laryngeal cannula is removed by simple traction on the india-rubber tube attached to its upper extremity.

These laryngeal cannulae can also be used in artificial respiration and in

direct pulmonary insufflation, but with the condition of keeping the mouth and nostrils tightly closed, as the cannula cannot be kept in sufficiently close contact with the laryngeal wall to prevent the escape of air around it. This object can be attained by adapting to the laryngeal tube the annular elastic receptacle of Trendelenburg's cannula. But such a complication appears to us all the less useful, inasmuch as these elastic envelopes are rarely found in a state of perfect functional capacity.

2. TUBAGE OF THE PHARYNX.—In the majority of cases it is unnecessary to practice tubage of the larynx, and it suffices to introduce at the base of the tongue the apparatus represented in Fig. 301, the metallic tube of which is connected by an india-rubber tube with Trendelenburg's funnel. The metallic tube can turn on its axis at the pharyngeal end, so that it can be inclined for convenience of use towards either right or left labial commissure. The pharynx is plugged with a roll of gauze at the level of the base of the tongue.

Accidents observed at the Time of Sudden Opening of the Pleura.

Aspiration of Air contained in the Pleura.—The sudden opening of the pleura, when there are no adjacent adhesions, is characteristically accompanied by a sharp hissing sound. When the orifice is small, this sound is repeated with every inspiration. The accident sometimes occurs during the removal of adherent tumours of the supraclavicular region. I noticed it eight years ago, when detaching with a bistoury a large deep-seated erectile lipoma from that region. The accident is unimportant when the opening is small. The air which enters the pleural cavity is absorbed in a few days. But such is not the case when a healthy pleural cavity without adhesions is suddenly invaded with a large opening. The rapid entry of air produces in such a case immediate collapse of the corresponding lung, and consequent diminution of the respiratory capacity of the aerial tree. This accident is so much more serious in the child, as the mediastinal tissues are flexible and mobile, and immediate syncope may be a result. The visceral pleura is so thin at that early age that its transparency enables us to see the heart and great vessels through it. The whole mediastinum is displaced *en bloc* towards the healthy side, and the inspiratory efforts which immediately follow the accident have no other effect than to provoke aspiration of air through the wound into the opened pleural cavity without the entrance of any through the trachea into the pulmonary system. Death is all the more to be feared, inasmuch as every attempt at artificial respiration by the ordinary methods is ineffective, the movements of the arms producing aspiration of the air into the opened pleural cavity, and not into the lungs.

In such cases the danger is imminent. I met with one of those accidents of sudden syncope on opening the pleura in a little girl while I was engaged in removing a large sarcoma of the thoracic wall which was adherent to the ribs, and had extended to the parietal pleura. The diagnosis of malignant tumour involving the pleura having been made in advance, I had

intentionally preserved in the dissection of the tumour sufficient skin to cover the pleural opening. The little one was suffocated by the entrance of the air into the pleural cavity. The lung collapsed completely. Some spasms of cough caused some ineffective expansion at the expense of air drawn over from the lung of the other side. Another expiration, and death was imminent. I detached the parieto-costal sarcomatous quadrilateral with four strokes of the shears, the skin was reapplied over the pleural orifice, and the lips of the incision were brought together and held between the jaws of two forceps with elastic pressure action.

The inspiratory efforts soon became effective. The lips, which had been of a pale blue tint a minute before, resumed their natural rosy hue in a few minutes, and the state of the pulse became satisfactory; then, on removal of the forceps for the purpose of securing hæmostasis of the intercostal vessels, the tendency to syncope was renewed. I applied ligatures to any vessels which bled appreciably, and the cutaneous wound was rapidly closed by continuous suture. The respiration then resumed a satisfactory rhythm. The quantity of air inspired continued, however, to be too small. The right pleura was full of air. An idea then occurred to me. Why not extract that air by aspiration? A glass tube was introduced between the sutures, and I proceeded to aspiration of the pleural contents. I then applied a dressing of occlusive wadding. In some hours after this operation the little patient was quite lively.

I have observed corresponding symptoms of grave dyspnoea in the course of operations on pulmonary cavities, hydatid cysts of the pleura, of the lung, and of the liver, which had opened into the bronchial tubes. So large a quantity of air escaped through the multiple broncho-omical orifices that asphyxia appeared imminent. In such cases it is necessary to effect tamponing and occlusion of the wound with the utmost rapidity, or to close the bronchial orifices with an interstitial circular ligature moderately tightened.

Disposition of the Patient on the Operation Bed.

Final Antiseptic Precautions.—When the patient has been brought under the influence of the anæsthetic, and placed on the operation table in a suitable position, we proceed to the final toilet of the field of operation—the skin is freely shaven, if it has not been already, then repeatedly washed with warm water and soap and with sublimate solution of 2 in 1,000. We use warm water in the same way for the vagina and for the rectal ampulla.* Finally, the region is washed with alcohol, so as to remove all traces of the mercury bichloride, of which the slightest contact affects the edge of the bistoury; and with ether. For the mouth we use boric water, or simply sterilized water. The conjunctiva should be washed with sublimate solution of 1 in 5,000, then with tepid boric water.

* I have already indicated the preventive employment of a solution of Labarraque's fluid.

Disposition of the Patient, Surgeon, and Assistants.

The operation theatre should receive its light through a wide glazed recess. Daylight coming from above at an angle of 45 degrees is the best source. The patient is so placed that the field of operation is in the fullest light. The glazed recess shown in Figs. 302 to 307 is situated opposite the face of the anaesthetist on the side on which the photographic apparatus was placed.

In all operations which are carried out on the trunk in the position of dorsal decubitus, the patient is placed horizontally with the head slightly raised and the legs hanging (Fig. 302). The lower limbs are then fixed to



FIG. 302. LAPAROTOMY.

The patient is placed in dorsal decubitus, with legs flexed. The surgeon is on the right.

the leg supports by two bands, one of which is placed just below the patella and the other above the ankle. A third may be sometimes used with advantage to fix the upper part of the thigh. When the patient is to be operated on in the position of lateral decubitus, we employ rectilinear leg supports, he may be turned on the right or the left side—neurectomy, Kraske's operation (Figs. 303 and 304)—where he should remain throughout the whole time of the operation before fixing the lower limbs which should be slightly flexed. The arms are secured laterally, sometimes behind the head. In operation on the axillary fossa the corresponding arm, which must be kept displaced during the procedure, is left free, and entrusted to an assistant. The various positions in which the operation table can be placed

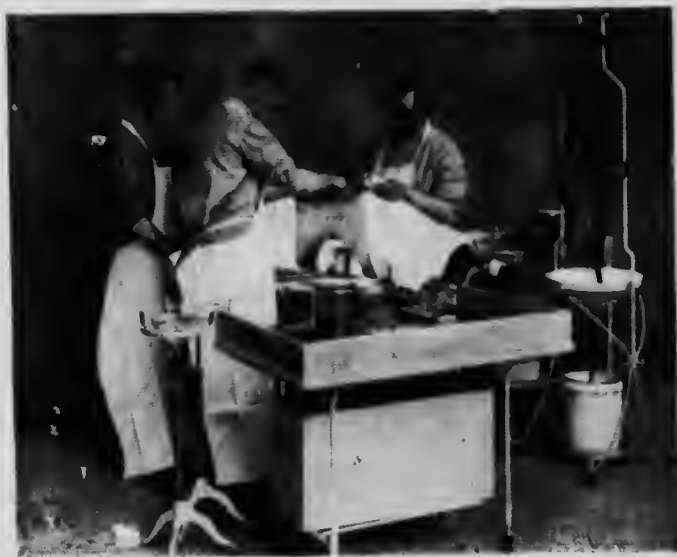

FIG. 303. — RIGHT NEPHRECTOMY.

The patient is lying on the left side; the renal region is raised by a sand cushion



FIG. 304. — EXTRACTION OF THE RECTUM BY THE SACRAL COURSE.

The patient is placed on the right side with a slight inclination towards the abdomen.

enable us to elevate it will the site of the operation (as in ablation of goitre, nephrectomy, etc.). For operations on the limbs, the patient is extended in the position of dorsal decubitus. In case of amputation of the lower limb, the healthy limb is fixed to the corresponding support, and the one to be removed is left free and held by an assistant. In dealing with a septic lesion, we envelop the affected part beforehand with a sublimate dressing and sterilized cloths, so as to avoid direct infection from the field of operation during the course of our surgical procedure. For operations of osteotomy, osseous evacuations, resections, etc., the limb to be operated on is placed on the small auxiliary table which has been already described. The other positions which it may be desirable to adopt for the patient are: the



FIG. 305. VAGINAL HYSTERECTOMY.

The patient is extended on the back; the vulva is exposed to the full light.

position for perineal section, that for vaginal hysterectomy, the declining position of Trendelenburg, and, finally, in operations on the head, the Rose position.

The position for perineal section is equally suitable for operation for vesico-vaginal fistula, colpoperineorrhaphy, ablation of hemorrhoids, and section of anal fistula. I realize this position either by the help of the leg-supporting antennae represented in Figs. 6, 7 and 16, and fixing thereto the legs and thighs, or with the aid of a broom-handle passed under the ham, and fixed behind the neck with a noose. For vaginal hysterectomy I place the patient so that the axis of the vagina is horizontal, and looking directly forward. This position, on which too much emphasis cannot be laid, is the



FIG. 306. ALVARO'S TABLE POSITION.
The patient is placed in the prone and oblique position.

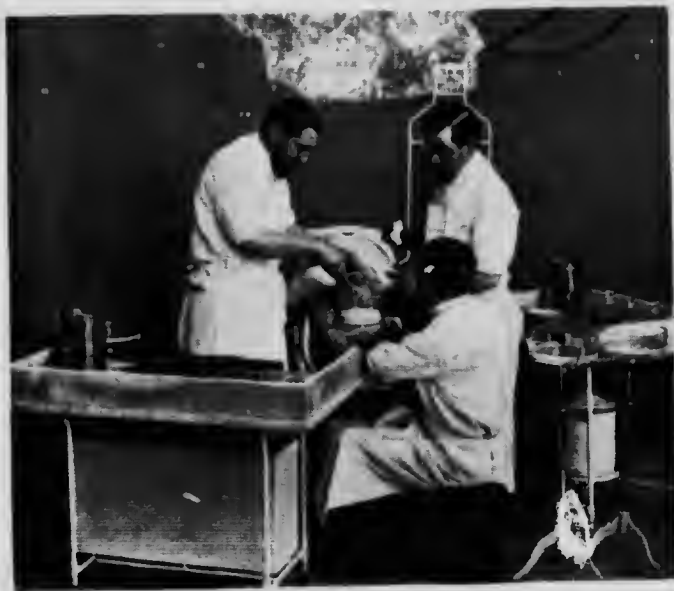

FIG. 307. OPERATION ON THE PALATINE ARCH.
Rose's position. The head is pendent; the legs are horizontal.

best not only for vaginal hysterectomy, but for operations on the body or neck of the uterus, and for those on the recto-vaginal septum. The axis of the lower strait, or section of the canal, which is slightly ascending when the legs and thighs are fully flexed, is thus brought to the horizontal or slightly declining direction. This position permits more direct traction on the pelvic organs. It is equally valuable in obstetric practice for applica-

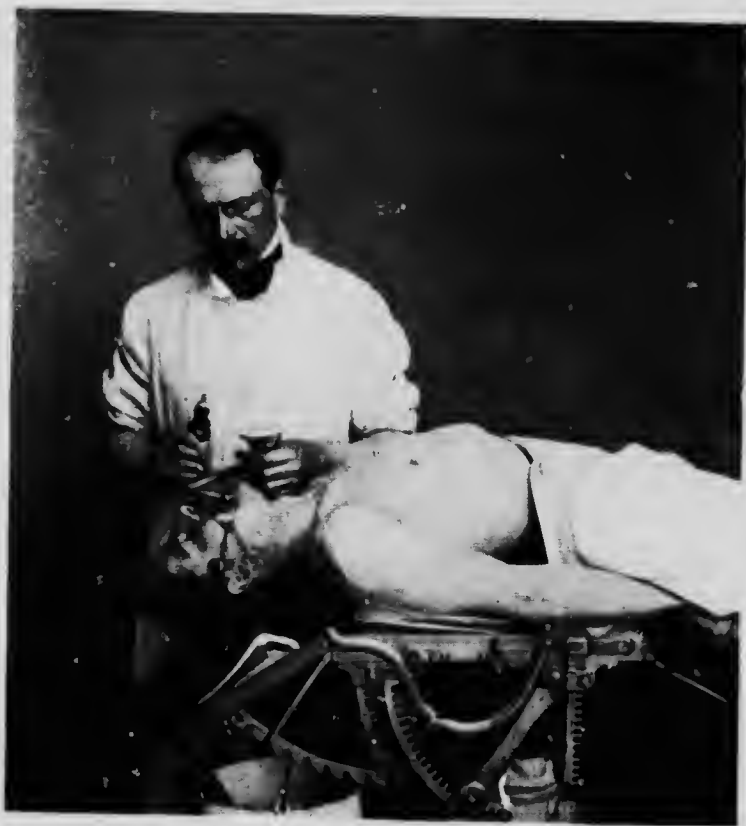

FIG. 398. TIEBAGE OF THE PHARYNX.
Direct anesthesia with Trendelenburg's funnel.

tion of the forceps and the procedure of version, both of which can be carried out with great facility on my operation table.

The Trendelenburg position is adopted in certain cases of hypogastric section and in operations on the pelvic cavity, also in cases of voluminous and adherent salpingites, fibromata so large as to justify total abdominal hysterectomy, etc. The legs are then fixed rectangularly on the supports, the length of the horizontal branch of which should be regulated by that of the

femur of the patient, while the body of the latter is so disposed that the coccyx rests exactly on the edge of the table (Fig. 306).

Finally, Rose's position is an excellent one in ablation of adenoid tumours of the pharynx or of naso-pharyngeal polypi; also in plastic operations on the palate (Fig. 307). In this position I place the leg-supports in the rectilinear position, so as to be able to draw the patient in the direction of the movable head-rest, which must be lowered so that the occiput occupies a position of forced extension. In this case, when the usual conical inhaler is inadmissible, we have recourse to tubage of the pharynx or of the larynx (see above). The chloroform is then administered from a distance by pouring drop by drop on the operculum of Trendelenburg's funnel. The special head-rest is used in operations on the eyelids or eyes. Figs. 302 to 307 indicate the respective positions of patient, operator, assistants, instrument tables, and accessories in the course of those various procedures.

CHAPTER IV THE OPERATION

Necessity of operating Rapidly and Well.

To act quickly, to abstain from every useless manœuvre such are the means of doing what is right, since the time given to the operation is then wholly employed in the interest of the patient. I have, indeed, been reproached with operating with too great rapidity. My reply is, I operate without haste, and the brief duration of my operations depends on the simplicity of my methods combined with suppression of every manœuvre and instrument that is not absolutely indispensable.

Incision of the Skin. The cutaneous incision should be made vigorously and at a single stroke, but with a lightness of hand which avoids wounding the subjacent tissues. Too vigorous an incision along the linea alba might involve a wound of the intestine or bladder. T-shaped incisions are defective, and should be exceptional. For nephrectomy or for ablation of goitre, a straight or slightly curved incision amply suffices.

Exposure and Extraction of the Tumour.—Exposure of the tumour should be immediate. We should not be delayed by those microscopic jets which spring from the skin or subcutaneous adipose tissue. Some compresses suffice to secure hæmostasis, and it is only the vessels which yield an appreciable flow of blood that are seized with hæmostatic forceps. In case of a neoplasm—and the same rules of procedure apply to all operations—it is rapidly reached, and recognized with the finger which quickly sweeps around it, explores its relations, and detaches it from its connections. This period of the operation is in most cases so brief that I have seen a fibroma of the pharynx or a small tumour of the neck actually leap from the wound, so rapid was the emuciation. If the isolation of the morbid mass has been carried out with due dexterity and celerity, the neoplasm is actually extracted before the large venous canals that furrow it have had time to yield any considerable quantity of blood. When a large artery is wounded, a forceps may be swiftly applied; or if there is special reason for haste, a simple compress, which is then controlled by an assistant. Invasion of the peritonæum calls for greater circumspection, especially in cases of uncertain diagnosis, when the intestine or bladder might unexpectedly come in contact with the cutting instrument.

Whatever be its special features, the field of operation should be exposed at once. It is then carefully examined. Sometimes an exploratory puncture is useful, followed or not by a bacteriological examination. This examination is made in the laboratory adjoining the operation theatre.

In a few minutes the tumour is fully exposed. The more abnormal the case, the more indispensable will be found that presence of mind and just appreciation of the resistance of the patient, without which a surgeon is unworthy of the name. Difficult cases demand a rapidity of decision which is so much the greater as the slightest hesitation may prove fatal. It is, above all, in the removal of large, solid subperitoneal neoplasms that the situation is prone to become really perilous. The capsule is incised, and the tumour is exposed; the patient is feeble, and the surgeon has promised not to proceed too far. The family prefer that, if the conditions seem too grave on opening the abdomen, the procedure should be left incomplete rather than the patient should be exposed to too great a risk. Such conditions are often met with. The patient has usually consulted a number of physicians without profit, and finally addressed himself in despair to him whom he had originally feared most. I have successfully operated under these conditions, especially in male patients, on tumours of extraordinary character and dimensions, immense cysts of the spleen and of the pancreas, and diffuse retroperitoneal hydatid masses of considerable volume. The first point, in presence of such difficulties, is to be able to know whether operation should be attempted. This question often reduces itself to solution of the dilemma: Is it, or is it not, a malignant neoplasm? The aspect of the patient and the signs revealed by exploration rarely deceive an observer of clear mental insight, for whom the slightest indications are proofs. The existing vital resistance of the organism may even be estimated with sufficient accuracy for limitation of the duration and extent of the operation within the vital powers of the patient. This faculty of appreciation of the vital energy and of the limit of resistance of the patient is perhaps, of all the aptitudes to be demanded of the surgeon who carries out grave operations, the most precious and the most rare.

When the operation has been decided on and the abdomen opened, the hand should recognize as quickly as possible the vascular connections of the neoplasm. This should then be rapidly isolated, decorticated, and drawn outside the wound. Thanks to Reverdin's elevator, which is very useful in such cases, I have in five minutes been able to lift out solid retroperitoneal tumours of 20 to 30 kilogrammes weight without considerable loss of blood. The vast cystic cavity, which has been instantly packed with compresses, is then carefully examined, and the bleeding vessels are secured and tied. In dealing with an ovarian cyst extensively adherent to the liver and omentum, but free in the true pelvis, on ascertaining the conditions I immediately draw towards me the uterine pedicle, which I secure with a forceps and divide, after which I detach the adhesions from below upward, and thus secure an easier mode of procedure.

The advantages of rapid enucleation of large neoplasms are the direct consequences of the arrangement of their vascular supply—and because, in accordance with indisputable anatomical conditions, the most voluminous abdominal tumours receive adventitious arteries of but small calibre, while their veins, on the other hand, are of enormous size, and emit large quantities

of blood when wounded.* The venous hemorrhage is directly proportional in amount to the duration of the operation. As soon as the tumour has been detached, the veins which groove its cellular capsule collapse of themselves, and very few of them require to be tied. Hemostasis of the large arteries is always easy to secure. Thus, rapid extirpation of neoplasms is much safer than the operations carried out slowly and with circumspection, in which abundant hemorrhage and attrition of tissues aggravate the shock of the operation. To *operate rapidly* does not mean to *operate rashly*. Rapid ablation of a neoplasm, by reducing the manœuvres of hemostasis to a minimum, diminishes in the same ratio the shock of operation. When the tumour has been removed, we seize and tie whatever bleeds. The hemorrhage is usually so slight that a small number of ligatures is sufficient. If there are many open arterioles, the larger are immediately secured. We must tie whatever is necessary to tie, but nothing more. As many as ten amputations of the breast can be carried out without having to apply more than one or two ligatures in any one operation. Sometimes not even one is required. Another operation may demand the use of five or even ten.

While recommending rapid procedure in operation, I have never advised the neglect of hemostasis, but I have shown that it may be simplified by avoiding the unnecessary application of forceps and ligatures on tissues which are not bleeding. The best procedure is that of tying the vessels separately, while the advocates of preventive hemostasis bind up voluminous pedicles, imperfectly secured by chain ligatures, and little suited for absorption. The simplification of hemostasis accordingly favours immediate union, even in the highest degree. In extraperitoneal operations I always satisfy myself that there is no bleeding before closing the external wound. The field of operation is instantly covered with sterilized compresses. These are removed after two or three minutes, and we see whether any blood issues from the depths of the wound. When this happens, the vessel is tied. If ligature appears unnecessary, the wound is plugged. After laparotomy, two or three compresses fixed on the ends of forceps are placed, one in the true pelvis, the others beneath the incision. When the suturing is nearly complete these are removed, one after the other. They should be bloodless. When there is an open vessel, one is soaked with blood. Some points of suture should then be removed, and the hemostasis completed. In case of a pelvic operation, this should be done after placing the patient in the Trendelenburg position.

A comparison between the procedures of hysterectomy, as carried out by Martin and myself, will bring into relief all the originality of the general operative method which I here present. Suppose an operation of thirty minutes. Martin, whose operative dexterity is universally recognized, but who divides the broad ligaments only after having tied and detached the tumour inside a serial chain of ligatures, spends, for instance, twenty to twenty five minutes in extirpation of the uterus. The last five or ten

* These remarks were made in 1868 by a Russian surgeon, Kraszewski, regarding the disproportion of the calibre of the arteries and veins, which is so striking in case of ovarian cysts.

minutes suffice for the toilet of the peritoneum and closure of the abdomen. Of such thirty minutes, I spend but three, four, or five in the removal of the neoplasm by my own rapid method. I then devote twenty or twenty-five minutes to haemostasis and closure of the peritoneum. I sacrifice in some instances the neoplasm, which is but a morbid production that should be completely separated from the organism; and I devote all my care to the repair of the tissues which should be helped to recover their integrity. Martin spends two-thirds or three-fourths of the time of the operation in removal of the tumour, and makes excessive haste in uniting the serous wound and in closing the abdomen. I prefer rapid removal of the tumour, and giving more time to suture of the pelvic peritoneum and the abdominal wound.

In operations for goitre, in simple cases, I finish by my own method in six to ten minutes, and with the use of four to eight ligatures; while I lose less blood than do surgeons who unnecessarily prolong the extirpation of the neoplasm for forty, fifty, sixty, one hundred minutes, and even more; while crowding the wound with forceps, and then with ligatures, both of which are mostly useless. Prolonged operations are very injurious to the patient, who suffers from these lengthy manœuvres in many cases. If the haemostasis is specially troublesome—as, for instance, in certain grave cases of exophthalmic goitre—the operation rarely lasts beyond fifteen to twenty minutes with my method inclusive of the suture of the skin. Follow my procedure, and you will find that, far from being dangerous, it is, on the contrary, simpler and safer than the methods which are apparently less risky.

Every surgeon who endeavours to shorten the period of operation by hasty application of sutures commits a grave fault. The rapid time of the procedure should be that of the extirpation of the tumour. On the other hand, the repair of the field of operation should be as complete as possible, and should last all the time necessary for a favourable issue. *The secret of your success, young surgeons, will then be that of rapid operation, but with the condition of carrying it out at the same time well and securely.* You should accordingly, aim at the outset at perfect operation in simple and easy cases, and not undertake the more complicated till after having acquired the necessary experience and dexterity. Let our continual pre-occupation be the rigid care of the interest of the human beings who entrust their existence to your charge. They demand life. You should neglect nothing in order to obtain their cure. Compare the brilliant and rapid operations which I recommend with the painfully laborious surgery of so many operators, and you will be convinced. A true appreciation of operative results, both immediate and remote, cannot fail to confirm you in regard to this great truth. The interest of the patient lies in being operated on rapidly, and a dexterous surgeon alone is capable of doing this well and simply.

The Operative Shock. How many patients actually succumb to that combination of depressing conditions which is comprised under the term "operative shock"! Every grave traumatism produces a general stupor of the organism. The typical traumatic shock is found in the con-

dition of an injured person who has just had both thighs crushed by a heavy vehicle. The accident has been brusque and of sudden occurrence. The pain and hemorrhage—there has been no wound—are in such cases nil, or nearly so. The whole being seems, nevertheless, to be effaced and stricken with stupor. Stretched out without consciousness, insensible, with pale and livid face, lips discoloured, nostrils pinched, pulse small and feeble, the injured person is under the influence of a general nervous concussion of reflex transmission. And this reflected concussion of the central nervous system may be so severe that death supervenes without visceral lesion, and without loss of blood, as the result of a progressive subsidence of the vital reaction. The prognosis is made worse by the previous existence of diseases or special dyscrasias—albuminuria, diabetes, etc.

Operative shock, which is a variety of *traumatic shock*, is proportional to the extent of the wound and duration of the operation; finally, also, to the loss of blood, which is almost always appreciable, and to which it is necessary to assimilate certain outflows of serous fluid, normal or pathological. It is manifested with special intensity in subjects affected with cancerous cachexia. The surface extent of the traumatism in subjects of operation presents the same importance as does the extent of injured surface in subjects of burns. The loss of blood or of special fluids (as in operations on the cranium or on the pleura) increases the degree of collapse either by producing general anæmia or by causing direct local complications, sinking of the brain, acute pulmonary œdema, etc. Excessive prolongation of an operation adds to the preceding factors, and presents the additional inconvenience of producing local mischief in the exposed tissues through the noxious effects of contact with the air and with the various materials used in the operation (compresses, instruments, etc.) on the living cells of the field of operation. This fact can be readily determined by ocular observation alone, if we but carefully compare before suture of the skin the fresh and satisfactory aspect of a surgical wound dexterously treated with the violet tint and ecchymotic condition of tissues too long malaxated by an operator of mediocre skill. The integrity of the tissues destined to the process of repair depends on the manual dexterity of the operator, and constitutes one of the essential conditions of a satisfactory result of the operation.

Slow and Rapid Methods of Procedure in Operative Technique.* Prolongation of the period of operation to an excessive degree has been a consequence of the approximately simultaneous discoveries of anesthesia and antiseptic methods. The question then became—Why operate rapidly? The patient is asleep and does not suffer. There were no further displays of such heroic scenes as that of the grenadier smoking his pipe while his leg was being amputated, and thus it came to pass that the double surgical conquest of pain and of infection came to mark a stage of retardation in operative technique, in which slow procedure took precedence of the somewhat brutal manly vigour of the surgeons of the pre-antiseptic period. That admirable operator, Maisonneuve, could extirpate the superior maxilla in a few minutes. Having incised the integuments, he divided the three

* Lecture to the Société de l'Internat., July 27, 1908.

apophyses with a shears of a cubit in length, and then extracted the bone, like an enormous molar, with a single movement of the elevator. The arteries were seized with a sliding-catch forceps, and the intern assistant had but to apply the ligatures.

The brief duration of operations before the discovery of antiseptics diminished greatly the nervous shock undergone by the patient, who had the advantage of feeling but for a minimum period the acute pain caused by contact of the instruments. But the slightest surgical intervention was dogged by the danger of septicaemia, erysipelas, purulent infection, hospital gangrene, and tetanus which raged everywhere, and were transmitted from one patient to another by the hands, instruments, ligatures, dressings, and bedding, which they did not know how to disinfect. Most pathologists of that period believed that purulent absorption took place through the open orifices of the veins in the wound of operation. This conception it was that inspired the invention of the *serre-nerf*, and then of the linear éraseur.

Maisonneuve's *serre-nerf* was a powerful instrument, and very different to those Lilliputian examples which were of little use except in extraction of nasal polypi. Maisonneuve even amputated the thigh with his instrument. He began the procedure by breaking the bone with a heavy blow of a mallet as it lay adjusted over blocks. The operation lasted a long time, and it was necessary to divide the skin and aponeuroses with a bistoury. When the patient groaned, he said to an assistant: "Give him a compress and let him chew it"; and, addressing himself to the sufferer: "You try to think of something else."

The chain of Chassaignac's éraseur, thanks to its alternating movements, divided the tissues more effectively than did the metallic thread of the *serre-nerf*; nevertheless, it was also necessary in using it to divide the skin, aponeuroses, and tendons with a bistoury. I refer to those now-forgotten procedures merely because they were the earliest examples of the slow methods of operation which were then taught *ex cathedra*. Chassaignac took nearly twenty-four hours to complete an amputation of the tongue with his own éraseur. Those slow procedures were inspired by the object of obtaining a greater degree of security, and preventing the accidents of infection that were then so troublesome, and which were an obstacle to even the boldest surgeons in all their tentative efforts. Operative technique was at a peculiarly hesitating stage in the period when peritoneal operations began to be generally practised. Whilst the practice of relative asepsis, which they had adopted as if by instinct, enabled the earliest ovariologists to invade the peritoneum without excessive risk, the degree of apprehension which those innovators felt prolonged to excess the time given to individual operations. The early laparotomies lasted several hours.

The more delicate technique of gastro-intestinal surgery required still greater expenditure of time. The first pylorotomies of Péan and of Billroth lasted up to five and six hours. So did the first operations of vaginal myomectomy in the Hôpital Saint-Louis. Thus we arrive at the conclusion, based on historic facts, that those slow procedures were adopted in surgical practice only because they were believed to offer greater security. The

excessive duration of operations of that period should be specially attributed to abuse of preventive hæmostasis and of slicing, which are merely round-about and uncertain methods. It was then believed that antisepsis was everything, and it was thought that, in order to carry out rigorously the method of Lister, there was more security in operating slowly, taking ample time, and always advancing with prudent caution in the field of operation. Less than twenty-five years ago I have seen ten or fifteen hæmostatic forceps placed on the subcutaneous arterioles and venules at the beginning of an ovariectomy, so that fifteen to twenty minutes had to be spent before opening the peritoneum—that is to say, before commencing the operation properly so called. Many surgeons then spent more than an hour in completing a single amputation, including hæmostasis and suturing. Accordingly, we need not be astonished at the almost incredible duration of six hours accorded to the early pylorotomies, and to certain vaginal hysterectomies by slicing. Indeed, it is evident that a surgeon who requires fifty to sixty minutes to finish an amputation would not be able to complete a resection of the pylorus within less than a certain number of hours.

When I protested in 1892 against the excessive duration of some operations, my object was not completely understood by all. Many would see therein but an unjustifiable desire to champion an operative vigour of action that was absolutely useless. My object was quite different. It matters little to the patient whether an amputation of the leg or thigh is prolonged for twenty or thirty minutes, but it is evident that a surgeon who is capable of performing a nephrectomy or pylorotomy rapidly and well would complete an amputation in much less time. I merely sustain the thesis that it is not a matter of indifference to prolong to excess the duration of one of the difficult procedures of abdominal surgery, and that such operations are likely to give favourable results only when performed with an irreplicable technique and in the briefest possible time. I wished to prove that one cannot operate rapidly and well until after a long course of manual education, and that, in order to acquire a sufficient vigour in the most delicate and prolonged operations, it is necessary first to become an operator of the first order in the ordinary current surgery.

Just as the surgeon who does not know how to complete an amputation in less than an hour must necessarily be a very mediocre operator in abdominal surgery, so must a surgeon who is thoroughly broken in to the technique of pylorotomy and hysterectomy make light work of an amputation and be able to conclude it swiftly and well in a very short time. The hand which is dexterous for one kind of operation is capable of doing all others as well. The sole object of the surgeon should be the cure of the patient; and, as there is no further question of the value of antisepsis, we have now but to choose the methods which are most susceptible of successful application. Now, as the fact is indisputable that, asepsis being absolute, wounds heal much better in proportion to their freedom from contusion during the course of operative intervention, it follows that there is an advantage in rapid detachment of the diseased part which has to be removed, and

devotion of the greater part of the time to hemostasis and dressing of the wound.

An abdominal hysterectomy, such as performed by Martin in 1892, would last in the speediest cases about thirty minutes. Martin operated with preventive hemostasis—that is to say, by a method closely analogous to that of Péan, with this difference; Péan applied forceps everywhere and divided the vessels between them, leaving the ligatures to the close of the operation; while Martin applied the ligatures immediately and divided the vessels on the distal side of each. In his technique of abdominal hysterectomy, he detached the fibromatous uterus only after the application of ten to twenty ligatures in succession; and, as he placed the ligatures only on the side nearer the broad ligament, the assistants had to sponge away continuously the blood which escaped from the open mouths of the divided vessels on the side of the tumour. With this technique Martin was unable to detach a fibromatous uterus in less than twenty to twenty-five minutes, and after its removal he had to complete the hemostasis, which was usually insufficient. There remained but one resource for the surgeon to prove that the operation did not last too long; to hasten to reach the period most important for the cure of his patient, that of treatment of the pelvic peritoneum and of closure of the wound. After such an operation the broad ligaments and pelvic cellular tissue, contused by all the movements made in application of those multiple and blindly placed sutures, were found laden with thirty to forty knots of silk or catgut, which were for the most part eliminated ultimately *per vaginam*.

On the other hand, by attacking the known connective-tissue spaces at once and limiting the ligatures to the main vascular trunks, there will be very little injury to the tissues, very little blood lost, and the tissues of the field of operation, being neatly divided, will be ready for healthy repair. Compare, as I did, as far back as 1897 (and with some additions of detail made since), my technique of abdominal hysterectomy with that taught by Martin in 1892, and it will be seen that Martin's method of ablation of the fibromatous uterus requires twenty to twenty-five ligatures and twenty to forty minutes, while my method completes it in three to four minutes, and with the use of four to six ligatures. When we proceed to the second stage of the operation—the treatment of the peritoneum and closure of the abdomen—we notice that Martin finished those parts of the procedure—the most important for the cure of the patient—in less than ten minutes; while, with my technique, for a corresponding total period of thirty minutes, the repair of the field of operation is carried out with far greater prudence and security, and costs me but twenty to twenty-five minutes. I have already cited this fact, which is absolutely demonstrative. Thus it is that I am accused of operating too fast, because I remove the tumour rapidly; while, on the contrary, I take far more care than most other surgeons with the hemostasis and repair of the field of operation.

In this very passionate discussion on the rapid and slow procedures of surgical operation, observation has generally been omitted of the fact that most of the major operations of surgery consist of two very distinct stages:

First, the *excresis*, which consists of the detachment of the diseased structure; second, the *repair*. Now, in order to complete an operation quickly and well, which means giving the patient all the chances of success, the diseased structure should be rapidly eliminated, and all necessary time and care should be given to the repair of the field of operation. The first stage of the operation should be brief, not as the result of the surgeon's haste, but because he knows how to suppress all useless manoeuvres in his technique. Follow the cellular interstices, arrive at once at the principal attachments of the tumour or organ to be extirpated; the ablation can then be rapidly completed, and with slight loss of blood, and the time of the repair of the field of operation will be also considerably abridged.

But besides these major operations which comprise the two stages just mentioned, there is another class which presents but one of these: for instance, my operation of removal of naso-pharyngeal polypi by abrasion of the basilar process. And there is still another class, including most auto-plastic operations, which consist almost exclusively of manoeuvres of repair, and are always slow in procedure. Thus are surgical operations divisible into three classes: (1) Operations which include the successive acts of *excresis* and *repair*; (2) operations limited to *excresis*; (3) *plastic* operations which are limited to repair and restoration.

At this date we can no longer *generalize* regarding the relative values of *rapidity* and slowness in surgical operations, but the controversies of recent years have led to the essentially practical conclusion that *excresis* should be effected in the *simplest possible* way, while *repair* demands the most rigorous attention to the minutie of procedure. Let us first take *excresis*. If we have to deal with a tumour, the neoplasm is isolated by taking advantage of the known anatomical cellular interstices, the vessels are seized and tied in the vicinity of implantation. In case of amputation, we carry out temporary hemostasis by digital compression, which diminishes the number of necessary ligatures—often more than doubled after a prolonged application of Esmarch's bandage. Thus there is little more than thirty seconds required by a dexterous operator in removal of a thigh; a good surgeon should be able to amputate that limb in two to three minutes at the very most.

The advantage of rapid procedure in everything concerned with *excresis* is considerable; the loss of blood is reduced to the possible *minimum*, and the field of operation is clear and ready for reunion, so that repair can be dealt with without sparing necessary time and yet without making the total period of the operation considerable. The first act, that of *excresis*, has but one aim, the separation of the diseased structure and preparation for the second, that of *repair*. It is then logical, in arranging the total period of every operation which includes these two stages, to simplify the first as much as possible, so as to be able to give all necessary time to the second, of which the good execution is the really essential condition of success.

It is necessary to do still further justice to this prejudice, that my rapid procedures of excresis consist of *hastening*. This suggestion conveys a far

too facile criticism from colleagues who do not wish to comprehend it. It is not by *haste* that I diminish the duration of the time of excision; for if we *hasten*, it is always to be feared that an imprudent manoeuvre may increase the duration of that period and, accordingly, of the whole operation, by producing some local mischief which may even prove irremediable. The period of duration of the act of *excision* depends solely on the *simplification of the technique*. It is an expression of the law of time: *a straight line is the shortest way from one point to another*.

The propositions which I have just developed are admirably demonstrated by the cinematograph. Follow on the luminous screen the total ablation of a fibromatous uterus by laparotomy, or even an amputation of the thigh, as I carry them out, you can see that the operation takes very little time, not because I make haste, but because I make no superfluous movement or even gesture. Those operations in which the act of excision lasts but some minutes permit no precipitate movement and no preoccupation of time. Every gesture is simple and precise, but it is followed by the effect required, and the hand never repeats a manoeuvre because the first gesture had been ineffective.

Let us now pass to the second act of intervention, that of *repair*. A part of its time is visible on one of my films of total abdominal hysterectomy, in which is seen the commencement of the suturing of the pelvic peritoneum. You may judge from the screen that this suture is made with such method and a precision that the duration is very short when it presents no special difficulty.

When a considerable extent of peritoneal laceration and the slight mobility of the pelvic peritoneum complicates this process of repair, the time expended thereon may amount to ten, fifteen, or twenty minutes; and we should never think of shortening it by undue haste, because it is on this repair that the life of the patient directly depends. Thus manual dexterity remains the prime qualification of the surgeon, for the operator who does not possess it cannot be master of himself. What would be the advantage of precision in diagnosis and operative indication if the *hand* were incapable of carrying out the procedure skilfully? All these examples confirm the conclusion that there should no longer be a question of whether *slow* or *rapid* procedure should be preferred in surgery. We should *operate rapidly* when there is an advantage in removing the diseased part in the least possible time, and where such rapid extirpation carries with it no danger to the patient. We should operate with *precision*, and consequently with all desirable care and *swiftness*, in those delicate cases of which the success depends on an impeccable technique.

In general, everything connected with *excision* should be done quickly and simply, and according to the indications of what I have called the *anatomical method*. Take an instance of removal of the breast and axillary glands in a case in which the tumour is mobile; circumscribe the neoplasm by two curvilinear incisions ending at an apex in the axilla, approach the pectoralis major by the supero-internal incision, and expose its surface; then proceed to the pectoralis minor, the thoracic wall, and the deep surface of the



latissimus dorsi. We have then but to detach the infero-external cutaneous flap; the mass, which includes both the diseased breast and the ganglionic packet, and is attached only above, at the level of the neuro-vascular bundle, from which we separate it in a few moments. Thus we are far removed from those amputations of the breast with cleansing of the axilla, in which the deep-seated glands were laboriously detached, one by one, with the index-finger. The operation, performed as it should be, is a dissection of the external portion and margin of the great and lesser pectoral muscles, a veritable anatomical preparation of the walls of the axillary fossa and the neuro-vascular bundle. You follow the outlines of the region with the bistoury, and the mass, which includes the mamma and the packet of axillary glands, falls into your hand. The *excresis* being concluded, we must then take the necessary time in carefully carrying out the hæmostasis, suturing, and drainage.

In gastro-intestinal surgery the *excresis* is of very special delicacy, and nothing should be neglected that promotes security. It is thus necessary to take the most minute precautions to prevent the escape of any of the gastro-intestinal contents. The period of *excresis* is simplified to an extreme degree by adoption of my method of immediate crushing, followed by application of ligature in the groove made by the *éraseur*; and, on completion of this ligature, exclusion of the stump from the peritoneal surface by a double purse-string suture. Thus gastro-intestinal operations, as regards *excresis* belong to the class which demand *relatively slow* procedure, and it is especially in such operations that excellence of results depends so largely on the manual dexterity of the surgeon.

We have already seen that certain operations consist solely of *excresis*, while others—such as the plastic—consist solely of *repair*. The first should, without exception, be carried out swiftly, while the others demand all the time and care necessary to a favourable result. Among the operations of *excresis*, which should be performed quickly and simply, are those of *opening abscesses*, evacuation of *empyema*, with or without costal resection, extirpation of naso-pharyngeal polypi, and also *temporary craniectomy*, in which, when the cranium is very vascular, the only way to prevent copious loss of blood is to proceed very rapidly. On the other hand, plastic operations and those on intestinal or vaginal fistulæ are, without exception, relatively slow operations. But it is evident that surgeons of extreme manual dexterity will carry out those delicate operations both with greater perfection and with relative rapidity.

As already noted, we must range among the *slow* procedure operations on the stomach and intestine, for the slightest technical error in such cases may be productive of irremediable accidents. And it is not less true that, while requiring to be carried out with method and precision, those operations demand from the surgeon a vigour sufficient to limit the duration to a period compatible with the safety of the patient. It is thus, too, with ligature of arteries—*e.g.*, lingual, external carotid, or hypogastric. These operations belong to the more delicate group, and consequently are of the class to be carried out with *slow movement*. Still, they can be completed

in a very short time by an experienced hand. Ablation of tumours and nearly all amputations—those of the stomach and intestine being the great exceptions—belong to the category of operations in which the act of *exeresis*, or separation of the diseased part, should be carried out quickly and simply; while the second stage—that of reparation of the field of operation—should be dealt with at a relatively slow pace, as its perfect accomplishment is one of the principal factors in the cure.

Thus there should no longer be a question of sustaining the thesis that *speed is dangerous* in operative technique. The term *speed* should not be taken in the sense of *precipitation*. A surgeon who laboriously completes a pylorotomy in three hours will obtain results inferior to those of a colleague who knows how to finish the same operation quickly and well in fifty minutes. Undue prolongation of the time produces a doubly mischievous result—(1) Unnecessary contusion of the tissues which border on the field of operation; and (2) endangering the life of the patient by the twofold increase of operative shock and risk of infection. In no case should the surgeon *hasten*, in the literal sense. The poet's metrical commandment, "*Festinu lente*," is peculiarly applicable in surgical procedure.

For instance, when we have to deal with a serious sudden hæmorrhage, it is not by precipitate movements and complicated and ill-judged methods of hæmostasis that we can overcome the danger. The duly confident surgeon remains calm in presence of such difficulties. He instantly compresses the bleeding vessel with his finger, sponges, relaxes and repeats the pressure several times, if so necessary, in finding the source of the bleeding. A single movement should place the forceps on the open vessel. By eight or ten movements, precise and preconsidered, and requiring but two or three minutes for all, the hæmorrhage is arrested without appreciable loss of blood; while if you hasten and precipitate your movements, try to pinch up the vessel before having clearly seen its orifice, you will miss it, and will not make sure of arresting the hæmorrhage till after eight or ten minutes, and after compromising the life of the patient. Success in surgery, as already observed of the practice of antiseptis, depends on the *best technique*, and the greatest quality of the surgeon is that of knowing how to execute every manœuvre with all the desirable simplicity and precision. It is as necessary to know how to enucleate a large naso-pharyngeal polypus in ten seconds as it is necessary to know how to spend an hour in the *repair* of a vaginal fistula of the ureter. We must know how to carry out in a brief time the precise and well-regulated movements which are comprised in the act of *exeresis*; we must know how to linger as long as the safety of the patient demands over the delicate manœuvres which constitute the perfect *repair* of the field of operation. The surgery of the future appertains to the most dexterous, to those possessed of the best technique.

Aspiration of the Blood and Fluids of the Wound for Cleansing of the Field of Operation and Facilitation of Hæmostasis.—In cases in which the oozing of blood is prolonged and copious enough to interfere with the continuation of the operation, and to prevent discovery of the bleeding orifice, we can move about the source of issuing blood a small sterilized tube of an aspirator, communicating through a thick-walled india-rubber tube either with an Alvergnat's vacuum tube or with a vessel of 5 or 6 litres in capacity in which a relative vacuum has been made with the aid of an aspirator. The fluids of the wound disappear instantly, and it suffices to displace the open end of the aspirator tube through a few millimetres to determine the position and dimensions of the orifice of the bleeding vessel. This artifice is invaluable in carrying out certain delicate operations, such as extirpation of the Gasserian ganglion, in which the surgeon may find his progress arrested for a time by an oozing hæmorrhage which effectively prevents proceeding with the operation.

Aspiration is also very useful in preventing the contamination of the field of operation by pathological fluids, which are invariably irritant even when not septic. I began this practice of aspiration of the fluids of the field of operation by Alvergnat's vacuum-tubes as far back as 1888 in my clinique at Rheims.

CHAPTER V

TREATMENT OF THE WOUND OF OPERATION

WHEN the operation has been completed, and haemostasis rendered satisfactory, we must proceed to the dressing. This varies according as the wound of operation is closed with or without drainage, or left open and treated by plugging.

Immediate Union.

Advantages of Immediate Union.—*Immediate union* is the ideal in surgical practice.

Ten or twelve days suffice—surgical experience has proved the clinical fact, and Cornil, by his brilliant experiments on vascular neoformations in phlebitis and on serous membranes, has furnished the scientific demonstration—to secure the complete repair of a wound and allow the patient to leave his bed. Immediate reunion should be tried for whenever there is no formal contra-indication. The essential conditions of success are—

1. Integrity of the integuments necessary to cover the field of operation without dragging.

2. Asepsis of the wound and vitality of the tissues.

When the operation has been concluded—inclusive of haemostasis, which in major operations, notably those involving the peritoneum, should always be perfect—the surgeon proceeds to the toilet of the field of operation. The application of some sterilized compresses, sometimes partial lavage with tepid saline solution in case of serous surfaces—for example, in the true pelvis—precedes the application of sutures. *Immediate union* depends more on the sound union of the skin than on the coaptation, by deep sutures, of the subjacent tissues—notably of the subcutaneous adipose tissue. *Deep sutures* are useless in amputations of the limbs, ablation of the breast, of subcutaneous neoplasms, etc. I reserve them for those cases in which they fulfil a definite function—closure of a serous cavity, junction of aponeurotic strata, union of tendons, of nerves, etc. Except in these cases, in which the union of special tissues is to be carried out at separate points, and with fine silk, I suture the skin only.

This suturing is preferably carried out with clips. Suturing with ilk or Florentine hair is advantageous only when clips cannot be applied (hairy scalp, exaggerated tension of the skin along the line of union, etc.). Folding of the skin should be carefully avoided. In suturing with silk or hair the needle should rarely pass to a depth of more than 5 or 6 millimetres. In cases in which folding is to be dreaded, I place superficial and

deep points of suture alternately—the latter moderately tightened, so as to avoid strangulation of the tissues. The deeper sutures should, on the latter account, be removed on the second or third day. It is easy, with the use of my clawed and rack forceps (Fig. 100), to apply sutures on even an extended scale without an assistant. For this purpose the edges of the wound can be first approximated at several points by the application of several of these forceps. The adjustment having been made, the suturing is carried out—interrupted or continuous, according to choice. Florentine hair is the best of all materials for suturing of the skin, by reason of its strength and its toleration by the living tissues. Sterilized catgut gives excellent results when there is no tension along the line of suture. Silk is, however, the material oftenest used, as it is always ready to hand.

Parallel of Immediate and Secondary Union.

Wounds should be classed in two categories—

- A. *Aseptic*, in which immediate union may be aimed at.
- B. *Contused and infected*, in which immediate union is dangerous.

A. **Wounds which are Aseptic, or may be regarded as such**—1. **SUPERFICIAL WOUNDS.**—Wounds of the skin and subcutaneous tissue, when clean-cut, aseptic, and without extensive detachment, may be united without drainage, especially if the topography of the region permits the employment of a compressive dressing. We can then at any time remove a point of suture and drain, if any retention of fluid has taken place beneath the line of union. If drainage is preferred, we insert at the most dependent angle of the wound a bundle of Florentine hairs, or a small drainage-tube of glass or india-rubber. I employ glass almost exclusively, as it is better tolerated than india-rubber, and the tube offers a larger lumen for the same external diameter. India-rubber drains are reserved for cases in which glass would be too rigid, or too much exposed to breakage. Union of the abdominal walls after laparotomy is usually effected without drainage. I use small glass drains sometimes, but only in fat patients, or when the field of operation is liable to infection—hypogastric section, appendicitis, suppurative cholecystitis, etc.

2. **DEEP WOUNDS—REMOVAL OF TISSUES, SUPERFICIAL OR DEEP.**—When a wound is deep, or complicated by the removal of a mass of tissue of some importance, drainage is indicated. Thus amputation stumps, the lateral thoracic region after removal of the breast, and the cervical region after ablation of goitre, should always be carefully drained. I habitually place two glass drains of appropriate length in the most dependent positions. Rubber drains should be preferred to glass in cases of pleurotomy, and in some articular resections where glass tubes would risk being broken between two osseous surfaces.

3. **DRAINAGE OF THE GREAT SEROUS CAVITIES.**—The large serous cavities, visceral and articular, should be closed without drainage whenever the wound can be regarded as aseptic, and the state of the membrane does not

imply a sero-sanguinolent oozing of a certain abundance. My rule is to close the knee-joint after extraction of foreign bodies when no complex intra-articular manoeuvres had been required; it is the same for the peritoneum after ablation of non-suppurating ovarian cysts. The knee-joint is drained when the synovial membrane is flocculent, inflamed, or has bled during the operation. The peritoneum is seldom drained; but when there has been a great deal of tearing of the pelvic serous lining, or when, in spite of adjustment and suturing, an unmanageable sanguinolent oozing persists in the depth of the cavity, the posterior *cul-de-sac* of the vagina is incised, one or two large glass drains are introduced, and an aseptic compress is placed thereon; the drained region is then isolated from the rest of the peritoneum by a delicate continuous suture attaching the peritoneum of the broad ligaments and bladder to that of the neighbourhood of the caecum, rectum, and sigmoid flexure. A complete partition is thus made, which shuts off from the general peritoneum that of the pelvic cavity, in which the drains and compress are placed.

B. Contused and Infected Wounds.—Contused and infected wounds should be treated in exactly the same way. The former are very subject to infection on account of the slight resisting power of the bruised and torn tissues. Both demand the most careful drainage of all the fluids which might propagate infection. Here glass and rubber drains must both give place to antiseptic plugging with compresses of sterilized gauze, soaked or not in phenol solution (2 per cent.), oxygenated water (5 or 10 per cent.), or Labarraque's liquid (5 or 10 per cent.). The wound should be distended in all its recesses. If large masses of tissue have been removed, it is well to make counter-openings and insert drains therein. It is important to prevent all retention of fluids in the deep parts. Tamponing with absorbent gauze is far better in those cases than simple tubular drainage, because the gauze finds its way into the slightest depressions of the wound, from which it extracts the fluids by capillarity. When any elevation of temperature occurs, seek at once for a focus of retention. A combination of plugging and drainage may be perfectly adapted to continuous irrigation, especially in the limbs. The gauze serves simultaneously to aspirate the fluids of the wound, and to enable the antiseptic fluid used for irrigation to penetrate into all its recesses. On the trunk, infected wounds of a certain extent are treated by temporary antiseptic plugging, with alternating periods of antiseptic powdering.

Extensive foci of suppurative appendicitis and pelviperitonitis, suppurating hydatid cysts, etc., are treated by tamponing. It is sometimes imprudent to place a plug of gauze directly between the free loops of intestine, and the cavity which we think necessary to plug should be isolated from the rest of the peritoneum by sutures if no inflammatory adhesions have already formed. If the peritoneal plugging is deep, it is well to place between the gauze and the investing wall one or two vertical drains. The treatment of an infected wound by plugging does not always exclude a partial reunion of the cutaneous incision. This partial reunion should be aimed at in every case in which it can considerably accelerate the healing.

The sutures can be extracted on the least alarm. I will now recur to the questions of drainage and plugging, and we shall also study the treatment of contused and infected wounds by continuous irrigation.

I. DRAINAGE.

Every wound of a certain extent furnishes, for a good many days, a sero-sanguinolent discharge, of which the retention exposes the patient



FIG. 300. — GLASS DRAINAGE-TUBES.

Drains for aseptic drainage of the peritoneum, large and small. Drains for drainage of peritoneum or large cavities, with lateral orifice, large and small. Perforated drains for current operations, large and small.

to the gravest accidents. Many wounds, indeed, heal without accident, although a strict examination of the fluid of the drainage-tubes shows the presence of some bacteria. The microbes sown on the field of operation are floated off in the sero-sanguinolent outflow. In fact, blood-

serum is not a very favourable culture medium when the bacteria are few, and healthy tissues only permit invasion when the development of pathogenic microbes has reached a certain degree. It is thus advantageous to change the external dressing every time that it is soaked with the oozing fluid of the wound. When a dressing originally aseptic has been left many days, it is rare to find that microbes from without have not developed in the serosity of that dressing, whence they soon contaminate the field of operation and the interior of the drains. Retention of the fluids of the wound is followed by similar accidents. It rarely happens that any germ, coming from air or skin, and following, for example, a line of suture, does not there become cultivated, as in a closed vessel, and form the starting-point of a more or less grave septicæmia.

If we have to deal with an operation for the evacuation of a purulent focus, the accidents due to stagnation of the fluids of the wound are still more obvious. The slightest elevation of temperature is an index; it is the "fever of retention." Examine the field of operation carefully—explore it with a long curved forceps—and you will discover a purulent or sero-purulent focus, immediate drainage of which will cause all accidents to disappear. *All stagnation* of fluids, normal as well as pathological, should be avoided.

The drainage of those liquids is secured sometimes by the insertion of drains at the most dependent points, sometimes by the application of pellets or large plugs of antiseptic gauze. I usually combine aseptic tamponing with drainage by glass tubes. I now proceed to examine the general rules for drainage, the selection of tubes, and the details of tamponing and combination of same with drainage.

2. TAMPONING OF WOUNDS.

When the tissues are bruised and infected, immediate union should always be proscribed as dangerous. Any small blood-clot thereby retained in a crevice of wound rapidly becomes the prey of bacteria, and the starting-point of a septicæmia which is all the more formidable inasmuch as the neighbouring tissues, bruised and lacerated, are deprived of vital resistance. Extensive purulent foci, and visceral or retroperitoneal hydatid sacs which cannot be totally extirpated, should always be treated by tamponing*. Also, with rare exceptions, osseous cavities which have been evacuated for tuberculous disease or osteomyelitis, etc.

I practise tamponing with simple sterilized compresses—either dry, or soaked in an antiseptic and non-irritating solution (see p. 61 *et seq.*). This process isolates the infected or threatened tissues, and secures the escape of the fluids of the wound by capillarity. In clinical practice we tampon sometimes *aseptic wounds*, and sometimes *infected ones*. The procedure varies in the different cases.

1. *Aseptic Wounds*.—Tamponing, which is carried out in these cases with *simple sterilized gauze*, is oftenest meant to ward off secondary infec-

* Communication to the Congrès pour l'Avancement des Sciences, August 13, 1889.
VOL. I. 18

tion of a serous cavity opened at one point of the wound, and which suturing would be powerless to protect (opening of knee-joint at the tibial surface in an osseous evacuation, cholecystotomy with embedded suture, etc.). In such cases the compresses remain odourless. They are withdrawn at the end of three or four days. The secondary union takes place, without suppuration, two or three days later.

Hemostatic Tamponing, with Provisional Closure of the Skin Wound.—When there is oozing hemorrhage, as after ablation of the parotid gland, we tampon with an aseptic compress, and suture the cutaneous wound completely with silk or by applying clips. Then a compressive dressing is applied. It suffices to keep these wounds tamponed and closed for twenty-four to forty-eight hours. The compresses are removed after two days at most, after partial separation of the adjusted edges of the wound. These are then brought together immediately, and the wound is drained.

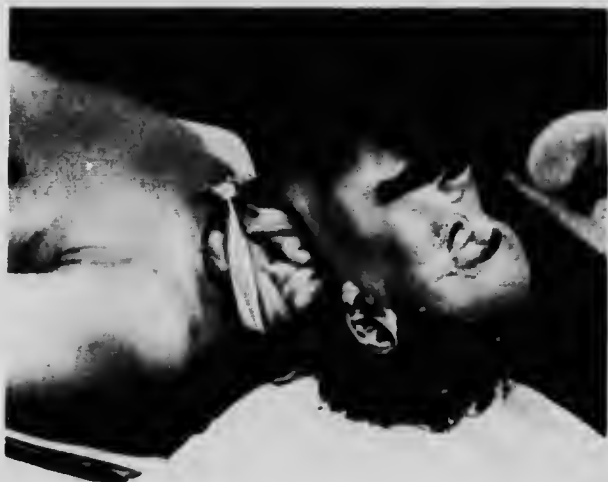

FIG. 310. TAMPONING OF THE WOUND MADE IN ABLATION OF CANCER OF THE BASE OF THE TONGUE AND CERVICAL GLANDS.

2. *Infected Wounds.*—When a wound is infected, or when we are dealing with the natural cavities (vagina, rectum), the tampon usually exhales a fetid odour on the second or third day. Those wounds, not being able to heal but by secondary union, and after suppuration, what matters what disagreeable odour if the presence of the tampon prevents the occurrence of local septicæmic accidents or infection at a distance, while securing—for example, after vaginal hysterectomy—rapid closure of the peritoneal cavity. Pulse and temperature are carefully watched in such cases, and the tampon, even when smelling, should be left in position for four, five, or six days if the patient remains apyretic. When the deep union has been effected, we may remove the compress and practise repeated lavage, or, when preferable,

apply twice a day fresh compresses soaked in sublimate or some other antiseptic solution.

Tamponing is also the best mode of treatment of simple abscesses of some considerable size—large mammary abscesses, for example. The suppurating cavity is freely opened under chloroform, and emptied; then, after antiseptic lavage, explored with the finger, which is directed into the various recesses, and breaks down all partitions capable of obstructing the penetration of the gauze compress. The latter is removed at the end of four or five days, and replaced by another much smaller one.

The compresses are detached by wetting them with a 20 per cent. solution of oxygenated water. The compress swells and separates without causing pain. If not, we can administer a little ethyl chloride. When the wound granulates, tamponing becomes useless. Nevertheless, it is well to keep the cutaneous orifice open till the deep part has been definitely filled up.

In addition to its favourable action where septicaemia is threatened, tamponing is also the procedure to be chosen in some other cases, notably for the arrest of oozing haemorrhages. Thus tamponing of the serous cavities and of certain wounds which yield a large sanguineous outflow enables us to dispense with the prolonged application of a quantity of unnecessary ligatures, by combining it with a compressive dressing.

3. CONTINUOUS IRRIGATION IN CASES OF CONTUSED WOUNDS OF THE LIMBS, AND IN CASES OF INFECTIVE SUPPURATION.

In some cases of contused and infected accidental wounds the treatment by tamponing, with application of moist antiseptic dressing, may not give sufficient security; and even the continuous bath, which is seldom applicable, except to the hand and forearm, is often badly borne.

I have always, since the first years of my medical studies, been in the habit—following an ancient practice—of treating those wounds by *continuous irrigation*. The crushed limb is placed on the edge of the bed, on a waxed cloth covered with gauze compresses, over which flows in a thin stream water from a vessel placed about 1.5 metres above. Ever since my intern hospital experience at Rheims, I have obtained most remarkable results from continuous irrigation of contused wounds of the limbs—partial crushing of the hands and feet, compound luxations, and complicated fractures. Continuous irrigation is, then, a most valuable resource. It gives unhopèd for results in cases of grave or multiple phlegmon, in osteomyelitis, and, in general, in every case in which a purulent focus is accompanied by a general disquieting condition. Formerly it was practised with pure water; to-day it is better to combine it with antiseptics, and add to the boiled water a small proportion of phenol 1 per cent., or of Labarraque's fluid—5 or 10 per cent., or so—or a 5 or 10 per cent. dilution of oxygenated water. The results are remarkable. Suppose the case of a finger crushed in a cog-wheel, or a contused wound of the hand or wrist, produced by the explosion of some firearm. It is difficult to disinfect those lacerated tissues, blackened by the carbon and the products of deflagration of the powder, and often studded

with osseous fragments—either free or adherent to strips of tendon and of periosteum. Such wounds are specially liable to partial mortification. Then what should the surgeon do? Amputation is a very radical procedure, especially in case of the hand, where repair is so readily carried out; the naturally imperfect hold given by the thumb and some remains of the palm and phalanges is surely better than that of the most remarkable of prosthetic apparatus. The sole reliable mode of treatment, which also permits us to await without increased danger the demarcation of the mortified parts, is, in such cases, that by continuous irrigation. The liquid employed should be at the temperature of the room, which is usually from about 14° C. (57.2° F.) to 18° C. (64.4° F.). A lower temperature is rarely tolerated.

The irrigation is carried out vigorously at first, afterwards drop by drop. The sinuous portions of the wound should be padded with wicks of gauze, so as to make sure of access of the antiseptic fluid by capillary attraction. The low temperature of the fluid is one of the main factors in the cure; pyogenic microbes flourish but little at a temperature below 18° C. (64.4° F.). Then the mechanical action of the water on the surface of the wound, where all stagnation of septic fluid is thereby prevented, is equally a preservative from infection. How often have I found that if the continuous irrigation was stopped on account of the apparently satisfactory conditions, both general and local, rapid development of fever and inflammatory accidents, which had previously been absent, was the result! Large baths and lavages at long intervals with more concentrated antiseptic solutions, combined with fixed moist dressings, are usually ineffective; and the wound takes on an unhealthy aspect in twenty-four hours. Re-establish the continuous irrigation, and orderly progress is restored at once. Granulation proceeds well under continuous irrigation, suppuration is almost nil, and the mortified parts are detached in two or three weeks, without pain or other inflammatory conditions.

Surgical intervention is then called for, to trim off the useless debris without destruction of a possibly useful particle of tissue. Thus, at the beginning of my intern hospital practice at Rheims, on meeting with a case of hand and wrist crushed by clogged wheels, in which amputation of the forearm seemed necessary at first, I was able, by the use of continuous irrigation, while sacrificing the three intermediate digits with the corresponding metacarpal bones and a portion of the carpus, which were completely crushed, to rehabilitate a mobile and appposable thumb and articular digit. This mode of procedure is specially useful in the country, too, where the wounded cannot always be placed under enlightened supervision. The practitioner can easily find persons who will fill, when necessary, the receptacle with cold boiled water slightly phenolized, and will thus be able, by making a short daily visit, to obtain a rapid and satisfactory cure. A daily subcutaneous injection of 10 to 20 c.c. of mycolysine (see p. 282 *et seq.*) should also be administered. If the wound is contused and soiled with mud or earth from the fields, a *parentine injection of antitetanic serum* should also be given, which must be repeated after six or eight days.

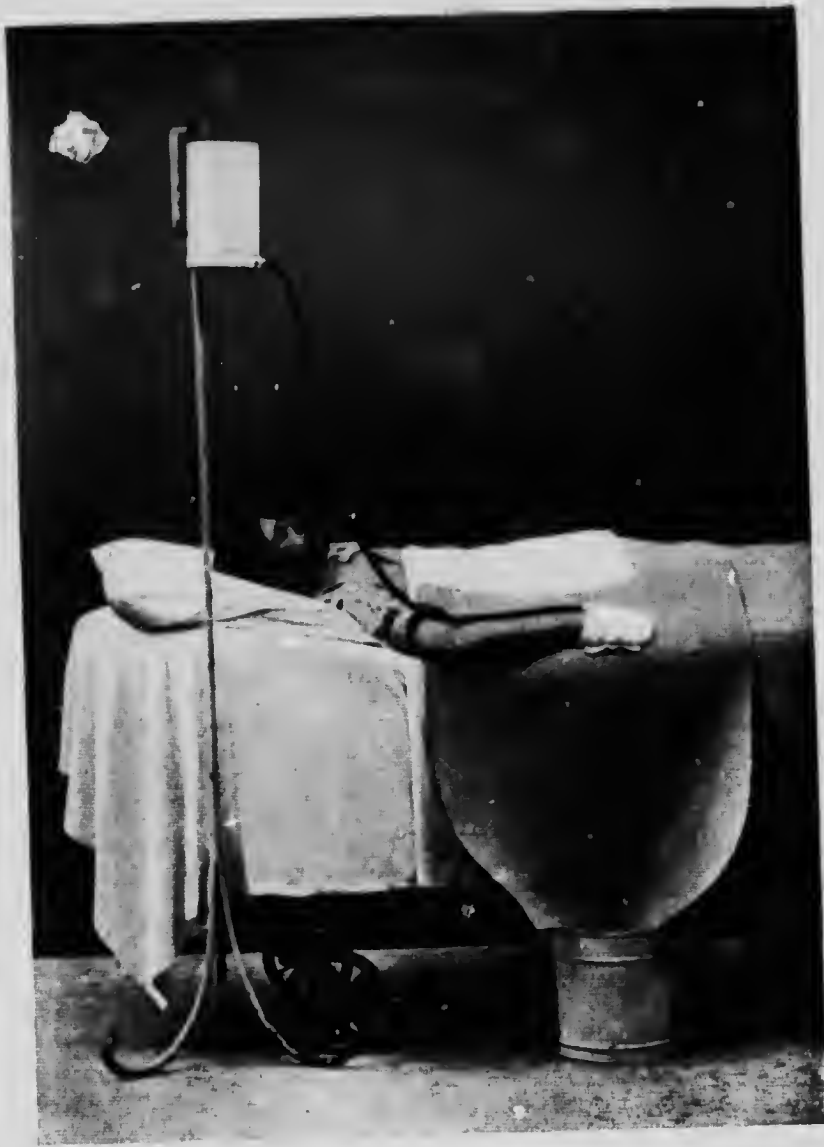

FIG. 311.—CONTINUOUS IRRIGATION IN A CASE OF CRUSHING OF THE HAND.

278 SURGICAL THERAPEUTICS AND OPERATIVE TECHNIQUE

Continuous irrigation is also the only really efficacious treatment in cases of infection of the uterine cavity. It can be set up after careful evacuation of the uterus with a blunt curette, or gouge-forceps, and it should be continued for a week after the fall of temperature has proved to be complete and definitive.

4. TREATMENT OF OPEN WOUNDS BY ANTISEPTIC POWDERING.

Continuous irrigation is hardly applicable to the trunk or to the proximal portions of the ribs. When an accidental or surgical wound




FIG. 312. —PULVERIZER OF J. LUCAS-CHAMPONNIÈRE.

of those regions presents a disquieting aspect—such, for instance, as in case of a large anthrax on the back, or a nephrotomy incision in a feeble and previously infected patient—we replace the continuous irrigation by antiseptic pulverization. This is practised, according to Verneuil's method, several hours daily by means of J. Champonnière's vapour pulverizer (Fig. 312). If the odour of phenol provokes coughing, we substitute for the phenolized water a 2 per cent. solution of resorein or a 10 per cent. dilution of Labarraque's fluid. Antiseptic pulverization is remarkably efficacious: the wound cleans in a few days, takes on a satisfactory appearance, and begins to heal. We then substitute a moist dressing for the spray.

5. THE DRESSING.

The dressing should be simple and aseptic. The line of sutures is cleansed by soaping with protéol, and then covered with aseptic gauze, which is retained with a piece of Vigier sparadrap. In laparotomy, if we fear a dangerous tearing of the surface of union, a long and broad band of the same is applied circularly, like an obstetric binder over the dressing, and is removed only after four to eight days. This adhesive circular bandage prevents any dragging on the deep sutures.

In every case in which the wound, whether drained or tamponed, yields an abundant flow of serosity, the aseptic compress is covered with a sufficiently thick layer of sterilized absorbent cotton, and we arrange at the lowest point—where the absorbent cotton should be in sufficient quantity—an impermeable leaf of laminated gutta-percha or gummed taffetas. Moist tamponing should be reserved for infected wounds. It is very advantageous when the fluids of the wound are of irritant quality, as in stercooral fistula, to soak the compresses in a 1 per cent. solution of sodium bicarbonate.

6. RENEWAL OF DRESSING—LAVAGE OF WOUNDS—CHANGE OF DRAINS AND OF GAUZE PLUGS.

When the wound has united without drainage, and all goes well besides, the dressing should not be renewed till the eighth day. If there be pain, fever, or local oozing, the state of the sutures should be examined on the second or third day. The clips, or Florentine hairs, are removed sometime between the third and fourth day, either at a single sitting or several, according to the position of the wound and the depth of the sutures. The deep threads, when there are any, should be cut on the second or third day.

When the wound of operation has been drained or plugged, there is a fairly copious sero-sanguinolent sweating during the early days. In those cases, the absorbent part of the dressing should be renewed as often as necessary. When such oozing is considerable, as in cases of enormous retroperitoneal cysts, the dressing should be renewed twice a day. We can then, with advantage, place large masses of wood fibre soaked in sublimate solution at the lower part of the wound. Frequent renewal of the outer absorbent layers of the dressing is the only means of avoiding infection of the wound, an accident which does not fail to occur when the fluids reach the surface of the dressing, where they always putrefy. In this way occurred a fatal case which I saw at the Rheims hospital, in which, after a very simple operation on a mammary tumour, a female patient suddenly contracted erysipelas. Renewal of the dressings had been neglected during the first three days; the fluids of the wound flowed round to the patient's back, where they were infected by contact with the mattress, which had previously been contaminated by streptococcal pus. I could cite many similar cases.

When the wound has been drained, it is generally useless to remove the

drainage-tubes on the first change of dressings, as it might be difficult to replace them. But from the third day they should be lifted out at each dressing, soaked in phenolized water or sublimate solution, and then returned to their places. When the wound has united, we should never use the smallest antiseptic injection in the passage left by the drainage-tubes sooner than the eighth or tenth day. A premature injection may compromise the process of deep union.

At the end of eight or ten days cicatrization of the uniting surfaces has taken place. If a fistulous opening remains, injections of a 2 per cent. phenol solution or a 20 per cent. oxygenated water will hasten the cicatrization by removing all traces of suppuration. When the field of operation is strongly infected, local swelling appears soon after the operation, with fever and general symptoms of disorder. In such cases it is best to remove all sutures at once, and have recourse to moist tamponing or antiseptic powdering. Injections of 20 c.c. of mycolysine should then be made three times a day.

INFECTIOUS DISEASES IN THEIR RELATIONS WITH SURGERY.

- (1) Suppuration: peritonitis; broncho-pneumonia; septicaemia; action of mycolysine, preventive and curative. (2) Tuberculosis: specific treatment and phymalose. (3) Cancer: Etiology. Diagnosis by a specific reaction with blood-serum. Treatment of deep-seated cancers by vaccination with toxins and the dead cells of *Micrococcus neoformans*. Treatment of superficial cancers by thermic electro-coagulation.

The infectious diseases against which the surgeon has to struggle every day are legion. From my very first years of the study of surgery I found that the methods of antiseptics, the object of which is to proscribe all external germs, frequently proved powerless to prevent infection. When infection supervenes, whether the germs have come from without or have pre-existed at the seat of the pathological lesion, the surgeon is obliged to second the efforts of Nature by evacuating and draining the purulent foci. When we find ourselves in the presence of other complications of wounds, we soon ascertain the fact that there exists, in the whole official armamentarium of therapeutics, no effective mode of treatment of erysipelas, of gaseous gangrene, of peritonitis, of septicaemia, or yet of broncho-pneumonia, which is one of the most fatal of the medical complications of the major operations of surgery.

I decided to investigate these diseases from the point of view of etiology and of pathology. And the biological and bacteriological researches which I pursued with this object have enabled me to establish a new form of therapeutics, which is based on stimulation of the phagocytes. I shall here sketch the results of these researches in a few lines. In 1881 and 1882 I commenced the study of the pathological histology

and bacteriology of erysipelas, of surgical suppuration, of osteomyelitis, and of tuberculosis. In 1884, having become a pupil of Professor Cornil, I obtained in his laboratory the first cultures of the comma bacillus of Asiatic cholera and of the *Bacillus typhosus* that were seen in France.

Having graduated as Doctor of Medicine in 1885, I settled in Rheims, my native city. I furnished a laboratory of bacteriology and histology at my own residence, in which I pursued the study of surgical suppurations. In the same year, too, I commenced the study of cancer, and discovered the *Micrococcus neoformans*. My first researches on cancer were summarized in a sealed communication deposited with Académie des Sciences, August 15, 1886.

In 1887 and 1888 I studied rabies, tetanus, gaseous gangrene, and urinary septicaemia; I established the identity of *Streptococcus pyogenes*, of the streptococcus of erysipelas, and of the streptococcus of puerperal fever. During the same period, and as a preparation for further researches on unknown microbes, I studied methodically all the species of microbes which up to that date had been successfully cultivated, including the moulds, saccharomycetes, and torulae, as well as the varieties of streptotrix and spirillum. In 1889 I was commissioned by the director of the Bureau of Hygiene of the city of Rheims to study the bacteriology of the potable waters of the city and neighbouring reservoirs in their relations with infectious diseases. In the same year I studied the etiology of eruptive fevers and of *la grippe* with their respective complications.

Side by side with my laboratory of histology and bacteriology I had arranged a laboratory for microscopic photography, in order to photograph the most interesting of my specimens and thus preserve precise documents for future reference and instruction; then, from 1890 to 1895, I completed those works of research by the study of ptomaines, of leucomaines, and of microbial toxins. Down to 1896—the date at which I settled definitely in Paris—my researches were limited to the etiology, pathological anatomy, and bacteriology of the infectious diseases of the human organism.

It was at that date when, having just acquired a knowledge of the earliest results obtained against furunculosis by the ingestion of beer yeast, I proceeded to investigation of this new therapeutic item. The use of crude yeast appeared to me to be too empirical, and I resolved to seek for its active essence. My experience of chemical manipulations enabled me to discover this active substance at the close of some months of research, and I afterwards determined its presence experimentally in every one of the series of natural ferments.

I then studied the therapeutic action of my preparations on furunculosis, and all other varieties of infectious diseases which presented themselves to my observation. By this means I determined their polyvalent action on a certain number of infectious diseases, notably pneumonia, erysipelas, puerperal infection, blenorhagic infection, and many infectious diseases of the respiratory and digestive apparatus. Examination of the blood demonstrated a rapid and continuous hyperleucocytosis in the patients under treatment; and I have been enabled by the results of methodically

conducted experiments, to define this biological form of therapeusis within precise limits. Those experiments have been controlled, in 1913, by Professor Yamanouchi, in Professor Metchnikoff's laboratory at the Institut Pasteur. Professor Yamanouchi has demonstrated the fact that the active substance of *mycolysine* acts by stimulating the leucocytes, of which it increases the phagocytic powers.

In my laboratory in Paris I continued my researches on cancer. In 1900 I succeeded in cultivating the microbe which I had discovered in 1886, and I named it *Micrococcus neoformans*. I immediately prepared a toxin from those cultures, analogous to Koch's tuberculin, and, beginning in 1901, I studied continuously the vaccination and serotherapy of cancer. In 1906, after having ascertained that anti-cancerous vaccination had much less effect on superficial cancers than on deep ones, I studied the effects of the various physical agents which seemed to me most capable of destroying them. After having recognized the insufficiency of the action of the X rays, I experimented with that of superheated air and of superheated vapour. Those preliminary essays demonstrated to me the fragility of cancer cells and the possibility of killing them by a temperature of 56° C. to 58° C. (132.8° F. to 136.4° F.)—that is to say, by a temperature below 60° C. (140° F.), which begins to destroy the healthy cells. I have experimented with radium: I have established the fact of its impotence in presence of confirmed cancer. On studying fulguration, the name given by Pozzi to the application according to Keating-Hart of sparks of high frequency and high tension, I found that this procedure was also ineffective.

Being convinced that heat was alone capable of destroying cancer cells, I studied the different ways of producing heat by high-frequency currents. Methodically conducted experiments enabled me, towards the end of 1897, to determine the characteristics of the indispensable apparatus. At the close of those experiments I had a new form of apparatus constructed for me by the Maison Gaiffe, of Paris, which enabled me to pass penetrating thermal currents of considerable intensity into the cancerous tissues (up to 10 ampères).

In that same year, having been encouraged by the results which I obtained against cancer by the combination of my anti-neoplastic vaccine and mycolysine, I devised, after the success of that anti-cancerous vaccination, a new method of anti-tuberculous vaccination. I submitted tuberculous patients to the action of mycolysine, and ascertained what dose of tuberculin could be borne at the same time; and I established the fact that tuberculous patients who had been submitted to the action of mycolysine, instead of being very sensitive to tuberculin, were able to support much larger doses of this toxin without inconvenience. I thus came to succeed in arranging the dosage of tuberculin and mycolysine in such a way as to produce by their combination a specific immunization against the bacillus of Koch.

1. Treatment Preventive and Curative of Suppuration, Bronchitis, Broncho-Pneumonia, Septicæmia and the Greater Number of Infectious Diseases by the Phagogenic Method.

As already mentioned, I have given the name of MYCOLYSINE to the preparation which I employ in combating acute infectious diseases, and which may be administered either by the mouth or by injection. The following extract gives the first pages and the conclusions of Professor Yamanouchi's memoir:

THE METCHNIKOFF LABORATORY: EXPERIMENTAL RESEARCHES ON A POLYVALENT THERAPEUTIC METHOD BASED ON THE STIMULATION OF PHAGOCYTES.*

By his experiments on intracellular digestion and on the rôle of the amœboid cells of the mesoderm, to which he has given the name of "phagocytes," Metchnikoff has given us the key to certain biological phenomena. The only phagocytes of the lower animals are the macrophages, which are mononuclear amœboid cells. In the higher animals those cells concur in the process of resorption of such organs as are destined to atrophy (such as the tail of the tadpole), as well as in the destruction of weakened or senile cells; they also, in exceptional cases, take a part in the struggle against the microbes (in chronic diseases). The polymuclear leucocytes, or microphages, are present in the higher animals. They convey the materials of assimilation and dissimilation; besides, they defend the organism against poisons, animal venoms, toxins, and microbes.

Thus the phagocytes are engaged at every instant of our normal and pathological life in playing a capital rôle. The following are the conclusions of Metchnikoff in his Nobel Lecture at Stockholm, May 14, 1909: "Everything which is capable of strengthening the phagocytes and of stimulating their activity increases at the same time the resistance of the organism against infectious diseases. The state of immunity is characterized by the intensity of the phagocytic process; when the disease is established, a very active phagocytosis is a favourable item of prognosis, inasmuch as it tends to cure by favouring the destruction and elimination of all noxious substances of pathological origin." And he adds, in conclusion: "Permit us to hope for the discovery, in the near future, of a new prophylactic and therapeutic method of combating infectious diseases—a method based on the reinforcement of the phagocytosis."

What are the stages of advancement that have been realized in this direction? Two factors have to be considered—augmentation of the number of the parasites and augmentation of their phagocytic activity. Hyperleucocytosis is present in all cases of suppuration proceeding to terminate in cure; it also exists in animals treated with the seton, and it is to its presence that should be attributed the cures: rarely obtained in case of human patients by the action of the seton or artery. We can pro-

* Control experiments made at the Pasteur Institut in the laboratory of Professor Metchnikoff (*Annales de l'Inst. Past.*, April, 1914, p. 420).

voke hyperleucocytosis artificially by injecting, hypodermically or into the general circulation, isotonic solutions of nucleinate of soda or of colloidal silver.

Doyen has produced a new immunizing preparation, which he extracts from selected alcoholic ferments, and to which he has given the name of *mycolysine*. This preparation is used in two forms, of which one is for drinking and the other for injection. It acts, according to Doyen, by stimulating simultaneously the processes of leucocytosis and phagocytosis; its action is polyvalent, and the organism, under its influence, becomes invulnerable to a certain number of microbes. According to Doyen, mycolysine acts as a preventive in presence of a threatening infection, and acts equally against the developed disease; while, in the latter case, its activity is so much the more rapid in proportion as it is employed at a date nearer the onset of the infection. The active principle of the mycolysine used for injection is a nitrogenous substance of vegetable origin, of which a chemical analysis reveals its presence in the proportion of about 6 per cent.

Having observed the therapeutic effects of mycolysine in man, in a certain number of diseases—staphylococcosis, pneumococcosis, gaseous gangrene, infection by the *Bacterium coli*—I thought it would be of interest to study the mode of action of this therapeutic agent, both on man and on the animals used in the laboratory, and I also compared the effects of mycolysine with those of nucleinate of soda and of colloidal silver. For sake of greater precision, I used the hypodermic method of administration. The doses of mycolysine which may be injected have varied in man from 10 to 50 c.c. In the case of laboratory animals I have injected it in doses of 1 to 2 c.c. per kilogramme of living body weight. The injections can be repeated every day for several days in succession without inconvenience. The liquid is absorbed very quickly after subcutaneous injection. In animals I have used subcutaneous, intraperitoneal, and intravenous injections. I have seen no accidents occur.

I have studied the action of mycolysine on leucocytosis and phagocytosis in man and in animals, in both normal and pathological states. I afterwards compared the action of mycolysine on the rabbit with that of nucleinate of soda and of colloidal silver respectively. The action of the veterinary preparation, panphagine, is identical with that of mycolysine.

Leucocytosis.—Numeration of the leucocytes was carried out before making the immunizing injection, and was afterwards repeated at a series of successive intervals. The coefficient of leucocytosis was established (1) in relation to the original number (which was a very high one in many of the pathological cases), and (2) in relation to the normal number (7,000 leucocytes per cubic centimetre).

Phagocytosis. The coefficient of phagocytosis was established *in vitro*, after mixture of an emulsion of leucocytes and microbes with either pure isotonic saline solution or with one of the respective titrated dilutions of mycolysine, nucleinate of soda, and colloidal silver with isotonic saline solution.

Hyperphagocytosis.—The product of the coefficient of leucocytosis by that of phagocytosis gives the coefficient of hyperphagocytosis. Let us suppose that the leucocytes are raised from the normal figure of 7,000 to 21,000 (coefficient 3), and that for 100 leucocytes the number of the phagocytosed microbes is raised from 200 (that of the control experiment) to 520 (coefficient 2), the coefficient of hyperphagocytosis will be $3 \times 2 = 6$.

After verifying the stimulating action of mycolysine on the leucocytes and on the phagocytes, I studied its action—both preventive and curative—in a certain number of experimental infections, and finally I sought whether mycolysine acted on the phagocytes alone or whether it really exercised a direct influence on the microbes.

Résumé of the Experiments.—(1) Injectable mycolysine increases both leucocytosis and phagocytosis in the human organism. The leucocytosis is produced from the first hour after the injection, and lasts for a period varying from twenty-four hours to four or five days. It lasts longer after a hypodermic injection of 50 c.c. than after one of 20 c.c. or 10 c.c. The leucocytosis is less pronounced in *very old and cachectic* subjects than in those in the prime of life and in children. The coefficient of leucocytosis, in proportion to the leucocytic unit of 7,000 per cubic centimetre, has varied, in a series of sixteen cases treated by mycolysine, from 1.4 to 7. The same coefficient, in proportion to the numeration of leucocytes obtained before injection of mycolysine, varied from 1.2 to 4.6, a certain proportion of the patients examined having previously presented a *pathological hyperleucocytosis*.

(2) In the *normal rabbit*, mycolysine and panphagine (a veterinary preparation identical with mycolysine) produce the same stimulating effect on leucocytosis and phagocytosis. The mean of the numerical evaluation of leucocytosis on the one part and of phagocytosis on the other, gives the coefficients of 2.77 for leucocytosis and 3.58 for phagocytosis, and accordingly, for the mean coefficient of hyperphagocytosis, $2.77 \times 3.58 = 9.91$.

(3) The injectable mycolysine, in a dilution of 1 in 600, exercises *in vitro* the maximum stimulating action on the leucocytes of the rabbit. The mean coefficient of phagocytosis in five experiments has been from 2.2 (minimum of 1.75, maximum of 2.48) in proportion to unity (control experiment in presence of isotonic saline solution).

(4) The numerical evaluation of the phagocytosis of the leucocytes of the rabbit in the presence of normal injectable solutions of mycolysine, of electrargol, of nucleinate of soda, and also of peptonized broth, in dilutions of from 1 in 50 to 1 in 700, has given for mycolysine a maximum coefficient of 2.41 in a dilution of 1 in 600. The dilutions of electrargol, of nucleinate of soda, and of peptonized broth have given the respective coefficients of 1.57, 1.4, and 1.33 in dilution of from 1 in 50 to 1 in 100 (mean of two experiments).

(5) For the same hyperleucocytosis of about 28,000, observed about five hours after respective injections of mycolysine, of electrargol, and of nucleinate of soda, the phagocytic coefficient has been: For mycolysine, 4.1; for electrargol, 1.15; for nucleinate of soda, 2.5.

(6) Prophylactic injection of mycolysine (2 c.c. into a vein) in the rabbit prevents the production of staphylococccic infection by subcutaneous injection in the abdominal region of 1 to 5 c.c. of a virulent broth culture. This preventive action is increased when the rabbit has been duly prepared for several days before.

(7) Injection of *mycolysine* provokes resolution of staphylococccic abscess, if we carry out the intravenous injection from the seventh to the ninth hour after the injection of the microbes—that is to say, at the moment at which the inflammatory infiltration begins to manifest itself.

(8) The preventive injection of *electrargol* or of *nucleinate of soda* does not prevent staphylococccic infection, while rabbits subjected to the same experiment, after having received the prophylactic injection of *mycolysine*, developed no lesion.

(9) The same experiments repeated with numerical evaluation of the leucocytosis and phagocytosis shows that—

(a) The highest coefficients of leucocytosis and of phagocytosis have been obtained with mycolysine:

			Leucocytosis.		Phagocytosis.		Coefficient of Hyperphagocytosis
Mycolysine	14.0	×	2.80	=	39.2
Electrargol	3.8	×	1.88	=	6.0
Nucleinate of soda	2.7	×	1.53	=	3.2

(b) Tracing the result of the experiment demonstrates that the reaction provoked by the mycolysine increases very rapidly from the time that the microbial infection has become established: this intense hyperphagocytosis leads to the resolution. On the other hand, the hyperphagocytosis produced by *electrargol* and by *nucleinate of soda* is much lower in degree and does not prevent the formation of abscess.

(10) Prophylactic intravenous injection of mycolysine has also prevented the death of a rabbit after the intravenous injection of 50,000,000 staphylococci, while the control rabbit died in twenty-four hours.

(11) The prophylactic action of mycolysine in the rabbit is less constant against streptococccic infection than against staphylococccic. I have preserved three of four rabbits by prophylactic injection of 2 c.c. of mycolysine into the veins *every day* for four days before the streptococccic injection.

(12) The prophylactic subcutaneous injection of mycolysine, repeated during two days, has preserved three white rats out of five against pneumococccic infection of the peritoneum, while the five control rabbits were all dead within twenty-four hours.

(13) Mycolysine exercises no action on microbes, either in way of agglutination or of sensitization: it acts by augmenting the opsonic power of the serum and stimulating phagocytosis.

Conclusions.—It results from these experiments that—

- (1) Mycolysine is a powerful stimulus of phagocytosis.
- (2) Under its influence the organism becomes hyper-resistant to a certain number of specimens of pathogenic virus. This polyvalent immunization acts preventively when infection threatens; it acts equally against the pro-

nonced disease; but in the latter case its therapeutic action is more intense in proportion as we intervene at a time nearer to the beginning of the infection.

(3) The general method of treatment of infectious diseases by mycolysine, as established by Doyen, is essentially based on the reinforcement of phagocytosis; it constitutes a rational application of the discoveries of Metchnikoff in the domain of medical therapeutics.*

Mycolysine has been officially experimented with in the military, maritime, and colonial hospitals in the years 1911 and 1912. At the close of those experiences it was adopted by the Minister of Marine (January 11, 1913), by the Minister of the Colonies (January 13, 1913), and by the Minister of War (June 26, 1913).

Prophylactic Action of Potable Mycolysine.—Mycolysine and the potable extract of mycolysine suffice, when used in suitable doses, to prevent the development of coryza, of *la grippe*, of the various forms of angina, and of each of the majority of the infectious diseases of the respiratory passages. In cold and humid weather it is necessary to absorb every morning 50 c.c. of mycolysine or 15 c.c. of the extract of mycolysine. Mycolysine is absorbed when given in the pure state; extract of mycolysine should be given in some effervescent water, in Vichy water, or, indeed, in an infusion, or in milk to which sugar has been added.

Prophylactic Action of Injectable Mycolysine against Post-Operative Complications.—Every time that we have to operate on a patient who is in a feeble condition or already the subject of infection, it is prudent to administer, as a prophylactic procedure, subcutaneous injections of mycolysine. On the day of operation I have 20 c.c.—in the majority of cases 50 c.c.—of mycolysine injected subcutaneously. This injection, which is made under anaesthesia, is borne very well, and it prevents the occurrence of nearly all post-operative complications—notably the broncho-pulmonary, which are frequently so grave. If the patient already presents evidence of infection, the injections of mycolysine are continued daily, in 20 c.c., or up to 50 c.c. doses, till the patient is out of danger.

Curative Method.—If infection already exists, for example, when we are dealing with a case of erysipelas or one of suppuration, 10 or 20 c.c. of mycolysine should be injected on the first day. When the case is very grave and general accidents already exist, the injection is repeated three or four times during the twenty-four hours. Injections of mycolysine, when administered a number of times daily, usually provoke rapid resolution of erysipelas, of broncho-pneumonia, and of pneumonia. In erysipelas and in the septicæmic diseases, we must act as soon as possible after the commencement of the infection. In most cases erysipelas is subdued in twenty-four hours if we take action in the first hours after the appearance of the rash. If the latter has already been fully developed, it will take a longer time to effect the cure, but a notable amelioration is usually obtained at

* *Annales de l'Inst. Past.*, April, 1914.

the end of twenty-four or forty-eight hours. The subcutaneous injections of mycolysine should be continued for two or three days after the disappearance of the symptoms; we thus avoid an obnoxious recurrence of the infection.

Patients who are submitted to the action of injectable mycolysine should also be made to absorb extract of mycolysine or the pure mycolysine several times a day, if the stomach is able to bear it; this internal treatment will augment the immunizing reaction. On the other hand, we must not forget that in gastro-intestinal affections, and especially in cases of acute or chronic enteritis, ingestion of mycolysine or of the extract of mycolysine by the buccal route is frequently followed by a more rapid therapeutic effect than is the subcutaneous administration of the injectable mycolysine.

2. The Specific Treatment of Tuberculosis with Phymalose.

Potable phymalose, extract of potable phymalose, and injectable phymalose are, respectively, combinations of potable mycolysine, of the extract of potable mycolysine, and of injectable mycolysine, with a suitable proportion of tuberculin. Phymalose only, of all the preparations destined to combat tuberculosis, presents the advantage of being able to combat simultaneously the bacillus of Koch and the various microbes associated therewith.

After the exclusive employment of injectable phymalose against tuberculosis, I have succeeded in preparing potable solutions, the therapeutic action of which is identical with that of the injectable phymalose. A table annexed to the special notice indicates how it is necessary to combine either the respective potable forms of mycolysine and phymalose, or the extracts of mycolysine and phymalose, in the treatment of patients by the buccal route.

Every patient usually absorbs, each day during the first days of the treatment, eight tablespoonfuls of mycolysine and two of phymalose. This is the primary period. At the end of one or of several weeks, we should each day administer seven tablespoonfuls of mycolysine and three of phymalose. When the treatment is well borne and the case is a torpid one, we administer daily six tablespoonfuls of mycolysine and four of phymalose. If, instead of the mycolysine and phymalose, we employ their respective extracts, we administer each day during the first period four teaspoonfuls of extract of mycolysine and two of the extract of phymalose; in the second period we give three teaspoonfuls of each of the extracts daily; in the third period two of each daily.

The dosage of those preparations has been arranged in such a way that the treatment is identical for each period and with the doses indicated—whether we use the combination of mycolysine and phymalose, or that of their respective extracts. When dealing with cases of local tuberculosis, we associate the use of injectable phymalose, which is administered hypodermically in carefully graduated and progressive doses.

Specific medication with phymalose is extremely effective in most cases of tuberculous adenitis. If operation is necessary, we content ourselves

by making a small incision and curetting through this the original suppurating gland and the neighbouring ones. Cauterization proceeds very favourably under the influence of phymalose. We also obtain rapid resolution of tuberculous synovitis and of tuberculous arthritis in a certain number of cases. This treatment is similarly indicated in cases of nephritis and of tuberculous cystitis, when the progress of the lesions has not reached too far.

3. Cancer.

Etiology and Treatment.—The microbe which I discovered in cancer and which I succeeded in cultivating in 1900 (the *Micrococcus neoformans*), produces, by inoculation on the lower animals, and especially in case of the white rat, lesions identical with those of the spontaneous cancer of man and animals. In 1908 (Société de Biologie, May 9) I demonstrated the fact that we can make a diagnosis in cases of deep-seated cancer by a reaction analogous to the Wassermann reaction for the diagnosis of syphilis. This reaction takes place in presence of an aqueous extract of the powder of *M. neoformans*.

To a convenient quantity of the patient's serum, previously heated to 56° C. (132.8° F.), is added a suitable proportion of the aqueous extract of the powder of *M. neoformans*, normal guinea-pig serum, and distilled water. After keeping this mixture one hour in the stove at a temperature of 38° C. (100.4° F.), we add to it an emulsion of the red blood-corpuscles of the sheep. The fixation of the complement prevents hemolysis when we are dealing with a case of confirmed cancer. In the course of my original researches in 1908 I demonstrated the fact that all deep-seated cancers— notably those of the œsophagus, stomach, intestine, and uterus—give a positive reaction (fixation of the complement). Very small tumours in the primary stage—that is to say, all adenomata and small superficial carcinoids, which have not yet infected the general economy—give a negative reaction in most instances. The serum of patients affected with diseases other than cancer give a negative reaction. Those researches were taken up in 1913 by Professor Yamanouchi and M. Lytekkowsky of the Institut Pasteur, in Professor Metchnikoff's laboratory.

SERO-DIAGNOSIS OF CANCER.

By M. M. T. Yamanouchi and M. Lytekkowsky.

We have studied the serum reactions of 279 cases—from both cancerous and non-cancerous subjects—in the presence of an aqueous extract of cultures of a micrococcus which we have isolated in a large number of cases of cancer. Of 20 cancerous cases, from which aseptic fragments of the tumour or of the glandular metastases were inoculated on non-neutralized broth*

* Macerate in the refrigerating apparatus for twenty-four hours 500 gramm. of cow's udder deprived of fat and minced up in 1,000 grammes of distilled water. Express the liquid and make the quantity up to 1,000. Add 1 gramm. of dried peptone and 0.5 gramm. of pure sodium chloride. Heat slowly up to 120° C. (248° F.).

Cool, filter, and place in tubes. Sometimes many filtrations are necessary before a completely clear fluid is obtained.

of cow's udder, 13 cases have furnished us with a pure culture of a micrococcus, the morphology and properties of which have been recognized as identical with those of the *M. neoformans* described by Doyen. In 7 cases we obtained a mixed culture of the same micrococcus and of *Staphylococcus aureus*. This micrococcus, of which the presence has thus been proved constant in cancerous lesions, was used as antigen.

Preparation of the Antigen. Pure culture of these microbes obtained from cancer cases and cultivated on the surface of gelose, were dried in vacuo. After being pounded up for a long time into a state of minute division 0.5 gramme of the powder was placed in contact with 100 c.c. of a physiological saline solution to which 0.25 per cent. phenol had been added. This emulsion was then shaken for a period of three hours, after which the maceration was continued for twenty-four hours at the temperature of the room; the liquid was then centrifuged. The reaction is properly produced only when the antigen has been prepared with great care. Fresh guinea-pig serum was employed as complement, in varying doses. We have not employed the autoceptor (prepared hemolytic rabbit serum). For each serum we prepare tubes with the following mixtures:

	Patient's Serum	Antigen	Guinea-pig Serum, suitably diluted (for example, 1:100)	Physiological Saline Solution
First tube	0.1	0.1	0.1	0.7
Second tube	0.1	0.1	0.15	0.65
Third tube	0.1	0.1	0.2	0.6
Fourth tube (control) ..	0.1			0.7

The tubes are placed in a stove at 38° C. (100.4° F.) for thirty minutes, and we then add to the contents of each tube 0.1 c.c. of a 5 per cent. suspension of the red globules of the sheep. They are then replaced in the stove till the contents of the fourth (the control) tube show complete hemolysis.

The serums examined had been obtained—some from Paris, at the clinic of Dr. Doyen; some from Dr. Bataille of Rouen; some from Dr. Lemonnière and Dr. Laurent of Havre.

We have also made comparative experiments with antigens derived from other pathogenic microbes—staphylococcus, streptococcus, *Bacillus coli*, pneumococcus—which exist in many subjects, cancerous and non-cancerous; as well as with non-pathogenic microbes, that of the cholera of fowls, sarcinae, and *B. subtilis*.

These control experiments have demonstrated the fact that fixation of the complement may take place as well in cancerous as in non-cancerous subjects, in the presence of an antigen prepared from microbes which often exist in the human body as a merely anal infection. On the other hand, fixation of the complement is never produced by antigens

derived from cultures of the cholera of fowls or those obtained from sarcine, or from *B. subtilis*.

The following table shows that establishment of the diagnosis of cancer has been made possible, and precision attained in cases previously doubtful from the clinician's point of view—that is to say, in cases of deeply situated cancer, the existence of which was afterwards verified, either by surgical operation, or, in hospital cases, by post-mortem examination:

Diagnosis.	Result		
	Number of Cases.	Positive (No. Hemody-esis).	Negative (Hemody-esis).
Cancer of tongue	12	12	
Cancer of larynx	3	3	
Cancer of oesophagus	4	4	
Cancer of stomach	32	32	
Cancer of pancreas	1	1	
Cancer of rectum	8	8	
Cancer of breast	37	30	7
Cancer of uterus	22	2	
Cancer of ovary	3	3	
Total	122		
Epithelioma in process of generalization:			
Small localized canceroids (at onset of growth)			
Adenoma of breast	8		8
Sarcoma	5		5
Sarcoma	5	2	3
Myoma	1		1
Fibroma of uterus	2		2
Total	21		
Tuberculosis	21		21
Hydrocele of testicle	1		1
Inguinal hernia	1		1
Hysteria	1		1
Fibrous stricture of rectum	1		1
Dilatation of stomach	1		1
Prolapse of uterus	1		1
Hemorrhoids	1		1
Exudative pleurisy	2		2
Chronic metritis	1		1
Purulent salpingitis	3		3
Acute appendicitis	1		1
Subcutaneous abscess	5		5
Purulent nephritis	3		3
Compound fracture of thigh	1		1
Angina	2		2
Chronic laryngitis	2		2
Intestinal fistula	1		1
Gastric ulcer	1		1
Biliary lithiasis	2		2
Renal lithiasis	1		1
Subjects in apparent health	11	1	13
Total	70		
Syphilis	11	10	31
Grand total	27		

We will consider here the diagnosis of cancer only. In the series above tabulated, representing a total of 279 serums examined, we have 144 cases, which presented the distinctive features of cancer, with 137 positive results (the 7 negative results were obtained in cases of small tumours of the breast, which were still localized). With small commencing canceroids, sarcomata, and benign tumours, we have, on the other hand, obtained but 2 positive results in a series of 29 cases. Finally, among 70 cases affected with other lesions, or in apparent health, we obtained but a single positive result, and that was in the case of an individual among whose immediate ancestors many cases of cancer had occurred; and of 44 syphilitics, 10 of the cases gave a positive reaction, while 34 presented each a negative one.

The ha-molysis was manifested in a very sharply defined way in all the fully characterized cases of cancer—that is to say, in those which were complicated with metastases or glandular infection. The prevention was also very clear in the deep-seated cancers which were still in the primary stage, especially in those of the cesophagus, stomach, pancreas, and ovary. On referring to the figures furnished in the above table, we find that of 37 cases of cancer of the breast 7 gave no reaction; these were all very small tumours in the beginning of their growth, clearly localized, and without glandular infection. It will be noticed that all the cases of epithelioma or canceroid of the skin that were accompanied with adenopathy gave a positive reaction; while, on the other hand, small localized and very limited canceroids gave a negative one. Such was also the case with a subcutaneous myxoma and with two fibromata of the uterus. Five cases of adenoma of the breast also gave in every instance a negative reaction. The reaction was also negative in all the other patients, who were the subjects of some other disease or of suppuration.

As control experiment, we also examined the serums of a certain number of subjects in apparent health, and of a large number of clearly defined syphilitic cases. Among fourteen subjects in apparent health the specific reaction of cancer was observed in one case. That individual, whose address we have preserved, will be kept under observation. He is a man aged forty-five, who sought advice because he felt his strength declining and believed himself affected with cancer; many of his immediate ancestors had been affected with cancer.

Among forty-four syphilitics who gave each a positive Wassermann reaction, fixation of the complement took place ten times in presence of our special antigen—that is to say, the reaction was identical with that obtained in cases of confirmed cancer. But when we come to consider the frequency of the occurrence of cancer in old syphilitic subjects, we may consider it possible that some of those cases were really affected also with latent cancer, while it is equally possible that fixation of the complement may, in certain cases of syphilis, be produced by a different mechanism. This is a question which we will endeavour to elucidate. Those ten patients will be watched in future with the object of ascertaining whether any of them become affected with malignant disease.

To summarize. If we except syphilis, in which fixation of the comple

ment on our special antigen may, perhaps, take place in cases in which no cancer exists, the reaction which we have just been studying seems to be of such a nature as to enable us to form a precise diagnosis, especially in cases of deep-seated cancer and those at the period of development in which they escape all clinical investigation.

Treatment of Cancer.— In February, 1901, I began to treat deep-seated cancers with toxins and the dead cells of *Micrococcus neoformans*. This vaccination gave remarkable results, for the first case treated—one of cancer of the testicle which had recurred six times in the course of seven months, and had come to be regarded as incurable—is now actually in perfect health. It is true that this case was operated on, and that the vaccination took place immediately after the last operation. Numerous cases of cancer of the stomach have been cured by simple vaccination; most of these cases had undergone the operation of gastro-enterostomy, and examination of the glands had enabled me to verify the diagnosis of cancer. Remarkable results have also been obtained by this anti-neoplastic vaccination in the early stage of growth of cancer of the intestine and of the breast. In many patients affected with a small cancer of the breast, the tumour has been completely absorbed, and the cure maintained for five, six, or seven years. In these cases we now find no more of the tumour, which had presented a diameter of 4 or 5 centimetres, than a nodule the size of a pea.

Vaccination is much less effective when the cancer is already in the stage of generalization. In many such cases I have, indeed, seen the oedema of the arm produced by pressure on the axillary vessels disappear as a result, but I consider that vaccination should always be carried out in the primary stage of the evolution of cancer. Anti-cancerous vaccination succeeds extremely well in cases of cancer of the stomach, and of the intestine; also fairly well in cancer of the breast during the primary stage. But it is much less successful in the superficial tumours, notably in cutaneous epithelioma and in canceroid. This observation, which I had made in 1906, induced me to seek out the best procedure to be adopted for destroying the virulence of cancer cells. I have already pointed out that the best method of destruction of superficial and accessible cancers is that of thermic electro-coagulation.

This procedure of thermic electro-coagulation consists of passing into superficial cancers an alternating thermo-penetrating current of sufficient intensity to strike dead the pathological cells of the growth. I have demonstrated the fact that the virulence of cancer cells is entirely destroyed by heating them to a temperature of 58°C . (136.4°F .). This process cures cancer only on one express condition: it is necessary that every one of the cancer cells, without a single exception, is heated to the temperature that destroys them.

In a certain number of cases, especially those of cancer of the tongue or pharynx, I content myself, after destroying the primary tumour, with combating the adenopathy at first by the use of anti-neoplastic vaccination. A certain number of those patients have remained permanently cured, and the enlarged glands have disappeared.

294 SURGICAL THERAPEUTICS AND OPERATIVE TECHNIQUE

Electro-coagulation gives remarkable results in all cases of cancer of the skin and accessible mucous membranes, notably those of the tongue and of the buccal, laryngeal, and pharyngeal mucous membranes, also in those of the vulva, vagina, and cervix uteri.

The technique of electro-coagulation will be afterwards described, as well as that of the thermo-electric bath, a method of thermo-penetration, which is applicable in some cases—as in tumours of the breast—where it is necessary to remove the neoplasm with the bistoury.

CHAPTER VI

THE GENERAL CARE OF THE PATIENT AFTER OPERATION

EVERY patient operated upon receives during the narcosis a preventive subcutaneous injection of 20 to 50 c.c. of mycolysine. This procedure is adopted without prejudice to corresponding injections that may have been carried out before the operation, either for the purpose of combating a pre-existent infection or of increasing the vital powers of the patient.

When the patient has regained consciousness after the chloroform, the most perfect quiet should be rigidly enforced. The room is kept comparatively dark. One or two attendants remain beside the patient, to observe the respiration and—when specially necessary—the degree of weakness. When the process of awakening appears retarded, the patient is made to inhale oxygen, and we administer an injection of *artificial serum* (isotonic saline solution). I have enumerated, apropos of narcosis, the most effective means to be employed in such cases. Many patients suffer pain when awaking after operation; we then administer a preliminary injection of a quarter to half a centigramme of morphine. The morphine solution is made with cherry-laurel water, at 1 per cent, and contains 1 per 1,000 of sulphate of atropine. The degree of pain felt by the subject of operation after awaking from the narcosis, is very variable; and depends more on the susceptibility of the individual than on the nature of the procedure itself. Very many patients feel no pain, and require no morphine, even after vaginal hysterectomy and with forceps in position; while others complain loudly after ovariectomy, with merely simple suturing of the abdominal wall. Exaggerated excitement after awaking from the chloroform narcosis is an unfavourable sign. The *state of the pulse* should be noted on the eve of the operation; the examination on the following days then gives most valuable indications. Rarely does a rectal temperature of 39° C. (102.2° F.) or 40° C. (104° F.) mean a grave prognosis if the pulse remains full and at a rate below 110, and *a fortiori* below 100 per minute. Grave peritoneal accidents are, on the other hand, revealed by a very special acceleration of the radial pulse, which then becomes also feeble and compressible. This so-called "peritoneal pulse" is a precocious index of graver accidents, and sometimes precedes by several days the tympanites and characteristic vomiting.

Some of the patients on whom I performed gastro-enterostomy or pylorotomy have been extremely cachectic, and the pulse before operation was at a rate of 40 to 60. One of my craniectomy cases, who suffered from encephalitis and cerebral compression, underwent that grave pro-

cedure passively, without chloroform, and with a pulse of 45 per minute, which rose to 80 as soon as the brain was freed from abnormal pressure. A woman who had been for some months affected with tachycardia—a result of influenza—and also suffered from uterine fibroma, had a pulse of 140. Under chloroform it fell to 80. On awaking it again attained the 140 rate. Some time afterwards she suddenly succumbed to cardiac syncope.

In discussing the preliminary precautions to be adopted in all cases of operation, I insisted on the necessity of previous administration of at least one energetic purgative (solution of sulphate of magnesium in water, with the addition of some citron-juice). Patients who have been well purged have much less tendency than others to suffer from chloroform nausea and vomiting. Purgation is also a priceless auxiliary in the treatment of the immediate sequelae of the operation. I have never seen a patient succumb after laparotomy in which previous care had been taken to keep the bowels free.

The slightest tendency to tympanites should be combated at once, even when there is no elevation of temperature.

Exception must be made in cases of operations on the intestine or anus, in which we seek to induce constipation by administration of opium in fractional doses.

When the abdomen remains flat, the temperature normal, and the pulse satisfactory, it is undesirable to purge before the third or fourth day.

Alvine evacuations prevent, in the absence of all peritoneal accidents, the gaseous distension of the intestine which is so painful after certain peritoneal operations, on account of the violent colicky pains which accompany the displacements of gas. If the sulphate of magnesia is vomited, we can administer Tactz's capsules of castor oil, or one or more pellets containing, each: Aloes, white resin of scammony, cream of tartar, of each 0.25 centigramme.

In grave cases, the tympanites and intestinal paralysis are the first indications of the onset of peritonitis. We then administer at once a subcutaneous injection of 50 c.c. of mycolysine, which is repeated every twelve or twenty-four hours, till the patient is out of danger.

Post Operative Internal Strangulation.—Is *true internal strangulation* of frequent occurrence after abdominal operations? I have observed two typical cases, both of which were cured by a new mode of procedure. Usually, however, the fatal cases attributed to internal strangulation are really ones of simple septic peritonitis, which run a subacute course, and are accompanied by paralytic pseudo-strangulation.

True post-operative strangulation is nearly always directly dependent on some local inflammatory complication. The symptoms are characteristic; the pulse continues satisfactory, and there is no elevation of temperature; the principal sign is the total absence of passage of gas *per anum*. The importance of this sign is such that the supervision of the patient in such a case should be confided only to persons of recognized experience. The patients usually suffer from violent colicky pains; the contracted intestine

is outlined beneath the skin. When unmistakably faecal vomiting comes to confirm the diagnosis, the intervention should be immediate.

Twice only, among many thousands of peritoneal operations, have I taken part in the treatment of true post-operative strangulation. Thanks to a rigorous analysis of the symptoms and examination of the vomited matters, I intervened at a proper time and with complete success. In each of the cases I had to deal with a volvulus of the small intestine fixed in its abnormal position by some pelvic adhesions, which had developed in the neighbourhood of a strong silk ligature. The second intervention took place in one of those cases after an interval of eleven days from the original operation; in the other, after twenty-eight days had elapsed. I refer to those exceptional cases in order to give the reader some precise indications which may guide him if he finds himself in presence of similar complications. Those accidents are fortunately very rare; and, when the operation has been well carried out, the subsequent treatment usually resolves itself into maintaining free action of the bowels, and regulating the diet.

Normal Post Operative Conditions should not be modified by Injudicious Treatment ("Primum non Nocere").—Every subject of operation who retains a normal pulse, with a rectal temperature below 38° C. (100.4° F.), and who exhibits neither vomiting, colic, nor tympanites, and is able to urinate freely, should be merely watched. *In such cases we should above all things guard ourselves against shackling Nature during her curative efforts.* For diet: On the first day, small quantities of cold Vals or Vichy water, administered as a mouth wash; on the next day, when the nausea has disappeared, a little broth; an egg on the fourth or fifth day; and on the following days a more substantial diet, which should be regulated according to the special conditions inherent in each case of operation. Absolute calm and regulated diet are, during the early days, excellent adjuvants of a rapid cure. Restoration is often so prompt that many patients seem able to leave their beds on the fifth or sixth day after such operations as gastro-enterostomy or hysterectomy, abdominal or vaginal. I allow them to make their first attempts at walking on the twelfth to fifteenth day. After the tenth day, an aseptic cicatrix is already solid, and the deep sutures prevent any disunion. Patients operated on for mammary tumours or goitre, and cases of craniectomy rise from bed usually from the third to the sixth day. After operations on bone the repair is slower. Nevertheless many of my cases of resection of the elbow-joint begin to use the limb, without dressings, about the fifteenth day; and often in young children an osteotomy wound of the femur is consolidated before the end of a month. Special indications relative to the surgery of bones will be given in their proper place.

GENERAL OPERATIVE TECHNIQUE.

Asepsis of the Field of Operation.

I have verified by recent experiment the fact that asepsis of the skin is very difficult to obtain. It is for that reason that I arrived at the decision of circumscribing the field of operation with sterilized napkins in



FIG. 313.

The border of the lower napkin is fixed to the lower lip of the elliptical incision in an amputation of the breast.

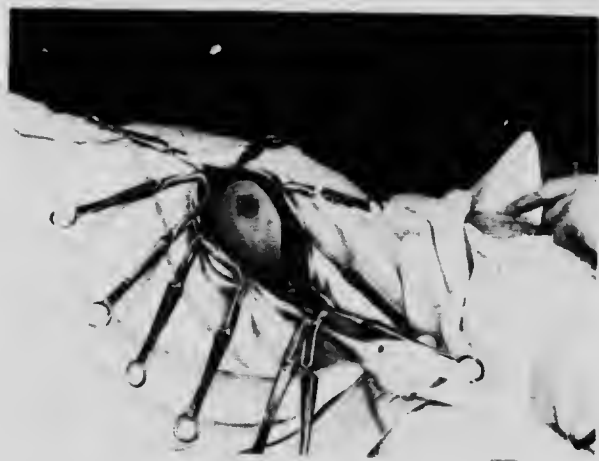

FIG. 314.

A second napkin has just been fixed to the upper lip of the incision, and the two are joined at each end of the wound with safety-pins.

every case of aseptic operation. Those napkins are fixed at the margin of the wound with the hooked forceps, which I have already described (see Fig. 181). In most cases I place the instruments above the sterilized napkins, as seen in Figs. 313 and 314. But in certain operations, and notably in laparotomy, I arrange the hooked forceps in such a way that they are covered by the aseptic napkins; for example, in Fig. 314, we see the napkin on the left side of the field of operation fixed, not to



FIG. 315. EXCISION OF AN AXILLARY CANCEROUS NODULE.

It will be observed that the skin remains invisible during the whole course of the operation.

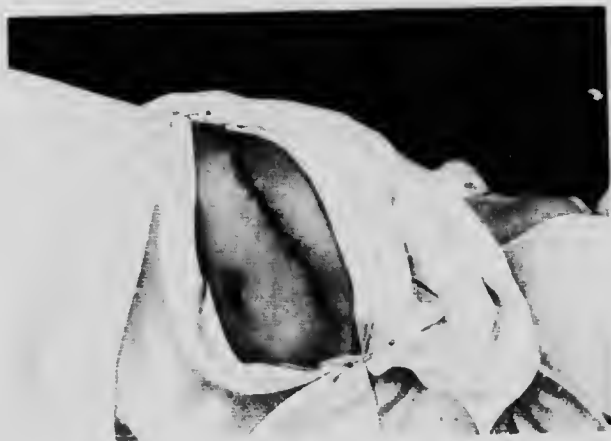

FIG. 316.

The operation is finished. The sterilized napkins have been removed to allow suture of the skin and insertion of a drainage-tube.

300 SURGICAL THERAPEUTICS AND OPERATIVE TECHNIQUE

the lower lip of the cutaneous incision, but to the upper. When thus adjusted, it suffices to fold it back over the hooked forceps in order to hide both this and the subjacent skin.

PROCEDURES IN SECTION AND REUNION OF THE VARIOUS TISSUES— AUTOPLASTY—TREATMENT OF FISTULE.

SECTION AND DIVISION OF SOFT PARTS AND OF BONES.

1. Instruments of Exeresis employed for the Soft Parts.

Bistouries. The instrument *par excellence* for division of the skin and dermoid mucous membranes is the *bistoury*. The best form of bistoury is




FIG. 317. STRAIGHT BISTOURY.



FIG. 318. CATARACT KNIFE.

the straight, with a handle which gives a firm hold. It is held like a writing pen, or like the bow of a violin, or grasped with the whole hand like an



FIG. 319.—DISSECTION OF A TUBERCULOUS SYNOVIAL SAC IN THE HAND WITH A BISTOURY.

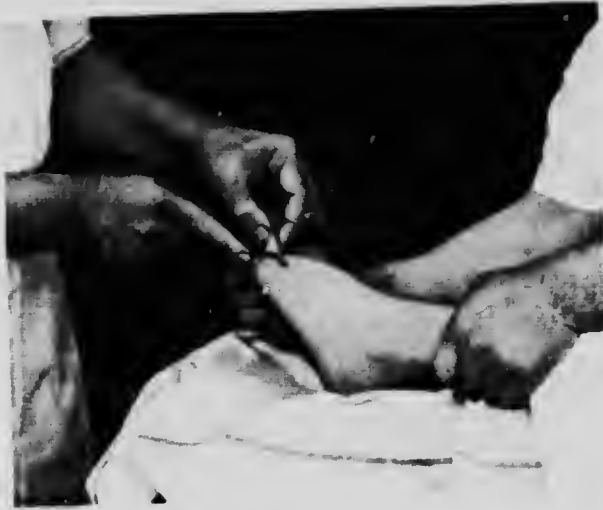

FIG. 320. AMPLIFICATION OF THE FIFTH TOE BY RACKET-SHAPED INCISION.
Commencement of the incision.



FIG. 321. TENOTOMES, POINTED AND BLUNT.




FIG. 322. AUTHOR'S BISTOURIES FOR OPERATIONS ON FISTULA.
These are five in number: two are bent at a right angle (1), (2); one with a rounded extremity (A), the other with a pointed extremity (B); one has a rounded blade, short, and slightly recurved (3).




FIG. 323. BISTOURIES FOR RESECTION.

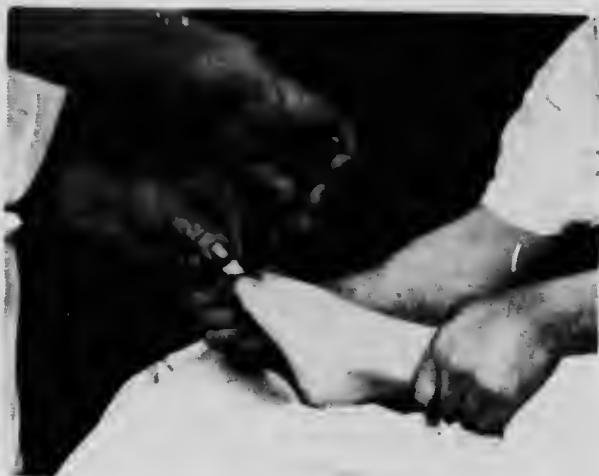

FIG. 324. AMPUTATION OF THE FIFTH TOE BY RACKET-SHAPED INCISION.
Termination of the incision.

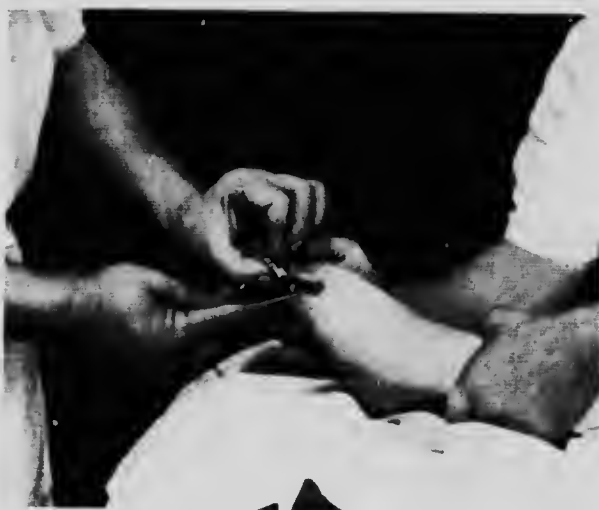

FIG. 325. AMPUTATION OF FIFTH TOE BY RACKET-SHAPED INCISION.
The knife penetrates the metatarsophalangeal articulation.

amputation knife. In certain cases the incision begins with a puncture. When on a plane, or nearly plane, surface, the skin is made tense with the fingers of the left hand; with or without the help of an assistant. Incisions by transfixion are limited to special cases—as in vivification of the margins of the fissure in operation for hare lip, or incision by transfixion of a fold of the skin in kelotomy. Incisions by section of a fold of the skin from



FIG. 326. AMPUTATION KNIVES.

Blades of 25, 22, 18, and 15 centimetres respectively.

without inwards have the same indications. I practise either advisedly in the exposure of a crural hernia. I employ a short and very strong bistoury in resections. Very small bistouries of special form are utilized in the departments of special surgery—cataract knife, iridectomy lance, bistouries for vivification in staphylorrhaphy and in operation for vesico-vaginal fistula, tenotomes, etc.



FIG. 327. PHALANGEAL KNIFE.



FIG. 328. INTEROSSEOUS KNIFE.



FIG. 329. LISFRANC'S KNIFE.

Amputation Knives. The strongest blades are to be preferred in amputation of the limbs—so called amputation knives. Knives of 12 to 25 centimetres in length for the foot, leg and thigh, the phalangeal knife, interosseous knife, and Lisfranc's straight-bladed knife, are those in most frequent use.

I have already presented the amputation case made by for me M. Collin.

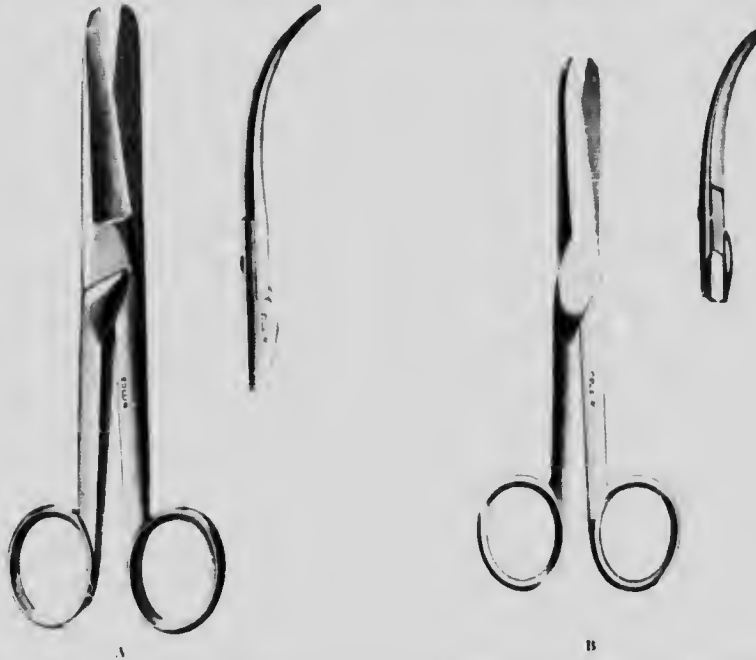


FIG. 330. FLAP AMPUTATION OF THE FORE-ARM AT THE LOWER FOURTH.
Formation of the palmar flap by transfixion.

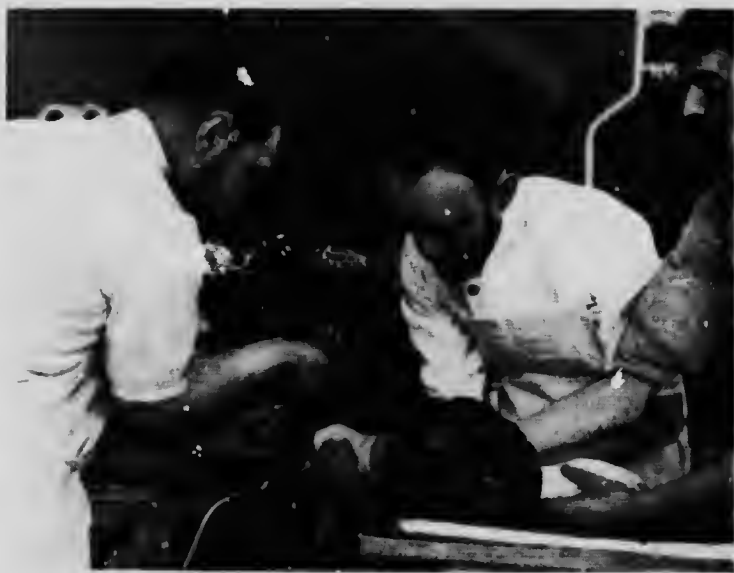

FIG. 331. CIRCULAR AMPUTATION OF THE ARM.
Termination of the circular section of the muscles.

Scissors—I use strong, straight scissors with blunt-pointed blades almost exclusively in my operations; such are easy to manipulate and of great value whenever it is necessary to obtain a clean section in a position



FIGS. 332A AND 332B.—STRAIGHT AND CURVED SCISSORS, OF 17 AND 14 CENTIMETRES RESPECTIVELY.

where it is impossible to give the tissues the tension requisite for the application of the bistoury. Thus the scissors is of great use in planing the margins of a long cutaneous incision for the extirpation of fistulous openings.



FIG. 333. SCISSORS FOR VAGINAL MYOMECTOMY.

and for resecting the posterior vaginal floating triangle in colpoperineorrhaphy. Vivification of the ends of tendons and nerves is well done with the scissors; we easily obtain a clean-cut, transverse section.

When there is a fistulous orifice, the scissors may be made to replace the

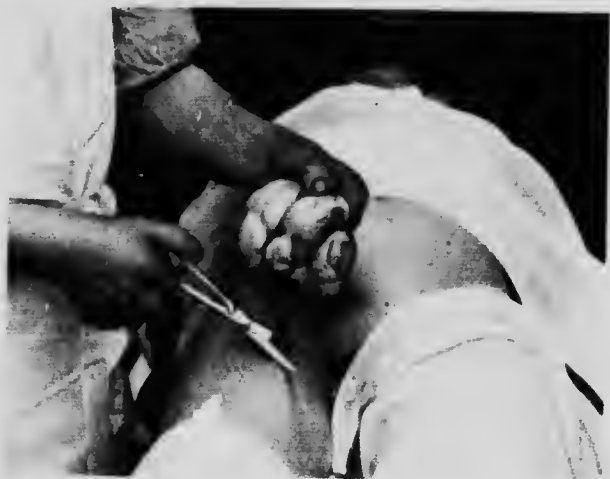

FIG. 334.—SECTION OF THE PEDICLE OF A MOLLUSCUM FIBROSUM OF THE UPPER PART OF THE THUMB.



FIG. 335.—ENUCLEATION OF THE EYE-BALL; DIVISION OF THE OPTIC NERVE.

bistoury for division of the wall of the sac or canal. We can introduce one blade into the orifice, and divide the investing tissues by one or several strokes. Similarly, one blade can be introduced through an orifice made in the skin, and pushed up to the point where the incision is to be ended, as



FIG. 336.—STRABOTOMY SCISSORS.

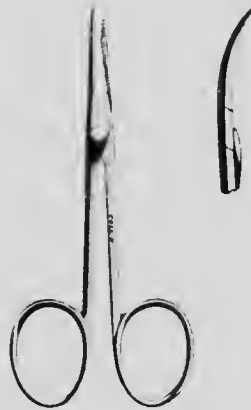

FIG. 337.—IRIDECTOMY SCISSORS.



FIG. 338. DE WEECKER'S IRIDECTOMY SCISSORS.

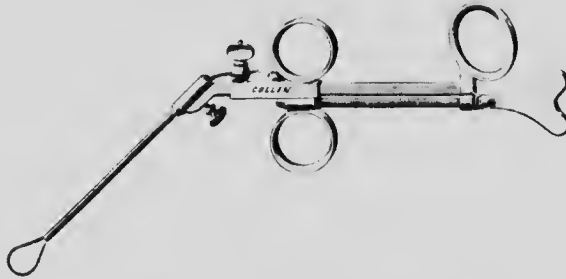


FIG. 339. SERRE-NEEL FOR THE NASAL FOSSE.

is my practice in perineorrhaphy. Section of muscles is made much more evenly with well-riveted scissors than with the bistoury, especially when we want an even surface made in a contused or jagged muscular wound. Special forms of scissors are required for gynecological operations, for ocular surgery, and in some other special operations.

Serre-Nœud. The *serre-nœud*, or polypus snare, is an almost forgotten instrument. It will be seen that the *serre-nœud*, formerly constructed for

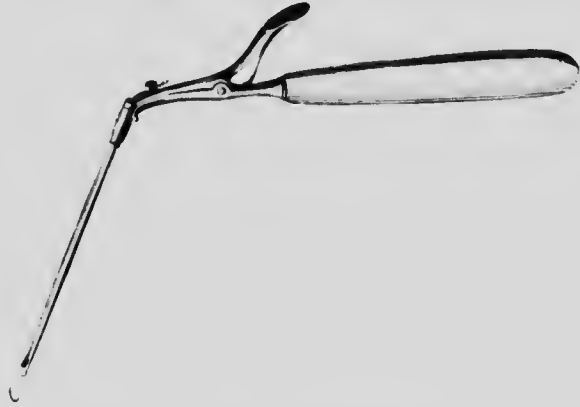


FIG. 340. SERRE-NŒUD FOR THE EXTERNAL AUDITORY CANAL.




FIG. 341. KNIVES FOR THERMO-CAUTERY: STRAIGHT AND CURVED.



FIG. 342. BLUNT AND POINTED KNIVES, USED IN OPHTHALMIC OPERATIONS.




FIG. 343. INSTRUMENTS FOR ELECTRIC CAUTERY.

the special purpose of removal of mucous polypi from the nasal fossæ, can be advantageously replaced by the form of polypus forceps which I have had



FIG. 344. —INTERRUPTING HANDLE USED IN GALVANO-CAUTERY.

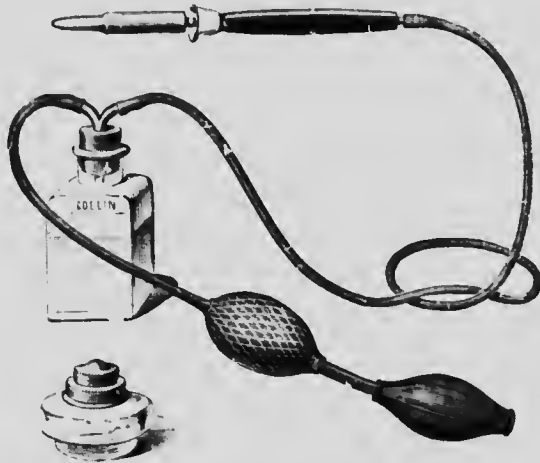


FIG. 345. —PAQUELIN'S THERMO-CAUTERY.



FIG. 346. —INCISION OF A DIABETIC WILLOW WITH THE THERMO-CAUTERY.

310 SURGICAL THERAPEUTICS AND OPERATIVE TECHNIQUE

constructed by M. Collin. There is a special form made for polypi of the external auditory canal.

Thermo-Cautery and Galvano-Cautery.—The thermo-cautery and galvano-cautery are little used for division of tissues, except in cases in which it

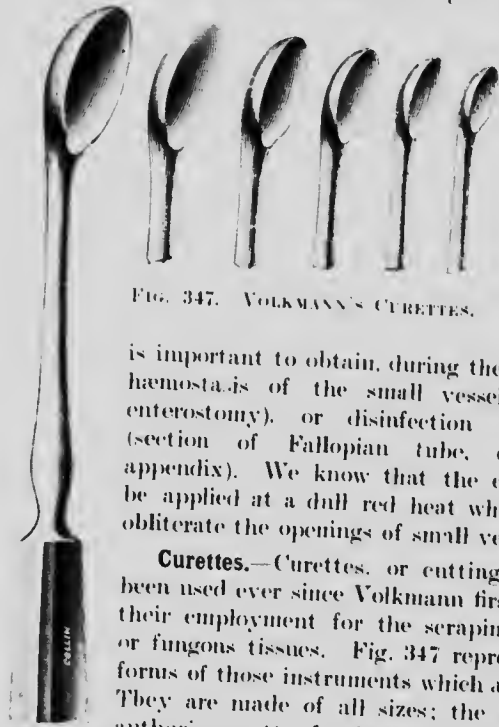


FIG. 347. VOLKMANN'S CURETTES.

is important to obtain, during the section, either hæmostasis of the small vessels (in gastro-enterostomy), or disinfection of a pedicle (section of Fallopian tube, or vermiform appendix). We know that the cautery should be applied at a dull red heat when we wish to obliterate the openings of small vessels.

Curettes.—Curettes, or cutting spoons, have been used ever since Volkmann first popularized their employment for the scraping of softened or fungous tissues. Fig. 347 represents the six forms of those instruments which are most used. They are made of all sizes; the largest is the author's curette for large cold abscesses. The smallest are those used in ophthalmic operations, especially that for chalazion; and, in dermatology, that for molluscum contagiosum; of which the diameter is but two or three millimetres. The very small curettes are



FIG. 348. AUTHOR'S CURETTE FOR LARGE COLD ABSCESS.
(Three-quarters natural size.)

usually made of oval form instead of circular, and we shall see that the stronger ones are devised for bones, which are furnished with fenestrated jaws.

Forceps-Gouges (Gouge Forceps).—The gouge-forceps, or forceps for removal of fragments, which I have had made for using on the soft parts, are



FIG. 349.—HYDATID CYST OF THE LIVER.
Extraction of the hydatids with the curette.

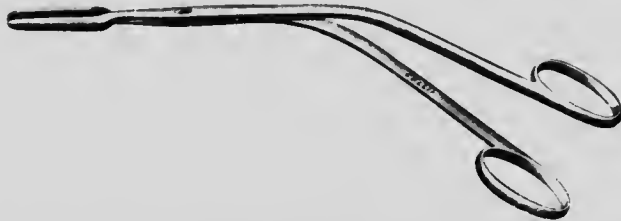


FIG. 350.—AUTHOR'S GOUGE FORCEPS FOR POLYPI OF THE NASAL FOSSE.
This forceps is made of various sizes.



FIG. 351.—HOLLOW-
ING OUT OF THE
JAWS, SEEN FROM
BELOW.

FIG. 352.—AUTHOR'S GOUGE
FORCEPS: SMALLER FORM,
USED FOR POLYPI OF THE
MIDDLE MEATUS.

FIG. 353.—AUTHOR'S GOUGE
FORCEPS: MEDIUM-SIZED
FORM, FOR DEEP-SEATED
POLYPI.



FIG. 354.—AUTHOR'S
GOUGE FORCEPS:
SPECIAL FORM, FOR
SUPERIOR MEATUS.



FIG. 355.—AUTHOR'S GOUGE FORCEPS: LARGE
FORM, USED FOR ABRASION OF THE FREE
BORDER OF THE INFERIOR TURBINATED
BONE.

intended for removal of adenoid vegetations of the pharynx, extraction of polypi from the nasal fossa, resection of the inferior turbinated bone, and, lastly, various applications in uterine surgery.



FIG. 356.—GOUGE FORCEPS FOR ADENOID VEGETATIONS OF THE PHARYNX.
There are three forms of this instrument (Figs. 357, 358, 359).

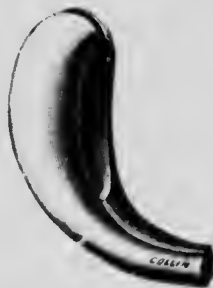

FIG. 357.—GOUGE FORCEPS FOR ADENOID VEGETATIONS OF THE PHARYNX: LARGE SIZE.



FIG. 358.—GOUGE FORCEPS FOR ADENOID VEGETATIONS OF THE PHARYNX: MEDIUM SIZE.



FIG. 359.—GOUGE FORCEPS FOR ADENOID VEGETATIONS OF THE PHARYNX: SMALL SIZE.




FIG. 360.—GOUGE FORCEPS FOR ENUCLEATION OF INTERSTITIAL FIBRO-MYOMATA AND EXTRACTION OF PLACENTAL DEBRIS.

There are three sizes, the respective dimensions of the jaws being 35 x 17, 30 x 13, and 17 x 8 millimetres.



FIG. 361.—COLLIN'S GOUGE FORCEPS, FOR USE IN HYPOGASTRIC SECTION.

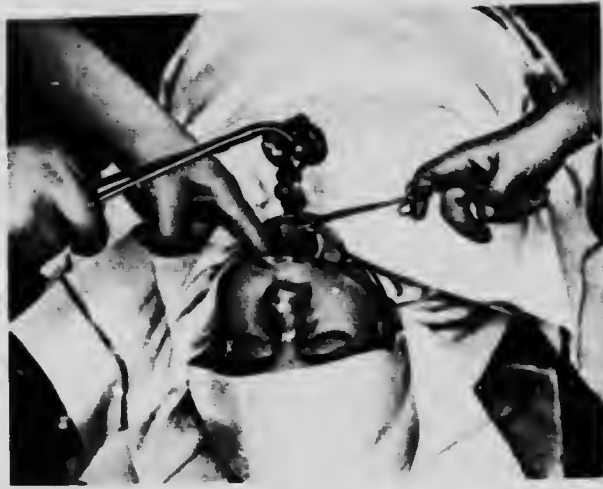

FIG. 362.—EXTRACTION OF AN ENORMOUS NASO-PHARYNGEAL POLYPU WITH THE GORGE FORCEPS.

The growth was detached from the basilar hypophysis with the author's raspatory.

Raspatories.—Raspatories are veritable scrapers with crude cutting edges, more resistant than the bistoury, and serving to detach from osseous surfaces the soft tissues that adhere to them. I have had special raspatories




FIG. 363.—ORDINARY RASPATORIES, STRAIGHT AND CURVED.

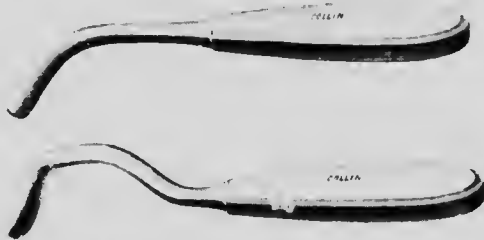

FIG. 364.—AUTHOR'S RASPATORIES, FOR NASO-PHARYNGEAL POLYPI.

constructed for rapid extirpation of naso-pharyngeal polypi, and for detachment of the periosteum from the ribs in the operation of costal resection.

314 SURGICAL THERAPEUTICS AND OPERATIVE TECHNIQUE

INCISION OF THE SKIN, OF DERMOID MUCOUS MEMBRANES, AND OF SUBCUTANEOUS TISSUES.— Incisions of the skin and subcutaneous tissues are usually made with the bistoury. I sometimes use scissors, when there is a pathological orifice. Every incision with the bistoury should be made freely, with a single movement, through the whole distance required, and without tailing.



FIG. 365. RASPATOIDES FOR USE IN STAPHYLOORRHAPHY: RIGHT AND LEFT.



FIG. 366. AUTHOR'S COSTAL RASPATORY.
(See also Author's new instruments, Figs. 243, 244, p. 200.)



FIG. 367. DENUDATION OF A RIB WITH THE AUTHOR'S COSTAL RASPATORY.

T-shaped, U-shaped, and racket-shaped incisions should be exceptional; a rectilinear or slightly curvilinear one made along the margin of the field of operation suffices for most cases. When a certain area of integument has to be removed, as in amputation of the breast, the surgeon should deal with the skin used in covering the wound so as to leave no dragging. For resection of flaps of mobile skin, I prefer the scissors to the bistoury. In

short, the bistoury suits all cases of incision in which the tissues can be made tense, and when they rest on a plane which presents a certain resistance. Vivification of nerves and tendons can be effected with a sharp bistoury, with the precaution of seizing the end to be resected with a strong-clawed forceps. But scissors should be preferred to the bistoury for division of floating and unsupported tissues, as they cut while fixing the tissues by the action of the opposed blades. Thus the scissors is almost exclusively used in gastro intestinal surgery, in vaginal hysterectomy, and in special operations such as strabismus or iridectomy, in which we use small and short scissors, either straight, or bent to an obtuse angle.

2. Instruments for the Division and Evacuation of Bone.

Bones cannot be divided with a bistoury, except in infants, and especially in the epiphysary planes. Volkmann frequently carried out his resections



FIG. 368. Mallet of Red Copper.

in children with a short strong knife. In most cases the density of even spongy osseous tissue makes the use of the bistoury impracticable. The

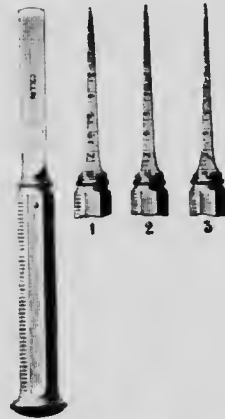

FIG. 369. MacEwen's Osteotomes.

instruments requisite for operations on bone are—(1) Chisels; (2) gouges; (3) shears; (4) gouge forceps; (5) enrettes; (6) straight-edged saws; (7) circular saws; (8) burrs and mortises.

(1) **Chisels.**—Many forms of chisel have been devised for operations on bones. The construction and use of those instruments have been greatly

improved since the popularization of MacEwen's osteotomes, the heavy, strong handle of which has generally been adopted in the various forms. The red copper mallets are also excellent, for they possess at the same time the effectiveness of the old leaden mallets and the elasticity of those of guaiacum wood.

MacEwen's osteotomy chisels, which were designed for division of long bones at the planes of epiphysary junction, have each a blade of 13 millimetres in width, slightly convex, and bevelled at the edge, on each of its surfaces. These chisels are made of three thicknesses. The operation is

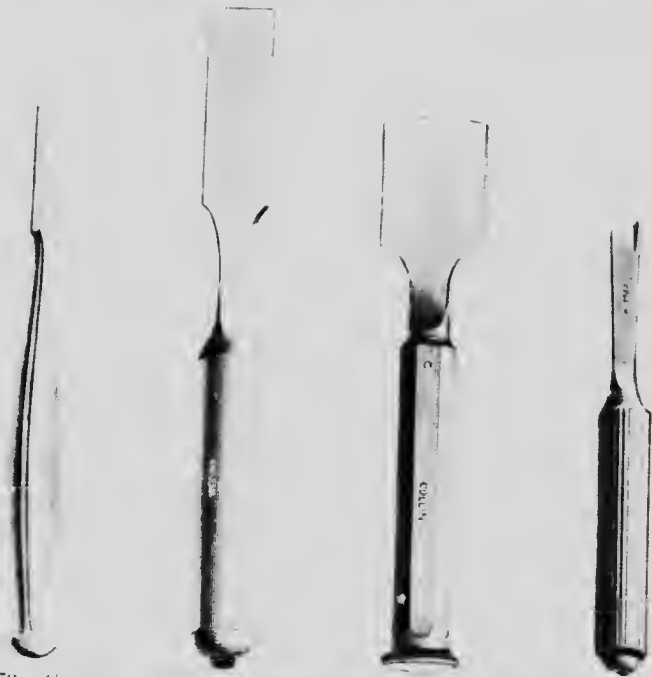


FIG. 370. CHISEL FOR DIVISION OF BONE.

FIG. 371. CHISEL WITH THICK BLADE.

FIG. 372. LEVASSIÈRE'S CHISEL.

FIG. 373. ALFORD'S CRANIOTOMY CHISEL.

commenced with No. 1, the thickest; this opens the way for No. 2; as does the latter for No. 3, the thinnest. In many cases section of the bone can be made with a single osteotome.

MacEwen has also devised a chisel with a straight extremity, with one surface bevelled at the edge. This chisel is intended for cruciform osteotomy, and serves to separate, at the plane of the section, the osseous wedge the ablation of which is necessary for adjustment of the limb.

Bone chisels should always be bevelled on one face of the edge only; they are made of all widths, from 2 to 50 millimetres. In cases in which we have to remove osseous chips of slight thickness, and with a very clear

line of division, it is necessary to use a chisel with thin blade, and well sharpened.

Lucas-Championnière has had a wide-bladed (60 millimetres) chisel made for completion of the resection of the epiphyses in operation on the knee-joint (Fig. 372). This fairly completes the series which I have described.

CHISEL FOR CRANIECTOMY.—I have had a special chisel made for craniectomy, to be used in fissuring the osseous intervals between the holes made with the burr. The active angle of this chisel is made blunt, to prevent its wounding the dura mater while the outer angle is prolonged into a finger-like protective process, thicker than the cutting blade, and designed to prevent too deep penetration of the instrument (Fig. 373).

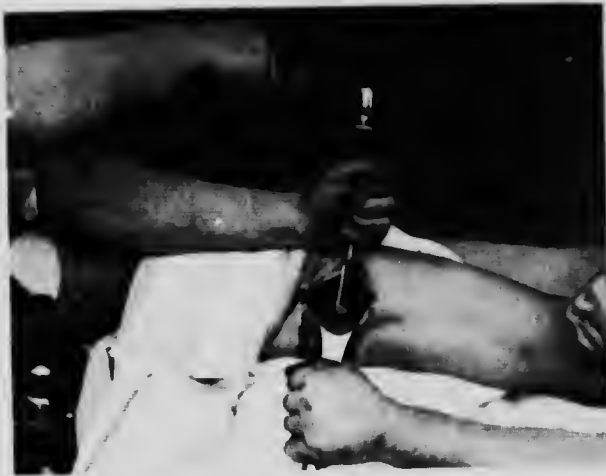

FIG. 374.—SUBTROCHANTERIC OSTIOTOMY OF THE FEMUR.

(2) **Gouges.**—Gouges are chisels with thick and rounded blades, the extremity of which, bevelled at the expense of its convex aspect, is so moulded as to form a hemispherical cavity. The harder the bone, the narrower and proportionally stronger should be the gouge used. In 1894 I had a gouge made for craniectomy and for evacuation of very hard bones, with a strong handle, and so formed as to present on one side a furrow of 3 millimetres in width (Fig. 377). This instrument penetrates readily into eburnated bones, which a larger and apparently more effective instrument would break, hardly making a superficial scratch. I have also had powerful gouges made by M. Collin, incurved along the whole length of the blade, the use of which is most valuable in evacuation of the long bones with the aid of hand and mallet.

(3) **Shears.**—The shears most used in the surgery of bones is that with bent blades, represented in Fig. 379, which is suitable for resection of ribs.

318 SURGICAL THERAPEUTICS AND OPERATIVE TECHNIQUE

of the superior maxilla, etc. I have had made, for trimming the marginal irregularities of the osseous flap along the line where it meets the flesh, two shears, a right and left, with thin blades of tempered steel. These shears



FIG. 375. ORDINARY GOUGE FOR EVACUATION OF LONG BONES.



FIG. 376. GOUGE IN-CURVED ON THE FLAT FOR LAVIGATION OF SHORT SPACES.




FIG. 377. - AUTHOR'S STRAIGHT GOUGE FOR THE CRANIUM.



FIG. 378. EVACUATION OF THE TIBIA.

Raising with the gouge the osseous shutter outlined with the burr and circular saw.

enable the operator to obtain a very clean resection of the irregularities of the cranial flap (Figs. 279 and 280).



FIG. 379. SCISSORS WITH BENT JAWS AND RECOIL SPRING.

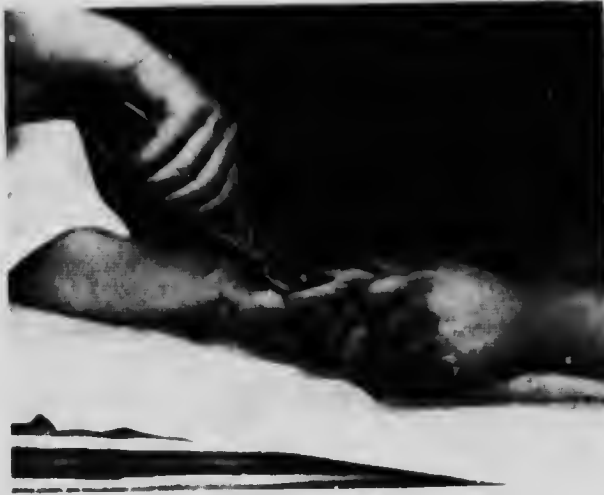

FIG. 380. RESECTION OF THE HEAD OF A METACARPAL BONE WITH THE BENT-JAW SCISSORS.



FIG. 381. NÉLATON'S GOUGE FORCEPS, WITH RECOIL SPRING.



FIG. 382. ALLOUÉ'S FORCEPS FOR REMOVAL OF FRAGMENTS IN CRANIOTOMY.

(4) **Gouge Forceps.**—The gouge forceps which I prefer is that of Nélaton, with fenestrated articulation and recoil spring. Nélaton's original form

320 SURGICAL THERAPEUTICS AND OPERATIVE TECHNIQUE

of the instrument is certainly preferable to any recent substitutions. It is made both in straight and curved forms. The jaws are 8 millimetres in width. It is necessary to have both models, straight and curved, made with narrower jaws, of about 6 millimetres.



FIG. 383. TRELAT'S FENESTRATED CURETTE.



FIG. 384. FARABEU'S FENESTRATED CURETTE.




FIG. 385. SAW WITH MOVABLE BACK, WITH HINGED AND SLIDING CALCEI.

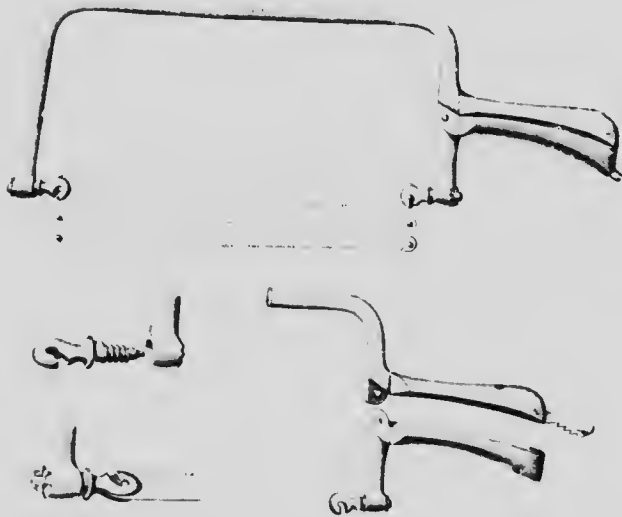


FIG. 386. SAW WITH RETRACTING BLADE, WITH VARIABLE TENSION.

(5) **Forceps for Removal of Fragments.**—The form of forceps for removal of fragments which is represented in Fig. 382 has been specially constructed

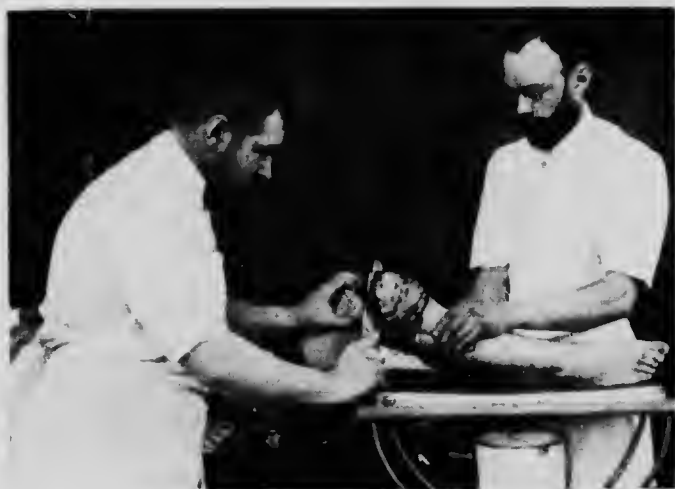

FIG. 387. RESECTION OF KNEE-JOINT.
Division of femur with the saw with movable back.




FIG. 388.—AMPUTATION OF THE LEG.
Division of bones with the saw with variable tension.

for use in craniectomy. It enables us to make a furrow of about 3 millimetres wide in the cranial vault. When the skull is very hard, it is advantageous to ease off the section by making a preliminary division, with the cursive saw, of the external table, down to the diploë.

(6) **Curettes.**—Curettes for use in osteal surgery are made very strong, fenestrated, and of small diameter. They serve for the evacuation of spongy osseous tissue, of epiphyses, and of diaphysary foci in osteomyelitis.

(7) **Ordinary Saws.**—The saws worked by the hand that are most employed in surgical practice are: the *saw with movable back*, which is made in two sizes, and is used for articular resections— even, too, by way of accessory function, for section of plaster apparatus; and the *saw with variable tension*, which is of special use in large amputations, in which it is more readily manipulated. I have had made by M. Collin two types of saw, worked by hand, and furnished each with a graduated sliding shield, which



FIGS. 389A AND 389B. AUJOUR'S CURSIVE SAWS, STRAIGHT AND CURVED.

enables the operator to limit the projection of the teeth of his instrument. One has a rectilinear blade (Fig. 389A), for craniectomy; the other has a convex blade, for section of the vertebral laminae (389B).

I employ neither the chain-saw nor the dentated steel wire, which can always be replaced by one of the forms above figured, or by a cutting forceps.

MECHANICAL INSTRUMENTATION FOR OSTEOAL SURGERY.

The use of mechanical saws, perforators, and burrs in trepanning the cranium dates back to very ancient times. Those instruments were manipulated either directly by the hand or with the aid of various rotatory apparatus such as those attributed to Hippocrates and to Andreas à Cruce. The form of the perforators used in opening the cranium were sufficiently various. The same perforators were adapted to the trepan by Andreas à Cruce and by Paré. We may judge from Seerig's plates of the diversity of forms of the perforators, burrs, saws, and trepan-crowns successively

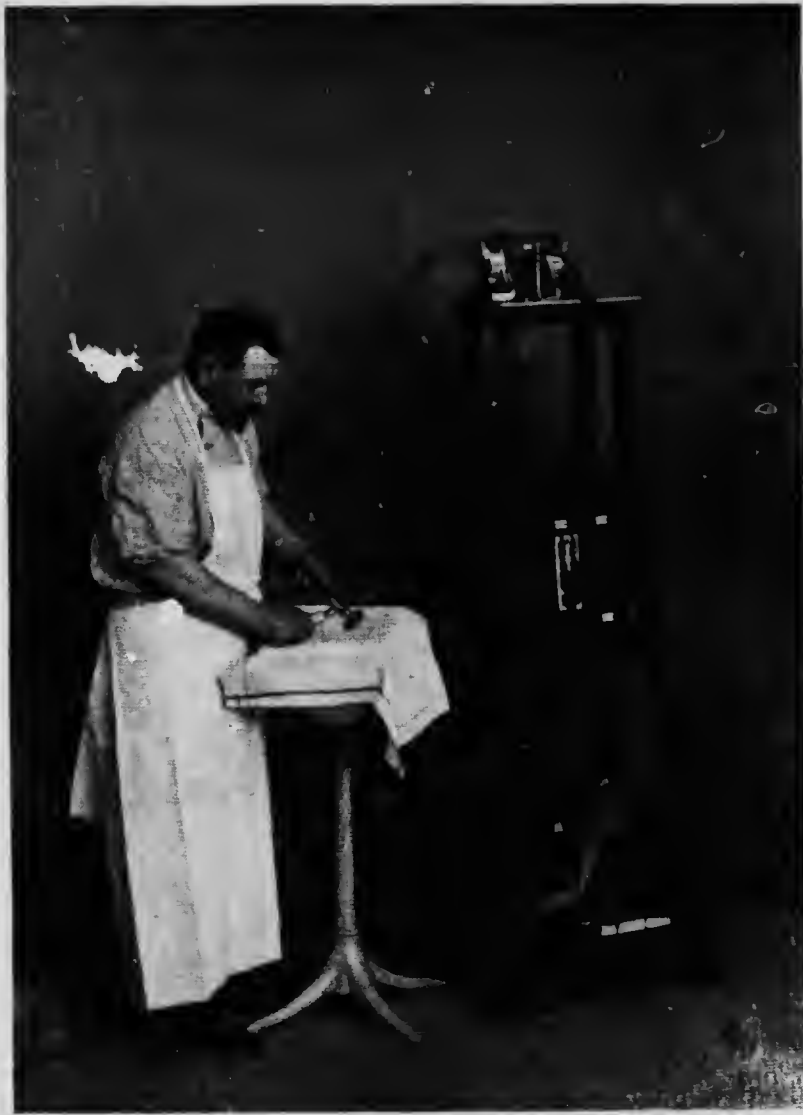

FIG. 399. ELECTRIC MOTOR, FLEXIBLE TRANSMITTING CABLE, HANDLE WITH VARIABLE INCLINATION, AND CIRCULAR SAW.

adopted by ancient surgeons. Circular saws could not then be of much assistance, as they used merely simple cog-wheels, which could give neither velocity nor power to the instrument. Conical perforators were given up as dangerous. Burrs of defective pattern could not deal satisfactorily with the bone.

ADVANTAGES OF ELECTRIC MOTORS.

The vulgarization of small electric motors has of recent years brought mechanical saws into general use, the older models of which were practically inapplicable. These electric saws, which were much weaker, had not much greater success than their surgical predecessors. When I studied the matter in connection with the surgery of the cranium, one fact at once appeared to me evident: that it was absurd to use, in attacking the cranium, motors of 5 to 10 kilogrammetres—a force much less than could be applied by a vigorous man. Familiar as I had been from my early years with the study of practical mechanics, I investigated the action of various forms of motors, and fixed on a power between 60 and 75 kilogrammetres—approximately a 1 horse-power. Such a motor, making about 2,500 revolutions per minute, can drive satisfactorily a saw of 15 centimetres in diameter, and cut through a femur without slowing. Is it not the rule in every mechanical workshop to use for the working of the various machines a force very much greater than that given by theoretical calculation?

FLEXIBLE TRANSMITTING CABLE.

A lacuna had now to be filled, to connect the motor with the various instruments to be used. The forms of flexible conducting cords submitted to me either were not sufficiently resisting, or were unable to bear so great a




FIG. 391. AUTHOR'S FLEXIBLE TRANSMISSION CABLE, FOR USE IN OPERATIONS ON BONES, WITH THE AID OF ELECTRIC INSTRUMENTATION.

velocity without spoiling. After full study of the requirements, I devised a new vehicle of flexible transmission, which satisfies all needs (Figs. 390 and 391).

(8) **Circular Saws.**—I employ various forms of circular saw in the surgery of bones: (1) Large saws of 150, 120, 100, 80, and 60 millimetres diameter respectively, for resection of the knee, elbow, inferior maxilla, and for opening the medullary canal of the long bones in osteomyelitis; (2) a small

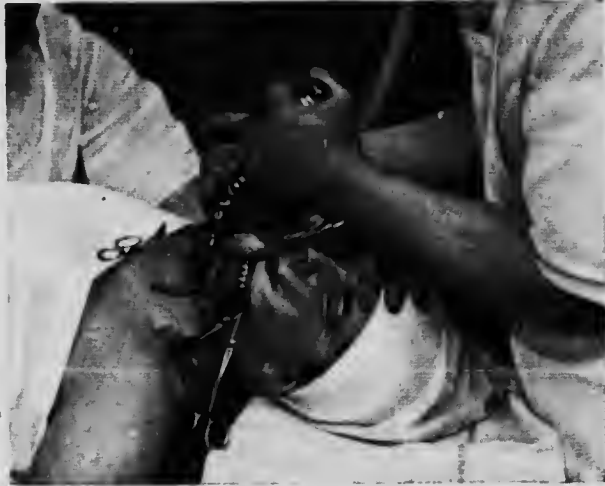

FIG. 392. SECTION OF INTERIOR MANILLA WITH THE CIRCULAR SAW.

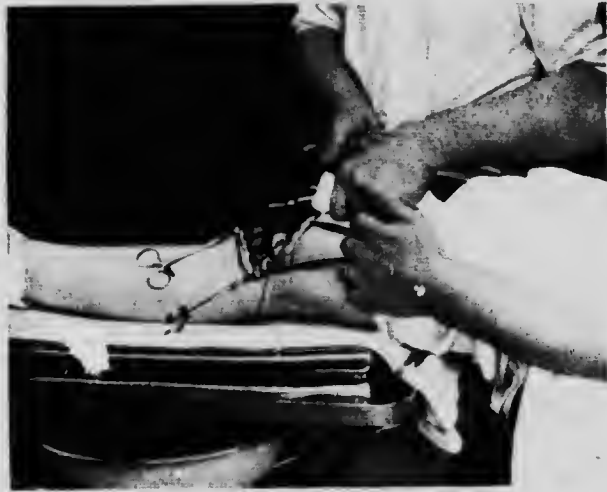

FIG. 393.—RESECTION OF KNEE.
Section of tibia with the circular saw.

saw of 35 millimetres, very thin, and furnished with a graduated disc, numbered with the millimetres corresponding to the projection of the teeth (Fig. 395), the numbers ranging from 2 to 10; (3) a saw of 45 millimetres, hollowed out in the centre, and with alternating teeth, which is to be guided by the handle, with vertical groove and intracranial guide, represented in Fig. 396.



FIG. 394.—SAW OF 35 MILLIMETRES DIAMETER.



FIG. 395.—SAW OF 35 MILLIMETRES DIAMETER, MOUNTED, AND FURNISHED WITH A PROJECTING RIM WHICH LIMITS THE DEPTH OF THE SECTION.

All these saws, as well as the other instruments about to be described, are worked by an electric motor of half a horse-power, with a velocity of 2,500 revolutions per minute. The flexible transmitting cable serves to




FIG. 396.—SAW OF 45 MILLIMETRES DIAMETER, WITH ALTERNATING TEETH, AND HANDLE WITH SLIDING BLADE WHICH DETACHES AND PROTECTS THE DURA MATER.

convey the force of the motor to the handle of the instrument, which is firmly held, in both the longitudinal and transverse directions, by the hands of the surgeon, with the aid of the handle adapted to variable inclination, which is represented in Fig. 390.



FIG. 397. — SPHERICAL BURR OF 12 MILLIMETRES DIAMETER.

(Actual size.)



FIG. 398. — SPHERICAL BURR OF 12 MILLIMETRES DIAMETER, MOUNTED ON A HANDLE ADAPTED TO ELECTRIC INSTRUMENTATION.

(9) **Burrs and Mortising Instruments.**—The spherical burrs and mortising instruments which I have had constructed for use in osteal surgery are

made with eight oblique teeth. The more used forms are—(1) The spherical burr of 12 millimetres, used in perforation of the cranial vault by electric instrumentation; (2) conical burrs of 8 and 12 millimetres diameter, for perforation of the bones of the limbs; (3) cylindro-spherical burrs, of 8, 12, and 16 millimetres. That of 8 millimetres serves for opening of the frontal, ethmoidal, and sphenoidal sinuses, and is mounted on a trepan, with a catch and an intermediate rod of 12 centimetres in length. The cylindro-



FIG. 399. CONICAL BURRS OF 8 AND 12 MILLIMETRES DIAMETER, RESPECTIVELY.

FIG. 400. — CYLINDRO-SPHERICAL BURRS OF 8, 12, AND 16 MILLIMETRES.

FIG. 401. — FLAT POINTED DRILL OF 12 MILLIMETRES DIAMETER, MOUNTED ON THE HOLDER OF A TREPAN À CLIQUET.

spherical burr of 12 centimetres serves as mortising instrument for the evacuation of long bones, and is also adaptable to the trepan for completion of the orifices in the cranial vault that have been commenced with the flat perforating drill (Fig. 401). The cylindro-spherical burr of 16 milli-



FIG. 402. — TREPAN WITH CATCH, AND HOLDER FURNISHED WITH A FLAT DRILL.

metres diameter is used exclusively with the trepan à cliquet, for evacuation of the mastoid apophysis and exploration of the mastoid antrum. (4) The flat rod drill represented in Fig. 401 should be used when operating with the hand, either in craniectomy or evacuation of the mastoid apophysis, in commencing the opening, which is then continued with a cylindro-

328 SURGICAL THERAPEUTICS AND OPERATIVE TECHNIQUE

spherical burr of 12 or 16 millimetres. This drill is mounted on the special holder made for the *trepan à cliquet*. (5) I have also had constructed small dentate mortising instruments of 3 millimetres diameter, the extremity of which is furnished with a button (for protection of the dura mater), or sharpened (for use on long bones); the use of those of small diameter is exceptional. The buttoned mortising instruments permit the very rapid performance of linear craniectomy in children under the age of eight years.



FIG. 403. — CONICAL BLUNT-POINTED DRILLS, ONE MOUNTED ON A HOLDER.

I thus possess two distinct surgical armamentaria for operations on the skeleton — one destined for manipulation with the hand alone, the other

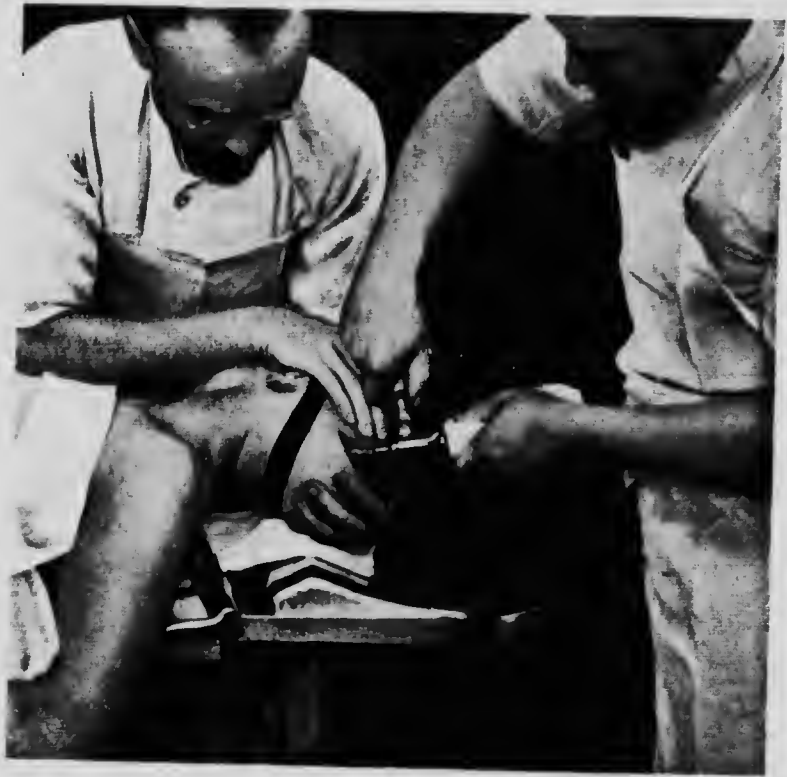

FIG. 404. CRANIECTOMY WITH ELECTRIC INSTRUMENTATION. Perforation of the cranium with spherical burr of 12 millimetres diameter.

worked by an electric motor of a certain power. Those instruments were all constructed, under my directions, in 1894 and 1895.

ELECTRIC INSTRUMENTATION.

Electric instrumentation for use on bones, which is the adaptation to osteal surgery of the progress realized in work in wood, ivory, and metals, comprises—(1) An electric motor of 60 to 75 kilogrammetres, with alternating or continuous current, according to installation (Fig. 350). (2) A flexible cable of sufficient strength to receive, without injury, the whole effect

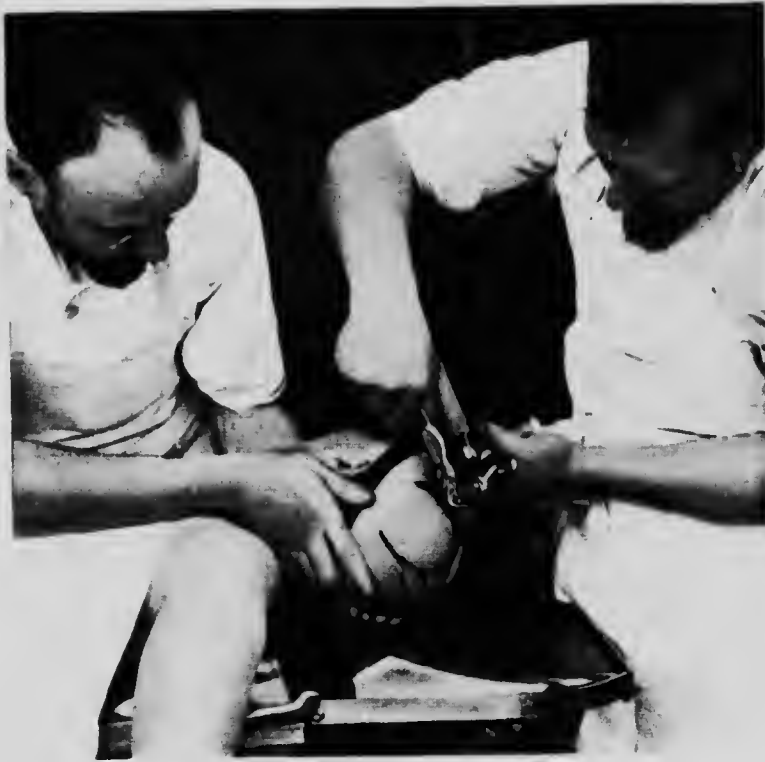

FIG. 405. CRANIOTOMY WITH ELECTRIC INSTRUMENTATION.

Section of cranium with saw furnished with alternating teeth and intracranial guide.

of the action of the motor, which, at a rate of 2,500 turns per minute, represents a considerable resistance (Figs. 390 and 391). (3) A handle with variable inclination (Fig. 390). (4) Projecting holders, for saws of various diameters (the largest are mounted directly on the extremity of the flexible cable), burrs, drills, mortising instruments, etc. (Fig. 398). (5) Burrs and mortising instruments: Perforation of the cranium is effected with the aid of the same motor. With this object I adapt to the end of the flexible cable a spherical burr of 12 millimetres diameter, formed, according to my

330 SURGICAL THERAPEUTICS AND OPERATIVE TECHNIQUE

directions, so that the dura mater cannot be wounded at the moment of perforation of the inner table (Fig. 397). Large cylindrical mortising instruments are used for evacuation of long bones (Fig. 400). I have employed in some cases dentate drills, some sharpened at the end and used for perforation of bone, others protected with a flat button (Fig. 403). These drills can be made, in dexterous hands, to form openings of the most varied outlines in the various bones. (6) Circular saws: The cranium

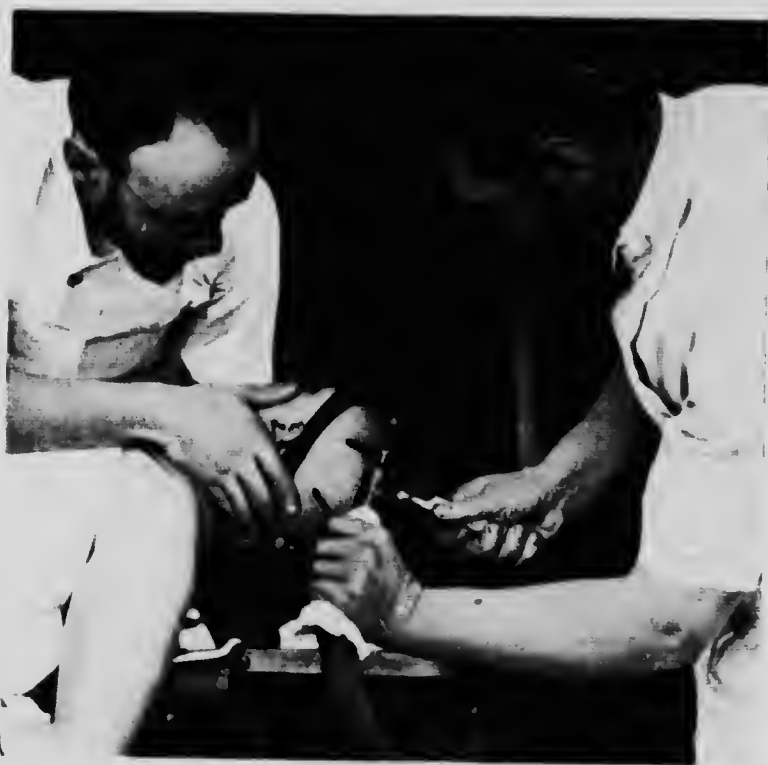

FIG. 406. CRANIECTOMY WITH ELECTRIC INSTRUMENTATION.
Section of the peripheral osseous bridges with the rowel saw.

is divided with circular saws between the orifices formed by burrs. I have devised a procedure for temporary craniectomy which enables me to divide the whole thickness of the skull at a single stroke, if I wish it, without risk of wounding the dura mater. This is done with the aid of a special saw handle, with a vertical groove and an intracranial guide. The calvaria being perforated with the burr, the dura mater is detached in the direction in which the section is to be made with the aid of a curved and grooved sound (Fig. 259) and decollator (Fig. 260), and the guide is introduced into the

opening. A suitable saw, hollowed out towards the centre, and furnished with alternating teeth, is mounted on the flexible cord, and placed in the vertical groove of the holder, in contact with the bone. The motor is then set in action; the saw at once reaches the bottom, cutting the bone down to the sliding plate. We then need only push the handle forward to secure a complete section for a length of 4, 6, 8, or 10 centimetres (Fig. 405). When I wish to limit the depth of the section to some millimetres, I attach to a saw

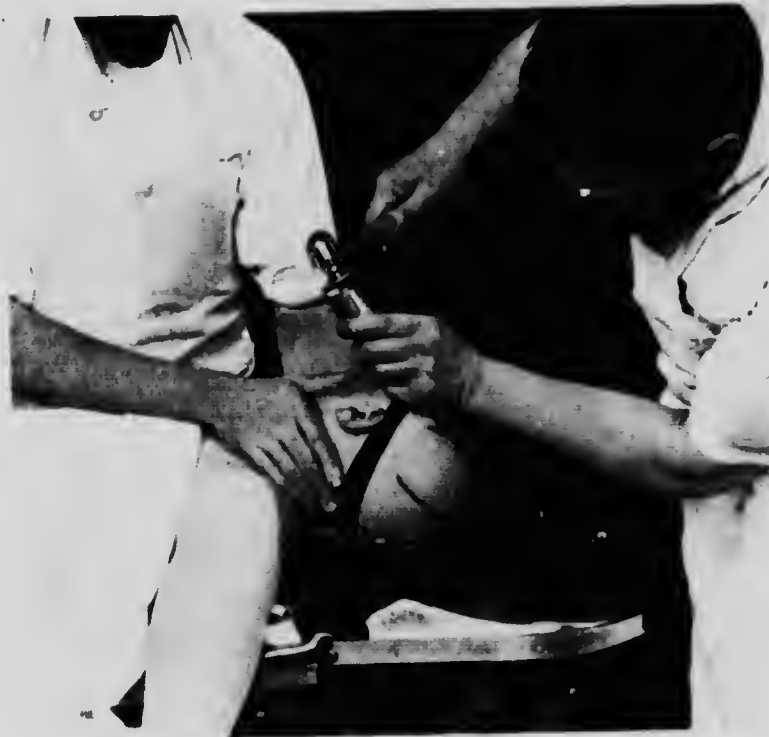

FIG. 407. CRANIECTOMY WITH ELECTRIC INSTRUMENTATION.

of a certain diameter a shield of nickel-plated metal, numbered 2, 3, 4, 5, 6, 8, 9, 10, according to the number of millimetres of the requisite projection of the teeth (Fig. 406). It is thus easy, in case of the cranium, to divide the outer table only; by adapting to the saw a shield marked with a number lower than that of the millimetres of the thickness of the bone, which is discernible at any of the openings made with the burr, and can be measured with the instrument represented in Fig. 261. I will describe in detail the manipulation of those instruments in dealing with the subject of temporary hemieraniectomy.*

* See Dr. Marcotte's 'Thesis,' Paris, 1897; and *Arch. de Neurologie*.

MANUAL INSTRUMENTATION.

The relative difficulties connected with the manipulation of mechanical instruments, which are also rather expensive, has led me to arrange an outline of operative manipulation more simple in practice, and accessible to all. I have had constructed by M. Collin, for adaptation to his older form of *trepan à cliquet*, holders of the calibre of our spherical burrs, and (as those do not penetrate the outer layer of compact osseous tissue fast enough) flat perforating drills and conical burrs which are intended to begin the formation of each opening. (Figs. 399 and 401).

The bone is first attacked with the conical burr or the perforating drill; another holder is then substituted, furnished with a cylindro-spherical



FIG. 408. PERFORATION OF THE ANTRUM OF HIGHMORE THROUGH THE CANINE FOSSA, WITH THE FLAT DRILL AND *TREPAN À CLIQUET*.

burr of 12 millimetres diameter guarded by a protective crown. The dura mater is thus reached in a few moments, and without danger of wounding it. A number of orifices are thus made, at points previously determined, and then joined, either with the cutting forceps or saw and chisel.

This instrumentation is also the best for evacuation of the mastoid apophysis. For this procedure I use a burr of 16 millimetres in diameter. The mastoid antrum is reached in a few moments, without danger of wounding the lateral sinus. I also use these perforators for opening through the nasal passages into the ethmoidal and sphenoidal sinuses, as well as for the trephination of long bones in cases of osteomyelitis. In the latter operation the two openings made at the limits of the lesion are united with the help of a convex sliding saw (Fig. 389b). For the cranium I employ in

division of the outer table a similar saw, but the intermediate portion of the edge of which is rectilinear; this form is to be preferred, as the cranial surface is often highly convex (Fig. 389). The division of the skull is completed with the help of the craniectomy forceps (Fig. 382), or with one



FIG. 409. EVACUATION OF THE MASTOID APOPHYSIS WITH THE CYLINDRO-SPHERICAL BURR OF 16 MILLIMETRES DIAMETER.

of my craniectomy chisels, which are characterized by blunt outlines, and are rounded at the lower angle, which thus cannot wound the dura mater, and furnished at the opposite angle with a protective digital process, which prevents too deep penetration (Fig. 373).

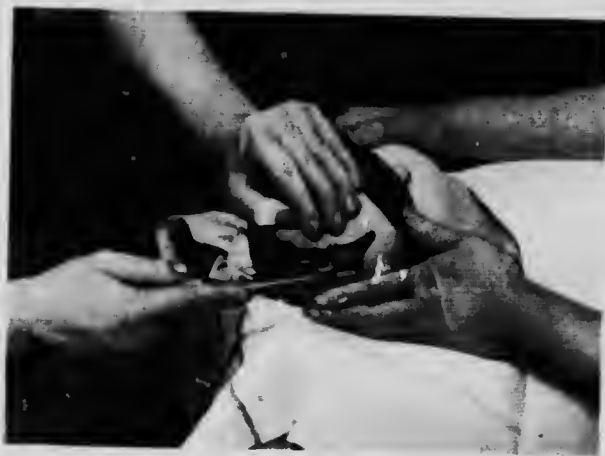

FIG. 410. — CRANIECTOMY WITH MANUAL INSTRUMENTATION.
Section of outer table with gliding saw.

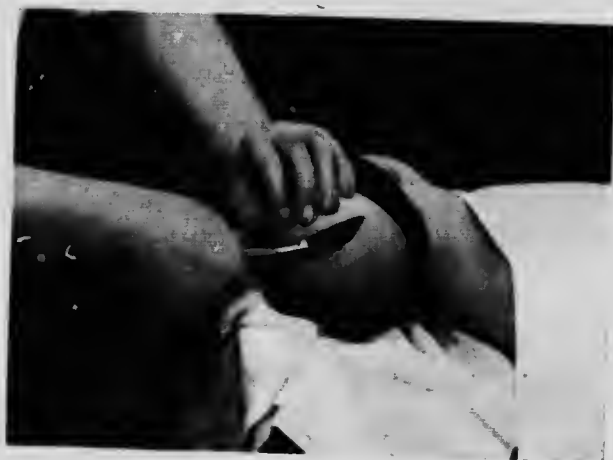

FIG. 411. — CRANIECTOMY WITH MANUAL INSTRUMENTATION.
Section of inner table, along the groove made by the saw, with the forceps for removal of fragments.

SUTURES.

The reunion of tissues requires the use of a certain number of instruments.

Instruments for the Suture of Soft Parts.

1. **Curved Needles, with Duplex Eyelet.**—I use these two forms: (1) a round needle for intestinal suture; (2) five sizes of cutting needles, for suture of the conjunctiva, lips, and other mucous tissues.

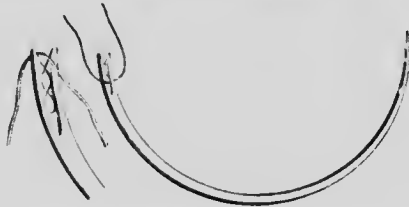


FIG. 412. NEEDLES WITH DOUBLE EYELET.

2. **Author's Needle with Triangular Eyelet.**—For suture of the abdominal wall after laparotomy I use needles with a triangular eye, placed *en raquette*, for the purpose of catching the thread.



FIG. 413.—AUTHOR'S NEEDLES WITH TRIANGULAR EYELET FOR CATCHING THE THREAD.

These needles are made with two varieties of curve, slight and semicircular.

3. **Needle-Holders.**—The two indispensable types of needle-holders are—(1) the forceps needle-holder with excavated jaws and ring handles (Fig. 414) or with automatic (Fig. 417) lock, for needles used in intestinal suturing, and both forms of curved needles; (2) needle-holder with eccentric plate, two types of which are made—the ring-handled (Fig. 415) and that with automatic lock—which are used with large needles. Those needle-holders with eccentric plate are of very simple construction, and enable us to hold and push the curved needles in every required direction—transverse, oblique, and even longitudinal—and, accordingly, to carry out the most difficult suturing, for which instruments of most complicated structure were formerly devised.

4. **Needles with Handles.**—I have had four types of needles made with handles. In two of these the curve is somewhat accentuated, and the smaller is exclusively employed for interrupted suture of the skin; the other




FIG. 414. —AUTHOR'S HEMOSTATIC FORCEPS WITH SHORT HOLLOWED JAWS, WHICH MAY BE USED AS NEEDLE-HOLDER.



FIG. 415. —AUTHOR'S NEEDLE-HOLDER, WITH ECCENTRIC PLATE AND RINGED HANDLES.



FIG. 416. —AUTHOR'S NEEDLE-HOLDER, WITH ECCENTRIC PLATE AND AUTOMATIC LOCK.





FIG. 417. —AUTHOR'S NEEDLE-HOLDER, WITH STRAIGHT, HOLLOWED JAWS AND AUTOMATIC LOCK, FOR GASTRO-INTESTINAL SUTURE.

two have each a large curve, and these are used for suturing the pelvic peritoneum and deep structures in general. In all: for the soft parts, three forms of needle, with duplex or racket-shaped eyelets; two needle-holders;

and four forms of needle mounted on handles. The threads used for suturing soft parts are Florentine hair, which is also employed for sutures of the skin: spun silk and catgut, for buried sutures.



FIGS. 418-421. CURVED SUTURE NEEDLES WITH HANDLES.

5. **Clawed Forceps.** I employ for prehension of tissues either the dissecting forceps with oblique claws, or the ring handled and clawed forceps (Figs. 185 and 186). The last can be placed in position previously by the surgeon himself, who can in this way carry out the suturing without an assistant.



FIG. 422. ALDOR'S DISSECTING FORCEPS, WITH OBLIQUE CLAWS.



FIG. 423. SHOWING THE OBLIQUITY OF THE CLAWS.

6. **Metallic Clips.** Michel's metallic clips give excellent results in suturing of the skin when this is sufficiently flexible and of moderate thickness.




FIG. 424. MICHEL'S CLIPS.



FIG. 425. MICHEL'S CLIP FORCEPS.



FIG. 426. REVOLVING CLIP-HOLDER.



FIG. 427. AUTHOR'S AUTOMATIC CLIP-HOLDER FORCEPS.



FIG. 428.—COLLIN'S FORCEPS FOR REMOVAL OF CLIPS.

Instruments for Osseous Suture.

Reunion of bone demands the use of perforators, which are of two types—(1) *simple perforators*, which are held in the palm, and worked like



FIG. 429.—PERFORATOR, WORKED BY THE HAND.




FIG. 430.—COLLIN'S MECHANICAL PERFORATOR.

a turn-screw. These suffice for operations on cancellous or slightly compact osseous tissues. (2) *Mechanical perforators*, in which rotation of the drill

is produced by the action of two pinions mounted on a winch-handle. The drill is pierced near the end with one or two openings, which permit the passage of the metallic thread into the osseous canal.



FIG. 431. —CLAMP WITH RECOIL SCREW FOR RETENTION OF THE FRAGMENTS IN POSITION IN A CASE OF COMPOUND FRACTURE OF THE FEMUR.

The apparatus is represented in position, and the screw fully tightened.

For osseous suture I employ, as a rule, specially prepared threads of gilt and twisted *maillechort*, which is far superior in power of resistance to the best silver wire.

Screw-Clamp for Retention of the Fragments in Compound Fracture.—In the case here illustrated the extent of the overriding of the fragments, after resolution of the inflammatory sequele, amounted to 7 centimetres, and, after liberating all adhesions, a traction force of 175 kilogrammes with the pulleys was found necessary to bring the surfaces of the broken ends into apposition. I had prepared for maintenance of the reduction a clamp formed of two pieces in the form of forks with incurved extremities, so that each could be placed with one prong above and the other below the seat of fracture, in a position similar to that of the blades of a forceps. The apparatus for compression is then placed in position. This consists of a conical tube and a screw which is fitted over the extremities of two juxtaposed semicylindrical stems. This clamp is figured on p. 339.

Technique of the Suturing of Soft Tissues.

I. Suture of the Skin.—The best mode of joining the edges of a skin wound is that of suture with metallic clips. In places in which the clips cannot be used, interrupted or continuous suture may be adopted, with silk or Florentine hair.

SETURES WITH CLIPS. The metallic clips secure excellent union in all positions in which the lips of the cutaneous wound can be perfectly adapted in contact. The part is grasped by the surgeon with clawed forceps at each extremity of the line of reunion, which is then made tense while the clips are being placed along the interval by the assistant, who

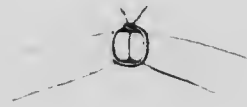

FIG. 432. UNION OF EDGES OF SKIN WOUND BY POINTS OF INTERRUPTED SUTURE.



FIG. 433. UNION OF EDGES OF SKIN WOUND BY STRAIGHT KNOT.

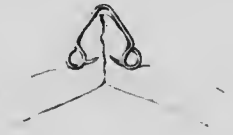

FIG. 434. UNION OF EDGES OF SKIN WOUND BY CLIPS.

picks them up one by one with the holder in his left hand. The use of clips gives a very satisfactory reunion. They must be removed from the second to the fifth day with Collin's forceps, beginning with those which seem to produce a little irritation. The cicatricial line is usually almost invisible.

SUTURING WITH SILK, FLORENTINE HAIR, OR CATGUT.—When the line of union is somewhat exposed to dragging, continuous suture gives less regular adaptation than does the interrupted; also, silk and catgut are far less tolerated in such cases than Florentine hair. In the absence of clips, I usually suture the skin wound with Florentine hair, applied with one of my handle mounted needles. The lips of the cutaneous wound are grasped with a clawed forceps, and the needle is made to penetrate the skin 8 to

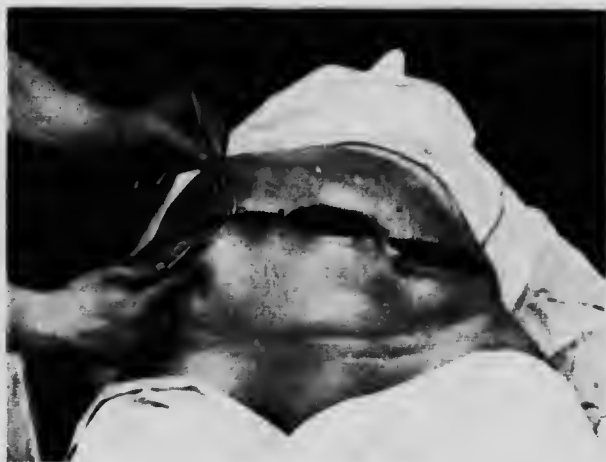

FIG. 435. —REMOVAL OF SUBCUTANEOUS FAT FROM THE ABDOMINAL WALL.
Placing of the first series of suture points; the first being on the middle line, the next on the respective mid-points of the right and left halves of the incision.

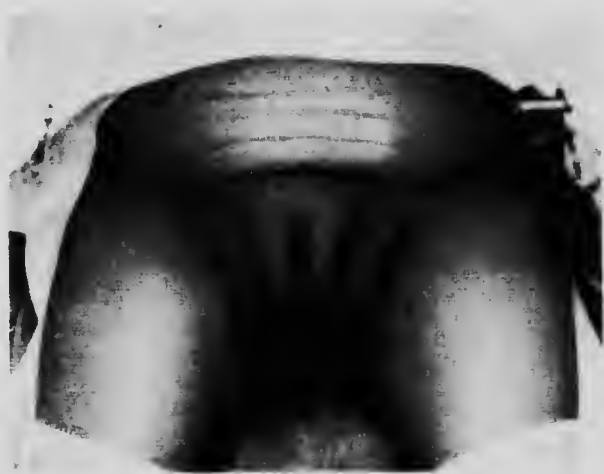

FIG. 436. —REMOVAL OF SUBCUTANEOUS FAT FROM THE ABDOMINAL WALL.
After placing of some separate points of silk suture, the closure of the skin wound is completed with hooks.

10 millimetres from the margin of the wound when the integument is thick (as on the scalp, outer surface of thigh, lumbar region); and at a distance of 2, 3, or 4 millimetres only when thin (abdominal wall, eyelids, dorsal surface of hand, etc.). The assistant eyes the needle with Florentine hair, which he pushes through for a length of 2 to 5 centimetres. The surgeon carefully adapts the edges of the wound along the line of union by bringing them together with a clawed forceps, and then draws back the needle eyed with the Florentine hair which is held at the end by the assistant; who makes a straight knot, tightened close to the surface, and holding the tissues in exact contact without strangulation. We must avoid the slightest folding in of the lips



FIG. 437. UNION OF THE EDGES OF A CUTANEOUS INCISION.

The first point of suture is placed exactly in the middle.

of the wound; the epidermal edge of one side should meet that of the other exactly. On this account the thinner the skin, the more closely should the needle be made to approach the margin of the wound in penetration. The stitches should be placed at an interval of 12 to 15 millimetres when the skin is thick and well supported by the subcutaneous tissue, of 5 to 8 millimetres only when the suturing is fine and delicate. When the first series of points of suture seem too widely spaced, other more superficial stitches are intercalated at the points where infolding of the skin seems possible. Union of the edges of the skin is rapidly effected with the use of the mounted needle and clawed forceps.



FIG. 438. UNION OF THE EDGES OF A CUTANEOUS INCISION.

Points 2 and 3 are next placed; then points 4, 5, 6, and 7.

When the incision is of a certain length, it may happen that at the close of the suturing there is a longer margin of skin on one side of the wound than can be satisfactorily adjusted to the other. Such a condition is specially liable to present itself after amputation of the breast. But you can obtain a perfect suturing in the following manner: Bring the two edges together by a point of suture exactly in the middle of their length; the wound is thus divided into two equal parts. Two other points are then placed, one exactly in the middle of each of the halves, and this process is repeated for each of the four divisions thus made. The wound is then divided into eight parts by seven sutures, and the further linear divisions can be satisfactorily made by application of intermediate points.

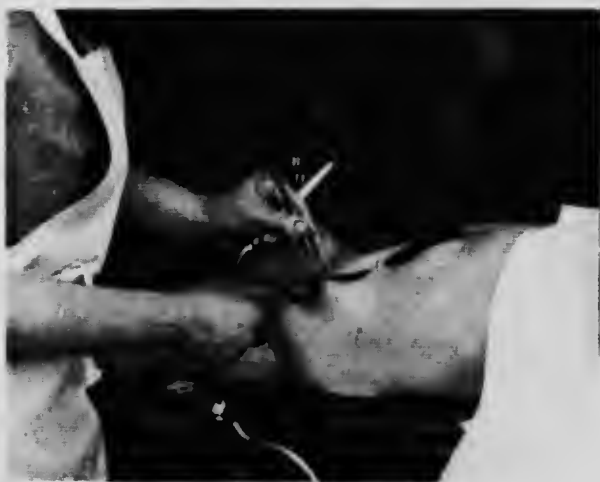

FIG. 439. AMPUTATION OF THE BREAST.

Placing of the first suture in the middle of the line of the wound, and the second in the middle of its external half.

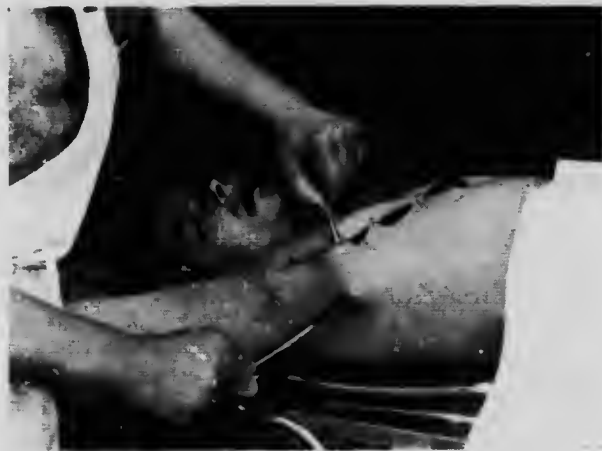

FIG. 440. AMPUTATION OF THE BREAST.

Pertoration of the skin for the passage of a drainage-tube.

344 SURGICAL THERAPEUTICS AND OPERATIVE TECHNIQUE

I use deep skin sutures but very exceptionally; they are indicated only in the union of those muscular strata which lie superficial to the subcutaneous adipose tissue when the latter is very thick. Such deep cutaneous sutures are passed at a distance of 2 or 3 centimetres from the line of union of the edges. They should be moderately tightened, and divided on the third or fourth day. These deep sutures wrinkle the tissues and tend to cut their way through in the long run. Whenever the mounted needle is not easily manipulated, I use the curved needle, which can be used either directly with the fingers or, more usually, with the aid of a needle-holder forceps (round needles for intestinal suture, and small cutting needles for the eyelids and in operations for hare lip), or indeed, with the needle-holder furnished with eccentric plate (in case of a needle of large curvature).

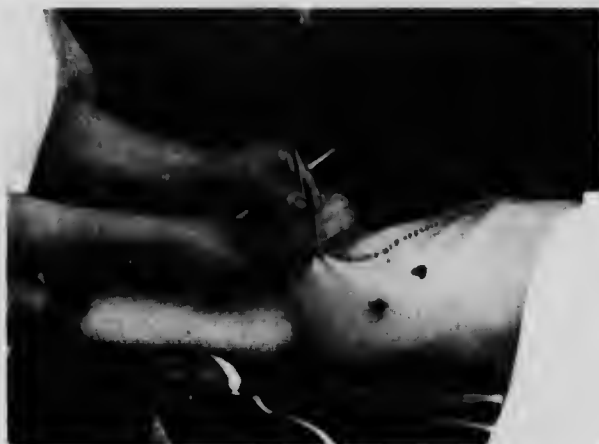

FIG. 441. AMPUTATION OF THE BREAST

Termination of the procedure of interrupted suture. The two glass drainage-tubes are shown.

The use of small curved needles is advantageous in autoplasmic operations, even the superficial ones, as they make far smaller skin punctures than do the mounted needles (in operations on hare-lip, eyelids, etc.). In those cases I use as material for sutures very fine Florentine hair or silk employed in intestinal suture. When in cases in which the skin cannot be satisfactorily disinfected, we fear contamination of the thread and the track of the needle, as they have to traverse the epidermis from without inwards, the suture can be applied by threading each end of the Florentine hair on a separate needle, and traversing each lip of the incision from within outwards. We can thus avoid with certainty the introduction by the needle and its thread of the staphylococci which frequently inhabit the pilosebaceous follicles. This method of suture is less rapid than that usually adopted, and is but rarely indicated.

SUTURE WITH ADHESIVE AGENTS.— In certain cases we obtain a good union by simply approximating the edges of the cutaneous wound with small strips of Vigier paradrap prepared from glue and oxide of zinc; or, indeed, by fixing, at separate points parallel to the line of suture, two small bands of fine linen to the skin with flexible collodion. On the eyebrow and on the hairy scalp we can obtain union of a skin wound by tying the adjacent hairs together with fine silk.




FIG. 442.—INTRADERMIC SUTURING WITH SILVER WIRE.

Passage of the metallic thread.

INTRADERMIC SUTURE.— Intradermic suturing can be carried out with catgut, fine silk, or silver wire. This procedure should be reserved for those localities where it is important not to leave a very visible cicatrix, and where the application of clips is difficult on account of the rigidity of the subdermic tissues. It is thus with the greater part of the skin of the face.

FIG. 443.—INTRADERMIC SUTURING WITH SILVER WIRE.

Adaptation of the cutaneous margins effected by drawing on the ends of the wire.

Intradermic sutures can be applied in one of two ways:

(1) *With Fine Silk, or, better, with No. 0 Catgut.*— The needle is made to penetrate, and to emerge on the divided margin of the skin, exactly at the level of the Malpighian stratum. A fine cutting needle is used, and catgut is preferred to silk, which may be eliminated at a later period.



FIG. 444. INTRADERMIC SUTURE BY HALVES OF A CLEVIS-SHAPED WOUND, WITH TWO SEPARATE METALLIC THREADS.

(2) *With Silver Wire.*— The same kind of very fine needle should be used with a forceps needle-holder for intestinal needles, eyed with a fine and resistant silver wire. The wire is passed into the border of the divided skin, as shown in Fig. 442. When the other extremity of the incision is reached, the two ends of the wire are seized with two short-jawed forceps, and drawn upon

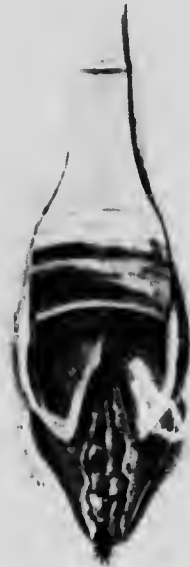

FIG. 445. RIFTURE OF THE RECTO-VAGINAL SEPTUM.
Vivification.



FIG. 446. RIFTURE OF THE RECTO-VAGINAL SEPTUM.
Position of the sutures.

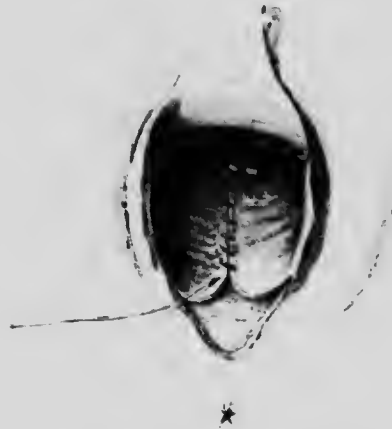

FIG. 447. COLPOPERINORRHAPHY.
Suture of the vaginal mucous
membrane.

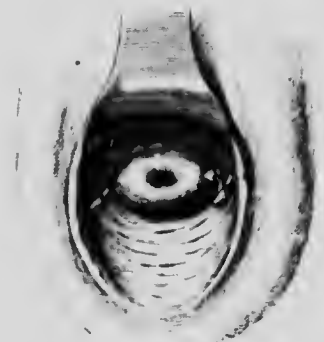


FIG. 448. ANTERIOR COLPECTOMY.
Suture of the vaginal mucous
membrane.

so as to make it tense along its whole length. This manoeuvre at once approximates the edges along the whole line of union without permitting the wire to appear anywhere on the surface except at the respective points of penetration and emergence (Fig. 443). The wire is removed after five or six days, according to the condition of the line of union. This is done by pulling upon one of the extremities, which are left projecting for a length of 3 or 4 centimetres each. Care is taken to cut off at the level of the cutaneous surface, before drawing on the wire, the projecting end opposite to that on which the traction is about to be made. This mode of suturing gives excellent union. After some experience, we succeed in uniting curvilinear surface wounds admirably by this procedure.

2. Suture of Dermoid Mucous Membranes. The union of wounds of dermoid mucous membranes is effected by interrupted sutures with silk or Florentine hair, introduced either with a mounted needle or one with double eye, used with a needle-holder. An exception must be made in case of the prepuce, where very fine silk or fine catgut should be preferred. Hair, on account of its rigidity, would cause continuous pain, and the same holds in the operation for phimosis. The buccal mucous membrane is a *dermoid* of which *should always be effected with curved eye*. Interrupted suture requires an interrupted suture with Florentine hair eyes, the hair small, cut in the month, and if the ends are cut off close to the knot it will be easy to find them on account of their rigidity.

Curved needles are manipulated with the aid of a needle-holder with recently placed, made according to my instructions by M. Collin, which enables us to hold the needle without breaking in every desired position—transverse, oblique, and even longitudinal—and at any required distance from the point. The possibility of using a needle in the direction of the long axis of the ureters is extremely useful in cases of ureteral or vesical fistule which are hard to reach from the fundus of the vagina.

The cervix uteri and the vaginal mucous membrane may be sutured with catgut. If we use silk or Florentine hair, the ends of the threads are left very long in case of interrupted suture; when the continuous suture is chosen, it is disposed so that the thread is fixed at each end by knotting over the end of a rubber drainage-tube. Such a suture is said to be "plugged." Accordingly, when it has to be removed, we have only to divide the most accessible loop about the middle of the suture and pull upon the two pieces of tube in succession. The adaptation of epidermic edges should be as perfect in case of mucous membrane as in that of the skin.

3. Suture of Muscles.—In case of muscles, a very slowly absorbable catgut should be used, whether the suture chosen be interrupted or continuous. If good catgut be not obtainable, very fine silk should be selected. It is necessary to avoid cutting through the muscular tissue by too great constriction.

4. Suture of Tendons.—In this case fine silk is the best material. I prefer using many sutures of fine silk to the much less perfect adaptation

348 SURGICAL THERAPEUTICS AND OPERATIVE TECHNIQUE

obtainable with a large thread. When a tendinous rupture is recent, it is usually very easy to find the central end, slightly retracted. When we have to deal with small tendons, such as those of the digits, the adaptation is easy



FIG. 149.
TRANSVERSE
SEWER OF
TENDON.

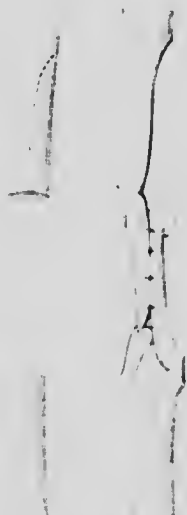


FIG. 150.
OBLIQUE
SEWER OF
TENDON.



FIG. 151.
POSTERIOR
POSITION OF
SEWERS.

and union is assured by applying four or five separate stitches with No. 1 silk, with a round needle of the form used in intestinal suture. In case of one of the larger tendons, I use silk of medium thickness, and insert all around



FIGS. 152 AND 153. LONGI-
TUDINAL
SEWING OF TENDON.



FIG. 154. LATERAL
IMPLANTATION OF TENDON.

the margin of the section the points of interrupted suture. When the tendon has been torn from its bony insertion, the torn surface is united to the periosteum itself, which is resistant enough to support the strain of the

sutures. If the periosteum be itself destroyed, we must hollow out a passage for the thread in the superficial strata of the bone, with either a strong mounted needle or a very fine drill. In a case in which the patellar tendon had been torn from its tibial insertion, I nailed the tendon to the bone with two curved pieces of pure nickel, furnished with teeth hooked at the end so as to hold them fast in the substance of the bone.

When the rupture of the tendon is one of old standing, sufficient muscular retraction may have been established to render coaptation almost impossible. In such a case we should assure ourselves by prolonged but moderate traction of the degree of elongation obtainable. We then split the tendon, the upper fragment only if the peripheral one be too short; in other cases, both the central and peripheral. Union is then secured by a series of points



FIG. 155. SUTURE OF TENDON AT LEVEL OF WRIST.

of interrupted suture made with very fine silk. We also have recourse to this splitting process when it is necessary to lengthen a retracted tendon. I have in this way, at a single operation, lengthened all eight flexor tendons of the fingers, which had been retracted for many years. I was able to estimate exactly the necessary degree of elongation. The functional result was perfect.

LATERAL IMPLANTATION. When the upper fragment of the ruptured tendon cannot be reached, the lower one is bevelled at the broken end and grafted laterally in a crevice made in a neighbouring tendon, which thus communicates its displacements to the grafted fragment. Shortening of a tendon is more rarely indicated. Sections are made when it is necessary, parallel and very oblique, so as to secure a good coaptation (Fig. 150).

5. Suture of Aponeuroses. Suture of aponeuroses is made either with fine silk or catgut. If we fear early occurrence of strong tension

(aponeurotic laceration or muscular hernia), we may combine the two forms, and make a continuous catgut suture, which is then reinforced by a series of points of interrupted suture made with silk.

I employ, however, for preference, an interrupted silk suture, which is a better barrier to future sagging.

6. **Union of Serous Membranes.** Lacerations of parietal serous membranes should be carefully repaired, especially in the major peritoneal operations. The solutions of continuity should be adjusted with a continuous suture of fine silk, made with a needle such as is used for gastro-intestinal sutures. The line of union should also be made as perfect as in case of intestinal suture; that is to say, it should prevent all external oozing. Deep serous sutures should be continuous, and made with fine silk. In case of the pelvic peritoneum, care should be taken not to wound with the needle the ureter, iliac vessels, bladder, or intestine. If the thread happens to break,



FIG. 456. CONTINUOUS SUTURE OF APONEUROSIS.

15 to 20 millimetres of the line of suture must be freed, beginning from the point of rupture, and a straight knot fixed there from which the suture is recommenced. The knot is made with the fingers and a hæmostatic forceps, which helps in catching the short end through the loop.

7. **Closure of the Abdominal Wall.** Closure of the abdominal wall is effected in the surest manner by interrupted silk sutures. In cases where there is little tension continuous catgut suture can also be employed. This includes, in turn, the muscular stratum, deep aponeurosis, and serous membrane; it then traverses, on the opposite side, serous membrane, deep aponeurosis, muscle, and superficial aponeurosis; and, lastly, on each side, the aponeurosis alone (see Laparotomy). We thus have a suture with loops alternately superficial and deep, and so adjusted that almost the whole of the superficial stitching is duplicated beneath the aponeurosis.

8. **Gastro-Intestinal Suture.** Gastro-intestinal suturing is carried out with round needles and fine silk. I use exclusively curved needles with double eyelet, which I manipulate with my forceps needle-holder. The union of hollow viscera covered with serous membrane involves at least two planes of sero-serous suture; and, in addition, a musculo-mucous plane, either partial or total. The best form of suture is the modification of the continued (*à points passés, or entrecoupe*) that I described in 1892,* in which wrinkling of the tissues along the line of union is prevented by passing the needle at every third, fourth, or fifth point, through the preceding loop. This prevents the suture from tightening or loosening

* *Arch. Prov. Chir.*

through the slipping of the thread. The suture should be so far perfect as to prevent, at each plane, any escape of gas. The finest silk thread, No. 1, should be used for the sero-serous planes; and the stronger, No. 2 for the strata which involve the mucous membrane. Success of operation on the gastro-intestinal tube depends on three essential factors: (1) Preservation of the vitality of the united segments; (2) asepsis of the

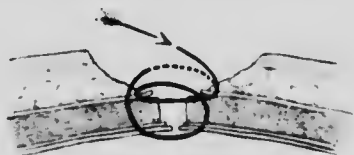


FIG. 457. DIAGRAMMATIC VIEW OF THE PASSAGE OF THE THREAD.

First through both margins of the superficial aponeurosis; then, in succession, through muscle, deep aponeurosis, and peritoneum; and, on the other side, peritoneum, deep aponeurosis, muscle, and superficial aponeurosis.

field of operation; (3) perfection of the sutures. Before opening or resecting the intestine or stomach, I isolate the part where the suture is to be applied with the help of one or more of my special curved forceps with elastic jaws. These forceps are applied with moderate pressure, so that any escape of gastro-intestinal contents is impossible; and without complete arrest of the arterial circulation. Such precaution is indispensable, notably in case of the transverse colon, if we want to make sure of the vitality of the intestinal segments about to be united. This moderate constriction also presents




FIG. 458. ALTHORP'S CONTINUED NON-SLIPPING SUTURE.

another advantage—that of permitting ligature or cauterization with the red iron of the bleeding vessels, the patency of which might cause dangerous hemorrhage after the operation.

Section of the stomach and of the intestine in gastro-enterostomy and in entero-anastomosis is advantageously effected with the thermo cautery. If the wounding of an arteriole of some importance was inevitable, and the bleeding cannot be arrested by application of the cautery at a dull red heat, a forceps should be applied at once, and then a fine silk ligature. In resection

352 SURGICAL THERAPEUTICS AND OPERATIVE TECHNIQUE

of the stomach and intestine. I cut off the part which is to be sacrificed outside one of my elastic-pressure forceps, or between two of these instruments.

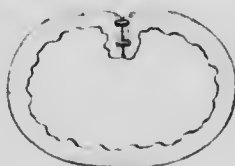

FIG. 459. PURSE STRING CLOSURE OF A SMALL PERFORATION OF THE INTESTINE, WITH A DOUBLE SERO-SEROUS SUTURE.

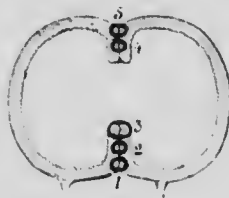


FIG. 460. GASTRO-ENTEROSTOMY.

Below, three deep sutures, first and second, sero-serous; third, musculo-mucous. Above, two superficial sero-serous planes.



FIG. 461. GASTRO-ENTEROSTOMY.

Muco-mucous suture uniting the jejunum to the stomach.

with two or three snips of the scissors, and in the same way I divide the mesentery after crushing and tying in the furrow made by the cerasem

I then complete the union of the mesenteric wounds with fine suture, thus avoiding the retention within the peritoneum of stumps or voluminous pedicles. Suture of the stomach and of the intestine is invariably carried out with silk thread, and fine, round, non-cutting, curved needles, with divided eyelet, manipulated with the aid of a hemostatic forceps needle-

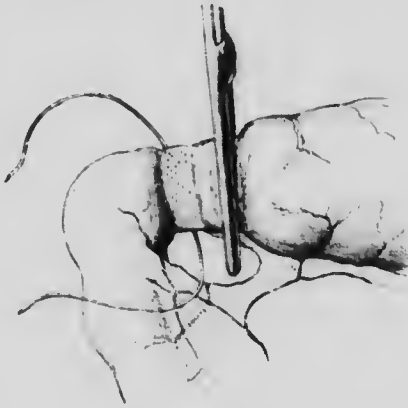


FIG. 462. PYLOROTOMY.
Result of cerasure of the duodenum.

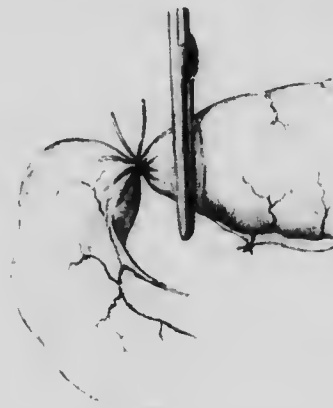

FIG. 463. PYLORECTOMY.
Ligature in the groove made by the cerasure.



FIG. 464. ASPECT OF THE DUODENUM
AFTER PASSING THE FIRST THREAD
IN THE FORM OF PURSE-STRING
SUTURE.



FIG. 465.
The purse-string suture is tightened,
and the stump of the circular thread
is dropped into the cavity.

holder, with hollowed jaws. This form of forceps enables us to hold those fine needles firmly, without too much risk of breaking; they break only when the temper of the steel is exaggerated. On this account we should have them retempered with care.

I have already figured, in discussing hamostasis, the form of forceps

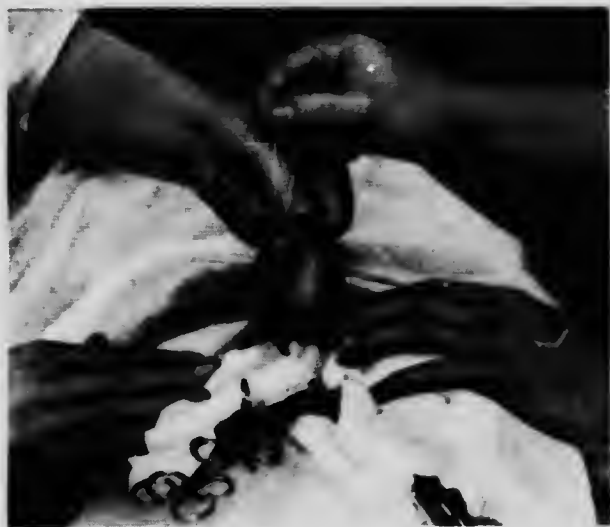

FIG. 466. PYLORECTOMY.
Ligature *en masse* of the stomach after crushing.



FIG. 467. PYLORECTOMY.
Withdrawal of the ligature *en masse*, beneath the first purse-string suture.

needle-holder which I use for intestinal suturing. It is one of my most frequently used forms of haemostatic forceps. My needle-holder with automatic lock may also be used for the purpose. The coaptation of the gastric and intestinal serous strata is effected much more thoroughly, and much more rapidly, even, with these forceps and curved needles than with straight needles, of which the employment is, besides, limited to cases in which the suture can be applied outside the abdominal cavity. I invariably apply the continuous suture in gastro-intestinal operations. The thread is fixed, when the position permits, by re-passing the needle, after every three or four points, through the passage just made. I have named this special suture variously: "*entre-coupe*," "*reinforced*," or that of "*passed points*."

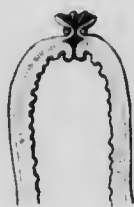

FIG. 468. SECTION OF INTESTINE, SHOWING CIRCULAR LIGATURE, WHICH INCLUDES THE SEROUS STRATUM ONLY.



FIG. 469. SECTION SHOWING CIRCULAR LIGATURE BURIED UNDER BOTH PLANES OF PURSE-STRING SUTURE.

When we have not to deal with a very wide opening, or an entero-anastomosis, but with a small perforation, this suture is advantageously replaced by a double sero-serous *purse-string* suture (see Treatment of Fistulae). This double purse-string suture is equally suitable in effecting the exclusion from the peritoneal cavity of the stump of the vermiform process after operation for appendicitis, and in securing closure of the intestine or stomach by my method of instantaneous crushing and ligature *en masse*. In some cases it will be prudent to apply above this purse-string suture a continuous suture at a distance of some centimetres.

9 **Suture of Canals not Invested with Serous Membrane.** Suturing of the oesophagus, ureter, or urethra, demands more delicate manipulation than that of the intestinal tube; for, in case of the latter, the adhesive properties of the serous membrane favour union very much. On this account I prefer interrupted suture for those canals, applied in two planes, with fine silk and the needles used on the intestine. If the tube is liable to retract it is desirable to fix the outer tunic firmly to the subjacent tissues, both above and below the line of junction. An antiseptic tent and a drainage-tube should be placed near, so as to secure the outflow of any fluids which may filter between the points of suture.

10 **Union of Osseous Tissues.** Osseous suturing should be carried out with a metallic thread. The osseous surfaces, which are usually vivified perpen-

dicularly to the axis of the limb, are, when of small extent, united by a single wire. When the bone is thicker, and subsequent displacement is to be feared, it is better to insert two sutures. Union by wire is equally useful in some cases of cuneiform osteotomy, when the limb shows a very pronounced tendency to recur to a vicious position.



FIG. 470. LONGITUDINAL OSSEOUS SUTURE FOR TRANSVERSE FRACTURE.

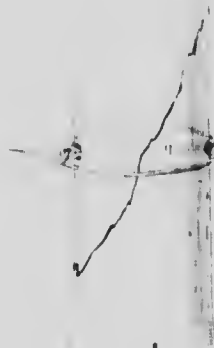


FIG. 471. TRANSVERSE OSSEOUS SUTURE WITH CIRCUMFERENTIAL BINDING FOR VERY OBLIQUE FRACTURE.

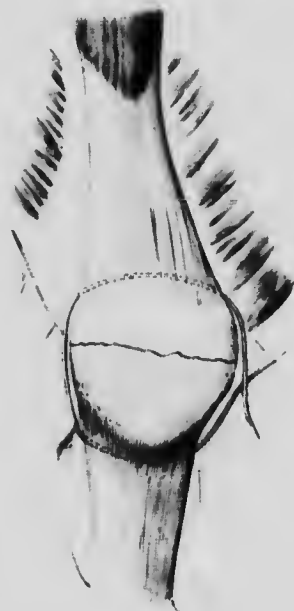


FIG. 472. CIRCUMFERENTIAL SUTURE OF THE PATELLA.

Perforators. The use of perforators is generally necessary in osseous suturing. In cases of pseudarthrosis we make small orifices for transmission of the silver wire or silk thread, usually in the diaphyses of the long bones—femur, tibia, humerus, clavicle. For osseous sutures which are liable to be exposed to much dragging, it is necessary to use sutures of gilt maillechort, which presents a considerable resistance. When the bone is very dense, I use a simple perforator with a strong handle (Fig. 420), which I turn in the palm of the hand. In other cases I use a rod of suitable diameter, which I mount either upon M. Collin's mechanical perforator, or on my own flexible cable, which is then worked by the electric motor. In most instances I make the small orifices with a perforator worked with the hand.

Osseous suture gives excellent results. One of my patients, aged fifty, who was operated on for old-standing pseudarthrosis of tibia and fibula, was rapidly cured by application of a double osseous suture. Suture of fractured clavicle, either immediate or tardy, secures perfect coaptation and

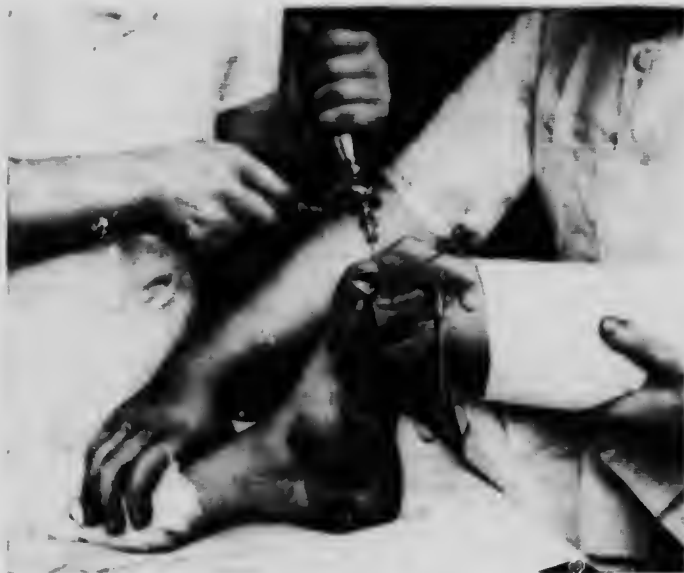

FIG. 473. SUTURE OF TIBIA.
Perforation of the upper fragment.

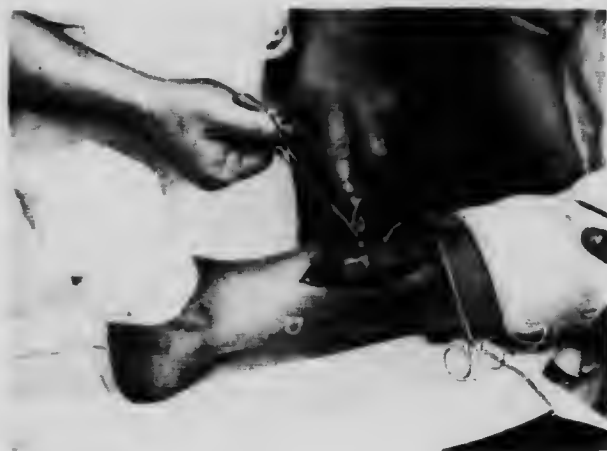

FIG. 474. SUTURE OF TIBIA.
Coaptation of fragments. The wire is tightened before twisting.

rapid restoration of the use of the arm. The broken surface is vivified with scissors, if not too resistant, otherwise with the saw or cutting forceps, and the ends are then placed in complete contact; they are now perforated at two points symmetrically placed at 12 or 14 millimetres from the line of section, and the metallic suture is then passed. In case of the femur, tibia, or humerus I make two openings in each fragment, and apply a double suture. One suffices for the fibula as well as the clavicle; two openings would necessarily be near, and might cause splintering. When the wires are in position, the two ends are carefully twisted together, and cut off at a distance of 8 or 10 millimetres from the point of crossing; we then bend the projecting ends down with a raspatory to the surface of the bone.

Epiphyses may be as well joined up to the shaft with the help of metal nails, driven in with a mallet, or with ivory pegs or pieces of fresh bone. These latter are placed in orifices prepared for their reception. In case of the patella, circumferential suturing ("ceinture") is adopted. Immediate union should be aimed at whenever the wound is aseptic. When the slightest trace of suppuration exists, the wound should be treated by plugging, and very carefully watched. If the suture provokes suppuration, it is removed after X ray examination.

SURGERY OF THE BLOODVESSELS.**VASCULAR SUTURE VASCULAR TRANSPLANTATION
— TRANSFUSION OF BLOOD.**

The suture of bloodvessels became possible only after the construction of curved needles so fine that their passage permitted no trace of blood to filter through.

Instruments for Vascular Suture and Transfusion. In 1908 I devised forceps with elastic and very flexible jaws, for momentary compression of large vessels. For small vessels the small spring compressors used by physiologists may be employed. For manipulation of the extra fine curved needles used for arteriorrhaphy I have had needle-holder forceps made with slender jaws which hold the needle firmly without breaking it. For direct transfusion from arm to arm, a small indiarubber tube is employed, furnished at each end with a conical glass cannula, and the whole coated with paraffin to avoid coagulation (see later).

I have studied, among others, an ingenious procedure for vascular transplantation with external tubage of the vessels whose extremity is inverted and ligatured on a tube of bird's quill. This procedure was successful in the dog. I prefer, however, to perform vascular transplantation in man without the interposition of a foreign body.

The details of technique, often ingenious, which have been applied in experimental surgery to small laboratory animals are generally inapplicable to man.

Vascular Suture.

1. **Purse-String Suture.** A small wound of a large vein or artery is easily closed, whether in case of an accidental wound, or after division of a collateral branch at its origin. The flow of blood is arrested either by digital compression or with the help of two small spring compressors, or simply by lateral traction on the vessel. The orifice is recognized and closed with a fine purse string suture. This technique is equally suited to both veins and arteries. I have applied it in the radical cure of an arterio-venous aneurism of the arm. (See Arterio-Venous Aneurism of the Neck.)

2. **Transverse Suture.** (a) **PARTIAL SUTURE.** When the wound involves but a small portion of the circumference of the vessel, it is closed with a fine continued suture. When properly carried out, it is seldom necessary to apply two layers. Indeed, the internal coat of an artery, and still more so that of a vein, forms a starting point for rapid cicatrization. Contact of the thread with the blood current is avoided as completely as possible, but it is not necessary to suppose that the presence of very small loops of thread within the lumen of the vessel exposes to inevitable thrombosis.

(b) **TOTAL OR CIRCULAR SUTURE.** In order to carry out circular suture of a vessel, it is useful to fix the divided ends at first with a single





FIG. 475. TEARING OF A COLLATERAL BRANCH AT ITS IMPLANTATION ON A LARGE ARTERY.
Application of the ligature.




FIG. 475A.—THE SAME.
The purse-string suture is drawn tight and knotted. Star-shaped wrinkling of the external tunic of the artery.




FIG. 475B.—THE SAME.
Wound of a large artery by a cutting instrument; the orifice is gaping.



FIG. 475C.—THE SAME.
Inconvenience of longitudinal suture which produces narrowing of the artery.

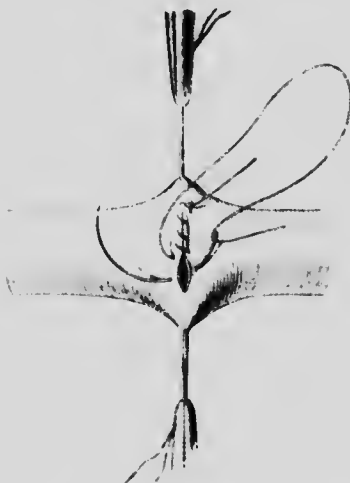


FIG. 476A.—THE SAME.
Transverse suture of the arterial wound shown in Fig. 3. Two silk ligatures passed in the external tunic at the extremities of the transverse diameter are drawn tight by an assistant in order to facilitate the suture.




FIG. 476B.—THE SAME.
The transverse continuous suture is finished. The initial and terminal extremities remain to be cut. The terminal knot will be noticed.

point of silk suture applied at each extremity of the transverse diameter of the lumen. An assistant pulls gently on each of the two threads, and the surgeon then unites, with continued suture, at first the posterior semi-




FIG. 477A. TRANSVERSE ARTERIORRHAPHY.
Two threads, 1, 1', and 2, 2', are passed, without being tied, at the extremities of the transverse diameter of the artery.



FIG. 477B. THE SAME.
Traction on the ends 1, 1', and 2, 2', bring the two ends of the vessel closer.

circumference of the vessel, and then the anterior. The terminal extremity of the suture thread is now knotted to the initial one, and the superfluous ends are cut off. All danger of constriction of the calibre of the vessel is avoided by adopting the artifice of the two traction threads.

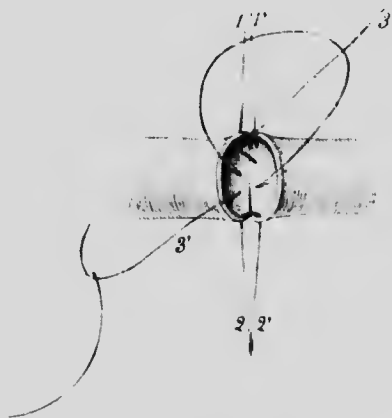


FIG. 477C. THE SAME.
Commencement of the posterior suture with No. 3 thread. An assistant exercises traction on the ends of 1, 1', and 2, 2'.



FIG. 477D. THE SAME.
The posterior continuous suture is finished. Thread No. 3 is stayed, passing it through the last point of the continuous suture. The forceps placed on the ends of 2, 2', is now placed on 3, in order to stretch the line of union during the completion of the anterior suture.

Phleborrhaphy and Arteriorrhaphy.—**PHLEBORRHAPHY.**— Extensive lacerations may take place in the walls of the large veins, such as the internal

jugular and, more rarely, the inferior vena cava at the opening of the right renal vein. The immediate hemorrhage is considerable, but is easily arrested by compression or lateral traction. The laceration should be at once repaired with a fine continued suture.

In December, 1909, I reconstructed an internal jugular vein, from the os hyoides to the subclavicular fossa, by utilizing the cellular sheath and even the muscular fibres of the sterno-mastoid. The case was one of cancer of the tongue which I had treated by electro coagulation, and which was complicated by a still mobile, bilateral cancerous adenopathy. In operating on the left side, I ascertained that the glands were softened; so I ennetted the bottom of the wound carefully, and then treated it by aero-cantORIZATION, followed by tamponing. The internal jugular vein seemed to be obliterated. Passing then to the right side, I first



FIG. 477E. THE SAME.

The anterior suture is commenced with the thread No. 3. An assistant makes moderate traction on threads 1, 1', and 3.



FIG. 477F. THE SAME.

The anterior suture is finished; the two ends 2 and 3 are knotted together.

removed a fluctuating glandular partition, and then exposed the bottom of the wound with the index-finger. The outer wall of the internal jugular vein, which had undergone softening, broke down over a considerable part of its length, and the blood welled up in the wound. I plugged rapidly, and then enlarged the incision, upwards towards the os hyoides and downwards towards the clavicle. The internal part of the wall of the internal jugular vein still remained, but the outer portion of its circumference had been destroyed. Tight plugging of the upper end was followed by cyanosis of the face; thus the application of a ligature was out of the question. I then removed the first plugs, and obliterated the upper and lower openings of the diseased vein provisionally, with rolls of gauze mounted on two long forceps; after which I proceeded to phleborrhaphy, beginning at the lower part by reconstitution of the missing outer wall of the vein at the expense

of the investing aponeurosis and the muscular fibres of the sterno-mastoid. Having reached the level of the middle of the wound, I repaired the upper half of the missing wall of the vein, beginning at the level of the hyoid bone. There then remained but an opening of about a centimetre in diameter, through which the two forceps emerged. I removed these successively, and blood appeared. I arrested the hæmorrhage by digital compression, and completed the suture. When the first plane of suture was completely staunch, I reinforced it with a second, fibro-cellular stratum. The circulation was immediately re-established. Suture of Skin Drainage Reunion took place by first intention; and at the end of a month, the patient noticed no vascular trouble. This operation is interesting from its immediate result.*

ARTERIOPLASTY.—Longitudinal arteriorrhaphy is carried out in certain cases of sacciform aneurism, when these are treated by partial resection. In 1909 I repaired the popliteal artery in this way, over a length of 11 centimetres; the dilatation of the artery had been produced specially at the expense of its posterior aspect.

In order to avoid exposure of the suture to an excessive blood-pressure, I conceived the idea of placing an incomplete ligature on the femoral artery above, so as to reduce its calibre considerably. An elastic clamp was then applied above the seat of aneurism, and the exuberant portions of the wall of the latter were resected. I carried out the longitudinal arteriorrhaphy with two superposed planes of continued silk suture. The suture proved to be staunch, and the circulation was immediately re-established on removal of the compressor. (See Aneurism of Neck.)

Vascular Transplantation.

According to circumstances, simple circular suture or circular suture with invagination is performed.

Circular End-to-End Suture.—In the case of the patient to whom I have just referred, the popliteal vein had been obliterated. Towards the end of July the persistent œdema of the leg decided me to try transplantation of a sheep's vein. It was impossible to obtain a vein of sufficient length and diameter from the patient's own body. The operation was carried out on August 9, 1909. I exposed in succession the femoral vein in Hunter's canal, and the popliteal vein at the termination of its two tibio-peroneal tributaries. After resection of the fibrous cord, I found that the central end of the vein was permeable, while below, bleeding took place from but one of the two tibio-peroneal veins. Immediately before the operation I had removed the external jugular vein of a sheep between two double ligatures, having also ligatured the collateral veins with very fine silk. This sheep's vein measured 25 centimetres in length. It was preserved in Ringer's solution for about a quarter of an hour.

I now sutured the detached sheep's vein at one end to the permeable tibio-peroneal vein of the patient. I next formed a tunnel between the two incisions for its passage, with the aid of a long curved forceps. I then passed

* *Rev. Critique de Med. et de Chir.*, No. 1, January, 1910.

the sheep's vein along this cellular canal and sutured the upper end, after resection of the exuberant portion, to the extremity of the femoral vein. Reunion took place by first intention. The circulation was re-established and the edema of the leg disappeared. The circulation had remained normal six months after the operation, when the patient was obliged to go abroad on account of important business. This operation proves that we can successfully replace a vein in man with the vein of a sheep. Besides, we know that venous blood coagulates less readily than arterial.*

Circular Suture with Invagination.—This suture can only be carried out where there is an excess of length of the vascular segments. It is also particularly applicable to *vascular transplantation*, where the grafted portion should always be chosen longer than the interval between the two vascular orifices over which communication is to be re-established.

OPERATION—Preliminary Stage.—Separation of the vascular segment which is to serve as a graft.

Although I was successful in the above case, where, in re-establishing communication between the peroneal venous trunk and the femoral vein, using a portion of the external jugular vein of the sheep as a graft, the grafted vessel was still permeable six months after operation, it is preferable to obtain a graft from an individual of the same species (that is, from a human being). For example, a segment of sufficient length can be taken of the external or internal saphenous vein.

Should it be impossible to obtain a human venous trunk, the graft may be made without hesitation with a sheep's vein, as I have done, especially if it is a vein which is to be replaced. As I have already pointed out, venous blood coagulates less readily than arterial.

Separation of the Vascular Segment in the Living Subject.—The vein exposed after a longitudinal skin incision is isolated carefully from the cellular fatty tissue, in order to expose all collaterals, which are divided between two ligatures. The vein is ligatured at the end nearest the heart, and is allowed to fill with blood; it is then ligatured at the distal extremity. Below this ligature and above the first ligature two other ligatures are placed at a distance of 10 millimetres, and the venous segment is then detached. The vein is placed in Ringer's solution at a temperature of 38° C.

First Stage: Exposure of the Field of Operation, Vascular Graft.—The region where the vascular transplantation is to be practised is exposed by a longitudinal incision, and the ends of the vessel are sought for several centimetres above and below the point of lesion, in order to find them in their anatomical relations. They are dissected carefully as far as the point of obliteration. Elastic compressors are placed on the upper and lower ends 3 or 4 centimetres from the point where the suture is to be placed, and the two ends are freshened by transverse section.

Second Stage.—The graft is closed at each extremity by a silk ligature. At a distance of 5 millimetres from the ligature, at *each* extremity a small

* Soc. des. Internats

incision is made with scissors; the blood escapes, and the calibre of the vessel is washed out with Ringer's solution at a temperature of 38° C.



FIG. 478A. ARTERIAL TRANSPLANTATION: PREPARATION OF A VEIN TO REPLACE AN ARTERIAL SEGMENT.

The vessel is seized with dissecting forceps several centimetres from its terminal ligatures. A transverse incision has been made between the forceps and the ligature.

The graft is seized in its long sense with a blunt dissecting forceps, about 20 millimetres from the small incision at one of its extremities, and the vessel is invaginated by pushing the part held in the teeth of the forceps until it bulges through the small orifice; the terminal ligature is then drawn backwards.



FIG. 478B.—THE SAME.

The portion of the vessel held between the teeth of the forceps is invaginated towards the ligature, and appears in the orifice.

Third Stage.—The end of the graft being thus invaginated, its calibre is kept gaping by the elasticity of the forceps. It is brought up to the vessel to which it is to be sutured. The graft is fixed at first to the vessel



FIG. 478C. THE SAME.

The terminal ligature is drawn towards the forceps so as to invaginate the vessel completely.

by two separate points of suture, placed, as shown in Fig. 478D, at the extremities of the transverse diameter. The posterior half of the circumference is then united with a very fine silk continuous suture, whilst an assistant draws upon the two threads, diametrically opposite one another to prevent any shrinking of the calibre (see arterial suture, Fig. 476A). The suture is then continued on the anterior half of the circumference, finishing

the suture by uniting the two terminal threads with a knot, and the extremities of the threads are cut. The forceps which holds open the orifice of the graft is withdrawn as soon as its usefulness ceases.



FIG. 478D.—THE SAME.

The central end of the artery, whose circulation has been arrested by means of a small compressor, is brought into relation with the extremity of the replacing vessel. The suture is prepared, as in Fig. 8, by means of two approaching threads, which facilitate the application of the first posterior and then the anterior continuous sutures.

Fourth Stage.—The part of the graft which has been turned back upon the forceps, and which ends in the terminal ligature, is drawn towards



FIG. 478E.—THE SAME.

The circumferential suture is finished as in Fig. 477F.

the vessel, to which the graft is now united in such a way that this vessel invaginates into the graft. The extremity of the graft is fixed to the



FIG. 479A.—THE SAME.

The dissecting forceps, which holds open the walls of the replacing vessel by its elasticity, is now removed, and the ligature at the extremity of this vessel is drawn towards the central end of the artery, which becomes covered by the tunic of the replacing vessel. The exuberant portion is cut from the replacing vessel following the dotted line.

external tunic of the vessel by two primary points of suture diametrically opposed; the exuberant portion is then cut away. Several sutural points

are placed on the anterior half of the circumference, and, drawing on the ends of threads A and B, which have been left long, several sutures are placed on the posterior half.



FIG. 479b. THE SAME.

The extremity of the replacing vessel is united to the external tunic of the artery. The same technique is employed for the suture of the opposite end of the replacing vessel to the terminal end of the artery, care being taken that it contains no air. The compressor is removed, and the course of the blood is re-established.

This procedure gives a more solid suture than a simple circular suture, to which it is preferable whenever it can be performed.

Fifth Stage.—Following an identical technique, the other extremity of the graft is united to the extremity of the vessel whose circulation is to be re-established.

Sixth Stage.—Reunion and drainage.

Transfusion of Blood.

The notion of transfusion of blood is very ancient, but it became a realizable proposition only when it became possible to associate strict antisepsis with a technique which prevents the coagulation of the blood of the donor. An Englishman, Richard Lower, was the first to realize direct transfusion from an animal to another animal of the same species. This experiment took place early in the year 1667, and was published in the year 1669. Richard Lower anastomosed artery to vein, using as cannula either small silver tubes with an arresting ring for purposes of ligature, or simply tubes formed of birds' quills, which were fitted into one another. He also conceived the idea of facilitating the operation by passing the donor's blood through a segment of a carotid artery taken from another animal.

The first successful transfusion from animal to man was performed by Denis and Emmery, of Montpellier, on June 15, 1667. They used silver tubes which fitted into one another. One tube was introduced into the animal's artery, which was compressed on the side nearest the heart, and the other was introduced into the patient's vein. The ends were then fitted together. The provisional ligature arresting the circulation of blood in the artery of the animal was then removed. As soon as the operation was finished the vessels were ligatured. Denis in his first case injected the arterial blood of a lamb. On another occasion he injected in the same patient, after an interval of two days, 300 grammes of calf's blood.

Denis knew of Lower's experiments, which he repeated before practising transfusion in man. In November, 1667, Lower and Ed. King injected the arterial blood of a sheep into the vein of a man. They observed that

grave complications ensued. The second patient operated upon by Denis died, and transfusion was condemned.

More than a century later, at the beginning of the nineteenth century, Blundell, Prevost and Dumas, Dieffenbach, Th. Bischoff and Brown-Séquard (*Acad. des Sciences*, 1855), came to the conclusion that to perform transfusion it is indispensable that it shall be carried out between animals of the same species.

In the middle of the nineteenth century transfusion was carried out from man to man. The blood taken from the vein of a healthy subject was injected into the central end of a vein in the patient. Various models of syringes and propulsers were used, all of which caused the blood to coagulate. Attempts were made also with delibrinated blood.

Two discoveries were indispensable before the transfusion of blood could enter the domain of surgery: the antiseptic method, and a procedure which is capable of preventing the coagulation of the donor's blood.

Coagulation of the blood can be prevented either by placing the artery of the donor in relation with the vein of the receiver, with no intermediary apparatus, or by interposing between the two vessels a paraffined tube, according to the technique invented by Bordet and Gengou in 1901.*

1. DIRECT TRANSFUSION FROM ARTERY TO VEIN WITHOUT INTER-MEDIARY TUBE.

Carrel perfected the primitive technique of Lower and Denis by introducing the artery into the calibre of a small metal cannula, on which he turned the walls of the vessel in the form of a sleeve. A ligature fixes them in this situation, the endothelium being on the outer side. The artery, externally tubed, is introduced into the vein, which is fixed on the same cannula with another ligature. The arterial and venous compressors are removed, and the transfusion commences; the blood does not cease to be in relation with the endothelium both of donor and receiver. Carrel prefers to suture the artery of the donor directly to the vein of the patient. These two procedures have one great inconvenience: they call for large incisions, and the dissection of the two vessels for a sufficient length in order that they may be brought together without dragging.

2. MEDIATE TRANSFUSION WITH INTER-ARTERIO-VEINOUS TUBAGE.

It is more practical to employ an intermediary tube, which may be either a double-curved silver cannula or a small rubber tube ending in two glass cannulae; a device of this kind will limit the exposure of the donor's artery and receiver's vein to a distance length of 4 or 5 centimetres at the most.

I will describe later the method of coating the intermediary tube with paraffin. Defective paraffining will cause the obstruction of the tube by a clot, with no risk to the receiver other than the immediate arrest of the

* *Ann. Pas. Inst.*, vol. xv., p. 429, 1901.

transfusion. Coagulation of arterial blood is more rapid than the coagulation of venous blood. It is probably due to this property that a fair number of transfusions from vein to vein have been successfully practised in man, using cups, syringes, or pumps, care being taken to maintain a temperature of 38° C.

I successfully performed transfusion at Rheims on two occasions, thirty years ago, at the request of several of my colleagues. The blood was taken from a phlebotomy incision, and was received into a nickel funnel, whence it passed, by means of a rubber tube and small cannula, into the patient's vein.

These operations were carried out with a strict asepsis, after thorough sterilization of the instruments. The transfusion apparatus was vaselined, following the technique recommended by E. Freund in 1886.

Indications for Transfusion.

Transfusion has been greatly misused of late years. It has been employed in cases where the repeated injection of isotonic saline solution or Ringer's solution would have been quite sufficient. Copious injections, subcutaneous, or intravenous, or even intrarectal, of warm isotonic saline solution have brought back to life many patients who were almost exsanguine, and their red cells have quickly reproduced themselves.

Injections of isotonic salt solution or Ringer's solution* are sufficient in cases where hemorrhage has not been very considerable, and where a *sufficient* reserve of red corpuscles persists in the vessels. I have already pointed out that if syncope threatens, the patient must be placed in an inclined position, the foot of the bed being raised. The circulation in the brain is assured by placing elastic bandages fairly tightly on the legs and thighs. The blood flows towards the heart and nerve centres, and the irritation caused by the elastic bands provokes an excitability in the patient which results in more intensely active respiratory efforts.

Transfusion of blood is only indicated in cases where the deficit of red cells is too considerable, and particularly when the loss of blood has been very rapid. The good results obtained in modern times from transfusion should not deter us from using every precaution to prevent hemorrhage and its consequences.

* Ringer's solution (1880-85):

Sodium chloride	8 grammes
Potassium chloride	0.075 gramme
Calcium chloride	0.075 ..
Sodium bicarbonate	0.075 ..
Distilled water	1 litre

Locke's solution (1895-1901):

The same formula, with the addition of glucose 1 gramme.

It is of the utmost importance to be sure that the isotonic salt solution or Ringer's solution has no hemolytic action on the human red cells, an accident which can occur in certain cases when the distilled water is not properly prepared.

Persons rendering first aid in a case of external hemorrhage should ligature the limb either with elastic ligature or tourniquet placed between the heart and the wound. Elastic compression and the tourniquet are very efficacious in the arm and the thigh, where the framework consists of one bone. Circular compression is useless where there are two bones, such as in the forearm and leg, since it cannot act in the interosseous space. If ligature between the heart and the wound is impracticable, direct or digital compression is applied with rigorous antiseptic precautions. Ligature of the vessel is carried out as quickly as possible. Compression of the aorta by Monboug's method may be of great utility in the case of wound of an abdominal artery, when the patient's life may be prolonged until the arrival of the surgeon.

A large number of cases of wounds of the abdominal vessels are on record where the patient has succumbed to intraperitoneal hemorrhage only after several hours have elapsed. On March 16, 1914, in one of these cases which is of sad notoriety, there was a lateral wound of the external iliac artery at its middle third, without intestinal perforation. The surgeons in charge of the case followed an expectant course for five and three-quarter hours, and death occurred when they were attempting to perform laparotomy on a patient *in extremis*. They had not even attempted to perform transfusion. But the loss of blood was much less than 10 grammes per minute, the quantity which is generally transmitted from the donor to the receiver. Not only could such a case have been cured, if a laparotomy had been performed according to sane surgical counsels during the two hours following the wound, but the operation could have been undertaken with every chance of success up to the fourth hour at least, if it had been preceded by a transfusion, the necessary quantity of blood being taken successively from the persons who were present. This unfortunate case will serve as a lesson to surgeons of the future. It shows the imperative necessity of an immediate diagnosis of internal hemorrhage. It also results, and the events of the present war have given ample proof, that henceforward every surgical installation and operating theatre should be considered defective which does not possess, in permanent readiness for use, the instruments necessary for performing vascular surgery and transfusion of blood at a moment's notice.

When the deficit of red cells is considerable, injection of isotonic saline solution or Ringer's solution must yield place to transfusion. This is only a repetition of the statement that transfusion becomes indispensable in cases where hemorrhage has not been stopped in time. If doctors in civil practice were attentive to the signs of internal hemorrhage (for instance, in cases of tubal rupture); if they were more capable of coagulating hemorrhages in accouchement which exact, by their suddenness, a prompt decision and an incomparable technique; and if every surgeon was sufficiently careful in ligaturing vascular pedicles and large vessels, the need for this performance of transfusion, however excellent this operation may be, would be exceptional. The same may be said of war surgery. How many wounded have succumbed at the Front to wounds of arteries of

secondary importance, such as the tibial, the radial, the ulnar, and the facial, etc., or to narrow wounds of larger arteries, such as brachial or the femoral, for want of the application of a simple tourniquet or direct compression!

Secondary hemorrhage after wounds are only grave when the wounded man is not properly looked after, or if he is not in the hands of a surgeon of experience. Diffuse aneurisma can be diagnosed, with very rare exceptions, before grave hemorrhage arises. If rupture takes place, it is rare that direct or indirect compression, especially direct digital compression of the wounded vessel, should be unable to secure the arrest of bleeding until the surgeon arrives. The surgeon ligatures between the heart and the lesion, choosing the most favourable point. Ligature in healthy tissue is the better procedure in such a case. Ligature of the lower end is seldom necessary.

Observations have been published of transfusion which has been performed in order to combat septicæmia and pyæmia in war surgery. Transfusion has been performed in such cases on patients where the surgeon has allowed infectious phenomena to develop by degrees without knowing how to prevent or how to treat them. To be reduced, from want of proper clinical knowledge and the necessary technique, to practise "transfusion *in extremis*" on wounded patients who are so enfeebled that they can no longer support an amputation surely is a confession of impotence meriting the severest criticism.

Transfusion should be practised in well-defined cases: in those where (I repeat) the red-cell deficit is too considerable to allow of blood restoration after injection of isotonic saline solution. The application of transfusion is restricted according to the intelligence and care with which the wounded have been treated.

CHOICE OF THE DONOR OF BLOOD.

The transfused blood should be human blood, and should pass from an individual whose general health appears to be perfect. It would be a most regrettable accident to transmit such a disease as syphilis by transfusion. When the family is at hand the blood of a close relation should be chosen for preference. Provided that the individual chosen be in perfect health, consanguineous serum enjoys the reputation of being less noxious to the patient's blood-cells. In some large hospitals where certain surgeons are enthusiasts for transfusion, and perform it on every possible occasion, they call first on individuals who consent to act as donors. Some surgeons prefer males to females, because the artery is of larger calibre and easier to expose. It is evident that an excess of adipose tissue in the forearm is a reason for not choosing too fat a subject.

The repair of red cells takes place, as a physiological fact, quicker in the female than the male. If there is time, the blood of the donor is examined with the Wassermann test, to be sure that it is negative. It has

also been suggested that the reciprocal reactions of the two bloods should be examined *in vitro*, which is a needless precaution, since healthy human blood is never hemolytic for the red cells of another human being.

PREPARATION FOR THE OPERATION.

The instruments necessary for transfusion should be sterilized beforehand in special metal boxes. The first box should contain two elastic Doyen's vascular compressors, six or eight small spring vascular compressors, such as have for a long time been employed in physiological laboratories, very fine dissecting forceps, round intestinal needles with their appropriate needle holders, and, finally, narrow nosed needle holders for the fine curved arteriorrhaphy needles. Another box contains instruments for incision of the skin, the exposure of the artery and the vein, and for reunion. Fine No. 3 and No. 1 silk are used for the vessels. The curved extra fine needles for vascular suture are threaded in advance, and kept with the silk after sterilization in sealed glass tubes.

PARAFFINING THE TRANSFUSING TUBE.

A tube of good quality rubber should be chosen—for instance, 6 or 7 centimetres of a red rubber No. 24 catheter. The tube is examined to see if the canal is regular. To prepare the glass cannulas, tubes of glass 6 millimetres in diameter are drawn out in the flame as in the preparation of laboratory pipettes, and with a file two conical cannulas 25 millimetres long are detached. The calibre of their thicker ends, which penetrate into the rubber tube, is about 5 millimetres. The calibre of the smaller end is, for the cannula for the artery, 2 or 3 millimetres (one of each dimension is prepared), and for the vein 4 millimetres. The orifices of these cannulas are passed through the flame of the Bunsen burner to round off the edges. Each orifice is also slightly widened, in order to hold the ligature. The rubber tube is secured by ligature on the two large ends of the glass cannulas. The whole is then boiled for five minutes in a 2 per cent. carbolic solution. It is washed with sterile distilled water and dried, wrapped in a sterile compress, in the dry oven at a temperature of 110° C. The tube and cannulas are then immersed in a test tube of sufficient dimensions, filled with 95 per cent. alcohol, where it remains five minutes. It is then placed in a tube of ether for the same period. It is then dried in the hot-air oven. These manoeuvres must be carried out with the aid of sterile forceps, as the fingers must not touch the tube or cannulas. The tube and cannulas are now immersed in a third test tube containing paraffin, whose melting point is 44° C. This paraffin must be carefully filtered before use. The whole is placed in the autoclave and heated to 160° C. for ten to fifteen minutes at least. The tube is extracted with sterile forceps; the paraffin in the tube is allowed to drain away, leaving a regular surface in the canal. Care is taken to be sure that the tube remains permeable. Several tubes are prepared in this way and preserved, wrapped in sterilized compresses.

POSITION OF THE PATIENT AND DONOR.

Temperature of the Room.

The hand of the person providing the blood should be directed towards the root of the patient's limb, and the axes of both limbs should be parallel in order to reduce the distance separating the artery of the donor from the

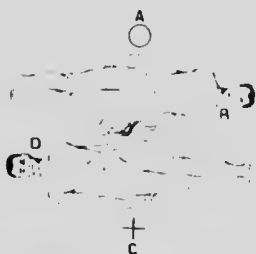


FIG. 480A. TRANSFUSION OF THE BLOOD.

Respective positions of donor, receiver, surgeon, and assistant when space is limited. The surgeon (C) is too far from the assistant (A) and operative manœuvre is rendered difficult. In this scheme the transfusion is made from the left radial artery into the left radial vein. The head of the donor is opposite the feet of the receiver.




FIG. 480B.—THE SAME.

If the donor and receiver can be placed as in this figure, the surgeon and the assistant are close to the field of operation. Transfusion is made as in Fig. 480A, from the left radial artery into the left radial vein.

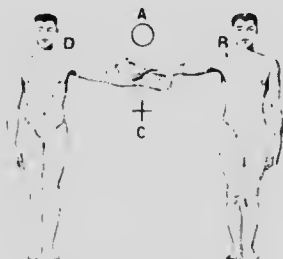


FIG. 480C. THE SAME.

If the head of the donor is opposite to the head of the receiver, transfusion is carried out from the left radial artery into a right ulnar vein of the receiver, or inversely.



FIG. 480D.—THE SAME.

Transfusion can also be made from the radial artery into a vein of the leg—for instance, from the left radial artery into the right internal saphenous vein.

vein of the patient. The respective position of the two subjects may therefore be variable, according to the space at the disposition of the operator. If space is restricted, the donor must lie on a narrow table placed next to

the patient's bed and at the same level, his feet being towards the head of the patient. The table is advanced more or less according to whether the transfusion is performed in the forearm or leg.

Transfusion, for example, may be performed from the right forearm or right leg of the patient, the limbs remaining parallel to the trunk. In this respective position of donor and patient the position of the surgeon and assistant is very inconvenient. If space permits, it is preferable to place



FIG. 481A. THE SAME.

Rubber tube used for direct transfusion from artery to vein, with its glass cannula prepared in Dr. Doyen's laboratory. The smaller cannula has a calibre of about 2 millimetres; it is for the artery. The cannula for the vein—the larger—has a calibre of from 3 to 4 millimetres. The diameter of the tube is 4 to 5 millimetres.

the arm of the donor in complete abduction—*i.e.*, at right angles to the axis of the trunk—and to place parallel to it one of the patient's forearms, also in abduction.

The heads of the donor and receiver are side by side if the right arm of one is in relation with the left arm of the other; but if the feet of the patient are directed towards the head of the donor transfusion is performed from the right radial artery into a right antibrachial vein or from the left radial



FIG. 481B. THE SAME.

This figure shows the relations of the forearms of donor and receiver in the position of Fig. 480—*i.e.*, from left radial artery into right ulnar vein.

artery into a vein of the left forearm. If the transfusion is carried out from the radial artery into a vein in the leg, the arm of the donor being in complete abduction, the axis of his body is perpendicular to the axis of the patient's body. The head of the donor may be placed either on the right or left side of the patient, in order to place the limbs in the best relationship, and to simplify the movements of surgeon and assistant. It should be impressed on the donor that the slightest sudden movement on his part may break the delicate ligatures uniting the vessels.

OPERATION—Preliminary Stage.—Local anaesthesia with cocaine is applied to the donor.

First Stage.—Exposure of the radial artery in the donor. Isolation of the artery for a length of about 6 centimetres. Ligature of the artery below. Passage of the second ligature, on the side of the heart, with knot prepared. Pose of a small elastic-nosed forceps below this ligature to arrest

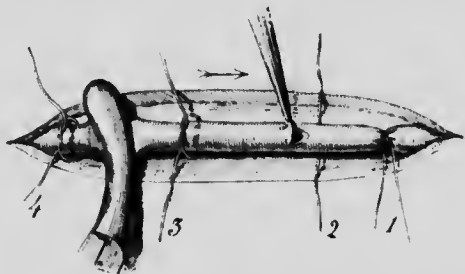


FIG. 482A. TRANSFUSION OF BLOOD: OPERATION.

Preparation of the radial artery. The artery is closed by ligature No. 1 on the peripheral side; a compressor is applied to the central end; ligature No. 2 is passed below the artery a centimetre above ligature No. 1; two ligatures, Nos. 3 and 4, are prepared below and above the compressor. The arrow indicates the direction of the blood-stream, which here is interrupted. A small transverse incision is made in the artery, whose walls are seized in a fine dissecting forceps.

the blood. A third and fourth ligature are passed below the compressor, and the first knot of each is prepared for tying. The anterior wall of the artery is seized with a fine forceps a centimetre above the inferior ligature, and a small incision is made with the bistoury, liberating from below upwards a triangular flap. The small quantity of blood in the arterial segment below the compressor flows out, and is immediately sponged away.




FIG. 482B. THE SAME.

The glass cannula of the transfusion tube is introduced into the artery.

Second Stage.—The small triangular flap is raised with the forceps and the finer of the glass cannulas is introduced into the artery. The third ligature fixes the artery on the cannula, and the fourth ligature is tied on

the rubber tube, to which it fixes the artery below the orifice for further security.

Third Stage.—Exposure of the vein either in the forearm or leg of the patient. A vein is chosen which has been brought into evidence by a moderate compression at the root of the limb, not sufficient to interrupt the arterial circulation. Isolation of the vein for a length of about 4 centimetres; ligature of the peripheral end; passage beneath the vessel in its upper part of a second ligature whose first knot is prepared; and application above the loop of the ligature of a small elastic forceps. A third and fourth ligature are passed under the vessel below the compress, and their knot is prepared without being tightened; the ligature compressing the root of the limb is removed.

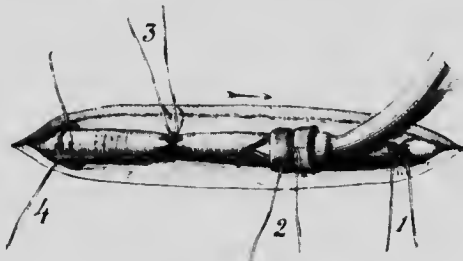


FIG. 482C. THE SAME.

The artery is fixed on the end of the rubber tube by No. 2. The vessel is then fixed 2 millimetres from the widened terminal portion of the cannula by ligature No. 2.

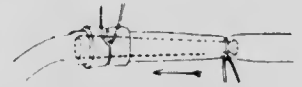

FIG. 482D. THE SAME.

The outline figure shows the situation of the cannula in the artery. The same manœuvres are carried out on the vein, but the compressor is removed before tying ligature No. 3, in order that the jet of blood drives out the air contained in the transfusion tube.

The anterior wall of the vessel is seized with fine forceps and incised a centimetre above the ligature, and the surgeon prepares to introduce the glass cannula of the transfusion tube into the orifice.

Fourth Stage.—The surgeon introduces the cannula into the vein as far as the small compressor, and the ligature No. 4, whose knot is already prepared, is tightened so as to fix the vessel on the rubber tube, where the latter is ligatured on the glass cannula. The cannula cannot escape, and the surgeon removes the compressor which is on the artery, the compressor on the vein remaining in place; the air in the tube is driven out through the orifice. The moment that blood flows out of the orifice in the vein the assistant removes the compressor placed on the vein on the side of the heart, and the surgeon ties No. 3 ligature on the glass cannula. The transfusion commences.

Fifth Stage: Duration of the Transfusion.—The duration varies from fifteen to thirty minutes. The donor, as a rule experiences no malaise at first; the lips of the patient, the conjunctivæ, and the ears, are noticed to colour. An assistant watches attentively the heart and pulse of the donor and patient, in order to stop the transfusion before the donor is attacked with appreciable malaise. There is no means of measuring accurately the quantity of blood transfused. It is estimated that the donor passes

between 15 and 21 cubic centimetres of blood per minute to the receiver. The quantity of blood which should be injected in a case of grave hæmorrhage may vary between 500 and 1,000 cubic centimetres, a quantity which a vigorous subject may give without the risk of anything but a passing anæmia lasting about a fortnight.

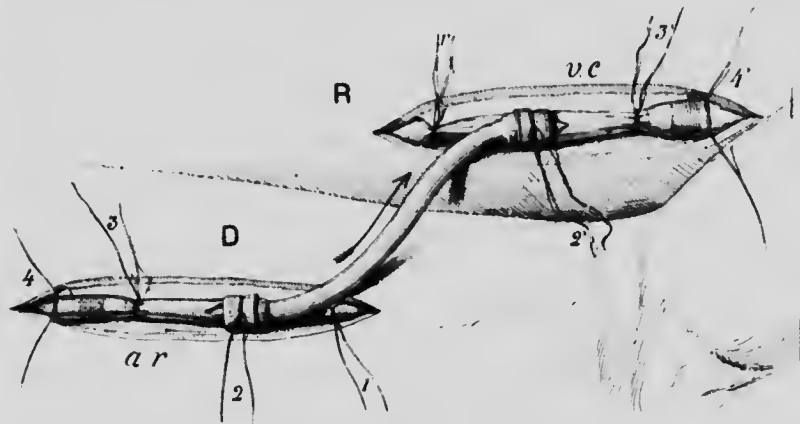


FIG. 482E. THE SAME.

This figure shows the double field of operation during the transfusion.

Sixth Stage.—The transfusion is arrested by ligaturing successively the donor's artery and the patient's vein, beneath which two ligatures were placed (No. 2) at the moment of their isolation. The intermediary



FIG. 483. THE SAME.

Aspect of the artery after transfusion. Ligature No. 4 is tightened and tied; ligatures 2 and 3 are then removed and the cannula. The same is carried out in the case of the vein.

tube is removed and its ligatures, and the wound is washed with Ringer's solution. The skin is then sutured either by means of interrupted sutures or clips.

After-Care.—The donor of the blood must be kept under surveillance as well as the patient, though the state of the former generally gives no reason for anxiety.

It may be useful to maintain the patient in the inclined position, the head lower than the pelvis, and also, as I have pointed out in grave hæmorrhage, to place an elastic band on the legs moderately tight from below upwards. After twenty-four hours rectal or subcutaneous injections of

isotonic saline solution or Ringer's solution are commenced, in order to augment the mass of blood in circulation. If the donor feels very weak, he is given immediately rectal or subcutaneous injections of isotonic saline or Ringer's solution.

REPETITION OF THE TRANSFUSION.

In cases of very great hemorrhage, when a primary transfusion has produced an evident amelioration, but where the condition of the patient remains grave, the transfusion may be repeated after a lapse of a few days.

SURGERY OF THE NERVES.

Symptoms following Wounds of Nerves.—Wounds of nerves are followed by phenomena which are both *painful* and *paralytic*. Neuritis is observed particularly when the nerve, almost intact, is compressed by a cicatrix or callus. It occurs also after a lateral injury of the nerve, affecting the neurilemma and superficial bundles, and followed by the formation of a tangential neuroma.



FIG. 484A. SUTURE OF NERVES: LATERAL NEUROMA FOLLOWING WOUND OF A PERIPHERAL NERVE BY SHELL WOUND.



FIG. 484B. THE SAME. Section of the nerve at the centre of the neuroma, showing the lateral wounding of a certain number of superficial nerve bundles.

Paralysis is observed in cases of compression or incomplete section of a nerve, as well as in cases of complete section. In the limbs it is at once sensory and motor.

Wounds of nerves in civil practice are frequently caused by broken glass; these wounds are occasionally aseptic, and in some cases immediate reunion of the cut nerve may be attempted at the same time as the repair of neighbouring tendons—in the wrist, for example.



FIG. 484C. THE SAME.

The nerve is sectioned, but the two extremities remain in relation with one another by the intermediary of a greyish band uniting the two neuromata. The neuroma of the central end is larger than that of the peripheral end, which is atrophied.

But the case is not the same for wounds incurred in war, the majority of which are infected, even small wounds, by various sorts of microbes, especially the streptococcus. It is known that the streptococcus can remain virulent for a long period in the depths of a wound which is apparently

cicatrized. In such cases a certain persistence of inflammatory thickening can be made out, and abnormal tenderness, which increases on pressure. In wounds of nerves by firearms, and in general whenever the wound has



FIG. 484D.—THE SAME.

The two ends of the cut nerve are at a greater distance from one another, but are joined by an intermediary band.

been infected, surgical intervention should be postponed until it can be decided with probable certainty that no trace of infection remains in the



FIG. 484E. THE SAME.

The two extremities of the nerve are free; the distance separating them may reach 6 to 8 centimetres. Large neuroma of the central end; small neuromata may be completely engulfed in the cicatrix.

wounded area. I do not here enter into a detailed description of the exploration of sensibility and mobility, which is a simple matter for anyone possessing the indispensable anatomical knowledge.

Electric Examination.

What indications can be drawn, from an examination of the electrical reactions, which may serve as a guide to the surgeon for intervention? It is generally admitted that the electrical reaction, known as the reaction of degeneration, is a contra-indication to any surgical interference. This opinion is erroneous. Reaction of degeneration follows central lesions. It is exceptional after the wounding of a peripheral nerve, and I repeat that when it appears to exist it should not be considered as a contra-indication to surgical operation.

I examine cases in the following way: a wet contact plate is fixed with a band over the course of the nerve, at the root of the limb; the active electrode is a wet pad which is applied to the paralyzed muscles below the wounded point. The contact plate is connected to the positive and the pad with the negative pole. As soon as a characteristic muscular contraction is obtained on contact of the pad the intensity of the current is noted in milliamperes. An assistant reverses the current so that the contact plate is connected with the negative and the pad with the positive pole. So called reaction of degeneration is present when for an equal intensity in milliamperes the muscular contraction provoked by the ascending current is distinctly more intense than that provoked by the descending current.

The ascending current being represented by A.C., and the descending current by D.C., reaction of degeneration is present when the examination gives the formula $A.C. > D.C.$

My personal observations have shown me in several cases that, although reaction of degeneration was admitted to be indisputable, yet operation, which consisted either in freeing the nerve from a cicatrix or in nerve suture, has been followed by cure.

Before deciding on operation I make several electrical examinations, and I note the intensity of the current necessary to provoke contractions. I note also presence or absence of the reaction of degeneration. But I do not consider the latter as a contra-indication to operation.

Indications for Operation.

I cannot insist too forcibly on the imprudence, in the case of an infected wound, of operating whilst the slightest trace of microbial activity may be suspected to remain in the depths of the wound. Operation may be performed when there remains *no* sign of local inflammation after several months. Digital exploration of the wounded region will provoke a shock, when the finger presses exactly on the nerve lesion, like that which is produced by the sudden passage of the faradic current: it is analogous to the shock provoked on rubbing the ulnar nerve in its epitrochlean groove. The neuritis is characterized by peripheral pain with functional troubles, which are variable. When peripheral neuritic symptoms are present, the nerve has generally been wounded laterally, and the muscles can contract under the influence of the faradic current. The rule having been established that no operation on nerves shall be undertaken until cicatrization of the original wound is complete and until pathogenic microbes have disappeared, I will outline the course of action to be followed by the surgeon.

1. THERE ARE SYMPTOMS OF NEURITIS.

Paralysis is, as a rule, incomplete, and signs of peripheric hyper excitability exist. The nerve is not severed; it has been partially wounded or it is compressed in a cicatrix (fibrous cicatrix or exuberant callus). In the former case a lateral neuroma generally is present; in the latter case the nerve is compressed, and its atrophy is imminent. Operation should be undertaken the moment that all danger of reawakening a latent microbial infection can be avoided.

OPERATION—First Stage: Exposure of the Nerve.—The incision should be sufficient to expose the central end of the wounded nerve 5 or 6 centimetres above the lesion. It is prolonged for an equal distance over the peripheral end. The incision attains a length of from 12 to 15 centimetres in the case of the radial nerve, and 18 to 20 centimetres in the case of deeply placed nerves such as the sciatic or the posterior tibial. The wider the field of operation, the more easy it becomes to carry out the necessary manoeuvres.

Second Stage : Dissection of the Nerve.—The nerve is isolated, care being taken to avoid wounding the collateral branches. Dissection is commenced at the central end, and the surgeon gradually approaches the wounded point; the nerve is disengaged carefully from the surrounding fibrous tissue and the dissection of the peripheral end is proceeded with. If no neuroma be present, the nerve trunk is carefully disengaged from all its adhesions. If a neuroma be present this is excised, care being taken not to injure the subjacent nerve bundles. Repair of the neurilemma is, as a rule, impossible.

Third Stage : Protection of the Nerve.—The wounded nerve is separated from the cicatricial zone to which it was adherent. This is accomplished by creating below it, with fine silk sutures, a musculo-aponeurotic cushion.

Fourth Stage : Reunion of the Wound, Drainage.—The superficial muscles are reunited where sectioned, the aponeurosis of the limb is then sutured, leaving room for the passage of two glass drains, one above and one below. The skin is then sutured.

After-Treatment.—The dressing should be lightly compressive. If there is sero-sanguineous oozing, the dressing is changed on the following day. The drains are then replaced and left in position for several days. I remove the drains, as a rule, on the sixth or seventh day. Their presence has never hindered union, whereas any retention of a sero-sanguineous oozing in the deeper parts of the wound may be the origin of a suppuration which will seriously compromise the result of the operation.

2. PARALYSIS IS PRESENT.

When, five or six months after cicatrization of the wound, sensibility and movement do not begin to reappear, operation must be performed. Sensory paralysis is a less important symptom than motor paralysis, for it may become less by collateral routes. Partial re-establishment of sensibility may be so noticeable after the section of the radial nerve in the arm that complete anesthesia after eighteen months is now localized only to the inner surface of the dorsum of the first phalanx of the thumb.

Muscular paralysis, on the contrary, persists, and the faradic current invokes no contraction in the affected muscles.

Galvanization by the descending current, however, causes evident contractions. The intensity necessary to provoke a contraction is noted in milliamperes, and when the current is reversed examination is made for the so called reaction of degeneration.

I attach but little importance to this reaction, being content merely to note it. When paralysis remains complete more than six months after the wound I consider it sufficient to justify operation if galvanization gives a positive result. The duration of the paralysis is not to be taken into consideration when it is less than eighteen months. I have obtained complete cures in cases where section of the nerve has been total, and which had lasted for a longer period.

In a small number of cases sensory and motor paralysis correspond only

to a portion of the area of the nerve affected. In the case of the ulnar nerve, for example, they may be limited to the interossei muscles. When such is the case, and a part of the area of the nerve has been respected by the accident, it is well to temporize. Operation will be indicated four or five months later if the originally observed amelioration ceases to continue.

When motor paralysis persists and palliative treatment produces no result, operation must be performed.

Operation consists either in *liberation of the nerve* or in *suture of the nerve*.

1. LIBERATION OF THE NERVE.

First Stage: Exposure of the Nerve (as above).

Second Stage: Dissection of and Disengagement of the Nerve (as above).—The dissection of the nerve should always begin at the central end. It will be seen at once if the neuroma at the end is or is not in relation with the peripheral end by means of an intermediary band. Several conditions may be observed.

A. The Lesion of the Nerve is not Profound.—In such a case there is no neuroma, and the trunk for a length of from 10 to 15 millimetres presents a fusiform enlargement, greyish-red in colour, which is adherent to the neighbouring cicatricial tissue. The nerve is liberated, care being taken not to damage the collateral branches. It is then separated from the cicatrice by the sliding of a musculo-aponeurotic layer, which is arranged below it to form a cushion (see above, operation in cases of neuritis).

B. The Two Ends of the Nerve are United by an Intermediary Greyish Band.—The band is voluminous, and both ends, at their junction with the band, end in a neuroma. The neuroma is always larger at the central than at the peripheral end. If the neuroma at the central end is not of considerable size, and if the intermediary cicatricial band is of about the same diameter as the nerve trunk, we should be content to separate them from the cicatrice, as in the preceding case.

C. The Neuroma at the Central End is Very Voluminous, and the Intermediary Band which Unites it to the Small Neuroma on the Peripheral End is Fairly Thin.—Experience shows that hardly any new-formed nerve tubes exist in the cicatricial band. Vivification or freshening should be resorted to, followed by nerve suture (see above).

D. The Two Ends of the Cut Nerve are at a Distance from One Another.—In such cases the neuroma at the central end is very voluminous, and that of the peripheral end, which is also atrophied, is hardly perceptible. Nerve suture is imperative; this is rendered more difficult by the separation of the retracted nerve trunks, which may be considerable.

2. NERVE SUTURE.

OPERATION—First and Second Stages (as above).—The search for the peripheral end of the sectioned nerve may be laborious when there is no

intermediary cicatricial band. The surgeon here has need of the most exact anatomical knowledge. The peripheral end of the radial nerve is notably difficult to find when it is retracted amongst the mass of the neighbouring muscles.

Third Stage: Elongation of the Central and Peripheral Ends.—Whether the two ends of the wounded nerve are quite isolated, or whether they are joined by an intermediary band, they must be lengthened before freshening is attempted. Indeed, it is only after elongation that we can ascertain the quantity of pathological tissues which can be resected in order to accomplish the suture without dragging. The central end is lengthened first, being seized above the wounded point in a sterile compress. The nerve slips

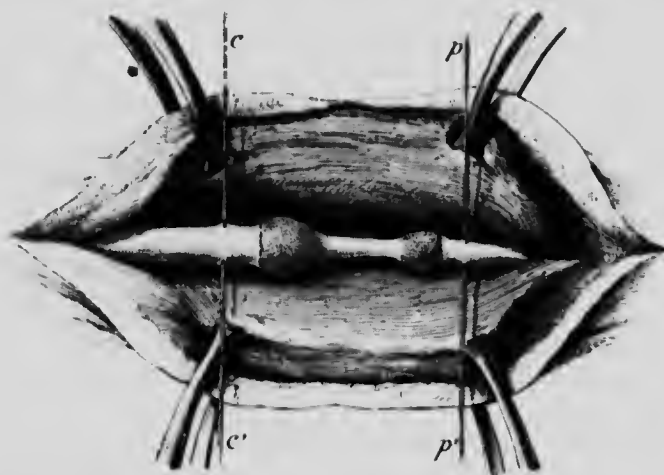


FIG. 485. THE SAME: EXPOSURE OF THE MEDIAN NERVE IN THE FOREARM TWELVE MONTHS AFTER WOUND.

The central and peripheral ends are united by a fibro-cellular band which contained no trace of any nerve elements. The loops C, C', in the central end and P, P', on the peripheral end are placed on the neurilemma sheath at opposite points on the transverse diameter of the nerve, in order to serve as marking points when the suture is being made. The dotted line shows the point of vivification.

quite easily in its cellular sheath. Elongation in the case of the radial nerve may attain 4 or 5 centimetres. The surgeon observes carefully the effect produced, and his hands should be delicate enough not to cause irremediable damage by exaggerated traction. The peripheral end is then lengthened in the same way.

Fourth Stage: Marking Out the External and Internal Borders of the Two Nerve Trunks.—To re-establish, as far as possible, the relations of the different nerve bundles to the position they occupied before the wound, I place in the neurilemma sheath, 5 or 6 millimetres from the point where the transverse section is to be made, two sutural loops, *c, c'*, and *p, p'*. These sutural loops divide each of the extremities of the nerve into two

surfaces, a superficial and a deep, as they present themselves at the moment of their dissection.

I divide the central end transversely with the bistoury at the superior part of the neuroma, which is often fairly large, and the lower end very close to its extremity, where the nerve seems to be healthy. The bundles of nerve fibre which are characteristic are at once distinguished. If only a few bundles make their appearance, I make a second section with the bistoury 2 or 3 millimetres higher. But I come, as a rule at the first section, to a point where the essential elements of the nerve are sufficiently intact for the repair to be made. It is not necessary to attain a segment of the nerve where the section has quite a normal aspect. It suffices to go beyond the region, which is profoundly altered by the cicatrix, where the microscope reveals generally only a very insufficient number of newly formed nerve elements. When the fasciculated aspect of the nerve is quite ap-

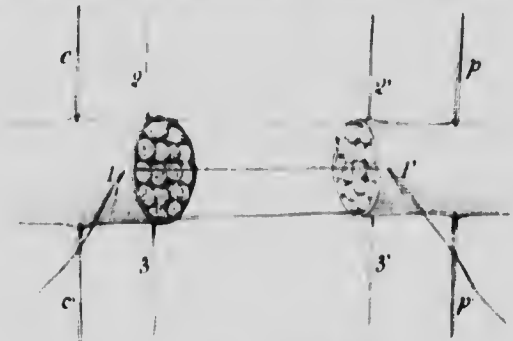


FIG. 480A. THE SAME.

The suture 1 is placed on the neurilemma in the middle of the half-circumference corresponding to the passage of loops C, C', P, P'. Sutures 2, 2', and 3, 3', are then placed opposite C, C', and P, P'.

parent, even when the bundles are surrounded by a certain thickness of greyish or reddish grey cicatricial tissue, suture may be proceeded with. The most important point is to reunite the two extremities of the nerve without dragging.

Resection of pathological tissue should not extend beyond that which is allowed by careful lengthening of the two ends of the sectioned nerve, as I have described.

Fifth Stage: Nerve Suture.—A first suture 1, 1', is placed exactly in the middle of the anterior half circumference of the two surfaces. No mistake can be made, owing to the presence of the four sutures *c, c', p, p'*, which separate the superficial from the deep surfaces. Suture should be made in case of the large nerves with curved intestinal needles, and for the smaller nerves with fine arteriorrhaphy needles. The two nerve extremities are united circumferentially by means of a large number of very fine sutural points. Let us suppose a suture of the radial nerve in the lower third of the arm.

I place at first the suture No. 1. When this is tied I place sutures 2 and 3 opposite the marking sutures *c, c', p, p'*—that is, to the extremities of the great transverse diameter. I then place in intermediary sutures 4, 5, 6, 7. All these sutures are superficial, taking in only the neurilemma, which is very resistant.




FIG. 486b. THE SAME.

Suture No. 1 is tightened, ligatured, and cut 2 millimetres from its knot; sutures 2 and 3 are tightened and tied, but the two ends are left long, and should be about 8 centimetres long.



FIG. 486c. THE SAME.

The threads *C, C'* and *P, P'* are removed; sutures 4, 5, 6, and 7, are applied to the anterior half of the circumference.

The anterior demi-circumference having been united, the ends of sutures 1 and 2 have only to be drawn upon to expose the corresponding portion of the posterior demi-circumference where the separate points 8, 9, and 10,



FIG. 486d. THE SAME.

Traction on No. 2 brings to view the corresponding part of the posterior half of the circumference on which sutures 8, 9, and 10, are placed. The last (No. 10) is diametrically opposite to No. 1.

are placed. Similar traction on the ends 1 and 3 exposes the corresponding half of the posterior demi-circumference where sutures 11 and 12 are placed. The sutures *c, c', p, p'*, are removed. Finally I place on the neurilemma,

without penetrating the interior of the nerve, a certain number of reinforcing sutures. All the knots are thus outside the surface of reunion.



FIG. 487A. THE SAME.

Thread No. 2 is cut, traction is made on the ends of No. 3, and the last sutures, 11 and 12, are placed. Thread No. 3 is then cut close to its knot. (The number of sutures is according to the size of the nerve.)

Sixth Stage: Security Sutures.—In cases where it has been necessary to lengthen the superior end of the wounded nerve greatly, it is prudent, to prevent ulterior retraction, to fix the nerve trunk in its new situation by a certain number of separate sutures, 3 or 4 centimetres apart, which fix it to the resistant fibrous plane to which it is in relation. Two or three security sutures are also placed on the lower end.




FIG. 487B. THE SAME.

The sutural points occupy the positions numbered 1-12

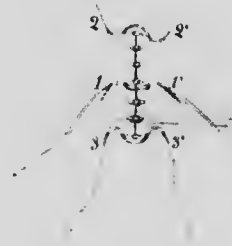

FIG. 488A. THE SAME.

Several reinforcing sutures are placed above and below the nerve section. The sutures 1, 1', 2, 2', and 3, 3', are placed successively and tied.

Seventh Stage: Closure of the Wound, Drainage.—Care is taken that the sutured nerve does not lie on an osseous bed, from which it is easily separated by uniting the musculo-fibrous planes beneath it (see above). The musculo-

aponurotic planes are then repaired over the nerve, and the skin is sutured. Two glass drains are introduced as a measure of security. The dressing and drains are changed after twenty-four hours. I have shown on several



FIG. 488B. THE SAME.

The ends of No. 1 are cut and the ends of Nos. 2 and 3 are left. Nos. 4 and 5 reinforcing sutures are then placed, and the ends are cut close to their knots.

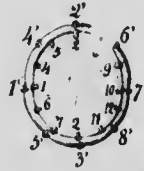


FIG. 488C.— THE SAME.

Traction on the end of No. 2 brings into evidence the posterior half of the circumference. Nos. 6 and 7 reinforcing sutures are then placed. The ends of Nos. 7, 6, and 2, are cut, and traction is made on No. 3 to place the last reinforcing suture 8, 8'.

occasions that when I removed these drains after six or seven days the clot contained by them was sterile. I consider that the presence of the drains is useful, as they conduct outwards sero sanguineous oozing, which would otherwise remain in the depths of the wound. I have never seen

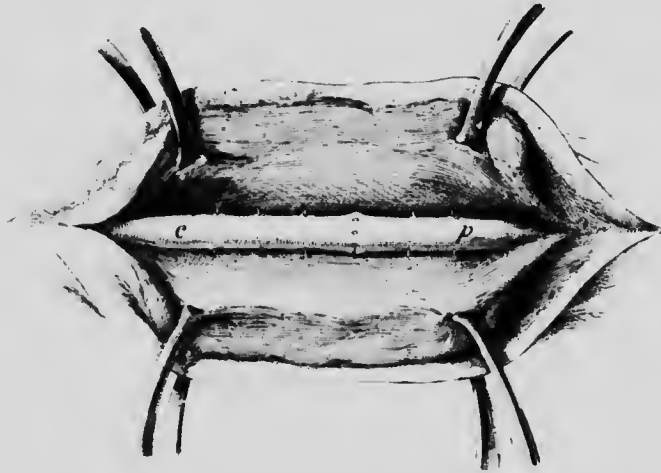


FIG. 489. THE SAME.

The nerve suture is finished on the central and peripheral end; several sustaining sutures are placed, which fix the neurilemma to the surrounding fibrous tissue.

the presence of these drains hinder cicatrization, which must be rigorously aseptic. The least trace of suppuration results in the disjunction of the reunited nerve surfaces, which constitutes a complete check.

Operative Sequelæ.—Sensibility may exceptionally return during the first few days in areas where it was previously absent. This I have observed carefully in several cases operated upon, in whom careful and repeated examinations were made before the nerve suture.

I immobilize the limb for four weeks, and I commence electrization with the continuous current after five or six weeks. The positive plate is placed at the root of the limb over the course of the central end. The negative pole, which consists of a wet pad, is passed fairly swiftly from above downwards over the course of the muscles and tendons whose mobility it is desired to reawaken. A careful note is taken before the operation of the number of milliamperes which were necessary to excite muscular contraction. The sensibility of the striated fibres to galvanization increases gradually, and voluntary movements commence to reappear after three or four months. A complete cure requires a long time, often more than a year. It is certain as soon as the first voluntary movements have made their appearance. The paralyzed muscles become sensitive to the faradic current only when the cure is almost complete.

AUTOPLASTIC OPERATION.

Autoplastic repair is subject to some general rules which may thus be enunciated:

1. Incisions should be limited to the strictly necessary; and, in case of extirpation of vicious cicatrices, they should pass beyond the limits of these only in exceptional cases.

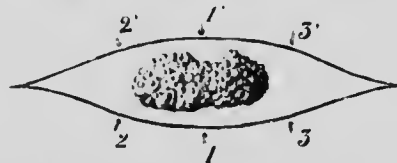


FIG. 490. EXTIRPATION OF A SMALL CUTANEOUS TUMOUR.

Outlined by two symmetrical incisions.

2. Curvilinear incisions—with simple or sigmoid curves—are more useful than the combined—T-shaped, or star-shaped—which suit only some special cases.

3. V-shaped incisions are suited only to the margins of the natural orifices of the body (mouth, nostrils, eyelids); the union in these situations demands two planes of suture—mucous and cutaneous. Deep cutaneous sutures are defective.

4. The process of grafting by approximation, from the person of the patient, is excellent when the loss of substance cannot be repaired by any other procedure.

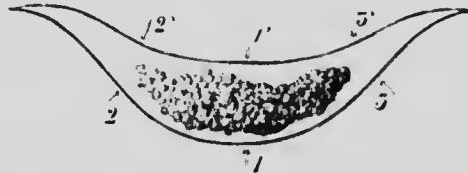

FIG. 491. EXCISION OF A CUTANEOUS TUMOUR.
Outlined by two concentric curvilinear incisions.

5. Cutaneous grafting by total transplantation gives excellent results at the time, but the grafts are subject to retraction and even to complete absorption.



FIG. 492.—SUTURING OF THE WOUND.
The sutures are placed in the numerical order of precedence.

6. Dermo-epidermic grafts, either in large patches or minute fragments, give fairly satisfactory epidermic cicatrices, but these have not the suppleness of healthy skin. These grafts should be used only where direct autoplasty and heteroplasty are materially impracticable.

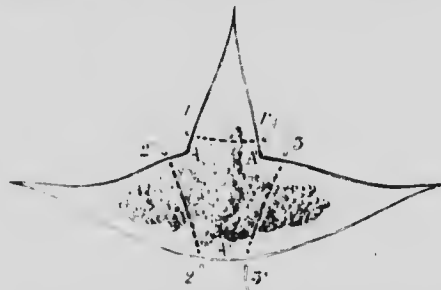


FIG. 493.—EXCISION OF A TRIANGULAR TUMOUR.
Outline of incisions.

7. Autoplastic operations, direct or by contribution from neighbouring tissues, are possible only in those regions where the integument is loose enough to allow some gliding. Loss of substance at the heel is almost irreparable by autoplasty, if of any considerable extent.

390 SURGICAL THERAPEUTICS AND OPERATIVE TECHNIQUE

8. Compensatory incisions: If it be impossible to obtain a sufficient quantity of integument from the surrounding tissues to cover the loss of substance, this may be remedied by mobilizing the flaps with the help of one or more compensatory incisions, and leaving the intervals to cicatrize on the level.

Thus the technique of autoplasty varies *ad infinitum*, according to the form and extent of the loss of substance which calls for surgical repair; and

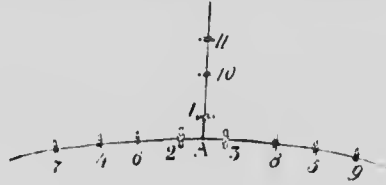


FIG. 494. SUTURING.

The sutures are placed in the numerical order here shown.

it must be modified according to the anatomical conformation of the region. Thus on the frontal region and scalp it is impossible to extirpate a transverse cutaneous band of more than 25 to 30 millimetres in width. Again, the sutures of autoplastic incisions should be applied according to an immutable rule. The first stitch, in the simplest cases (Figs. 490 and 491), should

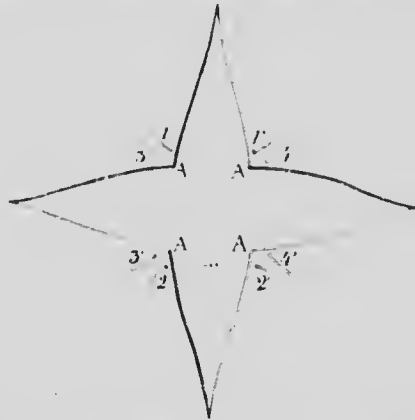


FIG. 495.—EXTIRPATION OF A CUTANEOUS TUMOUR BY A NUMBER OF INCISIONS ARRANGED IN STELLATE FORM.

unite the mid-points of the two lips of the wound; then we approximate the middle points of each of the two divisions of the line of reunion thus made; and so on. We thus obtain perfect adaptation along the line of union, even with the greatest difference in the lengths of the two original lips; and it is rare to have to resect anything at the commissures in order to avoid an ungraceful creasing or an exuberant cutaneous triangle. For example,

in the autoplasty represented in Fig. 492: we first unite the mid-points of the incisions at 1, and then insert points 2, 3, 4, 5, 6, and 7, in the numerical order indicated.

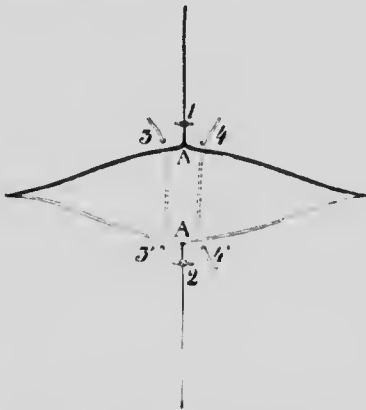


FIG. 496. SUTURE OF THE WOUND.
Points 1 and 2 are placed first.

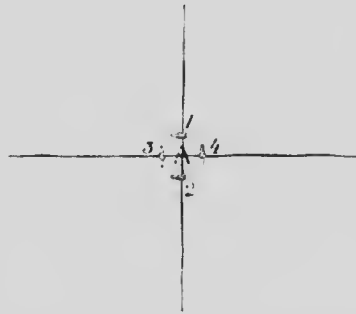


FIG. 497. ASPECT OF SUTURED WOUND
AFTER PLACING POINTS 3 AND 4.

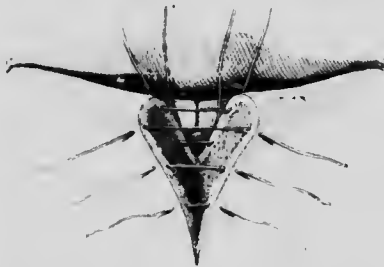

FIG. 498. V-SHAPED RESECTION OF A
SMALL CANCROID OF THE LOWER
LIP.

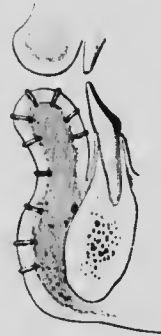

FIG. 499. SECTION OF THE PLANE OF
REFLEXION, SHOWING THE MUCOUS AND
CUTANEOUS SUTURES.



FIG. 500. SUTURE OF THE LIP.
Defective coaptation, due to passage of
the deep cutaneous sutures too near
the mucous membrane.



FIG. 501. SUTURE OF THE LIP.
Good coaptation, obtained by separate
suturing of skin and mucous mem-
brane.

In autoplasty of the lips, the skin and mucous membrane should be united with interrupted sutures; and when the latter has been united along the deep

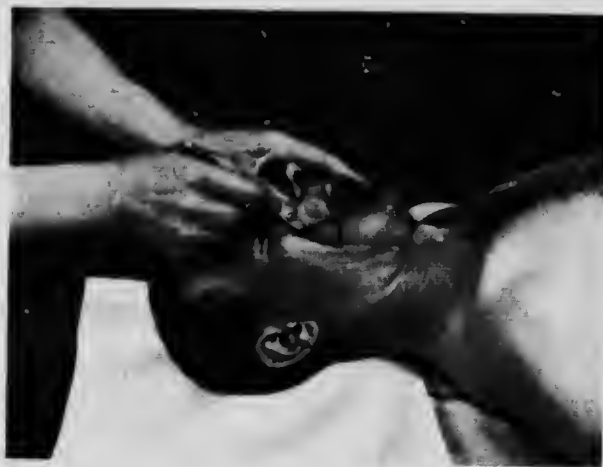

FIG. 502. RESECTION OF LATERAL HALF OF LOWER LIP.
Arrangement of triangles meeting at the apices.



FIG. 503. RESECTION OF LATERAL HALF OF LOWER LIP.
The buccal mucous membrane has been sutured to the skin, so as to reconstruct the labial margin. Reunion of the mucous membrane along the plane of the V-shaped incision.

aspect of the wound, two other points must be inserted for the purpose of securing the configuration of the free labial border. Lastly, the suture of the skin is completed in the way above indicated. The walls of the buccal cavity are admirably adaptable to the methods of autoplasmic repair, except the skin over the mental region.

The incisions most used on the face are represented in Figs. 490-497. Stellate incisions are indicated when the area of integument to be removed

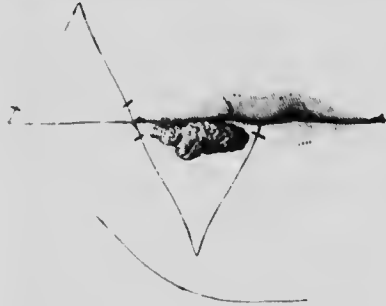


FIG. 504. RESECTION OF LATERAL HALF OF LOWER LIP BY THE METHOD OF TRIANGLES MEETING AT THE APEX.

Outline of incisions.

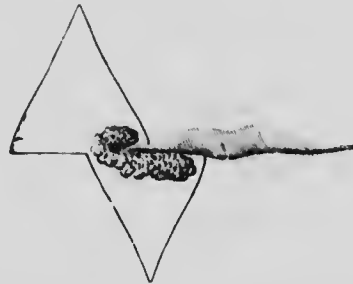


FIG. 505. RESECTION OF LATERAL HALF OF LOWER LIP, THE COMMISSURE, AND A SMALL PORTION OF THE UPPER LIP, BY THE SAME PROCEDURE.

Outline of incisions.

is approximately of that configuration (tuberculous ulceration, etc.). Repair of loss of substance at the root of the nose is fairly well carried out by displacement, from without inwards, of a cutaneous tongue-shaped flap, cut



FIG. 506. APPEARANCE OF FINISHED SUPERFICIAL SUTURE.



FIG. 507. SECTION OF A SMALL BUCCAL MUCOUS FLAP, TO BE SUTURED TO THE SKIN FOR RECONSTRUCTION OF THE FREE BORDER OF THE LIP.

between the palpebral and naso labial folds (Figs. 535-538). The reunion is effected with very fine Florentine hair (so-called English root), or with fine silk, the needles used being the round ones employed for gastro-intestinal suture.

Repair of the boundaries of the natural orifices of the body involves



FIG. 508. RESECTION OF LATERAL HALF OF LOWER LIP.
Median reunion of the skin.

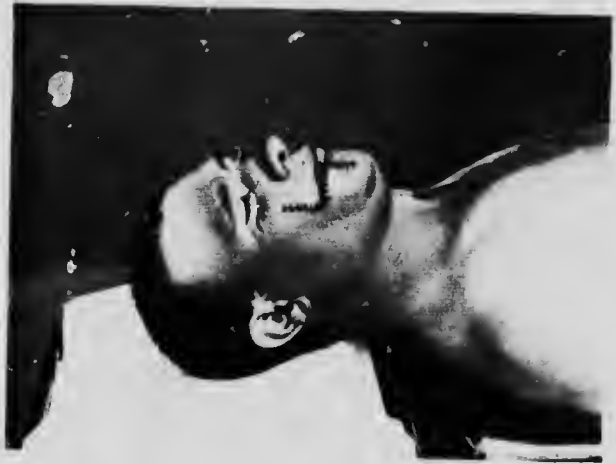

FIG. 509. RESECTION OF LATERAL HALF OF LOWER LIP.
Appearance of finished suture.

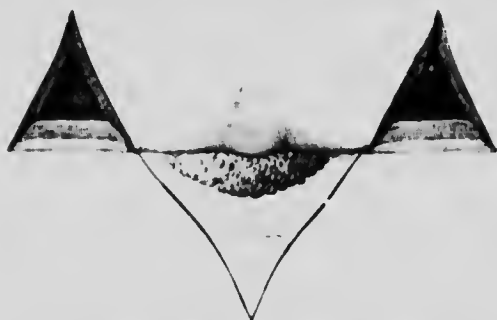

FIG. 510. COMPLETE RESECTION OF LOWER LIP.

Schematic outline of incisions. There can be seen, at the base of each of the two lateral triangles from which the skin has been removed, the small flaps of buccal mucous membrane which are to be sutured to the adjacent skin for reconstruction of the free border of the lip.



FIG. 511. COMPLETE RESECTION OF LOWER LIP.
Appearance of the finished suturing.

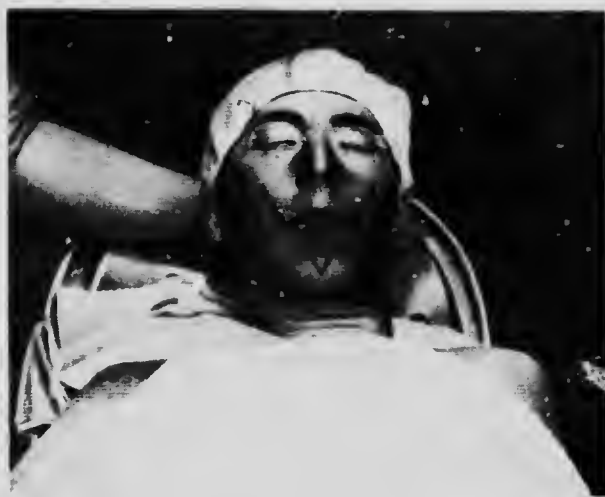

FIG. 512.—COMPLETE RESECTION OF LOWER LIP BY THE SAME METHOD.
Outline of incisions.

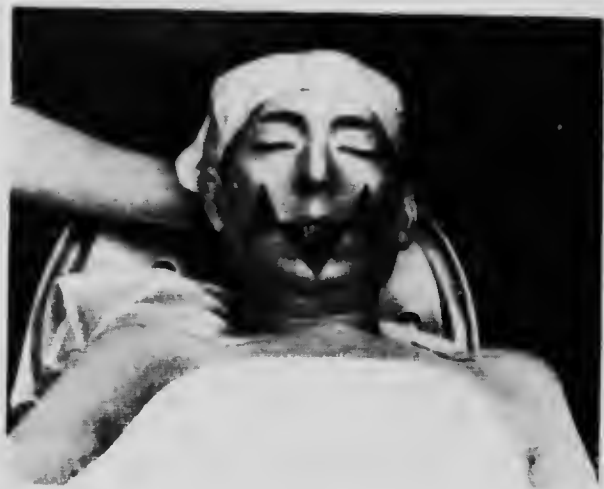

FIG. 513. COMPLETE RESECTION OF LOWER LIP.
Appearance of wound after extirpation of the lip and of the two chancous triangles.

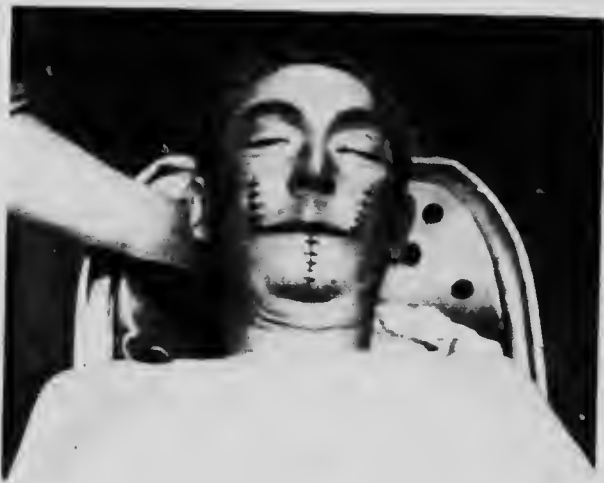

FIG. 514. COMPLETE RESECTION OF THE LOWER LIP.
The suturing has been completed. On comparing this figure with the preceding, it will be seen that the width of the upper lip has been increased as a result of the vertical reunion of the margins of the two lateral triangular wounds.

special procedures, the oldest and simplest of which is the V-shaped incision used in ablation of small caneroids of the lips (Fig. 498), and in artificial puckering of the lower eyelid in cases of atonic ectropion (Fig. 522). The V-shaped incision may, in operations for partial or total repair of the lower lip, be combined with unilateral or bilateral ablation of a cutaneous isosceles triangle with horizontal base on the right and left of the buccal orifice. The

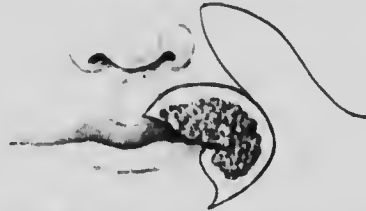

FIG. 515. EPITHELIOMA OF UPPER LIP AND COMMISSURE.
Outline of incision for extirpation and autoplasty.

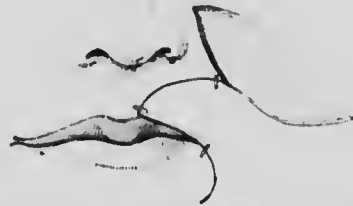

FIG. 516. EPITHELIOMA OF UPPER LIP AND COMMISSURE.
Fixation of autophastic flap.

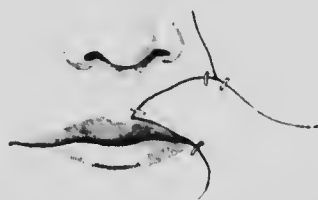

FIG. 517. EPITHELIOMA OF UPPER LIP AND COMMISSURE.
Suture of the wound made by displacement of that flap.

ablation of this triangle, on one or both sides, enables us to reconstruct the lower lip very satisfactorily, by suturing the wound as indicated in Figs. 474-484, and bringing down from each side beforehand a small mucous flap formed at the expense of the inner surface of the cheek. Interrupted sutures should be used, beginning with the mucous membranes, and taking care that the epidermic margins are adapted with complete exactitude. Deep

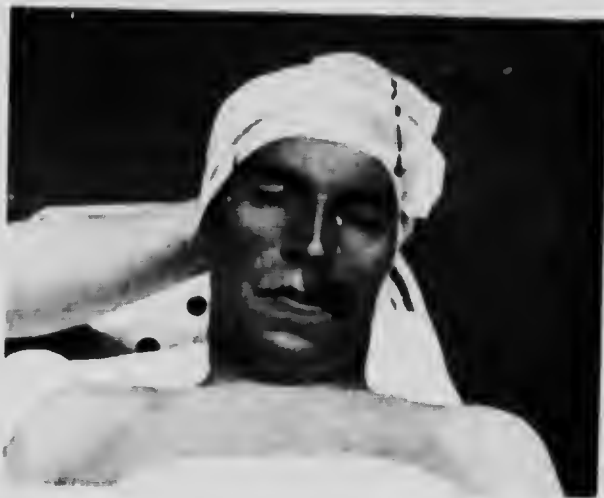

FIG. 518. EPITHEDIOMA OF UPPER LIP AND COMMISSURE.

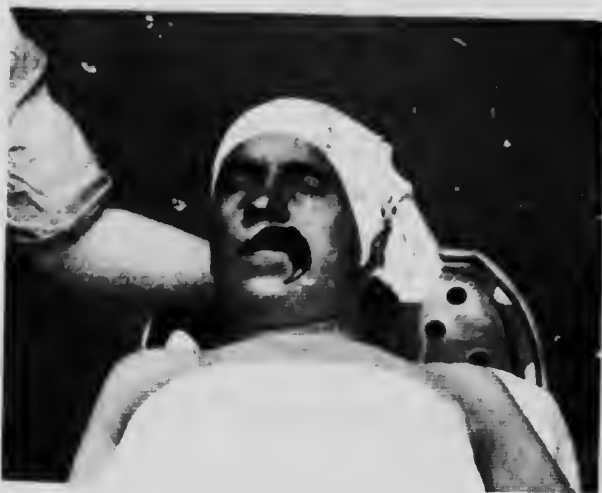

FIG. 519. EPITHEDIOMA OF UPPER LIP AND COMMISSURE.
Extirpation of tumour and of a small triangle of healthy skin approaching the skin

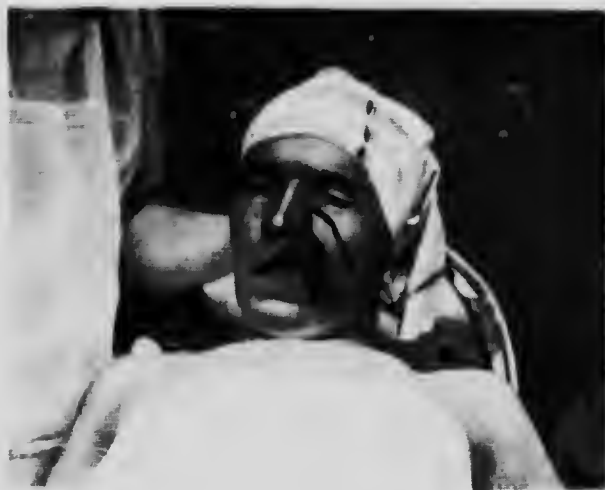

FIG. 520. EPITHELIOMA OF UPPER LIP AND COMMISSURE.
Outline of autoplasmic flap.

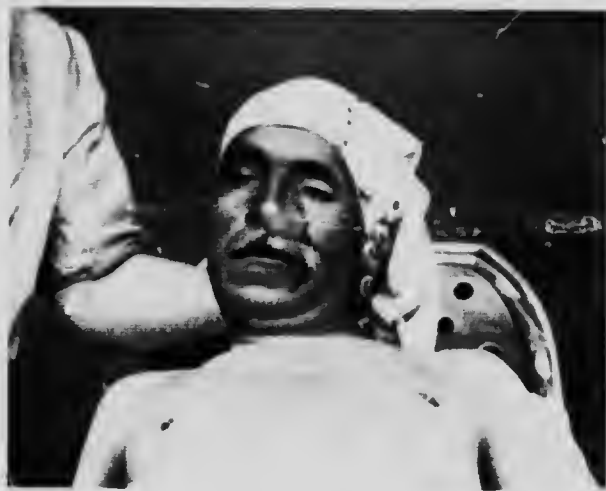

FIG. 521. EPITHELIOMA OF UPPER LIP AND COMMISSURE.
Appearance of finished suturing.



FIGS. 522 AND 523. ATONIC ECTROPION.
Dieffenbach's operation.

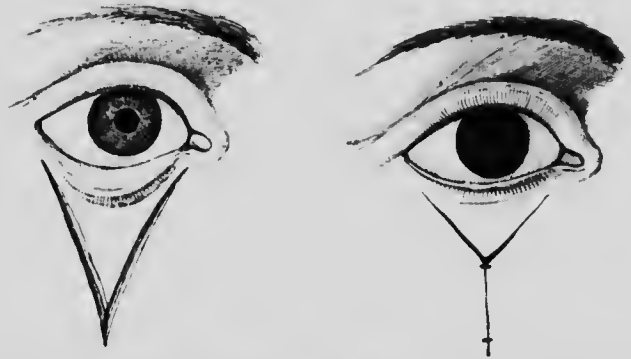


FIG. 524. CICATRICIAL ECTROPION. FIG. 525. CICATRICIAL ECTROPION.
Wharton-Jones's operation. Y-shaped suture, after removal of flap

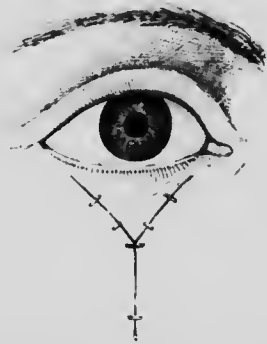

FIG. 526. CICATRICIAL ECTROPION.
Appearance of finished suture.

stitches should not be applied, so that the tissues which are to reform the lip shall preserve their entire thickness. The upper lip is repaired with a flap cut at the expense of the cheek, and united to the surrounding parts in the way shown in Figs. 515-521.

The procedure by triangular flap, which has been already illustrated in resection of the lower lip, is also resorted to in the cure of senile ectropion (Figs. 522 and 523). The ascent of the triangular area effects the cure of the condition, and the fixation of the new position is secured by the Y-shaped suture (Figs. 524-526). In cases in which the loss of substance of the lower

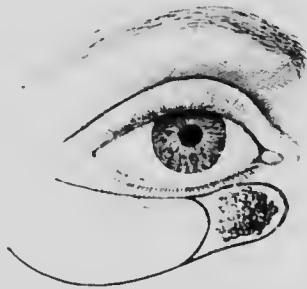

FIG. 527. EXTIRPATION OF A SMALL CANCROID OF THE LOWER EYELID.

Autoplasty by sliding displacement.

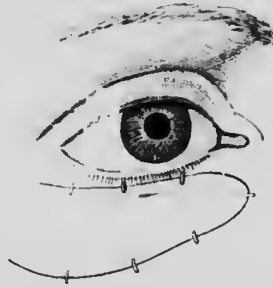

FIG. 528. EXTIRPATION OF A SMALL CANCROID OF THE LOWER EYELID.

Appearance of finished suture.

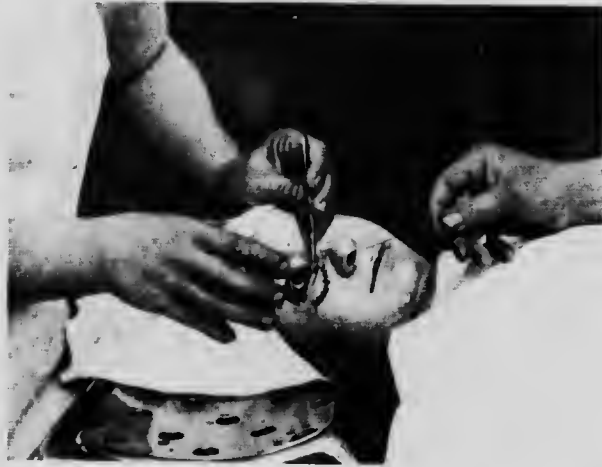

FIG. 529. PARTIAL REPAIR OF THE LOWER EYELID BY SLIDING DISPLACEMENT OF A HORIZONTAL FLAP.

lip is very extensive, the V-incision may be replaced by the displacement of an extensible cutaneous flap, as represented in Figs. 527, 528, and 529. By this procedure we may repair considerable losses of tissue by adapting the form of the autoplasmic flap to the requirements of each individual case (Figs. 530-533).

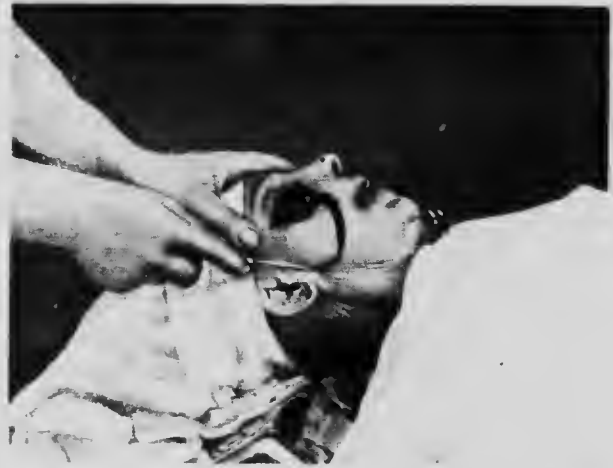

FIG. 530.—EXTIRPATION OF AN EXTENSIVE CANCROID OF THE LOWER EYELID.
Section and displacement of autoplasmic flap.

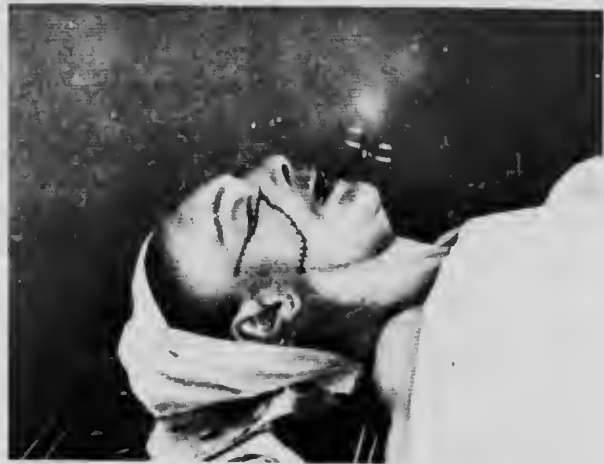

FIG. 531.—EXTIRPATION OF AN EXTENSIVE CANCROID OF THE LOWER EYELID.
Appearance of finished suture.

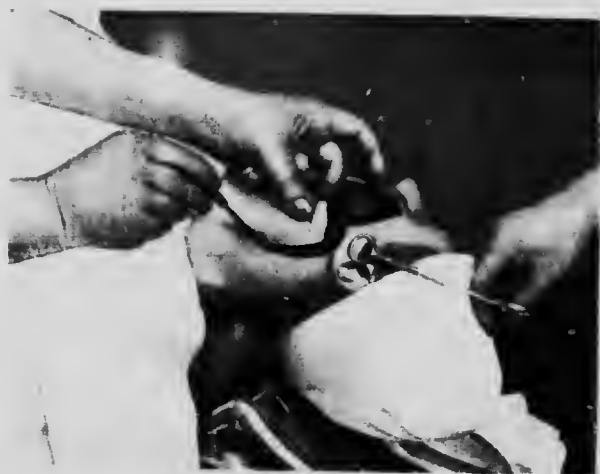

FIG. 532. ENTIRPATION OF A CANCROID OF THE MALAR REGION, ENGAGING THE ZYGOMATIC ARCH.

Outline of autoplasmic flap.

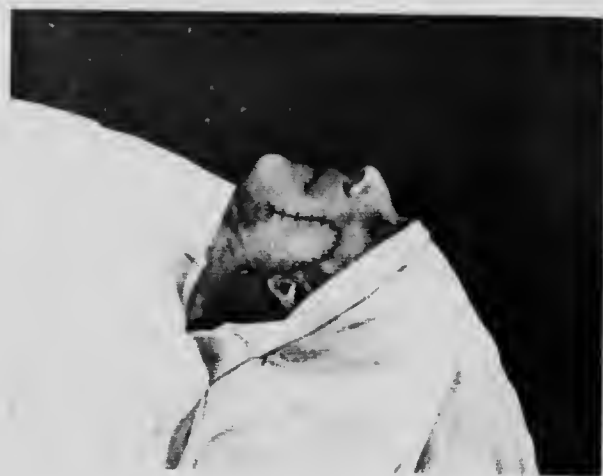

FIG. 533. ENTIRPATION OF A CANCROID OF THE MALAR REGION.

Appearance after completion of suture of wound left by resection of the extensive cutaneous triangle seen in Fig. 532, at the extremity of the jaws of the annular forceps.

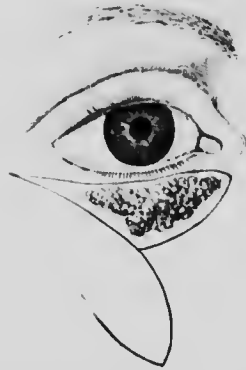

FIG. 534. EXTIRPATION OF A VERY EXTENSIVE CANCROID OF THE LOWER EYELID.

Outline of autoplasmic flap.



FIG. 535. EXTIRPATION OF A VERY EXTENSIVE CANCROID OF THE LOWER EYELID.

Appearance of line of union after insertion of most points of suture.

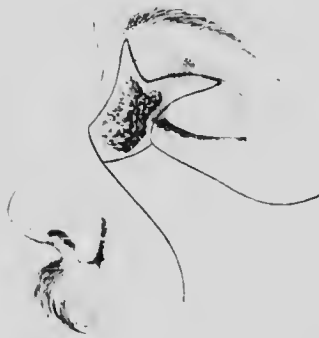

FIG. 536. EXTIRPATION OF A CANCROID OF THE LACHRYMO-NASAL REGION.

Outlines of the stellate incision and autoplasmic flap.

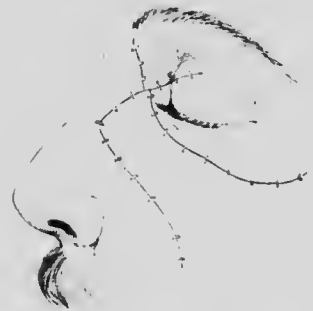

FIG. 537. EXTIRPATION OF A CANCROID OF THE LACHRYMO-NASAL REGION.

Result obtained by stellate suture, and sliding displacement of genial flap.



FIG. 538.—EXTIRPATION OF A CANCROID OF THE LACHRYMO-NASAL REGION.



FIG. 539. EXTIRPATION OF A CANCROID OF THE LACHRYMO-NASAL REGION.
Appearance of completed sutures.

406 SURGICAL THERAPEUTICS AND OPERATIVE TECHNIQUE

The dissection of two similar and symmetrical flaps has enabled me to reconstitute the integument of the anterior commissure of the anus, after extirpation of a canceroid.

In dealing with the skin of the forehead and upper eyelid, we have to resort to a series of Y incisions (Fig. 544), which may be repeated from

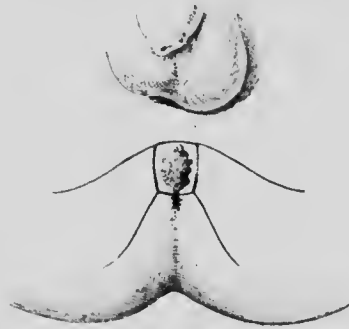


FIG. 540. EXTIRPATION OF A CANCEROID OF THE PERINEUM AND ANTERIOR PORTION OF MARGIN OF ANUS.
Outline of antoplastic incisions.

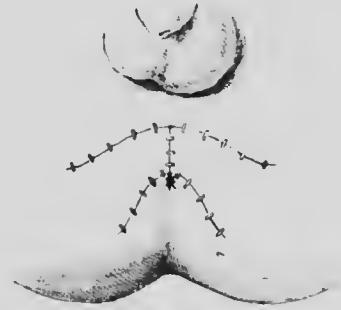

FIG. 541. APPEARANCE OF SUTURES AFTER REPAIR OF LOSS OF SUBSTANCE BY GLIDING DISPLACEMENT OF TWO LATERAL FLAPS.

before backwards over a considerable area, in order to free the integument sufficiently. The incisions are then sutured in V form. We thus obtain a side-to-side retraction of the skin of the scalp, combined with an antero-posterior elongation, which may amount to 15 to 20 millimetres.

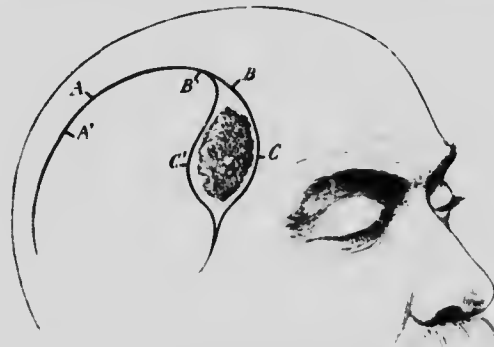

FIG. 542. EXTIRPATION OF A CUTANEOUS CANCEROID OF THE SKIN OF THE FRONTO-TEMPORAL REGION.

Compensatory incisions are of extreme value in regions in which the neighbouring skin cannot be displaced to a sufficient extent. The usefulness of those symmetrical liberating incisions, in the repair of a wound left by considerable loss of tissue in the popliteal space, is shown in Figs. 546-549.

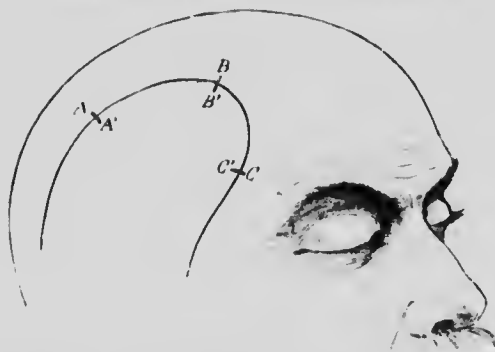


FIG. 543. EXTIRPATION OF A CUTANEOUS CANCROID OF THE SKIN OF THE FRONTO-TEMPORAL REGION.

Closure of the wound by gliding displacement of the temporo-parietal flap.



FIG. 544. COMBINATION OF Y-INCISIONS FOR VERTICAL ELONGATION OF THE SKIN OF THE SCALP.

The object is to close the space left by loss of tissue above the eyelid (Doyen).

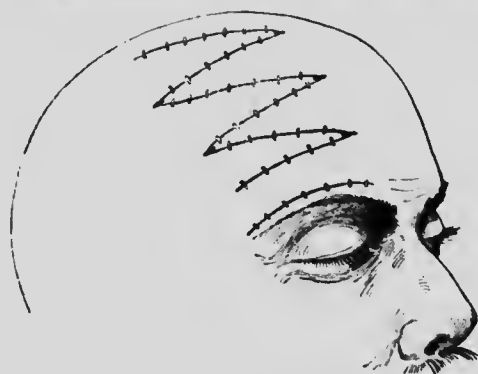


FIG. 545. V-SHAPED SUTURING OF Y-SHAPED INCISIONS, WHICH HAS THE EFFECT OF SHORTENING THE TISSUES FROM RIGHT TO LEFT, AND ELONGATING THEM IN THE VERTICAL DIRECTION.

Closure of the superciliary wound without dragging of the upper eyelid.

408 SURGICAL THERAPEUTICS AND OPERATIVE TECHNIQUE

Autoplastic operations are among the most delicate in surgical practice, as we realize on remembering that the result sought is the restoration of the normal form of the region to be dealt with, and that this is most frequently



FIG. 546. EXTIRPATION OF A POPLITEAL TUMOR ADHERENT TO THE SKIN. Outline of lateral incisions made to free the skin and permit union of edges of wound.

situated on the face. On the other hand, every intervention must be subordinated to a lesion the variety and extent of which may vary infinitely; so that we can establish only the most general rules, while the tracing of

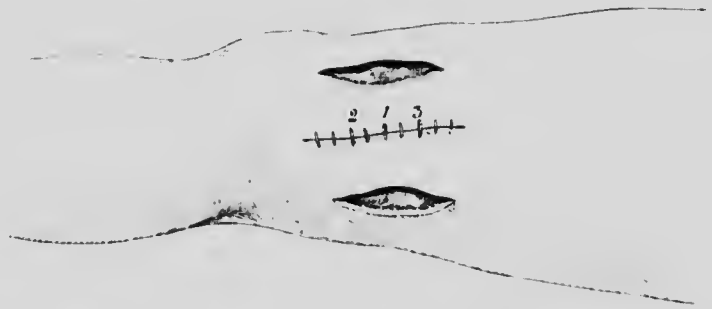

FIG. 547. EXTIRPATION OF A TUMOR OF THE POPLITEAL SPACE, ADHERENT TO THE SKIN.

Appearance of finished suture. The two lateral liberating incisions are left to cicatrize.

the incisions must be left in each individual case to the sagacity of the surgeon, who here, more than in any other instance, should be able to prove himself a true artist.



FIG. 548. EXTERPATION OF A TUMOR OF THE POPLITEAL SPACE, ADHERENT TO THE SKIN, WITH RESECTION OF THE LATER STRUCTURE.

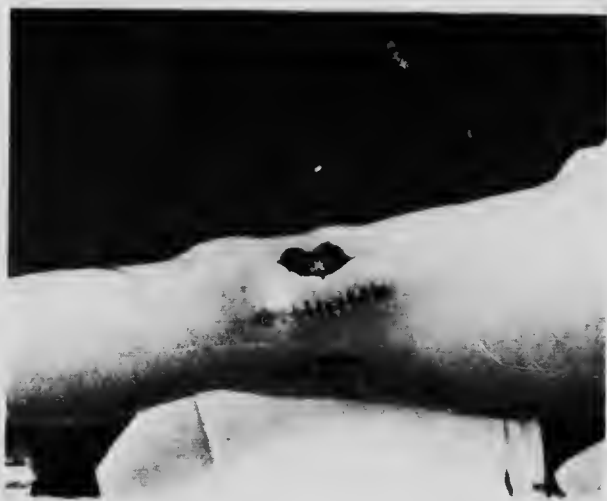

FIG. 549. EXTERPATION OF A POPLITEAL TUMOR AND THE ADHERENT SKIN. SUTURE OF WOUND, AFTER MAKING TWO LATERAL, PARALLEL, LIBERATING INCISIONS.

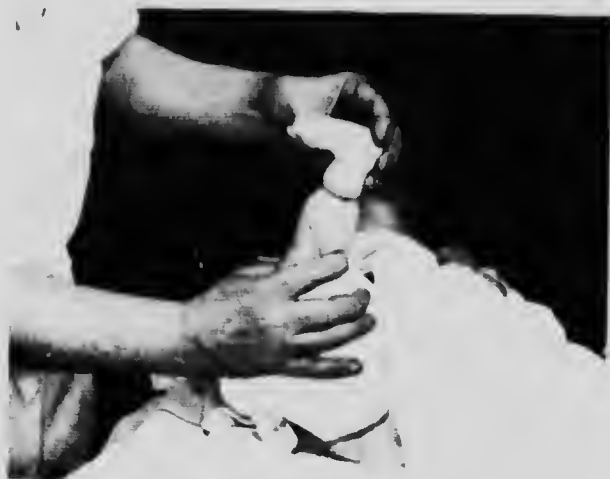

FIG. 550. CONGENITAL FIBROUS BAND OF THE LEG.

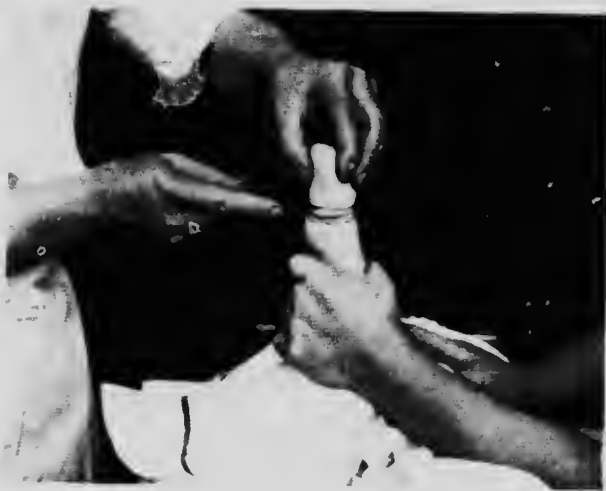

FIG. 551. CONGENITAL FIBROUS BAND OF THE LEG.
Double circular incision, above and below seat of strangulation.

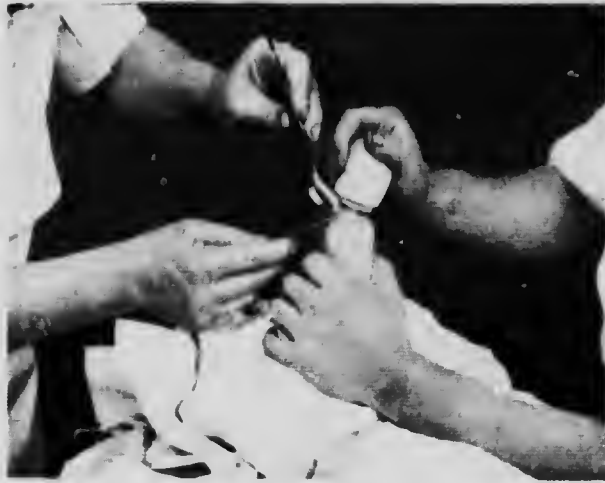

FIG. 552. — CONGENITAL FIBROUS BAND OF THE LEG.
Resection of the same.

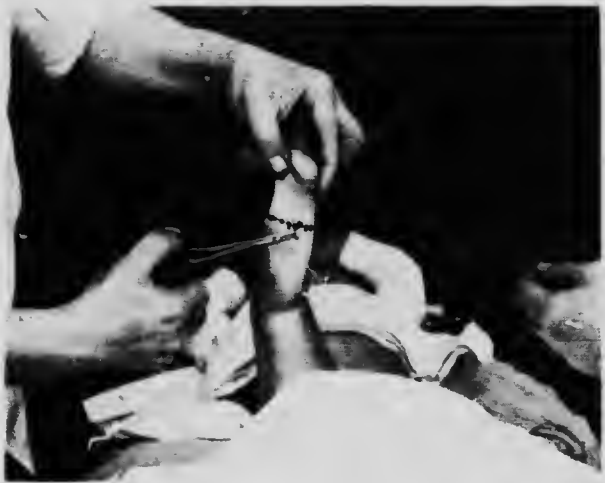

FIG. 553. — CONGENITAL FIBROUS BAND OF THE LEG.
Suture of the skin.

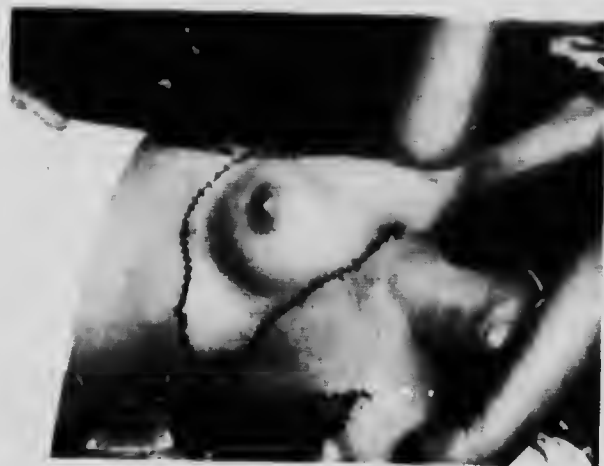

FIG. 554. CLOSURE OF LARGE WOUND LEFT BY AMPUTATION OF LEFT BREAST, BY SLIDING DISPLACEMENT OF THE RIGHT BREAST TOWARDS THE MIDDLE LINE.

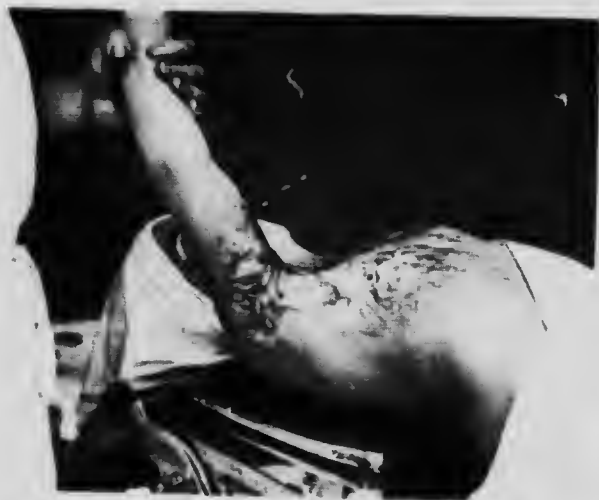

FIG. 555. AUXILIARY COARCTATE BANDS, THE RESULT OF A BURN.



FIG. 550.—ANILARY CIRCULAR BAND, THE RESULT OF A BURN.
Division of cicatrix and extension of arm, showing the extent of loss of substance
which has to be replaced.

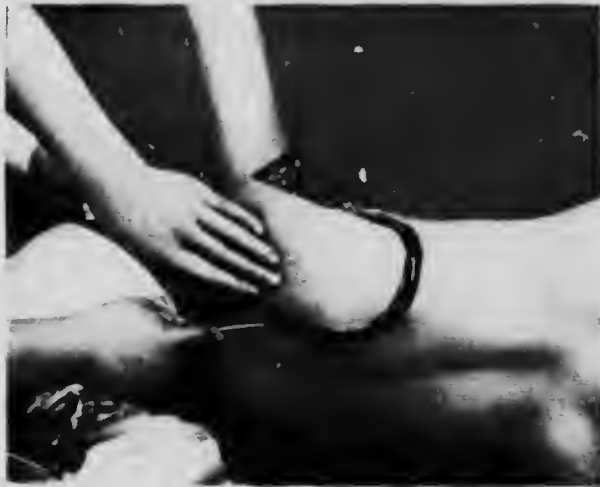

FIG. 557. ANILARY CIRCULAR BAND, THE RESULT OF A BURN.
Section of dorsal cutaneous flap.

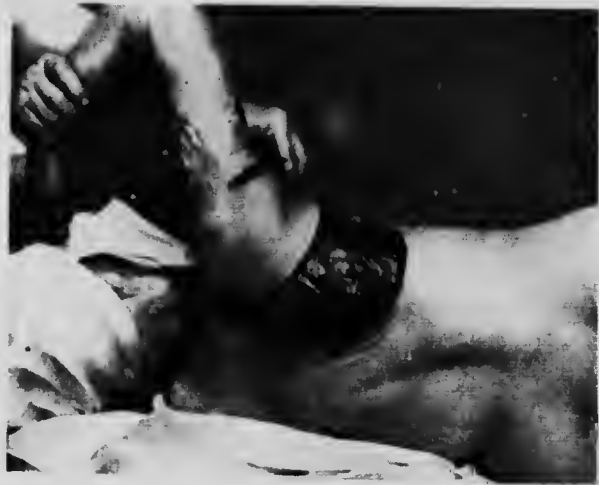

FIG. 558. AXILLARY CICATRICAL BAND, THE RESULT OF A BURN.
Application of the dorsal flap to the denuded surface of the axillary fossa.

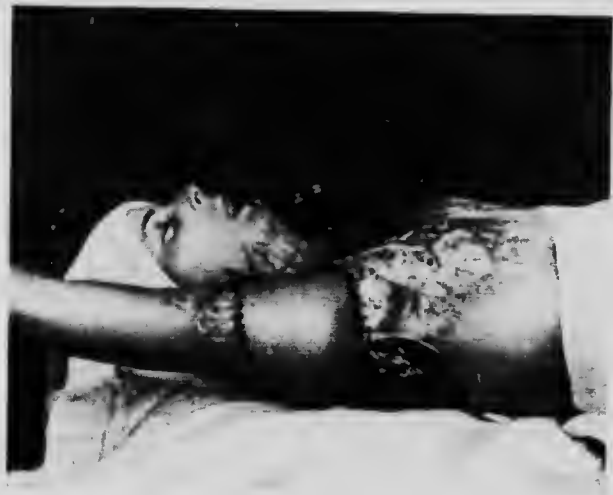

FIG. 559.—AXILLARY CICATRICAL BAND, THE RESULT OF A BURN.
Suture of the autoplatic flap, which repairs the loss of the axillary tissues. The dorsal wound will form a smooth cicatrix

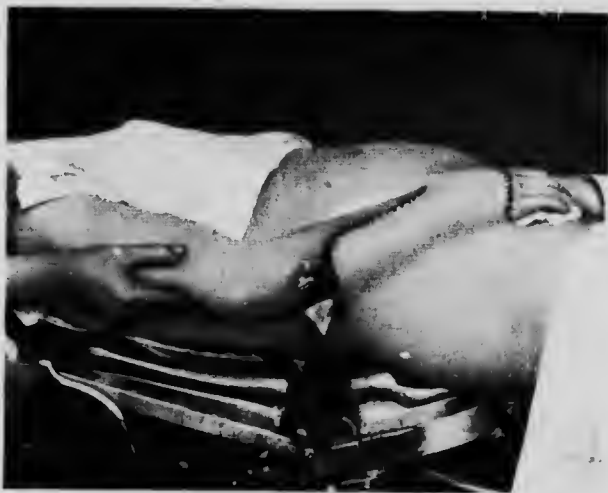

FIG. 560. REPAIR OF DESTRUCTION OF SKIN WHICH INVOLVED THE WHOLE DORSUM OF THE HAND, AND THE DORSAL AND EXTERNAL ASPECTS OF THE FORE-ARM.

The cicatrix has just been extirpated. The limb is passed under a cutaneous bridge dissected up at the fold of the gown.

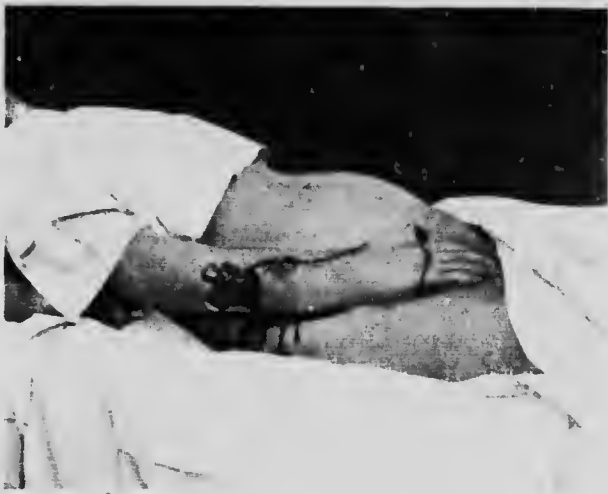

FIG. 561. REPAIR OF DESTRUCTION OF SKIN.

Union has been completed on dorsum of hand and radial border of forearm. Partial division of gluteal pedicle of cutaneous flap.

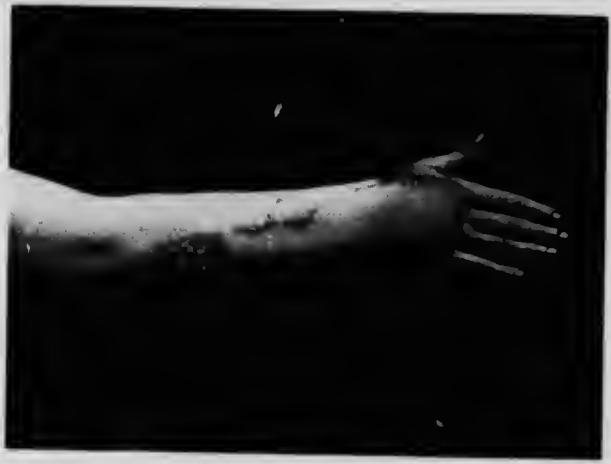

FIG. 562.—REPAIR OF DESTRUCTION OF SKIN.

Aspect of the part a month after operation. A small area of unrepaired skin, at the upper part, has been covered with dermo-epidermic grafts

TREATMENT OF FISTULE.

Fistulous canals should be totally extirpated along their whole length, and throughout the entire thickness of their walls. This process of extirpation should be completed, in case of communication with a viscus, such as the intestine or bladder, or with an excretory passage such as a biliary duct or Stensen's duct, by closure of the deep orifice, and re-establishment when possible of the normal excretory passage. The simplest case is that in which the fistula gives exit to a sero-purulent secretion coming from a serous cavity or a cystic pouch, either open or incompletely extirpated. The fistulae which come from a serous pocket or an inflamed dermoid cyst are easily healed by extirpation of the receptacle and the canal. If the parts are very much inflamed, immediate union is contra-indicated, and treatment by tamponing should be adopted instead. Fistula of the anus should be treated in the same way; extirpation and tamponing with or without partial suture of the skin. Extirpation of the fistulous passage and the whole suppurating wall is the sole method of radical cure. Extirpation of the cavity is seldom contra-indicated, except in cases in which it is very deeply seated, and the walls are adherent to vitally essential organs, such as the great venous trunks of the thorax or abdomen. In such instances, when the accessible part of the cavity has been isolated, it is well to draw cautiously on its wall, and then pursue the process of detachment into the depths with the help of the index-finger, so long as no notable resistance is experienced. If the fundus of the cavity resist such moderate traction, it is well to abandon

the attempt; the recess should then be treated by tamponing, leaving in the most dependent position a drainage-tube introduced by making a counter-opening. In this way I have abandoned the deepest part of the wall of a dermoid cyst of the mediastinum, which adhered very intimately to the broncho-vascular pedicle of the right lung; and in another case a portion of the wall of an enormous cyst of the pancreatic region. The tamponing, which was continuously practised for many months, was followed by secondary union.

Gynæcological fistulæ of the abdominal region, blind and external, were not rare in former times in women after marsupialization of adherent pelvic cysts. Such fistulæ, almost without exception, can now, be treated by extirpation of both pouch and canal. All the asepsis required in the practice of this operation is secured by protecting, before invasion of the suppurating

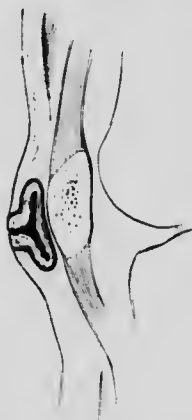

FIG. 563. FISTULA OF THE PATELLAR REGION, RESULTING FROM EVACUATION OF A SUPPURATING HYGROMA.

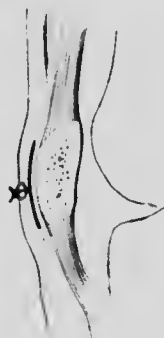

FIG. 564. FISTULA OF THE PATELLAR REGION.

Section of wound and suture after extirpation of suppurating cavity.

cavity, the rest of the surface of the peritoneum with large sterilized compresses. The uterus, when present, is left behind in those cases in which its presence facilitates the closure of the pelvic peritoneum (see Gynæcology).

The treatment of fistulæ which are kept open by the presence of a foreign body or an osseous lesion does not differ from that just described—extirpation of all the affected tissues. The wound of operation is treated—usually in the former case, and invariably in the case of an osseous lesion—by tamponing.

The technique is somewhat different when the fistulous passage communicates with viscera such as the intestine or bladder, or with the biliary ducts, Stensen's duct, the ureter or urethra. Two conditions are met with in those cases: either the issue of an abnormal fluid through the fistula is due to mere reflux of the contents of a passage which remains free, or it results from

the presence beyond the internal opening of a more or less pronounced constriction. In the former case extirpation of the fistulous canal should be completed by closure of the abnormal orifice; in the second case that duplex intervention should be followed by radical cure of the constriction, the persistence of which would almost inevitably determine the reproduction of the fistula.




FIG. 565. SMALL STERCORAL FISTULA OF THE INGUINAL REGION.

Incision of skin, for resection of the fistulous tract.

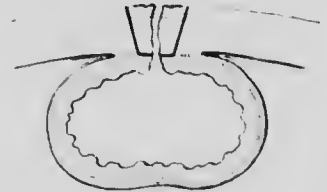

FIG. 566. —SMALL STERCORAL FISTULA OF THE INGUINAL REGION.

Transverse section of incision suitable for resection of the fistulous tract.

Let us take the case of an inguinal fistula, giving exit to a small quantity of the intestinal contents. The operation is carried out as follows: The cutaneous orifice is circumscribed by a double curvilinear incision, and held in the jaws of a ringed forceps. The fistulous tract is extirpated, as if it were a tumour, up to the peritoneum. The serous membrane is then incised. The finger recognizes the adherent loop, and follows it while



FIG. 567. SMALL STERCORAL FISTULA OF THE INGUINAL REGION.

The intestine has been freed from adhesions, and a small purse-string suture introduced.




FIG. 568. SMALL STERCORAL FISTULA OF THE INGUINAL REGION.

Closure of fistula by double purse-string suture. Appearance of superficial suture.

rotating it with the blunt scissors; it is thus freed to the extent of permitting the drawing out of the perforated intestine in the wake of the fistulous tract (Fig. 569). The field of operation is now covered with sterilized compresses, and the intestine is detached from the fistulous tract, after securing coprostasis by application of an elastic forceps. The orifice is then closed with a double purse-string suture, strengthened when necessary by a longitudinal or transverse continuous suture.

If the seat of communication of the intestine with the fistulous tract is situated at a great depth, it may be necessary, after protecting the field of operation with compresses, to detach the adherent loop forcibly and with a

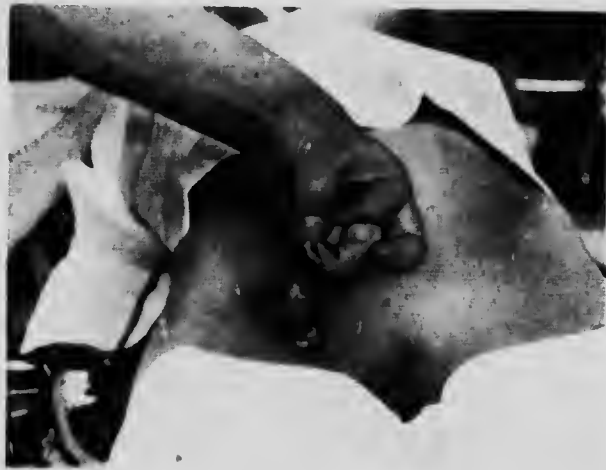

FIG. 569. STERCORAL FISTULA OF INGUINAL REGION, OF HERNIAL ORIGIN.
Elevation of fistulous tract, and liberation of intestine.

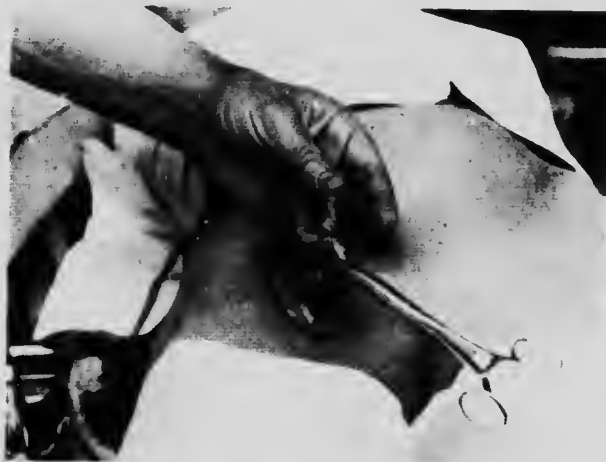

FIG. 570. STERCORAL FISTULA OF INGUINAL REGION, OF HERNIAL ORIGIN.
Application of elastic forceps to intestine, in order to facilitate aseptic closure of the fistula.

single movement; it is then grasped between the fingers and drawn outside the wound. The intestinal orifice is now closed and the parietal tract everted or, which is better, extirpated, and the wound is united by a sero-serous suture. Closure of the gall-bladder or of the urinary bladder is similarly effected with a double purse-string suture. Some intestinal fistulæ are complicated by a very pronounced contraction beyond the internal orifice. In such a case a derivative entero-anastomosis should be effected, or, indeed, the strictured segment may be completely resected.

Biliary, salivary, ureteral, or urethral fistulæ rarely persist when a permanent obstacle does not obstruct the normal outflow of the fluid beyond the seat of the internal orifices. Extirpation of the fistulous tract cannot then give a reliable result if not completed by resection of the strictured

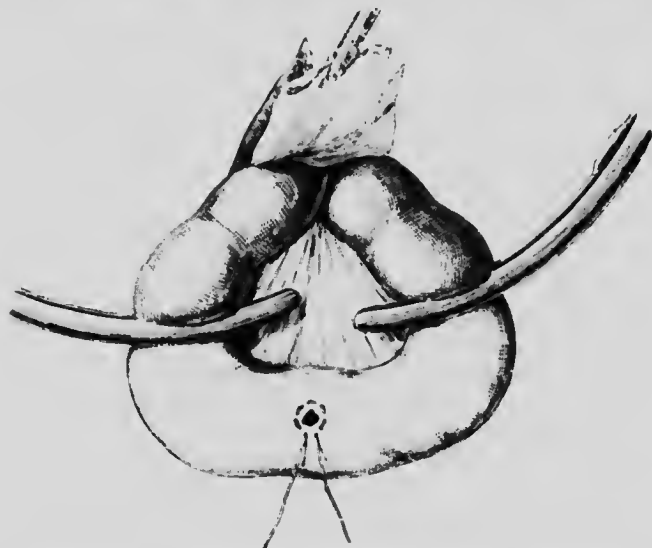


FIG. 571. CLOSURE OF AN INTESTINAL PERFORATION WITH A PURSE-STRING SUTURE.

segment, or by whatever other intervention is required for re-establishment of the calibre of the normal canal. In such cases it may be necessary to establish: for biliary fistula an intestinal anastomosis, for fistula of Stensen's duct and of the ureter a new and vesical orifice respectively; and finally, for urethral fistula, to have recourse to resection of the strictured segment, followed by union of the upper and lower segments of the canal by points of interrupted suture, with preservation of the full normal calibre.

Long penile fistulæ without stricture of the urethra are treated by vivification of the edges, both cutaneous and mucous, followed by longitudinal suturing on two or three planes. The technique of these operations will be described when dealing with regional surgery.

I now come to the last category of fistulæ, those in which the tract is limited to the back-to-back adjustment of two mucous membranes—vesico-

vaginal and recto-vaginal. Such fistula should be treated in the following way: The orifice is circumscribed by a circular or oval incision engaging the whole thickness of the more accessible mucous membrane—that of the vagina, for example. The surgeon then makes two incisions of 15 to 20 millimetres each, ending at the circular incision just mentioned, and either longitudinal or transverse, according as the vaginal mucous membrane presents a greater degree of laxity from side to side, or from above down-



FIG. 572.—SUPERFICIAL CONTINUOUS SUTURE OF THE INTESTINE.

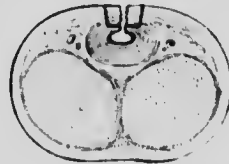


FIG. 573. FISTULA OF THE URETHRA. Outline of resection of fistulous tract.

wards. The mucous membrane is now freed with a small spatula, or with one of the blades of a short scissors, either from side to side, or—where the incisions have been made transversely—from before backwards from the fistulous orifice. When the detachment has been carried sufficiently far, the fistula is closed with a purse-string suture. The first silk ligature may be reinforced by a second much finer one (Figs. 579 to 586). The fistula is thus obliterated by a punctiform suture; the two mucous flaps are then united

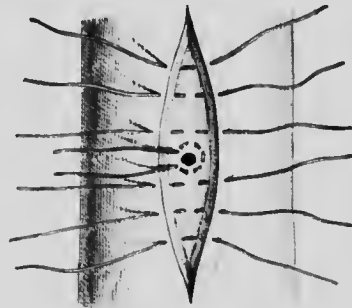


FIG. 574.—FISTULA OF THE URETHRA.

Closure of the orifice by purse-string suture. Union of superficial wound by interrupted suture.

longitudinally by six or eight separate points of Florentine hair suture. This procedure gives excellent results, and has the advantage over all others of not requiring any sacrifice of the margins of the fistulous orifice, while it closes the latter in the manner most favourable for rapid cohesion of the sanguineous surfaces, the extensive reabsorption of which is a cause of success.

Intestino-vaginal fistula may be closed by this procedure when there is no angular bend or intestinal stenosis beyond the seat of the fistula. When

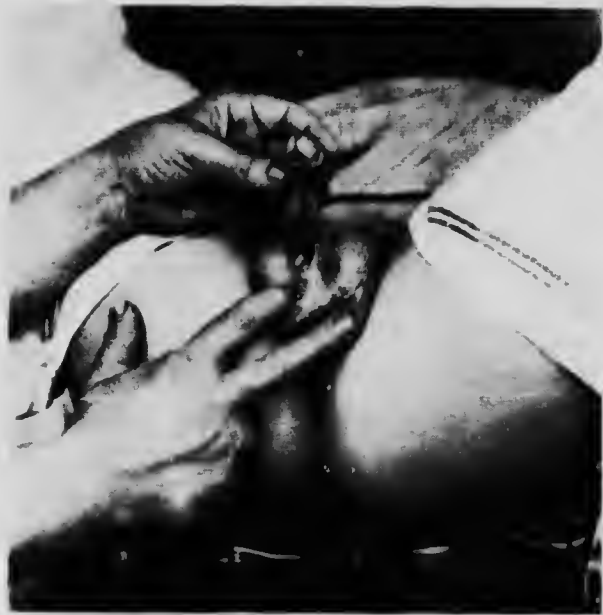

FIG. 575. —LARGE PENILE FISTULA, WITHOUT STRICTURE OF URETHRA.

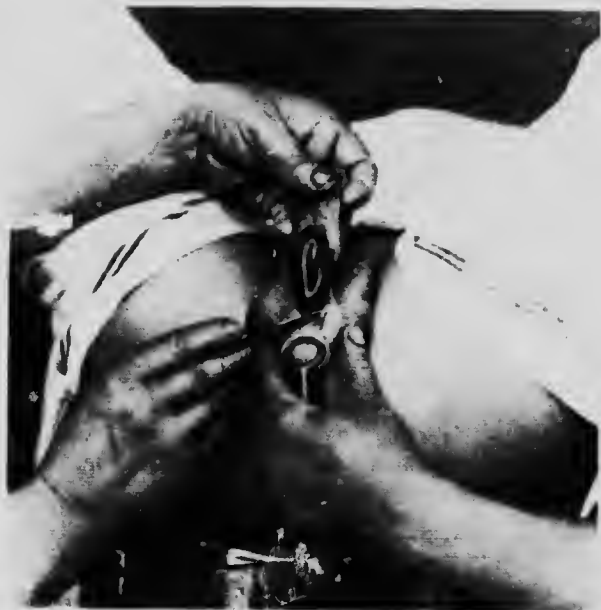

FIG. 576. —LARGE PENILE FISTULA, WITHOUT STRICTURE OF URETHRA.
Vivification by elliptic incision.

the opening yields an abundant flow of faecal matters, it is better to perform a laparotomy, detach the adhering fistulous loop, and then close the wound in the way above indicated. The peritoneum is sutured above the vaginal wound.

Operation through the vaginal passage or fistula of the ureter, as on vesico vaginal fistula, is carried out by circular vivification, followed by two transverse incisions, and detachment of two large anterior and posterior

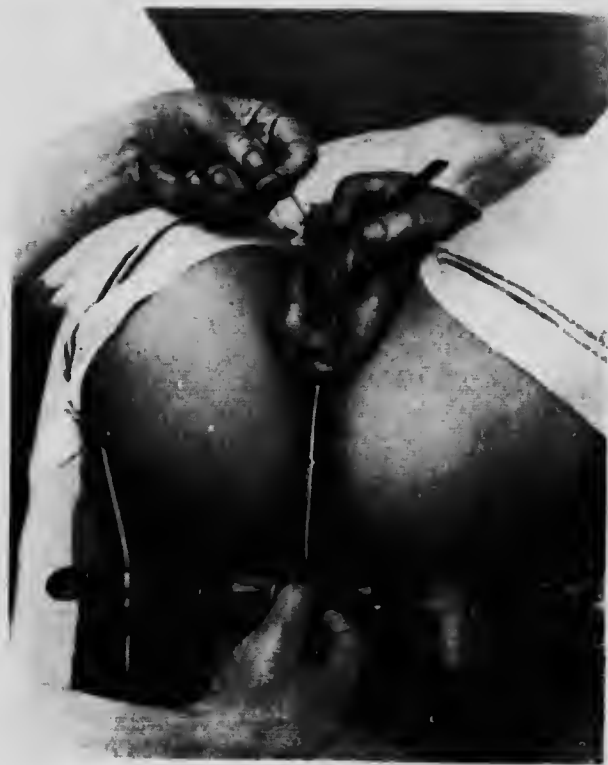

FIG. 577.—LARGE PENILE FISTULA, WITHOUT STRICTURE OF URETHRA.
Continuous suture of urethra.

flaps. The bladder is perforated at the extremity of a forceps in front of the ureteral orifice, into which is introduced a small sound which passes into the bladder, and emerges by the meatus urinarius; a second sound is then passed into the bladder, and both are fixed to the margin of the meatus by Florentine hair. A double purse-string silk suture now assures coaptation of the double orifice—ureteral and vesical—and its isolation from the vagina; the union of the two mucous flaps is completed with Florentine hair suture.

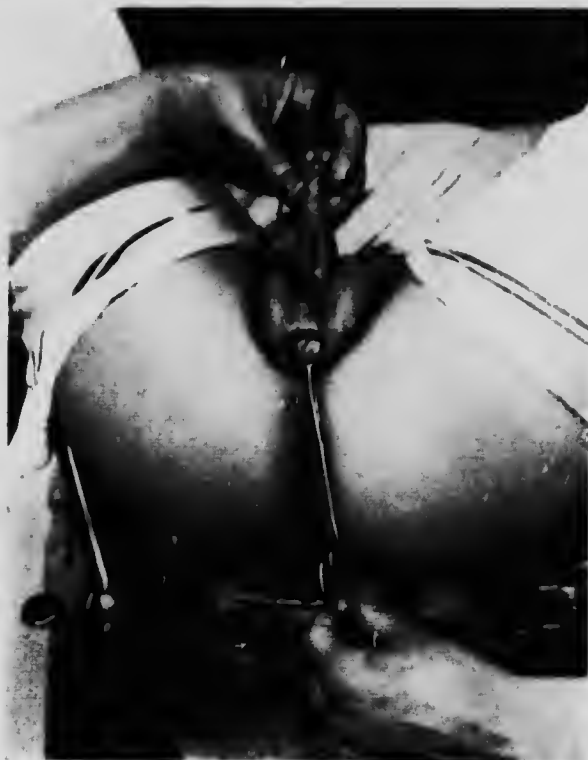

FIG. 578. —LARGE PENILE FISTULA, WITHOUT STRICTURE OF URETHRA.
SUTURE OF SKIN.



FIG. 579. — VESICO-VAGINAL FISTULA.
Vivification of the lips of the orifice.



FIG. 580. CLOSURE OF ORIFICE WITH A DOUBLE PURSE-STRING SUTURE.



FIG. 581. INTERRUPTED SUTURE OF VAGINAL MUCOUS MEMBRANE.




FIG. 582.
RECTO-VAGINAL FISTULA

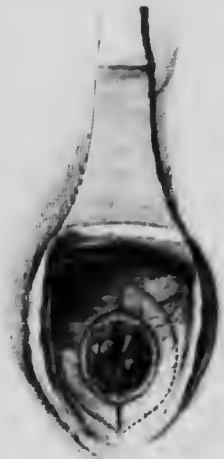


FIG. 583. OUTLINE OF INCISIONS
FOR VIVIFICATION.



FIG. 584. FLAPS DETACHED.
Passage of purse-string suture.

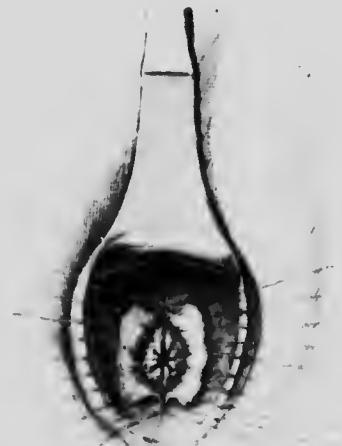

FIG. 585. PURSE-STRING SUTURE TIED.
Arrangement of vaginal sutures.

I will afterwards indicate at greater amplitude, in connection with the various regions, the special features of the treatment of the different forms of fistula.

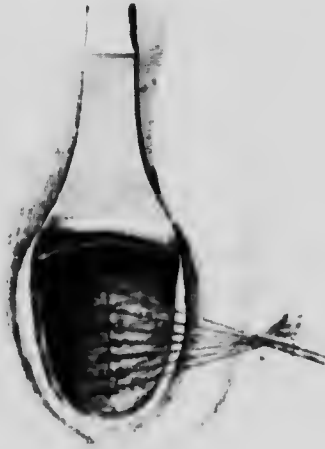

FIG. 580. —APPEARANCE OF LINE OF UNION.

DIVULSION OF TISSUES IN ORDER TO REACH DEEP-SEATED REGIONS WITHOUT HEMORRHAGE.

The skin and resistant tissues are the only structures which require to be divided with a cutting instrument. The interstices of the cellulo adipose structures are easily pierced by the finger and with blunt instruments, which have the advantage of not producing hemorrhage. Take a case of radical cure of inguinal hernia. The skin is incised, and blunt scissors are plunged into the aponeurosis, and then opened. Both index-fingers are introduced through the opening thus made and then forcibly divaricated; they expose and lacerate the cellulo-adipose subcutaneous tissue, and expose the orifice of the inguinal canal. No bleeding need be feared if the surgeon is dexterous enough not to tear the two arterioles and satellite venules which cross this region in a direction perpendicular to the arcade of Fallopius. In the operation for strangulated hernia, when the sac has been opened, we introduce into the peritoneal cavity, along the mesenteric pedicle of the intestinal hernia, the jaws of a long curved forceps, or the end of curved scissors, blunt and tightly closed. The instrument glides between the folded mesentery and the anterior abdominal wall. I grasp the rings with the whole hand and draw them upwards as if I wished to lift the patient from the operation-

table, while giving them at the same time some shaking and to-and-fro movements. The neck of the sac and the inguinal canal yield at once without hemorrhage to an extent which permits easy reduction of the hernial loop. This very simple manœuvre does away at once with the grooved and winged sounds and directors, and the famous bistouries which were formerly constructed for kelotomy.

In operation for empyema, or on incising an iliac phlegmon or any deep-seated abscess, I perforate the intercostal space, or the abdominal area engaged at the point of fluctuation, with the end of closed blunt scissors which cannot wound any important organ, and which I manipulate after the fashion of the old grooved sound (director). As soon as pus appears, I

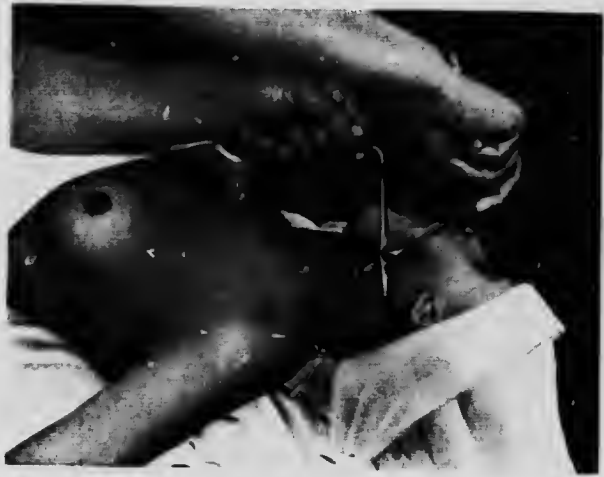

FIG. 587.—WIDENING BY DIVULSION OF AN INCISION MADE FOR ENTIRPATION OF CAROTID GLANDS.

separate the rings with both hands to the maximum degree of divergence, and I then withdraw the scissors with its blades open, so as to enlarge the original opening by divulsion.

Ever since 1887 I have adopted a similar technique in opening the posterior peritoneal cul-de-sac in vaginal hysterectomy. The peritonemum is usually divided with the scissors when dividing the vaginal wall transversely behind the cervix. The same scissors, closed, is introduced into Douglas's pouch, and then withdrawn opened. If the peritoneal cul de sac has not been incised, it is perforated with the point of the closed scissors, which is then withdrawn with the blades opened; the orifice is thus enlarged for admission of the index-finger. The deep recesses in colpotomy are opened with the same technique: guiding blunt scissors along the index finger, or with a long curved forceps. Abscesses of the liver or of the brain are explored in the same way by penetrating within the visceral parenchyma with a small arterial forceps with slender jaws. When there is room, the



FIG. 588. OPENING A LARGE ILIAC PYLEGMON WITH A CURVED FORCEPS BY PUNCTURE, FOLLOWED BY DIVULSION.

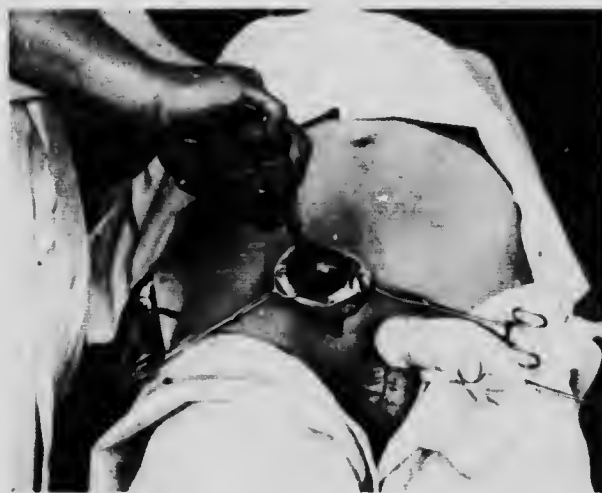


FIG. 589. TEARING OPEN THE NECK OF THE SAC OF A STRANGULATED INGUINAL HERNIA WITH A CURVED FORCEPS, BY DIVULSION OF THE BLADES.

430 SURGICAL THERAPEUTICS AND OPERATIVE TECHNIQUE

opening thus made is enlarged by divulsion. This general procedure is also the best for exposure of cervical, inguinal, and iliac glands, also of thyroid and all other encapsled tumours. In fact, it is but a process of dissection.

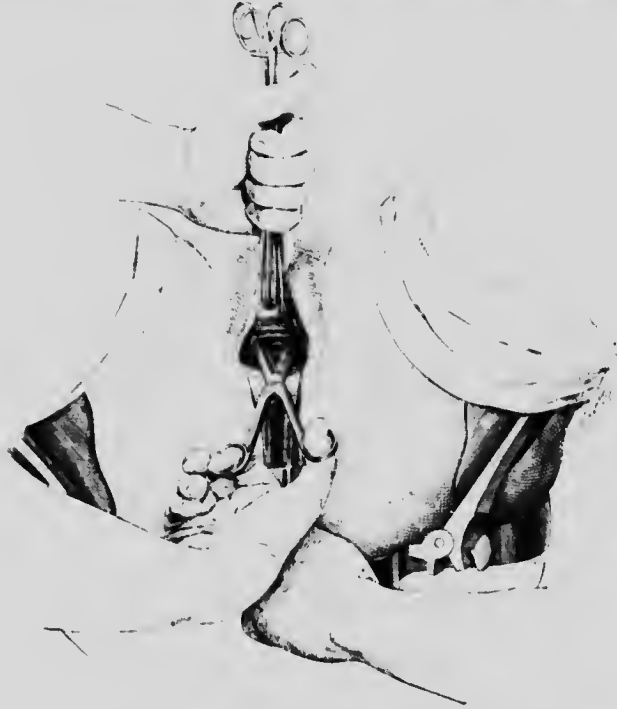


FIG. 590.—VAGINAL HYSTERECTOMY.

Incision of Douglas's pouch. Enlargement of the peritoneal orifice by divulsion.

since the blunt instrument, whatever it be, merely opens up the cellular interstices, and wounds no vessels or nerves of any importance, as it displaces them all beyond the limits of the field of operation.

METHODICAL TORSION COMBINED WITH INSTANTANEOUS
CRUSHING IN TREATMENT OF PEDICLES.

The method of rapid enucleation of tumours, such as I teach in this treatise, includes rapid liberation of all cellular attachments where there are no important vessels, and section of the vascular attachments after haemostasis. Two conditions have to be dealt with—either the vessels of the neoplasm must be tied in order of exposure during the course of the

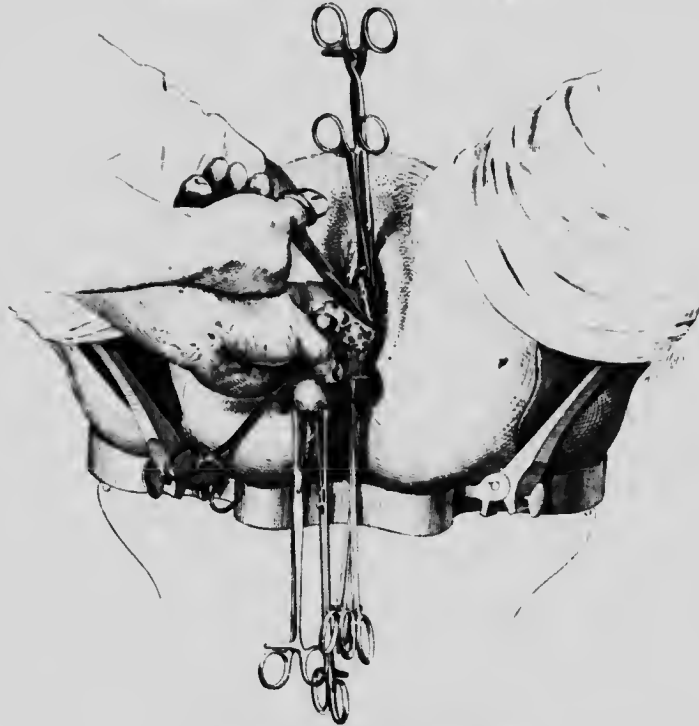


FIG. 591.—VAGINAL HYSTERECTOMY.

Forepressure and division of left broad ligament, which will be twisted when the handles of the two forceps are lowered between the legs.

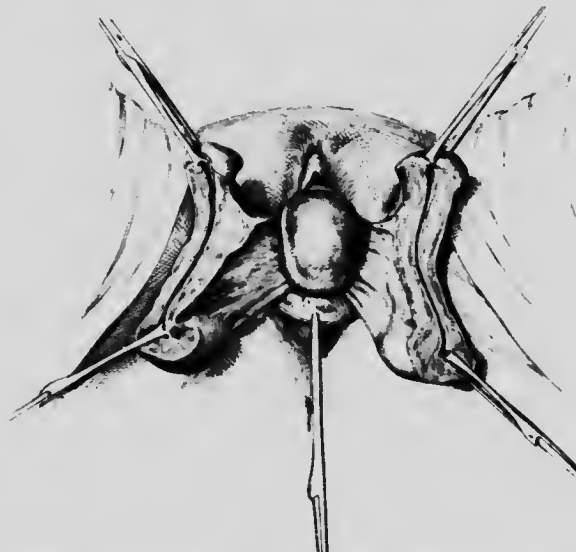


FIG. 592.—VAGINAL HYSTERECTOMY BY POSTERIOR HEMISECTION, FOR INVETERATE PROLAPSE.

Appearance of the two separated halves of the uterus. The cervix is above. Hernia of the bladder.

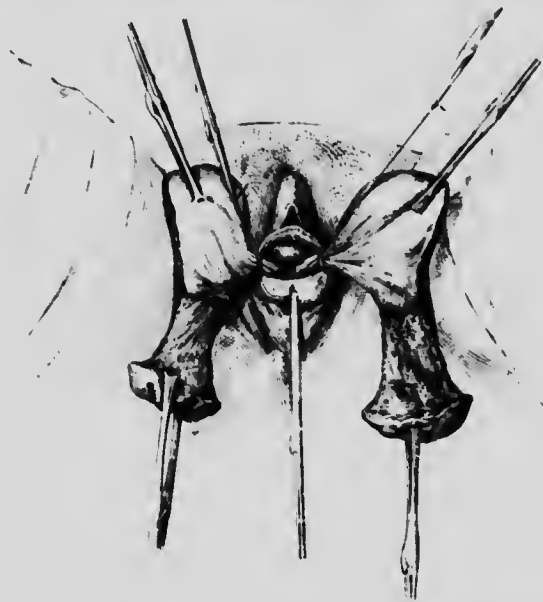

FIG. 593. VAGINAL HYSTERECTOMY BY POSTERIOR HEMISECTION, FOR INVETERATE PROLAPSE.

Pediculization of the broad ligaments by rotation of each half of the uterus, the fundus of which is drawn up towards the pubis. Ligation of the broad ligaments.

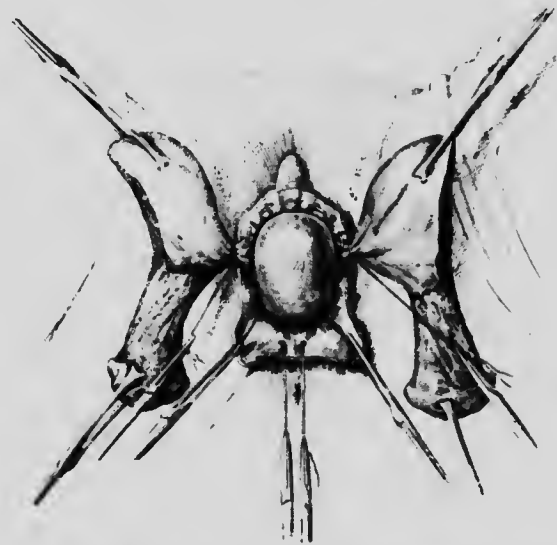


FIG. 594. — VAGINAL HYSTERECTOMY BY POSTERIOR HEMISECTION, FOR INVETERATE PROLAPSE.

Arrangement of silk purse-string suture for closure of the peritoneum.

isolation of the tumour; or the principal vessels, as most frequently happens, are found united in a veritable fibro-cellular sheath, which constitutes the fibro-vascular pedicle of the neoplasm or diseased organ which we are called on to extirpate.

The preparation of the pedicle had been one of the greatest of the preoccupations of the pioneer ovariologists. We have seen that the skilful employment of my *écraseur* permits the instantaneous reduction of most pedicles to a thickness so slight that a single ligature *en masse*, when applied with Dionis's knot, suffices to secure hæmorrhage, while surgeons who do not practise instantaneous crushing are obliged to apply a whole series of chained ligatures. The *écraseur* is preferably applied below a curved forceps, which is intended to prevent the pedicle from sliding, and thereby partially escaping the pressure of my instrument. The preparation of voluminous pedicles will be considerably facilitated in all cases in which they present a certain volume, by rotating the tumour or organ, which has now no support but a single pedicle, through one or two complete revolutions on its axis.

By this manœuvre the surgeon realizes, as has been already pointed out in discussing the application of deep ligatures, the well-known phenomenon of torsion of the pedicles of small ovarian cysts. The broad flat pedicle is immediately transformed into a spiral cord, after which the crushing and subsequent ligature are carried out at the most suitable position. I devised this procedure of torsion of pedicles in 1887 for vaginal hysterectomy, in which I adjust the forceps from above downwards on the broad ligament. I also recommended in 1897, torsion of the pedicle in the surgical technique of ligature of the broad ligament in vaginal hysterectomy cases of inveterate prolapse. This method is also applicable to many other operations, more especially to that of extirpation of the adnexæ by laparotomy.

LIGATURE OF VASCULAR PEDICLES.

As far back as the seventeenth century Dionis conceived the idea of ligature of vascular pedicles by transfixion. I have here figured the various stages of ligature by transfixion, as I now practise that procedure.

I first apply a circular ligature, and then a semi-ligature by transfixion, after which I repeat the semi-ligature by transfixion from the other side of the pedicle. I then divide the two loops of the thread, and apply, as a measure of security, with another thread a final circular ligature in the same groove as the former ones. Finally I divide the pedicle at an interval of 10 or 15 millimetres beyond the seat of ligation.




FIG. 595. SUCCESSIVE STEPS OF LIGATURE OF AN ADNEXIAL PEDICLE BY THE AUTHOR'S PROCEDURE.

1. Circular ligature; 2. partial ligature after transfixion; 3. second ligature by transfixion; 4. all three ligatures completed.

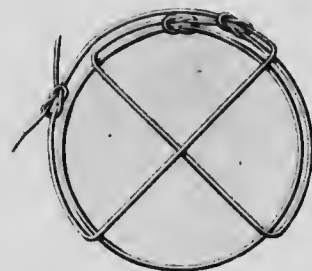


FIG. 596. SUCCESSIVE STEPS OF LIGATURE OF AN ADNEXIAL PEDICLE BY THE AUTHOR'S PROCEDURE.

Enlargement of Fig. 595¹, showing the course of the thread and the details of the ligature. The pedicle is divided, and a final circular ligature placed in the same groove with the former one.




FIG. 597. LIGATURE OF AN ADNEXIAL PEDICLE.

After application of a circular ligature, the thread is passed through the pedicle by transfixion.

DESTRUCTION OF PATHOLOGICAL TISSUES BY HEAT.

Aerocauterization and Thermic Electro-Coagulation.

Of all the physical means employed in the destruction of pathological tissues, the only certain method is that of *heat*.

The older methods for the application of heat had this disadvantage, that tissues could be destroyed by carbonization or severed with a red-hot iron; but the heat never penetrated to a depth of more than 2 or 3 milli-

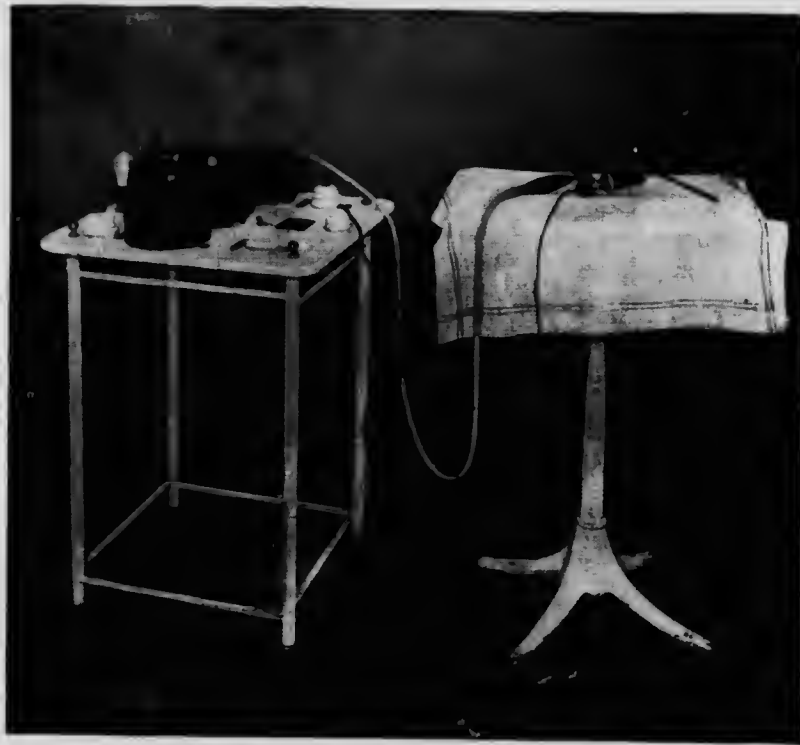


FIG. 598.—AUTHOR'S APPARATUS FOR AEROCAUTERIZATION.

metres from the carbonized surface. We shall see that the employment of high-frequency currents of *low tension* causes a complete change in the surgical treatment of certain disorders, since it enables us to bring about the penetration to a great depth of the heat produced by the transformation of alternating electric vibrations.

Aerocauterization.

Aerocauterization, or *cauterization by superheated air*, consists in projecting upon pathological tissues a current of air heated to a temperature of 600° to 700° C. My first experiments in aerocauterization were carried

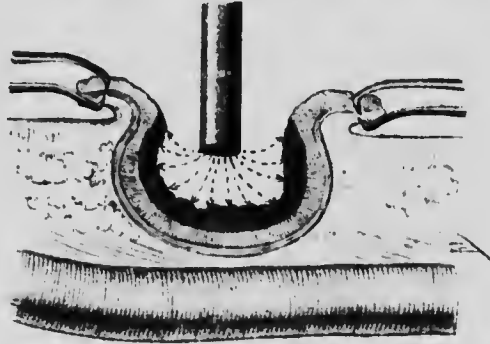


FIG. 599.—DIAGRAMMATIC SCHEME SHOWING THAT THE ACTION OF THE HOT AIR REMAINS LIMITED TO THE WALLS OF THE GLANDULAR POUCH.

out in 1896. I then caused to be constructed special tubular adjustments which were adapted to the knife of Paquelin's cautery. The hot gases which emerged by lateral orifices became again heated on coming into contact with the exterior surface of the incandescient platinum, and reached

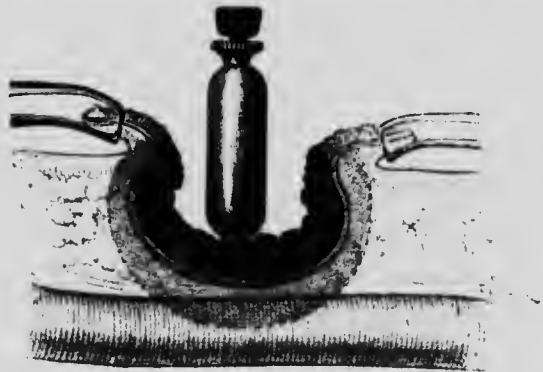


FIG. 600.—DIAGRAMMATIC SCHEME SHOWING THAT, ON THE CONTRARY, ELECTRO-COAGULATION OF A GLANDULAR RECESS CAN PRODUCE LESION OF NEIGHBOURING VESSELS.

a temperature sufficiently high to cause carbonization of the tissues. The actual arrangement is akin to numerous models of actual cautery, the source of heat being a metal spiral, which is rendered incandescient by electricity.

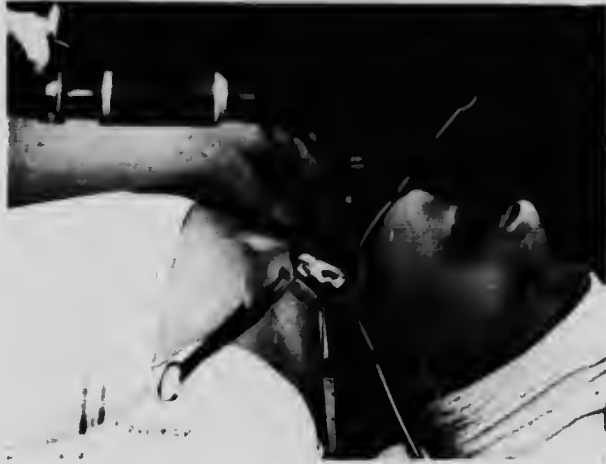

FIG. 601.—TUBERCULOUS GLANDS.

After protection of the vasculo-nervous bundle with a moist compress, we practise aérocauterization of the posterior portion of the glandular pouch.




FIG. 602.—TUBERCULOUS GLANDS.

Aérocauterization of the posterior portion of the glandular pouch.

Superheated air carbonizes the surface of the tissues on to which it is projected to a depth of 1 or 2 millimetres, and the subjacent zone is coagulated by the heat to a depth of 2 or 3 millimetres. Heat transmitted by superheated air penetrates no farther into living tissues than the heat from a thermo-cautery. This particularity—the limitation of the thermic action of superheated air to a feeble depth—allows of the application of aërocauterization, without hesitation and without danger, for the arrest of certain oozing hemorrhages and to the cauterization of the implantation surfaces of tuberculous fungosities after their extraction by curetting.

The advantage of superheated air over cauteries lies in its rapid dissemination over a wide surface. If the projecting tube be moved slowly, and is held a slight distance from the surface which is to be cauterized, an immediate carbonization is produced. The temperature of the heated air should be verified beforehand by means of a sheet of paper, which should be carbonized on being brought into contact. The violence of the jet of superheated air drives the blood from the surface of the wound, which becomes carbonized in a few seconds. Aërocauterization, by reason of the dissemination of the thermic effect, is peculiarly applicable to cavities—for example, those following the curetting of large tuberculous glands which are softened and inflamed, and where complete extirpation is often rendered impossible owing to the extension of the bacillary infiltration to the neighbouring tissues.

Since the carbonized surface has to be eliminated, the wound must remain open. It is treated by aseptic plugging. As soon as the whole surface is granulating, secondary reunion may be attempted, after freshening the cutaneous edges, and drainage.

LOCAL TREATMENT OF ACCESSIBLE CANCERS BY ELECTRO-COAGULATION.

THERMO-PENETRATING ACTION OF CURRENTS OF HIGH FREQUENCY AND LOW TENSION.

Inefficiency of Superheated Air, X Rays, and Radium in the Treatment of Cancer.

One brutal fact dominates the surgery of cancer—the frequency of its recurrence or of its re-inoculation in the wound. We cannot, indeed, apply the term “recurrence” to those eruptions of disseminated cancerous nodules such as occur two or three months after the very extensive ablation

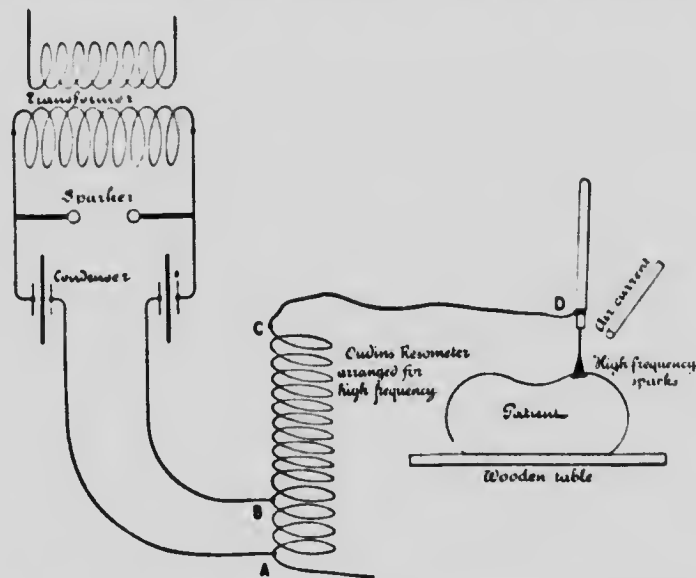


FIG. 603.—APPARATUS FOR RADIATIONS AND HIGH-FREQUENCY SPARKING (HIGH TENSION). (FULGURATION.)

of small mammary tumours, whose evolutionary course had previously been quite benign. In a case of this kind the operation acts as a veritable stroke of the whip to the cancerous infection by sowing the virus all over the surface of the field of operation. The pathological cells, which are able to

resist the action of the phagocytes, are disseminated like pollen by a gust of wind, and thus become the germinal foci of as many cancerous nodules. Radiotherapy seemed to give interesting results when it was first employed, and the X rays were for a time regarded as a specific cure for cancer. Some small superficial epitheliomata were resolved, and intralymphatic nodules of recrudescence disappeared. Nevertheless, the X rays remained ineffective in the treatment of cancer of the mucous membranes, even at the beginning of their growth, and in that of all the deep-seated cancerous growths. The fact was soon noticed also that most of the superficial can-

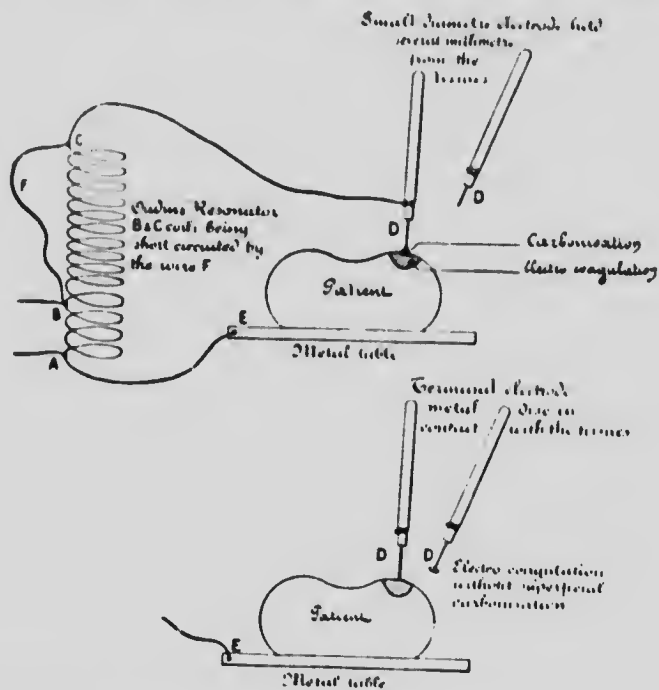


FIG. 601.—BIPOLAR VOLTIZATION AND ELECTRO-COAGULATION: APPLICATION BY CONTACT (AUTHOR'S ORIGINAL APPARATUS, 1907).

ceroids, although for a time apparently cured, did not fail to recur in deep-seated organs, and that the dissemination thenceforward proceeded very rapidly. The frequency of such cancerous generalization in the patients submitted to radiotherapy seems to me attributable to the destructive action of the penetrating rays of the Crookes ampulla on lymphoid structures, more especially in case of the lymphatic glands.

The effects of radium have been studied side by side with those of the X rays. Early observers were deceived in their estimate of the apparent results, which are practically very closely similar to those obtained by the

latter. The active radiations of the radium salts are, however, more penetrating; but the fact remains that they exercise no veritable selective action on the cancer cells. Again, the activity of radium may be estimated in calories. Radio-dermatitis and radium dermatitis are both very similar to the effects of sun-burn, and, like the latter, are rather slowly produced. The small bulk of the radium apparatus in use enables us to place them in the natural cavities, and even in the interior of tumours. I have long experimented on the action of the X rays and on that of radium in the treatment of malignant neoplasms. The apparent cicatrizations which are produced by these physical agents should be regarded, in the language of the highly descriptive simile of Dr. Tuffier, as a *cache-misère*, or "cloak of poverty." The deeply seated cancer cells escape their action completely, and become foci for the departure of rapidly infective processes.

Radiotherapy had already begun to fall into discredit when Professor Pozzi announced to the Académie de Médecine in 1907 the cure of superficial and even of some deep-seated cancers by the action of sparks of high frequency and high tension given off from the terminal of Oudin's resonator. This novel procedure he designated by a neologism of his own invention—*fulguration*. His conviction was not without the approval of his colleagues who had experimented on the clinical action of high frequency currents. But the ultimate therapeutic results were far from responding to their expectations. Indeed, Professor Pozzi himself came to recognize his error, and perceived that he had allowed himself to be mystified by a colleague who was as ignorant of electricity as of surgery. The procedure of fulguration, which owed its ephemeral success solely to the sensational communication of Dr. Pozzi, remained in vogue for a period even shorter than that accorded to radiotherapy, and its creator came, on June 10, 1909, to burn before the Société de Chirurgie the idol which he had publicly adored within the precincts of the Académie de Médecine but two years previous to that date. His conclusion was then formal: "Fulguration has no curative power in the treatment of cancer." I will return to consider the action of high-frequency sparking, and the observations which led me to the discovery of the method of thermic electro-coagulation.

There is one peculiar fact which should arrest our attention from the beginning: the apparent cures of certain superficial cancers by the action of the X rays, and of those of radium, bring into evidence the point of fact that cancer cells are less resistant than healthy cells when exposed to the influence of cytolytic radiations. It is on this account that, if we carefully regulate the action of X rays or of radium radiations, we can procure the disappearance of intradermic cancerous nodules, and of superficial canceroids, without any destruction of healthy cells, and with subsequent formation of an apparently healthy cicatrix.

Comparative Experiments on the Vitality of Cancer Cells and Healthy Cells in the Presence of Various Physical Agents: Superheated Steam, Superheated Air, X Rays, Radium, and Electro-Coagulation.

These observations led me to determine with precision the relative powers of resistance of cancer and of healthy cells. I took a very sensitive Centigrade thermometer as standard in ascertaining the tem-

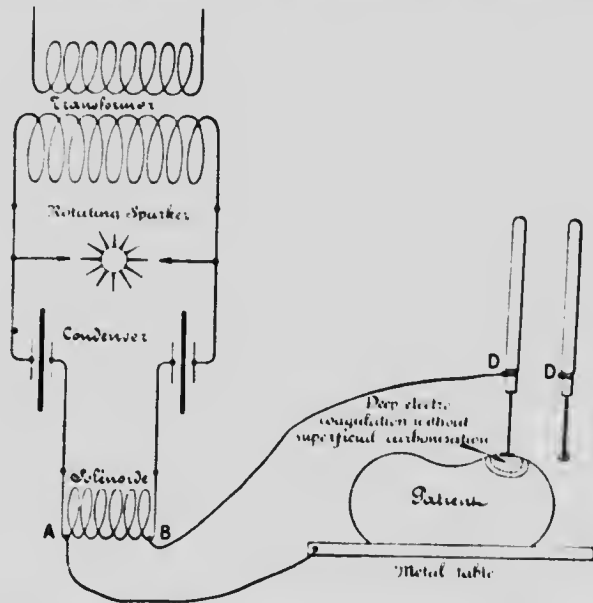


FIG. 605.—ELECTRO-COAGULATION WITHOUT SUPERFICIAL CARBONIZATION (AUSTIN'S MOST RECENT APPARATUS). (DIAGRAMMATIC.)

Carbonization can be obtained either by removing the electrode to a distance or by using a disc of too small diameter for intensity of current. Sparking then takes place, but the depth reached by electro-coagulation is lessened. Thus it is desirable to avoid superficial carbonization. Accordingly, it is necessary to proportion the surface of contact to the intensity of the current.

temperatures respectively fatal to each. I ascertained that healthy cells are usually killed only after the temperature has reached above 60° C. (140° F.), while cancer cells lose their virulence on being exposed to a temperature of 58° C. (137° F.). It is this particularity—the smaller resistance of cancer cells to various physical agents which are capable of causing the death of living tissues—which has led to the mistaken notion that X rays, the radiations of radium salts, and fulguration, have an elective action on cancer. In reality, none of these agents possess this elective action; but cancer cells are less resistant than healthy cells to their attack. This fact of the lower vitality of cancer cells domin-

ates the whole question of the local treatment of cancer. A new process was thus fully outlined: to cause heat to penetrate the depths of the living tissues in such a way as to expose the pathological structures to a temperature above 50° C. (122° F.). That problem was a difficult one. From my first comparative experiments* I ascertained the inefficiency of hot water

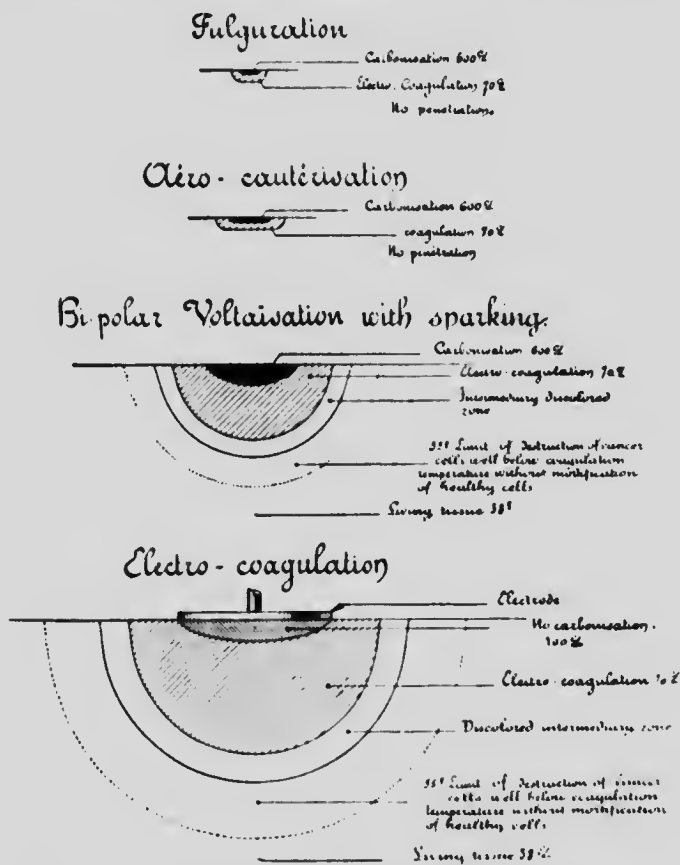


FIG. 606. SECTION REPRESENTING THE RESPECTIVE EFFECTS PRODUCED ON A PIECE OF MEAT IN ONE MINUTE BY THE SEVERAL PROCEDURES.

and of superheated vapour. The action of hot air reached a little deeper than superheated steam and its action is more localized, but the elevation of temperature which it produced does not penetrate very deeply not more than 4 or 5 millimetres into the healthy living tissues. I have already shown that the temperature of superheated air, which surpasses

* Plichetè, No. 7,288. Acad. des Sciences et Soc. de l'Internat., June 25, 1908.

600° C. (1112° F.) when emerging from the conducting tube, carbonizes all the tissues to a depth of 1 or 2 millimetres, and that the subjacent coagulation reaches a further depth of not more than 2 or 3 millimetres.

The sparks produced by high-frequency currents have an effect almost identical with that of superheated air. After the same period of application (two or three minutes) the respective zones of carbonization and of coagulation present for the same time of action, two or three minutes, a thickness practically identical. But superheated air has a much more extensive range of action, and it also possesses the advantage of being able to cauterize the whole internal surface of pathological cavities, where the use of high-frequency sparking is not applicable.

PHYSIOLOGICAL PROPERTIES OF HIGH-FREQUENCY CURRENTS.

High-frequency currents differ completely from all other forms of electrical current in their physiological action. Like alternating currents they do not produce electrolysis, but there the similarity stops. The ordinary alternating currents, such as are employed in faradic electrization, produce, even when of feeble intensity, a violent excitation of motor nerves, and may when of great intensity cause arrest of the heart and respiratory movements, whereas high-frequency currents can traverse the organism without harm, if the surface of contact is sufficiently considerable for the intensity employed.

The first apparatus for the production of high-frequency currents were inapplicable to medicine. The patient would have to be placed in direct relation with one of the poles of the source of high tension, in such a way that a rupture in the condenser might place him suddenly in communication with the second pole, and provoke a grave if not a fatal accident.

Professor d'Arsonval has modified this apparatus by introducing on either side, between the solenoid and the source of high tension, an appropriate condenser. I am here only concerned with high-frequency currents in their application to the destruction of malignant tumours.

Fulguration.—Fulguration is produced by directing upon the tumour sparks of high frequency and high tension, given off by a metal electrode of small diameter, either bare or surrounded by an isolating cylinder, which is connected with the end terminal of Oudin's resonator.

In this apparatus, which consists of a long spiral of copper wire, the receptor circuit is placed above the producter circuit of energy in such a way that a considerable difference of potential is observed at the extremity of the receptor or resonator.

This difference in potential is manifested by long effluves. The unipolar sparks which escape at the approach of any conductor connected with the end terminal of the resonator may reach a length of 25 centimetres.

These are the sparks of high frequency and high tension which are used in fulguration. They are regulated to a smaller length by the adjustment of one of the terminals of the resonator.

The tension of the current which escapes from the terminal of the resonator of Oudin, and which is employed in fulguration, is considerable, but its intensity is very feeble.

Thermic Electro-Coagulation.

Thermic electro-coagulation is the application of the thermic properties of currents of high frequency and *low* tension to the destruction of pathological tissues, and particularly of malignant tumours.

The thermo-penetrating action of currents of high frequency and low tension, such as I have employed for the destruction of pathological tissues, and particularly of malignant tumours, is quite special. The actual canterly, hot air, and superheated steam, produce but superficial effects, owing to the feeble caloric conducting power of the tissues.

The currents of high frequency and low tension alone possess the property of producing a *penetrating* heat in the tissues. The technique of the destruction of superficial and accessible cancers by means of electro-coagulation will be described later on.

History of Thermic Electro-Coagulation.

It was at the very time when special honours were accorded to high-frequency sparking—in August, 1907—that I discovered the method which I have since called thermic electro-coagulation. When Dr. Pozzi communicated to the Académie de Médecine (July 30, 1907) the marvellous results which he attributed to high-frequency sparking and to the method which he called "fulguration," I had immediately installed in my clinique the most powerful transformer constructed by the Maison Gaiffe, and one of Oudin's resonators.* The experience of a few days and of many microscopic specimens then sufficed for me to establish the fact that the sparks employed in fulguration had no action beyond a depth of 3 or 4 millimetres, and also that their action was exclusively a thermal effect. Indeed, I proved, by multiplying my histological preparations, the fact that it was enough to cool the surface of the cancerous structures, while submitted to the process of fulguration, with a very lively current of air in order to produce a considerable diminution of the thickness of the zone of their action.

Thus the method of treatment recommended by M. Pozzi, his so-called

* The favour with which Dr. Pozzi's communication on the results obtained by fulguration was received in 1907 by the Société de Chirurgie de Paris proves that surgeons are unanimous in their recognition of the inconveniences of the great bloody operations in dealing with cancer, and in their desire to investigate an efficacious method of destruction of accessible tumours. We now know that fulguration, which has been tested in all the great surgical services, has been universally judged as an insufficient and inefficacious method in every case in which the lesion is of more than a few millimetres in depth—that is to say, in all cases of undoubted cancer.

fulguration being manifestly insufficient when dealing with tumours of a certain extent, I immediately proceeded to study other modes of utilization of high frequency currents for the destruction of malignant tumours at a certain depth. With this object, I studied at first the effects of sparks derived directly from the induction coil, and for comparison those which

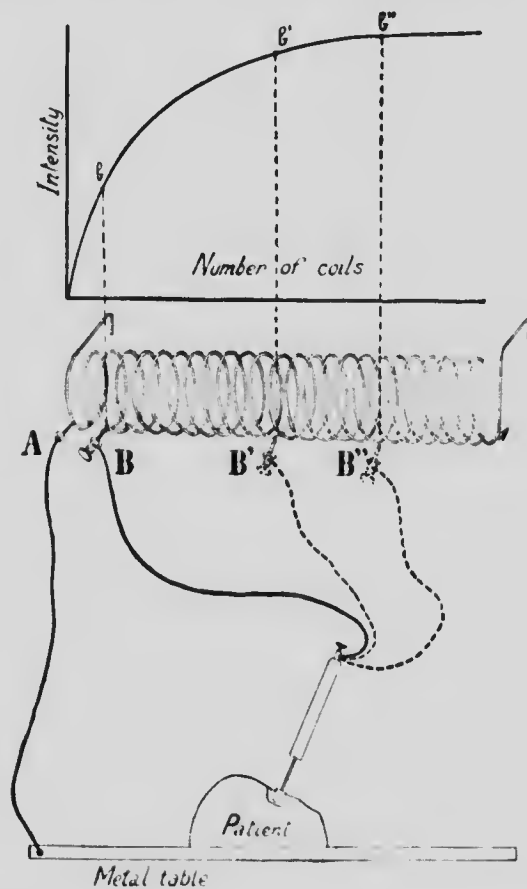


FIG. 607. DIAGRAMMATIC SCHEME INDICATING THE VARIATION OF INTENSITY OF CURRENT WHICH FOLLOWS INTRODUCTION OF A GREATER OR LESS NUMBER OF SPIRAL COILS INTO THE CIRCUIT.

were given by the various forms of apparatus used in the production of high frequency currents. During the course of those first experiments, which were carried out in August, 1907, I ascertained for myself the fact that the degree of excellence of result was not a function of the length of the spark used. On the contrary, the short branching sparks obtained by

using the primary current of Oudin's resonator proved more effective than the long sparks derived from the secondary. I also noticed that, in order to obtain powerful effects, it was necessary to connect the metallic bed on which the patient lay with one of the extremities of the self-induction oscillating current, while the active electrode was in contact with the other. Sometimes I held the electrode at a short distance from the patient, whose tissues were burnt by a short and brilliant spark. I then called this effect bipolar voltaization, and sometimes I placed it in contact with the surface of the wound so that the spark was suppressed (electro-coagulation). But I obtained—and more especially on removing the electrode to some distance from the surface of the patient's body—tetanic muscular contractions of such violence that this method was wholly inapplicable in certain regions; especially in either vaginal cul-de-sac, in case of cancer of the cervix. I succeeded in diminishing the violence of the muscular contractions by placing the terminals of the Oudin resonator and curvise plate in short-circuit relation, in order to obtain oscillating currents of greater frequency by this lowering of the self induction. In such a disposition the current actually utilized passes with a far higher intensity than that used in fulguration. This arrangement, which was devised by me in August, 1907, also presents another advantage over the technique of fulguration, in the fact that its utilization of currents of feeble tension only, expose neither surgeon nor assistant to the risk of electric shocks.

Since August, 1907, I have secured by use of this method the destruction of many superficial cancers. I have proved to myself the fact that it is easy to obtain the effects even to a depth of 6 or 8 centimetres, and to vary the mode of action according as we use either a narrow electrode or one of some extent of surface. The effect on cancerous tissues was found to be so rapid that it became possible to obtain in thirty seconds an extent of destruction of tissue a hundred fold more voluminous than that produced by fulguration in a good many minutes.

The action of the current differs somewhat, according as I operate either with short sparking or by placing the active electrode in direct contact with the tissues. In the former case I obtain a superficial carbonization, which is followed by a coagulation of tissue (comparable to that of white of egg which takes place in boiling water) to a certain depth, which varies according to the time of application of the electrodes. The temperature reaches a level of 500° C. (932° F.), or even 600° C. (1112° F.), at the surface of the carbonized tissues. On the other hand, when I place the electrode in contact with the tissues, coagulation occurs without any carbonization. This process of coagulation takes place only when the surface of contact is of sufficiently small extent to secure a great intensity of current, while the thermal effects are not too widely disseminated.

On October 10, 1907, I demonstrated to the French Surgical Congress this destructive action of currents of high frequency and *low tension*, by electro-coagulation, of the pathological tissues submitted to penetrating heat, in a case of cancer of the cavity of the uterine body.

I had destroyed, by high-frequency sparking and low tension, a superficial epithelioma of the vulva. In the interior of the uterine cervix no sparks occurred; the blood-stained serous discharge of the tumour became brown and emitted steam, and the cancerous tissues rapidly became destroyed to a great depth; an immediate curetting allowed the coagulated portions to be extirpated without hemorrhage, these coagulated portions having become whitish-grey in colour (*Rev. Crit. de Méd. et de Chir.*, Nos. 11 and 12, 1907).

It may happen that when the electrodes are placed in direct contact with the surface, the surrounding serosity enters into a state of ebullition. The heat reaches a level of from 65° C. (149° F.) to 70° C. (158° F.) at the limit of the zone of coagulation, while it penetrates to a distance of 10 or 15 millimetres in the non-coagulated tissues—that is to say, the tissues not altered in appearance—in which we can ascertain decreasing temperatures ranging from 65° C. (149° F.) down to 38° C. (100.4° F.).

Professor Czerny, the celebrated surgeon of Heidelberg, who attended on November 9, 1907, a demonstration of fulguration by Professor Pozzi, at the hospital Broca, came the same afternoon to visit my clinique.

I was quite unprepared for his visit. I showed him how my technique differed from that of fulguration, and I asked him to examine very convincing histological sections. These sections showed the comparative action of hot air, fulguration (unipolar action of sparks of high frequency and high tension emanating from the terminal of Oudin's resonator), and, lastly, the action of the technique which I had primarily named bipolar voltization and later thermic electro-coagulation, which consists of the employment of currents of high frequency and low tension of great intensity.

Professor Czerny ascertained, in my operating theatre, and by examining my sections, that hot air and fulguration carbonize the tissues in a stratum to a thickness of from $\frac{1}{2}$ to 1 millimetre, and, further, produce a zone of necrosis to a depth of about 2 millimetres; whereas my technique, either by means of sparks or by direct contact of the electrodes, produced, in the same space of one minute, coagulation of cancer cells to a depth of 12 to 15 millimetres.

On the other hand, I instituted a series of experiments which demonstrated for me the fact that the virulence of cancer cells is completely destroyed by exposure to a temperature of 55° C. (131° F.) or 56° C. (132.8° F.), and also the fact that the *Micrococcus neoformans*, which exists in cancer cells, loses its vitality when the temperature passes above 50° C. (122° F.). These comparative experiments enabled me to establish the fact that the effects of electro-coagulation are essentially thermal.

I presented the sum total of my researches on the etiology and the treatment of cancer, in 1909, at the International Congress of Medicine which was held at Buda Pest on August 28 (*Rev. Crit. de Méd. et de Chir.*, 1909, pp. 195-201).

I called special attention at this congress to the therapeutic effects of

thermic electro-coagulation in cases of cancers which are accessible and still localized.

On my return to Paris I pursued my studies on the thermo-penetrating action of high-frequency currents.

The question of muscular contractions demanded solution. With this object, I requested the engineers of the Maison Gaiffe, and especially M. Gallot (director) and M. Gunther (engineer-in-charge of the construction of apparatus for wireless telegraphy), to meet M. Maneuvrier (Professor of Physics at the École des Beaux-Arts), M. Guillet (Professor at the Faculté des Sciences), and Commandant Ferrié (specialist in wireless telegraphy), in my house for the purpose of determining precisely the characteristics of my experiments. As the voltmeters indicate values of little interest in this connection, we contented ourselves with estimating the tension by the length of spark obtained. The intensity was measured with the ordinary ammeters used with high-frequency currents. The wave-lengths, and consequent frequencies, were determined with the help of Commandant Ferrié's odometre.

The measures then carried out proved that the usual disposition of apparatus for fulguration utilized wave-lengths of about 600 metres—that is to say, of a frequency of 500,000—and a current-intensity of about from 250 to 300 milliamperes—that is to say, of a maximum of one-third of an ampere. On the other hand, my original technique of bipolar voltaization utilized wave-lengths of 400 to 450 metres, which correspond to a frequency of 700,000 and to an intensity of from 4 to 5 amperes.

The muscular contractions, which are intolerable with wave-lengths of 1,500 to 2,000 metres, diminish in intensity in proportion to the reduction of wave-length (and, consequently, with increase of frequency of the oscillation). They cease to be sensible in any way when the self-induction of the oscillating current is reduced by the small solenoid usually employed; the wave-length is then less than 100 metres. The passage of current into the tissues of the organism manifests itself only by the production of a sensation of heat. This is noticeable if we hold in each hand a metallic cylinder connected by a conducting wire attached to the corresponding terminal of the small solenoid of the Gaiffe apparatus for d'Arsonvalization. On completing the circuit, the sensation of heat ascends rapidly through the wrists towards the shoulders. Such sensation is, indeed, well known to all those who, since the introduction of the d'Arsonval apparatus, have personally studied the various medical applications of high-frequency currents. This phenomenon, to which the distinctive appellations of "thermopenetration" and "transthermic" have been given in Germany (Dr. Franz Nagelschmidt of Berlin, and Dr. Bernd of Vienna), is, accordingly, but a recent revelation, and the credit of its discovery belongs to Professor d'Arsonval.*

* *Zeits. f. physik und diät. therapie*, Band xii., Heft 3; and *Archives d'Electrologie médicale*, No. 272, October 25, 1909, pp. 813 and 815. Nagelschmidt employs an intensity of 2 to 3 amperes, with a frequency of 500,000 to 1,000,000 interruptions. Several weeks before, in the early part of September, 1909, M. Nagelschmidt demonstrated, at the Congress of Buda Pest, the action of thermo-penetrating currents on superficial cancers. He employed a resonator giving a current of 5 to 6 amperes.

The maximum current that I was able to obtain was one of an intensity of 5 amperes. I then requested my friends, the engineering experts of the Maison Guiffé, to devise an arrangement which would provide better utilization of currents of high frequency and low tension than any of those that I had hitherto obtained, and I presented for their solution the following problem, to obtain a high frequency current with a maximum wave length of 100 metres—that is to say, with a minimum of 3,000,000 periods per second, and an intensity of 10 or 15 amperes. To attain this object it was necessary to approximate the poles of the apparatus, and to diminish considerably the number of sparks which passed between them. The above-named gentlemen then suggested to me the employment of Commandant Ferrié's rotating sparker, which should be connected with a condenser of small capacity, furnished with a solenoid of small diameter formed of twenty four spiral turns. This gave me the desired current. The rate of current frequency is about 3,000,000, and the tension utilized is a very low one compared with that produced in the procedure of fulguration. The power attained with this apparatus is such that by contact with a circular electrode of 2 centimetres in diameter, electro-coagulation is produced in one or two minutes to a depth of 5 to 8 centimetres. We can carry the effect to a much greater depth by extending the period of contact of the electrode to a greater number of minutes. I have used this apparatus ever since with great satisfaction.

The results were presented by me to the Congrès de Chirurgie in 1907 and 1908, and at the Congrès Internationale de Chirurgie Budapest in 1909; they have since been confirmed, and are thoroughly demonstrative. Examination of patients cured since long periods by this procedure of thermic electro-coagulation shows that this new local treatment enables us to destroy superficial cancers which are still of localized growth, and throughout the whole depth of their structure, on the sole condition that they have not yet reached the essential organs. The curious point is that we can destroy by this method the pathological tissues which have begun to surround the great vessels without any actual injury to the vascular walls, which escape the coagulating process by the constant cooling effect produced on their coats by the passage of the blood current.

My procedure of electro-coagulation has realized an immense progress not only in the surgery of cancer, but in the treatment of all kinds of septic wounds, and even of obstinate tuberculous ulcerations. In cases of cancer, the rational use of this method of treatment, combined with antineoplastic vaccination, ends in the disappearance of all cancers of the skin, mucous orifices, and accessible mucous cavities, on the single condition that they

whose terminal, as I had devised in August, 1907, was connected in short circuit with the terminal of current B (see Fig. 601).

M. Nagelschmidt did not interpose the patient in the circuit. He attempted in my presence to destroy a small canceroid of the scalp by applying to the tumour two metal electrodes of small dimension, which he held at a distance apart of 8 to 10 millimetres. He only succeeded in provoking a superficial mortification of the interposed tissues. He can therefore claim no priority in the discovery of the destruction of superficial cancers by thermo-penetration.

are treated at a sufficiently early stage—that is to say, before the period of glandular or visceral generalization. This method to one who understands the technique is also equally applicable in treatment of cancer of the larynx or of the oesophagus at the outset of the disease, and should be substituted for extirpation in cases of a number of well-pronounced affections, such as tumours of the bladder, prostate gland, etc.

In 1911 I devised a new technique for heating to a temperature of 58° C. and 61° C. the walls of certain operation wounds, where I have been obliged to follow a malignant tumour with a bistoury, since electro-coagulation has not reached all the ramifications. As soon as the tumour is removed I fill the wound with salt solution, which serves as conductor to the electric current. In order to disseminate the heat over the whole surface of the wound it is indispensable to keep the electrode moving, and to follow at the same time the progress of the elevation of the temperature with a centigrade thermometer. (The current is stopped when the thermometer marks 60°.) It is prudent during the action of the thermo-electric bath to direct a jet of salt solution, heated to 56°, on to the edges of the cutaneous wound, to avoid the exposure of these edges to a temperature above 60°, which would prevent reunion.

The thermo-electric bath prevents, in a certain measure, local recurrence, but its action is limited, as is that of thermic electro-coagulation, to the zone of suspected tissues which has undergone a temperature superior to 58° (*Rev. Crit. de Med. et Chir.*, No. 6, p. 122, 1910).

This temperature may be obtained by my present technique as far as 1 or 2 centimetres in depth. It is to be hoped that new modifications of high-frequency currents will allow, in the immediate future, of the production of heat penetration to a still greater depth (*Congrès de Physiothérapie*, April, 1912, and *Rev. Crit. de Med. et de Chir.*, May, 1912).

We should have constantly before our minds this fact—Pathological cells offer less resistance than do healthy cells to all agents capable of destroying them.

I have shown that the superficial action of X rays and that of radium radiations are closely analogous to the effect of sun burn. But the vibrations emitted by a Crookes ampulla or a radium salt are much more penetrating than the solar rays. They are, in fact, capable of killing the cancer cells to a depth of several millimetres, while, in a certain measure, respecting the healthy cells the resistance of which is superior. Radium exerts a cruder influence than that of the X rays, and thus sometimes produces deep seated necroses. It has been pretended that the X rays and radium radiations were capable of destroying cancer cells alone, while allowing the surrounding healthy cells to escape, and that X rays are better suited for treatment of cancers situated on the surface, and radium radiations for that of small lesions of the cavities. It has been well known for a considerable time that the results obtained by radiotherapy or by radium in cases of true cancer are only apparent and temporary. A superficial cicatrix is formed, and the cancer which has become terebrating (perforating) continues to develop in the deeper tissues and soon becomes incurable.

452 SURGICAL THERAPEUTICS AND OPERATIVE TECHNIQUE

It would seem that the more satisfactory the appearance of the cicatrix, the cancer cells are disseminated all the quicker in the deeper structures. These two methods for the treatment of cancer should be abandoned as inefficient, and, wherever applicable, thermic electro-coagulation should be substituted.

Before describing the technique of electro-coagulation I will discuss the evolution of the different varieties of cancer.

EVOLUTION OF THE PRINCIPAL VARIETIES OF CANCER.

Evolution of Superficial Cancers.— Evolution of cancers of the skin and mucous orifices comprehends four periods or stages:

1. The period of onset, or pre-cancerous stage
2. The stage of invasion by local extension of the growth
3. The stage of initial glandular invasion.
4. The stage of generalization— that is to say, of distant glandular and visceral metastasis.

1. *Period of Onset or Pre-Cancerous Stage.*— The small cancers of the skin and mucous orifices begin, without exception, by forming a small and very superficial lesion, which may retain these physical features for a certain time. I have frequently extirpated caneroids of the size of a millet seed from the lips, and also small local ulcers of some millimetres in extent, the histological structure of which was in every case characteristic, although the thickness of the layer of diseased tissues was not more than 2 or 3 millimetres. And we do not even observe in such cases any prolongation of the growth beneath the skin or mucous membrane. But they are histologically, nevertheless, fully characteristic epitheliomata. The name of "caneroids" has been given to those small superficial lesions; they are not really true cancers, and they can be destroyed by any of the procedures which pass widely beyond the limits of the focus of infection. Since very ancient times they have been successfully treated by caustics and by excision. It is an interesting fact that in these small, very superficial lesions X rays and radium are inferior to the ancient caustics, which gave good results if their effect was deep enough. The X-ray and radium treatment respectively can in some cases make them disappear in a few weeks; the caneroid is replaced by a satisfactory-looking cicatrix, but the cure is not permanent; the tumour will be found to recur, either on the surface or in the deeper structures. We cannot, then, pardon the exploiters of X ray and the promoters of radium therapy for having deceived the medical faculty with the pretence of having cured true cancers. As a matter of fact, they cured but a certain number of caneroids which were merely superficial lesions, and did not deserve the name of cancer. Besides, the respective actions of X rays and radium are extremely irregular; thus, in cases of small caneroids of the skin, when treated at an early date, we sometimes observe a rapid improvement, but sometimes, on the other hand, a mischievous irritation, followed by an increase in the rate of extension, which must surely be attributed to their influence. In the case of a caneroid of the lip, tip of tongue, or of any of the mucous orifices, both the X rays and radium fail pitifully. (It may be of interest to mention here that I wrote the above lines on May 29, 1910, in a communication made to the Congrès de Physiothérapie, where I



protested energetically against the unjustifiable pretensions of the respective partisans of the X-ray and radium treatment of cancer.

2. *Stage of Invasion by Local Extension.*—After a variable period, the cancer cells are disseminated beyond the substance of the skin or mucous membrane; they pass into the lymphatic vessels, and generalization is now imminent. The extension of cancer is so variable in its course that it is impossible to say when the skin and mucous membrane have once been passed that the process of generalization is not actually taking place. I have seen caneroids of the lip, of 10 or 12 millimetres in width and 5 or 6 millimetres in depth, which had already infected the cervical lymphatic glands of both sides, even as far down as the supraclavicular fossa. On the other hand, we see cancers of the side of the tongue and of the floor of the mouth which are not accompanied by adenopathy. Here I speak of the cancers only which have been left to their own natural course of evolution: for, as I have already indicated, post-operative recurrences undergo a much more malignant type of evolution than do the original growths. Clinically, we regard the cancer as still localized when it is impossible to find any trace of adenopathy after a minutely careful examination.

In this category we should class the trephrating cancers of the face which begin to invade the bones, while no glandular infection has yet taken place.

3. *Stage of Initial Glandular Engorgement.*—This stage consists of invasion of the glandular group which receives directly the lymphatic vessels connected with the primary tumour. As a matter of fact, invasion of the first groups of lymphatic glands marks in most cases a period of arrest of the process of generalization. I have already pointed out that there is no definite relation between the extent of the original growth and that of the glandular invasion.

4. *Stage of Generalization—that is to say, of Metastases in the Remote Lymphatic Glands and Viscera.*—As soon as the glandular infection passes beyond the original group of lymphatic glands, the process of generalization commences. The metastases may be produced in all regions and organs, and their localization is regulated by no definite rule.

Evolution of Cancers of the Accessible Natural Cavities.—The process of evolution in those cancers comprehends four stages, which are the same as those observed in cases of cancer of the mucous orifices. But in cancer of the cavities the initial stage too often passes unperceived. The lesions of the primary period of growth of cancer of the tongue and buccal cavity are, indeed, often disregarded by medical men, who even aggravate them by a misapplied mercurial treatment. The same occurs in cases of malignant tumours of the tonsil, pharynx, larynx, and also in the initial stage of cancer of the cervix uteri. When the case is one of cancer of the body of the uterus, or of the rectal ampulla, it rarely happens that attention is directed to the affected part till hemorrhage appears, which is one of the first indications. In all these cancers, the second stage—that of local extension—which usually precedes the process of glandular infection, is of rather prolonged duration.

Evolution of Subcutaneous Malignant Tumours.—It is necessary to regard as members of this class all cases of myxoma, sarcoma—both subcutaneous and muscular—and epithelioma of superficial glands, such as the mamma. Sarcoma or myxoma of the subcutaneous tissues or muscles may remain localized for a considerable period, the glandular infection being less precocious than in cases of cutaneous epithelioma and in cancer of the breast. A very great variety of evolution is, nevertheless, observed in each of these types of tumour. Every conceivable grade of difference is met with, from the extraordinarily rapid dissemination of melanotic sarcoma to the torpid evolution of atrophic cancer of the breast. Such growths all pass, nevertheless, through the same stages: (1) Initial stage; (2) local invasion; (3) commencement of glandular invasion; (4) generalization. But the period of duration of each or all of these stages is very variable indeed.

TREATMENT OF ACCESSIBLE CANCERS BY ELECTRO-COAGULATION (1907).

Instruments used in Thermic Electro-Coagulation.

The installation which I use for thermic electro-coagulation has been constructed for me by Gaiffe of Paris.

The apparatus which I employ is capable of modification—that is the rheostat of the primary circuit, the transformer, the rotating sparker of Commandant Ferrié, d'Arsonval's condenser, and the solenoid, with which the electrodes are connected, can be arranged in a different manner.

A different form of sparker may be employed for example, provided that it produces a sufficient number of interruptions. Instead of connecting the two wires of the electrodes to the coils of the solenoid, they can be connected to fixed terminals, which are placed in connection with different coils of the solenoid by means of a rotative switch, which marks on its contacts from left to right the number of coils of the solenoid. My primitive instrument has given me such excellent results that I have not modified it. I use as current source an alternating current of fifty periods attaining 200 amperes.

Installation for Thermic Electro-Coagulation.

DOYEN'S OPERATING THEATRE.

This installation comprises:

1. A transformer.
2. A resistance table.
3. A table carrying the rotating sparker and the condenser of Arsonval.

1. *The Transformer.*—The transformer is placed on the left of the resistance table, behind the assistant, who has his right hand on the switch. The condenser is of the same type as is used in wireless telegraphy, and is enclosed in a hexagonal mahogany box. It has been specially designed to furnish in the high-frequency circuit a current of 10 to 15 amperes. It is fed by the alternating current.

2. *The Resistance Table.*—This table carries the resistance which is to vary the intensity of the current in the primary circuit of the transformer. This table holds an interrupter, switches, an amperemeter, and the "manette" or handle of the rheostat, which should be in relation with the first button (left) if the whole of the resistance is to be interposed. To

augment the intensity of the current in the primary circuit the handle is turned from left to right as far as the twenty-fifth button, which is the last.

3. *Table carrying the Rotating Sparker and d'Arsonval's Condenser.*—This table carries, above, the rotating sparker of Commandant Ferrié, which is actuated by a small electric motor. The rotator proper consists of a toothed wheel, which turns at a high number of revolutions between two copper plates, which are connected on the one hand to the high-tension



FIG. 608. —AUTHOR'S APPARATUS.

source, and on the other to d'Arsonval's condenser. This condenser is of the usual type, and is filled with paraffin. Above and in front of the condenser box is a small solenoid, whence the oscillating current of high frequency and low tension is obtained. Each coil is pierced with a hole, to which can be attached the wire connecting with the active electrode in the hands of the surgeon. A milliamperemeter placed on the condenser box measures the intensity of the current circulating in the patient; this intensity may reach 10 amperes.

Electrodes in Connection with the Patient.

The patient should be interposed in the oscillating circuit. He is placed in connection with one of the initial terminals of the small solenoid—the left, for instance—by means of a large-surface *damp* electrode, contact with which disposes no liberation of heat. This large-surface electrode

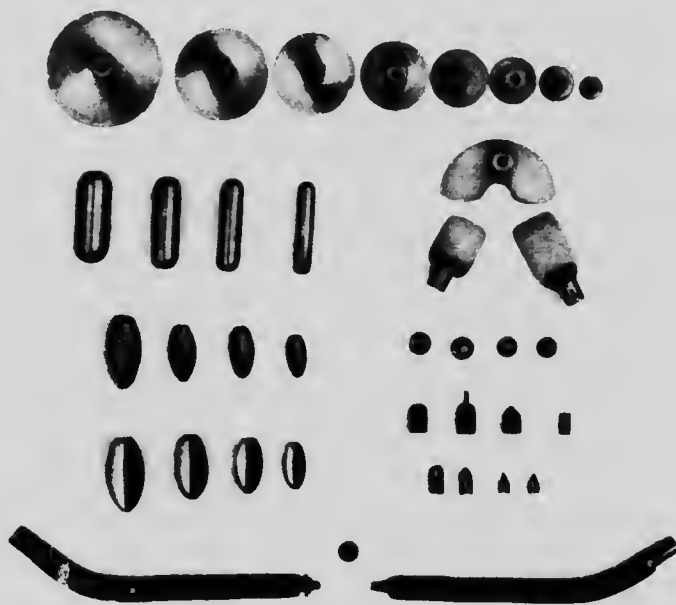


FIG. 609.

From above downwards, on the left: A series of discoid electrodes, four cylindrical electrodes, four semi-insulated olivary electrodes. On the right: Three silver electrodes of very malleable consistence, and other electrodes of various forms, for the treatment of small cutaneous lesions.

is *cold* and *inactive*. The active electrode or heating electrode has a contact surface reduced according to the feebleness of the current, in order that the heating of the tissues is instantaneous. Its form varies from a metal wire to a metal cylinder; it may also be olive-shaped or discoid. This electrode is fixed to the end of a variably shaped carrier, which is rectilinear or curved, according to whether the operation is to be carried out on the surface of the body or in a cavity such as the pharynx, vagina, rectum, etc.

In Fig. 609 are represented the heating electrodes which I had constructed for my first experiments, and two carriers.

In the same figure are represented the isolating sleeve, the carriers, and the active electrodes more generally used.




FIG. 610.—OLD APPARATUS FOR UNIPOLAR DESTRUCTION OF SMALL SUPERFICIAL EPITHELIOMATA, WITH SPARKS FROM HIGH-FREQUENCY CURRENTS.

The field of action of the sparks is limited by india rubber tubes arranged concentrically.

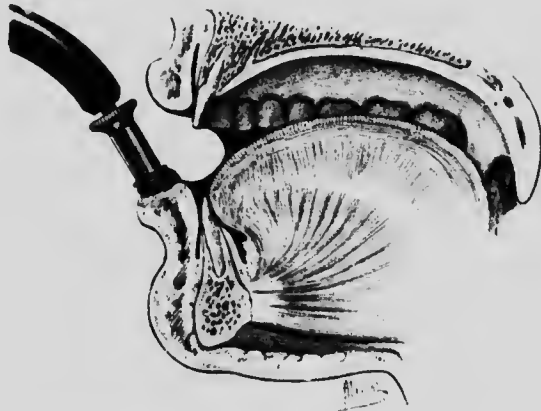


FIG. 611.—DESTRUCTION OF EPITHELIOM . . . LIP IN THE INITIAL STAGE BY ELECTRO-COAGULATION WITHOUT SPARKING.

1. THE WET, COLD, AND INACTIVE ELECTRODE.—The wet electrode is inactive; it closes the current on the surface of the patient's body at a point more or less distant from the situation of the tumour which is the sphere of action of the active electrode. The patient should be isolated from the surface of the operating table, should this be of metal, by a sheet of

rubber 6 millimetres thick or by six thicknesses of rubber sheeting (so-called hospital sheeting). The wet, inactive, cold electrode which unites the patient to the initial terminal of the solenoid should be of wide dimension. Two sizes are employed: their shape is rectangular with rounded angles. The largest, which is employed for the greater intensities, should measure 20 by 30 centimetres, and the smaller 10 by 20 centimetres. Each of these electrodes is formed of a tin plate, which is pierced with large holes, carrying at its centre the terminal, to which is fixed the wire communicating with the initial terminal of the small solenoid. Below the metal plate are fixed twenty thicknesses of absorbent cloth, which project beyond the borders for 2 centimetres, and are sewn together and to the plate which carries them. The large plate is used for the greater intensities, and the smaller for the feeble intensities (below 2 amperes).

Before operation the chosen electrode should be plunged into a basin of tepid water at a temperature of about 38° C.

For the larger intensities the large electrode is placed on the anterior surface of the thorax or abdomen, where it is fixed by two body bandages, which are arranged so as to leave exposed several of the holes in the metal plate.

Before commencing the electro-coagulation an assistant starts watering the metal plate with tepid water: the water penetrates the metal plate by means of the holes and soaks the absorbent material. The good conductivity of the water thus assures the spread of the current over a wide surface of the skin during the operation. The large plate (20 by 30 centimetres) is employed for electro-coagulation for various regions of the trunk, the vagina, the cervix uteri, and the rectum.

The small plate (20 by 10 centimetres), which is constructed in the same way as the large, is employed for medium and feeble intensities—*i.e.*, when less than ten coils of the solenoid are used. It is applied, as a rule, close to the point at which the electro-coagulation is carried out, whether the trunk or the limbs are concerned. When electro-coagulation of the face is practised, the wet electrode is placed on the upper part of the thorax close to the neck.

2. ACTIVE. HEATING, SMALL-SURFACE ELECTRODE.—The production of heat at the contact of the active electrode calls for a considerable density of current. The *density* of the current is the relation between its *intensity*, *I*, and the surface of contact of the active electrode with the tissues, *S*, and can be represented thus: $D = \frac{I}{S}$. For the same intensity the production of heat will be greater when the surface contact is reduced, and *vice versa*.

The wet plate which closes the circuit on the surface of the patient being in relation with the left terminal of the solenoid, the feeblest current is obtained by placing the wire of the active electrode in connection with coil No. 1.

To destroy an epithelioma of the conjunctiva about the size of a millet seed, I use an electrode which consists of a silver wire, and I interpose in the circuit one coil of the solenoid.

For medium intensities I employ a spherical or olive-shaped electrode 6 to 10 millimetres in diameter.

The greater intensities are used when electro-coagulation is desired, either in a cavity containing physiological or pathological fluids or in a cavity purposely filled with saline solution (see Thermo-Electric Bath).

The production of sparks should be avoided, since they carbonize the tissues and prevent the penetration of the heat-carrying vibrations; if the intensity of the current is too strong in relation to the surface of contact, effluvia and sparks are thrown off and the temperature mounts very rapidly, causing first drying and then carbonization of the tissues. This results in a greatly increased resistance to the penetration of the thermic current, and, in consequence, a diminution and attenuation of its effects in the deeper-lying tissues.

If, however, the current density is too weak—*i.e.*, if the surface of the active electrode is too large in relation to the intensity of the current—no elevation of temperature will take place in the neighbourhood of the electrode, which is simply what occurs at the contact point with the skin of the large-surface electrode, which closes the circuit.

Control of the Thermo-Penetration.

The intensity of the current is controlled in two ways:

1. According to the number of coils of the solenoid separating the two terminals, to which are attached the conducting wires, one ending in the wet plate and the other in the active electrode.
2. According to the number of buttons on the rheostat of the primary circuit, which regulates the intensity in the transformer.

1. CONTROL OF THE HIGH-FREQUENCY CURRENT BY THE NUMBER OF COILS OF THE SOLENOID WHICH ARE INTERPOSED IN THE CIRCUIT.

First Assistant.—An assistant is placed at the distribution switchboard to put into action—

1. The small motor which causes the rotative sparker to revolve.
2. The switch of the primary current.
3. The rheostat of the primary current.

Second Assistant.—A second assistant fixes the conducting wire of the active electrode on one of the coils of the small solenoid, following the orders of the surgeon.

Experimental Study of Thermic Electro-Coagulation.

Before attempting electro-coagulation on the human subject this method of thermo-penetration should be studied on a piece of butcher's meat 6 centimetres thick. This is placed on a small metal table, which is in connection with the initial terminal of the solenoid. The electrode carrier is connected at first with coil No. 1 of the solenoid: the current is so feeble

that an electrode of very small surface, such as a silver wire $\frac{1}{2}$ millimetre thick, must be attached to the end of the isolating carrier. At a given sign the assistant at the distribution switchboard starts the rotative sprker, and the surgeon orders him to "commence"; the interrupter is closed and the current passes.

The rheostat of the distribution switchboard should be at No. 1 button, thus giving the weakest primary current.

The end of the metal wire is brought towards the piece of meat; no effect is produced. The surgeon orders "Stop." The interrupter is closed and the current ceases. The surgeon now orders the assistant who is responsible for the solenoid to connect the active electrode to coil No. 2. The handle of the rheostat in the primary remains at button No. 1. The surgeon gives the order, "Commence"; the interrupter is closed, the surface of the meat becomes white where it is in contact with the silver wire, and if the electrode is withdrawn to a distance of $\frac{1}{2}$ millimetre small sparks will be seen to burst out. If the wire electrode is connected to the third coil of the solenoid the density of the current becomes too great, and sparking occurs all around the point of contact. The surgeon orders "Stop," and changes the wire electrode for a cylindrical electrode of $3\frac{1}{2}$ millimetres in diameter. The rheostat of the primary remains at button No. 1, and the active electrode remains in connection with No. 3 coil of the solenoid. The active electrode is placed in contact with the meat, and the surgeon orders "Commence." After fifteen seconds he notices a white zone nearly hemispherical in shape, 5 millimetres in diameter and 3 in depth. He now orders "Stop." The same electrode is now connected with the fourth coil of the solenoid, contact is made with the meat, and the current is again started. Sparking occurs at once, and the surface of the meat commences to carbonize. To obtain electrocoagulation without sparks and without carbonization an electrode 9 millimetres in diameter, for four coils of the solenoid, must be used for the piece of meat. If the density of the current is too strong, in proportion to the surface of contact of the electrode with the meat, a sheaf of sparks is given off immediately and the surface of the meat becomes carbonized; electrocoagulation occurs in the depths, but it is easy to see that the penetration of heat is less, when carbonization occurs, than when the surface of the meat in contact with the electrode remains humid.

2. CONTROL OF THE CURRENT BY THE RHEOSTAT OF THE PRIMARY CIRCUIT.

With the same number of coils of the solenoid in circuit the density of the current at the active electrode varies according as to whether the resistance of the rheostat of the primary circuit is increased or diminished. The following simple experiment will suffice for instruction: a metal disc 20 millimetres in diameter is screwed on to the end of the electrode carrier, and the wire is connected with the eighth coil of the solenoid. The rheostat is at button No. 1. The electrode is applied to the surface of the meat, and the current is started. After fifteen seconds the current is stopped.

It will be seen that the surface of the meat has become white around the circumference of the electrode in the form of a ring. The same electrode is now placed on another portion of the surface of the meat, and the assistant is told to change the rheostat "five points," placing the handle on the sixth button. He starts the current, and cuts the circuit after fifteen seconds. The whitened portion is more accentuated, but the central part of the meat in contact with the electrode is hardly lukewarm. Another place on the surface is chosen, and the surgeon calls for seven more points; the handle is pushed to button No. 13 (6 + 7). The current is restarted; after ten seconds the serosity in the meat appears round the electrode, and commences to boil; after fifteen seconds the current is stopped. Section of the meat shows that electro-coagulation is produced in a hemispherical zone 28 millimetres in diameter and to a depth of 15 to 18 millimetres.

If the same experiment be repeated when the handle of the rheostat is pushed to the twenty-fifth button (the last), boiling takes place in three to four seconds around the electrode. Sparking then begins, and the meat becomes carbonized, with no advantage to the thermo-penetration. Thus the surgeon has two methods for regulating the intensity of the thermo-penetrating current:

1. The rheostat of the primary is at No. 1. According to his experience, the surgeon causes 1, 2, 3, 4, 6, 10, or more, coils of the solenoid to be interposed in the circuit. It is rare that the twelfth coil has to be passed when electro-coagulation is obtained by direct contact of the electrode with the tissues. But all the coils (say twenty-three) must be used if we wish to disseminate the thermo-penetrating heat over a large surface by the intermediary of salt solution. This technique, which I call the thermo-electric bath, will be described later.

2. If the current intensity be not sufficient with the coil chosen, the surgeon instructs the assistant in charge of the switchboard to interpose successively two, three, or four points of the rheostat of the primary. When the handle of the rheostat is at the thirteenth button (the centre), if the intensity of the current be not sufficient, the surgeon stops the current and the rheostat handle is returned to No. 3, whilst the surgeon instructs the assistant in charge of the solenoid to interpose 1, 2, 3, or more, coils of the solenoid.

In the table on p. 464 are a few indications to guide the surgeon in the experiments I have just described.

It is indispensable to practise electro-coagulation on pieces of meat before commencing the treatment of patients. The intensity of electro-coagulation being in relation with the number of calories produced, the heating of a piece of meat whose temperature is about 18° C. is less rapid than the heating of pathological tissues whose temperature is usually above 36° C.

464 SURGICAL THERAPEUTICS AND OPERATIVE TECHNIQUE

RESULTS OBTAINED WITH THE INSTALLATION IN DR. DOYEN'S OPERATING THEATRE.

<i>Active Electrode Contact Surface.</i>	<i>No. of Cuts of the Salamoid.</i>	<i>Rheostat of Primary.</i>	<i>Result after Fifteen Seconds.</i>
1. Silver wire 0.5 millimetre in diameter	1	1st button	Nil.
	1	6-13th button	Good.
2. Diameter 3.5 millimetres	1	25th button	Sparking.
	3	1st button	Good.
	3	6th button	Carbonization and sparking.
	4	1st button	Good.
3. Diameter 9 millimetres	4	6th button	Boiling in ten seconds.
	4	13th button	Carbonization and sparking after five seconds.
	5	1st button	Good.
4. Diameter 10 millimetres	5	6th button	Boiling in five seconds, carbonization in ten seconds.
	6	1st button	Nil. Heating in ring.
5. Diameter 15 millimetres	6	6th button	Good.
	8	1st button	Nil. Heating in ring.
6. Diameter 20 millimetres	8	6th button	Nil. Circular discoloration.
	8	13th button	Good.
	10	4th button	Nil. Slight heating.
	10	6th button	Nil. Circular discoloration.
7. Diameter 30 millimetres	10	13th button	Boiling in ten seconds.
	10	25th button	Deep electro-coagulation.
	23	13th button	Nil. Circular heating.
	23	25th button	Boiling in four seconds; deep electro-coagulation in fifteen seconds.
9. Cylindrical electrode diameter 7 millimetres, length 40 millimetres, introduced into the midst of the meat	12	18th button	Electro-coagulation (spindle-shaped) most intense at the extremity of the electrode.
10. Hollow cylindrical electrode 24 millimetres in diameter, containing crushed ice	10	6th button	Heating in ring.
	10	18th button	Boiling in five seconds; after fifteen seconds the electrode still contains ice.
11. Iron box containing a litre of water at 22° C.	23	25th button	After five minutes temperature 73° C. Boiling in eight minutes.
12. If an elongated rectangular electrode be applied to the meat, commencing with a feeble current which is progressively increased, it will be remarked that heating begins at the angles of the electrode.			

ELECTRO-COAGULATION OF MALIGNANT TUMOURS.

1. Very Small Epitheliomata.

Small epitheliomata are often found, at the commencement of their evolution, whose volume is as yet no greater than that of a millet seed. I have observed such growths particularly on the conjunctiva, on the edge of the cornea, or even on the free edge of the lids.

They can easily be destroyed under local anaesthesia, the canterization of the point of implantation being alone of consequence. I first extirpate the small tumour with the bistoury, exactly following its limits, for histological examination; I then canterize the point of implantation by the method of electro-coagulation, fixing to the end of a curved electrode holder a silver wire about 2 centimetres in length. One coil of the solenoid is sufficient to interpose in the circuit, the handle of the rheostat standing at No. 6 button. The circuit is closed by applying the small wet plate on the upper part of the thorax or shoulder. The extremity of the electrode is placed on the small wound resulting from the ablation of the neoplasm, and the surgeon orders "Commence." Electro-coagulation is produced over an area of from 2 to 3 millimetres and to a depth of a millimetre. The surgeon orders "Stop"; he repeats this small operation several times should the first application appear to be insufficient.

If the density of the current is not great enough, the handle of the rheostat must be advanced two points at a time until the desired effect is reached. If the first coil of the solenoid does not give a current of sufficient intensity the surgeon stops the current. The rheostat is returned to the first button, and the active electrode is connected to the second coil of the solenoid. The electrode is again applied to the surface of the wound and the current is restarted, if the current is not of sufficient density, the surgeon instructs the assistant to advance the handle of the rheostat two points at a time until electro-coagulation is produced.

In delicate regions such as the globe of the eye and the region of the eyelids it is necessary to employ a wire 15 or 20 millimetres long and fairly flexible. In this way the extremity of the wire electrode is easily kept in contact with the wound if the patient should shrink.

2. Small Superficial Cancroids.

Let us suppose a commencing canceroid of the face or lip 5 millimetres in extent and 2 millimetres in depth.

Under local anaesthesia the neoplasm is removed close to its limits, for microscopical examination. Electro-coagulation is carried out forthwith with a small-diameter electrode (about 3-5 millimetres). Three coils of

the solenoid are employed, and the sixth button of the rheostat. The same small 10 by 20 wet electrode is used. If the current is not sufficiently intense, the rheostat is advanced two points at a time until the desired result is obtained.

Electro-coagulation—that is, the whitened and hardened zone—should reach to a depth of 3 millimetres, and on the surface should extend 2 or 3 millimetres beyond the extreme limits of the neoplasm.

3. Neoplasm of the Skin and Mucous Orifices.

A. The Lesion is still Limited to the Surface and No Glandular Infection Exists.—If the lesion is readily accessible and the patient is not too nervous, local anaesthesia with cocaine is employed, otherwise general anaesthesia is preferable.

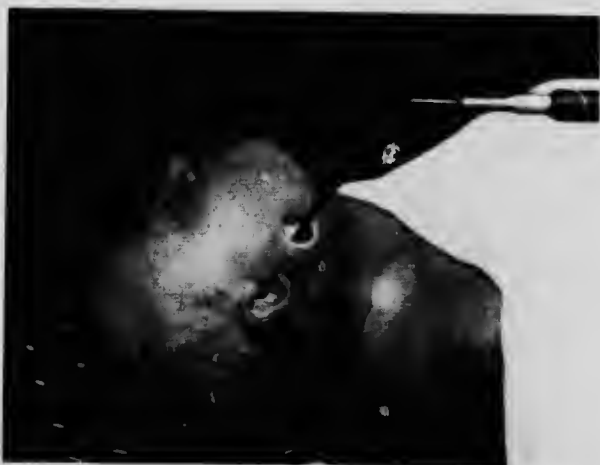

FIG. 612.

First the tumour is removed, exactly at its limits, for microscopic examination. If it is ulcerating and softened, a small portion is removed with the scalpel or scissors and placed in fixing solution. The remainder is energetically curetted until healthy tissue appears, which is more resistant and upon which the growth is implanted.

The smaller wet electrode is employed, and, as active electrode, a small sphere 8 millimetres in diameter is chosen, which is fixed to the end of a curved carrier by means of a screw. The active electrode is connected with the fourth coil of the solenoid, and the rheostat of the primary is at the first button. The electrode is applied and the word is given, "Commence." Electro-coagulation should begin after five or six seconds; if the effect is not sufficient, order is given to advance the handle of the rheostat of the primary two points at a time, until a sufficiently dense current is obtained

to produce an electro-coagulation to the depth of about 4 millimetres in a few seconds. As soon as this result is obtained the electrode is moved gently over the whole surface of implantation of the neoplasm so as to produce electro-coagulation to a depth of 4 millimetres, and for the same distance beyond its superficial limits.

B. The Lesion is Already Deep, and Accompanied with Glandular Implication.—A general anaesthetic is given, and a portion of the neoplasm is

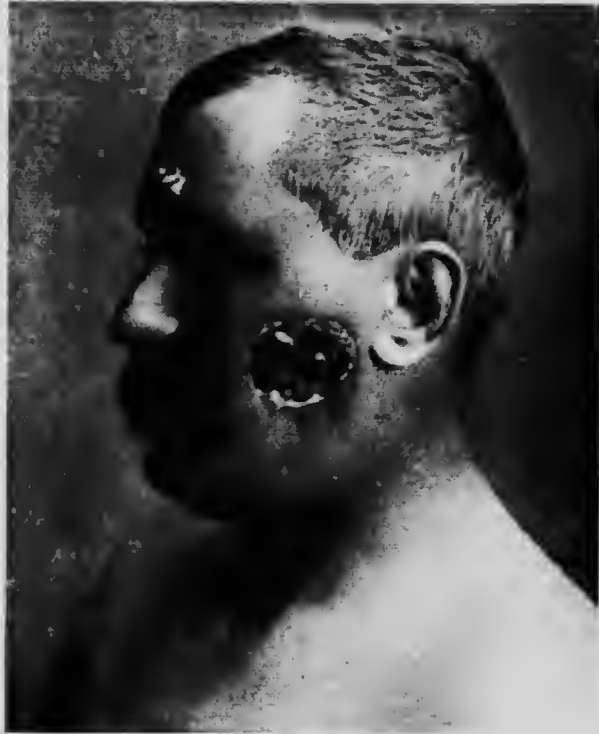

FIG. 613. —EPITHELIOMA OF SKIN OF CHEEK, UNSUCCESSFULLY TREATED WITH X RAYS AND WITH RADIUM.

removed for histological examination. The pathological tissues are then removed at their apparent limits, either with cutting instrument or enette.

Electro-coagulation is obtained with a spherical electrode 8-10 millimetres in diameter; five or six coils of the solenoid are used, and the rheostat of the primary is regulated according to the indications already given. Electro-coagulation should extend 5-6 millimetres beyond the apparent limits of the neoplasm. When the electro-coagulation is finished the glands are extirpated in the method described in the chapter concerning glands of the neck. The glands are exposed and isolated by division—that is, their cellular envelope is dissociated by opening the ends of blunt scissors.

They are extracted by first attempting to pass below them. The most accessible glands are first extirpated, followed by those which are more deeply placed.

If the operation is along the sheaths of nerves and vessels—for instance, in the neck, between the angle of the jaw and the bifurcation of the carotid—the external carotid and its branches are ligatured to prevent the return of blood by the numerous anastomoses of the terminal branches.

Indeed, when electro-coagulation has been profound in the face or the tongue, hæmorrhage may be produced as the sears are being eliminated. Electro-coagulation cannot be carried out in the carotid region, for it would destroy important nerves, and incur the risk of grave hæmorrhage. A



FIG. 614. EPITHELIOMA OF SKIN OF CHEEK: DESTRUCTION OF THE NEOPLASM BY ELECTRO-COAGULATION EFFECTED BY SPARKING (BIPOLAR VOLTAIZATION).

Technique employed in 1907.

careful extirpation, therefore, is all that can be carried out, followed by treatment with antineoplastic vaccine, which has already been described.

The zone surrounding the cancerous glands can be treated by electro-coagulation in the submaxillary region, or in the median suprahyoid region, especially when the external carotid and its branches have been ligatured, for no very important organs exist in these two regions except the hypoglossal nerve, which is easily avoided.

The same rules apply to other regions where cancerous adenitis may develop—that is, electro-coagulation should be reserved to the regions where it is impossible, in destroying suspected tissues, to reach important organs such as important bloodvessels and nerves. The latter may, however, be protected by covering them with a compress soaked in sterilized water, or Ringer's solution.

4. Burrowing and Ulcerating Epitheliomata in Anfractuous Cavities.

We will take for example a burrowing epithelioma of the malar region invading the sinus. It is impossible to determine beforehand the exact limits of the cancerous degeneration.

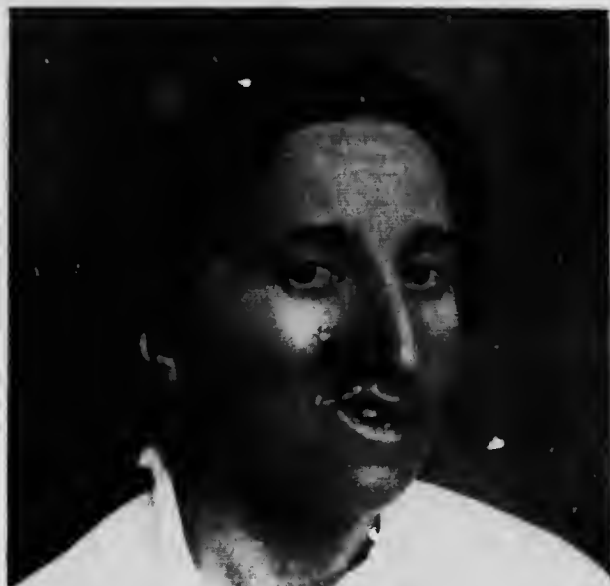

FIG. 615.—WOUND RESULTING FROM ELECTRO-COAGULATION OF A JUXTA-COMMISSURAL EPITHELIOMA.

Six months after the operation.

The patient is anesthetized; a portion of the pathological tissue is removed for microscopical examination, and the softened tissues are enucleated. If the oozing is very marked the wound is plugged, and electro-coagulation is proceeded with.

The smaller wet electrode is used, placed on the shoulder; the electro-coagulation is carried out with a curved carrier on the extremity of which is mounted a small sphere 8 millimetres in diameter; six coils of the solenoid are interposed in the circuit, and the rheostat is at No. 1. The electrode is moved steadily over the whole of the surface of implantation. If the oozing persists, the handle of the rheostat must be advanced until the blood-stained serous fluid becomes brown, coagulates, and begins to

boil around the electrode after several seconds. The intensity of the current should be increased in proportion as the sero-sanguineous oozing is abundant.

The penetrating heat caused by the oscillating high-frequency current is propagated more rapidly in the bones than in the soft parts, for the specific heat of the former is greater. The specific heat of adipose tissue, the most feeble, is about 0.3. The specific heat of blood-stained serous fluid and muscles approaches that of water—*i.e.*, unity. It is the same for osseous tissue, owing to its richness in calcareous salts.



FIG. 616. WOUND RESULTING FROM ELECTROCOAGULATION OF A JENTA-COMMISSURAL EPITHELIOMA.

Autoplastic result; there had been no recurrence.

This particularity has a very interesting result. It has been known for a long time that the bloody operation is incapable of impeding the evolution of the cancerous process in the interior of bones, and burrowing epitheliomata of the face were hitherto considered incurable. Recurrence occurred soon after operation, however extensive this may have been.

But numerous operations which I have performed since 1907, in cases of burrowing epitheliomata in the bones of the face, have shown me, on the contrary, that penetrating heat destroys cancer cells in bones to a much greater depth than in unseles; and it is thus that I have obtained many cures in cases where operation seemed only palliative.

5. Cancer of the Mouth.

Epithelioma of the inner surface of the cheek, alveolar epithelioma epulis, and tumours of the palate, are cured easily by electro-coagulation, provided that this operation is carried out in time, before the lesion has extended beyond the limits permitted to the surgeon.



FIG. 617.—TEREBRATING EPITHELIOMA OF THE MAXILLA, DESTROYED BY ELECTRO-COAGULATION: ASPECT OF CICATRIX, FRONT VIEW.

Operation is carried out as above after removal of a portion for histological examination, and ennetting of the tumour. In some cases electro-coagulation may be carried out immediately after removal of the portion for histological examination: the electro-coagulated tissues are removed by the curette, in order to judge of the precise limits of the cancerous degeneration. The whole of the implantation zone is then treated by electro-coagulation.

6. Cancer of the Tongue.

A. LOCALIZED MARGINAL EPITHELIOMA.

The patient is anesthetized, all the teeth in relation with the neoplasm are removed. A large silk thread 40 centimetres in length is then passed through the tongue behind the tumour with a curved needle. The two ends of the thread are knotted together.



FIG. 618. RESECTING EPITHELIOMA OF THE MAXILLA, DESTROYED BY ELECTRO-COAGULATION: PROFILE VIEW.

The labial commissures and the jaws are retracted by means of the author's metal commissural retractors, or with wooden retractors. The epithelioma can then be easily exposed by moderate traction on the silk thread. Before commencing electro-coagulation the lips, and the parts surrounding the epithelioma, are covered with damp compresses.

The surest method for electro-coagulation to extend beyond the limits of the neoplasm is to remove it first, with a cutting instrument, exactly



FIG. 619.—A SERIES OF PHARYNGEAL TUBES OF VARIOUS DIMENSIONS.

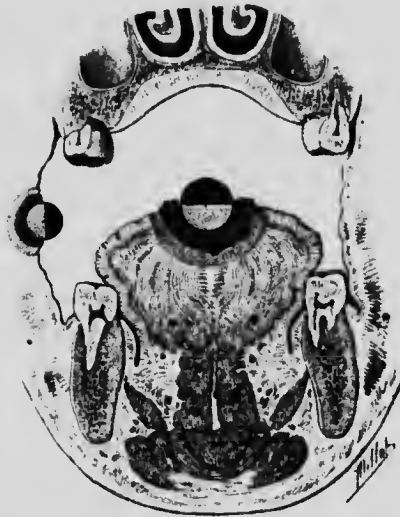

FIG. 620.—ELECTRO-COAGULATION OF AN EPITHELIOMA LIMITED TO THE JUGAL MUCOUS MEMBRANE, AND OF AN EPITHELIOMA OF THE DORSUM OF THE TONGUE WITH SEMI-INSULATED ELECTRODES.

beyond its borders. Careful observation is made to insure that the muscle is healthy, and that no cancerous prolongations remain in the depths. Electro-coagulation is then carried out, following the technique already described, using a curved electrode carrier and a small sphere 6 or 8 millimetres in diameter. In certain cases a cylindrical or olive-shaped electrode may be used (see Fig. 620).

The small wet-plate electrode is employed, and four or five coils of solenoid are interposed in the circuit. The current intensity is augmented, starting from the first button as far as is necessary to produce rapidly electro-coagulation to a depth of 4 to 5 millimetres.

The after-effects are not painful. Hardly any swelling is produced, and elimination of the sear takes place after fifteen days. Rarely a small hemorrhage occurs, the arterioles by this time being obliterated well beyond the groove of elimination.

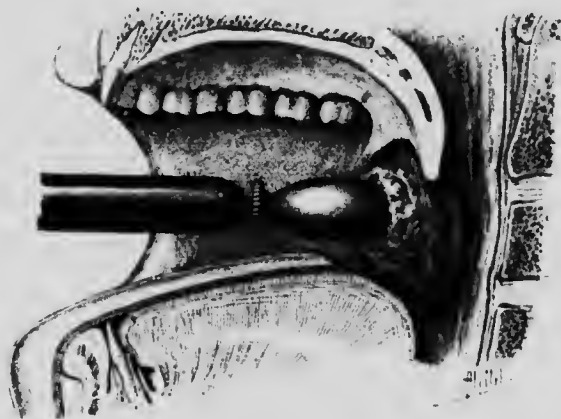


FIG. 621.—ELECTRO-COAGULATION OF A SARCOMA OF THE TONSIL.

Patients should not leave the nursing home until the wound is granulating. They should be examined again four weeks after operation, for at this moment it can be very well seen if the electro-coagulation has been insufficient, and if there exists, on the cicatrizing surface, a suspicious point, grey and indurated, which the experienced eye will recognize at once. If electro-coagulation has extended beyond the limits of the cancer, repair is rapid and very satisfactory, and no recurrence is observed.

Small cancers of the tongue must be diagnosed very early, and the mistake must be avoided of prescribing antisyphilitic treatment, which always accelerates the cancerous lesion. It is all the more necessary to make the diagnosis early and to perform electro-coagulation at the beginning, since in some patients the infection of the submaxillary or carotid glands is very precocious.

I have at times believed some patients completely cured, since the

cancer of the tongue had not recurred after two or three years, whereas a cancerous adenopathy of the submaxillary gland or carotid gland has necessitated a fresh operation.

B. EPITHELIOMA OF THE FRENUM OF THE TONGUE.

The patient is anesthetized. The four incisors and often the canines are removed, and the tumour is removed for histological examination. Care is taken that the limits of the tumour are passed, and electro-coagula-

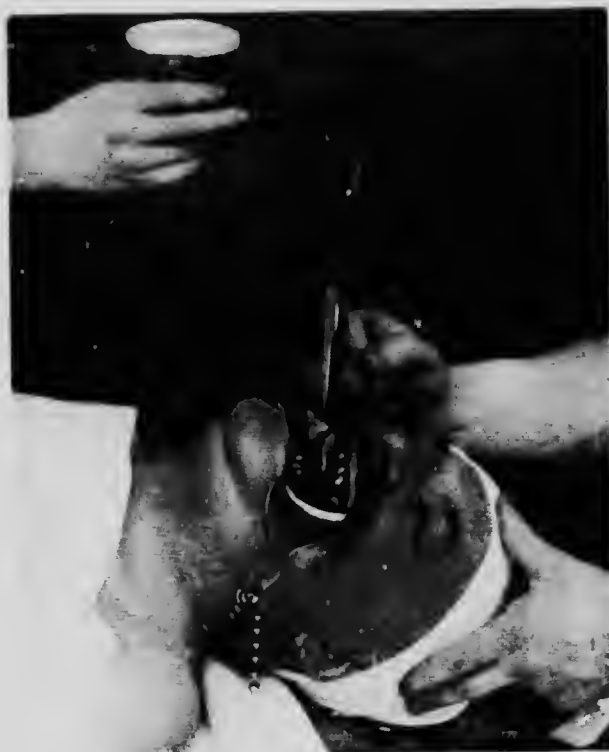

FIG. 622. EPITHELIOMA OF LEFT BORDER OF TONGUE, PREPARED FOR ELECTRO-COAGULATION.

tion is carried out, acting energetically on the alveolar border, on the internal border, and on the internal surface of the maxilla, where recurrence is most to be feared.

Should suprahyoid, median, or submaxillary glands exist they are removed, and the field of operation is submitted to electro-coagulation, care being taken to ligature the facial artery if it is exposed.

C. EPITHELIOMA OF THE BODY OF THE TONGUE.

Electro coagulation has given remarkable results in cases of massive epithelioma of the tongue, where I have gone well beyond the limits of the neoplasm. In fact, in a certain number of cases, where the anterior half of the tongue or quite a large proportion of the base are already cancerous, no glandular involvement has yet taken place. These cases of extensive cancer of the tongue without early glandular involvement are not more exceptional than the small epitheliomata of the tongue or even the lips with slow glandular infection, which in some cases only becomes manifest after several years.

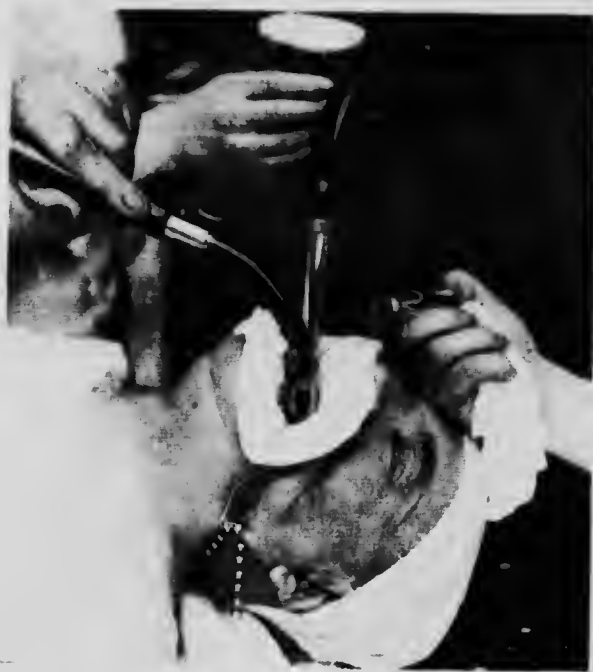

FIG. 623. EPITHELIOMA OF LEFT BORDER OF TONGUE; PROTECTION OF THE HEALTHY PARTS; APPLICATION OF THE ELECTRODE.

D. PREVENTIVE LIGATURE OF THE EXTERNAL CAROTID AND ITS BRANCHES.

Whenever electro-coagulation of the tongue is extensive, the operation should start with the ligature of the trunk of the external carotid, followed by ligature of its branches, notably the facial, the lingual, and the trunk of the external carotid below the latter, in order to avoid reflux of blood by

collateral circulation. This operation allows of the exposure and extirpation of the glands in the same region, which may already be the seat of congestion, and increased in volume, although they may be inappreciable to palpation.

The technique of the ligation of the external carotid artery and its branches will be described in treating of the surgery of the neck.

Before commencing electro-coagulation a portion is removed for histological examination, and as much as is possible of the neoplasm is removed with the cutting instrument, so as to judge its extreme limits. Electro-

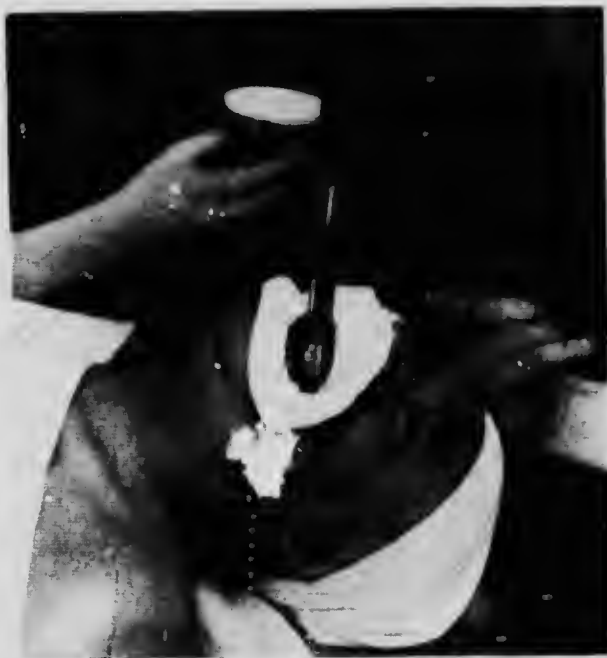

FIG. 624. EPITHELIOMA OF LEFT BORDER OF TONGUE: APPEARANCE OF THE ELECTRO-COAGULATED SURFACE.

coagulation is then proceeded with. The tongue, as already described, is drawn outwards by means of one or two loops of thick silk thread, and as soon as the retractors are in place the portions of the buccal cavity likely to be damaged by the heat are protected by means of gauze compresses soaked in sterilized water. The small wet electrode is used, and a curved electrode carrying a small sphere. Five or six coils of the solenoid are interposed. The handle of the rheostat of the primary is pushed progressively as far as the button, which gives a sufficient density of current to produce electro-coagulation in a few seconds on contact with the sphere of metal.

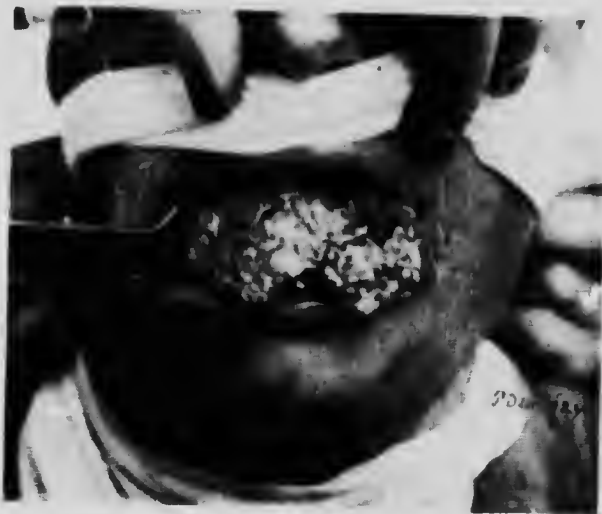

FIG. 625.—MASSIVE EPITHELIOMA OF ANTERIOR TWO-THIRDS OF TONGUE, SEEN FROM THE FRONT.

The teeth have hollowed out a median furrow in the growth.



FIG. 626.—MASSIVE EPITHELIOMA OF ANTERIOR TWO-THIRDS OF TONGUE: THE PATIENT HAS BEEN ANESTHETIZED. The tumour has been drawn out of the mouth. The deep limits of the disease cannot be seen.

I have also obtained very good results in cases of unilateral cancer of the base of the tongue, with no recurrence after more than a year. But the operation is delicate, and requires great experience in the technique of electro-coagulation. An extensive operation is necessary, and beginners as a rule do not dare to use a current of sufficient intensity.

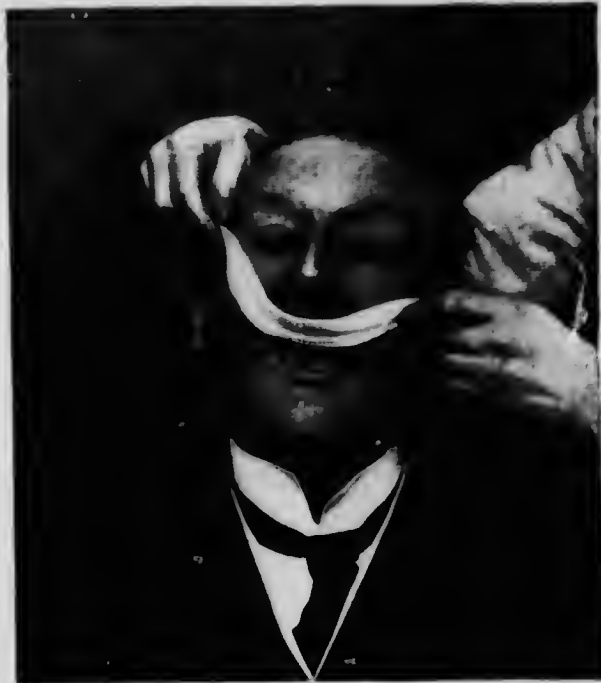

FIG. 627. MASSIVE EPITHELIOMA OF ANTERIOR TWO-THIRDS OF TONGUE: APPEARANCE OF THE TONGUE TWO YEARS AFTER THE OPERATION.

Among the extraordinary cases which I have treated by electro-coagulation without recurrence I will mention one particularly of massive cancer involving the anterior two-thirds of the tongue represented in Figs. 625, 626, and 627. I experienced the greatest difficulty in producing electro-coagulation beyond the limits of this tumor, which I had not previously removed. This operation was carried out in 1900. The thermo penetration extended in the tongue beyond the limits of the neoplasm, which was eliminated *en masse* like a core. Cicatrization was accomplished in several weeks, and repair was so satisfactory that speaking was not sensibly interfered with.

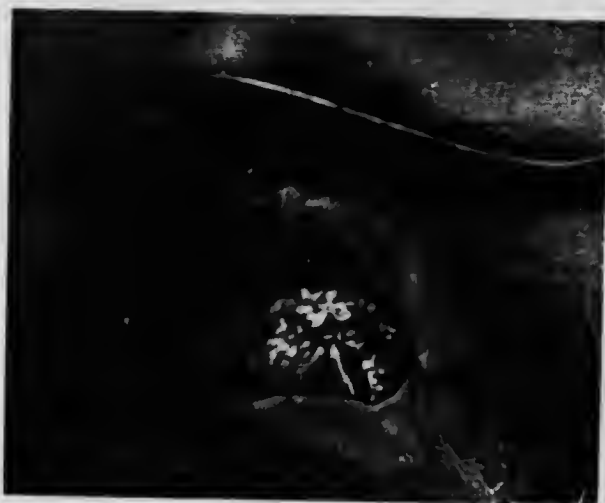

FIG. 628. MASSIVE EPITHELIOMA OF LEFT BORDER OF TONGUE, WHICH WAS SUCCESSFULLY TREATED BY ELECTRO-COAGULATION. In contact with the central part of the ulcer is seen a canine tooth, which was the original point of departure.

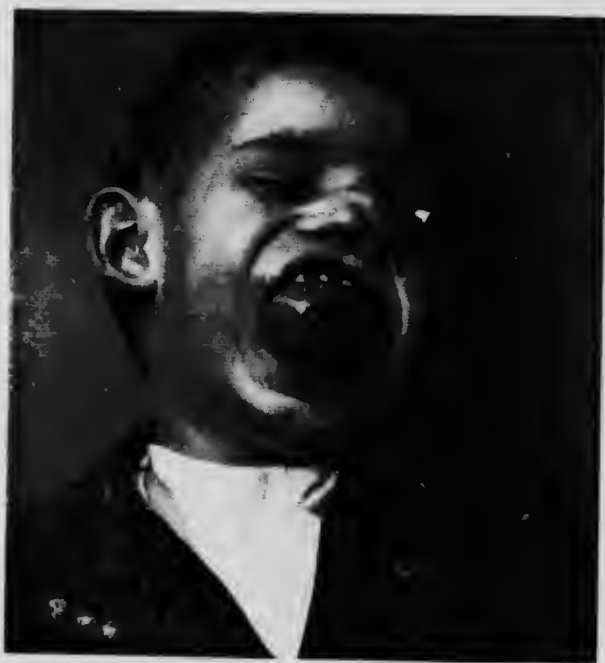

FIG. 629. FIBROUS POLYPUS OF NASAL FOSSA, IN A STATE OF COLLOID DEGENERATION. It has invaded the sinuses of the face and left orbit, and pushed forward the dental arches.

7. Cancer of the Superior Maxilla.

Since I have treated accessible cancers by electro-coagulation I approach tumours of the superior maxilla by way of the mouth, and make no cutaneous incision.

Operating by way of the mouth, it is quite easy to detach the tissues of the genial region, and then to perform extirpation, partial or total, of the maxilla according to the extent of the tumour. This can be accom-

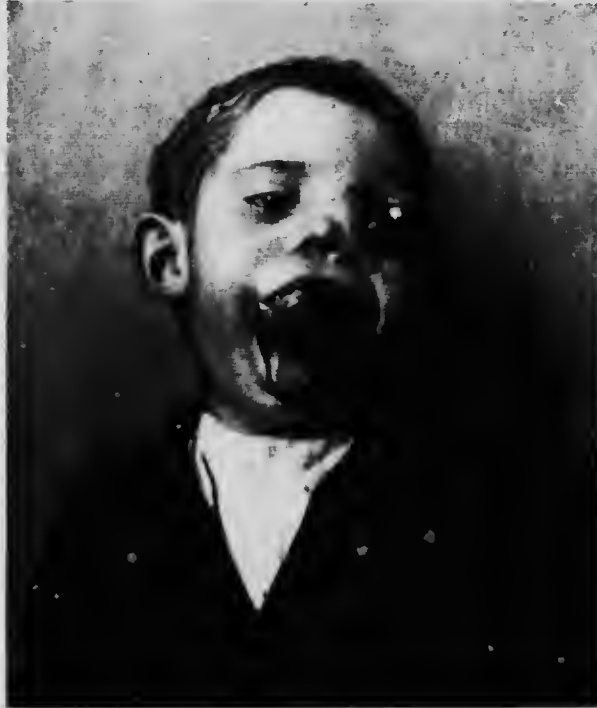

FIG. 630. —FIBROID POLYPUS OF NASAL FOSSA, IN A STAGE OF COLLOID DEGENERATION. PHOTOGRAPH SHOWING RELATIONS OF TUMOUR AND TONGUE.

The patient was wearing a tracheal cannula.

plished in a few minutes by one who is well versed in the technique of this operation by the classic method. The only artery which bleeds abundantly is the internal maxillary, on which a strong short-nosed artery forceps can be left. When the oozing prevents the surgeon from immediately carrying out electro-coagulation the field of operation is vigorously plugged, and the electro-coagulation is postponed until another day, perhaps ten or fifteen days later. Electro-coagulation is carried out as already described, after

all suspected tissues have been carefully removed with the eurette, in order to judge carefully the apparent limits of the neoplasm before application of the penetrating heat. Electro-coagulation for cancer of the superior maxilla has given me durable cures, even in cases already operated on by other surgeons, who have come to consult me for extensive recurrence.

8. Cancer of the Pharynx or Nasal Fossæ.

Electro-coagulation is useful for the destruction of malignant tumours of the nasal fossæ, the naso-pharynx, the tonsil, and the whole of the bucco-pharyngeal region.

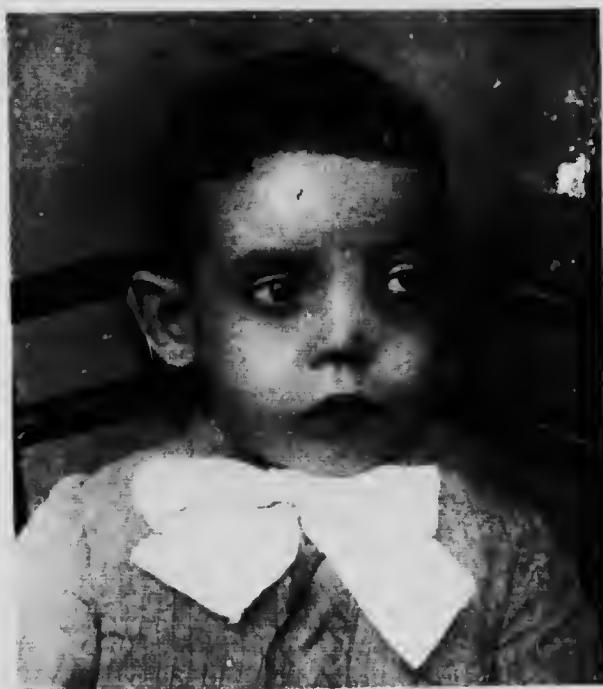

FIG. 631. PHOTOGRAPH OF THE CHILD FOUR MONTHS AFTER ENUCLEATION OF THE TUMOUR, FOLLOWED BY ELECTRO-COAGULATION OF THE PEDICLE.

Electro-coagulation has the advantage over bloody methods that the operation can be carried out through the natural passages. It is unnecessary to incise the skin, so long as it has not already become invaded.

For the tonsil and the pharynx I employ special electrodes, and I protect the healthy mucous membrane surrounding the neoplasm with strips of wet gauze.

When the surgeon is well versed in the technique of electro coagulation

commencing cancers of the tonsil or even cancers of the pharynx can be readily destroyed, to a depth sufficient to avoid the chance of a recurrence, the essential condition being that the operation shall be carried out in time—*i.e.*, when the tumour can be destroyed in its entirety without involving the destruction of essential organs.



FIG. 632.—CANCER OF THE ORBIT DESTROYED BY ELECTRO-COAGULATION CURETAGE

As soon as the density of the current is well regulated, the electrode is applied, and electro-coagulation is carried out until steam begins to be given off. The order is given, "Stop," and the index finger is used to

gauge the rise of temperature in the tissues and the extent of surface over which this rise of temperature has taken place. The electrode is replaced, and the order given, "Commence," and again, "Stop," when steam appears; the linger is again used for examination, and the technique is resumed until the electro-coagulation has attained the intensity and extent desired.

9. Cancer of the Larynx.

A. EPIGLOTTIS AND LARYNGEAL ORIFICE.

In order to treat cancer of the epiglottis and of the orifice of the larynx by electro-coagulation a preliminary pharyngotomy must first be carried out. The mucous membrane is sutured to the skin, and ten or fifteen days afterwards electro-coagulation is performed. A small-volume electrode and a current of appropriate density are used. The pharyngo-cutaneous wound is not closed for several months—indeed, until the cure appears certain.

B. CAVITY OF THE LARYNX.

The cancerous lesion is brought into evidence by practising a median laryngotomy. The same day electro-coagulation can be performed, after a fragment has been removed for microscopic examination.

10. Commencing Cancer of the Œsophagus.

Electro-coagulation can only be applied to cancer of the œsophagus when the lesion is extremely limited, such as can be discovered at the commencement of its evolution by œsophagoscopy. The electrode, which is of small diameter, is fixed on a long stem, bent at the level of the isolating sleeve in such a way that the surgeon can readily follow the progress of the thermo-penetration by direct endoscopy.

11. Cancer of the Bladder, the Vagina, the Cervix Uteri, and the Lower Part of the Rectum.

A. BLADDER.

Papillomata of the bladder and commencing cancer of the bladder should be treated by electro-coagulation after a preliminary cystotomy. The cystotomy is performed as a primary operation (see later) and the vesical mucous membrane is sutured to the skin. Electro-coagulation is performed ten or fifteen days later. I have devised special specula for this operation. These are either in wood or ebony, either valve-shaped or tubular, and are of various dimensions. The part submitted to electro-coagulation must be brought clearly into view. To avoid trouble by the urine an aspirating apparatus is placed in the fundus of the bladder, connecting with a pump attachment either by the hypogastric wound or the urethra.

B. VAGINA AND CERVIX UTERI.

Cancer of the orifice of the vagina or of its walls is also treated by electro-coagulation, either wooden retractors or cylindrical wooden specula with bevel ends being used. As is the rule for all neoplasms, a portion is removed for histological examination before proceeding to electro-coagulation. A cylindrical electrode of 7 millimetres is employed.




FIG. 633. INSTRUMENTS REQUIRED FOR USE IN ELECTRO-COAGULATION OF TUMORS OF THE UTERUS, RECTUM AND BLADDER.

Above, and to the left: Three series of wooden specula, of four different diameters. Above, and on the right: Wooden valve specula of various dimensions, of the form of the author's metallic valves for hysterectomy. Next below: A centigrade thermometer, ennettes, Cusey speculum, bistoury, and two clawed forceps. Lowest: Two insulator handles for electro-coagulation, each of which is furnished with a porte-electrode, one curved, the other bent at an obtuse angle. Above these insulating handles, and from right to left: A series of electrodes, which includes four cylindro-spherical electrodes, four olive-shaped semi-insulating electrodes, four olive-shaped metallic electrodes, six discoid electrodes of various diameters, and three electrodes of varied form and curvature. On the left: Six long curved forceps, a malleable rectal dilator, and a series of Hegar sounds.

C. RECTUM.

Cancer of the lower extremity of the rectum, at the commencement of its evolution, particularly when only a small portion of the circumference is invaded, can be definitely cured by electro-coagulation. The same wooden specula are used as for cancer of the cervix uteri.

If the cancer is situated 8 or 10 centimetres from the orifice, the lesion must be exposed by a posterior rectotomy, after extirpation of the coccyx.

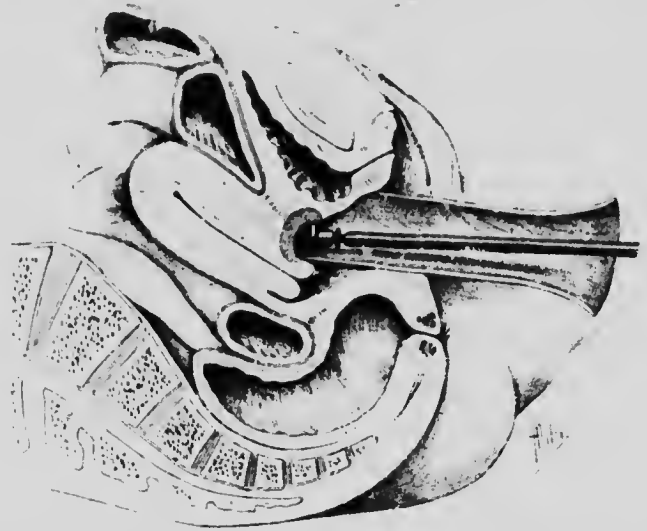


FIG. 634. —ELECTRO-COAGULATION OF A CANCER OF THE ANTERIOR VAGINAL CUL-DE-SAC WITH A DISCOID ELECTRODE.

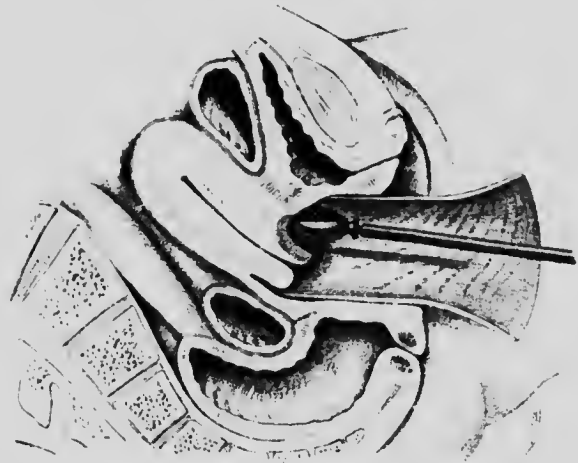


FIG. 635. —ELECTRO-COAGULATION OF A CANCER OF THE ANTERIOR LIP OF THE CERVIX UTERI WITH AN OLIVARY SEMI-INSULATING ELECTRODE.

and, if necessary, a portion of the sacrum. The sphincter is dilated and the posterior wound is left open till cicatrization is complete. It is closed later.

When the cancer is annular and is situated in the lower quarter of the rectum, it is possible that electro-coagulation *per vias naturales* after dilatation of the anus may not reach the upper limits of the growth. The tumour must be then exposed by the classical route.

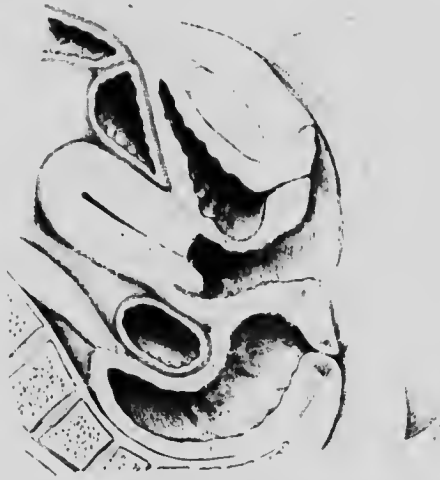

FIG. 636.—ASPECT OF CICATRIX LEFT BY ELECTRO-COAGULATION OF A CANCER OF THE ANTERIOR LIP.

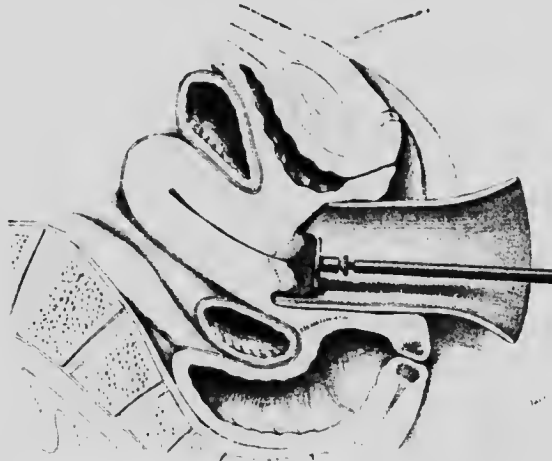


FIG. 637.—ELECTRO COAGULATION OF A CANCER OF THE OS UTERI WITH A DISCOID ELECTRODE.

It is useless to describe this operation at length, as it will be described fully later on. It is a combination of an open operation to expose the

488 SURGICAL THERAPEUTICS AND OPERATIVE TECHNIQUE

tumour and electro-coagulation, which is carried out either at the same time or at a later date, according to the necessities of each case. The length of time required for the elimination of the dead parts varies according

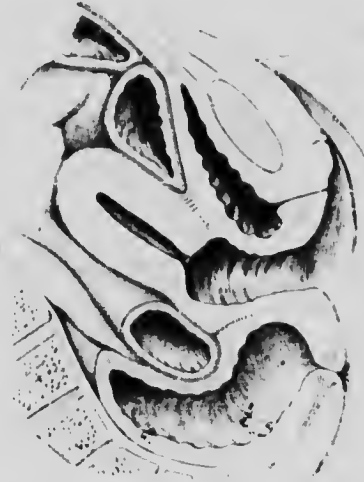

FIG. 638.—RESULT OF ELECTRO-COAGULATION OF BOTH LIPS OF OS, AFTER SPONTANEOUS DETACHMENT OF SPHACELUS.

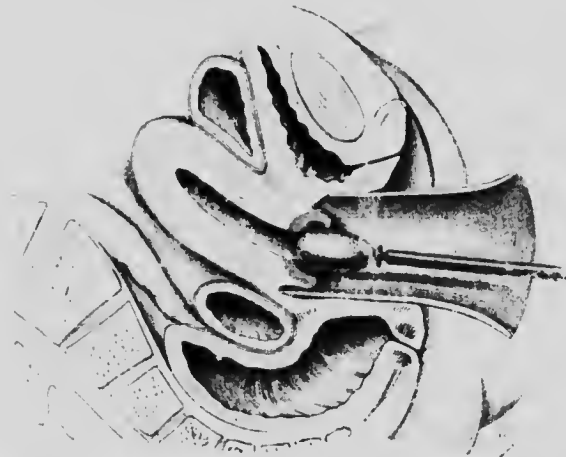


FIG. 639.—ELECTRO-COAGULATION OF A CANCER OF THE MUCOUS MEMBRANE OF THE CERVICAL ORIFICE WITH AN OLIVARY ELECTRODE.

to the case from fifteen to twenty days and this moment of separation is the time when one should be prepared for hæmorrhage, which, indeed, is rare if care has been taken to ligature the large vessels whose opening

would appear to be inevitable when the scars are eliminated. I need not dwell here upon these details, which are a part of general surgical technique. Each surgeon will act as is necessary in each case.

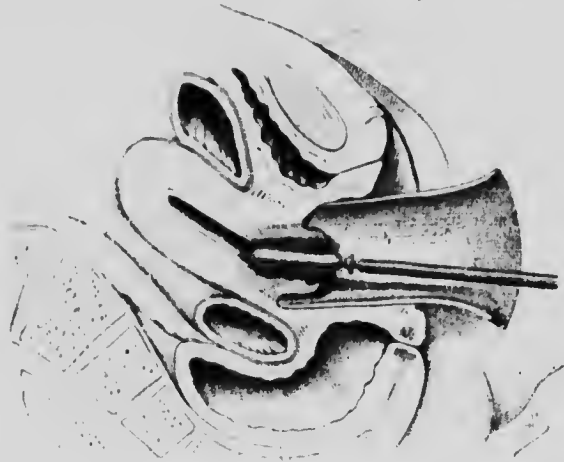


FIG. 640.—ELECTRO-COAGULATION OF A CANCER OF THE MUCOUS MEMBRANE OF THE CERVICAL CAVITY WITH A CYLINDRICAL ELECTRODE.




FIG. 641.—ELECTRO-COAGULATION OF THE MUCOUS MEMBRANE OF THE BODY OF THE UTERUS WITH A CYLINDRICAL ELECTRODE.

12. Electro-Coagulation of Malignant Tumours, Subcutaneous and Deep.

Subcutaneous tumours, especially sarcomata, should be destroyed by the same method of electro-coagulation, which has excellent results in the

prevention of recurrence of subcutaneous or muscular sarcomata. But it is of the utmost importance that treatment should be carried out before much extension has taken place. Electro-coagulation of deep-situated neoplasms is only possible when they are not in the proximity of large vascular or nervous trunks or organs essential to life.

Small malignant tumours of the dura mater or the cerebral cortex can be easily destroyed by electro-coagulation.

When a deep-seated tumour is treated with electro-coagulation the wound must be left open. The wound is aseptically plugged, and the cicatrization is supervised directly. After four weeks the wound can be definitely examined to see if the whole granulating surface is healthy or if suspicious

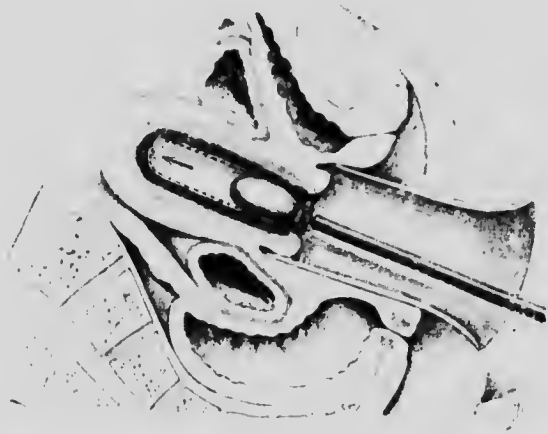


FIG. 642. ELECTRO COAGULATION OF THE WHOLE FELINE MEGAL'S MEMBRANE IN A STATE OF CANCEROUS DEGENERATION, BY A NUMBER OF SUCCESSIVE APPLICATIONS OF AN OLIVARY ELECTRODE.

spots remain, which an experienced eye can readily discern. If recurrence should take place after several electro coagulations have been performed at intervals of one month, the case must be recognized as incurable.

13. The Thermo-Electric Bath.

In certain cases of subcutaneous tumours which are not situated in immediate contact with large vascular or nervous trunks electro-coagulation of the surface is impracticable, owing to the difficulty of performing the operation uniformly over the whole surface of the wound. Electro-coagulation would be produced at a very variable depth in different parts of the cavity, particularly in those parts where sero sanguineous discharge accumulates. I decided to employ saline solution to disseminate the thermo-penetrating current over the whole surface of cavity wounds. Suppose we have a cavity resulting from the removal of a breast or muscular sarcoma.

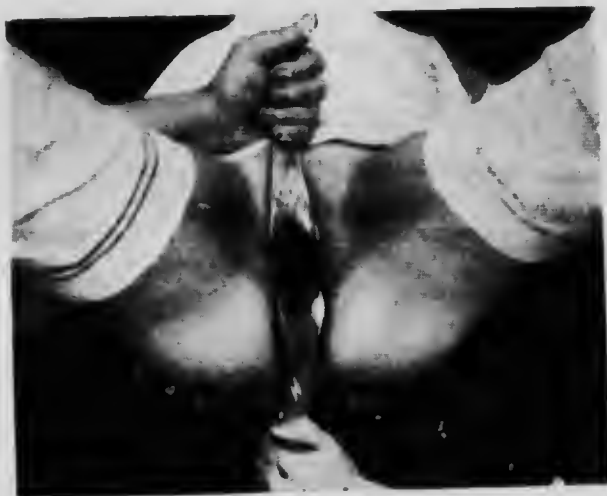

FIG. 63.—CANCER OF OS TINCTE, EXPOSED WITH THE HELP OF TWO WOODEN VALVES

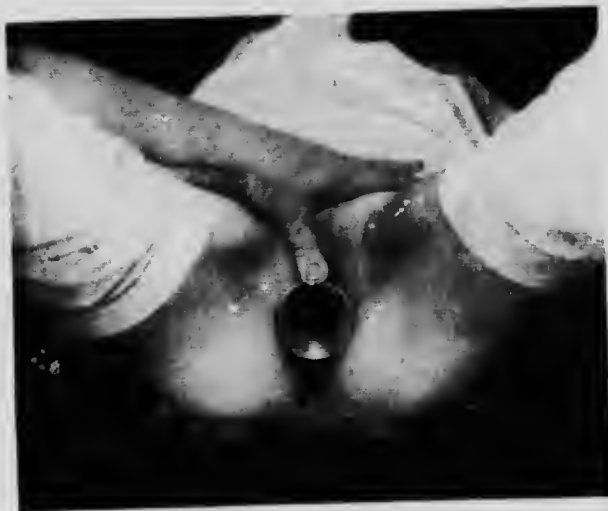

FIG. 64.—CANCER OF CERVICAL CANAL, EXPOSED THROUGH THE MOUTH OF A WOODEN SPECULUM.



FIG. 615. APPLICATION OF DISCIDAL ELECTRODE TO THE CERVIX UTERI.

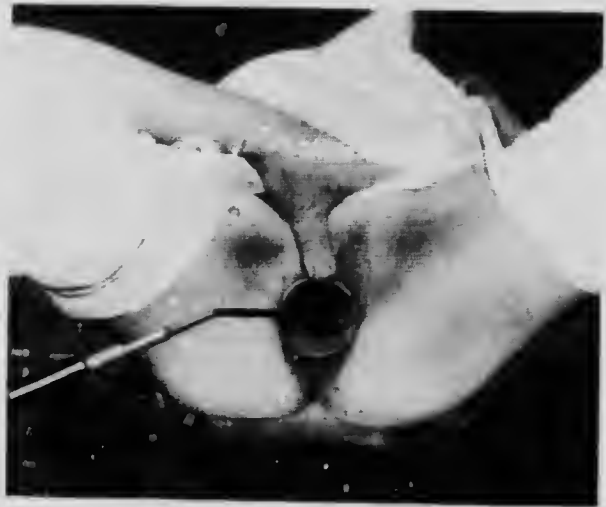

FIG. 616. APPLICATION OF OLVARY ELECTRODE TO CERVIX.



FIG. 647.—APPLICATION OF SEMI-INSULATING OLIVARY ELECTRODE TO LEFT COMMISSURE OF CERVIX.

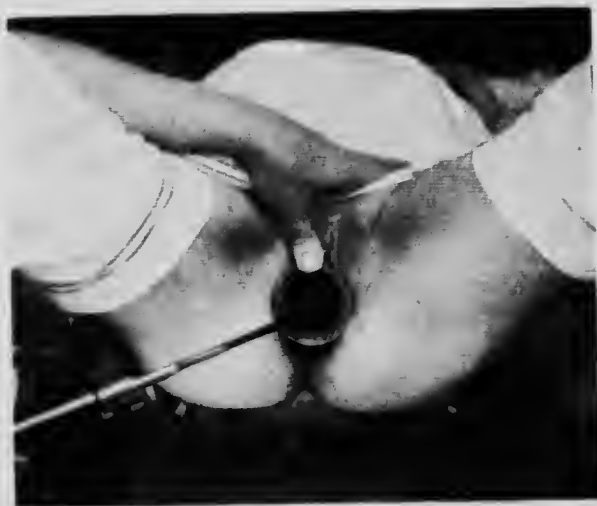

FIG. 648. CYLINDRICAL ELECTRODE ABOUT TO BE INTRODUCED INTO THE NEOPLASTIC UTERINE CAVITY.

94 SURGICAL THERAPEUTICS AND OPERATIVE TECHNIQUE

I pass several silk threads through the skin in order to narrow the orifice by traction, and also to enable the lips of the wound to be held on a horizontal plane.

In certain cases the lowest part of the wound must be sewn together provisionally with a continuous suture. If at one point a vasculo-nervous structure—for example, in the axilla—is exposed in the wound it is protected with one or two wet compresses. The whole cavity is then filled with salt solution, which is already heated to a temperature of 58° C. An assistant draws upon the silk thread so as to hold the edges of the cutaneous wound horizontal; another assistant pours over the surface of the section of the skin salt solution at the same temperature of 58° by means of a small jet. The temperature of 58° does not destroy cells, and does not prevent an attempt at immediate union.

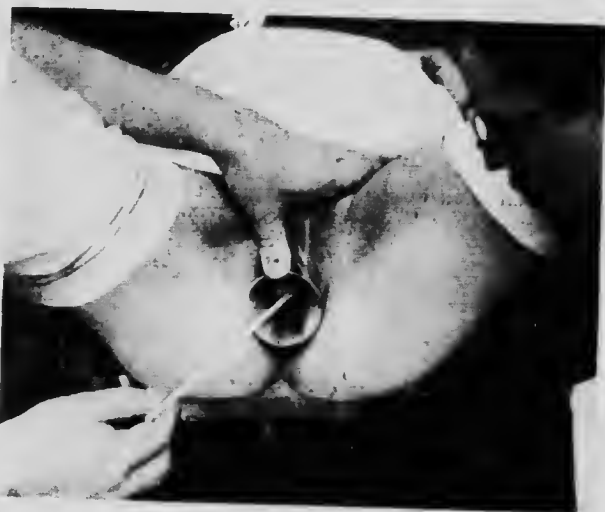

FIG. 69. ASSISTANT TAKING THE TEMPERATURE OF THE SITE OF ELECTRO-CAUTERIZATION WITH A CENTIGRADE THERMOMETER.

The large wet electrode is placed on the skin. The electrode carrier should be mounted with a metallic olive-shaped electrode 12 millimetres in diameter. The surgeon introduces the electrode into the solution, moving it about with one hand, while with the other he moves continuously a centigrade thermometer from place to place. As I have already pointed out, in order to heat the water rapidly all the coils of the solenoid should be interposed, the handle of the rheostat of the primary being pushed forwards according to the volume of the cavity filled with salt solution. At the word "Commence" the circuit is closed, and in a few instants the water, which is already at 56° or 58° C., is heated to 60° C.

The surgeon should constantly move about the active electrode and the thermometer. If the electrode is immobilized for an instant, a thermo-

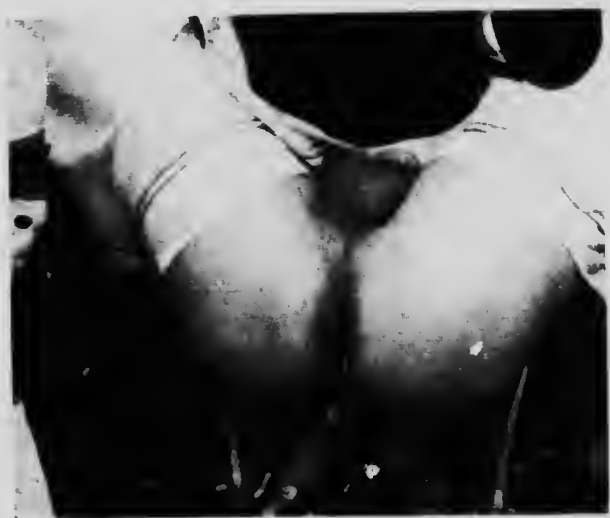

FIG. 650.—CANCER OF RECTUM.

The surgeon is estimating the degree of stenosis with the aid of a Hegar's bougie.

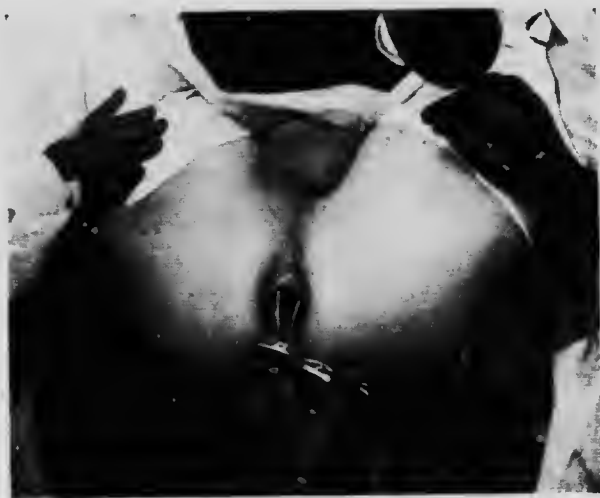

FIG. 651.—CANCER OF RECTUM.

First stage: Forceible dilatation of sphincter by Author's method.




FIG. 652.—CANCER OF RECTUM.

Second stage: The wooden speculum is easily introduced after coating with vaseline.

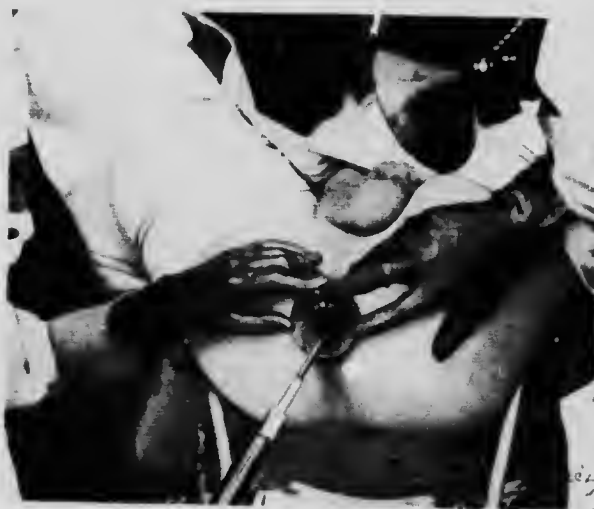

FIG. 653. CANCER OF RECTUM.

Third stage: The cylindrical electrode has been placed in contact with the tumour.



FIG. 654.—CANCER OF RECTUM.

The sanious discharge from the cancer is readily sponged away with a dossil of cotton wadding mounted on the extremity of a long forceps.



FIG. 655.—CANCER OF RECTUM.

Thanks to the Author's frontal mirror, the degree of penetration of the electro-coagulation can be exactly estimated.

penetrating action much too intense is produced at the point nearest to the surface of the wound. The thermo electric bath is stopped when a temperature of 60° C. is obtained throughout the whole of the cavity. If this temperature is not exceeded no lesion of the vasculo-nervous trunks is produced. These remain at a temperature of 55° C., being protected by compresses. Mortification is not provoked in the field of operation.

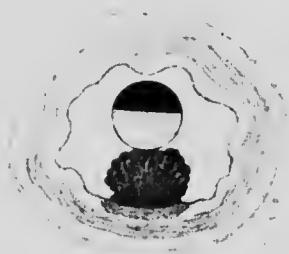


FIG. 656.—ELECTRO-COAGULATION OF A UNILATERAL PAPILLARY CANCER OF THE RECTUM WITH A SEMI-INSULATED ELECTRODE.

I have often obtained, after the thermo-electric bath following ablation of a breast or subcutaneous sarcoma, union by first intention, just as if I had not employed this special technique.

Surgeons who will methodically practise electro coagulation first in simple and later in difficult cases will soon appreciate the excellent results from this method, and the different cases in which it should be applied.

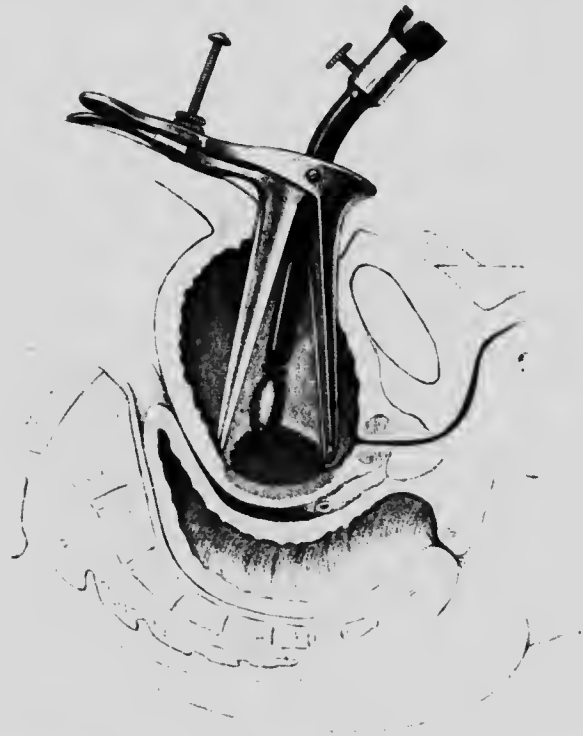


FIG. 657.—DESTRUCTION OF AN EPITHELIOMA GROWING FROM THE BAS-FOND OF THE BLADDER BY ELECTRO-COAGULATION.

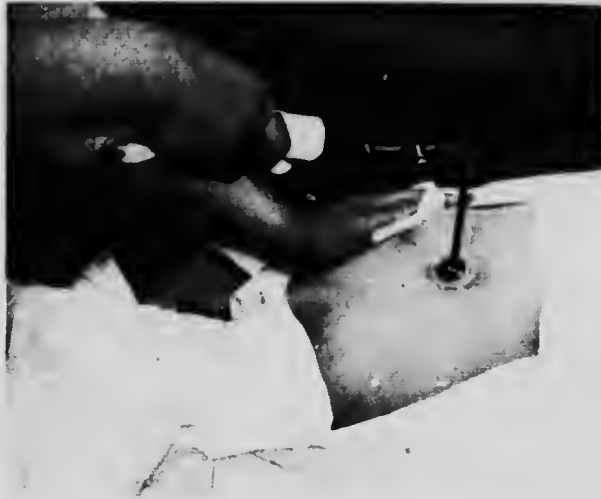

FIG. 658.—ELECTRO-COAGULATION OF A SUPERFICIAL TUMOUR.
We recognize the zone of the electro-coagulation around the electrode.

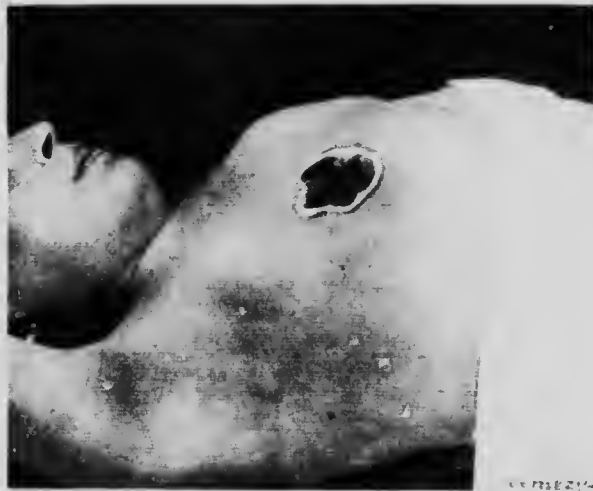

FIG. 659—APPEARANCE OF THE REGION AFTER ELECTRO-COAGULATION.
We recognize the spherulated zone.



FIG. 669. DIAGRAMMATIC SCHEME ILLUSTRATING THE DIFFUSION OF ELECTRO-COAGULATION PRODUCED BY THE EMPLOYMENT OF A TERMINAL PLATE FORMED OF A GOOD CONDUCTOR OF ELECTRICITY.

CONCLUSIONS.

My researches on the penetration of heat in the tissues date from 1896. I found in 1896 and 1897 that neither superheated air, at a temperature over 500° C., nor steam as employed by Professor Snguevireff of Moscow, penetrated to a depth of more than a few millimetres.

It is well known that the actual cantery cuts through the tissues, and that it causes no penetration of heat to any depth.

I recommenced these experiments a few years later, and studied in 1906 the action of radiating heat and heated water upon the tissues.

I found that in acting upon external tumours with hot water contained in a metal cylinder, opened at each extremity and applied by compression to the surface, that the vitality of cancer cells was destroyed in the neighbourhood of 55° C. On the other hand, normal cells were not killed until a temperature above 60° C. was reached.

A burn of the second degree is produced at a temperature of 70° to 72°, and a burn of the third degree is produced at about 75° should the caloric action be prolonged for several minutes.

Local treatment of cancer by physical means is dominated by this biological fact, for which I claim the discovery: "Cancer cells and all pathological cells in general are less resistant than healthy cells to any agents capable of destroying them."

It is to this phenomena that the specific action of X rays and radium on cancer and other lesions have been attributed. No specific action

exists. The penetrating rays of Crookes' tube or radium kill pathological cells slightly quicker than healthy cells, and that is all.

Just as the cancer cell loses its virulence at about 58° C., perhaps even at a slightly lower temperature, the *Micrococcus neoformans* is killed *in vitro* at a temperature of 55°. It is probable that the disappearance of virulence of the cancer cells is intimately related with the disappearance of their endoparasite.

In 1907, therefore, when fulguration was discovered by Professor Pozzi, I had already studied, for a considerable time, the resistance of cancerous cells. I soon found that the sparks of high frequency and high tension had no other than a thermic action, and that below the carbonized zone a zone of coagulation existed analogous to that produced by hot water or superheated steam.

Histological sections were immediately made, and I found that the cells in the coagulated zone were histologically fixed much as they are when fixed by absolute alcohol or formol.

My first experiments were sufficient to show the inefficiency of fulguration in the treatment of cancer.

It is not astonishing that doctors, unaccustomed to scientific experiments, should be led to take their hopes for reality. Thus in the case of X rays, radium, and fulguration, apparent cures have been published all too lightly. Incompetent observers have considered as final, results which are but ephemeral, and improvements which have only ended after several months in the death of the patient.

Continuing the study of the action of heat on cancer cells, I tried to see if high-frequency sparks produced a sufficiently considerable heating of the tissues to explain their action. The study of microscopical sections were quite demonstrative in this respect, but these sections show as well that high-frequency sparks of high tension applied in the ordinary manner have but a superficial action. Convinced of their inefficiency, I tried to obtain, in changing the apparatus, a deeper penetration of heat.

I replaced the fine high-frequency sparks, reinforced by an electric transformer. These sparks were very hot, but caused muscular contraction to such an extent that all the muscles became tetanized. Their local action was very energetic.

I then made use of sparks of high frequency and low tension which are obtained with the *self-induction* circuit on the inferior coils of Oudin's resonator. By this means I produced superficial carbonization, and I observed that I produced electro-coagulation to a depth of 15 to 20 millimetres below the carbonization. In spite of anaesthesia, the patients presented violent muscular contractions. I then observed that if the terminal pole of Oudin's resonator and its middle terminal were short-circuited, the muscular contractions were less, whilst electro-coagulation reached to a greater depth.

I had already treated a large number of tumours by this method, when I discovered that sparks were not necessary and that coagulation of the tissues was produced much better without carbonization if, instead of holding

the electrode at a distance of a centimetre from the tumour, it was held in contact with the pathological tissue.

I also observed that in cancer of the cervix uteri destruction of the cancer was quickly obtained by the introduction of the electrode extremity into the interior of the pathological tissue without the production of sparks.

These first experiments, published in August, 1907, together with my method of destroying accessible cancers by electro-coagulation, were completed in October of the same year, when they were presented to the members of the French Surgical Congress. Certain modifications of apparatus were introduced to obtain a greater production of heat, but the method remained the same as when I discovered it.

M. Nagelschmidt objected, at the Congress of Physiology at Paris, 1910, that Professor Czerny believed that bipolar voltaization was identical with fulguration. When Professor Czerny paid me a hurried visit (of twenty minutes) in 1907, at the time of his visit to study the fulguration of Professor Pozzi, I showed him my results, and I demonstrated to him my method, and indicated the points of difference between it and fulguration. I showed him also my histological preparations. I pointed out that fulguration employs currents of feeble amperage and considerable voltage—that is, of high tension—whilst electro-coagulation uses currents of very high amperage (up to 15 amperes) and *low tension*.

I showed Professor Czerny also that my electrodes are carried in an ebonite sleeve, in the centre of which is a metal conductor, but I receive no electric shock.

If such an isolating sleeve was used in fulguration, shocks would be received, since, owing to their tension, they would transverse the isolating material.

It is evident that my demonstration was of too short duration, and probably it is for this reason that Professor Czerny did not appreciate exactly the difference existing between the two methods.

It is nevertheless true that, during the past four years, a large number of confrères have witnessed this treatment at my clinique, and have been unanimous in agreeing that my method acts by the penetration of heat and the coagulation of the pathological tissues to a great depth.

The latest apparatus for electro-coagulation, which GaiFFE has constructed under my direction, is very interesting, for the slightest and most considerable effects can be obtained by the same apparatus.

The numerous cures obtained by the method of thermic electro-coagulation show that it should be substituted in every variety of cancer for the employment of X rays and radium. These physical agents, indeed, are incapable of acting in the depths, and in spite of what has been claimed to the contrary, have no elective action on cancer cells.

ld in
f the
mity
arks,
n my
com-
bers
were
ained

1910,
with
enty
essor
hod,
owed
ation
s, of
rage

n an
eive

l be
ting

rob-
ctly

ber
een
and

on-
most

ula-
the
are
l to

PART II
REGIONAL SURGERY



OPERATIONS ON THE HEAD

HAIRY SCALP AND PERICRANIUM.

Traumatic Lesions.

Wounds of the Head. Wounds of the head may vary from a simple division of the skin with a cutting instrument to detachment of a portion of the hairy scalp. The integuments are often contused, and the wound may be sown with foreign bodies (hairs, earth, gravel, etc.). Rapid coagulation of the blood frequently causes a certain degree of adhesion of the folded flaps, so that it is necessary to make a complete examination of the wound before proceeding to suture. The hairs are shaved to a distance of 15 to 20 millimetres from the margin of the wound, the skin is washed with soap and

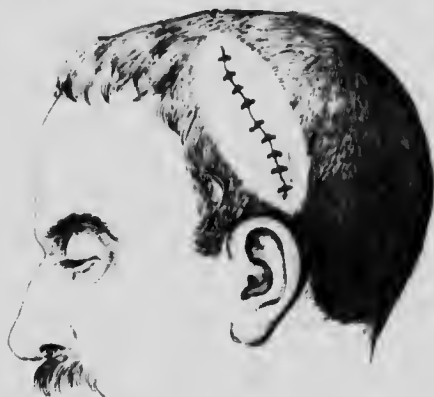

FIG. 561.—WOUND OF THE HAIRY SCALP: INTERRUPTED SUTURE.

hot water, next with sublimate solution of 1 in 1,000, and then with ether; and the flaps are folded back to the extent of their detachment. All foreign bodies are carefully removed. The clotted surfaces are now washed with a 2.5 per cent. phenol watery solution or a 20 per cent. oxygenated water, and we proceed to suture after placing at the limits of the area of detachment, when extensive, one or two india-rubber or glass drainage-tubes. These should be placed at the dependent points. When a counter-opening is necessary, it should be made where the cicatrix will not be conspicuous. In case of small wounds, we can drain with a bundle of Florentine hairs,

The skin wound should be united with points of interrupted suture, or with continued suture made with Florentine hair, silk, catgut, or hooks. When the lips of the wound are mangled, it is well to resect them with bistoury or scissors, in order to obtain sound union.

Complete Detachment of the Hairy Scalp. This accident, which is fortunately rare, occurs especially in women, when the hair is rolled round a machine-brush. Those immense wounds should be dressed on the flat

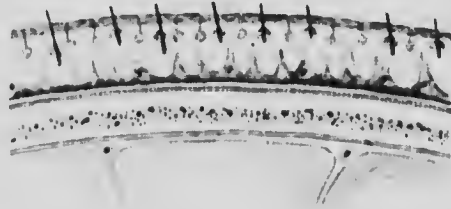


FIG. 662. SECTION OF CRANIAL TEGUMENTS SHOWING THE SUPERPOSITION OF THE VALDE'S STRATA.

The arteries run in the deep part of the skin, near the surface of the epicranial aponeurosis.

They heal only after a very long time, and with the application of dermo-epidermic grafts. These need not be used except when the wound is covered with exuberant fungous granulations.

Inflammatory Lesions.

ACUTE INFLAMMATORY LESIONS.

Phlegmon.—Subcutaneous phlegmon of the hairy scalp is nearly always a complication of an infected wound. The detachment of the scalp may proceed rapidly, especially when pus has formed between the epicranial aponeurosis and pericranium. These structures are very easily separated, and pus should be sought whenever any inflammatory œdema is noticed, even in the absence of definite fluctuation. Early incision and drainage are the only means of preventing further more or less grave complications. A moist dressing is applied. The occurrence of erysipelas is specially to be dreaded. A preventive injection of 10 c.c. of mycolysine (see p. 282) is administered at once, and repeated daily for at least three or four days.

Deep Abscesses of the Nuchal Region.—Deep abscesses of the nuchal region may give rise to very alarming pseudo-meningeal symptoms. They are usually accompanied by inflammatory œdema of considerable extent. I have seen one of those abscesses which formed beneath the epicranial aponeurosis, and the etiology of which had remained uncertain. The suppuration was accompanied by grave symptoms, and the state of the patient was considered desperate. The diagnosis had not been made, notwithstanding the presence of a characteristic inflammatory swelling, which set

me at once on the track. Incision permitted the exit of a great quantity of pus, and was immediately followed by complete cessation of the cerebral symptoms. A subcutaneous injection of mycolysine hastened the process of cure.

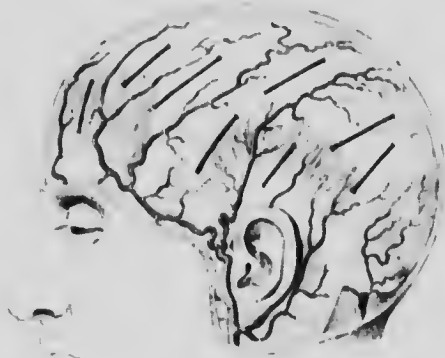

FIG. 661. SCHEMATIC FIGURE, SHOWING THE POSITIONS OF THE VARIOUS INCISIONS OF THE HAIRY SCALP, BY WHICH WE ARE ABLE TO AVOID THE PRINCIPAL ARTERIAL BRANCHES.

SEPIACITE AND CHRONIC INFLAMMATORY LESIONS.

Subcutaneous Tuberculous Gummata.—Subcutaneous tuberculous gummata and foci of superficial tuberculous periostitis of the cranial bones are not exceptional, and often synchronize with the evolution in other regions of subcutaneous gummata not engaging the skeleton. I have in one case operated on as many as sixteen of those tuberculous gummata in the same person, subcutaneous or periosteal, situated for the most part on the forehead and face, and around the scapula and clavicles. In many cases the skin is very much attenuated. It should then be resected between two curved incisions. Fistulae are treated in the same way. If the bone is affected, superficial crasion should be practised, and the wound treated by aero-catherization and plugging. Autoplastic operation should be postponed to a subsequent date.

Caries and Superficial Necrosis of the Cranial Bones.—Caries and necrosis, which are usually of tuberculous nature, may attack various parts of the cranial vault; notably the frontal region, margin of orbit, and malar and petrous bones. When there is a fistulous orifice, the incision should be made to pass through it. It should also be rectilinear or slightly curved. The osseous focus must be carefully curetted, and the wound treated by plugging. When the cicatrix is too conspicuous, it may be removed after the healing of the wound, and the part repaired by an autoplastic operation. The autoplasty consists of mobilizing the skin adherent to the bone, and repairing the deformity. The patient should also receive a continuous course of treatment with mycolysine and phymalose (see p. 288), which will increase the vital resistance to the invasion of Koch's bacillus.

Congenital Deformities.

Meningocele and Encephalocele of the Cranium.—The tumour is globular in form, and situated almost without exception in the occipital region. Its

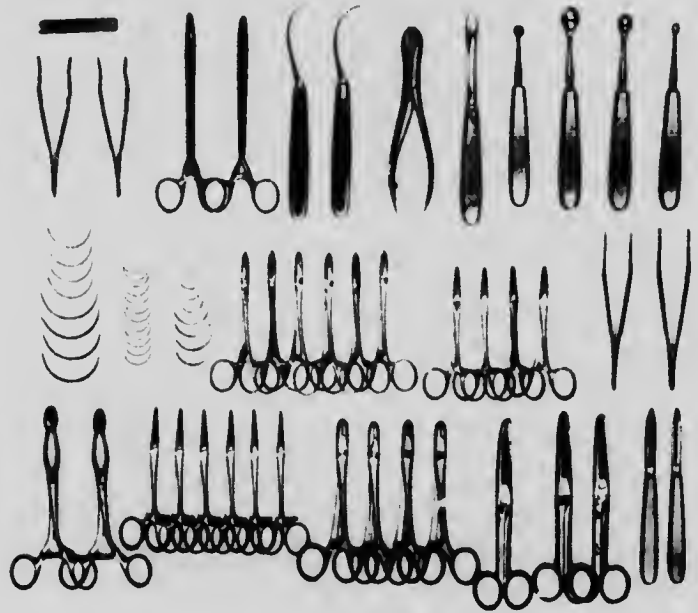


FIG. 664. INSTRUMENTS REQUIRED IN PREPARING FOR OPERATIONS ON THE Hairy SCALP AND OTHER PERICRANIAL SOFT TISSUES, INCLUSIVE OF THE PERICRANIUM.

The instruments are arranged as they should be on the table, to the right of the surgeon. Below, and from left to right: Two bistouries, two pairs of straight scissors, one pair of curved scissors, four forceps with short clawed jaws, six forceps with ring handles and nine oblique claws, two ring-handled forceps with oval jaws. Above: Two clawed forceps, four Champouinière's hemostatic forceps, six needle-holder forceps with short jaws, four types of cutting needles (four of each type), and twelve intestinal needles. In highest row: Three ordinary enettes, one spatula, one gouge forceps, two needles mounted on handles, two needle-holders with eccentric jaws, thirty clips, and two clip-holder forceps. Scale reduced to one-sixth.

NOTE. All plates of instruments the scale of which is not mentioned are reduced to the same scale as in Fig. 669.

volume is very variable. The portion of nerve tissues contained in the sac is usually a kind of exuberant product, and may be extirpated without danger.

First Stage: Outline of Cutaneous Flaps.—Tracing and dissecting up cutaneous flaps of an extent more than sufficient for good reunion.

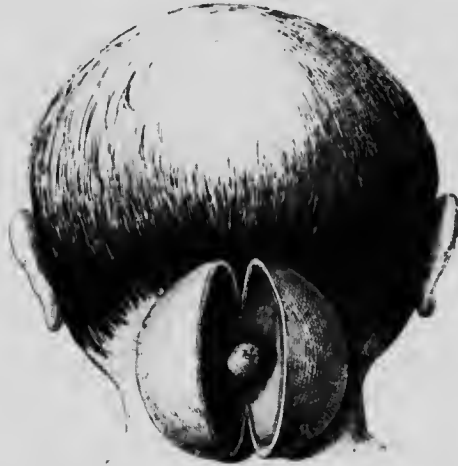

FIG. 665. OCCIPITAL MENINGOCELE: INCISION OF THE CYSTIC SAC.

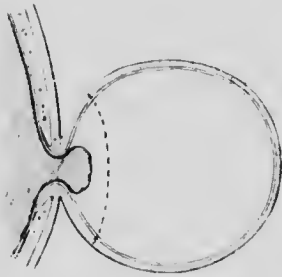
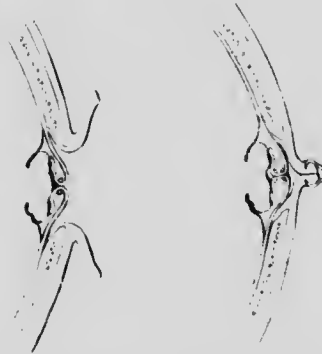


FIG. 666. SCHEMATIC SECTION SHOWING THE ENCEPHALIC HERNIA.

The dotted line indicates the seat of resection of the internal membrane of the cyst.



FIGS. 667 AND 668. ANTERO-POSTERIOR SECTION, SHOWING REDUCTION OF THE ENCEPHALIC HERNIA AND INVAGINATION OF THE COLLARETTE, THE UMBILICUS OF WHICH IS CLOSED WITH TWO SUTURES, DEEP AND SUPERFICIAL: SUTURE OF SKIN WITH HOOKS.

Second Stage: Freeing the Neck of the Sac and Suture of the Membranes.
— We recognize and isolate the margin of the bony orifice, and then open the sac, with the precaution of moderating the rush of cephalo-rachidian fluid. When the orifice is very small, a circular ligature may be applied, and we then bury that ligature under a purse-string suture, which is covered

in turn with a fine longitudinal continuous suture, the latter being applied in the direction in which the apposition of the dura mater can be effected most satisfactorily.

Third Stage—Reunion of the Integument.—Suture of the skin flaps, which must be trimmed if exuberant. Fine silk or clips are preferred for this purpose.

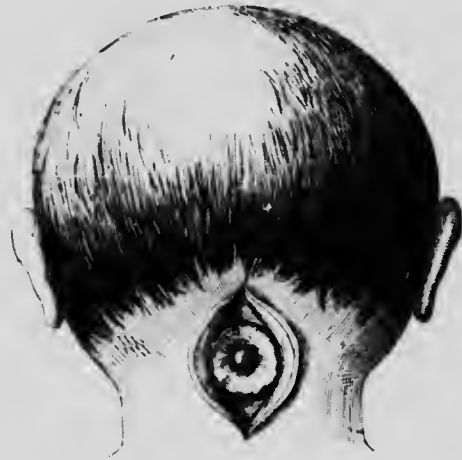

FIG. 660.

The exuberant skin has been resected, then the exuberant part of the internal membrane. The cephalic hernia has to be reduced, and the surrounding fibrous collarette invaginated.



FIGS. 670 AND 671.—DEEP PURSE-STRING SUTURE OF THE INVAGINATED COLLARETTE; SUPERFICIAL CONTINUED SUTURE.

Meningocele and Encephalocele of the Face.—Tumours which project into the nasal fossae or buccal cavity should be extirpated. The procedure may call for temporary resection of the superior maxilla as a preliminary.

Acquired Deformities.

Vicious Cicatrices—Keloids.—Except in case of exceptional laxity of the tissues, the possible extent of resection of the skin of the cranial vault is usually limited to a transverse band of 15 to 20 millimetres in breadth. The frontal region is that nearly always concerned in the question. The skin should be very neatly divided with a bistoury, and interrupted suture

of silk or Florentine hair adopted, commencing at the middle of the wound. If the loss of substance is too extensive, 10 or 12 millimetres may be gained in the antero-posterior direction by making on the affected side of the cranial vault a certain number of liberating Y-shaped incisions, to be sutured in V outlines. Or one of the lips of the wound may be mobilized



FIG. 672.—COMBINED Y-SHAPED INCISIONS, FOR VERTICAL ELONGATION OF THE CRANIAL TEGUMENTS.

We have here to close the superciliary wound which was left by ablation of a vicious cicatrix.

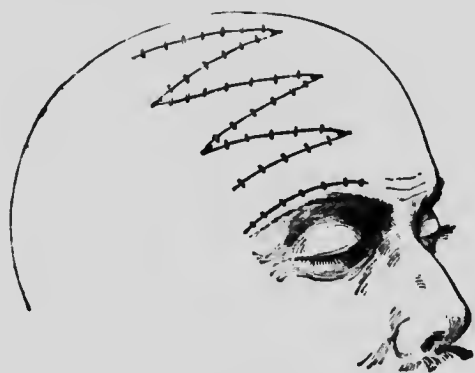


FIG. 673

The Y incisions have been sutured in V outline, a procedure which has had the effect of shortening the tegumental area from side to side and elongating it in the vertical direction. The superciliary wound has been closed without drag on the upper eyelid.

by a compensatory curved incision. If the suture appears to be too tense at the level of the compensatory incision, a small oval surface is left to cicatrize from the edges; or we may obliterate this by sliding displacement of a flap of adjacent skin, mobilized in the same way as the former one.

Tumours.

BENIGN TUMOURS.

Warts—Horny Growths.—These small tumours are removed between two curved incisions. A concealed intradermic suture can be made with silver wire (see Figs. 441, 442, and 443).

Invading Pigmentary Nævus. This variety of pigmentary and non-elevated naevus is observed more especially in the facial region, and tends to degenerate into pigmentary sarcoma. When its area is too extensive to permit complete extirpation of the affected skin, an excellent result may be obtained by practising a number of successive curettages sufficiently thorough for removal of the whole pigmented layer. A flat, compressive dressing should be applied.



FIG. 674. CUTANEOUS PAPPILLOMA: ABLATION BETWEEN TWO SYMMETRICAL CURVILINEAR INCISIONS.



FIG. 675. CUTANEOUS PAPPILLOMA: ABLATION BETWEEN TWO ASYMMETRIC CURVILINEAR INCISIONS.



FIG. 676. EXTIRPATION OF A SMALL CUTANEOUS PERICRANIAL TUMOUR; INTRADERMIC SILVER-WIRE SUTURE.

Erectile Tumours of the Hairy Scalp. Erectile tumours of the scalp are found especially in young children, and pursue a very rapid course of development in some cases. Coagulating injections are very dangerous to use, on account of the connection of those tumours with the intracranial sinuses. Jennerian vaccination sometimes gives good results, but, whenever practicable, I prefer ablation with a cutting instrument, followed by suture. The tumour should be removed in a few seconds between two curvilinear incisions. The hemorrhage is insignificant if the section is made 2 or 3 millimetres from the limits of the erectile tumour. The suturing usually suffices to arrest the bleeding. When arterioles of some size are divided, they are tied separately. A compressive dressing is applied. In the case of infants, the laxity of the tissues of the scalp always enables us, after removal of erectile tumours of some extent, to secure a perfect reunion.

Wens of the Hairy Scalp. If the teguments are intact, the operation is carried out as follows: The skin is shaved to a distance of 2 centimetres from the margin of the wen; it is then washed and disinfected. Interstitial injections of a 1 per cent. sterilized solution of cocaine are now made at

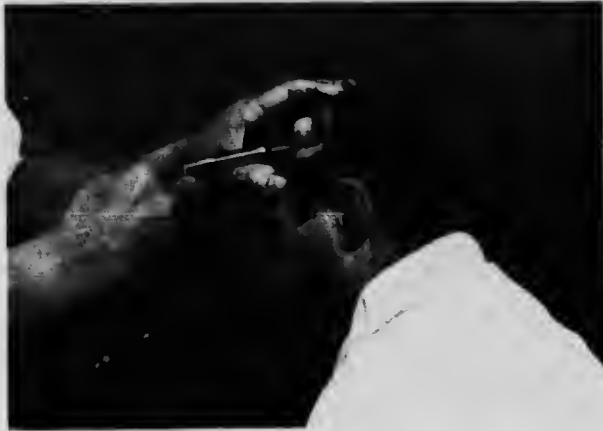

FIG. 677. WEN OF THE HAIRY SCALP.

Local anaesthesia by injection of 2 per cent. cocaine solution.

five or six points around the margin of the wen, according to its size. The field of operation is surrounded with a sterilized compress, which has a window large enough to allow the tumour to pass through. After the lapse of two or three minutes, the skin is incised longitudinally over the whole extent

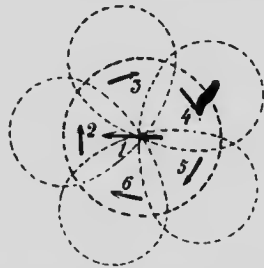


FIG. 678.—SCHEMATIC REPRESENTATION OF SIX SUCCESSIVE INJECTIONS OF COCAINE, REQUIRED FOR AN ESTHESIA OF THE FIELD OF OPERATION.

The arrows indicate the position and directions of the punctures of the tubular needles.

of the cyst without opening the latter. The right flap, and then the left, is folded back in turn with a clawed forceps, and the pouch is cauterized with the end of a blunt-pointed scissors or with a cauter of suitable diameter. A compressive dressing usually suffices. If some points of

512 SURGICAL THERAPEUTICS AND OPERATIVE TECHNIQUE

suture are applied, one of the extremities of the wound can be drained with a bundle of Florentine hairs. Immediate union is the rule, and should be completed in a few days.

This technique is far superior to the procedure of extirpation by *trans-fision*, which risks the introduction of the sebaceous matter over the whole

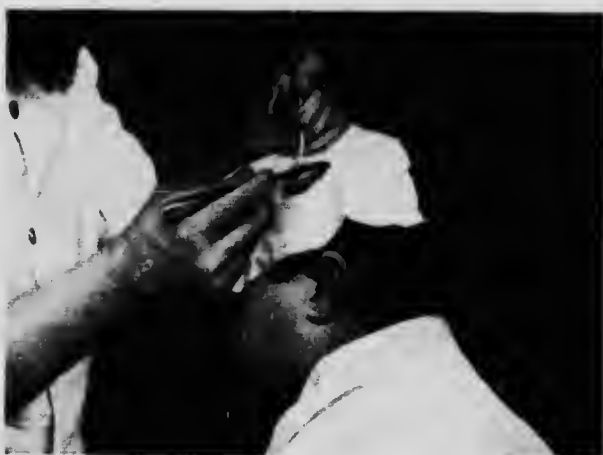

FIG. 679. EXTIRPATION OF A WEN OF THE HAIRY SCALP: INCISION OF THE SKIN AND DISSECTION OF THE UPPER LIP OF THE INCISION.

The skin is thinned by the growth, and it is necessary to try to avoid rupture of the sebaceous cyst.

area of the wound. When the wen is very voluminous, it may be desirable to resect with it the upper part of the covering skin, which is thinned and adherent; or the wen itself may be removed first, and the exuberant skin,

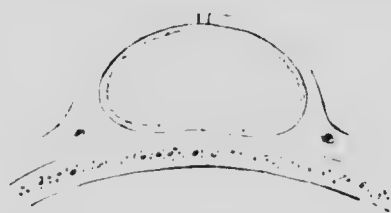


FIG. 680. EXTIRPATION OF A WEN OF THE HAIRY SCALP: INCISION OF THE SKIN.

Diagrammatic section showing two divided arterioles near the cranial wall.

which would retard the union by its presence, is then clipped off with scissors. In the case of a female patient, shaving of the part may be dispensed with. The toilet of the field should be made with the minutest care, and the hairs are then separated with a comb over the line of incision.

Fistulous and Ulcerated Wens.—When the wen is necrotic or fistulous, the cyst wall is in most cases isolated from its cellular envelope, and is found to be free when the skin is incised. We may secure rapid remission by touching the wound with a 20 per cent. oxygenated water or a 10 per cent. zinc chloride solution, and then applying a compress. A small drainage-tube secures the exit of pus if immediate union has not been obtained.



FIG. 681.—EXTIRPATION OF A WEN OF THE HAIRY SCALP.

Emucleation of the cyst by division with blunt-pointed scissors, introduced beneath the wen, and made to dislocate it outwards.

It is absolutely indispensable that the surgeon should observe all antiseptic precautions with the fullest rigour in those small operations. Disinfection of the hands, instruments, accessories (*e.g.*, suture materials), all rules and details of asepsis, in fact, should invariably be carried out with the most




FIG. 682.—EXTIRPATION OF A WEN OF THE HAIRY SCALP.

Diagrammatic section showing the thickening of the tissues around the cyst, and the depression of the skin left after its extraction.

exact care, however trifling the operation may appear to be. A prophylactic subcutaneous injection of 10 c.c. of mycolysine should be administered and repeated daily for three or four days.

The cyst is sometimes almost free in its adventitious cavity. If we want to obtain a really good local anaesthesia, it is indispensable that the stovaine injections be made very superficially under the epidermis; if this

544 SURGICAL THERAPEUTICS AND OPERATIVE TECHNIQUE

is not done, the anesthetic solution penetrates into the suppurating cavity and remains inactive. The thinned exuberant skin, which would retard the union if left, must be fully resected.

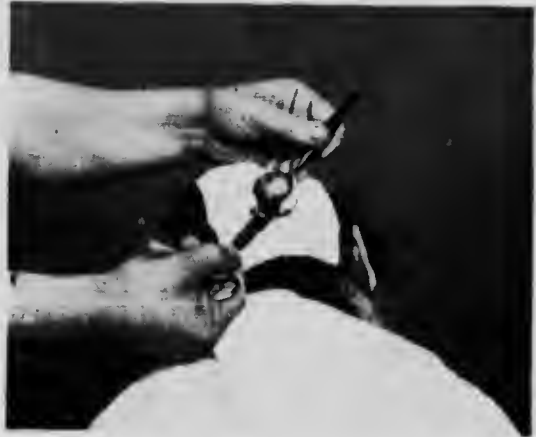

FIG. 683.—EXTIRPATION OF A LARGE OCCIPITAL WEN, WITH RESECTION OF THE EXUBERANT AND THINNED INTEGUMENT.

Dissection of the outer cutaneous flap and detachment of the deep aspect of the cyst with blunt-pointed scissors.

Dermoid Cysts of the Superciliary Border. Dermoid cysts of the superciliary region are often very adherent to the periosteum, to which they



FIG. 684.—EXTIRPATION OF A LARGE OCCIPITAL WEN, WITH RESECTION OF THE EXUBERANT AND THINNED INTEGUMENT.

Enucleation of the sebaceous cyst with blunt-pointed scissors.

are fixed by a fibrous pedicle. The incision should be made parallel to the superciliary arch, after anesthesia with 1 per cent. cocaine solution. It



FIG. 685. FISTULOUS WEN OF THE NECK.

Local anesthesia by interstitial injection of 1 per cent. cocaine solution.

is unnecessary to shave the eyebrow, which will be sufficiently disinfected by washing with warm water and soap, then ether, and finally sublimate solution. We thus avoid the prolonged period of ungracefulness produced by denudation of this region.

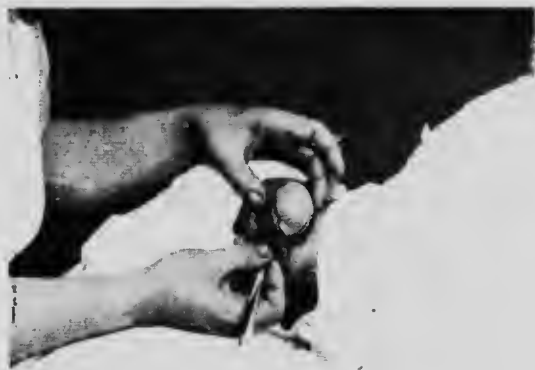

FIG. 686. FISTULOUS WEN OF THE NECK.

The exuberant skin has been circumscribed with two curvilinear incisions.

516 SURGICAL THERAPEUTICS AND OPERATIVE TECHNIQUE

OPERATION—First Stage: Incision of Integument.—The cyst is exposed by an incision parallel to the curve of the eyebrow.

Second Stage: Dissection of the Cyst.—We then detach it from its adhesions with the aid of a blunt scissors used as a spatula, or even with

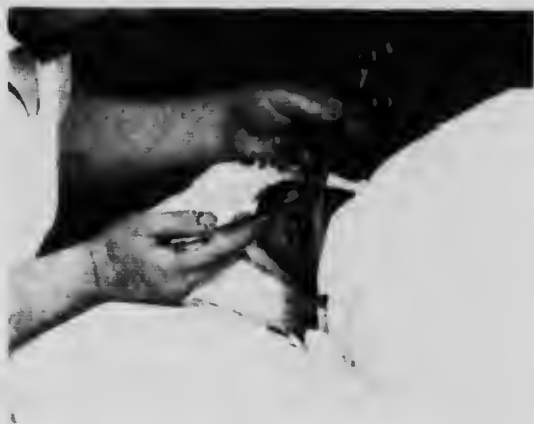

FIG. 687. — FISTULOUS WEN OF THE NECK.

Extirpation of the cyst, the contents of which have been evacuated through the orifice of the fistula.

a bistoury, and clawed forceps. The wall is nearly always sufficiently resistant to permit removal of the cyst without rupture. The tip of the scissors is introduced beneath the cyst, in order to separate the deep structures, and the little tumour is then seized with a clawed forceps and drawn out of the wound, to be liberated from its last attachments.



FIG. 688. — EXTIRPATION OF A DERMOID CYST OF THE EXTREMITY OF THE EYEBROW: CLAVICULAR INCISION.

Third Stage: Suture.—The suturing is carried out with fine needles and very fine Florentine hair, or with clips. If there be still a sanguineous oozing at the bottom of the wound, we drain with a bundle of four or six Florentine hairs. A compress dressing should then be applied for twenty-four to forty-eight hours.

Dermoid Cysts of the Mastoid Region.—Dermoid cysts of the mastoid region are very strongly adherent on their deep aspect, and it is indispensable, before proceeding to their ablation, to procure good local anaesthesia with a 1 per cent. cocaine solution, or to have recourse to general anaesthesia with ethyl chloride. The skin is first shaved and disinfected. A vertical incision is then made. Dissection and isolation of the cyst should be carried out, if possible, without rupture or perforation; as it is necessary to extirpate it completely. Suturing is effected with Florentine hairs or clips, and when the cyst is voluminous, a small drainage-tube is inserted for a period of twenty-four to forty-eight hours. The operation may prove a troublesome one, so that we should not undertake it carelessly, without previous arrangement of a sufficient supply of instruments.

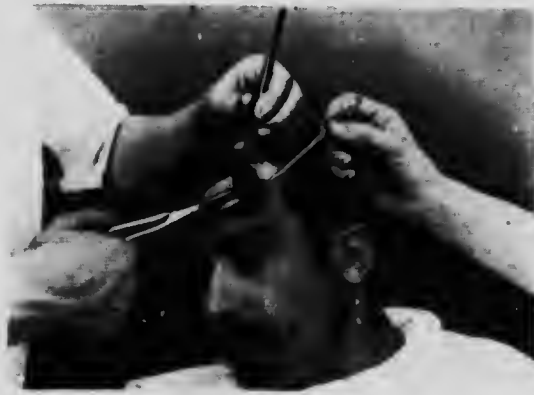

FIG. 689.—EXTIRPATION OF A SUBCUTANEOUS LIPOMA OF THE FOREHEAD: SECTION OF THE LAST ATTACHMENTS OF THE GROWTH.

Lipomata of the Frontal Region.—The differential diagnosis of a subcutaneous lipoma of the frontal region is sometimes difficult enough. We recognize it by its lobulated aspect and the special consistence of the tumour, which is usually flatter than the cysts with epidermic contents. The incision is made horizontally, along one of the folds of the skin of the forehead, and the tumour is lifted out with scissors, acting by division, and ring-handled forceps, care being taken not to leave any of the lobules behind. Usually we unite the edges of the wound without drainage, and all capillary hemorrhage is prevented by application of a compressive dressing.

Lipomata of the Nuchal Region—I. SUBCUTANEOUS LIPOMATA.—Lipomata of the nuchal region are often symmetrical and subcutaneous. I have removed some enormous specimens, which coexisted with other symmetrical lipomata of the mastoid and upper dorsal regions. The ablation is effected through an incision along the line of one of the grooves of the region affected, which tend to be horizontal in most

instances. The adhesion to the skin is often rather extensive, and the operation requires preparatory anaesthesia with chloroform when the growth is large or multiple.

2. **DEEP-SEATED LIPOMATA.**—I have observed deep-seated lipomata of the nuchal region placed between the deep stratum of the recti and obliqui muscles and the intermediate muscular layer. This lipoma, which was of the bulk of a large orange and rounded in form, had no adhesions to the surrounding tissues. It was easily enucleated. It is desirable in such cases to leave a glass drainage-tube in place for forty-eight hours.

Cirsoid Aneurysms.—As in case of erectile tumours, cirsoid aneurysms should be extirpated with the bistoury. The haemorrhage need not be treated if we take the precaution of incising the skin beyond the tumour without wounding the dilated vessels, and then making compression around the area. The afferent arteries are usually tied without difficulty. The most rapid procedure consists in circumscribing the whole tumour with a horseshoe incision reaching down to the perianial aponeurosis, and folding

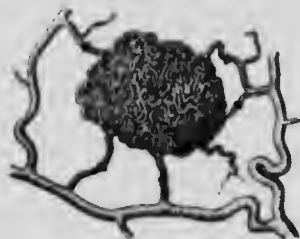

FIG. 690.—CIRSOID ANEURYSM.

Diagram of the arterial neoformations, showing the point at which the five afferent arteries should be tied.

down the entire flap over the temple. Very little blood is lost if the tumour is removed freely and rapidly. An assistant maintains pressure on the margin of the incision. The surgeon grasps in a compress the telangiectatic mass folded over with the skin. Two forceps with elastic jaws can command the pedicle till the conditions of haemostasis have been satisfied. The telangiectatic mass is extirpated, the bleeding vessels are tied with fine silk or catgut, and the skin is replaced and sutured. A glass drainage-tube is placed at the lowest point of the wound.

We also can expose the tumour through an appropriate cutaneous incision. The integument is detached beyond its limits, so as to expose the afferent arteries. All considerably exposed branches are tied, and the vascular mass is removed. Haemostasis is now completed, the skin sutured, drainage arranged, and compressive dressing applied.

Plexiform Neuroma.—This form of tumour has often been confounded with a lymphadenoma, or even with a subcutaneous erectile tumour. It is most often seen in the temporal and external orbital regions. The removal

can be effected without difficulty with a cutting instrument. The processes of the neoplasm must all be followed up; they resemble in form large filaments of teased and tangled vermicelli.

MALIGNANT TUMOURS.

Epithelioma of the Hairy Scalp.—Epithelial tumours of the hairy scalp habitually affect the form of vegetating papillomata.

1. *The Bloody Method of Operation*—I will describe—as an aid to the reader's memory—the bloody method, which will soon be replaced by that of electro-coagulation. Extirpation should be adopted at an early stage, and on a large scale. The direction of the incisions should be perpendicular to that in which the skin glides most readily. The skin is shaved and disinfected. The tumour is circumscribed, at 10 or 12 millimetres from its periphery, with two free curvilinear incisions, reaching down to the pericranium. Immediate remotion of the wound is adopted.

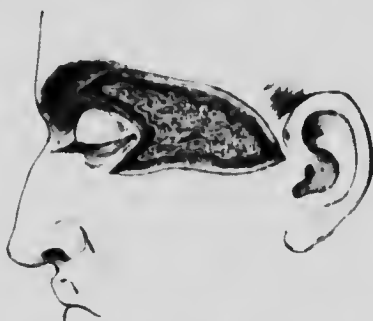

FIG. 691. PLEOMORPH NEUROMA, EXTENDING FROM THE TEMPORAL TO THE ORBITAL REGION, AND INVOLVING THE TISSUES OF THE EYELIDS.

and drainage is used when the wound is large. In cases in which the remotion of the edges is difficult to effect, a compensatory curvilinear incision is made (Fig. 697). The points of suture are placed as indicated in the figure: first at *C*, the seat of maximum separation of the edges of the wound; then at *A*, *B*, and so on, in such a way as to permit approximation of the edges of the opening: first, of the points most widely separated; then by division of the intermediate spaces into halves. Good coaptation is thus secured, and we attain to perfect contact of the two lips of the wound without difficulty.

If the tumour is adherent to the pericranium, it is prudent to remove a certain portion of the subjacent outer table of the skull. This procedure is effected with a mallet and chisel, the latter having a fine cutting edge. When the bone is involved, the vault of the skull must be sacrificed through its whole thickness, by attacking it with burr, saw, craniectomy forceps, chisel, and gouge forceps (see subsequent description).

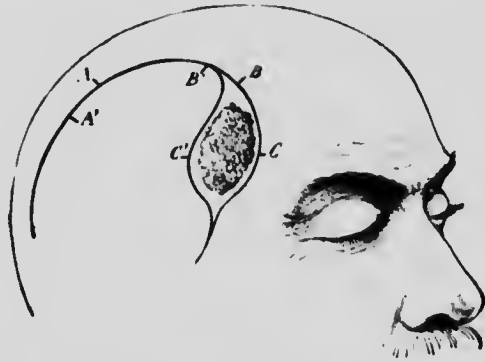


FIG. 692. EXTIRPATION OF A CANCROID OF THE SKIN OF THE TEMPORO-FRONTAL REGION.

Outline of autoplasmic flap. The letters *A', B', C'*, indicate the points of the periphery of the cutaneous flap, which are to be sutured to *A, B, C*, respectively.

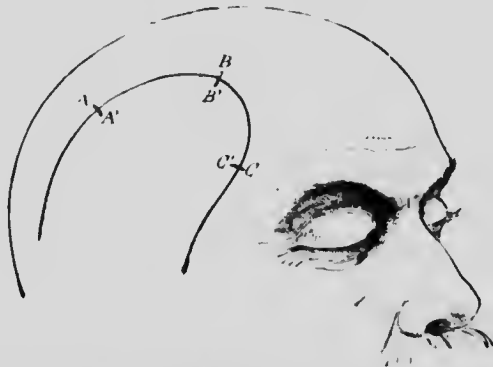


FIG. 693. EXTIRPATION OF A CANCROID OF THE TEMPORO-FRONTAL REGION.

The flap is adapted to the loss of substance, and covers the exposed space without dragging.



FIG. 694. EPITHELIOMA OF THE HAIRY SCALP INVADING THE EXTERNAL TABLE OF THE SKULL.

Diagrammatic section.



FIG. 695. EPITHELIOMA OF THE HAIRY SCALP WHICH HAS PERFORATED THE CRANIAL VAULT.

Diagrammatic section.

2. *Electro-Coagulation*.—I have now completely given up all the bloody methods of operation for superficial malignant tumours. It is far better to extirpate those growths with the eurette, and then destroy the zone of implantation by thermic electro-coagulation. Flat dressings are then applied.

Sarcoma : Simple or Melanotic.—Simple or melanotic sarcoma is most often found in the mecal region, where it rapidly invades the muscular stratum. Extensive extirpation with a cutting instrument must always be resorted to.

Pericranial Sarcoma of the Calvaria.—This variety of growth, which is fairly common, is nearly always of traumatic origin. At first it is often



FIG. 696.—PERICRANIAL SARCOMA OF THE CALVARIA.
Diagrammatic section.

mistaken for a wen. These sarcomata gradually invade the cranial bones, and soon become wholly inoperable. The diagnosis should be verified by histological examination. When this error has been committed and a subsequent diagnosis attained by incision, ablation must be carried out on an extensive scale, followed by electro-coagulation of the outer table of the cranial vault to an extent well beyond the limits of the tumour.

Carcinomatous Metastases.—Cutaneous and subcutaneous cancerous metastases of the skin of the cranial vault are not very rare in cases of generalization of cancer of the breast or of that of other organs. Extirpation is useless; electro-coagulation and antineoplastic vaccination should be tried.

CRANIUM AND ENCEPHALON.

GENERAL OPERATIVE TECHNIQUE OF OPERATIONS ON THE CRANIUM.

Trepanning of the cranium has been practised from the remotest antiquity; and the orifices which have been found in fossil crania do not differ sensibly from those made within the last 150 years with the various forms of dentate crowns. The realization of temporary craniectomy by Vagner has constituted a considerable progressive movement in cranial surgery, as the new operation permits much more extensive exposure of the encephalon without sacrifice of the osseous shutter, which Vagner left adhering to a large cutaneous pedicle with a free blood-supply. Opening of the cranium had always remained a protracted and laborious operation. In 1895 I had

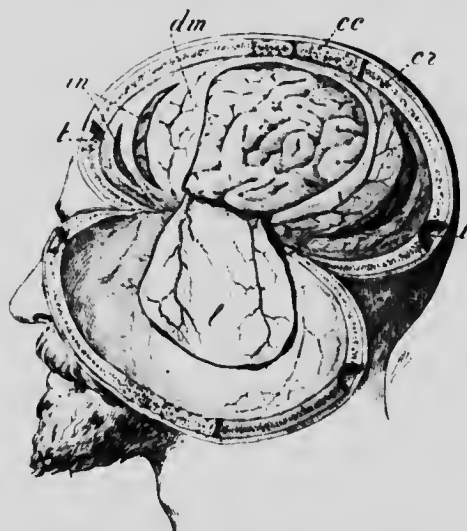


FIG. 697. FIGURE DEMONSTRATING THE POSSIBILITY OF EXPOSING THE WHOLE OF A CEREBRAL LOBE BY TEMPORARY CRANIECTOMY.

t. Openings made with the burr; *cc*, fissures made with the chisel, so as to secure exact readjustment of the osseous flap; *in*, incision of the dura mater, *dm*.

a completely new instrumentation prepared by MM. Collin and Begot, destined to replace the crowned trephine and other instruments then in use (see Figs. 389 to 411). Perforation of the cranium is effected with burrs of 12 or 16 millimetres in diameter, specially formed for application to osseous tissue, and which may be mounted either on a trepan furnished with a catch, or on a holder which is worked by an electric motor. I will describe later on the manipulation of saws worked by the hand, circular saws, chisels, and other instruments used in those operations. The cranium can be opened in a few minutes, and the osseous shutter thus mobilized may have a superficial area of even 100 to 150 square centimetres—that is to say, may be

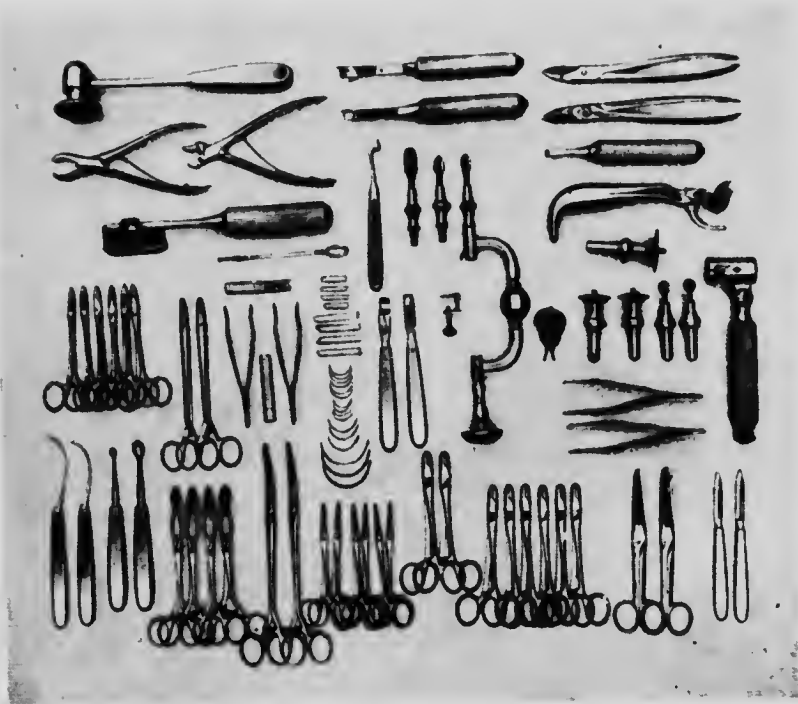


FIG. 698.

Below, from right to left: Two bistouries, two pairs of straight scissors, two clawed forceps, six forceps with short clawed jaws, two forceps with short jaws to be used for veins, six ring-handled forceps with nine oblique claws, two large forceps with curved jaws, four ring-handled forceps with oval jaws, two curettes, two needles with handles.

Instruments for ordinary craniectomy: One trepan *a cliquet*, with holder and flat perforator of 12 millimetres; one holder, with cylindro-spherical burr of 12 millimetres; one compressor, for sinus hæmorrhage; two raspatories, straight and curved; one measuring instrument, to ascertain thickness of cranium; one decollator of dura mater; one *scalp à carreau*; one forceps for removal of fragments of cranial bones; one gouge forceps; two craniectomy chisels; one mallet; two cutting forceps, right and left, for asperities of the osseous flap.

Electric instrumentation: One handle with vertical inclination; two holders, with spherical burrs of 12 millimetres; two holders, with circular saw of 35 millimetres, and protecting disc; one arrangement of discs graduated in millimetres; one saw of 45 millimetres, with alternating teeth; one saw-holder, with intracranial guide; one turn-screw.

For suturing: Six needle-holder forceps, with short jaws; two needle-holders with eccentric jaws; 3 assorted varieties of cutting-edged needles, and six intestinal needles; sixty clips, and two clip-holders; one small glass drainage-tube. [Scale reduced to one sixth].

of dimensions sufficient to permit exploration of the whole of one of the cerebral hemispheres.

Thickness of Cranial Wall.—The thickness of the cranium varies greatly with the individual, and may, in some cases of hyperostosis, be as much as 15 to 20 millimetres at the vault, or even still more. Since my first operations I have observed that it is easy to determine approximately, by percussing with one finger, whether the skull was thin, moderately thick or very thick. In certain cases of cerebral cyst, especially in the infant, the cranial bone at the summit of the tumour may be reduced to a shell, depressible under the finger, and yielding, under strong pressure, a sound of parchment crepitation. The radiographic test enables us to complete those imperfect data of exploration.

Opening of the Cranium (Cranicectomy).

Opening of the cranium, which always includes excision of a small portion of osseous tissue, is either temporary or definitive, according as we practise definitive ablation of a fragment of a certain area, or mobilization of an osseous flap which is left adhering to the soft parts, and is replaced immediately afterwards. The indications of cranicectomy are very various. From the ablation of an osseous fragment depressed by a traumatism (definitive excision) to mobilization of an extensive flap of the fronto-parieto-temporal region, the operation may range, according to the indications proper to each case, through a very great variety of locality and of extent. Cranicectomy, with formation of osteo-cutaneous shutter, is suitably destined for either exploration of the whole motor region (temporary cranicectomy), or search for an abscess of the brain, a neoplasm, or an epileptogenic centre.

PERFORATION OF THE CRANIUM.

In certain cases the surgeon contents himself with making one or more holes in the cranial wall. This procedure is carried out with the object of facilitating the elevation of a depressed fragment of bone, or the introduction of some therapeutic substance which has to be placed in contact with the encephalon. It was by this procedure that on November 17, 1913, I injected for the first time a specific antispirillar preparation into the surface layer of each cerebral hemisphere of a patient affected with general paralysis.

I have replaced the old trepan, which was furnished with a dentate crown, with burrs of 12 or 16 millimetres in diameter, the penetration of which can be controlled with a slide in form of a crown. Those burrs are worked either with the hand or with the help of the trepan *à cliquet*, or through the agency of an electric motor. I will here describe the procedure of perforation of the cranium with the help of manual instrumentation. The method of using electric instrumentation will be described in connection with temporary cranicectomy.

*Manipulation of the Author's Hand-Instrumentation—Perforation
of the Cranium.*

This operation is performed with the *trepan à cliquet*, which is first furnished in its holder with the flat drill with projecting ears, and afterwards with the shielded burr. For a long time I have used only the unshielded burrs. I have attached on the circumference of the burr a sliding shield, which is fixed at a suitable height—6 millimetres in case of the temporal bone; 8 or 10 millimetres for the thicker portions of the cranial vault, for the purpose of neutralizing the objection that the employment of my technique might prove dangerous in inexperienced hands.

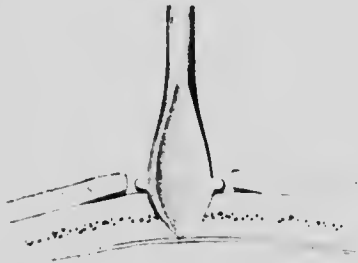


FIG. 699. ATTACK ON EXTERNAL TABLE OF THE SKULL WITH TREPAN À CLIQUET AND FLAT DRILL OF 12 MILLIMETRES WITH SAFETY SHOULDERS.

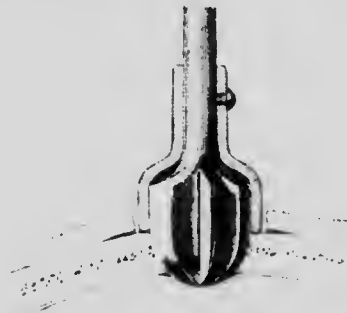

FIG. 700. PERFORATION OF THE CRANIUM WITH THE CYLINDRO-SPHERICAL BURR OF 12 MILLIMETRES WITH ADJUSTABLE CROWN.

The perforating drill should not be allowed to penetrate farther than the outer surface limit of the inner table.

The dura mater permits displacement, without being wounded, by the active pole of the instrument.

Surgeons who are familiar with this technique can employ, as I do, the flat drill and burr, without protection (see Figs. 251 and 255).



FIG. 701.

This figure shows how the crown of an ordinary trepan, when applied in the situation of a ridge of the internal table, may wound the meninges and even brain substance deeply.

First Stage.—Incision, straight or curved, which is made to expose the point of the cranial surface at which the perforation is to be made.

Second Stage.—On exposure the cranial wall is perforated with the flat drill as far as the diploe. A holder is then substituted on which a cylindro-spherical burr of 12 to 16 millimetres is mounted, the corona-shaped shield of which is adjusted for the attainment of a further depth of 3 or 4 milli-

metres beyond the probable thickness of the cranial wall at the seat of operation. No inconvenience is caused by allowing the burr to project internally to a depth of 3 or 4 millimetres before the minor surface of the skull, as its active pole is formed in such a way that it cannot wound the dura mater. We very readily perceive the moment at which the internal table yields under the instrument.

When the skull happens to be an extremely thick one, and complete perforation cannot be carried out with the first adjustment, the corona is pushed up to a distance of 3 or 4 millimetres, and the process of trepanning is finished.

Third Stage.—The operation is continued. This stage varies according as the object of the procedure is to elevate a depressed fragment of bone or to introduce a therapeutic preparation.

Superiority of my Burrs to De Martel's Trepan.

De Martel's crowned trepan is furnished with a mechanism for detachment, which renders the dentate crown dangerous when no longer opposed by the resistance of the bone. This mechanism, which is fragile and also difficult to sterilize, gives the surgeon a merely apparent security. Let us suppose the case represented in Fig. 704, where the crown of the trepan is applied at the seat of a crest of the inner table; the detachment is not effected when the division of the osseous crest is completed, and accordingly the instrument would at that moment have already wounded the dura mater and brain on each side of the crest. This accident need never be anticipated with the use of my instrumentation.

Temporary Craniectomy.

Temporary craniectomy consists of the mobilization of an osseous flap or shutter of a certain extent; this osseous shutter remains adherent to the deep aspect of the cutaneous flap, and is found replaced in its original position at the suturing of the wound. This operation, designed in 1889 by Vagner of Königsbrunn, includes the following stages: Mobilization of the osseous shutter; exploration and other intracranial manœuvres; and suture of the wound. The most important of the stages—that of mobilization of the osseous flap—necessitates a special technique to secure its successful issue. I will preface the description of the operation with some general considerations.

Incision of the Solt Parts.—In most cases it is a question of reaching the fissure of Rolando and the motor centres. In such instances the incision begins on a horizontal line situated a little above the superciliary arch, and at a point which is placed farther forward, as the osseous flap is intended to be of more extensive area; thence it passes to its culminating point at 10 millimetres from the middle line, and terminates behind the pavilion of the ear at the level of the temporo-parietal suture. We may then cut for ourselves either a large fronto-parieto-spheno-temporal shutter or a small fronto-

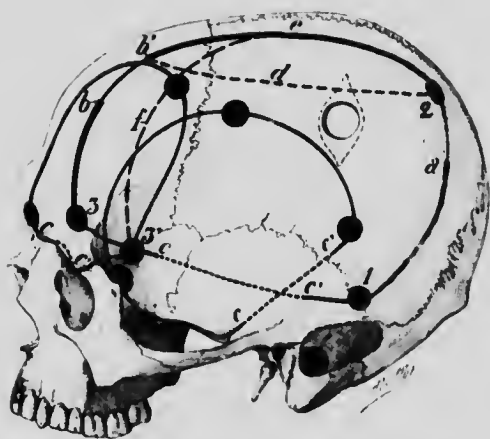


FIG. 702.—OUTLINE OF SHUTTERS FORMED IN CRANIECTOMY; FRONTAL; FRONTO-PARIETO-TEMPORAL, AND FRONTO-PARIETO-SPHENO-TEMPORAL.

Each osseous flap involves three orifices made with the burr (electric instrumentation); *b'*, *d'*, *2'*, *c'*, osseous segment to be resected definitively in essential epilepsy. In the middle of the parietal bone is seen an orifice for the drainage of a cerebral cyst; the incisions of the dura mater are indicated by pointed lines.

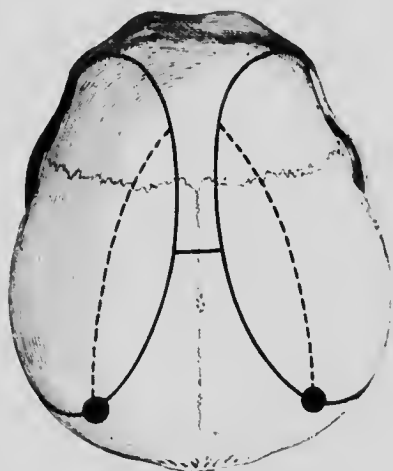


FIG. 703.—DIAGRAM OF THE TWO LATERAL SHUTTERS WHICH MAY BE MOBILIZED, AT AN INTERVAL OF SOME MONTHS, IN THE CASE OF BACKWARD CHILDREN.

A transverse section is made, to permit elevation of the median osseous band. The dotted lines indicate the osseous segments which may be finally extirpated in cases of essential epilepsy.

parietal one. This latter serves for the approach to the upper segment of the fissure of Rolando. For resection of the Gasserian ganglion, Krauss cuts a small fronto-spheno-parieto-temporal shutter, which exposes the lowest portion of the temporal fossa. We may in like manner form an anterior flap for the purpose of reaching the anterior cerebral fossa, or an occipital one with the object of reaching the cerebellar fossa.



FIG. 704.—TRACING OF A LARGE OSSEOUS SHUTTER IN FRONTAL CRANIECTOMY. The fissure at the base of the osseous flap increases on the roof of the orbit, with the object of complete exposure of the anterior lobe of the brain.

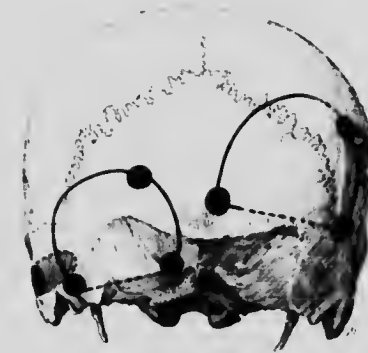


FIG. 705. TRACING OF THE TWO OCCIPITAL SHUTTERS WHICH ARE RESPECTIVELY DESTINED—THE RIGHT, FOR EXPOSURE OF THE OCCIPITAL LOBE OF THE BRAIN; THE LEFT, FOR EXPLORATION OF THE CEREBELLAR FOSSA AND LATERAL SINES.

On the left is shown the position for trepanning of the mastoid process.

When the operation involves the fronto-temporo-parietal region, I almost invariably adopt preventive hemostasis of the pericranial arteries with the aid of a band which compresses the peripheral margin of the cranial vault; this being applied at the level of the occiput, mastoid apophyses, and superciliary arches. The two ends of the elastic band are fixed together with a ring-handled forceps

Ligature of the Subcutaneous Vessels.—Ligature of the subcutaneous vessels is rarely required in young subjects. On the other hand, it is indispensable in adults, in whom the pericranial arteries and veins often acquire a considerable diameter. As a general rule, every vessel of a certain importance, which carries with it a risk of bleeding after removal of the elastic band, should be seized and tied. If not very large, it may suffice to crush them with short-jawed forceps, which are left in position for three or four minutes. When the pericranial circulation is exceptionally developed, as in a case of large tumour in the adult, it is advisable to seize and tie all the divided vessels at the level of each of the two lips of the incision; for the peripheral opening may yield as much blood as the central. If ligatures have been used, we may remove the elastic band before attacking the cranium. In young subjects, on the other hand, it must be left in place up to the moment of applying the dressings, and is removed only after suture of the wound. The sutures, which embrace the whole thickness of the integuments, suffice, with them, to secure hæmostasis.

Mobilization of the Osseous Shutter.—This stage of the operation can be carried out either by the hand alone, or with the help of an electric motor. I now proceed to describe, in succession, the manipulation of the instruments worked by the hand, and the management of the electric instrumentation. This description must be in sufficient detail, and requires for the reading more time than is occupied by the operation. I will then describe the operation as practised on the living patient.

MANIPULATION OF THE AUTHOR'S HAND INSTRUMENTS.

Perforation of the Cranium.—The outer table of the skull is attacked with a conical perforating drill, which is made to reach the diploë. This is worked by a *trepan à cliquet* (see Figs. 401 and 402). It is useful to practise craniectomy beforehand on dried bones which have been soaked for twelve to twenty-four hours in a 2 per cent. phenol solution. The *trepan* is manipulated like a bit and brace. When the perforator has reached the diploë, we proceed to make another orifice, and so on for the five or six openings that may be deemed necessary, according to the position and extent of the flap to be formed. That part of the instrument which is furnished with the catch that holds the conical perforator is then replaced by another form of holder, on which a cylindro-spherical burr of 12 millimetres in diameter is mounted (Fig. 705). Each orifice is completed in a few moments down to the *dura mater*, which is thus reached without the possibility of being wounded. We also recognize perfectly, by the difference of resistance met by the burr when it reaches the inner table, and again when it has passed through it, that the osseous wall has been completely perforated. When we dread going too far, it is easy to verify, by sponging and careful examination of the wound, if the inner table is still intact. Manipulation of the burr with the *trepan* should be studied, as I have described it, on anatomical specimens, before attempting the first operation on the living subject; and we should even learn to reach the inner table on a dried skull with a cylindro-

spherical burr (see Fig. 255), without protecting crown, without complete perforation, and without going too far. The operating hand can tell by the small shocks produced by the saw teeth the moment when the pole of the instrument commences to perforate the internal table. The inner lamella of this table, when pressed by the active pole of the burr, can be seen from the inner side of the skull as a thin layer of opaline aspect.

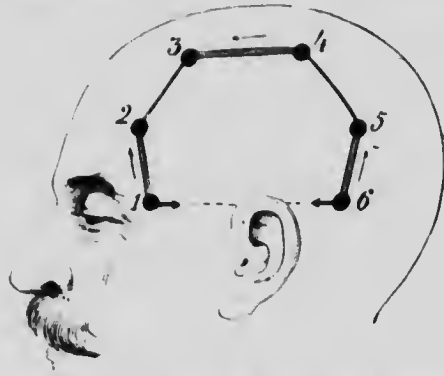


FIG. 706. SCHEMATIC OUTLINE OF SHUTTER-CRANIECTOMY, CARRIED OUT WITH THE ORDINARY INSTRUMENTATION.

1, 2, 3, 4, 5, 6, orifices made with the flat drill and burr. 1-2, 2-3, 3-4, 4-5, 5-6, Sections of external table only, made with a guarded saw (Fig. 708). 1-2, 3-4, 5-6, Resection of the whole thickness of the skull with the nibbling-forceps (Fig. 714). 2-3, 4-5, Breaking through the inner table with the blunt-angled chisel (Fig. 715). 1-6, Treatment of the base of the shutter with the same instrument.

Section of Intermediate Bridges.—The orifices made by the burr must be united, two by two, by complete section of the cranial wall. The thickness of the latter is measured, when we wish to have a precise limiting-point, with the instrument shown in Fig. 707; the saw, the sliding shield of which is graduated in millimetres, should be controlled so as not to penetrate too deeply. The bony orifices made at the margin of the shutter are united, two by two, with the saw, which should reach the inner table of the skull




FIG. 707. MEASUREMENT OF THE THICKNESS OF THE CRANIAL WALL WITH A GRADUATED REULER.

without completely dividing it. The division of the bone is then completed either with the nibbling forceps, or a mallet and chisel with protective digit. We should previously exercise ourselves in the use of these instruments on anatomical specimens, as in that of the trepan with a catch,

flat perforating drill, and cylindro-spherical burr. The forceps for removal of fragments can be manipulated very rapidly after a little practice. We may use it in case of infants without the previous partial division with the saw. In case of adults, section of the bone is not very neatly effected

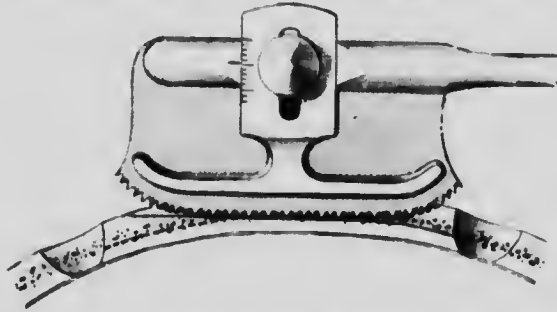


FIG. 708. SECTION OF THE OUTER TABLE WITH SCIE A CURSEUR.

unless the outer table has been divided with the scie à curseur quite down to the diploë. It is not necessary to complete the division of all sections prepared by the saw with the nibbling forceps; but it is well to do so for a



FIG. 709. RESECTION OF THE WHOLE THICKNESS OF THE SKULL WITH THE NIBBLING FORCEPS, WHICH FOLLOWS THE GROOVE MADE BY THE SAW.

portion, so that the manipulation of mallet and chisel may not be over-prolonged. If only two bridges of the inner table are left at the junction of the middle third of the periphery of the osseous shutter with




FIG. 710. BREAKING OF THE INNER TABLE OF THE SKULL ALONG THE LINE OF THE FURROW MADE IN THE OUTER TABLE WITH THE SAW.

its anterior and posterior thirds (Fig 706, 2-3 and 4-5), two applications of the chisel and a few blows of the mallet will suffice to complete the section.

Fracture of the Osseous Pedicle. The base of the flap is also divided with the mallet and chisel in the same way. The hand which holds the chisel

should be firmly supported on the head of the patient. Some rapid and crisp blows of the mallet will then suffice to break the bone throughout the required extent without seriously shaking the brain. The breakage should begin on the side opposite the position of the surgeon. The operator then clearly perceives, when the chisel comes to be applied on the side next to him, the moment at which the fissure is completed. As the rounded angle of the chisel cannot wound the dura mater, and the protective digit safeguards

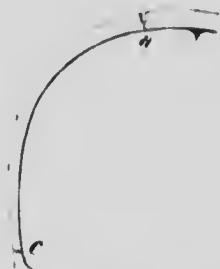


FIG. 711.—DIAGRAM OF A LARGE CRANIAL ECTOMY SHUTTER, RESTORED TO ITS PLACE.

The replacement is exact, for there is no loss of substance, either at *c*, the base or hinge of the shutter, nor at *a*, where the inner table has been fissured.



FIG. 712.—DIAGRAM OF A SMALL SHUTTER IN TEMPORARY CRANIECTOMY, FORMED BY MALLET AND CHISEL.

An angular loss of substance around the whole contour of the shutter, the coaptation of which would be very unstable.



FIG. 713.—DIAGRAM OF THE SAME OSSEOUS SHUTTER SHOWN IN FIG. 712 WOBBLING AT *a* INTO THE INTERIOR OF THE CRANIAL CAVITY.

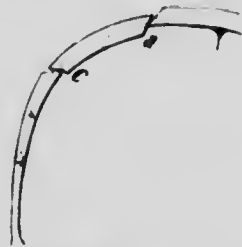


FIG. 714.—DIAGRAM OF A SIMILAR SHUTTER DROPPING INTO THE CRANIAL CAVITY IN THE WHOLE EXTENT OF ITS CIRCUMFERENCE.

from any slipping into the depths, the base of the osseous shutter is fissured in a few moments and without danger. It is necessary to take care not to separate the bone from its vascular cutaneous pedicle, to which it must remain adherent. In this connection we must remember that the pericranium is detached from the cranial surface by very slight violence.

Advantages of this Technique.—The technique which I have just described enables us to prevent with absolute security any penetration of the osseous shutter into the interior of the cranial cavity (see Fig. 711). There

is, in fact, no loss of substance, either at the level of the hinge *c* or at the periphery *a*, where the inner table has been fissured by the chisel. Such a shutter or lid may then remain raised—that is to say, it may permit an expansion of the cranial cavity—but it cannot fall into the interior. But this accident is a necessary consequence when we cut out small osseous shutters with instruments which produce an appreciable loss of substance over the whole extent of their periphery (Figs. 57 and 58, p. 714).

MANIPULATION OF THE AUTHOR'S ELECTRIC INSTRUMENTS.

The burrs and saw which I use for craniectomy should be worked by an electric motor of 0.5 horse-power (35-40 kilogrammetres), rotating at the rate of 2,500 revolutions per minute. I have also had constructed, in 1895 on account of the insufficiency of the flexible conductors then in use, a flexible conductor of great efficiency, which can be used with perfect security—*that is to say*, without fear of unexpected break in transmission or sudden arrest of function (Fig. 391). The whole of this instrumentation has been made with very great care, and I recommend careful pursuit of my instructions on all points during its use. In order to practise manipulation of electric instrumentation, we require a motor of about one-half horse-power, furnished with a flexible transmitter of about 1.5 metres in length, terminated by a double attachment to which the holders of the instruments may be fixed. A special handle with variable inclination is attached to the end of this cable; the construction of this handle enables us to hold burrs and saws at the same time in two directions—longitudinal and perpendicular, or oblique. For craniectomy, the movable handle should be fixed perpendicularly to the axis of rotation.

Motors with continuous current of one-half horse-power nearly always rotate at a velocity of 2,000 to 2,500 revolutions per minute. Those with alternating current rotate at a velocity of about 1,000 turns. We must accordingly, when using the alternating current, add on a multiplication of a little more than two units. As the motors with alternating current should be placed in action before the operation, and cannot be stopped till it is terminated, I have devised an arrangement with automatic curb, which enables us to obtain an instantaneous arrest of the movement of burr or saw on issuing the command. This arrest is secured by a drag adapted to a spring, which blocks the pulley that commands the cable at the precise moment that the transmitting cord passes over to the dummy pulley. The holder to which the cable is adapted should be situated at a height of about 1.5 metres. When the cable is mounted and furnished with its handle fixed at a right angle, we must prepare a number of holders, one form of which is furnished with a spherical burr of 12 millimetres; a second with a saw of 45 millimetres, furnished with alternating teeth; two others with fine saws of 35 millimetres, provided with discs No. 4 and No. 5—for example—to be used with a cranium of medium thickness, and which can deal with the bone to a maximum depth of 4 or 5 millimetres. The manipulation of those instru-

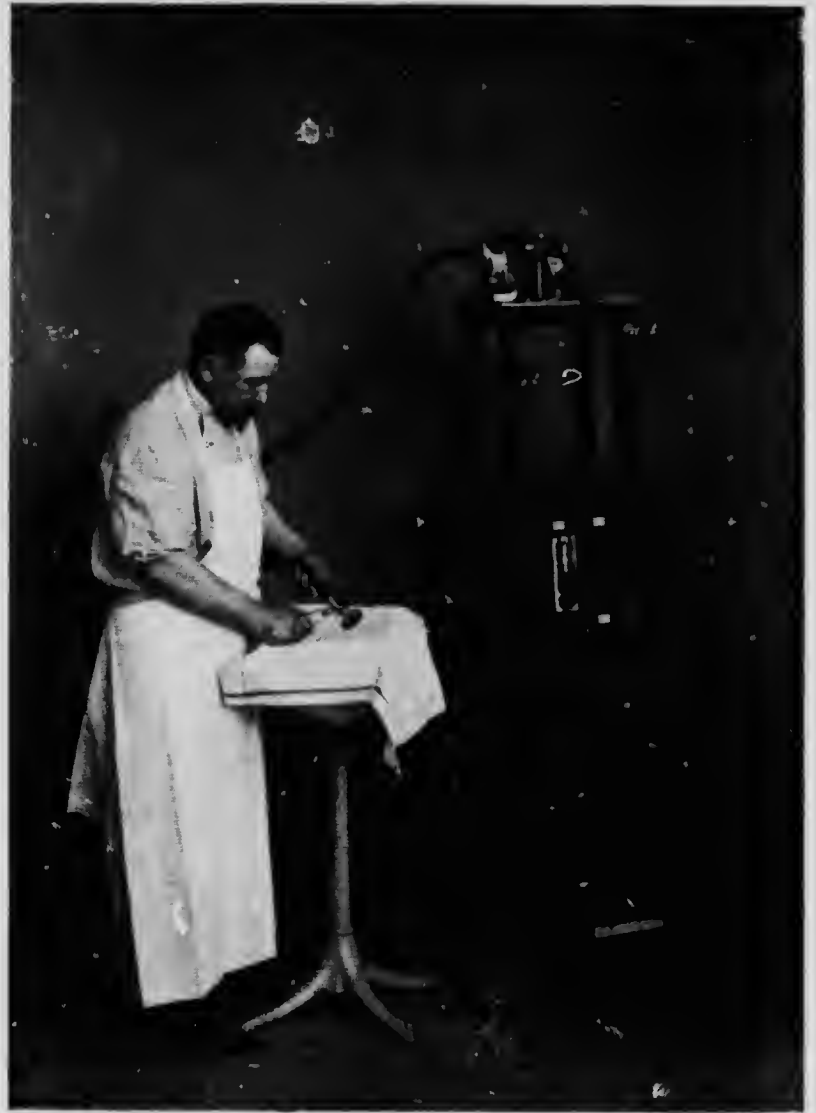

FIG. 715. SUPPORT FURNISHED WITH TWO ELECTRIC MOTORS.

Below, a motor with alternating current, driving by a strap the pulley placed above, which commands the cable. At the word "Stop!" a lever pushes the strap on to a dummy pulley. Above, on the right, is a motor with continuous current, on which is attached the flexible cable, furnished with handle adapted for variable inclination, and a saw of 35 millimetres. (Scale reduced to one-fiftieth.)

ments on osseous anatomical specimens is identical with that applied to the living body. We may practise ourselves in this way on femurs and skulls fixed in a wooden vice.



FIG. 716. INCLINATION OF THE BURR AT THE MOMENT OF ATTACKING THE OUTER TABLE BY ITS LOGARITHMICAL ZONE. This inclined position of the burr is indispensable to secure safety.



FIG. 717. THE BURR PIVOLED ON THE MARGIN OF THE OBJECT. It has perforated the inner table and pushed back the dura mater, pivoting on its neck.



FIG. 718. VERTICAL POSITION OF BURR.

This is dangerous, for the instrument may cut through the dura and perforate the brain.

Perforation of the Cranium. To make an opening with the burr, before giving word to set the machinery in action, we must firmly support the

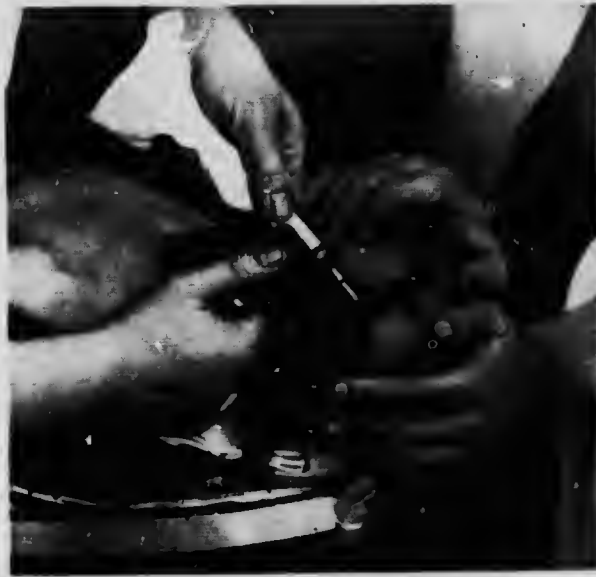

FIG. 719. PERFORATION OF THE CRANIUM WITH THE SPHERICAL BURR OF 12 MILLIMETRES.

hands in the vicinity of the field of operation; the left holding the cable, and the right the handle fixed perpendicularly. The operator's elbows are kept

pressed to the sides, the bust semillexed and well balanced. The burr is firmly held at a distance of 1 centimetre from the point to be attacked. We now give the order, "Go on!" The burr is brought gently into contact with the bone at an intermediate point between its pole and its equator. The surgeon's muscles are firmly contracted, so as to prevent all danger of slipping. The bone is grazed. The burr is then inclined (see Fig. 716), and as the internal table is approached, the operator takes care to form a point of support on the periphery of the orifice for the neck that carries the burr, which affords a certain means of prevention of slipping into the depths—that is to say, into the cranial cavity.

Each orifice requires for completion, down to the dura mater, a period of five or six seconds, according to the thickness and hardness of the vault. Three or four openings are enough in most cases—for example, two at the two

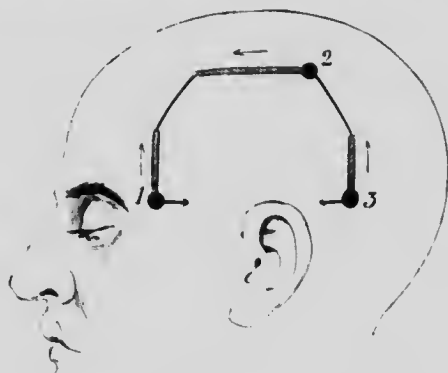


FIG. 720. SCHEME OF SHUTTER-CRANIECTOMY WITH ELECTRIC INSTRUMENTATION.

1-2-3. Openings made with the burr. The three double lines indicate the three complete sections of the cranial wall, made with saw furnished with intracranial guide (Fig. 729). The thin lines indicate the two sections of the outer table made with the *scie à curseur*. The inner table should be divided at the same points with the blunt-angled chisel. We then deal with the base of the shutter, 1-3. If we want to perforate the cranial wall in a direction perpendicular to its surface, we must use a shielded burr. The sliding corona which forms the shield is previously adjusted at a height of 3 or 4 millimetres beyond the probable thickness of the skull. We should carefully verify the firmness of its fixation before proceeding to operate, so that there will be no danger of slipping at the moment of perforation.

extremities of the incision, then one or two, at the union of the middle third with the anterior and posterior third, respectively. The dura mater may be detached from the inner table with the aid of a curved and grooved sound, the extremity of which is bent to an obtuse angle, so that the beak can follow exactly the inner surface of the cranial wall. This instrument also serves to protect the brain when the dura mater is incised. I have recently had constructed by M. Collin the special instrument represented in Figs. 722 and 723 for detachment of the dura mater from the inner table; it presents the advantage of being flexible.

Section of the Intermediate Osseous Bridges. The interval between the orifices made with the burr is divided with the saw with intra-cranial guide, for an interval of some centimetres in length. Two small periph-



FIG. 721.—AUTHOR'S GROOVED AND BEAKED SOUND FOR DETACHMENT OF THE DURA MATER FROM THE CRANIAL VAULT.

eral bridges of 20 to 30 millimetres must, indeed, be left, to prevent the dropping of the osteo-cutaneous shutter into the cavity, and in these the section made with the circular saw should not involve more than the



FIG. 722.—AUTHOR'S NEW DECOLLATOR OF DURA MATER.

outer table and diploë. The inner table must then be divided with the mallet and special chisel. This artifice serves to prevent the dropping in of the osseous shutter when it comes to be replaced.



FIG. 723.—THE DURA MATER DETACHED FROM THE INNER TABLE OF THE SKULL WITH THE AUTHOR'S DECOLLATOR.

The saw furnished with intra-cranial guide, is thus manipulated: The handle is grasped, say with the right hand (as it is necessary to




FIG. 724.—SAW OF 45 MILLIMETRES, WITH ALTERNATING TEETH, AND HANDLE WHICH CARRIES A GLIDING INTRACRANIAL PLATE FOR DETACHMENT AND PROTECTION OF THE DURA MATER.

practise manipulation with either hand), and the guide is introduced into the first orifice between the dura mater and internal table. The saw is

538 SURGICAL THERAPEUTICS AND OPERATIVE TECHNIQUE

adapted to the groove of the handle. At the moment when it has almost touched the outer table we order the electrician to "Go on!" The saw instantly descends, attacks the bone, and reaches the bottom of the vertical

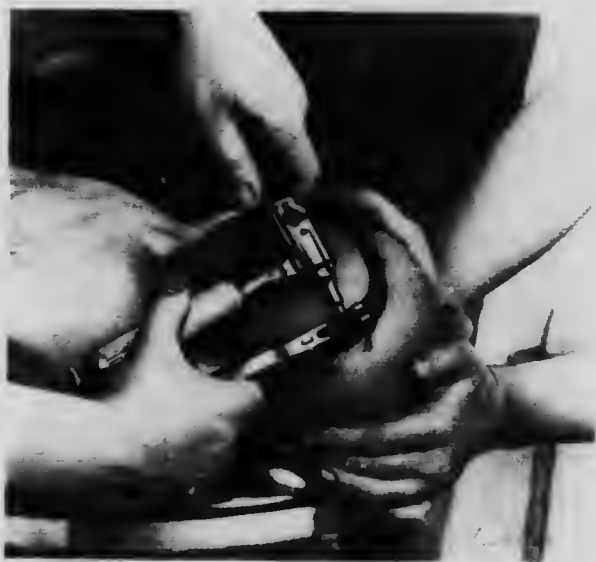


FIG. 725. SECTION OF SKULL THROUGH ITS WHOLE THICKNESS, WITH SAW FURNISHED WITH INTRACRANIAL GUIDE.

groove. The whole thickness of the skull is thus divided, and it suffices to push forward the cable and the handle of the guide, which direct the saw, with the combined energetic action of both hands, and we obtain a corresponding section of the whole thickness of the bone.

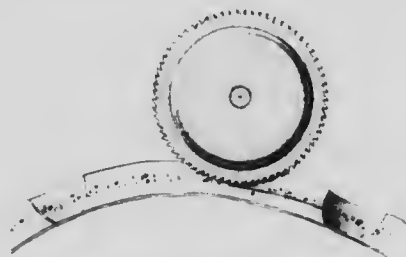


FIG. 726. SECTION OF OUTER TABLE OF SKULL WITH SAW OF 35 MILLIMETRES, FURNISHED WITH A DISC WHICH LIMITS ITS PENETRATION.

The points at which the two osseous bridges have been left are then attacked with a saw of 35 millimetres, furnished with a protective rim, marked by a figure lower than that which gives the thickness of the bone

(Figs. 726 and 727): the thickness of the skull should have been previously measured with the ruler represented in Fig. 707. By a practised eye it can be estimated approximately in millimetres. The saw is brought into action, and the two last sections are made in a few seconds. We then give the word "Stop!" and the motor is removed.

The two bridges of the inner table which have been left intact are fissured with mallet and chisel as already described when discussing manual instrumentation.

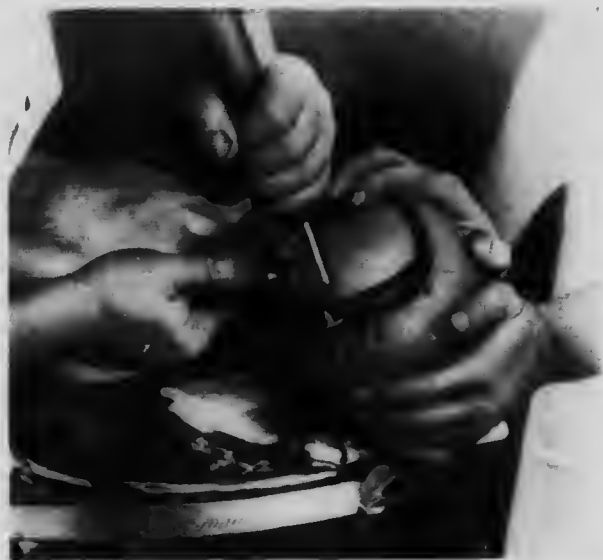

FIG. 727. SECTION OF UPPER TABLE OF SKULL WITH SAW FURNISHED WITH ROWEL.

Fracture of the Osseous Pedicle. Fracture of the osseous pedicle is then carried out as above described.

Elevation of the Osteo-Cutaneous Shutter. The osseous shutter is raised at its periphery with the aid of a raspatory; it is then grasped with the three major digits of each hand while the thumbs are applied at the level of the pedicle, in order to provide there a point of support and prevent any unsuitable displacement. The simous fissure of the osseous pedicle is completed, and it instantly yields; the osteo-cutaneous shutter is raised and held in position by the soft parts which form the hinge, and the dura mater is now completely exposed.

Reapplication of the Flap. Irregularity of the fissuring of the pedicle, and angular projections displaced at the time of elevation of the bone, may, in some cases, render reapplication of the osteo-cutaneous flap very difficult. In order to avoid this complication, it is necessary to verify at the moment of elevation of the osseous shutter the prospective mode of

its reapplication. If it cannot be readjusted without difficulty, we must lay it back at once on the temple, and divide the exuberant osseous projections with the special shears which I have had constructed for that purpose (Figs. 748 and 749). There are two of those instruments—one for the right side, the other for the left.

NEW TECHNIQUE OF TEMPORARY CRANIECTOMY.

I simplified my craniectomy technique at the beginning of the year 1909. A special feature of this change consisted of the suppression of the saw with intracranial guide, which involved some danger of wounding the dura mater, and demanded a considerable manual force in its application. I have modified my latest model of decollator of dura mater, and increased the respective diameters of the saws furnished with protective disc. The small rowel or shielded saws which I formerly used were intended for division of the outer table only. For this purpose I used a saw furnished with a protective disc of 3 to 5 millimetres smaller diameter, which could penetrate to a slight depth only. Notwithstanding that precaution, the dura mater was sometimes wounded at a point at which the thickness of the bone suddenly diminished.

This new technique is based on the use of two decollators of the dura mater, curved longitudinally, and enclosed in a spiral wire spring of 5 millimetres in diameter. These decollators are incurved, one towards the right and the other towards the left, so that their extremities meet at the tip of the osteo-cutaneous shutter. The thickness of this spring thus removing the dura mater from the surface of the bone for a minimum distance of 5 millimetres, we can use circular saws of the largest diameter, and allow them to penetrate to the internal table.

Operation.

First Stage.—Horse-shoe incision of soft parts, reaching down to the bone.

Second Stage.—Perforation of the cranial wall with spherical burr of 12 millimetres. Four openings are made: two at the extremities of the incision, at the base of the shutter, and the other two at the extremities of its middle third.

Third Stage.—The dura mater is detached between those orifices with a straight decollator. We then introduce, through the orifices made at the base of the shutter, two curved decollators furnished with spiral springs, so adjusted that their curvatures respectively follow, on the inside of the cranial wall, that of the cutaneous incision on the outside. We are then certain that the dura mater has been removed from the surface of the inner table of the skull to a distance of at least 5 millimetres along the entire length of the external incision.

Fourth Stage.—A circular round saw is mounted on the flexible conducting cable, bearing a number corresponding to the maximum thickness of the skull. This number indicated the difference between the radius of the




FIG. 728. AUTHOR'S NEW INSTRUMENTS FOR THE OPERATION OF CRANIECTOMY.

From above downwards: Three circular saws of 5 centimetres diameter, furnished with protective discs, which permit penetrations to a degree of 4 millimetres for the first, 6 millimetres for the second, and 8 millimetres for the third.

A straight decollator of dura mater, a spiral spring, and a similar spiral mounted on the straight decollator to augment the retraction of dura mater.

Two curved decollators, each furnished with a spiral spring.



FIG. 729.—DETAICHMENT OF THE DURA MATER WITH THE AUTHOR'S NEW DECOLLATOR BETWEEN TWO CRANIAL ORIFICES MADE WITH THE BURR.



FIG. 730. A MORE CONSIDERABLE DEGREE OF SEPARATION EFFECTED WITH THE SAME DECOLLATOR FURNISHED WITH A STEEL SPIRAL.



FIG. 731. DIVISION OF WHOLE THICKNESS OF CRANIAL WALL WITH A DISCOID SAW PARALLEL TO THE DECOLLATOR WHICH IS FURNISHED WITH A STEEL SPIRAL. THE DURA MATER IS SEEN TO BE DETACHED TO A CONSIDERABLE DEPTH.

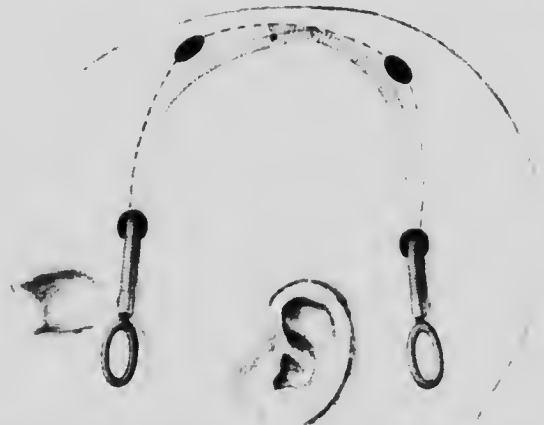

FIG. 732. DIAGRAM WITH A SKETCH SHOWING BOTH CERVICAL DECOLLATORS IN POSITION, THIS ALLOWING DIVISION OF THE SKULL THROUGH ITS ENTIRE THICKNESS, IN THE RESPECTIVE PLANES OF THE THREE OSTIAL BRIDGES (ANTERIOR, SUPERIOR, AND POSTERIOR) ON THE PERIPHERY OF THE PLATE.

saw and that of the disc—that is to say, the range of its penetration. The three osteal bridges are then divided in succession, and, if we want to establish a permanent loss of substance at the upper margin of the shutter, a fourth application of the horizontal saw is made, after denudation of the bone as far as the requisite level.

Fifth Stage.—We now fissure the base of the osteal shutter with mallet and blunt-angled chisel, after having introduced the straight decollator furnished with spiral wire spring for detachment of the dura mater. This instrument penetrates to any portion of the internal table that had not been reached by the saw, which is then fissured with the chisel. The osteo-entaneous shutter is then raised.

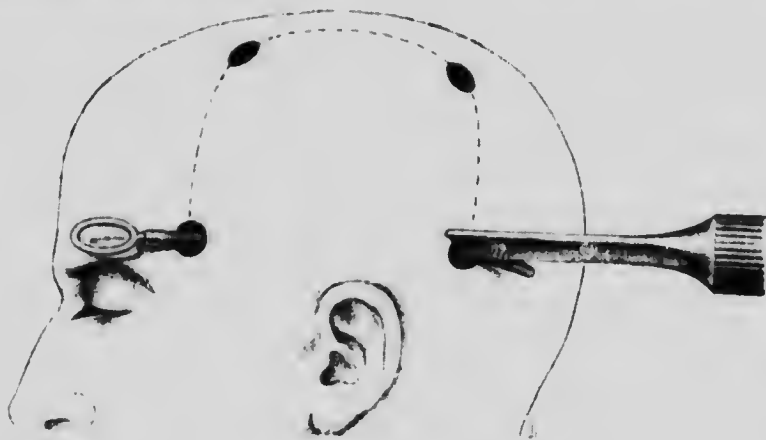


FIG. 733. APPLICATION OF STRAIGHT DECOLLATOR FURNISHED WITH SPIRAL SPRING TO THE BASE OF THE OSSIFIED SHUTTER, WHICH CAN THEN BE EASILY FISSURED WITH MALLEE AND CHISEL, WITHOUT DANGER OF WOUNDING THE DURA MATER.

Sixth Stage.—Planing the base of the osteal shutter, where it is nearly always necessary to reset a number of irregular projections. If the middle meningeal artery has been torn, hemostasis is effected by tying each of the ends with a fine silk ligature, which is passed beneath the vessel with one of the curved needles used in intestinal suture.

Seventh Stage.—Readjustment of the shutter and suture of the skin.

Intracranial Manœuvres.—In all cases of very extensive craniectomy the opening of the dura mater and the intracranial manœuvres are resorted to only on a second intervention, which is carried out after an interval of five days. Sometimes in urgent cases, such as an abscess which is definitely localized, if it is necessary to open the dura mater at once, a small shutter of only 5 or 6 millimetres in diameter should be made.

ACCIDENTS IN THE COURSE OF OPERATION.

1 **Hæmorrhage at the Time of Section of the Bone.**—The loss of blood during the time of perforation of the cranium with the burr, and section with the circular saw, is rarely of considerable amount. If the burr has traversed a large sinus of the diploë in the adult, a compress is at once applied; this compress is kept in position by the assistant, who holds the head. If the diploë yields much blood, the operation must be hastened, as this bleeding usually ceases spontaneously when the flap is raised. If blood continues to escape, we obliterate the osseous sinus by écrasement, or it may be pegged with a fragment taken from the vicinity. If a great quantity of blood is lost, as in case of craniectomy for a very vascular tumour in the adult, section of the outer table should be very rapidly completed with the rowel saw, and the shutter immediately mobilized with mallet and chisel. The osteo-cutaneous flap can be immediately reapplied between two compresses—one placed on the dura mater, the other external. I have already shown that as a rule, excepting when the case calls for an immediate decompression, the opening of the dura mater should always be postponed; it can be carried out five or six days after the craniectomy.

2 **Wounding of Dura Mater and Brain.**—I mention wound of dura mater and brain only to bring them to memory, as neither is likely to be injured with burr, saw, or scissors, when applied by skilful practised hands. Besides, if superficial, they are of little consequence.



FIG. 734. COMPRESSOR FOR THE LACONAL SINUS.

3. **Wound of a Venous Sinus of the Dura Mater.**

The hæmorrhage is of oozing character, but very abundant, and may produce anaemia of the encephalon. Digital compression must be applied at once, and the bone resected with the gonge forceps, so as to allow suturing of the dura mater to the skin. The continued suture is employed, and is made to include the lips of the wound of the venous sinus. The compressor represented in Fig. 734 may be applied; it should be left in position for four or five days. Those details of general technique which demand a complete description having thus been settled, we now proceed to describe the operation as it is practised on the living person.

Technique of Typical Craniectomy.

Preliminary Precautions.—The head must be shaved and carefully washed on the eve of the operation, and then covered with a moist antiseptic dressing. The patient is placed in the position shown in Fig. 738 or 739, according as the operation is to be on the left side or the right. The elastic ligature is applied. The elastic band should be carefully disinfected in a

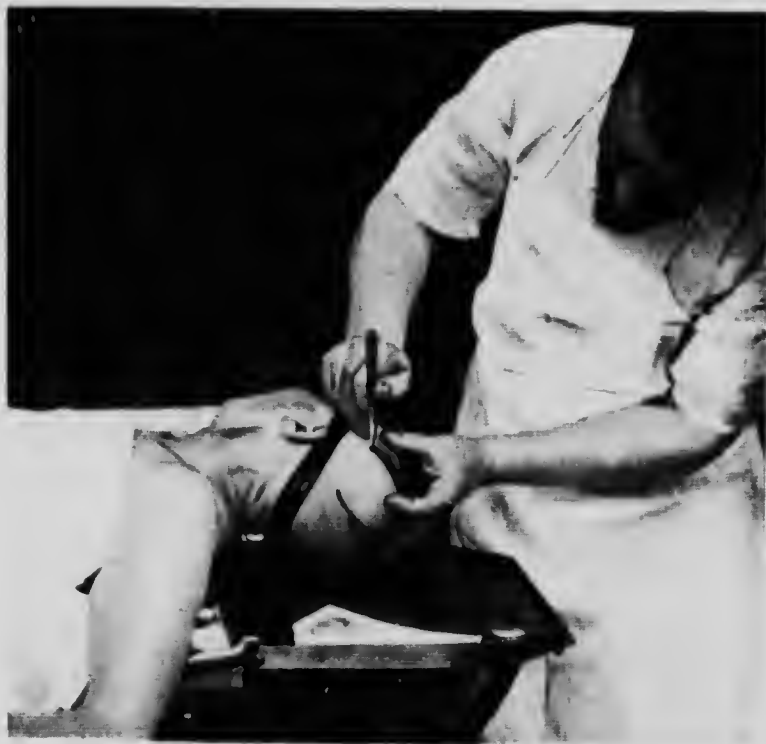

FIG. 735. FRONTO-TEMPORO-PARIENTAL CRANIOTOMY.
Section of the soft parts.

1 per cent. oxycyanide solution. We fix it between the jaws of a ringed forceps, which is adjusted near the ear, and on the side opposite to that of the field of operation. The assistant holds the head of the patient firmly between his hands; the head should project a little beyond the rest provided on the operation-table. He indicates with the ends of his fingers the position of the median plane, which is that of the superior longitudinal sinus.



Operation.**FIRST STAGE: INCISION OF THE SOFT PARTS.**

The incision should be of horseshoe form, made with a single movement and reaching down to the bone. The bistoury should be made to traverse the wound a second time, and complete the division of the pericranium, if this had not been effected at first. The vessels should be seized and tied only in adults, and in other cases when very much developed. The immediate hemorrhage is usually negligible, and ends after a few seconds. We must take great care not to detach the pericranium from the surface of the bone, to which it is but moderately adherent.

SECOND STAGE: MOBILIZATION OF THE OSSEOUS SHUTTER.**Operation with Ordinary Instrumentation.**

Perforation of the Cranium.—We prepare four, five, or six openings, according to the area of the flap, with the trepan *à cliquet* and conical drill. The perforating drill is then replaced with a cylindro-spherical burr of 12 millimetres, and the openings are carried down to the dura mater; taking care to stop before the great diameter of the burr has passed the inner table of the bone. We can easily perceive when the inner table begins to yield. The beginner should use, for reasons of prudence, the protected instruments figured in Figs. 704, 705.

Section of the Intermediate Osteal Bridges.—We then divide with the straight-edged scie *à curseur* the osseous intervals which separate the



FIG. 736.—CRANIECTOMY WITH MANUAL INSTRUMENTATION.

Section of the outer table with scie *à curseur* saw furnished with graduated sliding shield.

orifices made with the burr, the pedicle of the flap alone being excepted. The graduated shield which limits the action of the saw has been arranged before the operation at a distance of 4 or 5 millimetres from the edge. We may change its position, if necessary, when the orifices have been pierced, in case the thickness of the skull differs considerably from that which we had anticipated. The reader should here note the fact that an experienced surgeon can estimate to nearly within a margin of 2 millimetres, before operation and through the soft parts, the thickness of the cranial vault by mere percussio with the index or middle finger. From my very earliest operations I have taught this particular item of knowledge to the medical men who followed my clinique.

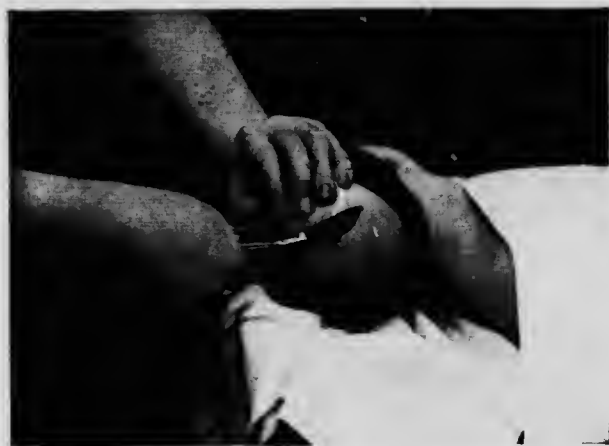

FIG. 737. CRANIECTOMY WITH MANUAL INSTRUMENTATION.

Division of the cranium with nibbling-forceps along groove made by saw.

The section is then completed with the nibbling forceps along the whole lengths of the grooves made with the saw, excepting two small bridges of 15 to 30 millimetres, arranged on the periphery of the flap. At the level of these two bridges the inner table must be fissured with the chisel, so as to avoid having anywhere on the margin of the osseous shutter a complete loss of substance—a condition which would permit it to drop to some little distance into the interior of the cranium.

In case of young children the use of the shielded saw is unnecessary, and the nibbling-forceps divides the bone without splintering, because it is less thick and at the same time less brittle.

It now suffices to fissure the two bridges of the inner table with the mallet and chisel, to liberate the osseous shutter around its whole periphery, with the exception of the pedicle.

Fracture of the Osseous Pedicle.—We divide the base of the osseous shutter by working with the chisel in turns, first on one side, then on the other. The osseous flap is then raised with the fingers, as already described.

Operation with Electrical Instrumentation.

Perforation of the Cranium.—When the bone has been exposed by division of the soft parts, we remove the pericranium with the raspatory at the points to which the burr is to be applied. Three or four orifices are then pierced with the spherical burr of 12 millimetres—the first and second at the ends of the incision, the third at the junction of its middle third with

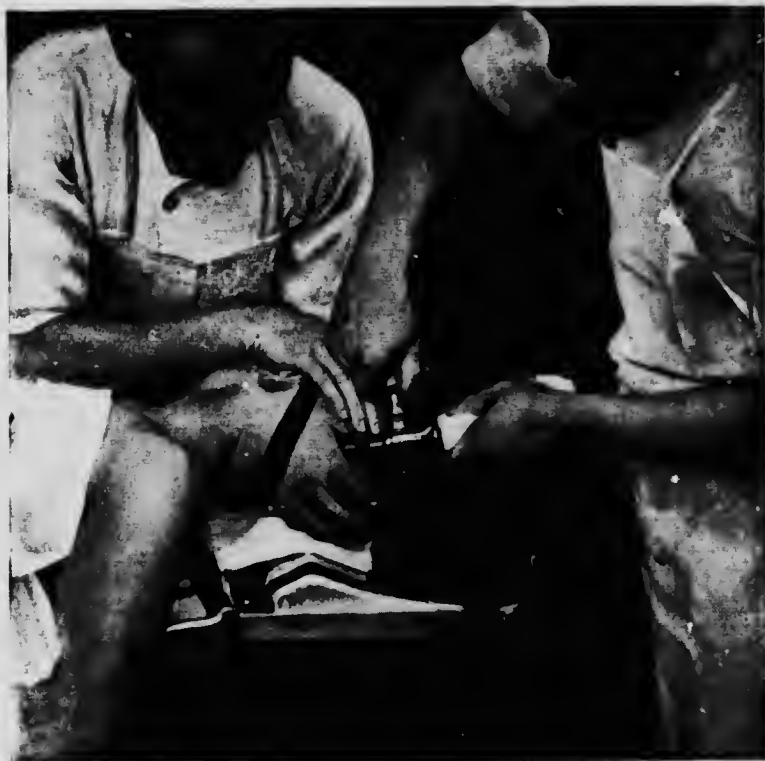

FIG. 738. —CRANIECTOMY WITH ELECTRICAL INSTRUMENTATION.
Perforation of the cranium with spherical burr of 12 millimetres.

either the anterior or posterior. When four openings are made, the two last are placed at the two extremities of the middle third of the peripheral margin of the flap. To avoid wounding the dura mater and the brain, the precautions described on p. 529 must be followed.

Section of the Intermediate Osseous Bridges.—The dura mater is carefully detached between the cranial orifices with the decollator. Partial section of the cranial vault is then made with the saw with alternating teeth, mounted on handle with gliding shield, taking care to leave at the anterior and posterior extremities of the middle third of the peripheral margin of the fl.

two osteal bridges of 15 to 20 millimetres in width. This *scie à curseur* cannot be safely manipulated by any other than a very practised hand. It is necessary to be able to direct the saw, sometimes with the right hand and sometimes with the left, so as not to displace the electrical motor every time. We can see from Fig. 738 to 740 with what power the two hands grasp the handle of the gliding shield and the saw-holder, which they maintain in directions perpendicular to one another. The elbow nearest the body

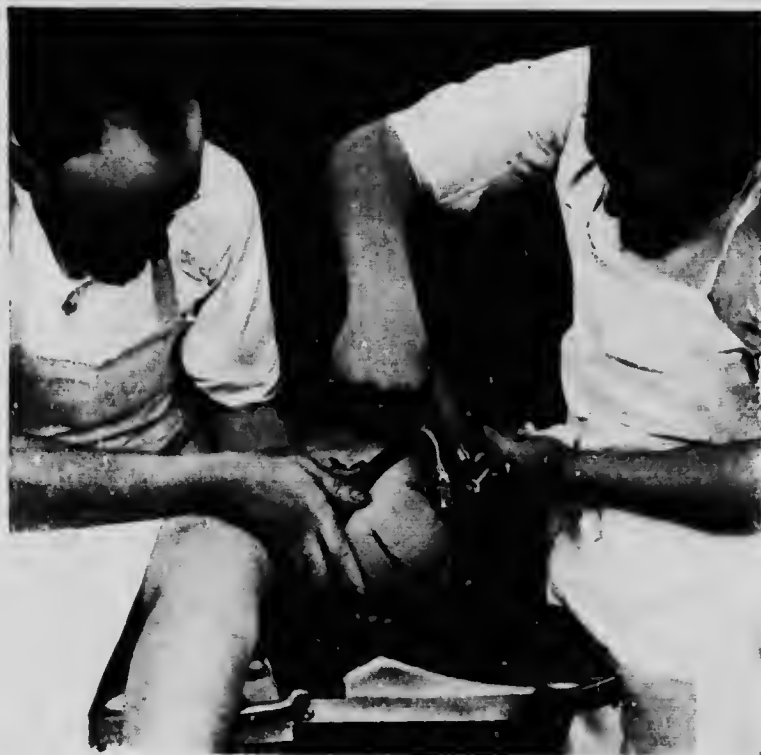

FIG. 739.—CRANIECTOMY WITH ELECTRICAL INSTRUMENTATION.

Section of cranium with saw furnished with alternating teeth and intracranial guide

should be kept tightly pressed thereto, in order to avoid any slipping of the instrument. The whole of this technique can be studied at leisure in the projections of my cinematograph films.

We have now to deal with the two osteal bridges which were left at the peripheral margin of the shutter. Those are attacked with a saw of 35 millimetres, furnished with a suitable disc, and divided therewith down to the inner table. Two such saws, each provided with a graduated disc, are prepared before the operation, and mounted on the nozzles of suitable holders. The saw of 35 millimetres is extremely thin, and demands from

the surgeon for its safe manipulation as much muscular vigour as manual dexterity. The slightest slip entails a risk of wounding the fingers of the operator, which are placed at the margin of the field of operation.

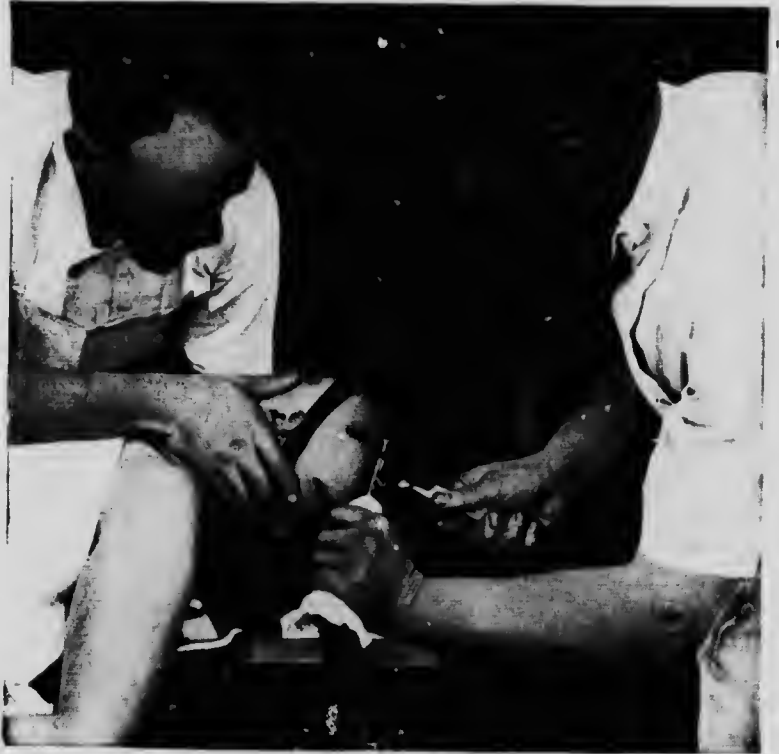

FIG. 740.—CRANIECTOMY WITH ELECTRICAL INSTRUMENTATION.
Section of peripheral osseous bridges with rowel saw.

Fracture of the Osseous Pedicle.—The breaking through of the inner table of the osseous bridges with mallet and chisel, and the fracture of the base of the flap, are carried out in the way above described.

Rapid Mobilization of the Osseous Shutter with Rowel Saw and Chisel.

When the surgeon is possessed of practised dexterity in operation, and it is necessary to proceed rapidly, it may be possible to dispense with the use of the gliding saw: we simply divide the external table with the rowel saw along the whole length of the cutaneous incision, leaving the inner table, which is then severed with mallet and chisel in a few moments. It is of great importance to manipulate the mallet and chisel with skilled caution. Their employment by an experienced hand causes no appreciable shaking

of the encephalon. Some strokes of the mallet, crisp and vigorous at the same time, produce a fissure which is propagated to a distance in the desired direction, without splintering and without sensible transmission of shock to the subjacent structures.

To perform a rapid craniectomy by this method, the new instruments and technique described on pp. 533-543 must be employed.

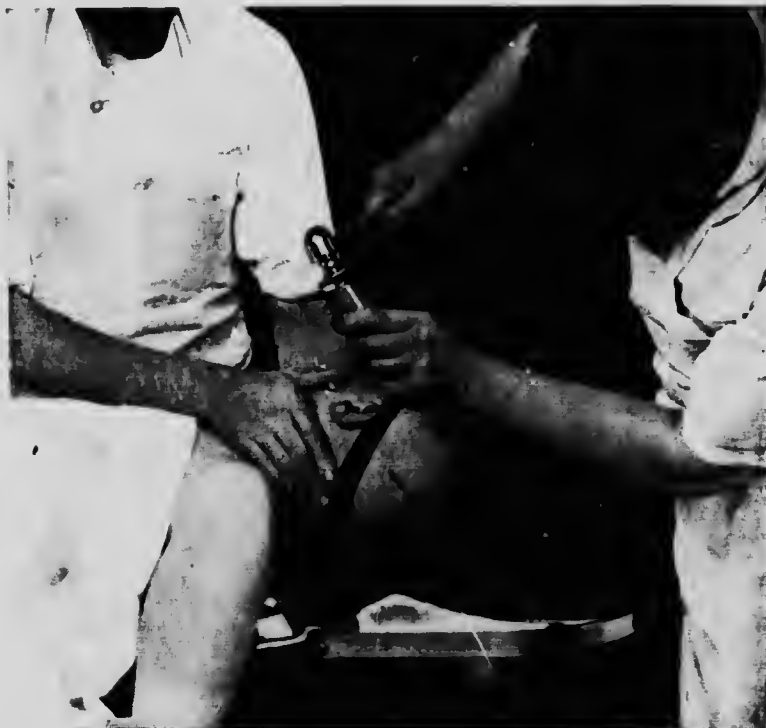

FIG. 741.—CRANIECTOMY WITH ELECTRICAL INSTRUMENTATION.

Breaking through the bridges of the inner table with mallet and chisel furnished with protective digit.

THIRD STAGE: ELEVATION OF THE OSSEO-CUTANEOUS SHUTTER.

When the osseous shutter appears to be fully isolated, we verify its mobility by trying to elevate it at the periphery with a straight raspatory. The osseous margin is then seized with both hands, and the three larger fingers penetrate beneath it, the thumbs being applied at the line at which the hinge is to be made. Fracture of the pedicle is now brusquely effected with a crisp stroke, but with great dexterity, so as to avoid any splintering of the cranial fragment, and the shutter is then raised to the vertical position. We have already pointed out that the mobilization of the osseous shutter should be accelerated when the diploic veins yield much blood. It is not,

indeed, arterial hemorrhage that we have to fear; it is that from the venous sinuses of the diploë, which communicate freely with the sinuses of the dura mater. In cases where the blood flows in waves we must hasten; the flap is rapidly raised, and as rapidly laid back; taking care to place a compress beneath it, between the bone and dura mater, and another over it. We then use pressure for some moments to arrest the escape of blood.

FOURTH STAGE: EXPLORATION OF THE DURA MATER.

When the dura mater has been exposed, the first care is to arrest any hemorrhage proceeding from the middle meningeal artery or its branches. In some cases, indeed, on account of an anatomical peculiarity, we tear a branch of this artery at a point at which the dura mater adhered to the cranial vault; sometimes we observe the laceration of a vein which formed an anastomosis between the diploë and superior longitudinal sinus. The

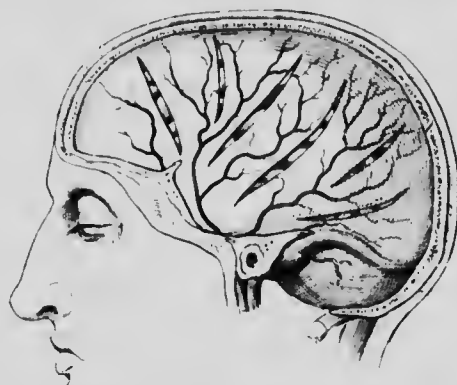

FIG. 742.—MULTIPLE INCISIONS OF DURA MATER BETWEEN THE PRINCIPAL BRANCHES OF THE MIDDLE MENINGEAL ARTERY.

branches of the middle meningeal artery are tied, when necessary, with a silk ligature passed beneath with a round curved needle (of the form used in enterorrhaphy). When a vein which anastomoses with the superior longitudinal sinus has been wounded, we make temporary hemostasis by applying pressure with the finger; we then resect a small portion of the bone with the gouge forceps, and suture the dura mater to the skin. The pressure of this membrane on the bony surface suffices to arrest the bleeding. In case of wound of a peripheral sinus, we may likewise employ the small compressor represented in Fig. 734. Hemostasis of the arterioles of the diploë is effected by crushing down the bone on the artery with a short-jawed forceps of the form used in ligation of the large veins.

The exploration of the dura mater should be carried out rapidly when the patient is feeble or if he has already lost very much blood. Besides these, there are cases in which it is necessary to relieve extreme intra-

cranial tension on the spot; it is then suitable to reclose the cranium rapidly, and suture the skin, without opening the dura mater in the first operative séance.

FIFTH STAGE: INCISION OF THE DURA MATER.

Incision of the dura mater should not be carried out at once, except in cases where it is necessary to give vent to a large purulent collection, or when there is considerable intracranial tension demanding immediate

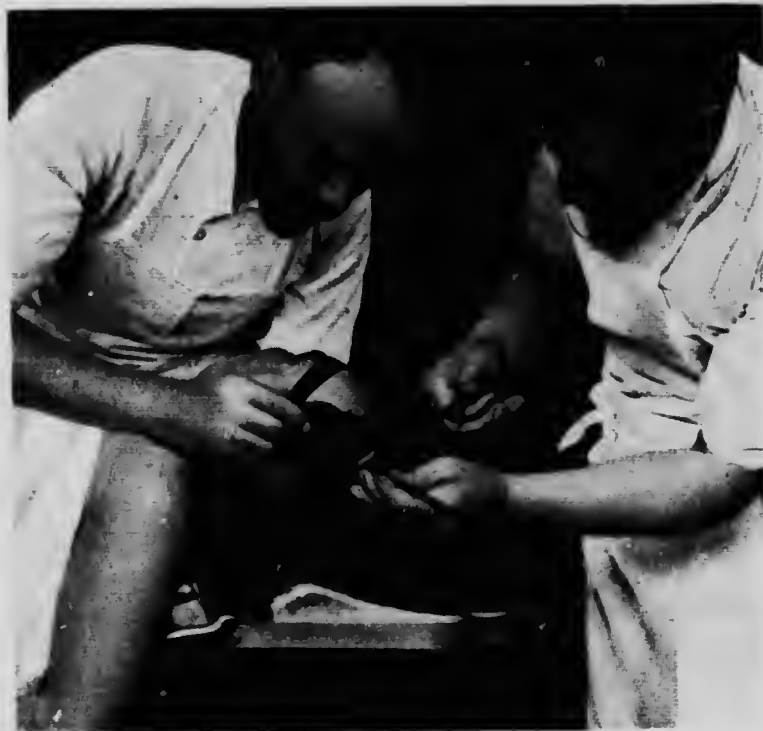

FIG. 743.—EXPLORATION AND SECTION OF DURA MATER.

The membrane is held with clawed forceps and divided with blunt-pointed scissors.

decompression. This immediate incision should not be more than some centimetres in extent. In those cases, too, we seldom cut an osseous flap of more than 6 or 8 centimetres each side—a dimension which suffices to obviate the uncertainties of cranio-cerebral topography. We can always enlarge the orifice a little with a gonge-forceps—for instance, at a point where it may be necessary to introduce a small plug of gauze or a glass drainage-tube (purulent focus).

When the dura mater is greatly distended, we may, without inconveni-

ence, make two longitudinal incisions parallel to the branches of the middle meningeal artery. The decompression suffices to produce a remission of

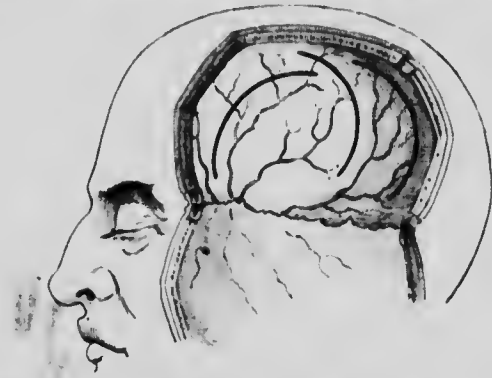

FIG. 744.—CURVILINEAR INCISIONS OF THE DURA MATER, AVOIDING THE PRINCIPAL RAMIFICATIONS OF THE MIDDLE MENINGEAL ARTERY.



FIG. 745.—INCISION OF THE DURA MATER.

Introduction of grooved sound through the first opening made in the membrane.

symptoms, and we have seen a deep purulent focus, too difficult to recognize, come to the surface only on the day next but one after the operation. The patient was *in extremis* at the time of operation, and so completely insen-

sible that anesthesia was unnecessary (pupils dilated; pulse, 45). As soon as the liberated brain formed a hernia through the incision in the dura mater, the pulsations rose to the rate of 80 per minute. In the afternoon he pronounced some words. On the following day the pus escaped on the




FIG. 746.—INCISION OF THE DURA MATER.

Section of the dura mater with a bistoury guided by a grooved sound. The dura mater will be opened a little farther on with scissors, on the extremity of a grooved sound. We then proceed to the second incision.

dressing. In the cases in which the dura mater is not distended it is better to close the incision afterwards, at least partially, by continuous silk suturing of the membrane. It is necessary to operate quickly; it is always dangerous to prolong intracranial procedures.

SIXTH STAGE: REPLACEMENT OF THE OSSEOUS SHUTTER.

We have seen that irregularities of fissuring of the osseous pedicle may render replacement difficult. If the bone is not easily laid back in its original place, and if there is an obstacle on that side, it suffices to elevate

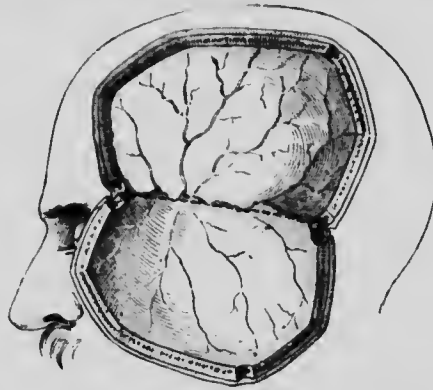


FIG. 747—CRANIECTOMY WITHOUT INCISION OF THE DURA MATER.

The osteo-cutaneous shutter is folded back. The dotted line indicates where the irregularities at the base of the osseous shutter should be removed, to facilitate replacement.

556 SURGICAL THERAPEUTICS AND OPERATIVE TECHNIQUE

the osteo-cutaneous shutter again, and turn it outward. We thus expose the exuberant osseous spicule; they are then resected with special forceps constructed for that purpose. There are two symmetrical forms of this instrument, so that the resection can be effected without difficulty.



FIGS. 748 AND 749. RIGHT AND LEFT SHEARS FOR RESECTION OF THE EXUBERANT SPICULE AT THE BASE OF THE OSSEOUS SHUTTER.

SEVENTH STAGE: SUTURE OF THE WOUND

When the osseous shutter has been returned to its place, the skin is sutured. I habitually employ a continuous silk suture. It is carried out

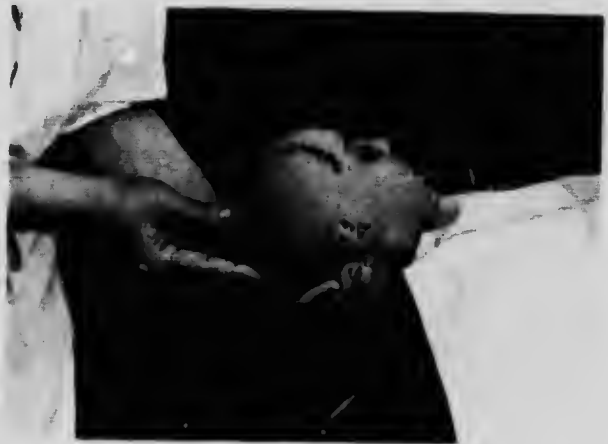

Fig. 750.

The osteo-cutaneous shutter is replaced. The skin is united by interrupted suture. Placing of glass drainage-tubes.



FIG. 751.—DIAGRAM SHOWING THAT EACH LOOP OF THE SUTURE SHOULD PASS IN CONTACT WITH THE PERICRANIUM.

very rapidly with large curved needles. In the majority of cases it suffices at the time for the prevention of all hæmorrhage from the pericranial vessels.

and to secure a perfect reunion. We may, however, use interrupted sutures with silk or Florentine hair. The suture should reach down as far as the pericranium in order to secure hæmostasis.

EIGHTH STAGE: DRESSING.

When the suture has been finished, two or three small glass drainage-tubes are placed, if required, at the level of the osseous openings made with the burr, and the cranium is now covered with sterilized compresses, and then with sterilized cotton. If the operation has been performed on a mechanical table, it is well, in applying the dressing, to have the patient's shoulders raised and the head-rest lowered; we are thus enabled to wash the nuchal region with sterilized water, and the dressing is effected with

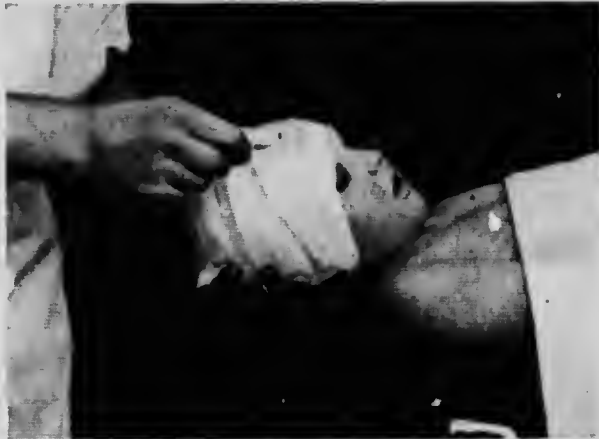

FIG. 752.—COMPRESSIVE MUSLIN BANDAGE.

every necessary detail of asepsis. It is not desirable to cover the cotton with impermeable gutta-percha leaf, as this would mask all soaking of the cotton with blood coming from the field of operation.

The best compressive bandage for the dressing is a broad one of gauze, rolled and moistened, of 12 centimetres in width and 6 to 8 metres in length. We must avoid passing the bandage under the chin, as we would thereby risk impeding the respiration of the patient, which may be somewhat feeble during the first few hours after the operation. As a rule the occipital protuberance is sufficiently prominent to fix the dressing, which should be arranged as indicated in Fig. 752. If the compression requires to be very firm, I apply a linen bandage over the gauze one. The dressing should be watched, and lifted off on the slightest indication of hæmorrhage.

When all goes well, the dressing is not changed till the fourth or fifth day, and it will be renewed once or twice before complete cicatrization. If there are drainage-tubes applied, and the dura mater is open, a con-

siderable quantity of cephalo-rachidian fluid may escape. In such cases the indication is to change the dressing and remove the drainage-tubes on the third, fourth, or fifth day. The orifices must be covered with proteol powder. If the cephalo-rachidian fluid elevates the osseous flap or the skin, we allow its escape at the time of dressing by removing the suture with a small forceps, or even with a grooved sound; and then powder the small opening with proteol. When a pellet has been inserted, we remove it on the second to the fifth day. Tamponing is continued only in cases of abscess of the brain or suppuration of osseous origin (infected fracture, caries, or necrosis). If we except those cases in which closure of the wound is notably retarded, cicatrization after craniectomy is habitually completed in six to eight days. The reapplication of the osseous shutter may be so perfect that, at the end of many months, a minute local examination would be found indispensable for making out the extent of the operation.

Atypical Craniectomy.

I have now studied in all its details the technique of temporary craniectomy, such as should be carried out when the operation is deliberately

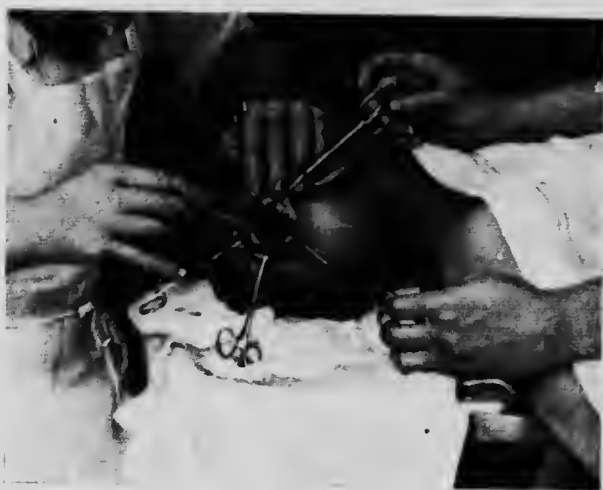

FIG. 753. — EXPLORATION OF A FRACTURE OF THE SKULL WITH DEPRESSION.

practised, and with well-determined indications. It is no longer the same when we have to deal with traumatic depression of the cranial bones or with gunshot wounds. The general technique is nevertheless identical; we may employ either manual or electrical instrumentation. But the details of each intervention will vary according to the indications of the individual cases.

TRAUMATIC LESIONS.

Fractures of the Skull.—I need not here discuss the indications for intervention in cases of fracture of the skull. I may, however, affirm that craniectomy is innocuous when practised by a dexterous surgeon. It should be performed in every case in which there are probable signs of intracranial extravasation or of cerebral compression. The operation forces itself upon the surgeon when there is depression. In most cases it is not indispensable to have recourse to a special instrumentation. Suppose

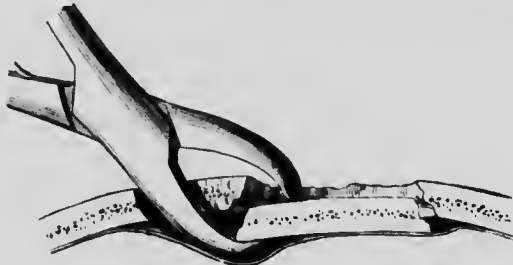

FIG. 754.—GOUGE-FORCEPS, ONE JAW OF WHICH HAS BEEN INTRODUCED THROUGH AN ORIFICE MADE WITH A BURR, SEIZES AND REMOVES A DEPRESSED OSSEOUS FRAGMENT.

a case of fracture with depression of the fragments. When the seat of fracture has been exposed, it is enough to introduce at one point one of the jaws of a strong gouge-forceps into the cranial cavity. A small osseous fragment is removed, and this orifice suffices for removal with the same instrument, of the other fragments which have been buried in the cranial cavity. The great point is to make a large cutaneous incision, and freely expose the seat of the traumatic lesion.




FIG. 755.—EXTRAVASATION OF BLOOD BENEATH A FRACTURE OF THE CRANIUM BY DIRECT VIOLENCE.

The focus will be evacuated by dealing with the osseous fragment.

If the osseous fragments have been pegged in deeply, we may effect at the part of the periphery which is the most easily mobilized a perforation of 12 millimetres in diameter with the *trepan à cliquet* and flat perforating drill, followed by the cylindro-spherical burr. These instruments should be present in all the drawers of the urgent surgery departments. The first orifice serves for introduction of one of the jaws of the gouge-forceps, with which the buried fragments may be removed. Those atypical operations

present no difficulty when we are practised in the technique of temporary craniectomy such as I have described it.

Traumatic Intracranial Extravasations.—When there is no external wound or sign of depression, the operation may be necessitated by the presence of an intracranial extravasation. The indications are then less clearly defined. Nevertheless, I believe craniectomy to be an operation sufficiently safe to feel justified in recommending it in nearly all cases of grave fractures. An extensive decompression may save the patient. If he is destined to succumb to the existing concussion or contusion of the brain, the result of irremediable traumatic lesions, the operation cannot be incriminated, for it gave him the only chance of recovery.

When signs of compression exist which make us suspect a sero-sanguinolent or sanguinolent extravasation between the dura mater and the cranium, two or three orifices of 12 millimetres diameter are made on the side on which the compression appears to be present—the dilatation of the pupil is usually more marked on that side—and over the position of the supposed extravasation. Those orifices may suffice for evacuation of the extravasated fluid and for drainage. If we find a considerable intracranial focus, we can in every such case continue the operation by a temporary craniectomy.

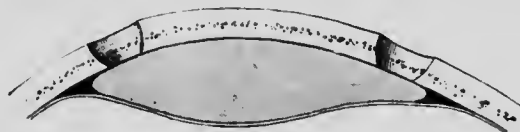


FIG. 756. EXTRAVASATION OF BLOOD AT A DISTANCE FROM THE SEAT OF FRACTURE (BY CONTRECOUP).

Orifices made with the burr for the discovery and evacuation of the focus.

Penetrating Wounds of the Cranium produced by Heavy Blunt Instruments.—Wounds of the hairy scalp may be complicated with fracture accompanied by depression, without giving the injured person at the moment of the accident the appearance of having been so gravely affected. I have seen a patient of the working class present himself at the Rheims Hospital with a parietal wound of limited extent, produced by a blow from a pick-axe. The traumatism had actually disorganized a great part of the corresponding cerebral lobe, yet the injured man had come by himself, and passed into coma only in the course of the following night.

Procedure to be adopted in Case of Penetrating Wound of the Cranium.—When the wound has been examined and a diagnosis of perforation established, the patient is placed under the influence of an anæsthetic, and after toilet of the field of operation, we proceed to intracranial exploration. The opening is enlarged with the gouge-forceps, and the index-finger is introduced, which may penetrate the injured cerebral tissue without danger if guided without undue force.

The bony fragments are recognized and removed with the aid of an ordinary forceps or a bullet forceps. By this technique Dr. Roussel, in

February, 1900, at my clinique in Rheims, successfully removed a fragment of the right parietal bone, of 20 millimetres in diameter, which had been driven in to a depth of 6 centimetres, by a bar of iron which had fallen vertically from a height of more than 10 metres (Fig. 757). The wound should be plugged with a wick of sterilized gauze and drained with a glass tube. The wick of gauze is removed on the third to the sixth day, and the drainage-tube about the tenth day, if there is no evidence of deep-seated suppuration. When there has been great loss of bony substance, we must apply a flat dressing. If necessary, we can afterwards have recourse to an autoplasty with displacement; by borrowing from a neighbouring part of the outer table of the skull, to repair a loss of substance which cannot be filled up by the sole effort of Nature.

Penetrating Gun-Shot Wounds of the Cranium.—Gun-shot wounds of the cranium are now very different from those of former times. The diminution of calibre of the portable firearms, which also transmit their very small projectiles a greater force of penetration, has sensibly reduced

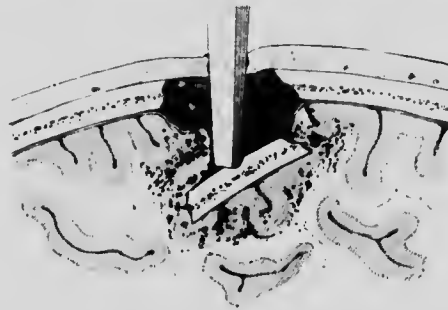


FIG. 757.—BURIAL OF A FRAGMENT OF THE UPPER PORTION OF THE PARIETAL BONE IN THE BRAIN SUBSTANCE BY THE FALL OF A HEAVY METALLIC BAR.

The immediate mortality of penetrating wounds of the cranial cavity. Reduction of the calibre of rifles used in battle from 11 millimetres (1870) to 8 millimetres (France), 7.9 millimetres (Germany), 7.7 millimetres (England), and 6.5 millimetres (Holland), and even to 6 millimetres (United States) has considerably diminished the phenomena of shattering of the cranial vault by hydraulic pressure.

The shock of a deformable bullet from an *express rifle* of 12.5 millimetres fired at close quarters completely shatters the cranial vault, with projection of the cerebral matter to a distance. It is quite otherwise in the case of a small bullet with a hard envelope. During recent wars soldiers have recovered who have had the head traversed by a rifle-bullet with a hard envelope and a maximum diameter of 8 millimetres. If we except the irremediable cases, in which a grievous wound causes the individual to succumb after a few minutes or a few hours, most of the penetrating wounds of the cranium are not inevitably mortal.

Whether the weapon has been directed by the wounded person or by

another, and whether the projectile has penetrated into the frontal, temporal, or occipital region, the first preoccupation of the surgeon should be to determine the gravity of the case. The wounded patient should be undressed, exposed in full light, and carefully examined. The face, respiration, pupils, and pulse will enable us to decide rapidly whether there is any hope. The external wound is disinfected, and the patient is resuscitated, when possible, by the usual procedures— injections of ether, of caffeine, of artificial serum. The wounded person revives— what is to be done? Bullets of small calibre and with hard envelope usually traverse the cranium from end to end. We then have but to disinfect the traumatic focus, and apply a moist aseptic



FIG. 758. LEADEN BULLET OF 9 MILLIMETRES DIAMETER ENCYSTED IN THE ENCEPHALON IN THE NEIGHBOURHOOD OF THE SELLA TURCICA, AND PERFECTLY TOLERATED.

dressing. Leadén bullets of small calibre, on the other hand, rarely traverse the cranium. In such cases we find the orifice of entrance only. How should the surgeon then proceed? Should he explore the depth of the wound, and attempt immediate extraction of the projectile? The answer in almost every instance must be: *No*. Cases are, in fact, continually becoming more numerous of individuals carrying a projectile in the cranium and experiencing no very appreciable trouble therefrom. How many of those wounded who have been cured by the resources of Nature alone would have survived if they had fallen into the hands of those apostles of "urgent surgery" who would have hastened to open the cranium, and increase tenfold—possibly,

too, without succeeding in extraction of the projectile—the mischief produced by the original traumatism.

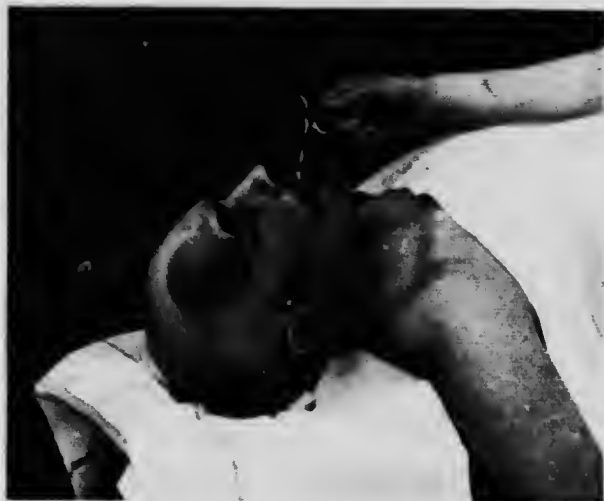

FIG. 759.—PENETRATING GUN-SHOT WOUND OF THE CRANIUM IN THE RIGHT FRONTAL REGION.

The wounded person should then be kept under observation, as in cases of fracture of the cranium, and the surgeon must hold himself in readiness

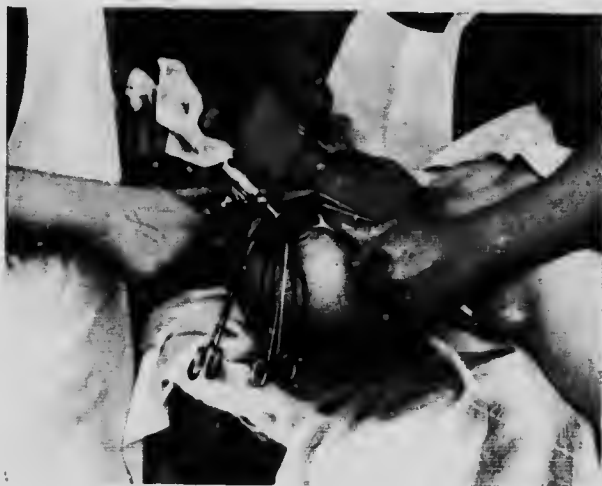

FIG. 760.—PENETRATING WOUND OF CRANIUM BY BULLET FROM REVOLVER PLACED IN MIDDLE OF RIGHT FRONTAL REGION.

Right frontal craniectomy with small shutter, for exploration and toilet of the traumatic focus.

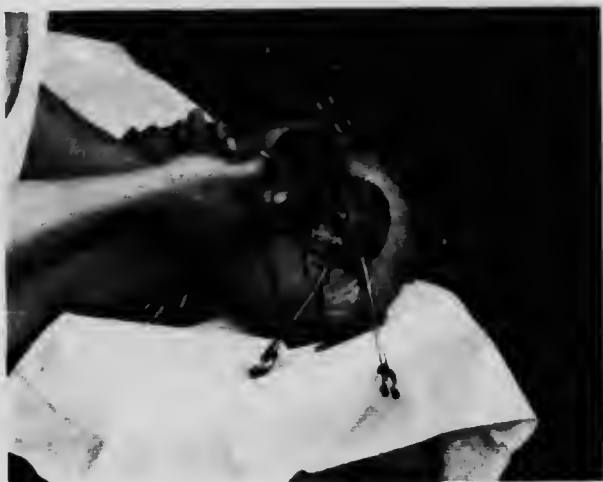

FIG. 761.—PENETRATING WOUND OF CRANIUM BY BULLET FROM REVOLVER PLACED IN MIDDLE OF RIGHT FRONTAL REGION.

The toilet of the traumatic focus in the right frontal region has been made. The projectile had been arrested at the surface of the brain in the right motor region of the opposite side. It is exposed by another craniectomy, on the left side, and extracted by the surgeon with bullet forceps.

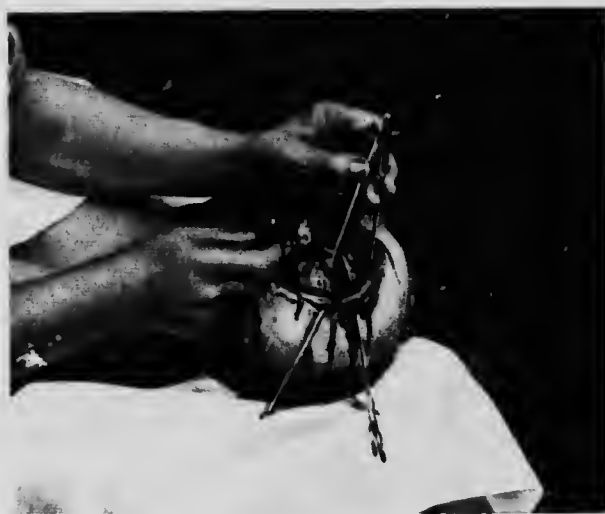

FIG. 762.—PENETRATING WOUND OF CRANIUM BY BULLET FROM REVOLVER PLACED IN MIDDLE OF RIGHT FRONTAL REGION.

Mapping out the traumatic focus which contains the bullet. Two measurements are made with the graduated compass from two well-defined points—for example, *D*, anterior, 65 millimetres; *d*, posterior, 58 millimetres.

to intervene if any alarming symptom comes to demand operation. Thus it is that it suffices, for the cure of many cases of penetrating wound of the skull with firearms, to disinfect the external wound and remove any superficial fragments that may be present. The wound is treated by antiseptic plugging, care being taken that the plug is not too tight, which might cause symptoms of compression.

If the state of the wounded, after a period of apparently satisfactory progress, becomes suddenly altered for the worse, we must operate at once. An anæsthetic is

a. the cranial opening is widened with the burr and gonge-forceps, and the encephalon is explored with the finger. I have thus been able to save some persons wounded with a projectile of considerable size, which had been arrested at a depth of some centimetres in the temporal lobe of the brain. In a case of revolver-shooting into the ear, I have been able to extract three bullets of

9 millimetres diameter from the petrous bone in which they were deeply embedded. In most cases, when the projectile is a revolver bullet of

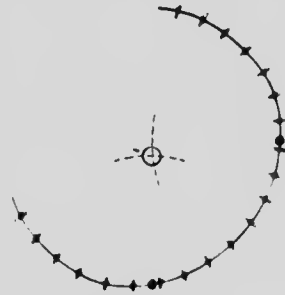


FIG. 763.— DIAGRAM SHOWING HOW WE MAP OUT THE POSITION OF THE INTRACRANIAL FOCUS ON THE SURFACE OF THE SKIN BY THE INTERSECTION OF TWO ARCS DERIVED FROM THE TWO CENTRES OF THE FIRST MEASUREMENT.

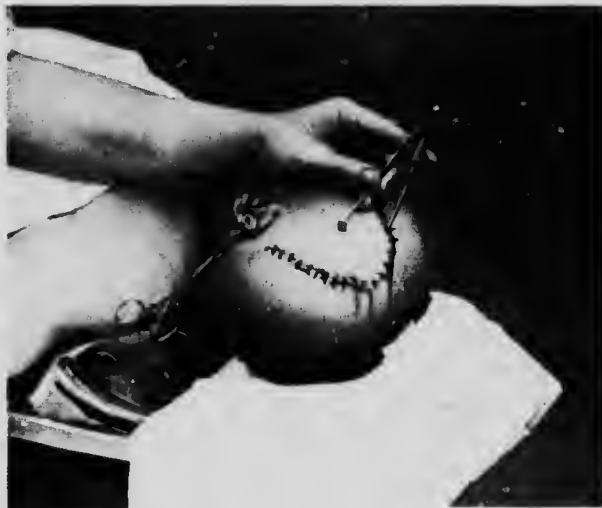

FIG. 764. PENETRATING WOUND OF CRANIUM BY BULLET FROM REVOLVER PLACED IN MIDDLE OF RIGHT FRONTAL REGION.

The focus has been mapped on the surface of the skin, after suture of the shutter, by tracing from the same pair of centres two arcs of circle, the respective radii of which have been previously determined with the graduated compass.

small calibre, and the wounded person has not succumbed after the injury, the question of the extraction of the bullet should not be discussed till a later stage, and after the patient has been examined with the X rays. The position of the projectile having been determined within a possible range of a few millimetres, it can be extracted by temporary craniectomy. There is no need for complicating the operation by the mappings out recommended by certain surgeons. Two good radiograms—the first in the antero-posterior or postero-anterior direction, according as the projectile has been previously shown by its shadow to be located nearer the sinciput or occiput; and the second in the transverse direction—enable us to determine the position with great precision. This first research may be completed by the taking of two stereoscopic *clichés*. Then a final examination on the screen enables us to map out on the skin the position of the foreign body beneath.

When the osseous shutter has been raised, the cerebral cicatrix, which is very apparent, will conduct us directly to the osseous fragments and the projectile; which we locate, when necessary, by the use of long, slender acupuncture needles. Accordingly, tardy extraction of intracranial projectiles is possible in most cases, unless the bullet happens to be situated in an almost inaccessible position; as in the case represented in Fig. 758, in the vicinity of the sella turcica, where it cannot be reached without production of irreparable mischief. This tardy extraction is, however, seldom indicated. In fact, operation can be beneficial to the wounded only in those cases in which the projectile produces indications of *manifest irritation* by its presence. If there be a localized and definitive paralysis produced by the division of a nerve bundle which lay in the course of the bullet, the extraction of the latter will be useless, as the operation can give no curative result. On the other hand, extraction is indispensable if, after traversing the substance of the brain, the projectile has reached the internal table over the motor region of the cortex, where it may produce irremediable mischief. Thus I have had occasion to extract a revolver-bullet fired through the mouth which had severed the left optic nerve, and the motor nerve of the levator palpebrae, and lodged in the motor centre of the right lower extremity. The operation was followed by recovery of the functions of the paralyzed limb; the muscles remained slightly sensible to faradization, and voluntary motion began to be regained some weeks after extraction of the bullet.

Preventive Anti-Tetanic Serotherapy: Polyvalent Immunization with Mycolysine. When wounds of the head are infected and soiled with organic detritus (by the kick of a horse, etc.), it is well, especially in case of a penetrating wound, to administer immediately, and afterwards daily, while the gravity of the symptoms continues, subcutaneous injections of mycolysine, of 20 to 50 c.c. of each. Two preventive injections of 10 to 20 c.c. of Xocard's anti-tetanic serum are also given, with an interval of eight days between.

Post-Traumatic Jacksonian Epilepsy.—When the crises are distinctly Jacksonian, and the localization of the irritated cortical centre ap-

proximately corresponds to the traumatic focus, there should be no hesitation. Thus I showed, at the opening of the International Congress of Medicine in 1900, before Professor Virchow and numerous colleagues,

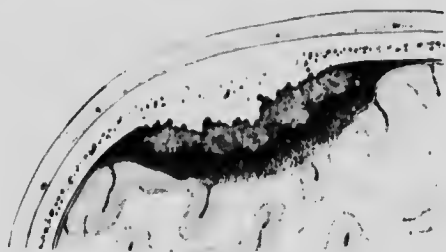


FIG. 765. POST-TRAUMATIC EXOSTOSIS OF THE INNER TABLE WHICH HAS DETERMINED THE FORMATION OF A CORTICAL SEROUS CYST.

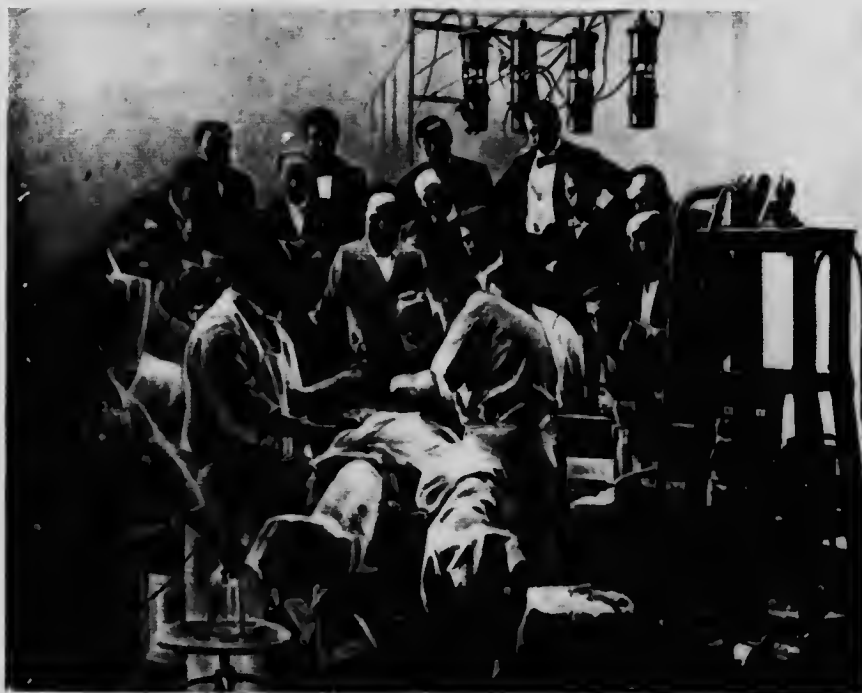

FIG. 766.—THE LATE PROFESSOR VIRCHOW AND THE MEMBERS OF THE INTERNATIONAL CONGRESS OF MEDICINE WITNESSING A CRANIECTOMY BY THE AUTHOR, AUGUST 7, 1900.

a cortical cyst of the brain generated in a young man of thirty years by the development of a traumatic exostosis of the internal table of the

cranium (Fig. 765). The cyst was opened and plugged, the exostosis planed down with the electric burr, and the osseous shutter then replaced. The patient recovered. In such a case it is necessary to make an opening in the osseous shutter at the level of the traumatic focus, for the passage of a wick of gauze.

In some cases we may practise definitive craniectomy instead of temporary—that is to say, we resect the pathological osseous area completely, between three or four orifices made with the burr. The area of the loss of substance can be increased with the gouge-forceps. Those permanent losses of substance cause no inconvenience when they are not too extensive.

Foreign Bodies in the Brain.—Many foreign bodies of the brain may prove quite innocuous. I have already cited the case of a woman who carried, and without the least inconvenience, a revolver-bullet of 9 millimetres encysted in the neighbourhood of the sella turcica (Fig. 758). It cannot be questioned that an attempt to extract that foreign body would be dangerous. If the projectile gives very pronounced evidence of its presence, we must operate. Two radiograms, an antero-posterior and a transverse, suffice, as already pointed out, for location of the foreign body. Before taking those radiograms, we should take care to place a small cylinder of lead in each auditory canal; and fix two metallic clips, one at the external occipital protuberance and the other on the intersuperciliary space. Then, before operating, we again verify the localization of the foreign body by radioscopy; and we now proceed to mobilize, in the position designated by those various proceedings, an osteo-cutaneous shutter of at least 6 to 8 centimetres in diameter. If the position of the foreign body is intracerebral, it is then sought for with long, slender acupuncture needles. Very dense foreign bodies, especially leaden bullets, are very often found in a dependent position—fronto-ethmoidal fossa, temporal fossa, occipital fossa. The operative technique should be adapted to each individual case.

INFLAMMATORY LESIONS.

Suppurations consecutive to Fractures and Penetrating Wounds of the Cranium.—When there is a fracture or even a penetrating wound of the skull, it often suffices to enlarge the orifice a little with the gouge-forceps to enable us to evacuate a superficial purulent focus. If the symptoms persist after such limited first intervention, a typical craniectomy may be practised, in the way above indicated.

Localized Meningitis.—The gravity of the symptoms of meningitis corresponds in great measure to the excess of intracranial tension which accompanies the inflammatory evolution.

If the patient seems sufficiently resistant, and the lesion appears little likely to end in resolution, it is desirable to practise a decompressive craniectomy, and thus diminish the immediate danger of exaggeration of the intracranial pressure. Decompressive craniectomy is so much the

more strongly indicated in certain cases of meningitis, as observations have been published of recent years of cases of children who had succumbed

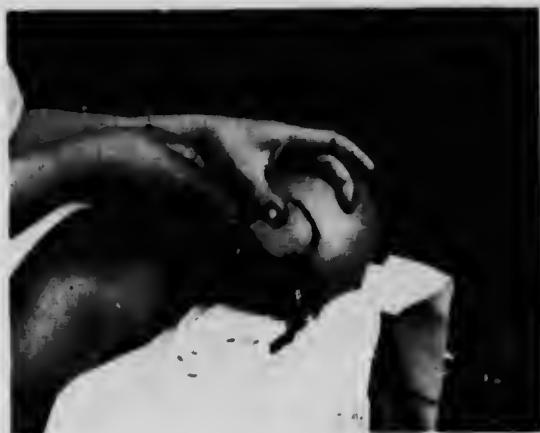

FIG. 707.—OCCIPITAL CRANIECTOMY FOR LOCALIZED CHRONIC MENINGITIS; INCISION OF THE INTEGUMENT.

In cases in which the intracranial pressure might produce hernia of the brain the shutter should be of small dimensions.

with all the symptoms of simple or tuberculous meningitis. Although no characteristic meningeal lesion was found on autopsy. se pseudo-

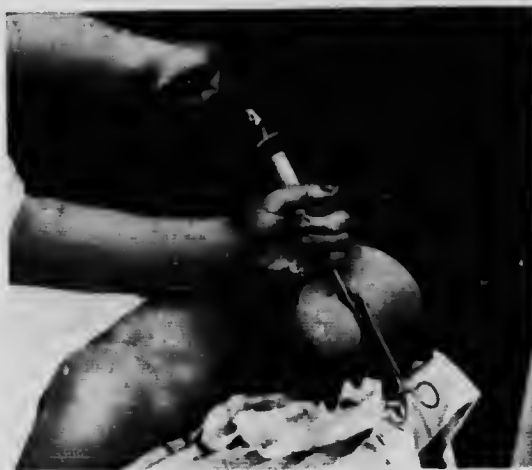

FIG. 708.—OCCIPITAL CRANIECTOMY FOR LOCALIZED CHRONIC MENINGITIS; BREAKING THROUGH THE INNER TABLE ALONG THE PERIPHERY OF THE SHUTTER WITH MALLET AND BLUNT-ANGLED CHISEL.

570 SURGICAL THERAPEUTICS AND OPERATIVE TECHNIQUE

meningitis had, however, led to fatal results after a series of phenomena of excitement, followed by coma and dilatation of the pupils; all symptomatic of increase of intracranial tension.

Hitherto I have intervened in but one case of tuberculous meningitis. There was extraordinary intracranial tension, and the osteo-cutaneous shutter was left raised 10 or 15 millimetres. Although there was an improvement for six or eight days, the operation had no appreciable influence on the final result.

I have intervened successfully, on the other hand, in a case of subacute occipital meningitis (with relapses) in a woman of thirty, who had previously had an attack of meningitis, accompanied by vomitings and coma. The pia mater was milky and thickened, especially along the vessels; and incision of the brain substance, which was oedematous, gave

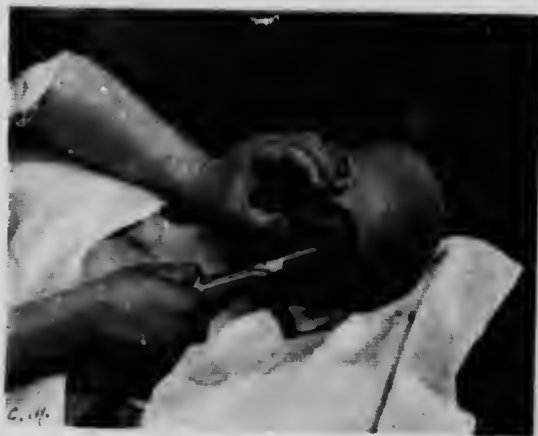

FIG. 760.—OCCIPITAL CRANIECTOMY FOR LOCALIZED CHRONIC MENINGITIS: INCISION OF DURA MATER AND EXPOSURE OF THE FOCUS OF CHRONIC MENINGITIS.

exit to about 50 grammes of serosity. The patient recovered without further incident. Thus it is certain that decompressive craniectomy is indicated in certain cases of meningitis, and that this operation can, by terminating the conditions of encephalic compression, give the organism an opportunity of victoriously pursuing its struggle against the pathogenic microbes.

In cases of lateral craniectomy we may leave a temporal bony orifice for the purpose of placing there a wick of gauze, or even a glass drainage-tube, to drain the temporal lobe of the brain. This orifice can be utilized, too, for puncture of the lateral ventricle, in which there may be an accumulation of fluid. The lateral ventricle is found at a maximum depth of 4 centimetres, and the needle should be made to penetrate obliquely, upwards and inwards, towards the bregma.

In another case of non-tuberculous meningeal lesion in a girl of fourteen,

I have simultaneously drained the temporal and the occipital fossa. That patient recovered.

Abscess of the Brain.—Search for abscess of the brain not connected with mastoid suppuration is often a very delicate procedure. The collection of pus may, indeed, have formed far enough away from the focus of infection to which it owed its origin, and the symptomatology is often very obscure. I have seen a case of abscess of the brain run a subacute course, of which the etiology appeared to me to have been dependent on two previous attacks of osteomyelitis. Many of the most authoritative clinicians had made a diagnosis of cerebral tumour, probably tuberculous. There was no localizing symptom, and the seat of the cephalalgia could alone enable one to decide on which side the operation should be carried out. The patient was *in extremis* when operated on without anaesthesia. An extensive decompressive craniectomy enabled him to regain his senses. Puncture of the brain not having revealed the focus, an orifice was made in the osseous shutter in the suspected position, in order to secure deep drainage with a wick of gauze. After forty-eight hours the dressing was found suddenly innundated with pus, and the patient recovered.

In another patient an abscess of the size of a pigeon's egg owed its origin to traumatic necrosis of the lower jaw. The wounded man was, after some hours, attacked with violent headache, and presented the classic symptoms of *agrafia*, and then of aphasia. An osseous shutter of 6 centimetres enabled me to locate and incise a deep-seated abscess which had formed at the level of the second frontal convolution. There were two cases of abscess of the brain which had developed at a distance from the source of primary infection, and of which the symptomatology proved wholly dissimilar. The first focus, which was very deeply seated, gave no precise indications for its localization, and the seat of pain alone pointed to the affected side. An extensive decompressive operation was the only procedure that could save the patient, who at the time of intervention had been comatose for forty-eight hours; with a pulse of 45, and both pupils dilated.

The small subcortical abscess of the second observation was, on the other hand, indicated by characteristic signs of localization. The patient was under treatment at my clinique for fracture of the ascending ramus of the lower jaw on the left side, followed by suppuration. Operation had been suggested and carried out. As the abscess had formed at some distance from the primary source of infection, the localization was very difficult. Such is not the case when the suppurating focus is formed by contiguity, close to the seat of a traumatic or inflammatory lesion. In this category are ranged the abscesses consecutive to fractures of the skull complicated with external wound, with or without the presence of a foreign body; also the abscesses consecutive to suppurating otitis. We must always remember that the seat of abscess may vary notably, and that the focus may form at a certain distance from the osseous parietal lesion. Thus, after having vainly sought for an abscess of otitic origin in the temporo-sphenoidal lobe, which was absolutely intact, and then in the cerebellar fossa, I have found at the

autopsy the collection of pus above the tentorium cerebelli, at the posterior part of the occipital lobe. At the time of operation the brain had been raised from that membrane even near the seat of the focus, and no trace of inflammation existed at any part of the region examined. This observation proves the necessity of carrying out the exploration to the utmost limits of the dural area in which the abscess is sought for, and raising up the brain as far as possible with a blunt retractor.

OPERATIVE TECHNIQUE.—In cases of cerebral abscess, craniectomy is ordinarily limited to a shutter of 6 to 8 centimetres in diameter. The first observation, cited on p. 571, is thus wholly exceptional. In that patient it had, indeed, been decided to carry out an extensive decompressive operation, and the nature of the lesion was wholly undetermined. It was only

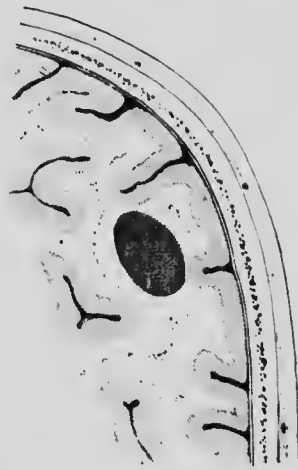

FIG. 770. SUBCORTICAL ABSCESS OF THE SECOND FRONTAL CONVOLUTION.

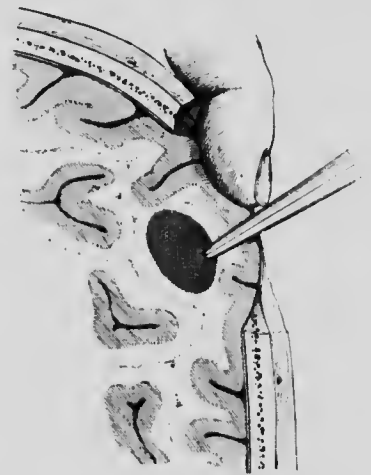


FIG. 771.

The suppurating focus is recognized by digital palpation, and evacuated by puncture with blunt forceps.

the rapid progress of the symptoms (three weeks) that led me to oppose the erroneous diagnosis of cerebral tumour, which had been debated in my presence, in favour of that of abscess.

When the diagnosis has not been decided, and there is considerable intracranial tension, the mobilization of a vast parietal flap presents the double advantage of permitting extensive exploration of the exposed hemisphere and a sufficient decompression, without exposure to the danger of hernia or strangulation of a portion of brain tissue caught in too small an opening of the dura mater. If, on the other hand, the indications of localization are precisely marked, as in the second case above cited, and the patient does not present symptoms of considerable augmentation of intracranial tension, it will be sufficient to mobilize an osseous shutter of some centi-

metres in diameter. It is never necessary to have recourse to those fastidious tentatives of mensuration and mapping-out of surface areas, which were exacted by the older method of trepanning with crowns of 15 to 20 millimetres in diameter.

The osseous shutter should be sufficiently large to allow us to recognize the exposed convolution with absolute precision, and to explore with the pulp of the index-finger the surface of the brain and adjacent dura mater for some distance around the margin. Palpation of the brain is, in fact, the only means of discovering subcortical tumours or collections. These

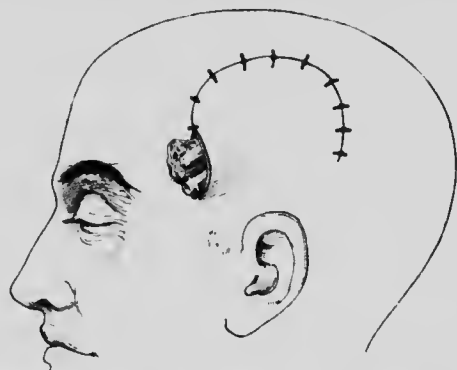


FIG. 772.—SUTURE OF SHUTTER: TAMPONING AND DRAINAGE OF FOCUS OF SUPPURATION.

give a very characteristic sense of resistance, and the alteration in consistence can be at once recognized by an observer who has often practised palpation of the living cerebral cortex. In the second case above referred to, the abscess gave the finger the same sensation as a subcortical tumour of the size of a pigeon's egg.

When the pus has been evacuated, the osseous shutter should be abraded with the gonge-forceps at the point most favourable for drainage; a glass or india-rubber drainage-tube, reaching to the seat of suppuration, is then placed in that orifice, surrounded with a wick of sterilized gauze, destined to prevent diffusion of pus beneath the dura mater. The rest of the wound should be sutured. Small acute abscesses of the brain are usually healed up after eight to ten days.

Craniectomy in Two Stages

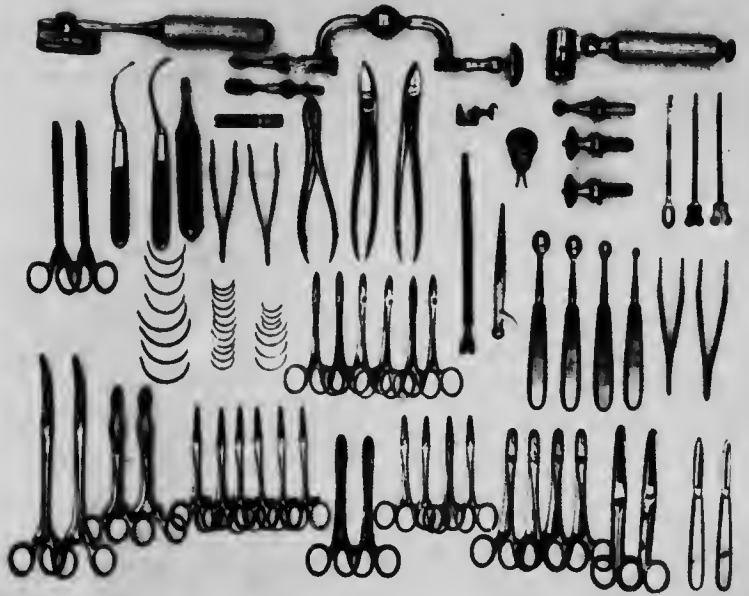


FIG. 773. INSTRUMENTS TO BE PREPARED FOR SECOND INTERVENTION.

Below, and from right to left: Two bistouries, two straight scissors, four forceps with short jaws and claws, four Championnière's hæmostatic forceps, two short-jawed forceps for veins, six ring-handled forceps with nine oblique claws, two ring-handled forceps with oval jaws, two large forceps with curved jaws. Above, and to the right: Two clawed forceps, four curettes, two curved grooved sounds and one decollator of the dura mater, one measuring compass, one exciter for electric exploration of the motor centres, six needle-holder forceps with short jaws, two needle-holder forceps with eccentric jaws, four forms of cutting needles, twelve intestinal needles, two needles mounted on handles, thirty clips, two clip-holder forceps.

It is necessary to add special instruments for ordinary craniectomy and for electric craniectomy. The surgeon should be at the disposition of the surgeon for cases in which it may be necessary to enlarge the existing osteal breach or to create a new one: one trepan *à cliquet* and accessories; one saw; two shears, right and left; two compressors for sinus hæmorrhage; one handle with variable inclination; one holder with spherical burr of 12 millimetres; two saws of 35 millimetres, with series of graduated discs; one turnscrew. (Scale reduced to one-sixth.)

MALFORMATIONS: CONGENITAL AND ACQUIRED.

Microcephaly.—Cranicectomy can give good results in microcephalic subjects only if the infant has begun to speak, and presents signs of at least some relative intellectual development. The operation can be carried out in two parts, with an interval of four or five days.

First Intervention.—We form, on the *left* side, a large shutter extending from the occipital bone to the external orbital apophysis, and, above, to within 10 or 15 millimetres from the superior longitudinal sinns. The osseous shutter is then raised, its base is trimmed with the cutting bone forceps, and it is replaced after section of the dura mater. The skin is then sutured with a continuous silk suture, and a compressive dressing is applied without drainage.

Second Intervention.—Four or five days later the cutaneous suture is removed, stitch by stitch, taking care to divide each loop at the exact level of the skin, so as to diminish the risk of infection of the field of operation. We

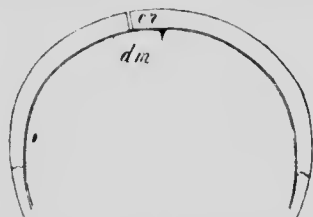


FIG. 774.—EXTENSIVE FRONTO-PARIETO-TEMPORAL CRANIECTOMY.

Osseous shutter replaced with exactness.

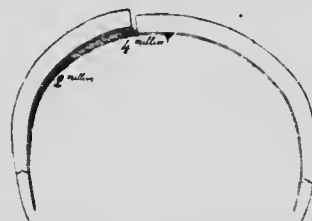


FIG. 775.—OSSEOUS SHUTTER RAISED AT PERIPHERY TO A HEIGHT OF 4 MILLIMETRES.

The mean elevation is of 2 millimetres.

then separate the edges along the line of remion with the index-finger. The osteo-cutaneous shutter is raised, and any coagulated blood present is removed with compresses and enrette. This second operation is carried out without the elastic band, for there is no bleeding. The dura mater is punctured with the clawed forceps and bistoury, then incised with grooved sound and scissors at 10 or 12 millimetres from the margin of the osteal flap. Its base is left intact; two or three liberating incisions are practised, if the brain presents any appearance of strangulation, on the peripheral lip of the opening made in the dura mater. Hæmostasis of the branches of the meningeal vessels is carried out on the dura mater by application of short-jawed forceps to the veins, which are kept tightly closed for two or three minutes. If blood happens to escape from a cerebral arteriole or venule by accident, hæmostasis should be effected with a double ligature of fine silk, passed around the vessel with a fine curved needle on either side of the bleeding-point. When the bleeding has ceased, we partially mite the edges of the dura mater with a fine silk suture, and replace the osteo cutaneous flap. I habitually practise

definitive suture of the skin, either with interrupted suture of Florentine hair or continuous suture of silk, and place two or three small glass drainage-



FIG. 776.—SECOND INTERVENTION IN CRANIECTOMY FOR MICROCEPHALY.
Exploration of brain by X-shaped incision of dura mater.

tubes in the orifices made with the burr. These drainage-tubes are left for two to five days. They are withdrawn very early in case of copious flow

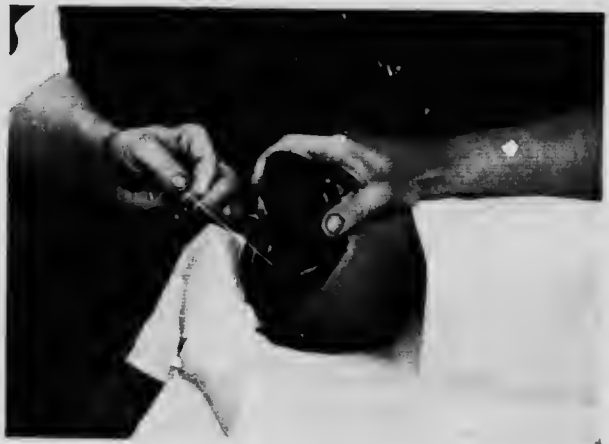

FIG. 777.—SECOND INTERVENTION IN CRANIECTOMY FOR MICROCEPHALY.
Partial interrupted suture of flaps of dura mater with fine silk.

of cephalo-rachidian fluid, and the tunnel left is filled with powdered proteol. The flap is raised higher on the succeeding days. We give it to the fluid by removing a stitch from the line of reunion, with a small forceps or grooved sound; then powdering over at once with proteol. Complete reunion is effected at an interval of five to eight days from the second intervention.

The aspect of the infant in nearly every case becomes more animated as soon as the immediate effects of the operation have passed off, and a

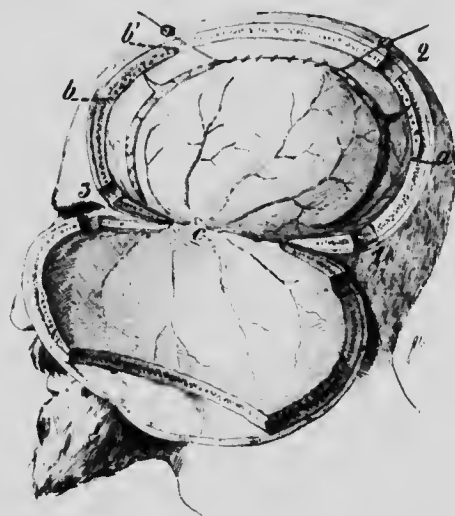


FIG. 778.—EXTENSIVE CRANIECTOMY FOR ESSENTIAL EPILEPSY, PERFORMED WITH ELECTRICAL INSTRUMENTATION.

b-b. 2-*a.* Points of the periphery of the flap where the inner table has been fissured. At the upper border of the shutter we see the definitive loss of substance resulting from extirpation of the osseous segment. The continued suture of the dura mater is fixed outside the skin on two grooved spheres of lead, so that after the complete cicatrization of the wound we can withdraw the thread and free the dura mater.

very manifest awakening of the intellectual functions takes place. The education of the infant should be commenced with care and method as soon as the cicatrization is completed.

When the result is satisfactory, the same operation is carried out some months afterwards on the opposite side; and, at a later date, we may divide the median bridge which unites the frontal and occipital bones (Fig. 708), taking care to detach the sinus with a grooved curved sound, or with a decollator specially constructed for this purpose. This section of the bi-parietal osseous bridge is preferably made with the nibbling forceps. Administration of thyroïdine is useful in case of infants, and more especially in those in which the thyroid body appears to be insufficiently developed.

This medication is quite innocuous when we take care to watch the pulse and the state of the nervous system. In cases of backward children and those affected with thyroid insufficiency, it facilitates the development of the intellectual faculties.

Hydrocephalus.—This affection has hitherto given place to no intervention worthy of notice. Puncture is useless, and gives no results.

Essential Epilepsy.—The operation is carried out in two séances, at an interval of four or five days.

First Intervention.—As in the case of microcephaly, the osseous shutter is made very large, and divided preferably with the help of electrical

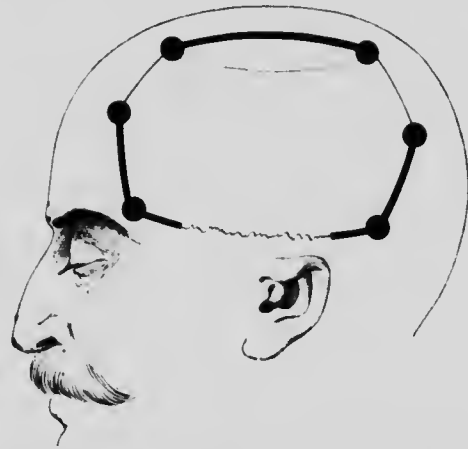


FIG. 779.—CRANIECTOMY FOR ESSENTIAL EPILEPSY, WITH ORDINARY INSTRUMENTATION.

Six orifices are made with the burr. The thin lines indicate the points of the periphery of the shutter, along which the outer table only will be attacked with the saw. Above it we see the osseous segment which will be completely removed.

instrumentation. Before mobilization, we trace with the rowel saw, at an interval of 6 or 8 centimetres inside the line *ABC*, a parallel line, *abc*, involving the outer table only of the cranial wall. The flap is then raised, and the irregularities of the base are removed with the bone-forceps along the line *ac*. The upper osseous segment is resected in its turn: this resection is easily effected, and without splintering, with the aid of the bone-forceps, which has now but the inner table to resect. The osteo-cutaneous shutter is then returned to its place, and the skin is sutured.

Second Intervention.—The dura mater is incised at a second séance, after an interval of four or five days. It has not yet been demonstrated that the dura mater should be resected, as has been recommended, around the entire margin of the osteal breach. I believe it preferable to incise it at a short distance from the margin of the osseous shutter, as represented

in Fig. 778, in order to avoid any adhesion of the cerebral cortex to the cicatrix of the cutaneous incision. In the case of epilepsy, it is indispensable to perform the operation in two stages, as the incision of the dura mater at the first séance exposes to the risk of an accumulation of blood under that membrane. This accident is specially to be dreaded in patients between the ages of sixteen and thirty, who bleed freely; especially if an epileptic paroxysm occurs soon after the opening of the cranium. Besides, it is enough to have once performed the operation in two stages, separated by five or six days, and be obliged to remove the mass of clots which are found between the bone and dura mater at the second operation, to make us finally renounce the idea of exposing the brain on the first occasion. The

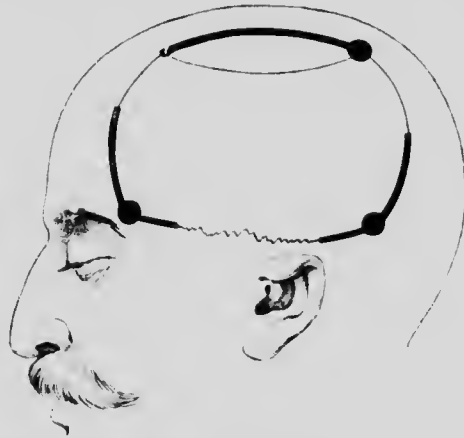

FIG. 780.—CRANIECTOMY FOR ESSENTIAL EPILEPSY, WITH ELECTRIC INSTRUMENTATION.

It is enough to make three openings with the burr. The thin lines show the parts of the periphery of the flap, where the outer table alone will be attacked with the rowel saw. Above we see the osseous segment which is to be completely removed.

extensive incision of the dura mater at the first operation would surely expose the patient to the risk of almost immediate death by diffusion of hæmorrhage between that membrane and the brain, or of tardy sequelæ resulting from the irritation produced by a coagulum of immense volume. I have actually operated on many cases of essential epilepsy by this method, which have now remained cured since many years. The intelligence of these patients has been very favourably influenced by the operation, which, in grave cases, should be practised on both sides, with an interval of some months between.

I have already pointed out that in cases of arrest of intellectual development the first operation should be practised on the left side (Broca's convolution). In cases of essential epilepsy, if the intelligence is approximately intact, there is no choice of a side except predominant characteristic symptoms

are present—localized cephalalgia, weakness of one side of the body, traumatism of old date, etc. When there is no index to localization, I prefer to operate on the left side.

Hyperostosis of the Cranial Vault.—Craniectomy may present special difficulties when the thickness of the bone is very considerable. We avoid surprise by attacking the bone with the burr in three or four different places, so as to make sure of the thickness. The *scie à curseur* may then be used to divide the whole of the vault up to a thickness of 10 to 12 millimetres. If there be a voluminous exostosis on the inner surface of the cranium, it is enough to divide the bone with the saw in that position through two-thirds of the thickness. The internal osseous lamina thus left can then be broken through with mallet and chisel. If the internal exostosis be very small, it may be filed off with the burr while preserving the outer table, or the entire thickness of the bone may be removed after opening a shutter sufficiently large. On the other hand, if the exostosis be very extensive, it is better to leave the outer table of the osseous shutter intact, and file off the projection from the inner surface. This abrasion of an exostosis of the inner table requires from both operating surgeon and assistant ample physical vigour and very great manual dexterity. There is great difficulty in holding the osseous shutter firmly, as the adhesion to the pericranium is not very strong; and it is still more difficult to manipulate the burr, acting as a mortising instrument, so as to smooth down the inner surface of the vault and diminish its thickness without shaking the bone rather violently. If we hesitate to abrade the exostosis, we should take care in replacing the osseous shutter to adjust it in such a way as to leave it raised some millimetres, and thus to diminish the compression of the encephalon.

Jacksonian Epilepsy.—The cases of localized epilepsy for which we have recourse to surgical intervention are nearly always the result of irritation of the motor zone. The epileptogenic centre should, almost without exception, be sought for in the vicinity of the fissure of Rolando. The middle of the flap should correspond to the bregmatic plane. The osseous shutter need not be more than 6 to 8 centimetres in diameter. It is quite useless to have recourse to preliminary extracranial mapping-out of motor centres. The opening should always be made large enough for recognition of the principal subjacent convolutions. The operation should be carried out in two stages, with an interval of four or five days.

First Intervention: Opening of the Cranium.—The opening of the cranial cavity, which is effected in the way already described, may be followed by some exceptional manoeuvres. Thus, in the case of the young man on whom I operated in the presence of Professor Virchow (August 2, 1900), the principal lesion was formed by a series of bony stalactites of the inner table. Beneath those growths a serous meningeal cyst had formed, which pressed the brain substance down deeply. When the osteo-cutaneous flap was folded down over the ear, I had it firmly held by my assistant, and I rasped away the exuberant osseous excrescences from its inner surface

with the burr. I must add that this is a very delicate procedure; one which demands from the assistant, who has to hold the osseous shutter, much experience and great manual strength, and from the operating surgeon as much vigour as dexterity. The V-projection of an osseous ridge which has formed an old depression on the cerebral surface can also be abraded in the same way. The dura mater should not be incised in this first intervention but to a very slight extent, and only for the purpose of recognizing a subjacent lesion which had already been evidenced by translucency or was perceptible to the touch.

Second Intervention.—The patient is again anesthetized, four or five days after the first procedure. The osteo-cutaneous shutter is freed and raised, and any clots which may have formed are removed. The dura mater is incised and folded back, and the brain exposed. Perhaps there is an obvious lesion (old-standing hæmorrhage with pachymeningitis, superficial cyst, small neoplasm); perhaps the cortex and pia mater are both found to be absolutely normal.

Cysts of the Brain.—If a cyst is present, it is evacuated, and its position is mapped out with the compass, taking as centres the three orifices made with the burr. The shutter is folded back, the skin sutured, and the exact seat of the cyst is indicated on the skin by drawing two segments of circles, the centres of which are at the depressions corresponding to the orifices made with the burr, and the radius of which was noted on a diagram when mapping out the position. The bone is then immediately perforated with the burr for insertion of a drain or of a wick of gauze.

Cortical Tumours.—When dealing with a small neoplasm, the tumour is lifted out with a curette in a single piece. It is well to tie beforehand the vessels of the pia mater connected with its surface, when these are large. The ligature used here is one of fine silk, and is passed under the vessel with a small curved needle. Apparent vascularity of a neoplasm is no contra-indication of its rapid removal, for the large veins by which it is grooved usually communicate with the neighbouring vessels by very small anastomoses, and any considerable loss of blood may be avoided by detaching the tumour rapidly while maintaining pressure on the healthy cerebral tissue around. If the bleeding does not cease readily, a plug of sterilized gauze may be left beneath the osseous shutter for two or three days. This plug is then removed through an orifice made at the suitable point in the osseous shutter, as above indicated.

Resection of Epileptogenic Centres.—When the cerebral cortex appears healthy, we may search for the epileptogenic centre with the aid of the electric explorer. The research is carried out in this way: the chloroform is stopped till the cornea regains sensibility, so as to elicit some little reflex muscular contraction when artificially irritated. The cortex is then explored with the sterilizable conductor represented in Fig. 782. This stimulating electrode is connected with the large wire of an ordinary bobbin for faradization. We immediately obtain, according to the convolution stimulated, contraction of extensor or flexor muscles of the fingers, forearm, face, etc.

Suddenly, when we reach the cortical centre for the muscular group involved in the paroxysms of localized epilepsy, we produce a complete paroxysm, such as had been known to occur on previous occasions. We then examine

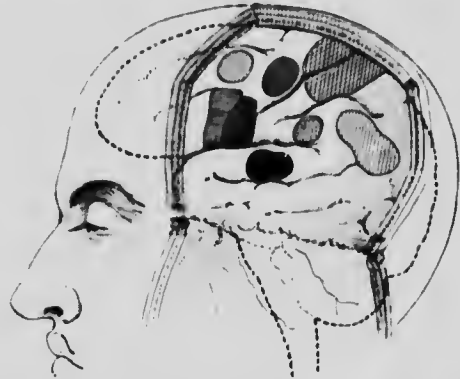


FIG. 781.—PRINCIPAL CORTICAL MOTOR CENTRES.

Above, from left to right: Agraphia; lower limb, upper limb. Below: Aphasia; muscles of tongue and face; hemianopsia; verbal blindness. At bottom: Verbal deafness.

the whole area of the epileptogenic zone by this method of electric exploration, and prepare for its extirpation by tying all its afferent vessels. The zone is then extirpated with bistoury and curette to a depth of 10 or 12 millimetres. We then rapidly apply plugs, and reclose the cranium.

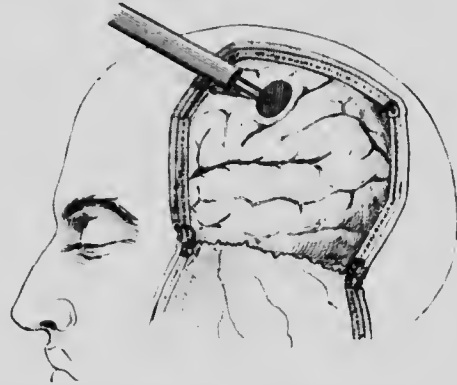


FIG. 782.—ELECTRIC EXPLORATION OF A LEFT EPILEPTOGENIC CENTRE, CORRESPONDING TO THE EXTENSOR MUSCLES OF RIGHT WRIST AND FOREARM.

Following the extirpation of the cortical centre, complete paralysis of the corresponding groups of muscles is always observed. The epileptic crises disappear if the operation has been completely carried out; and the

voluntary movements, which at first were abolished, are re-established by degrees; without, however, attaining their original vigour and precision.

The research of epileptogenic centres by direct faradization of the

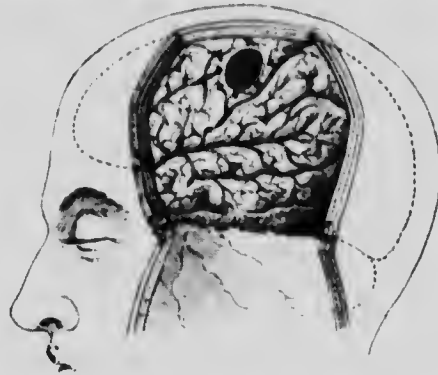

FIG. 783.—LIGATURE OF VESSELS OF PIA MATER AROUND THE EPILEPTOGENIC CENTRE.

brain is one of absolute precision. In the case of a patient of Professor Raymond, I extirpated, without having seen it, a glioma of the size of a small pea, which lay at the very centre of the cortical fragment indicated by the effect of electrification, and was recognized only on microscopic examination. Thus electric exploration may even reveal the presence of a sub-cortical lesion still in its infancy, and still imperceptible to sight and touch; and which, in the absence of this delicate exploratory test, would necessarily escape the investigation of the surgeon.

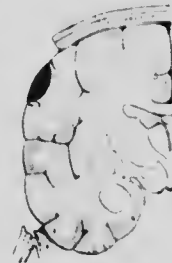

FIG. 784.—DIAGRAM SHOWING THE DEPTH TO WHICH THE EPILEPTOGENIC CENTRE SHOULD BE EXTIRPATED.

TUMOURS OF THE BRAIN.

Operation has no chance of giving a successful result except when the tumours are well localized and of benign nature. As their nature can be known only after histological examination, we must describe in the same chapter the extirpation of all kinds of cerebral tumours tubercle, gumma, glioma, sarcoma, endothelioma. We naturally pass over in silence the metastases of an extracranial cancer which has proceeded to generalization.

I will not dwell on the symptoms of cerebral tumours, which are very variable; but I must call attention to the incredible tolerance of the encephalon for certain malignant tumours, even cortical. Many cerebral tumours are accompanied by hypervascularization of the bone, and even of the subcutaneous stratum of tissue. This increase of vascularity demands a methodical and rapid technique. We will here deal only with

cerebral tumours properly so called. Ablation of perforating pericranial tumours has already been mentioned, and requires no special technique.

Extirpation of Cerebral Tumours.—Extirpation of cerebral tumours should preferably be carried out in two stages.

First Intervention.—Temporary craniectomy is performed over the presumed seat of the tumour. Hemostasis of the subcutaneous arteries is necessary; for, in the adult, cerebral tumours of a certain volume are always accompanied by an augmentation of surrounding vascularity. The osteal shutter should be large, but without reaching the extreme dimensions which we give it in decompressive operations. If the diploic hemorrhage prove considerable, the flap must be mobilized rapidly and replaced; the skin is then sutured, and a compressive dressing applied with drainage. The hemorrhage is arrested by the formation of a clot between the dura mater and bone. The bleeding is rarely considerable, however, when the operation is carried out on a cranium not affected by any previous tentative procedure. I have met with dangerous hemorrhage only in two patients who had been operated on at a former date, and in whom the procedure, which was scarcely even exploratory, had determined the production of intimate and very vascular adhesions between the tumour, pia mater, and skin.

Immediate exploration of the brain is possible only in cases in which there has been no appreciable loss of blood. We may, in such a case, make a small exploratory incision in the dura mater, and even a decompressive incision if the encephalic tension is greatly exaggerated. The osteo-cutaneous shutter is then replaced, the skin sutured, and the dressing applied. The patient is treated, if necessary, with injections of artificial serum, and we proceed to the second intervention at an interval of four to seven days from the opening of the cranium, according to the state of the patient.

Second Intervention.—The shutter having been folded back, and the coagulated blood removed, the dura mater is incised, and the brain explored with the finger. Tumours, even when subcortical, are perfectly recognizable on palpation, and the index-finger is the best instrument for the discovery and their enucleation. I proceed as follows: If the tumour be superficial or subcortical, and is not larger than an egg—this is to say, if it appears to be removable—I circumscribe it with the index-finger, and enucleate in a few seconds, by rapidly isolating it with the finger from the soft cerebral tissue which invests it. In this way we have no serious hemorrhage, even in cases in which the growth was vascular enough to pass for an "erectile tumour"; for the vascular sinuses of the neoplasm anastomose with the cerebral vessels only by ramifications of minute diameter, which are easy to catch and tie when at all appreciable. I have in this way extirpated many subcortical neoplasms of the size of a hen's egg, without any other procedure of hæmorrhage than plugging for five to ten minutes.

The condition of the patient should be watched from the moment that the finger isolates and lifts out the tumour, for a tendency to syncope is produced at that moment. If bleeding appears, we must plug at once with

a compress, and return the flap to its original position. When the patient has been restored, the plug is withdrawn—which may, if necessary, be left



FIG. 785. EXPOSURE OF A TUMOUR OF THE BRAIN.

two or three days inside the cranium—and we suture the wound, taking care to indicate on the skin the point at which an orifice must eventually be

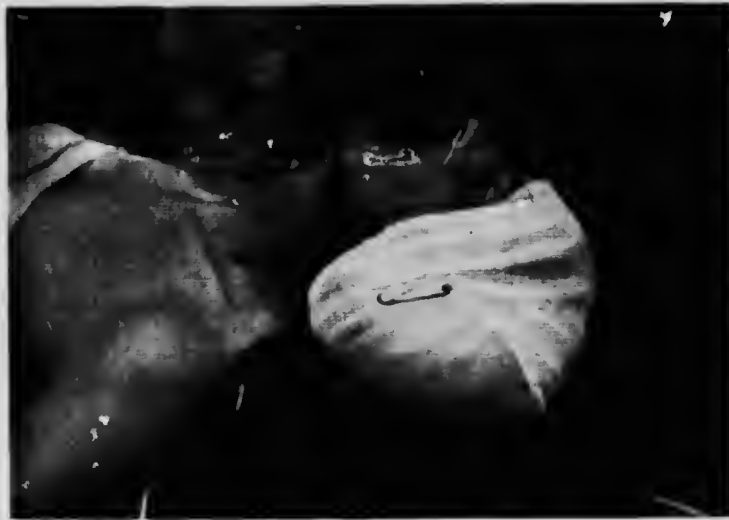

FIG. 786.—DRESSING OF A PATIENT AFTER CRANIECTOMY.

The lead is raised on the ledge of the operation-table, in order to facilitate the toilet of the region and the application of the dressing.

made, in the common enough case of the formation of a serous cyst in the place formerly occupied by the tumour. It will be necessary in such a case to perform a third operation in order to expose freely the position of the original focus of the neoplasm thus affected by cystic transformation, and evacuate it. Fig. 787 represents one of those serous cysts which developed after some months in the position formerly occupied by an enormous subcortical tubercle. The patient died a long time after the operation, of pulmonary tuberculosis.

I have specially insisted in the above paragraph on the importance of hæmorrhage, because it constitutes a veritable danger in the removal of




FIG. 787.—SEROUS CEREBRAL CYST CONSEQUENT TO THE REMOVAL OF AN ENORMOUS SUBCORTICAL TUBERCLE OF THE MOTOR AREA.

large cerebral tumours. It is in such cases that the presence of mind of the surgeon is thorougly revealed. How many operations have been left unfinished because the operator was too timid, and did not possess the appropriate instrumentation. The flap must be mobilized in two or three minutes at the farthest. When there is a flow of blood, the surgeon must hasten even more rapidly. When the bone yields, he places a compress beneath it, and makes energetic pressure.

Some cortical tumours are so extensive that extirpation is impossible. But those tumours could have been easily removed if they had been attacked months or years previously. I have seen one case in which the growth of an endothelioma of the pia mater had lasted over ten years. I believed, on account of that slow rate

of progress, that it must have been a benign growth. On exposure, I found a neoplasm which involved two-thirds of a cerebral lobe, and of which I could not have attempted the extirpation.

I obtained from the patient's family permission to take the specimen. The macroscopic examination showed that we were dealing with an enormous tumour of the pia mater. It had compressed the brain, and produced atrophy of its substance, but without invading the cerebral tissue except at a few points and to a very limited extent.

Another class of encephalic tumours still escapes us—those at the base of the brain, and notably those of the neighbourhood of the third ventricle, which are not very rare, and for which the surgeon's intervention is limited merely to a decompressive operation.

RESECTION OF THE GASSERIAN GANGLION.

I will now close this section on Craniectomy with a description of the resection of the Gasserian ganglion, which is one of the most delicate of intracranial operations. We know that the Gasserian ganglion lies included in a fold of the dura mater on the anterior aspect of the petrous bone, above the horizontal portion of the carotid canal. It is about 6 millimetres above the foramen ovale, which serves for the passage of the inferior maxillary nerve. Dissection of the ganglion clearly shows that it is easy enough to reach it by the temporal route; which gives a good light, but obliges us to raise the dura from a large area of the temporal fossa before reaching the ganglion itself.

The early operations, first of Rose (April 2, 1890) and then of Horsley, could not be regarded as true resections of the Gasserian ganglion. Trepanning of the sphenoid bone at a point anterior and external to the foramen ovale, after complete resection of the zygomatic arch, coronoid process, and muscles of the region, does not furnish a sufficient field for the exposure and extirpation of the Gasserian ganglion in its entirety. Rose endeavoured to divide the trigeminal trunk, and then extract the ganglion with crotchets and curettes of suitable curvature. The patient recovered from the operation, but lost the eye of the side operated on. This suppuration of the eyeball was not surprising; it was then taught in all textbooks of physiology that it was a normal consequence of experimental section of the trigeminal nerve in animals. Preservation of the eye in all its integrity in the cases of complete extirpation of the Gasserian ganglion operated on by Krause and by myself proves that the physiologists, as also happened to Rose in dealing with the human body, did not succeed in extirpating the ganglion *without destruction of the carotid twigs of the sympathetic*.

When I first removed the Gasserian ganglion, the case was that of a patient from whom I had at a previous date removed Meckel's ganglion, and the superior maxillary nerve at the foramen rotundum, by the transmaxillary route. The recurrent neuralgic pains had become intolerable, and radiated throughout the whole area of trigeminal innervation. After having studied the normal anatomy of the Gasserian ganglion, I decided to expose it through the speno-temporal route, after definitive resection of the zygomatic arch, the coronoid apophysis, and the corresponding muscles. The foramen ovale is found in the base of the skull at the root of the great wing of the sphenoid bone, at a distance of 20 millimetres inside the horizontal antero-posterior crest which separates the temporal fossa from the zygomatic. The small round foramen which transmits the middle meningeal artery is placed some millimetres behind and outside the foramen ovale, in the base of the spine of the sphenoid. The distance between the foramen ovale and foramen spinosum may vary from 2 to 10 millimetres. The two openings sometimes run into one large one. The technique of the operation will now be described.

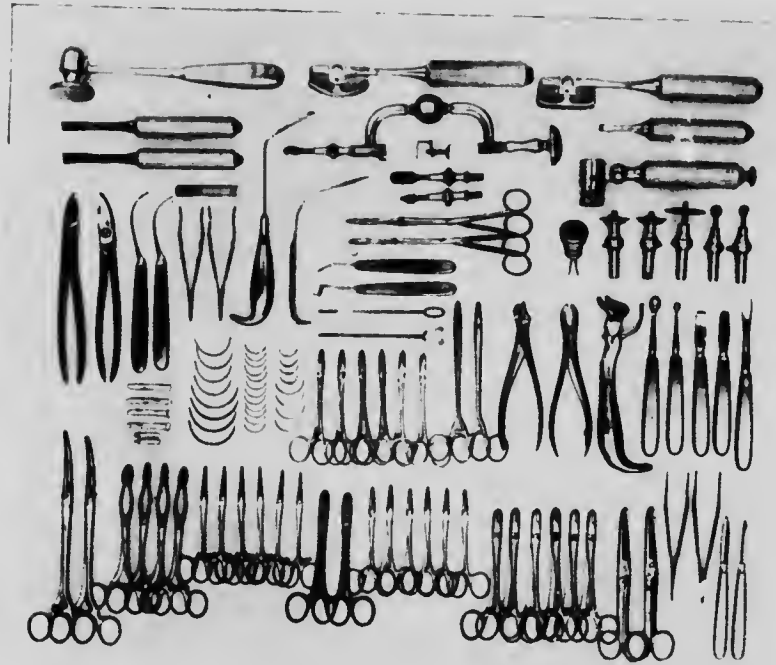


FIG. 788. INSTRUMENTS FOR RESECTION OF THE GASSERIAN GANGLION.

Below, and from right to left: Two bistouries, two clawed forceps, two pairs of strong straight scissors, six short-jawed artery forceps, six small hemostatic forceps, two short-jawed forceps for veins, six ring-handled forceps with nine oblique claws, four ring-handled forceps with oval jaws, two long forceps with curved jaws. Above: Six small needle-holder forceps, two needle-holders with eccentric jaws, four varieties of cutting needles and twelve intestinal needles, two needles with handles, two clip-holder forceps and fifty clips, some small glass drainage tubes.

For craniectomy with manual instrumentation: One trepan *à cliquet* with flat perforator, one conical burr, one cylindro-spherical burr of 12 millimetres, one turn-screw, one Sims compressor, one measurer, two decollators of dura mater, two shielded saws, one craniectomy forceps, one gouge-forceps, two craniectomy chisels, one mallet.

For craniectomy with electric instrumentation: One handle with variable inclination, two spherical burrs of 12 millimetres mounted on fittings, one saw of 45 millimetres with alternating teeth and handle furnished with intracranial guide, two rowel saws of 35 millimetres and complete assortment of graduated discs, two craniectomy shears.

In the intermediate space: Two oblique retractors, one small raspatory for elevation of the dura mater, two gouge-forceps with curved jaws for extraction of the ganglion. (Scale reduced to one-sixth.)

Resection of the Gasserian Ganglion by the Temporo-Sphenoidal Route—

First Stage: Incision of the Integument.—A vertical incision is made in the skin, beginning in the temporal region, and crossing the zygomatic arch at a point 2 centimetres anterior to the external auditory meatus, to terminate inferiorly at the level of the lobule of the ear. This avoids the branches of the facial artery, which will be kept retracted downwards during the whole time of the intracranial manipulation.

Second Stage: Exposure of the Inferior Maxillary Nerve.—The bistoury is again introduced into the incision, and passed down to the squamous portion of the temporal bone, and to the level of the zygomatic arch. The bleeding vessels are seized and tied. The zygomatic arch is then denuded with the raspator, and divided posteriorly close to the condyle of the lower jaw, and anteriorly at the limit of the temporal fossa. The masseter muscle is

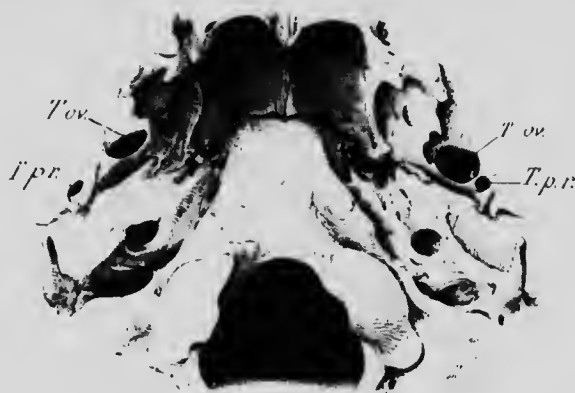

FIG. 789. BASE OF CRANIUM DISPLAYING TWO EXTREME CONFORMATIONS OF THE REGION OF THE FORAMEN OVALE, AND FORAMEN ROTUNDUM.

In this subject it would have been easy to excise the outer semi-circumference of the foramen ovale of the right side without wounding the middle meningeal artery.

now resected. The squamous portion of the temporal bone is laid bare with the raspator, also the squamous section of the sphenotemporal suture and the great wing of the sphenoid; then, lower down, the coronoid apophysis, which is resected with a Liston's forceps. We remove in turn the greater portion of the temporal muscle, also the external pterygoid; and we tie, in the depth of the wound, the middle meningeal artery just before its arrival at the foramen spinosum. The haemostasis being completed, the inferior dental nerve is clearly seen in the wound; also, on an anterior and internal plane, the lingual nerve, which unite above with the auriculo-temporal nerve to form the inferior maxillary trunk, which ends superiorly at the foramen ovale.

Third Stage: Opening the Cranium.—The opening of the cranium includes: (1) A vertical loss of substance, comprising, above and behind the squamoso-temporo-sphenoidal suture, an equal extent of the squamous

590 SURGICAL THERAPEUTICS AND OPERATIVE TECHNIQUE

portion of the temporal bone and of the great wing of the sphenoid, and terminating below at the level of the antero-posterior osseous crest, already described, which separates the temporal fossa from the zygomatic; (2) a horizontal loss of substance, ending at the foramen ovale. This horizontal



FIG. 790.—RESECTION OF GASSERIAN GANGLION: TEMPORO-SPHENOIDAL PROCEDURE (DOYEN).

Resection of the zygomatic arch; perforation of the cranium at the level of the sphenotemporal suture; increase of area of orifice at the expense of the great wing of the sphenoid and the squamous portion of the temporal bone.

loss of substance will comprehend posteriorly a very small portion only of the temporal bone, and must be carried out almost exclusively at the expense of the base of the great wing of the sphenoid.

The more simple technique is to pierce the cranial wall at the middle of the squamoso-sphenoidal suture, beginning with the flat drill, and finish-

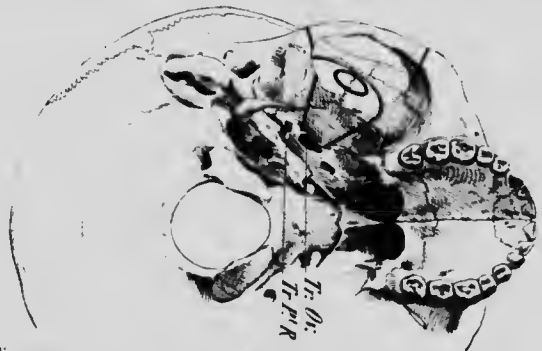

FIG. 791.—TRACING OF THE OSTEAL RESECTION ON THE BASE OF THE CRANIUM.

The gonge-forceps is employed to extirpate the external semi-circumference of the foramen ovale.

ing with the cylindro-spherical burr (Fig. 790). When the first orifice has been pierced through, a Nélaton gonge-forceps enables us to reach the foramen ovale in a few seconds, the outer semi-circumference of which must be completely extirpated (Fig. 791).

moid, and
t, already
tie; (2) a
horizontal

ROCEDURE

the sphenoid
ing of the

on only
y at the

iddle of
l finish-

NISM,
y of the

ice has
ch the
h must

We are thus able, instead of producing a small definitive loss of substance in the temporal fossa (Figs. 790 and 791), to cut open a small shutter of temporary craniectomy (Fig. 792) with a posterior hinge, in such a way that we produce a definitive loss of substance which reaches only from the rugged antero-posterior ridge above described

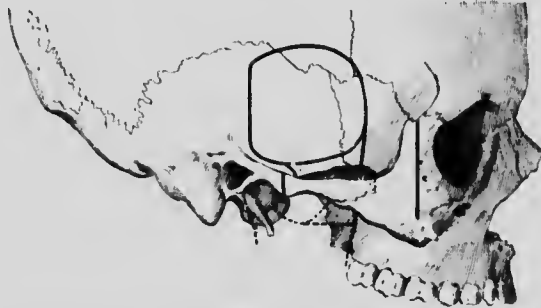

FIG. 792. RESECTION OF THE GASSERIAN GANGLION BY A MIXED METHOD.

Resection of zygomatic arch; combination of temporal shutter craniectomy with definitive resection of the base of the great wing of the sphenoid bone.

to the margin of the foramen ovale. This temporary craniectomy necessitates modification of the cutaneous incision on the temporal region, where it should present the outline of a horseshoe, and with its pedicle placed posteriorly. We should thus succeed in combining Krause's operation and mine—that is to say, ablation of the Gasserian ganglion by an exclusively temporal route, and that by the temporo-sphenoidal (Fig. 793).

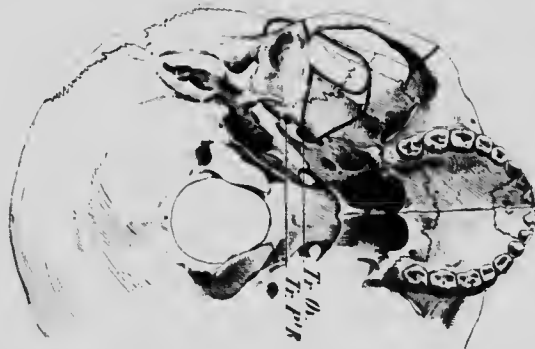

FIG. 793. RESECTION OF THE GASSERIAN GANGLION BY A MIXED METHOD.

Tracing of the outline of osteal resection, starting from the lower limit of the temporal shutter and ending at the foramen ovale.

The temporal procedure enables us to extirpate the ganglion without producing those considerable lesions in the zygomatic fossa which I have just described. But its adoption involves a much graver prognosis than does the other, as it obliges us to raise the temporo-sphenoidal lobe very

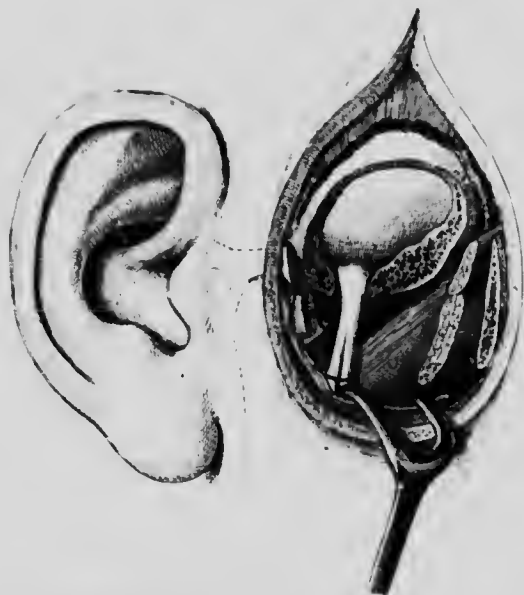

FIG. 794.—MINIMUM OSSEOUS RESECTION FOR DISCOVERY OF THE GASSERIAN GANGLION.

The ligature of the middle meningeal artery can be distinguished. Two lines mark the position of section of the inferior dental and lingual nerves.

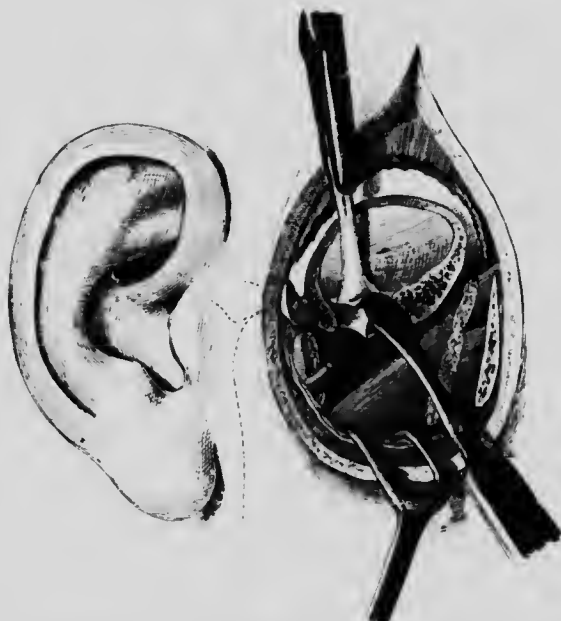


FIG. 795. MINIMUM OSSEOUS RESECTION FOR DISCOVERY OF THE GASSERIAN GANGLION.

The trunk of the inferior maxillary nerve is drawn upwards; the raspatory opens the fibrous investment of the Gasserian ganglion.

high out of the middle fossa in order to reach the ganglion. It is almost impossible to avoid making a small opening in the dura mater through which a notable quantity of cephalo-rachidian fluid escapes. This escape of fluid enables us to raise the dura mater and temporo-sphenoidal lobe

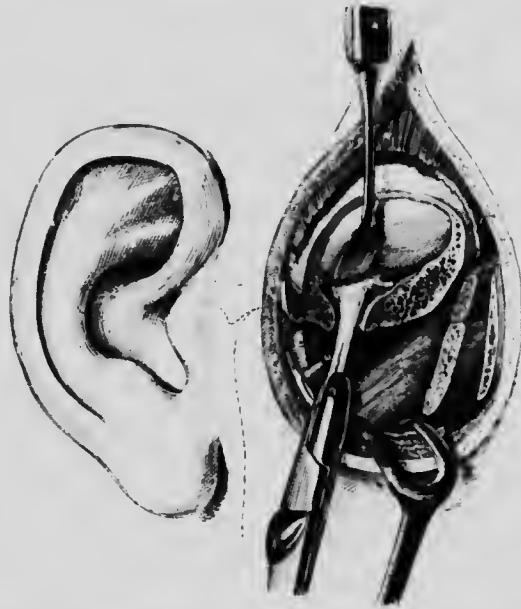

FIG. 796. MINIMUM OSSEOUS RESECTION FOR DISCOVERY OF THE GASSERIAN GANGLION.

The upper wall of the nidus of the ganglion is raised with a small angular raspatory.

more easily, but the use of the retractor may produce encephalic lesions which gravely influence the prognosis. My inclination is, accordingly, to obviate almost completely any loss of osseous substance in the temporal



FIG. 797. ANGULAR RASPATORY FOR ELEVATION OF DURA MATER.

fossa, and to attack directly the antero-posterior crest, which limits the zygomatic fossa externally, with the mallet and blunt-angled chisel. This is the procedure of which the result is represented in Fig. 794.

When the horizontal breach has been completed, and the outer margin of the foramen ovale extirpated with the gouge-forceps, we have then but to proceed to the exposure and extirpation of the Gasserian ganglion.

Fourth Stage: Exposure and Extirpation of the Gasserian Ganglion.—The lingual and inferior dental nerves are divided at the level of the spinous process, and held between the jaws of a powerful clawed forceps. It is enough to draw these branches then upwards and outwards, and in their wake the trunk of the inferior maxillary nerve, to bring into view above the foramen ovale the sheath of dura mater which ends at the seat of the



FIG. 798.—ANGULAR GOUGE-FORCEPS, USED FOR PREHENSION OF THE GASSERIAN GANGLION.

ganglion. This sheath is dissected, first on the inner side, and then on the outer, with a small cutting raspatory, so as to divide it into two valves of which the upper is raised as we draw the superior maxillary nerve toward the temporo-parietal region (Fig. 795). We then soon perceive, in front, the trunk of the superior maxillary nerve (Fig. 796), and, a little more deeply situated, that of the ophthalmic. These nerves are divided in turn. We



FIGS. 799 AND 800.—PREHENSION OF THE TRUNK OF THE TRIGEMINAL NERVE ABOVE THE GANGLION WITH THE GOUGE-FORCEPS, EITHER FROM BEHIND FORWARDS OR FROM BEFORE BACKWARDS, AFTER DIVISION OF THE SUPERIOR MAXILLARY AND OPHTHALMIC NERVES.

can then reach the Gasserian ganglion by following the trunk of the inferior maxillary nerve with the gouge-forceps with curved jaws, represented in Fig. 798, and divide the trigeminal trunk above it at the level of the superior border of the petrous bone and the superior petrosal sinus (Figs. 799 and 800). We must take care not to drag on the trigeminal trunk roughly, as this might produce grave lesions of the pons Varolii. If the trunk of the nerve cannot be divided with the gouge-forceps, the section must be completed with a bistoury or even with curved scissors.

ganglion.—
the spinous
ps. It is
d in their
above the
at of the

If the fourth stage of the operation prove impracticable through the persistence of oozing venous hæmorrhage from the neighbourhood of the Gasserian ganglion, we must plug the wound, and wait for forty-eight hours before proceeding to conclude the procedure. At the close of that interval we can proceed in a field of operation which is completely exsanguine, and the ganglion is extirpated without difficulty.

Fifth Stage: Closure of the Wound.—The nidus of the ganglion is plugged with sterilized gauze, and the external wound is similarly treated.

Therapeutic Results of Extirpation of the Gasserian Ganglion.—My first case of resection of the Gasserian ganglion was operated on on March 6, 1893.



FIG. 801. DIAGRAM OF THE ZONE OF ANÆSTHESIA WHICH DEVELOPED FROM COMPLETE EXTIRPATION OF THE GASSERIAN GANGLION.

We can distinguish the vertical cicatrix in front of the left ear. The zones of cutaneous anesthesia, complete and incomplete, are indicated by dotted lines.

The patient was then aged fifty-five, and she survived many years, during the whole of which period the cure remained complete and definitive. This is the state reported four years after the operation: An old cicatrix was observable beneath the left lower eyelid. It was from this position that I had formerly proceeded to removal of Meekel's ganglion and the superior maxillary nerve, without therapeutic success. The cicatrix left by the second operation was visible at the lower part of the temporal region. There was in that position a very manifest depression, of 5 or 6 centimetres in height, and very considerable diameter. Exploration of the sensibility of the whole area of trigeminal innervation gave the following results: The

GASSERIAN

en on the
ro valves,
e towards
front, the
re deeply
urn. We

VE ABOVE
FORWARDS
MAXILLARY

e inferior
sented in
superior
799 and
roughly,
nk of the
be com-

patient herself remarked that she had no wrinkles on the forehead on the left side. This peculiarity must have been owing to division of one of the upper branches of the facial nerve. The eye manifested no trophic troubles. The mobility of the iris was intact, and there was no trace of paralysis of the ocular muscles. (These details prove that in those cases in which, after even an unsuccessful attempt at extirpation of the Gasserian ganglion (in animals or in man), paralysis of certain ocular muscles and certain trophic troubles of that organ followed, the operator, in the endeavour to reach the trigeminal nerve trunk alone, having produced extensive lesions involv-

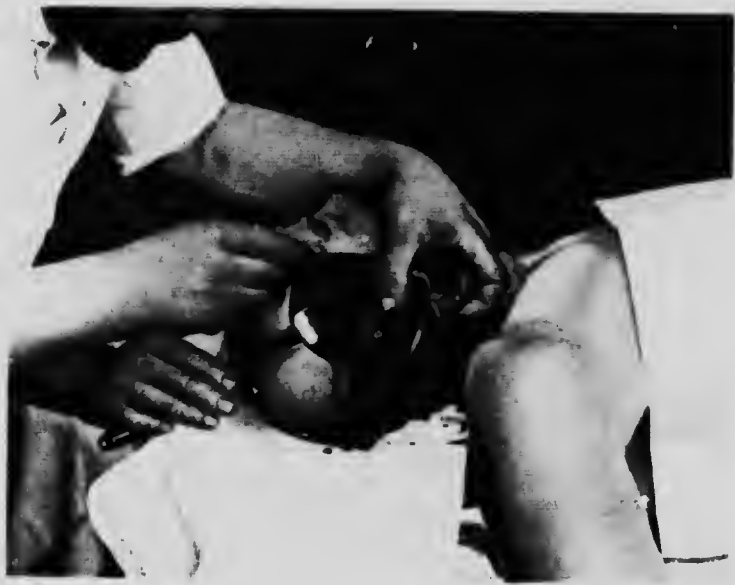

FIG. 802. EXTIRPATION OF THE GASSERIAN GANGLION, AFTER KRAUSE'S METHOD, BY THE PROCEDURE OF TEMPORARY CRANIOTOMY (SPILNO-TEMPORAL SKIN FLAP).

The intracranial lesions are much more extensive than in the operation represented in Figs. 794, 795, and 796.

the trophic branches of the sympathetic and neighbouring nerves.) Vision was intact, and audition was equally acute on both sides. The patient complained of a certain stiffness in the jaw; in fact, as both temporal and masseter muscles had been divided at one of their respective attachments, the cicatrix tied down the temporo-maxillary articulation to some extent.

The patient pointed out spontaneously that the cornea and conjunctiva of the left side were insensible, or nearly so. Nevertheless, she distinctly perceived the penetration of a foreign body between the eyelids; the contact produced a lachrymal hypersecretion, and the conjunctiva became congested, without appreciable pain. There was, so to speak, a simple p

head on the
one of the
trouble
analysis of
which, after
anglion (in
tain trophic
to reach the
involving

ception of contact, and reflex lachrymation. She had never been obliged to use any other precautions for the safety of that eye than the cares of her daily toilette. She laid emphasis on the complete insensibility of the skin of the left half of each of the lips; also of the cheek, temple, and upper frontal region. The superciliary region, both eyelids, and left half of nose preserved a real but obtuse sensibility. Both taste and tactile sensibility appeared to be equally diminished on the left side of the tongue. The buccal mucous membrane, lips, gums, teeth, jaws, and palate of the left side were completely insensible.

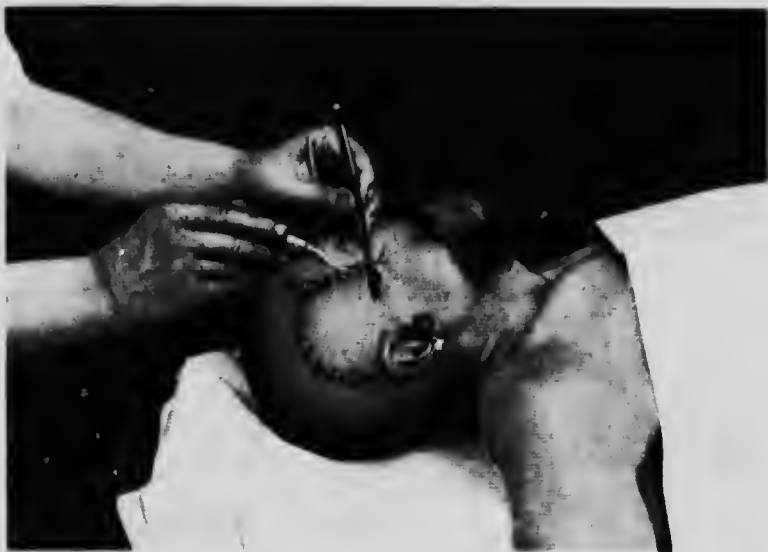

FIG. 802.—EXTIRPATION OF THE GASSERIAN GANGLION, AFTER KRAUSE'S METHOD, BY THE PROCEDURE OF TEMPORARY CRANECTOMY (SPHENO-TEMPORAL SHUTTER).

Reapplication of the osteo-cutaneous shutter. Union of the edges of the skin by interrupted suture.

Exploration of the Zone of Trigeminal Innervation.—Objective exploration of the different kinds of sensibility enabled us to recognize that the general sensibility was abolished over the whole of the sphere of the cutaneous innervation of the trigeminal nerve. The external limit of that zone of insensibility is indicated in Fig. 801 by a dotted line, which in front coincides with the middle line of the face; below with the inferior margin of the lower maxilla, and then, with a slight backward inclination, proceeds to a point behind the bregma on the parietal region. This wide area of insensibility presented, however, two regions, in which a certain degree of perception remained: one was located near the angle of the jaw; the other, which was more particularly marked, included the left eyebrow, both eyelids, and side of nose. Over those surfaces, painful sensations, such as

needle pricks, for example, were felt; though greatly lessened, and with notable retardation. When the skin was lightly scratched with the point of a pin, the patient perceived a sensation similar to that produced by weak faradic current. This sensation corresponds to that which I experienced personally for many years, in similar conditions, on the last phalanx of a digit of which the lateral nerve had been divided. Little but little the sensation came to be re-established. It is probable that in the two zones referred to, in which we observed a certain degree of sensibility after resection of the trigeminal nerve, we were in presence of a simple recurrent sensibility, produced by the numerous anastomoses which exist in the first of the two areas, with the superficial cervical plexus; and, in the second, with the branches of the fifth nerve of the opposite side. The patient herself noticed that the insensibility was particularly complete in the neighbourhood of the temporal cicatrix. The sensibility of the walls of the buccal cavity was abolished throughout the whole of the area of trigeminal innervation. On the tongue the tactile sensibility was preserved in the posterior third; while it had disappeared from the anterior two-thirds, where the stimulus produced by the application of the two needles connected with the poles of a battery with continuous current produced energetic fibrillar contractions, without any pain. The same current could not be borne on the symmetrical point of the opposite side, when it produced an intolerable burning sensation.

Exploration of the sense of taste showed that, when the tongue was kept outside the mouth, and the patient instructed to indicate her sensations by gesture, while the sapid substances were not given time to diffuse themselves, the anterior portion of the tongue recognized no sensation of taste from the contact of quinine and other very bitter substances. On the other hand, the posterior third of the surface of the tongue distinguished tastes on both sides; but, on the left, the perception of sapid sensations only followed a very pronounced and very obvious retardation.

The patient had herself noticed that her left nostril was drier than the right. The mucous membrane over the turbinated bones was insensible. A pinch of tobacco snuff caused no agreeable sensation, so that the patient, who was fond of snuff, took it now by the right nostril only. Testing of the sense of smell with various substances (menthol, camphor, ammonia) showed a notable retardation of the sense-perception on the left side; this slowing of functional activity appeared to be attributable to the relative dryness of the mucous membrane on that side.

Thus a complete cure of the neuralgic phenomena had permanently remained, while complete destruction of the Gasserian ganglion and the trigeminal nerve trunk had not produced any trophic trouble that could be prejudicial to the patient. She expressed no regret for the loss of general sensibility over one-half of her face, and the unilateral loss of the sense of taste; inasmuch as her two principal senses, sight and hearing, had remained quite intact. Besides, even death would appear preferable to the horrible suffering of the unfortunate victims of sclerosing neuritis of the Gasserian ganglion; and the results hitherto obtained suffice to show that the operation

l, and with
h the point
duced by a
high T ex.
on the last
Little by
at in those
sensitivity
f a simple
high exist-
s; and, in
osite side,
y complete
ty of the
ole of the
ibility was
e anterior
f the two
urrent pro-
ne current
ide, where

ongue was
licate her
n time to
sensation
stances
ne distin-
n of rapid
rdation
than the
nsensible
e patient.
Testing
mnoma
side; this
relative

manently
and the
at could
of general
sense of
remained
horrible
Gasser-
n
he op-er-

tion will become innocuous in all cases by which the patients avail themselves of it before becoming morphinomaniacs and euciestics, thus losing all power of physical resistance.

I recommend extirpation of the Gasserian ganglion by the inferior—that is to say, the temporo-sphenoidal—route after resection of the zygomatic arch, coronoid apophysis, masseter, temporal, and external pterygoid muscles; because this procedure permits extirpation of the Gasserian ganglion without production of any grave intracranial disorders. This operation, in which the ganglion is approached from below, appears to me to be much less grave than that by the superior route, as represented in Figs. 802 and 803. It is also easier of execution, with the additional advantage of satisfactorily exposing the field of operation.

RETRO GASSERIAN NEURECTOMY OF THE TRIGEMINAL NERVE, WITH THE AID OF INTRACRANIAL ENDOSCOPY.

The very real difficulties involved in the procedure of extirpation of the Gasserian ganglion have induced me to study the technique of division of the trigeminal trunk between the ganglion and the pons Varolii. This

Instruments required in Retro-Gasserian Neurectomy.

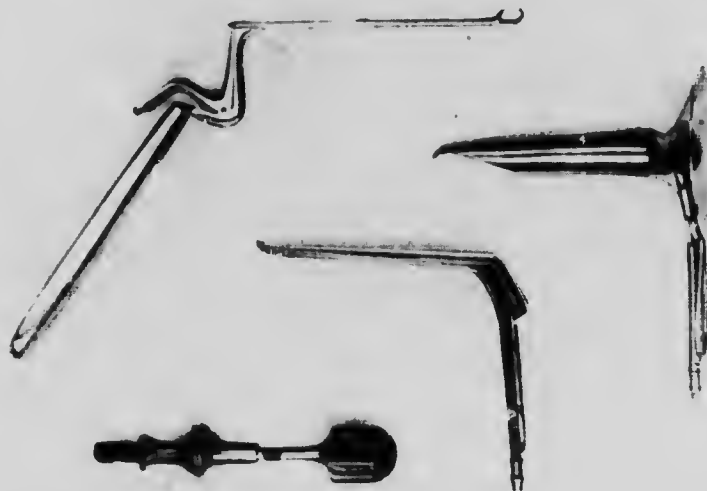


FIG. 804.

Below: Cylindro-spherical burr of 20 millimetres. Above: Protecting valve for cerebellum, furnished with tube for aspiration. Highest row: On the right side, speculum, with aspiration tube, for intracranial endoscopy. On the left: Author's neurotome for euretting the trunk of the trigeminal nerve.

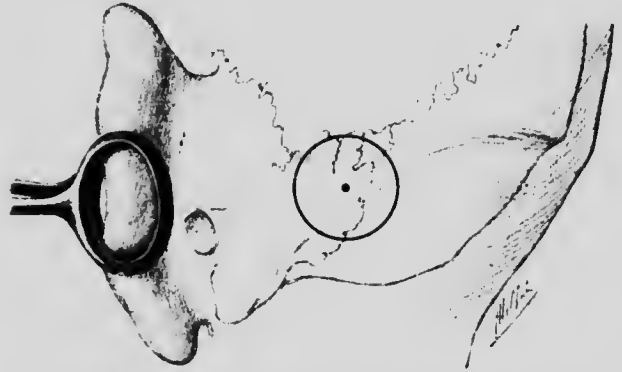


FIG. 805.—DIAGRAMMATIC FIGURE SHOWING THE POSITION OF THE ASTERION, AND POINT AT WHICH THE UPPER ANGLE OF THE MASTOID PORTION OF THE BONE SHOULD BE ATTACHED.



FIG. 806.—THE SPECULUM OF THE ENCEPHALOSCOPE HAS BEEN PLACED IN POSITION. INTRODUCTION OF THE NEURTOME.

division can be effected, thanks to the aid afforded by the employment of intracranial endoscopy, through an opening of 20 millimetres diameter made in the occipital bone at the level of the asterion. The technique of the operation is as follows:

Operation.

First Stage.—Vertical incision of 5 or 6 centimetres passing through the asterion, which is placed at approximately a finger's breadth behind the retro-auricular groove.

Second Stage.—Exposure of the temporo-parieto-occipital suture with the raspatory. The asterion is brought into view; its position corresponds to the concavity of the bend of the lateral sinus on the internal aspect of the skull.

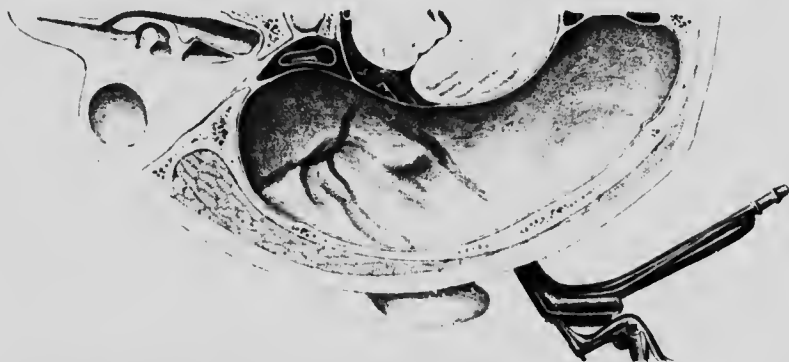

FIG. 807.—HORIZONTAL SECTION SHOWING THE RELATIONS OF THE ROOTS OF THE NERVUS TRIGEMINUS, AND THEIR EXPOSURE WITH THE AID OF THE VALVE OF THE ENCEPHALOSCOPE; GENERAL SKETCH. INTRODUCTION OF THE NEURITOME.

The splenium has not been placed in position, so as not to complicate the figure.

Third Stage.—Perforation of the bone. The occipital bone is penetrated with a flat drill mounted on the *trepan à cliquet*, as far as the inner table. The drill is then replaced with a cylindro-spherical burr of 20 millimetres in diameter, and the perforation is completed down to the dura mater, taking care not to allow the burr to pass into the cranial cavity. The wall of the lateral sinus is recognized by its bluish tint.

Fourth Stage.—Incision of dura mater, triangular or horseshoe, and exposure of the cerebellum, which is then cautiously retracted with the aspiratory valve from the dihedral angle of attachment of the tentorium cerebelli to the dura mater of the os petrosum.

Fifth Stage.—The intracranial endoscope is now introduced into this dihedral angle; its point should be made to pass above the auditory nerve. The course of its penetration is followed with the help of a Clarke's mirror. The endoscope is furnished with an aspiration tube, which is used to clear away from the field of operation the serosity which tends to obscure it. The

trigeminal trunk is now seen, at a level of 5 or 6 millimetres above the auditory nerve, and about 14 or 15 millimetres beyond it.

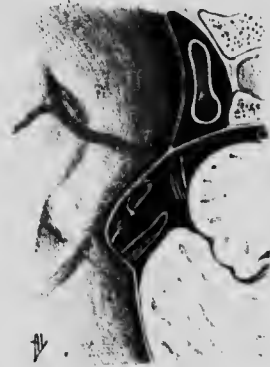

FIG. 808.—THE SAME.

The extremity of the encephaloscope has pushed off the cerebellum; the open neurotome passes above the auditory and facial nerves.

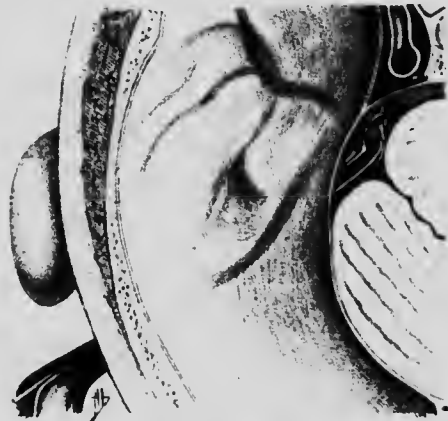

FIG. 809.

The tip of the neurotome has passed beyond the roots of the trigeminal nerve, which are now grasped and divided by the jaws.

Sixth Stage.—The neurotome which I have had constructed for this purpose is then introduced, and its terminal hook is passed beneath the trigeminal trunk, which is then divided by pressure on the pedal of this instrument. The neurotome and endoscope are then removed together.

Seventh Stage.—Suture of dura mater and of the skin.

AUDITORY APPARATUS.

Exploration of the Ear (Otoscopy).

The patient is usually seated. An otoscope of suitable diameter is introduced into the external auditory canal, and care is taken to adjust the passage by making traction on the helix in a direction upwards and outwards. We employ light from a luminous source, the rays of which are collected and reflected by a frontal mirror—daylight, solar light, the light of a powerful Carcel lamp, the Auer light, an incandescence lamp with polished glass, or even a frontal source of illumination, constituted by an electric lamp with a concave reflector of appropriate focus. Five or six bent stylets, each furnished at the tip with a coil of absorbent cotton, are ready for use on a sterilized plate. Some forceps with long, slender jaws, bent at a suitable angle, with a 5 per cent. solution of hydrochlorate of cocaine, complete the apparatus necessary for




FIG. 810.—EXAMINATION OF THE TYMPANUM WITH CLAR'S MIRROR AND TOYNBEE'S SPECULUM.

the surgical examination of the external auditory canal and tympanum. It is necessary to have in readiness, for using injections, a large india-rubber flask with a conical tip of red india-rubber, and two strong syringes, of 125 to 150 c.c. capacity. It is also desirable to have a tuning-fork ready, so as to be able to test the integrity of audition; a pneumatic speculum for investigating the mobility of the tympanic membrane and ossicles; some Toynbee's otoscopes; and a dozen sounds of vulcanized india-rubber, sterilized with formal. of three different sizes, for the Eustachian tube; with a No. 10 india-rubber bag, furnished with a nozzle adaptable to the pavilion of each.

Catheterism of the Eustachian tube through the inferior meatus is readily effected when we have had some practice. The catheter, which

is of moderate curvature, is introduced, point downwards, till it reaches the pharynx. It is then drawn forwards for 20 to 25 millimetres, till it meets the velum palati—the posterior border of the palatine arch; next, rotated upwards and outwards through an arc of about 150° ; and, finally,

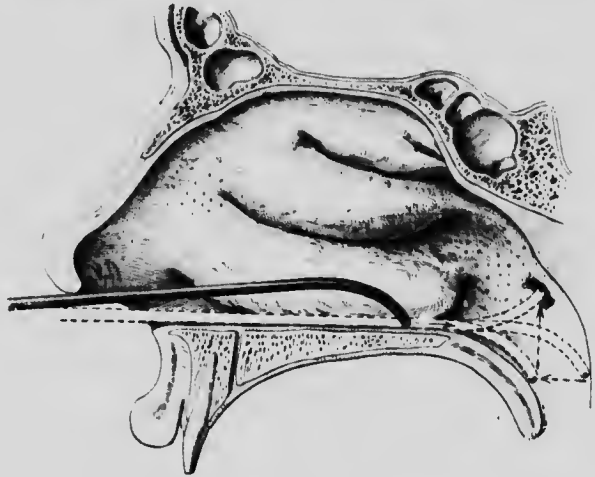


FIG. 811. CATHETERISM OF THE EUSTACHIAN TUBE.

The sound is introduced point downwards, and passed on till it meets the posterior wall of the pharynx; then drawn forwards in the direction indicated by the arrow; then rotated upwards and outwards, when it is readily passed into the orifice of the Eustachian tube.

pushed backwards to enter the mouth of the Eustachian tube (Fig. 815). We ascertain that the catheter has entered by insufflation with the bag, and listening with the otoscope tube for the penetration of air into the tympanum.

Pavilion of the Ear.

TRAUMATIC LESIONS.

Contusions. *Fracture of the cartilage* of the concha may produce overriding of the fragments. Immediate suture can be carried out with fine silk.

Subcutaneous Hæmatoma.—Extravasation of blood between the skin and cartilage, if extensive, is evacuated by puncture with a bistoury, made at the most dependent point.

Othæmatoma.—Subperichondral othæmatoma, either spontaneous or traumatic, is met with in the insane and paralytic, and sometimes in boxers and wrestlers, in the cavity of the helix. If spontaneous resorption proceeds too slowly, we have recourse to aseptic incision and local compression.

Wounds—1. WITH POINTED INSTRUMENTS—*Perforation of the Lobule of the Ear.*—This little operation is usually carried out with a small sharply pointed trocar, the ear being supported on a piece of cork. I prefer the use of the trocar and hollow cannula represented in Figs. 813A and 813B. We must take care to asepticize the skin, and the various articles used in the operation. This precaution must be recommended for this small operation, which is




FIG. 812.—INSTRUMENTS FOR TESTING ACUTENESS OF AUDITION, FOR EXAMINATION OF THE EXTERNAL AUDITORY CANAL AND TYMPANUM, FOR MINOR OPERATIONS ON THE EXTERNAL AUDITORY CANAL, FOR CATHETERISM OF THE EUSTACHIAN TUBE, AND FOR PERFORATION OF THE LOBULE OF THE EAR.

One Clar's frontal mirror with electric lamp, one tuning-fork with sliding clamps, three Toyne's speculums, four buttoned stylets, four stylets for cotton, two bent needles for paracentesis, one *trouxart* bistoury with angular blade, one Politzer's angular forceps, one ring-banded angular forceps, one straight forceps for foreign bodies, one needle and two cannulae for perforation of the lobule of the ear, one interrupter for galvano-cautery, four angular canteries, one dressing forceps, one Sexton's forceps with sliding catch, one Collin's *serre-nasal* (snare), two Duplay's angular forceps for extraction of foreign bodies and ossicles, ten lever eurettes and bistouries selected for extraction of ossicles and operations on the tympanic cavity, one pneumatic speculum, one otoscopy tube, three Politzer catheters for the Eustachian tube. (Scale, 1 : 5.)

Accessory instruments, such as the bag for insufflation and syringes for injection, are not figured in this plate.

often undertaken far too lightly. The perforation should be made in a plane strictly horizontal, and in a direction slightly oblique, from before backwards and from without inwards (Fig. 814), so that the pearl or other suspended precious stone may not appear to fall, and remains directed slightly forward.

Operation.—The lobule is perforated at its centre, horizontally, but from before backwards. The obliquity of the perforation depends on the conformation and direction of the lobule, which vary greatly in different individuals. When the trocar has perforated the lobule, a procedure which is effected gradually and without appreciable pain, its point is covered



FIGS. 813A AND 813B.—CONICAL TROCAR AND HOLLOW CANNULA FOR PERFORATION OF THE LOBULE OF THE EAR.

with one of the two hollow cannulae (Fig. 815), and the whole is drawn forward. The hollow cannula is thus made to replace the trocar, which is then removed. The extremity of the provisional gold ring is then introduced into the orifice of the cannula—where the point of the trocar had

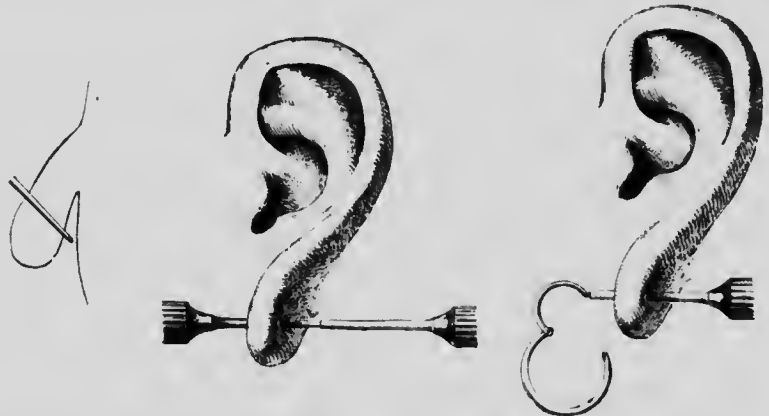

FIG. 814.—PERFORATION OF LOBULE OF LEFT EAR.

The needle should penetrate the lobule obliquely from before backwards.

FIG. 815.—PERFORATION OF LOBULE OF LEFT EAR.

The lobule has been perforated. The hollow cannula covers the needle, which is about to be withdrawn and replaced by the cannula, which passes painlessly through the tunnel thus made.

FIG. 816.—PERFORATION OF LOBULE OF LEFT EAR.

The opened beak of the gold earring is introduced into the hollow cannula, and traverses the lobule without causing pain as the instrument is withdrawn in the backward direction.

previously been (Fig. 816)—and it now suffices to draw the whole backwards to complete the insertion of the ring in the tunnel which it was meant to occupy.

2. WITH CUTTING INSTRUMENTS.—*Simple wounds* are sutured with fine silk. *Flap wounds* require adjustment, which is more rapidly and minutely carried out in proportion as the pedicle is more narrow. *Wounds with loss of substance* can in most cases be repaired by immediate suture of the detached

fragment with fine silk. In certain cases it will be necessary to have recourse to an ulterior autoplasty, which may be carried out either by a V-resection, followed by reunion of the edges; or by a double curvilinear resection, of which the outline will depend on the loss of substance.

3. **CONTUSED AND GUN-SHOT WOUNDS.**—These wounds are often followed by sphacelation of the edges. They must be treated with a moist

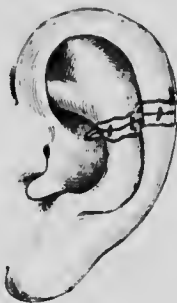

FIG. 817.—PARTIAL SECTION OF THE EAR.

Interrupted suture of the cartilage. The skin is then sutured.

antiseptic dressing, and compresses soaked in boric acid solution or, better, Labarraque's fluid of 1:20 dilution, alternating with oxygenated water of the same dilution.

Ultimately, we have recourse to autoplasty when necessary.

4. **BITES.**—Wounds of the pavilion of the ear produced by bites are often followed by intense inflammation, due to inoculation with the bacteria of the buccal cavity.

5. **FOREIGN BODIES.**—Foreign bodies in the tissues of the external ear, which are usually very small (grains of shot, etc.), are easy to recognize and to extract.

INFLAMMATORY LESIONS.

Lymphangitis—Abscess of the Pavllion.—Lymphaugitis of the pavilion, simple or suppurative, is treated with emollient and antiseptic applications (cataplasms of starch moistened with Labarraque's fluid, diluted to 5 or 2 per cent.). When suppuration has occurred the focus must be incised, under local anaesthesia. After diagnosis of the pathogenic microbe, phagogenic medication by means of mycolysine is employed.

CONGENITAL DEFORMITIES.

Exuberant Auricle (Hypertrophy of the Auricle).—A V-shaped autoplasmic resection of the exuberant portion is performed.

OPERATION.—A very clear section should be made with a bistoury or strong straight scissors. When we have secured satisfactory coaptation, the skin is joined by interrupted suture, commencing posteriorly. The edges of the divided cartilage are then united by three or four points of fine silk. Lastly, the skin is sutured in front.

Anomalies of Defect.—Anomalies of defect demand prosthesis; or, more simply, in case of the female, a wig or arrangement of the hair concealing the parts symmetrically.



FIG. 818. EXUBERANCE OF THE AURICLE: TRACING OF THE CUNEIFORM INCISION.

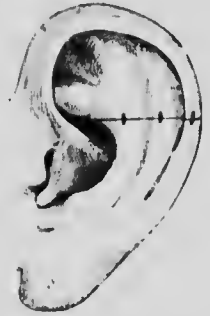

FIG. 819. EXUBERANCE OF THE AURICLE: UNION OF SKIN WOUND BY INTERRUPTED SUTURE.

Congenital Fistulæ.—A fistula which has an indurated part should be treated by extirpation of the whole tract; taking care to make but a very small cutaneous incision—circular or elliptical—so that the edges may be easily united.

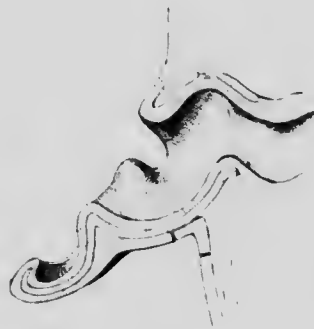

FIG. 820. EVERSION OF THE PAVILION: OUTLINE OF THE RESECTION OF THE RETRO-AURICULAR CUTANEOUS FURROW.

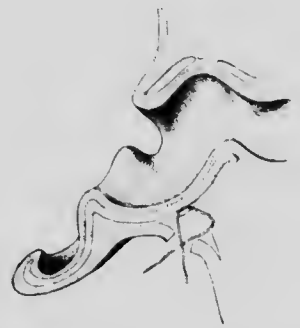

FIG. 821.—EVERSION OF THE PAVILION: DISSECTION OF TWO SMALL CUTANEOUS FLAPS. SUTURE OF PERICHONDRIUM TO THE CRANIAL PERIOSTEUM.

Vicious Direction of the Pavilion outwards.—This deformity is usually congenital. It may be exaggerated by the habit which some children adopt of holding the auricle curved forward with the hand, or even with a bandage. An autoplasmic operation is performed, which consists of the resection of a vertical cutaneous flap. If the cartilage is itself exuberant

we excise a vertical bandelette of cartilage from the retro-auricular groove. The edges of the cartilage are then united with interrupted suture of fine silk, and those of the cutaneous wound with silk or Florentine hair.

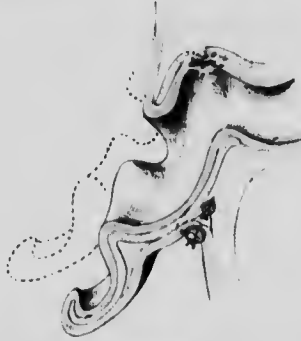

FIG. 822.—EVERSION OF THE PAVILION.

The operation is finished. The periosteal and cutaneous sutures are distinguished.

ACQUIRED DEFORMITIES.

Vicious Cicatrices—Cheloids.—Vicious cicatrices are extirpated, with some little encroachment on the adjacent healthy tissues. An immediate linear reunion must be obtained.

Cicatricial Adhesions.—Those adhesions necessitate an autoplasty, by sliding displacement or approximation of healthy skin. The lines of incision must vary with each individual case.

TUMOURS.

Benign Tumours.

Papillomata.—These small tumours are extirpated between two semi-elliptical incisions.

Erectile Tumours.—These tumours are removed with the bistoury through an incision made beyond the limits of the growth, and the repair is carried out according to the extent of the loss of substance, by an autoplasmic operation, either immediate or ulterior. In case of a very extensive and diffused erectile tumour, it is better to have recourse first to electrolysis or galvano-puncture. Where there are numerous arterial dilatations, we can make deep incisions around the pavilion, and tie all the dilated and newly formed vessels.

Fibrous and Fibro-Cartilaginous Tumours.—These should be extirpated with a cutting instrument, taking care to incise the skin whenever possible in positions in which the cicatrix cannot be too obviously seen, preferably on the posterior aspect of the auricle. In those cases of fibromata or fibro-chondromata, there may be a certain tendency to recurrence.

610 SURGICAL THERAPEUTICS AND OPERATIVE TECHNIQUE

Calcareous Concretions.—Such concretions are of frequent occurrence in gony subjects, and may become inflamed. We enucleate them with the enrette through a small incision, after effecting local anesthesia with cocaine.

Malignant Tumours.

Epithelioma.—Epithelioma is fairly frequent, and often in cases occurring among the unwashed peasantry, originates in the retro-auricular

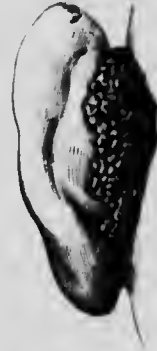

FIG. 823.—EPITHELIOMA OF THE RETRO-AURICULAR GROOVE.

furrow. The neoplastic tissues should be thoroughly curetted or extirpated, and the surface of implantation treated by electro-coagulation. All enlarged mastoid and carotid glands must then be extirpated; anti-neoplastic vaccination is then undertaken.

External Auditory Canal.

TRAUMATIC LESIONS.

Wounds.—Wounds of the external auditory canal heal readily if sufficient antiseptic precautions are taken to avoid any infective complication.

Fracture of the Osseous Wall.—A fall on the chin may cause the condyle of the inferior maxilla to crash through the osseous wall, and requires, if a permanent stenosis of the auditory canal is to be avoided, reduction of the fragments and tamponing of the external auditory canal.

Accidental Presence of Foreign Bodies.—Diagnosis should be made with the aid of the speculum and full illumination, either direct or reflected. The first attempt at removal should be by injection of a strong current of tepid water. This is done with a strong syringe furnished with lateral rings. The jet should have a diameter of about 2 to 3 millimetres. The auricle should be drawn firmly upwards and backwards, so as to rectify the

curvature of the outer portion of the canal. The patient is seated on a chair. The neck and shoulders are covered with two or three napkins, and a flat-bottomed reniform tray is held by an assistant for the reception of the

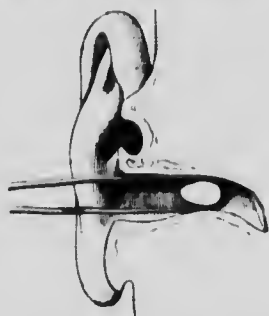


FIG. 824.—EXTRACTION OF AN OVOID FOREIGN BODY FROM THE EXTERNAL AUDITORY CANAL WITH A FORCEPS WITH SPOON-SHAPED JAWS.

returning foreign body. We must repeat the injection five or six times before declaring it ineffective. When the injections have given no result, the presence of the foreign body is again verified by use of the speculum, so

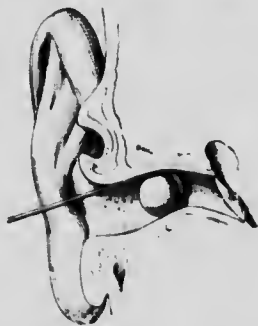

FIG. 825.—EXTRACTION OF A SPHERICAL FOREIGN BODY WITH A CROCHET BENT AT A RIGHT ANGLE, AND HAVING THE BENT EXTREMITY CURVED.

The crotchet, which is very slender, and appropriately curved, must be able to pass between the wall of the auditory canal and the contained foreign body, so as to penetrate beyond it.



FIG. 826.—SECTION PERPENDICULAR TO THE AXIS OF THE AUDITORY CANAL.

The crotchet is introduced between the foreign body and the wall of the canal. The handle is then rotated through an angle of 25 degrees, which movement places the hooked end behind the foreign body.

that an appropriate instrument may be chosen for its extraction, preferably a forceps with a very thin jaws, and capable of sliding between the wall of the external auditory canal and the foreign body (Fig. 824). A small flat and curved crotchet may also be used (Figs. 825 and 826), and introduced

between the wall of the canal and the foreign body, so as to act upon the latter from behind.

If the patient is very timid, and the foreign body difficult to seize, as in the case of a spherical pebble, we can always succeed in removing it by the natural route on anesthetizing the patient. Indeed, when the extraction is difficult, the foreign body is gradually pushed inwards towards the tympanum, which then serves as a point of support for its prehension. After the extraction we make a tepid injection without too much pressure, then an examination of the tympanic membrane with the otoscope, and finally a light tamponing of the orifice of the canal. The cicatrization of any parietal or tympanic lesions that exist should be carefully supervised.

Accumulation of Cerumen.—Concretions of cerumen are easily recognized with the aid of the otoscope, and are extracted with the help of injections of tepid water, which are carried out as indicated when describing the treatment of foreign bodies. The pressure of the jet of water should be diminished if it produces auricular vertigo. The evidence of the otoscope shows when complete evacuation has been effected, and a small cotton plug is then placed in the meatus. When the concretions have become hardened and adherent, they should be softened for twenty-four hours by installation of oil or glycerine, or, preferably, peroxide of hydrogen. Any adherent epidermic lamelle that may remain in the auditory canal can, if necessary, be removed with a forceps.

INFLAMMATORY LESIONS.

External Otitis—1. *Furuncles of the Auditory Canal.*—This affection, which is a very painful one, usually yields in a few hours to a course of phlogogenic medication: administration of mycolysine, both by the mouth and hypodermically.



FIG. 827.—INFLAMMATORY POLYPUS, SITUATED ON THE PROMONTORY.

2. *Periosteal Abscesses.*—Superficial inflammation may give rise to a suppurative periostitis. We examine the pus, so as to ascertain whether the case is one to be attacked by anti-staphylococcal medication. When incision is necessary, it should preferably be made behind the pavilion.

3. *Chronic Suppurative Otitis*.—Chronic suppurations are maintained by fungating surfaces, or polypi; sometimes, too, by the presence of a sequestrum. Those polypi are oftenest found on the promontory, and after previous destruction of the tympanic membrane they may be extracted with the snare under local anesthesia. The point of attachment is cauterized with a stylet on which is rolled a piece of bibulous cotton soaked in a concentrated solution of silver nitrate or chromic acid.



FIG. 828.—SNARE FOR POLYPI OF THE EXTERNAL AUDITORY CANAL.

4. *Sequestrum formed by Tympanic Ring*.—In a case in which the patient had presented grave meningeal symptoms, I at once recognized by otoscopic examination an annular sequestrum formed by the tympanic ring, and extracted it on the spot.

DEFORMITIES: CONGENITAL AND ACQUIRED.

Vices of Conformation.—Congenital atresia and stenosis of the external auditory canal are sometimes met with, and may call for operative procedure; which must be suited to each particular case.

Stenosis.—Stenosis, congenital or pathological, of the external auditory canal is not of exceptional occurrence. We can establish free communication between the tympanic cavity and the exterior, by making a wide tunnel through the mastoid apophysis with the *trepan à cliquet*, and cylindrical burr of 16 millimetres, as in the second stage of the operation for extraction of the ossicles by the mastoid route. Tamponing must be continued till we have obtained permanent epidermization of the walls of the space thus excavated.

TUMOURS.

Sebaceous Cysts.—When these are but slightly developed, the best treatment is destruction by galvano-cautery.

Exostoses.—When ablation is indicated by the volume and relations of the tumour, it should be carried out through a vertical retro-auricular incision. The exostosis is then detached with a chisel or gonge of suitable form. We must avoid as carefully as possible any perforation of the membranous portion of the external auditory canal.

Tympanic Membrane and Tympanum.

TRAUMATIC LESIONS.

Wounds and Lacerations.—*Wounds* of the tympanic membrane usually cicatrize spontaneously. Local antisepsis should be adopted. The initial hemorrhage is easily arrested by plugging of the external auditory canal.

Lacerations of the tympanic membrane usually cicatrize like ordinary simple wounds. When a perforation persists, it is irremediable.

INFLAMMATORY LESIONS.

Acute Otitis Media.—Acute inflammation, whether accompanied by meningeal symptoms or otherwise, yields in most cases to the action of mycolysine, administered in large doses, both hypodermically and by the mouth. When resolution does not take place and the sero-purulent fluid accumulates in the tympanum, paracentesis of that cavity must be resorted



FIGS. 829 AND 830.—OTOSCOPIC IMAGES OF LEFT AND RIGHT TYMPANIC MEMBRANES.

The place of election for paracentesis is marked with a cross.

to. Local anesthesia is obtained with the aid of a concentrated solution of cocaine hydrochlorate. The paracentesis is effected with a lancet-shaped needle, and at the most prominent point, which is most frequently situated behind the handle of the malleus. In some cases it is advantageous to evacuate the fluid collected in the tympanum by blowing air into the Eustachian tube. The cavity can then be washed out by injecting a tepid 4 per cent. boric solution into the external auditory canal. The fluid passes out through the Eustachian tube, if the lumen of the latter is free.

Chronic Otitis Media.—Chronic suppuration of the tympanum usually coexists with acquired perforation of the tympanic membrane. We have

already seen that this chronic suppuration may be complicated with the presence of polypoid excrescences. If the purulent excretion does not disappear after extraction of the polypoid vegetations, we must stimulate the process of epidermatization of the fungating surface. This process is secured by touching with a concentrated solution of silver nitrate in distilled water every eight days.

DEFORMITIES: CONGENITAL AND ACQUIRED.

These deformities are rarely remediable by any surgical procedure.

TUMOURS.

Benign Tumours.

Cholesteatomata.—The pearl-like tumours, or cholesteatomata of the tympanum, are veritable foreign bodies which are often produced in the course of chronic otitis media when there has been an obstruction to the free exit of the pus. They are formed by masses or concentric lamellæ of epithelium. The presence of these foreign bodies may determine caries of the ossicles and rarefying osteitis of the mastoid apophysis and petrous bone, where they tend to multiply.

If simple injections fail to secure their disappearance, we can employ the curet and then attack the foci of caries through the mastoid route.

Polypi of the Ear.—True aurial polypi can be removed with the snare after local anæsthesia with cocaine. Tamponing is then adopted, and we finally destroy the point of attachment by application of chromic acid or the use of the galvano-cautery.

Malignant Tumours.

Epithelioma and Sarcoma.—Cancer of the tympanum and tympanic membrane is a rare affection. Osteo-sarcoma and fungus of the dura mater may extend into the tympanum. Operation is usually impracticable. We must be contented with an anti-neoplastic treatment, the effect of which is generally palliative.

Eustachian Tube.

When true *obstruction* of the Eustachian tube occurs, it is not amenable to any surgical intervention. We have recourse to paracentesis of the tympanum, and try to prevent cicatrization of the opening.

Mastoid Apophysis and Petrous Pyramid.

TRAUMATIC LESIONS.

Fractures.—The resistance offered by the mastoid process is such as to require a traumatism of considerable force to produce a fracture thereof

616 SURGICAL THERAPEUTICS AND OPERATIVE TECHNIQUE

by direct violence, and such as nearly always determines a simultaneous fracture or penetrating wound of the cranial wall.

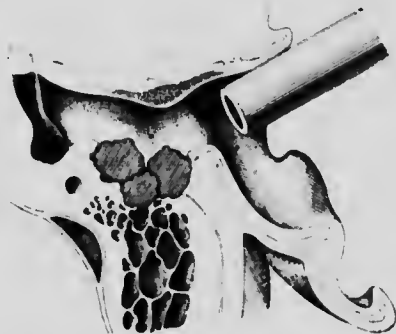

FIG. 831. LODGMENT OF THREE LEADEN BULLETS FIRED INTO THE EAR, AND ARRESTED IN THE PETROUS BONE IN FRONT OF THE AQUEDUCT OF FALLOPIUS AT A SHORT DISTANCE FROM THE TYMPANIC AND TRANSVERSE SINUS.

Gun-Shot Wounds. — Leaden bullets fired into the ear or mastoid apophysis from a revolver of medium calibre — 7 to 9 millimetres — may be arrested in

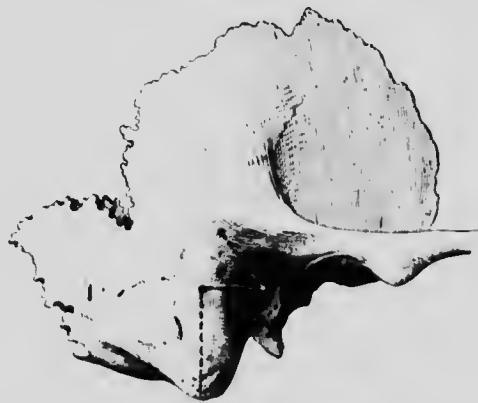

FIG. 832. EVACUATION OF THE MASTOID APOPHYSIS.

The perforating drill should attack the bone at the junction of a vertical line parallel to the axis of the mastoid apophysis and a horizontal one which intersects the axis of the external auditory canal. The autrum is situated in the axis of the zygomatic arch, on an oblique line passing above and behind the auditory meatus.

their course in the substance of the petrous pyramid, and remain fixed there. The extraction often proves difficult enough, and may require the use of the *trepan à cliquet* and the cylindro-spherical burr of 16 milli-

metres. The projectiles are moved from side to side with a small cutting spatula, and then extracted with a bullet-forceps or a ring-handled and clawed forceps.

INFLAMMATORY LESIONS.

Abscess of the Mastoid Apophysis—1. *Medical Treatment*.—The use of large doses of mycolysine or of its extract by the mouth, and mycolysine

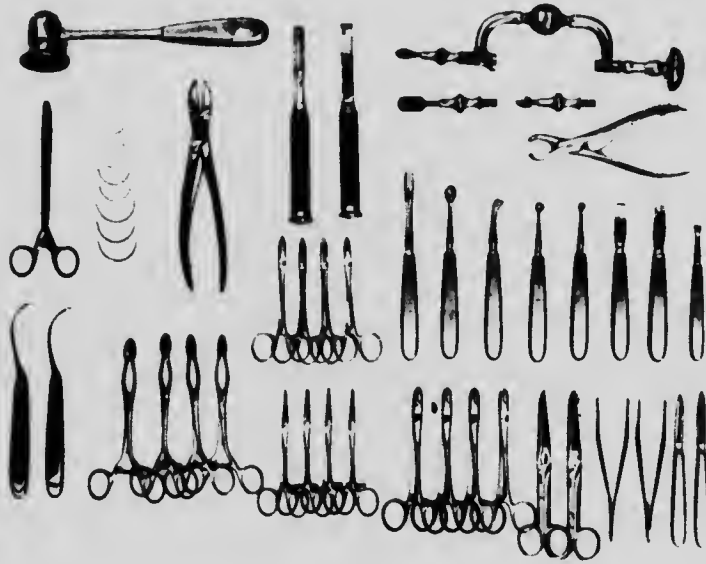


FIG. 833. INSTRUMENTS FOR EVACUATION OF THE MASTOID APOPHYSIS, AND OPENING OF INTRACRANIAL ABSCESSES OF OTITIC ORIGIN.

Below and from right to left: Two bistouries, two clawed forceps, two strong straight scissors, four short-jawed artery forceps, four ring-handled forceps with nine oblique claws, four forceps with oval jaws, two needles mounted on handles. One small straight raspatory; two raspatories, straight and curved; three Trelat's fenestrated curettes; one Volkmann's curette; one spatula; four small needle-holder forceps. Four types of assorted needles; one needle-holder forceps with eccentric jaws, one trepan à cliquet with flat perforating-drill, one conical burr of 12 millimetres, one cylindro-spherical burr of 16 millimetres; one chisel, one gouge, one mallet, one gouge-forceps, and one Liston's bone-forceps. (Reduced scale of one-sixth.)

hypodermically, may cause rapid resolution of certain inflammations of the mastoid cells, and will always prove a valuable adjuvant of the curative process when operation becomes necessary.

2. *Surgical Treatment.*—Evacuation of the mastoid apophysis is indicated in cases of acute or chronic inflammation of the mastoid cells. The consistence of the osseous tissue varies very considerably. In cases

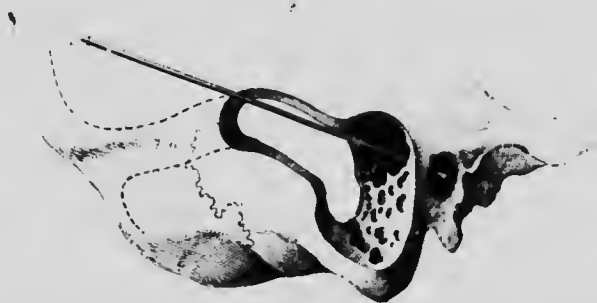


FIG. 834. PREPARATION SHOWING THE INTERIOR MASTOID CELLS AND THE LOSS OF SUBSTANCE OF THE INTERNAL TABLE, WHICH IS PRONE TO OCCUR IN CASES OF SUPPURATING PHLEBITIS OF THE LATERAL SINUS.

Above and in front is the mastoid antrum. A bent stylet, introduced through the opening, has passed through the ossicular corridor and emerged from the external auditory meatus.

of acute inflammation occurring in infants, the apophysis may be broken down with a raspator, in the same way as an epiphysis affected with caries. In most cases the external osseous lamellae offer a certain resistance. In the adult, and in chronic cases especially, the mastoid cells may be partially

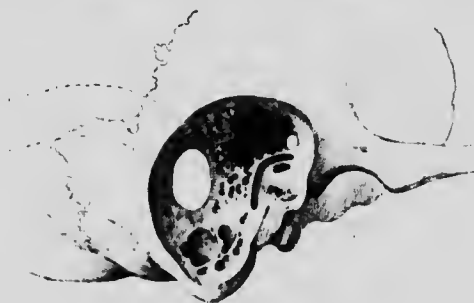

FIG. 835.

Preparation showing: Below, the interior mastoid cells; above, perforation of the internal table in the course of the lateral sinus, of which the position is traced by the dotted lines. At the highest part of the excavation: the antrum, and a small perforation which displays the thinness of the inner table at this point. Beneath this is the aqueductus Fallopii, bending, at right angles, around the fenestra ovalis, promontory, and fenestra rotunda.

filled up with the inflammatory products; and the apophysis, which is thus brought to a state of eburnation, offers an exceptional degree of resistance to surgical instruments.

The anatomical relations of the lateral sinus and mastoid apophysis are very variable. The dura mater is met with at a depth of 8 to 10 millimetres in those cases only in which the apophysis is rudimentary. The position and dimensions of the mastoid antrum, which must be broadly laid open in every procedure of evacuation of the mastoid apophysis, are also extremely inconstant. In order to represent with all desirable exactitude the surgical anatomy of the middle ear, I have been obliged to make a minute study of the tympanic cavity and its relations, in conjunction with my friend, M. Millot. Our figures have been designed from original anatomical preparations.

OPERATION.

First Stage: Incision of the Integuments.—A vertical incision of 4 to 5 centimetres is made down to the bone, behind the ear, and passing over the apex of the mastoid apophysis. The periosteum is detached with a curved raspatory; in front, as far as the border of the external auditory canal:

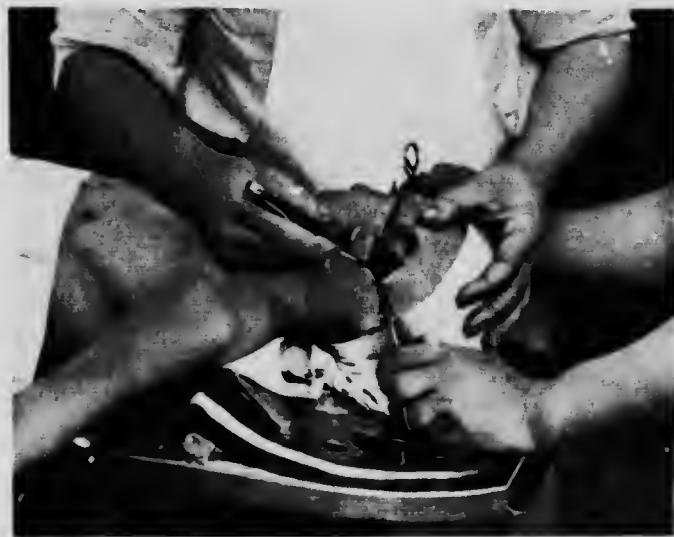

FIG. 836. — EVACUATION OF THE MASTOID APOPHYSIS: VERTICAL INCISION OF SOFT PARTS AND PERIOSTEUM, BEHIND THE EAR.

and the lips of the skin wound are held apart with the help of two ring-handled and clawed forceps, which are made to secure hemostasis at the same time if necessary.

Second Stage: Osseous Evacuation.—The flat perforator mounted on a trepan à cliquet is then applied to the bone, at a distance of 6 to 8 millimetres behind the orifice of the osseous auditory canal, and the superficial bony lamellæ are cautiously penetrated. The perforation of the bone

should then be carried out with great lightness of hand. If we act with too much vigour, there is a danger of penetrating, when the apophysis has been softened by disease, into the cranial cavity or the lateral sinus. When the flat perforating drill has penetrated to a depth of 4 or 5 millimetres, we replace it with the cylindro-spherical burr of 16 millimetres. In the case of very young children the burr of 12 millimetres may be used, and the trepanation of the bony tissue is pursued with the same precautions and the same lightness of touch.

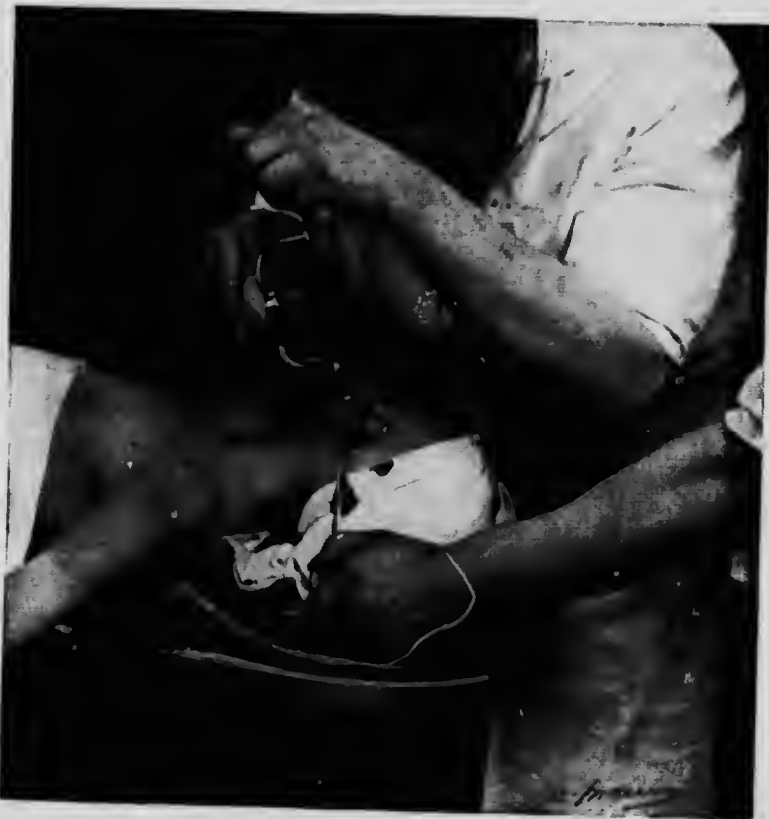

FIG. 837.—EVACUATION OF THE MASTOID APOPHYSIS WITH THE TREPAN À CLIQUET AND CYLINDRO-SPHERICAL BURR OF 16 MILLIMETRES.

We arrive at the wall of the sinus in a few moments, which recedes without being wounded from the almost blunt pole of the burr (first stage of the evacuation). The toilet of the wound is made, and we then direct the burr upwards and forwards, towards the mastoid *antrum*, which is soon found to be widely laid open (second stage of the evacuation). The pus and

act with
pophysis
al sinns.
5 milli-
limetres.
be used.
cautions

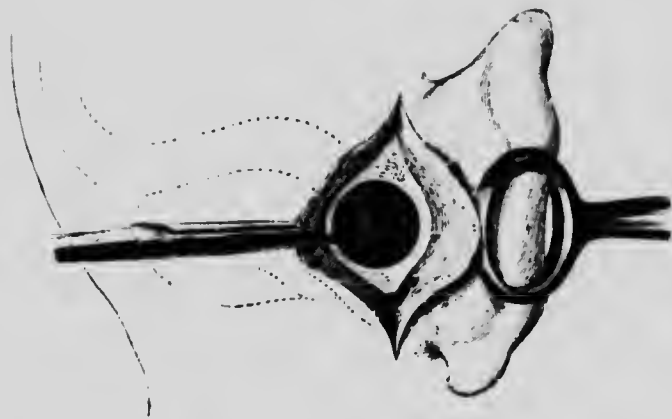


FIG. 838.—EVACUATION OF THE MASTOID APOPHYSIS.

The first evacuation has been carried out with the cylindro-spherical burr of 16 millimetres, and the wall of the lateral sinus has been exposed without wounding. The postero-inferior limit of the cranium and the course of the lateral sinns are marked with dotted lines.

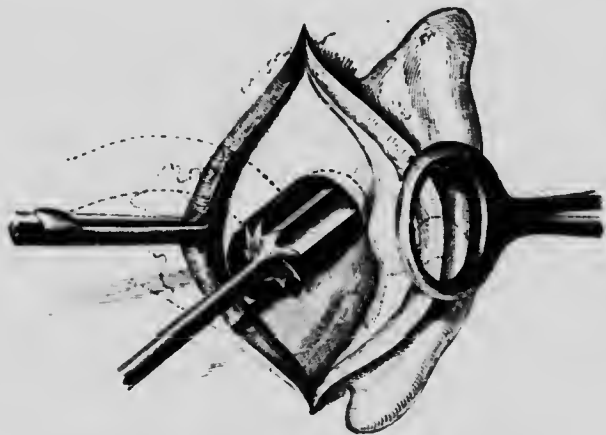


FIG. 839.—OPENING OF THE MASTOID ANTRUM.

The sinns has been exposed. The burr is directed obliquely upwards, forwards, and inwards. The cavity of the antrum is opened in a few moments. The curved dotted line which is seen at the extremity of the burr shows how this instrument penetrates obliquely within the surface of the temporal bone.

LIQUID

without
of the
ect the
s soon
ns and

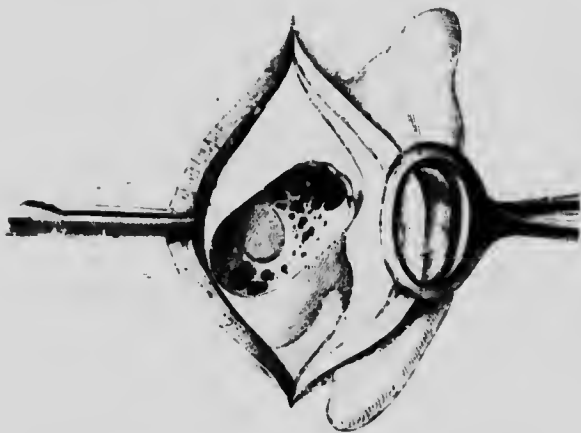


FIG. 840. OPENING OF THE MASTOID ANTRUM.

Appearance of loss of osseous tissue after the second stage of evacuation with the burr. The cavity of the antrum is seen below and behind, having been exposed by resection with the gonge-forceps of the osseous lamella cut out *en biseau* with the burr of 16 millimetres.

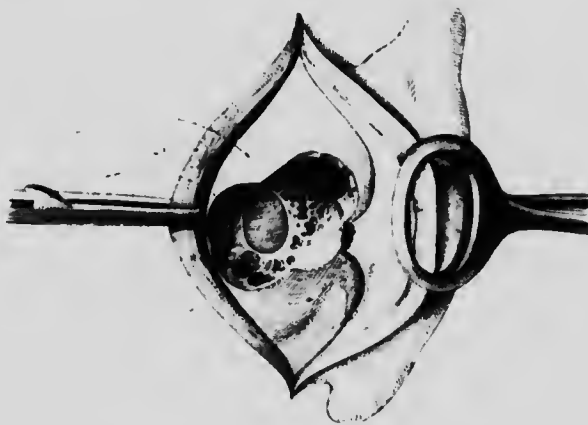


FIG. 841.—OPENING OF THE ATTIC AND EXTRACTION OF THE OSSICLES.

The burr is turned in a third direction— from behind forwards, and from without inwards— towards the deep-seated section of the external auditory canal. The acting pole of the burr pushes back the fibro-cartilaginous wall of the canal and opens the osseous tube immediately in front of the tympanic ring.

fungosities are then removed with the curette, and the sinus is, in its turn, explored and punctured, if we find it necessary to do so, for the purpose of ascertaining whether it has been affected with phlebitis.

The operation is carried out in this way in a very short time, and the technique is so simple as to be attainable by all. The *trepán à cliquet*, flat drill, and cylindro-spherical burr are instruments which should be in the possession of every medical man who is liable to be called on to act in cases of urgency. The manipulation of these instruments is far superior to that of the mallet and chisel, and does not expose us to the risk of those accidents which were formerly so frequent, such as extensive wound of the lateral sinus, perforation of the dura mater, and laceration of the brain

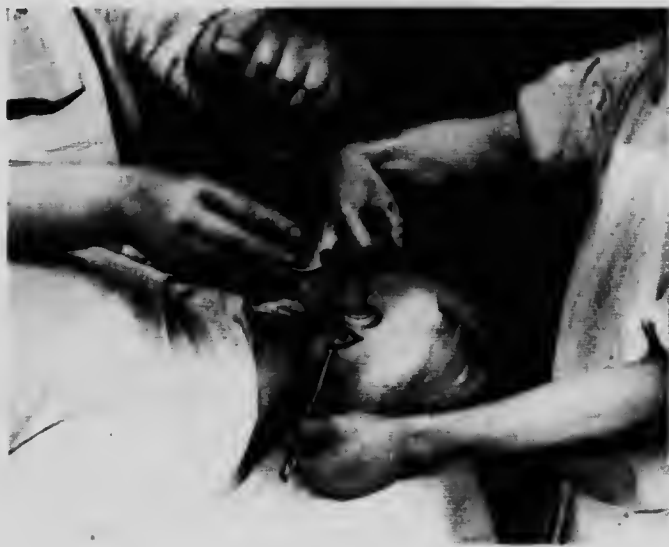

FIG. 842.—APPROACHING THE TYMPANIC CAVITY BY THE MASTOID ROUTE: ATTACK OF MASTOID APOPHYSIS WITH THE FLAT PERFORATING DRILL.

substance. Such accidents would be so much the more unfortunate, inasmuch as the inexperienced operator, while wounding organs and tissues which he would then have to attend to with great care, had not yet succeeded in reaching the principal focus of suppuration—the *antrum mastoideum*. But with my cylindro-spherical burr not one of those accidents need be feared if the instrument is manipulated with some precaution. Besides, we are always sure of reaching the cavity of the antrum, by taking care to direct the burr, after the apophysis has been hollowed out up to the wall of the sinus, obliquely upwards, forwards, and inwards, in the direction of the median frontal eminence.

Phlebitis of the Lateral Sinus.—When the symptoms have not yielded to the evacuation of the mastoid process and opening of the antrum, it is

necessary to ascertain whether there is phlebitis of the lateral sinus or a subdural abscess.

Exploration of the sinus is easy. If the evacuation of the mastoid has been carried out according to my technique, the outer wall of the sinus should have been exposed by the pole of the burr. To judge of its integrity, it is enough to puncture this outer wall with a narrow bistoury. If venous blood pours out, the mastoid cavity is firmly plugged with gauze, and a compressive dressing is applied. But if a small quantity of sanious liquid emerges through the small orifice, the wall of the sinus is at once more freely incised, and the suppurating clots are removed with the curette. In some cases it may be necessary to expose the outer wall of the lateral



FIG. 834. PERFORATION OF THE MASTOID APOPHYSIS WITH THE CYLINDRO-SPHERICAL BURR OF 16 MILLIMETRES.

The first movement of the burr is directed transversely.

sinus over a length of 2 to 3 centimetres, by attacking the cranial vault with the gouge-forceps. The position of the lateral sinus is indicated in Fig. 835, which represents the necessary amount of loss of osseous substance. The sinus having been exposed in the first stage of the evacuation (Figs. 835 to 838), it suffices, for the purpose of opening it throughout a sufficient portion of its length and evacuating its septic contents, to incise the soft parts towards the external occipital protuberance, and then resect the bone with the gouge forceps, along the outline traced in Fig. 834.

The inflamed sinus is tamponed with sterilized gauze. If, in carelessly curditing the clots formed in the sinus, we reach the healthy portion of the canal, the blood jets into the wound. We must then plug immediately with a wick of aseptic gauze, which should be fixed, according to the

conditions indicated, with a haemostatic forceps, or even with a silk ligature, which is passed beneath the sinus with a curved needle.

Approach to the Upper Portion of the Tympanic Cavity and Its Chain of Ossicles—Indirect Approach to the Tympanic Cavity by the Mastoid Route.—Suppurating foci of the upper and anterior portion of the tympanic cavity should be attacked along the transmastoid route. The use of the cylindrospherical burr enables us to recognize, by carefully looking out for contractions of the features of the patient, the moment of approaching the facial nerve. If the aqueduct of Fallopius has been touched by the burr,

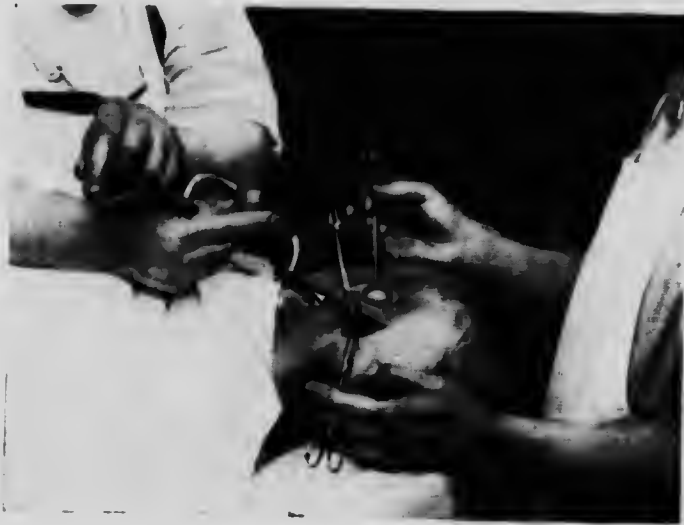

FIG. 844.—SAME OPERATION.

Second movement of the burr, which is directed obliquely upwards and then forwards, in order to reach the mastoid antrum.

we may easily avoid the nerve by inclining the active pole of the instrument outwards (Fig. 840). In some cases it may be necessary to dissect out the facial nerve with the gouge and mallet, and expose it throughout nearly the whole length of the bony canal.

As soon as the focus of infection has been reached, it is curetted and plugged. I have in this way operated, without wounding the facial nerve, on many deep-seated subdural abscesses, situated in the immediate neighbourhood of the aqueduct of Fallopius. If the nerve has suffered some little contusion during the operation, we may observe a transitory facial paresis which develops after some days. There can be no error of diagnosis between a paresis due to contusion or slight irritation of the facial nerve and paralysis produced by its section, inasmuch as the paralysis in the latter case is immediate, complete, and persistent.

Extraction of the Chain of Ossicles.—It is by the same operation of wide evacuation of the mastoid apophysis that we are able to expose with sufficient completeness the cavity of the tympanum and its attic, with the object of carrying out any operations on the chain of ossicles that may be indicated, especially their extraction. Extirpation of the ossicles is the indispensable complement of evacuation of the apophysis, and of antrectomy for old-standing suppuration of the antrum and attic. As has been above described, the first two stages of evacuation with the burr reach—the first, the wall of the lateral sinus; the second, the cavity of the antrum.

A third movement of the burr, in a horizontal direction, will pass in front of the aqueduct of Fallopius (Fig. 845) to open the external auditory canal at a distance of 2 to 3 millimetres in front of the promontory. The



FIG. 845. — HORIZONTAL SECTION PASSING ALONG THE AXIS OF THE EXTERNAL AUDITORY CANAL.

The direction of the burr is indicated, when used, as represented in Fig. 844, to expose the wall of the lateral sinus. When it has opened the antrum (second stage of evacuation), we have to attack the tympanic cavity. The burr is directed thereto horizontally. We see that it passes very close to the vertical section of the aqueduct of Fallopius, to open the osseous auditory canal 4 or 5 millimetres in front of the promontory. It should not be directed too far backwards. The operator is warned off by spasmodic contractions of the facial muscles. The instrument should then be turned more outwards in order to save the nerve, which an inconsiderate movement might injure irremediably.

burr could not be made to pass more deeply without wounding the facial nerve, the course of which is indicated in the figures. When the external auditory canal has been opened in front of the tympanic cavity, the attic is no longer concealed but by the wall of its corridor (Figs. 846, 847, 848). Two strokes of the chisel suffice for elevation of the latter, opening the aditus and attic at the same time. Extraction of the malleus and incus is usually followed by complete cicatrization. Hearing does not return satisfactorily till the suppuration has definitely dried up.

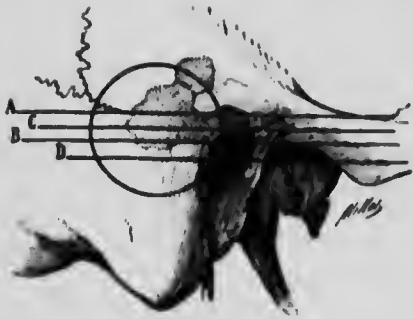

FIG. 846.—EXTERNAL SURFACE OF TEMPORAL BONE, SHOWING THE PETROUS PART OF THE AQUEDUCTUS, AND THE ANTRUM; 20. POSITION OF SEVERAL SECTIONS, A, B, C, AND AN EXTERNAL TRACING OF THE LAMINA OF THE PETRO-MASTOID FORAMEN.

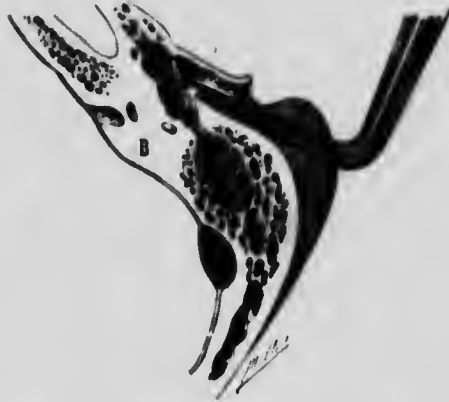


FIG. 848.—SECTION OF PETROUS BONE, PASSING THROUGH THE UPPER THIRD OF THE EXTERNAL AUDITORY CANAL, AND INVOLVING THE LOWER WALL OF THE PETRO-MASTOID CANAL, IN WHICH THE HOOK OF THE REFRACTOR IS FIXED.

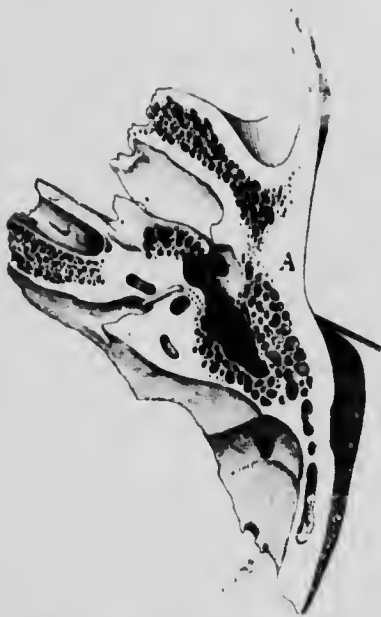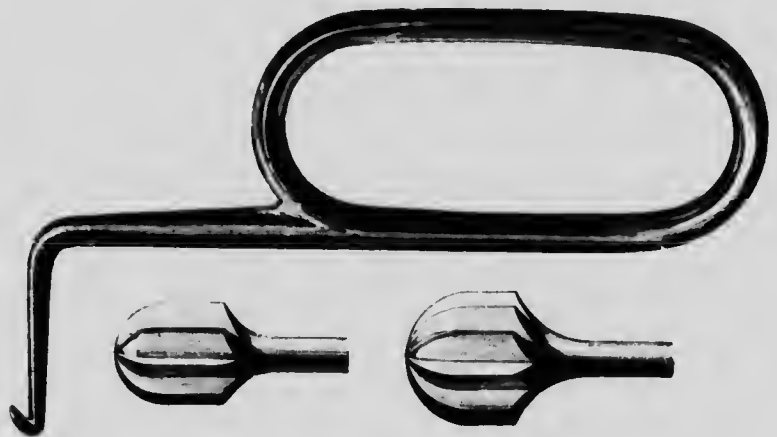


FIG. 847.—HORIZONTAL SECTION OF THE PETROUS BONE AT THE LEVEL OF THE SUPERIOR BORDER OF THE ZYGOMATIC ARCH, SHOWING THE RELATIONS OF THE ANTRUM, ADITUS, AND TYMPANUM, AND PASSING THROUGH THE FIRST PORTION OF THE AQUEDUCTUS FALLOPII.

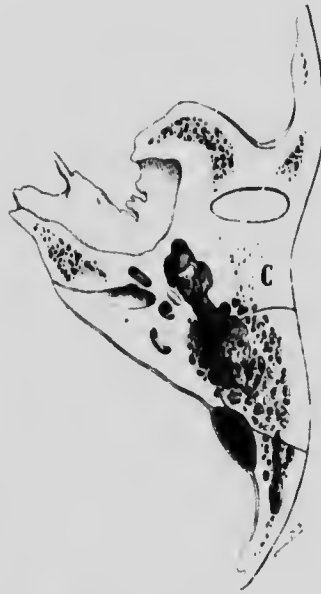

FIG. 849.—SECTION OF THE PETROUS BONE IMMEDIATELY ABOVE THE SUPERIOR WALL OF THE EXTERNAL AUDITORY CANAL, AND PASSING THROUGH THE INTERMEDIATE PORTION OF THE ADITUS AND OF THE INTERNAL AUDITORY CANAL. The ossicles are seen in position.

Direct Invasion of the Tympanic Cavity by the Petro-Mastoid Route.—We can also reach the antrum and the space which contains the ossicles by the direct route, without preliminary opening of the mastoid cells. I will preface the description of the operative technique with some anatomical reflections. For purposes of demonstration I have prepared a number of sections of the os petrosum. Fig. 848 shows the external surface of the temporal bone, on which has been projected the course of the facial nerve, and also the configuration of the corridor and the antrum. The antero-superior prolongation of the antrum—there separated by a dotted line from the principal cavity—does not exist in all subjects. Four horizontal lines—*A, B, C, D*—correspond to the sections represented in the following figures.



FIGS. 850, 851, AND 852. CROCHET FOR THE WALL OF THE TYMPANUM; CYLINDRO-SPHERICAL BURRS OF 16 AND 20 MILLIMETRES RESPECTIVELY.

Section *A* (Fig. 847) is made in the plane of the superior border of the zygomatic arch, and passes about 3 millimetres below the vault of the tympanum. It exactly divides the first portion of the aqueductus Fallopii, which is placed between the cochlea and vestibule. In this section we distinguish the aditus, which forms the communication between the mastoid antrum and the tympanic cavity that contains the ossicles. A crotchet, introduced through the external auditory canal, and touching the wall of the tympanum, serves to indicate simultaneously the obliquity of the osseous auditory canal in a direction forwards and inwards, and the exact position of the wall of the tympanic corridor. The second portion of the aqueductus Fallopii is indicated by dotted lines.

Section *B* (Fig. 848) is in a tangent plane to the inferior wall of the aditus. It divides the facial nerve at the level of the oblique turn which unites the second to the third portion. A special crotchet, represented in Fig. 848, has been introduced into the external auditory canal, and hitched

on the dihedral angle of the wall of the tympanum. We distinguish the tympanic membrane which has been perforated by the instrument.

Section *C* (Fig. 849) passes exactly above the superior wall of the auditory canal, which is not involved. In front of the letter *b* is the section of the roof of the glenoid cavity. In this figure we distinguish the antrum, aditus, tympanum, and ossicles, the second portion of the facial nerve, the vestibule, posterior semicircular canal, internal auditory canal, and the main curve of the cochlea.

From the above data we find that by carrying out the procedure of osseous evacuation, not along a horizontal line passing by the median portion of the auditory canal, but along a line tangent to its superior margin, and directing the burr with a slight obliquity from without inwards and from behind forwards, the instrument opens the antrum widely without

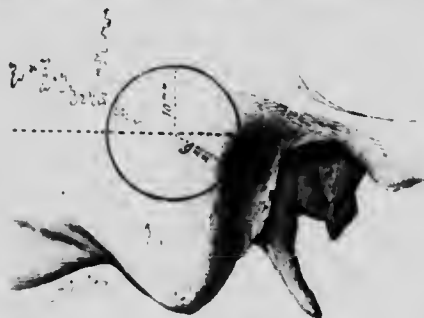


FIG. 853. PETRO-MASTOID EVACUATION IN THE ADULT: POINT AT WHICH THE FLAT DRILL SHOULD BE MADE TO PENETRATE.



FIG. 854. PETRO-MASTOID EVACUATION IN THE CHILD: POINT AT WHICH THE FLAT DRILL SHOULD BE MADE TO PENETRATE.

danger of wounding the facial nerve. We should employ, in case of a child, a cylindro-spherical burr of 16 millimetres; in case of an adult, one of 20 millimetres.

I have had two special burrs made for this operation by M. Collin (Figs. 851 and 852). The superior plane of each is placed at a distance of 17 millimetres from the active pole. This is the depth which must not be exceeded, in order to make sure of not wounding the aqueductus Fallopii. I have also had made the special crotchet represented in Fig. 848, which is used in cases of caries of the tympanum, in which the tympanic membrane has been destroyed, for hooking on the wall of the corridor, and forming a guide to the burr.

OPERATION—First Stage: Incision of the Integuments.—A vertical incision of 5 or 6 centimetres is made at a distance of 1 centimetre behind the retro-auricular groove, the median point thereof being at the level of the superior wall of the auditory canal. The periosteum is then incised, and the bone is laid bare with a raspator; care being taken to expose the postero-superior angle of the osseous wall of the auditory canal in front.

Second Stage: Osseous Evacuation.—Let us suppose that the tympanic membrane has been destroyed, and also the chain of ossicles. The temporal bone should be attacked on a line forming a horizontal tangent to the superior wall of the osseous auditory canal, as indicated in Figs. 851 and 852, which represent the operation in the adult and child respectively. The flat drill should perforate the bone on that line—in the child at 7 millimetres, and in the adult at 9 millimetres from the posterior wall of the auditory canal—so that the burr, which has a radius of 1 millimetre more, can be made to attack this posterior wall. When the point of the drill has penetrated the bone to a depth of 5 millimetres, and perpendicularly to its surface, it is replaced with one of the burrs represented in Figs. 851 and 852

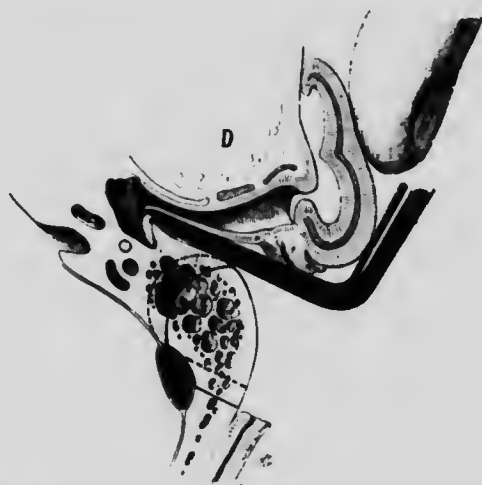

FIG. 855.—PETRO-MASTOID EVACUATION: SECOND STAGE OF THE OPERATION; INTRODUCTION OF THE CROCHET INTO THE OSSEOUS AUDITORY CANAL.

The commencing evacuation is indicated in the transparent part of the figure.

The crotchet represented in Fig. 850 is introduced in the way shown in Fig. 854, between the osseous and the fibrous wall of the external auditory canal, which have been separated at the depth of the wound with a small raspatory. As soon as the crotchet has reached the tympanic cavity, its bent limb can be directed towards the labial commissure of the same side, and the movement of resting it on the cheek suffices to make it hook on the wall of the corridor. The instrument is then entrusted to an assistant. The surgeon, using at first a flat drill and then a cylindro-spherical burr, carries out the petro-mastoid evacuation on a strictly horizontal plane; but in a direction slightly oblique from without inwards, and from behind forwards, and parallel to the posterior wall of the external auditory canal, which should be involved over a width of 4 or 5 millimetres. The evacuation is carried out with a burr of 20 millimetres in the case of an adult, and with

one of 16 millimetres in that of a child. The burr can, in normal cases, penetrate to a depth of 17 millimetres without risk of reaching the aqueduct of Fallopius. In nearly every instance, the instrument lays bare posteriorly the wall of the lateral sinus; and opens above, from the antrum, into the middle fossa of the base of the skull (Fig. 856).



FIG. 856.—PETRO-MASTOID EVACUATION: SECOND STAGE OF THE OPERATION; POSITION OF THE CROCHET WHEN THE BURR HAS JUST OPENED THE ANTRUM.

A slight effort suffices to tear open the wall of the tympanic corridor.

Third Stage: Tearing off the Wall of the Corridor.—When the antrum has been widely laid open, we can see, on sponging the wound, the extremity of the crotchet, which overlies the wall of the tympanum. To establish free access to the attic, it suffices to tear off that osseous lamina by a brusque movement of traction on the instrument, Fig. 856.

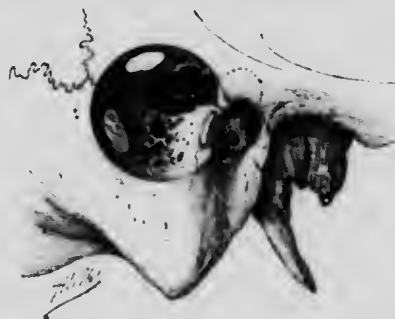

FIG. 857.—PREPARATION SHOWING THE POSITION IN WHICH THE BURR MAY WOUND THE FACIAL NERVE IF IT BE ALLOWED TO PENETRATE TOO FAR.

Fourth Stage: Extraction of the Ossicles.—The malleus and incus, if they still exist, are extracted with a small forceps and suitable curette, and we ascertain whether there is any necrosis of the superior wall of the attic.

Fifth Stage: Focus of Intracranial Suppuration.—The small foci of subdural caries in this region are thus exposed. It is easy to enlarge the

632 SURGICAL THERAPEUTICS AND OPERATIVE TECHNIQUE

opening in the lower part of the temporal fossa, by application to the antero-superior aspect of the bony orifice of a cylindro-spherical burr: of 16 millimetres in case of an adult, of 12 millimetres in that of a child. The carious focus should be carefully curetted.

Sixth Stage.—We tampon the artificial wound, and also the external auditory canal, in such a way as to restore its normal calibre.

RESULT OF THE OPERATION.—Fig. 857 shows a petro-mastoid evacuation from the front, and carried out so deeply as to involve the

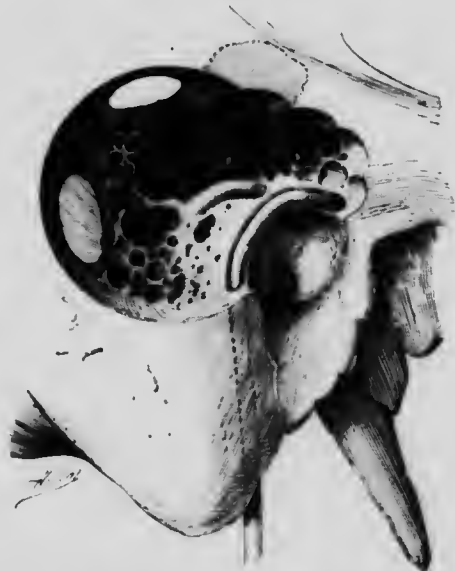

FIG. 858.—PREPARATION SHOWING THE PROJECTING CURVE OF THE EXTERNAL SEMICIRCULAR CANAL; ALSO THE SECOND AND THIRD SEGMENTS OF THE AQUEDUCT OF FALLOPII.

aqueduct of Fallopius. In Fig. 858 the whole of the external wall of the attic has been resected; also the external wall of that segment of the Fallopian aqueduct which lies in contact with the tympanic cavity. The projection of the external semicircular canal is also shown, tangential to the inferior wall of the antrum. This specimen, which has been magnified, is intended for demonstration of the fact that the aqueduct of Fallopius is horizontal only till it has attained the upper border of the fenestra ovalis; and that it is then directed very obliquely downwards, backwards, and outwards, to become vertical after leaving the vicinity of the fenestra rotunda. This curve, forming the union between the second and third portion of the intra-osseous section of the facial nerve, has not been described hitherto in a sufficiently precise manner.

Fig. 860 represents, after conclusion of the operation, the anterior segment of a frontal section of the right temporal bone, passing through the

stylo-mastoid foramen (in the plane of line *A* of Fig. 859). We here see that the posterior aspect of the external auditory canal has been invaded by the burr, as well as the temporal fossa (see Fig. 830). The mastoid antrum has been widely opened. Fig. 861 represents a section of the left temporal bone which has undergone the same procedure. This section also passes through the stylo-mastoid foramen, but in a plane parallel to the axis of the petrous pyramid (that of line *B*, in Fig. 859). The two segments of this section are juxtaposed in the figure. On the anterior segment we



FIG. 859. —INTERIOR ASPECT OF RIGHT PETROUS BONE, SHOWING THE ORIENTATION OF THE VERTICAL SECTIONS REPRESENTED IN FIGS. 864 AND 865.

FIG. 860. —ANTERIOR SEGMENT OF A FRONTAL SECTION OF THE RIGHT PETROUS BONE, PASSING THROUGH THE STYLO-MASTOID FORAMEN AND SHOWING THE RESULTS OF THE OSSEOUS EVACUATION.

recognize, on the right of the figure and from without inwards, the cavity evacuated by the action of the burr, the loss of substance of the posterior wall of the auditory canal, which is separated from the antrum by the wall of the tympanic corridor; above, a slight loss of substance of the temporal fossa; and more deeply, the anterior wall of the tympanic cavity, with the opening of the Eustachian tube, and the canal for the tensor tympani muscle. On the right-hand figure we have an eburnated osseous surface, on which is seen the helicotrema; then, and lastly, the anterior wall of the carotid canal. On the posterior segment, on the left of the figure, is seen the orifice

of the groove for the lateral sinus and the opening of the antrum; the pole of the burr had been arrested at a short distance from the aqueduct of Fallopius and from the external semicircular canal, the wall of which has here been divested of surrounding tissue for the purpose of exposing it more completely. This figure displays very clearly the course of the facial nerve, which is here figured, with its geniculate ganglion. The nerve passes beneath the external semicircular canal. Below the geniculate ganglion we recognize the base of the cochlea.

These researches lead us to describe, from the two view-points of the anatomist and the surgeon, *four portions* of the aqueductus Fallopii: (1) A first portion: horizontal, directed obliquely forwards and outwards

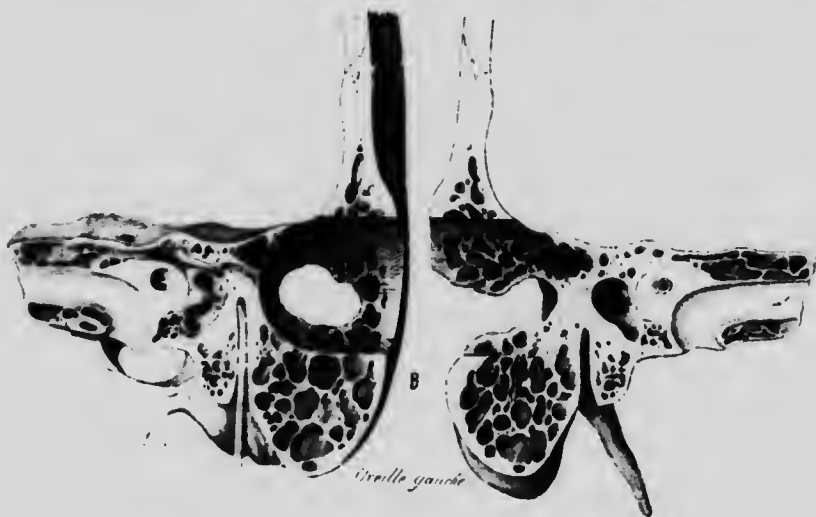


FIG. 861.—VERTICAL SECTION OF RIGHT PETROUS BONE ALONG LINE B OF FIG. 859.

The anterior and posterior segments of the divided bone are here displayed, showing the relations of the cavity hollowed out by the burr to the middle ear, the internal ear, and the facial nerve.

(Fig. 857), and ending at the corridor which contains the geniculate ganglion. (2) A horizontal or slightly descending portion: forming with the first segment an angle of 90 degrees, directed obliquely outwards and backwards, and terminating precisely in the space which separates the posterior border of the fenestra ovalis from the anterior extremity of the external semicircular canal (Figs. 858 and 859). At this point the osseous canal is usually incomplete, leaving the nerve covered with only a fibrous lamella. (3) The third portion is the most important from the surgical view-point, for it has often been wounded. Now, this third portion of the facial nerve, which has hitherto been insufficiently described, has a direction very sensibly oblique, from above downwards, from before backwards, and from within

outwards. Accordingly, we run the less risk of wounding the nerve in proportion to the higher level of our procedure of petro-mastoid evacuation. The one fact of all those which must be retained is: that the facial nerve, from its first angular bend (geniculate ganglion), is directed very appreciably from within outwards. (4) The fourth portion of the aqueductus Fallopii, the mastoid section, is sensibly vertical in direction, with a variable obliquity outwards.



FIG. 862. —ENLARGED FIGURE, SHOWING THE SECOND MOVEMENT OF THE BURR, WHICH OPENS THE ANTRUM; AND THE THIRD, WHICH TERMINATES IN FRONT OF THE TYMPANIC MEMBRANE, HAVING PASSED 1 OR 2 MILLIMETRES ANTERIOR TO THE FACIAL NERVE.

The aditus is indicated by the dotted outline in front of the second portion of the facial nerve.

Intracranial Abscesses of Otitic Origin.—Intracranial abscesses of otitic origin may be limited to a localized collection between the bone and dura mater, situated either above or below the tentorium cerebelli. Those purulent foci are, in most cases, opened by the burr, in the process of evacuating the mastoid apophysis. A sanious fluid, sero-purulent or purulent, then escapes in abundance. The opening is now enlarged with a small raspatory or with the gouge-forceps, and the cavity is drained and tamponed. I have had the experience in one day of opening abruptly with the burr of 16 millimetres and *trepan à cliquet*, while evacuating a

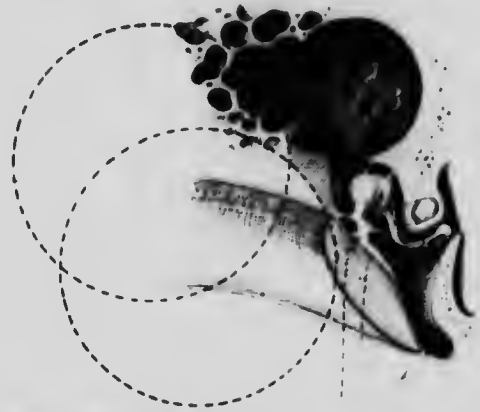


FIG. 863. TRANSVERSE SECTION IN THE PLANE OF THE AXIS OF THE AUDITORY TUBE. The burr has not destroyed the wall of the corridor occupied by the ossicles (represented in oblique strie). For clearness of illustration the chain of ossicles has been left in place; it is figured in perspective.

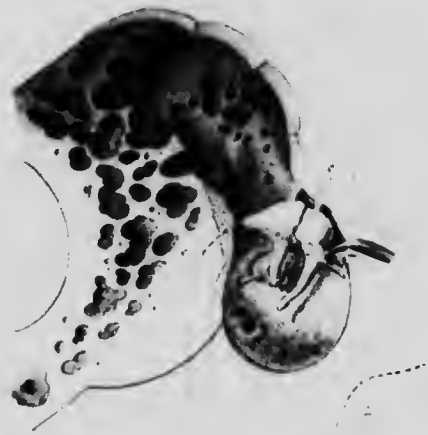

FIG. 864. The wall of the space occupied by the ossicles has been resected with mallet and chisel. Duplex section is figured with oblique strie. The ossicles are seen in position, also the promontory and fenestra rotunda, and, in dotted outline, the course of the facial nerve, with the geniculate ganglion and the two petrosal nerves.

suppurating mastoid apophysis, a supra petrous intracranial focus of suppuration in one patient, and, in a second, a vast purulent collection in the cerebellar fossa. In such cases we must content ourselves with allowing the pus to escape, cleansing the purulent focus with a wick of gauze, and then draining and tamponing. Every antiseptic injection is dangerous, and would risk the breaking up of the adhesions of the periphery of the suppurating cavity. Lavage should not be practised before the eighth or tenth day. Labarraque's fluid, of 5 to 10 per cent., and oxygenated water, are in such cases the best and most inoffensive disinfectants.

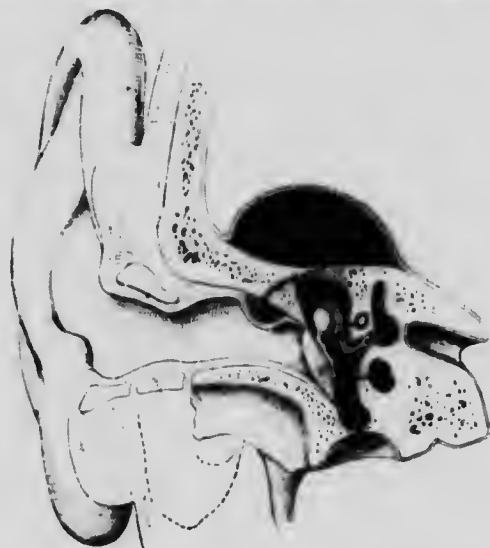


FIG. 865. PROPAGATION OF SUPPURATING PROCESSES FROM THE TYMPANIC CAVITY TO THE TEMPORAL CEILING, UPPER PART OF EXTERNAL AUDITORY CANAL, AQUEDUCTUS FALLOPII, AND LABYRINTH.

Exposure of the focus of suppuration is much more difficult when this is not in direct communication with the intramastoid focus. Indeed, the localizing indications are sometimes almost wholly negative. In such cases we must open the temporal or the cerebellar fossa, or both in succession. When the mastoid apophysis has been evacuated, some strokes of the gouge-foreceps, or the breaking-up of an osseous lamella with mallet and gouge, suffice to lay bare 4 or 5 square centimetres of the surface of the dura mater of the temporal fossa. When no pus is found between the bone and dura mater, the latter is incised, and the temporo-occipital lobe of the brain is raised with a blunt instrument from the petrous bone and the tentorium cerebelli, till the vicinity of the torcular Herophili is reached.

We have seen, in discussing abscess of the brain, that this may be situated at the posterior limit of the occipital lobe without any existing trace

of local inflammation in the neighbourhood of the petrous bone. When there is no collection beneath the temporo-occipital lobe of the brain, the surface of the convolution is explored with the finger, and incised with a bistoury, or perforated with a haemostatic forceps with long slender jaws. If pus escapes, the focus is drained and tamponed. If the incision produces but little flow of blood, a wick is introduced to facilitate the possible evacuation by that course of a deeply seated abscess which has not been reached; and we then proceed to exploration of the cerebellar fossa, or, possibly, of the occipital. Infective accidents are combated with daily injections of 10 or 20 centimetres of mycolysine.

Exploration of the Cerebellum.—The cerebellar fossa is very easily laid open with mallet and gouge. At the first step, it suffices to expose the superior curved line of the occipital bone. We then open the cranium with the gouge and mallet. It is easy to detach, with the first blow, an osseous chip which reaches the dura mater. The orifice is then enlarged with the gouge forceps, and the operation is thus terminated in a few moments. We may make a preliminary perforation of the bone if the condition of the patient gives time, either with the *trepan à cliquet* and flat perforating drill, followed by the cylindro-spherical burr; or with the electric burr. The orifice should be enlarged with the gouge forceps. The bone is sufficiently thin in that area, and as a definitive loss of substance in that region is not of serious importance, the formation of a hinged shutter is but rarely indicated.

We can, however, if thought desirable, perform a temporary craniectomy in the manner already described, making three or four openings with the burr, and uniting them with the fragment forceps, with the exception of the bridge corresponding to the cutaneous pedicle. The usual technique should be followed in fracturing the pedicle. When exposed to view, the dura mater is explored. It is then incised, and the cerebellum is explored in its turn.

Exploration of the Occipital Lobe of the Cerebrum.—Above the superior curved line the occipital bone is of considerable thickness. We make five or six orifices with the burr (manual or electrical instrumentation) at 25 or 30 millimetres from the middle line, and above the line which unites the base of the mastoid apophysis to the external occipital protuberance. The osseous shutter is mobilized in the usual way. In a case of mine, of which I had almost despaired after failing to find pus, I incised the occipital lobe deeply, and then tamponed the wound, after having penetrated the temporal lobe with a second bistoury, till its point came into contact with the first. The patient was a young girl who, before passing into the comatose state, had suffered from acute occipital pain, which was accompanied with subcutaneous oedema. Her condition was improved after the operation and she recovered after remaining in a grave condition for eight days. During the period of convalescence she presented the curious phenomenon of mirror verbiage; she inverted words and phrases, syllable by syllable beginning at the last. She is now married and mother of a family, and in enjoyment of perfect health.

Caries of the Petrous Bone.—Caries of the petrous bone, which generally arises from suppuration of the tympanum and mastoid apophysis, may extend as far as either the wall of the external auditory canal, the tympanic ring, the upper wall of the cavity, or even the mass of the petrous bone.

1. *Caries of the External Auditory Canal and Outer Wall of the Tympanic Cavity.*—Examination with the otoscope enables us to recognize the carious and denuded osseous surface. Symptoms of meningitis may appear. In one such case, of a young woman of twenty years, I discovered a sequestrum formed by the tympanic ring. This was removed with a forceps after cocaineization.

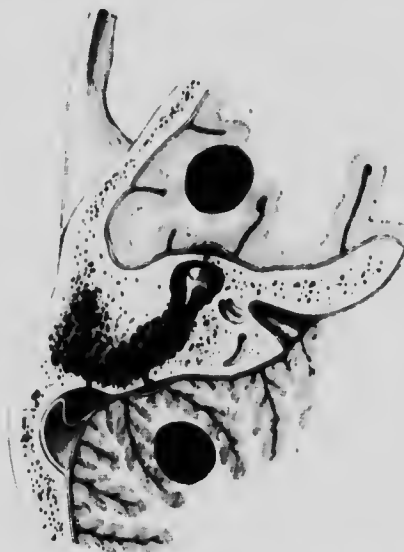

FIG. 800. —ABSCESS OF THE TEMPORAL LOBE; SUBDURAL ABSCESS WHICH HAS PUSHD BACK THE WALL OF THE LATERAL SINUS; ABSCESS OF THE TEMPORAL LOBE OF THE CEREBRUM; CEREBELLAR ABSCESS.

2. *Caries of the Superior Wall of the Tympanic Cavity.*—Small foci of caries may form in the neighbourhood of the upper wall of the tympanum, and beneath the dura mater, with dark-coloured, sanious, and extremely fetid contents; and the persistence of which is the cause of almost continuous pain with exacerbations, and may perhaps produce meningeal crises.

3. *Caries of the Petrous Pyramid.*—Lesions of the upper part of the tympanic cavity, and of the antrum, are frequently followed by caries of the petrous pyramid. The requisite operation is performed with the trepan *à cliquet* and burr of 16 or 20 millimetres. (See preceding description.) Accidents of infection are combated with mycolysine, and when the lesion is tuberculous with phymalose.



MALIGNANT TUMOURS.

Rodent Epithelioma.—This variety of tumour oftenest begins in the retro-auricular groove, and subsequently infiltrates the mastoid apophysis and the adjacent parts of the cranial wall. Those eroding neoplasms must be treated, if diagnosed in time, by curettage, combined with thermic electro-coagulation.

Sarcoma.—Sarcoma of the mastoid apophysis and petrous pyramid very rapidly produces a complete peripheral facial paralysis. Electro-coagulation should be tried if the diagnosis has been made sufficiently early.

OPERATIONS ON THE VISUAL APPARATUS.

Methods of Exploration.

Objective Examination of the Eye and its Adnexæ—1. **EXAMINATION BY DIRECT ILLUMINATION.**—The patient is seated before a window. The surgeon places himself opposite without intercepting the daylight, and proceeds at first to estimate the patient's general appearance; then the state of the adnexæ of the eye and the ocular globe itself, not forgetting the mobility of the latter. Examination of the conjunctival cul-de-sac is easy in case of the lower one, if the patient looks upwards, while the surgeon draws the lower eyelid firmly downwards with the aid of a compress. Examination of the superior cul-de-sac requires inversion of the upper eyelid, which is effected by drawing the ciliary border upwards; while, with the other hand, the tarsal cartilage is luxated with the aid of a blunt stylet. It is useful to instil previously a 1 in 20 solution of hydrochlorate of cocaine. I prefer the use of the blunt stylet for eversion of the upper eyelid, to employment of the ordinary palpebral retractor. The lid is found, after luxation of the tarsal cartilage, hanging on the free extremity of the retractor. This permits its elevation through a number of millimetres, and enables the operator to place the whole conjunctival cul-de-sac in evidence. The conjunctiva can then be examined with a lens. We can next proceed to examination of the cornea, pupil, and iris, and of the contractility of the latter.

2. **EXAMINATION BY LATERAL ILLUMINATION.**—Examination by lateral illumination can be made with ordinary daylight, by placing the patient opposite a window, and directing the rays from a lens with short focus upon the cornea and crystalline lens. It is better to make this examination in a dark chamber, and with artificial light, preferably a small electric lamp, furnished with a converging lens. Lateral illumination with electric lamp and converging lens can in like manner be employed in broad daylight, in the operating theatre, for detecting the presence of foreign bodies in the cornea or iris, iridic adhesions, and nuclei of secondary cataract.

3. **OPHTHALMOSCOPIC EXAMINATION.**—Ophthalmoscopic examination is carried out in a dark chamber. The simplest ophthalmoscope is the best.

and there is no medical practitioner who cannot educate himself in this method of exploration. The use of an atropine collyrium for dilatation of the pupil facilitates clinical examination of the fundus of the eye greatly for beginners. I refer readers to the special treatises for study of the lesions made visible by the ophthalmoscope, and for the methods of diagnosis of emmetropia, myopia, and hypermetropia with the aid of keratoseopy.

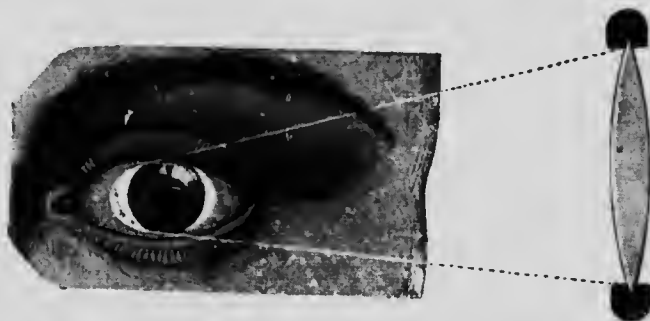


FIG. 867.—EXAMINATION OF THE EYE WITH LATERAL LIGHT.

A foreign body is seen in the upper part of the cornea.

4. EXAMINATION OF OCULAR TENSION.—The state of the ocular tension is detected by gently resting the pulp of the index and middle fingers on the globe of the eye, through the upper eyelid, and without the use of effort or muscular contraction. Any increase or diminution of intra-ocular

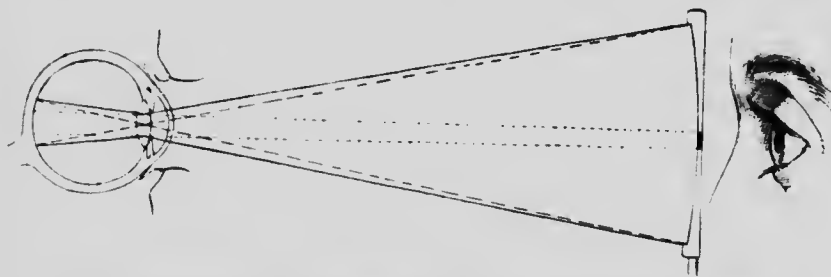


FIG. 868.—SCHEME OF OPHTHALMOSCOPIC EXAMINATION, SHOWING ZONE OF ILLUMINATION OF THE RETINA, AND THE COURSE OF THE VISUAL RAYS.

The ophthalmoscopic examination is habitually facilitated by the interposition of a convex lens, which is held by the observer in front of the cornea.

tension is in this way perceived with the utmost readiness. The examination is carried out by comparison with the eye of the opposite side if healthy, or with that of another healthy individual.

5. FUNCTIONAL EXAMINATION OF THE EYE.—The normal healthy eye should distinguish, at a distance of 33 centimetres, lines of 0.1 millimetre in thickness, which are separated by intervals of the same width. It is on

these data that all visual scales have been constructed. If a patient, placed at a distance of 5 metres from the tableau, recognizes only those letters which should be distinguished by the normal eye at 10 or at 15 metres, his visual acuteness is reduced to $10 : 5 = \frac{1}{2}$, or to $15 : 5 = \frac{1}{3}$.

Before having recourse to the operation for cataract, we should make sure that the eye which is to be operated on is able to distinguish clearly the presence of the light of the flame of a taper, in a dark room, at a distance of 5 metres. The eye which is being examined is alternately covered with the hand and exposed to the light.

I do not propose to describe here the procedure of determining the extent of the field of vision, examination for phosphenes, measurement of refraction, etc. I will note, however, apropos of operation for cataract, that the crystalline lens represents, on the average, a refractive power of 14 diopters.

General and Local Care in Operations on the Visual Apparatus.

ANÆSTHESIA.

Local Anæsthesia.—The form of anæsthesia *par excellence* for adoption in operations which do not involve the depths of the orbit, is the local variety induced by instillation of a 1 in 20 solution of cocaine hydrochlorate. This procedure is frequently the first act of the surgeon, who may then proceed to examination of the ocular globe. Stovaine is not suitable for ophthalmic surgery, owing to its irritating action.

INTERSTITIAL INJECTION OF COCAINE.—In cases in which deeper anæsthesia is requisite, as in operations for chalazion or strabismus, we administer, after securing superficial insensibility by instillation of cocaine solution of 1 in 20, or a subconjunctival interstitial injection of a 1 in 50 or 1 in 100 solution. For the operation for chalazion, complete anæsthesia of the upper lid can be obtained by beginning with instillation of cocaine solution of 1 in 20, and administering, after application of Desmarres' annular forceps, a subconjunctival and subcutaneous injection of 2 to 3 drops of the same solution. For surgery of the lachrymal passages, injection of a cocaine solution of 1 in 20 into the lachrymal puncta and sac is made with a blunt cannula, straight or bent to an angle, mounted on an ordinary syringe of 1 to 2 c.c. capacity. For incision of the lachrymal puncta, we use, after instillation and intracanalicular injection of the 1 in 20 solution, an interstitial injection of a 1 per cent. cocaine solution into the superficial lymph space; then another, more deeply, in the vicinity of the sac.

General Anæsthesia.—When the patient is pusillanimous or refractory *general anæsthesia* is necessary. This is carried out with pure ethyl chlorid (kélène), followed, or not, by administration of chloroform (strabismus, enucleation of the eyeball, operations on the orbit). We may in like manner have recourse to general anæsthesia for the operation of *sclerotomy* or *iridectomy*. When the *corneal incision must be pretty large*, as in operation for cataract, it is better to be content with local cocaine anæsthesia.

Disinfection of the Field of Operation.—For some days before the operation, the eyes are bathed several times a day with a warm 4 per cent

boric solution. When some conjunctival oozing is present, irrigations are made, with an india-rubber bag furnished with a conical mouthpiece of red india-rubber, of a tepid aqueous solution of bichloride of mercury of 1 in 10,000; or Labarraque's fluid diluted to 1 in 200. This treatment is also suitable in cases of purulent ophthalmia.*

Before surgical intervention, the eyelids are closed without use of force, and bathed with tepid water and pure soap, then with boric solution. The conjunctiva then receives a final washing with tepid boric solution. It is well, before commencing this lavage, to luxate the superior cul-de-sac completely outwards by supporting the everted eyelid on a retractor furnished with a handle.

If the lachrymal passages are inflamed, and, above all, when the patient has to undergo operation for cataract, it is necessary to treat the dacryocystitis beforehand, and extirpate the lachrymal sac if necessary. When suppuration appears to have subsided, we can make an experimental occlusive dressing for forty-eight hours, so as to be able to judge of the state of the conjunctival secretion. When this dressing is removed, a microscopic and bacteriological examination of the conjunctival fluid is made on the same day. Operation is not proceeded with till after demonstration of the absence of any risk of infection. A series of mycolysine, preventive injections of 10 c.c. each should be administered.

SPECIAL INSTRUMENTS FOR OPERATIONS ON THE EYEBALL.

Blepharostat.—There are many satisfactory forms. I prefer a hinged blepharostat, which can be effectively applied at either the internal or external canthus, and furnished with an oscillatory catch, which allows its rapid removal on the slightest indication.

Cutting and Pricking Instruments.—The most useful edged instruments are the following:

- Two Von Graefe's knives.
- One capsulotomy hook.
- Two triangular curved knives.
- One lanceolate knife.
- One falciform needle.
- Two needles with catch for dissection.
- One curette with cutting edge for chalazion.
- Two selected hooks.
- Four scissors, straight and curved.
- One de Wecker's scissors-forceps.
- One forceps for capsulotomy.
- One Weber's probe-pointed knife.
- One Stilling's knife.
- One bistoury for chalazion.
- One scarificator.

* "Traitement de la Blennorrhagie et de l'Ophthalmie Blennorrhagique" by E. Doyen (Rueff, 1895). Also notes on the "Traitement de la Blennorrhagie," by Lebeault.

Blunt Instruments.—A certain number of blunt instruments must also be added:

- One iridectomy forceps.
- Two fixation forceps, with and without catch.
- One curette for anterior chamber.
- Two annular curettes for luxation of the crystalline lens.
- One curette for extraction of the crystalline lens.
- One spatula with catch for the cortical layers.
- One blunt hook for iridic adhesions.
- Two strabotomy hooks.
- One conical stylet for the puncta lachrymalia.
- Three Bowman's dilating sounds.
- One Weber's biconical dilating sound.
- One epilation forceps.
- One Desmarres's spatula-forceps.

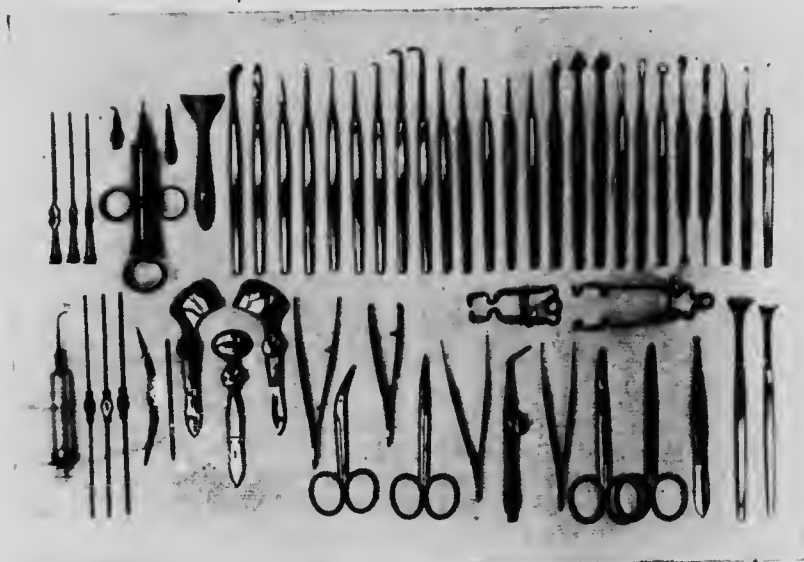


FIG. 869.—INSTRUMENTS NECESSARY FOR OPERATIONS ON THE EYE.

From right to left, and from below upwards: Two retractors of the eyelids; one fixation forceps; two blepharostats; two scissors, straight and curved; one iridectomy forceps; one de Wecker's forceps-scissors; one capsulotomy forceps; one forceps for ciliary epilation; one small dissecting forceps; two pointed scissors, straight and bent; one oval Desmarres's forceps; two chalazion forceps, right and left; one dilator of the puncta lachrymalia; one Bowman's double conical sound; three Weber's double stylets; one glass syringe and one metallic syringe, with cannule for the lachrymal passages.

Two Graefe's knives; one crotchet for capsulotomy; one curette; one spatula for cortical debris; two fenestrated curettes, round and oval; one straight spatula for the iris; two bent triangular knives; one lanceolate knife; one falciform needle; two needles for discission; two chalazion curettes, solid and fenestrated; two blunt hooks for strabotomy; one blunt hook for iridic adhesions; two hooks; one Weber's probe-pointed knife; one Stilling's knife; one straight bistoury; one scarificator; one strabometer. (Scale reduced to one fourth.)

Superciliary Region.

TRAUMATIC LESIONS.

Wounds.—Wounds of this region, whether complicated or not with fracture or depression, are treated either by suturing, with or without drainage : or, when the lesion is deep and danger of infection probable, by antiseptic tamponing. In the latter case antiseptic reparation will be carried out subsequently.



FIG. 870.—WOUND OF SUPERCILIARY REGION.
Interrupted suture used.

It is useless to shave the eyebrow, as it will be sufficiently disinfected by a series of lavages with soap and warm water, ether, and finally with boric solution, or even sublimate.

INFLAMMATORY LESIONS.

Furuncle.—Furuncle is not very rare. Phlebitis of the cavernous sinus is seen as a fairly frequent complication. This affection rapidly yields to mycolysine, given both by the mouth and hypodermically. If the core has



FIG. 871.—ASYMMETRY OF THE EYEBROW: S-SHAPED INCISION, FOR ELEVATION OF THE EXTREMITY OF THE EYEBROW.




FIG. 872.—SAME OPERATION.

The extremity of the eyebrow is inserted in the upper branch of the incision, which is then united in Z form.

formed, we extirpate it with the curette, and cauterize the cavity with tincture of iodine; or we may tampon it with gauze soaked in Labarraque's liquid, diluted to 20 per cent. The use of the thermo-cautery is but very rarely indicated, even in diabetic cases.

the fixation
trideotomy
the forceps
s, straight
s, and left;
and; three
h cannula

or cortical
or the fist;
two needles
unt hooks
e Webber's
carriest or;

DEFORMITIES: CONGENITAL AND ACQUIRED.

Asymmetry of the eyelids and vicious cicatrices of the superciliary region can be readily repaired by autoplasty, of which the tracery must vary with each individual case.

Let us suppose that the extremity of the left eyebrow is placed 7 millimetres too low down. We circumscribe it with a double >-shaped incision (Fig. 871), which is prolonged upwards and outwards, in the form of a reversed Z. The small upper flap is then mobilized and inserted in the upper branch of the incision (Fig. 872). Interrupted or intradermic suture is then applied.

TUMEURS.

Benign Tumours.

Sebaceous Cysts.—Sebaceous cysts are removed by simple incision, or, when the skin has thinned at the summit of the swelling, by a double curvilinear incision. We should pass below the level of the cyst at one of the extremities of our incision, so as to be able to raise it through the wound for detachment of the skin from behind forward.

Dermoid Cysts.—Those cysts, which have their seat of election at the outer extremity of the eyebrow, are often very strongly adherent on their deep aspect. They are removed through an incision parallel to the eyebrow. We need not dread denuding the frontal bone, and the diverticulum, which is sometimes found embedded in an anfractuosity of the surface of the bone, should be carefully extirpated. Shaving the eyebrow is useless. It is disinfected in the way above described. Local cocaine anæsthesia suffices in case of an adult patient. In that of a child it is better to procure general anæsthesia with ethyl chloride.

Angiomata—Lipomata—Fibromata.—The other subcutaneous tumours—*angioma, lipoma, fibroma*—are less frequent. *Small angiomata* are extirpated with the bistoury; also electrolysis may be practised. *Lipomata* and *fibromata* are, as in case of cystic tumours, extirpated through a horizontal incision.

MALIGNANT TUMOURS.

Epithelioma.—In its early stage, epithelioma can be extirpated, as in case of a simple papilloma, between two curvilinear incisions; electro-coagulation is preferable. When the frontal bone has been invaded by the growth, we must practise electro-coagulation.

The Eyelids.

TRAUMATIC LESIONS.

Contusions—Extravasations of Blood.—Those extravasations become rapidly diffused and reabsorbed, and demand no surgical intervention.

Wounds: 1. BY PRICKING INSTRUMENTS.—A very small wound of the eyelid may be perforating, and may have been produced by the penetration of a pricking instrument to a certain depth. We must take care to examine the conjunctival cul-de-sac, especially the superior, when dealing with a wound of the corresponding eyelid; then the eyeball, and the cavity of the orbit (subconjunctival oedymosis). In most cases the cutaneous opening mites spontaneously.

2. BY CUTTING INSTRUMENTS.—We must separate the lips of the wound, and make sure whether it involves the skin only, or the orbicularis muscle as well; or, in case of the upper eyelid, the aponeurosis of insertion of the



FIG. 873. OBLIQUE WOUND OF UPPER EYELID, INVOLVING THE APONEUROSIS OF INSERTION OF THE LEVATOR PALPEBRÆ SUPERIORIS MUSCLE.

Suture of the tendinous insertion of the same with interrupted points. The skin is then united.

levator palpebræ superioris. Suture of this aponeurosis should be made with No. 1 silk, and an intestinal suture needle. Suture of the skin must also be carried out with the same thread and same needle, and should, whenever possible, be intradermic, so as to avoid all cicatrices produced by the passage of the needle. In case of very small wounds, we may content ourselves with application of adhesive oxide of zinc plaster, or a strip of adhesive taffetas.

3. CONTUSED WOUNDS.—Contused wounds of the eyelid may complicate contused wounds of the eyebrow, or of the malar eminence. In those cases immediate reunion can often be secured by resecting the lacerated edges with scissors after local disinfection.

Wounds of the Puncta Lachrymalia.—We can establish coaptation of the divided ends before suturing, by the introduction of a fine extremity of a Florentine hair, which can then be fixed in position with a fine No. 1 silk ligature.

Emphysema of the Eyelids.—Traumatic emphysema of the eyelids is usually a complication of fracture of the wall of either the frontal or maxillary sinus, with laceration of the mucous membrane. Local compression is applied. The patient should for some days avoid any effort in blowing the nose.

INFLAMMATORY LESIONS.

Sty and Furuncle.—A sty is a small staphylococcal abscess which may present a core. The general treatment should consist of internal and hypodermic administration of mycolysine, and local application of boric emollients.

Abscess and inflammatory swelling in the eyelids should be readily recognized, and demand early incision. A bacteriological diagnosis should be made. We must take care to avoid confounding these phlegmonous swellings with the œdema which is found in erysipelas, in purulent ophthalmia, in deep-seated phlegmon of the orbit, and in phlegmonous dacryocystitis.

Cold Abscess.—Tuberculous cold abscesses are not rare, and require extirpation of the sac, followed by suture of the skin. In certain cases it is better to have recourse to curettage and tamponing. An autoplasmic operation can be carried out afterwards if an ugly cicatrix is left. Phymalose should be administered as a mode of general treatment.

Malignant Pustule.—The eyelid is one of the seats of election for malignant pustule and the œdema of charbon. Bacteriological examination should be made whenever there is the slightest suspicion. The best means of eradicating the evil are, when the lesion is definitely localized, the red-hot iron and interstitial injections of either Labarraque's fluid in 50 per cent. dilution, or a 5 per cent. iodo-iodized solution.

Anti-charbon serotherapy is still in an experimental stage. It would be desirable to have a certain quantity of very active animal anti-bacterial serum in readiness in each of the populous centres, prepared and reserved for the treatment of bacterial charbon in man.

CONGENITAL DEFORMITIES.

Palpebral Coloboma.—The palpebral fissure should be closed by excision of its margins and application of a V-suture. If there be a prolongation adherent to the cornea, it should be excised and the conjunctiva sutured.

Epicanthus.—Epicanthus consists of a semilunar cutaneous fold, normal in the Mongolian race, which is found almost exclusively in front of the internal palpebral commissure.

Rhinorrhaphy has been proposed as a procedure suitable to remove that malformation. This consists of a stretching of the exuberant segments of skin of each side by resection of a vertical oval flap, with its axis in the middle line. I prefer the simple excision of the exuberant semilunar fold.

This curved excision, which can be carried out very neatly with a sharp gouge-forceps, should suffice to permit a favourable reunion without creasing of the neighbouring skin.

Ankyloblepharon.—Occlusion of the lids is most frequently a persistence of the normal adhesion of the margins of the lids which exists during intra-uterine life. Total ankyloblepharon may be noticed at birth. Freeing



FIG. 874.—EPICANTHUS.

The internal dotted curved line represents the limit of the resection on the side of the nose, the external one that on the side of the commissure.



FIG. 875.—EPICANTHUS.

Resection of the semilunar fold has been carried out. Interrupted suture has been adopted. This should produce no dragging of the eyelids.

of the lids is easy. Some fine sutures should be applied between the conjunctiva and skin, especially at the external commissure. When this procedure is limited to the external commissure, the operation is given the name of *external canthoplasty*, or extension of the palpebral fissure.



FIG. 876.—EXTERNAL CANTHOPLASTY: HORIZONTAL INCISION ENGAGING BOTH SKIN AND CONJUNCTIVA.



FIG. 877.—EXTERNAL CANTHOPLASTY: PLACING OF THE FIRST THREE STITCHES FOR REUNION OF THE NEW PALPEBRO-CUTANEOUS COMMISSURE.

Blepharophthalmosis.—Congenital narrowing of the palpebral fissure is likewise treated by external canthoplasty, which consists of a horizontal incision of the external commissure, followed by suture of conjunctiva, and skin. This suture should be carefully applied in the plane of the new commissure, so as to assure good reunion.

EXTERNAL CANTHOPLASTY.—The external commissure is incised horizontally from within outwards, for a distance of 10 to 15 millimetres, engaging

successively skin, orbicular muscle, and all the various soft parts down to the bone. The skin is sutured with fine silk. The commissure of the conjunctiva is thus carried some millimetres outwards. The operation may be divided into three stages:

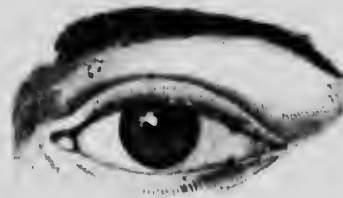

FIG. 878. EXTERNAL CANTHOPLASTY: APPEARANCE PRESENTED BY THE DOWNEDD SCISSURE.

First Stage.—Horizontal external incision of 6 to 8 millimetres, parting from the palpebral commissure and involving the conjunctiva.

Second Stage.—Removal of the conjunctiva at the external angle of the incision.

Third Stage.—Suture of the conjunctiva to the upper and lower lip, respectively, of the cutaneous wound.

FUNCTIONAL TROUBLES AND ACQUIRED DEFORMITIES.

Blepharospasm.—Contraction of the orbicularis muscle may be a reflex phenomenon, produced by inflammation of the conjunctiva, with or without the presence of a foreign body. In the latter case, the body must be sought out and extracted. In case of obstinate subacute conjunctivitis, the inflammation may be kept up by the blepharospasm.

Partial resection of the orbicularis muscle is practised. External canthoplasty is indicated when prolonged duration of the blepharospasm has caused a notable narrowing of the palpebral fissure.

Essential Blepharospasm.—Painful tonic or clonic contraction of the orbicularis muscle is a phenomenon analogous to the tic douloureux of the face. The original cause of this contraction is usually located somewhere in the area of distribution of the trigeminal nerve.

Resection of the *infra-orbital nerve* is carried out. If this operation does not suffice for the cure, intracranial resection of the ophthalmic branch is effected at its origin. This operation will be described in connection with that of resection of the other branches of the trigeminal nerve.

Paralysis of the Orbicularis Muscle.—When the constantly open eye is threatened with grave inflammatory lesions, we have recourse to the operation of *cantorrhaphy*, external or total.

EXTERNAL CANTORRHAPHY—First Stage.—We vivify, by inlining, the external commissure and adjacent margins of the eyelids for a distance of 6 to 10 millimetres, taking care to resect the eyelashes and their follicles.

Second Stage.—Reunion of the conjunctiva with two or three sutures of very fine catgut, which is eliminated spontaneously.

Third Stage.—Interrupted suture of the skin with fine silk, taking care to reconstruct the palpebral commissure.



FIG. 879.—EXTERNAL CANTHORRHAPHY: VIVIFICATION OF THE EXTERNAL PALPEBRAL COMMISSURE. Position of the first catgut suture.



FIG. 880.—EXTERNAL CANTHORRHAPHY. The deep sutures are completed. We proceed to reunion of the lips of the cutaneous incision.

TOTAL CANTHORRHAPHY.—When the vitality of the cornea has been gravely compromised, it is necessary to suture four-fifths of the extent of the fissure between the eyelids, leaving but an opening of 5 to 8 millimetres on the inner side, to permit the flow of tears, and preserve the integrity of the lachrymal puncta.



FIG. 881.—SUBTOTAL CANTHORRHAPHY. Vivification of both eyelid margins by folding back of the lining; bedded suture of conjunctiva with fine catgut.



FIG. 882.—ANTERO-POSTERIOR SECTION. Diagram showing the dihedral angle of the groove of vivification and the position of the deep catgut suture.

First Stage.—Vivification of the two eyelid margins by folding back the lining of the ciliary margin, taking care to respect the cilia (Fig. 881).

Second Stage.—Suture of conjunctiva with separate points, made with very fine catgut (Fig. 882).

Third Stage.—Suture of skin with separate points, preserving the line of implantation of the bulbs of the eyelashes (Figs. 883 and 884).

It is well to resect the ciliary bulbs only to a distance of 2 or 3 milli-

metics from the fold of the palpebral lining. We thus obtain a better plastic result, for the persistence of the ciliae at the outer part leaves the narrowed palpebral window with its aspect almost normal.



FIG. 883.—SUBTOTAL CANTHORRHAPHY. The suturing of the conjunctiva is finished; interrupted suture of the skin with fine silk.



FIG. 884.—SUBTOTAL CANTHORRHAPHY: ANTERO-POSTERIOR SECTION. Passage of the silk suture for reunion of the cutaneous wound.

Ptosis or Blepharoptosis—1. *Blepharoptosis from Section of the Levator Palpebrae Superioris*.—Section of the aponeurosis of insertion of the levator palpebrae muscle may be repaired by suture even after the lapse of a very long interval. The muscle should be sought for at the superior wall of the orbit, where it is found in relation with the external frontal nerve. We dissect off, if it has become retracted, the aponeurosis of insertion, which is then fixed to the tarsal cartilage with a fine continuous silk suture.




FIG. 885.—PARALYTIC PTOSIS: THIRD STAGE OF THE OPERATION. The cutaneous flap, divested of its epidermis, has just received the three loops of thread which were passed beneath the musculo-cutaneous bridge.

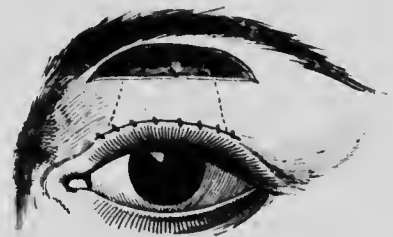


FIG. 886.—PARALYTIC PTOSIS: FOURTH STAGE OF THE OPERATION. The palpebral cutaneous flap, drawn under the musculo-cutaneous bridge, is now united to the occipito-frontalis muscle; suture of the wound in the upper eyelid.

2. *Paralytic or Congenital Blepharoptosis*.—The best surgical treatment of paralytic or congenital blepharoptosis is by suture of a cutaneous flap from the upper eyelid to the occipito-frontalis muscle.

OPERATION—*First Stage*.—We dissect up from the surface of the upper eyelid, which is kept stretched on a spatula, a small quadrangular flap with

its base below. The epidermic layer of this flap is extirpated, and we then detach it from the deep tissues down to the tarsal cartilage (Fig. 885).

Second Stage.—Horizontal incision along the whole length of the superior border of the eyelid, involving only the skin and the thick subjacent muscular stratum which is formed by the fibres of the occipito-frontalis and corrugator supercilii muscles.

Third Stage.—We now mobilize, by transfixion with the bistoury, the intermediate musculo-cutaneous bridge, and then draw under this latter.



FIG. 887.—TRICHIASIS OF THE UPPER EYELID: THIRD AND FOURTH STAGES OF THE OPERATION.

Passage of stitches and suture.

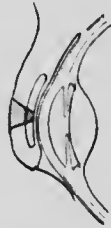

FIG. 888.—TRICHIASIS OF THE UPPER EYELID: ANTERO-POSTERIOR SECTION, SHOWING THE RESECTION OF THE SKIN AND THAT OF THE TARSALE CARTILAGE.

with the aid of a forceps introduced through the superior wound, the palpebral flap divested of its epidermis, in order to fix it to the occipito-frontalis muscle with a fine continued silk suture.

Fourth Stage.—Suture of the skin at the seat of the inferior palpebral incision; then, reunion of the upper wound.



FIG. 889.—TRICHIASIS OF THE UPPER EYELID: ANTERO-POSTERIOR SECTION, SHOWING THE SUTURE OF THE TARSALE CARTILAGE AND THAT OF THE SKIN.



FIG. 890.—OPERATION FOR TRICHIASIS OF THE LOWER LID: THIRD AND FOURTH STAGES.

Passage of the sutures.

Trichiasis.—Deviation of the ciliae backwards, towards the eyeball, can be corrected by transplantation of the ciliary area combined with tarsotomy. The condition is limited almost exclusively to the upper eyelid.

OPERATION.—General anæsthesia.

First Stage.—The eyelid is sustained vertically on a spatula, with two clawed forceps. A cutaneous incision is made, at a distance of 3 millimetres from the free margin; extending from the external commissure to the punctum lachrymale, and laying bare the tarsal cartilage. Resection of a small transverse cutaneous flap may be indicated (Fig. 888).

Second Stage.—Dissection of the ciliary border till the ciliary bulbs have been exposed, and dissection of the upper lip of the incision beyond the superior margin of the tarsal cartilage; which is then incised horizontally along its median plane, throughout its whole thickness (Figs. 887 and 888), so as to permit bending at the moment of suturing.

Third Stage: Suture of the Tarsal Cartilage.—The opening made by the loss of substance of the tarsal cartilage is closed with three or four separate points of suture of No. 1 silk.

Fourth Stage: Suture of the Skin.—Finally, reunion of the cutaneous wound is effected with points of interrupted suture; taking care to pass the needle between the ciliary border and the margin of the incision.

The same operation may be indicated for overcoming the condition of trichiasis in the lower eyelid; it is carried out with a corresponding technique (Fig. 890).

Entropion.—The curvature of the eyelid inwards, which brings its cutaneous margin in contact with the surface of the eyeball, is more frequently met with in the upper lid. Spasmodic or temporary entropion is treated by applications of flexible collodion to the eyelid, after removal of fatty matter with ether. Chronic entropion demands surgical intervention.

OPERATION.—*First Stage.*—Resection of a horizontal cutaneous flap of sufficient extent, semilunar in outline, and with its concavity directed towards the eyeball.

Second Stage.—Resection of a cuneiform strip of the tarsal cartilage.

Third Stage.—Suture, deep and cutaneous, with fine silk.

This operation is analogous to that for trichiasis, and we may refer for illustration to the preceding figures (Figs. 887 to 890).

Ectropion.—Eversion of the eyelid, exposing the inflamed conjunctiva, may be either complete or partial, and it affects the lower lid in the majority of cases.

ECTROPION OF THE LOWER EYELID: 1. MUCOUS OR INFLAMMATORY ECTROPION.—Chronic swelling of the inflamed conjunctiva, which is sometimes complicated with an outward curvature of the tarsal cartilage, constitutes this first degree.

Operation.—Transverse excision of the hypertrophied mucous membrane, and continued suture with fine silk.

2. MUSCULAR ECTROPION.—Relaxation of the orbicularis palpebrarum is of frequent occurrence in the aged. It may be complicated with spasm of the orbital fasciculi of the muscle, which accentuates the eversion of the tarsal cartilage.



FIGS. 891 AND 892.—ATONIC ECTROPION.
Operation by the procedure of Dieffenbach.

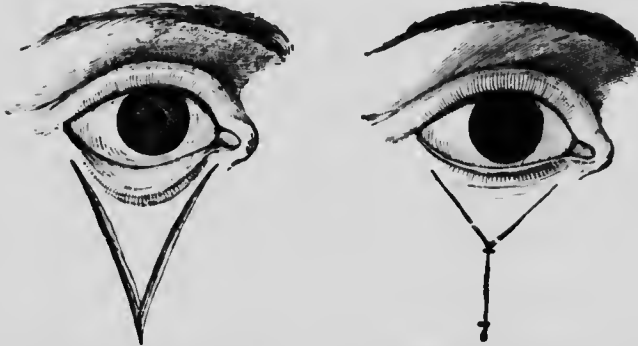

FIG. 893.—ECTROPION OF THE LOWER EYELID.

FIG. 894.—ECTROPION OF THE LOWER EYELID.

Operation by the method of Wharton Jones (V-shaped incision).

Suture of the wound in form of Y, after mobilization of the flap.

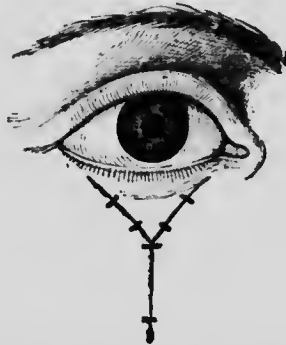

FIG. 895.—ECTROPION OF THE LOWER EYELID.
Appearance of the half-finished suture.

Operation: 1. Dieffenbach's Procedure—First Stage.—Tracing and excision of a small cutaneous isosceles triangle, of which the base is horizontal and looks upwards ($A^1 B^1$); forming an outward prolongation of the external commissure.

Second Stage.—Resection (shown at *AB*) of the exuberant portion of the free margin of the lower eyelid.

Third Stage.—Remion at the points *A* and *A'*, *B* and *B'*.

Fourth Stage.—Suture of the conjunctiva, and of the skin.

II. Wharton Jones's Procedure—First Stage.—A **V**-shaped incision is made on the lower lid, and the cutaneous flap thus marked out is mobilized so as to reduce the ectropion.



FIG. 896.—SYMBLEPHARON.
Division of the bulbar adhesion.

Second Stage.—The **V**-incision is sutured in **Y** form (Figs. 894 and 895), so as to produce a permanent vertical elongation of the integument of the lower lid.

3. **CICATRICIAL ECTROPION.**—The best procedure consists of an exact resection of the retracting and non-utilizable cicatrix, followed by sliding displacement of a cutaneous flap with a broad base, which has been raised from the surface of the temporal or malar region, between two curvilinear incisions.



FIG. 897.—SYMBLEPHARON.
Liberation of two lateral mucous flaps;
position of the sutures.



FIG. 898.—SYMBLEPHARON.
Closure of the wound, effected by sliding
displacement of the lateral mucous flaps.

Operation—First Stage.—Ablation of the cicatrix with the subjacent cicatricial tissues, and liberation of the eyelid.

Second Stage.—Section of autoplasmic flap after verification of the laxity and displacability of the tissues, which vary with the individual.

Third Stage.—Commencement of the suturing, and verification of the proper adaptation of the autoplasmic flap.

Fourth Stage.—Definitive suture (see Blepharoplasty).

ECTROPION OF THE UPPER EYELID.—Cicatricial ectropion is a grave deformity of the upper eyelid, on account of the form and structure of the membrane, which, in those cases, is more or less completely destroyed. The condition may be complicated with destruction of the aponeurosis of insertion of the levator palpebræ muscle. In that case the tendon of the muscle should be sought out and folded back, if possible, to its normal position, so as to enable it to give the requisite mobility to the repaired eyelid.

Operation.—The autoplasty is carried out by a procedure analogous to that which has been already described for cicatricial ectropion of the lower lid. The extent and outline of the autoplasmic flap must vary according to the extent of the wound which results from extirpation of the cicatrix (see Blepharoplasty).

Symbblepharon.—Symbblepharon is in most cases acquired and cicatricial.

The cicatrix is extirpated with care, including the deep-seated portions of contracted tissues, and the wound made in this way is closed with fine suture. It may be necessary to intercalate a small conjunctival flap.

OPERATION—First Stage.—Section of the conjunctival adhesion with Graefe's knife.

Second Stage.—Liberation of two small lateral mucous flaps, which will fill on displacement the loss of substance thus produced.

Third Stage.—Vertical interrupted suture, with fine silk; care having been taken to re-establish the inferior conjunctival cul-de-sac.



FIG. 899.—REMOVAL BY V-SHAPED INCISION OF A PAPILOMA OF THE FREE MARGIN OF THE EYELID.



FIG. 900.—THE SAME.

Antero-posterior section, showing the arrangement of the mucous and cutaneous sutures.

TUMOURS.

Benign Tumours.

Papillomata—Warts—Horns.—In case of small warts excision without suture is sufficient. If the tumour presents dimensions of more than 4 or 5 millimetres, we have recourse to extirpation with the bistoury and immediate resection.

Angiomata. The very small angiomata are extirpated with the bistoury.

The progressive and invading angiomata can hardly be attacked in any other way than by electrolysis. If electrolysis is not successful, we have recourse to incision of the angioma beyond the branches of the facial artery, and separation with the finger and blunt scissors, followed by tamponing with sterilized gauze. This method has given me excellent results in grave cases, without involving any very apparent cicatricial deformity, or trace of facial paralysis.

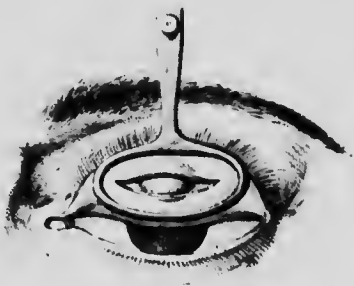


FIG. 901.—EXTIRPATION OF A CHALAZION BY THE CONJUNCTIVAL ROUTE.

The eyelid has been luxated with the aid of Desmarres's forceps, the spatula of which supports the cutaneous surface.

Cysts.—Small transparent cysts are often met with, which are easy to incise and to remove. Parasitic cysts, each containing a single scolex, have been observed in the eyelid.

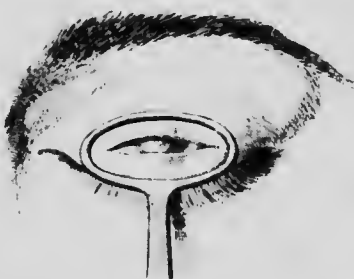


FIG. 902.—EXTIRPATION OF A CHALAZION WHICH PROJECTS UNDER THE SKIN.

The spatula of the Desmarres's forceps has been introduced into the superior conjunctival cul-de-sac.

Chalazion.—Chalazion presents intimate relations with the tarsal cartilages, and appears to develop at the expense of the Meibomian glands. The chalazion may be reabsorbed (after many inflammatory attacks).

OPERATION.—Local anesthesia with a 5 per cent. solution of cocaine. Desmarres's spatula forceps is applied in such a way that we can operate from the side on which the little tumour is most prominent—preferably from



FIG. 903. EXTERMINATION OF A CHALAZION BY THE CUTANEOUS ROUTE.

the side towards the conjunctiva. The chalazion is exposed by a small incision, then seized with a slender clawed forceps, and detached from the tarsal cartilage. We insure the emuculation of its last vestiges from the

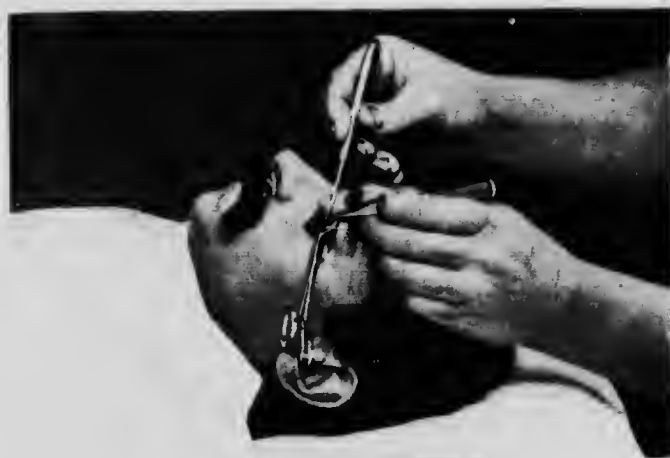

FIG. 904.—EXTERMINATION OF A CHALAZION BY THE CONJUNCTIVAL ROUTE.

substance of the tarsal cartilage by the use of a small curette. It is unnecessary to unite the conjunctival edges. If the operation is carried out through a cutaneous incision, it will be sufficient to insert a single point of suture, with No. 1 silk thread.

Lipomata.—Lipoma of the eyelid is rare; the tumour would be easy to enucleate.

Plexiform Neuromata.—These tumours are of congenital origin, and are formed of clusters of large white nerve filaments, swollen and varicose, twisted and tortuous, which appear to be derived from a common trunk, and are invested by a capsule of dense fibrous tissue. They should be extirpated at an early date, while preserving the twigs of the facial nerve and taking care not to compromise the autoplasmic procedure of reparation, which must be deferred to a later period.

Lymphangeloma and Elephantiasis.—Simple lymphangioma and elephantiasis form projecting tumours, which are removed with the bistoury between two curvilinear incisions made in a horizontal plane.

Malignant Tumours.

Epitheliomata.—Epithelioma of the eyelid is either exuberant or ulcerous. The growth should be destroyed at the earliest possible date by thermic electro-coagulation, which is carried out with a current of feeble intensity. Reparation of the loss of substance is ultimately effected. The same treatment is adopted in the case of sarcoma.

BLEPHAROPLASTY.

Blepharoplasty is either partial or total.

We have already studied partial reparation of the eyelids in dealing with the subject of ectropion. We now proceed to study total reparation of the eyelids under the name of "blepharoplasty."

Total blepharoplasty demands at least the integrity of the conjunctiva and of the fibro-cartilaginous skeleton of the eyelids. It is rare to have the ciliary border completely destroyed, for the eye closes instinctively at the moment of the traumatism. In a case in which the traumatism surprises the eye when completely open, the lesion nearly always destroys the conjunctiva and the organ itself, so that an attempt at autoplasmic reparation would either be useless, or necessarily remain defective.

The various procedures adopted are derived from four distinct methods:

1. That of sliding displacement of flaps (the French method).
2. That of transplantation by torsion, or by rotation of the pedicle (Indian method).
3. That of transplantation of a pedunculated flap taken from a distance, on either the same or another subject (Italian method).
4. That of applying cutaneous graft.

Blepharoplasty of the Upper Eyelid.—The operation comprises the following stages:

First Stage.—Extirpation of the cicatrix, inclusive of the subjacent cicatricial tissue; and freeing of the eyelid.

Second Stage.—Section and mobilization of the autoplasmic flap.

Third Stage.—Commencement of suture, and verification of precise adaptation of the autoplasmic flap.

Fourth Stage.—Definitive suture.

If the extent of the cicatrix is such as to prevent the formation of a flap of healthy skin, as in the case of an extensive burn, we endeavour to transplant a cutaneous flap raised from the skin of the abdomen, near the fold of

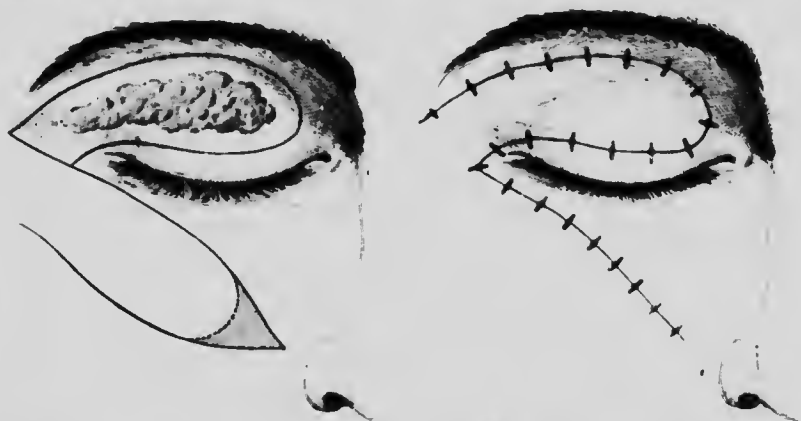

FIG. 905.—EXTIRPATION OF A CICATRIX OF THE UPPER EYELID.

FIG. 906.—EXTIRPATION OF A CICATRIX OF THE UPPER EYELID.

The suturing is completed.

the groin; or attach one taken from the skin of the arm, held in position till adhesion has taken place. In a case of ectropion produced by the cicatrix of a burn, I obtained an excellent result from transplantation of a cutaneous flap raised in the vicinity of the fold of the groin; and of dimensions twice as long and twice as wide as the area of loss of substance.

Blepharoplasty of the Lower Eyelid.—*Total reparation* of the lower eyelid can be effected readily enough when the neighbouring skin is intact and mobile.

PARTIAL BLEPHAROPLASTY.—The wound made by ablation of a canceroid growth of the inner third of the lower eyelid is readily repaired by the displacement of a suitable flap.

Operation—First Stage.—Extirpation of the tumour, and tracing of a \combox -shaped external flap (Fig. 903).

Second Stage.—Mobilization and suturing of the cutaneous flap, which is elongated sufficiently to enable it to close up the area of loss of substance (Figs. 908 and 909).

662 SURGICAL THERAPEUTICS AND OPERATIVE TECHNIQUE

COMPLETE BLEPHAROPLASTY.—When the loss of substance has been more considerable, it will be necessary to raise a flap from below, from the adjacent surface of the cheek (Fig. 914), and to displace it by slight rotation of its pedicle, as represented in Fig. 915. The outline of the autoplasmic flap varies with the individual case.

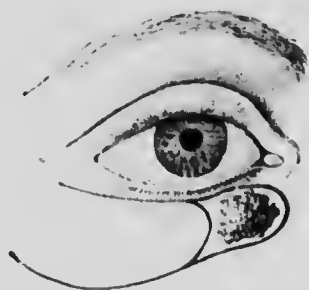

FIG. 907.—EXTIRPATION OF A SMALL CANCROID OF THE LOWER EYELID. Autoplasty by sliding displacement.



FIG. 908.—EXTIRPATION OF A SMALL CANCROID OF THE LOWER EYELID. Appearance of the finished suture.

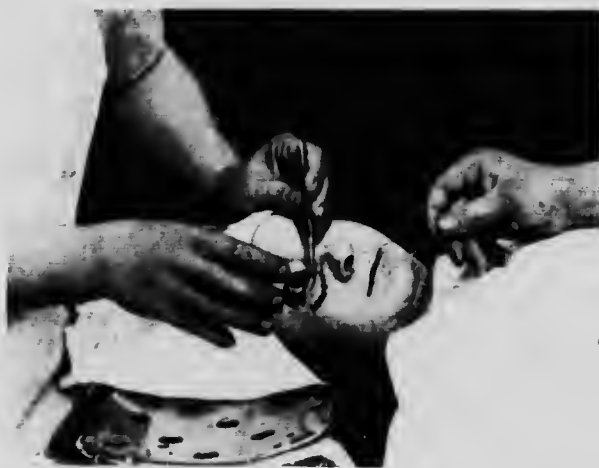

FIG. 909.—PARTIAL REPAIRATION OF THE LOWER EYELID BY SLIDING DISPLACEMENT OF A HORIZONTAL CUTANEOUS FLAP.

The flaps represented in Figs. 907, 911, and 914 can be raised anywhere in the neighbourhood of the loss of substance, provided that the skin is intact, or nearly so. That should be selected which is most easily adjusted, and will suffer no dragging.

Reparation of the Commissures.—The cutaneous flap is mobilized at the root, or on the side, of the nose, when we are dealing with the internal angle of the palpebral fissure: in the neighbourhood of the



FIG. 910. EXTIRPATION OF A VERY EXTENSIVE CANCROID OF THE LOWER EYELID.

Outline of the autoplasmic flap.




FIG. 911. EXTIRPATION OF A VERY EXTENSIVE CANCROID OF THE LOWER EYELID.

Aspect of the line of reunion after insertion of the first points of suture.

external orbital apophysis, when the external angle is concerned. The free extremity of the flap is to be incised, in the direction of its long axis, for a sufficient distance so that it can be united, \angle outline to the skin and conjunctiva. A corresponding result is obtained by resecting a small lozenge at the extremity of the autoplasmic flap (Fig. 916).



FIG. 912. EXTIRPATION OF A CANCROID OF THE INTERNAL COMMISSURE.

Outline of the autoplasmic flap.



FIG. 913. EXTIRPATION OF A CANCROID OF THE INTERNAL COMMISSURE.

Adjustment of the flap: aspect of line of reunion.

Blepharoplasty by the Italian Method.—When the destruction of the eyelid has been complete, and the burn has also involved the greater part of the skin of the cheek, it is impossible to realize autoplasmic repair by sliding displacement. We must then have recourse to the Italian method. In the

664 SURGICAL THERAPEUTICS AND OPERATIVE TECHNIQUE

case represented in the figure below, we see that the skin has been extensively destroyed, from the free margin of the lower eyelid to the left labial commissure, and from the left nostril to the carotid region. In those cases the cicatricial and retractile pathological tissue should be extirpated throughout its whole thickness.



FIG. 914. DESTRUCTION OF THE LOWER EYELID AND SKIN OF CHEEK BY A BURN.
Considerable inferior ectropion.

OPERATION. The operation consists of two successive interventions.

FIRST INTERVENTION—*First Stage.*—Freeing the internal conjunctivo-palpebral border.

Second Stage. Suture of brachial cutaneous flap, with broad pedicle, to the conjunctivo-palpebral margin.

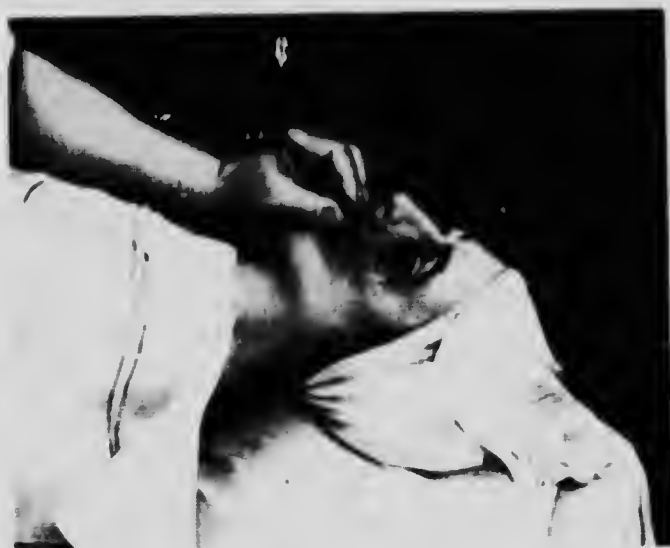

FIG. 915. —THE SAME.

First incision, first stage of operation: Freeing the inferior conjunctivo-palpebral margin.

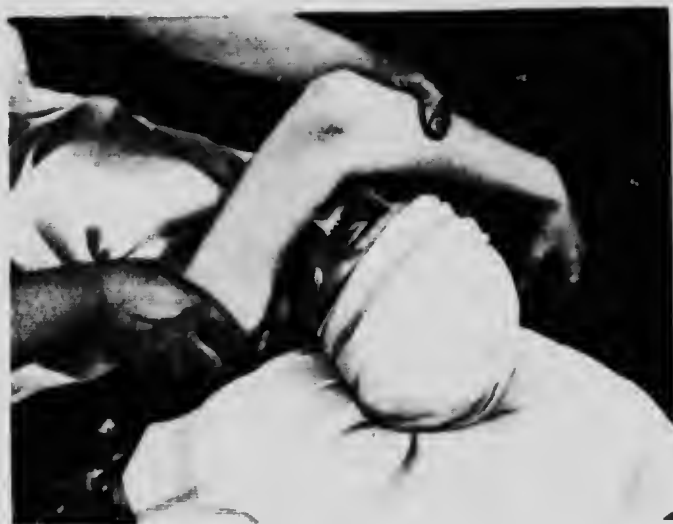

FIG. 916. —THE SAME.

Second stage: Suture of the brachial cutaneous flap to the margin of the conjunctiva.

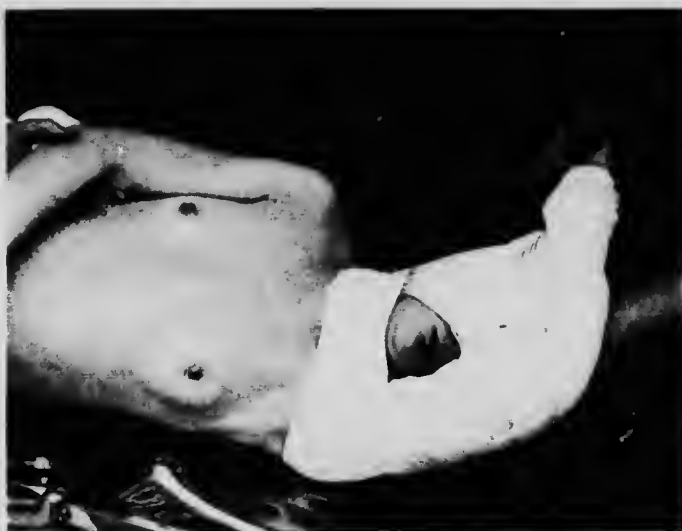

FIG. 917.— THE SAME.

Fixation of arm and head with plaster bandage, after completion of operation.

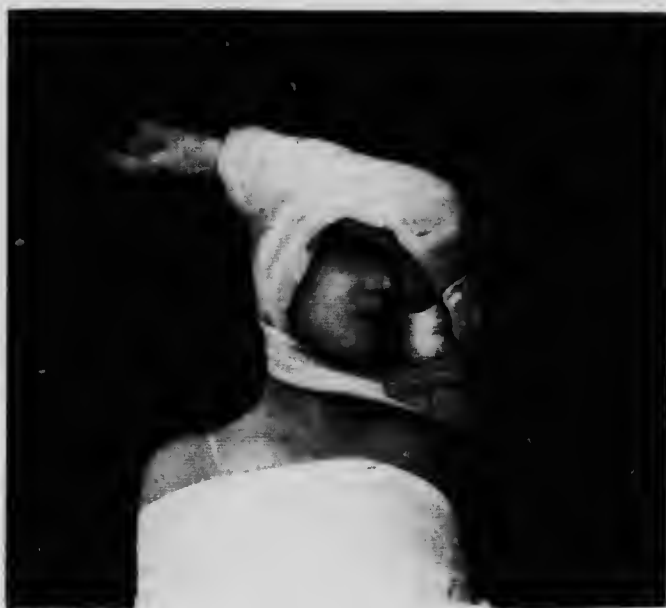

FIG. 918.— THE SAME.

Position of arm and head, maintained in their relative position by the plaster bandage

Third Stage.—Application of plaster bandage destined to maintain the left arm in contact with the head. This apparatus should remain in position for ten days.

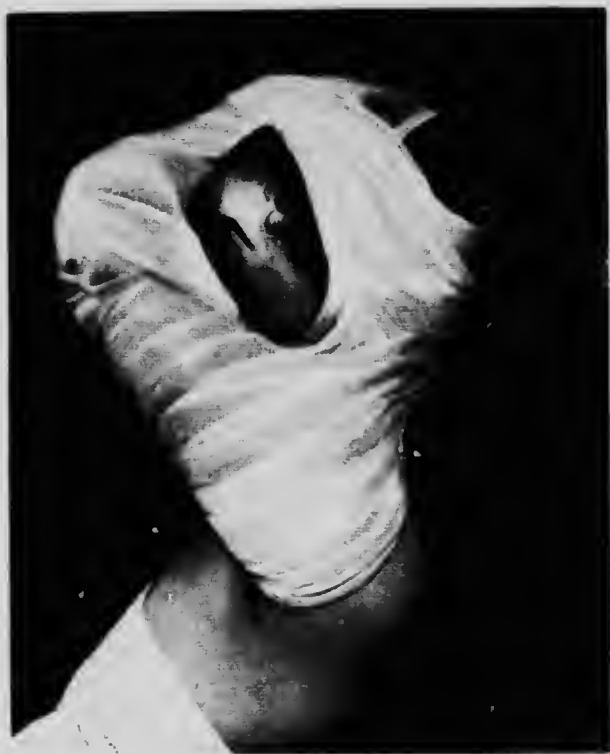

FIG. 919.—THE SAME.

Position of arm and head, as seen from left side; the autoplasic flap is shown

SECOND INTERVENTION.—The plaster bandage is removed, and the toilet of the region is made.

First Stage.—Dissection of the brachial cutaneous flap, which should be somewhat larger than the area of loss of substance which it is intended to repair.

Second Stage.—Extirpation of entire cicatrix, as far as the left labial commissure.

Third Stage.—Reunion of the autoplasic flap.

In this case, the lower portion of the brachial cutaneous flap has been eliminated. The cicatrization has been obtained by the adjustment of a supplementary cutaneous flap.

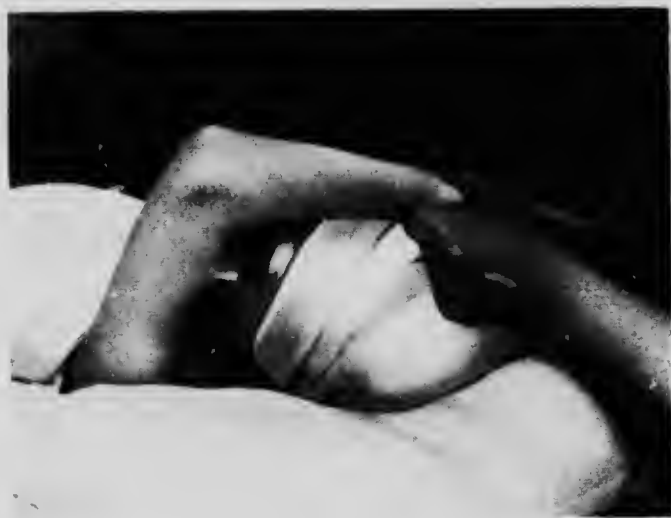

FIG. 920.—THE SAME.

Second intervention: The plaster bandage has just been removed; aspect of autoplasmic flap at the moment when it is about to be detached from the arm.

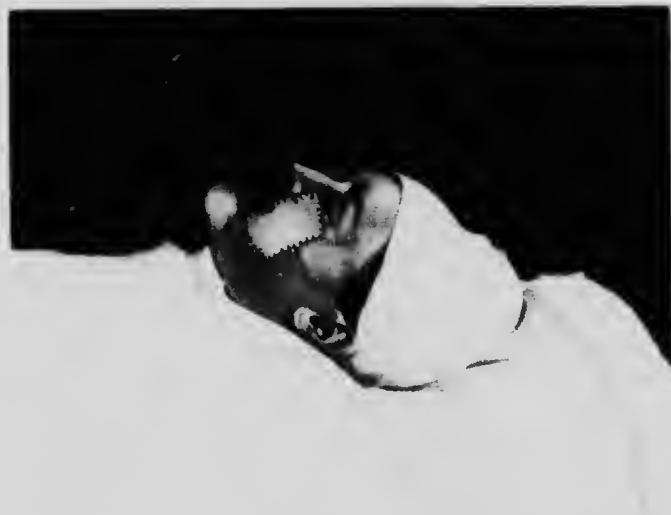

FIG. 921.—THE SAME.

Third stage: Reunion of autoplasmic flap and complementary sutures.



FIG. 922.—THE SAME.

Result of operation: Mortification of the lower portion of the brachial flap has necessitated the adjustment of a second flap in that position.

Diseases of the Excretory Lachrymal Passages.

TRAUMATIC LESIONS.

Wounds.—The treatment of wounds of the lachrymal canals has been described in connection with the treatment of those of the eyelids. Wounds of the *lachrymal sac* and *nasal duct* are treated with superficial suture, if the lips of the line of suture are clean cut; in the case of contused wounds (gun-shot, etc.) by tamponing; to be followed by autoplasmic reparation—either at an early date or after cicatrization.

INFLAMMATORY LESIONS.

Epiphora.—Inflammatory lesions of the lachrymal puncta and canaliculi frequently produce eversion or inversion, narrowing, or obliteration of the puncta or of the canals; conditions which necessarily produce epiphora. So also do chronic inflammation and narrowing of the lachrymal sac and nasal duct.

TREATMENT.—The epiphora is treated by dilatation and incision of the lachrymal puncta and canals, and by dilatation and incision of the nasal canal according to the seat of the cause.




FIG. 923.—INTRODUCTION OF CONICAL STYLET INTO THE INFERIOR LACHRYMAL PUNCTUM.

Dilatation of the Puncta Lachrymalia.—The lachrymal puncta are dilated with a conical stylet, after cocaineization (with 5 per cent. solution). The stylet is introduced perpendicularly, and then turned obliquely; it should be made to pass for a certain distance into the lachrymal canal.

Incision of the Puncta Lachrymalia.—The incision is made with Weber's knife, which ends, like a stylet, in a bulbous extremity. The blade is directed, first inwards, almost in a horizontal direction, till it reaches the wall of the lachrymal sac; the edge being turned towards the free margin of the eyelid, and a little backwards towards the eyeball. Penetration of the blade into the lachrymal sac is facilitated by drawing the external palpebral commissure outwards. The handle is then *depressed*, in case of operation on the inferior punctum; *depressed*, in case of the superior, by a movement in the arc of a circle; and the cutting edge is now found directed, in case of the inferior lachrymal canal, upwards and backwards; in case of the superior, downwards and backwards. The movement of rotation is arrested when the lachrymal canal has been incised through a length of 3 to 5 millimetres.

For the ensuing four or five days we should separate the edges of the little wound every morning with a blunt stylet, as they tend to unite spontaneously. Care should be taken to catheterize the lachrymal canal for a considerable time after the cicatrization of both lips of the incision. Cath-

terism of the lachrymal passages can be carried out with a straight cannula, with which we make at the same time an injection of artificial serum, so as to verify the permeability of the course.

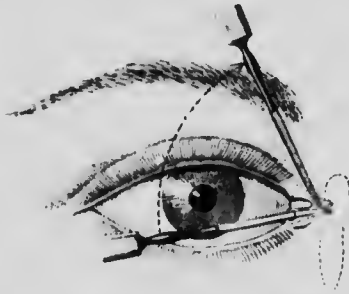


FIG. 924. INCISION OF THE INFERIOR LACHRYMAL CANAL.

Weber's knife has been introduced into the sac; the arc of rotation is indicated by the arrow.



FIG. 925. —INCISION OF THE INFERIOR LACHRYMAL CANAL.

Appearance of complete incision of the inferior canal after cicatrization.

When the lachrymal canal is strictured and hard to dilate, we effect the catheterism with one of Bowman's graduated sounds, and the incision is prolonged as far as the lachrymal sac.

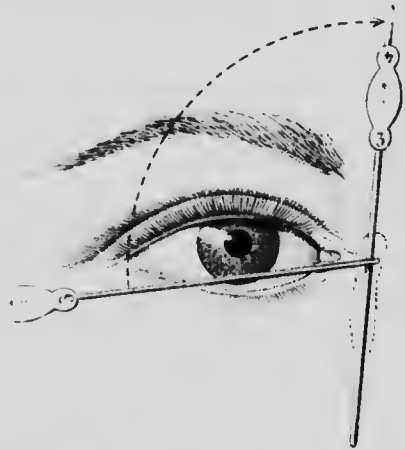


FIG. 926. CATHETERISM OF THE NASAL DUCT WITH BOWMAN'S SOUND.

The sound is passed into the lachrymal canal till it comes into contact with the wall of the lachrymal sac, and its free end is then raised so as to place it in the direction of the nasal duct, which is slightly oblique from within outwards and from behind forwards.

Catheterism of the Nasal Duct.—When the sound is in the lachrymal sac, we should make sure of the permeability of the nasal duct by raising the catheter till it reaches the inner end of the orbital arch, so that its direction

is slightly oblique, from within outwards, and from behind forwards. The sound should be pushed very gently, and made to penetrate by applying a moderate and sustained pressure. If there is constriction, we should use Weber's conical sound.

Incision of the Nasal Duct.—When the constriction is very narrow, the nasal duct is incised. The superior lachrymal canal is incised with Weber's knife, as far as the sac. We then penetrate the lachrymal sac with Stilling's blunt-pointed conical knife; the blade of which is introduced towards the

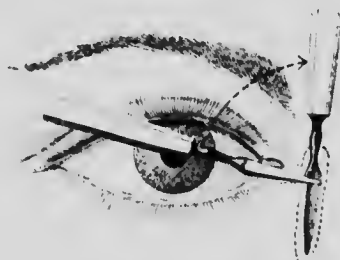

FIG. 927.—INCISION OF THE STRICTURED NASAL DUCT WITH STILLING'S KNIFE. The blade, the extremity of which is blunt, should be introduced horizontally as far as the internal wall of the lachrymal sac, then raised, as in using Bowman's sound, till it takes the direction of the nasal duct.

nasal duct, and pushed into its depth, in such a way as to divide whatever tissues resist. The knife is thus pushed on, three or four times in succession; turning the cutting edge in a new direction each time. A Bowman's sound, No. 3 or No. 4, is then introduced, and left in position for ten minutes each day.

Lachrymal Tumour and Phlegmonous Dacryocystitis.—Dilatation of the lachrymal sac may be complicated with phlegmon. This condition should be treated by incision. Anti-staphylococccic serum medication may, however, be tried beforehand.

Stenosis of the nasal duct is treated finally, after cicatrization of the wound.

Lachrymal Fistula.—Lachrymal fistula is a frequent consequence of phlegmonous dacryocystitis, and may be complicated with osseous lesions in the vicinity. Obstinate cases may require extirpation of the *lachrymal sac*, followed or not by extirpation of the lachrymal gland, in order to get rid of the persistent lachrymation.

EXTIRPATION OF THE LACHRYMAL SAC — Operation — First Stage. Curvilinear incision of the skin, parallel to the naso-palpebral fold.

Second Stage.—The anterior wall of the sac is exposed with the edged spatula, seized with a clawed forceps, and twisted as far as its superior pole, which is freed with the aid of the spatula, and then detached from the osseous groove behind and at its deep aspect. The sac is resected as far down as possible in the nasal groove.

If the condition of the integuments does not permit immediate suturing, the wound should be treated by tamponing, and autoplasmic reparation may be resorted to subsequently.

Extirpation of the lachrymal gland will be subsequently described, in connection with the surgery of the orbit.

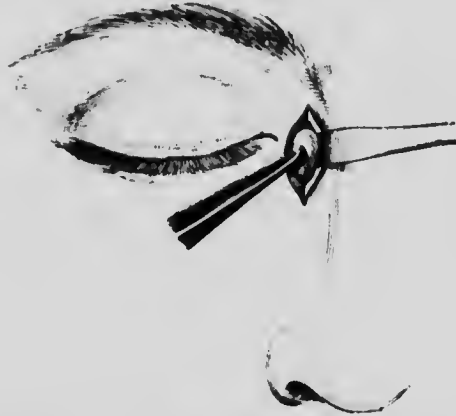

FIG. 928.—EXTIRPATION OF THE LACHRYMAL SAC.

The fibrous sac is drawn outwards with a clawed forceps, while it is detached from its furrow with a small raspatory.

Foreign Bodies of the Excretory Lachrymal Passages: Dacryoliths.—

Those calculi are usually phosphatic concretions of but slight consistence. Concretions of vegetable origin have also been observed, which were formed of filaments of the lower vegetable growths; the several species of these should be determined by culture in series.

Sometimes hairs, barbs of ears of wheat, etc., penetrate into the inferior punctum lachrymale; they should be removed with a forceps. Vegetable or phosphatic concretions require incision of the lachrymal canal, which is the most frequent seat of suppurative inflammation.

Foreign Bodies of the Lachrymal Sac and Nasal Duct.—Those foreign bodies are rarely met with, and have the same origin as those of the lachrymal canals. Extraction is effected with a curette, after free incision of the sac.

TUMOURS.

Polypi.—Polypi of the lachrymal puncta and canals are removed by a snip of the seissors. The pedicle is cauterized with the galvano-cautery.

Polypi of the lachrymal sac and nasal duct are pretty rare, and are removed through an external vertical incision.

Epithelioma.—Epithelioma of the lachrymal sac is not very rare, and should be extirpated as early as possible, on account of the rapid extension of

the neoplasm towards the ethmoid bone and base of the skull. The growth is destroyed by electro-coagulation, after curettage of the pathological tissues.

Operations on the Conjunctiva.

TRAUMATIC LESIONS.

Wounds.—Isolated wounds of the conjunctiva are seldom serious, requiring, at most, fine No. 1 silk sutures, which are applied under local cocaine anesthesia.

Foreign Bodies.—Foreign bodies in the conjunctival *cul-de-sac* are sought out after local anesthesia with cocaine. The superior *cul-de-sac* is completely exposed after cocainization, by luxating the upper eyelid on a palpebral retractor furnished with a handle.

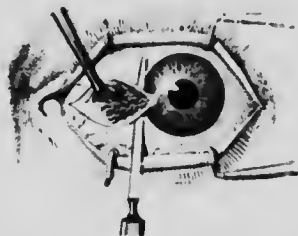


FIG. 929.—OPERATION FOR PTERYGIUM.

The pathological growth is seized with a clawed forceps, and detached from the cornea, then excised.

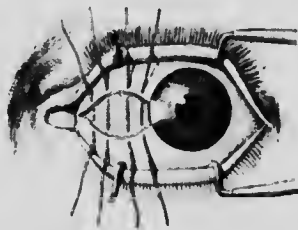


FIG. 930.—OPERATION FOR PTERYGIUM.

Wound resulting from complete excision of pterygium.



FIG. 931.—OPERATION FOR PTERYGIUM.

Transverse suture of the conjunctiva.

INFLAMMATORY LESIONS.

Granular Conjunctivitis—Trachoma.—Surgical intervention may be indicated in granular conjunctivitis or trachoma of the conjunctiva. The grave form of this affection is treated by brushing the inner aspect of the eyelids, the free border of which is rolled back on a long forceps, and by resection of those which are very gravely affected.

Pterygium.—Pterygium is seldom seen, except in the adult. It is most frequently seated on the nasal side. It is sometimes treated by simple excision; sometimes transplantation is carried out.

OPERATION — Excision.—The pterygium is seized at its summit with forceps, and detached from the cornea with a bistoury; taking care to involve the tissue of the latter as little as possible. The sclerotic coat is then scratched beneath the pterygium with the cutting edge of the bistoury, and the pedicle is divided, after having crushed it with a short-jawed forceps. We then suture the conjunctiva in a transverse direction.

Transplantation.—Transplantation consists of suturing the summit of the pterygium, after detachment from the cornea, in a button-hole of the conjunctiva, which is made on a plane 4 millimetres higher up. This procedure should be adopted but very exceptionally.

Encanthis.—Benign encanthis, or inflammatory hypertrophy of the caruncula lachrymalis, is treated by excision and suture.

TUMOURS OF THE CONJUNCTIVA.

Benign Tumours.

Pinguecula.—Pinguecula is a small adipose tumour of the conjunctiva, of the size of a pin's head, and of a yellowish or reddish colour.

OPERATION.—Excision is practised. A single point of suture suffices for union of the edges of the conjunctival wound.

Lipoma.—Subconjunctival lipoma is of rather rare occurrence.

OPERATION.—Enucleation of the lipoma, and suture of the conjunctiva.

Angelomata.—The best treatment for angioma is extirpation with the bistoury, followed by peripheral ligature of the afferent vessels. Cauterization, with the galvano-cautery, can be utilized as an adjuvant.

Polypi.—Pediculate papillomata, or polypi, of the conjunctiva are treated by excision, followed by suture, and cauterization of the point of attachment with the galvano-cautery.

Cysts.—*Scrons* or *dermoid cysts* of the conjunctiva should be dissected with care, and extirpated with the entire envelope. Cysticercus of the conjunctiva is easily recognizable, and the parasite can be distinguished by its transparency.

OPERATION.—Enucleation. Suture of the conjunctiva.

Malignant Tumours.

Epithelioma.—Primary epithelioma of the conjunctiva frequently begins at the margin of the cornea. When the tumour takes on an infiltrating character, it is necessary to intervene. Figs. 930 and 931 represent the excision of the tumour, followed by suture of the conjunctiva. I have abandoned the bloody operation, which always exposes the patient to recurrence of the growth and loss of the eye. On the other hand, I have

obtained a permanent cure by the use of thermic electro-coagulation. A filiform electrode is employed, with a current of feeble intensity.



FIG. 932. EPITHELIOMA OF CONJUNCTIVA SITUATED NEAR THE CORNEAL MARGIN.




FIG. 933. EPITHELIOMA OF CONJUNCTIVA SITUATED NEAR THE CORNEAL MARGIN.

Outline of the incision necessary for extirpation of the neoplasm.

Malignant Encanthis.—*Malignant encanthis*, or epithelioma of the carunculus lachrymalis, also demands the employment of thermic electro-coagulation after curettage. The same is the case with *secondary epithelioma of the carunculus*, which usually comes from extension of an epithelioma of the eyelids or lachrymal passages.

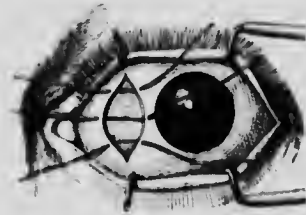


FIG. 934.—SUTURE OF THE CONJUNCTIVA.

Sarcoma: Melano-Sarcoma.—Sarcoma, and more especially melano-sarcoma, of the conjunctiva, is, in **most cases**, an extension of a primary sarcoma of the choroid. The only surgical treatment of this formidable affection is early enucleation of the eyeball, followed by thermic electro-coagulation of the retro-bulbar tissues.

Operations on the Bulbar Insertions of the Motor Muscles of the Eyeball.

Strabismus.—Strabismus has given rise to many surgical devices. *Tenotomy*, unilateral or bilateral, is sometimes practised; sometimes drawing forward of the muscle, or of the capsule, is resorted to; the effect of which may be completed by tenotomy of the antagonizing muscle.

A deviation of 10 to 15 degrees can be effectively corrected by a unilateral *tenotomy*, and a deviation of 20 to 30 degrees by a *bilateral tenotomy*. *E-*

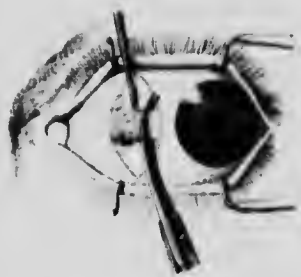


FIG. 935. TENOTOMY OF TENDON OF INTERNAL RECTUS.

The tendon is raised on a blunt hook.*

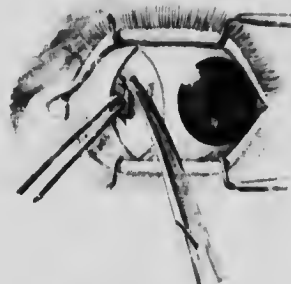

FIG. 936. TENOTOMY OF TENDON OF INTERNAL RECTUS.

Division of the subconjunctival aponeurotic expansion of the tendon.



FIG. 937. MUSCULAR ADVANCEMENT OF THE INTERNAL RECTUS.

Passage of the two principal sutures into the conjunctiva and the peripheral end of the divided tendon.

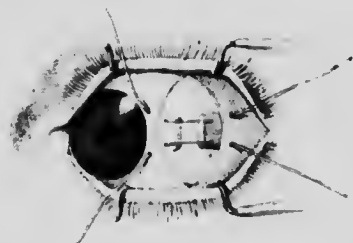


FIG. 938. MUSCULAR ADVANCEMENT OF THE INTERNAL RECTUS.

Section of the tendon. The sutures are passed through the conjunctiva very near the corneal margin.



FIG. 939. MUSCULAR ADVANCEMENT OF THE INTERNAL RECTUS.

The suturing is partially completed.

* The vertical length of the conjunctival wound, which should be very small, has been exaggerated in this and the following figure, with the object of giving a better view of the field of operation.

lateral tenotomy is preferable to capsulo-muscular advancement, which often leaves a visible cicatrix. It also gives a better plastic result, by dividing the correction between the two eyes.

In case of young children, general anesthesia is to be preferred to local.

Tenotomy—**OPERATION.**—The blepharostat is applied. A fold of conjunctiva, parallel to the circumference of the cornea, is seized with the clawed forceps, at about 6 millimetres from the sclerotic margin; and incised transversely, in the line of the axis of the tendon which is to be divided. The conjunctiva is then separated from the tendinous insertion with two or three



FIG. 940.—STRABOTOMY OF INTERNAL RECTUS
Division of the conjunctival fold.

snips of a blunt scissors, and the tendon is now raised with a strabotomy hook. The tendon is then divided with small snips of the scissors, closely shaving its insertion on the sclerotic coat. The degree of correction may be augmented by completing, with curved scissors, the liberation of the ligamentous subconjunctival expansions of the divided tendon. It is unnecessary to suture the conjunctiva.

Muscular Advancement—**OPERATION.**—Section of the tendon at its insertion presents no inconvenience, and gives a better cicatrix than the folding process, which produces a subconjunctival projection.

First Stage.—The tendon is raised, as in the operation of tenotomy, with a strabotomy hook, and over as wide an extent as possible.

h often
ing the
local
of con
elawed
trans
The
or three

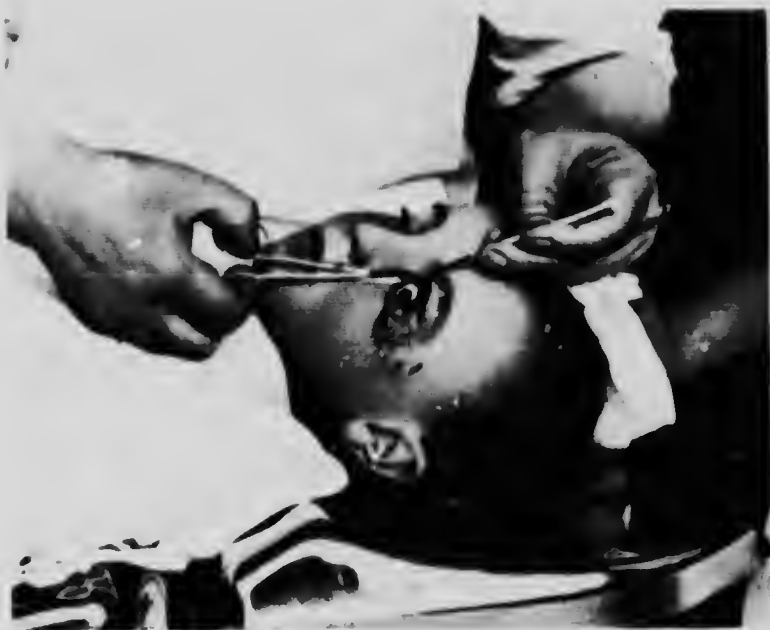

FIG. 041.—STRABOTOMY OF INTERNAL RECTUS.
Section of tendon, which is raised on a blunt hook.

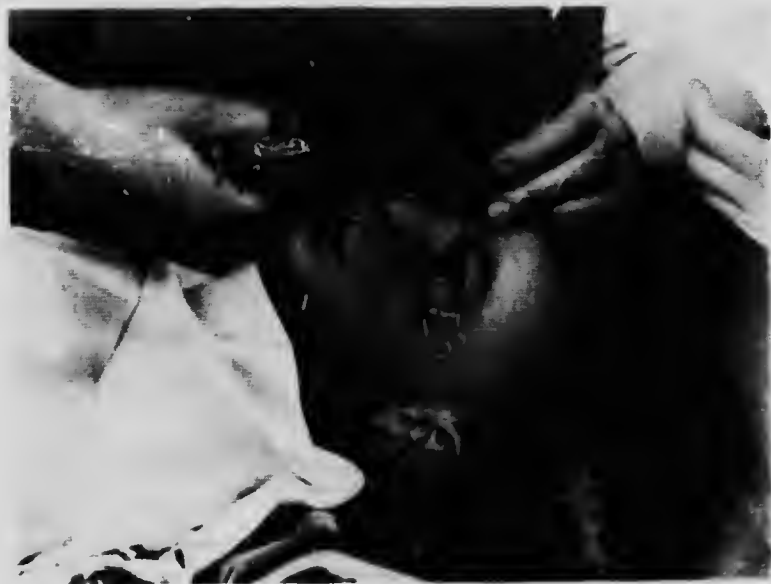

FIG. 042.—SUTURE OF CONJUNCTIVA.

otomy
closely
may be
of the
t is un

at its
man the
y, with

Second Stage.—It is transfixed with two threads of No. 1 silk, which are passed with a fine needle at a distance of 5 or 6 millimetres from the insertion.

Third Stage.—It is then detached from the sclerotic, taking care to deal with its ligamentous expansion.

Fourth Stage.—The peripheral end is united to the subconjunctival connective tissue and conjunctiva by two separate points of suture made with No. 1 silk.

Fifth Stage.—The incision in the conjunctiva is reunited by two sutures of No. 1 silk. The deep sutures, which are made with very fine silk, become encysted without leaving any external trace.

Capsular Advancement.—Capsular advancement consists of suturing the wings of the tendon near its insertion without shortening the tendon itself. This operation may be carried out as the complement of muscular advancement.

Cornea and Anterior Chamber.

TRAUMATIC LESIONS.

We will describe, at the same time, traumatic lesions of the cornea and those of other parts of the eyeball.

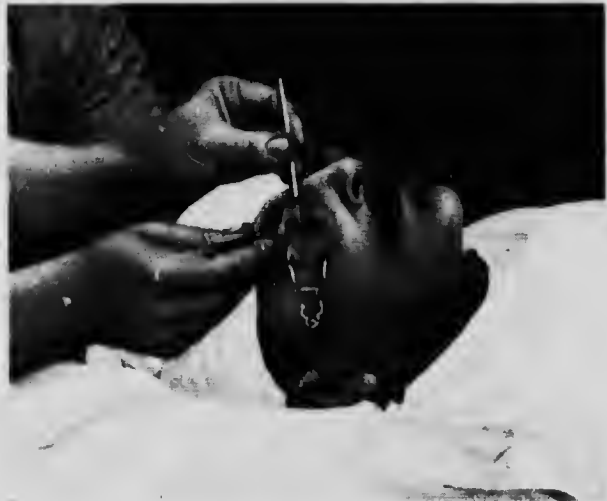

FIG. 943. EXTRACTION OF A FOREIGN BODY FROM THE CORNEA.

Foreign Bodies. The foreign bodies most frequently met with in the eye are metallic particles. Extraction is easily effected under local anaesthesia when the foreign body is superficially located. It can be displaced with a cataract needle.

When the foreign body occupies an interstitial position, and does not project externally, we must take care not to push it into the anterior chamber. In such a case, the use of the blepharostat is indispensable. The cornea is fixed with the help of one cataract needle, which is made to puncture its substance, and the extremity of which steadies the posterior corneal surface. The extraction is effected with a second needle, acting from the anterior surface of the cornea (Fig. 943).

Wounds made by Cutting or Pricking Instruments.—Wounds made with cutting or pricking instruments may divide the cornea and sclerotic, and involve the iris, without producing loss of the visual function. I have seen many such cases perfectly cicatrized when examining in the military wards of the hospital in Rheims, with the principal medical officer of the Service, the recruits who presented themselves to the commission of reform.

When the surgeon is called immediately after the accident, the eye must be anesthetized with cocaine, and we proceed to disinfect the conjunctiva, and to reduce, or resect, a prolapse of the iris, if such exist. A moist boric compressive dressing is then lightly applied. A preventive injection of anti-staphylococccic serum is administered. A good form of compress is that formed by applying on the upper eyelid, lowered, but not contracted, and then on the lower eyelid, layer by layer, a number of flattened patches of sterilized lamibulous cotton soaked in boric solution; and over these a roll of laminated gutta-percha, some dry cotton, and a Velpeau's crêpe bandage.

The dressing should be renewed every day. If there is suppuration of the conjunctiva, we use warm boric solution frequently repeated, *without fixed dressing*, as it is necessary to avoid stagnation of pus; and mycolysine is carefully administered.

If the wound is infected, it may be very difficult to avoid panophthalmitis, which necessitates enucleation. In the more alarming cases, large doses of mycolysine, both by the mouth and hypodermically, will prove a priceless resource.

Blood extravasated into the anterior chamber may be extracted after keratotomy, when the absorption proves too slow. This procedure may also be adopted in case of hypopyon, the cure of which will be greatly promoted by the use of mycolysine.

Wounds made with aseptic cutting or pricking instruments may reach the choroid, and even the retina; and permit evacuation of one-fourth, or even one-third, of the vitreous body, without gravely compromising the existence of the ocular globe.

It is sometimes difficult to diagnose a wound of the crystalline lens, when examining a small wound of the cornea. Wounds of the lens are habitually followed by evolution of traumatic cataract.

Gun-Shot Wounds.—*Gun-shot wounds* are of frequent occurrence. We will here pass over the cases of destruction of the eye by projectiles of a certain volume, and consider those oftenest met with—wounds with the small shot used for game.

I have twice seen non-penetration of the eyeball by shot of large diameter, No. 5 and No. 4, which had struck the margin of the cornea, and penetrated laterally, to a certain distance under the conjunctiva. I extracted them some months afterwards, while keeping the eyeball drawn towards the opposite side with a fixation forceps. No persistent visual trouble resulted.

Small shot, such as No. 8 and No. 9, penetrate much more readily into the interior of the eyeball, and this accident occurs frequently in the beating of forests for game, where the sportsmen fire horizontally towards the faces of the beaters.

When vision has been completely destroyed, and inflammatory accidents have followed, emelcation must be resorted to before the onset of symptoms of sympathetic ophthalmia.

Contused Wounds—**LUXATION OF THE EYEBALL.**—Contused wounds may produce luxation of the eyeball, without entirely destroying the globe. The luxated globe may be reduced with preservation of distinct vision, if the vital functions have not been completely abolished by the traumatism. When this is not the case, we must content ourselves with the attempt to preserve the eye from the plastic point of view, or we may have to resort to emelcation.

Rupture of the Eyeball.—Rupture of the ocular globe usually takes place at some distance outside the corneal circumference, and is accompanied in most cases with displacement of the crystalline lens or vitreous body beneath the conjunctiva. We must, in such cases, be ready to practise emelcation.

Burns.—Incandescence substances and strong chemical caustics produce in most cases irremediable lesions. After deflagration of explosives, I have seen the upper fourth of each of the cornea remain transparent, because it had been protected by the upper eyelid in each case. In this case the vision was sufficiently re-established by a double superior optical iridec-tomy.

INFLAMMATORY DISEASES.

Abscess of the Cornea.—The pus is evacuated by a puncture made with a paracentesis needle. Mycolysine is administered.

Ulcerative Keratitis.—If the ulcer prove refractory, we may try Soemisch's operation, which consists of a transverse incision of the cornea, made with Graefe's knife. The instrument should be made to penetrate within and emerge beyond the margin of the ulcer in such a way as to divide the affected region of the cornea throughout its whole extent.

Concreted masses of pus are removed with a slender forceps. Repeated borie lavages are used. The general treatment consists of mycolysine, given in large doses.

Staphyloma—**PELLUCID STAPHYLOMA.**—Pellucid staphyloma is seldom improved by the tentative procedure of partial incision, followed by compression.

OPAQUE STAPHYLOMA.—*Opaque staphyloma* should be avoided so long as it does not constitute either a repulsive deformity or a painful affection, of which the existence threatens sympathetic ophthalmia.

The only radical treatment consists of enucleation of the eyeball.

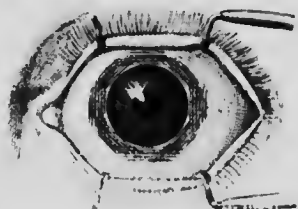


FIG. 944. PERITOMY.

The cornea should be circumscribed with eight or ten rows of scarification, of which the extremities should intersect.



FIG. 945. PERITOMY.

The scarifications should involve the superficial layer of the sclerotic, where a portion of the vessels of the pannus have penetrated.

Vascular Keratitis - Pannus.—Vascular keratitis demands destruction of all the capillaries which have invaded the surface of the cornea. This procedure is known as "peritomy."



FIG. 946.—PARACENTESIS OF ANTERIOR CHAMBER WITH BENT LANCEOLATE KNIFE. The eyelids are separated by the blepharostat.

PERITOMY.—This operation has for its object the checking of the abnormal vascularization of the cornea produced by the invasion of peripheral vessels.

Local anaesthesia with cocaine.

First Stage.—Circular abrasion of the hypertrophied pericorneal conjunctival corona with curved scissors over a width of 3 or 4 millimetres.

Second Stage.—Scarifications, parallel and intersecting, of the whole periphery of the cornea. The bistoury should invade the superficial stratum of the sclerotic.

Third Stage.—Energetic scraping of the margin of the cornea and exposed sclerotic. Moist dressing.

The result of the operation should be carefully watched.

The pericorneal scarification and scraping should be repeated if new vascular formations follow. I have practised this operation with very satisfactory results in a certain number of cases.

Hypopyon.—Whether hypopyon be symptomatic of ulcerative or parenchymatous keratitis, the pus should always be evacuated if a tendency to rapid resorption does not appear. The use of mycolysine, both by the mouth and hypodermically, often produces resorption of the exudate. If the latter remains, we have recourse to operation.

OPERATION.—Paracentesis of the anterior chamber at its most dependent point with a lanceolate knife. The pus is often rather conereted. It is extracted with an iridectomy forceps. Paracentesis of the anterior chamber has no inconveniences. The operation is followed by a cure which is the more rapid in progress as the exudate is less virulent.

Operations on the Iris.

TRAUMATIC LESIONS AND FOREIGN BODIES.

The iris is rarely wounded without implication of the crystalline lens. A wounded iris forms in most cases a hernia through the corneal wound.

It is nearly always advantageous to resect the protruding and fixed portion, except when there is no trace of inflammation. In such cases reduction is attempted.

Foreign bodies are removed by iridectomy, or after mobilization, when free in the anterior chamber, with the aid of a paracentesis needle.

Traumatic Cysts of the Iris.—Small traumatic cysts of the iris may require extirpation by iridectomy.

Iridectomy. Iridectomy, or resection of a fragment of the iris, is carried out for the purpose of forming an artificial pupil—optical iridectomy, or diminishing intra-ocular tension—antiphlogistic iridectomy, or as an accessory to the operation for cataract, or to that of ablation of a cyst of the iris.

OPTICAL IRIDECTOMY. *Operation. First Stage: Incision of the Cornea.*

The cornea is incised opposite the position intended for the artificial pupil. The lanceolate blade should be plunged perpendicularly into the cornea. It is held like a writing-pen, the auricular digit being supported on the margin of the orbit. When the point has entered the anterior chamber, the handle of the knife is lowered, so that the blade passes in a direction parallel to the surface of the iris without danger of wounding it. A little aqueous humour escapes.

Second Stage: Prehension and Resection of the Iris.—The iris is carefully seized along one of its radii with an iridectomy forceps, and drawn into the corneal wound. The section is made either with a curved scissors or with Wecker's iridectomy scissors. We thus obtain a narrow round pupil, sufficiently dilatible and contractile, and very well suited for avoidance of dazzling effects.

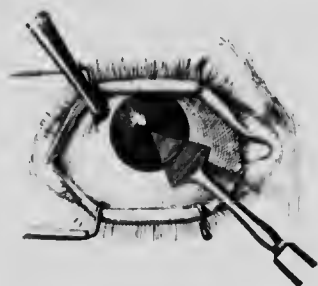

FIG. 947.—OPTICAL IRIDECTOMY.

Incision of cornea with lancet knife.

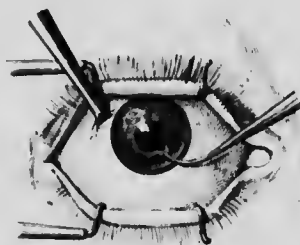


FIG. 948.—OPTICAL IRIDECTOMY.

The iris is seized with iridectomy forceps along one of its radii.

It is necessary to take care to reduce the peripheral portion of the iris, which might become fixed in the corneal wound. The latter is closed after twenty-four to forty-eight hours. Such fixation of the iris is recognized by the appearance of local inflammation. This requires either liberation or resection of the entangled portion.

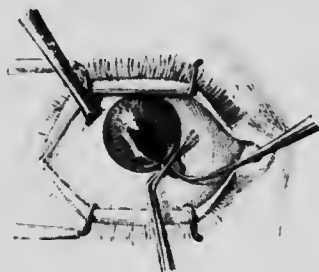


FIG. 949.—OPTICAL IRIDECTOMY.

The iris is drawn out and divided with de Wecker's scissors forceps.



FIG. 950.—OPTICAL IRIDECTOMY.

The iris has been reduced; appearance of the artificial pupil.

ANTIPHLOGISTIC IRIDECTOMY *Operation First Stage.*—The incision is made exactly at the periphery of the cornea with the bent lancet knife, or, if the iris is very bulging, with a Graefe's knife. We may enlarge the first incision, if it be too small, with blunt scissors or with the probe-pointed bistoury.

Second Stage.—The iris is seized obliquely with an iridectomy forceps, and drawn out through the wound. The resection is quite easy, the scissors

(de Wecker's very convenient form of small scissors with special curve) being placed in tangential contact with the periphery of the cornea, so that a broad strip of the iris can be resected, reaching up to its peripheral margin. When the iris prolapses through the corneal wound after withdrawal of the

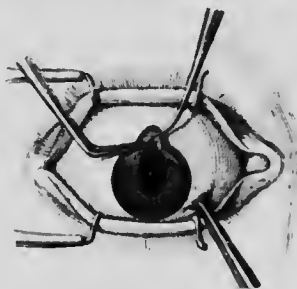


FIG. 951.—THE SAME.

Incision of the upper third of the cornea. The iris is seized transversally.

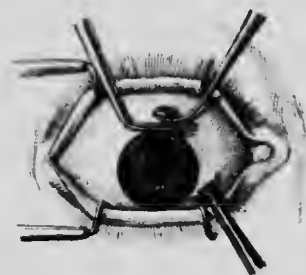


FIG. 952.—THE SAME.

The section of iris is made in two stages, so as to excise its circumference.

knife, we can seize it with the iridectomy forceps in a direction (not in this case parallel to one of its radii, but) tangential to the circumference of the cornea. The division is made in the same direction. The angles of the iridic section are carefully reduced. Moist antiseptic dressing is applied.




FIG. 953.—THE SAME: ANTIPHIOGISTIC RESECTION.

Form of the artificial pupil.

Iridectomy for Extraction of Cataract will be described in the corresponding chapter.

Adhesions of the Iris.—When adhesions of the iris have been definitively established, we may try to destroy them with the help of a crotchet with cutting edge and blunt extremity, which is introduced through a small corneal incision.

Iridotomy.—These operations are intended for the formation of a new pupil in cases of complete obliteration of the normal one.

OPTICAL IRIDECTOMY.—When the pupil has been completely obliterated, the iris necessarily remains in a state of great tension. If the *crystalline lens is transparent*, an incision of the cornea should be made, large enough to enable the operator to seize the iris at the suitable point, and proceed to

make a simple incision therein; or, what is far better, to carry out a partial excision.

The iris often presents a very pronounced resistance to the traction of the forceps.

If the *crystalline lens has been luxated*, or we are dealing with a *secondary cataract*, the Graefe's knife can be plunged directly into the iris, and made to emerge therefrom at a little distance, and then perforate the cornea from behind forwards.

TRIANGULAR IRIDECTOMY.—In such cases we can also make two sections in V-outline of the iris, by plunging a small knife with concave blade down to the posterior aspect of the iris, and then cutting from behind forwards, taking a point of support on the posterior surface of the cornea. The triangular flap thus included is then extracted through an iridectomy incision made in a position diametrically opposite the point of entrance of the falciform blade.

Cysts or Cysticercus of the Iris.—Extraction is performed with a technique corresponding to that of simple iridectomy.

Operations on the Sclerotic.

SCLEROTOMY.

Sclerotomy is an operation which is suitably concurrent with the anti-phlogistic iridectomy which is performed for glaucoma. The sclerotomy may be either anterior or posterior.

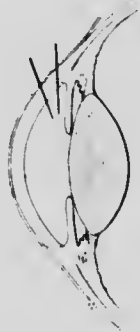

FIG. 354.—ANTERO-POSTERIOR SECTION, SHOWING ON THE UPPER PART OF THE CORNEA THE VERTICAL DIRECTION OF THE INCISION IN THE ANTERIOR PART OF THE SCLEROTIC, AND IN FRONT THE SLIGHT OBLIQUITY OF THE CORNEAL INCISION FOR IRIDECTOMY AND EXTRACTION OF CATARACT THROUGH WOUND WITH SUPERIOR FLAP.

Anterior Sclerotomy—OPERATION—First Stage.—We make the narrow-bladed Graefe's knife penetrate, with the edge looking upwards, at a point 1 millimetre outside the margin of the supero-external quadrant of the cornea. The point of the instrument is passed into the anterior chamber.

and is then made to emerge at a point precisely symmetrical with the point of entrance in relation to the vertical diameter of the cornea.

Second Stage.—We divide the superior sclero-corneal bridge incompletely by to-and-fro movements of the knife, leaving a thin lamella of the sclerotic in the middle. This operation leaves a filtering scleral cicatrix.

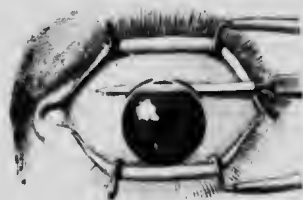

FIG. 955.—ANTERIOR SCLEROTOMY.

The Graefe's knife is manipulated so as to leave a superficial sclerotic bridge.

Posterior Sclerotomy—**SCLEROTOMY WITH SCLERAL BRIDGE.**—The incision is made at a distance of at least 1 centimetre from the periphery of the cornea, beyond the ciliary body and the vasa vorticosa. We operate as in anterior sclerotomy, leaving a small median bridge of fibrous tissue.

Antiphlogistic Sclerotomy—**SCLEROTOMY WITH T-SHAPED INCISION.**—In case of painful glaucoma with obliteration of the anterior chamber, we plunge the Graefe's knife to a depth of 5 millimetres, at a point between the inferior and external recti muscles, and make the blade before withdrawal rotate through an angle of 90 degrees, so as to obtain a T-shaped incision on making the second section, which is directed from behind forwards.



FIG. 956.—POSTERIOR ANTIPHLOGISTIC SCLEROTOMY WITH T-SHAPED INCISION.

Sclerotomy for Foreign Bodies.—The extraction of a grain of shot or a cysticercus from the vitreous body requires a lateral incision of 5 or 6 millimetres at least. [This operation is exceptional, and requires great manual dexterity.]

Operations on the Crystalline Lens.

OPERATION FOR CATARACT.

General Treatment.

In addition to careful toilet of the conjunctiva and lachrymal passages, a hypodermic injection of 10 c.c. of mycolysine is administered on the eve of the day appointed for the operation, and this is repeated daily if any infectious complications are dreaded.

Soft Cataract.

Aspiration. The soft, non-nucleate cataract of young subjects, and also of some recent traumatic cases, may be evacuated by *aspiration*. This procedure is best carried out with the aid of a hypodermic syringe, furnished with a cannula of a millimetre in calibre, which is plunged obliquely into the crystalline lens. *Buccal* aspiration should be proscribed, as it does not enable us to measure the effect produced.

Dissection.—We may practise dissection some days before, and aspirate the substance of the softened crystalline lens through a small incision of the cornea made with a lanceolate knife.

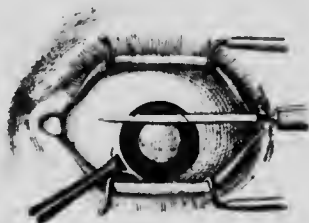


FIG. 957.—OPERATION FOR CATARACT.

Extraction by small superior flap; incision of the cornea.

OPERATION. Preliminary dilatation of the pupil with neutral solution or atropine sulphate of 1 to 200. The eyeball should be steadied with fixation forceps, which are fastened close to the internal margin of the cornea. The cataract needle, with stop is then entered near the circumference of the cornea, at first perpendicularly. It is now passed across in front of the iris, and with care not to wound the latter, till it reaches the capsule of the crystalline lens. This is torn along a double V-shaped section, and the needle is then carefully withdrawn. When necessary, the procedure is repeated a number of times. If resorption proves too tardy, it will be necessary to practise extraction with the small flap incision.

Senile Cataract.

Extraction with Small Flap.—The procedure of extraction with small flap suits nearly all cases without exception, from the semiliquid cataract, the incision for which may be reduced to 2 millimetres, to solid cataracts of the largest volume.

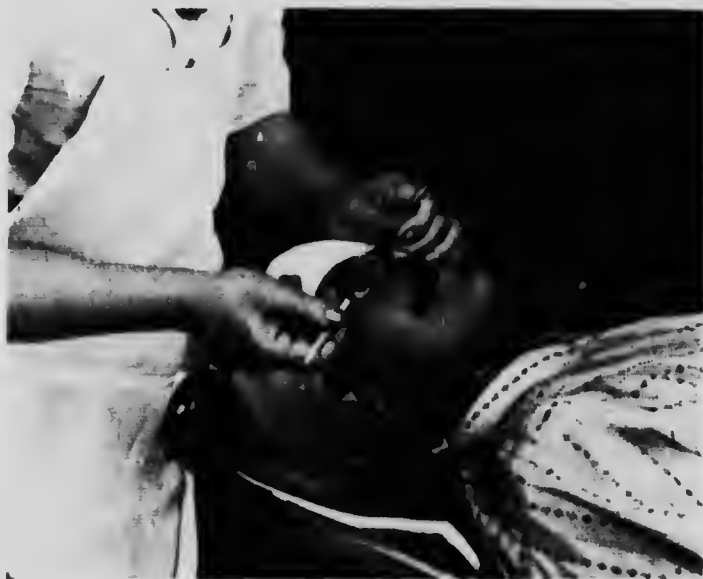

FIG. 958.—OPERATION FOR CATARACT WITH A SMALL SUPERIOR FLAP
Incision of the cornea.

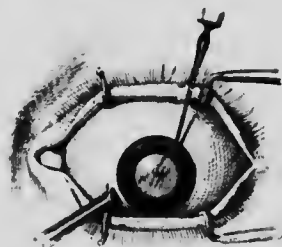


FIG. 959.—OPERATION FOR CATARACT.
Incision of capsule with cystotome.

PRELIMINARY IRIDECTOMY.—The iridectomy is in certain cases performed some weeks, or even many months, before the extraction; with the object of hastening the maturation of the cataract. Preliminary resectio

E

a small
starect
acts of

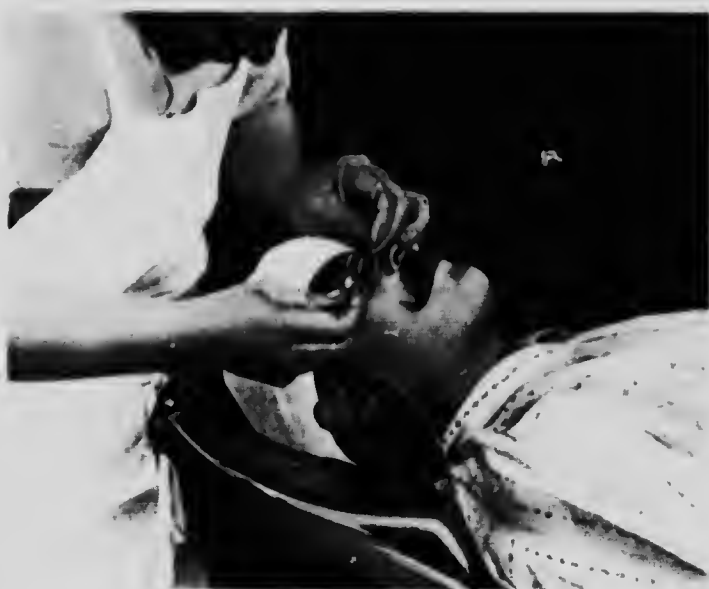

FIG. 960. —OPERATION FOR CATARACT.
Iridectomy.

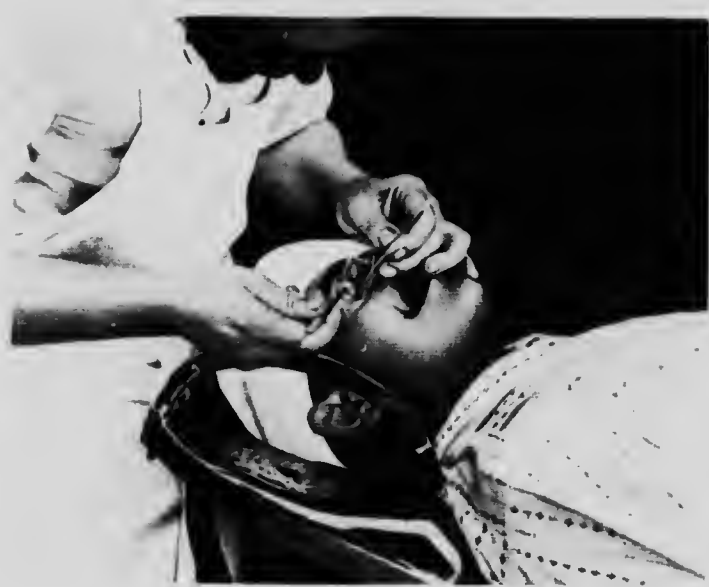

FIG. 961. —OPERATION FOR CATARACT.
Extraction of crystalline lens.

ses pe
with th
resectio

602 SURGICAL THERAPEUTICS AND OPERATIVE TECHNIQUE

of the iris simplifies greatly the extraction of the cataract. We now proceed to describe the extraction with a small superior flap.

OPERATION.—Anesthesia with cocaine. Blepharostat.

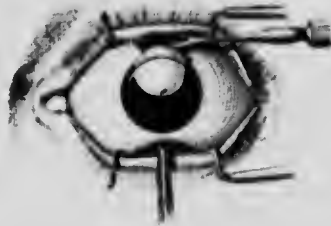

FIG. 962. OPERATION FOR CATARACT.

EXTRACTION of crystalline lens. The upper lip of the incision is depressed with a blunt snout, while the forceps acts from below upwards for expulsion of the lens.

First Stage: Incision of Cornea.—The eyeball is immobilized with a fixation forceps, which grasps the conjunctiva below the transverse diameter of the cornea. The patient should look downwards. If the operator can use only the right hand, he should place himself behind the patient's head when operating on the right eye, and on his left side when operating on the left eye.



FIG. 963.—OPERATION FOR CATARACT.

Dressing.

The Graefe's knife is made to penetrate the sclero-corneal border perpendicularly, and in such a way as to divide nearly one-third of the circumference of the cornea. The point of the knife is now passed horizontally across the anterior chamber, and is made to emerge at a point exactly symmetrical with the point of entrance in regard to the vertical diameter of the cornea, and the section of the flap is then completed.

The section requires a keen-edged Graefe's knife, preferably a *new* one. The aqueous humour escapes externally, and a hernial protrusion of the iris often emerges with its current.

Second Step: Incision of the Capsule.—The capsule is lacerated with a cystotome, or torn off with a capsule forceps. Care must be taken not to wound the iris when introducing those instruments.

The lens now projects into the anterior chamber, and the fixation forceps is immediately removed.

Third Step: Extraction of the Crystalline Lens.—We direct the patient to look downwards. The extraction is facilitated by depressing the upper lip of the incision slightly with the silver curette, while the lens is pushed from below upwards with the fixation forceps, which is held in the left hand after being removed from its grasp of the conjunctiva.

If the expulsion prove difficult, we must supplement the laceration of the capsule by performing an iridectomy. It is rarely desirable to enlarge the corneal incision. When the lens has been extracted, the retractor is removed, and the patient is instructed to close the lids gently. A tampon of cotton soaked in tepid boric solution is then applied.

Fourth Step: Expulsion of the Cortical Fragments.—The cortical fragments, when such exist, are pressed into the anterior chamber by gentle friction, applied through the lower eyelid on the inferior segment of the ocular globe. They are then extracted with the silver curette, and the capsular opacities are removed with the capsule forceps.

Fifth Step.—The iris is reduced with the spatula, and we direct the patient to close the lids gently. We then immediately apply a tampon of cotton soaked in *very cold* boric solution. The patient should be forewarned of this application, so as to prevent any brusque movement of the eyelids. It produces immediate contraction of the iris, and greatly diminishes the risks of its entanglement in the wound.

DRESSING.—Instillation of eserine salicylate solution of 1 in 200. Verification of exact coaptation of the corneal flap, and application over the closed lids of a series of small pieces of bibulous cotton soaked in boric solution, and gently pressed down with some gutta-percha leaf, dry cotton, and application of a Velpéau's bandage.

The other eye, which had been covered with an exactly similar but somewhat less voluminous dressing before the operation, is allowed to retain the same.

The moist and slightly compressive dressing realizes perfectly the immobilization of the eyeball, which is the essential condition for good cicatrization. When there is no pain, the first dressing should not be removed till the third or fourth day.



FIG. 1044. OPERATION FOR CATARACT.

Antero-posterior section, showing the simultaneous action of the curette and forceps in expulsion of the lens.

SUBSEQUENT CARE.—The dressing is removed in a dark chamber under lateral illumination of slight intensity—for instance, a wax taper. We wash the ciliary margin with a small plug of moist bibulous cotton, and examine the eyeball after gently separating the lids. The dressing is permanently removed on the next day but one. We thenceforth content ourselves with the use of tepid boric lotions.

The patient should be kept in semi-obscurity till the redness of the conjunctiva has disappeared. He should then wear smoked glasses. Cold and wind should be carefully avoided on the early occasions of his going about. Cataract glasses should not be used till after the lapse of six to eight weeks.

An emmetropic eye should wear for distant vision a glass of 10 to 12 diopters; for near vision, a glass of 3 to 4 diopters stronger. The numeration of the glasses must be determined experimentally. Visual acuity with cataract glasses will vary between normal and $\frac{1}{2}$.

ACCIDENTS OF OPERATION FOR CATARACT.

Wounds of the Iris.—A wound of the iris with a Graefe's knife or a cystotome causes a little bleeding, but is not a serious accident.

Escape of Vitreous and Luxation of the Crystalline Lens.—Exaggerated pressure with the cystotome may cause laceration of the zonule and escape of vitreous. Luxation of the lens into the vitreous body at the moment of attempted extraction demands its immediate extirpation with an annular curette, after performing an iridectomy. This instrument should be plunged freely into the vitreous body, and made to extract the lens with a single movement.

Escape of vitreous at the moment of removal of the lens is not an irremediable accident if the quantity expelled is less than one-third of the total mass.

POST-OPERATIVE ACCIDENTS.

Failure of immediate union of the wound of operation is one of the most frequent causes of *locking of the iris*, which takes place within the first twenty-four or forty-eight hours.

Locking of the Iris.—A *locked iris* should be resected as completely as possible at the time of the first dressing. It will be necessary ultimately either to perform a secondary iridectomy by detaching the hernial portions with a Graefe's knife, and resecting them completely, or to destroy them with the galvano-cautery. Non-excision of a locked iris exposes the patient to prolonged inflammatory complications, which may lead to complete loss of the eye, or at least to keep up a local inflammatory condition for many weeks. The complication necessitates occupation of a half-darkened room for the time.

Secondary Cataract.—Secondary cataracts should be treated by discission, in some cases by extraction. The adhesions formed by the iris are freed with the falciform needle. We obtain a perfect discission by passing two falciform needles into the anterior chamber, each of which is adapted

to its own function, one being used to fix the opaque patches, which are lacerated with the second. The operation can also be carried out by manipulating the falciform needle with one hand and an ordinary discission needle with the other (Fig. 965).

Obliteration of the Pupil.—Obliteration of the pupil necessitates iridec-tomy, or, preferably, a triangular iridectomy; or we may resect a trapezoid fragment of the iris by plunging the lanceolate knife into its substance near

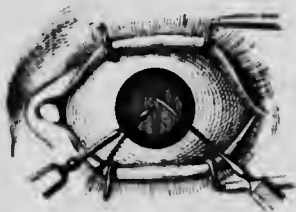

FIG. 965.—DISCISSION OF A SECONDARY CATARACT WITH A CATARACT NEEDLE AND A FALCIFORM NEEDLE.

the periphery, and making its point to emerge anteriorly as far off as possible. The iridic bridge thus formed is resected by dividing with scissors or a suitable knife its two attached extremities.

Antisepsis of conjunctiva and of eyeball. Anæsthesia, general and local.

Operations on the Eyeball.

Partial Amputation of the Eyeball.—Partial amputations of the eyeball are dangerous procedures, which expose the patient without any prothetic advantage to all the dangers of sympathetic ophthalmia.

Enucleation of the Eye.—Enucleation of the eye is indicated in all cases in which the organ is affected with a grave traumatism, or with inflammatory conditions which are not merely capable of permanently abolishing the function of the affected eye, but of producing a sympathetic ophthalmia in the healthy eye. As a general rule enucleation is requisite whenever the vision has been completely destroyed on the side involved in the traumatism, and more especially when a foreign body is present. The loss of one eye has already caused to the patient a loss of more than half of his visual faculties, a considerable diminution of the total field of vision, impairment of the notion of relief, of estimate of distances, etc. When vision has been destroyed on one side, we cannot be too energetic in our efforts to safeguard the integrity of the healthy eye.

Total enucleation of the eyeball is the sole procedure of election. I adopt a very simple technique for this operation. The lids are separated with a blepharostat applied at the external canthi. The conjunctiva, which is grasped from above downwards with clawed forceps at the right margin of the cornea, is very freely divided with curved scissors; also the tendon of the corresponding rectus muscle. The points of the scissors are then



FIG. 966.—ENUCLEATION OF THE EYEBALL.
First stage: Division of conjunctiva and of tendon of internal rectus.



FIG. 967.—ENUCLEATION OF THE EYEBALL.
Second stage: Luxation of eyeball, and section of optic nerve.

plunged at once into the depths of the orbit, and the optic nerve is divided behind the eyeball; which is now elevated by the leverage of the instrument, and made to project externally. A third section frees the globe of the eye at its superior aspect from its muscular and conjunctival attachments. A fourth section detaches it from its inferior connections, and a fifth and last snip of the scissors completes the division on the left side of the remaining portion of the conjunctival attachment with the tendon of the corresponding rectus muscle.



FIG. 968. — ENUCLEATION OF THE EYEBALL.

Third stage: The tendon of the external rectus has been divided; section of the remaining conjunctival attachments.

Enucleation of the eyeball, carried out in this way, is a very rapid form of procedure, and gives excellent results, inasmuch as it preserves in the interest of prosthesis the totality of the peribulbar tissue.

I will now proceed to describe the various periods of the operation, which comprises four quite distinct stages:

OPERATION.—Anæsthesia, general or local. Blepharostat at external angle.

Instruments: Clawed forceps, and ordinary curved scissors.

First Stage.—Section of conjunctiva along a fold made by grasping with clawed forceps, and of the external rectus muscle in case of the right eye, of the internal rectus in case of the left; the surgeon operating with his

right hand and standing behind the patient. In case of the left eye, it is desirable to commence the process of enucleation by section of the tendon of the external rectus; the surgeon placing himself on the left side of the patient, who is brought to the edge of the operation-table.

Second Stage.—The blades of the scissors are made to pass behind the globe, and divide the optic nerve at its ocular extremity, and then luxate the eyeball outwards.

Third Stage.—A third snip of the scissors is made to divide the tendons of the superior muscles and conjunctiva as close to the sclerotic as possible.

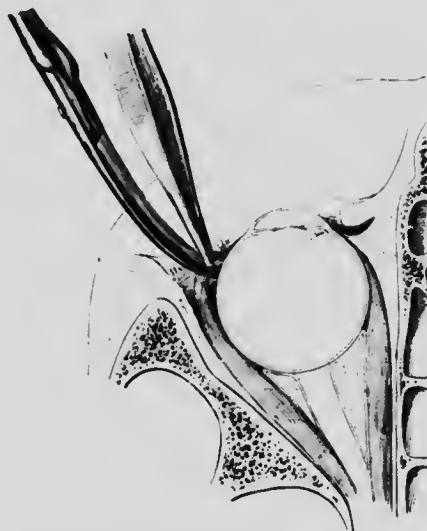

FIG. 1069.—ENUCLEATION OF LEFT EYEBALL.

First stage: Section of conjunctiva and of tendon of external rectus.

Fourth Stage.—Section of inferior muscles and conjunctiva below the corner.

Fifth Stage.—Section of internal rectus in case of the right eye, of external rectus in case of the left, and of the last flap of the conjunctiva.

Tamponing of wound.

The operation occupies hardly *one minute*.

The stump is very satisfactory as regards prosthesis.

Affections of the Orbit.

TRAUMATIC LESIONS.

Wounds. *Deep wounds of the orbit*, if somewhat contused, should be treated by tamponing.

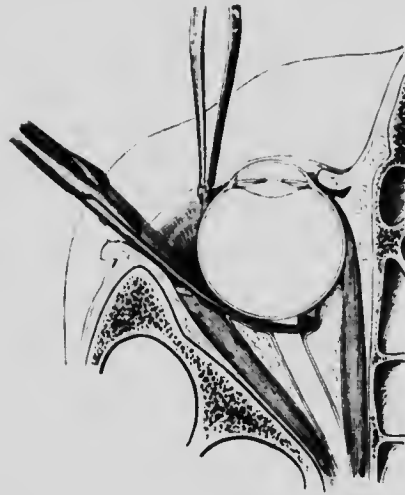


FIG. 970.—ENUCLEATION OF RIGHT EYEBALL.
Second stage: Section of optic nerve.

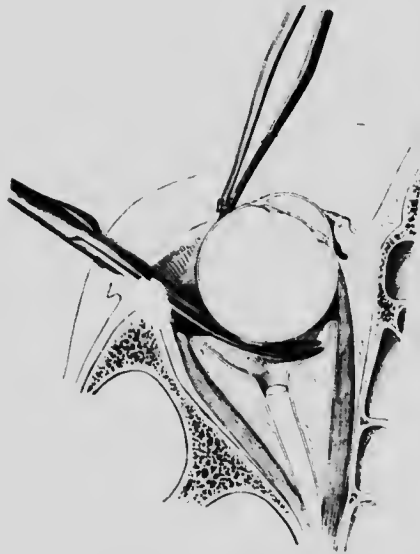


FIG. 971.—ENUCLEATION OF RIGHT EYEBALL.
Third stage: Luxation of the eyeball.

Fractures—Foreign Bodies.—*Fractures* and *foreign bodies* are revealed by radiography, and the latter are removed, if present. Grains of shot are usually inoffensive when they have not wounded either the eyeball or orbital nerves. A young man of eighteen, who had received 84 grains of No. 9 shot in the face, eventually experienced no appreciable trouble. A large number of the pieces had penetrated to the vicinity of the eyeballs. They could be counted on a radiographic proof.

Hæmatoma.—Traumatic hæmatoma of any considerable size should be evacuated with the curette, and then treated by tamponing. Antoplastic reparation of the cicatrix is carried out subsequently.

INFLAMMATORY LESIONS.

Phlegmon of the Orbit.—The prognosis of orbital phlegmon is grave. Suppuration is objectively recognized by the local inflammatory condition, which is usually very much accentuated, and confirms the subjective symp-

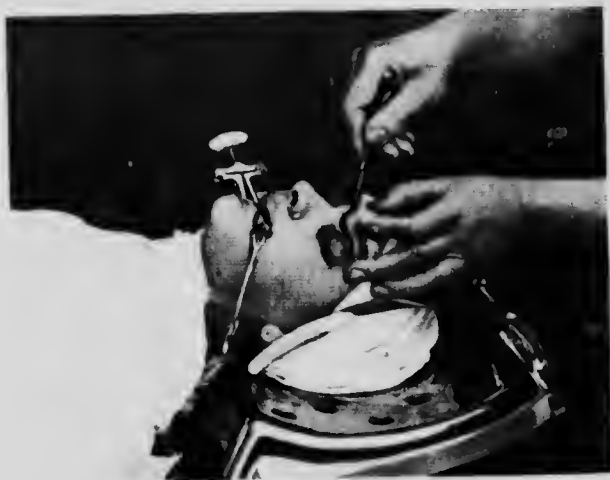

FIG. 972. INCISION OF AN ORBITAL PHEGMON CONSECUTIVE TO SUPPURATION OF THE FRONTAL SINUS.

tons. If energetic treatment with mycolysine does not bring about resolution, operation should be carried out as early as possible, in order to anticipate the formation of the purulent gathering in the cellular tissue which would inevitably supervene.

OPERATION.—If the suppuration is not very abundant, we try to avoid a cutaneous cicatrix by incising the inferior conjunctival cul-de-sac, in which an india rubber drainage-tube of 5 to 6 centimetres in length should then be placed, with a silk ligature attached.

In other cases we must make an incision along the orbital margin in the position from which the focus of suppuration appears to be most readily accessible.

In the former case the incision should involve only the conjunctiva; in the latter, we divide only skin and subcutaneous cellular tissue. We then plunge a curved forceps or blunt scissors into the depths of the cavity, and as soon as pus appears externally we increase the opening by divulsion or forcible separation of the blades of the instrument.

The pus is carefully examined. The general treatment consists of the administration of mycologyne, both by the mouth and hypodermically, which is remarkably efficacious even in cases in which the infection is complicated with phlebitis of the facial vein and of the cavernous sinns. Injection of 10 to 20 c.c. of mycologyne habitually causes a recession of the infective phenomena after an interval of two or three hours, and thus produces a rapid cure.

TUMOURS.

Benign Tumours.

Lipomata - Fibromata - Cysts — **OPERATION.** — Extraction is effected through an incision which is preferably made parallel to the lower border of the eyebrow. We must take care not to wound the levator palpebre superioris muscle. The lipomata and fibromata are easily enucleated. Lymphangiomata and plexiform neuromata often present very extensive ramifications, and require a minutely careful dissection. Cysts should be removed in their totality. Orbital encephalocele is difficult to diagnose, and exposes the surgeon to dangerous operative surprises.

Vascular Tumours. These tumours demand extensive extirpation, and ligature of all exposed vessels. In the very grave cases we resect the external orbital apophysis, which also secures more ready access.

Osseous tumours are easily recognizable with the assistance of radiography.

Osteomata. The enucleation of these tumours should be complete, and in the same way demands temporary or definitive resection of the external orbital apophysis.

Malignant Tumours.

Sarcomata. Malignant tumours are fairly frequent during infancy, and demand extirpation of the whole contents of the orbit; followed by thermic electro-coagulation of all suspected tissues. Most specimens are encephaloid sarcomata of rapid growth. When the tumour had originated in or near the orbit, the coincidence of exophthalmos and facial paralysis proves that the case is inoperable, and that the petrous bone is involved.

RESECTION OF THE EXTERNAL WALL OF THE ORBIT.

Resection of the outer wall of the orbit is an operation destined to procure free access to the depths of the orbital cavity.

First Stage: Incision.— A curvilinear incision is made, bending along the

lower margin of the external third of the eyebrow, and reaching down as far as the level of the middle of the lower eyelid.

Second Stage: Definitive Resection of the External Orbital Apophysis.—The external orbital apophysis is laid bare with a raspatory. The resection is carried out with a cutting forceps. We increase the loss of substance, when necessary, with the gonge-forceps.

Temporary Resection.—For temporary resection we must make two sections of the bone—a superior and an inferior—with the saw with movable back or with the electric saw, and luxate the osseous fragment outwards, preserving its musculo-periosteal connections on that side.

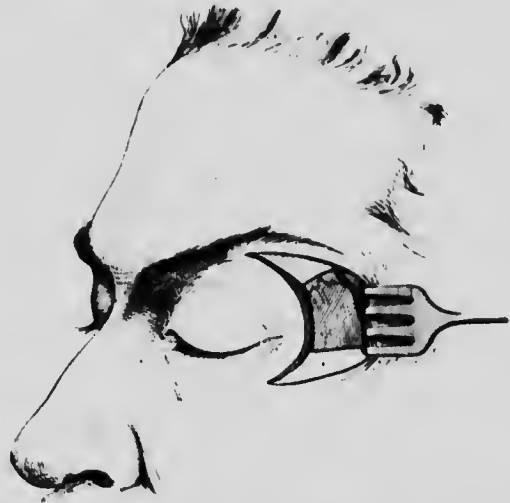

FIG. 973A. RESECTION, TEMPORARY OR DEFINITIVE, OF THE EXTERNAL ORBITAL APOPHYSIS.

Third Stage: Intra-Orbital Manœuvres.—The intra-orbital manœuvres vary according to the lesion which has necessitated the intervention, and are facilitated by traction backwards and outwards of the external lip of the cutaneous wound. This artifice enables us to avoid compromising the motility of the orbicularis palpebrarum muscle in any way, as we leave its nerve filaments intact. The pathological tissues are thoroughly destroyed by curettage followed by electro-coagulation.

Fourth Stage: Suture and Drainage.—A preliminary tamponing is carried out, and the wound is sutured after two or three days. In cases of deep suppuration, we have recourse to tamponing, and ultimately perform a plastic operation.

ELECTRO-COAGULATION OF THE CONTENTS OF THE ORBIT.

When a cancerous growth has infiltrated the whole contents of the orbit, the pathological tissues are destroyed by a combination of curettage and

thermic electro-coagulation. This method is far to be preferred to the procedure of exenteration of the orbit, which exposes the patient to almost inevitable recurrence. Fig. 973*n* represents the cicatrization of an enor-



FIG. 973*n*. ELECTRO-COAGULATION OF MASSIVE CARCINOMA OF THE ORBITAL CAVITY: CICATRIZATION.

mous cancer of the orbital cavity and parietes. A great part of the frontal bone was removed, and the dura mater was exposed over a considerable area; yet the wound has undergone superficial cicatrization. The photograph here reproduced was taken forty months after the operation.

Operations on the Lachrymal Glands.

TRAUMATIC AND INFLAMMATORY LESIONS.

Wounds and Abscess.—A wound or abscess of the lachrymal gland may be followed by a cutaneous or palpebral fistula, complicated or not with a retention cyst—*fistulous dacryops*. Such fistulae are treated by extirpation of the lachrymal gland and fistulous tracts. The general treatment consists of administration of mycolysine, both by the mouth and hypodermically.

Extirpation of the Healthy Lachrymal Gland.—Extirpation of the lachrymal gland and its two processes, orbital and palpebral, is carried out in obstinate cases of epiphora.

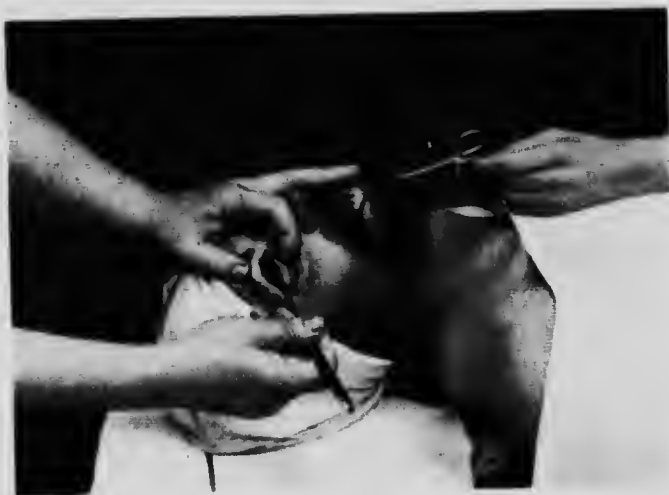

FIG. 974. ABLATION OF LACHRYMAL GLAND.
Cutaneous incision

1. **Extirpation of the Orbital Gland—First Stage.**—Incision of the skin along the lower margin of the eyebrow in its outer half.

Second Stage. Incision of orbicularis muscle, and exposure of the superciliary arch in the vicinity of the lachrymal fossa, after incision of the aponeurotic expansion of the upper eyelid.

Third Stage.—The gland, when recognized by the index-finger, is grasped with a ringed forceps or drawn out with a curette; it is then removed after crushing its neuro-vascular pedicle, which must be tied with fine silk if some bleeding continues.

Fourth Stage.—Suture of skin with separate points; drainage.

2. **Extirpation of the Palpebral Gland—First Stage.**—The patient lies on his back, and the upper eyelid is turned back with a Desmarres' retractor; the globe of the eye is drawn downwards and inwards with a fixation forceps.



FIG. 975. EXPOSURE AND EXTRACTION OF THE ORBITAL LACHRYMAL GLAND.

Beneath it is seen a lobule of the palpebral lachrymal gland.

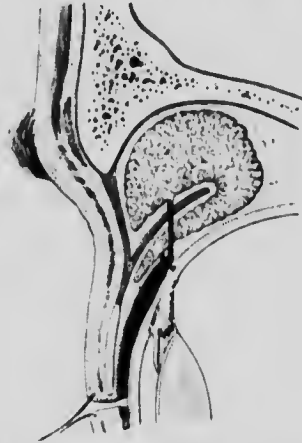

FIG. 976. VERTICAL ANTERO-POSTERIOR SECTION, SHOWING THE LOCATION OF THE ORBITAL LACHRYMAL GLAND AND OF ITS EXCRETORY CANAL; ALSO THAT OF THE PALPEBRAL PROLONGATION OF THE GLAND.

which is placed on the upper and outer aspect of the cornea. This manoeuvre causes the palpebral lachrymal gland to project in the outer part of the conjunctival cul-de-sac.

Second Stage.—Incision of conjunctiva from within outwards; exposure and excision of the glandular lobules, which are surrounded with a resistant cellular sheath.

TUMOURS.

Benign Tumours.

Cysts.—Simple cysts (dacryops) are rare, and are removed by the conjunctival route; if voluminous and in relation with the orbital part of the gland, the operation should be carried out by cutaneous incision.

Malignant Tumours.

Malignant tumours of the lachrymal gland are in most cases formed of a special tissue, to which has been given the name of *cyliadroma*. These tumours may undergo a rapid evolution, with invasion of the cervical glands. Epithelioma may also be met with.

Extirpation is effected while limiting the incision, so far as is possible, to the circumference of the orbit, and avoiding injury to the orbicular branches of the frontal nerve. The same technique is adopted as in ablation of the

healthy gland. We must avoid slicing or tearing the tumour, and complete hæmorrhage must be carried out. The wound may be tamponed, and left for forty-eight hours before suturing the skin. In grave cases we must extirpate the affected cervical glands, and treat the walls of the cavities which contained the original growth and the affected glands, respectively, with thermic electro-coagulation produced by a current of medium intensity.

Resection of the Branches and of the Trunk of the Ophthalmic Nerve.

Resection of the Frontal Nerve.—Resection of the frontal nerve is easily effected through an incision parallel to the eyebrow in its median portion, and without previous shaving of the hairs. The supra-orbital notch is found about two fingers' breadth from the middle line.



FIG. 977.—RESECTION OF FRONTAL NERVE.

Second stage: Exposure of the external frontal nerve at its exit from the supra-orbital notch.



FIG. 978.—RESECTION OF FRONTAL NERVE.

Third stage: Drawing downwards the contents of the orbit.

When the external frontal nerve has been exposed, we can find the internal a little to the inner side of the supra-orbital notch; also the supra-trochlear branch, when present. The eyeball is pressed out from the orbital cavity with a spatula, and the nerve is followed backwards as if we wished to resect the ophthalmic trunk in the vicinity of the sphenoidal fissure. The arteries of the region are of no importance. We tie those which are found bleeding.

OPERATION.—First Stage.—Curvilinear cutaneous incision parallel to the lower margin of the eyebrow, and continued along the orbital border.

Second Stage.—Section of the orbicularis muscle. Exposure of the internal frontal nerve at its emergence from the supra-orbital foramen or notch.

Third Stage.—The eyeball and levator palpebre, above which the frontal nerve passes, are depressed with a spatula; and the bifurcation of the main trunk is then exposed at a depth of about 2 centimetres. The two branches are drawn up with a strabotomy hook (Fig. 978), and the common

trunk is divided as near the sphenoidal fissure as possible (Fig. 979). Care must be taken to isolate the nerve fully, so as not to injure the neighbouring trunks.

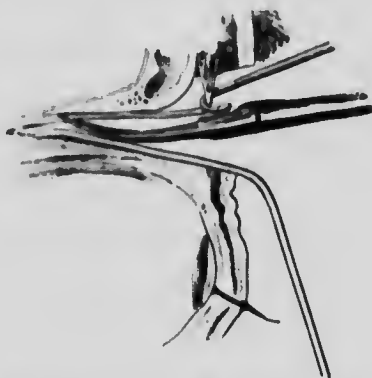

FIG. 979.—RESECTION OF FRONTAL NERVE.

Third stage.

Fourth Stage.—Extirpation of the diverging branches of distribution of both nerves, the external and internal frontal, which are rolled on a hemostatic forceps. We tear them off as completely as possible from the superciliary region where they are distributed.

Fifth Stage.—Suture of the skin; drainage.



FIG. 980.—RESECTION OF FRONTAL NERVE.

Fourth stage: Tearing off the fibres of distribution of both nerves—the external and internal frontal.

Resection of the Nasal Nerve.—The trunk of the nasal nerve is difficult of access. For simultaneous resection of both internal and external nasal branches—that is to say, for attainment of the trunk of the nasal nerve itself—we must make a curvilinear incision of about 4 centimetres in length along the inner part of the eyebrow.

OPERATION—First Stage.—Curvilinear cutaneous incision along the lower border of the inner half of the eyebrow, ending above the tendon of the orbicularis.

Second Stage.—Incision of the orbicularis and detachment of the muscle and subjacent tissues with the raspatory.

Third Stage.—Elevation with a strabismus hook of everything lying on the periosteum, behind the orbicularis and inside the internal rectus muscle. We recognize and isolate the two or three nerve bundles, taking care not to tear any of the fibres.

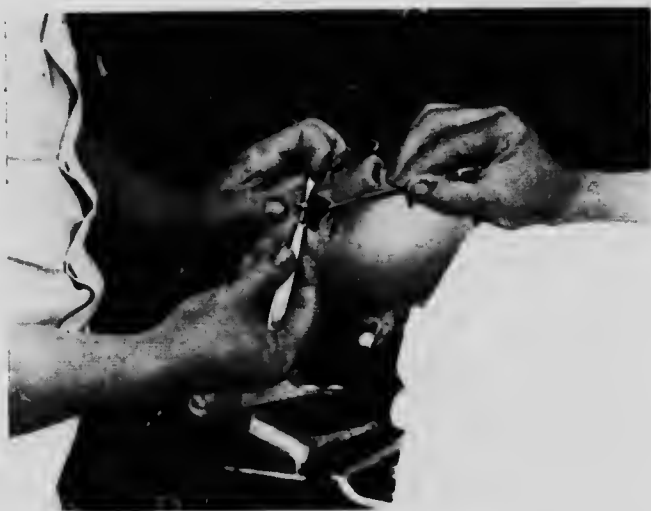

FIG. 981. EXPOSURE OF THE FRONTAL NERVE AT ITS EXIT FROM THE SUPRA-ORBITAL NOTCH.

Fourth Stage.—The decollation is continued into the depth of the orbital cavity and in contact with the periosteum till the internal nasal nerve is recognized, stretched like a small white cord, passing into the antero-internal nasal canal at a distance of about 3.5 centimetres from the inner margin of the orbit.

We may also strip the periosteum from the subjacent bone, starting from the margin of the orbit, till we perceive this same nasal nerve stretched at the bottom of the wound.

Fifth Stage. We now need but to follow the internal nasal nerve backwards, and the bifurcation is almost immediately reached, and the common trunk is then divided beyond.

Sixth Stage.—Tearing off the peripheral ends of both nerve branches and the terminal twigs of the external nasal.

Seventh Stage.—Suture of skin; drainage.

Resection of the Lachrymal Nerve—**OPERATION**—*First Stage*.—Curved incision along the outer half of the margin of the eyebrow.

Second Stage.—Incision of orbicularis, and exposure of margin of orbit.

Third Stage.—Exposure of lachrymal gland, which is recognized with the index-finger. We find the lachrymal nerve lying along its upper surface. The gland may be extracted in order to facilitate the discovery of the nerve.

Fourth Stage.—Section of the trunk of the nerve as far back in the orbit as possible, and tearing away of the peripheral extremity and its branches.

Fifth Stage.—Suture of skin; drainage.



FIG. 982. RESECTION OF NASAL NERVE.

First stage: Exposure of the external nasal branch.

Resection of the Trunk of the Ophthalmic Branch of the Trigeminal Nerve.—The trunk of the ophthalmic branch can be reached at the bottom of the orbit by following the external frontal nerve backwards.

OPERATION—*First Stage*.—Incision of the skin along the lower border of the eyebrow from the external to the internal orbital apophysis, and exposure of the external frontal nerve, as above described.

Second Stage.—All the tissues lying below the periosteum of the roof of the orbit are depressed with a spatula, and the trunk of the frontal nerve is raised on a small hook, which is then pushed backwards to the origin of the lachrymal nerve. The nasal nerve branches off from the ophthalmic trunk at a few millimetres from that point, so that it is enough to divide the latter at a distance of 10 or 12 millimetres behind the origin of the lachrymal nerve, to make sure of having reached the main trunk.

Third Stage.—Suture; drainage.

We ascertain the insensibility of the cutaneous area supplied by the terminal filaments of the external nasal branch.

Resection of the Superior Maxillary Nerve and of Meckel's Ganglion.

Resection of the Infra-Orbital Nerves—*OPERATION*—*First Stage*.—Curvilinear cutaneous incision of 4 to 5 centimetres, parallel to the inferior margin of the orbit.

Second Stage.—Incision of the orbicularis muscle, and exposure of the orbital margin with the raspatory; which is then used to remove the periosteum in front and below, so as to bring the infra-orbital nerve into view at the point of its emergence from the infra-orbital foramen.

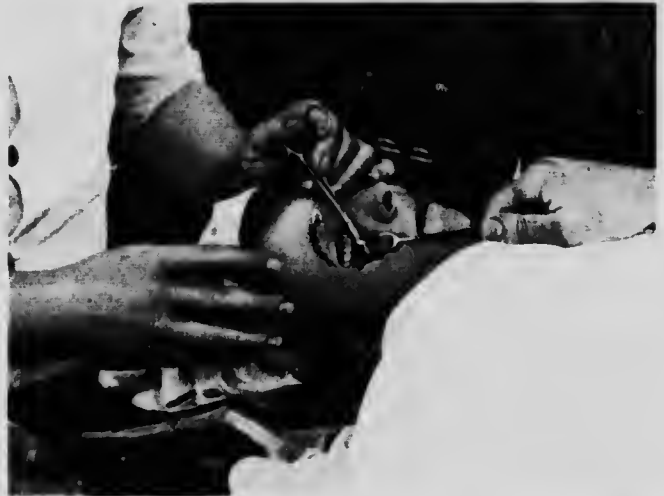

FIG. 983. EXPOSURE OF THE EXPANDING BUNDLE OF THE INFRA-ORBITAL NERVE AT ITS POINT OF EXIT THROUGH THE INFRA-ORBITAL FORAMEN.

The frontal nerve had been previously resected.

Third Stage.—Exposure of the infra-orbital nerve in its osteo-fibrous groove. The soft parts of the orbital cavity have been raised with a spatula, and the nerve laid bare by incision of its fibrous sheath.

Fourth Stage.—Section of the nerve and tearing away the terminal nerve-bundle. The nerve is raised on a hook and isolated down to the back of the orbit. It is then divided at that point. The nerve trunk is now drawn outwards with a blunt hook through the infra-orbital foramen, and torn off with its bundles of fibres diverging for terminal distribution.

Fifth Stage.—Suture of skin with clips. Small glass drainage-tube.

Resection of the Trunk of the Superior Maxillary Nerve and of Meckel's Ganglion. Complete resection of the superior maxillary nerve and of Meckel's ganglion is very much to be preferred to resection of the infra-orbital nerve. This operation is carried out through a cutaneous incision similar to that used in resection of the infra orbital nerve.

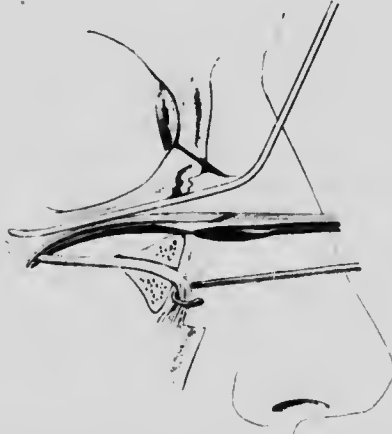

FIG. 984.—RESECTION OF THE INFRA-ORBITAL NERVE.

The contents of the orbital cavity have been raised with a retractor; section of the infra-orbital nerve with curved seissors.



FIG. 985.—RESECTION OF SUPERIOR MAXILLARY NERVE AND OF MECKEL'S GANGLION.

Exposure of the infra-orbital nerve in the osseous infra-orbital canal.

712 SURGICAL THERAPEUTICS AND OPERATIVE TECHNIQUE

First Stage.—Cutaneous incision of 5 centimetres, parallel to the inferior margin of the orbit.

Second Stage.—Incision of the orbicularis muscle and exposure of the orbital margin, the infra-orbital nerve trunk, and the expanding bundle of its fibres.

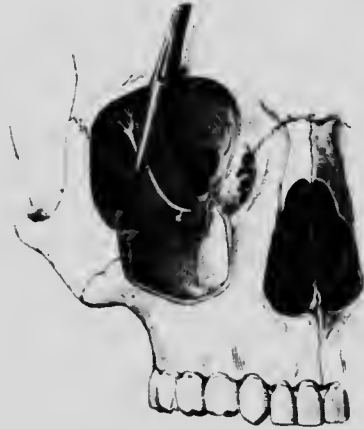

FIG. 986.—RESECTION OF SUPERIOR MAXILLARY NERVE AND OF MECKEL'S GANGLION.

Fourth stage: The infra-orbital nerve is drawn upwards; resection of the antero-superior wall of the maxillary sinus, then exposure of its postero-superior wall and of Meckel's ganglion.

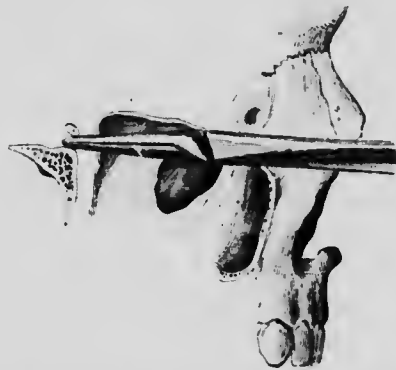


FIG. 987.—RESECTION OF SUPERIOR MAXILLARY NERVE AND OF MECKEL'S GANGLION.

Fifth stage: After section of the superior maxillary nerve at the orifice of the foramen rotundum, the extremity of a haemostatic forceps is introduced into this foramen in order to destroy by rotatory movement the last vestiges of the nerve trunk.

Third Stage.—Opening of the infra-orbital canal, and section of the terminal part of the nerve just before the divergence of its fibres.

Fourth Stage.—The trunk of the infra-orbital nerve is seized with a small haemostatic forceps (Fig. 986), and drawn upwards, while the contents

of the orbit are raised with a retractor. (The soft parts, with exception of the nerve, have been suppressed in Figs. 986 and 987, in order to make these more demonstrative.) We then resect the antero-superior wall of the maxillary sinus with the gouge-forceps; we thus attain the postero-superior wall and the sphenomaxillary fissure. Meckel's ganglion can be clearly distinguished appended to the trunk of the superior maxillary nerve, which we divide at its exit from the foramen rotundum and extirpate with the attached ganglion.

Fifth Stage.—The hemostatic forceps used for prehension of the nerve is introduced at the bottom of the wound into the orifice of the foramen rotundum, and we give it some vigorous movements of rotation, in order to destroy the last traces of the nerve therein contained.

Sixth Stage.—Suture and drainage of the cutaneous wound.

This operation secures the destruction of the whole trunk of the superior maxillary nerve and of its branches, including the sensory root of the sphenopalatine ganglion and the posterior dental nerves.

OPERATIONS ON THE OLFACTORY APPARATUS.

Exploratory Procedures.

EXTERNAL INSPECTION.

Before proceeding to explore the nasal fossae, the surgeon should carefully note the external aspect of this region. The degree of permeability of each nasal fossa can be estimated by making the patient breathe and sniff through each nostril exclusively in its turn.

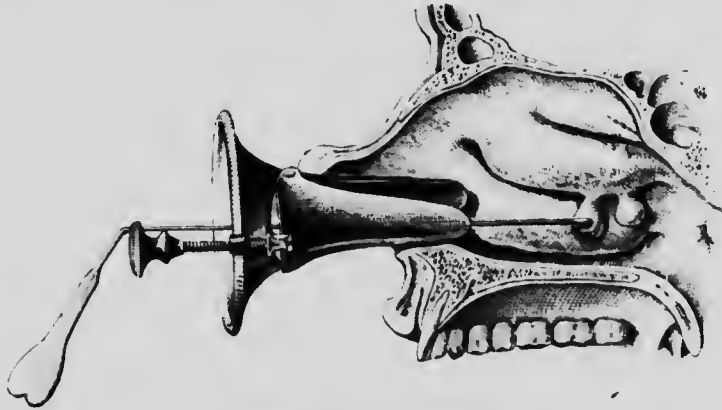


FIG. 988. ANTERIOR RHINOSCOPY.

Exploration of a polypus of the middle turbinated bone with bulbous stilet.

Rhinoscopy—1. **ANTERIOR RHINOSCOPY.**—Rhinoscopy, or examination of the nasal fossae, is habitually carried out in a dark chamber. The pro-

cedure requires a strong light—petroleum lamp, Auer burner, incandescent lamp with polished glass and frontal mirror, or perhaps a Clar's frontal electric lamp with convergent mirror.

The patient is seated before the surgeon. The nasal speculum is introduced, and opened very gently, taking care not to injure the anterior extremity of the inferior turbinated bone. The patient should hold the head upright, without leaning it backward; he must allow himself to be guided by the surgeon, who will explore all parts of the nasal fossæ.

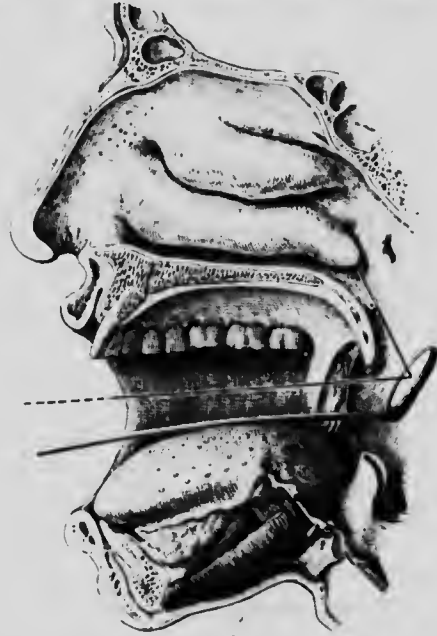


FIG. 989.—POSTERIOR RHINOSCOPY.

Examination of the extremity of the inferior turbinated bone.

2. POSTERIOR RHINOSCOPY.—Posterior rhinoscopy is carried out with a laryngeal mirror of small diameter. The patient should breathe through the nose with closed lips; then open the mouth partly, letting the tongue fall within the circumference of the inferior dental arch by its own weight, the soft palate remaining pendulous. The mirror is passed completely behind the soft palate, in docile patients without use of a tongue-depressor, which is necessary in some in order to lower the base of the tongue and permit introduction of the mirror.

DIGITAL EXPLORATION.

Digital examination of the pharynx enables us to recognize readily the volume of adenoid vegetations

EXAMINATION OF THE FRONTAL SINUS BY TRANSLUCENCY.

This examination is carried out in a perfectly dark enclosure, with a small electric lamp which is furnished with a special fitting for each locality to be explored.

Illumination of the Frontal Sinus.—The lamp, which is furnished at its extremity with a cylindro-conical tube, is applied beneath the superciliary arch, at the level of the superior wall of the orbit. We thus recognize above the eyebrow the roseate tint which characterizes the extent of the vacuous space of the sinus.



FIG. 990.—DIAPHANOSCOPY OF THE FRONTAL AND MAXILLARY SINUSES.

Illumination of the Maxillary Sinus.—The lamp, furnished with a gutter-shaped mantle, which leaves it exposed on its superior aspect, is placed within the patient's mouth in the middle line. The antero-external wall of the sinus then appears as a large roseate crescent, which, in a case of empyema, is absent on the affected side.

Thermal Galvano-Cautery.—Whenever cutting instruments cannot be employed galvano-cautery is the method of election in the modifying surgery of the nasal fossæ. The best cautery is a platinum loop of 18 to 20 millimetres in length, to which the surgeon has given the appropriate form. Flat and button cautery instruments are inconvenient and useless.

Serre-Nœud.—The *serre-nœud* is still in current use for ablation of polypi of the nasal fossæ. I prefer to it the new polypus-forceps, described in Figs. 390 to 399). The mode of application will be subsequently described.

Affections of the Nose and Nostrils.

TRAUMATIC LESIONS.

Wounds.—Wounds of the nose require very careful reparative treatment. An agglutinating application will suffice for small wounds (Vigier's oxide of zinc plaster).

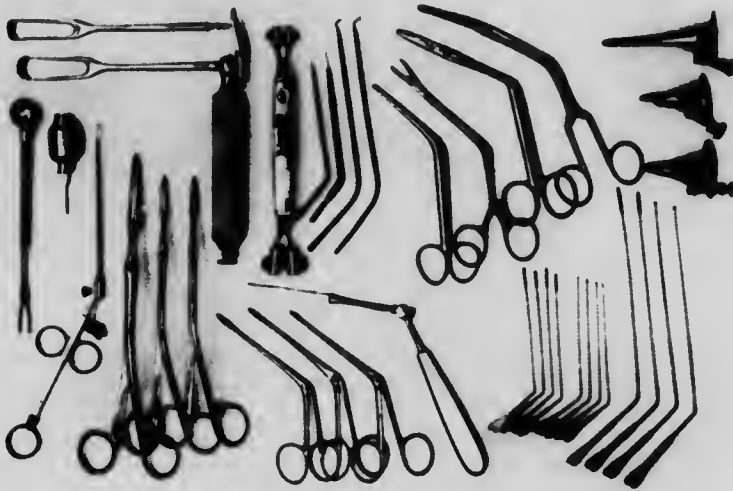


FIG. 394. INSTRUMENTS FOR EXPLORATION OF THE NASAL FOSSÆ AND FOR OPERATIONS ON THE TERMINATED BONES AND MEATUSES.

From right to left: One long rhinoscope, one shorter rhinoscope with mobile valve for the meatus, one ordinary rhinoscope, two long buttoned stylets, two long stylets for introduction of cotton, four short hollow stylets, four short stylets for cotton, two fragment forceps, one forceps for foreign bodies, one bent scissors, four selected cauteries, and one handle for interrupting. Below: One detachable saw for spurs of the meatus and three bent forceps; to the left and above: two Lermoyez planes for spurs of the meatus; below: A diaphanoscope for illumination of the maxillary sinus and a mantle for illumination of the frontal sinus, one *serre-nœud*, and three Hoyer's gouge-forceps for ablation of mucous polypi and abrasion of tungating inferior turbinated bones. (Scale of 1 : 4.5.)

When suturing is indispensable, we apply an intradermic suture of silver wire, or very fine Florentine hair, or of No. 1 silk.

Complete Amputation of the Nose.—Suture of a part of the nose which had been completely detached has often been followed by complete success. We have seen the procedure succeed when adopted after the lapse of an hour. The detached portion should be preserved in a tepid 1 per cent. saline solution. Interrupted suture is adopted, made with very fine silk.

Gun-Shot Wounds.—Wounds of the nasal fossæ with revolver bullets are often complicated by penetration of the projectile into the cavity of a sinus, or its fixation in the base of the skull. The diagnosis is made with the help of the X rays.

Fractures.—Comminuted and compound fractures, with contused surrounding tissues, are treated by tamponing. Such fractures may extend into the anterior fossa of the base of the skull. I have seen, with my friend Dr. Bourcart of Cannes, a case of fracture of the root of the nose and ethmoid bone produced by the stroke of the end of a ladder of 5 metres in height. The wounded man was thrown to the ground in a state of unconsciousness. Cicatrization was obtained after removal of the splinters and tamponing, followed by secondary suture; but—an inexplicable fact!—the injured man, who was then thirty years old, was struck with *absolute impotence* from the date of the accident. This state of absolute impotence has persisted ever since.

Fractures of the nasal bones are easily reducible by massage, which enables us to restore the organ to its normal form. Reduction of the depressed fragments is effected through the nostrils, and must be maintained by firm plugging, which should be repeated as often as appears necessary.

INFLAMMATORY AFFECTIONS.

Furuncles of the alæ nasi are very painful, and may be complicated with facial and ophthalmic phlebitis. Rapid amelioration is procured by the use of mycolysine by the mouth and hypodermically. If suppuration takes place, we must remove the core through a small opening made with the thermo-cautery.

DEFORMITIES: CONGENITAL AND ACQUIRED.

Absence of the Skeleton of the Nose.—Absence of the skeleton of the nose is met with in some cases of complicated hare-lip. The subjects of it present an almost normal facial aspect: a profile view, however, shows that the prominence of the nose is almost completely absent. This deformity can be remedied by one of the operations subsequently described.

Bifid Nose Double Nose.—A bifid nose must be treated by a plastic operation, which varies with the individual case, with subsequent osteo-cartilaginous resection of the portions of the skeleton which happen to be exuberant.

Asymmetry of the Alæ Nasi.—The narrower nostril is detached, a small crescent of skin is then removed, and the nostril is sutured in a position more removed from the median plane.



FIG. 992. BIFID NOSE.

The cuneiform resection necessary to remove the deformity is indicated by the dotted line.



FIG. 993. ASYMMETRY OF THE ALÆ NASI.

The two curvilinear incisions circumscribe the small flap to be excised in order to establish symmetry.



FIG. 994. ASYMMETRY OF THE ALÆ NASI.

The narrower nostril is mobilized and carried outwards, to be sutured to the external lip of the artificial wound.

The margin of the narrower wing of the nose is circumscribed by a curvilinear incision along the nasogenial groove. A second incision, external to, and meeting the former at both extremities, then circumscribes

the cutaneous flap, which must be excised in order to establish the symmetry of the nostrils (Fig. 993). The reunion is made by interrupted suture with fine silk.

Deviation of the Nose.—Spontaneous or traumatic deviation of the nose may, when very pronounced, require surgical intervention. This is effected through the subcutaneous route.

OPERATION First Stage.—Transverse horizontal incision along the gingivo-labial fold. In this way no visible cicatrix is left.

Second Stage. Subcutaneous section and mobilization, with a chisel of suitable size, applied from below upwards and parallel to the skeleton of

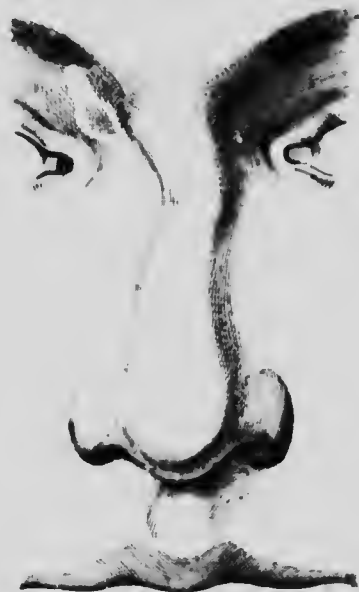

FIG. 995. ABNORMAL DEVIATION OF THE NASAL BONES.

This deformity can be corrected by osteoclasis.

the jaws, of the whole nasal skeleton; which then remains attached only at its upper part, by the junction of the nasal bones to the frontal and perpendicular plate of the ethmoid.

Third Stage. Fracture of the base of the nasal bones by sharply striking the root of the nose on the bulging side with a mallet.

Fourth Stage. Fixation of the nose in its new position, with the aid of some points of suture introduced through the buccal incision. The reunion should be attentively watched; the nose must be supported in its new position for two weeks by a prothetic piece, or with two rolls of gauze kept in position by a circular dressing.

Osteoclasis. When the projection of the nasal bones is extremely limited, the condition may be corrected by osteoclasis.

OPERATION.—The cutaneous elevation is protected with a tartarian compress of fifteen or twenty folds, or by a piece of india-rubber of 4 or 5 millimetres in thickness. It is then broken down with a violent stroke of a mallet. The copper mallet used produces, when dexterously manipulated, a comminuted fracture of the whole of the projecting region. It suffices then to mould it with the fingers in order to establish the form desired. A temporary prothetic gutta-percha apparatus can be applied.

Depression of the Nasal Bones.—The ungraceful depression which is produced in certain diathetic affections, and which may also be the effect of traumatism, can be repaired through the subcutaneous route.

OPERATION: 1. BY THE BUCCAL ROUTE—First Stage.—Incision of the gingivo-labial fold, and denudation with a raspatory of the outer wall of the maxillary sinus.

Second Stage.—Mobilization with mallet and gouge at the expense of the orbital ankylosis of the superior maxilla of an osseous fragment of



FIG. 996.—DEPRESSION OF THE NASAL BONES.

appropriate dimensions and form, which must be slid into the nasal depression after detachment of the skin with a staphylorrhaphy raspatory.

2. NASAL ROUTE.—The osseous fragment is first procured from another part of the skeleton. This is washed in a tepid 1 per cent. saline solution, and then introduced into the hollowed locality through an incision made either in the interior of a nostril or at the level of the nasal lobule (Fig. 998).

First Stage.—Aseptic detachment of an osseous fragment of suitable dimensions and form from the posterior border of the scapula. This fragment is preserved in tepid saline solution. It must be cut in tile shape in cases in which the hollow is very deep.

Second Stage.—Transverse incision of the skin, either inside one of the nostrils or at the junction of the nasal lobule and the lower margin of the

septum, followed by detachment of the integuments, with a suitable raspatory to a level beyond that of the depression.

Third Stage.—Introduction of the osseous fragment into the hollow, and suture of the wound.

A compressive dressing is used for a period of eight to fifteen days.

Spur-like Projection of the Dorsum of the Nose.—Resection of spontaneous or traumatic spurs on the dorsum of the nose is carried out as follows: Whether the projection be lateral or median, congenital or acquired, the operation is always performed by the subcutaneous method, by approaching through one or both nostrils. After careful study of the deformity and



FIG. 997. FRESH OSSEOUS FRAGMENT PREPARED FOR THE PURPOSE OF FILLING THE HOLLOW OF THE BRIDGE OF THE NOSE.

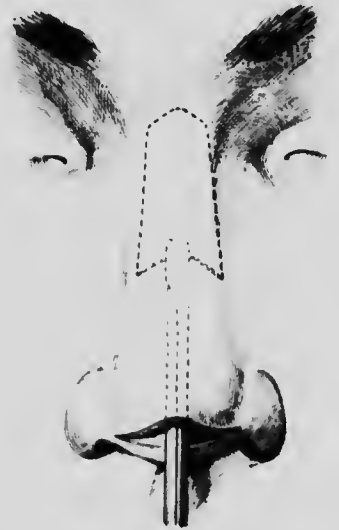


FIG. 998. FRESH OSSEOUS FRAGMENT PREPARED FOR THE PURPOSE OF FILLING THE HOLLOW OF THE BRIDGE OF THE NOSE.

Introduction of the osseous fragment through the subcutaneous route.

evaluation of the result that we wish to obtain, we must prepare two or three gonges with different curves; of which the active extremity is of crescentic form and levelled at the expense of its convex surface (Fig. 1000).

OPERATION. First Stage. Transverse incision of the skin within the margin of one of the nostrils, at a certain distance from the projection which has to be resected.

Second Stage. Detachment of the skin, which is often thinned, to a level beyond that of the elevation to be resected. We must take care to detach the whole thickness of the skin without thinning or perforation.

Third Stage. Mobilization of the osseous projection with mallet and

special gouge, and extraction of the detached fragment with a clawed forceps or curette.

A compressive dressing is applied.

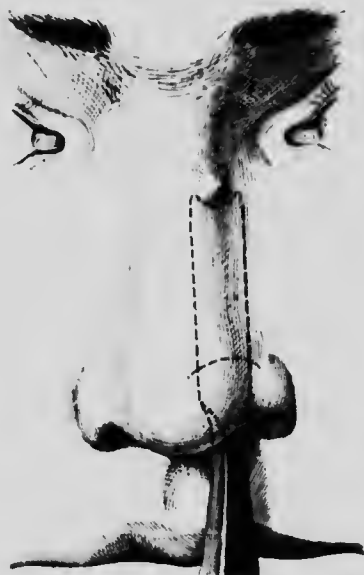

FIG. 999. RESECTION OF AN OSSEOUS SPUR AT THE ROOT OF THE NOSE THROUGH THE SUBCUTANEOUS ROUTE WITH THE AUTHOR'S CRESCENTIC GOUGE.

This technique, which was devised by me in 1902, as well as the special form of gouge represented in Fig. 1000, has given me excellent plastic results in two cases.

Enlargement of the Root of the Nose. Exaggerated post-traumatic enlargement of the root of the nose constitutes a very unpleasant deformity.



FIG. 1000. AUTHOR'S GOUGE, WITH CONCAVE EDGE, BEVELLED AT THE EXPENSE OF ITS CONVEX ASPECT, FOR RESECTION OF EXOSTOSES OF THE NASAL BONES.

more especially in the female. Ablation of the exuberant osseous development is carried out through the subcutaneous *buccal* route.

OPERATION *First Stage*—Incision of the superior gingivo-labial fold on the right side.

Second Stage—Subperiosteal detachment of the soft parts as far as the vicinity of the orbit.

Third Stage—Abrasion of the exuberant osseous tissues with an ordinary gouge of suitable curvature, which has a straight extremity bevelled at

the expense of its convex aspect, followed by extraction of the fragments with forceps.

The operation is repeated on the opposite side.

Compressive dressing.

Vicious Cicatrices—Loss of Substance from the Dorsum of the Nose.—

In cases of vicious cicatrix, or loss of substance dependent on cicatrization of a perforating wound, spontaneous or accidental, or in consequence of the ablation of a small tumour, the procedure of reparation is carried out differently, according as it is concerned with the median or a lateral portion of the nasal organ.

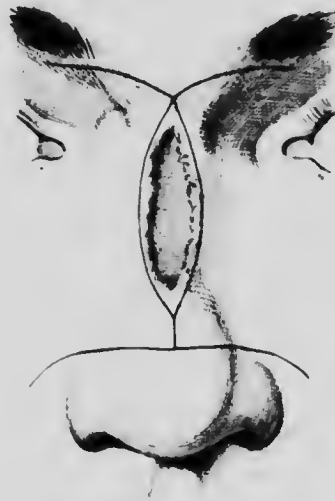


FIG. 1001.—REPARATION OF A CICATRIX ON THE DORSUM OF THE NOSE.

Tracing of antiplastic incisions.
The scar is removed.

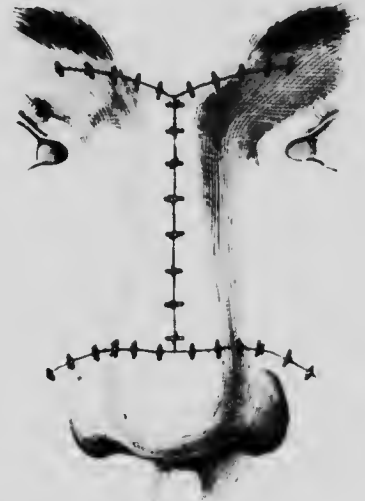

FIG. 1002.—REPARATION OF A CICATRIX ON THE DORSUM OF THE NOSE.

Edges of cutaneous wounds united with interrupted suture.

MEDIAN RHINOPLASTY—First Stage.—When the cicatrix or perforation is in a median position, and in general when it is of small dimensions, the peripheral tissues are left in a healthy and mobile state. The lesion is then circumscribed with two clearly defined curvilinear incisions, and extirpation of the affected tissues is carried out.

Second Stage.—Two lateral incisions are made on each side, one above and the other below the level of the cicatrix (Fig. 1001), for the purpose of freeing the skin which is then detached from the periosteum on each side as far as seems necessary.

Third Stage.—Interrupted suture, with fine silk or Florentine hair.

LATERAL RHINOPLASTY—First Stage.—The lesion is circumscribed by a very clearly defined incision made in the healthy tissues, and the affected parts are extirpated.

Second Stage.—The surgeon estimates with the fingers the displaceability of the skin of the cheek in a direction parallel to the naso-genial groove, and traces with a double incision downwards and outwards, and slightly divergent, a trapezoid flap of skin which can be made to fill the place of the loss of substance by sliding displacement.

Atresia of the Nostrils.—Reparation of atresia of the nostrils, whether congenital or cicatricial, requires sliding displacement of a cutaneous flap raised from the naso-genial furrow. The flap is cut in the manner (represented in Figs. 1003 and 1004) adopted in reparation of the ala nasi.

Obliteration of the Nostrils. Obliteration of the nostrils, congenital or cicatricial, is often constituted by the presence of a membrane of only slight thickness; but this membrane is reproduced after its removal with

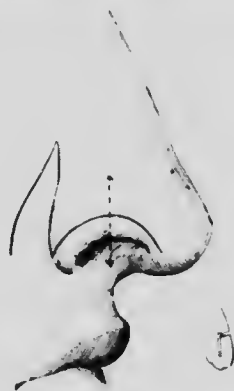

FIG. 1003. LOSS OF SUBSTANCE OF THE ALA NASI.

Autoplasty by sliding displacement of vertical cutaneous flap.



FIG. 1005. SECTION SHOWING THE DISSECTION OF THE MARGIN OF THE NOSTRIL.

Loss of substance of ala nasi; suture.

FIG. 1004. SECTION SHOWING THE DISSECTION OF THE MARGIN OF THE NOSTRIL.

FIG. 1006. SECTION SHOWING COMPACTION OF FLAP.

the bistoury, followed by formation of a circular cicatrix. It is then necessary to carry out an autoplasty with sliding displacement, by a procedure similar to that described under the heading of "Atresia of the Nostrils."

Loss of Substance of the Ala Nasi.—Reparation of the ala nasi, after partial or complete destruction, can be effected by detachment between two incisions of a cutaneous bridge formed from the side of the nostril and nasolabial fold, to be raised in the form of a loop for the reconstitution of the ala nasi. This procedure has given me a satisfactory plastic result in a case of almost complete destruction of the ala nasi by burn.

When the skin adjoining the loss of substance is healthy, we can obtain satisfactory reparation by tracing and mobilizing a small triangular vertical

flap in the naso-genial groove (Fig. 1003). The seat of loss of substance is circumscribed with a curvilinear incision, and the little cutaneous flap is brought down in such a way as to obtain the remnant represented in Fig. 1005 and adjoining diagram.

Restoration of the Nasal Septum.—The septum can always be repaired, with a flap cut from the naso-labial fold on the side more favourable for the adaptation, or, if there appears to be an advantage in the direction of symmetry, with two symmetrical flaps with labial pedicles. These flaps are united, first to the lobule of the ala nasi, then on either side to the lower part of the septum, and finally to one another in the median line.

Restoration of the Lobule of the Ala Nasi.—Restoration of the nasal lobule depends simultaneously on the extent of the loss of substance and the condition of the tissues. If the loss of substance has reached a certain extent, we must adopt the procedure of bringing up and fixing in position for eight or ten days a cutaneous flap raised from the inner surface of the arm.

Total Rhinoplasty. Complete restoration of the nose requires the existence of a sufficient skeleton. We cannot rely on artificial prothetic applications, which are never to be depended on for a durable result. I will here first describe the reproduction of the nasal skeleton at the expense of the ascending process of the superior maxilla. I will then proceed to describe the restoration of the nose. The Italian method is preferable to the Indian, inasmuch as it demands no further loss of substance in the neighbourhood of a deformity which is sufficiently disfiguring already.

The flap is taken from the anterior aspect of the arm, and in the position at which the coaptation will be least irksome to the patient. The left arm is to be preferred. We must always calculate on a contraction of nearly half the measurement of the flap, both in length and breadth.

1. RECONSTRUCTION OF THE SKELETON OF THE NOSE. When the skin still exists, and the question is one of re-establishing the normal projection of the skeleton of the nose, the best procedure is that of cutting out two suitable nasal bones from the respective ascending processes of the superior maxillary, then bringing these to meet in the middle line and uniting them in that position. This operation requires complete mobilization of the skin of the nose, with preservation of its superior pedicle.

The reconstruction of the skeleton of the nose can be attempted by the same procedure when the teguments have been partially destroyed. In such case the procedure will form the preliminary to that of rhinoplasty after the Italian method.

OPERATION. *First Stage.* Vertical median incision, followed by dissecting up the nasal integuments laterally, which are turned over to the respective right and left sides, with the help of liberating superior and inferior incisions (Fig. 1007).

Second Stage. Two osseous shutters are traced out with the cutting forceps as shown in Fig. 1007, at the expense of the ascending process of the

superior maxilla. Those two osseous shutters, isolated below and on the outer side, remain fixed at the respective sutures with the frontal bone and with what remains of the nasal bones. The shutters are then grasped each in turn with a strong forceps, and the superior pedicle is fractured so as to permit their coaptation along the middle line (Fig. 1008).

Third Stage.—Reunion of the osseous shutters along the middle line by four points of interrupted suture with fine silk, and suture of the inferior extremity of each to the corresponding projecting angle of the ascending process of the superior maxilla, in such a way as to re-establish the skeleton of the nose with its normal prominence.




FIG. 1007. RECONSTRUCTION OF THE NASAL SKELETON AT THE EXPENSE OF TWO OSSEOUS SHUTTERS CUT FROM THE ASCENDING PROCESSES OF THE RESPECTIVE SUPERIOR MAXILLÆ.



FIG. 1008. THE SAME.

Mobilization of the two osseous shutters, which are then united in the median line, and fixed below to the projecting angle of the ascending process of the superior maxilla.

Fourth Stage.—The edges of the skin are brought together with points of interrupted suture, as represented in Fig. 1002.

If the available skin proves insufficient to cover the nasal skeleton thus reconstructed the wound must be left to granulate, and restoration of the integument by the Italian method can be resorted to at a later date.

2. RESTORATION OF THE INTEGUMENT OF THE NOSE. Restoration of the nasal integument by the Italian method requires two successive operations. In the first we affix to the nasal region a brachial cutaneous flap, which remains adherent to its nutritive pedicle. In the second operation we detach the flap, which has now become part of the living tissue of its new position from the arm, and complete the procedure of rhinoplasty.

FIRST INTERVENTION—First Stage.—Vivification of the skin bordering the area of loss of nasal substance, above and at each side.

Second Stage.—Mobilization of a brachial flap of exaggerated dimensions, which must be left adherent in its new position of implantation for an interval of ten to twelve days.

Third Stage.—Suture of the brachial cutaneous flap to the vivified surface prepared for its reception. Fixation of the arm and forearm to the head with an immovable apparatus.

SECOND INTERVENTION.—At the end of five or six days, when the vitality of the brachial flap has been assured, we partially divide it, and ascertain whether the circulation in the mobilized flap is satisfactory.

THIRD INTERVENTION.—Three days later we detach the brachial flap completely and finish the autoplasty.

First Stage.—The cutaneous brachial flap, wholly detached from its nutritive pedicle, is adapted to the area which it is intended to cover. It requires to have exuberant dimensions.

Second Stage.—Vivification of the inferior nasal region is carried out. This stage of the operation varies greatly with the individual case, and is largely subordinate to the pre-existing deformity.

Third Stage.—Definitive adaptation and autoplastic suture of the flap.

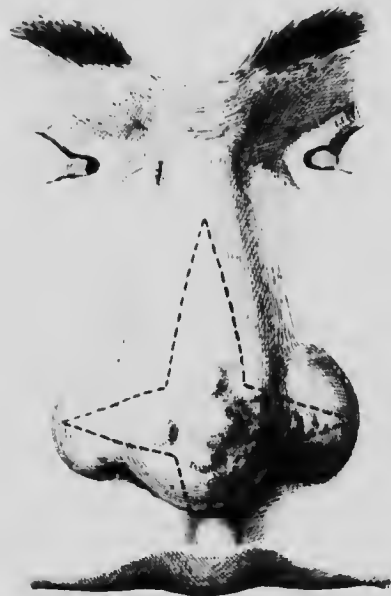

FIG. 1009. — ELEPHANTIASIS OF THE NOSE.
Stellate resection of exuberant parts.

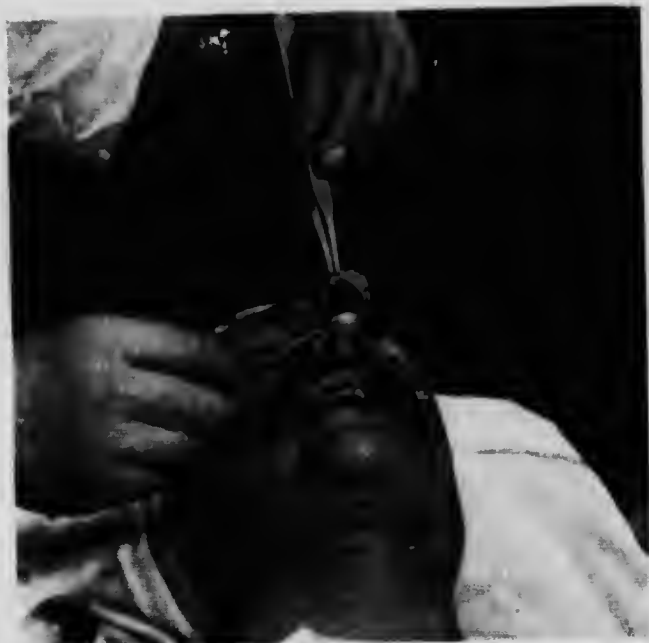

FIG. 1010.—ELEPHANTIASIS OF THE NOSE.
Resection of the exuberant tissues.

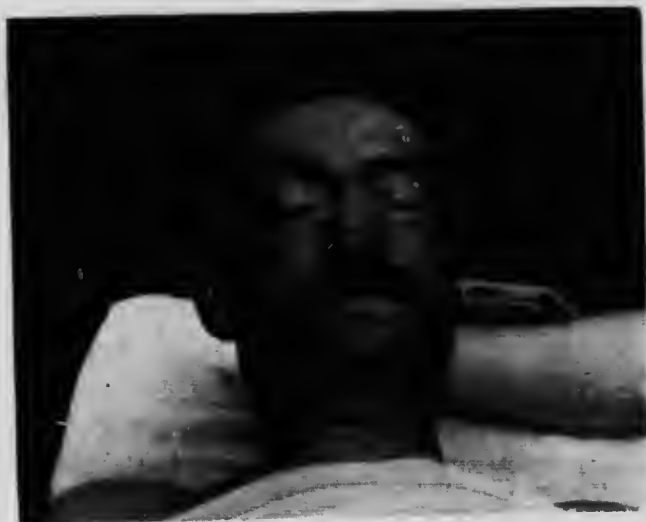

FIG. 1011. ELEPHANTIASIS OF THE NOSE.
Suture of the wound.

TUMOURS.

Benign Tumours.

Elephantiasis of the Nose—Hypertrophic Acne.—This affection is treated by resection of the exuberant parts. The operative technique is subordinated to the individual case. A cruciform resection of the parts which are most altered is carried out, while preserving, with a view to restoration, those intervening portions of skin which are nearly healthy. The osteo-cartilaginous skeleton must be adjusted with great care.

The resection of a hypertrophied lobule of the nose is outlined in Fig. 1009; the tracing is that of a star with four rays. In some cases we can avoid partial resection of the septum, as shown in Figs. 1010 and 1011.

Malignant Tumours.

Superficial Epithelioma. Epithelioma should be destroyed at the earliest possible date. The small superficial sessile epitheliomata can be removed with the curette; the surface of implantation is then treated by thermic electro-coagulation. Finally, if the condition of the cicatrix demands it, we perform an autoplasmic operation.

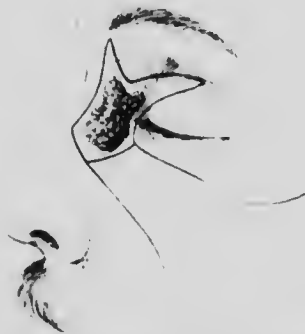

FIG. 1012. EXCISION OF A CANCEROID OF THE LATERAL PORTION OF THE ROOT OF THE NOSE.

Tracings of the stellate incisions and autoplasmic flap.

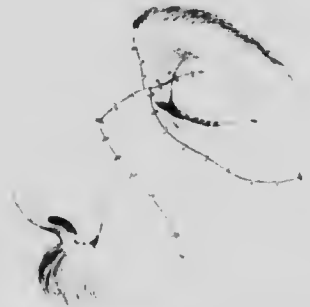


FIG. 1013. EXCISION OF A CANCEROID OF THE LATERAL PORTION OF THE ROOT OF THE NOSE.

Result obtained by stellate suture combined with sliding displacement of the infra-orbital flap.

Ablation of a lateral epithelioma of the root of the nose may involve a rather extensive loss of substance. The resulting cicatrix may ultimately be covered in by the sliding displacement of an infra-orbital cutaneous



FIG. 1014.—EXTRACTION OF A CANCROID OF THE LATERAL PORTION OF THE ROOT OF THE NOSE.

Stellate incision made to facilitate sliding displacement of the autoplasmic flap.



FIG. 1015.—EXTRACTION OF A CANCROID OF THE LATERAL PORTION OF THE ROOT OF THE NOSE.

Tracing and mobilization of infra-orbital flap destined to cover the principal loss of substance.

flap. The operation is represented by the designs shown in Figs. 1012 and 1013, and by Figs. 1014 and 1015, which make clear all the details.

Osteosarcoma.—Osteosarcoma of the ascending process of the superior maxilla may first develop in the direction of the cavity of the nasal fossa, and is then recognized by rhinoscopy. The diagnosis is confirmed by the microscope, and the tumour is then destroyed by thermal electro-coagulation. This intervention is carried out either through the natural passages or an incision of sufficient extent to expose the neoplasm.

Affections of the Nasal Fossæ.

FRAGMENTIC LESIONS.

Hæmatoma of the Septum.—Hæmatoma consecutive to fracture of the septum is bilateral, and the two foci communicate. The contents are evacuated by a small incision. The nostrils are plugged in order to secure reposition of the mucous membrane in contact with the deeper tissues.

Obstinate Epistaxis.—Obstinate epistaxis is treated by plugging of the nasal fossæ with a long compress of gauze. This compress should be drawn

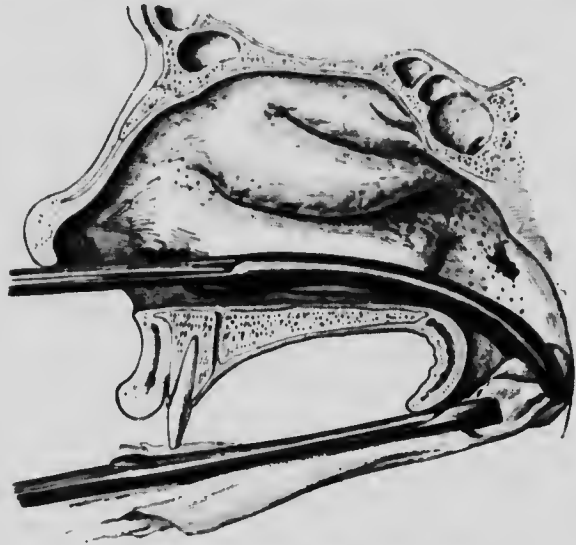


FIG. 1016. PLUGGING THE NASAL FOSSA.

The compress, pushed behind the palate with a bullet forceps, is seized with a curved forceps introduced through the nostril.

from behind forwards with the aid of a thick silk thread which had previously been passed from before backwards with a small urethral bougie, a No. 12 or 14 of the Charrière gänge. The bougie is passed through the nostril into the pharynx, where it is seized with a long curved forceps and drawn

forwards; a large silk thread is then tied to its extremity, which is now drawn upon in turn till the end is brought outside the orifice of the nostril.

The buccal end of the thread is then firmly tied on the angle of a long compress of sterilized gauze, which is guided by the index-finger, and drawn by traction on the attached thread above the velum palati, and made to emerge at the anterior opening of the nasal fossa. It is seldom necessary to complete the anterior tamponing. We cut off the projecting parts in front and behind, and push the posterior extremity of the compress above the veil of the palate with the tip of the finger.

Or a long curved forceps may be introduced through the nostril, which can be made to seize, behind the edge of the soft palate, the extremity of a compress that had been pushed to the back of the mouth (Fig. 1016).

The plug is removed after three or four days by seizing it above the veil of the palate with a curved forceps.

Foreign Bodies and Calculi.—Foreign bodies found in the nasal fossae are of very various origin. Rhinoliths are, on the other hand, of rather rare occurrence. The diagnosis is usually easy.

OPERATION.—Extraction is effected with a polypus forceps. When the foreign body is friable, or has been broken in pieces, the extraction is completed with a curette. We then secure antiseptics of the locality, which is usually the seat of intense inflammation, by injections of Labarraque's fluid of 1 in 200, or saline solution of 8 in 1,000.

INFLAMMATORY AFFECTIONS.

Acute Inflammatory Lesions.

Acute Coryza.—I here mention acute coryza but for the purpose of indicating its rapid cure with large doses of mycolysine. Administration of this remedy during the period of invasion makes the cephalalgia, gravedo, and general feeling of malaise all yield in one or two hours.

Abscess of the Septum.—Abscess of the septum can be recognized by rhinoscopy, and should be incised after coagulation. We may endeavour to procure resolution by adopting a course of medication with mycolysine, administered both by the mouth and hypodermically.

Chronic Inflammatory Lesions.

Hypertrophy of the Mucous Covering of the Turbinated Bones.—Chronic coryza is maintained by a hypertrophic condition of the mucous membrane covering the turbinated bones. This affection yields to cauterization with the galvanic loop after local anaesthesia with cocaine. In cases in which general anaesthesia with ethyl chloride is indicated we can extirpate the exuberant mucous membrane at a single stroke, and even the osseous margin of the inferior turbinated bone, with the longest of my gouge-forceps for the nasal fossae. The margin of the turbinated bone is seized between the jaws of the instrument, and detached by two vigorous rotatory movements—first to the right, then to the left.



DEFORMITIES: CONGENITAL AND ACQUIRED.

Occlusion of the Nasal Fossæ ; Congenital or Acquired—OPERATION.—Resection of all the exuberant osseous tissue is carried out with the gouge-forceps and curette; when necessary, with mallet and chisel.

Hypertrophy of the Osseous Structure of the Turbinated Bones.—The hypertrophy of the mucous covering is frequently enough complicated with hypertrophy of the subjacent osseous tissues. The hypertrophied margin of the turbinated bone is easily removed with the gouge-forceps represented in Fig. 1024. The longest form of the forceps is specially intended for removal of the free border of the inferior turbinated bone, mucous membrane, and subjacent skeleton together.



FIG. 1017.—DEVIATION OF THE SEPTUM NASI.

Division with the saw would probably involve perforation.

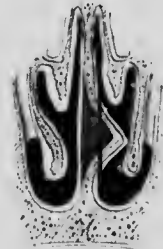

FIG. 1018.—THE SAME.

Detachment of the mucous membrane from the concave side in order to avoid perforation.

OPERATION.—The forceps is introduced obliquely: one branch into the inferior meatus, the other between the internal surface of the turbinated bone and the nasal septum. The rings are then approximated, and with a brusque movement of torsion the margin of the turbinate bone is fractured and removed. The bleeding is insignificant.

Deviation and Spur of the Septum.—Deviation of the septum is usually developed during the period of adolescence—the period at which the nose acquires its definitive development. Resection of spurs of the septum is carried out after procuring local anaesthesia with cocaine, or general anaesthesia with ethyl chloride. We use either the small saw represented in Fig. 991 or Lermoyez's nibbling-forceps. In order to avoid perforation it is well to detach the mucous membrane from the concave side with an injection of saline solution.

Nasal Synechiæ.—Adhesions between a turbinated bone and the septum are treated by tearing off the exuberant tissues and, when necessary, the margin of the turbinated bones with a polypus forceps. It is necessary to separate the bleeding surfaces by daily dressing with a small gauze compress or piece of impermeable protective. This dressing should be continued till the epithelial investment has been completely reproduced.

TUMOURS.

Benign Tumours.

Mucous Polypi of the Nasal Fossæ.—The mucous polypi are either sessile, pedunculated, or disposed in bunches.

OPERATION—1. With the *Serre-Nœud*.—Ablation with the snare after cocaineization is the procedure most frequently adopted. The effect of the cocaine causes retraction of the tumefied mucous membrane, and even of the




FIG. 1019.—AUTHOR'S GOUGE-FORCEPS FOR POLYPI OF THE NASAL FOSSÆ.

There are three forms of this forceps.

tissue of the polypi, which thus become more visible and more readily accessible. The snare acts very often as an instrument of prehension only, and the surgeon tears off the polypus as soon as he has secured a firm hold.



FIG. 1020.—AUTHOR'S GOUGE-FORCEPS FOR POLYPI OF THE NASAL FOSSÆ.

The small size, for polypi of the middle meatus.



FIG. 1021.—AUTHOR'S GOUGE-FORCEPS FOR POLYPI OF THE NASAL FOSSÆ.

Intermediate type size, for deeply seated polypi.




FIG. 1022.—AUTHOR'S GOUGE-FORCEPS FOR POLYPI OF THE NASAL FOSSÆ.

Hollowing of the jaws, seen from below.



FIG. 1023.—AUTHOR'S GOUGE-FORCEPS FOR POLYPI OF THE NASAL FOSSÆ.

Special form for the superior meatus.




FIG. 1024.—AUTHOR'S GOUGE-FORCEPS FOR POLYPI OF THE NASAL FOSSÆ.

Largest form, for abrasion of the free border of the inferior turbinate bone.

2. *With the Polypus Forceps.*—I prefer the use of *my own polypus forceps*, which are so constructed as to empty the nasal fossæ at a single sitting of all the polypi they are able to contain. These are small gouge-forceps, which

are made in three forms—one with straight slender jaws for polypi, which are readily accessible; a second, a little stronger; a third, with curved jaws for the superior meatus; a fourth has long and powerful jaws for abrasion of the whole margin of the inferior turbinated bone.

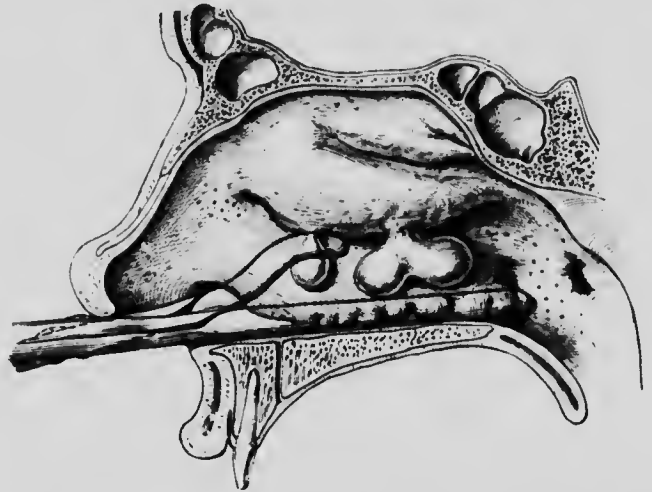


FIG. 1025.—EXTRACTION OF A POLYPUS OF THE MIDDLE TURBINATED BONE WITH THE POLYPUS FORCEPS.

Resection of margin of inferior turbinated bone with the large form of the nasal gouge-forceps.



FIG. 1026.—EXTRACTION OF A POLYPUS OF THE MIDDLE TURBINATED BONE WITH THE POLYPUS FORCEPS.

Transverse section, showing the manner in which the gouge-forceps seizes polypi of the nasal fosse or the hypertrophied margin of the inferior turbinated bone.

Polypi can be extracted with those forceps after local anaesthesia with cocaine. The patient is placed facing the surgeon, who illuminates the field of operation with a frontal mirror. In case of a timid patient, or when the

polypi are both numerous and voluminous, it is much simpler to have recourse to general anaesthesia with ethyl chloride, and extract all existing polypi at a single sitting. My polypus forceps are so constructed that they can be used, when so desired, for abrasion of the whole of the polypus-strewn margin of the inferior or middle turbinated bone, after recognition by rhinoscopy. The escape of blood can be rapidly arrested, and plugging is adopted if thought necessary.

SEQUENT TREATMENT.—Whether the nasal polypi have been removed with the snare or torn off with the forceps, we must verify the integrity of the nasal fossæ about twelve to fifteen days after the extraction, so that we can then extirpate any deeply seated polypi that chanced to have escaped, and cauterize the points of implantation with the galvanic cauter.

Diffuse Benign Myxoma of the Nasal Fossæ.—I have seen two cases of benign diffuse myxoma of the nasal fossæ. This affection requires complete curettage of the nasal fossæ, the operation being repeated at intervals of several weeks till the neoplasm ceases to reappear. Each of my two cases exacted a number of interventions under chloroform, but they finally presented a satisfactory cure, and there was no further recurrence.

The myxomatous mass is rapidly evacuated by the following procedure: A long curved forceps is introduced, under general anaesthesia, into each nostril, and there seizes the extremity of a compress of gauze which had been introduced through the mouth. This compress is then drawn from behind forwards, dragging the myxomatous masses before it (see Fig. 1016).

Osteomata of the Nasal Fossæ and of the Sinuses.—These productions develop spontaneously during adolescence, and may have hardly any connection with the skeleton proper. They are readily recognized by direct examination or by radioecopy.

They can nearly always be extirpated without cutaneous incision: through the nasal passage, or by an incision made in the gingivo-labial fold, followed by breaking open the outer wall of the maxillary sinus.

Malignant Tumours.

Sarcoma.—It is not rare to meet with a case of development in the posterior part of the inferior or middle meatus of a whitish and resistant swelling, which extends little by little till it reaches the base of the skull, and complicates its presence by intracranial prolongations. Those tumours, which are histologically fusiform sarcomata, may prove very nearly similar in course to epithelioma or carcinoma. They are developed at the expense of the mucous membrane or submucous tissues of the nasal fossæ in the vicinity of the cartilage of the Eustachian tube, sometimes at the expense of the vestiges of a branchial arch. Infection of the carotid chain of glands indicates the commencement of generalization.

OPERATION.—The destruction of these tumours is effected through the transmaxillary route.

First Stage.—Incision in 7-form along the lower margin of the orbit and the naso-genial groove.

Second Stage.—Exposure of the external wall of the sinus and breaking open and resection of that wall with the raspatory, chisel, and gouge-forceps; or even with the electric mortiser.

Third Stage.—Resection, with chisel and gouge-forceps, of the internal wall of the sinus, and extirpation of the tumour.

Fourth Stage.—Thermic electro-coagulation of all the surface of implantation of the tumour.

Fifth Stage.—Tamponing of the wound with a long wick of gauze.

Sixth Stage.—Suture of the skin.

This operation enables us to reach the ethmoidal and sphenoidal cells and the base of the skull, even as far as the vicinity of the basilar apophysis. The plug can be removed through the nostrils.

Enchondroma.—Enchondroma of the nasal fossa requires ablation followed by electro-coagulation through the same cutaneous incision. The transmaxillary route is that which gives most light, and at the same time produces least destruction of tissue. We can, however, when the tumour is very localized, try to carry out curettage and thermic electro-coagulation through the natural passages.

OPERATIONS ON THE SINUSES OF THE FACE.

Frontal Sinus.

TRAUMATIC LESIONS.

Penetrating Wounds—Foreign Bodies.—There is usually a fistula which leads to the foreign body. In case of a metallic projectile, the exact position will be indicated by radiography. Operation is by the external route. The incision is made parallel to the internal half of the eyebrow.

Atheroma of the Frontal Sinus.—The sinus may be found filled with an atheromatous mass similar to that met with in sebaceous cysts. Evacuation of the sinus requires a long incision parallel to the internal half of the eyebrow. It is necessary to secure free communication with the superior meatus of the nasal fossa. This communication is easily established with the *trepan à cliquet*, furnished with a cylindro-spherical burr of 8 millimetres diameter.

INFLAMMATORY LESIONS.

Empyema of the Frontal Sinus.—Empyema of the frontal sinus is recognized by testing the local transparency with a small electric lamp, covered with an opaque mantle of cylindrical form, which is applied beneath the superciliary arch. This examination is carried out in a dark room. The affection is often indicated externally by an inflammatory swelling, with redness and œdema of the eyelid. The subacute cases produce only a persistent local pain, with purulent flow into the superior meatus of the nasal fossa, but without external signs.

GENERAL TREATMENT.—I have cured many cases of sinusitis—frontal, ethmoidal, sphenoidal, superior maxillary—by the use of mycolysine, administered both by the mouth and hypodermically, and without being obliged to have recourse to trepanning. In order to obtain a permanent cure, it is sometimes necessary to repeat the hypodermic injections for a number of weeks, or even of months.

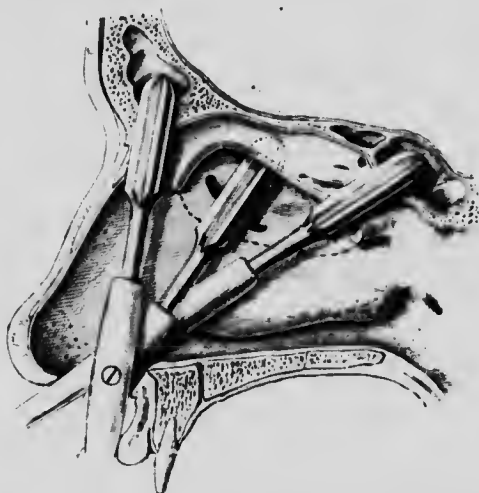

FIG. 1027.—TREPPANNING OF THE FRONTAL SINUS OF THE ETHMOIDAL CELLS AND OF THE SPHENOIDAL CELLS, WITH THE CYLINDRO-SPHERICAL BURR OF 8 AND OF 12 MILLIMETRES. THE BURR OF 8 MILLIMETRES SUFFICES FOR THE FRONTAL SINUS; THE BURR OF 12 MILLIMETRES CAN BE USED FOR THE ETHMOIDAL CELLS AND THE SPHENOIDAL SINUS.

OPERATION.—When there is no cutaneous fistula, empyema of the frontal sinus should be operated on through the nasal passage.

Perforation of the frontal sinus is carried out under chloroform with a cylindro-spherical burr of 8 or 12 millimetres diameter, adjusted to a metallic rod of suitable length (Figs. 1027 and 1028). The rod, which thus serves




FIG. 1028. SUPPLEMENTARY ROD USED FOR ELONGATION IN EVACUATION OF THE FRONTAL, ETHMOIDAL, AND SPHENOIDAL SINUSES.

as elongator, is mounted on a burr-holder of the *trepan à cliquet*. The instrument, on penetrating into the cavity, gives the hand a very distinct sensation of having surmounted an obstruction, and then touches the superior wall of the sinus.

In the exceptional case in which empyema of the frontal sinus is complicated with external periostitis, and more especially when a cutaneous fistula is present, it is necessary to incise the skin above the super-

ciliary arch, and perforate the sinus in that position with the cylindro-spherical burr of 12 millimetres, mounted on the *trepan à cliquet*.

In one case in which suppuration had occurred in a woman of nearly sixty, I found a communication between the two sinuses beneath the nasal spine of the frontal bone. In another case in which suppuration of the frontal sinus had been of traumatic origin, I was obliged to extirpate the superior wall of the cavity in order to evacuate a purulent focus situated beneath the dura mater.

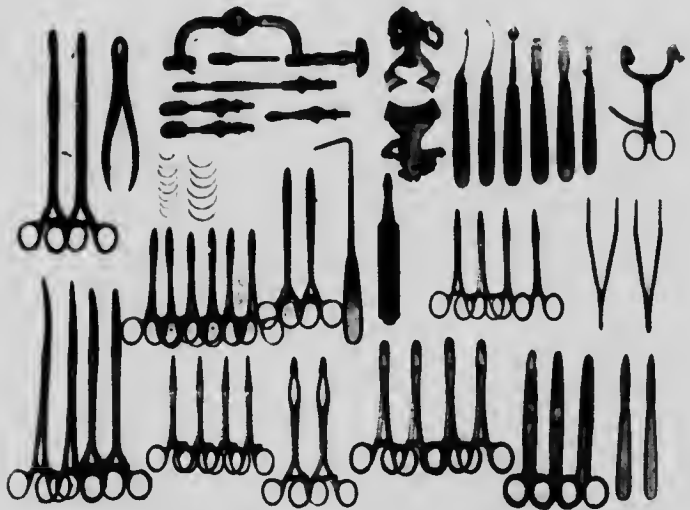


FIG. 1029.—INSTRUMENTS FOR OPERATIONS ON THE SINUSES OF THE FACE.

Below, and from right to left: Two bistouries, two strong straight scissors, one strong curved scissors, four artery forceps with short jaws, two forceps with oval jaws, four ringed and clawed forceps, four forceps with jaws curved on the borders. Above: Two clawed forceps, four Champonnière's forceps, one turn-screw, one retractor, two needle-holder forceps with eccentric plate, six needle-holder forceps with excavated jaws, and two types of curved needles. In the uppermost row: One gag, three raspatories, one curette, two needles mounted on handles, one bicommissural retractor, one *trepan à cliquet*, and numerous forms of perforators and cylindro-spherical burrs of 12 to 16 millimetres, one cylindro-spherical burr of 8 millimetres mounted on a supplementary rod for trepanning the frontal sinus and ethmoidal and sphenoidal cells, one gouge-forceps, two ringed forceps with eccentric jaws. (Reduced scale to one-sixth.)

Fistula of the Frontal Sinus.—When a foreign body is present, it must be extracted. When dealing with a simple purulent fistula, we establish a wide communication with the nasal fossa. This operation requires the use of a

trepan *à cliquet* and cylindro-spherical burr of 8 or 12 millimetres, mounted on a supplementary rod (Fig. 1027). Autoplastic reparation is carried out some weeks later.



FIG. 1030.—APPLICATION OF THE RETRACTOR OF THE LABIAL COMMISSURES.

TUMOURS OF THE FRONTAL SINUS.

Benign Tumours.

Glandular Cysts and Encysted Hydropsies.—We soon notice on palpation a parchment crepitation due to thinning of the osseous wall. Operation is carried out with the usual incision. Drainage through the superior meatus.

Mucous Polypi—Osteomata.—These tumours justify wide opening up of the sinus.

Malignant Tumours.

Eplithelioma—Osteosarcoma. These tumours demand very early employment of thermic electro-coagulation, which is carried out through the frontal passage.

Ethmoidal Cells.

INFLAMMATORY LESIONS.

Empyema of the Ethmoidal Cells. Suppuration in the ethmoidal cells is recognized by the purulent outflow, which is shown to exist by direct exploration. Empyema of the anterior ethmoidal cells often coexists with that of the frontal sinus, and empyema of the posterior ethmoidal cells with that of the sphenoidal sinus. Before proceeding to operate, a course of mycolysine treatment should be tried, both by the mouth and hypodermically.

OPERATION.—Breaking down of the nasal wall of the cells is effected through the natural passages, but this procedure requires special manual dexterity. I employ the *trepan à cliquet* and cylindro-spherical burs of 8 or 12 millimetres diameter, mounted on a graduated rod of 12 centimetres in length. We reach the ethmoidal cells by directing the burr towards the central part of the middle meatus, and slightly outwards.

Sphenoidal Sinus.

TRAUMATIC LESIONS.

Foreign Bodies.—The presence of foreign bodies is exceptional, and is detected on opening a sinus affected with empyema.

INFLAMMATORY LESIONS.

Empyema of the Sphenoidal Sinus.—Empyema of the sphenoidal sinus is recognized by direct observation. It may be necessary to extirpate the hypertrophied middle turbinate bone in order to explore the nasal orifice of the sphenoidal sinus. We should first endeavour to obtain a cure by administration of mycolysine. If this fails we proceed to operation. The best procedure for free opening of the sphenoidal sinus is the use of the *trepan à cliquet* and cylindro-spherical burr of 12 millimetres diameter, mounted on a rod of 12 centimetres in length.

The operation is performed under general anaesthesia. The burr is aimed directly at the posterior and superior aspect of the middle meatus. The adoption of this technique enables us to avoid any slipping into remote regions.

TUMOURS.

Benign Tumours.

Mucous Polypi.—Mucous polypi are not productive of grave accidents. Fibromata, chondromata, and osteomata are rare; they may produce compression of the optic nerve as a result of their extension.

Malignant Tumours.

Sarcoma.—Sarcoma of this region becomes rapidly generalized.

OPERATION.—Tumours of the sphenoidal sinus which give rise to alarming symptoms should be extirpated through the transmaxillary route.

First Stage.—Incision in form of 7 along the inferior margin of the orbit and nasogenial groove.

Second Stage.—Exposure and resection of the anterior wall of the maxillary sinus, then of its internal and posterior wall respectively.

Third Stage.—Direct invasion of the sphenoidal sinus.

Fourth Stage.—Electro-coagulation of the pathological tissues.

Fifth Stage.—Tamponing of wound; the compress is so disposed as to be removable through the corresponding nostril.

Sixth Stage.—Suture of the skin.

Maxillary Sinus.

TRAUMATIC LESIONS.

Wounds.—Traumatic extravasations of blood may proceed to suppuration, and thus require the operation for empyema of the sinus.

Foreign Bodies.—Foreign bodies may be of traumatic or surgical origin—drainage-tubes, metallic cannulae. They are extracted through the canine fossa, with the same technique as in operation for empyema.

INFLAMMATORY LESIONS.

Empyema of the Maxillary Sinus.—Empyema of the maxillary sinus is easy to recognize in the dark chamber by intrabuccal illumination with a suitable electric lamp. The degree of recognizable opacity even permits us to estimate to a certain extent the nature of the contents. I have twice

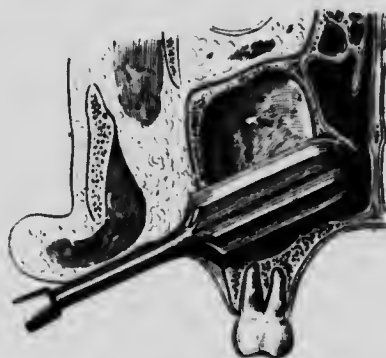


FIG. 1031.—TREPPANNING THE MAXILLARY SINUS THROUGH THE CANINE FOSSA ACROSS ITS WHOLE WIDTH, WITH A CYLINDRO-SPHERICAL BURR OF 16 MILLIMETRES' DIAMETER, WHICH OPENS WIDELY THE INFERIOR MEATUS OF THE NASAL FOSSA.



FIG. 1032. TREPANNING THE LEFT MAXILLARY SINUS.
Elevation of the superior maxilla over the canine fossa.

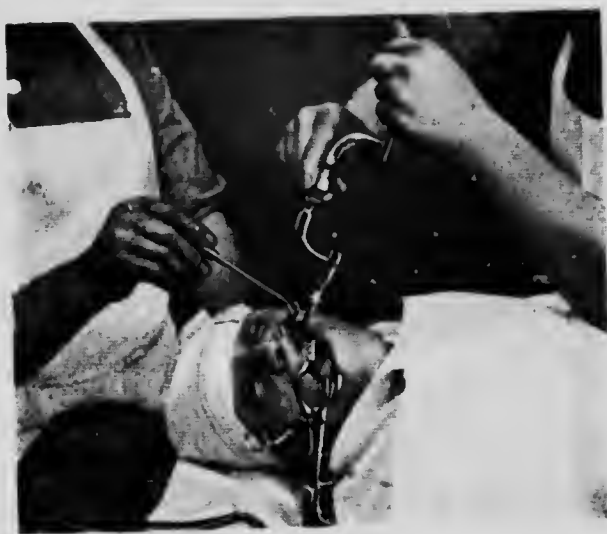

FIG. 1033. TREPANNING THE LEFT MAXILLARY SINUS.
Perforation of the maxillary sinus through the canine fossa with trepan à cliquet and
flap perforator.

found the maxillary sinus filled with a foetid sebaceous paste, similar to the contents of a suppurating wen; the opacity in each case was complete. In another case the sinus contained a number of mucous polypi.

OPERATION—1. Simple Empyema: Nasal Route.—The outer wall of the nostril is perforated at its most dependent part with a conical burr of 12 millimetres. If the orifice of the nostril will admit it, the cylindrical burr of 16 millimetres is now introduced. The toilet of the sinus is then made, and the cavity is plugged.

2. Polypus of the Sinus: Buccal Route.—The buccal route is preferable for direct endoscopy of the cavity of the sinus and for extirpation of polypi therein contained. The labial commissures are drawn back with the special retractor represented in Fig. 1030, and the tongue is held with a tongue forceps.

First Stage: Exposure of the External Wall of the Sinus.—The upper lip is raised with a ringed forceps or a small retractor, and the gingivo-labial fold is incised for a length of 15 millimetres, starting from the canine fossa.



FIG. 1034. TREPASSING THE LEFT MAXILLARY SINUS.

Toilette of the sinus with a wick of gauze.

Second Stage: Perforation of the Sinus.—The external wall of the sinus is laid bare with the raspator, and penetrated with the *trepan à cliquet* and flat perforator. The orifice is enlarged with the cylindrical burr of 16 millimetres, which should be made to traverse the sinus and penetrate its nasal wall at its most anterior and most dependent point.

Third Stage: Toilet of Wound and Tamponing.—The cavity is emptied and sponged. A large wick is introduced, which traverses the sinus from side to side, from the corresponding nostril to the canine fossa, and is left in position for two or three days. We then tampon the two orifices separately.

When the wall of the sinus has been profoundly altered, it will be judicious to keep the external orifice open for some weeks. This should be wide enough to allow introduction of the index-finger, and easy exploration of the whole cavity in a dark chamber, with the help of a suitable mirror. We tampon the nasal orifice, which must be permanently maintained, and utilized for irrigations of the cavity. The opening in the canine fossa usually closes spontaneously. When it remains fistulous, we close it by stripping off the mucous membrane, and drawing it by a sliding movement of displacement in front of the orifice, and suturing it in that position to the adjacent gingival mucous membrane.

Fistulæ. The treatment of fistula of the maxillary sinus, whether by origin—traumatic, spontaneous, or surgical—by location—cutaneous, gingival, alveolar, or palatine—demands in every instance the preliminary establishment of a communication between the antrum and the inferior meatus. The fistula is closed by extirpation of its tract, followed by an autoplasty by sliding displacement. The technique must be suited to the individual case.

OPERATION—First Stage. We trepan both walls of the maxillary sinus with the cylindro-spherical burr of 16 millimetres (see Fig. 1031) in such a way as to open widely into the inferior meatus (*vide supra*).

Second Stage. Extirpation of the fistulous tract; autoplasty.

TUMOURS.

Benign Tumours.

Mucous Cysts of the Sinus—Hydrops of the Cavity—Dental Cysts Mucous Polypi. A large opening is made in the wall of the sinus through the canine fossa after incision of the gingivo-labial fold (*vide supra*). A large opening is established leading into the inferior meatus of the nasal fossa.

Fibroma Osteoma. Solid, voluminous tumours may require invasion of the sinus by the cutaneous route. The incision should follow the nasogenital groove, and curve outward below towards the canine fossa.

Malignant Tumours.

Sarcoma Epithelioma Carcinoma.—These tumours demand early electro-coagulation, applied on a wide scale. We operate through either the cutaneous or the buccal route, according as the position of the tumour demands resection of the external or the inferior wall of the sinus.

Operations on the naso-pharynx will be described in connection with operations on the pharyngeal region.

END OF VOL. I.

be
be
ion
or.
and
lly
ing
dis-
the

by
in-
ary
ior
an
he

us
a a

gh
A
sal

on
so-

ely
er
he
is.
th

