


A Large Cystic Tumor Developing from the Iliopsoas Bursa

CONTAINING LARGE FREE CARTILAGINOUS MASSES,
AND COMMUNICATING WITH THE HIP-JOINT

THOMAS S. CULLEN
BALTIMORE

*Reprinted from The Journal of the American Medical Association
April 9, 1910, Vol. LIV, pp. 1181-1184*

COPYRIGHT, 1910
AMERICAN MEDICAL ASSOCIATION
FIVE HUNDRED AND THIRTY-FIVE DEARBORN AVENUE
CHICAGO



A LARGE CYSTIC TUMOR DEVELOPING FROM THE ILIOPSOAS BURSA

CONTAINING LARGE FREE CARTILAGINOUS MASSES, AND
COMMUNICATING WITH THE HIP-JOINT

THOMAS S. CULLEN

BALTIMORE

History.—In November, 1908, I was asked by Dr. A. H. A. Mayer to examine a man aged 46 who had what appeared to be a very unusual pelvic tumor. About ten years before the patient had begun to limp, and a year later consulted a physician who told him that he had a tumor of the left hip. The condition gradually had become worse. For about a year the man had noticed that every time he put his weight on his left leg "something slipped" in his hip.

Examination.—The patient was a tall, rather anemic looking man. The chest sounds were normal. The left leg was stiff and when walking he held the left hip-joint as immobile as possible. Occupying the left iliac fossa and extending beyond the median line was a firm oval mass, 8 by 10 cm. This was continuous with a smaller mass which passed below Poupart's ligament and extended to the left of the hip-joint anteriorly. The large mass seemed to fill the left half of the pelvis. In some places it appeared to consist of bone, but at other points felt cystic. It seemed to be intimately connected with the pelvic bone. The glands in both groins were palpable. The left leg was three-quarters of an inch shorter than the right. On flexion of the leg the pelvic mass receded somewhat, but on extension the tumor again became prominent. Flexion, extension, adduction and abduction were accompanied by dull crepitation in or near the hip-joint. On carefully questioning the patient it was learned that the swelling had been first noticed just below Poupart's ligament.

Operation.—An incision was made just above and parallel with Poupart's ligament and the extraperitoneal tumor exposed. After displacing the anterior crural nerve, which was markedly stretched over the tumor, and splitting the muscle which lay over it, it was found necessary to sever Poupart's ligament as a portion of the tumor lay beneath it. The pelvic portion of the mass was loosened up easily on its anterior and

posterior aspects, but on the outer side was firmly attached to the ileum, and below seemed intimately related to the anterior portion of the hip-joint. After being walled off with gauze it was opened and there was an escape of clear viscid fluid, yellowish in color. Lying free in the cavity were five irregularly lobulated, hard cartilaginous masses (Figs. 1, 3). After these had been removed a sixth was found fastened down beneath Poupart's ligament. When this nodule had been taken out a

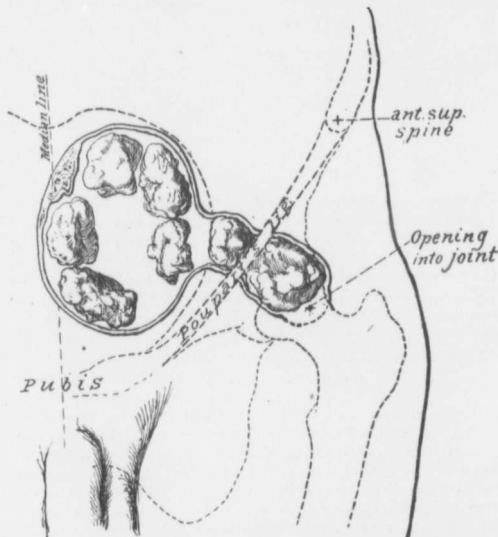


Fig. 1.—A cystic tumor developing from the left iliopectineal bursa containing large free cartilaginous masses and communicating with the hip-joint. Occupying the left half of the pelvis is a cystic tumor which on its outer side was firmly attached to the pelvic wall. The cyst walls were composed chiefly of fibrous tissue. The thickening in certain areas noted in the walls is due to deposits of bone. The cyst cavity was distended with clear yellowish, tenacious fluid and also contained five free and irregular cartilaginous masses. A narrow prolongation of the cyst passed downward and forward beneath Poupart's ligament and opened directly into the hip-joint. Filling this portion of the cyst was a large free cartilaginous mass. All the cartilaginous masses are shown in their natural size in Fig. 3.

finger carried downward and forward passed directly into the hip joint anterior to the head of the femur. The bones of the joint were perfectly smooth. The pelvic sac was gradually dis-

sected free at a point considerably below Poupart's ligament. It was then cut away and the remaining portion which formed the margin of the entrance into the joint was trimmed, turned in on itself, and snugly brought together with catgut sutures, thus securely closing the hip-joint. A small drain was laid in the upper angle of the wound far removed from the joint and the incision closed.

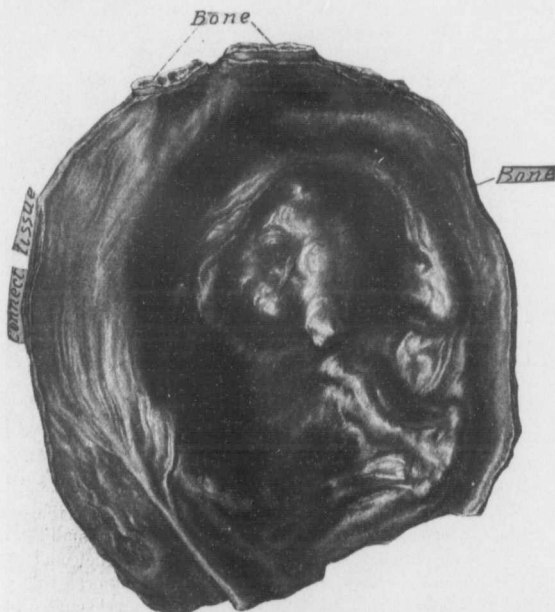

Fig. 2.—Part of the sac of a cystic tumor developing from the iliopectoral bursa. The picture represents the inner surface of the cyst. The walls vary from 1 to 2 mm. in thickness and in them are seen cross sections of plaques of bone. In other portions of the walls cartilage was noted. The inner surface presented a distinctly trabeculated appearance evidently due to the uneven stretching of the sac. Projecting into the cavity is an irregular bony mass fully 3 cm. in diameter. The sac was lined with a smooth glistening membrane; it contained clear yellow tenacious fluid and the six cartilaginous masses depicted in Fig. 3.

Result.—For a few days the patient did remarkably well but then became delirious and talked incoherently. It was learned that on a previous occasion he had shown similar cerebral dis-

turbances and that it had been necessary to confine him for a time in a sanitarium. Dr. Henry J. Berkley, who saw him in consultation, felt that his mental condition had nothing to do with the operation. The wound after draining for a few days closed completely and the patient left the hospital in excellent physical and mental condition five and a half weeks afterward. He was able to walk without much difficulty.

Subsequent History.—Dec. 6, 1909: Dr. Mayer informs me that the patient occasionally has some discomfort in his leg but no pain in the hip-joint. He still uses a cane.

Description of Specimen.—The walls of the sac were composed of fibrous tissue and scattered throughout them were plaques of cartilage and definite bony masses (Figs. 1, 2). Some of these fragments of bone were very small; others reached 3 cm. or more in diameter. The inner surface of the sac presented a trabeculated appearance (Fig. 2) evidently due to the unequal and gradual distention of the cystic tumor. Notwithstanding the uneven appearance the inner surface was everywhere covered by a smooth membrane. The fluid contents were clear, yellowish in color and rather sticky. The six irregular, white, cartilaginous masses filling the cavity are shown in their natural size in Figure 3. They were lying perfectly free and five of them popped out as soon as the sac was opened. The sixth could not escape as it was firmly held down by Poupart's ligament and its lower end entered the hip-joint.¹

ORIGIN OF THESE CYSTIC TUMORS

One of the largest, if not the largest, bursa in the body is that situated beneath the tendon of the iliopsoas muscle. This complex muscle arises from the body of the twelfth dorsal vertebra, from the bodies of all the lumbar vertebræ, from the transverse processes of all the lumbar vertebræ and from the iliac fossa. The combined tendon is inserted in the trochanter minor. In order to reach this the iliopsoas muscle must curve around the crest of the ilium. It is beneath the muscle where it curves over the bone that the bursa is found. It lies beneath Poupart's ligament below and lateral to the iliopectineal eminence. According to some authors it may attain the size of a hen's egg.

1. The specimens were demonstrated to the class and then drawn. During my absence in Europe they were unfortunately mislaid and have not yet been located; consequently I have thus far been unable to make a careful histologic examination to determine definitely whether the central portion of the cartilaginous masses contained bone or not.

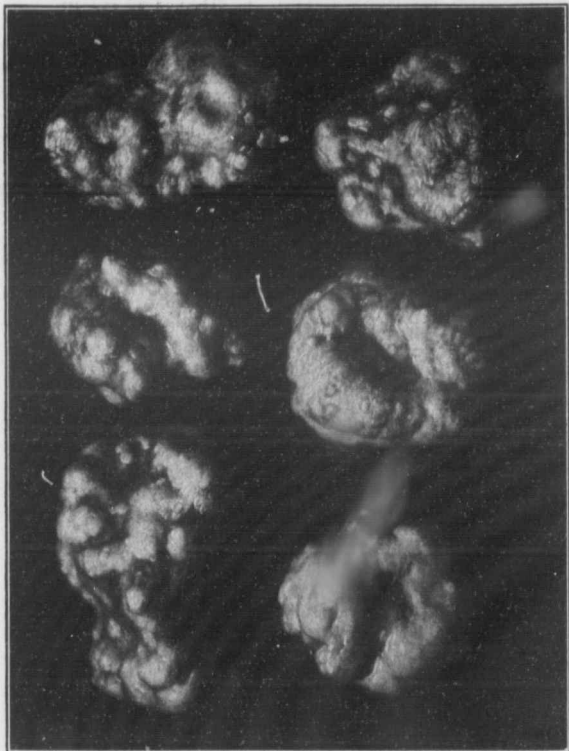


Fig. 3.—Cartilaginous masses lying free in a cystic tumor developing from the iliopectus bursa (natural size). These masses were pearly white, very irregular, but perfectly smooth. They were rather lighter in weight than bone. Their general arrangement in the cyst is shown in Fig. 1.

According to Joessel² the iliopsoas bursa or the bursa mucosa subiliaca lies between the partly tendinous portion of the iliac muscle and the front of the iliopectineal eminence. Anteriorly, it is firmly attached to the iliopsoas muscle, posteriorly to the iliopectineal eminence, and likewise to the thin portion of the capsule of the hip-joint.³ It is bounded on the outer side by the iliofemoral ligament, below by the pubofemoral ligament and on the inner side by the cotyloid ligament.

Joessel further finds that occasionally the fibrous capsule at the thin point of the joint is wanting and then nothing but the synovial membrane separates the joint from the bursa. Occasionally the synovial membrane is lacking at the thin point and in these cases there is a direct communication between the hip-joint and the bursa. This opening explains how purulent accumulations of the joint may extend to the iliopsoas bursa and then appear under the iliopsoas muscle and also how psoas abscesses may travel down the muscle and eventually cause involvement of the hip-joint. An extended consideration of the subject would necessitate a discussion of practically all diseases of the hip and would naturally lead us too far afield. I shall consequently limit my remarks chiefly to those cases in which cystic tumors similar to this have been noted and in which little or no evidence of inflammation has existed.

When consulting the literature I found a most instructive and painstaking article on "Diseases of the Bursæ of the Hip" by R. Zuelzer.⁴ I have examined in the original the references given by this author and have found them in the main so well epitomized that I shall draw largely on his descriptions and conclusions.

It has been noted that the bursæ that are regularly found are usually developed during fetal life, while the less constant ones appear at a later date. Virchow and Schuchardt found that the small subcutaneous bursæ developed out of a connective-tissue network resembling cavernous tissue. Eventually a cavity was formed in which as a result of the continuous movements and rubbing the connective tissue gradually atrophied. The walls of these bursæ consist of dense connective tissue

2. *Topographisch-Chirurgische Anatomie*, 1, 169.

3. This thin spot is well seen in Figure 232 of *Cunningham's Anatomy*, 1909, p. 296.

4. *Deutsch. Ztschr. f. Chir.*, 1899, L, 148.

and contain a very little elastic tissue. The inner surface is lined with one layer of so-called endothelium and the contents of the bursa resemble those of the joint. They are slightly tenacious, thick and usually just enough in amount to keep the walls of the sac smooth.⁵

CASES OF CYSTIC DEVELOPMENT OF THE ILIOPSOAS BURSA AS COLLECTED BY ZUELZER

HOFFA: The patient, a workman, was struck on the right foot and the left arm. He walked home at once a distance of about two miles, remained without treatment for fourteen days and again went to work. A year later he complained of pain in the region of the right hip. On examination the leg was found slightly flexed, abducted and rotated outward. At the hip was a painful tumor which was clearly visible and palpable; it lay under Poupart's ligament between the psoas and the pectineus muscles and was of the consistence of bone. On flexion of the leg, however, fluctuation could be detected. The trochanter was in its normal position and movements of the hip-joint were easily made. Adduction, flexion and rotation inward were, however, somewhat limited. The pain extended down to the knee. The corresponding leg was somewhat thinner than the other. This case was diagnosed by a colleague as an impacted fracture of the neck of the femur and the tumor was thought to be a callus formation pressing on the crural nerve and causing pain. There was no shortening of the leg.

EHRLE: A cooper, aged 33, for thirteen years had suffered with pain in the leg and down its inner side. Four months before coming under observation he noticed a tumor situated slightly below Poupart's ligament. This was ovoid in shape and lay under the large vessels. On extension of the leg the tumor became hard. On flexion fluid could be detected. Extension and rotation outward produced pain. By flexion it was clearly seen that the psoas muscle was lifted up. The hip-joint was free.

HERDTMANN: The patient had been squeezed between two cars, the chief pressure coming on the left hip. The patient was carefully watched as he was supposed to be a malingerer. On examination, however, a painful swelling of the bursa beneath the tendon of the iliopsoas muscle was found. Flexion of the leg or rotation inward caused much pain in the joint.

MOMMSEN: This surgeon saw a patient who had an elevated, clearly fluctuating painless tumor which projected from the region of the iliopsoas muscle and passed out beneath Pou-

5. Those interested in the development of bursæ should not fail to read the excellent paper on Luetic Bursopathy of Verneuil by Dr. John W. Churchman, Resident Surgeon in the Johns Hopkins Hospital (The Am. Jour. of the Med. Sc., September, 1909).

part's ligament. It lifted up the femoral artery. On pressure the tumor diminished in size.

MOMMSEN: The same author reported a case of a man 50 years old who without apparent trauma complained of difficulty in walking on account of a gradually increasing swelling in the right inguinal region. The tumor was as large as two fists and was situated deep in the right iliac fossa. It was firm in consistency and only slightly movable. It was thought to be a sarcoma of the fascia of the hip. At operation its lower pole was found firmly attached to the joint capsule. The cyst walls varied from 3 to 5 mm. in thickness and the failure to detect fluctuation was due to over-distention of the cyst.

SCHÄFER: The patient, a man coming to Volkmann's clinic, complained of a tumor the size of a child's head situated at the flexion of the thigh and lying under Poupart's ligament. The man had fallen and injured his hip a year and a half before. The tumor projected only slightly above the normal skin surface. It was buried deeply in the muscle of the thigh, was elongate oval and followed the long axis of the psoas muscle. The thigh was markedly flexed. When the leg was extended the tissue was of stony hardness. With extensive flexion some fluctuation could be detected. A second tumor the size of an apple was present at the edge of the gluteus maximus. This tumor also on extension was tense, but on flexion of the hip it became softer. Its contents could be made to disappear and as a result the anterior tumor became more distended. The cystic tumors communicated with one another. The movement of the hip joint was free. The pain radiated from the hip to the knee.

FRICKE: This author described a case of a carter who without apparent cause had a tumor in the hip region. It lay over the right trochanter and passed inward under Poupart's ligament and extended downward over the upper third of the thigh. It really formed three tumors. The outer portion was as large as a child's head and markedly distended. The second lay on the inner side of the thigh and the third, the smallest, lay between them. All three fluctuated and the fluid could be pressed from one tumor into the other. The position of the thigh was normal but movement of the hip was impossible on account of the severe pain which was caused especially by flexion and rotation. The tumor itself was not painful on pressure but pain was reflected down to the knee.

HEINEKE: This author observed a case in the Greifswald clinic in which after a rheumatic inflammation of the hip-joint a prominent and distinctly fluctuating tumor developed. This followed the direction of the iliopsoas muscle from Poupart's ligament downward and raised up the femoral artery. On pressure the tumor diminished but on removal of the pressure the tumor again became prominent. Passive motion of the hip-joint was free and painless. In this case there was accumula-

tion of fluid in the iliac bursa and this communicated with the hip-joint which also contained an excess of fluid.

WOOD⁶ reported a case in a thin man 28 years old, who two years previously, while convalescing from typhoid fever, had sprained his left hip. Walking was associated with severe pain. Six weeks later he noticed a swelling in this region. There was swelling both in front of and behind the hip and fluctuation was definite. A diagnosis of gluteal abscess was made. The patient, on account of well-marked contraction of the iliopsoas muscle, was unable to extend the leg. The tumor ruptured and there was a spontaneous expulsion of particles of bone as large as beans. The hip-joint was freely movable and not painful. This is one of the very few cases in which the bursa contained foreign bodies.

COUTEAUD: This patient was a man, aged 31, who was very strong and had done heavy work. Six years previously he had had syphilis. In the left inguinal region and on the inner side of the thigh was a prominent tumor the size of an egg. This was smooth, rounded, painless and could not be made to disappear. The skin over it was freely movable. On examination fluid could be detected in the pelvis and this fluctuation communicated with the tumor. The hip joint was normal. The tumor was punctured and clear citron yellow slightly tenacious fluid came away. In this case the chief pain was in the region of the knee.

Since Zuelzer's paper several cases have been recorded. The most interesting one is that of DELBET.⁷ This surgeon gives a very short account of a case in which he diagnosed a cystic tumor of the iliopsoas bursa (a hygroma) before operation. On opening the sac he found three foreign bodies each of which was the size of a large nut.

DIAGNOSIS

In summing up his article Zuelzer points out that these tumors may be of various sizes and that the swelling indicates primarily the anatomic position of the subiliac bursa. As the tumor increases it may extend far below Poupart's ligament, sometimes reaching to the middle of the thigh. It may consist of one tumor or be made up of several. It may spread out on either side of the iliopsoas muscle or extend in various directions, and may communicate with the joint. When more than one tumor

6. This is the only case of Zuelzer's that I could not confirm, as the reference is incorrect and consequently I have not been able to obtain Wood's original article. I was unable to trace the case either in the *Index Medicus* or the Index Catalogue of the Surgeon-General's Library.

7. Corps étranger contenu dans un hygroma de la bourse du psoas, Bull. et. mém. Soc. de chir. de Paris, 1902, xxviii, 1264.

exists it is often possible to press the fluid from one tumor into another. On releasing the pressure the fluid at once comes back. The tumor may extend forward beneath Poupart's ligament and then backward along the course of the iliopsoas muscle as in our case.

In some cases fluctuation can be detected, but in others the tension is so marked or the cyst walls so thick that the tumor is supposed to be solid.

The skin is, as a rule, freely movable over these tumors provided inflammatory conditions are absent. Many of the tumors are painless, but when one remembers that the growth develops beneath the crural nerve and puts it on marked tension as in the case reported, it is but natural that any excessive movement of the hip-joint should be accompanied not only by local pain but also by pain referred to the knee.

Zuelzer found that the typical position of the leg in these cases is in abduction, outer rotation and slight flexion of hip. In this position there is naturally a minimum tension on crural nerve and iliopsoas muscle.

In these cases the hip-joint is, as a rule, perfectly normal, the great trochanter bears its normal relation and there is no shortening of the leg. In this way it is possible to exclude completely fracture of the neck of the femur, fluctuations and diseases of the hip. In my case there was three-quarters of an inch shortening. The joint itself was perfectly normal.

ETIOLOGY

The majority of these cases have followed some injury, although syphilis and rheumatism are also supposed to be contributing factors. In my case the connective-tissue walls of the cyst contained bone. This should occasion no surprise as this fibrous tissue is similar to and continuous with that forming the joint. The presence of large free foreign bodies in the sac is most unusual, but when we remember that small free cartilaginous bodies are not infrequently found in the knee-joint, it should not appear strange that a sac communicating with the hip-joint might contain similar products. The foreign bodies in the case reported, however, were exceptionally large.

TREATMENT

In times past, local applications were sometimes made; at a later date some of the tumors were aspirated, but the fluid tended to return. In cases similar to mine complete removal of the sac is the only satisfactory solution of the problem. Here it was necessary not only to get rid of the secreting surface, but also to remove the large free foreign bodies. Under no circumstances should irritants be injected into the sac as was formerly done. The surgeon cannot, as a rule, determine definitely before operation whether these bursæ communicate with the joint or not. The results from operative treatment should be most satisfactory.

Monroe's beautiful atlas containing a description of all the "Bursæ Mucosæ" of the human body, published in Edinburgh in 1788, should be read by every surgeon. It will undoubtedly stimulate increased study of this subject and materially help to clear up many imperfectly understood conditions originating in the bursæ in various parts of the body.

3 West Preston Street.

