

Wardner

A D E N O M Y O M A

OF THE

U T E R U S

BY

THOMAS STEPHEN CULLEN

ASSOCIATE PROFESSOR OF GYNECOLOGY IN THE JOHNS HOPKINS UNIVERSITY
ASSOCIATE IN GYNECOLOGY IN THE JOHNS HOPKINS HOSPITAL

ILLUSTRATED


BY

HERMANN BECKER and AUGUST HORN

PHILADELPHIA AND LONDON

W. B. SAUNDERS COMPANY

1908



Copyright, 1908, by W. B. Saunders Company

PRINTED IN AMERICA

PRESS OF
W. B. SAUNDERS COMPANY
PHILADELPHIA

1913 - 92500

TO THE MEMORY OF

MY FATHER

The Reverend Thomas Cullen

WHO WAS BORN IN THE COUNTY OF FERMANAGH, IRELAND,
IN 1836, AND DIED IN LONDON, CANADA, IN 1895,

THIS BOOK

IS AFFECTIONATELY DEDICATED

1913 - 9.20.11.

24482



PREFACE

ONE afternoon in October, 1894, while making the routine examination of the material from the operating room I found a uniformly enlarged uterus about four times the natural size. On opening it I found that the increase in size was due to a diffuse thickening of the anterior wall. Professor William H. Welch, when consulted, said that the condition was evidently a most unusual one and suggested that sections be made from the entire thickness of the uterine wall. Examination of these sections showed that the increase in thickness was due to the presence of a diffuse myomatous tumor occupying the inner portion of the uterine wall, and that the uterine mucosa was at many points flowing into the diffuse myomatous tissue. A few months later a second adenomyoma was met with. Both of these cases were reported at the Johns Hopkins Hospital Medical Society in March, 1895, and published in the Johns Hopkins Hospital Reports, Vol. 6, 1896.

Since that time we have carefully inspected all our material for adenomyoma and have encountered over ninety adenomyomata of various kinds in the uterus.

Our material has been obtained chiefly from the Gynecological Department of the Johns Hopkins Hospital, from Dr. Kelly's private sanatorium and from my cases at the Church Home and Infirmary and elsewhere. The exact source in each case is given in the tables of cases at the end of the book, from which also the reader can find at a glance the page number of any gynecological or pathological number mentioned in the book.

After the publication of von Recklinghausen's work on Adenomyoma in 1896 considerable controversy arose as to the origin

of the gland elements in adenomyomata. Our first cases had clearly shown that the glands in the diffuse myoma owed their origin to a flowing outward of the normal uterine mucosa. In all subsequent cases these tumors were examined most carefully from this standpoint. Sometimes the mucous membrane origin was easily proved, but in many cases not only were numerous sections necessary, but in some instances a clear idea of the condition was obtainable only after an examination of very large sections embracing the entire uterine wall. This labor yielded fruit, as in nearly every case in which diffuse adenomyoma existed we have been able to trace the mucous membrane origin of the glands. Much credit for the large and beautiful sections is due to our laboratory assistant, Mr. Benjamin O. McCleary.

While endeavoring to ascertain the method of development of adenomyomata I have likewise been trying to determine how these growths can be recognized clinically. I cannot help feeling that any one who reads the chapter on symptoms will agree with us that diffuse adenomyoma has a fairly definite clinical history of its own and that in the majority of cases it can be diagnosed with a relative degree of certainty. This definite gain in our knowledge certainly emphasizes the fact that any morbid process should be studied carefully both from its histological and also from its clinical aspects and shows the importance, for all those who do surgical work, of a thorough familiarity with the histological appearances of the pathological processes they are dealing with.

In this book the publishers have deemed it wise to use a larger type than usual. At the beginning of each case an epitome is given and in the succeeding paragraphs the essential features are emphasized by the employment of spaced type. This arrangement will permit those who wish to obtain the gist of the book to do so in a few hours, without going into all the minor details, provided that their reading is supplemented by a careful study of the illustrations.

I wish to express my thanks to Dr. Henry M. Hurd for his advice on numerous occasions, to my brother, Dr. Ernest K. Cullen,

for the manifold details he has looked after for me, and to Miss Cora Reik, my secretary, for the continued interest she has taken in the preparation of this volume.

I am under especial obligation to Dr. Frank R. Smith for his revision of the manuscript, and for correcting the proof-sheets.

To my friends Mr. Hermann Becker and Mr. August Horn I am deeply indebted for their excellent and faithful illustrations.

With the publishers, W. B. Saunders Company, my relations have been most cordial and I am especially mindful of the many kindnesses shown by Mr. R. W. Greene, one of the vice-presidents of the company.

THOMAS S. CULLEN.

Baltimore, May 1, 1908.



CONTENTS

	PAGE
CHAPTER I	
ADENOMYOMA OF THE UTERUS.....	1
CHAPTER II	
CASES OF ADENOMYOMA IN WHICH THE UTERUS RETAINS A RELATIVELY NORMAL CONTOUR.....	29
CHAPTER III	
CASES OF ADENOMYOMA IN WHICH THE UTERUS RETAINS A RELATIVELY NORMAL CONTOUR.....	52
CHAPTER IV	
CASES OF ADENOMYOMA IN WHICH THE UTERUS RETAINS A RELATIVELY NORMAL CONTOUR.....	88
CHAPTER V	
SUBPERITONEAL AND INTRALIGAMENTARY ADENOMYOMATA.....	125
CHAPTER VI	
SUBMUCOSAL ADENOMYOMATA.....	156
CHAPTER VII	
CERVICAL ADENOMYOMATA.....	165
CHAPTER VIII	
CONDITION OF THE TUBES AND OVARIES WHEN ADENOMYOMA OF THE UTERUS EXISTS.....	171
CHAPTER IX	
THE CLINICAL PICTURE IN CASES OF ADENOMYOMA OF THE UTERUS.....	173
CHAPTER X	
DIFFERENTIAL DIAGNOSIS IN CASES OF ADENOMYOMA OF THE UTERUS.....	177
CHAPTER XI	
TREATMENT OF ADENOMYOMATA OF THE UTERUS.....	186
CHAPTER XII	
PROGNOSIS IN CASES OF ADENOMYOMA OF THE UTERUS.....	187

	PAGE
CHAPTER XIII	
ORIGIN OF ADENOMYOMATA OF THE UTERUS.....	193
CHAPTER XIV	
CAUSES OF ADENOMYOMA OF THE UTERUS.....	199
CHAPTER XV	
HYPERTROPHY OF THE CERVIX AND DIFFUSE ADENOMYOMA OF THE BODY OF THE UTERUS.....	200
CHAPTER XVI	
ADENOMYOMA IN ONE HORN OF A BICORNATE UTERUS.....	203
CHAPTER XVII	
DIFFUSE ADENOMYOMA OF THE BODY OF THE UTERUS OCCURRING IN CASES OF SQUAMOUS-CELL CARCINOMA OF THE CERVIX.....	206
CHAPTER XVIII	
ADENOCARCINOMA AND ADENOMYOMA OCCURRING INDEPENDENTLY IN THE BODY OF THE SAME UTERUS.....	218
CHAPTER XIX	
ADENOCARCINOMA OF THE BODY OF THE UTERUS DEVELOPING FROM AN ADENOMYOMA.....	222
CHAPTER XX	
A MULTIPLICITY OF PATHOLOGICAL CHANGES IN THE PELVIS.....	228
CHAPTER XXI	
DIFFUSE MYOMATOUS THICKENING OF THE UTERUS BUT NO GLANDULAR INVASION.....	230
CHAPTER XXII	
ADENOMYOMA OF THE UTERINE HORN.....	235
CHAPTER XXIII	
PREGNANCY IN THE LEFT FALLOPIAN TUBE; DISCRETE UTERINE MYOMATA; DIFFUSE ADENOMYOMA IN THE RIGHT UTERINE HORN WITH THE DEVELOPMENT OF DECIDUAL CELLS AROUND THE GLANDS IN THE ADENOMYOMA.....	246
CHAPTER XXIV	
ADENOMYOMA OF THE ROUND LIGAMENT.....	250
SUMMARY.....	260
INDEX OF CASES ARRANGED ACCORDING TO THEIR GYNECOLOGICAL NUMBERS... ..	263
INDEX OF GYNECOLOGICAL-PATHOLOGICAL NUMBERS.....	265
INDEX.....	267

LIST OF ILLUSTRATIONS

FIG.	PAGE
1. DIFFUSE ADENOMYOMA OF THE POSTERIOR WALL OF THE UTERUS.....	10
2. DIFFUSE ADENOMYOMA OF THE POSTERIOR UTERINE WALL.....	12
3. DIFFUSE ADENOMYOMA OF THE POSTERIOR UTERINE WALL.....	19
4. DIFFUSE ADENOMYOMATOUS THICKENING IN THE FUNDUS AND POSTERIOR UTERINE WALL WITH EXTENSION <i>en masse</i> OF THE MUCOSA INTO A LARGE CREVICE BETWEEN MYOMATOUS MASSES.....	26
5. DIFFUSE ADENOMYOMA FORMING A COMPLETE ZONE AROUND THE UTERINE CAVITY.....	35
6. DIFFUSE ADENOMYOMA OF THE UTERINE WALL WITH MARKED EXTENSION OF THE MUCOSA INTO THE GROWTH.....	37
7. EXTENSION OF THE MUCOSA INTO A DIFFUSE MYOMA OF THE UTERUS.....	38
8. DIFFUSE ADENOMYOMA OF THE ANTERIOR UTERINE WALL.....	42
9. DIFFUSE ADENOMYOMA OF THE ANTERIOR UTERINE WALL.....	43
10. MODE OF EXTENSION OF UTERINE GLANDS INTO A DIFFUSE ADENOMYOMA	44
11. DIFFUSE ADENOMYOMA OF THE UTERUS WITH SEVERAL DISCRETE MYOMATA ..	48
12. DIFFUSE ADENOMYOMA OF THE POSTERIOR UTERINE WALL.....	49
13. DIFFUSE ADENOMYOMA OF THE UTERUS INVOLVING THE ANTERIOR AND POSTERIOR WALLS AND FUNDUS.....	55
14. DIFFUSE ADENOMYOMA OF THE ANTERIOR AND POSTERIOR UTERINE WALLS ..	56
15. METHOD OF PENETRATION OF THE MUCOSA IN A DIFFUSE ADENOMYOMA OF THE UTERINE WALL.....	57
16. EXTENSION OF UTERINE GLANDS INTO THE DIFFUSE MYOMATOUS TISSUE OF AN ADENOMYOMA.....	59
17. INTERSTITIAL AND SUBPERITONEAL UTERINE MYOMATA. INTERSTITIAL ADENOMYOMA.....	65
18. SMALL ADENOMYOMA OF THE FUNDUS OF THE UTERUS.....	66
19. DIFFUSE ADENOMYOMA OF THE UTERUS.....	69
20. DIFFUSE ADENOMYOMA OF THE UTERINE WALL.....	70
21. CYST-LIKE SPACES JUST BENEATH THE PERITONEUM IN DIFFUSE ADENO- MYOMA OF THE UTERUS.....	72
22. THE MUCOSA LINING ONE OF THE CYST-LIKE SPACES SITUATED JUST BENEATH THE PERITONEUM IN A DIFFUSE ADENOMYOMA OF THE UTERUS.....	74
23. DIFFUSE ADENOMYOMA OF THE ANTERIOR UTERINE WALL.....	77
24. DIFFUSE ADENOMYOMA OF THE ANTERIOR UTERINE WALL.....	78
25. CROSS-SECTION OF A GLAND TAKEN FROM FIG. 24 AT D.....	80
26. A BRANCHING GLAND FROM A GLANDULAR AREA IN AN ADENOMYOMA.....	81
27. DIFFUSE ADENOMYOMA OF THE BODY OF THE UTERUS.....	90
28. EXTENSION OF THE MUCOSA INTO THE MUSCLE IN A CASE OF DIFFUSE ADENO- MYOMA OF THE UTERUS.....	91

FIG.	PAGE
29. METHOD OF PENETRATION OF A SINGLE UTERINE GLAND INTO THE DIFFUSE MYOMATOUS GROWTH OF AN ADENOMYOMA.....	92
30. DIFFUSE ADENOMYOMA OF THE BODY OF THE UTERUS.....	96
31. DISCRETE UTERINE MYOMATA. DIFFUSE ADENOMYOMA WITH THE GLANDS ORIGINATING FROM THE MUCOSA. ADENOMYOMA OF THE LEFT UTERINE HORN.....	101
32. LONGITUDINAL SECTION OF DISCRETE MYOMATA; DISCRETE ADENOMYOMA NEAR THE LEFT UTERINE HORN.....	102
33. SUBPERITONEAL, INTERSTITIAL AND SUBMUCOUS UTERINE MYOMATA; DIFFUSE ADENOMYOMA OF THE ENTIRE FUNDUS.....	107
34. DISCRETE MYOMA OF THE CERVIX; DIFFUSE ADENOMYOMA OF THE BODY OF THE UTERUS.....	111
35. DIFFUSE ADENOMYOMA OF THE BODY OF THE UTERUS.....	116
36. DIFFUSE ADENOMYOMA OF THE FUNDUS WITH CYSTIC SPACES IN THE LEFT UTERINE HORN.....	120
37. A CYSTIC SUBPERITONEAL ADENOMYOMA OF THE UTERUS.....	130
38. A CYSTIC SUBPERITONEAL ADENOMYOMA OF THE UTERUS.....	131
39. A SUBPERITONEAL CYSTIC ADENOMYOMA OCCURRING IN THE CASE OF A LARGE MYOMATOUS UTERUS.....	134
40. CYSTIC SUBPERITONEAL ADENOMYOMA OF THE UTERUS.....	136
41. SUBPERITONEAL AND INTERSTITIAL UTERINE MYOMATA. ADENOMYOMA OF THE BODY OF THE UTERUS. ADENOMYOMA SPRINGING FROM THE LEFT UTERO-OVARIAN LIGAMENT.....	142
42. CROSS-SECTION THROUGH A PEDUNCULATED SUBPERITONEAL ADENOMYOMA ..	144
43. AN INTRALIGAMENTARY AND ALSO PARTLY SUBMUCOUS CYSTIC ADENOMYOMA OF THE UTERUS.....	151
44. A CYSTIC INTRALIGAMENTARY AND PARTLY SUBMUCOUS ADENOMYOMA OF THE UTERUS.....	152
45. THE SUBMUCOUS PORTION OF A CYSTIC ADENOMYOMA OF THE UTERUS.....	154
46. SUBMUCOUS ADENOMYOMA OF THE UTERUS.....	159
47. SUBMUCOUS ADENOMYOMA OF THE UTERUS, THE MYOMATOUS MUSCLE BEING RIDDLED WITH MINIATURE UTERINE CAVITIES.....	162
48. INTERSTITIAL UTERINE MYOMATA WITH A SMALL DIFFUSE ADENOMYOMA IN THE CERVIX.....	168
49. ADENOMYOMA IN THE OUTER PORTION OF THE CERVIX NEAR THE BROAD LIGAMENT ATTACHMENT.....	169
50. A CYSTIC MYOMA MACROSCOPICALLY SIMULATING A CYSTIC ADENOMYOMA	176
51. A SMALL UTERINE POLYP.....	178
52. LARGE VENOUS SINUSES IN THE UTERINE MUCOSA CAUSING SEVERE HEMORRHAGES.....	179
53. THICKENING OF THE UTERINE MUCOSA. MARKED DILATATION OF SOME OF THE GLANDS WITHOUT ANY ATROPHY OF THEIR EPITHELIUM; VERY DENSE STROMA.....	181
54. A PORTION OF A DIFFUSE ADENOMYOMA OF THE POSTERIOR WALL OF THE UTERUS.....	188
55. DIFFUSE ADENOMYOMA.....	189

FIG.	PAGE
56. VERY EXTENSIVE HYPERTROPHY OF THE CERVIX; DISCRETE MYOMA AND DIFFUSE ADENOMYOMA OF THE BODY OF THE UTERUS.....	200
57. ADENOMYOMA IN ONE HORN OF A BICORNATE UTERUS.....	204
58. DIFFUSE ADENOMYOMA IN THE BODY OF THE UTERUS.....	207
59. SQUAMOUS-CELL CARCINOMA OF THE CERVIX; DISCRETE SUBPERITONEAL AND INTERSTITIAL MYOMATA; DIFFUSE ADENOMYOMA OF THE POS- TERIOR UTERINE WALL.....	209
60. COMMENCING DIFFUSE ADENOMYOMA OF THE BODY OF THE UTERUS ASSO- CIATED WITH ADVANCED SQUAMOUS-CELL CARCINOMA OF THE CERVIX....	215
61. ADENOCARCINOMA OF THE BODY OF THE UTERUS ASSOCIATED WITH A SMALL SUBPERITONEAL ADENOMYOMA.....	219
62. ADENOCARCINOMA DEVELOPING FROM A DILATED GLAND IN AN ADENO- MYOMA OF THE UTERUS.....	224
63. MYOMA, ADENOMYOMA AND PRIMARY ADENOCARCINOMA OF THE BODY OF THE UTERUS; PYOSALPINX AND PRIMARY ADENOCARCINOMA OF THE OVARY..	228
64. ADENOMYOMA OF THE UTERINE HORN.....	237
65. ADENOMYOMATA OF BOTH UTERINE HORNS; DISCRETE MYOMATA; DIFFUSE ADENOMYOMA OF THE UTERUS.....	243
66. LEFT TUBAL PREGNANCY; DISCRETE UTERINE MYOMATA; ADENOMYOMA OF THE RIGHT UTERINE HORN WITH DECIDUAL FORMATION IN THE STROMA SURROUNDING THE GLANDS.....	247
67. ADENOMYOMA OF THE ROUND LIGAMENT.....	256
68. ADENOMYOMA OF THE ROUND LIGAMENT.....	257

ADENOMYOMA OF THE UTERUS

CHAPTER I

ADENOMYOMA OF THE UTERUS

In 1903, in a review of the literature published in a supplement to Orth's Festschrift, I reported 22 cases of adenomyoma examined by me up to that date.¹ Since then I have paid especial attention to these growths and have been astonished at the striking frequency with which they occur. Out of a total of 1283 cases of myoma examined from April 1, 1893, until July 1, 1906, 73²—that is, about 5.7 per cent.—were instances of adenomyoma.³ I have included only interstitial, subperitoneal and submucous adenomyomata and large adenomyomata of the uterine horns. The smaller nodules so frequently present in the cornua have been purposely omitted.

Glandular elements have from time to time been noted in myomata, and according to Breus,⁴ Schroeder, Herr and Grosskopf had been able to collect a total of one hundred cases up to 1884. But not until the appearance of the masterly work of von Reckling-

¹ Cullen, Thomas S.: Adeno-Myoma des Uterus, Verlag von August Hirschwald, Berlin, 1903.

² The following adenomyoma cases have been operated upon between July 1st, 1906, and Dec. 31st, 1907: Path. Nos. 10,109, 10,499, 10,560, 10,596, 10,617, 10,669, 10,677 (Gyn. 13,423), 10,767, 10,844 (Gyn. 13,590), 10,972, 11,078 (Gyn. 13,679), 11,120, 11,149, 11,191, 11,195, 11,849, 11,859, 11,863, 12,007, making a total of 19 cases; showing beyond peradventure that this disease is particularly prevalent. We have had in all 92 cases of adenomyoma.

³ In some of the cases no microscopic examination was made. To positively exclude the presence of adenomyoma it would have been necessary to take sections from many parts of the uterine wall. This would have entailed an enormous expenditure of labor that was often impossible. It will thus be seen that a certain number of cases of adenomyoma have probably been overlooked.

⁴ Breus, Carl: Ueber wahre epithelführende Cystenbildung in Uterus-Myomen. Leipzig und Wien, 1894.

hausen,¹ published in 1896, had this subject received much attention.² These growths, as their name implies, consist of gland elements and myomatous tissue. They form a distinct class of their own, and on microscopic examination their recognition is easy. Even in the gross specimens it is often possible to render a positive diagnosis.

For the use of clinicians we divided these growths into three classes, although it will be readily seen that one class may merge imperceptibly into the other. The divisions are:

- (1) Adenomyomata, the uterus preserving a relatively³ normal contour.
- (2) Subperitoneal or intraligamentary adenomyomata.
- (3) Submucous adenomyomata.

ADENOMYOMA IN WHICH THE UTERUS PRESERVES A RELATIVELY NORMAL CONTOUR

The uterus may be nearly normal in size, as in Fig. 5 (p. 35), or it may be two or three times the natural size, as noted in Fig. 13 (p. 55) and in Fig. 23 (p. 77). When the organ is considerably enlarged, it is frequently partly covered with adhesions. In these uteri there is a myomatous transformation of the muscle; the thickening extends from the mucosa outward, sometimes involving the wall in half its thickness, or at other times reaching even as far as the peritoneum (Fig. 13, p. 55). Sometimes it is limited to the anterior or posterior wall (Fig. 1, p. 10, and Fig. 23, p. 77), but may

¹ Von Recklinghausen, Friedrich: Die Adenomyome und Cystadenome der Uterus und Tubenwandung, ihre Abkunft von Resten des Wolff'schen Körpers. Berlin, 1896. (I wish to express my deep sense of obligation to Professor v. Recklinghausen for his kindness in examining sections from several of the cases and for his valuable criticism of the same.)

² Probably the best article written in this country on adenomyoma of the uterus was that by Dr. J. M. Baldy and Dr. W. T. Longcope, presented to the Philadelphia Obstetrical Society and published in the American Journal of Obstetrics, 1902, vol. xlv, p. 788.

³ I use the word "relatively" because if operative interference be long delayed some of the discrete myomata so frequently found may assume large proportions and almost completely overshadow the adenomyoma, while at the same time greatly altering the contour of the uterus.

involve both (Fig. 5, p. 35). Where such is the case, we have a uterine cavity lined with a mucosa which is surrounded by a thick zone of myomatous muscle and covered externally with a mantle of normal muscle of variable thickness. The myomatous thickening is diffuse in character, consists of bundles of fibres running in all directions and along the advancing margin gradually merging into the normal muscle, in contradistinction to the condition found in simple myomata, which are sharply circumscribed. Given such thickenings of the uterine wall, we may always suspect the presence of gland elements.

On examining the uterine cavity it is usually found that the mucosa at one or more points extends into the diffuse myomatous tissue beneath (Fig. 1, p. 10). This point is more readily verified by examining with a loup, when a careful scrutiny of the diffuse myomatous growth will discover small, round, irregular, triangular or oblong areas, composed of a waxy, fairly homogeneous tissue, lying between myomatous bundles. These areas correspond closely in appearance with the uterine mucosa, and with the glass one can make out punctiform openings, which are cross-sections of glands. Frequently such areas contain cyst-like spaces varying from .5 to 5 mm. or more in diameter (Fig. 5, p. 35, Fig. 19, p. 69). Other and larger cyst-like spaces are occasionally found. These have smooth inner surfaces and a lining of mucosa often 1 mm. in thickness. They are in reality miniature uterine cavities. Many of these cyst-like spaces contain fresh blood or yellowish blood pigment, the remains of old hemorrhages. The small cyst spaces may readily be mistaken for blood-vessels, but the larger ones are easily recognized. Among the most instructive cases reported are those of Lockstaedt.¹ In his Case 5 there was a diffuse myomatous thickening invading the posterior and part of the anterior wall. At several points the myoma had penetrated the outer muscular covering and sent prolongations as far as the peritoneum. On section

¹ Lockstaedt, Paul: Ueber Vorkommen und Bedeutung von Drüsen-schläuchen in den Myomen des Uterus. Monatschrift f. Geburtshülfe und Gynaekologie, 1898, Bd. vii, p. 188.

of the tumor numerous round lumina were seen. These had a diameter of 2 mm. In the fundus were six roundish depressions of the mucosa, into all of which one could easily pass a metallic sound, and a bristle could be inserted for a distance of from 1 to 1.8 cm. into the myomatous tissue. These canals branched with one another and also with those in the middle of the tumor. All were lined with a clear membrane which was easily loosened from the underlying myomatous tissue. In short, the small canals in the myomatous tissue were channels from the uterine cavity and had a lining of uterine mucosa.

In his Case 7 Lockstaedt found a diffuse myomatous thickening of the posterior wall and of the right side of the uterus. Near the fundus he saw five roundish depressions of the mucosa, and from these it was possible to pass into the myoma for a distance of 1.5 cm. One of the canals was broad enough to be easily opened with the scissors, and here one could see that the mucous membrane was directly continuous with that of the uterine cavity. Scattered throughout the diffuse growth were many cyst spaces, most of them filled with reddish-brown or chocolate-colored fluid. In order to determine whether these also communicated with the uterine cavity, Lockstaedt introduced a solution of Berlin blue into all of them, and was thus enabled to show that isolated cyst spaces were indirectly connected with the uterine cavity. From such cases we see that the uterine mucosa penetrates the diffuse myoma at several points and that these down-growths branch in all directions.

In Fig. 4, p. 26, we see just the earliest stage of such a condition as was found by Lockstaedt. Here in the fundus coarse myomatous masses are welling into the cavity and a large area of mucosa is passing down into the crevice between. With the continued growth of the myoma a portion of the uterine cavity would soon be drawn into the depth, and in all probability would eventually lose its continuity with the parent uterine cavity.

Rarely, if ever, do we find the slightest trace of glands in the outer covering of normal muscle. In the majority of these cases besides the diffuse myomatous growth a few circumscribed myomata

are present. These are irregularly scattered, being submucous, interstitial, or subperitoneal. They are usually only a few centimetres in diameter, but many attain to 15 cm. or more before the uterus is removed. When the uterus is not enlarged, the uterine cavity generally presents the usual appearance and is in no way altered, as the diffuse myoma does not usually press inward, as a submucous myoma invariably does. Case 2754, however, is an exception (Fig. 8, p. 42). Here there is a considerable bulging into the cavity.

The uterine mucosa is usually smooth, save for the occasional depressions as noted in Lockstaedt's cases; it is of the usual breadth or may reach a thickness of from 7 to 8 mm., as is seen in Fig. 1, p. 10, and Fig. 23, p. 77. Polypi, so common in cases of discrete myomata, are usually absent.

Histological Appearances.—The surface of the mucosa is usually smooth and has an intact surface epithelium (Fig. 6, p. 37, Fig. 14, p. 56, and Fig. 24, p. 78). The glands present the normal appearance as seen in Fig. 3, p. 19, and Fig. 7, p. 38. The stroma of the mucosa just beneath the surface epithelium is often slightly edematous or rarefied. The diffuse thickening in the uterine walls consists of characteristic myomatous tissue, the muscle bundles, however, showing much more interlacing than is found in the ordinary discrete myomata. Along the outer or advancing margin of the growth the myomatous cells gradually and imperceptibly merge into the normal muscle cells. The myomatous tissue, as was noted macroscopically, extends up to but usually does not encroach upon the mucosa. In most cases the mucosa can be seen dipping down into the diffuse myomatous growth, and at such points the muscle bundles run at right angles to the mucosa, thus allowing the latter to dip down between them. Sometimes a single gland penetrates the myoma. Such a gland presents a perfectly normal appearance (Fig. 29, p. 92), and is usually accompanied by the stroma of the mucosa which separates it from the muscle. In favorable sections such a gland can be traced far into the myomatous tissue. If it meets a barrier in the form of a muscle

bundle running parallel with, instead of at right angles to, the uterine mucosa, it is deflected along the surface of this until other muscular bundles are encountered that are again at right angles to the uterine cavity. It then passes still further outward between them. In other words, the gland follows the path of least resistance, winding in and out in all directions like a rivulet, but always making toward the peritoneal surface. While single glands sometimes penetrate, larger portions of the mucosa, as a rule, find their way into the muscle; for example, in Fig. 16, p. 58, three glands, accompanied by their stroma, can be seen extending into the muscle and spreading out in the depth, where more room is met with. In other words, they form a funnel with its smaller calibre directed toward the mucosa. In Case 3136 the mucosa (Fig. 24, p. 78) invades *en masse*, while in Fig. 6, p. 37, and in Fig. 7, p. 38, the mucosa is seen penetrating as the roots of a tree, there being a main trunk with many rootlets piercing the myoma in all directions. These glands retain their normal appearance and, as can be noted from the drawings, are invariably surrounded by the normal stroma of the mucosa. These extensions of the normal mucosa in many cases can be traced by direct continuity for at least 1 cm. In Fig. 6, p. 37, they can be followed for over 1.5 cm. Of course, with the windings in and out of the down-growths of the mucosa the continuity will be lost in the depth. Nevertheless, serial sections and injection in favorable cases, as carried out by Lockstaedt, show that the bunches of glands found in the depth are direct extensions from the mucosa. In the out-lying portions of the diffuse myoma round, oval, triangular, or irregular islands of glandular tissue are encountered. These consist, as a rule, of essentially normal uterine glands (Fig. 14, p. 56), lined with one layer of cylindrical ciliated epithelium and surrounded by the normal stroma of the mucosa.

Not infrequently these glands become cystic, the dilatation varying from 1 to 9 or more millimetres in diameter. Such dilatations are easily explained by the kinking and bending to which the glands are subjected by the surrounding and ever-growing myomatous tissue. The epithelium of the dilated glands is usually pale-

staining and somewhat flattened. The cyst spaces frequently contain desquamated epithelium, sometimes are partially filled with blood pigment and also contain a varying quantity of blood. In several instances we have noted round giant cells containing from four to eight nuclei in their centres and probably originating from the coalescence of degenerated epithelial cells. Some of the large spaces are not dilated glands, but represent cross-sections of the deep depressions from the mucosa, as noted in Lockstaedt's cases. Here the entire mucosa is carried into the myoma, and on cross-section we have a space lined with one layer of surface epithelium and surrounded by typical uterine mucosa. Of course, the mucosa on one side may be thinned out on account of the irregular stretching of the myomatous tissue, and then we have a picture corresponding to the chief canal—the Hauptkanal of von Recklinghausen. The miniature uterine cavity seen in Fig. 21, p. 72, although situated near the peritoneal surface, is probably similar in origin. From the pathological description it is seen that the uterine glands were found extending into the diffuse myoma; and again, a reference to Fig. 22, p. 74, which is an enlargement of a portion of Fig. 21, shows a mucous membrane indistinguishable from that lining the uterine cavity—a mucosa that is peculiar to the uterus and never found elsewhere. The glands in the diffuse myoma occasionally show some branching, as noted in Fig. 16, p. 58, Fig. 22, p. 74, Fig. 26, p. 81. This finding is sometimes noted in a normal uterus, and here, where the mucosa has such free play and where the glands are so long, we would naturally expect some branching. On the whole, however, they are remarkable for their regular shape.

The glands are naturally most abundant in the vicinity of the mucosa; they gradually diminish in number in the outer myomatous zone and are completely wanting in the normal outer muscular capsule. In short, where the myoma ends they cease. This is well shown in Fig 3, p. 19, Fig. 6, p. 37, Fig. 9, p. 43, and Fig. 24, p. 78. In some cases, although the glands in the diffuse myoma are identical with uterine glands, their origin from the mucosa cannot be clearly proved. In the majority of these cases, however, careful

examination of serial sections will show that at several points at least the glands of the mucosa are continuous with those in the depth.

CASES OF DIFFUSE ADENOMYOMA IN WHICH THE UTERUS RETAINS A
RELATIVELY NORMAL CONTOUR

Had we been told several years ago that in an examination of 1283 myomatous uteri diffuse adenomyomata were found 73 times, that is, in about 5.7 per cent., we should certainly have been tempted to doubt the veracity of the author. Nor can such a statement even now be accepted without ample proof. Accordingly it has been deemed advisable to give the essential features of each of the cases. In the brief description which we have just given of this disease only the salient points were discussed. Many other interesting data may be gleaned from a careful perusal of the individual records.

Gyn. No. 3418. Path. No. 661.

Diffuse adenomyoma of the posterior uterine wall (Figs. 1 and 2).

K. B. N., married, aged forty, white. Admitted April 3, 1895. Complaint on admission: Painful and profuse menstruation. The patient began to menstruate when fourteen years of age. The periods occurred at intervals of from three to four weeks, were profuse, but not accompanied by much pain. She has been married seventeen years; had one difficult, but non-instrumental, labor sixteen years ago, after which she was confined to bed for six weeks on account of chills and fever, which were followed by abdominal pains. Eleven years ago she had a miscarriage. Immediately after the birth of the child the menses became profuse and there was a discharge of dark, clotted blood. Pain was felt in the lower abdomen, also in the back. It commenced a few hours before the flow and lasted until the menses were over. The patient has never been strong; when twelve years of age she had malaria, and when fifteen, pneumonia. Her family history on both sides is decidedly tuberculous, both grandfathers, her mother, one aunt, and two cousins having died of phthisis.

Present Condition.—The patient is a well-nourished but rather anemic woman, weighing 140 pounds. Her tongue is coated; appetite good. She has an occasional headache; experiences no difficulty in locomotion; her feet and ankles occasionally swell; urine normal; the last menses ceased two weeks ago after a duration of ten days. On vaginal examination myoma uteri was diagnosed.

April 6, 1895. Operation.—An incision 15 cm. long was made in the median line, and the tumor lifted out of the pelvis. The ovarian vessels, round ligaments, and uterine vessels were tied and the uterus was amputated low down. The cervical lips were then brought together, and the peritoneum from the posterior pelvic wall was united with that from the anterior. The patient was discharged May 3d feeling perfectly well.

Gyn.-Path. No. 661.—The specimen consists of the enlarged uterus with its appendages intact. The uterus is pear-shaped and measures 12 cm. in length, 10 cm. in breadth, and 8 cm. in thickness. It is pinkish in color, smooth and glistening. A portion of the cervical canal measuring 2 cm. in length is present; its mucosa is pearly white in color, smooth and glistening, and has almost entirely lost its rugous appearance. The uterine cavity measures 4.5 cm. in length and is 5.5 cm. in breadth in its upper portion. The posterior wall bulges slightly into the cavity. The mucous membrane is smooth, but presents a mottled appearance, being the seat of extensive hemorrhage. It is 8 mm. in thickness. The anterior uterine wall averages 2.5 mm. in thickness. The posterior wall is 5 cm. thick and may be divided into two portions: an inner and thickened, which is coarsely striated and which looks very much like myomatous tissue, and an outer, resembling normal uterine muscle (Fig. 1). The contrast is much sharper after the specimen has been hardened in Müller's fluid, the coarsely striated portion staining lightly, the normal muscle deeply.

On careful examination of the hardened specimen, grayish-

brown granular areas are seen scattered throughout the thickened portion of the wall. These are round or irregular in contour,

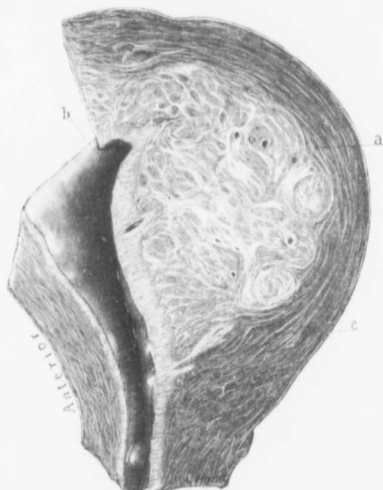


FIG. 1.—DIFFUSE ADENOMYOMA OF THE POSTERIOR WALL OF THE UTERUS. (Natural size.)

Gyn.-Path, No. 664. The uterus has been amputated through the cervix. The anterior uterine wall is unaltered. The posterior wall from cervix to fundus is greatly thickened, owing to the presence of a diffuse myomatous growth lying between the mucosa and the outer covering of normal muscle. This diffuse growth consists of fibres forming whorls but also passing in all conceivable directions. It encroaches to a slight extent on the uterine cavity. At *a* is seen the junction between the diffuse myoma and the normal muscle. The fibres of the one, however, blend imperceptibly with the other, and it would be impossible to shell this growth out, as can be done with discrete myomata. Near the internal os is a small polyp. The uterine cavity is somewhat lengthened. The mucosa lining the anterior wall is of the normal depth, but that covering the posterior wall is considerably thickened, and at two points indicated by *b* it can be traced for a considerable distance into the myoma. At *c*, just along the lower margin of the growth, the mucosa can be seen penetrating into the uterine wall for fully 1.5 cm. (For the histological appearance of the posterior wall see Fig. 2.)

and as one approaches the uterine cavity are seen to merge directly into the mucosa. Even on macroscopic examination it is evident that at least in the superficial areas are portions of the mucosa that dip down into the tumor.

Scattered here and there throughout the tumor are cavities, the largest of which is about 5 mm. in diameter. They have a smooth, glistening inner surface. Some of them are filled with blood. Along one margin of the tumor is a myomatous nodule 1 cm. in diameter. The outer portion of the uterine wall, which corresponds to the uterine muscle, averages 1 cm. in thickness.

Right side: The tube is 9 cm. long, 6 mm. in diameter. It is free from adhesions and has a patent fimbriated extremity. The parovarium

is intact. The ovary is 3.5 by 2.5 by 1.8 cm. It is free from adhesions, and on its under surface contains two slightly dilated Graafian follicles.

Left side: The tube is 7 cm. long and .8 cm. in diameter. It is free from adhesions and has a patent fimbriated extremity. The parovarium is intact.

The ovary is 3.5 by 2.5 by .5 cm. and is slightly cirrhotic. On its under surface is a corpus luteum, 2.5 by 1 cm.

Histological Examination.—The cervical glands are in most places normal, but here and there have proliferated. The epithelium covering the surface of the cervical mucosa is of the high cylindrical variety; near the junction of the internal os, however, it suddenly changes and the mucosa is covered with several layers of squamous epithelium. Above this point the typical cervical epithelium is again found. The mucosa covering the posterior wall of the uterus has an intact surface epithelium. Here and there little knob-like masses of the mucosa project into the uterine cavity. The uterine glands in the superficial portion are moderate in number and are small and round on cross-section. In the deeper portions they show considerable branching, and in some places it looks as if one gland gave off three or four branches; this appearance is probably due to a marked convolution of the glands. In several places the glands are seen extending down into the underlying tumor. This is most noticeable near the upper part of the uterine cavity, where longitudinal sections of two or three glands can be seen passing between muscle bundles into the depth of the tumor. This is clearly demonstrable to the naked eye. The stroma is rarefied (Fig. 2).

The individual stroma cells have oval vesicular nuclei and are slightly swollen. Scattered here and there throughout the stroma are small round cells occurring either singly or in clumps. The superficial portions of the mucosa show considerable hemorrhage. The coarsely striated thickening in the posterior wall is composed

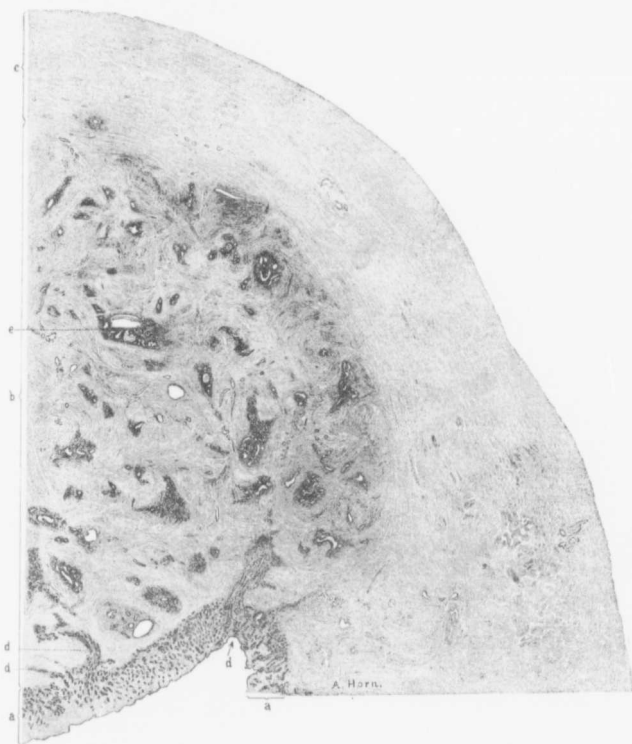


FIG. 2.—DIFFUSE ADENOMYOMA OF THE POSTERIOR UTERINE WALL. (3 diameters.)

Gyn.-Path. No. 661. The section represents the upper half of the posterior wall of the uterus seen in Fig. 1. The wall is divided into three distinct zones, an inner, *a*, consisting of the uterine mucosa; a middle zone, *b*, thick and coarse, made up of diffuse myomatous tissue; and an outer zone, *c*, composed of normal muscle. The mucosa, although increased in thickness, is normal. The surface epithelium is intact and the glands present the usual appearance. The diffuse myomatous growth has many islands of glands scattered throughout it. These consist of practically normal uterine glands and are surrounded by the characteristic stroma of the mucosa. Some of the glands are much dilated. Occasionally a gland occurs singly and lies in direct contact with muscle. At *c* the gland has retracted from the surrounding stroma. The origin of the gland elements in this diffuse myoma is clear, as at *d* we see the uterine mucosa extending directly into the myoma.

of non-stripped muscle fibres, which are cut longitudinally and transversely. This tissue is denser than normal uterine muscle, but otherwise closely resembles it. Between the bundles of muscle fibres, and also between the individual fibres, there is considerable infiltration with small round cells. Scattered freely throughout the tumor are glands. The majority of these are found in groups; some, however, occur singly. In many places they are seen on cross-section, where they appear as rows of oval or round glands. Some have been cut longitudinally and are cylindrical; others are curved. A few appear to have secondary glands opening into them. The glands as a whole are lined with one layer of cylindrical epithelium, on which it is possible in many places to make out cilia. A few of them are dilated. The epithelium of some is intact; in others it has become flattened or has disappeared. Some of the dilated glands are empty, others contain desquamated epithelium and granular material. Some of the desquamated cells are swollen and their protoplasm contains yellowish-brown, granular pigment.

The largest gland is filled with blood. In many of the glands the epithelium has become desquamated, and the gland is only recognized as a space partially or completely filled with desquamated cells. The groups of glands, and also most of those occurring singly, are surrounded by stroma which separates them from the muscle. This stroma is similar to that of the normal uterine mucosa. Here and there cross-sections of three or four glands are seen where the epithelial cells lie directly in contact with the muscle. In a good many places stroma cells contain brown, granular pigment. At one or two points a very curious picture is noted. At one end of a space between muscle bundles it is possible to make out a gland undergoing degeneration; on tracing this a little further, we see three oval spaces forming a chain; these are almost completely filled with small, round cells and cells having oval vesicular nuclei, which look a little like those of epithelioid cells. Each of these masses of cells contains one or more giant cells, which are round, oval, or elongated-oval; their nuclei are vesicular and situated in the centre of the cell or around the periphery. They remind one

somewhat of tubercles, but we believe them to be degenerated glands. No tubercle bacilli could be detected in these areas; nor was there any caseation.

There is no definite arrangement of the muscle around the bunches of glands. It looks as if the glands just filled in the spaces between muscle bundles. At one side of this new growth is a typical myomatous nodule, 1 cm. in diameter; this is entirely devoid of gland elements. The outer zone of the posterior wall, consisting of uterine muscle, is normal. The mucosa covering the anterior uterine wall is normal. Both tubes and ovaries are normal.

Gyn. No. 12,681. Path. No. 9517.

Diffuse myomatous thickening of both anterior and posterior uterine walls; large polyp in the body of the uterus; diffuse adenomyoma of the posterior wall; slight adenomyomatous tendency in the anterior wall.

F. Y., married, aged fifty-nine, white. Admitted Feb. 7, 1906; discharged March 12, 1906. The menses commenced at fourteen and were regular until ten years ago. At this time the periods became irregular and were from three to seven weeks apart. The flow is now more profuse and there is flooding. The patient has had pain in the region of the uterus for some time. The last period came on three weeks ago. The patient has been married thirty-nine years, has had eight children and two miscarriages. The oldest child is thirty-eight, the youngest twenty. Two years ago she consulted a physician, who removed several small polypi from the cervical canal. The bleeding diminished somewhat after this, but has been increasing again of late, and is now as abundant as before the operation. The patient has had no pain except a feeling of dull aching about the bladder. She is constipated. There is shortness of breath and a slight increase in frequency of micturition.

Protruding from the os is a polyp 5 mm. in diameter. The fundus is not definitely outlined.

Operation.—Removal of small cyst from the left labium

majus; hysterectomy; double salpingo-oöphorectomy. The patient's highest temperature was 100.8° F. She made an uneventful recovery except for a superficial breaking down of the incision.

Path. No. 9517.—The specimen consists of a myomatous uterus 10 cm. in length, 9 cm. in breadth, and 8 cm. in its antero-posterior diameter. It is smooth and glistening. The anterior wall varies from 3.5 to 4 cm. in thickness and presents a coarse striated appearance. In the fundus is a discrete myoma 3 mm. in diameter. The posterior wall varies from 2.3 to 3 cm. in thickness. It also presents a rather coarse striation. Just to the left of the cervix is a myoma 2.5 cm. in diameter, and below the cervix is a myoma approximately 6 cm. in diameter. The right tube offers nothing of interest. The ovary is covered with a few adhesions. It is very small. The left tube is normal. The ovary is somewhat mutilated. The mucosa varies from 2 to 4 mm. in thickness, and projecting from the left side is a polyp 2 cm. in length, 1 cm. in thickness.

Sections taken from the posterior wall show an intact surface epithelium. The glands are normal. The stroma presents the usual appearance. The most striking point observed with the dissecting microscope is that at many points the glands can be traced into the depth. At one point they can be followed by continuity for 3 mm. In other places several glands run down in the form of a funnel. Scattered throughout the thickened diffuse myomatous wall are glands and islands of uterine mucosa. Some of them contain only a single gland, others cross-sections of eight or more. Very few of these glands show dilatation.

Sections from the anterior wall also show a great deal of diffuse thickening. We have an intact surface epithelium, normal glands, and a stroma which in its superficial portion shows considerable hemorrhage. At several points far down in the depth we have a few isolated glands. There is here an adenomyomatous tendency, which is not, however, very marked. In the anterior wall

we have several discrete myomata, the largest being 1.5 cm. in diameter.

Diagnosis.—Diffuse myomatous thickening of both anterior and posterior uterine walls with marked extension of the mucosa into the posterior wall and slight penetration of the uterine mucosa into the anterior wall; discrete myomata chiefly in the cervical tissue; normal appendages.

Gyn. No. 11,850. Path. No. 8197.

Diagnosis: Interstitial and subperitoneal uterine myomata. Diffuse adenomyoma in the uterine walls, the glands originating in the mucosa.

C. B., aged thirty-nine, white, married. Admitted January 30, 1905.

Complaint: abdominal tumor. The patient had one child, eight years ago; no miscarriages. Menses at sixteen. Were regular every four weeks. Flow lasted four days, but lately has been of only one day's duration. Flow very scant, with clots. The pain was formerly cramp-like, but lately only slight. There has been no bleeding since the last period. After the birth of the child, eight years ago, she had what was supposed to be an abscess of the uterus. This opened spontaneously. She made a satisfactory recovery, and in 1900 she had a second abscess, which opened spontaneously.

Operation.—Hystero-myomectomy.

The uterus was small. On its anterior surface was an irregular myomatous tumor about 18 by 5 cm. The tubes and ovaries on each side were very much adherent from a chronic inflammatory process. The myoma was first bisected and loosened from the bladder. The uterus was removed and later the appendages. The left ovary was firmly adherent to the rectum. In cutting it away a small piece of ovarian tissue was left behind. Convalescence was not complicated. The highest temperature was 100.4° F., twenty-four hours after operation.

Path. No. 8197.—The specimen consists of the uterus amputated above the cervix. It has been bisected. Attached to the anterior wall is a large interstitial myoma. Both tubes and a part of the left and of the right ovary are present. The uterus is normal in size. Its cavity measures 4 cm. in length. Springing from the anterior wall of the uterus is a myomatous growth, 18 by 5 cm. The tumor does not encroach at all upon the uterine cavity. There are several small myomatous nodules scattered throughout the uterine wall. These are interstitial. There are dense adhesions over the surface of the tumor. The right tube and ovary are adherent. The fimbriated end is lost in the tubo-ovarian mass. The left ovary is cystic. The left tube is normal. Only a portion of the left ovary has been removed.

Sections from the endometrium show that the glands are perfectly normal except that here and there there is a dilatation. At some points there is a distinct tendency for the glands to extend into the depth, and at one point we have definite islands of mucosa at least 4 mm. from the surface. A direct connection between these and the surface mucosa can be traced. Around these islands the muscle shows a definite myomatous tendency. Sections from one of the myomata yield the usual appearance. There is some hyaline transformation.

Diagnosis.—Interstitial and subperitoneal uterine myomata; definite adenomyoma with the glands originating from the mucosa.

Gyn. No. 2573. Path. No. 163.

Diffuse adenomyoma occupying both the anterior and posterior uterine walls (Fig. 3); discrete subperitoneal, interstitial and submucous myomata. Hysterectomy. Recovery.

M. B., married, aged fifty, white. Admitted Feb. 7, discharged March 10, 1894.

The patient has been married twenty-eight years and has had five children, the youngest of whom is now sixteen. Flow usually

returned in ten months. One miscarriage, thirteen years ago, at six weeks.

Menses irregular until marriage, with profuse flow and some pain; periods regular after marriage. Last spring the menses began to decrease gradually, the pain also became less. The last period occurred in June, 1893 (menopause?). After the cessation of the flow in June, 1893, the patient felt very well. In August, 1893, she had a slight flow at about the menstrual period, and at this time commenced to feel weak and to have a profuse yellowish leucorrhœal discharge. Since November, 1893, she has had constant hemorrhages.

Examination.—Douglas' cul-de-sac is filled with a hard, immovable mass, from which the uterus cannot be differentiated.

Operation. Feb. 10, 1894. Dilatation and curettage. Double salpingo-oöphorectomy. Hystero-myomectomy. Uterus dilated and curetted with removal of a large quantity of mushy endometrial tissue. Retroflexed adherent myomatous uterus removed.

Maximum temperature 100.8° F. on eleventh day. Varied between 98.6° and 100.5° F. for over three weeks. Recovery.

Gyn. - Path. No. 163.—The specimen consists of the uterus, tubes, and ovaries. The uterus is uniformly enlarged, being 8 cm. in length, 7 in breadth, and about 7.5 in its antero-posterior diameter. It is smooth and glistening, but situated on the posterior surface are two small, hard nodules about 5 mm. in diameter. These are myomata. The anterior uterine wall varies from 2 to 3 cm. in thickness. Its muscular tissue is rather coarse, especially in its inner half, and scattered throughout it are numerous myomata, some reaching 1.5 cm. in diameter. The posterior uterine wall varies from 2 to 3.5 cm. in thickness. Its muscular tissue near the uterine cavity is coarse in texture. Scattered throughout it are several small myomata. Some of these encroach to a slight extent on the uterine cavity. The uterine cavity is 7 cm. in length and 7.5 cm. in breadth at the fundus. A description of the mucosa can

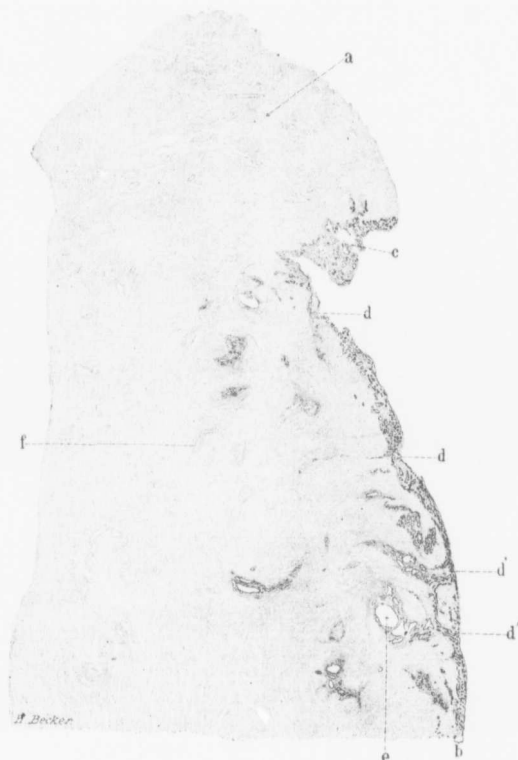

FIG. 3.—DIFFUSE ADENOMYOMA OF THE POSTERIOR UTERINE WALL. (3½ diameters.)

GYN.-Path. No. 163. The section is taken from the upper part of the uterine cavity, as shown by the position of *a*, which denotes the fundus. The uterine walls with the higher power show a slight myomatous transformation. There is considerable encroachment of the growth on the uterine cavity. At *b* the mucosa is of the usual thickness and is normal in appearance. At the fundus as seen at *c* it is thickened, but mechanically injured. At *d* the mucosa penetrates the diffuse growth for a short distance and at *d'* can be traced far into the muscle. At the latter point there is also a direct communication between the two down-growths. *e* is a cystic uterine gland. Scattered throughout the inner half of the uterine wall are numerous islands of uterine glands surrounded by deeply stained areas—the normal stroma of the mucosa. Here and there is a small gland lying in direct contact with the muscle. There are also numerous deeply stained areas, as represented by *f*. These consist of stroma of the mucosa devoid of gland elements. That the glands of this growth are derivatives of the uterine glands is evident.

be of little value, as the greater portion of it had been removed with the curette prior to operation.

HISTOLOGICAL EXAMINATION.—Sections from protected portions show that the surface epithelium is intact. The uterine glands present the usual appearance; some of them, however, are considerably dilated. The stroma of the mucosa presents the usual appearance. On the whole, we should consider the mucosa normal. At one point, however, near the fundus the glands show a peculiar branching and the epithelium is somewhat flattened, but the individual cells show no suspicious changes. The diffuse thickening in both the anterior and posterior walls is due to a myomatous transformation of the muscle. In some places this is very pronounced, but it is to a great extent limited to the inner half of the uterine walls. In many places the mucosa has penetrated the diffuse myoma for a distance of 1.5 cm. and in several places the direct extension into the depth can be traced for a distance of 6 mm. (Fig. 3). In the depth these downgrowths of the mucosa are recognized as islands of mucous membrane surrounded by myomatous tissue. These islands sometimes contain a dozen or more glands, normal in appearance and surrounded by the characteristic stroma. Some of the glands are much dilated, and occasionally an isolated gland is found lying between muscle bundles, but even then it is usually separated from the muscle by the stroma of the mucosa. The diffuse adenomyomatous condition, although present in both the anterior and posterior walls, is more pronounced in the posterior. Both tubes and ovaries are normal.

DIAGNOSIS.—Diffuse adenomyoma occupying both the anterior and posterior uterine walls; discrete subperitoneal, interstitial, and submucous myomata; normal appendages.

H. A. K. Sanitarium No. 1931. Path. No. 9367.

Subperitoneal, interstitial, and submucous uterine myomata; commencing adenomyoma.

J. H., aged forty-nine, white. Admitted May 11, 1905. The patient complains of an excessive flow. In 1893 a myoma was diagnosed. This has apparently not increased in size. The patient now suffers chiefly from pressure on the bladder. There is a great deal of pain in the region of the left ovary and in the lower part of the abdomen. On May 12, 1905, with a pair of forceps, a myoma was drawn down out of the body of the uterus. Examination per rectum showed that the tumor was the size of a coconut and that there were several others. She soon left the hospital, but returned on October 6th. The last menstrual flow had been very severe.

Operation Nov. 18, 1905.—Hystero-myomectomy, right salpingo-oöphorectomy. The patient made a very satisfactory recovery.

Path. No. 9367.—The specimen consists of the uterus, which is rather uniformly enlarged, and which has been amputated through the cervix. It is 11 cm. in length, 12 cm. in breadth, and 12 cm. in its antero-posterior diameter. Occupying the anterior wall is an oval mass, 8 by 6 cm., presenting a typical myomatous appearance. Scattered throughout the uterine walls are numerous interstitial myomata, and there are also two submucous nodules, the larger 2.5 cm. in diameter. The uterine mucosa is apparently very thin. The right tube and ovary look normal.

Histological examination shows the endometrium to be perfectly normal. Over the surface of a submucous myoma from the fundus, there is a distinct myomatous thickening, and covering its surface is an intact surface epithelium. Riddling the myoma for a short distance are normal uterine glands, some of which show a direct connection with the uterine mucosa. A little further on are two small myomata projecting into the cavity, and on either side of them is normal mucosa. This is rather remarkable, as there is really no encroachment upon the uterine cavity, the myomata just taking the place of the normal uterine mucosa.

Diagnosis.—Subperitoneal, interstitial, and submucous uterine myomata; commencing adenomyoma.

Gyn. No. 12,599. Path. No. 9366.

Slight grade of endometritis, diffuse thickening of both the anterior and posterior uterine walls; diffuse adenomyoma of the anterior wall with the glands originating in the mucosa.

S. A. B., married, aged forty-three, white. Admitted January 10, 1906; discharged January 31, 1906. Complaint: uterine hemorrhages. The menses commenced at eleven and occurred every three or four weeks until a year ago. Since then the periods have been irregular and prolonged, with flooding, at times accompanied by cramps, which, however, have not been severe. Flow normal, lasting from six to eight days. The last period began one month ago and has persisted up to the present time. The patient has been married twenty-one years, has had three children and two miscarriages. The oldest child is twenty, the youngest fourteen.

For fourteen years the patient has noticed that ten days after the menses the abdomen would swell markedly and she would have the sensation as if everything were falling out of the abdomen. Six months ago she had her menstrual period and the bleeding persisted for one month; it could not be controlled with medicine. Three days before admission the bleeding became so marked that the uterus was packed.

Operation.—Hysterectomy, amputation through the cervix. The history was somewhat suggestive of carcinoma, and as the uterus had been recently curetted we prepared to do an abdominal hysterectomy, if necessary, but on opening the abdomen noted the coarse striated appearance of the uterus and consequently amputated through the cervix. The patient made a satisfactory recovery. The highest post-operative temperature was 100° F.

Path. No. 9366.—The specimen consists of the uterus amputated through the cervix and of the appendages on both sides. The portion of the uterus present is 7 cm. in length, 8 cm. in breadth, and 6.5 cm. in its antero-posterior diameter. Anteriorly it is smooth and glistening. Posteriorly it is covered with a few adhesions. The uterine walls are firm. The posterior wall varies from 2.5

to 3 cm. in thickness. The anterior also reaches 3 cm. in diameter. The mucosa is apparently thin on the posterior wall and on the anterior reaches 2.5 mm. in thickness. The right tube is covered with a few adhesions. Its fimbriated end is patent. The right ovary, apart from a few adhesions, is normal. The left tube is normal. The left ovary is slightly adherent.

Sections from the anterior uterine wall show that it is riddled with islands of uterine mucosa. In a good many places these islands are irregular and are surrounded by a zone of muscle fibres lying parallel with the islands. External to this parallel zone is a circular zone. In a good many places the glands occurring in the muscle are dilated and at numerous points are seen miniature cavities. These are lined with one layer of epithelium resting on the underlying stroma, in which typical uterine glands are situated. The myomatous tissue forming this diffuse growth is not very sharply differentiated from normal uterine muscle. Some of the glands have two layers of cells which stain palely, and the appearances are rather suggestive of pathological changes. It will be noted that the glands in such an adenomyoma might very readily have undergone carcinomatous changes.

On examining further sections it is found that the mucosa of the anterior wall can be traced into the depth for 1.5 cm. Here it ends abruptly. The endometrium shows numerous polymorphonuclear leucocytes. The posterior wall shows diffuse myomatous thickening but contains no glands.

Diagnosis.—A mild grade of endometritis; diffuse myomatous thickening of the anterior and posterior uterine walls; definite adenomyoma of the anterior wall with the glands originating from the mucosa.

Gyn. No. 3614. Path. No. 788.

Diffuse myomatous thickening of the uterine walls with extension of a large area

of mucosa into the depth between the myomata (Fig. 4). Interstitial uterine myomata; hemorrhage into and thickening of the mucosa; general pelvic peritonitis.

Mrs. D. G., aged forty-three. Admitted June 29, 1895. Complaint: pain in the lower part of the abdomen and profuse, painful menstruation. She has been married twenty-five years, but has never been pregnant. Menstruation began during the sixteenth year and continued to be regular until five years ago. It has always been free and at times painful. Her family history is negative. At seventeen she had typhoid fever with meningeal symptoms, and since then her health has been poor. The present illness dates back five years. At this time she passed several dark, tarry and red masses from the vagina. These appeared to be covered with a thin membrane and their passage was accompanied by paroxysms of pain. After this, menstruation became irregular and very profuse, sometimes lasting two weeks. The discharge was very dark in color and frequently clotted. About the second day of menstruation severe pain would commence. This would last throughout the period, and has at times been so severe that it was necessary to keep her under the influence of chloroform. The last period came on four weeks ago, the one before that six months previously. Four weeks ago she noticed a tumor in the lower part of the abdomen. This was freely movable.

In January, 1894, an exploratory section was made. Nothing was done, as the tumor was supposed to be malignant. After the operation the pain diminished and the patient left improved.

Present Condition.—The patient is emaciated and anæmic, the tongue is clean, the bowels are constipated. She has had a watery discharge which has persisted for the last four years. This is slightly offensive and varies considerably in color; at times it is yellow; at other times it has a greenish tinge. It is often tinged with blood, and is profuse. Menstruation is frequent and at times painful, and during recent years there have been sensations of weight and pain in the region of the rectum. Locomotion and exercise

occasion a great deal of pain in the lower abdomen. Abdominal pressure, however, does not cause any discomfort.

Operation July 1, 1895.—After breaking up numerous adhesions to the anterior abdominal wall the uterus could be lifted up. It was amputated from left to right in the usual manner and a drain was brought out through the vagina. On the second day the temperature rose to 100.6° F. For several days it ranged between 100° and 101° F. On July 15th the cervix was dilated, and about 70 c.c. of pus escaped. On the twenty-fifth day the temperature reached normal, and on August 12th the patient was discharged feeling perfectly well. The abdominal wound in this case broke down and discharged for a few days, but on July 20th had healed completely.

Path. No. 788.—The specimen consists of the uterus with intact appendages. The uterus is 11 by 9 by 9 cm. Anteriorly and posteriorly it is covered with dense adhesions. It is soft and yielding on pressure. The uterine cavity measures 6 cm. in length and 6 cm. in breadth. At the fundus the mucosa is bluish-red in color, very irregular, and presents numerous nodules which vary from 1 to 3.8 cm. in diameter. The surface of the mucosa over some of these nodules is smooth and glistening, but for the most part it presents a rough appearance. Over the fundus are numerous adhesions passing from the anterior to the posterior surface. The mucosa varies from 1 to 7 mm. in thickness. The uterine muscle averages 3 cm. in thickness. Situated in the anterior wall is a firm nodule, 1.5 cm. in diameter, presenting the typical myomatous appearance (Fig. 4). The fundus is occupied by a tumor approximately 9 cm. in diameter. On section the central portion of this tumor over an area 6.5 cm. in diameter has undergone degeneration. It consists of a soft, yielding, whitish tissue held in position by delicate bands.

Right side: The tube is 8 cm. in length. It is covered with dense adhesions. Its fimbriated end is patent. The ovary is 2.5 by 2.5 by 1 cm. and shows a dilated follicle.

Left side: The tube is 7 cm. in length and averages 5 mm. in

diameter. It is free from adhesions. The ovary is small and covered with delicate vascular adhesions.

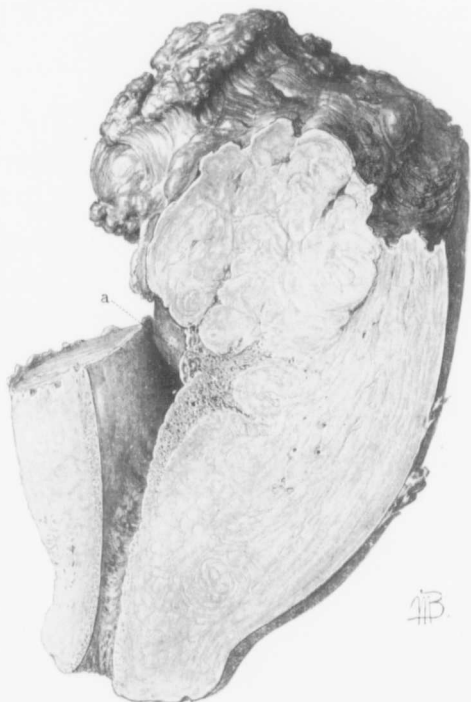

FIG. 4.—DIFFUSE ADENOMYOMATOUS THICKENING IN THE FUNDUS AND POSTERIOR UTERINE WALL WITH EXTENSION EN MASSE OF THE MUCOSA INTO A LARGE CREVICE BETWEEN MYOMATOUS MASSES. (Natural size.)

Gyn.—Path. No. 788. The myoma is welling into the uterine cavity, and into the space between myomatous masses a large area of mucosa is flowing. With the continued growth of the myomatous tissue this mucosa would in all probability be nipped off and carried outward, thus forming a large island of mucosa surrounded by myomatous tissue.

On section of the specimen after hardening in Müller's fluid, the uterine walls are found to be divided into two distinct layers.

In the anterior wall the inner layer is 2 cm. in breadth. This differs from the outer layers and does not stain as deeply. In a few places small myomata are seen scattered throughout the thickened part of the wall. Eight mm. beneath the mucosa is an area of mucous membrane 8 mm. in diameter. In some places the uterine mucosa can be seen flowing into the myomatous growth. The outer muscular covering looks like normal muscle. The posterior wall varies from 4 to 5 cm. in thickness. It is also divisible into two layers, but the coarse myomatous arrangement occupies nearly the entire wall. The uterine mucosa extends out for a distance of fully 2 cm. and is invading the myoma.

Histological Examination.—The epithelium covering the cervical mucosa is intact and the cervical glands are normal. In the vicinity of the broad ligament are a couple of glands lined with cylindrical epithelium. They resemble uterine glands and are surrounded by a small amount of stroma similar to that of the uterine mucosa. The uterine mucosa has an intact surface epithelium. Its glands are very abundant. In its superficial portions they are for the most part small and round; and on cross-section, in the vicinity of the muscle considerably dilated. In favorable sections one can trace the gland, which is narrowed in its upper portion, downward until it becomes dilated. The gland cavities are either empty or contain swollen desquamated cells or blood; in a few are polymorphonuclear leucocytes. The stroma of the mucosa is, on the whole, denser than usual. Scattered throughout the superficial portion of the stroma are a few small round cells and a few polymorphonuclear leucocytes. Here and there the glands are seen to extend a short distance into the muscle. Where the muscle is gathered up into folds its surface is covered by cylindrical epithelium. Here and there individual glands are seen extending down into the muscle, but at some points glands can be traced down by direct continuity for a distance of 2 cm. This appearance is found to represent noth-

ing more than a dipping down of the normal glands. They are accompanied by characteristic stroma, and many of the glands are dilated. The epithelium lining those lying in the muscle has in many places fallen off and is lying free in the cavity of the glands. It looks as if the glands in the deeper portion were being forced out of existence and in the myomatous portion only fine remnants are visible. The stroma of the mucosa, however, in such areas still persists. The thickened portions of the uterine walls are composed of irregular bunches of non-striated muscle fibres cut longitudinally and transversely. They have a rich blood-supply and present the usual appearance. The large nodule situated in the fundus is composed of non-striated muscle fibres cut longitudinally and transversely. In many places this tissue has undergone complete hyaline degeneration, and at some points this hyaline material has completely melted away, leaving small cavities.

Diagnosis.—Diffuse myomatous thickening of the uterine walls; definite adenomyoma; general pelvic adhesions.

CHAPTER II

CASES OF ADENOMYOMA IN WHICH THE UTERUS RETAINS A RELATIVELY NORMAL CONTOUR—(Continued)

Gyn. No. 2706. Path. No. 245.

Multiple uterine myomata, commencing diffuse adenomyoma. Adenomyoma of the left uterine horn. Right hydrosalpinx; left tubo-ovarian cyst.

M. A., white, aged forty-seven, married. Admitted April 6, 1894; discharged May 12, 1894. The patient has been married twenty years. She has had no children and no miscarriages. The menses are regular, with a free flow and severe pain the first day. Since marriage the flow has lasted twice as long, is more profuse, and the pain is more severe. Moderate leucorrhœa at times. For over two years she has had pain in the left ovarian region, only constant for the past month. During that time there has been a continuous hemorrhage from the uterus, profuse at first, now less.

Operation.—Hystero-myomectomy. Part of the growth was submucous and was removed through the vagina. After the operation the patient had persistent nausea and vomiting until the fourth day, when, after the vomiting of an *ascaris lumbricoides*, 14 cm. long, the nausea and vomiting ceased. The maximum temperature was 100.5° F., on the third day. The patient made a satisfactory recovery.

Path. No. 245.—The specimen consists of the uterus, the dilated tube from the right side, and an ovarian cyst, together with the left tube and ovary. The uterus is 7 by 9 by 5.5 cm. It has been amputated through the cervix. The peritoneal surface is smooth. On the right side about the middle of the fundus is a myomatous nodule, 1.5 cm. in diameter. At the junction of the left tube with the uterus is a myomatous nodule 1.5 cm. in diameter.

The uterine walls average 3 cm. in thickness. They contain three or four myomata, the largest 2 cm. in diameter. The uterine mucosa averages 2 mm. in thickness.

Right side: The tube is 21 cm. long, .8 cm. in breadth, and dilated at the uterine end. After passing outward 6 cm. it becomes convoluted and occluded. Behind this it forms a sac 5 by 6 cm. This somewhat resembles a pipe-bowl. On the surface are numerous adhesions. The ovary is 4 by 4 by 1 cm. The lower extremity is occupied by a cyst, 2 by 3 cm.

The left side is for the most part occupied by a cyst, 13 by 12 by 11 cm. It is smooth and glistening and traversed by numerous small vessels. Posteriorly there are many adhesions and a distinct sensation of fluctuation is perceptible. The tube is 17 cm. long, 1.5 cm. broad. After passing outward 6 cm. it spreads over the surface of the tumor and finally merges into the tumor itself. The ovary is 5 by 3 by 1 cm.

Histological Examination.—The cervical glands are normal. In the body of the uterus the mucosa is somewhat edematous. Some of the glands run parallel with, instead of at right angles to, the underlying muscle. As one approaches the fundus the mucosa reaches 5 mm. in thickness. The glands are very long. Their epithelium is intact. Some of the glands have extended down into the muscular layer. The stroma in places is infiltrated with small round cells, and in the deeper portions of the mucosa are a few lymphoid cells. The blood-vessels of the mucosa appear to be more numerous than usual and in places are dilated.

The right cornu is normal. The left contains numerous cyst-like spaces, some of them situated on the side of the tube, others lying 2 to 4 mm. beneath the peritoneal surface. These glands are small and round or are irregular and dilated. They are lined with one layer of cylindrical epithelium, which in some places rises directly from the muscle. In other places it is surrounded by a faint amount of stroma similar to that of the uterine mucosa. The glands are dilated. The muscular tissue around these glands

presents a distinct myomatous appearance. One of the glands contains a little finger-like ingrowth.

Diagnosis.—Multiple uterine myomata. Commencing diffuse adenomyoma; adenomyoma of the left uterine horn; right hydrosalpinx; left tubo-ovarian cyst.

Gyn. No. 3809. Path. No. 881.

Discrete subperitoneal and interstitial uterine myomata. Commencing diffuse adenomyomatous formation with the glands originating from the mucosa. General pelvic adhesions, probable remains of the Wolffian body in the left ovary.

S. F., aged thirty-six, white. Admitted September 21, 1895; discharged October 19, 1895. The last period appeared two weeks ago; the flow was somewhat free and there was much pain. The bowels are constipated, defecation is painful. Micturition is scant and painful and at times it is necessary to catheterize.

Operation.—Hystero-salpingo-oöphorectomy. Considerable difficulty was experienced owing to the omental adhesions to the abdominal wall. The uterus was everywhere adherent. It was removed entirely. The highest temperature was 100.5° F., four days after the operation. The patient made an uninterrupted recovery.

Path. No. 881.—The specimen consists of the uterus with the appendages intact. The uterus is 7 by 6.5 by 6.5 cm.; it is covered by dense adhesions. On the posterior surface are two flat pedunculated nodules, 1.8 cm. in diameter. These are covered by adhesions. The uterine cavity is 4.5 cm. in length and 4 cm. in breadth. At the fundus the mucosa presents a slightly roughened, granular appearance, and projecting into the cavity from the lower third of the posterior wall is a myomatous nodule, 5 by 3 cm. The uterine mucosa averages 1 mm. or more in thickness. The uterine muscle averages 2.5 cm. in thickness. It contains several firm nodules averaging 1 cm. in diameter. On the right side the tube

is 5.5 cm. in length and varies from 5 to 8 mm. in thickness. Its surface is covered by a few adhesions and it contains a cyst 1.5 cm. in diameter, near the fimbriated end. The fimbriated extremity is patent and measures .8 cm. in diameter. It is also covered by adhesions. On pressure pus exudes from the fimbriated extremity. The ovary is normal in size, much mutilated, and covered by adhesions.

Histological Examination.—The uterine mucosa has not been well preserved. The glands, where present, are normal and have an intact epithelium. The stroma of the mucosa shows a moderate amount of small round-cell infiltration and the uterine glands exhibit a peculiar tendency to extend a short distance into the muscle. Most of these are surrounded by normal stroma, but a few lie in direct continuity with the muscle. Sections through the nodules present a typical myomatous appearance.

Right side: The tube presents the usual appearance, but the tube lumen contains a moderate amount of blood. Sections through the left cornu show that the epithelium in places is slightly swollen and that it has here and there cyst-like spaces which contain a few polymorphonuclear leucocytes and apparently some desquamated epithelial cells. Situated apparently in the hilum of the left ovary is an irregular, deeply staining area composed of irregular spindle-shaped cells which suggest connective tissue; and scattered through this tissue are irregular gland-like spaces, each of which is lined with one layer of cylindrical epithelium. The spindle-shaped cells are arranged in layers around the gland-like spaces. They are probably remains of the Wolffian body.

In further sections through the adhesions on the posterior surface of the uterus, the uterine muscle just beneath the mucosa is seen to contain in some places one, in others three or four gland-like spaces. These are, however, slit-like in contour. They are lined with one layer of cylindrical epithelium in which cilia are in many places visible. These cavities are either empty or contain granular detritus, and here and there some desquamated epithelium. Some of

the glands lie in direct contact with the muscle. Others have a definite stroma surrounding them. This stroma is similar to that of the uterine mucosa. Around one of the glands the muscle is arranged in a circular manner. It looks as if it were forming a definite coat.

Diagnosis.—General pelvic adhesions. Discrete sub-peritoneal and interstitial myomata. Commencing diffuse adenomyoma; probable remains of the Wolffian body in the left ovary.

Gyn. No. 9069. Path. No. 5229.

Commencing diffuse adenomyoma of the uterus; slight pelvic peritonitis.

M. M., aged thirty-five, white, married. Admitted September 17, 1901; discharged October 2, 1901. Father, brother, and grandfather died of pulmonary tuberculosis. The patient has always been rather delicate and has had pneumonia three times. Her menses began at twelve, were regular, lasting two or three days; the flow was scant and painful. She has had a leucorrhœal discharge since childhood. In 1897 the uterus was suspended. In 1899 she returned with a retroversion. This time she complained of more severe pain than she had had before the suspension was done. The most prominent symptoms were backache and frequency of urination. There is no history of any severe hemorrhage.

Operation.—Hystero-salpingo-oöphorectomy. The patient made an uninterrupted recovery.

Path. No. 5229.—The specimen consists of the uterus, tubes, and ovaries. The uterus, including the cervix, is 5.5 by 4.5 by 2.5 cm. Its peritoneum is smooth and glistening. At the fundus is a tag of tissue the result of the suspension of two years ago. The cervical canal appears as a transverse slit 5 mm. broad. The mucosa is exceedingly thin in the upper part of the cavity; it is granular and much congested. The appendages on both sides are covered with adhesions.

The cervical mucosa is normal. Many of the glands, however, are much dilated.

Sections from the endometrium show the mucosa in places to be very ragged, possibly the result of curettage. In other places the surface epithelium is intact. The stroma is slightly edematous. At some points the underlying muscle shows a distinct myomatous tendency and we have a direct extension of the glands into the underlying tissue, the picture presented being typical of adenomyoma.

Diagnosis.—Pelvic peritonitis; commencing adenomyoma; small cyst of the ovary.

Gyn. No. 7153. Path. No. 3429.

Diffuse adenomyoma occupying the anterior, posterior, and lateral uterine walls; in short, forming a mantle around the uterine cavity (Figs. 5, 6, 7). Slight pelvic peritonitis. Hysterectomy. Recovery.

S. W., aged fifty-six, white, married. Admitted August 24, 1899; discharged September 26, 1899. Complaint: pelvic tumor and hemorrhages from the uterus. The patient has been married thirty-four years, has had thirteen children; the youngest is thirteen years of age. She has had one miscarriage. The menses commenced at thirteen, were regular, and lasted a week. For the last ten years they have been very profuse. Sometimes recently she would lose as much as a quart of blood.

There has been a slight leucorrhœal discharge. The patient is very anemic and presents a blanched appearance. She has a slightly intermittent pulse. The outlet is markedly relaxed and the vaginal walls are redundant. The cervix is in the axis of the vagina and points slightly to the right. It is about four or five times the normal size. The cervical lips are thin and rigid. The uterus is somewhat enlarged and irregular in outline. The lateral structures cannot be palpated.

Operation August 28, 1899.—Hystero-salpingo-*oö*phorectomy. The patient made a satisfactory recovery.

Gyn.-Path. No. 3429.—The specimen consists of the uterus with the appendages intact. The uterus is slightly enlarged. It has been amputated at the cervix. The body is 6 cm. in length, 6 cm. in breadth, and 4.5 cm. in

its antero-posterior diameter. The outer surface is covered with adhesions. These are especially abundant over the fundus and posterior surface of the uterus. Both the anterior and posterior walls average 2.5 cm. in thickness and are readily divisible into two zones. The inner consists of dense muscular tissue; the fibres run in and out in all directions and form definite whorls (Fig. 5). Situated in this diffuse growth are also a few small circumscribed myomata. The coarse myomatous tissue

extends directly to the mucosa, but apparently does not encroach upon it. At one or two points brownish areas, rather porous in appearance and faintly resembling uterine mucosa, are found in the myomatous tissue some distance from the mucosa. The outer portion of the uterine wall consists of normal muscle. This forms a

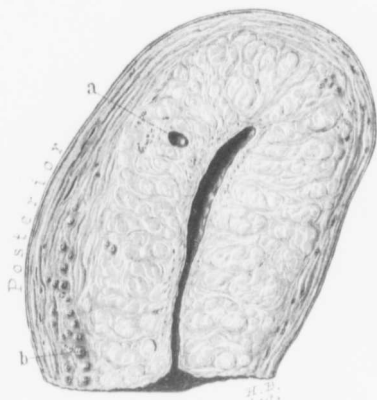


FIG. 5.—DIFFUSE ADENOMYOMA FORMING A COMPLETE ZONE AROUND THE UTERINE CAVITY. (Natural size.)

GYN. No. 3429. The figure represents an antero-posterior section through the entire uterus which has been amputated through the cervix. The uterine cavity is of the normal length and appearance and the mucosa is probably thinner than usual. The inner two-thirds of the muscular wall have been completely transformed into a diffuse myomatous tissue which extends to, but does not encroach upon, the uterine cavity. At *a* is a small cyst with a smooth inner lining. The outer portion of the uterine wall consists of perfectly normal muscle. Scattered throughout it are many cross-sections of small blood-vessels, well shown at *b*. Although the myomatous muscle sharply contrasts with the normal muscle, the two gradually merge into one another and are intimately blended. For the histological appearance see Figs. 6 and 7.

covering varying from 3 to 5 mm. in thickness and is sharply differentiated from the diffuse myoma. The uterine cavity is 5 cm. in length and at the fundus 4 cm. broad. The mucosa is perfectly smooth and is apparently not over 1 mm. in thickness. Just within the internal os, however, is a polypoid outgrowth, 1.2 by .6 by .4 cm.

Right side: The tube is 10 cm. long and varies from 4 to 11 mm. in diameter. It is covered with vascular adhesions and its fimbriated extremity is occluded and adherent to the ovary. The ovary is senile in character; it measures 2.5 by 1.8 by 1.5 cm. and is covered with adhesions.

Left side: The tube is 10 cm. in length and 5 mm. in diameter. Its fimbriated extremity is patent, but the fimbriae have here and there become agglutinated; the ovary is senile; it measures 3 by 1.8 by 1.3 cm.

HISTOLOGICAL EXAMINATION.—Sections through the polyp near the internal os show that it is composed almost entirely of cervical tissue. The glands are abundant, and apart from being dilated offer little of interest. The mucosa lining the uterine cavity has for the most part an intact surface epithelium. This epithelium is low cylindrical in type. The uterine glands present the usual appearance and are lined with one layer of cylindrical epithelium. At numerous points the mucous membrane extends directly into the underlying myomatous tissue (Figs. 6 and 7). Sometimes it is possible to trace it for a distance of 6 or 7 mm. The extension into the muscle varies in different places. At some points prolongations 4 or 5 mm. broad extend from the mucosa into the depth. At other points a large area of mucosa in the depth will communicate with the surface by an actual isthmus. The thickening of the anterior and posterior uterine walls is due to the presence of myomatous tissue. As was noted macroscopically, this forms a broad zone between the mucosa and the outer covering of normal muscle. The fibres of this myomatous tissue are particularly well preserved and wind in and out in all directions. Scattered everywhere throughout the myomatous zone are islands of mucous membrane identical

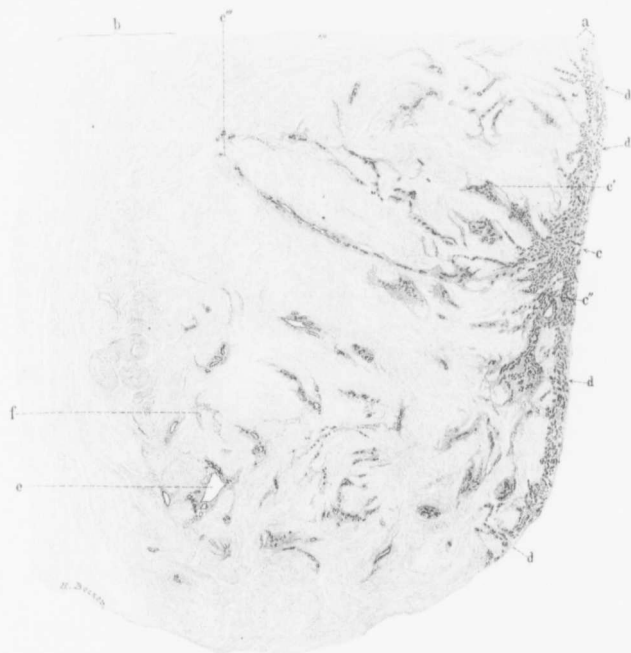


FIG. 6.—DIFFUSE ADENOMYOMA OF THE UTERINE WALL WITH MARKED EXTENSION OF THE MUCCOSA INTO THE GROWTH. (4 diameters.)

Gyn.-Path, No. 3429. This is a section through the entire uterine wall in Fig. 5. *a* indicates the uterine mucosa; *b*, the outer covering of normal muscle. The intervening portion, comprising the major part of the uterine wall, consists of diffuse myomatous tissue. The uterine mucosa at *a* is of the normal thickness and presents the usual appearance. It is immediately noticeable that the surface is perfectly even, there being no tendency toward the formation of outgrowths. At *c* there is a wholesale extension of mucosa into the diffuse myoma. At *c'* and *c''* the mucosa can be traced for a considerable distance, but at *c'''* a most instructive picture is seen. Here we are able to follow the extension of the mucosa fully two-thirds of the way through the uterine wall and almost to the point where the diffuse growth ends and the normal muscle begins. It will be noted that the usual stroma accompanies the glands. At numerous other points, indicated by *d*, the mucosa is seen penetrating the myoma. Scattered throughout the diffuse growth are many islands of uterine mucosa containing anywhere from one to a dozen or more sections of glands embedded in the characteristic stroma. A few of the glands are dilated as shown at *e*. Here and there there are islands of stroma (*f*) devoid of glands. The glandular invasion in this case is remarkable, but it will be noted that no epithelial elements are found in the normal muscle.

with that lining the uterine cavity. Some of these are not more than 1 mm. in diameter; others much larger. Frequently they are cut lengthwise and can be traced for a distance

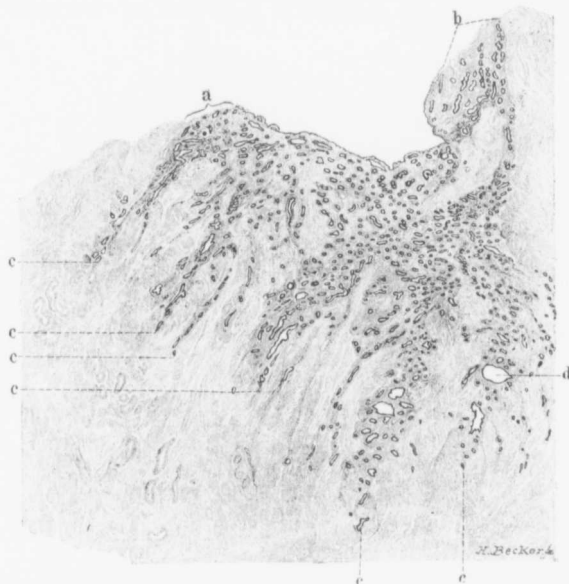


FIG. 7.—EXTENSION OF THE MUCOSA INTO A DIFFUSE MYOMA OF THE UTERUS. (12 diameters.)

Gyn.-Path. No. 3429. The section is from the body of the uterus represented in Fig. 5. A very low-power picture of this is seen in Fig. 6. *a* represents the thickness of the normal mucosa. The surface epithelium is intact and the surface of the mucosa is comparatively smooth. At *b* we have an angle where the lateral wall joins the top of the uterine cavity. The greater number of the uterine glands are normal in size, but a few are dilated. The normal mucosa is everywhere extending into the diffuse myoma, as indicated by *c*. The mucosa in the down-growths differs in no way from that lining the uterine cavity save for the fact that some of the glands, as seen at *d*, are dilated. This is another example of what we have many times reiterated, namely, that the mere extension of uterine glands into the muscle is not necessarily indicative of a malignant growth.

of at least 1 cm. and, as was said before, near the mucosa their direct connection with the mucous membrane is established. The glands forming these islands can in

no way be differentiated from those of the mucous membrane. They are similar in shape and are lined with one layer of the characteristic cylindrical ciliated epithelium. Surrounding these glands is the typical stroma of the mucosa. Some of the glands are dilated, and at least three or four of them reach a diameter of 2 mm. The epithelium of the dilated glands is somewhat flattened, stains palely, and the gland cavities contain desquamated epithelium. In one of the cavities two ill-defined giant cells are present, produced apparently by a coalescence of desquamated epithelium. Not infrequently are seen little islands of stroma staining deeply and having the characteristics of that of the uterine mucosa, lying in between muscle bundles. The outer covering of uterine muscle is perfectly normal.

In this case it is possible to trace a definite relation between the islands of the mucosa and myomatous muscle. Where the mucosa is seen extending into the depth the myomatous fibres run parallel with the penetrating mucosa. Where this penetrating mucous membrane is cut transversely, we accordingly find the islands of mucous membrane surrounded by bundles of myomatous tissue also cut transversely. External to this zone we usually find a second in which the fibres run at right angles to the projection.

This case is certainly a most interesting one. We have a fairly large uterine cavity and the inner two-thirds of the anterior, posterior and lateral walls are replaced by a diffuse myomatous growth. The underlying layers of the mucosa have penetrated this diffuse myoma in all directions, exactly in the same manner as roots enter the soil. Accordingly, at favorable points where we have obtained longitudinal sections we are able to trace a direct extension into the depth. At many points, however, these rootlets in the depth have been cut transversely, and are then recognized as isolated islands of mucous membrane surrounded by myomatous tissue. Where the diffuse myoma ends, this extension of the mucosa into the depth ceases and the entire myoma is covered with a layer of normal uterine muscle. This growth is without a doubt benign in character. The appendages offer nothing of interest.

Diagnosis.—Diffuse adenomyoma occupying the anterior, posterior, and lateral uterine walls; slight pelvic peritonitis.

Path. No. 8760.

Diffuse adenomyoma of the body of the uterus with the glands originating from the uterine mucosa.

A. H. Operated upon at the Church Home on June 9, 1905. Operation: complete hysterectomy. The specimen consists of the entire uterus with the tubes and ovaries attached, and there is also a portion of the vaginal mucosa. The uterus measures 9 by 5 by 4 cm. Its anterior surface is normal; its posterior slightly irregular, owing to the presence of two small myomatous nodules averaging 1 cm. in diameter. These project a few millimetres from the surface. The uterine walls vary from 1.5 to 2.5 cm. in thickness. The uterine mucosa appears normal except for the presence of a polyp, which for .3 cm. projects into the cavity from the posterior wall.

Right side: The tube contains two ostia. The right ovary contains a small cyst. The left appendages are normal.

Histological Examination.—Sections from the uterine mucosa show an intact surface epithelium. Many of the glands are dilated and the stroma generally appears normal. In numerous places the glands with their accompanying stroma can be traced directly into the muscular tissue. The muscle shows diffuse myomatous transformation. Some of the glands in the myomatous areas are markedly dilated. Isolated gland spaces are found scattered throughout the diffuse myomatous tissue, but none are visible in the neighborhood of the peritoneal surface.

Diagnosis.—Diffuse adenomyoma of the body of the uterus; normal tubes and ovaries.

H. A. K. Sanitarium No. 2144. Path. No. 9705.

Diffuse adenomyoma involving the entire body of the uterus with the glands distinctly

rising from the mucosa: slight endometritis; discrete interstitial myomata.

F. M. R., white, aged thirty-nine, married. Admitted April 6, 1906; discharged May 22, 1906. The patient has had no children, no miscarriages. She entered complaining of dysmenorrhœa, free uterine hemorrhage, and some leucorrhœa. On admission her hæmoglobin was 70 per cent.

Operation.—Hystero-myomectomy. The patient made an uneventful recovery. Her highest post-operative temperature was 101.6° F., twenty-four hours after operation.

Path. No. 9705.—The specimen consists of the uterus, considerably enlarged, which has been amputated through the cervix. It is 10 cm. in length, 10 cm. in breadth, and 17 cm. in its antero-posterior diameter. Situated in the anterior wall is a myoma 3 cm. in diameter. The posterior wall varies from 2.5 to 4.5 cm. in thickness; the anterior wall from 2 to 2.5 cm. The increase in thickness is due to a diffuse myomatous transformation of the posterior wall, which is also present in the anterior wall.

Sections from the endometrium show that the surface epithelium is intact. The mucosa in the superficial portion shows typical gland hypertrophy and there is a great deal of small round-cell and polymorphonuclear cell infiltration, giving a picture of subacute endometritis. The mucosa in the deeper layers is perfectly normal and can be followed directly into the myomatous tissue. Scattered throughout the anterior and posterior walls everywhere are large and small islands of uterine mucosa. The glands are normal. The diffuse myomatous tissue is everywhere riddled with islands of mucosa, some of them 2 mm. in length, and in one section it is sometimes possible to make out thirty or more islands of mucosa scattered throughout the myoma.

Diagnosis.—Diffuse adenomyoma involving the entire body of the uterus with the glands distinctly arising from the mucosa; slight endometritis. Discrete interstitial myomata.

Gyn. No. 2754. Path. No. 290.

Diffuse adenomyoma of the uterine wall

(Figs. 8, 9, and 10).
Hysterectomy;
Recovery.

R.M., married, aged fifty-four. Admitted May 2, discharged June 5, 1894. The menses commenced at eighteen, were regular, profuse but painless. Five months ago the menstrual flow became profuse and lasted much longer, with flooding each month.

The patient has been married thirty-two years and has had ten children and one miscarriage. After the third labor there was puerperal fever. At present she complains of a dull aching pain in the right lower abdomen. On examination the left side of the pelvis is found filled with a mass which cannot be differentiated from the uterus. It is firm, sensitive, and immobile.

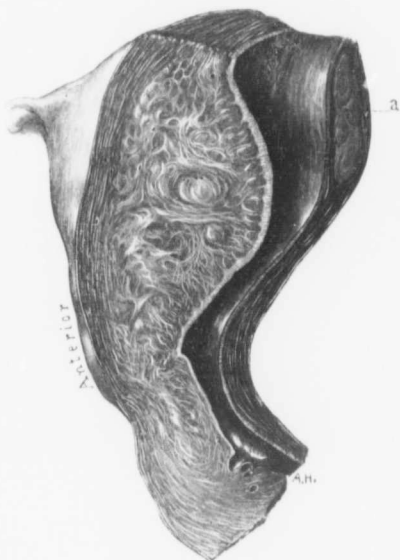

FIG. 8.—DIFFUSE ADENOMYOMA OF THE ANTERIOR UTERINE WALL. (Natural size.)

Gyn., Path. No. 290. This is an antero-posterior section of the uterus. The organ has been amputated through the cervix. The anterior lip of the cervix is considerably thickened. The anterior uterine wall is increased in thickness. It is covered externally with a zone of normal muscle, but the major portion of the thickening is composed of a diffuse myomatous growth which has encroached to a marked degree on the uterine cavity. In this diffuse myoma several small discrete myomata are visible. A few of the cervical glands are dilated and lying in the cervical canal is a polyp. The uterine cavity is considerably lengthened. The mucosa of the anterior wall is of the usual thickness, but at numerous points it can be seen penetrating the diffuse myoma for a short distance. The posterior wall is relatively normal, but at *a* contains a submucous myoma. Attached to the uterus is the proximal end of the right tube. For the histological picture of the diffuse growth in the anterior wall see Figs. 9 and 10.

Operation.—Vaginal hysteromyomectomy. Double salpingo-oophorectomy. The base of the bladder was opened for

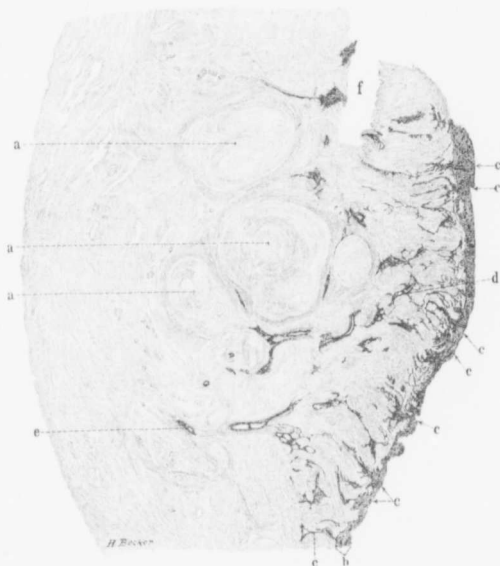

FIG. 9.—DIFFUSE ADENOMYOMA OF THE ANTERIOR UTERINE WALL. (2½ diameters.)

GYN.-PATH. No. 290. This is a section through the anterior uterine wall in Fig. 8. Almost the entire wall consists of diffuse myomatous tissue, but at the points indicated by *a* three discrete nodules are visible, and between these and the mucosa is a fourth one. *b* represents the usual thickness of the mucosa, and it will be seen that it is normal. In many places, as indicated by *c*, the mucosa is seen extending into the myoma and there sending off numerous secondary branches. At *d* is an island of mucosa situated deep in the muscle, but showing at several points continuity with the mucosa lining the uterine cavity. Scattered throughout the inner half of the uterine wall are glands occurring in bunches or singly. They are invariably surrounded by dark zones which represent normal stroma of the mucosa. The glands can be traced as far outward as *e*. *f* represents a tear in the specimen. It is clear that the glands in this diffuse adenomyoma have originated from the uterine mucosa.

4 cm. during the operation. It was sutured. After the operation the patient complained of pain in the bladder for several days and passed some pus.

GYN.-PATH. No. 290.—The specimen consists of the

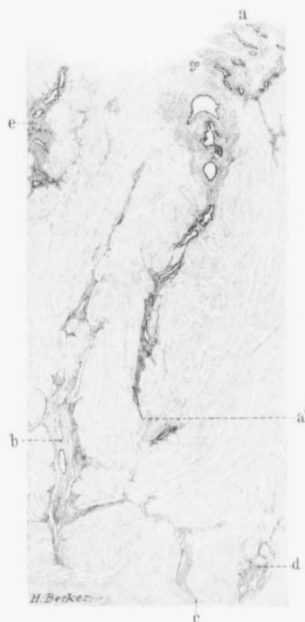


FIG. 10.—MODE OF EXTENSION OF UTERINE GLANDS INTO A DIFFUSE ADENOMYOMA. (10 diameters.)

GYN.—PACH., No. 290. The section is from the diffuse adenomyoma in the anterior wall of the uterus in Fig. 8. *a* is a portion of the normal uterine mucosa. The superficial layers have accidentally been removed by mechanical injury. The mucosa can be traced by direct continuity to *a'*. It will be seen that the glands, apart from some dilatation, are perfectly normal, and that they are accompanied by the stroma of the mucosa. *b* is an island of stroma containing one uterine gland. This stroma can be traced upward nearly to the surface, downward as far as *c*. The irregularity in its course is undoubtedly due to the unequal pressure of the ever-growing diffuse myoma. *d* is an island of stroma devoid of glands; *e*, another point where the mucosa is penetrating the myoma.

uterus, tubes, and ovaries intact. The uterus is 12 cm. long, 7 cm. broad, and 6.5 cm. in the antero-posterior diameter. Both anteriorly and posteriorly it is smooth and glistening. The cervix is 4 cm. in diameter. The posterior uterine wall is about 2.5 cm. in thickness and somewhat striated. It contains a submucous myoma, 2.5 cm. in diameter. The anterior wall near the cervix is 2 cm. in thickness, but rapidly becomes thicker and forms a diffuse growth 3.5 cm. thick (Fig. 8). This encroaches to a considerable extent on the uterine cavity. It presents a very coarse striation resembling a diffuse myoma, and scattered throughout it are several well-defined myomata, varying from 2 to 6 mm. in diameter. The cervical mucosa presents the usual appearance. The uterine cavity is 6.5 cm. long and its mucosa, which is intact, is apparently 1 mm. in thickness.

Right side: The tube is normal in size but covered by numerous adhesions. The ovary is unaltered.

Left side: The tube and ovary seem to be normal.

HISTOLOGICAL EXAMINATION.—The cervical glands

are normal. The uterine mucosa is about 1 mm. in thickness; its surface epithelium is intact, but is low cylindrical or cuboidal in character. The glands are few in number and are here and there slightly dilated. The gland epithelium is low cylindrical in type and is intact. The stroma of the mucosa is somewhat lax and is made up of cells having elongated or oval nuclei which are separated from each other by red corpuscles and large vacuolated spaces. In other words, the tissue of the stroma is edematous, more especially in the superficial portions. The diffuse thickening in the posterior wall is due to a myomatous transformation of the uterine muscle, with here and there the development of young circumscribed myomata. Where the diffuse myoma is present in the anterior wall the uterine mucosa is found extending into the depth at many points, and in some places direct continuity with the surface can be traced for a distance of 1.2 cm. (Fig. 9). Often the mucosa is recognized as islands of mucous membrane far down in the myomatous tissue and completely surrounded by it. The mucosa throughout the myoma differs in no way from that lining the uterine cavity. The glands are identical with those of the mucosa and are surrounded by the typical stroma (Fig. 10). The picture then represents a diffuse adenomyoma of the anterior uterine wall extending almost to the peritoneal surface. That the gland elements are derived from the uterine mucosa is evident. Histological examination of the tubes shows that they are very slightly altered.

Diagnosis.—Diffuse adenomyoma of the anterior uterine wall with the presence of a few small circumscribed myomata. Right side: Slight perisalpingitis; normal ovary. Left side: Normal appendages.

Gyn. No. 12,080. Path. No. 8715.

Chronic endometritis; diffuse adenomyoma of the uterine walls with direct extension of the mucosa into the depth, acute puru-

lent and chronic salpingitis; general pelvic adhesions.

E. B., aged thirty, colored, married. Admitted April 28, 1905; discharged June 17, 1905. Complaint: pain in the lower part of abdomen. Her menses began at twelve, were not painful, lasting several days. Her periods of late have increased in duration; the last one continued for fourteen days. She has been married thirteen years and has had six children, no miscarriages. The youngest child is seven months old. Deliveries normal. On April 12, 1905, the menstrual flow began and appeared to be normal, but on the fourteenth day the patient suddenly felt very weak, and on April 17th, while doing her washing, she felt a sudden severe bearing-down pain in the lower abdomen, especially on the right side. The pain was not constant, but occurred every few minutes. Numerous clots were passed at this time, and the pain became so severe that the patient was forced to come to the hospital for relief.

Note of May 22d: This patient has been in the hospital two weeks. On admission she apparently had peritonitis, and it was deemed wiser to delay operation for a time. At operation a large pus tube was found on the right side. This curved over the surface of an ovarian cyst and passed down into the cul-de-sac behind the uterus. On the left side a large pus tube could be seen winding out to the pelvic wall. This curved back into the depth. The rectum was adherent to the base of the broad ligament on the left side and also to the posterior surface of the uterus. The upper three-fourths of the uterus was free from adhesions, but below this point the organ was firmly fixed. The uterus was removed with a great deal of difficulty.

After operation the patient showed signs of shock, but gradually improved, and was discharged on June 17, 1905. Her temperature on admission was 101° F., ran a regular course, reaching its highest point, 102.2° F., on June 2d. From this time it gradually dropped.

Path. No. 8715.—The specimen consists of the uterus, which is 6 by 6 by 5 cm. and covered with many adhesions, especially posteriorly. The uterine walls show considerable thickening.

On examination of the slide with the naked eye it is possible to trace the uterine mucosa for 4 mm. into the depth by direct continuity. The mucosa has an intact surface epithelium. This, however, is swollen and the underlying tissue shows a great deal of small round-cell infiltration, especially in the superficial layers. There has been a chronic endometritis. The glands in the deeper layers are perfectly normal. At the junction of the mucosa with the muscle, glands are seen penetrating into the depth. Examination of further sections shows practically the same appearance of the mucosa. There are dome-like projections which extend directly into the muscle for a long distance, then split up into branches.

Sections from the tube show a chronic pyosalpingitis.

Diagnosis.—Chronic endometritis, diffuse adenomyoma of the uterine walls with the glands coming from the mucosa; acute purulent and chronic salpingitis.

Gyn. No. 2806. Path. No. 334.

Diffuse adenomyoma of the uterine wall (Figs. 11 and 12). Interstitial and subperitoneal myomata, general pelvic peritonitis. Right side, tubo-ovarian abscess. Left side, healed salpingitis. Hysterectomy. Recovery.

M. G., widow, white. Admitted May 30; discharged July 12, 1894. The patient entered the hospital in October, 1893, when a diagnosis of myomatous uterus was made, but operation was not advised at that time. Since then the patient has felt well until two and a half months ago, when she had a feeling of "her womb being out of position," followed in one month by an acute attack of pain in the lower abdomen. Since then this pain has been constant. She has also had chilly sensations accompanied by sweating.

Operation.—June 14, 1894. Hystero-myomectomy. Double salpingo-oophorectomy. The myomatous uterus was densely adherent to the pelvis. There was an abscess involving the left tube and ovary. This abscess contained 150 c.c. of thick, creamy,

sterile pus. The omentum and vermiform appendix were adherent to the rectum. The patient had much nausea and abdominal pain after operation, and there was great nervousness, and at times a certain degree of delirium.

Gyn.-Path. No. 334.—The specimen consists of a

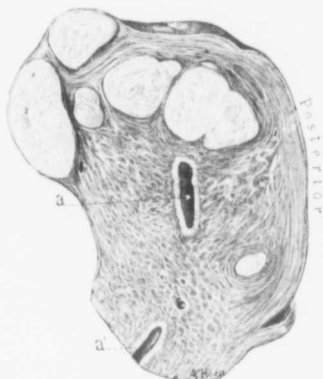

FIG. 11.—DIFFUSE ADENOMYOMA OF THE UTERUS WITH SEVERAL DISCRETE MYOMATA. (Natural size.)

Gyn.-Path. No. 334. This is an antero-posterior section of the uterus and to one side of the median line, as we are only able to see portions of the uterine cavity *a* and *a'*. Situated in the anterior wall and fundus are six myomata, and in the posterior wall near the cervix there is a small interstitial nodule. Both uterine walls show a rather coarse arrangement of the muscle and the posterior wall is somewhat thickened. The uterine mucosa as seen at *a* is of the normal thickness and appears to be unaltered. For the histological picture see Fig. 12.

moderately enlarged uterus with adherent appendages. The uterus is 8 by 7 by 7 cm.; it is bright red in color and everywhere covered with dense vascular adhesions. On its anterior surface are two myomata, the one 2.5 cm., the other 1.5 cm. in diameter. On section the cervical mucous membrane presents the usual appearance. The anterior uterine wall averages 2 cm. in thickness, the posterior slightly less. Situated in the fundus are several small myomata (Fig. 11). One of these encroaches slightly upon the uterine cavity. At the junction of the cervix with the body is another myoma 1.5 cm. in diameter, and scattered throughout the walls are several minute myomata. The uterine cavity is 2.5 cm. in length and the mucosa is scarcely more

than 1 mm. in thickness. Right side: The tube is 17 cm. in length, densely adherent to the ovary, and reaches 2.5 cm. in thickness. It is filled with pus. The ovary is considerably enlarged, somewhat cystic, and is the seat of an abscess which communicates with the tube. Left side: The tube and ovary form a densely adherent mass 5 by 3 cm.

Histological Examination.—The right tube is seen to be the seat of a salpingitis. The left tube also shows an inflammatory process, but partial healing has taken place.

The chief interest lies in the condition of the uterine mucosa. The surface epithelium has disappeared, evidently owing to mechanical removal. The glands are somewhat degenerated, probably owing to faulty hardening. Where preserved, they present the usual appearance. In places there is small round-cell infiltration. The stroma as a whole presents a wavy appearance. Its cells have spindle-shaped nuclei which closely resemble those of the normal muscle. They also run in definite bundles. They, however, stain more deeply. At some points isolated glands or bunches of glands are seen extending down into the muscle (Fig. 12). These glands present the usual appearance and most of them are surrounded by stroma. A few, however, lie in direct contact with the muscle bundles. Down in the depth the muscle is gathered up into irregular bundles and presents the characteristic myomatous appear-

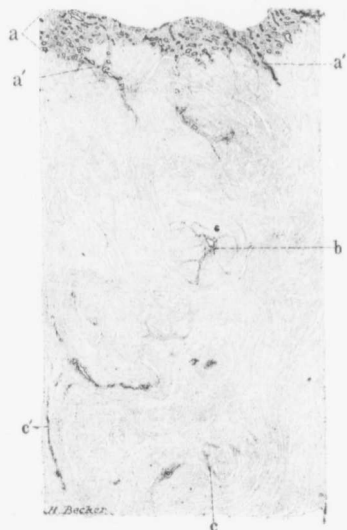


FIG. 12.—DIFFUSE ADENOMYOMA OF THE POSTERIOR UTERINE WALL. (10 diameters.)

Gyn., - Path. No. 334. The section is from the posterior wall in Fig. No. 11. *a* represents the uterine mucosa; owing to imperfect hardening, the surface epithelium is wanting. The glands and stroma are, however, perfectly normal. The uterine walls are composed of myomatous muscle. At *a'* the mucosa is seen penetrating the muscle, and scattered throughout the deeper portions are cross-sections and longitudinal sections of glands. These are surrounded by stroma separating them from the muscle. At *b* the stroma around the gland seems to be sending off prolongations in all directions. The dark areas *c* and *c'* are also areas of stroma, but are devoid of glands.

ance. Here also glands are present, in places surrounded by the characteristic uterine stroma. These glands are found at a distance of at least 1 cm. from the uterine cavity. We have, then, in this uterus faint evidences of an old endometritis and diffuse myomatous transformation of the uterine wall, with extension of the uterine glands into this myomatous tissue, especially in the posterior wall. As was noted, there are also well-defined subperitoneal and interstitial myomata.

Diagnosis.—Subperitoneal and interstitial uterine myomata; diffuse adenomyoma of the uterine wall; general pelvic peritonitis; right side, tubo-ovarian abscess; left side, partially healed salpingitis.

Gyn. No. 3204. Path. No. 526.

Edema of the uterine mucosa; commencing adenomyoma in the body, the gland elements coming from the mucosa; general pelvic adhesions; small ovarian cyst.

M. S., married, aged thirty-six, colored. Admitted November 22, 1894; discharged January 15, 1895. The menses began at fourteen; flow regular, lasting from three to five days. On November 11th her last period was accompanied by severe pain. The patient has been married eleven years and has had two children and probably one miscarriage. Following this there seems to have been puerperal sepsis.

Operation.—Hystero-salpingo-oöphorectomy. The patient's temperature after operation was 101.5° F. It gradually fell, but on the sixteenth day there was another rise to 101.6° F. The pulse immediately after the operation, which was exceedingly difficult, was 145, but gradually fell to normal.

Path. No. 526.—The specimen consists of the uterus with tubo-ovarian masses on either side. The uterus measures 7 by 5 by 5 cm. Its anterior surface is smooth and glistening. Posteriorly it is fastened to the masses on either side by broad vascular adhesions. The under cut surface is 2 cm. in diameter.

The cervical mucosa is pale and glistening. The uterine walls average 2 mm. in thickness and are pinkish-white in color and slightly striated. The uterine cavity is 5 cm. long; at the fundus it is 2.5 cm. in breadth. The mucosa in the lower part is yellowish-white, smooth and glistening, but in the fundus presents numerous patches of ecchymosis. It varies from 3 to 5 mm. in thickness.

HISTOLOGICAL EXAMINATION.—The uterine mucosa in the vicinity of the external os shows small round-cell infiltration, but otherwise is normal. In the upper part of the uterus the mucosa is considerably thickened. The surface epithelium is intact. The glands are tortuous and abundant. The stroma in the superficial portion is very edematous, but in the deeper portion it is normal. With the low power the mucosa at many points is seen extending down into the depth and constrictions are forming, almost cutting off some areas from the uterine mucosa. This can be traced in many places for at least 2 to 3 mm. Some of the glands are dilated, but the majority are perfectly normal. The uterine muscle, chiefly beneath the mucosa, is being divided up into whorls; in other words, the appearances suggest myomatous tissue. Where the glands extend into the depth, they are usually surrounded by stroma, but in some places lie in direct contact with the muscle.

On the right side there are numerous adhesions, and there is a unilocular ovarian cyst, probably a dilated Graafian follicle. On the left side is a unilocular cyst, also probably a Graafian follicle. There are general pelvic adhesions.

Diagnosis.—Edema of the mucosa; early diffuse adenomyoma of the body of the uterus; pelvic adhesions with small bilateral ovarian cysts.

CHAPTER III

CASES OF ADENOMYOMA IN WHICH THE UTERUS RETAINS A RELATIVELY NORMAL CONTOUR—(Continued)

Gyn. No. 3192. Path. No. 525.

Commencing diffuse adenomyoma. Adenomyoma of the left uterine horn.

M. D., white, aged forty-five, married. Admitted November 19, 1894; discharged December 15, 1894. Complaint: Pain in the lower abdomen. The patient has had frequent attacks of malaria, but otherwise has been perfectly healthy. Her menses began at nineteen and were regular, lasting two or three days. For the past year, however, the periods have occurred every three weeks, and there has been considerable pain for three days preceding the onset of the flow. The last period came on three weeks ago. The patient states that there has been frequent pain and a thin white but not copious discharge. She has been married twice, the first time twenty-four years ago; the second time two years ago. She has had five children. She had a miscarriage at the second month eleven years ago. For the past year the patient has complained of rather severe and persistent backache and pain extending downward and reflected to both lower limbs. Walking or any exertion has caused an aggravation of this pain. The patient appears to be debilitated and is pale. Her appetite is poor.

Operation.—Hystero-salpingo-oöphorectomy. The uterus was enlarged and on attempting to separate the adhesions the bleeding was somewhat profuse. Convalescence was uninterrupted and the patient was discharged on December 15th. The highest post-operative temperature was 100.5° F.

Path. No. 525.—The specimen consists of the uterus, tubes and ovaries intact. The portion of the uterus present measures 6.5 by 7 by 6 cm. The anterior surface over its lower half is smooth

and glistening. The upper portion of the anterior surface and the posterior surface are covered with rich vascular adhesions. The uterine muscle averages 2.8 cm. in thickness and is grayish-pink in color and has numerous vessels scattered throughout its walls. The largest of these is 2 mm. in diameter. The uterine cavity is 3.2 cm. long, but at the fundus 4 cm. broad. The mucosa is glistening, somewhat translucent, but on the left side presents a large patch of ecchymosis.

On the right side the tube at the uterine cornu measures 6 mm. in diameter. After passing outward 3 cm. it merges into a tubo-ovarian mass 5 by 4 by 1.5 cm. This is too mutilated for description. On the left side the tube is 8 cm. long, 5 mm. in diameter at the uterine extremity. The fimbriated end is occluded; it measures 1.5 cm. in diameter. This tube is free from adhesions. In the outer end of the parovarium is a thin-walled cyst, 2 cm. in diameter. This is covered with peritoneum which can be readily shelled off. It is seen to be intimately connected with the parovarium. The ovary is 3 by 3 cm. and much mutilated.

Histological Examination.—The uterine mucosa varies from 3.4 to 5 mm. in thickness. The surface epithelium is intact but somewhat swollen. The glands are abundant and somewhat tortuous. In a few places they are dilated. The lumina of the glands contain a small amount of granular material. The glands extend downward into the muscle at numerous points. Most of these are surrounded by stroma. A few, however, lie between muscle bundles. The stroma of the mucosa in the superficial portion is lax, but scattered everywhere throughout it are lymphoid cells with here and there a few polymorphonuclear leucocytes. In many places are clear spaces filled with a homogeneous substance which stains with eosin. The uterine muscle near the mucosa is being divided up into myomatous bundles, and we are able to trace the mucosa for a considerable distance into the depth. Just beneath such areas we find isolated glands and glands surrounded by their normal stroma. There is no doubt that we are dealing with a commencing adenomyoma.

Examination of the left uterine horn shows numerous gland-like spaces just beneath the cross-section of the tube. These in many places show evidence of communicating with one another. The majority of them are irregular and are lined with cuboidal epithelium. The epithelial cells lie in direct contact with the muscle. At other points, however, the epithelium is separated from the muscle by a faint amount of stroma. In this case we also have a gland-like space lying just beneath the peritoneal adhesions. This space is surrounded by muscle and has a lining of one layer of cylindrical epithelium.

Diagnosis.—Diffuse adenomyoma of the uterus; adenomyoma of the left uterine horn.

Gyn. No. 5768. Path. No. 2066.

Adenomyoma occupying both the anterior and posterior uterine walls; in other words, forming a complete zone around the uterine cavity (Figs. 13, 14, 15, and 16). Hysterectomy. Recovery.

J. W., single, aged thirty-eight, white. Admitted January 3; discharged January 31, 1898. The menses commenced at fifteen, were regular, copious, and accompanied by many clots. The patient has had severe dysmenorrhœa as long as she can remember, this being more pronounced during the first three days of the flow. She has had a rather profuse leucorrhœal discharge, occasionally yellowish-red in color. The bowels are constipated. Micturition is frequent and burning and she has pain in the lower abdomen, especially on the left side, which is particularly severe at the menstrual period.

The outlet is intact, the uterus about 7 cm. in diameter, regular, hard and smooth.

Operation Jan. 5, 1898.—Hystero-myomectomy. The right ovary was left *in situ*. The highest post-operative temperature was 100.6° F. The pulse did not rise above 92. She made an excellent recovery.

Gyn.-Path. No. 2066.—The specimen consists of a pear-shaped uterus, considerably enlarged. This has been amputated at the cervix; it measures 8 cm. in length, 9 cm. in breadth, and 8

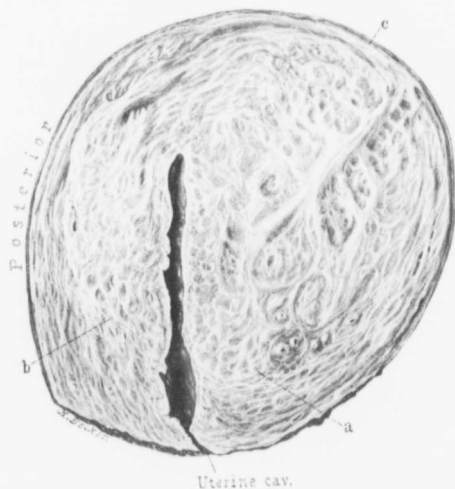
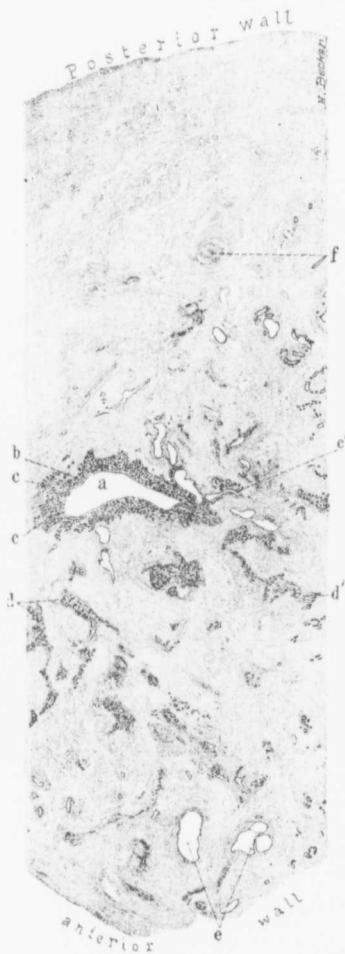


FIG. 13.—DIFFUSE ADENOMYOMA OF THE UTERUS INVOLVING THE ANTERIOR AND POSTERIOR WALLS AND FUNDUS. ($\frac{1}{2}$ natural size.)

Gyn.-Path. No. 2066. The uterus has been amputated through the cervix. Almost the entire body has been transformed into a diffuse myomatous growth represented by several large coarse bands of fibres with many smaller bands passing off from them and winding in every conceivable direction. The thickening is most marked in the anterior wall, where the growth extends almost to the peritoneal surface. There is, however, a thin muscular covering, as indicated by *c*. The lower margin of the growth in the anterior wall is indicated by *a*. In the posterior wall the growth extends downward to *b*. The entire growth, although well defined, is intimately blended with the normal muscle. The uterine cavity is of the normal length and, although there are a few inequalities in the surface of the mucosa, it is comparatively regular and of normal thickness. Fig. 14, from a section through the entire body of the uterus, illustrates the structure as seen with the low magnification. The finer details are shown in Figs. 15 and 16. Clinically a bimanual examination of this uterus would show a moderately enlarged, globular, but smooth, firm fundus. No clue would be gained from introducing a sound into the uterine cavity.

cm. in its antero-posterior diameter. It is perfectly smooth, but has a rather uneven surface. On section the uterine cavity is found to be 6 cm. in length. It is recognized as a narrow slit (Fig. 13). Its mucosa is of the normal thickness and seems unaltered. The



increase in size of the uterus is due to a diffuse thickening of its walls. This is general, but more prominent in the anterior than in the posterior wall. The anterior wall varies from 4 to 5 cm. in thickness, the posterior from 3 to 3.5 cm. This diffuse thickening which is found in both uterine walls consists for the most part of myomatous tissue. Glistening bands are found running in and out in all directions and forming definite whorls. Scat-

FIG. 14.—DIFFUSE ADENOMYOMA OF THE ANTERIOR AND POSTERIOR UTERINE WALLS. (3 diameters.)

GYN.-Path. No. 2066. This is an antero-posterior section through the entire thickness of the uterus in Fig. 13. It is however, taken nearer the side, hence only a small portion of the uterine cavity (*a*) is seen. At this level the anterior and posterior walls are practically of equal thickness. The myomatous transformation of the muscle is hardly recognizable with this power. At *b* the uterine mucosa is of the normal thickness, but at *c* can be seen penetrating the surrounding muscle. At *c'* it can be followed for quite a distance. The mucosa penetrates *en masse*, carrying with it the normal stroma. Scattered throughout both walls, but more particularly the anterior, are bunches of mucosa. These are well shown at *d* and at *d'*. We can trace the mucosa in its windings for a considerable distance. A goodly number of isolated glands or glands in small bunches are distributed throughout the walls. At *e* are several dilated glands with little or no intervening stroma separating them from the muscle. *f* is a discrete myomatous nodule. It is clearly evident that the glands in this diffuse myoma are due to down-growths from the mucosa. (For the finer structures of the adenomyoma see Figs. 15 and 16.)

tered everywhere throughout the growth are minute, cyst-like spaces varying from a pin-point to 2 mm. in diameter.

Histological Examination.—The uterine mucosa




FIG. 15.—METHOD OF PENETRATION OF THE MUCOSA IN A DIFFUSE ADENOMYOMA OF THE UTERINE WALL. (8 diameters.)

Gyn.-Path. No. 2066. The section is from the body of the uterus in Fig. 13. *a* represents the thickness of the uterine mucosa. The surface epithelium has been mechanically lost except over the small area indicated by *b*. The uterine glands are perfectly normal. At three points, however, the mucosa can be seen extending into the underlying myomatous tissue. This is especially well marked at *c*, where a large mass of the normal mucosa is flowing into the growth. It can be traced to the lower margin of the section at *c'*. At *d* we have an island of mucosa (*c*) which can be traced upward to *d'*; in other words, almost to the mucosa. The island of mucosa (*c*) resembles in every particular that lining the uterine cavity. Here and there a gland shows some dilatation.

has an intact surface epithelium which presents the usual appearance (Figs. 14 and 16). The uterine glands are somewhat convoluted, slightly branching, and are lined with one layer of cylindrical

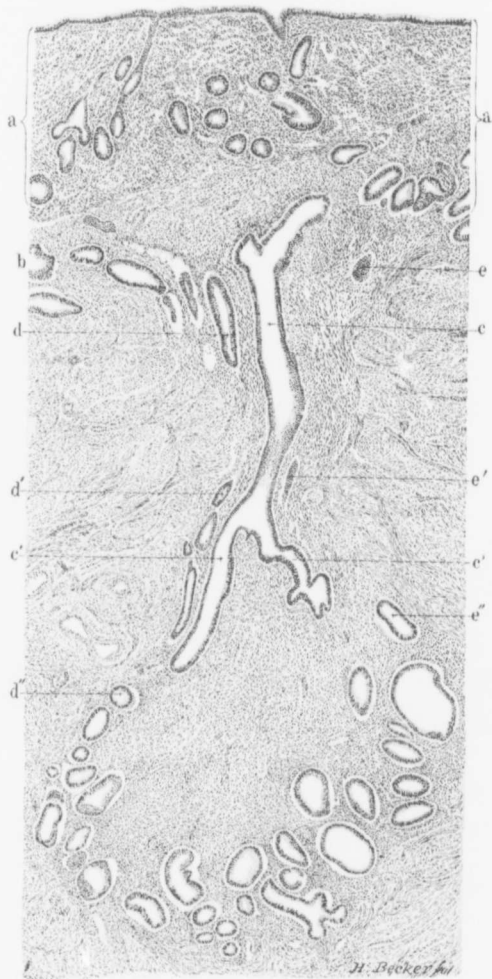


FIG. 16.

epithelium. The stroma of the mucosa is normal and here and there are a few small round cells. At many points a most striking picture is noted. The mucosa extends down into the underlying muscle for a distance of 1 cm. or more, and at such points the glands are perfectly normal and are surrounded by the characteristic stroma of the mucosa (Figs. 14, 15, and 16). It looks as if the mucosa were just falling down quietly into the clefts between muscle bundles. The diffuse thickening in the uterine wall is due to a myomatous transformation of the muscle, with here and there the formation of a small, sharply circumscribed myoma. Scattered everywhere throughout this myomatous tissue are irregular areas of uterine mucosa, near the surface directly continuous with that lining the uterine cavity, but in the depth appearing as bands of mucous membrane surrounded by myomatous tissue. The glands in the depth frequently show some dilatation giving rise to the cyst-like spaces noted macroscopically. Nearly all of the glands are surrounded by the characteristic stroma of the mucosa.

Covering the outer surface of the uterus is a zone of normal muscle, averaging 4 or 5 mm. in thickness. This is totally devoid of gland elements.

The case is a most instructive one. We have a small uterine cavity surrounded on all sides by normal mucous membrane. This mucous membrane has an outer covering varying from 3 to 5 cm. in thickness and consisting of diffuse

FIG. 16.—EXTENSION OF UTERINE GLANDS INTO THE DIFFUSE MYOMATOUS TISSUE OF AN ADENOMYOMA. (50 diameters.)

Gyn.-Path. No. 2066. The section is from the body of the uterus in Fig. 13. *a* represents the limits of the mucosa; the surface epithelium is intact and normal. The mucosa is of the usual thickness and its glands are unaltered. The stroma between the glands is slightly rarefied in the superficial portions owing to a slight edema. In the vicinity of *b* are a number of glands lying in the muscle. At *c* we have fortunately been able to trace a gland by continuity from the mucosa for a considerable distance into the diffuse myoma. It divides into two branches (*c'*), which extend further into the growth. Accompanying the gland *c* are *d* and *e*. These have been much convoluted, as only occasionally we catch a glimpse of them, at *d''* and *d'''* and *e'* and *e''*. In following the glands *c*, *d*, and *e* from above downward, one gathers the impression that all the cross-sections seen in the lower third of the field are cross-sections of the terminal portions of the three glands. Accompanying the glands and separating them from the diffuse myomatous growth is the stroma of the mucosa.

myomatous tissue which has innumerable chinks everywhere traversing it and allowing the normal mucous membrane to flow in and fill them up. The whole of this adenomyomatous mass is enveloped in a thin capsule of normal uterine muscle.

The Fallopian tubes accompanying the uterus are normal.

Diagnosis.—Adenomyoma, occupying both the anterior and posterior uterine walls; in other words, forming a complete zone around the uterine cavity. Normal Fallopian tubes.

Gyn. No. 9457. Path. No. 5668.

Multinodular myomatous uterus with marked adhesions: Diffuse adenomyoma in the fundus with a definite tendency for the mucosa to penetrate into the muscle. Discrete adenomyoma near the uterine horn. Adenomyomatous tissue in the left uterine wall at the junction of the broad ligament. Large cyst of the right ovary, probably undergoing carcinomatous transformation.

M. H., married, white, aged forty-five. Admitted March 10, 1902; discharged April 8, 1902. Comes for removal of a tumor and cure of inguinal and umbilical herniae. For the past year the patient has menstruated every four to six weeks, and recently there has been a yellowish, non-irritating, vaginal discharge. She has been married eight years, has had no children and no miscarriages. Three or four years ago she noticed a lump in the right lower abdomen. This has greatly increased in size until the present time. The growth has apparently been more rapid during the last six weeks.

Operation.—Pan-hystero-salpingo-oöphorectomy; radical cure of herniae, the abdominal incision extending from the ensiform to the symphysis. The bowel was adherent to the cyst and also at the hernial ring. The ureters were misplaced and the rectum

was adherent to the uterus. The cyst was everywhere adherent to the lateral abdominal wall. The ureters ran from the pelvic brim almost straight across to the uterine cornua, being about 5 to 6 cm. long, from the pelvic brim to the point of attachment of the uterus.

Each ureter was dissected free for a distance of 8 to 10 cm.; then the adherent peritoneum was gradually worked away, exposing the uterine vessels which were tied. The right ureter was accidentally caught in a large pair of artery forceps but freed two or three minutes later. The patient's convalescence was slow, owing to her great weakness. She was discharged well on the twenty-eighth day. Her highest temperature after operation was 102° F.

Path. No. 5668.—The specimen consists of the uterus, left tube and ovary, and a very large ovarian cyst. The uterus is 11 cm. long, 9 cm. broad, and is covered with dense adhesions, some of which contain adipose tissue. Its removal has evidently been associated with great difficulty. The enlargement of the uterus is due chiefly to the presence of a myoma, 9 by 8 cm., in the anterior wall. There is also a nodule, 3 cm. in diameter, situated just anterior to the left tube. The posterior wall of the uterus is considerably thickened owing to the presence of a diffuse myomatous condition.

The left tube and ovary are enveloped in adhesions; otherwise they appear normal. The right tube is 8 cm. long and attached to a cyst. The cyst is approximately 20 cm. in diameter; it is hard and smooth, but is covered with many adhesions, and has projecting from its surface numerous hard nodules. These vary from 3 to 4 cm. in diameter. On section they are whitish-yellow in color, homogeneous in consistency, and divided up into alveoli by a septum of connective tissue. The cyst walls vary from 3 to 4 cm. in thickness. The inner surface is in places smooth, but at numerous points the thickening is due to a shaggy growth which in places is covered by recent clots. At one point is a nodule, 4 cm. in length and 3 cm. in breadth, projecting into the cavity. This nodule is porous and closely resembles a carcinomatous growth.

Histological Examination.—Sections from the uterus show that the epithelium is intact. The mucosa is normal but shows a decided tendency in places to penetrate the underlying muscle *en masse*. Situated just posterior to the left uterine cornu is a circumscribed adenomyomatous nodule, fully 2 cm. in diameter. The gland elements in this case are clearly visible to the naked eye. The islands of mucosa vary from a pin-point to 2 or 3 mm. in length. They differ in no way from normal mucosa. Sometimes isolated glands are found. These are invariably separated from the muscle by the normal stroma of the endometrium. A few of the glands are dilated and are filled with brownish pigment. The nodule is very sharply circumscribed from the surrounding tissue. In the wall of the uterus where it joined the left broad ligament one of the glands is fully 3 mm. in diameter. It is filled with pigment and fresh blood-cells.

The ovarian cyst has an inner lining of one layer of cylindrical epithelium. At many points there has been hemorrhage with subsequent partial organization of the clots. The inner epithelial lining in many places has proliferated, forming new glands, and these at some points are so crowded together that the masses of epithelial cells resemble sarcomatous tissue. The individual cells are fairly uniform. Some of them, however, are considerably enlarged and stain intensely. Although the growth may be now considered as an adenocarcinoma, it has originally been a simple cyst.

Diagnosis.—Multinodular myomatous uterus with marked adhesions. Diffuse adenomyoma of the fundus, discrete adenomyoma. Adenomyomatous tissue in the left uterine wall at the junction of the broad ligament. Cyst of the right ovary probably undergoing carcinomatous transformation.

H. A. K. Sanitarium No. 469. Path. No. 1758.

Diffuse adenomyoma of both the anterior and posterior uterine walls with the glands coming from the mucosa.

W. J. R., white, married, aged fifty-five. Admitted May 21, 1897; discharged July 2, 1897. The patient has had six children. The menses began at nineteen and occurred every three weeks. They were very free. Eight years ago she had a prolapsus, and during the last year it has been exceedingly difficult to keep the uterus within the vagina.

Operation.—Hystero-salpingo-oöphorectomy.

The uterus was removed entirely. The patient made a very satisfactory recovery.

Path. No. 1758.—The specimen consists of the uterus and the right tube and ovary. The uterus measures 9.5 by 7.5 by 5 cm. It is free from adhesions. At the left uterine cornu is a myomatous nodule 2.5 cm. in diameter. The cervical canal is 2 cm. in length. The uterine cavity is 5.5 cm. long. The mucosa lining the cavity is much thickened and there is a distinct projection from the posterior wall. The anterior uterine wall presents a diffuse myomatous appearance and here and there one can see fine porous areas varying from 1 to 3 or more millimetres in diameter. At some points, especially at the fundus, the mucosa can be seen with the naked eye extending for 7 mm. into the myoma. The same picture is found in the upper part of the cavity. The projection from the cavity into the posterior wall is due to a diffuse myomatous thickening. The posterior wall reaches 3.5 cm. in thickness. Here also are a few porous areas, evidently islands of uterine mucosa.

On histological examination the vaginal portion of the cervix is found to be normal. Sections from the anterior and posterior walls show normal uterine mucosa. At numerous points this mucosa is found flowing into the underlying myoma. This is clearly demonstrable throughout the entire uterine cavity. The islands of mucous membrane everywhere are perfectly normal save for dilatation of the glands. The islands are most abundant near the mucosa and are totally absent in the vicinity of the peri-

toneum. We have here another example of a diffuse adenomyoma occupying both the anterior and posterior walls, with the gland elements everywhere derived from the uterine mucosa.

Gyn. No. 2744. Path. No. 274.

Diffuse myomatous thickening of the uterine walls, partly of the adenomyomatous type (Figs. 17 and 18). Well-defined subperitoneal and interstitial myomata; subacute endometritis; slight pelvic peritonitis. Hysterectomy. Recovery.

S. J., married, aged thirty-two, colored. Admitted April 28; discharged June 23, 1894.

Menses regular up to two years ago, since when they have increased in frequency, with pain at the periods.

She has had six children, four still-born, two dying at seven months. The last child was born six months ago. The bowels have been constipated; micturition has been frequent. For the past year she has had pain in the left side and back, growing gradually worse.

Examination.—Five distinct myomata could be felt on the surface of the uterus, varying in size from 1 cm. to 6 cm.

Lips and mucous membranes pale. Hemoglobin 39 per cent.

First Operation.—April 2, 1894. Dilatation and curetting. Uterine cavity tortuous. A considerable amount of endometrial tissue was removed. The patient was discharged on April 13, 1894.

Second Operation.—April 28, 1894. Hystero-myomectomy. Double salpingectomy. Incision 10 cm. The uterus was myomatous and contained irregular and nodular masses, which had developed mostly from the posterior wall and fundus. There was a double salpingitis with hydrosalpinx and double peri-oöphoritis. There was some suppuration of the abdominal incision.

The temperature varied between 99° and 102° F. for nine days after the operation, reaching 102.2° F. on the ninth day. Pulse 80 to 114 (maximum on the third day). The temperature for a

month occasionally rose to 100° F. The pulse was below 88 after the eleventh day.

Result: Recovery.

Gyn.-Path. No. 274.—The specimen consists of the uterus and appendages intact. The uterus has been converted into an irregular mass 7 cm. long, 8 cm. from side to side, and 11 cm. in its antero-posterior diameter. It is pinkish in color, smooth and

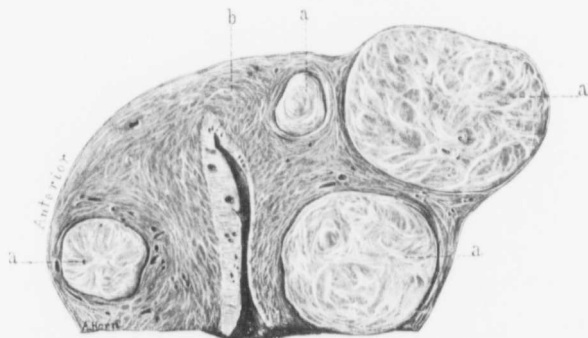


FIG. 17. INTERSTITIAL AND SUBPERITONEAL UTERINE MYOMATA. INTERSTITIAL ADENOMYOMA. (Natural size.)

Gyn.-Path. No. 274. This is an antero-posterior section of the uterus. The figures *a, a, a, a*, indicate myomata, one in the anterior wall and three in the posterior. The anterior wall, not implicated by the myomata, is considerably thickened. The organ has been amputated through the cervix. The uterine cavity is of the normal length. The mucosa of the anterior wall is much thickened, but its surface is relatively smooth. Some of the glands are dilated, forming small cysts. The mucosa of the posterior wall is little altered, but it also shows some glandular dilatation. The area represented by *b* has been magnified and is shown in Fig. 18. It contains a small diffuse adenomyoma.

glistening. Scattered here and there over the surface are bright red vascular adhesions. Springing from the posterior surface is a firm nodule, 5 cm. in diameter; from the left side is a similar one, 2.5 cm. in diameter. The under cut surface of the uterus is 7 by 5 cm. (Fig. 17). The uterine walls average 3.5 cm. in thickness, are pinkish in color, and contain several nodules, the largest of which is 2.5 cm. in diameter. The nodule situated in the posterior wall and also those scattered throughout the uterus are pearly white in

appearance, are composed of concentrically arranged fibres, and are firm and non-yielding. The portion of the uterine cavity present measures 2.5 cm. in length. The mucosa is apparently 1 mm. in thickness, is pale and glistening, and in places presents ecchymoses.

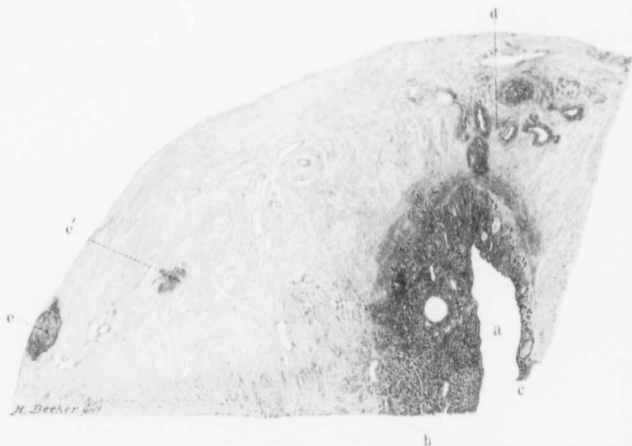


FIG. 18.—SMALL ADENOMYOMA IN THE FUNDUS OF THE UTERUS. (3 diameters.)

GYN. - Path. No. 274. The section represents the area *b* seen in Fig. 17. *a* is the upper part of the uterine cavity; *b* is the thickened mucosa of the anterior wall. The glands on the whole are normal, except that there is dilatation of some few of them. The line of demarcation between mucosa and muscle is irregular and not well defined. The glands show a tendency to invade the muscle. *c* represents the mucosa in the posterior wall. This is thin, and there is some gland dilatation, but the mucosa is sharply outlined from the muscle. At *d* there is a regular colony of glands deep down in the muscle. They bear a marked resemblance to the normal uterine glands. From the text it will be seen that some of them are surrounded by the characteristic stroma of the mucosa. Others lie in direct contact with the muscle. The surrounding tissue and the uterine walls generally are made up of a diffuse myomatous tissue. At *e* and *e'* are discrete myomata.

Near the fundus is a polyp 1.5 cm. in diameter, 5 mm. in thickness. (The uterus was curetted one month ago.)

HISTOLOGICAL EXAMINATION.—A description of the uterine mucosa is unsatisfactory, as the uterus has so recently been curetted. Sections from portions that have been unmolested show that the surface epithelium is intact. The glands are few in

number and some of them are considerably dilated. The stroma of the mucosa shows a good deal of small round-cell infiltration. At several points near the fundus the glands are seen extending fully 3.5 mm. into the muscle. Here they are somewhat dilated, but are still surrounded by the stroma of the mucosa. At the fundus the muscle contains an irregular area 7 mm. in diameter and everywhere traversed by cyst-like spaces (Fig. 18). These represent dilated uterine glands which are surrounded by a small amount of stroma. Scattered throughout such an area are also numerous glands of normal size. These, however, lie directly between muscle bundles. The epithelium of some of the glands stains very palely. The thickening in the uterine walls is to a great extent due to a diffuse myomatous transformation of the muscle. The nodules scattered throughout the uterus present the typical myomatous appearance and in many places these have undergone hyaline degeneration.

In this case we have a diffuse myomatous thickening of the uterine walls with localized infiltration by normal uterine mucosa; also the presence of several well-defined myomata. The right tube and ovary are covered with numerous adhesions. The left tube and ovary are normal.

Diagnosis.—Subacute endometritis, diffuse myomatous thickening of the uterine walls, partly of the adenomyomatous type; well-defined subperitoneal and interstitial myomata; slight pelvic peritonitis.

Union Protestant Infirmary (Dr. Russell). Path. No. 9858.

Commencing adenomyoma in the body of the uterus; early adenomyoma of the right uterine horn; general pelvic adhesions.

The specimen consists of a small uterus with appendages. The uterus has been amputated through the cervix and is 5 cm. in length, 6 cm. in breadth, and 4 cm. in its antero-posterior diameter. The appendages on both sides are thickened and adherent. Projecting from the fundus is a myoma, 3 cm. in diameter, and there are several

adhesions. The uterine walls are slightly thickened. The mucosa looks normal. The right tube is cystic and reaches 1 cm. in diameter near its outer end, where it is adherent to the slightly enlarged and cystic right ovary. The left tube and ovary are enveloped in adhesions.

Histological Examination.—The surface epithelium is intact. The stroma of the mucosa is normal. At some points the mucosa is seen extending into the depth for a short distance and bands of myomatous muscle are coming in and gradually separating off this mucosa that is penetrating the depth. The underlying muscle is more wavy than usual and looks somewhat myomatous. It is evidently a very early adenomyoma. Sections from the right uterine horn show that the tube at this point is normal. The muscle just beneath shows a distinct myomatous tendency. Near the peritoneal surface and also near the tube are gland-like spaces, some of them occurring singly, others in small colonies. These gland-like spaces lie in direct contact with the muscle and have a very high cylindrical epithelium. Where they occur in groups they are also in direct contact with the muscle and are lined with high cylindrical epithelium, in each case surrounded by a definite zone of myomatous muscle. Just beneath the peritoneum is a gland-like space lined with cuboidal epithelium. Elsewhere throughout the muscle in the vicinity we find recent myomata which are being gradually differentiated from the normal muscle.

The right tube shows a hydrosalpinx, but, apart from adhesions, nothing abnormal.

Diagnosis.—General pelvic adhesions and commencing adenomyoma of the right uterine horn.

Gyn. No. 6083. Path. No. 2356.

Diffuse adenomyoma involving the anterior wall, left side, and a portion of the posterior uterine wall, and containing miniature

uterine cavities just beneath the peritoneal surface (Figs. 19, 20, 21, and 22). Hysterectomy. Recovery.

M. T., married, aged twenty-three, black. Admitted May 26, 1898; discharged June 6, 1898. She complained of an enlargement in the lower abdomen. This was associated with pain. She had had one child, no miscarriages. Menstruation had been regular, every four weeks, lasting from four to five days; flow scanty. She had had no pain until five years previously. Since then the menses had been irregular and the flow excessive, lasting at times for two months and necessitating her remaining in bed.

At present the pain in the lower abdomen is sharp and intense. During the last month there has been constant bleeding, except for intervals of two or three days. There is no increase in frequency of micturition.

The lower half of the abdomen is distended and there is marked tenderness on the left side, as well as in the inguinal and hypogastric regions. The outlet is well lifted up, the cervix is small.

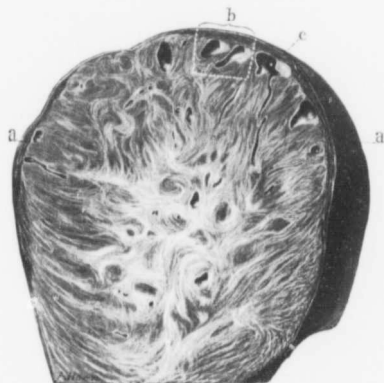


FIG. 19.—DIFFUSE ADENOMYOMA OF THE UTERUS. (Natural size.)

Gyn. - Path. No. 2356. The section is an antero-posterior one through the left side of the uterus. At this point nearly the entire uterine wall is composed of a diffuse myomatous growth. At points *a, a*, however, a small amount of normal uterine muscle remains. In other places the growth reaches the peritoneum. Scattered throughout the myoma are round, oval, irregular or slit-like cavities with smooth inner linings. They are most abundant and reach their greatest diameters just beneath the peritoneum. Here they have a lining resembling mucosa which in places reaches 1 mm. or more in thickness. The two cyst spaces, seen at *b*, are in reality merely two cross-sections of one convoluted cavity. (See Fig. 21.) At *c* one of the cyst-like spaces can be traced as a slit for a considerable distance into the growth. On histological examination the large cyst-like spaces proved to be miniature uterine cavities. (See Figs. 21 and 22.)

The os admits the index-finger and the uterus is represented by a mass approximately 10 cm. in diameter. The lateral structures cannot be outlined.

Operation.—Hystero-myomectomy. The patient made a perfect recovery.

Path. No. 2356.—The left side of the fundus shows some faintly raised bosses, which can be traced a short distance over the left posterior aspect. They are slightly yielding on pressure. The uterine cavity is 4.5 cm. in length and 3.5 cm. in breadth at the

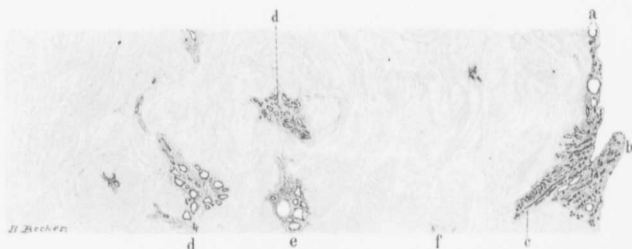


FIG. 20.—DIFFUSE ADENOMYOMA OF THE UTERINE WALL. (4 diameters.)

GYN - Path. No. 2356. The section is from the body of the uterus. A glance at *a* shows that the mucosa is very thin and that some of the glands are dilated. At *b* is a small polypoid outgrowth consisting of normal mucosa. The uterine wall is transformed into the diffuse myomatous growth. At *c* the normal mucosa is seen extending for quite a distance into the diffuse myoma, and at points *d, d'*, we have islands of the mucosa in the depth. At *e* there is considerable gland dilatation. Distributed here and there are isolated glands accompanied by their stroma, and at *f* is an island of stroma devoid of gland elements. The glandular elements of this diffuse adenomyoma have undoubtedly arisen from uterine glands.

fundus. The mucosa has a roughened surface, is about 2 mm. in thickness, and has springing from it several small polypi, varying from 2 to 8 mm. in length. The posterior uterine wall varies from 2.5 to 3 cm. in thickness. It is easily divisible into two portions; an inner, about 2.5 cm. in thickness, very dense in character, consisting of strands running in all directions and closely resembling myomatous tissue. This can be traced as far as the mucosa, but is easily differentiated from

it. The outer portion of the posterior wall consists of normal uterine muscle. The anterior uterine wall is about 4 cm. in thickness and differs materially from the posterior. It consists almost entirely of coarse bands of tissue running in all directions and forming definite whorls. In the fresh state, small cyst-like spaces were seen scattered throughout the myomatous tissue, but the differentiation was not marked. After hardening in Müller's fluid, however, these cyst-like spaces, which vary from .5 to 5 mm. in diameter, are found to be situated in a fairly homogeneous tissue devoid of fibres and totally different from the surrounding myomatous tissue. Furthermore, in this homogeneous tissue are many small openings, somewhat punctiform in character. These areas resemble uterine mucosa, and on examining the mucosa of the anterior wall we can at some points see the mucous membrane penetrating the muscle for at least 4 mm. These islands of homogeneous tissue, which resemble mucosa, vary greatly in shape. Some are comparatively round, others oblong, but the majority are triangular (Fig. 19). They are abundantly scattered throughout the myomatous tissue. The growth occupying the thickened anterior uterine wall, and consisting, as we have seen, of myomatous tissue and islands of mucosa, also involves the left side and to some extent the left posterior aspect of the uterus. It has an outer covering of uterine muscle, averaging 3 mm. in thickness. But at the points at which we noted the bosses on the left and posterior aspects of the uterus it has practically reached the peritoneal surface. On making an antero-posterior section through the uterus, near the insertion of the left tube, it is seen that the diffuse myoma contains several irregular cyst-like spaces a short distance beneath the peritoneal covering. The largest of these is 6 mm. in diameter. All have smooth inner linings which resemble mucous membrane. This inner covering is fully .5 mm. in thickness.

Histological Examination.—Sections from the posterior wall of the uterus in the mid-line show that the surface of the mucosa has in part disappeared. The underlying glands show no change, but the muscle directly beneath the mucosa reveals con-

siderable proliferation of the connective tissue around the smaller blood-vessels. The muscle bundles are denser than usual and show a greater tendency to wind in and out. No glands are demonstrable

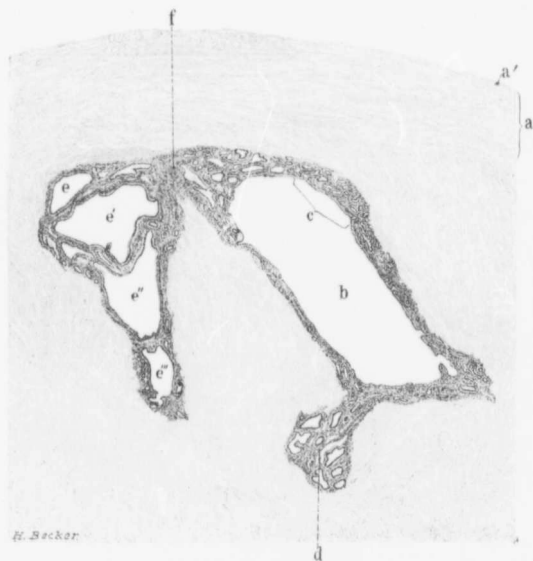


FIG. 21. — CYST-LIKE SPACES JUST BENEATH THE PERITONEUM IN A DIFFUSE ADENOMYOMA OF THE UTERUS. (12 diameters.)

Gyn.-Path, No. 2356. The section represents the area *b* in Fig. 19. *a* is the thin outer covering of normal muscle; *a'* the peritoneum. *b* is one of the cyst-like spaces; it is lined with a definite mucosa. This mucosa has a surface epithelium and beneath it a mucous membrane containing many glands. The majority are small and round. Some of them are, however, dilated and convoluted. For the finer structures see Fig. 22, which is the area *c* much enlarged. The mucosa cannot be distinguished from the normal uterine mucosa and the entire cyst resembles a small uterine cavity. At *d* is an area of mucosa identical with that normally found lining the uterine cavity. *e*, *e'*, *e''*, *e'''*, *e''''* are evidently cross-sections of one cavity which is much convoluted. The mucosa in them resembles that lining the cavity *b*. The cyst space *b* and those represented by *e*, *e'*, *e''*, *e'''*, *e''''* are also evidently part of the same cavity as seen by the connecting link of the mucosa *f*.

in the muscle. The mucosa of the anterior wall has also lost its surface epithelium except at protected points. This loss is undoubtedly due to the faulty preparation of the specimen. The glands

in the mucosa, on the whole, are normal. A few of them, however, are dilated. At one point the mucosa is seen extending 4 mm. into the underlying muscle (Fig. 20). Here the glands and stroma seem to penetrate in the form of a wedge, and the muscle is to some extent arranged parallel with this entering wedge. The thickened anterior uterine wall is composed of myomatous tissue presenting the usual appearance and traceable up to the mucous membrane. Scattered freely throughout the myomatous tissue are islands of glands. These glands are usually circular or oblong in form and lined with one layer of fairly high cylindrical ciliated epithelium. They are invariably surrounded by stroma similar to that of the uterine mucosa. In fact, they appear to be nothing more than large and small islands of uterine mucosa scattered throughout the myomatous tissue. Some of the glands are dilated, and where such dilatation has occurred, the epithelium is usually paler and somewhat flattened. Such glands often contain desquamated epithelial cells and granular material—evidently coagulated serum. A few of the desquamated cells contain pigment droplets, the result of an old hemorrhage. Occasionally we find an isolated gland in the muscle or a small amount of stroma lying alone between muscle bundles. The muscle covering the outer surface of this diffuse myoma is normal.

The large cyst-like spaces seen in the myoma in the vicinity of the left horn are throughout lined with mucous membrane identical with that of the uterine mucosa (Figs. 21 and 22). The inner surface of each has a covering of one layer of epithelium, cylindrical in character, except where the space is very much dilated. Here the epithelium is pale-staining and cuboidal or almost flat. Occasionally, there is a little tuft of epithelium projecting into the cavity, but the individual cells of such tufts are in no way suspicious. Here and there the epithelium is raised by an old blood-clot which is partially organized. Beneath the epithelium are typical uterine glands, normal in appearance and

separated by the characteristic stroma of the mucosa. If we were to take a section through a portion of one of these cyst walls, it would be impossible to differentiate it from the mucosa lining a normal uterine cavity (Fig. 22).

We have in this uterus a diffuse adenomyoma consisting of coarse myomatous tissue, everywhere invaded by islands of uterine

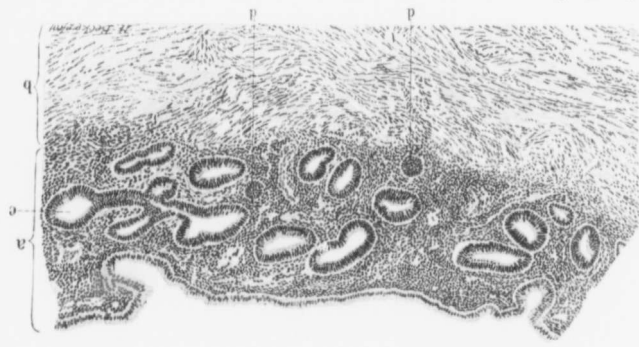


FIG. 22.—THE MUCOSA LINING ONE OF THE CYST-LIKE SPACES SITUATED JUST BENEATH THE PERITONEUM IN A DIFFUSE ADENOMYOMA OF THE UTERUS. (50 diameters.)

GARDNER, Path. No. 2356. The section is the area *c* in Fig. 21 much enlarged. *a* represents the mucosa; *b*, the myomatous muscle. The surface of the mucosa is completely covered with cylindrical epithelium. At two points glands are seen opening on the surface. The glands of the mucosa are round or oval on cross-section, and are lined with cylindrical epithelium, surrounding the glands and separating them from the muscle in a definite stroma. In this the endothelial cells of the blood capillaries are moderately swollen. *c* is a gland showing some branching; *d* and *e* are the bases of glands so cut as to resemble solid nests. This mucous membrane resembles uterine mucosa in every particular, and given such a section, not knowing its source of origin, we should unhesitatingly say that it was normal mucosa from the uterine cavity.

glands, differing in no way, except for their dilatation, from normal uterine mucosa. The growth occupies the entire anterior uterine wall, the left side, and also the left portion of the posterior wall. This diffuse adenomyoma has, as was noted, an outer covering of uterine muscle, but on the left

side has reached the surface and is recognized as small bosses. The growth is certainly benign.

Gyn. No. 3136. Path. No. 497.

Diffuse adenomyoma of the anterior uterine wall (Figs. 23, 24, 25, 26). Glandular uterine polyp; small interstitial and subperitoneal myomata. Hysterectomy. Recovery.

L. W., aged forty-six, white, single. Admitted October 24, 1894. Complaint: Pain in lower part of the abdomen, painful and profuse menstruation. Menstruation commenced when she was eleven years of age and was always regular. For the past ten years she has had severe pains in the right ovarian region at the menstrual period. These pains radiated down both limbs, were accompanied by backache, and for the last two years have been so severe that she has been confined to bed for three or four days at each period. At present the flow lasts from ten days to two weeks and there is a considerable amount of clotted blood. Her last period ceased one week before admission. Her parents are both living and healthy. One brother died of tuberculosis. With the exception of an attack of diphtheria several years ago and influenza three years ago, she has always been well.

Present Condition.—The patient is a rather anæmic woman and does not appear to be very strong. Her tongue is pale and flabby; the appetite is fair, the bowels are regular. She is unable to walk much and cannot lift heavy weights. Vaginal examination: The outlet is very much relaxed, and presenting at the orifice is a hard, irregular mass which proves to be the cervix. The external os is patulous, admitting the index-finger, and projecting from the os is what appears to be a myomatous nodule about 2 cm. in diameter. The cone-shaped cervix is continuous with the enlarged uterus, which is apparently freely movable.

Clinical Diagnosis.—Myoma.

Operation Oct. 31, 1894.—On opening the abdomen it was found impossible to raise the uterus out of the pelvis,

and the operator was compelled to work in the narrow space between the uterus and the pelvic walls. The ovarian and uterine vessels on both sides were controlled and the uterus was amputated. The lips of the stump were then brought together, and, lastly, the peritoneum from the posterior wall was sutured to that of the anterior, thereby completely covering over the stump. The patient made an uninterrupted recovery, and was discharged December 1, 1894.

Gyn.-Path. No. 497.—The specimen consists of the enlarged uterus with its tubes and ovaries intact. The uterus is 13 cm. long, 12 cm. broad, and 10 cm. in its antero-posterior diameter. It is approximately globular and in its contour resembles a normal but enlarged uterus. Anteriorly it is smooth and glistening; posteriorly over its lower two-thirds it is denuded of peritoneum. Situated in the posterior wall in the vicinity of the left uterine cornu are four sessile nodules, which are approximately circular. The largest of these is 2 cm. in diameter. On section they are whitish in color and are composed of fibres concentrically arranged. They present the usual myomatous picture. The under cut surface of the uterus measures 12 by 11 cm. In the centre of this is the cervical opening, which is 1 cm. in diameter. Projecting from the right side of this opening is a nodule 2.5 cm. in diameter; this is apparently covered with mucous membrane which is somewhat hemorrhagic.

The anterior uterine wall is 7 cm. in thickness (Fig. 23); it can be divided into two distinct portions; the outer, 1 cm. thick, resembles normal uterine muscle; the remainder of the wall presents a coarsely striated appearance, the striae running in all directions. Scattered throughout this thickened and striated portion of the uterine wall are round, oval, or elongate, brownish-yellow, homogeneous areas, some of which merge directly into the uterine mucosa. In one or two places small cysts, varying from 1 to

4 mm., can be seen scattered throughout this thickened portion of the uterine wall. The striated appearance can be traced directly

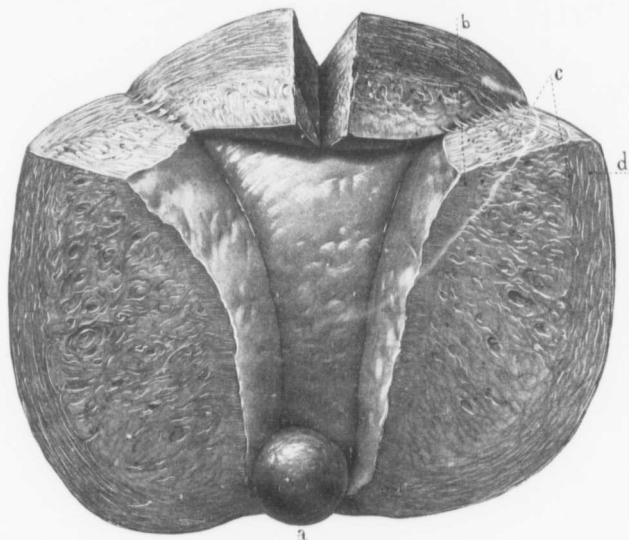
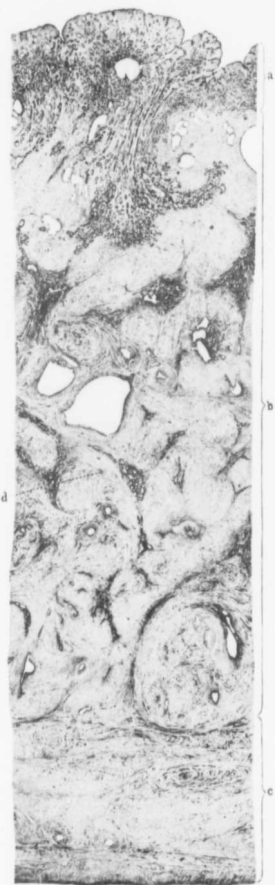

FIG. 23.—DIFFUSE ADENOMYOMA OF THE ANTERIOR UTERINE WALL. ($\frac{1}{2}$ natural size.)

Gyn. No. 497. The uterus has been cut open and is seen from the front. The drawing is from the specimen hardened in Müller's fluid. A small portion of the cervix is present. Projecting through the cervical opening is a globular nodule (*a*) whose pedicle springs from the uterine cavity just within the internal os. On histological examination this was found to be a myoma everywhere penetrated by glands. The anterior uterine wall is much thicker than usual. It is divisible into two portions, an inner coarsely striated and an outer but narrower zone which is the normal uterine muscle. This outer zone presents a parallel arrangement of its muscle bundles. On examining the fundus carefully the coarse striation is seen to be confined to the anterior wall. The uterine mucosa, apart from slight undulation of the surface, is smooth. The small folds described as occurring near the internal os are obscured by the polyp. One of the most striking features is that there is practically no encroachment of the growth on the uterine cavity, the anterior wall showing little, if any, convexity. This is in marked contrast to what takes place in cases of submucous myomata. For the histological picture see Figs. 24, 25, and 26.

up to the uterine mucosa, and in some places into it. After hardening the specimen in Müller's fluid the contrast between the normal uterine muscle and the thickened



striated portion is very sharp, the uterine muscle being much darker in color than the striated portion. The posterior wall of the uterus varies from 2.5 to 3.5 cm. in thickness. It is rather dense, but does not present any coarse striations. Situated in the posterior wall are two interstitial nodules 1 and 1.5 cm. in diameter; they are pearly white in color and are composed of concentrically arranged fibres.

FIG. 24.—DIFFUSE ADENOMYOMA OF THE ANTERIOR UTERINE WALL. (3 diameters.)

Fig. 24 is a cross-section from the thickened anterior uterine wall in Fig. 23. *a* indicates the uterine mucosa, *b* the adenomyomatous zone and *c* the normal outer covering of uterine muscle. The surface of the mucosa presents a wavy outline. The surface epithelium is intact and the glands are for the most part normal in size. A few of them are dilated, one reaching a considerable size. On passing to the muscle large numbers of longitudinal glands are seen penetrating downward into the growth between the muscle bundles. These are surrounded by a tissue darker than the muscle—the typical stroma of the mucosa. The greater part of the specimen is composed of bundles of muscle fibres. Some of the bundles present a circular arrangement, others are oblong and some wind in and out in all directions. These large bundles are again subdivided into smaller ones. Scattered everywhere through the thickened zone are dark areas. Some of these are triangular; some are semicircular, while others are irregular in shape. On examining these areas closely, the majority are found to contain longitudinal or cross-sections of glands. Some of these glands are dilated and irregular in contour. A longitudinal section of a gland with a dilatation on one side is seen near the junction of the myomatous zone with the uterine muscle. The large clear spaces scattered throughout the myomatous zone are dilated glands. Here and there a dark patch is seen in which no glands are present. Islands of stroma devoid of glands also occur. The glandular elements diminish in number in the outer portions of the growth and at the point where the uterine muscle commences they are absent. The outer zone consisting of uterine muscle presents

The uterine cavity is 7.5 cm. in length, and at the upper part 8 cm. in breadth. The mucous membrane of the anterior uterine wall varies from 7 to 8 mm. in thickness, is yellowish-white in color, smooth and glistening. In many places, however, it presents echymoses in the superficial portions. In the vicinity of the internal os and extending upward for about 2.5 cm. are three or four longitudinal folds of the mucosa. The depressions between these are about 4 or 5 mm. in depth. The mucosa covering the posterior wall varies from 3 to 4 mm. in thickness.

Right side: The tube is 11 cm. long, and averages 7 mm. in diameter. Its fimbriated extremity is patent; the parovarium is intact. The ovary measures 8 by 2.5 by 1.5 cm., is pale white in color, smooth and glistening. It contains two corpora lutea, the larger of which is 2.5 cm. in diameter.

Left side: The tube is 9 cm. long and 6 mm. in diameter. Its extremity is patent; the parovarium is intact. The ovary measures 4 by 4 by 1 cm., is yellowish-white in color and somewhat lobulated. It contains a cyst 2.5 cm. in diameter. The walls of this are 2 mm. in thickness and the inner surface is dirty brown in color.

HISTOLOGICAL EXAMINATION.—The nodule projecting into the uterine canal is composed of non-striated muscle fibres. Its outer surface is in places covered with cylindrical epithelium, but in most places apparently with several layers of spindle-shaped connective-tissue-like cells. Scattered everywhere throughout this muscle are gland-like spaces varying from a pin-point to 3 mm. in diameter. These are lined with one layer of epithelium, which in the smaller glands is of a high cylindrical variety. In the dilated glands, however, it is cuboidal, or has become almost flat. The protoplasm of the cells takes the hematoxylin stain. The nuclei are oval and vesicular, and in many places it is possible to make out the cilia. The glands are empty or contain a granular material that takes the hematoxylin stain. These glands resemble to some extent those of the cervix.

The surface of the mucosa covering the anterior uterine wall

presents in places a wavy outline (Fig. 24). Its epithelium is of the high cylindrical variety and is everywhere intact. In a few places it is swollen and somewhat flattened. The glands are moderate in number, are small and round on cross-section, and have an intact epithelium. A few of them are slightly dilated and contain desquamated epithelium. The glands may be traced for from 7 to 10 mm. before any muscular substance is encountered; they then end abruptly or continue into the muscle, where they

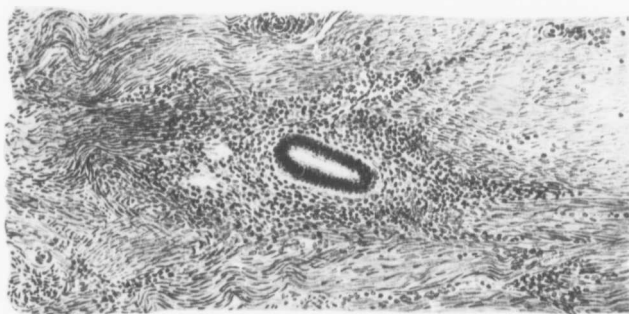


FIG. 25.—CROSS-SECTION OF A GLAND TAKEN FROM FIG. 24 AT *d*. (150 diameters.)

The gland is lined with one layer of cylindrical epithelium and is surrounded by cells having oval vesicular nuclei. Its appearance is identical with that of the normal uterine gland. Surrounding the stroma of the gland are non-striated muscle fibres, the majority of which are cut longitudinally.

can in places be traced for at least 1 cm.; this down-growth is visible in many places. The stroma of the mucosa is composed of cells whose nuclei vary from the oval vesicular type, as seen near the surface, to deeply staining ones, as noticed in the depth of the mucosa. In some places the stroma cells have elongate oval nuclei; so that it is impossible to distinguish them from muscle fibres. The superficial portions of the stroma show marked signs of hemorrhage, which is localized to certain areas. The stroma as a whole does not appear to be very vascular.

The thickened and striated portion of the anterior uterine wall is composed of non-striated muscle fibres, which are for the most part cut longitudinally. The fibres run in all directions, are closely packed together, but only in a few places are concentrically arranged. Scattered throughout this tissue are numerous cells having small, round, deeply staining nuclei which resemble those of lymphoid

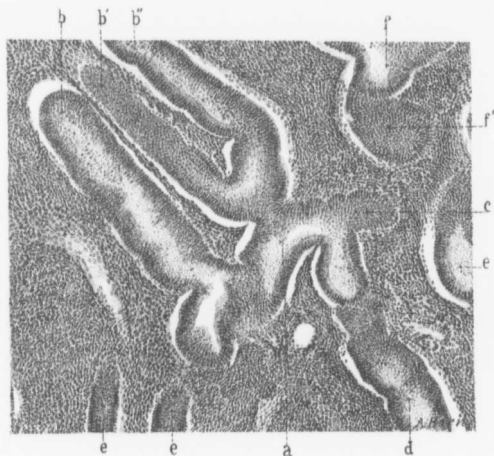


FIG. 26.—A BRANCHING GLAND FROM A GLANDULAR AREA IN AN ADENOMYOMA. (85 diameters.)

Gyn. - Path. No. 497. The section is taken from the diffuse growth in the anterior uterine wall in Fig. 23. *a* appears to be the main trunk of the gland. Upward we have three branches *b*, *b'*, *b''*, downward it can be traced to *d* and to the right as far as *c*. The gland with its various branches appears to be lined with numerous layers of cells. This is due to the thickness of the section. It is in reality lined with a single layer. There is nothing in the least suggestive of malignancy. At points *e* are sections of other glands. The gland *f* is cut on the bevel at *f'*. The stroma surrounding the glands is exceptionally dense owing to the unusual number of stroma cells.

cells. Under the microscope it is impossible to tell where the coarsely thickened zone ends and the normal uterine muscle commences, the transition of the one into the other being so gradual. Traversing this thickened portion of the uterine wall are small clusters of glands, precisely similar to those of the uterine mucosa (Fig. 24). These glands are round or oval and are lined with one layer of cylindrical

ciliated epithelium. A few longitudinal sections of the glands are here and there visible. Some of the glands are dilated, one of them reaching 5 mm. in diameter. The epithelium of the dilated glands is in places somewhat flattened or has entirely disappeared.

In one place two glands are seen opening into a dilated gland. Nearly all of the glands are surrounded by stroma similar to that of the uterine mucosa (Fig. 25). A small isolated gland is occasionally found lying directly between the muscle fibres, and a few of the cysts have no stroma surrounding them. The invasion by the glands can be traced to the point at which the coarsely striated tissue joins the uterine muscle. They are most abundant near the uterine mucosa and gradually diminish as one passes outward. They may be scattered anywhere throughout the myomatous growth, but appear for the most part to occupy the spaces between the muscle bundles. In only a few places can any concentric arrangement of muscle fibres be made out around the glands. The glands themselves show no evidence of degeneration.

From the above it will be seen that there is a diffuse muscle thickening of the anterior uterine wall, and that there is a down-growth of normal uterine glands into the newly formed muscle. Along the lower margin of the growth is a typical myomatous nodule 5 mm. in diameter.

The mucosa covering the posterior wall is normal.

The right tube and ovary are normal.

The left tube is normal. The small cyst of the left ovary has no epithelial lining, hence its exact origin cannot be ascertained.

Gyn. No. 12,807. Path. No. 9699.

Diffuse adenomyoma of the anterior wall with commencing adenomyoma of the posterior wall. Gland elements derived from the uterine mucosa; a few discrete myomata; general pelvic adhesions; small Graafian follicle cyst on the right side.

A., colored, April 14, 1906. Operation: Hysterectomy; right salpingo-oöphoro-cystectomy; left salpingo-oöphorectomy.

The specimen consists of the uterus which has been amputated through the cervix. It measures 7 by 7 by 6 cm. and is everywhere covered with adhesions. Just posterior to the utero-ovarian ligament is a myoma 15 cm. in diameter. The anterior uterine wall is dense and varies from 1.5 to 2.5 cm. in thickness. The posterior wall is also dense and slightly thicker. In the fundus is a myoma somewhat diffuse in character, 1.5 cm. in diameter. The uterine mucosa is very thin.

The right tube is bound down by adhesions, but its fimbriated end is patent. The right ovary is converted into a cyst approximately 6 cm. in diameter. This is likewise covered with adhesions.

Sections from the anterior uterine wall show that the surface is ragged, suggesting that the curette has previously been used. The mucosa is dense and the glands are flattened and several are running at right angles to the surface. The stroma of the mucosa is apparently normal. Just beneath the mucosa the tissue is definitely myomatous, being divided up into large and small bundles, and between these are isolated glands. In some places the mucosa can be traced down into this myomatous tissue, and cross-sections of isolated glands accompanied by stroma can be seen at least 1 cm. from the mucosa. In the posterior wall the mucosa presents essentially the same picture as in the anterior. There is, however, little tendency for the mucosa to extend into the depth, except here and there, where isolated glands project down into the myomatous muscle.

We have here a definite adenomyomatous thickening of the posterior wall with commencing adenomyoma; dense adhesions covering the uterus; a few discrete myomata and general pelvic adhesions with a small Graafian follicle cyst on the right side.

Gyn. No. 12,841. Path. No. 9744.

Subperitoneal, interstitial, and submucous uterine myomata. Commencing adeno-

myoma; general pelvic adhesions; old salpingitis.

A. R., single, aged forty-three, white. Admitted April 13, 1906; discharged May 17, 1906. The patient entered the hospital complaining of a tumor of the uterus and irregular menstruation. Her menses commenced at fifteen, were regular, lasting from two to three days. For the past year they have been somewhat irregular and were prolonged a day or two longer than usual, associated with some pelvic discomfort, and pain in the leg. For the last two or three years she has had some slight leucorrhœa. Urination was somewhat frequent and there was dysuria for a time five or six months ago. At that time it was necessary to catheterize the patient. Three and a half years ago the patient had a slight uterine prolapsus. About seven months ago she had what was said to have been "inflammation of the bowels" lasting some weeks.

Operation.—On entering the abdomen it was found that the bladder extended half-way to the umbilicus and the pelvic tumor was so adherent that its release was exceedingly difficult. During the manipulation a tear was made in the outer coat of the rectum. The tear was $2\frac{1}{2}$ inches long and about $1\frac{1}{2}$ inches broad. The surfaces were brought together with fine black silk. The highest post-operative temperature was 101.5° F., on the third day. The patient made a satisfactory recovery and was discharged on May 17, 1906.

Path. No. 9744.—The specimen consists of a myomatous uterus, 8 by 8 by 5 cm. Projecting from the anterior surface is a pedunculated nodule 3 cm. in diameter and another 1 cm. in diameter. Scattered throughout the uterine walls are several myomatous nodules, the largest being about 3 cm. in diameter. Attached to the posterior surface of the uterus over almost its entire extent is an irregularly lobulated tumor, 17 by 12 by 12 cm. It is covered with dense adhesions and on the surface is apparently becoming necrotic. The uterine walls average about 2 cm. in thickness. The mucosa has not been well preserved.

Sections from the mucosa show that the surface epithelium is

intact. There is a moderate amount of gland hypertrophy and also some polypoid formation. The mucosa shows a distinct tendency to project into the depth. We have at one point an area that stains sharply with eosin and which might very readily be mistaken for an area of necrosis or for a recent tubercle. Examination with the high power shows no resemblance to tuberculosis.

A section from one of the myomata shows a great deal of hyaline degeneration and commencing liquefaction. The tube shows evidence of chronic inflammation.

Diagnosis.—Subperitoneal, interstitial, and submucous uterine myomata; a practically normal uterine mucosa with a distinct tendency to penetrate into the depth; general pelvic adhesions; old salpingitis.

Gyn. No. 9788. Path. No. 6008.

Diffuse adenomyoma of the anterior wall and fundus and diffuse thickening of the posterior wall with but little tendency for the glands to invade the muscle.

E. S., aged thirty-two, white, married. Complaint: "Bearing-down" in the lower abdomen and uterine hemorrhage. The menses began at fifteen, were regular, lasting from five to six days, but not profuse. The patient had some pain with her periods until after the birth of her child seven years ago. Since December, 1900, she has had several severe hemorrhages at the time of her periods. She has been married eight years, has had one child, but no miscarriages. Profuse leucorrhœa has been present for the last year. In December, 1900, the patient had a severe hemorrhage which started at the time of the regular period and lasted for six weeks. She was in bed for four weeks after this. She had slight hemorrhage at the time of the period in February, 1902, when for a week she had a very profuse flooding, but not so severe as the first time. Since February the patient has had almost constant but very slight bleeding. This is apparently brought on by exertion. For two or three weeks the patient has had a good deal of bearing-down pain, which

is partially relieved by lying down. She is in a good condition, but shows slight pallor of the mucous membranes.

Operation.—Hystero-myomectomy; left salpingo-oöphor-ectomy; right salpingectomy. The patient made an uninterrupted recovery.

Path. No. 6008.—The uterus has been amputated through the cervix. It is 9 cm. in length and nearly 9 cm. in breadth. The uterine mucosa has been almost entirely curetted away, but near the right cornu some of the thickened mucosa still remains. The uterine walls, both anteriorly and posteriorly, show diffuse myomatous thickening. They vary from 3.5 to 4.5 cm. in thickness.

The appendages are normal.

On histological examination the uterine glands show some hypertrophy. The diffuse growth in the anterior wall has everywhere been invaded by islands of uterine mucosa. The glands composing these are for the most part normal, but in some places there is moderate dilatation. The uterine mucosa can be seen extending down in large quantities into this diffuse growth, and there is no doubt that the gland elements are derivatives from those of the mucosa.

Sections from the fundus and from the upper part of the posterior wall also show infiltration with islands of mucosa. In the lower part of the posterior wall is a diffuse thickening, but there is little tendency for the glands to penetrate into the depth.

Gyn. No. 10,519. Path. No. 6754.

Diffuse adenomyoma of the uterus, the glands originating from the mucosa.

S. R., single, aged forty-nine, white. Admitted May 29, 1903; discharged June 17, 1903. Complaint: Dysmenorrhœa. Her menses are regular, always painful. The patient had no bleeding from October to December, 1902. Then the periods were regular for five months. For the last three months there has been a foul yellowish discharge. At times, since the bleeding commenced, the

patient has had difficulty in holding her urine. For the last three years the pains at the periods have been much worse, not only in the back but in both legs and groins. Haemoglobin 50 per cent.

Operation.—Hystero-salpingo-oöphorectomy. The patient made a satisfactory recovery and was discharged on the twentieth day.

Path. No. 6754.—The specimen consists of a very evenly enlarged uterus with the tubes and ovaries attached. The uterus is rather dense and hard. It measures 7.5 cm. in length, 4 cm. in breadth. The uterine mucosa in places presents a polypoid appearance. This is especially seen in the vicinity of the internal os. The uterine walls have a coarsely striated appearance and there are little openings, suggesting the gland-like spaces of an adenomyoma. The thickening is uniform in both the anterior and posterior walls.

The tubes and ovaries appear normal.

Histological Examination.—Sections from the body of the uterus show that the mucosa is perfectly normal, that it is much thickened, and in numerous places there is a tendency for the mucosa to penetrate into the depth. In the inner zone of the uterus, where the diffuse thickening is noted, the tissue is myomatous, and scattered throughout this are islands of uterine mucosa similar to those found in an adenomyoma. One cm. from the outer surface of the uterus is a miniature cavity 4 mm. in diameter. At other points there are dilated glands filled with old hemorrhage. There is no doubt that the glands in this case have originated from the mucosa.

Diagnosis.—Diffuse adenomyoma of the anterior and posterior uterine walls; normal appendages.

CHAPTER IV

CASES OF ADENOMYOMA IN WHICH THE UTERUS RETAINS A RELATIVELY NORMAL CONTOUR—(Continued)

Gyn. No. 7569. Path. No. 3903.

Diffuse adenomyoma of the anterior and posterior uterine walls, most pronounced in the fundus and posterior wall (Figs. 27, 28, and 29).

L. C., married, white, aged forty-six. Admitted February 12, discharged April 26, 1900. The patient complained of discharge of urine through the vagina and of incontinence of feces. Her mother, who died of leprosy at the age of forty-seven, had two children while suffering from this disease. Both are living and well.

When the patient was twelve years of age she had rheumatism, and since that time has complained of shortness of breath. At twenty years of age she had a second attack of rheumatism.

Her menses commenced at sixteen, were regular every four weeks, lasting four days. The flow, however, was accompanied by pain and she had to remain in bed for two days. The flow has always been profuse. For the last two years the menstrual periods have been painful and irregular; sometimes an interval of two months will elapse. There has been no change in the character of the flow. Her last period came on on December 24, 1899. The previous period had occurred two months before.

The patient was married at nineteen and had two children, both stillborn, no miscarriages. She had convulsions at the onset of the first labor twenty-five years ago and was badly torn. At the second labor, twenty-three years ago, there was a complete tear in which the bladder was implicated. Ever since the birth of her first child the patient has been suffering from incontinence of feces. The condition was not improved after the birth of the second child. At that time a vesicovaginal fistula developed. Nineteen years ago the patient

was operated upon and an attempt was made to close the fistula with silver wire. A second attempt was made two years later, but both were unsuccessful.

Following the birth of the second child the patient had phlebitis of the left leg. The leg has since been more or less swollen and at times painful.

Apart from a presystolic murmur at the apex of the heart the thorax is clear. Both labia minora and majora are inflamed, apparently owing to the escape of urine. Protruding from the vagina is what appears to be a rectocele. The perineum shows a complete tear extending 4 or 5 cm. into the rectovaginal septum. The mucosa over the rectum protrudes slightly and is very red in appearance. In the upper part of the anterior wall, about 1 cm. from the cervix, is a scar which extends across the vagina, and at the left angle of the scar is a vesicovaginal fistula. The cervix is deeply lacerated. The external os is patulous.

February 14th. Aniline solution and methylene-blue were used to determine the condition of the ureters and the relation of the fistula to the left ureter and the bladder.

Diagnosis: A left ureteral fistula into the vagina and a vesicovaginal fistula; also a rupture of the rectovaginal septum.

February 19th. The ureter was cut around on all sides and turned into the bladder. The rectovaginal septum was restored.

March 11th. The stitches were removed from the vesicovaginal fistula. They were covered with incrustations. An area of granulation 4 cm. long was found with urine escaping from it. The site of operation for complete tear was entirely separated except for the two triangular areas in the vagina.

An opening was now made into the peritoneal cavity. The uterus was found to be myomatous and the tubes and ovaries were adherent. The uterus, the left tube and left ovary were removed in the usual way. The ureter was then turned into the bladder and the vesicovaginal fistula repaired.

Convalescence was slow and the patient complained of much

discomfort, especially of nausea and vomiting. There was considerable vaginal pain.

March 30th. She had a chill, the temperature rising to 102.8° F. On April 6th she developed phlebitis in the right leg.

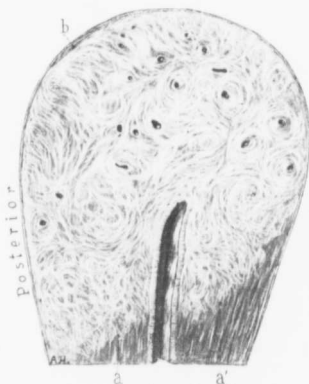

FIG. 27.—DIFFUSE ADENOMYOMA OF THE BODY OF THE UTERUS. (Natural size.)

Gyn. - Path. No. 3903. The uterus has been amputated through the cervix. Occupying nearly the entire body of the organ is a diffuse myomatous growth. In the upper part all trace of the normal muscle has disappeared except at *b*. Downward the growth can be traced to *a* and *a'*. The myomatous portion is composed of coarse bands of tissue passing in all directions and often forming definite whorls with small round or irregular cavities in their centres. Some of these cavities are cross-sections of blood-vessels; others are small cysts. The portion of the uterine cavity seen presents the normal appearance and the mucosa shows no change. For the histological picture see Figs. 28 and 29.

April 24th. The fistulous tract in the abdominal incision appears to have entirely closed. The perineum is in the same condition as at the time of admission. The ureterovaginal fistula appears to have been converted into a vesicovaginal fistula. The patient was discharged on April 26th.

Gyn. - Path. No. 3903.—The specimen consists of the uterus with its left appendages. The uterus, which has been amputated at the cervix, is 8 cm. in length, 6.5 cm. in breadth, and 5.5 cm. in its antero-posterior diameter. The anterior surface is smooth and glistening. The posterior aspect is covered with a few adhesions. At the fundus is a slightly rounded boss, 3 cm. in diameter. The uterine cavity is 2.5 cm. in length and at the fundus 3.5 cm. in breadth.

The anterior uterine wall averages 2.5 cm. in thickness and in its inner portion is slightly coarse in texture. The posterior wall varies from 2.5 to 3.5 cm. in thickness and from the peritoneal surface to the mucosa is coarsely striated, resembling diffuse myomatous tissue (Fig. 27). Scattered through-

out this coarse tissue are small cyst-like spaces, some reaching 1 mm. in diameter. No definite myomatous foci can be found.

The left tube and ovary are covered with adhesions.

Histological Examination.—The uterine mucosa has an intact surface epithelium which in some places is considerably

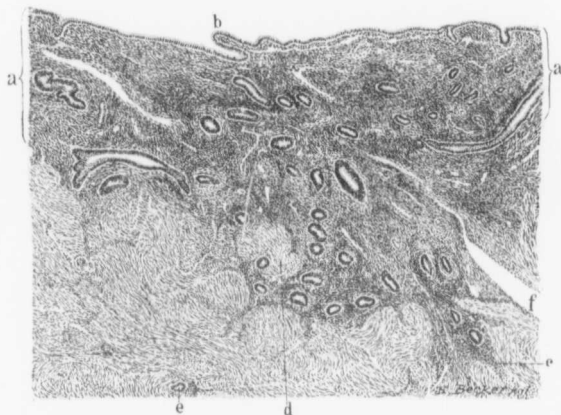


FIG. 28.—EXTENSION OF THE MUCOSA INTO THE MUSCLE IN A CASE OF DIFFUSE ADENOMYOMA OF THE UTERUS. (50 diameters.)

Gyn.-Path. No. 3903. The section is from the body of the uterus in Fig. 27. *a* represents the thickness of the mucosa which is smooth save for the slight projection *b*. The uterine glands are normal in appearance and the stroma is dense, resembling that normally found after the menopause. The mucous membrane is extending *en masse* into the myomatous tissue and can be followed as far as *c*. *d* is a small tuft of myomatous muscle almost completely encircled by mucosa. *e* is an isolated gland in the muscle and partially surrounded by the characteristic stroma. *f* is a vein.

flattened. The mucosa is thin and its glands are very small, resembling those seen after the menopause. The gland epithelium is everywhere intact and normal. The stroma of the mucosa, as in old individuals, is very dense. The coarse and striated appearance of both uterine walls, more particularly of the posterior, is due to an almost complete myomatous transformation of the uterine muscle. As a matter of fact, in the posterior wall this diffuse myomatous

condition can be followed to the peritoneal surface. The uterine mucosa in both the anterior and posterior

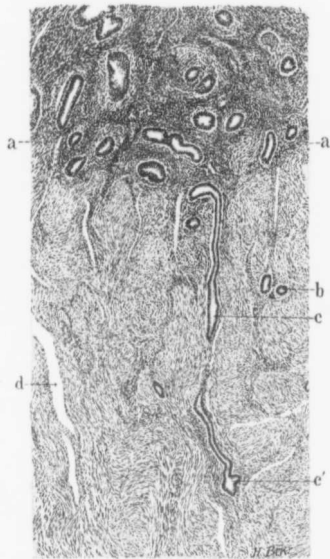


FIG. 29.—METHOD OF PENETRATION OF A SINGLE UTERINE GLAND INTO THE DIFFUSE MYOMATOUS GROWTH OF AN ADENOMYOMA. (30 diameters.)

Gyn.—Path. No. 3903. The section is from the body of the uterus seen in Fig. 27; in the upper part of the field is the uterine mucosa, the lower limits of which are represented by *a*. The glands present the normal appearance, but the stroma around some of them is pale-staining, while that in the vicinity is denser than usual. There is, however, no evidence of inflammation. At *b* are cross-sections of two small glands. The origin of such glands is indicated by *c*, where we have a longitudinal section of one commencing in the mucosa and penetrating the myomatous muscle. It is lost for a space, but again recognized at *c'*. Near the mucosa it seems devoid of stroma, but in the deeper portions it is partially surrounded by stroma. *d* is a vein.

walls dips down at many points into this myomatous tissue (Fig. 28). In the anterior wall it is possible to trace an individual gland 3 mm. into the depth (Fig. 29). In the posterior wall a similar extension of the mucosa into the myomatous tissue is demonstrable, and scattered everywhere throughout the posterior wall, but more particularly at the fundus and extending almost to the peritoneal surface, are islands of mucous membrane. In this particular case they are very small, individual islands rarely containing more than two glands with their surrounding stroma. These glands resemble typical uterine glands and their stroma is identical with that of the mucosa. Some of the glands are dilated and irregular, and form the cyst-like spaces noted macroscopically. Where the glands are moderately dilated their epithelium frequently stains quite palely. Occasion-

ally an island of stroma is found devoid of gland elements, and now and then a small gland is seen devoid of stroma and lying directly between muscle bundles.

In this case we have a diffuse myomatous transformation of both uterine walls, but more pronounced in the posterior. Normal uterine mucosa has grown into this diffuse myomatous tissue, producing the typical picture of adenomyoma. This case demonstrates very well the ease with which the connection between the uterine mucosa and the glands in the depth can be overlooked. We examined section after section without finding this down-growth, but the study of further tissue showed us the direct connection between the mucosa lining the uterine cavity and that situated in the myomatous tissue.

D i a g n o s i s.—Diffuse adenomyoma of the anterior and posterior uterine walls most pronounced in the fundus and posterior wall; slight pelvic peritonitis.

Gyn. No. 2699. Path. No. 246.

Interstitial and submucous uterine myomata; slight diffuse adenomyomatous thickening of the uterine wall with the glands originating in the mucosa; small cyst of the ovary.

S. L., married, white, aged fifty. Admitted April 5, 1894; discharged May 11, 1894. Married at forty-eight. She probably had a miscarriage several months after. The menses appeared at fourteen, always regular, profuse, although somewhat more so for the last three or four years. The patient has had a slight leucorrhœal discharge. Eight months ago a small tumor was noted in the left lower abdomen. It has been gradually increasing since then. She complains of weakness and of backache.

O p e r a t i o n.—Hystero-myomectomy. For the first forty-eight hours after operation she had almost constant nausea. Her temperature was 100.8° F. on the second day. She made a satisfactory recovery.

Path. No. 246.—The specimen consists of the enlarged uterus with the tubes and ovaries attached. The uterus measures 16 by 17 by 14 cm., is irregular in outline, smooth and glistening. Its under cut surface measures 13 by 11 by 11 cm. Attached to the right side of the cervix is a somewhat irregular tumor, 7 cm. in diameter. It is firm and non-yielding. To the left of the cervix a similar nodule 6 cm. in diameter is found, and the fundus is occupied by a tumor, 10 cm. in diameter.

The cut surface of this tumor presents a somewhat striated appearance. It is pearly white in color and very hard in consistency. The other nodules are similar in character and all of them are covered with a layer of muscle about 2 mm. in thickness. Scattered throughout the uterine walls are other smaller and similar nodules, while projecting into the uterine cavity is a tumor mass, 7 cm. in diameter. The uterine cavity is 6 cm. in length. Its mucosa averages 1 mm. in thickness; it is pale and glistening. Over the submucous nodules it appears atrophic. At the fundus is a broad based polyp, 1 cm. in diameter. Here the mucous membrane is dark red and injected.

Histological Examination.—The mucous membrane over the large submucous nodule is somewhat atrophic and the glands are moderately dilated. Their epithelium is intact and their lumina contain a pink-grayish material. The stroma is very lax and is made up of cells having round or oval nuclei. The blood-vessels of the stroma are very abundant and in several places red corpuscles have escaped into the tissue. As one passes toward the fundus the glands in the depth are seen to run parallel with the surface instead of at right angles to it. A few lymph-nodules are found in the muscular coat of the stroma. At the fundus the mucosa penetrates into the muscular coat for a distance of 3 mm. The glands are not typical, but appear as cavities filled with epithelial cells and the muscle shows a distinct myomatous tendency. All the nodules scattered throughout the uterus are composed of non-striated muscle fibres cut longitudinally and transversely. There are areas of hyaline

degeneration scattered here and there throughout the myomatous tissue.

Both tubes are normal. The right ovary contains a Graafian follicle cyst 2 cm. in diameter. The left ovary contains a cyst 3.5 cm. in diameter, the exact nature of which it is impossible to determine.

Diagnosis.—Interstitial and submucous uterine myomata; small cysts of both ovaries; commencing diffuse adenomyoma.

Gyn. No. 12,944. Path. No. 9970.

Diffuse adenomyomata of both the anterior and posterior uterine walls with the gland elements coming from the uterine mucosa (Fig. 30).

Mrs. B. D., aged thirty-three, white. Admitted May 19, 1906; discharged June 19, 1906. The patient entered complaining of too frequent menstruation with pain in the back and lower abdomen. She has been a chronic invalid for ten years. She had entered the hospital on April 13, 1904. The cervix was repaired, the perineum restored, and the uterus dilated. She was discharged much improved. At that time the menses occurred every two weeks and lasted from six to eight days, and were accompanied with severe pain in the back and lower abdomen. Two months after leaving the hospital all the patient's former symptoms returned, and since that time she has had her menses every two weeks, lasting from ten to twelve days, and accompanied by severe pain in the back and lower abdomen. She passes large clots at times and the flow is very excessive. The patient is incapacitated on account of the pain and profuse flow, which weakens her greatly. She has numerous varicose veins about the ankles and the legs swell at times.

There is much adipose tissue in the abdomen; some increase in resistance in the median line. The outlet is moderately relaxed; the cervix is low; the fundus is slightly irregular in outline, enlarged, about the size of a three-months pregnancy. There is no tenderness laterally. The uterus was removed in the usual way. The ap-

pendix, which was partially obliterated over its base, was also removed. The patient made a satisfactory recovery. The highest temperature was 101° F., twenty-four hours after the operation.

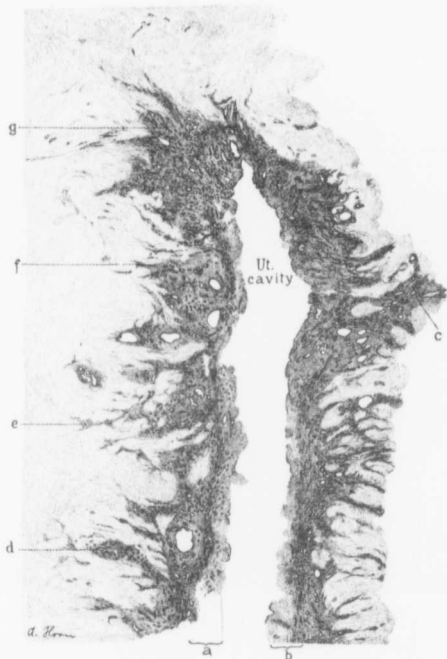


FIG. 30.—DIFFUSE ADENOMYOMA OF THE BODY OF THE UTERUS. (6 diameters.)

Gyn.—Path. No. 9970. The section embraces the upper part of the uterine cavity. *a* and *b* indicate the relatively normal thickness of the mucosa. The ragged inner surface is due to a recent curettage. The mucosa is everywhere much thickened and is extending into the underlying myomatous muscle. This down-growth is strikingly well seen at *c*, and is also extensive at *d*, *e*, and *f*. At *g* there is marked thickening of the mucosa as well as an invasion of the muscle. At no point do the glands appear abnormal.

Path. No. 9970.—The specimen comprises the uterus, appendages, and the appendix. The uterus is approximately twice

the natural size, measuring 9 cm. in length, 9 cm. in breadth, and 6 cm. in thickness. Both the anterior and posterior walls show diffuse myomatous thickening, and here and there throughout the myomatous areas are little cyst-like spaces. Macroscopically it looks very much as if we are dealing with an adenomyoma. The anterior wall varies from 2 to 3 cm. in thickness. The posterior wall also reaches 3 cm. in thickness. The uterine mucosa is apparently considerably thinned out, being not over 1 mm. in thickness.

The tubes and ovaries are apparently normal.

Histological Examination.—The uterine mucosa is of the normal thickness and is rather dense. The glands present the usual appearance and the underlying muscle shows diffuse myomatous thickening. The glands flow down into the depth from both the anterior and posterior walls (Fig. 30). They can be traced for a considerable distance. The mucosa extends down like little bays into the depth. In some places we have miniature uterine cavities. In the islands of mucosa the glands show a good deal of dilatation. We have here, both in the anterior and posterior walls, diffuse adenomyoma with the gland elements coming from the uterine mucosa and diminishing as one passes outward toward the peritoneal surface.

Gyn. No. 4364. Path. No. 1170.

Diffuse adenomyoma of the anterior uterine wall; interstitial uterine myomata; dilatation of uterine glands; uterine polypi; very large adenocystoma of the left ovary; general pelvic adhesions. Hysterectomy and cystectomy. Recovery.

M. H., aged fifty-nine, white, married. Admitted May 8, 1896; discharged June 12, 1896. Complaint: Abdominal tumor. The patient has had three children; no miscarriages. The menses began at fourteen and were regular until ten years ago. She has always

had severe dysmenorrhœa, beginning two days before the period and lasting until the flow was fully established. The menopause occurred ten years ago. Two years ago she had a profuse hemorrhage from the uterus lasting three days. She has had no leucorrhœa. The bowels are constipated; micturition is frequent. Operation, May 12, 1896. Cystectomy and hysterectomy. The ovarian cyst was intimately adherent to the surrounding structures and was removed with difficulty. The uterus was then amputated through its cervical portion. The patient made an uneventful recovery.

Gyn. - Path. No. 1170.—The uterus measures 6 by 7 by 4 cm. Its surface is covered with dense vascular adhesions. The anterior wall varies from 3 to 4 cm. in thickness and is very coarse in texture. The fundus is also somewhat thicker than usual. The posterior uterine wall averages 1.8 cm. in thickness and in the vicinity of the cervix contains two interstitial uterine myomata .6 and .5 cm. in diameter. The uterine cavity is 6 cm. in length and at the fundus 4 cm. in breadth. The mucosa is smooth and glistening, but contains numerous slightly dilated glands. Springing from the anterior wall are two small polypi: the one, 5 by 3 mm., also containing dilated glands; the other, a tongue-like process, 8 mm. in length and scarcely 1 mm. in thickness. This slender polyp is markedly hemorrhagic, especially at its tip, and contains dilated glands.

Left side: The Fallopian tube is 6 cm. in length, 5 mm. in diameter, and covered with adhesions.

The cyst removed is multilocular and measures 42 by 34 by 22 cm. It is pinkish or bluish-gray in color and covered by numerous adhesions.

HISTOLOGICAL EXAMINATION.—The epithelium covering the surface of the mucosa has been poorly preserved, but is intact and normal. The mucosa presents a wavy outline and in places is gathered up into small polypoid projections or into definite polypi. The uterine glands are fairly abundant; some are small and tubular and frequently present forked extremities, but many of them are dilated, reaching 2 mm. or more in size. The stroma

is in some places denser than usual. The muscle of the anterior uterine wall is dense, resembling myomatous tissue, and scattered throughout it are glands occurring singly or in groups. Although the outer uterine walls are considerably mutilated, these glands can be traced laterally to the broad ligament attachment. They are lined with one layer of epithelium, are identical with uterine glands, and are surrounded by a stroma, similar to that of the uterine mucosa. Some of the glands are moderately dilated and at one point in the depth of the muscle there is a miniature uterine cavity, there being surface epithelium lining the cavity and numerous glands opening into it, while lying between the glands is a typical stroma. At some points the uterine mucosa can be traced into the myomatous tissue for a distance of 3 mm. or more. The glands in the depth evidently arise from the uterine mucosa. The uterine muscle shows little degeneration, but quite a number of its blood-vessels are undergoing obliterative changes, and some of them contain calcareous plates beneath the intima.

The multilocular ovarian cyst has connective-tissue walls and the inner surfaces of the cyst are lined with one layer of high cylindrical epithelium; in other words, it presents the typical appearance.

Diagnosis.—Diffuse adenomyoma involving the anterior uterine wall. Interstitial uterine myomata. Dilatation of the uterine glands. Uterine polypi. Very large adenocystoma of the ovary. General pelvic adhesions.

Church Home and Infirmary (Dr. Hunner). Path. No. 6319.

Diffuse adenomyoma of the uterine wall with the glands coming from the mucosa.

November 22, 1902. The uterus is considerably enlarged. The walls reach 1.5 cm. in thickness. In some places the mucosa forms distinct polypoid outgrowths.

Sections from the endometrium show that it has been curetted

and that the mucosa presents a very ragged appearance. Extending down into the underlying tissue are uterine glands. These do not penetrate singly, but large areas of mucosa flow directly into the depth. We are in places able to trace the mucosa by continuity 6 mm. into the depth. The glands are perfectly normal except for here and there a dilatation. They are likewise accompanied by normal stroma of the mucosa. Where the glands are dilated, the epithelium sometimes is pale-staining. The muscular tissue in places presents the typical myomatous picture.

Diagnosis.—Diffuse adenomyoma of the uterus with the mucosa flowing directly into the myomatous tissue.

Gyn. No. 11,120. Path. No. 7351.

Multinodular myomatous uterus, the nodules being subperitoneal and interstitial. Diffuse adenomyoma in the uterine wall; discrete adenomyoma in the left uterine horn with formation of a miniature uterine cavity (Figs. 31 and 32).

E. S., single, aged fifty-one, white. Admitted March 17, 1904; discharged April 10, 1904. Complaint: Uterine hemorrhages. The patient had inflammatory rheumatism and typhoid fever at twenty-six. Her menstrual history has been normal until the present illness. For two years the periods have been more profuse than usual, gradually increasing until now she has very severe hemorrhages. During the last year the periods have been two or three weeks apart and lasting from one to three weeks. She has lost considerable weight and strength. The patient is well nourished but looks anæmic.

Operation March 21, 1904.—Hystero-myomectomy. Convalescence uneventful. The highest post-operative temperature was 100.8° F., which was on the fourth day.

Path. No. 7351.—The specimen consists of a myomatous uterus with the appendages intact. The uterus measures approximately 9 by 10 by 10 cm. (Fig. 31). Projecting from the left uterine

horn is a subperitoneal nodule approximately 6 cm. in diameter. There are also several smaller subperitoneal nodules. Occupying the anterior wall are two myomata, one 5 cm. the other 2 cm. in diameter. On section it is found that the uterine cavity has been somewhat mutilated. The nodule in the anterior wall presents the usual appearance.

The growth in the left uterine horn is sharply circumscribed and

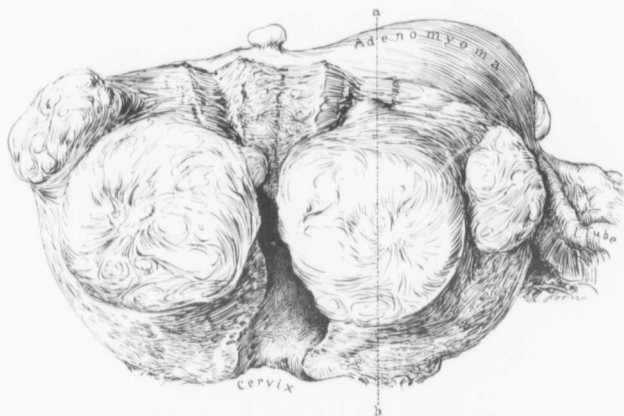


FIG. 31.—DISCRETE UTERINE MYOMATA. DIFFUSE ADENOMYOMA WITH THE GLANDS ORIGINATING FROM THE MUCOSA. ADENOMYOMA OF THE LEFT UTERINE HORN. ($\frac{1}{2}$ natural size.)

Gyn.-Path. No. 7351. Scattered throughout the uterus are one medium-sized and several small myomata. Near the uterine horn is a distinct prominence which on section is seen even on macroscopic examination to be a diffuse adenomyoma. Histological examination of the uterus shows diffuse adenomyoma with the glands originating from the mucosa. For a longitudinal section of the uterus between points *a* and *b* see Fig. 32.

has on its margin two or three smaller ones. This myoma is diffuse in character and has scattered throughout it whitish-yellow porous areas, evidently islands of uterine mucosa, and at one point a cystic dilatation 1 cm. in diameter (Fig. 32), lined with a definite membrane and filled with a brown putty-like material.

In the hardened specimen the uterine mucosa can be seen

macroscopically penetrating into the myoma, the mucosa extending into the myoma fully 6 mm. Surrounding the outer surface of the myoma is a zone of normal muscle varying from 3 to 6 mm. in thickness.

On histological examination the endometrium is found to be

much thickened. The surface epithelium is intact. The majority of the glands are normal. A few of them, however, are dilated. The mucosa shows a tendency in some places to penetrate the uterine wall and at one point can be traced into the depth for a distance of 4 mm. The underlying muscle shows several small myomata scattered throughout the wall. The large porous growth occupying the left uterine horn is seen to contain many islands of mucosa. One island is 1.8 cm. in length and varies from 1 to 4 mm. in breadth. The uterine

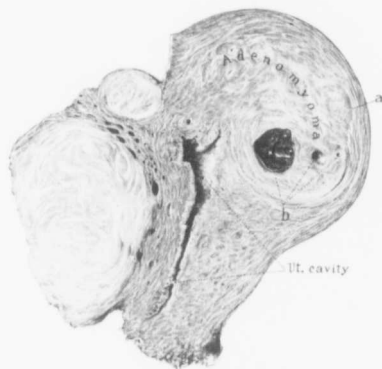


FIG. 32.—LONGITUDINAL SECTION OF DISCRETE MYOMATA; DISCRETE ADENOMYOMA NEAR THE LEFT UTERINE HORN. (½ natural size.)

Gyn.-Path. No. 7351. Fig. 32 is a longitudinal of Fig. 31 from point *a* to *b*. In the anterior wall are sections of two discrete myomata. The posterior wall shows slight thickening. The discrete adenomyoma, although clearly defined, nevertheless is intimately associated with the surrounding muscle *a*, and could not be shelled out as could the other two myomata. It contains cystic spaces as indicated by *b*. The larger space has a definite smooth lining and was filled with yellowish putty-like material,—old and inspissated menstrual blood.

mucosa composing these islands differs little from the ordinary mucosa. Some of its glands are dilated and contain old blood, otherwise it is identical.

Diagnosis.—Multinodular uterus, the nodules being sub-peritoneal and interstitial. Diffuse adenomyoma of the uterine walls; discrete adenomyoma in the left uterine horn, containing a miniature uterine cavity.

H. A. K. Sanitarium No. 2178. Path. No. 9803.

Small interstitial uterine myomata; very early adenomyoma with the mucosa extending into the depth; slight pelvic adhesions.

C. S., aged forty-six, white. Admitted May 2, 1906. The patient has been married twenty seven years and has had one child and one miscarriage. Her menses have always been excessive and lately the flow has almost amounted to a flooding. No leucorrhœa. The patient has been greatly debilitated from excessive loss of blood.

Operation, May 3d. Hystero-myomectomy, double salpingo-oöphorectomy and appendectomy. This patient had been operated upon by Dr. Kelly several years ago and a number of myomata had been removed. At that time in addition to the myomata there were many adhesions on the left side and the intestines were slightly adherent on the right side. The highest post-operative temperature was 101.2° F. The patient made a satisfactory recovery.

Path. No. 9803.—The uterus, both anteriorly and posteriorly, is enveloped in adhesions. It is very little increased in size and contains three myomata, the largest 1 cm. in diameter. The right tube is bound down to the uterus. Its fimbriated end however, is free. The ovary is but little altered. The left tube and ovary have a few adhesions, but the fimbriated end of the tube is normal.

Sections from the endometrium show that the tissue has been very poorly hardened and that the surface epithelium is in few places intact. The glands, where preserved, are normal. They show a considerable tendency to extend into the depth. Sections from the body of the uterus show an island of mucosa, 2 mm. in length, a short distance below the normal mucosa. The direct continuity with the surface can be traced. The muscle beneath the mucosa shows commencing diffuse myomatous transformation.

Diagnosis.—Small interstitial uterine myomata; very early

diffuse adenomyoma with the mucosa extending into the depth; slight pelvic adhesions.

Gyn. No. 12,678. Path. No. 9466.

Subperitoneal, interstitial, and submucous uterine myomata; commencing adenomyoma with the glands originating from the mucosa.

A. T., married, aged fifty-three, white. Admitted February 5, 1906; discharged February 26, 1906. Complaint: Pain at menstrual period, menorrhagia, difficulty in voiding. The patient was in the hospital ten years ago for nervous prostration.

Her menses were regular, at first every four weeks, the flow lasting four days and being normal in amount. There has always been marked dysmenorrhœa and the patient has remained in bed three or four days. There has been a gradual increase in the amount of flow for the past ten years. About six weeks ago she noticed a marked increase in amount, and from that time to the present the flow has been greatly augmented. Now the periods last from fourteen to eighteen days. The pain is cramp-like and so severe as to require morphin at times. Large clots are passed. The patient has never had any children. For some time the patient was treated for anæmia, the real trouble not being suspected. She has been constipated for some time and has occasionally had hemorrhoids. There is a constant desire to urinate, and a feeling of pressure in the bladder. On opening the abdomen a small amount of straw-colored fluid escaped. On reaching with the hand down into the pelvis a myomatous mass was with some difficulty delivered. No adhesions were present. The uterus was removed from left to right without any difficulty. The convalescence was uneventful.

Path. No. 9466.—The uterus is irregular in shape, measuring approximately 12 by 7 by 9 cm. It is free from adhesions and contains at least four good-sized myomata, the largest reaching 6 cm. in diameter. The uterine cavity is 4.5 cm. in length and is much distorted by a submucous myoma 3 cm. in diameter which completely fills the cavity.

On histological examination we have an intact surface epithelium, normal glands, with here and there hemorrhage into the stroma. We also have a commencing diffuse thickening of the anterior uterine wall with a flowing down of the glands into the depth. In other words, the picture is one of a typical commencing adenomyoma.

Diagnosis.—Subperitoneal, interstitial, and submucous uterine myomata; commencing adenomyoma of the anterior uterine wall.

H. A. K. Sanitarium No. 1552. Path. No. 6536.

Interstitial uterine myomata; marked penetration of the uterine mucosa into the depth with slight diffuse myomatous tendency.

F. McC., white, aged fifty-three. Admitted March 10, 1903; discharged April 16, 1903. The patient has had five children. The menopause occurred six months ago.

Operation.—Vaginal hysterectomy; removal of the left tube; repair of perineum and excision of a vaginal cyst. The patient made a satisfactory recovery.

Path. No. 6536.—The specimen consists of a mutilated, bisected uterus. In the uterine walls are small myomata. The uterus itself is about normal in size. Sections from the uterine wall near the fundus show that the mucosa is normal. At numerous points, however, the mucosa can be seen extending into the underlying tissue for a considerable distance, and farther out in the muscle are islands of mucosa or individual glands surrounded by a small amount of stroma. There is a distinct myomatous tendency, as evidenced by the discrete myomata. The uterine walls themselves, however, show little tendency toward diffuse thickening. Sections from the discrete myomata show the typical appearance and hyaline degeneration.

Diagnosis.—Interstitial uterine myomata, marked pene-

tration of the uterine mucosa into the depth, with slight diffuse myomatous tendency.

Gyn. No. 11,363. Path. No. 7593.

Subperitoneal, interstitial, and submucous uterine myomata. Diffuse adenomyoma in the fundus with the glands coming from the mucosa (Fig. 33), slight salpingitis; normal ovaries.

A. L., colored, aged forty-five, married. Admitted June 21, 1904; discharged July 9, 1904. Complaint: Uterine hemorrhages. Four brothers of the patient died of consumption. Her previous history is negative. Her menses were normal until four years ago, when the menopause occurred. She had one child, thirty years ago; two miscarriages about twenty years ago.

Present illness: Nine months ago—that is, three years and three months after the menopause—she commenced to have some slight uterine hemorrhage. This has lasted on and off until the present time, but was never profuse. No other symptoms. She is well nourished. Her lungs are normal.

Operation.—Hystero-myomectomy. Convalescence normal. The highest temperature was 101° F., on the third day. Her pulse varied from 110 to 130 for the first three days. She was discharged on the sixteenth day.

Path. No. 7593.—The specimen consists of the uterus with the tubes and ovaries attached. The uterus is smooth and its anterior surface is covered with several nodular elevations. It measures 12.5 by 8.5 by 10 cm. and is rather soft.

On section it is found to contain submucous, interstitial, and subperitoneal myomata. The largest measures 7 by 6 cm. The uterine cavity is 7 cm. in length. The mucosa in the lower part of the body appears to be atrophic. Near the fundus and projecting into the cavity is a polyp 2.5 cm. in length. The uterine walls in the vicinity of the fundus are coarsely striated and there is a general diffuse myomatous tendency (Fig. 33). From the character of

the growth we should not be surprised to find that it was an adenomyoma.

On further examination it is seen that the entire fundus is occupied by a diffuse and almost circular myoma which is ap-



FIG. 33.—SUBPERITONEAL, INTERSTITIAL AND SUBMUCOUS UTERINE MYOMATA; DIFFUSE ADENOMYOMA OF THE ENTIRE FUNDUS. (□ natural size.)

Gyn.-Path. No. 7593. The uterine cavity has been cut in two. In the right half several polypi are seen. Scattered throughout the uterine walls are subperitoneal and interstitial myomata, and at the cervix a fairly large submucous nodule. The uterine muscle in the body shows a very coarse diffuse myomatous appearance which instantly suggests adenomyoma. The pathological report shows that the uterine glands penetrate this diffuse myomatous tissue.

proximately 7 cm. in diameter. Scattered throughout this are a few spongy areas indicative of mucosa, and at one point is a definite area of mucosa 1 cm. in diameter, surrounded by typical

myomatous tissue. At another point just beneath the mucosa is a circumscribed myoma in the diffuse growth. This contains three or four small cystic spaces.

On histological examination some dilatation of the glands of the endometrium is noticeable, especially where the polyp is present. Here many of the glands are fully four or five times their normal size. At numerous points the mucosa is found to extend into the underlying tissue. Sections a little farther up in the cavity show large areas of mucous membrane penetrating into the depth, and in the underlying tissue are many islands of mucosa differing in no way from the normal except for gland dilatation. Some of the dilated glands contain a few desquamated epithelial cells. The ovaries are normal. There is a slight degree of salpingitis.

D i a g n o s i s .—Subperitoneal, interstitial, and submucous uterine myomata; diffuse adenomyoma with the glands coming directly from the uterine mucosa.

Gyn. No. 7011. Path. No. 3289.

Multiple uterine myomata; diffuse adenomyoma, the glands originating from the mucosa. Peri-oöphoritis.

E. B. S., aged thirty-three, white, single. Admitted June 20, 1899; discharged August 1, 1899. Complaint: Menorrhagia; abdominal tumor; dysmenorrhœa. The menses began at thirteen and were always regular, lasting seven days. There was no severe pain, but a cutting sensation in the left side. For over a year the flow has been very profuse, amounting to hemorrhages. The bowels are, as a rule, constipated. Micturition is frequent.

O p e r a t i o n , June 24. Hystero-salpingo-oöphorectomy. The right ovary was left *in situ*. In addition to the uterus, a calcareous nodule was removed from the mesentery of the ileum about 10 cm. from the ileocaecal valve. The highest post-operative temperature was 100.9° F., on the ninth day. The patient made a satisfactory recovery.

Path. No. 3289.—The specimen consists of the uterus, left tube and ovary, and several myomata, the largest measuring 7.5 by 5 by 4.5 cm. The uterus independent of some of these large nodules measures 9 by 7.5 by 8 cm. Its peritoneal surface is somewhat injected. The uterine cavity is 6 cm. long, 5 cm. broad. At the fundus the walls are approximately 6 cm. in thickness. Small myomata are seen scattered throughout them. The mucosa is 3 mm. in thickness. Its surface is very irregular owing to the presence of submucous myomata. It is, for the most part, smooth and glistening.

The right appendages are covered with adhesions. On the left side the tube measures 6 cm. in length, 7 mm. in thickness. It is free from adhesions. The ovary measures 5 by 4 by 2.5 cm.; is soft and fluctuating, being apparently cystic. It is covered with a few vascular adhesions.

On histological examination sections from the decalcified calcareous nodule (3 by 2.5 by 2 cm.) removed from the mesentery, show that it possesses a capsule of fibrous tissue which contains a few connective-tissue cells. The centre of the calcareous area is practically devoid of cell elements. The nodule appears to be a calcified lymph-gland.

Sections from the uterine wall show diffuse thickening with direct extension of the glands into the depth.

Diagnosis.—Multiple uterine myomata, subperitoneal, interstitial, and submucous; diffuse adenomyoma. Pelvic adhesions; hydrosalpinx.

Gyn. No. 7859. Path. No. 4122.

Multinodular myomatous uterus; diffuse adenomyoma of the fundus (Fig. 34), with the glands originating from the mucosa; general pelvic adhesions; right hæmatosalpinx.

A. B., married, white, aged fifty-two. Admitted May 29, 1900; discharged June 30, 1900. Complaint: uterine hemorrhage. The

patient has been married thirty-six years, and had one child, thirty-five years ago, no miscarriages. Her menses were normal until the menopause. The patient has not been in good health for four years. She has had shortness of breath and palpitation for the last three years and has been having excessive hemorrhages, the bleeding lasting from one week to one month. She has lost as much as a basin of blood in a few minutes, and has had to go to bed at these times. The bleeding always comes on after exertion. There has been no pain. She was formerly a robust woman, but has been reduced to a condition of great anæmia. The lungs are normal. There is a soft systolic murmur over the entire cardiac region. Hamoglobin 30 per cent. The urine contains a large amount of pus and some casts. For the last three years the patient has had a greenish, offensive discharge.

Operation: Hystero-myomectomy. At the time of her discharge, on June 29th, her hamoglobin was 59 per cent. Just about an inch external to the anus was a fistulous opening. This probably accounted for her temperature, which on the third day rose to 103.5° F.

Path. No. 4122.—The specimen consists of an enlarged uterus, the right dilated tube and ovary, and the left tube and ovary. The uterus is converted into a nodular tumor measuring approximately 12 by 10 by 10 cm. Its anterior surface is smooth, but posteriorly it is covered with a few adhesions. The under cut surface is 3 cm. in diameter. The uterine cavity is 6 cm. in length and 4 cm. in breadth at the fundus. The mucosa is smooth, pale and glistening, but is gathered up into folds, ridges, or polypoid-like masses, in places 8 or 9 mm. thick. Situated in the posterior wall, near the junction of the cervix and the tube, is an interstitial myoma 5 cm. in diameter. Other smaller nodules are found in the fundus, just beneath the peritoneum. Both the anterior and posterior walls as well as the fundus are thickened to an average of 5 cm. (Fig. 34). This hypertrophy is most marked near the mucosa. Covering the outer surface of the uterus is a mantle of normal muscle, 1 cm. thick. The thick-

ened portion on section shows an unusually coarse arrangement, the fibres forming an irregular meshwork, with here and there a whorl-

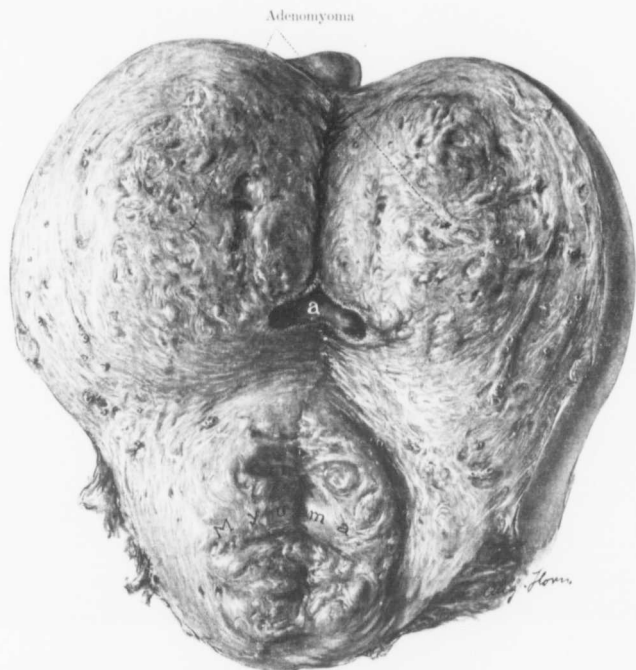


FIG. 34.—DISCRETE MYOMA OF THE CERVIX; DIFFUSE ADENOMYOMA OF THE BODY OF THE UTERUS.
(Natural size.)

Gyn.-Path. No. 4122. *a* represents a small portion of the uterine cavity. Situated at the cervix is a discrete myoma. The uterine walls are greatly thickened as a result of a diffuse myomatous change. Scattered throughout this coarse tissue were large and small yellowish, porous areas at once recognized as islands of uterine mucosa. On histological examination the uterine mucosa was seen literally pouring into the diffuse myomatous muscle. Covering the outer surface is a mantle of normal muscle of varying thickness.

like arrangement in the interstices. In this meshwork are creamy looking areas, evidently islands of mucosa. The line of junction between the mucosa and

the muscle is poorly defined and the muscle bundles apparently extend into the mucosa.

The right tube is converted into a pipe-like cyst. The stem itself is about 12 cm. long and varies in diameter from 5 mm. at the cornu to 14 cm. at the occluded fimbriated extremity. The tube is covered with a few adhesions. Its walls are extremely delicate and it contains dark, bluish-black fluid. The ovary is small and is covered with adhesions. Situated in the utero-ovarian ligament is a myoma, 2.5 cm. in diameter. On the left side the tube is 8 cm. long and is covered with adhesions. The ovary is small and is also involved in adhesions.

Histological Examination.—The uterine mucosa has an intact surface epithelium, as was noted macroscopically. It is much thicker than usual. The gland elements are perfectly normal. Extending everywhere into the depth are large rivers of mucosa; in fact, the mucous membrane in the diffuse myoma of the fundus is more abundant than that lining the uterine cavity. The glands in the depth show a certain amount of dilatation, and many of them contain necrotic material. The isolated myomatous nodule shows considerable hyaline transformation. In places this is quite sharply defined and many of the remaining bundles stand out in marked contrast, reminding one at first sight of a malignant change. The right tube is the seat of a hydrosalpinx into which there has been hemorrhage. The extensive invasion of the normal uterine mucosa into the myoma evidently accounts for the alarming hemorrhages that at times took place. We have here a myomatous uterus with discrete myomata and a widely diffuse myoma occupying the fundus. There is no question as to the origin of the glands.

Diagnosis.—Multinodular myomatous uterus; diffuse adenomyoma of the fundus with the mucosa literally running into the depth. General pelvic adhesions; right hæmatosalpinx.

Church Home and Infirmary No. 1019. Path. No. 9407.

Large interstitial and submucous uterine myomata showing hyaline degeneration, especially pronounced in the walls of the blood-vessels. Diffuse adenomyoma in the walls of the uterus, the glands coming from the mucosa.

W. B., married, aged thirty-nine, white. Admitted January 15, 1906; discharged February 12, 1906. Complaint: Persistent hemorrhage from the uterus. The menses commenced at eleven and were normal except that they were rather profuse. The date of the last period is uncertain. For the past four months the patient has bled continuously, and the bleeding has been especially profuse during the last month. She has had no pain. She had two miscarriages thirteen years ago, but has never borne children. On pelvic examination a mass is found extending half-way to the umbilicus, occupying the entire superior strait of the pelvis. It is rounded in outline and not especially tender.

Operation: Abdominal hysterectomy. The highest temperature was 100.8° F., twenty-four hours after the operation.

Path. No. 9407.—The specimen consists of the upper part of the uterus. It is globular and contains a myoma measuring 12 by 10 by 10 cm. The uterine cavity measures 7 cm. in length and 7 cm. in breadth. The mucosa, which is somewhat granular and hemorrhagic, is put on tension by a large submucous myoma. This on section shows some cystic areas and a moderate degree of degeneration.

Sections from the endometrium show that the mucosa, apart from some hemorrhage, is perfectly normal. In some places the mucous membrane can be seen extending into the depth for a considerable distance, and in the vicinity we have isolated glands or bunches of glands surrounded by stroma, and lying in the depth. The muscle shows a definite myomatous tendency. Sections from the myoma show a good deal of hyaline degeneration, particularly pronounced around the blood-vessels.

We have here a large interstitial and partly submucous myoma showing hyaline degeneration, and also a fairly well-defined diffuse adenomyoma of the body of the uterus with the glands originating in the mucosa.

Gyn. No. 11,252. Path. No. 7507.

Subperitoneal and interstitial uterine myomata; diffuse adenomyoma of the uterine walls; subperitoneal adenomyoma.

F. S., colored, aged forty-four. Admitted May 5, 1904; discharged June 2, 1904. Complaint: Pain in the left side. The patient had always had considerable dysmenorrhœa. She had been married twenty-one years, but had never been pregnant. She complained of a burning discomfort during the first two days of menstruation, and for some years had had continued pain in the left ovarian region. She was well nourished. Several small myomata were detected and the uterus was retroflexed and adherent. It was decided to remove the uterus, as the patient was near the menopause and as she had come such a long distance for treatment (Jamaica).

Operation: Hystero-myomectomy. The highest temperature was 100.5° F., on the second day. Convalescence normal.

Path. No. 7507.—The uterus has been amputated through the cervix and is 4 cm. in length. On the posterior surface is a pedunculated myoma, 1 cm. in diameter. Just above this is a slight elevation. On section the uterine walls are found to vary from 1.5 to 1.8 cm. in thickness. Scattered throughout the uterine tissue are a few minute myomata. In the anterior wall about its middle is an irregular mass, 1 cm. in diameter. This is not sharply circumscribed, but gradually blends with the surrounding uterine muscle.

On histological examination the uterine mucosa shows much thickening. The surface epithelium is intact. The stroma cells immediately beneath are swollen, somewhat resembling decidual cells, and the tissue shows a great deal of small round-cell and polyphosphonuclear infiltration. The glands in the depth show marked

hypertrophy and there is a peculiar tendency for them individually or in bunches to extend quite a distance into the underlying muscle, usually accompanied by their stroma.

The myoma in the anterior wall is diffuse in character and contains islands of uterine mucosa and also isolated glands, the majority of which are associated with the characteristic stroma of the mucosa. Some of the glands, however, lie in direct contact with the muscle.

We have here a uterus smaller than normal, one subperitoneal and several interstitial myomata, an endometrium which is thicker than usual and which shows definite invasion into the muscle. We also have a partially subperitoneal adenomyoma which is somewhat diffuse in character and blends with the surrounding muscle. We have not the slightest doubt that such a uterus in time would be the seat of a wide-spread diffuse adenomyoma.

H. A. K. Sanitarium No. 1453. Path. No. 6216.

Diffuse adenomyoma of the anterior and posterior uterine walls (Fig. 35). The gland elements are derived from the uterine mucosa.

H. C., married, white, aged forty-seven. Admitted October 20, 1902; discharged December 11, 1902. The patient has had four children. Her menses, which were regular, have lately become irregular and more frequent.

Operation: Pan-hysterectomy; repair of the perineum; removal of a urethral caruncle. The patient made a satisfactory recovery.

Path. No. 6216.—The uterus is 13 cm. in length, 10 cm. in breadth, and 9 cm. in its antero-posterior diameters. Its surface is smooth and glistening, except near the fundus. There are a few adhesions and the tubes and ovaries are bound down. The uterus is about the size of that of a three and a half months' pregnancy. The cervical canal, which is curved, is about 3 cm. in length. The increase in size of the uterus is due to a marked

diffuse thickening of the anterior wall, which reaches 7 cm. in thickness (Fig. 35). Scattered throughout the thickened and diffuse myo-

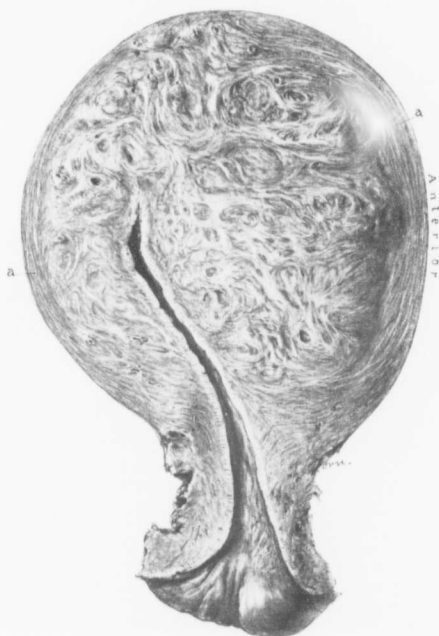

FIG. 35.—DIFFUSE ADENOMYOMA OF THE BODY OF THE UTERUS. ($\frac{1}{4}$ natural size.)

Gyn.-Path. No. 6216. A longitudinal section through the entire uterus. Surrounding the uterine cavity, which looks normal, is a broad zone of diffuse myomatous tissue, much thicker in the anterior than in the posterior wall. Covering this is a mantle of normal muscle, *a*, but at the fundus the coarse myomatous tissue almost reaches the peritoneum. Sections show that the uterine mucosa extends into the depth and that many islands of mucous membrane are scattered throughout the myomatous tissue.

matous tissue are a few cystic spaces lined with a delicate velvety membrane. The posterior uterine wall varies from 2.2 to 2.5 cm. in thickness. Its texture is

also coarse, but the striation is not as marked as in the anterior wall. Covering the diffuse growth in both the anterior and posterior wall is a mantle of normal uterine muscle. The uterine cavity is small, about 4.5 cm. in length.

On histological examination the uterine mucosa is found to be slightly thickened, but otherwise normal. The diffuse thickening in the anterior wall is due to a diffuse myomatous transformation of the muscle. Scattered abundantly through the myomatous muscle are large and small islands of uterine mucosa. Some of these are fully 8 mm. in length. Here and there the glands are dilated; otherwise this mucosa differs in no way from that lining the uterine cavity, and at many points the uterine mucosa can be traced directly into the myoma. In the posterior wall there is also a diffuse adenomyoma. Here likewise the continuity with the surface mucosa can be traced.

In this case there is a diffuse mantle of myomatous tissue surrounding the entire uterine cavity, markedly developed in the posterior wall; and penetrating this mantle are large areas of uterine mucosa.

Diagnosis.—Diffuse adenomyoma of the anterior and posterior uterine walls. The gland elements are derived from the uterine mucosa.

Gyn. No. 12,358. Path. No. 8983.

Subperitoneal, interstitial and submucous uterine myomata; slight endometritis; diffuse adenomyoma with the uterine glands extending into the depth; adenomyomatous areas in the left uterine horn.

S. S., aged thirty-one, black, married. Admitted September 11, 1905; discharged October 2, 1905. Complaint: A painful lump in the left side of the abdomen and uterine hemorrhages. The menses commenced at thirteen, were always regular but painful, and are now profuse. The flow lasts three days. There is some pain for twelve hours previous to the flow. She has been married twice.

She had one pregnancy six or seven years ago, normal until the sixth month, when a premature labor came on as the result of a fall. The child was born dead. Nine months ago patient noticed a lump in the left side, which has been almost constantly painful. She knows nothing about the growth of the tumor. She says that the tumor pushes upward and causes discomfort, which she can relieve by pressing down upon it with her hand. There have been no changes in the menstrual flow until two months ago, when there was increased pain and the flow was excessive, but without clots. One month ago the period did not appear at the expected time, but there was an excessive flow of a clear watery fluid. There has been much tenderness since she first noticed the tumor. No nausea or vomiting.

Operation: Hystero-myomectomy; double salpingectomy, left oöphorectomy. The highest post-operative temperature was 101.4° F. Convalescence was uninterrupted.

Path. No. 8983.—The specimen consists of an irregularly globular uterus, 12 cm. from side to side, 12 cm. in length, and 14 cm. in its antero-posterior diameter. Posteriorly it is covered by tags of adhesions, none of which are very dense. In the anterior wall is a myoma 7 cm. in diameter. In the posterior wall is a myoma measuring 8 by 9 cm. Attached to the right side just behind the tube is a nodule 7 cm. in diameter. This is attached by a pedicle, 2 cm. in breadth, 5 mm. in thickness. This myoma on section presents a dark appearance in places and has undergone slight necrosis.

The left tube is normal. The ovary is covered with a few adhesions. The right tube is normal.

Sections from the endometrium show that it has been poorly hardened. The glands show a moderate degree of hypertrophy. Here and there they extend for a short distance into the muscle. There is some small round-cell infiltration. Sections from the fundus, which are better preserved, show considerable small round-cell infiltration in the superficial layers, and in the depth far down are here and there glands some of which show the characteristic

pseudo-glomeruli described by von Recklinghausen, the spaces being lined with cuboidal epithelium and a projection of stroma into the cavity being noted. This projection also is covered with epithelium, and in the spaces between this and the so-called capsule is desquamated epithelium. Near the outer surface the gland-like spaces are much more abundant. They are everywhere surrounded by muscle, and some of the larger spaces reach 2 mm. in diameter. They are lined with one layer of cuboidal epithelium which rests directly on the muscle.

On further section of the uterine mucosa we find a tendency for the glands to extend into the depth in the form of a wedge. Sections taken from near the left cornu show that the tube presents some slight degree of small round-cell infiltration just beneath the epithelium. Surrounding this in many places are glands lined with one layer of epithelium resting directly on the muscle, or separated from it by a small amount of stroma. Some of the gland-like spaces are dilated, their epithelium is flattened, and they are filled partly with blood, partly with serum.

Diagnosis.—Subperitoneal, interstitial, and submucous myomata; slight endometritis; diffuse adenomyoma of the uterine wall with invasion of the mucosa into the depth; adenomyomatous areas in the left uterine horn; slight adhesions of the ovaries.

Emergency Hospital, Frederick, Md. Path. No. 8393.

Diffuse adenomyoma of the anterior and posterior uterine walls; large cystic spaces in the uterine horn due to dilatation of portions of the adenomyomatous elements (Fig. 36). The gland elements in the diffuse growth are clearly shown to be derivatives of the uterine mucosa.

V. W., aged fifty-three. Operated upon February 3, 1905. The patient has been suffering for some time from a myomatous uterus and has had frequent uterine bleeding. On opening the abdomen we found a myomatous uterus about the size of that of a

four months' pregnancy. Numerous nodules were present. The cervix was adherent. Posteriorly and on the right side was a hydrosalpinx. The tumor was removed with little difficulty and the patient made a satisfactory recovery.

Path. No. 8393.—The specimen consists of a large globular uterus and of the appendages on both sides. The uterus has been amputated through the cervix. It is 12 cm. in length, 15 cm. from side to side, and 10 cm. in its antero-posterior diameters. Covering its surface posteriorly are a few delicate adhesions. On

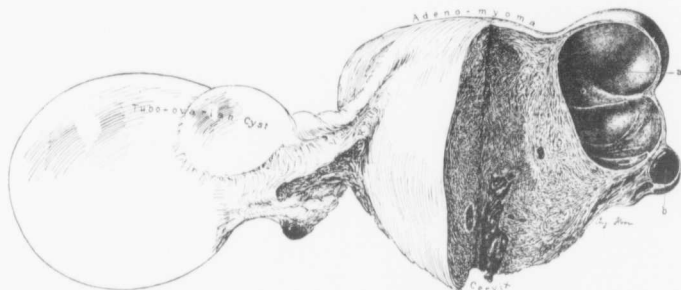


FIG. 36.—DIFFUSE ADENOMYOMA OF THE FUNDUS WITH CYSTIC SPACES IN THE LEFT UTERINE HORN. ($\frac{1}{3}$ natural size.)

Gyn.-Path. No. 8393. The entire fundus is converted into a diffuse myomatous tissue and with the low power the uterine mucosa can be seen penetrating the myoma in all directions. The cystic space *a*, in the left uterine horn is due to gland dilatation, it being lined with cylindrical ciliated epithelium. The space *b* is filled with blood. On the right side is a tubo-ovarian cyst. The inner pole of the right ovary is normal.

examination it is found that the thickening in the uterus is due to a diffuse myomatous arrangement around the uterine cavity (Fig. 36). The thickening in both the anterior and the posterior wall reaches 5 cm. There is likewise a tendency toward a circumscribed diffuse area 2.5 cm. in diameter. The uterine mucosa is apparently considerably thickened. The general picture instantly reminds one of a diffuse adenomyoma occupying both the anterior and the posterior wall and encircling the fundus.

In the left uterine cornu is an irregular cystic space, 6 by 4 cm. This is partially divided by septa and has delicate trabeculae passing from side to side. The cyst walls in the outer portion vary from 1 to 3 mm. in thickness. The right tube has been converted into a hydrosalpinx, which at its outer end is 9 cm. in diameter. The right ovary is apparently normal. The left tube is enveloped in delicate adhesions. Its fimbriated end is patent. The ovary is very small and apparently contains a corpus luteum cyst 1 cm. in diameter.

In the lower portion of the uterus is a myomatous whorl 2 cm. in diameter, and near the centre of this is a cystic area 8 mm. in diameter filled with yellowish contents.

Sections from the body of the uterus show that the uterine mucosa has not been well preserved owing to faulty hardening. It can at several points be traced directly into the depth for a considerable distance. Scattered abundantly throughout the diffuse myomatous growth, in the anterior as well as in the posterior wall, are islands of uterine mucosa, sometimes also an individual gland surrounded by stroma, and then again an area of mucosa containing imperfectly preserved glands. The same picture is noted no matter where the section comes from. Where the diffuse myomatous growth ends the glands also end.

Sections from the cyst in the left cornu show that it is lined with one layer of ciliated epithelium. The myomatous nodule with the cystic centre, containing yellowish material, presents a very interesting picture. The nodule consists of typical myomatous tissue. The cystic space is filled with coagulated contents, fragments of nuclei, and a few polymorphonuclear leucocytes, and the walls of this cavity, partly organized, contain numerous small round cells. This has evidently been a portion of a miniature uterine cavity from which the epithelium has disappeared and a partially organized blood-clot has taken its place.

Diagnosis.—Diffuse adenomyoma of the anterior and posterior uterine walls; large cystic spaces in the left uterine horn, evidently due to dilatation of portions of the adenomyomatous

elements. The gland elements in the diffuse growth are clearly shown to be derivatives of the uterine mucosa.

H. A. K. Sanitarium No. 1913. Path. No. 8641.

Subperitoneal and interstitial uterine myomata; commencing diffuse adenomyoma of the uterine walls; normal appendages.

McC., white, aged fifty-two, married. Admitted April 27, 1905; discharged June 9, 1905. In 1885 the patient had pulmonary tuberculosis, a left pyelonephritis, and an infected bladder.

Present condition: The periods are regular but profuse. The patient has had a tumor which has been increasing in size for some time.

Operation: Hystero-myomectomy and appendectomy. The patient was of a very nervous temperament, but made a satisfactory recovery.

Path. No. 8641.—The specimen consists of a myomatous uterus which would be practically normal in shape were it not for a subperitoneal nodule projecting far out from the left side. The uterus with the nodule is 9 cm. in length, 8 cm. in breadth, and 11 cm. in its antero-posterior diameter. It is smooth and glistening. Projecting from the posterior surface just behind the insertion of the left tube is a myomatous nodule approximately 7 cm. in diameter. The uterus on section is found to be riddled with myomata. In the upper part the nodule is 3 cm. in diameter. The uterine cavity is 5 cm. in length and the mucosa 2 mm. in thickness.

The appendages on both sides are normal.

Sections from the mucosa show that the surface epithelium is intact. The glands are normal. There is a tendency for the glands to dip down into the depth, and here and there it is possible to trace them for a considerable distance. Undoubtedly we have here a commencing adenomyoma.

Diagnosis.—Subperitoneal and interstitial uterine myomata; commencing diffuse adenomyoma.

H. A. K. Sanitarium No. 1944. Path. No. 8807.

Multiple uterine myomata, subperitoneal, interstitial, and submucous; diffuse adenomyomatous thickening in the anterior and posterior uterine walls with direct extension of the uterine mucosa into the depth, together with the formation of a miniature uterine cavity.

A. C., married, aged forty-eight. Admitted May 17, 1905. Discharged June 21, 1905. The patient has been married twenty-two years, has had three children and one miscarriage three years ago. The menses are normal. There has been some watery leucorrhœal discharge. The patient is very frail and has lost somewhat in weight. Her hæmoglobin is 40 per cent. She has had chronic constipation. Her family and previous history are not important. For about a year she has noticed that her abdomen has been growing rapidly and she has had constant backache. She suffers from frequent vesical irritation and obstinate constipation.

Operation, May 18. Hystero-salpingo-oöphorectomy. After the operation this patient had a slight infection about the cervix which caused some elevation in temperature—100.4° F. on one occasion. The temperature gradually subsided.

Path. No. 8807.—The specimen consists of a nodular myomatous uterus with appendages. The uterus is approximately 12 cm. in length, 12 cm. in breadth, and 8 cm. in its antero-posterior diameters. It is for the most part smooth and glistening. Projecting from the surface are pedunculated and sessile myomata, and scattered throughout the walls are a few other nodules. Projecting from the right side and extending out into the broad ligament is an irregular, nodular, myomatous growth, which measures 15 by 18 by 14 cm. This is partly covered by peritoneum, but beneath the smooth surface is a good deal of adipose tissue, evidently from the broad ligament, and coursing over the anterior surface is the right round ligament, which can be traced for a distance of 12 cm. Very little of the uterine cavity is to be seen except in the upper portion.

The uterine mucosa varies from 2 to 3 mm. in thickness. Three mm. beneath the mucosa is a miniature uterine cavity, 4 mm. in diameter, filled with coagulated chocolate-colored fluid, and lined with a mucosa 1 mm. in thickness. Just beneath the peritoneal surface of the uterus are a few cyst-like spaces, the largest 2 mm. in diameter. The tubes and ovaries look normal.

Sections from the fundus show a most instructive picture. The surface epithelium is intact. The glands are to a great extent normal, but some are much dilated, others skein-like. The mucosa is flowing down everywhere into the underlying tissue. In some places it can be traced by direct continuity for 6 or 7 mm. The mucosa that flows into the depth is perfectly normal except for here and there some gland dilatation. On the opposite side of the cavity we are able to trace the mucous membrane for 1 cm. into the underlying myomatous muscle. Here and there a small band of mucosa will pass down and then branch out in all directions. The brownish area apparently surrounded by a definite mucosa and noted macroscopically is a miniature uterine cavity. This cavity is filled with blood and is lined with one layer of high cylindrical epithelium. Opening into it are numerous glands surrounded by the characteristic stroma of the mucosa.

Diagnosis.—Multiple uterine myomata, subperitoneal, interstitial, and submucous; diffuse adenomyoma of both the anterior and posterior walls, the gland elements being distinctly derivatives of the uterine mucosa.

The presence of adenomyoma was immediately suspected as soon as the chocolate-colored area surrounded by a definite lining of mucosa was detected. As a rule, no other condition in the uterus would give rise to such a picture.

CHAPTER V

SUBPERITONEAL AND INTRALIGAMENTARY ADENOMYOMATA

Subperitoneal and intraligamentary adenomyomata are considered together, inasmuch as the process is similar in both instances, namely, the extension to the outer surface of the uterus. If situated above the middle of the uterus, the adenomyomata tend to become subperitoneal; below this point and lateral to the uterus they are likely to spread out between the folds of the broad ligament.

SUBPERITONEAL ADENOMYOMATA

Subperitoneal adenomyomata may be very small and completely isolated, as seen in Fig. 61, p. 219,¹ in which an adenomyoma less than 1 cm. in diameter was found in a patient operated upon for adenocarcinoma of the body of the uterus. The two processes were entirely independent of each other. This small nodule, to the unaided eye, differed in no way from an ordinary myomatous nodule.

Subperitoneal adenomyomata may, on the other hand, be of goodly size. Fig. 37 represents a subperitoneal nodule measuring 13 by 10 by 8 cm. and attached by a broad base. As seen from the drawing, it was partly cystic, partly solid. The distal or free portion had been converted into a thin-walled and irregular cyst partially filled with blood. The solid portion consisted of myomatous tissue traversed by several small cysts, some not more than 1 mm. in diameter, others are more than 1 cm. On histological examination the large cyst was found to be in the vicinity of the solid area, lined with one layer of cylindrical epithelium; but where the walls were very tense and thin, the epithelium had become very low or had entirely disappeared. In Fig. 38, a low magnification, it is seen that the cystic spaces scattered throughout the solid portion are

¹Cullen, Thomas S.: *Cancer of the Uterus*, 1900, p. 460.

dilated glands lined with one layer of cylindrical epithelium. Some of these are separated from the muscle by the typical stroma.

In neither of the foregoing cases was there any evidence of adenomyomata in the body of the uterus.

In Case 3293 we have another example of a cystic subperitoneal adenomyoma. As noted in the history, the uterus was greatly increased in size, chiefly owing to the presence of a large submucous myoma and a huge subperitoneal and pedunculated myoma springing from the left side. Projecting from the right side of the fundus was a nodule measuring 6 by 5.5 by 5 cm. This was soft and boggy, and over an area fully 5 cm. in diameter was made up of thin-walled cysts (Fig. 39). On histological examination the cyst walls were found to consist of myomatous tissue and the cavities were lined with one layer of cylindrical, ciliated epithelium (Fig. 40). The cells closely resembled those of the normal uterine mucosa. In some places the walls of the cavity were gathered up into little papillary-like folds. In other places, irregular gland-like cavities were found scattered throughout the walls. These closely resembled the gland hypertrophy so often seen in the uterine mucosa. In a few places the walls of the cysts showed evidence of old hemorrhages, their cells having taken up large quantities of fine yellow granular pigment. Here also we have a subperitoneal adenomyoma with elements closely resembling uterine mucosa.

San. No. 1872 is the most striking example of a subperitoneal myoma that we have ever seen. Fig. 41, p. 142, gives the relative contour of the uterus. It was the seat of a diffuse adenomyoma. At *a* is a subperitoneal and pedunculated myoma which is partly cystic. On section of this subperitoneal nodule we found large islands of mucosa, and the cystic areas formed miniature uterine cavities filled with chocolate-colored contents. The islands of mucosa and also the cystic spaces are depicted in Fig. 42, p. 144.

Of interest is the case of Neumann.¹ In a woman forty-four

¹Neumann, Siegfried: Ueber einen neuen Fall von Adenomyom des Uterus und der Tuben mit gleichzeitiger Anwesenheit von Urnierenkeimen im Eierstock. Arch. f. Gynaek., 1899, Bd. lviii, S. 593.

years of age he found an interstitial myoma, the size of a fist, and on the anterior surface of the uterus in the vicinity of the cervix a subserous myoma, the size of a walnut. Lying in close proximity to this was a cyst as large as a hen's egg. This had a broad base. The walls of the cyst were composed of uterine muscle, near the base having a thickness of 3 mm., but becoming thinner until at the convex and free surface they were not thicker than parchment. The inner surface of the cyst was smooth and the cavity contained a coagulated, friable, grayish mass. In the vicinity of these cysts were two others, the size of hazelnuts and with very thin walls. Situated in the tissue, at the base of these two, was still another cyst about as large as a bean. This was subdivided into several smaller cavities. The large cyst had a wall composed of muscular tissue and was lined with a single layer of cylindrical ciliated epithelium. This rested on a connective-tissue stroma, which separated it from the muscle. Scattered throughout the myomatous muscle were glands bearing a marked resemblance to uterine glands and surrounded by stroma similar to that of the uterine mucosa. Neumann says that this was undoubtedly a large adenomyoma of the uterus, cystic in character. There was also an adenomyomatous polyp in the uterine cavity and another adenomyoma in one of the uterine horns. He was unable to trace any connection between the uterine mucosa and the adenomyomata.

Among the most remarkable subperitoneal adenomyomata of the uterus ever reported was the "voluminous" tumor of Pick,¹ which occurred in a woman forty-one years old, sprang from the posterior surface of the uterus, and was adherent to the anterior abdominal wall and to the intestinal loops. Landau experienced much difficulty in its removal. The tumor, as shown in the illustration which Professor Pick kindly sent me, presented a very coarse shaggy appearance. It consisted of many large, blunt, papillary masses, and in the vicinity of the median line the mass contained a glistening, slimy, cystic tumor, about the size of a man's head. It

¹Pick, Ludwig: Ein neuer Typus des voluminösen paroophoriden Adenomyoms. Arch. f. Gynaek., Bd. liv, S. 117.

was everywhere adherent. The cyst cavity contained clear mucocolloid material. On the surface of the growth were many isolated nodules consisting of myomatous tissue and containing large and small spaces. Pick found that the solid portions of the tumor consisted of a fibromyomatous substance surrounding well-formed glandular tissue. This glandular tissue consisted of cylindrical glands lined with a single layer of cylindrical epithelium. Sometimes the glands occurred in groups and were surrounded by a definite stroma; others showed cystic dilatation. From the description it is seen that this tumor was a subperitoneal and adherent adenomyoma.

CASES OF SUBPERITONEAL ADENOMYOMA

Gyn. No. 8647. Path. No. 4838.

Diffuse adenomyomatous thickening of the uterine walls; interstitial and subperitoneal myomata; slight edema of the uterine mucosa with extension of the glands into the depth. Subperitoneal, cystic adenomyoma. (Figs. 37 and 38.)

F. M. R., single, aged forty, white. Admitted April 8, discharged May 2, 1901. The patient was operated upon for hemorrhoids two years ago. Her menses began at twelve and were regular, lasting three days. For several years at the menstrual period the patient has complained of headache and nausea. There has been no marked disturbance of menstruation at any time, but occasionally the period has been delayed a few days. The last period occurred one week ago.

The patient does not know when she first noticed a lump in the right side of the abdomen. In the beginning it was about the size of an egg, but for the last year has been increasing. There has been no pain or discomfort associated with it. The general condition has been good.

In the right lower abdomen is a definite prominence. This is firm on palpation, distinctly movable, and reaches to a point 2 cm.

below the umbilicus. It is smooth and oblong in shape. The inguinal glands are palpable, but not tender.

Operation April 10th.—A large multinodular myomatous uterus was exposed. The uterus was bisected and removed. The tubes were likewise removed, but the ovaries were left *in situ*. The patient was discharged in excellent condition on the twenty-third day.

Gyn.-Path. No. 4838.—The specimen consists of a bisected, multinodular uterus and of both tubes. One nodule, which projected from the right cornu and was attached by a pedicle, 4 cm. in diameter, measures 13 by 10 by 8 cm. Its inner half is firm and dense; its outer portion is soft and cystic, but everywhere covered with smooth peritoneum (Fig. 37). On section the solid portion of this nodule is seen to be made up of typical myomatous tissue, but at two points are seen irregular cystic areas 1 and 2 cm. in diameter respectively. The smaller of these has a smooth inner surface and apparently a definite lining. The large cystic portion of the subperitoneal myoma contains a single cavity, approximately 7 cm. in diameter. The walls of this vary from 1 mm. to 1 cm. in thickness; the cavity contains a thick, viscid, chocolate-colored substance. The uterus is very irregular in form and has projecting from its surface numerous small myomatous nodules. It measures 8 by 8 by 5 cm. The tubes are apparently normal, but attached to the fimbriated extremity of one of them is a subperitoneal cyst measuring 1.5 by 1 cm.

Histological Examination.—Sections from the uterine cavity show that, where the mucosa has been protected, there is an intact surface epithelium, slightly flattened but perfectly normal. The uterine glands are normal in number. Near the cavity they are narrow, but in the vicinity of the muscle are much convoluted. The gland epithelium is normal. The stroma of the mucosa just beneath the surface epithelium shows considerable edema. At one point in the uterine cavity the mucosa is seen penetrating the muscle to a depth of 1.5 mm. Here the glands are dilated and surrounded by diffuse

myomatous tissue. The uterine walls show partial myomatous transformation of their muscle bundles, and scattered throughout the walls are numerous small myomata. Some of these are not more than 1 mm. in diameter.

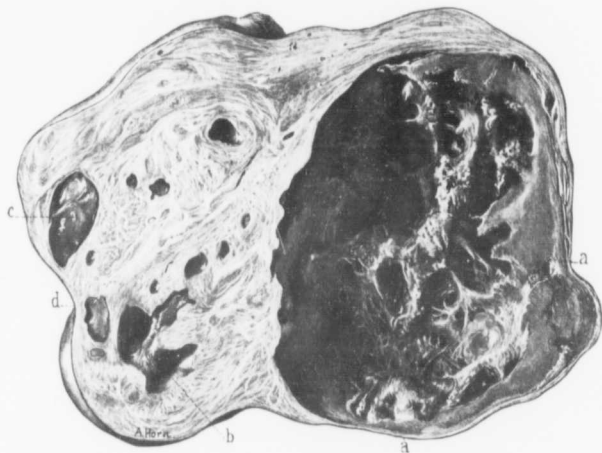


FIG. 37.—A CYSTIC SUBPERITONEAL ADENOMYOMA OF THE UTERUS. (Natural size.)

G. Y. H. - P. H. T. No. 4838. The drawing represents one-half of the tumor, which was attached to the enlarged fundus by the very short broad-based pedicle situated in the vicinity of *d*. The tumor is roughly divided into a semi-solid and a cystic portion. The cyst is irregular in outline and, as seen in Fig. 38, at *a* it connects with little bays extending off into the solid portion. In some places the cyst wall is very thin, as at *a*. The ragged appearance in the interior of the cyst and the smooth homogeneous substance just within the cyst wall are due to coagulated cyst contents. The inner surface of the cyst is in reality smooth and velvety. The solid portion of the tumor is composed of a diffuse myoma. Scattered throughout it are large and small cyst-like spaces. *b* is such a cavity. It is, however, irregular in form and branches out considerably. It has a smooth inner lining. In the space *c* the coagulated contents still remain. There are also numerous smaller spaces scattered throughout the myomatous tissue. These spaces, on careful study, do not convey the idea of cysts, but it seems as though the muscle were being tunnelled in various directions by spaces of variable size. For the very low magnification see Fig. 38.

Sections from the large subperitoneal myoma show a very interesting picture. This nodule consists essentially of myomatous tissue, but here and there bundles of normal muscle still remain (Fig. 38). The small cyst-like spaces noted in the solid portion of the tumor have an inner lining of a single layer of cylindrical and

apparently ciliated epithelium. This is in most places separated from the surrounding myomatous tissue by a stroma somewhat resembling that of the uterine mucosa; and scattered throughout the stroma are occasional small glands identical with those of the uterine mucosa. At some points in these cysts the epithelial lining

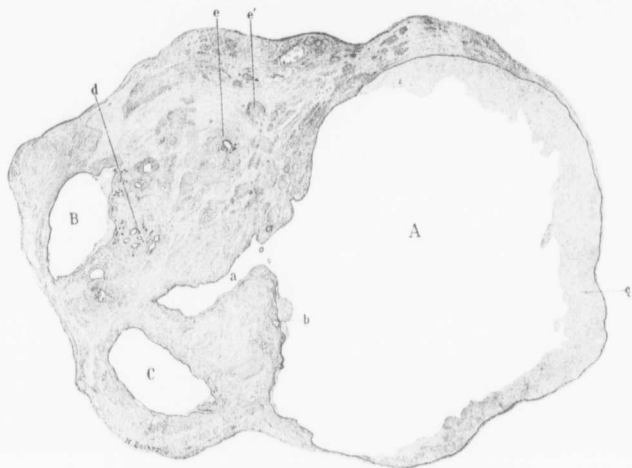


FIG. 38.—A CYSTIC SUBPERITONEAL ADENOMYOMA OF THE UTERUS. (14 natural size.)

Gyn. - Path. No. 4838. The section is through the same tumor as Fig. 37, but at another level. *A* is the same large cyst cavity. It has a small bay (*a*) extending off to the left. It is lined with a single layer of epithelium, which from the text is seen to be cylindrical. Just beneath the epithelial lining at *b* is a small gland; *c* represents the coagulated cyst contents. *B* and *C* are irregular cyst-like spaces lined with one layer of epithelium. In the neighborhood of *d* are numerous small glands, also lined with cylindrical epithelium. Some of the glands, notably at *e*, are surrounded by a definite circular zone of myomatous muscle. The deeply staining areas, as seen at *e'*, are the myomatous muscle bundles. The intervening pale framework is a somewhat rarefied connective tissue. We should not be much surprised if at one time all the large cyst cavities communicated with one another.

has disappeared and the underlying tissue shows distinct evidences of old hemorrhage. These cyst-like spaces contain a variable quantity of blood. Scattered throughout the solid portion of this subperitoneal nodule are numerous smaller cysts varying from 1 to 3 mm. in diameter. These are lined with one layer of cylindrical epithe-

lium and are separated from the muscle by a definite stroma. They contain a good deal of blood. One of these cysts may be roughly likened to a cross-section of a miniature uterine cavity, as it is partially surrounded by glands similar to those of the uterine mucosa. Scattered here and there throughout the myoma are similar glands, the majority lying in direct contact with the uterine muscle and not being surrounded by stroma. It is particularly interesting to note that the myomatous tissue is most dense immediately around the cyst-like spaces. The large cystic portion of the subperitoneal myoma consists essentially of one cavity. Near the solid portion, where there has not been much opportunity for stretching, this cyst is lined with one layer of fairly well preserved cylindrical and apparently ciliated epithelium. Sometimes this epithelium rests directly on the muscle, but in many places is separated from it by stroma similar to that of the mucosa; in this stroma the blood-vessels are often greatly dilated. As we gradually approach the more prominent portion of the cyst, where the walls are very thin, the epithelial lining becomes thinner and thinner and entirely disappears. Clinging to the inner surface here is fibrin, holding in its meshes a variable quantity of blood. As is clearly evident from the description, this is a subperitoneal adenomyoma which has become cystic. Although we have cut many sections, it has been impossible to trace a direct connection between the uterine mucosa and the glands of the subperitoneal adenomyoma. Nevertheless, we have seen that the uterus shows a diffuse myomatous transformation and that the uterine glands, at one point at least, are commencing to extend into the depth.

Diagnosis.—Diffuse myomatous thickening of the uterine walls; interstitial and subperitoneal myomata; slight edema of the uterine mucosa with commencing extension of the glands into the depth; subperitoneal cystic adenomyoma.

Gyn. No. 3293. Path. No. 583.

Subperitoneal, interstitial, and submucous myomata. Multiple cysts in a sub-

peritoneal myoma (Figs. 39 and 40). Atrophy and edema of the uterine mucosa. Double perisalpingitis and perioöphoritis. Hysterectomy. Recovery.

P. S., single, aged forty, colored. Admitted January 23, 1895; discharged February 24, 1895. One child, twenty years ago; no miscarriages. The menses appeared at fifteen; they were regular but painful. Since the onset of the present trouble they have been much more profuse, lasting three days and accompanied by intense pain. The patient has had a thin bloody, offensive, leucorrhœal discharge, containing shreds for two weeks after each menstrual period, then giving place to a white, offensive discharge lasting until the next period.

Ten years ago she noticed a small lump in the abdomen, more prominent during menstruation. The tumor has grown steadily and now practically fills up the abdomen; there has been some dull pain over the region of the mass (following an accidental blow thereon), the pain being more severe at menstrual periods.

Examination.—The abdomen is much distended by a hard, sensitive, irregular mass. The cervix is pushed against the symphysis; the whole vaginal vault is filled with a hard immovable mass.

Operation. January 30, 1895. Panhystero-myomeectomy. General peritoneal adhesions, three large subserous myomata; submucous myoma; involvement of posterior lip of cervix necessitating panhysterectomy. Recovery.

Gyn.-Path. No. 583.—The specimen consists of a large irregularly shaped uterus, with tumors springing from both sides. The portion of the uterus present is approximately 14 cm. long, 14 cm. broad, and 15 cm. in its antero-posterior diameter. The anterior surface is roughened and anteriorly and posteriorly it is covered with many dense adhesions. Springing from the anterior and posterior surfaces are somewhat flattened nodules, varying from 1 to 4 cm. in diameter. The under cut surface of the uterus is 9 cm. in diameter and the cervical canal, which is completely

blocked by a reddish injected mass, is 5.5 cm. from side to side. The uterine walls average 3 cm. in thickness. Their muscle fibres are

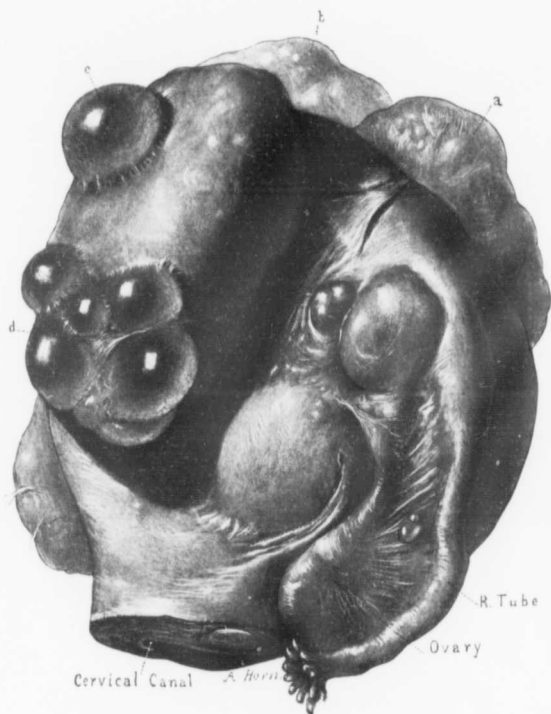


FIG. 39.—A SUPERPERITONEAL CYSTIC ADENOMYOMA OCCURRING IN THE CASE OF A LARGE MYOMATOUS UTERUS. (½ natural size.)

Gyn.-Path, No. 583. The uterus is much enlarged, owing to the presence of myomatous tumors. Projecting through the cervix is a small portion of a submucous myoma and situated anteriorly and to the left are the large myomata *a* and *b*, only dimly outlined. The right tube, although lengthened, is little altered. It is attached to the ovary by a few bands. Scattered over the posterior surface of the uterus are several sessile nodules and one of moderate size with several cysts springing from its surface. *c* is a single cyst and at *d* a group of seven are seen. All are thin-walled and semi-transparent. As learned from the text, they are not subperitoneal cysts, their walls being composed of myomatous tissue, and furthermore they are lined with a single layer of cylindrical epithelium. For the histological picture see Fig. 40, which is taken from the area *d*.

much coarser than usual, and scattered here and there throughout the walls are whitish nodules varying from .5 to 2.5 cm. in diameter. The portion of the uterine cavity present is 12 cm. in length, and springing into it are several nodules, the largest reaching 2.5 cm. in diameter. The uterine mucosa is pinkish-white in color and averages 1.5 mm. in thickness. Over the large nodule it is somewhat atrophic. Projecting into the cavity from the left side is an irregular, globular, pear-shaped mass measuring 16 by 10 by 10 cm. It is the lower portion of this that projects through the cervix. This nodule presents depressions corresponding to the small submucous nodules. It is covered with mucosa which is apparently very edematous. The mucosa averages 1 mm. in thickness, but where edematous is fully 4 or 5 mm. thick. Springing from the right side of the uterus is a nodule, 6 by 5.5 by 5 cm. This is covered with adhesions, and has springing from it numerous subperitoneal cysts forming a mass fully 5 cm. in size. The tumor is soft and boggy. Projecting from the left side of the body of the uterus are two kidney-shaped masses. The larger measures 22 by 13 by 11 cm., is pinkish in color, slightly lobulated, and is covered with numerous adhesions binding it to the uterus and the adjoining tumor. The adhesions are very vascular. The smaller tumor measures 12 by 7 by 8 cm. and closely resembles its neighbor. The uterine tumors on section are pinkish-white in color and for the most part consist of fibres, having a concentric arrangement. The large tumor to the right of the uterus contains areas, fully 2.5 cm. in diameter, consisting of a fine network of fibres traversing a cavity filled with clear transparent fluid. Numerous smaller but similar areas are scattered throughout the tumor. They are undoubtedly areas of degeneration. The small kidney-shaped nodule springing from the fundus presents numerous small, yellowish-white, granular areas—foci of calcification. The small and soft nodule to the right of the uterus shows some degeneration. This nodule on section is found to be partially cystic over an area 5.5 cm. (Fig. 39). These cysts in the hardened specimen vary from the size of a pea to 3.5 cm. in diameter; they have exceedingly thin walls, smooth inner surfaces, and at once suggest a multilocular ovarian

cyst. There are numerous similar areas scattered throughout the tumor. There is absolutely no connection between the ovary and this tumor, as the latter is situated 8 cm. from the ovary.

The tubes and ovaries are enveloped in dense adhesions.

Histological Examination.—The uterine mucosa is much atrophied, but near the fundus, where it is somewhat protected, it reaches 3 mm. in thickness. The surface presents an intact epithelium. The glands are in places abundant, in other parts



FIG. 40.—CYSTIC SUPERPERITONEAL ADENOMYOMA OF THE UTERUS. (6 diameters.)

Gyn., -Path., No. 583. The section is from point *d*, Fig. 39. *a* is the solid myomatous portion of the tumor; *b* is the thin myometrium forming the outer walls of the cysts *c* and *d*. The outer peritoneal covering is represented by *b'*. The cyst spaces, *c* and *d*, have convoluted inner surfaces and at many points (*e*) there are gland-like depressions. The cysts and also the depressions are lined with a single layer of cylindrical ciliated epithelium. Situated in the myometrium tissue at *f* and *f'* are two gland-like spaces which bear a most striking resemblance to hypertrophic uterine glands. *g* is the edge of a neighboring cyst.

scanty. Some are small and round on cross-section, others are slightly dilated, but all have an intact epithelium. The stroma of the mucosa is of a moderate density and is composed of cells having oval or elongate-oval nuclei. Over the small submucous nodule at the fundus the mucosa has almost entirely disappeared. The surface is here covered with epithelium which in some places is cylindrical, in other places almost flat, while at some points it is two or three layers in thickness, is swollen, and resembles squamous epithelium. Beneath the surface epithelium are a few stroma cells and beneath

these are numerous small round cells. The glands at this point have entirely disappeared. The mucosa over the large submucous nodule in the most prominent portions is represented by one layer of epithelium, which is poorly defined, being almost flat. Beneath this is a small amount of stroma, but all of the glands have disappeared. Where the mucosa looked edematous the epithelium covering the surface is intact, but rests directly on the muscle, there being no intervening stroma. The muscle has undergone partial or complete hyaline degeneration and has in many places practically disappeared, leaving a colorless tissue, scattered throughout which are a few small round cells, red blood-corpuscles, and polymorphonuclear leucocytes. The portions that have not yet broken down show numerous cells which have taken up golden-yellow pigment. Taken as a whole, the mucosa, where present, is normal, but where subjected to pressure has undergone partial or almost complete atrophy. In some places it shows considerable edema.

The nodules scattered throughout the uterus or situated on its outer surface are composed of non-stripped muscle fibres which have been cut in various directions. They all show a moderate amount of localized or diffuse hyaline degeneration.

The cystic portion of the nodule situated to the right of the uterus presents a very unusual picture. The cyst walls are composed of tissue that cannot be distinguished from the muscle fibres of the part and the cyst cavities are lined with a single layer of cylindrical epithelium (Fig. 40). The nuclei of the epithelial cells are oval or almost round and are situated near the centres of the cells. These cells are ciliated and closely resemble the epithelium covering the surface of the uterine mucosa. In some places the walls of the cavity are gathered up into little papillary-like folds; in other places irregular, convoluted, gland-like cavities are found scattered throughout the walls. These are very strongly suggestive of gland hypertrophy as seen in the uterine mucosa. In a few places the walls of these cysts show evidence of hemorrhage, their cells having taken up large quantities of fine yellow granular pigment. These glands and cysts occurring in the myoma are evidently due to embryonic

displacements. I am inclined to think that they have been derived from Müller's duct: (1) because the epithelium bears such a striking likeness to that of the uterine mucosa; and (2) because of the pigment in the cyst wall. If these cysts are derivatives of Müller's duct, we should naturally expect them to take part in the menstrual flow. The blood resulting cannot escape and must needs be taken up by the cyst walls. This will account for the pigment. The appendages are covered with numerous adhesions, but are otherwise normal.

D i a g n o s i s.—Subperitoneal, interstitial, and submucous myomata. Multiple cysts in a subperitoneal myoma, these cysts probably being due to remains of Müller's duct. Atrophy and edema of the uterine mucosa. Double perisalpingitis and peri-oöphoritis.

Gyn. No. 9024. Path. No. 5187.

Subperitoneal and partly interstitial adenomyoma removed by excision through the abdomen.

L. C., married, aged thirty-eight. Admitted August 30, 1901; discharged September 2, 1901. The patient entered complaining of constant uterine hemorrhage. Her periods have never been regular. Since she had typhoid when twenty years of age, the duration of the flow has been increased and the intervals have been gradually growing shorter. In July of this year (1901) she was admitted to the hospital, and previous to this had had constant bleeding for nine weeks, with considerable dysmenorrhœa. Shortly after admission to the hospital she was curetted. Three weeks after leaving the hospital she had another period, and bleeding has continued ever since, becoming more and more profuse and occasionally being clotted. The patient has pain in her back and lower abdomen.

O p e r a t i o n.—Abdominal myomectomy, hysterotomy, curettage and suspension of the uterus. Two small nodules were found in the posterior surface of the uterus. These were removed. The uterus was then split, the cavity exposed, and the mucous mem-

brane found to be apparently normal. The cervix was dilated from above. The uterus was then suspended in the usual way. The patient made a satisfactory recovery.

Path. No. 5187.—The specimen consists of a small amount of curettings and of a piece of tissue 1.8 cm. in diameter. The surface of this tissue presents a smooth peritoneal covering. Beneath this is a dense nodular myoma, 5 mm. in diameter. In the centre of this nodule is a cavity, 2 by 1 mm., lined with a very thin smooth membrane. Sections show the tumor to be a typical myomatous growth, and scattered throughout it are several cysts lined with a definite mucosa. The epithelium lining the cavity is of the cylindrical variety. The underlying stroma is similar to that of the uterine mucosa. The growth is a typical adenomyoma. Of course, it is impossible for us to trace any relationship with the uterine mucosa, as the uterus was not removed.

Gyn. No. 9637. Path. No. 5840.

Adenomyoma apparently subperitoneal; removed through the abdomen.

I. D., colored, married, aged nineteen. Complaint: Cramps in the lower left side of the abdomen. Her menses were normal up to a year ago. Since then there has been cramp-like pain in the lower abdomen. She has had one child and one miscarriage. Her periods now last longer than formerly.

Operation: Abdominal myomectomy. The patient made a satisfactory recovery and was discharged on the twentieth day.

Path. No. 5840.—The specimen consists of a mutilated myoma which is oval in shape and approximately 2.5 cm. in diameter.

On histological examination this presents the typical myomatous appearance, and scattered throughout it are areas which resemble uterine mucosa. It is a clear case of adenomyoma, apparently subperitoneal.

Diagnosis.—Adenomyoma, apparently subperitoneal.

Gyn. No. 12,585. Path. No. 9336.

Gland hypertrophy. Small uterine myomata. Adenomyoma, apparently subperitoneal, 4 mm. in diameter.

K. H., married, aged thirty-five, white. Admitted December 28, 1905; discharged January 17, 1906. Complaint: Pain in the lower abdomen; a leucorrhœal discharge and a bearing-down sensation in the pelvis. The menses began at twelve and were regular every twenty-eight days. The flow was rather scanty and occasionally clotted. The last period occurred three weeks ago. The patient has been married four years but has had no children. She is somewhat emaciated; the mucous membranes are rather pale.

Operation: Dilatation and curettage. Abdominal myomectomy, resection of right ovary. Several small myomata were removed from the uterus. The patient made a very satisfactory recovery. The highest post-operative temperature was 100° F.

Path. No. 9336.—The specimen consists of a moderate amount of curettings and of two nodules from the right ovary and two myomata from the uterus.

On histological examination we find gland hypertrophy, a corpus luteum, and two small myomata. One myoma presents the usual appearance and shows hyaline transformation. A note was made that macroscopically one of these small nodules from the uterus looked like a little black vesicle and somewhat resembled a thrombosed vein. It is a myoma containing small cystic spaces. The cystic spaces are lined with one layer of epithelium and are filled with blood. In the immediate vicinity are several small gland-like spaces and some stroma. The growth is a typical adenomyoma. It is not over 4 mm. in diameter.

Diagnosis.—Gland hypertrophy; discrete uterine myomata and discrete adenomyoma.

H. A. K. Sanitarium No. 1872. Path. No. 8433.

Uterine myomata, subperitoneal and interstitial nodules, adenomyoma of the uter-

ine walls; discrete adenomyoma of the utero-ovarian ligament, showing large islands of mucosa, typical miniature uterine cavities (Figs. 41 and 42).

D., white, married, aged fifty-one. Admitted March 22, 1905. Died April 15, 1905. Patient has always been a frail woman. Since the menopause there has been a slight vaginal discharge. She has been aware of the presence of an abdominal tumor for the past six months. There has been a great deal of pain and a feeling of weight in the abdomen. She apparently had an attack of pelvic peritonitis in January. Her hemoglobin is 50 per cent.

Operation.—Hystero-myomectomy, repair of the perineum. The patient after operation was exceedingly nervous and had a great deal of pain. On the fourth day she was as bright as usual, when she suddenly began to scream and became unconscious and died in a very short time. Embolism was thought to have been the cause of death. Her highest post-operative temperature was 100° F.

Path. No. 8433.—The specimen consists of a multinodular myomatous uterus which has been amputated through the cervix. It is 14 cm. in length, 13 cm. from side to side, and perfectly smooth. The nodules seen on the outer surface vary from 2 to 9 cm. in diameter. The right tube and ovary are normal. The left tube presents the usual appearance. The left ovary contains what appears to be a corpus-luteum cyst, 3 cm. in diameter, at its outer pole. Perfectly independent from the uterus and attached to the utero-ovarian ligament on the left side is a myoma, 6 cm. in length, 4 cm. in breadth, and 3 cm. in thickness (Fig. 41). Projecting slightly from the surface are a subperitoneal cyst, 1 cm. in diameter, and numerous smaller ones.

On making sections of the nodule projecting from the left utero-ovarian ligament we find in the lower part cystic spaces reaching 1.5 cm. in diameter. Sections through the middle portion show cystic spaces 1 mm., others 2 mm., and some 4 mm. in diameter. Section through the attachment of the myoma to the utero-ovarian ligament reveals a cystic space, 7 mm. in length and approximately

3 mm. broad. It has a definite yellowish lining and encloses chocolate-colored contents. Several of the spaces are filled with a brown-

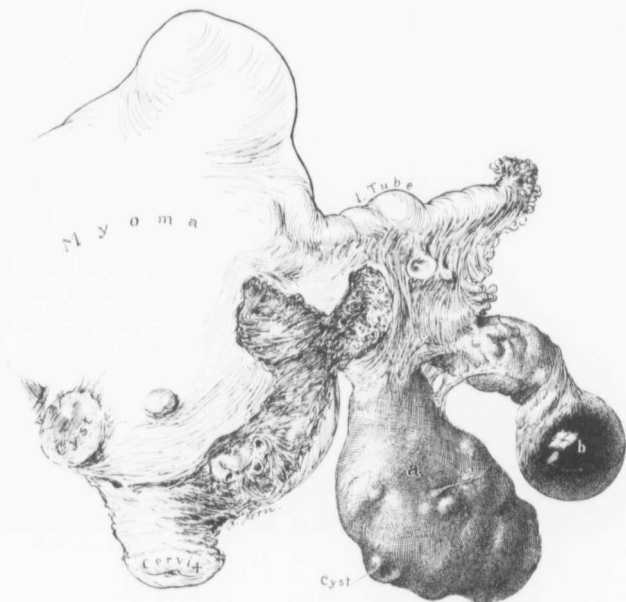


FIG. 41.—SUBPERITONEAL AND INTERSTITIAL UTERINE MYOMATA; ADENOMYOMA OF THE BODY OF THE UTERUS. ADENOMYOMA SPRINGING FROM THE LEFT UTERO-OVARIAN LIGAMENT. (Natural size.)

Gyn.-Path. No. 8433. The uterus is the seat of subperitoneal and interstitial myomata. Near the cervix on the anterior surface is a small cyst. The left tube is normal. The left ovary contains a small corpus-luteum cyst, *b*. Projecting from the left utero-ovarian ligament is a subperitoneal myoma, *a*. This has a few cysts projecting from its surface as indicated. On section this nodule was found to contain cysts, 1 cm. or more in diameter, lined with mucosa and filled with chocolate-colored blood, miniature uterine cavities, also whitish yellow areas, and normal uterine mucosa. (See Fig. 42.)

It may be of interest to know that the uterine mucosa extended into the myomatous uterine walls.

ish putty-like material and have yellowish margins. The ovary contains a cystadenoma.

On section the uterine cavity is 7 cm. in length and the mucosa

in places reaches 9 mm. in thickness. Some of the glands are dilated. The muscular layers of the uterus present a rather coarse, striated appearance.

On histological examination the cervical mucosa is perfectly normal in many places; at other points, however, there is a great deal of gland dilatation, and there is a large thin-walled cyst lined with one layer of flat epithelium and filled with coagulated material presenting a picture almost identical with one of the thyroid. This appearance is due to massive dilatation of some of the cervical glands. We also have small cysts presenting a sieve-like appearance. This picture is due to a polypoid formation at certain points. The uterine mucosa in places reaches 11 mm. in thickness. In many places it has been most imperfectly preserved. The surface, however, is practically intact. The glands are ribbon-like owing to degeneration, and we are unable to tell why the mucosa was so thickened, on account of this degeneration. There is, however, not the slightest evidence of any malignancy. The underlying muscle is somewhat dense, and in it near the mucosa we find isolated glands which have extended down from the surface. In one of the sections an island of mucosa with the characteristic stroma surrounding it can be seen at least 3 mm. from the mucosa. The growth is a definite adenomyoma, with the glands coming from the mucosa. Sections from the nodule springing from the left utero-ovarian ligament show a most instructive picture (Fig. 42). A transverse section over the point of attachment of the utero-ovarian ligament, where we noticed several spaces, shows that these are lined with one layer of cylindrical epithelium. This at times projects out as little tufts and beneath it, and separating it from the muscle, is a certain amount of characteristic stroma. In other portions of this nodule we have little gland-like spaces extending out into this main cavity. Still other sections contain glands resembling uterine glands in every way. These are separated from the muscle by a characteristic stroma. Sections from the centre of the nodule show a most interesting picture. We have cyst-like spaces similar to those above described, and

likewise miniature uterine cavities. Some of the glands are dilated. In the vicinity is a group of glands similar in appearance. We have here subperitoneal and interstitial uterine myomata; marked thickening of the endometrium with definite adenomyomatous formation, and adenomyoma of the left utero-ovarian ligament. This myoma is diffuse in character, contains cyst-like

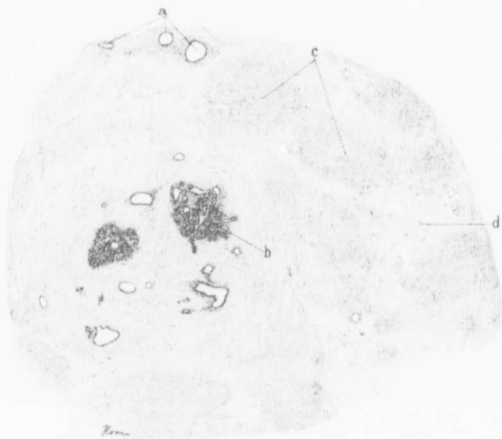


FIG. 42.—CROSS-SECTION THROUGH A PEDUNCULATED SUBPERITONEAL ADENOMYOMA. (4 diameters.)

Gyn.,-Path. No. 8433. The picture represents a cross-section through the subperitoneal adenomyoma *a* in figure 41. Scattered throughout the tissue are isolated cystic and dilated glands (*a*). Near the centre are two large areas of typical uterine mucosa; one of these contains a miniature uterine cavity as indicated at *b*. The darker tissue as seen at *c* indicates the myomatous muscle. This stands out in sharp contrast to the paler staining stroma as indicated at *d*.

spaces and miniature uterine cavities. In other areas it is a typical adenomyoma, differing in no way from an adenomyoma with the glands originating from the mucosa. The mucosa in this case shows a definite adenomyomatous tendency as it extends into the underlying muscle. It seems reasonably probable that the adenomyoma of the utero-ovarian ligament at one time lay next to the uterine mucosa, and that it was gradually pushed outward until it became

subperitoneal and to all intent and purpose lost its continuity with the uterus.

Gyn. No. 12,036. Path. No. 8579.

Subperitoneal and interstitial uterine myomata, one of which was an adenomyoma.

M. Y., aged forty-six, white, married. Admitted April 8, 1905; discharged May 22, 1905. Complaint: Right inguinal hernia; descensus and retroposition of the myomatous uterus, ulceration of the vagina. One aunt has cancer. The menses commenced at eighteen. The menopause occurred in November, 1904. The patient has been married fourteen years and has never been pregnant. The inguinal hernia was noticed two years ago. In the posterior vaginal wall there is a granulating area about 8 mm. in diameter just two inches from the outlet.

On opening the abdomen a small flat myoma was found in the posterior wall near the cervix. This was removed, and some small interstitial nodules were shelled out. The hernia was repaired and the patient made a good recovery. The highest post-operative temperature was 99° F.

Path. No. 8579.—The larger specimen consists of a myoma, 4 by 2 by 2 cm. This is partly subperitoneal. There are also small interstitial nodules. On section numerous cyst-like spaces are to be made out in the myoma, which presents a coarse striation and suggests adenomyoma. Throughout this myoma definite spaces can be seen. These are lined with a single layer of columnar epithelium. At one or two points the glands can be traced for a distance of 5 mm. As the uterine cavity was not opened, of course it is impossible for us to trace the continuity with the mucosa.

Diagnosis.—Subperitoneal adenomyoma; small interstitial nodules.

INTRALIGAMENTARY ADENOMYOMATA

Case 8780 is a very good example of this variety, although the growth also projects into the uterine cavity. As seen in Fig. 43,

it is a goodly sized tumor which extends far out into the right broad ligament, the folds of which it widely separates. Where it becomes submucous, its character is more evident. It is covered over with mucosa, but presents a rather lobulated appearance owing to the presence of cysts of varying size projecting inward from the growth. From the soft character of the growth sarcoma was suspected at the time of operation, particularly as the mucosa was intact and showed no evidence of a carcinomatous process. Fig. 44 is a cross-section of the opened uterus, taken near the fundus. The growth is seen to be a myoma covered externally with a layer of normal muscle and internally with mucosa. Traversing it everywhere are large and small irregular cyst cavities. On histological examination some of these cavities were found to communicate with one another. They were in part empty, in part filled with coagulated serum or blood. They had a smooth inner lining resembling mucosa. This in places was of appreciable thickness. The microscopic examination revealed the fact that some of them resembled miniature uterine cavities, having an inner lining of cylindrical epithelium beneath which were typical uterine glands embedded in their usual stroma. At *c* in Fig. 45 we even noted hypertrophy of some of the glands so characteristic of the uterine mucosa in some cases. Others of the cysts had no glands, merely a row of cylindrical cells separating them from the myomatous muscle. The uterine mucosa was normal and no connection was found between the adenomyoma and the mucosa lining the uterine cavity.

Kroenig¹ reports a very interesting instance of a cystic adenomyoma springing from the posterior wall of the uterus and extending backward beneath the peritoneum of Douglas' pouch. It consisted of one large, thin-walled cyst containing a litre of brownish-red fluid, and of a more solid portion consisting of about thirty small spaces so arranged that they resembled a honeycomb. The walls of the large cyst, especially of that portion lying free in the abdominal

¹ Kroenig, B.: Ein retroperitoneal gelegenes voluminöses Polycystom entstanden aus Resten des Wolff'schen Körpers. Beiträge zur Geburtshilfe und Gynäk., 1901, Bd. iv, p. 61.

cavity, were very thin, in places measuring scarcely more than 1 mm. The cyst walls were composed of fibrous tissue and of a varying amount of muscle. The inner surface was in places lined with cylindrical ciliated epithelium. The more solid portion of the tumor was a typical cystic adenomyoma which, as Kroenig says, in form, in arrangement of glands and in the cystic spaces, corresponded in practically all points with the adenomyomata of von Recklinghausen. There were definite groups of glands surrounded by the characteristic stroma. Kroenig thinks that the tumor originated in the uterine wall, and was later pushed out into the connective tissue of Douglas' pouch.

Hartz¹ observed a similar case in Sänger's clinic.

While considering intraligamentary adenomyomata we must not omit the two interesting cases reported by Breus² in 1894. In his Case 1 a large, partly cystic and partly solid myoma was met with in the right broad ligament. On removal it was found to be made up of a framework of myomatous tissue containing several large cysts. Their dimensions may be imagined from the fact that 7 litres of thick grayish-brown fluid were evacuated prior to the removal of the tumor. The cyst cavities had smooth inner surfaces and appeared to be lined with mucous membrane. In the more solid portions, definite myomatous nodules as large as a fist were found. Such nodules on section contained large, smooth-walled cavities, which were filled with either light or dark brown, friable or thick, fluid contents similar to those of the large cyst. The tumor proved to be a typical myoma. The large cyst was lined with a single layer of cylindrical ciliated epithelium. Breus thought that the tumor was of uterine origin and that it had spread out between the folds of the broad ligament.

Breus' Case 2 is even more instructive than the first. The patient was fifty-one years of age. There was a tumor the size of a child's

¹ Hartz, A.: Neuere Arbeiten über die mesonephrischen Geschwülste. Monatschrift f. Geburtshülfe und Gynäkologie, Bd. xiii.

² Breus, Carl: Ueber wahre epithelführende Cystenbildung in Uterusmyomen. Leipzig, 1894.

head springing from the posterior surface of the uterus and covered by the peritoneum of Douglas' sac and the left broad ligament. The tumor on its upper and posterior surface was hard. On section it was seen to be composed of myomatous tissue, but the central portion contained several cavities. These varied from a pea to an apple in size and were in part separated from one another by thick partitions. Several of them, however, communicated one with the other. The cysts had smooth inner surfaces and were filled with a thick, chocolate-brown fluid. The largest cyst communicated directly with the uterine cavity by a funnel-shaped opening just above the internal os. The cysts were lined with cylindrical, ciliated epithelium, and where the large cyst communicated with the uterine cavity the surface epithelium of the uterine mucosa was directly continuous with that of the cyst. Breus considered the tumor as a subperitoneal and intraligamentary cystic myoma of the uterus.

The intraligamentary cystic adenomyomata differ in no way from the subperitoneal growths except for the fact that they spread out between the folds of the broad ligament, and hence offer greater difficulty in removal. All of the tumors consist of myomatous tissue and contain characteristic glands and stroma, and furthermore all the cysts are lined with cylindrical and usually ciliated epithelium. Particularly instructive is Breus' second case, in which the epithelium of the uterine mucosa was directly continuous with that of the large cyst. Nearly all of the intraligamentary cysts are also partially filled with blood.

It will be noted from the foregoing cases that wherever the subperitoneal or intraligamentary adenomyomata reach any size they become cystic. In some the cysts were single, but they were usually multiple. The cyst walls were made up of myomatous tissue and their inner surfaces were lined with cylindrical epithelium, on which the cilia were usually demonstrable. The cysts almost without exception contained a chocolate-colored or bloody fluid. In the solid portion of the tumor tubular glands were found, surrounded by a definite stroma; in short, a definite mucosa, identical with that normally found lining the uterine cavity, was present.

Subperitoneal adenomyomata differ in no way from the diffuse uterine myomata save for the fact that they become cystic; and this difference is easily explained inasmuch as the subperitoneal tumors are released from the contracting and controlling influence of the uterine muscle. Their glands are occluded, and from the constant accumulation of the epithelial secretion and the frequent hemorrhages, which undoubtedly occur at the menstrual period, rapidly become larger. It will be noted that the large cysts are invariably found where the least amount of muscle is present.

AN INTRALIGAMENTARY ADENOMYOMA OF THE UTERUS

Gyn. Nos. 6855 and 8780. Path. No. 4966.

Intraligamentary adenomyoma of the uterus extending into the right broad ligament and also becoming submucous (Figs. 43, 44, and 45). Gland hypertrophy of the uterine mucosa, slight pelvic adhesions. Hysterec-tomy. Recovery. (See page 160, for first operation.)

A. B. W., aged thirty-six, white, married. Admitted May 21; discharged June 11, 1901. Complaint: Continuous bleeding from the uterus and pain in the right lower abdomen. The patient has been married sixteen years and has had three children. The menses commenced at twelve, and were regular, lasting about four days. There was no pain and the flow was moderate.

On April 22, 1899, a vaginal myomectomy was done, a submucous adenomyoma being removed. Before this operation there had been a slight bloody discharge at irregular intervals. Menstruation was normal after the operation until five years ago, when the patient began to have continuous profuse bleeding from the uterus and pain in the right side. She was curetted two or three times and the last two periods were normal. For the past two or three years leucorrhœa has been profuse. At times there has been dysuria, when the uterus seemed to press on the bladder. On such occasions it was necessary for her to push the uterus up before she could urinate. The bowels are constipated.

The outlet is very much relaxed. The cervix is lacerated and the orifice is 2 cm. in diameter, slightly bluish. The uterus forms a mass filling two-thirds of the pelvis, the organ being about the size of that of a three and a half or four months' pregnancy. The uterine cavity is 13 cm. long and is displaced somewhat to the left.

Operation, May 22, 1901. Panhysterectomy. Suspension of the corners of the vagina to the round, infundibulo-pelvic and sacro-uterine ligaments on either side. On opening the abdominal cavity the appearance strongly suggested a sarcoma involving the right uterine walls and extending into the right broad ligament. The right tube and ovary were adherent to the pelvic floor. The left tube and ovary were normal except for slight ovarian adhesions.

Gyn. - Path. No. 4966.—The specimen consists of an enlarged uterus with the tubes and ovaries intact. The uterus is somewhat pear-shaped and irregular in outline. It is 14 cm. in length, 13 cm. in breadth, and 12 cm. in its antero-posterior diameters. Anteriorly it is smooth and glistening; posteriorly, much injected and covered with a few recent adhesions. The increase in the size of the uterus is in great part due to a tumor occupying the right side of the body and extending out into the folds of the right broad ligament and also to the posterior and right side. This tumor is approximately 10 cm. in diameter, is exceedingly soft, and feels like a cyst with the walls probably 5 mm. thick. On opening the uterus the external os is found to be 2.5 cm. in diameter; the mucosa of the vaginal portion is intact, but just beneath the mucous membrane are a few Nabothian follicles. The cervical canal is much dilated and is 3.5 cm. in length. Its mucosa is intact, but apparently somewhat thickened (Fig. 43). The cavity of the uterus is 8 cm. in length and averages 5 mm. in breadth in its middle portion. The uterine walls vary from 2 to 3 cm. in thickness. Projecting into the uterine cavity and apparently continuous with the mass on the right side is a somewhat globular tumor, 7 cm. in length and 6 cm. in breadth. This has a very broad basal attachment, presents a fairly lobulated surface, and is everywhere covered with mucosa,

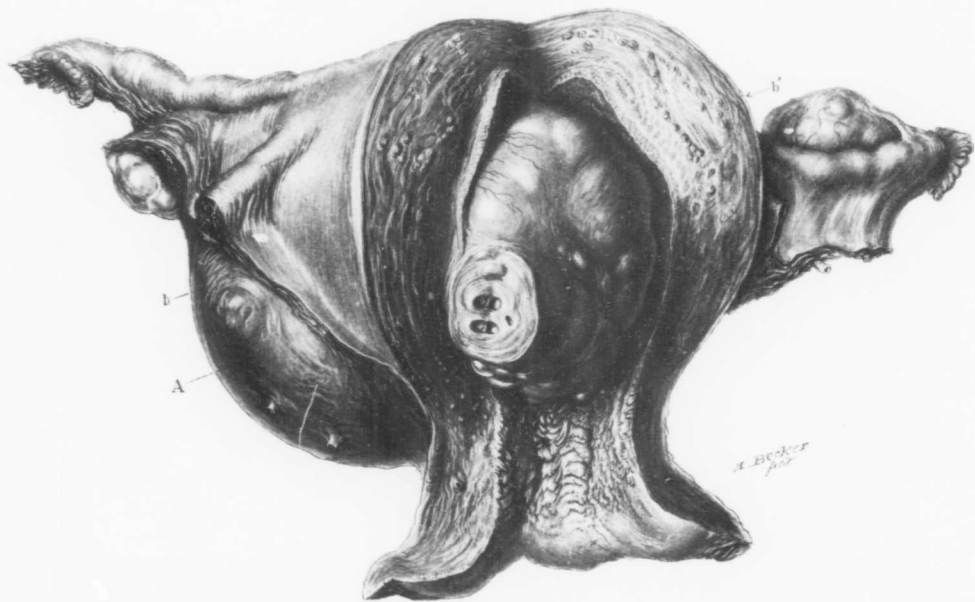


FIG. 43.—AN INTRALIGAMENTARY AND ALSO PARTLY SUBMUCOUS CYSTIC ADENOMYOMA OF THE UTERUS. (Natural size.)

Gyn. - Path. No. 4966. The uterus, which is much enlarged, has been opened anteriorly. The vaginal portion of the cervix is considerably thickened. The external os is dilated and the cervical mucosa is more shaggy than usual. The anterior uterine wall is considerably thickened. Occupying the right broad ligament is a globular tumor A. This has extended through the right uterine wall, projects into and completely fills the uterine cavity. The submucous portion projects from the posterior and right uterine wall. It is smooth and glistening but lobulated, owing to the presence of cysts varying from 1 mm. to 1.5 or more cm. in diameter, which project slightly from the surface. Over some of these the blood-vessels are slightly dilated. At one point the submucous myoma has been cut for a distance of 2 cm. and we see the smooth inner surfaces of three cysts. The appendages on the right side are normal, those on the left are also normal, except for a band of adhesion between the outer end of the tube and the ovary. Fig. 44 represents a transverse section through the uterus on a level with the line between *b* and *b'*. The histological picture is shown in Fig. 45.

which, however, is somewhat thinned out. On pressure the submucous tumor gives the impression of being cystic. The uterine mucosa averages 2 mm. in thickness, is smooth and grayish-white in appearance.

Right side: The tube is 12 cm. in length and near the uterus averages 5 mm. in diameter; it is free from adhesions. The fim-

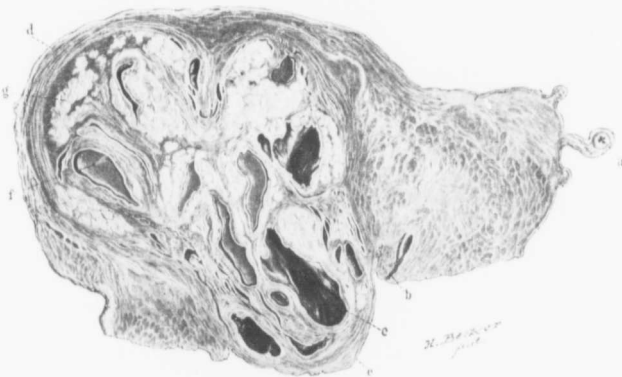


FIG. 44.—A CYSTIC INTRALIGAMENTARY AND PARTLY SUBMUCOUS ADENOMYOMA OF THE UTERUS. (Natural size.)

Gyn. - Path., No. 4966. The drawing illustrates a section through Fig. 43 between *b* and *b'*. *a* is a cross-section of the left tube, *b* is a small portion of the uterine cavity, *c* is the submucous portion of the cystic adenomyoma and *d* its intraligamentary pole. *e* is one of the irregular cyst-like spaces with a smooth velvety inner lining resembling mucosa. Just above it is a similar but smaller one. The other spaces, as indicated by *f*, also irregular in outline, are filled with glistening coagulated contents which have not been removed. The coagulation, of course, was due to the hardening fluid. *g* is the characteristic myomatous tissue. The outline of the myomatous growth is well defined, but notwithstanding this fact the tumor merges gradually into the normal muscle.

bricated extremity is occluded and covered with adhesions. The tube in the vicinity of its outer end is 8 mm. in diameter and very firm. Situated just beneath the tube and within 3 cm. of its fimbriated end is a firm bean-shaped area 1.2 cm. in length. On section it is found to be a cyst-like space lined with smooth mucosa and filled with a brownish-yellow material, partly soft, but at one point evidently organized and adherent to the cyst wall. The ovary measures 3 by

2.5 by 1 cm. and is partially enveloped in adhesions and adherent to the tube.

Left side: The tube is 11 cm. in length, and throughout its entire extent is very small, averaging not more than 3 or 4 mm. in diameter. The fimbriated extremity is patent, but the tube near its outer end is attached to the ovary by fan-like adhesions. The ovary measures 4 by 3.5 by 2 cm. It contains a recent corpus luteum and apart from the tubal adhesions is free.

On making a transverse section of the uterus after the specimen has been hardened in Müller's fluid it is found that the tumor occupying the right side and extending out into the right broad ligament is directly continuous with the submucous nodule which occupies the uterine cavity. In other words, we have an interstitial myoma, which on its inner side has become submucous and on its outer side extends into the broad ligament. This nodule is fully 8 cm. in diameter and is sharply differentiated from the uterine muscle, which on its outer side forms a covering 5 mm. in thickness. The myoma is irregular in contour and in places presents the usual picture. It contains at least eight medium sized cyst-like spaces, the largest reaching 2.5 cm. in length and 1 cm. in breadth (Fig. 44). Each of these has a smooth lining membrane, waxy in appearance and varying from .5 to 1 mm. in thickness. The cavities of nearly all of these spaces are filled with a jelly-like material, evidently coagulated serum. One contains coagulated blood. The cyst-like spaces are more abundant in the central portions of the growth and toward the uterine cavity. They are similar to those noted beneath the surface of the submucous myoma.

Histological Examination.—The mucosa lining the vaginal portion of the cervix and the cervical canal is normal. That covering the anterior portion of the uterine cavity is thickened; the surface epithelium is somewhat flattened and its glands show marked hypertrophy. The stroma between the glands shows considerable small round-cell infiltration and is very lax. In the deeper portions it is unaltered. The mucosa covering the submucous portion of the tumor is somewhat thinned out. The surface epi-

thelium is intact, but the glands show slight hypertrophy. One of the cysts, 1.5 cm. in length, .5 cm. in breadth, and situated directly beneath the mucosa, has a lining in no way distinguishable from uterine mucous membrane (Fig. 45). Its inner surface is covered with one layer of cylindrical and, in places, slightly flattened epithelium. Beneath this the characteristic stroma of the mucosa is

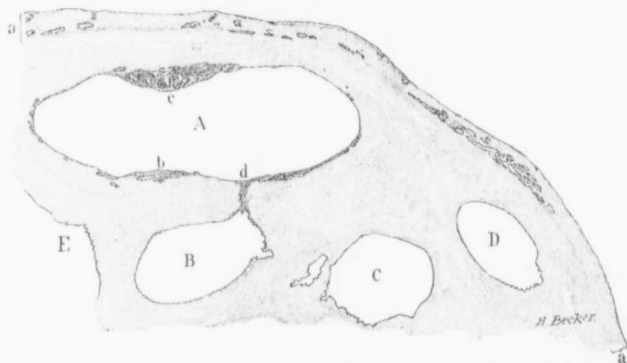


FIG. 45.—THE SUBMUCOUS PORTION OF A CYSTIC ADENOMYOMA OF THE UTERUS. (5 diameters.)

Gyn.-Path. No. 4966. The section is from the submucous myoma seen in Figs. 43 and 44. *a* represents the uterine mucosa, which has an intact surface epithelium and perfectly normal uterine glands. The stroma of the mucosa is rarefied but normal. *A* is one of the cyst-like spaces. At some points it is lined with a layer of cylindrical epithelium lying directly on the muscle. At other points this is separated from it by a small amount of stroma similar to that of the uterine mucosa. While in some places, as at *b*, there are definite uterine glands beneath the epithelial lining, at *c* we have a uterine mucosa equally as thick as that covering the surface of the submucous myoma and consisting of a typical gland hypertrophy. *B*, *C*, *D* and *E* are other cyst-like spaces lined with cylindrical epithelium. *A* and *B* are evidently one and the same cavity, communicating as they do with one another by the bar *d* consisting of the characteristic stroma of the mucosa and containing two small glands.

found, and scattered throughout the stroma are normal or hypertrophied glands precisely similar to those noted in the mucosa lining the uterine cavity. Some of the cyst spaces, which are rather small, are lined with a layer of epithelium closely resembling that lining the uterine cavity. In a few places the nuclei of the epithelial cells are slightly drawn out and irregular. The myomatous tissue as a whole presents the usual appearance. It has

scattered throughout it, however, many small round cells, but practically no polymorphonuclear leucocytes. The tubes and ovaries offer nothing of interest.

We have, then, in this case a rather large and sharply defined myoma situated in the right uterine wall. This contains large and small irregular spaces lined with mucous membrane identical with that of the uterine mucosa. This myoma on its inner side has become submucous and its cyst-like spaces are seen projecting into the uterine cavity and lying just beneath the mucous membrane.

Diagnosis: Adenomyoma of the uterus extending into the right broad ligament and also becoming submucous. Gland hypertrophy of the uterine mucosa, slight pelvic adhesions.

CHAPTER VI

SUBMUCOUS ADENOMYOMATA

These are certainly not very common. We have already discussed Case 8780 (Fig. 43, p. 151) under the heading of intraligamentary adenomyoma, but fully one-third of the growth is submucous, projecting into and filling the uterine cavity from cervix to fundus. The surface is smooth but lobulated, on account of the underlying cysts which project toward the uterine cavity. As was said elsewhere, the growth was a typical adenomyoma and the cyst spaces were lined with cylindrical ciliated epithelium. Case 5973 offers a very good illustration of a small submucous adenomyoma. The mucosa over the nodule has to a great extent disappeared, but here and there a gland is still visible. The growth is essentially a myoma. It contains three definite bunches of glands resembling uterine glands and surrounded by the typical stroma of the mucosa (Fig. 46). There are also a few isolated glands, some surrounded by stroma, others lying in direct contact with the muscle. Near the free surface is a cystic gland. In this case there were other myomata, necessitating the subsequent hysterectomy.

In Case 6855 the submucous nodule contains a few small uterine glands. In Case 10,872 the myoma contains three cystic spaces, each 1 cm. in diameter and with a smooth lining, which on histological examination is seen to consist of one layer of columnar epithelium. In Case 10,314 (Fig. 47, p. 162) we have a typical example of a submucous myoma containing collapsed and dilated spaces lined with a definite mucosa. Some of these cavities are filled with chocolate-colored contents.

On histological examination they are found to be miniature uterine cavities. In this case the uterine mucosa can be followed directly into the myoma.

In 1896, when reporting two cases of diffuse adenomyoma of

the uterus,¹ attention was directed to cases of submucous adenomyomata reported by Diesterweg and Schatz.² In Diesterweg's case a nodule the size of a hen's egg presented at the external os. Its surface was somewhat eroded; it was attached above the internal os and projected downward by a pedicle an inch in thickness. The nodule was composed of myomatous tissue, and in the centre was a large cavity lined with mucosa and traversed by numerous small depressions, producing an appearance suggestive of a ventricle. There was a smaller cavity the size of a cherry. These cysts were lined with cylindrical ciliated epithelium and filled with brownish-black blood. Two years later, after the administration of ergotin, a submucous myoma, 9 by 7 by 6 cm., was expelled. This contained a cyst the size of a walnut. The cyst was lined with cylindrical ciliated epithelium and filled with blood.

In Schatz's case the uterus was 16 cm. long, 8.5 cm. in diameter, and its walls varied from 2 to 2.5 cm. in thickness. The uterine cavity contained five rows of broad-based polypi. Each row consisted of from two to six polypi. Between the rows were deep depressions. The polypi pointed toward the internal os and varied from a pea to a hen's egg in size. The uterine cavity was completely filled with them. On section the polypi were found to have a rich blood-supply and in several places bundles of muscle fibres could be seen extending into them and reaching almost to the free surface. Where the muscular elements predominated, the polypi were firm. Scattered throughout the uterine wall were small myomata which were not easily shelled out. In the myomata near the peritoneal surface no cysts were to be seen, but in those near the uterine cavity and also in the muscle they were present. The outer portions of the uterine wall were entirely free from cysts. The polypi consisted

¹ Cullen, Thomas S.: Adenomyoma Uteri Diffusum Benignum. Johns Hopkins Hospital Reports, 1896, vol. vi.

² Diesterweg: Ein Fall von Cystofibroma uteri verum. Zeitschr. f. Geb. u. Gyn., 1883, Bd. ix, S. 191. Schatz: Ein Fall von Fibro-adenome cysticum diffusum et polyposum corporis et colli uteri. Arch. f. Gyn., 1884, Bd. xxii, S. 456.

of spindle-shaped cells, and scattered throughout them were gland-like cavities lined with high cylindrical epithelium.

It would appear that in these cases there had been a diffuse adenomyoma and that the uterus was trying to free itself of the new growth in the same manner in which it extrudes ordinary myomata. A polypoid condition had naturally resulted.

Remembering the diffuse adenomyomata of the uterus and subsequent extension of the growth to the outer surfaces, with the formation of subperitoneal or intraligamentary cystic adenomyomata, it is easily understood that portions of the growth, at least, are forced inward and become submucous. In the submucous adenomyomata we do not generally expect much cystic dilatation of the glands, since the growth is continually subjected to the uterine pressure from all sides.

CASES OF SUBMUCOUS ADENOMYOMA OF THE UTERUS

Gyn. No. 5973. Path. No. 2250.

Submucous adenomyoma of the uterus (Fig. 46). Removal per vaginam. Subsequent hysterectomy on account of uterine myomata. Recovery.

S. G., single, aged thirty-nine, black. Admitted March 22, 1898; discharged June 3, 1898. Complaint: continuous bloody vaginal discharge. The patient had one miscarriage twenty years ago. Her menses commenced at twelve and were regular, but for the past two years the flow has lasted about twice as long as heretofore. Since December there has been an almost continuous bloody discharge, at times profuse.

About two years ago the patient commenced to have pain in the lower abdomen. This pain lasted about six months. For the last three years she has been short of breath, and since August, 1897, her feet have been swollen. For several months there has been a profuse yellowish leucorrhœal discharge.

First operation, March 24, 1898. Myomectomy per vaginam; evacuation of a pelvic abscess. A polyp was removed through the

vagina. The uterine cavity at this time varied from 10 to 12 cm. in length and in the posterior wall was a myoma. The pelvic abscess was opened and a small amount of necrotic material and pus came away.

Second operation, April 27, 1899. Hystero-myomectomy, right salpingo-oophorectomy. There were general intestinal adhesions and the bladder was markedly lifted up. A right tubo-ovarian abscess was removed together with a myomatous uterus. Conva-

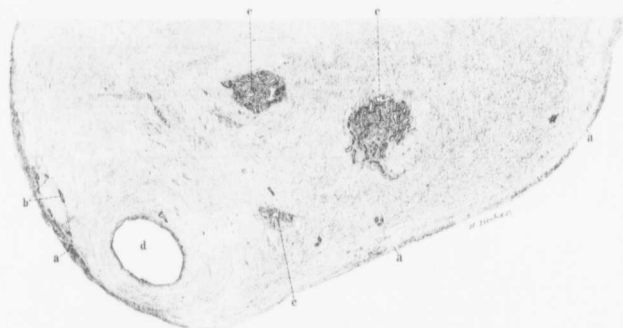


FIG. 46.—SUBMUCOUS ADENOMYOMA OF THE UTERUS. (7 diameters.)

Gyn.-Path. No. 2250. Nearly all trace of the mucosa formerly covering the growth has disappeared. Nevertheless, some of the stroma remains and is recognized at *a*. In some places are a few isolated uterine glands (*b*). The growth is composed chiefly of myomatous muscle and at points *cc* are the characteristic islands of uterine mucosa, consisting of glands enveloped in the usual amount of stroma. Scattered here and there throughout the growth are isolated glands, some surrounded by, others devoid of, stroma. *d* is a dilated gland.

lescence was uninterrupted save for slight swelling of the legs, not associated with any pain or with any urinary disturbances.

The temperature at the first operation reached 102° F. on the third day, but was normal by the ninth day. After the second operation it rose to 101.4° F. on the second day and remained below 100° F. after the sixth day.

Gyn.-Path. No. 2250.—The specimen consists of a submucous nodule measuring approximately 4.5 by 2.5 by 1.5 cm. Its surface is roughened. On section it presents the usual myo-

matous appearance, but just beneath the surface at one point is a cystic space 5 mm. in diameter.

Histological Examination.—The surface of the myoma is over a considerable area covered with thinned-out mucosa without any surface epithelium (Fig. 46). The glands are few in number, are small, and have a normal epithelial lining. The stroma of the mucosa is fairly dense and near the surface contains numerous small blood-vessels. The myomatous tissue presents the usual appearance, but here and there, in the depth of the tissue, are groups of small tubular or slightly convoluted glands resembling in every particular uterine glands and surrounded by a stroma similar to that of the uterine mucosa. Occasionally one or two isolated glands are found lying in direct contact with the muscle. The small cystic space noted macroscopically is a dilated gland.

Diagnosis.—Submucous adenomyoma of the uterus.

Gyn. No. 6855. Path. No. 3107.

Submucous adenomyoma. (See page 149 for the subsequent hysterectomy.)

A. B. W., white, aged thirty-four, married. Admitted April 20, 1899; discharged June 1, 1899. The patient has had three children, the oldest thirteen, the youngest nine. The menstrual history is normal, but there has been a profuse and offensive leucorrhœa for the last month. The patient has had prolapsus since the birth of her first child, thirteen years ago. One year ago some operation was performed, apparently a removal of a submucous nodule. Six weeks ago the patient noticed that there was a tumor protruding from the cervix. During the last two weeks there has been slight hemorrhage. The patient feels that she is growing weaker and has lost flesh. She has not been able to do any work for the last six weeks.

Operation.—A vaginal cyst, measuring 3 by 2 cm., was removed from the left side, just behind the hymen. There was a myomatous growth, 4 by 3.5 by 4 cm., protruding from the cervix. This was drawn well down and ligated, and a large tubo-ovarian

abscess on the right side was opened and thoroughly drained. Convalescence was uninterrupted.

Path. No. 3107.—The specimen consists of a submucous myoma and of a vaginal cyst. The myoma measures 4 by 3 by 1.5 cm., is irregular in shape and somewhat discolored. On section it is hard and dense.

Histological Examination.—The myoma presents the usual appearance. Blood-vessels are abundant and, as a rule, small. In one section the protoplasm appears to be swollen, pale-staining, and has somewhat the appearance of fibrous tissue. At another part of the tumor gland-like spaces are seen, two of them being in close proximity to each other, and three some distance away. They are lined with a single layer of cylindrical epithelium. The specimen is a submucous adenomyoma in which the gland elements are few in number.

Gyn. No. 10,314. Path. No. 6531.

Double vagina; double cervix; large submucous adenomyoma with the glands originating from the uterine mucosa and containing quantities of miniature uterine cavities (Fig. 47).

E. K., white, aged fifty, married. Admitted March 7, 1903; discharged April 17, 1903. Complaint: uterine hemorrhages. Her father died of dropsy; her mother of cardiac failure. She had scarlet fever at thirteen, but otherwise was healthy until the present illness. Her menses were normal until ten years ago. Since then she has had considerable pain at her periods, which came on at irregular intervals, from two to five weeks, and were more profuse than usual. She has been married twenty-one years, but has never been pregnant. For two years the periods have been profuse, coming on every two to three weeks, accompanied by much pain. She has lost 18 or 20 pounds. The patient is fairly well nourished; the hemoglobin 55 per cent. Fine crackling sounds are heard over the right upper back and lower right front. On vaginal examination

a double vagina, with the septum extending the entire length of the vault, a double cervix and a double cervical canal were discovered. There was a submucous myoma within the uterus. This was apparently the size of a goose's egg.

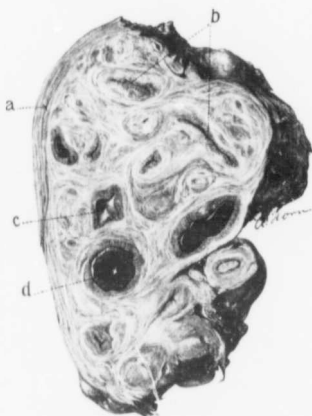


FIG. 47.—SUBMUCOUS ADENOMYOMA OF THE UTERUS, THE MYOMATOUS MUSCLE BEING RIDDLED WITH MINIATURE UTERINE CAVITIES. (Natural size.)

Gyn. - Path. No. 6531. This is a longitudinal section of the mutilated submucous myoma which was associated with a double vagina and a double cervix. The greater part of the tissue consists of myomatous tissue, diffuse in character. On the left is a partial covering of normal uterine muscle (*a*). Scattered everywhere throughout the myomatous tissue are collapsed and dilated miniature uterine cavities. *b*, *b*, are collapsed cavities, lined with a definite mucosa. *c* is a slightly dilated cavity likewise lined with mucosa, while *d* represents a miniature uterine cavity distended with blood. These cavities on histological examination are found, as their names would imply, to be lined with typical uterine mucosa.

miniature uterine cavities. All these spaces are dilated and are filled with chocolate-colored contents, evidently old menstrual hemorrhages.

Operation.—The septum was first removed and the myoma brought away in fragments. Her highest post-operative temperature was 100° F. on the second day. On the twenty-first day there was phlebitis of one of the small veins in the left leg. The patient was discharged well on the twenty-seventh day.

Path. No. 6531.—The specimen consists of a large mutilated submucous myoma, measuring approximately 11 by 7 by 7 cm. On section it presents the typical myomatous appearance. Scattered throughout it, however, are numerous irregular islands of mucosa. At other points are spaces fully 8 mm. long by 2 mm. broad, lined with mucosa, which almost completely fills the cavity (Fig. 47). They are easily recognized as

On histological examination the specimen presents a typical myomatous appearance. Scattered throughout the muscle are miniature uterine cavities, some of them reaching 1 cm. in length; also islands of perfectly normal uterine mucosa. The glands lining these miniature cavities, and also forming the islands of perfectly normal mucosa, are accompanied by the usual stroma. Here and there a gland is dilated or has a cavity filled with old menstrual clots which have become partly disorganized. The spaces contain fragments of nuclei and polymorphonuclear leucocytes, while surrounding them are many small connective-tissue cells, some containing granular pigment and remnants of blood. At other points the blood is still well preserved. At some points are spaces fully 2 mm. in length, evidently dilated glands. They are lined with cylindrical epithelium resting on a stroma which separates them from the muscle. The uterine mucosa in a few places is preserved. Over the myoma here and there one is able to trace the uterine mucosa as it penetrates into the depth.

We have in this case a typical submucous adenomyoma, where we are able to show that the gland elements are derived from the normal uterine mucosa.

Gyn. No. 10,872. Path. No. 7076.

Submucous adenomyoma.

H. D., single, aged thirty-three, colored. Admitted November 12, 1903; discharged December 11, 1903. The patient complains of a watery discharge which has persisted for six months. This has at times been profuse. The patient is well nourished, but her haemoglobin is only 60 per cent. The entire vagina is filled with a globular mass which projects from the cervical canal. This tumor was bisected and found to be attached by a small pedicle which was tied off. Her highest post-operative temperature was 100.5° F. When she left the hospital her haemoglobin was still 60 per cent.

Path. No. 7076.—The specimen consists of a bisected, considerably mutilated myoma measuring 10 by 7 by 4 cm.

On section the tumor presents the usual appearance save for three cystic spaces, each about 1 cm. in diameter, and filled with fluid. These have smooth inner linings.

On histological examination the myoma shows marked richness in muscle cells. There is also considerable hyaline degeneration. The cyst walls are lined with cylindrical epithelium similar to that of the uterine mucosa.

D i a g n o s i s .—Submucous adenomyoma.

CHAPTER VII

CERVICAL ADENOMYOMATA

From the study of adenomyomata of the body of the uterus we have seen that, in the first place, there is a diffuse myomatous thickening of the inner muscular walls accompanied by a down-growth of the normal mucosa into this diffuse growth. Portions of this adenomyoma may become subperitoneal or intraligamentary, and often form a large cystic adenomyoma. Portions of the diffuse growth were also found to project into the uterine cavity, forming submucous adenomyomata. Should an adenomyoma develop in the cervix, we would expect it, judging from analogy, to consist of cervical glands enclosed in a tissue made up of myomatous muscle and the dense stroma characteristic of the cervical mucosa. In Case 3898 (Fig. 48) we found a small myomatous uterus, in which remnants of an adenomyoma were present along the outer border of the cervix, *i. e.*, near the broad ligament or vaginal attachment. A glance at Fig. 49 shows that the glands in this small growth correspond to those of the body of the uterus, and in addition they are surrounded by the usual stroma found in the mucosa above the internal os. Landau and Pick¹ report a case in which the cervical canal was entirely obliterated by an adenomyomatous nodule which completely shut off the uterine cavity from the vagina. In this case also typical uterine glands with their accompanying stroma were the epithelial elements present.

In 1896 when reporting two typical cases of diffuse adenomyoma of the body of the uterus² I described an adenomyoma of the cervix

¹Landau, L., and Pick, L.: Ueber die mesonephrische Atresie der Müller'schen Gänge, zugleich ein Beitrag zur Lehre von den mesonephrischen Adenomyomen des Weibes und zur Klinik der Gynatresien. Arch. f. Gynäk., 1901, Bd. lxiv, S. 98.

²Cullen, Thomas S.: Adenomyoma Uteri Diffusum Benignum. Johns Hopkins Hospital Reports, vol. vi.

consisting of cervical glands, muscle, and a moderate amount of fibrous tissue. This finding is very rare, as from the literature I have been unable to glean a single similar case. In Fig. 23, p. 77, a round submucous nodule, 2.5 cm. in diameter, is seen projecting from the cervix.

On histological examination the outer surface of the nodule is found to be in places covered with cylindrical epithelium. Scattered everywhere throughout the muscle are gland-like spaces varying from a pin-head to 3 mm. in diameter. These are lined with a single layer of epithelium, which in the smaller glands is of the high cylindrical variety. In the dilated glands, however, it is cuboidal or has become almost flat. The cell protoplasm takes the hæmatoxylin stain, as is so characteristic of the cervical epithelium. The nuclei are oval and vesicular, and in many places it is possible to make out cilia. The gland cavities are empty or contain a granular material that takes the hæmatoxylin stain. The glands tally in every particular with the cervical glands. This nodule is undoubtedly a cervical myoma and appears to be the only one of its character on record. It has evidently started near the internal os. Otherwise we would not have had so much muscular tissue.

Gyn. No. 3898. Path. No. 934.

Submucous and interstitial myomata and an adenomyoma situated near the broad ligament attachment of the cervix (Figs. 48 and 49). General pelvic peritonitis, left side hydrosalpinx simplex; small papillocystoma of the ovary.

M. J., married, aged thirty-eight, white. Admitted October 22, 1895. This patient has never been pregnant. The menses began at thirteen and were regular until four years ago. Since then they have occurred at intervals of from two to ten weeks. At these times the flow is often profuse, at other times scanty.

Four years ago a tubo-ovarian cyst was removed by Dr. Senn.

Two years ago she had several hemorrhages, and during the next year was curetted four times. For ten years she has felt a stabbing-like pain at intervals in the left ovarian region. Two years ago she noticed a swelling in the left side and the enlargement reached halfway to the umbilicus. This appeared suddenly, and gradually disappeared in the course of six weeks. Since January, 1895, she has had a burning pain in the right ovarian region.

Operation, October 23, 1895. Hystero-salpingo-oöphor-ectomy. Removal of hamatoma in the right broad ligament and a left hydrosalpinx. Adhesions were found binding down the tube and ovary and there was encysted peritonitis. The myomatous uterus choked the pelvis. The omentum, rectum and small intestine were densely adherent. During removal of the uterus the external coats of the ileum were ruptured in one place, requiring three sutures.

After the operation the temperature gradually rose, reaching 103.2° F. on the day of her death.

On the second day after the operation the patient complained of excruciating pain in the right side over the site of the intestinal suture. This became more and more intense and abdominal distention developed. The abdomen was opened without anaesthesia and a perforation of the intestine found at the site of the intestinal suture. The patient died that same evening.

Gyn.-Path. No. 934. The specimen consists of the uterus, the left tube and ovary, portions of the wall of a hamatoma from the right side, also of a small piece of the abdominal wall.

The uterus measures 7.5 by 5 by 7 cm. and is covered with vascular adhesions. Projecting from the anterior surface is a sessile nodule, 5.5 by 5 by 4 cm. This for the most part is smooth and glistening, but shows a few delicate vascular adhesions on its under surface. On its right side it presents a slightly convoluted appearance and over an area 1.5 cm. is covered with a yellowish tissue resembling mucous membrane. The uterine cavity is 4.5 cm. in length and 3 cm. in breadth at the fundus (Fig. 48). Its mucosa presents a finely granular surface, but is smooth and glistening and the upper

portion shows considerable ecchymosis. Projecting into the cavity at the left cornu is a fold of mucous membrane, 5 by 2 mm. The uterine walls are occupied by numerous firm white nodules varying from .5 to 4.5 cm. in diameter. All of the nodules present the typical myomatous appearance.

Right side: The tissue removed consists of portions of the wall

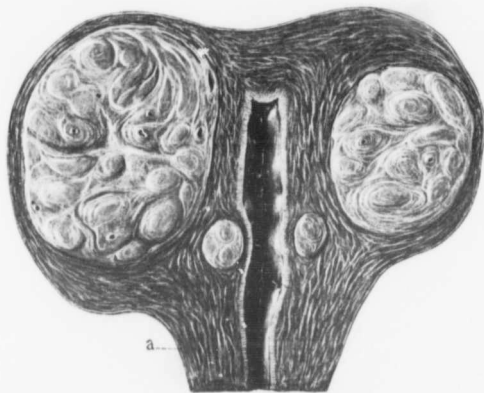


FIG. 48.—INTERSTITIAL UTERINE MYOMATA WITH A SMALL DIFFUSE ADENOMYOMA IN THE CERVIX. (Natural size.)

Gyn.-Path. No. 934. The uterus has been amputated through the cervix and opened anteriorly. Situated in the anterior wall is a myoma. This has not been cut through the centre and consequently one portion is larger than the other. Near the uterine cavity is a myoma, about 1 cm. in diameter. This has been cut in two. The uterine walls, were it not for the myomata, would be of normal thickness. The uterine cavity is of the normal length and its mucosa unaltered. On the right side of the cervix at a point approximately corresponding to *a* was a small diffuse adenomyomatous thickening, part of which is represented in Fig. 49.

of a hematoma. (The appendages had been removed at a previous operation.)

Left side: The tube at a point 1.5 cm. from the uterus is 4 mm. in diameter, but gradually dilates, and after passing outward for 6.5 cm. forms with the ovary a tubo-ovarian mass, measuring 6 by 5 by 2.5 cm. The tube is covered with dense adhesions, has thin transparent walls, through which the folds of the mucosa can be seen, and contains a clear transparent fluid. The tubo-ovarian mass

has been, for the most part, converted into a thin-walled cyst containing clear transparent fluid. The ovary also contains a firm, oval, movable body, 1.3 by 8 cm. This, on section, is seen to be made up of numerous small cysts, in the walls of which calcareous material has been deposited.

Histological Examination.—The cervical glands present the usual appearance. The uterine mucosa is normal in thickness; its surface epithelium is intact and its glands are abun-




FIG. 49.—ADENOMYOMA IN THE OUTER PORTION OF THE CERVIX NEAR THE BROAD LIGAMENT ATTACHMENT. (4 diameters.)

Gyn.-Path. No. 934. The section is through the right side of the cervix in Fig. 48 at a point approximately indicated by *a*. *a* is the normal cervical mucosa. The surface epithelium is intact and the characteristic racemose glands are seen. Beneath them is the normal stroma. At *b* is an island of mucosa situated in myomatous muscle. The glands in this island resemble uterine glands. Some of them are dilated. At *c* and *c* they spread out in "goose march" fashion—that is, in single file. All of these glands are surrounded by the characteristic stroma. At *d* are seen isolated glands lying in direct contact with the muscle.

dant and slightly convoluted. A few are dilated, but all have an intact epithelium and many of them contain hyaline material. Here and there a gland extends a short distance into the muscle, being accompanied by stroma. The stroma of the mucosa in its superficial portion shows slight hemorrhage.

All of the nodules scattered throughout the uterus present the typical myomatous appearance and the large nodule in the anterior wall shows considerable hyaline degeneration. The whitish-yellow area attached to the right side of the uterus, and resembling mucous

membrane, is covered with one layer of cylindrical epithelium, on which it is in places possible to detect cilia. Beneath the epithelium is a varying amount of stroma similar to that of the uterine mucosa. This stroma shows considerable small round-cell infiltration and has here and there throughout it oval or round glands lined with cylindrical epithelium. The tissue external to this stroma is composed of non-stripped muscle fibres and connective tissue. Scattered throughout this muscular tissue are glands, in some places as many as eight being seen on cross-section (Fig. 49). Some are oval or round, others are dilated. All have an intact epithelial lining and in many places it is possible to make out cilia. These glands are surrounded by the typical stroma. Scattered here and there throughout the thickened wall are numerous glands, some lying in the myomatous muscle immediately beneath the peritoneum, others in what appears to be normal muscle. Some of the glands contain blood and one has become cystic. The growth is an intraligamentary adenomyoma, but its exact relations cannot be determined, as the tissue was much mutilated during operation.

Left side: The tube is covered with dense adhesions, but its mucous membrane is normal. The cyst of the ovary is apparently lined with a single layer of epithelium; it has several papillary masses springing from its inner surface.

Diagnosis.—Submucous and interstitial myomata. Cervical adenomyoma. Normal uterine mucosa. General pelvic peritonitis.

Left side: Hydrosalpinx simplex. Small papillocystoma of the ovary.

CHAPTER VIII

CONDITION OF THE TUBES AND OVARIES WHEN ADENOMYOMA OF THE UTERUS EXISTS

In forty-five cases we have carefully examined the tubes and ovaries to see if there might be any causal relation between them and the development of adenomyoma in the uterus. We have failed to find proofs of any such relation. In fifteen cases we found the appendages on both sides normal. In the remaining thirty cases the appendages on one or both sides were covered with adhesions, there being a mild degree of pelvic peritonitis, in part probably due to the discrete myomatous growth, but to a greater extent undoubtedly caused by the diffuse myoma. In Case 2806 there was a right tubo-ovarian abscess and a partially healed salpingitis on the left side. The left ovary in Case 3136 contained a small cyst; in Case 3898 the left tube was the seat of a hydrosalpinx, the left ovary of a small papillocystoma. There was a very large multilocular cystadenoma of the left ovary in Case 4364.

In a few cases there was a healed salpingitis. In Gyn. No. 2706 and in Path. No. 8393 a hydrosalpinx was present. In Gyn. No. 12,080 an acute salpingitis was found, and in Gyn. No. 2806 a tubo-ovarian abscess.

Where pelvic adhesions are present the normal maturing of the follicle is often interfered with, and we consequently find small Graafian follicle or corpus-luteum cysts. In Gyn. No. 2706 we found an ovarian cyst measuring 13 by 12 by 11 cm.; in Gyn. No. 3898 a very small papillocystoma of the ovary. In Gyn. 9457 one ovary contained a large cyst with changes very suggestive of an early carcinoma. These pathological changes in the ovaries are not in excess of those usually found in a corresponding number of abnormal adnexa examined in the laboratory. Adenomyoma of the uterus

does not seem to materially increase the incidence of pathological changes in the tubes or ovaries.

In forty-nine cases in which we examined the uterus for adhesions, in twenty-five the organ was perfectly smooth and in twenty-four was more or less adherent. The adhesions, as a rule, were confined to the posterior surface of the organ; only rarely was the anterior surface implicated.

CHAPTER IX

THE CLINICAL PICTURE IN CASES OF ADENOMYOMA OF THE UTERUS

This will, of course, vary with the situation of the growth and also with the size and situation of the discrete myomata so often associated with adenomyoma.

Where the diffuse growth is the chief factor, the patient usually gives a history of lengthened menstrual periods, accompanied by a great deal of pain, sometimes limited to the uterus, but often also referable to the back and extending to the legs. This pain may be dull, aching, or grinding in character. As the disease progresses the menorrhagia may be replaced by a continuous hemorrhagic discharge, as was observed in Cases 2573 and 6083; or alarming bleeding may occur, as in Case 7153. This hemorrhage is readily accounted for when we take into consideration the greatly increased amount of uterine mucosa existing under such circumstances, comprising that lining the uterine cavity and also that liberally distributed throughout the diffuse myomatous growth. The pain is also easily explained when we remember that the myomatous tissue is treated as a foreign body. In cases of discrete myomata there is also pain, but the uterus readily forces the nodule toward the peritoneal or submucous surface. In the diffuse growth, while this is also possible, the difficulties in its accomplishment are much greater, as the mass is so intimately interwoven with the normal muscle. At each menstrual period the uterine mucosa is congested and thickened. In adenomyoma with an increased amount of blood in the islands of the mucosa scattered through the diffuse growth we should naturally have increased tension, producing a tenderness or sharp pain, referred to the uterus, during the period.

Discharge.—In analyzing the clinical histories of thirty-seven cases for vaginal discharge we find that twenty-six were free from any flow between menstrual periods or between hemorrhages.

In eleven there was a distinct flow, chiefly leucorrhœal in character and usually non-irritating. In a few instances it was greenish or yellowish in color and offensive. In case No. 3192 there was a frequent white discharge and in Sanitarium No. 1944 a watery discharge was present. This might readily be accounted for, as the patient had a hæmoglobin of only 40 per cent. We are naturally surprised to see that so few of the patients gave a distinct history of vaginal discharge. When we remember, however, that the uterine mucosa and that situated deep down in the muscle are practically normal, this relative absence of the vaginal discharge is readily explained. In those cases in which the adenomyoma becomes subperitoneal or intraligamentary and forms large cysts, pressure symptoms may occur, and such cysts are usually firmly fixed in the pelvis. This is especially true of the intraligamentary variety, where the tumor is prevented from rising into the abdomen by the broad ligament.

Age.—We have found this disease in women as young as nineteen and as old as sixty. In sixty-six patients in whose cases the age was obtained the following incidence was noted:

At nineteen.....	1 case
Between twenty and thirty.....	3 cases
Between thirty and forty.....	21 "
Between forty and fifty.....	19 "
Between fifty and sixty.....	21 "
At sixty.....	1 case

This table goes to show that the period between the fourth and sixth decades presents the highest incidence of this disease. The process seems to be a slow one, as is evidenced by the clinical history. Some patients dated their trouble back five or ten years, while others had been complaining for only a few months. We have found this disease equally prevalent in the colored and white races.

Relation to Pregnancy.—We have examined the clinical histories in forty-nine of the cases of diffuse adenomyoma of the uterus to determine the relative frequency of pregnancy, with the following results: nine patients were single, six were sterile, two had had miscarriages, thirty-two had had children.

One of the sterile patients had not married until over forty years of age, and accordingly might be equally well classed with the single patients from that standpoint.

In thirty-one of the thirty-four patients that had had either children or miscarriages we have accurate records of the number of children. In all, one hundred and forty-one children were born, approximately four children to each woman. In a few instances a woman had had only one child, while in one case the patient was the mother of thirteen, in another of eleven, in a third case of ten. These figures show that the disease is found in single as well as in married women, and furthermore that it does not seem in any way to militate against normal pregnancy.

Physical Examination.—On making a vaginal examination, when the growth is confined to the uterus we find the cervix practically normal, the body of the uterus considerably enlarged and very hard. In the majority of the cases we also feel definite small round bosses due to discrete myomata. In the early cases the organ may be free, but very often it is enveloped in adhesions and firmly fixed. In some cases (Fig. 13) the organ will be symmetrical, very firm, and the size of that of a two or three months' pregnancy. Where the growth is large and cystic and lies in the abdominal cavity, it is impossible to differentiate it from an ordinary myomatous uterus pure and simple or associated with an ovarian cyst. If the growth be intraligamentary, it is more firmly fixed in the pelvis, and is then comparable to a broad ligament myoma or to an intraligamentary cyst, although it may simulate a large pelvic abscess. The clinical history of pus will, however, be wanting.

From the preceding it will be seen that if we have a patient giving a history of an ever-increasing menstrual flow, and showing on pelvic examination a moderately enlarged and firm and possibly nodular uterus, which on curettage yields a rather thick but normal mucosa, we may reasonably suspect an adenomyoma. Of course, however, the hemorrhages may occasionally be due entirely to the presence of discrete submucous myomata.

Where carcinoma of the body of the uterus is present the organ

is likely to be soft. Rarely small and isolated myomata are found on its surface, and curettage yields adenocarcinoma instead of normal mucosa.

Where an adenomyoma is subperitoneal or intraligamentary the diagnosis is impossible until the abdomen is opened. But then, given a myomatous uterus containing large cystic areas with smooth velvety linings and chocolate-colored contents, adenomyoma will

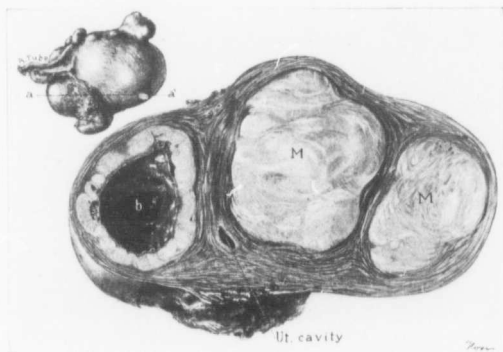


FIG. 50.—A CYSTIC MYOMA MACROSCOPICALLY SIMULATING A CYSTIC ADENOMYOMA. ($\frac{1}{3}$ natural size.)

Path. No. 10,771. The picture represents a cross-section through the tumor as seen in the upper left corner, the section being made from *a* to *a'*. A small portion of the uterine cavity is seen. On one side of it are cross-sections of two simple myomata. At *b* we have a cystic myoma with a slightly irregular cavity that was filled with chocolate-colored blood. We felt confident that a histological examination would reveal a cystic adenomyoma. The walls of the cavity were, however, composed of myomatous tissue that had undergone partial hyaline degeneration and the cavity was totally devoid of any epithelial lining. There had evidently been simple cystic formation as a result of the breaking down of hyaline tissue. Hemorrhage had taken place later. This is the only one of our cases in which a tumor presented such a gross appearance and did not yield adenomyoma on histological examination.

usually be found. Fig. 50 represents the only exception that we have noted. Here the uterus contained several myomata. One of them had a central cavity which was filled with chocolate-colored contents. This myoma had undergone a good deal of hyaline degeneration. In the centre was a cystic area and into this hemorrhage had taken place. It was not an adenomyoma.

CHAPTER X

DIFFERENTIAL DIAGNOSIS IN CASES OF ADENOMYOMA OF THE UTERUS

Diffuse adenomyoma of the uterus has, thanks to the work of von Recklinghausen, become a definite pathological entity, but heretofore it has not impressed surgeons as having a very definite and peculiar train of symptoms.

In the early years of our investigations we also failed to detect it clinically, but in the early and fairly advanced stages of the process so definite are the symptoms that the hospital assistant now frequently comes and says that a given case has all the signs of an adenomyoma and that he feels sure that this is the cause of the bleeding. His diagnosis can, of course, be greatly strengthened by the histological appearances of the uterine mucosa, and then the gross appearance of the uterine wall on section often suffices to clinch the diagnosis after the uterus has been removed, even before a histological examination has been made. We accordingly see that this disease has very characteristic symptoms and must be given its proper place in our list of uterine diseases which may be clinically recognized.

Clinically adenomyoma has to be differentiated from any pelvic condition that may cause uterine hemorrhage. The following are those diseases that are likely to produce or be associated with uterine bleeding.

1. Uterine polypi.
2. Large venous sinuses in the mucosa.
3. Marked proliferation of the stroma of the mucosa.
4. Very large and dilated uterine glands with overgrowth of the stroma of the mucosa.
5. Uterine myomata.
6. Sarcoma.

7. Abortion.
8. Chorio-epithelioma.
9. Tubal pregnancy.
10. Salpingitis and endometritis.
11. Carcinoma of the uterus.

UTERINE POLYPI

These may be situated in the cervix or body, and are usually associated with a slight irritating uterine discharge and often with bleeding. This bleeding may manifest itself as an exacerbation of the usual flow at the period or there may be a slight discharge of blood between periods.

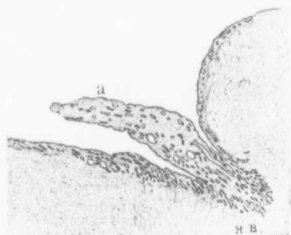

FIG. 51.—A SMALL UTERINE POLYP. (4 diameters.)

GYN.-PATH. No. 659. This section is from the fundus of the uterus. The mucosa lining the uterine cavity is rather thin and has a smooth surface covered with one layer of epithelium. Scattered throughout the mucosa are a small number of normal uterine glands. Projecting from it is a tongue-shaped polyp (a), which points downward. Its surface is covered with one layer of epithelium, continuous with that covering the surface of the mucosa. Its substance contains glands differing from those in the mucosa only in that a few of them are dilated. The stroma of the polyp merges imperceptibly into that of the normal mucosa and is of the same character. It is evident that this is in reality the result of a partial extrusion of the normal mucosa.

If the growth projects through the cervix, the recognition of the polyp is easy and its removal is followed by a total cessation of the symptoms. Should the polyp be in the cavity of the uterus, it may be brought away with the curette, and then all symptoms cease.

Polypi, whether situated in the cervix or in the body, are nothing more than portions of normal mucosa which have for some reason been partially or completely extruded (Fig. 51).

On histological examination they are recognized by their oval or oblong shape and by the fact that they are covered on three sides by epithelium.

In cases of diffuse adenomyoma curettage gives only temporary

relief, and on histological examination nothing but perfectly normal mucosa can be detected in the scrapings.

LARGE VENOUS SINUSES IN THE UTERINE MUCOSA CAUSING FREE
HEMORRHAGES

In "Cancer of the Uterus" I reported a case in which, on account of the frequent uterine hemorrhages, carcinoma was suspected and hysterectomy contemplated. Examination of the scrapings showed

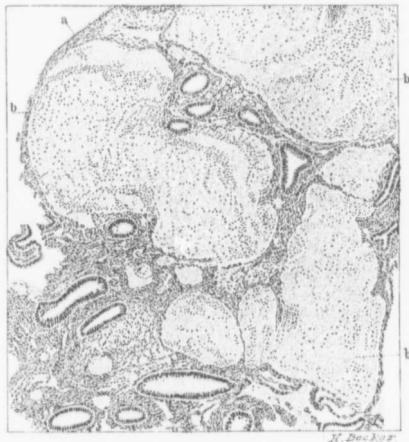

FIG. 52.—LARGE VENOUS SINUSES IN THE UTERINE MUCOSA CAUSING SEVERE HEMORRHAGES.
(80 diameters.)

Gyn.-Path, No. 2048. *a* is a portion of the surface epithelium, which is greatly flattened. In the lower part, as well as in the upper third of the field, are several uterine glands of the usual size and shape, and lined with one layer of cylindrical epithelium. They are perfectly normal, and are surrounded by the normal stroma of the mucosa. Over one half of the section is made up of three large venous sinuses (*b*), showing exceedingly delicate walls. That there is no malignant process is clear. It is little to be wondered at that free hemorrhages should have taken place, when such large blood sinuses existed.

that the bleeding was due to enormous sinuses scattered throughout the uterine mucosa. The patient was greatly benefited by the curet- tage. A year later she was again curetted, and in a short time she felt better than she had for years.

The difference between the mucosa in this case and that in a case of adenomyoma is very plain, as can be gathered from Fig. 52.

MARKED PROLIFERATION OF THE STROMA OF THE MUCOSA ASSOCIATED WITH COPIOUS UTERINE HEMORRHAGES

On page 478 of "Cancer of the Uterus" I described several cases in which free uterine hemorrhage was apparently due to a marked proliferation of the stroma of the uterine mucosa, the glands remaining perfectly normal. The stroma was very rich in cellular elements; the nuclei were slightly larger than normal. Numerous nuclear figures could be seen scattered throughout the stroma, and were it not for the fact that the spaces between the glands were everywhere approximately equal, one might have suspected sarcoma.

The histological picture shows clearly the difference in the mucosa of cases of this character and those of diffuse adenomyoma. Clinically, the contrast is even more striking. All the patients were under twenty-five years of age and in each case the hemorrhages ceased in the course of a few years.

A THICK UTERINE MUCOSA; VERY LARGE AND DILATED UTERINE GLANDS WITH AN OVERGROWTH OF THE STROMA OF THE MUCOSA

Clinically we have a by no means small group of cases in which a patient, usually between forty and fifty, comes complaining of a very profuse menstruation and at times of an intermenstrual flow or a leucorrhœal discharge, and in which carcinoma of the body of the uterus is suspected.

On histological examination we find a most characteristic picture (Fig. 53). The mucosa is much thickened. The glands are large and many of them are dilated. This dilatation is, however, not due to occlusion and cyst formation, as the gland epithelium is proliferated and higher than usual instead of flattened. Many of the enlarged glands are irregular in outline.

The stroma of the mucosa is very rich in cell elements and nuclear figures can at times be detected.

I have examined the mucosa in many such cases and am at a

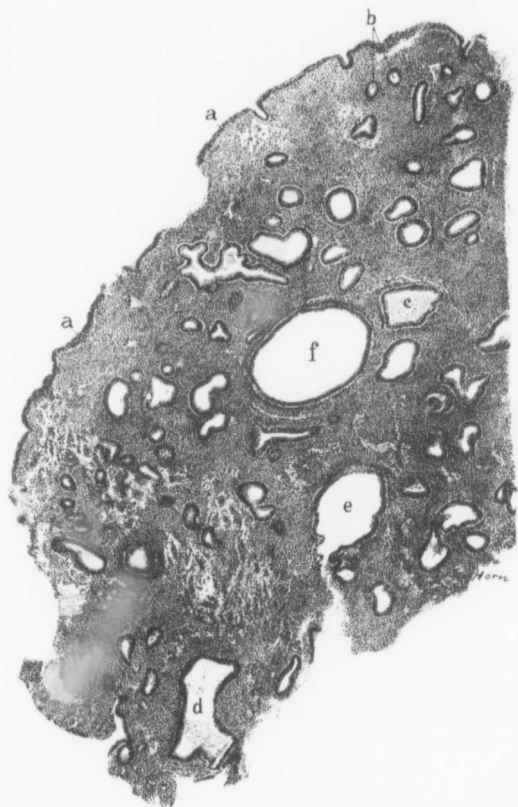


FIG. 53.—THICKENING OF THE UTERINE MUCOSA. MARKED DILATATION OF SOME OF THE GLANDS WITHOUT ANY ATROPHY OF THEIR EPITHELIUM; VERY DENSE STROMA. (38 diameters.)

Gyn. - Path. No. 7026. The section is a portion of a scraping. The surface epithelium is intact as seen as *a* and *a*. At *b* are two normal uterine glands. Fully half of the glands are more or less dilated. At *c* is an irregular and dilated gland filled with coagulated serum. *d* and *e* are also dilated but not spherical glands. The gland *f* is markedly dilated and spherical. In none of the dilated glands is there any atrophy of the epithelium. The stroma between the glands is very dense. In some of these cases large veins are found scattered throughout the stroma. Given such a mucosa as this, one can say with almost absolute certainty that the patient has had very profuse menstrual bleeding.

loss to give the condition a definite name. With such a mucosa one can say with absolute certainty that the patient has been subject to very free uterine bleeding. It is not malignant.

The clinical picture in this condition resembles to some extent that of diffuse adenomyoma of the uterus, but, as noted, the histological patterns are totally different.

UTERINE MYOMATA

Myomata are primarily interstitial and may become subperitoneal or submucous. Often these give rise to no symptoms whatever save those of pressure. When the myomata become submucous, more or less menorrhagia is present. This is due to the fact that the uterine mucosa is put on tension by the myoma, which is gradually forcing its way into the cavity of the uterus. I have known a small submucous myoma give rise to almost fatal hemorrhage, while, on the other hand, a patient with an 89-pound myoma had never had any excessive menstruation. The hemorrhage depends entirely on the situation of the tumor.

Bimanual examination will often reveal the presence of a large myomatous uterus.

On curettage normal or atrophic uterine mucosa will be found, provided the tubes and ovaries are normal.

The differential diagnosis between a uterus containing simple discrete myomata and one the seat of a diffuse adenomyoma is often difficult, if one of the simple myomata be submucous. The difficulty is increased by the fact that there is a marked tendency for discrete myomata to be associated with a diffuse adenomyoma. However, where simple myomata exist there may not be the marked tenderness at the menstrual period, so frequently noticed in adenomyoma, and further, examination of the curettings will usually demonstrate a much thicker mucosa in the adenomyomatous uterus.

SARCOMA OF THE UTERUS

In the examination of over twelve hundred myomata we have found sarcoma developing in or associated with uterine myomata in seventeen cases.

The points of difference between cases of uterine myomata and diffuse adenomyoma apply equally well to those of sarcoma of the uterus. In sarcoma, however, we have a history of a tumor which has probably lain dormant for years, and then suddenly has commenced to grow rapidly. If portions of the growth project into the uterine cavity, the diagnosis of sarcoma can readily be made from pieces removed with the curette.

Where sarcoma arises primarily from the uterus and not from a pre-existing myoma, the growth may also be correctly diagnosed from scrapings, if portions of it project into the uterine cavity.

ABORTION

Uterine bleeding often follows a miscarriage, especially when remnants of the placenta have been left behind. This bleeding is usually continuous, while in adenomyoma the bleeding usually consists in an exacerbation of the menstrual period. Further, in the one case there is likely to be a history of a recent conception; in the other the bleeding has been noticed for months or years and has gradually increased.

Where an abortion has occurred placental villi or decidual remains are usually obtained on curettage. In diffuse adenomyoma a perfectly normal uterine mucosa is found.

CHORIOEPITHELIOMA

Chorioepithelioma is infinitely rarer than adenomyoma, and follows an intrauterine or extrauterine pregnancy—usually a hydatid mole.

The clinical history is generally sufficient. Examination of the scrapings will aid materially in settling the question. Where chorioepithelioma exists we usually have placental villi showing marked

proliferation of the syncytium and usually of Langhans' layer. There are also many vacuoles between and also in the masses of cells of the growth.

While one cannot from the scrapings differentiate absolutely between a very active hydatid mole and chorioepithelioma, yet one can say with certainty that a pregnancy has existed and that the growth, if not actually malignant, is very suspicious. In the cases of diffuse adenomyoma the mucosa is perfectly normal.

TUBAL PREGNANCY

Pregnancy in the Fallopian tube is usually associated with a cessation of the period for one or two months, followed by a slight continuous uterine bleeding. In some cases the periods have been perfectly regular, but the last period has never completely stopped and the patient has continued to lose a little blood. Later she complains of pain in one side, and if she does not consult a physician she suddenly collapses from internal hemorrhage. Pelvic examination before rupture of the tube will show slight enlargement of the uterus with a small mass on one or the other side.

In adenomyoma the periods remain regular, but are profuse, and there is usually no intermenstrual bleeding. Moreover, there is little or no intermenstrual pain. Examination of the uterine mucosa in the one case usually yields a slight decidua formation; in the adenomyoma, a normal mucosa.

SALPINGITIS AND ENDOMETRITIS

The patient with pelvic inflammation usually gives a history of an acute infection followed by a profuse uterine discharge and pain laterally. Bleeding is occasionally present and may suggest adenomyoma.

On examination of the scrapings we usually find a thinning out of the mucosa and definite infiltration with small round cells or polymorphonuclear leucocytes. In those cases in which tuberculosis is present typical tubercular areas or areas of caseation are seen.

Both pictures are totally different from that presented by the normal uterine mucosa associated with diffuse adenomyoma of the uterus.

CARCINOMA OF THE UTERUS

Carcinoma of the uterus is clinically divisible into two varieties:

1. Carcinoma of the cervix.
2. Carcinoma of the body of the uterus.

Usually the first symptom of a carcinoma, whether situated in the cervix or body, is uterine hemorrhage. This is frequently sudden and may be meagre or abundant. The hemorrhages are usually intermenstrual. In adenomyoma the bleeding is usually profuse at the periods and there is no hemorrhage between the periods. In carcinoma a watery or purulent and usually offensive discharge is present between the periods. This is due to disintegration of the degenerating carcinomatous tissue. In adenomyoma there is usually no such discharge because there is no dissolution of tissue.

Where carcinoma of the cervix exists the growth can usually be detected on digital examination. Sometimes it is recognized as a cauliflower-like outgrowth from the cervical lips, but in the later stages a crater-like cavity is present where the cervix should be, and the vaginal vault is board-like in consistency as a result of carcinomatous infiltration. In cases of diffuse adenomyoma of the uterus the cervix is usually perfectly normal.

Where carcinoma of the body of the uterus exists, uterine scrapings yield the characteristic pattern of adenocarcinoma and the cell changes leave no doubt as to the malignant nature of the growth. In cases of adenomyoma the mucosa lining the uterine cavity is, on the contrary, perfectly normal.

CHAPTER XI

TREATMENT OF ADENOMYOMATA OF THE UTERUS

Not infrequently the case will be looked upon as one of simple myoma and its true character will be determined only after operation. Should a diagnosis be made, abdominal hysterectomy is indicated provided the bleeding is so severe that the patient's health is being undermined. Myomectomy is inapplicable, as the growth is so interwoven with the normal muscle that it cannot be shelled out. In cases of intraligamentary and cystic adenomyomata evacuation of the cyst contents will often be found necessary, before it is possible to shell the tumor and the uterus out from the pelvic floor. As these growths will lift up the peritoneum of Douglas' sac, it will be advisable to dissect the peritoneum back so that it can be replaced after removal of the tumor, thus avoiding a raw area on the pelvic floor. If this precaution be not taken, intestinal loops are apt to drop down and become adherent.

In these cases supravaginal hysterectomy is all that is required. This occasionally greatly diminishes the dangers of the operation. For example, in one of our recent cases in which we suspected carcinoma of the body a complete abdominal hysterectomy was commenced. Release of the cervical portion proved to be very difficult on account of the very long cervix. With the gradual loosening up of the uterus we found strong suggestions of adenomyoma. The uterus was accordingly amputated through the cervix and at once opened. The diagnosis of adenomyoma was immediately confirmed. In this case complete removal of the uterus would have entailed much painstaking dissection and would have prolonged the operation in the case of a very anæmic woman.

CHAPTER XII

PROGNOSIS IN CASES OF ADENOMYOMA OF THE UTERUS

When considering these growths in 1896, I agreed with von Recklinghausen that they are benign.¹ The glands are perfectly normal uterine glands and are surrounded by the normal stroma of the mucosa. They are confined entirely to the new growth and do not show the slightest tendency to invade the normal muscle. Wherever possible, it is always well to back up the impressions gained from histological study by the clinical sequence. And in two of our cases this has been unconsciously and yet admirably done. In Case 3600, on opening the abdomen, a diffuse myomatous thickening was found in the posterior uterine wall. It was considered to be only a myomatous thickening, and a wedge-shaped piece of the growth was removed; in other words, a partial myomectomy was performed (Fig. 54).

The histological picture as seen in Fig. 55 shows that the growth was a typical and diffuse adenomyoma of the uterus. The patient made a good recovery, and eleven years afterward, in response to an inquiry as to her condition, said that she had been greatly benefited by the operation and that she was in perfect health. The mass was certainly not entirely removed, and the subsequent history confirms what was indicated by the histological findings, namely, the benign character of the growth.

In Case 4415 we were also dealing with a diffuse myomatous uterine growth. A wedge, 5 by 2 cm., was removed through the abdomen. This patient also recovered. On examination the growth proved to be an adenomyoma. Here, also, notwithstanding the fact that portions of the growth were left behind, the patient was

¹ Von Recklinghausen, Friedrich: Die Adenomyome und Cystadenome der Uterus und Tubenwandung; ihre Abkunft von Resten des Wolff'schen Körpers, Berlin, 1896.

much improved. For two years she had no trouble, but since then the periods have been longer, and sometimes last for weeks. She has, however, been completely relieved of pain at the menstrual periods.

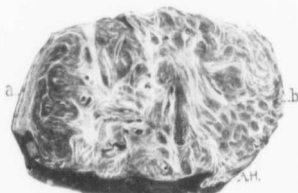

FIG. 54.—A PORTION OF A DIFFUSE ADENOMYOMA OF THE POSTERIOR WALL OF THE UTERUS. (Slightly enlarged.)

GYN.—Path. No. 777. At operation the posterior uterine wall was found much thickened. A wedge was removed and the cut surfaces were brought together as in an ordinary myomectomy. *a* is the peritoneal surface; just beneath it is a narrow zone of normal muscle. The growth presents the typical appearance of a diffuse myoma. Along the outer margin it gradually merges into the normal muscle. *b* corresponds to the point nearest the uterine cavity. The uterine cavity was not opened. Scattered throughout the myoma are small round oval or oblong spaces. Some are dilated glands, others cross-sections of small blood-vessels. For the histological findings see Fig. 55. At the time the operation was performed we were unfamiliar with these adenomyomatous growths.

years, but has never been pregnant. Her menses began at thirteen, were regular and always associated with severe pain, dull and grinding in character, with sharp paroxysms referred to the abdomen and in the back. This pain has been growing much worse recently and has been associated with nausea. It is only present during the periods. The flow is very profuse and is growing more so. It is occasionally clotted. The patient has a slight leucorrhœal discharge.

We see, therefore, from the histological and clinical pictures that these growths are benign.

Since these two cases were published¹ we have had several similar instances under observation.

CASES GRAPHICALLY ILLUSTRATING THE BENIGN CHARACTER OF ADENOMYOMATA OF THE UTERUS

Gyn. No. 3600. Path. No. 777.

Diffuse adenomyoma of the posterior uterine wall (Figs. 54 and 55). Removal of a wedge-shaped portion of the growth. Complete relief from former symptoms.

G. H. W., married, white, aged twenty-five. Admitted June 24; discharged July 20, 1895. The patient has been married ten

¹ Cullen, Thomas S.: Adenomyome des Uterus, Berlin, 1903.

Two months ago she noticed that the abdomen was larger than normal.

Operation, June 26, 1895. Myomectomy. A myomatous thickening was noted in the posterior wall. This thickening extended from the cervix to the fundus, and the uterus was the size of that of a three months' pregnancy. A wedge-shaped piece was

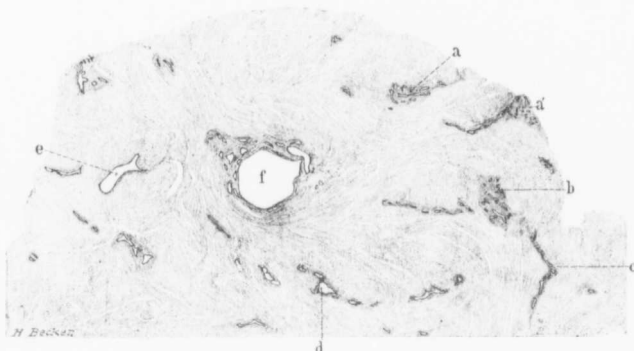


FIG. 55.—DIFFUSE ADENOMYOMA. (6 diameters.)

Gyn.-Path. No. 777. The section is taken from Fig. 54. The growth under the higher power was recognized as a diffuse myoma. At *a* and *a'* we find groups of glands resembling uterine glands both in form and in their even distribution. They are embedded in a definite stroma which separates them from the muscle. Some of the glands in the islands of mucosa show slight branching. At *c* the glands are arranged in "goose march" fashion. They are in all probability sections of one and the same gland which has been much convoluted. At *d* one of the glands is moderately dilated. *e* shows a more marked dilatation, and here so much tension has taken place that little of the surrounding stroma remains. *f* corresponds very well to a miniature-uterine cavity. On the one side it has become flattened out so that there is merely a layer of epithelial cells and a faint amount of stroma. On the opposite side is a well developed mucosa. Isolated glands are scattered throughout the growth. Without exception they are surrounded by the characteristic stroma and nearly all closely resemble uterine glands. The cystic dilatation is to be expected where the glands are subjected to the myomatous pressure.

excised from the posterior wall and the uterine walls were brought together. The length of the incision in the uterus was 8 cm. The patient made a satisfactory recovery.

January, 1907. The patient is perfectly well eleven years after operation.

Gyn. Path. No. 777.—The specimen consists of sev-

eral large and small pieces of tumor. All of the tissue is pinkish-white in color, firm on pressure, and apparently composed of coarse fibres arranged in interlacing bundles (Fig. 54).

HISTOLOGICAL EXAMINATION.—The tissue consists of non-striped muscle fibres cut in various directions. Scattered here and there throughout it are glands occurring singly or in groups (Fig. 55). They are lined with high cylindrical ciliated epithelium and are surrounded by a stroma identical with that of the uterine mucosa. These glands are precisely similar to uterine glands. Some of them are dilated.

Diagnosis.—Adenomyoma uteri diffusum benignum.

Gyn. No. 4415. Path. No. 1207.

Removal of a wedge-shaped piece of an adenomyoma of the posterior uterine wall. Complete cessation of the previous symptoms for two years, followed again by profuse menstruation.

I. C. R., white, married, aged forty. Admitted May 28; discharged July 11, 1896. The patient has been married eighteen years and has never been pregnant. The menses commenced at twelve and were regular up to two or three years ago. Since that time they have occurred every twenty-second or twenty-third day. The flow is profuse, dark and clotted, and associated with bearing-down pains in the abdomen and also with backache and pains in the legs. Micturition is frequent and the patient has a constant feeling of pressure on the bladder. The bowels are constipated. She suffers but little discomfort except at her menstrual periods. For the past year she has noticed a slight increase in the abdominal girth.

Operation. June 1, 1896. Myomectomy. A wedge-shaped piece of the diffusely thickened wall was removed; also a pedunculated and partly cystic myoma, 5 by 2 cm. Convalescence was interrupted by an attack of phlebitis and one of pleurisy. The pleurisy developed at the base of the left lung and persisted for nine

days. The phlebitis developed in the femoral vein on the twenty-second day. The patient made a satisfactory recovery.

She remained well for two years and then again began to have profuse menstruation.

Gyn. Path. No. 1207.—The specimen consists of a subperitoneal myoma and several fragments of an interstitial myoma.

The subperitoneal myomatous nodule measures 5 by 5 by 4.5 cm.; it is pinkish in color and on pressure is firm. Springing from its surface is a cyst 2.5 cm. in diameter. This is whitish in color, its walls are semi-transparent, and it contains clear yellow fluid. On section the nodule presents the typical myomatous appearance. The walls of the cyst average 3 mm. in thickness and are rather soft. The inner surface on one side is smooth; on the other, roughened. The cyst appears to be a portion of the myoma that has undergone degeneration. The tumor also contains another area of degeneration measuring 2.5 by 1 cm.

The fragments of the interstitial myoma are nine in number and the largest measures 4 by 3 by 1.5 cm. All of them are composed of bundles of coarse fibres forming an irregular network, in the meshes of which are minute cystic areas. One of these pieces is covered with peritoneum and the outer covering of normal muscle at that point is 4 mm. in thickness. The line of junction between the myomatous tissue and the normal muscle is sharply defined, but it is impossible to shell the tumor out at any point.

Histological Examination.—The subperitoneal nodule is composed of non-striped muscle fibres, which in places have undergone moderate hyaline degeneration, at other points complete hyaline transformation. The line of demarcation between the intact muscle fibres and the degenerated portions is abrupt.

The interstitial myomatous tissue is also composed of interlacing bundles of smooth muscle, but shows very little tendency toward hyaline degeneration. Scattered between the muscle bundles almost to the peritoneal covering are groups of glands or single gland-like spaces.

These glands are small and round and sometimes send off one or more branches; some are dilated, reaching 1 to 2 mm. in diameter. They are lined with cylindrical epithelium, having oval vesicular nuclei situated in the centres of the cells. Surrounding the glands and separating them from the muscle is a moderate amount of stroma consisting of oval or elongate cells having oval vesicular nuclei. These cells are identical with the stroma cells of the uterine mucosa and the glands are in every respect similar to those of the uterus. The myomatous tissue has a moderately abundant blood-supply.

D i a g n o s i s.—Subperitoneal myoma. Interstitial adenomyoma of the uterus.

CHAPTER XIII

ORIGIN OF ADENOMYOMATA OF THE UTERUS

In 1896 von Recklinghausen reviewed the literature of adenomyomata and added many new cases. After a careful consideration of all, he concluded that in the vast majority of instances the glandular elements were derivatives of the Wolffian duct. This opinion was based upon the supposed close analogy between the elements of the Wolffian duct and the glandular structures present in adenomyomata of the uterus. In only one case was he certain that the glands were due to down-growths of the uterine mucosa. This case of von Recklinghausen was included in the appendix to his most instructive treatise. Since his publication appeared, much attention has been devoted to this subject and quite a number of new cases have been reported. Many writers have espoused von Recklinghausen's theory, but not a few have claimed that nearly all, if not all, of these cases owe their origin to the uterine mucosa or to a portion of Müller's duct. It would be unnecessary for us to review at length this lively controversy, but to those wishing the full details we would recommend the careful presentation of the subject as given by von Recklinghausen,¹ Meyer,² Pick,³ and Kossmann.⁴

In my previous publication⁵ I reported nineteen cases of diffuse adenomyoma and pointed out that in the majority of these cases the process was still limited to the uterus, thus enabling us to determine definitely the origin of the glands in most of the cases. Since then

¹ Von Recklinghausen, Friedrich: Die Adenomyome und Cystadenome der Uterus- und Tubenwandung; ihre Abkunft von Resten des Wolff'schen Körpers. Berlin, 1896.

² Meyer: Ueber Drüsen, Cysten und Adenome im Myometrium bei Erwachsenen. Ztschr. f. Geb. u. Gyn., 1900, Bd. xlvii, S. 618; xlviii, S. 130 u. 329.

³ Pick: Archiv. für Gyn., Bd. liv.

⁴ Kossmann, B.: Die Abstammung der Drüseneinschlüsse in den Adenomyomen des Uterus und der Tuben. Arch. f. Gynaek., Bd. liv, S. 359.

⁵ Cullen, Thomas S.: Adeno-Myoma des Uterus, Berlin, 1903.

we have subjected each myomatous uterus to the most careful scrutiny, and wherever adenomyoma was suspected we have had very large sections made from many parts of the uterine cavity. If adenomyoma was present and no connection between the glands in the depth and the uterine mucosa could be detected, we kept on cutting more tissue, until finally in the vast majority of the cases we found that the gland elements were derivatives of the uterine mucosa. I have been greatly helped in this work by Mr. Benjamin O. McCleary, our laboratory assistant.

We have had fifty uncomplicated cases of diffuse adenomyoma of the uterus, some very extensive, others in their early stages. In every one of these cases we have been able by persistent search to trace the uterine mucosa into the myomatous tissue. In other words, islands of mucosa in the diffuse myomata originated from the mucosa lining the uterine cavity in every case. Any one can verify this statement for himself by studying the pathological description in each case.

In six other cases there was squamous-cell carcinoma of the cervix and diffuse adenomyoma of the body. In five of the six cases the origin of the gland elements in the myoma could be traced to the mucosa. In one case (Gyn. 9971), where the process was a rather indefinite one, it was impossible to show the origin of the glands from the mucosa.

We thus see that in fifty-five out of fifty-six cases of diffuse adenomyoma of the body of the uterus the gland elements were shown to be derived in part at least from the uterine mucosa.

In Gyn. 8438 and also in Sanitarium No. 1852 diffuse adenomyoma of the body and adenocarcinoma of the body were present. In both of these the uterine mucosa has been destroyed, and the carcinomatous growth so overshadowed the picture that the origin of the glands in the myomatous growth was naturally totally obscured.

SUBPERITONEAL ADENOMYOMATA

In eight cases we have found subperitoneal adenomyomata. In Case 8647 there was a large subperitoneal adenomyoma, and exami-

nation of the uterine mucosa showed that the glands extended 1.5 mm. into the muscle. Of course, no continuity with the subperitoneal nodule could be traced. In Case 3293 subperitoneal cysts of an adenomyomatous type were found, but in this case the uterine mucosa was normal. In Sanitarium No. 1872, in which the most typical adenomyoma lay perfectly free from the uterus, being attached to the utero-ovarian ligament (Fig. 41), the uterine mucosa extended into the muscle and the uterus was also the seat of discrete myomatous nodules. In Gyn. 5782 the adenomyomatous nodule was small and the uterine mucosa had been completely destroyed by the adenocarcinoma. In the remaining case of subperitoneal adenomyoma the nodule alone was removed, and we had no chance to examine the uterine mucosa to determine if any continuity with the adenomyoma persisted.

SUBMUCOUS ADENOMYOMATA

We have had seven cases of submucous adenomyomata. Some consisted of diffuse myomatous growths containing only a few small glands. In others the glands had become cystic; in one case the myoma was riddled with miniature uterine cavities. In this case the direct continuity with the uterine mucosa was readily established.

Where the uterine glands are seen penetrating the myomatous muscle, as in Figs. 2, 3, 6, 15, and 30, there is no question as to their being derivatives of the uterine mucosa, and, as will be seen from a study of our cases, in the majority of which the uterus was removed, the mucous-membrane origin was established. This fact is very significant when compared with the figures of those claiming the Wolffian duct origin. With the increase in thickness and the irregular growth of the diffuse myoma it is very natural that the continuity of the uterine glands into the depth should be lost after a time, as is evidenced by the formation of cysts. It is not necessary that the uterine glands be traced by continuity to establish the mucous-membrane origin. The islands of glands lying deep down in the myomatous muscle correspond identically with those seen in cases in

which the continuity is traceable, and moreover they are precisely the same as in normal uterine mucosa. Furthermore, they are surrounded by a stroma identical with that surrounding the uterine glands. In some cases miniature uterine cavities are scattered throughout the myoma. Fig. 22, taken from a cavity near the peritoneal surface of an adenomyoma, could not be distinguished from normal uterine mucosa. From the uterine mucosa there is a periodic hemorrhage every month. According to Hartz,¹ Sanger, when speaking to his students of the uterine mucosa, said: "This is no simple mucous membrane, but is an organ which has an important function to fulfil." With Sanger's view I am in thorough accord. In no other part of the body do we find a mucosa with a similar function, and nowhere else do we meet with such histological peculiarities. Now, if portions of this uterine mucosa be far removed from the parent mucosa, we should still expect them to retain their function, and this they do. In nearly every instance in which cyst spaces are present, the cavities are, in part or almost completely, filled with blood; and even in the small and undilated glands blood is frequently present, or the epithelial cells contain blood pigment, the remnants of old hemorrhages. It is natural that the cysts in the uterine walls should remain small, as they are compressed by the muscle; on the other hand, when they have once become subperitoneal they may dilate until they can contain several litres of blood, although even in these cases they still show the evidence of the menstrual phenomenon as seen in their chocolate-colored contents. In the solid portions of these growths islands of typical uterine mucosa are still demonstrable. It is so easy to understand how interstitial myomata become subperitoneal or submucous, and yet in considering the subsequent history of adenomyoma the majority of authors have forgotten to apply the same principle. When the growth becomes subperitoneal, we should expect its glandular elements to gradually lose their continuity with those of the mucosa, and such is the case. Hence the confusion as to their origin. Case

¹ Hartz, A. L.: *Neuere Arbeiten ueber die mesonephrischen Geschwulste*. Monatschrift f. Geburtshilfe und Gynaekologie, 1901, Bd. xiii, S. 95 u. 214

2 of Breus' and Kroenig's case¹ illustrate very well the intraligamentary variety. In Kroenig's case we have all the elements of normal uterine mucosa, and also large cysts. In Breus' case we find the same, but fortunately the communication between the uterine mucosa and the cystic tumor still persists, showing beyond doubt that the gland elements in this case were from the uterine mucosa.

A definite example of a portion of a diffuse adenomyoma becoming subperitoneal is furnished by Lockstaedt.² The adenomyoma occupied the posterior wall and right side, and in the gross specimen it was possible, in at least five places, to see the mucosa extending deeply into the myoma. In this case there was a subperitoneal adenomyoma, the size of a cherry, that by its pedicle was in direct communication with the diffuse growth, so that its glands were undoubtedly derivatives of those of the uterine mucosa.

Were we in need of still further proof that these islands of mucosa are identical with normal uterine mucosa the case reported by J. Whitridge Williams³ would certainly tend to convince the most skeptical. In examining the uterus of a patient entering the hospital in a desperate condition and dying two hours after labor he found that it was the seat of a diffuse adenomyoma and that the stroma of these islands had been converted into typical decidua.

A somewhat similar decidual formation is reported on page 247. In this case I found a subperitoneal myoma near the right uterine horn. On the left side was an unruptured tubal pregnancy. The stroma of the adenomyoma had been in part converted into decidual cells, although the adenomyoma was at least 9 cm. away from the tubal pregnancy.

¹ Breus, Carl: Ueber wahre epithelführende Cystenbildung in Uterus-Myomen. Leipzig und Wien, 1894.

² Kroenig, B.: Ein Retroperitoneal gelegenes voluminöses Polycystom entstanden aus Resten des Wolff'schen Körpers. Beiträge zur Geb. u. Gyn., 1901, Bd. iv, S. 61.

³ Lockstaedt: Ueber Vorkommen und Bedeutung von Drüsenschläuchen in den Myomen des Uterus. Monatschr. f. Geb. u. Gyn., 1898, Bd. vii, S. 188.

⁴ Williams, J. Whitridge: Decidual Formation Throughout the Uterine Muscularis: A Contribution to the Origin of Adenomyoma of the Uterus. Transactions of the Southern Surgical Association, 1904, vol. xvii.

RESUME

In the examination of fifty uncomplicated diffuse adenomyomata of the uterus the mucous-membrane origin of the glands could be traced in every case. In six additional cases where squamous-cell carcinoma of the cervix complicated adenomyoma of the body the continuity was established in five cases. In the two remaining cases of diffuse adenomyoma of the body the clue as to the origin of the glands was destroyed by the presence of adenocarcinoma of the body. Thus in only one case out of fifty-six in which we expected to find the glands originating from the mucosa, if our view as expressed in 1896 was correct, did we fail to find it substantiated. In the remaining fifteen cases of subperitoneal or submucous adenomyomata we would naturally not expect to trace the relationship between the mucosa and the glands in the myoma; nevertheless in one case, Gyn. No. 10,314, the mucosa had literally flowed into the myoma. It will thus be seen that when we include adenomyomata of every kind, out of subperitoneal, submucous, or diffuse, we have been able in fifty-six out of seventy-three cases to trace the origin of the gland elements to the uterine mucosa.

All adenomyomata of the uterus in which the gland elements are similar to those of the uterine mucosa, and are surrounded by stroma characteristic of that surrounding the normal uterine glands, owe their glandular origin to the uterine mucosa or to Müller's duct, no matter whether they be interstitial, subperitoneal, or intraligamentary, whether solid or cystic.¹

¹ Frequently there are small cyst-like spaces apparently just beneath the peritoneal surface of the uterus. These are lined with a single layer of cuboidal cells and rest directly on the muscle. They are due to depressions from the peritoneal surface, but at another level. In favorable sections their continuity with the peritoneal cavity can be traced. Meyer has recently pointed them out. We thoroughly agree with his findings, and have also often met with them on the under or protected side of tubal adhesions or lining the small depressions occurring on the surface of the ovary. The peritoneal cells, where protected, tend to become cuboidal.

CHAPTER XIV

CAUSES OF ADENOMYOMA OF THE UTERUS

We thought that possibly pregnancy with its incident extensive stretching of the uterus might leave crevices into which the mucosa could later flow. A reference to page 174, however, shows that fifteen out of forty-nine patients had never been pregnant, so that even were this a possible cause we must find another solution for those cases in which the adenomyoma had developed in a uterus that had never been subjected to the stretching incident to pregnancy. From a study of the clinical history we gain no clue as to the causation.

Histological examination in a number of cases gives a decided impression that the diffuse myomatous growth is the primary factor. In these cases there is a myomatous tendency, as evidenced by the almost constant presence of discrete myomatous nodules. The uterine mucosa flows into the chinks of the diffuse myomatous growth. As has been pointed out so frequently, the surface of the mucosa is perfectly regular and intact and the uterine glands are in no wise altered. The only pathological change, in such cases, lies in the extension of normal glands into the crevices throughout the myomatous growth.

CHAPTER XV

HYPERTROPHY OF THE CERVIX AND DIFFUSE ADENOMYOMA OF THE BODY OF THE UTERUS

In the examination of thousands of specimens this is the most unique we have ever encountered. There is a marked increase in the size of the cervix due to simple hypertrophy, while the fundus has kept pace by the development of an adenomyoma. We accordingly have a uterus which, although greatly enlarged, still has retained its relatively normal proportions.

Gyn. No. 6240. Path. No. 2532.

Very extensive hypertrophy of the cervix; diffuse adenomyoma of the anterior and posterior uterine walls (Fig. 56) with glands originating from the uterine mucosa.

L. C., aged fifty-two, married, white. Admitted July 15, 1898; discharged September 20, 1898. Complaint: Prolapsus of the uterus and uterine hemorrhage; pain in the abdomen. Her menses began at sixteen and were profuse, occurring every three weeks and lasting from seven to eight days. They have been irregular for the last two years and have been more profuse, the bleeding assuming the proportions of a hemorrhage. There has been a leucorrhœa and profuse vaginal discharge for many years. The patient has had nine children, the eldest thirty years, the youngest fourteen. On examination a large tumor is found projecting through the outlet—apparently

FIG. 56.—VERY EXTENSIVE HYPERTROPHY OF THE CERVIX. DISCRETE MYOMA AND DIFFUSE ADENOMYOMA OF THE BODY OF THE UTERUS. (Natural size.)

Gyn. - Path. No. 2532. We have purposely had the specimen drawn the natural size so that an accurate idea of the great and almost uniform increase in size of this organ is obtained. The cervix shows a very extensive hypertrophy, but is everywhere intact. A few of the cervical glands are dilated. At the fundus the subperitoneal myoma is seen. The uterine walls show considerable diffuse myomatous thickening, and scattered throughout them are seen islands of typical uterine mucosa. The continuity between them and the parent mucosa has in places been traced.

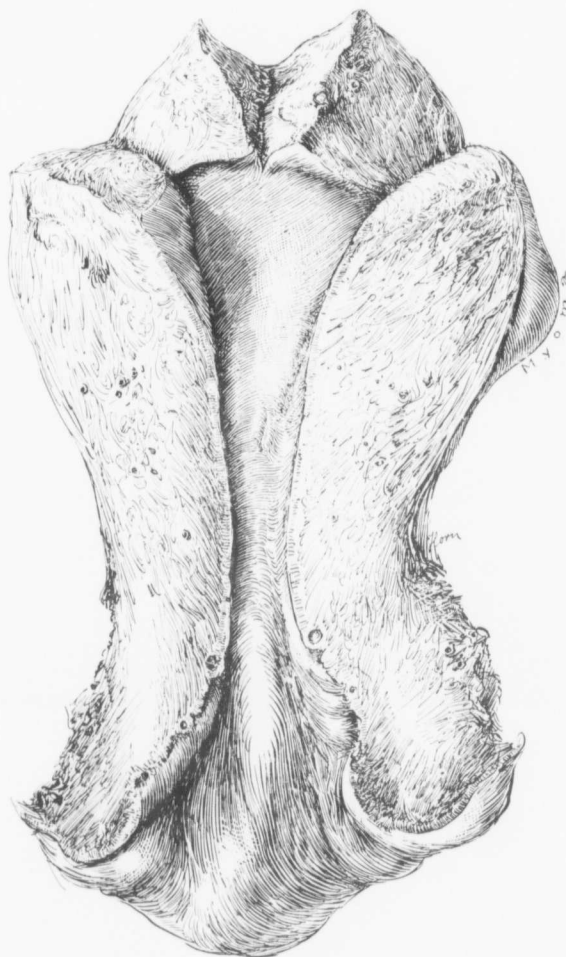

FIG. 56.

a complete prolapsus. The cervix is very prominent, 7 cm. in diameter and apparently ulcerated.

Operation.—Vaginal hysterectomy; repair of perineum.

Path. No. 2532.—The specimen consists of the uterus, tubes and ovaries intact. The uterus is exceedingly long, being 16 cm. in length, 7 cm. in breadth, and 4 cm. in its antero-posterior diameters (Fig. 56). It is free from adhesions. The posterior surface presents a more or less even appearance, while the anterior surface is round and shows a nodular mass just beneath the attachment of the left tube. The great length of the uterus is due to hypertrophy of the cervix, as the cervical portion is fully 8 cm. long. The outer portion of the cervix is rough and nodular and everywhere covered with mucosa. The mucosa lining the cervix is gathered up into folds. The mucous membrane of the body of the uterus in some places reaches 3 mm. in thickness. Both uterine walls present a coarse myomatous striation.

Histological Examination.—The hypertrophy of the cervix is confined chiefly to the over-growth of the stroma. The surface epithelium is everywhere intact. The papillae are in places long and branching and the overlying epithelium shows more hornification than usual.

Sections from the anterior wall show that the mucous membrane is normal, but slightly thicker than usual. The wall is composed of diffuse myomatous tissue and scattered throughout it are typical islands of uterine mucosa. In a few places direct continuity from the mucosa into the depth can be traced. The posterior wall also shows normal uterine mucosa with some thickening. Here there is likewise a diffuse adenomyoma. The islands of mucosa throughout the myoma closely resemble normal mucosa. In many places extension of the mucosa into the depth can be traced.

Diagnosis.—Very extensive hypertrophy of the cervix; diffuse adenomyoma of both the anterior and posterior uterine walls.

CHAPTER XVI

ADENOMYOMA IN ONE HORN OF A BICORNATE UTERUS

It is interesting to find one horn of a bicornate uterus the seat of an adenomyoma. Whether the opposite horn was likewise involved we cannot say, as the uterus was not removed. From a clinical standpoint it is also instructive, as in this case there was absolutely no connection between the vagina and the uterine cavity, there being practically no cervix. The condition in this case absolutely excludes any possibility that pregnancy has necessarily any causal relation to the development of the adenomyoma.

Gyn. No. 10,516. Path No. 6764.

Early adenomyoma in the left rudimentary horn of a bicornate uterus (Fig. 57), the glands coming from the uterine mucosa.

V. P., black, aged twenty-four, married. Admitted May 27, 1903; discharged June 25, 1903. Complaint: Absence of menstruation. The menses did not commence until she was twenty-one. Then there was just a slight stain once, and none since. There has been severe pain in the left side and back every month for the past nine years. She was married at twenty-one, but has had no children. On ether examination a normal vagina was found extending inward for 5 cm., but no apparent opening could be made out between the vagina and the pelvic organs above. Bimanual examination of the left side showed a uterus apparently larger than normal. The cervix was separated from the vagina by a distance of at least 1 or 2 cm. and apparently was not connected with it by adhesions or any bands of tissue. The cervix projected to the left.

Operation, June 4, 1903. An attempt was made to form a new cervical canal, but this was given up because no connection could be made out between the cervix and body, and also

because the external os was not patulous. Through the abdominal incision the following conditions were made out: On the left side was a small rudimentary uterus, 3 by 1.5 cm. There was no cervix and the organ was directly connected with a band of tissue, the latter in turn being connected with the cervix on the right side. Above the uterus was a large flattened tube with a normal fimbriated extremity and a normal ovary. On the right side the uterus was well developed and a little larger than normal. The cervix was poorly formed and had no external opening. The tube on this side had a normal fimbriated end and the ovary was normal. There were a number of

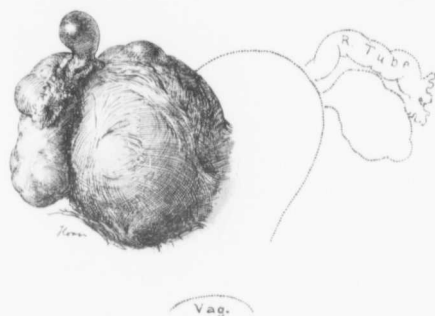


FIG. 57.—ADENOMYOMA IN ONE HORN OF A BICORNATE UTERUS. (1/2 natural size.)

Gyn.-Path. 6764. The left horn, which was removed, is sketched, but the right horn is merely outlined. In this case there was no trace of any connection between either uterine horn and the vagina.

adhesions to the upper part of the fundus and to the ovary, and several cysts containing clear fluid. Owing to the condition of the cornu on the left side, it and its appendages were removed. The patient made an uninterrupted recovery.

Path. No. 6764.—The globular body of the uterus is 5 cm. in diameter and covered with adhesions (Fig. 57). To it is attached a small left tube 5 cm. long, apparently normal, and an ovary measuring 3 by 2 by 1 cm. The lower third of the body of the uterus contains no uterine cavity. In the upper third is seen a cavity 1 cm. long. The lining mucosa apparently shows no change.

On histological examination the uterine mucosa is found considerably thickened and the skein-like arrangement of the glands is particularly well marked. Scattered everywhere throughout the uterine wall, particularly abundant in the vicinity of the mucosa, are islands of uterine mucosa. These sometimes consist of large areas of mucous membrane and sometimes of a single gland surrounded by stroma and often much dilated. The muscle shows just the faintest tendency toward myomatous transformation. This is more evident macroscopically than microscopically. With the naked eye the uterine mucosa can be traced directly into the depth in places for a distance of 3 mm. We have here a diffuse adenomyoma in which the glands play the major rôle. It is particularly interesting to find an adenomyoma in one half of a bicornate uterus. The histological picture in this case would lead one to infer that the glands first existed and that the myomatous change was a secondary phenomenon. This is the first case that has suggested this origin to us.

CHAPTER XVII

DIFFUSE ADENOMYOMA OF THE BODY OF THE UTERUS OCCURRING IN CASES OF SQUAMOUS-CELL CARCINOMA OF THE CERVIX

Since the appearance in 1903 of a previous communication,¹ in which I reported a case of squamous-cell carcinoma of the cervix associated with diffuse adenomyoma of the body of the uterus, I have examined five similar cases. The simultaneous occurrence of both these processes in six cases in the records of one laboratory certainly indicates that the coexistence of these two diseases is no rarity. When we see what a large number of adenomyomata have been detected when the uteri are carefully and systematically examined, and knowing how wide-spread is squamous-cell carcinoma of the cervix, it is little wonder that these two processes are frequently found in the same uterus. The symptoms of the carcinoma of the cervix would naturally completely overshadow those of the adenomyoma. Consequently the marked extension of the uterine glands into the depth would not be suspected until after removal of the uterus.

Gyn. No. 12,918. Path. No. 9841.

Squamous-cell carcinoma of the cervix; diffuse adenomyoma of the uterine walls with direct extension of the uterine mucosa into the depth (Fig. 58).

H. G., married, aged forty-two, black. Admitted May 9, 1906; discharged June 2, 1906. The patient has been married twenty-four years and has had four children, the oldest nineteen, the youngest fifteen. The clinical history is of little importance, as the symptoms of the carcinoma of the cervix and adenomyoma of the body merge so imperceptibly one into the other.

¹ Cullen, Thomas S.: Adenomyome des Uterus, Berlin, 1903.

Operation.—Pan-hysterectomy. The entire growth was apparently not removed. The appendages were adherent to the

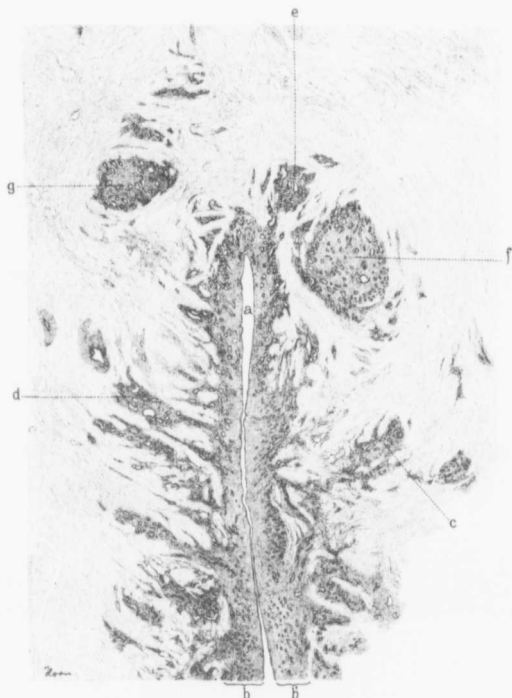


FIG. 58.—DIFFUSE ADENOMYOMA IN THE BODY OF THE UTERUS. (6 diameters.)

Gyn.—Path. 9841. The section is from the upper part of the uterus. *a* indicates the uterine cavity and *b* and *b'* the normal thickness of the mucosa. The surface epithelium is intact and the glands are of the normal appearance, but the mucosa is everywhere flowing into the underlying myomatous muscle, as is particularly well seen at *c*, *d*, and *e*. Sections at another level would show that the apparently isolated islands *f* and *g* are also continuous with the mucosa lining the uterine cavity.

posterior surface of the uterus and were enlarged. The patient made a very satisfactory recovery. Her highest post-operative temperature was 101.8° F.

Path. No. 9841.—The specimen consists of the uterus entire. It is 10 cm. in length. The cervical portion presents a worm-eaten appearance and this growth apparently extends to the cut surface anteriorly. Upward the growth can be traced as far as the internal os. In the body of the uterus the muscle varies from 2 to 2.5 cm. in thickness. On making an examination through the right cornu we find that the inner zone of muscle over an area 2.5 cm. in diameter presents a diffuse myomatous thickening. There is an area covered by muscle 6 mm. in thickness. Exactly the same condition is noted on the left side, except that the myomatous muscle extends almost entirely through the wall. The uterine walls are covered, both anteriorly and posteriorly, with dense adhesions. The tube on the right side is involved in adhesions and is the seat of a hydrosalpinx. On the left side we have a typical follicular hydrosalpinx.

Histological examination was made of sections embracing the uterine cavity and the anterior and posterior walls.

Even with the dissecting microscope a most complete idea of the condition is obtainable. The surface epithelium is intact, the glands are normal, and the mucosa is seen penetrating the muscle in all directions. Nearly everywhere in the depth one is able to trace the continuity of the islands of mucosa with that lining the uterine cavity (Fig. 58). In the depth we have large areas of uterine mucosa, some of them 5 mm. in thickness. Occasionally some of these deep-seated uterine glands are dilated. At one point in the depth is a miniature uterine cavity, 9 mm. in length, varying from 2 to 3 mm. in diameter. It is lined with one layer of epithelium which has taken up a great deal of blood pigment. Beneath this is a zone of stroma separating it from the muscle. The cavity is filled with blood—the remains of the former menstrual flow. The inner layers of the uterine muscle show diffuse myomatous transformation.

We have here a squamous-cell carcinoma of the cervix, diffuse adenomyoma of the anterior and of the posterior uterine wall, with the gland elements originating from the mucosa.

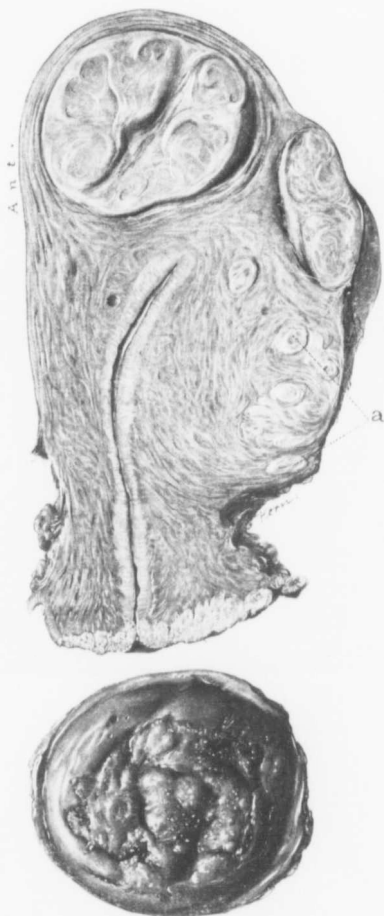Gyn. No. 9971. Path. No.
6150.

Squamous-cell carcinoma of the cervix (Fig. 59); diffuse adenomyoma of the body of the uterus.

A. S., married, aged forty, white. Admitted October 8, 1902; discharged November 12, 1902. Complaint: Uterine hemorrhage and a watery discharge. The patient has been married twenty-four years and has had four children; the oldest twenty-three, the youngest seventeen.

FIG. 59.—SQUAMOUS-CELL CARCINOMA OF THE CERVIX; DISCRETE, SUBPERITONEAL AND INTERSTITIAL MYOMATA; DIFFUSE ADENOMYOMA OF THE POSTERIOR UTERINE WALL. (Natural size.)

Gyn. No. 9971. Gyn.-Path. No. 6150. The lower picture represents the cervix with a small cuff of vaginal mucosa surrounding it. The cervix presents a roughened and slightly nodular appearance due to the carcinoma. From the upper picture we see that the growth has invaded the cervix to a considerable extent. Situated in the fundus are two discrete myomata. The posterior wall shows diffuse myomatous thickening and at several points, indicated by *a*, discrete myomata are scattered throughout the diffusely thickened myomatous tissue. Histological examination shows islands of mucosa scattered abundantly throughout the diffuse myoma.



The labors were normal. The patient was well until May of this year, when she had a slight hemorrhage and later noticed a slight serous discharge, which was irritating.

Operation.—On examination of the cervix so strong was the suspicion of carcinoma that a complete hysterectomy was done. The appendages were adherent to the posterior surface of the uterus and the cervix was released with a great deal of difficulty. After operation there was excessive nausea and fecal vomiting for several days. For the first ten days the patient's life hung in the balance, but later on convalescence was rapid. The highest post-operative temperature was 100° F., on the second day.

Path. No. 6150.—The specimen consists of a myomatous uterus which has been removed entire. The myoma developing in the anterior wall is 4 cm. in diameter. Below this and posterior to it is a similar one. The uterus is 12 cm. long and 6.5 cm. broad. The anterior lip is denser than the posterior and suggests a new growth. On careful examination both lips are seen to present a finely granular appearance (Fig. 59). The uterine cavity measures 3.3 cm. in length. The posterior uterine wall is fully 3 cm. in thickness and presents a fine diffuse myomatous appearance.

On histological examination the cervix is found to be the seat of a squamous-cell carcinoma. This has not been entirely removed. Sections from the posterior wall of the uterus show that it is everywhere infiltrated with irregular islands of uterine mucosa. The tissue is made up of diffuse myomata. In the anterior wall there is a thickening of the uterine mucosa, but it is normal. In the examination of many sections only at one point is noted a slight tendency for the mucosa to extend into the depth, and one cannot with any degree of certainty say that there is a direct continuity with the glands in the endometrium.

We are here dealing with squamous-cell carcinoma of the cervix, interstitial myomata, and diffuse adenomyoma of the posterior wall.

C. H. I. No. 511. Path. No. 8426.

Squamous-cell carcinoma of the cervix; diffuse adenomyoma of the body with the gland elements coming from the mucosa.

E. J. R., married, aged sixty, white. Admitted March 21, 1905; died March 24, 1905. Complaint: Uterine hemorrhages and pain. (The patient had a definite squamous-cell carcinoma of the cervix which obscured the other symptoms.) The patient has had ten children, the eldest thirty-six, the youngest ten years; no miscarriages. In September, 1904, she was paralyzed on the right side. It was three months before she regained complete control over her right hand.

Operation.—Complete hysterectomy was performed. The patient did well for the first day, was restless on the second day. There was complete suppression of urine, although the ureters had been carefully dissected out and had been found to be in no way obstructed. She soon became cyanosed and there was muscle twitching; she died on the second day after operation.

Path. No. 8426.—The specimen consists of the uterus and of a part of the vagina; also of the tubes and ovaries. The cervix is the seat of an extensive carcinoma which involves the posterior lip and a portion of the vagina. There are also some nodules in the vagina. Posteriorly the growth apparently extends to the line of incision and out into the left parametrium. The body of the uterus looks normal.

On histological examination the cervix presents a far advanced squamous-cell carcinoma.

The chief interest is centered in the endometrium. The uterine walls are atrophic, and with the low power one can see very large blood-vessels in the outer layers. These show beginning obliterative changes. The muscle of the uterine wall is exceedingly dense and looks myomatous. The endometrium is atrophic, but at several points we can trace it extending a long distance into the depth. We have here a mild grade of adenomyoma.

Diagnosis.—Squamous-cell carcinoma of the cervix; moderate diffuse adenomyomatous formation in the body of the uterus.

Gyn. No. 12,060. Path. No. 8602.

Squamous-cell carcinoma of the cervix; diffuse adenomyoma of the body of the uterus with the glands originating from the mucosa.

L. N., married, aged fifty-six, white. Admitted April 18, 1905; discharged May 21, 1905. The patient has had four children, the youngest fourteen years old. The menopause occurred two years ago.

Operation.—Panhysterectomy. As the growth was far advanced the operation was fraught with much difficulty. The highest post-operative temperature was 101.4° F. The patient made a satisfactory recovery.

Path. No. 8602.—The specimen consists of the uterus, which is almost normal in size, and of the appendages. The uterus with the enlarged cervix is 9 cm. in length, 6 cm. in breadth, and 4 cm. in its antero-posterior diameters. Anteriorly it is smooth and glistening. Posteriorly it is almost free from adhesions. The cervix has been converted into a crater-like cavity approximately 5 cm. in diameter. The outer vaginal portions of the cervix are normal, but posteriorly and anteriorly it is wanting, the tissue presenting an eaten-out wormy appearance. Anteriorly the growth extends almost to the cut surface. On section, macroscopically the growth can be traced for at least 1 cm. into the underlying tissue. The uterine muscle shows little or no thickening, but the inner layers are somewhat coarser than usual. The mucosa varies from 1 to 2 mm. in thickness.

Histological examination shows a typical squamous-cell carcinoma of the cervix with a good deal of small round-cell infiltration along the margins. The cervical glands are considerably dilated and the stroma in the cervical portion has not quite the ordinary appearance and somewhat resembles muscle.

Sections from the mucosa show that the surface epithelium is in places intact; at many points, however, it has been mechanically removed. The glands are normal in size, but at other points are dilated, and the cell protoplasm is undergoing disintegration. At some points we have isolated glands penetrating the muscle and extending into the depth in funnel-shaped forms. In other places two or three glands can be traced for at least 4 mm. into the underlying tissue. This extension into the depth is noted at several points, and in the underlying muscle are islands of perfectly normal mucosa. The muscle surrounding the uterine cavity is denser than usual and is undergoing a diffuse myomatous transformation. The muscle in the outlying portion is fairly normal. We have here an adenomyoma in which the gland elements are derived from the uterine mucosa.

Diagnosis.—Primary squamous-cell carcinoma of the cervix; diffuse adenomyoma of the body of the uterus.

Gyn. No. 12,304. Path No. 8890.

Squamous-cell carcinoma of the cervix. The chief interest lies in the adenomyoma of the body.

L. S., aged fifty, white. Operation, August 18, 1905. Pan-hysterectomy.

Sections from the endometrium show that the mucosa can be in places traced for at least 3 or 4 mm. into the underlying muscle. It shows a typical myomatous picture. We have here a diffuse adenomyoma with carcinoma of the cervix.

Gyn. No. 3126. Path. No. 493.

Squamous-cell carcinoma of the cervix (Fig. 60). Adenomyoma of the body of the uterus.

L. E. H., white, aged fifty-six, a widow. Admitted October 21, 1894; discharged November 25, 1894. The patient entered the

hospital complaining of pain in the rectum and lower part of the back. She had had some hemorrhage. Two paternal aunts had died of phthisis, and her mother of cancer of the uterus at forty-nine years of age. Her paternal grandmother was also supposed to have died of cancer of the uterus.

Menstrual History.—The periods commenced at sixteen; they were always regular, but painful during the first few years. She suffered from membranous dysmenorrhœa. For the last ten years there has been an offensive odor at the menstrual period. The menopause occurred at fifty-three. She had had several children.

Present Illness.—For five or six years before the menopause, which occurred three years ago, the patient suffered with irregular and severe hemorrhages from the uterus. From the time of the menopause no hemorrhages occurred, but the patient complained of nervousness. In July of this year she noticed a yellowish vaginal discharge. In August she complained of pain in the lower abdomen and of some swelling in the legs.

In July and August the desire to urinate was constant. These symptoms have subsided since then. The bowels are markedly constipated and defecation is accompanied by hemorrhage. There is, however, no tingeing of the stools with blood.

The patient is very anæmic and nervous, but there is no marked emaciation.

Operation.—The carcinoma of the cervix was curetted away as far as possible with the finger. After thorough cleansing of the uterus the vagina was incised, an area around the margin of about 1 cm. of normal mucosa being loosened up with the cervix. An abscess between the uterus and rectum was then opened and about 2 c.c. of creamy pus escaped. The vaginal edges were brought together so that the diseased area of the cervix was completely walled off. The abdomen was then opened and the uterus removed from above. Considerable difficulty was experienced, however, on account of the extension of the growth to the broad ligament. The patient made a good recovery and was discharged on November

25th. The nervous symptoms were, however, prominent. Re-appearance of the growth was noted and the patient died sixty days after operation, apparently of exhaustion.

Gyn.-Path. No. 493.—The specimen consists of the

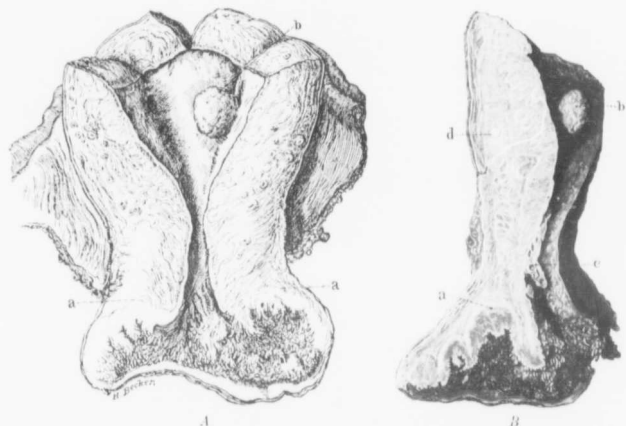


FIG. 60.—COMMENCING DIFFUSE ADENOMYOMA OF THE BODY OF THE UTERUS ASSOCIATED WITH ADVANCED SQUAMOUS-CELL CARCINOMA OF THE CERVIX. ($\frac{1}{10}$ natural size.)

Gyn.-Path. No. 493. *A*. The lower part of the cervix and surrounding portions of the vaginal vault are replaced by a new growth having a shaggy surface due to myriads of finger-like outgrowths. Laterally this growth extends practically to the broad ligament attachment; upward its confines are indicated by the letters *a, a*. The upper part of the cervix and body seem little altered. At *b* is a small polyp. The mucosa in the upper part of the cervix and in the body is very thin but smooth. *B*, a longitudinal section of *A*. The extent of the growth in the posterior wall is clearly outlined at *a*. The cystic cervical polyp is seen at *c*. The posterior wall is made up of two distinct portions, an outer consisting of normal muscle and an inner presenting a diffuse myomatous appearance. This coarse tissue extends directly to the mucosa. At *d* is a small discrete myomatous nodule. From the text it will be noted that the uterine walls show a commencing myomatous transformation and that the glands in many places penetrate the muscle for a distance of 9 mm.

uterus with its appendages intact. The uterus measures 8 by 6 by 3 cm. and both anteriorly and posteriorly is smooth and glistening. Occupying the outer portion of the cervix, both anteriorly and posteriorly, is a worm-eaten and in part papillary-like surface (Fig. 60). In the latter portion the little elevations are found to

consist of small finger-like or knob-shaped processes, some of which apparently branch. Anteriorly the growth extends out to the vagina, while posteriorly it involves the vault for at least 1.5 cm. On section it is found that only the outer portion of the cervix is implicated and that the cervical mucosa for a distance of 2.5 cm. is still intact. Several of the cervical glands are dilated, and projecting into the canal is a small polyp. The uterine cavity is 3 cm. long. Its mucosa, which appears to be less than a millimetre in thickness, is smooth and glistening. Situated on the left side of the cavity is a pale bluish-white polyp 1 cm. long, 1.2 cm. broad, 4 mm. thick. The tubes and ovaries present their usual appearance.

HISTOLOGICAL EXAMINATION.—The worm-eaten cervix shows considerable necrosis of its surface. The underlying tissue is everywhere infiltrated by masses of cells having a finger-like or branching arrangement. Some of these have been cut across and appear as circular nests. Scattered throughout the alveoli are numerous areas in which the cell protoplasm stains intensely with eosin. The concentric arrangement of the cells is suggestive of epithelial pearls. The new growth appears to extend nearly to the margin of the incision. Whether or not it has been entirely removed, it is impossible to say. The tissue surrounding the alveoli shows marked small round-cell infiltration along the advancing margin of the growth.

The cervical glands, just within the external os, are normal, but as one approaches the internal os many of them are dilated. The uterine mucosa near the internal os and also that throughout the cavity shows considerable dilatation of its glands and scattered throughout the stroma are numerous small round cells. Penetrating the muscle in many places to a depth of 9 mm. are bunches of very small glands, which are separated from each other and also from the muscle by the usual amount of stroma. They are abnormal dippings-down of the mucosa, which do not, however, show the least sign of malignancy. The uterine wall shows some hyaline degeneration. The muscle tends to become myomatous and in one place contains a myoma 4

mm. in diameter. The uterine polyp consists of mucosa and a few of its glands are dilated. The appendages are practically normal.

D i a g n o s i s.—Squamous-cell carcinoma of the cervix; extension of the uterine glands into the muscular walls, which show a tendency to become myomatous; small interstitial myoma; normal appendages.

CHAPTER XVIII

ADENOCARCINOMA AND ADENOMYOMA OCCURRING INDEPENDENTLY IN THE BODY OF THE SAME UTERUS

The following case is interesting on account of the fact that an adenocarcinoma of the body of the uterus and a small but typical subperitoneal adenomyoma are associated in the same uterus. Of course, the one is in no way dependent on the other.

Gyn. No. 5782. Path. No. 2084.

Adenocarcinoma of the body of the uterus (Fig. 61); small myoma in the anterior wall; small adenomyoma in the posterior wall; hysterectomy.

M. K., aged fifty-six, admitted January 12, 1898, complaining of pain in the lower abdomen. The menses were irregular, occurring at intervals of from two to six weeks. They were very painful and lasted from three to seven days. They ceased four years ago. About a year and a half ago a bloody discharge was noticed which at times was clotted. During the last six months it has been frequent, but at no time has it been offensive. The patient has been married twenty-one years. She has had one child and no miscarriages. She has never been strong, and during the past year has had severe pain in the lower abdomen extending down the legs. At present the bowels are constipated. On January 12th the cervix was dilated and a small amount of tissue was removed for examination. The uterus was slightly enlarged but freely movable. Two nodules could be seen on the posterior surface.

Gyn. - Path. No. 2075.—The specimen consists of a considerable amount of curettings. The tissue is composed of small pieces which do not present the smooth glistening surface of normal

mucosa. They are finely granular or show minute, papillary-like out-growths. On histological examination adenocarcinoma of the body of the uterus was found and hysterectomy was advised. The uterus was removed in the usual way. The patient made a good recovery and was discharged February 15, 1898.

Gyn. - Path. No. 2084.—The specimen consists of the uterus with the appendages. The uterus is 8 cm. in length, 5.5 cm. in breadth, and 5 cm. in its antero-posterior diameter. Its surface is deep red in color and free from adhesions, but projecting from the posterior portion is a small, firm nodule 1.2 cm. in diameter (Fig. 61). The outer surface of this nodule is covered with a calcareous plate 2 mm. in thickness. On section the growth is found to be continuous with the uterine muscle, with which it is intimately associated, the sharp line of demarcation so characteristic of myomata being wanting. The calcareous deposit has extended into the

nodule at one point. The cervical canal is 3 cm. in length. Its mucosa is finely granular and slightly injected. The uterine cavity

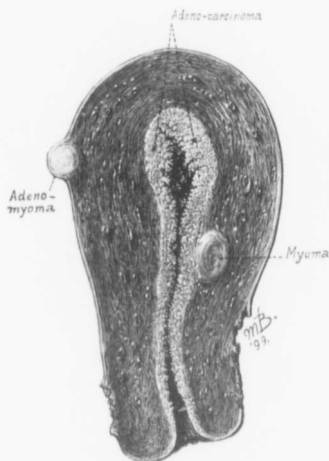

FIG. 61.—ADENOCARCINOMA OF THE BODY OF THE UTERUS ASSOCIATED WITH A SMALL SUBPERITONEAL ADENOMYOMA. (Natural size.)

Gyn. - Path. No. 2084. The uterus is of normal size. The left half appears in the figure. Attached to the posterior surface near the fundus is a small subperitoneal myoma, which on histological examination is found to contain mucosa resembling that of the uterus. In the middle of the anterior wall is a small interstitial myoma; the cervix is intact. The mucosa in the lower part of the cervical canal is normal, but that of the body is replaced by a new growth. The inner surface presents an eaten-out appearance due to the finger-like growths. The growth itself is light in color and appears to be friable. It does not seem to penetrate the uterine walls very far, but as the subsequent history showed the case was one of the most malignant we have encountered. It is rather interesting to find a myoma, an adenomyoma and an adenocarcinoma of the body of the uterus in the same patient.

is 5 cm. long and 4 cm. in breadth at the fundus. The mucosa in the lower portion of the cavity is roughened and granular. On passing further upward it is found to be thicker and more furrowed. The upper half of the cavity is occupied by a new growth consisting of papillary masses varying from 1 to 6 mm. in size. These tree-like growths consist of delicate papillae which often show secondary branching. Some of the papillae are glistening, some are translucent; others are yellowish and opaque, while not a few are deeply injected. The growth has extended for 8 to 10 mm. into the uterine muscle. The deeper portions consist of a fibrillated waxy material, which is sharply differentiated from the surrounding muscle. The growth penetrates the muscle more deeply on the left side. Downward it reaches to within 1 cm. of the internal os.

The appendages are senile, but present nothing of importance.

Histological Examination.—The vaginal portion of the cervix is practically normal. The folds of the mucosa lining the cervical canal present the usual appearance. The surface epithelium is to a great extent intact and the underlying glands are normal. Sections from the body of the uterus show that the greater part of its cavity is occupied by a neoplasm. Along the advancing margin this appears in the form of irregularly branching outgrowths, consisting of delicate stems of stroma covered by one or more layers of cylindrical epithelium. On passing toward the older portions of the growth this papillary-like arrangement becomes more complex. In the deeper portions the glandular arrangement is more in evidence, and along the advancing margin where the growth has penetrated the muscle, large bunches of glands are seen. The gland-like arrangement in many places is perfectly preserved and the epithelial cells are remarkably uniform in size. In some places the stroma is fairly abundant, but at other points it is only just sufficient to support the delicate blood-vessels. The preservation of the glands, which show practically no coagulation necrosis, is rather remarkable, and is more probably due to their slight deviation from the normal than to any increase in blood-supply, since the latter is by no means

abundant. Along the advancing margin of the growth the muscle shows small round-cell infiltration.

The small nodule situated on the posterior uterine wall consists of non-striped muscle fibres cut in various directions. The blood-vessels are few in number and frequently show obliteration. At a few points 2 or 3 mm. beneath the peritoneal covering are deeply staining areas, at first sight suggesting small round-cell infiltration, were it not for the fact that they are too sharply circumscribed and that with the higher powers it is impossible to distinguish them from the stroma cells of the uterine mucosa. Some of these areas contain glands irregular or elongate in form and lined with one layer of low cylindrical epithelium on which cilia can sometimes be demonstrated. Some of the gland cavities contain desquamated epithelium; others enclose a varying amount of blood. The nodule is a myoma. The glands and their surrounding stroma resemble more or less the uterine mucosa. We are dealing with a small subperitoneal adenomyoma. Sections from the tubes show nothing abnormal. Both ovaries contain a few small gland-like spaces, but are otherwise normal.

Diagnosis.—Adenocarcinoma of the body of the uterus, associated with a subperitoneal adenomyoma and an interstitial myoma.

CHAPTER XIX

ADENOCARCINOMA OF THE BODY OF THE UTERUS DEVELOPING FROM AN ADENOMYOMA

From our consideration of adenomyomata of the uterus, it is seen that the gland elements are practically normal uterine glands in both their histological and physiological aspects. From normal uterine mucosa we often have developing an adenocarcinoma. Consequently we should not be surprised if an adenocarcinoma were sometimes detected in an adenomyoma. Von Recklinghausen in his entire series of adenomyomata found only two cases in which he thought there was a carcinomatous change. Meyer also had a suspicious case, but from his description we would hardly venture a positive diagnosis of malignancy. In Gyn.-Path. No. 4656, an instance of carcinoma of the body of the uterus, we noted several dark areas deep in the muscle. They consisted of typical islands of uterine glands surrounded by the stroma of the mucosa. Some of the glands were dilated, forming cyst-like cavities. In one of these cavities (Fig. 62), lined by a single layer of cylindrical epithelium and separated from the muscle by a definite stroma, the epithelium had proliferated, forming new glands and papillary outgrowths consisting almost entirely of solid masses of cancer cells. This case is undoubtedly one of adenocarcinoma developing in part from a cystic gland situated in the adenomyoma.

In Sanitarium No. 1852 we found a similar condition. The body of the uterus was the seat of a typical adenocarcinoma and deep in the muscle areas of adenomyoma were found. At one point the carcinoma was seen developing from one of the glands in the adenomyoma. In this case the histological picture also strongly suggested the independent development of sarcoma of the body of the uterus.

CASES ILLUSTRATING THE DEVELOPMENT OF ADENOCARCINOMA OF THE BODY OF THE UTERUS FROM ADENOMYOMA

Gyn. No. 8438. Path. No. 4656.

Adenocarcinoma of the body of the uterus developing, in part at least, from the glands of an adenomyoma (Fig. 62).

M. S., married, aged fifty-six, white. Admitted January 9; discharged February 9, 1901. The patient entered complaining of uterine hemorrhages. The menses commenced at seventeen and were not painful. The menopause occurred at fifty-three. The patient has had five children, the eldest thirty-three years of age.

One year after the menopause, *i. e.*, two years ago, the patient noticed a slight uterine discharge, usually blood tinged. This has been a little more profuse of late and has contained some blood. She has neither pain nor discomfort and has lost no weight. The only symptom has been the uterine bleeding.

January 19, 1905: Vaginal hysterectomy. The patient made a satisfactory recovery.

Gyn. - Path. No. 4656.—The specimen consists of the uterus, which is little, if at all, enlarged, measuring 8 by 6 by 4 cm. The outer surface is smooth and the vaginal portion of the cervix presents the usual appearance. The cervical mucosa is injected but normal. In the uterine cavity nearly all trace of the normal mucosa has disappeared and we have fine finger-like processes or small polypoid masses, some reaching 1 cm. in length, springing from the surface. The deeper portions of this growth have invaded the muscle in the vicinity of the cornu for a distance of from 5 to 7 mm. The uterine walls are of the normal thickness, but at some points the tissue is coarser than usual and is somewhat suggestive of a diffuse myoma.

HISTOLOGICAL EXAMINATION.—The cervical mucosa is perfectly normal. Near the internal os the epithelial lining of the glands is altered. Some of the cells are quite regular and uniform. Others are swollen, have light-staining nuclei, and are several layers thick. High in the cavity the glands have proliferated and are

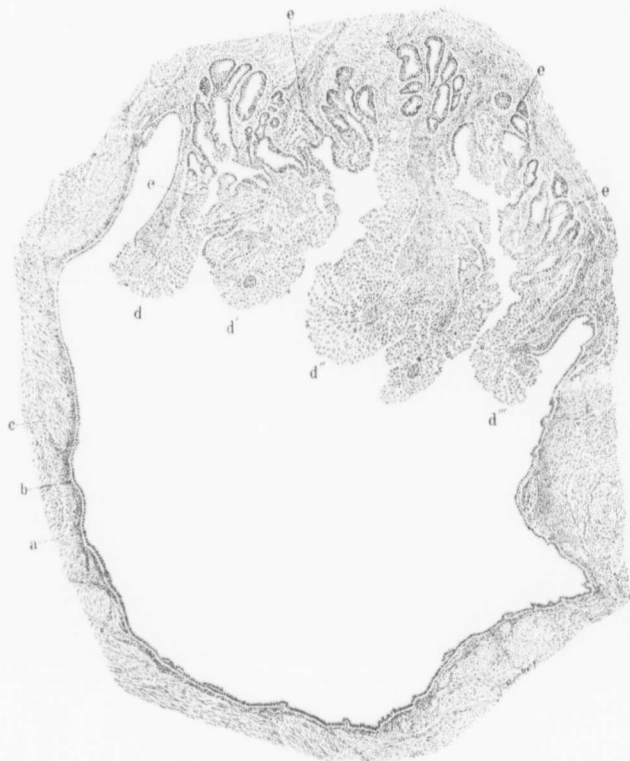


FIG. 62.—ADENOCARCINOMA DEVELOPING FROM A DILATED GLAND IN AN ADENOMYOMA OF THE UTERUS. (45 diameters.)

Gyn.-Path. No. 4656. Occupying the centre of the field is a large cystic space lined with one layer of cylindrical epithelium (*a*) and separated from the surrounding myomatous muscle (*c*) by a faint zone of characteristic stroma (*b*). In the upper part of the field numerous glands (*c*) are seen opening into the large cavity. These glands are also lined with cylindrical epithelium. Projecting into the cavity are the four large folds *d*, *d'*, *d''* and *d'''*. These new folds have a stroma very rich in small round cells and are surrounded by many layers of epithelial cells. At points *e, e, e* the gland epithelium is seen to become swollen and greatly thickened and this thickened epithelium is directly continuous with that covering the folds. As is clearly evident, the growth is an adenocarcinoma. In this case the carcinoma was seen developing from other similar areas as well as from the mucosa lining the uterine cavity.

invading the muscle. The gland type, as a rule, is well preserved, but in some places the epithelium has so proliferated that the gland cavities are obliterated. Deep down in the muscle are groups of carcinomatous glands, which in places extend to within 1 cm. of the peritoneal surface. In some places there is a moderate infiltration with polymorphonuclear leucocytes. In some portions of the uterus the muscle fibres stain more deeply than usual and show a tendency to become myomatous. Here the tissue suggests a diffuse myoma. Scattered throughout it are isolated islands of uterine mucosa consisting of the characteristic glands with their surrounding stroma. At several points these glands are dilated, and in at least two places the gland epithelium has proliferated, forming new glands of an undoubted carcinomatous type. Fig. 62 illustrates a carcinoma developing from one of these cystic and dilated uterine glands. It shows conclusively that carcinoma may develop from the gland elements of an adenomyoma. This, however, is nothing more than we might expect, since the gland elements of adenomyomata are, as a rule, nothing more than normal uterine glands which have grown into the muscle.

H. A. K. Sanitarium No. 1852. Path. No. 8347.

Adenocarcinoma of the body of the uterus; diffuse adenomyoma with the glands becoming carcinomatous. Independent sarcoma of the body of the uterus.

B. H. C., aged fifty-four, white, married. Admitted March 31, 1905; discharged April 21, 1905. Operation: Panhysterectomy, colostomy and removal of vaginal implantation.

The patient has been married twenty-seven years and has had four children but no miscarriages. The menopause occurred four years ago. For three months there has been a constant leucorrhœa with a bloody vaginal discharge.

Operation, March 8th. Panhysterectomy. The patient did not improve well after operation, and finally on the fifth

day it was found necessary to bring out a loop of small intestine. This was fastened to the abdominal wall and was opened with a cautery. At a later date the patient became insane. She had a return of the growth in the vaginal wall. For this radium was used. Later she went to Dr. John McCoy, of Paterson, N. J., for x-ray treatment.

In May, 1905, her condition was much worse, and her physician removed a vaginal mass under cocaine. At the time he made a note that there was a tremendous amount of infiltration of the tissue between the vagina and rectum. Pathological examination of the vaginal specimen showed it to be a typical sarcoma.

Path. No. 8347.—The uterus is 10 cm. long, 8 cm. broad, and 6 cm. in its antero-posterior diameters. The cervix looks normal. The uterine walls vary from 2 to 4 cm. in thickness. The increased thickening in the posterior wall is due to a new growth which projects into the cavity. The superficial half of this is bluish-black in color. The outlying portions are white and somewhat porous in appearance and sharply differentiated from the normal outer muscular covering. The appendages on both sides appear to be unaltered.

Histological Examination.—Sections from the cervix show that the surface epithelium is the seat of chronic infiltration, there being a marked round-cell infiltration, also polymorphonuclear leucocytes, and the underlying stroma is exceedingly vascular. Sections from the uterine mucosa show that there is in places loss of surface epithelium. In other places it is intact.

The endometrium in the lower part of the body shows considerable hemorrhage, evidently the result of curettage. The stroma is infiltrated with small round cells to a limited extent and the glands are seen projecting into the underlying muscle. Sections from the upper part of the body, where the growth is present, show that the surface of the growth is almost entirely necrotic and that this necrotic material contains quantities of polymorphonuclear leucocytes and blood. At other points in the necrotic material we have longitudinal sections of blood-vessels surrounded by many layers of cells

having oval, deeply staining nuclei. Such areas suggest very much an angiosarcoma. In other portions of the growth the cells are closely packed together; nevertheless with the low power it is possible to make out an indefinite glandular arrangement. In other words, down near the muscle we have a typical adenocarcinoma of the type so frequently found in the body, the skein-like arrangement of the glands and the papillary outgrowths, and all of these covered by one and sometimes several layers of epithelium. There are also numerous minute glands. The line of junction between the portion of the growth that looks sarcomatous and that which is distinctly cancerous is sharply outlined. Sections from other portions of the growth leave little doubt that we are dealing with a sarcoma, there being large fields with cells uniform in size and having very little stroma, just sufficient to carry the blood-vessels. Numerous nuclear figures are found scattered through this tissue.

Another most interesting point in this connection is the presence of islands of normal glands in the depth. Some of these have surrounding stroma and present the typical appearance of adenomyoma. Islands of mucosa are surrounded by myomatous tissue, and in one of these islands we have an adenocarcinoma developing directly from the mucosa of one of the normal glands. One is able to trace the direct continuity from the epithelium in such an island into the carcinomatous tissue. The muscle external to the point of growth shows a good deal of small round-cell infiltration.

We have here a subacute inflammation of the cervix, an adenocarcinoma of the body of the uterus, and an adenomyoma of the body of the uterus. To a certain extent the adenocarcinoma is derived directly from islands of normal mucosa in the adenomyoma, but in part evidently from the uterine mucosa lining the cavity. There is an apparently independent round-cell sarcoma in the body of the uterus. Fortunately we are able to clinch the diagnosis absolutely, as the metastases which occurred subsequent to removal of the uterus showed typical sarcoma.

CHAPTER XX

A MULTIPLICITY OF PATHOLOGICAL CHANGES IN THE PELVIS

- (a) Subperitoneal myoma.
- (b) Adenomyoma.
- (c) Primary adenocarcinoma of the body of the uterus.
- (d) Pyosalpinx.
- (e) Primary adenocarcinoma of the ovary.

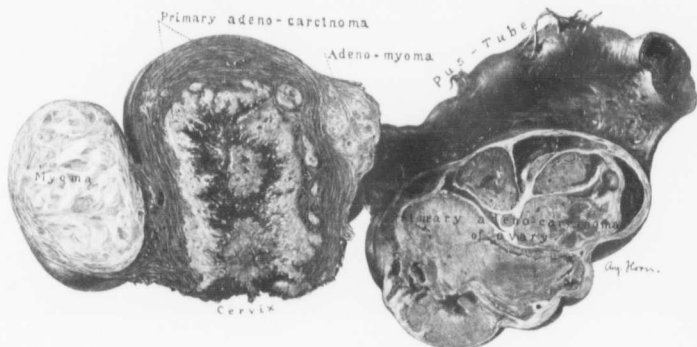


FIG. 63.—MYOMA, ADENOMYOMA AND PRIMARY ADENOCARCINOMA OF THE BODY OF THE UTERUS; PYOSALPINX AND PRIMARY ADENOCARCINOMA OF THE OVARY. ($\frac{1}{3}$ natural size.)

Specimen sent by Dr. Joseph Price, of Philadelphia. Path. No. 9312. Occupying the body of the uterus is an adenocarcinoma. Isolated carcinomatous nodules are scattered throughout the muscular walls and at one point have nearly reached the peritoneal surface. On one side is a discrete myoma. On the other near the uterine horn a diffuse adenomyoma, which on histological examination presented the typical appearance. The tube is thickened in its outer portion and was filled with pus. The ovary has been converted into a porous growth, partly cystic and divided off into smaller areas by trabeculae. This carcinomatous growth was of a totally different pattern to that occupying the uterus.

About two years ago I received a rather unpromising-looking specimen from my friend, Dr. Joseph Price, of Philadelphia. On careful examination, however, it was evident that it was a most unusual one.

From Fig. 63 we see that the body of the uterus is extensively involved in an adenocarcinoma. On one side is a discrete myoma, while on the opposite side is an adenomyoma. One tube is markedly distended with pus and has been densely adherent, as is indicated by adhesions. One ovary is much enlarged and occupied by a new growth.

Histological examination showed that the growth was a primary adenocarcinoma of a totally different type from that occupying the uterus. There were in this pelvis five distinctly independent pathological processes.

We often make a very positive diagnosis before operation, only to find, when the abdomen is opened, a condition totally different from that we had expected. No surgeon could possibly have given an accurate diagnosis in such a case as this. From the contour one might readily have diagnosed a multinodular and adherent myomatous uterus. The carcinoma could, of course, have been readily recognized upon examination of scrapings from the body.

CHAPTER XXI

DIFFUSE MYOMATOUS THICKENING OF THE UTERUS BUT NO GLANDULAR INVASION

Whenever the uterus is the seat of diffuse myomatous thickening, adenomyoma will immediately be suspected. On histological examination in the vast majority of cases, gland elements will be found scattered throughout the growth. There are a few cases, however, in which the diffuse growth exists and yet no invasion of glands has occurred. The following cases belong to this group. In Sanitarium No. 1847 there was also a suppurating submucous myoma. In Case No. 12,221 the increase in size of the uterus was due in part to a diffuse myomatous thickening, but chiefly to a recent pregnancy. Even in cutting the uterus open adenomyoma was suspected, and not until the histological examination showed no gland invasion, and decidua cells were demonstrated, was an exact diagnosis made.

H. A. K. Sanitarium 1847. Path. No. 8346.

Diffuse myomatous thickening of both the anterior and posterior uterine walls; breaking down of a submucous myoma with suppuration, producing in all probability a mild endometritis of the body and of the cervix; normal appendages on the left side; Graafian follicle cyst on the right.

W. J., aged thirty-four, married. Admitted March 1, 1905; discharged April 12, 1905. The patient has been married eleven years, has had two children and no miscarriages. Labors normal. The menses have been irregular and profuse for the last year, occurring every three weeks. For the last two weeks she has noticed a vaginal discharge. The patient has a sallow appearance; the

hemoglobin is 50 per cent. There was apparently a passage of a small tumor from the vagina a few weeks ago. Since then there have been chills and fever accompanied by a good deal of abdominal pain in the region of the ovaries.

Path. Nos. 8346 and 8346 $\frac{1}{2}$.—The specimen consists of the uterus, about twice the natural size, the left normal tube and ovary, the right tube, and a cystic right ovary. The body of the uterus itself is 10 cm. in length, 9 cm. in breadth, and 8 cm. in its antero-posterior diameters. It is smooth and glistening. The thickening in the uterus is found to be due to a diffuse thickening in both the anterior and posterior walls. The anterior wall varies from 2 to 4.5 cm. in thickness; the posterior from 2 to 3 cm. in thickness; and projecting from the fundus into the cavity is a submucous myoma, 2.5 cm. in diameter. In the vicinity of this are hard areas rather difficult to explain. In the myoma there are areas of hyaline transformation. The uterine cavity itself is 6 cm. in length, the mucosa 1 mm. in thickness. At first it looks as if we had a diffuse adenomyomatous thickening of both the anterior and posterior walls, but at no point macroscopically is one able to trace the mucosa into the depth. The left tube and ovary are normal. The right tube is normal. The ovary is somewhat thickened and contains one cyst, approximately 4 cm. in diameter, and adjoining this is an oval cyst, 6 cm. in its longest diameter. The inner surfaces of these are perfectly smooth, and one would have soon merged into the other. They seem to be Graafian follicle cysts.

Histological Examination.—The cervical glands are in places much dilated, and covering the surface of the cervix are here and there quantities of polymorphonuclear leucocytes which have come down from the body of the uterus. The stroma is to a slight extent infiltrated with small round cells. There is, however, very little infiltration of the cervix itself and the glands in the depth are perfectly normal. Sections from the body of the uterus show a submucous myoma, which to a great extent has been transformed into hyaline material. We have here and there spindle cells, chiefly fibrous in character, and in other places cells which have taken up

yellowish-brown pigment, evidently the remains of old hemorrhages. Here also we have thrombosed vessels. The surface of the myoma consists essentially of granulation tissue containing polymorphonuclear leucocytes in its meshes, and covering the surface are fibrin and quantities of leucocytes. In this tissue are large and small blood-vessels. The majority of these are filled with fibrin and leucocytes. In other words, there has been coagulation necrosis. At no point do we find any evidence of glands in the depth.

Sections from the larger cyst of the right ovary show that it is lined with cuboidal epithelium, the nuclei being situated in the middle of the cells. There is no doubt that the growth is a Graafian follicle cyst.

Diagnosis.—Diffuse myomatous thickening of both the anterior and posterior uterine walls; breaking down of a submucous myoma with suppuration, producing a mild endometritis. The appendix in this case shows chronic inflammation.

Gyn. No. 12,221. Path. No. 8832.

Thickening of a recently pregnant uterus which clinically gave symptoms simulating myoma. The uterus on removal was strongly suggestive of a diffuse adenomyomatous condition.

L. D., aged thirty-seven, married, white. Admitted July 7, 1905; discharged August 4, 1905. The diagnosis on admission was infected submucous myoma. The patient began to menstruate at fifteen, was regular until after the birth of her first child, but has been somewhat irregular since then. She has been married for eighteen years, and has had seven children and one miscarriage at the eighth week, a year and a half ago. She had some irregular bleeding several months ago. Five months ago she ceased bleeding, but the last two months she has been in bed. The periods recurred, appearing every two or three weeks. The hemorrhages were profuse. It is rather difficult to get the exact date of the last period. The patient has lost 9 pounds in the two weeks previous to her admission to the

hospital. Her haemoglobin is 62 per cent. and she presents a rather emaciated appearance.

Operation.—Vaginal hysterectomy. The highest post-operative temperature was 100.2° F. She made a satisfactory recovery.

Path. No. 8832.—The specimen consists of the uterus. It is 10 cm. in length, 7 cm. in breadth, and 6 cm. in its antero-posterior diameters. It is free from adhesions. The cervix looks normal. The posterior uterine wall varies from 1 to 3.5 cm. in thickness and presents a coarse appearance. In the anterior wall the mucosa is 2 mm. in thickness, in the posterior it reaches 5.6 mm., where there is localized thickening. The general appearance is very suggestive of adenomyoma.

On histological examination the cervix is found to present a rather suspicious appearance. We have an intact vaginal epithelium, then a proliferation of the cervical epithelium, the glands having formed many new and smaller ones. The proliferation in places is solid and here suggests squamous epithelium. At other points there is loss of the surface epithelium, and we have typical granulation tissue. There has evidently been an inflammation here, giving rise to the proliferation. The infiltration, however, is not wide-spread, as in the underlying stroma it is not extensive. In the body of the uterus the mucosa in places is intact and the glands look normal or are somewhat dilated. At other points the surface consists entirely of necrotic tissue or of canalized fibrin, and deeper still are small glands and a few decidual cells in the stroma. The blood-vessels in the mucosa show a marked change. The cells are swollen and are typical decidual cells. In the stroma there is a good deal of small round-cell infiltration and at a few points what appear to be villi, devoid to a great extent of their epithelial covering. For a short distance into the muscle we can trace glands, and deep in the muscle there are what appear to be decidual cells together with swollen muscle fibres.

In this case, as seen from a clinical standpoint, the diagnosis of probable myoma of the body of the uterus was made. The uterus

was enlarged and there was evidently uterine hemorrhage and a certain amount of discharge. Moreover, the menstrual history was not satisfactory. Even after the uterus had been removed the thickened wall strongly suggested adenomyoma, but, as we see on histological examination, there are typical evidences of pregnancy. There is no discrete myoma, although there is a definite tendency toward myomatous thickening.

CHAPTER XXII

ADENOMYOMATA OF THE UTERINE HORN

Meyer has very justly divided these into two groups according to their situation and source of origin. The uterine mucosa is continued up into the cornu, where it becomes very thin, there being merely the surface epithelium, a small amount of stroma of the mucosa, and a few glands. The mucosa becomes still thinner, and at the interstitial portion of the tube, which is within the uterine horn, gradually passes over into the tubal epithelium. This epithelium is identical in character with that lining the uterine cavity, but the peculiar stroma found in the uterine mucosa is entirely wanting and no glands are present.

ADENOMYOMATA ARISING FROM THE UTERINE PORTION OF THE UTERINE HORN

These consist of small diffuse thickenings of the uterine cornu. As a rule, they are not larger than 1 centimetre in diameter, but occasionally may reach the size of a walnut (Fig. 65, p. 243). They consist of gland-like spaces, usually cystic, and are surrounded by a diffuse myomatous muscle. The cysts are lined with cylindrical ciliated epithelium and contain desquamated epithelium and blood. Where the glands are much dilated, they may lie in direct contact with the myomatous muscle, but the smaller ones are separated from the muscle by the characteristic stroma of the mucosa. The myomatous tissue seems to be circularly arranged around the gland spaces, and it frequently appears as if the myomatous thickening was due almost entirely to the irritation set up by the glands. These myomata may be near the tube lumen, in the vicinity of the peritoneum or lie near the broad ligament. The origin of the gland elements was referred by von Recklinghausen and others to the Wolfian duct, but in the last few years their continuity with the uterine

glands has been traced, and it is probable that the majority, if not all, of these adenomyomata owe their glandular elements to the uterine mucosa. The only difference between these and the diffuse growths in the uterine cavity is their small size and their relative poverty in gland elements. When we remember that the glands in the uterine horn are few and far between, this scanty glandular distribution is readily understood.

ADENOMYOMATA FROM THE TUBAL PORTION OF THE UTERINE HORN

These growths, likewise situated in the uterine horn, also consist of small myomata containing isolated gland-like spaces or small cysts. These spaces are lined with a single layer of cylindrical, ciliated epithelium. They may be situated in the inner muscular layers of the tube or penetrate nearly to the peritoneal surface on the one side, or to the mesosalpinx on the opposite side. They differ from those originating in the uterine portion of the uterine horn in that the epithelium rests directly on the muscle instead of being separated from it by the characteristic stroma (Fig. 64, p. 237). The reason for this was at first sight difficult to understand, but after von Franqué,¹ Meyer,² Gottschalk,³ and Lœkstaedt⁴ had shown conclusively that the gland-like spaces were nothing more than prolongations outward of the tubal mucosa, the solution was clear, as in the tubal mucosa the characteristic stroma of the uterine mucosa is wanting. The origin of the gland-like spaces in these growths was likewise formerly attributed to remains of the Wolffian body, but we now know that the majority of these represent prolongations outward of the tubal mucosa, probably followed secondarily by the myomatous development, as is evidenced by the fact

¹ Von Franqué, O.: Salpingitis nodosa isthmica und Adenomyoma Tubae. *Centrabl. f. Gynaek.*, 1900, Bd. xxv, S. 660.

² Meyer: *Ztschr. f. Geburtshülfe und Gynaekologie*, Bd. xlii, H. 1.

³ Gottschalk: Demonstration zur Entstehung der Adenome des Tubenisthmus. *Ztschr. f. Geburtshülfe und Gynaekologie*, 1900, Bd. xlii, S. 616.

⁴ Lœkstaedt, Paul: Ueber Vorkommen und Bedeutung von Drüsenschläuchen in Myomen des Uterus. *Monatsschr. f. Geb. u. Gyn.*, 1898, Bd. vii, S. 188.

that these outgrowths are often found independent of the myomatous growth.

Clinically, these small myomata in the uterine horns are of little importance. They are not recognized until the organ has been removed for some other cause, usually myomata or pus tubes. For a period of over five years (1893-1898) we had sections taken

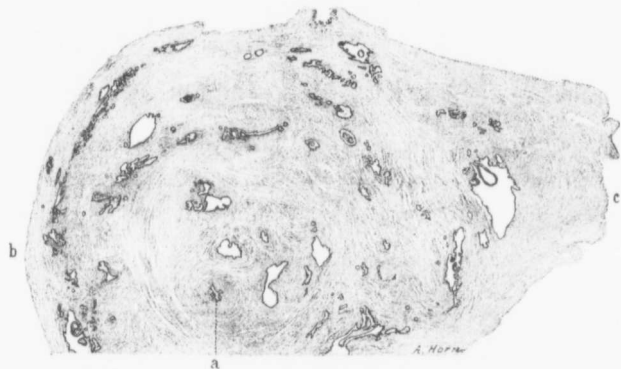


FIG. 61.—ADENOMYOMA OF THE UTERINE HORN. (8 diameters.)

Gyn. - Path. No. 4820. *a* is a cross-section of the Fallopian tube; *b* the outer or peritoneal surface; *c* the tissue near the broad ligament. Scattered everywhere throughout the tissue, which under a higher power was seen to be myomatous, are round, oval or irregular, elongate glands, occurring singly or in bunches. These were lined with cuboidal or cylindrical epithelium which in most places rested directly on the muscle. This appears to be an adenomyoma originating from the tubal portion of the uterine horn.

from both uterine horns as a routine procedure, and found groups of these gland-like spaces, with or without myomatous thickening, to be very common.

CASES IN WHICH ADENOMYOMATA WERE DETECTED IN THE UTERINE HORN

In this group we have not attempted to divide the cases into those originating from the uterine portion of the horn and those derived from the tubal portion, but have included them all in the same class.

Gyn. No. 11,572. Path. No. 7800.

Subperitoneal and interstitial uterine myomata; adenomyoma of the left uterine horn; normal appendages.

R. J. R., aged thirty-three, black, married. Admitted September 27, 1904; discharged October 27, 1904. The patient has been married thirteen years, but has never been pregnant.

Operation.—Hysterectomy. The patient made a satisfactory recovery.

Path. No. 7800.—The specimen consists of a greatly enlarged uterus and of the tubes and ovaries. The body of the uterus is normal in size, but springing from its surface are several small pedunculated myomata. In the left uterine horn is a distinct thickening, the nodule being 1.5 cm. in diameter. The tube lies perfectly free. Attached to the fundus by a pedicle, 2.5 cm. in diameter, is a large myomatous tumor, 20 by 15 by 10 cm. It is irregular and nodular. The tumor and the uterus are free from adhesions. The appendages are apparently normal.

Sections from the nodule in the left horn show what appears to be the lumen of the tube surrounded by several definite glandular areas. Embedded in this stroma and scattered throughout the nodule is a diffuse myoma. There are gland spaces lying in direct contact with the muscle. These glands are lined with one layer of high cylindrical epithelium. They appear to have originated from the uterine portion of the tube, although it is impossible to state this with certainty.

Diagnosis.—Subperitoneal and interstitial uterine myomata. Adenomyoma of the left uterine horn; normal appendages.

Path. No. 3721.

A small uterus with somewhat suspicious changes; adenomyoma of the left uterine horn; cystadenoma of the right ovary with carcinomatous changes; cystadenoma of the left ovary.

The specimen consists of the uterus, both tubes, and a cyst on each side. The uterus is exceedingly small and as far as can be determined measures 4 cm. in length, 3 cm. in breadth and 1.4 cm. in thickness. The uterine walls are very soft and vary from 7 to 9 mm. in thickness. The cavity is seen as a slit-like depression. It is 3 cm. in length. The mucous membrane is 2 mm. in thickness. The anterior and posterior surfaces of the uterus are smooth save for a few delicate adhesions.

On histological examination the uterine mucosa shows marked senile atrophy. Its surface is smooth. The glands are moderate in amount and in some places are considerably dilated. The epithelium, as a whole, is lower than usual. The glands are flattened. Some are irregularly arranged and present little papillary growths. Immediately beneath the left cornu is a nodule. This is composed of myomatous tissue containing glands lined with a low columnar epithelium of uniform appearance. On the right side there is a cystadenoma, portions of which show carcinomatous changes. On the left side there is a simple cystadenoma.

Diagnosis.—Small uterus with suspicious change; adenomyoma in the left uterine horn; cystadenoma of the right ovary with carcinomatous change; cystadenoma of the left ovary.

Gyn. No. 6635. Path. No. 2845.

Adenomyoma in the uterine horn with commencing subperitoneal adenomyoma.

P., aged thirty, white. Operation, January 14, 1899. Sections from the uterine wall show that the mucosa reaches 5 mm. in thickness. An oblique section through the stump of the right tube shows a small lumen of the tube with irregular outlines, lined with normal, low, cylindrical, epithelial cells. Situated some distance from the tube, surrounded by a definite circular zone of muscle, is an island of mucosa, perfectly normal in character. This is surrounded in numerous places by irregular glands lined with cylindrical epithelium and filled with desquamated epithelium and old hemorrhage. We have here the foundation for a subperitoneal adenomyoma.

Gyn. No. 3805. Path. No. 892.

The tube at the uterine horn is represented by three gland spaces instead of a lumen.

M. W., aged thirty-one. September 22, 1895. Pathological diagnosis: Right hydrosalpinx, left perisalpingitis, gland-like spaces in the uterine cornu. We have sections from the left uterine horn. The uterine horn is represented by three glands instead of a lumen, a very unusual picture. This is readily recognized, as we have the two definite layers of muscle surrounding them. We have here gland-like spaces which are irregular or round, some of them oblong. They are lined with cylindrical epithelium and characteristic stroma. This is the first case in which on examination of the uterine horn we have found the lumen represented by three distinct spaces.

Gyn. No. 3715. Path. No. 843.

Adenomyoma of the uterine horn.

E. S., white. August 15, 1895. Diagnosis: Remnants of an old endometritis; commencing abscess in the right uterine cornu; gland-like spaces in the uterine cornu; double perisalpingitis; double perioöphoritis. On examination of sections from the left uterine horn we find in the upper part a few small gland-like spaces a short distance beneath the peritoneum. These are round or oblong on cross-section and beneath the tube we also find some gland spaces. All the glands are lined with cylindrical epithelium. Some of them are rather complex, and instantly suggest an origin from a Wolffian duct; others resemble uterine mucosa. The tube lumen is much degenerated and is filled with pus.

Gyn. No. 3395. Path. No. 649.

Partial atrophy of the uterine mucosa; gland-like spaces in the uterine horn. Right side: chronic salpingitis, miliary abscess of the ovary. Left side: chronic salpingitis and perioöphoritis.

H., white. March 30, 1895. Sections from the uterine horn

show numerous adhesions and some gland-like spaces. These are small and round on cross-section. They are lined with cylindrical or cuboidal epithelium and are filled with desquamated epithelium. They lie in direct contact with the muscle. The tissue is evidently the seat of chronic inflammation, as is evidenced by the presence of many small round cells. Sections from the left tube show only one or two gland-like spaces and there is much less evidence of inflammatory reaction.

Gyn. No. 3401. Path. No. 647.

Partial atrophy of the uterine mucosa, gland-like spaces in both uterine horns, accessory ostium of the right tube, large simple hydrosalpinx of the left tube; slight adhesions on both sides.

Examination of the uterine cornu with the low power is most confusing at first, and one is hardly able to recognize the cross-section of the tube. Surrounding the tube on all sides, but particularly between the tube and the peritoneum covering the surface, are colonies of glands. Covering one surface are numerous adhesions consisting chiefly of omentum. The gland-like spaces to a great extent communicate with one another, as is evidenced by the little bridges here and there. Some of the gland spaces lie almost beneath the peritoneum and seem to be foreign to the uterus. The majority, however, are in direct contact with it. They are lined with cuboidal or cylindrical epithelium. The picture is a most interesting one.

On the left side sections from the cornu show a similar condition, although the picture is not so confusing. We are able to trace a definite channel which looks very much as if it were an outgrowth of the uterine mucosa. In this case we have a portion of adenomyomatous tissue definitely cut off and forming an independent subperitoneal adenomyoma. In none of these do we find much evidence of stroma.

C. H. I. No. 1517. Path. No. 10,669.

Adenomyoma in both uterine horns (Fig. 65); diffuse adenomyoma of the uterus; miniature uterine cavity.

S. E. W., married, aged forty-three. Admitted December 2, 1906. The patient has not been well for the last five or six years. Her periods during this time have been profuse, at times lasting as long as twelve days. She has had no children and no miscarriages. She has had some retention of urine at times; at other times there is frequency of micturition. There has been leucorrhœa for five or six years.

Operation.—Hystero-myomectomy and appendectomy. The patient made a satisfactory recovery. The highest post-operative temperature was 101.6° F.

Path. No. 10,669.—The specimen consists of a multinodular, myomatous uterus, 10 cm. in length, 13 cm. in breadth, and 11 cm. in its antero-posterior diameters. The uterus is everywhere smooth and glistening. The increase in size is due to subperitoneal, interstitial, and submucous myomata. The largest nodule, 8 cm. in diameter, is situated anteriorly and to the right. The uterine cavity is very small and is much distorted. In the left uterine horn is an area of thickening (Fig. 65). This is directly continuous with the tube and is 4 cm. in length, and varies from 1 to 2.5 cm. in breadth. It appears to be cystic and on section presents a sieve-like or polypoid appearance. There are also irregular cystic spaces, varying from 1 to 5 mm. in diameter. At least seven or eight of these are seen in one cross-section. The right tube is occluded, and reaches 4 cm. in diameter. The ovary is slightly mutilated. The right tube at the uterine horn presents an area of thickening 1.5 cm. in diameter. On section this horn is also seen to contain cystic spaces, one of them at least 3 mm. in length.

Histological Examination.—Sections taken from the right uterine horn show a most instructive picture. Cross-section of the tube shows that it is perfectly normal. Just to one side is a miniature uterine cavity lined with one layer of epithelium.

In other portions there are numerous uterine glands, the majority of which are dilated. Some lie in direct contact with the muscle. Others are separated from it by a small amount of stroma. A most interesting picture is noted in some places, namely, that the bunches of uterine glands are surrounded by a circular layer of myomatous

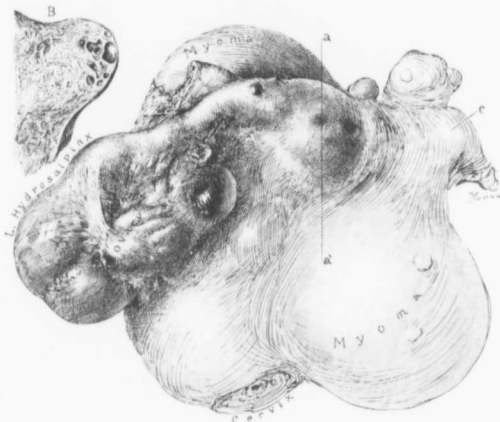


FIG. 65.—ADENOMYOMA OF BOTH UTERINE HORNS; DISCRETE MYOMATA; DIFFUSE ADENOMYOMA OF THE UTERUS. ($\frac{1}{4}$ natural size.)

C. H. I., No. 1517. Gyn.-Path, No. 10,669. Occupying the uterus are several myomatous nodules. The left tube is the seat of a hydrosalpinx; it is firmly fixed to the ovary and to the surface of the uterus. At the left uterine horn is a definite thickening. This area appeared cystic and on making an incision from *a* to *a'* the picture in *B* was found. The cyst spaces were irregular in form and varied from 1 to 5 mm. in diameter. A similar and smaller cystic tumor was present at the right uterine horn, as indicated by *c*. This on examination presented the same picture as did that of the left. On histological examination the thickenings in both horns were found to be due to the presence of adenomyoma. The glands were of the uterine type and in many places were surrounded by the characteristic stroma of the mucosa. Near *c* was a typical miniature uterine cavity. The uterine walls were the seat of a diffuse adenomyoma.

tissue. Riddling the mucosa everywhere at the uterine horn are uterine glands occurring singly or in bunches. Near the peritoneal surface, as noted macroscopically, some of the glands reach 2 mm. or more in diameter. The gland cavities in places contain desquamated epithelium and the epithelium has taken up blood-pigment

and some polymorphonuclear leucocytes. The origin of these glands it is impossible to determine.

Sections from the left uterine horn also show many cyst spaces, as noted macroscopically. Some of these reach 3 mm. or more in diameter. They may be circular, oval, or irregular in shape, and looking at the specimen macroscopically one sees islands of uterine mucosa surrounded by a definite and well-defined zone of muscle. With the low power we find the large cyst spaces lined with one layer of epithelium resting directly on the muscle. Such cyst spaces may be found beneath the peritoneum. At other points are colonies of glands, and in the depth we find typical islands of normal uterine mucosa, many of which are surrounded by the characteristic stroma. It is impossible to definitely determine the origin of these glands in the lower portion. The gland-like spaces are either empty or filled with desquamated epithelium and swollen cells that have taken up pigment.

Diagnosis.—Adenomyoma in both right and left uterine horns. In this case the uterine mucosa has everywhere riddled the myomatous uterine walls.

Gyn. No. 3399. Path. No. 645.

Slight atrophy of the uterine mucosa; small interstitial uterine myomata; gland-like spaces in the uterine cornu. Small abscess in the cornu. Right side: chronic salpingitis; general adhesions. Left side: adhesions and a small cyst springing from the left ovary.

The interest lies in the fact that only one tube is involved.

B., aged twenty-four, colored. March 28, 1895.

Sections from the right uterine cornu show with the low power several gland-like spaces between the cross-section of the tube and the peritoneal surface. They lie about 2 or 3 mm. from the lumen. The majority of them are irregular and are lined with cuboidal or cylindrical epithelium. One of these cysts in several places has

stroma projecting into it. These are covered with somewhat flattened epithelium and the cavities contain a few polymorphonuclear leucocytes. There are also numerous other minute glands lined with cylindrical epithelium and lying in direct contact with the muscle.

Gyn. No. 3379. Path. No. 633.

The uterine mucosa is normal, but contains numerous lymphoid nodules; gland-like spaces in adhesions over the uterine cornu; gland-like spaces in the uterine cornu; general pelvic adhesions; a small cyst of the ovary, probably from a Graafian follicle.

On examination of the right uterine horn the spaces are of little interest, but on the left side, where the section represents a field closer to the uterus,—in other words, where the tube is just beginning,—we have gland-like spaces practically just beneath the adhesions of the peritoneal surface. They are lined with cylindrical epithelium. A little beneath the peritoneum and running into the muscle is a similar gland space lined with a definite layer of cylindrical, ciliated epithelium and surrounded by a zone of lymphoid cells. Lying at the lower level, even with the tube, are irregular gland spaces lined with a similar epithelium and filled with blood, while still further down are irregular spaces which communicate with one another and are likewise filled with blood. The latter bear a striking resemblance to those in the uterine mucosa, although they have no definite stroma surrounding them.

CHAPTER XXIII

PREGNANCY IN THE LEFT FALLOPIAN TUBE; DISCRETE UTERINE MYOMATA; DIFFUSE ADENOMYOMA IN THE RIGHT UTERINE HORN WITH THE DEVELOPMENT OF DECIDUAL CELLS AROUND THE GLANDS IN THE ADENOMYOMA

This case was particularly interesting from a clinical standpoint, as we were able to make a diagnosis of tubal pregnancy from the velvety feel of the tube.¹ From a histological and etiological point of view the transformation into decidua of the stroma of the glands of the adenomyoma, in the uterine horn on the opposite side from tubal pregnancy, is in itself strong presumptive evidence that these glands are derivatives of the uterine mucosa.

Gyn. No. 12,380. Path. No. 9281.

Subperitoneal and interstitial uterine myomata; gland hypertrophy of the endometrium with extension of the uterine glands into the depth. Pregnancy in the left Fallopian tube (Fig. 66). Diffuse adenomyoma in the right uterine horn with decidual cell formation in the stroma of the adenomyomatous area.

E. P., aged thirty, colored. Admitted September 19; discharged October 26, 1905. Complaint: uterine hemorrhage, pain in the back and right side for seventeen days. Her menses began without disturbance at fifteen and were regular for two years. The periods were at first painless. At present the flow usually lasts from six to eight days. Her last period occurred on August 24th and the previous one in July.

The patient has been married fourteen years and has had no

¹Cullen, Thomas S.: The Velvety Feel of an Unruptured Tubal Pregnancy. Johns Hopkins Hospital Bulletin, 1906, p. 154.

children. There was a miscarriage at the second month four years ago.

On examination under anesthesia I made out definite myomatous nodules in the uterus and on the left side a thickening differing materially from the nodules in the uterus. The nodule on the




FIG. 66.—LEFT TUBAL PREGNANCY; DISCRETE UTERINE MYOMATA; ADENOMYOMA OF THE RIGHT UTERINE HORN WITH DECIDUAL FORMATION IN THE STROMA SURROUNDING THE GLANDS. (Natural size.)

GYN. No. 12,380. GYN.-Path. 9281. The uterus is occupied by several small subperitoneal and interstitial myomata. The left tube contains an unruptured pregnancy (*a*). The surface of the tube is covered with markedly dilated blood-vessels. In the right uterine horn are two small nodular thickenings which encroach upon the tube. Histological examination showed that they were adenomyomata. The stroma around many of the glands had been converted into typical decidua.

left side on gentle palpation gave the impression of being rather soft, but on firm pressure was found to be hard. In other words, it had a velvety feel. On account of this peculiar sensation imparted to the examining finger I made a diagnosis of tubal pregnancy in addition to uterine myomata.

Operation.—Hystero-myomectomy, double salpingectomy.

The left tube had not yet ruptured. The patient made a satisfactory recovery.

Path. No. 9281.—The specimen consists of a myomatous uterus and of the tubes. The uterus is approximately 10 cm. in breadth, 10 cm. in length, and 7 cm. in its antero-posterior diameter (Fig. 66). Projecting from the surface are several myomatous nodules. The largest is 3.5 cm. in diameter. Scattered throughout the uterine walls are several smaller nodules. Covering the surface of the uterus posteriorly are numerous adhesions. The uterine cavity is 6 cm. in length. The mucosa is thickened, in places reaching 5 mm.

In the right uterine horn is a nodular thickening 2.5 cm. in diameter. This is at the seat of the tubal attachment. The outer end of the tube is free from adhesions.

On the left side of the uterus is a globular thickening, 4 cm. in diameter. It is smooth and covered over with dilated vessels. The central portion is filled with blood and placental tissue. The fimbriated end of the tube is intact.

HISTOLOGICAL EXAMINATION.—Sections from the endometrium show typical gland hypertrophy. There is little evidence of decidual formation. Here and there the glands extend a short distance into the muscle. Sections from the right cornu show diffuse myomatous thickening. We have in many places glands lying in direct contact with the muscle. The gland epithelium is cylindrical and here and there, where dilatation has taken place, the cells are flattened or are almost round. The gland cavities contain desquamated epithelium, a few polymorphonuclear leucocytes, some blood, and coagulated serum. At other points the glands show budding, and in numerous places there is a typical gland hypertrophy. This gland hypertrophy is especially noticeable where the glands are surrounded by the characteristic stroma of the mucosa. These places show a most instructive picture. The stroma cells are swollen and have undergone typical decidual cell formation. Between these decidual cells are a good many small round cells and here and there a few poly-

morphonuclear leucocytes. The gland epithelium at such points is also cuboidal or flat. We also have stems of stroma projecting into some of the glands. These stems are covered over by one layer of epithelium, and the stroma cells are so swollen that they might very readily be mistaken for placental tissue. Some of the glands are gathered in groups and are surrounded by parallel and circular layers of muscle fibres.

The left tube is the seat of a typical tubal pregnancy.

D i a g n o s i s .—Subperitoneal and interstitial uterine myomata; pregnancy in the left Fallopian tube; diffuse adenomyoma in the right uterine horn, showing decidual formation and also gland hypertrophy.

This is a most instructive case. We have in many instances been able to trace the extension of the gland elements in the adenomyoma from the uterine mucosa. In this case we have an adenomyoma of the uterine horn and the stroma elements surrounding the glands have taken on a sympathetic decidual development, just exactly as does the uterine mucosa at times when tubal pregnancy exists. This is another point convincing us that even where we are unable to trace the direct continuity between the uterine mucosa and the gland elements in an adenomyoma they are in all probability derived from the same source, because they react in precisely the same manner as does the normal uterine mucosa; and, furthermore, they pour out their quota of menstrual blood at the period, as is evidenced by the fact that many of the glands are filled and markedly dilated with blood either recent or old.

CHAPTER XXIV

ADENOMYOMA OF THE ROUND LIGAMENT

Tumors of this character are comparatively rare, and until the publication of our case in May, 1896, this pathological condition seems to have been unknown. Similar cases have since been reported by Pfannenstiel,¹ Blumer,² Bluhm,³ Meyer,⁴ Aschoff,⁵ and others. Such a growth may vary from 1 to 2 or 3 cm. in diameter and is usually situated near the external inguinal ring. It consists of a very firm nodule, coarse in texture and intimately blended with the surrounding adipose tissue. On section it usually presents the picture of a diffuse myoma, and the fibres can be seen spreading out into the adjoining tissue (Fig. 67, p. 256). Scattered throughout this coarse tissue are cyst-like spaces varying from a pinhead to several millimetres in diameter. They may be irregularly oval or slit-like. Their inner surfaces are smooth and their cavities usually contain chocolate-colored contents. Yellowish or brownish pigmented areas are also frequently noted.

On histological examination the framework of these growths is found to be composed of non-stripped muscle fibres forming a dense irregular network and very suggestive of the diffuse myomata of the uterus. Occasionally, however, as in Aschoff's case, the major portion of the growth may consist of fibrous tissue. Scattered

¹ Pfannenstiel: Ueber die Adenome des Genitalstranges. Verhandlungen der Deutschen Gesellschaft für Gyn., 1897.

² Blumer: A Case of Adenomyoma of the Round Ligament. American Journal of Obstetrics, 1898, xxxvii, p. 37.

³ Bluhm, Agnes: Zur Pathologie des Ligamentum Rotundum Uteri. Arch. f. Gynaek., 1898, lv, S. 647.

⁴ Meyer: Ueber Drüsen, Cysten, und Adenome im Myometrium der Erwachsenen. Ztschr. f. Geb. Gyn., 1900, xliii, S. 329.

⁵ Aschoff, L.: Cystisches Adenofibrom der Leistengegend. Monatschr. f. Geburtshilfe und Gynaekologie, 1899, ix, S. 25.

throughout the diffuse myoma are islands of glands, round on cross-section (Fig. 68, p. 257), or irregular in form. They are lined with one layer of cylindrical, ciliated epithelium and the gland cavities are frequently filled with blood. These glands are surrounded by a stroma identical with that of the uterine mucosa. The gland epithelium and also the stroma cells often contain yellowish or brown granular pigment. The cyst-like spaces, noted macroscopically, are likewise lined with a single layer of cylindrical ciliated epithelium and the chocolate-colored contents are the remnants of old hemorrhages. All of the adenomyomata so far reported have the same general characteristics. In our case¹ nodules were found, both in the right and in the left round ligaments.

Pfannenstiel found such a growth in the right inguinal region, and in the same case a second in the vaginal vault. In Blumer's case there were primarily two distinct nodules in the right groin, each about 6 mm. in diameter. These had gradually coalesced, and at the expiration of twenty-three years formed a nodule the size of a hen's egg. In Aschoff's case the nodule was situated in the left labium majus, and when first observed was no larger than a pea. It gradually became as large as an almond, and at one point was in close proximity to the skin. Bluhm's patient had a firm elastic tumor the size of a plum and situated at the internal inguinal ring. As was noted in Pfannenstiel's case, besides the nodule in the inguinal region, there was a second, similar in character, situated in the vaginal vault. Cases of this character have also been reported by von Herff² and Pick.³ In Pick's case the myoma was as large as a hazelnut and situated in the posterior vaginal vault.

The foregoing cases are definite examples of adenomyomata,

¹ Cullen, Thomas S.: Adenomyoma of the Round Ligament. Johns Hopkins Hospital Bulletin, May, 1896; Further Remarks on Adenomyoma of the Round Ligament. Johns Hopkins Hospital Bulletin, 1898.

² Von Herff: Ueber Cystomyome und Adenomyome der Scheide. Verhandlungen der Deutschen Gesellsch. f. Gyn., 1897.

³ Pick, Ludwig: Die Adenomyome der Leistengegend und des hinteren Scheidengewölbes; ihre Stellung zu den paroophoralen Adenomyomen der Uterus und Tubenwandung, v. Recklinghausen's Arch. f. Gynaek., Bd. lvii, 461.

and, as noted, the tumor may be situated in one or both round ligaments, in the labium majus or in the posterior vaginal vault; or such growths may occur simultaneously in the inguinal region and vaginal vault.

Clinical History.—These nodules are usually of slow growth. In our own case it had been present eight years; in Blumer's case for twenty-three years. The tumors may appear as early as the twentieth year, as in Blumer's case, or as late as the forty-second year, as noted in Aschoff's case. They are most common during the child-bearing period. The tumor at first causes little annoyance, but with its increase in size there is pain on walking, probably on account of the intimate association of the tumor with the surrounding structures, as well as considerable distress on menstruation. At the period the lump may be increased in size and become very painful, again diminishing in size after the flow is over.

Prognosis.—Our case was of eight years' duration, and on histological examination gave no sign of malignancy, proving that the growth was benign in character. Blumer's case is even more convincing, as it had been under observation twenty-three years, the growth in that time not becoming larger than a hen's egg. Microscopic examination also showed its harmless character.

Treatment.—Excision of the nodule is indicated solely on account of the discomfort produced by its presence.

ORIGIN OF ADENOMYOMATA OF THE ROUND LIGAMENT

As in the case of adenomyomata of the uterus, controversy has arisen as to whether the growths are derivatives of the Wolffian or of the Müllerian duct. Many authors claim that portions of the Wolffian duct have been nipped off during the development of the embryo and have been carried down the round ligament, and that in after-life they develop. They base their assumption on the fact that the Wolffian duct comes in close contact with the round ligament prior to its descent to the inguinal region. They also think that the gland elements of the adenomyoma bear some resemblance to portions of the Wolffian duct. Those dissenting from this view hold

that there is strong evidence that misplaced portions of Müller's duct are responsible for the growth of these tumors. As has been noted, the glands in these adenomyomata cannot be distinguished in many instances from normal uterine glands. They are small, round, and lined with cylindrical ciliated epithelium. Furthermore, they are surrounded by the characteristic stroma of the normal uterine mucosa. Clinically, it has been noted that these growths may have a sympathetic relationship with the menstrual period, as seen in their increase in size at that time, followed in the intermenstrual period by a diminution in their volume. This increase in size is undoubtedly due to the hemorrhage into the glands at the periods, as is proved by the hemorrhagic contents at operation. In our case menstruation had commenced on May 18th and ceased on May 23d or just three days before operation; and on making sections the glands were found filled with well preserved blood. A further point in favor of the Müller's duct origin is that these adenomyomata resemble in every particular the diffuse adenomyomata of the uterus, in which the glands are seen to be direct derivatives of the uterine mucosa. As was said when discussing the origin of adenomyomata of the uterus, there is no other place in the body in which mucosa similar to normal uterine mucosa is found, and furthermore no other mucous membrane that periodically discharges blood. These round ligament adenomyomata fulfil every requirement of normal uterine mucosa. It would be unwise to say absolutely that these growths cannot possibly be derived from remains of the Wolffian duct, but the evidence is overwhelmingly in favor of the Müller's duct origin.

Before concluding a consideration of these cases we must briefly refer to the case reported by Martin¹ in 1891. A patient aged seventy consulted him about a rapidly growing tumor. He opened the abdomen and removed 12 litres of chocolate-colored fluid from a tumor springing from the left round ligament. This was attached to the ligament by a definite pedicle. Pommorsky, who made the microscopic examination, found that the cyst containing the choeco-

¹ Martin A.: Zur Pathologie des Ligamentum rotundum. Ztschr. f. Geb. u. Gyn., Bd. xxii, S. 444.

late-colored fluid had very thin walls, and that its inner surface was in places covered by clots. The pedicle of the tumor contained several small cysts which were filled with clear fluid and which communicated with one another. One of these cysts was lined with low cylindrical ciliated epithelium. It is quite probable that this was an adenomyoma of the round ligament situated nearer the uterine horn than usual. I noted in speaking of adenomyoma of the uterus that when the tumor became intraligamentary, as in the case represented in Fig. 43 (p. 151), or in those of Breus and Kroenig, large cysts developed. These were filled with chocolate-colored fluid and at some points small cysts were still visible. In adenomyoma of the round ligament situated in the inguinal region or in the labium majus, we have a continual surrounding pressure, as in the uterus. In Martin's case, on the other hand, there was nothing to prevent cystic formation. The process appears to be analogous to the cystic development occurring in subperitoneal or intraligamentary adenomyomata of the uterus.

ADENOMYOMATA OCCURRING IN BOTH THE RIGHT AND LEFT ROUND
LIGAMENT IN THE SAME INDIVIDUAL (Figs. 67 and 68)

Gyn. No. 3891.

L. N., aged thirty-seven. Admitted October 18, 1895. The patient has been married thirteen years and had one instrumental labor seven years ago. Her menses commenced at fourteen and were regular until the birth of the child, since which time they have occurred every three weeks, have been very copious, and have lasted from four to five days. The latter part of each period has been accompanied by a good deal of pain, which persists for several days after the flow. The last menstrual period occurred two weeks before admission. About eight years ago the patient noticed a slight swelling in the right inguinal region. This has gradually enlarged, more especially during the last two years. She has had severe cutting pain in the nodule and radiating to the back. This has been most severe after exertion or during the menstrual period. The patient is much debilitated. The vaginal examination is negative.

The mass occupies the upper part of the right labium, is irregularly ovoid and firmly fixed in the deeper tissues. It is, however, movable to the extent of one centimetre.

October 19th: An oval incision was made over the site of the nodule. The mass was freed laterally and posteriorly. Above it was closely connected with a band of tissue, 1 cm. broad. This proved to be the right round ligament. The round ligament was traced upward to the internal ring, and midway between the external and internal ring it contained a nodule, 1 by .6 cm. The round ligament was pulled down, clamped, and cut off at the internal ring. Several enlarged lymph-glands were then dissected out. The pillars of the ring were brought together with silver wire and the round ligament was sutured into the canal. The patient was discharged on November 3, 1895.

Gyn.-Path. No. 926.

The specimen consists of a piece of tissue measuring 7 by 4 by 3.5 cm. One surface of this is covered with normal skin. The underlying tissue is composed of fat, embedded in which is an exceedingly firm nodule, measuring 3.5 by 3 by 2 cm. (Fig. 67). This nodule on section is composed of interlacing bundles of fibres which form a dense network. Scattered throughout the nodule are many small, irregular, pale, translucent, homogeneous areas. On examining the specimen after hardening in Müller's fluid some of the homogeneous areas are found to contain round, oval, or irregular spaces.

Histological Examination.—The nodule is to a great extent composed of non-striated muscle fibres which wind in and out in all directions, but do not show any concentric arrangement. In many places the muscle fibres are swollen and the cell protoplasm contains large quantities of yellowish-brown granular pigment. At several points the muscle has undergone hyaline degeneration. This is especially noticeable around blood-vessels. The blood-supply is abundant. Scattered here and there throughout the muscle substance are small islands of adipose tissue. Traversing the nodule in all directions are glands (Fig. 68). Some of these

are small and round on cross-section; the others are cut lengthwise. These glands are surrounded by stroma similar to that of the uterine mucosa. It would be impossible to distinguish some of these from uterine glands. A few of the glands present slight dichotomous branching. Some of them contain round masses of protoplasm, scattered throughout which are several nuclei. These giant cells appear to be cross-sections of tufts of epithelium. In many places the glands present a peculiar arrangement and correspond to von Recklinghausen's pseudo-glomeruli, which consist of stroma resembling that of the uterine mucosa. They contain numerous

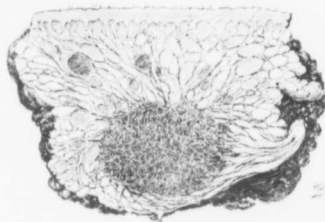


FIG. 67.—ADENOMYOMA OF THE ROUND LIGAMENT. (Natural size.)

GYN. PATH. No. 928. The figure represents a longitudinal section of the tissue removed. The greater part consists of fat and the surface is covered with skin. Occupying the lower part is an oval area, dark in color and composed of fibres running in all directions—the myoma. Passing off from it are numerous strands which merge into the adipose tissue. The small dark areas in the myoma represent dilated gland cavities. The large and small dark masses in the adipose tissue are hemorrhages. For the histological picture of the adenomyoma see Fig. 68.

capillaries and may have one or more glands situated in their depth. In some places there has been hemorrhage into their stroma. The pseudo-glomeruli are half-moon-shaped, cone-shaped, or irregular in contour. They are covered with one layer of cylindrical ciliated epithelium. What corresponds to Bowman's capsule consists of a layer of cells resting directly upon the muscle fibres. The cells of the capsule opposite the convexity of the glomerulus are almost flat. On passing off laterally they are seen to be cuboidal or cylindrical. The cells of the so-called capsule are directly continuous with those of the pseudo-glomerulus. The space between the cap-

sule and the glomerulus may be empty. Many, however, contain desquamated epithelial cells, some of which are vacuolated and have brown, granular pigment in their interior. Numerous spaces contain blood-corpuses. On tracing one of the spaces laterally it is found to be directly continuous with the lumen of a gland. The capsule forms one wall of the gland and the pseudo-glomerulus the other (Fig. 68). In other words, the space between the capsule and the so-called glomerulus is nothing more than a dilatation of the

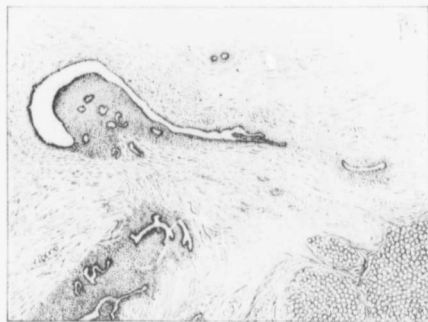

FIG. 68.—ADENOMYOMA OF THE ROUND LIGAMENT. (20 diameters.)

Gyn.-Path. No. 928. The section is taken from the oval nodule in Fig. 67. The framework consists of non-striated muscle fibres cut chiefly longitudinally. Scattered throughout the muscle are glands which occur singly or in groups. They are round, oval or irregular and show some branching. All are lined with one layer of cylindrical epithelium and even the smaller ones are surrounded by a definite stroma which with the high power is seen to be identical with that of the uterine mucosa. In the right lower corner is adipose tissue. A few stray fat cells are found in the myoma. In the left upper corner is a so-called pseudo-glomerulus.

gland cavity or of a miniature uterine cavity. In numerous places the gland epithelium on one side is found to be cylindrical; on the other side, cuboidal or almost flat. On examining these more closely it is found that where the epithelium is separated from the muscle by a moderate amount of stroma it is cylindrical, but where the epithelium rests directly upon the muscle, it is invariably cuboidal or flat. A few small glands are seen lying directly between muscle bundles.

Extending into the myomatous growth from the periphery are numerous bands of connective tissue. The adipose tissue surrounding the myoma shows considerable hemorrhage. The skin covering the surface of the specimen is normal. Unfortunately we were not able to obtain the smaller nodule of the round ligament for examination and cannot say whether it was an adenomyoma or not.

The patient was readmitted on May 25, 1897. Shortly after the previous operation she noticed a swelling in the opposite (left) inguinal region immediately above the pubes. This has gradually increased in size and is quite painful. The menstrual period has not been regular, occurring at intervals of from three to five weeks. The last menstruation commenced May 18th and ceased May 23d. On May 26th I removed the nodule with little difficulty and found that it was directly continuous with the left round ligament.

Gyn. - Path. No. 1741.—The specimen consists of an irregular mass, approximately 3 cm. in its various diameters. It comprises a firm central portion, 1.5 cm. in diameter, and is surrounded on all sides by adipose tissue. Traversing the central portion are numerous delicate fibres and at several points are brown or yellow homogeneous areas. Several pin-point cavities are demonstrable. At one point is a semicircular slit, 2 mm. long, and in the immediate vicinity an irregular cavity averaging 3 mm. in diameter. The walls of this cavity are rather uneven and are slightly granular.

Histological Examination.—The adipose tissue in the outlying portions is comparatively normal, but as one approaches the firm nodule the blood-vessels increase in number and size. Young capillaries are found wandering in between the fat cells, the fat cells becoming gradually separated from one another. At the margin of the firm nodule the growth is composed almost exclusively of connective tissue. Here and there this connective tissue encircles round or oval clumps of cells having oval, somewhat deeply staining nuclei. Scattered between these are a few small round cells and occasionally polymorphonuclear leucocytes. Such areas are very striking on account of their richness in nuclei,

in contrast to the surrounding tissue, which is poor in cell elements. The cellular areas resemble closely the stroma of the uterine mucosa. On passing toward the centre of the nodule similar areas are found containing one or more glands lying in their centre or at the periphery. These glands, according to the angle at which they have been cut, are round, elongate, or slightly branching. Their epithelium is cylindrical, apparently ciliated, and their nuclei are oval and situated at some distance from the bases of the cells. In short, these glands cannot be distinguished from uterine glands. The majority of the gland cavities are completely filled with blood and desquamated epithelial cells. The stroma of the central portion of the nodule is composed almost entirely of non-stripped muscle fibres, and here the glands are abundant and present a more complicated picture. They are branching, form narrow channels and little bays, and in places can be traced in their continuity for at least 4 mm. On one side of the gland there is usually a considerable amount of stroma separating the epithelium from the underlying muscle. At such points the epithelium is cylindrical, but on the opposite side, where the cells rest directly on the muscle, it is frequently flattened. There are a few areas corresponding to von Recklinghausen's pseudo-glomeruli. Some of these contain glands, others do not.

The nodules in both round ligaments are typical adenomyomata.

SUMMARY

In cases of adenomyoma of the uterus we usually find a diffuse myomatous thickening of the uterine muscle. This thickening may be confined to the inner layers of the anterior, posterior, or lateral walls, but in other cases the myomatous tissue completely encircles the uterine cavity.

This diffuse myomatous tissue contains large or small chinks, and into these chinks the normal uterine mucosa flows. If the chinks are small, there is only room for isolated glands, but where the spaces are of goodly size large masses of mucosa flow into and fill them. We accordingly have a diffuse myomatous growth with normal mucosa flowing in all directions through it. The mucosa lining the uterine cavity is perfectly normal.

After a time portions of the diffuse myoma may be nipped off and are carried toward either the outer or inner surfaces of the uterus. If they become submucous growths, they are gradually expelled. If they pass toward the outer surface, they become either subperitoneal or intraligamentary. We have accordingly divided adenomyomata into the following groups:

1. Adenomyomata in which the uterus preserves a relatively normal contour.
2. Subperitoneal or intraligamentary adenomyomata.
3. Submucous adenomyomata.

A diffuse adenomyoma presents a very coarse appearance, owing to the fact that the myomatous muscle bundles run in all directions. In the spaces between bundles and occasionally surrounded by circular rings of muscle we find spaces filled with translucent and slightly punctiform tissue—areas of uterine mucosa. Sometimes its direct connection with the mucosa of the uterine cavity can be traced. Often are noted cyst-like spaces scattered throughout the diffuse myoma. These are filled with a chocolate-colored fluid and are lined

with a definite membrane, often 1 to 2 mm. thick. They are miniature uterine cavities and the chocolate-colored fluid is old menstrual blood that could not escape.

When an adenomyomatous nodule becomes subperitoneal, the menstrual flow in the growth may gain the upper hand and the myoma become cystic, the contents, of course, being formed from the accumulation of old menstrual blood.

Symptoms.^{*}—Our youngest patient was nineteen, our oldest sixty. The disease is most prevalent between the thirtieth and sixtieth years; it does not in any way tend to sterility.

Lengthened menstrual periods are the first symptom. The flow gradually assumes the proportions of hemorrhages and eventually the period may become continuous.

At the period there is often discomfort, and occasionally a grinding pain in the uterus, evidently due to the increased tension, since all the islands of mucosa scattered throughout the diffuse myoma naturally swell up at the menstrual period, and thus increase the size of the organ.

In over two-thirds of our cases there was no intermenstrual discharge. This is perfectly natural, as in these cases the uterine mucosa is normal and no disintegration of tissue is going on.

Clinically the diagnosis of diffuse adenomyoma is relatively easy, for the following reasons:

1. The bleeding is usually confined to the period.
2. There is usually much pain, referred to the uterus, at the period.

^{*}While von Recklinghausen was carrying on his work on the pathology of adenomyoma W. A. Freund was carefully analyzing the symptomatology in such cases to determine, if possible, whether the clinical picture was sufficiently characteristic to enable the surgeon to make a diagnosis before operation. In contrast with his findings, our experience goes to show that neither an infantile condition of the uterus nor sterility is in any sense a prominent feature.

Von Rosthorn (Med. Klin. Berlin, 1905, I, 201-203), in a recent publication, reports two cases, in one of which the clinical picture before operation strongly suggested diffuse adenomyoma. He says that in the future, with our increased knowledge, a provisional diagnosis of adenomyoma is sometimes possible before operation.

3. There is usually no intermenstrual discharge of any kind.

4. The uterine mucosa is perfectly normal and may be rather thick.

No other pathological condition of the uterus, as a rule, gives this characteristic picture.

Treatment.—The patient's health is often gradually undermined by the uterine hemorrhages, and the only way to control them is to remove the uterus. A supravaginal hysterectomy is all that is necessary. The ovaries should be saved.

The *prognosis* is good, as the glands of the adenomyoma are perfectly normal uterine glands and are surrounded by the characteristic stroma of the mucosa.


Origin.—The glands in the adenomyoma originate, in the vast majority of the cases at least, from the uterine mucosa. The reader will be thoroughly convinced of this after studying the various histological pictures in the book.

Cause.—The cause of adenomyoma is still unsolved.

INDEX OF CASES ARRANGED ACCORDING TO THEIR GYNECOLOGICAL NUMBERS


CASES OBSERVED IN THE JOHNS HOPKINS HOSPITAL

PAGE		PAGE	
Gyn. No. 2573	17	Gyn. No. 10516	203
Gyn. No. 2699	93	Gyn. No. 10519	86
Gyn. No. 2706	29	Gyn. No. 10872	163
Gyn. No. 2744	64	Gyn. No. 11120	100
Gyn. No. 2754	42	Gyn. No. 11252	114
Gyn. No. 2806	47	Gyn. No. 11363	106
Gyn. No. 3126	213	Gyn. No. 11572	238
Gyn. No. 3136	75	Gyn. No. 11850	16
Gyn. No. 3192	52	Gyn. No. 12036	115
Gyn. No. 3204	50	Gyn. No. 12000	212
Gyn. No. 3293	132	Gyn. No. 12080	45
Gyn. No. 3379	215	Gyn. No. 12221	252
Gyn. No. 3395	210	Gyn. No. 12304	213
Gyn. No. 3399	214	Gyn. No. 12358	117
Gyn. No. 3401	211	Gyn. No. 12380	246
Gyn. No. 3418	8	Gyn. No. 12585	140
Gyn. No. 3600	188	Gyn. No. 12599	22
Gyn. No. 3611	23	Gyn. No. 12678	161
Gyn. No. 3715	240	Gyn. No. 12681	14
Gyn. No. 3805	240	Gyn. No. 12807	82
Gyn. No. 3809	31	Gyn. No. 12841	83
Gyn. No. 3891	254	Gyn. No. 12918	206
Gyn. No. 3898	166	Gyn. No. 12944	95
Gyn. No. 4364	97		
Gyn. No. 4415	190	San. No. 469	62
Gyn. No. 5798	54	San. No. 1453	115
Gyn. No. 5782	218	San. No. 1552	105
Gyn. No. 5973	158	San. No. 1847	230
Gyn. No. 6083	68	San. No. 1852	225
Gyn. No. 6240	200	San. No. 1872	140
Gyn. No. 6635	239	San. No. 1913	122
Gyn. No. 6855	100	San. No. 1931	20
Gyn. No. 6855	149	San. No. 1944	123
Gyn. No. 7011	108	San. No. 2144	40
Gyn. No. 7153	34	San. No. 2178	103
Gyn. No. 7569	88		
Gyn. No. 7859	109	Church Home and Infirmary.	
Gyn. No. 8438	224	Case No. (G. L. Hummer)	99
Gyn. No. 8647	128	Case No. 511 (Thomas Cullen)	211
Gyn. No. 8780	149	Case No. 1019 (Thomas Cullen)	113
Gyn. No. 9024	138	Case No. 1517 (Thomas Cullen)	242
Gyn. No. 9069	33		
Gyn. No. 9457	60		
Gyn. No. 9637	139	Dr. W. W. Russell's patient	67
Gyn. No. 9788	85	Emergency Hospital, Frederick, Md.	
Gyn. No. 9971	209	(Thomas Cullen)	119
Gyn. No. 10314	161	Dr. Joseph Price's case	228



INDEX OF GYNECOLOGICAL-PATHOLOGICAL NUMBERS

	PAGE		PAGE
Gyn.-Path. No. 163.....	17	Gyn.-Path. No. 5668.....	60
Gyn.-Path. No. 245.....	29	Gyn.-Path. No. 5840.....	139
Gyn.-Path. No. 246.....	93	Gyn.-Path. No. 6008.....	85
Gyn.-Path. No. 274.....	64	Gyn.-Path. No. 6150.....	209
Gyn.-Path. No. 290.....	42	Gyn.-Path. No. 6216.....	115
Gyn.-Path. No. 334.....	47	Gyn.-Path. No. 6319.....	99
Gyn.-Path. No. 493.....	213	Gyn.-Path. No. 6531.....	161
Gyn.-Path. No. 497.....	75	Gyn.-Path. No. 6536.....	105
Gyn.-Path. No. 525.....	52	Gyn.-Path. No. 6754.....	86
Gyn.-Path. No. 526.....	50	Gyn.-Path. No. 6764.....	203
Gyn.-Path. No. 583.....	132	Gyn.-Path. No. 7026.....	181
Gyn.-Path. No. 633.....	245	Gyn.-Path. No. 7076.....	163
Gyn.-Path. No. 645.....	244	Gyn.-Path. No. 7351.....	109
Gyn.-Path. No. 647.....	241	Gyn.-Path. No. 7507.....	114
Gyn.-Path. No. 649.....	240	Gyn.-Path. No. 7593.....	106
Gyn.-Path. No. 659.....	178	Gyn.-Path. No. 7800.....	238
Gyn.-Path. No. 661.....	8	Gyn.-Path. No. 8197.....	16
Gyn.-Path. No. 777.....	188	Gyn.-Path. No. 8346.....	230
Gyn.-Path. No. 788.....	23	Gyn.-Path. No. 8347.....	225
Gyn.-Path. No. 843.....	240	Gyn.-Path. No. 8393.....	119
Gyn.-Path. No. 881.....	31	Gyn.-Path. No. 8426.....	211
Gyn.-Path. No. 892.....	240	Gyn.-Path. No. 8433.....	140
Gyn.-Path. No. 928.....	255	Gyn.-Path. No. 8579.....	145
Gyn.-Path. No. 934.....	166	Gyn.-Path. No. 8602.....	212
Gyn.-Path. No. 1170.....	97	Gyn.-Path. No. 8641.....	122
Gyn.-Path. No. 1207.....	190	Gyn.-Path. No. 8715.....	45
Gyn.-Path. No. 1741.....	258	Gyn.-Path. No. 8760.....	40
Gyn.-Path. No. 1758.....	62	Gyn.-Path. No. 8807.....	123
Gyn.-Path. No. 2066.....	54	Gyn.-Path. No. 8832.....	232
Gyn.-Path. No. 2048.....	179	Gyn.-Path. No. 8890.....	213
Gyn.-Path. No. 2075.....	218	Gyn.-Path. No. 8983.....	117
Gyn.-Path. No. 2084.....	218	Gyn.-Path. No. 9281.....	246
Gyn.-Path. No. 2250.....	158	Gyn.-Path. No. 9312.....	228
Gyn.-Path. No. 2356.....	68	Gyn.-Path. No. 9336.....	140
Gyn.-Path. No. 2332.....	200	Gyn.-Path. No. 9366.....	22
Gyn.-Path. No. 2845.....	239	Gyn.-Path. No. 9367.....	20
Gyn.-Path. No. 3107.....	160	Gyn.-Path. No. 9407.....	113
Gyn.-Path. No. 3289.....	108	Gyn.-Path. No. 9466.....	104
Gyn.-Path. No. 3429.....	34	Gyn.-Path. No. 9517.....	14
Gyn.-Path. No. 3741.....	238	Gyn.-Path. No. 9690.....	82
Gyn.-Path. No. 3903.....	88	Gyn.-Path. No. 9705.....	40
Gyn.-Path. No. 4122.....	109	Gyn.-Path. No. 9744.....	83
Gyn.-Path. No. 4656.....	223	Gyn.-Path. No. 9803.....	103
Gyn.-Path. No. 4829.....	257	Gyn.-Path. No. 9841.....	206
Gyn.-Path. No. 4838.....	128	Gyn.-Path. No. 9858.....	67
Gyn.-Path. No. 4966.....	149	Gyn.-Path. No. 9970.....	95
Gyn.-Path. No. 5187.....	138	Gyn.-Path. No. 10771.....	176
Gyn.-Path. No. 5229.....	33	Gyn.-Path. No. 10669.....	242



INDEX

- ABORTION** and adenomyoma, differentiation, 183
Abscess, in uterine cornu, 244
 miliary, of ovary, 240
 tubo-ovarian, 47
Adenocarcinoma, and adenomyoma occurring independently in same uterus, 218
 developing from adenomyoma, 222
 cases of, 223
Adenocystoma of ovary, 97
Adenomyoma, 1
 adenocarcinoma developing from, 222
 cases of, 223
 and abortion, differentiation, 183
 and adenocarcinoma occurring independently in same uterus, 218
 and carcinoma, differentiation, 175, 185
 and chorioepithelioma, differentiation, 183
 and endometritis, differentiation, 184
 and large and dilated uterine glands with overgrowth of stroma of mucosa, differentiation, 180
 and myoma, differentiation, 182
 and polyp, differentiation, 178
 and proliferation of stroma of uterine mucosa associated with copious uterine hemorrhages, differentiation, 180
 and salpingitis, differentiation, 184
 and sarcoma, differentiation, 183
 and tubal pregnancy, differentiation, 184
 and venous sinuses in uterine mucosa, differentiation, 179
 arising from uterine portion of uterine horn, 235
 benign character of, cases illustrating, 188
 cases of diffuse, 8
 causes of, 199, 202
 cervical, 165
 clinical picture in, 173
 commencing, 20, 29, 31, 33, 50, 52, 67, 83
 condition of tubes and ovaries in, 171
 diagnosis of, 175, 201
 differential, 177
 diffuse, cases of, 8
 and squamous-cell cancer of cervix, 206
 hypertrophy of cervix and, 200
Adenomyoma, diffuse, of uterine horn, 235, 246
 origin of, 193
 prognosis in, 187, 262
 symptoms of, 173, 261
 treatment of, 186, 261
 discharge in, 173
 discrete, 60, 140
 in left uterine horn, 100
 of utero-ovarian ligament, 141
 from tubal portion of uterine horn, 236
 hemorrhage in, 173
 incidence of, 174
 in one horn of bicornate uterus, 203
 in right and left round ligament in same person, 254
 interstitial, 138
 intraligamentary, 145
 case of, 149
 cystic, 148
 of round ligament, 250
 origin of, 252
 of uterine horn, 29, 52, 67, 100, 117, 119, 235, 237, 239, 240, 241, 242, 244, 245, 246
 decidua developing in adenomyoma of, 246
 origin of, 193
 pain in, 173
 physical examination in, 175
 prognosis in, 187
 relation of, to pregnancy, 174
 submucous, 156
 cases of, 149, 158, 160, 161, 163
 origin of, 195
 subperitoneal, 125
 cases of, 114, 128
 cystic, 128
 origin of, 194
 summary of, 260
 treatment of, 186
 uterus preserving relatively normal contour, 2
 cases of, 8
 cystic glands in, 6
 cyst-like spaces in, 3
 dilated glands in, 6
 glands in, 4, 5, 7

- Hemorrhage from venous sinuses in uterine mucosa, adenomyoma and, differentiation, 179
 in adenomyoma, 173
- Hydrosalpinx, 29, 166, 241
- Hypertrophy, gland, of endometrium, 140, 149, 246
 of cervix and diffuse adenomyoma, 200
- INTERSTITIAL adenomyoma, 138
- Intraligamentary adenomyoma, 145
 case of, 149
 cystic, 148
- LIGAMENT, round, adenomyoma of, 250
 origin, 252
 right and left, adenomyoma in, in same person, 254
 utero-ovarian, discrete adenomyoma of, 141
- MILIARY abscesses of ovary, 240
- Miniature uterine cavities, 3, 69, 100, 141, 161
- Mucosa, uterine, atrophy of, 133, 240, 241, 244
 edema of, 50, 128, 133
 hemorrhage into and thickening of, 24
 hypertrophy of, 140, 149, 246
 in adenomyoma in which uterus preserves relatively normal contour, 6
 polypi of, 75, 97, 178
 stroma of, proliferation, associated with copious uterine hemorrhage, differentiation from adenomyoma, 180
 venous sinuses in, and adenomyoma, differentiation, 179
- Multiple cysts in subperitoneal myoma, 128, 132
- Myoma and adenomyoma, differentiation, 182
- Myomatous thickening, diffuse, but no glandular invasion of uterine walls, 230
- OSTIUM, accessory, of Fallopian tube, 241
- Ovary, adenocystoma of, 97, 238
 condition of, in adenomyoma, 171
 cyst of, 34, 50, 60, 82, 93, 97, 166, 238, 245
 with carcinomatous changes, 238
 miliaire abscesses of, 240
 papillocystoma of, 166
- PAIN in adenomyoma, 173
- Papillocystoma of ovary, 166
- Pathological changes, multiple, in the pelvis, 228
- Pelvic adhesions, 24, 31, 33, 34, 46, 47, 50, 64, 67, 82, 84, 97, 103, 108, 109, 138, 149, 166, 171, 240, 245
- Pelvis, pathological changes in, 228
- Physical examination in adenomyoma, 175
- Polyp, and adenomyoma, differentiation, 178
 glandular uterine, 75, 97
- Pregnancy, in left Fallopian tube, 246
 relation of adenomyoma to, 174
 tubal, and adenomyoma, differentiation, 184
- Proliferation of stroma of uterine mucosa associated with copious uterine hemorrhages, adenomyoma and, differentiation, 180
- Purulent salpingitis, acute, 46
- ROUND ligament, adenomyoma of, 250, 252
 right and left, adenomyoma in, in same person, 254
- SALPINGITIS, 84, 171
 acute purulent, 46
 and adenomyoma, differentiation, 184
 chronic, 46, 240, 244
- Sarcoma and adenomyoma, differentiation, 183
- Sinuses, venous, in uterine mucosa, and adenomyoma, differentiation, 179
- Squamous-cell cancer of cervix, diffuse adenomyoma of body, 206
- Stroma of uterine mucosa, proliferation of, associated with copious uterine hemorrhages, adenomyoma and, differentiation, 180
- Submucous adenomyoma, 149, 156, 158, 160, 161, 163
 cases of, 158
 origin of, 195
- Subperitoneal adenomyoma, 114, 125, 138, 139, 140, 145
 cases of, 128
 cystic, 128, 132
 origin of, 194
 multiple cysts in, 128, 132
- THICKENING, and hemorrhage from uterine mucosa, 24
 in adenomyoma in which uterus preserves relatively normal contour, 2, 3
 diffuse of uterine wall, but no glandular invasion, 14, 22, 64, 230
- Tubal portion of uterine horn, adenomyoma from, 236
 pregnancy and adenomyoma, differentiation, 184

- Tubes, condition of, in cases of adenomyoma, 171
- Tubo-ovarian abscess, 47
- cyst, 29
- UTERINE glands, large and dilated, with overgrowth of uterine mucosa, adenomyoma and, differentiation, 180
- horn, abscess in, 244
- adenomyoma in, 29, 52, 67, 100, 117, 119, 235, 237, 239, 240, 241, 242, 244, 245, 246
- tubal portion of, adenomyoma from, 236
- uterine portion of, adenomyoma arising from, 235
- mucosa, atrophy of, 133, 240, 241, 244
- edema of, 50, 128, 133
- hemorrhage and thickening of, 24
- hypertrophy of, 140, 149, 246
- in adenomyoma in which uterus preserves relatively normal contour, 5
- Uterine mucosa, polypi of, 75, 97, 178
- stroma of, proliferation, associated with copious uterine hemorrhages, adenomyoma and, differentiation, 180
- venous sinuses in, and adenomyoma, differentiation, 179
- polyp, 75, 97
- walls, adenomyoma of, 2.
- benign character, 188, 190
- myomatous thickening of, 14, 22, 23, 64, 230
- Utero-ovarian ligament, discrete adenomyoma of, 141
- Uterus, bicornate, adenomyoma in one horn of, 203
- VAGINA, double, 161
- Vaginal discharge in adenomyoma, 173
- Venous sinuses in uterine mucosa and adenomyoma, differentiation, 179
- Von Recklinghausen's canal, 7